

Remarks on operations on the Gasserian ganglion : with a report of five additional cases / by W.W. Keen.

Contributors

Keen, William W. 1837-1932.
Royal College of Surgeons of England

Publication/Creation

[Philadelphia] : [Lea Bros.], 1896.

Persistent URL

<https://wellcomecollection.org/works/tneh5mw5>

Provider

Royal College of Surgeons

License and attribution

This material has been provided by This material has been provided by The Royal College of Surgeons of England. The original may be consulted at The Royal College of Surgeons of England. where the originals may be consulted. This work has been identified as being free of known restrictions under copyright law, including all related and neighbouring rights and is being made available under the Creative Commons, Public Domain Mark.

You can copy, modify, distribute and perform the work, even for commercial purposes, without asking permission.

967

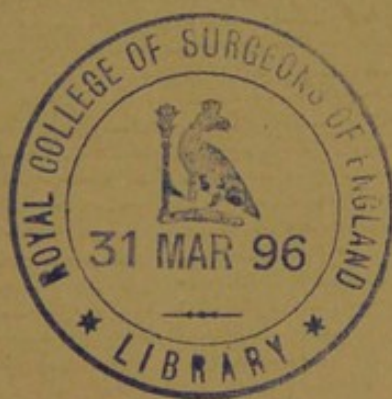
9.

*Remarks on Operations on the Gasserian
Ganglion, with a Report of Five
Additional Cases.*

BY


W. W. KEEN, M.D.,


PROFESSOR OF THE PRINCIPLES OF SURGERY AND OF CLINICAL SURGERY,
JEFFERSON MEDICAL COLLEGE, PHILADELPHIA.



FROM

THE AMERICAN JOURNAL OF THE MEDICAL SCIENCES,
JANUARY, 1896.





REMARKS ON OPERATIONS ON THE GASSERIAN GANGLION,
WITH A REPORT OF FIVE ADDITIONAL CASES.¹

By W. W. KEEN, M.D.,

PROFESSOR OF THE PRINCIPLES OF SURGERY AND OF CLINICAL SURGERY, JEFFERSON MEDICAL
COLLEGE, PHILADELPHIA.

On February 14, 1894, I reported to this Society, in conjunction with Dr. John K. Mitchell, a case of *tic douloureux*, in which I operated on the Gasserian ganglion. The patient, after the lapse of twenty-six months, has remained entirely free from pain with the exception of some slight twinges of pain, which I am inclined now to attribute rather to nervousness than to a real return of his disorder.

The two methods of reaching the ganglion are, first, that devised by Rose, and, secondly, the Hartley-Krause operation. All of the six operations that I have done have been by the latter method, which I regard as much superior to the former: First, because of its smaller mortality, due largely to the more complete asepsis that can be obtained; secondly, because the access to the ganglion is by a large instead of a small and cramped opening; and, thirdly, because we can actually remove the entire ganglion with its roots.

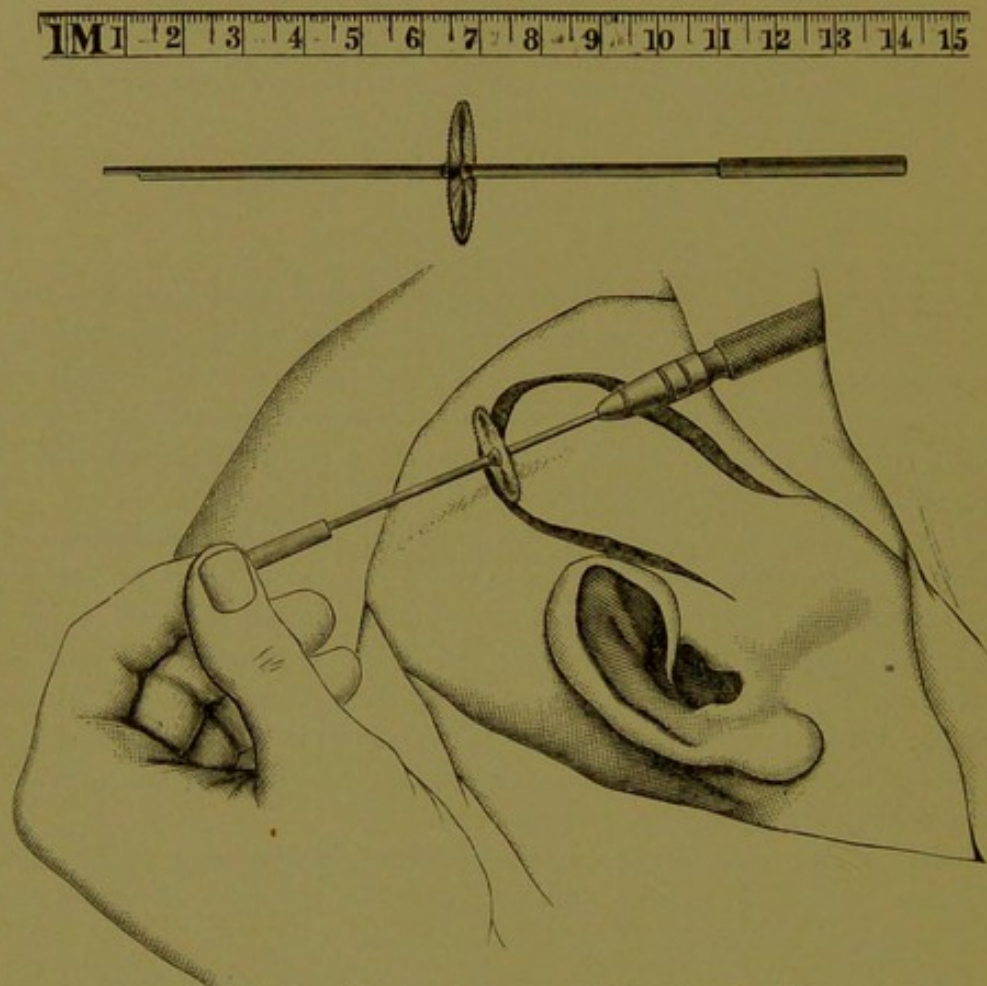
I shall take up the various stages of the operation and make some remarks upon each, based on my experience in six cases, of which five recovered and one died from accidental sepsis.

First. Access to the cranial cavity. This is by means of an osteoplastic flap formed in the temporal region by a large horseshoe-shaped incision, one end of which begins immediately in front of the ear, the other about an inch behind the orbital margin of the external angular process. If the anterior incision goes nearer to the orbit than this point the operator will have to chisel through the thick bone at the lesser wing of the sphenoid and invade the anterior fossa of the skull. The incision should be three inches vertically and three inches horizontally at its widest part. The two ends of the incision should go down toward the zygoma, in order to reach well toward the base of the middle fossa of the skull. I have had no experience with Krause's circular saw actuated by the surgical engine. (Fig. 1.) Prof. Krause last summer told me

¹ Read before the Philadelphia County Medical Society, Dec. 11, 1895.

that he had found it a very safe and expeditious method of reaching the interior of the skull. One great improvement he has introduced in the saw is the prolongation of the handle directly through the centre of the saw, so that it can be held by two hands, and thus held much more firmly. In two of my cases the skull has been opened by means of Dr.

FIG. 1.



Krause's method of using the circular saw with two hands. (KRAUSE.)

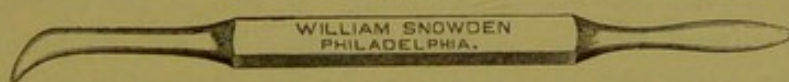
Cryer's drill, a very ingenious and useful means of entering the skull. My other four operations have been done by a chisel, either Hartley's or, what I rather prefer, that of Pyle.

Second. Hemorrhage from the middle meningeal. As soon as the osteoplastic flap, made up of scalp and bone, is turned downward, there will be some hemorrhage from the middle meningeal. Even if the anterior branch does not run in a canal in the bone or in a groove so deep as to be practically a canal, some of its larger branches to the bone are torn and, usually, require ligation of the artery by means of the smallest semicircular needle of Hagedorn, threaded with silk, on account of its greater strength as compared with fine catgut.

It has been my misfortune in three of the cases to wound the posterior branch of the middle meningeal by the chisel penetrating the thin squamous portion of the temporal bone, and at the same time I have had to fight hemorrhage from the anterior branch by its being torn, owing to its passage through a complete or almost complete canal. I have met this accident by placing two fingers over the bleeding points, rapidly gnawing away the bone over the posterior branch by the rongeur forceps, securing this by a ligature, and, when once secured, releasing my finger on the anterior branch and securing that in the same way.

In one case (VI.), while lifting the temporo-sphenoidal lobe from the middle fossa of the skull, with what at the time I deemed to be great gentleness, the main trunk of the artery ruptured about one-quarter of an inch above the foramen spinosum. I was able to secure it in the same way as before, but after much trouble and the loss of a great deal of blood. The broad spatula, by which the temporo-sphenoidal lobe and dura are lifted, was of great service in controlling the hemorrhage temporarily. In two cases the artery ruptured at a still more unfortunate place, namely, immediately at the foramen spinosum, so that it was impossible to ligate it. The expedient adopted in both cases was very satisfactory in controlling the hemorrhage. The moment that I found the source of the bleeding I plugged the foramen spinosum by the curved end of the Allis blunt dissector.¹ (Fig. 2.) I then quickly substituted my left forefinger for the blunt dissector, thus leaving my right hand free.

FIG. 2.



Allis's blunt dissector.

Next, I quickly substituted a narrow strip of iodoform gauze for my finger and packed it rather tightly into the opening. This strip of gauze I carefully removed on the third day, and in neither case was there any further hemorrhage. A similar accident occurred in one of Krause's cases, and was controlled in a similar manner. To anticipate the hemorrhage from the middle meningeal Fowler tied the external carotid. From my experience I think this is unnecessary. Of course, the external carotid should be ligated, and not the common carotid, since the latter operation is not by any means free from the danger of producing softening of the cerebral hemisphere on the same side in case the circle of Willis is incompetent to re-establish the circulation.

Third. Lifting the temporo-sphenoidal lobe from the middle fossa of

¹ This most useful yet simple surgical instrument is not as well known as it deserves to be, hence I figure it here. In all blunt dissections, which are so largely employed, it is simply invaluable, especially by the facility with which adhesions are torn through by its curved end.

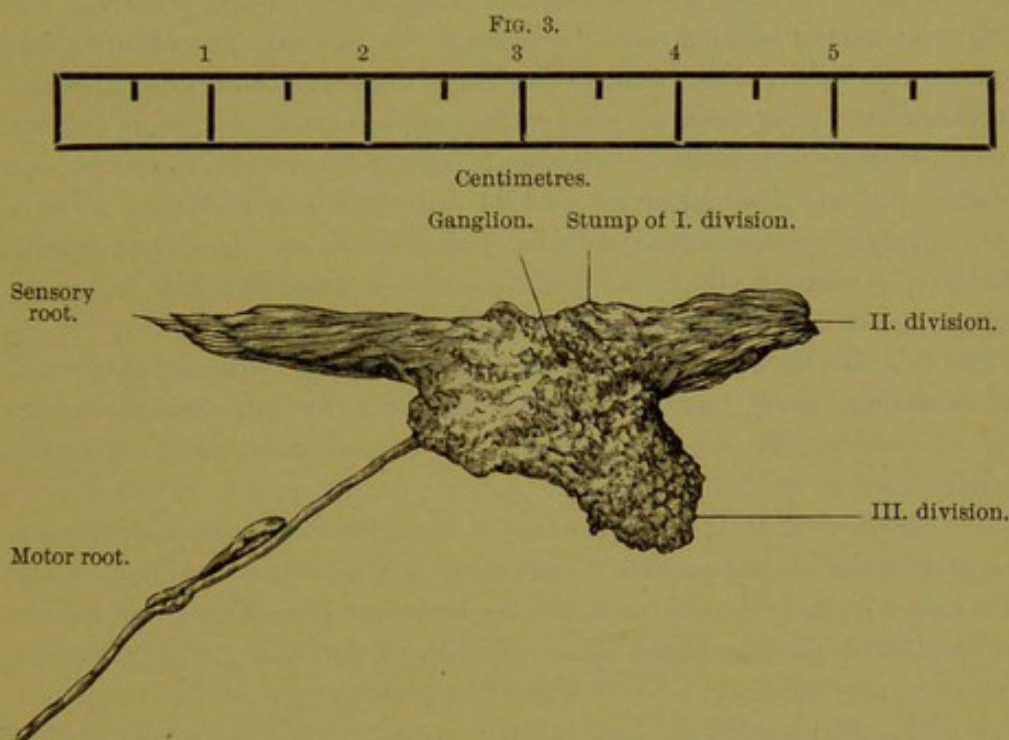
the skull. This is best done gently by the forefinger, and the brain, with its membranes, is then held up by a broad spatula. Separating the dura from the bone of the middle fossa is always attended with rather profuse hemorrhage, owing to the rupture of many small vessels going from the dura to the bone. This can usually be controlled by packing. In my first case I was fearful that I had torn the cavernous sinus so profuse was the hemorrhage. But experience has taught me that the source of the hemorrhage is as stated. The cavernous sinus has been torn by Finney, Krause, and others, but the hemorrhage, though alarming, has been readily controlled by packing with gauze.

In case the hemorrhage from the middle fossa is very severe I have in three cases done the operation in two stages. First, opening of the skull, separation of the dura from the middle fossa, and packing the cavity with iodoform gauze to check the hemorrhage, and three days later reopening the skull and completing the operation. The amount of packing which the brain will stand has surprised me. In one case I packed a piece, afterward found to be 37 inches by 6 inches, or 222 square inches of gauze; in another, a piece 23 inches by 14 inches, or 322 square inches of gauze; and in the third a piece 16 inches by 6 inches, or 96 square inches. In each instance the gauze remained in place for three days without any material symptoms.

I much prefer, however, to do the operation in a single stage. The danger of infection is much increased by doing it in two stages, and with a growing experience I have been able to control the hemorrhage better by temporary packing, and also have learned to facilitate the operation by the position of the head. In two of the operations the head was turned sidewise, so that the ganglion and its branches lay practically at the bottom of a well, and a few drops of blood were quite sufficient to prevent my seeing the ganglion and its branches. It is needless to say that at such a depth and with the carotid artery and cavernous sinus so near no prudent surgeon will manipulate unless he can see clearly exactly what he is doing. I find, as would naturally be supposed, that it is much better to operate with the head resting on the occiput and with a bright side-light. By this means the blood runs out as rapidly as it accumulates and does not obscure the parts, and I have found that a good side-light, with the head in this position, obviates the need for an electric light.

Fourth. Recognition and treatment of the ganglion and its second and third divisions. As soon as the hemorrhage in the middle fossa is stopped by temporary packing and sponging, the points of exit of the second and third divisions of the ganglion through the foramen rotundum and foramen ovale can be recognized by the folds or lines of traction produced by lifting the dura. These lines of traction converge at the foramina. Another guide to the third division also is the main

trunk of the middle meningeal, which lies at a distance outside the foramen ovale, varying, as Taylor has shown, from $\frac{2}{16}$ to $\frac{9}{16}$ of an inch. The ganglion lies at the junction of the axes of the second and third divisions, and the object of the operator is now to completely uncover and separate the second and third divisions, and then the ganglion itself, from the dura. For this purpose I have found the best instrument to be the curved end of the Allis dissector. The dura is gently but firmly drawn back in the axis, first of the second, and later of the third divisions of the nerve, and when the ganglion is reached, by still further traction on the dura, the entire ganglion can be disclosed. It appears



Gasserian ganglion with the II. and III. divisions and the sensory and motor roots removed from Case VI. The nerve fibres are well shown. The motor root is elongated by the accidental reversal of one of its bundles. (From a photograph which unintentionally was enlarged, about one-third, but the scale of centimeters which was photographed with the specimen will serve for comparison.)

like a network of fibres. Having isolated the ganglion and the two divisions, not only from the dura above, but also underneath them, the best way to remove the ganglion with its divisions and its roots is as follows: First, *seize the ganglion itself* with a pair of hæmostatic forceps; then, and not before, as Krause¹ has pointed out, cut the second and third divisions at their foramina; and lastly by a gentle but firm rotation of the forceps the ganglion and its divisions can be avulsed, usually bringing with the mass the sensory root, and, as in my own last case, the motor root all the way back to the pons. (Fig. 3.)

¹ Archiv klin. Chir., 1895, I. 469.

If the second and third divisions are cut at the foramina before the ganglion is seized and an attempt is made to tear them and the ganglion out, I found in several cases that the two divisions will generally tear off from the ganglion and the latter be left behind.

It is then difficult, if not impossible, to seize and remove the ganglion. In fact, I believe that in almost all, if not absolutely all, of the cases heretofore reported except those of Krause¹ and my last case (Case VI.), the operation has consisted in dividing and tearing away the second and third divisions and then "breaking up" the ganglion by the curette, hooks, or other instruments. It is very doubtful to my mind whether by the method we do more than partially destroy the ganglion; certainly we do not "remove" it. In only two of my cases were any ganglion cells found in the tissue removed from the supposed position of the ganglion, and yet I endeavored to break it up and remove it as completely as possible. Whether it is actually needful to remove the entire ganglion, or whether its partial destruction is sufficient to cure the neuralgia permanently, will be discussed later. If it be needful wholly to remove it, then the *technique* above described will be necessary. The establishment of this *technique* we owe to Krause.

The first division is, of course, not meddled with, since it penetrates the cavernous sinus, but the ganglion is torn away from it. Occasionally a considerable part of the first division comes away with the ganglion.

Mr. Horsley² is of the opinion that it is impossible to remove the entire ganglion without seriously wounding the cavernous sinus, but the specimen which I show you from my last case (see Fig. 3) as well as the specimens photographed by Krause prove that the ganglion can be removed in its entirety. Until I saw the photographs of Krause I had been of Horsley's opinion, but I have been compelled to change that opinion.

Clinically, therefore, cases of intra-cranial neurectomy of the fifth should be carefully divided hereafter into two classes: First, those in which the ganglion has been merely more or less broken up; and, secondly, those in which it has been wholly removed; and the result of any recurrence or non-recurrence of the neuralgia should be carefully correlated with the removal or non-removal of the ganglion itself.

Mr. Horsley,³ in one case, opened the dura, lifted the middle lobe of the brain, and tore out the roots of the ganglion from the pons. The operation, as I have described it, accomplishes the same result with a considerably less danger of mechanical injury because the brain tissue is protected by the fibrous dura, and there is less danger of infection.

The connection between the ganglion and its sensory root apparently

¹ Loc. cit., Pl. VI.

² Brit. Med. Journ., 1891, ii. 1249.

³ Loc. cit.

is so strong that this root almost always comes away with the ganglion (see Krause's photographs). In my last case the slender cord, passing under the ganglion, cannot, it seems to me, be other than the motor root. Whether it would be possible to separate the motor root from the ganglion and the third division, I do not yet know. I should propose in another suitable case to see whether it is not possible to lift the ganglion, separate it and the third division from the motor root, and then by cutting the third division of the fifth in a direction away from the motor root, possibly to preserve this nerve.

Fifth. Effects of operation on the ganglion upon the cornea. The first operation done by Mr. Rose resulted in the loss of the eye from the trophic changes, induced by the destruction of the ganglion. He, therefore, recommended and practised later stitching together of the eyelids, which, however, has been done in very few cases. I have not seen reported any other cases of serious trouble with the cornea.

In my first four cases I had no such trouble, though I did not stitch the lids together. In Case V., in which the destruction of the ganglion was more complete than in the first four, though the ganglion itself was probably not removed, a corneal ulcer formed shortly after the operation, though I protected the eyeball for four days by an occlusive dressing. I suspect, however, that the lids were opened under the dressing and abrasion of the cornea took place without the patient's knowledge, since it was of course entirely anæsthetic. This led me in Case VI. to prevent the opening of the eyes by passing three stitches through the skin of the lids. After four days, there being some slight irritation around the stitches, I cut them and found the eyeball in perfectly good condition. Twenty-four hours later a corneal ulcer had begun to form, and the conjunctiva was very distinctly reddened. To prevent further trouble Dr. de Schweinitz freshened and stitched together the middle fourth of the lids, so as to get union of the two lids. This left the two ends of the palpebral fissure open for the escape of the normal secretions and for syringing. After a few days the lids separated by the giving of the adhesions, and in two days required to be restitched on account of renewed trouble. After a time, if we may judge from experiments upon animals, the lids may be separated and the cornea will not suffer from ulceration. Turner (*Brit. Med. Journ.*, November 23, 1895, p. 1279), from a number of experiments upon animals, concludes that "there is no evidence of trophic influence exerted by the Gasserian ganglion upon the cornea; and that, provided septic organisms are excluded, the ophthalmic branch may be safely divided or the Gasserian ganglion removed without fear of the disorganization of the eye." If this be true the explanation of the trouble in my cases lies in the imperfect asepsis of the eye. But the contrast between my first four and my last two cases, in the latter of which more

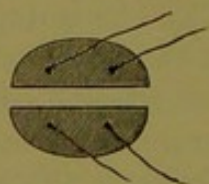
care was used than in the former, and the speedy relief following protection of the cornea by stitching the lids make one doubtful of its truth in man. V. Hippel (*Archiv f. Ophthalm.*, 1889, xxxv. 2, p. 217) considered the subject from the experimental side, and says that micro-organisms are of no etiological importance, but ascribes the changes chiefly to drying of the cornea, which he remedies by a moist atmosphere. My own case seems to support this view and the theory of traumatism from exposure of the anæsthetic cornea.

It is noticeable that this corneal ulceration followed only in the two cases: one of extensive destruction and the other of absolute removal of the ganglion. Krause has reported eight such complete removals with one death. One of the seven that recovered was suffering from chronic conjunctivitis at the time of operation. A corneal ulcer formed, but was cured. None of the others suffered.

In future I shall unite the two lids in the centre and keep them united for some time after the operation, in order to make sure of the safety of the eye, or else advocate the expedient which has occurred to me since my last case was operated on. The late Dr. Levis, after his cataract operations, to keep the eyelids closed, used to place a semi-oval piece of adhesive plaster on each lid, the plasters acting as splints and preventing the separation of the eyelids. I should propose to use the same means, supplemented, if necessary, by two threads sewn through the plaster only (Fig. 4). Should the plaster not be sufficient to keep the lids together, the threads could be tied in a bow-knot, thus enabling one to separate the lids for inspection of the cornea and for medication of the eye, and at the same time to readjust them and keep them in approximation. The plasters should be of the entire width of each lid.

Since the above was written I have tried another method, suggested by the nurse in charge of Case VI. A large oval piece of plaster, with

FIG. 4.



Two pieces of adhesive plaster with threads, to be applied to the two lids and tied together.

a narrow slit corresponding to the fissure of the lids, is applied to the lids and seems to retain them well in apposition, and at the same time allows of inspection and medication of the cornea.

This raises also the question as to whether the more or less complete destruction of the ganglion, which has been done by most operators, is not sufficient to cure the neuralgia and whether the avulsion of the en-

tire ganglion may not be a needlessly severe operation, especially by the peril to the eye. It does not seem thus far to have increased the mortality, but I suspect it does increase the danger to the eye in spite of Krause's happy experience and Turner's recent experiments. If time shows that the cure of the neuralgia by simply breaking up the ganglion is permanent, I should certainly be content with that. The fact that there have been a few moderate relapses, however, makes me suspect that the removal of the ganglion itself may be necessary. The intracranial avulsion of the second and third divisions from the ganglion, leaving the ganglion intact, does not seem to suffice, for in one such case Krause was obliged later to remove the ganglion itself to cure a return of the neuralgia. We shall be in a position within a few years to decide this question positively.

Sixth. Results as to recovery and cure. The most complete statistics that have been given of the mortality of the operations are those in Krause's recent paper, in which he has reported that in twenty-two cases done by Rose's method, the mortality has been 4 or 18 per cent., whereas in fifty-one operations by the Hartley-Krause method, the mortality has been only 5 or 9.8 per cent. The mortality, therefore, is much less by the latter method. It is quite certain also that if we regard the removal of the ganglion itself as an important step in the operation, this is impossible by Rose's method, since we are working in so small a space as to make it impracticable to see and manipulate the ganglion.

As to the permanence of the cure this seems to be thus far more satisfactory than the results from any of the peripheral operations. The only recurrences that I have seen reported are one case of Rose's and two of my own. Rose's was only a partial return, and my own two are very probably not true recurrences which will lead to a relapse. At the same time I have thought it right to state the facts exactly as they exist (see Cases I. and II.).

To give all my six cases to date I reproduce a short summary of the first (published in full in the *Transactions* of the Philadelphia County Medical Society for 1894), with rather fuller histories of the other five heretofore unpublished cases.

CASE I. *Breaking up of the Gasserian ganglion after thirteen prior operations. Done in two stages on account of packing to arrest the hemorrhage; recovery; cure for twenty-six months; possible slight return(?)*.—Dr. K., aged forty-one years. He had suffered from neuralgia for thirteen years and had had thirteen operations done, including removal of a large part of the upper jaw, as well as various branches of the nerves. The anterior branch of the middle meningeal passed through a canal and was, of course, torn in turning down the flap. In chiselling the posterior portion of the flap, the posterior branch was also divided and the dura wounded. Both vessels were secured after much trouble. The hemorrhage, on lifting the middle lobe, was so great that the cavity was packed and the operation completed in a second stage after three days, the

ganglion being broken up. The piece of gauze was found to measure thirty-seven by six inches, or two hundred and twenty-two square inches. This remained in the skull for three days, during which time his temperature had risen to 100.8° , and the respiration had gone down to from six to ten in a minute, with a slight aphasia. Immediate recovery followed the completion of the operation. He has suffered from temporary twinges of the pain, but except these he has been free from pain, and is present to-night for your examination.

CASE II. *Breaking up of the Gasserian ganglion in two stages after eight prior operations; recovery; cure for eighteen months; possible slight return.*—C. H. B. was kindly sent to me on June 14, 1894, by Dr. John B. Roberts (who was leaving town). His neuralgia began in April, 1886, shortly after a dentist hammered the gold filling into a tooth so hard as to give him great pain. Soon after the neuralgia began, all his teeth on the right side of the upper jaw were removed. A large number of drugs were tried without relief. In 1889 subcutaneous neurotomy was twice done. In March, 1890, the antrum was drilled. In April, 1890, Dr. Roberts removed several polypi from the nostrils, straightened the septum, and, later, resected a portion of the right infra-orbital nerve. In May, 1890, and again in November, 1890, the infra-orbital was resected for the second and third times by Dr. Roberts. January 31, 1891, Dr. Roberts tied the right carotid. In March, 1890, before Dr. Roberts saw him, the sight of his right eye began to fail, and in February, 1891, his physician in Florida stated that he had a glaucoma of the right eye, for which he removed the crystalline lens. When I first saw him in June, 1894, the right eyeball was shrunken, the cornea opaque and thickened, and the eye utterly useless. The lids could not be completely closed. The right face was shrunken over the region of the antrum. For three years he had never been free from excruciating pain.

Operation, June 18, 1894, at the Orthopedic Hospital. The anterior branch of the middle meningeal ran in so deep a groove as to be practically a canal, and the artery was torn in turning the flap down. It was immediately secured by a ligature. On lifting the temporo-sphenoidal lobe, the hemorrhage was so profuse that I finally packed the wound with gauze and closed it temporarily for three days.

June 21, 1894. The gauze, when removed, measured sixteen by six inches. A culture was made at the first stage of the operation, and again at the second stage another culture was made from the inner end of the iodoform gauze, which had been in the skull for three days and looked as if there were pus on the end of it. Dr. Kyle reported that both tubes proved to be entirely sterile.

The second and third divisions were torn loose from the ganglion, the pocket for the ganglion readily found, torn open, and the ganglion broken up. The tissue, which was supposed to be removed from the site of the ganglion, was given to Dr. C. W. Burr, the pathologist of the hospital, who reported that there were neither nerve-tubules, nor nerve-cells to be found. During the three days between the first and second stages of the operation, the temperature had gone up to 102° . The day after the gauze was removed and the ganglion broken up, the temperature fell to 99° . In four days he was out of bed, and in ten days entirely well.

On July 3d Dr. de Schweinitz enucleated the right eyeball, both as a

cosmetic operation and to avoid possible mischief to the other eye. The operation was done without an anæsthetic. He complained slightly of pain, the worst being felt when the scissors were thrust well back of the eyeball and the optic nerve divided. At no time has there been a single spot of complete anæsthesia over the entire face. He writes me November, 1895, that he had lately had a short attack of pain. Whether this is a precursor of a return of his neuralgia time must determine. From the experience of Case I. there is reason to believe that it will not prove to be so.

CASE III. *Breaking up of Gasserian ganglion after two prior operations; rupture of the middle meningeal at the foramen spinosum; infection during operation; death from septic meningitis.*—Mrs. E. E. H., aged sixty-three years, was admitted to the Jefferson Hospital, February 19, 1894. At Christmas, 1882, she fell, striking the nape of her neck on the edge of a marble step. A month later she began to suffer lancinating pains, starting above the left mental foramen and radiating over the entire lower and upper jaws and in the temporal fossa, sometimes also as far down as the clavicle and extending to the tip of the tongue.

In 1889, at the Orthopedic Hospital, Dr. Morton removed a portion of the inferior dental nerve. The pain was entirely relieved in the lower jaw, but later returned there and at the tip of the tongue.

Second operation. She was admitted to the Jefferson Medical College Hospital, February 23, 1892, when I removed the inferior dental and lingual nerves by trephining the vertical ramus of the jaw. This method, which weakens the ramus less, I judged better than that of Horsley (*Brit. Med. Journ.*, 1891, ii. 1192), in which he deepened the sigmoid fossa between the condyle and the coronoid process of the jaw. She was entirely free from pain until November, 1893, when it recurred again, especially in the region of the left side of the nose and cheek, the pain being described as resembling "forked lightning." It is typical of the worst form of tic douloureux. At no place is there complete anæsthesia on the left side of the face, but, on the contrary, a large part of the skin is hyperæsthetic. The pain now exists in both the second and third divisions of the fifth.

Operation, Jefferson Hospital, February 20, 1895. The anterior branch of the middle meningeal ran in a canal and was ruptured. The bone was divided by Dr. Cryer's drill.

In lifting the temporo-sphenoidal lobe, the middle meningeal ruptured directly at the foramen spinosum. The hemorrhage was arrested by plugging the foramen with the Allis dissector, then substituting my left forefinger for the dissector, and then substituting a piece of gauze for my finger.

During the operation an assistant, when my back was turned, inadvertently placed one of the drills in his mouth, and, without disinfection, it was used in completing the section of the bone. From this, to me unknown, source of infection, unquestionably, the wound became infected. On the second day her temperature rose rapidly, and at the end of a week she died. The post-mortem showed that death resulted from septic meningitis, pyogenic cocci being found by culture.

The hemorrhage of the middle meningeal, which I arrested with a small bit of gauze, was not a serious element in the case, since the amount of blood lost was not very great, and on the third day after the operation the gauze was removed without further hemorrhage.

CASE IV. *Breaking up of Gasserian ganglion after five prior operations; done in two stages on account of hemorrhage; packing with gauze for three days; recovery; cure for seven months; necrosis of the bone in the flap.*—Mrs. S. R., aged sixty years. She was kindly referred to me by Dr. Clara T. Dercum, May 21, 1895. She has been a typical sufferer with facial neuralgia for five years in the second and third divisions of the right fifth, for which Dr. Steinbach has done five operations on these two divisions, the last one being a division of both branches just beyond the foramen rotundum and foramen ovale.

Operation, May 23, 1895. Profuse hemorrhage occurred on turning down the flap, in consequence of rupture of the anterior branch of the middle meningeal, which ran in a very long canal in the bone. It was secured by catgut ligature, when the hemorrhage ceased. Again on lifting the temporo-sphenoidal lobe, the hemorrhage was so great that after spending a good deal of time I found it impossible to see clearly the later steps of the operation, and therefore packed with a piece of gauze, afterward found to measure 23 inches by 14, or 322 square inches. Three days later, May 26th, I reopened the wound, removed the second and third divisions, and broke up the ganglion. Five days later, all the stitches were removed and the wound was found united excepting at the two ends of the incision. From these a few drops of pus escaped. While the gauze remained in the head, her temperature was 100° to 101° and she seemed a little drowsy; the latter may have been due to opium which was required to quiet her pain, which did not cease until a number of days after the operation. Two days after the gauze was removed and the second stage of the operation completed, her temperature fell to the normal, and she went home shortly after. A slight discharge has continued from the two ends of the incision, and at a third point, which later reopened, and some fragments of bone have been discharged. She has, however, remained entirely free from pain.

Dr. Kyle reports that he found "undoubted ganglion cells in the tissue removed. The central portion of the section showed slight, if any, variation from the normal, but the outer portion showed some inflammatory infiltration. Sections of the nerves showed a thickened neurilemma (inflammatory) with infiltration of round and spindle cells. There was no apparent change in the axis cylinders or the white substance."

CASE V. *Curetting of the Gasserian ganglion after two prior operations. Rupture of the middle meningeal at the foramen spinosum. Post-operative corneal ulcer; recovery; cure for two months.*—Mrs. F., aged fifty-four years; first consulted me at the instance of her son, Dr. F., July 15, 1891. Twelve years previously she had a small abscess at the root of a lower right molar tooth, and from that trouble dates her neuralgia. The pain was at first confined to the inferior dental nerve. All of her teeth were removed and various drugs used with more or less success. In 1887 she consulted Dr. William Pepper, and on April 29, 1888, Dr. Agnew removed a half-inch of the inferior dental nerve. This gave relief for eighteen months, when her neuralgia returned, involving the superior maxillary division. In 1891, when she saw me, the pain existed in the distribution of both the second and third divisions of the fifth. It was the usual frightful pain of tic douloureux. Her face was extremely hyperæsthetic.

Second operation, July 17, 1891. At the former trephine opening in the lower jaw just above its angle was a small opening through which

some fibrous tissue passed. I trephined at the same point and found the nerve reproduced and thickened to about the size of the median nerve. I removed an inch and a half of the nerve by avulsion and then removed the superior maxillary nerve, dividing it well back of the infra-orbital canal.

This operation gave her relief for another eighteen months or two years, when the pain returned as bad as ever. Her physician, Dr. Moore, of Spartanburg, S. C., brought her to see me early in October, 1895. I recommended and she accepted an operation on the Gasserian ganglion.

Third operation, October 6, 1895. The ordinary Hartley-Krause osteoplastic operation was done. In chiseling the lower part of the incision just in front of the ear, the posterior branch of the middle meningeal was divided, although I took every precaution not to go through the bone, as in a woman of her age and so thin as she, I judged that the bones of the skull were probably very thin.

As soon as I turned down the flap of bone, I found that the anterior branch of the middle meningeal went through a canal and was torn, and the posterior went through a very deep groove, in which my chisel had divided it. In addition to this, there was a rent in the dura, which must have been made by the chisel penetrating, without its being perceived, into the interior of the skull cavity. I finally succeeded, with great difficulty, in securing the posterior branch; the anterior was comparatively easily controlled. I then carefully lifted the dura from the middle fossa, but in doing so the middle meningeal tore directly at the foramen spinosum, and a profuse hemorrhage followed. I was able, however, to arrest this by getting the curved end of the Allis blunt dissector into the canal and then substituted, first, the forefinger of the left hand and then a piece of iodoform gauze, by which I controlled the bleeding completely.

I then exposed and cut the second and third divisions at their foramina, grasped them with forceps, and endeavored to avulse the ganglion with them. The two branches each tore off from the ganglion, but I was able to scoop out most of the ganglion with a curette. What I took to be the cavernous sinus was perfectly visible and avoidable.

The small piece of gauze packed into the foramen spinosum was brought out through the wound and the wound closed with interrupted silk-worm-gut sutures.

Dr. Kyle reported on the tissue which was supposed to be the ganglion that it was undoubtedly portions of the ganglion, since he found nerve cells as well as tubules in the tissue.

Three days after the operation, I very carefully removed the small bit of iodoform gauze which blocked up the middle meningeal artery, and no hemorrhage followed. The wound was healed in the course of a week.

On the third day after the operation her eye became red and a corneal ulcer began to develop. I placed her in charge of Dr. de Schweinitz for the ulcer of the cornea. In spite of the utmost care, this broadened and deepened to a considerable extent, and at one time was very threatening, but by long-continued treatment by atropine, boric-acid solution, hot compresses, bandaging the eyes with the greatest care, etc., she finally went home, November 27, 1895, with a distinctly healing ulcer and without any pain.

CASE VI. *Removal of the entire Gasserian ganglion, with its second and third sections and its sensory and motor roots back to the pons in a piece 4 centimetres long, after four prior operations; recovery; cure for three weeks; post-operative corneal ulcer.*—C. H. E., aged thirty-three years, was kindly placed under my care in the Orthopedic Hospital by Dr. M. H. Cryer, November 16, 1895. Family and prior personal history negative. Five years ago had an attack of diphtheria, and soon after this his trigeminal neuralgia began on the right side of his face. At first the attacks occurred about once in a month, but increased in frequency and severity until September, 1894, when they became almost constant. In March, 1895, the teeth on the right side of the upper jaw and the alveolar process were removed. Since then he has had three other operations done, including removal of the infra-orbital nerve and opening of the antrum. The most tender spot in his face is at the angle of his mouth, though the pain includes both the first and third divisions of the nerve, as well as the second. Even conversation is scarcely possible to him.

Medical treatment has been employed without any permanent relief. Dr. de Schweinitz and Dr. Archibald Thomson kindly took charge of his eyes. The latter examined his eyes November 18, 1895, and reported the pupils, disk, fundus, and muscular balance normal, but that he had hypermetropic astigmatism 2 D. in each eye.

Operation, November 22, 1895. In view of the trouble which I had with the eye in Case V. I decided to stitch the lids together as the first step of the operation.

The Hartley-Krause operation by an osteoplastic flap was done. When the skull cavity was opened the anterior branch of the middle meningeal was torn at a point where a large branch penetrated the bone. This was ligated with catgut. On lifting the temporo-sphenoidal lobe from the middle fossa a furious hemorrhage took place in spite of the fact that I had done it only with my finger and with the greatest gentleness. I packed it for a few moments with iodoform gauze, and then on withdrawing the gauze and lifting the brain by a spatula I found that it came from the middle meningeal, about one-quarter of an inch above the foramen spinosum, where the artery had ruptured. I could see no reason for its rupture at that point. With very great difficulty I was finally able to pass a fine silk ligature under the dura, encircling the vessel and securing it. I soon brought into view the second, and, later, the third divisions of the fifth nerve. With the curved end of the Allis blunt dissector I was able to uncover the second division and then the third as far back as the ganglion, and then with the same instrument gradually to push the dura back and disclose the entire ganglion. Following Dr. Krause's advice (*Arch. klin. Chir.*, l. 469), I then seized the ganglion itself with a pair of hæmostatic forceps before I divided the two branches at the foramina. I next cut the branches at their foramina, and then slowly and most carefully twisted the forceps which had hold of the ganglion itself, and the sensory root as far back, I judge, as the pons tore out quite readily. With it also was a much more slender filament, which went under the ganglion, and which I deemed to be the motor root. (See Fig. 3.)

The length of the entire specimen from the anterior end to the end of the sensory root is 4 cm., and to the end of the motor root 5 cm. From the ganglion the second division measured 13 mm., and the third

division 9 mm. From the ganglion to the end of the sensory root was 2 cm.; to the end of the motor root 3 cm. The moment that the ganglion was torn out it was unfolded and photographed, and then placed in Müller's fluid.

On tearing out the ganglion quite a profuse hemorrhage occurred at that point. I judged it to be at the aperture in the cavernous sinus, where the first branch was torn loose. I packed it quickly with iodoform gauze, and, finding that temporary packing did not arrest it, I packed it with a fresh strip 10 inches long and 1½ inches wide, and then closed the wound.

The operation was long (two hours) on account of the difficulty in dealing with the hemorrhage. I did not use any electric light, as I found a good side-light with the head resting on the occiput was very excellent, and this position of the head is more favorable to manipulation, since the blood flows out more readily than if the head is turned with the operation side up, when the blood accumulates at the bottom of the cavity, the very place where one wishes to see well.

He was placed in bed in very good condition with very moderate shock. Later in the afternoon I was called to see him on account of some bleeding. I found two small vessels on the edge of the flap had been bleeding somewhat, but the hemorrhage ceased immediately on my ligating them.

The next day, November 23d, I found that he had passed an uncomfortable night; was complaining greatly of frontal headache, and his temperature had steadily risen until it reached 104°. I was persuaded that this was due either to pressure from the gauze or to the retained wound-fluids and the absorption of their fibrin ferment, or to both causes. That pressure alone could do it I doubted, in view of my experience with three prior cases. I was very loth to remove the packing as early as twenty-four hours, fearing the recurrence of hemorrhage, but I was forced to do it. Accordingly, I removed it very gently, and was happily surprised in finding no bleeding; only about an ounce of bloody serum escaped. The wound in the skin was kept open by a small bit of iodoform gauze to the depth of half an inch. Within an hour his temperature was down to 99° and his headache gone. From that time he made a speedy and uneventful recovery, and the stitches were all removed on the eighth day.

Four days after the operation it was thought that the stitches in the eyelids, which were producing a little irritation, could be removed with safety. The eyeball appeared entirely normal. Within twenty-four hours, however, signs of corneal ulceration began, and on the sixth day Dr. de Schweinitz, without any anæsthetic, freshened the edges of the lids and stitched them together in the middle, the ends being left open in order that the secretions might escape, and also for purpose of irrigation. No pain attended the operation.

When Dr. de Schweinitz stitched the eyelids together he noted the following conditions of the cornea: The exact centre of the cornea is occupied by an area 3 mm. by 4 mm. of loss of superficial epithelium, with a slightly corrugated edge. Upward and outward from this is a small corneal infiltration; there is slight œdema of the upper lid. Vision in the right eye, 20/100; in the left eye, 20/40. In four days the corneal irritation subsided entirely. The adhesion between the lids gradually yielded, and the lids were separated after five days. The eye was meantime protected by a gauze dressing. In two days after the separation of the lids the cornea again became ulcerated, and the

conjunctiva reddened so that the lids were again stitched together. The eye is now improving.

Dr. John K. Mitchell kindly examined the sensation for me and reported as follows:

"November 28, 1895 (sixth day). The right half of his face is wholly anæsthetic to touch, pain, and temperature change (the tongue included). Sensation is dull for pain upon the whole left (sound) side; perception slow; prick only felt as touch if superficial; when pricked deeply says it gives "pain, but not severe." This paræsthesia exactly follows the same distribution as the total anæsthesia of the operated side, ceasing upon the under surface of the inferior maxilla, so that the central part of the throat back of the chin is normally sensitive, and normal sensation is present from there downward. Sensation to heat and cold was accurate upon the left side, and their perception and differentiation were as rapid as in health. It was not possible to test taste at this time.

"December 7, 1895 (fifteenth day). The left side presents wholly normal sensibility in all forms to-day, and no delay in appreciation of touch or pain is to be discovered. The line is sharply drawn at the median line of the face. Total anæsthesia and analgesia upon the right, normal sense-perception on the left.

"Taste is wholly lost to all forms of stimulation upon the right half of the tongue and all the way back to the root, if the patient's statements are correct. Tests were made with salt solution, sugar solution, and vinegar.

"Touch and pain sense are absent upon the right side of the tongue also, and upon the gums of the right jaw."

The specimen has not yet been examined. Dr. Kyle will make a full report of its condition hereafter.