

On luxation downwards and backwards of the three internal metatarsal bones : a form of dislocation of the foot not previously described / by Jolliffe Tufnell.

Contributors

Tufnell, Jolliffe.
Royal College of Surgeons of England

Publication/Creation

Dublin : Hodges and Smith, 1854.

Persistent URL

<https://wellcomecollection.org/works/z7yz7t77>

Provider

Royal College of Surgeons

License and attribution

This material has been provided by This material has been provided by The Royal College of Surgeons of England. The original may be consulted at The Royal College of Surgeons of England. where the originals may be consulted. This work has been identified as being free of known restrictions under copyright law, including all related and neighbouring rights and is being made available under the Creative Commons, Public Domain Mark.

You can copy, modify, distribute and perform the work, even for commercial purposes, without asking permission.



Wellcome Collection
183 Euston Road
London NW1 2BE UK
T +44 (0)20 7611 8722
E library@wellcomecollection.org
<https://wellcomecollection.org>

From the Author.
12

ON

LUXATION DOWNWARDS AND BACKWARDS

OF

THE THREE INTERNAL METATARSAL BONES,


A FORM OF

DISLOCATION OF THE FOOT NOT PREVIOUSLY DESCRIBED.

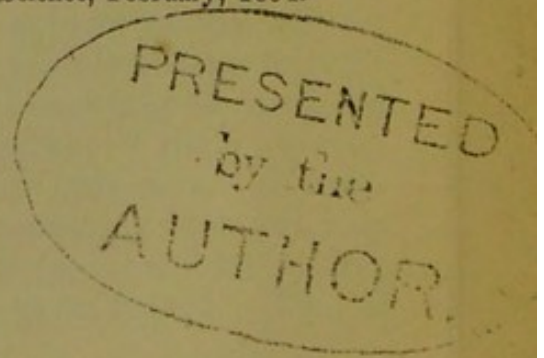
BY

JOLLIFFE TUFNELL, F. R. C. S. I., M. R. I. A.,

SURGEON TO THE CITY OF DUBLIN HOSPITAL; LECTURER ON MILITARY SURGERY; ETC. ETC.



From the Dublin Quarterly Journal of Medical Science, February, 1854.



DUBLIN:

HODGES AND SMITH, GRAFTON-STREET,

BOOKSELLERS TO THE UNIVERSITY.

1854.

DUBLIN:
Printed at the University Press,
BY M. H. GILL.

ON
LUXATION,

&c. &c.

THROUGH the extension of pathological investigation, cases of injury and disease are now brought under the notice of the profession which were formerly supposed incapable to exist. This remark applies to the subject of the present communication, namely, luxation of the metatarsal bones, a species of dislocation which, for a long time, was regarded as not possible to occur. Sir Astley Cooper, in referring to the subject^a, says: "The metatarsal bones I have never known luxated; their union with each other, and their irregular connexion with the tarsus, prevent it." Desault and Petit, as if not anticipating its occurrence, say nothing respecting this injury, whilst Boyer, contemplating the anatomical arrangement of the arthrodial articulations, strengthened as they are by surrounding ligaments, positively denies the possibility of this dislocation taking place.

Instances of the luxation of the metatarsus *upon* the tarsus have, however, been at intervals adduced, but so rarely that even recent writers have scarcely given the subject notice. Syme does not mention the accident^b. Miller^c merely alludes to it by saying: "One or more of the metatarsal bones may be displaced upon the tarsus." Ferguson^d but remarks: "Such injuries must be of rare occurrence;" and Erichsen^e only says, "Dislocation of the metatarsal bones, though exceedingly rare, yet does occasionally occur." At the present time (so far as I am aware) there are but six cases of this accident upon record. Two of

^a Dislocations and Fractures of the Joints, by Sir Astley Cooper, edited by Bransby Cooper. 1842. Page 339.

^b Principles of Surgery.

^c Principles and Practice of Surgery. 1853.

^d Practical Surgery. 1852.

^e Science and Art of Surgery. 1853.

these occurred to Dupuytren. They were first published in the *Révue Médicale*, for December, 1822; and have since been republished by the Sydenham Society. Two more came under the observation of Professor R. W. Smith, and are to be found in his admirable treatise on fractures and dislocations^a. One is mentioned by South in his translation of Chelius^b; and the last is related by Liston. These six cases had all one point in common,—they were displacements *upwards* and *backwards* upon the tarsus; whilst that I am now about to record is, on the contrary, luxation in the opposite direction, viz., *downwards* beneath the sole of the foot, and is, I believe, the very first instance of the kind which has been brought under the notice of the profession. In saying this, I would by no means infer that it is the only case that has occurred; for happening under the agency of causes which must ever have existed equally as at present, we cannot but reasonably suppose that such accidents must have befallen individuals then as now, and that the want of a more careful record by surgeons of their several experience has alone prevented this peculiar dislocation from being known.

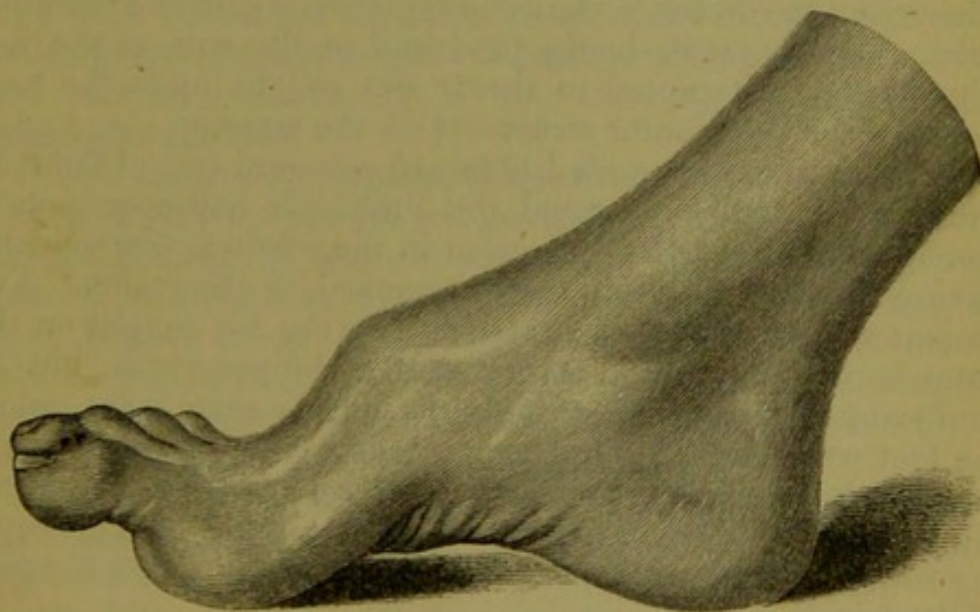
For the opportunity of witnessing it I am indebted to Mr. Dolmage, surgeon of the 7th Dragoon Guards, in whose regiment the accident occurred, and in the following manner: A trooper was returning off duty to Portobello Barracks, Dublin, on the 30th of November, 1851, and was walking his horse cautiously, the road being very slippery from frost. Whilst turning a corner, bordering upon the canal, the animal suddenly slipped, and fell with his whole weight upon the soldier's right leg and foot, crushing it against the ground. The horse rose instantly, the man remaining in the saddle, but suffering such agony that, unconscious of what he was doing, he reined the animal back into the canal. Here a violent struggle ensued, the horse eventually disengaging himself from his rider, who, assistance being at hand, was dragged out and taken to his regimental hospital close by. He was seen by Mr. Dolmage within a very few minutes of the accident having occurred, and before any considerable degree of swelling had taken place.

The foot was found to be much shortened, curved inwards and bent, the tarsus presenting a hard bony projection, overhanging the metatarsus, whilst deep under the plantar structures a second bony mass could be felt lying obliquely across the sole of the foot.

^a Dublin, 1847, page 224.

^b Page 814.

Reduction was at once attempted by placing the patient on his back, fixing the pelvis, flexing the leg upon the thigh, and extension then made by pullies attached to the extremity of the foot and to the toes, and persevered in for a considerable time, during which every possible movement of the metatarsus upon the tarsus, calculated to assist reduction, was resorted to, and leverage also made upon the dislocated extremity of the metatarsal bone of the great toe, where projecting in the sole, by means of a ruler being applied to it, and drawn upwards and forwards, whilst the clasped hand of a powerful assistant, placed upon the instep, held that part downwards and backwards. As great a degree of force as it was considered justifiable to employ was expended in the effort at reduction, and continued for one hour, but not the slightest alteration in the position of the bones could be effected. Considerable effusion and ecchymosis followed, the latter extending up almost to the knee. Leeches, fomentations, &c., were prescribed, and the ordinary treatment for violent contusions had recourse to. Under this treatment swelling subsided; and ten weeks after the accident the foot presented the appearance represented in the cast^a, from which the annexed engraving was made.



All swelling and thickening had now disappeared, the outline of the tendons and every portion of the extremity being most accurately defined. In its general aspect the foot somewhat resembled a case of *pes equinus*, being considerably shortened and arched upon its inner border, the distal extremity of the metatarsal bone and first phalanx of the great toe being

^a This cast is in the Museum of the Royal College of Surgeons, Ireland.

adducted, the last phalanx at the same time pointing somewhat outwards. The instep presented a normal condition from the malleoli to the extremity of the internal cuneiform bone, which projected in a sharp point, raising the integument, which was stretched over it, white and glistening like a tightly bent knuckle; from the outer border of the cuneiform bone ran an evident ridge, marking the division between the tarsus and metatarsus, and defining the line for Hey's amputation of the foot.

The measurements of the injured member, as compared with those of the opposite foot, were the following:—Length of the dislocated extremity from the point of the great toe to the heel, $9\frac{1}{2}$ inches; of the uninjured foot, $10\frac{1}{4}$ inches. Breadth of the dislocated foot across its widest part at the base of the great toe, $4\frac{1}{4}$ inches; of the uninjured foot, $3\frac{1}{2}$ inches. The extensor tendons of the injured foot stood out in strong relief, raising the toes; the tendons of the sound foot could be but indistinctly seen.

These were the principal appearances which presented themselves. The patient at this time had made no effort to walk, for upon the few occasions on which he had tried to use the limb, supported by crutches, he found a total inability to move otherwise than on the heel, in consequence of pain of a burning, lancinating character being produced in the sole of the foot whenever he attempted to throw any weight upon the toes, and to place the plantar structures on the stretch.

Six months afterwards I obtained a second cast of the foot, and again carefully inspected the limb. It had now become more inverted, and the projection in the sole was less evident, having been rounded and partly removed by absorption. The patient walked freely with a stick, bearing his weight on the outer border of the foot, as in a case of talipes varus, but he could not make any effort at progression, or even move, when the foot was placed flat upon the ground, from the same burning pain before referred to, and which he described as resembling the feeling that might be imagined to result from attempting to walk in a very tight boot with a marble under the sole of the foot.

In reviewing this case, there are three points deserving of consideration:—first, the mode in which the accident was produced; secondly, the causes which prevented reduction of the displaced bones; and thirdly, the principal signs which characterize this peculiar dislocation.

By reference to the details of the case it will be seen that there were two occurrences immediately succeeding one another, in either of which the accident might have taken place.

First, the fall upon the road, and second, the struggle in the water, the foot being entangled in the stirrup. I consider, however, that the excruciating pain experienced from the former places it beyond doubt that it was then that the injury occurred. I conceive that the horse falling on his side, the man's foot was crushed against the ground inverted, with the heel fixed, and incapable of receding. In this position the three inner bones of the metatarsal range would form the segment of an arch, unsupported, upon which the stirrup-iron, coming to act in a flattened direction (pressed horizontally by the superimposed weight of the body of the animal) drove these three bones downwards and backwards amongst the plantar structures beneath the tarsus, whilst the two outer bones, from resting on the ground, escaped detachment from their articulation with the cuboid bone, and in this way the luxation was produced.

Secondly, as to the prospect of reduction in dislocation of the metatarsal bones. The sources from which our experience must be derived upon this head are limited to the cases of Dupuytren, South, Liston, and the one now under consideration, those of Professor Smith being inapplicable to the purpose: they were discovered only after death, and under circumstances which prevented that surgeon from ascertaining whether reduction had been attempted or not; they cannot, therefore, be taken into account.

Five cases then present themselves. In three reduction was affected; in two all efforts failed. In Dupuytren's first case little difficulty was experienced in accomplishing the reduction by extension, with a bandage fastened to the foot, and firm pressure made on the dislocated bones. In the second, when a period of three weeks had elapsed, several attempts to reduce the dislocation were made, but all without effect. In these cases all the bones were displaced.

In South's case of luxation of the fourth and fifth metatarsal bones from the cuboid, they were, by continued extension, reduced with much difficulty.

In Liston's case of dislocation of the first metatarsal bone upwards, from direct violence, reduction also took place.

Judging from these, then, the conclusion might be formed, that, if attended to soon after the accident, reduction may without much difficulty be effected; but the case now under consideration shows that such is not the invariable rule. What, then, is the reason for this exception? I believe it to consist in the form of dislocation. In that upon the dorsum of the tarsus the bones rest upon a smooth and oval surface, with nothing

to hinder traction forwards, excepting muscular retraction. In that of dislocation downwards beneath the tarsus, on the contrary, the proximate ends of the metatarsal bones become locked in amongst the inequalities of the tarsal; and that of the great toe, in particular, becomes immovably fixed behind the tuberosity of the internal cuneiform bone, wedged in the cavity which exists between it and the cuboid bone, and, held there by the peroneus longus tendon, it defies all efforts at reduction. Failing, then, in reducing this displacement, should we leave the case to nature, or make a further effort after dividing the tendon of the peroneus longus muscle by subcutaneous section at the ankle? I am inclined to say, leave the case to nature, and withhold operative interference for this reason—that I believe it is not the muscular contraction alone, as I have stated, but the locking of the metatarsal bones in the cavity of the tarsal arch also, which prevents reduction.

Finally, we come to the signs diagnostic of this dislocation. The foot is shortened three-fourths of an inch or more, curved inwards, and at the base of the great toe broader than its fellow by an inch. The instep stands out sharply defined, with a sudden angular prominence and marked deficiency in front. The arch of the foot on its inner border is preserved, but the centre of the sole is occupied by the tarsal extremities of the displaced metatarsal bones.

The characters of this injury are very striking, and clearly indicate the nature of the accident, and, as has been stated by Professor Smith, are so marked that it is not likely to be confounded with any other injury of the parts. In describing dislocation of the metatarsus upwards, he says, "there is, it is true, a remarkable foreshortening of the foot, and the foot is greatly deformed, but the relations which the bones composing the ankle-joint bear to each other are undisturbed. There is no elongation of the heel, as in displacement of the tibia forwards; the foot, in front of the ankle-joint, is shortened to the extent of an inch or more, but the heel preserves its natural relation to the bones of the leg."