

Glaucoma, and its cure by iridectomy : being four lectures delivered at the Middlesex Hospital / by J. Soelberg Wells.

Contributors

Wells, John Soelberg, 1834-1879.
Royal College of Surgeons of England

Publication/Creation

London : John Churchill & Sons, 1864.

Persistent URL

<https://wellcomecollection.org/works/gbg4ze93>

Provider

Royal College of Surgeons

License and attribution

This material has been provided by This material has been provided by The Royal College of Surgeons of England. The original may be consulted at The Royal College of Surgeons of England. where the originals may be consulted. This work has been identified as being free of known restrictions under copyright law, including all related and neighbouring rights and is being made available under the Creative Commons, Public Domain Mark.

You can copy, modify, distribute and perform the work, even for commercial purposes, without asking permission.



Wellcome Collection
183 Euston Road
London NW1 2BE UK
T +44 (0)20 7611 8722
E library@wellcomecollection.org
<https://wellcomecollection.org>

10

GLAUCOMA,

AND

ITS CURE BY IRIDECTOMY.



GEORGE M. A.

THE GREAT BRITISH



10
GLAUCOMA,

AND

ITS CURE BY IRIDECTOMY;

BEING

Four Lectures

DELIVERED AT THE MIDDLESEX HOSPITAL.

BY

J. SOELBERG WELLS,

OPHTHALMIC SURGEON TO, AND LECTURER ON OPHTHALMIC SURGERY AT, THE HOSPITAL.



London:

JOHN CHURCHILL & SONS, NEW BURLINGTON STREET.

MDCCCLXIV.

GLAUCOMA.

ITS CURE BY IRIKCTOMY.


Four Figures

PRINTED AT THE MIDDLESEX HOSPITAL.

LONDON :

PRINTED BY HARRISON AND SONS, ST. MARTIN'S LANE.

J. BOWEN WICKS.



London

THE CENTRAL & WEST END BOOKSELLERS, 10, MARK LANE.

VIETNAM

P R E F A C E.

THE great interest which has lately been excited in the profession by the controversy which has appeared in the *British Medical Journal*, as to the beneficial effects of Iridectomy in Glaucoma, has led to the expression of a wish in several quarters that a short and practical treatise should be written, embodying an account of the modern doctrine of glaucoma. I have been led to publish these lectures in the hope that they might be found, in some degree, to meet this want. I have purposely made them as practical as possible, touching but lightly upon those theoretical questions which are still *sub judice*, but bestowing greater attention upon the symptoms which the disease may exhibit in its different forms and stages, the prognosis which may be given of the beneficial effects of iridectomy, and, finally, the method of performing this operation. In order to render the last more easy of comprehension, numerous woodcuts are given, illustrating each step of the operation.

16, Savile Row, April, 1864.

TABLE OF CONTENTS.

LECTURE I.

Historical sketch of glaucoma, pp. 1-4. Classification of glaucoma, 5. Method of estimating the degree of tension of the eyeball, 6. Mr. Bowman's designation of the various degrees of tension by special signs, 7, 8. Different modes of examining the field of vision, 8-12. Acute inflammatory glaucoma—Premonitory symptoms—Increased tension of the eyeball—Marked increase of presbyopia—Venous hyperæmia—Haziness of the aqueous and vitreous humours—Dilatation and Sluggishness of the Pupil—Periodic dimness of sight—The appearance of a halo round a candle—Ciliary neurosis—Contraction of the visual field, 13-19.

LECTURE II.

Acute inflammatory glaucoma—Symptoms and course of the disease, 20-24. Sub-acute and hæmorrhagic form, 24. Glaucoma fulminans, four cases, 24-29. Chronic inflammatory glaucoma, symptoms and course, 29-32. Apparently non-inflammatory glaucoma. (Amaurosis with glaucomatous excavation of the optic nerve. Glaucoma simplex.)—Symptoms and course, 32-37. Secondary or consecutive glaucoma, supervening upon Iritis—Posterior staphyloma—Traumatic cataract—Prominent corneal cicatrix, 37-44.

LECTURE III.

Glaucoma supervening upon cataract, and upon atrophy of the optic nerve, 45-47. The nature and causes of the glaucomatous process.—Doctrines as to its inflammatory or non-inflammatory nature, 48-53. Ophthalmoscopic symptoms of glaucoma—Pulsation of the central vessels of the retina, 53-55. Excavation of the optic nerve—Various forms of excavation—The congenital physiological excavation, 55, 56. The excavation from atrophy of the optic nerve, 56, 57. The glaucomatous or pressure excavation, 57-61.

LECTURE IV.

Prognosis of glaucoma, 62. Prognosis of the beneficial effects of iridectomy in the various stages of the disease, viz., In the premonitory stage—In acute inflammatory glaucoma, and glaucoma fulminans—In chronic inflammatory glaucoma—In glaucoma simplex—In glaucoma absolutum, 63-71. Description of the method of performing iridectomy, 71. The direction of the iridectomy, 72. Description of the various instruments, 73-76. The mode of performing the operation, 76-81. The after-treatment, 81. Certain disadvantages which may arise from the performance of iridectomy—Acceleration of the outbreak of the disease in the other eye—Formation of cataract—Cystoid cicatrix, 82-86.

GLAUCOMA.

LECTURE I.

GENTLEMEN,

WE have now to turn our attention to one of the most important and dangerous diseases of the eye, viz., glaucoma. A disease, whose timely treatment by iridectomy, will yield the most favourable results, but which, if allowed to run its course unchecked, except perhaps by inefficient remedies, sooner or later dooms the eye to irremediable blindness. It is, therefore, of the utmost consequence, that you should make yourselves thoroughly conversant with the different symptoms which it may present in its various forms, so that you may hereafter be able at once to recognise this dangerous and insidious affection, and to combat and subdue it before it is too late.

The term glaucoma was applied by Hippocrates to all opacities situated behind the pupil. After a time it was confined to those which presented a green appearance, the nature of which was not, however, understood, although the fact was recognised that such green opacities were not curable by operations*. By some, the seat of the affection was supposed to be in the vitreous, by others, in the retina and optic nerve. At a later period it was thought that glaucoma was due to a peculiar inflammation of the choroid, which occurred most frequently in gouty persons, hence it was termed *arthritic ophthalmia*, a name still retained by some writers. Lawrence considered that

* For an interesting historical resumé of glaucoma, I would refer the reader to Dr. Haffmann's excellent Paper upon Glaucoma. *Archiv. f. Ophthalmologie*, viii, ii.

the symptoms of glaucoma were caused by an affection of the retina and choroid. Weller gave a most excellent and graphic description of the symptoms of glaucoma, including in it many of the principal and most important points, *e. g.*, the intermitting course of the disease, the sluggishness and dilatation of the pupil, the circumorbital pain, the rainbows round a candle, &c. He also made mention of the tenseness of the eyeball, but Mackenzie first pointed out (in 1830) the importance of the latter symptom.

In 1851, Helmholtz discovered the ophthalmoscope, which has proved of such incalculable value in diseases of the eye, and has so completely revolutionized ophthalmic surgery. The first results of the ophthalmoscopic examination of cases of glaucoma were negative; soon, however, it was ascertained that there always existed a peculiar alteration in the optic disc in all cases of well-marked glaucoma. In 1854, Edward Jäger gave an excellent illustration of the ophthalmoscopic appearances of the optic nerve entrance in a case of glaucoma, showing the peculiar displacement of the vessels at the edge of the disc, the slight rim surrounding the latter, &c. It was, however, reserved for the great genius of von Graefe to unite these various and disjointed links of the chain of symptoms presented by glaucoma, and, welding them into one connected whole, not only to found the modern doctrine of glaucoma, but, at the same time, to bless humanity with a cure for this hitherto irremediable disease. Soon after Jäger's delineation of the ophthalmoscopic appearances of the optic disc, von Graefe described these peculiar appearances still more accurately, and at the same time pointed out a most important fact, *viz.*, that an arterial pulsation exists in the optic nerve in glaucoma, being either spontaneous, or producible by a very slight pressure upon the eyeball, a pressure far less than is necessary for its production in the normal eye. Within a short time afterwards, he also discovered that the peculiar appearance of the optic disc, which had been supposed by him and other observers to be due to an

arching forward of the optic nerve entrance, was in reality due to its being excavated or cupped. He at once recognised the connection of these two symptoms (the excavation and the spontaneous, or easily producible arterial pulsation) with the increased hardness of the globe, and his clinical observations soon showed him that all the other symptoms were also closely connected with this augmented tension. The next problem was, to solve how this tension might be permanently diminished. All the usual remedies, such as mercurials, antiphlogistics, diuretics, diaphoretics, had proved as insufficient in his hands, as in those of other practitioners. Mydriatics, which had been found to diminish intraocular pressure, were next had recourse to, but they also proved of no avail. He then tried tapping the anterior chamber, but this was only followed by a temporary benefit, which soon passed away again. The disease gradually progressed, nor could the relapses be stayed by a methodical repetition of the paracentesis, for he found that its therapeutical effect became each time less, and finally null, as far as the sight was concerned. In only two cases, out of a great number thus treated, did it prove of lasting benefit.

Paracentesis having been of no avail in permanently reducing the intraocular pressure, he next had recourse to iridectomy, having found that it proved of great benefit in ulcerations and infiltrations of the cornea, by diminishing pressure; and that in cases of partial staphyloma of the cornea, and in staphyloma of the sclerotic, the protruding part often receded completely after this operation.

He first tried iridectomy in glaucoma in 1856, and soon found that it not only permanently diminished the intraocular pressure, but that it might indeed be regarded as a true curative treatment of the glaucomatous process; having, however, like every other therapeutic agent, its natural limits. Since that time iridectomy has been recognised by most of the eminent oculists in Europe, as the only cure known, at present, for glaucoma; but although

it has achieved most brilliant results in the hands of many of our most distinguished English ophthalmic surgeons—amongst whom I would more particularly instance, Messrs. Bowman and Critchett, who have from the commencement been its staunch and warm supporters—there are yet some English oculists of repute who either condemn the operation completely, or uphold it in so luke-warm a manner as in reality to “damn it with faint praise.”

My own wide experience of the beneficial effects of iridectomy in glaucoma enables me, not only to recommend the operation most strongly to you, but even to urge you to trust to no other remedies, as they have all proved insufficient, and as you would thus permit the most valuable time, when an iridectomy might still save the eye, to pass irrevocably away. We shall see hereafter that an accurate prognosis of the benefits to be expected from iridectomy may be made in the majority of cases, and it will be shown why the operation may have proved unsuccessful in the hands of some practitioners. But too frequently impossibilities were expected of it; it was tried, for the first and only time, perhaps, in chronic cases of glaucoma, which were beyond all help; it proved, as might have been foretold, unsuccessful, and was then at once discarded as useless.

The commencement of the disease, the development of the different symptoms, and the course which glaucoma may run, present numerous variations, and for this reason, a precise classification is somewhat difficult. But on closer observation it will be found that the several varieties also shew a great tendency to pass over into each other. The family resemblance of these different forms is very marked, for they are distinguished from the commencement by certain characteristic symptoms, and although they will vary somewhat in their course, they all, but too surely, lead, sooner or later, to that last hopeless condition, in which the eyeball is stony hard, the pupil widely dilated and fixed, the refractive media clouded, the optic disc cupped, and the sight either entirely, or

nearly entirely, lost; that condition, in short, to which our forefathers confined the term glaucoma. The modern school of ophthalmology, however, no longer limits the name glaucoma to this last hopeless condition, but embraces in it all the varieties of the disease from their commencement, which lead to this last stage. In regarding the different varieties of glaucoma from a clinical point of view, we are particularly struck by the fact, that one class of cases is distinguished from the commencement by more or less marked inflammatory symptoms; whilst another appears, in the commencement at least, to be free from inflammation, although in its course inflammatory symptoms, even of an acute kind, generally make their appearance. We may, therefore, divide cases of glaucoma into two principal classes:—

I. Cases attended with inflammatory symptoms.

II. Cases in which there are *apparently* no inflammatory symptoms present.

Glaucoma may exist as a primary disease, or may complicate a previously existing affection.

We find that the different varieties of glaucoma show certain common characteristics, and we may generally recognise the four following stages:—

1. A premonitory stage (glaucoma imminens, incipiens, of von Graefe);

2. A stage in which the glaucoma is fully developed (glaucoma evolutum, confirmatum, von Graefe);

3. A stage in which quantitative perception of light has been completely lost for some time (glaucoma absolutum, consummatum, von Graefe);

4. A stage in which the eye undergoes glaucomatous degeneration (von Graefe).

I. INFLAMMATORY GLAUCOMA.

We distinguish two principal forms of inflammatory glaucoma, the acute and the chronic.

As it is of consequence in the examination of cases of glaucoma, that the observer should know how to estimate

the degree of intraocular pressure, and the extent of the field of vision, I shall, before entering upon a description of the symptoms of glaucoma, explain in what manner the tension of the eyeball is to be estimated, and the extent of the field of vision ascertained.

A just appreciation of the degree of tension of the eyeball is of great importance in glaucoma, for in the majority of cases it is considerably increased. Although there is some difference in the degree of tension met with in perfectly normal eyes, according to the age of the patient, the temperament, and individual peculiarities, it is but seldom very marked, and generally varies, but inconsiderably, from the normal standard. But the amount of tension may undergo occasional variations, at times becoming more increased; this augmented tension lasting for a certain time, and then again diminishing. It is necessary, therefore, to examine the tension of the eye at different times, if other symptoms of glaucoma be present, without a marked increase in the tenseness of the eyeball.

The degree of tension is to be ascertained in the following manner:—The patient being directed to look slightly downwards, and gently to close the eyelids, the surgeon applies both his forefingers to the upper part of the eyeball behind the region of the cornea. The one forefinger is then pressed slightly against the eye so as to steady it, whilst the other presses gently against the eye, and estimates the amount of tension, ascertaining whether the globe can be readily dimpled, or whether it is perhaps of a stony hardness, yielding not in the slightest degree even to the firm pressure of the finger. The beginner will do well to make himself thoroughly conversant with the normal degree of tension, by the examination of a number of healthy eyes, and then, if he should be at all in doubt as to the degree of tension in any individual case, he should test the tension of the patient's other eye (if healthy), or that of some other healthy eye, so as to be able to draw a comparison between them. If there is

much oedema of the lids, or conjunctival chemosis, or if the eyes are small and deeply set, it may be difficult accurately to estimate the degree of tension.

I would call particular attention to the signs which Mr. Bowman has devised for the designation of the different degrees of tension of the eyeball, as they will be found most useful, not only in practice, but also in the reporting of cases, or in the preservation of an accurate record of the state of tension.

Mr. Bowman introduced this subject to the attention of the profession in 1862, in his admirable paper "On Glaucomatous Affections, and their Treatment by Iridectomy," read before the Annual Meeting of the British Medical Association,* in which he says, "I have long paid special attention to the subject of tension of the globe, and particularly since it has assumed so much additional importance in the last few years. I have found it possible and practically useful to distinguish nine degrees of tension; and, for convenience and accuracy in note-taking, have designated them by special signs. The degrees may be thus exhibited.†

"T represents *tension* ('t' being commonly used for 'tangent,' the capital T is to be preferred). Tn, *tension normal*. The interrogative, ?, marks a *doubt*, which in such matters we must often be content with. The numerals following the letter T, on the same line, indicate the *degree of increased tension*; or if the T be preceded by —, of *diminished tension*, as farther explained below. Thus:

"T 3. *Third degree, or extreme tension*. The fingers cannot dimple the eye by firm pressure.

"T 2. *Second degree, or considerable tension*. The finger can slightly impress the coats.

"T 1. *First degree, slight but positive increase of tension*.

"T 1 ?. *Doubtful if tension is increased*.

* British Medical Journal, Oct. 11th, 1862, p. 378.

† "Since this paper was read I have simplified the signs, with the concurrence of my friend, Professor Donders, in order to adapt them for general use. The simplified form has been substituted above."

"Tn. Tension normal.

"— T 1?, Doubtful if tension be less than natural.

"— T 1. First degree of reduced tension. Slight but positive reduction of tension.

"— T 2 } Successive degrees of reduced tension, short

"— T 3 } of such considerable softness of the eye as allows the finger to sink in the coats. It is less easy to define these by words.

"In common practice, some of these may be regarded as refinements; but in accurate note-taking, where the nature and course of various diseases of the globe are under investigation, I have found them highly serviceable, and they have as much precision as perhaps is attainable or desirable.

"It is also to be borne in mind that the normal tension has a certain range or variety in persons of different age, build, or temperament; and according to varying temporary states of system as regards emptiness or repletion. Experience will make every one aware of these varieties, which do not encroach on the above abnormal grades of tension. Medical men may understand how important is this matter of the *degree of tension*, by considering how priceless would be the power of accurately estimating it *by the touch* in the case of various *head affections*."

The extent of the field of vision may be ascertained in the following manner:—The patient being placed straight before us, at a distance of from 15 to 18 inches, is directed to look with the eye under examination (closing the other with his hand) into one of our eyes, his right eye being fixed upon our left, and *vice versâ*. In this way any movement of his eye may be at once detected and checked. Whilst he still keeps his eye steadily fixed upon ours, we next move one of our hands in different directions throughout the whole extent of the field of vision (upwards, downwards, and laterally), and ascertain how far from the optic axis it is still visible; we then approach the hand nearer to the optic axis, and examine up to how far from it he is able to count fingers in different directions. The

number of the extended fingers is to be constantly changed, and the examination to be repeated several times, so that we may ascertain whether the patient can count them with certainty, or whether he hesitates in his answers, or only guesses at their number. We may thus readily discover whether the field of vision is of normal extent, or whether it is defective or obliterated in certain directions.

We may term that part of the field in which the patient can still distinguish an object (a hand, a piece of chalk, &c.) the *quantitative* field of vision, in contradistinction to that smaller portion in which he is able to count fingers, and which may be designated the *qualitative* field.

The following method of examining the field is still more accurate, and I should advise its adoption in all cases where it is of importance to have an exact map of the extent of the field, as in glaucoma, detachment of the retina, &c., so that a record may be kept of the condition of the field during the progress of the disease, or that we may be able to compare its extent before and after an operation. The patient being placed before a large black board, at a distance of from 12 to 16 inches, is directed to close one eye and to keep the other steadily fixed upon a chalk dot, marked in the centre of the board and on a level with his eye. A piece of chalk, fixed in a dark handle is then gradually advanced from the periphery of the board towards the centre, and the spot where the chalk first becomes visible is then marked upon the board. This proceeding is to be repeated throughout the whole extent of the field; the different points at which the object first becomes visible are then to be united by a line, which indicates the outline of the *quantitative* field of vision. The extent of the *qualitative* visual field is next to be examined, and it is to be ascertained how far from the central spot the patient can count fingers in different directions. The points thus found are also to be marked on the board, and the marks afterwards united with each other by a line, which should be of a different colour or character to that indicating the extent of the quantitative field, so that the

two may not be confounded. It need hardly be mentioned that care is to be taken that during the examination the patient's eye remains steadily fixed upon the central spot, that the other eye is kept closed, and that his distance from the board is not altered. The extent of the field inwards will, naturally, vary according to the prominence of the patient's nose.

It is still more convenient to map out the field upon a large piece of blue paper placed against the board, as this saves us the trouble of copying the map from the board. Such maps are to be kept for future reference, or for comparison with others that may be taken of the same case at a later period. If this, however, cannot be done, we may keep a record of the shape of the field and of the distance to which the patient can see in different segments of it, by the following simple expedient which I have lately adopted.

The board is to be divided into four equal parts by a vertical and horizontal line (of about 4 feet in length), cutting each other at the central cross; each quadrant is then again to be divided into two equal parts by another line, so that the whole is divided into eight equal segments, as in the accompanying figure, which represents the division of the field for the left eye. For the right eye the position of the letters must be reversed, thus, *u i* (upwards and inwards), would be *u o* (upwards and outwards), and so with all the others.

The meaning of the letters is as follows:—

V M Vertical Meridian, dividing the field into two lateral halves (inner and outer).

H M Horizontal Meridian, dividing the field into an upper and a lower half.

The upper half of the field is subdivided into four segments:—

u o upper and outer segment.

o u outer „ upper „

u i upper „ inner „

i u inner „ upper „

The lower half is also subdivided into four segments :

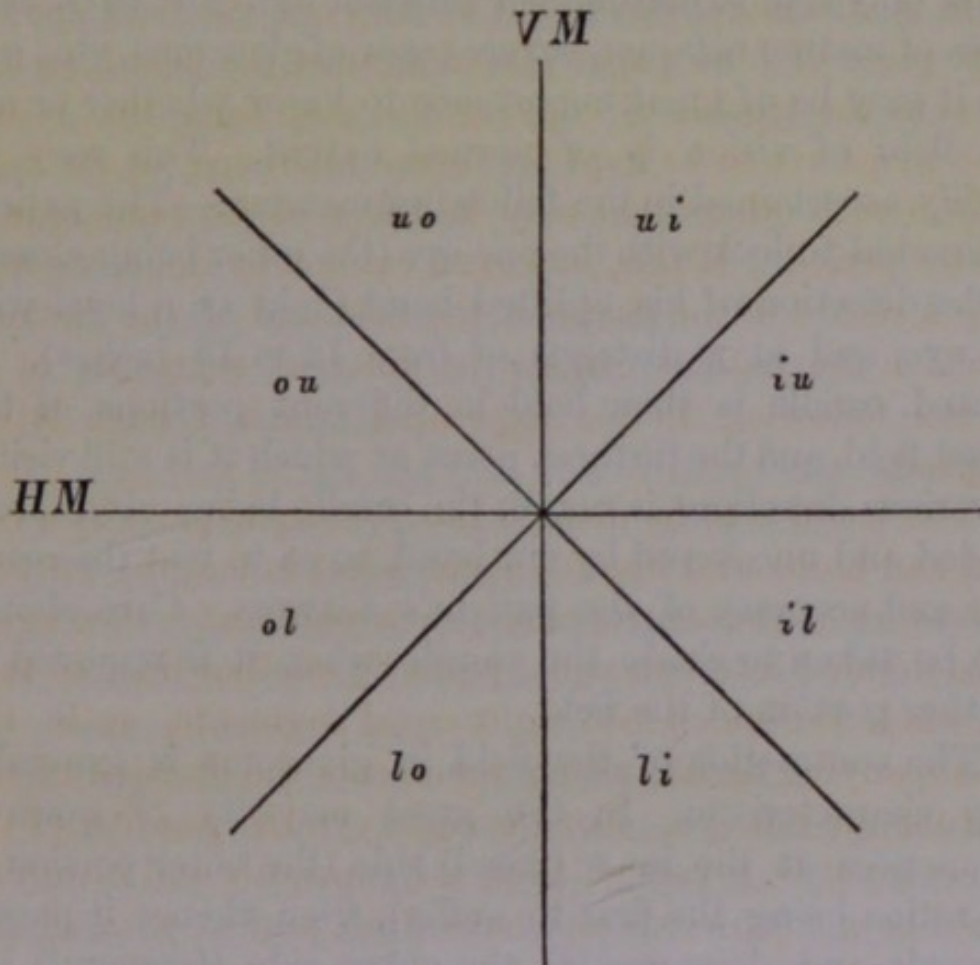
o l outer and lower segment.

l o lower „ outer „

i l inner „ lower „

l i lower „ inner „

Fig. 1.
LEFT EYE.



The method of examining the patient's field of vision is to be the same as that above described, when a plain board was used. The object of the divisions is only to furnish a kind of framework for the map of the field, which enables us to sketch it with more ease and rapidity. The boundary of the quantitative and qualitative fields is to be marked both upon and between each of the divisional lines, and the distance of each of these marks from the centre of the board is then to be measured, and, its extent, in inches, is to be placed against each mark. A small facsimile of the field of vision thus mapped out, may then be

drawn in the note-book, the field being here also divided into eight segments, the boundaries and measurements of the map being likewise copied; so that we may preserve, in a small and convenient form, an accurate record of the shape and extent of the visual field.

But the sight of the patient may be so much impaired that he can no longer count fingers even in the optic axis, being only able to distinguish between light and dark, as in cases of mature cataract, severe cases of glaucoma, etc., and yet it may be of great importance to know whether or not the field of vision is of normal extent. This may be readily ascertained in the following manner:—The patient is directed to look with the one eye (the other being closed) in the direction of his uplifted hand (held on a level with his eye, and at a distance of from 12 to 18 inches). A lighted candle is then held in different portions of the visual field, and the furthest point at which it is still visible in various directions is noted, the candle being alternately shaded and uncovered by our hand, so as to test the readiness and accuracy of the patient's answers. Care should also be taken to shade the candle when it is removed to another portion of the field.

The contraction of the field in glaucoma is generally very characteristic. In the great majority of cases it commences at the inner (nasal) side (the outer portion of the retina being the first to suffer), from thence it passes upwards and downwards; the outer side (temporal) becomes last affected. The contraction is generally diagonal, but may occasionally be concentric; sometimes the field of vision is nearly completely obliterated, only a small slit-shaped portion remaining. Chronic glaucoma furnishes the best instances of the mutilation of the visual field. It does not constitute one of the earliest symptoms of glaucoma. In cases of cerebral amaurosis complicated with glaucoma, the field of vision appears to become contracted first at the outer side, and not at the inner, as is usual in glaucoma,

1. ACUTE INFLAMMATORY GLAUCOMA.

Synon. Ophthalmia arthritica.

Premonitory Stage.—In the great majority of cases (75 p. c.) there is a premonitory stage, which is characterised by the presence of several or all the following symptoms, which are, however, of *periodic* occurrence, there being in the interval a *perfect intermission*. When this ceases to be the case, when there are no longer perfect intermissions, but only remissions of the symptoms, we can no longer designate it the premonitory stage, but must regard it as confirmed glaucoma.

The following symptoms are met with in the premonitory stage:—

1. Increased tension of the eyeball.
2. Marked increase of any existing presbyopia.
3. Venous hyperæmia.
4. Haziness of the aqueous and vitreous humours.
5. Dilatation and sluggishness of the pupil.
6. Periodic dimness of sight.
7. The appearance of a halo or rainbow round a candle.
8. Intermitting pains in and around the eye; these are not always present.
9. Slight contraction of the field of vision.

The intensity of these symptoms varies with the severity of the attack. They may be so slight as to escape all observation, or they may be very marked if the attack is severe, and then there are often added to the symptoms above enumerated, diminution in the size of the anterior chamber, arterial pulsation, and indistinctness of eccentric vision, particularly if the illumination be but slight. Let us now consider these premonitory symptoms more in detail.

1. *The Increased Tension of the Eyeball.*—This is generally not very considerable; it varies, in degree, however, but it never reaches that stony hardness in which it is impossible to dimple the eyeball. In families in which glaucoma is hereditary, a marked increase in the tension is met with even in early life, although the disease does not break

out, perhaps, till a much later period, or even not at all. In such cases there can be no objection to look upon this abnormal tension as a predisposing element of glaucoma, more particularly if it be accompanied by hypermetropia, and a disproportional diminution of the range of accommodation. It has been supposed by some that the increased degree of tension always precedes, for a longer or shorter period, the other symptoms of glaucoma; von Graefe has, however, met with several marked exceptions to this rule. In some cases in which he operated for glaucoma in the one eye, the other was found to be of a perfectly normal tension at the time of operation, but was soon after attacked by glaucoma, in one case even by glaucoma fulminans. But an increase in the tension of the eyeball should always excite our suspicion, and should at once lead us to examine as to the presence of other symptoms of glaucoma; if we find none, we should still watch the eye with care, and warn the patient carefully to observe whether any other symptoms begin to show themselves, *e.g.*, rainbows round a candle, rapidly increasing presbyopia, periodic dimness of vision, &c. We must be upon our guard against the but too frequent error, that a sense of fulness or tension within the eye experienced by the patient, is any proof of the increased hardness of the eyeball. For this feeling of fulness may exist without the slightest increase of tension. Another frequent error is to suppose that all acute inflammations of the eye are accompanied by an increase in the intraocular pressure. A careful examination of ordinary cases of acute inflammation of the conjunctiva, cornea, iris, &c., will at once prove the fallacy of this opinion, for the tension will be found normal. If the degree of tension is increased, we must regard it as a dangerous complication, which is to be carefully watched, lest it be the precursor of other glaucomatous symptoms.

2. *Rapid Increase of any pre-existing Presbyopia.*—As the persons attacked by glaucoma are mostly beyond 45 or 50 years of age, some degree of presbyopia is generally already

present, but it is found that this often increases in a very rapid and marked manner during the premonitory stage of glaucoma; so that the patient may be obliged, in the course of a few months, frequently to change his reading-glasses for stronger and stronger ones. This rapid increase in the presbyopia appears to be not so much due to a flattening of the cornea through an increase in the intra-ocular pressure, as to the action of this pressure upon the nerves supplying the ciliary muscle, thus causing paralysis of the latter. Haffmann has called particular attention to the fact that hypermetropia very frequently occurs together with glaucoma. It does not appear that hypermetropic eyes are more prone to glaucoma than others, but rather that hypermetropia is developed in the course of the disease. The cause of this is, however, still quite uncertain, it is probably to be sought for in some changes in the crystalline lens (rapidly progressive senile involution), by which the refractive power of the latter is considerably diminished.

3. *Venous Hyperæmia*.—The congestion of the ciliary veins is generally slight during the premonitory stage, and they never present that peculiar tortuous, dilated appearance, so characteristic of chronic glaucoma. Generally, only a few scattered, dilated veins are seen running over the sclerotic. On examination with the ophthalmoscope, the retinal veins are also found to be dilated and tortuous, there may be likewise spontaneous venous pulsation, or this may be produced by slight pressure upon the eyeball.

4. *Cloudiness of the Aqueous and Vitreous Humours*.—The aqueous humour is often found slightly but uniformly hazy, rendering the structure of the iris somewhat indistinct, and causing a slight change in its colour. The vitreous humour also becomes a little clouded, but uniformly so, for on ophthalmoscopic examination, we do not find dark masses floating about in the vitreous humour, but only a diffused cloudiness, which renders the details of the fundus more or less indistinct. This haziness of the humours is very variable in its degree and duration, some-

times it is so slight as to be hardly perceptible, at others it is so considerable as to prevent any ophthalmoscopic examination. In the majority of cases, however, it is but moderate in the premonitory stage. It may come on several times a day, lasting but for a few minutes at a time, or it may be less frequent, or of longer duration.

5. *Dilatation and Sluggishness of the Pupil.*—On comparing the pupil of the eye affected with premonitory symptoms of glaucoma, with that of the other (supposing this to be healthy), the former will be found somewhat dilated and sluggish, reacting but slightly on the stimulus of light. The dilatation is never so considerable as in the advanced stages of glaucoma, when we often find the pupil widely dilated and quite immovable, its sluggishness is, however, generally well marked. It is always necessary to examine the state of the pupil of each eye separately, for occasionally we find that the pupil of the affected eye may be of the same size as the other, when both eyes are open and exposed to the light, but that it dilates at once when the healthy eye is covered, and then reacts but slightly on the stimulus of light, and even under a strong light does not diminish to the same size as when the other eye is open. Sometimes the dilatation is irregular, which is owing to some of the nerves being more compressed than others.

6. *Periodic Dimness of Sight.*—The patient is troubled by occasional intermittent dimness of sight. At such times, surrounding objects appear veiled and indistinct, as if they were shrouded in a grey fog or smoke. The degree of dimness varies considerably, as does also the duration of these attacks; sometimes they may last for several hours, at others only for a few minutes. At such a time, there may also exist a slight contraction of the field of vision; generally, however, there is only indistinctness of eccentric impressions in certain directions. These obscurations may be due to transitory cloudiness of the aqueous and vitreous humours, but they are caused, for the most part, by disturbances in the circulation of the eye. The character of these obscurations may be imitated by pressure upon the

healthy eye, and Donders has found that the dimness of vision shews itself as soon as arterial pulsation is produced by this pressure upon the eyeball. I have experimented a good deal upon this point, and have arrived at the same results. I have also found, by experiments upon myself, that by regulating the amount of pressure, I have been able to produce any kind of obscuration, from the slightest, in which only the objects lying quite at the periphery of the field of vision appeared somewhat clouded, to that excessive dimness in which the light of a bright lamp was rendered quite unapparent. The increased intraocular pressure, acting directly upon the retina, does not, therefore, appear to be so much the cause of these obscurations; but we must seek for it rather in the impairment of the circulation, the stagnation and fulness of the veins, and perhaps, the emptying of the arteries. The increased pressure produces the changes in the circulation, and the latter causes the obscurations. The truth of this assertion is also proved by the fact that these attacks of dimness are generally brought on by anything that causes congestion of the blood-vessels of the eye—for instance, a full meal, great excitement, long-continued stooping, violent exercise, etc.

7. *The appearance of a Halo or Rainbow round a Candle.*—This is also a very constant symptom of the premonitory stage. On looking at a candle the patient sees a coloured halo, or rainbow, round the light. The outer side of the ring is red, the inner bluish-green. This has been supposed by some to be a mere physical phenomenon, due to a diffraction (interference) of the rays of light, owing to some change in the refractive media, especially the peripheral portion of the lens.

It is seen when the pupil is dilated, but disappears when the patient is directed to look through a small opening. It may, however, be also due to congestion of the vessels, for I have seen it sometimes brought on by stooping for some time.

8. *Ciliary Neurosis, i.e., pains, more or less acute, in the*

forehead and temples, and passing down the side of the nose, occur occasionally at an early period, sometimes only at a later part of the premonitory stage, at the same time with the intermittent obscurations. Sometimes, however, they are quite absent.

9. *The field of vision* is occasionally somewhat contracted; generally, however, there is only some indistinctness of eccentric impressions in certain directions, more particularly if the illumination is but slight.

At the commencement, these symptoms only show themselves at long intervals, of perhaps several months. At first the patient only notices that the surrounding objects appear somewhat hazy and indistinct, that there is a rainbow round a candle, accompanied perhaps by a slight pain round the eye, and down the side of the nose. On examining his eye during one of these attacks, we find the tension increased, the veins on the sclerotic somewhat dilated, with perhaps a delicate, rosy zone round the cornea, the aqueous humour slightly clouded, the pupil somewhat dilated, and sluggish on the stimulus of light. With the ophthalmoscope, the vitreous humour is perhaps found somewhat hazy, the retinal veins dilated and tortuous, showing either a spontaneous venous pulsation, or this may be readily produced by slight pressure upon the globe. If the attack be severe, these different symptoms may be more strongly marked, and there may, in such a case, be superadded spontaneous arterial pulsation, dimness in certain portions of the field of vision, and diminution in the size of the anterior chamber. In other cases all the premonitory symptoms are so slight that they are unnoticed by the patient. He may have only remarked that he is getting rapidly far-sighted, and that he has had frequently to change his reading-glasses. If, therefore, a person complains to us of this rapid increase of presbyopia, we should at once ascertain whether any other premonitory symptoms of glaucoma are present.

Gradually the intervals between these periodic attacks become less and less. At first perhaps months elapse

between each attack, then weeks, then days; and when they occur at intervals of a few days only, the second stage, the glaucoma evolutum, may be expected, although this may even occur when the intervals are still distant. If the periodic attacks no longer leave behind them a normal pupil, and a normal acuteness of vision, still more, if the optic nerve is already cupped, we must no longer designate it as the premonitory stage, but as a case of glaucoma evolutum, with periodic increase of the symptoms (von Graefe).

The premonitory stage may last for an indefinite period; years may even elapse before it leads to confirmed glaucoma; but in the majority of cases it does not extend beyond a few months, or it may pass over into glaucoma even after the second or third attack, there being only remissions, and not clear and well defined intervals between the attacks. Sometimes, as has been mentioned above, the premonitory symptoms are so slight, as quite to escape the notice of the patient, particularly if the other eye is still perfectly healthy. It is different, however, where one eye has already been lost by glaucoma, for then the patient's attention and anxiety are at once aroused by any of the premonitory symptoms, and he early consults his medical attendant, fearful lest he should also lose the sight of the second eye.

LECTURE II.

ACUTE INFLAMMATORY GLAUCOMA.

IN the great majority (about 75 per cent.) of cases acute inflammatory glaucoma is preceded by a more or less marked premonitory stage of varying duration. The intervals between the premonitory attacks become less and less frequent, until the attacks recur perhaps every two or three days, or even every day. The patient is then suddenly seized, frequently at night time, and after having passed perhaps several sleepless nights, by a severe, often excruciating, pain in and around the eye, which extends to the forehead, temple, and down the corresponding side of the nose, as far as the extremity of the bone. Sometimes this pain extends also to the corresponding half of the head, and even to the occiput, which causes it often to be mistaken for an attack of rheumatism. At the same time there may be considerable constitutional disturbance, febrile excitement, and severe nausea and vomiting, and these symptoms may be of such prominence that the patient is supposed to be suffering from a severe bilious attack, and the affection of the eye is either overlooked, or is thought to be dependent upon this. But the eye shows marked symptoms of acute internal inflammation. The eyelids may be much swollen, red, and puffy. The conjunctival and sub-conjunctival vessels are injected, the veins in particular being dilated and gorged. There may also be very considerable serous chemosis, which completely hides the deeper subconjunctival vascularity, and the rosy zone round the cornea. There is also much photophobia and lachrymation, but accompanied by very little mucus discharge, and this chiefly of a thin, frothy character. The cornea is clouded on its posterior surface, being perhaps studded with minute opacities, deposited from the aqueous humour. The

sensibility of the cornea may be also somewhat diminished, but this anæsthesia never attains the same degree as in chronic glaucoma, where it is often so great, that the cornea may be touched, or even rubbed with a roll of paper or the brush of a quill pen, without it being felt. Occasionally the anæsthesia is only partial, being confined to a certain portion of the cornea. This loss, or diminution, in the sensibility is due to the compression of the nerves supplying the cornea by the increased intraocular pressure, as is proved in cases of acute glaucoma, where the sensibility at once returns after diminution of the tension by iridectomy or paracentesis. The sensibility of the cornea is best tested by touching it delicately with a finely-rolled spill of silk paper, care being taken to keep the eyelids well apart, so that the conjunctiva is not touched. In healthy eyes the cornea is so exquisitely sensitive that the slightest touch of a foreign body will be felt and resented.

The anterior chamber is found to be somewhat more shallow, the iris being pressed forward, and, even perhaps, in contact with the cornea, the aqueous humour clouded, the iris somewhat discoloured and of a dirty hue,—in some cases there may even be acute iritis, with deposits of lymph at the edge of the pupil,—the pupil is dilated and sluggish, and in elderly people a peculiar green reflex is often seen, coming, apparently, from the back of the eye.

It has already been stated that this green reflex was formerly considered as the principle and pathognomonic symptom of glaucoma. It is due to the following cause: The lens undergoes certain physiological changes after the age of forty, amongst others assuming a yellowish tint; now if the eye of an elderly person (and they are the most prone to the disease) is attacked by glaucoma, the aqueous humour becomes turbid and of a dirty, bluish-gray colour, and this bluish-gray tint, mixing with the yellow of the lens, gives rise to this peculiar green reflex. The latter is the more marked on account of the dilatation of the pupil which exists in glaucoma, as more light is thus reflected

from the lens, more particularly its periphery, than when the pupil is of the normal size. The grayish haziness of the vitreous humour, moreover, also tends to increase the intensity of the reflected light. Two facts prove that this is the true explanation of this green reflex. 1st. If the anterior chamber is tapped, and the aqueous humour flows off, the green reflex at once disappears. 2nd. If a youthful eye is attacked by glaucoma, this green reflex is not visible, for at this period of life the lens has not yet acquired a yellow tint, and in such a case the pupil looks, therefore, only of a dirty, bluish-gray colour.

The eyeball will be found abnormally hard. The refractive media are generally so clouded as to render an ophthalmoscopic examination impossible. If they are, however, sufficiently clear to permit our seeing the details of the fundus, we find the retinal veins dilated and tortuous, and perhaps pulsating, the optic disc may be slightly reddened or of a dirty-yellow appearance, and there is either spontaneous arterial pulsation, or this may be readily produced by slight pressure on the eyeball. In the first attack of acute glaucoma, no cupping of the optic nerve is found, for this only occurs when the increased tension has lasted for some time. We also occasionally find choroidal ecchymoses, which are mostly situated at the equator of the eye, and generally numerous patches of retinal ecchymoses, chiefly at the point of division of the retinal veins. These are particularly seen after iridectomy, where the sudden relief of tension causes a rush of blood through the vessels, and the finer capillaries then give way.

Vision may be either greatly impaired, so that the patient is only able to distinguish letters of the largest type, or to count fingers, or it may be lost completely and suddenly, as at one stroke, being diminished to a mere quantitative perception of light, *i. e.*, to a mere distinction between light and dark, not an appreciation of colours and objects. In some very severe cases even this is lost. The field of vision is generally somewhat contracted,

often concentrically. The patient is in the most cases also troubled with subjective appearances of light, balls of fire, showers of bright stars, etc.

The inflammatory symptoms may gradually subside, but the blindness continue; this is, however, very exceptional. In most cases the inflammatory attack passes off after a few days or weeks, having undergone, during this time, perhaps, several remissions, and vision may be entirely restored. Such a temporary recovery may occur spontaneously, or after treatment by antiphlogistics, mercury, opium, leeches, etc. But the eye does not return to its normal condition; the anterior chamber mostly remains somewhat shallow, the iris discoloured, the pupil dilated and sluggish, and the field of vision somewhat contracted, the tension of the eyeball more or less augmented. But the disease is not arrested. The acute inflammatory attacks may recur again and again, leaving the sight each time in a worse condition, and the visual field more contracted, until the sight is finally completely destroyed. In other cases, no further acute inflammatory attacks occur, but chronic inflammatory exacerbations take place. Or the disease may progress insiduously, without any apparent recurrence of the inflammatory symptoms; the eyeball becomes more and more tense, the field of vision more contracted, often to a slit shape, the sight gradually lost, the fixation becoming perhaps eccentric,* the cornea roughened and anæsthetic, the anterior chamber very small, the pupil greatly dilated and fixed, the iris discoloured and atrophied, and shrivelled up to a narrow rim, the subconjunctival veins turgid and tortuous, forming loops round the cornea. If the refractive media are sufficiently clear to permit an ophthalmoscopic exami-

* By the term central fixation is meant, that a line drawn from the object through the centre of the cornea of the observer would strike his yellow spot; his optic axis being in fact fixed upon the object. Eccentric fixation, therefore, means that some other portion than the yellow spot is directed to the object, having retained more sensibility than the macula lutea.

nation, we find that there is a progressive excavation of the optic nerve, that the retinal veins are dilated and tortuous, and that there is either a spontaneous or easily producible arterial pulsation. We not unfrequently find, even after the disease has thus insiduously run its course without any inflammatory exacerbation since the first acute attack, that at a later stage these inflammatory attacks, even of a very acute kind, may recur again. When the disease has run its course, and all, even quantitative perception of light is lost, von Graefe calls it *glaucoma consummatum, absolutum*.

Sometimes we meet with a *sub-acute* form of glaucoma, in which all the inflammatory symptoms are much diminished in intensity, the pain is also less, nor is the sight so much impaired as in the acute cases.

There is also a hæmorrhagic form, which is peculiarly dangerous, as it is far less favourably influenced by iridectomy. The glaucomatous inflammation sometimes supervenes upon certain hæmorrhagic affections of the retina, particularly those met with in kidney disease. In these there is very considerable congestion and stagnation of the intraocular circulation. Now, although iridectomy may yield some temporary benefit, yet relapses but too frequently recur, and the operation is occasionally followed in this form by great intraocular hæmorrhage, which often destroys the eye. The power of absorption is also very much impaired in these cases, for we find that hæmorrhage into the anterior chamber for instance, which is frequently produced by a very slight cause, such as a fit of coughing, &c., is very slowly and imperfectly absorbed.

Von Graefe* has lately called attention to a class of cases in which the march of acute glaucoma is most rapid, so that the sight, even all quantitative perception of light, of a previously perfectly good eye, may be perfectly lost within a few hours, or even within half an hour, of the outbreak of the disease. He has termed this *glaucoma fulminans*.

* Archiv. vol. viii, 2.

It is a very rare form in comparison with the common acute glaucoma, for up to the publication of his last paper on Glaucoma (1862), he had only met with four cases, and these all occurred in patients above the age of 55.

He has found that cases of glaucoma fulminans are also occasionally distinguished by a very rapid development of the other symptoms of increased intraocular pressure, viz., intense ciliary neurosis, rapid dilatation of the pupil, soon reaching its maximum extent, rapid diminution in the size of the anterior chamber, anæsthesia of the cornea, stony hardness of the eyeball. Sometimes, however, these symptoms are not more pronounced than in the common form of acute glaucoma, and yet the sight may be completely destroyed within an hour or two. The phenomena of vascular excitement may appear simultaneously with the loss of sight, but they occasionally lag behind in a peculiar manner. On ophthalmoscopic examination, the aqueous and vitreous will be found to be diffusely clouded, but if they are sufficiently clear to permit the details of the fundus to be seen, a considerable overfulness of the retinal veins will be observed. Decrease of the arteries and excavation of the optic nerve appear, comparatively, very rapidly. Von Graefe has in one case noticed the latter in a very deep form, even within a few weeks after the outbreak of the disease. He thinks that we must assume that, in this form, the increase in the tension is either more considerable or more sudden than in the ordinary cases. On account of a peculiar unyielding rigidity of the sclerotic on the one hand, or a peculiar disposition of the optic disc to yield (or a functional inability of the retina to bear compression) on the other, an otherwise still bearable hypersecretion may already exert a deleterious effect upon the vision. An explanation may also perhaps be found in a too slight propulsive power of the heart, and in material changes in the coats of the vessels; causing a more ready development of the arterial pulsation (impeding the retinal function), and a complete cessation of entrance of blood into the retina. The

four cases which von Graefe narrates are of such interest and importance, that I shall give a short summary of them.

1st Case.—The left eye had been lost from absolute glaucoma. Without the occurrence of any premonitory symptoms, the patient, on awakening one morning, noticed a cloud before the right eye, which increased very rapidly, and within one hour and a half led to complete blindness; it was accompanied by rather severe ciliary neurosis. There was no vascularity or lachrymation till a few days afterwards. Von Graefe saw the patient for the first time five weeks after the outbreak, and then found the iris discoloured and reduced to a narrow rim, the cornea partially anæsthetic, the aqueous, and probably the vitreous humour slightly, though diffusely clouded, the eyeball stony hard, the optic disc deeply excavated, the retinal veins considerably dilated. As all quantitative perception of light had been lost for five weeks, and as the pain had subsided, no operation was performed.

In two other cases the result was more satisfactory, the one was operated upon the very day of the attack, the other on the third day after it. Both patients had been blind upon the other eye for some time previous. The external visible symptoms were similar to those in the last case, but the diffuse opacity of the refractive media more considerable, so that in the first case, it could only be ascertained with difficulty that there was an overfulness of the retinal veins and a normal level of the optic disc, but in the second case the fundus was completely obscured. In the first, there might still have been some remnant of quantitative perception of light, but the patient's answers on this point were so uncertain that it remained doubtful. Von Graefe operated eight hours after the blindness began. The day after the operation the patient could distinguish the movements of a hand, and on the third day she could count fingers. The field of vision was very irregular, with many great interruptions due to extensive retinal hæmorrhages, which disappeared very gradually. With their absorption, vision became very satisfactory (type No. 3 at

10 inches, field of vision normal), and has remained thus until now ($1\frac{1}{2}$ year).

In the other case, which was operated upon on the third day, there was absolutely no quantitative perception of light remaining, it being said to have become extinguished within the first few hours after the attack. Nor till the second day after the operation was there any quantitative perception of light, and then it was only very feeble, and confined to certain portions upwards and outwards. From thence it gradually extended. On the eighth day he could count fingers in a small portion of the visual field. In this case there also appeared unusually numerous and extensive retinal hæmorrhages. The improvement of sight reached its maximum degree in about two months, when the patient was able to read No. 6 at 10 inches, with the proper convex glasses. There still remained, however, an indistinctness of eccentric vision inwards (beyond 20°), and a peripheral defect (beyond 40°) in the same direction. The optic nerve was very white, and slightly cupped. Vision afterwards deteriorated slightly (from No. 6 to No. 8 of the test-types), but has now remained in this state for nearly a year. This case shows us that iridectomy, performed on the third day of glaucoma fulminans, no longer yields a perfect result.

In the following (the 4th) case the operation, performed a fortnight after the outbreak of the disease, hardly exercised any influence upon the sight, and proved in the end of no benefit whatever.

The right eye of this lady, who was 55 years of age, and of very delicate constitution, had been lost from glaucoma absolutum, which had existed several years. On the morning of the 16th of December, 1860, the patient, without ever having experienced any premonitory symptoms, suddenly, during breakfast-time, noticed a fog before the hitherto perfectly healthy left eye, which so rapidly increased in density, that in the course of an hour she could only distinguish the outlines of very large objects, and at noon she was completely blind, being no longer able to

perceive the strongest sunlight. On the night of the 16th the eye became painful, the next day vascularity and lachrymation appeared; and on the following days the ciliary neurosis was so severe as to deprive the patient of all sleep. These symptoms had all continued in spite of the employment of derivatives at the back of the neck, and local bleeding which had been prescribed by her medical attendant. Von Graefe first saw the patient on the 1st of January, 1861, worn out with the fatigue of the journey and the sufferings she had undergone. He found the pupil very widely dilated, the iris reduced to a narrow strip, and grayishly discoloured, the anterior chamber very shallow, the upper portion of the cornea anæsthetic, the aqueous humour and the cornea (as well in its deeper as superficial layers) diffusely clouded, rendering the fundus of the eye undistinguishable; the eyeball stony hard, moderate injection of the anterior ciliary vessels, slight lachrymation, *and no trace of perception of light remaining*. He performed iridectomy on the same day. Within the next few days the ciliary neurosis had completely disappeared, the aqueous humour and cornea became more clear, the sensibility of the latter returned, the tension diminished, and the iris became somewhat broader and assumed a better appearance. But no perception of light had returned within the first few days; on the fifth day a trace seemed to appear, but this only in a narrow portion upwards and outwards. Some days later, she could, however, distinguish between the light and darkness of a brightly-burning lamp held at a foot distance, and in the orbital axis, or a little to its outer side. This perception of light gradually increased up to the middle of the third week, when it reached its maximum extent; at the end of this period she could see a medium bright lamp at about three feet distance in a slit-shaped visual field lying to the outer side, the breadth of which equalled an opening of about 20° . The ophthalmoscopic examination was made at the end of the second week, the refractive media were then found perfectly clear, the optic nerve whitish and

deeply cupped, the veins being much displaced at the edge of the disc, the arteries small, and showing no pulsation. There were immense retinal ecchymoses, situated at different depths, some at the inner surface of the retina, others in the layer of the vessels, and behind the vessels, and, finally, some at the outer surface of the retina. In the vitreous humour there were likewise hæmorrhagic opacities. It was hoped that perception of light would improve as these ecchymoses became absorbed, but the contrary was the case, for at the end of the next week the slit-shaped visual field decreased in size, and six weeks after the operation all perception of light was again lost. The optic nerve also became more and more atrophied. In this case iridectomy had only afforded relief to the inflammatory symptoms, but had caused no improvement in the sight; and this teaches us the imperative necessity of operating as early as possible in these cases of glaucoma fulminans. The unusually extensive hæmorrhages, which supervene upon the operation in these cases, speak for the fact that great venous stagnation occurs from the commencement of the disease. But it is still doubtful here, as in acute glaucoma, whether the absolute blindness depends upon the disturbances of the circulation, particularly the interruption of the entrance and exit of the blood, or to a direct compression of the conducting fibres.

2. CHRONIC INFLAMMATORY GLAUCOMA.

This disease may be insidiously developed from the premonitory stage. The premonitory symptoms become more frequent and continue for a longer period; the intermissions are of less duration, until there are no longer any distinct intermissions, but only remissions, and the disease gradually and almost imperceptibly passes over into chronic glaucoma, the eye assuming the same condition as it did in the acute form, after the conclusion of the inflammatory process. It becomes more and more tense, until it may at last assume a stony hardness, so that it cannot be

dimpled by even a firm pressure of our finger (T. 3). The subconjunctival veins become dilated and tortuous, the sclerotic assuming in the late stages of the disease a peculiar waxen hue, which is due to atrophy of the subconjunctival tissue, and to a diminution in the calibre of the subconjunctival arteries. The cornea gradually loses its sensibility more and more, frequently, however, only in certain portions. It also becomes flatter. The anterior chamber becomes shallow, the aqueous humour clouded, and this turbidity may change with great rapidity, occurring perhaps several times a day. It may be produced by any excitement or fatigue, often coming on after a full meal, excessive exercise, etc. The iris is pushed forward, so as to be perhaps almost in contact with the cornea. It is dull and discoloured, its fibrillæ being more or less obliterated, and not showing a clear and distinct outline. The pupil is widely dilated, and either immovable or extremely sluggish on the stimulus of light. The field of vision becomes greatly contracted, assuming perhaps a slit shape. As has been before pointed out, the contraction of the field in glaucoma begins, as a rule, at the inner side, extending from thence upwards and downwards, so that the outer portion is the last to become affected. Vision progressively deteriorates, the fixation often becomes eccentric, and finally the sight may be completely destroyed, so that not even a remnant of quantitative perception of light is left, even although the light be intensified by means of a powerful biconvex lens. On ophthalmoscopic examination, we find that the fundus always appears, more or less, clouded, often to such an extent as to prevent our distinguishing the details of the background of the eye. This haziness is due to opacity of the aqueous and vitreous humours, and in some cases also of the cornea and lens. But if the media remain sufficiently clear to permit an examination, we find the retinal veins widely dilated and tortuous, the arteries diminished in calibre, and presenting either a spontaneous or easily producible pulsation; the optic nerve more or less deeply cupped, and the vessels

displaced at its periphery. The chief and characteristic difference between the acute and the chronic inflammatory glaucoma is, that the latter may lead to even complete destruction of sight, without any symptoms of severe inflammation or severe pain. There may only be insidious attacks of chronic, frequently recurring inflammation, leading gradually to loss of sight. At first, these inflammatory attacks may be intermittent, occurring at considerable intervals, but later they may only show remissions. In other cases again, after the eye has been suffering for some time from these insidious chronic inflammations, it may be suddenly attacked by a severe acute exacerbation, causing very great pain and suffering. These acute exacerbations may recur again and again. The pain may be so severe that recourse must be had to an iridectomy for its relief, even although there is no chance of restoring any sight. In such cases, the patient and his friends must be warned beforehand that the operation is not performed for the sake of giving any sight, but only in order, if possible, to relieve the pain. In many cases, particularly if the iridectomy be made sufficiently large, the relief may be permanent; in others it is only temporary. When speaking of acute glaucoma, it was mentioned that after the first acute attack the disease might gradually pass over into chronic inflammatory glaucoma, no fresh acute attack occurring, but only chronic, latent inflammatory exacerbations. Sometimes, the course of chronic glaucoma is so insidious that the sight of the eye may be completely lost without the patient being aware that anything was the matter with this eye, the other being well. Perchance he closes the good eye, and then discovers the blindness of the other, and thus often supposes the vision to have been suddenly lost. On being questioned, he may remember that he occasionally experienced slight pain in and around the eye, which he supposed to be rheumatic; that it occasionally became somewhat reddened, and watered a little, which was attributed to a cold; but otherwise he noticed nothing peculiar. This may not only occur amongst the

humbler classes, following pursuits which require but little employment of sight in reading, etc., as among labourers; but it may even happen amongst men of literary habits and avocations, employed for many hours daily in reading and writing.

When the disease has run its course, and all sight is lost, von Graefe terms it *glaucoma absolutum*. Then all chance of benefiting the sight by an operation is past. The lens frequently becomes opaque, assuming the peculiar greenish hue so characteristic of glaucomatous cataract. The *glaucoma absolutum* may exist for a length of time without the eye undergoing any changes, except that atrophy of the iris, choroid, and optic nerve, become more and more apparent. In other cases frequent—often very acute and violent—inflammatory symptoms shew themselves, accompanied by intense ciliary neurosis and headache. In the last stages of the disease other changes occur; the iris becomes reduced to a narrow streak, the cornea opaque and softened, more particularly in its central portions, and hæmorrhagic effusions take place into the anterior chamber, the vitreous humour, and the inner tissues of the eyeball. Sclerotic staphylomata are formed, and suppurative inflammation may even occur, leading to atrophy of the globe. Von Graefe calls this the stage of glaucomatous degeneration. In it, iridectomy no longer proves a sure remedy for the inflammatory complication. Generally sight is completely lost. Sometimes the one eye may be lost from chronic inflammatory glaucoma, or from the apparently non-inflammatory form (*glaucoma simplex*), and the other be attacked by acute glaucoma.

II.—THE APPARENTLY NON-INFLAMMATORY GLAUCOMA. AMAUROSIS WITH GLAUCOMATOUS EXCAVATION OF THE OPTIC NERVE (Graefe). GLAUCOMA SIMPLEX (Donders).*

This disease was for a long time considered as distinctive from glaucoma, with which it was supposed to

* Haffmann, *Archiv.* viii, 2.

have nothing in common but the excavation of the optic nerve. Von Graefe described it first under the title of "Amaurosis with excavation of the optic nerve." But he has now also admitted it into the glaucomatous group of diseases.

The course of the disease is often exceedingly insidious, so that it may be considerably advanced before the patients pay any particular attention to it, supposing, but too frequently, that the increasing weakness of sight is simply owing to old age. Though this impairment of vision may be noticed also for distance, it makes itself particularly felt in reading, writing, sewing, etc., and convex glasses are found but of slight assistance. There is generally no premonitory stage, for the intermittent obscurations, rainbows round a candle, etc., are mostly due to some slight inflammatory attack, accompanied by cloudiness of the refractive media.

The external appearance of the eye may be perfectly healthy. The refractive media may be quite clear, the cornea sensitive, the anterior chamber of the normal size, the iris healthy and not discoloured, or but very slightly so, this being only apparent on comparison with the iris of the other, healthy eye; the pupil perhaps slightly dilated and a little sluggish. But the eyeball is generally found to be abnormally tense, and with the ophthalmoscope we observe that the optic nerve shows a glaucomatous excavation. Sometimes this increase in tension varies greatly, being very marked at one time, and hardly, if at all, apparent at another; it is of great consequence, therefore, to examine such eyes frequently, and at different periods of the day. There is still a good deal of discrepancy of opinion as to the invariable presence of increased tension of the eyeball in this form of glaucoma. Some assert that tension is always increased in all cases of glaucoma simplex; others, again, think that although this undoubtedly does occur in the majority of cases, yet that in others it is absent. Von Graefe, in particular, maintains that the intraocular tension is not in all cases

increased in a marked manner. He thinks that the occurrence of glaucomatous excavation of the optic nerve, without any marked increase in the tension of the eyeball, may be explained thus:—That perhaps the resisting power of the optic papilla varies in different individuals, perhaps also at different ages. Just as Iritis and Iridocyclitis serosa may occasionally be observed, particularly in young individuals, to exist for some length of time with an unmistakeable increase of tension, without any excavation; may not, on the other hand, the power of resistance of the optic papilla be absolutely (?) or relatively so diminished, that an exceedingly slight increase of tension, not exceeding the normal range of variation of tension, may already cause an excavation? But every, even the most considerable increase of tension, requires to act some time before it leads to cupping. The truth of this is shown in cases of acute glaucoma, where there is no cup directly after the first acute attack, although this may have lasted for some weeks, during which the intraocular pressure was greatly increased. In glaucoma fulminans it is somewhat different, there it appears to supervene early. But a long-continued, though slight, increase of tension will lead gradually to an excavation of the optic nerve, which increases more and more in depth; the vessels then become interrupted at its edge, and there is spontaneous or easily producible arterial pulsation. The veins appear dilated, and perhaps somewhat tortuous. If the tension continues, the optic nerve gradually atrophies, the arteries become diminished in calibre, and complete blindness may supervene. It is found that if the increase in tension is very slow and gradual, the excavation of the optic nerve may become very considerable in depth, without the sight or field of vision being markedly impaired. Increased intraocular tension is, therefore, generally the first symptom of glaucoma simplex, accompanied perhaps by a relatively rapid increase of presbyopia, and some hypermetropia; gradually, however, the optic nerve becomes cupped, and these symptoms may last for a considerable time without

others supervening. In some cases, however, the augmented tension may exist for a long period without the presence of other symptoms.

Occasionally, glaucoma simplex may run its course, even to complete blindness, without the appearance of any inflammatory symptoms. The disease slowly, but surely, progresses, the eyeball becomes more and more hard, the cornea anæsthetic, the anterior chamber narrower, the vessels more turgid and congested, the pupil dilated and sluggish, the retinal veins gorged, the arteries diminished in calibre, and perhaps pulsating, the optic nerve deeply cupped and whitish in colour, the visual field more and more contracted, and the sight finally destroyed. But in the majority of cases inflammatory symptoms show themselves during the progress of the disease, and these may assume an acute, a chronic, or an intermittent type. They are accompanied by the same symptoms as in acute or chronic inflammatory glaucoma; rapid diminution of vision, obscurations, rainbows round a candle, augmentation of tension, dullness of the aqueous and vitreous humours, etc. Sometimes, however, these inflammatory symptoms may not appear until the disease has long run its course, and the sight has been completely lost. In other cases, they may be so transitory as to escape our observation, and their previous existence may not be ascertained, except by a very close examination into the history of the case. Where manifest symptoms of inflammation are apparently wanting in a case of glaucoma simplex, the condition of the other eye, if healthy, should be ascertained; and then, on a comparison of the two, we may often detect slight changes in the colour and structure of the iris, and slight haziness of the aqueous humour of the affected eye, which, but for this comparison, would have escaped our attention. Von Graefe also points out the necessity of examining such patients at a period of the day most favourable for the observance of any inflammatory symptoms, and calls attention to the important fact that whilst the inflammatory symptoms, particularly the deeper injection, become commonly more apparent soon after

sleep, the reverse obtains in glaucoma; for here they become the more prominent the longer the patient keeps awake, more particularly if he remains up beyond his customary time for retiring to bed. He mentions an interesting case, illustrative of the peculiar transitory character which the inflammatory symptoms may occasionally assume. The right eye of the patient in question ordinarily presented a perfectly healthy appearance, but for several years past, it assumes a well-marked glaucomatous condition when he has been playing cards for some length of time, and only then. On such occasions, the anterior chamber becomes shallower, the aqueous humour diffusely clouded, the pupil somewhat dilated and sluggish, the retinal veins dilated, particularly towards the edge of the optic disc, and arterial pulsation may be produced by the faintest pressure upon the eyeball; together with these symptoms, there is indistinctness of vision, surrounding objects appearing to be covered by a veil or cloud. Not till the following morning, have all these symptoms disappeared, then the sight is again normal (No. 1 of Jäger's types at 12 inches), and the increase in the tension of the eyeball, which was very manifest during the attack, is no longer appreciable. We often find that in glaucoma simplex the second eye becomes affected soon after the disease has manifested itself in the other; it, moreover, often attacks myopic eyes. In both of these points it differs materially from the majority of cases of inflammatory glaucoma.

Haffmann considers that glaucoma simplex is identical with the premonitory stage of glaucoma of von Graefe, and maintains that all the symptoms enumerated as existing in the premonitory stage are present in glaucoma simplex; but I think it of the greatest practical importance to maintain the existence of a premonitory stage, for we find, after all, that its course is generally very different from that of glaucoma simplex. The premonitory stage may exist even for many years without producing any glaucomatous changes in the eye, the symptoms may only show themselves at long intervals, and in

their intermissions the eye may be perfectly healthy; or they may recur at more frequent intervals, and pass over into acute or chronic glaucoma. In other cases they may pass over into developed glaucoma after only a few premonitory attacks. Besides this, we find that the most brilliant results of iridectomy are to be expected in the premonitory stage; but this is by no means the case in glaucoma simplex.

SECONDARY OR CONSECUTIVE GLAUCOMA.

We may meet with this complication in several groups of eye diseases; and we are here again indebted to von Graefe, for discovering the glaucomatous nature of the changes which these diseases may undergo in their course; a remedy for which is also to be found in the operation of iridectomy. We find that glaucomatous symptoms may supervene in the following diseases:—

- I. Iritis.
- II. Posterior staphyloma.
- III. Traumatic cataract.
- IV. Prominent corneal cicatrix (staphyloma).

I. *Iritis*.—We find that there is a great tendency to a recurrence of the disease in those cases of iritis in which considerable posterior synechiæ exist, so great a tendency, indeed, that any slight exciting cause will often suffice to produce a relapse. After each of these, further adhesions of the pupil will take place, further changes occur in the iris, and perhaps also in the neighbouring structures, the ciliary body and choroid. How important is it, therefore, thoroughly to dilate the pupil by atropine during the early stage of acute iritis, so as to prevent the formation of adhesions between the edge of the pupil and the capsule of the lens, and thus to obviate the most frequent cause of recurrent iritis. On account of its diminished action in acute inflammation of the iris, the solution of atropine must be strong (gr. iv. to ʒi. of water), and must be applied to the eye from 10 to 12, or even 20 times daily, and the dilatation of the pupil must be continued for some weeks

after the subsidence of the inflammation. If it be found to irritate, it should be changed for a collyrium of extract of belladonna and water.

If there is perfect exclusion of the pupil (that is, if the whole of the free margin of the pupil is adherent to the capsule of the lens, the pupil being, however, perfectly free from exudation), we find that other complications, together with progressive loss of sight, generally ensue. Amongst the most frequent of which, are chronic irido-choroiditis, effusion into the vitreous humour, detachment of the retina, chalky opacity of the lens, etc., the eyeball gradually shrinking, and becoming at last quite atrophied. Though this is very often the course pursued by the disease, von Graefe has pointed out that it may be very different, that the eye may become glaucomatous. The tension of the eyeball increases, the sight rapidly deteriorates, and the field of vision becomes contracted. On ophthalmoscopic examination, we find, if the pupil and the refractive media are clear, progressive excavation of the optic nerve. In such cases, the increasing loss of sight is due to the increased intraocular pressure, which produces compression of the retina, and cupping of the optic nerve. If the disease is permitted to run its course unchecked, the eyeball, after remaining tense for some length of time, generally becomes gradually softer and finally atrophies.

II. *Sclerotico-choroiditis posterior* (posterior staphyloma).—This disease is hardly ever absent in cases of considerable myopia. Its ophthalmoscopic symptoms are generally most marked and unmistakeable. "The characteristic symptom* is a brilliant white crescent at the edge of the optic nerve entrance, generally at the outer side (with the reverse image it would of course appear towards the nasal side of the patient). This crescent varies much in size, from a small white arc to a large zone, extending perhaps all round the optic nerve, and embracing even the region

* Vide the author's work "On Long, Short, and Weak Sight, and their Treatment, by the scientific use of Spectacles," p. 61.

of the macula lutea, its greatest extent being always in the direction of the latter.* Its edges may be either sharply and distinctly defined, or may be irregular and gradually lost in the surrounding healthy structures, irregular patches of pigment are strewn about its margin, and also perhaps on its surface, so that little dark islets of varying size and form appear in its expanse. The crescent itself is of a brilliant white colour, so much so, indeed, that the entrance, by contrast, appears abnormally pink. The small retinal vessels can, on account of the white background, be traced more distinctly, and their minute branches be more easily followed over this patch than in the neighbouring fundus. This white crescent is due to a thinning or atrophy of the stroma of the choroid (indeed the latter has occasionally been found quite wanting in this situation); the pigment cells are not necessarily destroyed, but there is an absence of the pigment molecules, for those irregular black patches, mentioned above, are pathological agglomerations of pigment. On account of the loss of pigment, and the atrophy or thinning of the stroma of the choroid, the glistening sclerotic shines through the latter, and lends the brilliant white appearance to the figure." Although such patients may be extremely shortsighted, we do not generally find that the acuteness of vision is impaired, except the disease has extended to the region of the yellow spot, or, as is frequently the case, it has become complicated with opacities of the vitreous humour, detachment of the retina, cataract, etc. But apart from these causes, the sight may become very much impaired, the field of vision contracted, the eyeball more tense, and we then find that glaucoma

* "We must, however, be careful not to call every little white rim at the edge of the entrance, sclerotico-choroiditis posterior, for this may be caused simply by the choroid receding somewhat from the entrance, and permitting the light to fall at this spot through the retina upon the denuded sclerotic, thus affording the appearance of a white, glistening rim. But this arc is very narrow, and there are no appearances of atrophy of the choroid, irregular patches of pigment, etc., at its edges." *Op. cit.*

has supervened upon the original disease. The eye then presents the following symptoms: it is abnormally hard, the sclerotic vessels perhaps somewhat injected, the anterior chamber of normal size, the pupil wide. On ophthalmoscopic examination, the optic nerve shows symptoms of excavation. The edge of the optic disc contiguous to the arc, which was before indistinct, so that it was perhaps difficult to determine where the margin of the optic disc really began, now again becomes sharply defined. But there is no considerable change in the position of the vessels, they are only somewhat displaced and curved at the edge of the excavation, but the latter extends quite up to the margin of the nerve, which distinguishes it from the physiological cup, this being confined to the centre of the disc. Von Graefe at first met with this glaucomatous condition, supervening upon sclerotico-choroiditis, only in elderly persons, who were suffering from very considerable myopia, which had increased rapidly during their youth, but had afterwards remained nearly stationary. In elderly persons, this complication may be due to the fact that when the sclerotic becomes thickened with advancing years, it loses some of its elasticity, and cannot, as heretofore, yield to the increased intraocular pressure and bulge backwards (at the posterior staphyloma), and thus the optic nerve entrance, which is the next least resisting part, will yield before the pressure and become excavated. In old persons the excavation is generally not of a deep form. He has lately, however, seen some cases of glaucoma following sclerotico-choroiditis posterior in young individuals; in all these, the eyes appeared very prominent, the myopia varying from $\frac{1}{8}$ to $\frac{1}{2}$, the symptoms of increased tension were slight, and less than in the cases observed in older individuals, in two there was, indeed, no perceptible increase of tension. The excavation was deep and abrupt. Both eyes were generally simultaneously attacked. Iridectomy proves also most beneficial in these cases, saving the sight of eyes which would otherwise have become completely blind.

But the operation must be performed very early, as no other remedy will stay the progress of the affection. Great care must, however, be taken that the aqueous humour flows off very slowly indeed, as there is in these cases (on account of the primary disease) great tendency to intraocular hæmorrhage, detachment of the retina, etc.

III. *Cataract*.—When the capsule of the lens has been divided, and the aqueous humour comes in contact with the lens, the latter swells up through imbibition of the fluid, and often sets up a considerable amount of inflammation. This division of the capsule may either be due to an operation for cataract (needle-operation), the object of which is to cause the absorption of the cataract by the breaking up of the lens and admission of the aqueous humour; or it may be due to an accidental wounding of the capsule by a foreign body. Now the amount of swelling of the lens varies considerably according to the age of the patient and the condition of the lens itself. The more closely the consistence of the translucent or cataractous lens approaches that of the normal lens, the greater is the amount of swelling it undergoes upon the admission of the aqueous humour; and for this reason, those forms of cataract in which the opacity is confined to certain portions of the lens, as, for instance, the lamellar cataract, swell up very considerably after a needle operation, as a great portion of the lens still retains its normal consistence. In the hard cataracts of older individuals the absorption of the fluid is but slight, and they swell up but very little, even although they may have been very freely divided by the needle. Any accidental wounding of the capsule of the lens is frequently followed by a rapid formation of cataract, great imbibition of the aqueous humour, and very considerable swelling of the lenticular substance. Now the danger to be apprehended from such imbibition is far less in children than in the adult. We constantly find that after the division of cataract in children, or after some accidental wounding of the lens, great imbibition and swelling of the lens ensue, and yet that they give rise to

hardly any inflammatory symptoms. But in the adult it is different; here a division of the capsule, even of moderate extent, will often lead to most severe and disastrous inflammatory complications; for with advancing years the iris appears to get more and more impatient of the pressure and irritation produced by the swelling and contact of the lens substance. We find in many cases that after the division of the capsule, be it operative or traumatic, the lens becomes swollen and presses against the iris and ciliary body, producing a violent inflammation of these structures, accompanied by exudation of plastic lymph, the formation of thick membranes behind the iris, effusion into the vitreous humour, detachment of the retina, etc., leading to destruction of the sight. As to the diagnosis of the iritis which occurs in such cases, I need say nothing. But I would call attention to the symptoms of inflammation of the ciliary body (cyclitis) which often supervenes in cases of traumatic cataract, needle-operations, and reclinatio*n* of the lens (couching). The symptoms of cyclitis are shortly as follows:—

1. There is a more or less considerable amount of subconjunctival vascularity (sclerotic injection), the colour of the iris is somewhat changed, and if there is considerable iritis, it may even be greatly altered.

2. The veins of the iris are dilated. This is a very pathognomonic symptom of cyclitis, and is due to the following cause:—On account of the inflammatory changes in the ciliary body, the venous reflux is somewhat impeded, and the blood does not flow off readily from the veinlets of the iris, and hence they become gorged and dilated.

3. Tenderness of the region of the ciliary body to the touch. If we press with the point of a probe upon the sclerotic just behind its junction with the cornea, we find that at certain points it produces exquisite pain; and whenever this is the case, we may be certain that there is inflammation of the ciliary body.

4. The formation of hypopium in the anterior chamber. The exudation giving rise to the hypopium may be pro-

duced in three ways:—From the cornea, the iris, or from the ciliary body; for at the rim of the anterior chamber the ciliary body is only separated from the latter by the division of the membrane of Descemet, through which, matter easily exudes into the anterior chamber, where it become precipitated in the form of hypopium.

Cyclitis is a far more frequent complication in cases of cataract than is generally suspected, and the inflammation often extends from the ciliary body to the choroid, for we must remember that in reality the iris, the ciliary body, and the choroid are almost one structure, the uveal tract of some authors, and that an inflammation commencing in the one, is very liable to extend to the other portions of this tract.

But the sight may also be lost in another way in traumatic cataract, the eye may become glaucomatous. During the swelling of the lens it is found that the intra-ocular pressure increases, the eyeball becomes more tense, the field of vision contracted, the cornea anæsthetic, the anterior chamber more shallow, the iris discoloured, the pupil dilated and sluggish. If the disease is allowed to run its course unchecked, the lens may become completely absorbed and the pupil clear, but the patient remains blind; with the ophthalmoscope we then find a deep excavation of the optic nerve. "The process has been this: from the irritation caused by the swollen lens a state of internal congestion was caused, hypersecretion of fluid into the vitreous body, increase of intraocular pressure, which has continued for some time, and which has caused excavation by its action on the surface of the papilla of the optic nerve."*

We must be constantly upon the watch in cases of division of cataract, traumatic cataract, and after the operation of couching (if this should ever be performed at the present day) for the occurrence of inflammatory complications, more particularly cyclitis and choroiditis, and if these make their appearance, or any symptoms

* Von Graefe's article on Glaucoma. New Sydenh. Society, vol. v., p. 372.

of a glaucomatous complication begin to show themselves, the lens should be at once removed. If it be sufficiently softened, it may be removed through a linear opening, and then these symptoms will soon subside. But if the patient is an adult, the nucleus may still be hard, although the cortical substance is softened and swollen; it is then necessary to combine iridectomy with the linear extraction (modified linear extraction), and remove the nucleus with a spoon. It is essentially necessary to remove the lens as soon as possible if a foreign body has entered and remained in it; for when the lens becomes swollen and partially absorbed, to say nothing of the dangerous inflammatory complications to which this may give rise, the foreign body may disengage itself from the lens substance, and sink down to the bottom of the posterior chamber, giving rise, most probably, to panophthalmitis, which soon leads to atrophy of the eyeball. It is, therefore, urgently necessary to remove the lens and foreign body as soon as possible; this is best done by making an iridectomy, and removing the lens together with the foreign body by means of one of Waldau's spoons.

IV. *Projecting Corneal Cicatrix*.—Glaucomatous symptoms may also supervene upon this form of corneal cicatrix; indeed it has been long observed, that in cases of partial or complete staphyloma, of leucoma prominens, etc., the degree of blindness was quite disproportionate to the optical condition. In such cases there is very frequently contraction of the field of vision, eccentric fixation, augmentation of the intraocular pressure, and excavation of the optic nerve. If glaucomatous symptoms should supervene upon projecting corneal cicatrix, the latter becomes markedly prominent after it has already become thickened. There appears to be an increase in the vitreous humour, giving rise to intraocular pressure, and it is of consequence that this complication be detected at an early stage, as nothing can be done for the sight when the disease has run its course.

LECTURE III.

GLAUCOMA may complicate diseases which stand in no wise in any causal relation to it. For instance, it may supervene upon common cataract, or upon cerebral amaurosis.

We may find that an eye affected with mature, senile cataract, is attacked by glaucoma, and we then have the usual glaucomatous symptoms, in addition to the original cataract. The eye becomes tense, there is more or less ciliary neurosis, the conjunctival and subconjunctival vessels are injected, the cornea perhaps somewhat anæsthetic, the anterior chamber more shallow, the aqueous humour hazy, the iris discoloured, the pupil dilated and sluggish, the opacity of the lens very evident. Together with these symptoms, the perception of light is deteriorated (the patient being unable to distinguish between light and dark as well as a person suffering from simple mature, uncomplicated cataract should be able to do), and the field is contracted. These glaucomatous symptoms vary, of course, in intensity. There may be a well marked premonitory stage which passes over into typical acute, subacute, or chronic inflammatory glaucoma. Generally, there can be no difficulty in the diagnosis of the nature of the disease; that it is a case of simple cataract which has become complicated with glaucoma. Nor will the cataract be readily mistaken for a glaucomatous cataract, although, if it be amber-coloured, the haziness of the aqueous humour will lend it a somewhat greenish tint. But a careful examination into the history of the case will prevent the occurrence of such a mistake. The question now arises, How is such a case to be treated? The glaucoma is to be in the first place cured by an iridectomy, and then, when the glaucomatous symptoms have disappeared, when the

eyeball has regained its natural tension, when the intraocular circulation has been restored to a normal condition, the cataract may be operated upon. But some length of time—some months at least—should intervene between the two operations, in order that the improvement in the circulation and in the nutrition of the eye may have become thoroughly established, otherwise the extraction of the lens might lead to severe and very dangerous intraocular hæmorrhages. The length of time which should elapse before the performance of the second operation, must of course depend upon the state of the eye before the iridectomy; if there was great increase in the intraocular pressure, if this had existed for some time, and if the congestion and stagnation in the vessels was very considerable, a longer period should elapse before the operation for the removal of the cataract is undertaken, than if the glaucomatous symptoms were but slight and only of short duration.

The lens should never be removed at the same time that the iridectomy is made, for we know that when the increased tension is at all considerable, the sudden diminution of pressure by the escape of the aqueous humour, is generally accompanied by hæmorrhage into the retina, etc. Now the tendency to intraocular hæmorrhage will be greatly increased if not only the aqueous humour flows off, but the lens is also removed.

Atrophy of the optic nerve, dependent upon cerebral amaurosis, may also become complicated with glaucoma. In the generality of cases, there is no difficulty in detecting that the atrophy of the optic nerve was the primary affection, more particularly if it be found that the other eye is suffering from a similar disease, and the history of the case be inquired into. But in some cases it is difficult to arrive at a certain conclusion. Thus Von Graefe has lately called attention to a peculiar form of complicated glaucoma, which he has only met with in four cases; all occurring in elderly females. The external symptoms were those of chronic inflammatory glaucoma with exacerbations, the

optic disc became somewhat slowly excavated, but very rapidly assumed a whitish colour. This form is particularly characterized by the peculiar contraction of the visual field, which commences at the outer side (and not at the inner as in cases of common glaucoma), and by the severity of the cerebral symptoms. Together with more or less severe ciliary neurosis, the patients suffer from noises in the head, dizziness, and faintness, also from great sleeplessness, which yields but slightly to opiates. In three of these cases the patients were greatly emaciated, and were affected with advanced arterio-sclerosis, which was particularly evident in the carotid and temporal arteries. The fourth patient had insufficiency of the aortic valves. In three of the cases Von Graefe had not, unfortunately, seen the patients previous to the glaucomatous attacks, otherwise he thinks that he would probably have found a pre-existing whitening (atrophy) of the optic disc, and contraction of eccentric vision; nor could he ascertain this with certainty from an inquiry into their history. Although iridectomy removed the glaucomatous inflammation, the ciliary neurosis, and temporarily improved the sight, the head symptoms persisted, and after a few months the vision progressively deteriorated again, the optic nerve at the same time becoming more and more atrophied. He thinks that these symptoms make it very probable that there was either a pre-existing cerebral amaurosis, dependent upon sclerosis of the cerebral arteries, or that this arose simultaneously with the glaucomatous affection. In the fourth case, the patient was under his care for several months prior to the glaucomatous attack, and was affected with amblyopia, accompanied by indistinctness of peripheral vision (outwards), whiteness of the optic nerve, and severe cerebral symptoms, more particularly noises in the head, and giddiness approaching nearly to fainting. Some months after he came under Von Graefe's care, premonitory symptoms of glaucoma showed themselves, soon passing over into subacute, though typical glaucoma.

ON THE NATURE AND CAUSES OF THE GLAUCOMATOUS PROCESS.

The nature of the glaucomatous process is evidently inflammatory, accompanied by an increase in the intraocular pressure. The seat of the inflammation is chiefly in the uveal tract, the choroid, ciliary body, and the iris; although other structures may afterwards become involved as the cornea, sclerotic, and the retina. This irido-choroiditis is accompanied by diffuse imbibition of the aqueous and vitreous humours, causing an augmentation of the intraocular pressure. The characteristic symptoms of glaucoma, which have been already described at length, are all due to this increased tension, as for instance: the hardness of the eyeball, the contraction of the visual field, the obscurations, the ciliary neurosis (caused by pressure upon the ciliary nerves), the anaesthesia of the cornea, the dilatation and sluggishness of the pupil (due to paralysis of the nerves supplying the iris), the excavation of the optic nerve, and the pulsation of the retinal vessels. This augmentation of the intraocular pressure appears to be due to an increase in the volume of the vitreous humour, owing to the inflammation of the uveal tract, which is the chief secreting organ of the ocular fluids. Together with this increase in the vitreous humour, it appears also that the powers of absorption are diminished in glaucoma, and this may explain why such effusions are not, as in other forms of choroiditis, removed by increased activity of the absorbents. This diminution in the power of absorption may be, in part, due to the changes met with in the coats of the vessels, and to the great tendency to over-fullness and stagnation in the blood vessels which occurs in glaucoma, more particularly during the inflammatory exacerbations, as is evidenced by the dilatation and tortuosity of the conjunctival and retinal veins, and by the frequency of hæmorrhagic effusions into the retina, optic nerve, and choroid. Attention has lately been called to the fact, that the sclerotic appears peculiarly rigid and

unyielding in glaucoma, and it has been supposed that this is not unfrequently congenital or hereditary, and may form a predisposing element to glaucoma. Now, if such an abnormal rigidity of the sclerotic exists, we can easily understand how any rapid though slight augmentation in volume of the contents of the eyeball, must not only give rise to a disproportionate increase in the intraocular pressure, but must also augment the tendency to stagnation in the blood-vessels. Coccius has lately found in a case of glaucoma that the sclerotic had undergone a fatty metamorphosis, that the cellular tissue had become fattily degenerated; and he thinks that the affection of the sclerotic may perhaps have been the cause of the increased intraocular pressure.

When considering the different forms of glaucoma we had frequent occasion to point out the great variations in the intensity of the inflammatory symptoms. We saw that in acute glaucoma the inflammation might be very severe during the first attack, but that after its subsidence, the inflammatory exacerbations might assume an insidious chronic character, and the disease gradually pass over into glaucoma absolutum, without the recurrence of any acute attack. Again, that in the chronic form the inflammatory symptoms might, at the outset, be but little marked, but that in the course of the disease acute exacerbations, even of a very severe character, might show themselves. In the third form (amaurosis with glaucomatous excavation, glaucoma simplex), it was stated that the disease might occasionally run its course without the apparent occurrence of any inflammatory symptoms—the eyeball becoming stony hard, the optic nerve deeply excavated, the sight destroyed, but the refractive media remaining perfectly clear. But in the vast majority of cases of glaucoma simplex, inflammatory symptoms, of varying severity, do show themselves during the progress of the disease. Now, on account of the fact that glaucoma simplex may occasionally run its course without the apparent presence of any inflammatory symptoms, and on

account of the increased tension being sometimes the first manifest symptom of the disease, it has been supposed by Donders that the inflammation is not the integral part of the glaucomatous process, but only a complication, which, though occurring in the majority of cases, need not necessarily be always present. He considers the increase in the intraocular pressure as the essence of the disease, and, therefore, the glaucoma simplex, which runs its course without any inflammatory symptoms, as the primordial type of the disease; and he thinks that the acute or chronic inflammation which shows itself in the majority of cases of glaucoma is but a complication, which is of secondary importance, and not necessary to the glaucomatous process. He, therefore, speaks of glaucoma simplex, and glaucoma cum ophthalmia. The anomaly in the secretion of the fluids of the eye he thinks due to an abnormal irritation of the nerves regulating the intraocular secretion. It has also been urged that inflammatory glaucoma (glaucomatous ophthalmia) cannot occur primarily in a hitherto healthy eye; that an increase in the tension of the eyeball pre-existed; that, in fact, glaucoma simplex had existed, perhaps quite unknown to the patient, and that the inflammation supervened upon this. But we sometimes meet with cases of acute glaucoma in which there was no trace of increased tension, or any other glaucomatous symptom, prior to the outbreak of the disease. Thus Von Graefe mentions cases in which he has operated for glaucoma upon the one eye, the other being, at the time of operation, of quite a normal degree of tension; and yet the latter was soon after attacked by glaucoma, in one case even by glaucoma fulminans. He thinks, moreover, that the mere increase of tension should not be allowed to constitute a premonitory stage, as even a considerable increase of tension may exist for an indefinite period without the appearance of other glaucomatous symptoms. In families in which glaucoma is hereditary, an increased resistance, often of a marked degree, exists even in infancy, and the disease may not show itself till middle age, or even not at all.

The question is certainly a most important one, whether the inflammation be but of secondary importance or not. The great difficulty lies in those cases (although they are but rare) in which we find the glaucomatous disease running its course without any, even the slightest, symptom of inflammation; for if this be possible, then, indeed, we cannot look upon the inflammatory symptoms as the *sine quâ non* of the disease. At present, however, this subject still remains in doubt. Von Graefe maintains the inflammatory nature of glaucoma, accompanied by an increased secretion of the fluids of the eye, and by augmented tension. He thinks that in the cases of apparently non-inflammatory glaucoma a lengthened observation will generally show us that transitory inflammatory exacerbations (perhaps of a very ephemeral nature) do mostly occur. Such exacerbations may be but very slightly marked, and easily escape the attention of the patient or his medical attendant; or they may only occur at certain periods, or be produced only by certain causes, as, for example, in the case mentioned at page 36, in which they only came on whenever the patient played at cards. The absence of any externally visible symptoms of vascularity is no proof of the non-existence of internal inflammation, for the ophthalmoscope constantly reveals to us the presence of even considerable inflammation of the choroid and retina, without the existence of any increased vascularity of the external tunics of the eyeball. The haziness of the aqueous and vitreous humours which may arise during such an ephemeral exacerbation may likewise be so slight and delicate as to escape detection with the ophthalmoscope, for we know that fine diffuse opacities of the aqueous humour are often quite invisible by transmitted light.*

Glaucoma is a disease of old age. It is most frequently

* For further information upon this interesting and important subject, I must refer the reader to Von Graefe's and Dr. Haffmann's papers on Glaucoma, Arch. viii. 2.

met with between the ages of 50 and 60, but may occur even at a much later period. It is seldom met with in early life, or before the age of 30. Females appear to be much more subject to it than males, and it is most apt to occur soon after the cessation of menstruation. We find that the males who are attacked by glaucoma frequently suffer from gout and disorders of the digestive organs, and are often subject to hæmorrhoids. There is no doubt that glaucoma may be hereditary, and, as has been already mentioned, the eyes of the individual members of families in which this disease is hereditary often show, even in early life, a peculiar increase in the resistance of the eyeball, and a rigidity and unyieldingness of the sclerotic; and these symptoms may exist for many years without any glaucomatous outbreaks. In fact, the latter does not generally occur until middle age.

We have stated that glaucoma may appear as a primary or a secondary disease. In the former case, it may occur after severe external injuries, or without any apparent external or internal cause. It always attacks one eye first, and may remain confined to this; but when once the one eye has become affected by glaucoma, there is a great tendency in the disease to invade the other also. We must, therefore, always prepare such a patient for the eventuality—the great likelihood even—of the other eye becoming also affected. By careful and judicious treatment, and by abstinence from excessive fatigue and exertion of the eye, much may be done to retard the attack, and to break its force. The nature of the glaucomatous process in the first eye is no criterion as to the form which may occur in the other. We find, for instance, that the first eye may be suffering from glaucoma simplex, or chronic inflammatory glaucoma, and the other be attacked by the acute form, or even by glaucoma fulminans. The time which may intervene before the second eye becomes affected varies greatly; sometimes a few days only elapse, in other cases many months, or even years. In the secondary glaucoma, which may supervene upon another affection (traumatic cataract,

irido-choroiditis, etc.), this disposition to extension of the disease to the other eye is far less than in primary glaucoma; but still such a tendency does exist, and may be called into activity by any injury to, or operation upon, the sound eye.

OPHTHALMOSCOPIC SYMPTOMS OF GLAUCOMA.

The characteristic ophthalmoscopic symptoms of glaucoma are—pulsation of the central vessels of the retina, and excavation of the optic nerve.

The stagnation in the venous circulation of the retina is often very considerable, the veins are dilated and tortuous, the smaller veinlets assuming a corkscrew appearance; if the stagnation be very great, the larger venous branches may even show peculiar bead-like swellings. This is, however, very rare. I have seen one case in which there was a distinct tendency to these swellings, but Liebreich figures a case in his admirable "*Atlas d'Ophthalmoscopie*" in which it existed in the most marked manner. After diminution of the pathological increase in the intraocular pressure, the stagnation in the venous circulation ceases, the calibre of the veins diminishes in size, and they lose the tortuosity. Thus, after the performance of iridectomy, and the consequent diminution in the tension of the eyeball, we frequently have an opportunity of observing the change in the venous circulation. Extensive retinal ecchymoses are perhaps met with, and the veins, which, before the operation, were very dilated and swollen, are now much diminished in size and paler. The retinal arteries in glaucoma appear very thin and small, and much paler than in the normal eye.

The pulsation of the central veins and arteries may be spontaneous in glaucoma, or producible by slight pressure upon the eyeball—a pressure far slighter in degree than would produce it in the normal eye. The venous pulsation may, however, occur spontaneously in normal eyes; hence it is not so pathognomonic of glaucoma as

the arterial pulsation, which never occurs spontaneously, except the intraocular pressure is considerably increased. The venous pulsation is characterised by an alternating increase and diminution in the calibre of the vein; the emptying of the vein commences at the centre of the optic disc, and extends to its periphery; the re-filling, on the other hand, begins at the periphery, and extends to the centre. The venous pulsation is mostly only visible in the expanse of the optic disc, but in very rare cases it may extend beyond its margin. On increasing the intraocular tension by a slight pressure upon the eyeball, the venous pulsation may be rendered still more distinct, and we may thus alternately cause a complete emptying and re-filling of the vein. On a sudden relaxation of a pressure which has continued for some little time, the veins become rapidly over-filled and swollen, which dilatation lasts for about a minute, when they resume their normal calibre. The respiration also affects the retinal circulation somewhat; thus an increase in the size of the vein may be noticed during strong expiration, whereas a deep inspiration causes it to diminish. The vein and artery are in an opposite state of fulness, the arterial systole being synchronous with the venous diastole.

The arterial pulsation is synchronous with the radial pulse, but occurs slightly later than the pulsation of the carotid. It is not spontaneously present in a normal eye, and requires a considerable amount of pressure upon the globe to produce it, far more so than is required for the venous pulse. I have before pointed out the important fact that, together with the appearance of the arterial pulsation, there occurs an obscuration of the field of vision, which disappears together with the pulsation upon the cessation of the pressure. If the augmentation in the intraocular pressure be at all considerable, the arterial pulsation is often spontaneous in glaucoma; or, if not, it may be produced by slight pressure upon the eyeball. It is confined to the optic disc, and may occur in one or all the principal branches of the central artery of the retina. It

is recognised by a rapid to-and-fro movement, a rythmical filling and emptying of the arteries, the pulsation being synchronous with the radial pulse. The arterial diastole is characterised by a rapid, jerky entrance of a column of blood into a previously empty artery, and takes far less time than the systole, which shows itself by a slow, centrifugal emptying of the vessel. On augmenting the intraocular pressure the diastole will diminish more and more, whilst the systole increases in duration. If the pressure be increased to a maximum degree we may blanch the optic disc completely, the veins will become emptied, the arterial pulsation will also disappear, and a peculiar oscillation of the blood in the veins may show itself near the optic disc.

Excavation of the Optic Nerve.—The excavation of the optic nerve which is met with in glaucoma, and is due to the increased intraocular pressure, is so peculiar in character that in the majority of cases there is no difficulty in at once distinguishing it from the excavation which may be met with in a perfectly normal eye, or may occur in atrophy of the optic nerve. Before considering the characteristic symptoms of the glaucomatous or "pressure" excavation, it will be well to notice the appearances met with in a physiological cup, and also in the excavation due to atrophy of the optic nerve.

In the *congenital physiological excavation* we find that the cupping is limited to the central portion of the optic disc, that it is generally very small and shallow, and that it may continue throughout life without undergoing any changes. Sometimes the excavation is well marked and easily recognisable, the central portion of the optic disc presenting a peculiar white, glistening appearance, of varying size and form. This central glistening spot may be oval, circular, or longitudinal, and its size is generally very inconsiderable in comparison with that of the optic disc; it is surrounded by a reddish zone, which may even be almost of the same colour as the background of the eye. The width of this zone varies with the extent of the excavation; if the latter be

small, the zone will be very considerable ; but if it be large, the zone will be narrow, and limited to the periphery of the disc. The edges of the cup are generally slightly sloping, and never abrupt or steep ; but the excavation passes gradually over into the darker zone, without there being any sharply-defined margin. But if the excavation is conical or funnel-shaped, the edges are more abrupt, and the margin more defined. We find that the retinal vessels also undergo peculiar changes in their course from the periphery towards the centre of the disc, for when they arrive at the margin of the excavation, instead of passing straight on, they describe a more or less acute curve as they dip down into it. This curve may be very slight and gradual if the cup is shallow, but if it is deep and extensive, the curve may be abrupt, giving rise to a displacement of the vessels. In the expanse of the excavation the vessels generally assume a slightly darker shade, but in other cases they appear of a lighter, more rosy hue, and seem to be enveloped by a delicate veil.

In the excavation from atrophy of the optic nerve, attention should also be paid to the characteristic symptoms of such atrophy. The retinal vessels will be found greatly diminished in calibre, the arteries small and threadlike, perhaps hardly apparent ; the veins may at first retain their normal size, or be even slightly dilated, but in the course of the disease they also diminish greatly in diameter. The colour of the disc is likewise changed ; instead of the rosy-yellow appearance which it presents in the normal eye, it assumes a more or less grayish-white or bluish-white colour, which may be limited to a portion of the disc or extend to its whole expanse, lending it a peculiar glistening, tendinous, or mother-of-pearl appearance. The bluish-gray colour of the optic nerve is particularly met with in spinal amaurosis ; indeed, it may be almost considered characteristic of this affection. The excavations from atrophy, although perhaps extensive on the surface, are generally very shallow, the descent is gradual and sloping, not abrupt ; consequently, the retinal

vessels, on arriving at the edge of the cup from the periphery of the disc, do not show any marked displacement, but only describe a more or less acute curve. Sometimes this curve is so slight that it is hardly perceptible. Even in those rare cases in which the excavation is tolerably deep, the descent is not abrupt, and for this reason there is no marked displacement of the vessels at its edge; and on moving the convex lens of the ophthalmoscope to and fro, so as to make it act as a prism, the bottom of the excavation does not move as a whole, but only certain portions of the excavation undergo a slight displacement; and this parallax is very different to, and easily distinguishable from, that met with in the glaucomatous cup. Moreover, the sudden interruption of the over-filled veins at the edge of the excavation, which is so very characteristic in the glaucomatous form, is also wanting.

The glaucomatous or pressure excavation is distinguished by the following typical symptoms. The cup is not partial and confined to the central portion of the optic disc as in the physiological form, but it extends quite to the edge of the disc, its diameter equalling that of the latter, and the lamina cribrosa is stretched and pushed backwards. Even although it may not yet have attained a considerable depth, the edge is always abrupt and precipitous, thus differing greatly from the atrophic excavation, in which the descent is gradual and sloping. The edges may also overhang the cup, which has undermined the margin. The optic disc is surrounded by a light yellowish-white ring, which is probably caused by the reflection of light from the anterior laminae of the scleral ring. This zone varies in width according to the depth of the excavation; the deeper and more advanced the latter, the broader and more marked will be the ring. The colour of the disc is also much changed. Instead of the yellowish-pink appearance of the normal disc, the central, highly shining portion is surrounded by a deep bluish-gray or bluish-green shadow, which gradually increases in darkness towards the periphery of the disc, where it may

assume the appearance of a dark well-defined rim. On slightly moving the mirror or the object lens, this shadow will vary in intensity, more particularly in the central portion. On account of this peculiar shading of the disc, the latter looks, at the first glance, rather arched forward than hollowed and excavated. The course of the retinal vessels at the edge of the cup is also very peculiar. They do not pass, as in the normal eye, straight over the margin of the disc on to the retina without showing any curve or displacement; but if we trace their course from the retina, we find that when they arrive at the margin of the excavation the dilated veins increase somewhat in size, and, making a more or less abrupt curve, descend into the cup; at the point of curvature the veins also appear somewhat darker in colour. If the excavation is deep, the veins seem to curl round over the edge, and are considerably displaced, so that the prolongations of the veins on the optic disc deviate so considerably from those at the retinal edge of the cup that they do not appear to belong to the same vessel. Their continuation seems interrupted, and this displacement of the two portions may equal the whole, or even more, of the diameter of the vessel. The extent and suddenness of this displacement varies with the depth of the cup. In the disc, the vessels appear indistinct and faded, and diminished in calibre; sometimes they may almost completely disappear, so that they can only be traced with difficulty. If the object lens be moved, so as to give it the action of a prism, a very marked parallax will appear; the whole bottom of the excavation shifts its position, and the broad scleral ring may seem to move over it, as if a frame were moved over a picture, the different portions of the excavation, however, shifting their individual positions but very slightly. The degree of the parallax also varies according to the depth of the excavation. It is particularly well seen, stereoscopically, with the binocular ophthalmoscope. The peculiarity of this parallax distinguishes, in a marked manner, the glaucomatous excavation

from that met with in atrophy of the optic nerve; for in such a case, as has been already pointed out, certain portions of the excavation may shift their position, but the bottom of the cup does not move as a whole. The displacement of the vessels in the glaucomatous excavation will also enable us to distinguish between this and the physiological form. In the former the displacement is more or less abrupt, and occurs at the edge of the disc, whereas in the partial or physiological cup the displacement or curvature is not abrupt, but slight and gradual, and does not occur at the edge of the disc, but within its area, at a greater or less distance from the margin, according to the extent of the excavation. Should a glaucomatous cup supervene upon a physiological one, we may at the outset of the disease sometimes observe the two existing together, the vessels showing the double displacement—the one at the edge of the physiological excavation and within the area of the disc, the other more abrupt and marked, and situated at the edge of the optic disc. But at a later period the appearances of the physiological cup are lost, the latter becoming involved in the glaucomatous excavation.

In the majority of cases it is not difficult to distinguish the glaucomatous excavation from the others, even before it has reached any considerable depth; the extent of the cup, the abrupt and precipitous edges, the peculiar displacement of the vessels at its margin, and the spontaneous or easily producible arterial pulsation, will be found the surest guides. Where symptoms of atrophy of the optic nerve accompany the formation of a glaucomatous excavation, there may be some difficulty in ascertaining which is the primary affection, more particularly in those cases in which atrophy of the optic nerve, dependent upon cerebral amaurosis, has become complicated with inflammatory glaucoma. In such, a comparison of the two eyes, and a careful and searching examination into the history of the case, will generally clear up the difficulty. But we

must remember that in glaucomatous excavation the optic nerve often undergoes atrophic changes and becomes very white.

At the commencement of the glaucomatous excavation the cupping may be partial, being confined to one portion of the optic disc; but it will already show the typical symptoms of the pressure excavation. The optic disc is perhaps completely surrounded by a broad scleral zone, the veins become somewhat dilated and abruptly displaced at the edge of the cupped portion, and there is a bluish shadow at the periphery of the latter, which is gradually shaded off to a lighter colour towards the centre.

Von Graefe has pointed out the very interesting and important fact, that a glaucomatous excavation may become shallower after the operation of iridectomy, thus proving that the cup depends upon an increase in the intraocular pressure. The best cases to illustrate this fact are those in which acute symptoms have supervened upon chronic glaucoma. I have already stated that no excavation is found after the first attack of acute glaucoma, from the simple fact that the increase in the intraocular pressure requires to act for a certain length of time in order to produce cupping, and that even a slight increase of tension may suffice to do so if it be continued for some length of time. In glaucoma fulminans it is different, for here the increase in the tension is so excessive that it rapidly leads to excavation.

If acute inflammatory exacerbations attack an eye which has been suffering for some length of time from chronic glaucoma, with but slight deterioration of vision, moderate increase of intraocular pressure, and but an inconsiderable excavation, the latter may rapidly increase in size. If iridectomy be performed some days after the acute attack, or some weeks after the first sub-acute symptoms (dilatation of the pupil and diffuse opacity of the refractive media), Von Graefe states that we may generally perceive a diminution in the depth of the excavation. The cup becomes more shallow and saucer-like,

the ends of the vessels less abruptly displaced, and their interruptions disappear, so that the continuation of the vessel from the retina on to the disc may be traced, although it may be somewhat curved: we may notice also that vessels, which were slightly curved at the edge of the cup, become straight again.

LECTURE IV.

Prognosis of Glaucoma.—If the disease be left to itself, or be treated by inefficient remedies, the prognosis is most unfavourable, as it leads sooner or later to destruction of sight. The old treatment, which consisted in leeching, cupping, mercury, opium, etc., fails, and is sure to fail, in staying the progress of the disease. The acute inflammatory attack may subside under their use, or even without any treatment whatever; the inflammatory symptoms may diminish, the refractive media again become transparent, the sight restored, and the patient and his medical attendant may deceive themselves with the fond hope that the dangerous disease has passed away and is cured. But this is not so. Sooner or later the eye again becomes attacked, perhaps by acute exacerbations, perhaps by insidious chronic inflammations, which gradually lead to total and irremediable blindness.

The chief and most important indication in the treatment is the diminution of the abnormally increased intraocular pressure, for as long as this exists we cannot hope to arrest the progress of the disease. Paracentesis of the cornea has long ago been tried in the treatment of glaucoma, and has lately been again strongly recommended as a cure for this disease; but we know that its effect is but transient, that it relieves the intraocular pressure for a short time, but that this relief is not permanent, for increased intraocular tension and other glaucomatous symptoms soon manifest themselves again. Division of the ciliary muscle (as it has been termed) has also been much vaunted as a cure for glaucoma. That it may temporarily relieve tension by causing the escape of the aqueous, and perhaps some of the vitreous humour, cannot be denied; but tapping the anterior chamber will do the same thing. If a con-

siderable amount of vitreous humour flows off, the tension may even be permanently diminished. But the escape of vitreous in glaucoma is a thing to be avoided if possible, and not to be desired or courted; for we find that the loss of vitreous (for instance, in the operation of extraction of cataract) always renders the eye more prone to chronic inflammatory affections of the choroid, accompanied by opacities of the vitreous humour, etc. At present no evidence has been brought forward by the supporters of this operation that would permit our placing it, even for a moment, side by side with iridectomy in the treatment of glaucoma.

Iridectomy, on the other hand, has been proved to diminish (and in the vast majority of cases permanently), the abnormally increased intraocular pressure. The admirable results of this operation in the treatment of glaucoma have long admitted of no doubt, tested and endorsed, as they have been, by most of the distinguished oculists of Europe.

Some opposers of the operation have, apparently, thought that its supporters claimed for it the power of restoring sight in all cases of glaucoma, whatever their stage or nature might be. But none of its advocates have ever done this; they have only upheld its curative powers in those cases in which irreparable changes in the structures of the eye had not yet taken place. The extent of the benefit which may be expected from iridectomy will, therefore, depend upon the stage and form of the disease in which it is had recourse to. It may be laid down as an axiom, that the sooner the operation is performed when the premonitory symptoms have become marked and frequent, or after the outbreak of the disease, the better; so that the affection has not yet had time to produce material changes in the structures of the organ. Let us now shortly consider what prognosis may generally be given of the beneficial effects of iridectomy in the various stages and forms of glaucoma.

The Premonitory Stage.—As long as the premonitory

symptoms only occur at distant intervals, and the intermissions are complete, the eye returning to its normal condition during the intervals, we may postpone the operation with safety. We should, however, warn the patient against any excessive fatigue or exertion of the eyes, their exposure to very bright light and rapid changes of temperature; against everything, in fact, that may produce hyperæmia and irritation of the organ, and which may thus hasten the outbreak of the disease. He must also abstain from excesses of every kind. But the system of lowering and starving patients suffering from glaucoma is not advisable, indeed often most injurious, more particularly if they are elderly, and have been very free livers. Such patients should be placed upon an easily digestible, nourishing, and even, perhaps, generous diet, and should be permitted a moderate allowance of stimulants, the quantity being regulated by their former habits and the condition of their general health.

If the intermissions are no longer complete, but there are only remissions of the symptoms; if the periodic obscurations, the ciliary neurosis, the iridizations, occur at short intervals of a day or two; if the eccentric vision becomes impaired, or the field even contracted, the vessels congested, and the eyeball tense, it would be dangerous to delay the operation any longer. The acute attack is then probably imminent, and we cannot foretell what its severity may be, and whether it may not burst forth in a very acute form, even that of glaucoma fulminans, and rapidly lead to such serious lesions of the structures as greatly to imperil, or even to spoil, the integrity of the organ, before operative aid can be obtained. But there is another reason why we should not wait for the acute outbreak of the disease, for we cannot be certain that it will occur, as the affection may gradually, and perhaps almost imperceptibly, pass over into chronic glaucoma with excavation of the optic nerve, accompanied by such a deterioration of the retina and other tissues that the operation may then prove of but little avail. If iridectomy is performed during the premonitory

stage, when the symptoms become marked and the attacks frequent, but before any structural changes have taken place, the prognosis is most favourable, the progress of the disease is arrested, and the sight of the eye saved.

In *acute inflammatory glaucoma* the prognosis is also favourable if only the operation is performed sufficiently early. If the impairment of vision increases very rapidly, if the sight is already diminished to a mere quantitative perception of light, or if the visual field is much contracted, the delay of the operation would be most dangerous, and it should be performed at once. We may generally expect a nearly perfect result if iridectomy be had recourse to within a fortnight after the outbreak of acute glaucoma; always remembering, however, that at least good quantitative perception of light must still be present. But we should never voluntarily wait so long, as there is always a risk that during the delay the tissues may undergo serious changes. Von Graefe lays particular stress upon the fact that the immediate necessity for the operation depends less upon the intensity of the inflammatory symptoms, the acuteness of the pain, or the amount of increased tension, than upon the state of the vision. If this be not greatly impaired, if the patient is still able to read large type, the operation may be postponed, if it be necessary, for a day or two. But in the interim the patient must be closely and anxiously watched, and if rapid diminution of vision occurs, no further delay must be permitted. Sometimes the question may arise, whether a patient suffering from an attack of acute glaucoma may be permitted, if necessary, to undertake a journey in order to have the operation performed, or whether he may be safely allowed to wait until the inflammation has subsided, and the eye has again become "quiet." Here I must strongly urge the necessity of not delaying, for, if the journey be postponed until the inflammation is allayed, the eye may be found to be irretrievably lost. The journey would have proved far less dangerous than the delay. But even if the most favour-

able event should occur, if the inflammation should subside, and the eye apparently regain its former condition, we know but too well that the disease is not cured, that it will sooner or later recur, either in the acute form or as chronic glaucoma. In the latter case, the progress may be so insidious that serious and irreparable changes in the optic nerve, the retina, and the coats of the vessels may have occurred before the patient's attention has been attracted to the state of his eye.

In glaucoma fulminans the operation must be performed as soon as possible. The structures undergo such great and rapid changes, that the effect of the operation is not perfect even when it is performed within three days after the outbreak of the disease (vide Von Graefe's case, p. 27).

In those cases of acute glaucoma in which the pain is very intense, and there is much inclination to vomit, but the impairment of vision is only moderate, Von Graefe thinks it may be better to wait a day or two before performing iridectomy. Here he employs the subcutaneous injection of morphia, gr. $\frac{1}{8}$ to $\frac{1}{3}$, in the region of the temple, in order to procure a good night's rest, and to quiet the nervous system before operating. But if we give chloroform the operation need not, I think, be postponed on this account. In fact, iridectomy proves the best antiphlogistic, and its beneficial effects in acute glaucoma are most marked and brilliant if it be performed sufficiently early. The relief of the pain, often agonising, is generally immediate; patients soon fall into a tranquil and refreshing sleep, after having perhaps passed several sleepless, miserable nights; the inflammatory symptoms rapidly subside; the sight is greatly improved, partly from the diminution in the intraocular pressure, and partly from the escape of the turbid aqueous humour. This improvement rapidly increases during the first fortnight, which is generally due to the absorption of the retinal ecchymoses which occurred during the operation. The improvement of sight reaches its maximum extent about two months after the operation. If the latter has been performed sufficiently early,

vision is generally perfectly restored, the patient being able to read the very finest print (with, of course, the proper glasses, if he is presbyopic), and this improvement is, in the vast majority of cases, permanent. Such a result may even be expected up to within a fortnight after the outbreak if, at the time of the operation, there was still good perception of light and no considerable contraction of the field.

In the later stages of acute glaucoma the results of the operation vary. In such cases the prognosis will depend upon the extent to which degenerative alterations in the tissues have already taken place. The prognosis may be favourable if the visual field is only moderately contracted, more particularly if it is not slit-shaped, but the contraction concentric, the fixation central, and vision not very greatly impaired, especially if the impairment depends upon cloudiness of the refractive media and increased intraocular pressure. The operation will generally not only restore an excellent and useful amount of vision, but this improvement will mostly be permanent. It is different, however, if the field is greatly contracted, especially if it be slit-shaped, if the fixation is eccentric, vision much impaired, and the latter due, not to opacity of the refractive media, but to an already considerable excavation of the optic nerve and deterioration of the retina. Here the prognosis must be guarded, for, although the operation may do much even in such cases, the good results may sometimes not be permanent, but the sight be gradually lost again, either through recurrence of inflammatory attacks, or through progressive excavation and atrophy of the optic nerve.

We have already stated that iridectomy sometimes proves of but little avail in the hæmorrhagic form of glaucoma, on account of the extensive intraocular bleeding which ensues upon the operation. It may afford temporary relief, but relapses are but too frequent; and although these may be alleviated by repeating the operation, yet the eye cannot generally be finally rescued, although in

some cases a certain amount of sight may be perhaps preserved.

In chronic inflammatory glaucoma the prognosis must also be guarded. The progress of the disease is but too often so insidious that the patients do not apply for medical aid until very considerable changes have taken place in the tissues, more particularly the optic nerve and retina. Iridectomy will, however, generally arrest the disease, and preserve the existing amount of vision, or even improve it. This is particularly the case if the fixation is still central, the sight not too much impaired, the optic nerve not deeply excavated, and the field of vision not slit-shaped, but contracted laterally or concentrically. In such cases the progress of the disease and of the structural changes is generally stayed, and the existing amount of vision permanently preserved. The beneficial effects of the operation are, however, far more slowly developed than in acute glaucoma. Months elapse before the improvement has reached its maximum degree, or before we can be certain that the effect will be permanent. But even when the field is greatly contracted and the fixation very eccentric, we may yet occasionally be able permanently to preserve a certain amount of sight, enough perhaps to enable the patient to find his way about. And even this little must be looked upon as a great boon in comparison with total blindness. But in such cases the effect of the operation is sometimes only temporary, the eye increases again in tension, the vision slowly but steadily deteriorates, leading at last to complete loss of sight. This is far more frequently due to progressive atrophy of the optic nerve than to a recurrence of the glaucomatous symptoms. Should a recurrence of the glaucomatous inflammatory symptoms, with increased tension, take place, the operation may be repeated with benefit. This is particularly the case when the original iridectomy has not been sufficiently large, or the iris has not been removed quite up to its ciliary insertion.

Von Graefe has called attention to the fact that a

whitish discoloration of the optic nerve (which is generally a symptom of progressive atrophy) sometimes occurs in glaucoma, and even increases in intensity for some months after the operation (particularly in cases of some standing), without endangering the sight. The discoloration progresses up to a certain point and then remains stationary. It is only dangerous when this increasing whiteness is accompanied by a simultaneous deterioration of vision.

Even in those cases of glaucoma which are not accompanied by manifest inflammatory symptoms (amaurosis with glaucomatous excavation, glaucoma simplex), iridectomy proves of service. Here, as in chronic glaucoma, the misfortune often is that the patient does not apply until the disease has far progressed. If only one eye is affected, this may be nearly lost before the patient even discovers that anything is the matter with it, and then on examination we find that the disease has nearly, if not completely, run its course, that there are such serious changes in the structures that the operation can prove but of little if any avail. It is otherwise if the second eye becomes affected with the same form of disease; then they speedily seek medical aid, and will consent to a timely operation, even although their sight may still be good. In order to arrest the disease permanently, the operation must be performed early, before irreparable changes in the tissues have been produced. Graefe particularly urges that the operation should be performed in time, and should not be delayed until considerable impairment of vision or inflammatory symptoms manifest themselves. Here also the beneficial effects of the iridectomy show themselves slowly and gradually. If the atrophy of the optic nerve has not proceeded too far, a steady, though slow, improvement will take place. He has seen cases in which, during a period varying from half a year to three years, the field of vision and the sight had gradually but persistently deteriorated, and where, after iridectomy (during a period of observation extending from one to three years), either a

complete arrest, or even a considerable improvement, occurred. Such improvement also occurred in two cases in which, together with a perfectly typical excavation, all appreciable increase of tension was absent. He considers that the improvement is the more likely if the impairment of sight depends not only upon the condition of the optic nerve, but is also due to a still evident impediment in the conducting power of the retina.

In *glaucoma absolutum*, in which all sight, even the quantitative perception of light, is lost, iridectomy is never indicated except to diminish any inflammatory symptoms or severe pain. For these purposes it is to be performed, care being taken to impress upon the patient and his friends that the object of the operation is to ameliorate his sufferings, and not to restore the sight. The iridectomy should always be of large size. In cases of glaucomatous degeneration it may also be necessary to employ it for the same purpose. Should it prove unable to arrest the inflammatory exacerbation, should it be followed by extensive hæmorrhages, or should these occur spontaneously, and all sight is lost, the question may arise whether it would not be better to remove the eye altogether, for there may be a fear of the other eye sympathizing.

I have endeavoured to point out as plainly and simply as possible the facts which should guide us in forming a prognosis of the beneficial effects to be expected from iridectomy. Nor have I made any statement the accuracy of which I have not myself frequently tested. This part of the subject demands the most earnest attention, as too slight a regard for the different facts which should influence our prognosis of the effect of iridectomy in glaucoma has been one of the chief reasons why this operation has proved unsuccessful in the hands of some practitioners.

How iridectomy diminishes the abnormally increased intraocular pressure in glaucoma has not yet been decided. That it does in the vast majority of cases permanently relieve the tension, is an undoubted and incontrovertible fact. Various theories have been advanced in order to

explain the *modus operandi*. Amongst other hypotheses some have thought that the tension was diminished by the excision of a considerable portion of the secreting (iris) surface; others, that the removal of the iris quite up to its ciliary insertion, and the consequent exposure of the zonula Zinnii, facilitate the interchange of fluid between the vitreous and aqueous humours, and thus diminish the difference in the degree of tension between these humours. We must admit, however, that this problem has not at present been satisfactorily solved. Now some opponents of the operation apparently reject it, because the solution of the *modus operandi* has not yet been found. They would rather deprive their hapless patients of the benefits of iridectomy, which would, in all probability, either restore or preserve vision; they would rather permit them to lose their sight, than perform an operation the effect of which in diminishing tension, though fully proved, they cannot at present satisfactorily explain.

THE METHOD OF PERFORMING IRIDECTOMY.

Some writers have stated that the operation of iridectomy, as it is to be performed in glaucoma, is just the same as the old operation for artificial pupil. Nothing could be more erroneous. The principle of the two operations is perfectly different. In the old operation, an opening was made in the cornea, and a small portion of iris, in proportion to the desired size of the pupil, excised. In the modern operation of iridectomy for glaucoma, the chief point is to make the incision in the sclerotic, or at the sclero-corneal junction, and of a sufficient extent to permit the removal of a large segment of the iris (about one-fifth), quite up to its ciliary attachment. The more intense the symptoms, the more considerable the increase in the intraocular pressure, the larger should the iridectomy be. Many of the negative, or only partially successful, results which have followed the employment of iridectomy in glaucoma, are undoubtedly often due to some fault in

the performance of the operation. Either too small a portion of the iris was excised, or it was not removed quite up to its ciliary attachment. We sometimes find that if only a small portion is removed, and this not up to the ciliary insertion, the symptoms do not completely yield, and more or less increase of tension remains. If, in such a case, a second and larger iridectomy is made, and the iris removed quite up to its ciliary attachment, the beneficial effects at once become apparent, the tension diminishes, the inflammation subsides, and the vision improves.

Now as to the *direction* of the iridectomy. The outward operation (to the temporal side) is undoubtedly the easiest, as the straight knife will be used, and as the beginner will find it more easy to lay the handle well back and keep the blade quite horizontal, than if the latter be bent at a more or less acute angle. Though the direction inwards (towards the nasal side) is to be preferred to this, more particularly for optical reasons, I think that the upward is the best of all, as the upper lid covers the greater portion of the artificial pupil, and thus not only hides the slight deformity, but also cuts off much of the irregularly refracted light. But the latter operation is undoubtedly more difficult than that in either of the former directions. Moreover, if the assistant is not very reliable and experienced, he is too apt, in drawing down the eye in the second step of the operation (excision of the iris), to press upon the eyeball, instead of simply rolling it in its bed, and thus escape of vitreous may be produced. For my own part, I mostly employ the upward operation, not only for cosmetic but also for optical reasons, as the horizontal iridectomy often gives rise to considerable circles of dispersion on the retina. The beginner will, however, do well to operate first towards the temporal side, and then, when he has acquired dexterity, this may be exchanged for the inward or upward direction.


The following instruments are required for the operation ;—

1. A wire speculum to keep open the eyelids. Weiss's new stop-speculum will be found the best, as by means of an easily-adjustable screw, it permits the eyelids to be kept fixedly apart at any desired distance, so that they cannot press the branches together and thus narrow the aperture. If such a one is not at hand, the common wire speculum may be employed; but if the eyelids should press its branches together, an assistant must hold it forward a little, so as to prevent the narrowing of the aperture and pressure upon the globe; or it should be exchanged for a pair of Desmarres' broad silver lid-holders, one of which is to be placed under each eyelid. These keep the lids wide apart, without exerting the slightest pressure upon the eyeball, but they necessitate the aid of an extra assistant.

2. A pair of forceps for steadying the eyeball. They must catch accurately, and the tooth should not be too sharp and pointed, as if so they will easily tear through the conjunctiva. If the latter is thin and rotten (as is often the case in old decrepid persons), it will be well to employ a pair of Waldau's fixation forceps, which, instead of being toothed, are finely serrated, so that they obtain a firm hold of the conjunctiva without tearing through it.

3. A broad lance-shaped knife. It should be about the same width as that represented in Fig. 2.* If it be much broader, the internal wound will be considerably smaller than the external, and in order to enlarge it to the same size as the latter, the edge of the knife will have to be considerably tilted in withdrawing the instrument from the anterior chamber. But this proceeding is often somewhat difficult, and may prove dangerous in the hands of an inexperienced operator. The shape of the knife must vary with the direction of the iridectomy. If it is to be made at the temporal side, the straight knife (Fig. 2) is to be used. When the

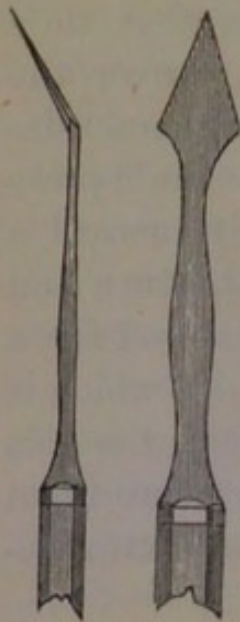
Fig. 2.



* These instruments are copied from Weiss's Illustrated Catalogue.

upward operation is performed, the blade must be bent at a more or less acute angle (Fig. 3; in this figure a narrower blade, curved at a medium angle, is shown), according to the prominence of the upper edge of the orbit.

Fig. 3.



The blade must be bent at a still more acute angle if the iridectomy is to be made at the nasal side. If the anterior chamber is almost wanting, so that the iris is nearly in contact with the cornea, it may be preferable to use a common extraction knife instead of the lance-shaped one.

4. *The iris forceps* should catch most accurately, and, when closed, should be perfectly smooth at the extremity, for if they are rough they will tear and scratch

the iris and the lips of the incision, and thus perhaps set up some irritation. They may be straight (Fig. 4) when the operation is made outwards, although I, even here, prefer to have them slightly bent (Fig. 5). For the upward, or the nasal operation, they must be bent at a more acute angle.

5. *A pair of iris scissors.* Maunoir's (Fig. 6; I generally use a pair of this shape, but somewhat smaller) are the most useful. They are bent at an angle; though sharp, they are not too finely pointed. Care should be taken that the blades close tightly and do not override each other, which may easily occur in such slight scissors if the joint be not sufficiently strong and firm. Instead of these, a pair of scissors curved on the flat (as shown in Fig. 8) may also be employed.

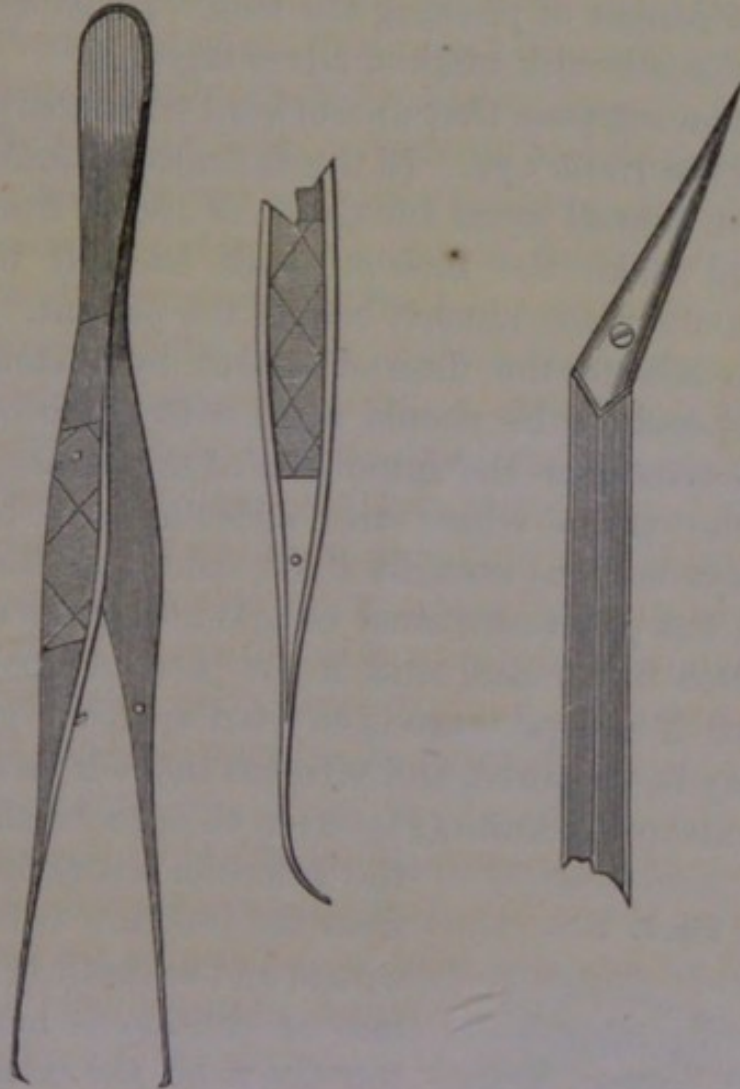
The patient is to be placed in the recumbent position, either in bed or on a couch, the head being slightly elevated. Chloroform should be administered. I prefer to use it in all cases of glaucoma, as the operation is often very painful, particularly if the eye is acutely inflamed; and however courageous and determined the patient may be, he may find it impossible to control some sudden, in-

voluntary movement of the eye or head, which may endanger the result of the operation, or even imperil the safety of the eye. But if chloroform is employed, it should

Fig. 4.

Fig. 5.

Fig. 6.



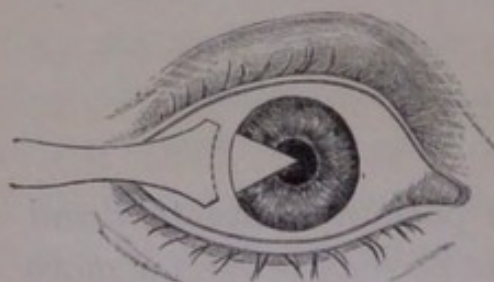be given so as to anæsthetise the patient completely and render him quite passive, otherwise he may prove far more unruly than if none had been administered; and the operation is of so delicate a nature that absolute quietude of the eye is necessary. If the patient should become sick, the further steps of the operation must be delayed until this has passed away.

As the pupil is generally much dilated in glaucoma, and the anterior chamber very shallow, it will be at once evident that there must be a considerable risk of wounding

the capsule of the lens and producing traumatic cataract, if the operator is not extremely careful. For this reason a little of the extract of the Calabar bean should be applied to the eye about half an hour before the operation, as it will produce great contraction of the pupil, and thus prevent the danger of pricking the lens. I have employed it in several cases with marked advantage.

Let us now suppose that an outward iridectomy is to be made upon the right eye. If the operator is ambidexter, he may seat himself upon the couch or bed in front of the patient, and make the incision with his left hand. If not, he should place himself behind the patient. Having opened the lids to the desired extent by means of the wire stop-speculum, he should seize with a pair of forceps the conjunctiva near the inner side of the cornea, exactly opposite the place where the incision is to be made. Thus the eye is to be steadily fixed, and its rolling about prevented, but great care must be taken that the eyeball is simply rolled in its bed, and is not pressed upon by the forceps; for if any pressure is exerted upon the globe, the hyaloid may be ruptured, and vitreous humour escape. The straight iridectomy knife (Fig. 2) is then to be thrust into

Fig. 7.



the sclerotic about half a line from the junction between the cornea and sclerotic (Fig. 7; the line of incision is here a little too far from the cornea), and, the handle of the instrument being well laid back towards the temple, the point is to be passed into the anterior chamber at its

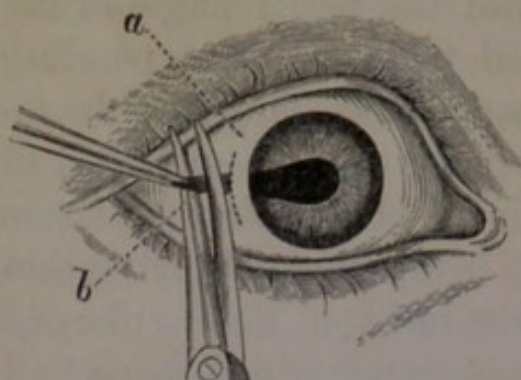
very rim, and carried on slowly and steadily towards the opposite side until the incision is of the desired extent. The knife is then to be slowly and gently withdrawn, the aqueous humour being allowed to flow off as slowly as possible, so that the relief of the intraocular pressure may not be sudden; otherwise this will cause a rapid overfilling of the internal blood-vessels, and a rupture of some

of the capillaries of the choroid and retina, producing sometimes very extensive hæmorrhages. When the knife has been nearly withdrawn from the chamber, the handle is to be somewhat depressed, so that the upper edge of the blade is slightly elevated, and the upper angle of the internal incision may be enlarged to a size corresponding to the external incision. The same proceeding may be repeated downwards. Or the incision may be enlarged to the required extent with a pair of blunt-pointed scissors curved on the flat, the one point being inserted just within the anterior chamber, and the incision then enlarged upwards and downwards. The beginner will perhaps find it easier to do this by means of the scissors than by tilting the edge of the knife. The object of keeping the handle of the knife well laid back towards the temple during all the time that the instrument is in the anterior chamber, is to tilt the point of the blade forwards towards the cornea, so as to prevent its pricking the lens, of which there is the more chance as the anterior chamber is often exceedingly shallow, and the iris almost in contact with the cornea. Should the chamber be extremely small, it may be well to use a narrow extraction-knife in place of the lance-shaped one. The point of the former is to be run along the edge of the chamber to the required extent, and then the counter-puncture made, just as in the operation of extraction of cataract, the incision being of course smaller and more peripheral. In this way we completely avoid the pupil and lens. The only objection to this mode of operating is, that we cannot regulate the escape of the aqueous humour so well, it does not flow off so gently, but is apt to gush forth; and this, as we know, is particularly dangerous in glaucoma.

On the withdrawal of the knife, the iris may either remain in the anterior chamber or protrude through the lips of the wound (prolapse). In the former case, the operator passes the straight or slightly curved iris forceps (closed) into the anterior chamber; then, opening them somewhat widely, he seizes a fold of the iris, and drawing it out

through the incision to the requisite extent, he cuts it off with the scissors quite close to the lips of the wound

Fig. 8.



(Fig. 8). The latter may be done by the operator himself or by an assistant. In the former case the iris forceps should be held in the left hand and the scissors in the right, as it requires some practice to use the scissors with the left hand.

If the iris has prolapsed, there will be no occasion to introduce the forceps into the anterior chamber, but the protruding portion is to be seized, and, if necessary, drawn forth somewhat more and divided. Should the eye be unsteady, it must be fixed by an assistant.

Mr. Bowman has introduced a valuable modification in this step of the operation. He describes it thus: * "The iris is then brought outside the chamber and divided with small scissors, on one side of the forceps, from the pupillary to the ciliary border, the forceps pulling it gently at the same time, so as to ensure this complete division of it. The end held by the forceps is then torn from the ciliary attachment as far as the angle of the incision, and even dragged upon a little, so as to detach it beyond the angle, and then divided with the scissors quite close to the angle. The cut end then retreats within the chamber. The opposite side of the prolapsed part is then seized and dealt with exactly in the same manner. No iris should be left in the angle of the incision, lest the healing process be imperfect, and subsequent irritation occur."

This proceeding is shown in Fig. 9. *a* the prolapse, divided into two portions at *b*. The lower portion is to be drawn, in the direction of *c*, to the lower angle of the

* British Medical Journal, 1862, vol. ii, 2, p. 382.

incision, and snipped off. The upper portion is then to be drawn in the direction of *d*, and also divided.

Instead of dividing it into two portions, the prolapse may be drawn to one angle of the incision, and partly divided close up to the angle; the other portion, being then gently torn from its ciliary insertion (slight snips with the scissors aiding in the division), and drawn to the opposite angle, is there to be completely cut off. This is illustrated in Fig. 10.

a, the prolapse drawn down to the lower angle *a'* of the incision, where the inferior portion is to be divided, and the other drawn up, in the direction of *b*, to the upper angle of the incision.

The latter proceeding is perhaps to be preferred if there is much bleeding, for then it is not always easy to find the uncut portion, more particularly if it has slipped back between the lips of the wound. Either method will yield an excellent artificial pupil. The iris will be torn away quite up to its ciliary attachment, and the pupil will consequently reach quite to the periphery (Fig. 11).

If there is any hæmorrhage into the anterior chamber, it should be permitted to escape before coagulation. A small curette should be inserted between the lips of the wound, slight pressure being at the same time made upon the eyeball with the fixation forceps, so as to facilitate the escape of the blood. The scoop should never be inserted into the anterior chamber. If the blood does not flow off

Fig. 9.

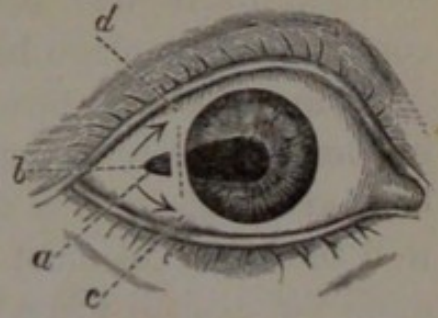


Fig. 10.

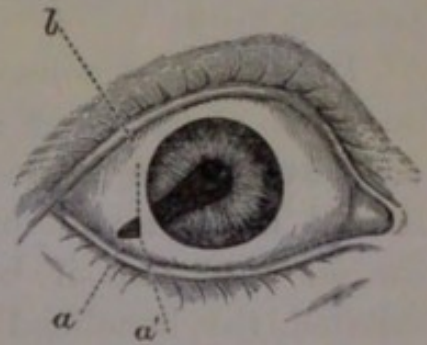
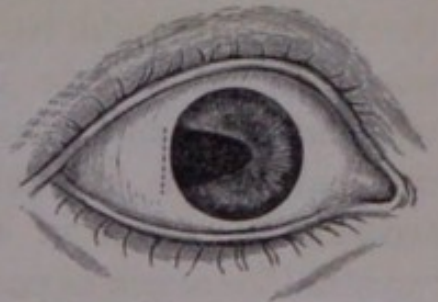


Fig. 11.



readily, it should not be forced out, but be permitted to remain, for it will soon be absorbed, particularly if a compressive-bandage be applied.

The iridectomy upwards or inwards is to be performed in the same manner, but the knife and iris forceps must be bent at a more or less acute angle. In the upward operation the assistant must be extremely careful not to press upon the eyeball when he rolls it downwards in order to enable the operator to snip off the iris. The globe should merely be rolled in its bed, without being dragged or pressed upon.

It is of great consequence that the iridectomy should be made of sufficient size (embracing about one-fifth or one-sixth of the whole circle of the iris), and that the iris should be removed quite up to the ciliary attachment; for we find that if both of these requirements are not fulfilled, the beneficial effects of the iridectomy are either greatly diminished or not permanent. In such cases it is, therefore, necessary to repeat the operation, so as to make the iridectomy of the required size, and at the same time to excise the iris quite up to the margin. If the second operation be not delayed too long it will generally afford the best results. In order that the iris may be removed quite up to its ciliary attachment, the incision should be made, as above directed, in the sclerotic; for if it be made in the cornea a more or less wide marginal rim of iris will be left standing. But, as we shall point out below, the wound in the sclerotic occasionally heals in an imperfect manner, so that a "cystoid" cicatrix is produced, which may prove troublesome and irritating. In order to obviate this, and yet to gain a complete excision of the iris, Arlt advises that the incision should not be made in the sclerotic, but at the very edge of the cornea. In doing so, the blade must be passed perpendicularly through the cornea, so as not to penetrate the latter in a slanting direction, otherwise the internal incision would be too far from the edge of the cornea. But as soon as the point has gained the anterior

chamber, the handle must be laid well back towards the temple, so that the blade lies quite horizontal to the plane of the iris. The inexperienced operator, however, will find this proceeding often somewhat difficult; nor is it free from danger if the anterior chamber is extremely shallow, or the patient very restless.

The after-treatment of iridectomy is mostly very simple. The intense pain of acute glaucoma generally disappears directly after the operation, and only a slight feeling of uneasiness in and around the eye may remain for a day or two. If the eye becomes painful again soon after the operation, a few leeches should be at once applied to the temple, and free after-bleeding encouraged; they will generally speedily relieve the pain. Their application should on no account be delayed, for we find that a few leeches applied within a few hours after the operation, prove of far greater service than a more considerable number at a later period. Some belladonna ointment should also be rubbed over the forehead. If the patient complains that the eye aches and itches a little, the eyelids should be bathed with warm water, in order to remove any crusts that may have formed upon the lashes; and the lids are then to be slightly opened to permit the exit of any accumulation of tears which had probably given rise to the feeling of itching. A little cold cream or olive oil may be applied to the edges of the lids, so as to prevent their becoming glued together. An opiate is to be administered if the patient is restless and unable to sleep. Generally, however, he sinks into a calm and refreshing slumber soon after the operation.

A strip or two of plaster is to be applied to the lids to keep them in apposition, or a moist piece of lint may be placed over the eye, so as to keep it cool and comfortable. The eye may be examined two or three days after the operation, care being taken that the light is not too strong.

If there was hæmorrhage into the anterior chamber, or loss of vitreous, it will be better to apply a compressive

bandage, which greatly hastens the absorption of the blood. It must, however, be very carefully adjusted, otherwise it will do more harm than good. The principle of this form of bandage is to produce a slight amount of pressure at the outer and inner canthus, and thus to stretch the eyelid across the eyeball. If this principle be not attended to, but the pressure applied to one point of the eyeball, it will soon give rise to pain and discomfort, and will require removal. The compressive bandage should be about $1\frac{1}{3}$ yard in length and $1\frac{1}{2}$ inch in width, its central third consisting of knitted cotton, its two ends of fine elastic flannel. It is to be applied in the following manner:—A small oval piece of fine linen is to be laid over the eyelid in order to prevent any of the threads of the charpie* from getting in between the lids, and also to soak up some of the discharge which would clog and harden the charpie. A succession of small oval pledgets of charpie should then be placed over the ligamentum palpebrale, so as to fill out the hollow at this situation, the padding being thence extended to the furrow, beneath the superior edge of the orbit, and, finally, to the outer canthus. When all these hollows have been well packed, and the padding is on a level with the centre of the eyeball, a few pledgets of charpie are to be placed in this situation, and the palm of the hand applied to the compress to ascertain whether it is perfectly level, or whether a little more has been applied in one place than in another; if so, this must be corrected. The end of the bandage being placed just in front of the ear of the affected side, the roller is to be carried across the forehead and above the ear of the opposite side to the back of the head, then brought beneath the ear and up across the compress to the forehead, where a second turn is to be made round the back of the head,

* Charpie consists of the threads of very fine Irish linen. The latter is to be cut into small square pieces of from 3 to 4 inches in diameter, and the individual threads are then to be pulled out, these forming the charpie, which should be folded up into small pledgets. It will be found much more cool and comfortable than cotton wool.

and the end of the bandage pinned firmly down. In this way the roller may be firmly applied without exerting too much pressure upon the eye. Should it prove too tight it must be at once somewhat relaxed. It should be removed twice or thrice within the twenty-four hours, and the eye bathed so as to remove any discharge and permit the escape of tears.

The patient should be kept in bed for a day or two after the operation, and should be for some days guarded against exposure to the air or strong light. If all things are going on favourably and the weather is fine, he may be perhaps permitted to go into the open air a week or ten days afterwards, and should gradually accustom his eyes more and more to the light. He should not be allowed to use his eyes until all symptoms of irritability have subsided. In those cases of fully developed glaucoma, in which iridectomy has only been able to preserve a certain amount of sight, considerable benefit is occasionally obtained by the application of artificial leeches (Heurteloup's) to the temples some months afterwards. They should be applied four or five times, at intervals of eight or ten days. Von Graefe has seen great improvement from them in some cases. I have also myself tried them with benefit, particularly in those cases in which the circulation of the inner tissues was somewhat impeded, and progressive changes in the optic nerve were threatening.

I must now point out certain disadvantages which may arise from the performance of iridectomy; but they are slight indeed when compared to the inestimable boon which the operation affords.

Under certain circumstances the operation upon the one eye may accelerate the outbreak of the disease in the other. The second eye may become affected by acute inflammatory glaucoma within a few weeks after the operation. Now such a rapid succession is quite exceptional in the common course of inflammatory glaucoma, for the second eye is generally not attacked for several months, or even years, after the first outbreak of the disease upon the

other eye. This acceleration, however, only occurs when the operation is employed in the first stages of acute glaucoma; it does not obtain in the later periods of the affection. Generally in such cases the second eye has already shown some premonitory symptoms before the operation, but the attack may even occur in a hitherto perfectly sound eye. The patient must, therefore, always be warned beforehand that the disease may perhaps affect the second eye soon after the iridectomy. But this contingency must not, for a moment, be allowed to influence our minds, and thus perhaps induce us to postpone the operation, for we know how very dangerous all delay is in acute glaucoma. Besides, the disadvantage of the disease breaking out, within a few days or weeks, upon the second eye, is more than compensated for by the fact that the patient will generally still be under the operator's care, and that the operation can be performed at once, with the greater chance of an admirable result as it will be employed at the very outset.

It has been thought by some that iridectomy may cause a rapid development of cataract, but this does not appear to be the case. "When,* shortly after *iridectomy*, cataract is formed in a previously sound lens, the cause must be assigned to a solution of continuity of the capsule, and not to the *iridectomy*." This is generally due to a direct wounding of the capsule by the instruments, more particularly the point of the knife; and for this reason the blade must be kept very horizontal, and the pupil should be contracted by the Calabar bean. But Von Graefe thinks that a spontaneous rupture of the capsule might be also produced by the sudden discharge of the aqueous humour, which in glaucoma, on account of the great increase of the tension, may spirt out with much force. In order to prevent this, it is most necessary that the blade of the knife be well laid back as the instrument is slowly withdrawn from the

* Von Graefe's article on Glaucoma. Arch. viii, 2.; Roy. Lond. Ophth. Hospital Reports, iv, 50.

anterior chamber, so that the aqueous may flow off very gently indeed. If the operation is carefully and well performed, there is but a very slight chance indeed of the lens being wounded, and cataract being produced.

I have already stated that the incision in the sclerotic may heal somewhat imperfectly. Generally, hardly any scar is left, indeed, in some cases, no trace of the line of incision remains; but in others, the lips of the incision do not meet, but are separated by a kind of web of cicatricial fibres, which shows a tendency to become bulged. This structure is composed of coarse cicatricial fibres running across the line of incision in a diagonal direction, the intervening spaces being filled up by a delicate transparent tissue. The intraocular pressure causes this to yield and bulge out between the fibres, in the form of small vesicular or bead-like elevations. It often even gives way, and the aqueous humour then escapes under the conjunctiva, giving rise to a bulging of the latter on the sclerotic. This giving way of the cicatricial tissue may occur several times, even for some months after the operation; indeed, Von Graefe mentions cases in which it took place for two years afterwards. He has termed this peculiar form of healing "cystoid cicatrix." It occurs chiefly in those cases in which there has been considerable and marked increase of tension for some time before the operation, and also where glaucomatous excavation has supervened upon sclerotico-choroiditis posterior. It is not of very unfrequent occurrence, and may produce a considerable amount of discomfort and irritation, or even supuration. Von Graefe, indeed, has met with this cystoid cicatrix in a considerable and typical form in about $\frac{1}{15}$, and in a less degree in more than $\frac{1}{3}$ of the eyes operated on for glaucoma. If any tendency to this form of cicatrization shows itself, a compressive bandage should be at once applied, and continued for several days, or even longer, as it is the best prophylactic, and it should afterwards be periodically repeated, if necessary. Such eyes must also be guarded for a longer time after the operation

than others, against over-exertion, fatigue, and exposure to external injuries. If the bulge is considerable it should be removed, being first partially divided with an extraction-knife, which will cause the escape of the fluid and collapse of the membrane, which should then be snipped off with the scissors, a compress being afterwards applied. Mr. Bowman recommends that the pellucid vesicular cicatrix should be pricked with a broad needle, and that this is to be repeated at more or less frequent intervals if there is any appearance of an obstinate return of tension. He has found that the cystoid scar occurs chiefly in those cases in which the tension remains somewhat in excess after the iridectomy, this increase even existing with a large, thin, vesicular cystoid cicatrix; whereas Von Graefe thinks that in the latter case it is generally less than normal. Should suppuration have supervened, lukewarm fomentations are to be applied, which are afterwards to be alternated with the compressive bandage. Atropine drops are to be applied to the eye, and in a case of purulent iritis the patient should be rapidly brought under the influence of mercury.

The question naturally arises whether the scleral incision should not be abandoned, in order to escape the disadvantages arising from this form of cicatrization. I have already stated that, for this reason, Arlt makes the incision at the sclero-corneal junction; but this requires considerable skill on the part of the operator, more particularly if the iridectomy is made upwards or inwards. If the incision is made in the cornea, a marginal rim of the iris will be left standing, which will invalidate the result of the operation. For these reasons, I prefer the scleral incision, especially as careful after-treatment will greatly diminish, or even obviate, the tendency to cystoid cicatrization.

ERRATA.

Page 20, 4 lines from bottom, *for* mucus, *read* mucous.

Page 29, 12 lines from bottom, *for* or to a direct, *read* or upon a direct.

