

## **Case of supra-sternal luxation of the clavicle / by Robert W. Smith.**

### **Contributors**

Smith, Robert William, 1807-1873.  
Royal College of Surgeons of England

### **Publication/Creation**

Dublin : Printed for the author, by John Falconer, 1872.

### **Persistent URL**

<https://wellcomecollection.org/works/ccdxfxpxa>

### **Provider**

Royal College of Surgeons

### **License and attribution**

This material has been provided by This material has been provided by The Royal College of Surgeons of England. The original may be consulted at The Royal College of Surgeons of England. where the originals may be consulted. This work has been identified as being free of known restrictions under copyright law, including all related and neighbouring rights and is being made available under the Creative Commons, Public Domain Mark.

You can copy, modify, distribute and perform the work, even for commercial purposes, without asking permission.

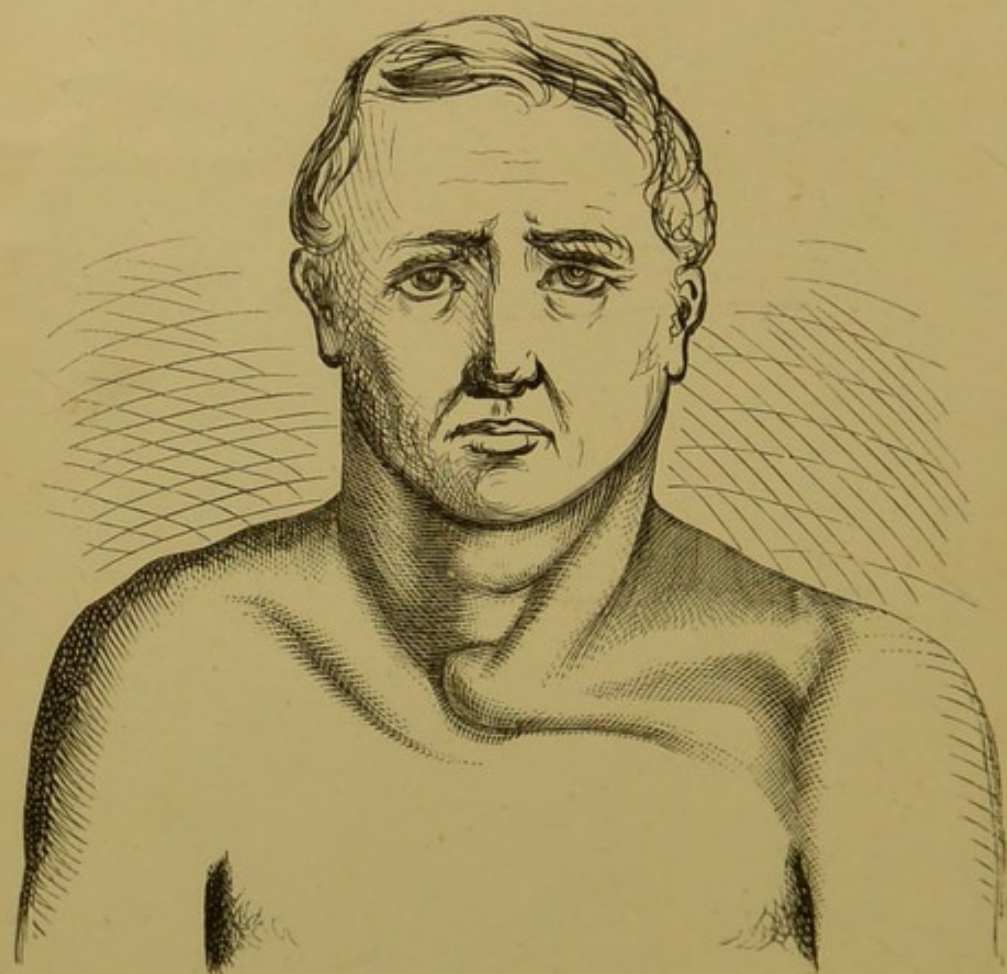


Wellcome Collection  
183 Euston Road  
London NW1 2BE UK  
T +44 (0)20 7611 8722  
E [library@wellcomecollection.org](mailto:library@wellcomecollection.org)  
<https://wellcomecollection.org>

3

5

11



CASE OF

---

SUPRA-STERNAL LUXATION

---

OF THE

---

CLAVICLE.

---

BY

ROBERT W. SMITH, M.D., M.R.I.A.,

PROFESSOR OF SURGERY IN THE UNIVERSITY OF DUBLIN ;

SURGEON TO THE RICHMOND HOSPITAL ;

ETC., ETC.

Reprinted from the Dublin Journal of Medical Science—December, 1872.

PRINTED FOR THE AUTHOR

BY JOHN FALCONER, 53, UPPER SACKVILLE-STREET, DUBLIN.

1872.



1810

STERNAL EXAMINATION

CLAUDE

THE HISTORY OF THE

THE HISTORY OF THE

CASE OF  
SUPRA-STERNAL LUXATION  
OF THE  
CLAVICLE.

---

I DEEM the following case of supra-sternal luxation of the clavicle worthy of a place in the annals of surgical science, inasmuch as it is the first of its kind in which observation during life has been combined with examination after death, and both sources of knowledge brought to bear upon the elucidation of an injury of confessedly very rare occurrence.

William Baker, 60 years of age, was admitted into the Richmond Hospital, under my care, at half-past five o'clock on the morning of Sunday, the 7th of April, 1872. He was returning from races that had been held at Fairy House, some sixteen miles from Dublin, in charge of a float, laden with luggage of various kinds, and was sitting on the shaft of his float. When within a few miles of the city, he fell asleep, overcome by fatigue, and shortly afterwards dropped from his seat to the ground. The wheel did not pass over him, as he fell inside of it, but the horse, still going on, dragged the float over him obliquely, there not being room for his body between the ground and the bottom of the vehicle. After some time he was found lying on the road by the police, and was brought to the hospital without delay. I saw him between nine and ten o'clock, and found that he had sustained a compound luxation of the astragalus of the right foot, outwards. The resident student on duty had, without difficulty, replaced the bone before my arrival. There was an extensive gaping wound upon the outer side of the dorsum of the foot, through which the head of the astragalus had protruded.




In addition to this formidable injury, I found that the sternal end of the left clavicle was dislocated. The shoulder had fallen in towards the mesial line so far, that the end of the clavicle was pressing strongly on the trachea, causing a very great amount of dyspnœa. It formed a very striking projection in front of the trachea, giving to the sternal portion of the mastoid muscle an arched outline. It was a complete luxation, the articular extremity of the bone lying above the fourchette of the sternum, and apparently in contact with the inner margin of the sterno-mastoid muscle of the right side. From the acromion the axis of the bone was directed upwards, forwards, and inwards, so that between its sternal extremity and the first rib, a considerable hollow or interval existed, into which the point of the finger could be sunk.

When the man was placed in the sitting posture in bed, the deformity was increased, and the pressure of the displaced bone upon the trachea and œsophagus became manifested by distressing dyspnœa, hoarseness of the voice, and extreme dysphagia. The motions of the shoulder were, of course, impaired, and were productive of much pain.

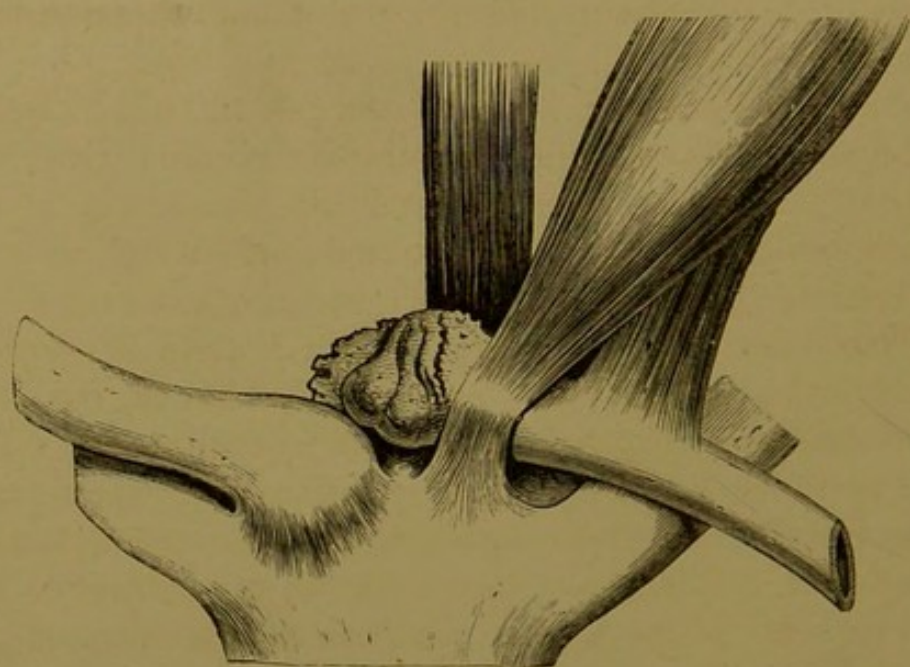
When he was placed in the recumbent position, the pillow taken from under his head, and the hollow of the back of the neck well filled by a folded sheet, so as to allow the head to hang a little, the dislocated extremity of the clavicle retired, and the symptoms of pressure on the air-tube and œsophagus ceased to present themselves; but, although the end of the bone no longer projected, it still remained placed above its natural level.

As long as this position was maintained, the patient did not suffer any distress; but whenever he sat up in bed, or even made the effort to do so, the original features of the injury were at once re-established and the dyspnœa and dysphagia renewed.

For some short time nothing worthy of note occurred, the man made no complaint and was cheerful, but after the lapse of about four days he became somewhat restless, his appetite was impaired, he suffered from thirst, and his sleep was broken. The tongue was furred, but the pulse remained undisturbed, indeed, it was rather slower than natural. The most unfavourable sign, however, connected with the case at this period was the condition of the wound, through which the astragalus had protruded. Its surface was of a greenish yellow hue, not painful when touched, quite dry, and its edges pale; with the exception of a few drops of matter under the skin at the lower extremity of the wound, there was no







sign of suppuration or vital action of any kind. It looked like a sore on the body of a corpse. The general symptoms already mentioned gradually increased, the pulse became more frequent, the tongue dry, brown, and crusted, the lips parched, and the countenance expressed great vital depression. Still the man made no complaint, and evinced an amount of apathy that was remarkable. He died on the eleventh day from the occurrence of the accident.

Shortly after his death a careful examination of the state of parts connected with the dislocation of the clavicle was made, and gave the following results, which were confirmatory not only of the diagnosis, but also to a great extent of the opinions respecting the anatomical relations of the bone, expressed by those who have recorded cases of this luxation, without having had an opportunity of verifying their opinions by *post-mortem* investigation.

When the integuments were removed, the end of the left clavicle was seen lying above the sternum, beyond the centre of which it had so far passed as to be in contact with the inner edge of the right sterno-mastoid muscle. The sternal portion of its own muscle, crossed in front of it at some distance external to its articular surface, was arched forward, and in a state of tension, while the clavicular portion was relaxed. Posteriorly, the bone rested on the sterno-hyoid muscles and front of the trachea. The anterior and posterior ligaments of the joint were, of course, ruptured, as was likewise the costo-clavicular or rhomboid ligament. The intra-articular cartilage was torn from its attachment to the sternum and cartilage of the first rib, and was carried upwards and inwards along with the clavicle. The only deviation from its normal state observable in the subclavian muscle was that it appeared relaxed and altered in direction.

CASE I.—Duverney, who was, I believe, the first to observe this luxation, mentions the case of a girl sixteen years of age, who died in consequence of a fall from a considerable height, and in whom the sternal end of the clavicle was displaced towards the larynx. “Se portait vers le larynx.” All the ligaments were torn. This statement is so very brief and vague that we are left in doubt as to the precise seat and direction of the displacement.

CASE II.—In the *Edinburgh Medical and Surgical Journal*, Vol XLVII., Mr. Macfarlane, Senior Surgeon to the Glasgow Royal Infirmary, has recorded a case of the injury under con-



sideration. A labourer, when in a state of intoxication, fell down stairs and alighted on his right shoulder, which was supposed to be dislocated. Two days after the occurrence of the accident he applied at the Infirmary for advice. He was able to use the hand and forearm but not the shoulder. At first sight the clavicle appeared to be fractured, but on more accurate examination an unusual swelling was observed immediately above, and in close contact with, the upper edge of the sternum, which, on tracing the clavicle, was found to depend on a dislocation of that bone into the supra-sternal space. There was a distinct tumour at the sterno-clavicular articulation, and the shoulder, upon the side of the injury, had fallen forwards, but the functions of respiration and deglutition were not affected, the end of the bone not being so far displaced, as to press on the trachea or œsophagus.

CASE III.—In his memoir upon luxations of the clavicle, Baraduc relates the following case:—Gabriel Paris, aged forty-three years, was admitted into the hospital, "Saint Antoine," on the 4th of October, 1839. In a wrestling-match he had been thrown backwards with violence, the summit of the left shoulder and the left side of the head striking the ground; but the former principally sustained the shock.

Upon examination, the internal extremity of the clavicle was found resting upon the upper border of the sternum. When the head was bent forward strongly upon the chest, and pressure made in the V-shaped space between the tendons of the sterno-mastoid muscles, the articular surface of the bone could be plainly felt. The tendon of the left sterno-mastoid was projected forward by the luxated extremity of the clavicle, across which it was carried. The sterno-hyoid muscle, it was presumed, lay directly behind the end of the bone.

Below the internal third of the clavicle there existed a very evident depression, into which the finger could be sunk; it was limited below by the first rib, gradually faded away externally, and ceased about two inches from the sternum. From the facility with which the finger could be sunk into this depression, it was considered as almost certain that the subclavian muscle was torn. This want of resistance, and the separation (amounting to nearly an inch) between the first rib and the lower surface of the clavicle, appeared to demonstrate that the costo-clavicular ligament was likewise ruptured.



CASE IV.—In the 14th volume of the *Buffalo Medical Journal*, Dr. Rochester has recorded the case of a man aged forty-four, who, in August, 1858, while seated upon a load of wood, was caught under the bar of a gateway and violently crushed, the right shoulder being forced downwards and a little backwards. Dr. Rochester saw him very soon after the accident, and found, on examination, that the sternal end of the right clavicle had been luxated upwards, so far as to rest upon the front of the thyroid cartilage, causing much pain, dyspnœa, and loss of speech.

CASE V.—In the 3rd volume of the *Dictionnaire des études médicales*, Sedillot has briefly described the symptoms which were present in a case of *incomplete* luxation of the sternal extremity of the clavicle upwards. The right shoulder was slightly depressed, and the superior and external angle of the scapula was carried downwards, forwards, and two or three lines inwards, while its inferior angle, approximated to the spine, elevated the integuments.

Between the sternal and clavicular attachments of the sternomastoid muscle, there was discovered an osseous projection formed by the sternal extremity of the clavicle. The sternal portion of the muscle was stretched, the clavicular relaxed; the head was inclined towards the affected side.

CASE VI.—A man named Etienne Caréron, aged thirty-nine, was admitted into the hospital of La Charité, under the care of Velpeau, for an injury of the left clavicle, caused by his having been squeezed between a loaded cart and a post. He was endeavouring to back the wheel of the cart, when the horse, making a false movement, threw the shaft against his left shoulder in such a manner as to push it downwards and forwards, while, at the same time, the right shoulder, pressed against a post, aided the impulsion inwards.

On examination, the sternal extremity of the left clavicle was found to have been luxated upwards and driven inwards so far that its articular extremity corresponded to the right sterno-clavicular articulation, and was covered by the sternal portion of the sternomastoid muscle.

CASE VII.—Malgaigne states that an example of this rare luxation occurred in his own practice in the hospital of St. Louis, but he has given no particulars of the case.



It will be seen from the preceding *resumé*, that the archives of surgical science, previous to the publication of the present case, contained only seven examples of the injury under consideration. The case I have described constitutes the eighth, and is peculiarly valuable as being the first (as far as I am aware) in which the anatomical characters of the injury were accurately established by *post-mortem* examination, for the account given by Duverney is totally destitute of value, as a dissection of the injury.

It is a luxation of necessarily rare occurrence, for it not only requires for its production that the force applied should be very great, but that it should also act upon the shoulder in an unusual direction, viz., downwards, inwards, and probably backwards. The result of this threefold impulsion is that the clavicle, converted into a lever of the first order (the fulcrum of which is constituted by the first rib) is forced at its sternal extremity upwards and inwards.

[NOTE.—Upon the principle of “better late than never,” I wish to correct an error which appeared in my paper on “Fractures of the Sternal End of the Clavicle,” published in the number of the *Dublin Journal of Medical Science* for August, 1870. At line seven from the bottom, page 16, the words “sterno-clavicular” should be “acromio-clavicular.”—R. W. S.]