

**Case of deformity of the mouth, after sloughing of the cheek from fever :
operation and recovery / by Thomas Bryant.**

Contributors

Bryant, Thomas, 1828-1914.
Royal College of Surgeons of England

Publication/Creation

[London] : [publisher not identified], [1862]

Persistent URL

<https://wellcomecollection.org/works/c7j764q8>

Provider

Royal College of Surgeons

License and attribution

This material has been provided by This material has been provided by The Royal College of Surgeons of England. The original may be consulted at The Royal College of Surgeons of England. where the originals may be consulted. This work has been identified as being free of known restrictions under copyright law, including all related and neighbouring rights and is being made available under the Creative Commons, Public Domain Mark.


You can copy, modify, distribute and perform the work, even for commercial purposes, without asking permission.



Wellcome Collection
183 Euston Road
London NW1 2BE UK
T +44 (0)20 7611 8722
E library@wellcomecollection.org
<https://wellcomecollection.org>

J. & W. Phipps
1862

7.



CASE
OF
DEFORMITY OF THE MOUTH,
AFTER SLOUGHING OF THE CHEEK FROM FEVER.
OPERATION AND RECOVERY.

BY THOMAS BRYANT.

THE following case is recorded in these pages on account of the complete success which attended the operative measures adopted for its relief, terminating, as it will be observed, in the perfect restoration of the mouth to its normal position. My thanks are due to my friend Mr. Birkett for the treatment of the case, as he kindly passed it into my hands for operation.

Kate B—, æt. 4, was admitted into Guy's Hospital in the autumn of 1859, with an extreme deformity of the mouth, and necrosis of the right upper maxillary bone, when the following history of the case was obtained:

Five months prior to her admission she had been attacked with typhus fever, which was followed on the fifth week by intense swelling of the face and lips, and subsequent suppuration; for this she was admitted into the parish workhouse, where she remained for two months; but as her face was still swollen two months subsequently, and her health was bad, she was brought to Guy's. When admitted, an examination readily revealed the fact that the upper jaw was perfectly necrotic;

the bone was lying loosely in the soft tissues, and was at once removed, a pair of dressing forceps readily raising it from its natural position. The parts subsequently granulated and healed, but the mouth and cheek gradually sank and contracted, leaving the deformity as well represented in No. 1 Drawing.

In July, 1861, she was passed into my hands for operation, when the following measures were carried out for her relief:

The first preliminary point which seemed essential, was to loosen freely the whole cheek from its attachment to the dense fibrous material, thrown out as a substitute for the superior maxillary bone which had been removed; this was effectually done by the introduction of a bistoury into the mouth, sweeping from its posterior boundary forwards, and the division of all the tissues attaching the soft parts to the new products, and the right nostril. By this incision the whole cheek was readily raised from its position, and perfect mobility of the soft parts was allowed.

The second and more essential step of the operation remained to be performed, having as its object the reformation of the mouth. Being anxious to preserve the small piece of lower lip which already existed, I made an incision through the thickness of the right cheek from the junction of the mucous membrane of the lip, downwards and outwards, for about one and a half inch; I then brought the cheek well forward, making the upper border of the incised surface an upper lip, and bringing down the piece of lip which already existed for a lower; I next dissected from the mucous membrane lining the interior of the cheek a flap of membrane, which I turned outwards, and fastened by fine sutures to the angle of the new mouth, by this means insuring a good covering for its angle, and preventing all risks of its subsequent contraction.

Several other sutures were then introduced, and good union followed; Drawing 2, illustrating the results of these operative measures. To complete the cure, a simple operation as for hare-lip alone remained to be performed; this was executed in November last with complete success, and the child left the hospital quite well, hardly a trace of the original deformity remaining, as will be seen in Drawing 3.

PLATE I

Illustration of the ...

...

Plate I. ...

Plate II. ...

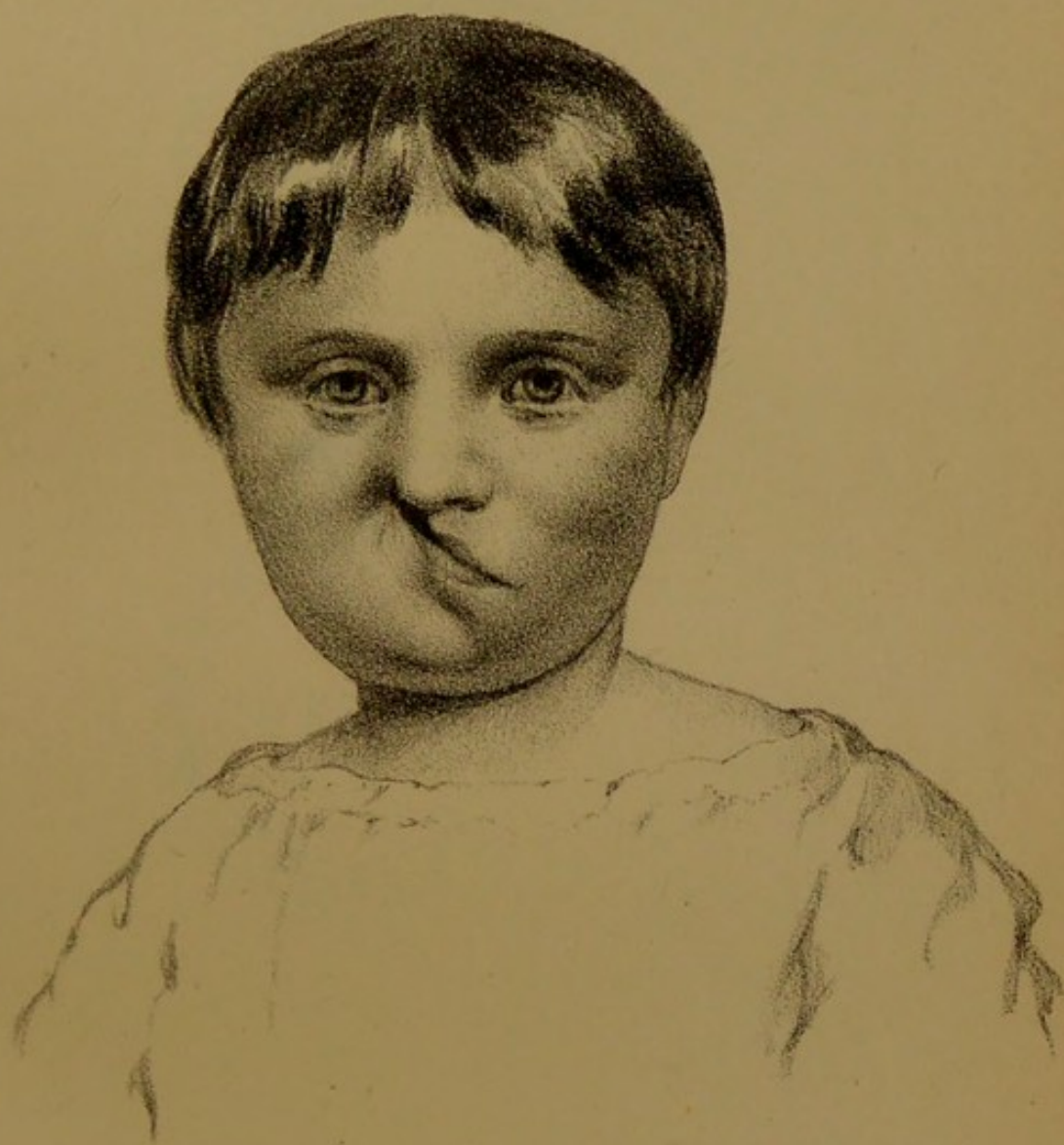Plate III. ...

THREE PLATES

Illustrating Mr. Bryant's Case of Operation for Deformed Mouth.

- Plate 1. Exhibits the child's face before the operation.
Plate 2. „ „ after the first operation.
Plate 3. „ „ after the second operation.

Fig. 1.



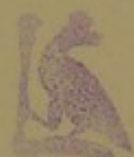


Fig. 2.

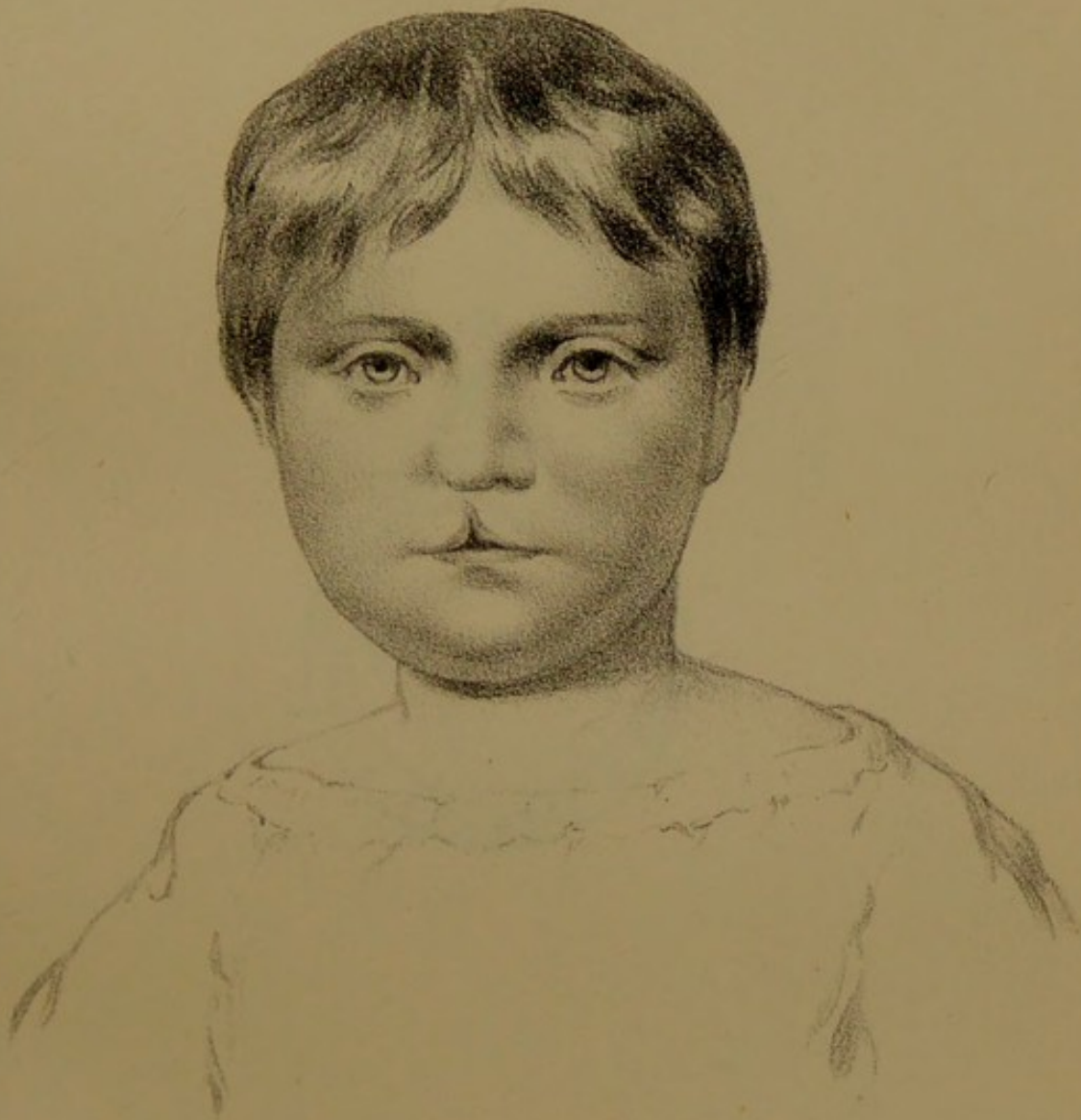



Fig. 3.

