

**Enormous oval hemorrhoid encircling the anus : Whitehead's operation, entire cure : read before the Section on Surgery of the College of Physicians of Philadelphia, March 8, 1894 / by W.W. Keen.**

**Contributors**

Keen, William W. 1837-1932.  
Royal College of Surgeons of England

**Publication/Creation**

Detroit, Mich. : George S. Davis, 1894.

**Persistent URL**

<https://wellcomecollection.org/works/w3frzbz7>

**Provider**

Royal College of Surgeons

**License and attribution**

This material has been provided by This material has been provided by The Royal College of Surgeons of England. The original may be consulted at The Royal College of Surgeons of England. where the originals may be consulted. This work has been identified as being free of known restrictions under copyright law, including all related and neighbouring rights and is being made available under the Creative Commons, Public Domain Mark.

You can copy, modify, distribute and perform the work, even for commercial purposes, without asking permission.



Wellcome Collection  
183 Euston Road  
London NW1 2BE UK  
T +44 (0)20 7611 8722  
E [library@wellcomecollection.org](mailto:library@wellcomecollection.org)  
<https://wellcomecollection.org>

(6)

---

# ENORMOUS OVAL HEMORRHOID ENCIRCLING THE ANUS; WHITEHEAD'S OPERATION; ENTIRE CURE.

*Read before the Section on Surgery of the College of Physicians of  
Philadelphia, March 8, 1894.*

BY

W. W. KEEN, M.D.,

Professor of the Principles of Surgery and of Clinical Surgery in the  
Jefferson Medical College.


REPRINTED FROM THE THERAPEUTIC GAZETTE, APRIL 10, 1894.

DETROIT, MICH. :

GEORGE S. DAVIS, PUBLISHER.

1894.








Enormous Oval Hemorrhoid encircling  
the Anus; Whitehead's Operation;  
Entire Cure.

---



REV. DR. E., aged sixty, was brought to me at the Jefferson Hospital by Dr. J. T. Rugh, December 4, 1893. There is marked tuberculosis and insanity in the family; he had enteric fever in youth and several attacks of dysentery; has always been markedly constipated. He has had trouble with hemorrhoids and prolapse of the rectum for about thirty years. For the last twenty years it has been a serious disability, and for the last two years it has practically prevented his doing any work in his profession, or, in fact, work of any kind whatever. He has scarcely begun his service in the pulpit before protrusion of the mucous membrane and the hemorrhoids takes place, and his discomfort is so great that he is unable to preach. Seven years ago he consulted the late Dr. Agnew, who advised him, in view of the severity of his condition, not to have any operation done. He has lost large amounts of blood of late, and never has a stool without the protrusion.

*Status Præsens.*—A well-nourished, large, heavy man. On examining the anus, it resembles more than anything else a large,



swollen vulva after delivery (Fig. 1). It measures four inches long by three inches wide, the outer margin being one enormous, oval hemorrhoid about an inch and a quarter in diameter and surrounding the anal aperture as though it were a great oval piece of rope. The aperture of the oval is filled with the prolapsed and ulcerated mucous membrane.

*Operation, December 9, 1893.*—I began the operation posteriorly by an incision, which finally encircled the entire anus, at about the middle of this marginal hemorrhoid. In doing so it was very curious to notice how the fibrous tissues, being put on the stretch, were divided, but the softer, dilated hemorrhoidal veins yielded before the sharp knife without being cut; the moment that there was an aperture, the dilated veins would form herniæ of large size between the fibres.

I first went directly towards the anal aperture until I recognized the sphincter muscle; then by a blunt dissection of the tissues I reached the mucous membrane on the inner border of the sphincter. Following this, two fingers were inserted into the calibre of the rectum, and the pile-bearing area seized between the thumb and palm. The moment I recognized the mucous membrane at one point, from that as a point of departure I proceeded with the blunt dissection, all the way around, with but little trouble. Only three ligatures were required, and the amount of blood lost was moderate,—nothing whatever of a severe character. The operation, which had looked most formidable before it was begun, was quickly performed with comparative facility. The whole pile-bearing area was cut away, step by step, and


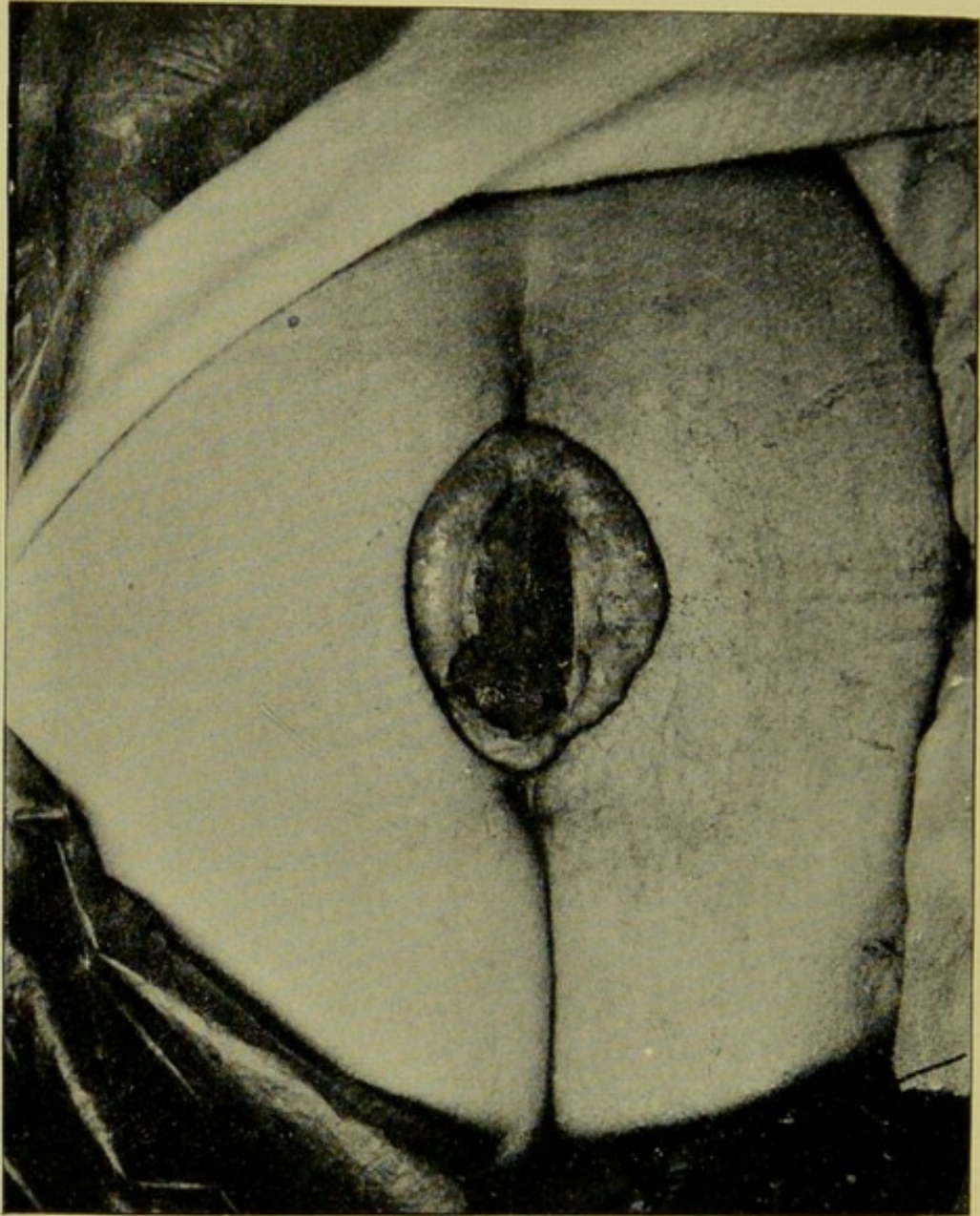


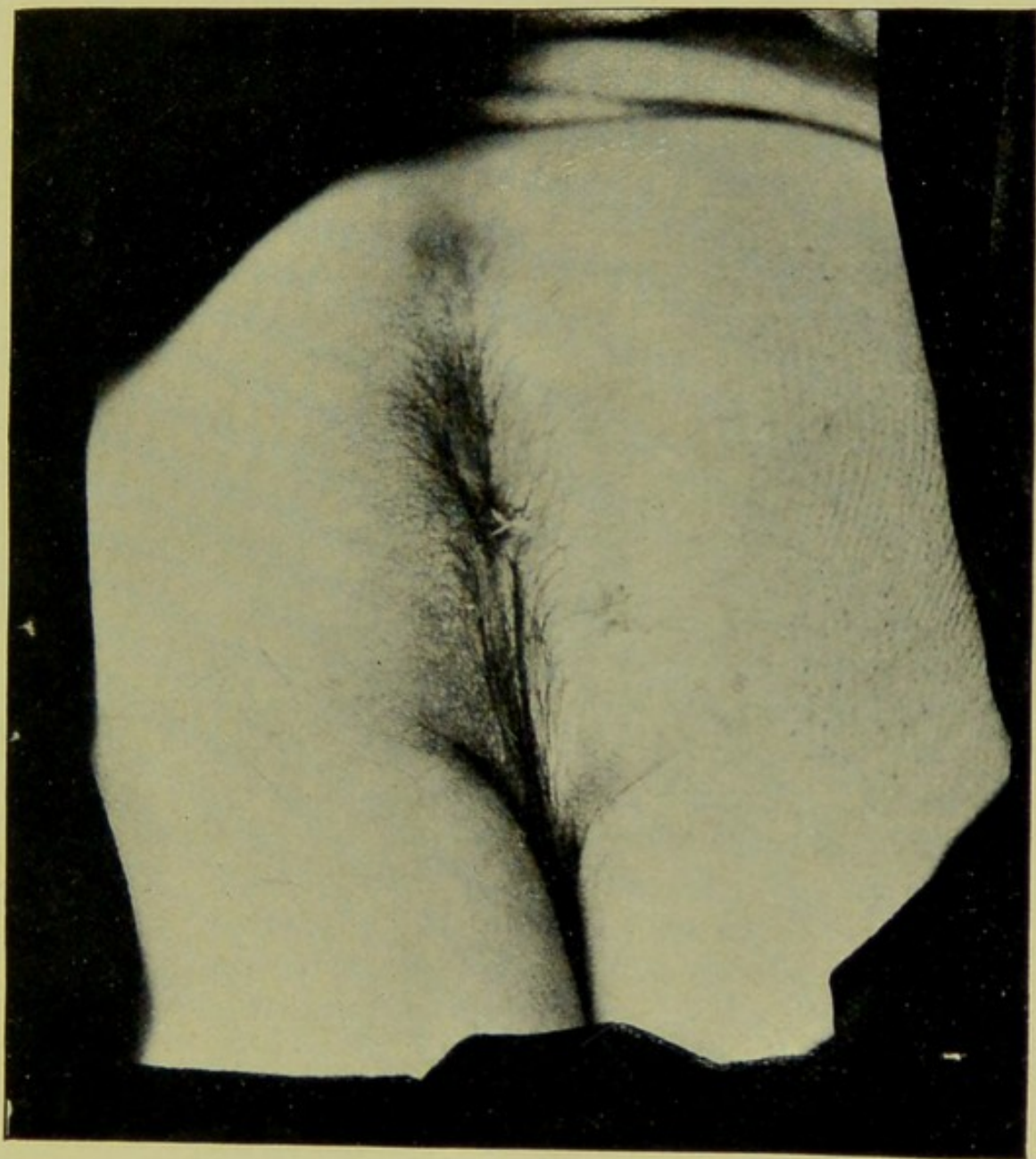


FIG. I.



Showing the oval hemorrhoid and the prolapsed mucous membrane in its centre.

FIG. 2.



Showing the result two months after operation.





the mucous membrane stitched to the skin *pari passu* with the cutting. When the operation was finished the anus was little more than its normal size.

After the operation the patient reacted well, without nausea. The wound was dressed with careful antiseptic precautions. His highest temperature was  $101^{\circ}$  F., which was only reached once, on the third day, and again on the eighth day, in consequence of constipation. With these exceptions, the temperature ran from  $98.5^{\circ}$  to  $100^{\circ}$  F. He was perfectly comfortable almost from the moment when the operation was completed. On the third day his bowels were opened by an enema of sweet oil and citrate of magnesia by the mouth. He had but little control of the sphincter muscle. On the eighth day the stitches, which had begun to cut out, were removed. Union by first intention took place, excepting at two small points, where the mucous membrane and skin gaped a little. He was out of bed in two weeks, and went home in three weeks, perfectly comfortable. The gaping points were not quite healed. He was directed for a year to keep the bowels in a soluble condition by means of enemata and laxatives, and whenever possible to have his bowels evacuated in a bedpan in the recumbent position. His control over the sphincter had returned almost entirely by the time that he left the hospital.

*Remarks.*—The case is quite exceptional, in my experience. I have never before seen such an enormous pile encircling the anus,—four inches long and three wide. I confess that when I first saw him I was not a little in doubt as to what ought to be done. The re-



sult has shown that the Whitehead operation was not only the best thing to do, but I think the only thing.

Since he left the hospital I have heard from him repeatedly and always with the most favorable report. Since the middle of January he has preached every Sunday, sometimes three sermons in a day, has done pastoral work, travelling as much as twenty miles, and at home splits kindling-wood, carries coal, shovels snow, and can walk several miles without any fatigue. The result leaves nothing to be desired.