

On disease of the supra-renal capsules, or morbus Addisonii / by Samuel Wilks.

Contributors

Wilks, Samuel, Sir, 1824-1911.
Royal College of Surgeons of England

Publication/Creation

London : Printed by J.E. Adlard, 1892.

Persistent URL

<https://wellcomecollection.org/works/d6epa8qy>

Provider

Royal College of Surgeons

License and attribution

This material has been provided by This material has been provided by The Royal College of Surgeons of England. The original may be consulted at The Royal College of Surgeons of England. where the originals may be consulted. This work has been identified as being free of known restrictions under copyright law, including all related and neighbouring rights and is being made available under the Creative Commons, Public Domain Mark.

You can copy, modify, distribute and perform the work, even for commercial purposes, without asking permission.



Wellcome Collection
183 Euston Road
London NW1 2BE UK
T +44 (0)20 7611 8722
E library@wellcomecollection.org
<https://wellcomecollection.org>

With the Authors Compts

ON

15

DISEASE

OF THE

SUPRA-RENAL CAPSULES,

OR

MORBUS ADDISONII.

BY

SAMUEL WILKS, M.D.


FROM 'GUY'S HOSPITAL REPORTS.'


LONDON :

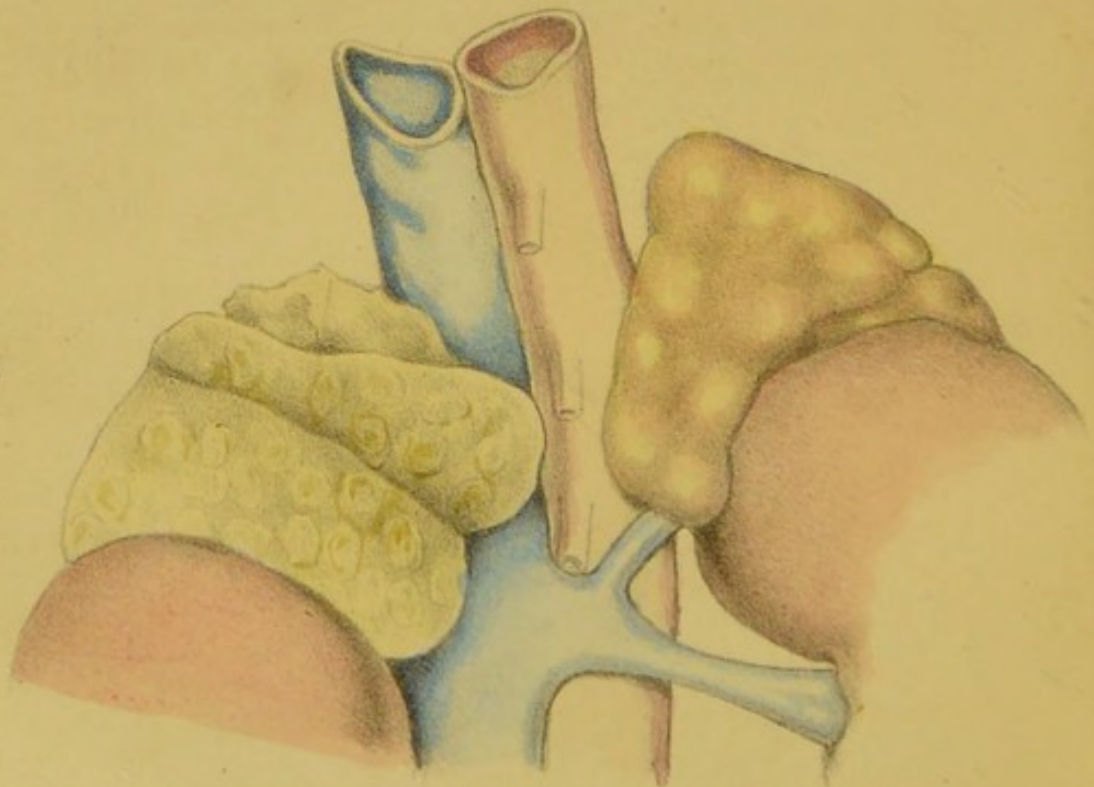
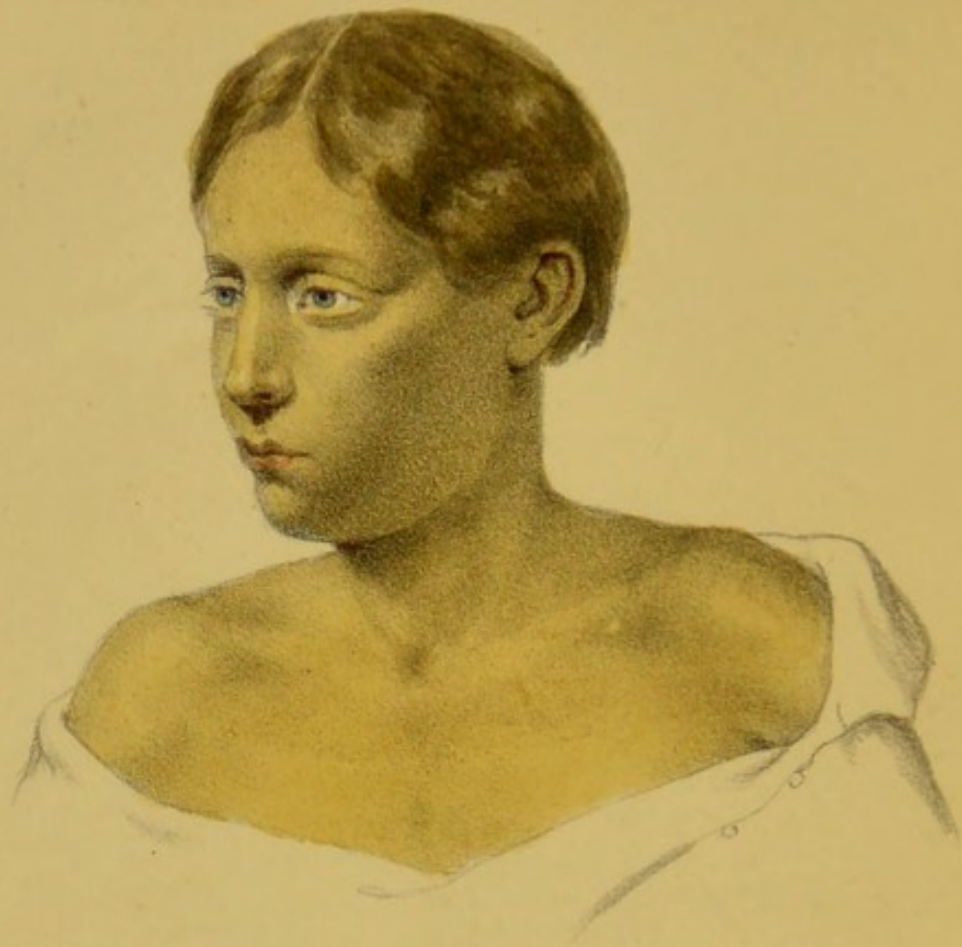PRINTED BY

J. E. ADLARD, BARTHOLOMEW CLOSE.

1862.







ON
DISEASE
OF THE
SUPRA-RENAL CAPSULES;
OR,
MORBUS ADDISONII.

BY SAMUEL WILKS, M.D.

SEVERAL years having now elapsed since the publication of Addison's treatise on 'Diseases of the Supra-renal Capsules,' a fitting opportunity would seem to have arrived to undertake an examination of the additional facts which have in the mean time been collected, in order to discover whether they tend to strengthen or to weaken his conclusions. I may say at once, that my own observations entirely uphold his argument; and the cases, therefore, which I shall bring forward, will be found to substantiate (I consider), beyond disputation, his original facts.

It may be said, I think, with truth, that Addison's views have by no means received the support of the profession at large; but this scepticism, as far as I can judge from the circumstances which have induced it, can carry no important weight against their ultimate reception; for, when it is remembered that all true and valuable discoveries require a long time to strike root, and that a hasty and general acceptance of a novelty is to be regarded in the light of a bad omen

as to its truthfulness, this hesitation only shows that long observation and study are necessary to place this, like all other new doctrines, on a sure and stable foundation.

My principal purpose, therefore, in bringing the subject before the profession is not only to strengthen the original facts by fresh instances, but to point out how Addison had somewhat overstepped his own boundaries, by including, amongst his cases, some which did not present the true features of the disease ; and thus I hope, by purging his treatise of these examples, to place this remarkable affection on a much surer basis than it has hitherto had. The disease, in fact, will have more unique and special characters of its own, and may be regarded with more justice in the light of a true discovery than Addison himself conceived, and even more worthy to be honoured with his name than would a disease having the undefined nature which he himself assigned to it. I may at once admit that this want of definition and precision as to its true pathological character has constituted the great hindrance to the progress of the discovery ; the belief of Addison being, at the time of the publication of his work, that any disease which affected the integrity of the supra-renal capsule would be attended by the remarkable phenomena which he described ; and consequently his cases include a variety of morbid conditions of these organs which are clearly not true forms of the disease. Dr. Addison was, I believe, beginning to see the truth of what is now evident, that some of the cases which he had published have only stood in the way of the full development of his discovery ; for all subsequent observations have shown that, so far from his early conclusions being correct, we have no recorded instance of the affection being connected with cancer, or indeed, with any other kind of disease of the organ than the one which was found in the genuine cases which he first described, and which all subsequent experience has shown to constitute the true form of the malady.

Unfortunately, too, Addison had placed in his work the drawing of a patient in whom no necropsy was made to reveal the true nature of the disease, and that illustration has, in all probability, misled many, by giving a false representation of the usual character of the discoloration of the skin.

If these doubtful cases be eliminated from Addison's list, there remain *five* which constitute a sufficient basis for his conclusions; I might say also that these were his early ones, and those on which his own opinions were formed; it is therefore to be lamented that in the ardour of a fresh discovery, he was led to include cases of which he had no opportunity of proving their genuineness. Fortunately for myself, I was well acquainted with all the cases which Dr. Addison describes, and have also had the opportunity of examining every subsequent example of it which has occurred in Guy's Hospital, as well as of seeing and discussing with the late lamented physician many of his private cases; and I know, had he been spared to bring before the profession another edition of his work, he would have cropped his pages of those doubtful instances which have done much to retard the spread of the discovery. I may say also, that Dr. Addison was in the habit of submitting to me all the specimens which he was constantly receiving from various parts of the country, taken from patients who were supposed to have suffered from the affection bearing his name. I have thus had a very good opportunity of corroborating or falsifying his original opinions; and I may, in consequence, state (as the convictions of a writer are of some weight with the reader as well as the bare facts which he may enumerate), that having no doubts of the facts whilst Addison was preparing his work, I certainly have none now, after having witnessed or had knowledge of tenfold the number of instances which he himself first brought before the notice of the profession.

By clearing the ground of some of the extraneous matters which Addison introduced into his work, the subject will stand much as the author himself would have understood it at his death; and we shall, by this means, also be in a much safer path for the further elucidation of the disease, since there can be no doubt that much of the scepticism which exists is due to the unfortunate errors which at first crept in. As regards the prevailing disbelief, it may be further said, that it arises not only from those natural reasons which spring from a want of familiarity with the disease, but from mistaken notions of Addison's real statements, by those who have not had an opportunity of perusing the original work. On the

other hand, it may be said that the disease is of so striking a character, and accompanied by so remarkable symptoms, that when any practitioner has met with a single case, he has been so struck with its peculiarities that he has become at once a convert; since with the light of a post-mortem examination the case could bear no other explanation than the one attempted.

My first idea in commencing this paper was to collect all the cases which had been recorded, and thus by a formidable array of facts produce an overwhelming credit in favour of the discovery. On my attempt, however, to do so, I found cases not sufficiently well reported, or the necroscopic inspections too vague to enable me to make use of them with justice to the subject; and on a second intention, to select other and better authenticated cases, I found I should be adopting a system which might be open to the imputation of unfairness. I have, therefore, been reduced to the plan of putting before my readers the few cases which have been brought under my own notice, or, having been well made out during life, or diagnosed as good examples of the disease, the organs have been sent to me for examination. The advantage of confining myself to these is, that all the specimens are preserved, and are now before me, and can be examined (by reference to the numbers), by any visitor to Guy's Hospital museum. They form a perfect series in themselves, amounting to twenty-five in number, and present an array of facts which cannot, I think, be withstood. I must state that many of these cases have already been published, and are found scattered through the medical journals.

In order to place before my readers the subject as it at present stands, with the latest light I can throw upon it, I cannot, as I should have wished, simply detail the symptoms of the disease, and offer my conclusions upon it in the manner which is usually adopted in a treatise on an established form of disease, but I must necessarily be discursive; for in dissecting Addison's work, in order to discover where the truth lies, and where the error, a controversial or critical style cannot be avoided.

General features of the disease.—In the first place, the important features of the disease as enforced by Addison, are

these:—a remarkable progressive feebleness of the patient without any apparent known cause, or, as it is styled, *asthenia*; a discoloration of the skin; and a disease of the supra-renal capsules. The principal exceptions or modifications to be made in reference to these three great truths are, that discoloration may occasionally be absent, and that when present, it is characterised by a general change of hue over the whole body, and also that it is not unimportant as to the nature of the morbid material in the capsule, but that the change in the organs is of a peculiar character. If then, these propositions be so modified, it may be stated very positively that when these two former conditions—the *asthenia* and discoloration—have existed for any period, that the third, or disease of the capsules, may be very safely predicated.

The constitutional symptoms.—It was on these especially that Addison founded his diagnosis. The following may be regarded as an epitome of his work, which I need scarcely say consists of but a few pages:¹

“For a long period I have from time to time met with a very remarkable form of general anæmia, occurring without any discoverable cause whatever—cases in which there had been no previous loss of blood, no exhausting diarrhœa, no chlorosis, no purpura, no renal, splenic miasmata, glandular, strumous, or malignant disease. Accordingly, in speaking of this form of anæmia in clinical lecture, I, perhaps with little propriety, applied to it the term *idiopathic*, to distinguish it from cases in which there existed more or less evidence of some of the usual causes or concomitants of the anæmic state.”

“It was whilst seeking in vain to throw some additional light upon this form of anæmia, that I stumbled upon the curious facts which it is my more immediate object now to make known to the profession.”

“The leading and characteristic features of the morbid state to which I would direct attention are, anæmia, general langour and debility, remarkable feebleness of the heart’s action, irritability of the stomach, and a peculiar change of colour in the skin occurring in connexion with a diseased condition of the supra-renal capsules.”

“The patient becomes languid, weak, indisposed to either

¹ About seven pages.

bodily or mental exertion, the appetite is impaired, or entirely lost, the whites of the eyes become pearly, the pulse small and feeble, or perhaps, somewhat large, but excessively soft and compressible; the body wastes, without, however, presenting the dry and shrivelled skin and extreme emaciation usually attendant on protracted malignant disease; slight pain or uneasiness is from time to time referred to the region of the stomach, and there is occasionally actually vomiting, which in one instance was both urgent and distressing, and it is by no means uncommon for the patient to manifest indications of disturbed cerebral circulation. Notwithstanding these unequivocal signs of feeble circulation, anæmia, and general prostration, neither the most diligent inquiry, nor the most careful physical examination tends to throw the slightest gleam of light upon the precise nature of the patient's malady, nor do we succeed in fixing upon any special lesion as the cause of this gradual and extraordinary constitutional change."

"With more or less of these symptoms we discover a most remarkable, and as far as I know, characteristic, discoloration taking place in the skin; sufficiently marked, indeed, as generally to have attracted the attention of the patient himself, or the patient's friends. The discoloration pervades the whole surface of the body, but is commonly most strongly manifested on the face, neck, superior extremities, penis and scrotum, and in the flexures of the axillæ and around the navel. It may be said to present a dingy or smoky appearance, or various shades of deep amber or chestnut brown, and in one instance the skin was so universally and so deeply darkened that, but for the features, the patient might have been mistaken for a mulatto. In some cases this discoloration occurs in patches, or perhaps, rather, certain parts are so much darker than others as to impart to the surface a mottled or somewhat chequered appearance."

"If these statements be correct—and I quite believe them to be so—the chief difficulty which remains to be surmounted by further experience in this, I fear, irremediable disease, is a correct and certain diagnosis—how we may at the earliest possible period detect the existence of this form of anæmia, and how it is to be distinguished from other forms of anæmic disorder. As I have already observed, the great distinctive

mark of this form of anæmia is the singular dingy or dark discoloration of the skin; nevertheless, at a very early period of the disorder, and when the capsules are less extensively diseased, the discoloration may doubtless be so slight and equivocal, as to render the source of anæmic condition uncertain. Our doubt, in such cases will have reference chiefly to the sallow, anæmic condition, resulting from miasmatic poisoning, or malignant visceral disease; but a searching inquiry into the history of the case, and a careful examination of the several parts or organs usually involved in anæmic disease, will furnish a considerable amount of at least negative evidence; and when we fail to discover any of the other well-known sources of that condition, when the attendant symptoms resemble those enumerated, or accompanying disease of the capsules, and when to all this is superadded a dark, dingy, or smoky looking discoloration of the integument, we shall be justified in entertaining a strong suspicion in some instances, almost amounting to certainty in others. It must, however, be observed, that every type of yellow or mere sallowness throws a still greater doubt over the true nature of the case, and that the more decidedly the discoloration partakes of the character described, the stronger ought to be our impression as to the capsular origin of the disorder."

Analysis of symptoms.—We will now analyse some of the symptoms above referred to, as well as others which have been subsequently observed.

Asthenia.—I cannot too much impress upon the reader the above characteristic description, given by the discoverer, in order that he may not be misled by some of the mistaken views of the subject which have now and then appeared in print; as, for example, that Addison had alluded to an ordinary debility, with emaciation, when he described the constitutional symptoms of the disease. Emaciation, it must be remembered, is not a necessary accompaniment of asthenia; and thus suprarenal affection is not to be sought for in those who, without any apparent reason, are wasting away. Some writers, however, have used the term emaciation as if it had been almost synonymous with want of power, even when wasting did not really exist; for we find cases spoken of where emaciation was present, and yet after death the body is described as covered

with fat. It must, therefore, be particularly remembered, that emaciation is not one of the symptoms of supra-renal disease ; for although the body certainly wastes to a certain degree, it is not to that extent witnessed in phthisis or malignant affections ; and this makes the case so much the more remarkable, that feebleness should exist without any apparent disease to account for it. Although this symptom is a prominent one in all cases, yet it varies in degree ; in some it is most remarkable and striking, whilst in some other exceptional cases death has occurred rather suddenly, when the patient, if he were a male, had only lately desisted from his work.

The cause of this remarkable prostration was constantly discussed by Dr. Addison, and, in ignorance, like all others, of the exact function of the supra-renal capsules, he could not but conjecture that the intimate connection of these bodies with the organic system of nerves had a large share in the production of the symptoms. He in consequence repeatedly requested me to examine the semi-lunar ganglia, but, with the exception of varying amounts of colouring matter in the ganglionic cells, nothing conclusive was arrived at. It is clear, however, that some very large nerves running from the ganglia are lost or destroyed in the morbid material into which these bodies are changed, although it may be fairly doubted whether these organs themselves are so richly supplied with nerves as is supposed. That they are in close contiguity with one of the centres of the nervous system, and thus surrounded by offsets from it, may be due to the accident of position, and not that they themselves are physiologically intimately connected with these important nerves. Although, therefore, anatomists may show, by further dissection, that the supra-renal capsules are not highly nervous organs, as described, yet the fact may be no argument against the theory of the symptoms being due to the implication of the nerves, since in a morbid enlargement of these organs such implication could scarcely be avoided.

The supposition that the implication of the nerves in this disease might produce the result spoken of, is sanctioned by analogous instances of excessive depression where these nerves are involved. In cases, for example, of disease of the pylorus, Glisson's capsule, &c., where there is not much vomiting, and where the appetite is still tolerably good, the depression may

sometimes become daily more and more intense until death takes place, without our being able to assert the exact reason. Cases also must have been observed where aneurism of the cœliac axis, and other tumours in this region, have been attended with extreme depression, and sometimes with sudden death of the patient, and yet no post-mortem examination has been able to account for the fact. Allusion also might be made to the instances where the periphery of the nerves are more generally affected, as in peritonitis, and to the remarkable depression which exists in this disease, so that whilst the patient converses, and excites no fear in the bystanders, yet his pulse is no longer to be felt, and he is on the very threshold of the grave. All these facts rightly suggested to Dr. Addison's mind that the implication of nerves so contiguous to the semilunar ganglia and solar plexus might be connected with the remarkable depression noticed in the disease of the supra-renal capsules. He never ventured upon any other surmise, and considered the question still open for further elucidation, or, to use his own words,¹ "We know that these organs were situated in the direct vicinity, and in contact with, the solar plexus and the semilunar ganglia, and received from them a large supply of nerves; and who could tell what influence the contact of these diseased organs might have on these great nervous centres, and what share that secondary effect might have on the general health, and in the production of the symptoms presented."

Whether, then, the supra-renal capsules are physiologically associated with the ganglionic nervous system, or whether from their own large supply of nerves (as is said), or whether it be only by their enlargement, and thus by accident involving those nerves, there would seem, from all analogy, a probability that it is through this important nervous centre that the remarkable symptoms occur. An explanation would be afforded by such a theory of the character of the symptoms; for example, after a long depression of system, the patient may die suddenly, or, what has happened in one or two cases, the patient has been able to take exercise, or even to work, within a short period of his death—results more attributable to a failure of nervous force acting on the heart, than by any disease

¹ At a discussion of the Med. and Chir. Society.

of an organ whose integrity is necessary to life. In the latter cases, the symptoms are commensurate with the gradual decay of the organ ; whereas in the nervous system a certain amount of destruction may be produced by disease, and accompanied by only a moderate share of bad symptoms, when at last a cessation of function shall suddenly occur, and all is over. So also we sometimes see, in cases of aneurism of the abdominal aorta, and of tumours about the neighbourhood of the ganglionic system, a certain amount of pain and depression, and the death at last sudden, although the pressure producing these has been uniformly constant ; the cause of death here being the same as in those recorded cases where life has instantly fled in consequence of blows on the pit of the stomach, and also as in those instances of sudden death in children, occurring soon after a heavy meal. Thus it will be seen that our cases fully bear out the statement of the vivisecting physiologists, that the capsules are not essential to life ; for we see that in many instances their perfect destruction must have occurred for a period of months or years before death actually took place.

Mode of death.—This has already been referred to in the last paragraph. In most cases the feebleness which has been the marked symptom for months or years has increased to that extent that during the last few weeks of life the prostration has necessitated the patient keeping his bed, and preventing him sometimes assuming even the upright posture. Death has thus occurred gradually, the heart becoming utterly powerless, as if its natural stimulus was gone. In some cases the patient has for a time become so much better under treatment as to be enabled to resume his work, and then it might have been surmised that the disease was cured. This was so in Case 12, which was one of the best marked examples in the series, and a case which showed the characteristic symptoms towards its close as well as any which I have ever witnessed. Such instances have been published and quoted in opposition to Addison's views ; but in some there could be no doubt as to the correctness of the diagnosis, had the cases been followed to their completion, for it will be seen that in some cases death was almost sudden where the prostration had not been more excessive than in many others.

All these facts would point to the very remarkable nature

of the complaint, and that the symptoms cannot be due simply to a destruction of the organs, since this must have happened in many instances long before death occurred, and is one reason, as before said, to suggest some implication of the organic system of nerves.

Special nervous symptoms.—In the monograph it is stated that symptoms may be observed in the course of the disease, which denote disturbed cerebral circulation. It might be more strictly said that the nervous centres are impaired, and that various symptoms result therefrom. Whether this impairment be due simply to feebleness, as witnessed in many exhausting diseases, or arises from special causes, remains to be seen. It will be observed that in a case related by Addison, delirium and convulsions occurred, and the same also in No. 18. Numbness of the fingers was mentioned in Nos. 3 and 16. In the latter, the boy was also said to have had neuralgic pains in his limbs, and was finally delirious.

Pain in the back.—This symptom was not mentioned by Addison, but having been present in several cases it is worthy of notice. In the three instances where the spine was diseased, sufficient cause may be found therein for this symptom, but in other cases the pain was due, no doubt, to the implication of the nerves which are in connection with the capsules. It will be observed that the pain was of that kind which is usually styled gastric, being situated in the epigastrium and passing through to a spot between the shoulders—the same kind of pain which exists when other forms of malady affect this region, as in disease about the lesser curvature of the stomach. In some cases, where the vomiting was excessive, this sensation was exactly of this same character, but aggravated, of course, by the perverted action of the stomach. The fact of the occurrence of pain in some of our cases and not in others is due purely to accident or to the amount of implication of sensitive nerves, just as in the case of cancer about this part, where in one instance pain may be altogether absent, and in another agonising.

Discoloration or pigmentation of the skin.—This is certainly one of the most remarkable changes which is known to occur in the course of any disease, and is that especially by which Addison's disease has been at first suspected to exist by those

who have only casually heard of his researches. It is no wonder, therefore, that so prominent and marked a condition should have led to many mistakes, and that a brown skin should have been supposed to have necessarily denoted a disease of the capsules. Such an imperfect view of the nature of the disease has led to numberless errors, and caused much doubt to be thrown upon the correctness of the original views. Having already alluded to this subject,¹ I shall repeat mainly what I said on that occasion.

The discoloration of the skin, although a striking feature of the complaint, was not the main one insisted on by Addison, but since it is that which can be portrayed in a drawing, and, consequently apt to strike the eye on turning over the pages of his monograph, it is not surprising that it was at once regarded as the most remarkable part of the complaint, and would, therefore, be especially dwelt upon in our ordinary mode of communicating to one another the facts relating to the disease, until at last the erroneous opinion would be reached that Addison's disease and discoloration of the skin were convertible terms. Now, it is stated by the author himself that he was led to the discovery by a very different method than by studying the changes in the skin—that it was owing to a peculiar interest which he took in a class of cases styled simple and fatal anæmia that this allied affection came under notice, and that it was whilst watching such cases the fact of the discoloration was also observed, and, subsequently, on post-mortem examination, its connexion with disease of the supra-renal capsules. The extreme prostration of all muscular power was the most remarkable circumstance attending these cases ; and, indeed, in some forms of supra-renal affection no discoloration has occurred at all. This was the case in the instance of a man whose case is described as No. 8, in whom there was no discoloration of the skin, the only symptom being the most utter prostration of strength, and yet after death these organs were found completely diseased. The most prominent symptoms, then, of the affection are due to this asthenic condition, denoted by the loss of muscular power, weakness of pulse, breathlessness upon exertion, dimness of sight, weakness of stomach, &c. ; and if the case has been of

¹ 'Guy's Hospital Reports,' Series iii, vol. v, p. 93.

long duration, in addition to these, a discoloration of the skin. A sufficient number of cases have now been observed to suggest whether the change in the skin does not depend on the chronicity of the disease, and that if it should progress rapidly no discoloration would be observed, the symptoms being merely those of asthenia.

As regards the character of the colour when it occurs, the observation of several instances, since the publication of the original memoir, has shown that a great similarity has existed in all of them, both as regards the hue itself and its method of affecting the body by a uniform implication of the whole surface. It is true that a case is represented where the body is covered with patches of colour, checked with white; but here no post-mortem examination took place to verify the diagnosis, and thus the fact is left as we state, that in the first related cases, as well as in all subsequent ones, there has existed a uniform discoloration of the whole integument. So remarkable has this been, that the body has presented the appearance of a person with dark blood, rather than that of a European. Wherefore the answer which Dr. Addison was continually making to interrogatories respecting the peculiarities of the discoloration was, that he regarded only those cases as characteristic, where the surface of the body was seen to be gradually approaching in colour that of an inhabitant of some southern nation. The similarity is proved by examination of the integument itself, which, if placed beneath the microscope, is seen to contain a layer of pigment in the rete mucosum, just as in the dark races of mankind; so that no difference, as far as we are aware, can be discovered between them. Moreover, in the latter, certain parts, as the axillæ and pubes, are darker than the rest of them; so in this morbid discoloration these same parts are those most affected, the only difference being that the parts most exposed are those first and most affected, as the face and hands. Also those parts where a blister or an eruption may have excoriated the surface; and in one case (No. 21) it will be seen that there was a darker mark round the leg where the garter had been tied. The affect of the sun is most important to remember, as it may be a source of fallacy, by creating a suspicion as to the presence of supra-renal disease, just as it may divert attention from the true nature of the disease, when

the supra-renal affection is actually present. This occurred in two of our cases. It must also be noticed that those parts where most pigment naturally exists become darker than other parts of the skin.

Without denying that the colour may sometimes occur in patches, we think we are correct in saying that all experience has hitherto shown that the discoloration has been uniform over the whole surface of the body. The exact hue is difficult to describe, but it may be said to resemble that of a mulatto's skin, and therefore is of a brownish cast, having sometimes an olive-green tinge, and thus the term bronzing of the skin has come into use ; or it has often what our artist calls a walnut-juice shade. To say, however, in short, that the appearance produced is exactly that of a person of dark blood, is to speak as accurately as description will allow. The anatomical characters are probably not very peculiar, and resemble those of many other pigmental changes arising from various causes, since the true seat of the colouring matter is in the cells of the rete mucosum, as described in the following cases. This is also its position in the dark races. An examination of a portion of the skin, therefore, would not determine the nature of the case, although, if the colour should be universal, there would be a strong suspicion of the existence of supra-renal affection ; that is, I do not know of any other disease which changes a white man into the appearance of a black one. It is well to remember that the pigment is seated beneath the epidermis, and thus is to be distinguished from pityriasis and many other conditions with which Addison's disease has been confounded. It would seem scarcely needful to say that it is impossible to confound it with jaundice, had the mistake not often been made ; indeed, in nearly all instances of the affection which have come before me, an hepatic disease has been suspected ; but a moment's observation would be sufficient to show that no bile is circulating through the body—the urine contains none ; nor is the conjunctiva yellow, which is the first part affected in jaundice, but here, on the contrary, is remarkably pale and anæmic. It is true, however, that in jaundice the yellowness of the skin is due to a deposition of biliary pigment in the rete mucosum.

Pigmental deposit in the internal organs.—Of this we cannot

yet speak with any certainty, seeing that there are only two recorded cases in the present list where such internal discoloration has been found; and it will be seen that in one of them the case was of so doubtful a character, that it is the only one in the series which I have hesitated to insert. If this, therefore, had been the solitary example, we should have dismissed the subject for the present; but in another well-marked instance (No. 21) the serous membrane of the peritoneum was covered with so considerable an amount of pigment that it could not be overlooked. A single case, however, is not a sufficient basis on which to found a general statement of this kind, especially when our hesitation is caused, not by the rarity of such a condition, but because it is not unfrequently found under other circumstances, pigmentation occurring often as a result of a former peritonitis. In inflammation of the peritoneum, if any blood be effused, as is often the case, the hæmatine undergoes changes which result in the formation of a black pigment, which shall permanently stain the serous membrane. The question, therefore, is still open for further elucidation. The character of this internal pigmentation is well shown in one of the plates of Addison's monograph in connection with the doubtful case above mentioned.

Odour.—It was observed in one or two cases, recorded by Mr. Hutchinson, that the surface of the body exhaled a peculiar odour, such as is evolved in the dark races of mankind. This had not been previously noticed by Addison, nor remarked by others, but should it be substantiated by further observation, the fact would be very remarkable. It is noticed in Case 7.

Order of symptoms.—Dr. Addison was impressed with the belief that the constitutional symptoms existed long before the discoloration of the skin, and he was led to this conclusion by the fact of certain patients dying without discoloration, in whom the changes in the morbid material of the capsules had not reached that final degree which is sometimes met with. By this he referred to the cretaceous matter which is regarded by all as an evidence of a very chronic change in an adventitious product—that change which depends upon disintegration, subsequent to the complete deposition of morbid matter, and destruction of the organ. Previous to this the material is of a softer and uniform character, which may be likened in the

first place to a lardaceous, and subsequently to a scrofulous matter. In one or two striking cases, Dr. Addison's opinion was verified, but I cannot say that subsequent experience has proved it to be always correct, although the difficulty which exists in obtaining a true history of the time of the occurrence of the symptoms in a disease which progresses so insidiously must leave the subject in some obscurity. If in every case we had had a succinct history that the symptoms had preceded the discoloration, and then, if occasionally the patient had died before the occurrence of the latter, and disease in the capsules was found not to have advanced to its latest change, Addison's opinion would be satisfactorily confirmed; but if we analyse the cases before us we cannot discover that the history declares the existence of constitutional symptoms before the change in the skin, but that the latter was often the first alteration noticeable. Thus in Case 7, the account is, that the lady's friends remarked how dark she was becoming, she herself not knowing that she was ill. In Case 24, the patient's wife observed the same—this, however, is quite an exceptional occurrence. The history either being that the patient had been ailing for some time, and then the skin was observed to grow dark; or, seeking medical aid the doctor first observed it; or, as occurred in most cases, no period could be fixed between the occurrence of constitutional symptoms and the discoloration. The account usually being, that about a certain period the patient began to feel ill, and at the same time, a discoloration of the skin was observed.

When we consider, however, the remarkable nature of the disease, and that the organs strictly speaking are not vital, so that probably they may be diseased for a very lengthened period of time, not, perhaps, without danger to life, but without tending immediately to a fatal issue, it is possible that they may be undergoing a morbid change, or a complete destruction for an indefinite period, and yet the symptoms so few and obscure, that they may be never observed. On the supposition, I say, that the destruction of the organs is not that which leads to the symptoms, but rather the implication of a portion of the nervous system, it may very well happen that although a long time is required for the development of the skin pigment, that long before this occurs the organs may

have been destroyed. The only fact, as before said, which exists for such a view is, the case of death from supra-renal disease, where no discoloration has been present. As, however, it is impossible to assert the existence of disease before the occurrence of symptoms, we are not in a position to speak with certainty as to the time of the formation of the pigment, and whether necessarily occurring at the latest stage. We must wait until a further collection of cases enables us to obtain more minute histories, and then we may be in a position to compare the condition of the organs as found after death with the amount of discoloration of the skin.

Duration of symptoms.—It will be evident from the above remarks how difficult it is to determine the duration of the disease, for if the organs affected be not vital, they may be destroyed for a considerable period before any symptoms make the fact known, just as we see in the analogous example of ovarian disease, whose existence may not be manifested through the constitution for a great length of time, and yet we know from the fact of the enlargement that the disease may have existed for years before. A somewhat similar fact probably obtains here, and therefore in speaking of the duration of supra-renal disease, I cannot do more than refer to the commencement of the symptoms.

On looking at our cases we find that in one, the symptoms had existed for five years; in another, four; and in another, three. In both of the last named the discoloration had been complete during the term mentioned, and therefore, in all probability, the destruction of the organ was then perfected, and necessarily the disease of much longer date. In other cases the symptoms had existed for two years and one year respectively, and in one their duration was as short as six months. If we take the whole number of cases, and strike the average, we find the duration of symptoms is one year and a half. It is probable, however, from the observation of other instances, that this would be below the average, if a larger number of cases were taken, and that the future will show that the duration will be fixed for a much longer period.

Age.—The oldest patient in my list is fifty-eight years of age, and the youngest thirteen years. The majority of patients, it will be seen, are comparatively young, or are young adults.

By striking an average, we obtain thirty years as the age of the patient. From an observation, also, of other cases which have come before my notice, and from many recorded instances, I should certainly say that the disease is more prone to affect young persons.

Sex.—A much more extended experience than I have at my command would be necessary, in order to decide positively which sex was most prone to the disease. In the twenty-five cases, it will be seen that nineteen were in men, and six in women—a very disproportionate relation, and shows, as far as the facts warrant, the greater liability of the male sex to the disease than the female. A much larger number of cases, however, must be collected before this conclusion could be spoken of with absolute certainty.

Nature of the disease of the capsules.—I have already said that nothing is known of any other than one disease which produces the remarkable symptoms seen in morbus Addisonii, and that alone I shall describe. I have never known the supra-renal capsules primarily affected by cancer, melanosis, nor other deposits, excepting the one mentioned; nor do we yet recognise any degeneration of the tissue itself; these have yet to be studied. I speak, therefore, of that change only which is seen to exist in all the following cases, and which, in the earlier ones of Addison, was simply styled scrofulous. The latter term has been very loosely applied to all deposits of a yellow, amorphous, friable character; but whether deserving of the appellation or not, depends much upon the opinion held respecting the nature of tubercle; with some it being a matter of indifference whether the ill-formed cells of such deposit were styled tubercle or simply caco-plastic. Judging from the material itself, it would be difficult to form an opinion of its nature, seeing that a degenerating inflammatory substance would produce a very similar appearance to a scrofulous one, a supra-renal organ so affected being not much unlike the section of a scrofulous lymphatic gland. As regards any assistance to be derived from the general condition of the system, this would rather favour the non-tubercular view of the disease, seeing that it is in only the exceptional cases that any well-marked tubercular deposit has been found in the other viscera. At the very commencement of the discovery in

connection with one of the earliest cases which occurred, I mentioned this fact; and my remarks then made are found appended to Case 7.

From an examination of the cases before us, it will be seen that when the disease is recent, the organ is somewhat enlarged, and changed into a material which is semi-translucent, of a gray colour, softish, homogeneous, and which, when examined microscopically, is found to be without structure, or sometimes slightly fibrillated, or containing a few abortive nuclei or cells. This lardaceous kind of material is the first deposited, and resembles what is often seen in the early stages of scrofulous enlargement of the lymphatic glands. Subsequently it undergoes a decay or degeneration, as in these glands, and changes into an opaque, yellowish substance, and thus the two materials are constantly found associated—a gray, translucent matter, mixed with a yellow, opaque substance. At a still later period, as in a scrofulous gland, this may soften into a putty-like matter, or it may dry up, leaving the mineral part as a chalky deposit, scattered through the organs. These, then, are the changes: first, the deposition of a translucent, softish, homogeneous substance; subsequently the degeneration of this into a yellowish-white, opaque matter; and afterwards a softening into so-called abscess, or drying up into a chalky mass. Occasionally, also, some fibrous tissue may be found around the organs, being the product of an inflammation which has united them to the kidney, liver, and adjacent parts.

It is not sufficiently remembered that some years are necessary for the production of the changes to which we have referred; and therefore, if a cretaceous substance be found in the deposit, there can be no doubt as to the very lengthened duration of the disease. This great length of time corresponds with our knowledge of the duration of the symptoms in some of the best-marked cases, and should compel us to keep under notice suspected instances of the disease for several years.

Connection with tubercle.—It was just now stated, in reference to the question of the scrofulous nature of the disease, that in the best-marked cases there was no appearance of tubercle in any part of the body. In four only was tubercle found in the lungs, and this in two cases existed only as an indurated chronic disease of the apex of the lung, which had

a granular surface when incised. In one only was the deposit scattered through the lungs, and in this case it was of so peculiar a nature, that it might be questioned whether it was ordinary tubercle or not. I think, until tubercle can be more strictly defined, that all yellow amorphous deposits ought not to bear the name; and as regards this individual case, the whole character of the lung suggested rather a secondary deposit, as seen in cancer, than one of primary tubercle—an appearance, indeed, which suggested whether the disease in the supra-renal capsule had not been the original affection, and that a secondary deposit had taken place in the lungs of a low organized material, of a similar character, and which could not in strict justice be styled tubercle. When, therefore, it is seen that in most cases there was no evidence whatever of tubercle, and in a few only a little scattered deposit in the apices, as frequently found in post-mortem examinations of those who have died of various ailments, and in one case only where there was abundant of deposit, this was of so peculiar a character as to raise a doubt as to its scrofulous character, it will be evident on how slender a basis does this disease in the capsules in morbus Addisonii rest for the name of tubercle.

I might also observe, that in cases of general tuberculosis, which are very common, I have not yet met with an instance where the supra-renal organs have been affected in the manner of Addison's disease—a very remarkable fact, if the disease should be simply a tuberculous one.

Complication with other diseases.—In one of our cases, a cutaneous eruption existed, and in another *ramollissement* of the brain. With these exceptions we have only one disease to speak of in connection with morbus Addisonii, and that is, *caries of the spine*. It will be seen that this existed in three of our cases; it has also been observed in one or two other instances, and also in a patient who was long in the hospital with supposed supra-renal disease. In these cases the inference is natural that the two affections are associated, since the caries of the spine has always been in the lower dorsal or upper lumbar vertebræ, and in immediate contact with the supra-renal capsules, and in all probability the spine has been affected first, and the supra-renal organs afterwards. In all these cases it had existed for years, and in one there

was a distinct history of injury. Such a case strongly suggests the opinion that the capsules were secondarily affected; and if so, it would show that the change is simply of that kind which often occurs in the organs and closed parts of the body, and which is usually styled inflammatory.

Any difficulty arising from the statement that a constitutional cause exists for a disease, and yet may be excited by a local influence, prevails equally with reference to other maladies; as for example, in the lung, where an acute pneumonia or a chronic phthisical change may arise from a general constitutional cause, and yet be induced, by an external injury, as from fractured rib.

Gastro-intestinal irritation.—I have said that, in the majority of instances, no disease has been found in the body; but I may state that, in connection with the gastro-intestinal disturbance observed during life, a condition of mucous membrane is found which may be called one of irritation. The stomach is often ecchymosed, and in the intestines the glands are much enlarged. In several cases Brunner's glands in the duodenum, and the solitary in the lower end of the ileum and colon were very prominent. This has been so often the case, that in the later instances of the disease which have come before me I have especially looked for this condition, and generally found the enlargement present. How far this state is intimately connected with the disease I cannot say, since it may arise from various causes which produce irritation of the stomach or intestine, and may exist as a consequence of a morbid action, which has its origin elsewhere; it may be a consequence of such irritation and not a cause of it. Thus it is found in cholera, probably as a consequence of the disease, and it is well known in children, in cases of diarrhœa arising from external causes, improper food, &c., where such enlargement of the glands and signs of intestinal irritation is very common.

Objections against Addison's observations.—The objections which have been raised against the accuracy of Addison's conclusions are mostly of this nature: that if a large collection of cases be made where disease of the supra-renal capsules has been met with, and also that if a large number of cases be collected of discoloration of the skin, and the whole of such cases be put together, those instances where disease of the

capsules and discoloration of the skin are combined are so few, that the occurrence cannot be regarded in any other light than a coincidence. This argument has appeared to some conclusive.

Also that a complete destruction of the capsules, such as Addison has described, has been met with accidentally, or in patients who have died of various diseases.

Also that the supposed inference of Addison that these organs are vital, is incorrect, since they can be removed from the living animal with impunity.

At first view these objections may appear important, but to those who have perused the preceding pages, it will be seen that they are of little value. As regards the first objection, I have already reiterated the error of Addison, in being not content with the publication of his genuine cases, but in endeavouring to seek minor degrees of the disease, whereby he complicated his subject, and overwhelmed it with much extraneous matter. If, however, as before said, we limit ourselves to that peculiar change in the organs already described, and put aside altogether the cases of cancer, tubercle, and similar affections, we shall rid ourselves at once of the great majority of cases which have been brought against Addison's observations. Thus, in a list of cases published some time since, in not a single instance was the true disease present, but merely those minor changes due to cancer, tubercle, or lardaceous infiltration. As, however, Addison had himself suggested the mistake, no surprise can be manifested when an eminent professor, in reviewing such cases, states that the correctness of Addison's views is still *sub-judice*.

As regards the second argument, that discoloration of the skin has existed without disease of the supra-renal capsules, the fact must be admitted, although I believe that the cases reported are remarkably few where that uniform discoloration has occurred, resembling the mulatto, which Addison described. In most of the cases published to disprove the connection, the pigmentation has occurred in patches, and in others there can be little doubt that jaundice, pityriasis, ephelis, and ichthyosis, have been mistaken for the true discoloration. It should be remembered, however, that true pigmentation of the skin occurs always in the rete mucosum, and probably

may arise from several causes. Addison's statements may be comprised in a few words—that if a pigmentation of the kind described occurred in combination with peculiar constitutional symptoms, certain pathological changes in the supra-renal organs might be inferred, with as much certainty as the diagnosis of any other disease.

The two remaining objections may be considered together: the objection that these changes in the organs have been met with accidentally—that is, in cases where there was no suspicion of the disease—and also the objection arising from the fact, that their removal from the lower animals may be effected with impunity, showing that they are not vital organs, as Addison's observations would imply. In answer to these, it must be remembered that Addison never stated that they were vital, but that, in all probability, the symptoms of the disease were due to implication of the adjacent organic nerves; and there is every reason to believe that his opinion was correct.

Addison did not fail to appreciate the difficulty, that whilst in certain cases, when discovering no disease in the body except in the supra-renal capsules he was bound to connect them with the fatal issue as cause and effect, he at the same time was equally certain that these organs had been totally destroyed for a lengthened period, perhaps for months or years before death. He felt the difficulty of describing such organs as vital in the same sense as those viscera in the body whose destruction would inevitably lead to death. If, however, it be true, as Addison surmised, that the symptoms are due to implication of adjacent parts, we can understand how prolonged may be the period of disease, and why it may sometimes be met with quite accidentally; and how also, indeed, the organs may be removed from living animals with impunity. Their excision during life, without manifest symptoms following, is quite in accordance with these facts. It must be remembered that an organ may not be vital, and yet, when diseased, may cause death by implication of other parts; this is true of disease of the ovary, of cancer of the testes and lumbar glands, as well as of the various diseases affecting the extremities of the body, which are not vital parts, but may lead to death when diseased. Why a disease which is equally

severe any time during several months should kill on one day rather than another is difficult to explain, but it is a difficulty to be met with in organic diseases of other organs, as the brain, kidneys, &c.

If, then, we look once more on Addison's disease in its true light, we shall see how all these arguments sink into insignificance. We see a disease which slowly affects the capsules until it has entirely destroyed them ; it is not until then, or even after a much longer period, and when still further changes have occurred, that death takes place, and then, perhaps, according to the theory before advanced, by implication of the ganglionic nerves ; and this disease is accompanied by an extreme asthenia or feebleness, and generally by a uniform discoloration of the skin. It is not said that every case of extreme feebleness depends on supra-renal disease ; nor that every case of discoloration of the skin has the same cause ; nor is it said that any deposit in the supra-renal organs is productive of the symptoms just named, but that a peculiar disease in the capsules will be found in cases of general discoloration combined with asthenia, and especially when there is an absence of any other malady. The fact, too, is not incompatible with the statement that a patient may be cut off suddenly by an acute disease or accident, and the total destruction of these organs then be found. Thus are all the opposing arguments futile.

It must be remembered that the belief in the production of the symptoms by implication of the nerves is purely theoretical, and it will depend much upon the truth or error of this, as to the true course for further investigation. If this view be not correct, but the symptoms be due to a disease of the organs themselves, there must of necessity be lesser changes in their structure, attended by corresponding symptoms, but which are of necessity of so obscure a character, that they have not yet been observed. All these morbid changes, however, remain to be studied.

Importance of a knowledge of the healthy anatomy of the organs.—It might seem superfluous to state that the healthy anatomy and position of the supra-renal capsules should be understood before any knowledge of their diseases can be obtained, but experience has shown us that mistakes have oc-

curred from this ignorance. I could refer to cases described at great length, in which the capsules were supposed to be diseased although quite healthy; also cases where it was said they were destroyed from the mere clumsiness of their removal. This want of knowledge, however, of the true character of the organ will not be considered so remarkable when it is remembered that anatomists themselves have differed in their descriptions. Thus from the central portions of the organs becoming soft, they have been described as being hollow. Frey¹ described the section of the capsules as exhibiting an external portion of a buff or yellowish colour, and an internal or brown; the former was the cortical, and the latter the medullary. This writer appears to have entirely overlooked a central portion which is always found in the healthy organ, and which is of an opaque white colour, and of firm consistence. This is the true medullary substance, as Kölliker rightly describes. So little was this true description known, that at the time of Addison's discovery several cases were sent to me for examination on the supposition that they were diseased, the white medullary substance being regarded in some instances as cancer. Whether the more minute anatomy is of importance to be known, depends upon the fact whether the minor changes in the organs are attended with symptoms or not.²

The following is a table of the cases about to be described, with the number of the preparation attached. By this a facility is offered to those who should wish to examine the specimens for themselves—

¹ Todd's 'Cyclopædia of Anatomy.'

² I might also remind my readers (although I should hesitate to do so were it not absolutely necessary) that the supra-renal capsules are not attached to the kidney, as the name might imply, and that it is necessary to make a special search for these organs before the other viscera are removed, and not to take out the kidneys on the supposition that the supra-renal bodies will be extracted with them. These remarks are warranted by the fact that on more than one occasion I have had the kidneys sent to me from the country, with the request to examine the capsules, on the supposition that they have been attached, when, as may be supposed, they have been left behind in the body.

List of Cases.

No. of Case.	Preparation.	Name.	Age.	Sex.	Colour of Skin.	Diagnosed during life.
1	2020 ⁵⁵	James W.	32	M.	Very dark	First case.
2	2021 ⁴⁰	James J.	35	M.	Ditto	Yes.
3	2022 ⁹	Henry P.	26	M.	Ditto	Yes.
4	2020 ²⁵	Ann R.	—	F.	Ditto	Old case.
5	2021 ³⁰	Thos. C.	58	M.	Dark	?
6	2020 ⁵⁰	Mary C.	38	F.	?	Old case.
7	2022 ¹¹	— W.	58	F.	Very dark	Yes.
8	2020 ⁵⁰	Henry M.	38	M.	No discoloration	No.
9	2022 ¹²	Chas. W.	24	M.	Very dark	Yes.
10	2020 ⁵⁵	Anthony B.	28	M.	Slight discoloration	No.
11	2020 ⁶⁰	Wm. M.	35	M.	Very dark	Yes.
12	2020 ⁹⁰	Thos. L.	32	M.	Ditto	Yes.
13	2020 ⁹⁵	Geo. Y.	25	M.	Slight discoloration	No.
14	2020 ⁶⁶	W. S.	21	M.	Very dark	?
15	2020 ⁵⁷	Martha M.	26	F.	Ditto	Yes.
16	2020 ⁶²	John F.	15	M.	Ditto	Yes.
17	2020 ⁶⁴	Wm. B.	39	M.	Ditto	Yes.
18	2020 ⁶⁸	Robert B.	13	M.	Ditto	Yes.
19	2020 ⁷⁰	Henry G.	33	M.	Ditto	Yes.
20	2021	Wm. P.	30	M.	Ditto	Yes.
21	2021 ⁵⁵	Sarah S.	37	F.	Ditto	Yes.
22	2021 ⁶⁰	Geo. A.	23	M.	Slight discoloration	No.
23	2021 ⁶⁵	Edward P.	32	M.	Very dark	Yes.
24	2021 ⁷⁰	Wm. C.	46	M.	Ditto	Yes.
25	2021 ⁷⁵	Sarah W.	26	F.	Slight discoloration	No.

CASE 1.—The following is the first case related by Dr. Addison, and the first one in which a connection was shown to exist between discoloration of the skin and disease of the supra-renal capsules. The patient was under the care of Dr. Golding Bird, and as may be supposed created much interest at the time, from the remarkable colour which he presented. I well remember interrogating him as several others had done, as to his native country and parentage, and was astonished to find that he was a tradesman in London. Dr. Addison, who took an especial interest in skin diseases, and, as before mentioned, in those affections whose characteristic symptoms were those of anæmia and asthenia, was much struck with the case. The discovery after death, of disease of the supra-renal capsule made a deep impression on all, and on none more than Dr. Addison, who, as may be imagined, was then awakened to the reception of any similar cases which might present themselves.

It will be observed that the parts most affected by the pigmentation were those exposed to the sun, as the face and hands; and also the genital organs, as in the dark races of mankind. Death, it will be seen, was immediately due to pericarditis, a circumstance which by no means took away from the value of the previous symptoms as connected with the supra-renal disease, and, yet most remarkably, the same having occurred in a case of more recent date, was supposed to deprive it of the importance which Addison would have attached to it.

James W—, æt. 32, admitted into Guy's Hospital, under Dr. Golding Bird, February 6th, 1850. Has been residing at Moorfields, and by occupation a baker. States that he was attacked with a cough three years since, which he was unable to get rid of by ordinary remedies for a considerable time. From this period his skin, previously white, began to assume a darker hue, which has been gradually increasing, and in twelve months he was laid up from excessive weakness. His cough also returning, he became a patient at St. Thomas's, where his cough was cured, and the discoloration of skin treated as jaundice. He left the hospital in tolerable health, but subsequently lost flesh and became so excessively weak, the colour of the skin at the same time getting rapidly darker, that he applied for admission here.

Present appearances.—The whole of the skin of the body is now of a dark hue, and he has just the appearance of having descended from coloured parents, which he assures us is not the case, nor have any of his family for generations, that he can answer for, manifested this peculiarity. The colour of the skin does not at all resemble that produced by the absorption of nitrate of silver, but has more the appearance of the pigment of the choroid of the eye; it seems to have affected some parts of his body more than others, the scrotum and penis being the darkest, the soles of the feet and palms of the hands being the lightest; the cheeks are a little sunken, the nose is pointed, the conjunctivæ are of a pearly whiteness; the voice is puny and puerile, the patient speaking with a kind of indescribable whine, and his whole demeanour is childish. He complains of a sense of soreness in the chest, about the scrobiculus cordis. The chest is well formed and perfectly resonant; the sounds of the heart are also healthy; there is some slight fulness in the region of the stomach. The urine is of a proper colour, and contains neither sugar nor albumen.

Feb. 8th.—Dr. Bird wished a likeness to be taken, so as to be able to watch any alterations in his colour, and considering the case one of anæmia, ordered Syr. Ferri Iodidi, ʒj, ter die. This he took until his discharge in April, when he left, rather stronger, but the colour remaining precisely the same.

Shortly after his discharge from the hospital he was seized with acute pericarditis and pulmonic inflammation, under which he speedily sank and died.

Post-mortem examination.—Lungs universally adherent, the adhesions being very old. The upper lobe of right lung contained some recent pneumonia; no tubercles in lungs. The pericardium was distended with fluid of a deep brown colour, amounting to about half a pint; recent lymph was effused over the whole serous surface. Liver and spleen healthy. Gall ducts pervious, and gall-bladder healthy.

Thoracic duct pervious, and no obstruction to any of the arteries or veins. Kidneys quite healthy, and of full size. The *supra-renal capsules* were diseased on both sides, the left about the size of a hen's egg, with the head of the pancreas firmly tied down to it by adhesions. Both capsules were as hard as stones. Lumbar glands natural. No tubercular deposit was discovered in any organ. The head was not examined.

CASE 2.—In the next case, which is also described by Dr. Addison, the latter says that he was indebted to Dr. Gull for first suspecting the true nature of the malady during the life of the patient, and drawing his attention to it. It will be observed that, apart from the more usual and very common cerebral symptoms occurring in the final stages of the complaint, from mere exhaustion, this man is described as having had, at an early period of his illness, delirium and loss of consciousness, which lasted for some hours. As the brain was healthy, these symptoms were probably connected with the supra-renal disorder, and tend to show some close intimacy between it and the nervous centres.

James J—, æt. 35. The subject of this disease was admitted into Guy's Hospital, under Dr. Addison, on November 11th, 1851, and died December 7th.

A married man, residing at Gravesend, and by occupation a tide-waiter in the Customs. Of a bilious temperament, dark hair, and sallow complexion, which, since his illness, has much deepened, so that now it is of a dark olive brown. His wife says:—"This obvious change in his complexion has been from the beginning of his illness, and gradually came on at that time." There can be no doubt about this change in the complexion depending on increase of pigment; for, if the lips be turned down, the mucous membrane is seen to be mottled by a deposit of pigment, and a closer examination shows that the dark colour of the lips, which at first sight had the appearance of sordes, is dependent upon the presence of a black pigment, which is not movable by moistening or washing the lips. There is an expression of anxiety in the face, and the brow is contracted. He gives the following history of himself—

His occupation subjects him to much anxiety, he is exposed to all the vicissitudes of the weather, both night and day, and sometimes for weeks together his food consists of salt provisions. Eight years ago he had rheumatism, accompanied by great nervous depression; since that time he has enjoyed general good health, with the exception of some attacks of bilious vomiting. His present illness came on six months ago, with headache, vomiting, and constipation. About the sixth day of his illness he became delirious, and was insensible for twenty-four hours. On recovering his consciousness he was unable to move the fingers of either hand, nor could he move the legs below the knee; the same parts were numb, as was also the tip of the tongue. He continued weak during the whole summer. Two months ago he resumed his occupation, and remained at it until ten days back, when the old symptoms of headache, vomiting, and constipation, returned. Dr. McWilliam saw him at this time,

and found his symptoms to have an intermittent character, and regarded the case as one of miasmatic poisoning, not only from his general symptoms, but also from the dark, poisoned look of his face, not altogether unlike that presented on the approach of the asphyxic stage of cholera.

On his admission into the hospital the pulse was extremely small and feeble, the expression of the face pinched, the brows knitted. He vomited mucus, containing altered blood of a dark brown colour. Tongue clean; epigastric region full, especially towards the left side, where he has had some twitching pain and slight tenderness on pressure; urine natural in quantity, colour, and not coagulable by heat. He went on day by day, but with slight symptoms of change. Skin cool; pulse moderate in frequency, but extremely feeble, so as scarcely to be felt at the wrist. On several occasions the depression was so great as to require the exhibition of stimulants. There was a continued tendency to sickness. Abdomen soft, with marked aortic pulsation. Bowels constipated. Chest everywhere resonant. Heart sounds normal.

Probable diagnosis.—Is it some affection of the liver? or is it, as Dr. Addison supposes, disease of the supra-renal capsules?

Post-mortem examination.—Lining membrane of stomach finely injected, of a bright-red colour, with two or three spots of ecchymosis; structure of membrane thickened and pulpy, and surface covered with tenacious mucus; in some parts there were irregular superficial abrasions. Brain, lungs, heart, spleen, liver, and kidneys, were normal. The *supra-renal capsules* contained, both of them, compact, fibrinous concretions, seated in the structure of the organ; superficially examined, they were not unlike some forms of strumous tubercle.

CASE 3.—The following is the third case in Addison's work. It is one which I myself closely watched, and afterwards had an opportunity of examining after death, as well as dissecting out the organs for the drawing in the monograph. So perfect an example of the disorder did it represent, that it determined Addison at once to publish his observations.

It will be seen that this patient had disease of the spine in the neighbourhood of the capsules—a fact of great interest, and one already alluded to as a probable origin of the affection. It will be observed, however, that the spinal affection will not account for that remarkable feebleness which existed in this case, and which, therefore, is attributable only to the supra-renal disease.

Henry P—, æt. 26, a carpenter, residing at Walworth, was admitted November 9th, 1854, having been for some time an out-patient under Dr. Rees. His habits have been somewhat intemperate, his drink chiefly malt liquor and spirits. With the exception of a sister who died of phthisis, all his relations are healthy. He has been married four years. The patient states that up to six months ago, he enjoyed very good health, but then began to be troubled with what he called rheumatic

pains in the right leg, which, without laying him up, gradually extended to his hips and side, and thence to the bottom of the spine. His back latterly has been very tender, a jerk or jarring movement giving him great pain at that part. He has noticed his lips to have become dark coloured for the last three months, and more lately his face to be similarly discoloured in patches. For the last month he has discontinued work on account of attacks of giddiness and dimness of sight, accompanied by a peculiar pain at the back of the head, and partial loss of consciousness. These attacks would occur several times in the course of the day upon any unusual exertion, always whilst in the standing posture, and were instantly relieved by sitting or lying down. Since he has discontinued his employment, they have only occurred on getting out of bed in the morning. It is for the pains and tenderness at the back, and occasional attacks, as above described, with general debility, that he has been attending this hospital as an out-patient.

The patient presents a highly strumous appearance, being thin, pale, and the hair dark and dry. Over the face and forehead which are of a general yellowish hue, are several patches of darkened skin, and similar black patches on the lips. There is angular curvature at the second and great tenderness on pressure over the upper three lumbar vertebræ; he complains also of pain at this part upon moving in bed. There is no paralysis, but considerable general debility. His bowels are regular, tongue clean, but the appetite is impaired; the urine is healthy, and not albuminous. Heart sounds feeble. He was ordered tonic medicines and good nourishment, and continued with no appreciable difference until the 24th, when he had a fainting fit upon rising to have his bed made. He has also been occasionally sick. After this he became much weaker, and the vomiting continued with occasional hiccough. On December 2nd, he was almost in a torpid state from feebleness, he lay quiet with his eyes half open, but roused up on speaking to him; he thus continued until the 6th, when he died quietly.

Post-mortem examination.—Not much emaciation, countenance paler than in life, but presented the same olive hue, with the dark patches on the face, forehead, and lips. There was a psoas abscess on the right side, extending from Pouparts ligament to the diseased vertebræ, and holding about a pint of flaky pus. The disease was between the first and second vertebræ, commencing in the cartilage, and nearly destroying the neighbouring vertebræ at their centres. Lungs contained hard masses of gray strumous pneumonic deposit, mostly in the apices, but also in the lower lobes. Heart healthy; other organs healthy. Each *supra-renal capsule* was completely destroyed, and converted into a mass of strumous disease, the latter of all degrees of consistency. The left supra-renal capsule had formed at the upper part a close connexion with the outer coat of the stomach. The upper part of this capsule seemed fluid, and of the colour of pus; the lower firmer, and of the consistence of putty. The right capsule had all degrees of consistency from the bottom to the top; the lower part almost fluid, and resembling pus; the centre putty-like, and above this the latter could be detached in flakes, and at the top it was quite earthy, separate angular pieces being easily detached.

CASE 4.—The next case is a very interesting one, as it occurred more than thirty years ago, and presents, beyond all doubt, a good example of the disease. The patient had sick-

ness, was drowsy, and somewhat delirious. After death, the only marked disease found in the body was that of the supra-renal capsules, and, what is remarkable, a discoloration of the skin is distinctly noticed. It is published in Bright's 'Reports'.¹

Ann R— was admitted into the hospital under Mr. Key, in July, 1829, on account of an obscure tumour in the left breast; but as she was suffering more from constitutional symptoms, she was placed under the care of Dr. Cholmeley. Her complexion was very dark, her whole person emaciated; she had no cough, nor any pain about the abdomen. She had difficulty in opening her jaw, from swelling of the parotid. Her stomach soon became irritable, and she had bilious vomiting, which reduced her strength, and for a day or two before her death, which took place on the 18th of August, she became drowsy, yet capable of being roused, complaining of some pain over the forehead, and occasionally wandering a little in her intellects.

In the absence of all positive symptoms, I (Dr. Bright says) concluded that it was possible some glandular disease, similar to that which had shown itself below the mammæ and under the jaw, might exist internally, giving rise to emaciation and vomiting; and it appears that serous effusion had been going on in the head for the last few days.

Post-mortem examination.—Considerable emaciation. A small abscess beneath the mammæ. Brain atrophied, and excess of fluid externally and in ventricles. Lungs, upper lobe of each was puckered, and contained one or two masses of earthy matter, besides several small incipient tubercles; the greater part of lung, however, was in a healthy condition. Heart small, but healthy. Intestines healthy. Liver healthy. Some lymphatic glands in abdomen slightly enlarged. The only marked

¹ I cannot but allude here as I have had occasion to do before to the very remarkable accuracy of description manifested in all the cases published by Dr. Bright, and thus here we have the main features of Addison's disease accurately observed. There seems indeed scarcely a pathological discovery of late years of which some illustration may not be found in his 'Medical Reports.' So wonderful a power of observation had Bright, without a corresponding theorising or inductive faculty, that he scarcely seemed aware of the importance or the novelty of the facts which he himself first brought to light. It has even been questioned and with much apparent reason, whether the very disease which bears his name throughout the world, was regarded in its full importance by Bright himself, until it had been pointed out by others, and therefore, whether his merit as a true discoverer is not somewhat diminished thereby. However this may be, it is certain that his descriptions are wonderfully accurate, and thus we find in these 'Medical Reports,' the first mention of the assimilation of fat by the pancreatic fluid; also the discoloration of organs by melanemia or miasmatic influence; atelectasis of the lung in hooping cough; cases of lymphatic and splenic disease; besides several interesting examples of cerebral and spinal disease, which have been used to illustrate some modern theories of nervous affections. And now I have to mention this case of bronzed skin with diseases of the supra-renal capsules, and which only wanted to be impressed on his mind, or to be noticed by his readers to have deprived the disease now called Addison's of its name, and made it coeval with Bright.

disease was in the renal capsules, both of which were enlarged, lobulated, and the seat of morbid deposits, apparently of a scrofulous character; they were at least four times their natural thickness, feeling solid and hard; on the left side, one part had gone into suppuration, containing two drachms of yellow pus. The kidneys themselves healthy. The uterus held down by adhesions in the pelvis.

CASE 5.—I insert the following case, because the preparation is retained in our museum, and the case from which it came constitutes one of Addison's illustrations. As, however, small portions only of the organs have been preserved, and these have been so previously dried, that it is impossible at the present time to draw any conclusion as to their condition, and as, moreover, in all the other cases the specimens are in as good condition as when they were first removed from the body, I am loath to introduce a case which can afford any misgiving as to its true character. As, however, it finds a place in Addison's work, I shall not exclude it, but I am thereby admitting a case into the present series, of whose nature I am in doubt. I lament that I cannot speak of it with more certainty, since it is the only one of the author's examples in which pigment was found in the internal organs—a feature of the disease about which more facts are required to be noticed. If, indeed, this had been the only case in our present list where internal pigmental deposit had been observed, much doubt would have been thrown upon its occurrence as a symptom of supra-renal disease. As, however, another instance has subsequently occurred, the subject must be regarded as still in abeyance.

Thomas C—, æt. 58, admitted into Guy's Hospital February 11th, 1852, under Dr. Barlow. A muscular and strong-built man, of a sanguine temperament and dark complexion. His occupation had been that of a sailor, and according to his own statement, he had led a very sober life. His general health had been very good. About two months ago he came from Liverpool, in which place he had settled, not intending to go to sea again, and was taken on board the Dreadnought for stricture. His general health was quite good at this time; but while in the Dreadnought, he began to lose his appetite, and to feel generally unwell. He had likewise some affection of the left eye, in which he is now nearly blind. On the 8th he left the ship at his own request, thinking that he might be better on land; after waiting two or three days, he found that he got no better, and his friends advised him to come to the hospital.

He complains of a sensation of sickness, without actual vomiting, and tightness over the epigastrium. His countenance is anxious; no pain in any part. He has rigors, followed by mild sweats, which last about an hour. Abdomen tympanitic; lungs and heart natural. He continued getting weaker, the appetite failing, and

sickness persisting; at the same time it was thought that the countenance grew darker, and he died on the 25th.

Post-mortem examination.—None was allowed beyond the brain and abdomen. Of the former there was considerable softening, and a large amount of subarachnoid fluid. The kidneys were slightly enlarged, mottled, and in some parts the cortical substance was entirely degenerated into fat. A few tubercles were strewed on the surface. Tubercles were also observed on the spleen and on the peritoneum covering the termination of the ileum. Tubercular deposit was also found in one of the supra-renal capsules.

CASE 6.—Another specimen, placed in the museum by Dr. Hodgkin, was from a patient of Dr. Bright. The case is very briefly related in the post-mortem records, and no allusion is made to any interest bestowed upon it by Bright, or even that he witnessed the examination. The specimen affords a well-marked example of the change which occurs in Addison's disease, of which no doubt it was a case, since there is no other morbid condition mentioned in explanation of the patient's death. It will be seen that it occurred only a few months previous to the one first related (No. 4), and in both of them the specimens were preserved, showing that due attention was bestowed upon the morbid condition of these organs, although no suspicion seemed to be excited as to its being the cause of death, nor, indeed, as far as I am aware, was anything advanced connecting the symptoms with these organs.

Mary C—, æt. 38, admitted into Guy's Hospital under Dr. Bright, October 29th, 1828, and died on November 11th. She complained of pain in the chest, had a cough, and was supposed to be labouring under phthisis.

Post-mortem examination.—The lungs were found to contain tubercles; but the other organs were healthy, with the exception of the supra-renal capsules, which were enlarged, and occupied by a yellow, adventitious deposit, which in parts was softening down.

In this description there is not sufficient disease mentioned to account for death apart from that discovered in the supra-renal capsules.

CASE 7.—The following is as interesting a case as any in the series, and to an unprejudiced mind must constitute, I think, a proof beyond all shadow of doubt as to the truthfulness of Addison's discovery, since it will be seen that it was one of the first which was observed after the publication of the monograph, and what is deserving of especial notice is that the disease was foretold by the publication of the diagnosis long before it was verified by the death of the patient.

It will be observed that Dr. Ranking, after having read a review of Addison's work, was immediately struck with the resemblance between the features of the cases there described and those which existed in a patient of his own ; and, in order to test the accuracy of this belief, he immediately sent an account of it to a medical journal, with his opinion affixed. Some months afterwards the diagnosis was completely verified by the death of the patient and by the condition of the capsules, which were transmitted to Dr. Addison, and are now before me.

In illustration of the striking characters of the disease, it may be interesting to observe that a similar history attaches to another case at the end of the series, where a gentleman, on perusing Addison's work, was immediately struck with the resemblance of the cases therein given to that of a boy then under his care. He immediately decided on its nature, sent the case to Addison for corroboration, who very shortly afterwards was enabled to prove the correctness of the supposition.

In the general account of the symptoms of the disease, it has been observed that emaciation does not occur ; but in the present case the term is used, but evidently only in a comparative sense, for the post-mortem description states that the skin was still loaded with yellow fat. It will be seen also that a disagreeable odour existed, as first pointed out by Mr. Hutchinson, and also some very remarkable nervous symptoms. I may allude to my own remarks, appended to the case when the diseased organs were referred to me for examination, showing that at that time, and soon after the publication of the original work, the disease was seen to be a peculiar one, and that its essential characters lay in that change which has been observed in all subsequent cases, and not due to any or every accidental disease, as Addison first conceived.

The first knowledge which we had of this case was in the following letter to the ' *Medical Times and Gazette*.'¹

" To the Editor of the ' Medical Times and Gazette.' "

" SIR,—My attention has been forcibly arrested by reports of the supposed relation between a peculiar discoloration of the skin, attended with increasing and

¹ Dec. 22nd, 1855.

apparently inexplicable debility, with disease of the supra-renal capsules. Such a case is at present under my care, in conjunction with Mr. Vincent, of Dereham, who has also noticed its similarity to the cases recorded by Dr. Addison. The subject is new and interesting, which must be my excuse for troubling you with the notes of a case which has not yet become fatal.

"Mrs. W—, æt. 58, a lady of large frame and masculine appearance, consulted me on the 28th of August last. She has been habitually a large eater, especially of highly seasoned dishes and butter, the latter in extravagant quantities. I was struck with her altered appearance, having known her as a woman of, at a rough guess, fifteen stone weight. She was now much shrunk, but still a large person, and complained mainly of great and increasing loss of strength, with sinking at the pit of the stomach, nausea, and complete loss of appetite. She was also greatly annoyed at a gradual change of colour which the exposed surface of the skin had undergone. The face was dark brown, as dark, in fact, as that of a Japanese, and might be called bronzed, without any great stretch of the imagination. The hands were also discoloured, especially at the knuckles. I have not seen the skin of the back or body, and therefore cannot speak as to the extension of the change to those parts, but I have observed that the arms are discoloured, though to a much less degree. Her heart's action is very feeble, and suggests the idea of fatty degeneration; but excluding this, I could not satisfactorily account for the extreme debility and her resistance to all restorative measures, medicinal and dietetic. The secretions of the liver and intestines are perfectly natural, and the urine is healthy. This lady has improved somewhat under citrate of iron and quinine, and nitro-hydrochloric acid, but as yet the progress has been very little, and I confess that, until I became aware of Dr. Addison's researches, I could not devise an explanation of the case at all to my satisfaction. Whether a morbid condition of the supra-renal capsules is the true solution, I trust may long remain uncertain, but I shall not fail to keep the idea in view, should the case, as I fear it will do, ultimately prove fatal.

"I am, &c.,

"W. H. RANKING, M.D.,

"*Physician to the Norfolk and Norwich Hospital.*"

Some months after the publication of this letter the lady died, and the truthfulness of the diagnosis was perfectly established. A detailed account of the case was therefore sent to Dr. Addison by Dr. Vincent, the main features of which were as just described, but may again be repeated in that gentleman's own language, as follows :

Mrs. W—, æt. 59, a married lady, in affluent circumstances, the mother of five children, very tall, and has been very stout, but at the same time of active habits. In May, 1855, she first observed that the skin of her face and hands was discoloured, and was often annoyed, when making calls, by friends offering water to wash her hands. Her appetite failed, and the stomach rejected almost everything. She also got thinner. Between this time and the following October she travelled twice to Norwich to consult Dr. Ranking. She continued to get worse, and on October

11th Dr. Vincent met Dr. Ranking in consultation, and then took charge of the case. She then had constant sickness. Complete loss of appetite. Tongue clean. Bowels constipated, but stools not deficient in bile. Conjunctiva clear, not having the slightest yellow hue. Urine natural. Much faintness, so as to be unable to sit upright. No pain in head, or cerebral symptoms. Irritability of body and mind. Chest sound. Pulse 80, and feeble. Nothing discoverable in abdomen. The discoloration of the skin was very remarkable upon the forehead, face, neck, and hands; it resembled, Dr. Vincent said, more the colour of a copper coin that had become dirty and greasy. This colour was much less marked where the dress covered the skin. There was also a tendency for the skin to peel off. Also a peculiar sickening exhalation from the skin about the neck.

From this time until her death, in April, 1856, in addition to the above symptoms, she suffered from neuralgia in various parts. At one time she rallied, regained strength, and sickness abated, but the colour deepened. She died greatly emaciated, April 25th, having been in a state of muttering delirium for the last thirty hours of her life.

Diagnosis.—This for a long time completely puzzled both Drs. Ranking and Vincent, the symptoms negating any of the ordinary diseases of the abdominal organs; but, in December, 1855, Dr. Vincent read in the 'Lancet' a review of Dr. Addison's work, where the similarity of the description there given, and the case of the lady was most striking, and this was agreed to by Dr. Ranking.

Post-mortem examination.—The skin was still deeply loaded with yellow fat; the muscular tissue also seemed infiltrated with it. Lungs healthy, heart fatty, and so with other organs, which were found healthy. *Supra-renal capsules*, much enlarged, and feeling like enlarged scrofulous glands, were about the size of chestnuts, and appeared to cut like very tough leather. One of these was forwarded, with the previous account, to Dr. Addison, who handed it to me for further examination. The following was the report which I furnished:

Report by Dr. Wilks :

"The supra-renal body was rather larger than natural, and, although much altered in shape, bore a general resemblance to the original form of the organ. The first superficial observation, however, by the naked eye, presented no appearance of healthy structure, but, instead, the organ was seen to be composed of a hard, yellowish-green mass, like dried putty. This was tolerably firm, although friable and easily broken down by pressure. A section showed the interior to be composed of the same substance as the exterior, and that the whole was similarly affected throughout. This putty-like mass was not of a uniform colour or consistence, but was made up of two substances, in about equal quantity, the one firm, smooth on section, and of a dull-green colour; the other yellow and more friable. The partial distinction and separation of these had caused the surface of the capsule to appear nodulated. As the microscope afterwards discovered, it appeared as if the whole organ had been pervaded by a morbid product, which was fast undergoing degeneration, the different degrees of decay causing the variety of structure and colour witnessed on examination.

"*Microscopic examination.*—The most important fact elicited was that not the

slightest trace of original structure could be found in any part of the organ, its place being occupied by the morbid material above mentioned. This presented no great peculiarities, but resembled the product of degenerated lymph or inflammatory matters, as seen in various other parts of the body. The two substances of which it was composed differed, in the one being firmer and tougher and slightly more transparent than the other, and thus by the microscope presented a few delicate fibres, amongst which were found cells or nuclei of all sizes and shapes. The yellow, more friable matter was composed of irregularly formed cells of the same kind, many fatty granular molecules, and a refracting amorphous material, which was partly an organic albuminous substance and partly saline, soluble by acetic acid. It appeared, thus, as if the original adventitious matter had been a fibro-nucleated structure, but which had degenerated into broken-up cells, granules, fat, amorphous albuminous matter, and crystalline forms. It presented no peculiarity over the degenerate lymph found in various other organs. This change is one to which the supra-renal body seems subject, for in this new branch of pathological inquiry several examples have been already noticed. There are, in the first place, the first three of Dr. Addison's cases, the case published by Dr. Gull,¹ &c. All these instances were more or less alike, differing only in the degree of consistency and the amount of earthy or mineral degeneration which the organs had undergone. The general term strumous was at first applied to this disease, but there is no other reason for the designation than the resemblance which the morbid material has to strumous matter. A very similar substance is found in various organs to which the latter term is still with little reason applied, as the yellow amorphous masses seen in the lymphatic glands, and very frequently in the testes, placenta, and other structures. In the testes such masses of degenerate lymph are constantly found in the midst of carcinomatous disease, which, under other circumstances, would be called strumous.

"In the case of supra-renal disease to which we have alluded there has been no evidence of constitutional tuberculous affection; and thus it would appear that these bodies are subject to their own peculiar malady, but whether this be allied to an ordinary inflammatory condition, accompanied by an effusion of lymph and subsequent degeneration, or other morbid change, requires still further investigation. The fact of the two organs being simultaneously affected, while other parts of the body are healthy, is an evidence of their importance in the system."

CASE 8.—The next case has a peculiar point of interest, as being the only one in the series in which no discoloration of the skin occurred. It was this, amongst others, which gave rise to the opinion, in Addison's mind, that pigmentation was one of the latest symptoms of the disease, seeing that here the organs had not undergone cretification or other changes which are known to occur, after a lengthened period, in these low organizable deposits.

The debility or utter want of muscular power which existed in this man was most remarkable, and his wasting was much

¹ Case 9.

more than usual. This appeared to be due probably to his severe gastric symptoms, and also, perhaps, in part to the deposit in the lungs. This case specially suggested the remarks before made, as to the disease of the capsules being one *sui generis*, or only a phase of tuberculosis.

Henry M. M—, æt. 38, admitted under Dr. Rees into Guy's Hospital, on May 6th, 1857, and died May 21st. He was a married man, living at Fulham, and by trade a wheelwright. During a twelvemonth past his health had been failing, his principal complaint being pains in the limbs and general debility. Of late he had also had a cough, which caused him to attend the Consumptive Hospital. During the last nine weeks he had been getting thinner and becoming weaker and weaker.

On admission, his most marked symptoms were those due to an utter prostration of strength, being so feeble that he could scarcely move in bed, and did not care to speak. He was thin, especially in the face, the eyes being sunken, and the temporal muscles wasted; his pulse was exceedingly feeble, and he had frequent vomitings. Although respiration was not good, there were no signs of disorganization of the lungs, and thus all the symptoms suggested some carcinomatous affection in the region of the stomach.

Post-mortem examination.—Body thin, but not emaciated; the face still presenting the same haggard, worn expression. Skin pale, no discoloration to be discovered on any part; the exposed parts of the face being only slightly darker than the rest of the body. Brain healthy, including pituitary body. Lungs contained a number of yellowish deposits scattered throughout them, and diffused equally in all parts. They were mostly about the size of peas, and in their manner of distribution resembled more the secondary deposits of cancer than the ordinary strumo-pneumonic deposits; they were also harder, and had somewhat of a translucent appearance, thus resembling very much the adventitious deposit in the supra-renal capsules. Heart, stomach, liver, spleen, and kidneys, healthy; lumbar glands slightly enlarged.

Supra-renal capsules.—These were entirely destroyed, and their place taken by an adventitious material, which increased them to about twice their natural size, each organ being about two inches in length, and one inch in breadth, besides being of considerable thickness. They were of white colour, firm, and hard. When cut through, they presented no appearance of structure, but were seen to consist of two materials, one an opaque-yellow substance, and the other a firm, translucent substance; the former was such as is generally seen in decaying organized matter, and was probably, therefore, only a later stage of the latter, resembling exactly the uniform yellow material which is seen so commonly in lymphatic glands, and called scrofulous. The translucent material, when examined by the microscope, was found to be made up of a fibro-lardaceous substance, consisting in great measure of transparent layers, which were fibrillated, and amongst which was much fibre-tissue and nucleated fibres. The latter were especially rendered distinct by acetic acid. It thus appeared as if an albuminous matter had been poured out, which had remained partly corpuscular, and had become partly fibrillated. The yellow, opaque substance which constituted the bulk of the disease consisted of the same material, with the addition of broken-up tissue, together with granular masses and free granules dispersed throughout.

CASE 9.—The following case occurred early in the history of the discovery of the disease, and one of the first in Guy's Hospital after the publication of the original cases. The patient, it will be seen, was followed home from the hospital, and although on his death no general examination of the body was permitted, yet the supra-renal bodies being extracted, were found diseased in the usual way. That a small opening could be made in the body, the hand placed within it, and the precise seat of the disease fixed upon, needs no comment of mine in proof of the accuracy of the diagnosis.

I give the case as already published in the 'Medical Times and Gazette.'¹

Charles W—, æt. 24, was admitted into Guy's Hospital, under the care of Dr. Barlow, July 24th, 1855. A well-formed man, of temperate habits, employed as a carpenter at the Crystal Palace. He had always robust health until five months ago, since which time he has been ailing with debility, breathlessness on exertion, nausea, and what he terms biliousness, with a gradual darkening of the complexion. He attributed the onset of his symptoms to over-exertion in running to catch a train. He continued to work until within a fortnight of his admission into the hospital, but was under medical treatment for what was considered to be dyspepsia. On admission, his principal symptoms were great debility, emaciation, irritability of stomach, and a tawny colour of the complexion. The pulse was regular, but very soft and feeble, 70. Tongue clean; entire loss of appetite. The vomiting continued unchecked; the tint of the skin rapidly became of a deeper brown. On the day before his death the following notes were made of his condition:—Great malaise and exhaustion; no cerebral disturbance. Constant nausea, and frequent vomiting; tongue rather dry and injected; abdomen retracted to the spine; sharp aortic pulsation; radial pulse very feeble, 120. No tenderness in loins; skin of a sallow olive-brown. Inside of lips mottled with black pigmentary deposit, and surface of lips dark, so as to give to a superficial observer the appearance of sordes. The dark colour of the skin is most marked in the lower extremities, about the knees. Hair dark-brown; irides blue; nails pearly white. Blood drawn from a puncture of a bright and full colour, but rich in white corpuscles. Urine of a pale-straw colour, free from albumen. He suddenly sank a few hours after these notes were taken.

The body was removed to Hatfield without examination; but as the case appeared to be a striking instance of disease of the supra-renal capsules, Dr. Gull determined with Dr. Bealey to follow it. After much opposition from the friends, they succeeded so far as to be allowed to make a small incision in the abdomen, with a promise to do no more than remove the capsules. Both were found diseased. The left one was much atrophied, and in the place of the original structure were several cysts, one as large as a hazel nut, containing rather turbid, colourless fluid. The right capsule was also much wasted, and in its substance were many round, indurated masses, varying from the size of a small pea downwards; they were firm, opaque, and fibroid in structure.

¹ Jan. 19th, 1856.

CASE 10.—This appears to be the only exceptional case in our series in which any other disease was associated with that of the capsules sufficient to bring the patient to an end before the supra-renal had perfected itself. Such a case, however, cannot be made use of, as some have done, to prove that, because the disease was found accidentally, therefore its importance could not be great; since this argument would apply with equal force to disease of every other viscus in the body. Moreover, a distinct pigmentation had occurred. It will be observed that this man had been exposed to the sun's rays, and thus the discoloration did not receive that attention which it deserved. The same oversight occurred in another case, to which reference has already been made.

Anthony B—, æt. 28, admitted, under Dr. Addison, on August 9th, 1857, and died August 11th. He was a coachman by occupation, and about a year before his death he suddenly became hemiplegic, and has never regained the use of his limbs since. During the last few weeks of his life he had felt very ill, complaining of his head, &c. He then had another paralytic attack, and for this he was brought to the hospital, where he shortly died. He is described by the reporter as being quite insensible, paralysed on the right side, and his complexion stated as being very dark.

Post-mortem examination.—The body presented the appearance of a man who had not died from any wasting disease. The skin was of an unusually dark colour, but not to an extreme degree; the face and hands were of an olive tint; over the last phalanges of the fingers the brown tint was very striking. Brain.—The arachnoid recently and slightly inflamed; the ventricles contained an abundance of fluid; at the junction of the left corpus striatum and thalamus opticus was a mass of softened structure, about the size of a hazel nut; pituitary body healthy. Few scattered tubercles in upper lobes of both lungs. Liver, spleen, and kidneys, healthy. In one testis was a small mass of scrofulous deposit. *Supra-renal capsules* quite disorganized, from the presence of the same adventitious material which we have seen in other cases, this being homogeneous, and of a gray, semi-transparent appearance; scattered through this were small masses of yellow, cheesy material, which, probably, was the same substance in a state of decay; none of the original structure of the organs could be discovered. The masses of disease corresponded in shape and size to the organs themselves, though not quite so regular in form, and slightly larger.

CASE 11.—In the following case, forwarded by Mr. Valentine, of Somerset, the diagnosis was made some time before death. It will be observed that the patient, like some others, suffered from pain in the back and epigastrium; and the same remarkable fact may be here noticed as in several others, that he was able to walk about a few days before death, and yet at that time a total destruction of the organs must have existed—

a proof sufficient that the supra-renal bodies are not, in the ordinary sense of the term, vital organs.

William M—, æt. 35, by trade a mason, of slight build and sallow complexion. He had always had good health until the close of the year 1857, when he first came under my notice. He then complained of considerable pain in the back, between the lower dorsal and upper lumbar vertebræ. This was accompanied by partial loss of power of the lower extremities. He was cupped and blistered, and Hyd. c. Cret., with Dover's powder, was given every four hours. The mercury was not continued sufficiently long to affect the system, as the symptoms abated, and he was soon able to resume his usual work.

In March, 1858, he again applied to me, complaining of general debility, loss of appetite, and depression of spirits. It was at this time that the darkness of his complexion first attracted my notice, especially that of the forehead close to the hair, which part was completely protected from the sun by his cap. There was a sallowness over his whole body, but the parts more especially discoloured were the face, neck, and arms. This bronzing of the skin suggested that he was suffering from disease of the supra-renal capsules. He had, at intervals, pain in the epigastric region, which was very intense, attended with frequent vomiting. From the administration of steel, combined with tonics and opium, and the use of sinapisms, he derived some partial relief, so that he was enabled to resume his work for a short time; but in consequence of excessive debility and languor, he soon became totally incapacitated. From this time he gradually succumbed to the disease, his face becoming of such a dark hue that he might well have been taken for a man of colour. In the epigastrium, where mustard-plasters had been frequently applied, the skin was of a particularly dark colour. Three days before death took place he was able to walk out, but complained of intense pain at the pit of the stomach, which, however, was not constant. I saw him on the night previous to his decease; he was then suffering very much, his pulse was weak and quick. I prescribed half a grain of the acetate of morphia, to be repeated in three hours if he was not relieved. After the second dose he soon went to sleep, but died on the following morning, at half-past five.

Post-mortem examination, thirty-six hours after death.—Rigor mortis present. Body emaciated; skin peculiarly dark. There was a fair amount of fat on the walls of the abdomen. The right supra-renal capsule was wasted, the left much enlarged. The remaining abdominal viscera were healthy, with the exception of slight enlargement of the mesenteric glands. The chest was not examined, as he had never had any symptoms of pulmonary disease.

For the following observations on the condition of the supra-renal capsules I am indebted to Dr. Wilks, to whom I sent them:—"Both capsules are affected in a manner almost peculiar to this organ. I can find no trace of healthy structure, but in its place a grayish, amorphous, lardaceous matter, of the consistence of wax, which exactly resembles numerous other specimens in the Guy's museum."

CASE 12.—I would draw attention in the following case to the long duration of the disease and to the well-marked symptoms attending it, indicated by the discoloration of skin and debility, and yet, at the same time, to the amount of

physical power which remained, enabling the patient from time to time to resume his employment, and even to continue it to within a short period of his death, which at last occurred suddenly. In this case the intestinal glands were found much enlarged.

Thomas L—, æt. 32, was admitted into Guy's Hospital under Dr. Addison, on July 2nd, 1858, in an extremely debilitated condition, and died rather suddenly three days afterwards. The case was well known, as the patient had been under observation for more than two years. He lived at Walworth, and was employed as driver of a stationary engine in a seed-bleaching factory. He was first admitted into the hospital on October 10th, 1856, under Dr. Habershon, having already been an out-patient under that gentleman's care for five months previously. He stated that he had been rather a free liver, and had suffered from gonorrhœa and syphilis, and that about twelve months before (the last date) he observed that he was losing strength, and that his skin was becoming of a dark hue. He sought medical advice in consequence, and was said to have liver disease; he also had at that time pain in his side. On admission he had a haggard, worn expression of countenance, he was of spare frame, and his skin was of a dark colour, resembling that of a mulatto, and almost black on the scrotum, the mucous membrane of lips and gums also darkened in hue. Heart feeble; pulse 64, weak; chest healthy; urine natural; his eyesight was dim, and he suffered from faintness after the least exertion. The case was at once recognised as one of Addison's disease, and Dr. Habershon, in discussing what could be done for him, considering that the symptoms of asthenia were due to some loss of function of the semilunar ganglia and solar plexus (these parts being intimately connected with the supra-renal capsules), proposed the use of electricity. This was adopted, with the internal administration of iodide of potassium and bark, and the man left relieved after a few weeks. After leaving the hospital, he stated that he was better, and was able to follow his employment until three weeks before his last admission, when he took cold and become much worse. He then returned on July 2nd, 1858. He stated that his strength had been good, but it was evident that he had become accustomed to an unnatural condition, for he would not admit his extreme weakness even then, although he could scarcely stand. The skin was of a dark-brown colour, and of a deeper tinge at navel, nipples, and scrotum; mucous membrane of gums and mouth stained with patches of a leaden hue. He had dizziness and failure of vision on attempting to walk; no appetite. He after this got still weaker, and died rather unexpectedly on the morning of the 5th July.

More particulars might be added to this report from the memories of those who saw this man, who was so long under notice, but suffice it to say that the case was always headed in the report books as *Melasma Supra-renale*.

Post-mortem examination, taken from Dr. Wilks' report.—External appearance of body, spare, but not wasted; an average amount of subintegumental fat, and also fat to the usual amount in the abdomen. Muscles red and of good size, as if they had been exercised of late. The colour of the body was most remarkable, resembling that of a mulatto or one of dark blood, and contrasting strongly with the white skin of another body which lay by its side, and which it had resembled three years before. The colour was of a slight greenish brown, and the subject would

undoubtedly have been taken for a man of colour had not the previous history been known. The brown hue was universal, except on the lower parts of the legs, which were lighter, and was remarkably uniform, there being no lighter nor darker patches on any parts, excepting two black specks on the face. The axillæ, umbilicus, and genital organs, however, were of a darker shade. No distinct patches of pigment on the lips, but the margin next the skin of a dark hue. Hair darkish, but not black; eyes gray. Brain healthy; pituitary body healthy. Lungs healthy. The apex of the right lung contained a dry cretaceous mass, the size of a pea. This lung adherent by old cellular tissue. Heart.—Weight, eight ounces, small; muscle firm, red, and healthy; a small, loose coagulum on right side. Veins full of blood. Stomach.—Mucous membrane highly injected, and the surface covered with tenacious mucus, as if gastritis or a low form of inflammation had existed. Intestines healthy, with the exception of a remarkable prominence of Peyer's patches and the solitary glands at the lower end of the ileum. Mesenteric and other lymphatic glands healthy. Liver (weight, three pounds five ounces) healthy. Spleen (weight, six ounces) and pancreas healthy. Kidneys healthy, with the exception of the top of one presently to be mentioned. *Supra-renal capsules*.—Both organs quite destroyed in structure by adventitious deposit, an albumino-cretaceous material. There appeared also to have been an inflammation of their investing capsules, as they were firmly united to the surrounding parts, and were with difficulty dissected out; thus, the right was adherent to the liver and top of the kidney, and the surrounding fat could not be stripped off in the ordinary way, but, being adherent, the organs could only be rendered clean by scraping. The right supra-renal capsule was about the size of the healthy organ, but the left was puckered into a roundish mass, about the size of a walnut. When cut through they presented the usual appearance of the disease which so frequently attacks these organs, being converted into a whitish, amorphous matter, which was formerly called scrofulous. This consisted mainly of two parts—a white, brittle, cretaceous matter, and a semi-translucent, soft, dry matter, resembling a dirty coloured blancmange. The latter was probably the original or primary deposit, and the former the same having undergone degeneration. The right capsule, in addition, was softening in its middle, and contained about a drachm of a cream-like fluid. The disease on this side had slightly encroached on the kidney, the top of which contained a soft, whitish spot. The microscope showed the adventitious matter to be structureless; the softer, semi-transparent parts consisted of an amorphous substance mixed with granules; the latter being collected in small groups put on the appearance of cells and nuclei, and probably they were such degenerating, but no cell or fibre-structure could be distinctly made out. The yellower, friable matter consisted of little else than fatty and cretaceous granules. The white spot at the top of the kidney, in contact with the right capsule, contained some nuclei and nucleated fibre, and appeared to consist of a simple inflammatory product.

The semi-lunar ganglia appeared healthy, but their nerve-branches ran quite into the diseased capsules, and were lost in them. The skin, when a section was made, showed most admirably the position of the pigment. It was situated beneath the epidermis, in the rete mucosum, following the course of the papillæ, and thus exactly resembling the integument of a black man.

It will be seen that the discoloration of the skin had existed for three years, and therefore it is in the highest degree probable that the man had lived for more than that period with both capsules completely disorganized.

CASE 13.—The following is an example of death taking place at an early period of the disease, and before any marked symptoms or discoloration of the skin had occurred, or, at all events, of so slight a kind as not to attract attention until especially sought for after the death of the patient, and after supra-renal disease was known to exist. It will be observed that the man died after two or three days' severe illness, being at the time in the hospital under treatment for a cutaneous disease. It was at first thought that the symptoms might be due to the medicine which he was taking ; but, from a strict investigation of all the circumstances connected with his death, I am convinced that such was not the case. It might, however, be fairly suggested whether, with this disease of the supra-renal capsules and proneness to gastric affection, the arsenic did not excite such a condition, which was quite uncontrollable, and was the immediate cause of death ; just as a man in tolerable health, but with disease of the kidneys, may require but a slight cause to set in action all the symptoms generally associated with renal affection. Thus, the vomiting which this man had is the most frequent symptom of supra-renal disease, and, therefore, in itself not remarkable, except as regards the sudden manner in which it occurred. Should this sudden seizure not have been excited by the administration of the arsenic, the case affords another instance of the remarkable nature of the function of the supra-renal organs, a function which seems to be altogether in abeyance for an indefinite period, and yet of so important a character, or so intimately connected with the due operation of vital parts, that death may at any time result from its cessation.

George Y—, æt. 25, came to me, amongst the out-patients, on June 10th, 1858, suffering from acute eczema of both arms and hands, there having been some appearance of the eruption for six weeks previously. On the following week, being worse, I took him into the hospital. He appeared a strong, healthy looking young man, with the exception of the cutaneous surface, which formed large scabs on his arms, hands, and legs. He was not ill enough to take to his bed. The disease being acute, local emollients and alkaline remedies were given ; but the disease persisting, I ordered him, on July 6th, the following medicine :

Liq. Potass. Arsenit., $\mathfrak{m}\mathfrak{v}$;
 Tr. Opii, $\mathfrak{m}\mathfrak{v}$; ex
 Inf. Calumbo, ter die.

At the end of a week I increased the dose to $\mathfrak{m}\mathfrak{vj}$, and in a few days the scabs began

to fall from his limbs, and he commenced to improve. The cure went on rapidly; the arms were rough and of a dark colour where the eruption had been (which caused an inquiry as to syphilis), and the man was allowed to walk out of doors. On July 25th he was out in the hospital grounds, and appeared very well. On the morning of the following day, July 26th, about eight o'clock, the sister of the ward was called to him, as he was too ill to rise, and he was vomiting violently; he was afterwards purged, and again the vomiting recurred. Mr. Stocker was called to him, and found him so depressed that he was not able to articulate, and his feet were cold; he was ordered some effervescing medicine. In the evening I saw him; the vomiting and purging had then ceased for some hours, and his skin was now very hot; his pulse was very feeble, and above 100. He had spoken and recognised a friend, but he now resembled a person with delirium tremens, throwing his head about in a quick, excited way, and evidently not conscious. As to the cause of the symptoms, both Mr. Stocker and myself were afraid that he had been poisoned by the remedy, as we could not account for the symptoms in any other way. Considering, however, that the effects of the drug, when given in small doses, never come on suddenly, and that he had not yet taken as much as three grains, I was forced to suppose that a mistake had been made in the administration of the medicine, or in its preparation, or that the patient himself might have swallowed the whole contents of the bottle. Suffice it to say that, at four o'clock on the following morning, the man died, being about twenty hours after the first occurrence of the symptoms. The apothecaries' assistants were called, and a most searching inquiry took place as to the possibility of any mistake, but no error could be discovered. In the afternoon I proceeded to examine the body.

Post-mortem inspection.—The brain was healthy; the lungs also, except being highly congested, and a few ecchymosed spots near the roots; the heart also healthy. The stomach was carefully examined (for my mind was still upon the effect of poison), but, with the exception of a slightly arborescent, vascular patch at one part, there was no indication of any inflammation or irritation. It contained bilious fluid, but no mucus. The liver and all other organs were found quite healthy, when, on coming to the supra-renal capsules, these organs, to our surprise, were found perfectly disorganized by adventitious deposit. The right one was about twice its natural size, and converted into a firm, lardaceous material, such as has been before noticed in disease of this organ; the whole mass was of the consistence of wax, uniform throughout, displaying no softening nor cretaceous material in any part. The left one was much smaller; the material was whiter and more friable, but not cretaceous. The organ appeared contracted, as if the deposit was older than that in the other. The microscope showed a semi-translucent, amorphous substance, sprinkled with granules. There were peritoneal adhesions between the liver and diaphragm; and in the abdominal walls there was a small cyst, apparently an old abscess, containing some putty-like matter. *External appearance of body.*—Well nourished; limbs of good size; muscles large and red. The arms and legs were covered with brown, rough patches where the eruption had existed, and on examining the skin by the microscope a small amount of pigment was seen beneath the epidermis, in the rete mucosum. There were brown spots on the thighs, but whether these had been the seats of the rash was uncertain. The skin of the body was pale and natural, that of the face was slightly sallow. The skin of the genital organs and nipple was dark. My own impression, as well as that of others who

now looked at the skin with a critical eye, was that, apart from the spots affected by the eruption, there was no discoloration ; it may be mentioned, however, at the time while the patient was in bed, and when the nurse observed a sallowness of the skin, that Dr. Steele, the superintendent, on going his rounds, thought the man might be dying of supra-renal disease. There were no morbid appearances whatever indicative of arsenical poisoning, and thus the conclusion is justly arrived at that the death, as well as the symptoms, were due to the disease of the supra-renal organs.

CASE 14.—In the following case, which occurred in the north of England, it will be observed that the skin was unusually dark, and that the ordinary symptoms of Addison's disease existed. Although, therefore, only one supra-renal capsule was sent me, I should think it most probable that the other was similarly affected ; at least, I have never yet met with an instance of one organ alone being the subject of the disease. It will be seen, also, that the further description of the other organs has reference merely to such slight changes as congestion, &c., and due, in all probability, to the mode of death. The following is the history, as forwarded by Mr. Welford, of Bishopwearmouth, in whose practice the case occurred :

W. S—, æt. 21, a pupil to a druggist, was first seen by me on February 21st, 1859, for rather a severe attack of inflammatory sore throat ; but he had for some months previously been complaining of excessive debility, without anything to account for it, although his friends remarked that his complexion was getting darker ; indeed, they thought he had jaundice. During this time he had taken various kinds of medicine, without experiencing any relief. After two or three days, the throat affection was quite relieved, but the great weakness and rapid pulse, together with his dusky appearance, induced me very carefully to examine the surface of his body, when I found several dark olive-coloured patches, one or two on his shoulders and chest, one on each side of the umbilical region ; but the most marked discoloration, amounting to almost an ecchymosed appearance, was on the integument covering the penis and scrotum ; so dark were the genital organs, that his friends asked me if they were not mortified. I also detected considerable enlargement of the liver during my attendance ; vomiting was persistent, and there was also great thirst ; urine dark, and occasionally passed in large quantities. The skin could not be said to be dry, yet the moisture did not amount to perspiration. The debility increased daily, and was accompanied, during the last few days, by stupor, from which, however, he could be roused by loud speaking. He derived no benefit from the treatment pursued, but gradually got worse, and died on the 5th of March.

Post-mortem examination.—Body not emaciated, but had a livid, dusky appearance ; the genital organs were not near so dark as during life. On cutting through the abdominal walls on the surface of the left rectus muscle, near the umbilicus, was

a patch of black exudation, more like melæna than anything else, penetrating the muscle to about a line in depth; a similar patch was found on the under surface of the right rectus, a little below the umbilicus. The liver was enormously distended by portal congestion, but perfectly healthy. The left kidney was about twice the natural size, but healthy in structure, as was also the corresponding supra-renal capsule. The right kidney not so large as the left, but yet larger than natural, and healthy in structure. The right supra-renal capsule was diseased, containing a small collection of cheesy matter, with a drop or so of thinner fluid in the centre. Other organs healthy.

The supra-renal capsule was examined by Dr. Wilks, and found wholly changed in structure, from the deposition of a firm, albumino-cretaceous deposit throughout its substance.

CASE 15.—The next case occurred in the hospital, but as the patient was only under notice a few hours before death, her earlier symptoms had not been observed. The case then however was so marked, that the diagnosis was at once made, and the true nature of the disease insisted on. Attention may be drawn to the peculiar choreal symptoms which this patient manifested, as well as the more usual ones of prostration and sickness.

Martha M'C—, æt. 26, admitted under the care of Dr. Pavy, July 27th, 1859. Her skin presented a marked example of the appearances characteristic of the morbus Addisonii, and was at once recognised as such by several independent observers. She had been engaged in service, and brought with her a letter of recommendation from a gentleman in whose house she had formerly lived. He used the expression, "She seems to have been overworked, and is now suffering either from heart disease or impaired digestive powers." We cite this in order to show the impression which her constitutional symptoms had conveyed to an intelligent but non-medical observer.

It appeared that the change of colour had been noticed as gradually increasing for eight months past. There had been no jaundice, and the sclerotics were of a pearly whiteness. Her face, neck, and shoulders were of a peculiar dirty olive tint; on other parts of the body the colour was not specially remarkable. She was not much emaciated. While being questioned, certain twitchings were noticed, resembling those of chorea. She had been more or less ill for about a year, feeling weak and ailing, but without being able to specify any particular complaint. She attributed her ailments to overwork. Soon after her admission vomiting set in, which persisted in spite of remedies, and produced great prostration. Stimulants were freely used, but death took place on the 30th of July, four days after admission.

Post-mortem examination.—The appearances of the body were again observed, and it was noticed that the complexion was very dark, brown as bistre about the neck, axillæ, and flexures of elbow-joints; elsewhere irregularly so, especially on the forehead, which was patched irregularly with darker parts on a sufficiently dark ground. The patient's body was very well developed and in good condition, with

plump and muscular limbs. None of the organs were found diseased except the supra-renal capsules. The lungs were dark from venous engorgement, but tissue healthy. Heart healthy, and contained coagula. Mucous membrane of stomach healthy, except a slight ecchymosis at the cardiac end. Liver healthy; to its inner surface was adherent the right supra-renal capsule, which, like its fellow, was imbedded and lost in a mass which was bounded externally by lymph, which occupied the cellular tissue originally surrounding the capsule, the whole being a mass of about the size of three segments of an ordinary-sized orange, and roughly of the same shape. In section, the interior presented masses of a yellow substance, in a more or less softened state, in the centre of the capsule. A quantity of encysted, puriform fluid was found in the left capsule. They were about equally affected. The kidneys, even though closely in contact with the diseased capsules, were quite unaffected and healthy, their containing fibrous tunics being non-adherent.

CASE 16.¹—The following case is one like many others in our series, a case observed by a gentleman who was familiar with the disease, and yet quite unprejudiced in his views, affording, therefore, at the time of its occurrence, additional proof of the truthfulness of Addison's researches. Mr. Bacon had not long left Guy's Hospital, in order to practise at Norwich, when he was requested to see the subject of the following case, just previous to the death of the patient. It is no disparagement to the other medical men, who were unfamiliar with the peculiarities of the supra-renal affection, to state that the case had been regarded as hepatic; but Mr. Bacon, with his practised eye, at once declared the true nature of the disease, and death soon came to verify the correctness of the diagnosis. We may here allude, as in several other cases, to the nervous symptoms associated with the disease, this lad having, during the last two days of his life, anæsthesia of the hands and feet, attended with pain.

John F—, æt. 15, a well-made lad, of average size, had always had good health till the present illness, which commenced about seven months ago with loss of appetite, nausea, and gradual diminution of strength, without any apparent cause. Cachectic sores soon appeared on his thighs and legs, which healed but slowly, and he began to complain of giddiness and pain in the head. These symptoms continued for many weeks, at times being so far mitigated as to induce the boy to attempt a return to his work, which was that of a plasterer; but two or three such attempts only resulted in failure, and on one occasion he fainted on the road, and was brought home by a fellow-labourer. He had medical advice from two or three sources, and was supposed to be much benefited at one time after a long course of treatment. It

¹ "Case of Melasma Supra-renale. By G. Mackenzie Bacon." From 'Med. Times and Gazette,' August 6th, 1859.

is worthy of note that his appearance was attributed by his medical attendants, as well as by his friends, to jaundice; with a view to cure which the latter performed several superstitious rites with great assiduity, one of which consisted in the daily evaporation of a portion of his urine. As soon as a month after his first attack his complexion, from being quite fair, was noticed to have become darker, and his face was of a dirty yellow colour. This increased in intensity as the end of life approached. During the last week he vomited constantly all he took, and was much troubled with hiccough, became gradually weaker, and died quietly and rather unexpectedly. During the last two days he had anæsthesia of feet and partly of legs, with pain in toes and fingers. From these symptoms I was led to diagnose Addison's disease.

Post-mortem, eighteen hours after death.—Rigor mortis well marked. Almost the entire surface of the body, with the exception of the upper portion of the chest, which was of an ordinary flesh colour, was of a dusky olive hue. The face, hands, and legs, were the darkest; but the back, outside of thighs and buttocks, were of a most decided tawny colour; on the face there were patches of a brown colour, and on the front of both knees, and along the course of the spine in the dorsal region, were others of two or three inches in extent of a *very dark brown*. The scrotum was much discoloured, almost black, a change of comparatively recent date, and the penis also, but to a less degree. The boy had quite the appearance of a mulatto. The conjunctivæ were quite white and pearly. There was no opportunity of examining the urine, but the amount secreted for the last few days was but small. Body not much wasted. The left supra-renal capsule was rather larger than usual, and much altered in character, the distinctions between the various portions quite obliterated. The stroma was pale and flabby, and in it were numerous patches of a firm, light-yellowish material, having the look of strumous deposits, one nearly as large as a hazel nut. The right capsule was about its normal size, and studded with yellow spots similar to those on its fellow, but not so large—the deposits being evidently of the same nature, but of longer duration, and undergoing degeneration. The mesenteric glands were enlarged, but not to any great size. There existed some fine pleuritic adhesions on the right side, but the pulmonary tissue of both lungs was *positively healthy*, and neither in the kidneys nor elsewhere was there any trace of disease.

The lad's father died of phthisis pulmonalis, as had also other relatives.

The early age at which the disease occurred in this case is worthy of notice.

CASE 17.—The following is interesting, as being one of those already referred to in the preceding remarks as associated with disease of the spine, and therefore suggesting the question whether the change in the supra-renal organs be not actually set up by their contiguity to an inflammatory process in another part. If this be the case, the disease in this instance might be said to have been produced by a fall. The nervous symptoms here described appeared to be due, not to the supra-renal affection, but to the disease in the spine; these, of course, must be carefully distinguished. The case occurred in

the practice of Dr. Glover, of Newcastle, and is thus described by him.¹

William B—, æt. 39, of middle height, but small in bulk ; temperate ; a furnace-man in chemical works ; father fair ; mother darkish ; brothers fair. The father and one brother died of phthisis, and two or three sisters in infancy. Had been delicate in childhood. The best idea of his appearance and symptoms will be gathered from a few of the notes of his case taken at different times, only premising that about eight years ago he had an awkward fall, which he felt at the time to hurt his back, and that about five years ago he became yellow (his wife's account,) as to be treated for jaundice, without, however, any improvement in his colour.

June 19th, 1856.—Since about Christmas has had pain in the loins and abdomen, with sensation of great heat. Skin very dark, yellow-brown colour ; since end of January bowels costive ; stools variable in colour, light and dark ; tongue clean ; vomits his food at times ; urine scanty ; is very deaf.

22nd.—Has had pain in the back, on both sides, increased on coughing ; pulse 80, intermitting.

30th.—Colour much the same. This bronzed colour seems to have preceded the pains in the back and belly, &c.

January 3rd, 1857.—Sick last night ; twisting pain in stomach.

7th.—Sick this morning ; lifting sensation at end of stomach.

March 14th.—Very dark ; weak in the back ; complains of something holding him from the umbilicus to the back. Owing to his extreme deafness, of thirty years' standing, he is very unintelligent and unintelligible in describing his sensations. He was able to work at cleaning bricks in the sitting posture for a little time after this.

March 25th, 1859.—Pulse 96 ; watery expectoration, with a little cough ; sad complaint of pain holding him below and to the right of the umbilicus, and in the right iliac region, causing the right thigh to shake when he attempts to stand, and prevents walking or standing in the erect posture ; thinner ; has been darker, to his sister's knowledge, fifteen years. About this time, too (April, 1859), there was observed an acute prominence of the spine in the upper lumbar region.

June 7th.—The case evidently closing. Has a hollow cough ; pulse very feeble ; emaciated ; pain in the right hypochondrium ; vomits nearly everything. Died on the 10th.

The principal features of the case were—

1. Darkness of the skin, obvious even to a cursory observer, general over the body, but worse at parts, as around the nipple, a dark patch on the outside of the knee, the hands, the mucous membrane of the lips, and especially the generative organs. The tint was a dark, yellow brown, generally like that of a mulatto, and that of the organs of generation approaching that of the negro. He had always been dark, but much more so of late.

2. A sensation of something "holding" him from navel to back ; great weakness in the back ; lately inability to walk or stand, excepting in a bent position, and with great pain and acute curvature of the lower dorsal and upper lumbar vertebræ.

3. Vomiting and waterbrash, more two years ago than lately, until the last few days of life, when vomiting was again troublesome.

¹ Described in the 'Edin. Med. Journal,' May, 1859.

4. Cough and expectoration; nothing very noticeable in the chest sounds; pulse weak, 90—100, occasionally intermitting.

5. Gradual emaciation, exhaustion, and death.

Autopsy.—Thorax.—The left lung adherent at many points to the side, but quite crepitant; right lung indurated at apex, but containing no recent tubercle, and generally crepitant.

Abdomen.—Here were noticed only two lesions—(1) Hardness of the left supra-renal capsule, which, on being opened, was found to be filled with a dryish, white, cheesy matter; and (2) psoas abscess, bulging on either side of the two last dorsal and two upper lumbar vertebræ, which were much diseased by caries; the adjoining vertebræ were soft. The right supra-renal capsule was only imperfectly removed, but from the shreds of it examined it seems to have been affected as the left. Both were sent to Dr. Addison, and examined by Dr. Wilks, pathologist, of Guy's Hospital. The following is Dr. Wilks' account of the specimen, addressed to Dr. Addison:

"I have examined the specimen of supra-renal capsule, and it appears to be a capital example of *the disease*. The organ is quite destroyed by the peculiar unorganizable and cretaceous matter we have before so often seen. This matter exists in the specimen in all its stages, as if the destruction of the organ had been proceeding with the utmost possible slowness. Thus, some parts of the diseased mass, especially the edges, consist of a peculiar gray, semi-pellucid matter, of cheesy consistence, which we have hitherto looked upon as the more recent deposit, and seen especially in the acutely fatal form of the disease, or when associated with maladies elsewhere. The great bulk of it, however, consists of a material of an opaque white colour, of the same consistence as the former, and, in fact, being the same substance undergoing decay. The microscope exhibits no more than usual; that is, an almost amorphous matter, containing a few ill-formed nuclei and granules, the latter being fatty in the opaque white part. There are also scattered through it some pieces of cretaceous matter. The smaller portion, which is said to be a portion of the other capsule, consists almost entirely of this cretaceous matter.

From the occasional association of this disease of the supra-renal capsules with tubercle, I imagine it right to consider it nearly allied to a scrofulous affection of the organ, and comparing this specimen with others of a like kind, and from considering the time necessary for cretaceous changes to occur in tubercular deposits, I think there can be no doubt that the disease has been of very long duration, and therefore the necessity, as you often observe, for having such cases under notice for several years, a fact which does not seem to be generally understood. It may be interesting to remember that in one of your published cases¹ the spine adjacent to capsules was diseased, and the same also occurred in another case, reported, I think, in the 'Medical Times' about three years ago, from St. Bartholomew's Hospital."

CASE 18.—The following was the last case which Dr. Addison had in hospital, and he pronounced upon it at once, and most unhesitatingly, as a most characteristic example of the disease known by his name. In the present state of

¹ Case 3 of present series; also Case 25.

opinion respecting this remarkable affection, I may be allowed to deviate from the strictly scientific delineation of the cases, and allude to any circumstances affecting the history of its discovery, and bearing on the probabilities of its being a truly scientific deduction or not. Thus, in the present case, I may be allowed to state, in answer to those who have hinted at the diagnosis being nothing more than a guess, that, being away from the hospital during the time this case was in the institution, I was urgently written to by Dr. Addison to have a drawing or model made of the patient; also, that I myself wrote to Mr. Hutchinson, who was collecting cases for the 'Medical Times and Gazette,' informing him that he had an opportunity of seeing a model case of *morbis Addisonii*. Unfortunately neither Dr. Addison's nor my own wishes were accomplished, as the lad soon died; but so certain was the feeling of the correctness of the diagnosis, that a special appointment was made with Mr. Towne at an early hour of the morning, in order to model the organs when removed. It is thus seen that the diagnosis was as positive and as much believed and persisted in as any opinion which is formed as to the nature of a disease can possibly be. I make these remarks in reference to Addison's last case, in order to show that he had no doubt as to the correctness of his first conclusions.

Robert B—, æt. 13, admitted under Dr. Addison into Guy's Hospital, on August 17th, 1859, and died August 20th. The case was sent in by Dr. Aldis as one of supra-renal disease, and as soon as Dr. Addison saw the patient he recognised it as a very perfect example of the disease. The boy was universally discoloured, being of a yellowish-brown hue, though not so dark as has been observed in some other instances; he was so weak as to be unable to stand, and when made to sit up in bed to undergo a physical examination of the chest, he was so feeble that he requested to be immediately laid down again, so powerless and utterly exhausted did he appear to be. Dr. Addison unhesitatingly declared his conviction of the correctness of the diagnosis, and that it was a most characteristic example of the affection.

The following is the history of the case as given by Dr. Aldis :

Robert B—, æt. 13, was admitted under my care at the Surrey Dispensary, on March 29th, 1859. The skin was tinged in every part of the body with a dark-olive colour, accompanied by nausea, occasional vomiting, great pain in the back, and prostration. He always felt languid, and disposed to lie down, which he frequently did whilst waiting to see me at the dispensary. The eyes were sunken, with a dark-

blue areola; conjunctivæ of a pearly white colour; the pulse was extremely feeble, and the urine dribbled away. He had lost flesh, and the muscles were flabby, but a stethoscopic examination of the chest produced no evidence of pulmonary disease.

It appeared, from the statement of the mother, that he began to droop about four months previously, became tired and inclined to sleep. Before these symptoms were remarked he was very stout, with a very fresh colour and clear skin. Two months after the eyes were observed to sink in his head, the appetite failed, and nausea supervened, which was followed by vomiting. The skin became yellow, and afterwards "bronzified." The doctors said it was jaundice or liver. The water soon began to dribble, with wasting of the body and drowsiness. He used to fall asleep, and was roused with difficulty; he complained frequently of great pain in the back, pit of the stomach, and on the clavicles, with extreme feebleness.

The vomiting ceased during the use of effervescing medicine, and the pain in the back, with the dribbling of water, subsided while he took steel combined with other tonics. But nothing seemed to relieve his extreme debility and flabby state of the body, cod-liver oil being tried to no purpose. At length his feebleness became so urgent that I recommended him to be placed under the care of Dr. Addison, at Guy's Hospital, believing that he suffered from disease of the supra-renal capsules, and I sent a message to that effect to Dr. Addison, who replied that I was right in my opinion. The lad only survived three days, and during this time he was often delirious and had slight convulsive attacks.

Post-mortem examination.—Body spare, but not wasted, and having a moderate amount of integumental fat in all parts. It was universally discoloured, being of a brown hue, and uniformly so, no parts being unaffected, except the palms of the hands and the soles of the feet. There was a greater intensity of colour over the back of hands and feet, especially over the joints, but there were no defined patches in any part. There was also a little pigment-deposit on the lips. The colour on the body was of a light brown, and so universal that, unless the contrary had been known, the boy might have been looked upon as a native of some southern climate, or, at all events, as having some dark blood in him.

The body was opened, and no disease was found in any part save the supra-renal bodies. There were no tubercles in the lungs, nor was there any evidence of scrofulous affection elsewhere. Peyer's patches in small intestine were much raised, and the solitary glands were very distinct. The *supra-renal bodies* were both diseased in the usual manner. They were slightly larger than natural, and were wholly converted into a tough, yellow, amorphous matter, interspersed with some grayer and more translucent substance. There was not a trace of the original tissue to be found, and the change must have been progressing for a very long period. There was no chalky matter present.

[Preparation, Skin, 1641 ⁴⁰. Wax Models, 246 ^{10 11 12}.]

CASE 19.—The following case¹ occurred in the country, in the practice of Dr. Houseley, of Worsop, near Mansfield, a stranger to our hospital, and a perfectly independent observer, but, struck with the remarkable nature of the case he was

¹ Published in the 'Lancet,' July 28th, 1860.

treating, he believed that it might be an example of Addison's disease, corresponding, as it did, in all its symptoms with the description which he had read. He, of course, could not positively insist on the diagnosis, seeing that he had not at that time any previous experience of the disease. The result proved that Addison's description must have been pretty correct.

Henry G—, æt. 33, farm-labourer, unmarried, states that he had gonorrhœa in November, 1858; was ill in March, 1859, which he attributes to extra work during the lambing season. He consulted the late Mr. Hammond, and was a week absent from his work. After resuming his occupation for two or three weeks he was again compelled to rest. He was now ordered to live as well as he could, and take cod-liver oil. On this occasion he was away from work for three weeks, and then returned to his occupation, and continued until the end of June, since which time he has been unable to work. At this time I saw him; he complained of weakness, loss of appetite, nausea, occasional vomiting, pain at the epigastrium, bowels constipated. The colour of his face and hands was brown, which I thought might be caused by the hot weather, for he was not confined to the house. About August, 1859, I considered the case might be one of Addison's disease. In the beginning of September, at my request, he was seen by a medical friend, who looked upon the case as hepatic disease.

This gentleman advised him to have as good diet as he could procure; at the same time I had prescribed the Tinctura Ferri Sesquichloridi. After this I saw very little of him until February 26th, 1860, when he sent for me. I was now informed that he had been at home during the last five months, and was becoming weaker; appetite bad; at times feels sickly; complains of pain a little to the left of the navel; bowels rather constipated; stools dark-coloured; urine acid, lightish colour; pulse 94, soft and feeble; slight dulness on percussion below left clavicle; sounds of heart feeble. The brown colour of the face and hands still continues; over the chest it is almost natural, but becomes much darker over the abdomen and thighs; whilst that of the penis and scrotum is a dingy black, which he has noticed for the last two years. There is also a dark ring around the umbilicus. No odour is perceptible about the body of the patient. I attended him for a short time, and he felt somewhat better.

I was requested to see him on April 20th, when the chief symptoms requiring treatment were constipation and sickness, the latter being incessant for the last few days. He died on the evening of April 27th.

The *inspection* took place twenty hours after death. Mr. Ward, of Wellow, kindly assisted me. Rigor mortis well marked; body somewhat wasted. Colour of skin lightest over legs and chest; darkest on penis and scrotum. Portions of the organs, with the supra-renal capsules, I forwarded to Dr. Wilks, who favoured me with a note, from which I extract the following remarks:—"I have no doubt that yours is a genuine example of the disease (Addison's), and that the capsule which is now before me is a true specimen of the morbid change. It consists of a hard mass of fibro-albuminous tissue, degenerating in parts, exactly as we have before seen. This tissue is smooth, firm, and of a pinkish colour. When examined by the microscope, it is found to be composed of nucleated fibre. In the midst of this are some yellow, softer

masses of the same, in a state of degeneration, and resembling what is ordinarily called scrofulous matter. The skin shows the true pigmental change in a very beautiful manner. I have made a section, and the colouring matter is seen beneath the cuticle, in the rete mucosum, following the course of the papillæ, such as is met with in the skin of dark races of men. The kidneys, liver, and spleen are quite healthy. The liver has, near the surface, some cretaceous masses, which are probably the remains of some old tubercular disease."

CASE 20.—MR. Valentine, of Somerset, having already sent us one specimen of the disease (Case 11), was in a position to recognise it when it again presented itself before him; thus, after three years, he was enabled to forward specimens of another good example of the *morbus Addisonii*.

The patient, it may be remarked, had pain in his back, but after death no especial cause could be found for it, and therefore it must be placed amongst the symptoms of the supra-renal disease. It was here noticed, as in several other instances, that the parts of the body most exposed were those which were of the darkest hue.

William P—, æt. 30, a marine-store-dealer, had always enjoyed good health until about June, 1860, when he discovered that he was gradually losing flesh and strength. He continued to follow his occupation until August, on the 7th of which month he first came under my care. I found him extremely prostrated, suffering from great irritability of the stomach, acute pain in the lower part of the back, and loss of appetite. The skin of his face and body was of a dark, dusky hue; the pigment was not deposited in patches, as I have observed in some cases, but equally diffused, and having a deep-bronzed appearance. As he had always a sallow complexion, I thought his symptoms might possibly have arisen from a disordered stomach, and gave him a gentle emetic, and afterwards quinine. On the 9th I again saw him; the irritability of the stomach still continued, attended with distressing weakness. It then occurred to me that he was a victim to disease of the supra-renal capsules, and that the sickness was only caused by sympathy. I tried several remedies to relieve the sickness, but without any permanent success; it continued, together with great pain in the back, until his death, on September 22nd.

I made a post-mortem examination on the 24th. The body much emaciated, the whole surface being of a dark-tawny colour, particularly the parts exposed to the sun. In the neck I observed cicatrices of old scrofulous abscesses. The lungs healthy. Head not examined. On opening the abdomen every organ was found healthy, with the exception of the supra-renal capsules, which were wholly disorganized. Their normal structure was destroyed, and their place occupied by a scrofulous deposit, in a softening condition.

These organs were sent to me by Mr. Valentine, and found, as he states, totally destroyed by a yellow, amorphous deposit.

CASE 21.—This case was sent to the hospital by Mr. Toulmin, of Hackney, who recognised the nature of the disease, the symptoms being remarkably characteristic. It has already been remarked that, with the exception of the case already described by Dr. Addison, this is the only one where pigment was found in the internal organs; also it may be noticed that the parts most exposed were those most discoloured; also the parts where blisters had been applied, and where the garters had been bound, were darker than the remaining surface of the body.

Sarah S—, æt. 37, admitted, under Dr. Gull, on May 31st, 1861.¹ Two years before, she noticed that her skin gradually assumed an orange tint, which had increased since. Concomitant with this her health declined, until she was unable to take food or exercise, and became quite prostrated. Up to this time her health had been good, and her family showed no hereditary disease. She was, at first, a patient under the care of Mr. Frederick Toulmin, of Hackney, who, recognising the case as one of Addison's disease, sent her to Guy's Hospital. On admission, her skin was coloured like an Arab; the darkest parts were those round the nipples. Conjunctivæ pearly white. She was much wasted, and unable to leave her bed. Pulse 80, small, and scarcely perceptible; the pulsation was so feeble that she had lost motion and sensation in her left arm by leaving it out of bed. The breath had a faint saccharine smell. Bowels regularly opened. Urine natural in quantity, contained no sugar nor albumen, pale-straw colour. She was sick, and unable to take anything but brandy. She died on June 15th.

Autopsy.—The following is Dr. Wilks' account of the autopsy:—Body in a tolerable condition as regards robustness and fat, the limbs being not at all wasted, and there being sub-tegmental fat on the abdomen. The colour of the whole body was dark, but not so intense as seen in many other cases. There were pigmental patches, but the discoloration was tolerably uniform, though more in some places than others. Thus, the face was the darkest, and presented the very characteristic appearance of the disease, the eyes being sunken, and the expression indicative of utter exhaustion, as is witnessed in those who have died of peritonitis or cholera; the lips covered with spots of pigment; the axillæ were dark, and there was a dark line above the knees, where the garters had been tied. Brain healthy, rather pale and soft. The apices of the lungs indurated by chronic pneumonia. Heart very small and feeble; the left ventricular walls were very thin. Muscular fibre pale. The omentum, which was thin and contained but little fat, was found covered with specks of pigment of a black colour; also, here and there, a black speck on the peritoneum. The surfaces of the ovaries were particularly noticed as thus spotted. The stomach was healthy. The glands of the duodenum slightly enlarged. Mucous membrane, near the pylorus, covered with black points of pigment. The solitary glands were very prominent; also Peyer's patches much raised and well-defined. The solitary glands in

¹ Reported by Mr. Forman, and published in the 'Med. Times and Gazette' of July 20th, 1861.

the cæcum, in like manner, were very distinct. The mesenteric glands and the liver were quite healthy. On removing the other abdominal viscera, the supra-renal capsules were found to be converted into hard masses of disease, and adherent to adjacent parts by tough, inflammatory tissue; thus, the left adherent to the pancreas, and the right to the upper part of the kidney and under surface of the liver. These organs, however, could be dissected off, their structure being in no way implicated. The supra-renal bodies, or, rather, the diseased masses which took their places were not very large—in length about that of the organs themselves, but not so broad. On cutting them through they were found softening in the interior, the exterior being composed of yellow, firm material, such as is observed in other cases, but the interior had softened into a cream-like matter, like pus, or rather like purulent mucus, the fluid being viscid.

CASE 22.—The next was a case in which the discoloration was slight, and not sufficient to attract attention at once, it being attributed to exposure to a tropical sun. This absence of marked pigmentation, combined with the short period during which an opportunity existed for watching the patient, accounted for the want of a decided diagnosis. I happened, however, to see the patient with Dr. Habershon, whose case it was, and a discussion took place as to the nature of the complaint. Supra-renal disease was suggested, but not insisted on, for reasons above stated. The prostration was most remarkable. The case was reported in the last volume of this journal.

George A—, æt. 23, admitted under Dr. Habershon, on April 10th, 1861. He had been a lighterman, and until twelve months previously had enjoyed good health. At that time he was working very hard, and had slept in imperfectly ventilated cabins; several times he had got his clothes wet from falling into the river, and soon afterwards he began to feel weak, and unable to do his work in his usual manner. Still he did not suffer from any cough nor from pain at any part. He stated that three years previously his skin became sallow, but this discoloration disappeared; for five months, however, it assumed the colour observed on admission. Some time previously he had had syphilis, and he had been on the coast of Africa. Three weeks before admission he went to Sydenham, with the hope of recovering his health; but after taking a dose of castor oil, violent vomiting came on and continued, along with great prostration of strength. When brought to Guy's Hospital he was spare, and had a peculiar sallow, semi-jaundiced appearance of the face, and numerous dusky-red blotches were observed on the cheeks and forehead; the discoloration was very much less on other parts of the body. He was almost pulseless, and was cold and faint; he had had violent vomiting a short time before. The eyes were sunken, and the breath was short; the abdomen was contracted, and no tumour could be felt, neither was there any evidence of disease of the chest. The tongue was clean; the motions were dark, and the urine was high-coloured.

On the 17th he was rather more comfortable; the mind was clear, but the vomiting continued; food was at once rejected, and he also brought up a considerable quantity of green fluid and mucus. On the 20th the vomiting continued, and he was more prostrate; the tongue was injected and dry; the pulse was slow, very compressible, and irregular. He appeared sleepy, and was entirely free from pain. He died on the following morning.

Post-mortem examination.—Body not wasted; face olive brown colour; genital organs very dark; body and limbs only slightly discoloured. One or two lobules at the apex of the right lung were found to be white and consolidated; the other viscera were healthy. The stomach had a considerable quantity of tenacious mucus covering its membrane. There were numerous patches of arborescent injection of the capillaries, and some points of ecchymosis; this was most marked at the greater curvature. The mucous membrane of the first part of the duodenum was injected, and Brunner's glands were remarkably distinct. The *supra-renal capsules* were much enlarged, hard, and dense, their external surface was irregular, and the section presented dense, whitish, semi-translucent tissue, with yellowish, cheesy matter; also some cretaceous material. The nerves, as they entered the capsule, appeared contracted in the fibrous deposit, but the semi-lunar ganglia had their usual appearance.

CASE 23.—The following is a most marked example of the disease. In reference to it, I may say that Mr. Stedman, who sent the specimen, was formerly a practitioner in Southwark, and a frequent visitor at Guy's Hospital. He thus became conversant with the disease, and his ready diagnosis is accounted for. It will be seen in his description of the case that only one supra-renal capsule could be found, and he inquires of me the cause of the absence of the other. In answer to this, I may state that cases are recorded where no supra-renal capsules existed in the body, and this has been already used as an argument against Addison's conclusions as to their importance in the animal economy. It has, however, never yet fallen to my lot to note their absence, and this being so, I am naturally sceptical as to the statement, especially when I have found students at a loss to find them when the body has been before me, whilst on a stricter search they have been discovered mutilated by the act of manipulation, having, perhaps, previously undergone a softening process from decomposition. If, too, suppuration had existed, the organ would no doubt have been destroyed, for as soon as the abscess had been burst no trace of the organ would be left.

I may add that a brother of Mr. Stedman saw the man who was the subject of this case, and he tells me the change in the colour of the skin was most remarkable.

Mr. Stedman will pardon me, I am sure, for introducing his first short, hasty note, accompanying the preparation when sent to me, and before he had written the following detailed history, and, of course, previous to his having had any communication from me. I do so because it shows that Mr. Stedman's mind was fully made up as to the nature of the case, and that a diagnosis of the disease is open to any one who is unprejudiced and cares to take a little trouble in the matter.

DEAR DR. WILKS,—I have sent you off this evening per train the left kidney and supra-renal capsule of a man, æt. 32, who died yesterday, after an illness extending over four years, variously described by various *savans* (?), but, thanks to Guy's, recognised at once by your humble servant. The capsule on the right side was totally absent, there was no trace left; rather a singular feature, and one I have never realised before—have you? Perhaps it had been a congenital *non est*—or had it degenerated to *nil*? The discoloration of skin was beautifully marked; the back was like mahogany; the penis and scrotum as black as a nigger's; the conjunctivæ pearly white, and the corneæ glassy. A peculiar sinking at the epigastrium was his most marked complaint; great vital prostration, of course, and constant vomiting during the last three days. He had begotten a child within these last twelve months—a fine healthy product at present. Will it inherit?

I am, very truly yours,

Godalming.

JOHN B. STEDMAN.

Edward P—, æt. 32, born of healthy parents, and himself enjoying a good state of health until four years since, when he was seized with vomiting and purging, which continued on him some time; and although he kept at his work (which was agricultural), he did not recover his powers, feeling a constant lassitude. He suffered no pain, but had a constant *sinking* feeling in the abdomen, being frequently sick and very flatulent. His skin from the first assumed a yellowish tint, which continued increasing in intensity until a darker hue was attained, and his eyes had a wild expression about them.

About nine months after his first seizure he was unable to continue his work, his strength almost entirely failing him. He sought advice, but derived no benefit, his maladies being ascribed to various causes. He continued in the same condition, except that his skin became darker, until February, 1861, three and a half years after the date of his first illness, when he came under my care, and the disease having then assumed all the striking characters of *melasma supra-renale*, was at once diagnosed. The watery and pearly eye, with the mulatto-like colour of the face, with darker patches of colour in various parts of the body, such as the back, the thighs, the folds of scrotum and penis, were well marked. Ammonia, iron, quinine, &c., were given with some apparent benefit. He died on August 5th, 1861, his death being preceded for forty-eight hours by constant sickness, with total prostration.

In April before his death a healthy child was born to him, whose future career I shall watch with interest.

Post-mortem examination, twenty-four hours.—A deep layer of fat lined the abdominal parietes, an inch and a half in thickness. No emaciation anywhere. The different organs presented no abnormality. The right supra-renal capsule was entirely wanting—not a trace existed; the left was found large, hard, and nodulated, and sent to Dr. Wilks for elucidation.

“This afforded a capital specimen of the disease. The capsule was converted into a roundish mass, and which, on section, showed a tough, albumino-fibrous substance, constituting its circumference, whilst within was an opaque, friable matter, in which were some chalky grains.”

CASE 24.—Just as in the previous case Mr. Stedman, being well acquainted with the disease, at once pronounced upon its nature, so in the following, Mr. Harris, who had no previous knowledge of it excepting through written descriptions, could do no more than form a surmise as to the nature of the case from the resemblance which these had to the case under his notice. His suspicion, however, was completely verified by the post-mortem revelation. The following is the history, as sent to me by Harris, of Hackney, on October 17th, 1861:

W. C—, æt. 46, a master painter and glazier. His habits were extremely temperate. He worked at his trade to within six months of his death. He was the father of eight children, all living, and at present in good health. His father and one brother died of phthisis. About six months back he complained of cough and night perspirations. His wife noticed that his skin became very much darker, but she had observed this gradual darkening for the last two years. Two months back he called on me, as his face and hands were so discoloured that his friends told him that he had the jaundice. I soon convinced him that he was not suffering from this complaint, as all the symptoms of jaundice were absent. He complained very much of want of appetite, sickness, and great weakness. It was a common thing for him to bring up his dinner, and sometimes his breakfast. His pulse was quick, his tongue clean, the urine natural in appearance, and the evacuations from the bowels healthy. I discovered tubercles in the upper part of each lung, and I also put the case down as one of disease of the supra-renal capsules, described by the late Dr. Addison. A month before his death he had an attack of hæmoptysis, which soon subsided. Latterly his cough was not very troublesome, and he had little expectoration; his own words were, “I don’t think much of my cough.” He complained principally of extreme weakness and great sickness. Three days before his death I was called to him, on account of the constant vomiting; all remedies proved useless, and he died October 6th, 1861, not being able to retain anything on his stomach. His skin was the colour of the darkest bronze; I think I never saw a mulatto darker; the hands and face were the darkest parts of the body.

Post-mortem appearances.—The body was much emaciated; there was no fat under the skin. The lungs were studded with tubercles; in the apices these were collected in masses, and some were in a softened state; portions of the lung sank in water like pieces of lead. The left lung was adherent throughout to the costal

parietes. All the other organs of the body were healthy, except the supra-renal capsules; these I sent to Dr. Wilks, of Guy's Hospital. "These organs were considerably enlarged, and wholly converted into a yellow, friable substance, like scrofulous matter. This, as in other cases, was in isolated masses, with some firmer and whiter albuminous substance between."

CASE 25.—I report the following case, not as a good example of the affection under notice (although I have no doubt that the patient died of supra-renal disease), but because I wish, in all fairness, to omit no case which has come before me where the organs have been found affected. It is interesting, as making a third case in the series where caries of the spine co-existed in immediate contact with the supra-renal capsules, suggesting, of course, the necessary conclusion that the latter had been affected by contiguity; for in this case, as in the others, the disease of the spine had, without doubt, been long anterior to that of these organs. This would show that the change in the part is due rather to a chronic inflammatory process than to tubercle, seeing that it was due to a local rather than a constitutional cause.

The speedy death of the girl in the present case entirely precluded any strict observation as to her symptoms, but the history seemed to show that, although, she suffered much pain from the disease of the spine, there was no other affection than the supra-renal which would account for her progressive debility and her final dissolution. No symptoms attributable to her distorted chest were observed during the two days she was in the hospital, nor was there anything in the post-mortem examination to show that any great pulmonary obstruction had existed; in fact, there was nothing to account for death but the supra-renal disease.

Sarah W—, æt. 26, admitted into Guy's Hospital on April 16th, and died April 19th, 1862. She was excessively deformed, owing to an angular curvature of the spine, which had existed from infancy. She had been in the habit of walking about on crutches, and was employed at needlework. During the last three years she had been much worse, having suffered considerably from pain in her back and side. She was compelled often to lie down from excessive debility, and often had sickness, her appetite being very bad. Her aunt, with whom she lived, stated that during these three years her skin had been observed to have become much darker. She had been under the care of Dr. MacDonogh, of Clapham, who, being asked for his own observations on this point, stated that her skin was discoloured and of a bronze hue, but that, owing to the distortion of the chest, he had attributed this to

non-aëration of blood in the lungs. She was, when under his notice, excessively weak, and always complained of being bilious.

When brought to the hospital she was so prostrate that she was obliged to be carried to bed; she could take no nourishment, and two days afterwards she was found dead in her bed. She did not suffer from dyspnœa nor other symptoms manifestly due to the malformed chest.

On *post-mortem examination* the skin was observed to be dark, and the face more so than the body, but this was of so slight a kind that it possibly would have passed unnoticed unless especially regarded. The lungs were not congested, nor heart gorged, nor hypertrophied, as in cases of impeded respiration. The spine was found greatly diseased, several of the lower dorsal and one or two upper lumbar being almost destroyed, and surrounding them was a quantity of cretaceous and putty-like matter, the remains of an old abscess. Adjacent to this, on either side, were the supra-renal capsules, which were quite destroyed, firm albuminous and cretaceous material occupying their place. The left was about three times the natural size, and was of lardaceous consistence, consisting of a yellow material, with a little translucent substance, which was firmer and fibrous. Also scattered through it here and there were some portions of a dead-white, soft matter. The right organ was not much enlarged. The deposit was in nodules, and in some of these was a little cretaceous matter.

Conclusion.—It will be observed that in this series of twenty-five cases, in only one of them was there a total absence of pigmentation of the skin. In four the discoloration was not sufficiently marked to attract notice, or the patient was not under treatment for a sufficient time so as to afford an opportunity for a correct diagnosis. In all the others the skin was observed to have been of a very dark colour. In some of the earlier cases, of course, the discoloration had not been yet connected with disease of the capsules; but in the seventeen remaining ones the skin was very dark, and in all (save one) the correct diagnosis was made. In some of these an opinion was formed by those who had had some experience of the disease, in others a conclusion was arrived at by those who had only a written knowledge of it.

If the fact be contemplated, that in so large a number of cases a disease was suspected to exist in a particular part of the body, and that this was found in every case as anticipated, a conclusion is arrived at, proving the connection of the symptoms with that disease, which can admit of no doubt; indeed, it strikes the writer that more remarkable than any of the phenomena of the disease is the fact that any other conclusion than Addison's can be arrived at concerning it.

I cannot do better, in concluding this paper, than quote

the words of the author of the discovery on the only occasion when the subject was brought before the notice of a medical society in his presence:—"If he saw a patient who presented this peculiar discoloration of the skin, he offered no explanation as to where, or why, or how it came. He observed associated with that discoloration a certain train and combination of general symptoms—a pearly eye, a feeble pulse, a disposition of strongly marked anæmia, and a few other symptoms less constant and less urgent; and when he met with that combination he said, 'There is a case in which you will find disorganization of the supra-renal capsules.' The body is examined, and no other organs are found diseased."

the words of the author of the discovery on the one hand
and the subject was brought before the notice of a number
of his contemporaries. It is not possible to say
the precise moment in the life of the subject
but we know of what a low degree of civilization
and a state of barbarism a certain time and civilization
of general appearance. It is not possible to say
of study, which is not a few years ago
and the low spirit; and when he met with the
highest in each. There is a great deal of
the subject of the subject. The body is
examined and the other organs are found normal.