

**The treatment of prolapse of the uterus and vagina, especially in the aged :
with illustrative cases / by Charles M. Green.**

Contributors

Green, Charles M. 1850-1928.
Royal College of Surgeons of England

Publication/Creation

Boston : Cupples, Upham, 1887.

Persistent URL

<https://wellcomecollection.org/works/e3kq2729>

Provider

Royal College of Surgeons

License and attribution

This material has been provided by This material has been provided by The Royal College of Surgeons of England. The original may be consulted at The Royal College of Surgeons of England. where the originals may be consulted. This work has been identified as being free of known restrictions under copyright law, including all related and neighbouring rights and is being made available under the Creative Commons, Public Domain Mark.

You can copy, modify, distribute and perform the work, even for commercial purposes, without asking permission.



Wellcome Collection
183 Euston Road
London NW1 2BE UK
T +44 (0)20 7611 8722
E library@wellcomecollection.org
<https://wellcomecollection.org>





THE
Treatment of Prolapse of the
Uterus and Vagina,


ESPECIALLY IN THE AGED.

WITH ILLUSTRATIVE CASES.

BY
CHARLES M. GREEN, M. D.,
BOSTON.

[*Reprinted from the Boston Medical and Surgical Journal
of December 30, 1886.*]

BOSTON :
CUPPLES, UPHAM & CO., PUBLISHERS,
Old Corner Book Store.
1887.



THE UNIVERSITY OF CHICAGO

LIBRARY

1911

1911

1911

1911

1911

1911

1911

1911

1911

1911

1911

1911

With the Compliments of
C. M. Green.

ROYAL COLLEGE OF SURGEONS OF ENGLAND
-9 FEB 91

THE TREATMENT OF PROLAPSE OF THE
UTERUS AND VAGINA, ESPECIALLY IN THE
AGED, WITH ILLUSTRATIVE CASES.¹

BY CHARLES M. GREEN, M.D.

It is not intended in this paper to consider the treatment of those minor degrees of prolapsus uteri of such frequent occurrence during the child-bearing period, which are generally associated with anterior, posterior or lateral displacement, and complicated with, if not caused by, inflammatory changes in the parametrium. In these cases treatment is primarily directed to the removal of inflammatory exudations; and the use of pessaries, or the application of any operative procedure, is expressly contra-indicated until that result shall have been accomplished. But attention is invited to the consideration of a class of cases of less frequent occurrence, in which the uterus and vagina are wholly or in part without the vaginal introitus, — constituting in effect a genital hernia, the bladder and rectum usually sharing in the hernial protrusion. These cases occur chiefly in multiparous women advanced in years, still obliged to lead laborious lives; but they are sometimes seen in the nulliparous under favoring conditions.

Prolapse of the uterus and vagina originates principally in one of two ways:

a. The perinæum has been badly torn, and the anterior vaginal wall thereby deprived of the normal support of the perineal body: a cystocele thus develops. The recto-vaginal septum also bulges forward

¹ Read before the Boston Society for Medical Improvement, December 13, 1886.

and downward. The descending vagina thus drags down the uterus, even though it be of normal size and weight until its position shall have induced secondary changes from disturbances of circulation: a frequent result of this traction on the uterus is an hypertrophic elongation of the cervix.

b. Frequent child-bearing, with insufficient rest in bed, has resulted in a condition of subinvolution both of uterus and vagina, and the consequent increase in the weight of the uterus unduly taxes the sustaining powers of the peritoneal folds which suspend that organ: thus the unsupported uterus descends by its own weight, and drags with it the vagina. Not infrequently the cervix has been badly lacerated, and has undergone hyperplastic changes which add to its size and weight. In the nulliparous, prolapse of the vagina and uterus may occur from the presence of uterine tumors, the enlarged and heavy uterus distending the vagina and finally dragging it into complete inversion.

While partial or complete prolapse may occur strictly in either one of the two ways above mentioned, it is probable that in most instances both factors are operative: the heavy uterus presses from above, and the descending vagina drags from below. Although the foundations of future trouble are laid during the child-bearing period, external protrusion often does not occur until after the menopause. Owing to the disturbed circulation of the prolapsing parts, the atrophic senile changes do not take place. A potent factor in causing genital hernia then becomes operative, namely, the enfeebled muscular tonicity of advancing years, the descent of the parts being favored in a manner analogous to the formation of intestinal hernia in old men.

Unless produced suddenly by some great strain or unusual effort, genital hernia is developed gradually

from the causes above alluded to, and entails symptoms which usually lead the patient to seek relief before extreme degrees of prolapse have occurred. Such cases are, therefore, never seen among the well-circumstanced, except in those rare instances in which a morbid sense of delicacy has prevented the patient from taking advice until the extrusion of the parts has compelled her to do so. But among the laboring poor, accustomed to lift and carry heavy burdens, who often bear uncomplainingly the minor ills of life, and especially in the aged and neglected drudge, early symptoms are often ignored; and in this class, therefore, complete inversion of the genital canal is not infrequently seen. When the prolapse has reached any considerable degree, the inevitable attrition soon results in abrasions and ulcerations: want of cleanliness and the fetid discharge from sloughing tissues make the patient an object of offence to all about her. The usual displacement of the bladder renders the complete emptying of that viscus no longer possible, and the distress of cystitis is added to the discomfort and pain from the hernial protrusion. The condition of the patient is indeed pitiable: she can neither stand, sit, nor walk, is at last unable to work, and becomes a burden to herself and her family.

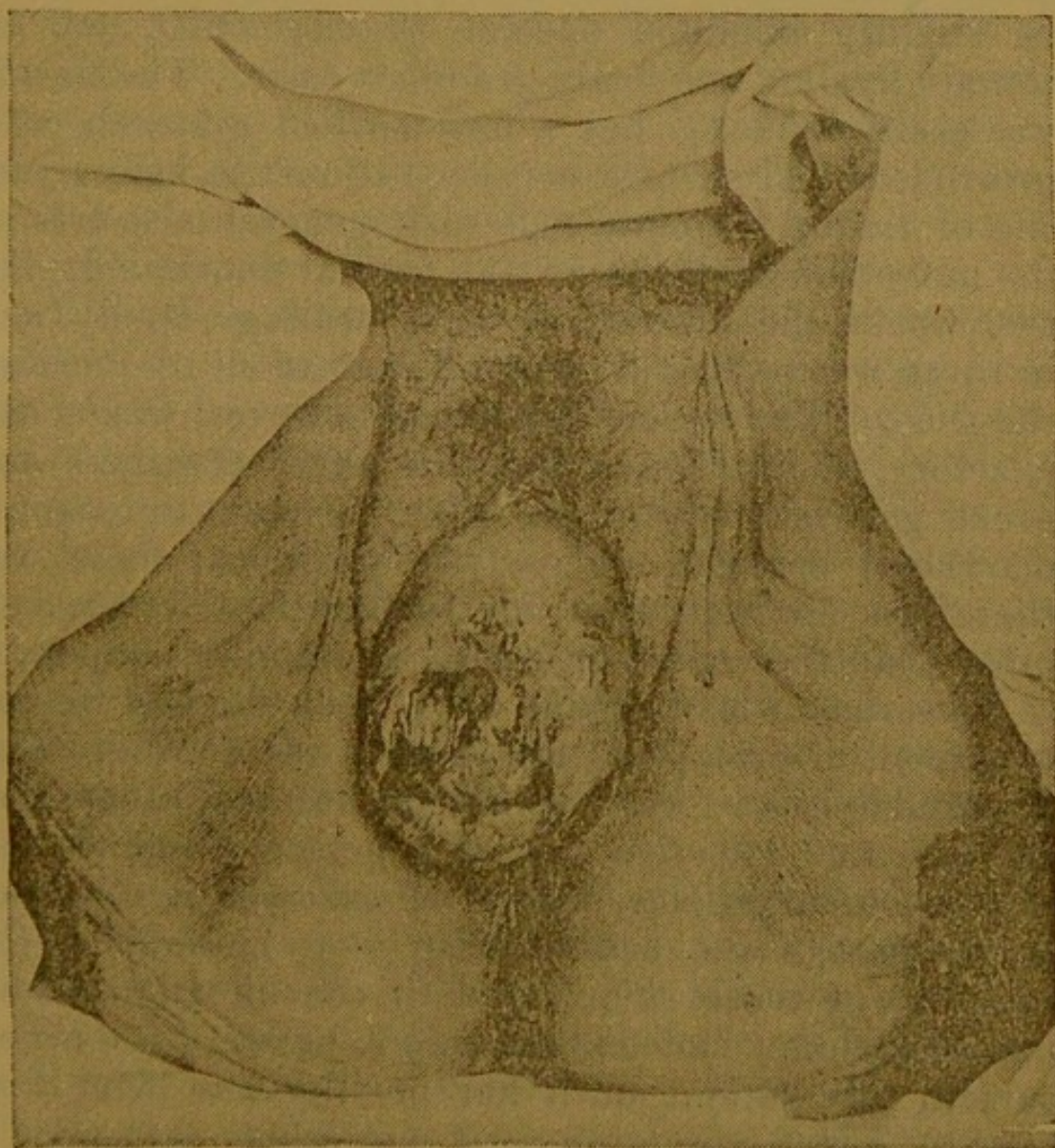
The treatment of these cases is usually most trying and unsatisfactory in ambulatory practice: after the digital reposition of the prolapsed parts, temporary rest in bed is generally indispensable to success in the application of any method of treatment. The means at our command, from which we are to choose according to the circumstances and indications of each case, are the astringent tampon, pessaries, and the various surgical procedures,—colporrhaphy, anterior and posterior, colpo-perineorrhaphy, amputation of the infra-vaginal cervix, removal of the uterus, shortening of

the round ligaments, and the formation of cicatricial contractions of the vagina by the use of the thermo-cautery. Such of these measures as have been utilized in my own experience will be commented on *seriatim*.

The temporary use of the astringent tampon is a valuable antecedent to any method of treatment: by its means, the patient remaining recumbent, not only are the parts retained *in proprio situ*, but abrasions are healed, the circulation is improved, the drawn-out cervix is enabled to retract, and the uterus is often considerably diminished in size. These changes are materially aided by the depleting effect of glycerine, with which the tampons are moistened,—the copious watery discharge relieving the congested vessels. The astringent most applicable is tannin, and it is my custom to use it in a twelve and a half per cent. solution in glycerine. To be most effective the tampon should consist not of a single large wad of cotton, which may indeed retain the parts *in situ*, but of small pieces applied with care in such a way as to bring the medication in contact with every part of the vagina. Common carded cotton is preferable to the absorbent, being more elastic and less easily matted together. After from ten days to two weeks in bed, the patient may be allowed to sit up and walk about; and were it not that this method required the frequent services of the physician, the long-continued use of the tampon would be advisable in many cases not suitable for more radical treatment. Intelligent women may often be taught to make and use themselves a cotton ball of suitable size to retain the parts, when the uterus is not much enlarged, and when other measures are contraindicated. The value of the tampon is well illustrated by the following case:

Mrs. T., widow, seventy-two years of age, bore her third child at the age of forty-eight, and passed the

climacteric at fifty. For twenty years she had been troubled with prolapse, but had become much worse in the past three years. She had never sought medical advice, her family ignoring her complaints until her presence became obnoxious to them on account of the offensive odors of her person. When she entered my consulting-room at the Boston City Hospital, I judged from the usually unmistakable odor that her case was one of uterine carcinoma; but examination revealed a condition well shown in this photograph.



The hernia was as large as a cocoanut, and consisted of the entire vagina and uterus and part of the bladder. There were several erosions and ulcerations, emitting a foul, purulent discharge. The vaginal wall was thickened. The uterus measured only a little over three inches in depth and was not therefore sufficiently heavy to have dragged down the vagina, but rather was dragged down by the gradually prolapsing vaginal walls. The patient for some time had been unable to empty her bladder, but passed urine frequently and in small quantities. Examination showed the urine to be slightly alkaline, specific gravity 1010, and to contain hyaline and finely-granular casts. The hernia was easily reduced; but a well-marked cystocele still protruded. Treatment consisted of rest in bed, glycerite of tannin tampons, and such general measures as the enfeebled condition of the patient demanded. In two weeks the ulcerations were healing rapidly, and in three weeks Mrs. T. was allowed to sit up most of the time. The mental condition, however, was unsatisfactory, and several attacks of unconsciousness and great general prostration (due in part to chronic diarrhoea) presaged an early lethal issue; there was therefore no indication for further local treatment, other than the continued use of a retaining tampon.

Pessaries of many kinds have been devised for the treatment of prolapsus, and some of them are of value in suitable cases; but experience has taught me that the safe and effective use of a pessary demands the exercise of a greater degree of care and intelligence on the part of the patient than is to be found in the majority of those suffering with the affection under consideration. Indeed, my rule is never to use a pessary in any patient until her docility has been thoroughly tested, preferring, if no other measure is available, to do no good rather than to accomplish

temporary good at the risk of subsequent harm. It is well known, but not always remembered, that, if a pessary is efficient in retaining the parts, subsequent senile atrophic changes will often so narrow the vagina that the instrument is imprisoned and may cause serious ulcerations before the patient, by subjective evidences, is aware of it. Such cases are occasionally seen, in which the pessary has to be broken up before it can be removed. Within a year I have seen a case of cervical epithelioma undoubtedly caused by a long-worn and neglected pessary. This instrument should be used, therefore, only when it can be watched, the patient returning at stated intervals for the removal and cleansing of the pessary and for the inspection of the parts. Sometimes a patient can remove, cleanse, and replace her own instrument: in such cases the physician's attendance may be less frequent.

With those forms of pessary consisting of a cup supported by a stem and kept in place by external bands and belts I have had no experience, believing their use to be attended with too much annoyance and irritation about the external genitals and perinæum. When the prolapse is not extreme, I have often found the inflated, soft-rubber, doughnut-shaped pessary to be effective and safe. It will not, of course, raise the uterus to its proper place; but with care it will keep the parts within the introitus, and serve as a palliative measure when the various surgical procedures are contraindicated.

Mrs. C., aged seventy-six, multiparous, had probably suffered with a gradually-increasing prolapse for many years, but had borne her affliction in silence, and it was only in the latter months of her life that the protrusion was discovered by her nurse. It was found that the uterus had undergone senile atrophy, and in the recumbent position was still within the in-

troitus; but the vagina was prolapsed, and there was also a considerable prolapse of the urethra. Only palliative treatment was indicated, and this was successfully accomplished, after several trials, by the use of the inflated, soft-rubber pessary, by the help of which the parts were retained, and the patient enabled to go down stairs and go out driving. The prolapsed urethra retracted under the use of astringents, and gave no further trouble.

The opinion is held by many that the surgical treatment of genital hernia in the aged is unwise and unwarrantable, and the various objections given are, — that it is often unsuccessful; that, even if successful at first, the prolapse will recur; that it is not always safe to operate; that it is not worth while. Excluding from consideration the Alexander-Adams operation of shortening the round ligaments, and the operations for the removal of the uterus, I am unprepared to believe that the usual surgical methods are attended with more danger in the aged, if the patient is in suitable condition, than in those less advanced in years. Organic disease of vital organs should of course be given due prognostic importance in either old or young in considering the advisability of operative treatment; but age alone I do not recognize as a contraindication. Nor has experience taught me that primary and lasting success is less frequently attained in the aged than in the young: in fact, if intelligently performed, the restoration of prolapsed parts in those who have passed the child-bearing period and who have for whatever reason discontinued marital relations should be attended with better chances of lasting benefit than in younger women; not only because in the former senile changes diminish the possibility of subsequent prolapse, but also because the celibate condition warrants an almost complete closure of the vagina.

Whether or not operative treatment is worth while, the patient will often decide; but I never hesitate to advise a woman suffering with this infirmity, but otherwise in good health, to give up two or three months or less to radical treatment with a good prospect of entire relief, rather than to subject herself during the remainder of her life to the never-ending annoyance, inconvenience, and sometimes danger, of treatment with pessaries, which may be only partially successful.

Mrs. D., multipara, sixty years of age, for ten years a widow, came from another State to seek relief from prolapse of the uterus and vagina, which began to protrude twenty years before and for ten years had been outside the genital fissure. She complained of pain in the head and back; was unable to walk, stand, or sit without pain and discomfort in the prolapsed parts, and was comfortable only when lying down. Her general condition was fairly good; but her nervous system was in a measure unstrung by discomfort and pain. Defecation was always difficult: urination was frequent and sometimes painful on account of the prolapse of the bladder.

Physical Examination: Perinæum torn to sphincter, perineal body gone; vagina subinvolted, thickened, and entirely prolapsed; uterus external to the vulva, enlarged, the cavity measuring four and a half inches; the cervix and vagina were the seat of many abrasions and ulcerations.

Treatment: The uterus and vagina were replaced and retained with tampons, the patient remaining in bed; a ten per cent. solution of nitrate of silver and a twelve and a half per cent. solution of tannin in glycerine were used to heal the abrasions. In less than three weeks the size of the uterus was reduced to three and a half inches in depth, the diminution of

one inch being doubtless due in great measure to a retraction of the cervix. There being no apparent contraindication, the patient was then etherized, a large elliptical piece removed from the whole length of the thickened anterior vaginal wall, and the wound closed with sixteen sutures: a moderate venous oozing was controlled with hot water. Ten days later the parts were exposed and the stitches removed: the lower angle had failed to unite well; but two weeks later, when the patient was again etherized for posterior colporrhaphy, it was noticed that there had been no prolapse of the as yet unsupported anterior wall. The denudation for the second operation was carried well up the posterior and lateral walls of the vagina, and the wound closed with seven silver sutures, thereby narrowing the vagina and building up a large perineal body. During the convalescence the patient had considerable nervous disturbance with hallucinations, and several times she got out of bed in the momentary absences of the nurse; but on the removal of the stitches on the thirteenth day it was found that there was good union except externally, that is, at the base of the perineal triangle.

Ten weeks later Mrs. D. presented herself at my office, happy in entire relief. Examination showed a firm perineal body, the vagina would admit only the index finger, and the uterus was high in the pelvis: not wishing to distend the parts with a speculum, I did not measure the depth of the uterine cavity. The patient then returned to her distant home, and I have no proof that the result obtained was permanent; but apart from the probability that I should have heard from the case had the prolapse returned, it seems to me hardly possible with the vagina narrowed to the size of the index finger, the uterus diminished in size and weight and under favorable conditions for under-

going senile atrophy, that the parts could again descend to their previous position.

Mrs. R. C., a widow, sixty-five years of age, had borne six children, the youngest being thirty-two years old. She was a sober, industrious housewife, and her health had always been good until about a year before I saw her: at that time she was somewhat debilitated and began to suffer with "falling of the womb." At the time of consulting me she declared she was in perfect general health, and wished only to be relieved of the local trouble, which alone prevented her from performing her usual household duties.

Examination disclosed a complete prolapse of the anterior vaginal wall, which was thickened and whitened from attrition and exposure: the cervix protruded from the vulvar cleft, and the perinæum was torn; but there was no marked protrusion of the posterior vaginal wall. The uterus was not enlarged. The patient readily acceded to operative treatment; she was therefore kept in bed for a week and the parts retained with astringent tampons. It was at first proposed to remove a portion of the anterior wall before closing the perinæum; but, as the uterus was not heavy, it was finally decided to make a more extensive denudation of the posterior wall and practically close the vagina, in the belief that in this way efficient support would be given to the anterior wall and subsequent prolapse prevented. The denudation was therefore carried well up on the sides of the vagina and to Douglas's cul-de-sac posteriorly: the wound was closed with silver sutures and dressed with iodoform by insufflation. The vagina would not admit the index finger.

The patient was comfortable after the operation, having scarcely any pain or constitutional disturbance:

the temperature was normal on the third day. The next day, however, there was pain in the right labium, and a small abscess formed: this was opened externally and in no way interfered with the success of the operation. The stitches were removed on the ninth day, and two weeks later the patient was allowed to sit up and begin to walk about. Examination showed that perfect union had taken place and that the vagina would admit only a large-sized lead pencil. The general condition was excellent, and the patient returned to her family in just a month from the time of beginning treatment.

About five months later Mrs. C. returned for inspection of the parts: she was in perfect health, the vagina would admit only the index finger, there was no protrusion, the uterus was high in the pelvis and undergoing senile atrophy. Six months after this visit the patient again returned at my request. During this time she had performed her usual duties and had remained in good health: there had been no change in the local condition, the uterus still remaining high and the vagina narrow. It seemed to me, therefore, that her relief would be permanent.

The following case is reported not as a surgical success, but for its intrinsic ætiological interest and as an illustration of what is perhaps the best method of dealing with such cases under similar circumstances:

E. M., fifty-two years of age, single and nulliparous, a retired serving-woman, had passed the menopause ten years previously, at the age of forty-two. She had always been well and strong, but for the past twenty years had noticed a hard lump above the pubes and to the right: this, however, gave her no trouble, and she now sought relief from "falling of the womb."

It was found on examination that the vagina was

entirely inverted and protruding from the *rima pudendi*: the uterus measured four and a half inches in depth and also protruded as far as the length of the vagina would allow. The pelvic brim was occupied by a hard, non-fluctuating tumor as large as a cocoanut, which was evidently a sub-serous, fibroid enlargement of the fundus uteri. Various pessaries had been tried to retain the parts within the vulva; but they either failed of their purpose or caused ulcerations necessitating their removal; the future treatment of the case therefore caused me serious consideration. Removal of the uterus seemed to afford the only sure hope of curing the prolapse; still as the tumor gave rise to no symptoms other than those caused by the hernia, so serious an operation was to my mind unwarrantable. On the other hand, with such a heavy mass pressing from above, narrowing the vagina, seemed an almost futile procedure. In the hope, however, that with advancing years the uterine tumor would diminish in size, I determined to perform the latter operation, and afford at least temporary relief.

After preliminary treatment with rest in bed and astringent tampons, the vagina was narrowed by colporrhaphy posterior, and three weeks later the patient was allowed to be on her feet again. Examination a week afterwards showed firm union to have taken place, the vagina would barely admit the index finger, the uterus was high and the cervix only just within reach.

The patient was not seen again until two months afterwards, now three weeks ago. It was then found there was some dilatation of the ostium vaginae and a slight protrusion of the vaginal walls. The future issue of the case is doubtful; but, if the patient continues under my care, I shall endeavor to keep the parts within the vulva with a soft-rubber pessary, or

with a cotton wad and T-bandage. And if this object can be successfully accomplished, senile atrophic changes in the tumor may ultimately so far reduce the weight of the uterus that a hard-rubber pessary can be worn.



THE
LIBRARY OF THE
MUSEUM OF NATURAL HISTORY
AND
ZOOLOGY
OF THE
CITY OF LONDON
1871



