

**Acute pancreatitis : a consideration of pancreatic hemorrhage, hemorrhagic, suppurative, and gangrenous pancreatitis, and of disseminated fat-necrosis : the Middleton-Goldsmith lecture for 1889 / by Reginald H. Fitz.**

### **Contributors**

Fitz, Reginald H. 1843-1913.  
Royal College of Surgeons of England

### **Publication/Creation**

Boston : Cupples and Hurd, 1889.

### **Persistent URL**

<https://wellcomecollection.org/works/r3vrnktj>

### **Provider**

Royal College of Surgeons

### **License and attribution**

This material has been provided by This material has been provided by The Royal College of Surgeons of England. The original may be consulted at The Royal College of Surgeons of England. where the originals may be consulted. This work has been identified as being free of known restrictions under copyright law, including all related and neighbouring rights and is being made available under the Creative Commons, Public Domain Mark.

You can copy, modify, distribute and perform the work, even for commercial purposes, without asking permission.


**wellcome  
collection**

Wellcome Collection  
183 Euston Road  
London NW1 2BE UK  
T +44 (0)20 7611 8722  
E [library@wellcomecollection.org](mailto:library@wellcomecollection.org)  
<https://wellcomecollection.org>

Acute Pancreatitis.

R. H. FITZ, M.D.

*Reprinted from  
The Boston Medical and Surgical Journal.*



8

# ACUTE PANCREATITIS:

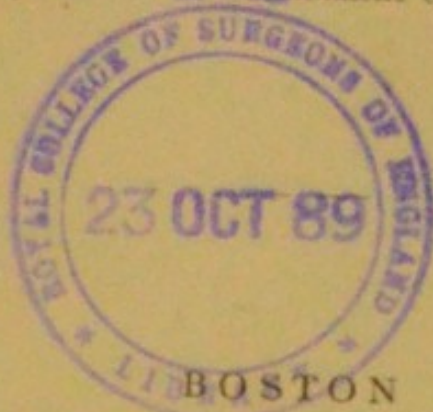
A CONSIDERATION OF PANCREATIC HEMORRHAGE,  
HEMORRHAGIC, SUPPURATIVE, AND GANGRE-  
NOUS PANCREATITIS, AND OF DISSEMI-  
NATED FAT-NECROSIS.

The Middleton-Goldsmith Lecture for 1889.

BY

REGINALD H. FITZ, M.D.,


*Shattuck Professor of Pathological Anatomy in Harvard University,  
and Physician to the Massachusetts General Hospital.*



CUPPLES AND HURD, PUBLISHERS

The Algonquin Press

1889



## ACUTE PANCREATITIS.

A CONSIDERATION OF PANCREATIC HEMORRHAGE,  
HEMORRHAGIC, SUPPURATIVE, AND GANGRENOUS PANCREATITIS, AND OF  
DISSEMINATED FAT-NECROSIS.<sup>1</sup>

BY REGINALD B. FITZ, M.D.,

*Shattuck Professor of Pathological Anatomy in Harvard University  
and Physician to the Massachusetts General Hospital.*

UNTIL the time of Clässen<sup>2</sup> the evidence of an acute inflammation of the pancreas was almost wholly theoretical, and was not controlled by any considerable number of anatomical observations. Mercury was known to produce salivation, and the watery diarrhœa following its use was supposed to be due to irritation of the pancreas.

Influenced by this and other considerations, Schmackpfeffer<sup>3</sup> having found certain alterations of the pancreas in a syphilitic woman who had been liberally treated with mercury, attributed her symptoms to the pancreatic changes. The latter he regarded as anatomical evidence of an acute inflammation. He describes<sup>4</sup> these changes as follows: "The pancreas was unusually dense, dry, and very much swollen; it was inflamed and red throughout, although more in the right than in the left side. Numerous drops of blood escaped from the cut surface. The duct was very much dilated, especially at its mouth. The gland weighed five and three-quarter ounces.

<sup>1</sup> The Middleton Goldsmith Lecture for 1889, delivered before the New York Pathological Society, Feb. 16, 1889.

<sup>2</sup> Die Krankh. d. Bauchspeicheldr., 1842.

<sup>3</sup> Diss. Inaug. de quibusd. Pancreatis Morbis, 1817, 26.

<sup>4</sup> *Op. cit.*, 25.

Some years later Neumann<sup>5</sup> stated that "death might take place within a few hours from a fatal metastasis of the buccal salivation to the pancreas. This happens when in the midst of profuse salivation the pulse sinks and quickens or the swelling of the salivary glands subsides, and salivation is replaced by a green diarrhœa, while the skin is dry and shrunken." Under such circumstances the pancreas is found decidedly swollen, although but slightly reddened.

Clässen<sup>6</sup> knows of no observations in confirmation of Neumann's statement, and doubts its truth. He collects, however, a half-dozen cases, among them Schmackpfeffer's, of what he regards as fatal pancreatic inflammation, and from them he establishes the symptomatology of acute pancreatitis. The views thus obtained essentially prevailed until the publication of Friedreich's article in Ziemssen's Cyclopædia in 1875.

The lesions found were as follows. In the second case, that of Jupp<sup>7</sup> "a section was made through the pancreas. Its tissue was dense and friable. It was a third larger round than normal; it encircled two-thirds of the duodenum, which it compressed, and it affected the pylorus also. . . . The pyloric opening was almost entirely closed and the tip of the little finger could be introduced only with great difficulty and after repeated efforts. A vertical section through the pylorus showed it to be of almost cartilaginous density."

The third case is credited to Casper.<sup>8</sup> "All the organs of the remarkably handsome, though excessively fat, body were wholly normal with the exception of the pancreas. This was swollen to the size of a large fist, of cartilaginous density, firmly united to the duodenum, and in part to the stomach, and was of a brownish-red color. Its structure was not recognizable."

The fourth observation is also from Casper.<sup>9</sup>

<sup>5</sup> Von den Krankh. des Menschen, Berlin, 1836; Clässen, *op. cit.*, 192.

<sup>6</sup> *Op. cit.*, 193.

<sup>7</sup> Journ. de med. chir. pharmac., 1791, lxxix, 73; Clässen, p. 200.

<sup>8</sup> Wochenschr. f. d. ges. Heilkde., 1836, 437. Clässen, *op. cit.*, 207.

<sup>9</sup> Wochenschr. f. d. ges. Heilkde., 1836, 439. Clässen, *op. cit.*, 213.

"The pancreas was so much enlarged that its head was a half hand's-breadth wide, much infiltrated with blood, very dense, its structure not recognizable. In consequence of the enlargement of the gland its shape was more globular than round.

Rahn<sup>10</sup> is the authority for the fifth case. The stomach was dilated "almost to bursting," and was filled with clotted blood. "In the middle of the abdomen there projected from the abdominal aorta a dense, scirrhus tumor as large as the fist. It was intimately united to the aorta, and so compressed it that, when the aorta was opened, the finger would not pass through the narrowed canal. The narrowed portion was immediately below the origin of the cœliac artery. On close examination of the tumor with reference to its origin, the head of the pancreas was degenerated in this scirrhus mass, while the left part of the gland was in a wholly healthy state."

The sixth case<sup>11</sup> is from Morgagni.<sup>12</sup> "The pancreas was unusually large, and contained round, tolerably large tumors of a density somewhat approaching that of cartilage."

To these is added another possible case, from Lieutaud,<sup>13</sup> in which after an acute attack of gastric pain, fever, vomiting, anxiety, and frequent fainting "the pancreas was found much enlarged, hard and scirrhus throughout. The left kidney was in a state of liquefaction."

The first case may have been one of mercurial poisoning, the second was one of, probable, malignant disease. The third and fourth are possibly of inflamed pancreas, but the evidence is insufficient to clearly establish the diagnosis. The fifth case may have been one of aneurism, while the last two are more suggestive of malignant disease than of acute, pancreatic inflammation.

The common symptoms were deep-seated pain near the stomach, producing a peculiar anxiety,

<sup>10</sup> Scirrhusi pancreatis diagnosis, 1796, obs 1. Clässen, *op. cit.*, 218.

<sup>11</sup> Clässen, *op. cit.*, 212.

<sup>12</sup> De sedibus et caus. morb., 1765, iii, Epist. xxx, art. 10.

<sup>13</sup> Hist. Anat. Med., 1767, l. obs. 1021.



restlessness, perhaps frequent fainting. The pain bore no definite relation to the vomiting or other symptoms, and was not increased in proportion to external pressure. The vomiting was forcible, more or less greenish material being expelled. The abdomen was moderately tense, there was slight fever, and the appetite was but little disturbed and might be increased. There was a moist tongue, thirst, and constipation.

The effect of Clässen's treatment of the subject may be seen nearly thirty years later in the statement by Wardwell<sup>14</sup> that the prominent symptoms of acute pancreatitis are, deep-seated, dull, epigastric pain, distention, sickness, and vomiting of a clear, greenish, viscid fluid; thirst, faintness, moist tongue, constipation, and slight pyrexia.

The first step towards an essential modification of these views was made by Klebs, in 1870.<sup>15</sup> He preferred to say nothing about inflammation of the pancreas, but described the various lesions which have been found in and around this gland, without attempting to show their possible relations to each other. He availed himself of the cases published by Portal, Hooper, Löschner, Haller and Klob, and of one in his own experience, to associate pancreatic hemorrhage with severe symptoms and to recognize the possibility of a hemorrhagic inflammation of the pancreas, already admitted by Rokitansky,<sup>16</sup> as a very rare occurrence. Klebs further recognized that this hemorrhagic inflammation might possibly result in a purulent peripancreatitis with partial sequestration of the gland.

Friedreich,<sup>17</sup> however, undertook to present a complete picture of acute pancreatitis more in accordance with the anatomical treatment of Klebs than with that of Clässen. He availed himself of the cases used by Klebs; in addition, of one reported by Oppolzer, and of another under his own observation. He suggested that acute pan-

<sup>14</sup> Reynold's Syst. of Med., 1871, iii. 414.

<sup>15</sup> Handb. d. path. Anatomie, 1876, i. 2, 553.

<sup>16</sup> Lehrb. d. path. Anat., 3te Aufl., 1861, iii. 309, 242.

<sup>17</sup> Ziemssen's Handb. d. Path. und Therap., 1875, viii. 2

creatitis was either primary or secondary. The former appeared to have a tendency to hemorrhage in the pancreas or in its vicinity, in which case a termination in gangrene and ichorous peripancreatitis might occur. If the acute pancreatitis became suppurative, multiple, minute abscesses were to be found, which tended to become confluent and to produce a resulting peritonitis.

The secondary variety of acute pancreatitis was either the granular degeneration found in infective diseases, or the circumscribed "metastatic" abscess. The possibility of a metastatic pancreatitis in the course of a parotitis was not to be absolutely denied, especially in virtue of the case reported by Schmackpfeffer.<sup>18</sup>

As there is a doubt of the existence of a pancreatitis in this case, it may be safely stated that there is no reason for admitting the existence of a metastatic pancreatitis secondary to inflammation of the parotid gland. It is evident<sup>19</sup> that an acute parotitis may arise during the course of a pancreatic inflammation. This single instance of association is presumably analogous to the occurrence of parotid inflammation in septic conditions of various origin.

Since Friedreich's anatomical recognition of an acute pancreatitis was based upon the consideration of four cases, he admitted his symptomatology of this affection to be neither precise nor complete. Furthermore, he seems<sup>20</sup> to include under the head of pancreatic hemorrhage those cases where this lesion is associated with necrosis and gangrene, and others where hemorrhage into the pancreas appears to be the sole cause of sudden death.

Klebs<sup>21</sup> had already recognized the existence of a suppurative peripancreatitis, and stated, presumably from his own observation, that, in most instances, this proceeded from lymph-glands. These were either the seat of metastatic abscesses or were primarily diseased by traumatic agencies or injuri-

<sup>18</sup> P. 1.

<sup>19</sup> Case LVIII.

<sup>20</sup> *Op. cit.*, 273.

<sup>21</sup> *Op. cit.*, 556.

ous food. Such abscesses were regarded as occasional causes of thrombosis of the mesenteric and portal veins. He recognized a possible, eventual separation of the pancreas from its surroundings by the extension of the suppurative process.

He thought it possible that the case of Haller and Klob<sup>22</sup> already admitted as of hemorrhagic pancreatitis, might belong in this series, and regarded that reported by Gendrin as illustrative.

In the light of the observations published up to the time of his article, Klebs regarded as of doubtful existence any pancreatic abscesses which did not arise from a peripancreatitis or from a suppurating cyst.

Important evidence as to the possible method of origin of a peripancreatitis was furnished by Chiari,<sup>23</sup> who found a round ulcer of the stomach communicating with the cavity of the omentum. The latter contained a spacious abscess with several openings into the jejunum. Lying free within this cavity was a shreddy mass of tissue, 12 cm. long. It was brownish-black, friable, and presented the structure of the pancreas.

Four years later, Chiari published the report of a case<sup>24</sup> by Schlossberger, in which the sloughing pancreas was discharged through the bowels. He reported still another,<sup>25</sup> of earlier occurrence, in 1862. The sloughing pancreas, discharged from the bowels, was brought to Rokitansky by Trafoyer.

The next communication of especial importance in connection with the subject of pancreatic inflammation is that of Balser.<sup>26</sup> He calls attention<sup>27</sup> to the presence of nodules and patches of necrotic fat-tissue in the mesentery and in the contents of a cavity behind the mesentery. In the latter lay the pancreas also, attached only to the duodenum, and its lobules appearing as if macerated. A second case was reported by him,<sup>28</sup> in which

<sup>22</sup> Case LVI.

<sup>23</sup> Case LVIII.

<sup>24</sup> Case LIX.

<sup>25</sup> Case LVII.

<sup>26</sup> Virchow's Arch., 1882, xc. 520.

<sup>27</sup> Case LXIV.

<sup>28</sup> Case XXIV.

there were patches of necrosis of the abdominal fat associated with similar appearances in the pancreas. In addition there was evidence of old and recent hemorrhage in the gland.

My own interest in this subject was first, particularly, aroused in 1876. At the request of Dr. Maynard, of Dedham, I made the post-mortem examination of a lady of uncertain age, not especially fat, who fell on the floor while apparently in her usual good health. She died within thirty minutes. In the meantime she complained of pain in the lower part of the chest. Her respiration became hurried, the pulse feeble; a short convulsion occurred, and death took place. The abnormal appearances found were several nodules and patches, the largest of the volume of a walnut, of freshly extravasated blood at the periphery of the posterior portion of both, lower, pulmonary lobes. There were several patches, of considerable size, of submucous hemorrhage near the ileo-cæcal valve along the mesentery. The pancreas was thin and very flaccid, with occasional slight, subperitoneal hemorrhages. Section through the organ showed similar hemorrhages in its substance. The gland-lobules were of a reddish-gray color, the general surface spotted with white specks. Microscopic examination showed extensive fatty degenerations of the gland-cells, many fat-drops being exceedingly minute. The interstitial fat was frequently crystallized, and, at times, bundles of orange, acicular crystals (hæmatoidin?) were found.

The cœliac plexus was examined and nothing abnormal found. The heart was contracted, its cavities contained mainly fluid blood. The mesenteric veins near the cæcum were injected. The liver and kidneys were injected; the spleen and suprarenal capsules were normal. Nothing abnormal was found in the brain or heart. It was considered, at the time, that the history of the case and the appearances found were best explained on the ground of Zenker's communication,<sup>29</sup> which will be soon referred to more particularly.

<sup>29</sup> *Deutsche Zeitschr. f. pr. Med.*, 1874, ii. 351.

Since then it has been my opportunity, largely owing to the zeal of Drs. Gannett and Whitney, to have seen at least a dozen examples of pancreatic hemorrhage, with or without necrosis of fat-tissue, and of necrosis of fat-tissue without pancreatic hemorrhage. I have been present at several of the post-mortem examinations at which the diseased pancreas has been found, and have demonstrated to the students of the Harvard Medical School many of the specimens which have been removed by my friends and colleagues.

Having thus been impressed with the importance of the subject, I take this opportunity of utilizing the material which has been gradually accumulated by Dr. Whitney, the curator of the Warren Anatomical Museum. The value of this material is greatly enhanced by the records of the clinical course of the disease in question, which have been furnished by those in charge of the patients. In addition, a collection of similar cases has been gathered from medical literature, which of late years has been especially prolific in this subject.

This paper will include a consideration of —

The liability of the pancreas to hemorrhage;

The association of hemorrhage with acute pancreatitis;

The occurrence of acute pancreatitis without hemorrhage; and —

The relation of acute pancreatitis to fat-necrosis.

#### PANCREATIC HEMORRHAGE.

Although Klob<sup>30</sup> regarded interstitial, pancreatic hemorrhage as not rare, he found it only, and then not constantly, in extreme portal stagnation.

Spieß, however, in 1866,<sup>31</sup> reported to the Frankfort Medical Society a case<sup>32</sup> of sudden death due to an extensive, interlobular, pancreatic hemorrhage. His observation, though unique, escaped attention.

Klebs, as already stated,<sup>33</sup> had associated pan-

<sup>30</sup> Oesterreich Zeitschr. f. pr. Heilkde., 1860, v. 529.

<sup>31</sup> Schmidt's Jahrb., 1867, cxxxiv. 270.

<sup>32</sup> Case I.

<sup>33</sup> P. S.

creatic hemorrhage with severe symptoms, and suggested that the hemorrhage might be due, in the absence of inflammatory changes in the interstitial tissue, to the corrosive action of the pancreatic secretion.

Zenker<sup>34</sup> then reported three cases as of fatal pancreatic hemorrhage. This lesion, however, existed in only two of them,<sup>35</sup> while in the third the hemorrhage was near the pancreas, in the hilus of the spleen. In this last case, and in one of the others, there was a striking venous injection of the solar plexus. He regarded this as the immediate cause of the sudden death, in accordance with the results of Goltz's experiment of cardiac paralysis by a blow on the frog's abdomen. He found in one of his cases a flabby heart with distended, empty cavities associated with marked injection of the abdominal organs, as in the frog experimented upon.

Prince<sup>36</sup> then published a paper on this subject, and Draper reported<sup>37</sup> a series of cases of sudden death from pancreatic hemorrhage.

Virchow, however, in most recent times, has stated<sup>38</sup> that nothing is more rare than hemorrhage in the pancreas.

The relative frequency and absolute importance of pancreatic hemorrhage is thus, unquestionably, a discovery of recent origin. There is, however, a considerable number of recorded cases which show that sudden and unexpected death may occur and a conspicuous hemorrhage be found in or near the pancreas as the sole, significant lesion. Such hemorrhage may occur in a previously diseased pancreas or individual, or it may take place when the person is apparently in his usual health, and the pancreas gives no evidence of any acute disease.

Both groups illustrate the liability of the pancreas to hemorrhage, but the conditions of its occurrence must vary in each.

<sup>34</sup> *Loc. cit.*

<sup>35</sup> Cases III and IV.

<sup>36</sup> Boston Medical and Surgical Journal, 1882, cvi. 28.

<sup>37</sup> Trans. Assn. Am. Phys., 1886, i. 243.

<sup>38</sup> Berl. klin. Woch., 1887, ix. 155.

In the first series the hemorrhage is associated with certain lesions of the pancreas of a chronic character. The earliest case of this sort, and one which has been quoted in evidence of pancreatic hemorrhage as a cause of sudden death, is that by Störck.<sup>39</sup>

A woman, æt. twenty-eight, during the catamenial period, was seized with severe vomiting. The flow was arrested; chills, dyspnoea and palpitation followed. Although she gradually improved, an epigastric pulsation became apparent, synchronous with the heart-beat. After the next menstrual period this pulsation became more severe, and a resistant pulsating tumor could be felt below the stomach. The tumor increased in size, and there was a sense of weight in the epigastrium. During the subsequent three and a half months the symptoms improved, the palpitation became less and the tumor smaller and softer. Sudden weakness then occurred, there was a rust-colored vomit, bilious stools, sudden increase in the size of the tumor, rapid emaciation, and death.

The pancreas was found so large and heavy as to weigh thirteen pounds. It formed a sack filled with blood, partly grumous, and partly laminated. The stomach, intestines, and omentum were displaced and compressed.

The evidence here presented is not sufficient to exclude the possibility of the chief lesion in this case being an aneurism of some artery in the vicinity of the pancreas. If Störck's view be accepted that there was a hemorrhage within the pancreas, we have merely an illustration of what has been repeatedly found since his time, namely, hemorrhage into a pancreatic cyst.

The first indubitable case of this sort on record is to be found in the museum of the Harvard Medical School. It was published by Gross<sup>40</sup> from the MSS. furnished by the late Dr. J. B. S. Jackson, and has also been published by the latter.<sup>41</sup>

<sup>39</sup> *Annus Med. Secund.* 1762, 245.

<sup>40</sup> *Elements of Path. Anatomy*, 1839, ii. 209.

<sup>41</sup> *Catalogue of the Museum of the Boston Med. Improvement Soc.*, 1847, 174.

For several months before the patient's death a tumor was noticed in the epigastric and right hypochondriac regions. There were also signs of advanced phthisis. The patient sat up every day until a short time before his death. The day before this took place he was found partially comatose. The tumor was a cyst of the pancreas, containing from ten to fourteen ounces of bloody-looking, serous fluid without coagula.

The conspicuously hemorrhagic contents of pancreatic cysts have also been noticed by Anger,<sup>42</sup> Küster,<sup>43</sup> Bull,<sup>44</sup> Kocher,<sup>45</sup> Wölfler,<sup>46</sup> Hagenbach,<sup>47</sup> and Steele.<sup>48</sup> The case reported by Pepper<sup>49</sup> as one of fatal hemorrhage from a pancreatic cyst admits of another explanation. The patient, an intemperate man, had frequently recurring, intestinal hemorrhages for six months. He had two attacks of bloody vomit within five weeks, and finally an attack of gastro-intestinal hemorrhage, proving fatal in an hour. The blood came through an opening in the duodenum, a half-inch in diameter, near the common duct. A probe, passed through the opening, entered a cavity in the head of the pancreas, of the size of a walnut. Its walls were trabeculated, but "everywhere covered by a smooth mucous membrane," numerous crystals of hæmatine were lying on the surface. "But little of the proper gland-tissue to be seen in this part of the organ, its place having been apparently usurped by dense, fibrous tissue. The same state of affairs is also observable in the body and tail of the gland, although in a less marked degree." It seems more probable, from the symptoms in this case, the seat of the cavity, the nature of the duodenal opening, and the history of pancreatic cysts, that this was rather a case of perforating, duodenal ulcer with corrosion of the pancreas, than of pancreatic cyst opening into the duodenum.

<sup>42</sup> Bull. Soc. Anat. de Paris, 1865, xi. 192.

<sup>43</sup> Berliner klin. Woch., 1887, ix. 154.

<sup>44</sup> N. Y. M. J., 1887, xlv. 376.

<sup>45</sup> Corresp. bl. f. Schweizer Aerzte, 1888, 279; British M. J., 1888, i. 1297.

<sup>46</sup> Zeitschr. f. Heilkde., 1888, ix. 119.

<sup>47</sup> Deutsche Zeitschr. f. Chirurgie, 1888, xxvii. 110.

<sup>48</sup> Chicago M. J. and Exam., 1888, lvi. 205.

<sup>49</sup> Proceedings Phila. Path. Soc., 1870, iii. 182.



Doubts are also to be entertained concerning Rugg's case,<sup>50</sup> reported as one of fatal hemorrhage from the pancreas. In 1843 he had a male patient, æt. thirty-two years, who was rapidly recovering from a severe attack of acute rheumatism, but was up and dressed on the day before his death. He had frequently complained of severe pains in the epigastrium, but these had left him a few days before his death, and were replaced by acute pains in the left lumbar region. He was suddenly seized with agonizing pain in the latter place. His countenance became anxious, his lips pale, pulse imperceptible, skin cold and sweating, and death took place in an hour. The pancreas was somewhat larger and harder than usual, and had a cavernous rupture in its anterior surface, having all the appearance of an excavated ulcer. Its cavity contained a bloody substance, about the size of a walnut, in concentric layers. On longitudinal section of the organ several of these sanguineous deposits were found, varying in size from that of a horse-bean to a hazel-nut, in appearance like aneurismal deposits. A large quantity of blood was extravasated over the left kidney. The probability of this case being rather one of aneurismal than of pancreatic hemorrhage is very strong.

Finally the somewhat irregular case of pancreatic hemorrhage reported by Satterthwaite<sup>51</sup> may be mentioned. The patient, a man of thirty-six years, intemperate, syphilitic, had three attacks of jaundice in eight years. The last began five months before, and continued until his death. Toward the end of life he had a persistent bleeding from the lip, frequent intestinal hemorrhages, and constant drowsiness. The pancreas was distended beyond the usual size by a clot of blood. There was an extravasation of blood between the coats of the upper part of the ileum. The symptoms in this case are so different from those occurring in immediately fatal, pancreatic hemorrhage, or in hemor-

<sup>50</sup> *Lancet*, 1850, i. 608.

<sup>51</sup> *N. Y. M. R.*, 1875, x. 541.

rhagic pancreatitis, that the hemorrhage may best be attributed to the jaundice, like that from the lip and from the intestine. The pancreatic localization of hemorrhage in jaundice is exceptional, but need not be unexpected.

There remains, then, the following series of sixteen cases (page 18) where pancreatic hemorrhage was apparently the sole cause of sudden and unexpected death, in persons not presenting evidence of other causes of death. Nine of them have occurred in or near Boston, and three of these are now, for the first time, published.

The following more detailed report of Case XV. is compiled from notes sent by Dr. Holt, of Cambridge, who made the post-mortem examination.

The patient, fifty-eight years of age, was a gentleman of leisure, thin, white-haired, his body looking like that of a considerably older person. He was at a club-dinner the evening before his death.

He awoke about 2 o'clock the following morning, complaining of severe pain in the bowels, nausea, and great prostration. He was pale, and his pulse was very weak. He soon vomited, became collapsed, and died within half an hour.

The duodenal half of the pancreas was of a bluish-red color, and was sharply contrasted with the yellowish-gray splenic end. The darker portion was infiltrated with blood, which lay in the interlobular tissue and could be readily squeezed from the cut surface.

Nothing abnormal was found in the brain. Both sides of the heart contained a little fluid blood; the valves, cavities, and muscular substances appeared normal. The stomach was empty, and in the intestines were the products of digestion. The liver was normal in size and appearance and the cortex of the kidneys was paler than the pyramids.

I am indebted to Dr. Williams, of Charlestown, Mass., for the notes of Case XVI., which occurred in his practice. It is included in the series, with the full recognition that it is open to criticism since the post-mortem examination was necessarily partial and hurried.

SIXTEEN CASES OF PANCREATIC HEMORRHAGE.

No.	Authority.	Sex	Age.	Antecedents.	Symptoms.	Lesions.
I.	Spiess, L. Schmidt's Jahrb., 1867, cxxxiv. 270.	M.	Adult.		Sudden death.	Extensive, interlobular, pancreatic hemorrhage, and considerable hemorrhage behind the pancreas and spleen, between the peritoneum and abdominal wall.
II.	Klebs. Handb. d. Path. Anat., 1870, 1, 2, 555.				Unexpected death.	Extravasation of fresh blood in the pancreas, no interstitial inflammatory changes, no thrombosis of large vessels near pancreas.
III.	Zenker. Deutsche Zeitschr. f. prakt. Med., 1874, ii. 351.	M.	48	Very fat. Heart disease in early life. Previous pulmonary disease. 3 years ago slight digestive disturbance.	Awoke suddenly at night; unwell, desire to defecate, got out of bed, slight tendency to vomit. Retained to bed. Immediate death.	Entire pancreas of an intense, bloody color, and so fatty infiltrated that only fatty detritus was visible. Slight cardiac aneurism, not in such a condition as to be accused of causing sudden death.
IV.	Zenker. <i>Loc. cit.</i>	M.		Drunkard.	Found dead in the water. Well on the same day.	Hemorrhagic infiltration and fatty degeneration of the pancreas.
V.	Maynard and Fitz. MSS. Notes, 1875, v. p. 11.	F.	Adult.	In usual health.	Sudden pain in lower chest. Hurried respiration, feeble pulse. Death in a half-hour.	Thin, flaccid pancreas, with slight subperitoneal and intraglandular hemorrhages. Cut surface dotted with white specks. Extensive fatty degeneration of gland cells. Fat-crystals and blood-crystals. Nothing abnormal in cœliac plexus.

VI.	Kollman. Aerztl. Intell. Bl., 1880, xxvii, 421.	F.	Adult.	Mitral stenosis. After a hearty meal frequent, Pleurisy in left solid defecations. Restless and chest. Frequent anxious in night. Cold. Sense of abdominal pain. Constriction in chest. Ate breakfast with appetite, Died suddenly while talking with companion. Able to work.	Injected pancreas surrounded, as far as the spleen, with extravasated blood. Hemorrhage in mucous membrane of the duodenum. 400 grammes of yellow fluid in left chest; 100 grammes in the pericardium. No appearance of fatty degeneration of the pancreas.
VII.	Gerhardt. V. Kollman, <i>loc. cit.</i>	F.	47	Bronchial catarrh, emphysema, anaemia, ascites, albuminuria, cyanosis.	Inconsiderable, interlobular, pancreatic hemorrhage. Tissue behind pancreas as far as the spleen, infiltrated with blood. Duodenal mucous membrane almost black, and peritoneum over its convexity infiltrated with blood. Ecchymosis in mucous membrane of caecum. Pancreas enlarged one-half. Consistency diminished. Cut surface reddish-black from much extravasated blood nearly uniformly distributed. Blood-vessels and pancreatic duct unaltered.
VIII.	Reynolds and Gannett. Boston Med. and Surg. Jour., 1885, cxli, 275.	M.	66	Abundant fat-tissue	Suffered from epigastric pain and constipation. Felt better on the next day, but in the evening found pulseless and collapsed. Death within 36 hours from the attack of pain.
IX.	Draper. Trans. Asso. Am. Phys., 1886, i, 243.	M.	45	Strong, rugged. Drunk at long intervals.	Found dead in a chair, as if asleep. Seen well within 48 hours.
X.	Draper. <i>Loc. cit.</i>	F.	44	Addicted to liquor, though rarely drunk.	Found dead in bed, to which she went dressed, complaining of a headache. Seen well within 30 hours.
XI.	Draper. <i>Loc. cit.</i>	F.	26	Very fat, intemperate. Kicked in abdomen a week before death, but afterwards appeared in usual health.	Went to bed complaining of great abdominal pain. Some hamoptysis, 14 hours later cold, pulseless. Mind clear. Complained of intense, abdominal pain and of thirst.
					Pancreas infiltrated with and surrounded by extravasated blood. Moderate, retro-peritoneal hemorrhage. 8 ounces of thin, red fluid in the peritoneal cavity. Pancreas enlarged, sodden, soft, and slimy, filled with effused blood. Infiltrated blood behind mesenteric peritoneum, behind and below stomach, between stomach and colon, over right kidney. 22 oz. thin, red fluid in abdomen. No peritonitis.

SIXTEEN CASES OF PANCREATIC HEMORRHAGE. — Continued.

No.	Authority.	Sex	Age.	Antecedents.	Symptoms.	Lesions.
XII.	Draper. <i>Loc. cit.</i>	M.	55	Exemplary habits.	Well in the morning. Cramps in the forenoon. Found dead eight and a half hours later.	The abnormally large pancreas uniformly infiltrated with fresh blood. Subperitoneal tissue of each side of the pancreas, for about 2 inches, filled with blood. Pancreas and adjacent tissue infiltrated with blood; with microscope granular gland-cells and blood in interlobular tissue.
XIII.	Draper. <i>Loc. cit.</i>	M.	31	Intemperate.	While in good health, sudden epigastric pain, nausea, collapse and death in 45 minutes.	Pancreas doubled in size, dark-red, firm. The cut surface mottled with capillary hemorrhage, separated by a grayish-red, translucent material. Fatty degenerated tubules and acini. Cellular tissue around pancreas blood-stained.
XIV.	La Fleur. 1888, Medical News, 1888, liii. 80.	M.	50	Obscure dyspepsia for several years.	Severe, epigastric pain, vomiting, collapse. Death in 24 hours.	Duodenal half of the pancreas infiltrated with blood. Each side of the heart contained a little fluid blood.
XV.	Driver and Holt. MSS. Notes, 1888, v. p. 17.	M.	58	At a dinner party the night before his death. Thin.	Awoke at 2 A.M. with severe, abdominal pain, nausea, weak pulse and prostration. Speedy vomiting, collapse. Death within a half-hour.	Tail of pancreas infiltrated with blood. Slight mesenteric hemorrhage. No evidence of peritonitis.
XVI.	Williams. MSS. Notes, 1888, v. p. 17.	M.	70	Thin, temperate, always well.	Sudden epigastric pain, vomiting, weak pulse, slight epigastric swelling, collapse in a few hours, and death in 16 hours.	

The patient, a man seventy years old, was a night-watchman. His health had been good, and he had wholly abstained from liquor since early manhood.

In the evening he was suddenly seized with colicky pain in the epigastrium. After five hours the pain was almost constant, sharp and cutting, extending towards the left and downward nearly to the navel. The abdominal muscles, especially the recti, were very rigid. There was a slight, circumscribed, epigastric swelling at the left of the median line, extending from the costal margin to the navel. It was non-resistant and not sensitive to pressure, which rather relieved than increased the abdominal pain.

There had been vomiting of a yellowish fluid. The pulse was 95, regular, small, the radial and temporal arteries were rigid, the skin dry and not cool. The vomiting persisted, and in six hours the patient was collapsed, but conscious. He then became restless, the pain was less agonizing, and death took place sixteen hours after the beginning of the attack.

Dr. Williams' diagnosis was pancreatic hemorrhage.

After death he was allowed to make an incision over the tumor and found the pancreas enlarged from the median line of the body to the splenic end of the gland. The enlarged portion was more easily cut than the rest and infiltrated with blood. On section, two or three ounces escaped into the peritoneal cavity. Slight mesenteric hemorrhages had occurred. There was no evidence of peritonitis, nor was any blood found in the peritoneal cavity before the pancreas was incised.

The following case, reported by Zenker, is not inserted in the table, since it is not, strictly speaking, one of pancreatic hemorrhage, though important in suggesting the possible manner of death in this affection.

A man, aged twenty-eight years, strong, very fat, and epileptic, was found dead, having been seen alive an hour before. There was a hemorrhagic

infiltration in the hilus of the spleen and a venous hyperæmia of the solar plexus. The abdominal organs were strongly injected and the pancreas was fatty degenerated.

The consideration of this series of cases shows that most of the individuals concerned were in their usual health at the time of the attack, or when last seen alive. They were invariably adults and usually beyond the age of forty, when the age was given. Some were conspicuously fat and strong, while a few were weak and thin. Although several were of intemperate habits, others were not so reported, and two were exemplary in this respect.

Two had complained of previous digestive disturbance, and one suffered from frequent abdominal pain. One had received a kick in the abdomen a week before death.

From the evidence here collected there is evidently nothing in sex, habits, condition, or exposure which will indicate the likelihood of pancreatic hemorrhage.

The cases and data are insufficient in number and detail to permit an exact clinical picture of this affection which shall be of especial value in a differential diagnosis.

We learn that pain was an early symptom in nearly one-half of the cases; that it was usually severe, and might be intense, and was to be found in the abdomen or lower chest. Although mention is made of its presence in the epigastrium in one-fifth of the cases, this region is not conspicuously designated as the seat. On the contrary, there may be little or no pain, or merely a sense of constriction of the chest. Nausea or vomiting is but occasionally mentioned; constipation or a desire for frequent stools are still more rarely noted.

The most constant symptoms are those of collapse, and are more or less intense and more or less prolonged.

Death may take place within a half-hour after the onset of the symptoms and may be delayed for thirty-six hours. It is questionable in the latter instance whether the case should not, more properly, be included under the head of hemorrhagic pancreatitis than of pancreatic hemorrhage.

The appearances found after death are conspicuously the hemorrhage within and near the pancreas.

The gland may be of normal size or enlarged, and its density may not be modified, or the pancreas may be flaccid, soft, and friable. The hemorrhagic infiltration is to be found in the subperitoneal tissue around the pancreas as well as in the interstitial tissue of the gland. The former may be continued into the omentum and mesentery, behind the colon, and into the perinephritic fat-tissue. The entire pancreas may be infiltrated, or either half, or the central portion alone may be conspicuously involved. The hemorrhage is usually diffused, but it may be in numerous patches, both beneath the peritoneal investment and in the interlobular tissue. The color and moisture of the cut surface indicate that the extravasation is recent. It may take place into a normal pancreas or into one which is either fatty infiltrated, or fatty degenerated, or into one which shows a granular condition of the epithelium.

In a single instance evidence of an older hemorrhage was to be found in the presence of round, orange-colored bundles of acicular crystals. In the same pancreas were also to be seen colorless, acicular crystals, probably of fat, in clumps visible to the naked eye, corresponding to the appearances to be described under fat-necrosis. The microscopic examinations of one of Draper's cases showed occasional patches of hemorrhage within the lobules, although the infiltration was essentially in the interlobular tissue.

Hemorrhages might also be found in the wall of the duodenum and cæcum, and in the lungs in a single instance.

Although the splenic artery is reported to have been tortuous in one case, there is no evidence in any of a circumscribed aneurism. The splenic vein, when examined, was free from obstruction.

The conditions found by Zenker, viz., injection of the portal, venous system and of the capillaries of the solar plexus, with distended and empty cardiac ventricles, were not generally met with.



Fatty degeneration and fatty infiltration of the pancreas were not necessarily present in these cases, and frequently occur without a trace of hemorrhage.

The seat, extent, and rapidity of the bleeding suggest that it is rather arterial than venous, and no evidence of venous obstruction has been found. Such hemorrhages are most likely to be of aneurismal origin, but aneurisms have not been discovered. An embolic source has been sought for in vain. It is possible that the pancreatic secretion may have corrosive properties, as suggested by Klebs, in which case the condition should occur oftener. Suggestive evidence in favor of this view is the fact, well-known to demonstrators of anatomy, and called to my attention by my colleague, Dr. Mixer, that arterial injections are likely to break through and escape in the region of the pancreas.

Hemorrhages in a diseased or dead pancreas might be thus explained, but in the great majority of the cases collected there is no sufficient evidence of such disease. It is also possible that the hemorrhage may be of nervous origin, as in the pulmonary infarctions sometimes associated with cerebral lesions.

The only fact in favor of this view is the association of such pulmonary nodules with the pancreatic hemorrhages in one case. This observation, compared with the relative frequency of pulmonary hemorrhages of apparent central, nervous origin, makes the single instance of but little value as evidence.

That fat-necrosis is not a cause for such hemorrhage is obvious from its presence being suggested only in a single instance.

It is evident that the first step towards a more accurate knowledge of the immediate cause of this affection must lie in a more careful search for the actual source or sources of the leak.

## HEMORRHAGIC PANCREATITIS.

In considering the relation of hemorrhage to acute pancreatitis, it is important to agree upon what shall be understood by the latter term.

It has already been shown that the views advanced by Clässen and his predecessors give no aid in this matter. Klebs is non-committal on account of the paucity of evidence, and Friedreich elaborated his systematic description of acute, primary pancreatitis from the consideration of four cases. In the one pancreas were multiple abscesses; in another a bloody exudation, and infiltrated blood in the vicinity; in a third were spots of finely granular, yellow exudation with interlobular hemorrhage; while the fourth pancreas was gangrenous.

The material which has been accumulating since the publication of Friedreich's article, in 1875, is already so considerable and varied as to make possible a more complete description of the subject.

The acute inflammation of a gland, from the anatomical point of view, demands the presence of degenerative changes in the parenchymatous cells, or an exudation in the interstitial tissue, or both these factors.

The first, the parenchymatous inflammation or granular degeneration of the pancreas, such as occurs in infective diseases, or as the result of mineral poisoning, is of no immediate concern. It is the interstitial variety which, with or without associated parenchymatous changes, may be regarded as the genuine, acute pancreatitis; and it is in the interstitial tissue of the pancreas that the inflammatory exudation is to be sought. But this tissue is both fibrous and fatty, one or the other variety predominating in different individuals, and, perhaps, at different periods in life. These tissues bear a continuous relation to the peritoneum, and to the subperitoneal and retropancreatic fat-tissue. It is, therefore, most probable that an inflammatory process of this fat-tissue might arise within the pancreas, or be continued to the pancreas from some more remote place of origin. Thus a primary and a secondary, acute, interstitial pancreatitis might

occur. The results in either case would be the same; the sources and progress of the disease might vary.

Whenever the anatomical evidence is insufficient to establish the diagnosis of inflammation it is permissible to utilize the symptoms for this purpose. If the general symptoms of inflammation are present and the pancreas is described as infiltrated with blood, such an association of symptoms and lesion is rather classified among the inflammations than among the hemorrhages.

Thus Cases VIII. and XX. have many features in common; the latter, however, is tabulated as hemorrhagic pancreatitis, since it was considered clinically as a case of peritonitis from perforation. The former was placed among the hemorrhages, since the clinical picture was not that of an inflammatory process.

The series of cases which form the basis of this part of the subject naturally fall into three groups.

In the first hemorrhage is conspicuous, in the second suppuration, and in the third gangrene.

These may be designated respectively as hemorrhagic, suppurative, and gangrenous pancreatitis.

Before calling attention to the first of these groups it is desirable to exclude certain cases which have been regarded as possible illustrations of a hemorrhagic pancreatitis. Fearnside<sup>52</sup> reported the case of a man, æt. forty-nine, not remarkably temperate, but who had enjoyed good health till within a year, since which time deep-seated pains in the region of the stomach had existed, with occasional heat or coldness in the same region, gastrorrhœa, pyrosis, constipation, pallor, and loss of flesh. For three months before death the pains became more severe and frequent, eventually constant, generally most distressing a few hours after food. Three days before death a sudden, excruciating pain occurred, followed by jaundice and a dark-brown vomit. On the following day there was intermitting vomiting and frequent hiccough. On the day of his death he was collapsed, although his intelligence was good.

<sup>52</sup> London Medical Gaz., 1850, xlv. 967.

The epigastric pain was severe, and on pressure between the navel and the ensiform cartilage a deep-seated transverse tumor could be felt. The pancreas was four times the normal size, and was adherent to the stomach by some firm adhesions. The neighboring peritoneum showed spots of soft and firm exudation. The greatest increase in size was in the head, which extended deeply into the right lumbar region. It was blackish-brown, pultaceous, grumous, and contained distinct blood-clots. In the more consistent portions there was no trace of natural gland-tissue. The body was firm and close in texture, of a dark-red color mottled with black lines and points, and became paler towards the lip.

The probability of this being a case of malignant disease with hemorrhage is very strong, especially as the appearances do not correspond with those to be stated later as found in hemorrhagic pancreatitis.

Rigal<sup>53</sup> reports the case of a man, *æt.* fifty-two, previously in perfect health, who suffered for seven days from intermittent fever, daily, with short remissions. The abdomen and legs then became swollen, and some pain was complained of at the right of the navel, where was a sensitive, indurated spot. Jaundice then occurred, also progressive weakness and epistaxis. Finally fever was noticed, and death took place about seven weeks from the beginning of his sickness. The pancreas was large, the head being twice the normal size. The latter was brown, both on inspection and section. On microscopic examination there was advanced fatty degeneration, and numerous crystals of margarine were seen. There was also fatty degeneration of the right kidney and an enlarged and friable spleen. The liver was normal in size and consistency, the bile-ducts and gall-bladder were dilated.

This case is excluded from the series which is to follow, from the inability to determine the nature of the changes in the head of the pancreas. At the same time it is admitted that certain characteristics are presented which render it not unlikely

<sup>53</sup> *Gaz. des Hôp.*, 1869, xlii, 562.

to have been an instance of the disease under consideration.

The case reported by Huber<sup>54</sup> must be excluded from those of hemorrhagic pancreatitis. His patient died within twenty-four hours after the onset of an attack of severe, epigastric pain. There was a tumor of the head of the pancreas surrounding the common duct, which was passable. The tumor descended into the mesentery. It looked like Förster's carcinoma simplex, but had many pigmented and hemorrhagic spots.

The case of pancreatic hemorrhage reported by Challand and Rabow<sup>55</sup> is also not wholly clear with reference to its relation to pancreatitis.

The patient, sixty-two years of age, an insane woman and inmate of an asylum, had an ovarian cystoma for several years.

She was found, at bedtime, pale and groaning feebly, without known cause. The next day she was collapsed. She complained of suffering, especially in the lumbar and epigastric regions. The pain was not increased on pressure and there was repeated vomiting. She remained in a condition of extreme weakness, with frequent vomiting and groaning, a quick pulse and a subnormal temperature, till her death on the fourteenth day. The pancreas appeared doubled in size. On tearing its tissue a certain quantity of thick, black blood escaped. In making a longitudinal section a cavity as large as the fist was opened, filled with large, black clots. The pancreatic tissue was dark brown, and so softened and friable that it was impossible to determine the point of origin of the hemorrhage. The duct was moderately dilated and the tissues in the immediate vicinity of the gland were strongly discolored with blood.

This case is not included among those of hemorrhagic pancreatitis, since the described appearances do not correspond with those usually found and the possibility of a pancreatic cyst or of an aneurism is not eliminated.

<sup>54</sup> Deutsches Arch. f. klin. Med., 1875, xv. 455

<sup>55</sup> Bull. Soc. Med. de la Suisse Romande, 1877, xi. 345.

The table of seventeen cases (page 31) includes the instances of associated pancreatic hemorrhage and inflammation which present common features of symptoms and anatomical changes. Of these cases three have occurred within the vicinity of Boston; two of these are now, for the first time, reported, and the gross and microscopic specimens from the latter are submitted to your inspection.

I am indebted to Drs. Pinkham and Whitney for their notes of Case XXVIII. The patient was a man, forty years of age, by occupation a caterer. He was liable to attacks of acute indigestion, and, for a year or more before his death had suffered from general malaise and debility. His discomfort was attributed to indigestion. His last illness was of six days' duration and was characterized by epigastric pain, vomiting, and by great cardiac weakness. Death occurred from heart-failure after the pain and vomiting had ceased.

There was a large quantity of abdominal fat, and the post-mortem examination was negative, with the exception of the appearances described below. The pancreas was very large, weighing, with some adherent fat, four hundred and ten grammes. The cut surface showed throughout dark-red streaks and patches between the lobules and separating them to a slight degree. On microscopic examination there was no evident alteration of the gland-cells. A considerable quantity of free blood-corpuscles was found in the intralobular tissue. The fat-tissue was everywhere filled with small, opaque-white spots, often with a well-defined, dark border. Their diameter varied from a few millimeters to several centimeters. They were present within the pancreatic fat-tissue and in that outside the organ. Microscopic examination showed that the fat-tissue was changed to a finely granular mass in which were numerous, very fine, acicular crystals. In the vicinity of the patches of necrotic fat-tissue were found colonies of micrococci.

For the purposes of this paper a more extended,

microscopical examination has been made of the above pancreas.<sup>56</sup>

There is an extensive inter- and intra-lobular infiltration of fat-tissue. The interlobular fibrous tissue is increased in places and the contained duct is widely dilated.

The pancreatic lobules are, at times, diffusely stained of a brownish-yellow color. Certain lobules contain clusters of orange-colored, acicular crystals, especially in the vicinity of the fat-tissue.

The interlobular fat-tissue shows circumscribed, as well as diffused, hemorrhagic infiltration. There is, in addition, an excessive accumulation of round cells, in places wholly cellular, again fibrino-cellular, entirely replacing the fat-tissue. There are sharply defined islets of fat-tissue in which the individual cells are indistinct, without nuclear staining, the whole filled with acicular fat-crystals. The border is often sharply defined by a zone, in which are small, round clumps of orange-colored, acicular crystals, and outside of which a line of round-celled accumulation is frequent. Bacterial clumps and venous thrombi are present.

The described changes in the interlobular fat-tissue are likewise seen in the parapancreatic fat.

The following is the history of Case XXXIII., for the notes of which I am indebted to Drs. J. J. Putnam and Whitney. The patient was a gentleman, forty-eight years of age, who had been hemiplegic for several years. He was well nourished but not excessively fat. He had suffered from several attacks of pain in the region of the stomach, with chilly sensations, from which he recovered in the course of twenty-four hours. They were usually attributed to indigestion, but no exciting cause was ever discovered. He had one severe attack of this sort a year before his death, and became collapsed, and was covered with cold sweat. His mind was dulled and his talk somewhat incoherent. He rallied under the use of stimulants,

<sup>56</sup> Unless otherwise specified, the sections from the specimens hardened in alcohol are made with a microtome, stained in hæmatoxylin, carmine, or aniline blue or brown, dehydrated, and mounted in glycerine or balsam.

SEVENTEEN CASES OF HEMORRHAGIC PANCREATITIS.

No.	Authority.	Sex	Age.	Antecedents.	Symptoms.	Lesions.
XVII.	Löschner, <i>Beitr. Weitenweber's Med. z. Med.</i> , 1842. Schmidt's <i>Jahrb.</i> , 1843, xxxix, 31.	M.	26	Strong. Drinks and smokes. 5 years ago, from excesses, attacks of belching, nausea, cardialgia, colic, diarrhoea, burning sensation in upper abdomen.	For 16 days colicky attacks in upper abdomen, becoming more frequent. In past 5 days paroxysms of have become more intense; nausea, vomiting, constipation, fever, anxiety, now collapsed. Burning, stabbing, gripping pain from duodenum to spine, towards navel, back, and right shoulder, most severe along curvature of stomach. No stool for several days. Upper abdomen hot, swollen, sensitive. Death in 8 hours. Sudden cardialgia, without known cause, becoming violent on strong epigastric pressure. Constant bilious vomiting, obstinate constipation. High fever, quick pulse, collapse. Death in 3 days or more. No evidence of poisoning; diagnosis, perforating gastric ulcer.	Pancreas doubled in size, firm, violet. Lobules much enlarged, dark, injected; interstitial tissue infiltrated with blood. Here and there in the head, between the lobules, a fluely granular, yellow exudation. Connective-tissue around the pancreas swollen, friable, bluish-purple, infiltrated with blood.
XVIII.	Oppolzer, <i>Allg. Wien. Med. Zeit.</i> , 1858, xlv, Mediz. Neuigk., 1859, ix, 105; <i>Weiner Med. Woch.</i> , 1867, vii, 7.	M.	Adult, young.	Strong.	Sudden, severe pain below left breast, nausea, constipation, tympany, weak pulse. 2nd day: black vomit, defecation (alvine) exhaustion. Death in collapse on the third day.	Pancreas at least doubled in size, dark-red. Hemorrhage between the lobules, and much extravasated blood in the vicinity of the pancreas, between the mesenteric folds.
XIX.	Hooper, <i>Beale's Arch. of Med.</i> , 1860, ii, 282.	M.	44	Active, fat, florid, temperate.	Sudden, severe pain below left breast, nausea, constipation, tympany, weak pulse. 2nd day: black vomit, defecation (alvine) exhaustion. Death in collapse on the third day.	Pancreas enlarged, hard, friable, contained several small, scattered extravasations of blood. The seat of several lobules occupied by large lobules of fatty matter, from which much margarine crystallized out. Very many small granular cells in interval between follicles.



SEVENTEEN CASES OF HEMORRHAGIC PANCREATITIS — Continued.

No.	Authority.	Sex	Age.	Antecedents.	Symptoms.	Lesions.
XX.	Hilty. Corresp.-Bl. f. Schweiz. Aerzte, 1877, vii. 666.	M.	30	Strongly built, fat looked f o n d o f spirits. In past ew years frequent palpitation and oc- casional dyspnoea.	Sudden, abdominal fulness and tension attributed to new beer. Anxious, restless, uncomfortable. Feeble pulse, rapid breathing, cold sweat, subnormal tempera- ture. Then abdominal pain, dis- tended, tympanitic upper ab- domen. Nausea. 2 n d d a y : Collapse, spontaneous dejection, no fever. Sudden, violent, delir- ium; diagnosis, peritonitis from perforation. Death in 36 hours. In delirium tremens for a few days, then death.	Pancreas doubled in size, firm, dark violet. Extensive interlobu- lar, hemorrhagic infiltration. In the head many nodular hemor- rhages as large as cherry-stones, marked bloody infiltration of the peripancreatic tissue.
XXI.	Guillery. Ueber d. Entz. d. Pan- kreas. Inaug. Diss., 1879, 26.	M.		Intemperate.		Pancreas trebled in size from pres- ence of fat-tissue within and around the gland. Minute hemor- rhage in places. Microscopic ex- amination showed hemorrhage between the cells, and a small- celled infiltration in the inter- stitial tissue. A peripancreatitis with gradual extension into the parenchyma.
XXII.	Farge. Bull. Soc. de Méd., 1880-82, N. S. viii. 188.	M.	42	Fat, temperate. Has had repeated attacks of severe abdominal pain, with bilious vomit. Watery vomit every morning for some	Severe, abdominal pain, worst in left side on palpation. No vomit- ing. Subnormal temperature. Abdomen tympanitic, distended, especially below navel. 2nd day: pain less, pulse weak. Death.	In head of pancreas a cavity with butter-like contents. A hem- orrhagic mass in the tail, ap- parently the starting point of a peritonitis along the pancreas. Omentum thickly strewn with small, dirty-white, rounded, flat-

XXIII.	Whitney, Boston Med. and Surg. Jour., 1881, cv. 592.	M.	Adult.	time, and before present attacks. Robust. Occasional easily relieved, painful indigestion. A year ago jaundice lasting 2½ months, accompanied with some epigastric pain.	Epigastric pain, unable to continue occupation. 2nd day: Symptoms of peritonitis with great prostration. Death on the following day.	tened patches, composed of cheesy-degenerated fat. Pancreas dirty red, containing brownish-black nodules, mottled with opaque-white spots. The microscope showed diffuse blood, and amorphous clumps of the same. The white spots due to short, staff or spindle-shaped crystals in the fat-tissue. Outline of gland-cells lost, nuclei indistinct. Peritoneum reddened.
XXIV.	Ral-er, Virchow's Arch., 1882, xc. 525.	M.	54	Enormous quantity of subcutaneous fat.	Sick for 2 or 3 days before death. With slight, gastric difficulties. Soon followed by vomiting, symptoms of peritonitis, and collapse. Diagnosis, internal strangulation.	Pancreas enlarged, soft, pale, dirty-yellow, speckled with numerous opaque-white streaks and spots, also dark-brown and reddish-black spots. Numerous ducts filled with blood-clots. Head of pancreas infiltrated with blood, and surrounded with clotting blood. Numerous hemorrhagic patches in the mesentery. Also opaque, bright-yellow patches, up to the size of a cherry-stone in the subperitoneal fat of the abdominal walls, and in that of the omentum and mesentery.
XXV.	Haidlen, Cbl. f. Gyn., 1884, viii, 609.	F.	33	During first pregnancy much gastric disturbance and headache. In the last three months abdomen moderately distended. The violent epigastric pain persisted, meteorism took place. Collapse and death in 5 days.	Sudden, violent pain near pylorus, 37 days after delivery. Occasional vomit, some collapse, no fever. Sensitive epigastrium, and meteorism moderately distended. The violent epigastric pain persisted, meteorism took place. Collapse and death in 5 days.	Pancreas enlarged, almost wholly transformed into a brownish-red, bloody mass. The microscope showed a small-celled infiltration and hemorrhage, which may have continued for some days. Duct somewhat dilated. Adjacent omentum slightly suffused with blood.

SEVENTEEN CASES OF HEMORRHAGIC PANCREATITIS — *Continued.*

No.	Authority.	Sex	Age.	Antecedents.	Symptoms.	Lesions.
XXV.	(Continued)			tion. Slow recovery. Two attacks during the 5 weeks after delivery.	The patient died of ileus.	There was a hemorrhagic pancreatitis and peripancreatitis. The pancreas was as large round as a man's arm, and was so wedged between the spleen and the duodenum as to completely obstruct the latter.
XXVI.	Eichhorst, Eulenbergs Real-Encyclopädie, 1885, ii. 434.					
XXVII.	Amidon, Boston Med. and Surg. Jour., 1886, cxv. 594.	M.	Adult.	In perfect health.	Sudden nausea, vomiting, and slight diarrhoea. Some hours later severe gastric and abdominal pains and cramps. 2nd day: pains more frequent, intense thirst, collapse. Slight albuminuria. 3rd day: no defecation. Subnormal temperature. Unexpected death on the fourth day.	Pancreas enlarged, hard. Between it and the duodenum, encroaching on the former, but adherent to both, was a flattened mass of blood an inch and a half in diameter.
XXVIII.	Pinkham and Whitney, MSS. Notes, 1886, p. 29.	M.	40	For a year or more general malaise and lack of strength, attributed to indigestion.	Epigastric pain, vomiting, weak heart. Death on the sixth day, preceded by cessation of the pain and vomiting.	Pancreas very large, on section, dark-red streaks and patches between the lobules. The fat-tissue of the abdomen, especially near the pancreas studded with opaque white spots of fat-necrosis, with a well-defined, blackish edge. Colonies of micrococci found near these spots.

XXIX.	Oster and Hughes. Trans. Phila. Path. Soc., 1887, xiii, 24.	M.	58	Intense, epigastric pain for several days. Sensitive epigastrium, hemorrhage, with clots in the tail. In the body of the gland the acini appeared as grayish-white areas surrounded by the dark-red hemorrhagic exudation. Increased round-cells in the semilunar ganglia whose ganglion-cells were cloudy and indistinct. Oedematous Pacinian corpuscles behind duodenum and pancreas. Pancreas greatly enlarged, black from hemorrhage, fatty-degenerated. General peritonitis with adhesions and hemorrhagic exudation. Yellowish-white spots, up to the size of lentils, were seen beneath the parietal and visceral peritoneum, both at the operation and after death. They were composed of crystalline fatty acids.
XXX.	Hirschberg. Berl. Klin. Woch., 1887, xxiv, 287.	F.	56	Attacked with vomiting, abdominal pain; complete obstruction. A swollen, intestinal convolution to be felt in the right side. On the 4th day, sudden collapse, mind clear, abdomen distended, very painful, no palpable tumor. Laparotomy. Death 5 hours later.
XXXI.	Birch-Hirschfeld. Lehrb. d. Path. Anat. ome, 3te Aufl., 1887, ii, 639.	M.	38	Sudden, violent, colicky pains above the navel. Soon, high fever, delirium, copious green vomit and death on the 2nd day.
XXXII.	Birch-Hirschfeld <i>op. cit.</i>	M.	42	Pancreas markedly enlarged, dirty, brownish-red color. On section, dirty, grayish-red plugs were squeezed from the lobes and lobules. The microscope showed the interstitial tissue infiltrated with round-cells and red blood-corpuscles. The epithelium enlarged, granular, in many acini transformed into a finely granular detritus, a bloody, ichorous fluid in the pancreatic duct. Considerable swelling, hyperemia and ecchymosis of the duodenum and jejunum.

Very fat.

Both drunkards.

SEVENTEEN CASES OF HEMORRHAGIC PANCREATITIS — Continued.

No.	Authority.	Sex	Age.	Antecedents.	Symptoms.	Lesions.
XXXIII.	Putnam and Whitney. MSS. Notes, 1888, p 30.	M.	48	Abundant fat-tissue. Hemiplegic vomiting, later collapsed. 2nd for several years. day: Restless, but comfortable near pancreas, and in root of mesentery discolored red. Mesenteric fat-tissue showed numerous opaque-white spots. The fat-tissue in places discolored, soft, and foul-smelling. Thrombosis of splenic, pancreatic, and mesenteric veins. No infiltration about semilunar ganglion.	Awoke with severe gastralgia. 2nd day: Restless, but comfortable near pancreas, and in root of mesentery discolored red. Mesenteric fat-tissue showed numerous opaque-white spots. The fat-tissue in places discolored, soft, and foul-smelling. Thrombosis of splenic, pancreatic, and mesenteric veins. No infiltration about semilunar ganglion.	Pancreas doubled in size. On section, dark-red, mottled with opaque-white spots. Fat-tissue near pancreas, and in root of mesentery discolored red. Mesenteric fat-tissue showed numerous opaque-white spots. The fat-tissue in places discolored, soft, and foul-smelling. Thrombosis of splenic, pancreatic, and mesenteric veins. No infiltration about semilunar ganglion.

and in the course of a day or two appeared in his usual health.

At 5 A.M. he was seized with a severe stomach-ache, and a few hours later vomited, with temporary relief to the pain. Throughout there was considerable dull, epigastric pain and occasional nausea and vomiting. In the evening, immediately after vomiting, he suddenly became collapsed. There was constant pain throughout the night, and restlessness. During the second day he improved somewhat, although annoyed by hiccough. He vomited chiefly mucus, in which were found several small, dark-red lumps about the size of peas.

Early in the third day he was very restless, cold, and livid, his breathing rapid and his pulse almost imperceptible. He was conscious but anxious, and died within six hours after the collapse became extreme.

The pancreas was about twice the normal size; on section, of a dark-red color mottled with opaque white spots and patches, which lay between the lobules of the gland. These changes were most marked in the body of the gland, the head being relatively normal. The fat-tissue near the pancreas, that in the root of the mesentery, and in the mesocolon near the spleen was of a dark-red color. In places it was soft, discolored, and foul smelling. Numerous opaque, grayish-white spots were visible beneath the mesenteric peritoneum. The splenic vein contained a soft, dark, adherent thrombus which was continued into some of the pancreatic veins. Recent thrombi were also found in some of the mesenteric veins. The spleen was slightly enlarged, the pulp increased and dark-red.

There was no infiltration in the vicinity of the solar plexus and semilunar ganglion.

There was no evidence of a peritonitis.

In the microscopic examination of the hardened pancreas there is seen a sharp differentiation of the section into three zones.

The intermediary zone represents the interlobular fat-tissue which is continuous with that around the pancreas. It is not only extensively infiltrated

with blood, but is often transformed into a porous structure from the apparent destruction of fat-cells. Elsewhere it contains a fibrillated meshwork, finely granular material, bacteria, and numbers of acicular fat-crystals. There is also an occasional, round-celled infiltration of this fat-tissue between the relatively normal portions of the pancreas and the hemorrhagic and necrotic, interlobular fat-tissue.

On the one side of this intermediary zone the acini are distinctly defined and the nuclei clearly stained. Occasional lobules are seen with granular epithelium and indistinct nuclei. There are, in places, an intra- and inter-lobular infiltration of blood-corpuses and numerous accumulations of round cells. The interlobular tissue shows a fibrillated meshwork, apparently clotted fibrine; in the smaller ducts are numerous leucocytes.

On the other side of the hemorrhagic zone, although the lobules are distinct, the borders of the acini are often confused. The cells are granular, frequently not differentiated, and there is no staining of the nuclei. At times the lobules are replaced by a granular detritus or the cells are widely separated from each other. Here and there among these necrotic acini are stained islets, apparently bacterial colonies, thrombotic veins, and, more rarely, small accumulations of round cells.

At the edge of the pancreas is a large venous thrombus containing innumerable bacteria.

Of the seventeen cases of hemorrhagic pancreatitis fourteen were males and two were females, the sex of one person not being stated. Their ages were as follows:—

Years of age.	Number of cases.
From 25-30.....	1
“ 30-35.....	2
“ 35-40.....	1
“ 40-45.....	4
“ 45-50.....	1
“ 50-55.....	1
“ 55-60.....	2

One was described as a young adult, two as adults, and nothing was stated concerning the age of two.

The patients were usually in good health at the time of the attack, a few of them being conspicu-

ously strong and robust. Nearly one-half of them were abundantly or superabundantly provided with fat-tissue.

A small fraction, nearly one-sixth, was addicted to the abuse of alcohol. Nearly one-half of the cases suffered from previous attacks of indigestion.

These attacks were usually characterized by pain, which was colicky, gastric or abdominal, and so severe in one instance as to suggest impending perforation. Vomiting, either watery or bilious, or both, was noted. Nausea, belching, and diarrhœa were recorded. Jaundice occurred in a single instance.

It is obvious from the above statement that the previous digestive disturbances were rather gastric or gastro-duodenal than enteric.

The immediate attack began in the great majority of cases, with abdominal pain, usually without known cause, though rarely some irregularity in diet appears to have been an immediate predecessor. The pain was violent, intense, or severe, either constant or paroxysmal. Its seat was usually in the upper abdomen, and, in one instance, was stated to have followed the course of the pancreas; subsequently, in one-fifth of the cases, the abdominal pain became general.

The initial pain was usually followed by vomiting, more rarely by nausea alone. In one case there was a conspicuous record of no vomiting. The vomiting was constant, repeated, or occasional. It might be copious. It was bilious at times, or black, and contained, in one instance, dark-red clumps the size of peas.

Constipation was a symptom of frequent occurrence and a diagnosis of intestinal obstruction was made in three instances, in one of which laparotomy was performed. The occurrence of diarrhœa was noted in but one case. Hiccough and albuminuria each were reported in a single case.

Fever was an inconstant symptom. When present it was of early occurrence, and might be high on the second day. On the contrary, the temperature might be normal on the first day and subnormal on



the following day. Delirium was present in three cases.

A tympanitic swelling of the abdomen was of no infrequent occurrence. It was usually general, or in the upper abdomen, and was rarely localized in the lower abdomen. In one case, thought to be of intestinal obstruction, a swollen, intestinal convolution was to be felt in the right side.

Symptoms of collapse were almost invariably present, and usually directly preceded death.

This occurred as follows:—

On the 2nd day in.....	3 cases.
“ 3rd “ .....	5 “
“ 4th “ .....	3 “
“ 5th “ .....	1 “
“ 6th “ .....	1 “

It took place after a few or several days, each in one case.

The diagnosis lay between intestinal obstruction, perforative peritonitis, and an irritant poison.

The pancreas was found enlarged, either throughout or at one extremity, usually at the head. The gland was frequently doubled in size, and might seem still larger when abundant fat-tissue was present. The enlargement has been compared to the size of a man's arm.

The gland was generally dense, sometimes friable, and has been noticed to be of diminished consistency.

The existence of hemorrhage was usually suspected by the appearance of the surface, which is of various shades of red. On section, however, the color may be dark-red, reddish-brown, violet, reddish-black, or even black. The modification in color may be uniformly distributed, or lie in patches, or in specks. The patches correspond with nodules which may project above the surface. These discolored patches may show white specks or streaks, and the red color may lie in the interlobular tissue of the pancreas.

The color of the section may be affected by the presence of associated alterations, one of which is accidental, the other may be incidental. The former is due to an excessive quantity of fat-tissue in the pancreas, sometimes appearing to form nodules as

large as hazel-nuts and to treble the size of the gland. Bands and spots of a translucent yellow are thus produced which are mottled with shades of red. The incidental appearance is due to the presence of opaque-white specks, spots, and streaks, which are generally known, since the publication of Balser's<sup>57</sup> article, by the term fat-necrosis.

These were seen in six of the cases, and it is not improbable that the granular exudation described by Löschner may have been of the same nature.

The pancreatic duct may contain a bloody, ichorous fluid, and its branches may be plugged with clotted blood. The duodenum and jejunum may show swelling, injection, and ecchymosis.

The hemorrhagic infiltration may be found beyond the pancreas, both in the parapancreatic tissue, mesentery, meso-colon, and in the omentum. It may extend downwards behind the descending colon, nearly to Poupart's ligament, and may be found at the outer border of the left kidney.

The splenic artery and vein are usually free from changes. The latter may contain a thrombus. The portal vein has been found free from thrombosis.

The conditions of the other organs is essentially negative.

The heart may contain liquid blood, or a differentiated clot may be found in the right ventricle.

The spleen may be small, with wrinkled capsule, or it may be slightly enlarged and injected.

The peritoneum usually shows no alterations, although evidence of recent peritonitis may, at times, be found.

The microscopical changes to be found in the diseased pancreas have been sufficiently detailed in the reports of Cases XXVIII. and XXXIII. They consist essentially in the evidence of an extensive hemorrhagic infiltration limited more particularly to the interlobular tissue. Also in the presence of cellular and fibrino-cellular formations in the same tissue. Smaller accumulations of round cells and hemorrhages may be found within the lobules, and

<sup>57</sup> *Loc. cit.*

the ducts may be filled with indifferent cells. The appearances characteristic of a coagulation necrosis, also thrombosis of the smaller veins, are to be found in many lobules as early as the third day, as are all the other changes above described. The spongy condition of the hemorrhagic region and the numbers of associated bacteria are indicative of putrefactive changes. Whether these are of ante- or post-mortem origin the evidence at hand does not decide. Finally, the discovery by Osler and Hughes<sup>58</sup> may be mentioned, where an increased number of leucocytes was found in the semilunar ganglia, and an indistinctness and cloudiness of the ganglion-cells.

In summing up the clinical and anatomical characteristics of these cases we have the following brief description of an affection which wholly justifies the term acute, hemorrhagic pancreatitis.

It is a disease which may take place without any well-defined cause, but is most likely to occur in persons who have had previous attacks of gastric or gastro-duodenal dyspepsia.

It begins with intense pain, especially in the upper abdomen, soon followed by vomiting, which is likely to be more or less obstinate, and not infrequently by slight, epigastric swelling and tenderness, with obstinate constipation.

A normal or subnormal temperature may be present and symptoms of collapse precede by a few hours, death, which is most likely to occur between the second and fourth days.

The gross lesions are due to hemorrhage in and about the pancreas, and the microscope shows cellular and fibrino-cellular exudations in its interstitial tissue and necrosis of its lobules.

#### SUPPURATIVE PANCREATITIS.

In order to more fully appreciate the relation which hemorrhagic pancreatitis may bear to pancreatic inflammation and hemorrhage, it becomes necessary to consider the evidence in favor of other varieties of acute pancreatitis. Although the authorities of the present day make but little

<sup>58</sup> Case XXIX.

mention of a suppurative inflammation, Lieutaud<sup>59</sup> in the last century alludes to cases of pancreatic abscess reported by Bartholinus, Tulpius, Aubert, and Patin.

To these may be added those of Riolanus, Bonz, and Gautier, referred to by Ancelet.<sup>60</sup> Clässen<sup>61</sup> states that Blancard, in 1688, described the occurrence of small, purulent points on the surface of the pancreas of a child who died of small-pox. Also that Tonnellé found a suppurating pancreas in two cases of puerperal fever. But the cases thus referred to are almost invariably of but little value for purposes of comparison. Döring,<sup>62</sup> for instance, found the enlarged and indurated pancreas connected with an abscess in the mesentery of the transverse colon, which held some four ounces of offensive, yellow pus, apparently proceeding from the pancreas. But the evidence is wanting to show that the pancreas was the source of the disease.

Portal<sup>63</sup> saw the pancreas soaked in pus in the body of a man who died after a violent attack (of gout?). Again,<sup>64</sup> he found the contents of the abscess often enclosed, as in a pocket, in a membranous sack formed by the cellular tissue which covers the pancreas. He declares that he has seen more than a quart (*deux livres*) thus enclosed. Here again the question may be raised as to the nature of the abscess and its relation to the pancreas. His mention<sup>65</sup> is worthy of note, of the man who died after extirpation of the testicle and ligature of the spermatic cord. A large quantity of pus was found in the cord, and a considerable abscess around the pancreas.

It is supplemented by the case reported by Moore,<sup>66</sup> of a young man who was seized with a sudden, abdominal pain which in the course of twenty-four hours became worse, and fixed in the right iliac fossa. There was vomiting, constipation,

<sup>59</sup> *Op. cit.*, l. 244.

<sup>60</sup> *Maladies du Pancreas*, 1804, 19, 20.

<sup>61</sup> *Op. cit.*, 64.

<sup>62</sup> *Altenburger Jour.*, 1817; Clässen, *op. cit.*, 264.

<sup>63</sup> *Anat. Med.*, 1803, v. 352.

<sup>64</sup> *Op. cit.*, 353.

<sup>65</sup> *Op. cit.*, 353.

<sup>66</sup> *Trans. Lond. Path. Soc.*, 1882, xxxiii. 186.

and chills. For several days the patient was not confined to his bed, but he died on the nineteenth day. The diagnosis was typhlitis. The perforated vermiform appendix led into an abscess which had penetrated the iliac muscle and communicated with the cæcum.

There were one large and several small abscesses in the pancreas. The two main veins were filled with thrombi; there was a portal thrombosis continued to the liver, and a parietal thrombosis of the vena cava.

There were numerous small abscesses in the brain.

The case reported by Percival,<sup>67</sup> as of pancreatic abscess, must be regarded as of somewhat doubtful nature. A man of middle-age was sick for three months with jaundice, bilious vomit, and a hard, epigastric tumor.

Blood and, finally, fetid pus were discharged from the bowels. Eventually anasarca occurred. The epigastric tumor proved to be the greatly enlarged pancreas, which was scirrhus, and contained a considerable abscess.

The common duct was impervious from the pancreatic pressure, and the liver was "much diseased."

Andral<sup>68</sup> found two small abscesses in the middle of the pancreas.

In order to determine the relative frequency of suppurative pancreatitis, the conditions of its occurrence, its symptomatology and results, the following cases (page 46) have been collected.

They are twenty-two in number. One was of recent occurrence in Boston, for the notes of which I am indebted to Drs. Sears, Thompson, Jones, and Whitney.

The more detailed history of Case LV. is as follows:—The patient was thirty-nine years of age, rather fat, intemperate. For a year or two before her fatal illness she had suffered more

<sup>67</sup> Trans. Asso. K. and Q. Coll. Phy. Ireland, 1818, ii. 132.

<sup>68</sup> Précis d'Anat. Path., 1829, ii. 582.

or less from poor appetite, distress after eating, wind in the stomach, and costiveness.

She was seized with sudden, epigastric pain, without known cause, followed by vomiting, and the bowels were constipated. On the following day the pain became worse, but was somewhat relieved after vomiting. The next day, after a dinner of roast goose and cabbage, the pain became much aggravated. It was intense on the fourth day, and there was constant hiccup and vomiting. The epigastrium was sensitive, and the abdomen swollen. Pulse 120; temperature 103.4° F. She remained in this condition for several days, without any movement of the bowels, and intestinal obstruction was suspected. Castor oil finally produced a dejection which was followed by a lowering of the pulse and temperature.

For nearly a fortnight she was not seen by a physician, and she was then admitted to St. Monica's Home, where she remained two weeks. During her stay she was dull and stupid, suffered from moderate, epigastric pain and sensitiveness, nausea, and vomiting, and inability to eat solid food. The skin was not hot to the touch. Pulse 80. Her bowels were kept open by laxatives or enemata. There was a trace of albumen in the urine. The abdomen was full and rounded, and nothing abnormal was discovered on palpation. During the latter part of her stay she was able to sit up, daily, for a short time. She left the home without the knowledge of the physician, walked some distance, and was supposed to have drunk to excess.

Three days later she was seen by Dr. Sears, who found her suffering from severe pain in the right hypochondrium and epigastrium, with marked prostration. Her thirst was intense, but she immediately vomited everything swallowed. There was constant expectoration of thick, frothy mucus. Pulse 120; temperature 99.4° F. The abdomen was distended, the walls rigid. There was especial prominence of the epigastrium and right hypochondrium. This condition persisted during the three following days, at the end of which she

TWENTY-TWO CASES OF SUPPURATIVE PANCREATITIS.

No.	Authority.	Sex	Age.	Antecedents.	Symptoms.	Lesions.
XXXIV.	Baillie, 1833, Morbid Anat., 221, 223.	M.	20		General abdominal pain, nausea, sense of distention and weight in stomach after eating. Tendency to purge. Dropsy.	Pancreas a good deal enlarged and contained a considerable quantity of pus.
XXXV.	Perle. De pancreate ejusque morbis, Diss. Inaug. Berl., 1837, 33.	M.	Adult.	Feeble, scrofulous, phlegmatic.	Dull epigastric pain for several weeks, then becoming violent, with nausea, offensive, loose stools, quick pulse, dry skin, sensitive epigastrium. Temporary improvement. Return of diarrhoea, fever, emaciation, weakness. Death at end of more than 4 months.	Pancreas in part hardened, in part full of pus. The pus had escaped into the abdomen. Other organs normal.
XXXVI.	Fletcher. Prov. Med. and Surg. Jour., Lon., 1848, 20		Adult.	Corpulent, apparently much addicted to food and drink	Great epigastric pain, distention after meals, continued dull pain extending into both hypochondria above navel, relieved by purgatives, vomiting, constipation. Progressive emaciation and debility. Stools finally fetid, bloody. Temporary improvement, hectic, and death after 9 months of illness and 4 months in house. Intestinal obstruction suspected.	Enlarged pancreas formed a purulent mass without healthy structure. Its extremity had ulcerated into the duodenum at lower curvature, through which pus must have passed into the intestine. Liver enlarged, spleen normal.
XXXVII.	Kilgour. Lond. Journal of Medicine, 1850, ii. 1052.	M.	41	Indolent; large eater, fond of sweets. For some years attacks of bilious dyspepsia. Last attack seven months ago,	Emaciated, feeble, dispirited, restless; frequent vomiting, eventually of thin,ropy mucus. Sensation of distended stomach and bowels, in which much gas. No appetite, no thirst, sluggish bowels, consistent	Pancreas much enlarged, envelopes thickened. Entire gland formed a trabeculated cavity filled with creamy pus and a few cheesy masses about the size of a bean. The duodenum contiguous to the

<p>did not recover as usual.</p>	<p>stools, unmix'd with bile and very fetid. No pain nor tenderness, nor tumor. Left abdomen dull, tympany in right abdomen and over stomach.</p>	<p>After 2 months of slight, downward tendency, frequent chills and fever. Region between navel, lower border of stomach, and left flank dull, doughy, inelastic, not sensitive. After 2 weeks chills ceased and a resistant sore spot appeared above navel and at the left. (Edema of feet and legs. Death after 11 months.</p>	<p>Pancreas wholly suppurating. Spleen natural. Gall-bladder full of bile.</p>
<p>Robust. Some months ago, an attack of disturbed digestion with loss of appetite, flesh and strength, chilliness, morning belching, thin, viscid, liquid vomit. Recovery.</p>	<p>Some months ago, an attack of disturbed digestion with loss of appetite, flesh and strength, chilliness, morning belching, thin, viscid, liquid vomit. Recovery.</p>	<p>After 2 months of slight, downward tendency, frequent chills and fever. Region between navel, lower border of stomach, and left flank dull, doughy, inelastic, not sensitive. After 2 weeks chills ceased and a resistant sore spot appeared above navel and at the left. (Edema of feet and legs. Death after 11 months.</p>	<p>Pancreas wholly suppurating. Spleen natural. Gall-bladder full of bile.</p>
<p>Upper part of pancreas a dense, gray callus, in which a few remains of gland-substance and round cavities, up to the size of peas, filled with thick, white fluid; also several small pus-cavities. In the lower part of the pancreas an abscess as large as a walnut. The duct narrowed at the mouth, gradually widened towards the tail. Posterior wall of the stomach</p>	<p>After 2 months of slight, downward tendency, frequent chills and fever. Region between navel, lower border of stomach, and left flank dull, doughy, inelastic, not sensitive. After 2 weeks chills ceased and a resistant sore spot appeared above navel and at the left. (Edema of feet and legs. Death after 11 months.</p>	<p>After 2 months of slight, downward tendency, frequent chills and fever. Region between navel, lower border of stomach, and left flank dull, doughy, inelastic, not sensitive. After 2 weeks chills ceased and a resistant sore spot appeared above navel and at the left. (Edema of feet and legs. Death after 11 months.</p>	<p>Pancreas wholly suppurating. Spleen natural. Gall-bladder full of bile.</p>

XXXVIII.

Riboli, Gazz. Sard., 1858,  
Schmidt's Jahrb.,  
1859, cil. 177.

54

F.

XXXIX.

Klob, Oester. Zeitschr. f. pr. Heilkde., 1860, vi. 529.

64

F.



TWENTY-TWO; CASES OF SUPPURATIVE PANCREATITIS — Continued.

No.	Authority.	Sex	Age.	Antecedents.	Symptoms.	Lesions.
XXXIX.	(Continued.)					
XL.	Drasche. Ber. d. k. k. Kranken- anst. Rud-Stift. in Wien, 1868, 301.	M.	23	Well.	Severe gastric pain, without cause, loss of appetite, sluggish stools, slight fever, sensitive epigastrium, rapid emaciation. In the course of a fortnight violent paroxysms of stabbing pain spreading laterally from the epigastrium, which was swollen, tense and tympanitic. Paroxysms attended with transient collapse. In the 4th week a feculent diarrhoea, which suddenly became thin, profuse, watery, with nausea and bilious vomit. After decided improvement, fever and diarrhoea returned in the 7th week, and the abdomen became much distended. The tympany increased, there was occasional hiccup, progressive weakness, extreme emaciation, and death on the 65th day.	firmly adherent to pancreas and contained a submucous abscess. Pancreas large, firm, yellowish-red. Sclerosis of peripancreatic tissue. On section, several abscesses, some larger than a bean, at times communicating by sinuous tracts, two of which opened into the adherent posterior wall of the stomach and two into the duodenum. Spleen of normal size, firm, pale-red. Splenic vein obstructed by a reddish-yellow thrombus, in front of which the vein-wall was shredded and its cavity communicated with a large abscess. A lumbricus lay half in the vein and half in the abscess and in a sinuous passage leading from it to the duodenum. An abscess as large as a hen's egg in the left lobe of the liver. Fibrinous peritonitis, especially in upper abdomen.
XLI.	Roddick. Canada Med. Jour., 1869, v. 385.	M.	30	Intemperate, much exposed when drunk, and then has diarrhoea. Has had two attacks of intermittent fever.	After 2 days of constipation, slight epigastric pain and vomiting, thirst, hot skin, no appetite. The bowels were moved freely. A chill occurred, followed by chills and diarrhoea towards the	Pancreas firmly adherent. On section of the enlarged head an abscess opened, the walls thick; contents, an ounce of pus. The dilated duct in the head held several calculi. Spleen weighed 11½

XLII.	Nathan, Med. T. & Gaz., 1870, ii, 238.	M.	25	<p>Chronic cough for end of the week, then slight jaundice, persistent chills, and diarrhoea, and death in a collapse on the 12th day.</p> <p>For two days gastric irritability, nausea, constipation. Then incessant hiccough, epigastric distended, tympanitic, no pain, no tenderness, constant copious vomiting of thin, brownish, stringy fluid, no jaundice, increasing loss of flesh and strength. Death from exhaustion in 6 days from the onset of the symptoms of gastric disturbance. Diagnosis, <i>heus</i>.</p>
XLIII.	Smith, Dublin Jour. Med. Sci., 1870, 201.	M.	30	<p>Pancreas closely connected with neighboring organs. Spleenic end contained a small abscess, with thick greenish-yellow pus. Several small, lymphatic glands near duodenal end contained similar pus. Abscess in the diaphragm above the spleen.</p>
XLIV.	Frison, Marseille Méd., 1875, xii, 257.	M.	28	<p>Continued fever, severe abdominal pain at level of spleen, which was supposed to contain an abscess. Death in a month.</p>
XLV.	Frison, <i>Loc. cit.</i>	M.	28	<p>Loss of appetite, epigastric pain, jaundice, no fever. In 3rd month pain in right hypochondrium and shoulder, swollen abdomen, testicles, and feet. Sudden increase of appetite and thirst, abundant saccharine urine. In the 10th month intense jaundice, extreme emaciation, great weakness, lower</p> <p>Pancreas enlarged threefold, indurated, infiltrated with pus. A large collection of thick, yellow pus in the tail. Numerous small abscesses in the left lobe of the liver. Enormous dilatation of the common bile-duct. Spleen not enlarged.</p>

TWENTY-TWO CASES OF SUPPURATIVE PANCREATITIS — Continued.

No.	Authority.	Sex	Age.	Antecedents.	Symptoms.	Lesions.
XLV.	(Continued.)					
XLVI.	Friedreich. Ziemssen's Handb. d. sp. Path. u. Ther., 1875, vii. 2, 243.	M.	40		abdomen dull, upper abdomen distended and tympanitic. Diabetes persisted, return of fever. Death in coma, at end of 10½ months. An attack of severe abdominal pain, without cause, followed by tense, tympanitic abdomen, which was sensitive. Frequent regurgitation and bilious vomit, constipation, high fever. Death in the course of a week.	Pancreas enlarged threefold, reddened, consistency increased, studded with hundreds of abscesses up to the size of beans, many, projecting, had burst into the abdomen. General fibrino-purulent peritonitis, especially in the upper abdomen.
XLVII.	St. George's Hosp. Rep., 1877-8, 1879, ix. 95.	M.		Strong, temperate. After a month of cough and dyspnoea, 6 months ago, came diarrhoea, wasting, loss of appetite and aches, left inguinal hernia.	After a month of cough and dyspnoea, 6 months ago, came diarrhoea, wasting, loss of appetite and jaundice. After 7 weeks, a month of considerable oedema. For 10 days epigastric and interscapular pain. Death from exhaustion after 5 months of abdominal symptoms.	Head of pancreas enlarged. A diffuse abscess followed the course of the ducts and opened into the lesser omental cavity, which was full of pus and communicated with the duodenum. Fibrinous serous peritonitis. Thrombosis of femoral vein. Cheesy apices, cirrhotic liver, distended bile-ducts.
XLVIII.	Shea. Lancet, 1881, ii. 791.	F.	29	Fifteen months ago pain in region of liver, increasing and shooting. no nausea, poor appetite, bowels regular, nausea, bilious vomit, jaundice,	Jaundice for 2 weeks, tenderness of over gall-bladder, cough, disturbed sleep. After 2 weeks, apparent convalescence for four days, then return of pain over gall-bladder,	The enlarged and hard pancreas contained an abscess. A round worm, 7 inches long, lay partly in the duodenum, partly in duct. Large, fatty heart, pale kidneys. Large, pale, soft liver.

XLIX.	M.	58	<p>restless, rapid breathing, unconscious, death in 36 hours.</p> <p>After an error in diet, vomiting and severe abdominal pain. Swollen, sensitive abdomen. Pains in both hypochondria. After four days, increasing meteorism, fever, return of vomit, sleepless, progressive weakness, collapse and death on the 11th day.</p>	<p>faces dark.</p> <p>A year ago loud belching, abdominal fulness, no sensitivity. Nine months ago pale, sensitive epigastrium, black, tarry stools. Recovered from these symptoms but was pale and emaciated. After five months another attack of intense gastric disturbance lasting a fortnight. Then improvement and gain in weight.</p>	<p>Pancreas swollen, anterior surface dotted with numerous yellowish-white prominences, up to the size of hemp-seed, alone and in groups, forming cavities with smooth walls and pap-like contents. A group of these gray, gangrenous, covered with shreddy peritoneum. The contents of these cavities were fatty, granular corpuscles and detritus. The smallest had a wall of small-celled infiltration, similar foci on section, also narrow and broad bands and diffused growth of fat-tissue. Similar prominences in the transverse mesocolon and mesentery, in the former a circumscribed necrosis with floating shreds and fresh peritoneitic adhesions. Abundant sub-peritoneal fat.</p>
L.	M.	25	<p>Obscure symptoms of peritonitis.</p>	<p>Pancreas extensively destroyed by suppuration. The remaining, splenic end, infiltrated with pus, showed a ragged surface, forming part of the wall of an abscess, bounded below by the lowest 4 inches of the ileum and above by the stomach, spleen, abdominal wall and coils of intestine.</p>	<p>Pancreas extensively destroyed by suppuration. The remaining, splenic end, infiltrated with pus, showed a ragged surface, forming part of the wall of an abscess, bounded below by the lowest 4 inches of the ileum and above by the stomach, spleen, abdominal wall and coils of intestine. Head of the pancreas, partly broken down, formed one wall of an abscess elsewhere bounded by peritoneal adhesions.</p>
LI.	M.	74		<p>Moore. Lond. Path. Sec., 1882, xxxiii. 186.</p>	<p>Moore. Loc. cit.</p>

TWENTY-TWO CASES OF SUPPURATIVE PANCREATITIS — Continued.

No.	Authority.	Sex	Age.	Antecedents.	Symptoms.	Lesions.
LII.	Moore. <i>Loc. cit.</i>	M.	35		Slight jaundice.	A large part of the head of the pancreas destroyed by an abscess bounded by pancreas, duodenum, and under surface of stomach. The dilated, common duct communicated with the abscess and the latter opened into the peritoneal cavity and eroded the pancreaticoduodenal artery.
LIII.	Musser. <i>Am. Jour. Med. Sci.,</i> 1886, n. s., xci. 449.	M.	42	Intemperate, exposed to hardship.	For some weeks increasing debility. One attack of vomiting, marked ascites. For the next 25 days, dull, listless, without appetite, fever, pain	In the head of the pancreas an abscess as large as an orange. The rest of the gland dense, containing numerous pus-pockets, Ducts dilated. The large atresia opened into a pus-cavity, bounded by posterior wall of stomach, pancreas, duodenum, transverse colon and peritoneum. Portal vein filled with a puriform thrombus extending into hepatic, splenic and mesenteric veins. Slight cirrhosis, small, soft spleen. Recent peritonitis, bronzed skin.
LIV.	Bamberger. <i>Wiener Clin. Woch.,</i> 1888, xxxiii., Allg. <i>Med. Centr. Zeit.,</i> 1888, lvii., 1870, 1886.	M.	20		Ate a probably putrid sausage, sudden nausea, violent vomiting, prostration, alternating heat and cold, severe headache. The next day chill, cutting pains in abdomen, diarrhoea. On the 5th day	Head of the pancreas contained an abscess as large as a hen's egg, and filled with greenish-yellow pus. The greatly enlarged liver agglutinated to the diaphragm, anterior abdominal wall and stomach, num-

<p>high fever, meteorism, dilated jejunal abscesses present, the largest gastric and ileo-caecal regions. A the size of a hen's egg, also dark-week later jaundice. After 5 days violet nodules. Vena portae at the liver became enlarged, painful, most obstructed by a brownish-red and sensitive. The abdomen eventrally distended and tense, the thrombus continued into the stools thin and pap-like, the splenic vein. Behind the pancreas frequently contained peptones, one obstructed, the portal vein wholly or two daily chills with atypical gray, in a state of puriform soft- and abrupt changes of tempera- ture. Eventually, repeated watery- vomit, hiccup, death in collapse- dense, brownish-red. Recent fib- at the end of the 6th week.</p>	<p>Intemperate. Has Sudden, epigastric pain, vomiting suffered for a year or two from poor constipation; in the course of a few days, after an error in diet, the pain became intense, accompanied with fever. There was constant hiccup and vomiting. The abdomen became swollen and the epigastrum sensitive. The constipation persisted and intestinal ob- struction was suspected. 6 days before death, after indulging in alcohol, the symptoms became ag- gravated, and death occurred on the 48th day.</p>	<p>Mass. Gen'l Hospital Records and MSS. Notes, 1888, v. p., 44.</p>
<p>high fever, meteorism, dilated jejunal abscesses present, the largest gastric and ileo-caecal regions. A the size of a hen's egg, also dark-week later jaundice. After 5 days violet nodules. Vena portae at the liver became enlarged, painful, most obstructed by a brownish-red and sensitive. The abdomen eventrally distended and tense, the thrombus continued into the stools thin and pap-like, the splenic vein. Behind the pancreas frequently contained peptones, one obstructed, the portal vein wholly or two daily chills with atypical gray, in a state of puriform soft- and abrupt changes of tempera- ture. Eventually, repeated watery- vomit, hiccup, death in collapse- dense, brownish-red. Recent fib- at the end of the 6th week.</p>	<p>Intemperate. Has Sudden, epigastric pain, vomiting suffered for a year or two from poor constipation; in the course of a few days, after an error in diet, the pain became intense, accompanied with fever. There was constant hiccup and vomiting. The abdomen became swollen and the epigastrum sensitive. The constipation persisted and intestinal ob- struction was suspected. 6 days before death, after indulging in alcohol, the symptoms became ag- gravated, and death occurred on the 48th day.</p>	<p>Mass. Gen'l Hospital Records and MSS. Notes, 1888, v. p., 44.</p>

LV.

39

Mass. Gen'l Hospital Records and MSS. Notes, 1888, v. p., 44.

was taken to the Massachusetts General Hospital, where she died in the course of a few hours, at the end of the seventh week of her illness.

Dr. Whitney, who made the post-mortem examination, found the pancreas of normal size and density, in general of an opaque-gray color.

At the lower part of the head was a trabeculated cavity with dirty-green, shreddy walls and containing cheesy, necrotic material. A large branch of the duct, with a ragged edge, opened directly into this cavity. Its wall, near the cavity, was green and soft. The main duct was intact, but contained, near its outlet, a small quantity of dirty-brown, viscid fluid. The parapancreatic fat-tissue formed a part of the wall of the cavity above mentioned; near the splenic end of the pancreas was a hole in the fat-tissue, as large as a walnut and containing a dirty-green fluid. Elsewhere in the neighboring fat-tissue, and in that of the mesentery, meso-colon, and posterior abdominal wall were numerous opaque-white, pap-like nodules from the size of a pin-head to that of a pea. They were, at times, aggregated in clumps; the contents could be squeezed out. The smallest nodules were frequently surmounted by an injected border.

There was nothing abnormal in the portal vein or its immediate radicles. The liver was in a condition of brown atrophy, and there were minute, pale-yellow calculi in the gall-bladder and common duct. There was no evidence of a general peritonitis, but on cutting through the meso-colon the stomach and colon were found slightly adherent. The microscopic examination of the fat-tissue showed characteristic, necrotic patches with a margin of round-celled infiltration. Also occasional small abscesses and more diffused infiltrations of leucocytes.

In addition, occasional, circumscribed, round spots were seen, composed of more or less elongated and flat cells, enclosed within a fibrous border. The cells varied in size, some being considerably larger than fat-cells and containing several nuclei, while the smallest had a diameter four times that of a red blood-corpuscle. These patches suggested a

lymph-vessel plugged with desquamated and œdematous endothelium.

Dr. H. Jackson, under the supervision of Dr. Ernst, made a bacteriological analysis of the necrotic fat-tissue from the above case. From Dr. Ernst's report it appears that four varieties of bacteria were isolated:—

(1) A liquefying, fluorescent organism, which proved to be a fine, short rod, half the size of the bacillus of tuberculosis.

(2) An organism closely resembling the staphylococcus pyogenes citreus, both in the manner of its growth and in its microscopical appearances.

(3) Very short, rather thin, non-liquefying rods, which formed thin, grayish, almost translucent and much-wrinkled pellicles on the surface of the gelatine and agar-agar, around the mouth of the needle-track.

(4) The only organism found in large numbers. The cultures grew as finely beaded colonies along the needle-track, with a flat, pearl-gray top extending two or three millimetres over the surface of the nutrient material. Microscopic examination showed the organism to be composed of very short, thick rods, resembling somewhat the appearances found in one or two of the sections of the necrotic tissue. It did not liquefy the gelatine.

Of twenty-one patients, seventeen were males and four were females; all were adults, whenever ages were mentioned, and in eighteen cases the age was given as follows:—

Years of age.	Number of cases.
From 20-25.....	3
" 25-30.....	4
" 30-35.....	2
" 35-40.....	2
" 40-45.....	3
" 45-50.....	0
" 50-55.....	1
" 55-60.....	1
" 60-65.....	1
" 65-74.....	1

Previous attacks of indigestion of greater or less frequency and severity were present in about one-fourth of the cases. These attacks were usually regarded as gastric or bilious. One patient suffered



from sick-headache, while another was subject to diarrhœa during his drinking-bouts. Three were distinctly intemperate, two might be regarded as gluttonous, and one was exposed to hard work and extra hours.

The immediate attack was precipitated in two instances by errors in diet, in the one case a probably putrid sausage having been eaten. The attack was greatly aggravated in a third case by a dinner of roast goose and cabbage. Two weeks of catarrhal symptoms with great debility were the antecedents of another case.

A striking feature in the history of these cases of suppurative pancreatitis is the tendency of this affection to become chronic. Of fourteen cases six were fatal in the first month, three during the second month, and five at various periods between four and eleven months. Death might take place at the end of the first week and even the more chronic cases often began with distinctly acute symptoms.

It is therefore desirable in the consideration of this series of cases to group them with particular reference to the rapidity of their course.

The cases of acute, suppurative pancreatitis usually began suddenly, with severe, generally intense, gastric, epigastric, or abdominal pain, vomiting, and sometimes great prostration. The vomiting might be incessant and distressing, or it might give temporary relief to the pain. The ejected fluid was sometimes stringy and brown. The bowels were usually constipated, although diarrhœa might occur within the first twenty-four hours. This latter symptom was not infrequent at a later date of the disease.

Fever, usually slight, was the next conspicuous symptom, being manifested about the third day. At the same time the upper abdomen, especially the epigastrium, was likely to become distended, tympanitic, and sensitive. Hiccough, sometimes quite obstinate, was not infrequent at this stage, and occasional chills were to be met with. The abdomen, in general, then became moderately swollen, tense, and tympanitic.

With the violent onset and persistence of these symptoms death might occur, perhaps in the course of a week or more.<sup>69</sup> The pancreas then was markedly enlarged, reddened, and studded with hundreds of small abscesses, many of which had burst into the peritoneum. The associated fibrino-purulent peritonitis was most marked in the upper abdomen. In the second case,<sup>70</sup> where death resulted in eleven days, the attack was apparently recurrent in a corpulent person who had suffered for a year from symptoms which might be attributed to pancreatic disease. There were found in the pancreas numerous small, yellowish-white prominences, alone and in groups, with soft, pap-like contents. They were present on section as well as superficially. The contents were fatty-degenerated cells and detritus. The wall of the smallest cavities was infiltrated with round cells, while that of the others was smooth. A group of these prominences were grayish discolored, gangrenous, the superficial peritoneum being perforated and shreddy. Similar nodules were found in the mesentery and in the transverse meso-colon. In the latter was a circumscribed necrosis with floating shreds and fresh, peritonitic adhesions. The pancreas was irregularly traversed by narrow and broad bands and by a diffused development of fat-tissue. Not only does the clinical history of this case suggest a recurrent and finally fatal attack, but the pancreatic lesions also point to a long-standing process. Fibrous bands, fatty-degenerated cells, and smooth-walled cavities filled with detritus favor this view. The description of these nodules suggests that many of them were probably foci of fat-necrosis, with gangrenous sloughing of the superjacent peritoneum.

An acute, suppurative pancreatitis, however, very rarely terminates at this early date. The symptoms already described may persist for three or four weeks, with progressive emaciation and debility, and death occur from exhaustion. Under such circumstances the single abscess has been found surrounded with adhesions.

<sup>69</sup> Case XLVI.

<sup>70</sup> Case XLIX.

In another series of cases, beginning equally violently, there may be frequent chills and irregular, atypical, often high, fever, the maximum temperature being 105.8°. Slight jaundice may be associated. The pains extend into the hypochondria and may spread from this point downwards.

The liver, perhaps the spleen, may be palpably enlarged—the symptoms are conspicuously those of blood-poisoning, and the patient dies collapsed in the sixth or seventh week. An abscess as large as a hen's egg, filled with greenish-yellow pus, may then be found in the pancreas. Death at the end of seven weeks may result from the extension of the pancreatic abscess to the parapancreatic fat-tissue, with the production of multiple nodules of fat-necrosis.<sup>71</sup> In this case the symptoms of epigastric pain, vomiting, constipation, and swelling were interrupted by a period of several weeks of comparative comfort, to be followed by marked prostration, incessant vomiting, severe epigastric pain, and fever.

Another event in the history of acute, suppurative pancreatitis is to be found in the course of the third or fourth week of the tense and swollen, painful and sensitive, upper abdomen which follows the pain, vomiting, constipation, and fever. A diarrhœa then becomes conspicuous, perhaps preceded by violent paroxysms of lancinating pain shooting laterally in the epigastrium, producing temporary collapse.

The loose stools may be thin, yellow, and feculent at the outset and then become profuse and watery. This symptom may then subside, with a lowering of the fever and a general improvement, to recur after a few weeks with fever and abdominal distention, progressive emaciation and increasing weakness, ending in death in the tenth week.

Several small abscesses have then been found in the enlarged and firm pancreas, with sclerosed peripancreatic tissue. Communicating sinuses unite these abscesses and open into the adherent stomach and duodenum. A splenic thrombo-phlebitis and a hepatic abscess may be associated, also a fibrinous

<sup>71</sup> Case LV.

peritonitis especially marked in the upper abdomen.<sup>72</sup>

The early symptoms may be less severe and the disease be announced by progressing weakness and emaciation. Loss of appetite, slight jaundice, perhaps diarrhoea, may occur. There may be neither fever nor pain, or there may be obscure symptoms of peritonitis. Finally, anasarca or ascites becomes apparent, and death occurs from exhaustion, perhaps at the end of five months. The pancreas may then contain a diffused abscess, following the course of the ducts and opening into the cavity of the lesser omentum, which was filled with pus, and in its turn emptying into the duodenum through a sinus in the mesentery, these conditions being associated with a fibrino-serous peritonitis. The pancreatic abscess may extend, at an earlier date even, to the omental cavity, thus forming a great pus-cavity extending as low as the lowermost coils of the ileum, and walled in by adherent intestines and stomach. The greater part of the pancreas may be destroyed. The common duct may open abruptly into the abscess of the pancreas, and leave it at the hepatic end. There may be an associated thrombosis of the portal vein continued into its primary sources, and the pancreaticoduodenal artery may be eroded, with hemorrhage into the cavity of the abscess. A recent peritonitis may be associated, and in one of these, somewhat protracted, cases with extension to the omental cavity, a bronzed skin was present.

Finally, there are the most chronic cases, which extended over a period of nearly a year. As a rule no severe pain occurs at the outset, but the patient gradually becomes weak and thin, vomiting may be frequent, and a sense of distention of the stomach after meals or of epigastric pain be complained of. There may be little or no fever, or periods when chills and fever occur. The stools may be consistent, not colored with bile, and very fetid, or later they may be very offensive and mixed with blood. There may be a free communication between the

<sup>72</sup> Case XL.

pancreatic abscess and the duodenum, or the latter may break into pultaceous shreds when handled. The entire pancreas may be converted into a trabeculated cavity filled with creamy pus and cheesy masses, or it may be indurated and infiltrated with pus. In one of these protracted cases<sup>73</sup> diabetes appeared after the third month.

Noteworthy in these cases of suppurative pancreatitis is the rarity with which a circumscribed tumor is to be found. A swollen, tympanitic epigastrium is the rule, and very rarely a circumscribed resistant spot was to be felt above the navel, to the left of the median line.

Jaundice occurred in less than one-fourth of the cases. It was then usually slight. Its intensity in one case was connected with abscesses in the liver and dilated bile-ducts.

Another fact of considerable importance is the usually small size of the spleen. The rule was that no enlargement was noticeable even in those cases in which the thrombotic obstruction of the splenic or portal vein was recorded. The small spleen was usually of normal density.

From the above consideration it is evident that there are cases, few in number, of acute, suppurative pancreatitis, which run a course similar to that described in connection with hemorrhagic inflammation. They may begin with equal suddenness, present the same grouping of symptoms, but are not so early fatal. They are more rarely associated with evidences of fat-necrosis, which were present in but two instances.

Although Klebs<sup>74</sup> regarded pancreatic abscesses, not arising from a peripancreatitis or from suppurating cysts, as of doubtful existence, it is apparent that this view is opposed by the evidence here recorded. It is also evident that the extension of an abscess from the neighboring lymph-glands to the pancreas is of extreme rarity. The only evidence in favor of this view is that offered by Portal<sup>75</sup> and in the case<sup>76</sup> reported by Smith. The

<sup>73</sup> Case XLV.

<sup>74</sup> P. 10.

<sup>75</sup> P. 43.

<sup>76</sup> Case XLIII.

possibility that a pancreatic abscess may be due to inflammation of the appendix is evident from Moore's case, although the connection between the two may have been through a mesenteric thrombo-phlebitis, arterial embolism, or through the coexistence of acute pancreatitis and appendicular inflammation.

The possibility that a pancreatic inflammation may be excited by the passage of a lumbricus into the pancreatic duct is admitted in connection with the appearances in Case XLVIII. It is still more probable, however, that the worm entered the pancreas after the establishment of the inflammation. Its presence there might be merely accidental, even taking place after death, as is likely to have been the fact in Case XL.

#### GANGRENOUS PANCREATITIS.

But the subject of acute pancreatitis deserves attention from another event, viz., its possible termination in gangrene.

The earlier medical writings contain occasional references to gangrene of the pancreas, but the evidence presented is so slightly objective as to make them of but little value for present needs.

Grisellius,<sup>77</sup> for instance, has been generally considered to have first called attention to this matter.

His patient, a man forty-two years of age, suffered from frequent colic, which was easily relieved. He was suddenly, without cause, seized with a chill and severe colic and died quietly in the course of eighteen or nineteen hours. The post-mortem examination showed an extreme quantity of abdominal fat. The pancreas was found sphacelated, in a large mass of fat. "In whose absence nature had supplied another like round mass, on the right towards the liver and attached to the sphacelated part. Veins ran through the middle, like Wirsungian ducts, but without order. This sphacelated pancreas distributed a like contagion, penetrating not only adjacent parts, but even the diaphragm, consuming the left lobe of the lung as in phthisis."

<sup>77</sup> *Misc. cur. Med. phys. Acad., etc.*, 1681, Ann. iii. 65.

The liver is said to have resembled grumous blood, in color and in substance. There were several calculi in the gall-bladder.

"Other membranes were adherent at the bottom of the gall-bladder and held another stone larger than all."

Although the evidence does not permit an exact diagnosis to be made, it would seem as if the sufferings and death of this individual were rather attributable to biliary calculi than to pancreatic disease. The penetration of the diaphragm and the consumption of the left lung suggest that post-mortem softening of the stomach may have aided in producing the described appearances. The clinical history, brief as it is, affords quite a different picture from that to be presented as connected with pancreatic gangrene.

Bonetus<sup>78</sup> credits Barbette with stating that in a case of obstinate vomiting the pancreas was found wholly putrid, rather sphacelated. Again<sup>79</sup> he refers to the statement of Verzaschka that Glaserus found a semi-putrid pancreas in a case of dropsy.

Bonetus himself<sup>80</sup> records a case of dropsy in a boy in whom the pancreas is stated to have been semi-putrid.

In Lieutaud<sup>81</sup> there is extracted the case of a woman with obstinate vomiting, severe renal symptoms and pubic pain, in which the pancreas was semi-putrid, almost destroyed.

Also<sup>82</sup> that of a girl with swollen abdomen, hypogastric pain, purulent urine, and diarrhœa. The omentum and a large part of the mesentery were rotten. The liver filled almost the entire abdominal cavity. The pancreas was putrid and the whole left kidney purulent.

Again,<sup>83</sup> in an infant with dropsy, there was found a putrid omentum and pancreas. He reports<sup>84</sup> that Helvigiuss found a sphacelated pancreas, omen-

<sup>78</sup> Sepulchretum, 1700, lib. iii. sect. viii. obs. 54, vol. ii. 113.

<sup>79</sup> *Op. cit.*, ii. lib. iii. 478.

<sup>80</sup> *Op. cit.*, ii. lib. iii. 415.

<sup>81</sup> *Op. cit.*, i. 34.

<sup>82</sup> *Op. cit.*, i. 62.

<sup>83</sup> *Op. cit.*, i. 64.

<sup>84</sup> *Op. cit.*, i. 183.

tum and mesentery, also a shrivelled and putrescent liver, with a gall-bladder containing more than a hundred calculi, in a man sixty years of age, who was seized with gastric pain, obstruction of the liver, and dyspnoea; there was black jaundice and œdema of the legs.

He also <sup>85</sup> refers to a case of extreme dilatation of the bile-duct, where the head of the pancreas was swollen, dense, scirrhus, and pressed upon the opening of the cystic duct. The left portion of the pancreas was putrid. Finally, he credits <sup>86</sup> Bonetus with reporting a case of oft-recurring, obstinate, tertian fever, in which the pancreas and mesentery were found somewhat corrupted and sanious.

Schmidtman <sup>87</sup> speaks of finding induration of the pancreas with appearances of inflammation and beginning gangrene in a case of chronic suppurative nephritis with destruction of the bladder.

The case reported by Portal <sup>88</sup> is perhaps the first which demands recognition, as illustrating the relation of pancreatic gangrene to hemorrhagic pancreatitis. He writes as follows:—

“Gangrene of the pancreas is the frequent result of inflammation. I have found it in several corpses, and especially in that of a merchant of St. Denis street, who during a period of more than two years suffered from severe attacks of colic. They were deep-seated, below the navel, and were often preceded or followed by nausea or vomiting. There was neither swelling nor induration of the lower abdomen; no dryness of the tongue nor thirst. He became much emaciated, the pains increased, the pulse quickened, the heat of the skin became acrid and very strong. The slightest touch of the lower abdomen became very painful. The urine was scanty and red. This state lasted some twenty days, when the patient died unexpectedly. I was present at the autopsy.

“The pancreas was violet-red and soft, a black moisture escaped from its surface, it was almost

<sup>85</sup> *Op. cit.*, i. 236.

<sup>86</sup> *Op. cit.*, i. 246.

<sup>87</sup> *Hufeland's Journ.*, d. pr. Arzneykde, 1799, vii. 4te St. 16.

<sup>88</sup> *Anat. Med.*, 1803, v. 353.



wholly gangrenous. The stomach and the duodenum appeared inflamed in places."

Although the above case is probably one of the disease now under consideration, the lack of detail in the clinical statement and account of the anatomical appearances makes its value rather historical than useful in determining the relations of the hemorrhage to the gangrenous affections of the pancreas.

Gendrin<sup>89</sup> reports a case which is likely to belong to the series, but which is deprived of a considerable part of its possible value by the lack of sufficient details, clinical as well as anatomical. He states: "We have seen a vast cavity in the region of the pancreas communicating with the jejunum, which was perforated an inch from its origin. The pancreatic tissue was lost in a dense, friable, reddish mass which formed the wall of the cavity, which was filled with a grayish, very fetid pus. The surrounding cellular tissue and the intestinal walls united in forming this suppurating tumor.

The table of fifteen cases of pancreatic gangrene (page 66) represents all, with the above possible exceptions, I have been able to collect. Twelve of them have been observed in the past eight years, five of them have occurred in Boston or its vicinity, and three of them are now published for the first time.

The records of the Boston City Hospital give the following details concerning Case LXVI. The patient, married, 40 years old, with abundant fat-tissue, strained herself two years before her death, while lifting a heavy tub. There was immediate umbilical pain and swelling, but she was not compelled to give up work. Until two weeks before she entered the hospital she was able to replace the umbilical hernia. Since then the swelling and pain have increased.

On the day following her admission as patient she vomited after breakfast, and was seized with a severe paroxysm of colic. The pulse became small and flickering. On the following day there

<sup>89</sup> Hist. Anat. des Inflam., 1826, ii. 239.

was nausea and bilious vomiting, the pulse remained very weak, at times not perceptible, and the face was pinched and anxious. The temperature was not elevated. On the third day the vomiting had ceased, but the face was flushed, the temperature  $100.8^{\circ}$  F. and the pulse 144. She became comatose the next day, and died. Pallor, gasping respiration, a temperature of  $100.8^{\circ}$  F., and a pulse of 124 were recorded. The coils of intestine in the immediate vicinity of the pancreas were united together, and to the diaphragm, by recent, fibrinous adhesions. On removing these the pancreas was found to be doubled in size, of a dark-red color and of a somewhat diminished density. On section, the tail was of a nearly uniform red color, soft, and its tip was shreddy. The duodenal portion was of normal density and of a mottled, red and gray, color.

The splenic vein was filled with a reddish thrombus, in places softened at the centre. The under surface of the diaphragm presented a dirty, grayish-white, shreddy appearance. A section through the diaphragm showed it to be four times as thick as usual and to contain numerous small collections of dirty-gray, puriform fluid. The diaphragmatic tissue was quite shreddy. There was an acute, fibrinous pericarditis and a sero-fibrinous pleurisy. The umbilical hernia was omental and adherent.

Case LXVII. has the following record. The patient was an Irish laborer, forty-nine years of age, abundant fat-tissue.

In the past three years he has had three attacks of jaundice, with bilious vomiting, severe pain and tenderness over the xiphoid cartilage. He has suffered also from severe paroxysms of abdominal pain and had been told by a physician during the past winter that he had passed a gall-stone.

After dinner he suffered from a burning sensation in the stomach, followed by nausea and severe abdominal pain, not paroxysmal, but increased on motion. He became jaundiced on the next day and vomited a dark-green fluid and considerable mucus. For the subsequent three days the vomiting per-

FIFTEEN CASES OF GANGRENOUS PANCREATITIS.

No.	Authority.	Sex	Age.	Antecedents.	Symptoms.	Lesions.
LVI.	Haller and Klob, Zeitschr. d. k.k. Ges. d. Aerzte zu Wien, 1859, xv. 577.	M.	63	Always well.	For 16 days gastric disturbance, vomiting. Now pale, cachectic, thin, yellow, bitter vomit. Epigastrium somewhat distended, tense, tympanitic, sensitive. Abdomen elsewhere moderately swollen. In the evening repeated nausea, vomiting, great prostration, collapse, violent epigastric pain, thence extending over whole abdomen. Traces of blood in vomit. No albuminuria. Death, after rapid collapse, on the 18th day.	The pancreas thin, flabby, friable, grayish band soaked in fluid. It lay in an ichorous cavity, bounded by the posterior wall of the stomach, spleen, and duodenum, and communicating with the stomach by three openings in its posterior wall. The pancreas was united in front by a few shreds to the omental bursa. Its cells were either disintegrated, or swollen, or opaque. Certain lobules were separated from each other, in part collapsed, with intervening molecules and fat-drops. Pus-cells were present. Splenic vein obstructed by a dark-red thrombus extending to the portal vein.
LVII.	Trafoyer, 1862. v. Chiari, Wiener Med. Woch., 1880, xxx. 139, 164.	M.	52	Digestive disturbances for 2 months, with decided emaciation.	Sudden, severe colic. After several days a diagnosis of gall-stones by Oppolzer. The attacks were repeated for 3 or 4 weeks, when 18 gall-stones were discharged. Three days later another intense attack with vomiting, prognosis grave. On the following day a slough discharged from the bowels. Recovery in 3 weeks, and the patient well 17 years later.	Rokitansky examined the slough and recognized it as the sequelated pancreas.

<p>Chiari. Woch., Wiener Med. Woch., 1876, xxvi. 291.</p>	<p>F.</p>	<p>Corpulent, alico. Violent pains in region of stomach. Swollen abdomen, painful epigastrium, and occasional vomiting after meals. Irregular course of defecation. Stools often black. A few attacks of jaundice.</p>	<p>Pancreas, cylindrical, brownish-black, shreddy, and friable. It lay in the omental cavity, which formed a spacious pus-cavity, the walls densely fibrous with purulent infiltrations of the innermost layers. The liquid contents an offensive black fluid. A round ulcer of the stomach opened into the cavity, there was also a second opening between the two, and five openings into the jejunum. There was a thrombus in the splenic vein, and necrosis of fat-tissue.</p>
<p>Chiari. Woch., Wiener Med. Woch., 1880, xxx. 142.</p>	<p>M.</p>	<p>Biliary colic a year ago.</p> <p>Slight, nocturnal, abdominal pain for 10 days not interfering with occupation. It then became more severe, with sensation of twisting in left, gastric region. On the 14th day suddenly awoke with persistent vomiting, followed by a dejection. Violent, gastric colic. Soon anxiety, collapse, the epigastrium swollen, tense, sensitive. For a few days signs of intestinal obstruction, the abdomen swollen, epigastrium sensitive. No fever. After repeated enemata offensive stool and improvement. At end of a fortnight a sudden, febrile attack lasting 3 days, with symptoms of stenosis. After a fortnight a slough was discharged from the bowels. Recovery in five weeks, the entire illness lasting some 12 weeks.</p>	<p>The slough proved to be the larger part of a gangrenous pancreas.</p>

FIFTEEN CASES OF GANGRENOUS PANCREATITIS — *Continued.*

No.	Authority.	Sex	Age.	Antecedents.	Symptoms.	Lesions.
LX.	Chiari. <i>Loc. cit.</i> , 139.	F.	46	Strongly built, abundant fat-tissue; often suffered from cramps of the stomach.	Severe, abdominal pains for some days, frequent vomit. Signs of a general peritonitis. Slight jaundice. After a chill, copious, black, offensive vomit, which continued till death. Duration of disease some three weeks.	Pancreas dark-brown, friable, lying, attached only by a few rotten, fibrous threads, in the omental cavity. The latter contained also abundant, ichorous, bloody fluid, and communicated with the duodenum and transverse meso-colon. Purulent infiltrations of the mesentery. Necrosis of fat-tissue. Numerous calculi in the gall-bladder. General peritonitis. The microscope showed merely remains of the pancreatic acini, but no evidence of hemorrhage. Head of the pancreas, not abnormal, formed the right pole of an ovoid cyst, the wall of which arises immediately from the thickened and fibrous capsule, which is intimately connected with the posterior wall of the stomach and with a small part of the colon. The contents are 300 grammes of opaque fluid surrounding the tail of the pancreas, the tip floating free. The pancreas thus situated is flabby, macerated, and impregnated with large hæmatoidin crystals and acicular, orange crystals.
LXI.	Israel. Virchow's Arch., 1881, lxxiii. 184.	F.	27	Typical case of diabetes. A year in the hospital, under treatment.	No particulars given.	Pancreas dark-brown, friable, lying, attached only by a few rotten, fibrous threads, in the omental cavity. The latter contained also abundant, ichorous, bloody fluid, and communicated with the duodenum and transverse meso-colon. Purulent infiltrations of the mesentery. Necrosis of fat-tissue. Numerous calculi in the gall-bladder. General peritonitis. The microscope showed merely remains of the pancreatic acini, but no evidence of hemorrhage. Head of the pancreas, not abnormal, formed the right pole of an ovoid cyst, the wall of which arises immediately from the thickened and fibrous capsule, which is intimately connected with the posterior wall of the stomach and with a small part of the colon. The contents are 300 grammes of opaque fluid surrounding the tail of the pancreas, the tip floating free. The pancreas thus situated is flabby, macerated, and impregnated with large hæmatoidin crystals and acicular, orange crystals.

LXII.	Whitney, Boston Med. and Surg. Jour., 1881, cv. 593.	F.	Adult.	Well till within 4 months. In this time has had discomfort at the pit of the stomach, and debility, but is able to be about.	Sudden, severe, epigastric pain, with vomiting of a copious, dark-green, viscid fluid. Frequent stools resembling the vomit. Patient sleeps, temperature normal. Death in 5 days.
LXIII.	Rosenbach, Cblatt, I. Chirurgie, 1882, ix. Bell. 66.	F.	57	8 weeks ago, violent pains, without obvious cause, constipation, speedy improvement, 3 weeks ago, constipation again. For 3 days no defecation. Now, frequent, green vomit, great prostration, marked swelling of left half of abdomen. Behind and below the dilated stomach a fluctuating tumor, immovable, size of a child's head. Laparotomy. Death in collapse after 6 hours.	Pancreas large, firmly adherent to adjacent parts, which were infiltrated with a discolored, purulent fluid. The entire gland transformed into a dark, slate-colored, stinking mass, to within 3 cm. of its attachment to the intestine, where it was sharply defined from the remaining, more normal portion. Spleenic vein contained a soft, dark thrombus where it was in contact with the pancreas. Pancreas necrotic, from which arose the suspected cyst, which was an abscess between the stomach and small omentum. The contents were an opaque, stinking fluid. There was fecal accumulation from pressure of the cyst upon the upper part of the small intestines, which were adherent to it.
LXIV.	Balseer, Virchow's Arch., 1882, xc. 523.	F.	32	Strong; abundant fat-tissue.	Pancreas, often appearing as if macerated, lay free, with the exception of its duodenal attachment, in a cavity, holding about a litre, which was exposed by separating the fibrous and fibrinous adhesions of the root of the mesentery to the transverse meso-colon. It lay on both sides of the spine, extending to the pelvis, behind the caecum and descending colon, and, in places, separated the muscles which

FIFTEEN CASES OF GANGRENOUS PANCREATITIS — Continued.

No.	Authority.	Sex	Age.	Antecedents.	Symptoms.	Lesions.
LXIV.	(Continued.)				Great abdominal distention, flanks dull. 5 days later sudden death, preceded by increased dyspnoea.	were covered with shreds. The contents were a greasy, grayish-yellow detritus, mixed with larger fragments, some nearly as large as a hen's egg. These appeared to have been shelled out of cavities, the walls of which were in part of an iron-rust color, in part dark brown, in part infiltrated with blood. The wall surrounding this necrosed fat was opaque, grayish-yellow or yellowish-white, narrow and sharply defined, without purulent infiltration. The mesentery contained numerous large and small, opaque-white patches, with here and there, rust-colored edges. These had a centre of necrotic fat-tissue.
LXV.	Prince and Gannett, Boston Med. and Surg. Jour., 1882, cvii. 28.	M.	22	Strong, abundant fat-tissue. A week ago, immediately after turning a collapsed, anxious, restless hand-spring, felt abdominal cramps, circumscribed by a sharp pain in the tenderness near navel. Tempera-	In the night, sudden, severe cramp of stomach, vomiting, chills, and sweating. A few hours later severe abdominal cramps, circumscribed by a sharp pain in the tenderness near navel. Tempera-	There was recent pleurisy, a fatty heart, thrombosis of the left femoral vein and embolism of the pulmonary artery. Site of the pancreas occupied by a black, shreddey, sloughy, soft, gangrenous mass, these characteristics most marked in the central region of the organ. The head and tail were represented by a central por-

<p>LXVI.</p>	<p>Homans and Gannett, Boston City Hospital, MSS. Records, 1883, v. p. 64.</p>	<p>M.</p>	<p>40</p>	<p>lower abdomen.</p> <p>Umbilical hernia for two years. Irritable for two weeks, with pain and swelling. Abundant fat-tissue.</p>	<p>ture normal. On the following day fever and diarrhoea. After temporary improvement lasting a week, there was persistent diarrhoea, pains, and tenderness of the navel, slight fever and considerable tympany just before death, on the 15th day.</p> <p>On the day after entering hospital for treatment of hernia, vomited breakfast, severe paroxysms of colic, small, flickering pulse. Nausea and bilious vomiting persisted on the next day, the face became anxious and pinched, the pulse 100, at times indistinguishable, the temperature normal. The pulse became 140, T. 100.8° F., and she became pale, gasping, and comatose, and died on the 4th day.</p>	<p>tion of a black, sloughy, mass in which no trace of gland-structure was to be made out, which was encapsulated by the external portion. On raising transverse colon a ragged blackish mass appeared, from a rent in which flowed a large quantity of thin, chocolate-colored fluid, also two or three soft clots size of an egg. No cardiac source of embolism. Acute peritonitis. Hemorrhagic infiltration and gangrene of the pancreas. Circumscribed peritonitis, gangrenous phrenitis. Acute pleurisy and pericarditis. Thrombosis of the splenic vein.</p>
<p>LXVII.</p>	<p>Whittier and Fitz, Mass. Genl. Hospital, MSS. Records, 1884, v. p. 65.</p>	<p>F.</p>	<p>49</p>	<p>In past three years, three attacks of jaundice, bilious vomit, severe pains and abdominal tenderness, most marked near xiphoid cartilage.</p>	<p>After dinner burning in stomach, much abdominal pain. On the following day jaundice, bilious vomiting. The latter persisted for several days with frequent belching, and loose dejections. The abdomen became resonant except in the right flank, generally tender; temperature on the 8th day 100.8° F. Pulse and respiration rapid. On the 10th day he fell to the floor while</p>	<p>Hemorrhagic infiltration, necrosis and sequestration of the pancreas, and multiple, disseminated necrosis of the subperitoneal fat-tissue.</p>



FIFTEEN CASES OF GANGRENOUS PANCREATITIS — Continued.

No.	Authority.	Sex	Age.	Antecedents.	Symptoms.	Lesions.
LXVII.	(Continued.)	M.	42	For 4 years repeated attacks of abdominal pain, swelling of abdomen, vomiting, without colic, followed by jaundice lasting 4 or 5 days.	<p>trying to leave the bed, and soon died comatose.</p> <p>During first 5 days paroxysms of abdominal pain, swelling of abdomen, vomiting, jaundice, 2 to 3 daily chills, fever; on the 6th day T. 100.4°. Some green vomit. Pulse hardly quickened, no albuminuria. Abdomen inordinately distended and resistant, very sensitive, dense, and dull in left upper quadrant. Sudden collapse on the 9th day. Death on the 13th day.</p>	Tail and part of the body of the pancreas very soft, gray, discolored, infiltrated with a thin, ichorous fluid, the peripancreatic tissue partly purulent, partly ichorous. Spleen greatly enlarged, soft, splenic vein contains a soft, partly puriform thrombus, extending to portal vein. Acute leptomenigitis.
LXIX.	Gerhardi. Virchow's Arch., 1886, cvi. 310.	M.	36	Powerful frame, abundant fat. In habit of drinking. From early youth attacks of abdominal pain, without constipation. A year ago the attacks became more frequent.	<p>After a hard day's work intense pain in mid-abdomen. In the course of three days no defecation. T. 100.4° F. Slight jaundice then appeared. There was a feeling of abdominal tension, although the abdomen was tympanitic and not remarkably distended. The nausea became lessened, the jaundice increased, the abdomen more distended, there was no excess of indican in the urine. On the 7th day the abdomen tended to retract except in the left upper part where it was very sensitive. Laparotomy.</p>	Pancreas dense, nodular, with hemorrhagic coating, acini dull, yellowish gray. Dry, hemorrhagic masses with yellow spots of softening. In the head is fatty softening and a hemorrhagic infiltration extending into the surrounding tissue. At the back of the pancreas a narrow line of hemorrhagic and necrotic tissue, beneath it the duct with necrotic wall. Left kidney and supra-renal capsule showed extensive, subperitoneal hemorrhage. The microscopic examination of the pancreas showed necrosis of

LXX.	Foster and Fitz. MSS. Notes, 1887, v.p. 76	M.	59	<p>The abdominal pain remained se- the fat-tissue with hemorrhagic vere after the operation; there was no stool; and death, preceded by collapse, took place on the tenth day.</p>
			<p>Weight 200 lbs. The attack began with intense pain Strong and healthy. in the left abdomen, without fever, Two weeks ago apparent improvement for 3 days, thrown from car- then labored and jerking breath- riage, but did not ing, rapid, extreme exhaustion, and consider himself death in ten days after the onset injured. of the pain.</p>	<p>The pancreas and mesentery showed a gangrenous parapancrea- titis and necrosis of the mesenteric fat-tissue.</p>

sisted and there were frequent gaseous and bitter eructations, also several loose, dark-green dejections.

He entered the hospital on the fifth day. The jaundice was conspicuous, the abdomen was resonant, except in the right flank, and sensitive. The pulse was 100 and the temperature rose abruptly from 97.4° F. to 100.8° F. During the subsequent four days the diarrhœa persisted. The urine contained a trace of albumen and a variety of casts. The pulse varied from 120 to 150, the respirations were very rapid, and the temperature remained moderately elevated.

On the eighth day he dressed himself, but did not seem conscious of his actions. He became mildly delirious on the following day, and while trying to escape from the ward, fell forward, was temporarily unconscious, and his pulse could not be counted. The temperature became subnormal, but rose to 100° F. in the evening. On the tenth day, while trying to leave the bed he fell to the floor, his pulse became weaker and more rapid, his breathing resembled the Cheyne-Stokes rhythm, and he died comatose.

The posterior wall of the stomach and the upper part of the mesentery were united by fibrinous adhesions to the pancreas, which lay in a cavity, within a spongy meshwork, infiltrated with dirty-green fluid. The pancreas was dark-brown, dry and firm. On section the lobules were indistinct, and the surface granular. Numerous, opaque-white patches were seen, resembling those to be described in connection with the abdominal fat-tissue. The splenic vein contained a mixed thrombus, four inches long and one-half the thickness of the little finger, and continued into several of the pancreatic branches. The spleen was soft and small. The liver was moderately granular and fatty. The gall-bladder was contracted about several calculi, the largest nearly the size of the end of the thumb, and projecting into the cystic duct. The walls were thick and tough, the mucous membrane thin and streaked with opaque-white lines. The cystic and common ducts were dilated.

The subperitoneal fat-tissue of the abdominal wall, mesentery, omentum, and perinephritic region contained numerous, superficial and deep-seated, small, circumscribed, rounded, opaque-white and saffron-colored patches. In general they were elongated, measuring an inch by a quarter of an inch. Rarely they were nodular, as large as a filbert, and on section contained dark-brown, discolored centres. Sections of the frozen fat-tissue showed numerous cavities containing a shreddy tissue, infiltrated with opaque-pink fluid of creamy consistency. Microscopical examination of the fresh specimens showed numerous leucocytes and large, round cells, with granular detritus, opaque-white specks, and bundles of small, acicular or rod-like crystals.

There was nothing abnormal in the appearance of the stomach or intestines.

The microscopic examination of the hardened pancreas shows a small quantity of interlobular fat-tissue. In this are numerous islets of necrosis, their appearances being essentially the same as those found in the parapancreatic fat-tissue.

The larger ducts are filled with clumps of coherent, detached, cylindrical epithelium with distinctly stained nuclei.

The gland-cells in certain parts, especially in the immediate vicinity of the necrotic fat-tissue, are swollen, granular, confluent, and without evident nuclei. The outlines of the acini are irregular or indistinct. Certain of the lobules present a diffused infiltration of round cells. Many of the acini show a central accumulation of homogeneous, hyaline material with corresponding flattening of the gland-cells.

Sections of the subperitoneal and parapancreatic fat-tissue present numerous patches, varying in extent and shape, all more or less rounded, oblong or leaf-like. They are sharply defined by a limiting zone, varying in width, of small, round-celled infiltration between the fat-cells. Next this cellular layer is often found a narrow, orange-colored streak, in which are frequent granules and round clumps of small, orange-colored aci-

cular crystals. Within the patch the outlines of the fat-cells are often distinct over considerable areas, but elsewhere are almost wholly, if not entirely, obliterated by the clusters of large and long, acicular crystals and granular material. These crystals were isolated, dissolved, and recrystallized by Dr. Harrington, assistant in chemistry at the Harvard Medical School, and are pronounced by him to be identical with those obtained from ordinary tallow.

In addition to the crystals and granules, bacteria were found, both as circumscribed colonies within, and as diffused accumulations without, the patches.

In the fat-tissue surrounding the patches of necrosis are occasional, hemorrhagic spots with distinct outlines of red blood-corpuscles. Small and irregular patches of leucocytes, without intercellular substance, are to be seen, occupying more space than that of several fat-cells.

Occasionally, elongated bands are found considerably wider than any visible blood-vessels. They are composed of agglomerated round-cells with solitary, larger corpuscles containing granular pigment. At each side of the central streak are numerous isolated, round and larger, flat, polygonal cells with large nuclei. These, in turn, are defined externally by a margin of clustered leucocytes. Arteries and veins are free from obvious changes.

The following record of Case LXX. is given as fully as possible. It is to be regretted that neither the specimen nor a detailed description of the pancreas was preserved. A gentleman, fifty-nine years of age, temperate, strong, and healthy, weighing 200 lbs., was thrown from his carriage, but did not consider himself injured. Four days later he was seized with intense pain in the left abdomen, associated with nausea and vomiting. At the outset the pulse was 80 and the respiration 24. There was no fever at any time. After a few days the pain and tenderness were relieved. From the outset extreme exhaustion was a conspicuous symptom. Eventually rapid and labored breathing came on, and the patient died on the tenth day. A memorandum on

the back of the letter accompanying the specimens and giving the clinical details, states that the conspicuous lesions were a gangrenous peripancreatitis and necrosis of the mesenteric fat-tissue. From the lack of further details the question might be raised as to the exact method of origin of the gangrene and necrosis. At the time I was satisfied that the case was analogous to that which immediately precedes, viz., Case LXVII.

Of these fifteen cases seven were males and eight females. Their ages were as follows:—

Years of age.	Number of cases.
From 22-25.....	1
" 25-30.....	1
" 30-35.....	1
" 35-40.....	2
" 40-45.....	2
" 45-50.....	2
" 50-55.....	2
" 55-60.....	2
" 60-63.....	1
Past middle life.....	1
	15

They were from all walks and conditions of life. Five were very fat, one was decidedly lean; five were strong and two of them were addicted to alcoholic drinks.

Eight of these patients had been subject to earlier more or less repeated, attacks of digestive disturbance. These were always attended with pain, usually referred to the region of the stomach or stated to be biliary colic. They were frequently accompanied with vomiting, and, in one-third of the number, with jaundice. Constipation or irregular defecation might occur, and in the latter case the stools were black.

At first sight, the etiological importance of perforating gastric ulcer and of gall-stones seems immediate, as illustrated by Cases LVII., LVIII., LXVII.

The comparison of these cases with others in the series would suggest that these affections were more important from the associated inflammation of the mucous membrane, with its opportunity of extension into the pancreatic duct, than from the actual or possible perforation of the biliary or digestive canal.

A traumatic cause for the fatal illness was possible in two instances.

In the one the patient was seized with a sudden pain in the lower abdomen, while turning a hand-spring, a week before the fatal illness. In the other the patient was thrown from his carriage five days previous. One person was seized with her attack while under treatment for an umbilical hernia of two years' duration. A midday meal and a hard day's work were each the immediate antecedent of the attack.

The illness usually, in four-fifths of the cases, began suddenly, without definite cause, with abdominal pain. This was rarely slight, but often intense or severe. It was referred to the stomach, left hypochondrium, navel, mid-abdomen, and left loin and back. The pain might be constant or paroxysmal like a biliary colic, and a diagnosis of gall-stones was made in one instance.

Vomiting was the next symptom of importance, being recorded in three-fifths of the cases. Partly digested food was ejected, or a viscid or slimy fluid, often green, sometimes black or bloody. Constipation was, at times, so conspicuous that, in connection with the other symptoms, a diagnosis of intestinal obstruction was made in three cases, and laparotomy performed in two. On the contrary, frequent bilious stools might occur.

The urine might contain albumen and casts. In one case an excess of indican was repeatedly sought for, in vain.

Jaundice, usually slight, occurred after a few days in one-fifth of the cases.

Chills were occasional, sometimes at the onset, and fever was frequent after a few days. The temperature was likely to be low, in the vicinity of 100° F., although it might be as high as 104° F. There might be no conspicuous fever throughout the course of the disease.

Swelling of the abdomen was present in one-half of the cases, usually occurring as a late symptom.

It might be slight or enormous, general, or limited to the epigastrium, or to the left half where

a fluctuating tumor was to be recognized. The abdominal swelling was usually tympanitic, although dulness might be present in the flanks. The spleen was palpable in a single instance, and the parotid became acutely swollen in another case.

As the disease ran its course, weakness became apparent. Vomiting, perhaps diarrhœa, and abdominal pain were noticeable, suggestions of peritonitis were frequent, and symptoms of collapse were likely to take place, being followed more or less rapidly by death, which occurred as follows:—

On the 4th day in .....	1 case.
“ 5th “ .....	1 “
“ 10th “ .....	3 “
“ 13th “ .....	1 “
“ 15th “ .....	1 “
“ 18th “ .....	1 “
At the end of 3 weeks in.....	1 “
“ “ 5 “ .....	1 “
“ “ 7 “ .....	1 “
“ “ 8 “ .....	1 “
Not stated in .....	1 “

Two patients recovered with the discharge of a slough through the bowel, one at the end of eight weeks. One of these patients was living seventeen years later.

The diagnosis lay between intestinal obstruction, biliary calculi, and peritonitis.

The appearance of the pancreas varied according to the duration of the disease. About the fourth day<sup>90</sup> the pancreas may be doubled in size, dark-red, and of somewhat diminished consistency. It may be red, on section, or mottled, red and gray. The tip may be shreddy, or the entire gland may be transformed into a dark, slaty-colored, stinking mass. The adjacent parts may be infiltrated with a discolored, purulent fluid, or the coils of intestine near the pancreas may be united by recent adhesions together and to the under surface of the diaphragm.

The latter may show a dirty, grayish-white, shreddy appearance, and its thickened substance may contain small collections of dirty-gray puriform fluid, the tissue itself being quite shreddy.

On the tenth day<sup>91</sup> the pancreas may be dark-

<sup>90</sup> Cases LXII., LXVI.

<sup>91</sup> Cases LXVII. and LXIX.



brown, dry, firm. It may have a hemorrhagic coating or lie in a sponge-like meshwork infiltrated with dirty-green fluid.

On section, there may be dry hemorrhagic masses, with yellow spots of softening, or the lobules may be indistinct, with intervening, opaque-white patches like those to be found in the neighboring fat-tissue. The hemorrhagic infiltration may extend beyond the gland. The wall of the duct and the overlying tissue may be necrotic and hemorrhagic. The perinephritic fat and that near the supra-renal capsule may contain extensive hemorrhages.

Towards the end of the second week <sup>92</sup> the pancreas may be a soft, black, shreddy, sloughy, gangrenous mass, the central part being encapsulated by the peripheral portion. Between the pancreas and the transverse colon may be a large quantity of chocolate-like fluid and large, bluish-black clots. Or the tail and a part of the body may be soft, gray discolored, and infiltrated with a thin, ichorous fluid, while the parapancreatic tissue is partly purulent and partly ichorous.

A few days later <sup>93</sup> the pancreas may be a thin, flabby, friable, grayish band, lying in a cavity behind the stomach and attached by a few shreds to the omental wall. The cavity may contain ichorous fluid and communicate with the stomach by several openings with frayed edges.

At the end of three weeks <sup>94</sup> the dark-brown pancreas may lie nearly free in the omental cavity, attached only by a few, rotten shreds of fibrous tissue. The cavity may contain abundant ichorous, bloody fluid and communicate with the duodenum. During the fourth and fifth weeks the pancreas may be discharged as a slough from the bowels.

In the fifth week <sup>95</sup> the pancreas may lie free, as if macerated, in a cavity extending behind the cæcum and descending colon, on both sides of the spine, as far as the pelvis. The contents may also be a greasy, grayish-yellow detritus, with fragments

<sup>92</sup> Cases LXV. and LXVIII.

<sup>93</sup> Case LVI.

<sup>94</sup> Case LX.

<sup>95</sup> Case LXIV.

of necrotic fat-tissue nearly as large as hen's eggs. The latter are apparently sequestered from spaces with walls of a dark-brown or iron-rust color.

At the end of seven weeks<sup>96</sup> the pancreas may be transformed into a cylindrical, shreddy mass of brownish-black, friable tissue. This may lie in the omental cavity, which is filled with offensive, black fluid and communicates with the stomach and jejunum.

Thrombosis of the splenic vein frequently accompanies the pancreatic lesion and is usually parietal. The thrombus in the early stages is soft and dark-red, or it may be of a reddish-gray color. It has been found partly puriform, and extending to the portal vein, at the end of the second week.

A little later it has been found completely obstructing. The spleen may be soft, and is either large or small. Disseminated fat-necroses are often seen.

From the frequent mention of the position of the pancreas in the omental cavity filled with ichorous pus, it is evident that an acute peritonitis with liquid exudation is a frequent, if not the usual, occurrence. The pus may be prevented from entering the general peritoneal cavity by adhesive obliteration of the foramen of Winslow.

Peritoneal adhesions between coils of intestine are not infrequent, especially in the vicinity of the root of the mesentery. A general, suppurative peritonitis is of comparatively rare occurrence.

The inflammatory process may be extended to the pleural and pericardial cavities, and an acute lepto-meningitis has been found on the thirteenth day. At a late stage of the disease, death may result from pulmonary embolism.

The possibility of an arrest of the processes resulting in pancreatic necrosis and parapancreatitis is evident from Case LX. Although the patient died of diabetes, the symptoms of which lasted at least a year, the tail of the pancreas was flabby and macerated, and its tip lay free in a cyst arising immediately from the pancreatic capsule.

<sup>96</sup>Case LVIII.

It is obvious from the anatomical appearances in this group of cases of gangrenous pancreatitis, para- and peri-pancreatitis, that the lesions are associated with a hemorrhagic pancreatitis in a considerable number of cases. In at least one-half there is mention of hemorrhage into the pancreas or of such discoloration as to suggest a hemorrhage.<sup>97</sup>

A comparison of the clinical history of this series of cases with that of hemorrhagic pancreatitis will show a strong resemblance in predisposing causes and in the nature of the symptoms. These are essentially identical in nearly all. In many of the remaining cases the symptoms are those which would favor the diagnosis of a hemorrhagic pancreatitis.

In any event they represent the termination of acute pancreatitis in gangrene, with an extension of the process to the continuous tissue.

Viewing the subject from the anatomical side it is evident that cases of hemorrhagic pancreatitis may terminate fatally within a few days, either with or without necrosis of the gland and parapancreatic fat-tissue. They may also prove fatal in from one to four weeks, in consequence of an extension of the disease to the para- and peri-pancreatic tissues, with gangrene of the parts concerned.

#### DISSEMINATED FAT-NECROSIS.

Considerable prominence has necessarily been given to the necrosis of fat-tissue associated with pancreatic inflammations.

Hooper<sup>98</sup> probably intended to describe certain of the appearances to be met with, but Ponfick<sup>99</sup> first distinctly recognized the condition. He called attention to a disseminated necrosis of bone-marrow in a case of empyema and extensive amyloid degeneration. The appearance was that of innumerable, submiliary, yellowish-white specks in the amber-colored marrow. They proved to be composed of an agglomeration of large cells crowded

<sup>97</sup> See Cases LVIII., LX., LXI., LXII., LXV., LXVI., LXVII., LXIX.

<sup>98</sup> Case XIX.

<sup>99</sup> Virchow's Arch., 1872, lvi. 541.

with fine granules. These were enormous granular corpuscles, which, from their size and shape, were regarded as identical with fat-cells. There were also narrow and elongated, fatty-degenerated cells, so disintegrated in many places as to form a finely granular detritus. Ponfick attributed these spots of necrosis to a fatty degeneration of the marrow.

Balser,<sup>100</sup> who became an assistant of Ponfick, then professor at Göttingen, found similar appearances in the marrow and in the subpericardial fat, each in an old man. In the examination of twenty-five unselected cases he found such patches in the region of the pancreas, in five instances. Two of these patients died of cancer of the stomach, and the remaining three were cases of pulmonary consumption, hepatic cirrhosis, and aortic endocarditis respectively. There remain two additional cases in which he found fat-necrosis.<sup>101</sup>

These he regarded as illustrative of the fatal effect of a disease, fat-necrosis, which, when extensive, was associated with old and fresh hemorrhage. Such hemorrhages near the pancreas might produce death in the manner resembling that described by Zenker as pancreatic apoplexy.

He regarded the fat-necrosis as the result of an excessive growth of fat-tissue which destroyed the tissue it surrounded. From its association it was a special source of danger to fat persons. His conclusion is:<sup>102</sup> "An excessive growth of the fat cells near the pancreas occurs in many men. It may become so excessive, in very fat people, that a large part of the abdominal fat dies, and it thus proves fatal, either on account of the quantity destroyed or the associated hemorrhage.

Chiari<sup>103</sup> had also found fat-necrosis associated with pancreatic disease,<sup>104</sup> although in his published report he made no note of the characteristic appearances. He confirmed Balser's statements concerning the occurrence of fat-necrosis in and near the pan-

<sup>100</sup> *Loc. cit.*

<sup>101</sup> Nos. XXIV., LXVII.

<sup>102</sup> *Loc. cit.*, 534.

<sup>103</sup> *Prager Med. Woch.*, 1883, viii. 285.

<sup>104</sup> Cases LVIII., LX.

creas. Since he had observed it in five out of six cases of pancreatic disease, a certain connection between the two was suggested. Three of these were cases of sequestration of the pancreas. The remaining three were a phthisical diabetic, a case of chronic Bright's disease and interstitial pneumonia, and an infant with congenital syphilis.

He found no evidence of an excessive, circumscribed growth of fat-tissue as claimed by Balsler, but regarded the necrosis as a degenerative process; analogous to the retrograde metamorphosis in other tissues, and the result of a severe marasmus. He admitted it as a cause of pancreatic hemorrhage and that it might, hence, prove fatal. He did not regard the sequestration of the pancreas as the result of this necrosis, since he could not understand how extensive circumscribed necroses about the pancreas could isolate so large an organ.

Finally, Van Giesen<sup>105</sup> presented to the New York Pathological Society microscopical sections illustrative of fat-necrosis. They came from the pancreas of a woman eighty years of age. There were two nodules, the larger five mm. in diameter. Nothing is stated with reference to any associated lesions, and the necroses were regarded as degenerative.

There is a general agreement as to the appearance of these nodules. They are multiple, disseminated, are found in the subperitoneal fat-tissue of the abdominal wall, mesentery, omentum, and in that within and around the pancreas. Chiari<sup>106</sup> found them also in the subpericardial, subpleural, and subcutaneous fat. Their presence in marrow has already been mentioned.

Such nodules were present in one case of pancreatic hemorrhage; certainly in one, probably in two, cases of acute, suppurative pancreatitis. They were seen in six cases of hemorrhagic and in six of gangrenous pancreatitis.

These nodules, in most of the cases, occurred in great numbers, the smallest not larger than a pin-head, and strongly suggestive of miliary tubercles

<sup>105</sup> N.Y. Med. Rec., 1888, xxxiii. 477.

<sup>106</sup> *Loc. cit.*, 285.

or malignant new formations. The largest were of the size of a hen's egg. All were more or less rounded, of an opaque-white or yellowish-white color, and of soft, tallowy consistency. They occurred alone or in groups, superficially and deep-seated. The smallest were often surrounded by an injected, vascular wreath, while many were bounded by a distinct, narrow, reddish-brown zone indicative of hemorrhage.

Chiari<sup>107</sup> found the larger nodules (although he does not state in which of his six cases) incrustated with lime, and surrounded by a distinct, fibrous capsule, from which threads occasionally ran into the surrounding fat-tissue.

The tallowy material could be readily picked out of these nodules, and, when examined microscopically, consisted largely of acicular crystals resembling those found in fat, in addition to fat-drops and a granular detritus. Dr. Harrington's micro-chemical examination of these crystals shows their identity with those obtained from tallow. He regards them as stearine. In this view he confirms the conclusion reached by Balser.<sup>108</sup>

The microscopical appearances have already been described in sufficient detail.

Balser states<sup>109</sup> that his examination shows that the same process is concerned in the mild and fatal cases. Neither he nor Chiari were able to find any evidence of a bacterial or mycotic process, nor was the latter able to discover any changes in the neighboring vessels.

The microscopical appearances found in Case LXVII. make evident certain features in the more serious fat-necrosis, which supplement the results described by other observers.

Tracts of round-celled infiltration were found at the border of the patches. Chiari also states that the fibrous threads continued from the capsules were infiltrated with round cells.

The surrounding fat-tissue gave frequent evidence

<sup>107</sup> *Loc. cit.*, 299.

<sup>108</sup> *Loc. cit.*, 528.

<sup>109</sup> *Loc. cit.*, 522.

of an acute lymphangitis, of abscesses, and of thrombosis.

Bacteria were found in and near the patches of necrosis. They were likewise present in a neighboring vessel and in a venous thrombus.

The association of these appearances with the evidences of fat-necrosis indicate most directly that the latter condition, in fatal cases at least, instead of being simply the result of a hyperplasia or of a degeneration, is connected with an acute, inflammatory process, somewhat akin to the phlegmonous inflammation of the subcutaneous fat.

The cause of its dissemination would thus, probably, depend upon the transfer of an infecting material, either through vascular currents, especially lymphatics, or by direct inoculation of the peritoneum in case of the superficial nodules. The multiple disseminated fat-necrosis found associated with fatal pancreatic disease is thus to be regarded as the result of the inflammation of the fat-tissue extended from the pancreas or its vicinity. The pancreas is usually the seat of the primary process, but the necrotic inflammation of the fat-tissue may be secondary to a possible primary lesion of the biliary tract or stomach, as suggested by cases LVII. and LVIII.

The spots of dead fat-tissue observed in the marantic cases may be degenerative as claimed by Ponfick and Chiari. They certainly are neither necessarily nor exclusively found in fat persons. There is no confirmatory evidence of their hyperplastic nature.

The inflammatory fat-necroses, in most cases, were associated with evidences of putrefactive conditions.

It would thus appear that there is a necrobiotic necrosis of the fat-tissue, and an inflammatory necrosis, the latter tending to become gangrenous, both of which may be found within or near the pancreas. The inflammatory and gangrenous varieties are of especial importance in permitting the sloughing of the pancreas, and in most instances are the result of an acute inflammation of the gland.

Although the serious varieties of fat-necrosis may be recognized as causes for sequestration of the pancreas, their relation to pancreatic hemorrhage must be expressed in different terms from those employed by Balser and Chiari.

A simple, necrobiotic fat-necrosis may be associated with fatal, pancreatic hemorrhage, as suggested by Case V., but there is no necessary etiological significance in this association. Most fatal cases of pancreatic hemorrhage occur without either variety, and the simple necrosis usually takes place without hemorrhage.

When the severe varieties of fat-necrosis accompany pancreatic hemorrhage, inflammation of the pancreas is present. The fat-necrosis cannot be regarded as the essential cause of the hemorrhage in such cases, since it occurs in suppurative pancreatitis when there is no hemorrhage in the pancreas.

Furthermore, when hemorrhages are found near the necrotic patches, they are usually very slight, and limited to the immediate vicinity of the patch.

#### CONCLUSIONS.

The evidence presented in this paper is intended to establish the fact that —

Acute inflammation of the pancreas is both a well-characterized disease, and one which is much more frequent than is generally thought.

It is of great consequence that it should be recognized, for the following reasons : —

It represents a serious complication of what, by itself, is a relatively simple affection, viz., gastro-duodenitis.

It is an important cause of peritonitis, and one readily overlooked.

It has been repeatedly confounded with acute, intestinal obstruction, and has thus led, in several instances, to an ineffective laparotomy; an operation which, in the early stages of this disease, is extremely hazardous.



## METHOD OF ORIGIN.

Acute pancreatitis commonly originates by the extension of a gastro-duodenal inflammation along the pancreatic duct. It may also be induced by the occurrence of hemorrhage in the pancreas. This may be of traumatic origin, although usually arising from unknown causes. The pancreatic hemorrhage may likewise be secondary to inflammation of the pancreas.

## PATHOLOGICAL ANATOMY.

The anatomical varieties are the suppurative, hemorrhagic, and gangrenous. The first may be acute, but is usually subacute or chronic. The second is generally peracute or apoplectiform. The gangrenous variety runs an acute course.

Suppurative pancreatitis may result in an evacuation of the abscesses into the stomach or duodenum. Or they may open into the cavity of the great omentum, which, transformed into a large peritoneal abscess, may, in turn, open into the digestive tract. Pylephlebitis and abscesses of the liver may follow. Disseminated fat-necrosis is comparatively infrequent.

Hemorrhagic pancreatitis usually proves fatal in from two to four days. The gross lesions are then those of hemorrhage within and near the pancreas, extending into the subperitoneal fat-tissue, perhaps as far as the pelvis. Peripancreatitis may be expected, and disseminated fat-necrosis is common.

Gangrenous pancreatitis, although it may be secondary to a perforating inflammation of the gastro-intestinal or biliary tracts, usually results from a hemorrhagic pancreatitis, and proves fatal in the course of a few weeks. The gangrenous processes extend to the parapancreatic tissue, and produce more or less complete sequestration of the pancreas. The peritoneal wall of the omental cavity becomes inflamed, that covering the pancreas may be destroyed, and the sequestered gland may lie in the omental cavity, soaked in pus, and attached only by a few shreds. Both pus and pan-

creas may be discharged into the intestine. Splenic thrombophlebitis is not uncommon, but hepatic abscesses are rare. Disseminated fat-necrosis is frequent.

#### SYMPTOMS.

The common symptoms of acute pancreatitis are sudden, severe, often intense, epigastric pain, without obvious cause, in most cases followed by nausea, vomiting, sensitiveness, and tympanitic swelling of the epigastrium. There is prostration, often extreme, frequent collapse, low fever, and a feeble pulse. Obstinate constipation for several days is the rule, but diarrhœa sometimes occurs. If the case does not end fatally in the course of a few days, recovery is possible, or a recurrence of the symptoms in a milder form takes place, and the characteristics of a subacute peritonitis are developed.

#### DIAGNOSIS.

The symptoms are essentially those of a peritonitis beginning in the epigastrium and occurring suddenly, during ordinary health, without obvious cause.

The diagnosis, therefore, is based on pain, tenderness, and tympany limited to the region of the pancreas, and on the gradual development of a deep-seated peritonitis in the same place.

#### DIFFERENTIAL DIAGNOSIS.

The differential diagnosis lies, practically, between an irritant poison, perforation of the digestive or biliary tracts, and acute, intestinal obstruction.

An irritant poison is excluded by the history of the case, and by the examination of the vomit.

Perforating ulcer of the stomach or duodenum is to be excluded by the absence of pain after eating, hemorrhages from the digestive canal, and cachexia.

Acute perforation of the transverse colon is rare, and the resulting peritonitis progresses more rapidly and is likely to be general. Perforation from gallstones is usually preceded by attacks of biliary colic and jaundice, while the seat of the pain is

rather in the region of the gall-bladder than in that of the pancreas.

Acute, intestinal obstruction is most likely to give rise to doubt. It is to be eliminated by determining, through injection, the patency and capacity of the large intestine, by the rarity, in the epigastrium, of an obstructed small intestine, by the immediate presence of localized tenderness, and by the usual absence of conspicuous, general tympany or limited distention of intestinal coils.

#### TREATMENT.

It is evident that all treatment, at the outset, can be nothing but palliative. With the formation of pus in the omental cavity comes the opportunity for the surgeon. The possibility of the successful removal of the gangrenous pancreas is suggested by the healthy condition of a patient seventeen years after he had discharged this organ from his bowels.

---

An unexpectedly early verification of the above conclusions has occurred within the week following the delivery of this lecture.

The case was that of a well-known gentleman of Boston, and presented, so fully, the symptoms above mentioned, that, when called as consultant, I was able to make a diagnosis of acute pancreatitis, which was eventually substantiated.

The following is a brief summary of the essential features of this case, which will, hereafter, be more fully reported.

The patient was suddenly seized, February 19th, while apparently in his usual good health, with a severe pain and tenderness a short distance above and to the left of the navel. This was followed by vomiting and a certain degree of prostration. The administration of nearly a grain of morphia gave relief. I saw him in the evening, and during the subsequent two days of his life. He died on the third day. The localized pain was more or less constant, with occasional severe twinges, and was also to be elicited by intercostal pressure in the splenic region.

The sensation of a constricting band in the epigastric region was likewise mentioned. At the close of the second day the lower abdomen became sensitive in spots. There was vomiting on the first day, but not later, and the bowels were confined. The abdomen was somewhat distended, and dull, except in the epigastrium. The pulse was moderately accelerated, and the temperature slightly elevated.

The diagnosis lay between acute, mechanical, intestinal obstruction, perforative peritonitis, and acute pancreatitis. The majority of the consultants agreed to the first as the most probable condition, and advised a laparotomy, which was performed on the third day. Spots of fat-necrosis were seen in the omentum, but there was no evidence of mechanical obstruction.

At the post-mortem examination the characteristic appearances of hemorrhagic pancreatitis were found, also numerous spots of disseminated fat-necrosis.

