

The laryngoscope : directions for its use, and practical illustrations of its value in the diagnosis and treatment of diseases of the throat and nose : two lectures delivered at the Royal College of Physicians / by George Johnson.

Contributors

Johnson, George, 1818-1896.
Playfair, W. S. 1836-1903
Royal College of Surgeons of England

Publication/Creation

London : Robert Hardwicke, 1864.

Persistent URL

<https://wellcomecollection.org/works/e5h9e9zy>

Provider

Royal College of Surgeons

License and attribution

This material has been provided by This material has been provided by The Royal College of Surgeons of England. The original may be consulted at The Royal College of Surgeons of England. where the originals may be consulted. This work has been identified as being free of known restrictions under copyright law, including all related and neighbouring rights and is being made available under the Creative Commons, Public Domain Mark.

You can copy, modify, distribute and perform the work, even for commercial purposes, without asking permission.




Wellcome Collection
183 Euston Road
London NW1 2BE UK
T +44 (0)20 7611 8722
E library@wellcomecollection.org
<https://wellcomecollection.org>

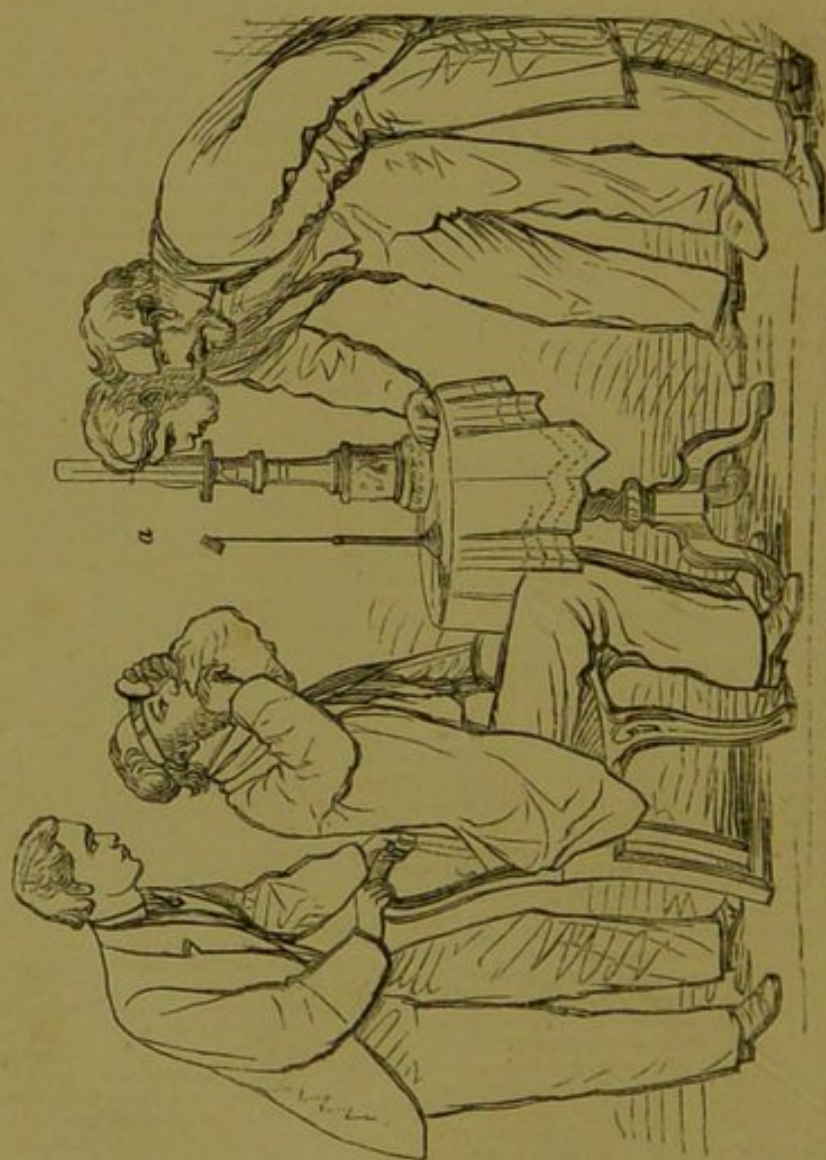
Dr Playfair
with the Antislavery regard



THE LARYNGOSCOPE.

COX AND WYMAN,
GREAT QUEEN STREET, LINCOLN'S INN FIELDS,
LONDON, W.C.





AUTO-LARYNGOSCOPY AND DEMONSTRATION.—See p. 25, et seq.

Gr. 1548. (1)

THE LARYNGOSCOPE.

DIRECTIONS FOR ITS USE,
AND PRACTICAL ILLUSTRATIONS OF ITS VALUE IN THE
DIAGNOSIS AND TREATMENT OF
DISEASES OF THE THROAT AND NOSE.

TWO LECTURES
DELIVERED AT THE ROYAL COLLEGE OF PHYSICIANS.

BY
GEORGE JOHNSON, M.D., F.R.C.P.

PROFESSOR OF MEDICINE IN KING'S COLLEGE; PHYSICIAN TO KING'S COLLEGE
HOSPITAL.

LONDON:
ROBERT HARDWICKE, 192, PICCADILLY.
1864.

75

By the same Author.

Preparing for publication, a new edition, entirely re-written,

THE DISEASES OF THE KIDNEY:


THEIR PATHOLOGY, DIAGNOSIS, AND TREATMENT.

P R E F A C E.

THE two lectures which are here reprinted from the *Lancet*, with but few alterations and additions, were delivered during the spring of the present year at the Royal College of Physicians. It is hoped that by the republication of these lectures in a separate form, the object with which they were originally delivered may be in some degree promoted.

11, SAVILE ROW,

November, 1864.



THE LARYNGOSCOPE.

LECTURE I.

MR. PRESIDENT AND GENTLEMEN,

The object of the two lectures which, by your appointment, Sir, I am to deliver in this room, may be stated in a very few words. Some amongst the Fellows of the College having given their attention to the subject of the laryngoscope, and having formed a high estimate of the value of the instrument as an aid in the diagnosis and treatment of disease, desire that it should, as speedily as possible, come into general use. They wish to combat the notion that the art of laryngoscopy is so difficult that it can be successfully practised only by a select few, who would make of it a speciality. They, on the contrary, believe that the difficulties which attend the use of the laryngoscope are few, and for the most part such as may be easily overcome by a very moderate amount of practice and perseverance; and they have thought that good might result from the subject being brought before the College by one of their body who, having no claim to the possession of a special knowledge of

the art or of particular aptitude for its practice, but having studied and practised it in the ordinary course of his daily work, is willing to communicate the results of his experience, and anxious that others should share with him the pleasure and advantage of possessing a new instrument for exploring a large and important class of diseases.

And now, what is the laryngoscope? The laryngoscope is a small mirror, fixed on a stem, or handle, of convenient length. This mirror, having first been warmed to prevent the dimming of its surface by the patient's breath, is placed in such a position obliquely beneath the palate that, while it reflects the light from the mouth into the larynx, it reflects back an image of the larynx to the eye of the observer. There are various means, as we shall presently see, for throwing a strong light upon the mirror, but the laryngoscope is simply a small looking-glass—a contrivance “whose end is to hold, as 'twere, the *mirror* up to nature.”

Now, it appears not a little remarkable that a method of exploring the larynx at once so simple and so effectual should not have come earlier into use,—that it should have been reserved for the workers of the present time to devise a plan by which literally a new light has been thrown upon a very common, painful, and fatal class of diseases.

And here it will not, I think, be a departure from the strictly practical design of my lectures if I allude very briefly to the history of this invention, indicating the attempts to examine the larynx which have from time to time been made by various observers, and the successive steps by which the laryngoscope has been improved and simplified.

Attempts to examine the larynx by means of a mirror have, at different times, been made independently by various experimenters. One of the first, if not the very earliest, of these attempts was made by a distinguished Fellow of this College—I mean Dr. Babington, who showed his instrument at a meeting of the Hunterian Society in March, 1829—*i. e.*, thirty-five years ago. The instrument was essentially the same as that now in use, and the following description of it was published in the third volume of the *Medical Gazette*, p. 555:—"It consisted of an oblong piece of looking-glass set in silver wire, with a long shank. The reflecting portion is placed against the palate, whilst the tongue is held down by a spatula, when the epiglottis and the upper part of the larynx become visible in the glass." The report adds that "the Doctor proposed to call it the *glottiscope*." Dr. Babington afterwards had his mirror made of polished steel, and in one he combined a tongue-depressor with the mirror. He also had one mirror of ovoid shape, which was convenient for use when the tonsils were enlarged. Dr. Babington tells me that he was in the habit of illuminating the throat by reflecting the light of the sun from a mirror held in the left hand. It was long after Dr. Babington had published the account of his glottiscope that Mr. Liston, in his "Practical Surgery" (1840), referred to the use of a dentist's mirror for obtaining a view of the glottis.

MM. Trousseau and Belloc, in a treatise on Laryngeal Phthisis, which was published in the year 1837, refer to a *speculum laryngis*. It was made by a M. Selligie, an ingenious mechanic, who had himself

suffered from laryngeal phthisis. The instrument consisted of two tubes, through one of which the light was thrown on the glottis, while through the other the image of the glottis was reflected from a mirror placed at its guttural extremity. The authors state that the instrument was very difficult of application, and that not one person in ten could bear its introduction.

The late Mr. Avery worked long and successfully in the construction of a laryngoscope and other instruments for the examination of internal organs; but he published nothing on the subject.*

In the year 1844 the late Dr. Warden invented a prismatic speculum, with which he succeeded in seeing disease of the glottis in two cases.†

It is a well-known fact that the first experimenter who succeeded in obtaining a view of his own larynx is a distinguished professor of music in this town, M. Garcia. M. Garcia had long studied the anatomy and physiology of the larynx as the organ of the voice, and he had a great desire to see the movements of the living larynx. At length he attained the desired object by a very simple plan. Standing with his back to the sun, he held a looking-glass in his left hand before his face; the sun's rays were thus reflected by the glass into his open mouth. Then he introduced a dentist's mirror, previously warmed, into the back of his mouth, and thus he saw the reflection of his larynx in the looking-glass.

* Introduction to the Art of Laryngoscopy. By Dr. Yearsley. 1862.

† British and Foreign Medico-Chirurgical Review, Jan. 1863, p. 210.

M. Garcia gave the results of his observations in a very interesting paper, entitled "Physiological Observations on the Human Voice," which was published in the "Proceedings" of the Royal Society in the year 1855. This paper was destined to be the germ of further important observations and discoveries. It became known to Dr. Türck, of Vienna, and it induced him to use the laryngeal mirror in the wards of the General Hospital there during the year 1857. Towards the end of that year Dr. Türck lent his mirrors to Dr. Czermak, who set to work with great zeal and energy. He soon made the important step of adopting the large ophthalmoscope reflector as a means of concentrating artificial light, thus making the laryngoscope available at all times as a means of inspecting the larynx, and of guiding the hand in the application of local remedies. Czermak soon saw, as he says, the practical value of the instrument, and he has been most energetic and most successful in his efforts to secure its recognition by the whole civilized world.

It appears to me that, without injustice to those who had preceded him—Garcia's claims to originality in the matter of auto-laryngoscopy being obviously quite distinct and indisputable,—Czermak may be considered to be the discoverer of the art of laryngoscopy *in its application to the diagnosis and treatment of disease*. He was also the first to practise the kindred art of *rhinoscopy*.

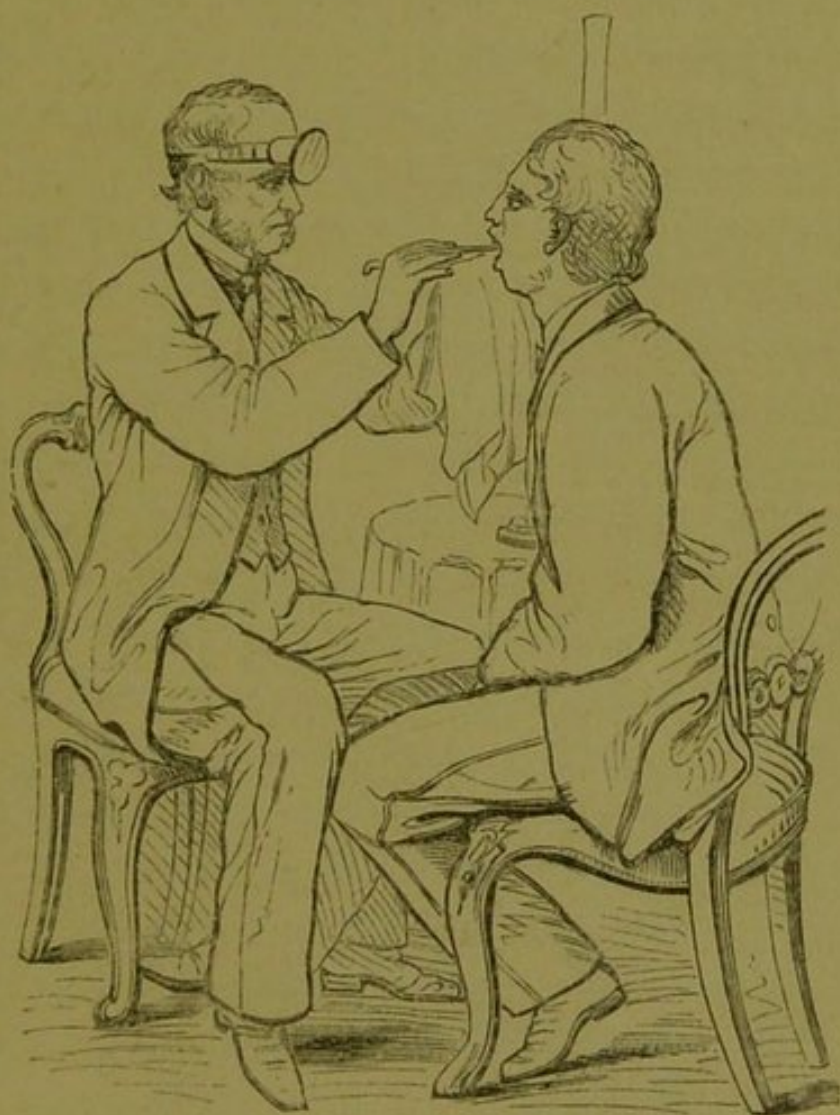Sydney Smith, in discussing the rival claims of discoverers, has said, "That man is not the first discoverer of any art who first says the thing; but he who says it so long, and so loud, and so clearly, that he compels mankind to hear him—the man who is so deeply

impressed with the importance of his discovery that he will take no denial; but, at the risk of fortune and fame, pushes through all opposition, and is determined that what he thinks he has discovered shall not perish for want of a fair trial." On grounds such as these—not of priority in time, but of persevering and successful efforts to render the method practically available—Czermak has established strong claims to be considered the *discoverer*, as he has unquestionably been the great *improver* and the great *teacher* of the arts of laryngoscopy and rhinoscopy, in their application to the diagnosis and treatment of disease.


I propose now to describe the *method of using the laryngoscope*.

And, first, as to the mode of illuminating the throat. The plan which is generally adopted is to reflect the light of the sun or of a lamp into the throat by means of a concave mirror, which is fixed on the forehead or in front of one eye of the operator. (*See woodcut.*)

The operator always sits opposite to the patient. When sunlight is used, the patient is placed with his back to the sun. When a lamp is employed, it is placed usually to the right side of the patient's head, and on the same level, or a little above. In using artificial light, it is unnecessary to darken the room more than may be done by simply drawing down a blind, so as to lessen the glare of daylight. Now the question arises, should the reflector be perforated and placed in front of one eye, so that we look through it into the patient's throat, or is it better placed on the forehead just above the eyes? in which case it is unnecessary to have the mirror perforated. *I believe that the best position for the reflector is above both eyes,*



Laryngoscopic Examination of a Patient.—*See p. 14.*



and not in front of one; and as this is a point of considerable importance, I must give the reasons for my belief.

With the reflector on the forehead we avoid the discomfort and inconvenience resulting from the effort required to keep one eye applied to the opening in the mirror. We have the free and unimpeded use of both eyes, and we consequently find it much easier to direct the light into the patient's throat, to introduce the laryngeal mirror, and to practise any other manipulation that may be required either for diagnosis or treatment. Another incidental advantage attending the position of the reflector on the forehead is, that we thus get a more extended movement of the reflector in all directions. This free movement enables us readily to change the direction of the light when we are examining our patient, and it also facilitates a very simple mode of auto-laryngoscopy of which I shall presently have to speak. The question, then, arises, are there advantages to be gained by looking through a perforated reflector which in any degree compensate for its manifest inconveniences? I know of none, and I believe that none exist. The practice of using a perforated reflector was borrowed from the ophthalmoscope; but the conditions which attend the exploration of the interior of the eye through the small opening of the pupil are very different from those which exist when we are looking through the wide open mouth at an image of the larynx reflected from a mirror of considerable size. In the latter case there is nothing gained by looking through the centre of a perforated reflector. I have fully tested this, not only in the examination of the larynx, but also by an

experiment of this kind. Place a stethoscope, with the ear-piece downwards, on the table in front of you. Hold a laryngeal mirror obliquely over the upper end of the stethoscope, so as to reflect the interior of the tube, throwing the light of a candle on the mirror by means of the concave reflector placed at one time on the forehead, at another in front of one eye. You will find that, as regards the facility of illuminating the interior of the tube and seeing its image in the mirror, the position of the reflector makes not the slightest difference.

I have met with very few persons who, having tried both methods, fail to appreciate the great convenience and advantage of having the reflector on the forehead, rather than in the front of one eye. Some who have become accustomed to the latter plan are unwilling to change it. Czermak not only keeps the reflector in front of the right eye, but he holds the apparatus between his teeth—a practice in which he has found very few imitators. M. Garcia* states, with regard to the use of a perforated mirror, that he tried it in order that Drs. Sharpey and Williamson might observe his larynx while he experimented upon himself. He found, however, that this was not attended by any marked advantage. They could see the reflected image of his larynx as well by looking over the top of the mirror as by looking through its perforated centre.

I made the same observation when looking into Czermak's throat while he was using his auto-laryngoscopic apparatus: I could see his larynx as

* Notice sur l'Invention du Laryngoscope, par Paulin Richard. Paris: 1861. P. 14.

well by the side of the reflector as through its centre. When I am examining the larynx of a patient, if I wish to make the parts visible to another, I can readily do this by turning the face of the laryngeal mirror slightly towards one side, and directing the observer to look over my shoulder at the mirror in the throat. In order to see the image of the larynx, it is unnecessary that the eye should be even *near the margin of the reflector*, much less is it necessary that the eye should look through the *centre of the reflector*.

The reflector, when in front of the eye, therefore, being a source of much discomfort and inconvenience, without any compensating advantage, is better placed on the forehead just above the eye, as in the woodcut at page 15.

The *faucial or laryngeal mirror* is made of different forms—square with the angles rounded off, circular, or oval. The form of the mirror is of little consequence. I find, however, that a circular mirror irritates the back of the pharynx less than a square one; I therefore prefer the circular form. Silvered glass mirrors are to be preferred to those made of steel or other metal. Metallic mirrors soon lose their polish, and they quickly cool, and thus become dimmed by the breath.

The mirror is to be warmed by holding it over the lamp or by dipping it into warm water. Its temperature should be tested by bringing it in contact with the cheek or the hand of the operator. It should be warm enough to prevent its being dimmed by the patient's breath. There are two reasons for not overheating the mirror—first, the patient's mouth will be burned; and second, the silvering of the mirror will be spoiled.

The mirror is to be held like a pen, between the thumb and two fingers, and introduced so as to slightly raise the uvula and soft palate. Care must be taken to avoid touching the tongue, and as much as possible, the back of the pharynx, with the mirror, these being the most sensitive parts within the mouth. The hand of the operator may be kept steady by resting the third and fourth fingers on the chin of the patient.

I have said that we must not touch the tongue with the mirror; but how is this to be avoided? You will find that very generally as soon as the mirror is introduced between the teeth, the tongue involuntarily rises towards the roof of the mouth, so as to come in contact with the mirror and obstruct the view; and, in fact, the tongue is one of the most frequent and most serious impediments in the way of laryngoscopy. There are various modes of dealing with this unruly member.

In some few cases the patient has sufficient control over the tongue to hold it down by a voluntary effort while the laryngeal mirror is being introduced. This power, however, is rarely acquired until after a considerable amount of practice, and in most instances the tongue has to be kept out of the way by some mechanical means. The plan which usually succeeds best is to hold the tip of the tongue between the thumb and the forefinger, and to draw it gently forward over the lower teeth. This may be done by the operator with his left hand, or by the patient, the thumb and finger which hold the tongue being covered by a cotton glove, or by a towel or handkerchief.

In some cases a *metallic tongue-depressor* may be used with advantage, or the tongue may be pressed

down by the forefinger of the operator's left hand. But it will usually be found that one effect of depressing the tongue in front is to push it backwards at the base, so that it nearly or quite touches the back of the pharynx, thus intercepting the light; while another result is to make the tongue arch upwards, so as nearly to touch the roof of the mouth. This arched position of the tongue obstructs the passage of the light to and from the larynx; often, too, it brings the tongue in contact with the mirror, and this excites nausea. For these reasons the attempt to depress the tongue is usually less successful than its gentle traction forwards.

I have before said that the laryngeal mirror is to be introduced so as slightly to raise the uvula and soft palate. The uvula must not be allowed to project below the mirror. The end of a long uvula hanging below the mirror has its image reflected in the glass, and this obscures the view of the larynx. The uvula and the soft palate are the least sensitive parts with which the mirror can come in contact. The posterior wall of the pharynx is usually more sensitive, and care should be taken to disturb it as little as possible. Frequently, however, the pharynx bears the touch of the mirror as well as the uvula and soft palate.

The mirror being placed in an oblique position below the palate, we usually at once obtain a view of the larynx. A little practice will enable you to make such changes in the position of the mirror, or of the patient, or in the direction of the light, as may be required to bring the parts fully into view. It should be borne in mind that the larynx, as it appears in the mirror, is reversed; so that we get the same view as we have

when, examining the larynx after death, we look at it from behind. The arytenoid cartilages appear nearest to the eye; the insertion of the vocal cords into the thyroid cartilage is more distant. We also see the anterior wall of the trachea as if we were looking into the tube from behind. We see that during inspiration the glottis is a wide triangular opening of considerable size, the vocal cords being of a pearly white colour. During speaking—as in pronouncing the syllable “eh”—the glottis closes, and the cords vibrate with the impulse of the expired air.

It is important to practice the introduction of the laryngeal mirror with the *left* hand as well as with the right. In applying local remedies to the larynx the patient is instructed to manipulate his own tongue, while the operator, holding the mirror with the left hand so as to obtain a view of the larynx, uses his right hand for the introduction of the brush or other instrument.

But how does the throat bear the contact of the mirror? Does not its introduction excite retching and cough and dyspnoea, and other unpleasant sensations? These questions are often asked by those who have had no experience of laryngoscopy; but those who have experience are unanimous in declaring that, in the great majority of cases, none of these unpleasant results attend the introduction of the mirror into the fauces. Sometimes, however, we met with difficulties in the use of the instrument. I will briefly refer to some of these, and will give some hints as to the best mode of meeting them.

First, then, some persons have a propensity to throw the tongue forcibly upwards towards the roof

of the mouth; and they do this with a provoking pertinacity just as the mirror is being introduced between the teeth. This position of the tongue offers a serious impediment to the introduction of the mirror, and the obstruction is greater in proportion to the size of the rebellious tongue. It is usually a result of nervousness on the part of the patient, and is sure to be made worse by any appearance of petulance in the operator. The better plan is to endeavour to reassure the patient. Sometimes the occupation of holding his own tongue between the thumb and finger has a good effect by diverting his attention, and occasionally, while he is holding the tip of his tongue, you may depress the dorsum with a spatula or with your forefinger. In some instances, after making one or two attempts, it is better to defer the examination to a future day. After two or three sittings, there is usually less nervousness, and the tongue comes more under control.

[Dr. Watson, after hearing this lecture, told me that in the case of patients who have this tendency to arch up the tongue, and so to prevent the examination of the fauces, he directs them to practise by sitting in front of a looking-glass with the mouth open. The inspection of the tongue, while they are endeavouring to acquire the power of controlling its movements, is found to be a great assistance.]

Another impediment to the examination of the larynx results from unusual sensitiveness of the fauces, so that the touch of the mirror excites contraction of the pharynx and retching. This excessive sensibility is common when the fauces are in a state of inflammatory congestion; so that, seeing the throat engorged and red, we may anticipate a difficulty in the

examination of the larynx. There are two modes of lessening the sensibility of the throat in such cases. One is, to direct the patient to keep a lump of ice in his mouth for ten or fifteen minutes before the examination, and as the ice melts to swallow the cold water. Another, and I think a more effectual plan, is to put twenty drops of chloroform on a handkerchief and let him inhale it for a minute : I have found this successful in quieting the most irritable throats, and that without rendering the patient in the least degree drowsy or uncomfortable. The bromide of potassium, when swallowed or used as a gargle, has long been supposed to have the effect of lessening the reflex sensibility of the fauces, but in the few cases in which I have tried it for this purpose it has appeared to be quite inert. Semeleder states, too, that he has not obtained the desired result from this salt.

It will usually be found that the repeated introduction of the faucial mirror at intervals of a day or two has the effect of lessening the sensibility of the throat, so that after a short time the most sensitive throat becomes tolerant of the mirror.

I have found that patients labouring under acute laryngitis and other organic diseases which are attended with much suffering usually bear the examination well, and often better than others who have but trifling ailments, or none at all. The man who is threatened with suffocation will submit to any proceeding which affords him hope of relief, and the distress in his larynx is so great that he is scarcely conscious of the trifling irritation caused by the faucial mirror ; so true is it that

“Where the greater malady is fixed
The lesser is scarce felt.”

Enlargement of the tonsils may render the examination of the larynx difficult or impossible. A small mirror may be used when the enlargement is not excessive; but if the tonsils are so much enlarged as nearly to touch each other, a laryngoscopic examination is impracticable.

The epiglottis is sometimes very long, and projects obliquely downwards and backwards, so as to make it impossible to throw the light beneath it, and to get a view of the larynx. The arch of the epiglottis, too, is sometimes so contracted as to obstruct the entrance of the light.

Semeleder* gives as the result of his experience that in about 25 per cent. of adults he got a perfect view of the larynx easily at the first examination; in about 5 per cent. it was impossible to see the larynx at all; in the remainder he succeeded more or less completely after repeated examinations. I think I may safely assert that at the present time I obtain a complete view of the larynx at the first sitting in three-fourths of the cases of adults. In children from two years of age and upwards the proportion of failures is greater.

Auto-laryngoscopy.—One of the most useful means of acquiring skill and confidence in the examination of the larynx is the practice of auto-laryngoscopy—that is, the examination of one's own larynx. Various methods of auto-laryngoscopy have been proposed and practised. The simplest and most satisfactory plan is one which is very easy of execution, and which re-

* Die Laryngoskopie und ihre Verwerthung für die aertzliche Praxis. Von Dr. Friedrich Semeleder. Wien, 1863.

quires no special apparatus. The concave reflector on the forehead, and the laryngeal mirror which is used in the examination of others, with a common looking-glass and a lamp, constitute the whole of the apparatus. The method of operating is this. Sitting at a table of a convenient height, I place a looking-glass at a distance of about eighteen inches in front of me, and a moderator or a gas lamp on one side of the glass, but two or three inches further back, so that the light may not pass directly from the lamp to the mirror. Now, with the reflector on my forehead, I direct the light as it were into the open mouth of my own image in the looking-glass; then, introducing the laryngeal mirror into my mouth, I see the reflection of my larynx and trachea in the glass before me, and any one looking over my head or shoulder can see the image at the same time. This method therefore serves for auto-laryngoscopy and for demonstration; in other words, the experimenter can, by this means, see his own larynx and show it to others.*

This method certainly possesses some advantages over that employed by Czermak. In the first place, Czermak's plan requires a special apparatus, which is too complicated and costly to allow of its coming into general use. Although I possess Czermak's instrument for auto-laryngoscopy, I have quite ceased to use it, because I find the other plan easier and more satisfactory. I find, for instance, while I am holding the

* The description of this simple method of auto-laryngoscopy was first published by the author in the *Medical Times and Gazette*, Feb. 14, 1863, p. 157. In the same paper the arguments in favour of placing the concave reflector on the forehead rather than in front of one eye were set forth.

laryngeal mirror with my right hand, and changing the position of my head so as to obtain different views of the larynx, I can with the greatest readiness make any required change in the direction of the light by adjusting the frontal reflector with my left hand. This adjustment of the light cannot so readily be made with Czermak's apparatus, on account of the distance at which the reflector is fixed on a brass stem opposite the experimenter.

For beginners in the art of laryngoscopy this method affords a very useful means of training and practice. One of the chief difficulties at first is to keep a steady light in the patient's mouth while the laryngeal mirror is being introduced. Now, the student, after arranging his looking-glass and his lamp, may direct the light from the frontal reflector into his own open mouth in the looking-glass. This process differs scarcely at all from that which he will have to practise on his patients. Then, having learned to keep the light steady, he may practise the introduction of the faucial mirror, and he will soon see the interior of his own larynx and trachea. I have seen several of my medical friends and pupils succeed in doing all this within less than half an hour of their first attempt.

It is important to observe that in practising this method of auto-laryngoscopy both eyes may be protected from the glare of the lamp. The lamp is most conveniently placed by the side of the glass to the left of the operator. The right eye is then shaded by the lower margin of the reflector on the forehead, and the left eye may readily be shaded by one or two fingers of the left hand placed at the edge of the

reflector. The fingers thus placed serve at once as a shade for the left eye, and a means of moving the reflector when the direction of the light has to be changed. If the experimenter desire to show his larynx to several persons at once, he can readily do this by having the mirror in front of him of small size, about three inches square, and fixed at a convenient height: the small flat mirror belonging to Czermak's auto-laryngoscopic apparatus may be used for this purpose. (*See* frontispiece—the mirror is marked *a* in the engraving.) Thus, while two or three persons standing behind him can see the reflection of his larynx in the glass, two or three others standing in front of him, and looking over the top and by the sides of the glass into his mouth, may see the direct reflection of the larynx from the faucial mirror.

In the practice of laryngoscopy, whether in the examination of one's own larynx or that of others, it is of primary importance that the operator should have the power of readily changing the direction of the light, so as at once to adapt it to the varying position of the body, which is often required for the thorough exploration of the larynx. A feebler light which can readily be reflected in any required direction, is of more practical value in laryngoscopy than a stronger light which is fixed.

Some laryngoscopists on the Continent, and Dr. Walker of Peterborough, do not use the reflector for the purpose of lighting the throat, but in place of it they get a direct illumination of the fauces by means of a concentrated fixed light. A globular bottle of water in front of a lamp is used as a powerful condensing lens. In this way, certainly, a very bright

light is obtained; but the objections to this mode of illumination are—1st, that the apparatus is clumsy, and cannot easily be carried about; and, 2nd, the chief objection is that the direction of the light cannot be readily and instantaneously made to follow the movements of the patient's head. The fact of the light moving with the movements of the operator, which some consider an objection to the method of illuminating the throat by means of the reflector on the forehead, does, in fact, constitute one of its chief advantages.

With regard to the source of light, I find it not difficult to see and to demonstrate my own larynx, as well as to examine the larynx of another, by the light of an ordinary candle; but a bright light of course renders the examination much easier and more satisfactory. The best artificial light is a moderator lamp, or an argand gas burner. The light may be much intensified by placing a metallic reflector behind the lamp, and a bull's-eye condensor at the proper focal distance in front, the flat side of the lens being next the lamp. I find that with a single bull's-eye condensor I get a better light than with Tobold's condensor, which consists of three lenses in a brass tube, and which is a more cumbersome as well as a more costly apparatus.

All observers agree in opinion that the light of the sun, when it can be obtained, is the best means of illuminating the throat. The patient sits with his back to the sun, and the operator directs the light into the throat by means of the reflector. For this purpose the reflector need not be concave; a flat surface will give sufficient light. In using a concave

reflector with sunlight, you must be careful not to burn the throat by concentrating the rays into a focus. *Solar* caustic, be it remembered, may be made even more powerful than *lunar* caustic. [Since this lecture was given I have found that the best mode of using sunlight in laryngoscopy is to place a looking-glass in such a position that it shall deflect the sun's rays on the frontal reflector, but leave the eyes of the operator in the shade. In this way we avoid the serious inconvenience which results from exposing the eyes to the direct rays of the sun. Both the patient and the operator are in the shade, a column of light being turned upon the frontal reflector by the looking-glass.] With sunlight it is not absolutely *necessary* to use the frontal reflector. The patient may face the sun, so that the rays fall directly upon the laryngeal mirror. But here, again, the advantage of the reflector consists in the facility with which it enables you in a moment to change the direction of the light.

The reflector on the forehead is a very useful means of lighting the throat for the purpose of examining the tonsils, palate, and pharynx. Placing a lamp or a candle by the side of the patient, or using sunlight when it is available, the operator, with the reflector on his forehead, throws the light into the throat, and has both his hands free to depress the tongue and to apply caustic or other local remedies. In cases of diphtheria and scarlatina, by this method of illumination a thorough examination of the throat can be made in a much shorter time than by the ordinary method, and without the necessity of raising the patient's head from the pillow. The operator in this way runs less risk of infection from inhaling the patient's breath,

or from the morbid secretions being coughed into his face.

In the presence of a learned assembly such as I have now the honour to address, it is scarcely necessary to assert, that if in the laryngoscope we have an important aid in the diagnosis of laryngeal disease, such aid is by no means superfluous or uncalled for. The experience of every practitioner will enable him to recall cases in which there has existed the most painful doubt as to the nature of disease within the larynx. Mr. Porter, writing in the year 1837, says, "How is a man of experience, when he meets with a case of laryngeal disease, to know whether it is caused by an œdematous condition of the submucous tissue—by a chronic thickening of the mucous membrane itself—by laryngeal ulceration—by destruction of the cartilages—by the presence of abscess or tumour, or by any other of those numerous affections which dissection so frequently shows us to be the occasion of death?" And he suggests that, "perhaps by reason of the difficulty of the subject, it will be long before we possess the same accuracy of information with reference to affections of the windpipe that has been attained in other diseases." What, now, has been the effect of that simple contrivance, the laryngeal mirror? May it not be said without exaggeration, that it has rendered the diagnosis of the diseases of the larynx more simple and more certain than the diagnosis of the diseases of any other internal organ? In fact the larynx has ceased to be an internal organ, in the sense of being hidden from view, for it has been brought within the range of vision. And the answer to Mr. Porter's question is simply this, that

the man of experience has now only to *look into* the larynx, and he will *see* what is the form of disease with which he has to deal.

In my next lecture I propose to give some illustrations of the valuable aid which the laryngoscope is capable of affording in both the diagnosis and the treatment of disease. During the few minutes that remain to-day, I propose to advert very briefly to the subject of rhinoscopy.

Rhinoscopy.—Czermak, in his first publication on the laryngoscope, pointed out that the same method of examination was applicable to the inspection of the posterior surface of the soft palate, the posterior openings of the nasal fossæ, and the superior parts of the pharynx.

In the practice of rhinoscopy the patient should sit erect, without throwing the head back, while the light is thrown into the mouth by the frontal reflector. The tongue is to be kept down by means of a metallic depressor, which may be held either by the operator or by the patient. A small mirror is required, and it is better made of glass than of metal, on account of the rapidity with which a metallic mirror cools and condenses vapour on its surface. I have two circular mirrors, which I find very convenient for rhinoscopy, one the size of a threepenny piece, the other the size of a sixpence.

When you are about to introduce the mirror, the patient should be directed to breathe quietly. A deep inspiration draws the uvula and soft palate upwards and backwards, and so interferes with the examination. The mirror is to be introduced by the side of the uvula, beneath the palate, with its surface directed

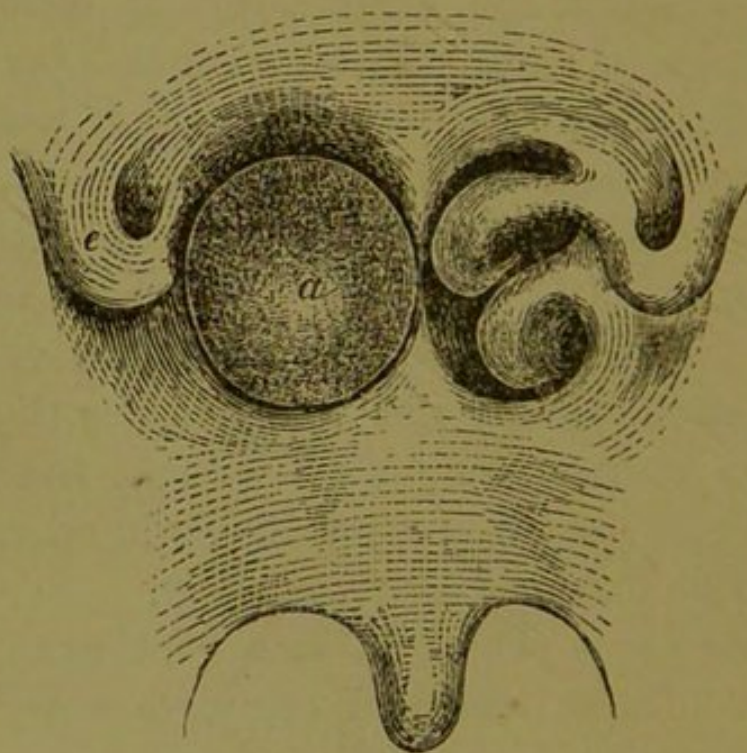
upwards and forwards. The facility with which the examination can be made depends mainly upon the space which exists between the palate and the posterior wall of the pharynx. When the interval is a moderately wide one, the mirror can be introduced without touching the uvula or palate, and the posterior openings of the nasal fossæ, the turbinated bones, the opening of the Eustachian tube, the septum narium, the roof of the pharynx,—all these parts may be distinctly seen.

In some cases the examination is facilitated by drawing the uvula and palate forwards by means of a blunt hook; but this is better avoided if possible, for it is always attended with much discomfort, and frequently the contact of the hook excites contraction of the palate, which is then drawn upwards and backwards so as completely to obstruct the view. The most successful rhinoscopic examinations that I have made have been accomplished without touching the uvula and soft palate. Very valuable information may sometimes be obtained by rhinoscopy.

Last year I was consulted by a gentleman, twenty-four years of age, who had complete obstruction of the right nostril. It had commenced two years ago, after a severe cold; and it had steadily increased until at the end of about a year, it was so complete that he was unable by any effort either to inspire or to expel air through the right nostril. The left nostril remained pervious; but in consequence of the obstruction on the right side the patient habitually kept his mouth open, respiration being impeded when the mouth was shut; and the voice had somewhat of a nasal character. Examination of the nostril in front discovered no

obstruction, nor was any abnormal appearance visible on examination of the palate and pharynx in the ordinary way through the open mouth.

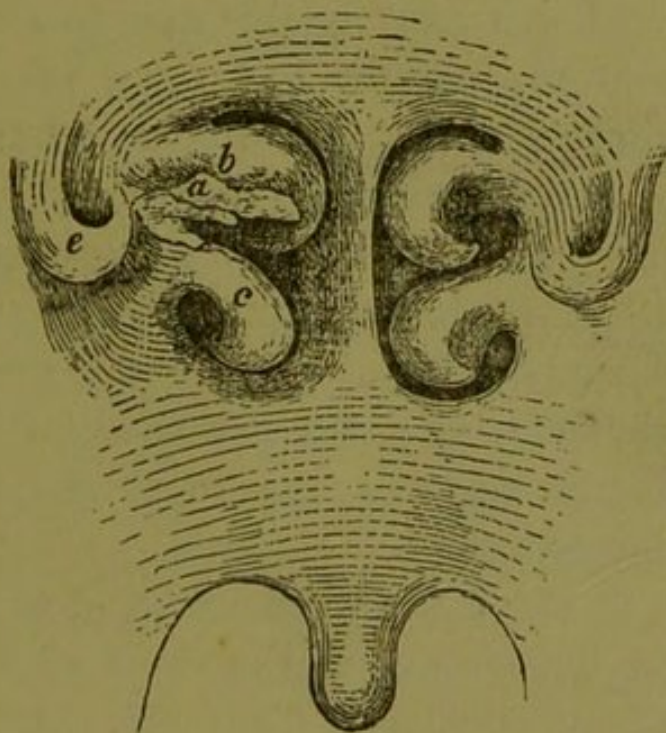
He had a throat favourable for rhinoscopy : a small uvula, with the soft palate at some distance from the back of the pharynx, so that the mirror could be introduced without disturbing these parts. The left nasal fossa was quite normal ; but the right was seen to be completely obstructed by a tumour, apparently of globular form, having a slightly granular surface



Posterior view of uvula, soft palate, and nares, as seen in the mirror. The tumour, *a*, on the left of the figure, fills up the posterior opening of the right nasal fossa ; *e*, the orifice of the right Eustachian tube.

and a yellowish-green colour. It touched the floor and septum of the nose ; and externally it pressed upon and concealed the turbinated bones. I could touch the tumour with a bent probe introduced behind the palate. I now asked my friend and colleague, Mr. John Wood, to see the patient with me, and to devise a plan for removing the tumour. He intro-

duced a pair of slender curved polypus forceps through the anterior opening of the nostril, grasped the tumour, and as he was drawing it forward there was a sudden rush of a glairy fluid, like white of egg, and some membranous shreds came away between the blades of the forceps. The patient felt immediately that the obstruction was gone. On rhinoscopic examination the tumour had disappeared; the turbinated bones were plainly visible; and on the under side of the middle turbinated bone there was an abraded surface, from which, apparently, the tumour had been



The posterior nares after the removal of the tumour. *a*, the abraded surface from which the tumour was torn; *b*, the middle, and *c*, the inferior turbinated bone; *e*, the Eustachian tube.

torn. The tumour had evidently been a globular cyst containing fluid. On the second day after the operation a portion of the cyst wall came away. This I have preserved. It is smooth on its inner concave surface, but uneven on its outer surface, by which apparently it had been attached to the mucous membrane. During the first few days after the operation

the abraded surface of the mucous membrane was covered by a purulent secretion : this quickly healed. The patient has lost all sense of obstruction in the nostril ; he can breathe comfortably with the mouth closed ; and the voice has recovered its natural tone.

The practical value of rhinoscopy in this case can scarcely be called in question. It is doubtful whether, by any other mode of examination, the position and nature of the tumour could have been determined with sufficient certainty to warrant an operation for its removal. I was relating this case to a friend, who remarked that my patient had more reason to congratulate himself than one about whom he was consulted. One nostril was obstructed, and it was supposed that a polypus was the cause of obstruction. A surgeon had made an unsuccessful attempt to remove the supposed polypus by the forceps : this caused much suffering ; and it was at last discovered that the obstruction was due to thickening of the turbinated bones.

Czermak, in the last German edition of his work,* gives a good illustration of the value of rhinoscopy in correcting an erroneous diagnosis. A young man deaf on the left side was found to have a tumour at the back of the nostril, which conveyed to the finger the impression of a polypus. An operation was contemplated ; but a rhinoscopic examination discovered a tapering swelling of the mucous membrane, nearly as thick as the finger, surrounding the orifice of the

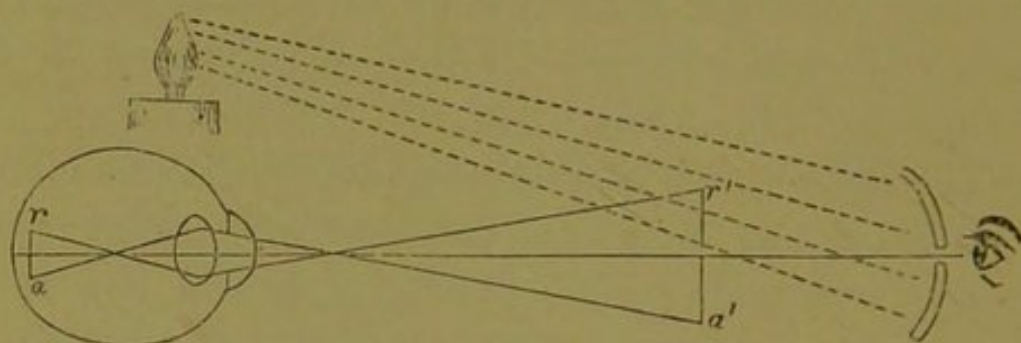
* *Der Kehlkopfspiegel und seine Verwethung für Physiologie und Medizin*, pp, 127-8. Leipzig, 1863.

left Eustachian tube ; also great swelling of the middle and inferior turbinated bones ; but no polypus, nor any tumour which an operation could have removed or lessened.

Note.—Mr. Ernest Hart, ophthalmic surgeon to St. Mary's Hospital, has been good enough to send me, at my request, the following note on *Ophthalmoscopy as compared with Laryngoscopy*. I am happy to avail myself of his clear statement of the optical principles which render a *perforated* reflector necessary in the one case and not in the other.

“The light which penetrates the eye is not wholly absorbed by the choroidal pigment, and must therefore pass out again ; and, obviously, if the eye of an observer were brought into such a position as to receive these rays which emerge, he would see the image of the tunics behind the retina, which act as the reflecting screen. But as the eye is an optical apparatus composed of refracting media (lenses), the rays in passing out are refracted anew, and the image of the retina is formed in the air (and according to the *law of conjugated foci*) on the same side as the luminous object, and at a distance regulated by the accommodation of the eye, the distance of the object, and the shape which the lens of the eye assumes, for the purposes of distinct vision. Hence, if a light were placed in front of an eye, and the head of an observer could be interposed between that light and the eye to be observed, he should, at the distance of distinct vision, be able to see the retina by virtue of its reflected image. But the head of the observer stops the light from entering. This difficulty, however, is got over by putting a light by the side of the


eye to be observed, and with a concave mirror reflecting the light into that eye. If now the eye of the observer be placed at a small aperture of the mirror, he will be in a position to receive the luminous ray emerging from the eye observed and returning towards the mirror, and therefore to see the image of the fundus oculi from which it is reflected. I think this diagram makes this part of the matter sufficiently



clear. ra is the circle of diffusion of the retina, and the lines indicate how the rays reflected from that position will be refracted by the media of the eye, and form at $r' a'$ a *real, enlarged, but inverted* image of the fundus of the eye. And it will be seen also that to get this image, the mirror must be placed at the limit of distinct vision—where the image is formed, and which varies for each eye. There are other points necessary to be attended to in ophthalmoscopy, and which render it difficult for beginners. But none of these exist for laryngoscopy. Laryngoscopy requires only the illumination of plain or curved surfaces and tubes; and as there are no series of lenses through which the rays reflected by them are refracted, so none of these optical difficulties exist. The practice of looking through a central aperture of the reflecting mirror used is one which has no foundation that I can perceive in any law or rule of optics, and is simply an

inconvenient restriction of the field of vision and the facility of observing, which may probably have arisen from the mechanical imitation of the practice of ophthalmoscopy, without sufficient consideration of the peculiar optical difficulties which exist in the latter art.

“It matters nothing (optically) for laryngoscopy whether the light be direct or reflected, and the light of a lamp concentrated through a lens answers perfectly well without any reflection. The laryngeal mirrors are, of course, necessary to deflect the rays into the tube of the larynx.”



LECTURE II.

THE larynx, being the door-keeper of the lungs, as well as the organ of the voice, is largely supplied with nerves and endowed with exquisite sensibility. Its muscular apparatus is therefore readily thrown into a state of spasm, not only by direct irritation of the larynx itself, but by disturbing influences transmitted from a distance through the nerves. That distressing disease, laryngismus stridulus, or crowing inspiration, in children, affords a good illustration of a purely spasmodic affection of the larynx, yet one which is often fatal. Even in cases of organic disease of the larynx, and in adults, there is very commonly a tendency to spasm; and before the introduction of the laryngoscope, it was often impossible to determine to what extent the symptoms were the result of structural change within the larynx, and how far they were due to spasm of the laryngeal muscles. Now, by the aid of the mirror, this difficulty has been in a great degree removed.

Many years ago (in February, 1847), I was asked by a friend to examine the body of a man who had died, at the age of twenty-nine, of what was believed by two gentlemen who attended him to have been acute laryngitis. The symptoms had been cough, hoarseness, dyspnoea with stridor, a hot skin, and a quick pulse. The dyspnoea was increased from time to time in paroxysms; at length one of these paroxysms resulted in suffocation. The larynx was found quite healthy, but in the chest there was a large cancerous

tumour, which filled up the arch of the aorta and involved the branches of the pneumogastric nerve. The laryngeal symptoms had been purely spasmodic—a result of irritation of the nerves by the cancerous tumour in the chest.

The laryngoscope was not then in use. Now that we have that instrument, an error of diagnosis in such a case could result only from negligence.

In July last year a man, thirty-one years of age, was admitted into the hospital under my care with symptoms which were at first supposed to indicate laryngitis. He had cough with dyspnœa, loud laryngeal stridor, and hoarseness. On examination of the larynx by the mirror with sunlight, I found only very slight congestion of the mucous membrane, and I at once declared that the laryngeal symptoms were the result of spasm and not of inflammation or other structural disease within the larynx. Aneurism of the aorta was then suspected and carefully sought for; but no physical sign of aneurism could be found. There was no abnormal dulness on percussion, no pulsation, no morbid sound, no inequality of the pupils or of the pulse at the wrists. One suspicious symptom, however, was a difficulty in swallowing solids, which had come on about eight days before his admission. It was likely, therefore, that a tumour—probably an aneurism—was pressing on the œsophagus and on the recurrent nerve. Four days after his admission he died from the bursting of an aneurism into his œsophagus. Some blood was ejected from the mouth, but the greater part passed into the stomach. An aneurism about the size of a small orange was found at the back of the transverse portion of the arch of the aorta:

it had pressed on the œsophagus and opened into it. The stomach was full of blood. The left pneumogastric nerve passed in front of the aneurism, and was somewhat flattened; the recurrent branch passed behind the tumour, and had evidently been stretched and compressed by the aneurism.*

In this case the laryngoscope was of considerable use. It clearly showed the absence of laryngitis, and thus rendered it probable that an aneurism was the cause of the laryngeal symptoms. The patient, therefore, was spared the ordinary treatment for laryngitis. Nauseating doses of antimony or ipecacuhana would probably have excited vomiting, and might have hastened the rupture of the aneurism.

Pressure on the nerves within the chest may *paralyse* them, or rather the muscles which they supply, and cause *aphonia* without laryngeal spasm.

In March, 1863, a man was under my care in the hospital with extensive cancerous disease within the chest. The whole of the left lung was solid, and impervious to air; the superficial veins over the chest and on the head and neck were much enlarged. He had a mass of cancerous glands above the right clavicle. He spoke only in a faint whisper; but there was no sign of obstruction in the larynx—neither stridor nor dyspnœa. The laryngoscope showed the tips of the arytenoid cartilages resting against each other, and quite motionless. The glottis was always open to the extent of about one-eighth of an inch; it neither opened wider during inspiration, nor closed when he attempted to vocalize. This immobility of the glottis was, without doubt, a result of paralysis

* The preparation is in the museum of King's College.

of the laryngeal muscles consequent on pressure upon the nerves by the cancerous mass within the chest. The poor man determined to leave the hospital before his death, so that we had no post-mortem examination; but the nature of the disease was very evident.

In most cases of inflammation of the larynx there is more or less of spasm; but the tendency to spasm varies much in different cases, depending probably upon the varying degrees of susceptibility of the nervous system in different individuals. Two cases of laryngitis which have recently been under my care in the hospital afforded a striking contrast with regard to the excitability of the larynx. Both patients were women. One was thirty-two years of age, of very nervous, excitable temperament. She had cough, hoarseness, dyspnoea, and loud laryngeal stridor. On examination with the laryngoscope, the mucous membrane of the larynx was seen to be congested and swollen; but it was evident that the stridor during inspiration and much of the apparent distress were the result of spasm. She closed the glottis during inspiration, and the air was drawn through it with a loud noise; but that there was no mechanical impediment to the opening of the glottis was clear, from the fact that immediately after inspiration was over the glottis *opened to its full extent*. There was a perverted muscular action which *closed* the glottis during *inspiration*, and *opened* it during *expiration*. In this case the symptoms were greatly relieved by the internal use of morphia and chlorodyne, and by the local application of a solution of morphia in glycerine to the larynx by means of a brush.

In marked contrast with this case was that of a

woman, aged twenty, who complained of some pain in the throat, dyspnœa, difficulty in swallowing, and hoarseness; yet, withal, as my clinical clerk, Mr. Shuttleworth, noted, there was "marked absence of restlessness and anxiety, her countenance wearing an expression of profound indifference." The manner and the physiognomy of the patient were such as to excite a suspicion that the throat symptoms were simply nervous and hysterical; yet, on examination with the mirror, I found the epiglottis much congested, the false cords red and swollen, and over the left arytenoid cartilage a red inflammatory swelling of the mucous membrane as large as a marble. The swelling soon subsided under the use of antiphlogistic remedies, and she left the hospital well.

Without the aid of the laryngoscope in these two cases, we should have formed a very incorrect opinion as to the state of the larynx. In the first case we should have over-estimated, in the second we should have under-estimated, the amount of structural change. In each case, too, a correct diagnosis suggested a more appropriate treatment than would otherwise have been applied.

In some cases of *syphilitic laryngitis* which have come under my observation during the last two years, laryngoscopic examination has afforded some very interesting results.

A woman, aged forty-one, was admitted under my care on June 8th, 1863. There was a history of primary syphilis two years before, and this was followed by sore-throat, bronchitis, and eruption on the skin. For six months before her admission there had been hoarseness and occasional dyspnœa.

At the time of admission the dyspnœa was very urgent, inspiration being prolonged and heaving, and attended with loud laryngeal stridor. The voice was very thick and husky; the skin and lips of a dusky hue.

Examination by the laryngoscope, which was well borne, showed considerable thickening of the mucous membrane over the arytenoid cartilages and at the side of the larynx—that is, in the situation of the false cords. No ulceration was apparent. The glottis was much narrowed, so that she breathed through a small triangular opening at the back part of the glottis. The epiglottis was slightly injected, but not thickened. There were patches of syphilitic psoriasis on various parts of the body. Three leeches were applied outside the larynx. She was directed to inhale steam, and to take five-grain doses of iodide of potassium three times a day. During the twenty-four hours after her admission the dyspnœa became more urgent and alarming.

Now the advantage of the laryngoscope in the case was this: it showed such an amount of swelling and obstruction in the larynx as the most successful medicinal treatment could not be expected to remove within a period of several days, while the narrowing of the glottis was so great as to threaten speedy suffocation. We were therefore emboldened to resort to tracheotomy before the lungs had become gorged to such an extent as to render the operation useless. Accordingly tracheotomy was performed by Mr. Antonini (the house-surgeon) the day after admission: the relief was great and immediate. She then took corrosive sublimate and iodide of potassium until the

gums were slightly affected. Meanwhile we were enabled to watch the gradual diminution of the swelling within the larynx, and the gradual opening of the glottis, until at length it expanded to its full extent.

The tube was removed on the 15th of July, and she left the hospital on the 1st of August. There was then only a slight huskiness of the voice, the sole morbid appearance in the larynx being a slight roughness and a dull-red colour of the true cords.

Quite recently, a case of syphilitic disease of the throat has been associated with a remarkable alteration in the form of the epiglottis. A woman, aged twenty-five, was admitted on the 11th of March with syphilitic ulcers on the soft palate and on the back of the pharynx. There was some thickness of the voice and difficulty of swallowing, and there had been occasionally dyspnoea. On examination with the laryngoscope, I saw that there was an ulcer on each side in the glosso-epiglottidean fold, just beyond the margin of the epiglottis. The epiglottis itself was red and thickened, and so much folded downwards that the two sides of its laryngeal surface were nearly in contact, and it was impossible to see into the larynx. This remarkable doubling up of the epiglottis was evidently a result of inflammatory swelling, extending from the ulcer at its margin over the lingual surface of the epiglottis. I have seen the reverse of this in some cases of tubercular ulceration commencing within the larynx. The mucous membrane on the laryngeal surface of the epiglottis has become thickened and swollen, and the result has been that the epiglottis has been flattened out, and has lost its usual arched form.

To return to our case of folded epiglottis. The woman was ordered to have a calomel vapour bath every night, and one-sixteenth of a grain of corrosive sublimate with five grains of iodide of potassium three times a day. In ten days the gums became slightly sore; the ulcers all rapidly healed; and as the thickening of the epiglottis diminished it became unfolded, opened out, and returned to its normal form. We could then see under it into the larynx, which was healthy.

I watched this case with much interest and with some anxiety; for two years ago I had under my care a similar case, which ended fatally in a very sudden and unexpected manner. A man was admitted on the 15th of May, 1862, with an ulcer on each tonsil, and a syphilitic eruption on the skin. There was some stridor with inspiration, but no dyspnœa, except after swallowing food, when he had occasional attacks, during which he was nearly suffocated. At that time we had not learned to use the laryngoscope, and we were therefore in the dark as to the condition of the epiglottis and larynx; but the house-surgeon was requested to hold himself in readiness to perform tracheotomy if necessary. On the evening of the third day after his admission he was again seized with a fit of suffocation after swallowing food. The house-surgeon was sent for, and he opened the trachea; but it was too late—the man was dead. We found that the syphilitic ulceration had extended from the tonsils to the edge of the epiglottis, and the epiglottis itself was thickened and doubled up exactly as in the case which I have just now related.

The probable explanation of the attacks of dyspnœa after swallowing appears to be this:—During deglu-

tition the opposed surfaces of the folded epiglottis were pressed together by the action of the pharyngeal muscles ; the elasticity of the epiglottis being impaired by the inflammatory swelling on its outer surface, the opposed surfaces would not immediately separate when the act of deglutition was over, and then probably the pressure of the atmosphere during a forcible effort at inspiration would tend to keep the surfaces together and prevent the opening of the fold. Thus the folded epiglottis would act as a valve, and prevent the entrance of the air. Another explanation which suggests itself is that, in consequence of the irregular swelling of the epiglottis, the food entered the larynx during the process of deglutition, and excited suffocative spasm. Whatever may be the immediate cause of the distressing symptoms, it is evident that cases of this kind require very careful watching. And if we find, on laryngoscopic examination, that the epiglottis has assumed this folded appearance, the occurrence of one or more attacks of urgent dyspnoea after swallowing food would call for the immediate performance of tracheotomy, in order to prevent sudden death from suffocation before our remedies have had time to act on the disease.

On the 21st of July, 1863, I first saw, with my colleague, Mr. Mason, a gentleman twenty-two years of age, who for about a year had been suffering from secondary syphilis. His face was much scarred by ulcers, which had all healed. At the time of my visit he complained of great pain and difficulty in swallowing, and the voice was husky. On examination with the laryngoscope, I saw an ulcer in the inter-arytenoid

fold, in the boundary wall between the larynx and the pharynx, and just in the position to be irritated by the passage of food. He was treated by calomel vapour baths, with iodide of potassium and bark internally; and the ulcer was occasionally touched with a solution of nitrate of silver by means of a brush on a curved whalebone handle. The ulcer healed, the patient gained flesh and strength, and for a time the cure appeared to be complete. In the autumn, however, he returned to me, complaining of dyspnœa on exertion, a loud ringing cough, and stridor during a deep inspiration. Now, on examination of the larynx, we found that the cicatrix of the ulcer had contracted, and drawn together the arytenoid cartilages, so that the vocal cords are scarcely more than one-tenth of an inch apart; and through this narrow fissure he breathes. That is his condition at the present time. I have asked several of my laryngoscopic friends to examine this gentleman. We all agree as to the condition of the larynx. I have had it in my mind to cut the cicatrix, so as to set free the cartilages; but fearing that the same contraction would follow the healing of the incision, I have done nothing but watch the symptoms. A distinguished surgeon, who saw the patient and heard the stridulous breathing, but who did not look into his larynx, suggested that he should take more mercury for the removal of the obstruction in the throat; but it is certain that mercury could have no more influence upon this scar in the larynx than it would have upon the scars which have disfigured his face.

A man, about forty-five years of age, was admitted

under the care of my colleague, Dr. Beale, on the 12th of December, 1863. His habits had been very intemperate. He said that five days before his admission he had been seized with sore-throat, hoarseness, and difficulty of breathing. At the time of admission these symptoms were still present, and inspiration was attended with loud stridor. He was so feeble that it was difficult for him to sit up in bed while I examined him with the laryngoscope. I found the mucous membrane of the larynx somewhat congested, but not swollen; but I saw clearly that the vocal cords were nearly in contact and motionless. This position of the cords accounted for the dyspnœa and stridor. But why were the cords thus in contact? I thought that possibly inflammation might have involved the crico-arytenoid articulation, and so rendered the cartilages immovable by a kind of ankylosis.

Tracheotomy was performed by Mr. Wood, but the man sank, and after death it was found that the arytenoid cartilages had become necrosed, and apparently had escaped each through an ulcerated opening in the mucous membrane; a small calcareous fragment only of each cartilage remained. This destruction of the cartilages accounted for the collapse of the glottis and the immobility of the cords.

I have seen two patients in whom *difficulty of swallowing* was a chief symptom, and who on that account were supposed to have stricture of the œsophagus, until the laryngoscope revealed the true nature of the disease.

One was a man sixty-four years of age, who came under my care at the hospital in March, 1863. He

had experienced difficulty in swallowing solids for about seven months, and of late there had been difficulty in swallowing liquids. There was neither dyspnœa nor hoarseness, but his voice had somewhat of a nasal sound. On examination by the laryngoscope, the epiglottis was seen greatly deformed and thickened; its surface, moreover, granular, and here and there ulcerated; it was so large as nearly to fill up the pharynx, and thus the difficulty in swallowing solids was fully explained. When the tongue was much depressed the epiglottis could be partly seen without the aid of the mirror. Examined by the finger, it had a hard and inelastic feel. Without doubt the disease is of the nature of epithelial cancer. On one occasion a piece the size of a horse-bean became detached and was expectorated: its microscopic characters were those of epithelial cancer. I have seen this man from time to time up to within the last few days. The disease has made very little progress, the lymphatic glands are unaffected, and his general health has suffered little impairment.*

The other case of dysphagia was that of a farmer, seventy-five years of age, who was sent to me by Mr. Roberts, of Dunster, in Somersetshire, in December, 1863. He had complained of cough, with rather copious expectoration, and great difficulty in swallowing, for about ten weeks. The voice was somewhat husky. On examination I found œdematous swelling of the mucous membrane of the larynx, the swelling

* This case has since terminated in death by suffocation, and the larynx with the cancerous epiglottis may be seen in the museum of King's College.

being most prominent over the arytenoid cartilages. This swelling evidently prevented complete closure of the larynx in deglutition, and caused the dysphagia. Mr. Erichsen afterwards saw this patient, passed an œsophageal bougie, and declared that there was no stricture. The swelling was rapidly reduced, and the difficulty of swallowing relieved by scarification over the most prominent part of the tumour, followed by the application of solution of nitrate of silver on a brush.

Amongst the most interesting results of the use of the laryngoscope, has been the clear light which it has thrown upon the *causes of hoarseness and aphonia*. These are very various, but they have usually this in common, that they in some way interfere with the close apposition or with the free vibration of the vocal cords. I will briefly refer to some of those which I have myself seen.

A wart, the size of a large pea, between the anterior insertion of the cords had rendered a man hoarse for seven years. This occurred in a patient of Dr. Morell Mackenzie, and I saw Dr. Mackenzie remove the wart very skilfully by means of his forceps. In another case, a tumour the size of a split pea projected from the left cord inwards towards the opposite cord.

In several cases the true cords have had an uneven granular surface. In some the natural white colour has been retained, but in others the surface has been of a dull-red colour.

Lately Dr. Tyler Smith sent me a mechanic who had been hoarse for twenty years. He had taken medicine incessantly for the first ten years, with the effect of injuring his health, but without improving his

voice. The cause of the aphonia in this case is a warty excrescence covering two-thirds of the length of the right vocal cord. The left cord, too, is somewhat uneven and granular. This patient tells me that he has repeatedly coughed up small seed-like particles from his throat. These have probably been portions of the warty growth forced off by the effort of coughing.*

A gentleman has been hoarse for many years, since suffering from syphilitic disease of the larynx. In this case the right vocal cord, near its middle, had evidently been divided by an ulcer. The divided ends of the cord are thickened and nodulated, and there is a great gap in the glottis when he vocalizes.

A frequent cause of hoarseness and aphonia in different degrees, is swelling of the so-called false cords to a sufficient extent to fill the ventricle of the larynx. The swollen mucous membrane presses on the true cords, and damps their vibrations. This is the condition of the larynx which is most commonly found in cases of inflammatory sore throat with hoarseness. These are, in fact, cases of mild laryngitis.

A less frequent cause of hoarseness is thickening and swelling of the inter-arytenoid fold of mucous membrane. This prevents the approximation of the cartilages and the closure of the glottis.

In cases of *tubercular ulceration of the larynx*, many of which I have examined with the laryngoscope, there is usually much swelling, and often ulceration, of the mucous membrane at the sides and back of the larynx;

* I have since removed a large proportion of this warty growth by the wire *écraseur*.

and this sufficiently accounts for the hoarseness which is commonly present. Less frequently the true cords are thickened and ulcerated.*

I have before mentioned the case of a man who had aphonia, from paralysis of the laryngeal muscles, the result probably of pressure on the recurrent nerves by cancerous disease in the chest. Also a case of aneurism of the aorta, in which, amongst other symptoms, there was hoarseness from pressure on the recurrent nerve.

The cases of *hysterical* or *nervous aphonia* constitute another interesting class. In these cases we find, on examination, that the larynx appears in every respect quite normal, except that during attempts at speaking the glottis does not close: the patient whispers through a widely open glottis. It would appear that the power of closing the glottis is for the time lost. There is no stridor during deep inspiration, for the open glottis does not resist the entrance of the air. These patients not only cannot speak, but they cannot cough or "hem;" for all of these acts require that the glottis should first be closed. Another interesting feature of these cases is the suddenness with which the voice often returns, and often, too, is again lost, to the disappointment of the practitioner, who is disposed to boast of having effected a permanent cure.

There is yet another class of cases—cases of the so-called *clergyman's sore-throat*, or *dysphonia clericorum*. These are not all of the same character. In

* At the present time (Nov. 1864) I have a phthisical patient at the hospital, with a linear ulcer extending the whole length of the true cord on the right side.

some there is permanent hoarseness or thickness of voice. In these we usually find redness and thickening of the mucous membrane, which may be general or partial. In one case which I have lately seen the right vocal cord is of a dull red colour, and its surface is roughened. In other cases there is no hoarseness or dysphonia, except after a sustained effort of speaking; then there is a sense of fatigue and uneasiness in the throat, which may be so great as to render a continuance of the effort impossible, and the speaker breaks down in the middle of his discourse.

In cases of this kind we commonly find only a slight increase of vascularity and redness in the mucous membrane of the larynx. This evidently does not account for the phenomena of the disease; to explain which we must look below the surface which is reflected in the mirror. On inquiry into the early history of the disease, we frequently find that it began with an attack of inflammatory sore-throat and hoarseness; and we learn that, either from heedlessness or from necessity, the patient continued his preaching and reading—in short, he continued to exercise an inflamed and suffering organ. After a time the hoarseness passed away; but the painful sense of fatigue with long speaking remained. The probable explanation is, that the nutrition of the laryngeal muscles has become impaired through the extension of a morbid action from the inflamed mucous membrane. Such extension of disease is very likely to be provoked by much exercise of the voice when the lining membrane of the larynx is in a state of in-

flammation. And the practical inference from this doctrine is obvious: that an inflamed larynx, like an inflamed joint, should be left as much as possible at rest.

We have something analogous to what I have here described as happening to the laryngeal muscles in the impaired nutrition and loss of tone of the muscular fibres of the intestine, consequent on inflammation of either the serous or the mucous coat.

A French physician, Dr. Fauvel, has recently published a pamphlet entitled "Aphonie Albuminurique." The author states that aphonia from œdema of the larynx is a common result of Bright's disease of the kidney, and he speaks of it as occurring frequently without any other sign to excite a suspicion of the renal disease. It appears to me that Dr. Fauvel has considerably over-estimated the frequency and the importance of œdema of the larynx as a result of Bright's disease. In this country it is one of the rarest of the many complications of that malady. Some months since a woman under my care at the hospital with general dropsy, from chronic Bright's disease, had hoarseness and great dyspnœa. It was a point of some practical importance to ascertain whether the dyspnœa was a result of obstruction in the larynx. The laryngoscope showed sufficient œdema of the false cords to cause the hoarseness, but certainly not enough to obstruct the breathing. The dyspnœa was a result of pulmonary engorgement and œdema, and therefore would not have been relieved by tracheotomy.

In several of the cases to which I have referred it

will have been seen that the information which the laryngoscope afforded as to the precise morbid condition of the larynx was of great value in indicating the appropriate plan of treatment. Now, this is a point upon which I feel bound to insist very emphatically: namely, that the treatment of laryngeal disease has by the aid of the laryngoscope been placed upon an entirely new basis—the solid basis of an exact diagnosis. How often in past times has the treatment for laryngitis been applied when the laryngeal affection has been of a purely spasmodic character!—and how much more frequently when the symptoms of a supposed laryngitis were the result of a warty, or cancerous, or other tumour in the larynx!

Shortly before I had learned to use the laryngoscope, I was attending, with Mr. Christopher Heath, a lady about fifty years of age who had suffered for several weeks from symptoms of laryngeal disease—hoarseness, cough, noisy and laborious inspiration. For several days we treated the case as one of laryngitis. Day by day the dyspnœa became more urgent, and at length tracheotomy was performed. She continued to breathe through the tube until her death, which occurred five months afterwards. The disease was cancerous: a cancerous tumour completely filled up the glottis. We should have seen this easily enough with the laryngoscope. And having seen it, we should have given fewer drugs, and we should have been spared much painful doubt and perplexity as to the necessity for tracheotomy.

The effect of a misapplication of antiphlogistic remedies in cases of this kind is not only mischievous

to each individual patient who is the subject of the erroneous treatment, but the practitioner's confidence in himself and in his remedies must of necessity be lessened by witnessing their repeated want of success. I suppose it to be very generally admitted that the most certain plan for cutting short an attack of acute catarrhal laryngitis—laryngitis, *i. e.*, from exposure to cold, and not the result of any specific poison or of a constitutional diathesis—the most certain plan, both in adults and in children, consists in the administration of nauseating doses of ipecacuanha or antimony, with hot baths and the inhalation of steam; the object being to *sweat* both the skin and mucous membrane, and so to lessen the inflammatory congestion and swelling within the larynx. These remedies, directed against a wart, or a cancerous tumour, or the cicatrix of a syphilitic ulcer, will fail to do good; and if the error of diagnosis be not discovered, to some extent our confidence in the plan of treatment for acute laryngitis must be lessened.

One good result of the use of the laryngoscope will be, that henceforth fewer drugs will be consumed in cases of laryngeal disease, and those which are given will be administered with a more definite object and with a truer aim than heretofore. This in itself would be no slight gain; but the laryngoscope does more than this: it opens the way to methods of local treatment which, without its aid, would have been impossible and inconceivable.

Perhaps the greatest triumph of treatment by the aid of the laryngoscope has been the removal of tumours, polypi, and warty growths from the interior

of the larynx. This feat has been accomplished now in numerous cases, and with the most satisfactory results. On the table are a variety of instruments that have been used by different operators; amongst others, Dr. Mackenzie's forceps, made by Kröhne, and Dr. Gibb's écraseur, by Weiss. The one seems better adapted to remove warty growths; the other, pedunculated tumours. Dr. Walker, of Peterborough, was the first who in this country succeeded in removing a tumour from the larynx by means of a wire.* In all operations for the removal of tumours the instrument is guided to the exact site of the tumour by the aid of the laryngeal mirror, which is held in the left hand of the operator.

In some cases of inflammatory swelling and œdema of the interior of the larynx, *scarification* is of great service.

I have already mentioned one case in which puncturing the mucous membrane rapidly reduced an œdematous swelling over the arytenoid cartilages. Here is a very convenient scarificator made under the direction of Dr. Morell Mackenzie by Messrs. Kröhne. It will be seen that the point of the instrument is guarded by a metallic tube until it is pushed out by a lever.

One of the most splendid illustrations of the good which may result from scarification of the larynx was afforded by a case which Mr. Durham lately communicated to the Royal Medical and Chirurgical Society.†

* The *Lancet*, vol. ii. 1861, p. 444. † Ibid. vol. ii. 1863, p. 593.

A boy, eleven years of age, was admitted into Guy's Hospital, under the care of Dr. Wilks, on June 10th, 1863. He had for three years suffered from gradually-increasing impairment of voice, and difficulty of breathing and swallowing. On admission all the symptoms were very severe. During the night of the 14th he was seized, as he had previously been on several occasions, while asleep, with a very severe attack of dyspnœa. Tracheotomy was on the point of being performed, but was delayed by the desire of Dr. Wilks, and on the following morning Mr. Durham was requested to make a laryngoscopical examination. On doing so, the epiglottis could not be distinguished in its normal form, but instead there appeared a large round tense tumour, projecting backwards and downwards, and completely covering in and concealing the glottis. The tumour could be just reached by the finger. Feeling certain that it contained fluid, Mr. Durham, with the concurrence of Dr. Wilks, incised it with a long, curved, sharp-pointed bistoury, covered except at its point with sticking-plaster. The incision was followed by a sudden gush of thick, glairy mucus, mixed with a little pus and blood. All the patient's symptoms were at once relieved, and in the evening he was singing in his bed. In the course of a few days he was perfectly well. When examined four months afterwards, he was in every respect well. There was no appearance of the cyst, but the cicatrix of the incision was just visible on the lower part of the laryngeal aspect of the epiglottis.

In many cases of laryngeal disease the application of *caustics* and *astringents* is very beneficial. There

are various modes of applying these remedies. The safest and most convenient mode of applying solid caustic—to a syphilitic ulcer for instance—is that employed by Dr. Mackenzie. An aluminium wire, bent at a proper angle, has its end covered with a small bulb of nitrate of silver by being repeatedly dipped into the fused salt. A solution of nitrate of silver may be injected by a laryngeal syringe with a finely perforated nozzle, such as is used by Dr. Gibb, and made by Messrs. Weiss. I have frequently used this syringe, but I find that this fine shower of a solution of nitrate of silver causes much more spasm and distress than the application of the same solution by means of a brush fixed on a bent whalebone or on a bent wire.

Glycerine is a very convenient and useful vehicle for various local applications to the larynx. It is an excellent solvent for tannic acid. Tannic acid may be dissolved in glycerine in the proportion of two drachms to an ounce. This is a very useful topical astringent. Glycerine will also, by the aid of heat, dissolve as much as one-fifth of its weight of hydrochlorate of morphia. We seldom require so strong a solution as this, but a moderately strong solution of morphia in glycerine is a most useful soothing application in cases of irritable larynx. Glycerine, as a vehicle for other remedies, has this advantage, that being viscid, it adheres to the surface of the mucous membrane, and retains there the astringent or the sedative which it holds in solution. On this account it may very usefully be mixed with a solution of nitrate of silver. A mixture of glycerine with a solution of perchloride of iron is a

useful topical astringent. Glycerine may also be made the vehicle for *alum*. Whenever glycerine is applied to the larynx, it must be done by means of a brush; it is too thick a liquid to pass through a syringe.

Amongst local applications to the larynx, I may mention that Dr. Mackenzie has successfully applied *electricity* in some cases of nervous aphonia. By means of a simple instrument, one pole of a magneto-electric machine is applied to the interior of the larynx, the other to the skin of the neck outside. The sudden shock excites a spasm of the laryngeal muscles, and this often restores the voice. A strong solution of caustic applied to the larynx has sometimes had the same effect. And in other cases of this kind a sudden and violent mental emotion, whether joyous or painful, has immediately brought back the voice.

Since this Lecture was delivered, I have applied electricity with great success in one case of nervous aphonia. In May last a young gentleman, aged 17, was sent to me by Dr. Dixey of Baldock. The patient had been unable to speak above a whisper since the beginning of the year. There was no cough, no dyspnoea, no stridor in breathing. The laryngoscope showed a healthy larynx, but the glottis did not close when he attempted to vocalize. On the 25th of May, and again on the 30th, I applied a solution of nitrate of silver in the proportion of ʒj to ʒj, without effecting any improvement in the voice. On the 6th June, with the assistance of Dr. Dixey, I applied electricity by means of Dr. Mackenzie's instrument. The natural voice was restored at once, and he has retained it to the present time.

Having said thus much of the local remedies for laryngeal diseases, and having shown, as I trust, that I am not disposed to undervalue them, I yet feel it a duty to remark upon the possibility that the larynx may get too much of local treatment. The laryngoscope has brought this organ so completely within our reach, that we are all exposed to the temptation of being too meddlesome. We may be too apt to forget that a structural disease, strictly limited to the larynx, may yet be constitutional in its origin, and require a plan of treatment based upon the recognition of that fact. If we can avoid the error to which I have here alluded, the introduction of the laryngoscope will be an unmixed good both to ourselves and to our patients, and it will soon be acknowledged to be one of the most valuable additions that have ever been made to our means of diagnosis and treatment.