

**Eye-ball-tension : its effects on the sight and its treatment / by W. Spencer Watson.**

**Contributors**

Watson, Sir William Spencer, 1836-1906.  
Royal College of Surgeons of England

**Publication/Creation**

London : H.K. Lewis, 1879.

**Persistent URL**

<https://wellcomecollection.org/works/eesdh3mc>

**Provider**

Royal College of Surgeons

**License and attribution**

This material has been provided by This material has been provided by The Royal College of Surgeons of England. The original may be consulted at The Royal College of Surgeons of England. where the originals may be consulted. This work has been identified as being free of known restrictions under copyright law, including all related and neighbouring rights and is being made available under the Creative Commons, Public Domain Mark.

You can copy, modify, distribute and perform the work, even for commercial purposes, without asking permission.



Wellcome Collection  
183 Euston Road  
London NW1 2BE UK  
T +44 (0)20 7611 8722  
E [library@wellcomecollection.org](mailto:library@wellcomecollection.org)  
<https://wellcomecollection.org>

7113 11/18 34

EYEBALL-TENSION.

LONDON :

PRINTED BY H. K. LEWIS, 136 GOWER STREET, W.C.

1879.

293

# EYEBALL-TENSION

ITS

## EFFECTS ON THE SIGHT

AND ITS

## TREATMENT

BY

W. SPENCER WATSON, F.R.C.S. ENG.


B.M. LOND.

SENIOR SURGEON TO THE ROYAL SOUTH LONDON OPHTHALMIC HOSPITAL  
CONSULTING OPHTHALMIC SURGEON TO THE SOUTH LONDON  
MEDICAL AID INSTITUTE, ETC.; FORMERLY ASSISTANT-  
SURGEON TO KING'S COLLEGE HOSPITAL.

PRINTED

AUTHOR.


WITH WOODCUTS AND ILLUSTRATIVE CASES.



LONDON

H. K. LEWIS, 136 GOWER STREET

1879.



## P R E F A C E .

---

INTENDING my little book to be mainly devoted to the *Treatment of Eyeball-tension*, I have only briefly alluded to the theories of its causation. A full consideration of all the theories would have occupied too much space and would but have presented to my readers "the husks of contending opinions." I have therefore contented myself with giving a bare statement, unsupported by detailed evidence, of the theory which appears to me to be most satisfactory and most in accordance with the clinical and pathological data we at present possess. This must be my excuse for a somewhat dogmatic style in my first chapter. I trust that the third chapter will be considered by my readers in the light of a supplement to it, and that the *analysis* of the cases may be regarded as a test of the soundness of the views advanced under the head of *definitions* and *theories*. Under the head of *Treatment* I have in the main followed the teachings deduced from the facts that have come under my own immediate observation. These teachings and deductions may be considered by

some untrustworthy or imperfect. Such as they are, however, I lay them before the medical profession with a conviction that they will be fairly but not harshly judged. I have adopted the term *Eye-ball-tension* in preference to *Glaucoma*, as being more expressive of the acknowledged condition of the eye in the disease in question, and as being less liable to the imputation of mysteriousness and vagueness; as being in fact an appropriate English and not an irrelevant Greek term. Still the long-continued use of the word *Glaucoma* has given it a respectability, and I have therefore retained it in many places, especially where the passage involved allusion to authors who have been accustomed to use it in their works. I hardly expect that my humble protest against the word will have much effect in driving it out of use, but I am inclined to think that its days are numbered, and that it will in time pass into the same gulf of oblivion into which 'amaurosis,' 'hebetudo visûs,' 'amblyopia' and similar terms are gradually falling, to the great relief of students and practitioners.

7 Henrietta Street,

Cavendish Square,

July, 1879.

# CONTENTS.



|   | PAGE |
|---|------|
| CHAPTER I.  |      |
| DEFINITIONS AND THEORIES . . . . .  | I    |
| CHAPTER II.   |      |
| THE TREATMENT OF EYEBALL-TENSION . . . . .  | 9    |
| CHAPTER III.  |      |
| AN ANALYSIS OF THE CAUSES OF EYEBALL-TENSION<br>IN TABLES I. II. AND III., IN APPENDIX A. . . . . | 34   |
| APPENDIX A—TABULATED CASES . . . . .  | 41   |
| APPENDIX B—DETAILED CASES.  |      |
| CASES, ILLUSTRATING THE EFFECTS OF IRIDEC-<br>TOMY . . . . .                                      | 56   |
| CASES ILLUSTRATING THE EFFECTS OF SCLERO-<br>TOMY . . . . .                                       | 58   |
| CASES ILLUSTRATING THE EFFECTS OF ESERINE   | 65   |
| CASES OF ACUTE EYEBALL-TENSION BROUGHT ON<br>BY MENTAL EMOTION . . . . .                          | 66   |



## APPENDIX B—DETAILED CASES.

|  |    |
|--|----|
| A CASE OF KERATITIS WITH PUNCTIFORM DE-<br>POSITS IN WHICH T WAS NOTED . . . . .   | 68 |
| A CASE OF TRAUMATIC OPHTHALMITIS WITH<br>EYEBALL-TENSION IN WHICH DR. ARGYLL<br>ROBERTSON'S OPERATION OF TREPHINING THE<br>SCLEROTIC WAS PERFORMED . . . . . | 69 |

# EYEBALL-TENSION.

---

---

## CHAPTER I.

### DEFINITIONS AND THEORIES.

*Eye-ball-tension*, technically called *glaucoma*\* is a group of symptoms of which the prominent and essential one is perceptible hardness of the eyeball. It is accompanied by a progressive centripetal contraction of the "field" of vision, by impairment of the "acuteness" of vision, by the subjective perception of coloured haloes, by pain in the regions adjacent to the eye, and by the following physical and ophthalmoscopic signs; viz., shallowness of the anterior chamber, haziness of the dioptric media, and sometimes a visible excavation of the optic nerve, and visible pulsation of the retinal bloodvessels on the optic disc.

*Eye-ball-tension* may be (a) *Primary*, i.e., dependent upon idiopathic intraocular nutritional changes, or upon constitutional nervo-vascular disturbance; or it may be (b) *Consecutive*, i.e., the result of organic changes in the structures of the eyeball, due to precedent disease or injury.

\* The word *glaucoma* etymologically alludes to a mere accident of the affection.

Whether *Primary* or *Consecutive* it may assume the form of (1) Simple or Chronic (2) Acute, or (3) Fulminating glaucoma. *Simple* or *chronic* glaucoma is characterised by a long prodromal stage, by the absence of severe pain, by very slight turbidity of the media, and as a general rule marked excavation of the optic nerve:—*Acute* glaucoma by severe pain, great congestion of the eyeball and turbidity of the media, and by its comparatively rapid course:—while in *fulminating* glaucoma, all the stages seem to be merged in one, and loss of vision, with severe pain and sudden intense hardness of the eyeball, is the work of a few hours.

*Absolute* glaucoma is a term applied to cases in which there is permanent tension and total loss of vision as the result of precedent glaucoma in one or other of its forms.

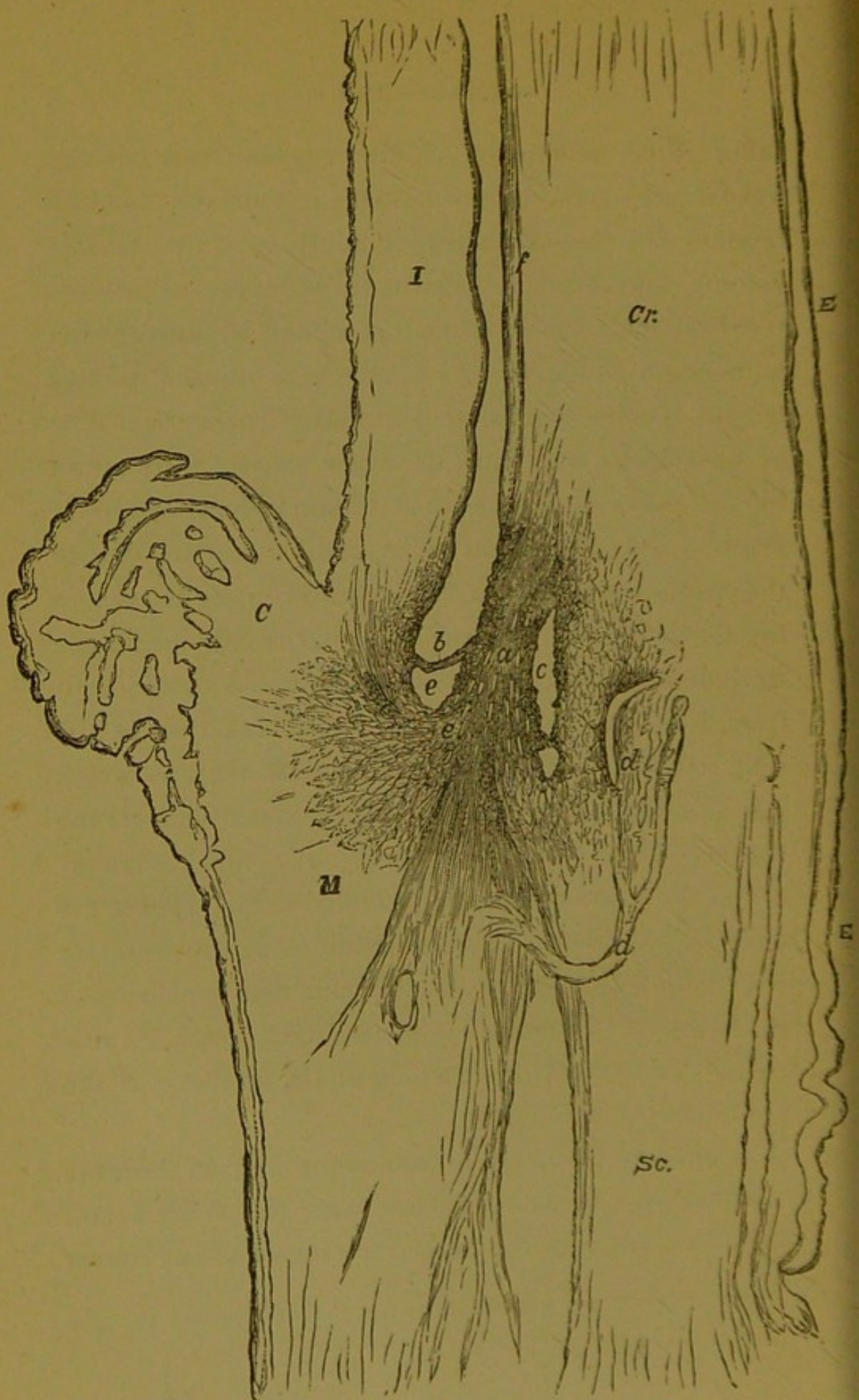
The *Theories* to account for the hardness of the eye in eyeball-tension are numerous, and have been classified as (1) The theory of Inflammation, (2) The Neuropathic, and (3) The Mechanical Theory. I am in favour of a *modified mechanical theory*. An abnormal rigidity of the sclerotic is, according to my view, a predisposing cause of the disease rather than its actual basis, and the loss of distensibility of the lamina cribrosa is also an important factor in the actual outbreak of the acute, and in the continuance of the chronic form of the affection. If the contents of the

eyeball are increased in volume from any cause, in the absence of the regulative influence of the healthy sclerotic and lamina cribrosa, tension of the globe-capsule is inevitable. The causes of increased volume of the contents I hold to be (1) either hypersecretion of vitreous fluid, or (2) obstruction to the outlets whether of the venous or lymphatic channels. The hypersecretion may have its origin in nerve-irritation in some cases, or it may be of inflammatory origin in others. The obstruction to the outlets may be due to sudden engorgement of the veins such as occurs in sudden emotional excitement,\* to violent spasmodic cough such as occurs in fits of asthma, or to the suppression of menstruation, or to the cessation of the same function. The same change of texture which produces rigidity of the sclerotic generally affects the region of Schlemms' canal (see fig. 1, *c*) and the trabecular tissue surrounding it (see fig. 1, *a*). Hence the obstruction to the passage of fluids from the anterior chamber through the lymphatic channels which open into it through Fontana's spaces (see fig. 1, *b. c.*) and convey fluid towards the surface of the sclerotic at the corneo-scleral junction.

The venous plexuses in the same region become engorged by the same causes, and the venous and lymphatic outlets in the posterior pole of the eye must

\* The instances are quoted in the Appendix (Appendix B, cases ix, x, xi).

FIG. I.



*a.* Trabecular tissue.—*b.* Continuation of Iris forwards.—*c.* Canal of Schlemm.—*d. d.* Bloodvessels.—*e.* Fontana's spaces.—*f.* The membrane of Descemet.—*I.* Iris.—*C.* Ciliary body.—*M.* Ciliary muscle.—*Cr.* Cornea.—*Sc.* Sclerotic.—*E. E.* Epithelium. (After De Wecker).

suffer in the same way. If there is, as Gräfe has suggested, atheroma of the vessels, it must increase the tendency to venous obstruction. Iridectomy and sclerotomy, and similar operations, relieve the tension in the first instance by allowing a drain of the aqueous humor and an emptying of the ciliary veins. On cicatrization being completed, there is a permanent drain of fluid in the case of iridectomy both from the opening a passage between the anterior and posterior chambers, and a facility for transfusion of fluids from the vitreous into the aqueous, and through the trabecular tissue and lymphatic channels of the sclerotic at its junction with the cornea (see fig. 1.); and also from the anastomosing veins and capillaries, in the scar-tissue, which become united with the superficial sclerotic and conjunctival vessels. But chiefly through the scar-tissue itself, which is membranous in form and of much looser texture than the original sclerotic, an easy escape is provided for fluids in the aqueous and vitreous chambers. Sclerotomy is often followed by the formation of a similar cicatrix, (the filtrating cicatrix of De Wecker), and offers almost the same facilities for the escape of intra-ocular fluids as the scar after iridectomy. (See Case xii. in Appendix B.)

All the other phenomena of the disease are capable of explanation by reference to intra-ocular pressure. The ultimate results of the pressure must depend, 1st on its amount; 2nd on its duration; 3rd on the re-

sistance offered to it by the tissues pressed upon. A very high degree of pressure on the optic nerve-fibres, and retina, if met by a resisting lamina cribrosa and very rigid sclerotic, will be destructive of vision in a very short time. A very prolonged pressure of less intensity with a gradual yielding of the lamina may take years to produce the same effect; while if the lamina be very lax and yielding, moderate pressure even may be sufficient to cause a deep excavation and extensive stretching of the nerve fibres on the brink of the cup, and a consequently serious and rapid impairment of vision. Intermissions, however, may occur in the two latter conditions, and the time may therefore be indefinitely prolonged before permanent impairment of vision is consummated.

While my theory is thus chiefly mechanical and partly neuropathic, I do not altogether exclude the possible influence of inflammation in certain cases. Many cases of eyeball-tension are really consecutive to irido-choroiditis of rheumatic, or gouty, or syphilitic origin; with synechiæ so slight as to have been overlooked. Others are the sequelæ of serous iritis, or the so-called aquo-capsulitis with punctiform deposits on the cornea.\* Sclero-choroiditis is a prelude to others, most often in connection with rapidly progressive myopia and posterior staphyloma. In all these cases the precedent inflammation may be easily

\* See Case xiii. in Appendix B

over-looked, and the cases consequently regarded as instances of idiopathic glaucoma. But in spite of the great authority of Gräfe and Stellwag, who evidently regard acute glaucoma as an inflammatory disease, I cannot but think that there is such an affection as idiopathic, *i.e.*, non-consecutive acute glaucoma without true inflammation. On the other hand, the neuro-pathic theory taken by itself, without reference to the previous tissue-changes in the sclerotic, the ciliary body and the lamina cribrosa, does not account for the premonitory stages, nor for the persistence of the intra-ocular pressure when it is once excited, nor for the results of operative treatment. The gradual increase of presbyopia, the gradual contraction of the field of vision, and the occasional obscurations are conceivable as the slowly developed results of progressive tissue-change, but not as the effects of nerve irritation. The persistence of the intra-ocular pressure before the relief given by operative treatment, is also more consistent with the idea of a supposed obstruction than with that of any nerve-lesion of which we have any experience. Lastly, operative treatment for glaucoma is much more uniformly successful than we should expect if it is to be regarded as a neurotomy.

A plausible and attractive argument in favour of the nervous origin of glaucoma is the suddenness and explosive character of the attack of acute glaucoma.



But, setting aside the fact that in simple glaucoma there is no such sudden outbreak, the same argument would apply with equal force to an attack of gout, the phenomena of which are fully explained without reference to a supposed nervous explosion. In the case of the eyeball as in that of the podagrous foot or toe, there is for a time a steady accumulation of fluids within the fibrous capsules enveloping the nervous structures involved: at length the margin of physiological variation of pressure is overstepped, the climax is reached, secretion and absorption no longer counterbalance each other, and a fit of the gout in one case and of glaucoma in the other is the result.

## CHAPTER II.

### THE TREATMENT OF EYEBALL-TENSION.

THE history of the rational treatment of glaucoma dates back to the time of Mackenzie and Middlemore (about 1830) who are said to have performed paracentesis of the sclerotic, and used instillations of belladonna for glaucoma. No details, however, are known as to the success or failure of their plans of treatment, and with the exception of the Wenzels (father and son), who performed extraction of the lens for the treatment of glaucoma, no one attempted anything till the time of the discoverer of the powers of iridectomy in this disease. Von Gräfe published his results of this operation in 1857. He had already noticed its good effects in the treatment of staphyloma of the cornea, and in different forms of irido-choroiditis, but without being fully alive to the curative power of the remedy as relieving tension of the globe. Nevertheless, he was aware even then that iridectomy performed on relatively sound eyes (*e.g.* eyes affected with leucoma) left them softer to the touch than before the operation. He had also observed in experiments on the eyes of healthy animals that the tension was reduced by the excision of a piece of iris. He proved this, not only by the sense of touch, but by ob-

servations of the rise of fluid into an Anel's syringe the canula of which was carefully introduced into the anterior chamber. (*New Sydenham Society's Selected Monographs*, 1859, page 311). Under these circumstances the whole of the aqueous did not ascend through the action of intra-ocular pressure, as is usually the case, but only a part of it. In cases of abscess and ulcers of the cornea he had found iridectomy very beneficial, and small staphylomata disappeared rapidly after it had been performed. He was therefore led by induction to try the operation in acute glaucoma, the effect being to restore the transparency of the media, to reduce tension, to remove the inflammatory appearances and to restore vision. These good results, however, were obtained only if the operation was performed within a fortnight or thereabouts of the outset of the disease. When performed at a later period, especially if the papilla had become excavated and the field of vision much contracted, the operation did not effect so much. In his second essay (1858) von Gräfe announced his further experience of the beneficial effects of iridectomy, this time in a series of cases of chronic glaucoma, or, as he called it, chronic inflammatory glaucoma, and showed that in these cases the operation was followed not only by an immediate arrest of the malady, but also by a steady progressive diminution of the shrinking of the field of vision and of

the excavation of the optic nerve. In his last essay (1862) he insisted on the advantages of iridectomy in chronic simple glaucoma. Two points were, he affirmed, very important in the operation; 1st, to include a large piece of iris in the section; 2nd, to excise this membrane close up to its ciliary attachments. For this purpose the sclerotic incision must be made at a distance of one or one and a half millimeters from the corneal margin, and it must have a width of at least six or eight millimeters, so that the internal aperture of the incision, which should be just in the circumference of the cornea may be six millimeters long. (*Archiv. f. Ophth.*, t. viii., b. 2, p. 252).

In order to remove a sufficiently large piece of iris two methods may be employed, according to the depth of the anterior chamber. If this is tolerably deep Gräfe's lancet-shaped knife bent at an angle may be used. Having chosen the point at which the incision into the sclerotic is to be made, the conjunctiva of the opposite side of the globe is seized and held firmly in position by the fixing forceps. The point of the knife is then thrust into the anterior chamber at its extreme margin, with the blade parallel to the plane of the iris from the first; it is thrust onwards in this direction until the wound is sufficiently wide, but if necessary the incision is enlarged by the sides of the blade as it is withdrawn. The wound should generally be co-extensive with about one-sixth ( $\frac{1}{6}$ ) or

one-fifth of the circumference of the cornea. When the anterior chamber is very shallow, it is better to use a very narrow cataract knife and to make a section of the corneo-sclerotic junction by means of a puncture and counter-puncture, as in cataract extraction, and to allow the knife to skirt only the extreme outer limits of the anterior chamber. This second method (Mr. Bowman's see *Brit. Med. Journal*, Oct. 11th, 1862) is specially designed to avoid the possibility of wounding the lens-capsule, which, when the anterior chamber is very shallow, (see fig. 2), approaches close to the posterior surface of the cornea and is therefore scarcely avoidable if the lancet-shaped knife is used. Whichever method is adopted the knife should be withdrawn very slowly from the wound, in order to allow of a very gradual escape of aqueous, and to prevent a too sudden diminution of intra-ocular pressure. Rupture of the choroidal or retinal vessels may occur if the pressure to which they have been subjected is too suddenly withdrawn, and there is also danger that the lens-capsule may be ruptured by being suddenly brought with violence against the posterior surface of the cornea. Should this occur, a subsequent cataract is almost inevitable. In order to favor a gradual escape of the aqueous, von Gräfe advised iridectomy to be made downwards, there being less strain upon the eye capsule during the performance of the operation in this than in the upward

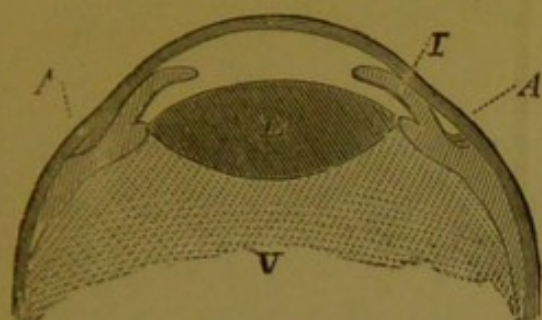


Fig. 2

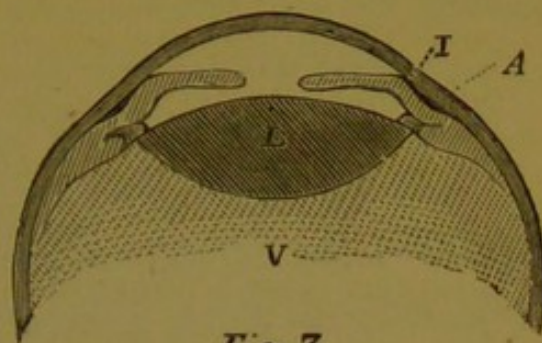


Fig. 3.

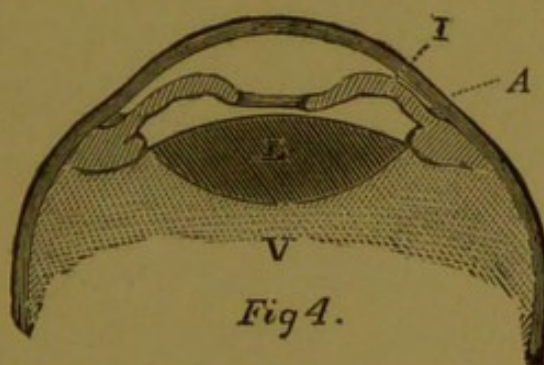


Fig 4.

FIG. 2. An imaginary section of an eyeball affected with glaucomatous tension, showing the crystalline (L) and the iris (I) thrust forward so as to diminish the antero-posterior depth of the anterior chamber, and to produce pressure on (A) the iridian angle and the adjacent ciliary region. V. the vitreous humor. FIG. 3. A section of the same parts in an eyeball in which the iris is adherent to the cornea towards the iridian angle (A) and so shuts off this angle from the anterior chamber. This sometimes occurs in *consecutive eyeball-tension*. The letters in figs. 3 and 4 refer to the same parts as in fig. 2. FIG. 4. A section to show the relative position of the parts, when the pupillary margin of the iris is occluded by organised membrane, and the anterior chamber is thus cut off from the posterior or vitreous chamber. The accumulated fluid behind the iris gives rise to a convexity of this membrane anteriorly (*iris bombé*) and to pressure on the ciliary region and the iridian angle (A).

operation. The disfigurement, however, is much more perceptible if the lower part of the iris be excised,

while the gap left by an upward-iridectomy is scarcely visible in ordinary positions of the eyelids.

The *time* for operating cannot be too soon after the outbreak of an acute attack. If, however, from any cause delay is unavoidable, morphia by hypodermic injection or by inunction\* on the brow and temple gives temporary relief, and bromide of potassium in 20 gr. doses calms the excitability of nervous patients. Dr. Schweigger speaks highly of the instillation of a 1 per cent. solution of sulphate of eserine where there is an avoidable postponement of the operation.† De Wecker uses eserine invariably as a preliminary to sclerotomy or iridectomy, and also for several days after these operations. I have now adopted this plan of treatment also, with the best results. (See Cases xiii and xiv in Appendix B.)

In chronic glaucoma, though there is generally much less urgency as regards immediate operation, there is always some danger in delay, not only because the continuance of pressure on the nerve and retina endangers their integrity, but because an acute attack may at any time be engrafted on the chronic affection, and the vision may be suddenly and irretrievably lost in a few days or hours. Eserine is very valuable in chronic cases.

\* I sometimes prescribe the following ointment:—One ounce of vaseline, 4 to 8 grains of Acetate of Morphia, 12 minims of Dilute Acetic Acid, and 30 minims of glycerine.

† See *Therapeutique Oculaire*, p. 385.

There is sometimes a question of operating in the *premonitory stage*, when the first eye has either been lost by glaucoma or saved by an operation. Under these circumstances the patient recognises the prodromal symptoms at an early stage in the second eye, and may very possibly suggest an early operation, but if not, the Surgeon should certainly propose it as soon as there are decided intermittent obscurations, ciliary neurosis and chromopsiæ, even though vision may be perfectly good during the intervals. Von Gräfe in 1858 used the words (*Archiv f. Ophthalm.* B iv., Abth. 2, S. 127), "I cannot too strongly recommend the operation in the premonitory stage when the other eye has become blind from the same affection." He proceeds to state that he had operated 10 or 12 times under these circumstances with very good results.

Another question, however, arises in reference to chronic as well as acute cases. How long after glaucoma has been going on is an operation justifiable? The answer must depend mainly on the amount of vision remaining. If vision is so nearly lost as to scarcely amount to perception of light, is there any prospect of restoring it by an operation? To this I answer in the affirmative without the least hesitation. Several of the cases in Tables I. and II. were in this condition, and in several the results were very good. In acute glaucoma there is every prospect of restoring vision by an operation even if no perception of light



can be detected, provided not more than 2 or 3 days have elapsed since the onset of the acute symptoms. In chronic glaucoma, however, if there is no perception of light, there is every probability that the optic nerve has become deeply excavated and atrophied by a very long continuance of pressure. Hence in any case of chronic glaucoma with an equal amount of vision, the prognosis is less favourable than in an acute case. In acute cases the smoky cloudiness of the media has a considerable share in the deterioration of visual acuteness, and the improvement of vision after iridectomy or sclerotomy is in great measure due to the clearing off of this turbidity. In chronic cases on the other hand, the relief of tension is the chief cause of the expected improvement, and therefore, if there is a permanent loss of function of the optic nerve referable to pressure, irremediable blindness is the result. The latest period after loss of perception of light at which iridectomy has been successful, is recorded by Mr. Bowman, who operated 35 days after the total loss of perception, with the effect of giving the patient the power of reading No. 8 of Jäger's test-types. Dr. Heymann (*Klin. Monatsbl.*, t. v., p. 148), cites a case of recovery of sight by iridectomy, 4 weeks after blindness had become absolute. Such facts as these are very encouraging, but must be taken as quite exceptional, and cannot therefore be looked upon as precedents or as a justification of delay in operating.

Sometimes it is necessary to operate even when there is no hope of restoring vision, simply for the purpose of relieving neuralgic pains dependent on extreme tension. Under these circumstances, unless there are very extensive synechiæ or an occluded or excluded pupil, I should prefer sclerotomy or Dr. Argyll Robertson's operation of trephining the sclerotic. An eye affected with absolute glaucoma is very liable to intra-ocular hæmorrhage, and this is less likely to occur during or after the performance of sclerotomy, or trephining than during or after iridectomy; but it is always better to prepare the patient for the possibility of enucleation being necessary under such circumstances; and if the pain is very severe and the second eye sound, but at all affected by symptoms indicating sympathetic irritation, enucleation should be proceeded with at once, without any tentative iridectomy or sclerotomy or trephining.

Several objections to iridectomy in the treatment of glaucoma have been brought forward. It is said that iridectomy performed on one eye hastens the access of the disease in the other. There is no question that the second eye has often been attacked a few days after iridectomy in the first, but it is not clear that a *sound* second eye has ever been thus attacked. The evidence seems rather to be in favour of there having always been some premonitory symptoms in the second eye, before the operation on the first. Still

it seems very probable that there is some foundation for the objection so far as regards acute glaucoma. There is no foundation for it as regards the chronic form of the disease. It is therefore well to warn a patient affected with acute glaucoma of one eye, that the second eye may be shortly affected in the same way as the first, and that a second operation may be required for its treatment sooner or later.

It has also been objected that iridectomy has caused cataract. The operation performed with care and skill is not fairly to be charged with this result. In cases in which the anterior chamber is very shallow the risk of wounding the capsule of the lens is very great, but is very much diminished by making the sclerotic incision by means of a narrow cataract knife as recommended and practised by Mr. Bowman. Cystoid cicatrices following the operation are alluded to by most authors as troublesome. If large, they are certainly apt to cause irritation, but I have never seen any serious inconvenience from them in my own practice. A compressing bandage applied soon after the operation will often prevent the further development of a threatening protrusion, but if that does not succeed, a portion of the prominence may be snipped off by means of a curved pair of iris scissors, or punctured with a cataract needle, and a compressing bandage then applied. A small but slightly prominent cystoid cicatrix should not be meddled with.

It is I believe a positive advantage in some cases, and gives a permanent drainage outlet by which any tendency to return of intra-ocular T is counter-acted.

Ophthalmic surgeons are not quite agreed as to the answer to be given to the question—Why does iridectomy reduce tension? That its *immediate effect* is due simply to the escape of the aqueous, is sufficiently proved by the facts first published by Gräfe as to the temporary relief of tension and of all the symptoms of glaucoma by a simple paracentesis of the anterior chamber. (*Archiv. f. Ophthalm.* Bd. i. Abth. 2). Gräfe found that in only 2 cases out of a number treated by paracentesis was there any permanent cure. The effects, however, were so uniformly good for a time that the immediate effects of iridectomy can be satisfactorily accounted for on the principle of its being a paracentesis. The *permanent* effects may be due in the early period after the operation to relief of the congestion of the blood-vessels by the abstraction of a certain quantity of blood from them, or as Gräfe would say, by the antiphlogistic effects of this abstraction of blood. At a later period some effect must be attributed to the diminution of the secreting surface, proportionate to the extent of iris removed; and still later the excess of fluid in the anterior chamber finds a more ready outlet through the channels opened in the cicatrix, and perhaps through the reopened venous

channels of the region of the corneo-sclerotic junction, and especially in Schlemm's canal. (See fig. 1, *c.*)

When there has been adhesion of the iris to the cornea at its outer margin, as in fig. 3, the effect of the iridectomy is to reopen the free passage of fluids between the vitreous and aqueous chambers, and consequently to allow of filtration from the former to the latter, and thence through the trabecular tissue and lymphatic channels of the iridian angle. (See fig. 1, *a, b, c.*)

It is also probable that the re-opening of Fontana's spaces (fig 1, *e,*) allows of infiltration of fluid through them after the excision of the margin of the iris which was previously obstructing them. In consecutive glaucoma with iritic adhesions, there is often an absolute exclusion of the pupil, and this tends to shut off the passage of fluids between the two chambers, and to prevent the infiltration of fluid from one to the other. (Fig. 4.) An iridectomy under these circumstances reopens the communication, and in this way tends to restoration of the balance between secretion and absorption in the vitreous chamber. The peculiar curved form of the plane of the iris (*iris bombé*) in these cases (fig. 4,) is an indication of the presence of pent-up fluid behind it:—the restoration of its normal plane after iridectomy, a proof that this fluid now finds vent through the gap in the membrane.

The operation of *paracentesis oculi* or puncture of the sclerotic is as old as Reverius (about 1679) who per-

formed it, but whether for glaucoma or not we are not informed (*Lancet*, Feb. 11, 1860. Lecture on Glaucoma by H. Hancock Esq.). It was suggested as a means of relieving tension in glaucoma by W. Mackenzie about 1835, and was performed by him and also by Middlesmore and Desmarres. This operation, however, fell into disuse and was entirely superseded by v. Gräfe's operation. Of late years, however, several substitutes for iridectomy have been proposed, viz., (1.) Hancock's operation of division of the ciliary muscle, (2.) Vose Solomon's intra-ocular myotomy (3.) Sub-conjunctival sclerotomy, which may claim as its originators Quaglino, Mauthner, and De Wecker, and has been very well received by a number of English as well as foreign oculists, and (4.) Dr. Argyll Robertson's operation of Trephining the sclerotic.

(1.) Hancock's operation consists in thrusting the point of a cataract knife into the lower and outer border of the cornea and the adjacent sclerotic; the point of the knife is passed obliquely from before backwards, and from above downwards, until the fibres of the sclerotic are divided to the extent of about  $\frac{1}{8}$  part of an inch. (See Hancock's Lecture in the *Lancet*, Feb. 11, 1860).

(2.) Mr. V. Solomon's operation of *intra-ocular myotomy* is thus described by him:—"Intra-ocular myotomy is performed by making an incision with a cataract knife, on a line parallel with one of the equators of

the eye through the corneo-sclerotic junction, pillars of the iris, and ciliary muscle."\*

(3.) *Sub-conjunctival Sclerotomy* may be performed at any part of the circumference of the cornea, but the upper margin is the part perhaps least liable to objections. A narrow Gräfe's cataract knife is made to penetrate the sclerotic at about one line from the apparent corneal margin, and carried across the anterior chamber at right angles to the vertical diameter of the cornea, at a level with its upper or lower sixth ( $\frac{1}{6}$ ). The knife skirting the extreme upper margin of the anterior chamber emerges at a point exactly opposite the point of entrance. The edge of the blade is then made to cut its way through the sclerotic (keeping the blade parallel with the plane of the iris), until it is visible through the super-jacent conjunctiva. This latter membrane is left undivided and the knife slowly withdrawn from the wound. After completing the section the iris sometimes prolapses into the wound, but it is more commonly drawn slightly upwards, leaving a distorted balloon-shaped or oval pupil, but

\* A fuller description of the operation appeared in the *Medical Times and Gazette* 1861. In that account it is quite clear that a *mere puncture* was intended. The Beer's knife was to be entered at the corneo-sclerotic union, and pushed through the pillars of the iris into the muscle which was to be divided to the extent of 2 or  $2\frac{1}{2}$  lines. I cannot but regard this plan as being somewhat hazardous, and much inferior to sub-conjunctival sclerotomy.

without actual prolapse. There is a free escape of aqueous humor and a good deal of bleeding. The blood, however, does not generally find its way into the anterior chamber, but flows out through the conjunctival punctures. During the operation it is a good precaution to apply the forefinger to the centre of the cornea during the escape of the aqueous, and to close the eyelids and apply pressure as quickly as possible by means of a firm wet compress and bandage. The compress should not be removed for several hours. These precautions are necessary on account of the danger of intra-ocular hæmorrhage, and apply therefore with still more force to iridectomy. In order to guard against restlessness after the operation, an opiate or some bromide of potassium is occasionally necessary, but in most cases the relief of pain is so great that sleep comes on spontaneously. During the next week a 4-grain solution of eserine sulphate is dropped into the eye twice or thrice daily.

In choosing between iridectomy and sclerotomy, the much larger experience of the former operation tells very much in its favour. I have been led to give the preference to the latter in many cases for the following reasons:—*a.* Iridectomy cannot well be performed in some cases of absolute glaucoma in which the iris is wasted, and in which, therefore, an attempt to seize a portion of it for excision endangers the lens-capsule or ligament.



*b.* Iridectomy cannot well be performed in nervous patients without an anæsthetic, and when an anæsthetic is inadmissible sclerotomy is more suitable, inasmuch as it shortens the operation and gives less pain to the patient.

*c.* In all cases of glaucoma with total loss of vision, in which the only object of the operation is to relieve pain, sclerotomy is preferable.

*d.* Sclerotomy is preferable in persons who have been affected with eczema or any similar eruption on the head or face. Any operation under these circumstances is likely to aggravate the eczematous tendency, and therefore the less severe operation is preferable when it is considered undesirable to risk any delay. Case No. 21, in Table I. affords an opportunity of comparing the results of the two operations on two eyes of the same patient,  $2\frac{1}{2}$  years after the date of treatment.\*

There are other conditions besides those enumerated under which sclerotomy might be preferable. For instance, with a very shallow anterior chamber the

\* M. de Wecker (*Therapeutique Oculaire*, p. 385, and *seq.*), though still in doubt as to whether sclerotomy may not be applicable as the operation for glaucoma under all circumstances, advises its adoption in preference to iridectomy whenever we have to deal with a case of *hæmorrhagic glaucoma*, in cases of *absolute glaucoma* in which there is always a danger of internal hæmorrhages, and in all cases in which there is extreme atrophy of the iris, and consequent danger of sub-luxation of the lens.

danger of wounding the lens-capsule would be much lessened, and as the wound is protected by the undivided conjunctiva, there is a somewhat slower escape of the aqueous after the withdrawal of the knife than in iridectomy, and on this account a less tendency to intra-ocular hæmorrhage. These, however, are opinions formed rather on theoretical grounds than on those of experience. Some surgeons on the other hand have met with sympathetic irritation of the second eye after sclerotomy on the first. I cannot but think that in such instances there is a possibility that the incision may have been carried too far into the ciliary region; for if sclerotomy be performed in the way above described the incision lies in precisely the same position as that of iridectomy. A somewhat unsightly and troublesome prolapse of the iris occurred in one of my cases, but with this exception I have met with no untoward results.

(4.) Dr. Argyll Robertson's operation of trephining the sclerotic has been very successful in his hands, and deserves I think a more extended trial in cases unsuited to iridectomy. It requires extreme delicacy of manipulation, and in Dr. Robertson's last modification must be especially difficult. He now removes only a disk of the sclerotic coat and leaves the choroid undivided. There is, however, no doubt that with great care and skill such as Dr. Robertson employs, this operation is feasible. I have succeeded in one in-

stance in removing a disk of sclerotic without dividing the choroid. The T which was extreme was only slightly reduced at the time of the operation, and on the third day was as high as before it (Case No. 7 in Table III.). In a more recent case (Case xiv in Appendix B.) the relief of tension and of the most threatening symptoms lasted for some weeks. The tension however reappeared about six weeks after the operation. Dr. Robertson's results have been exceedingly good thus far, and in one patient the cure has been permanent in a trephined eye. He believes that "the thin yielding tissue that replaces the disk of sclerotic removed will permit of ready transudation of fluid from the vitreous chamber, and this acts as a permanent means of keeping down the intra-ocular tension."

M. de Wecker sometimes employs a fine thread of gold wire as a seton or means of drainage from the the vitreous. He passes the wire either through the sclerotic near the margin of the cornea, or behind the ciliary body if the eye seems to be irritated by the presence of the wire in the former position. This is suggested as a plan of treatment for absolute glaucoma when enucleation is the more reasonable proceeding, but is objected to by the patient (*Therapeutique Oculaire*, p. 388).

A certain number of cases will occur in which none of the above described operations are admissible, or

in which they have failed from various causes. In some of these the eye will be not only tense and sightless, but may become painful. This is especially likely to be the case if the eyeball-tension is consecutive to an injury or to a long-continued ophthalmitis from any causes. *Enucleation* is in such cases urgently required, and if there is any sight left in the second eye, should not be delayed lest sympathetic irritation or inflammation should be set up in it, and the remaining sight be lost irrevocably.

In one instance (Case xiv in Appendix B.) I trephined the sclerotic in substitution for enucleation. Doubtless trephining is a temporising measure, but in cases in which the consent of the patient to the removal of the eye-ball cannot be obtained, it is a matter of great moment to be able to gain time, and especially if a tangible benefit can be relied upon as in the case related. An eyeball in which the tension is excessive is as a rule much more likely to be dangerous to its fellow than one in which the tension is normal. If by trephining the tension can always be relieved, as I believe it can, there is a good reason for preferring it to less certain measures in traumatic cases of ophthalmitis, especially when there has been somewhat prolonged iritis with matting together of the iris and ciliary processes. In such cases attempts at iridectomy almost always fail, and sclerotomy is hardly less likely to succeed. Hence in

Dr. Argyll Robertson's operation we have an alternative which when enucleation is declined, offers perhaps the best chance of averting the terrible calamity of sympathetic ophthalmia, and the inevitable blindness which it involves.

Von Gräfe did not resort to operative methods before giving *medical treatment* a fair trial. He tried antiphlogistics, diaphoretics, diuretics, purgatives and a mercurial course carried even to salivation. They proved useless in his hands as they had done in those of his predecessors. He then turned to mydriatics, but was more thoroughly disappointed than ever. Belladonna and atropine as local applications seem even to aggravate the symptoms, when they affect the pupil of a glaucomatous eye, though as a rule the extreme T seems to prevent absorption, and hence the result is generally negative. A recent instance (*Zehend. Klin. Monatsbl.*, 1876, xiv., p. 386,) seems to make it probable that an eye in which there is no glaucoma, may become glaucomatous from the effects of a single instillation of atropine employed to facilitate the examination of a cataract. The patient in this instance was 72 years of age. As evidence in exactly the opposite direction see case No. 1. in Table I., in which the instillation of atropine into an eye affected with glaucoma, caused or seemed to cause a temporary return of transparency to media which were before turbid. (*Oph. Hosp. Rep.*, vol. iv., p. 449).

My recent experiences enable me to confirm fully the observations of Drs. Schweigger and Laqueur, who speak positively of the power of sulphate of eserine to relieve *temporarily* all the symptoms of acute glaucoma and of the latter gentleman also who found it beneficial in simple glaucoma; I believe however, that no permanent results are obtainable by its use. Dr. Schweigger uses a 1 per cent. solution. (For Dr. Schweigger's opinion see *Sammlung Klin. Vortrage, Ueber Glaucom.*, No. 124). (See cases viii and xiii in Appendix B. and a note by the author in the *Med. Times and Gazette*, June 14, 1879, p. 644.

M. de Wecker has been very successful in the use of eserine *after* iridectomy and sclerotomy, and he believes that its good effects are very much aided by the administration of quinine internally at the same time. I can quite confirm his views on this point. In cases in which there are premonitory symptoms of glaucoma after an operation on the first for an acute attack, he also uses the same combination of eserine and quinine, the former as an instillation and the latter internally. But the most powerful action of eserine is that of preserving an eye from the threatened dangers of consecutive glaucoma. Perforation of the cornea whether spontaneous or traumatic should always be treated by instillations of eserine, more especially if there is a prolapse of the iris into the ulcerated aperture. It seemed also to be beneficial

in a case of keratitis with punctiform deposits, in which I employed it recently. (Case xiii in Appendix B). If, however, as sometimes happens, the eserine drops cause excessive conjunctival irritation and pain, the muriate of pilocarpine may be used as a collyrium instead, the solution being of 1 per cent. strength, (*Therapeutique Oculaire*, p. 387).

Pilocarpine, the active principle of jaborandi, has been administered hypodermically by Dr. Grandmont as a remedy for glaucoma (*Annales d'Oculistique*, Sept. Oct. 1878, p. 180). The general effect of this drug is to reduce the temperature of the body by about one degree very rapidly, the lowered temperature being maintained for several hours. Dr. Grandmont employs the nitrate in preference to the hydrochlorate. Whether this plan of treatment deserves any further consideration, time will prove, but the fact that the resources of medicine have hitherto failed to arrest the disease, and that there is strong evidence in favour of a mechanical theory of glaucoma being the true one, renders it probable that all internal remedies, and pilocarpine among them, will have but a transitory reputation, and that except as palliatives they will give place to surgical treatment.

Under the province of medicine, however, come the *preventive measures* that may be properly adopted during the premonitory stages. In these stages the patient should be directed to avoid all causes calcu-

lated to overstrain the eyes, such as reading, needle-work, or other similar occupations, and especially the use of the eyes with insufficient or badly-contrived means of artificial illumination. The eyes should also be protected against exposure to too strong light by the employment of tinted glasses, and against cold winds, dust, or acrid vapours. The bodily health should also be carefully attended to, and if there are any gouty or rheumatic tendencies, or any inclination to bronchitis, asthma, or emphysema, the patient should live in appropriate climates and use the means specially adapted to combat the unhealthy tendencies to which he is prone. If there are neuralgic pains and chromopsiæ, cold applications to the eyes and morphia inunctions to the brow and temple should be employed. At the same time great attention should be given to the state of the bowels, and occasional purgatives given if required; the saline purgatives being generally preferable. Mental causes of uneasiness are also to be avoided, and night-watching and sleeplessness especially guarded against. A liberal allowance of sleep, a plain but generous diet, moderate exercise in the open air with frequent intervals of repose, and the total abstinence from malt liquors and strong wines, are among the most important measures to be insured. During this more strictly medical treatment, the sight should be carefully tested from time to time and the field of vision measured. The tension also



must be watched, and should there be evidence of a retrograde tendency in these respects the question of an operation should be considered. The frequency of the obscurations, if any, should be noted and the intervals between them compared, and thus data will be stored up and a warning will be given in time, so that if at length an operation is decided upon, the patient may have been in some measure prepared for its possible necessity.

Some kind of *anæsthetic* is as a rule required, and the decision as to an immediate operation is very much facilitated if the patient is assured that it can be done without pain. The choice of an anæsthetic is somewhat important in any case of eyeball tension, and whatever form of vapour is inhaled, the administrator should allow it to be mixed with a large proportion of air so that there may be no struggling for breath on the part of the patient. Clover's apparatus for the administration of the nitrous oxide gas followed by ether, seems to fulfill these indications better than any other method with which I am acquainted. If ether alone be given there is almost always a great deal of congestion of the head and eyeball, and the risk of intra-ocular hæmorrhage is thereby increased. In one or two instances, in which neither ether nor chloroform nor nitrous oxide gas seemed to be admissible, I have adopted the plan of giving a hypodermic injection of morphia, and repeat-

ing it if necessary until it produces decided narcotism. The operation may then be performed with as little risk of disturbing movements on the part of the patient as if his voluntary muscles were entirely under the influence of an anæsthetic.

## CHAPTER III.

### AN ANALYSIS OF THE CASES OF EYEBALL-TENSION IN TABLES I. II. AND III. IN APPENDIX A.

1. As to sex:—Out of the 46 cases, there were 32 women and 14 men, or more than twice as many women as men. This disproportion in the liability of the sexes to eyeball-tension may perhaps be due partly to the fact that elderly women are from necessity or habit particularly exposed to the risk of overstrain of the eyes in doing needlework. Others are compelled to occupy themselves in nursing and night-watching, whether as professional nurses or otherwise. Men on the other hand, if in advanced life they feel a strain upon their eyes from the special work of their callings, can often relieve themselves materially by leaving the finer work to be done by their juniors, and their occupations rarely expose them to the necessity of night watching. These remarks apply more especially to the lower classes, but will also be applicable with certain modifications to the middle and upper classes. In the Tables, however, the majority of the cases were those of hospital patients, and they were therefore liable to exposure to the risks indicated.

2. As to age:—12 only were under 50 years, most of the rest were above 60. Two were under 30, viz.

no. 13 and no. 31 in Table I. In both these cases the glaucoma had been brought on by an injury. I am aware that there are recorded cases of glaucoma occurring even in infancy, and in explanation of these very exceptional cases would suggest that congenital rigidity of the sclerotic had probably been present.

3. As to occupation:—Of the women 23 out of the 32 were either married women, or widows with no occupation, or unmarried but with no known occupation. Of the remaining 9, 3 were needlewomen, 2 dressmakers, 1 a domestic servant, 1 a charwoman who had also been a nurse, and 2 were nurses.

Of the 14 men there was 1 printer, 1 compositor, 1 barometer-maker, 1 shoe-maker, 1 turner, 1 silversmith, 1 blacksmith, 1 waiter, 1 porter, 1 labourer, and 1 engineer; the other three had no known occupation. The occupation of the 6 first-named all implied a possible strain upon the eyes; and when we consider in connection with this fact the large proportion of needlewomen and dressmakers among the women affected with glaucoma, we have strong evidence of the influence of such occupations in the development of a tendency to the disease. That 3 out of the 9 women whose occupation was known should be sick-nurses is a striking fact. Here the strain may well be supposed to be on the general powers of resistance as well as on the vitality of the eyes in particular.

4. The previous history and aspect of the patients

point in almost all cases to debilitating influences having been at work for long periods. Two women, besides those engaged in nursing professionally, had been overstrained by nursing relatives or friends and by disturbed rest in consequence. Several men and women had suffered from bronchitis or asthma. Several had suffered or were still suffering from nervous disorders such as epilepsy, neuralgia, chorea, or from nervous depression due to illness, privation, or grief. Two or three had had rheumatism, but only one had had articular rheumatism, viz., Eliz. B., No. 24 in Table I. On enquiry of those who stated that they were rheumatic, I have generally found that the account given was more like that of neuralgia than true rheumatism, and that it affected the head in one or two instances. This was the case in No. 29 in Table I. I have met with no instance of genuine gout associated with glaucoma though I have made special inquiries on this point. No. 3 in Table III. was subject to a form of dyspepsia, which may have been gouty in its nature, but which was not associated with any affection of the joints.

A large proportion of the persons affected are described as being "depressed and nervous" or "haggard" in appearance, and nearly all were "spare" in frame. There were two or three exceptions to the rule that the eyes were highly pigmented and the hair dark. In only one case did

there seem any grounds for assuming an hereditary tendency (Case No 25 in Table I). As far as the Tables go, therefore, the evidence is in favour of the view that any occupation or condition which lowers the general vitality or exhausts the nervous energies, especially if it tends to disturb sleep and to overstrain the eyes, predisposes to glaucoma. There seems no evidence in these Tables in support of a theory of a degeneration of the fibrous tissues generally, except in so far as they are affected by senile changes. In the only case (No. 29 in Table I.) in which there seemed at first sight to be an association of contraction of the palmar fascia with glaucoma, and which seemed therefore confirmatory of Mr. Jonathan Hutchinson's views on this point, it turned out that the contraction had been brought on by a thecal abscess in the finger and hand affected.

5. The Tables do not give any very clear evidence as to the efficacy of the different modes of treatment adopted, though the failures in one or two instances point out what should be avoided in the future.

In Table I. 25 iridectomy operations were performed with 5 failures; but in only two out of these 5 failures was the eye operated-on in a worse condition than before the operation. In one (No. 18) intra-ocular hæmorrhage came on, but though the eye shrunk, it ultimately became painless, and this was a positive gain to the patient, for there had been severe and

constant pain before treatment and the sight was hopelessly gone. In the other case (No. 19) an attempt to perform iridectomy, where the iris was atrophied, was followed by ophthalmitis. In this case the disastrous result was probably due to an attack of acute eczema, or rather perhaps to the patient's unhealthy state of which the eruption was the manifestation, and the operation may not be so much to blame as may at first sight appear. In any other similar case, however, in which there seemed a tendency to acute eczema, any operation would be better postponed, but if delay seemed undesirable, sclerotomy would be less liable to objection as a means of meeting the emergency.

Sclerotomy was performed 9 times in acute or sub-acute cases, and failed twice. The failure, however, was redressed in one instance by a repetition of the sclerotomy (case No. 21 in Table I.), and in the other (No. 23 in Table I.) the report leaves it doubtful whether the eye was left in a worse position than before treatment.

In Tables II. and III., with the exception of 2 or 3 cases, the treatment was uniformly unsuccessful as regards the restoration of sight, though in most cases the pain and tension were relieved. In one instance (No. 6 in Table II.) sclerotomy was followed by a troublesome prolapse of the iris in one eye. This was not, as far as the case could be followed, attended

with any further mischief, but it is noteworthy as indicating one of the inconveniences of sclerotomy and the desirability of not extending the incision too far back in the sclerotic, and of not making the section longer than about  $\frac{1}{6}$  of the circumference of the cornea. In both these respects the incision in the case in question was excessive. If the incision is restrained within the limits assigned to that for iridectomy, there is little risk of this kind of troublesome complication arising.

The results of treatment taken altogether as they appear in the Tables, give perhaps a less favourable impression of their successful nature than is due to them and to the methods adopted. The faults of refraction and accommodation are not all corrected in the tabulated statements, though as a matter of fact in some cases spectacles were afterwards ordered for the patients without the resulting improvement in vision being recorded. It is also probable that some improvement in vision took place in many cases after the operation. This was so in cases 26 and 21 in Table I., but in the majority of the tabulated cases the post-operation history extended only over a few weeks or months. Hence some of them present an unfavourable aspect, which might have been reversed if circumstances had allowed of a longer period of observation and a more accurate record. No cases of recurrent iritis with eyeball-tension as a complication



have been included among the tabulated cases. Had they been, the results of treatment would have been much more favourable:—Iridectomy being often in such cases very successful as regards improvement of vision and relief of tension.

## APPENDIX A.

### *Appendix of Tabulated Cases.*

IN the following *tables of cases* the abbreviations used have the technical meanings generally understood in ophthalmological works.

|   |            |  |
|---|------------|--|
| V.  | stands for | Vision as tested in the usual way.   |
| V. o.   | „ „        | Total loss of perception of light as far as could be ascertained by the usual tests. |
| J.  | „ „        | Jäger's Test-types.  |
| J.1. J.2. J.3. &c.                              | „ „        | No. 1, 2, 3, &c. of Jäger's Test-types.  |
| V. J.1.   | „ „        | V. amounted to an ability to read No. 1. of Jäger's Test-types, so of J.2. to J.20.  |
| V. fingers.                                     | „ „        | V. amounted to ability to count fingers.   |
| V. J.20, letters.                               | „ „        | V. amounted to ability to distinguish letters of No. 20. Jäger, but not to read it.  |
| V. Perception Lt.                               | „ „        | V. amounted to perception of light only.   |
| T.  | „ „        | Tension of the eyeball increased.  |
| Tn.   | „ „        | Tension normal.  |
| T <sub>1</sub> T <sub>2</sub> T <sub>3</sub>    | „ „        | Tension increased to the 1st, 2nd, or 3rd degree.                                    |
| —T <sub>1</sub> —T <sub>2</sub> —T <sub>3</sub> | „ „        | Tension diminished to 1st, 2nd, or 3rd degree.                                       |
| Sn. I, II, III, &c.                             | „ „        | Snellen's Test-types, No. I, II, III.  |
| H.  | „ „        | Hypermetropia.   |
| My.   | „ „        | Myopia.  |
| R.  | „ „        | Right eye.   |
| L.  | „ „        | Left „   |
| O. D.   | „ „        | Optic Disc.  |
| O. S.   | „ „        | Ophthalmoscopic examination.   |

M. stands for Man.

F. stands for Woman.

TABLE I.  
31 Cases of Acute and Subacute Eyeball-Tension; Idiopathic or Traumatic.

| Number, Name, Age and Occupation.  | Constitutional condition or Aspect, and Previous History.  | State of Vision and Tension before treatment.   | Treatment.   | Result of treatment.  | Remarks.  |
|--|--|---|--|---|---|
| 1. Eliz: B—, æt 40 years.<br>(This case was the subject of a note in Ophthalmic Hospital Report, Vol. iv, p. 449.) | Very low spirited and nervous, with a worn haggard expression. Had 5 temporary obscurations.   | V. 0. or (?) mere perception of light, T <sub>3</sub> .   | Iridectomy upwards.  | V. J. 20. Tn. 3 months after the operation.   | Atropine was used for the purpose of Ophthalmoscopic examination before dilatation of the pupil, the media which had before been turbid became quite clear. |
| 2. ——— woman æt 50 years.  | In constant pain.  | V. fingers. T <sub>2</sub> .  | Iridectomy and opiates.  | Good results. V. Sn. 12.  | Cystoid cicatrix formed.  |
| 3. Eliz: Rose, æt 62 years. Dressmaker, unmarried.   | Had been nursing a sick relative some time before the attack, often losing her night's rest. Has had a chronic cough.<br>Aspect depressed and haggard, very spare. | R. V. J. 20 letters, F. much limited especially above and below. T <sub>1</sub> L. V. J. 19, letters T <sub>2</sub> . | R. and L. Iridectomy and subsequent extraction of cataract in R. and Iridectomy for the purpose of forming an artificial pupil in R. | L. V. J. 10 and with glasses J. 2. R. V. good with use of cataract glass. Tn one year after the last operation. The left eye became affected 5 months after 1st operation on the Right. |   |

|   |  |  |  |   |  |
|---|--|--|--|---|--|
| 4. Mrs. G—, æt. 75 years, married, no occupation. | Very feeble health and languid circulation. Entropion.   | V. could not be ascertained on account of the photophobia, great turbidity of the media.       | Application of colloid to lower lid and use of a clip to remedy the entropion.                                     | covered V. and to have been quite free from pain or discomfort as soon as the entropion was overcome. | The successful result is somewhat doubtful and was not verified by the author's own observations.                |
| 5. Mary G—, æt. 60 years.                         |  | Acute attack supervening on chronic glaucoma.<br>V. Perception of light only, T <sub>2</sub> . | 1. Paracentesis of vitreous through the sclerotic.<br>2. Morphia by injection and Bromide of Potassium internally. | Temporary relief but rapid return of pain. V. o.  |  |
| 6. Louis E—, M., æt. 70 years, printer.           | Anxious expression as if from severe pain. Hair white, eyeballs prominent, acute glaucoma for a week or 10 days. | V. fingers T <sub>3</sub> .  | Iridectomy.  | V. J. 14. Relief complete and permanent. Still T <sub>1</sub> one month after operation.              |  |
| 7. W. H. F—, M., æt. 40 years, waiter.            | A hard drinker, subject to epileptic fits.   | Very severe pain, V. not noted T <sub>1</sub> .  | Paracentesis of anterior chamber, opiates and bromides.<br>Subsequent Iridectomy.                                  | V. improved and no pain nor tension 2 months after the operation.                                     | The relief after tapping the anterior chamber very transient.<br>Two days after the T <sub>1</sub> had returned. |
| 8. Frank H—, æt. 62 years, barometer maker.       | Stout with dusky complexion as if from deficient oxygenation of the blood. Sight failing for 3 or 4 months.      | V. Perception of light. T <sub>2</sub> .   | Iridectomy, opiates and bromides.  | Quite free from pain and slept well since the first night after the operation.                        | State of vision not ascertained.   |

TABLE I. (Continued).

| Number, Name, Age and Occupation.                       | Constitutional condition or Aspect, and Previous History.  | State of Vision and Tension before treatment.            | Treatment.  | Result of treatment.             | Remarks.  |
|---|--|--|---|----------------------------------|---|
| 9. Ann Rose, æt. 45 years, domestic servant, unmarried. | Spare, delicate, nervous and hysterical was struck in the eye 3 weeks before the attack by a piece of wood thrown at her. Premonitory chromopsiæ for some years. | V. not fingers T <sub>1</sub> .                          | Iridectomy<br>2nd " "<br>3rd " "<br>Extraction of cataract. | V. not improved<br>No pain.      | The tension and pain continued after the 1st 2 operations but were ultimately relieved.   |
| 10. F. 45 years, needlewoman.                           | Excessively nervous and depressed. Had been sleepless for many nights from severe pain.  | V. bare perception of light T <sub>2</sub> .             | Iridectomy, bro-mides internally.                           | Sight improved and pain removed. |   |
| 11. F. 50 years.  | General health much impaired by severe privation. Injured in the eye affected 11 days before operation. Partial dislocation of lens.                             | V. J <sub>20</sub> letters indistinctly T <sub>3</sub> . | Iridectomy.   | Pain and tension relieved.       | Under observation for a very short time. At the time of the operation the patient struggled violently and a very small piece of Iris was excised. |

|   |   |   |  |   |
|---|---|---|--|---|
| <p>12. Mrs. B—, F.<br/>50 years.</p>            | <p>Suffering from chronic bronchitis and asthma, (?) emphysema.</p>   | <p>V. R. J.18 words.<br/>T<sub>2</sub>.<br/>V. L. Not fingers, T<sub>2</sub>.</p> | <p>Iridectomy R. and L.</p>  | <p>completely removed.<br/>Sight good enough to enable her to read and do needlework with the aid of spectacles.</p>  |
| <p>13. M., æt. 28 years,<br/>engineer.</p>      | <p>Traumatic Keratitis from an injury due to a chip of iron lodging on the cornea.</p>                                      | <p>V. fingers, T<sub>2</sub>.</p>   | <p>1. During the inflammatory stage free use of atropine drops.<br/>2. Iridectomy and morphia by inunction and internally.</p> | <p>V. T<sub>1</sub>. J.19 within a week after pain and tension relieved at once by the operation.</p> <p>Eyeball-tension at a comparatively early age.</p>                  |
| <p>14. M., æt. 65 years,<br/>turner.</p>        | <p>Supraorbital pain and other symptoms for 6 weeks.<br/>Iris thrust forward against the cornea.</p>                        | <p>V. fingers, T<sub>2</sub>.</p>   | <p>Iridectomy after failure of the local application of opium and the internal use of bromide.</p>                             | <p>V. J.16 one month after the operation, F. extended.<br/>At last note 6 months after V. the same as before the operation, T<sub>n</sub>. Only occasional slight pain.</p> |
| <p>15. Mary V—, æt. 50 years, needle-woman.</p> | <p>Spare frame, very eccentric, and probably of weak intellect.<br/>Glaucoma supervening on the extraction of cataract.</p> | <p>V. Perception of light, T<sub>1</sub> or T<sub>2</sub>.</p>                    | <p>Sclerotomy.</p>   | <p>V. J.20 letters and with cataract glass J.16. T<sub>n</sub>.</p>   |

TABLE I. (Continued).

| Number, Name, Age and Occupation. | Constitutional condition or Aspect, and Previous History.   | State of Vision and Tension before treatment.  | Treatment.   | Result of treatment.  | Remarks.   |
|-----------------------------------|---|--|--|---|--|
| 16. Eliza Newman, æt. 63 years.   | Short, stout and asthmatic. Said to have lost the sight of the right eye by acute rheumatism. L. attack 2 or 3 days before admission. | L. V. Tells the time by watch. T <sub>1</sub> or T <sub>2</sub> . R. T <sub>3</sub> . V.o. | R. Iridectomy. L. Iridectomy.  | R. V.o. No pain or tension except at times.<br>L. V. J.16. No pain.   |  |
| 17. F. 52 years.                  | Sight failing for 6 years. Has had intermittent obscurations and severe headaches. Before admission could see a little with each eye. | R. V. quantitative perception of Light. T <sub>3</sub> . L. V.o. T <sub>3</sub> .          | R. Iridectomy.   | R. Pain relieved Tn. but no improvement of V.   | Subacute attack in the course of chronic glaucoma.                                 |
| 18. F. 60 years.                  | L. Sight gone 5 or 6 weeks before admission. Severe and constant pain.  | L. Vo. T <sub>3</sub> .  | L. Iridectomy large upper section made well in the sclerotic margin and a large piece of Iris excised. | Intraocular hæmorrhage at the time of the operation. Crystalline lens thrust out with a portion of the vitreous. Ultimately shrinking of the eyeball which became quite painless. R. remained free from irritation and with good vision 6 weeks after the operation on I. | The operation performed for relief of pain and with no expectation of improving V. |

|   |   |  |  |   |   |
|---|---|--|--|---|---|
| <p>19. Hannah S—, æt. 56 years.</p>                               | <p>Suffered while under treatment from severe <i>eczema</i> of scalp, ear and side head.<br/>Both eyes glaucomatous and optic discs excavated.</p>                                  | <p>R. J.16 T<sub>1</sub>. or T<sub>2</sub>.<br/>L. J.19 T<sub>1</sub>. or T<sub>2</sub>.</p> | <p>L. attempt to perform Iridectomy which failed from the extremely atrophied condition of the Iris.</p> | <p>L. total loss of V. eyeball shrunk.</p>  | <p>The unhealthy condition of this patient and the acute <i>eczema</i> coming on immediately after the operation, probably explain the unfortunate result of treatment.</p> |
| <p>20. John W—, æt. 45 years, porter, formerly in the police.</p> | <p>Bronchitis in winter months. Has a barrel-shaped chest.<br/><i>Aspect</i> fair hair and blue irides.</p>   | <p>L. V. J.20 T<sub>2</sub>.<br/>O.D. excavated.</p>   | <p>L. Iridectomy and application of ice-compresses followed by Morphia and Bromides internally</p>       | <p>L. V. J.1 Tn. This result was ascertained and noted 2 years after the operation.</p>   | <p>The optic disc remained cupped notwithstanding the improvement of V. and normal tension.<br/>The optic disc of R. was normal.</p>  |
| <p>21. Ann L—, æt. 59 years, a monthly nurse.</p>                 | <p><i>Hist.</i> Sitting up for many nights with an invalid.<br/><i>Aspect.</i> Small, spare dull grey Irides.<br/>States that her father, mother, and a brother died of asthma.</p> | <p>R. V. fingers, T<sub>2</sub> or T<sub>3</sub>.<br/>L. V. Sn. xii. T<sub>2</sub>.</p>      | <p>R. Sclerotomy repeated on the return of tension.<br/>L. Iridectomy.</p>                               | <p>R. temporary improvement after the first Sclerotomy, but return of T<sub>2</sub> 2 months later. Permanent relief after 2nd Sclerotomy in R.<br/>2½ years after the last operation, R. V. J.16 Tn. L. V. J.16 Tn. and with spectacles (of + 9) reads J.2</p> | <p>The patient herself thinks the L. or Iridectomised eye the best but the tests go to prove that there is little or no difference in the two eyes.</p>                     |



TABLE I. (Continued).

| Number, Name, Age and Occupation.                | Constitutional condition or Aspect and Previous History.   | State of Vision and Tension before treatment.                      | Treatment.  | Result of treatment.   | Remarks. |
|--|--|--|---|--|----------|
| 22. F—, M., æt. 60 years, labourer in the docks. | Haggard, worn, and depressed, with sharp features. Premonitory symptoms for 7 months. Sudden access of pain, &c., with vomiting 1 week before admission. | R. V. good perception of light. T <sub>2</sub> or T <sub>3</sub> . | R. Sclerotomy.  | 2 months after R. V. J.16 Tn. No pains. The pupil a little updrawn or balloon shaped. A semitransparent filtrating cicatrix left in the line of incision.  |          |
| 23. H. D—, F., æt. 60 years.                     | Symptoms of 1 month's duration. Distinct pulsation of Retinal arteries. Spare built, intelligent, and with good features.                                | R. V. fingers (?) T <sub>2</sub> .                                 | R. Sclerotomy. Subsequent attempt to remove the protruded Iris. | Pupil updrawn and sclerotic wound occupied by a portion of prolapsed iris, or ciliary uveal membrane. In the 2nd operation vitreous was presented and was partly lost. 2 months after the operation V. perception of light. T <sub>2</sub> or T <sub>1</sub> . No pain. Incision traceable by a distinct black line in the sclerotic |          |

|   |  |   |  |  |
|---|--|---|--|--|
| <p>24. Eliz. Mary B—, at. 46 years<br/>Widow, Dress-<br/>maker.</p> | <p>Had severe rheumatism some years ago. Pulse intermittent. Thinks she has overstrained her eyes at needlework. Chromopsiæ occasionally for 2 years.</p>                                  | <p>V. fingers T<sub>2</sub>.<br/>V. lost suddenly in R. with severe pain in brow and eyeball.</p> | <p>R. sclerotomy 2 days after the attack followed by morphia ointment and mixed bromides internally.</p> | <p>after and with spectacles (+10) is able to read, Tn. Pupil updrawn as if from Iridectomy. The ophthalmoscope shows the media to be clear and <i>no excavation</i> of the O.D.</p>   |
| <p>25. Mrs. D—, at. 50 years, widow, no occupation.</p>             | <p><i>Aspect.</i> Worn and haggard and short-breathed. Lately recovered from a very severe attack of pleuro-pneumonia. Was formerly subject to spasmodic asthma. Fair hair and Irides.</p> | <p>V. fingers (?) T<sub>3</sub>.</p>  | <p>R. sclerotomy 1 week after the attack followed by morphia injection and bromides internally.</p>      | <p>6 months after operation V. reads large type, about J.12, Tn. O.D. normal. The relief of pain was very slow. Pupil a little updrawn, and small protrusion at site of incision.</p> <p>The mother of this lady had sudden loss of vision with severe pain a fortnight before her death at the age of 86 years. This was presumably acute glaucoma.</p> |
| <p>26. Ann C—, at. 66 years, nurse.</p>                             | <p>Health good till the last month. In pain for several weeks before the operation. No rheumatism nor other ailment. Struck her head against a chimney piece.</p>                          | <p>V. Perception of light T<sub>3</sub>.</p>  | <p>L. sclerotomy followed by opiate injection and bromides internally.</p>                               | <p>1 year after, V., J.17 without spectacles Tn. with spectacles (+9) can see to do fine needlework. Pupil remains circular, and scar of incision only traceable by a lens.</p>  |

TABLE I. (Continued).

| Name, Number, Age and Occupation.                    | Constitutional condition or Aspect, and Previous History.   | State of Vision and Tension before treatment.     | Treatment.                                  | Result of treatment.   | Remarks.  |
|--|---|---|---|--|---|
| 27. M., 72 years.                                    | Sight of L. lost some years ago. Always Myopia.<br>R. sudden failure of V. with orbitalgia and Rhinalgia.   | V. doubtful perception of light, (?) Tt.          | R. sclerotomy followed by opiate injection. | 6 weeks after. V. J 20. No pain. The tension was not relieved by the operation at first. |   |
| 28. M., 47 years.                                    | An intemperate man looking much older than his years.<br>Severe lacerated wound of lens and cornea 3 weeks before operation.  | V. doubtful perception of light, T3.              | Iridectomy and retraction of cataract.      | Pain and tension relieved. Some prospect of restoration of useful V.                     |   |
| 29. F., charwoman, æt. 55 years, used to be a nurse. | Had rheumatism in the head only, never in the joints (? Neuralgia). A contraction of the palmar fascia extending to the ringfinger is attributed to an old whitlow. A contracted little finger on the other hand was caused by an | V. not noted, all the symptoms of acute glaucoma. | Iridectomy.                                 | V. fingers and Tn.   | The remarkable association of contraction of the palmar fascia (here of traumatic origin) is scarcely traceable to a tendency to degeneration of the fibrous tissues generally. |

|   |  |   |  |  |  |
|---|--|---|--|--|--|
| <p>30. Margaret S—, F., 40 years, married, no family no occupation.</p>     | <p>Has heart disease and palpitations, no rheumatism.</p> <p>Aspect. Well fed and with good color.</p> <p>The eye had at first an appearance more resembling iridochoroiditis than glaucoma.</p> | <p>V. J. 20 letters T<sub>2</sub>.</p> <p>Posterior synechia and pupil irregular.</p>   | <p>Sclerotomy after the failure of treatment by mercurials internally and by inunction after the iodide of potassium internally and morphia inunction.</p> <p>Subsequent iridectomy.</p> | <p>A week after V. J. 16 Tn. anterior chamber clear and round pupil.</p> <p>3 weeks after V. J. 16 Tn. Has had no pain since the operation.</p> <p>After iridectomy Tn. but V. J. 18.</p> <p>O. S. O. D. slightly excavated and pale. Veins full and tortuous.</p> | <p>Iridectomy would have been preferable had the patient been in a condition to take an anæsthetic safely.</p> <p>Still under treatment by instillations of sulphate of eserine.</p> <p>Temperature of eye operated on remained at 100° 0 the sound eye being 99° 4.</p> |
| <p>31. A. P—, M., æt. 14 years, stunted youth with deformity of L. arm.</p> | <p>Traumatic glaucoma. Had convulsions as an infant, and was operated on for Zonular cataract 2 months before.</p> <p>Always very delicate. Teeth with jagged points.</p>                        | <p>V. Perception Lt. great photophobia T<sub>3</sub>.</p> <p>Pupil obliterated by lymph and the remains of the crystalline.</p> | <p>Argyll Robertson's operation of trephining the sclerotic.</p>   | <p>Some improvement of vision and tension normal.</p> <p>6 weeks after T<sub>1</sub> V. fingers. Eye free from congestion and no photophobia.</p>  | <p>Eye-ball-tension at a very early age.</p> <p>Mercurials and belladonna were given for 3 weeks before the operation with some improvement of the condition, but tension remaining.</p>   |

TABLE II.

*Cases of Chronic Eyeball-Tension.*

| Number, Name, Age and Occupation.        | Constitutional condition or Aspect, and Previous History.   | State of Vision and Tension before treatment. | Treatment.                                      | Result of treatment.   | Remarks. |
|--|---|---|---|--|----------|
| 1. F. 75 years, housewife.               | Very spare, skin shrivelled. Hands gouty. Complexion dark. Hair white, L. lost by glaucoma 5 or 6 years before R. became affected |   | R. Iridectomy.                                  | Pain and Tension relieved but no improvement of V.                                 |          |
| 2. F. 60 years.                          | L. lost 20 years, R. failing for a year.  | R. V. perception of light.                    | R. Iridectomy, opiates and potassium, bromides. | V. slightly if at all improved. Pain and T. relieved.                              |          |
| 3. Joseph H—, æt. 38 years, silversmith. | Injury of forehead 16 years ago. Neuralgia 18 months ago since which sight has failed. Has a child subject to epilepsy.           | Both V. mere perception of light.             | R. and L. Iridectomy.                           | R. V. somewhat improved, L. V. J.14 or with a glass of + 10 focal length, V. J.10. |          |

|   |  |  |  |
|---|--|--|--|
| 4. Emma W—, F.<br>33 years, labourer's<br>wife.   | V. J.20 R. and L.<br>excavation of both<br>O. D. D.  | 1° Opiates endermi-<br>cally and bromides.<br>2° R. and L. Iridec-<br>tomy.<br>3° R. Repetition of<br>Iridectomy.<br>4° Extraction of<br>Cataract. | For about a month<br>after the operations<br>V. improved so that<br>R. V. J.10 L. V.<br>J.18.<br>3 years after both<br>eyes became totally<br>blind. |
| .Elizabeth G—,<br>æt. 74 years.                   | Night's rest much<br>broken by nursing<br>a sick husband.  | L. Iridectomy.   | V. not improved but<br>remained as before<br>a month after oper-<br>ation.   |
| 6. M., æt. 54 years,<br>shoemaker.                | Rapidly increasing<br>presbyopia.  | R. and L. sclero-<br>tomy.   | R. V. as before. Tn.<br>L. V. much impair-<br>ed, a prolapse of iri-<br>s into the wound and<br>much congestion of<br>eyeball.                       |
| 7. Miss —, æt. 60<br>years, no occupa-<br>tion.   | No cachexia, tall and<br>spare but well built,<br>very intellectual,<br>and a great reader,<br>of an excitable tem-<br>perament. | Sclerotomy.  | V. little or not at all<br>improved, Tn.   |
| 8. Mary A. G—,<br>æt. 64 years, needle-<br>woman. | Very deaf and in<br>feeble health.   | Sclerotomy.  | V. fingers but with<br>spectacles reads and<br>does needlework.  |

TABLE III.  
*Cases of Absolute Glaucoma. (Eyeball-Tension).*

| Name, Number, Age and Occupation.          | Constitutional condition or Aspect, and Previous History.                                   | State of Vision and Tension before treatment. | Treatment.   | Result of treatment.   | Remarks.  |
|--|---|---|--|--|---|
| 1. M., æt. 45 years.                       | R. previously iridectomized successfully.<br>L. long affected and very tense and painful.   | V. O.   | L. Iridectomy.   | Temporary relief of pain and tension.  | The only treatment that would have been successful would have been enucleation. |
| 2. James K—, M., æt. 54 years, blacksmith. | The eye operated on had been lost for 17 years. The other lost by a blow some years before. | V. O.   | Iridectomy.  | Partial relief of pain and tension but no improvement of sight.              |   |
| 3. F., 60 years.                           | Very bulky woman with gouty dyspepsia and probably renal disease.                           | V. O.   | Iridectomy.  | Tension relieved and V. slightly improved.                                   |   |
| 4. Mary A. D—, æt. 52 years, housewife.    | Spare, feeble and depressed.<br>Blow on eye one year before.                                | V. O.   | 1° Opiates followed by Iridectomy.<br>2° Paracentesis of anterior chamber. | No relief from Iridectomy. A year after the tapping tension remained normal. |   |

|                                       |  |  |   |  |   |
|---------------------------------------|--|--|---|--|---|
| 5. S—, M., æt. 60 years, compositor.  | Thin spare man. iris lying in contact with cornea and pupil adherent.  |  | Attempt to perform Iridectomy which failed from the rotten condition of the iris. Loss of vitreous humor.         | Temporary relief which lasted six months. 18 months after the operation acute ophthalmitis supervened.   |   |
| 6. F., 55 years.                      | General health good. No cachexia. K. injured by a child's gun 6 months before.   | V. O.  | Enucleation.  |  | Eyeball distended with a staphyloma of sclerotic.<br>Excavation of optic nerve. |
| 7. F., 55 years, inmate of workhouse. | Chronic chorea with contortions of the facial muscles, impaired intellect.<br>Both eyes affected with glaucoma of old standing.<br>Spare, dark complexion and dark hair. | R. V. O. T <sub>2</sub> . or T <sub>3</sub> .<br>L. V. O. T <sub>2</sub> . or T <sub>3</sub> . | 1° Instillation of solution of sulphate of eserine.<br>2° R. Trephining sclerotic (Argyll Robertson's operation). | 1° No effect on the tension from use of eserine.<br>2° Trephining did not at first affect the tension to any appreciable extent, though there was a distinct protrusion of the choroid through the aperture in the sclerotic. About the 5th day the choroid ruptured and there was an escape of vitreous fluid after which the tension became normal or nearly so, 14 days after the operation it was T <sub>1</sub> . |   |



## APPENDIX B—DETAILED CASES.

### CASES OF EYEBALL-TENSION, ILLUSTRATING THE EFFECTS OF IRIDECTOMY.

CASE I.—*Traumatic Eyeball-Tension.—Iridectomy.—Recovery with useful vision.* (Date of operation, Nov. 19th, 1872.)

An engineer, about 28 years of age, was struck in the eye by a chip of cold iron. When seen a fortnight after the accident the cornea was abraded, the globe tense and congested, sight so imperfect that he could only just count fingers, pupil dilated, and constant pain in brow and temple preventing sleep. A small iridectomy was made upwards and inwards. A week afterwards all the symptoms had disappeared, but the sight had only so far improved that he was able to read No. 19 of Jäger's test-types.

*Remarks.*—The noteworthy feature of this case was the age of the patient. Very few cases are recorded of glaucoma below the age of 30, and it is possible that in this case there was some deep-seated ophthalmitis, set up by the injury which gave rise to the glaucomatous condition.

CASE II.—*Double Eyeball-Tension.—Iridectomy in both.—Result good.* (Date of operation, Oct. 3rd, 1873.)

Eliza N——, æt. 63, had suffered from glaucomatous symptoms in the right eye for two months, and in the left for two or three days. The *right eye* has  $T_3$ . V. = 0. *Left*  $T_2$ . V. Tells the time by the watch.

Iridectomy upwards in both eyes, a rather smaller piece of iris being removed in the right eye than in the left.

Four days after operation.—*Right eye*. Still tension, pain very severe. *Left eye*. Vision much improved, pupil clear.

Ten days after.—*Right eye*. Tension normal, less pain, and anterior chamber more formed. *Left eye*. Vision improving. Tension, no pain.

Six weeks after the operation.—*Right eye*. Slight pain occasionally. V. = 0. *Left eye*, V. = J.16. Tension normal, no pain.

*Remarks*.—The patient in this case was suffering from asthma and bronchitis, and her general health was very defective. The results of the operation were therefore less satisfactory than in some cases, but quite as good as might have been anticipated.

CASE III.—*Chronic Eyeball-Tension*.—*Iridectomy*.—*Success*. (Date of operation, April 24th, 1874.)

Elizabeth Gill, æt. 74, sight failing the last two years.

*Right eye*. V. = J.16. F. limited. Optic disc excavated. *Left eye*. V. = J.16. F. limited. Optic disc

white and excavated. T. $\frac{1}{2}$ . Orbital and nasal pain. Chromopsiæ.

*April 24th.*—L. Iridectomy upwards.

*May 18th.*—L. Tn. V. as before. No pain, no chromopsiæ.

*Remarks.*—This appears a very limited amount of success as compared with the results obtained after iridectomy for acute or sub-acute glaucoma, but is more than can always be reckoned upon in the chronic form of the disease, especially if, as in this case, there happens to be incipient atrophy of the disc and great limitation of the field of vision, as well as of its acuteness. No improvement of sight was obtained, but the eye was placed in such a condition that it will not become rapidly deteriorated, and it is not exposed to the danger of a sudden acute attack.

#### CASES ILLUSTRATING THE EFFECTS OF SCLEROTOMY IN THE TREATMENT OF EYEBALL-TENSION.

CASE IV.—James F——, æt. 70 years, a pensioner, but 2 years before admission a labourer in the docks, was admitted into the hospital on Jan. 28th, 1876. His general appearance was haggard and careworn, and his manners and gait depressed; his features sharp but general nutrition fairly good.

*History.*—Has had rheumatic pains but no severe illness. His sight began to fail 2 or 3 years ago, but

during the last seven months has become much worse in his right eye, and he has been further troubled by chromopsiæ and orbital pains. A week ago very severe pain came on in the right eyeball and orbit, and with this, rapid deterioration of sight. He had also vomiting at this period of the case.

*Present Condition* (Jan. 28, 1876).—The right pupil is widely dilated and immovable, the colour of the iris being of a dull grey tint, and the anterior chamber turbid. There is greatly increased tension ( $T_2$  or  $T_3$ ), severe pain in the right brow, temple, and side of the nose and cheek. The ophthalmoscope gives only a dull red reflex from the fundus, the details of which cannot be made out. With the right eye the vision amounts to quantitative perception of light only; with the left No. 10 Jäger's test-types can be read.

*Jan. 28.*—Ether was given and subconjunctival sclerotomy performed in the way described, the incision being carried upwards and a little inwards. Immediately after the operation the pupil was noticed to be a little displaced upwards, but there was no prolapse of iris into the wound.

*Feb. 1.*—The tension is less; he complains of no pain, and has had none since the operation; he can now count fingers with the eye operated on. The line of the sclerotic incision is marked by a translucent dark cicatrix.

*Feb. 4.*—Vision improving. No pain.

*Feb.* 11.—Vision. Reads No. 16 (Jäger). Tension very little above normal. The details of the fundus can now be seen with the ophthalmoscope. The optic disc can be seen of a dirty-grey tint but not excavated, all the vessels lying on the same plane. The optic nerve is surrounded by an irregularly shaped atrophic patch of choroid.

*March* 10.—Vision remains good, and there is no pain. The tension is still slightly above normal.

CASE V.—*Double Eyeball-tension. Iridectomy in the Left and Sclerotomy in the Right Eye.*

Ann Langley, æt. 59 years, widow, a monthly nurse, who had been sitting up for many nights consecutively before the attack of glaucoma, was suddenly seized on Dec. 24, 1875, with severe pain in the right eye, accompanied by coloured haloes and bilious vomiting. She does not appear to have had any premonitory symptoms before this date, but has long been very presbyopic. The sight of her right eye was at once very much impaired, but she did not apply for relief till Jan. 22, 1876, the left eye having been also attacked on the previous day.

Has never had asthma but has suffered from slight cough in the winter months. Says her father and mother and a brother all died of asthma. (? Emphysema).

She is slightly rheumatic.

On admission the symptoms of glaucoma in both

eyes were marked and severe. The right eye was extremely hard, and she could only distinguish fingers held at a distance of 4"; with the left, almost as hard, she read words of No. XII. of Snellen's test-types. The details of the fundus of neither eye could be made out with the ophthalmoscope, and only a dull reflex was obtainable from the pupil of the left. In the right eye the pupil appeared to be absolutely dark when light was thrown into it by the mirror.

*Jan. 22.*—Mr. Dunnage gave the mixed anæsthetics—alcohol, ether, and chloroform—and I performed sclerotomy on the right and iridectomy on the left eye. A marked improvement of vision and relief of all the glaucomatous symptoms were noticed on the next day, and continued steadily till three weeks after the operations (Feb. 12), when she could read type of J.11 with the right eye and J.10 with the left, and the tension of both was normal. With spectacles of + 9 she could read J.4, or type the size of the leading articles of the *Times*.

About a month after the operation she again began to see coloured haloes with her right eye, and the tension had returned, and a few days later I repeated sclerotomy (March 4).

Seven days later (March 11) the tension of her right eye was normal and vision had improved, but up to the present date it has never recovered the sight it had gained after the first operation. The left eye

remained perfectly good for all ordinary purposes, and she has again gone out nursing.

*July 5, 1878, V. R., J.16, L., J.10.* Can read and do needlework, and is still employed as a nurse.

*Nov. 1, 1878, with + 9, reads J.2 R. and J.2 L., no pain nor tension.*

It must be noted here that sclerotomy was used on an eye that had been suffering a whole month and was in imminent danger, while the left eye on which iridectomy was performed had been attacked only twenty-four hours before, and was much less severely affected. The more perfect result obtained after iridectomy is therefore in this case only due to the more favourable conditions under which it was employed.

CASE VI.—Eliza Mary B——, æt. 46 years, a widow with grey (originally dark) hair and dark brown irides. By trade a dressmaker working almost exclusively at black dresses.

*History.* She suffered severely from rheumatism 6 or 7 years before admission, but not recently, and her night's rest has not been disturbed.

Her left eye was occasionally the subject of chromopsiæ 4 years ago, and the same thing has been noticed in her right eye occasionally during the last 2 years, but the sight remained good till April 3rd, 1876, when sudden and severe pain attacked the right eye and the neighbouring regions of the brow and orbit. The sight of the eye affected was rapidly lost.

She thinks she has overstrained her sight at her work.

*Present condition.* Right eye. T<sub>2</sub> pupil fixed, not widely dilated. No details of the fundus oculi obtainable by the ophthalmoscope. No severe pain. Pulse intermittent. Her right eye could distinguish fingers.

On *April 5th* the mixed anæsthetics having been administered, sclerotomy upwards was performed.

*April 6th.* R. Tn. No pain. Slept well last night though for several nights before she had scarcely slept at all. V. fingers, pupil updrawn, lens turbid and iris prolapsed.

*April 12.* Tn. V J. 20. V for distance improved. *May 20.* V J. 17. Tn. O.S. media clear.

The optic disc is white but not excavated, uses a biconvex lens of 10-inch focal length for reading, but soon gets fatigued.

*CASE VII.—A case of Recurrent Iritis with glaucomatous tension treated by Sclerotomy. Temporary improvement but subsequent relapse. Iridectomy. Partial restoration of vision and permanent reduction of tension.*

Margaret S—, æt. 40 years, married, applied at the South London Ophthalmic Hospital in Dec. 1878. The left eye had been affected with Irido-choroiditis for 6 weeks which was probably syphilitic in origin; no history of primary syphilis could be obtained and no rheumatism was or had been present. The patient



was married but had no family; suffered from occasional palpitations and was said to have a fatty heart.

Mercurials were given for a short time without reducing tension or causing any improvement in the condition of the pupil, which was tied down in nearly its whole circumference by firm old-standing adhesions. She could distinguish letters of J. 20.

On *Dec. 13.* No details of the fundus could be seen through the pupil and the tension was  $T_2$ . In consequence of the state of the heart it was thought unadvisable to give any anæsthetic and sub-conjunctival sclerotomy was performed in the downward direction.

On *Dec. 20* V J.16 Tn to use eserine.

*Jan. 6, 1879.* V. has become more impaired, viz. to J. 10, and tension has returned.

*Jan. 7.* Iridectomy upwards.

„ 10. V. J.16.—T.

„ 27. V. not so good.  $T_{\frac{1}{2}}$  Complains of much discomfort after the use of the eserine which causes watering of the eye.

After this date V. became more impaired and on *Feb. 10* it was V. J. 18 but Tension was normal. The optic disc was now visible by the ophthalmoscope and was abnormally pale and slightly excavated. The Temperature of the eye operated on was  $100^{\circ} \cdot 0$ , that of the sound eye  $99^{\circ} \cdot 4$ .

*Feb. 24.* V. not improved, temperature  $100^{\circ} \cdot 2$ .

*March 27.* V. not improved. Tension normal.

After this date the patient disappeared; the ultimate result is therefore doubtful.

CASE ILLUSTRATING THE EFFECTS OF ESERINE.

CASE VIII.—A married woman, 39 years of age but looking 49, with 6 children, and lately nursing a sick husband and consequently much disturbed at nights, came to the hospital with double glaucoma on Dec. 30th, 1878. The tension was much increased in the right eye, less so in the left. Her sight was rapidly going and for eight months previously she had been troubled with the appearance of colored halos round the candle. The optic nerve-discs were both deeply cupped, and there was distinct pulsation of the veins over the right optic disc. The right pupil was dilated and immovable, that of the left slightly moveable. V.R. J.20, L. J.10.

She was advised to come into the hospital and have iridectomy performed on both eyes. At the same time I told her that unless the operation was done soon she would almost inevitably become blind. She, however, declined the operation urging the necessity of continuing her attendance on her husband and children. The operation was still urged, but in vain. I therefore ordered her to use eserine twice a day. She did so and came again on Jan. 3rd declaring she could see much better, and had now no colored halos before her eyes. On testing her vision she could read J. 8

with the left and J. 10 with the right eye. Both anterior chambers were clear, and the planes of the iris almost natural in position. The pupils were too small to allow of ophthalmoscopic observations. She continued the treatment with the addition of some quinine internally, and on Jan. 17th, her whole aspect had improved wonderfully, and the sight of both eyes also. She could now read J.4 with left, and J.10 with right. The tension of the right eye still remained a little above normal ( $T_{\frac{1}{2}}$ ) but that of the left was normal. She had not seen any colored rings. I have seen her once or twice since. She still uses the eserine, and the improved condition is maintained.

CASES OF ACUTE EYEBALL-TENSION BROUGHT ON BY  
MENTAL EMOTION.

CASE IX.—(Alluded to at page 3\*). A lady 60 years of age, very much distressed by losses at cards, but preserving, in consequence of her social position, an appearance of external impassiveness lost the sight of one eye by glaucoma. Being forbidden to play again, she resisted the temptation for a long time, but at last yielded. She unfortunately lost heavily, and the same night was seized by an attack of fulminating glaucoma in the second eye. She became perfectly blind, iridectomy being at that time unknown as a remedy.

\* This case is quoted from Fischer by De Wecker in his *Therapeutique Oculaire*, at p. 372.

CASE X.—(From De Wecker, *loc. cit.*) A distinguished engineer left Paris in a balloon during the siege. The balloon fell in an enemy's country. This gentleman, 56 years of age, was taken and put in prison, and was at once seized with simple glaucoma of both eyes. M. De Wecker performed iridectomy in 1871 with good results.

CASE XI.—(Also from De Wecker, *loc. cit.*). A lady of good position in society was caught in the act of abstracting some article of trifling value from a fashionable shop in the capital; arrested and taken to prison, she was seized with chronic irritative glaucoma of both eyes, accompanied with rapid excavation of the optic nerves, and considerable diminution of vision. The progress, however, was arrested by a double iridectomy.

CASE XII.—(De Wecker's *Therapeutique Oculaire*). *A case illustrating the formation of a filtrating cicatrix after iridectomy.* "Some years ago I operated on a young officer for consecutive glaucoma following a perforation of the cornea with 'enclavement' of the iris. A large pupil was made upwards to disengage the iris as fully as possible. This operation succeeded in preserving vision and relieving all symptoms; at the same time the opacity of the cornea cleared perceptibly. The reunion of the edges of the wound was effected by a cystoid cicatrix. Meeting my patient one day I asked

him how the eye was. Without having the least knowledge of the discussions which had been going on on the subject, he replied, 'I still from time to time experience some sensations of weight in the forehead; my eye then appears to become hard, but I have now discovered a means of relieving myself of this disagreeable sensation; I knead, as it were, my eye through the eyelids, and as I watch the effects in a looking glass, I succeed in making a certain quantity of fluid flow under the conjunctiva, which continues raised by it for some hours. As soon as I have obtained this drainage I feel my eye easy.' The patient having repeated this manœuvre before me I was able to convince myself of the accuracy of his observation."

CASE XIII.—*A case of (so-called Aquo-Capsulitis) Keratitis with punctiform deposits, in which T was noted as being present.*

Jane B—, a housemaid, of spare frame but healthy complexion, æt. 32 years, was attacked without any premonitory signs with severe pain in the left brow, temple, and eyeball. On examination the pupil was half dilated, sluggish and inclined to an oval. The cornea had a slight haziness at the lower and inner quadrant but was perfectly clear elsewhere. On ophthalmoscopic examination the vitreous chamber was obscure and the pupil though well illuminated returned no detailed view of the fundus; not even the position

of the optic disk could be ascertained. At the lower and inner side of the pupil and behind the lens a dense opacity of a size occupying a small portion of the pupillary area was now and again visible. The tension was  $T_2$ ; the V. J16, or "can tell time by a watch." Sulphate of eserine not being obtainable, a solution of extract of Calabar bean (grs. 4 to 1 f. oz.) was dropt into the eye affected twice daily. The next day the pupil had become contracted but V and T as before. She was now ordered solution of corrosive sublimate (Liq. Hyd. Perchlor. in half-drachm doses) three times a day and to continue the extract of calabar bean. On the 4th day T was normal, and the field of vision which had not been tested before did not seem to be contracted. V, however, remained as before.

CASE XIV.—*A case of Traumatic Ophthalmitis with Eyeball-Tension following the operation for juvenile cataract. —Argyll Robertson's operation of Trephining the Sclerotic.—Relief of the more urgent symptoms.*

A. P. a delicate lad, æt. 14 years, with juvenile cataracts and a congenital deformity of the left arm, was operated on by the needle operation in February, 1879. Acute ophthalmitis set in, and treatment by mercurials and the local application of belladonna produced some improvement, but the eyeball remained tense and congested, and with doubtful perception of

light, but great photophobia till May 2nd. On that date the friends having resisted the proposal to perform enucleation, which was strongly urged upon them, I determined to trephine the sclerotic as an alternative. The lower and outer quadrant of the sclerotic between the outer and lower recti muscles was the spot chosen, and a disc of sclerotic was removed. The patient was under the influence of the mixed anæsthetics but was not very quiet, and the trephine penetrated the choroid as well as the sclerotic, allowing a protrusion of the vitreous, which was tolerably healthy in appearance. Part of the protruding vitreous was cut away by the scissors. No bad symptoms had followed and the eye-ball up to May 30 was free from congestion and normal as to tension. On June 11, however, tension had returned. Photophobia has now disappeared, and there is some little improvement of vision, though not sufficient to be able to measure its amount accurately. The operation of trephining has in this case been so far a perfect substitute for the more severe measure of enucleation. The latter may possibly at some future time be required, but for the present the danger of sympathetic irritation of the fellow eye is not imminent. The relief of tension was for a time complete, and the patient himself and his friends are convinced that the operation has been highly beneficial to him.