

## **Syphilis of the larynx, trachea, and bronchi / by J. Solis Cohen.**

### **Contributors**

Solis-Cohen, Jacob da Silva, 1838-1927.  
Royal College of Surgeons of England

### **Publication/Creation**

Philadelphia : Wm.J. Dornan, printer, 1888.

### **Persistent URL**

<https://wellcomecollection.org/works/c5e68b9s>

### **Provider**

Royal College of Surgeons

### **License and attribution**

This material has been provided by This material has been provided by The Royal College of Surgeons of England. The original may be consulted at The Royal College of Surgeons of England. where the originals may be consulted. This work has been identified as being free of known restrictions under copyright law, including all related and neighbouring rights and is being made available under the Creative Commons, Public Domain Mark.

You can copy, modify, distribute and perform the work, even for commercial purposes, without asking permission.



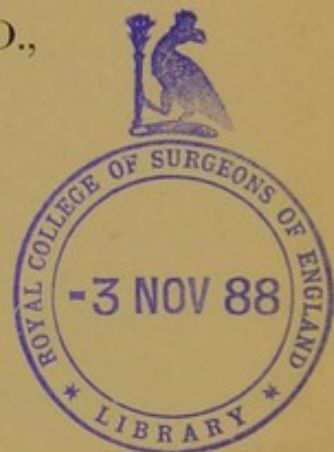
Wellcome Collection  
183 Euston Road  
London NW1 2BE UK  
T +44 (0)20 7611 8722  
E [library@wellcomecollection.org](mailto:library@wellcomecollection.org)  
<https://wellcomecollection.org>

3

SYPHILIS OF THE LARYNX, TRACHEA,  
AND BRONCHI.

BY


J. SOLIS COHEN, M.D.,  
OF PHILADELPHIA.



REPRINTED FROM THE

TRANSACTIONS OF THE PHILADELPHIA COUNTY MEDICAL SOCIETY,  
SEPTEMBER 12, 1888.


<sup>c</sup> PHILADELPHIA:  
WM. J. DORNAN, PRINTER.  
1888.



# SYPHILIS OF THE LARYNX, TRACHEA, AND BRONCHI.

By J. SOLIS COHEN, M.D.

[Read September 12, 1888.]



SYPHILITIC processes are among the most important morbid processes affecting the larynx and trachea. Not only do they injure the structural integrity of the organs directly, but, by their location in the regions occupied by the origin and course of nerve supply, they lead to denutrition of the tissues generally, and to serious motor impairments of the muscles of the larynx. So varied are the manifestations of syphilis, and so important to the welfare of the patient their timely recognition, that considerable detail is proper in their elucidation. In hardly any other department of living pathology has the laryngoscope been of more signal service than in dispelling obscurities in the conception and comprehension of syphilitic disease of the larynx.

The distinctions between secondary and tertiary syphilis, as manifested in the upper air-passages, are so irregular and uncertain, that many writers prefer the terms recent and tardy. In fact, however, secondary lesions are sometimes tardy and tertiary lesions sometimes precocious. Secondary lesions are sometimes present as the sole manifestation of that period. Sometimes they precede cutaneous manifestations. Most frequently they occur in subjects already affected with what are known as mucous patches in other portions of mucous membrane, or with early cutaneous syphilides. Tertiary lesions sometimes present without any history of secondary lesions.

*Pathology.*—The earliest and far most frequent manifestations are subacute and diffusely hyperæmic conditions of portions of the mucous membrane, of varied extent and intensity; an erythema with turgescence, but without hypersecretion, occurring within from six to ten weeks after infection. The affected surface exhibits at first the usual rose-color of congestion, but, as stases, infiltrations, and hæmic transu-



dations occur, it becomes more or less livid in patches which present mottled or flaky discolorations. Superficial erosions often ensue. Occasionally, deep-seated ulceration occurs. Sometimes paresis of the muscles of the larynx is produced. The erosions may be due simply to denutrition of epithelium from mere pressure by infiltrations; or to disintegration of a characteristic proliferative lesion known as the papule or mucous patch, by some termed broad condyloma, a product, according to Virchow, of the same histological character as the indurated chancre and the various gummous formations, namely, an infiltration of tissue with nucleated embryonic cells. These papules are characteristic, but by no means frequent syphilitic products in the larynx; and are so infrequent in the trachea that their occurrence there is denied by authorities the very highest. They are multiple recurrent lesions, almost invariably associated with mucous patches on other mucous membranes; usually lasting from three to five weeks, and sometimes much longer. They are observed from within a few weeks to a few months after infection; sometimes earlier, occasionally as late as eighteen months. They are far the more frequent in tuberculous subjects who have contracted syphilis.

Histologically they are composed of small-celled infiltrations into the corium and into dilated hypertrophied papillæ. Hence they occur in localities where papillæ exist. Consequently they cannot occur below the vocal bands. They are quite red when recent, but soon change to light gray as the epithelium thickens; they then appear as small, wrinkled, opalescent, flattish, ovoidal elevations, varying in size from pin-heads to small peas; depressed in the centre when mature, and when recent circumscribed with a peripheric inflammatory areola. They may subside without trace. When erosion takes place, the surface becomes punctatedly red from exposure of the papillæ. They may undergo destructive ulceration. The opinion is held by some that superficial ulceration is always due to their disintegration; and that they must have existed in many cases in which they have not been observed. They may become the starting-points of small pointed vegetations, histologically identical with papillomata. These are probably non-specific in character, though due to irritation excited by specific processes. They do not undergo ulceration, and rarely undergo absorption under specific medication. When forcibly removed, they repullulate quickly. Similar vegetations sometimes project from the edges of ulcerated patches of tissue. Though usually small, sessile, and multiple, they may acquire such bulk as to interfere seriously with respiration.



The erosions which occur on the surface of the papules or upon simply erythematous mucous membrane are usually superficial, but may extend through the mucous membrane and beneath it, under bad hygienic conditions. Under slight provocative exposures to cold and wet, fluxionary œdema sometimes takes place in their vicinity, occasionally to such an extent as to be menacing to life. The epiglottis often becomes very much thickened; the vocal bands thickened and dentatedly eroded. There seems to be no tendency for secondary lesions to extend from the larynx to the trachea.

Tertiary lesions come under notice most frequently in the stage of ulceration, usually following the liquefaction of gummous nodules, gummous infiltrations, or true gummata, as may be. The epiglottis is the most frequent seat; so frequent, that its lingual and lateral ulceration has been erroneously deemed pathognomonic of syphilis; but destructive lesions may occur in every portion of the larynx. The ulceration is both serpiginous and deep-seated, and while more commonly unilateral, there seems practically to be little limit to its phagedenic destructive ravages under unfavorable conditions, as it destroys and penetrates all the tissues, soft and cartilaginous. Slight provocation may produce fluxionary œdema in this stage also, which may be of the most serious character. Serious hemorrhages may occur from penetration of bloodvessels; and apnœa may ensue from incarceration of fragments of necrosed cartilages and soft tissues. Ulceration may be attended with proliferative vegetations which may occlude the air-passages. Superficial ulceration may heal with moderate cicatrization which eventually becomes hardly noticeable. Deep and extensive ulcerations heal under peculiar whitish, lustrous, stellate, retractile cicatrices, similar to those which follow burns. Instead of cicatrization, adhesions may take place between contiguous raw surfaces, and strictures of various kinds be formed in consequence.

The gummous lesions preceding these ulcerations are of three kinds: small gummous multiple nodules or nodular syphilides; diffuse gummous infiltration; and gummata proper, usually isolated.

Small gummous nodules (nodular syphilide, Lewin) vary in size from that of small bird-shot to that of peas, and are usually grouped in well-defined determinate figures in the body of the mucous membrane, and often so contiguous as to appear confluent. Gummata proper present as firm hemispherical nodules or tumors, usually isolated, from the size of peas to that of cherries or almonds, and sometimes much larger in the connective tissue beneath the mucous membrane; usually uniform in outline, sometimes lobulated; undis-



colored or reddish at the base, and yellowish at the summit. Gummous infiltrations present as more or less longitudinal or more diffuse sub-mucous thickenings corrugating the surface of the mucous membrane. All these products may undergo absorption.

When not absorbed, gummous nodules undergo purulent liquefaction. At this time they become softer, and more yellowish at the summit, the mucous membrane at the base becoming more inflamed and thickened; the whole mass looking not unlike a furuncle. The summit becomes perforated, and gives exit to thickened, yellow pus, with granular admixture of *débris* at first. The orifice rapidly enlarges by ulceration until it becomes fully as large in circumference as the nodule was, or larger; and readily coalesces with ulcerations from contiguous nodules. The ulceration extends in depth until it occupies the entire volume of the nodules, and then may penetrate all the tissues beneath, even to the perichondrium and cartilage.

The ulceration of the nodulous syphilide, as studied in a series of cases by Lewin, is said to take place more from periphery to centre than the reverse, being shallow at first, and then gradually deepening. The ulcer is round, depressed, and sharply bordered. Its bed is covered with a secretion which, from previous fatty degeneration, or purulent metamorphosis, is either thickish, or nearly lardaceous, or composed of purulent detritus.

The more longitudinal and the diffuser gummous infiltrations undergo liquefactive ulceration much more slowly; but the subsequent ulceration, when unchecked, extends much more rapidly, and becomes more readily serpiginous and phagedenic; so that, coalescing with similar conditions in the vicinity, large surfaces in continuity become involved in its ravages. As it extends in superficies it penetrates slowly in depth until it also involves the deeper structures close to the perichondrium, and sometimes to the cartilage. Ulceration varies in rapidity, extent, and penetration according to the succulence or resistance of the tissues contiguous. The ulceration from diffuse gummous infiltration is preceded, according to Lewin, by extensive fatty degeneration of its surface, which gives it an almost grayish-white tinge. This is soon followed by actual defects which, at first shallow, increase in depth, and gradually penetrate to the perichondrium and the cartilage. These ulcers are characterized, like those from the nodules, by sharp definite circumscription, and by their being surrounded with an inflammatory swollen zone. They appear often as though a piece of swollen tissue had been cut out. The edges are often beset with slight crenations which give them a gnawed appear-



ance, but are never undermined; and their bottom is covered with a yellowish-white adherent mass, composed of pus, fatty detritus, and shreds of tissue. Gummata proper sometimes remain unchanged for prolonged periods. When they undergo degenerative metamorphosis there is formed, according to Lewin, only the characteristic viscid fluid, suppuration being exceptional. Ulceration takes place, however, in some instances, and penetrates deeply into the tissues beneath, as in the other two forms. Under unfavorable hygienic conditions of system, or of surroundings, the phagedenic ravages may become uncontrollable. They have been known to attack an artificial opening made to prevent suffocation by a gumma (Holden, *New York Medical Journal*, January 29, 1887).

Perichondritis and chondritis being set up after either form, the ulceration may penetrate the cartilage to the tissues external, forming a perichondrial abscess, which ruptures externally by a more or less circuitous route, whence the fragments of dead tissues are discharged.

Taken in point of frequency the cartilaginous structures seem to be vulnerable in the order following: epiglottis, posterior vocal processes, arytenoids, supra-arytenoids, cricoid, cuneiform, and thyroid. Coming to the softer parts, the vocal bands are attacked next in frequency to the epiglottis, the left band far more frequently than the right; the interior supraglottic walls of the larynx, the aryepiglottic folds, the interarytenoid fold, the posterior wall, the ventricular bands, the subglottic walls of the larynx, the exterior of the soft parts in the pyriform sinus. When the cartilages are attacked, whether primitively or consecutively, the chain of morbid phenomena is perichondritis, chondritis, calcification, caries, necrosis, and elimination of sequestra in crumbled masses and in fragments. The elimination of dead cartilages may consume months, and even years. It usually takes place by the interior route, occasionally by the exterior. In both instances abscess and fistula are formed; and elimination of large fragments by the interior route sometimes produces suffocative paroxysms, and occasionally actual suffocation.

The epiglottis, as repeatedly noted, is especially vulnerable to the syphilitic process, and every variety of lesion possible may ensue in any extent, from insignificant erosion to complete destruction, the character of the lesion depending upon that of the structure destroyed. It is this, as pointed out by Seiler, which gives such an irregular conformation to the epiglottis when its glands have been destroyed.

Exulceration of the entire mucous membrane at the edge reveals the exposed cartilaginous structure as a yellowish-white stripe em-



bedded between two thickened masses of spongy-looking tissue. Ulceration of the cartilage often commences at the anterior surface in the form of a round ulcer with thickened excavated edges. Destructive ulceration usually progresses from the side and from the edge. When the valve is only partially destroyed, its remains may present two or more irregular fragments separated by fissures of varying depth, or a single fragment of any breadth, from a small stripe to nearly the entire bulk.

When totally destroyed, the orifice of the larynx is separated from the post-lingual sulcus by a more or less irregular ridge of ulcerated tissue, which, after cicatrization, presents as a pale, deformed stump. This, however, does not, as a rule, prevent gluttony, and in some instances does not even interfere with it; the occlusion of the larynx being effected by the base of the tongue, on the one hand, and by close approximation of the ventricular bands and sphincter-like approximation of the aryepiglottic folds, on the other.

The other cartilages, when the subject of destructive progressive ulceration, are macerated out of their investments, as it were. The ulcerative process extends into the cartilage, surrounding it, if a small one, or circumscribing a portion of it, if it be a large one. The cartilage then perishes by necrosis, is laid bare, and becomes detached from its connections, in some instances remaining entangled in a sort of pocket scooped out of the soft tissues. The necrosed cartilage finally breaks through to the interior, and is usually discharged by expectoration. If it be situated below the glottis, paroxysms of suffocation may ensue, or even actual apnoea, as from any other foreign body. Exfoliations of the cricoid cartilage are the most frequent source of these untoward results, which, however, sometimes ensue from exfoliations of the thyroid.

The ulcerative process sometimes penetrates bloodvessels and hemorrhage follows. Such hemorrhage has been known to terminate fatally (Türck, *Klinik d. Krank. d. Kehle*, p. 413, Wien, 1886, illustrated).

The vocal bands frequently sustain permanent lesion varying from minute losses of substance to entire destruction. Transversal denuded erosion of the border is not uncommon, and detachment from the posterior vocal processes not infrequent. Sometimes abundant irregular papillary proliferations take place, forming mobile, projecting, pyramidal, or irregular dendritic vegetations, which project like soft, mobile stalactites into the interior, and which are large enough, in exceptional instances, to demand operative interference. Similar conditions and productions may prevail with the ventricular bands.



Superficial ulcerations may heal with moderate cicatrization, which eventually becomes hardly noticeable. In deep and extensive ulcerations, when cicatrization occurs, a peculiar lustrous, whitish, stellate, contractile cicatrix is formed, similar to the syphilitic cicatrix in other mucous membranes. Instead of cicatrization, adhesions often take place between ulcerated surfaces, and thus a variety of injurious morbid conditions occur. The vocal bands may become united by a broad fibrinous band stretching between them, or by a similar obturator, formed of their thickened and distended mucous membrane. The membranous web, thus formed between the vocal bands, usually unites them for a variable distance, commencing at the commissure; the posterior border of the structure being crescentic in outline. Exceptionally the cords may become involved their entire length, with an orifice in the central portion of the web (Navratil).

This membranous union has been known to take place in six days (Rossbach : *Langenbeck Archives*, vol. xiv.). In a case watched by Sommerbrodt (*Berlin. klin. Woch.*, April 1, 1878) the anterior third united in fourteen days, and the union of the bands was complete in six weeks. In other cases the vocal bands become united without any membrane intervention.

Other adhesions sometimes take place which may seriously impair glutton, phonation, and even respiration. These comprise depression of the epiglottis to one side or the other, or to an aryepiglottic fold, and preventing proper closure of the valve or complete elevation; adhesion of the epiglottis to either lateral pharyngeal wall; adhesion of ventricular to vocal band, sometimes preventing closure of the glottis, and often producing a shrill, weak, piping voice; adhesions anteriorly of the two vocal bands or of the two ventricular bands; adhesions of the inner surfaces of the mucous membrane of the arytenoid cartilages, so as to fix the vocal bands immovably in the median position. Other results of syphilitic laryngitis are hypertrophies, diffuse and discrete, of mucous membrane, connective tissues, or muscular substance, and consequent stricture, varying in extent, locality, and interference with function; myopathic paralyses; muscular atrophy, and the development of morbid growths.

Perichondritis or chondritis, whether following ulcerative destruction of the soft tissues or preceding it, usually excites considerable fibrinous infiltration into the adjacent submucous connective tissue, producing a chronic fibrinous œdema. When extensive, this produces suffocative symptoms, and may threaten asphyxia. Sometimes the submucous infiltrations become organized and transformed into dense fibrous tis-



sues incapable of undergoing absorption, and thus they produce deformity, occlusion of the larynx, and stricture. The strictures are often incapable of yielding to systematic dilatation, even when instituted early; and hence tracheotomy is usually necessary to provide artificial means for respiration below the seat of obstruction. After tracheotomy, the process may progress to complete obliteration.

These strictures are of the most varying form and calibre, some of them distorting the configuration of the interior of the larynx almost out of recognition. Fortunately, most of them occur in the supra-glottic region, where they are far more accessible to effective treatment.

Lesions of either soft tissues or cartilage in the neighborhood of the important crico-arytenoid articulations excite non-specific inflammation of the joint which may produce true or false ankylosis. Syphilis is probably the most frequent cause of this lesion. When the specific process invades the joint, the ligaments and perichondrium suffer; and then true ankylosis, or luxation, or disarticulation, and even discharge of the arytenoid and supra-arytenoid cartilages may ensue.

In the latter stage of unrestrained lesion, the cachexia is much the same as in analogous advanced stages of tuberculosis.

Myopathic paralyses of the muscles of the larynx may occur in the later periods of secondary syphilis, and at any period of tertiary syphilis. They are most frequently unilateral, the left side being affected far oftener than the right. The onset is often sudden or acute, following severe or sudden exposure to cold and dampness. The paralysis often affects the dilator muscles, and bilateral paralysis of the dilators is not infrequent. Paralyses of the arytenoid muscle and of the entire constrictor group are the most frequent varieties. These paralyses differ in their pathological origin from other examples of paralysis in syphilis, which are due, respectively, to compression of the tract of the nerve-supply by diseased tracheo-bronchial glands or other structure, and to neural or cerebral lesions which present in the latter stages of the confirmed dyscrasia.

Tertiary lesions of the trachea are first observed so very frequently in the stage of ulceration, that it had been assumed that tertiary syphilis of the trachea always produces ulceration (Vierling). Schech and others have reported instances of resorption of gummata under specific medication. The clinical tendency, however, is to ulceration. Tracheal ulcerative lesions are sometimes unassociated with lesions elsewhere in the aërial tract. Much more commonly they are found associated with similar lesions in the larynx, in the bronchi, or in both.

Pharyngeal syphilis exists in many instances (thirty out of forty-six,



collated by Vierling), and pulmonary syphilis in not a few (six out of fifty, Scheck). They are often found associated with additional syphilitic lesions at a distance. In a large proportion of instances a primitive bronchus is affected, the left one the more frequently; in some, both primitive bronchi; in a few, the smaller ramifications (Vierling); and, exceptionally, even the minutest (Lancereaux). In some instances syphilitic lesion is confined to the bronchi (five cases, by Vierling). The upper portion of the trachea suffers most when the larynx is involved; the lower portion, when the disease is isolated or associated with syphilis of the bronchi. In some instances the middle portion alone suffers (Vigla and Charnal, Berger, Mackenzie, of Baltimore, Semon); exceptionally, the two extremities, with complete conservation of the middle portion (Tessier, cited by Rey).

When not occurring in direct continuity with similar lesion in the larynx, the most frequent seat of ulceration is in the anterior surface of the lower portion of the trachea just above the bifurcation, whence it extends upward, or in patches continuously sometimes as far as the cricoid cartilage; sometimes almost completely around the interior in periphery, occasionally completely around. Multiple perichondritis is easily set up and results in abscess, denudation of cartilage, calcification, caries, and necrosis. Portions of dead cartilage are sometimes coughed up in fragments. Sometimes semi-detached portions project into the interior and interfere seriously with respiration and with expectoration. The ulceration usually begins in a number of small ulcers which extend in depth and in periphery, baring the perichondrium, and causing portions of the cartilaginous rings, or entire rings, to undergo denudation, necrosis, and exfoliation. Coalescence with similar ulcerating surfaces, or phagedenic extension sometimes produces very extensive ravages which may involve nearly the entire circumference of the trachea, and nearly, occasionally quite, its entire length. Flaps of detached membrane sometimes fall over, producing valvular impediments to inspiration, or to expiration, according to the position of the attachments. The cicatrization of annular ulcerations produces stricture often so low down as to be beyond relief even from tracheotomy, the parts not being well adapted to respond to artificial dilatation. The strictures are irregularly ovoidal in shape, sometimes funnel-shaped, and of varying thickness from a few lines to that of several rings.

These cicatrices may reduce the calibre of the trachea so considerably as to prevent respiration. Occlusion to the calibre of a crowquill is not uncommon, and still greater occlusion has been noted in some



instances. Annular stricture at the bifurcation may become so great as barely to admit the passage of a delicate probe. (Obtulowicz: *Cent. f. Chir.*, 1879, No. 7.)

Irregular annular dilatation of the trachea is often produced by the pressure of the air current above the stricture and sometimes below it; and dilatation of the bronchi is not uncommon.

Projecting ridges of cicatricial tissue below the point of stricture are sometimes so located as to occlude the inferior orifice of a tracheal canula more or less, a point not sufficiently recognized, for it might be practicable in some instances to push a canula into a position which would allow its inferior extremity to pass the obstruction.

Stricture of the bronchi is rare. It affects the left bronchus more frequently (Verneuil, *et al.*); sometimes the right one (Wilks, *et al.*); occasionally both (Virchow, *et al.*). The connective tissue around the strictured portions usually undergoes permanent sclerotic proliferation. Sometimes there is great peritracheal sclerosis, sometimes none. The peritracheal glands may undergo great enlargement. All these conditions superadded to the internal stricture may greatly increase stenosis.

Ulceration sometimes penetrates through the trachea producing abscess opening into the œsophagus or the mediastinum, the aorta (Rokitansky: *Path. An.*, Bd. 111, p. 22; Wilks: *Trans. Path. Soc.*, London, 1865, p. 52), the pulmonary artery (Kelly: *Id.*, 1872, p. 45), or the vena cava (Turner: *Id.*, xxxvii. p. 117). In at least two instances of ulceration of the left bronchus, the left branch of the pulmonary artery has been found perforated (Vierling).

Inflammation around the trachea or bronchi sometimes produces adhesions to the œsophagus or to other tissues, which depresses the trachea and larynx and impairs their upward movements in glutition. Sometimes it produces peritracheal or tracheo-bronchial abscess. Abscess of a bronchus, sometimes deeply seated, has occurred under my own observation after tracheotomy; apparently as a result of too assiduous swabbing of the canula and pushing the feather beyond its outlet.

The lesions of hereditary syphilis are almost identical with those of the gummous infiltrations of tertiary syphilis. They sometimes appear very early. Ulcerations have been noticed in infants at two months of age (Parrot: *Prog. Méd.*, 1878, p. 653). Stricture from perichondritis has been noticed at the same age (Fränkel: *Wien. med. Woch.*, 1868, No. 18; Parrot: *loc. cit.*).

*Symptomatology*—The laryngeal symptoms of secondary syphilis



are not characteristic. They are chiefly comprised in dissonant alterations of the voice, either hoarseness, dysphonia, and in some cases occasional or temporary aphonia. The hoarseness is supposed to have some peculiarity which has been termed *raucedo syphilitica*; but this is not the case. In some instances it is simply due to the catarrhal laryngitis, in others to paresis of one or more of the constrictor muscles, or possibly to paralysis of the tensors. Respiration is not affected except in those instances in which œdema occurs in such a position as to occlude the passage for air, when it will be announced by dyspnœa and stridulous respiration, the characteristic symptoms of that condition. Titillation and cough are not as frequent as in inflammations of other origin. In many instances there is no tickling and no cough, no pain and no dysphagia.

Dysphagia is not present unless there be œdema of the parts utilized or pressed upon in glutition.

In tertiary syphilis of the larynx the symptoms are usually those of impairment of phonation, followed in severe cases by dyspnœa and stridor also, chiefly inspiratory. The stridor is worse at night from inaction of the auxiliary muscles of respiration. Should the mechanical impediment to respiration increase, inspiratory depression of the soft parts below the sternum takes place. If relief is not obtained, artificially or otherwise, asphyxia supervenes from imperfect aëration of the blood. Suffocation may occur suddenly from impaction of detached cartilage; but is more frequently slow enough in its approaches to allow time for tracheotomy.

Titillation and cough are more frequent in the earlier stages than in secondary syphilis; but they diminish after ulceration has taken place, except in so far as they are produced from time to time by morbid products detained upon diseased and adjacent surfaces. Pain is infrequent before the period of ulceration; after that it may be severe, and radiate into the ears as in other ulcerative diseases. In the early stage there is no expectoration. The earliest expectoration is of collateral catarrhal products only. As ulceration progresses it becomes muco-purulent, and then purulent and sanguineo-purulent, and mixed with detritus according to the stage and location of the lesion.

If gangrene takes place the odor becomes fetid; and the expectoration contains fragments of dead soft and cartilaginous tissue, as may be.

Dysphagia ensues when the disease is in a locality to interfere with glutition, and odyphagia when ulcerations have occurred in the same localities.



In tertiary syphilis of the trachea the symptoms affect mainly the function of respiration, the voice often remaining normal even when breathing is seriously embarrassed.

Pain along the course of the trachea, if constant, is indicative of lesion at that particular point. Cases may run their entire course without any special symptom, even in the presence of stricture of the trachea, and of the bronchi, and of extensive disorganization as revealed at the post-mortem examination.

In hereditary syphilis, the symptoms are sometimes congenital and may remain practically continuous for years. Respiration and phonation are both affected. The cry of the infant sometimes possesses a shrill metallic resonance which has been compared to that of a tin trumpet. Cough is more frequent in the child than in the adult. Glutition is often difficult and sometimes painful. Expectoration occurs in the suppurative stages when the child is old enough to expel the products, which by infants are swallowed or retained in the air-passages. Laryngismus is a symptom of frequent occurrence in young children.

*Etiology.*—The probable condition attracting the manifestation of constitutional syphilis to the larynx is superficial catarrhal laryngitis from hereditary or acquired proclivity, or from exposure, or from abuse of tobacco, alcohol, or other indulgence, or from misuse of the voice. Such exposures cause more males to be affected than females, as there is no assignable sexual reason for preponderance. Tracheal lesions, on the other hand, have been reported more frequently in females, probably because the laryngeal lesion is attended to more promptly by the male. Syphilitic disease often extends by continuity from the oropharyngeal region to the larynx, principally along the pharyngo-epiglottic fold to the epiglottis, and thence along the aryteno-epiglottic fold, and from the two structures to the interior. Hereditary syphilis has been observed in intrauterine life (Monti: *Med. Times*, Phila., April 28, 1877, p. 336). Hereditary syphilis of the intensest character has been occasionally observed at a very early age, as in the case of an infant whose symptoms began with coryza in the tenth week of life, and terminated in death by suffocation from stenosis nineteen days later. Post-mortem, with examination, revealed, in addition to syphilitic lesions in the liver, destructive perichondritis of cricoid and left arytenoid cartilage, and fatty degeneration of arytenoid and both posterior crico-arytenoid muscles and the left superior nerve (Fränkel: *Wien. med. Woch.*, 1868, Nos. 69, 70, cited by Ziemssen and by Mackenzie). Children less than a year of age often show



laryngeal lesions of hereditary syphilis, and ulcerative lesions have been seen at two months of age (Parrot: *Prog. Méd.*, 1878, p. 635). Many cases occur in children but a few years of age, and sometimes the manifestations are deferred to the period of puberty or even later. Indeed, in opposition to the received opinion of syphilographers, I have reason to believe that in a few instances I have seen its manifestations delayed as late as the third and even the fourth decennium. True, in such instances as the latter it is quite possible that infection may have been acquired in some method unknown, without having been followed by any secondary manifestations, or that early hereditary manifestations may have escaped recognition. The secondary manifestations occur most frequently in adolescents and young adults. They appear most frequently at periods varying from a few weeks to a few months after infection, sometimes as late as the fourteenth or seventeenth month (Morgan). Tertiary lesions are most frequent at rather maturer ages, and occur occasionally in quite advanced life. They have been reported as early as the sixteenth month (Türk, *op. cit.*), and as late in their first appearance as the thirtieth (Türk), and even the fiftieth year (Mackenzie). Tracheo-bronchial tertiary lesions have been reported as appearing as early as the ninth month after infection, but these lesions are usually coincident with the laryngeal lesions when not immediately consecutive to them.

Most of the instances of tracheal syphilis occur in individuals whose employments expose them to irritation from dusts of various kinds (Vierling: *Deutsches Arch. f. klin. Med.*, 1878, Bd. 21). Hereditary tracheo-bronchial syphilis is far less frequent than the laryngeal forms. It has been observed before the age of puberty.

*Diagnosis.*—Differential diagnosis between secondary and tertiary lesion is sometimes difficult, particularly in the transitional period especially described by Whistler. The discriminating characteristics are less well marked in laryngeal syphilis, perhaps, than in any other variety.

It may, however, be broadly stated that secondary lesions, erythematous, papular condylomatous, or paralytic, are superficial; and that tertiary lesions are gummatous, ulcerous, carious, necrotic, and deep-seated. Laryngitis occurring within a few months of infection, is almost invariably secondary. Lesions appearing before the termination of the third year are presumptively secondary: those appearing within the third year, secondary, or transitional: and those appearing after the termination of the third year, tertiary. Nevertheless, secondary lesions may be ulcerous, and undoubted tertiary manifestations have been recognized even within nine months of infection.



The history of the case, and the previous or actual presence of manifestations of syphilis elsewhere, are the main positive factors in the diagnosis of specificity, especially in the early stages of either variety. The later lesions of tertiary syphilis are often sufficiently characteristic; sometimes not at all so. In cases of doubt, antisyphilitic treatment will almost always detect a lesion of syphilitic origin, but not invariably. Hence, in instances of strong suspicion, the various methods of antisyphilitic medication should be thoroughly tried before that test is abandoned. This suspicion is justifiable in cases of obstinate chronic laryngitis, whether ulcerative or not, in individuals in whom no other appreciable local or constitutional cause can be detected.

Laryngoscopic inspection is an invaluable aid in diagnosis; though practically indispensable, it is inadequate for fully appreciating the extent of deeply seated lesions; and its revelations are not always sufficient to establish the diagnosis in the absence of corroborative lesions elsewhere. Erythematous and catarrhal inflammation of secondary syphilis, when diffuse, are not to the ordinary eye distinguishable from similar non-specific conditions. Circumscribed erythema, though usual in syphilis, occurs in non-specific laryngitis also; consequently, that condition alone is insufficient for discrimination. Patchy erythema on the vocal bands, and elsewhere, may be regarded as characteristic. Not so, however, the shaded pigmentations at the extremities of the vocal bands.

Symmetric bilateral localization of erythematous and other patches is highly characteristic of secondary syphilis; but a contrary condition by no means excludes the diagnosis. Isolated bilateral congestions of the supra-arytenoid structures and of the Wrisbergii have been cited as pathognomonic. Nothing can be more fallacious or misleading. Enlarged inguinal and post-cervical glands furnish excellent corroborative testimony of syphilis.

Papules, or condylomata, upon an erythematous mucous membrane, are to be considered pathognomonic. Their recognition may require an exceptionally good light on the one hand, or repeated examinations on the other. They must be carefully discriminated from minute collections of mucus or of saliva.

Diffuse gummous infiltration is to be distinguished first from inflammatory syphilitic infiltration by the coexistence of gummous processes elsewhere, its more circumscribed contour, and its sharper definition. Differential diagnosis is much easier after it has reached the stages of liquefaction and ulceration.

Syphilitic ulceration usually proceeds from above downward, rarely



in the opposite direction, and often in extension from ulceration in the pharynx. Repair usually proceeds from below upward. Apart from these guides there is nothing positively characteristic enough to determine an ulceration to be syphilitic in character by mere inspection.

The absence of pain has been regarded as characteristic; but, on the one hand, carcinomatous ulceration often exists without pain, and, on the other hand, the ulcerative lesions of syphilis are sometimes attended with lancinating pains of the most severe character.

In the gummatous stage of tertiary syphilis diagnosis is not difficult. Nodular syphilides and gummata are recognized in the forms and at the localities mentioned under pathology, page 220. They may be confounded with other neoplasms, and with abscess. In cases of doubt, antisiphilitic treatment should clear up the diagnosis. The physical distinction between gummata and condylomata may in some instances be obscure (Semon).

The main reason why gummata are so infrequently seen, as to have led some observers to an erroneous opinion as to their rarity, is that many patients do not present themselves until after the stages of liquefaction and ulceration have become established. When this stage has not been observed, and the larynx, as is more usual, is not inspected until after ulceration has considerably progressed, the appearances are not always characteristic. They may be confounded with those of lupus, carcinoma, and tuberculosis. The general diathesis, the clinical history, the existence of enlarged submaxillary and post-cervical lymphatic glands, the character of concomitant affections of the skin and mucous membrane, the aspect of the patient, assist in discrimination. Sometimes, too, tuberculous and syphilitic lesions coexist.

The typical tertiary ulcer, sharply defined, and below the surface of the mucous membrane, is more or less circular when recent, more or less crenated when reparation is taking place at one or more points of the circumference, and looking as though cut out with a punch when in œdematous tissues. Its borders are sharp, elevated, but not often undermined, and more or less rounded in their visible outline, and are surrounded by a more or less circumscribed inflammatory areola in the mucous membrane. The bottom feels hard to the probe on palpation. The bed of the ulcer is grayish, or lardaceous, yellow from fatty detritus, and covered with adherent concrete pus, through which, here and there, prominent rosy granulations often project. The surrounding tumefaction is harder and more indurated than in other varieties of ulcer. Purulent accumulations are rather indica-



tive of the syphilitic process. At a later date denuded or necrosed cartilage may be visible in suitably located ulcers.

In cases in which neoplasms have become developed at the seat of existing ulcerations, or of cicatrized ulcerations or erosions, it is often impossible to pronounce as to their nature, even by the test of anti-syphilitic treatment. Not only do such neoplasms exist independently of the syphilitic process, or as the result of irritation provoked by syphilitic process in the vicinity; but when undoubtedly syphilitic in origin, they rarely disappear under specific medication. Tertiary syphilis is usually recognizable in the stages of œdema of the larynx; and almost always in the reparative stages of cicatrization, or in the subsequent stages of stenosis, whether from cicatricial retraction or from organization of effused products.

Tracheal syphilis is recognized by laryngoscopic detection of the lesion or by the special symptoms narrated. It is often beyond laryngoscopic detection when in the lower portion of the trachea, frequently so when in the middle, and occasionally so even when in the upper portion; sometimes on account of tumefactions above the lesion, sometimes because the lesion itself is out of the line of vision. Tracheal and tracheo-bronchial obstructions are often differentiable by the absence of retraction of the head and of extensive downward and upward movements in respiration, as occur in obstructions within the larynx (Gerhardt: *Deutsch. Arch. f. klin. Med.*, 1867, Bd. ii.); the descent in infra-laryngeal obstructions being no greater than one centimetre.

*Prognosis.*—Secondary lesions, even when ulcerative, are most frequently curable without cicatrix or without any other sequel. Exulceration of the vocal bands sometimes leaves permanent defect of tissue. The prognosis is good except during temporary conditions of œdema, when it may be grave for the time being. The inflammatory congestion and turgescence are more chronic than in catarrhal inflammations, and are often recurrent. Actual hyperplasia is apt to remain permanent, even after cure of the syphilitic lesion, despite the most assiduous treatment; and when it occupies a vocal band the voice may be permanently impaired. The singing voice may remain imperfect, although the conversational voice be fully restored; the injured tissues being unequal to the nicety of adjustment requisite for cantation.

In tertiary lesions the prognosis depends mainly on two factors: First, on the impairment of the general health, and the significance of lesions elsewhere, especially in the brain and meninges, and in other important organs. Second, in the extent of ulceration and the char-



acter of deformation or stricture which may follow. Temporary gravity exists in the presence of œdema; during the period of exfoliation of necrosed cartilages, and in acute bilateral paralysis of the dilator muscles, the result of exposure to cold or other cause, or to unilateral paralyses when the opposite side is immobile from gumma, or from crico-arytenoid ankylosis (Charazac: *Rev. Mens. de Lar.*, Sept. 1884), any of which conditions may demand prompt tracheotomy to prevent death by suffocation. Ulcerative lesions of the trachea may be fatal by hemorrhage from penetration of large bloodvessels; by pneumonia from access of food through perforation of œsophagus (Berger); or by septic processes due to rupture of the mediastinum. Permanent impairment of the voice is to be expected in all cases in which the vocal bands undergo serious injury, and in many in which permanent changes are likely to take place in other structures contiguous to the glottis.

Gluttony is rarely affected, even after complete destruction of the epiglottis; and in exceptional cases difficulty is mainly confined to fluids swallowed without deliberation.

Stricture rapidly supervening upon hyperplasias is often amenable to active treatment, sometimes with striking rapidity (Krishaber, Lewin, Schech, etc.); but the more frequent stricture of slow progression can only exceptionally be brought under control.

Serious danger attends even cure of extensive ulcerative lesions in the interior of the larynx, for the resulting stricture, if severe, is likely to necessitate tracheotomy, with great probability of permanent retention of a canula. Stricture is rarely amenable even to excision of cicatricial tissue by external access. Subglottic stricture is much more serious than supraglottic, and tracheal far more serious than laryngeal stricture. Stricture of the trachea, when low down, is practically unsusceptible of amelioration; and death by slow apnœa, or by sudden suffocation, is the usual outcome.

When the syphilitic cachexia has advanced so far as to have produced incurable lesions in important viscera or in the cerebrum, death may ensue from these causes despite sustained cure of syphilitic lesions in the larynx. In cases complicated with paralysis of the dilator muscles of the larynx from cerebral lesion, the death may take place by occlusion of the glottis and suffocation, or by encephalitis and coma.

In hereditary syphilis the prognosis is very much the same as in tertiary syphilis; being much worse in infancy and childhood than in more delayed manifestations. The small size of the larynx renders



stricture and intercurrent œdema far more significant; and the tendency to spasm of the larynx inherent to all laryngeal affections in childhood presents an additional element of danger. Fatal issues from these three causes are not infrequent. An element of uncertainty as to the final result remains in all varieties of syphilis of the larynx and trachea, due to the fact that permanent liability to recurrence prevails in many instances, despite the best apparent results of the most judicious treatment; and often, too, after prolonged intervals of immunity from any further manifestation of constitutional syphilis.

*Treatment.*—Fortunately, lesions even of great destructive and menacing tendency are amenable, as a rule, to treatment; often promptly.

The treatment, broadly stated, is that applicable to constitutional syphilis in general; mercury in the early manifestations and iodides in the late ones. In many of the latter, if not most, the mixed treatment combining the two specifics is the most serviceable. In congenital syphilis the gray powder is believed to be the most efficacious form of the drug. While willing to admit that secondary lesions often subside without traces and without much risk of subsequent tertiary manifestations, although mercury be withheld, I deem it the more prudent practice, and, therefore, the best practice, to employ mercury; in the belief that its specific constitutional influence affords the patient better protection as to future manifestations. As to the value of iodides in tertiary syphilis, there is no difference of opinion. Tonics are often indicated. All sources of irritation, exposures, excessive use of the voice, alcohol and tobacco, are to be avoided.

Sedative inhalations in vapor or spray are often of great topical benefit in subduing collateral inflammation; and antiseptic inhalations are indicated in gangrenous cases.

Secondary syphilis. Mercury may be administered by the stomach or by the skin. When the lesions are moderately severe or slow in progress, the corrosive chloride may be administered in doses of from one-sixteenth to one-eighth grain, three times a day. The green iodide may be given in doses gradually increased from one-sixth of a grain three times daily to the point of tolerance. The addition of extract of belladonna may cause it to be better borne by the stomach. In individuals in whom serious gastric disturbance is produced before any specific effect has been noted, and in seriously severe cases and cases of rapid progress, inunctions of a drachm of mercurial ointment daily are preferable, or pencillings with solutions of oleate of mercury in oleic acid, ten per cent. Lewin prefers hypodermatic injections of



corrosive chloride. Concurrent stomatitis is to be combated by the internal administration of potassium chloride, or the use of a saturated solution of that salt, or of a weak solution of potassium permanganate as a mouthwash. It is hardly necessary at the present day to mention that salivation is to be avoided. In my own experience topical medication is, as a rule, superfluous in non-ulcerative secondary syphilis, and often unnecessary in the presence of ulceration. When topical medication seems necessary, inhalations of sprays of corrosive chloride (Demarquay), half an ounce or more daily of a solution containing one grain to four ounces of water, are useful locally and constitutionally. In particularly obstinate conditions, especially in the presence of hyperplasias, the topical application of solutions of iodine and potassium iodide in glycerine (Schnitzler) half a drachm and a drachm respectively to the ounce, made daily or at longer intervals, sometimes accelerates the cure.

In the transitional stage and in the tertiary stages, the mixed treatment has been the most beneficial in my own practice; one-sixteenth to one-eighth of a grain of the corrosive chloride, five to ten grains of potassium iodide in half an ounce or more of the compound syrup of sarsaparilla, three times a day. It may sometimes be necessary to increase the dose of the iodide up to the point of tolerance. In such cases the "grain to drop" solution is the most convenient preparation. The danger of inducing œdema of the larynx by sudden large doses must not be ignored. When necessary, sodium or ammonium iodide may be substituted for the potassium salt, or hydriodic acid may be employed.

In the presence of œdema, hypodermatic injections of corrosive chloride (Lewin), one-thirtieth of a grain, twice a day for a day or two, and after improvement, at intervals of three days or more, have proved quite efficacious. If amelioration is not prompt, and if the patient cannot be carefully watched by an attendant competent to interfere in an emergency, it is best, in my opinion, to perform prophylactic tracheotomy, instead of awaiting its urgent indication. The same rule is applicable to threatening cases of extensive hyperplasia whether from specific or from non-specific infiltrations.

Nevertheless, remarkably happy results, even in urgent cases of these kinds, have frequently followed active treatment by inunction (Krishaber) and by hypodermatic injection (Lewin). Intubation of the larynx from the mouth (O'Dwyer) has been recommended as applicable in many instances of œdema and constriction heretofore



treated by tracheotomy. As yet, I know of no experience with intubation in this special connection.

Ulcerations heal more promptly when the constitutional treatment is seconded by topical cauterizations with fused silver nitrate, or with mercuric nitrate one part to from four to ten of water, or with cupric sulphate in crystal or in saturated solution. Chromic acid, one part in from five to eight of water, has long been extolled (Isambert). Some prefer iodoform (Morgan). On the other hand, extensive ulceration often heals promptly under the influence of constitutional treatment alone.

Vegetations, detached flaps of mucous membrane, and semi-detached fragments of necrosed cartilage call for operative removal with cutting forceps, evulsion forceps, or snares, as may be most convenient, when these products are so located as to interfere with freedom of respiration or to threaten such interference. When these manipulations are impracticable, tracheotomy may be requisite. When tracheotomy has been performed under any of the conditions mentioned, the canula is to be removed as soon as it has become apparent that its retention is no longer essential to the safety of the patient. Cicatricial stricture of the larynx may be treated by the introduction of the intubation tube through the natural passages (O'Dwyer). From recent observations I fear that intubation will fail, unless supplemented by occasional incision and divulsion. This treatment may possibly be applicable to stricture high up in the trachea. Stricture in the middle portion of the trachea requires low tracheotomy and the introduction of a canula long enough to reach beyond the constriction. O'Dwyer proposes incision of the trachea, introduction of the tube, and closure of the trachea over it. Stricture at the bifurcation is hopeless.

Paralyses, even those of the posterior crico-arytenoids, are usually amenable to anti-syphilitic treatment even when of considerable standing. This fact seems to indicate that the atrophy found in neurotic paralysis is not due to simple inaction of the muscle, but rather to trophic impairments of neurotic origin. Electrization may be employed when relief does not ensue from systemic medication.

Membranous webs, occluding the glottis from side to side, are to be divided by incision or by electric cautery, the edges cauterized, and readherence prevented, if possible, by frequent introduction of dilating sounds. These laryngoscopic operations are often rendered futile by insurmountable tendency to recicatrization, whereby the morbid condition is reproduced. Success in cases of this kind would seem to require exposure of the interior of the larynx by external division of



the thyroid cartilage, and excision of the whole of the cicatricial tissue (Mackenzie: *Med. Times and Gaz.*, August 19, 1871, p. 218).

When syphilitic laryngitis has existed for a long time, such an amount of destruction may have taken place, and such a degree of systemic poisoning, as to render recovery impossible. The constrictions produced by the cicatrices of extensive ulcers, and the adhesions between adjoining surfaces, in cases that recover, are often such as to render tracheotomy necessary, with the permanent use of the tube; for the constrictions following syphilis are not, as a rule, amenable to dilatation.

Threatened asphyxia or unconquerable dyspnœa, from gumma, loose cartilage, morbid growth, abscess, or œdema, may necessitate tracheotomy. Tracheotomy for the purpose of conquering dyspnœa due to tumefactions in the larynx is perfectly justifiable, and usually successful. It is likewise justifiable for the mere purpose of securing rest to the organ—much more so, indeed, than in analogous conditions attending tuberculosis.

The treatment for local adhesions consists in relieving the tension as far as possible by laryngoscopic division of the constricting bands of tissue, with knife or with electric cautery, and then cauterizing and recauterizing the adjacent surfaces, to prevent fresh adhesions. These cases require careful watching and prompt attention to overcome the disposition to recurrence, which is very apt to take place in spite of all efforts. When the epiglottis is implicated, much good can be done by teaching the patient to move the organ frequently by means of his forefinger.

In a case of stenosis due to "concentric hyperchondrosis," as a result of the hyperplastic chondro-perichondritis, Prof. Heine performed a successful resection of the anterior portion of the thyroid cartilage, splitting that structure in the middle line, separating the perichondrium and superjacent soft tissues with the elevator, to the distance of one-half its surface on the two sides, and then removing the denuded portions by longitudinal section with bone forceps. The patient rallied so well from the operation that an artificial vocal apparatus could be substituted for the ordinary canula on the fifth day. He became able to resume work after a while; but the disease made new inroads, and he died, eleven month later, in an advanced stage of tuberculosis.

Despite the most judicious treatment, and the most satisfactory immediate results, recurrence or recrudescence takes place in many instances at variable intervals, requiring resumption of specific treat-



ment. The most satisfactory results claimed by any writer have been in cases actively treated by Lewin with hypodermatic injections. It is advisable to keep patients under observation for many months after active treatment has been discontinued. Mercuric iodide (biniodide) in small doses, one-twentieth to one-tenth of a grain, three times daily, may judiciously be given for prolonged periods during which apparent health exists. Potassium iodide, in diminishing doses, should be administered from time to time for a few days every month until the patient begins to show susceptibility to physiological effects from small doses; and then this susceptibility should be tested from time to time at intervals of a few months. Such supervision for two years at least seems to present the best prospect for riddance from the diathesis.

It may be mentioned in conclusion that, under intercurrent attacks of erysipelas, obstinate cases of tertiary syphilis of the larynx and trachea have undergone cure after having resisted all medicinal treatment.