Presented to the Library
of the
Royal College of Surgeons
of
England
by
Dr Lee
19 Nov 1858

ENGRAVINGS

OF

THE GANGLIA AND NERVES

OF THE

UTERUS AND HEART.

ENGRAVINGS

OF

THE GANGLIA AND NERVES

OF THE

UTERUS AND HEART.

For the Use of Students in Anatomy and Physiology.

BY ROBERT LEE, M.D., F.R.S.

LONDON: JOHN CHURCHILL, NEW BURLINGTON STREET.

MDCCCLVIII.

LONDON:
REED AND PARDON, PRINTERS,
PATERNOSTER ROW.

PREFACE.

THERE being no correct description or delineation of the Nervous Systems of the Uterus and Heart, accessible to Students of Medicine, the Author has been induced to publish these Engravings in the present form, in the hope that a department of Anatomy and Physiology of such importance in Medical Practice may no longer remain in that obscurity and error in which it has been left involved in the most recent Works on Anatomy published in Great Britain, and on the Continent of Europe.

PLATE I.

PLATE I.

Represents the ganglionic nervous plexuses on the posterior surface of the gravid uterus in the sixth month of pregnancy, continuous with the spermatic and hypogastric nerves. This and all my other dissections were made while the parts were covered with alcohol, and a lens magnifying six diameters was always used to assist the sight. Without the alcohol and the magnifier, the nervous structures of the uterus could not have been clearly displayed in the preparations from which these Engravings were made. This, my first dissection, was made in 1839.

A. The fundus of the uterus.
B. The right ovarium.
C. The rectum.
D. The left ureter.
a. The great sympathetic nerve where it is about to divide into the two hypogastric nerves.
b. The right hypogastric nerve and plexus.
c. The left hypogastric nerve and plexus.
d. Trunk of a nerve proceeding from the left hypogastric plexus to the left ganglionic plexus on the body of the uterus.
e. Nerves passing from the right hypogastric plexus to the ganglionic plexuses on the body of the uterus.
f. Trunk of the left uterine vein.
g. Trunk of the right uterine vein.

PLATE II.

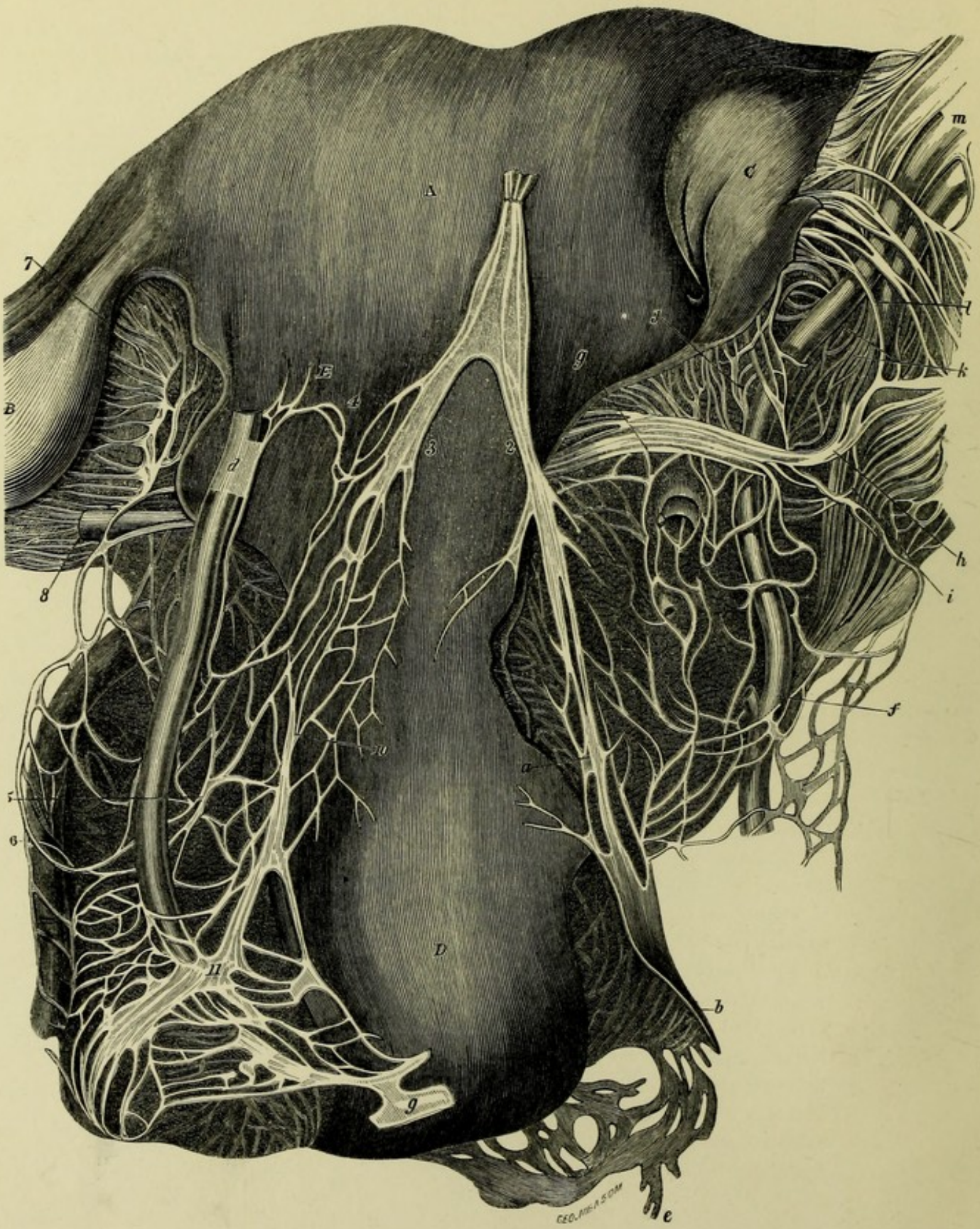

PLATE II.

Represents the ganglia and nerves of the gravid uterus in the sixth month of pregnancy.

A. Posterior surface of the fundus and body of the uterus.
B. Left ovarium.
C. Right ovarium, drawn upward to the fundus uteri.
D. Peritoneum covering the back part of the cervix uteri.
E. Left ureter.
1. Aortic plexus of the great sympathetic nerve, which was situated over the last lumbar vertebra, at the bifurcation of the aorta.
2. Right hypogastric nerve.
3. Left hypogastric nerve, dividing into branches to form the left hypogastric plexus.
4. Filaments from the left hypogastric plexus to the left ureter.
5. A nerve proceeding from the same plexus, which passes between the ureter and uterus to a plexus of nerves surrounding the uterine artery and vein.
6. A plexus of nerves around the trunk of the uterine vein, from which branches proceed to the superior part of the uterus along with this vessel.
7. Filaments of nerves ramifying on the blood-vessels and muscular coat of the uterus, and on the inner surface of the peritoneum.
8. A branch of the spermatic veins which anastomoses on the side of the uterus with the principal uterine vein.
9. Third sacral nerve, sending branches to the posterior part of the ganglion at the cervix uteri.
10. The trunk of the left hypogastric nerve prolonged through the hypogastric plexus to the ganglion.
11. The ganglion at the cervix, from which branches proceed to the plexus surrounding the uterine vessels, the bladder, vagina, and rectum.
a. The right hypogastric nerve and plexus.
b. Ganglion at the cervix drawn away from the uterus, and all the small soft nerves which passed from it to the cervix removed.
c. Sacral nerves entering the ganglion.
d. Nerves from the ganglion and hypogastric plexuses spreading out on the posterior surface of the uterus, and ramifying under the peritoneum, and upon the muscular coat.
f. Trunk of the right uterine vein, with the nerves accompanying it to the upper part of the uterus.
g. A great plexus, extending across the posterior surface of the uterus; with nerves from the ganglion, and hypogastric plexus entering it.
h. Termination of this plexus in the anterior plexus.
i. Nerves passing from the anterior plexus into the nerves accompanying the uterine vessels.
j. Branches of these nerves passing behind the vein to the fundus uteri.
k. Branches from the spermatic nerves joining the posterior plexus.
l. Slender filaments passing from the anterior and posterior plexus to the ovarium.
m. Spermatic blood-vessels, nerves, and absorbents.

PLATE III.

Phil. Trans. MDCCCXLI. Plate XXVI. p. 274

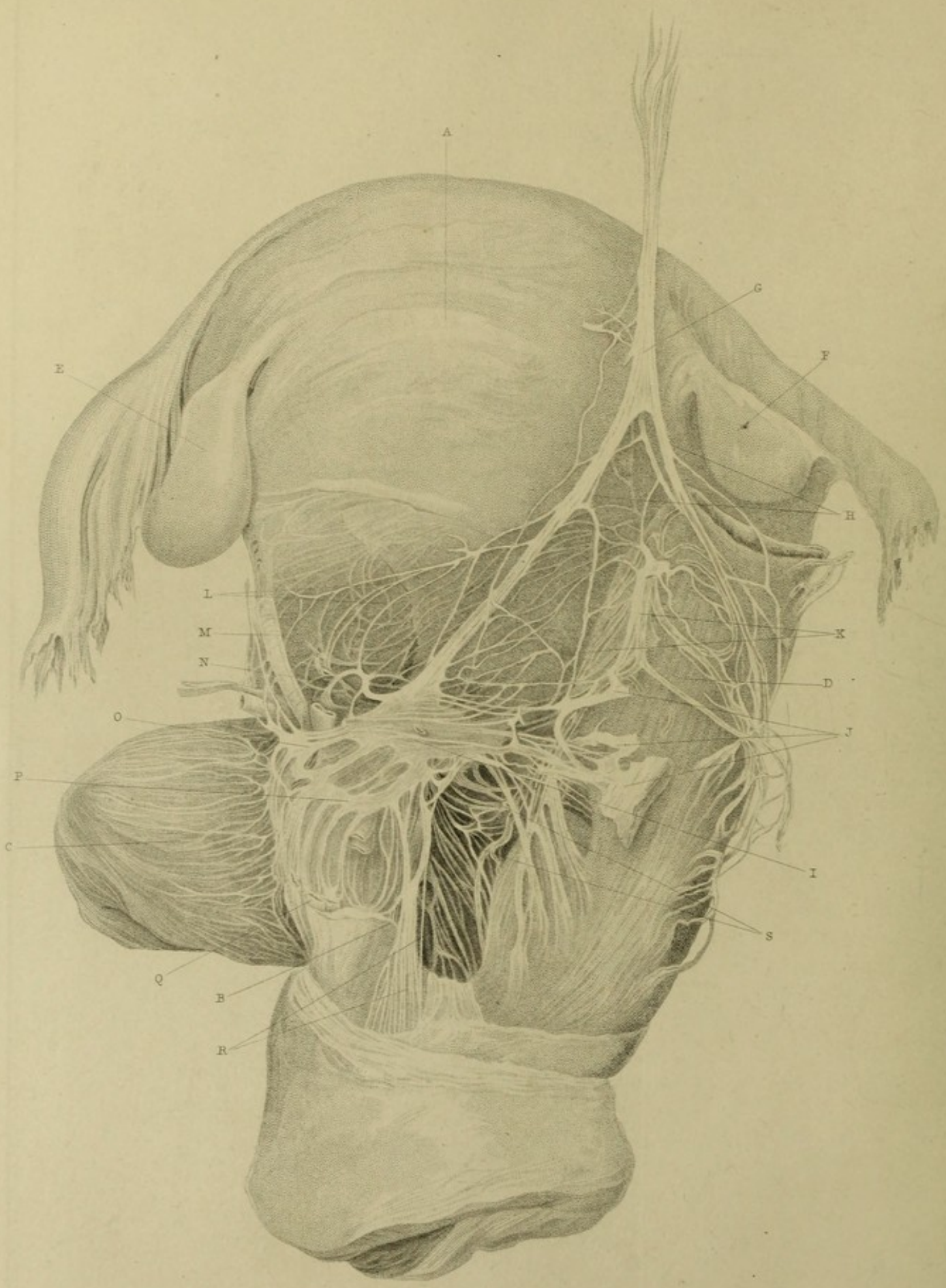

Joseph Perry del.

¾ the Natural Size.

J. Basire sculp.

PLATE III.

Exhibits a posterior and lateral view of the gravid uterus in the fourth month of pregnancy, of the vagina, rectum, and bladder, with their ganglia and nerves.

A. The fundus and body of the uterus covered with peritoneum.

B. The vagina.

C. The bladder.

D. The rectum.

E, F. The ovaria.

G. The great sympathetic nerve where it divides into the two hypogastric nerves and plexuses. The arteries and veins of the great sympathetic are all injected in the preparation from which the drawing has been made. A little above the bifurcation of the great sympathetic nerve there is a deposit of cineritious matter in its substance, and the nerve itself is enlarged as high as the kidneys.

H. The right and left hypogastric nerves and plexuses. The artery of the right is injected, and accompanies the nerve to the great ganglion at the cervix, in which it terminates.

I. The left hypogastric or great utero-cervical ganglion, with an artery passing into it near the centre.

J. The third and other sacral nerves, sending numerous large branches into the posterior border of the ganglion, and the whole of its outer surface.

K. The hemorrhoidal nerves accompanying the arteries to the rectum, and sending numerous branches to anastomose with nerves sent off from the posterior edge of the ganglion.

L. Branches of nerves with ganglia sent off from the left hypogastric nerve, which pass down on the inside of the ureter to the trunks of the uterine artery and veins, and enter ganglia which surround these blood-vessels.

M. The left ureter, with a nerve accompanying it, which passes into the vesical ganglion, situated on the anterior part of the ureter.

N. Rings of nerve, surrounding the uterine blood-vessels.

O. The middle vesical ganglion, into which large nerves enter, which are sent off from the anterior border of the left hypogastric ganglion, and pass on the outside of the ureter.

P. Broad, flat ganglia, formed on the great plexus of nerves which covers the upper part of the vagina.

Q. The orifices of the divided veins of the vagina, which are completely encircled with ganglionic plexuses of nerves.

R. Filaments of vaginal nerves passing under the sphincter.

S. Large nerves covering the posterior wall of the vagina, and anastomosing with the hemorrhoidal nerves.

PLATE IV.

Phil. Trans. MDCCCXLI. *Plate* XXVII. *p.* 275.

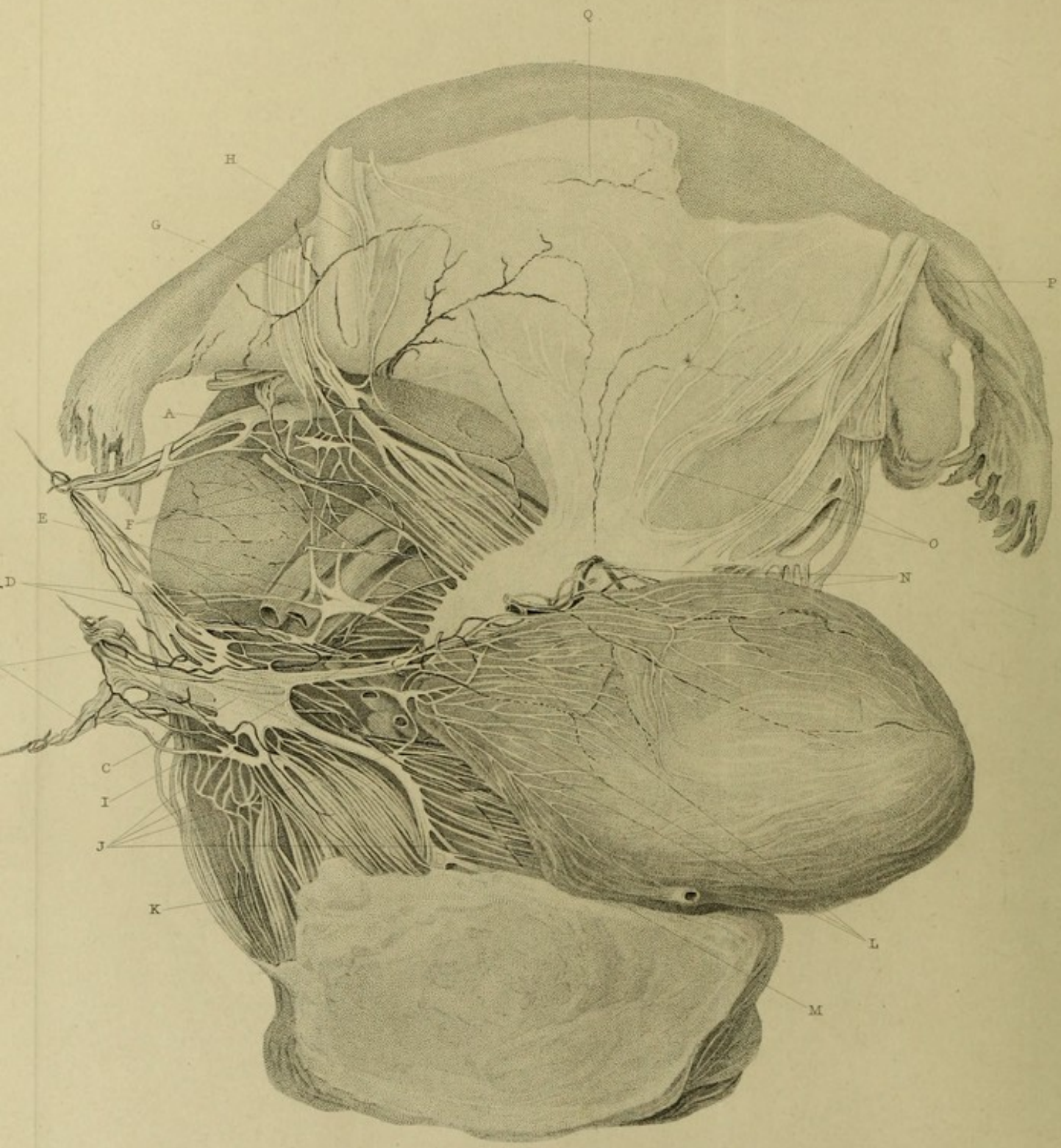

Joseph Perry del.

¾ *the Natural Size.*

J. Basire sculp.

PLATE IV.

Exhibits an anterior and lateral view of the gravid uterus in the fourth month, and of the vagina and bladder.

A. The right hypogastric nerve.
B. The sacral nerves.
C. The right hypogastric ganglion.
D. Nerves from the hypogastric nerve to the ganglia on the blood-vessels of the uterus.
E. Ganglia surrounding the uterine artery and veins.
F. Ganglionic plexus, under the peritoneum on the fore-part of the uterus.
G. Filaments from this plexus passing out with the round ligament.
H. The round ligament.
I. The right ureter and trunk of the vaginal and vesical veins surrounded with nerves.
J. Ganglia and nerves of the vagina.
K. Nerves passing between the vagina and rectum.
L. Ganglia and nerves of the bladder.
M. Vaginal nerves passing into the bladder around the ureter.
N. Blood-vessels and nerves of upper part of the bladder.
O. Plexus of nerves under the peritoneum on the left side of the uterus, the blood-vessels of which have not been injected.
P. Filaments from this plexus passing out with the round ligaments.
Q. The peritoneum of the anterior part of the body and cervix of the uterus reflected upwards, to expose the ganglionic plexuses situated below.

PLATE V.

Phil. Trans. MDCCCXLII. *Plate* XIV. *p.* 178.

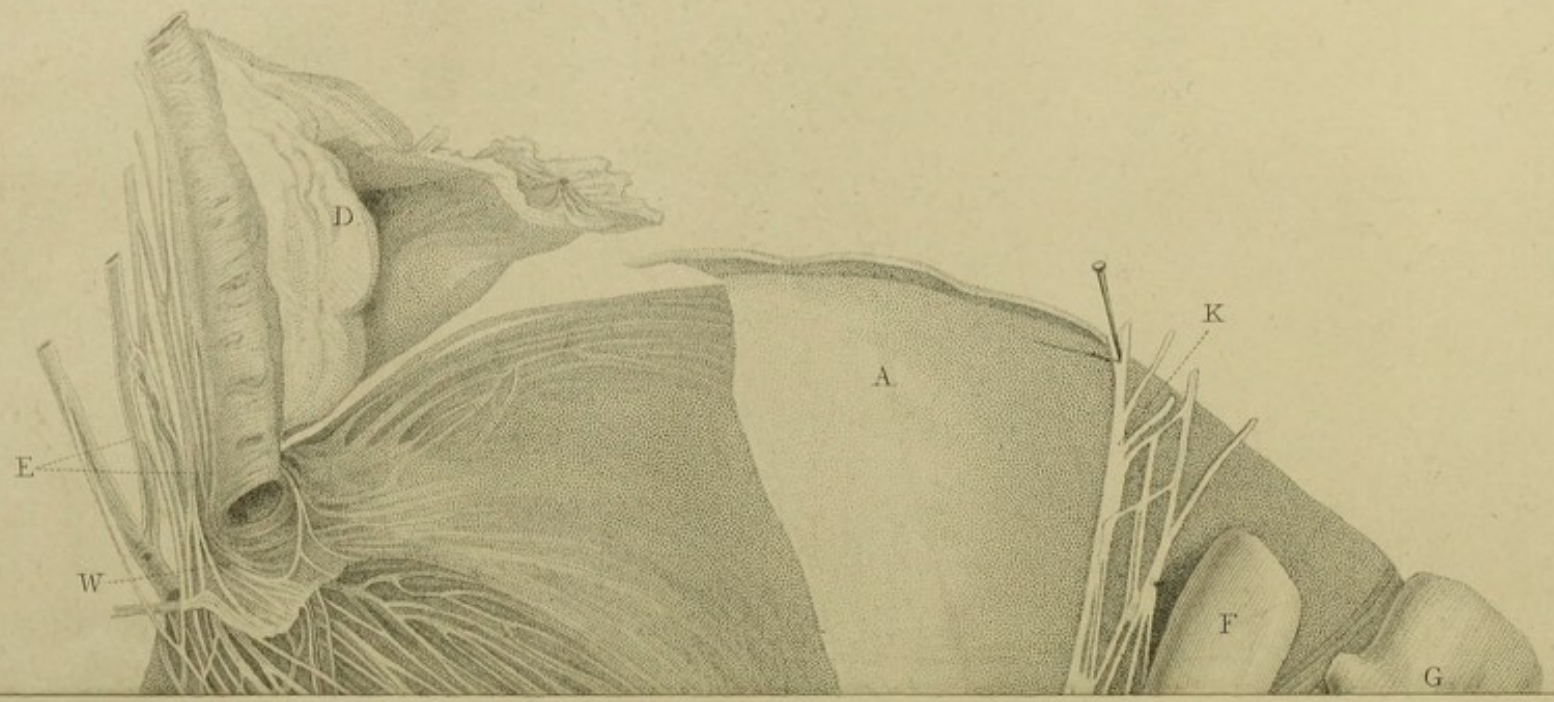

...ph Perry del. 1842.

J. Basire sc.

PLATE V.

Exhibits the ganglia and nerves on the posterior and left side of the gravid uterus at the end of the ninth month of pregnancy.

A. The fundus and body of the uterus, having the peritoneum dissected off from the left side.

B. The vagina covered with nerves proceeding from the inferior border of the left hypogastric ganglion.

C. The rectum. D. The left ovarium and Fallopian tube.

E. The trunk of the left spermatic vein and artery surrounded by the left spermatic ganglion.

F. The aorta divided a little above the origin of the right spermatic artery, and about three inches above its division into the two common iliac arteries.

G. The vena cava.

H. Trunk of the right spermatic vein entering the vena cava.

I. Right ureter.

K. The two cords of the great sympathetic nerve passing down along the front of the aorta.

L. Trunk of the inferior mesenteric artery, passing off from the aorta, and covered with a great plexus of nerves sent off from the left and right cords of the great sympathetic.

M. M. The two cords of the great sympathetic passing down below the bifurcation of the aorta to the point where they separate into the right and left hypogastric nerves.

N. The right hypogastric nerve with its artery injected proceeding to the neck of the uterus, to terminate in the right hypogastric ganglion.

O. The left hypogastric nerve where it is entering the left hypogastric ganglion, and giving off branches to the left subperitoneal ganglion.

P. Hemorrhoidal nerves accompanying the hemorrhoidal artery and proceeding from the great plexus which surrounded the inferior mesenteric artery.

Q. The sacral nerves entering the whole outer surface of the hypogastric ganglion.

R. The left hypogastric ganglion with its arteries injected.

S. The nerves of the vagina.

T. Nerves with an injected artery proceeding from the upper part of the left hypogastric ganglion along the body of the uterus, and terminating in the left spermatic ganglion.

U. Continuation of these nerves and the branches which they give off to the subperitoneal plexuses.

V. The same nerves passing upward beneath the subperitoneal plexuses, and anastomosing freely with them.

W. The left spermatic ganglion, in which the nerves and artery from the hypogastric ganglion, and the branches of the left subperitoneal plexuses terminate, and from which the nerves of the fundus uteri are supplied.

X. The left subperitoneal plexuses covering the body of the uterus.

Y. The left subperitoneal ganglion, with numerous branches of nerves extending between it and the left hypogastric nerve and ganglion.

Z. The left common iliac artery cut across and turned aside, that the left hypogastric nerve and ganglion might be traced and exposed.

PLATE VI.

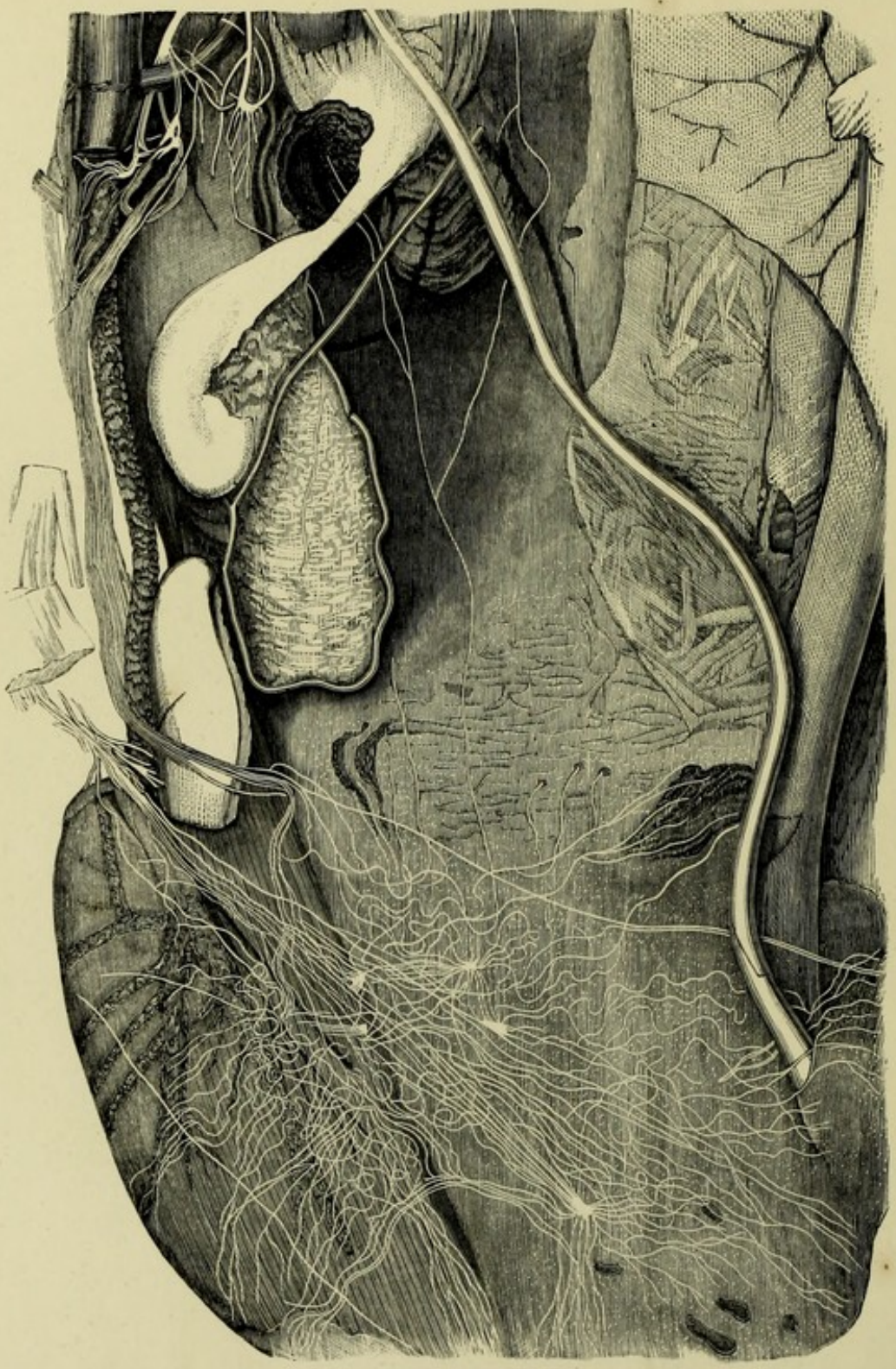

PLATE VI.

Exhibits the nervous structures of the gravid uterus at the full period of utero-gestation, on the right side, in a mutilated condition. All the blood-vessels and the nerves which accompanied them were cut away in the preparation, and the great ganglion at the cervix destroyed. Eight months were spent by the dissector on the preparation, in picking away with forceps and needles not merely the cellular tissue which surrounded the nerves which remained, but the neurilemma *even. The engraving from which this has been copied, half the natural size, does not therefore represent the ganglia and nerves of the gravid uterus, but only a few of the filaments of the nerves deprived of one of their constituent tissues, the neurilemma.*

A similar proceeding, though unwarrantable and unprecedented, I adopted in the dissections of the ganglia and nerves of the virgin uterus delineated in Plates VII. and VIII. to shew the differences in the appearance of the structures in a perfect state, and when deprived of an essential component part, the neurilemma.

PLATE VII.

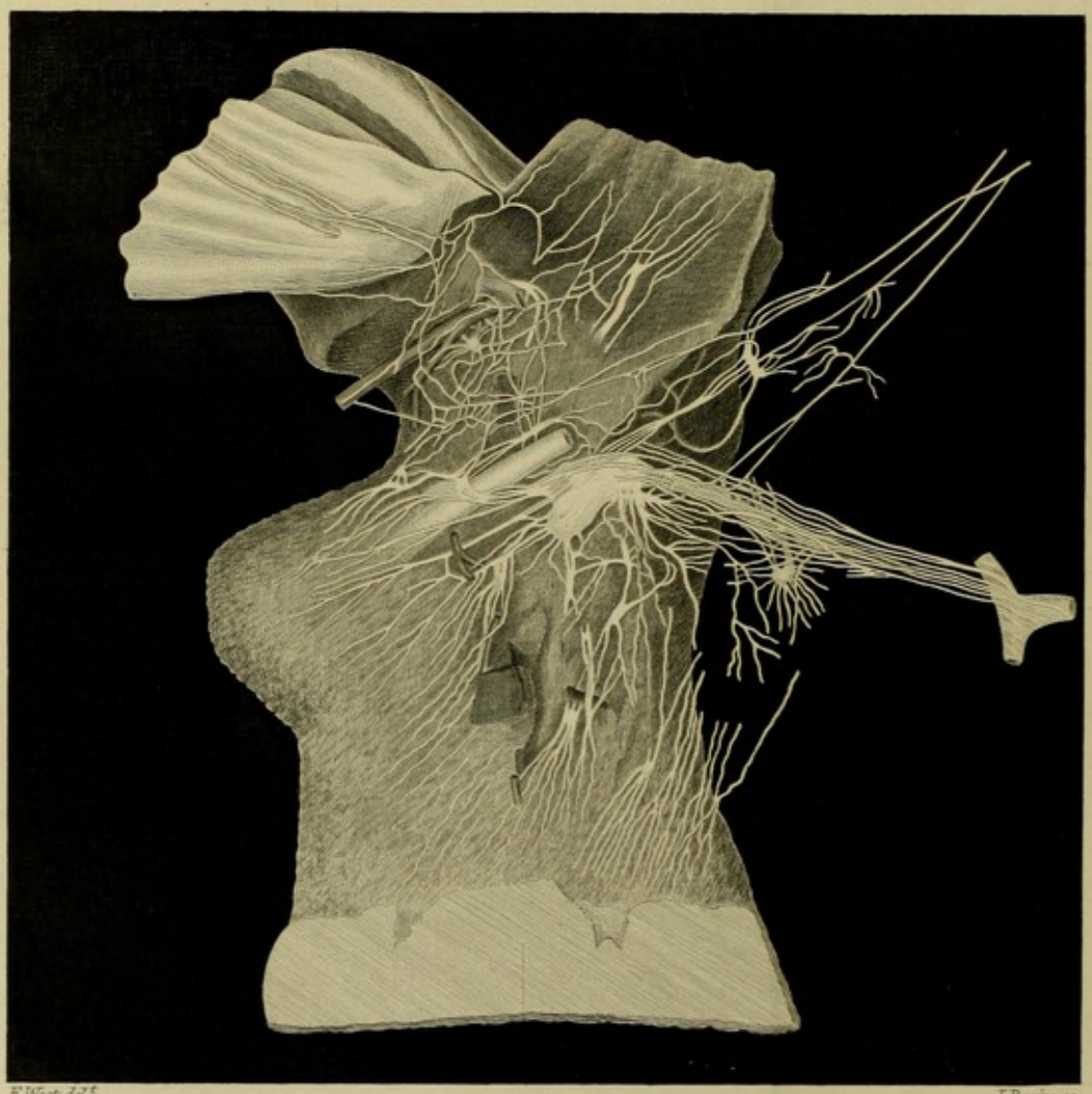

E. West, del.t

J. Basire, sc.

PLATE VII.

Represents the left hypogastric and sacral nerves entering the hypogastric ganglion, and the blood-vessels, ganglia, and nerves of the virgin uterus, a portion of the neurilemma being removed, and the ganglia and nerves thereby greatly reduced below the natural size.

PLATE VIII.

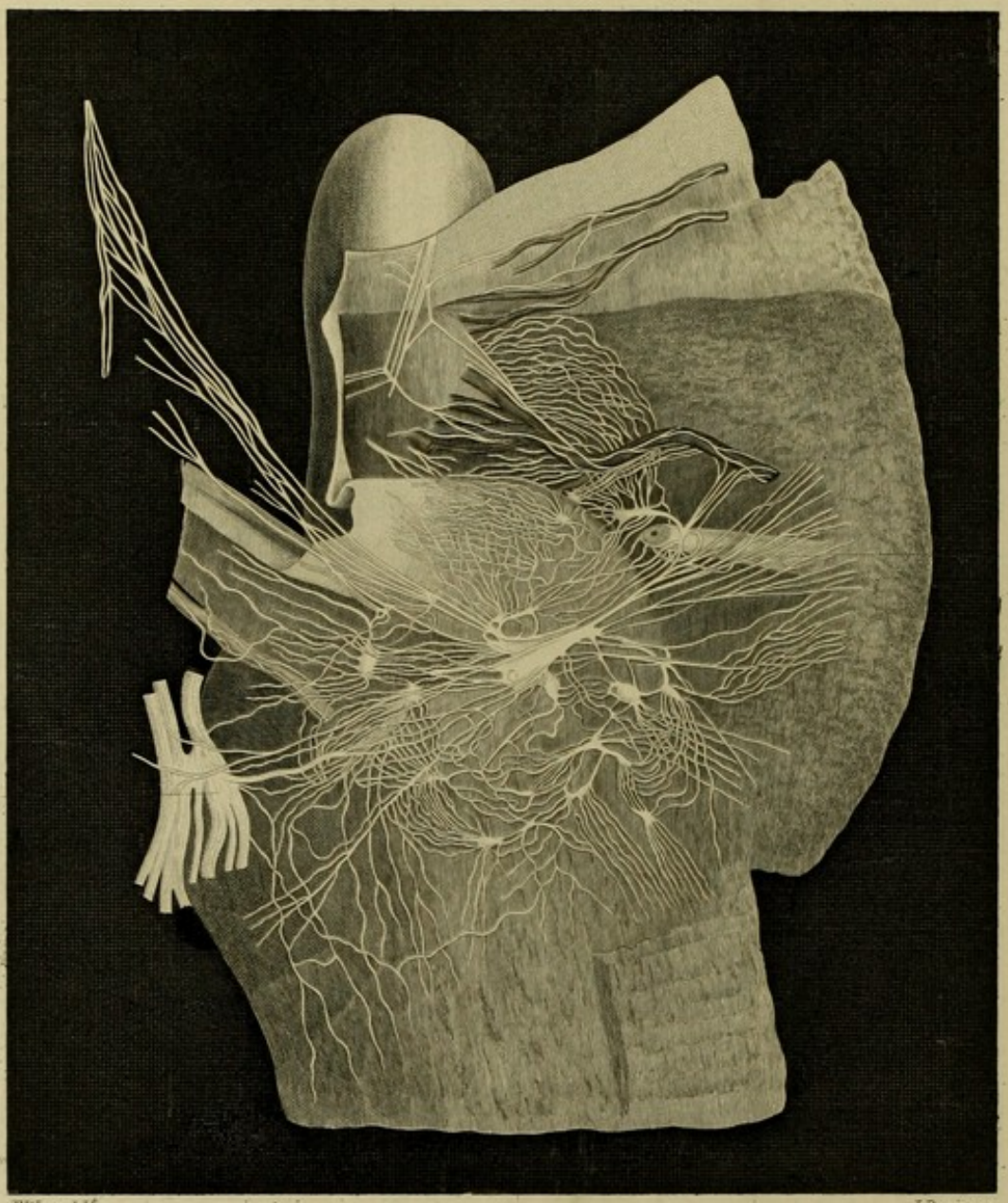

E.West. del.t *J.Basire sc.*

PLATE VIII.

Represents the right hypogastric nerve and ganglion, and the ganglia and nerves of the same virgin uterus, with a great part of the neurilemma dissected off. The ganglia and nerves, in the natural state, are about four times the size here represented.

PLATE IX.

Fig. 1.

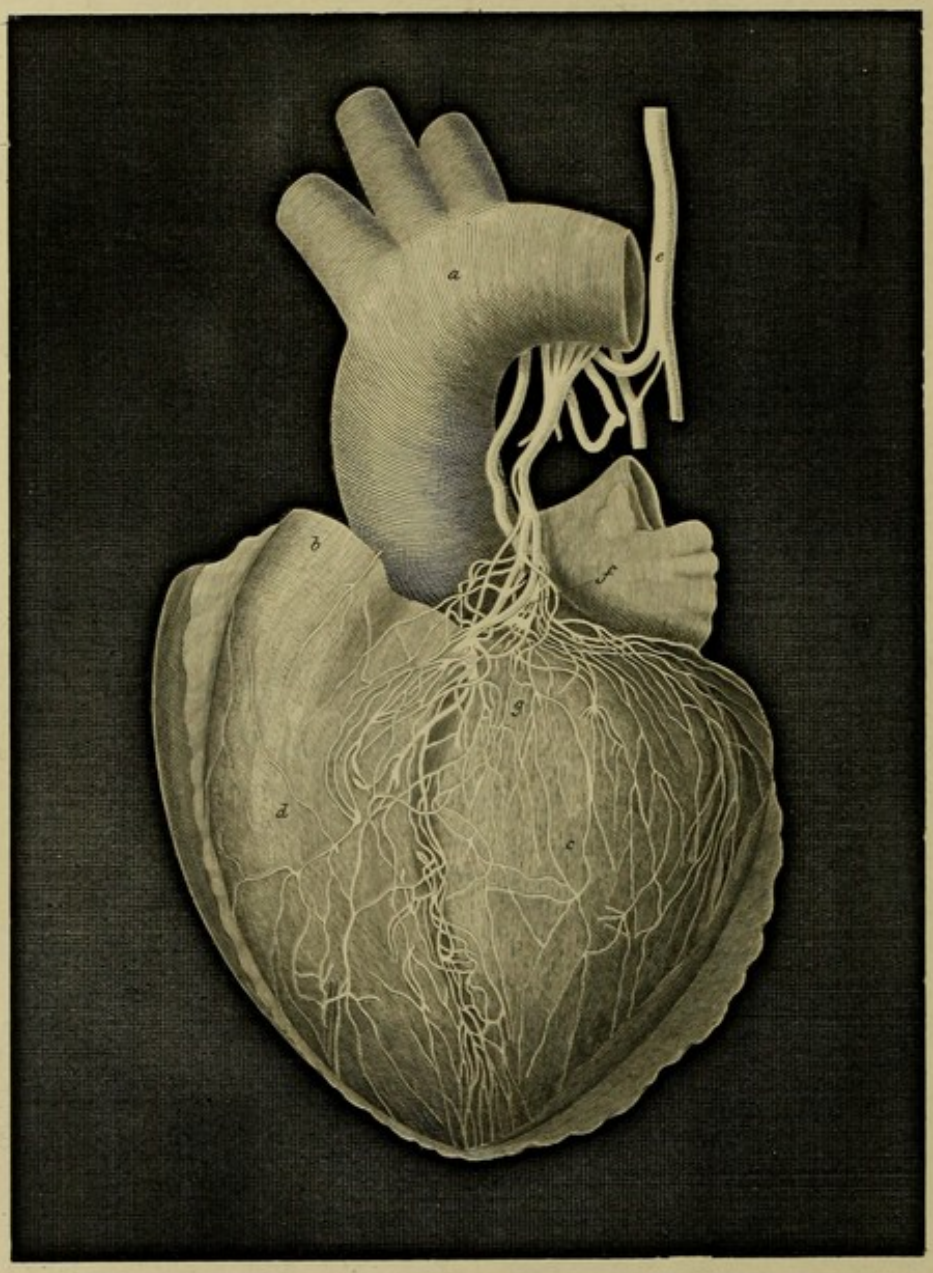

Fig. 2.

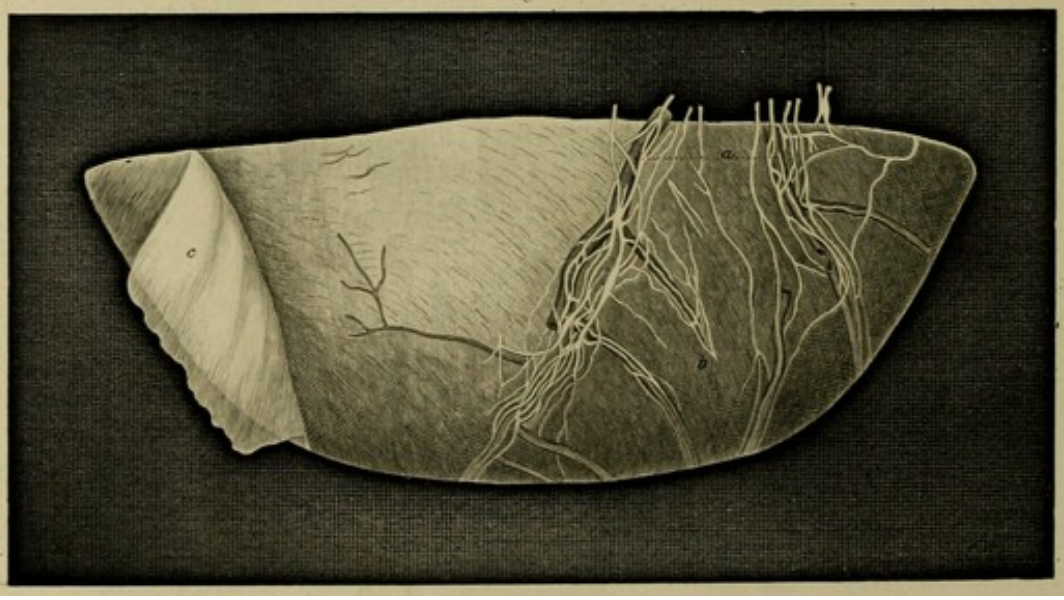

PLATE IX.

FIG. 1, *represents the great cardiac ganglionic plexus of nerves, situated between the aorta and pulmonary artery, which receives branches of nerves from the sympathetic, par vagum, and recurrent nerves of both sides: and likewise the ganglia and nerves distributed over the surface of the left ventricle of the heart of a child nine years of age. Natural size.*

a. The arch of the aorta.
b. The pulmonary artery truncated at its origin.
c. The anterior surface of the left ventricle of the heart.
d. The anterior surface of the right ventricle.
e. The left par vagum and recurrent nerve.
f. The great cardiac ganglionic plexus of nerves situated between the aorta and pulmonary artery, from which all the principal cardiac nerves are derived.
g. The ganglionic plexus of nerves accompanying and surrounding the trunk and branches of the left coronary artery, and the ganglia and nerves distributed over the muscular substance of the left ventricle to the apex; the serous membrane and cardiac fascia having been removed.

FIG. 2, *represents the ganglia and nerves at the apex of the anterior surface of the adult human heart in the natural state, with a portion of a cardiac fascia dissected off from the blood-vessels, nerves, and muscular substance, to which it firmly adhered.*

a. The branches of the coronary artery at the apex of the heart surrounded by ganglia and nerves.
b. Ganglia and nerves on the muscular substance of the heart at the apex not accompanying blood-vessels.
c. The cardiac fascia.

PLATE X.

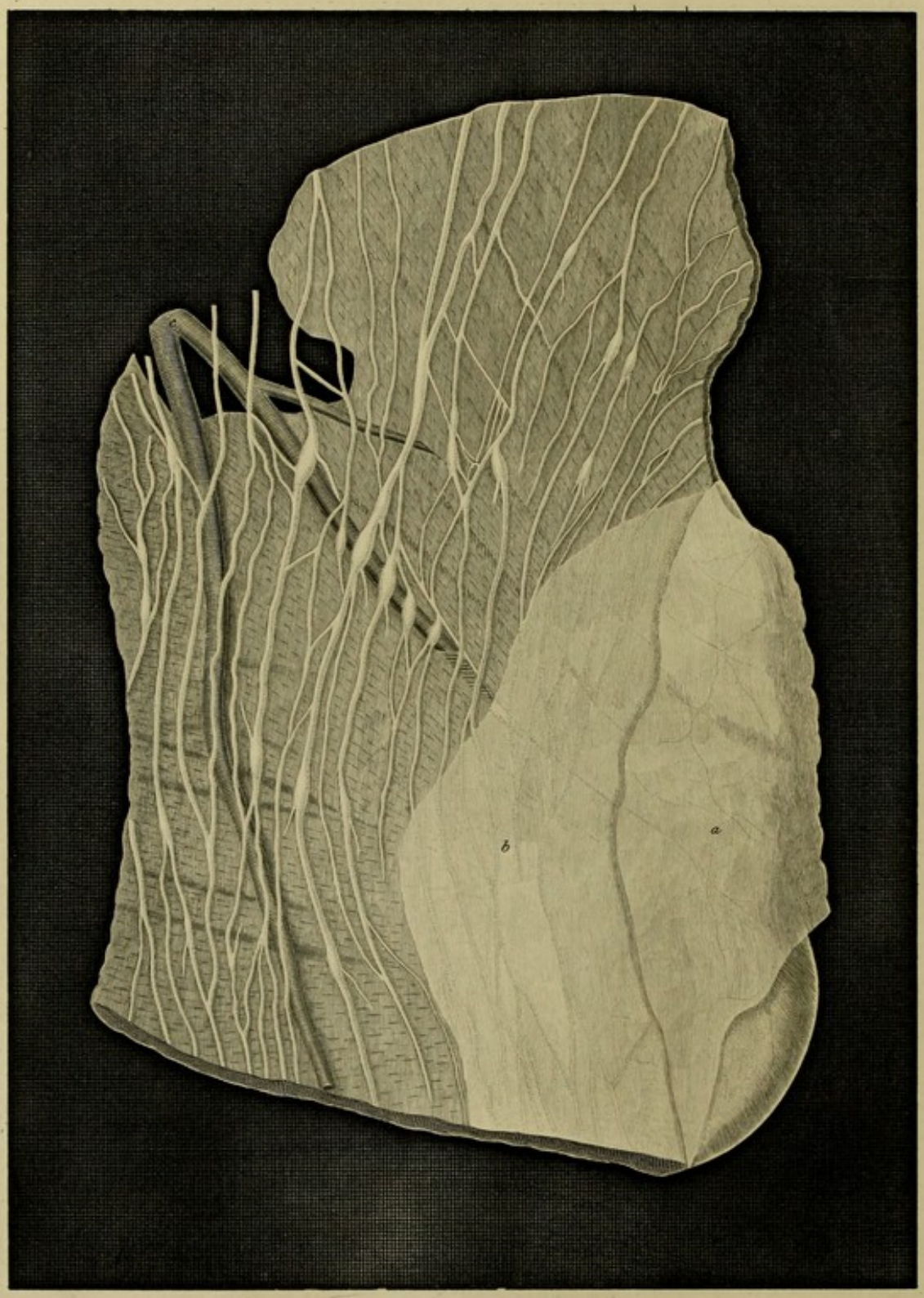

E. West del.

J. Basire sc.

PLATE X.

Represents a portion of the cardiac fascia, and the ganglia and nerves on the surface of the left ventricle of the Heifer's heart. Natural size.

a. A portion of the serous membrane dissected off from the cardiac fascia.

b. The cardiac fascia, with the numerous ganglia and nerves seen through it, undisturbed by dissection.

c. Branches of the left coronary artery, with ganglia on the nerves where they cross the blood-vessels.

PLATE XI.

Phil. Trans. MDCCCXLIX. *Plate* III. *p.* 48.

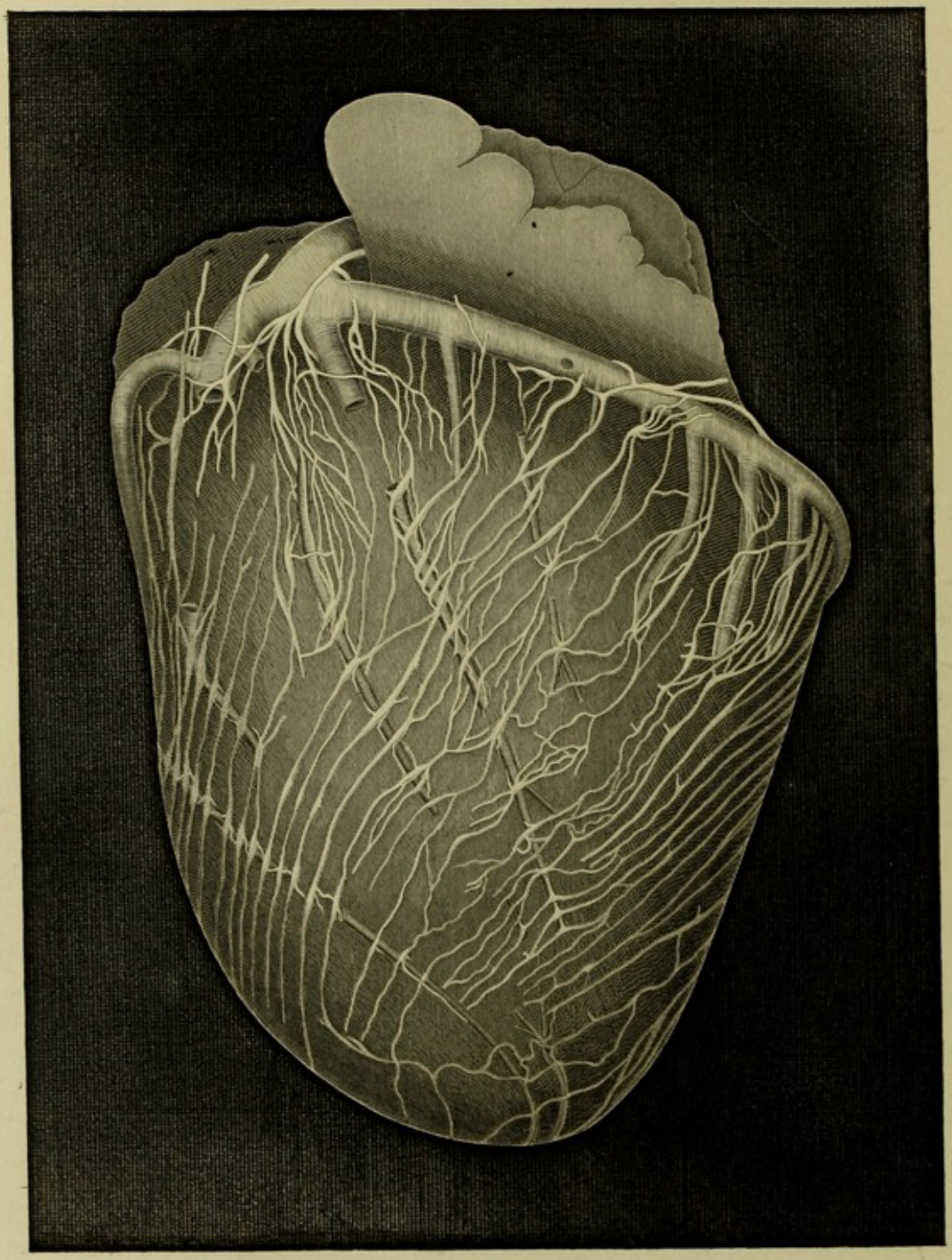

E. Wart. del.! *J. Basire sc.*

PLATE XI.

Exhibits the trunk and branches of the coronary arteries, and the ganglia and nerves distributed over the anterior surface of the ventricles of the young Heifer's heart; the serous membrane and cardiac fascia having been wholly removed.

PLATE XII.

Phil. Trans. MDCCCXLIX. *Plate* IV. *p.* 48.

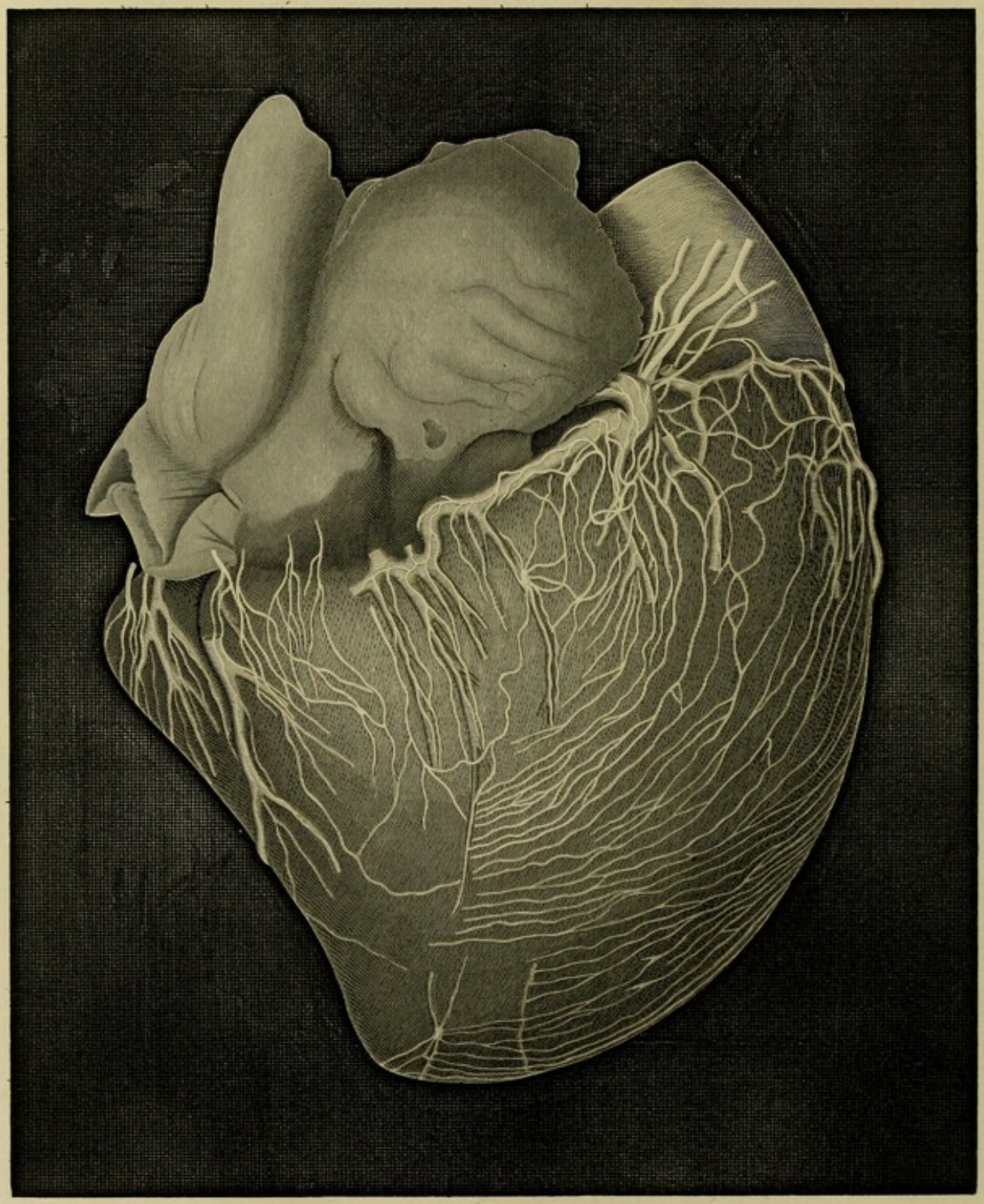

E. West del.t

J. Basire sc.

PLATE XII.

Represents the posterior surface of the same heart covered with ganglia and nerves from the base to the apex. Natural size.

PLATE XIII.

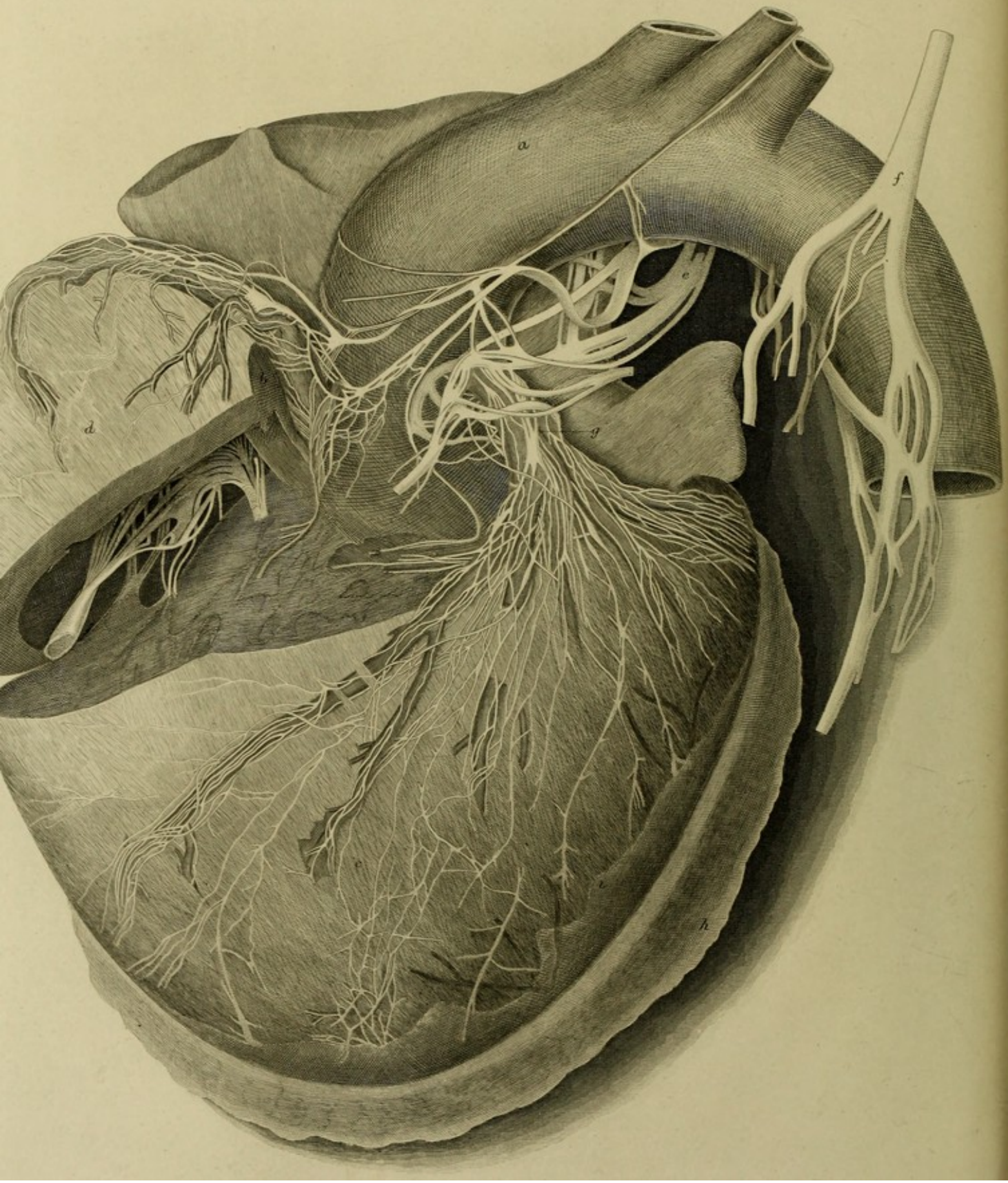

PLATE XIII.

Represents the aorta and the anterior surface of a human heart which was hypertrophied, and weighed four pounds. The trunk and some of the branches of the left coronary artery were ossified. The pulmonary artery has been cut away close to the right ventricle. A portion of the wall of the right ventricle has been removed to expose the cavity and the septum between the ventricles. The serous membrane has been reflected off from the cardiac fascia, a small portion only of which has been left covering the ventricle. Natural size.

a. The arch of the aorta.
b. The origin of the pulmonary artery, which has been completely removed.
c. The anterior surface of the left ventricle.
d. The anterior surface of the right ventricle.
e. The great ganglionic plexus of nerves into which branches from the par vagum, recurrent, and sympathetic nerves of both sides enter, and from which the principal cardiac nerves take their origin.
f. The par vagum of the left side.
g. The trunk of the left coronary artery ossified and completely surrounded with ganglia and nerves, which are distributed over the whole surface of the ventricle to the apex.
h. The serous membrane reflected off from the cardiac fascia, a small portion only of which is left covering the ganglia and nerves near the apex.
i. The cardiac fascia.

POSTSCRIPT.

In these engravings, the ganglia and nerves on the surface of the uterus and heart only have been represented. There are preparations in the possession of the author, by which it can be clearly demonstrated that every artery distributed throughout the walls of the uterus and heart, and every muscular fasciculus of these organs, is supplied with nerves upon which ganglia are observable.