*(Reprinted from the Birmingham Medical Review, June, 1890.)*




# SOME POINTS IN THE PATHOLOGY OF GOITRE, WITH REMARKS UPON THE TREATMENT BY OPERATION.

ILLUSTRATED BY CASES, SPECIMENS AND PHOTOGRAPHS.*

BY JAMES BERRY, B.S. LOND., F.R.C.S.,
ASSISTANT SURGEON, ROYAL FREE HOSPITAL, LONDON;
SURGEON ALEXANDRA HOSPITAL FOR HIP DISEASE;
LATE DEMONSTRATOR OF ANATOMY, ST. BARTHOLOMEW'S HOSPITAL.

Mr. President and Gentlemen,

When invited, a few weeks ago, by your Secretary, to read a paper on Diseases of the Thyroid Gland, it seemed to me that I should interest you most by shewing photographs and specimens illustrating the subject, and by making remarks partly upon these and partly upon the clinical aspects of this branch of surgery. With this view I have with me to-night a series of photographs that I have collected in the last five or six years, and as many specimens and casts as I could conveniently bring. I may say that the photographs are all of cases that have come under my own observation. They have been taken either by myself or by my friend Mr. Charles Cosens. To read anything like an exhaustive paper on the pathology and operative surgery of goitre is, of course, quite impossible in

* A Paper read at Birmingham on Feb. 28th, 1890, before the Pathological and Clinical Section of the Midland Counties Branch of the British Medical Association.

the short time at my disposal. I propose, therefore, simply to discuss a few points, illustrating them as far as possible by the photographs and specimens before you and to give some account also of three cases in which I have performed removal of a goitre.

All innocent forms of goitre may be divided conveniently into two tolerably well marked classes, those in which the whole gland is more or less uniformly enlarged, and those in which the enlargement is due to the development of one or more definite cysts or solid tumours, generally in one lobe only of the gland. I shall deal with these two classes separately.

First, bilateral and uniform enlargement of the whole gland.—This is the form of goitre which is usually met with in young people and may be regarded as the first stage in the development of nearly all goitres. Examples are shewn in eight of the accompanying photographs and specimens. The goitre consists in some cases of a mere hypertrophy of all parts of the gland, but in most the enlargement is due chiefly to increase in the amount of colloid material in the thyroid vesicles. Each vesicle, instead of containing a small amount of colloid material, as in the normal gland, is much dilated and contains a greatly increased amount of secretion. In fact it would be correct in most cases to look upon the enlargement as being due to a hypersecretion of colloid material into all the vesicles of the gland. There is also some increase in the connective tissue and glandular elements; rarely I believe is the enlargement due mainly to hypertrophy of the solid constituents. That this hypersecretion is brought about, in the great majority of cases, by some material introduced into the body by means of drinking water admits, I venture to think, of but very little doubt. What is the exact nature of that material is a most interesting question, but it is not one that I can enter into to-night.

A due appreciation of the anatomical structure of this kind of goitre is, however, important, as I shall shew presently, in relation to the treatment. Although these goitres do not usually produce any very serious symptoms, yet it is not uncommon to

meet with cases in which troublesome and even dangerous symptoms are produced by pressure upon important structures in the neck, notably upon the trachea and recurrent laryngeal nerves, less commonly upon the œsophagus, great vessels of the neck, the sympathetic and spinal nerves.

An instance of goitre producing death by pressure upon the trachea is shewn in this photograph, taken from a specimen in St. Bartholomew's Hospital Museum. It will be seen that the trachea is narrowed laterally, the point of greatest constriction being one inch below the cricoid cartilage. I believe it may be laid down as a rule, to which there are few if any exceptions, that goitres involving uniformly the whole thyroid gland always compress the trachea in such a manner as to cause *lateral*, never antero-posterior, flattening.

Turning now to the various operative measures that may be adopted for the cure of parenchymatous goitre, I propose to discuss the following three :—

1. Division of the isthmus with or without removal of a portion of it.

2. An operation which has recently been introduced by Mikulicz, of Cracow, under the name of resection, and which consists in removing all the goitre except a small piece on each side of the trachea.

3. Extirpation of one-half or more of the gland.

Into the subject of injecting goitres I cannot enter. The use of setons has been, and I think deservedly, abandoned on account of its danger and the uncertainty of its effecting a cure. Ligature of the thyroid arteries is an operation which has recently been revived by Wölfler and Billroth. I need not say more about it than that there is very little evidence of its being of any value.

Division of the thyroid isthmus was first performed in this country by Mr. Holthouse, at the Westminster Hospital, in 1874, at the suggestion of Sir Duncan Gibb. For some years subsequently it appears to have attracted little or no attention. In 1883, however, it was revived by Mr. Sydney Jones, of St.

Thomas's, and since that time it has been practised extensively by many surgeons, and has met with much favour. Mr. Jones was the first to point out that the operation not only often gave relief to the dyspnœa, but that it caused a remarkable diminution in the size of the goitre, or, to use his own words, "an atrophy of the lateral lobes."

That both these results, namely, relief from the dyspnœa and diminution in size of the goitre, at any rate for a time, do usually follow the operation there can I think be very little doubt, judging at least from cases that have come under my own observation and from numerous published cases. But the points that I wish to raise in connection with this operation are: What is the mode in which the relief from the dyspnœa is effected? Is the diminution in size of the goitre, and with it the relief from dyspnœa, permanent? It is frequently stated that as the isthmus is a band uniting the two lateral lobes, division of it will allow these lobes to separate from each other and so relieve the dyspnœa. This seems, at first sight, a plausible explanation, but it is nevertheless, I believe, not the correct one. That this may be the result of the operation in some cases I am not prepared to deny; that it is so in all, or nearly all, I certainly cannot admit. In the first place, I have seen the operation performed many times, and noticed that frequently, after the division has been effected, the cut surfaces have not separated from each other at all. More than this, in one case that I well remember not only was the isthmus divided, but a considerable portion of it was removed; what happened then was that the lateral lobes actually came nearer to each other, to fill up the place of that portion of the gland that had been removed. Then, again, the relief from the dyspnœa frequently does not occur immediately, but only after the lapse of a few days; and I know of several unpublished cases in which no relief whatever followed the operation. But relief should follow immediately if this constricting band were the cause of the dyspnœa.

It has been asserted by some, including the originator of the

operation, that it is the isthmus itself which presses directly backwards upon the trachea; hence, that division or removal of the isthmus relieves the trachea from pressure. I venture to think that this view is utterly untenable. In the first place, the pressure upon the trachea does not cause an antero-posterior but a *lateral* flattening, as I have shewn you in one of these photographs. I have not been able to find any evidence that the trachea is ever flattened antero-posteriorly by any parenchymatous goitre; that is, by any form of general and uniform enlargement of the gland. When the isthmus *alone* is involved without the lateral lobes, as in the two photographs and the cast which I now shew you, there may be a slight amount of antero-posterior flattening of the trachea, but such goitres *never cause serious dyspnœa;* of that I am sure. Among all the specimens contained in 21 pathological museums that I have examined in this country and in Switzerland, I have not been able to find more than four with any distinct antero-posterior flattening, and in none of these cases had there been any dyspnœa worth mentioning. One of these four specimens is before you. It was kindly sent to me by Dr. Claye Shaw, of Banstead. It had been removed from the body of a woman who had died of some cause quite unconnected with the goitre, and who had had during life little or no dyspnœa.

I believe that the cause of the dyspnœa must be sought not so much in the condition of the isthmus as in that of the lateral lobes of the goitre. In suffocating parenchymatous goitres all parts of the gland are swollen, and exert pressure upon everything in contact with them. That is, they exert pressure not only on the muscles and other structures outside of and around them, but also upon the trachea, which lies upon their inner sides. Hence it happens that mere division of the connecting isthmus will not of itself free the trachea from pressure. The real cause, then, of the relief from the dyspnœa lies, I believe, in the shrinking of the gland which follows the operation, and not in the mere mechanical separation of the two halves of the goitre.

The next question is: How is this shrinking caused? If we

bear in mind what I have already said about the structure of a parenchymatous goitre, the cause of the shrinking is not difficult to explain. The enlargement of the gland being due chiefly to over-distension of the vesicles with secretion, removal of that secretion will naturally cause diminution of the swelling. This is shewn by the fact that the diminution does not occur at once, but in the course of the few days following the operation. During this time the viscid colloid material has had time to ooze slowly away from the surface of the wound. Indeed, it is not uncommon actually to see this colloid secretion coming away from the wound. Thus, in the case from which this photograph was taken there formed in the neck, a few days after the operation, a fluctuating swelling, which was at first taken to be an abscess, but which, when opened, was found to contain a quantity of viscid colloid material. In the case of the girl from whom I removed one of the goitres on the table before you, a similar oozing of colloid substance took place; and notes of a similar occurrence will be found in the records of a good many published cases. Again, the more fibrous the goitre is in nature, the less diminution in its size will be produced by the operation. I should like to mention here, however, that I believe fibrous goitre to be far more rare than is generally supposed. The great majority of hard goitres (such as the one I shew in this photograph), often diagnosed as fibrous, really do not deserve that name, as the hardness is caused by the tenseness of the material in the cysts rather than by the presence of hard connective tissue. In a rare case of truly fibrous goitre, in which division of the thyroid isthmus was performed a few years ago at St. Bartholomew's, little or no diminution in size followed the operation, and the dyspnœa was not relieved.

Lastly (and this is the point to which I wish especially to draw your attention, and to ask you whether your experience of these cases does not agree with mine), as the wound heals and the further escape of colloid material is thus stopped, the goitre often slowly reappears, if the conditions which originally produced

the goitre continue to act. This reappearance of the goitre is doubtless due to reaccumulation of the colloid material. The case depicted in the photograph I now shew to you is of much interest in relation to this point. The girl had a bilateral parenchymatous goitre, which caused such extreme dyspnœa that she was almost suffocated by it. Division of the isthmus was performed by Mr. Langton at St. Bartholomew's. Not the least relief followed; tracheotomy became necessary. Within a week of the operation the goitre had shrunk so much, as the result of the division of the isthmus, that scarcely any swelling of the neck was noticeable. Then, as the wound healed, the goitre gradually re-enlarged until, at the end of some weeks, it had nearly regained its former size. At this period I took the photograph shewn to you. As dyspnœa was found to occur whenever the tracheotomy tube was removed, it became necessary to do some further operation. The right half of the gland was therefore removed. The same sequence of events now occurred in the remaining half of the goitre. At first it gradually diminished in size, and then, as the wound healed, it gradually and slowly re-enlarged. Numerous similar cases have been recorded in which removal of one half of a goitre has been followed at first by diminution in size, subsequently by re-enlargement of the remaining half. The exact manner in which the colloid material of the vesicles passes from the interior of them to the cut surface of the gland is a point upon which I cannot express a very decided opinion. There is a good deal of evidence in support of the view of Boéchat and others that all the thyroid vesicles communicate with each other. If this be so, it follows that any incision into the gland will tend to drain all the vesicles. Possibly, however, the drainage is effected not directly, but through the medium of lymphatics.

All these facts point, I venture to think, to the following conclusions:—

That division of the thyroid isthmus usually relieves dyspnœa not by mechanically allowing the two halves of the goitre to separate, but by draining the gland of its colloid secretion.

That the relief afforded may be permanent, but that frequently the goitre reappears when the wound has healed and the secretion is again pent up in the gland.

That in many cases where very urgent dyspnœa is present a mere division of the isthmus will not relieve the dyspnœa sufficiently quickly, and it is necessary to do some further operation, either tracheotomy or, better, removal of some considerable portion of the goitre.

I will now describe the case in which I removed one of the specimens before you by an operation in some respects like resection of the isthmus, in some like the proceeding next to be described.

Case 1.—*Removal of the isthmus and part of each lateral lobe of a bilateral parenchymatous goitre.*—Priscilla T., æt. 18, admitted into the Royal Free Hospital under my care Sep. 6th, 1889. She had had a swelling in the neck for about eighteen months. In the last few months it had grown considerably larger and had produced so much dyspnœa that she was quite unable to follow her occupation as a servant. On admission she had a bilateral parenchymatous goitre of moderate size, all parts of the gland being involved in the disease. The circumference of the neck opposite the most prominent part of the swelling was fourteen and a half inches. Considerable stridor was present during exertion.

On September 14th the following operation was performed:—A vertical incision was made in the middle line of the neck down to the goitre. A large pyramid of goitrous gland tissue was seen to extend upwards over the front of the larynx. This was freed from the neighbouring parts and turned down. The crico-thyroid membrane was thus exposed at an early stage of the operation, so that had serious dyspnœa subsequently occurred, laryngotomy could, if necessary, have been speedily performed. The muscles were easily separated from the anterior surface of the tumour. Great care was taken to avoid opening the capsule of the gland. The various veins leaving the goitre below and on either side were then tied and divided. The

lower part of the goitre having been thus freed an oblique section was made through the lower part of the left lateral lobe and a somewhat similar section then made on the right side. In this way the whole of the isthmus and a large part of each lateral lobe was removed. The portion of goitre removed weighed six ounces. The section of the gland was made in such a manner as to leave undisturbed the inner and back part of each lateral lobe where the recurrent laryngeal nerve is in contact with it. A few bleeding points were secured by fine ligatures, and the wound then closed by a continuous silk suture. The operation presented no especial difficulty.

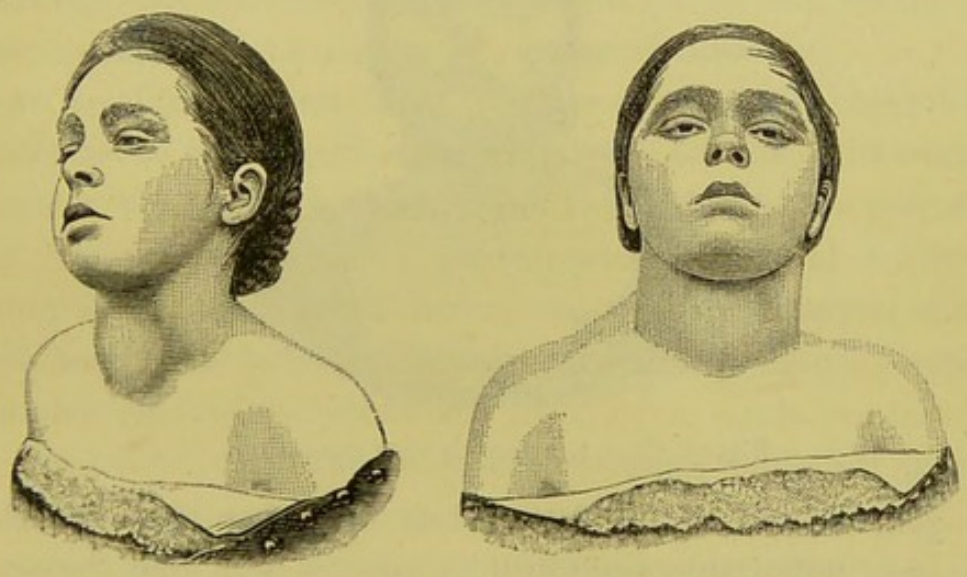

Figs 1 and 2, Case 1, before operation.

The after treatment consisted in keeping the patient absolutely at rest for the first few days. The patient was propped up in bed in a semi-recumbent position and the head and neck fixed by means of sand bags on either side. She was fed by nutrient enemata for the first five days. On the third day after the operation the wound was dressed for the first time, and was found to have healed almost completely by first intention. The drainage tube and all sutures were removed. The temperature was almost normal throughout. On one occasion only in the first ten days did it reach the height of 100° On the tenth day the patient was allowed to get up; the wound appeared to be soundly healed everywhere except at the lower end where a small

granulating surface marked the place where the drainage tube had been. A week later a slight swelling occurred at the upper end of the wound and about two drachms of viscid mucoid material mixed with a little pus was let out. A few days later the wound was thoroughly and soundly healed, and on October 17th the patient left the hospital quite well and entirely relieved from all dyspnœa. She has had no bad symptom of any kind since. The condition of the neck before the operation and a month afterwards are shewn in the accompanying photographs.*

Fig. 3, Case 1, a month after operation.

No goitre could at the latter date be either seen or felt. The only undesirable result in this case has been that the scar in the neck, which was at first a mere linear one, has unfortunately undergone some keloid hypertrophy and is more unsightly than it ought to be.

I come next to the operation that has recently been introduced by the Polish surgeon, Mikulicz, but of which no description has yet, so far as I am aware, found its way into English literature. To the operation, which is particularly suited to cases of parenchymatous goitre, he gives the name of resection. He performs the operation in the following manner:—He first isolates one lobe of the goitre in the ordinary way, as if he were about to remove it, but takes care to leave untouched the connections on the inner side where it is in contact with the

* See Figs. 1, 2, and 3.

larynx, trachea and recurrent laryngeal nerve, and where the inferior thyroid artery enters. In this region a good-sized piece of gland—enough to carry on the functions of the organ—is left intact, all the rest of the lobe being cut away. The same proceeding is then executed, if necessary, on the other side of the neck. In this operation the dangerous region above mentioned is not interfered with, consequently there is no fear of injuring the recurrent nerves. The goitre is almost completely removed, but the small portions left behind obviate any danger of the supervention of cachexia strumipriva (so-called artificial myxœdema). I have not yet had an opportunity of performing this particular operation myself, but I think it is well worthy of serious attention and is likely to yield good results.

An excellent account of twenty-three cases of this operation will be found in Langenbeck's "Archives" for 1888. In twenty of these the wound healed by first intention; in two only did suppuration occur, one of these being a case in which a tracheotomy had necessarily prevented primary union; one patient died from recurrent hæmorrhage, the ligature having slipped from the superior thyroid artery.

The remaining operation, suited to cases of bilateral parenchymatous goitre, is removal of one lobe of the gland. This operation may be sometimes advantageously performed for these cases, although I should say that, as a rule, one or other of the operations I have already mentioned would be found more suitable. It has the advantage that it is more easily performed than any operation by which large portions of both lobes are removed. The objections to it, however, are that the opposite lobe almost always undergoes some degree of subsequent hypertrophy. This may form an ugly swelling in the neck, displacing the larynx and trachea. The operation when performed for bilateral goitre is exactly the same as when performed for unilateral goitre, so I shall consider the details of it later.

Leaving now the subject of bilateral general enlargement of the thyroid gland, I come to the other very important class of

goitres in which the goitrous enlargement affects one side only of the gland, or in which one side is affected very much more than the other. To these it will be convenient to apply the term unilateral goitre Such goitres are exemplified by sixteen of the specimens, casts, and photographs on the table before you.

Now the first point to which I wish to draw your attention is that unilateral goitres never consist of simply hypertrophied gland tissue. The enlargement is due in all cases to the development in the gland of one or more distinct tumours, either cysts or adenomatous growths of some kind. It is true that, as I have already stated, such cystic or solid growths are rather apt to occur in glands that have been, or perhaps still are, the seat of some general parenchymatous hypertrophy. Thus the two forms—the general enlargement and the local enlargement—run, more or less, into each other Still, for practical purposes, they form two tolerably distinct classes.

Strictly unilateral goitres less often cause actual death by suffocation than do bilateral parenchymatous ones. Nevertheless, I need hardly remind anyone here that they are frequently, especially when large, a source of considerable inconvenience and even of some danger to the patient. They may press upon and displace the trachea and larynx, thus often causing severe stridor and dyspnœa, paralysing occasionally a vocal cord, and producing various other symptoms which I need not mention here. Frequently, therefore, it is desirable that such goitres should be removed; and fortunately, within the last fourteen or fifteen years, so many improvements in the operation have been effected, chiefly by Swiss surgeons, that, if carefully performed, it may fairly be said to be attended with very little danger.*

I had intended to have made some remarks upon tapping, injecting, and incising cystic goitres. I have spent so much

* See an excellent paper by Dr. Kocher in the *Correspondenz Blatt für Schw. Aerzte*, Jan., 1889. Of 250 consecutive cases of extirpation of goitre only *six* died, a mortality of 2·4 per cent.; or, excluding 25 cases of malignant disease and exophthalmic goitre, *two* deaths occurred among the remaining 225 cases, a mortality of 0·8 per cent.

time, however, upon other parts of my subject that I cannot do so, but must pass on at once to removal of goitre.

There are two chief methods by which unilateral goitres may be removed. First, removal of the tumour alone from the interior of the gland, everything else being left behind. To this operation the name of enucleation has been restricted by Swiss and German surgeons, and I think it advisable to adopt their nomenclature. The method is obviously suited only to those cases in which the goitre forms a well-defined tumour imbedded in the glands. It is well illustrated by the case from which I enucleated the specimen now shewn to you. The condition of the patient's neck before and after operation is shewn by the two accompanying casts. The second method consists in removing the whole of the affected lobe of the gland. To this operation it is best to restrict the term extirpation, following again the nomenclature adopted by the Swiss. This operation I am able to illustrate by the accompanying specimen, which was removed by Dr. Edward Jessop and myself from a patient at East Retford. The condition of the neck before and after operation is shewn by casts. As these two operations form excellent types of the two kinds of operation that I wish to recommend, I think I cannot do better than describe them, and mention the points in each which I consider to be of practical importance. First, the case of enucleation.

Case 2.—*Intra-glandular Enucleation of a Thyroid Cyst.*—Henry S., aged 64, transferred to my care at the Royal Free Hospital on January 11th, 1890, by my colleague, Mr. Gant. For many years he had had a swelling in the left side of the neck. During the last year it had increased considerably in size, and had caused him so much dyspnœa that he had been unable to follow his occupation, that of a sailor. The left lobe of the thyroid gland was occupied by an oval, moderately firm swelling about as large as a lemon. This had pushed the larynx and trachea over to the right side, and had displaced the carotid artery outwards in the usual manner. The patient's voice had recently become somewhat hoarse, although there

was no definite paralysis of either vocal cord. Treatment by means of iodide of potassium internally and lin. iodi externally had previously been employed without any benefit.

On Jan. 14th the tumour was enucleated in the following manner:—An antiseptic dressing was applied to the neck for some hours before the operation. An oblique incision was made through skin and superficial structures down to the capsule of the thyroid gland, a few small vessels requiring ligature.

The capsule of the gland was then opened, and a thin layer of thyroid tissue stretched over the front of the tumour was also divided. I came then upon the surface of the cyst, which was easily recognised by its thick, tough, yellow wall. In order to diminish the size of the tumour, I made a small opening into it and squeezed out some of the partly-solid, partly-liquid contents. By means of an ordinary, flat hernia-director the whole cyst was then easily shelled out. The only special precaution taken was to keep close to the wall of the cyst. In this way I avoided removing any of the thyroid tissue, and of course did not run any risk of removing the neighbouring structures. There was so little bleeding that no ligatures were applied to the surface of the cavity from which the cyst had been enucleated. I was careful to abstain from washing out the wound with any kind of irritating lotion. A damp sponge was laid in the wound while the sutures were being inserted, and withdrawn just before these were tied. Directly this sponge had been withdrawn, firm pressure was applied from outside by an assistant by means of another sponge. By these means all oozing into the interior of the cavity was prevented, a small point which I venture to think of considerable importance A special form of continuous deep silk suture, which I had learnt from Dr. Girard, of Berne, was used, together with a continuous silk suture for the edges of the wound. A layer of salalembroth dressing was applied to the wound; then, over this, a large, flat sponge to fill up the hollow caused by the removal of the cyst; and then the remainder of the dressing. Bandages were applied firmly, and made to include head, neck, and shoulders.

The patient was placed in bed, not lying down, but propped up at an angle of 45°. The whole operation lasted twenty-five minutes. The subsequent progress of the case was perfectly satisfactory. The temperature remained normal, only once reaching the height of 99·4°.

For the first four days the patient was fed almost entirely by the rectum, in order that movements of swallowing should not disturb the union of the wound. On the second day after the operation the wound was dressed, the drainage tube and all sutures being removed. On the fourth day the wound was soundly healed. On the fifth day the patient was allowed to get up. On the ninth day he left the hospital in perfectly good health and completely relieved of all his trouble.

The accompanying cast shews the condition of the neck six weeks after the operation.*

The chief points in the case to which I wish to direct your attention are—

1. Antiseptic treatment of the neck before operation.

2. The small amount of hæmorrhage which occurs if care be taken to keep close to the cyst wall.

3. Avoiding the application of carbolic or perchloride or any other irritating solution to the interior of the wound.

4. Preventing subsequent oozing of blood into the wound by means of carefully applied elastic pressure kept up for several days.

5. Giving complete rest to the neck during the first three or four days, by fixing head, neck, and shoulders, *and by impressing upon the patient himself before the operation the importance of keeping absolutely still for at least three days;* also by feeding by the rectum at first.

6. The semi-recumbent posture in which the patient was placed after the operation; the patient being much more comfortable in this position than when lying down.

---

* I saw this patient again some weeks after the above was written; his condition remains quite satisfactory, and the scar, which is a fine linear one, is hardly noticeable.

The surgeon who has performed the largest number of these intra-glandular enucleations of goitre is undoubtedly Prof. Socin, of Basle, who practically originated the operation. Details of his operation have been published in an excellent monograph by Dr. Keser, of Vevey.* Seventeen of the enucleations were of cystic, twenty of solid tumours. Not a single death occurred in the whole series of thirty-seven cases.

Mr. Charters Symonds recently brought before the Clinical Society of London an excellent series of several cases in which he had operated in a somewhat similar manner with complete success.

I turn now to the third case, that of complete extirpation of one-half of a goitrous thyroid gland. The operation was performed by Dr. Edward Jessop, late of East Retford, and myself. This case has already been published by us in full in vol. xxv. of St. Bartholomew's Hospital Reports, so I will describe it less fully than the last.

Case 3.—*Extirpation of the left Lobe of a large Goitre.*—John W., æt. 27. He had had a large bilateral goitre for many years. From its size and weight and the pressure which it exerted upon other structures in the neck, it gave him great trouble, and quite prevented him from following any occupation. The operation was performed in April, 1888, in the following manner:—An oblique incision was made over the middle of the tumour, and skin, fascia, and superficial muscles divided. The capsule of the gland was easily recognised by the network of very large veins which ramified beneath it. Great care was taken not to open the capsule, in order to avoid the hæmorrhage which would otherwise have occurred. The various vessels entering or leaving the goitre above, below, and at the sides were then carefully exposed, isolated, tied in two places, and then divided. The superior thyroid artery and vein were tied separately at an early stage of the operation. Both were much enlarged, being about the size of an ordinary cedar

* L'énucléation ou extirpation intraglandulaire du goitre parenchymateux. Par le Dr. Samuel Keser. Paris. 1887.

pencil. The three largest veins tied were the superior thyroid, at the upper border of the tumour, and two others below, at the inner and outer borders respectively. By dealing in this manner with the vessels, all serious hæmorrhage was avoided. I do not suppose that the blood lost during the whole operation amounted to half an ounce; and yet many of the vessels were of very great size, as may be seen in the specimen, in which an injection of both arteries and veins has been made. The internal jugular vein lay spread out upon the outer surface of the goitre, and had to be carefully separated from it.* After the tumour had been isolated above, below, and on the outer side, it was turned over towards the front of the trachea, and the various branches of the inferior thyroid artery were divided close to the tumour, the main trunk being not even seen. Great care was taken at this stage of the operation to avoid wounding the recurrent laryngeal nerve, which lies close to the thyroid gland at its inner and back part.

The dressing of the wound in this case was similar to that which I have described in connection with Case 2. The subsequent progress was equally satisfactory. On the third day the drainage tube and all sutures were removed, and the wound was found to have healed by first intention, except along the track of the drainage tube. On the fourth day the patient was allowed to get up and take solid food. After the eighth day all dressings were discontinued. The condition of the neck before and after operation is shewn by the casts and photographs before you.

The right lobe, which had not been removed, decreased in size for some weeks after the operation, and then slowly re-enlarged; but this has not given the patient any trouble. His

* It is worth remembering that the relation of this vein to the carotid artery in cases of large goitre is apt to be abnormal. Both vessels are usually displaced outwards, but the artery more so than the vein. The result of this is that the vein, instead of being outside and slightly in front of the artery, comes to lie well in front of and internal to it. Consequently, the pulsation of the artery is not a safe guide to the position of the vein. A want of knowledge of this altered relation of vein and artery is probably the chief cause of wound of the internal jugular vein, an accident by no means uncommon in removal of goitre.

dyspnœa disappeared completely and he was able to resume his ordinary occupation. I last heard of him a year and a half after the operation. The tumour after removal weighed eighteen ounces. A portion of it is before you; the structure is that of a multilocular cystic tumour with solid nodules of a fibro-adenomatous nature.

It will be noticed that the mode of dressing the wound and the after treatment were practically the same in all the three cases that I have described. Although some of the details may have seemed to you almost trivial, yet I venture to think that they are not really so, and that it was largely by careful attention to these small details in the performance of the operation and in the after treatment that the successful result in all three cases was due.

Although I can say truly enough that I have not yet lost a patient after removal of a goitre, yet I ought in fairness to allude to the case from which the specimen that I now shew you was taken. It was that of an elderly woman whom I first saw in consultation with Mrs. Marshall, M.D., of the New Hospital for Women. The patient had had, for many years, a goitre of moderate size on the left side of the neck. In the last year of her life she had had several very severe attacks of dyspnœa, and it appeared clear that unless some attempt were made to remove the goitre she could not live more than a few weeks. Chloroform was administered, and the operation for removal of the tumour was commenced. But directly after I had made the first incision through the skin, the patient's breathing suddenly ceased, and, although tracheotomy and artificial respiration were at once performed, recovery did not take place. It is, I think, scarcely fair to attribute the death altogether to the operation, since the patient would certainly have died very shortly had no operation been performed. On the other hand, it would hardly be right to omit mentioning the case; for although the goitre itself had not been touched, yet I was about to remove it. Whether it was the mere incision through the skin or the effect of chloro-

form or the feeble condition of the patient's health that was the immediate cause of death I am unable to say. With reference to the first point, however, I may add that it was noticed that the pulse continued to beat for some little time after respiration had ceased. This is not what one would expect to have found had death been caused by the shock of a surgical incision. At the *post mortem* no satisfactory cause of death could be discovered. The goitre consisted chiefly of a large, cystic, adenomatous tumour of the left lobe.

There are many other interesting points in connection with diseases of the thyroid gland that I should like to have discussed, but my paper has been a long one and I must bring it to an end. It remains only for me to thank you for the kind way in which you have listened to me this evening.

Printed by HALL & ENGLISH, No. 71, High Street, Birmingham.