

Case of chronic arthritis in a child : characterised by fibrous contraction of several joints and associated with some thickening of the middle of each tibia and with marked enlargement of groups of lymphatic glands / by Thomas Barlow.

Contributors

Barlow, Thomas, Sir, 1845-1945
Royal College of Surgeons of England

Publication/Creation

[London] : [Printed by Adlard and Son], 1889.

Persistent URL

<https://wellcomecollection.org/works/dwdu7n8s>

Provider

Royal College of Surgeons

License and attribution

This material has been provided by This material has been provided by The Royal College of Surgeons of England. The original may be consulted at The Royal College of Surgeons of England. where the originals may be consulted. This work has been identified as being free of known restrictions under copyright law, including all related and neighbouring rights and is being made available under the Creative Commons, Public Domain Mark.

You can copy, modify, distribute and perform the work, even for commercial purposes, without asking permission.



Wellcome Collection
183 Euston Road
London NW1 2BE UK
T +44 (0)20 7611 8722
E library@wellcomecollection.org
<https://wellcomecollection.org>






(4)

Barlow. Chronic Arthritis





Case of Chronic Arthritis in a child, characterised by fibrous contraction of several joints and associated with some thickening of the middle of each tibia and with marked enlargement of groups of lymphatic glands. By THOMAS BARLOW, M.D. *Exhibited May 24, 1889.*

A LICE A., æt. 11½, was admitted to the Hospital for Sick Children, Great Ormond Street, on April 23, 1889, on account of contractions of several joints with pains in them.

Family history.—Father died three years ago in Colney Hatch Asylum. He had been more or less insane for eight years; had at first symptoms very like drunkenness, delusions of grandeur, but a little before his death he became homicidal. One of his sisters suffered from St. Vitus's dance. There was no history of gout or rheumatism. Mother was also free from gout and rheumatism. She has had seven children, of whom six are living and healthy. One child, died aged nine months, from inflammation of the lungs. There have been four miscarriages alternating with the last four living children, and there has been one stillbirth.

Previous history of the patient.—She was a full-term healthy infant; was weaned at sixteen months. She has had whooping-cough, measles, and chicken-pox. The last-mentioned occurred when she was five years old. No other illness of importance.

History of present illness.—Twelve months ago the mother found that the child could not get up from the sitting posture without pain. The pain was greatest in the knees but subsequently extended to other joints. At the same time the knuckles were found to be swollen and tender. She was taken to the infirmary at Norwood and remained there one month, and after an interval was readmitted and remained there six months, but the mother says without benefit. She has got weaker and thinner, and unable to walk more than a very short distance. Her appetite is poor and she is constipated.

Present condition.—She is a dark-haired, pale child of good mental development and free from any congenital bodily defect. She is very thin and has wasted a great deal, but the covering of her limbs, especially of the upper limbs, is tough

and firm. There is no actually *glossy skin*, and yet the attempt to squeeze up the skin and subjacent tissues of the arm and forearm suggests approximation to the "hide-bound" condition. The palms are generally a little cold and moist. Sometimes the dorsal surface of the knuckles presents slight bluish discolouration, but the finger-tips are white and tapering. There is no anæsthesia, and no definite nerve tenderness. The muscles of the upper limbs are much more wasted than those of the lower, and those of the front of the forearm and the inner aspect of the arm rather more wasted than those of the extensor aspect. The muscles of the palm are considerably wasted, but all these muscles respond fairly well to faradism.

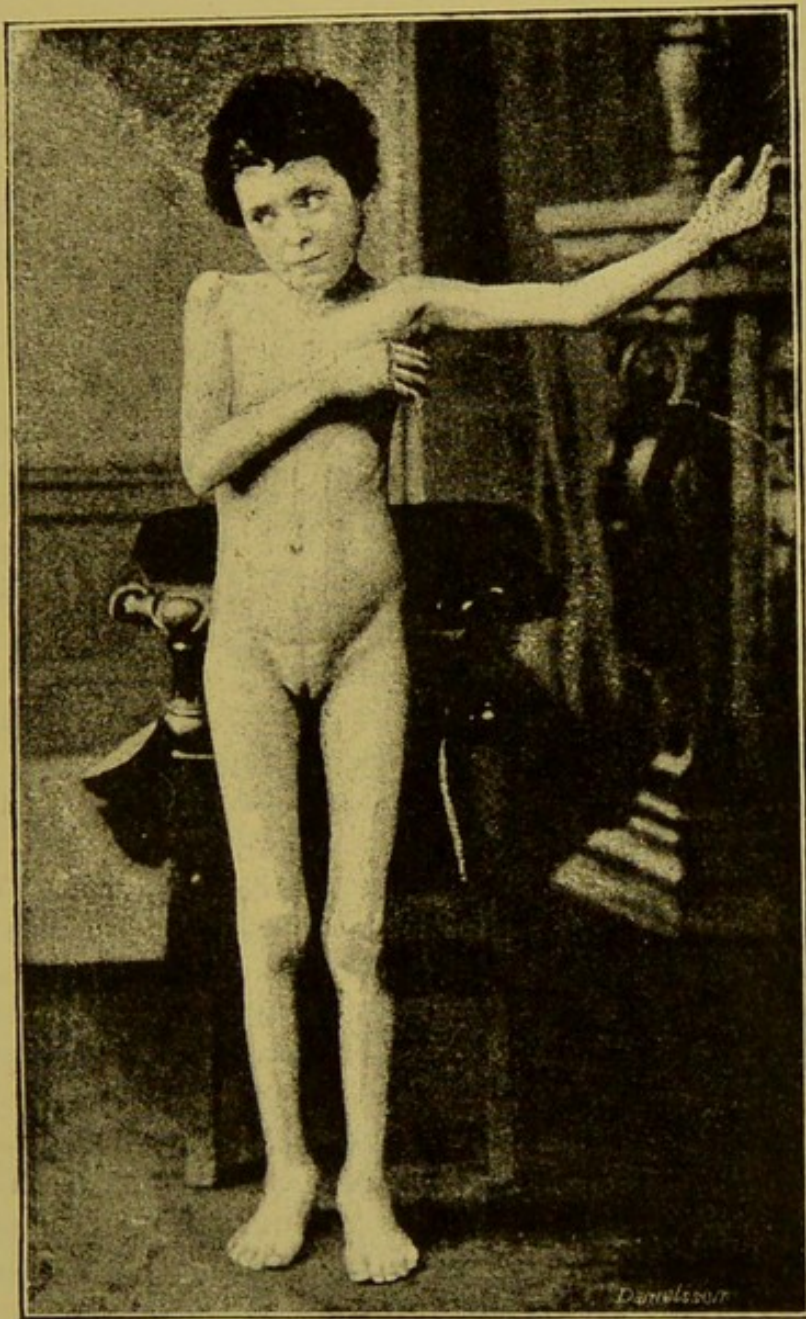
Joints of upper limbs.—The sterno-clavicular joints are natural. There is a little limitation to upward movement of both shoulders, but no grating can be obtained. There is decided limitation of movement of both elbows. They cannot be completely extended, and this, together with the wasting of the forearm-muscles, gives a certain concavity to the whole anterior aspect of the upper limbs. I am inclined to think that the long axis of each ulna, and in less degree of each radius, is slightly altered in the sense of being a little concave anteriorly.

The child can pronate well but cannot supinate completely. Forcible supination or extension of the elbow gives pain. There is slight prominence over the back of each wrist, due, I think, to a little effusion in the sheaths of the tendons. Both flexion and extension of both wrists are limited and painful, and there is a little tendinous (?) creaking on the left side. The palmaris longus tendon on both sides just above the wrist shows some very minute nodular thickenings. The condition of the hands is well shown in the photograph. There is hollowing of the palm, the metacarpo-phalangeal joints are slightly flexed, the middle phalanges are extended, the terminal phalanges slightly flexed. The extremities of the metacarpal bones and of the phalanges are not enlarged, and there is only the slightest possible indication of ulnar deflection of the digits on the right side.

In the lower limbs there is less atrophy and induration of the soft parts than in the upper. The hip-joints seem natural. There is some pain and limitation to flexion of the knees. The child lies in bed with her lower limbs extended; when she walks she takes short steps and does not bend her knees properly. There is a slight nodular thickening about the upper

edge of each patella, and occasionally a little (?) tendinous creaking to be got on manipulation.

FIG. 28.



Chronic arthritis, showing contractions of finger joints, wrists, and, to slight extent, of elbows in flexed position. No enlargements of ends of bones. Some atrophy and slight "hide-bound" condition of muscles and skin. Torticollis on right side. Some thickening of middle third of each tibia. Lymphatic glands enlarged, especially in left axilla and right Scarpa's triangle.

The middle third of each tibia on its inner aspect is definitely thickened. This is more marked on the right side

than on the left. There is no tenderness or redness of the skin over this thickening. The thickening is rather massive in character although it is only slight in amount. There are no projecting eminences but rather a rounded smooth elevation.

There is slight limitation of the ankle movements but no deformities of the ends of the tibiæ or of the bones of the feet.

Back.—There is a little torticollis (shown in the photograph). The chin is pointed towards the left shoulder, the face looking directly forwards. The child has difficulty in turning her chin towards the right shoulder, but she can depress the head towards the shoulder. Though the right sterno-mastoid comes into marked relief when the child stands up, it is quite supple when she lies on her back.

Nothing definitely abnormal can be felt about any of the cervical vertebræ. Except for the torticollis the back seems natural. There is a little limitation to the up and down and lateral movements of the lower jaw but the child can chew well.

In general it may be said with regard to the joint structures that there is very little spontaneous pain and that the child has good nights, but there is pain on attempting to overcome any of the contractions. This applies to the neck, the elbows, and most of all to the wrists and fingers.

Next in importance to the joint structures and the thickening of the tibiæ comes the condition of the lymphatic glands. Several of the superficial glands are enlarged. About one inch above the internal condyle of the humerus the usual gland in that situation is enlarged. In the left posterior triangle they are slightly enlarged, also two above the middle of the left clavicle. In both axillæ they are considerably enlarged, and along both Poupart's ligaments and in Scarpa's triangle on the right side. The glands are, however, discrete and there is no tenderness or redness over them.

There is no sign of cardiac or pulmonary disease. The blood, estimated shortly after admission, gave 28·5 red corpuscles per square instead of 50, and one white corpuscle to 171 red instead of 1 to 300.

The child has not a good appetite and is a long time over her food, perhaps partly because the movements of the jaw are a little impaired. The right side of the tongue is deeply indented, but I think this corresponds to the impressions of the upper teeth, which are crowded and overlap one another. She is a little constipated. There is no abnormal abdominal sign except that the child passes too little urine. For seven-

teen days after admission the quantity in twenty-four hours varied between 8 oz. and 16 oz. The specific gravity was 1020 to 1022. There was no albumen, but the percentage of urea was low.

Remarks.—I have seen a few cases of rheumatoid arthritis in children in which the swelling of the soft parts about the joints was very considerable, resembling the exuberant form of the disease which is met with in young adults. But the present case is quite different in character. The main features here are the contractions in the flexed position without enlargements of the extremities of the bone or sign of grating, but with marked atrophy and induration of the muscles and skin. The minute nodules on each palmaris tendon, and the slight effusion in the sheaths of the tendons on the back of each wrist deserve notice as almost the only indubitable rheumatic features. The very slight amount of pain, except when attempts are made to overcome the contractions, is very noteworthy. The slight massive thickening of the tibiæ, and the general enlargement of lymphatic glands are also noteworthy, but how far they are essential it is impossible to say.

In the case of a little boy lately transferred to my care by my colleague Dr. Sturges there was not only ankylosis of many joints with enlargement of lymphatic glands, but also splenic enlargement. On post-mortem examination, besides a considerable amount of fibrous ankylosis, there was in some of the joints considerable overgrowth of the synovial fringes with some absorption of cartilage, but there was no development of lip-like osteophytes and no exposure of articular ends. The shafts of the bones were somewhat atrophied. In both these cases there was just a possibility of syphilis being present, but I cannot say more than that. I have seen another case very like the one now exhibited in a little girl in which contractions of many joints with atrophy, &c., came on after an acute specific disease, probably measles; the morbid condition was progressive for a time and then remained stationary. I may also mention that a case very like this was shown in the early part of this session to this Society by Dr. Pasteur in which there was the same fibrous ankylosis and atrophy of soft parts with tendency to hide-bound conditions. Attractive as the hypothesis might be of a nervous origin for these cases there is, so far as I can see, no proof of primary involvement of nervous structures either central or peripheral.

It appears to me that at present we are not in a position

to classify them, but that we must content ourselves with recording their clinical characters as completely as may be with the hope that their etiology and true affinities may by degrees become unfolded.

Addendum (July 1, 1889).—I have treated this child with lamp baths every second or third day, followed by tepid sponging and also with hot douches, inunction with oil, and passive movements for the wrists and fingers.

It is too early to speak of the ultimate result, which I fear will be unsatisfactory. The movements are, however, decidedly a little freer than they were, and the child bears the treatment well. The body weight has not increased, but the child passes more urine since the baths were commenced. The quantity now averages about 19 oz. daily. The last estimation of the number of red blood-corpuscles to the square showed some increase, viz. 38 per square as compared with 28·5 on admission.



