

Bovine tuberculosis in man : an account of the pathology of suspected cases / by Charles Creighton.

Contributors

Creighton, Charles, 1847-1927.
Royal College of Surgeons of England

Publication/Creation

London : Macmillan, 1881.

Persistent URL

<https://wellcomecollection.org/works/qs25bkыр>

Provider

Royal College of Surgeons

License and attribution

This material has been provided by This material has been provided by The Royal College of Surgeons of England. The original may be consulted at The Royal College of Surgeons of England. where the originals may be consulted. This work has been identified as being free of known restrictions under copyright law, including all related and neighbouring rights and is being made available under the Creative Commons, Public Domain Mark.

You can copy, modify, distribute and perform the work, even for commercial purposes, without asking permission.

313

5

2

BOVINE TUBERCULOSIS
IN MAN



BY THE SAME AUTHOR

CONTRIBUTIONS TO THE
PHYSIOLOGY AND PATHOLOGY OF THE BREAST
AND OF ITS LYMPHATIC GLANDS

See, pp. 200, with Thirty-five Woodcuts and a Plate. 1878. 2s.

MACMILLAN AND CO.

2

BOVINE TUBERCULOSIS

IN


MAN

*AN ACCOUNT OF THE PATHOLOGY OF
SUSPECTED CASES*

BY

CHARLES CREIGHTON, M.D.,

M.A. CANTAB., DEMONSTRATOR OF ANATOMY IN THE UNIVERSITY
OF CAMBRIDGE.



WITH ILLUSTRATIONS.

Dupl

London:

MACMILLAN AND CO.

1881.

NEILL AND COMPANY, EDINBURGH,
GOVERNMENT BOOK AND LAW PRINTERS FOR SCOTLAND.

P R E F A C E.

THE title of this book has been chosen for its brevity, and with no intention of being dogmatic. If the designation had not been too cumbrous for a modern title-page, I should have preferred to describe the work as relating to a form of tuberculosis in man, which had the characters of an infection, and at the same time a suggestive likeness, in the morbid products, to the bovine form of tuberculosis (*Perlsucht*). I preserved the affected parts from the earlier cases without any anticipation of the views that I now express, and merely because they seemed likely to repay study. The examination of them pointed to the pearl-disease of the bovine species as the source of the infection, and each succeeding case confirmed me in that opinion. It was from the tenth case, in order of time, that I took the distinctive appearances shown in the first plate; and it was from a case that occurred after the work had all been sent to the press, that I obtained the specimens of pearl-nodules which are represented in the woodcut in Appendix B. I am thus encouraged to believe that the attention of the profession requires only to be directed

to certain points of morphological resemblance, in order to elicit evidence that will be sufficient to settle this question of a conveyance of tuberculous disease from the bovine species—if, indeed, the evidence of likeness in form and structure can settle it.

My opportunities for pathological study, in the intervals of teaching another subject, are owing to the good-will and liberality of the PHYSICIANS and the SURGEONS of ADDENBROOKE'S HOSPITAL, and I owe my especial thanks to Dr LATHAM and to Dr BRADBURY for the privilege of using the cases upon which the present work is based.

CAMBRIDGE,
24th December 1880.

CONTENTS.

CHAPTER I.

DEFINITION OF THE SUBJECT.

	PAGE
Anomalous cases of general tuberculosis—Bovine tuberculosis suggested by the form and structure of the morbid products—Structural mimicry of infection—The bovine disease colloquially named from the serous-membrane affection—Not identical with human tuberculosis in general—The latter an unassorted group of morbid conditions—Morphological evidence of identity not without value: criticism of the statements of Cohnheim — Opinion of Virchow that pearl-nodules have never been acquired by man .	1-10

CHAPTER II.

SUMMARY OF THE PATHOLOGICAL ANATOMY OF TUBERCULOSIS IN THE BOVINE SPECIES.

Frequency of tuberculosis or pearl-disease in the bovine species—Condition of the serous membranes—Condition of the lungs: observations of Trasbot—Smooth-walled vomicæ in the lungs not always dilatations of bronchi—Criticism of Virchow's statements on bronchiectasis in the bovine disease—Condition of the lymphatic glands—The disease in other organs	11-20
--	-------

CHAPTER III.

COMMUNICABILITY OF BOVINE TUBERCULOSIS TO ANIMALS BY EXPERIMENT.

Experiments of Gerlach—Morbid anatomy of a cow from which experiment-material was taken—Details of Gerlach's feeding	
--	--

	PAGE
experiments with milk and with the pearl-nodules—Conclusion of Gerlach: how far the induced disease identical—Case of bovine tuberculosis communicated to pigs by accident through the milk (Walley)	21-26

CHAPTER IV.

CASES IN MAN.

Cases 1-12, from the medical practice of Addenbrooke's Hospital, Cambridge: under each case a brief commentary, with references to the plates	27-46
---	-------

CHAPTER V.

THE FORMATIONS ON THE SEROUS MEMBRANES.

Difficulty of separating distinctive bovine tubercle in man from human tubercle in general: microscopic definition of tubercle by Schüppel and by Rindfleisch probably includes bovine tubercle—Distinctive characters of latter best seen in serous-membrane outgrowths—"Duckweed" on the serous membranes—Under surface of diaphragm a favourite situation—The formations may be soft and membranous, or hard and solid—May grow into adhesions: the latter not of inflammatory origin—Cord-like outgrowths—Especially round sharp margins of lung—Same as Gerlach found in experiment-animals—These marks of identity often slight, but not the less reliable	47-53
--	-------

CHAPTER VI.

THE DISEASE IN THE LUNGS.

Process in the lungs mostly acute—Whitish medullary character of nodules in acute lung infection—Encapsuled, firm, round yellowish nodules in chronic cases—Large size of nodules: conglomerates of small tubercles—Sometimes wedge-shaped masses of new growth in periphery of lung, both in chronic and acute cases—Vascularity of outer zone of nodules—Clean separation of necrosed centre from vascular periphery—Closed vomicae with smooth walls—Other kinds of central softening—Smooth-walled	
--	--

vomicæ not due to bronchiectasis—Vascularity of periphery leads to appearance of encapsulation of nodules—Vascularity of new growth approximates it to sarcoma—Giant-cells in the new formation—They mark the limited degree of vascularisation—Their vaso-formative significance—Physiological type in placental giant-cells—Abundance of giant-cells and epithelial-like cells in bovine pearl-nodules—And in suspected cases in man—And in pearl-disease communicated to rabbits by experiment—Experiments of Orth on rabbits—“Scrofulous tubercle” of Rindfleisch—Giant-cells in many other conditions both of health and disease—Vascularity of pearl-nodules greater than that of human tubercle in general—Affinities to sarcoma illustrated by an additional case (*note*)—Pneumonia, both croupous and catarrhal, may coexist with tubercles—Observations of Orth on coexistence of pneumonia with tubercles in rabbits infected with pearl-disease—Histogenesis of lung-nodules not discussed . . . 54-72

CHAPTER VII.

THE CONDITION OF THE LYMPHATIC GLANDS.

Conventional opinion that caseous lymphatic glands are a primary source of general tuberculosis—Caseous lymphatic glands may themselves contain tubercles, which are co-ordinate with the tubercles in other parts—Details of lymphatic-gland tuberculosis in the series of cases—Tubercle-conglomerates visible to the naked eye—When caseation advanced, tubercles found only in periphery of gland—They begin in follicular tissue—Hyperæmia of follicular tissue around tubercle-centres—Large size of tuberculous glands—Calcareous degeneration—Orth’s observations on lymphatic glands in rabbits infected with bovine disease—Schüppel’s *Untersuchungen über Lymphdrüsen-Tuberculose*—Schüppel’s argument for identity of tuberculosis with Perlsucht—His disregard of distinctive naked-eye features of the latter—Carswell’s plate of the lung of a tuberculous cow—Value of the microscopic evidence—Theory of Schüppel and of Rindfleisch as to the place of lymphatic-gland tuberculosis in general tubercular infection—Its place is not causally intermediate, but co-ordinate—Analogy between infection of tuberculosis and that of syphilis—Summary . . . 73-85

CHAPTER VIII.

THE INTESTINAL LESION.

PAGE

Account of case 10: tubercular infection issuing from thickened floor of healed intestinal ulcer—Analogy with syphilitic sore—Case 10 originally a case of typhoid fever: the infection due to introduction of the bovine virus—Similiar cases from Hoffmann's work on morbid anatomy of typhoid—J. Harley's cases of "tubercular fever"—Remarkable outbreak of typhoid-like tuberculosis at Bristol: observations of W. H. Spencer—Epidemics of typhoid due to poisoned milk—Is there ever anything in morbid anatomy of such cases to suggest pearl-disease of the cow?—Intestinal lesion in cases 11 and 12—And in a case of scrofulous disease of hip-joint: the microscopic test of bovine tubercle—Intestinal lesion in the rabbits in Orth's experiments	86-97
---	-------

CHAPTER IX.

SUMMARY.

Distinctive characters of pearl-disease in the bovine species—How far the disease communicated to animals by experiment resembles it—Probability of its having been communicated to man—Actual proof of its communication must rest on identities of form and structure in the morbid products—In what class of cases in human pathology instances of pearl-disease may be looked for—Virus of the pearl-disease compared to that of syphilis—Usually absorbed from alimentary canal—Varies much in intensity—The infection not such as would be due to minute organisms	98-104
--	--------

APPENDIX A.

GIANT-CELLS AS VASO-FORMATIVE CELLS.


PAGE

- (Extracts from two papers by the author, in the *Journal of Anatomy and Physiology*, January 1879, vol. xiii. p. 173, entitled "Further Observations on the Formation of the Placenta in the Guinea-Pig," and "The Physiological Type of the Giant-Cells of Tubercles and Granulations.")
- Secondary or additional placenta of Guinea-Pig—Differs from primary or discoid part chiefly on account of its matrix-tissue—Summary of primary decidua hyperplasia, and its adaptations to form discoid placenta—Differences in secondary or deeper vaso-formative process: hyperplasia in a less highly vascularised stratum—Giant-cells entering into the formation of blood-channels—Necrosis of some of the multinuclear blocks of tissue—Blood-channels formed by parallel rows of nuclei—Contrast between vaso-formative process in the superficial and in deep layers of decidua: giant-cells in the latter—Placental giant-cells a physiological type of pathological giant-cells—Vaso-formative process in placenta a clearer analogy than vessel-formation in the embryo—Particular giant-cells from tubercles compared with particular giant-cells from placenta—Necrosis of giant-cells both in the physiological and in the morbid process indicates failure of their vaso-formative activity—Defective vascularity of products of inflammation in scrofulous subjects: local tuberculosis—Mimicry of structure in general tuberculosis . . . 105-112

APPENDIX B.

ABSTRACTS OF CERTAIN PUBLISHED CASES OF TUBERCULOSIS.

- Besides abstracts of and references to anomalous cases of tuberculosis published in medical journals and treatises, contains short notes of two original cases not included in the text (pp. 114, 115), one of them being illustrated by a woodcut of pearl-nodules from under surface of diaphragm 113-119



BOVINE TUBERCULOSIS IN MAN.

CHAPTER I.

DEFINITION OF THE SUBJECT.

THE occurrence of anomalous or unaccountable cases of general tuberculosis would appear, from the published records, to be by no means uncommon. But the pathology of tuberculosis in man has in the past been surrounded by so many difficulties, the interpretation of the morbid appearances and of their relation to each other, has depended so much upon an ever-shifting theory of the disease, that even the most unaccountable and mysterious cases have been regarded as only a degree more puzzling than the general run of tuberculous cases, and have been lightly consigned to that limbo of unexplained or half-explained cases which occupies so large a part of every *post-mortem* register. The group of cases that form the subject of this paper are probably not different from many that have occurred before. If they shall have escaped the fate of being thrown into the general unassorted heap of tuberculous cases, it is because they occurred in rapid succession, presenting day after day the same associated appearances, and thus arresting the attention and provoking curiosity to a degree that isolated cases, occurring at wider intervals of time, would probably have failed to do.

On the 17th April 1880, the *post-mortem* examination at Addenbrooke's Hospital was on the body of a man, aged twenty-one, who had been admitted with pulmonary symptoms, and had

died suddenly after being thirty-six hours in the hospital. The lungs contained a number of soft whitish masses, up to the size of a walnut, softened in the centre, most of them round, and one or two, on the periphery, wedge-shaped. The question was whether they were not secondary tumours; but they differed from the sarcomatous or other new growths that occur secondarily in the lung, and they differed still more markedly from cheesy deposits. Four days later there was a *post-mortem* examination on the body of a woman, aged thirty-eight, who had been in the hospital six months before with typhoid fever, and had been readmitted with obscure abdominal symptoms. Acute tuberculosis had been diagnosed, and both lungs were found full of very minute translucent tubercles, and one lung contained a single large sharply-defined wedge-shaped infarction on the periphery. This infarction recalled the wedge-shaped masses of the former case, but it differed from them in being firm and tough, and of a brownish-yellow colour, like a gumma. There were two small healed ulcers in the ileum, and the peritoneum generally was covered by an eruption of large flat tubercles. About a week afterwards (28th April), there was a *post-mortem* examination of the body of a girl aged seventeen. The under surface of the diaphragm and other parts of the peritoneum were covered with the same large flat tubercles as in the preceding case, and one lung contained precisely the same white medullary tumour-like masses as in the first case. One of the white masses (figured at the top of Plate III.) was distinctly wedge-shaped. A few days later (4th May) the body of a child, aged eight, was examined. The case had been a typical one of acute tuberculosis, of about five weeks' duration. The tubercles in the lungs were large and white, and at one apex they were so close together as to form on the periphery of the lung a solid wedge-shaped mass an inch long. Lastly, on the 14th May, an examination was made of the body of a man, aged 42, who had died of acute pulmonary disease after being four days in the hospital. The appearance of the left lung was remarkable; it was intensely œdematous; it presented a number of large cavities, more or less smooth in the interior, and containing putrid-looking greyish fluid; one or two of the cavities in the periphery of the lung were wedge-shaped, and the lung tissue

between the cavities was everywhere occupied by round nodules as large as peas, of a uniform size, and of a dirty grey colour.

I had in the meantime been examining carefully all the material that I had collected from the cases as they occurred, and, after a time, it occurred to me, from certain points of likeness in the morbid products, that we had here to deal with bovine tuberculosis communicated to man. Certain of the morbid appearances led me to go back upon three equally unaccountable cases of tuberculosis in adults that had died in the hospital in February and March, and from which I had preserved portions of the affected organs. I did not hesitate to include those three cases along with the others as cases of distinctive and specific bovine tuberculosis. Having examined the whole of this material, and having been kindly permitted by Dr Latham and by Dr Bradbury, in whose respective services at the hospital the patients had been, to make use of the cases, I communicated my observations to the Cambridge Medical Society on 4th June, and the communication was published in the *Lancet* of 19th June 1880. After recording the cases, I continued:—

“My contention is that these cases of tuberculosis are all of them cases of bovine tuberculosis; that they show the distinctive and specific characters of that disease in their pathological anatomy and are related to it in their etiology, and that they have precisely that relation to bovine tuberculosis which glanders in the human subject has to equine glanders. Bovine tuberculosis (*Perlsucht, Pommelière*) is a disease by itself, as much as glanders is. It is only from directing too concentrated an attention upon its histology that one would be led to conclude, with Schüppel,¹ that bovine tuberculosis is identical with the ordinary indigenious or autochthonous tuberculosis of man. It has well-marked distinctive characters,² which appear to me to be reproduced more or less in all the cases above related. I must content myself for the present with summarising in the briefest way what may be considered to be the salient features of the cases that I have grouped together, without attempting to make out the identity with bovine tuberculosis from point to point.”

The summary related chiefly to distinctive appearances, microscopic and other, in the lungs, in the lymphatic glands, and on the serous membranes.

Since the first series of eight cases were published, four more

¹ Virchow's *Archiv*, vol. lvi. (1872), p. 38.

² See Virchow's *Lectures on Tumours* (French translation). vol. iii. p. 184.

cases of precisely the same nature have occurred at Addenbrooke's Hospital, and these I include in the present paper by permission of Dr Bradbury. They were examined *post-mortem* on 26th June and 1st July, and on 2d and 4th September. The case on 1st July has afforded me the best specimens that I possess of the characteristic pleural outgrowths (figured in Plate I.), and those on the 2d and 4th September have afforded good examples of the intestinal lesion. These additions bring up the number to twelve. I have omitted three cases that occurred within the same period of seven months, as being somewhat ambiguous.

In attempting to detach any particular group of tuberculous cases from the great unassorted congeries of such cases, one is met by difficulties of no ordinary kind. The characters exemplified by the present series of twelve cases, characters which I shall maintain in the sequel to be distinctive of the specific tuberculosis of bovine animals, have doubtless all of them been already noted and included, in one place or another, among the manifold characters of tubercle. There is probably nothing in the coloured plates which those who frequent the dead-house are not more or less familiar with; while, as regards the microscopic drawings, the definition of tubercle as given by Rindfleisch¹ and by Schüppel² would cover nearly all that they show.

By what means, then, do I hope to isolate this particular group of cases, and to determine for them such specific characters as would satisfy the classification test of a systematic zoologist or a systematic botanist? It is not by tracing the individual cases to particular sources of poisoning or of infection, nor is it by the test of experimentally inducing the disease by the inoculation of the substance in animals. I rely solely upon the specific and distinctive characters of the tuberculosis that affects the bovine species, and on the morphological identity that I shall prove between that kind of tuberculosis and the disease that occurred in the group of twelve cases in man. The bovine disease, in being communicated to man, may be somewhat modified; just as glanders in man is not precisely the same

¹ Rindfleisch in Ziemssen's *Handbuch*, vol. v. 2, p. 162, fig. 1.

² Schüppel, *Untersuchungen über Lymphdrüsen-Tuberkulose*, Tübingen, 1871.

as equine glanders. The specific tuberculous disease of the cow or ox is a very slow disease, which may escape notice for years and not seriously interfere with nutrition, and it is probably in most cases inherited; the corresponding disease in man is of the nature of a more or less acute infective disease, with the clinical symptoms of an infection predominating. But so remarkable is *the structural mimicry that resides in infection*, that the disease communicated to man reproduces the special anatomical characters of the bovine disease with a surprising degree of accuracy. The older German veterinary surgeons designated bovine tuberculosis as *Meerlinsigkeit* or "Duckweed," from the curious resemblance that the outgrowths on the serous membranes have to the dense masses of small round or oval leaves that float on the surface of a pool, presenting a somewhat convex surface, and imparting the notion of solidity. The coloured plates of the disease in man show several instances of this or the allied appearances, and the upper figure in Plate I., showing the pleural surface of the concave base of the lung, from one of the latest cases, will probably serve to suggest "duckweed." The later and more usual German name for the bovine disease is *Perlsucht*, or "pearl disease," the French name is *Pommelière*, or "potato disease," the name in Scotland is *Angle-berries*, and the most usual colloquial English name is *Grapes*. All these names are popular designations; they all relate to the same somewhat superficial condition, or different degrees of the same condition, viz., the formations on the serous membranes; they involve no theory of the disease; but they are as if the outcome of the everyday observation of those who have to do with cattle in various European countries. "Duckweed," "pearls," "potatoes," "angle-berries," and "grapes" present certain differences among themselves, but it is admitted on all hands that the disease of which they are the colloquial names is always one and the same. It is a specific disease, and *it is primarily a disease of the ox and cow*. It is to the bovine species what glanders is to the equine, and what syphilis is (perhaps) to the human species. If we look at bovine tuberculosis in the light of any one of its various colloquial names, we cannot but admit that it possesses specific characters, which would satisfy the classification test of a

systematic naturalist, and which are, as far as they go, sufficiently fixed and determinate for an argument of morphological identity in the human subject to be based upon them.

If the bovine disease had been limited in its manifestations to the serous outgrowths from which its names are taken, no one would ever have said that it was the same as human tuberculosis. It always affects the lungs as well, and an almost equally constant character is the implication of the lymphatic glands. I hope to show in the next chapter that the affections of the lungs and lymphatic glands are themselves special and distinctive of the disease in bovine animals, equally with the serous-membrane outgrowths. If the naked-eye characters alone are relied on, there need be no question of the distinctiveness of the morbid condition, whether in the lungs and lymphatic glands, or on the serous membranes. It is only when the microscope is applied, that the disease is resolved into the same fundamental textural processes as we suppose to be characteristic of tuberculosis in man. That is the contention of Schüppel¹; I shall have to examine the argument of that author at some length in subsequent chapters, and more particularly in Chapter VII.

In the meantime, an obvious objection may be taken to the histological argument of Schüppel, that bovine tuberculosis and human tuberculosis are two concurrent and identical forms of one disease, and to the corresponding arguments from experiments put forward by Chauveau, Villemin, and Klebs. The two terms of the comparison, or the two sides of the identity, do not stand on the same footing. The disease in the cow and ox is a specific disease, about the distinctive characters of which there is no difference of opinion. Treatises on veterinary pathology enumerate certain morbid conditions in the lungs from which it is to be distinguished; but the diseases most likely to be mistaken for it are hydatids in the cow, lymphoma (chiefly of the horse and dog), and strongylus in sheep. It does not appear that it can be readily confused with pleuro-pneumonia, and, within the bovine species itself, its *post-mortem* diagnosis may be said to be singularly free from difficulty. But can the same be said of "tuberculosis" in man? What are called tubercular diseases

¹ Schüppel, "Ueber die Identität der Tuberculose mit der Perlsucht."—Virchow's *Archiv*, lvi. (1872), p. 38.

in man are a congeries of morbid conditions which half-a-century of sifting and sorting has not served to reduce to order. That this ill-assorted congeries of cases, this dust-bin of pathology should contain some (if not a large proportion of) cases of the specific bovine disease is conceivable. But the one known quantity in this problem is the specificity of the bovine disease, and it is only such cases in the human subject as have the specific marks of bovine tuberculosis that can be said to be identical with it. If, on the other hand, any given case or cases of tuberculosis in man are taken as the starting-point of a comparison, and the same characters are found to obtain in the tuberculosis of the cow and ox, that only proves that the particular human cases *are* cases of the specific bovine disease. It would simplify greatly the problem of human tuberculosis if all cases of the disease in man presented the bovine characters. There would be no question at all as to the origin of the human disease, as to where it had come from. But there is naturally no such simplicity for tuberculosis in man. A class of cases, which I have referred to above as autochthonous or indigenous cases of tuberculosis, doubtless exists; they are said to be due to the self-infection of the organism from a primary focus of suppuration or caseation, and in favour of that hypothesis there is the strict analogy of metastatic tumours and of metastatic abscesses. After that somewhat restricted class of cases, we come at once to the residue which pathologists find it so difficult to assort. I maintain that the unassorted residue contains some (if not many) cases of the specific bovine disease communicated to man. But the only way to track such cases is to take one's departure from the clearly-marked specific characters of the bovine disease, and to search closely among the human cases for such as have an exact and complete identity of morphological features. It is only to the most unbounded faith in the *structural mimicry of infection* that success in this quest will be given. Whoever has followed closely the infective process in tumours, and has observed in the secondary nodules the marvellous mimicry of the complex structural details of the primary, will not find it hard to believe that the singular appearance on the pleura in Plate I. is due to infection from a case of that disease to which the name of *Meerlinsigheit* or "Duckweed" is sometimes given. The conviction that such

cases are of bovine origin is greatly strengthened by the discovery that the lungs and lymphatic glands reproduce the condition of the corresponding organs in the cow in a no less accurate copy.

In trusting so much to a morphological test of identity, I may appear to some to be resting my whole case upon an obsolete and discarded method of procedure. The utterances of Professor Cohnheim on this matter are certainly disquieting.¹ "To tuberculosis," he observes, "belongs all that can, by its inoculation on suitable experiment-animals, produce tubercle, and nothing is tuberculous which produces no effect after inoculation. How much is gained by this definition, those only can sufficiently appreciate who have seriously taken pains to study the anatomical history of chronic pulmonary tuberculosis in the body of the ordinary consumptive. Let one endeavour as much as he will, it is of no avail; the anatomical definition is of no use any longer for tubercle, but it must yield to the aetiological. To those who deplore this—and I do not ignore the fact that a certain amount of inconvenience has thereby arisen for *post-mortem* diagnosis—I would say that they should not give up hope of even the anatomical definition again coming to its rights. That the problem of assigning morphological characters to the tuberculous virus is already solved, I would not venture to say, even after the latest labours of Klebs, distinguished as these are by care and diligence. But, whoever is convinced of the parasitic nature of the infective kinds of virus, will not hesitate to believe in the corpuscular nature of the tuberculous poison also, and will so remain in confident expectation that, in a not too distant future, proof will be furnished of the existence, in the interior of tubercle-nodules and scrofulous products, of specific corpuscular elements which those who are fond of historical names may again designate as 'tubercle-corpuscles.' So long, however, as this end is not reached, there is no other sure criterion for tuberculosis than its infectiveness."

The minute organism, when found, will probably turn out to have a close family likeness to some other minute organisms, and its value as a morphological test may not be so great as the seekers for it expect. But as regards our existing means of anatomical or morphological definition, it is hard to agree with

¹ Cohnheim, *Die Tuberculose vom Standpunkte der Infectionslehre*, pp. 13, 17, 18. Leipzig, 1880.

Professor Cohnheim that they are so hopelessly bad as he makes them out to be. The picture presented by "chronic pulmonary tuberculosis in the body of the ordinary consumptive" is no doubt varied enough to drive even experienced observers to distraction. In like manner, the microscopic definitions of tubercle as a lymphoid growth, or as a growth of lymphoid tissue and giant-cells, or as a nodule with giant-cells in the centre and epithelial-like cells round about, are not good working definitions suitable for all cases. But we should be throwing away a useful weapon, if we abandoned the morphological or anatomical test altogether. According to Professor Cohnheim, all tubercle is due to infection from without; but though Professor Cohnheim generalises infection to the utmost extent and looks forward to the day when the "tubercle-corpuscle" shall have been discovered in the form of a minute organism, he does not assert that the tubercle-infection is always one and the same infection. Tuberculosis, according to him, is for the most part transmitted by infection from individual to individual within the human species, the infecting germs being for the most part introduced with the inspired air;¹ but he allows a place to the conjecture, often repeated since Klebs² and Gerlach first made it in 1868, that the milk of tuberculous cows may also be an agent of infection, and is specially to be held accountable for the tuberculosis of children.³ Like most of those who touch on this subject, he readily assumes that the tubercle of man and the tubercle of the cow are one and the same thing and interchangeable terms; the only question is whether it is "tubercle," and the answer is found in testing its communicability by experiment. I say that this modern method of treating the question is to make an unjustifiable surrender of valuable morphological details. The tuberculosis of the ox and cow has well-marked distinctive characters; infection carries with it a remarkable degree of structural mimicry; and if human beings are infected with the tuberculosis of the bovine species, the new formations in their bodies will be like the new formations in the

¹ *Loc. cit.* p. 21.

² Klebs, "Ueber die Entstehung der Tuberculose und ihre Verbreitung im Körper."—Virchow's *Archiv*, xliv. (1868), p. 266.

³ *Loc. cit.* p. 25.

bodies of bovine animals. To establish the proof of a communication of the bovine disease to man, I rely upon identities of structure, and upon these alone. The experimental test is obviously out of the question, and the micro-organism test is not yet ripe for general use. The only alternatives are, either to make conjectures and work out hypotheses in the prevailing manner of Professor Cohnheim's suggestive essay, and so to fail in making any headway with one's ideas in the estimation of practical men, or to put together as carefully and exhaustively as possible, all the evidence of identity in structure between the disease in the bovine species and the suspected cases in man. Whoever believes in the marvellous mimicry of infection will not be afraid to look for, and will not be astonished to find in the infected human body a wide-spread and varied condition, which reproduces, in the respective localities and as a whole, the condition in the bovine animal out of which the infection has proceeded. It is chiefly in the serous membranes, in the lungs, and in the lymphatic glands that the typical lesions are found both in the infecting and in the infected organism.

I have thus sought to define the scope of my inquiry. It purports to trace the tuberculosis of twelve cases in man to infection or poisoning from the cow or ox, and the evidence relied on is the identity of the diseased product. Professor Virchow, who lays much stress on the specific and distinctive characters of bovine tuberculosis (*Perlsucht*), said, in an address to the Berlin Medical Society on 10th March 1880, "We must in any case bear in mind that no man has ever yet acquired pearl nodules through partaking of tuberculous (*perlsüchtig*) flesh."¹ I maintain that the twelve cases recorded in the sequel show precisely those specific characters of which the "pearl nodules" are the most familiar example. These cases are, so far as I know, the only cases hitherto published which formally claim to be cases of the specific bovine tuberculosis communicated to man.

¹ Virchow, "Ueber die Perlsucht der Hausthiere, und deren Uebertragung durch die Nahrung."—*Berliner Klin. Wochenschr.* No. 14 (5th April) 1880.

CHAPTER II.

SUMMARY OF THE PATHOLOGICAL ANATOMY OF TUBERCULOSIS IN THE BOVINE SPECIES.

Bovine tuberculosis is a widely-spread disease among cows and oxen; accurate statistics are not generally procurable, and the estimates of its frequency vary within wide limits. One of the most precise statements that I have met with is that relating to the town of Augsburg;¹ 2·16 per cent. of all the oxen and cows slaughtered in the course of the year 1877 were affected with the disease, and among cows alone the percentage was 4·75. The larger number of animals affected were over six years of age, which accounts for the higher percentage in cows.

According to other statements, the slighter indications of the disease, such as the growths on the serous membranes (which, according to Williams,² have no great pathological significance, being "external to the general economy of the animal"), are much more common. Bad cases of the disease are sometimes condemned by the inspectors, but the disease is not mentioned in any of the acts relating to the diseases of animals, and inspectors appear to have insufficient powers to deal with it. It is a matter of much greater practical importance that the use of the milk of tuberculous cows is entirely uncontrolled.

The disease is generally admitted to be hereditary, and the intensity of its course to depend on bad hygienic conditions. Its progress is usually very slow, and it may exist for years unsuspected. It ultimately declares itself by wasting and cough, and by certain physical signs. Cows in an advanced state of tuberculosis give a diminished quantity of milk, and the milk is thin and of a bluish colour.

¹ Adam, reported in the *Jahresbericht* for 1878, p. 611.

² Williams, *Veterinary Medicine*, p. 346.

The parts chiefly affected are the serous membranes, the lungs, and the lymphatic glands.

1. *The condition of the Serous Membranes.*—It is from the morbid appearances on the serous membranes that all the colloquial names of the disease are derived. Thus, it has been called *serous tuberculosis*, *Meerlinsigkeit* ("duckweed"), *Perlsucht* ("pearl disease"), *Pommelière* ("potato disease"), "angle berries," "grapes." The name of "duckweed" relates to the small round outgrowths on the pleura and peritoneum, sometimes thin and membranous, but also nodular or solid, like the duckweed leaf itself. *Perlsucht* relates to the same round or flat nodules on the serous membranes, but includes the more pendulous variety, like strings of pearls. The remaining names of *Pommelière*, "angle-berries," and "grapes," relate to a still further development of the same kind of serous outgrowths; the smaller size is the most common (miliary or lentil-sized nodules), but the larger nodules, being more striking, have in some countries given the name to the disease. The following account of the development of the serous-membrane eruption is given by Walley¹:—"The early stages in the process are diffuse and intense capillary congestion, followed rapidly by the formation of innumerable villous-like vascular processes, very minute, and giving the membrane an appearance closely resembling the pile on red velvet. In the course of time the extreme vascularity of these little processes passes off; they assume a definite shape, and become converted into small hard globular nodules, of the colour of connective tissue. Gradually, however, they become grey, and somewhat translucent on section, and constitute the so-called grey or fibrous tubercle. These grey miliary nodules may remain discrete, and scattered over the surface of the membrane, like millet seeds; or they may become connected together by delicate bands of new connective fibrous tissue. When tuberculation is very rapid, distinct polypoid processes, as seen in fig. 7, Plate X., may be formed on the membranes. These bodies are often at the outset very vascular, in fact, hæmorrhagic." Besides the illustration referred to in the quotation, a good picture of the large form of polypoid outgrowths on the pleura will be found

¹ Walley, *The Four Bovine Scourges*, p. 169, Edinburgh, 1879.

in Carswell's plate of the lung of a tuberculous cow.¹ A critical analysis of the bovine disease is given by Virchow in his great work on Tumours (vol. iii.). With reference to the serous-membrane outgrowths, he observes—"Whatever analogy this development may present in general with the tuberculosis of man, the size and the pedunculated disposition of the nodules always afford a striking means of distinguishing it."

2. *The condition of the Lungs.*—The morbid anatomy of bovine tuberculosis has been carefully studied by M. Trasbot, Chef de Clinique at the Veterinary School of Alfort. The following is Trasbot's account of the pulmonary lesion:²—"The tubercles in the lungs are essentially all of small size, from a point scarcely visible to a millet or hemp seed. The larger masses are formed by the confluence of a number of the small tubercles. The colour is at first greyish-white, and semitransparent, but when the development is complete, it is somewhat yellow and opaque. A tubercle is found to be developed along a small artery, most frequently at the angle formed by a terminal division of the vessel; sometimes around a capillary, on which it forms a kind of bead, or in the network of an anastomosis which envelops it on every side. When the tubercle is fully developed, it contains no vessel in its interior. *Vessels are more numerous in the tissue around the nodules, and in the septa or interstices of the large masses of tubercle, than in the healthy connective tissue; there the vascularity is oftentimes so great as to be mistaken for inflammation.*

"This absence of vessels in the tissue of tubercles serves to explain why, *nourished exclusively at their periphery*, they have only acquired small dimensions before the central necrobiosis commences; and this special peculiarity distinguishes them from sarcomatous tumours, with which Virchow has unrestrictedly assimilated them. The tubercles so developed undergo successive modifications, which so alter their character

¹ Carswell, *Pathological Anatomy*, Tubercle, fig. 4, Plate I. London, 1838.

² I take this account from Fleming's *Manual of Sanitary Science and Police*, 2 vols. 1875, vol. ii. 376. It is there compiled from Reynal's *Traité de la Police Sanitaire*, Paris, 1873. I have learned on inquiry that M. Trasbot's observations are contained in several papers in veterinary journals, to which I am, unfortunately, not able to refer.

that many observers have denied their identity. The two chief modifications are calcification and softening.

"*a. Calcification.*—The centre becomes calcified, while the periphery remains fibrous, and *simulates a capsule.*

"*b. Softening.*—This alteration commences at the centre, and extends towards the circumference of the tubercle, until there remains nothing but the surrounding connective tissue; and its appearance would lead superficial examiners to think that it was encysted, as it forms a badly-defined cavity, the contents of which are easily detached. Sometimes several contiguous tubercles break up simultaneously, and the septa between them disappear, leaving cavities sometimes larger than a walnut. These vomicæ are of various shapes and dimensions, and *are often confounded with other cavities which are formed in a very different manner.* The vomicæ have no proper walls, but are merely surrounded by the more or less indurated connective tissue that constitutes the stroma of the tubercular masses, and their interior is not vascular like that of cavities resulting from inflammation. These vomicæ are closed, and have no communication with the bronchi or pleural sacs. There is no natural demarcation between them and their contents, as in cysts and abscesses, the gradation being insensible. The central mass is more or less coherent, according to the degree of softening at which it has arrived; it is white and plaster-like if calcification has already occurred, and it has a greyish-yellow colour and cheesy consistency in the contrary case."

To this account of Trasbot, which I regard as of the highest importance for the proof of identity which I shall set up for the lung lesions, I shall add an extract from the work of Walley:—"The degenerative processes are principally softening, which commences centrally, and cretification, though the latter may succeed the former if it is not very rapid in its progress; usually, as the nodule softens, the amount of surrounding tissue condenses, constituting a veritable capsule (the old so-called encysted tubercle), which in rapid softening becomes extremely hyperæmic." Under the head "Lung," he writes:—"As the softening process goes on, the tuberculous deposits become surrounded by a tolerably thick insulating wall or envelope of condensed and new connective tissue;

and, as in encysted pleuro-pneumonia lung, the inner surface of this boundary wall frequently becomes very active—granulations forming and interpenetrating the tuberculous mass. In some instances, these softened masses coalesce, and, if the boundary wall preserves its integrity, form large tubercular abscesses, the contents of which, owing to the absorption of the fluid, may again become dry and caseous; but if the cyst wall becomes the seat of ulceration (a comparatively common occurrence), a communication is formed with the nearest bronchial tube, and the contents evacuated into it. In these cases, the boundary wall is frequently very hyperæmic, with numerous small yellow nodules adhering to its internal surface, and with evidence of recent hæmorrhage. I have in my possession a specimen of concurrent hydatid disease and tubercle, in which a communication exists—by ulceration between the hydatid cyst and the tuberculous cavity” (p. 186).

Fleming divides the pulmonary lesions into essential and accessory or contingent. The essential are—tubercles, and closed vomicæ resulting from the central softening of these. The accessory are—acute or chronic inflammation of the pleuræ, bronchitis, with cavernous dilatations, &c. It is to be observed, that while he includes cavernous dilatations of the bronchi among the accessory conditions, he places among the essential “closed vomicæ resulting from the central softening of tubercles.” Fleming states that the tubercular matter in the lungs appears to be first deposited in the cortical or peripheral portion, and always in the subpleural and interlobular connective tissue.

From the above extracts, it may be concluded that the tubercles in the lungs have a vascular periphery simulating a capsule, and a non-vascular centre. The centre becomes calcified or softened, and the periphery remains as the vascular capsule of a caseous or calcareous nodule, or as the wall of a vomica. Several small single tubercles, forming a larger tubercular nodule, undergo the degeneration together, and the excavated centres of several nodules may communicate and form a large and irregularly-shaped vomica. The careful observations of Trasbot appear to have established that process as characteristic of the pulmonary lesion in bovine tuberculosis. Strange to say, this

rational and in every way credible account of the condition of the lungs, given by competent veterinary pathologists, has either been overlooked or it is disputed by writers on human pathology who have approached this subject. Thus, Schüppel, writing on the identity of tuberculosis with *Perlsucht*,¹ and naturally seeking to have the two sides of his proposed identity each clearly defined, was disconcerted at the outset by "the variety of processes that occurred side by side" in the lung of the tuberculous cow from which he derived his material. "Apart," he says, "from the large and somewhat numerous cavities filled with inspissated pus (bronchiectasies), I found only about one-twentieth or one-thirtieth of the lung lobules to be diseased." He distinguished in the lung two kinds of morbid product—first, the inflammatory infiltration; and, second, the nodules. The latter were grey, fairly translucent, projecting nodules of miliary or sub-miliary size, partly separate and partly confluent. These alone, he admitted, to belong essentially to the tuberculous condition, and the "identity between tuberculosis and *Perlsucht*" rested, as regards the lung, on the exceedingly narrow basis of certain points of agreement in the ultimate analysis of the structure with the microscope.

The fallacy that all smooth-walled vomicae in the lung are nothing but portions of dilated bronchi—a fallacy of comparatively recent origin, and mostly prevalent abroad—had doubtless led Schüppel to set aside, as an accessory of the disease, one of the most constant and characteristic indications of bovine tuberculosis in the lung. I cannot but think that a similar laxity of opinion on the subject of smooth-walled vomicae is to be held accountable for the following opinions of Virchow. On the 10th of March 1880, Professor Virchow gave, before the Medical Society of Berlin, an account of the present state of the question relating to the experimental communication of bovine tuberculosis to other animals, with special reference to a series of experiments that had been going on for several years under his own direction.² I shall refer, in the next section, to the general evidence on that subject. After four years ex-

¹ Virchow's *Archiv*, vol. lvi. (1872), p. 38.

² Virchow, "Ueber die Perlsucht der Hausthiere, und deren Uebertragung durch die Nahrung."—*Berliner Klin. Wochensch.* Nos. 14 and 15 (5th and 12th April) 1880.

perimentation under Virchow's direction, a decided conclusion had not been reached, owing to the great difficulties, demanding an almost portentous amount of caution, that beset the experimenters on every hand. The difficulties were of two kinds, theoretical and practical. Among the theoretical difficulties was that which had formerly disconcerted Schüppel, viz., the variety of conditions that occurred side by side in the tuberculous lung. "As in the human lung," says Virchow, "so also in that of the cow, certain chronic inflammatory diseases, which might easily be taken for tuberculosis, are remarkably frequent. Since I have studied this subject more closely, I have myself been surprised at their frequency. But I have been equally surprised at the want of information concerning them in the writers of the profession. Quite especially frequent in cattle are forms of bronchitis, with retention of the contents, and every possible kind of bronchiectasis. They are so frequent that they must be considered to be, even as contrasted with what we find in man, a very usual occurrence. These forms of bronchitis and bronchiectasis nearly all have the peculiarity that the secretions remain in the canals, accumulate more and more, gradually become inspissated, and finally assume a compact, dry, caseous consistency, and not seldom even pass into petrification, as indeed happens in man in a similar way. If, now, a great part of the lung has become changed in this wise, if there is found at various places a series of irregularly dilated bronchi with saccular or bead-like recesses, so it easily comes to pass, on section of the lung, that one finds a number of hard fibrous nodules with calcareous deposits. Indeed, there is no mistaking the fact that this picture may in a high degree come to resemble that which is furnished by cross section of those tuberous masses which represent the peculiar and characteristic elements of *Perlsucht*. I must state with emphasis that in many cases the most extensive bronchitic and bronchiectatic changes, with accumulation of whole masses of caseous substance, may occur in cattle, without a single trace of *Perlsucht* being present. Those who call all these things tubercle, because something caseous or calcareous is contained therein, have certainly a wide field before them. I have by chance within the last day or two, when engaged in procuring some fresh material for demonstration this evening,

met with the lung of an ox in which, besides pearl-nodules on the surface, a wide-spread condition of bronchiectasis was to be seen." When Virchow, in the above passage, expresses surprise that veterinary writers have not discussed that remarkable condition of lung which he so graphically describes, I cannot but think that the writings of Trasbot have remained unknown to him. It is precisely to that condition of lung that Trasbot's minute investigations have been directed; he gives a rational and credible account of the origin of the smooth-walled cavities, and he expressly states: "These vomicæ are of various shapes and dimensions, and are often confounded with other cavities which are formed in a very different manner." Again Fleming writes: "These vomicæ [in the lungs], according to Trasbot, appear to be closed, and have no communication with the bronchi or pleural sacs." One recalls to mind how Virchow's penetrating analysis of the condition of the lung in the ordinary chronic phthisis of man, assailed Laennec's doctrine of the unity of phthisis, and resolved the disease, for the most part, into chronic inflammatory conditions of the tissues. The maxim "Distinguo" is one that is constantly called for in pathological anatomy, but I do not doubt that a still more rigorous application of that maxim would have prevented all those remarkable cavities or dilatations in the bovine lung from being swept into the general class of bronchiectasis.

I have delayed over this part of the subject, because it has a most important bearing on the identification of bovine tuberculosis in man. In several of the cases in my series, the lungs presented the crumpet-like condition of numerous smooth-walled vomicæ; when the first case occurred, showing that condition of lung, I had not yet been led to think of bovine tuberculosis, and I then took it to be bronchiectasis. Not only so, but I communicated it to the Cambridge Medical Society on the 5th March, as a case of bronchiectasis combined with miliary tuberculosis. Another case, showing precisely the same condition of lung, occurred shortly after, and in going into the matter more minutely, and in conjunction with cases which were suggestive, in other ways, of the bovine disease, I could find no evidence of dilated bronchi, but, on the contrary, evidence of that softening process of tuberculous nodules which Trasbot

describes for the bovine lung. I included that observation in my preliminary notice in the *Lancet*, at a time when I was unaware of the observation of Trasbot, or of the significance of this condition for the identity of the two diseases. The figure on the lower part of Plate III. represents the condition which I at first took for bronchiectasis.

3. *The condition of the Lymphatic Glands.*—The thoracic and abdominal glands are so often affected in bovine tuberculosis that one of the numerous names of the malady is "gland disease."¹ According to Spinola, the glands are affected in an inverse proportion to the affection of the serous membranes, and *vice versa*, an observation which Virchow sees no reason to controvert.² The affection of the serous membranes is supposed to be the first manifestation of the disease. It is chiefly the bronchial and mediastinal clusters of glands, and the mesenteric and retroperitoneal that are affected. They sometimes grow to an enormous size. They are liable to the same degenerations as the morbid products elsewhere, and especially to cretaceous deposits.

In the section of an enlarged gland, numerous separate round nodules are found; externally also the individual glands have sometimes a nodular appearance from the growth of several independent centres within them. Schüppel found that the tubercles or nodules take origin at various centres in the follicular tissue, and that they do not arise either in the lymph-sinuses or in the substance of the trabeculæ. Like the tubercles in all other parts of the animal, those in the lymphatic glands contain numerous giant-cells. A somewhat remarkable statement is made by Trasbot, viz., that the tubercles do not form within the lymphatic gland, but in the connective tissue that unites the several glands in one cluster. I shall refer to that point in speaking of the condition of the lymphatic glands in the cases in man.

4. *Tuberculosis in other Organs.*—In the *liver*, according to Walley, "the tubercular masses vary materially in size, and are not encysted in the true sense of the word, though, if softening has been rapid, a distinct boundary wall of new connective tissue is formed, which is sometimes very vascular" (*loc. cit.* p. 174).

In the *intestine*, according to the same authority, ulcers some-

¹ Virchow, *Tumours*, iii. 185 (French transl.)

² *Ibid.* p. 187.

times occur. "The edges and base are thickened, and the former are in some instances intensely hyperæmic. Prior to the irruption of the ulcer, in chronic cases, the mucous membrane is elevated by the tuberculous nodule, which is readily distinguished by its yellow colour; after irruption, small masses of tubercle are seen adhering to the submucous tissue" (p. 175).

The disease also affects the *genito-urinary system*. It in some cases affects the *joints*, the lameness so produced being not unfrequently the first symptom to call attention to the existence of the disease in the animal.¹

Lastly, in the *mammary gland*, according to Walley, "the tubercle is usually of the fibrous form. The nodules are very numerous, developed in the acini; but even when the gland has been extensively invaded, I have not been able to trace any tendency to cretification. The acini are hypertrophied, and the interglandular tissue increased, giving the gland, on section, a coarse rarified appearance. Some nodules may be developed in the mucous membrane of the ampullæ or the ducts, but I have neither seen softening nor ulceration. The gland in the areas of invasion is of a reddish hue, from increased vascularity.

"Involvement of this organ, especially if ulcers are developed on the mucous membrane, is a matter of great danger, inasmuch as the irritation of the tubercle gives rise for a time to increased functional activity of the gland, the secreted milk becoming contaminated with the tuberculous products, and propagating the disease to any animal (or man) which may be unfortunate enough to partake of it" (p. 172).

The condition of the udder in tuberculosis of the cow has been made the subject of a special investigation by Kolessnikow, at the instigation of Virchow. The tubercles were found to grow in the stroma of the gland, and to contain the same elements (including giant-cells) as elsewhere.²

¹ Williams, *Veterinary Medicine*, p. 348.

² Kolessnikow, *Virchow's Archiv*, vol. lxx. (1877) p. 531.

CHAPTER III.

COMMUNICABILITY OF BOVINE TUBERCULOSIS TO ANIMALS BY EXPERIMENT.

The credit of reviving attention to the danger incurred by the human species from tuberculous cows and oxen, is assigned by Virchow to the late Herr Gerlach, Director of the Veterinary School of Hanover, and afterwards Director of the Veterinary School of Berlin. To test the communicability of bovine tuberculosis, Gerlach experimented with animals such as the rabbit, sheep, goat, calf, and pig, inoculating the nodules from the cow under the skin, or feeding the animals with the actual morbid products, or with the milk of the diseased animal. Numerous other experiments of the same nature have been made, some of them contemporary with, or nearly contemporary with those of Gerlach, and some of them more recent; an excellent account of most of these is incorporated in an article by Fleming, which deals mainly with the somewhat wider question raised by the historical discovery of Villemin.¹ I shall confine my summary entirely to the experiments of Gerlach, for the reason that Gerlach primarily occupied himself with the communicability of bovine tuberculosis as a specific disease, and that the record of his experiments makes note of and emphasises precisely those minute identities of structure in the infecting and in the infected animal, upon which the stress of my own argument for cases of the disease in man also falls. The observations of Gerlach are those of an experienced veterinary pathologist, well acquainted with the disease as it exists primarily in the bovine species, and his statements as to the morphological identity of the communicated disease are of quite exceptional

¹ Fleming, "The Transmissibility of Tuberculosis."—*British and Foreign Med. Chir. Review*, vol. liv. (1874) p. 461.

value. I have introduced an account of the experiments and observations of Orth in Chapters VI. and following.

The paper by Gerlach, from which I shall quote somewhat freely,¹ using *italics* where necessary, records two classes of experiments, the first being a series of eight inoculations under the skin of nodules from the cow, and the second a series of eight feeding experiments with the nodules or with the milk of the animal. I shall quote one of the former class, and three (wholly or partially) of such of the latter as refer to feeding with milk. Before doing so, I shall quote the facts relating to a tuberculous cow which furnished the material for several of the experiments.

A cow, seven to eight years old, was procured for the purpose of the experiments. The animal was wasted, had difficult breathing and cough. Râles in the chest were audible, but there was no dulness. Fever had not yet set in, and the appetite was good. The daily yield of milk was 1500 grammes. Killed after three months; during that interval the wasting had increased, and the amount of milk had become less (during the first month the daily average was 600 grammes, during the second month 500 grammes, and during the last eight days it was almost absent, the animal being well fed all the time).

Post-mortem.—Parietal, diaphragmatic, and mediastinal pleura covered with innumerable smooth glancing nodules from size of lentil to that of pea; the pulmonary pleura more sparsely studded with nodules. There were present no conglomerates of nodules nor grape-like masses on the serous membranes. The lungs were voluminous and of double the usual weight. On handling them, they felt normally elastic in some parts, and in other parts firm and nodular. The bronchial glands were remarkably enlarged, hard and nodulated to the feel, and creaking under the knife. On the cut surface of the lung, a considerable amount of destructive change—small and large cavities, some with muco-purulent, others with caseous contents, and with thick smooth walls; also miliary tubercles from size of a mere visible point to that of millet seed, partly scattered and partly aggregated together.

Commenting afterwards on this case, he observes—"It is quite usual to find destructive changes in the lungs in *Perlsucht*, besides the nodules on the serous membranes. I have never found the nodules of *Perlsucht* associated with sound lungs and normal bronchial glands. In the lungs I have found either

¹ A. C. Gerlach, "Ueber die Impfbarkeit der Tuberculose und der Perlsucht bei Thiere, sowie über die Uebertragbarkeit der letzteren durch Fütterung" (Auszug aus dem Jahresbericht der K. Thierarznei-Schule zu Hannover, 1869, S. 127-151).—Virchow's *Archiv*, vol. li. (1870) p. 290.

tubercles or larger centres of caseation, or both together, as in the case of the cow described."

I shall now quote one of the inoculation experiments.

Exp. 8. A goat, one year old, was inoculated under the skin with small nodules from a tuberculous cow. Within the first fourteen days there appeared, at the point of inoculation, two walnut-sized nodules, which were at first 1 inch apart, but afterwards became fused. Six months after, the goat was killed for anatomical purposes.

Post-mortem.—(1.) At the point of inoculation there was a grape-like cluster 2 inches long, $1\frac{1}{4}$ inch broad, and $\frac{1}{4}$ to $\frac{1}{3}$ inch thick, composed of nodules from size of a pea to that of a millet seed, round, smooth, yellowish-grey in colour; they lay together loosely, being joined by firm cicatricial tissue. Each consisted of a friable and almost dry caseous interior and a *thick connective-tissue capsule*. (2.) The bronchial glands were enlarged, and the cut surface showed a number of caseous centres, the size of lentils or peas. (3.) The lungs contained six nodules from hazel-nuts to peas in size, and at least thirty nodules the size of from pin-head to millet seed. All lay directly under the pleura, projected more or less, and showed a somewhat firm interior. The smaller nodules were grey and translucent, with an opaque central point; the larger were opaque throughout; the largest formed mulberry-like conglomerates, each nodule having a caseous centre; *on pressure there issued at various points of the cut surface, thick caseous cords, like worms*. The pulmonary pleura showed, on the sharp border of the lung, fringes at certain places, and, over the larger nodules, a filamentous new formation, rich in vessels. No nodules in the abdominal viscera; mesenteric glands normal.

Microscopic.—The caseous contents consisted of formless broken-down masses. The translucent grey substance consisted of large free nuclei, *of somewhat larger round cells distinguishable from the free nuclei by a clear ring (of protoplasm) between nucleus and cell-membrane*, of larger multinuclear cells, and of round heaps of granules. The small cell-elements lay grouped close together. In the larger, less translucent but not yet caseous nodules, the same elements occurred, but there was more connective-tissue intercellular substance, and in places even a fibrous stroma.

Next follow three of the experiments on animals fed with the milk of the tuberculous cow above referred to.

Exp. 12. A healthy and well-nourished calf, eight days old, was fed almost exclusively with milk obtained from the tuberculous cow during the last fifty days of her life, getting at first 1000 grammes daily, and latterly 300 grammes, or an average some 650 grammes daily, and over the whole fifty days of the feeding experiments 30 to 32 kilogrammes of milk. The calf got also some other milk and fodder. It showed no symptoms of disease, or of disturbed nutrition. One

hundred days from the commencement, and fifty days after the end of the feeding experiment, the calf was killed for anatomical purposes.

Post-mortem.—(1) The pleura over the greater part of the sharp border of the right lung was covered with *delicate, red filamentous excrescences, which hung like a fringe about one centimetre over the lung margin*, at certain places being united like a membrane, and in some places containing glancing pin-head nodules; the parietal pleura at various points covered with delicate filamentous new formations, rich in vessels. (2) The lungs showed a variety of nodules, but were otherwise normal. Immediately beneath the pleura, and projecting more or less, lay four nodules the size of peas, and six nodules the size of millet seeds, and in the loose interlobular connective tissue there were eight miliary nodules. The small nodules were the more translucent; all were grey in colour and of firm texture (small delicate new-growths); the cut surface showed several clear points; in one of the larger nodules a yellow cheesy mass lay in the centre. (3) *Bronchial glands* all much swollen, and occupied in their interior with numerous pin-head sized purulent and caseous centres, which here and there contained calcareous matter; these tubercle-centres stood out very conspicuously on section. (4) *Mesenteric glands* all much swollen, and in places nodulated on the surface, of the size of walnuts, the half next the intestine being most swollen. The section showed, especially in the nodulated enlargements, the same picture, but more pronounced, as in the bronchial glands. *All these diseased glands were exactly like the recently affected lymphatic glands in Perlucht of the cow.*

Exp. 13. An eight-month's lamb, fed with milk from the same cow, killed after three months. Among other *post-mortem* appearances [chiefly omitted]; on the sharp margin of each lung a patch of atelectasis the size of a shilling, in which was situated a nodule the size of a bean, abruptly bounded, of grey colour and medullary consistence on section. On microscopic examination, giant-cells were missed from the above nodules, but they contained capillary vessels distended with blood-corpuscles.

Exp. 14. A pig, six to eight weeks old, was fed for twelve days with milk (400 grammes daily) from the same tuberculous cow. It was killed thirty days after the end of the feeding experiment.

Post-mortem.—(1) The whole lower sharp margin of the right lung was occupied in some places with a border, in other places with a fringe; *i.e.*, the pleura presented a constricted thickening, composed of filamentous excrescences of 2 mm. diameter and up to 1 cm. in length; the filamentous out-growths contained clear pin-head nodules *surrounded by a wreath of distended blood-vessels*. On dipping the lungs into water, these new formations showed to best advantage. (2) In the right lung, middle lobe and parts next mediastinum, were found grey-coloured nodules, the size of a walnut; they lay under the pleura, which here and round about was covered with red villi, rich in vessels; near these nodules, there lay several clear grey miliary nodules, *surrounded by a circlet of distended blood-vessels*. On

section, both kinds showed clear points, and small caseous centres. (3) *Bronchial glands*, and still more the *mesenteric glands*, much swollen, presenting on section numerous caseous centres of miliary size. Liver, spleen, kidneys, and intestine healthy.

In summing up the morbid conditions induced by the experiments, Gerlach found "on the one hand an agreement with the *Perlsucht* of bovine animals, and on the other hand an agreement with tuberculosis as it appears in man and the apes." He found the same grey translucent tubercles as in man and the apes, more particularly in the experiments with rabbits. He continues—"At the same time, the peculiarity (*Eigenthümlichkeit*) of *Perlsucht* is unmistakable, more especially in the experiments of the calf, sheep, and pig (Exp. 12, 13, and 14). In all the nodules there occurred, before the caseous process set in, an organic union of the lymphoid bodies by means of a delicate connective-tissue substance; the latter was especially marked in the large grey nodules, which, on that account, showed a certain resemblance to small sarcomas; and the same large nodules came still further to resemble the new formation of *Perlsucht*, in that even *capillary vessels appeared in them*. *But quite especially are we reminded of Perlsucht by the growths on the pleura, round the sharp margin of the lung, in the 12th and 14th experiments; they demonstrate to us the beginnings of Perlsucht.*"

The condition referred to in the concluding sentence of the quotation is one that I shall strongly rely on as proving the identity of the disease in the series of cases in man, with the specific disease of the cow. On that point, and in other respects, I shall endeavour to make out an identity of minute details, including certain of those which Gerlach has noted in his experimental inquiry.

The experiments that are still being conducted at Berlin and elsewhere in Prussia, under the direction of Virchow, are a continuation of those of Gerlach on a more extensive scale. Details which could be utilised, as I shall utilise those given by Gerlach, are not yet available. We are assured by Virchow that the experiments have not been altogether free from ambiguity as to the general question of communicability, but that, on the whole, more experiments succeed than fail. I must simply refer to the article by Mr George Fleming, already quoted, for an account of

numerous other experiments to the same or an allied purpose. A non-experimental piece of evidence mentioned by Walley may be introduced here:—¹

“Only a few days ago I received a communication from Mr William Bromley, M.R.C.V.S. of Lancaster, in which he says—‘A short time ago two pigs were killed in a farm in this neighbourhood, which had been fed with milk from a cow afterwards found to be the subject of tuberculosis, and from which she died, and upon *post-mortem* examination characteristic pulmonary and pleural tubercular lesions were discovered.’ In a subsequent letter Mr Bromley further says:—‘The mother of the two pigs to which I referred in my last has, within the past few days, been slaughtered. She was perfectly healthy, no trace of tubercular or other deposits being discoverable in any part of her body.’”

¹ *Loc. cit.* p. 155.

CHAPTER IV.

CASES IN MAN.¹

CASE. 1—*Greyish-white medullary nodules in the lungs, some of them wedge-shaped.*

C. P—, male, aged twenty-one, labourer, Histon, Cambs, admitted into Addenbrooke's Hospital 14th April 1880, under Dr Bradbury. Parents healthy; no consumption in the family. Has had cough for about six months, and has been losing flesh and been subject to night-sweats for the same period. For four months has had pain in the left chest, increased by inspiration. Has had frequent attacks of shivering, and has vomited from time to time. Nine weeks ago the pain in the chest became more severe, and he began to suffer from dyspnœa, and, a week later, noticed that there was blood in the sputa. During the past week the dyspnœa has increased; sputa have been rusty.

Present condition.—In left chest inspiration harsh and wavy at apex, accompanied by a few râles. Posteriorly the left chest was everywhere duller than the right; considerable degree of dulness from middle of infrascapular fossa to base; respiratory sounds from angle of scapula downwards are deficient, and vocal fremitus and resonance diminished. On next day (13th April) the cough was troublesome; considerable amount of muco-purulent expectoration, slightly blood-stained in parts. Complains of pain in left mammary region, and of shortness of breath; there was a sound as if of fine crepitation at the seat of pain, heard only at the close of deep inspiration. The urine was alkaline, sp. gr. 1031; no albumen; efflorescence on addition of nitric acid, and copious deposit; large number of crystals of phosphate of lime under microscope. After being thirty-six hours in the hospital, he died suddenly. He slept quietly till about two or three minutes before his death; he suddenly began to gasp for breath, and died almost immediately.

Post-mortem, 17th April.—The pulmonary arteries were searched for

¹ I am much indebted to Mr A. Shaun, house-physician at Addenbrooke's Hospital, for the use of his notes of the cases. I was present at the *post-mortem* examination of all but two of the cases, and the morbid anatomy is chiefly compiled either from my observations then made, or from the subsequent examination of the material preserved.

a clot, but none was found. The left *lung* contained a number of centres of disease, varying from the size of a walnut to the size of a pea; some of them were in the periphery of the lung, projecting on the pleural surface, others were in the centre. They were remarkable for their white medullary appearance. The centre of the mass was usually softened. In the base of the lung was an extensively excavated mass, into which a branch of the pulmonary artery appeared to open freely, although there was no appearance of hæmorrhage having taken place. The right lung contained only one mass, which was felt as an isolated nodule in the midst of the compressible lung substance; it occupied the hinder border of the lower lobe at its upper margin, and it was distinctly wedge-shaped, about an inch and a half long, of the same medullary consistence and colour as in the other lung, and softened in the centre. The *spleen* was very large, and the surface of it was covered with small flat white bodies of a pearly appearance, such as are sometimes described as occurring on the spleen without any particular pathological significance being assigned to them.

No material was preserved from this case for microscopic examination. The nodules in the lungs were of exactly the same colour and consistence as those of the next case; they differed from ordinary tubercles by their vastly greater size, and by having occasionally the shape of a wedge, and they differed from secondary tumours in their greyish-white colour.

CASE 2.—Greyish-white medullary nodules in the lungs, some of them large and wedge-shaped, most of them small; tuberculosis of serous membranes.

E. P.—, female, aged seventeen, Stanstead, Cambs, admitted into Addenbrooke's Hospital on the 14th April, under Dr Bradbury. Parents alive, healthy; five brothers and sisters, all healthy; maternal grandfather and grandmother died of consumption. Had good health till four months ago, then caught a "violent cold." Has had constant cough since then. Three months ago began to suffer from pain in the left chest, and, shortly afterwards, the right side became painful. At this time frequently felt chilly, but had no rigors proper. Has been gradually losing flesh. No hæmoptysis.

Present condition.—The left chest is nowhere so resonant as the right; marked dulness from angle of scapula to base; over same area breathing distant, and fremitus and vocal resonance both absent. Heart's position and sounds normal. Urine alkaline; phosphates. On 17th April, well-marked epileptic fit, and remained in a stupid condition for the next day; sordes on lips and teeth, tongue dry; restless nights. No urine passed for about thirty-six hours. On 20th April there was a decided trace of albumen in the urine, sp. gr. 1030. Vomited two or three times in afternoon and evening. Another fit of an epileptiform character during the night. Meanwhile the

temperature had been from 102° to 103° in the evening, with a drop of sometimes three degrees in the morning; but the morning temperature was on several occasions somewhat above or somewhat below 101° . On the 22d April noisy and delirious during the night. On 23d in a semi-conscious condition, and could be roused with difficulty. Pulse 140. Perspiring freely. Slight "tache cerebrale." Right pupil somewhat larger than left. On 24th and 25th perfectly conscious. On 25th well-marked "tache cerebrale;" right pupil again larger; urine passed involuntarily. Some loss of power in left arm. On 26th, 9 P.M., remained conscious till 7 this evening. Face now dusky; respirations very rapid; pulse too rapid and too feeble to be counted. Retracted abdomen. Marked paralysis of left arm and leg since the morning. Doubtful slight paralysis of left side of face. Pupils equal. Died at 1 A.M. on 27th.

Post-mortem, 28th April.—Body wasted. Left lung adherent, especially to diaphragm, its pleural surface covered with adhesions containing translucent tubercles. The upper lobe was of a healthy rose-red colour. In the lower lobe, near its upper and posterior angle, was a single well-marked wedge-shaped embolic infarct, 1 inch long and nearly 1 inch broad at base, of greyish-white medullary colour, into which a branch of pulmonary artery entered underneath the thin end. The wedge-shaped area of white substance was composed of a number of round masses, the size of peas or smaller, touching each other. There was another whitish mass at the extreme base, where the lung adhered to the diaphragm. A number of smaller white masses, with round central space, as if lined by a membrane. The right lung contained only the smaller kind of nodules. The *pleura* was studded with minute nodules. *Bronchial glands* enlarged and caseous. The peritoneal surface of the *diaphragm* on the right side was the seat of a most remarkable eruption of large, flat, sometimes confluent and lobulated nodules, from the size of a split pea downwards. This eruption was more like that of tumour infection of the serous membranes. The same kind of flat nodules occurred in the peritoneum covering the back of the bladder, and in the parietal peritoneum of the right iliac fossa. On the broad ligaments and surface of uterus the nodules were smaller, more glancing and sessile. The left *Fallopian tube* contained, about an inch from its open end, a nodule about the size of a bean, broken down in the centre. This was not observed until it had been sometime in spirit, and the character of the growth could not be made out satisfactorily. There was an embolic infarct in the anterior end of the temporo-sphenoidal lobe of the *right hemisphere*, yellow softening extending for a short distance on each side of the middle cerebral arterial branch. Miliary tubercles in the *Sylvian fissure* on both sides.

This case has furnished several of the illustrations in the Plates. The wedge-shaped mass in the left lung is represented at the upper part of Plate III. The original freshness of colour of the new formation had been lost before the drawing was made; it

suggested, when first seen, the medullary whiteness of a secondary tumour, but it was at the same time more opaque, yellowish or grey. The microscopic drawings on Plate IV. are both made from the same wedge-shaped nodule. With the naked eye, one can see that it is made up of the confluence of several round nodules, and these, again, resolve themselves under the microscope into many small tubercles. The tubercles are interstitial formations in the connective tissue of the lung; they have a tendency to necrosis in the centre, the necrotic and sometimes softened centre breaking away, by a very uniform margin, from the growing and vascular periphery (fig. 11, Plate IV.) The central tubercle of the same figure shows a number of giant-cells, and vessels penetrating into the centre of it. The tubercle of fig. 12 (Plate IV.) represents a very usual and characteristic appearance; the nodule is surrounded by a remarkable wreath or circlet of wide blood-vessels of capillary structure, distended with blood; a small vessel passes right through the substance of the tubercle, and several others are found in its periphery.

To the naked eye, the smaller whitish nodules that occurred throughout the right lung had a peculiarity which I shall have often to refer to; on the cut surface, they appeared sometimes to be perforated with a narrow lumen, the appearance suggesting the broken stem of a clay pipe or a piece of macaroni; at other times, the section showed them to be hemispherical bodies with the centre excavated to a limited extent, and with a substantial thick wall, the interior being uneven.

The enlarged bronchial glands were found, on microscopic examination, to contain tubercles, as in fig. 14, Plate V., from another case. The remarkable appearance represented in fig. 3, Plate II. is taken from this case. The whole under surface of the diaphragm, on the right side, corresponding to its area of contact with the liver, was covered with that kind of eruption. The tubercles were large and flat, sometimes partly free from the surface, and surrounded by filamentous tissue. Examined with the microscope, some were found to consist of several centres of new formation, while in others the interior had undergone a general necrosis, and it was only round the periphery that any structure could be seen. The structure is that of fig. 15, Plate VI., from another case. It is the tubercle composed of

giant-cells, of other large cells with one or more nuclei and resembling epithelial cells, and of lymphoid cells,—the tubercle spoken of by Schüppel and by Rindfleisch, about which I shall have more to say afterwards.

CASE 3.—*Typical acute tuberculosis in a child; remarkable pleural outgrowths; whiteness and large size of the lung nodules.*

A. T——, girl, aged eight years, Cambridge, admitted into Addenbrooke's Hospital on the 22d April, under Dr Bradbury. For five weeks previous to admission was noticed to be dull and heavy, and complained of headache. A week before admission began to vomit frequently. Restless at night, crying out, and complaining of pain in the head and in the back. Has lost flesh progressively since beginning of illness. Constipation throughout.

Present condition.—Delicate-looking child, with long eye-lashes, hair fine, skin thin. Face flushed; complains of frontal headache. Typical progress of acute tuberculosis. Died on the 2d May.

Post-mortem, 4th May.—Large packet of caseous *bronchial glands*. Abundant tubercles on *pleura*, both pulmonary and parietal; the tubercles were soft in texture, white in colour, sessile, and even pedunculated. Both *lungs* were full of tubercles of unusually large size, and white medullary substance. At the right apex a dense collection of white nodules, having the general outline of a wedge, with some lung-tissue within the outline not occupied by the white substance. The scattered white nodules appeared often to be perforated in the centre by a smooth-walled aperture. Tubercles on the surface of the *spleen* and in the *fissure of Sylvius*.

From this case is taken the coloured drawing (fig. 5, Plate II.), showing the outgrowths on the pleura. I have preserved one of the lungs entire, and one may observe on the surface of it a considerable variety of the characteristic pleural outgrowths—flat, sessile, pendulous, tongue-shaped, or sometimes round, and arranged in a row like a string of pearls. The microscopic drawing (fig. 13, Plate V.) is taken from the wedge-shaped nodule in one of the lungs of this case. It shows a tubercle surrounded by an extensive plexus or wreath of wide blood-vessels, distended with blood.

The enlarged bronchial glands showed, in the microscopic examination, the same appearance of tuberculosis of the lymphatic glands as is figured in fig. 14, Plate V., taken from Case 5. They were, however, more generally caseated, and it was only in the peripheral and more translucent portions that giant-cells

and the other indications of the presence of minute tuberculous centres could be detected.

CASE 4.—*Lung containing several sloughing or putrid cavities; large round tubercles in the intervening lung substance.*

J. B.—, male, aged forty years, falconer, Sawston, Cambs, admitted into Addenbrooke's Hospital on the 9th May, under Dr Bradbury. Health good till four years ago, then had inflammation of the lungs. Continued in good health during the two years immediately following this attack. During the last two years has had more or less constant cough, and has gradually lost flesh. Hæmoptysis six months ago, and again four months ago. At the latter date also had a severe attack of bronchitis, and was confined to bed for five weeks. Never well since. For several weeks expectoration of very fetid sputa.

Present condition.—Face somewhat congested, tremors of tongue and muscles of face. Much prostration. Frequent cough, with expectoration of very offensive purulent sputa. Breath also very offensive. Tongue thickly coated. Pulse feeble, intermits occasionally. Left chest universally dull. In pectoral region, fremitus abolished, respiratory sounds very deficient. Metallic tinkling heard in neighbourhood of nipple. Rough double creaking sound in cardiac region accompanying each beat of the heart. Posteriorly, absolute dulness over lower half of left chest. Vocal fremitus and vocal resonance absent. Respiratory sounds extremely deficient. Right chest everywhere resonant. Heart's apex displaced to right. The temperature on the evening of the 10th May was $104^{\circ}2$, and next morning $101^{\circ}4$; the fall seems to have continued in the evening to 100° , and for the rest of the time it is recorded at about 102° . The dyspnoea varied in degree from day to day; before death on the 13th, it was very severe; face dusky, perspiration standing on forehead.

Post-mortem, 14th May.—Remarkable appearance in thorax. *Bronchial glands* formed a diffuent white mass, like the softer variety of lymphosarcoma. *Left lung* firmly adherent; extensively oedematous; contained a number of gangrenous cavities, one of them (on the periphery) distinctly wedge-shaped; and, in the intervals between the cavities, the lung-tissue was occupied by a number of greyish nodules, of uniform size, as large as peas. The bronchial mucous membrane intensely congested. I did not see the right lung, but the note is that it "contained a considerable quantity of caseous substance, just beginning to break down."

None of the organs from this case were kept for examination. The case was evidently one of intense or virulent infection. The cavities had resulted from the breaking down of solid masses, one at least of which, on the periphery, had been wedge-shaped. Their interior was formed by what might be called an

uneven membrane, of a greyish sloughing appearance. A striking feature of the case was the occurrence of a large number of round nodules, all about the size of peas, of dark-grey colour, situated in the œdematous lung tissue between the cavities.

CASE 5.—*Enormous cluster of enlarged portal lymphatic glands containing round nodules; bronchial and mesenteric glands also enlarged; characteristic outgrowths of the serous membranes; tubercles and closed vomicæ in the lungs; large encapsuled tubercles of liver and spleen.*

J. B——, male, aged eighteen, baker, Cambridge, admitted into Addenbrooke's Hospital on the 6th March, under Dr Latham. Five months before, he had to give up his occupation of baker on account of weakness and shortness of breath. During the last month the dyspnœa has been constantly present. Four days before admission he was obliged to take to his bed. Physical exploration of chest reveals disease on both sides (details omitted). Delirious next day, and picking the bedclothes. Died on the 8th.

Post-mortem, 9th March.—The parietal *pleura* was thickly studded in parts with tubercles. A few adhesions at base of both lungs. Glancing whitish tubercles all over the surface of the lungs; same on the *spleen*, but more distinctly pedunculated, and sometimes tongue-shaped. The peritoneal surface of the *diaphragm* was thickly covered with large flat nodules, exactly as in Case 2. *Intestines* showed no appearance of tuberculosis. The striking feature of the *post-mortem* examination was the condition of the *portal glands*. They hung down from the portal fissure as an extensive tuberous mass, about 5 inches long; the glands composing it were united by connective tissue, but they were rarely confluent; some of them were very nearly the size of a hen's egg. The portal vein and the splenic and superior mesenteric before their junction were closely involved in the growth, the glands appearing to grow into their walls. The substance of the growth was very firm, hard, creaking under the knife, brownish yellow (like the embolic infarct of Case 10). This kind of substance occurred in each gland in the form of several round centres, separated by bands of translucent tissue, the whole being enclosed in a thick translucent capsule. There were several *bronchial glands* which presented exactly the same appearance of round yellowish-brown nodules, the size of peas, scattered through their black pigmented substance. Nodules, also the size of peas, and surrounded by a translucent thick capsule, in liver and spleen, along with smaller tubercles. Small tubercles in left Sylvian fissure. The condition of the *lungs* was like that of the next case, and will be referred to under it.

This is one of the most complete cases of the series. The characteristic appearance of closed vomicæ in the lung (what

might be called the "crumpet-lung") in the coloured drawing (fig. 9, Plate III.) is taken from the left apex in this case. The drawing of the characteristic flat and pendulous outgrowths on the surface of the spleen (fig. 6, Plate II.) is also taken from it. The pleural outgrowths were equally characteristic, and the eruption of flat nodules on the under surface of the diaphragm, corresponding to its area of contact with the liver, was precisely the same as that of Case 2, drawn in fig. 3, Plate II. The microscopic characters were also the same.

The thoracic and abdominal lymphatic glands were equally characteristic; the cluster of enlarged portal glands, a lobulated mass as large as a cocoa-nut hanging down from the portal fissure, at once arrested the attention. The glands were for the most part hard and tough, creaking under the knife, and the cut surface showed them to contain each several round nodules, up to the size of peas, bounded by a well-defined belt of more translucent tissue. The section of one of the bronchial glands is shown in fig. 10, Plate III. A larger drawing, to the same effect, might have been obtained from one of the portal glands, which had not, however, been cut into at the time the drawings were being made. The microscopic appearance of the tubercles in one of the bronchial lymphatic glands is shown in fig. 14, Plate V. I shall defer notice of it until I treat of the condition of the lymphatic glands generally.

The liver and spleen each contained a number of large round tubercles, up to the size of peas, which were remarkable for their well-marked peripheral belt of translucent tissue, simulating a capsule. Numerous minute tubercles, detected only in the microscopic sections, occurred near the larger nodules, both in the liver and spleen.

CASE 6.—Rapid tuberculosis in a previously healthy man, commencing from the tonsil; tubercles and closed vomicæ in the lungs.

T. C.—, male, aged fifty-seven, Downham, Norfolk, admitted into Addenbrooke's Hospital on 11th February, under Dr Latham. Quite well till seven weeks ago; then had quinsy. The throat was lanced by a surgeon, and a quantity of matter evacuated. Lost his voice at that time, and still speaks in a whisper. No cough or night-sweating, but has had sometimes shortness of breath. On admission there is no pain in chest or elsewhere, but constant slight dyspnoea. Tem-

perature on two successive days : $101^{\circ}\cdot 8$ morning, and $103^{\circ}\cdot 4$ evening ; $100^{\circ}\cdot 8$ morning, and $103^{\circ}\cdot 8$ evening. Before death severe dyspnœa. Death on 15th February.

Post-mortem, 16th February. — Both *lungs* firmly adherent all round. In the right lung a cavity the size of a walnut at the apex ; the rest of the lung thickly studded with tubercles, smaller and more translucent in upper part, greyish-white, opaque, and becoming confluent at the base. The special interest centres in the condition of the left apex, which exactly resembled the condition in the corresponding apex of Case 5, and which is probably characteristic of the bovine disease. The lung was as if honey-combed with smooth-walled cavities from the size of a pin-head to that of a large pea, or even a hazel-nut. To use a homely illustration, the lung resembled the substance of a crumpet. I at first took this condition for bronchiectasis ; but the cavities are found to result from the central softening of large tuberculous nodules, the periphery of the nodules being formed of translucent and highly vascular tissue, which remains as a smooth membrane like the wall of a cyst. Solid whitish nodules of various sizes, up to that of a pea, were seated as if on the outer walls of the excavations, or in the lung-tissue between them.

The chief interest of this case lies in the rapid course of tuberculosis in a previously healthy man, aged fifty-seven, and in the exact resemblance of the condition in the lung to that of Case 5. The coloured drawing (fig. 9, Plate III.), taken from the latter, might have been matched from the left apex of the lung in this case.

CASE 7.—*Cavities in the lungs, with dense semi-cartilaginous walls ; encapsuled large round nodules in the lungs ; pendulous outgrowths on pleura, and beaded condition of the sharp margin of the lung.*

A. P——, female, aged eighteen, Cambridge, admitted moribund into Addenbrooke's Hospital on 27th Feb., under Dr Latham. Died shortly after.

Post-mortem, 28th February.—Body well nourished. The whole upper lobe of the left *lung* was occupied by one enormous cyst or cavity, on the inner surface of which there was not a trace of friable caseous substance. Its wall was compact like the wall of a cyst, and its inner surface was smooth or slightly granulated, and of a red colour, as if from blood. In the walls of the cyst and in other parts of the lung there were hard brownish-yellow opaque nodules from the size of a pea to that of a hazel-nut, sometimes slightly confluent, surrounded by a thick translucent capsule, and with lighter or caseous points in their centre. In the right lung, at the apex, there was a round cavity with a uniform inner surface, the size of a billiard-ball ; its walls were of great density or firmness, creaking under the knife ; a branch of

the pulmonary artery appeared to end in its periphery. In the lung-substance, round the cavity, the same yellowish-brown encapsuled nodules as in the left lung. In the middle lobe of the lung the opaque nodules were smaller and more uniform in size, and at the extreme base they formed grape-like clusters. There were extensive pleuritic adhesions on both sides. On the *surface of the lung* there were a number of flat pendulous nodules, one of which, about three-eighths of an inch in diameter, was suspended by a piece of the adhesion, like a small medallion. Round the sharp margin of the right lower lobe there were a few small pleural nodules, partly fused into a cord, giving the margin a beaded appearance.

From this case is taken the drawing of the sharp margin of the lung, lower lobe (fig. 4, Plate II.), showing an appearance of flat nodular outgrowths, constricted to a kind of pedicle at the base, fused into a cord towards the right-hand side. This appearance occurs in other cases, and is probably characteristic. The largest pleural nodule that I have found in any of the cases occurred in this case. It was about three-eighths of an inch in diameter, flat and transparent (suggesting fat-tissue), and suspended by a long and narrow band of connective tissue. The pleural surface elsewhere showed the usual varieties of the characteristic pleural outgrowths.

From this case also is taken the coloured drawing (fig. 8, Plate III.), showing large round encapsuled nodules in the lung substance. I believe the appearance to be very characteristic of the more chronic form of the disease in the lung.

The peculiar appearance of fig. 17, Plate VI., is taken from this case; it occurred uniformly in connection with the smaller tubercles in the lower lobe. The tubercle-nodule has evidently broken through and grown into the nearest bronchus. The same encroaching process probably takes place in the case of larger nodules and larger bronchi, and would account for the communication sometimes found to exist between the softened centre, or the cavity of the nodule, and the lumen of the bronchus.

CASE 8.—*Rapid tuberculosis in a previously healthy man; characteristic pleural outgrowths; small greyish-white medullary nodules, with softened centres, throughout both lungs; swollen bronchial glands.*

C. F.—, male, aged twenty-eight years, fireman, Ely, admitted into Addenbrooke's Hospital on 4th June, under Dr Bradbury. Had

good health till six weeks ago; then began to have a dry cough. A month ago felt he was losing strength, and noticed that he was losing flesh. Three weeks ago the cough became severe, and he complained of dyspnoea. The cough and dyspnoea have gone on increasing till admission. Sleep much disturbed during the last few nights. Has not felt feverish; no sweating.

Present condition—Face extremely dusky; considerable dyspnoea; small quantity of muco-purulent expectoration. The patient is a well-built man, and shows no sign of emaciation. Pulmonary resonance impaired somewhat at right base; abundant medium-sized crepitation at both bases; no increase of voice sound; chest elsewhere resonant. Fine crepitation heard in almost every part of chest, with occasional rhonchi. Heart sounds healthy.

His general condition appeared to improve for the next week or two; the cough and expectoration continued; crepitation became coarser. The temperature was generally between 99° and 100° in the morning, and a degree higher in the evening. On 21st June there was considerable œdema of the legs. The chest signs became more intense, and lividity of the face increased. On the 22d the respirations were 36, and at the same date the temperature rose from $97^{\circ}\cdot8$ in the morning to $102^{\circ}\cdot8$ in the evening, falling next morning to $97^{\circ}\cdot8$. He continued to take his food well. Some diarrhoea; skin universally dusky; frequent short dozes, but no continuous sleep; breathing more difficult. Died at 9 P.M. on 25th June.

Post-mortem, 26th June.—Skin everywhere dusky; no emaciation; a few soft pleuritic adhesions posteriorly on both sides. The *pulmonary pleura* of the right lung, along the thick posterior border, on the concave base, and in the interlobar fissures, was covered in parts with pleural outgrowths, which sometimes were like small round leaves, close to the surface; at other times pendulous and tongue-shaped. They were occasionally in the form of larger confluent patches, of which the margins and point of attachment to the surface were well defined. The pleural outgrowths sometimes took the form of rounded cords, either dependent freely from the surface or attached at two or more points, forming loops. The same occurred round the sharp margin of the lung. The left lung was adherent everywhere, except at the apex. The pulmonary pleura of the apex (where there were no adhesions to make the appearances ambiguous) showed a few scattered villous and leaf-like outgrowths. The condition of the *lung substance* was almost the same in the two lungs, and was on the whole uniform from apex to base. The lungs were studded with greyish-white medullary nodules up to the size of a lentil. The nodules were softened in the centre, showing, on cross section, either like the broken stem of a clay pipe, or like a partly-excavated hemisphere, the surface of the excavation being somewhat uneven. The process of excavation had advanced most at the apex. The *bronchial glands* were considerably enlarged, but soft; no nodules visible in them with the naked eye. In the *heart* the flaps of the mitral were united so as to form a single valve; two of the tricuspid flaps were in like manner joined

together. The *peritoneal cavity* contained a small quantity of fluid. No traces of tubercle on the serous membrane, which was carefully examined in various places. In the *intestine* were several ecchymosed patches on the mucous membrane of the ileum, but no ulceration.

This case agrees with several of the preceding in the greyish-white medullary substance and large size of the nodules in the lung, and in the remarkable appearance of an excavation or perforation of the centres of the nodules. The characteristic pleural outgrowths were especially well marked in various parts of the surface of the right lung.

CASE 9.—*Long-continued high evening temperature; valvular disease of heart (vegetations); caseous enlargement and softening of ovary; enlarged and calcareous mesenteric glands; minute tubercles in the lungs; "duckweed" on the pleura.*

E. P—, female, aged twenty-two, Cambridge, admitted into Addenbrooke's Hospital on 30th March 1880, under Dr Bradbury. For a year past has had shortness of breath on exertion. No history of rheumatism. Has enjoyed fairly good health. Three months ago began to suffer constant pain in the cardiac region; shortness of breath became aggravated, and patient began to complain for the first time of palpitation of the heart. Six weeks ago the legs were noticed to be swollen, and have continued to be more or less œdematous ever since. Three weeks ago noticed that the abdomen was increased in size. For a fortnight past has had slight cough. Menstruation regular till two months ago.

On admission—Forcible apex beat of the heart in fifth space, just within the nipple line; visible impulse in same position. Transverse dulness not obviously increased. At the apex is heard a presystolic murmur running up to a loud thumping first sound. At the base is a diastolic bruit, plainly heard to the right of the sternum, but culminating in the third left space, and conducted down the sternum. Chest resonant throughout; healthy breathing all over. The temperature on the evening of admission was 104°, next morning 98°; the character of the temperature remained quite the same for the next week, and much the same to the end of her illness, the difference between morning and evening temperature being seldom less than four degrees. An elevation of 104° evening was often reached, and on one occasion 105°.

Two days after admission a globular swelling was detected in the hypogastrium, extending into the left iliac region; dulness over the swelling, and hypogastric pain complained of.

On 5th April slight shivering attack in the afternoon. On 12th April complained of pain in the chest; sharp inspiratory râles in left inferior axillary region; some crepitation at both bases.

The hypogastric tumour continued to increase, and was discoverable much more definitely to the left of the median line. Occasional diarrhoea. Hypogastric pain. On 4th May complained of pain in hypochondriac regions; abundant crepitations, medium size, at base of both lungs. Abdomen distended; tumour cannot be felt. On 16th May, a blocked vein in right arm, perceptible cord-like painful swelling. Aphthæ on the tongue. On 1st June the abdominal tumour could again be felt. Meanwhile the patient had become paler and thinner, the temperature having the character already mentioned. On 25th June and following days considerable œdema of left leg and thigh. Trace of albumen in urine. Purpuric spots on the arms; slight bleeding from the gums; passed a small quantity of blood with the motions. On 29th complains of shortness of breath; respirations 40. Œdema of both legs. The dyspnœa increased during the night, the patient being obliged to sit up in bed the greater part of the night. Died at 5 A.M. (30th June).

Post-mortem, 1st July.—A few soft adhesions in both pleural sacs. The *pulmonary pleura* at the base of one of the lungs showed the leaf-like "duckweed" variety of pleural outgrowths in the most exquisite form; the margin of the lung was occupied by a cord-like border of new growth for a considerable distance, and on the adjoining convex surface the same rounded cord-like outgrowths occurred, some of them projecting half an inch free from the surface (fig. 1, Plate I.). In the substance of both *lungs* whitish tubercles of considerable size could be seen dotted about under the surface; on section both lungs were found to be densely studded with very fine miliary tubercles. *Heart* very little larger than natural; mitral orifice stenosed, admitting the end of the middle finger; vegetations, apparently of recent formation, on the auricular surface of the valves, which were much thickened; aortic valves also thickened, and covered with villous-like vegetations. *Liver* partly adherent to diaphragm, and, where free, covered with the kind of flat leaf-like outgrowths represented in fig. 2, Plate I. Besides these, a few translucent bodies, like miliary tubercles, were seen on the surface. Substance healthy. *Spleen* adherent to diaphragm. *Intestine*, for a space of about 6 inches in the right iliac region, was studded on the serous surface with a narrow tract of villous outgrowths, up to a quarter of an inch in length; they occupied the free border of the bowel exactly opposite the mesenteric attachment. *Mesenteric glands*, one of them enlarged to the size of a hen's egg, hard, calcareous, feeling like a stone embedded in the mesentery; near it some quite small glands also petrified with chalky substance. The left *ovary* was 4 inches long in its long axis; the surface ecchymosed; the centre softened (leaving a periphery of solid substance about three-eighths of an inch thick), and containing flaky caseous matter with an offensive smell.

From this case I have had drawn what I am inclined to consider a perfectly typical form of the pleural outgrowths in bovine tuberculosis. It is the coloured drawing, fig. 1, Plate I., repre-

senting the concave base and the adjacent rounded lateral aspect of the lung, with the intervening margin. The concave base shows the "duckweed" condition, the rounded lateral surface shows some typical examples of the cord-like outgrowths, and the margin shows the beaded or corded condition, of which fig. 4, Plate II., is another example. On these characters alone I should be inclined to rest the identification of the form of disease in this case. The liver, where not adherent, showed the appearance of fig. 2. The growths are well-defined excrescences of the peritoneal capsule, and it is not difficult to see that they acquire their large size from the confluence of a number of the smaller leaf-like outgrowths of fig. 1. It is a remarkable fact that a narrow strip of villous outgrowths was found also over a limited portion of the intestinal serous membrane in the right iliac region.

The enormous size and calcareous infiltration of one of the mesenteric glands is significant; the quite small glands found near the large one were also calcareous.

The case may appear to be complicated by the existence of a so-called scrofulous ovary; but the ovary may be tuberculous, like the testicle in the male. Another interesting complication is the formation of vegetations on the mitral and aortic valves.

Some of the tubercles in the lungs were large and of greyish-white colour, but the pulmonary lesion as a whole (apart from the pleural) is not distinctive.

CASE 10.—Typhoid fever six months before; tuberculosis of lungs and peritoneum; two healed ulcers of ileum; wedge-shaped infarct of new growth in one lung.

S. J—, female, aged thirty-eight, Little Eversden, Cambs, admitted into Addenbrooke's Hospital on 13th March, under Dr Bradbury. Had typhoid fever in August 1879, and has never been quite well since. Now admitted for certain ill-defined abdominal symptoms. Eight weeks ago the abdomen began to swell, first in the right inguinal region. At the same time began to have pain in the right inguinal region. Menstruation has been suspended, and patient has had occasional attacks of vomiting at intervals of three or four days. During the last week, the pains in the right inguinal region have been more frequently felt. Pain at epigastrium and between the shoulders after food. Much troubled with wind.

Present condition.—Abdomen distended. Chest resonant throughout; respiratory sounds healthy. Heart sounds normal. March 20: Complaining for two days past of pain in right inguinal region. On 24th March, cough and a little frothy expectoration. No signs in chest. Face began to be flushed. Cough increased, especially at night. The evening temperature on 4th April was $102^{\circ}\cdot6$. From this date the evening temperature averaged over 103° , on several occasions reaching 104° . The morning temperature was generally about three degrees lower. Acute tuberculosis was diagnosed. The cough continued, and on 11th April a few sharp metallic râles were audible at the end of inspiration in left axilla and at left base; no loss of resonance. On 14th April, abundant fine crepitation in right infra-mammary region; no loss of resonance in any part of chest. On 16th, rhonchi universally heard; abundant crepitation in both infra-mammary regions; afterwards also at base. April 20: Appeared to be doing moderately well till last night. Face then became dusky, and respirations rapid. Did not sleep much during the night. Frequent cough; hardly any expectoration. Pulse very small; tongue very dry. Urine albuminous. Symptoms continued till death on 21st.

Post-mortem, 22d April.—Abundant soft adhesions obliterating the cavity of the left *pleura*. Miliary tubercles seen on the surface of the lung, and in the interlobar fissures. Both *lungs* studded with miliary tubercles of unusually small size from apex to base. Both in a semi-pneumonic condition throughout, and containing little air; the apices were the most solid, but there was no part that did not float. At the apex of the right lung there was a patch of fibrous tissue, embedded in the interior of which were several small caseating masses. In the lower lobe of the right lung there was a well-marked infarct, wedge-shaped, about two inches long, and one inch and a quarter broad at its base on the *pleura*. It was quite firm and somewhat tough, not at all broken down, of dry texture, and brownish-yellow colour, not everywhere of the same shade. In the abdomen there was recent peritonitis, the intestines being glued together. The whole *peritoneum* was covered with an eruption of large flat nodules, up to the size of a split pea, sometimes confluent, most abundant in the right iliac region, where there were old adhesions enclosing some fluid. They contained minute points of black pigment. Recalling the fact of typhoid fever six months before, and that healed typhoid ulcers may have black pigment in the cicatrix, I referred the peritoneal eruption to that source, and proceeded to unravel the matted intestines, so as to examine the *ileum*. I found only two healed ulcers; one of them was of considerable size, just above the valve, and another half an inch in diameter, about a foot higher up. The latter I kept for microscopic examination, and a thickening, partly in the floor of the cicatricial depression, but more to one side of it, has afforded very remarkable specimens. Both cicatricial depressions had minute points of black pigment in their extreme centre. The peritoneal covering of the *liver* and *spleen* was studded with the same

large flat tubercles as elsewhere. *Mesenteric glands* not altered in colour nor enlarged.

From this case I have taken the microscopic drawing, fig. 15, Plate VI., showing the structure in the thickened base of one of the healed ulcers in the ileum; and I shall discuss in Chapter VIII. the large and important question that the case raises with reference to typhoid fever, and especially with reference to epidemics of typhoid fever traceable to the milk of a particular dairy. The large flat tubercles were precisely the same as those of Cases 2 and 5; over the intestines, especially of the right iliac region, they were often raised clear of the serous surface, and situated in the meshes of a filamentous new growth covering the peritoneum. I unfortunately neglected to keep the remarkable wedge-shaped mass that occurred in one lung. It had exactly the form and position of an embolic infarct; it was hard, firm, and tough, with a brownish-yellow colour, broken by paler or more translucent lines, and it resembled most nearly the nodules drawn in fig. 8, Plate III.

CASE 11.—*Symptoms of acute rheumatism; afterwards cough and wasting, with continued high evening temperature; white medullary tubercles of lungs; tuberculous ulcers of intestine; caseous thoracic and abdominal lymphatic glands.*

L. D.—, female, fifteen, Cambridge, admitted into Addenbrooke's Hospital on 5th May 1880, under Dr Bradbury. Acute rheumatism (?) in 1877. Typhoid fever in 1878. Three weeks ago began to suffer from headache and pains in the shoulder-joints and dorsal region of spine. Has had more or less pain ever since in arms and back; the pain is not limited to the joints. Never any pain in the knees or ankles. Has been feverish throughout; perspiration also noticed to be excessive. On admission, face flushed, skin hot, but not moister than natural. Complains of pains in both shoulders and arms, and also of pain in the left hypochondrium. No swelling of any of the joints. Tongue much coated. The temperature was $103^{\circ}\cdot 2$ on the evening of admission, and $100^{\circ}\cdot 2$ next morning. Subsequently it was at or somewhat over the normal in the morning, and a degree higher in the evening, until three weeks after admission, when it began to be about 100° in the morning and 103° in the evening. During the period of lowered temperature the pains were only occasional; frequent free perspiration; strong rheumatic odour. The heart-sounds were natural, and there were no pulmonary symptoms. When the temperature began to rise on 30th May the patient complained of nothing. On 8th June frequent dry cough is noted; no other complaint; the

respiratory sounds under the left clavicle were harsh. The temperature keeps at about 103° in the evening and from three to four degrees lower in the morning. On the 17th June and following days the cough is troublesome; some muco-purulent expectoration; perspires very freely at night: abundant sonorous rhonchi over whole of left pectoral region; no loss of resonance; crepitation most abundant behind, in subspinous fossa. Some albumen in urine. Cheeks generally flushed. Losing flesh. From 22d to 27th June, the temperature is noted between 100° and 101° for both morning and evening. On 27th the evening temperature again rose towards 103° , falling three degrees in the morning. The temperature remained of much the same character till death, occasionally reaching 104° at night. On 2d July there was abundant sharp crepitation of large or medium size over the whole of left chest; less marked on right side. No dulness. Breathing rather short. These symptoms continued till death, with progressive wasting, dryness of skin, flushed face, some œdema of feet. Sordes. Dyspnœa. Wandering. Death at 9 P.M. on 1st September.

Post-mortem, 2d September.—Body emaciated; considerable œdema of feet. *Pleura*, long filamentous cords growing out from sharp margin of lower lobe. Left lung firmly adherent to chest-wall laterally, and to diaphragm at base. *Lung* substance, in the lower lobes shotty to the feel, from presence of a few scattered whitish tubercles. In middle portion, and at apex of right lung, large white nodules, the size of peas, yielding, on pressure, white milky or creamy puriform substance, and, when excavated, presenting the appearance of smooth-walled cavities. The formation in the left apex was most extensively broken down, the whole upper lobe of the lung being occupied with a semi-gangrenous excavation. In another part of the lung occurred an oval cavity about one inch in length, with a thick vascular wall, and showing in its interior the appearance of a red granulating surface. *Intestine* contained numerous ulcers, the largest being in the ileum, of round shape, one inch, more or less, in diameter. The floor of the ulcer was occupied by a number of scattered and distinct small whitish tubercles, which projected on the peritoneal covering of the intestine. The highest ulcer occurred within three inches of the pylorus, of the size of a pea, situated on the side and base of one of the valvular folds. The *lymphatic glands* in the mesentery, especially at its upper part, much enlarged, some caseous, one or two with calcareous deposit in centre, and many of them showing a number of small independent centres of new formation, of medullary white colour. Those near the cœcum were of deep red colour, and soft. The enlarged glands extended into the thorax behind the aorta, and on both sides of the thoracic duct; the latter was dissected clear of the glands for a considerable distance towards the neck, and did not appear to have any new growth within or upon it. The bronchial cluster was much enlarged, and the enlarged chain extended upwards into the neck. In one of the bronchial glands an interesting appearance was found, which throws light on the softening of the

lung nodules; the white medullary nodule within it had become softened in the centre, and the cross-section had exactly that macaroni-like appearance so often mentioned in the preceding cases as having been observed in the lung nodules. A single small translucent nodule was observed on the surface of the liver, and one also on the spleen.

The condition of the lungs in this case was like that observed in several other cases. The noteworthy points are the medullary softness and whitish colour of the nodules, and their tendency to form a more or less sharply defined excavation in the centre. The extensive implication of the lymphatic glands is significant, as well as the cretaceous deposits in some of them. The isolated round nodules or centres within the individual lymphatic glands had, in the less advanced stages, the same whitish colour as the nodules in the lungs. The tubercles in the floor of the intestinal ulcers had also that colour; to speak of them either as grey or as yellow would not be strictly accurate.

CASE 12.—Rapid tuberculosis; unusually high evening temperature; greyish-white medullary nodules in the lung, and wedge-shaped masses; white medullary scelling and ulceration of follicles of intestine.

G. E.—, twenty-seven, male, tailor, Ely, admitted into Addenbrooke's Hospital on 4th August 1880, under Dr Bradbury. Family history good; no consumption. Eight years ago lost a leg through railway accident. Health good until seven weeks ago; began to suffer from cough, and lost appetite and flesh. During the past three weeks there has been profuse night sweating; never any hæmoptysis. Since two weeks has noticed that he becomes feverish about 6 P.M.

On admission—Pale sickly aspect; thin; scars on neck, apparently from suppurating glands in childhood; cough, with frothy greenish expectoration. Bad appetite. Tongue coated. Trace of albumen in urine. Percussion note not good at apex of either lung. Respiratory sounds throughout the chest in front normal; resonance behind good; respiratory sounds less distinct at right base than at left. The temperature throughout his whole illness in hospital had a tolerably uniform character; it averaged about 103°·5 in the evening, and was from two to three degrees (and occasionally four degrees) lower in the morning. On four occasions it reached to near 105°, and on the afternoon on which he died it stood at 107°·4. On 19th August the examination of the chest revealed—Expansion good; harsh expiratory sound over left apex; occasional minute râles. Percussion note dull behind, particularly over left base. Vocal fremitus and resonance not increased. Tubular breathing over left lung posteriorly. Muco-purulent expectoration.

Feels faint. On 24th August—Absolute dulness in both supra-clavicular regions. Tubular breathing below both clavicles. Bronchial breathing over right lung. Crepitation at left base. Some blood in sputa.

On 3d September he did not seem altogether conscious; later, very excited; subsultus tendinum; face livid. Death at 1.30 P.M.

Post-mortem, 4th September.—Body emaciated; right foot has been amputated above ankle. One or two soft and vascular adhesions of *left pleura*. Adhesions of lobe to lobe in *left lung*; in the upper lobe, near the outer surface, a broad shallow cavity, with whitish puriform substance in its interior, and irregular walls; in lower lobe a number of smooth-walled cavities from $\frac{1}{4}$ in. to 2 in. diameter, containing whitish puriform substance. In *right lung* (which was adherent), several nodules could be felt in the midst of the compressible lung substance, mostly near the surface; on section, one mass in particular was found to be wedge-shaped, and made up of the confluence of a number of smaller round whitish nodules; it was broken down at the apex. Another larger and very distinct wedge occurred, its base on the pleura being $1\frac{1}{2}$ inch square; it was uniformly firm, and resembled grey hepatitis; the portion of pleura exactly corresponding to its base was covered by a layer of fibrinous membrane. The most dependent anterior portion of the upper lobe was in a state of grey hepatitis. The thin lower margin of the lung was shotty, with a few whitish nodules; its pleural surface showed a few of the leaf-like outgrowths. The bronchi did not appear to communicate in any instance with the cavities in the lungs. On pressure, small cylindrical masses of whitish substance, like worms, could be made to issue from the centre of the better preserved nodules. In the *intestine*, the lymphatic follicles were everywhere swollen and of medullary white appearance. They were observed of small size throughout the whole jejunum; with here and there a larger one, prominent, injected, and ulcerated. The highest Peyer's patch was found at a point before the valvular folds had ceased; it was 4 inches long and about $\frac{3}{4}$ inch wide, and it was studded all round the margin and partly in its centre with swollen and white medullary follicles, a small injected vessel appearing to lead up to each of the swollen follicles. Peyer's patches, in a similar condition, were found to the number of ten, and near the ileo-cæcal valve there were two or three true ulcers with thickened edges. The *mesenteric glands* were not at all conspicuous. The *large intestine* was entirely unaffected. The *brain* and *membranes* were normal.

This case resembled Case 11, which was examined only two days before it, in some particulars. In the lungs in both cases nodules of medullary whiteness occurred, softened at the centre, and yielding at every section of the lung a milky or creamy puriform fluid. The intestinal lesion was not quite the

same in the two cases, and in Case 12 the lymphatic glands appeared to be entirely unaffected. Again, in Case 12, the wedge-shaped character of the lung nodules, already referred to in the earlier cases, was a distinguishing feature. Besides the wedges of medullary substance, made up of the confluence of a number of large round tubercles, there occurred one very large and clean-cut wedge, with compressible lung tissue on both sides of it, which had on section the character of grey pneumonic hepatisation.

CHAPTER V.

THE FORMATIONS ON THE SEROUS MEMBRANES.

The task of tracing an identity of structural details between the foregoing cases of tuberculous disease and the specific bovine form of tuberculosis, is one that is attended with the greatest difficulty. I venture to think that if the appearances which I have recorded had been observed and described for the first time in the human subject, the correspondence with the bovine disease would have been made out more easily. But there are few or none of these points of structure that have not been noted before, in one connexion or another; they have been for the most part added to the extensive and perplexing catalogue of the characters of tubercle, as it may be compiled from works on human pathology. My position is that the cases of bovine tuberculosis in man, which have occurred (doubtless in large numbers) in the past, have been, without discrimination, swept into the general heap of tuberculous cases, and the specific characters which they have shown have only served to swell the list of the characters of tubercle regarded as a single and indivisible malady. I think it is possible, however, by a careful attention to minute details of form and structure, to restore such cases to an independent place among the diseases of the human body, and to detach them from the indiscriminate heap of all that is called tubercle. It is usual to say that there are few diseases more Protean than tubercle; but we may safely infer that the Protean characters of tubercle are partly a reflex of the confusion in our own minds. Experiments have made it more than probable that the specific bovine disease has in some, if not in many cases, been communicated to man. From the circumstances of the case, the number of persons infected from the cow or ox would, if they occur at

all, be infinitely greater than the cases of glanders in man traceable to the specific disease of the horse. There is a reasonable presumption that such cases make up a considerable part of the cases of tuberculosis observed in medical practice, and, on that hypothesis, it is tolerably certain that we have already incorporated all or most of the characters of the bovine disease, as it appears in the human body, in our current conception of human tuberculosis.

For example, as regards the conditions in the lung, the treatise by Rindfleisch on "Chronic and Acute Tuberculosis,"¹ makes reference, or implies reference, under one head or another to probably the greater part of the characters of the pulmonary lesion which I shall regard as distinctively belonging to the communicated bovine disease. Indeed, the definition of tubercle that Rindfleisch adopts, appears to me to have been mainly determined by the large infusion of the distinctive bovine characters into his general conception of tuberculosis. Again, as regards the lymphatic glands, the conclusive work of Schüppel on "Lymphatic-Gland Tuberculosis"² has deprived one of the opportunity of proving for the first time that many cases of apparently simple and primary scrofulosis or caseation of the glands in man are really cases of tuberculosis within the glands, and of so making out an unprejudiced point of identity with the bovine disease. In like manner, the question of the intestinal lesion has grown to be one of great intricacy, and the lesions of the genito-urinary organs have become part of the problem of scrofula. It is perhaps the condition of the serous membranes that offers the clearest and least prejudiced ground for establishing an identity with the specific bovine disease, and that is also the lesion that is most distinctive of the bovine disease itself. I shall begin my general resumé with the condition of the serous membranes, and follow with some account of the condition of the lungs, of the lymphatic glands, and of the intestine.

The formations on the serous membranes in the ox and cow have been so conspicuous a feature of the disease, that they have determined all the various names that the disease has been called by in different countries. Some have even gone so far as

¹ Rindfleisch, in Ziemmsen's *Handbuch*, vol. v. Leipzig, 1874.

² Schüppel, *Untersuchungen über Lymphdrüsen-Tuberculose*, Tübingen, 1871.

to say that the disease is confined to the serous membranes and the lymphatic glands; there is, however, abundant evidence that the lungs are affected, and we have the emphatic statement of Gerlach, already quoted, that he has never seen a case of "pearls" on the serous membranes without disease in the lungs and bronchial glands. The "pearls" on the pleura, pericardium, and peritoneum are formations of a very uniform and characteristic appearance, and, according to Virchow, their size should distinguish them from other tubercles. They are, for the most part, an eighth of an inch in diameter, or, as nearly as possible, the same as the leaves of duckweed. It is the curious resemblance to the dense masses of that plant that has suggested the early German name of bovine tuberculosis, viz., *Meerlinsigkeit*. The resemblance consists in the uniform size and flatness (with convex upper surface) of the serous nodules, and in their occurrence in dense masses. That general resemblance is close enough, without bringing in the occurrence of stalks or runners appearing here and there among the leaves. The serous nodules have also a tendency to become confluent, two or three or more uniting partially at their edges to form a broad lobulated patch. They are also apt to become detached from the serous surface out of which they grew, and they are not unfrequently found as if entangled in or supported by a mesh-work of fibres on the surface of the membrane. Such are the most characteristic appearances of the serous eruption. But it may be observed also in its earlier and in its more developed stages. I have already quoted from Walley an account of the mode of origin of the serous-membrane nodules, according to which they begin as vascular villi, within which a certain consolidation or cellular formation takes place, leading to sessile or pedunculated nodules. According to Virchow (*loc. cit.* p. 189), the eruption may sometimes put on the sub-miliary form; "but the formation of nodosities is the rule, and, if their number is very great, the lung is covered by them as stagnant water is with duckweed." It is only occasionally that the large polypoid masses, sometimes weighing several pounds, are found; in the case of the cow, quoted from Gerlach, it is specially noted that the larger growths were wanting.

In the twelve cases in man, which I have recorded, a considerable variety of serous-membrane outgrowths occurred. The flat round

or oval nodules, of the size of duckweed leaves, occurred in at least three cases, the under surface of the diaphragm, where it comes in contact with the liver, being the favourite situation. Fig. 3, Plate II., represents the appearance on the under surface of the diaphragm. The largest nodule that I have found occurred in the pleura in Case 7; it was round and flat, about three-eighths of an inch in diameter, and it hung suspended by a long narrow band like a small medallion. But the most usual kind of outgrowth, one that occurs almost universally in the series of cases, is not so much a solid and firm nodule, as a papular, or button-like, or leaf-like, or villous or tongue-shaped formation of softer texture. The size of them corresponded to the prevailing size of the duckweed leaf, but they wanted the thickness and density of an actual nodule. Fig. 5, Plate II., represents a piece of the lung surface from Case 3, covered with such outgrowths; in this case they were always of an opaque white colour. Fig. 6, in the same Plate, shows a very similar condition of the surface of the spleen in Case 5. Another variety of the same condition is shown in fig. 1, Plate I., from the base of the lung in Case 9. It is hardly possible to avoid the conclusion that there is something quite distinctive and characteristic in this latter appearance. The base of the lung is covered with a number of flat round leaf-like bodies attached to the surface by a slightly constricted pedicle; they are, for the most part, membranous, and the edges are sometimes turned up, thereby showing the clear space between the pleura and the under surface of the leaf. In the actual specimen, they want the solidity of the duckweed leaf; but that is because they represent an earlier stage of the formation. The earliest condition in which I can identify these outgrowths, is that of a number of red (vascular) papules slightly raised above the surface of the lung in Case 12. The leaf-like outgrowths tend to become confluent, just as the more solid nodules do (see fig. 3, Plate II., from under surface of diaphragm); and the confluence of several of them leads to the appearance of remarkable growths, such as occurred on the upper surface of the liver in the same case (Case 9), and are represented in fig. 2, Plate I. They are of loose, delicate texture, as if rarified in the interior, and partly suggestive of collapsed bullæ. Their connexion

with the serous surface is generally by a not very constricted short pedicle, and the margin of the leaf-like expansion is always free for a certain distance. The liver, in this case, was partly adherent; the drawing is taken from a portion of it that was not adherent, and there can be no suggestion of the appearances having been produced artificially by the tearing through of adhesions. The same remark applies to the apex of the lung in Case 8 (see notes of cases). There can be no doubt that such outgrowths lead to the formation of adhesions; but it is equally certain that such adhesions are not due to what is assigned as the universal cause of adhesions, viz., pleurisy or peritonitis. A circumscribed patch of such outgrowths may attach themselves by their free extremities or surfaces to the opposite pleura or peritoneum, and so form an adhesion; but pleurisy or peritonitis, as the cause of an adhesion under such circumstances, is probably out of the question. The true analogy is rather the case that is sometimes seen of an eruption of tumour-nodules on the under surface of the diaphragm, leading to a firm union of the latter with the liver. In Case 9, there occurred also the peculiar narrow band of villous outgrowths on the peritoneum over about six inches of the ileum (see notes of cases).

It remains to mention another and not less important variety of the formations on the serous membranes. It is especially apt to occur round the sharp margins of the lung, more particularly that of the base. In fig. 1, Plate I., the marginal formation is shown, and fig. 4, Plate II. is another representation of the same kind of growth. The formations round the sharp margins of the lung are very commonly met with in the above cases, and they are sometimes *the only indication of the disease present on the serous membranes*. These outgrowths occasionally form a villous or membranous fringe (of which the membranous prolongation on the right hand side of fig. 8, Plate III., may be a more advanced condition), but it is in the form of a number of independent cord-like processes that they are most distinctive. The best examples of them that I have met with are those drawn on the convexity of the lung in fig. 1, Plate I. They sometimes hang free from the surface to the length of half an inch, both on the lateral aspects of the lung (as in the figure) and on its sharp margin; but, in the latter situation, we may

find a braided or corded appearance of the border. In fig. 4, Plate II., the outgrowths on the sharp margin are partly isolated and of unequal height, and on the right hand side they are fused into a straight cord; in both forms, a constriction occurs between the attached margin of the growth and the pleura, forming a sort of pedicle in the isolated growths and a groove for the piece of cord. The margin shown in fig. 1, Plate I., is somewhat more complex; there is a more or less continuous outgrowth of some breadth, like a thick frill, and cord-like outgrowths running above it or alongside of it. Sometimes the formations are quite short, in the form of conical papillæ or warty excrescences, at other times they are long and slender, and occasionally they are in the form of a loop. Generally speaking, an injected vessel or vessels may be made out with a lens, occupying the centre of the outgrowth.

That these formations on the pleura, and more particularly on the thin margin of the lung, are something special and distinctive appears to be beyond doubt. It may be thought, however, that they are too slight in themselves to serve as trustworthy indications of any particular disease. It must be admitted that in most of the cases we have only the beginnings of the serous-membrane eruption; it is only in Cases 2, 5, and 10 that the actual large flat tubercles of *Perlsucht* can be said to have occurred fully developed. The more usual condition is only the first indication of the serous-membrane lesion, but it is quite conceivable that the bovine disease, when it is communicated to man in the form of an acute infection, would not present the same degree of development, and to the same extent in the various organs, which it attains to in the course of several years within the body of the ox or cow. But slight indications may be sufficient for the purpose of identification, provided the indications be true ones. Now, on that point we have the excellent authority of Gerlach. Referring to the fringes of filamentous excrescences that were found growing from the thin margin of the lung in two of the animals experimented on, he observes—"But *most especially are we reminded of Perlsucht* by the growths on the pleura, round the sharp margin of the lung, in the twelfth and fourteenth experiments; *they demonstrate to us the beginnings of Perlsucht.*"

This statement, coming from a competent veterinary pathologist, may be accepted implicitly.

The large flat tubercles that occurred in Cases 2, 5, and 10, are mentioned in works on human pathology; Virchow, however, states that the size and tendency to become pedunculated (another author, Perls, includes their flatness), should distinguish the nodules of Perlsucht from other tubercles of the serous membranes. I have not found any reference, in human pathology, to the earlier condition of the serous-membrane outgrowths, with which I have chiefly occupied attention in this section. Their undeveloped state is not against them as valuable diagnostic marks, and there is no doubt that they do grow to be the nodules, and the conglomerates of nodules, that are admittedly characteristic of the disease. I have provided two plates of accurate coloured drawings, showing a considerable variety of the appearances that these serous-membrane outgrowths present. I believe that a case of bovine tuberculosis in man may sometimes be detected by these curious formations alone, and I have been at some pains to have the appearances that I believe to be characteristic accurately produced in colours, for the easier detection of future cases and for the further elucidation of the subject.

I defer noticing the microscopic structure of the serous-membrane nodules to the next chapter (p. 63).

CHAPTER VI.

THE DISEASE IN THE LUNGS.

In the twelve cases in man, the nodules and cavities in the lungs divide themselves, in the first instance, into two main classes; one of the classes is represented by the formations in a single case only (Case 7), the other class comprising those of the remaining eleven. The nodules in Case 7 are clearly distinguished by their brownish-yellow colour, their hardness or toughness, their definite round or oval shape, and their thick capsule of translucent tissue (fig. 8, Plate III.); the cavities in the same case are distinguished by their dense fibrous and semi-cartilaginous walls and their granulation-like interior. In the more decided of the other eleven cases, the nodules in the lungs are remarkable for their medullary softness and greyish-white colour, for their tendency to central excavation, and for the want of a regular periphery and the absence of anything like a capsule; the cavities, in like manner, are obviously the softened interiors of nodules, or conglomerates of nodules; their walls are sometimes uneven or ragged, and sometimes smooth, and their contents are whitish, milky or creamy, and of muco-purulent consistence. The difference between the two classes of cases is nothing more than the difference between a chronic case and a preponderating number of acute cases. The cases that most nearly represent an intermediate class are Cases 5 and 6, where the condition of the lung was the very significant crumple-like condition of fig. 9, Plate III.; the round vomicae, with smooth thick walls, appear to be the round encapsuled nodules of fig. 8, with the central substance removed. A partial exception to the morbid appearances in the class of acute cases should also be made for Cases 9 and 10; these were the only two cases in

which the lungs were filled throughout with minute translucent grey tubercles. The infection, when it reaches the lungs, appears, for the most part, to run an acute course, and to be the immediate cause of death. But evidences of an acute process of infection in the lungs may coexist with more chronic indications of the disease elsewhere, as on the serous membranes (Cases 2 and 5), or in the lymphatic glands (Case 5). Also, Case 10 may be taken as showing that an acute infection of the lungs, viz., with minute grey translucent tubercles, may be added to the traces of more chronic disease in the same organ, viz., the remarkable solitary wedge-shaped mass, which had a yellowish-brown colour and toughness of texture exactly corresponding to the chronic nodules of fig. 8, Plate III., which I take as the sole representative of the chronic class. The tubercles of the serous membranes in the same case (Case 10) were evidently of some standing, and it is an interesting fact in the case, that the patient had been in the hospital six months before for "typhoid fever;" it may be assumed that something had occurred in the interval to reawaken or intensify the disease in the form of the miliary or sub-miliary tuberculosis in the lungs, of which the patient died. In this case (Case 10) the interest centres rather in the healed ulcers of the ileum, and I shall practically disregard the tuberculosis in the lungs, and take the case in a separate chapter along with the two cases that have the intestinal lesion. The other case, with miliary or sub-miliary tuberculosis of the lungs (Case 9), has afforded what I consider the most typical form of serous outgrowths, and apart from the co-existence of a "scrofulous" ovary, it is distinguished by enormously enlarged and calcareous or petrified mesenteric glands.

With these partial exceptions, the twelve cases divide themselves, in respect of the condition of the lungs, into two main classes, one of them containing a preponderating number of cases of acute lung disease, and the other a single case of chronic or long-standing pulmonary infection. The chronic condition joins on to the acute condition in the most intelligible way; and within the more diversified acute class itself, the diversities are only such as mutually explain each other. Taking, first, the latter class of morbid appearances in the lungs, their most

general character is the *medullary or greyish-white substance* composing the nodules. In Cases 1 and 2, it was certainly a doubtful point, during the *post-mortem* examination, whether the masses in the lungs, mostly on the periphery and sometimes wedge-shaped, were not secondary tumours, sarcomatous or other. Greyish-white, like the white marble of an old building, was also the colour of the nodules in the other cases, and the medullary softness was generally associated with it. It would be quite misleading to speak of the substance in the lungs as "caseous" in any one of the acute cases.

The next salient feature of the pulmonary new formation is *the large size of the nodules*. The largest masses were those that could be felt distinctly isolated, with compressible lung substance round about them, as in Cases 1 and 2, and also in Cases 11 and 12; such large masses were usually in the periphery of the lung, and they had sometimes the unmistakable wedge-shape of an embolic infarct; it happened in three cases that one of the lungs contained only one or two such masses, their presence being detected by feeling the lung all over. Fig. 7, Plate III., is a coloured drawing of one of them (from Case 2). The mass occurred on the posterior thick border of the lung, in the lower lobe close to the great interlobar fissure. It was distinctly wedge-shaped, with the broad end on the pleura, and a branch of the pulmonary artery nearly as large as a goose quill was traced until it disappeared as if to one side of or beneath the thin end of the wedge. The colour of the mass, when newly incised, was a purer white than it appears to be in the drawing, which was made after the lung had been for some time in spirit. The upper lobe of the lung was of a bright rose-red colour, and perfectly healthy; the lower lobe, in which the mass was situated, differed chiefly in being somewhat more congested, and in having some portion of the base carnified. The cut surface of the wedge-shaped mass showed it to be made up of the confluence or conglomeration of a number of round nodules, which were themselves nearly as large as peas (see Drawing). But when a portion of the tissue (from the other half of the wedge, which had been preserved in potassium bichromate and afterwards in spirit and water, and pure spirit) was examined in microscopic sections, the nodules of the size of peas were found to be not the

ultimate unit of the nodular formation, but to be themselves made up of a large number of minute round nodules. The appearance under the microscope of a group of the small nodules is given in fig. 11, Plate IV., and a single nodule is shown in fig. 12 in the same plate. It may be said that the whitish masses in the lungs varied in size from a walnut down to a lentil or even a smaller object, but that, whatever their size as naked-eye tubercles, they all proved to be *conglomerates of smaller tubercles*.

The most significant fact in the agglomeration of a number of small tubercles to form larger masses, is that the latter not unfrequently occurred on the periphery of the lungs in *the shape of a wedge*. Wedge-shaped masses of whitish medullary substance occurred in the lungs in Cases 1, 2, 3, and 12, and in the last case there was also a very well-marked large wedge of consolidation that resembled the grey hepatisation of pneumonia. In Case 10, the most definitely bounded and the sharpest of all the wedges occurred, but it was of brownish-yellow colour, and of hard or tough consistence. These masses had precisely the form of embolic infarcts, and in the case from which fig. 7, Plate III. is taken, a branch of pulmonary artery led up to and disappeared beneath the thin end of the wedge. Perhaps all that one may infer from this is that the conglomerate of tubercles corresponds to the territory supplied by a terminal branch of the pulmonary artery. The artery may have been blocked by an actual embolus, and an embolus charged with specific properties would perhaps be capable, in some unknown manner, of setting up the corresponding kind of interstitial new growth at a number of points within the vascular area. At all events, in Case 2, from which the coloured drawing is taken, there was embolism also of the middle cerebral artery, and a distinct patch of yellow softening round about the blocked artery; a microscopic examination of which brought out nothing that one could lay hold upon for the theory of specific infection. The doctrine of Waldenburg might be applied to explain both the wedge-shaped masses and the much more common rounded masses of various sizes as due to embolisms. However that may be, there can hardly be any doubt that the new formation is in all cases intimately associated with the distribution of the pulmonary artery.

We come next to certain points of *microscopic structure*. Figs. 11 and 12, Plate IV., are from the other half of the wedge-shaped mass drawn in fig. 7, Plate III., and fig. 13, Plate V., is from the wedge-shaped mass in Case 3 (tuberculosis in a child). Figs. 12 and 13, from different cases, show one of the most remarkable, and perhaps also one of the most characteristic microscopic appearances of the disease. The small nodule or ultimate tubercle is *surrounded by an extensive wreath or zone of vessels*, which, in the preparation, are so distended with blood corpuscles, that they stand out very conspicuously. The vessels are of considerable size, but they have always the structure of capillaries or of small veins. They are apparently tortuous, and they seem to form a kind of plexus round the tubercle. It is only on the periphery of the tubercle-conglomerate that small tubercles so distinctly isolated and so completely invested with blood-vessels are found; in the preparation that fig. 12 is taken from, there are a considerable number of them, forming the periphery of the larger mass. Not only is the small tubercle surrounded by a coat or capsule of blood-vessels, but branches of blood-vessels sometimes penetrate its interior. In fig. 12 a blood-vessel may be seen running right through the substance of the tubercle; in one of the tubercles of fig. 11, also, there are indications of blood-vessels in the very heart of the nodule. It is the exception to find vessels going through and through the tubercles; but their outer zone commonly shows traces of them. Wherever vessels exist in a tubercle, there the new formation is vigorous; and in the stained preparations, the cells are deeply coloured. The marginal zone of the tubercle, to a greater or less breadth, is nearly always made up of such deeply-stained and well-preserved elements, but the non-vascularised centre has undergone a more or less complete necrosis.

The central necrosis of the small tubercle is well seen in the preparation from which fig. 11 is taken. In two of the tubercles there is an extensive necrotic area in the centre, and the necrotic centre has separated from the vigorous periphery by a crack or fissure running round in a somewhat uniform line. This *clean separation of the necrosed centre from the vascular periphery* is an important point in the pathology of the disease. It applies

in the first instance to the ultimate small tubercles that make up the conglomerate, but it applies also to the large or conglomerate tubercles as a whole. The explanation of the central softening of the larger masses appears to be, that it is only such of the ultimate tubercles as lie around *their* margins that have the most perfect vascular coat or capsule, as in fig. 12. They form the ultimate effective barrier or resistance to the spreading necrosis, while the more centrally situated tubercles of the conglomerate have united their severally softened interiors, and have so formed one large central cavity.

The central softening of the larger or conglomerate tubercles is one of the commonest appearances in the series of cases. It is found equally in the larger walnut-sized conglomerates and in the masses of the size of a hazel-nut or pea or lentil. In the former, it amounts simply to an irregular breaking down of the medullary substance; in the latter it gives rise to more definite appearances, more useful for diagnosis. It was remarked in the smaller nodules in Case 2 and in the prevailing kind of nodules in Case 3, as the cases occurred one after the other, that the whitish masses in the lung were as if perforated with a more or less even round aperture, giving an appearance in cross section that might be roughly compared to the broken stem of a clay pipe; so much did the central aperture look like the lumen of an actual tube, that it was for the moment a question whether the whitish periphery of the nodule was not a formation round the wall of small branches of the pulmonary artery. The same characteristic appearance was found throughout the whole of the lungs in Case 8. In Cases 5 and 6, and again in Cases 11 and 12, that condition was found to some extent (and in one of the latter it was remarked in the *post-mortem* room that whitish cylinders like small worms could be made to issue from the centres of the nodules on pressure); but more usually in these cases, the nodules on section showed the appearance of a partly scooped-out hemisphere, the interior being either smooth or slightly ragged. The best examples of the smooth-walled cavities occurred in Cases 5 and 6, in the apex of the left lung in each case; it is the appearance represented in the coloured drawing, fig. 9, Plate III. *The walls of the*

cavities are so smooth that they have sometimes been taken for portions of dilated bronchi.

The condition of lung shown in fig. 9 is, I believe, characteristic of the bovine disease. It is the condition to which Trasbot has specially called attention as occurring in the lungs of tuberculous-cows and oxen. I have already quoted a summary of his views; the nodules are nourished exclusively at the periphery; vessels are more numerous in the tissue around the nodules, and in the septa or interstices of the large masses of tubercle than in the healthy connective tissue; there the vascularity is often so great as to be mistaken for inflammation; softening begins at the centre and extends towards the circumference of the tubercle-conglomerate, until there remains nothing but the surrounding connective tissue, and its appearance would lead superficial observers to think that it was encysted. It is perhaps worth mentioning, that I had already arrived at a similar explanation of the appearance of the vomicæ of fig. 9 (after mistaking it for bronchiectasis), and had published it in my preliminary notice, before I became acquainted with Trasbot's explanation of the condition as found in the lungs of bovine animals. The explanation in both cases is briefly, that the periphery of the nodule is well-vascularised, and resists the necrosis which befalls the interior of it, and that the clear separation of the necrosed centre from the vascular periphery gives to the latter the appearance of a smooth wall. That clean separation is shown in two of the small tubercles of fig. 11, Plate IV.

It is the *vascularity of the periphery of the nodule* that accounts for most of the distinctive appearances of the new formations of the bovine disease, not only in the lungs, but also in the lymphatic glands, in the liver and spleen, and to some extent also of those upon the serous membranes. The appearance of nodules as if encapsuled, which was so marked a feature in Case 7 (fig. 8, Plate IV.), depends on the translucency and vascularity of the periphery of the nodules. The same appearance was distinctly seen in the nodules of the liver and spleen in Case 5; and I have already quoted from Walley to the effect that such is also the appearance of the tubercles in the liver of bovine animals (p. 12). Again, nothing can be more striking than the complete isolation and sharp definition of a number of round nodules,

as large as peas, within the lymphatic glands of the same case (see fig. 10, Plate III.). This peripheral vascularity, then, tends in some cases (chronic) to the appearance of *nodules as if encapsuled*; in other cases it gives rise to *smooth-walled cavities* of various sizes, the "closed vomicae" of veterinary authors (Fleming); and we refer to it also by contrast all the intermediate degrees of *central softening*.

The vascularity of the periphery of tuberculous nodules is only the most lasting manifestation of a tendency towards vascularisation which shows itself elsewhere in the new formation. It is because the new formation of bovine tuberculosis is so well vascularised that it has *affinities* (pointed out by Virchow) to *lympho-sarcoma*. The abundant blood-supply of the tissue is also seen in the walls of cavities such as those of Case 7; the interior of the cavities might be said to have had the look of being covered with granulations, and the microscopic sections of the dense tissue forming the wall were quite like granulation tissue both as regards the lymphoid and spindle-shaped cells, and also as regards the parallel vessels ending on the surface in loops. But we are never permitted to lose sight of the *imperfect vascularity* of this new formation; and the best index of its imperfect vascularity is the constant occurrence of *giant-cells*.

Giant-cells occur in large numbers in the new formations in all situations,—in the nodules on the serous membranes, in the nodules in the lymphatic glands, in the masses in the lungs, and in the more occasional tubercles elsewhere. They are often of very great size, and they may contain an enormous number of nuclei; the nuclei, when most numerous, are usually ranged round the margin of the cells, and are often elongated or rod-shaped. Examples of giant-cells with marginal nuclei are drawn (under a low power) in fig. 11, Plate IV., from the lung nodules, and in fig. 14, Plate V., from those of a lymphatic gland. A somewhat different variety of them, the kind that usually occurs in the tubercles of the serous membranes, is shown in fig. 15, Plate VI. The central part of the tubercle, in the latter case, is made up of multinuclear cells of various sizes, lying somewhat loosely together; they are evidently derived from the cells that are found in their earlier state in the more peripheral parts of the tubercle, and these latter are simply

the pre-existing cells of the ground-substance, or the connective-tissue cells of the part, that have acquired a certain investment of protoplasm round the nucleus, and thereby a certain resemblance to epithelial cells. The close-set margin of nuclei in the giant-cell is the highest development that it reaches as a giant-cell; by developing further in the same direction it becomes a *portion of a blood-vessel*. The giant-cells with margin of nuclei and with protoplasmic centre are usually found in tubercles just internal to the zone of blood-vessels, or between the vascular periphery and the necrotic centre. The blood-vessels are, generally speaking, new formations, as in granulation tissue, and the giant-cells are, as it were, the imperfect developments of them extending more into the interior of the nodules, and they are the signs of failure in the complete vascularisation of the new-formed tissue.

That view of the office and significance of giant-cells in tuberculosis is held by Brodowski, Ziegler, Malassez, Charcot, and others. In former papers, I showed that the formative processes in the placenta afford us an exact physiological type or paradigm for the giant-cells of tubercles.¹ The formative process in the placenta is largely that of new blood-vessels and blood-sinuses, and there is no mistaking the part that giant-cells play in that process. They are found chiefly in the deeper strata of the new formation (circular muscular coat of the uterus in the Guinea-pig), and in those deeper strata the vascularisation appears to proceed more sluggishly or under greater difficulties than in the surface layers of the decidua. Multinuclear tracts or blocks of tissue, and clusters of smaller multinuclear cells, can be seen co-operating in various ways towards the formation of new blood-channels. The range of variety in the deeper layers of the placenta covers all the modifications of giant-cells that are found in tubercles, and affords, in fact, a perfect physiological type for the latter. The giant-cells of tubercles have no specific significance, other than that they indicate the imperfect vascularity or difficult vascularisation of the new growth. I have

¹ Creighton, (1.) "On the Formation of the Placenta in the Guinea-pig," *Journal of Anatomy and Physiology*, vol. xii. (1878). (2.) "Further Observations on the Formation of the Placenta in the Guinea-pig." (3.) "The Physiological Type of the Giant-cells of Tubercles and Granulations," *Ibid.*, vol. xiii. (1879).

placed side by side in Plate VI. a drawing of one of the centres of new formation in the floor of the healed ulcer of the ileum in Case 10, and a drawing of a group of cells in the deepest layer of the Guinea-pig's placenta. In neither case do the cells show any approach to a true vaso-formative function, but in both cases they show remotely or in a feeble degree that tendency to the formation of new blood-vessels which the placenta shows to perfection in its more superficial layers, and the tubercle shows in its periphery. This brings us to the consideration of the question in what sense giant-cells are characteristic of the specific bovine disease.

Giant-cells were discovered by Virchow in the tuberculous nodules of the bovine species ten years before they were described for tuberculosis in man;¹ and the giant-cells that Virchow described and figured are of the largest and most perfect kind. The earlier discovery of giant-cells in the bovine nodules was doubtless owing to their greater prominence in the bovine disease. Giant-cells are characteristic of bovine tuberculosis, whether as it exists in the bovine animals themselves, or as it is directly communicated to man, on the broad ground of their number and perfect type. By perfect type I mean great size, regular marginal arrangement of nuclei, and broad central area of granular protoplasm; for in those particulars they come near to forming that which they always tend to form, viz., portions of new blood-vessels. Along with the giant-cells of large size and perfect type, the other cells of the nodule frequently have the character of large epithelial-like cells with one or more nuclei (as in fig. 15, Plate VI.) The nodules of the serous membranes, the actual "pearls" of the bovine disease, afford perhaps the most numerous and the most perfect examples of the giant-cells, and of the associated large epithelial-like cells. In the three cases of the above series, from which I preserved specimens of the large flat tubercles of the serous membranes, the number and the uniform characters of the largest giant-cells were very noticeable in the marginal zones of those tubercles that were caseous in their interior, and the large epithelial-like cells, with one or more nuclei, were found with equal uniformity in the smaller and more recent centres of new formation. So much did the numerous giant-cells,

¹ Virchow's *Archiv*, vol. xiv. (1858) p. 47.

with marginal nuclei and free protoplasmic interior, associated with groups of epithelial-like cells in the younger tubercles, seem to me, after examining these cases, to characterise a specific form of disease, that, when I found a new formation in all respects the same in sections of a tuberculous testicle, which I was using for my class of pathological histology, I felt much disposed to conclude that the particular tuberculous testicle must have come from a case of the communicated bovine disease.¹

A similar conclusion as to the giant-cells of bovine tuberculosis may be gathered from the observations of Orth on the tubercular disease which he induced in rabbits by feeding them with nodules from tuberculous cows.² As Professor Orth gives special attention to the microscopic characters of the disease which he induced by experiment, I shall include here a brief summary of his experiments, by way of supplement to the observations of Gerlach noticed in Chapter III. (p. 23). It is no doubt true that Orth does not clearly assert the identity of the induced disease in the rabbit with the original disease in the cow. He points out that the nodules on the pleura were not pedunculated, nor were they joined together like strings of pearls, in the manner characteristic of the bovine disease. In another place he remarks on the absence of calcification, also a characteristic of the bovine disease. But pedunculated nodules, and nodules strung together like pearls, are by no means invariably found in the tuberculous cow, nor is calcification present in every case, and still less is it the only form of degeneration found in the nodules. Both the pendulous form of the serous-membrane nodules and the calcareous degeneration appear to depend on the age of the new formations. The disease induced by experiment is in every case a more acute

¹ The testicle was obtained, along with other organs, from the *post-mortem* room at Addenbrooke's Hospital on 15th August 1878. The patient, aged 25, a navy, had suffered for four years from weakness in the back (ending in caseous disease of lower dorsal and upper lumbar vertebræ), which came on immediately after an attack of scarlet fever. The testicles were not observed to enlarge until three months before he died. The lungs, liver, spleen, and kidneys contained tubercles. The brain contained numerous very large nodules, up to the size of a hazel-nut, both in its substance (cerebellum especially), and also adhering to the branches of the anterior cerebral and middle cerebral arteries. It is to be observed that the disease was a sequel of scarlet fever.

² Orth, "Experimentelle Untersuchungen über Fütterungs-tuberculose."—Virchow's *Archiv*, vol. lxxvi (1879) p. 217.

process than the spontaneous bovine disease; as measured by time, the disease in the cow is more chronic by several years. It ought to suffice for a proof of identity if one finds what Gerlach, in the passage above quoted, calls "the beginnings of Perlsucht." Orth, however, goes so far as to speak of the disease in rabbits as "*Kaninchen-Perlsucht*," and I would in like manner be content to establish the foregoing cases in man as cases of "*Menschen-Perlsucht*." But when due allowance is made for the induced disease being a more or less acute infection, and the original disease one of several years' standing and gradual progress, it must be admitted that the disease which Orth found in the infected rabbits has sufficient points of identity with the specific disease in the cow.

Experiments of Orth.—There were two series of experiments. In the first, eleven rabbits were employed, four of them being simply kept beside the others without being fed with the tuberculous substance, as a control on the experiments; the remaining seven were fed with fresh tuberculous substance from the cow, and only two of these took the disease, the result of the experiment in the other five being negative. The second series of experiments proved to be much more important. Four rabbit-hutches were used, and in each were placed five rabbits. One rabbit in each received fresh tuberculous substance from the cow, and another the same substance boiled; one rabbit received fresh caseous substance from the human body, "from the firm caseous masses of caseous pneumonia," and another the same substance boiled; and the fifth rabbit in each box was simply allowed to live beside the others, so as to control the experiment. The remarkable result of the experiment was that all the four rabbits fed with fresh tuberculous substance from the cow took the disease, as did also three of those fed with the same substance boiled; but all the rabbits fed with caseous masses from the human body remained unaffected, as did also the four unfed rabbits used for control. The animals were made to swallow pieces of the substance introduced into the mouth by a blunt-pointed forceps, and there was no wounding of the mucous membrane. Of the bovine material, each rabbit received at one time five or six pieces as large as peas. Those of the first series were fed twenty-seven times on almost consecutive days; those of the second series were fed ten times on consecutive days, and a certain number of them were again fed after a long interval. The animals were kept alive for various periods. Those that were killed or died after a minimum period of four and a quarter months, ten in number, were all tuberculous except two, while of those that died or were killed sooner, only one was tuberculous, and that was a rabbit that died after three months. In three rabbits fed with bovine tubercles, which were killed within the first two months, there was no trace of infection. The nodules in the successful experi-

ments were found in the whole of the digestive tract, in the lymphatic glands, in the lungs, on the pleura and peritoneum, in the kidneys, in the liver, in the spleen, in the choroid, and (in a single case) in the iris, brain, and testicle. I shall refer to the new formations in the lymphatic glands and in the intestine under the respective headings. In the present section I shall quote the observations relating to giant-cells in the serous-membrane nodules, and some remarks on the lung lesion.

“In one of the larger nodules on the pleura,” says Orth, “the giant-cells were so abundant that, in a field of the microscope under Oc. 3 and Obj. 4 of Hartnack, several dozens of them could be counted. They gave here the impression of being the centres of lamination round which the smaller, but still large, epithelioid cells had grouped themselves. At the edge of the nodule, giant-cells occurred either isolated or merely with single epithelioid cells near them” (*l. c.* p. 230). Elsewhere, Orth describes the largest giant-cells as having for the most part a regular marginal circlet of nuclei and a free central space of finely-granular protoplasm.

The largest giant-cells, and those with the most regular marginal arrangement of their nuclei, are found mostly in the periphery of nodules that are more or less caseous or otherwise necrosed in their centre. The smaller multinuclear cells, showing all gradations down to the epithelial-like cells with a single nucleus, are found in such centres of new formation as I have drawn in fig. 15, Plate VI. The figure is taken from the thickened tissue in or near the floor of the healed ulcer of the ileum in Case 10. Such are the tubercle-centres that Orth found very uniformly in the infected rabbits. In the pathological handbook of Perls, the characters and the grouping of the cells therein shown are said to be distinctive of the tubercle-nodules of the bovine species.¹ But the epithelial-like cells of tubercle are claimed, on the other hand, by Rindfleisch as the “specific product of scrofulous tubercle.” The large epithelial-like cell is, he says, “a histological acme which the growth perhaps in all cases strives after, but does not always attain to.” The woodcut which Rindfleisch gives of them is drawn from the floor of a fresh tuberculous ulcer of the ureter. In like manner, Schüppel found them in a number of cases of tuberculosis of the lymphatic

¹ Perls *Lehrbuch der Allgemeinen Pathologie*. Stuttgart, 1877. Vol. i. p. 399, and fig. 96.

glands, as well as in the new formations from a tuberculous cow, and he adds to his description of this kind of tubercle the unlikely theory that the giant-cell is the central point in the formation of the tubercle, and that the epithelial-like cells that surround it are budded off from the central and parent giant-cell.¹ The tubercle composed largely of epithelial-like cells has thus already acquired a footing in human pathology. Rindfleisch would even make the large epithelial-like cell the specific cell of tubercle, or, as he says, of "scrofulous tubercle." For the specific cell of "scrofulous tubercle," I should be inclined to substitute the specific cell of "bovine tubercle," although I would not rest the specificity of the disease on the form of cell. I shall endeavour to show in the next chapter that the occurrence of the large epithelial-like cells in tuberculous lymphatic glands, as originally described by Schüppel, is on the whole in favour of their being characteristic of the bovine disease.

Although my contention is that the tuberculosis of the bovine animals is a specific disease, and that the cases herein recorded are identical with it both in general and naked-eye characters and in points of minute structure; yet I would rest neither the specificity of the bovine disease, nor the identity with it of the disease in man, upon the occurrence of elements such as giant-cells. Nothing that I can say on the futility of looking for the specific marks of a disease with the microscope would be so illustrative or so weighty as the remarks of Dr Wilson Fox, made before the Pathological Society of London in a discussion on Tubercle in 1873.² Giant-cells, like lymphoid cells and other embryonic forms of cells, have become the common property of many kinds of growths and of a variety of processes, both normal and diseased. They have been found in the nodules of lupus, in the nodules of the nasal mucous membrane in glanders, in syphilitic gummata and sores, in granulations, &c. I lately found (and hope soon to give an account of) remarkable instances of giant-cells in the wall of a dermoid cyst of the ovary and of a subcutaneous dermoid near the orbit, where they play the curious part of rudimentary follicles for the new-formed hairs. They may well occur in tuberculous formations that have originated in

¹ Virchow's *Archiv*, vol. lvi. (1872) p. 46.

² Wilson Fox, *Pathological Transactions*, vol. xxiv. (1873) pp. 366-70.

the body independently of a direct infecting virus from without, just as they occur in anæmic granulations. Nothing can be made of giant-cells for differential diagnosis unless their significance be kept in view. I have already expressed the opinion that one of their meanings, both in normal and in morbid processes, is difficult vascularisation of the new growth, and I have as yet had no reason to think that their obvious significance in the placental new formations is not a good physiological clue to their significance elsewhere.¹ Their numbers and their often highly-developed forms (with marginal nuclei) in the bovine nodules are in proportion to the relatively high vascularity that these growths attain to, and the occurrence, in the same disease, of centres of epithelial-like cells with one or more nuclei, has its exact analogy as a part, if not a perfectly intelligible part, of the vaso-formative process in the placenta, as represented in fig. 16, Plate VI.

It is the tendency towards complete vascularisation that gives the nodules of the bovine disease that affinity to sarcomatous growths which Virchow has specially drawn attention to. In the 13th experiment of Gerlach (quoted on p. 23) the lungs of the animal (a lamb) contained large nodules of grey colour and medullary consistence, which, he says (see p. 24), had "a certain resemblance to small sarcomas; and the same large nodules came still further to resemble the new formations of *Perlsucht*, in that even capillary vessels appeared in them." The nodules contained no giant-cells, but they contained capillary vessels.² The same

¹ The papers on this physiological analogy are reprinted in Appendix A.

² In August 1880 I received from Dr Bradbury portions of the lungs from a case in his private practice, which is of interest in the present connexion. The patient, a woman, aged about sixty, had come to Cambridge for advice, and the symptoms at that time pointed to rheumatism. There was, however, no rise of temperature. On returning to the country, she died somewhat suddenly. There was a freely movable nodule, about the size of a hen's egg, under the skin above the clavicle, probably an enlarged lymphatic gland. Both lungs were occupied throughout with greyish-white nodules, of the average size of a hazel-nut, definitely rounded and circumscribed, and readily shelling-out from the lung substance. On section, the surface was somewhat fibrous. In the portions of lung that I obtained there were also several smaller nodules, not larger than peas, and these were darker in colour, and, as it proved, hæmorrhagic. On the sharp margin of the lower lobe I found the long and solid cord-like outgrowths that I have elsewhere described, as well as faintly-marked leaf-like outgrowths on the concave pleural surface of the base. The microscopic examination of the larger nodules showed them to be composed of spindle-shaped or rod-shaped cells, which were regularly arranged in close decussating bundles, showing alternately, in the section,

observation applies to the small tubercle that I have figured on Plate IV. fig. 12; it contains even numerous vessels, but no giant-cells, and it may be said of many other nodules in the series of preparations that the giant-cells begin where the vessels cease, and that the necrosis or caseation exists where the giant-cells have been powerless to avert it. Rationally interpreted as vaso-formative cells, giant-cells are distinctive of bovine tubercles, from their numbers and their highly-developed type; and the epithelial-like cells, passing into multinuclear cells (fig. 15, Plate VI.), are equally characteristic of a decided tendency towards vascularisation, on the analogy of the perfectly similar epithelial-like cells passing into multinuclear cells that may be seen co-operating in the vaso-formative processes of the placenta (fig. 16, Plate VI.)

To return more particularly to the nodules in the lungs, I have spoken of them hitherto as purely interstitial connective-tissue growths. In some of the cases they certainly are uncomplicated interstitial tubercle-conglomerates, as in Cases 2 and 3, from which drawings (fig. 7, Plate III.; figs. 11 and 12, Plate IV.; and fig. 13, Plate V.) have been made; in Case 2 the air-vesicles near the nodules were either empty or they contained a number of red blood-corpuscles. But in four other cases in which whitish masses were found in the lungs, there occurred, besides numerous

the transverse view or the longitudinal view of the spindle-shaped cells. The forms of the cells and the interweaving of the bundles corresponded to what one finds often in sarcomatous tumours, and to the stroma of the normal ovary in some animals. Here and there in the microscopic section, there occurred regular round or oval spaces lined as if by an epithelium of small cubical cells. In some instances the appearance was that of giant-cells with the nuclei all on the margin, and the central substance more or less fallen out. (I had previously found this peculiar appearance in an extensive sarcomatous tumour growing from the fascia lata of the thigh in a boy aged twelve, and I referred to it in a paper in the *Journal of Anatomy and Physiology*, April 1880, on "Illustrations of the Pathology of Sarcoma" (p. 321).) The peripheral portions of the nodules were penetrated with numerous large blood-vessels full of blood, and the smaller nodules differed from the larger in having their spindle-shaped tissue as if infiltrated with blood. It was nothing but the sarcomatous character of the nodules that prevented me from classing the case among the twelve that I have reported; the naked-eye characters, and especially the peculiar outgrowths from the pleura, were all in favour of that view. Taking the movable nodule above the clavicle to be a lymphatic gland, there was nothing found that could be called a primary tumour, from which the nodules in the lungs might have proceeded, and the existence of the latter is most easily explained on the hypothesis of an infection from without.

interstitial tubercles, a wide-spread pneumonic condition of the air-vesicles. In Cases 5 and 6, which had the remarkable closed vomicae at the apex (fig. 9, Plate III.), the thick belt of tissue forming the walls of the vomicae was the ordinary embryonic connective tissue found in the interstitial lung-nodules, and giant-cells were not wanting; but the neighbouring air-vesicles were occupied by pneumonic or inflammatory products, the croupous form, with numerous threads of fibrin, being on the whole more conspicuous than the catarrhal form of swollen and detached epithelial cells; and I would even admit that some, if not many, of the whitish nodules that were seated as if on the periphery of the closed vomicae, or in the intervals between them (see fig. 9), corresponded to circumscribed groups of air-vesicles within which the exudative or catarrhal products had undergone necrosis. But Case 5 was, in other respects, as I have already said, "one of the most complete cases of the series;" and in Case 6 I found, elsewhere in the lung, uncomplicated interstitial tubercles in the tissue surrounding a large branch of the pulmonary artery. Again, Case 8 was complicated with a very general catarrhal condition of the air-vesicles all round the giant-cell tubercles, which did not, however, amount to a nodular formation; and the same remark applies to Case 10, in which the tubercles were very small and translucent. I have already mentioned that in Case 12 there were, in one of the lungs, two large and sharply-defined masses of grey hepatisation, one of them wedge-shaped. It is necessary to particularize these occurrences of coexisting pneumonia, so as to avoid appearing to ignore them.

On this point of coexisting pneumonia, the observations of Orth on the condition of the lungs, in the rabbits which he succeeded in infecting with the bovine tuberculous substance, are of the most direct interest. The infection attacked the digestive tract and lymphatic glands in most cases, and almost invariably the lungs and pleurae, peritoneum, kidneys, &c. The nodules in the lungs varied much in size, some being as large as a cherry. Tracts of air-containing lung tissue, usually of a deep red colour, occurred between the solid circumscribed nodules, the larger of which were grey in the periphery and opaque yellowish in the centre. The composition of the large nodules out of a number of smaller ones was very clearly made out round their

edges. In several lungs small cavities had resulted from the softening of the caseous masses, like the vomicae of the human lung, and, he might have added, like the still more numerous vomicae of the bovine lung. To meet the objection that the lung nodules were "nothing more than simple miliary pneumonias," he had a special investigation of them made under his direction, by one of his pupils, of which he gives the main conclusions. In the lungs, just as in other organs, there occurred nodular new formations which did not arise from the filling up of the alveoli; they were in parts of an obvious reticular structure, often contained very large cells, and, in several lungs, fine examples of giant-cells. They were nodules, therefore, that corresponded in all essential respects with those which he had previously described for the digestive tract and the lymphatic glands, as well as with those which he subsequently describes for the serous membranes, kidneys, and other organs; and they could on no account be regarded as "simple miliary centres of pneumonia." He continues:—"No doubt such undoubted tumour-nodules make up only the smallest part of the changes in most of the lungs; coexisting therewith, in greater amount, are inflammatory appearances, especially in the alveoli; in their lesser degrees these consist of swelling of the epithelium, whereby the alveoli return to an embryonic character, but in some cases the inflammatory changes are so extensive that wide-spread pneumonic hepatisations result. In consequence of this it is often quite impossible, in the case of the larger centres of disease, to decide whether any, or how much, of the changes present should be attributed to the formation of nodules. Just as in chronic inflammations of the human lung, and even in the chronic pneumonias of rabbits (Friedländer), there occurred manifold changes both in the walls of the bronchi and also in those of the vessels. In the one situation there was, for example, a typical growth of epithelium (Friedländer), and, in the case of the vessels, changes in the adventitia and in the intima. The changes in the vessels are partly referable to obliterative endarteritis, but they are also, in my opinion, partly to be considered tuberculous. The tubercles are seated partly in the adventitia, and have pressed forwards towards the intima; but they are in part confined to the latter, and are to be regarded as primary tubercles of the intima."

It is not part of my present purpose to go into minute questions of the histogenesis of the lung nodules, how far they are perivascular or peribronchial, or how they are related to the lymphatic system. This subject has been ably treated of and illustrated with admirable drawings by Klein in this country, in connexion with the lung-nodules in Guinea-pigs, which he describes as those of "artificial tuberculosis."¹ The same minute points of histogenesis might equally arise in connexion with the lung-nodules of glanders. There may well be points in common for the various kinds of pulmonary infection, when we come to the ultimate histogenesis; but over and above those matters in which infective processes in the lung agree, there are points, microscopic and other, special to each. It is with the latter that I have chiefly occupied attention in this chapter; and I would further stipulate that even those characters in the lung which I have endeavoured to single out as special to the bovine disease, may not be taken by themselves, but always in connexion with the less ambiguous associated formations on the serous membranes, described in the preceding chapter, and with the implication of the lymphatic glands to be described in the chapter immediately following.

¹ Klein, *The Anatomy of the Lymphatic System*. Part II.—"The Lung." London, 1875.

CHAPTER VII.

THE CONDITION OF THE LYMPHATIC GLANDS.

Lymphatic glands in the human body that are, to the naked eye, simply enlarged, and caseous or calcareous, are by no means likely at the outset to prove distinctive of that specific disease which I have already attempted to identify by means of the serous-membrane and pulmonary lesions. Caseous lymphatic glands have the misfortune to be so common, they enter so largely into the everyday observations of practitioners, that any attempt to discover in them traces of an outlandish specific disease cannot but appear, on the face of it, to be unlikely. Even those cases in which general tuberculosis has been found associated with caseous lymphatic glands, are subject to so fixed and conventional an explanation that we seem to have reached the ultimate truth about them. When a patient dies of general tuberculosis, it is the caseous bronchial or mesenteric gland that we point to with conclusiveness as the source of the tuberculosis. No matter how unaccountable the disease may have been in its onset, as in so many cases of general tuberculosis in previously healthy children; if the *post-mortem* examination discovers a caseous gland at the root of the lung or in the mesentery, the chances are that the practitioner will go away satisfied, feeling that the case has at least ranged itself beside many more of the same kind, and has somehow become a good deal clearer to him. There are naturally hypotheses current to explain the connexion of the caseous gland with the disseminated tuberculosis. The gland had undergone a simple swelling or hyperplasia, owing to some irritant process, such as catarrh, going on in the locality to which the glands respectively belong; but physicians would be sometimes puzzled to discover that there had actually been any sufficient preceding catarrh or local irrita-

tion, such as the hypothesis requires. Next, the swollen gland, instead of returning to its normal state, becomes caseous. That peculiar degeneration is accounted for by the scrofulous disposition of the individual; but there is no doubt that the scrofula is in many cases an afterthought, and that the patient had not shown the usual manifestations of scrofula during life. Lastly, the caseous detritus of the swollen gland is absorbed, and it is the absorption of it that has led to the disseminated tuberculosis. But our satisfaction with this familiar explanation would diminish if it were shown that the caseous gland itself is full of tubercles, just as the lungs are full of them and the serous membranes covered by them. That, however, is the conclusion that we are led to from the examination of the lymphatic glands in the cases above recorded. They contain the same tubercle-nodules that occurred on the serous membranes and in the lungs. It is probable that the formations in the lungs, in most cases, come last in point of time; but, in cases where the serous membranes and lymphatic glands are both implicated, it is practically impossible to say which of those two had been first affected. In the tuberculosis of the bovine animals themselves it is usually said that the serous-membrane eruption appears first, and then the nodules in the lymphatic glands. It is also said of the bovine disease that the lymphatic glands are little affected when the serous membranes are extensively covered by nodules, and *vice versa*. In the cases in man, there is probably a certain sequence observed in the spread of the infection within the body, although that sequence may not be the same in all cases. But, whatever be the order in point of time, there is sufficient identity of structure in the nodules on the serous membranes, in the lymphatic glands, and in the lungs, to show that these formations are all co-ordinate as the effects of a common cause, and their morphological characters are such as to point to the specific disease which is indigenous in the bovine species as being the source outside the body from which the common virus has issued.

The lymphatic glands were observed to be implicated in more than half the cases. In Case 10, which had by far the most abundant eruption of the large flat tubercles on the peritoneum, the abdominal lymphatic glands appeared to be perfectly normal. In Cases 1 and 6, their condition is not noted; in Case 4 there

was near the root of the lungs a large quantity of whitish substance like a diffuent tumour, which I took to be the bronchial glands, but did not preserve for examination. In Case 8 the bronchial glands were merely swollen and soft, and a microscopic examination did not reveal any well-defined tubercles; and in Case 12 no obvious change of the abdominal or thoracic lymphatic glands was observed. In all the other cases lymphatic glands were found which proved, on microscopic examination, to contain tubercles (with giant cells, &c.), and some of them contained isolated round nodules visible to the naked eye, or conglomerate tubercles. The most remarkable cluster of glands was found hanging down from the portal fissure in Case 5 (see notes of cases), and the bronchial glands in that case showed also the same condition. A coloured drawing of one of the latter in section is given in Plate III. (fig. 10); the section shows a number of yellowish round nodules, in size up to that of a pea, each with a well-defined margin or apparent capsule. The microscopic appearance of the same gland is given in fig. 14, Plate V.; the figure shows four distinct tubercles occurring close to each other in the follicular tissue. The tubercle on the left side of the figure is of the reticular sort, with a large giant-cell near the centre; the other three are more advanced towards caseation, though in varying degrees; and it is worthy of note that the uppermost tubercle was caseous throughout its whole extent, and that the only evidences of vitality in it were the two large giant cells which lay at its extreme periphery and in immediate contact with the neighbouring follicular tissue. In Case 11 also, where the whole abdominal and thoracic glands were affected in various degrees, a number of separate round centres could be seen with the naked eye in most of the glands, and some of these centres were so much softened in their interior as to resemble small abscesses. But in the other four cases the glands were for the most part caseous throughout almost their whole extent. It was only the thickened capsule and periphery of each gland, and the tissue joining the several glands, that retained their translucency and vascularity; and it was, generally speaking, only in these belts of translucent tissue that the traces of the small ultimate tubercles could be satisfactorily seen. Such less opaque peripheral portions of tissue contained giant

cells lying among embryonic connective-tissue cells, and there could be little doubt, on the analogy of the appearance shown in the upper part of fig. 14, that the marginal belts of tissue containing giant-cells and the other component elements of tubercles, were the peripheral portions of tubercle conglomerates which had become caseous throughout the greater part of their substance. In glands where the caseation is well advanced, the traces of tubercles will hardly be found elsewhere than in the more translucent peripheral belts of tissue; and that is perhaps the reason why Trasbot, writing on the disease in the bovine animals, asserts that the lymphatic-gland tubercles develop in the connective tissue that unites the several glands in a cluster (see p. 20).

Thus far the subject has been the detection of tubercles in lymphatic glands. Their histogenesis has also to be noticed, though very briefly. It is no doubt in the follicular tissue of lymphatic glands that the small ultimate tubercles first arise. Schüppel pointed that out, and it may be seen at a glance in sections of a gland in a tolerably early stage of invasion (fig. 14). The small circumscribed tubercles in the figure appear to be minute and sharply-defined portions of the follicular tissue undergoing a series of transformations, which may be otherwise described as a series of steps in the resistance to the general necrosis that will finally overtake the tubercles, all and singly. The giant cells and the epithelial-like cells associated with them are, as I have already argued from a perfect analogy in the department of physiology, the evidence of difficult vascularisation in a hyperplastic tissue. They are the only indications of vasoformative activity within the tubercle nodules, and their activity appears to be for the most part abortive.

While there are these evidences within the tubercle-nodule that its tissue is cut off from the general blood supply of the part, and that its elements, as if for self-preservation, are attempting to form themselves into new blood channels, it is a striking fact that the neighbouring tissue of the lymphatic gland is traversed in all directions by wide blood-vessels over-distended with blood. Two or three such vessels are seen in the midst of the follicular tissue occupying the left upper corner of fig. 14. The appearance occurs with much uniformity in the series of affected

lymphatic glands. If the vessels are nothing more than the pre-existing capillaries, these at least are enormously dilated, and in some cases the dilatation is so great that actual blood-filled sinuses or *lucunæ* result. The appearance of large blood-vessels traversing the follicular tissue, as in fig. 14, is not usually met with in the examination of healthy lymphatic glands.

Besides containing undoubted instances of small round tubercles, sometimes united (as in fig. 10, Plate III.) to form conglomerates, the lymphatic glands were distinguished by their occasional great size and their tendency to calcareous degeneration. The most remarkable instance of the two latter characters occurred in Case 9, where the mesentery contained one enormous round mass, as large as a hen's egg and as heavy as a stone; near it were a number of quite small mesenteric glands, also calcified throughout. Calcification was also observed in several of the abdominal glands of Case 11, in the very striking form of well-defined calcareous spots in the very centre of the gland. In the extensive cluster of portal glands in Case 5, one or two of which were as large as a hen's egg, calcification could not be asserted positively, but the glands were of extreme hardness, creaking under the knife.

Two characters that are often found in the lymphatic glands in bovine tuberculosis are the great enlargement and the tendency to calcification. But greatly enlarged and calcified lymphatic glands are not always found in the bovine disease; the glands may be only moderately enlarged, and the degeneration may be simply caseous. A third and more constant character of the bovine disease is that the lymphatic glands contain distinct small tubercles in their substance,¹ and that these are often united to form tubercle-conglomerates visible to the naked eye. The same characters were noted by Gerlach and by Orth in the kind of bovine tuberculosis which they induced by experiment. I have already quoted from the evidence of Gerlach (p. 22), and the following is from that of Orth:—"Lymphatic glands were found in seven out of nine cases of the induced disease, containing numerous yellowish caseous centres; in one case, a yellowish nodule of exceptional size enclosed in its centre a small spot of calcareous substance. In the microscopic sections, there ap-

¹ Schüppel, *Virchow's Archiv*, lvi. (1872), p. 52.

peared a grouping of the cells to form minute tubercle-like nodules. The cells composing the nodules were, generally speaking, several times larger than colourless blood corpuscles, with a large and sharply-defined smooth nucleus and an extensive body of cell substance, and, in fact, meriting the name of 'epithelioid' cells. Among them there lay, in several glands, giant-cells, round or elongated, often with broad or delicate processes, and with many nuclei often arranged in the form of a marginal wreath. The size of these cells, as well as their number, varied much, and it was easy to trace a succession of them down to the simple epithelial-like cells. There was often seen, round the largest giant-cells, a number of smaller but still multinuclear cells, which, again, were succeeded by the simpler epithelial-like cells."¹

Are these characters of the lymphatic glands in man good evidence of the disease being the communicated bovine tuberculosis? The difficulty of maintaining the specific quality of the bovine disease and the strict identity of the cases in man is nowhere more directly felt than here. Professor Schüppel published, in 1871, a work entitled *Untersuchungen über Lymphdrüsen-Tuberculose*, in which he gave an account of the minute anatomy of the caseous or scrofulous glands in forty cases observed at Tübingen in the space of about two years. In six of the cases the glands were extirpated by operation; in five fatal cases, all of them of young children, the lymphatic-gland affection was the chief feature and there was no general tuberculosis; twenty-one of the cases may be taken as cases of more or less generalised tuberculosis; five were old museum specimens; and of the remaining three, one was a case of retro-pharyngeal abscess, one a case of pyæmia, and one a case of "fibrous cancer" of the pylorus. The notes of the cases are limited for the most part to the morbid anatomy, and some of them are too fragmentary for judging of the case as a whole. In all of these glands (including, strange to say, the greyish-white fibro-caseous glands lying along the greater curvature of the stomach in the case of fibrous cancer of the pylorus) Schüppel found tubercles either commencing or in full development. From their study he

¹ Orth, "Experimentelle Untersuchungen über Fütterungs-Tuberculose."—*Virchow's Archiv*, lxxvi. (1879), p. 223.

arrived at that definition of tubercle which Rindfleisch adopts for "scrofulous tubercle," and which I have several times referred to. The tubercles contained at least one large giant-cell, usually in the centre, with epithelial-like cells in large numbers round about; they are precisely the same kind of tubercles that I have drawn in fig. 15, Plate VI. from the subserous thickening near a healed intestinal ulcer in Case 10.

In 1872 Professor Schüppel published an investigation on "The Identity of Tuberculosis with Perlsucht."¹ The paper contains an account of the microscopic structure of nodules from a tuberculous cow, chiefly of the large flat tubercles on the serous membranes, and, more briefly, of certain selected nodules in the lung, and of the nodules in a bronchial gland. The microscopic characters of the tubercles were practically the same in the three situations, although it is of the serous-membrane nodules that the full description is given; and those characters were precisely the same as he had described, the year before, for the caseous or scrofulous, and, in reality, tuberculous, lymphatic glands in man. But Schüppel goes much further, telling us, in so many words, that he had satisfied himself, by numerous examinations, that just the same kind of tubercle occurred also in all the other situations in which he had found tubercles in the human body; and he enumerates the lungs, the tracheal mucous membrane, the liver, the spleen, the testicle, the bones, the synovial membranes, the sinuses of tuberculous osteitis, tuberculous pericarditis, and tuberculous ulcers of the intestine.² After this sweeping stroke of identity we naturally look for a strong conclusion. But the conclusion merely is—"We are thus justified in designating Perlsucht as that anatomical form in which tuberculosis presents itself in bovine animals" (*loc. cit.* p. 53). This appears to be little more than the truism that the particular disease of cows and oxen which we call bovine tuberculosis is a form of tuberculosis affecting that species, just as there is a tuberculosis of the human species. Elsewhere, he speaks of the tubercle which he histologically defined, as being the "Urform" or primitive type of tubercle, reappearing, as it were, both in the bovine and in the human species. But if that is all that the "identity of tuberculosis and Perlsucht" comes to, it is perhaps a not very

¹ Virchow's *Archiv*, lvi. (1872), p. 38.

² *Loc. cit.*, p. 45.

profound discovery; bovine tubercle is like human tubercle much as the river in Macedon was like the river in Monmouth. All that Professor Schüppel can be got to say is, that "the result of his histological investigations cannot prejudice the question of the specificity of tuberculosis, or the question of the ætiological connexion between human tuberculosis and Perlsucht."

Not only is Schüppel's identity, on his own showing, quite harmless and neutral, but it is from the outset too narrow in its scope to be of any use. At the beginning of his paper he recognises frankly the striking naked-eye differences between the bovine tuberculous disease and tuberculosis in man. Chiefly following Virchow, he observes that Perlsucht is always primary on the pleura and peritoneum, whence it invades the lymphatic glands of the thorax and abdomen; more rarely it extends to the lungs, liver, and Fallopian tubes. Further, the pearl nodules, at least those of the serous membranes, are only to a small extent in the form of (miliary) tubercle, "as we see it in man;" for the most part, they are extensive nodules of the size of a pea, a cherry, or a potato, and these nodules have more resemblance to a fibrous tumour than to large conglomerates of tubercles, "as they appear in many organs in man." Still further, the larger pearl nodules of the pleura or peritoneum are not situated in or under the serous membrane, but they develop from a new-formed mass of tissue, finely villous and highly vascular, which grows out above the free surface of the serosa, and they are not unfrequently connected with the serosa by a thin stalk of connective tissue. "In spite of these differences," says Schüppel, "I do not hesitate to declare Perlsucht and tuberculosis to be anatomically the same." But these naked-eye differences are just the characters upon which veterinarians rest the specific quality of the bovine disease, and Virchow maintains its separateness partly on the same grounds. Another instance of the tacit disregard of striking differences is furnished by Carswell. Fig. 4 of Carswell's first plate illustrating "Tubercle" is a large drawing of the lung of a tuberculous cow, showing, in the section, a number of yellowish-white nodules, and cavities; and, on the pleural surface, a number of the larger (and rarer) pendulous pear-shaped masses. The figure, he says, "represents a portion of the lung of the cow, which may be said to present a panoramic

view of the seat of tuberculous matter, and the forms which it assumes in the human species, as shown in the preceding figures." Now, Carswell here speaks of the interior of the lung only, and he omits to mention, in that context, that the bovine disease has what (in his figure) the human disease wants, viz., a condition of the serous membrane which, in his own picture, is, to say the least, as prominent a feature as the condition of the lung substance, and which, in the estimation of the veterinarians of all countries, is the most obvious and not the least distinctive mark of the disease. If Carswell had figured a human lung which resembled the lung that he figures from the cow not only in its interior cavities and nodules, but also in its unique pleural outgrowths, would any one have doubted that the disease in and upon the human lung was the bovine disease, and that it was a case of tuberculosis contracted from the cow? The evidence that I have put together in Chapter V. is not so perfect as that evidence would have been, but it is the same in kind.¹ It is supported by the evidence as regards the lung itself given in Chapter VI., and I have still to show in this chapter how far the minute structure of the tubercles in the lymphatic glands in the recorded cases can be turned to the same account.

The minute structure of the tubercles is practically the same in all situations, although the large flat nodules of the serous membranes show the typical characters most uniformly; and I agree with Schüppel that the tubercle, with one or more giant-cells and with a large number of epithelial-like cells, is precisely the same tubercle that occurs in the bovine species, and in its most typical form in the nodules on the serous membranes. But I would simply add that argument from histology to the other and less complex evidence of morphological identity, taking the minute structure of the nodules as evidence *pro tanto* of the disease being the specific bovine disease. I do not understand how that evidence of identity can be used to bring down the bovine disease to the level of human tuberculosis, or to some primitive type (*Urform*, as Schüppel says) common to both, and, in the face of the striking and invariable naked-eye peculiarities of the former, to rob it of its specific character. The facts seem to me rather to point to a selection of certain cases of tuberculosis

¹ An additional case, with true pearl-nodules, is given in Appendix B, p. 115.

in man, as being cases of the specific bovine disease; and, in going through the cases upon which Schüppel bases his argument, one might single out several which have naked-eye characters not unlike those that I would regard as characteristically bovine. It is further significant that the tubercle with giant cells and epithelial-like cells (fig. 15, Plate V.) is by no means the common tubercle of authors, and that Rindfleisch qualifies his acceptance of it by calling it the "scrofulous tubercle."

The discovery of well-defined small round tubercles (such as I have drawn in fig. 14, Plate V.) in lymphatic glands that are commonly supposed to be merely caseous, and to be themselves the centre or focus from which a tubercular infection issues—this discovery has been interpreted by Schüppel (who first made it) in the sense that the lymphatic glands are primarily affected with tuberculosis, being especially liable to it, and that, in most cases of general tuberculosis, the tubercles of the various organs are referable to the primary tuberculosis of the lymphatic glands. But Schüppel does not suppose that the primary tuberculosis of lymphatic glands is an idiopathic disease, the source of which cannot be traced farther. He quotes with approval the words of Virchow: "The primary gland-tuberculosis is primary only as tuberculosis; as an irritative process it is not primary, but the irritant always proceeds from some focus or centre." The focus or centre is that locality from which the respective lymphatic glands receive lymph, and some inflammatory or irritative process is at work in it. Thus the primary irritation may be in the intestine, in which case the mesenteric glands become tuberculous; or it may be in the air-vesicles or bronchi, and then it is the bronchial glands which become the seat of tuberculosis.

Almost to the same effect is the opinion of Rindfleisch. Rejecting the doctrine that the essential change in lymphatic glands that become caseous is a purely hyperplastic one, and of an inflammatory kind, he says,—“I have satisfied myself, by repeated investigation, of the correctness of Schüppel's assertion that the 'scrofulous' gland is in all cases a 'genuine tuberculous' gland." The analogy that he would set up is that of tumour-infection of lymphatic glands, "only that we are not yet justified in calling the primary lesion tuberculous." The

primary lesion should only be called tuberculous when, in addition to scrofulous catarrh, for example, there is also a tuberculous ulcer of the mucous membrane. A tuberculous element might be sought in the catarrh itself; but that extension of the idea should be resisted, and the anatomically specific tubercle asserted only for the second stage of the invading disease, viz., the tuberculosis of the lymphatic glands. With this reservation, Rindfleisch speaks of a primary, a secondary, and a tertiary tuberculosis. By primary tuberculosis, he means local affections of the various organs of the body, affections in which scrofulous-inflammatory and tuberculous elements may be mingled, although often only the former are present. By secondary tuberculosis, he understands the tuberculosis of lymphatic glands. Under tertiary tuberculosis, he includes the disseminated tuberculosis of various organs not primarily diseased, namely, the liver, the spleen, the lungs, the kidneys, the serous membranes, the pia mater, the marrow of bone, &c. (*loc. cit.* p. 160).

Both Schüppel and Rindfleisch regard the tuberculosis of lymphatic glands as something in the causation intermediate between the scrofulous inflammation, or catarrh, or ulceration of a certain locality, and the general tuberculosis of which the patient dies. It is only when the disease reaches the lymphatic glands that it assumes, in many cases, the anatomically specific character of tuberculosis, and the tuberculosis so established in the lymphatic glands is the source of the infection through which the tubercles of the serous membranes, of the viscera, of the bones, &c. are produced. For the cases upon which I rest my contention of an infection from the bovine species, I find no reason to place the tuberculosis of the lymphatic glands in that causally intermediate position. In the first place, there was, as a matter of fact, no obvious inflammation or catarrh, scrofulous or other, which might be taken for the primary irritant. Secondly, the manifestations of the disease throughout the body were, in respect to its source, all on an equal footing or coordinate; in no organ or locality could the disease be said to be primary, while it was secondary elsewhere. The morbid products were doubtless of various ages; but one might as well argue, for a certain number of cases, that the tubercles of the

serous membranes were the primary as that those of the lymphatic glands had appeared first. But, whatever the succession in time, there is not the smallest ground for asserting a causal succession; no one set of tubercles were the cause of any other set, but they were all equally due to some common cause. The obvious suggestion is a virus introduced from without, and the closest analogy is syphilis. The tuberculosis in the cases herein recorded may, if necessary, be called primary, secondary, and tertiary; those stages are, however, not subordinate but co-ordinate, just as the primary, secondary, and tertiary manifestations of syphilis are co-ordinate with respect to the initial infection. In an important article by Klebs, the occurrence of tuberculosis is attributed in a general way to a virus or an infection from without, on the analogy of syphilis. With reference to the stages of invasion, he observes:¹ "If we set out from the point of view that tuberculosis, like syphilis, owes its origin to a virus, the virus may be considered to enter the circulation in a soluble form, and then we should have numerous centres of disease established; or there may be a storing up of the virus in the lymphatic glands, followed by long periods of relatively good health, until, from these organs as centres, an infection of the blood or of the neighbouring tissues should arise. What Virchow has so well shown for syphilis, would thus hold good for tuberculosis." The same parallel between syphilis and tuberculosis is stated by Cohnheim in the paper already quoted.²

The evidence as regards the condition of the lymphatic glands would stand, therefore, as follows. They are not merely swollen by an inflammatory hyperplastic process, afterwards becoming caseous or cretaceous, but they are in the first instance occupied by small microscopic tubercles and the conglomerates of tubercles, and the tubercles become caseous or cretaceous. The tuberculosis of the lymphatic glands is not the origin of the tuberculosis elsewhere in the body, but it is a co-ordinate part of a general infection. The

¹ Klebs, "Ueber die Entstehung der Tuberculose, und ihre Verbreitung im Körper."—Virchow's *Archiv*, xliv. (1868), p. 265.

² Cohnheim, *Die Tuberculose vom Standpunkte der Infectionslehre*. Leipzig, 1880, p. 36.

tuberculous or scrofulous lymphatic glands would thus lose the property that is so often assigned to them, of being the initial source or starting-point of the general tuberculosis; and, if the lymphatic glands are not that source, then there is no such primary starting-point of the disease within the body. All the manifestations of the disease within the body are on an equal footing as regards the origin of the disease, and that origin must be looked for, according to analogy, in a virus introduced from without. That the virus is the bovine tuberculous virus is made probable by the likeness in form and structure of the lymphatic glands in the cases in man, to the affected glands in the specific disease of the bovine animal, and by the fact that the disease of the lymphatic glands, both in the bovine species and in man, is associated respectively with the same structural processes in the lungs and on the serous membranes.

CHAPTER VIII.

THE INTESTINAL LESION.

The small intestine was affected in the three cases which I have placed last in the series. In two of these the intestinal lesion was recent, amounting in the one to little more than white medullary swelling of the lymphatic follicles ("psorentery"), with occasional ulceration of the follicles, and in the other to round ulcers of the ordinary tuberculous kind. But in the third case (Case 10), the circumstances are somewhat different and much more instructive, and it is chiefly to that case that I here direct further attention.

In Case 10, the patient, a married woman aged thirty-eight, from a village near Cambridge, had been in the hospital in August 1879 with typhoid fever. I have not succeeded in finding the notes of that illness, and it is therefore impossible to say whether the symptoms were in any way different from those of ordinary typhoid fever. Several other cases of typhoid were admitted into the hospital about the same time. The disease ran its course, and she was discharged and went home; but she never was quite well from the time of leaving the hospital to her readmission in March 1880. On her return to the hospital, the symptoms were at first distension of the abdomen, pain in the left inguinal region, &c. (see notes of cases). After a few days a regular rise of several degrees in the evening temperature began to be noted, and the symptoms of an acute infection, diagnosed as tuberculosis, continued till her death on the 20th April. Both lungs were full, from apex to base, of minute translucent tubercles. In the abdomen there was recent peritonitis, the intestines being glued together. Besides the recent peritonitis, there were old adhesions in the right iliac fossa, and a small quantity of fluid was sacculated in a space formed by the

adhesions. Chiefly in these adhesions, but also all over the peritoneum, there was an abundant eruption of large flat tubercles of about the size of a lentil. It at once arrested the attention that each tubercle was as if sparsely sprinkled over with minute black points, like powdered charcoal or coal dust. The lower part of the ileum contained two healed ulcers, which appeared as smooth shallow depressions, one of them half an inch in diameter, the other rather larger, amidst the villous mucous surface; a small spot of black pigmentation was visible on close examination in the extreme centre of each. The floor of the ulcer, or the cicatricial tissue, was an eighth of an inch thick, and on section was found to consist of a large number of distinct centres of new formation of the kind drawn in fig. 15, Plate VI. Only a few of the small tubercle centres were found in the sub-mucous tissue; the great bulk of the new formation was between the serous coat and the outer muscular. Each centre of new formation is a tubercle such as I have described several times before; it consists of large multinuclear cells, of epithelial-like cells with a single nucleus, and of numerous forms intermediate between those two. Sometimes the central substance is caseous, and then there are only two or three of the largest and most perfect giant-cells with close-set marginal nuclei, which occupy the periphery of the tubercle. Each of the large flat tubercles which lay (sometimes loosely) on the peritoneum both visceral and parietal, had precisely the same structure as the thickened floor of the healed ulcer, being composed of a number of contiguous but distinct centres of the same new formation. The pigmentation, about which there could be no doubt when the viscera were first exposed, was not apparent in the sections; nor, indeed, could it be detected with the naked eye after the parts had been preserved.

About the same time that I was examining this case, a case occurred of scirrhus cancer, secondary in a number of places, and starting apparently from the thickened base of a healed ulcer of the pylorus. There was a thickening under and around the smooth shallow depression of the mucous membrane of the pylorus, just as there was under and around the smooth shallow depression in the mucous membrane of the ileum; and the scirrhus case appeared to be a good analogy for the tubercular.

As the secondary cancer nodules had emanated from the infiltration of an old ulcer of the pylorus, having precisely the same structure as that infiltration, so the large flat tubercles of the peritoneum had emanated from the ulcers of the ileum. The pigmentation of the tubercles also seemed to point to the pigmented cicatrices of the intestinal ulcers. But that analogy may be easily pushed too far. For other purposes, a primary syphilitic sore is a better analogy for the primary ulcer of the intestine; the ulcer of the ileum must be supposed to have been charged with specific properties from the first, and these to have been communicated by a virus from without. They were originally the ulcers of typhoid fever, but in their healing, or in their subsequent induration, they retained the specific infective property which afterwards manifested itself in the general tuberculosis of the peritoneum, and still later in the acute miliary (or submiliary) tuberculosis of the lungs. The large flat tubercles of the peritoneum are such as I take to be distinctively those of bovine tuberculosis, and I do not hesitate to conclude that the original infection in August 1879, which ran its course as typhoid fever, was an acute attack caused by the introduction of the bovine virus.

The literature of typhoid fever and of tuberculosis contains a good many cases of the same kind, which have either been accounted for by various hypotheses, or have been passed over lightly (in the systematic treatises) as troublesome anomalies. I do not refer to the well-known difficulty, in many cases, of making the diagnosis between typhoid fever and acute tuberculosis; even if all the doubtful cases which recover are admitted to be pure typhoid cases, there are a considerable number of fatal cases which run the course of typhoid and die after a longer or shorter interval of tuberculosis.¹ In the case which I have described, the patient recovered from an acute attack of typhoid, and died several months after of a disease of a tuberculous nature, which was not a new disease, but a further development of the former. For such anomalous cases of typhoid fever and tuberculosis, I regard the doctrine of the specific bovine tuberculosis communicated to man as affording a rational explanation. I proceed to mention some of the more remarkable cases in the recent literature, to which the explanation may be applied.

¹ Curiously enough, this is still more the case in measles.

One of the most valuable pathological records of an extensive series of typhoid cases is that of the great Basel epidemic of 1865-67, published by Professor C. E. E. Hoffmann.¹ Among the 250 fatal cases enumerated in his conspectus of the *post-mortem* examinations, I find five put down as having miliary tuberculosis in the lungs and other organs. With reference to them, Hoffmann remarks, that the tuberculosis "is a sequel of typhoid, and always makes its appearance first after the proper typhoid process has run its course" (p. 279). His explanation of these cases is that an absorption of detritus into the juices of the body takes place from the seats of typhoid deposit. Quite distinct from these cases with "miliary tuberculosis," he found 38 cases which had small round grey nodules in the liver, and occasionally also in the kidney; these nodules had been already described by E. Wagner and by Friedreich, and are regarded as the specific products of typhoid in the liver. He further distinguishes from "miliary tuberculosis" a certain kind of nodules that were sometimes found on the serous coat of the ileum near the ulcers, and even on the peritoneum generally and on the pleura. It is to these cases that I wish more particularly to call attention. These nodules had already been noticed by E. Wagner,² who went so far as to say that they were found in all cases of typhoid, and belonged to the same class as the small grey nodules in the liver. Their occurrence is noted in only a few of Hoffmann's cases, and he gives a full record of four cases in which they were found. The nodules were of the size of hemp-seed or lentils, flat, of clear greyish colour, and sometimes of considerable density. They were seated on the peritoneal covering of the intestine in clusters corresponding in the first instance to the ulcerated patches of mucous membrane, but, if they once appear in considerable numbers on the serous coat of the intestine, "they often give occasion to more extensive inflammations, through which a multitude of such nodules may arise over great stretches of the peritoneum" (p. 68). Hoffmann's theory about them is, that they are extensions of diseased lymphatic follicles to the depth, or towards the serous surface, and he holds to that

¹ C. E. E. Hoffmann, *Untersuchungen über die Pathologisch-anatomischen Veränderungen der Organe beim Abdominal-typhus*. Leipzig, 1869.

² *Archiv der Heilkunde*, ii. (1861), p. 183.

view despite the want of correspondence between their structure and the structure of the diseased follicles. One of the cases is so like the case which I described at the beginning of this chapter that I shall give a brief abstract of the *post-mortem* appearances.

In the apices of both *lungs* are old and firm deeply pigmented cicatricial indurations, through which are scattered a small number of sharply-bounded tough yellowish-grey nodules up to the size of lentils. Over a limited part of the upper lobe of the right lung there are several hundred flat and not sharply-bounded small grey nodules on the *pleura*, which nowhere penetrate into the interior. Similar grey nodules on a part of the *pleura diaphragmatica*. A quantity of yellowish-brown fluid in both pleural cavities. Similar fluid in the abdomen. The *intestines* partly glued to the parietal peritoneum, the union intimate at some places. The *peritoneal surface* of all the viscera, as well as of the abdominal walls, is sown with flat, round, somewhat diffused, nodules of the size of hemp-seed or lentils. Close above the ileo-cæcal valve, a large cicatrix in the mucous membrane, having a delicate smooth surface, the tissue near it pigmented bluish black. Further up the ileum all the Peyer's patches are marked with points of bluish-green pigment and depressions corresponding. In the *liver* a large number of small grey nodules. In the *kidneys*, in the deeper parts, a small number of greyish nodules, in parts darkly pigmented, up to the size of millet seed.

This case is Hoffmann's tenth detailed case of typhoid fever. He does not even admit that the nodular eruption is tuberculosis as a sequel to typhoid, but he inclines to the opinion that these flat nodules of the serous membrane, found most commonly over the lower part of the ileum, but liable to extend all over the peritoneum and even to the pleura, belong to the specific manifestations of typhoid. But he cannot altogether agree with the opinion of E. Wagner, that they are a constant occurrence in typhoid. I do not doubt that these flat nodules of the serous membrane, which may be as large as lentils, of clear grey colour, and sometimes of firm texture, apt to be ill-defined at their margins, and, it may be, not more than half a line raised above the serous surface, are the same which I have described and figured as the more or less immature tubercles or pearls of *Perlsucht*. It is to be regretted that Hoffmann's account of their microscopic anatomy is too indeterminate to be used for the purpose of close comparison. However, it is partly on the ground of their minute structure that he refuses to admit them

as miliary tubercles. They consist, he says, "of a granular ground substance traversed by delicate fibres, in which cells and nuclei are deposited, sometimes in large and sometimes in small numbers. They show therefore the same structure as the nodules in the case of Griesinger,¹ according to the investigations of Rindfleisch" (p. 61). He promises further particulars in a subsequent part of his work, but the only other reference that I can find is on p. 108, where "the grey nodules of the serosa" are attributed to an infiltration or wandering of the overgrown cells of the lymphatic follicles through the interstices of the muscular coats and into the sub-serous and serous coats.

Under the title of "Tubercular Fever," Dr John Harley has recorded a group of cases that were under his observation at the London Fever Hospital.² He observes: "Medical authors, it is true, have noted the occasional association of tubercle and enteric fever, but they have all regarded it as a rare and accidental complication, or as a sequel arising from the debility caused by a prolonged attack of the enteric disease. The evidence which I lay before the reader will, I believe, be sufficient to convince him, not only that tubercle may form an actual component of enteric fever, but that fully developed enteric fever may be solely caused by the simultaneous eruption of miliary tubercle in the intestinal glands and in the lungs." In support of this position he gives thirteen cases, most of which appear to me rather to raise the old question of diagnosis as between "typhoid fever" on the one hand, and "acute tuberculosis" on the other. One of the cases was scarlet fever, with "psorentery" of the intestinal lymphatic follicles, and in the left lung, "tunnel-like ragged cavities" in the firm upper lobe, and in the lower lobe "numerous fine granules of yellow tubercle, some of which were confluent in masses the size of a pea." His tenth case, which was a typical case of typhoid, with rose-coloured spots on the abdomen, had also numerous small nodules in the lungs, which, he says, were equally typical of tuberculosis.

The most remarkable group of typhoid and tubercular cases

¹ *Infections-krankheiten*, 1864, p. 170.

² John Harley, "Tubercular Fever and its relation to Enteric Fever."—*St Thomas's Hospital Reports*, New Series, vol. iv. (1872), p. 63.

that I have found is that of Dr W. H. Spencer.¹ Upwards of twenty boys in an industrial school in Bristol fell ill with the same sort of illness; four of them died and the rest recovered. "Epidemics of illness and enteric fever," says Dr Spencer, "had occurred in the school many times before, and the circumstances always pointed to defects in the drains as their source. At length, after one of the later outbreaks of illness, the then old brick drains (found to be very defective), were replaced by new stoneware soil-pipes. When the next outbreak occurred, it was found that some of the new stoneware pipes had cracked, and the sewage had soaked out underneath the floor of a wash-place used by the boys. After the last outbreak—the one with which we are now concerned—an inspection of the place was made by the Sanitary Authority. It was then found that some blasting operations (necessitated by alterations to the school-house) had disturbed the connections between the drain-pipes, and that the sewage had again soaked out under the floor of the wash-place. I am told by the Medical Officer of Health that the defects then again, for the third time, discovered in the drains, allowed a free current of sewer-gas to blow into the building; that, in fact, the interior of the building was brought into direct and open communication with a very large portion of the sewer-system of Bristol. The Medical Officer of Health came to the conclusion that this last outbreak of illness in the school was one of enteric fever; and, under all the circumstances, his only wonder was that any of the inmates of the school escaped." The symptoms noted in all the cases were "malaise, headache, foul tongue, and gastric irritation; in some cases tenderness in the right flank and epigastrium, and in some cases diarrhœa; in all the cases fever. There were some twenty or twenty-five cases in all. Most of the boys got well under treatment. Four boys were more ill than the rest, and because of the severity of these cases, and because they were considered to be bad cases of enteric fever, the boys were sent to the Bristol Infirmary. In these four cases sent to the Infirmary the symptoms began in the same way as in the other slighter cases, and were similar, but the temperature from

¹ W. H. Spencer, "On Fever as a connecting link between Scrofula and Tuberculosis."—*Bristol Royal Infirmary Reports*, 1878-79.

the first was higher and all the symptoms were more severe." The age of the boys was from twelve to fourteen; death occurred from three to four weeks after the commencement of the illness. Now, what was the disease found *post mortem*?

Case I. had tubercles of the *arachnoid*; tubercles throughout the left *lung*; a patch of tubercles on the *diaphragmatic pleura* of the left side, tubercles on the *surface of the liver*, *surface of the spleen*, and surface of the right *kidney* (under the capsule); a caseous *bronchial gland*; and ulcerated *Peyer's patches*.

Case II. had tubercles of the *arachnoid*; both *lungs* full of tubercles; tubercles on the *surface of the liver*; tubercles in the *spleen* and *kidneys*; caseous *bronchial glands*; ulcerated *Peyer's patches*; tubercles in the *duodenum*.

Case III. had tubercles of the *arachnoid*; tubercles throughout the right *lung* and caseous mass at the apex; tubercles over the whole right *pleura*, and recent adhesions; caseous *bronchial glands* of the right side; ulcerated *Peyer's patches*.

Case IV. had tubercles of the *arachnoid*; tubercles (not numerous) throughout both *lungs*; tubercles all over both *pleurae*; *peritoneum of diaphragm*, *liver*, *spleen*, *intestine*, and *abdominal wall* studded with tubercles, and *melanotic in places*; tubercles in substance of *liver*, *spleen*, and *kidneys*; a caseous *bronchial gland*; ulceration of *Peyer's patches* and of the *follicles of the large intestine*. The mesenteric glands were not caseous, but enlarged and indurated in all the cases. Dr Spencer does not describe the tubercles more particularly.

This is a clear case of an *epidemic of tuberculosis* in upwards of twenty boys at an industrial school, the disease proving fatal in four cases only. The medical practitioner who had attended at the school for many years told Dr Spencer this fact: he had noted that when the boys of this school got enteric fever, and "it went hard with them," they almost invariably had tubercles when examined *post mortem*, and Dr Spencer had observed the same association in many cases of boys from the school admitted to the Bristol Infirmary "with febrile diseases of various kinds." Dr Spencer's theory is, that the original disease in the epidemic in question *was* typhoid fever, and that the tuberculosis was secondary; that the boys were all scrofulous, as shown by the existence of caseous bronchial glands, and that the fever was the "connecting link between scrofula and tuberculosis." He appears to think that the boys in that industrial school were generally scrofulous, and that their tendency to tuberculosis, as

manifested in repeated outbreaks of acute disease over a number of years, was the evidence of it. But why should the boys of an industrial school be habitually scrofulous?

I have quoted from the beginning of Dr Spencer's paper an account of defective drains, which will remind us of many sanitary reports that we have read before; there are our old enemies, the leakage of sewage and the escape of sewer gas, entering into the tale like the cock and the bull of romance. Leaking sewage and currents of sewer gas are no doubt unwholesome and sometimes even dangerous things, but had they anything to do with the epidemics in the particular industrial school? There can be little doubt that the boys were poisoned by a tuberculous virus, and the fact that the serous membranes and the lymphatic glands were uniformly implicated, although minute details are unfortunately wanting, points to the virus having been the bovine tuberculous virus, which might possibly have entered the school through inadvertence in the milk that was supplied to it. There are many tuberculous cows about, and as they get older their disease gets worse, and their secretions more abnormal. The milk of a cow well advanced in tuberculosis is probably unwholesome, although, fortunately, it becomes at the same time poor in quality, and unattractive to the discriminating milk-drinker.

Epidemics of typhoid fever are constantly taking place, in which the virus is conclusively traced to the milk from a dairy. But, on the part of all those who inquire into such outbreaks, there appears to be a fixed determination to prove that the virus which was in the milk when it was distributed, had come into the milk after it was taken from the cow. By way of explaining the outbreaks of typhoid fever that are traced to the milk supply, innumerable sanitary defects of dairies and of cow-houses have been pointed out, but, curiously enough, no one seems to have thought of the sanitary defects of the cow. We have had elaborate hypotheses of isolated cases of typhoid in the dairyman's household, of typhoid excreta carelessly thrown into the dung-heap, of the percolation of the typhoid poison into the well, of the water from the well taken to cleanse the milk-pails or to water the milk—in short, a chain of many links, and at least one link a hypothesis. When a case of extensive

typhoid poisoning through milk came into a law court the other day, the dairyman's counsel properly pointed out that the alleged percolation of sewage into the water was a physical impossibility, and that, as a matter of fact, his client did not water his milk. Even in those cases of typhoid milk-epidemics in which a case of typhoid fever is found among the inmates of the dairy-farm, it does not follow that the contamination of the milk—an enormous quantity of it, be it remembered, and over a long period of time—had come from that case. If the virus is in the milk as it comes from the cow, why should there not be cases of poisoning by it among the inmates of the dairy, as well as among the more distant customers of the dairy?

I am not in a position to bring forward any original pathological evidence that cases of typhoid infection traced to milk are cases of bovine tuberculosis. Pathological records of such epidemics doubtless exist, although I have not been so successful as to find them. Medical officers of health, and the medical inspectors of the central office, would add to their important services to the community if they were to relax somewhat the routine of their inquiries, and the fixedness of their theories, and give some attention, on the one hand, to the question whether unusually bad cases of tuberculosis may not exist among the cows of the suspected dairy; and on the other hand, to the question whether the bodies of those who die of the milk-typhoid, or of its sequelæ, do not show, even if it were only in occasional instances, those conditions of the serous membranes, of the lymphatic glands, and of the lungs and other viscera, which correspond, with certain allowances for the acuteness of the infection, to the morbid anatomy of the bovine disease. That cases of typhoid fever do occur, with nodular eruptions on the serous membranes, is sufficiently clear from the evidence that I have collected in this chapter. Do such fatal cases of typhoid occur among the mortality of an epidemic due to milk?

Of the three cases in my series that had the intestines affected, one was undoubtedly a case of typhoid, and it appears to belong to that class of typhoid cases of which instances are given by Hoffmann, E. Wagner, and Griesinger, and with which the series of cases recorded by Spencer may also be classed. Of the two

other cases in my series, the patient in one of them, Case 11, had had an illness, supposed to be acute rheumatism, three years earlier, and, eighteen months before, she was treated in Addenbrooke's Hospital for typhoid fever. On the latter occasion she was admitted under Dr Paget, on the 6th December 1878, the first symptoms dating from the 29th November. The onset of the disease was accompanied by headache, shivering, pain in the abdomen, epistaxis, loss of appetite, and thirst. Some rose-coloured spots appeared in the course of the illness. After she had been a fortnight in the hospital, the temperature appears to have fallen to the normal, both morning and evening. Discharged convalescent on the 22d January 1879. On her re-admission, in May 1880, or eighteen months after, the symptoms were at first those of acute rheumatism, and it was only after those symptoms had subsided, and a period of nearly normal temperature had intervened, that the symptoms of the acute infection, which ultimately proved fatal, showed themselves. The microscopic examination of the intestinal ulcers did not yield anything characteristic. I examined also the swollen follicles and the ulcers from the other case (Case 12), but there was nothing distinctive in the minute structure. But both cases were distinctively marked in other respects. I found, however, in a case which I have not included with the others, so distinctive appearances in the microscopic sections of the intestine, that I am inclined to rest a diagnosis of bovine tuberculosis upon them, just as I was led to suspect the presence of the bovine virus from the same microscopic characters in the tuberculous testicle referred to on p. 64. The patient was a boy, aged about twelve, in Addenbrooke's Hospital, under the care of Dr Humphry, with extensive scrofulous disease of the hip-joint. He died of tubercular meningitis; the head and neck of the femur were completely destroyed, and the place of the joint was occupied by flaky caseous substance. The small intestine (the only part of the organs which I saw) was occupied in its lower two or three feet with eight or ten round ulcers, which were remarkable for their deep red hæmorrhagic character. I preserved them with the greatest care, and they have yielded microscopic sections which show with remarkable clearness all those characters of tubercle which I have already dwelt upon;

the new formation was in some parts well preserved and vascularised, like granulation tissue, and in other instances, where the centre of the nodule was caseous, the periphery of it was occupied by giant-cells of enormous size, and with the most perfect marginal arrangement of rod-shaped nuclei. Some of these vaso-formative tracts were in the form of dense cylinders of closely-set nuclei, and they were occasionally branched or forked at one end. If there is a microscopic test for bovine tuberculosis, the intestinal ulcers in that case certainly answered to the test. Corresponding to the diseased portion of intestine, there were a number of large flat tubercles the size of lentils, situated in loose adhesions on the serous surface.

In Orth's experiments with rabbits fed on the tuberculous nodules from a cow, ulcers and nodules of the intestine occurred in seven out of nine cases. The minute structure corresponded with that of the new formations elsewhere in the rabbit, of which I have already given an account (pp. 66 and 77). The enormous giant-cells, with a multitude of nuclei regularly arranged on the periphery, and with a clear central area of finely granular protoplasm, figure in the intestinal lesion as they do in other situations, and in the same association with epithelial-like cells.

CHAPTER IX.

SUMMARY.

Perlsucht, or the pearl-disease of the bovine species, has a sufficient number of distinctive characters to separate it from all other diseases. The formations on the pleura and peritoneum are the main feature of the disease, and they are said also to be the earliest indications of its presence in the body of the animal. These formations of the serous membranes begin as soft vascular, villous-like outgrowths, which in course of time become consolidated, or develop nodules in their substance; and the nodules so formed are the pearls of the disease. They are often suspended as if on threads, being joined together by rounded cord-like processes proceeding from the poles of the nodules; they may become more or less confluent, and the confluent masses of nodules may grow to a great size, in which case they hang from the serous membrane by a stalk. Most commonly the pearl-nodules are about the size of lentils, and they may be even miliary and sub-miliary. The round or oval flattened nodules, of the size of lentils, are often found on the pleura or peritoneum in dense masses resembling the compact convex leaves of duckweed on the surface of a pool; hence the name of *Meerlinsigkeit*, by which the disease is known in the earlier German veterinary writings. While these tumour-like formations of the serous membranes have always ranked as the leading feature of the disease, it is generally admitted that the implication of the lymphatic glands is only second in importance as a constant character, and the "pearl-disease" has also been called the "gland-disease." The bronchial and mediastinal glands, and the mesenteric and retro-peritoneal are liable to be affected. They sometimes grow to an enormous size, from the formation of a number of nodules in their interior, and, like the pearl-nodules, they are liable to

cretaceous and cheesy necrosis. According to the best veterinary authorities, a cow with pearl-disease hardly ever escapes without disease of the lungs. The disease in the lungs takes the form of isolated nodules, mostly situated near the surface, which are made up of the confluence of a number of smaller nodules. These masses are sometimes found as if encysted or encapsuled, and when they begin to soften in the interior, the encapsulation becomes more marked. Closed vomicæ with thick smooth walls are another feature of the disease in the lungs; they arise from the softening of the encapsuled nodules, but they often communicate with the eroded end of a bronchus, and that fact has given rise to the mistaken opinion that the smooth-walled vomicæ of the lung in pearl-disease are portions of dilated bronchi. The lungs may contain, also, nodules much smaller, down to the size of a mere visible point. In a certain proportion of animals the disease extends beyond the serous membranes, the lymphatic glands, and the lungs, and attacks the intestine, the liver, the joints, the bones (bodies of vertebræ), the genito-urinary organs, and the udder. The new formation has, generally speaking, the same structure in all situations. That which at once arrests the attention in its microscopic anatomy, is the abundance of giant-cells; the most perfect of these elements have an enormous number of small round or oblong nuclei grouped along the sides, leaving a central space of granular protoplasm. The next most distinctive elements in the nodules are epithelial-like cells, which may have one or more nuclei, passing by transitions into the class of giant-cells. Those characters are best seen in the lentil-like nodules of the serous membranes. The new formations are liable to caseous and cretaceous necrosis; but they have a considerable power of growth, and they are often not ill-provided with blood-vessels, at least in their outer layers. Owing to their considerable degree of vascularity, the nodules of the pearl-disease have been compared to sarcomatous growths. There is, on the whole, much that is distinctive of this disease, and there is a certain unity in its various manifestations throughout the body of the animal. It may be said that the pearl-disease is to the bovine species what glanders is to the equine.

The pearl-disease of bovine animals has been communicated

to other animals by experiment. Prolonged feeding with the milk of a tuberculous cow, or with the actual pearl-nodules, has sufficed to set up a corresponding disease in the calf, lamb, goat, pig, and rabbit. The induced disease differs from the original disease of the cow in the important respect that the former is a somewhat acute infective process, whereas the latter, generally inherited, is of slow development. Corresponding to this difference in the intensity of the process, the morbid products in the cases of induced pearl-disease are not quite the same as in the indigenous bovine disease. They are not quite the same, but the identities of form and structure are sufficiently striking. Thus, although the serous membranes are, in the infected animals, seldom or never covered by pendulous nodules or conglomerates of nodules, they will be found on close examination to show traces of those soft vascular villous-like outgrowths which are known to be the early stage of the nodular formations. To use the convenient expression of Gerlach, they show "the beginnings of Perlsucht." The experiments which Orth made with rabbits did not result in producing a disease identical in every point with that of the cows from which the infecting material was taken; but the resemblance was sufficiently close to lead Orth to speak of the disease induced in the rabbit as "Kaninchen-Perlsucht." In particular, the microscopic structure is the same, and, on the crucial point of the vascularity of the new growth, Gerlach has noted a certain amount of evidence of identity. The implication of the lymphatic glands, also, is practically the same in the experiment-animals as in the cow. It is not difficult to suggest the reason why the induced disease as a whole is somewhat unlike the parent disease. In the disease communicated by the feeding experiments, the morbid process in the lungs seems to take precedence, owing to the mode of entrance of the virus, over that on the serous membranes. The latter is no longer the chief feature of the disease, but what there is of it is characteristic enough.

There is little doubt that the pearl-disease, modified only in the relative development of the process in the various organs, has been communicated to animals by experiment. There is evidence, also, that it has been communicated to animals by

accident. Has it ever been communicated by accident to man? There is no lack of reasonable presumption that it has. The analogous disease of the horse is now and then communicated to man; but we are brought into much closer contact with the bovine species than with the equine. Besides bread, there is hardly a more universal article of diet than cow's milk. There are many more tuberculous cows than there are glandered horses, and it would take a good deal to re-assure us that we do not sometimes partake of their tainted milk. Such arguments are plausible enough, but they do not prove that bovine tuberculosis ever has been communicated to man. I do not see how such communication ever can be proved, except by the evidence that the form and structure of morbid products in the human body are the same as those of the bovine pearl-disease. The preceding chapters are my contribution, such as it is, towards that not very easy proof. The obvious objection to the cases that I here record is, naturally, that we have known such cases for a long time, and have not called them bovine tuberculosis. But, if there is anything in the notion that bovine tuberculosis is communicable to man, the disease must be of long standing among human diseases, although it has never got into the nosology. Under what names, then, have we been speaking of bovine tuberculosis in the past?¹ First and foremost there are the sudden and unaccountable onsets of tuberculosis both in children and in adults. There is a growing conviction that such cases are due to the introduction of a specific virus into the body, and it is a question of morphological evidence whether, in any particular case, the morbid products are those that would be due to the specific bovine virus. It is the evidence of identity in form and structure that I have dwelt so much upon in this work; and I would claim no case of tuberculosis in man as a case of communicated bovine tuberculosis, unless I found on the serous membranes (especially on the sharp margins of the lungs, and on the under surface of the diaphragm), or in the lymphatic glands, or in the lungs, or in all these together, and occasionally in other parts and organs, those evidences both of form and minute structure which are

¹ References to some cases in the more recent literature which bear on this question are given in an Appendix.

distinctive of the bovine disease as it exists primarily and specifically in the cow.¹

The cases of tubercular peritonitis, tubercular pericarditis, and tubercular pleurisy, which every one must feel to occupy at present a very unsatisfactory position in pathological theory, appear to me to form one of the most likely groups of cases among which to look for instances of infection from the pearl-disease. There is even reason to think that still more characteristic instances of the serous-membrane new formations have occurred in the human subject, in the form of large pendulous nodules, and under the name of cancers.

There is much likelihood that some at least of the many things called scrofulous are manifestations in the human body of the specific bovine virus. No part of the experimental inquiry now going on under Virchow's direction at Berlin will be watched with greater interest than that which relates to the significance of the scrofula found in pigs which have been fed with substances from tuberculous cows. The result of those experiments will doubtless afford valuable indications as to the presence or absence of the same virus in particular cases of scrofulosis of the lymphatic glands, of the joints, of the genito-urinary organs, or of the brain, in the human subject.

Lastly, I have given, in Chapter VIII., certain reasons for thinking that bovine tuberculosis has sometimes appeared in man in the form of typhoid fever; and I have put the question whether the fatal cases in those epidemics of typhoid fever that are due to poisoned milk, have nothing in their morbid anatomy to suggest the pearl-disease of the cow. Certain it is that cases of typhoid fever, with flat nodules of the peritoneum, do sometimes occur.

The difficulty with typhoid fever, as with tuberculosis, which most naturally suggests itself, is that the disease is one and indivisible, and that it is exceedingly improbable that a certain proportion of cases, mixed up with and not clinically distinguishable from the others, should be cases of bovine tuberculosis. Typhoid fever is, without doubt, propagated in the larger

¹ Klebs (Virchow's *Archiv*, xlix. (1870), p. 291) observes that "the new formations of *Perlsucht* represent only a special development of tubercle, which corresponds in all points with the so-called *fibrous tubercle* of man."

number of cases from pre-existing cases of the same disease in the human subject; but is it altogether inconceivable that an acute infective process, not distinguishable from typhoid fever, should be set up in isolated cases by the bovine tuberculous virus? In like manner, if tuberculosis in man is an infective process, and in many cases propagated (as able pathologists believe) by infection within the human species, is it not conceivable that it may, in some other cases, be imported direct from the cow?

In the chapter on the lymphatic glands (Chapter VII.), I have contended that the best analogy for the bovine tuberculous virus is, in some respects, the virus of syphilis; and I quoted the opinion of Klebs that, as in syphilis, so in infective tuberculosis, the stages of invasion may succeed each other rapidly, or may be separated by long intervals. Those cases in which the lymphatic glands are most affected would be the most chronic, and those cases in which the virus reaches the pulmonary circulation most directly would be the most acute. The virus would probably enter the body in the great majority of cases by way of the digestive tract; but it must often be absorbed from an intact mucous membrane. When ulcers of the intestine do occur, they are not always the primary seat of the disease in the body.

Like other kinds of virus or animal poison, the virus of the pearl-disease must be considered to vary much in intensity, and to be uncertain in its action. The variations in its intensity, and the uncertainty of its action, would depend partly on the inherent qualities of the particular virulent substance, and partly on the predisposition of the individual who is subject to its action. Its effects are probably slight in many cases; and even if the onset is attended with fever and the symptoms of an acute infection, the attack may be recovered from. According to the observations of Orth on rabbits, it required the administration of considerable quantities of the tuberculous substance, and a period of not less than three months, before the disease could be communicated in a well-marked form (p. 65).

The doctrine of a tuberculous virus was stated by Klebs in 1868, and has been advocated by him, as well as by Cohnheim, in recent writings.¹ In its latest form, this doctrine asserts the

¹ Klebs, *Prager Medicin. Wochenschrift*, 1877, No. 72.

existence of a specific minute organism to whose agency the infection is due. The minute organism is called by Klebs *Monas tuberculosis*. The method of proof which I have followed in this work makes it impossible that the infective agency of a minute organism should in any way come into my view of the communication of bovine tuberculosis to man. I have rested the whole case upon certain minute identities of form and structure in the infected body, due to the mimicry of infection. Among other points, there were the leaf-like and cord-like outgrowths of the pleura and peritoneum, these being the early stages of the lentil-like or pearl-like nodules and their connecting threads; the lymphatic glands, with distinct nodular formations in their substance; the lungs, with smooth-walled closed vomice or with encapsuled nodules. In the new formations generally there was a particular pattern of microscopic structure, in which giant-cells and epithelial-like cells figure largely, and there was a relatively high degree of vascularity. In all these points the disease in man is a mimicry of the parent disease in the bovine animal. That mimicry is not only in single features, but it is of the whole disease. It is possible to conceive of the juices and particles of the primarily diseased body acquiring a kind of spermatic virtue, which gave them the power to communicate the specific disease as a whole and in all its several manifestations to another body in which they should happen to lodge. But it is hardly possible to think of a neutral living organism being charged with the power of conveying so complex details of form and structure from one body to another.

APPENDIX.

A.

GIANT-CELLS AS VASO-FORMATIVE CELLS.

(Extracts from two Papers in the *Journal of Anatomy and Physiology*, Jan. 1879, vol. xiii. p. 173, entitled "Further Observations on the Formation of the Placenta in the Guinea-Pig," and "The Physiological Type of the Giant-Cells of Tubercles and Granulations," by C. CREIGHTON, M.D.)

"In a former paper on the formation of the placenta in the guinea-pig (this *Journal*, vol. xii. 1878), I described, in the fifth and concluding section, the remarkable secondary or additional placental organ that grows up in the form of a semicircle of villi in an interval at the back of the discoid placenta. . . . The formative processes in the deeper layers of the guinea-pig's uterus are somewhat unexpectedly found to supply a physiological type for the cellular phenomena that are characteristic of tubercles and certain kinds of granulations. Both the periodical sexual process and the pathological processes exemplify that somewhat feeble or imperfect vaso-formative activity of tissue, which is associated with the production of giant-cells. I shall, for convenience, give my observations on that subject, in the paper that follows this, under a separate title. . . .

"Although the secondary or additional portion of the placenta is widely different in appearance from the earlier, it owes its origin, as I have already observed, to a continuance of those vaso-formative processes that resulted in the building up of the discoid body. There is no break in the continuity of the histogenetic process; but there is a more or less abrupt break in the continuity of the matrix tissue.

"The discoid body is formed by the adaptation of the rich and succulent perivascular cells of the sub-epithelial region to become the formative cells of a new system of vessels, superseding the original capillaries of that region. The new vessels have thick walls of nucleated protoplasm, and their terminal or capillary loops form ridges or bud-like outgrowths of spongy substance (see Section 4 of former paper). These adaptive changes proceed from the epithelial surface to the deeper parts, and at length the circular muscular coat is reached. It is when the hyperplasia and the subsequent

adaptive changes reach the nearest strata of plain muscular fibres that the vaso-formative process assumes a new character. The approach to a different kind of matrix tissue does not probably explain of itself the extraordinary demarcation of the discoid placenta from the villous semicircle; in my former paper (pp. 574 and 586), I pointed out that the remarkable invagination of the blastodermic membrane appeared to have the effect of defining the discoid form of the first placental growth. But it is the invasion of the muscular coat and the associated differences of vessel-formation that I am now solely concerned with.

“The explanation of the peculiar secondary placenta of the guinea-pig is, from one point of view, to be sought for in the fact that the deeper tissues of the uterine wall, from whose hyperplasia it is derived, differ in important respects from the tissues nearer to the epithelial surface. . . .

“When the decidual hyperplasia begins, the round or spindle-cells of the sub-epithelial tissue swell up, becoming large, spherical, or cubical elements with a central nucleus and a large zone of clear protoplasm. They are found at the same time to have attached themselves more definitely to the walls of the parallel and radial capillaries, and the whole sub-epithelial tissue becomes in the most obvious manner a perivascular tissue (see fig. 4 of the former paper). This tissue is, in the nature of things, as highly vascularised as any tissue can be. In the subsequent course of the placental formation, the perivascular cells aggregate themselves in rows to become the vaso-formative tracts of a new system of vessels, superseding the original capillaries; they form the walls of the new vessels, and, as the walls of the new vessels, they retain their whole thickness of protoplasm. It is not necessary to repeat here the description that I have given of these thick-walled vessels, or of the spongy protoplasmic substance which represents their terminal expansions and which constitutes the bulk of the discoid placenta. The above resumé will enable me to contrast the process of new formation in the deeper layers.

“The same hyperplasia that showed itself first in the layers immediately beneath the epithelium, extends after a time through the whole thickness of the sub-epithelial stratum, and at length reaches the cells of the circular muscular coat. As early as the fifteenth day the muscle-cells are found to be enormously enlarged, and the somewhat slender staff-shaped nucleus has swollen to an enormous bulk, assuming at the same time an oval or spherical shape. The degree of hyperplasia is no less in the deeper strata than in the superficial; and, up to a certain point, there is a close resemblance between the swollen individual cells in the two regions. The line of demarcation between the sub-epithelial stratum and the muscular stratum continues in the hyperplastic state much the same as in the resting or relaxed condition. In both conditions, the demarcation is not so much in the change from one shape or character of cell to another, but by reason of the greater compactness of the muscle-cells, of the general circular disposition of the stratum, and of the transverse direction of the blood-vessels through it. The sub-epithelial tissue readily assumes the character of a rich perivascula

tissue, which again no less readily becomes the vaso-formative tissue of the placenta. Being a perivascular tissue it is vascularised to the highest possible degree. On the other hand, the muscle-cells stand in a very different relation to the blood-vessels. The radial vessels, while traversing these, may be called transmitting vessels on their way to the region of their distribution or their capillary territory, viz., the sub-epithelial stratum. The muscular layer is clearly separated from the sub-epithelial layer, if not by the character of its cells, yet by the nature of its blood supply; and the wide divergence in external form between the placental formations in the two regions, depends in a great measure upon the different conditions of the matrix tissue as regards vascularity. The explanation of the peculiar destiny of the hyperplastic cells in the deeper strata lies in this, that it is a *hyperplasia taking place in a region inadequately supplied with blood*. The blood supply is disproportionate to the growth of tissue. The most singular effect of that disproportion is the abundant production of the large multinuclear blocks or masses of tissue known as giant-cells. I have now reached the point where the illustrations come in.

“Fig. 1¹ represents a group of cells of the circular muscular coat, showing all gradations from somewhat elongated elements with a single nucleus to large cubical or spherical masses with many nuclei. These cells are drawn exactly as they lie in the preparation, and they may serve, without further explanation, to show the origin of the giant-cells of that region from the hyperplasia of the ordinary cells of the tissue. Fig. 2 represents a much more complex condition of the deeper placental area, including the circular muscular coat. Beginning at the lower side, there is seen a portion of the circular muscular coat, no longer distinguishable as such owing to the great enlargement of its cells. The hyperplasia of the cells is frequently observed (in other preparations) to be greatest round about a blood-vessel; in such groups of muscle-cells, the nuclei may reach an enormous size without dividing. Beyond the crescentic belt of hyperplastic muscle-cells in the figure, multinuclear masses begin to appear. They are of various sizes and shapes. Very commonly their nuclei (which are small beside those of the cells with a single nucleus) are arranged in close order along one side of the cell, or round a part of its periphery, or, it may be, round the entire periphery; but they sometimes occur scattered irregularly throughout the substance of the cell. On the right hand side, the multinuclear masses are elongated, having a radial direction towards the upper surface. In the same part of the figure, they have the appearance of being continuous outgrowths of the enlarged muscle-cells of the deeper layer. Towards the left side of the figure, there are two larger multinuclear masses, one of which is excavated and has a dense cluster of nuclei exactly opposite the excavation. To the right of it, there is a blood-space, filled with red corpuscles, and having its boundaries indicated here and there by deeply-stained elongated nuclei.

“What, then, is the special significance of such multinuclear masses in

¹ This figure, somewhat extended, is introduced in Plate VI. (fig. 16).

that region? The answer to this will be partly found in tracing their further development. It must be admitted at the outset that they have not all the same destiny. There is sufficient evidence that some of them become excavated so as to form portions of blood-sinuses, their marginal nuclei forming the wall of the sinus. Two cells showing that transformation are represented in fig. 3; in *b* it is conceivable that the peculiarly tinted and coarsely granular protoplasm would break up into a mass of red blood-discs. The most usual adaptation, however, of the giant-cells to become vaso-formative cells is somewhat different. The blood-channel is not usually formed in the centre of one cell, but it is an intercellular passage bounded by the close-set nuclei of two contiguous giant-cells. Many of the multinuclear masses have their nuclei only along one edge or side, and the nucleated sides of two such cells, coming into near apposition, form the nucleated walls of a blood-vessel. The non-nucleated protoplasm of the cells then appears to decay. Following the rows of red blood-corpuscles from the deeper strata, they may be often observed to lie in the clefts between the cells; as the vaso-formative process advances, such intercellular clefts become blood-channels with definite nucleated walls. Two such blood-vessels, with deeply-stained nuclei, are drawn in the upper part of fig. 2. It will be observed, also, that the multinuclear mass below them has a dense cluster of nuclei on the side next to the vessel; that cluster or row of nuclei becomes in its turn the limiting or defining wall of another blood-channel, the new channel being the space between the marginal row and the independent blood-vessel already mentioned. Thus the lower side of the latter serves as a wall common to two blood spaces, and is, in fact, a mere partition in the midst of a common vascular tract.

“Such vascular tracts, made up of a number of parallel blood-channels having their walls in common, are very characteristic of the deeper region of the guinea-pig's placenta, and especially of its secondary and cotyledonary portion. One of them is represented in fig. 4. When it is followed upwards towards the surface, it runs into villus-like processes such as those drawn in fig. 5 (under a somewhat lower power). These villus-like processes are taken from the semicircular row that constitutes the peculiar secondary or cotyledonary placenta. Their margins and their free extremities contain close-set nuclei, but their interior is a nearly uniform expanse of granular protoplasm. At the lower end, however, there occur linear rows of nuclei in its midst. These are the terminations of the parallel nucleated septa of the vascular tract already described; the rows of nuclei come to an end gradually in the granular protoplasm of the villus or cotyledon. Blood is also seen here and there inside the villus, not contained in definitely bounded spaces, but rather in the sponge-like protoplasmic substance. . . .

“The contrast between the vaso-formative process in the deeper layers and in the more superficial is easily stated. In the surface strata the large perivascular cells become fused into vaso-formative cords, each cell retaining its individuality up to a particular point. In the deeper layers the vaso-

formative elements are multinuclear blocks or masses, and the walls of blood-vessels may be said rather to be carved out of a matrix-tissue of nucleated protoplasm. The linear pieces of tissue are those most serviceable for the new blood-vessels. The more cubical or spherical masses are found in the intervals between the linear vascular tracts, and they very frequently undergo necrosis. The hyperplasia in the deeper layers may be looked at from two points of view,—firstly, as a means towards a definite end, viz., the production of another type of placenta; and, secondly, as exemplifying the spontaneity or natural behaviour of the cells of the region under the stimulus of the periodical sexual hyperplasia. Confining the attention solely to the latter aspect of the case, one observes, first of all, a tendency to the formation of multinuclear masses of tissue, and, in the next place, the decay or necrosis of the greater number of the multinuclear masses so formed. Those that survive do so by virtue of becoming the walls of blood-vessels; and those that decay incur that fate because they are left on one side by the vascular tracts forming throughout the region. The formation of multinuclear masses, instead of a multitude of small independent cells, appears to depend on the circumstance, that the vascular supply of the region is inadequate to the degree of the hyperplasia. The subsequent changes in the multinuclear masses exemplify one or other of two things; they show either the successful effort of the hyperplastic tissue to vascularise itself, or they show its failure to do so. There is, in fact, a selection of some of the elements to form vascular tracts, and the decay of those not selected. The giant-cells, or the portions of them that enter into the formation of a blood-sinus, do not decay. But for the giant-cell that does not participate in the vaso-formative process, there is no other alternative but to become caseous, or otherwise to break up into detritus from want of nourishment. Some of the giant-cells, as I have mentioned, contribute to form one side of a blood-channel, as in fig. 2; while others appear to become excavated so as to transmit the blood through their midst, as in fig. 3, *b* and *c*. . . . The position of the excavated mass in the line of the blood supply, or the adaptation of its cavity as a portion of a blood-channel, is the special concurrence of means to end, through which those masses play an intelligible part in the normal process of building up the placenta.

“In the foregoing pages I have described the occurrence of giant-cells in the placental area of the guinea-pig’s uterus, and I have endeavoured to arrive at the circumstances under which they occur. They are derived from the ordinary cells of the deeper strata (muscular) of the uterine wall, apparently by the intracellular subdivision of the original single nucleus. The particular form of periodical uterine hyperplasia, which leads to the formation of giant-cells, occurs in the denser and less vascular region of the circular muscular coat; the sub-epithelial tissue, which contributes most to the building up of the placenta, is looser in texture and much more perfectly vascularised, and it is not the seat of giant-cell formation. Its cells, after remaining for a time as perivascular cells, become vaso-formative

cells; and that is also the destiny of the giant-cells in the deeper region. In both situations the hyperplasia of the tissue is followed by the production of new vessels. It may be said that the pre-existing vessels are inadequate to the nourishment of the greatly over-grown tissue. However that may be, there is soon observed a process of formation of new and larger vessels throughout the entire region of hyperplasia. The cells that go to form the new vessels are the hyperplastic elements themselves, and the peculiarity of the placental new formation is, that it consists simply and solely of thick-walled vessels, and of the spongy or cavernous protoplasmic tissue which represents their capillary territory. The hyperplastic cells become vaso-formative cells; and those of them that do not share in the vaso-formative process undergo either a change into mucous-like fluid, or into granular or caseous detritus. The decay of the cells in the intervals between the newly formed vascular tracts is obvious both in the superficial layers and in the deeper. It takes place most extensively in the latter, which is the region of giant-cells, and these multinuclear elements are constantly found in various stages of necrosis or breaking-up.

"The giant-cells of the placenta resemble in form and general characters the giant-cells of tubercles and other morbid products, and they appear to me to furnish an almost perfect physiological type or analogy for the pathological giant-cells. The latter have been considered by certain writers, whom I shall proceed immediately to quote, to be vaso-formative cells, on the evidence derived from the pathological conditions themselves. Whatever physiological analogy has been sought for them, has always been looked for in the vaso-formative processes of the embryo, and no complete correspondence has been found therein. But the vaso-formative processes in the uterine wall, which result in the building up of the placenta, are recurring periodical processes in the adult, having the mature tissues for their basis. It is not surprising, therefore, to find that the correspondence with the pathological vaso-formative phenomena is very much greater. Further, the differences between the new formation of vessels in the superficial and in the deeper strata of the guinea-pig's uterus, correspond to certain differences between one kind of granulation-tissue and another. Both in the normal and in the pathological cases, giant-cells appear to be the index of hyperplasia associated with feeble or imperfect vascularity. . . .

"I have given in fig. 7 three cells showing the vaso-formative agency of giant-cells. The cell *a* is from the peripheral zone of a large caseous tubercle (so-called solitary tubercle) of the choroid plexus in a case of caseous osteo-myelitis of vertebræ, caseous or scrofulous or tuberculous testicle, numerous large tubercles of the pia mater, and especially of the interior of the cerebellum, and smaller miliary tubercles of other places. The brain tubercles were opaque and caseous in the centre, but with a narrow peripheral zone of translucent or non-caseous tissue. In the peripheral zone were numerous blood-channels, and it was not difficult to find here and there elongated multinuclear masses, such as in the figure, that were obviously on the way to become portions of the vascular channels. The cell *b*, from a

tubercle of the spleen in a case of acute miliary tuberculosis in an adult, shows equally well the marginal arrangement of the nuclei; the giant-cells in the particular spleen-tubercles had a greater resemblance to the sections of blood-vessels than any that I have seen, owing to the very regular and close order of their nuclei round the margin, and owing also to the very granular and yellowish appearance of the cell contents, suggesting a mass of somewhat broken-down red blood-corpuscles. The cells *b* and *c* of fig. 3 are illustrative cases from the placenta, where the vaso-formative agency of the giant-cells was put beyond doubt by the large amount of collateral evidence.

“The vaso-formative giant-cells of the placenta may be represented as the fortunate members of their class, which have happened to lie in the direction of the blood-stream, and have been adapted to form one side (in most cases) of a new-formed blood channel. But the greater number of the multinuclear masses in the placenta undergo a necrotic or caseous decay. Between the vascular tracts crossing the deeper layer of the placenta, are found numerous large opaque masses, in the better preserved of which the outlines of their many nuclei may be still visible. The same juxtaposition of vigorous and decaying giant-cells may be observed in the large caseous tubercles of the brain. In the narrow peripheral and vascularised zone, one sees multinuclear masses with the appearances of vitality, and to a certain extent advanced in the vaso-formative process; while, in the wide area of caseous substance which forms the centre of the tubercle, opaque masses may be seen, and even their marginal brood of nuclei may be sometimes made out indistinctly. The caseous giant-masses in the centre of the tubercle are those that have failed in the vaso-formative effort; and the caseous or necrotic giant-masses in the placenta are those that have been passed by in the selection of the vascular tracts. If we have regard only to the spontaneity of the cells, and not to the vaso-formative process as an end, it may be said that those giant-cells which lie in the track of the blood-stream, or which develop a fluid within themselves, are in a position to survive, and ultimately to confer on their many nuclei their long-delayed independence. In other giant-cells, the more or less perfect marginal arrangement of the nuclei marks the degree of success, if one may so speak, that has attended the effort towards vascularisation. Those hyperplasias that are characterised by the presence of giant-cells, are hyperplasias that have advanced out of proportion to the blood-supply of the part; and the new-formed nuclei, instead of becoming at once independent, have remained within the circuit of the parent-cell, and have so formed a giant-cell. The best illustration of that statement is found in comparing the hyperplasia in the highly vascular sub-epithelial stratum of the guinea-pig's uterus, with the later and equally intense hyperplasia in the less vascular region of the circular muscular coat. The blood-making power and the blood-vessel-making power of the latter region are inadequate to the formative activity that has been set up. So it happens that in a scrofulous subject the issue of an inflammatory hyperplasia is not the safe issue of cicatricial tissue, but

the dangerous issue of local tuberculosis.¹ The local inflammation takes on a formative instead of a healing character, and the formative issue of the local inflammation appears to be at least one circumstance that determines the infectiveness of the tubercles.

"If rapidly growing secondary tubercles in the serous membranes and in the viscera are found to contain giant-cells, the occurrence of the latter may be set down to that law according to which all secondary new growths (or products of infection) resemble the primary in the details of their structure. Giant-cells, which in local tubercles mean hyperplasia with defective vascularity, signify in secondary tubercles nothing more than mimicry of the primary or infecting nodule.

"The remarkable resemblance, both in structural characters and in the circumstances of their occurrence, between the latter or deeper hyperplasias in the formative processes of the placenta, and various local inflammatory hyperplasias that take on the form of tubercles, affords an illustration of that inspiring doctrine of the cellular pathology, that 'even the heterologous tissues have physiological types.'"

B.

ABSTRACTS OF CERTAIN PUBLISHED CASES OF TUBERCULOSIS.

I give here the references to, and short abstracts of, a number of cases from the current medical literature, which may be read beside those treated of in the text. These cases have been for the most part published by the respective authors as exemplifying the anomalies of tuberculosis or its relation to other diseases.

VIRCHOW, "Ueber die Beziehungen des Typhus zur Tuberculose," reprinted from *Wiener Medicin. Wochensch.*, 1856, Jan., Nos. 1 and 2, in his *Gesammelte Abhandlungen aus dem Gebiete der Oeffentlichen Medicin.*, 2 Bde. Berlin, 1879; Bd. i. p. 418.

The case upon which Virchow's observations are based was reported by E. Hæckel, now Professor of Zoology at Jena, and gave rise to a controversy. The patient, a woman aged thirty, had morbus coxæ (head and neck of right femur completely destroyed). Admitted for an acute attack, with typhoid symptoms. Ulcers in the *ileum*, and *mesenteric glands* simply swollen. Indurations and caseous deposits in the apex of both *lungs*. A number of flat, round, greyish-red tubercle nodules on both *pleural surfaces*, and especially in the adhesions between them. These formations of the lungs

¹ When this was written, I was inclined to hold the opinion that tubercles might form in the body after the manner of primary tumours, and, like tumours, give rise to a general infection.

and pleuræ were of old standing. But there was recent or acute miliary tuberculosis of the *pia mater*. The question whether the intestinal ulcers were tuberculous or typhoid is discussed at length.

C. E. E. HOFFMANN, *Untersuchungen über die Pathologisch-Anatomischen Veränderungen der Organe beim Abdominal-typhus*. Leipzig, 1869.

The 69th case of "Typhoid," p. 279. In both *lungs* large numbers of small grey and yellow nodules, sometimes conglomerate, in parts softened, so as to form at certain places, especially the apex, small caverns up to the size of a cherry-stone quite filled with somewhat firm greyish-yellow detritus. *Mesenteric glands* enormously enlarged, forming in the ileo-cæcal region a packet as large as the fist. Single glands the size of a hen's egg; reddish yellow on the surface from injection of vessels; dense texture, occasionally softened in the centre. Ulcerated condition of the lower part of the *ileum*. Adhesions between liver and diaphragm at several points; *capsule of liver* thickened at these points, and occupied by numerous small round and yellow nodules. In substance of *spleen*, 20-30 yellow cheesy round nodules, from size of a pea to that of cherry-stone. Small grey nodules in *kidneys*. In *brain*, grey and yellow nodules up to size of lentil in fissure of Sylvius; a nodule the size of a pigeon's egg in thalamus opticus.

The reasons for including this case as one of typhoid fever are not stated.

The following anomalous cases are enumerated in Hoffmann's conspectus of the Basel epidemic:—

No. 145.—Ill since 18th Jan.; death on 24th April. Healed pigmented ulcers in the ileum, covered by grey nodules. Phthisis pulmonum.

No. 162.—Ill since 12th March; death on 13th Sept. Healed typhoid swellings in the ileum. Deep ulcers with raised edges in the ileum. Miliary tuberculosis of lungs, liver, spleen, and meninges. Round-celled sarcoma of the brain.

No. 165.—Ill since 5th April (?); death on 21st April. Ulcers in the ileum. Miliary tuberculosis of the pleura and the lungs.

No. 168.—Ill since the middle of April; death on 5th Sept. Typhoid cicatrices in ileum. Inspissated peritoneal exudation in the midst of firm adhesions. Pleurisy. Tuberculosis of the lungs. Tuberculosis of the kidneys.

No. 184.—Ill since 12th July; gave birth to a child on 18th July; death on 20th July. Ulcers in ileum. Grey nodules of serosa.

No. 185.—Ill since 4th July; death on 13th July. Infiltration, sloughing and ulceration in the ileum, cæcum, colon and rectum. Flat miliary nodules of the peritoneal covering of the intestine.

No. 199.—Ill since 8th Aug.; death on 26th Aug. Moderate swelling and pigmentation of the Peyer's patches. Ulcers in ileum. Typhoid nodules on the peritoneal covering of the intestine.

No. 240.—Long unwell, and especially since 16th August; death on 28th Oct. Deep pigmentation of ileum, and cicatrices of ulcers. Peritonitis and pleurisy, with extensive development of grey nodules. Grey nodules in liver and kidney. (I have referred to this case at greater length in the text, Chapter VIII.)

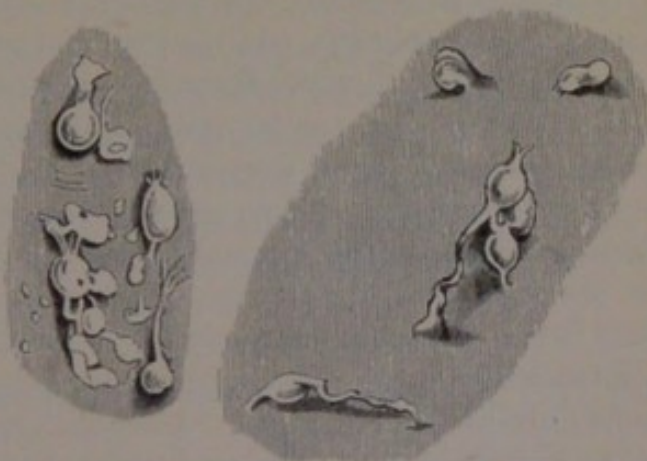
W. H. SPENCER, "On Fever as a connecting link between Scrofula and Tuberculosis."—*Bristol Royal Infirmary Reports*, 1878-79.

In addition to the four cases which I have referred to in the text, Dr Spencer gives towards the end of his paper the following case, of which he says: "Such cases are usually regarded as cases of scrofulosis, and not tuberculosis":—A boy, aged 13, from the same Industrial School as that mentioned in the text (Chapter VIII). Ill of fever for a fortnight; died after being three days in the hospital. *Arachnoid* here and there covered with lymph, thickened and infiltrated (probable beginnings of tubercle). In the right lung, several communicating cavities at the apex, having thick fibroid walls; no tubercle of lungs or pleuræ. On each side of thorax, moulded between the compressed lungs and the diaphragm (in the pleural cavities), a large collection of greyish-white cheesy matter, easily scraped off from the *pleural surfaces*; these two collections of cheesy matter united, behind the œsophagus, by an isthmus of the same kind of material; no breach of continuity in the pleuræ. In the *abdomen*, general but not firm matting of all organs by cheesy material; liver firmly adherent to the diaphragm throughout; a cheesy mass, four inches in diameter and half an inch thick, immediately under the central tendon of the diaphragm; in the right flank, two cheesy masses, the size of large peas, adherent to the peritoneum by a thin melanotic membrane and surrounded by a zone of peritoneal injection; a similar nodule adherent to the mesentery; *mesenteric glands* enlarged and indurated, none caseous; small encysted collections of caseous matter in the *liver* and *kidneys*; abdominal organs otherwise healthy; no tubercle within the abdomen.

The serous-membrane outgrowths, which I have described and figured, are, I believe, liable to become large conglomerate caseous masses, especially round the sharp margin of the lower lobe of the lungs, and on the contiguous surfaces of the liver and diaphragm. The latter situation is the most likely place to look for indications of the pearl-disease. In a case of rapid phthisis pulmonum in a robust and previously healthy man, aged 40, I lately found (15th November 1880), besides small white tubercles on the surface of the somewhat fat mesentery, the following condition on the under surface of the diaphragm: A few long adhesions to the liver. About a dozen flat yellowish-white patches, mostly round, a quarter of an inch or more in diameter, and raised about half a line above the surface, well defined, and fixed by short pointed processes all round their margin, giving the periphery a somewhat stellate appearance. Towards the tendinous part of the

diaphragm, these caseous patches become confluent and form a broad lobulated thin stratum. On the extreme right and posterior dependent surface, the outgrowths were in the form of hard and white nodules like grains of pearl barley, for the most part detached from the surface, and joined at their poles by round cords of the same colour and texture. I do not hesitate to say that these pearls, which I have kept as a specimen, are, although few in number, as characteristic of

Perlsucht as the growths on the surface of the cow's lung in the very distinctive wood-cut in Virchow's work on Tumours (French transl., vol. iii. p. 188). In another case at Addenbrooke's Hospital (October 23, 1880), I found on the under surface of the diaphragm, on both surfaces of the liver, on the surface of the spleen, and on the anterior surface of the stomach, the same delicate greyish translucent outgrowths, sometimes



Two groups of pearl-nodules from under surface of diaphragm, in a man aged 40, who died of rapid phthisis (Addenbrooke's Hospital, 15th Nov. 1880).

flat and leaf-like, at other times elongated and cord-like, which I have described in Chapter V. The case was that of a man aged 21, with long-standing scrofulous disease of both kidneys, tubercular ulcers of the ureters and bladder, greatly enlarged and caseous retro-peritoneal lymphatic glands, recent white medullary nodules and patches of various sizes in the lungs (at one apex also a firm and definitely encapsuled white fibrous nodule the size of a hazel nut), and small grey translucent tubercles of the pleura.

GOODHART, "A Case of Progressive Caseous Disease of the Lymphatic Glands after Disease of the Knee-Joint."—*Guy's Hospital Reports*, vol. xviii. (1872-73) p. 401.

Scrofulous disease of the knee-joint of two years' duration. Limb amputated. Death. Cervical, axillary, inguinal and retro-peritoneal *lymphatic glands* enlarged and caseous. The glands at the root of the lung extremely enlarged, some more than an inch long, presenting a very curious marbled appearance, with black masses of pigment contrasting with the yellow parts. On the concave surface of left lung at the level of the root, numerous masses of cheesy material; these masses had a flat surface turned towards the pleura, as big as a shilling, and were perhaps of a quarter of an inch maximum thickness. Immense numbers of minute grey miliary tubercles in both lungs; semicalcified nodules at left apex.

Compare also Dr Goodhart's case in *Pathological Transactions*, vol. xxix. (1878), Case 6, p. 325.

FAGGE, "A Case of Progressive Caseous and probably Tuberculous Disease of the Lymphatic Glands and Spleen."—*Path. Trans.* vol. xxv. (1874) p. 235.

COUPLAND, Case in *Path. Trans.* vol. xxv. (1874), p. 142.

Male, aged 46, admitted with abdominal distension. Tapped. Old adhesions between the diaphragm, and the liver and spleen. The *surface of the liver* presented yellowish-white fibrous-looking nodules of the size of peas. On section of the *liver*, similar nodules, the majority about the size of dried peas, none being larger, were found scattered more or less sparsely throughout the parenchyma. These nodules were of very firm consistence, and but loosely attached to the surrounding tissue; so that they stood out in relief on the surface of the section. They were thus very readily enucleated; they were mostly unencapsuled, but some appeared to shell out from a smooth-walled sac. They were opaque yellowish-white, and not softened; most numerous in right lobe. *Mesenteric glands* all nodular, and enlarged up to size of a walnut; their substance opaque yellowish-white, save in the neighbourhood of the capsule, which was much thickened. Both *lungs* contained in upper lobes firm masses of old pigmented and indurated tubercle, with a few small vomicæ and cretified nodules in the midst of the dense tissue. *Bronchial glands* enlarged and pigmented. Cervical glands enlarged and cheesy, and some of them softened in the centre. In some of the microscopic specimens, small vessels containing blood could be seen in the growth. The question was whether the formations were syphilitic or tubercular. "But they do not conform in many particulars to the received descriptions of tubercular growths or of syphilitic gummata."

P. H. PYE SMITH, "Primary Caseous Degeneration of Lymphatic Glands."—*Path. Trans.* vol. xxvi. (1875) p. 202.

A woman, aged 47. Enlarged and caseous cervical, axillary, thoracic, abdominal and inguinal *lymphatic glands*. Over the parietal *pleura* and *pericardium*, and on the *serous surface of the stomach*, smooth round nodules from size of pin-head to that of a pea, opaque and cheesy, irregularly distributed and widely scattered. "None were like the grey granulations of the ordinary tuberculosis of serous membranes." No tubercles in lungs or in other viscera.

SCHÜPPEL, *Untersuchungen über Lymphdrüsen-Tuberculose*. Tübingen, 1871.

A large proportion of Schüppel's forty cases of primary tuberculosis of the lymphatic glands were also cases of tuberculosis of one or more of the serous membranes.

HUMPHREYS, Report of Case at Children's Hospital, Pendlebury, Manchester, in *Med. Times and Gazette*, vol. lvii. (1878) p. 127.

Child, aged 6. Sudden onset of illness; died after twelve days. In *brain*, a complex condition, including miliary tubercles of the arachnoid. Parietal and visceral layers of *pericardium* joined by unusually firm adhesions, on separating which, each layer was found to be thickly covered with large semi-transparent tubercles. The condition of both *pleurae* resembled that of the pericardium in all respects. Enormously enlarged and caseous *bronchial glands*. Convex surface of liver everywhere adherent to diaphragm by firm cellular bands. On being separated, the *under surface of the diaphragm* was seen to be covered by clusters of large flattened tubercles. The condition of the rest of the *peritoneum* was similar to that of the diaphragm. *Testicles* enlarged and firm; two or three small caseous nodules in epididymis.

BURROWS, "Tubercular Pericarditis."—*Med. Chir. Trans.* vol. xxx. (1847).

SUTTON, "Fibroid Degeneration of the Lungs."—*Med. Chir. Trans.* vol. xlviii. (1865) p. 300.

Case of four months' duration, man aged 26. On the *pleura* over the lower lobes of both lungs were a number of hard grey bodies the size of split peas. The *bronchial glands* much enlarged, some of them as large as a walnut; several of them intimately united together by a very firm greyish-red looking material. The glands were all very firm and tough, and increased in density, and many appeared as if they had been converted into fibrous tissue; others were yellowish in the centre and firm in the periphery, and a few were beginning to be white and chalky. In both *lungs* consolidation and induration, in patches or diffused.

VALENTIN, "Zur Casuistik der Tuberculose."—*Virchow's Archiv*, vol. xlv. (1868) p. 296.

This paper is intended to illustrate the doctrine laid down by Klebs, in the paper immediately preceding it, that tuberculosis is due to an infective virus. Tables are given of a large number of cases examined at Berlin and at Bern, and seven cases are recorded in detail.

Case III. Tuberculosis caseosa peritonæi, &c. Left *lung* firmly united to the diaphragm; in the lower part of the pleural cavity a yellowish-white mass adhering loosely. *Intestines* firmly united to one another and to the anterior abdominal wall. Extensive flat nodules of yellowish-white colour, up to 1 cm. in thickness, adherent to the abdominal wall, covered by a layer of peritoneum; it was obvious at their periphery that they were made up of a number of closely-packed round nodules. The same formation continued down towards the pelvis in two narrow cords to end in another thick mass. Liver united to the diaphragm and the stomach; in the midst of the adhe-

sions in the præcordial region an extensive greyish-yellow greasy mass. Hepatic flexure of colon adherent to liver. Spleen united to diaphragm ; near it, and especially at the hilus, numerous white nodules. Two caseous masses as large as apples in the adhesions of the sigmoid flexure. In the hilus of the liver, nodular masses like the before-mentioned. In the *liver* a limited number of whitish nodules up to the size of peas, especially round about the gall-bladder. Old interstitial orchitis.

Case IV. Man, aged 28. Tuberculosis peritonæi. In the anterior mediastinum a number of nodules as large as walnuts. In left *lung*, miliary nodules, and on the *pleura*. Right lung firmly united to the costal pleura and the diaphragm ; in the adhesions numerous grey nodules. *Bronchial glands* small and deep red ; contained only two or three yellowish nodules. Caseous nodules under the *peritoneum* of the anterior abdominal wall, along the epigastric arteries ; the parietal peritoneum of the anterior wall everywhere much thickened and densely covered with clear yellow nodules. The same occurred throughout the whole peritoneal cavity, in the recesses of the adherent intestines, and more sparsely between the peritoneum and the liver. Surface of diaphragm covered by the same grey nodules. Numerous nodules on surface of *kidneys* ; some in the *spleen* and *liver*. *Mesenteric glands* enlarged and partly caseous. The tuberculosis in this case is considered to have spread from the peritoneum, and to have reached the lungs and pleura direct through the diaphragm.

Case V. Female, aged 55. Ulcus faciei forsitan tuberculosum. Tuberculosis miliaris peritonæi et uteri. Ulcera tuberculosa ventriculi et coli ascendentis.

Under *surface of diaphragm* covered with numerous grey nodules. *Serous covering* of small intestine sown with numerous miliary nodules. Same in Douglas's space. Tuberculous ulcers in the *stomach* and in the ascending colon, with numerous pin-head nodules in their floor or in the neighbouring serosa.

Case VI. Female, aged 68, for twelve years in a lunatic asylum ; death sudden and unexpected.

Tumours of the occipital bone. In the apex of the right *lung*, pigmented nodules of tough consistence. The whole *peritoneum* covered with an immense number of small grey nodules, very dense on the mesentery, the omentum, and the serous coat of the intestine. On the upper surface of the liver, fibrous adhesions to the diaphragm, which contain numerous grey nodules. Capsule of the spleen covered with nodules. Seated on the peritoneum of Douglas's space, a thick gelatinous nodulated mass. A small round ulcer of the *stomach*, apparently *ulcus simplex*.

LITTEN, "Ulcus Ventriculi Tuberculosum."—Virchow's *Archiv*, vol. lxxvii. (1876) p. 615.

An oval ulcer along the lesser curvature of the *stomach*, its base and


edges ridged and hæmorrhagic. Isolated nodules in its floor and on the thickened serosa. The new formation contained giant-cells with marginal nuclei. Extensive caseation of epigastric *glands* (especially on the back of the stomach) and of mesenteric glands. Moderate amount of deposit of miliary tubercles on the *peritoneum*. Tubercular ulceration of larynx, bronchi, and lungs. No other ulceration of digestive tract except that in the stomach, which gave rise to no symptoms during life.

ORTH, "Ueber Localisirte Tuberculose der Leber."—*Virchow's Archiv*, lxvi. (1876).

The second case, pp. 115–117, a woman, aged 59. *Lungs* occupied by a number of tough greyish-white or yellow caseous centres, surrounded by a kind of capsule, each with a small lumen in the centre. Upper *surface of the liver* united to the diaphragm by short strings of adhesions; in these lie numerous nodules from the size of a lentil to that of a pea, the smaller grey and translucent, the larger yellow and opaque. The whole *peritoneum* covered with submiliary nodules. The anterior margin of the *liver* occupied by a very extensive nodulated tumour-mass of conglomerate tubercles; towards the left lobe, the nodules occur isolated, and of the size from peas to cherries. The liver contained also a few submiliary grey nodules. Portal and lumbar *lymphatic glands* enlarged and caseous.

BRISAUD, "Étude sur la Tuberculose Articulaire."—*Revue Mensuelle de Médecine et de Chirurgie*, iii. (1879).


Obs. 2, p. 464. Man, aged 22, ill with symptoms of sub-acute rheumatism since six days. After admission into hospital dyspnœa appeared, and symptoms became aggravated. Diagnosis of sub-acute rheumatism changed for that of acute tuberculosis. Remarkable degree of cyanosis before death. Miliary granulations in great abundance on the *pleura* and disseminated through the whole of each *lung*. No old disease in the lungs. On the *pericardium* granulations as large as a pin-head, remarkable for their transparency, like small drops of dew. Tubercles on the great *omentum*, *peritoneum* of diaphragm, capsule of liver and spleen, on *kidney*, and under the mucous membrane of the *intestine*. In the *pons Varolii*, four tubercles as large as peas, and one in the *medulla oblongata*. On the *synovial membrane* of the right knee-joint, a large number of greyish granulations the size of a pin-head, flattened where there was pressure. In all the situations the tubercles contained large nucleated cells in their outer layers, and a great number of giant-cells with granular protoplasmic interior and marginal nuclei.



EXPLANATION OF PLATE I.

Fig. 1. Concave base of *lung* and adjoining convex lateral aspect, covered with leaf-like and cord-like pleural outgrowths ; margin of the lung, showing a border or frill of pleuritic new formation. From Case 9.

Fig. 2. Upper surface of the *liver*, showing patches of delicate membrane-like outgrowths, with free and sometimes upturned edges ; they are formed by the coalescence of the smaller kind of outgrowths of fig. 1. From Case 9.




BOVINE TUBERCULOSIS IN MAN

1.



2.





EXPLANATION OF PLATE II.

Fig. 3. Under surface of *diaphragm*, covered with an eruption of large flat nodules, for the most part uniform in size, sometimes confluent; membranous appearance at lower part of the figure. From Case 2.

Fig. 4. Sharp margin of lower lobe of *lung*, showing characteristic pleural outgrowths. From Case 7. (The brown colour of the lung substance is owing to its having been preserved for a time in potassium bichromate.)

Fig. 5. Lateral convex surface of *lung*, showing sessile and pedunculated pleural outgrowths, of various sizes and of whitish colour. From Case 3. (Typical acute tuberculosis in a child.)

Fig. 6. Surface of *spleen*, showing sessile, pedunculated, and tongue-shaped outgrowths of the peritoneal covering. From Case 5.



BOVINE TUBERCULOSIS IN MAN.






EXPLANATION OF PLATE III.

Fig. 7. *Lung*, with whitish wedge-shaped mass near interlobar fissure; the mass is dimly seen to consist of a number of confluent round nodules; a branch of the pulmonary artery runs up to and disappears beneath the thin end of the wedge. The interlobar fissure is bridged over by pleuritic membrane. From Case 2. (Spirit preparation.)

Fig. 8. Piece of *lung*, with membranous expansion of pleura on right-hand edge, and the substance occupied by a number of yellowish-white nodules definitely encapsuled by translucent tissue. From Case 7. (Bichromate of potash preparation.)

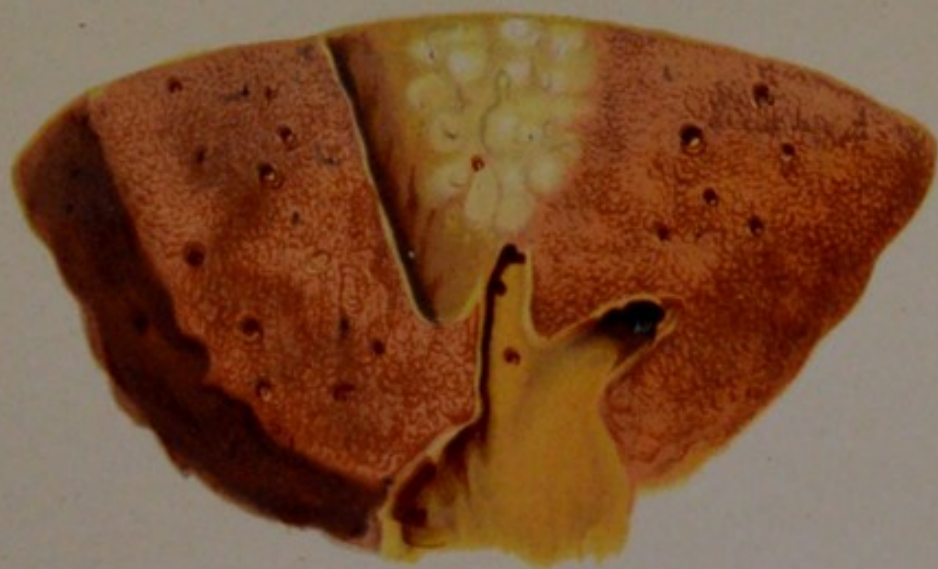Fig. 9. Piece of *lung*, showing a number of smooth-walled cavities of various sizes and shapes; yellowish nodules in the intervening lung substance. From Case 5. (Bichromate of potash preparation.)

Fig. 10. Section of bronchial *lymphatic gland*, showing a number of round nodules in its interior, each definitely bounded by a translucent capsule. From Case 5. (Bichromate of potash preparation.)



BOVINE TUBERCULOSIS IN MAN.

7.



8.



9.



10.





EXPLANATION OF PLATE IV.

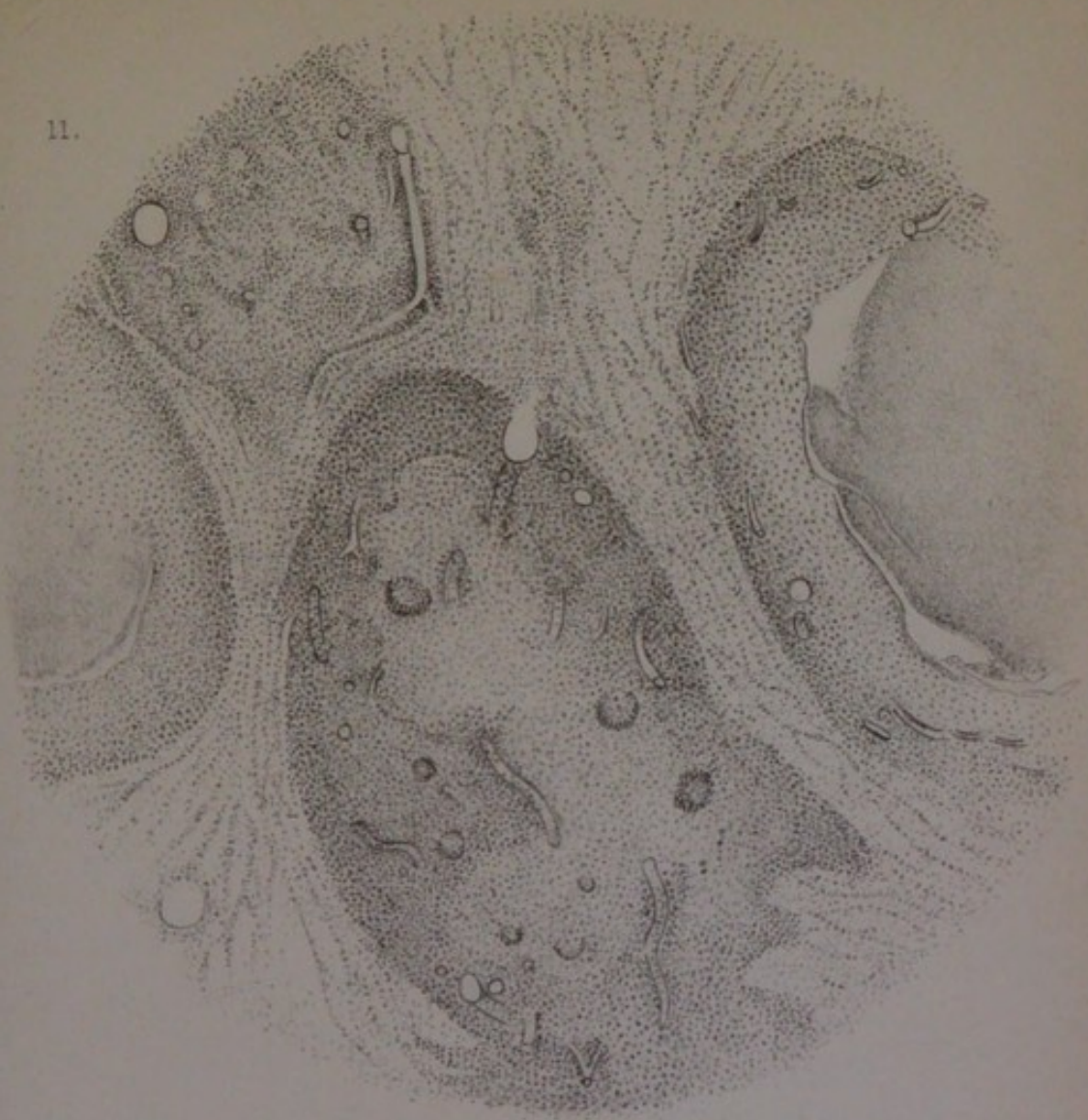
Fig. 11. From the wedge-shaped mass in the *lung* in fig. 7 (Case 2); four of the small tubercles that make up the conglomerate; partial vascularisation of the new growth; separation of the necrosed centre from the vascularised periphery. (\times about 60.)

Fig. 12. From the edge of the wedge-shaped mass in the *lung* in fig. 7 (Case 2); a single ultimate tubercle, partly vascularised in its interior, and with an extensive investment of tortuous blood-vessels on its periphery. (\times about 150.)

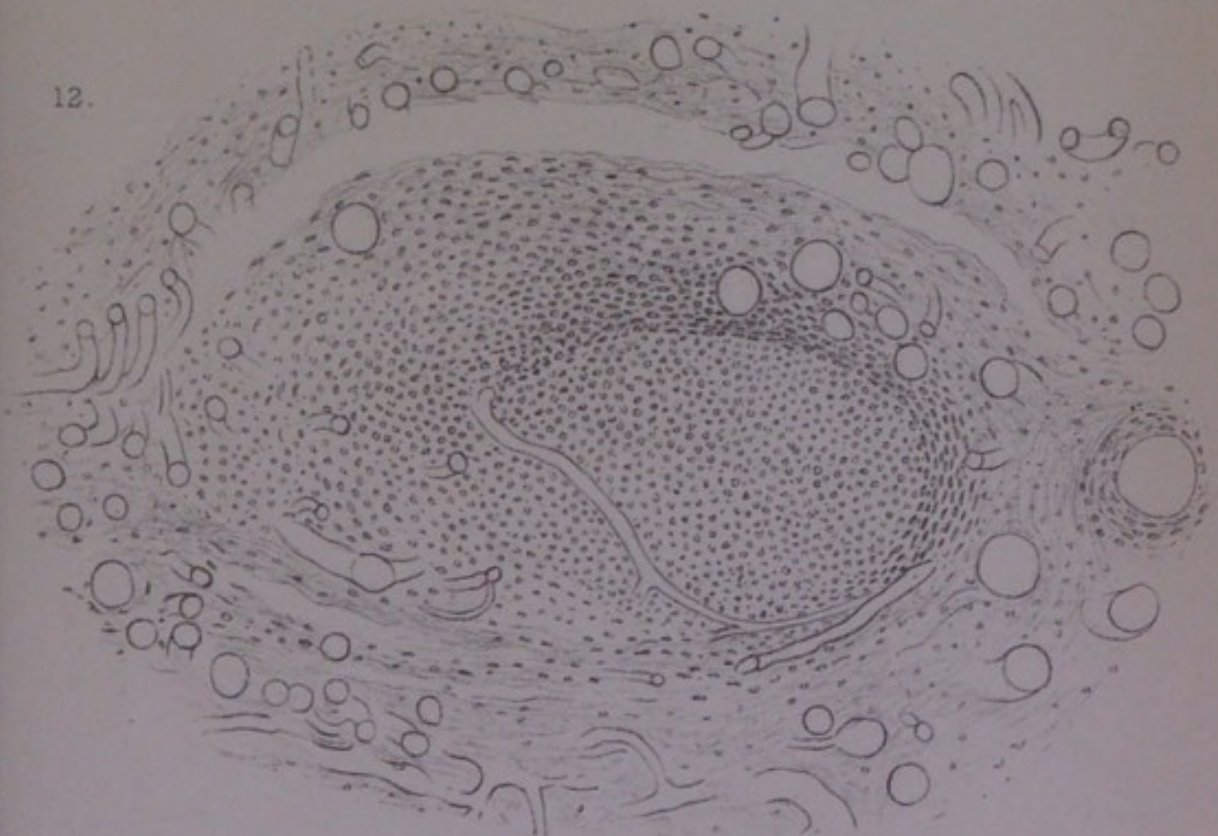


BOVINE TUBERCULOSIS IN MAN.

11.



12.






EXPLANATION OF PLATE V.

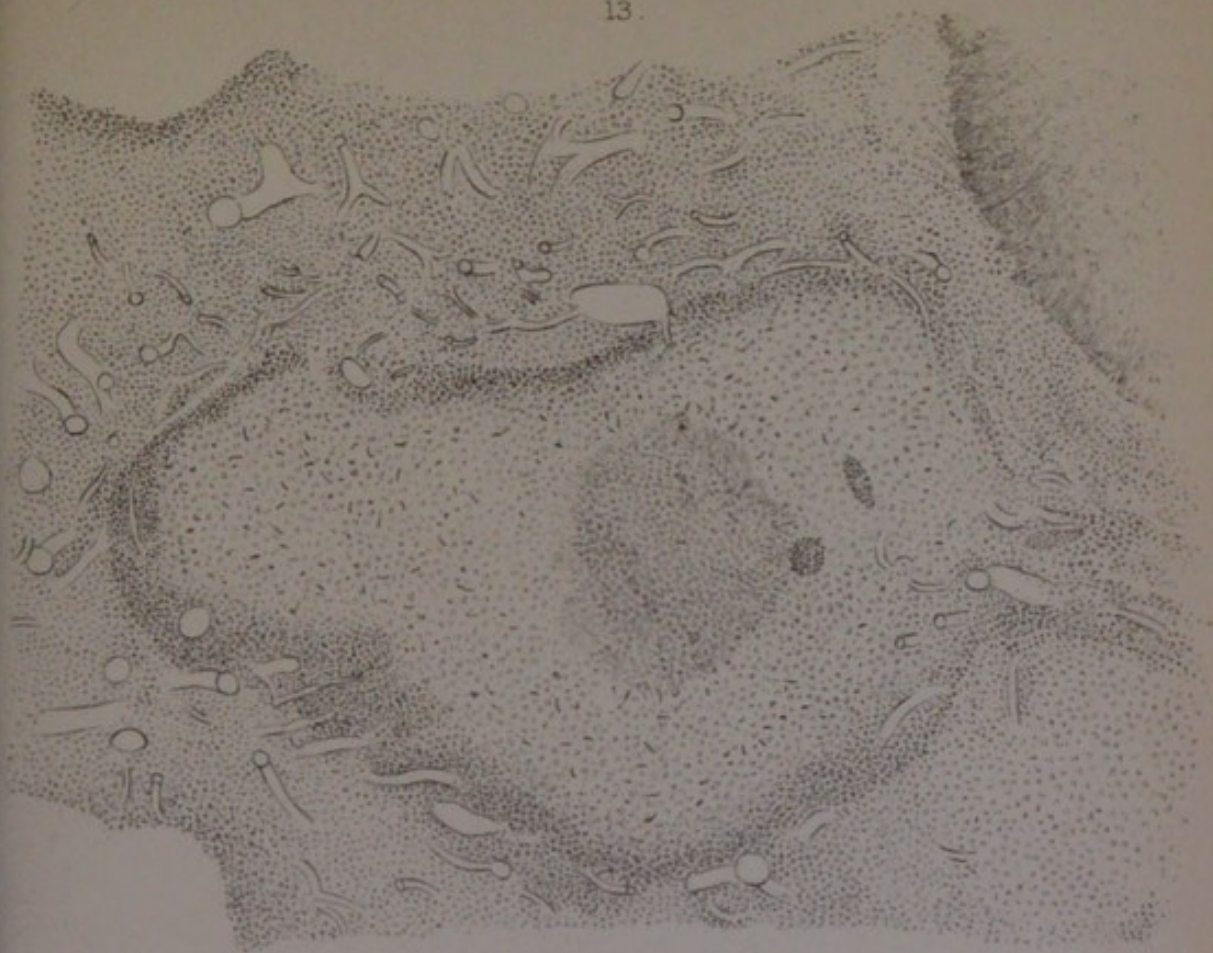Fig. 13. From the wedge-shaped mass of whitish substance in the *lung* in Case 3 (typical acute tuberculosis in a child); a single tubercle surrounded by an extensive plexus of distended blood-vessels. (× about 60.)

Fig. 14. From a bronchial *lymphatic gland* in Case 5; several tubercles occupying the follicular tissue; the cortical lymph sinus contains red blood-corpuscles; the tubercles contain giant-cells, and are partly necrosed or calcified. (× about 60.)

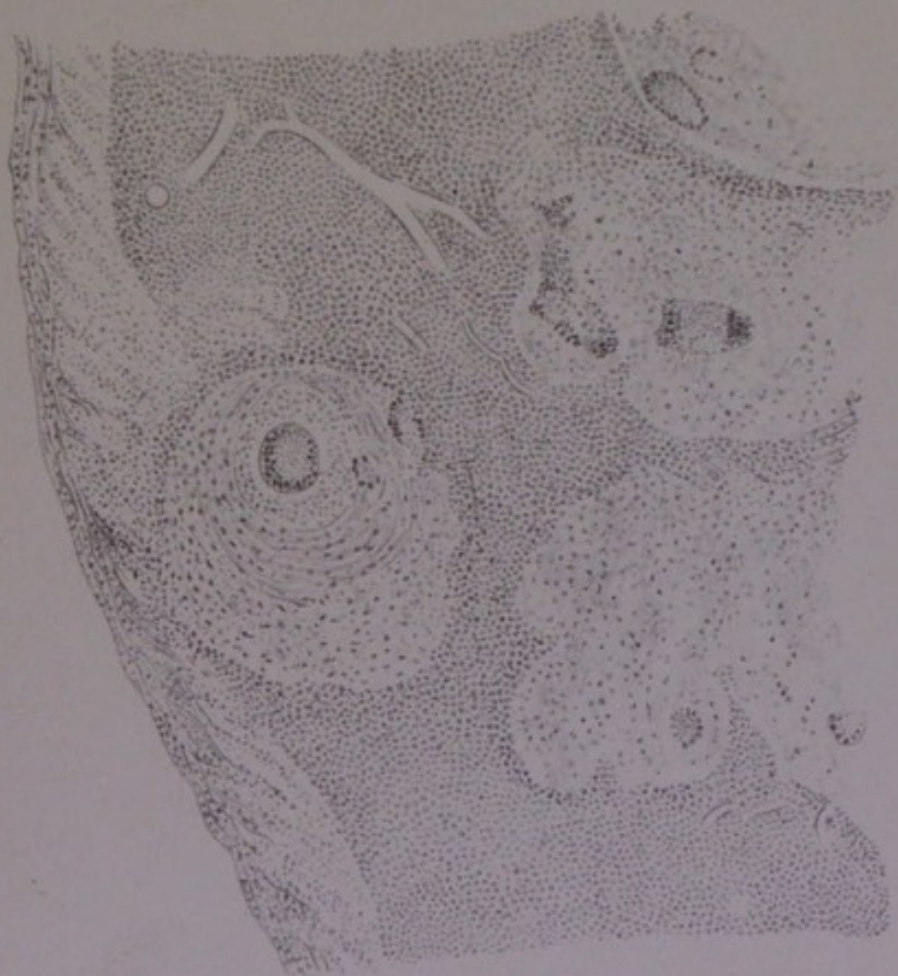

BOVINE TUBERCULOSIS IN MAN.

13.



14.






EXPLANATION OF PLATE VI.

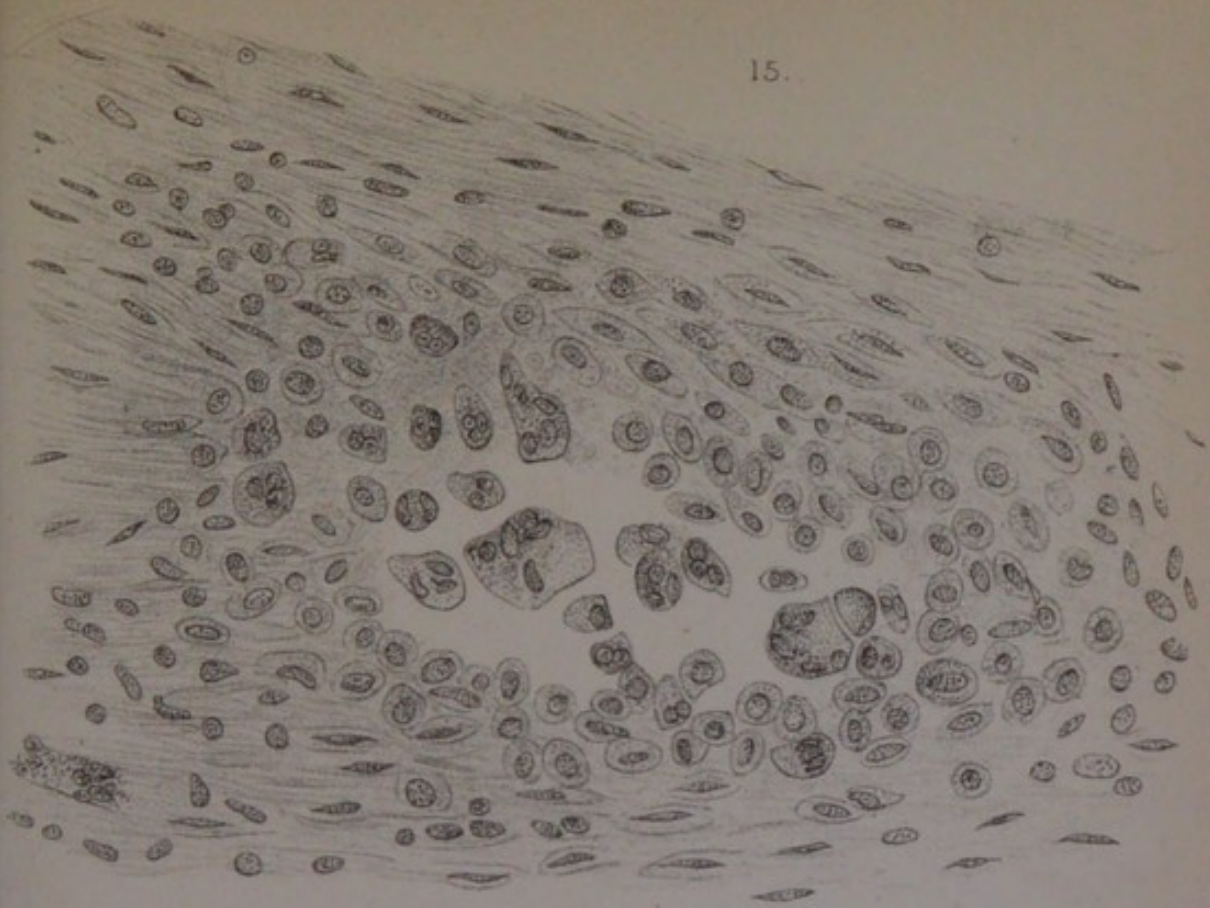Fig. 15. From thickened floor of healed *ulcer in the ileum* in Case 10; a tubercle with multinuclear cells lying loosely in the centre, and epithelial-like cells in the periphery; transition of the connective-tissue cells of the region to become the epithelial-like cells. ($\times 250.$)

Fig. 16. Similar appearance to that of fig. 15, from the *normal placenta* of the Guinea-pig; transition of the enlarged and epithelial-like cells of the circular muscular coat to become multinuclear cells. ($\times 150.$)

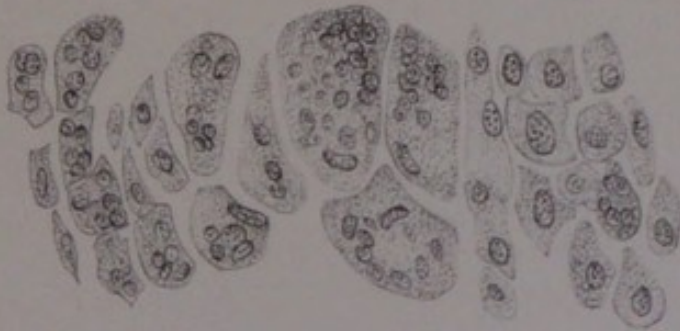Fig. 17. Appearance found near one of the small scattered nodules in the lower lobe of the *lung* in Case 7; the bronchial wall broken through, and the lumen of the tube filled up by a portion of the tubercle. ($\times 90.$)



15.



16.



17.

