Practical anatomy of the nerves and vessels supplying the head, neck and chest / [Edward Cock].

Contributors

Cock, Edward, 1805-1892.

Publication/Creation

London : A. Schloss, 1835.

Persistent URL

https://wellcomecollection.org/works/fm7mdxhy

License and attribution

This work has been identified as being free of known restrictions under copyright law, including all related and neighbouring rights and is being made available under the Creative Commons, Public Domain Mark.

You can copy, modify, distribute and perform the work, even for commercial purposes, without asking permission.

Wellcome Collection
183 Euston Road
London NW1 2BE UK
T +44 (0)20 7611 8722
E library@wellcomecollection.org
https://wellcomecollection.org

18194/A

7/

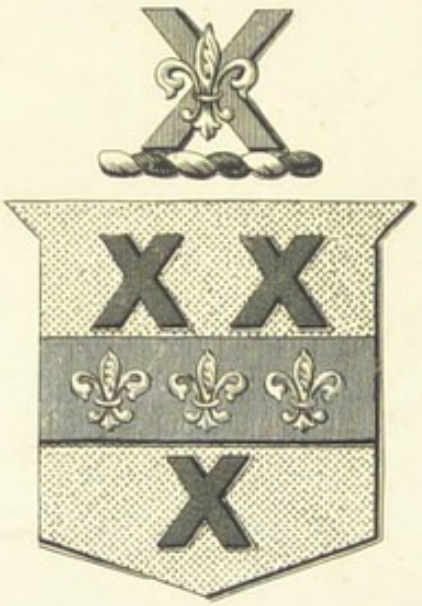

E. BARCLAY-SMITH, M.D.

Digitized by the Internet Archive
in 2015

https://archive.org/details/b22020809

46073

PRACTICAL ANATOMY

OF

THE NERVES AND VESSELS

SUPPLYING THE

HEAD, NECK, AND CHEST:

INTENDED AS

A GUIDE FOR THE USE OF STUDENTS IN THE DISSECTION OF THOSE STRUCTURES.

BY EDWARD COCK,

DEMONSTRATOR OF ANATOMY AT GUY'S HOSPITAL.

LONDON:

A. SCHLOSS, 2, GREAT RUSSELL STREET, BLOOMSBURY.

1835.

WELLCOME
HISTORICAL
MEDICAL
LIBRARY

PREFACE.

Some apology may, perhaps, appear necessary from the author who has ventured to add *one more* to the long list of Manuals, Guides, and other anatomical works, which have been published from time to time, with a view of assisting the labors of the dissector.

I was long since impressed with the conviction, that a work like the present would form a useful companion to the practical anatomist; and, as nothing which embraced my own views on the subject has hithero presented itself, I have at length been induced to make the attempt.

The only recommendation which I can claim for this little book, is founded on its being the result of a tolerably active experience during some years in the dissecting room, and on the assurance that every part of it which may appear to deviate from ordinary anatomical precept, has been subjected to the careful and repeated test of the scalpel.

Every surgeon who has studied anatomy must retain a lively impression of the difficulties, not to say vexations and disappointments which he encountered, whilst attempting to unravel the vessels and nerves of the head and neck: and as it has long been my daily occupation to assist the student in overcoming these difficulties, I have entertained the hope that I shall render myself still further useful, by presenting to him in a permanent form, that plan, order, and detail of dissection, which experience has taught me to be the most efficient, but which hitherto

has been communicated to him, either by oral instruction, or by manual assistance.

In a part of the body so complicated as the head and neck, where the nerves and vessels cross and intersect each other in every direction, it will be found impossible to trace them by following the arrangement necessarily adopted in works of descriptive anatomy: because every description there laid down commences with the original trunks, and as they are all deeply buried beneath the surface, they are consequently the last parts to be laid bare by the knife of the dissector. Such a system is admirably adapted for a course of reading, as it admits of tabular classifications, and other methods of technical memory, well calculated to stamp the tedious detail on the wearied mind of the student: but, when he sits down to verify the knowledge thus acquired on the dead body itself, it becomes requisite that he should begin his dissection with the more super-

ficial parts, containing the smaller branches of the vessels and nerves; and, by tracing them, he is at length guided to the more deeply-seated structures, or the roots from which those branches emanate. He then discovers that the anatomical arrangement on the subject which he is dissecting, is the reverse of that system which he has so carefully studied in his book; and, that in order to accommodate the one to the other, he must begin at the end of each chapter and read backwards.

With the intention of obviating these difficulties, I have followed up the dissection of the head, neck, and chest, by dividing it into regional portions, each forming a distinct section of the work, commencing with the subcutaneous structures, and proceeding to those which are more deeply seated.

In carrying out this plan, I have constantly held one main object in view; that of rendering the description of the vessels and

nerves, as continuous, and as little disjointed, as was compatible with the possibility of bringing them all successively uuder inspection: and without entering into prolix description or minute anatomical detail, I have endeavoured to afford an easy and efficient plan of dissection, and to enable the student to employ his time and labour to the greatest advantage.

It may be asked why I have limited myself to the description of vessels and nerves, excluding the bones and muscles, a knowledge of which is equally important to the surgeon. I answer, that I was unwilling to increase the size, and consequently add to the expense of this work, by treating of subjects which have been so ably handled by other authors, as to leave little room for improvement either in arrangement or description. I have only attempted to fill up a deficiency where I conceived it to exist, and to supply what I considered to be a desi-

deratum to the dissector. How far I have succeeded my readers must decide; but experience renders me confident in the expectation, that, by the method and order recommended in this work, the student will have the advantage of seeing every important part contained in the head, neck, and chest, during the dissection of a single subject; and, though he may sometimes feel disappointed, at leaving for a time a nerve or vessel which he has traced through a certain portion of its course, he will in the end be amply repaid by the economy thus insured in the materials of his labor, and the opportunity afforded of studying each part in its natural position, in relation to surrounding structures.

In conclusion, it will hardly be necessary to remind the student, that this volume can render him no service until he has made himself thoroughly acquainted with the bones and muscles of the different regions which

are described, together with the viscera of the thoracic cavity. When thus prepared, and not till then, he may proceed with confidence to the dissection of the nerves and vessels, as they are arranged in the following pages.

SYNOPSIS.

SECTION I.

Description of the Superficial Nerves ramifying on the Head and Neck.

PART I.

The superficial branches derived from the cervical plexus, and emerging from under the posterior edge of the sterno-cleido-mastoideus muscle. The accessory nerve coming through the muscle.

Situation of muscles 1
Superficial cervical nerves..... 2
Ascending set ..... ib.
Auricular branch 3
Transverse cervical branch ..... ib.
Small occipital branch 4
[Spinal accessory nerve] ..... ib.
[External jugular vein] 5
Descending set..... ib.
Supra-clavicular branches 6
Supra-acromial branches..... ib.
Sub-clavicular branches ..... ib.

PART II.

The branches of the facial nerve, as they pierce the parotid gland, and ramify over the face and cranium. p. 8.

Main trunk of the facial nerve..... 9
Digastric and stylo-hyoideal-branches .... ib.
Branches of junction ..... ib.
Posterior auricular branch .... ib.
Temporo-facial nerve 10
Temporal branches .... ib.
Superior facial branches .... ib.
Middle facial branches ..... ib.
Cervico-facial nerve..... 11
Inferior faciál branch 12
Descending facial branch..... ..... ib.

PART III.

Those branches of the fifth pair of nerves which make their appearance on the face and cranium.

Supra-orbitar nerve 13
Malar nerve 14
Infra-orbitar nerve.. .... ib.
Buccal branches ..... ib.
Mental nerve.... 15

SECTION II.

Description of the Vessels and Nerves situated in the Anterior Triangular Space of the Neck, and brought into view by removing the Platysma Myoides and Cervical Fascia.—The Arteries which ramify over the Face and Cranium.

PART I.

Preliminary observations on the position of the muscles and the fascia of the neck.

Anterior triangular space of the neck..... 16
Fascial coverings of the neck 17
Deep or proper cervical fascia..... ib.

PART II.

The common carotid artery, with the internal jugular vein and pneumo-gastric nerve.—The transverse portion of the lingual nerve with its descending branch.

Parts contained in the anterior triangular space of the neck 21
[Situation of muscles] ..... ib.
Descendens lingualis nerve 22
Transverse portion of lingual nerve 23
Accessory nerve..... 24
Carotid sheath and its contents .... ib.
Common carotid artery..... 25

PART III.

The course of the external carotid artery. p. 27.

PART IV.

The branches of the external carotid—The superior thyroideal, facial, sterno-mastoidean, posterior aural, and temporal branches, traced to their termination.—The lingual, occipital, and internal maxillary branches traced until they become concealed by muscles not yet removed.

Branches of the external carotid artery 29
Superior thyroideal artery 30
Hyoideal branch ..... ib.
Laryngeal branch..... 31
Muscular branches ..... ib.
Glandular branches..... ib.
Lingual artery—commencement of..... ib.
Facial artery..... 32
[Facial vein] 34
Inferior palatine branch 35
Glandular branches..... ib.
Submental branch ..... ib.
[Mylo-hyoid nerve]..... 36
Labial branch..... ib.
Inferior coronary branch ..... ib.
Superior coronary branch ..... ib.
Lateral nasal branch 37
Angular branch..... ib.
Muscular branches 38
Sterno-mastoidean artery 39
Occipital artery—commencement of ..... ib.
Meningeal branch 40
Posterior aural artery ..... ib.
Ascending pharyngeal artery—origin of 41
Internal maxillary artery—commencement of ..... ib.

Temporal artery 41
Transverse facial branch 42
Small branches ..... ib.
Temporo-frontal branch 43
Temporo-occipital branch ..... . ib.

SECTION III.

Description of Vessels and Nerves; brought into View by detaching some of the Muscles between the Os Hyoides and the Lower Jaw, and removing the Zygoma with the Ascending Ramus of the Inferior Maxillary Bone.

PART I.

The course and distribution of the lingual artery, with the distribution of the lingual and gustatory nerves. p. 45.

Lingual nerve—distribution of 47
Gustatory nerve—distribution of ..... ib.
Lingual artery—distribution of 48
Hyoideal branch..... ..... ib.
Dorsal branches 49
Sublingual branch..... ib.
Ranine branch..... ..... ib.

PART II.

The course and distribution of the internal maxillary artery, together with the second and third division of the fifth pair of nerves. p. 50.

Internal maxillary artery 52
Spheno-spinal branch 54
Dental branch 55

Muscular branches 56
[Spheno-maxillary fossa] 57
Superior dental branch 58
Spheno-palatine branch 59
Pterygoid branch ..... ib.
Infra-orbitar branch ..... ib.
Palato-maxillary branch ..... ib.
Second division of the fifth pair of nerves 60
Superior dental branch 61
Infra-orbitar branch ..... ib.
Malar twig ..... ib.
Branches of junction with Meckel's ganglion ..... ib.
Meckel's ganglion 62
Spheno-palatine nerve ..... ib.
Palato-maxillary nerve 63
Pterygoid nerve ..... ib.
Inferior branch ..... ib.
Superior branch 64
Third division of the fifth pair of nerves 65
Pterygoid branches 66
Temporal branches ..... ib.
Masseteric branches ..... ib.
Buccal branches ..... ib.
Gustatory branch 67
Dental branch 68
Mylo hyoid twig ..... ib.
Auricular branch ..... ib.

SECTION IV.

Description of Vessels and Nerves lying deeply seated upon the Cervical Vertebræ, immediately below the Base of the Skull, to the outer Side of the Pharynx; and brought into view by removing the Lower Jaw and Styloid Muscles.

PART I.

The ascending pharyngeal, and internal carotid arteries, passing upwards towards the base of the skull.

Ascending pharyngeal artery 71
Internal carotid artery 72

PART II.

The glosso-pharyngeal, pneumo-gastric, spinal accessory, and lingual nerves, descending from the posterior lacerated and condyloid foramina, and connected with the first cervical ganglion.

Reference to foramina at the base of the skull 74
Internal jugular vein 75
Glosso-pharyngeal nerve..... 76
Glossal branch..... 77
Pharyngeal branches ..... ib.
Carotid filaments 78
Pneumo-gastric nerve—cervical portion of ..... ib.
Pharyngeal branch 79
Superior laryngeal branch ..... ib.
Small filaments 80
Cardiac branches ..... ib.

Spinal accessory nerve 81
Pharyngeal branch ..... ib.
Muscular branches 82
Lingual nerve ..... ib.

SECTION V.

Description of some of the Parts Internal to the Cranium; viz. the Vessels of the Dura Mater—the Base of the Brain—the Arteries of the Brain—the Origin of the Cerebral Nerves.

PART I.

The dura mater as it appears on removing the calvarium—the vessels ramifying on its surface.

The dura mater..... 86
Meningeal arteries..... ib.
Longitudinal sinus..... 87

PART II.

The removal of the brain with the vessels and nerves necessarily divided in so doing.

Directions for removing the brain..... 88
Nerves and vessels connecting the brain to the base of the skull ..... ib.
First pair of nerves ..... ib.
Second ditto..... 89
Carotid arteries ..... ib.
Infundibulum ..... ib.
Third pair of nerves ..... ib.
Fourth ditto..... ib.

Fifth pair of nerves 89
Sixth ditto ..... ib.
Seventh and eighth ditto 90
Ninth and tenth ditto ..... ib.
Spinal-accessory nerves ..... ib.
Eleventh pair of nerves ..... ib.
Vertebral arteries ..... ib.

PART III.

Outline of the inferior surface of the brain.

The base of the brain..... 91
Division of the cerebral lobes ..... ib.
Cerebellum 92
Pons Varolii..... ib.
Crura cerebri ..... ib.
Tractus opticus ..... ib.
Commissure of the optic nerves ..... ib.
Tuber cinereum ..... ib.
Infundibulum..... ib.
Eminentiæ mammillares..... ib.
Substantia perforata..... ib.
Medulla oblongata..... ib.
Corpora pyramidalia 93
Corpora restiformia..... ib.
Corpora olivaria..... ib.
Tractus respiratorius ..... ib.
Fourth ventricle..... ib.
Calamus scriptorius..... ib.

PART IV.

Course and distribution of the internal carotid and vertebral arteries within the cranium.

Internal carotid artery 95
Ophthalmic branch—commencement of ..... ib.
Posterior communicating branch ..... ib.
Anterior cerebral artery 96
Transverse communicating branch ..... ib.
Middle cerebral artery ..... ib.
Branch to choroid plexus 97
Vertebral artery ..... ib.
Posterior spinal branch 98
Anterior spinal branch ..... ib.
Inferior cerebellar artery 99
Basilar artery ..... ib.
Auditory branch 100
Superior cerebellar artery ..... ib.
Posterior cerebral artery ..... ib.
Circle of Willis 101

PART V.

Origin of the cerebral nerves, and the course which they take, until they leave the cavity of the cranium, or become concealed by passing between layers of the dura mater.

Origin of the cerebral nerves 102
1.—The olfactory ..... ib.
2.—The optic 104
3.—The common oculo-muscular 105
4.—The inner oculo-muscular ..... ib.
5.—The trigeminal 106

6.—The outer oculo-muscular 106
7.—The auditory 107
8.—The facial .... ib.
9.—The glosso-pharyngeal 108
10.—The pneumo-gastric..... 109
[Tractus respiratorius] ..... ib.
[Spinal accessory nerve] ..... ib.
11.—The lingual 110

SECTION VI.

Description of the Third, Fourth, Fifth, and Sixth Pairs of Nerves, where they are enclosed between Layers of the Dura Mater, previous to their exit from the Cranium.

PART I.

The semilunar ganglion of the fifth pair.

Situation of the semilunar ganglion..... 113
First division .... ib.
Second division .... ib.
Third division ..... ib.
Motor and sentient portions of the fifth 114
[Pterygoid branch from Meckel's ganglion] 115

PART II.

The cavernous sinus and its contents.

Situation of cavernous sinus 115
Contents of cavernous sinus..... 116
Position of internal carotid artery .... ib.
Position of third, fourth, first division of fifth, and sixth pair of nerves..... 117

SECTION VII.

Description of the Nerves and Vessels situated within the Orbit.

PART I.

Distribution of the third, the fourth, the ophthalmic division of the fifth, and the sixth pair of nerves.

Contents of the orbit 120
Fourth pair of nerves 122
Ophthalmic division of the fifth pair ..... ib.
Supra-orbitar branch ..... ib.
Trochlear twig 123
Lachrymal branch ..... ib.
Nasal branch ..... ib.
Lenticular twig 124
Ciliary twigs ..... ib.
Internal nasal twig ..... ib.
External nasal twig ..... ib.
Sixth pair of nerves 125
Lenticular twig ..... ib.
Third pair of nerves 126
Superior branch ..... ib.
Inferior branch ..... ib.

PART II.

The lenticular ganglion and its branches.

Situation of lenticular ganglion 127
Ciliary nerves ..... ib.

PART III.

Course and distribution of the ophthalmic artery.

Course of the ophthalmic artery 128
Lachrymal branch 129
Central artery of the retina ..... ib.
Supra-orbitar branch 130
Short ciliary arteries ..... ib.
Long ciliary arteries 131
Muscular branches..... 132
Anterior and posterior ethmoidal branches..... ib.
Superior and inferior palpebral branches ..... ib.
Terminating branches..... 133

PART IV.

The ophthalmic vein. p. 133.

SECTION VIII.

Description of the Cerebral Sinuses.

General description of the sinuses..... 135
The great sinuses..... 136
Longitudinal sinus ..... ib.
Straight sinus ..... ib.
Torcular Herophili ..... ib.
Lateral sinuses 137
The small sinuses ..... ib.
Inferior longitudinal sinus ..... ib.
Occipital sinus..... ib.

Cavernous sinuses..... 138
Anterior and posterior clinoid sinuses..... ib.
Circular sinus of Ridley ..... ib.
Superior and inferior petrosal sinuses..... ib.
Transverse sinus..... ib.

SECTION IX.

Description of lhe Cervico-spinal Nerves.

PART I.

General remarks—the sub-occipital nerve—the seven cervical nerves. p. 140.

General arrangement of cervico-spinal nerves..... 141
The sub-occipital nerve ..... ib.
Anterior branch..... ib.
Posterior branch 142
The seven cervical nerves—general description .... ib.

PART II.

The three superior cervical nerves, forming the cervical plexus, by the union of their anterior branches.

First cervical nerve..... 144
Anterior branch ..... ib.
Posterior branch ..... ib.
Second cervical nerve 145
Anterior branch ..... ib.
Posterior branch ..... ib.
Third cervical nerve 146
Anterior branch ..... ib.
Posterior branch ..... ib.
[Phrenic nerve] ..... ib.

PART III.

The four inferior cervical nerves, and the first dorsal, forming, by the union of their anterior branches, the axillary plexus.

The four lower cervical nerves..... 147
Anterior branches.. .... ib.
[Axillary plexus] 148
[External respiratory nerve] ..... ib.
Posterior branches 149
First dorsal nerve .. .. ib.

SECTION X.

Description of Parts brought into view by raising the Sternum.—The Arch of the Aorta, and its relative position with regard to the Vessels, Nerves, and other structures, situated above the Pericardium and between the two Pleural Cavities.

PART I.

The arch of the aorta.

Arch of the aorta 151
Relative position of the arch 152

PART II.

The three great vessels given off by the arch of the aorta.

Arteria innominata 155
Left common carotid 156
Left subclavian 157

SECTION XI.

Description of the Course of the Subclavian Artery and Vein.

PART I.

Preliminary remarks.

Subclavian artery divided into three portions..... 159

PART II.

The first portions of the right and left subclavian artery; together with the passage of the pneumo-gastric and phrenic nerves into the chest.

First portion of the subclavian 160
Right side .... ib.
Left side 161
[Pneumo-gastric nerve] 162
[Right side] .... ib.
[Left side] 163
[Recurrent laryngeal branch] ..... ib.
[Phrenic nerve] 164

PART III.

The second portion of the subclavian artery. p. 165.

PART IV.

The third portion of the subclavian artery. p. 166.

PART V.

The subclavian vein.

Branches which form the subclavian vein..... 167
[Termination of thoracic duct] 168

SECTION XII.

Description of the Branches given off by the Subclavian Artery; their Course, and Distribution.

PART I.

The branches arising from the first portion of the subclavian artery—the Vertebral—the Thyroid Axis—the Internal Mammary—the Superior Intercostal,

Vertebral artery 170
Branches of the vertebral 171
Thyroid axis 172
Inferior thyroideal branch .... ib.
Ascending cervical branch 173
Transverse cervical branch .... ib.
Superficial cervical ..... ib.
Posterior scapular .... ib.
Supra-scapular branch 174
Internal mammary artery 175
Intercostal branches..... 176
Comes nervi phrenici .... ib.
Mediastinal branches 177
Intercosto-phrenic branch..... ..... ib.
Abdominal branch ..... ib.
Superior intercostal artery .. .. ib.

PART II.

The single branch given off from the second or third portion of the subclavian trunk; viz. The Deep Cervical Artery. p. 178.

SECTION XIII.

The Course of the Phrenic and Pneumo-gastric Nerves as they pass through the Chest, and their ultimate Distribution.

PART I.

The phrenic nerve. p. 180.

PART II.

The pneumo-gastric nerve.

Course of pneumo-gastric nerve 181
Œsophageal plexus 182
Bronchial plexus 183

SECTION XIV.

Description of the Dorso-spinal Nerves, their Origin, Course, and Distribution.

Dorso-spinal nerves—general description 185
Posterior branches 186
Anterior branches..... ..... ib.

SECTION XV.

Description of that Portion of the Sympathetic or Ganglionic System of Nerves belonging to the Head, Neck, and Chest.

PART I.

General outline of the sympathetic nerve. p. 191,

PART II.

Ganglia situated about the cranium and face. p. 194.

Ganglion of Meckel 195
Lenticular ganglion ..... ib.
Ganglion of Cloquet ..... ib.
Otic ganglion 196

PART III.

The cervical ganglia. p. 196.

Superior cervical ganglion..... 197
Middle cervical ganglion 200
Inferior cervical ganglion 201

PART IV.

The cardiac nerves. p. 203.

Cardiac plexus..... 204
Superior cardiac nerve..... 205
Middle cardiac nerves 206
Inferior cardiac nerves..... ib.

PART V.

The dorsal, or thoracic ganglia.

Dorsal ganglia—general description of 207
External branches.... 208
Internal branches ..... ib.

PART VI.

The splanchnic nerves. p. 208.

Greater splanchnic nerve 209
Lesser splanchnic nerve ..... ib.

SECTION XVI.

Description of the Descending Thoracic Aorta, and the Branches which it gives off.

[Situation of the primitive vessels at the base of the heart] 211
Descending thoracic aorta 213
Bronchial branches 214
Œsophageal branches 215
Intercostal branches.... ... . ib.

SECTION XVII.

Description of the Vena Azygos, and Vena Azygos Minor.

Vena azygos 219
Vena azygos minor 220
Superior intercostal vein—right side ..... ib.
Superior intercostal vein—left side 221
Intercostal veins..... ib.
[Thoracic duct] ..... ib.

SECTION XVIII.

Description of the Vessels and Nerves supplying the Posterior Regions of the Head, Neck, and Trunk.

PART I.

The vessels and nerves brought into view during the dissection and removal of the two first layers of muscles.

Cutaneous nerves of the back 224
Occipital nerve..... 225
Occipital artery ..... ib.
Accessory nerve ..... ib.
Superficial cervical artery ..... ib.
Posterior scapular artery..... 226

PART II.

The vessels and nerves which are deeply seated among the muscles of the back.

Occipital artery 272
Posterior divisions of the cervical nerves 228
Occipital nerve ..... ib.
Vertebral artery 229
Posterior division of the sub-occipital nerve..... . ib.
Posterior divisions of the dorsal and lumbar nerves .. ib.
Posterior branches of the intercostal and lumbar arteries .... ib.

APPENDIX.

In which is described the Best Method of tracing those Nerves and Vessels, the Dissection of which was not completed in the previous part of the Work. p. 233.

PART I.

The dissection of the laryngeal nerves. p. 234.

PART II.

Dissection of the terminating branches of the internal maxillary artery,—the second division of the fifth pair of nerves, and the branches from Meckel's ganglion, as they pass through the different canals and foramina which communicate with the spheno-maxillary fossa. p. 236.

PART III.

Dissection of the vessels and nerves situated within the cavity of the nose. p. 238.

PART IV.

The examination of the spinal cord with its membranes, and the origins of the spinal and the accessory nerves. p. 239.

ANATOMY OF THE NERVES, &c.

SECTION I.

DESCRIPTION OF THE SUPERFICIAL NERVES RAMIFYING ON THE HEAD AND NECK.

PART I.

The superficial branches derived from the cervical plexus, and emerging from under the posterior edge of the sterno-cleido-mastoideus muscle. The accessory nerve coming through the muscle.

Situation of muscles.

According to the plan laid down in the table of contents, we shall first examine the superficial cervical nerves; and before the student commences his dissection, he should consider the relation of the cervical region to the head and chest. He should likewise recall to his memory the coverings of these parts, and trace the outline of the muscles beneath; directing his attention more

particularly to the position of the sterno-cleido-mastoideus as it crosses the neck obliquely, and divides that region into two triangular spaces which are respectively terminated, in front by the median line from the chin to the sternum, and behind by the edge of the trapezius muscle.

Superficial cervical nerves.

The superficial nerves of the neck are derived from the cervical plexus, which is formed by the junction of the three first cervico-spinal nerves*, and lies under the sterno-mastoid muscle: they are seen emerging from beneath the posterior edge of the sterno-mastoideus, and may be divided into an ascending and descending set; the former turning over the edge of the muscle to gain its superficial surface, and taking their course under the platysma towards the head and face; the latter passing downwards towards the chest and shoulder.

Ascending set.

The ascending set are principally derived from the second cervical nerve, and may be found by cutting down on to the posterior edge of the sterno-mastoideus about its middle, where they

* In speaking of the cervical nerves, we shall consider them as seven in number, exclusive of the sub-occipital: the first cervical nerve leaving the spinal canal between the atlas and dentata, the seventh between the last cervical and first dorsal vertebra.

will be seen turning round the muscle to gain its superficial surface. We distinguish three branches by name; and the common trunk, from which they are derived, may, by turning up the edge of the muscle, be traced upwards to its root. Of these three branches, one is found to pass directly upwards to the ear, another upwards and forwards towards the chin, while the third takes a direction upwards and backwards to the occiput.

Auricular branch.

The first and most considerable is the auricular, which ascends vertically between the platysma and sterno-mastoid muscle, till it reaches the parotid gland where it divides into several branches. Some of these sink into the gland, and join with the facial; other larger ones pass to be distributed to the auricle of the ear, while one or two smaller twigs supply the skin over the mastoid process and immediately behind the auricle.

Transverse cervical branch.

The second nerve is called the transverse cervical, which turns over the edge of the sterno-mastoid, and, dividing into several branches, ramifies over the side of the neck, principally taking a direction upwards and inwards, some of the twigs passing on to the face. It is situated under the platysma, which, together with the skin, it supplies, and forms junctions with the descending facial. We sometimes find it accompanied by

two or three smaller filaments which are distributed in a similar manner.

Small occipital branch.

The third and last branch to be described, is the small occipital. This, the smallest of the three, passes obliquely upwards and backwards along the posterior edge of the sterno-mastoid, and on reaching the head, divides into twigs which supply the origin of the occipito-frontalis, and ramify on the lateral part of the occiput.

Spinal-accessory nerve.

In the early part of this dissection, the spinal-accessory nerve will probably have become exposed where it emerges from the sterno-mastoid muscle, and is freely connected with the cervical nerves; more particularly with the small occipital, which, crossing over it, forms so intimate a union as to give the appearance of being one of its branches. As the accessory comes from the cavity of the cranium, a more particular description of it must be given at a future period; as regards its situation in the region which we are now exploring, it will merely be necessary to observe, that it emerges from the edge of the sterno-cleido-mastoideus about one-third below the insertion of that muscle, and passes obliquely downwards and backwards, until it becomes lost to view under the edge of the trapezius, to the substance of which it is finally distributed.

External jugular vein.

Whilst we are tracing the ascending set of nerves, we can hardly fail to notice the external jugular vein descending along the side of the neck and crossing the sterno-mastoid muscle. It will be seen to emerge above, from the parotid gland where it is formed by the junction of the temporal, internal maxillary, and posterior aural veins. Just below the angle of the jaw it is generally connected by a pretty considerable branch to the deep-seated or internal jugular. It then passes downwards and rather outwards, between the platysma and sterno-cleido-mastoideus, and, having reached the clavicle, sinks beneath it just at the outer edge of the last-mentioned muscle, and enters the subclavian vein. The origin of the vessel is subject to many deviations; its size varies in different persons, and it sometimes terminates by dividing into two trunks, which separately enter the subclavian. The external jugular not unfrequently takes its course along the inner margin of the sterno-mastoid muscle, instead of crossing it, and occasionally a vein is found in each situation.

Descending set of nerves.

We shall now proceed to the dissection of the descending superficial cervical nerves, or those which, emerging from the posterior edge of the sterno-mastoideus, pass downwards and backwards and occupy the triangular space formed by that

muscle, the trapezius and the clavicle. They are brought into view by dissecting along the posterior edge of the sterno-mastoid, and clearing away the lymphatic glands, fat, and dense cellular membrane in which their filaments are involved. They will then be found coming from under the muscle, just below that point where the transverse cervical and auricular, formerly mentioned, are seen mounting upon its surface. They consist of from two to four branches derived chiefly from the third cervical nerve, and receive a filament or two from the second. They almost immediately divide into a number of branches which pass downwards with different degrees of obliquity.

Supra-clavicular branches.

Supra-acromial branches.

Sub-clavicular filaments.

The most internal, the supra-clavicular, will be seen descending over the middle of the clavicle, and passing along the origin of the sterno-cleido-mastoideus; others bearing the same name, cross the bone nearer to its scapular extremity; while the more external or supra-acromial pass over the anterior portion of the trapezius to reach the acromion. They are finally distributed to the skin of the shoulder and upper region of the chest, being therefore superjacent to the deltoid and pectoralis major muscles. Derived from this set of nerves, some smaller and more deeply-seated filaments can be traced, running under the clavicle

and terminating in the omo-hyoideus, serratus anticus and subclavius muscles. These may be termed subclavicular branches.

The dissection of these nerves through the triangular space, is rendered excessively tedious and difficult by their innumerable connections and the quantity of glands, fascia, and cellular membrane with which they are surrounded. At the lower part, they are involved with the superficial branches of the subclavian artery, and the termination of the external jugular vein. The student is recommended to trace their origins as far as possible underneath the sterno-mastoid, and to clear the edge of that muscle, which will facilitate its removal hereafter, in order to display the original trunks of the cervical nerves, and the remaining branches they give off. In doing this, he will come down upon the ascending cervical artery sent off by the subclavian*.

* Although forming a deviation from the plan laid down in the table of contents, the student is recommended to examine the parts contained in the small triangular space, bounded by the clavicle with the omo-hyoideus and sterno-mastoideus muscles, before he proceeds to the nerves of the face. He will thus embrace the most favourable opportunity of dissecting the terminating portion of the subclavian artery, and judging of its relative position with the scalenic muscles, the accompanying vein, and the lower cervical nerves, before the upper extremity is removed

PART II.

The branches of the facial nerve, as they pierce the parotid gland, and ramify over the face and cranium.

THE facial nerve also called Portio Dura, or eighth pair, issues from the base of the skull at the stylo-mastoid foramen, where it is not only concealed by the mastoid process of the temporal bone, but is likewise covered by the whole depth of the parotid gland, together with the external carotid artery, and the origin of the external jugular vein.

In order to reach the main trunk of the nerve, it is advisable to cut down on one of the branches which cross the face. This should be done by making an incision across the masseter muscle, in a line between the lower edge of the nose and the lobe of the ear. By carefully dividing the fat, a considerable filament will be laid bare, and at the

from the trunk. The surgical importance of these parts offers sufficient apology for this digression. The description will be found under the head, "Third portion of the Subclavian Artery."

same time the parotid duct and the transverse facial artery are brought into view. By tracing back this filament deep into the substance of the gland, we shall reach the main trunk of the nerve itself, and may then proceed to follow the branches into which it divides, taking care to avoid the carotid artery and its smaller vessels.

Main trunk of the facial nerve.

Immediately on leaving the stylo-mastoid foramen, the facial nerve gives some small branches to the posterior belly of the digastricus and stylo-hyoideus muscles, and also forms minute junctions with the sympathetic, glosso-pharyngeal, pneumo-gastric and accessory nerves. It likewise detaches a filament called the posterior auricular, which, passing backwards close to the bone between the ear and mastoid projection, ramifies on the auricle, and terminates by supplying the retrahentes aurem, and the origin of the occipito-frontalis muscles.

Digastric and stylo-hyoid branches. Junctions.

Posterior auricular branch.

The nerve then passes forwards towards the surface of the gland, and, while still within its substance, divides into two principal branches: an upper or Temporo-facial: a lower or Cervico-facial. These again divide into diverging twigs, which issuing from different points of the parotid gland, spread over the temples, the face, and the neck.

Principal division of the facial.

Temporo-facial nerve.

The temporo-facial branch passes upwards and forwards towards the articulation of the jaw, and, before leaving the gland, divides and joins again, forming a kind of plexus, from which three sets of nerves are given off—the Temporal—the Superior Facial—the Middle Facial.

Temporal twigs.

The temporal consists of two or three small twigs, which pass over the zygoma and ramify over the temples and forehead, supplying the upper part of the ear, the anterior and levator auris, the occipito-frontalis, orbicularis palpebrarum, and corrugator supercilii muscles, and forming junctions with the deep temporal and supra-orbitar branches of the fifth. These nerves are accompanied by a branch from the third division of the fifth, which comes from behind the neck of the lower jaw, and rises through the parotid gland close to the ear.

Superior facial twigs.

The superior facial consists of a few minute nerves, which pass upwards and forwards over the malar bone to the outer angle of the eye, and supply principally the orbicularis palpebrarum, anastomosing with the malar and lachrymal branches of the fifth pair.

Middle facial branches.

The middle facial is by far the largest division, consisting of three or four considerable nerves, which cross the upper part of the masseter muscle, in company with the transverse artery and parotid

duct. They spread over the side of the face as they advance, but are principally distributed to the parts between the orbit and the mouth. One or more small twigs generally pass superficially to the zygomaticus major, where they soon become lost: others penetrate the substance of that muscle; while two or three larger branches cross underneath it, in order to supply the levator anguli oris, the compressor naris, and levator labii superioris, behind which last they join very freely with the infra-orbitar branch of the fifth: in the space between the masseter and buccinator muscles, it may likewise be seen forming connexions with the buccal branches of the same nerve.

It may here be proper to observe, that the above subdivisions relate to the regions which the filaments supply; and appear arbitrary when we view the general distribution of the temporo-facial nerve, which may be described as ramifying under the skin over the parts we have mentioned, and forming an intimate plexus by the frequent inosculation of its branches.

Cervico facial nerve.

The inferior division of the portio dura, or the cervico-facial nerve, will be found to descend obliquely towards the angle of the jaw, and to divide into two branches – the Inferior Facial, and the Descending Facial.

Inferior facial branch. The inferior facial, after detaching two or three small twigs, which cross the lower part of the masseter to be lost in the buccinator muscle, is continued over the angle of the jaw and along its horizontal ramus towards the chin, being covered by the platysma myoides. It finally divides into filaments which are distributed to the muscles of the under lip, and join with the dental branch of the fifth, as the latter issues from the mental foramen.

Descending facial branch. The descending facial passes downwards on to the side of the neck, and divides into several twigs which ramify beneath the platysma myoides in the upper cervical region, taking a curved direction forwards and inwards. They form junctions with the superficial cervical branches of the cervical plexus.

In dissecting the ultimate ramifications of the portio dura, the student will find them much involved with the branches of the facial artery.

PART III.

Those branches of the fifth pair of nerves which make their appearance on the face and cranium.

HAVING thus completed the dissection of the nerve which imparts motion to the muscles of the face, we may proceed to examine the source from which those muscles, as well as the integuments which cover them, derive their sensibility. It consists of several branches from the fifth pair, which pierce the bones in different situations, and are named according to the foramina from which they issue. They have been already alluded to as forming junctions with the portio dura, but may be again enumerated as—the Supra-Orbitar from the first division of the fifth—the Infra-orbitar and the Malar, from the second—the Buccal and the Mental, from the third.

Branches of the fifth pair supplying the face and scalp.

The supra-orbitar nerve issues from the orbit through the foramen or notch of the same name, and, passing upward, ramifies over the forehead, some of its twigs reaching the vertex of the head and joining with the occipital. It is at first

Supra-orbitar nerve.

covered by the orbicularis palpebrarum, corrugator supercilii and occipito-frontalis, but becomes more superficial as it ascends. It is principally distributed to the skin.

Malar nerve.

The malar nerve is so small, as frequently to escape observation. It consists of one slender filament, which issues from the malar foramen on the prominent part of the cheek-bone, and is soon lost in the adjacent structures.

Infra-orbitar nerve.

The infra-orbitar nerve is by far the largest of the set. It may readily be brought into view by detaching the orbitar origin of the levator labii superioris, when the nerve is seen issuing from the foramen which terminates the infra-orbitar canal, and which is situated intermediate to the origin of the levator labii, and the levator anguli oris. Between these two muscles, and concealed by the former, the nerve divides into a great number of filaments, which radiating in every direction, supply the skin of the nose, the upper-lip, and the cheek, the muscles placed above the mouth, and the mucous membrane lining its interior.

Buccal branches.

The buccal branches consist of two or three twigs which issue from between the masseter

and buccinator, to supply the latter muscle the neighbouring integuments, and membrane of the mouth.

The mental nerve is seen emerging from the mental foramen by the side of the chin, where it ramifies amongst the muscles of the lower lip, and is finally distributed to the superjacent skin and to the lining membrane. **Mental nerve.**

Besides the junctions already mentioned as taking place between these nerves and the portio dura, thay form numerous and complicated inosculations with each other, the detailed description of which would be more tedious than useful.

[Observations.—Before he proceeds to the next section, the student should review the parts which he has now exposed, and make himself perfectly acquainted with the nerves already described; since these must necessarily be removed as the dissection proceeds.]

SECTION II.

DESCRIPTION OF THE VESSELS AND NERVES SITUATED IN THE ANTERIOR TRIANGULAR SPACE OF THE NECK, AND BROUGHT INTO VIEW BY REMOVING THE PLATYSMA MYOIDES AND CERVICAL FASCIA—THE ARTERIES WHICH RAMIFY OVER THE FACE AND CRANIUM.

PART I.

Preliminary observations on the position of the muscles and the fascia of the neck.

Anterior triangular space of the neck.

THE next step in our dissection, will be to examine the parts contained in the anterior triangular space of the neck, a space bounded in front, by the median line drawn from the symphysis of the chin to the sternum, behind, by the sterno-cleido-mastoideus muscle, and above, by the horizontal ramus of the lower jaw. It is covered in by the platysma myoides, the fibres of which extend obliquely over it, from below upwards, and from

behind forwards. This should be removed, together with the superficial nerves, and the external jugular vein covering the sterno-mastoid; which muscle, as well as the sterno-hyoideus, sterno-thyroideus, omo-hyoideus, thyro-hyoideus, stylo-hyoideus, and digastricus, should be carefully dissected as we proceed. In doing this, the cervical fascia must necessarily be removed; and it will be well in this part of our labors to make ourselves acquainted with its adaptation and extent.

Fascial coverings of the neck.

The cervical fascia is frequently described as consisting of two layers, a superficial and a deep; but the former hardly deserves the name of fascia, being nothing more than the common subcutaneous aponeurosis, which is found all over the body, assuming in different regions greater or less degrees of density. Thus, in the neck, it is seen covering the trapezius behind, and the platysma myoides on the fore part; while, at the upper and lower cervical boundaries, it becomes lost in the common cellular tissue, or in the deep-seated fascia beneath it, or else is continuous with the subcutaneous aponeurosis covering the trunk.

Deep or proper cervical fascia.

The deep-seated or proper cervical fascia is more complicated in its arrangement, and much

more important as respects the morbid and surgical anatomy of the parts which it envelops. It may be described as commencing, at the posterior median line, from the ligamentum nuchæ and the spinous processes of the cervical vertebræ, being situated beneath the trapezius, and consequently covering the splenius and levator scapulæ muscles. Emerging from under the trapezius, it extends forwards to the posterior edge of the sterno-cleido-mastoideus, covering in the space between those two muscles, involving the nerves already described, in its structure, and binding down the posterior series of glandulæ concatenatæ, while at the lower part it encloses the omo-hyoideus, and then stretching behind the clavicle to the attachment of the subclavius, serves to keep the former muscle in its situation, and to maintain the curved direction which it assumes. The fascia likewise forms a complete investment to the subclavian vessels, and lower cervical nerves accompanying them as they descend from the neck into the axilla, where it ceases to maintain a distinct character, partly by becoming lost on the sheaths of the vessels and nerves, partly by becoming blended in with the fascia, lining the muscular boundaries of the axillary space. By means of this prolongation, the vessels and nerves are protected and supported as they descend between the

clavicle and first rib, and the cellular communication which would otherwise exist between the axilla and the neck becomes closed up. At the posterior edge of the sterno-mastoid, the fascia splits into two layers, which enclose that muscle and join again at its anterior border; the one which passes superficially being continued upwards to cover the parotid gland, and to be attached to the cartilage of the ear and to the zygoma; while the posterior lamella, or that which lies behind the sterno-mastoid, becomes lost by forming connexions with the styloid process of the temporal bone and the muscles arising from it. At the lower part, this same layer continues to enclose and confine the omo-hyoideus. From the anterior edge of the sterno-mastoid muscle, the fascia is continued to the median line, where it joins with its fellow, thus covering in the anterior triangular space, forming attachments to the carotid sheath, and sending in thin processes between the muscles which lie upon the trachea and larynx. It is adherent above to the lower jaw and the submaxillary gland, while below it is very firmly connected to the upper edge of the sternum. Continuous with this last, a strong layer will also be found descending into the chest behind the sternum and the origins of the sterno-hyoideus and thyroideus muscles, where it

terminates by forming attachments to the pericardium, arch of the aorta, and pulmonary artery. Extensions from this are likewise more or less connected to all the structures entering or leaving the chest. It thus serves at once to support the parts occupying the upper opening of the chest, and to close the communication between the neck and the thoracic cavity.

Although the course and adaptation of the cervical fascia may at first appear rather complicated, its different bearings may be readily understood, by remembering that it envelops the whole of the neck, arising under the trapezius from the posterior median line, splitting to enclose the sterno-mastoideus, and terminating by joining the opposite portion at the anterior median line; that it covers every thing except the trapezius, and the platysma-myoides, together with a few superficial nerves, blood-vessels and absorbents; that it is more or less firmly attached to the bones of the head and face above, and the upper part of the chest below; lastly, that it is prolonged into the openings of the axilla and thorax, where it surrounds and supports the vessels and nerves.

PART II.

The common carotid artery, with the internal jugular vein and pneumo-gastric nerve.—The transverse portion of the lingual nerve with its descending branch.

Contents of the anterior triangular space.

INDEPENDENTLY of the muscles already enumerated, the following structures will be seen in the anterior triangular space, after removing the cervical fascia.—The upper half of the common carotid artery with the vein and nerve contained in its sheath. The bifurcation of the vessel. The external carotid and the branches it gives off. The lingual and descendens lingualis nerves. The submaxillary gland.

Situation of muscles.

It is, perhaps, hardly necessary to advert to the situation of the muscles; but particular attention should be directed to the precise course and bearing of the digastricus and stylo-hyoideus, which, together with the omo-hyoideus, traverse the triangular space, and are therefore important as marking the locality of the other structures contained in it. Besides these, a portion of the mylo-hyoideus may also be seen coming from

behind the anterior belly of the digastricus, and again, projecting from beneath the mylo-hyoideus, the external edge of the hyo-glossus becomes visible. Thus, these three muscles form a regular series, the one overlapping the other, the digastricus being the most internal and superficial, the hyo-glossus the most external and deeply seated. Resting on the portions of the mylo-hyoideus and hyo-glossus, thus exposed, is the submaxillary gland, whose excretory duct, accompanied by a portion of the glandular structure, becomes lost to view by passing between the two muscles.

We may now proceed to examine the common carotid artery, but in so doing must be careful not to injure the descending branch of the lingual nerve, lying anterior to it.

Descendens lingualis nerve.

By carefully cutting through the fascia and cellular membrane covering the artery, we shall expose this nerve, which above, is involved in the sheath of the vessels; but below, becomes superficial to it. Tracing the branch upwards, we shall find its origin from the lingual or hypoglossal nerve, and we may then pursue its course downwards and follow out its distribution.

Passing down on the fore part of the carotid sheath, but at first rather to the outer side of the artery, the descendens lingualis gives off no

branches until it reaches the omo-hyoideus muscle; immediately above, or often beneath which, it receives a twig from the first and second cervical nerves, which coming from under the sterno-mastoideus, join it, sometimes separately, but frequently by a common branch. At the point of junction, a small ganglionic enlargement, or occasionally a plexus is formed, from which several filaments proceed. Some of these pass upwards and inwards to supply the hyoideal portion of the omo-hyoideus, others downwards and outwards to its scapular extremity, while a third set follow the original course of the nerve downwards and inwards to enter the sterno-hyoideus and thyroideus which they supply.

In the upper part of its course, the descendens lingualis is not unfrequently connected with the par vagum.

Lingual nerve.

We may now lay bare the transverse or middle portion of the lingual nerve, which emerges from beneath the digastricus just at the junction of the posterior belly with the tendinous portion, and takes its course inwards with a slight curve, crossing over the external and internal carotid arteries. It is then situated between the tendon of the digastricus and the cornu of the os hyoides, and again passing behind the former, just where it

pierces the stylo-hyoideus, the nerve becomes lost to view between the mylo-hyoideus and hyoglossus muscles.

A small branch is sent off to the thyro-hyoideus, and thus we shall find that the lingual nerve supplies the four muscles which depress the os hyoides; viz. the omo-hyoideus, the sterno-hyoideus, and the sterno-thyroideus, by means of the descending branch; the thyro-hyoideus, by the filament just adverted to.

The commencement and termination of the lingual nerve must be completed at a more advanced stage of the dissection.

Accessory nerve.

The accessory nerve may now also be seen emerging from beneath the digastricus, to the outer side of the lingual, but much more deeply seated, and taking a direction downwards and outwards to enter the substance of the sterno-cleido-mastoideus.

Contents of the carotid sheath.

The sheath of the common carotid artery may now be removed, together with the absorbent glands which lie along the inner margin of the sterno-mastoid muscle; and the vessel should be exposed from the point where it is crossed by the omo-hyoideus to its bifurcation.

Inclosed within the same sheath, we shall find

the internal jugular vein on the outer side of the artery, and, between the two, the par vagum or pneumo-gastric nerve. The vein and the nerve both descend from the base of the skull; and as the latter lies on a plane posterior to the vessels, they must be separated from each other in order to bring it into sight.

By partially separating from each other, the muscles which cover the lower part of the sheath, a further view of its contents will be obtained.

Common carotid artery.

The right common carotid artery is given off from the arteria innominata, the left from the arch of the aorta; the former therefore is exterior to the chest from its commencement, while the latter is at first included within that cavity. In the neck, however, they are similarly situated, as the left artery leaves the chest exactly behind the sterno-clavicular articulation, which is precisely the same spot at which the innominata divides on the right side. From this point, therefore, the same description will apply equally to both.

From the margin of the chest, the common carotid artery passes upwards, as high as the space between the thyroid cartilage and the os hyoides, where it terminates by dividing into the internal and external carotids. The right and left vessels diverge from each other as they

ascend, being separated by the trachea and œsophagus below, but the larynx and pharynx above. Posteriorly, the artery corresponds at first to the bodies of the vertebræ, but afterwards to their transverse processes, being separated from the former by the longus colli muscle, from the latter by the rectus capitis anticus major. Anteriorly, the lower half of the vessel is concealed by the platysma, the cervical fascia, the sternal portion of the sterno-mastoideus, by the sterno-hyoideus and sterno-thyroideus: the omo-hyoideus also crosses the sheath about half way up, or opposite to the cricoid cartilage; and from this point, the artery becomes more superficial, being covered during the remaining part of its course merely by the platysma myoides and cervical fascia; although it still lies in the hollow formed by the projection of the sterno-mastoid muscle on the one hand and the larynx on the other. Along the inner side, the carotid is bounded by the trachea and œsophagus below, by the larynx and pharynx above.

The relative position of the jugular vein, par vagum, and descendens lingualis nerve, with regard to the carotid artery, has already been noticed: in addition to these, the sympathetic, recurrent laryngeal, and phrenic nerves are situated in proximity to the sheath, being respectively be-

hind, to its inner and outer side; but, as they do not belong to this part of the dissection, the account of them is postponed.

At the upper edge of the thyroid cartilage, or between that and the os hyoides, the carotid divides into its internal and external branches. The former continues the course of the original trunk, and may be observed passing behind the stylo-glossus and stylo-pharyngeus muscles, to reach the base of the skull and enter the cranium, where it is distributed to the brain. The latter passes more superficially, before the two muscles just mentioned, and is destined to supply the parts of the head and face external to the cranium. It is this artery which we shall now follow throughout its course and distribution.

PART III.

The course of the external carotid artery.

Course of the external carotid artery.

THE external carotid artery commences at the bifurcation of the common trunk, and takes a tortuous course upwards and backwards towards the angle of the lower jaw. At first it has a disposition to pass rather inwards towards the sub-

maxillary gland; but this direction is soon changed for the one above mentioned. Passing behind the angle of the inferior maxillary bone, it then ascends towards the zygoma, in the space which is enclosed by the ascending ramus of the jaw on the one side, and by the auditory and mastoid processes of the temporal bone on the other, where it terminates by dividing into the temporal and internal maxillary branches. In its course, the artery can hardly be said to rest upon, or to be covered by, any one particular structure, except the platysma myoides and the cervical fascia, both of which, together with some superficial veins, nerves and glands, must be removed in order to display it: the vessel may be rather described as winding its way between the different muscles, nerves and glands, which intersect its progress. Thus, soon after its commencement, it is crossed anteriorly by the digastricus and mylohyoideus muscles, and just below them by the lingual nerve; the facial, lingual and superior thyroideal veins also, commonly pass before it to reach the internal jugular. Posteriorly, the artery is crossed by the stylo-glossus and stylopharyngeus muscles, which, together with the glosso-pharyngeal nerve, pharyngeal branch of the par vagum, and styloid process of the temporal bone, separate it from the internal carotid. In

its course upwards from the angle of the jaw, it is deeply imbedded in the parotid gland, lies in close proximity to the commencement of the external jugular vein, and is crossed by the facial nerve.

PART IV.

The branches of the external carotid — The superior thyroideal, facial, sterno-mastoidean, posterior aural and temporal branches, traced to their termination. — The lingual, occipital, and internal maxillary branches traced until they become concealed by muscles not yet removed.

Branches of the external carotid.

HAVING now traced the course of the external carotid from its origin to the final division of the vessel, we may proceed to dissect its branches, according to the order in which they are given off. They are nine in number, and may be classed as anterior, posterior, internal, and terminating branches. The anterior set consists of three—the Superior Thyroideal—the Lingual—the Facial. The posterior are also three—the Sterno-mastoidean—the Occipital—the Posterior Aural; the internal branch is the Ascending Pharyngeal; the terminating vessels are—the Temporal—the Inter-

nal Maxillary. They are given off in the order in which they have been just enumerated, with the exception of the ascending pharyngeal, which is subjected to considerable varieties: neither is it uncommon to find two, or even three branches arising from a common trunk.

Anterior branches of the external carotid.

The three anterior branches all take a course, more or less forwards and inwards towards the median line, but diverge from each other. Thus the thyroideal descends on the neck below the os hyoides, the lingual passes nearly horizontally to the space between that bone and the lower jaw, while the facial ascends to ramify over the face.

Superior thyroideal artery.

The superior thyroideal artery is given off immediately after the division of the common carotid, just below or opposite to the os hyoides. It at first passes a little upwards, then curves down and descends along the side of the larynx, until it becomes lost behind the sterno-thyroideus muscle, under which the thyroid gland is situated. At its commencement or curve, the lingual nerve is seen just above it, and much more deeply-seated is the superior laryngeal nerve.

Two branches are given off in this situation—the hyoideal, of small size, or sometimes wanting altogether, which runs along the under edge of the

os hyoides; and the laryngeal, which pierces the thyro-hyoideal ligament, accompanied by the nerve mentioned above, to be distributed to the interior of the larynx.

The thyroideal then gives off a few inconsiderable branches to the muscles covering the larynx, and one of larger size which descends over the carotid sheath to the absorbent glands and sterno-mastoid muscle.

On reaching the thyroid gland, the artery divides into two, one skirting its upper edge, and the other, the largest, continued along its outer side: they are both expended in the substance of the gland, the former joining with the corresponding vessel of the opposite side, the latter with the inferior thyroideal of the same side.

Lingual artery.

The lingual artery, which is next in order, comes off either immediately opposite, or a little superior to the os hyoides, and takes a horizontal course inwards, just above the cornu of that bone, until it reaches the external edge of the hyoglossus muscle, behind which it then passes and becomes lost to view. The digastricus and stylohyoideus muscles cross over the vessel soon after its origin, while it lies on a quantity of loose cellular membrane interposed between it and the pharynx. Behind the artery, but much more

deeply-seated, is the superior laryngeal nerve; while directly above it, but more superficial, is the lingual nerve. The lingual artery and nerve separate at the edge of the hyo-glossus, the former going behind, the latter before that muscle; and here we must leave them for the present, as their distribution to the tongue cannot be traced until that organ has been brought more completely into view.

Facial artery.

The facial artery, the last of the three anterior branches, is generally given off a little above the lingual, and not unfrequently by a common trunk with that vessel. The course of the facial artery is upwards and forwards towards the horizontal ramus of the inferior maxilla, whence it is continued on to the face. While situated below the jaw, it is covered by the platysma and the fascia, and afterwards becomes imbedded in the fat as it ramifies over the side of the face, amongst the muscles of which its branches become lost. The artery is very tortuous throughout, in order that it may accommodate itself to the motions of the jaw, and the variations of form produced by the action of the muscles of the mouth. At its origin, the facial artery is covered by the digastricus and stylo-hyoideus, on emerging from which it almost immediately becomes concealed by the submaxil-

lary gland, through the substance of which it passes until situated behind the horizontal ramus of the jaw, between the origin of the mylo-hyoideus, and the insertion of the pterygoideus internus muscles. During this part of its course, it is nearly parallel to the external edges of the mylo-hyoideus and hyo-glossus, lying also superficially to the pharynx, fauces and tonsil glands, to the outer parietes of which it is loosely connected. The submaxillary gland should be raised from its situation, and either removed or laid open to shew the passage of the vessel through it. The facial artery then comes forwards from beneath the jaw, and winds over the bone exactly between the insertion of the masseter, and the origin of the levator anguli oris. Here it is merely covered by a few fibres of the platysma, and being in contact with the bone, may be felt and compressed with great ease. Winding upwards and inwards, it now passes over the buccinator to the angle of the mouth, where it is crossed by the zygomaticus major, although it occasionally passes superficially to that muscle. By this time the facial has become exceedingly reduced in size, but may still be traced onwards towards the inner angle of the orbit. It now, however, takes a more deeply-seated course, generally running underneath the levator labii superioris, and emerging as a very

small twig between its nasal and orbitar origins. Having thus gained the inner canthus of the orbit, the artery terminates by forming junctions with the ophthalmic branch of the internal carotid.

Facial vein.

It is worthy of remark, that the facial vein does not follow the sinuosities of the artery, but takes a straighter and more direct course from the inner angle of the eye to the ramus of the lower jaw, over which it is continued to the internal jugular, frequently forming a communication with the external jugular, and sometimes terminating in that vessel. It is of large size compared with the artery, as it returns a portion of the blood from the orbit, and generally passes superficially to the levator labii superioris.

Branches of facial artery.

The branches of the facial artery are numerous, and subject to great varieties as regards their size and distribution. Before the vessel reaches the maxilla, it gives off—the Inferior Palatine—the Glandular—the Submental Branches. On the face, it furnishes—the Labial—the Inferior and Superior Coronary—the Nasal—the Angular. All these last are very irregular, take a very tortuous course, and are involved in the distribution of the portio dura and fifth pair of nerves.

The inferior palatine branch arises before the facial has entered the submaxillary gland, and immediately becomes deeply-seated by passing upwards, backwards, and inwards, between the stylo-glossus and stylo-pharyngeus. Ramifying on the outer wall of the pharynx, it supplies the constrictor muscles, tonsil gland and soft palate, anastomosing with the superior palatine from the internal maxillary. The divisions of this artery are involved in the pharyngeal plexus of nerves, which comes from between the two carotids to supply the same parts. It frequently happens that the tonsils are furnished with a distinct branch from the facial.

Inferior palatine branch.

The glandular branches consist of several small twigs, given off while the artery is concealed within the submaxillary gland, to the substance of which they are distributed.

Glandular branches.

The submental branch arises just after the facial has emerged from the submaxillary gland, and runs inwards along the ramus of the jaw towards the symphysis, where it turns upwards to terminate in the depressor labii inferioris, and join with the dental artery issuing from the mental foramen. In its course, the submental supplies the mylo-hyoideus and digastricus muscles, piercing the former to anastomose with the lingual.

Submental branch.

Mylo-hyoid nerve.

Taking a course somewhat similar to the submental artery and concealed by it, is a small branch of the dental nerve which emerges from behind the jaw, between the insertion of the pterygoideus internus and the extreme edge of the origin of the mylo-hyoideus. This nerve, after detaching one or more twigs to the latter muscle as it passes over it, runs forwards to terminate in the anterior belly of the digastricus.

Labial branch.

The labial branch, which is the first that the facial gives off above the jaw, runs inwards and becomes lost among the muscles of the lower lip. It is extremely variable in size and situation, and instead of one, two or more are sometimes found.

Inferior coronary branch.

The inferior coronary branch arises just below the commissure of the mouth, and passes inwards behind the depressor anguli oris. It then pierces the orbicularis oris, and runs towards the median line between that muscle and the mucous lining of the mouth, forming junctions with its fellow on the opposite side, and with the labial below. It generally corresponds with the margin of the lip, but not unfrequently passes much lower down.

Superior coronary branch.

The superior coronary branch comes off just above the last, and takes a course precisely similar along the edge of the upper lip. In the middle,

where it anastomoses with its fellow, two or three small branches are sent upwards to the septum of the nose, supplying the extremity and part of the interior of that organ.

Both the coronary arteries are occasionally given off by a common trunk; and it frequently happens that one or the other are exceedingly small. When this is the case, the deficiency is always compensated by the greater capacity of the corresponding vessel on the opposite side of the face. The superior coronary is less subject to variation than the inferior.

Lateral nasal branch.

The lateral nasal branch comes off, either just before the facial artery passes behind the levator labii, or while the vessel is concealed by it. In the former case, it passes inwards superficially to the muscle; in the latter instance, it will be seen emerging from beneath its inner edge. It then ramifies over the side of the nose, and inosculates with its fellow.

Angular branch.

The angular branch, or rather the continuation of the facial artery itself, has already been mentioned, as running beneath the levator labii, and passing between its two origins to reach the inner canthus of the eye, where it is in juxta-position with the commencement of the facial vein. It supplies the muscles above the mouth, and terminates in the lower eyelid and lachrymal sac,

forming junctions with the infra-orbitar branches of the internal maxillary, and with the terminating branches of the ophthalmic.

Muscular branches.

Besides the vessels already enumerated, the facial gives off a number of smaller muscular branches, which arise chiefly on the outer side and pass to the buccinator and masseter. The most considerable of these supply the latter muscle, and anastomose with the transverse facial branch from the temporal.

Posterior branches of the external carotid.

The three posterior branches of the carotid, the sterno-mastoidean, the occipital, and the aural, should now be traced, and, if we substitute a posterior for an anterior direction, they will be found to take a course very similar to the set we have just described: thus, the sterno-mastoidean artery passes backwards and downwards, the occipital nearly horizontally backwards, the posterior aural backwards and upwards. The analogy between the two sets is still farther maintained by their situation, as the first and last are comparatively superficial, like the thyroideal and facial, while the occipital resembles the lingual, by sinking deeply beneath the muscles. Moreover it sometimes happens that two of these branches, or occasionally all three are given off by a common trunk.

The sterno-mastoidean artery generally comes off from the early part of the external carotid, and not unfrequently from the thyroideal or occipital. It passes obliquely downwards and backwards towards the edge of the sterno-mastoid muscle, to which, and to the absorbent glands in the vicinity, it is distributed. It runs nearly parallel to the accessory nerve, but is lower, more internal and superficial. A small artery generally accompanies the nerve into the substance of the muscle. Sterno-mastoidean artery.

The occipital artery arises either immediately below or behind the digastricus, and passes backwards and slightly upwards, concealed by the posterior belly of that muscle, to reach the space between the mastoid portion of the temporal bone and the transverse process of the atlas. It soon therefore becomes covered by the sterno-mastoideus, and continuing its course behind the splenius and trachelo-mastoideus, rises to spread over the occiput. By turning the digastricus aside and removing the lower part of the parotid gland, we may trace this artery for a short distance, until it is concealed by the sterno-mastoid muscle. In this first part of its course, it crosses over the internal carotid artery, the pneumogastric nerve and the jugular vein, which however can be seen but indistinctly beneath it. Much Occipital artery.

more closely connected to the occipital, is the lingual nerve, which curves round the origin of the artery and runs inwards towards the tongue. Sometimes, indeed, the nerve descends lower than the occipital, and turns round the sterno-mastoidean branch.

Meningeal branch.

The only branch given off by this portion of the occipital is the posterior meningeal, a small vessel which ascends by the side of the internal jugular vein, to enter the cranium at the foramen lacerum basis cranii posterius, and ramify on the dura mater. The remainder of the occipital must be dissected hereafter.

Posterior aural artery.

The posterior aural artery arises where the carotid is covered by the digastricus, and passing upwards and backwards through the lower part of the parotid gland, gains the space between the auricle of the ear and the mastoid process of the temporal bone. In this part of its course it separates the portio dura from the accessory nerve. The artery finally divides into two branches, one of which ramifies on the back of the auricle, and the other over that part of the head immediately behind it, forming anastomoses with the temporal and occipital. Previously to its division the posterior aural branch gives off muscular twigs, and one also which enters the stylo-mastoid canal to

supply the tympanum and mastoid cells. While tracing this artery, the commencement of the facial nerve may be more distinctly brought into view.

Internal branch of the external carotid.

The next branch, according to the order in which they have been enumerated, would be the ascending pharyngeal. It is however generally sent off nearer to the origin of the external carotid, and often from the bifurcation of the common trunk. Its course is so deep as to preclude the possibility of tracing it, until the superjacent parts have been removed.

Terminating branches of the external carotid.

We shall therefore pass on to the terminating branches of the external carotid—the Temporal and Internal Maxillary.

Both of these at their origin are buried in the parotid gland.

Internal maxillary artery.

The maxillary continues deeply-seated, and passes inwards behind the ascending ramus of the lower jaw, where we shall now leave it, in order to pursue the temporal, which is rather the smaller of the two.

Temporal artery.

The temporal artery takes its course directly upwards, between the condyloid portion of the lower jaw and the auditory process of the temporal bone, becoming more superficial until it

emerges from the parotid gland just below the root of the zygoma. Passing over that process, immediately behind the articulation of the maxilla, it ascends on the temporal fascia, still covered by the continuation of the parotid aponeurosis, and after running about an inch and a half, terminates by dividing into two branches—the Temporo-frontal, and Temporo-occipital.

Previously to its division, the artery gives off several branches.

Transverse facial branch.

The first and largest of these is the transverse facial, not unfrequently arising from the carotid itself. This vessel passes forwards and a little upwards, crossing over the ascending ramus of the jaw, where it disengages itself from the parotid gland. It then runs across the masseter at a short distance below the zygoma, and is accompanied by the parotid duct which is below it, and by the middle divisions of the facial nerve which surround it. At the anterior edge of the masseter, it divides into branches which supply the muscles of the face, anastomosing freely with the infra-orbitar and facial arteries.

Small branches.

The temporal then gives off glandular twigs: also some to the ear and to the articulation of the jaw; and just above the zygoma, it furnishes a branch which pierces the fascia and ramifies deep in the substance of the temporal muscle.

The terminating branches of the temporal are situated immediately beneath the skin, between it and the aponeurosis of the muscle.

Temporo-frontal branch.

The anterior, or temporo-frontal artery runs upwards and forwards towards the forehead, taking a slightly curved direction and following the line at which the hair begins to grow. It expends itself in branches to the scalp, to the occipito-frontalis and orbicularis palpebrarum muscles, joining with the supra-orbitar of the ophthalmic.

Temporo-occipital branch.

The posterior, or temporo-occipital branch curves backwards and upwards, supplying the back and lateral parts of the scalp, and anastomosing with the posterior aural and occipital arteries.

[Observations.—We have now completed the dissection of the more superficial branches of the external carotid; — the Superior Thyroideal—Facial—Sterno-mastoidean — Posterior Aural — and Temporal. We have likewise seen the commencement of the four remaining branches ;—the Lingual — Occipital — Ascending Pharyngeal — and Internal Maxillary. In the next section, we shall follow up the course of some of these deep vessels, at the same time describing the nerves which accompany them. As some delicate dis-

section will be required to accomplish this, it is indispensably necessary, that we should be thoroughly acquainted with the situation and attachment of the muscles connected with the jaw, the tongue, and the fauces.]

SECTION III.

DESCRIPTION OF VESSELS AND NERVES; BROUGHT INTO VIEW BY DETACHING SOME OF THE MUSCLES BETWEEN THE OS HYOIDES AND THE LOWER JAW, AND REMOVING THE ZYGOMA WITH THE ASCENDING RAMUS OF THE INFERIOR MAXILLARY BONE.

PART I.

The course and distribution of the lingual artery, with the distribution of the lingual and gustatory nerves.

Mode of displaying the lingual artery and nerves.

In order to display the lingual artery and nerves, the insertion of the digastricus muscle must first be detached from the chin, and the anterior belly turned back as far as the os hyoides. This will expose the entire surface of the mylo-hyoideus, which muscle should also be separated from its attachment to the hyoid bone below, and its fellow in the median line, and turned upwards over the

jaw. By this last step we shall have laid bare the genio-hyoideus, hyo-glossus, stylo-glossus, and part of the genio-hyo-glossus muscles, together with the lingual and gustatory nerves, the submaxillary duct, and the sublingual gland. The nerves and the duct are seen passing inwards across the hyo-glossus, the lingual immediately above the os hyoides, the gustatory immediately below the jaw, with the duct between them: this last, however, does not maintain its situation; for, running upwards, it crosses under the gustatory nerve, is then concealed by the sublingual gland, and enters the mouth by the side of the frœnum of the tongue, where the orifice may be discovered by passing a bristle through the canal.

To complete the dissection of the lingual artery and nerves, we should now saw through the jaw close to the symphysis, so as just to leave the origin of the genio-hyo-glossus muscle: then, by slitting up the mouth from the angle to the edge of the masseter, and dividing the mucous membrane which connects the inner surface of the jaw with the tongue, as far as the insertion of the pterygoideus internus muscle, we shall be enabled to turn the bone upwards and backwards, and thus obtain a complete lateral view of the tongue.

The nerves may be first traced to their ultimate distribution.

Lingual nerve.

The lingual nerve has already been seen accompanying the artery, as far as the outer edge of the hyo-glossus (p. 23). It then passes inwards superficially to that muscle, to which, as also to the genio-hyoideus, stylo-glossus, and lingualis, it furnishes a number of small filaments, and becomes finally lost in the genio-hyo-glossus, to which by far the greater portion of the nerve is distributed. These ultimate branches run the whole length of the muscle, and are interwoven as it were with its fibres.

Gustatory nerve.

The gustatory nerve is a branch of the third division of the fifth, and in this part of the dissection, is seen descending from behind the ramus of the jaw, immediately to the inner side of the insertion of the pterygoideus internus. It then crosses the hyo-glossus, exactly where that muscle joins with the stylo-glossus; and having reached the under surface of the tongue, divides into a number of filaments. Some of these are continued close beneath the mucous membrane, while the greater number pierce the substance of the tongue between the insertion of its muscles: they are all, however, ultimately distributed to the papillæ,

covering the dorsum, sides, and apex of the organ. Although the entire surface of the tongue is supplied by the gustatory nerve, yet by far the largest twigs will be found to terminate in those prominent and vascular papillæ, situated at the sides and apex, where the sense of taste is most distinctly manifested. In its passage towards the tongue, the gustatory nerve is closely connected with the submaxillary and sublingual glands, to both of which it sends branches.

The dissection of the lingual artery may now be completed.

Lingual artery.

The lingual artery has already been seen separating itself from the nerve to pass behind the outer edge of the hyo-glossus (p. 31). Beneath this muscle, and lying on the middle constrictor of the pharynx, it continues its course until it reaches the surface of the genio-hyo-glossus, between which and the inner edge of the hyo-glossus, it again comes into contact with the nerve, and divides into two terminating branches—the Sublingual, and the Ranine.

Hyoideal branch.

In the early and superficial part of its course, the lingual sends off a hyoideal branch, which runs along the os hyoides, and supplies the muscles attached to that bone.

While covered by the hyo-glossus, which should now be divided across, it gives origin to the dorsales linguæ, sometimes consisting of one branch, but more commonly of several twigs which turn upwards over the side of the tongue to reach its superior surface, affording a supply also to its muscles and to the fauces. **Dorsal branches.**

The sublingual, the smallest of the two terminating branches, ramifies under the mylo-hyoideus, and is distributed to the sublingual gland and to the adjacent muscles. It frequently is very small, and its place is then supplied by a branch sent from the submental of the facial; a free communication always existing between the vessels. **Sublingual branch.**

The ranine branch, which may be considered as the continuation of the lingual, passes forwards along the under-surface of the tongue, between the lingualis and genio-hyo-glossus muscles, distributing branches to them and to the substance of the organ. The two ranine arteries anastomose but slightly with each other, although they are only separated by the thickness of the genio-hyo-glossi muscles: some inosculations may be traced at the tip of the tongue. **Ranine branch.**

PART II.

The course and distribution of the internal maxillary artery, together with the second and third division of the fifth pair of nerves.

We now proceed to the complicated and intricate dissection of the internal maxillary artery.

Mode of displaying the internal maxillary artery.

To expose this vessel, we should first clear away the remains of the parotid gland, so as to display the edge of the ascending ramus of the jaw and the insertion of the pterygoideus internus muscle, together with the termination of the external carotid and the commencement of the internal maxillary artery. This will be facilitated by dividing the stylo-maxillary ligament and turning the angle of the bone upwards; then removing the zygoma, by sawing through its temporal portion close to the articulation of the jaw, and through its malar portion just to the outer side of the orbit. We thus detach the masseter, which should be dissected down and entirely removed from its insertion into the inferior maxillary bone; in

doing which, we necessarily divide the masseteric nerve from the third division of the fifth, and one or more accompanying arteries, which rise into the muscle from between the condyloid and coronoid processes.

We shall thus have laid bare the ascending ramus and coronoid portion of the lower jaw, together with the insertion of the temporal and the origin of the buccinator muscle; furthermore, by turning the bone upwards and backwards, we expose the inner margin of the pterygoideus internus.

The next step is, to saw out the coronoid process along with that part of the ascending ramus from which it arises, so as to preserve the maxillary foramen with the insertions of the pterygoid muscles, and leave the condyloid portion attached to the angle by a narrow shaft of bone; then turn up the detached piece together with the temporal muscle, the lower part of which should be separated from its origin, but carefully, so as not to injure the deep temporal arteries and nerves which run close to the bone.

Parts exposed by the dissection.

The parts now brought into view consist of the two pterygoid muscles, and emerging from between them the internal maxillary artery, with the dental and gustatory nerves, while the buccal nerve is commonly seen piercing the pterygoideus

externus. They are all involved in a quantity of fat and cellular membrane which must be carefully removed. The three nerves which all proceed from the third division of the fifth take an inferior direction. The most external is the dental, which passes downwards and outwards behind the neck of the jaw to reach the maxillary foramen. Immediately on the inner side is the gustatory, which descends nearly vertically between the ascending ramus of the jaw and the pterygoideus internus, until it makes its appearance below the bone as has been already described. The most internal nerve, and the smallest of the three, is the buccal, which passes rather downwards and inwards to the buccinator muscle.

Having noticed these, the maxillary artery may now be traced from its origin in the parotid gland, to its ultimate distribution in the spheno-maxillary fossa.

Course of the internal maxillary artery.

The internal maxillary artery has already been mentioned as arising from the external carotid, about midway between the angle of the jaw and the root of the zygoma. From this point it takes a very tortuous course, the general direction of which is inwards and slightly upwards, to reach the spheno-maxillary fossa, where the trunk of the vessel may be said to terminate. It first

passes behind the neck of the jaw, between the bone and the internal lateral ligament; it then lies in the space between the pterygoideus externus and internus, having the former above, the latter below it. Rising from between the two pterygoids, the artery now gains the surface of the outer muscle, being immediately covered by the insertion of the temporalis, but soon sinking deeply between the maxillary and sphenoidal origins of the pterygoideus externus, it again becomes concealed, and in that manner enters the spheno-maxillary fossa. It not unfrequently, however, runs completely over, instead of through this last muscle, and more rarely passes altogether behind it. In the former case it is more superficial than common, in the latter it is deeper: in the one it enters the fossa from above, in the other from below.

Branches of internal maxillary. Three sets.

The branches derived from the maxillary artery have been divided with much judgment into three sets:—those given off while the vessel is behind the neck of the jaw;—those arising where it is connected with the pterygoid muscles;—and, lastly, its final division in the spheno-maxillary fossa. This arrangement not only assists the memory in retaining the distribution of the artery, but will enable us hereafter to learn with greater facility

the second and third divisions of the fifth pair of nerves.

First set.

The first order includes two branches;—the Spheno-spinal, and the Dental; the former passing directly upwards, the latter downwards. To facilitate their dissection, the neck of the jaw may be sawn through just below the insertion of the pterygoideus externus, and the two portions gently separated from each other.

Spheno-spinal branch.

The spheno-spinal branch or arteria meningea media ascends vertically, between the external pterygoid muscle and the circumflexus palati, to the base of the skull, which it enters through the spinous opening of the sphenoid bone. In tracing it thither, the chorda tympani nerve will probably be seen passing from the glacerian fissure to join with the gustatory nerve. The course of the artery within the cavity of the cranium may be traced by the grooves which it forms on the internal surface of the bones, between which and the dura mater it is situated, being however closely adherent to the latter. Thus, from the entrance of the foramen spinosum, its track will be marked as it ascends along the squamous portion of the temporal bone to the anterior inferior angle of the parietal bone, which there be-

comes deeply grooved or frequently converted into a complete canal to receive it. The vessel then divides into a lash of branches, which ramify on the parietal bone, the most considerable passing to the vertex of the skull behind the coronal suture: some minute twigs are detached anteriorly which run as far as the foramen lacerum orbitale, where they join with the ophthalmic artery, while the posterior branches inosculate with the vessels supplying the occipital portion of the dura mater. Although this artery is inseparably adherent to the dura mater, yet by far the greater number of its ultimate divisions pass into the bones of the skull, through small foramina which may be seen opening from the grooves; and it is this vascular connexion which produces the principal union between the interior of the cranium and its lining membrane.

Dental branch.

The dental or inferior maxillary branch given off nearly opposite to the last, passes vertically downwards, between the neck of the jaw and the internal lateral ligament, to enter the dental foramen. It then passes through the maxillary canal as far as the symphysis of the chin, supplying the cancellated structure of the bone, the teeth, and the alveolar sockets: a branch, or more properly the termination of the vessel escapes from the jaw at the mental foramen, and becomes lost in the muscles of the

lower lip, where it anastomoses with the facial artery. The dental artery is accompanied throughout its course by the nerve of the same name.

Second set, supplying the muscles of mastication.

The second order of vessels given off by the internal maxillary, consist entirely of muscular branches, distributed to the muscles of mastication, and they are accordingly divided into pterygoid, temporal, masseteric, and buccal branches, which are all more or less connected with the nerves supplying the same parts. They need no particular description, as they take the shortest course to their point of destination. The temporal are the largest, and ascend in the temporal fossa close to the bone: the masseteric pass forwards between the condyloid and coronoid processes of the jaw; while the buccal, consisting of two or three long, slender and tortuous twigs, run downwards and reach the face between the buccinator and masseter muscles. This set of vessels anastomose with the branches of the facial and temporal artery which supply the same structures superficially.

Third set.

The third order of vessels may be considered as the terminating branches of the internal maxillary, and are given off after it has entered the spheno-maxillary fossa. They cannot be wholly exposed without sawing away the bones in different direc-

tions; but their course may be traced in the skull, by following the different canals and foramina which issue from the cavity into which the artery is received, and where it makes its final divisions. It will be more advantageous for the student to adopt this latter method, than to sacrifice the remainder of his dissection, by attempting to lay bare the vessels along their entire distribution.

Spheno-maxillar fossa.

The spheno-maxillary fossa is a cavity, or rather a fissure, situated behind and below the orbit; bounded anteriorly, by the tuberosity of the superior maxillary bone; posteriorly, by the pterygoid process of the sphenoid bone; and internally by the nasal plate of the palate bone, which separates it from the nose: externally, the cavity is open along its whole length, facing the lower part of the temporal fossa; above, it is continuous with the back part of the spheno-maxillary fissure or foramen lacerum orbitale inferius; below, it is terminated by the junction of the palate bone with the pterygoid plates of the sphenoid.

The openings into the fossa are—first, the External, by which the artery enters (this is hardly to be considered as a foramen, since it includes one whole side of the cavity); secondly, the Internal, or Foramen Spheno-palatinum, leading into the posterior part of the superior chamber of the nose; thirdly, the Posterior or Foramen Pterygoideum,

forming the entrance to the pterygoid canal, which, passing directly backwards, terminates on the external base of the skull, close to the foramen lacerum basis cranii anterius; fourthly, the Posterior and Superior, or Foramen Rotundum of the sphenoid bone, communicating with the cranial cavity; fifthly, the Anterior, consisting merely of a groove leading to the infra-orbitar canal; sixthly, the Inferior or Palato-maxillary canal, which descends vertically and terminates on the roof of the mouth by the palato-maxillary or posterior palatine foramen.

With the exception of the foramen rotundum, which is occupied by the second division of the fifth pair of nerves, each of these apertures transmits one of the terminating branches of the internal maxillary artery. They are therefore five in number—the Alveolar—the Spheno-palatine—the Pterygoid—the Infra-orbitar—and the Palato-maxillary.

Superior dental branch.

The alveolar or superior dental is given off just at the entrance of the fossa, or sometimes before the trunk of the maxillary has reached the cavity, so that it may rather be considered as intermediate between the second and third order of branches. It runs round the tuberosity of the upper jaw, just above the alveolar process, and terminates by minute twigs which pierce the bone, some to supply the

molar and bicuspides teeth, and others to enter the antrum of Highmore.

The spheno-palatine or lateral nasal, reaches the cavity of the nose through the opening of the same name, and spreads upon the pituitary membrane. Some of its branches pass backwards to the pharynx, while a remarkable one may be traced downwards along the septum to the foramen incisivum, where it inosculates with the palato-maxillary. Spheno-palatine branch.

The pterygoid branch is exceedingly minute, and after passing through the pterygoid canal becomes lost about the base of the skull. Pterygoid branch.

The infra-orbitar is the most considerable of the whole set, and runs upwards and forwards to enter the canal. It there detaches some twigs to the orbit, to the antrum of Highmore, to the incisor and cuspidati teeth, and then emerges at the infra-orbitar foramen, between the levator labii and levator anguli oris muscles, where it divides minutely, and anastomoses with the facial and transverse facial arteries. Infra-orbitar branch.

The palato-maxillary or descending or posterior palatine branch, passes downwards through the canal of that name, and reaches the roof of the mouth, where it is continued forwards by the side of the alveolar process, lying between the bone and Palato-maxillary branch.

the lining membrane of the mouth, both of which it supplies. It terminates by entering the foramen incisivum and joining with the descending branch of the spheno-palatine. While still within the palato-maxillary canal, this vessel detaches one or more small twigs which pass through small holes in the palate bone, to be lost in the velum pendulum palati.

Although these terminating branches of the internal maxillary cannot be followed throughout their course, yet we may generally obtain a view of the division of the artery, by carefully clearing away the fat and cellular membrane which fills up the opening of the spheno-maxillary fossa; and at a future time this may be enlarged by sawing away a portion of the walls.

Second and third division of the fifth pair of nerves.

The student may now with advantage make himself acquainted with the second and third divisions of the fifth pair of nerves, both of which are intimately associated with the branches of the internal maxillary artery.

Second division.

The second or superior maxillary division of the fifth pair leaves the cranium through the foramen rotundum, and becomes lodged in the upper part of the spheno-maxillary fossa, where it divides into three portions—the Alveolar Branch—the Infra-

Its branches.

orbitar Branch—Branches which join the spheno-palatine ganglion.

The alveolar or superior dental branch, leaves the fossa through the external opening, and passing round the tuberosity of the superior maxilla, enters several minute canals which convey it to the molar and bicuspides teeth. This nerve generally comes off by two or more filaments, and is partly distributed to the buccinator and pterygoideus internus muscles. **Superior dental branch.**

The infra-orbitar branch, which is the largest, and apparently the continuation of the original trunk, passes forwards across the upper part of the fossa and enters the infra-orbitar canal, whence it emerges at the foramen of the same name, and spreads under the levator labii superioris muscle. Its ultimate distribution on the face has already been described (p. 14). Just before it enters the canal, the infra-orbitar nerve sends off the malar twig, which, after traversing the malar bone, makes its appearance on the cheek (p. 14). A second filament is detached just before the nerve arrives at the infra-orbitar foramen, which descends through the anterior walls of the maxillary antrum, and is distributed to the lining membrane of the cavity, as well as to the cuspidatus and incisor teeth. **Infra-orbitar branch,** **Malar twig.**

The third portion of the second division of the fifth consists of three or four short thick nerves, **Branches of junction with Meckel's ganglion.**

which descend in the fossa for the space of a few lines, and terminate in an enlargement which has received the name of the spheno-palatine ganglion, or the ganglion of Meckel.

Although Meckel's ganglion is justly considered to form part of the sympathetic system, which has not yet come under our observation, yet, as it is intimately connected with the second division of the fifth by the third portion just described, and as its branches accompany those of the internal maxillary artery through the spheno-palatine, pterygoid, and palato-maxillary foramina, it will be better to follow them up at the present time.

Meckel's ganglion.

The ganglion of Meckel is situated nearly in the centre of the spheno-maxillary fossa, immediately opposite to the spheno-palatine foramen, where it is closely invested with dense cellular membrane, and involved in the divisions of the maxillary artery. It sends off three branches—the Spheno-palatine—the Palato-maxillary—the Pterygoid.

Its branches.

Spheno-palatine nerve.

The spheno-palatine or lateral nasal nerve, divides immediately into four or five branches which enter the nose through the foramen of the same name. These again subdivide into very minute fibrillæ which are distributed to the pituitary membrane lining the nasal cavity: one filament larger

than the rest is continued along the septum to the foramen incisivum, where it joins with the palato-maxillary nerve. At the point of junction there is an enlargement called the Ganglion of Cloquet.

Palato-maxillary nerve.

The palato-maxillary or posterior palatine nerve, descends through the canal of that name, and reaches the roof of the mouth by the posterior palatine foramen. It then spreads in the membrane lining the hard palate, the principal branches being continued forwards towards the foramen incisivum, where they terminate in the ganglion of Cloquet. Before entering the palato-maxillary canal, this nerve sends two filaments to the soft palate and fauces, one of which passes through a separate canal in the palate bone, while the other runs down between the pterygoideus externus muscle and the tuberosity of the superior maxilla.

Pterygoid nerve.

The pterygoid or vidian nerve consists of two branches, which however are so closely united on leaving the ganglion, as to present the appearance of but one trunk. It passes horizontally backwards through the pterygoid canal, and pierces the fibrous structure which fills up the foramen lacerum basis cranii anterius. Here the two branches separate from each other: the one, called the Inferior, enters the carotid canal, and terminates by forming junctions with the ascending filaments sent up from the first cervical ganglion of the Sympathetic: the

other branch or superior pterygoid nerve passes through the lacerated opening into the cranium, runs along a groove in the petrous portion of the temporal bone, and, entering the foramen innominatum, reaches the canal of Fallopius, where it becomes firmly and inseparably united to the facial nerve. It has, however, generally been described as passing through the canal in contact merely with the facial, and without any actual junction of their fibres: moreover, it is said to be the identical branch, which, under the name of chorda tympani, separates itself from the portio dura just above the stylo-mastoid foramen, and enters the tympanum by the side of the pyramid. It then crosses the tympanum between the long crus of the incus and the manubrium of the malleus, being closely attached to the latter, and finally leaves the skull at the glenoid fissure, making its appearance on the external base, just behind and internal to the temporo-maxillary articulation. Passing downwards and inwards behind the neck of the jaw, the chorda tympani becomes attached to the gustatory nerve just as the latter is emerging from between the two pterygoid muscles: it is represented, however, as again separating itself, in order that it may finally terminate in the submaxillary gland, being in fact the branch which has already been mentioned as given off to that organ from the gustatory nerve

(p.48), which latter probably furnishes some additional filaments. Before the nerve enters the gland, a small ganglion or rather plexus is produced.

On comparing the distribution of the second division of the fifth (inclusive of the nerves emanating from Meckel's ganglion), with the vessels previously described, we shall find that the nerves precisely correspond with the third order of branches sent off by the internal maxillary artery; that they both arise in the same region, that they both leave the spheno-maxillary fossa by the same foramina, they are distributed to the same parts, and are designated by the same names.

Third division of the fifth pair.

Following up the analogy which we have just described as existing between the nerves and vessels of these parts, we may now proceed to trace the distribution of the third division of the fifth pair, the branches of which will be found to coincide with the first and second order of vessels given off by the internal maxillary artery.

Mode of displaying it.

By carefully disarticulating the condyle of the lower jaw, and then cautiously raising it together with the pterygoideus externus muscle, we shall bring into view the main trunk of the third division of the fifth or inferior maxillary nerve, as it issues from the foramen ovale of the sphenoid bone.

This nerve, at its exit from the cranium, is situated between the pterygoideus externus and circumflexus palati muscles, where it separates into two portions, one of which is destined to supply the muscles of mastication, while the other descends to the tongue and lower jaw*.

Its division.

Firstportion. Muscular branches.

The first or muscular portion of the third division of the fifth immediately separates into several twigs, which, according to the muscles they supply, are respectively denominated—Pterygoid—Temporal—Masseteric—Buccal.

Pterygoid.

The pterygoid twigs are deeply seated and difficult to expose; they are generally two in number, and pass immediately to enter the muscles of that name.

Temporal.

The temporal twigs are larger, consisting of two or sometimes more branches, which ascend in the temporal fossa closely applied to the bone; after ramifying through the muscle, some of their filaments pierce the fascia to join with the temporal portion of the facial nerve.

Masseteric.

The masseteric is a single twig which comes forwards above the pterygoideus externus, and passing through the semilunar notch between the

* It will be shewn hereafter that these two portions of the third division of the fifth arise separately from the brain; that the one is a nerve of motion, the other of sensation.

condyloid and coronoid processes of the lower jaw, or rather between the internal lateral ligament and the edge of the temporal muscle, reaches the posterior surface of the masseter. This nerve was necessarily divided when the muscle which it supplies was removed (p.50).

Buccal.

The buccal twig passes downwards and forwards, and makes its appearance from between the two origins of the external pterygoid muscle, where it has already been noticed (p.52). Continuing this course, it reaches the buccinator, ramifying on its surface, and sending some superficial filaments between that muscle and the masseter to join with the facial nerve.

All these muscular branches are more or less connected with the corresponding arteries.

Second portion.

The second portion of the third division of the fifth is much the largest, and divides behind the pterygoideus externus into three branches—the Gustatory—the Dental—the Auricular. The two first of these pass downwards and forwards, and have been already noticed at the commencement of this section as emerging between the pterygoid muscles (p.52).

Gustatory nerve.

The gustatory nerve, while still behind the pterygoideus externus, receives the chorda tympani, and also forms one or sometimes more junctions with the dental. It then descends between the ascending

ramus of the jaw and the internal pterygoid muscle, and emerging below, between the insertion of this last and the origin of the mylo-hyoideus, passes to the tongue, as has already been detailed (p.47).

Dental nerve.

The dental nerve passes downwards and forwards to reach the maxillary foramen. It lies external to the gustatory, and becomes separated from it by that slip of the internal lateral ligament which is attached to the edge of the foramen, between which and the ascending ramus of the jaw it is situated, close contact with the artery. Before entering the bone, the nerve detaches the mylo-hyoidean branch, which, descending along a groove in the vertical plate, is distributed to the mylo-hyoideus and digastricus muscles (p.36). The main trunk of the nerve is then continued along the maxillary canal, where it supplies the whole of the lower teeth, and transmits a considerable branch through the foramen mentale, which ramifies in the under lip (p.15).

Auricular branch.

The auricular or superficial temporal branch passes behind the neck of the jaw to enter the parotid gland; it there communicates with the facial nerve, and detaches filaments to the temporo-maxillary articulation, to the meatus externus, and the auricle of the ear. Then, rising through the substance of the gland, it passes just behind the root of the zygoma, and dividing into two or more twigs,

ascends over the temporal fascia, to supply the integuments covering the side of the cranium (p. 10).

In comparing the distribution of the third division of the fifth, with the first and second order of branches from the internal maxillary artery, the analogy will be found slightly defective, for on the one hand we find a nerve, the gustatory, with no corresponding artery; on the other, we shall see an artery, the spheno-spinal with no accompanying nerve. The auricular nerve is likewise destitute of any regular comitant vessel.

[OBSERVATIONS.—We have now completed the dissection of all the branches from the external carotid artery, with the exception of the ascending pharyngeal; and we have likewise traced the nerves which are distributed about the face, the jaws, the tongue, the mouth, and the fauces. The next section will comprise the more deeply seated parts immediately beneath the cranium; to understand which, an accurate knowledge of the external base of the skull, the points to which muscles are attached, and the relative position of the foramina, is absolutely necessary].

SECTION IV.

DESCRIPTION OF VESSELS AND NERVES LYING DEEPLY SEATED UPON THE CERVICAL VERTEBRÆ, IMMEDIATELY BELOW THE BASE OF THE SKULL, TO THE OUTER SIDE OF THE PHARYNX, AND BROUGHT INTO VIEW BY REMOVING THE LOWER JAW AND STYLOID MUSCLES.

PART I.

The ascending pharyngeal, and internal carotid arteries, passing upwards towards the base of the skull.

Mode of displaying the deep-seated vessels and nerves.

THE lower jaw should now be removed or turned to one side, in order to display the vessels and nerves which lie directly anterior to the spinal column, and pass to or from the base of the skull. Those branches of the external carotid already traced, may also be divided, and the trunk turned aside. The styloid process of the temporal bone

should (after the muscles arising from it have been carefully dissected) be sawn through close to its root, and thrown over towards the inner side, but still preserving the insertion of the muscles so that it can easily be restored to its former position.

Deeply seated vessels and nerves.

Thus we shall be enabled to lay bare the deeply seated parts of this region, consisting of—1st, the Ascending Pharyngeal Artery—the Internal Carotid Artery, both of which ascend towards the cranium; 2nd, the Glosso-pharyngeal Nerve—the Pneumo-gastric Nerve—the Spinal Accessory Nerve—the Lingual Nerve—the Internal Jugular Vein, which issue from the skull through the posterior lacerated and condyloid foramina, and pass downwards in different directions. All these structures, together with the first cervical ganglion of the sympathetic, are resting on the rectus capitis anticus and lateralis muscles, bounded internally by the pharynx, externally by the vaginal and mastoid processes of the temporal bone. They are all placed in close juxta-position, the nerves more especially being most intimately connected to each other.

Their situation.

Ascending pharyngeal artery.

The pharyngeal artery should first be dissected in order to complete the branches of the external carotid; but in tracing it we must be careful to avoid the filaments of the nerves just enumerated,

many of which are in close connection with the vessel.

The ascending pharyngeal branch commonly arises from the early part of the external carotid, but is often given off much higher up. It dips behind the stylo-glossus and stylo-pharyngeus muscles, and then ascends towards the base of the skull between the pharynx and the internal carotid artery. In its course, it detaches internal and external branches; the former, also the largest, are three or four in number, and supply the pharynx, fauces, and tonsil glands; the latter are distributed to the recti muscles, and to the nerves lying upon them, more especially to the first cervical ganglion, with which the trunk of the vessel is more or less connected. On reaching the base of the skull, the ascending pharyngeal divides into several twigs, some of which ramify on the Eustachian tube, whilst others enter the cranium through the anterior and posterior lacerated, and the condyloid foramina. These last are distributed to the dura mater, or rather to the bones which that membrane lines.

Internal carotid artery.

The internal carotid artery may now be traced upwards from its origin, to the carotid foramen of the temporal bone by which it enters the skull. The dissection requires considerable care, to avoid

injuring the nerves descending from the cranium, some of which cross before the vessel.

The internal carotid is given off from the common trunk about opposite to the third cervical vertebra, and, curving slightly outwards in the first part of its ascent, lies on the rectus capitis major, which separates it from the roots of the transverse processes. It then turns a little inwards, still corresponding to the above muscle, but separated from it by the superior cervical ganglion, and higher up by all the nerves which issue from the posterior lacerated and condyloid foramina, on which therefore the vessel may be said to lie. On the outer side of the artery is the internal jugular vein, which sinks to a plane somewhat posterior as they approach the base: on the inner side we find the ascending pharyngeal artery and the pharynx. Anteriorly, the internal carotid is crossed by the stylo-glossus and stylo-pharyngeus muscles, by the glosso-pharyngeal nerve and the pharyngeal branch of the par vagum, which, together with the styloid process of the temporal bone and a portion of the parotid gland, separate it from the external carotid. The lingual nerve also crosses before the artery lower down, but does not separate the two great trunks.

No branches are given off by the carotid prior to its entrance into the skull.

PART II.

The glosso-pharyngeal, pneumogastric, spinal accessory, and lingual nerves, descending from the posterior lacerated and condyloid foramina, and connected with the first cervical ganglion.

Reference to foramina at the base of the skull.

It will be found rather difficult to display the upper portion of the internal carotid artery, together with the jugular vein and the nerves, as they emerge from the base of the skull; but their precise relative situation may easily be ascertained, by examining the position of the different foramina which allow their passage.

The artery, the vein, the glosso-pharyngeal, pneumo-gastric, accessory, and lingual nerves, occupy three foramina, which although widely separated from each other at their internal or cranial orifices, are crowded together into a very small space at the external base of the skull. Of these three openings, the carotid canal is the most anterior, and contains, besides the artery, some small twigs which ascend from the first cervical ganglion

of the sympathetic. Immediately behind this, is the foramen lacerum basis cranii posterius, a somewhat lengthened fissure, extending obliquely forwards and inwards in the direction of the petrous portion of the temporal and corresponding edge of the occipital bone. A process of dura mater, and frequently a septum of bone, divides this opening into two canals, the outer and posterior of which constitutes the jugular fossa, and contains the commencement of the internal jugular vein, while the inner and anterior transmits the glosso-pharyngeal, pneumo-gastric and accessory nerves, which pass out, the one behind the other, in the same order as they are mentioned. A little posterior to the foramen lacerum, and completely to its inner side, is the anterior condyloid opening for the passage of the lingual nerve.

A view of the skull will soon make us familiar with the relative situation of these structures where they are connected to the base, and will facilitate the dissection of the four nerves; all of which, as they emerge from the cranium, pass behind the carotid artery and make their appearance between that trunk and the jugular vein.

The internal jugular vein is formed by the union of the sinuses which convey the blood from the brain, and leaves the cranium through the outer

Jugular vein.

and back part of the lacerated opening, situated therefore externally and posteriorly to the entrance of the carotid. From this artery it is at first separated by the glosso-pharyngeal, pneumo-gastric, accessory and lingual nerves; but soon gaining the same plane, it descends along the neck on the outer side, first of the internal, and afterwards of the common carotid. Just above the opening of the chest, the vein meets the subclavian at right angles, and the junction of the two is denominated the vena innominata, right or left.

About opposite to the angle of the jaw, the internal jugular vein is connected to the external by a pretty considerable branch: a little lower down, it receives the pharyngeal, facial, lingual, superior thyroideal, and occipital veins. It will thus be seen, that the internal jugular receives all the veins corresponding to the branches of the external carotid artery, with the exception of the temporal, internal maxillary, and posterior aural, which, by their junction, form the external jugular. This arrangement, however, is subject to frequent varieties. In its subsequent course down the neck, the internal jugular receives no branches of importance.

Glosso-pharyngeal nerve.

The glosso-pharyngeal nerve leaves the cranium anteriorly to the pneumo-gastric and accessory, and passing downwards, outwards, and forwards,

crosses behind the carotid, and makes its appearance between that vessel and the internal jugular vein. In this situation, it descends behind the stylo-pharyngeus muscle, at the under edge of which, it comes more distinctly into view, and there divides into a glossal and a pharyngeal branch.

Glossal branch.

The glossal is the largest and most distinct. It passes inwards before the carotid, closely adherent to the under surface of the stylo-pharyngeus which it supplies; but, previous to the insertion of the muscle, the nerve winds over it, and enters the side of the base of the tongue, immediately below the attachment of the stylo-glossus. Here it divides minutely; some fibres pass downwards to the fauces and tonsil glands, others are lost in the muscles at the base of the tongue, more particularly the hyo-glossus; but by far the largest twigs run under the mucous membrane, to terminate in the follicles and the papillæ capitatæ which are situated at the root of the organ.

Pharyngeal branch.

The second or pharyngeal division of the glosso-pharyngeal nerve, consists of four or five delicate filaments which sometimes come off separately, sometimes from a common branch. These all cross before the carotid, and pass inwards with different degrees of obliquity towards the pharynx, forming, in conjunction with some twigs derived from other sources, the pharyngeal plexus, and finally distri-

buted to the constrictors and lining membrane of that cavity. A few slender fibrillæ also pass down along the carotid to assist in the composition of the carotid plexus.

The glosso-pharyngeal forms communications with the nerves which accompany it from the cranium, also with the lingual, facial, and sympathetic.

Pneumo-gastric nerve.

The pneumo-gastric nerve, or par vagum, leaves the cranium through the lacerated opening, immediately posterior to the glosso-pharyngeal, crosses behind the carotid artery, and then descends between it and the jugular vein. This last situation it maintains throughout the whole of the neck. Directly after leaving the skull, the nerve becomes enlarged into a sort of ganglion, which is surrounded by a very strong dense membrane, including the glosso-pharyngeal, lingual, and accessory nerves, with the ascending branches of the sympathetic, and involving the upper part of the first cervical ganglion. All these structures thus become firmly and almost inseparably united to each other, both by the cellular tissue which encloses them, and by numerous nervous filaments passing from one to the other. In its course down the neck, the par vagum is contained in the posterior part of the carotid sheath, having first the internal and subsequently

the common carotid artery to its inner side, while the jugular vein is external, and likewise covers it in such a manner, that on opening the sheath, you do not discover the nerve until the two vessels are separated from each other. At the bottom of the neck, the par vagum enters the chest through its upper opening; on the right side, crossing between the subclavian artery and vein; on the left side, passing behind the left vena innominata, and afterwards before the arch of the aorta, just where that vessel detaches the left subclavian artery. The entrance of the nerve into the thoracic cavity will be better seen at a future period, when the sterno-cleido-mastoideus muscle has been removed.

Its branches.

The branches given off from the pneumo-gastric nerve during its cervical course are—the Pharyngeal—the Superior Laryngeal—the Cardiac—some small twigs of connexion.

Pharyngeal branch.

The pharyngeal branch is detached a little way below the base of the skull, and passes downwards and inwards before the internal carotid, where it divides into several filaments, some of which descend upon the artery, while the others join with the glosso-pharyngeal twigs to assist in forming the pharyngeal plexus.

Superior laryngeal branch.

The superior laryngeal branch comes off from the trunk of the par vagum, a short distance below the former, and also passes downwards and inwards,

but behind the carotid. It continues deeply seated till it reaches the space between the thyroid cartilage and the os hyoides: here it rises towards the superior thyroideal artery, and piercing the broad ligament, enters the upper part of the larynx. Previously to this, it sends off a twig which descends by the side of the larynx, furnishes a long slender branch to the crico-thyroideus muscle, and forms junctions with the inferior laryngeal nerve. The distribution of the superior laryngeal, after it has pierced the thyro-hyoideal ligament, must be traced when the larynx has been removed. It will then be found to divide into a number of filaments which ramify in the space between the side of the thyroid cartilage and the mucous membrane, lining the interior of the cavity. Some of these supply the arytenoidei obliqui and transversus muscles, the thyro and aryteno-epiglottidei, while the rest are lost on the mucous membrane of the pharynx and larynx, more especially about the epiglottis and the rima. Numerous junctions are also effected between this nerve and the inferior laryngeal.

Cardiac branches.

The remaining branches of the par vagum consist, of a twig joining the descendens lingualis about opposite to the bifurcation of the common carotid, of small branches to the coats of that artery, and of cardiac filaments. The latter are sent off in the

lower part of the neck, and passing into the chest, become lost in the cardiac plexus which surrounds the commencement of the aorta.

These are all the branches sent off by the par vagum in its course through the neck; but after it has entered the thorax, it detaches a considerable nerve called the recurrent or inferior laryngeal, which ascends again towards the larynx, and is distributed to those parts of the organ which were left unsupplied by the superior branch of the same name just described. This branch may be traced with greater facility at a future period of the dissection.

Accessory nerve.

The spinal accessory nerve is the last and the most posterior of the three trunks which descend through the lacerated opening of the skull. Like the other two, it passes behind the carotid artery, making its appearance between it and the internal jugular vein. It then crosses before the latter vessel, and continues its previous course downwards and outwards, to enter the inner edge of the sterno-cleido-mastoideus about one-third below the insertion of the muscle.

On leaving the skull, the accessory is closely attached to the pneumo-gastric nerve, and afterwards becomes adherent to the lingual, to both of which it gives branches of connexion, and also fur-

nishes one or more twigs which generally pass before the carotid, to join the pharyngeal plexus.

While within the substance of the sterno-mastoideus, it detaches several filaments which ramify through its interior, but the main trunk of the nerve re-appears at the outer edge of the muscle, forms junctions with the cervical nerves, and becomes finally lost in the trapezius, as has already been described (p. 4).

Although the description of these three trunks, the glosso-pharyngeal, pneumo-gastric and accessory may appear somewhat intricate, yet their general course may be simplified by remembering, that they all pass out of the cranium through the posterior lacerated opening, that they all cross behind the internal carotid artery and make their appearance between that vessel and the internal jugular vein: then, that the middle nerve, or the pneumo-gastric, descends vertically between the two great vessels; that the anterior, or glosso-pharyngeal passes downwards and inwards to the tongue and pharynx, crossing before the artery; that the posterior, or the accessory, runs downwards and outwards, crossing before the vein.

Lingual nerve.

The last nerve we have now to speak of, is the lingual or hypo-glossal, which leaves the cranium

at the anterior condyloid foramen, behind, and a little to the inner side of the three preceding trunks. Like them it passes, first behind the carotid artery, and then between that vessel and the jugular vein. From this situation it descends towards the neck, at the same time coming forwards and approaching the surface. In the early part of its course it lies anterior to the first cervical ganglion, and is closely adherent to the par vagum. Disengaging itself from these, it continues to descend behind the styloid muscles and the posterior belly of the digastricus. Immediately below the last muscle, the lingual nerve becomes more superficial, and assuming a sudden curve inwards, runs round the origin of the occipital artery, passes before both carotids, crosses again behind the tendon of the digastricus and the stylo-hyoideus muscle, and, disappearing under the outer edge of the mylo-hyoideus, is distributed to the muscles of the tongue.

With the exception of two or three small twigs of communication with the par vagum and sympathetic, this nerve gives off no branches until it has passed round the occipital artery. It then detaches the descending branch, and a filament to the thyro-hyoideus muscle, both of which, together with the ultimate distribution of the trunk, have been already noticed (pp. 22 & 47).

The dissection of the deeply seated nerves and vessels which has thus been completed, necessarily involves that of the first cervical ganglion of the sympathetic, together with the branches it sends off, especially those which ascend to enter the carotid canal. The description of this nerve is, however, reserved to a future period, when it may be more conveniently traced throughout the whole extent of the neck.

[OBSERVATIONS.—The dissection of the nerves which descend through the stylo-mastoid, the round, the oval, the posterior lacerated, and the condyloid foramina (excepting the par vagum which has been traced no further than the chest), is now complete. The course of the internal jugular vein has likewise been shewn, from the jugular fossa to its junction with the subclavian. The spheno-spinal, ascending pharyngeal and internal carotid arteries, have also been traced into the cranium. Our next step consists in sawing off the calvarium and removing the brain. We shall then be enabled to pursue the distribution of the vessels which supply that organ, and also to examine the origin of the nerves which we have already dissected, together with those which pass into the orbit, and

which therefore have not yet come under our observation. Lastly, we shall have an opportunity of tracing the different sinuses which return the blood from the brain, and unite to form the jugular vein.

[As our labors will now have reference to the internal surface of the cranium, its general appearance and detail should be studied with the same care and attention which has been devoted to the external base.

[Previously to opening the head, it would be well to trace the ramifications of the occipital artery and nerve, which pierce the origin of the trapezius near the median line, and spread over the occiput.]

SECTION V.

DESCRIPTION OF SOME OF THE PARTS INTERNAL TO THE CRANIUM: VIZ. THE VESSELS OF THE DURA MATER — THE BASE OF THE BRAIN — THE ARTERIES OF THE BRAIN—THE ORIGIN OF THE CEREBRAL NERVES.

PART I.

The dura mater as it appears on removing the calvarium—the vessels ramifying on its surface.

Dura mater

On removing the calvarium, the external or adherent surface of the dura mater will be brought into view, together with the arteries which ramify upon it, and supply the bones.

Meningeal arteries.

The principal of these is the spheno-spinal branch of the internal maxillary, the course of which has already been noticed (p. 54), and which may now be seen emerging from the deep groove at the anterior

inferior angle of the parietal bone, and spreading over the side of the cranium; its anterior branches extending as far as the foramen lacerum orbitale, where it inosculates with the ophthalmic, while posteriorly it joins with a branch of the occipital that enters the skull through the foramen lacerum posterius (p. 40).

The dura mater covering the base of the skull, is chiefly supplied by twigs from the internal carotid, and the terminating branches of the ascending pharyngeal.

Longitudinal sinus.

In the median line of the dura mater, a depression is observed, marking the situation of the superior longitudinal sinus, on each side of which are the glandulæ Pacchioni. The whole length of the sinus may be slit open, and it will be found to extend from the foramen cæcum of the frontal bone, backwards along the vertex of the skull, as far as the internal occipital protuberance, where it terminates in the torcular Herophili. The openings of the veins, the chordæ Willisii and glandulæ Pacchioni are seen within it.

PART II.

The removal of the brain with the vessels and nerves necessarily divided in so doing.

Directions to remove the brain.

THE dura mater should now be cut through all round, on a level with the skull, dividing at the same time the commencement of the falx major, which will allow of its being drawn from between the hemispheres and turned backwards. The brain may then be removed, by dividing in succession the different structures which connect it to the base of the cranium.

Should the cerebral mass have become too far decomposed to permit of its removal entire, it may be washed out so as to leave the arteries which ramify in its substance; but, if possible, the removal of the organ in a perfect state is much to be preferred.

Nerves and vessels divided.

First pair.

On raising the anterior lobes of the cerebrum, the first structures to be observed connecting the brain with the base of the skull, are the olfactory nerves or first pair, which, from their extreme softness, generally separate from the cribriform plate of the ethmoid bone.

We next come to the optic or second pair, which disappear through the optic foramina. Second pair.

On dividing these, we discover the carotid arteries, rising from under the anterior clinoid processes of the sphenoid bone, and becoming applied to the surface of the brain. Carotid arteries.

Between the vessels is the infundibulum, connecting the base of the cerebrum with the pituitary gland. Infundibulum.

Posterior to the arteries, are the third pair or common oculo-muscular nerves, which enter a cavity of the dura mater situated at the side of the pituitary fossa, and called the cavernous sinus. Third pair.

Raising the brain still more, we bring into view the tentorium, or the process of dura mater separating the cerebrum from the cerebellum.

Ranging with the edge of this, and nearly concealed by it, will be seen the fourth pair or pathetic nerves, which also enter the cavernous sinus.—The tentorium should now be divided on both sides, in a direction outwards and backwards, for the purpose of enabling us to raise the cerebellum. Fourth pair.

The fifth or trigeminal pair is then seen piercing the dura mater, and passing over the ridge on the petrous bone to reach its anterior surface. Fifth pair.

Raising the pons Varolii from the basilar process of the occipital bone, we expose the sixth pair or abducentes, which enter the dura mater below the Sixth pair.

last, and much nearer the median line, passing upwards under the membrane to gain the cavernous sinus on either side.

Seventh and eighth pairs.

Below, and external to the fifth, are the seventh and eighth pairs, or the auditory and facial, closely connected to each other, and entering the foramina auditiva interna.

Ninth and tenth pairs.

In a line directly below these, the ninth and tenth pairs or the glosso-pharyngeal and pneumogastric are seen passing out of the skull through the posterior lacerated foramina; while immediately behind them is the spinal accessory nerve, coming forwards from the foramen magnum, and disappearing through the same opening.

Accessory nerve.

Eleventh pair.

The last nerves are the eleventh pair or lingual, situated on a level with the foramen magnum, and leaving the cranium through the anterior condyloid foramina.

Vertebral arteries.

The vertebral arteries will now be seen entering the skull on either side of the medulla oblongata.

The division of these vessels, together with the intervening medulla, will release the brain, and after separating it from the posterior parts of the tentorium and falx major, it may be entirely removed from the cranium, and laid with the base upwards, for the purpose of tracing the arteries and inspecting more closely the origin of the nerves.

PART III.

Outline of the inferior surface of the brain.*

THE pia mater should now be removed from the inferior surface of the cerebrum, from the pons Varolii, and the medulla oblongata, taking care to leave the vessels and the origins of the nerves.

The base of the brain will then present the following appearances:— Base of the brain.

The anterior and middle lobes are to be observed separated from each other by the fissura Sylvii, Division of the lobes.

* The dissection of the brain and its membranes has been altogether omitted in this work, for, as the student is seldom enabled to open the head until the viscus has become unfit for examination, it generally forms a separate part of his studies. It was likewise considered unnecessary to swell the size of this volume, by entering into the description of an organ which is amply dilated upon in every manual of anatomy. A brief sketch only, has therefore been given of the appearances which present themselves on the base, in order to render more intelligible the course of the arteries and the origin of the nerves.

For reasons similar to those mentioned above, the author has been induced to omit the description of the organs of the senses.

which, where the pia mater has been removed, will be found of very considerable depth. The two anterior lobes are likewise divided from each other by the common fissure separating the hemispheres, which at this part extends completely through the brain. The posterior lobes are nearly concealed by the hemispheres of the cerebellum resting upon them. Connecting these two hemispheres, is the pons Varolii, with the crura cerebri before it, the medulla oblongata behind.

Crura cerebri.

The crura cerebri appear to emerge from under the pons Varolii, and, diverging from each other, pass forwards and outwards to enter the middle lobes of the cerebrum. Just prior to their entrance into the hemispheres, they are crossed by the tractus opticus, or that portion of the optic nerve which is intermediate between its origin and the junction with its fellow. These nerves converge as they pass forwards, and become united immediately anterior to and between the crura. Behind this union or commissure, and between the crura cerebri, are seen successively, the tuber cinereum with the infundibulum, the eminentiæ mammillares, and the pons Tarini or substantia perforata.

Medulla oblongata.

The medulla oblongata is situated behind and below the pons Varolii between the hemispheres of the cerebellum, and forms the connexion of the brain with the spinal cord. It presents six raised

and slightly projecting portions, separated from each other by grooves. These are—the Corpora Pyramidalia before, seen as the brain now lies, and continuous with the anterior or motor columns of the spinal cord—the Corpora Restiformia behind, seen by raising the medulla oblongata, and continuous with the posterior or sentient columns of the spinal cord—the Corpus Olivare on either side, surmounting the lateral portion of the spinal cord. In the groove between the olivary and restiform bodies is a raised white line, which gives origin to to the nerves of respiration, and has been denominated by Sir Charles Bell, "Tractus respiratorius." Its fibres are apparently continuous with the lateral columns of the medulla spinalis.

On tracing the six portions of the medulla oblongata upwards or towards the brain, we shall find the pyramidal and olivary bodies passing through the pons Varolii to form the crus cerebri of either side; the latter, however, are said to terminate partly or wholly in the tubercula quadrigemina. The corpora restiformia on the other hand, diverge from each other and enter the hemispheres of the cerebellum.

Fourth ventricle.

On raising the medulla oblongata, a cavity will be discovered between it and the cerebellum, called the fourth ventricle, on the floor of which is a triangular space formed by the divergence of the

corpora restiformia; this is denominated the calamus scriptorius.

A knowledge of these different parts which constitute the base of the brain, will enable us to trace the course and distribution of its blood-vessels.

PART IV.

Course and distribution of the internal carotid and vertebral arteries within the cranium.

Arteries of the brain.

THE substance of the brain is supplied by two pairs of arteries—the Internal carotid and the Vertebral of either side. Neither these vessels, nor their immediate branches, enter at once into the structure of the brain, but they are found ramifying over its surface, dividing and subdividing so as to form an expanded plexus of vessels, which completely invest the viscus, and are connected and sustained by the membranous tunic called pia mater: innumerable circles of anastomoses are thus formed, from which long delicate branches may be seen descending into the cerebral mass itself.

The carotid artery has already been traced into the canal of the temporal bone at the external base of the skull (p. 72), and was again seen piercing the dura mater, to enter the cavity of the cranium at the side of the pituitary fossa, immediately behind the optic foramen (p. 89). During the intermediate part of its course, it is at first contained in the bony canal, and afterwards inclosed between the walls of the cavernous sinus, the description of which is reserved to a future period. On making its appearance within the dura-matral cavity as mentioned above, it gives off the ophthalmic branch to the orbit, and then bends upwards and backwards to reach the surface of the brain, on which we may now proceed to follow its course and distribution. Internal carotid artery.

The carotid artery becomes applied to the base of the brain, just at the commencement of the fissura Sylvii, and here the trunk of the vessel terminates by dividing into three branches—the Posterior communicating Artery—the Anterior Artery of the Cerebrum—the Middle Artery of the Cerebrum. These all diverge from one another, each taking the direction indicated by its name. Its division at the base of the brain.

The posterior communicating artery passes backwards, sends small twigs to the adjacent parts, and, scarcely diminished in size, terminates Communicating branch.

at the anterior edge of the pons Varolii by joining the posterior artery of the cerebrum, which is derived from the basilary. A communication is thus established on each side the brain, between the carotid and vertebral arteries.

Anterior cerebral artery.

The anterior artery of the cerebrum passes forwards and inwards to reach the fissure between the hemispheres, at the commencement of which, it comes nearly into apposition with its fellow of the opposite side; and here a junction is effected between the two, by a short thick trunk, called the Transverse Communicating Branch; by means of which, a communication is established between the carotids of either side. The vessel then turns upwards through the fissure, winds round the anterior extremity of the corpus callosum, and is continued backwards along the superior surface of that body, until it becomes lost at its posterior extremity. This artery, throughout its course, gives off numerous small twigs to the adjacent parts of the brain; and, soon after it has gained the upper aspect of the corpus callosum, detaches a considerable branch, which spreads along the inner surface of the hemisphere, ramifies in the pia mater, and supplies the anterior and middle lobe of the cerebrum.

Middle cerebral artery.

The middle artery of the cerebrum is by far the largest of the three, which the carotid gives off

to the brain. It becomes immediately received into the fissure of Sylvius, through which it takes a deep and tortuous course outwards and backwards, and expends itself in branches which ramify in the pia mater covering the anterior and middle lobes. One of these finds its way into the descending cornu of the lateral ventricle, and is there distributed to the choroid plexus. In order to expose the middle artery, the fissure of Sylvius must be laid open by separating the two lobes from each other.

From the foregoing description, it will be seen that the distribution of the carotid artery is confined to the anterior and middle lobes of the cerebrum: the remaining portion of the brain, that is to say, the posterior lobes of the cerebrum, the cerebellum, and medulla oblongata are supplied by the vertebral arteries which are derived from the subclavian, and have been already noticed, as piercing the dura mater immediately behind the condyles of the occipital bone, and entering the cranium at the foramen magnum. From this point we shall pursue their course along the brain.

Vertebral arteries.

The vertebral arteries, at their entrance into the cranium, are situated one on each side of the

medulla oblongata; but passing onwards, they cross obliquely the corpora pyramidalia, and, converging towards each other, join at the posterior edge of the pons Varolii. The vessel thus formed by the union of the right and left vertebral, is called the Basilar Artery.

Branches of vertebral.

Each vertebral artery gives off three branches —the Posterior Spinal Artery—the Anterior Spinal Artery—the Inferior Artery of the Cerebellum.

Posterior spinal branch.

The posterior spinal artery is very slender. It winds round the medulla oblongata to reach its posterior surface, and then descends along the spinal cord, forming innumerable anastomoses with its fellow, as well as with the other branches which enter the canal through the vertebral foramina. The identity of the artery is frequently lost in these junctions; but it may sometimes be traced as a continuous vessel as far as the lumbar vertebræ.

Anterior spinal branch.

The anterior spinal artery is equally small as the last: it passes down on the fore-part of the medulla oblongata, but inclines towards the median line to meet its fellow with which it joins. Thus, from the union of these two vessels a single artery is produced, which descends between the anterior columns of the spinal marrow, forms junctions similar to the posterior, described

above, and may occasionally be traced to an equal extent.

The inferior or posterior artery of the cerebellum, is occasionally a branch of the basilar trunk. It passes downwards and backwards between the spinal accessory and pneumo-gastric nerves, to reach the fissure which separates the two hemispheres of the cerebellum, and comes nearly in contact with its fellow, between the processus vermiformis and the medulla oblongata. It here divides into several branches, which ramify in the pia mater covering the under and back part of the cerebellum. This vessel is very tortuous, and frequently gives off one or both of the spinal arteries. Inferior cerebellar artery.

The basilar artery is formed by the junction of the two vertebrals at the posterior edge of the pons Varolii, and, passing forwards and upwards across that body, terminates at its anterior margin by dividing into the posterior arteries of the cerebrum. The vessel is short and thick, and suffers little diminution in size until its final bifurcation. It is lodged in a groove situated in the median line of the pons Varolii, and is thus protected from the cuneiform process of the occipital bone, which is in contact with its anterior surface. Basilar artery.

Branches of the basilar.

The branches of the basilar artery come off in pairs from each side of the vessel. They are three in number—the Auditory—the Superior of the Cerebellum—the Posterior of the Cerebrum—besides several smaller twigs which supply the pons and the adjacent parts of the brain.

Auditory branch.

The auditory artery is very small, and so frequently arises from the superior of the cerebellum, that it is sometimes described as a branch of that vessel. It takes a tortuous course to enter the meatus auditivus internus, and separates the facial from the auditory nerve, with the latter of which it is distributed to the labyrinth of the ear.

Superior cerebellar artery.

The superior or anterior artery of the cerebellum is given off immediately before the final division of the basilar, and passes outwards and backwards towards the upper and anterior surface of the cerebellum. It there detaches twigs to the pineal gland, corpora quadrigemina, and velum interpositum, and expends itself in long slender branches which ramify in the pia mater over the hemisphere.

Posterior cerebral artery.

The posterior arteries of the cerebrum constitute the termination of the basilar vessel, and pass outwards, along the margin of the pons Varolii and round the crura cerebri, to reach the under surface of the posterior cerebral lobes. Here they divide into several branches, which ramify over

that part of the brain, and anastomose with the anterior and middle arteries from the carotid.

Circle of Willis.

The communicating branches have already been described, as forming a direct junction on each side, between the posterior cerebral vessel and the carotid, and we shall now see that a vascular circle is thus produced at the centre of the base, for the purpose of connecting the four arteries of the brain. This anastomosis, called the circle of Willis, is formed in front, by the anterior cerebral arteries and their connecting transverse branch, laterally, by the two communicating vessels, and behind, by the two posterior cerebral arteries which have a common origin from the basilar. This circle incloses the junction of the optic nerves, the infundibulum, the eminentiæ mammillares, the substantia perforata, and the origins of the third pair of nerves.

PART V.

Origin of the cerebral nerves, and the course which they take, until they leave the cavity of the cranium, or become concealed by passing between the layers of the dura mater.

Origin of the cerebral nerves.

THE cerebral nerves have already come under our observation during the removal of the brain, when they were divided in order to release it from the base of the skull; and now, by clearing away the pia mater with the arteries from the cerebral surface, their origins may be brought more completely into view. They consist of eleven pairs, and will be found arising in the following order; commencing at the fore part of the base and proceeding backwards:—1, The Olfactory—2, the Optic—3, the Common Oculo-muscular—4, the Pathetic—5, the Trigeminal—6, the Outer Oculo-muscular—7, the Auditory—8, the Facial—9, the Glosso-pharyngeal—10, the Pneumo-gastric—11, the Lingual.

First pair.

The olfactory nerves appear to commence at the posterior edge of the anterior cerebral lobe,

about midway between the central fissure and the commencement of the fossa Sylvii. Three roots, however, converging towards this point, form the real origin of each nerve. The first, or inner root, arises near the median line, from the fore and under part of the corpus callosum; the second, or outer root, may be traced through the fossa of Sylvius to the anterior and outer surface of the corpus striatum, where it is also connected to the anterior commissure of the third ventricle, which thus forms a union between the olfactories of either side: both these origins consist of medullary matter, and present faint white lines along the surface of the brain. The third root is cineritious, and arises from the superficies of the cerebrum, immediately at the point where the other two join; the nerve must be raised to bring it into view, and it then presents a small pyramidal eminence. The olfactory nerve thus formed is triangular in shape, presenting a flat surface inferiorly, which is in contact with the base of the skull, and a ridge above, which is received into a groove of the anterior lobe. The nerves converge as they pass forwards, till they reach the cribriform plate of the ethmoid bone, where they each enlarge into a soft bulbous ganglion, from which numerous filaments descend into the nose. It is impossible, at this period, to trace

Its distribution within the nose.

the farther progress of these filaments, but if an opportunity be afforded hereafter of making a vertical section through the nasal cavity, they may be seen ramifying on the superior surface of its walls. Some anatomists divide them into three sets; viz. an external, which spread over the superior turbinated bone; an internal, which descend along the septum; and a middle set, distributed to the roof of the cavity. They are involved in the pituitary membrane lining the bones, forming by their junction a complicated network, and becoming completely identified with that tissue. Although a few of the filaments have been traced along the septum as far as the floor of the nose, yet the general distribution of the nerve does not appear to descend lower than the turbinated portions of the ethmoid bone.

Second pair. The optic nerves commence their origin as far back as the nates, or anterior protuberances of the corpora quadrigemina. The band of fibres descending from these structures, receives an addition from the corpus geniculatum externum, a projection on the under part of the thalamus nervi optici, to which it is closely adherent. From this origin, the nerve of either side passes forwards and inwards underneath the crus cerebri, being connected to that body by its outer edge. Converging thus towards each other, the optic

nerves join directly over the olivary process of the sphenoid bone, and this union terminates the first part of their course, called Tractus Opticus. From this junction or commissure, the two nerves again separate, and enter the orbit of either side through the foramen opticum. Immediately on gaining the orbitar cavity, the nerve becomes closely embraced by the four straight muscles of the eye, and is afterwards surrounded by a quantity of adipose structure: passing forwards it reaches the posterior surface of the globe, and pierces the sclerotic coat a little to the inner side of the central axis of the eye-ball, being considerably contracted in its passage through the tunic. It then passes through the choroid coat, and expands into a thin, pulpy, semi-transparent membrane, which is spread over the capsule of the vitreous humour and denominated the retina. Its termination within the orbit.

The common oculo-muscular, or motores oculorum, arise from the inner surfaces of the crura cerebri, and from the substantia perforata, just anterior to the pons Varolii. The origin of each nerve is within the circle of Willis, but it immediately leaves that space to pass between the posterior cerebral and superior cerebellar artery, then runs forwards and outwards to enter the upper part of the cavernous sinus. Third pair.

The pathetic pair arises on each side by two or Fourth pair.

more delicate filaments, from the processus e cerebello ad testes, and the valve of Vieussens, whence it passes downwards and forwards between the cerebrum and cerebellum, crosses under the crus cerebri, and is continued along the edge of the tentorium to pierce the dura mater at the upper and back part of the cavernous sinus.

Fifth pair. The trigeminal pair makes its appearance on the surface of the brain, near the junction of the pons Varolii with the hemispheres of the cerebellum: the nerve, however, does not arise from the former body, but may be traced through its substance to originate in two roots, the one from the corpus pyramidale, the other, which is by far the larger, from the corpus restiforme. These two portions are connected together by cellular membrane only, without any intermixture of fibre, and run forwards immediately under the tentorium. Piercing the dura mater, they pass over the ridge of the petrous bone to gain its anterior surface, where the larger root terminates in a ganglion, behind which the former is continued to the foramen ovale.

Sixth pair. The outer oculo-muscular, or abducentes, arise from the corpora pyramidalia just behind the pons Varolii, with the posterior edge of which they appear to be connected. The nerves pass forwards nearly parallel to each other, and, piercing the

dura mater, enter the back and under part of the cavernous sinus on either side.

Seventh pair.

The auditory nerve becomes visible on the surface of the brain, at the angle formed by the junction of the pons Varolii, cerebellum, and medulla oblongata; but, by raising the last, may be traced to arise from the calamus scriptorius on the floor of the fourth ventricle, where the white lines in which it originates are connected with those of the opposite side. This nerve, which from its extreme softness has received the name of portio mollis, enters the internal auditory canal, at the bottom of which it divides into a number of filaments, which pass through small foramina in the bone, to be distributed on the membrane lining the labyrinth of the ear.

Eighth pair.

The facial nerve, or portio dura, makes its appearance at the same spot, and in close contact with the auditory, being indeed partly received into a groove on the surface of the latter. By carefully separating the nerves, the facial will be found to arise from the upper part of the tractus respiratorius, between the olivary and restiform bodies, and immediately under the posterior edge of the pons Varolii, with which it is intimately connected. Passing forwards and upwards, it accompanies the auditory into the meatus auditivus internus, where a delicate union is said to

exist between the two nerves. At the bottom of the meatus, the facial commences a separate course by entering the canal of Fallopius, and, after winding through the petrous portion of the temporal bone, issues out at the stylo-mastoid foramen, where it becomes surrounded by the parotid gland (p. 8). The passage of this nerve through the temporal bone is exceedingly tortuous, for the purpose of avoiding the cavities of the ear: it first passes between the cochlea and vestibule, is then situated above the tympanum, and, lastly, descends along its posterior wall. Near the commencement of the Fallopian canal, the facial receives the pterygoid branch from Meckel's ganglion, which enters through the foramen innominatum, their union being marked by a small gangliform enlargement: it then sends off a filament to the tensor tympani muscle, and another to the stapedeus, and, just above the styloid-mastoid foramen, parts with the chorda tympani branch, which is reflected back through a separate canal to enter the cavity of the tympanum. This last nerve, and its probable identity with the pterygoid branch of Meckel's ganglion have already been spoken of (p. 63).

Ninth pair. The glosso-pharyngeal arises below the last from the tractus respiratorius, between the corpus olivare and corpus restiforme. It is generally

formed by the union of two or three filaments, and leaves the skull through the foramen lacerum basis cranii posterius (p. 76).

Tenth pair.

The pneumo-gastric nerve arises directly below the last, by a numerous set of filaments which come off successively from the same track, in the groove between the olivary and restiform bodies. The nerve thus formed is at first broad and flat, but becomes more rounded as it approaches the lacerated opening which transmits it from the cranium. It is at first in close apposition to the ninth pair, but a portion of dura mater generally separates them as they leave the skull (p. 78).

Tractus respiratorius.

The three last nerves, or the facial, the glosso-pharyngeal, and the pneumo-gastric, will thus be found to arise from the same line of medullary matter which has already been described as the tractus respiratorius of Bell. This appears to be a continuation of the lateral portion of the spinal cord, or at any rate to correspond with that track of medullary structure which is situated between the anterior and posterior roots of the spinal nerves. It is from this lateral surface of the spinal cord that the accessory nerve is derived, being formed by filaments which arise between the anterior and posterior roots of the cervical nerves. The lowest of these filaments generally comes off opposite to the fourth or fifth vertebra,

Accessory nerve.

but they sometimes commence as far down as the sixth or seventh. The last, or highest, commonly arises about the junction of the spinal cord with the medulla oblongata, or just below the origin of the tenth pair. The accessory does not belong to the cerebral nerves, nor can its origin be seen without laying open the vertebral canal; but it is noticed here, as the trunk is generally removed with the brain, and may be seen entering the cranium at the foramen magnum, and leaving it again through the lacerated opening (p. 81).

Eleventh pair.

The lingual nerve arises from the fore part of the medulla oblongata, being formed by several delicate filaments which spring from the groove between the olivare and pyramidal bodies, but are probably derived from the latter. The nerve passes forwards to the anterior condyloid foramen, through which it is transmitted frequently in two fasciculi, which are separated by a portion of dura mater, and join again on the external surface of the skull (p. 82).

[Observations.—The student will perceive that in the foregoing section, we have established the connexion of the facial, glosso-pharyngeal, pneumo-gastric, accessory, and lingual nerves, as

we had previously traced them on the exterior of the cranium, with their origins from the base of the brain within that cavity; and that, with the exception of the pneumo-gastric, their dissection is now completed. Our next step will consist in following up the remaining nerves, whose origins we have already examined, but whose farther course we have not yet pursued.]

SECTION VI.

DESCRIPTION OF THE THIRD, FOURTH, FIFTH, AND SIXTH PAIRS OF NERVES, WHERE THEY ARE ENCLOSED BETWEEN LAYERS OF THE DURA MATER, PREVIOUS TO THEIR EXIT FROM THE CRANIUM.

PART I.

The semilunar ganglion of the fifth pair.

HAVING now completed our view of the brain, we shall proceed to examine those nerves, which have not yet been traced to the foramina by which they leave the cranium, but became concealed by passing under the dura mater. These consist of the Third, Fourth, and Sixth pair, which have been mentioned as entering the cavernous sinus, and the Fifth pair, which was seen passing over the petrous ridge of the temporal bone. By following this last and removing the dura mater from its surface, the nerve will be found to terminate in the Semilunar or Casserian Ganglion.

The semilunar ganglion of the fifth pair is enclosed between two layers of dura mater, and lies in a shallow depression on the anterior surface of the petrous bone near its junction with the sphenoid. It presents a concavity which looks upwards and backwards, and receives the original trunk of the nerve, or rather that larger portion derived from the corpus restiforme; while the convexity of the ganglion is directed downwards and forwards, and sends off three branches called—the First, Second, and Third Divisions of the Fifth.

Semilunar ganglion of the fifth pair.

Its branches.

The first or ophthalmic division is the smallest and most internal: it passes under the dura mater forwards and somewhat inwards to enter the cavernous sinus.

First division of the fifth.

The second division or superior maxillary nerve is intermediate in size between the first and third, and comes off from the ganglion near the centre of its convex edge. It runs forwards, covered by dura mater, along the base of the skull to reach the foramen rotundum, through which it leaves the cranium and enters the spheno-maxillary fossa: the branches which it there sends off and its communication with Meckel's ganglion have already been described (p. 60).

Second division.

The third division of the fifth or inferior maxillary nerve is the largest and most external of the three, and comes off directly above the foramen

Third division.

ovale, through which it is immediately transmitted to the external base: its course within the cavity of the skull is therefore exceedingly short, or may rather be said not to exist at all. In shape, the nerve is broad and flat in order to facilitate its passage through the oval opening.

Motor and sentient portions of the fifth.

When speaking of the origin of the fifth pair from the brain, it was described as consisting of two roots, which, as they pass forwards, have merely a cellular connexion with each other. The larger of these roots, or that derived from the corpus restiforme, terminates, as already mentioned, in the ganglion. The smaller, or that which owes its origin to the corpus pyramidale, will be found passing behind the ganglion, between it and the bone, at the same time receiving a small filament from the former: it then accompanies the third division through the foramen ovale, and on reaching the exterior of the cranium, constitutes what has been previously described as the muscular portion of the third division of the fifth, supplying the muscles of mastication; while the true or ganglionic portion of the third division divides into the dental, gustatory, and superficial temporal nerves (p.65). It is hardly necessary to remark, that the restiform portion of the fifth pair, and consequently the branches from the ganglion, are nerves of sensation, while the

pyramidal root is for the purpose of imparting motion to the muscles it supplies.

Beneath the semilunar ganglion and closely applied to the bone, may now be seen the pterygoid branch from Meckel's ganglion, which, having passed into the cranium through the anterior lacerated opening, runs along a groove in the petrous bone, and enters the foramen innominatum (p. 63).

PART II.

The cavernous sinus and its contents.

As the third, the fourth, the first division of the fifth, and the sixth pair of nerves have already been traced into the cavernous sinus, our next step consists in laying open that cavity and following them onwards to the orbit. We may first, however, examine a little more closely the situation and structure of the cavernous sinus, as it differs essentially in many respects from the other sinuses of the cranium.

Cavernous sinus.

The cavernous sinus is situated on the outer side of the pituitary fossa of the sphenoid bone, extending from the foramen lacerum orbitale before, through which it receives the ophthalmic veins, to

the extremity of the petrous bone behind, where it empties its blood into the superior and inferior petrosal sinuses. It is formed, after the manner of all the other sinuses in the skull, by the separation of the two layers of dura mater, but differs from them in as much as it receives, between these layers, the nerves already mentioned, together with the carotid artery and several filaments from the sympathetic surrounding the vessel. These structures, however, although contained between the walls of the sinus, are not in contact with the blood flowing through it, from which they are separated by the membrane lining the interior of the cavity. By tracing the nerves towards the orbit, and removing the dura mater and cellular tissue forming the outer wall of the sinus, its contents will become exposed, and their relative position can be ascertained.

Its contents.

Position of carotid artery.

The carotid artery enters the posterior extremity of the sinus, from the termination of the carotid canal, having previously taken a winding course through the temporal bone, where it affords a few small twigs to the internal ear. The passage of the vessel through the cavernous cavity is likewise excessively tortuous: it at first passes vertically upwards towards the posterior clinoid process of the sphenoid bone, then curves forwards, and runs horizontally along the side of the pituitary fossa,

where a groove is formed in the bone for its reception, until it becomes concealed by the anterior clinoid process, under which it assumes a second curve, and then ascends to pierce the dura mater and leave the sinus, just on the outer side of the ophthalmic nerve and behind the optic foramen. During the whole of this course, the artery is closely applied to the sphenoid bone at the side of the pituitary fossa; consequently the nerves are all situated externally to the vessel, which they partly conceal. While within the cavernous sinus, the carotid gives off two or three minute twigs to the dura mater, the nerves, and the pituitary gland; and, immediately after leaving the cavity, detaches the ophthalmic branch, which passes through the optic foramen and enters the orbit to the outer side and rather beneath the optic nerve.

Position of nerves.

The relative position of the four nerves within the cavernous sinus varies considerably in different parts of the cavity; since, as they enter it from different points and pass forwards to reach the lacerated foramen, they bear towards each other with different degrees of obliquity. If, however, we take a line midway between the anterior and posterior extremities of the sinus, we shall find them situated in the following manner, always remembering that they are all to the outer side of the carotid artery. Superiorly is the third or

motor oculi nerve, which enters the sinus from above, and inclines downwards; external to this, and rather below it, is the fourth, generally involved in the dura mater forming the outer wall, and running nearly horizontally; just under the fourth, will be found the first division of the fifth, entering the cavity from below, and passing obliquely upwards; while nearly on the same level as the last, but considerably to the inner side and in close contact with the coats of the carotid, is the sixth nerve.

[OBSERVATIONS.—Before proceeding to the next section, the student should make himself acquainted with the formation of the orbit, and the different foramina by which it communicates on the one hand with the cranium, on the other, with the parts external to that cavity].

SECTION VII.

DESCRIPTION OF THE NERVES AND VESSELS SITUATED WITHIN THE ORBIT.

PART I.

Distribution of the third, the fourth, the ophthalmic division of the fifth, and the sixth pair of nerves.

Directions to open the orbit.

As the student has already traced the nerves of the cavernous sinus to the foramen lacerum orbitale, and as he has likewise seen the optic nerve and artery leaving the cranium through the optic foramen, his next business will consist in laying open the orbit for the purpose of examining the distribution of those structures within the cavity. With this object, the roof of the orbit should be removed by sawing through the frontal bone on each side; the internal incision to be carried along the side of the cribriform plate of the ethmoid bone, and terminate behind in the lacerated opening; the external

incision to begin some way to the outer side of the orbit, to be continued obliquely downwards and inwards, so as to include a considerable portion of the outer wall of the cavity, and terminate behind in the extremity of the lacerated foramen. The dissection will be further facilitated, by removing the upper part of the optic foramen together with the anterior clinoid process of the sphenoid bone, thus laying the optic and lacerated openings into one. The passage of the optic nerve and artery will thus become exposed where the former is surrounded by the origins of the four recti muscles, which are easily separated from the bone, but adhere strongly to the nerve.

Contents of the orbit.

Before proceeding to the dissection, we may briefly mention the structures contained within the orbit. These consist of — 1st, the globe of the eye, imbedded in fat, and connected to the optic foramen by the nerve; 2nd, the six muscles of the globe, together with the levator palpebræ superioris; 3rd, the four nerves which enter at the foramen lacerum, the lenticular ganglion, and the ciliary branches; 4th, the distribution of the ophthalmic artery, and the returning veins; 5th, the lachrymal gland with its ducts leading on to the surface of the conjunctiva. All these structures are surrounded by loose fat and cellular membrane, which

must be carefully removed as we proceed with the dissection. The intricacy of the parts will render it impossible to trace the nerves precisely according to the order in which they are described, while their relative position is so minutely complicated, that it would render a detailed account almost unintelligible to the reader.

Superficial view of the contents.

The periosteum which lined the roof of the orbit, and which always separates from the bone when the latter is removed, should now be stripped off. The superficial structures which then become exposed, are, (in the middle) the supra-orbitar nerve, lying on the levator palpebræ superioris, which muscle is again closely applied to, and partly conceals the levator oculi; (on the inner side) the superior oblique muscle, with the fourth pair of nerves entering it near its origin; (on the outer side) the abductor oculi muscle, and, running along it, the lachrymal nerve. These branches will be again brought under our observation, as we follow the trunks which give them off, in their course from the cavernous sinus to their ultimate distribution within the orbit.

Distribution of the nerves.

The fourth pair, or pathetic, or inner oculo-muscular, being the most superficial and accessible, should first be traced.

Fourth pair.

We have already spoken of this nerve as involved in the dura mater forming the outer wall of the cavernous sinus, situated to the outer side of the third pair, and above the first division of the fifth: as it approaches the lacerated opening, it attaches itself to the supra-orbitar branch of the latter nerve, and accompanies it into the orbit, where it soon assumes a separate course, and, passing inwards enters the obliquus superior muscle, to which alone it is distributed.

Ophthalmic division of the fifth pair.

The ophthalmic or first division of the fifth, which we shall next trace, pursues an oblique course through the sinus, being at first situated below, but afterwards in close apposition to the fourth. After receiving a small filament from the carotid plexus of the sympathetic, it divides, while still within the sinus, into three branches, which diverge from each other and enter the orbit separately through the lacerated opening. These are—a Middle, or Supra-orbitar Branch—an External, or Lachrymal Branch — an Internal or Nasal Branch.

Its branches.

Supra-orbitar branch.

The supra-orbitar nerve passes directly forwards, between the levator palpebræ muscle and the membrane lining the roof of the orbit, to gain the supra-orbitar foramen or notch, through which it is transmitted on to the forehead, where it ramifies

beneath the occipito-frontalis and skin, forming junctions with the facial nerve (p. 13). Before leaving the orbit this nerve sends off a considerable branch, which runs inwards towards the trochlea of the superior oblique muscle and divides into twigs; some of which are lost in the upper eyelid and skin about the root of the nose, whilst others spread in the orbicularis and the corrugator supercilii muscles, detaching filaments which ascend towards the forehead.

Lachrymal branch.

The lachrymal nerve is the smallest of the three branches furnished by the ophthalmic division of the fifth. It is at first closely invested by a sheath of dura mater, and passes through the foramen lacerum to the outer side of the origin of the abductor oculi, between which muscle and the periosteum lining the external wall of the orbit, the nerve takes its course until it enters the lachrymal gland: after supplying this structure, it is continued on to the upper eyelid and the conjunctiva, where its filaments are finally distributed. Before it has reached the gland, the lachrymal nerve sends off a small twig which descends to the spheno-maxillary fissure, and joins either with the infra-orbitar or the malar branch from the second division of the fifth.

Nasal branch.

The nasal nerve passes much more deeply than the two preceding branches of the fifth, and ac-

companies the third and sixth pair to enter the orbit through the lacerated opening, between the two origins of the abductor muscle, and just to the outer side of the optic nerve. It here detaches a minute filament which soon terminates in the lenticular ganglion. It is then directed obliquely inwards and forwards, crossing above the optic nerve and beneath the levator muscle, where it gives off two or three ciliary branches; approaching the inner wall of the orbit, the nerve passes between the adductor and superior oblique muscles, and there divides into two filaments:—an Internal Nasal or Ethmoidal,—an External Nasal or Angular. The first of these leaves the orbit through the foramen orbitale internum anterius, and, after just entering the cranium, although beneath the dura mater, passes through the cribriform plate of the ethmoid bone into the nose: here it again divides into two long filaments, one of which is continued along the septum of the nose as far as the tip of the organ, where it is lost in the skin, while the other descends along the outer wall of the cavity and reaches the inferior turbinated bone. The external nasal or angular branch is continued forwards, along the under edge of the superior oblique muscle, to the inner canthus of the eye, where it expends itself by supplying the caruncula lachrymalis, the lachrymal sac, and the adjacent integuments.

The entrance of the nasal nerve into the orbit together with the third and sixth pairs, will become more clearly exposed, by separating the upper origin of the abductor oculi from the levator muscle and the optic nerve; thus laying open the communication between the orbitar cavity and the cavernous sinus.

Sixth pair.

The sixth nerve, or abducens, or outer oculo-muscular has been already alluded to as entering the posterior extremity of the cavernous sinus, and running along its floor in close apposition with the carotid artery; where it receives one or more filaments, transmitted through the carotid canal from the sympathetic. On reaching the lacerated foramen it becomes closely attached to the third pair, and nasal branch of the fifth, and, with them, enters the orbit between the origins of the abductor oculi: the nerve is then continued forwards a short way along the ocular surface of that muscle, and, after penetrating it by numerous fasciculi, becomes entirely distributed to its substance.

Just at the foramen lacerum, the abducens nerve is said to detach a minute twig to the lenticular ganglion, which is possibly one of those filaments that it received from the sympathetic in the cavernous sinus.

Third pair.

The third nerve, motor oculi, or common oculo-muscular, enters at the roof of the cavernous sinus, and, passing very obliquely downwards and forwards, divides just behind the lacerated opening into two portions, which accompany the nasal nerve and the sixth into the orbit, and then separate from each other.

Superior branch.

The smaller of these divisions rises above the optic nerve, to enter the levator oculi near its origin; and after supplying it, detaches a twig which pierces the muscle and goes to the levator palpebræ.

Inferior branch.

The larger or inferior division inclines downwards, gets below the optic nerve, and separates into three branches; one of which enters the depressor muscle, a second supplies the adductor, while the third, a long slender filament, is continued forwards, between the edges of the depressor and abductor muscles, to terminate in the inferior oblique, which it enters not very far from its insertion. From the commencement of this last branch, a twig is detached to join with the lenticular ganglion.

PART II.

The lenticular ganglion and its branches.

Lenticular ganglion.

THE lenticular or ophthalmic ganglion is situated in the back part of the orbit, and lies, imbedded in fat, between the optic nerve and the abductor muscle. In size and shape it has some resemblance to a grain of linseed: posteriorly it receives the twigs from the third, fifth, and sixth nerves, which have already been alluded to, while from its anterior surface, spring several delicate filaments, which vary in number from eight to sixteen, and are termed ciliary nerves.

Ciliary nerves.

Slightly diverging from each other, these ciliary nerves pass forwards, and, receiving an addition on the inner side by some twigs sent off from the nasal branch of the fifth, they completely surround the optic nerve and pierce the sclerotic tunic of the eye: they then continue their course forwards between the sclerotic and choroid coats; and, after passing through the ciliary ligament, are ultimately distributed to the iris and ciliary body.

The lenticular ganglion is generally considered to form a part of the sympathetic system, and its connexion with the first cervical ganglion is probably effected by the branches which it apparently derives from the fifth and sixth pair; in other words, the latter nerves may perhaps serve as a medium for conducting the filaments, which they receive from the carotid plexus in the cavernous sinus, into the orbit, to terminate in the ganglion.

PART III.

Course and distribution of the ophthalmic artery.

While tracing the nerves of the orbit, the branches of the ophthalmic artery must also have become exposed, and to these we may now direct our attention.

Course of the ophthalmic artery.

The ophthalmic artery is given off by the internal carotid, just above the cavernous sinus, and passes into the orbit through the optic foramen, to the outer and under part of the nerve. It here becomes more or less entangled with the branches of the lenticular ganglion, but soon inclines

inwards, crossing over the optic nerve and reaching the inner wall of the orbit. It is then continued forwards, between the superior oblique and adductor muscles, and terminates at the internal canthus, by sending one branch upwards on to the forehead, and another downwards to ramify over the root of the nose, and join with the facial artery.

Its branches.

The branches which the ophthalmic artery detaches in its course are—the Lachrymal—the Central of the Retina—the Supra-orbitar—Ciliary Branches—Muscular Branches—the Anterior and Posterior Ethmoidal—Palpebral Branches—the Terminating Branches.

These may be divided, according to the situation of the main trunk, into three sets, viz.;—those given off on the outer side of the optic nerve—those given off above the nerve—those given off along the inner wall of the orbit.

First set.

While on the outer side of the nerve, the ophthalmic artery sends off—

Lachrymal branch.

1st. The lachrymal branch, which runs along the outer wall of the orbit, detaching small twigs in its course, until it reaches the lachrymal gland; after supplying which, it terminates in the upper and lower eyelids.

Central

2nd. The central artery of the retina, which

artery of the retina.

enters the substance of the optic nerve, and is thus conveyed into the interior of the globe of the eye, where it ramifies minutely on the inner surface of the retina, forming a delicate network of vessels called "Tunica vasculosa retinæ." These vessels appear to extend as far forwards as the corpus ciliare, where they probably anastomose with the arteries of that structure. The central artery also sends a branch into the vitreous humour, which may be traced as far as the posterior surface of the capsule of the lens.

Second set.

While crossing over the optic nerve, the ophthalmic artery gives off—

Supra-orbitar branch

1st. The supra-orbitar, which accompanies the nerve of the same name along the levator palpebræ muscle, and, leaving the orbit at the superciliary notch, ramifies over the forehead, and forms communications with the temporal and occipital arteries.

Ciliary arteries.

2nd. Ciliary arteries, which come off rather irregularly, either from the main trunk of the ophthalmic, or from some of its branches. They are divided into the short and the long; the former supplying the choroid coat, the latter the iris.

Short ciliares.

The short ciliares are very numerous, and surround the optic nerve, where they inosculate and divide, so that their number becomes doubled by

the time they reach the globe of the eye. They are intermixed with the ciliary nerves, and enter the eye in the same manner by piercing the back part of the sclerotic tunic, where a few remain and ramify in that membrane; but by far the greater number pass into the choroid coat, which, together with the ciliary body and processes, is profusely supplied by them. These vessels constitute the inner layer of the choroid, generally termed "Tunica Ruyschiana." Some of the twigs are also distributed to the iris. The long ciliares are only two in number, being at the same time much larger than the short, and pierce the sclerotic on either side at a greater distance from the optic nerve: they run horizontally forwards, in the plane of the long axis of the globe, and between the sclerotic and choroid coats, until they gain the anterior margin of the latter, when they pierce the ciliary ligament and enter the external or greater circumference of the iris. Here they divide, and, by inosculating with each other, produce a vascular circle, called zona major. From the interior of this circle numerous branches are given off, which radiate towards the pupillary margin of the iris, where they again unite to form a second anastomosis, called zona minor. Some anatomists also describe a third intermediate zone.

Long ciliares.

Muscular branches.

3rd. Muscular branches, which generally consist of a smaller twig supplying the levator oculi, the levator palpebræ, and the obliquus superior; and a larger branch which becomes distributed to the other muscles. From these muscular branches, generally arise what are called the anterior ciliary arteries, consisting of four or five small twigs which pierce the sclerotic, two or three lines behind its junction with the cornea, and become lost in the iris and choroid membrane.

Third set.

While running along the inner wall of the orbit, the ophthalmic artery gives off—

Anterior and posterior ethmoidal branches.

1st. The anterior and posterior ethmoidal branches, which pass through the corresponding internal orbitar foramina, give off twigs to the frontal sinuses and ethmoidal cells, and, having entered the cranium, divide into minute branches, some of which are lost in the dura mater, whilst others accompany the olfactory nerves into the nose.

Superior and inferior palpebral branches.

2nd. The superior and inferior palpebral branches, which ramify in the upper and lower eyelid, supplying the integuments, orbicularis muscle, cartilage, and meibomian glands: they also send twigs to the caruncle, conjunctiva, and lachrymal sac.

3rd. The terminating branches of the ophthalmic, consisting of a frontal and a nasal artery, distributed, the one to the forehead, the other to the root of the nose, as has been already described. Terminating branches.

PART IV.

The ophthalmic vein.

THE ophthalmic vein is formed at the posterior part of the orbit, by the union of the venæ comites, which accompany the different branches of the ophthalmic artery. It may be described as constituted by two sets of vessels; viz.—those derived from the interior of the globe, and those returning the blood from the appendages of the eye and the other contents of the orbit. The former arise principally in the iris, and the external layer of the choroid coat, and may be seen piercing the sclerotic at different points of its surface; the latter follow the course of the arteries to which they belong. The ophthalmic vein is situated below and external to the optic nerve, and passes through the foramen lacerum orbitale to terminate in the cavernous sinus. This vein, however, does not return all the blood sent into the orbit by the artery, as several Ophthalmic vein.

small vessels may be traced from the eyelids and adjacent integuments, converging towards the inner canthus, where they empty themselves into the commencement of the facial vein.

[OBSERVATIONS.—Our dissection of the nerves and vessels of the head is now completed, with the exception of the sinuses of the brain, which will form the subject of the next section. The situation of the sinuses being for the most part indicated by grooves on the internal surface of the cranium, the study of them will very much assist us in tracing the course of these vessels.]

SECTION VIII.

DESCRIPTION OF THE CEREBRAL SINUSES.

THE cerebral sinuses, or vessels returning the blood from the brain, are canals produced by the separation of the two layers of membrane which constitute the dura mater, and lined by a continuation of that tissue which forms the internal coat of the veins. Their shape is mostly triangular, and they are either in contact with the bony parietes of the cranium, or else are enclosed in the processes of dura mater, which project into the cavity. They may be examined by slitting up the dura mater, thus laying them open, and tracing them along their course to their ultimate conflux at the foramen lacerum basis cranii posterius of each side, where they form the internal jugular vein. Cerebral sinuses.

The cerebral sinuses may be divided into two sets: — the Great Sinuses, and the Small Sinuses. Divided into the great and the small.

The great sinuses.

The great sinuses are four in number—the Longitudinal—the Straight, or Horizontal—the Right Lateral—the Left Lateral.

Longitudinal sinus.

The longitudinal sinus is situated in the upper part of the falx major, and extends from the foramen cæcum of the os frontis, to the internal tuberosity of the occipital bone, where it empties itself into the right and left lateral: it follows the median line of the skull, and is therefore in contact successively with the frontal, the junction of the two parietal, and the upper portion of the occipital bone (p. 87).

Straight sinus.

The straight sinus is situated at the junction of the falx major, with the upper surface of the tentorium: it runs horizontally backwards, commencing at the free edge of the tentorium, where it receives the inferior longitudinal sinus with the venæ Galeni, and terminating at the occipital tuberosity where it joins the two lateral.

Torcular Herophili.

The conflux of the longitudinal sinus, the straight sinus, and the occipital sinus, which last comes up from below the tentorium, produces a sort of irregular cavity or slight enlargement, corresponding to the occipital tuberosity, and termed the torcular Herophili. This has five openings: viz.—the three sinuses just mentioned, which enter the cavity, and the right and left lateral which proceed from it on each side.

The lateral sinuses are contained, during the greater part of their course, in the attached margin of the tentorium. They commence at the torcular Herophili, and run outwards along the groove which marks the transverse ridge of the occipital bone: they then pass over the posterior inferior angles of the parietal bones, and leave the tentorium to descend over the mastoid portions of the temporal bones. Quitting these, they regain the occipital bone, and terminate on either side in the jugular fossa, which constitutes the outer and posterior part of the lacerated opening at the base of the skull, and lodges the commencement of the internal jugular vein. **Lateral sinuses.**

The smaller sinuses may be enumerated as—the Inferior Longitudinal—the Occipital—the Transverse—which are all single vessels:—the Cavernous—the Anterior and Posterior Clinoid—the Superior and Inferior Petrosal—which exist in pairs. **The small sinuses.**

The inferior longitudinal occupies the lower, or free edge of the falx major, being situated between the two layers of dura mater which form that process. It terminates behind in the straight sinus. **Inferior longitudinal sinus.**

The occipital sinus is situated in the falx minor, and corresponds to the inferior vertical ridge of the **Occipital sinus.**

occipital bone. It is formed below by a branch from each side of the foramen magnum, and empties itself above into the torcular Herophili.

Cavernous sinuses.

The cavernous sinuses have already come under our observation (p. 115).

Anterior and posterior clinoid sinuses.

The anterior and posterior clinoid sinuses are exceedingly small, and run in a slightly curved direction before and behind the pituitary fossa, joining on each side with the cavernous. The union of the four vessels which thus surround the pituitary gland constitutes the Circular Sinus of Ridley.

Superior and inferior petrosal sinuses.

The superior and inferior petrosal sinuses, commence by a common origin at the extremity of the petrous portion of the temporal bone, where they receive the blood from the cavernous sinus, and then separate from each other. The superior follows the groove along the upper ridge of the petrous bone, and terminates in the mastoid portion of the lateral sinus. The inferior runs downwards and outwards, lodged in the sulcus, formed by the junction of the occipital and temporal bones, and empties itself into the commencement of the jugular vein.

Transverse sinus.

The transverse sinus passes across the basilar process of the occipital bone, generally close to its junction with the sphenoid, so as to connect the common origin of the two petrosal sinuses of either side: sometimes, however, it is placed lower down, so as merely to effect a union between the inferior

petrosal canals. Occasionally, there are two, or even three transverse sinuses.

[OBSERVATIONS.—The dissection of the blood-vessels and nerves of the head may now be considered as completed: the common carotid artery has been traced throughout the whole of its distribution, and the eleven pairs of cerebral nerves have likewise been followed from their origin to their ultimate ramifications. The remaining part of our dissection will extend to the cervical and thoracic regions, and comprize the spinal nerves and the distribution of the subclavian artery. The cervical nerves will first occupy our attention, because they are now the most readily accessible; and, coming from the spinal cord, they succeed naturally to the description of those which arise from the brain.]

SECTION IX.

DESCRIPTION OF THE CERVICO-SPINAL NERVES.

PART I.

General remarks—the sub-occipital nerve—the seven cervical nerves.

In order to display the cervico-spinal nerves, the sterno-mastoid muscle should be divided through its middle, and carefully reflected; upwards, towards the mastoid process, and downwards, towards the sternum and clavicle. This will expose the three scaleni muscles, together with the rectus capitis anticus major, and the lower part of the longus colli, and the nerves will be seen making their appearance from between these muscles, which entirely conceal them at the point where they issue from the spinal canal through the intervertebral foramina. The commencement of the common carotid and subclavian arteries, with their corresponding veins, will likewise be brought into view.

The nerves which thus arise from the cervical portion of the spinal cord, are eight in number, viz. —the Sub-occipital which comes out between the occipital bone and the atlas—and the Seven Cervical, the first of which emerges between the atlas and dentata, the seventh between the last cervical and first dorsal vertebra. Some anatomists class the sub-occipital nerve as the first cervical, which arrangement, of course, changes the nominal situation of each succeeding nerve, rendering them eight in number instead of seven. Cervico-spinal nerves.

These nerves arise from the spinal cord by two sets of fasciculi, the one coming from the anterior, the other from the posterior column. Prior to the junction of these two roots, the posterior experiences a gangliform enlargement, after which, they leave the vertebral canal as one nerve.

The sub-occipital nerve arises almost on a level with the foramen magnum, or just at the junction of the medulla oblongata with the spinal cord, and is so deeply seated where it leaves the vertebral canal, as to be inaccessible in the present stage of the dissection. It is of small size, and divides into an Anterior and Posterior branch. Sub-occipital nerve.

The former passes forwards, and may now be recognized as it makes its appearance between the rectus capitis anticus minor, and the rectus lateralis, Anterior branch.

just above the root of the transverse process of the atlas. It then bends down to form an arch, by joining with a branch of the first cervical nerve sent up to meet it, detaches twigs to the lateral and two anterior recti muscles, and inosculates with the superior cervical ganglion of the sympathetic, with the glosso-pharyngeal and pneumo-gastric nerves.

Posterior branch.

p 229

The posterior branch of the sub-occipital nerve is the larger of the two, and, passing backwards under the complexus, is distributed to the posterior recti and to the oblique muscles of the head. It cannot be seen until the muscles of the back have been dissected.

The seven cervical nerves. General description.

The seven cervical nerves, like the sub-occipital, divide severally into a Posterior and an Anterior branch, as soon as they escape from the vertebral foramina. The former are principally distributed to the deep-seated muscles on the back of the neck, and consequently cannot be seen until those parts are dissected. The latter come forwards, and, emerging from between the muscles which arise from the transverse processes of the vertebræ, become covered by the sterno-cleido-mastoideus: it is therefore these anterior branches only, which we have exposed by raising that muscle. The three first make their appearance between the rectus capitis anticus major, and the scalenus medius

muscle; the four inferior are seen emerging between the scalenus anticus and medius, accompanied by the first dorsal nerve. The anterior branches of all the cervical nerves join with the one above, and the one below: the first likewise is connected with the sub-occipital, the last with the first dorsal. The three superior constitute by their union what is generally described as the cervical plexus, chiefly supplying the superficial parts about the neck; while the junction of the four lower nerves, together with the first dorsal, forms the axillary or brachial plexus, from which the upper extremity is supplied. It is worthy of remark, that the relative size of the anterior and posterior branches is rendered different in each nerve, by the progressive increase of the former, and decrease of the latter, as we pass down the neck.

Having thus made ourselves acquainted with the general arrangement and connexions of the seven cervical nerves, we may proceed to the more particular description of each trunk, as they successively make their appearance from between the deep muscles of the neck.

PART II.

The three superior cervical nerves, forming the cervical plexus, by the union of their anterior branches.

First cervical nerve.

Anterior branch.

THE anterior branch of the first cervical nerve makes its appearance between the rectus capitis anticus major, and the scalenus medius, and becomes nearly expended by joining with the sub-occipital above, and the second cervical below; it is likewise connected to the par vagum, and by several filaments to the first cervical ganglion. It detaches a small twig to the rectus major, and also a slender branch which passes downwards and inwards, to effect a union with the descendens lingualis. vel non

Posterior branch.

The posterior branch of the first cervical is generally called the great occipital nerve, and passes backwards between the obliquus capitis inferior, and the complexus muscles. Before arriving at the median line it pierces the latter, together with the trapezius, and, thus becoming subcutaneous, ascends and ramifies over the back of the head, joining with the supra-orbitar, temporal and auricular nerves. In the first, or deep-seated part of its

course, the occipital gives off several filaments to the surrounding muscles, more especially to the complexus.

Second cervical nerve. Anterior branch.

The anterior branch of the second cervical nerve issues from between the same muscles as the preceding, and unites with the first cervical above, with the third below. It forms junctions with the sympathetic and accessory, supplies the rectus anticus and levator scapulæ, and also detaches a little branch, which, after uniting with a corresponding twig from the nerve above, forms an arch with the descendens lingualis, just as the latter is crossed by the omo-hyoideus muscle: a very small filament is likewise sent down to assist in the composition of the phrenic nerve. The continuation of the nerve, after these branches have been given off, is directed downwards, until it becomes superficial by turning over the posterior edge of the sterno-mastoid muscle, where it divides into the aural, transverse cervical, and small occipital branches, which were described in the first section of this book (p. 3).

Posterior branch.

The posterior branch of the second cervical divides into filaments, which ramify amongst the muscles at the back of the neck, to which, and to the superjacent integuments, they are distributed.

Third cervical nerve. Anterior branch.

The anterior branch of the third cervical nerve also emerges between the rectus major and scalenus medius, and immediately becomes connected with the second and fourth nerves, with the sympathetic, accessory, and frequently with the descendens lingualis: it likewise gives some twigs to the neighbouring muscles, and has the principal share in the formation of the phrenic. The remainder of the nerve then divides into several considerable branches, which pass from under the sterno-mastoideus, and descend towards the chest and shoulder. These have already been noticed as the supra-clavicular, and the supra-acromial nerves (p. 6).

Posterior branch.

The posterior branch of the third cervical is distributed, like that of the preceding nerve, to the muscles and integuments on the back of the neck.

Phrenic nerve.

The phrenic nerve, which may now be examined, is given off from the anterior branches of the second, third, and fourth cervical. It owes its origin principally to the third, receiving an exceedingly slender filament from the second, and connected, by one equally small, to the fourth: it likewise forms some minute and irregular junctions with the lower cervical nerves, and the sympathetic. The phrenic descends on the anterior surface of the scalenus anticus, and, inclining inwards, gains the edge of the muscle just above its insertion. The nerve then crosses before the subclavian

artery, and behind, the vein to enter the chest, through which cavity it is continued, between the pericardium and the pleura, until it becomes lost in the diaphragm.

PART III.

The four inferior cervical nerves, and the first dorsal, forming, by the union of their anterior branches, the axillary plexus.

The four lower cervical nerves.

Anterior branches.

THE anterior branches of the four inferior cervical nerves are very large, and involve nearly the whole of the original trunks. They make their appearance between the scalenus anticus and medius, they furnish twigs to these muscles, as well as filaments of connexion with the second and third cervical ganglia, and then pass with different degrees of obliquity downwards and outwards towards the axilla, taking a deeply-seated course through the triangular space, formed by the clavicle with the sterno-cleido-mastoideus and omo-hyoideus muscles. The fourth and fifth nerves become united as soon as they emerge from between the scaleni; the seventh and the first dorsal are connected together in a similar manner; while the sixth nerve takes its

course separately, between the two trunks thus formed above and below it. The five nerves thus assume the appearance of three great trunks, the uppermost of which descends nearly vertically, the lower one passes almost horizontally, while the third maintains an intermediate direction between the other two. Thus converging towards each other, they traverse the bottom of the triangular space mentioned above, covered, and in great measure surrounded, by the cellular membrane and fat which it contains. On reaching the surface of the first rib, the three trunks become united by an intricate interlacement of their fibres, and thus the broad surface, which the five nerves conjointly exhibit as they make their first appearance from between the scaleni, is reduced to a single flattened cord, which leaves the neck, and passes into the axilla between the first rib and the subclavius muscle, the latter separating it from the clavicle. Within the axillary space, the filaments which compose the mass, again separate from each other, and re-unite in such a manner, as to form a complicated network, denominated the axillary or brachial plexus, which completely surrounds the artery, and from which the nerves destined to supply the upper extremity are given off.

External respiratory nerve.

By raising the axillary plexus, and turning it to one side, a remarkable branch will be seen, called

by Sir Charles Bell the external respiratory nerve. It is formed by the junction of filaments from the posterior surfaces of the fourth, fifth, and generally the sixth cervical, soon after they leave the scaleni muscles, and descends separately over the first rib, behind the united nervous mass, to be distributed exclusively to the serratus magnus anticus.

Posterior branches.

The posterior branches of the four lower cervical nerves are of small size, and pass backwards to ramify between the complexus and semi-spinales muscles: some of their filaments reach the skin after piercing the splenius and trapezius.

First dorsal nerve.

The first dorsal nerve leaves the spinal canal between the first and second dorsal vertebræ, and consequently within the cavity of the chest. It detaches a posterior branch to the muscles of the back, and a second to supply the first intercostal space; then, crossing over the neck of the first rib, leaves the thorax, and, passing between the scaleni, becomes connected with the last cervical, as has been already described.

[OBSERVATIONS.—While examining the nerves contained in the foregoing section, more than one branch of the subclavian artery must have crossed

the path of the student, and the close proximity of the last cervical and first dorsal to the main trunk of the vessel, can hardly have escaped his observation. It is the course and distribution of the subclavian which will next engage our attention; and in order to trace it from its commencement, it will be necessary to open the chest and lay bare the arch of the aorta; when we shall also obtain a more complete view of the lower portion of the common carotid artery, the subclavian and internal jugular veins, the par vagum and phrenic nerves; as these different structures enter or leave the thoracic cavity.

[The parts situated behind the sternum and occupying the upper opening of the chest, will therefore form the subject of the succeeding section, but before he proceeds, the student will do well to recall to his memory the formation and shape of the thoracic parietes, the situation of the heart and lungs, and the manner in which the pleuræ are adapted, so as to line the walls of the chest, to cover the viscera, and to constitute the mediastinal spaces.]

SECTION X.

DESCRIPTION OF PARTS BROUGHT INTO VIEW BY RAISING THE STERNUM.—THE ARCH OF THE AORTA, AND ITS RELATIVE POSITION WITH REGARD TO THE VESSELS, NERVES, AND OTHER STRUCTURES, SITUATED ABOVE THE PERICARDIUM AND BETWEEN THE TWO PLEURAL CAVITIES.

PART I.

The arch of the aorta.

After detaching the sterno-hyoidei and sterno-thyroidei muscles from the sternum, that bone may either be entirely removed; or, what will answer the purpose equally well, it may be sawn down the middle, and the sides forcibly separated from each other, so as to expose the anterior mediastinum and parts beneath.

On removing the fat, cellular membrane, and remains of the thymus gland, which occupy the Arch of the aorta.

anterior mediastinum, the pericardium will be laid bare, and above it the arch of the aorta will be seen: the arch being the only part of the vessel visible at this time, since the ascending portion of the aorta is concealed by the pericardium, and cannot be seen until that membrane is laid open; while the commencement of the descending aorta is hidden by the left pulmonary artery and the left bronchus crossing before it. The arch is thus intermediate between the ascending and descending portions, being situated in the upper and anterior part of the thorax, and is now more particularly the object of our attention, as it sends off the arteries which supply the head and upper extremities.

Its relative position with the surrounding structures.

The arch or transverse portion of the aorta is situated behind the first bone of the sternum, from which it is merely separated by cellular tissue and the remains of the thymus gland. It extends from the right to the left side, but at the same time is placed obliquely, passing from before, backwards, and slightly from above, downwards; that part which is continuous with the ascending aorta being nearly in contact with the right edge of the sternum, while its termination or junction with the descending aorta, becomes attached to the left side of the third dorsal vertebræ. The arch presents a slight convexity upwards, and a corresponding concavity below. To its right, but rather behind its plane, is

seen the vena cava superior, formed by the junction of the two venæ innominatæ, and receiving the azygos vein just before it becomes covered by the pericardium: to the left side is seen the par vagum, crossing before the arch just where the latter becomes attached to the spine. Below the arch, or within its concavity, is the bifurcation of the pulmonary artery, together with the remains of the canalis arteriosus, which, in the fœtal state, forms a communication between these two great vessels. From the upper or convex surface of the arch proceed the three great arteries, the innominata, the left carotid and the left subclavian, which diverge from each other with different degrees of obliquity, to escape at the upper opening of the chest: they are all crossed, immediately after their origin, by the left vena innominata which separates them from the first bone of the sternum. The latter vessel is formed just behind the sterno-clavicular joint, by the conflux of the left internal jugular and subclavian veins, and, after passing over to the right side, joins with the right innominata which is formed in a similar manner; the result of their union being the vena cava superior.

Between the origins of the arteria innominata and the left carotid, the trachea may be observed descending from the larynx, entering the upper opening of the chest, and lost behind the arch of

the aorta, where it divides into the two bronchi. Lying on the trachea are the inferior thyroideal veins, issuing from the under part of the thyroid gland and entering the thorax, to terminate in the left vena innominata and the commencement of the cava. Behind the trachea and concealed by it, is the œsophagus, continued from the pharynx, and passing down in contact with the spine until it enters the posterior mediastinum: to the left of the œsophagus and close to the vertebræ, is the thoracic duct, ascending to gain the upper opening of the chest.

Lastly, the phrenic nerves will be seen on either side in close contact with the pleura, while the left pneumogastric may be observed crossing before the arch of the aorta, to the left both of the origin of the subclavian vessel above, and the attachment of the canalis arteriosus below.

In order that the student may form an accurate conception of the relative position of the structures just described: viz.—the arch of the aorta with its three branches, the bifurcation of the pulmonary artery, the vena cava and venæ innominatæ, the trachea, œsophagus, and thoracic duct, together with the pneumo-gastric and phrenic nerves; he must remember, that they are all situated in the upper portion of the central division of the chest,

between the two pleural cavities; that the space which contains them is bounded, above, by the upper thoracic opening; below, by the pericardium; before, by the sternum; behind, by the three first dorsal vertebræ; and on either side, by the pleuræ, which do not here divide the middle region of the chest into mediastina, as is the case lower down; but pass in nearly a direct line from the margins of the sternum to the sides of the spinal column.

PART II.

The three great vessels given off by the arch of the aorta.

We now pursue our dissection, by tracing the three great arterial trunks sent off by the arch, from their origin to their exit from the chest. These are—the Arteria Innominata—the Left Carotid—the Left Subclavian.

The arteria innominata arises from the right extremity, and therefore from the highest part, of the arch of the aorta, and takes an oblique direction upwards and outwards towards the sterno-clavicular articulation, behind which it terminates, by dividing

Arteria innominata.

into the right common carotid and right subclavian arteries. The vessel is crossed at its commencement by the left vena innominata, which, together with the remains of the thymus gland, separates it from the first bone of the sternum: it just clears the thoracic cavity previously to its bifurcation, and is there covered by the platysma myoides, cervical fascia, the sterno-mastoideus, sterno-hyoideus and sterno-thyroideus muscles. The division of the artery may be said to correspond to the fissure generally observed between the sternal and clavicular origins of the sterno-cleido-mastoideus. The innominata is accompanied by its corresponding vein lying on the right side, and in close contact with the pleura. At its origin from the aorta, the artery is resting upon the trachea, which, however, it soon leaves, and during the remaining part of its course is situated to the right side of that tube, corresponding posteriorly to the longus colli muscle, although not in very close apposition, until it has gained the upper opening of the chest; and even there, we find the lower cervical ganglion of the sympathetic, and a considerable quantity of cellular membrane, interposed between the vessel and the muscle.

Left common carotid artery.

The left carotid artery comes off from the arch a short distance to the left side of the innominata, and passes upwards with a very slight obliquity

outwards, to gain the upper opening of the chest. It is separated from the sternum by the vena innominata and the remains of the thymus gland, while posteriorly, it corresponds to the longus colli muscle. To its right side is the trachea, which is at first behind, but afterwards on a plane anterior to the vessel; to its left lies the subclavian artery, which, however, diverges from it and is much more deeply seated. The point at which the left carotid quits the thoracic cavity, corresponds to the bifurcation of the innominata on the opposite side, with the exception that the latter is rather the more superficial of the two. The remaining or cervical course of the common carotid has been described in the second section of this book (p.25).

Left subclavian artery.

The left subclavian artery arises from the arch just before the aorta assumes the name of descending, and, taking a curved direction upwards and outwards, leaves the chest behind and rather to the external side of the sterno-clavicular articulation.

[Observations.—A more detailed account of the thoracic portion of the left subclavian artery is reserved for the next section, which will be devoted to the course of that vessel. The student should

previously make himself acquainted with the adaptation of the pleura to the upper opening of the chest; also with the attachments of the scalenus anticus and medius to the first rib, and the manner in which the neck and the axilla communicate, through the passage between that bone and the clavicle.]

SECTION XI.

DESCRIPTION OF THE COURSE OF THE SUBCLAVIAN ARTERY AND VEIN.

PART I.

Preliminary remarks.

THE subclavian artery on the right side, arises from the arteria innominata; that on the left, from the arch of the aorta: the one is consequently external to the chest from its commencement, the other is at first deeply situated within the thoracic cavity. They both take a direction outwards (the left having to rise considerably in order to clear the opening of the chest), and pass between the scaleni muscles: they then curve downwards towards the axilla, pass between the clavicle and the first rib, and at the lower edge of the latter bone assume the name of axillary. Subclavian artery.

We thus see the artery in three different situations:—1st, before it has reached the scaleni Divided into three portions.

muscles; 2nd, while it is situated between the scaleni; 3rd, after it has passed beyond the scaleni. As it is only in the first part of their course, or previously to their reaching the scaleni muscles, that the right and left arteries differ from each other, a separate description of each side will be necessary only as far as it relates to that portion of the vessel.

PART II.

The first portions of the right and left subclavian artery, together with the passage of the pneumogastric and phrenic nerves into the chest.

First portion of the subclavian.

Right side.

THE right subclavian artery is, of course, the shortest in this portion, and passes outwards and slightly upwards to the extent of about an inch, when it becomes concealed by the scalenus anticus. During this part of its course, the artery is covered by the sterno-cleido-mastoideus muscle, and by the cervical fascia, partly also by the sterno-hyoideus, and sterno-thyroideus. It is crossed by the pneumogastric and phrenic nerves; by the former, near its origin from the innominata, by the latter, close to the edge of the scalenus muscle: some filaments of

the sympathetic likewise pass in front of the artery. Posteriorly, the subclavian is separated from the longus colli muscle, by branches of the sympathetic connected with the last cervical ganglion, by the recurrent laryngeal nerve, and a quantity of cellular membrane. The under surface of the vessel is in close contact with the pleura, where that membrane rises to form a cul de sac above the upper opening of the chest.

Left side.

The first portion of the left subclavian is principally situated within the chest, and is altogether more deeply seated than on the right side. It comes off from the left extremity, consequently from the lowest and most posterior part of the arch of the aorta, and curves upwards and outwards, round the apex of the lung, to reach the scaleni muscles, leaving the thoracic cavity just on the outer side of the sterno-clavicular articulation: its concave surface is throughout in close apposition to the pleura lining the upper part of the chest. While the artery is rising to gain the opening of the thorax, it is covered or rather overlapped by the left lung: it is also crossed by the vena innominata, and by the pneumo-gastric nerve, the latter descending obliquely before it. Posteriorly the vessel corresponds to the longus colli muscle, which separates it from the spine: to its right side is the left carotid artery, the trachea and the œsophagus.

On emerging from the chest, the left subclavian attains the same relative position to surrounding parts as the vessel on the right side, except that it is rather more deeply seated, and ascends with a greater degree of obliquity to reach the scaleni muscles.

We may here with propriety bestow a little attention on the pneumo-gastric and phrenic nerves as they enter the chest, since they are more particularly connected with that portion of the subclavian artery which has just been described.

Par vagum. Right side.

The difference which exists with regard to the origins of the large arteries on the right and left side, produces a corresponding difference in the relative situation of the pneumo-gastric nerves at this part. Thus, the right par vagum, after descending through the neck within the carotid sheath, crosses before the subclavian artery close to its origin from the innominata, and immediately behind the junction of the subclavian and internal jugular veins: it passes, therefore, between the artery and the vein, and, entering the chest, sinks behind the root of the lungs to gain the posterior mediastinum. Immediately below the subclavian, and consequently just at the margin of the thoracic cavity, the nerve detaches the recurrent laryngeal branch, which curves round to assume a retrograde course;

and, after crossing behind the origins of the subclavian and carotid arteries, becomes situated in the groove between the trachea and œsophagus, along which it ascends towards the larynx.

Par vagum. Left side.

On the left side, we shall find the par vagum retaining its position by the side of the carotid, until it has fairly entered the chest, and then passing between the left subclavian artery and vena innominata, the former of which it crosses obliquely. The nerve then descends in front of the arch of the aorta, and passes suddenly backwards to enter the posterior mediastinum. The recurrent laryngeal branch of this side comes off immediately below the aortic arch, and after turning round behind that vessel, to the left of the canalis arteriosus, becomes situated in the groove between the trachea and œsophagus.

The farther course of the par vagum through the posterior mediastinum, and the branches it affords to the lungs, the œsophagus, and the stomach, must be reserved for a future period; but we may now follow the recurrent laryngeal branch.

Recurrent laryngeal branch.

The recurrent laryngeal nerve has already been seen passing upwards between the trachea and œsophagus, along the inner side of the carotid sheath. Directly after its origin, it detaches one or more branches to the cardiac plexus, and during

its ascent, furnishes twigs to the trachea and œsophagus: it also forms connexions with the sympathetic and superior laryngeal nerve. At the lower edge of the cricoid cartilage, it introduces itself between the œsophagus and pharynx, and immediately becomes lodged within the groove formed at the back of the larynx, between the thyroid and cricoid cartilages. The nerve here divides, and becomes expended, by supplying the crico-arytenoideus posticus, the crico-arytenoideus lateralis, and the thyro-arytenoideus, besides forming numerous communications with the superior laryngeal: a very minute filament may also be traced, passing under the crico-arytenoideus posticus, to be lost in the arytenoideus transversus muscle.

The dissection of these ultimate branches must be postponed until the larynx can be removed from the body, when the distribution of the superior laryngeal nerve may also be traced (p. 97).

Phrenic nerve.

The phrenic nerve has already been described as arising from the anterior branches of the second, third, and fourth cervical; whence it descends towards the chest, crossing obliquely over the scalenus anticus, so as to reach the inner margin of that muscle just above its insertion. It then crosses before the subclavian artery and behind the

vein, generally involved amongst the branches which arise from the former, and situated considerably to the outer side of the par vagum. On entering the thorax, the nerve immediately becomes applied to the surface of the pleura, along which it descends towards the heart, and is continued by the side of the pericardium, between that membrane and the pleura, until it reaches the diaphragm, to which muscle its filaments are finally distributed.

The right phrenic nerve, previously to its reaching the pericardium, will be found in close contact with the vena cava: in other respects, the same description will apply to either side.

PART III.

The second portion of the subclavian artery.

Second portion of the subclavian.

In this part of its course, the subclavian is situated between the scalenus anticus and medius muscles, the former of which conceals it from our view, and separates it from the vein. Immediately above, and rather behind the vessel, are the nerves going to form the axillary plexus, of which the last cervical and first dorsal are more directly in contact with the artery. Inferiorly, it is applied to the apex of the pleura, and to the edge of the first rib.

PART IV.

The third portion of the subclavian artery.

Third portion of the subclavian.

THIS division includes the shortest, but at the same time the most important, because the most accessible part of the subclavian, and extends from the point where the vessel emerges from between the two scaleni, until it enters the axilla and assumes another name at the lower margin of the first rib. It is here covered by the platysma myoides, together with the cervical fascia, and may be said to lie within a triangle formed by the sterno-cleido-mastoideus, the omo-hyoideus, and the clavicle. This space likewise contains the axillary nerves, some branches of arteries, and the termination of the external jugular vein. Immediately beneath the platysma and fascia, is a large quantity of cellular and adipose structure, upon removing which, the subclavian will be seen crossing the upper surface of the first rib; having the scalenus anticus on its inner side, and the axillary nerves above, behind, and external to it; in fact, the convex edge of the rib, the nerves, and the muscle form a second, more deeply seated triangle, containing the artery. The

junction of the last cervical with the first dorsal nerve is more particularly in contact with the vessel. The vein is here situated anteriorly, internally, and inferiorly to the artery.

PART V.

The subclavian vein.

Subclavian vein.

On comparing the course of the subclavian artery and vein, we shall find that the latter is situated below and superficially to the former. Commencing at the lower edge of the first rib, where it is continuous with the axillary, the subclavian vein passes horizontally inwards until it joins with the internal jugular, nearly opposite to the sterno-clavicular articulation. It passes before the scalenus anticus, which consequently separates it from the artery. The vessel is nearly concealed by the clavicle, and is likewise covered by the platysma myoides, the cervical fascia, and, during the greater part of its course, by the origin of the sterno-cleido-mastoideus muscle.

Branches which form it.

The subclavian receives the venæ comites which belong to the different branches of the artery, and likewise the external jugular, which last enters

nearly opposite to the centre of the clavicle, but sometimes more internally.

Thoracic duct.

The great thoracic duct may likewise be seen, terminating in the angle formed by the conflux of the internal jugular and subclavian veins on the left side. A corresponding duct, but much smaller and shorter, is found in the same situation on the right side.

[OBSERVATIONS.—The branches of the subclavian artery, which will form the subject of the next section, are large and numerous, extending into the cavity of the cranium above, and on to the walls of the abdomen below. They form important anastomoses with the carotids at the base of the brain, and with the vessels of the upper and lower extremity. Some of these branches have already come under our observation during the progress of our dissection.]

SECTION XII.

DESCRIPTION OF THE BRANCHES GIVEN OFF BY THE SUBCLAVIAN ARTERY; THEIR COURSE, AND DISTRIBUTION.

PART I.

The branches arising from the first portion of the subclavian artery—the Vertebral—the Thyroid Axis—the Internal Mammary—the Superior Intercostal.

Branches given off by the subclavian.

EIGHT branches are generally enumerated as furnished by the subclavian artery: four of the number, however, will be found almost constantly to arise from a common trunk, called the thyroid axis; thus reducing the branches which actually come off from the subclavian to five. Of these, four are given off on the inner side of the scalenus or from the first portion of the artery: viz.—the Vertebral—the Thyroid Axis—the Internal Mammary — the Superior Intercostal. The thyroid

axis subdivides into—the Inferior Thyroideal—the Ascending Cervical—the Transverse Cervical—the Supra-scapular. The fifth or last branch afforded by the subclavian is the Deep Cervical, given off while the trunk is concealed by the scalenus anticus, or just as it emerges from behind the muscle. The above description is subject to occasional varieties, although the general arrangement will commonly be found to obtain.

Of the four first branches arising from the subclavian, two pass upwards into the neck, while the remaining two descend into the chest: the former are the Vertebral and Thyroid Axis, the latter, the Internal Mammary and Superior Intercostal.

Vertebral artery.

The vertebral is the first branch of the subclavian; but on the left side it occasionally arises from the arch of the aorta. It lies deeply seated, and corresponds to the outer edge of the longus colli muscle, between which and the scalenus anticus, it ascends to enter the foramen in the transverse process of the sixth cervical vertebra, although it not unfrequently rises as high as the fifth, or even the fourth, before it passes into the bones. It then becomes concealed from our view, but continues its course upwards through the transverse foramina, and forms a remarkable curve between the

atlas and dentata, for the purpose of preserving the vessel from injury during the rotatory motion which takes place between these bones. On reaching the upper surface of the atlas, the vertebral suddenly bends backwards, and assumes a horizontal position between the atlas and occipital bone, being lodged in a deep groove of the former, and situated to the outer side of the condyle of the latter: in fact, it passes along the outer surface of the occipito-atlantoid articulation, immediately behind which, it pierces the posterior circular ligament and subsequently the dura mater, to enter the cranium at the foramen magnum. The course of the artery within the skull, and the junction with its fellow, to form the basilar trunk, have already been described (p. 97).

Branches of the vertebral.

The vertebral artery gives off a number of small twigs in its passage up the neck; some of which are transmitted through the intervertebral holes to the spinal cord, whilst others supply the deep muscles, and anastomose with the ascending cervical. Between the atlas and occipital bone, it affords two or three branches of larger size, which ramify amongst the muscles, and communicate with the occipital and deep cervical vessels.

The vertebral artery, soon after its origin from the subclavian, becomes involved in a plexus of nerves derived from the sympathetic, which con-

tinue to surround it during the remainder of its course.

Thyroid axis.

The thyroid axis arises from the upper surface of the subclavian, close to the inner edge of the scalenus anticus, and passes upwards by the side of that muscle for the extent of about an inch, when it terminates by dividing into the Inferior Thyroideal, Ascending Cervical, Transverse Cervical, and Supra-scapular branches. The precise origin of these four arteries is so irregular, as to admit of no certain description: the axis is sometimes so short, that they seem to arise in common from the same point of the subclavian trunk; while on the other hand, it is occasionally prolonged to a considerable extent.

Inferior thyroideal branch.

The inferior thyroideal is the largest of the four branches, into which the axis divides, and curves upwards and inwards to reach the lower part of the thyroid gland, crossing behind the carotid sheath and before the longus colli muscle, where it is surrounded by the filaments of the middle cervical ganglion. The artery is extremely tortuous, and sends off no particular branch until it reaches the side of the trachea, to which, as well as to the œsophagus, and the lower part of the pharynx, it detaches several twigs, and becomes finally lost in the substance of the gland, where it freely com-

municates with its fellow, and with the superior thyroideal of the external carotid.

Ascending cervical branch.

The ascending cervical branch passes directly upwards along the transverse processes of the vertebræ, between the scalenus anticus and medius on the one side, and the rectus capitis anticus major on the other, where it gives off small twigs which supply those muscles and join with the vertebral. Towards the upper part of the neck the vessel curves backwards, and terminates by anastomosing with the occipital of the external carotid.

Transverse cervical branch.

The transverse cervical branch is subject to occasional varieties, but commonly takes a horizontal direction backwards and outwards; first, passing before the scalenus anticus muscle and the phrenic nerve, and then crossing the posterior triangular space of the neck, where it lies superficially to the lower cervical nerves, and beneath the platysma myoides and the fascia. After affording some unimportant twigs to the surrounding membrane, fat and glands, the artery divides at the margin of the trapezius into two branches; viz.—the Superficial Cervical, and the Posterior Scapular. The first of these ramifies beneath the trapezius, sending twigs upwards and downwards, which anastomose respectively with the occipital and supra-scapular arteries. The posterior scapular branch becomes more deeply seated, and, after passing beneath the

levator scapulæ muscle to the posterior angle of the scapula, descends along the base of that bone as far as its lower angle, where it terminates in the latissimus dorsi and serratus anticus muscles, communicating freely with the infra-scapular branch of the axillary. During this course, the vessel is covered by the trapezius and rhomboidei muscles, and therefore cannot be traced until a future period of the dissection.

Supra-scapular branch.

The supra-scapular branch is generally larger than either of the two preceding, and, after crossing before the scalenus and phrenic nerve, passes obliquely downwards and outwards towards the clavicle. Sinking behind this bone, it is continued along its posterior surface as far as the superior costa of the scapula. Thence, after detaching a branch which ramifies on the acromion, the artery passes over the ligament of the notch and enters the fossa supra-spinata, where it furnishes one or more twigs to the muscle which covers it, and is continued under the acromion into the lower fossa of the scapula. Here it terminates by supplying the infra-spinatus muscle, and forming free inosculations with the inferior scapular branch of the axillary. By averting the edge of the trapezius, or separating it from the clavicle, we may trace the supra-scapular artery as far as the notch of the

scapula, but we cannot at this time pursue its course over the dorsum of the bone.

In order to expose the internal mammary and superior intercostal arteries, both of which descend into the chest, the first rib should be sawn through close to the insertion of the scalenus anticus, and the succeeding ribs also divided at a short distance from their cartilages. The sternum may then be separated from the clavicle and averted, so as to expose its posterior surface, together with the course of the internal mammary artery.

Internal mammary artery.

The internal mammary comes off from the under surface of the subclavian trunk, nearly opposite to the origin of the vertebral, and, as it descends obliquely forwards into the chest to gain the cartilage of the first rib, is crossed anteriorly by the phrenic nerve. It then passes through the thorax, behind the costal cartilages and parallel to the sternum, as far as the diaphragm, where it terminates by dividing into two branches: during this course, the vessel is bounded, before, by the cartilages of the ribs and the internal intercostal muscles; behind, by the pleura costalis, from which, however, it becomes separated at the lower part, by the intervention of the triangularis sterni muscle.

Its branches.

The branches given off by the internal mam-

mary, are—the Anterior Intercostals, from the outer side of the vessel—the Comes Nervi Phrenici and the Mediastinal, from the inner side—the Terminating, or the Intercosto-phrenic and the Abdominal branches. The division of the mammary into the two last takes place opposite the cartilage of the sixth rib.

Intercostal branches.

The anterior intercostal branches are generally five in number, and correspond to the five superior intercostal spaces, along which they pass, from the sternal towards the vertebral extremities of the ribs; at first lying in contact with the pleura, but afterwards received between the two layers of intercostal muscles. They inosculate freely with the aortic intercostals, and detach branches to the external parietes of the chest, which assist in supplying the mammary gland, together with the adjacent structures, and form junctions with the thoracic arteries from the axillary trunk.

Comes nervi phrenici.

The comes nervi phrenici is a long, slender, and tortuous branch, arising from the mammary near its commencement, and accompanying the phrenic nerve, along its course between the pleura and pericardium, to the diaphragm, where it anastomoses with the true phrenic arteries from the abdominal aorta. It also assists the mediastinal vessels in supplying the pericardium and pleura.

The mediastinal branches are sometimes of considerable size in the young subject, where the thymus gland has not yet disappeared, and are then principally distributed to that structure; but in the adult, they consist merely of a few twigs, which become lost in the fat and cellular membrane contained in the anterior mediastinum. Mediastinal branches.

The intercosto-phrenic branch pursues a course downwards and outwards along the inferior margin of the chest, and consequently follows the origin of the greater muscle of the diaphragm. It supplies the circumference of that muscle, and likewise sends branches to the six lower intercostal spaces. Intercosto-phrenic branch.

The abdominal branch may be considered as the continuation of the mammary itself, and leaves the thoracic cavity to enter the parietes of the abdomen, where it divides to supply the muscles. Some of its branches descend within the sheath of the rectus, and inosculate with the internal epigastric, while others ramify between the obliquus internus and the transversalis, to form junctions with the lower aortic intercostals, the lumbar, and circumflex ilii arteries. Abdominal branch.

The superior intercostal artery comes off from the under surface of the subclavian nearly opposite to the thyroid axis, and, descending into the chest Superior intercostal artery.

behind the pleura, passes before the neck of the first and second ribs, detaching a branch to each of the two first intercostal spaces, and forming a junction with the highest intercostal artery sent off by the aorta. The size of this vessel varies in different subjects, as it sometimes supplies the first space only, while occasionally it is extended to the third.

PART II.

The single branch given off from the second or third portion of the subclavian trunk; viz. The Deep Cervical Artery.

Deep cervical artery.

THE deep cervical artery, the last branch of the subclavian, is usually given off as the trunk is emerging from between the scaleni muscles. This vessel can only be traced for a short distance; as almost immediately after its origin it turns backwards, generally piercing the nerves which descend to form the axillary plexus, and passes between the transverse processes of the sixth and seventh cervical vertebræ to reach the posterior surface of the spinal column; where, at a future period, we shall see it ramifying amongst the deep-seated muscles

of the neck, and forming junctions with the vertebral and occipital arteries.

The deep cervical is very irregular, both as to its origin and its size. It is sometimes very large, and supplies the place of the transverse cervical, or perhaps gives off the supra-scapular branch: but when on the other hand the artery is smaller than usual, either the dimensions of the transverse cervical are found proportionably increased, or else, two or three extra branches are afforded from the subclavian trunk to make up the deficiency.

[OBSERVATIONS.—The remaining part of our dissection will be chiefly confined to the nerves and vessels passing through the chest, or distributed within its cavity to the viscera and the parietes: viz.—the Phrenic, Pneumo-gastric, Dorso-spinal, and Sympathetic nerves; and the branches of the descending Thoracic Aorta, with their corresponding veins. The phrenic and pneumo-gastric nerves, will form the subject of the ensuing section.]

SECTION XIII.

THE COURSE OF THE PHRENIC AND PNEUMOGASTRIC NERVES AS THEY PASS THROUGH THE CHEST, AND THEIR ULTIMATE DISTRIBUTION.

PART I.

The phrenic nerve.

Course of the phrenic nerve.

THE origin of the phrenic nerve, its entrance into the chest, and its course through that cavity have already been described (pp. 146 & 164); but, as a larger portion of the thoracic parietes have been subsequently removed, greater facilities are now afforded of examining its situation, as it descends anteriorly to the root of the lungs between the pericardium and the pleura, as well as its final distribution to the diaphragm.

It will be observed, that the inclination of the heart towards the left side, causes the corresponding nerve to assume a somewhat curved direction,

and renders it rather longer than that on the right side.

On reaching the diaphragm, the phrenic nerve divides into filaments which radiate towards the circumference of the muscle, and penetrate throughout its structure. On the right side, one or more twigs pass along the surface of the vena cava through the tendinous aperture, and become lost in the solar and hepatic plexuses; while a few filaments from the left phrenic either pierce the diaphragm, or descend with the œsophagus, to effect a similar junction with the sympathetic in the abdomen. Its termination.

PART II.

The pneumo-gastric nerve.

We have already traced the course of this nerve as it passes into the chest, and described its connection with the subclavian artery on the right side, and with the arch of the aorta on the left, below which it became lost to our view by sinking behind the root of the lungs and entering the posterior mediastinum (pp. 78 & 162). By turning the lungs over to the opposite side, and removing the pleura forming Course of the pneumo gastric nerve.

the lateral wall of the mediastinum, we shall expose the remaining part of its course through the thorax.

The nerve will first be observed crossing behind the bronchus, where it loses its rounded form, and assumes a flattened plexiform appearance produced by the partial separation of its fibres, which are rendered complicated and indistinct by dense cellular membrane, and are intersected by blood-vessels. From this intricate network, two sets of nerves may be said to proceed: the one constitutes the Bronchial, or Pulmonary Plexus, which accompanies the bronchial tubes to the lungs; the other consists of several larger cords which descend upon the œsophagus to form the Œsophageal Plexus, and are generally described as the continuation of the pneumo-gastric itself.

Œsophageal plexus.

On the right side, the œsophageal plexus consists of four or five cords, and is inclined towards the posterior surface of the œsophagus; on the left side, there are seldom more than two or three branches which occupy the anterior and lateral aspect of the tube. They are united to each other by a number of cross filaments, some of which pass before and behind the œsophagus, and thus form a connexion between the plexus of either side. Twigs are likewise afforded to the muscular parietes of the canal which they surround, and also to the surface

of the aorta, where they form junctions with the branches of the thoracic ganglia. Previously to reaching the diaphragm, the cords of each side reunite so as to form a single nerve, and the par vagum, having thus resumed its original shape, continues to descend and give off branches, until it escapes from the chest by the side of the œsophagus, and passes on to the parietes of the stomach. The right pneumo-gastric, which it will be remembered was the larger and posterior of the two, becomes situated on the corresponding surface of the stomach, where, after affording numerous twigs to the cardiac extremity, its fibres spread over the viscus and radiate towards the greater curvature. The left nerve passes on to the anterior surface of the stomach, where it is distributed in a similar manner. They both form numerous and complicated junctions, not only with the branches of the sympathetic sent to the stomach, but with the solar plexus itself.

Bronchial plexus.

The bronchial plexus, which has already been alluded to, consists of an anterior and a posterior set of fibres. The former are given off just before the pneumo-gastric sinks behind the root of the lungs, and, after receiving some twigs from the recurrent laryngeal, pass on to the anterior surface of the bronchus, sending at the same time a few filaments to the pulmonary artery. The posterior

set, which are by far the most numerous, come off directly behind the bronchus, and attach themselves to the corresponding surface of the tube. The union of these two sets of nerves, assisted by numerous filaments from the lower cervical, and the four or five superior dorsal ganglia of the sympathetic, forms an intricate plexus which surrounds the bronchus, and accompanies all its ramifications until lost in the parenchymatous structure of the lungs.

[OBSERVATIONS.—During the foregoing dissection, the student will doubtless experience considerable difficulty, in separating the pneumo-gastric nerve from the branches of the sympathetic, which pass from the thoracic ganglia to supply the same parts, and many of which must almost necessarily be divided before the bronchial and œsophageal plexuses can be exposed. The same remarks will also, in some measure, apply to the dissection of the dorso-spinal nerves, the description of which will form the subject of the next section.]

SECTION XIV.

DESCRIPTION OF THE DORSO-SPINAL NERVES, THEIR ORIGIN, COURSE, AND DISTRIBUTION.

Dorso-spinal nerves.

THE dorsal nerves are twelve in number. They arise from the spinal cord in the same manner as the cervical, and may be seen between the transverse processes of the vertebræ, as they issue from the lateral foramina of the spinal canal. To expose them it is merely necessary to strip off the pleura lining the posterior walls of the chest, and to remove the fat and cellular membrane which generally envelopes the nerves as they pass from the spinal column. The first dorsal nerve makes its appearance between the first and second vertebræ of the back, the twelfth between the last dorsal and first lumbar. They resemble each other so closely in their course and distribution, that the following general description will be applicable to all.

General description.

The dorsal nerves, at their exit from the spinal canal, divide severally into a Posterior and Anterior Branch. The point of division as well as the commencement of the posterior branch is partly concealed by the projection of the transverse processes and the heads of the ribs: the anterior branch passes forwards and becomes situated in the intercostal space immediately behind the pleura.

Posterior branches.

The posterior branches cannot now be followed, but they pass backwards between the transverse processes of the vertebræ, and, on reaching the posterior spinal region, divide into a number of filaments, which become distributed to the mass of muscles covering the arches of the vertebræ and the commencement of the ribs. Several of these filaments, after ramifying through the longissimus dorsi and sacro-lumbalis, may be seen piercing the trapezius and latissimus muscles, to be finally lost in the integuments of the back.

Anterior branches.

The anterior or intercostal branches of the dorsal nerves are by far the largest, and take a direction outwards between the ribs, each being connected by one or more filaments to the adjoining ganglion of the sympathetic. Until they have reached the angles of the ribs, they are situated in the centre of the intercostal space immediately behind the pleura. They then pass between

the two layers of intercostal muscles, and approach nearer to the lower edge of the rib, lying just inferior to the corresponding artery. About midway between the spine and the sternum, each nerve divides into two branches, a Deep and a Superficial: the former maintains the same situation as the original nerve, and passes as far as the sternum; the latter pierces the muscular parietes of the chest, and becomes distributed, according to its position, either to the thoracic or the abdominal integuments.

As the anterior or intercostal branches of the dorsal nerves are not all distributed in the same manner, it will be necessary to enter somewhat more into their detail.

Anterior branch of the first dorsal nerve.

The anterior branch of the first dorsal differs from all the rest, and must be excluded from the general description; for, after detaching a small intercostal twig which takes the usual course, it passes over the neck of the first rib, and joins with the last cervical nerve, to assist in the formation of the axillary plexus.

Anterior branches of the second, third, fourth, fifth, and sixth dorsal nerves.

The anterior or intercostal branches of the second, third, fourth, fifth, and sixth dorsal nerves are nearly similar in their disposition, differing only as regards their situation. They divide about the centre of the ribs into deep and

superficial branches. The former are continued between the two layers of intercostal muscles as far as the sternum, where they approach the surface, and become lost in the origin of the pectoralis major and the superjacent integuments. The latter immediately become superficial by piercing the external intercostal layer, and, with the exception of the second and third, are distributed to the skin of the thorax and abdomen: the second and third, instead of ramifying over the chest, turn into the axilla, and are continued down the inner side of the arm as far as the elbow, forming junctions with the internal cutaneous nerves derived from the axillary plexus; they have therefore received the name of intercosto-humeral branches.

Anterior branches of the seventh, eighth, ninth, tenth, and eleventh dorsal nerves.

The anterior or intercostal branches of the seventh, eighth, ninth, tenth, and eleventh dorsal nerves divide in the same manner as the preceding. Their deep portions run between the intercostal layers till they reach the extremities of the ribs, when they enter the abdominal parietes, and, after ramifying between the internal oblique and transversalis muscles, to which they furnish twigs, terminate in the rectus. The superficial branches pierce the external intercostal muscles, and become distributed to the external oblique to the serratus magnus, and to the integuments of the belly.

The anterior branch of the twelfth dorsal nerve, like that of the first, differs from all the rest, and, since no part of its course is within the chest, ought rather to be included as one of the lumbar set. It emerges from between the transverse processes of the last dorsal and the first lumbar vertebræ, and sends a twig to be connected with the first lumbar nerve. Instead of following the course of the last rib, it descends obliquely before the quadratus lumborum, between the muscle and the fascia covering it. The nerve then enters the abdominal parietes, divides into filaments which supply the muscles, and detaches a cutaneous twig which passes downwards towards the spine of the ilium.

Anterior branch of the twelfth dorsal nerve.

[Observations.—The student has now followed out the dissection of the nerves arising from the brain, and from the cervical and dorsal portions of the spinal cord. To complete the nervous system included within the limits of this work, it is necessary that he should in some measure retrace his steps, for the purpose of examining the grand sympathetic in its course through the neck and chest. To this complicated and extensive system, whose influence may be said to pervade

every part of the body, we have frequently had occasion to advert, where its filaments were seen surrounding the larger arteries, or forming junctions with the cerebral and spinal nerves. The student will therefore find less difficulty in recurring to parts which have already come under his observation, or supplying the deficiency from memory, where the sympathetic has suffered unavoidable mutilation in the course of the previous dissection.]

SECTION XV.

DESCRIPTION OF THAT PORTION OF THE SYMPATHETIC OR GANGLIONIC SYSTEM OF NERVES BELONGING TO THE HEAD, NECK, AND CHEST.

PART I.

General outline of the sympathetic nerve.

THE sympathetic or ganglionic system of nerves may be described as consisting of a series of ganglia situated along the spinal column, and consequently extending from the base of the skull to the junction of the sacrum with the coccyx. They differ considerably in size and shape, and are classed according to the region which they occupy: thus we have—three Cervical Ganglia—eleven Dorsal—from three to five Lumbar—and four or five Sacral. Each ganglion is joined, by one or more nervous filaments, to the ganglion above and below it, so that the whole series forms a

connected chain, extending down the spine on either side, and uniting at the lower extremity of the sacrum. Each ganglion also sends off branches, varying in number according to its situation, which form junctions with the adjacent spinal nerves; and this union is effected just as the latter issue from the vertebral foramina. In the cervical region, where the number of the ganglia is disproportionate to that of the spinal nerves, one of the former will be found to connect itself with two or more of the latter; while in the dorsal, lumbar, and sacral regions, the numerical correspondence between the ganglia and the spinal nerves is nearly complete. A junction, which is more complicated than the preceding, also takes place between the sympathetic and all the cerebral nerves, except those of specific sensation, this union being principally produced through the branches of the first cervical ganglion.

We have thus viewed the sympathetic system as forming a chain of communication between the other nerves of the body; but, in addition to the branches furnished for this purpose, the ganglia give off an infinite number of filaments, which for the most part accompany the arteries, and are principally distributed to the muscles of involuntary motion and to the organs of secretion; under which class nearly all the viscera are included.

The contents of the abdomen are almost wholly supplied by the sympathetic, the nerves being chiefly derived from two large ganglia, called Semilunar, which are not situated by the side of the vertebral column, and therefore do not form a part of the general chain; but are placed in front of the aorta and the crura of the diaphragm, on either side of the origin of the cœliac artery: they are connected with the lower dorsal and upper lumbar ganglia, and form the centre of a vast plexus, or rather of a number of plexuses which accompany the abdominal arteries to the viscera.

As our present dissection does not include that part of the sympathetic situated below the diaphragm, the more detailed description will be confined to the cervical and thoracic portions: we shall commence above, and trace the nerve in its descent. Many of the smaller filaments having unavoidably been injured or destroyed during the dissection of the blood-vessels, our examination in the present instance will be rendered somewhat imperfect. In order to follow the sympathetic minutely and perfectly, it is necessary to devote a subject to that especial purpose.

PART II.

Ganglia situated about the cranium and face.

ALTHOUGH we have previously described the sympathetic as forming a chain of ganglia extending along the spinal column, it is now requisite to observe that there are several smaller ganglia situated about the base of the skull; which, although they can hardly be said to form a part of the general chain already alluded to, must still be considered as entering into the composition of the sympathetic system, from the fact of their being connected, either directly or indirectly, with the first cervical ganglion. These little bodies or nervous enlargements are for the most part situated in the cavities formed by the bones of the head and face; but as almost every day brings to light new discoveries, or, at any rate, affords novel descriptions of this most complicated system, it is difficult to assign their number and situation with any degree of accuracy.

The most important of these ganglia, as regards their size and the probable function which they

exercise, have already been noticed in the preceding pages, and may again be enumerated as—the Ganglion of Meckel—the Lenticular Ganglion—the Ganglion of Cloquet.

Ganglion of Meckel.

The first of these or Meckel's ganglion is lodged in the spheno-maxillary fossa, and has already been described in connexion with the second division of the fifth pair (p. 62). Its communication with the first cervical ganglion is established, within the carotid canal, through the medium of the pterygoid or vidian branch.

Lenticular ganglion.

The lenticular ganglion is situated in the orbit, and probably derives its connexion with the sympathetic by means of the twigs it receives from the sixth pair and the first division of the fifth, perhaps through both (p. 127).

Ganglion of Cloquet.

The ganglion of Cloquet is placed within the foramen incisivum, and forms a communication between the spheno-palatine and palato-maxillary branches of Meckel's ganglion (p. 63).

Other small ganglia.

Intermediate between these three ganglia and the first cervical, involved as it were amongst the filaments by which the communication is effected, some smaller gangliform enlargements may be distinguished, situated within the cavernous sinus and carotid canal. Monsieur Ribes has also discovered an azygos ganglion, placed upon the transverse branch connecting the two anterior

cerebral arteries. To this little body, the existence of which appears to be a matter of considerable doubt, he attaches some importance, as receiving branches of the sympathetic from each cavernous sinus, and thus establishing a junction between the ganglionic system of either side of the body. A German anatomist, Arnold, has, within the last year, clearly demonstrated the presence of a ganglion called the Otic, which is placed immediately under the base of the skull, between the foramen ovale, and the origin of the tensor palati muscle from the Eustachian tube. He considers this to form a part of the acoustic apparatus.

PART III.

The cervical ganglia.

THE cervical ganglia are three in number—the Superior—the Middle—the Inferior. The first of these lies immediately below the base of the skull, the last is situated at the entrance of the chest, while the middle is generally placed between the fifth and sixth vertebræ of the neck: they vary considerably in size and shape, as also in

the number of filaments which proceed from them.

The superior cervical ganglion, or Ganglion Fusiforme, is a long, cylindrical, or rather spindle-shaped body, situated just below the base of the skull, lying on the rectus capitis anticus major and corresponding to the three first vertebræ of the neck. Its length and thickness are, however, subject to frequent varieties, the one being always in the inverse ratio of the other. The ganglion is covered anteriorly by the internal carotid artery, and is partially concealed by the nerves descending from the lacerated and anterior condyloid foramina, with all of which it is intimately connected. **Superior cervical ganglion.**

It is impossible to speak individually of the different filaments which arise from every part of the surface of this body, but they may be divided into—a Superior Set—an Internal—an External—an Anterior—an Inferior. **Its branches.**

The superior branches are two in number and generally of large size, being in fact the continuation, or rather bifurcation, of the ganglion itself. They accompany the carotid artery into its canal, where they divide to form a plexus around the vessel, and communicate with the ganglion of Meckel, by joining with the inferior branch of the **Superior branches.**

pterygoid nerve. A portion of the plexus ascends with the carotid into the cavernous sinus, where it becomes connected with the first division of the fifth and the sixth pair, while filaments may still be traced onwards, accompanying the artery towards the brain and finally lost on the coats of the cerebral vessels. By sawing out a triangular portion of the base of the skull, the carotid canal may be laid open, so as to present a view of the artery and the plexus surrounding it. For this purpose, an incision should first be carried through the anterior part of the meatus auditivus externus, forwards and inwards towards the foramen lacerum anterius; and a second to meet this, should be made in a direction outwards and backwards through the ala major and spinous process of the sphenoid bone: the portion of the base included between these two cuts is then easily detached by a slight blow.

Internal branches.

The internal branches of the first cervical ganglion may be briefly described, as consisting of a number of filaments, which, combining with the divisions of the glosso-pharyngeal nerve and the pharyngeal branch of the par vagum, assist in forming that plexus, which becomes distributed to the constrictor muscles and mucous membrane of the pharynx: some of these twigs may be traced

into the larynx, and even as far down as the thyroid gland.

The external branches from the ganglion are four or five in number, and divide to form junctions with the anterior divisions of the sub-occipital and three superior cervical nerves. The most distinct are those which become united to the nerve of connexion between the sub-occipital and first cervical. Some filaments prolong themselves to be lost in the cervical plexus. External branches.

The anterior branches consist—1st, Of those which form junctions with the cerebral nerves descending from the cranium: 2nd, Those which constitute the carotid plexus in the neck: 3rd, those which enter into the formation of the superior cardiac nerve. The first set come off from the upper part of the ganglion, and immediately become connected with the glosso-pharyngeal, pneumo-gastric, accessory, lingual, and facial nerves. The second set are derived from the middle portion of the ganglion, and, in conjunction with twigs of the glosso-pharyngeal similarly disposed, descend on the common carotid artery, under the denomination of carotid plexus: from these, filaments are derived which ascend to surround the external carotid and accompany all its branches. The third set arise from the lower part of the ganglion and unite to form the superior

Anterior branches,—three sets.

Filaments of connexion.

Carotid filaments.

Cardiac filaments.

cardiac nerve, which, however, sometimes comes off as a single branch.

Inferior branches.

The inferior branches are generally represented by a single cord of considerable size, which may be described as a continuation of the ganglion itself, and descends behind the carotid sheath to terminate in the second or middle cervical ganglion; thus establishing the first part of that communication which obtains throughout the whole of the sympathetic system. It frequently gives off the superior cardiac nerve; and twigs may often be seen connecting it on the one side with the fourth and fifth cervical, on the other with the laryngeal branches of the par vagum. Parallel to this inferior branch, and lying on its inner side, is the superior cardiac nerve, which may be traced as it descends to gain the upper opening of the chest.

Middle cervical ganglion.

The middle or second cervical ganglion will be found opposite to the fifth or sixth vertebra of the neck, lying on the longus colli muscle, covered anteriorly by the carotid sheath, and in close proximity to the inferior thyroideal artery, where the latter crosses to reach the thyroid gland. In shape, the ganglion is subject to many varieties, commonly assuming an irregularly rounded form, occasionally made up of two or more bodies

placed in juxta-position, and more rarely consisting merely of a plexus of intricate filaments interwoven with each other.

The branches of the middle cervical ganglion may be arranged as—the Internal—the External—the Anterior—the Inferior. **Its branches.**

The internal branches consist of filaments which principally entwine themselves around the inferior thyroideal artery, and accompany it to the gland, to the trachea aud the œsophagus, forming junctions with the recurrent laryngeal nerve. **Internal branches.**

The external branches are seldom more than two or three in number, and communicate with the fifth and sixth cervical and the phrenic nerve. **External branches.**

The anterior branches are the largest, and constitute, by their union, the middle cardiac nerve or rather plexus, which descends towards the chest. **Anterior or cardiac branches.**

The inferior branches consist of from three to six slender filaments, which pass downwards to terminate in the lower cervical ganglion, thus forming a part of the general sympathetic chain. In their descent, some pass before, and others behind the subclavian artery. **Inferior branches.**

The inferior or third cervical ganglion is situated just at the margin of the thoracic opening, **Inferior cervical ganglion.**

in contact with the head of the first rib and transverse process of the seventh cervical vertebra, behind and rather below the subclavian artery. Its shape varies, being sometimes round and thick, but occasionally flat and spreading, so as to extend upwards as far as the middle cervical ganglion, or downwards towards the first dorsal.

Its branches.

The branches of the lower cervical ganglion may be classed as—the Superior—the Internal—the External—the Anterior—the Inferior.

Superior branches.

The superior branches form a considerable plexus, which accompanies the vertebral artery through the transverse foramina, where many of the filaments become expended by entering the adjoining muscles, or forming junctions with the cervical nerves, whilst others ascend with the vessel into the cavity of the cranium.

Internal branches.

The internal branches are few and indistinct, apparently becoming lost among the cardiac nerves, and forming some junctions with the recurrent laryngeal.

External branches.

The external branches form a considerable plexus around the subclavian trunk, some filaments of which may be traced as they accompany the branches of the vessel, while others are continued along the axillary artery towards the arm. Twigs of communication are likewise seen between the ganglion and the lower cervical and first dorsal nerves.

The anterior branches constitute the inferior cardiac nerve. Anterior or cardiac branches.

The inferior branches rarely exceed two in number, and form the communication between the inferior cervical and the first dorsal ganglion: frequently there is only one nerve to effect this union. Inferior branches.

PART IV.

The cardiac nerves.

In order to complete the cervical portion of the sympathetic, it will now be necessary to retrace our steps a little and follow the course of the cardiac nerves, which have already been mentioned, as severally formed by the anterior branches of the cervical ganglia.

The cardiac nerves may therefore be described as three in number, or, in most instances, as three sets of filaments, distinguished, according to the ganglion from which each proceeds, by the name of —Superior—Middle—and Inferior. They all descend to enter the chest, forming in their course innumerable and intricate connexions with each other, as well as with the cardiac branches of the pneumo-gastric and recurrent laryngeal nerves. Cardiac nerves. Three sets.

The plexus of filaments which is in this manner produced on either side the neck, is situated for the most part behind the carotid sheath, and, on entering the chest, becomes separated by the three great trunks given off by the arch of the aorta, which vessel is in great measure surrounded by their branches. Some few and small fibrillæ are then continued before the arch, but by far the largest and most numerous pass posteriorly to it, and terminate in a dense and intricate interlacement, which always contains one or more distinct ganglia, and is called the Cardiac Plexus.

Cardiac plexus.

The cardiac plexus is situated between the middle portion of the arch of the aorta and the trachea, and forms the principal centre from which the heart is supplied. From it are derived the coronary plexuses, which accompany the coronary arteries to supply the ventricles; as likewise filaments which are lost in the parietes of the auricles; and others which are continued along the coats of the pulmonary arteries to enter the lungs: these last receive a considerable addition from branches given off by the pneumo-gastric and recurrent laryngeal nerves. Filaments from the four or five superior thoracic ganglia will also be found passing up the sides of the vertebræ, to join the different sets of nerves mentioned above; the whole forming a most

complicated web, investing the base of the heart with its great vessels, and much more easily conceived than either described or dissected.

Formation of the cardiac plexus.

It is almost impossible to adopt any definite arrangement, with regard to the three sets of nerves which thus combine to form the cardiac plexus, as they not only vary in different subjects, but are likewise deficient in uniformity on the right and left sides. The following description will, however, generally be found to obtain, as far as relates to the course of the more considerable filaments.

Superior cardiac nerve.

The superior or superficial cardiac nerve, is derived, either from the lower part of the first cervical ganglion, or from its inferior prolongation, often from both, and descends rather on the inner side behind the carotid sheath. On the right side, its identity becomes lost by means of the junctions it forms with the middle cardiac nerve, where, indeed, it may be said to terminate. On the left side, the superior cardiac nerve, although it forms many connexions, may yet generally be traced into the chest, where it passes before the arch of the aorta and round its inferior surface to terminate in the cardiac plexus. It also affords filaments which ramify over the arch and ascending portion of the vessel, more especially between the latter and the

Right side.

Left side.

pulmonary artery, where they communicate with the lower cardiac nerves of the same and of the opposite side; constituting an interlacement which may be called the Anterior Cardiac Plexus.

Middle cardiac nerves. Right side.

The middle cardiac nerves consist, on the right side, of large distinct branches which come off from the middle cervical ganglion, and descending before the subclavian artery, incline behind the innominata and arch of the aorta to terminate in the cardiac plexus.

Left side.

On the left side, the corresponding filaments are both fewer and smaller, and become associated with the inferior cardiac branches below them.

Inferior cardiac nerves. Right side.

The inferior cardiac nerves derived from the lower cervical ganglion, are scanty on the right side, but may be seen emerging from behind the subclavian artery, whence the greater number wind round the innominata to gain the anterior surface of the arch and ascending aorta, and terminate in the anterior cardiac plexus.

Left side.

On the left side, they consist of several considerable branches, which become again augmented by receiving the middle cardiac filaments from above. Some of the smaller twigs then pass before the left subclavian artery and the arch, to join the anterior cardiac plexus; while the greater number descend behind the vessels, and terminate in the posterior or great cardiac plexus between the aorta and the trachea.

PART V.

The dorsal, or thoracic ganglia.

Dorsal ganglia. General description.

THE dorsal ganglia and their branches are brought into view, by stripping the pleura costalis from the sides of the vertebræ and adjacent portions of the ribs. They are eleven in number, and are situated either on or between the heads of the ribs. The first thoracic ganglion is placed between the heads of the first and second ribs, just below the inferior cervical, with which it is often continuous: the eleventh, or last thoracic ganglion, lies between the eleventh and twelfth ribs: the others are situated indifferently, either on or between the heads of the ribs. Their relative size is also subject to constant variations. The anterior surface of each is closely covered by the pleura, while posteriorly, it is either applied to the head of the rib, or corresponds to the intercostal space.

Each dorsal ganglion communicates with the one above and below, the first being connected with the last cervical, the eleventh with the first lumbar. Each ganglion also gives off a number of branches,

which may be divided into—an External, and an Internal Set.

External set of branches.

The external branches vary in number from two to four, and pass to be connected with the corresponding intercostal nerve, just as the latter makes its appearance between the necks of the ribs. The last thoracic ganglion forms junctions both with the eleventh and twelfth intercostal nerves.

Internal set of branches.

The internal branches, which are much more delicate and numerous, pass on to the lateral surfaces of the bodies of the vertebræ, where they present the appearance of a plexus; the filaments of which, after forming communications with each other, are principally distributed to the contents of the posterior mediastinum, and likewise assist in the formation of the cardiac and bronchial plexuses. Several more distinct filaments will also be seen forming the splanchnic nerves.

PART VI.

The splanchnic nerves.

To the branches already mentioned, as afforded by the thoracic ganglia, must be added the formation of the Greater and Lesser Splanchnic nerves, which

are derived from filaments given off by the six or seven inferior ganglionic enlargements.

Greater splanchnic nerve.

The splanchnicus major is generally produced by the union of four branches, derived respectively from the sixth, seventh, eighth, and ninth ganglia: these pass downwards and forwards over the lateral surfaces of the vertebræ, and, uniting successively, constitute the greater splanchnic cord, which becomes completed on the eleventh dorsal bone, and is there situated just to the outer side of the azygos vein. It then pierces the crus of the diaphragm, enters the abdomen, and terminates in the great semilunar ganglion.

Lesser splanchnic nerve.

The splanchnicus minor is generally formed by the union of two branches, derived severally from the tenth and eleventh ganglia. It is situated posteriorly to the greater nerve, descends along the side of the last dorsal vertebra, and pierces the diaphragm to terminate principally in the renal plexus*.

* As the minute examination of the sympathetic nerve is seldom compatible with the ordinary course of dissection pursued by students, the author has been induced to give a general sketch, rather than a detailed account of this intricate and widely-spreading system. He has, therefore, confined the description to the more prominent of those innumerable filaments, which are so faithfully delineated in the elaborate engravings of Mr. Swan.

He also entertains the hope, that his colleague, Mr. Hilton, will, at no very distant period, undertake the task of illustrating, by description and by plates, the wax models

[OBSERVATIONS.—We have thus brought to a termination the dissection of the nerves of the head, neck, and chest, with the exception of the posterior spinal branches, which will be noticed hereafter Our examination of the arteries will likewise be rendered complete in the next section, which contains the description of the descending thoracic aorta and its branches.]

in the museum of Guy's Hospital, which have been constructed by Mr. Towne from his (Mr. Hilton's) own dissections, and under his immediate superintendance and inspection.

SECTION XVI.

DESCRIPTION OF THE DESCENDING THORACIC AORTA, AND THE BRANCHES WHICH IT GIVES OFF.

THE student may now expose the whole course of the thoracic aorta, from its origin at the upper part of the left ventricle, to its passage between the crura of the diaphragm at the bottom of the chest. For this purpose he should first remove the pericardium which envelops the great vessels at the base of the heart, and clear away the cellular tissue and the bronchial glands situated about the bifurcation of the trachea. He will thus bring into view the first, or ascending portion of the aorta, taking a direction upwards, forwards, and to the right, as high as the junction of the upper and middle bones of the sternum, where it terminates in, or rather becomes continuous with, the arch. He will see the connexion of the ascending aorta with the common pulmonary artery which crosses before it—with the right pulmonary artery which crosses

behind it—with the bifurcation of the pulmonary artery and the ductus arteriosus on the left side—and with the vena cava superior on the right side.

By partially separating the common pulmonary artery from the aorta, and laying bare the origin of the latter vessel, he will expose the first pair of branches given off by it, or the coronary arteries; which arise just above the left ventricle, and pass respectively to the right and left sides of the heart. Then, by raising the heart, and turning it towards either side, he will be enabled to trace the course of the right and left pulmonary arteries with the bronchial tubes into the lungs,—the entrance of the two venæ cavæ into the right auricle,—and the passage of the four pulmonary veins into the left auricle. He will likewise observe the relative position of the pulmonary artery, the veins, and the bronchial tube at the root of the lung.

Lastly, by turning the lungs over towards either side, the descending thoracic aorta may be traced through the posterior mediastinum, in connexion with the œsophagus, vena azygos, and thoracic duct, which are contained in the same space and lie parallel to the artery*.

* The relative position of the great vessels, situated about the base of the heart and the root of the lungs,

Descending thoracic aorta.

The descending thoracic aorta is continued, from the termination of the arch on the left side of the third dorsal vertebra, as far down as the anterior surface of the last dorsal, where it enters the opening between the crura of the diaphragm, and passes into the abdominal cavity. In this course the aorta is closely applied to the spinal column, except where it becomes separated by the lower intercostal veins from the left side, which pass behind the vessel to reach the vena azygos. In its descent, the aorta has a slight bearing towards the right; being situated at its commencement on the left side of the vertebral column, while, at the bottom of the chest it will be found to have attained the median line of the spine. It forms a part of the contents of the posterior mediastinum, and is covered anteriorly by the œsophagus, which, by a gradual inclination from the right to the left side has a tendency to cross the vessel. On the right side, and parallel to the aorta, but rather behind its plane, are the thoracic duct and the vena azygos. Its lateral surfaces are loosely connected with the pleura forming the sides of the posterior mediastinum.

together with the contents of the posterior mediastinum, have only been adverted to in this place; as their minute description belongs rather to the dissection of the thoracic viscera, than to the plan adopted in this work.

Its branches. Two sets.

The branches given off from the descending thoracic aorta, may be divided into two sets—an Anterior, and a Posterior. The former, small and irregular, are distributed to the thoracic viscera; the latter, larger and uniform, supply the parietes of the chest: the one are derived from the anterior, the other from the posterior surface of the artery.

Anterior set.

The anterior set consists of the Bronchial and Œsophageal arteries—together with some minute branches distributed to the pleura, the pericardium, and the cellular membrane of the posterior mediastinum.

Bronchial arteries.

The bronchial arteries are commonly described as two in number, a right and a left, although it will almost always be found that the former is derived from one of the intercostal vessels, and not from the aorta itself. Occasionally we find three, or even four, bronchial arteries, in which case they are proportionably smaller. They arise about opposite to the fifth or sixth dorsal vertebra, and almost immediately become attached to the posterior surface of the bronchus on either side. After supplying the lymphatic glands in the neighbourhood and the adjacent membrane, they divide minutely and accompany the ramifications of the

bronchial tubes throughout the lungs, the parenchymatous structure of which they apparently supply. The left artery is frequently observed to send a branch over to the right lung.

Œsophageal arteries.

The œsophageal arteries are so exceedingly irregular both in size and situation, as to preclude any definite arrangement. They vary in number from one to six, and are occasionally derived from the bronchial vessels. They ramify on the muscular coat of the œsophagus, and anastomose above with branches of the inferior thyroideal, below with the phrenic and gastric arteries.

Posterior set or Intercostal arteries.

The posterior set of branches from the descending thoracic aorta are the Intercostal Arteries, which arise in pairs and vary in number from eight to ten; this difference depending upon the size of the intercostal branch of the subclavian, which sometimes supplies only one, sometimes three intercostal spaces. They are given off from the posterior surface of the aorta, on each side of the median line of the vessel; and it is not uncommon to find one or more pairs arising from a common trunk. The only difference between those of the right and left side, is, that the former are rather longer, and cross under the vena azygos and thoracic duct, to reach the intervals between the ribs.

The superior arteries arise considerably below the intercostal space which they are destined to supply, and pass obliquely upwards and outwards: this obliquity decreases towards the lower part of the chest, so that the two or three inferior intercostals will be seen to pass off from the aorta in nearly a transverse direction. These vessels bear so great a resemblance to each other, that the dissection of one or two will afford a competent knowledge of all, more especially as they correspond with the dorsal nerves, both in course and distribution.

Each intercostal artery in the first part of its course is applied to the bodies of the vertebræ, and on leaving them, enters the space between the ribs, along the centre of which it is continued as far as the angles of those bones. Up to this point, it is merely covered by pleura, and crossed anteriorly by the sympathetic nerve: it then passes between the two layers of intercostal muscles, and becomes directed along the inferior edge of the upper rib, which is furnished with a groove for its reception: the corresponding vein is situated above the artery, the nerve below it; although the relative position of the three is subject to occasional variation. On approaching the anterior walls of the chest, the artery again inclines towards the centre of the intercostal space, and terminates near the ex-

tremities of the ribs by anastomosing with the internal mammary artery. The four lower intercostal arteries have a termination somewhat different; being continued beyond the extremities of the false ribs into the abdominal muscles, amongst which they ramify extensively, and inosculate with the other vessels supplying the same parts.

Branches of the intercostal arteries.

The intercostal arteries afford a number of small branches to the parietes of the chest. While situated on the bodies of the vertebræ, they send twigs to supply the bones and the intervertebral substance. Between the heads of the ribs they give off a posterior branch, which, after sending small vessels into the spinal canal through the lateral foramina, passes backwards between the transverse processes of the vertebræ, and is distributed to the muscles of the back. At the angles of the ribs, a long slender branch is generally detached, which takes its course, parallel to the main vessel, along the lower part of the intercostal space. Besides these, numerous small branches are found piercing the external layer of intercostal muscles, and anastomosing with the thoracic arteries given off by the axillary trunk.

[OBSERVATIONS.—The description of the veins, which correspond to the branches of the descending thoracic aorta, will be found in the next section.]

SECTION XVII.

DESCRIPTION OF THE VENA AZYGOS, AND VENA AZYGOS MINOR.

The vena azygos.

THE vena azygos is a vessel of considerable size, situated in the posterior mediastinum, where it receives the greater part of the blood returned from the branches of the descending thoracic aorta. It does not originate in the chest, but may be said to commence in the abdomen, being there formed by the union of the first and second lumbar veins of the right side, and branches of connexion from the renal and inferior cava. It accompanies the thoracic duct through the aortic opening of the diaphragm, and enters the posterior mediastinum, where it is situated on the right side of the bodies of the vertebræ, and consequently to the right of the aorta and thoracic duct. In its course upwards along the spinal column, the vein usually receives the nine inferior intercostals from the right side, and also the vena azygos minor formed by the junction of

the six inferior intercostals of the left side, together with some small œsophageal and mediastinal branches. It is continued as high as the fourth dorsal vertebra, where it receives the right bronchial vein from the lungs, and then, leaving the spine, curves round the right bronchus and pulmonary artery to terminate in the superior cava, just before that vessel becomes covered by the pericardium.

The vena azygos minor.

The vena azygos minor also commences in the abdomen, where it receives one or two of the left lumbar veins, generally forming a communication with the renal and phrenic of the same side. It then pierces the diaphragm, and ascends in the chest along the left side of the aorta, receiving in its course the six left inferior intercostals. Nearly opposite to the seventh dorsal vertebra it crosses the spine, in close contact with the bone, and terminates in the azygos of the right side. It is not, however, uncommon, to find the six lower intercostals crossing the spine separately, or else joining to form two or three distinct vessels, which pass in a similar manner behind the aorta to the right side.

Superior intercostal vein.

The blood from the first and second intercostal space on the right side, is returned by what is

generally termed the superior intercostal vein, which accompanies the artery of the same name, and terminates in the subclavian vein. This is sometimes altogether wanting, and more rarely extends to the three first spaces. Right side.

The five upper intercostal veins of the left side are received into, or rather form by their union, the left superior intercostal vein, which, passing upwards over the heads of the ribs, terminates in the subclavian trunk: it likewise receives the left bronchial vein returning the blood from the parenchymatous structure of the lung. Left side.

As respects the course of the intercostal veins, they will be found throughout in juxta-position with the arteries, situated above the latter, and closely lodged in the groove at the lower margin of each rib. Just before their termination, they receive the veins from the spinal cord, which are transmitted along with the nerves through the intervertebral foramina. Intercostal veins.

The thoracic duct, which has already been more than once alluded to, commences in the abdomen just behind the right renal artery, where it is formed by the junction of the lymphatics from the lower parts of the body, with the lacteals from the intestinal canal. It then enters the chest with the Thoracic duct.

aorta and vena azygos, and is continued between those two vessels along the posterior mediastinum, as high as the fifth or fourth dorsal vertebra. It then inclines towards the left side, crossing the spine obliquely behind the œsophagus and the arch of the aorta, and ascends to gain the upper opening of the chest between the left carotid and subclavian arteries, but on a plane posterior to them. On leaving the thorax, it continues to ascend for a short distance, and then, turning round, terminates in the angle formed by the junction of the internal jugular and subclavian veins.

[Observations.—We have now completed the dissection of the nerves and vessels, supplying the head, the neck, and the chest, with the exception of those branches which are distributed to the posterior spinal regions. The description of these will form the subject of the next or concluding section.]

SECTION XVIII.

DESCRIPTION OF THE VESSELS AND NERVES SUPPLYING THE POSTERIOR REGIONS OF THE HEAD, NECK, AND TRUNK.

THE dissection we are about to commence, and which will bring our labors to a close, necessarily extends over a considerable surface of the body, including the occiput above, and reaching as far down as the crista of the ilium. The whole of this space, on either side the spinous processes of the vertebræ, is occupied by the muscles of the back, between whose layers we shall find those vessels and nerves which we have hitherto been unable to trace.

The arteries supplying the back of the neck, are the branches of the Superficial and Deep Cervical, of the Vertebral and Occipital. On the dorsal region will be found the Posterior Branches of the Intercostals—and in the loins, the Posterior Branches of the Lumbar Arteries.

The nerves supplying the cervical, dorsal, and

lumbar regions, are all included in the posterior branches of the spinal nerves.

We shall divide this section into two parts—the first including the vessels and nerves brought into view during the dissection and removal of the two first layers of muscles, or those belonging to the upper extremity—the second describing the vessels and nerves which are situated amongst the more deeply-seated or proper spinal muscles.

PART I.

The vessels and nerves brought into view, during the dissection and removal of the two first layers of muscles.

Cutaneous nerves of the back.

In dissecting away the skin from the back, so as to expose the first layer of muscles, we necessarily divide the terminating or cutaneous twigs of the posterior branches of the cervical, dorsal, and lumbar nerves (pp. 142 & 186). These may be seen piercing the trapezius and latissimus dorsi, taking a general direction downwards, and distributed to the superjacent integuments. They are exceedingly small in the lower cervical and upper dorsal regions, but increase in size as we descend towards the loins.

The only one of this set of nerves deserving particular notice, is the great occipital or posterior branch of the first cervical (p. 144). It will be seen piercing the thin origin of the trapezius muscle near the tuberosity of the occipital bone, whence it ascends over the scalp supplying the skin and occipito-frontalis. A little to its outer side is the occipital artery, emerging from under the posterior edge of the splenius, and ramifying with the nerve over the back of the head, where it forms junctions with its fellow, with the temporal and posterior aural vessels.

Occipital nerve.

Occipital artery.

The trapezius should now be cut through in a line parallel to the spine, and about midway between its origin and insertion; after which the portions of the muscle may be reflected; and in so doing, we shall again divide the branches of nerves already mentioned which pierce its substance to reach the skin. The termination of the accessory nerve (p. 109) will also be brought more completely into view, as it ramifies on the under surface of the trapezius to supply its structure; and the final branches of the superficial cervical artery (p. 173), will likewise become exposed.

Accessory nerve.

Superficial cervical artery.

The muscles now laid bare consist of the levator scapulæ, the rhomboidei, part of the splenius, and a small portion of the complexus. Piercing the

latter just below its insertion and close to the median line of the neck, is the occipital nerve as it rises towards the back of the head.

Occipital nerve.

Posterior scapular artery.

Lower down, the posterior scapular branch of the transverse cervical artery may be seen (p. 173), crossing beneath the levator scapulæ muscle to reach the superior angle of the bone, and then descending along its base beneath the rhomboideus minor and major: by dividing those three muscles and turning them aside, the vessel may be traced throughout the whole of its course.

(The upper extremity may now be removed from the trunk.)

PART II.

The vessels and nerves which are deeply seated among the muscles of the back.

THE serratus posticus superior, and the splenius muscles should now be divided and turned back, by which the fifth layer, or the complexus, trachelo-mastoideus, transversalis colli, and cervicalis ascendens will become exposed.

Larger filaments from the posterior divisions of the cervical nerves, and some of the branches of

the deep cervical artery (p. 178), are now brought into view as they ramify between the muscles.

Occipital artery.

By reflecting the splenius capitis upwards as far as its insertion into the temporal and occipital bones, we shall display the whole of the middle or deeply-seated portion of the occipital artery, from the point where it becomes concealed by the sterno-mastoid muscle (p. 39), to where it emerges from under the posterior edge of the splenius: in this course it passes sometimes over, sometimes beneath the trachelo-mastoideus, lying at first in a groove of the temporal bone, but afterwards on the insertion of the complexus, and covered by the sterno-mastoid and splenius muscles. In this situation, the occipital artery forms anastomoses with the vertebral, and sends off two or three muscular branches which descend between the extensors of the head, and communicate with the ascending, superficial, and deep cervical branches of the subclavian: one larger than the rest is generally seen passing down between the complexus and trachelo-mastoideus muscles.

The complexus muscle may now be divided transversely at a short distance below its insertion, and the two portions reflected respectively, upwards towards the occipital bone, and outwards towards the transverse processes of the vertebræ: thus

bringing into view the sixth layer of muscles, consisting of the recti and obliqui capitis, with the semi-spinalis colli et dorsi.

Posterior divisions of the cervical nerves.

By separating the complexus from the semi-spinalis muscle, and dissecting down to the bones, the posterior divisions of the cervical nerves (p. 142) will now be seen, as they emerge from between the transverse processes of the vertebræ, and divide to supply the muscles and integuments, as has been already described. They diminish in size from the first downwards; but the posterior division of the first cervical (p. 144) is so much larger than any of the others, that it is at once distinguished. It may now be observed coming from between the atlas and dentata, and passing upwards and backwards, until it pierces the complexus, and assumes the name of the Great Occipital Nerve. In the part of its course which we have just exposed, it lies on the obliquus inferior and rectus capitis major muscles, and is covered by the complexus, to which it sends some large branches.

To complete our dissection of this region, the small triangular space formed by the two obliqui and the rectus major muscles should now be examined, in order to display the vertebral artery and the posterior division of the sub-occipital nerve, which are both deeply seated in the above triangle.

The vertebral artery (p. 170) will be observed as it passes through the transverse process of the atlas, above which it immediately assumes a horizontal course backwards, until it pierces the posterior occipito-atlantoid ligament, and enters the foramen magnum just behind the condyle: it is lying in a groove of the atlas, and covers the articulation between that and the occipital bone. **Vertebral artery.**

Crossing over the vertebral artery, and in close contact with its coats, is the posterior division of the sub-occipital nerve (p. 141), making its appearance from between the atlas and occipital bone, and distributed to the recti and obliqui muscles. **Posterior division of the sub-occipital nerve.**

To conclude our examination of the spinal region, we should now proceed to separate the deeply-seated muscles of the back from each other; for the purpose of displaying the posterior divisions of the dorsal and lumbar nerves (p. 186), as they emerge from between the transverse processes of the vertebræ, and ramify amongst the longissimus dorsi, sacro-lumbalis, semi-spinalis, and multifidus spinæ muscles, all of which they supply before terminating in the integuments. **Posterior divisions of the dorsal and lumbar nerves.**

The posterior branches of the intercostal and lumbar arteries (p. 217) will also be observed, taking a similar course and distributed in a similar manner. **Posterior branches of the intercostal and lumbar arteries.**

APPENDIX.

APPENDIX.

IN WHICH IS DESCRIBED THE BEST METHOD OF TRACING THOSE NERVES AND VESSELS, THE DISSECTION OF WHICH WAS NOT COMPLETED IN THE PREVIOUS PART OF THE WORK.

THE industrious student, who will doubtless be anxious to render his dissection as complete as possible before he abandons his subject, may recur with advantage to those few branches of arteries and nerves which were left unfinished, and which may now be followed to their ultimate distribution.

With the view, therefore, of facilitating his labors, we shall here offer a few directions, which may assist him:—1st, in exposing the ultimate distribution of the Laryngeal Nerves; 2nd, in tracing the terminating branches of the Internal Maxillary Artery, together with the Second Division of the Fifth Pair of Nerves and the branches from Meckel's Ganglion as they pass through the dif-

ferent canals and foramina which communicate with the spheno-maxillary fossa; 3rd, in examining the vessels and nerves which ramify within the Nasal Cavity; 4th, in laying open the vertebral canal to obtain a view of the Spinal Cord and the origin of the nerves.

For the description of these different structures the student is referred to the body of the work, where each will be found in its proper place; as it was not considered necessary to enter again into the detail of their course and distribution.

PART I.

The dissection of the laryngeal nerves.

THE superior, and inferior or recurrent laryngeal branch of the par vagum, have already been traced to where they enter the upper and lower part of the larynx:—the former by piercing the thyro-hyoideal ligament,—the latter by passing between the pharynx and œsophagus. In order to pursue them further, a posterior view of the larynx must be obtained.

For this purpose, the trachea and the œsophagus should be divided about midway between the cricoid

cartilage and the sternum; the larynx and pharynx are then to be raised from the spine, by dividing the cellular tissue connecting the latter with the bodies of the vertebræ, as high up as the base of the skull. The articulations between the spinal column and the occipital bone, together with the muscular connexions, should then be cut through, by which means the entire head, with the larynx and pharynx appended to it, will become detached from the rest of the body. The pharynx may now be laid open, by slitting up the constrictors along the posterior median line; and thus a complete view will be obtained, not only of the size, shape, and extent of the cavity, but also of the posterior nares, the Eustachian tubes, the velum palati, the fauces, the tonsil glands, the epiglottis, and the posterior parietes of the larynx.

Lastly, by removing the mucous membrane which separates the pharynx from the posterior walls of the larynx, the laryngeal nerves will be brought into view, situated as has already been described (pp. 79 & 163).

PART II.

Dissection of the terminating branches of the internal maxillary artery,—the second division of the fifth pair of nerves, and the branches from Meckel's ganglion, as they pass through the different canals and foramina which communicate with the spheno-maxillary fossa.

THE description of the spheno-maxillary fossa, and its connexion with the adjacent cavities of the cranium, the orbit, the nose, and the mouth, will be found in the third section of this work (p. 57). The student may now proceed,—first, to enlarge the entrance of the fossa, by which a clearer view of its contents will be obtained; and then, by a little dextrous management of the chisel, to follow the arteries and nerves through the bones to their various places of destination. The previous examination of the carotid canal (p. 198), when a portion of the base of the skull was removed, in order to display the passage of the vessel into the cranium and the nerves surrounding it, will be found to have greatly facilitated the present dissection.

The whole of the outer wall of the orbit may now be sawn off, by continuing the spheno-maxillary fissure through the junction of the malar with the maxillary bone; and as much of the pterygoid process and ala major of the sphenoid bone should be removed, as will lay open the foramen rotundum, and expose the entrance to the pterygoid canal. A distinct view may thus be obtained of the contents of the fossa, which will enable us to separate the vessels from the nerves.

The second division of the fifth may first be traced as it leaves the cranium through the round opening (p. 60), and, after crossing the upper part of the fossa (where it gives off the dental nerve and branches to Meckel's ganglion), is continued into the infra-orbitar canal. By cutting through the floor of the orbit, the contents of which should be previously removed, the infra-orbitar nerve may be followed through the canal, and the filaments observed which it detaches in that situation.

The student should next examine the ganglion of Meckel (p. 62), and, when he has separated it from the vessels and the dense cellular membrane which surrounds it, the three branches may be traced respectively,—through the pterygoid canal,—through the palato-maxillary canal, — and through the spheno-palatine foramen.

The pterygoid branch will be laid bare by

removing the outer part of the root of the pterygoid process, and following the nerve till it issues from the canal at the under part of the foramen lacerum basis cranii anterius, where it divides into the superior and inferior filaments. The palato-maxillary branch may be exposed by cutting away the junction of the palate, maxillary, and sphenoid bones, and so laying open the canal down to the roof of the mouth. In order to bring the third branch or spheno-palatine nerve into view, it will be necessary to make a section through the cavity of the nose.

The terminating branches of the internal maxillary artery, which correspond to the nerves we have just followed, will, of course, be traced at the same time (p.58).

PART III.

Dissection of the vessels and nerves situated within the cavity of the nose.

A PERPENDICULAR section is now to be carried through the bones of the cranium and face, either on the right or left of the median line, so as to pass through that side of the nose on which the student is conducting the dissection. Then, if the saw has been carefully applied, the one section of the head will

present a view of the lateral walls of the nose, the projection of the turbinated bones, and the openings of the sinuses:—the other will merely display the corresponding surface of the septum naris.

The spheno-palatine artery and nerve (p. 59 & 62), may now be traced from their entrance into the nose at the foramen of the same name, to their distribution on the pituitary membrane. The principal branch of each crosses the roof of the cavity, to descend along the septum towards the foramen incisivum, and has therefore been unavoidably divided in making the section.

The filaments of the olfactory nerve will also be found descending through the cribriform plate of the ethmoid bone (p. 102)—and perhaps, in addition to these, the student may be fortunate enough to discover and trace the internal nasal branch, from the first division of the fifth pair (p. 123).

PART IV.

The examination of the spinal cord with its membranes, and the origins of the spinal and the accessory nerves.

In order that the student may derive every possible advantage from the remains of his subject, he

should now proceed to open the spinal canal, and make himself acquainted with its contents.

For this purpose, the arches of the cervical vertebræ are to be removed, by sawing through them on each side, close to the roots of the transverse processes. The dura-matral sheath will thus become exposed, and it will be observed, not only covering the spinal cord, but sending off processes on either side, to accompany and invest the nerves as they pass through the intervertebral foramina, until it is insensibly lost on their neurilema.

The posterior portions of the transverse processes should then be removed, so as to lay open the intervertebral foramina situated between them, as well as the hole by which each is pierced. The course of the nerves may thus be traced, until they leave the vertebral column, and divide into their anterior and posterior branches (p. 140). The passage of the vertebral artery, as it ascends through the transverse foramina, will also be completely exposed, as well as the small branches which it gives off between the bones to supply the medulla spinalis (p. 171).

Lastly, the dura mater is to be split up, and dissected away from its attachment to the nerves. The spinal cord will thus be brought completely into view, with the ligamentum denticulatum, and

the origins of the nerves (p. 140). The posterior or sentient root of each nerve will be seen arising by several filaments, which come out distinctly, or, as Sir Charles Bell expresses it, abruptly, from the posterior column, and which converge as they enter the intervertebral foramen, where they become united in a gangliform enlargement: from this ganglion the fasciculi are again continued in a more compact and rounded form, and immediately join with the anterior root, in such a manner, that the union of the two, as far as regards the intermixture of their fibres, is rendered complete, before the nerve emerges from the side of the spine. The anterior or motor root will be found to arise by a greater number of fibrillæ, and to occupy a larger extent of surface along the anterior column.

The accessory nerve may be observed deriving its origin from the lateral portion of the spinal cord, between the anterior and posterior roots of the spinal nerves, and increasing in size, by the addition of successive filaments, as it ascends towards the foramen magnum (p. 109).

On removing the medulla and its sheath from the canal, the sinus venosus may be seen situated between the dura mater and the bones. It consists of one or more considerable vessels, which extend on each side along the whole length of the

spinal canal. They receive the blood from the medulla, and transmit it by small lateral veins which accompany the nerves, and terminate in the vertebral, intercostal, and lumbar veins: a communication also generally exists between the sinus venosus and the lateral sinuses of the brain.

THE END.

Wertheimer, Printer, 52, Leman Street.

WORKS

RECENTLY PUBLISHED BY

A. SCHLOSS, 2, GREAT RUSSELL STREET,

BLOOMSBURY.

WEBER'S ANATOMICAL ATLAS.
Part VI. Price 1*l.* 1*s.*

SEERIG'S ANATOMICAL DEMONSTRATIONS,
Or Coloured Illustrations of the Human Body, Parts I. & II.—Price, 8*s.* 6*d.* plain, 12*s.* coloured.

GURLT'S ANATOMY OF THE HORSE.
Part I. 35 folio plates.—Price 1*l.* 12*s.* 6*d.*

In Royal 32mo. neatly bound in cloth, & gilt edges, price 2s. 6d.
Dedicated, by permission, to SIR CHARLES MANSFIELD CLARKE.

THE MARRIAGE ALMANAC,

Or Ladies' Perpetual Calendar, in which every Day in the Year is marked with reference to three important Epochs. From the German of Dr. DESBERGER, of Erfurt, with additions by an ENGLISH PHYSICIAN.

"Accoucheurs could not do better than recommend it to the Ladies on their lists: it is very beautifully got up; the tables are clear and intelligible, and the short remarks are sufficiently practical.—*London Medical Gazette, March* 28, 1835.

ANATOMICAL MODELS IN WAX.

Comprising the most interesting and important Parts of the Human Body in every Branch of Anatomy, Surgery, and Midwifery.

N.B. Lately received, A MODEL of the Nerves distributed to the Globe of the Eye and its Appendages; exhibiting at the same time the Internal Surface of the Base of the Skull, the Cavities of the Orbits laid open, the Muscles within the Orbit, the Carotid Arteries and Ocular Branches, and the Origin, Course, and Connexions of the various Nerves supplying the Globe of the Eye and adjacent parts.—Price 4*l.* 14*s.* 6*d.*

WORKS RECENTLY IMPORTED BY A. SCHLOSS.

FRENCH WORKS.

1. BOYER. Traité des Maladies Chirurgicales et des Operations. 5 vols. 8vo. *Bruxelles.*— 1*l.* 18*s.*
2. CAPURON. Cours Théorique et Pratique d'Acouchemens. 8vo. *Bruxelles.*— 9*s.*
3. MAGENDIE. Précis Elémentaire de Physiologie. Fourth Edition. 8vo. *Bruxelles.*—10*s.*
4. RICHERAND. Nouveaux Elemens de Physiologie. Eleventh Edition. 8vo. *Bruxelles.*—10*s.*

GERMAN WORKS.

1. HEROLDI Disquisitiones Animalium Vertebris carentium in Ovo Formatione. Primus Fasiculus; folio, coloured plates, beautifully executed.—1*l.* 12*s.*
2. BUSCH. Theoretisch-praktische Geburtskunde durch Abbildungen erläutert. Part II. Plates 9—18.—12*s.*
3. BAER. Untersuchung über die Entwickelungs-Geschichte der Fische nebst einen Anhang über die Schwimmblase. 4to.—4*s.*
4. CARUS. Lehrbuch der Vergleichenden Zootomie. 2 vols. 8vo., and Atlas 4to.—1*l.* 10*s.*
5. EBLE. Encyklopädisches Handbuch für angehende Wundärzte. 2 vols., 8vo.—12*s.*
6. HOHL. Die Geburtshülfliche Explorationen. 2 vols. 8vo.—14*s.*
7. LANDGREBEN. Ueber das Licht. 8vo.—12*s.*
8. LANGENBECK. Nosologie und Therapie der Chirurgischen Krankheiten. Vol. 5, part 1. 8vo.—8*s.*
9. LEONHARD. Fremdenbuch für Heidelberg und die Umgegend. *Heidelberg*, 1835. Vols. 1 & 2.—15*s.*

"All medical and other visitors of the Musenstadt (as its literary friends love to call it) will be much pleased with this guide-book."
London Medical Gazette, Aug. 1835.