

The surgical anatomy of inguinal herniæ, the testis and its coverings / by Thomas Morton.

Contributors

Morton, Thomas, 1813-1849.

Publication/Creation

London : Printed for Taylor and Walton, 1841.

Persistent URL

<https://wellcomecollection.org/works/vfnrq3ng>

License and attribution

This work has been identified as being free of known restrictions under copyright law, including all related and neighbouring rights and is being made available under the Creative Commons, Public Domain Mark.

You can copy, modify, distribute and perform the work, even for commercial purposes, without asking permission.



Wellcome Collection
183 Euston Road
London NW1 2BE UK
T +44 (0)20 7611 8722
E library@wellcomecollection.org
<https://wellcomecollection.org>

a
c/28

A8

MEDICAL SOCIETY
OF LONDON



ACCESSION NUMBER

PRESS MARK

MORTON, T.

No plates



THE
SURGICAL ANATOMY
OF
INGUINAL HERNIÆ,
THE
TESTIS AND ITS COVERINGS.

BY THOMAS MORTON,
ONE OF THE DEMONSTRATORS OF ANATOMY IN UNIVERSITY COLLEGE, LONDON ;
AND FORMERLY HOUSE SURGEON TO THE HOSPITAL
OF THE SAME COLLEGE.

ILLUSTRATED WITH LITHOGRAPHIC PLATES
AND WOOD ENGRAVINGS.

LONDON:
PRINTED FOR TAYLOR AND WALTON,
BOOKSELLERS AND PUBLISHERS TO UNIVERSITY COLLEGE,
28, UPPER GOWER STREET.

1841.



Digitized by the Internet Archive
in 2016

THE SURGICAL ANATOMY

OF

INGUINAL HERNIÆ.

CHAPTER I.

SURGICAL DISSECTION OF THE STRUCTURES CONNECTED WITH THE ANATOMY OF INGUINAL HERNIÆ.

As inguinal herniæ are of much more frequent occurrence in men than in women, it is desirable that a male subject should be procured for this dissection; and, where a choice can be made, a body which is rather thin is to be preferred to one that is corpulent, provided that the muscular system be equally well developed.

Position of the subject. — The subject should be laid upon its back, and a large-sized block of wood placed underneath the loins; and, in order that the abdominal parietes may be rendered as tense as possible, the inferior extremities should be rotated outwards, and the knees bent, so that the legs and feet shall rest upon their external surface. Not unfrequently, however, it happens that the muscular walls of the abdominal cavity are so flaccid that these measures prove inadequate to produce the degree of tension requisite for their easy dissection, and then it will be found very advantageous to distend the peritonæal sac; inflating it by means of a coarse blow-pipe passed through a small puncture made in the upper part of the linea alba. The air which is in this manner introduced, is to be prevented from escaping by closing the aperture with the twisted suture at the same time that

the blowpipe is withdrawn. This method of proceeding will also be found very useful when a hernial sac is present in the subject which has been selected for making the dissection. The penis, together with the scrotum and testicle of the side upon which it is proposed to commence the dissection, should be drawn obliquely downwards and across the upper part of the opposite thigh, in which position they should be fixed by hooks, so that the skin covering them may be held upon the stretch.*

The dissection may now be commenced by an incision which is to be carried across from the crest of the ilium, at a short distance beyond the anterior superior spinous process of that bone, to the linea alba, where it should terminate a little below the umbilicus; from the termination of this cut let another be made downwards, in the course of the linea alba, as far as to the root of the penis. These incisions should divide the skin only. If the last-mentioned incision be prolonged a little way along the dorsum of the penis, and then turned down over the side of the scrotum, the future steps of the dissection will be greatly facilitated. (See Plate I.) The triangular flap of skin which is thus marked out, should, in the next place, be dissected up, commencing at the angle nearest to the umbilicus, and carefully detaching it from the subjacent layer of cellular and adipose tissue (the *superficial fascia*) by successive strokes of the scalpel, until opposite the crural arch; or, if it should be considered desirable, the dissection of the skin may be continued for a little distance upon the upper part of the thigh. While detaching this flap, the dissector should be careful to observe the white appearance of the internal surface of the skin, as he will thus be insured from cutting too deeply, and injuring the next layer, or the external lamella of the superficial fascia of the abdominal parietes.

The skin covering the penis and scrotum, will be found to be much thinner than elsewhere; and, upon the latter, its inner surface is rendered very uneven by the numerous sebaceous glands which abound in this situation, and appear as so many granular bodies, of a whitish colour.

Small superficial abscesses frequently form in this situation,

* It is recommended to those who are commencing their dissections of this region to dissect only on one side at a time, so that the other may be reserved for a repetition of the dissection, which will thus be executed with greater precision and exactness.

deriving their origin from some inflammatory affection of one of these glands. These abscesses, although small, frequently cause, during their formation, considerable pain and uneasiness; but they are quickly cured by making, as soon as suppuration has been fairly established, a simple incision, of sufficient extent to afford a free exit to the contents of the swelling.

The flap of skin which has thus been raised, may be reflected downwards upon the thigh, where, if necessary, it is to be fixed by means of a pin. (See Plate I. fig. *t*, and Woodcut No. 1, fig. *k*.)

The *superficial fascia* covering the lower part of the abdominal parietes, consists of two distinct layers, between which the superficial vessels and some small lymphatic glands are placed. The external layer (immediately subjacent to the skin) consists chiefly of a loose reticulated cellular tissue, with more or less of adipose substance deposited in its cellules, accordingly as the individual is corpulent or otherwise. The thickest portion of this layer is over the body of the os pubis, where a large mass or cushion of adipose tissue is deposited in it, the granules of which are much smaller than elsewhere; it is this mass of adipose substance which constitutes, in the female, the mons Veneris. The quantity of this fatty substance diminishes near the bend of the thigh, beyond which line the external layer of the superficial fascia is traversed at numerous points by several bands of condensed cellular tissue, which are disposed in a transverse direction.*

The external layer of the superficial fascia may be readily shown to pass over the crest of the ilium and Poupart's ligament, without being adherent to these structures, and afterwards to become continuous with the outer lamella of the superficial fascia of the groin; for, on drawing upon any part of the inguinal portion, we are also able to exercise a certain degree of traction upon the femoral division of the membrane.

The superficial vessels.†—If the subject be much emaciated, some small arteries and veins will be observed to run, in various directions, underneath the external layer of the superficial fascia; those which are situated near the centre of the space between

* *Vide* The Surgical Anatomy of the Groin and Femoral Hernia, p. 95.

† For a description of these vessels, see the Surgical Anatomy of the Groin, &c. p. 99, and also Plates I. and III. of the same work.

the anterior superior spinous process of the ilium, and the symphysis pubis, are named *the superficial epigastric artery and vein*; the first is a branch sent off from the common femoral artery, at a short distance below the crural arch; and, after escaping through a small opening in the iliac portion of the fascia lata, ascends, in an oblique direction, upwards and inwards, towards the umbilicus, giving branches to the integuments on either side of its course, some of which anastomose with the branches of the deep or internal epigastric artery which pierce the muscular and tendinous structures forming this portion of the abdominal parietes; the vein takes the same course as the artery after which it is named, and empties itself into the great saphena vein, as the latter is about to pass through the saphenous aperture of the fascia lata, in its course to reach the common femoral vein.* The other vessels, which are seen crossing over the spermatic cord, where it emerges from the external abdominal ring, are the *external or superficial pudic arteries and veins*, also branches of the common femoral artery and the great saphena vein; they issue from the saphenous opening of the fascia lata, and, after passing obliquely inwards and upwards, are distributed to the superficial investments of the cord and testicle, and to the integuments of the hypogastric region. (For a representation of the course and distribution of these vessels, see Plates I. and III. of the Surgical Anatomy of the Groin, &c.)

The external pudic artery is generally divided in the first incisions which are made in the operation for strangulated inguinal hernia, and, sometimes, the vessel will bleed so smartly as to require the application of a ligature for the suppression of the hemorrhage.

If the subject should be very corpulent, the superficial vessels will not at first be apparent; and, then, in such cases, it will be necessary to dissect up the external layer of the superficial fascia, which, lying upon the vessels, conceals them from our view. This is best done by carefully cutting down upon the

* In cases of long-continued distention of the abdomen, as, for example, in some instances of ascites, ovarian tumours, &c., the superficial epigastric vein is frequently greatly enlarged in its size and varicose. In a case of ascites I have seen it as large as the little finger.

vessels at a little distance above the crural arch, and then following them downwards in their course towards the saphenous opening of the fascia lata. As the external pudic vessels are very tortuous in their course, some caution is requisite during this dissection, in order that they may not be cut across unexpectedly; an accident which may be avoided by drawing the superficial fascia upwards and inwards, so as to efface the numerous curves which the vessels make as they are mounting over the spermatic cord. Some branches of the external circumflexa ilii artery and vein will be noticed near the crest of the ilium.

The superficial lymphatic vessels. — Three or four small absorbent glands will be found lying between the two laminae of the superficial fascia, parallel with, and immediately above Poupart's ligament. Numerous delicate lymphatic vessels may be shown, by a little careful dissection, to enter into these glands in their way from the hip, the hypogastric and umbilical regions, and external organs of generation, to the cavity of the abdomen, and hence it is that they frequently become swollen and inflamed in consequence of any disease in these parts; affections which are, in many instances, wholly unconnected with any venereal taint.

In persons of a strumous habit these glands are sometimes enlarged, without any very obvious cause, to an extraordinary degree, and at length, after suppurating imperfectly at several points, form a succession of troublesome abscesses, which, if neglected by the patient or his surgeon, frequently degenerate into numerous deep and irregular sinuses or fistulae, which generally prove exceedingly difficult of cure.

When the superficial vessels and glands have been thus exposed, the dissector should next proceed to raise up the deep layer of the superficial fascia, together with the other structures which rest upon it; he may commence at the angle nearest to the umbilicus, and then, holding the fascia tightly up from the tendinous aponeurosis of the external oblique muscle, he must divide, by successive strokes of the scalpel, the delicate cellular tissue which connects its internal surface to the tendon underneath. This cellular tissue should be divided close to the surface of the aponeurosis, the knife being carried in the same direction as the fibres of the external oblique muscle, that is to say, obliquely downwards and inwards. Great care is

required on approaching near to the situation of the external abdominal ring, lest the thin membrane which passes off from the margins of that opening downwards upon the spermatic cord (the *external spermatic fascia*) should be cut, and removed along with the superficial fascia.* To avoid this error an assistant should be instructed to hold the spermatic cord tense, by drawing the testicle obliquely downwards and to the opposite side.

While raising the deep layer of the superficial fascia from the tendinous aponeurosis of the external oblique muscle, it will be observed that it is particularly adherent, in the mesial line, to the linea alba, and, laterally, to the anterior or cutaneous surface of the ligament of Poupert and iliac portion of the fascia lata. The connection of the deep layer of the superficial fascia to Poupert's ligament, is much more intimate along the outer or iliac half of that structure than nearer to the spine or tuberosity of the os pubis, where it is rather attached to the pubic portion of the fascia lata, in front of Gimbernat's ligament.

When the deep layer of the superficial fascia is traced below the crural arch, it will be found to rest upon the fascia lata of the thigh, and to be spread over the saphenous opening, to the margins of which it is closely adherent.

The difference which exists in the structure of the two layers of the superficial fascia of the abdomen, is deserving of particular notice;—the external lamella is formed of a loose cellular tissue, and is always more or less loaded with adipose substance, which is deposited in its cellules, whilst the internal lamella is, on the contrary, very strong and elastic, and presents a smooth, compact, and glistening appearance, especially upon its internal surface, so that it may be said to be always membranous, and, occasionally, even aponeurotic, in its properties.†

The *dartos*.—The superficial fascia of the abdominal parietes changes its appearance in a remarkable manner as it descends over the spermatic cord to reach the scrotum, suddenly losing its adipose, cellular character, and assuming a fibrous structure, of

* The spermatic fascia is represented in Plate III. of the Surgical Anatomy of the Groin, fig. x.

† By many the deep lamella of the superficial fascia is known under the name of Scarpa's Fascia. Scarpa himself described it as an aponeurosis derived from the fascia lata of the thigh.—*Traité des Hernies*, p. 22.

a light brown or roseate hue. It is upon the dartos that the vermicular movements and gradual contractions of the scrotum, which occur so frequently when these parts are exposed to the influence of cold, are dependent. From these circumstances it has been regarded by some authorities as being muscular in its structure and properties, although no muscular fibre has ever been satisfactorily shown to exist in its composition.

The dartos is continuous, superiorly, with the superficial fascia of the abdomen; inferiorly, and posteriorly with the superficial fascia of the perinæum: its external surface is closely adherent to the skin of the scrotum; and, by its internal aspect, it is loosely connected by cellular tissue with the fibrous sheath which invests the spermatic cord and testicle. There is prolonged from it an imperfect septum of a fibro-cellular nature (the *septum scroti*), which separates the testicles from one another, and is capable of permitting fluids to pass without much difficulty from one compartment of the scrotum into the other.

It is underneath this structure, and into the lax cellular tissue which connects it to the fibrous sheath of the spermatic cord, that the serous fluid is deposited, in those cases of simple anasarca swelling of the scrotum and penis, so frequently observed in patients who are affected with general dropsy from diseases of the heart and liver. Blood is frequently largely extravasated underneath the dartos, in consequence of blows and falls upon this part, and upon the perinæum.* Occasionally it happens that the irritating fluids, employed for the cure of hydrocele of the tunica vaginalis, are, owing to the accidental slipping of the trocar from its proper situation, forcibly injected underneath it, producing high irritative fever, and extensive sloughing of the parts, if not speedily evacuated by a free incision. Acute anasarca of the scrotum, as it has been well termed by Mr. Liston, is another disease which, also, has its seat in the loose cellular tissue which is subjacent to the structure of the dartos.† Not unfrequently urine is effused underneath the dartos, as happens in those cases of extravasation of urine following a rupture of the urethra in the situation of the bulb, or

* *Vide* The Surgical Anatomy of the Perinæum, p. 69.

† See Remarks on the acute form of anasarca of the scrotum, by R. Liston, Esq. in the Med. Chir. Trans. London, 1839, p. 288.

any portion of the canal which may be anterior to the deep perinæal fascia or triangular ligament.*

The *aponeurosis of the external oblique muscle*.—The tendon of the external oblique muscle, which has been exposed by the dissection of the skin and superficial fascia, may next be examined. It will be observed, that, in the hypogastric and iliac regions, the external oblique muscle is altogether tendinous; but it does not present a perfectly continuous and unbroken surface throughout its entire extent, as, at several points, there are formed numerous apertures in it which serve for the transmission of the smaller branches of the deep epigastric artery which anastomose with the ramifications of the superficial vessels; several filaments of the lower dorsal and upper lumbar nerves also issue through these openings, in their course to be distributed to the cutaneous coverings of the lower part of the belly.

The distribution of these nerves sufficiently explains the sensation of being "*tightly girded*" which is so commonly complained of by those patients who labour under disease and curvature of the middle portions of the vertebral column.

The apertures in the tendinous aponeurosis of the external oblique muscle, are sometimes found to be very much enlarged in their dimensions, and to be filled with a small mass of adipose substance which is frequently connected with the outer surface of the peritonæum, which is itself now and then protruded in the form of a small pouch or sacculus.

When any of the contents of the abdominal cavity escape by these openings, the name of *ventral hernia* is given to the disorder.

The *external oblique muscle* arises, on each side, from the outer surface of the eight inferior ribs by as many fleshy processes, which correspond with, and indigitate with some of the costal attachments of the serratus magnus and latissimus dorsi muscles:—the posterior fibres of the muscle, which are fleshy in their structure, descend, in nearly a perpendicular direction, from the false ribs, and are inserted into the anterior half of the outer labium of the crest of the ilium, while the fibres from the superior ribs incline downwards and inwards, towards the mesial line, and terminate at the outer edge of the rectus mus-

* *Vide* The Surgical Anatomy of the Perinæum, p. 12 and p. 69.

cle, in a broad aponeurosis, which, after passing in front of the rectus, unites at the linea alba, with the tendon of the same muscle of the opposite side.

In front of the upper and middle portions of the rectus muscle the tendon of the external oblique is very thin and delicate, and is, moreover, intimately blended with the aponeurosis of the internal oblique, which lies underneath it; but, nearer to the pubes, it becomes much thicker and stronger, and is, also, much more easily separated by the knife from the sheath of the rectus.

On tracing the tendinous fibres of the external oblique muscle, as they pass downwards and inwards from opposite the anterior superior spinous process of the ilium towards their insertion into the inferior third of the linea alba and body of the os pubis, it will be found that, as they approach the crista of the os pubis, they separate from one another, so as to be divided into two distinct fasciculi, of which the innermost and superior is the broadest and weakest, while the external and inferior, though much narrower than the first, is, nevertheless, much thicker and stronger. The first of these fasciculi is inserted into the body and symphysis of the os pubis, where it also decussates with the corresponding portion of the tendon of the opposite muscle. (See the woodcut No. 1, at p. 220, fig. *d*.) The second or stronger fasciculus is fixed into the tuberosity or spinous process of the os pubis, and the adjacent portion of the ileo-pectineal line, where it mainly contributes towards the formation of Gimbernat's ligament, presenting there a free and sharp margin, somewhat concave in its outline, and directed towards the common femoral vein. (See fig. *b*, *c*, of the woodcut, No. 1.*) There is frequently a very great difference in many subjects as to the precise distance from the symphysis pubis at which the above mentioned divergence of the fibres of the tendon of the external oblique muscle commences; — in the greater number of instances it is about one inch and a half from the symphysis pubis, while in some it is much nearer than this; in other cases again it is still farther distant, so that it is situated almost opposite the anterior superior spinous pro-

* *Vide* The Surgical Anatomy of the Groin and Femoral Hernia, page 84, and the wood-engraving at page 85 of the same work, fig. *m. n*.

cess of the ilium. Occasionally another split is to be found in the tendon of the external oblique, which is situated above and to the inner side of that which forms the external abdominal ring, and through it the fleshy fibres of the internal oblique muscle may be clearly distinguished, as they are only covered by some of the fibres of the intercolumnar fascia.

EXPLANATION OF PLATE I.

Exhibits the first stage of the dissection of the anatomy of the structures concerned in inguinal herniæ.

The skin and superficial fascia have been reflected downwards upon the thigh, in order to show the tendinous aponeurosis of the external oblique muscle, the external abdominal ring, spermatic cord, and testicle, &c.

- a.* The anterior superior spinous process of the ilium.
- b.* The spinous process or tuberosity of the os pubis.
- c.* Poupart's ligament, which is extended between these two processes of bone.
- d.* The tendinous aponeurosis of the external oblique muscle.
- e.* The fleshy fibres of the same muscle.
- f.* The aponeurosis of the external oblique muscle, where it passes in front of the rectus muscle to be attached to,
- g.* The linea alba.
- h.* The linea semilunaris, which is situated at the outer edge of the rectus muscle.
- i.* The inferior and outer pillar of the external abdominal ring, which is formed by the pubal extremity of Poupart's ligament; it is thicker and stronger, though narrower than
- k.* The superior and inner pillar of the same opening.
- l.* The intercolumnar fibres, which serve to bind the two pillars of the external abdominal ring more strongly together.
- m.* The spermatic cord, after it has emerged through the external abdominal ring;—some of the fibres of the cremaster muscle are seen upon its outer side.
- n.* The testicle, concealed by the tunica vaginalis reflexa.
- o.* The iliac portion of the fascia lata of the thigh, which is attached to the lower edge of Poupart's ligament.
- p.* The pubic portion of the fascia lata, covering the pectineus and adductor longus muscles.
- q.* The falciform process of the iliac portion of the fascia lata, where it bends inwards, underneath Gimbernat's ligament, and arches over the upper part of the crural canal.
- r.* The deep layer of the superficial fascia of the abdomen reflected, along with the skin, upon the upper part of the thigh.

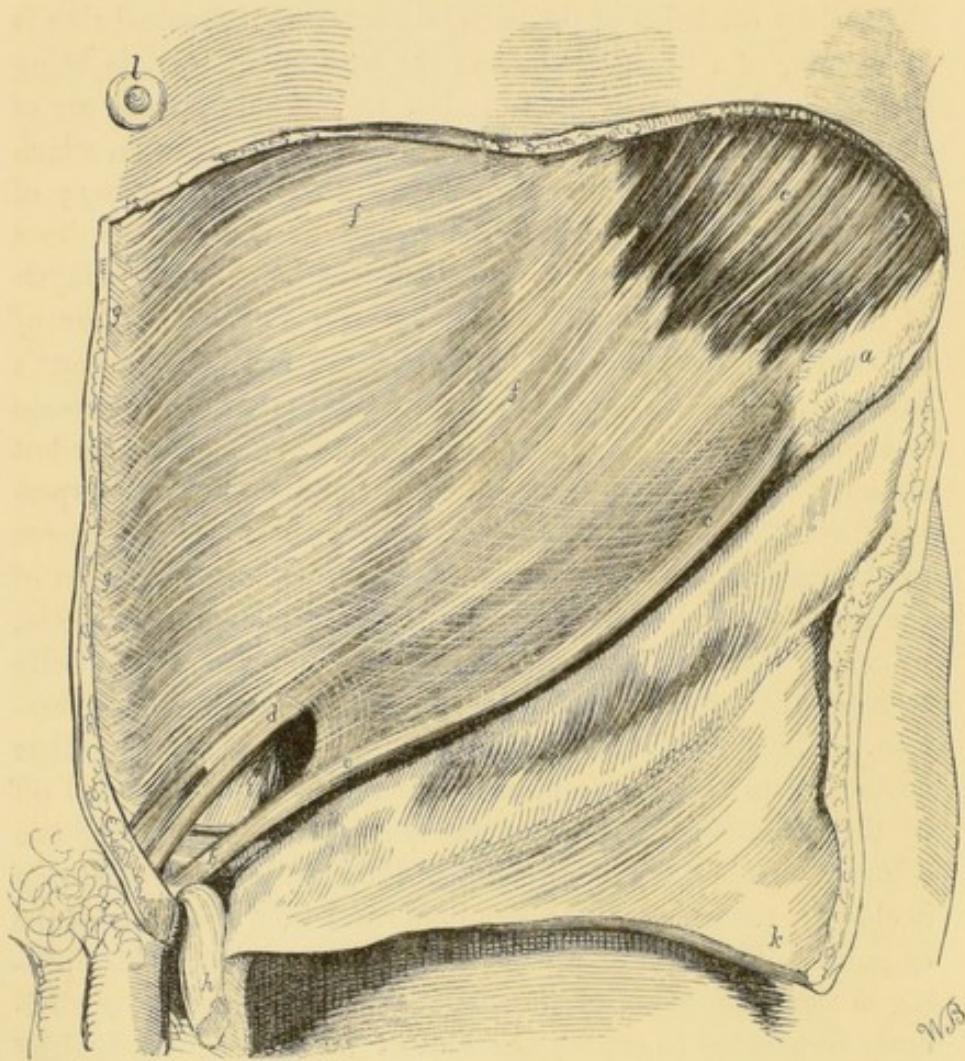
- s. The external circumflexa ilii artery.
- t. The superficial epigastric artery.
- u. The external pudic artery.
- v. The umbilicus.
- w. The suspensory ligament of the penis.
- x. The fascia lata covering the glutæus medius muscle.

The *external abdominal ring*.* — This name has been given to the aperture in the tendinous aponeurosis of the external oblique muscle, which is formed by the divergence of the tendinous fasciculi as they approach the crista of the os pubis. In the healthy condition of the parts, the external abdominal ring is an opening of a triangular figure, the base of the triangle being formed by the crista of the os pubis, and its sides, which are of unequal length, by the two bundles of tendinous fibres, which have been denominated the *columns*, or *pillars*, of the ring; of these, one is *superior* and *internal*, and descends, as has been already stated, to become inserted into the body and symphysis of the pubis; the other forms the *inferior* and *outer pillar of the ring*, and consists chiefly of the pubal extremity of Poupart's ligament, where it is about to be inserted into the spinous process or tuberosity of the os pubis. The external is the narrower but stronger of the two pillars of the ring, and supports the spermatic cord, in the male, and the round ligament of the uterus in the female, as they severally emerge from the lower part of the inguinal canal, or oblique passage in the abdominal parietes, by which these structures issue from the interior of the belly to reach their connections with the external organs of generation. The apex of the triangle is the part at which the pillars commence to separate from each other; here it is rounded off by the lowermost of the transverse fibres, which connect the two columns together. The direction of the external abdominal ring is oblique, stretching upwards and outwards from the crista of the os pubis. The term of ring which has been given to this opening in the aponeurosis of the external oblique muscle, is obviously ill-adapted to convey the idea of its figure in the healthy and natural state of the parts; but it should be recollected that, when a hernial sac has been protruded through it, it assumes a

* Also called the *ring of the external oblique*, *inguinal ring*, *lower or external aperture of the inguinal canal*; *anneau inguinal*, *anneau du grand oblique*; *annulus inguinalis anterior*.

circular form, and has always been thus described by surgical writers. Thus, then, the external abdominal ring is the opening which is formed by the divergence of the tendinous fasciculi of the aponeurosis of the external oblique muscle, and is situated immediately *above* the spinous process and crista of the os pubis, which circumstance it is of considerable importance to bear in mind when establishing a diagnosis between some obscure forms of inguinal and femoral hernia.*

No. 1.



The wood-engraving represents the figure and situation of the external abdominal ring, as it appears in the male subject. The skin and superficial fascia have been dissected from the aponeurosis of the external oblique

* See the Surgical Anatomy of the Groin and Femoral Hernia, p. 137.

muscle, and turned down upon the thigh; the spermatic cord was cut across as it escaped through the opening, and reflected downwards upon the scrotum.

a. The anterior superior spinous process of the ilium. *b.* The spinous process or tuberosity of the os pubis, into which the ligament of Poupart is inserted. *c. c.* Poupart's ligament, or lower edge of the tendinous aponeurosis of the external oblique muscle, which is extended between these points of bone, and constitutes the principal part of the crural arch. Between the letters *b* and *c* Poupart's ligament forms the outer and inferior pillar of the external abdominal ring. *d.* The superior and internal pillar of the ring; it is broader, but thinner than the inferior pillar. The curved white lines represent the intercolumnar fascia, which consists of a series of tendinous threads, which take their origin from the crural arch, spread upwards, diverging as they proceed, and are lost in the linea alba; they serve to bind more strongly together the oblique fibres of the aponeurosis of the external oblique muscle, and to connect the two columns of the external abdominal ring. *e.* The fleshy fibres of the external oblique muscle opposite the crista of the ilium. *f. f.* The aponeurosis of the external oblique muscle, the fibres of which are intersected nearly at right angles by the filaments of the intercolumnar fascia. *g. g.* The linea alba, where the tendinous fibres of the external oblique muscles decussate with one another. *h.* The spermatic cord which has been cut across as it emerged from the external abdominal ring, and reflected downwards upon the scrotum. *i.* The external abdominal ring; the letter is placed upon that part of the posterior wall of the inguinal canal, situated behind the external abdominal ring, which is formed by the conjoined tendons of the internal oblique and transversalis muscles. *k.* The skin and superficial fascia of the abdominal parietes dissected from the aponeurosis of the external oblique muscle and reflected downwards upon the upper part of the thigh.

The size of the external abdominal ring is considerably larger in men than in women; for a smaller opening suffices for the transmission of the round ligament of the uterus in the female, than that which is required for the passage of the spermatic cord and testicle in the male.* This obviously accounts for the greater frequency of inguinal hernia in the latter than in the former.

The *intercolumnar fascia*. — It will be recollected that the fibres which compose the aponeurosis of the external oblique muscle have been described as being arranged parallel with each other, and descending obliquely, downwards and inwards, to their at-

* The comparative size of the external abdominal ring in the male and female, is well represented in the wood-engravings, No. 4. and 5. p. 102 and 104 of the Surgical Anatomy of the Groin, &c.

tachments to the os pubis — a disposition of parts which alone could afford but a feeble resistance to the protrusion through the external ring, of the loose and floating viscera of the abdomen, when compressed by any unusual contraction of the muscular parietes of that cavity.

On a closer inspection, however, a regular series of strong tendinous fibres will be observed to lie closely upon the outer surface of the aponeurosis of the external oblique muscle, crossing, nearly at right angles, the proper fibres of the tendon, adhering very intimately to each, and thus materially serving to bind them more firmly together. As these fibres extend over from one pillar of the ring to the other, they have been named the *intercolumnar fascia*. The fibres of the *intercolumnar fascia* take their origin, in a great measure, from the anterior edge of Poupart's ligament, in the whole of the space between the anterior superior spinous process of the ilium and the root of the spinous process of the os pubis; near the last-mentioned point of bone some of them appear to spring from the pubic portion of the fascia lata binding down the pectineus muscle, immediately anterior to the ligament of Gimbernat; they thence ascend, in a curvilinear direction, towards the lower part of the linea alba, into which they are finally inserted. The convexity of the curve, which these fibres make in their course, is, for the most part, directed downwards towards the external abdominal ring, but near the apex of that opening they are disposed in the contrary direction. (See the woodcut No. 1. page 220, where the fibres of the intercolumnar fascia are represented by numerous white lines, upon the aponeurosis of the external oblique muscle.) Near the anterior superior spinous process of the ilium, these fibres are weak and scattered; but as they approach the outer extremity of the external abdominal ring they become much more numerous, and, at the same time, greatly increased in thickness and strength, and are thus well calculated to prevent the further divergence from one another of the pillars of the ring.

When the external abdominal ring is distended by the protrusion through it of the sac of an inguinal hernia, the intercolumnar fascia limits the excessive enlargement of the opening, and communicates the circular form to it, whence it has derived its name; and it is owing to the circumstance of the most inferior

fibres of the intercolumnar fascia being more closely aggregated together in such a case, that the constricted appearance usually observed towards the upper part of a large scrotal hernia is produced, an appearance which designs, with precision, the situation of the external abdominal ring.

The fibres of the intercolumnar fascia are commonly found to be more strongly developed in men than in women, and in some rare instances they may exist on both the surfaces of the aponeurosis of the external oblique muscle. They are, on the other hand, in some subjects so thin and delicate as to be demonstrated with great difficulty ; and occasionally may even be absent altogether.

The arrangement of the fibres of the intercolumnar fascia is well deserving of particular attention ; since their principal function must be the prevention of the farther separation from each other of the pillars of the external abdominal ring, and thus to oppose the formation of inguinal herniæ, since the tendency of the viscera to protrude through the inguinal canal will be in a great degree proportionate to the imperfect or weakly development of this structure. (The intercolumnar fascia is also represented in Plate I. fig. l.)

The *spermatic fascia*. — The margins of the external abdominal ring are not naturally so clearly defined as they have been represented in the first plate of this work, since they are somewhat obscured by the existence of a thin and delicate fascia, through which the fibres of the cremaster muscle may be distinguished. This membrane is the *spermatic fascia*, and descends from the circumference of the external abdominal ring upon the spermatic cord in the male, and the round ligament of the uterus in the female, as they emerge from the inguinal canal.* In the male subject the fascia descends upon the outer surface of the cremaster muscle, to which it is connected by loose cellular membrane ; and externally it is in relation with the sub-dartois cellular tissue. The spermatic fascia descends to the lower part of the testicle, completely surrounding both it and the cord. Some anatomists

* The spermatic fascia is well represented in Plate III. of the Surgical Anatomy of the Groin, fig. x. It has received various names from different authors :—*tunica aponeurotica*, *fascia cremasterica* ; by Scarpa it is called the aponeurotic web of the fascia lata ; *tunica vaginalis communis*, *tunique fibreuse du cordon spermatique*, &c. &c.

have regarded this membrane as derived from the intercolumnar fascia, which has already been described as lying upon the aponeurosis of the external oblique muscle, while others,—more correctly, I believe,—consider it as a separate and distinct structure, having its origin from the margins of the external abdominal ring.

By drawing the cord and testicle in various directions, it is easily shown that the spermatic fascia adheres very firmly to the circumference of the external abdominal ring, and that it descends thence upon the spermatic cord, gradually becoming narrower until it approaches the testicle, when it expands so as to cover the whole of that gland.

In some subjects the spermatic fascia is sufficiently thick and strong to admit of being easily dissected throughout its entire extent; but, in the greater number of instances, it becomes so extremely thin and delicate in its structure, as it descends upon the cord, as to render the proceeding very difficult and frequently unsatisfactory.

In the female subject the spermatic fascia is neither so strong nor so extensive as in the male; for it is soon blended with the cellular and adipose substance which covers the crista of the os pubis, and in which the round ligament of the uterus is inserted.

The use of this fascia is, according to Sir Astley Cooper, to furnish additional support to the testicle and its coverings; and, by its loose connections with it and the cord, to allow of the free motion of the gland, enabling it more easily to elude the consequences of pressure and violence.*

In cases of old and large scrotal hernia the spermatic fascia is commonly found to be much increased in its thickness and density.

General and surgical remarks.—It may prove useful, before proceeding any further in the dissection of this region, to replace the structures which have already been exposed, and to review them as they now appear.

Underneath the skin is placed the superficial fascia, which, as has been shown, consists of two lamellæ; of which the deeper one is the stronger and more membraniform in its structure,

* See Sir Astley Cooper's work on the Anatomy and Diseases of the Testis, 4to. p. 83.

and adheres closely to the anterior and inferior edge of Poupart's ligament, and to the iliac portion of the fascia lata, in the interspace between the anterior superior spinous process of the ilium and the spinous process or tuberosity of the os pubis; the superficial lamella is, on the other hand, of a much more loose and cellular texture, at the same time that its thickness is liable to frequent variations, which are dependent upon the quantity of adipose substance that may be deposited in its tissue. The superficial pudic and epigastric vessels, with three or four small absorbent glands, have also been seen as they lie betwixt the two lamellæ of the fascia, opposite the crural arch. The superficial fascia is more closely connected to the tendon of the external oblique muscle in the course of the linea alba than elsewhere, while opposite the crista of the os pubis it descends into the scrotum, covering the spermatic cord after its emergence from the external abdominal ring, and finally becomes continuous with the membrane of the dartos.

The delicate cellular tissue which connects the internal surface of the superficial fascia to the tendinous aponeurosis of the external oblique muscle should not be overlooked, as it is by the destruction of it that those dangerous extravasations of urine into the perinæal region, which occasionally supervene upon a rupture of the urethra from inveterate strictures situated in front of the triangular ligament, &c. are enabled to make their way with such alarming and frightful rapidity upwards upon the hypogastric region; a course which is the very opposite of that which would be indicated by the common law of gravitation of fluids, but which is satisfactorily explained by reference to the connexions and relations of the superficial fascia of the perinæum, the dartos, and superficial fascia of the abdominal parietes.* It is, also, in this structure that the diffused inflammation and extensive suppuration which not unfrequently follow injuries inflicted, and surgical operations performed upon this region, are commonly found to have their seat.

The mode of formation of the external abdominal ring, by the divergence from each other of the fibres of the aponeurosis of the external oblique muscle as they approach the crista of the os pubis, is deserving of particular attention; as are, like-

* *Vide* the Surgical Anatomy of the Perinæum, pp. 11 and 12, and Surgical Observations by Sir Charles Bell, p. 90. 8vo. Lond. 1816.

wise, the fibres of the intercolumnar fascia, which, resting on the outer surface of the aponeurosis, cross its fibres at right angles, and by adhering to each as they pass over them, tend to prevent their unnatural separation, and so diminish the frequency of hernial protrusions in this region.

The exact situation of the external abdominal ring must not be forgotten, since it forms a principal point in establishing a correct diagnosis in all difficult and obscure cases of inguinal and femoral herniæ: the ring is situated immediately *above* the crista and spinous process of the os pubis; its longest diameter is directed upwards and outwards, towards the anterior superior spinous process of the ilium; the size of the opening being limited by the inferior fibres of the intercolumnar fascia.* Through the opening projects the spermatic cord in the male, and the round ligament of the uterus in the female; both of which structures receive, as they emerge, a perfect tubular investment from the thin membrane or fascia which springs from the margin of the ring, and is called the spermatic fascia.

The influence which is exercised by the position of the inferior limbs upon the condition of the lower portion of the abdominal parietes, but principally upon the tendon of the external oblique muscle, should also be examined. The iliac portion of the fascia lata of the thigh is firmly attached, in the interval between the anterior superior spinous process of the ilium and the root of the tuberosity of the os pubis, to the inferior edge of Poupart's ligament and its reflected portion, denominated the ligament of Gimbernat; and consequently, when the lower extremity is extended and rotated outwards, the tendon of the external oblique muscle is rendered quite tense and unyielding, and the pillars of the external abdominal ring are brought more tightly together, so that it is with some difficulty that the extremity of the finger can be insinuated into the opening; but if the thigh should be raised and bent upon the pelvis, at the same time that the knee is rotated inwards and towards the opposite side, all the tenseness of the aponeurosis of the external oblique muscle will be removed, and the columns of the external abdominal ring so much relaxed as to admit of the introduction of the finger with the greatest facility.

* The Surgical Anatomy of the Groin, &c. p. 137.

It is with the view of producing a similar relaxation of the pillars of the external abdominal ring, and of the several structures which enter into the composition of the parietes of the inguinal canal, that surgeons are in the constant habit, previously to endeavouring to reduce the contents of a strangulated inguinal hernia by the taxis, of first taking the precaution of placing the lower limbs in such a position as shall most completely relax this portion of the abdominal walls.

The dissection of the inguinal canal.—The lower part of the tendinous aponeurosis of the external oblique muscle may now be raised, in order that the external abdominal ring may be examined from its inner surface, as well as the subjacent structures which are connected with the anatomy of the inguinal canal. For this purpose let an incision be made through the fleshy fibres of the external oblique muscle, about one inch beyond the anterior superior spinous process of the ilium, so as to expose the cellular interspace which separates its fibres from those of the internal oblique muscle; this incision should be prolonged in an oblique direction as far as the linea alba, and thence downwards to the symphysis of the pubes; observing, at the same time, to render the subjacent muscles tense, by drawing the linea alba towards the opposite side, and the cord and testicle downwards and across the right thigh. (See Plate II.) The tendinous and fleshy flap, thus marked out, is to be carefully dissected from the fleshy fibres of the internal oblique and cremaster muscles, and the sheath of the rectus. Near the umbilicus it will be found rather difficult to separate the tendon of the external oblique from the sheath of the rectus muscle; but, as we approach the crista of the os pubis, the connexion between these structures becomes much less intimate, in consequence of the presence of some loose cellular tissue which is interposed between them. The internal and superior pillar of the external abdominal ring should not yet be cut across, but may be allowed to remain entire in its attachments to the body and symphysis of the ossa pubis.

On raising the tendinous aponeurosis of the external oblique muscle, two nerves will be noticed lying between it and the fleshy fibres of the internal oblique (the *musculo-cutaneous* and *ilio-scrotal* branches of the lumbar plexus); they descend, after having successively traversed the transversalis and internal

oblique muscles, to the external abdominal ring, through which they emerge to be finally distributed to the superficial coverings of the spermatic cord and testicle. These nerves frequently adhere pretty closely to the inner surface of the tendinous aponeurosis of the external oblique muscle, and are therefore liable to be cut across when it is raised up to expose the internal oblique and cremaster muscles.

If the tendinous aponeurosis of the external oblique muscle be now taken up in one hand, and the forefinger of the other introduced through the external abdominal ring from its inner aspect, it will be clearly shown how the spermatic fascia passes off from the margins of the opening, and, descending upon the cord, invests both it and the testicle in a perfect tubular sheath. By the same proceeding it will also be readily understood that when the sac of an inguinal hernia protrudes through the external abdominal ring, it will necessarily receive a covering from this membrane.

While it is thus distended by the finger, the external abdominal ring will be observed to lose its natural triangular form, and to assume a circular appearance, which it constantly presents after a hernial sac has descended through it; and hence is derived the appellation of *ring*, which has been given to the opening. (See woodcut, No. 5, figs. *e*, *f*.)

If the dissector should choose to do so, he may now define the margins of the external abdominal ring by cutting with his scalpel lightly round the spermatic cord, as it emerges from the lower opening of the inguinal canal. The spermatic cord, after passing through the external abdominal ring, descends in a vertical direction to the testicle; so that the portion of the cord which lies within the inguinal canal is placed almost at a right angle with that part of it which is included between the ring and the testicle. It may also be here observed, that the spermatic cord, where it passes through the lower opening of the inguinal canal, is partly supported by the inferior pillar of the ring, as it is inserted into the spinous process or tuberosity of the os pubis, and partly by that process of bone itself.

The internal and superior pillar of the external abdominal ring may now be cut away from its insertion, and the aponeurosis of the external oblique muscle reflected downwards upon the thigh as before, so that the dissection of the lower portion

of the internal oblique and cremaster muscles may be proceeded with, as represented in Plate II.

EXPLANATION OF PLATE II.

This plate represents the second stage of the dissection of the inguinal region, in which the tendon of the external oblique muscle has been raised and reflected downwards upon the thigh, in order to display the lower part of the internal oblique muscle, with the fibres of the cremaster covering the front and sides of the spermatic cord and testicle.

- a.* The anterior superior spinous process of the ilium.
- b.* The situation of the spinous process, or tuberosity of the os pubis.
- c.* The curved line of Poupart's ligament, which is extended between these points of bone.
- d.* The lower part of the tendinous aponeurosis of the external oblique muscle, raised from its connexions and reflected upon the upper part of the thigh.
- e.* The fleshy portion of the external oblique muscle above the crista of the ilium.
- f.* A part of the tendinous aponeurosis of the external oblique muscle, where it covers the sheath of the rectus abdominis muscle.
- g.* The linea alba.
- h.* The situation of the linea semilunaris, where the fleshy fibres of the internal oblique muscle cease and become tendinous.
- i.* The superior and internal pillar of the external abdominal ring reflected upon the thigh.
- k. k.* The fleshy fibres of the internal oblique muscle as they arise from the anterior superior spinous process of the ilium and the iliac half of Poupart's ligament.
- l.* A part of the tendon of the internal oblique muscle, where it strengthens and supports the lower portion of the posterior wall of the inguinal canal, behind the external abdominal ring.
- m.* The tendon of the internal oblique muscle, where it forms the sheath of the rectus abdominis muscle.
- n.* The external head of the cremaster muscle, arising from the middle of Poupart's ligament.
- o.* The loops or inverted arches which the fibres of the cremaster muscle form in front of the cord and testicle.
- p.* The internal or pubic portion of the cremaster inserted into the lower part of the sheath of the rectus.
- r.* The posterior wall of the inguinal canal, where it is formed by the inner or pubic portion of the fascia transversalis.

- s. The skin and superficial fascia of the inguinal region reflected upon the upper part of the thigh. The external epigastric and pudic arteries are seen as they ramify in the deep lamella of the superficial fascia.
- t. The symphysis of the ossa pubis.
- u. The suspensory ligament of the penis.
- v. The corpus cavernosum penis of the left side.
- w. The corpus spongiosum penis.
- x. The umbilicus.

The internal oblique muscle.—This muscle is attached, superiorly, to the lower margin of the four inferior or false ribs; inferiorly, it is inserted into the anterior two-thirds of the crista ilii, and into the iliac two-thirds of Poupart's ligament; posteriorly, it is prolonged, by a tendinous aponeurosis (part of the fascia lumborum), to the spinous processes of the lumbar vertebræ; and anteriorly, it is inserted into the linea alba, the crista of the os pubis, and the inner part of the ilio-pectineal line. The direction of the superior fibres of the muscle is obliquely upwards and forwards; the central portion is directed transversely inwards to the mesial line; whilst the inferior set incline very obliquely downwards and inwards. At the linea semilunaris the tendon of the internal oblique muscle splits into two layers, one of which passes in front of, and the other behind the rectus muscle, reuniting at its internal edge, where it enters into the composition of the linea alba. In this manner is constituted the sheath of the rectus muscle. This division into two lamellæ of the tendon of the internal oblique muscle exists, however, only from the ensiform cartilage to about midway between the umbilicus and the symphysis pubis; below which point the whole of the tendon passes in front of the rectus, leaving that muscle only separated from the peritonæum by the fascia transversalis and subserous cellular tissue. The structure of the muscle is fleshy, except anteriorly and posteriorly, where it is aponeurotic and tendinous. Relations—superficially, with the external oblique muscle; by its internal surface, with the transversalis, rectus, and pyramidalis muscles; at its posterior part it is in relation with the latissimus dorsi and long muscles of the back. Its lowermost fibres contribute, in the greater number of instances, to the formation of the cremaster muscle.

The most inferior of the fleshy fasciculi of the internal

oblique muscle arise from the iliac two-thirds of Poupart's ligament; and, after arching over the spermatic cord as it lies in the upper part of the inguinal canal (see Plate II. fig. *k, l*), end in tendinous fibres opposite the lower part of the outer edge of the rectus muscle, in front of which they pass to reach the linea alba and crista of the os pubis, into which they are implanted. The tendinous aponeuroses of the muscles of each side are united with one another throughout the entire extent of the linea alba.

The portion of the internal oblique muscle which has its origin from the iliac portion of Poupart's ligament should, in the next place, be examined with particular care and attention. In this situation the fleshy fibres of the muscle pass obliquely downwards and inwards, almost parallel with Poupart's ligament, from which they spring; and opposite the outer border of the lower part of the rectus muscle end in a tendinous aponeurosis, which passes in front of it and the pyramidalis towards the linea alba, where it is joined with the tendon of the muscle of the opposite side. Some of the most inferior of the fibres pursue, however, a rather different course from those which are situated just above them; for they become very much curved as they pass over the spermatic cord in the upper part of the inguinal canal, and, becoming tendinous, descend behind the cord where it is contained in the lower part of the canal, and the external abdominal ring, to be finally inserted, along with similar fibres of the transversalis muscle, into that portion of the pectinated line of the os pubis which is situated behind the ligament of Gimbernat.

The cremaster muscle.—The principal fibres of the cremaster muscle spring from the middle portion of Poupart's ligament, between the internal oblique and transversalis muscles, and from this point nearly to the external abdominal ring. (See Plate II. fig. *n*.) Some of these fibres, thinner and paler than the rest, pass directly inwards in front of the upper part of the spermatic cord, and are implanted upon the tendinous aponeuroses of the internal oblique and transversalis muscles, forming the sheath of the rectus muscle (see Plate II. fig. *p*); but by far the greater number of the fibres of the cremaster descend along with the spermatic cord through the external abdominal ring, being at first closely aggregated together on the outer surface of the cord, soon

afterwards, however, separating from each other, and being spread out over the front and lateral aspects of it and the tunica vaginalis reflexa; after which, having ascended along the inner side of the cord, they terminate by being inserted into the crista of the os pubis and lower part of the sheath of the rectus muscle. (See Plate II. figs. *n*, *o*, and *p*.) In this manner the fibres of the cremaster muscle form a successive series of curves, the convexity of which is directed downwards towards the testis: the shortest of these curves consist of the superior fibres of the muscle, simply passing across the upper part of the spermatic cord as it lies beneath the external abdominal ring; whilst the inferior set are much longer, extending over the testis and lower part of the cord.

In this country the cremaster muscle is generally regarded as being derived from the internal oblique, since the disposition and appearance of many of its fibres greatly resemble those of the last-named muscle. The upper edge of the cremaster is, however, frequently separated from the inferior border of the internal oblique muscle by a considerable interval, which is occupied by common cellular tissue, in which sometimes a large mass of adipose substance is deposited. (*Vide* Plate II.)

In some cases, which are however very rare, the fibres of the cremaster are also found upon the posterior aspect of the spermatic cord; a disposition which, it would appear, depends upon the cord piercing the fibres of the internal oblique muscle, instead of merely emerging from beneath its lower edge.* This condition of these structures I have never seen.

M. Jules Cloquet, a distinguished anatomist and surgeon, has devoted considerable attention to the mode of formation of the cremaster muscle in the male subject, and has been led, in consequence of his researches, to the consideration that the cremaster does not exist in the foetus previously to the descent of the testicle into the scrotum; but that it is produced by the gubernaculum testis, and testis itself, contracting adhesions, as they descend through the inguinal canal into the scrotum, to the middle portion of the muscular fibres forming the lower edge of the internal oblique muscle; and that, by thus dragging these fibres along with them in their descent, (their origin and insertions remaining fixed,) a series of inverted loops or

* See *Recherches Anatomiques sur les Hernies*, p. 14—18.

arches are produced by the gradual displacement and elongation of their intermediate and more moveable portion.*

The cremaster muscle is supplied with blood by the cremasteric branch of the epigastric artery, and the principal division of the external spermatic nerve is distributed to its fibres.

In the female subject the cremaster muscle cannot generally be said to exist; yet, in some instances, the most inferior of the fibres of the internal oblique muscle are observed suddenly to become much paler than the rest, and also to be loosely scattered, as it were, over the round ligament of the uterus where it lies in the lower part of the inguinal canal.

When an oblique inguinal hernia is formed in the female subject, the front surface of the hernial sac derives a partial muscular investment from the lowermost fibres of the internal oblique, which are displaced and dragged downwards by the sac as the hernia is gradually protruded through the inguinal canal—very closely imitating, in fact, the mode of formation of the cremaster muscle by the descent of the testis in the male.†

Some individuals are possessed of a considerable voluntary power over the contractions of the cremaster muscle, and are enabled to retract the testes as high as the external abdominal ring, and in some instances even to withdraw them into the lower part of the inguinal canal. Persons endowed with the faculty of thus controlling at will the action of the cremaster muscles have been known to deceive medical officers appointed to examine the recruits of the army; pretending that they were affected with inguinal hernia, and, in consequence, unfitted for military service.‡

Dissection of the lower edge of the transversalis muscle.—

The lower portion of the internal oblique muscle may now be detached from its connexions to the crista of the ilium and Poupart's ligament, and reflected upwards on the sheath of the rectus, as is represented in Plate III. fig. *h*. This proceeding will be most easily effected if the fibres of the muscle be first divided opposite the anterior superior spinous process of the ilium, as in this situation the muscle is separated from the

* *Vide Recherches Anatomiques sur les Hernies de l'Abdomen; par Jules Cloquet: 4to. Paris, 1817, p. 15.*

† Cloquet, p. 21 (1).

‡ The Cyclopaedia of Pract. Medicine, vol. ii. p. 144, art. Feigned Diseases.

transversalis by some cellular tissue and branches of the internal circumflexa ilii artery. In this stage of the dissection it will be found very useful to render the fibres of the transversalis as tense as possible, by drawing the linea alba towards the opposite side, and removing, at the same time that the internal oblique is raised up, the layer of condensed cellular tissue which invests the outer surface of the muscle. When the separation of the internal oblique from the transversalis has been correctly made,—which in many subjects is by no means of easy execution, as these muscles are frequently blended with each other towards their inferior margin,—the fleshy fibres of the latter will, in general, be found to cease to arise from the iliac portion of the ligament of Poupart at the distance of about an inch and a half from the anterior superior spinous process of the ilium. In this situation the muscle terminates by a very clear and distinct edge, which is much curved in its outline, and is partly fleshy and partly tendinous in its structure. (See Plate III. figs. *m*, *n*, *r*.)

Since the fleshy fibres of the internal oblique muscle continue their attachment to Poupart's ligament for an inch, or an inch and a half, nearer to the spinous process of the os pubis than the point where the lower margin of the transversalis muscle is situated, it follows, as a necessary consequence, that the internal abdominal ring or upper aperture of the inguinal canal, by which the spermatic cord issues from the cavity of the abdomen in its oblique descent to the scrotum and testicle, is supported by it; which circumstance must frequently prove an additional source of prevention against the formation of an oblique or external inguinal hernia.

The *transversalis muscle* arises from the iliac half of Poupart's ligament, and from the inner margin of the crest of the ilium for three-fourths of its extent: it is inserted posteriorly, by a tendinous aponeurosis, which incloses the quadratus lumborum muscle between its laminæ, to the base and apex of the transverse processes of the lumbar vertebræ; anteriorly, the fleshy fibres end, at the outer edge of the rectus muscle, in a tendon, which, after passing conjointly with the posterior division of the aponeurosis of the internal oblique behind that muscle in the space included between the ensiform cartilage and a point situated about midway between the umbilicus and symphysis pubis,

is inserted into the linea alba; below this point, however, the tendon of the muscle passes altogether in front of the rectus muscle in its way to reach the lower part of the linea alba. Relations — externally, with the internal oblique muscle; internally, with the fascia transversalis, which is interposed between it and the peritonæum. Structure — muscular at the sides, and aponeurotic anteriorly and posteriorly.

In addition to the attachments of the transversalis muscle which have just been described, it should be particularly noticed that the lowermost fibres of the muscle, after arching over the internal abdominal ring and spermatic cord, are implanted into the crista of the os pubis, and for some distance into the sharp pectinated line of the horizontal branch of the same bone, behind the external abdominal ring and Gimbernat's ligament.

EXPLANATION OF PLATE III. FIG. 1.

The first figure of this plate represents the lower portion of the transversalis muscle and the posterior wall of the inguinal canal, as they appear when the cremaster muscle has been removed from the spermatic cord, and the internal oblique detached from its connexions with the spinous process and crista of the ilium. The spermatic cord is held slightly aside by the hook, in order that the structures which form the posterior wall of the inguinal canal may be more clearly seen.

- a.* Marks the situation of the anterior superior spinous process of the ilium.
- b.* The situation of the spinous process or tuberosity of the os pubis, into which the inferior pillar of the external abdominal ring (*c*) is inserted.
- c. c.* The ligament of Poupart, or lower edge of the tendinous aponeurosis of the external oblique muscle.
- d.* The internal surface of the tendinous aponeurosis of the external oblique muscle, which has been raised from its connexions, and reflected downwards upon the upper part of the thigh. The superior and internal pillar of the external abdominal ring is marked thus +.
- e.* Part of the fleshy fibres of the external oblique muscle, cut away from the rest and reflected with the aponeurosis.
- f.* The fleshy fibres of the external oblique muscle in their natural position, on the side of the belly.
- g. g.* The tendinous aponeurosis of the external oblique muscle, where it covers in the tendinous sheath of the rectus muscle.

- h.* The lowermost fibres of the internal oblique muscle, cut away from their origins from the iliac half of Poupart's ligament and the anterior superior spinous process and part of the crest of the ilium ; they have been reflected upwards upon the sheath of the rectus muscle, for the purpose of exposing the lower margin of the transversalis muscle, and also the internal abdominal ring and posterior wall of the inguinal canal.
- i.* A part of the internal oblique muscle, where it forms a portion of the lateral parietes of the abdomen.
- k.* The fibres of the lower portion of the internal oblique muscle, where they spring from the iliac portion of Poupart's ligament.
- l.* The lower part of the sheath of the rectus muscle, formed by the united tendons of the internal oblique and transversalis muscles.
- m.* The fleshy fibres of the transversalis muscle, which are not attached so far downwards to Poupart's ligament as the fibres of the internal oblique.
- n. n.* A part of the tendinous aponeurosis of the transversalis muscle.
- o.* A large branch of the internal circumflexa ilii artery, which runs in the cellular substance separating the fibres of the internal oblique and transversalis muscles.
- p.* The internal abdominal ring, or superior aperture of the inguinal canal, by which the spermatic cord issues from the cavity of the abdomen.

The letter is placed upon the fascia transversalis where it parts from the circumference of the ring to furnish the funnel-shaped sheath of the spermatic cord.

The boundaries of the internal abdominal ring are, superiorly, the lower fleshy and tendinous margin of the transversalis muscle ; internally, the epigastric artery ; and inferiorly, the ligament of Poupart.

- q.* The pubic portion of the fascia transversalis, where it forms the upper part of the posterior wall of the inguinal canal.
- r. s.* The conjoined tendons of the internal oblique and transversalis muscles, forming the lower part of the posterior wall of the inguinal canal, and which they greatly strengthen where it otherwise would be weakest, viz. behind the external abdominal ring.

The letter *r* is placed on the tendon of the transversalis, which extends a little farther outwards towards the epigastric artery than the tendon of the internal oblique muscle, which is marked by the letter *s*.

- t.* The spermatic cord, invested by the funnel-shaped sheath of the fascia transversalis. The cord is held aside by a hook at the point where it emerges from the internal abdominal ring, for the purpose of more clearly exposing to view the structures which form the posterior wall of the inguinal canal.
- u.* The testicle of the left side, withdrawn from the lower part of the scrotum.
- v.* The corpus cavernosum penis on the left side.
- w.* The corpus spongiosum penis.
- x.* The umbilicus.
- y.* The linea alba.
- z.* The skin and superficial fascia of the inguinal region, reflected downwards upon the upper part of the thigh.
- 1. The trunk of the epigastric artery, where it runs along the inner margin of the internal abdominal ring. The fascia transversalis has been cut open in the direction of the course of the vessel so as to expose it fully to view. Towards the umbilicus the artery is obscurely seen, as it lies underneath the tendon of the transversalis muscle.
- 2. The external pudic artery.
- 3 and 4. Branches of the external epigastric artery.

The posterior wall of the inguinal canal is formed by the fascia transversalis (*q*), and the conjoined tendons of the transversalis (*r*) and internal oblique (*s*) muscles: behind the first of these structures runs the epigastric artery (1), and more posteriorly are found the subserous cellular tissue and the peritonæum, with the ligamentous remains of the umbilical artery.

For the explanation of Fig. 2, the reader is referred to that part of this work which treats of the anatomy of the testicle.

The conjoined tendons of the internal oblique and transversalis muscles.—When the inferior fleshy fibres of the internal oblique muscle have been raised and reflected inwards towards the mesial line, as is represented in Plate III, they will be found to terminate, in front of the outer portion of the rectus muscle, in a thin but strong aponeurosis which soon becomes intimately blended with the tendon of the transversalis; a connexion which is so close, that it is absolutely impossible to separate them satisfactorily from one another with the knife. On this account it is usual to describe them together, under the name of the conjoined tendons of the internal oblique and transversalis muscles.

The *conjoined tendons* are partly situated in front of the pyramidalis and lower portion of the rectus muscle, being in-

serted into the linea alba and crista of the os pubis. But, in addition to these attachments, the most inferior fibres of the conjoined tendons are reflected, somewhat in a spiral manner, downwards and outwards, to be inserted, behind the ligament of Gimbernat, into the inner part of the ilio-pectineal line of the os pubis, passing behind the spermatic cord as it lies in the lower part of the inguinal canal. (See Plate III. figs. *r*, *s*.) It is in this manner that the conjoined tendinous fibres of the internal oblique and transversalis muscles close up a considerable portion of the space which is included between the epigastric artery and the outer edge of the rectus muscle; thus constituting a principal part of the posterior wall of the inguinal canal. (See Plate III. fig. *r*, *s*.)

The mode in which the conjoined tendons of the internal oblique and transversalis muscles form the lower part of the posterior wall of the inguinal canal may be very clearly demonstrated in the following manner: — Let the tendinous aponeurosis of the external oblique muscle be reflected, together with the spermatic cord, upon the upper part of the thigh, so that the entire of the triangular space which is included between the epigastric artery and the lower portion of the rectus muscle shall lie fairly exposed to view. (See Plate III.) The index finger of the left hand may now be placed upon this space a little above and parallel with Poupart's ligament, whilst with the other hand traction is made alternately upon the lower fleshy fibres of the internal oblique and transversalis muscles, which, for this purpose, should be separately detached from their respective connexions to the crista of the ilium and ligament of Poupart. When these instructions are observed, the finger which rests upon the posterior wall of the inguinal canal will be elevated, at every movement of the muscular fibres held in the right hand, by the tension of tendinous fibres belonging to each. It will be perceived, at the same time, that the tendinous fibres belonging to the transversalis muscle are more curved in their direction, and extend further outwards from the border of the rectus, than those appertaining to the internal oblique muscle. (See Plate III. fig. *r*.) By a tedious dissection we may, in some subjects, succeed in separating the tendinous fibres which are proper to each muscle from one another, and both of these from the fascia transversalis, which lies behind them: in many instances, however,

this is rendered impracticable, from the intricate manner in which the whole of these structures are interwoven with each other.

In some subjects the conjoined tendons of the internal oblique and transversalis muscles are by no means so clearly developed or so extensive as they have been described in the preceding pages; and in some instances, indeed, they would appear to be altogether absent from that portion of the posterior wall of the inguinal canal which they ordinarily strengthen and support. Under such circumstances, however, the fascia transversalis is generally much stronger in its texture than usual.

The conjoined tendons, being situated behind the external abdominal ring, form the principal obstacle to the direct protrusion of the viscera of the abdomen through this portion of the posterior wall of the inguinal canal; or, in other words, tend greatly to prevent the frequent formation of a direct or internal inguinal hernia.

The *internal abdominal ring*.*— The circumscribed space underneath the lower margin of the transversalis muscle (see Plate III. fig. *p*) has been named by Sir Astley Cooper the *internal abdominal ring*, to distinguish it from the opening in the tendinous aponeurosis of the external oblique muscle, which has already been described as the external abdominal ring, or lower opening of the inguinal canal. In the healthy condition of the parts, no aperture with clearly defined margins, such as the name which has been given to it might lead us to expect, will be found to exist in the situation of the internal abdominal ring; since the term by which it is customarily denominated has been applied to it, not so much from a consideration of the natural figure of the part, as on account of the form which it presents when a hernial protrusion has taken place through it. (See the wood engraving No. 4, fig. *o*.) The internal abdominal ring is situated in the fibrous membrane which lines the inner surface of the transversalis muscle, and named by Sir Astley Cooper the fascia transversalis.

The exact position of the internal abdominal ring is midway between the symphysis pubis and the anterior superior spinous

* Also called the *annulus inguinalis posterior* (Hesselbach); *upper inguinal* or *abdominal aperture* (Monro); *inner opening* or *end of the inguinal canal* (Langenbeck and Scarpa); *l'ouverture supérieure et externe du canal inguinal* (J. Cloquet); *l'orifice postérieur du canal inguinal* (Velpeau).

process of the ilium, being there placed about a finger's breadth above the ligament of Poupart. Its distance from the external abdominal ring is not always the same in different subjects; as it varies between an inch and a half to two inches in extent, according to the length of the inguinal canal, and the magnitude of its openings. (See the woodcut No. 3, fig. o.)

At the internal abdominal ring the fascia transversalis is not covered by the fibres of the transversalis muscle, as it is here that the spermatic cord in the male subject, and the round ligament of the uterus in the female, commence their oblique descent through the parietes of the inguinal region; receiving, as they emerge, a funnel-shaped investment from the fascia. (See the wood engraving No. 2, at p. 243, figs. i, k.)

The internal abdominal ring is bounded superiorly by the fleshy and tendinous margin of the transversalis muscle; inferiorly, by the grooved surface of Poupart's ligament; and internally, by the epigastric artery and its accompanying veins. (See Plate III. fig. p.)

As the epigastric artery, in this part of its course, runs along underneath the fascia transversalis, the dissector must either uncover it by an incision with the point of his scalpel, — as was done in the dissection from which the drawing was taken — or, — what is more advisable, — he may satisfy himself of its position and course by lightly pressing his fore-finger upon the inner edge of the ring, when, if the vessel has been injected, it will be clearly distinguished as it rolls underneath the tip of the finger.

It is through the internal abdominal ring that oblique or external inguinal herniæ, in all their various forms, commence to be protruded; and it is from the relation which the several structures here situated bear to the neck of the sac, and consequently to the surgical treatment of these diseases, that so much care and attention are demanded from the student in his dissections of this region. (See the woodcut No. 3, at p. 246, fig. o.)

The *fascia transversalis*. — The cellulo-fibrous membrane which lines the internal surface of the abdominal parietes has been thus named in that portion of its extent where it covers the interior of the transversalis muscle. This membrane has received different names in separate parts of its extent; thus, for example, it is called the *fascia iliaca*, where it covers the psoas and iliacus muscles, and the *fascia pelvica* where it

descends into the cavity of the pelvis, upon the inner surface of the levator ani muscles to reach the sides of the bladder and rectum and base of the prostate gland.*

A small portion of the fascia transversalis is now exposed to view (See Plate III. fig. *p*) between the lower margin of the transversalis muscle and Poupart's ligament, which will be observed, on a closer inspection, to furnish a funnel-shaped sheath or investment to the spermatic cord and round ligament of the uterus as they are passing through the internal abdominal ring. (See the woodcut No. 2, p. 243, fig. *i, k*.)

The testis and spermatic cord receive, as they descend from the abdomen into the scrotum, a complete covering from the fascia transversalis; and, although it may not always be possible for the dissector to exhibit this prolongation of the membrane upon the lower part of the cord as a distinct fascia, in consequence of its degeneration into a loose cellular tissue, it can, nevertheless, be always distinctly seen to invest the upper part of the cord and the round ligament of the uterus while they are as yet within the inguinal canal. The sheath which is thus furnished by the fascia transversalis to the spermatic cord, is rather wider and more loose above, where it parts from the circumference of the internal abdominal ring, than lower down, where it gradually contracts to the dimensions of the structures which it invests. From this arrangement, the tubular sheath which the spermatic cord and testis receive from the fascia transversalis, has been denominated the *infundibuliform*, or *funnel-shaped process* of the membrane.

Underneath the funnel-shaped process of the fascia transversalis, and in more immediate contact with the vessels which enter into the composition of the spermatic cord, is placed a similarly shaped process from the subserous cellular tissue of the abdominal parietes, but which is much more loose in its texture, and generally contains more of adipose substance than it.

These structures, comprised under one term, constitute what has been called the *fascia propria* of oblique inguinal herniæ.

It is sometimes recommended to carry the scalpel lightly round the spermatic cord as it is held upon the stretch by drawing downwards the testis, and in this manner to divide, close to the inferior border of the transversalis muscle, the funnel-

* *Vide* The Surgical Anatomy of the Perinæum, p. 29—30.

shaped sheath which it derives from the fascia transversalis, and thus to define what have been termed the margins of the internal abdominal ring. When this has been done, the circular form of the superior aperture of the inguinal canal becomes, on relaxing the traction upon the spermatic cord, more distinctly apparent.

There is, however, another plan of proceeding which is much more preferable, in several respects, than that which has just been mentioned, which consists in making a small cut in the fascia transversalis opposite the anterior superior spinous process of the ilium, — the lowermost fleshy fibres of the transversalis muscle having previously been detached from their attachments to Poupart's ligament and the crista of the ilium, and reflected inwards, as has been already directed to be done with the corresponding portion of the internal oblique muscle, — and then, gently to insinuate the handle of the scalpel between the membrane and the subserous cellular tissue. In this manner the handle of the scalpel may be passed downwards for a considerable distance upon the front of the spermatic cord.

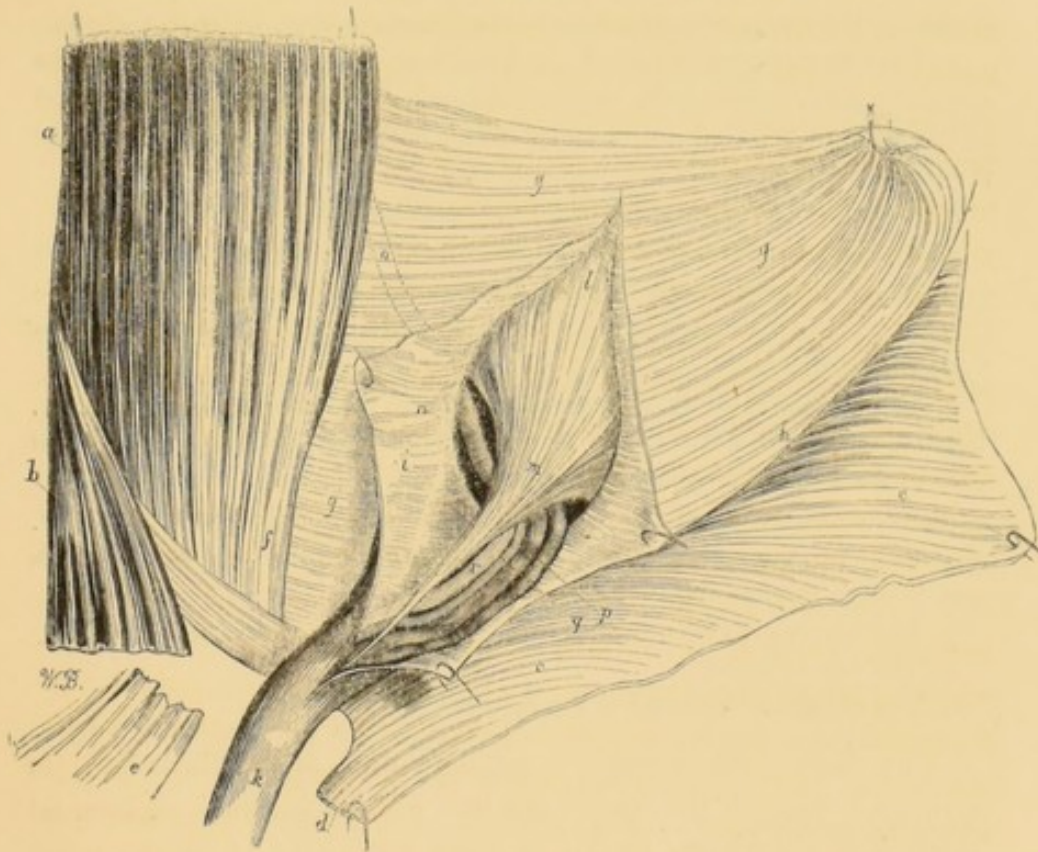
At the first view the fascia transversalis appears of a yellow tint; but this depends only upon its translucent nature, which permits the proper colour of the subserous cellular tissue, a structure which is always more or less loaded with adipose substance, to be seen through it.

The fibres of which the fascia transversalis is composed are arranged, for the most part, in an oblique direction, downwards and outwards from the edge of the rectus muscle; but these are, however, crossed in various directions by numerous others, which give to the membrane a reticular appearance. Not unfrequently the fascia transversalis consists of two laminæ, which are united with each other opposite the posterior edge of the ligament of Poupart. The anterior of these laminæ arises from the ligament itself, while the posterior is but the continuation of the fascia iliaca, which quits the iliacus internus muscle to be reflected upon the lateral and anterior parietes of the abdomen. On the outer side of the internal abdominal ring it is not difficult to separate these laminæ from one another, but, around the margins of that opening, and between it and the edge of the rectus muscle, they are so closely blended together that it is almost impossible to disunite them. When this division of the

fascia transversalis exists, the posterior lamina will be found to extend, behind the rectus muscle, to the linea alba, whilst the anterior is implanted into the outer edge of the same muscle. The epigastric artery sometimes runs behind, and sometimes in front of these laminæ, but not unfrequently it is found betwixt them.

The sheath which is furnished from the fascia transversalis to the spermatic cord in the male, and round ligament of the uterus in the female, is rather wider and looser above where it parts from the margin of the internal abdominal ring, than lower down, where it gradually contracts to the dimensions of the structures which it serves to enclose. (See the following woodcut, fig. *i, k.*)

No. 2.



The wood-cut represents the funnel-shaped sheath of the fascia transversalis laid open upon its front aspect, so as to show the manner in which it encloses the structures which constitute by their union the spermatic cord.

a. The rectus abdominis muscle of the left side dissected.

b. The pyramidalis muscle.

c. c. The tendinous aponeurosis of the external oblique muscle, dissected from its attachments, and reflected downwards upon the upper part of the thigh.

d. The internal and superior pillar of the external abdominal ring, cut from its connections with the body of the os pubis, and reflected downwards with the rest of the aponeurosis of the external oblique muscle, of which it forms a part.

e. The corresponding portion of the internal and superior pillar of the external abdominal ring, occupying its natural position in front of the body of the os pubis.

f. The outer border of the tendon of the rectus muscle, where it is continuous with the inner or pubic portion of the fascia transversalis (*g*).

g, g, g. The fascia transversalis where it lines the inguinal region.

h. The fascia transversalis blended with the posterior edge of Poupart's ligament, so as to form with it the floor of the inguinal canal. The fibres of the internal oblique and transversalis muscles have been dissected from their attachments to the iliac portion of the crural arch and wholly removed.

i. The funnel-shaped sheath of the fascia transversalis, laid open in front to display the component structures of the spermatic cord, which it encloses.

k. The funnel-shaped sheath of the fascia transversalis, where it invests the spermatic cord, between the external abdominal ring and the testis; behind this portion of the cord are observed some oblique fibres, which constitute the triangular ligament of the inguinal canal.

l. A portion of the great sac of the peritonæum.

m. A tubular process of the peritonæum, which is frequently to be found as a fibro-cellular band in front of the rest of the structures composing the spermatic cord; it consists of the obliterated portion of the original processus vaginalis peritonæi.

n. The epigastric artery, as it passes deeply in the subserous cellular tissue, betwixt the fascia transversalis and the peritonæum, and along the pubal side of the internal abdominal ring.

o. Dotted lines, which serve to indicate the course of the epigastric artery, as it ascends in an oblique direction behind the fascia transversalis in its way towards the umbilicus.

p. The spermatic veins.

q. The spermatic artery.

r. The vas deferens.

s. The triangular ligament of the inguinal canal.

The fascia transversalis is stronger and more fibrous in its structure around the circumference of the internal abdominal ring than elsewhere, and it is more especially so on the inner edge of that opening, between it and the epigastric vessels: in this situation, indeed, the fascia transversalis frequently presents the appearance of terminating by a well-defined edge, over which the spermatic cord turns, to descend from the interior of the belly into the inguinal canal. This sharp margin only exists, however, in consequence of the angular reflexion of this portion of the fascia transversalis, as it doubles upon itself in order to contri-

bute towards the formation of the funnel-shaped sheath of the cord. When the membrane is extended upon the handle of the scalpel, this angular appearance of it is effaced, and the whole is thus shown to constitute one continuous and uniform surface.*

It is principally owing to the presence of the fascia transversalis at the superior aperture of the inguinal canal, supported as it is there by the lower fleshy fibres of the internal oblique muscle, that the oblique form of inguinal hernia is not of more frequent occurrence; for, as we have already seen, neither the spermatic cord, nor the round ligament of the uterus, completely fill up the space included within the circumference of the internal abdominal ring.

In persons of an originally weak and sickly habit of body, and even in individuals of a contrary disposition, but in whom the muscular system has been temporarily enfeebled by acute and wasting diseases, such as fevers, &c. it will be frequently observed, on making an examination of the inguinal regions, that the abdominal parietes yield in a very perceptible manner, and become prominent opposite the situation of the internal abdominal ring, whenever they cough violently, or make any other similar exertion tending to excite a forcible contraction of the muscles bounding the abdominal cavity; and if, under these circumstances, the hand should be applied against this region, the impulse which is communicated to the viscera within will be very sensibly distinguished. In this manner inguinal herniæ may be frequently detected in the earliest stages of their formation, long before the patient is himself aware of the existence of the disease.

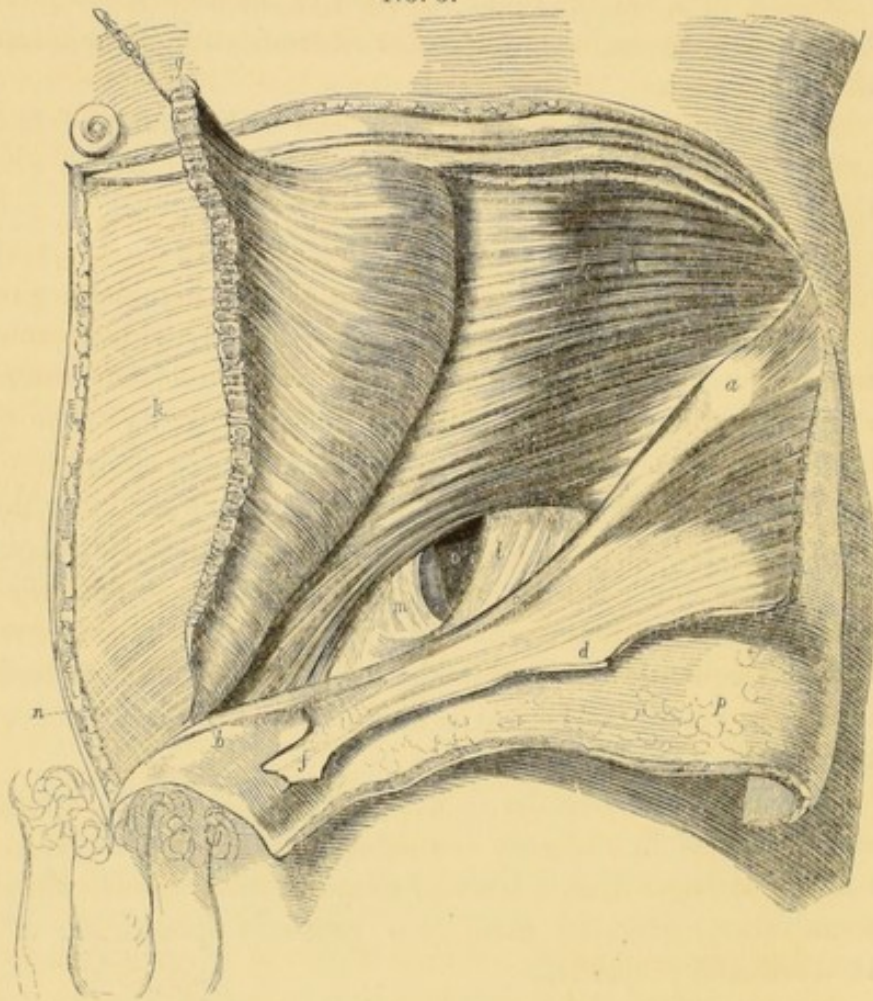
The fascia transversalis is not always of the same strength and thickness in different individuals; in some persons it is scarcely stronger than a layer of simple cellular tissue, while in some others, generally men, it is perfectly aponeurotic in its structure and properties.

Around the circumference of the internal abdominal ring, the

* As the fascia transversalis is very thin and delicate in its structure opposite the internal abdominal ring, it is not always acknowledged that the spermatic cord receives an investing sheath from it, as the latter passes through the opening: on the contrary, the spermatic cord has been described as emerging from the cavity of the abdomen betwixt two portions of the fascia, the free margins of which are described as the external and internal pillars of the internal abdominal ring.—See *Lawrence on Ruptures*, 5th edit, p. 189.

fascia transversalis adheres very closely to the inferior margin of the transversalis muscle, and is so intimately blended with the posterior surface of its tendon, that it is with much difficulty they can be separated from each other with the scalpel. The fascia transversalis is connected to the outer margin of the rectus muscle, and is regarded by some anatomists as ceasing here ; but, with a little care, it may be traced behind it as far as the linea alba, where it is continuous with the membrane of the opposite side.

No. 3.



The wood-engraving represents the posterior wall of the inguinal canal. The superficial fascia and the aponeurosis of the external oblique muscle have been reflected downwards upon the upper part of the thigh ; the lower portion of the internal oblique muscle has also been detached from its connections to the ligament of Poupart, and thrown upon the sheath of the rectus abdominis muscle. The spermatic cord and funnel-shaped sheath of the fascia transversalis have also been removed from the inguinal canal.

a. The anterior superior spinous process of the ilium. *b.* The insertion of Poupart's ligament, or inferior pillar of the external abdominal ring, into the spinous process or tuberosity of the os pubis. *c.* The ligament of Poupart, stretched between the spinous process of the os pubis and the anterior superior spinous process of the ilium. *d.* The tendinous aponeurosis of the external oblique muscle, dissected up from its connections, and thrown down upon the upper part of the thigh. *e.* A portion of the fleshy fibres of the same muscle, detached from the rest. *f.* The superior or internal pillar of the external abdominal ring reflected with the rest of the aponeurosis. *g.* The lower portion of the internal oblique muscle, cut away from its connections to Poupart's ligament and the crista of the ilium, and thrown upwards upon the sheath of the rectus muscle. *h.* The fleshy fibres of the transversalis muscle, in their natural situation. *i.* The tendon of the same muscle, as it is about to become blended with the tendon of the internal oblique muscle, and so form part of the conjoined tendons, where they constitute a portion of the posterior wall of the inguinal canal, strengthening it behind the external abdominal ring. *k.* The sheath of the rectus abdominis muscle, formed by the tendons of the internal oblique and transversalis muscles. *l.* The outer or iliac portion of the fascia transversalis, forming what has been termed the external pillar of the internal abdominal ring. *m.* The inner or pubic portion of the same membrane, the outer edge of which constitutes the internal pillar of the ring; it contributes also to the formation of the posterior wall of the inguinal canal. *n.* The triangular ligament, or diagonal brace of the inguinal canal, formed by some of the fibres of the tendon of the external oblique muscle of the opposite side. *o.* The internal abdominal ring, or superior aperture of the inguinal canal. The epigastric artery is seen as it runs deeply along the internal or pubic margin of the ring. It is by the dilatation of this opening that the various forms of external or oblique inguinal herniæ commence their descent from the abdomen. *p.* The skin and superficial fascia dissected, and thrown down upon the upper part of the thigh.

The posterior wall of the inguinal canal is formed, in its upper part, by the peritonæum, the subserous cellular tissue, and the fascia transversalis; and, in the lower part of its extent, by these structures additionally strengthened and supported by the conjoined tendons of the internal oblique and transversalis muscles, and the triangular ligament of the inguinal canal.

The inguinal canal. — This name has been given to the oblique passage through the iliac region of the abdominal parietes, by which the spermatic cord in the male, and the round ligament of the uterus in the female, descend from the interior of the belly to reach the structures with which they are connected externally.

The length of the inguinal canal varies between one inch and a-half to two inches in extent; being usually a little longer

and narrower in women than in men. The greater width of the inguinal canal in the male subject,—joined with the larger size of its apertures, the internal and external abdominal rings,—are circumstances fully adequate to account for the more frequent occurrence of inguinal herniæ in the male sex.

The direction of the inguinal canal is very oblique, passing downwards, inwards, and forwards; a disposition which, as it fortunately permits of the opposite walls of the passage becoming more closely approximated together under the ordinary pressure of the visceral contents of the abdomen, must tend greatly to prevent the formation of oblique inguinal herniæ during every unusual muscular exertion.

The inlet, or superior orifice of the inguinal canal, is the internal abdominal ring, the situation of which, opposite the centre of the space between the anterior superior spinous process of the ilium and the spinous process of the os pubis, and just above the ligament of Poupart, has been already described (see the woodcut No. 3, at page 246, fig. o). The external abdominal ring, placed immediately above the spinous process of the os pubis, constitutes the inferior aperture or outlet of the canal. (See the wood-engraving No. 1, at page 220, fig. i.)

The anterior wall of the inguinal canal is formed by the tendinous aponeurosis of the external oblique muscle, which is strengthened by the fibres of the intercolumnar fascia, and is covered by the skin and superficial fascia. (See Plate I. figs. b, d, and r.) The posterior wall—or that which is next the cavity of the abdomen—is formed, in the upper third of its extent, by the fascia transversalis, the subserous cellular tissue, and the peritonæum; but, in the lower or pubal two-thirds, by these several structures greatly fortified by the fibres of the conjoined tendons of the internal oblique and transversalis muscles, and the triangular ligament, as they descend towards their insertions into the inner part of the ilio-pectineal line of the os pubis, behind the ligament of Gimbernat. (See Plate III. fig. q, r, and s.)

The triangular ligament of the inguinal canal.—When the inner and superior pillar of the external abdominal ring is raised and reflected, as in Plates II and III. a thin layer of oblique tendinous fibres may be observed to fill up the angular space which is included between the outer edge of the tendon of the rectus

muscle and the pubal extremity of Poupart's ligament. These fibres belong to the aponeurosis of the external oblique muscle of the opposite side; and, after decussating with the corresponding fibres of the opposite muscle, are inserted into the crista and spinous process of the os pubis, and, also, into the inner third of the ilio-pectineal line of the same bone, behind the ligament of Gimbernat. By some anatomists this triangular fascia has been supposed to exert a considerable influence in preventing the formation of a direct inguinal hernia; but after a close inspection of its situation and extent, this opinion, I believe, can hardly be maintained.* These fibres are sometimes so very thin and indistinct, that it is with great difficulty that their existence can be demonstrated.

The inferior wall, or flooring of the inguinal canal, is constituted by the grooved surface which results from the union of the posterior border of Poupart's ligament with the fascia transversalis.

The inguinal canal contains, besides the lower edge of the obliquus internus in the male subject, the spermatic cord and upper portion of the cremaster muscle; and, in the female, the round ligament of the uterus.

The subserous cellular tissue.—Betwixt the inner surface of the fascia transversalis and the peritonæum exists a layer of loose cellular substance, which is frequently of considerable thickness, especially in corpulent persons, in whom it is so much loaded with adipose matter as to resemble, in a remarkable degree, the omentum, for which it has been not unfrequently mistaken during operations for strangulated inguinal and femoral herniæ.† Opposite the posterior wall of the inguinal canal, the subserous cellular tissue is frequently found to be nearly half an inch in thickness.

In cases of phlebitis originating in the veins of the lower ex-

* Dr. Quain considers that these fibres not only tend to support the conjoined tendons of the internal oblique and transversalis muscles, upon which they are laid; but that they also serve to connect the lower part of the linea alba and Poupart's ligament, on the principle of a diagonal brace, and by means of their elasticity tend to weaken the force of any pressure made upon the part, by diffusing it over a greater extent of surface. — *Elements of Anatomy*, 4th edit. p. 467.

† On this subject, see Sir Astley Cooper on Hernia, 2d edit. Part I, note at bottom of p. 14; and also Part II. p. 11 and 12. Also Scarpa on Hernia, translated by Wishart, 8vo. p. 269.

tremity and of the cavity of the pelvis, the subserous cellular tissue, lining the iliac fossa, is sometimes affected with diffuse inflammation, ending in extensive suppuration.

Previous to their entrance into the inguinal canal, the spermatic cord and round ligament of the uterus receive each an investment from the subserous cellular tissue, which accompanies them as far as their opposite extremities.

It is into the sheath which the subserous cellular tissue furnishes to the spermatic cord, that the sac of an oblique inguinal hernia descends, and it is to the great laxity and distensibility of this membrane that the disgregation of the component structures of the spermatic cord—so commonly observed in cases of large scrotal herniæ of long standing—is mainly attributable. Steatomatous tumours, which are liable to be mistaken for examples of incomplete inguinal herniæ, are occasionally developed in that part of this structure which serves to invest the spermatic cord. Considerable collections of serous fluid are sometimes met with, which are either contained in one cavity or cyst, as in some forms of the encysted hydrocele of the cord, or diffused throughout the whole extent of the membrane, as in that form of the disease (of rare occurrence) which has been denominated by Mr. Pott hydrocele of the cells of the tunica communis.*

The spermatic cord.—The spermatic artery and accompanying veins descend from the lumbar region, where they are placed in front of the psoas and iliacus muscles, to reach the internal abdominal ring, or superior opening of the inguinal canal (see Plate IV. figs. 5 and 6). At this point they join at an acute angle with the vas deferens, which here dips down into the cavity of the pelvis in its way from the testicle to reach the side and base of the bladder, to which it is closely applied, as it runs along to its termination in the prostatic portion of the urethra, where it opens upon the anterior and lateral surface of the veru-montanum. (See the Surgical Anatomy of the Perinæum, Plate IV. fig. p, and page 34.) In the inguinal canal, and between the external abdominal ring and the testicle, the

* For an excellent and interesting account of the various forms of Hydrocele, the student is referred to Mr. Pott's Treatise on that disease.

Mr. Pott operated upon one case of diffused hydrocele of the spermatic cord, and drew off eleven pints of water.—See *Pott's Works*, 2d edit. vol. ii. p. 270.

vas deferens is situated to the inner and posterior side of the rest of the vessels composing the spermatic cord.

The *spermatic arteries* spring from the sides of the aorta, at a little distance below the origin of the renal arteries. The artery of the left side passes in front of the vena cava, and both pass obliquely in front of the ureters, lying betwixt them and the peritonæum. In their course from their origin to the superior aperture of the inguinal canal, the spermatic arteries furnish several delicate branches to the cellular tissue, investing the ureters and outer surface of the peritonæum. For the manner of their distribution to the glandular structure of the testicle, the reader is referred to the description of the anatomy of that organ, as given in a future part of this work. In the female the spermatic arteries are distributed to the ovaries and fallopian tubes.

The *spermatic vein*, on the right side, ordinarily opens into the vena cava, a little below the junction of the renal vein with that vessel: on the left side, the spermatic vein usually empties its contents into the great trunk of the renal vein of the same side. The vascular plexuses which are formed upon the lower part of the spermatic cord, by the subdivision of these veins into several branches, which freely communicate with one another by frequent anastomoses, have been named by anatomists the *corpus pampiniforme*. These veins are, particularly on the left side, frequently greatly dilated and varicose; a condition which constitutes the complaint well-known under the denomination of varicocele or cirsocele.

The *lymphatics* of the testicle and spermatic cord are very numerous, and form, by their junction with each other, several trunks of considerable size, which ascend upon the spermatic veins, and terminate in the absorbent glands, which lie on each side of the aorta, in front of the lumbar vertebræ.

The disposition of the absorbent vessels of the testicle, renders necessary the precaution of previously examining with great care into the state of the lymphatic glands of the iliac and lumbar regions, before deciding upon the extirpation of the organ when affected by malignant and cancerous diseases, as, for example, fungus hæmatodes and schirrus.

The *nerves* which are situated among the structures composing the spermatic cord, are very numerous, consisting,—besides

the musculo-cutaneous and genito-crural branches of the lumbar plexus,—of numerous filaments from the mesenteric, renal and hypogastric plexuses of the grand sympathetic, and are sufficient to explain the sympathies which are well-known to exist under many circumstances between the stomach and testicle; as in orchitis, blows upon the testicle, &c.

At its entrance into the inguinal canal, the spermatic cord forms an acute angle with those portions of it which are situated within the cavity of the abdomen, and, after bending over the epigastric artery, follows the oblique direction downwards and forwards of the canal, passing successively underneath the lower margins of the obliquus internus and transversalis muscles. In the lower part of the inguinal canal the spermatic cord is covered anteriorly and upon the sides by the cremaster muscle, and then — continuing its descent towards the testicle — after emerging through the external abdominal ring, it again changes its direction, by making a second curve, the concavity of which is turned towards the outer pillar of the ring and spinous process of the os pubis.

The vessels and nerves which compose the spermatic cord, are enclosed, as has been already described, in sheaths derived from the subserous cellular tissue and the fascia transversalis; they are partially covered also by the cremaster muscle, and again completely by the external spermatic fascia, which is derived from the margins of the external abdominal ring.

Where the vessels of the spermatic cord enter the superior aperture of the inguinal canal, the peritonæum always presents a well-marked depression on its inner surface, the depth of which varies, however, in different subjects. This fossula, or depression of the peritonæum, is frequently prolonged externally, in front of the cord, under the form of a shallow funnel-like tube, which soon terminates in a delicate white fibro-cellular cord, that may be traced downwards until it expands into the tunica vaginalis of the testicle. (See the wood-engraving No. 2, at p. 243, fig. *m*.) This fibro-cellular band consists of the ligamentous remains of the processus vaginalis peritonæi, which is generally obliterated at, or soon after, the period of birth.

The epigastric artery.—This vessel usually arises from the inner side of the external iliac artery, about three or four lines above the inner margin of the crural arch. The epigastric artery

inclines at first a little downwards and inwards, so as to get under cover of the posterior surface of Poupart's ligament, after which it suddenly changes the direction of its course, and mounts obliquely upwards towards the umbilicus, passing, at the same time, underneath the commencement of the spermatic cord and along the inferior and inner margin of the internal abdominal ring. In the first part of its course the artery lies embedded in the subserous cellular tissue, between the fascia transversalis and the peritonæum; but about midway between the umbilicus and the symphysis pubis, it pierces the tendinous sheath of the rectus muscle (to which it is finally distributed), frequently anastomosing in the remainder of its passage with the terminal branches of the internal mammary, lumbar, and superficial epigastric arteries. (See Plate IV. fig. 3.)

The epigastric vein follows the same course as the artery, upon the inner side of which it runs. Occasionally two veins accompany the epigastric artery. (See Plate V. fig. 1, 2.)

Near its origin the epigastric artery furnishes three branches, of which the largest turns into the inguinal canal along with the spermatic cord, and, being distributed to the cremaster muscle, has been named the *cremasteric artery*; its branches anastomose with those of the spermatic and external pudic arteries. The second branch is much smaller than the preceding, and runs along the posterior surface of Poupart's ligament, to reach the symphysis pubis, behind which it inosculates with the corresponding vessel of the opposite side. The third branch descends behind the horizontal branch of the os pubis, and joins with some of the branches of the obturatrix artery. As it ascends towards the umbilicus, the epigastric artery gives off, on each side of its course, several other small branches, which are distributed to the inner surface of the transversalis and rectus muscles.

Varieties.—The epigastric artery sometimes arises high up from the external iliac, in some instances at least an inch and a half distant from the crural arch. It sometimes arises from the internal circumflex of the thigh, as well as from the femoral artery below the crural arch; it has also been found arising from the profunda femoris. Hesselbach states having seen it deriving its origin from the obturatrix artery; and in that instance it ran along the inner edge of the neck of the sac of an

internal inguinal hernia.* The epigastric artery frequently gives off the obturatrix artery, the relations borne by which, under various circumstances, to the neck of the sac of a femoral hernia have been already fully noticed in a former part of this work.†

It is important to bear in mind that the epigastric artery lies along the inner or pubic edge of the internal abdominal ring; for, as will be afterwards described, the two principal varieties of inguinal hernia that are of most frequent occurrence commence, either upon the outer, or the inner side of this vessel; circumstances which require that a certain direction should be given to the edge of the knife, while removing the stricture at the neck of the sac in the operation for strangulated inguinal herniæ, otherwise the artery may be wounded, and so give rise to a very troublesome and even fatal hemorrhage.‡

The great laxity of the subserous cellular tissue which connects the epigastric artery, in the first part of its course, to the adjacent structures, renders it very easy to alter the position of the vessel by any considerable pressure exerted on either side; and thus it is that we so frequently find the artery displaced inwards as far as the outer edge of the rectus muscle, in cases of large and long standing external inguinal herniæ.

The epigastric artery and its branches have been frequently wounded in the old operation of tapping for ascites, in which it was the custom to enter the trocar at a point midway between the umbilicus and the anterior superior spinous process of the ilium.§

The epigastric artery may also be wounded in the operation of placing a ligature upon the external iliac artery, if the internal extremity of the incision, which is requisite for exposing

* Dictionary of Practical Surgery, by S. Cooper, 7th edit. p. 718.

† *Vide* Surgical Anatomy of the Groin, &c. p. 114; and the wood engraving, No. 6. at p. 115; also, Plate V. fig. 4, 5, 6.

‡ For cases where this accident occurred, see Sir Astley Cooper on Hernia, 2d edit. p. 54, and Mr. Cooper's Dictionary of Surgery, 7th edit. p. 741; also the works of Scarpa, Bertrandi, Lawrence, &c.

§ *Vide* Medical Communications, vol. ii. p. 482; a Paper by Dr. Carmichael Smith; also, Mr. Cooper's Dictionary of Practical Surgery, 7th edit. p. 1081.

that vessel, should be prolonged too much inwards, towards the edge of the rectus muscle.*

The *internal circumflexa ilii* takes its origin from the outer side of the external iliac artery, at first lying in the subserous cellular tissue (see Plate IV. fig. 4): it soon, however, pierces the fascia iliaca; and taking the same direction as Poupart's ligament, runs along its posterior aspect as far as the anterior superior spinous process of the ilium, near which point it traverses the fibres of the transversalis muscle, and so gets between it and the internal oblique. Its branches are distributed to the muscles which form the lateral parietes of the abdomen, and anastomose with the branches of the lumbar and epigastric arteries.

The epigastric and internal circumflexa ilii arteries are of considerable importance in carrying on the collateral circulation, after the ligature of the common femoral and external iliac arteries.†

* *Vide* the Surgical Anatomy of the Groin, &c. p. 170.

† *Ibid.* p. 171.

CHAPTER II.

DISSECTION TO EXPOSE, BY AN INTERNAL VIEW, THE STRUCTURE AND RELATIONS OF THE POSTERIOR WALL OF THE INGUINAL CANAL.

THE cavity of the abdomen should now be exposed, by making an incision through its parietes from the crest of the ilium, a little distance beyond the anterior superior spinous process, to the linea alba, near the umbilicus; and thence in a vertical direction to the symphysis pubis, as is represented in Plate IV. The small intestines should likewise be removed from the cavity of the pelvis. When these directions have been executed, on holding upwards and forwards the triangular-shaped flap that has been marked out, the peritonæum which lines the interior of the abdominal parietes of the inguinal regions, will be found to present, on each side of the mesial line, three remarkable and distinct depressions, which may be denominated the *inguinal pouches* or *fossæ of the peritonæum*. The deepest of these fossæ is the most external of the three, and is situated on the outer or iliac side of the epigastric artery, and corresponds with the upper aperture or inlet of the inguinal canal. It is underneath this point that the spermatic vessels and the vas deferens join with each other, as they bend over the trunk of the epigastric artery, previously to their entrance into the inguinal canal, where they constitute the spermatic cord. If the finger be pressed pretty firmly upon the peritonæum at this situation, the membrane will readily yield under the influence of the pressure thus exerted, and may easily be protruded, in the form of a small pouch or sacculus, for some little distance upon the anterior surface of the spermatic cord, as it is resting in the upper part of the inguinal canal. In some subjects a probe or other blunt-pointed instrument will be found, if introduced into the bottom of this depression of the peritonæum, to pass, without the slightest impediment, for a consi-

derable distance downwards and forwards in front of the spermatic cord, or round ligament of the uterus; which circumstance is owing to the imperfect obliteration, in this situation, of the original processus vaginalis of the peritonæum. In the adult female subject a long process of a similar nature is occasionally found to exist, in front of the round ligament of the uterus, and is very well known to anatomists under the name of the *canal of Nuck*. In some few instances, the probe may be passed, in front of the spermatic cord, through a very narrow canal, or passage, as far as the testicle; and, in such cases, the sac of the tunica vaginalis testis still retains its primitive connection with the cavity of the great bag of the peritonæum; the processus vaginalis peritonæi not having been obliterated as usual, but only contracted in its original dimensions.†

Situated opposite the internal abdominal ring, the external inguinal fossa of the peritonæum is—in men at least—undoubtedly the weakest point of the abdominal parietes; and thus it happens, that cases of the common and congenital forms of inguinal herniæ are almost universally observed in individuals of the male sex.

If the processus vaginalis peritonæi should remain pervious during life, the intestines may, at any time, be forced down into its cavity, so as to constitute that form of external or oblique inguinal hernia, which has been named *congenital*, from the general belief which was formerly entertained, that it could only happen at or immediately after birth, before the obliteration of this process from the serous membrane lining the abdomen, which was presumed always to take place, had been effected.

When, under such circumstances, any considerable quantity of serous fluid is collected within its cavity, a *congenital hydrocele* is then said to be formed.

Sometimes the processus vaginalis peritonæi is not wholly obliterated, but only at several points of its extent between the testicle and the internal abdominal ring; and, then,—serous fluid collecting in the sacculi which intervene between each point where the obliteration has been effected,—a series of small *encysted hydroceles of the spermatic cord* may be produced.

† In many of the lower animals, as, for example, the dog, the processus vaginalis peritonæi remains permanently open.

The *second, or middle fossa of the peritonæum*, is not so deep as the preceding; it is situated on the inner or pubal side of the epigastric vessels, betwixt them and the ligamentous cord, which is formed by the obliteration of the umbilical artery of the fœtus.

If a hernial sac should commence to be protruded into the inguinal canal in this situation, it would at first be only covered by the subserous cellular tissue and fascia transversalis; since, at this point, these structures alone form the posterior wall of the inguinal canal. The hernia would also belong to that division of inguinal herniæ usually denominated *direct* or *internal*.

The *third, or most internal of the inguinal fossæ of the peritonæum*, is situated on the pubal side of the ligamentous cord, which results from the obliteration of the umbilical artery, between it and the outer edge of the rectus muscle. It is placed directly behind the external abdominal ring, and corresponds with the strongest portion of the posterior wall of the inguinal canal, where it is formed by—besides the subserous cellular tissue and fascia transversalis—the conjoined tendons of the internal oblique and transversalis muscles.†

A direct or internal inguinal hernia may also be formed by the protrusion of a hernial sac through this portion of the posterior wall of the inguinal canal; which would then be covered not only by the subserous cellular tissue and the fascia transversalis, as in the preceding instance, but also, in all probability, more or less completely, by the conjoined tendons of the internal oblique and transversalis muscles.‡

The peritonæum, and subserous cellular tissue, should now be detached from the inner surface of the inguinal region and iliac fossa, so as to expose to view the vas deferens and sper-

† The three inguinal pouches of the peritonæum have been distinguished by M. Velpeau under the names of *fossette inguinale externe*, *fossette inguinale interne*, and *fossette vésico-inguinale*. Vide *Traité complet d'Anatomie chirurgicale*. 3d edit. vol. ii. p. 72.

‡ Vide Sir Astley Cooper's work on *Hernia*, 2d edit. Plate X. in which six hernial sacs are shown. Two of the sacs on each side were protruded through that portion of the posterior wall of the inguinal canal which is comprised between the epigastric and umbilical arteries (figs. *h*, *i*, *l*, and *k*); and one on each side, between the remains of the umbilical artery and the outer edge of the rectus muscle (figs. *j*, *m*).

matic vessels, as they converge towards each other, in their course to the internal abdominal ring: — the same dissection will suffice, also, for the examination of the internal and external iliac arteries, and the origins of their principal branches. (See Plate IV.)

EXPLANATION OF PLATE IV.

This plate represents a view of the internal surface of the abdominal parietes, in the left inguinal region of the male subject; the peritonæum and subserous cellular tissue having been removed, so as to expose the other structures which are immediately external to them.

- a.* The crista of the ilium. The letter is placed about the distance of an inch outwards from the anterior superior spinous process of the bone.
- b.* The situation of the symphysis pubis.
- c.* The spinous process, or tuberosity of the os pubis.
- d. d.* The ligament of Poupart obscurely seen through the fasciæ iliaca and transversalis, which join with one another along its posterior margin.
- e.* Gimbernat's ligament; it is partially concealed from view by the fascia transversalis, and, also, by the conjoined tendons of the transversalis and internal oblique muscles, which here curve downwards to reach their insertions into the inner part of the horizontal branch of the os pubis.
- f.* The horizontal branch of the os pubis, forming a part of the ileo-pectineal line.
- g.* The inner surface of the rectu^s muscle, where its tendinous sheath is defective posteriorly.
- h.* The inner surface of the transversalis muscle, from which the fascia transversalis has been dissected, so that its muscular structure might be more clearly displayed.
- i.* The iliacus internus muscle, partially stripped of its covering from the fascia iliaca.
- k.* The fascia iliaca, which binds down the iliacus internus and psoas muscles.
- l.* The fascia transversalis, lining the inner surface of the transversalis muscle.
- m.* The cut edges of the muscles forming the lateral walls of the abdomen.
- n.* The lower part of the tendinous sheath of the rectus muscle, which ceases about midway between the umbilicus and symphysis pubis.
- o. o.* The linea alba.

- p.* A hook, inserted a little below the situation of the umbilicus, to suspend the triangular-shaped flap of the parietes of the inguinal region.
- q.* The internal wall of the inguinal canal, where it is formed by the fascia transversalis.
- r.* The internal abdominal ring, or funnel-shaped aperture in the fascia transversalis, by which the vas deferens and spermatic vessels in the male, and the round ligament of the uterus in the female, issue from the abdominal cavity, in their descent to reach the external organs of generation. The opening is situated just *above* Poupart's ligament. The spermatic vessels are seen to unite with the vas deferens, as they bend over the first portion of the epigastric artery, just before their entrance into the inguinal canal.
- s.* The crural ring, or aperture by the inner side of the femoral vein, by which a femoral hernia commences to descend from the cavity of the abdomen. It is *below* Poupart's ligament.
- t.* The external cutaneous nerve — a branch from the lumbar plexus — lying behind the fascia iliaca.
- 1. The trunk of the external iliac artery, as it runs along the inner edge of the psoas muscle, resting upon the fascia iliaca.
- 2. The external iliac vein, which runs along the internal border of the artery.
- 3. The epigastric artery, as it ascends from its origin behind Poupart's ligament, to pass along the inner edge of the internal abdominal ring.
- 4. The internal circumflexa ilii artery, after its origin from the external iliac artery, and before it pierces the fascia iliaca.
- 5. The spermatic artery; on each side of the artery runs an accompanying vein.
- 6. The vas deferens.
- 7. The internal circumflexa ilii vein, which crosses over the external iliac artery, in its way to open into the external iliac vein.
- 8. 8. 8. The convolutions of the small intestines, which have been removed from the cavity of the pelvis, and thrown over to the right side.
- 9. The parietes of the inguinal region of the right side, reflected upon the upper part of the corresponding limb.

CHAPTER III.

SECTION I.

OF INGUINAL HERNIÆ.

AFTER having made ourselves familiar with the natural form and relative position of the several structures which compose the inguinal portion of the abdominal parietes, it should be our next object to determine what are the changes from their healthy condition which are liable to be produced in them by the formation of inguinal herniæ.

There are two principal and leading varieties of this disorder, the distinguishing characteristics of which are derived from a consideration of the course which the hernial tumour pursues, as it is protruded forth from the cavity of the abdomen, and of the position which the neck or internal orifice of the sac bears relatively to the epigastric artery; points which are of considerable practical importance, since they are essentially different in each of the varieties alluded to.

1. *External or oblique inguinal hernia*.—The kind of inguinal hernia which is the most frequent in its occurrence, is that form of the complaint which has been named, in consequence of the hernial tumour pursuing the same course through the inguinal canal as the spermatic cord or the round ligament of the uterus, the *oblique inguinal hernia*; by some surgeons it is, also, named *external*, because the neck of the sac is situated upon the *outer* or *iliac* side of the epigastric artery. (See the woodcut No. 4, at page 263, figs. o, m.)

Of this form of inguinal hernia there are three different kinds, viz. the *common scrotal hernia*, the *congenital hernia*, and the *encysted* or *infantile hernia*.

2. *Internal or direct inguinal hernia*.—The second principal variety is that in which the hernial sac, instead of descending through the oblique course of the inguinal canal, is pro-

truded through some part of the posterior wall of that passage, on the *inner* or *pubal* side of the epigastric artery. (See the woodcut No. 9, figs. *r*, *p*.) This is named the *Direct* or *Internal inguinal hernia*.

SECTION II.

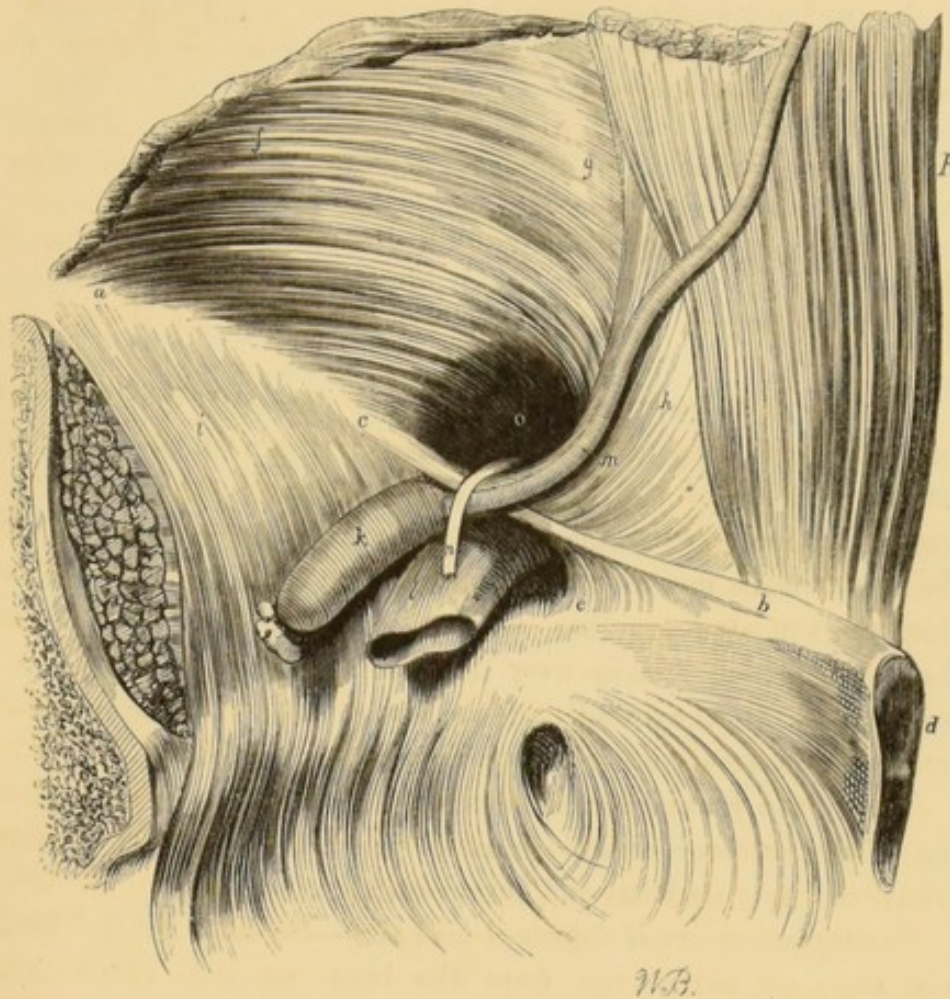
OF EXTERNAL OR OBLIQUE INGUINAL HERNIA.

It has already been observed, whilst making the dissection necessary to expose, by an internal view, the structure and relations of the posterior wall of the inguinal canal, that the external inguinal pouch, or fossa of the peritonæum, is situated directly opposite the internal abdominal ring, or superior aperture of the inguinal canal, and that, consequently, it is (at least in the male sex) the weakest point of the fasciæ which line the interior of this portion of the abdominal parietes, and, therefore, not unfrequently gives way under the pressure which is exerted against it by the viscera, when they are forcibly compressed by the contraction of the muscles which bound the abdominal cavity, as constantly happens during any violent or active exertion, such as, for example, leaping, running, &c. The intestines, on being thus propelled, as it were, into the external inguinal pouch of the peritonæum, carry that membrane before them, enlarging the little cul-de-sac, which it usually forms upon the front of the cord or round ligament of the uterus, where they occupy the upper part of the inguinal canal. (See the woodcut No. 2, at page 243, figs. *l*, *m*.)

As the hernial tumour descends into the inguinal canal, it derives investments from the subserous cellular tissue and the fascia transversalis, which, taken together, constitute that covering of the sac which has been termed the *fascia propria* of inguinal herniæ.

The lowermost fleshy and tendinous fibres of the transversalis muscle are, at the same time, displaced a little upwards, and moulded more completely into the form of a semi-circular border, which arches over the neck of the sac, and is thus capable, under certain conditions, of forming the seat of the stricture in some cases of strangulated oblique inguinal herniæ.

No. 4.



W.B.

This woodcut represents, by an internal view, the circular dilatation of the internal abdominal ring, which is caused by the protrusion through it of the sac of an external or oblique inguinal hernia. The peritonæum and the subserous cellular tissue have been removed from the iliac fossa, so as to expose more clearly the relation which the epigastric artery bears to the neck of the sac of an external inguinal hernia.

a. The crest of the ilium, near the anterior superior spinous process of the same bone. *b.* The spinous process, or tuberosity of the os pubis. *c.* The inner surface of Poupart's ligament, or the crural arch. *d.* The symphysis pubis. *e.* The posterior surface of Gimbernat's ligament, a part of the crural arch. *f.* The inner surface of the transversalis muscle, where it springs from the iliac portion of Poupart's ligament. *g.* The tendinous portion of the transversalis muscle. *h.* The inner or pubic portion of the fascia transversalis, where it forms the principal part of the posterior wall of the inguinal canal. *i.* The fascia iliaca covering the iliacus internus and psoas muscles, and which descends over the brim of the pelvis, to become continuous with the pelvic fascia. *k.* The trunk of the external iliac artery. *l.* The trunk

of the external iliac vein. *m.* The epigastric artery, as it runs along the under and inner margin of the neck of the sac of an external inguinal hernia. *n.* The vas deferens, where it descends, after its exit from the inguinal canal, in its course to the side of the bladder. *o.* The internal abdominal ring dilated by the protrusion through it of the sac of an external or oblique inguinal hernia. The aperture so produced generally limits what is termed the neck of the hernial sac. *p.* The internal surface of the lower part of the rectus abdominis muscle.

By contrasting this wood-engraving with No. 9, the reader will at once clearly understand the distinction which is made between external and internal inguinal herniæ.

In proportion as the hernial tumour increases, it descends farther into the inguinal canal, and soon passes underneath the inferior margin of the internal oblique muscle, the muscular fibres of which are displaced in a similar manner to those of the transversalis muscle already mentioned; and, becoming more closely aggregated together, form a thick and strong muscular fasciculus, which sweeps over the front and sides of the sac, nearly opposite the middle of the space which is included between the superior and inferior apertures of the canal.

When the hernial sac has descended beyond the lower margin of the internal oblique muscle, the fibres of the cremaster are spread over its front and lateral surfaces.

Incomplete external inguinal hernia.†—So long as the hernial sac does not emerge from the lower aperture of the inguinal canal, it is denominated an *incomplete external bubonocoele*, which, it should be remembered, is a very common form of the complaint, and is extremely likely to prove much more dangerous to those who are the subjects of it than the complete form of the disorder, inasmuch as its existence is frequently overlooked both by the patient and his medical attendant; so that it not unfrequently happens that much valuable time is lost, and the means which would be most suited to effect its cure, or, at all events, to prevent its further increase, permitted to remain unemployed, when—were the nature of the affection recognised—they might be had recourse to with the happiest results. The works of medical and surgical writers teem

† Boyer calls this form of inguinal hernia *intra-parietale*, and other French writers name it "*hernia inguino-interstitielle*." By Sir Astley Cooper it is described under the head of *small inguinal hernia*.

with the histories of cases in which the unfortunate sufferers have lost their lives, from the strangulation of a very small knuckle of intestine in the neck of the sac of an incomplete external inguinal hernia having been allowed to continue unnoticed, until it had become too late to attempt to interfere with the most remote chance of success by any operative proceeding.† In these, and many similar instances,‡ the rational symptoms of the disorder are only taken into account, whilst the physical signs of it are neglected (a tumour in the region of the inguinal canal, painful, tender under pressure, and resisting the taxis§), and are regarded only as indications of an attack of peritonitis, or some obscure form of inflammation of the bowels; and the patients are treated during many days in the same manner as persons who actually labour under such complaints;—how ineffectually it must be easy for any one, who is capable of considering the subject, to conceive.||

Whilst it remains within the inguinal canal, the hernial sac is supported—accordingly as it happens to occur in a male or female subject—by the upper part of the spermatic cord, or the round ligament of the uterus, which intervene betwixt it and the floor of the canal;—anteriorly, it is covered by the skin, the superficial fascia, the intercolumnar fibres, and the tendinous aponeurosis of the external oblique muscle, the lower fibres of the internal oblique, and upper part of the cremaster, underneath which are placed the several investments which it receives from

† *Vide* Sir Astley Cooper on Hernia, 2d edit. Part I. p. 65 and p. 83. Liston's Elements of Surgery, 2d edit. p. 586. Lawrence on Ruptures, 5th edit. p. 223; also, *Nouveaux Elémens de Médecine Opératoire*, par M. Velpeau, 2d edit. vol. iv. p. 177.

‡ *Vide* the Surgical Anatomy of the Groin, p. 130.

§ *Vide* a Paper, by the Author, in the Medical Gazette of 23d Dec. 1837, p. 506, "On the Symptoms of strangulated Intestine."

|| See also Sir Astley Cooper on Hernia, 2d edit. chap. xiv. p. 65. Of small inguinal hernia, Sir Astley Cooper says, "that this tumour occurs much more commonly than is usually supposed, for I have frequently found it in the dissection of the bodies of persons who have never been suspected of labouring under the disease, nor have ever worn a truss when strangulated. These cases more commonly fall under the care of the physician than the surgeon; for, as the patient himself is not conscious of having a tumour at the groin, the symptoms of strangulation are ascribed to inflammation of the bowels, and the patient dies, as is supposed, of idiopathic peritonitis."

the funnel-shaped sheath of the fascia transversalis and the cellular substance of the cord (the subserous cellular tissue); —posteriorly, it is separated from the great bag of the peritonæum by the several structures that compose the posterior wall of the inguinal canal. (See the wood-engraving No. 3, at p. 246, figs. *i* and *m*.)

Complete external inguinal hernia.—When the hernial tumour emerges through the external abdominal ring, or lower aperture of the inguinal canal, it is denominated a *complete inguinal hernia* or *oscheocele*. Under these circumstances, the outlet of the canal is more or less enlarged, and loses its natural triangular appearance. (See Plate V. figs. *b* and *c*, and also the wood-engraving No. 6, fig. *e*.) After passing through the external abdominal ring, the hernial sac descends in front of the spermatic cord until it rests just above the testis, and is now additionally covered by the spermatic fascia, the dartos, and the common integuments of the scrotum. (See the woodcut No. 6, figs. *f*, *g*, *h*, and *i*.)

EXPLANATION OF PLATE V.

This plate represents the coverings of the sac of an oblique or external inguinal hernia on the left side. It also shows that the obliquity of the inguinal canal is destroyed by the yielding of its posterior wall, under the long-continued pressure of the protruded viscera. It will likewise be observed, that the epigastric artery has, from the influence of the same causes, been removed from its natural course, and driven inwards as far as the outer edge of the rectus muscle, where it must almost inevitably be wounded, should the surgeon, while operating upon an individual affected with a strangulated inguinal hernia, in which those changes have taken place (a case by no means of unfrequent occurrence), direct the edge of his knife inwards, towards the linea alba, when enlarging the constricted neck of the sac.

- a.* The anterior superior spinous process of the ilium.
- b.* The inferior pillar of the external abdominal ring, somewhat displaced from its natural position, by the protrusion of the hernial sac through the inferior aperture of the inguinal canal.
- c.* The superior pillar of the external abdominal ring.

Between the letters *b* and *c* the lowermost of the inter-

columnar fibres are seen aggregated together, so as to form a strong and dense fasciculus, which constricts the hernial sac opposite this point, and gives the circular form to the external abdominal ring, which is so much insisted upon by surgical writers.

d. The ligament of Poupart.

e. e. The aponeurosis of the external oblique muscle, divided and turned back, so as to expose

f. the fleshy fibres of the lower part of the obliquus internus muscle.

g. The tendinous sheath of the rectus muscle of the left side, opened and turned back.

h. The rectus muscle of the left side, lifted up from its natural position and turned over, towards the mesial line of the body.

i. The fascia transversalis, where it lines the posterior surface of the rectus muscle, above the pubes.

k. The great trunk of the femoral artery.

l. The femoral vein.

m. A portion of the great bag of the peritonæum, which, after removing the iliac portion of the fascia lata, and raising Poupart's ligament, appeared externally, under the left crural arch.

n. The great crural nerve.

o. The saphena major vein, near its termination in the common femoral vein.

p. The sartorius muscle.

q. The iliacus internus muscle.

r. The adductor longus muscle.

s. The gracilis muscle.

t. The rectus femoris muscle.

u. The tensor vaginæ femoris muscle.

v. Part of the glutæus medius muscle.

w. The vastus externus muscle.

y. The umbilicus.

1. The epigastric artery, near to its origin from the external iliac artery.

2. The epigastric artery, behind the outer border of the rectus muscle, into which situation it has been brought by the long-continued pressure of a large and old-standing oblique inguinal hernia. The artery would most certainly be cut were the surgeon, when enlarging the neck of the sac in the operation for the removal of the stricture, to turn the edge of his bistoury inwards, in the direction of the linea alba. The epigastric veins are observed as they accompany the artery, the course of which they follow.

3. The internal circumflexa ilii artery; it springs from the external iliac artery opposite the origin of the epigastric.
4. The scrotum of the left side.
5. 5. The external spermatic fascia, cremaster muscle, and funnel-shaped sheath of the fascia transversalis, blended together by the pressure of the hernia, and constituting one of the principal investments of the hernial sac.
6. 6. The subserous cellular tissue, which is interposed between the sheath of the cremaster muscle and the proper hernial sac.
7. 7. The hernial sac, formed by the peritonæum.
8. A portion of the omentum contained in the sac, and lying in front of
9. A knuckle of the small intestine.

The fascia transversalis is, in the majority of cases of inguinal herniæ, but little altered from its usual healthy condition, excepting that the internal abdominal ring (see the woodcut No. 4, at page 263, fig. o) is greatly enlarged — principally towards the mesial line — by the protrusion through it of the hernial sac. Occasionally it presents, over the situation of the neck of the sac, the appearance of a narrow, circumscribed, and unyielding band of condensed cellulo-fibrous tissue, of the thickness of fine packing-twine.

In the operation for strangulated inguinal herniæ, this covering is not unfrequently mistaken for the peritoneal sac, in consequence of its uniform and delicate appearance and texture.

The subserous cellular tissue has been found, in several instances, to be a little increased in thickness, but unequally so, from the presence of a number of very small bundles of adipose substance that are deposited here and there in its texture. It frequently appears very vascular where it covers the neck of the sac. This investment of the hernial sac has been frequently mistaken in the operation for the omentum—an error which has, in some instances, caused the death of the patients, from the hernial sac being reduced, along with its contents, into the cavity of the abdomen, the strangulation of the bowel still remaining unrelieved.

The transversalis muscle undergoes little or no alteration in its form and appearance, by the protrusion of the hernial sac through the internal abdominal ring. In some instances, however, of large and old oblique inguinal herniæ, it is en-

croached upon by the hernial tumour, and its lower edge becomes in consequence rather more arched than ordinary, and the conjoined tendons of the two muscles (the internal oblique and transversalis),—where they descend together to be inserted into the inner extremity of the ileo-pectineal line of the os pubis, and form the inner part of the posterior wall of the inguinal canal,†—are displaced more or less inwards, nearer to the outer edge of the rectus muscle; so that instead of extending an inch, and even more than this, from the edge of that muscle, they do not reach more than a quarter of an inch, and frequently even a less distance from it than this. In the healthy condition of these parts, the conjoined tendons constitute a thin and flat band of fibres; but, when an oblique inguinal hernia has existed for a considerable period, and, at the same time, forms a large protrusion, they are no longer able to resist the tendency which the weight of the contents of the hernial sac has to drag inwards that portion of the posterior wall of the inguinal canal, which is composed of the fascia transversalis and the conjoined tendons, and hence they give way, and are pushed aside in the direction of the mesial line of the body, and so change their extended form for that of a thick, narrow, and strong band. (See Plate V. figs. 1 and 2, and woodcut No. 5, figs. *i*, *m*.)

Such of the fibres of the internal oblique muscle as take their origin from the middle portion of Poupart's ligament are more or less displaced by the hernial sac as it descends through the inguinal canal; so that they no longer run, in an oblique direction, downwards and inwards to their attachment to the os pubis, but are forced upwards by the rounded anterior surface of the sac, as it protrudes between the lower edge of the muscle and the spermatic cord, and are so made to form a thick muscular arch, the concavity of which embraces about two-thirds of the circumference of the tumour as it lies within the inguinal canal.

The cremaster muscle is frequently found very much altered from its natural and healthy condition, particularly if the hernia should be large and of long duration. The fibres of this muscle may be enlarged to three or four times their ordinary thickness, losing, at the same time, much of their muscular character, and

† *Vide* Plate III. fig. *r*, and woodcut No. 3, at page 246, figs. *i*, *g*.

becoming pale and semi-transparent. Towards the fundus or inferior extremity of the hernial sac, the fibres of the cremaster are so much displaced as to present the appearance of an irregular network, the meshes of which are of very unequal size and figure. (See Plate V. fig. 5, 5.)

The spermatic fascia, springing from the circumference of the external abdominal ring, is, in many cases of scrotal herniæ, considerably increased in its thickness and density. In some cases I have seen it twice and even three times thicker than it is naturally; nevertheless, in some cases of large scrotal herniæ, this investment of the sac undergoes very little alteration, and remains very thin and delicate.

The external abdominal ring is frequently distended to the magnitude of half-a-crown, but it rarely exceeds this size. At the same time the aperture loses the triangular figure which it naturally possesses. (See Plate V. figs. *b*, *c*, and the wood-engraving No. 6, fig. *e*.)

The intercolumnar fibres, or bands, which serve to connect together the pillars of the external abdominal ring, are pushed upwards and outwards by the hernial sac as it protrudes from the inguinal canal, and are thrust together in such a manner as to form, by their close approximation to each other, a broad and very strong fillet, which limits the farther distension of the ring, and thus communicates a circular form to the aperture when distended by the protrusion through it of an hernial tumour. The intercolumnar fibres become, at the same time that they are displaced upwards and outwards, very much increased in thickness and strength; and to this circumstance is owing that sudden constriction in the bulk of the hernial tumour, which, in every case of large scrotal hernia, serves to define with precision the situation of the external abdominal ring. (See Plate V. figs. *b*, *c*, and the woodcut No. 6, fig. *e*.)

The superficial fascia presents, in the majority of instances of oblique inguinal herniæ, its ordinary appearance; being separable only into two lamellæ, between which are situated the cutaneous vessels which supply the superficial coverings of the inguinal region. In other instances, again, it is very much thickened and greatly increased in density, admitting of being readily divided into three or four laminæ. The external pudic artery lies over the middle of the tumour formed by the hernia,

immediately after it has emerged from the external abdominal ring, or lower aperture of the inguinal canal, and hence must always be divided by the first incisions in exposing the sac of a complete bubonocoele. The superficial epigastric artery usually runs a little farther towards the anterior superior spinous process of the ilium than the commencement of the neck of the sac, and, therefore, it is very rarely injured by the knife in an operation for strangulated inguinal hernia, excepting when performed in cases of recent incomplete bubonocoele.

The peritonæum, which forms the proper sac of an inguinal hernia, is seldom found altered from its healthy structure and appearance, excepting at the neck or internal aperture of the sac. In this situation the peritonæum frequently forms a sharp angular fold, the free border of which projects towards the central axis of the sac. The increased action which is induced in the vessels which nourish this portion of the peritonæum, and the adjacent subserous cellular tissue, and that part of the fascia transversalis which is immediately external to it, by the excitement kept up by the presence of the hernial descent, and frequently, also, by the means employed to maintain it reduced, is followed, after the lapse of a longer or shorter period, by the deposition of new matter around the neck of the sac, which, probably, in the first instance, is closely allied in its nature and properties to coagulable lymph, but which eventually assumes the character of condensed cellulo-fibrous tissue. The neck of the peritoneal sac is also liable to become greatly thickened, from the changes which occur in it when a hernia has been maintained reduced for a considerable period, as, for example, by the application of a well-adjusted bandage or truss; for, in such cases, the peritonæum, where it passes through the narrow aperture of the internal ring, being no longer distended by the descent of the intestine forming the hernia, falls into loose folds, which present the appearance of the mouth of a purse, the strings of which have been drawn rather closely together. These folds of the peritonæum soon cohere to each other by their opposing surfaces, and in this manner the neck of the sac is increased in its thickness and density, in the same ratio as the diameter of the aperture is diminished.

It is by the co-operation of these several causes, that, in carefully dissecting herniæ of old standing, we so regularly meet

with a remarkable thickened and contracted condition of the neck of the sac; which, so far from presenting its ordinary delicate structure, forms an unyielding band of a dense cellulofibrous or even a semi-cartilaginous nature, that very frequently becomes, independently of the surrounding muscles, the seat of the stricture in numerous cases of strangulated herniæ. This deposition of new matter around the neck of the hernial sac is always followed by a diminution of the calibre of the mouth of the sac; and this circumstance may be satisfactorily explained by reference to the strong and firm structures which are situated around the circumference of the internal abdominal ring, and prevent its developement eccentrically, and, also, to the fact that there seems to exist in tissues of a similar nature and origin, an inherent tendency to contract the diameter of the circle, the limits of which they bound.

That this morbid alteration of the peritonæum forming the neck of the sac is of very frequent occurrence, my own observation permits me to state; and it is this condition of the parts which must ever prevent the attempt to relieve the stricture without opening the sac, in operations for strangulated inguinal and femoral herniæ, from being very generally practicable or successful.

The thickened and constricted condition of the hernial sac, just now described, will occasionally be found to exist at various other points of its extent, besides that portion of it which is included within the embrace of the internal abdominal ring, and, sometimes, they are situated even exterior to the lower apertures of the inguinal canal. These changes in the structure and appearance of the peritoneal sac are chiefly dependent upon the farther protrusion of an old hernial sac, consequent upon the descent of an additional quantity of the visceral contents of the abdominal cavity.†

Of the changes which are produced in the course of the epigastric artery, and in the extent of the posterior wall of the inguinal canal, by large old-standing external inguinal herniæ.—The epigastric artery is frequently observed to be very much displaced from its customary course, by large and old-standing oblique, or external inguinal herniæ. In such cases, this vessel no longer runs in an oblique course from

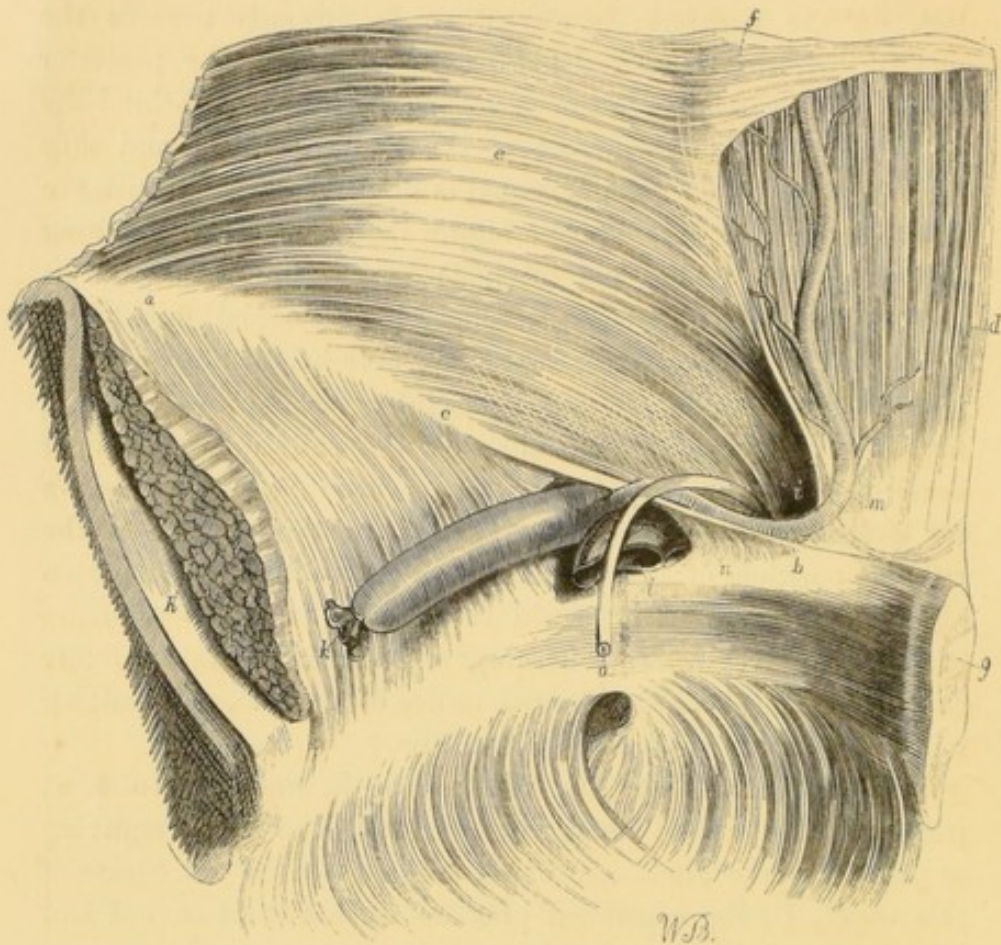
† *Vide* Sir Astley Cooper on Hernia, 2d edit. Plate V. figs. 1 and 3.

about the centre of the crural arch, up towards the umbilicus ; but, on the contrary, is carried so far inwards towards the mesial line, that it ascends, after running along the posterior surface of the pubic portion of Poupart's ligament, behind the outer edge of the lower part of the rectus muscle ; and thus the obliquity of the inguinal canal is destroyed, and an instance is afforded of the external or oblique inguinal hernia becoming apparently direct (but not internal) by the obliteration of its posterior wall ; a circumstance which, if overlooked, might lead a surgeon into considerable difficulty, were he, —mistaking the true nature of the case, and regarding it as one in which the hernia is protruded through the posterior wall of the inguinal canal, on the inner side of the epigastric artery—in an operation for a strangulated inguinal hernia, where this change in the relative position of the external and internal rings had been effected, to direct (as is taught to be done by some authorities in cases of direct internal hernia), while enlarging the stricture existing at the neck or internal orifice of the sac, the cutting edge of the knife towards the linea alba.†

By referring to Plate IV. fig. 3, or to the woodcut No. 4, at page 263, fig. *m*, and comparing them with the wood-engraving at page 274, the alteration which is produced in the course of this vessel, by the continued pressure against it of an old and large external inguinal hernia, will be at once easily comprehended.

The transposition of the epigastric artery from its natural course, and the corresponding alteration in the situation of the internal abdominal ring, are subjects of considerable interest to the practical surgeon, since it greatly tends to render the establishment of an accurate diagnosis between external oblique inguinal herniæ of long standing and direct or internal inguinal herniæ, previous to the operation, extremely difficult, and, indeed, in very many cases, totally impossible.

† For a case in which this accident occurred, and where the patient very narrowly escaped losing his life from the hemorrhage which ensued upon the division of the stricture inwards towards the linea alba, See Sir Astley Cooper's work on Hernia, 2d edit. Part i. pages 69 and 79. *Vide* also Scarpa on Hernia, translated by Wishart, p. 125.



The wood-engraving represents the change of position to which the epigastric artery is subject, in the greater number of instances of large and old-standing external or oblique inguinal hernia. The posterior wall of the inguinal canal is almost completely obliterated by the constant pressure which is exercised upon the several structures, of which it is composed, by the contents of the hernial sac; from the same cause the internal abdominal ring has been dragged inwards, until at length it is situated immediately behind the external aperture, or outlet of the canal.

a. The inner surface of the crest of the ilium, a little distance beyond the anterior superior spinous process of the same bone. *b.* The spinous process or tuberosity of the os pubis. *c.* The posterior surface of Poupart's ligament. *d.* The inner surface of the lower portion of the rectus muscle of the left side, where its tendinous sheath is deficient. *e.* The inner surface of the transversalis muscle; the letter is placed where the fleshy fibres of the muscle terminate in its tendon. *f.* A part of the posterior division of the tendinous sheath of the rectus muscle, which terminates by a free border about midway between the umbilicus and the symphysis pubis. *g.* The symphysis pubis. *h.* The cut surface of the iliacus and psoas muscles, which

are covered by the fascia iliaca. *i.* The internal abdominal ring displaced from its natural situation by the continual weight of the hernia, and dragged downwards and inwards, as far as the outer edge of the rectus muscle, in such a manner as to destroy the obliquity of the inguinal canal, by the gradual obliteration of its posterior wall. *k.* The trunk of the external iliac artery. *l.* The external iliac vein. These vessels lie upon the fascia iliaca, which separates them from the fibres of the psoas muscle. *m.* The epigastric artery displaced inwards from its usual course by the continual pressure exercised against it by an old and large external inguinal hernia. This vessel is observed to make a considerable bend in its course instead of at once mounting, in an oblique direction, towards the umbilicus; and, after running along the posterior surface of the pubic division of Poupart's ligament, to ascend along the outer edge of the rectus muscle, in order to reach its ultimate destination. *n.* The posterior surface of Gimbernat's ligament, a part of the crural arch. *o.* The vas deferens, cut across as it is descending into the pelvis, in its course from the inguinal canal to the side of the bladder.

Of the changes which are sometimes observed in the situation of the vessels of the spermatic cord, in large and old scrotal herniæ.—It has been already mentioned that the spermatic cord commonly lies behind the hernial sac, in cases of oblique or external inguinal herniæ;† a statement which will, on examination, be found to apply strictly only to the majority of instances of this form of the disorder, and more especially so, when they are as yet small, and of recent formation; but it should be known, also, that some important deviations from this general rule are not unfrequently met with in the dissection of large and old scrotal herniæ. In such cases, the component structures of the spermatic cord are oftentimes much loosened from the intimate connections which they naturally have with each other; and, instead of lying, as is usual, in close apposition with each other, at the back part of the hernial sac, are found widely separated from one another for a considerable distance, and in such a manner as to be situated rather upon the sides, or even in front of the swelling. The displacement and separation from each other of the vessels of the spermatic cord now described, are commonly most marked towards the lower part or fundus of the hernial sac, and diminish in the vicinity of the external abdominal ring, while within the inguinal canal the

† *Vide* the description of complete external inguinal hernia, at p. 266.

whole of the cord is almost invariably found lying behind the sac.†

This decomposition and separation of the vessels which compose the spermatic cord have been particularly investigated by Scarpa, who has shown in a very clear and satisfactory manner, that they are dependent upon the forcible distension of the common cellular sheath of the cord produced by the increased size of the hernial tumour.‡

Mr. Hey, of Leeds, has related the history of a case, in which he unexpectedly divided the vas deferens, while laying bare the sac of a large strangulated scrotal hernia; and it is well known that the same accident has several times happened in the practice of other surgeons.§

For this reason, among others, it is always advisable in the operation for strangulated scrotal hernia, more especially when the rupture is large and of long standing, not to extend the incisions quite to the lower part of the tumour; since, if any variety in the course of the spermatic vessels should exist, it is

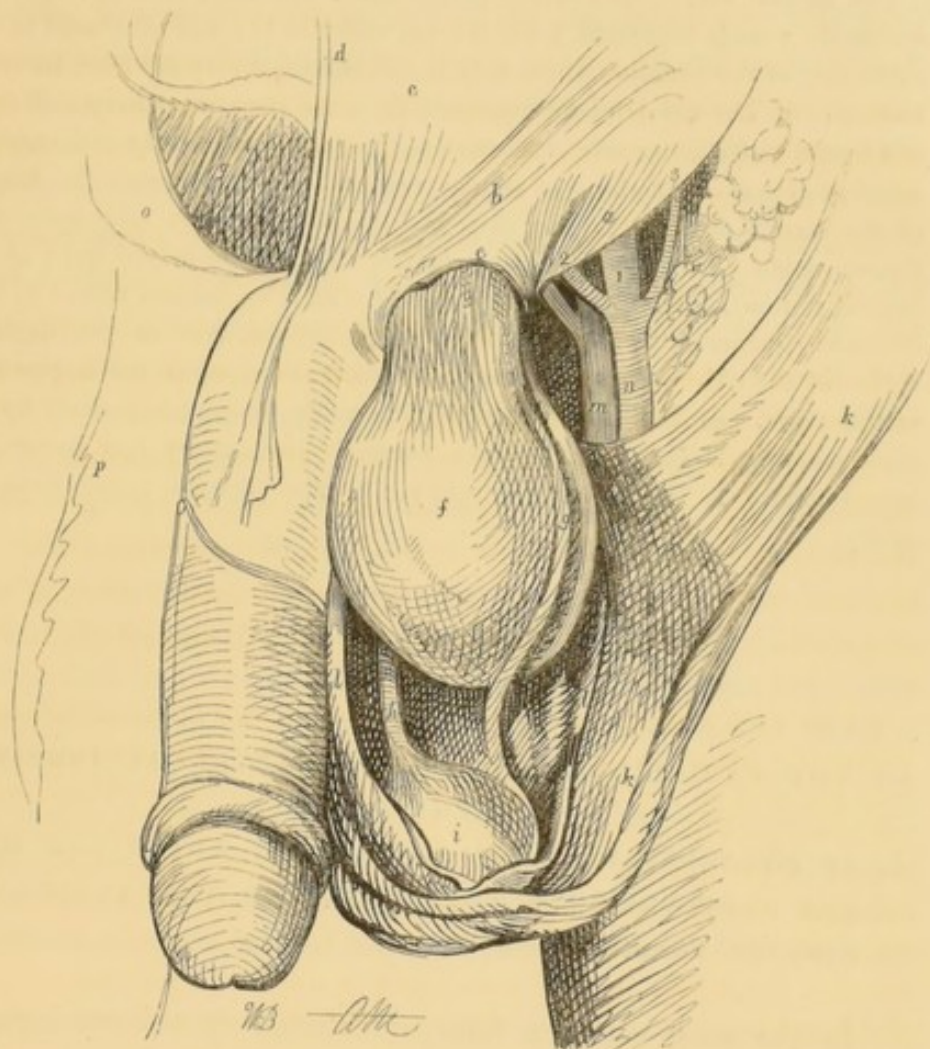
† That even a small hernial sac may, however, sometimes insinuate itself between the component parts of the spermatic cord, and cause their separation from one another, is shown by the history of the following case which occurred in the practice of Sir Astley Cooper:—"I was desired to see a boy, a patient of Mr. Clarke, surgeon in the Borough, who had a tumour which extended from the upper part of the scrotum, through the abdominal ring along the cord to the abdomen. The lad's father was anxious for the removal of the disease, but on examination it did not project sufficiently to enable me to judge whether there was either fluctuation or transparency. However, as it interfered with the boy's usual occupation, I resolved to cut down upon it with extreme caution. When I had reached by incision the surface of the cyst I found the spermatic vessels running upon it, and was obliged to open the cyst by its side to avoid these vessels. The cyst contained a portion of the small intestine, everywhere adhering to its inner surface, which had prevented the return of the bowel into the abdomen. The vas deferens could be discovered behind the sac, so that there was a hernia, the sac of which had insinuated itself between the spermatic blood-vessels and the vas deferens."—*Vide* Sir Astley Cooper on Hernia; 2d edit. Part i. p. 16.

‡ *Vide* Scarpa on Hernia, translated by Wishart, p. 70.

§ *Vide* Practical Observations in Surgery by Mr. Hey, 2d edit. p. 140. Sir Astley Cooper on Hernia, 2d edit. Part 1, p. 15. Nouveaux Elémens de Médecine Opératoire, par M. A. L. M. Velpeau, 2d edit. tom. iv. p. 209. Lawrence on Ruptures, 5th edit. p. 214.

most likely to be met with, as has been already explained, towards the fundus of the sac.

No. 6.



The wood-engraving represents, by a very clear and distinct view, the separation and displacement of the vessels of the spermatic cord, which frequently occur in large and old scrotal herniæ. The cremaster muscle and the other more superficial investments of the hernial sac have been dissected, and turned aside, so as to display more exactly the sac itself, and the relative position which it bears to the testicle and vessels of the spermatic cord. The drawing also serves to show the circular form which is assumed by the lower aperture of the inguinal canal, or external abdominal ring, when distended by the protrusion through it of the sac of a complete external inguinal hernia.

a. That part of the ligament of Poupart, which forms the lower and outer pillar of the external abdominal ring. *b.* The superior and internal pillar of the ring. *c.* Part of the tendinous aponeurosis of the external oblique muscle, covering the rectus muscle. *d.* The linea alba. *e.* The strong and

dense band which is formed by the lowermost of the fibres of the intercolumnar fascia being more closely aggregated together by the pressure of the sac of a large scrotal hernia. It constricts the hernial sac in this situation. *f.* The hernial sac, formed of the peritonæum, distended with air. *g.* The spermatic vessels separated from the vas deferens (*h*), and displaced to the outer side of the tumour, where they are situated not very far from its front surface. *h.* The vas deferens separated from the spermatic artery and vein, and forced to the inner side of the hernial tumour. *i.* The body of the testicle which, in the common form of scrotal rupture, lies underneath the fundus of the hernial sac. *k. k.* The skin and superficial fascia laid open and thrown aside. *l. l.* The cremaster muscle dissected from the front of the hernial tumour, and reflected to either side. *m.* The femoral vein. *n.* The common femoral artery, *o. p.* The abdominal parietes of the inguinal region of the right side laid open, and turned down upon the upper part of the thigh. *q.* The urinary bladder, partially covered superiorly by the peritonæum. 1. The trunk of the external iliac artery just below the crural arch. 2. The epigastric artery. 3. The internal circumflexa ilii artery.

SECTION II.

OF THE VARIETIES OF OBLIQUE OR EXTERNAL INGUINAL HERNIE.

I. OF CONGENITAL HERNIA. — CASE IN WHICH THE HERNIA DESCENDS INTO THE CAVITY OF THE TUNICA VAGINALIS TESTIS.

In the most common form of external or oblique inguinal hernia, the sac which contains the protruded intestines is a morbid production from the peritonæum lining the general cavity of the abdomen, and is usually situated in front of the spermatic cord; its fundus lying above, and being distinctly separated from the body of the testicle and its serous investment, the tunica vaginalis (see the woodcut No. 6, fig. *f, i*); but, in the congenital form of inguinal hernia the viscera, which are the subject of the disorder, descend into the natural cavity of the tunica vaginalis testis, the communication of which with the great bag of the peritonæum has never been obliterated; and, consequently, are permitted to come into close contact with the body of the testicle, to which they are sometimes adherent.

The appellation of *congenital hernia* was first given to this form of the complaint by Haller; who believed that it could not happen, except at or near the time of the birth of the individual, who became the subject of the affection; and previously to the usual period at which the process, by which the obliteration of the connection which originally exists between the cavity of the tunica vaginalis and that of the abdomen is ordinarily commenced.† This opinion of Haller has, however, been clearly proved, by later observers, not to be of such strict and universal application as he was inclined to consider it, and many examples are now satisfactorily established, in which this variety of external or oblique inguinal hernia could not have been formed until many years had elapsed since the birth of the patients; and even in some instances, indeed, not until the middle period of life had been arrived at.‡ There are sufficient grounds, however, for the belief that the majority of cases of inguinal herniæ which happen during early infancy, are likely to prove of the nature of congenital hernia; and, indeed, it is possible, also, that a congenital external inguinal hernia may occasionally be formed in the female subject, when the canal of Nuck remains unobliterated.

It will be recollected that in the fœtus the testes are at first situated within the cavity of the abdomen, in front of the psoas muscles, and at a short distance below the kidneys; and, also, that here they lie behind the peritonæum, which firmly adheres

† In sixteen out of seventeen newly born children, who were examined by Camper, the tunica vaginalis was not obliterated, as is usual, at its upper part, but its cavity remained continuous with the greater bag of the peritonæum. Hesselbach has seen the processus vaginalis peritonæi remaining open on both sides in the body of a man, aged thirty-eight years; but in whom no protrusion of the abdominal viscera had taken place.—*Vide* also *Recherches sur les Hernies*, par M. J. Cloquet, pages 40, 41, and Plate iv. of the same work.

‡ M. Velpeau has seen the congenital form of inguinal hernia occur for the first time in the persons of three young men, all of whom were above twenty years of age, and in whom the testes had descended at the ordinary period. The operation for strangulated hernia was performed by him in two of these instances:—one was cured, but the other died from an attack of peritonitis.—*Vide* *Nouveaux Elémens de Médecine Opératoire*, par Alf. A. L. M. Velpeau, 2d edit. tom. iv. pages 182 and 183.—For similar cases see *Lawrence on Ruptures*, 2d edit. pages 284 and 574.

to their anterior and lateral surfaces, leaving the posterior aspect of these glands wholly uncovered, except by the loose cellular tissue, through which the spermatic vessels run, in their way to reach their final distribution.† From this situation the testes slowly descend, passing through the inguinal canal, into the bottom of the scrotum, where they usually arrive about the eighth month; in this descent they bring along with them the same partial covering from the peritonæum which they had when situated just below the kidneys; which, with the production from the peritonæum already formed in the scrotum for their reception, constitutes the tunica vaginalis testis.‡

The formation of a congenital hernia would seem to be greatly promoted by the testicle not descending at the usual period, as in this case the communication between the cavity of the abdomen and the tunica vaginalis,—which always exists previously to the passage of the testis through the inguinal canal,—remains much longer open than ordinarily, and so a greater opportunity is constantly afforded for the escape of some portion of the intestines into it.

It is by no means an unfrequent occurrence, to find in the dissection of congenital herniæ that the descent of the testicle has been but very imperfectly effected, the gland remaining fixed, either within the inguinal canal, or, even still higher up, in the iliac fossa; and, under these circumstances, it will, also, generally be found that the developement of the organ is so incomplete, that reasonable doubts may be fairly entertained of its capability to execute its peculiar functions.

In other instances, again, a congenital hernia is produced by some portion of the intestines becoming adherent to the front surface of the body of the testicle, as it lies within the cavity of the abdomen, previously to its passage through the inguinal canal, and, in consequence of this unnatural connection, being dragged down along with the gland throughout its descent into the scrotum.§ It must not, however, be understood, from

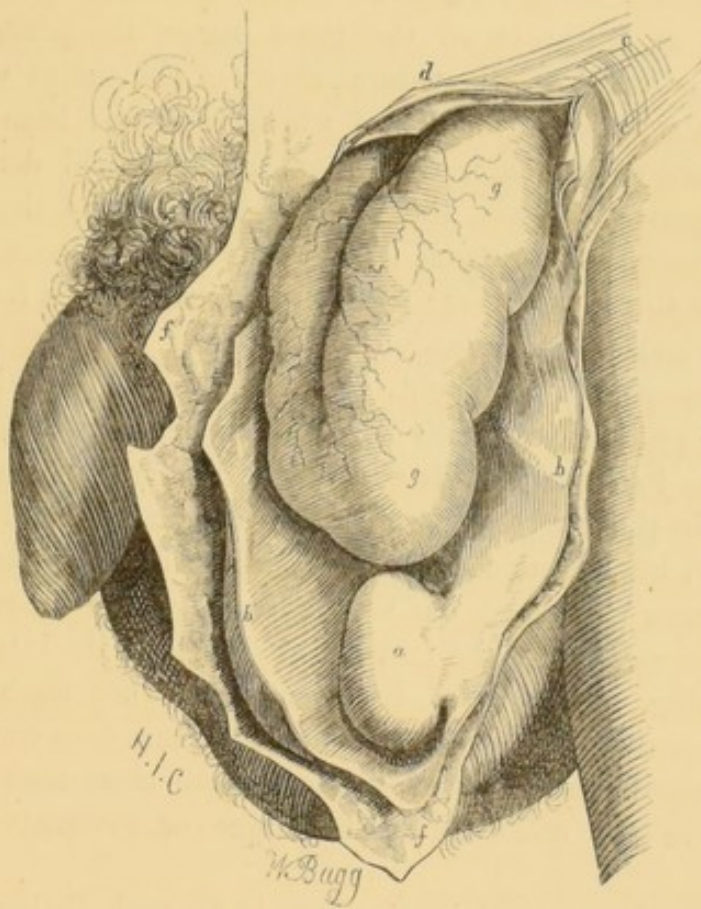
† *Vide* a description of the situation of the testis in the fœtus, with its descent into the scrotum, by John Hunter, Plate .fig. *r*.

‡ *Op. Cit.* Plate III, fig. *u* and *v*.

§ *Vide* Nouveaux Elémens de Médecine Opératoire, 2d edit. tom. iv. p. 184.—Lawrence on Ruptures, 5th edit. pages 567 and 568.—Pott's works, new edit. 1779, vol. ii. p. 162.

what has just been said, that all the adhesions which are so commonly observed between the portion of bowel which is protruded, and the body of the testicle, in cases of congenital hernia, have taken place prior to the descent of the testes into the scrotum, for they are frequently formed very long after this change in their position has been completed.

No. 7.



The wood-engraving represents the manner in which the prolapsed intestine, in a congenital hernia, is contained within the cavity of the tunica vaginalis testis. A comparison of this drawing with those represented in Plate V. at p. 266, and in the wood-engraving No. 6, at p. 277, will clearly demonstrate the characteristic differences which distinguish the common scrotal rupture from the congenital form of inguinal hernia.

a. The body of the left testicle, covered in front and upon its sides by the tunica vaginalis testis. *b, b.* The tunica vaginalis testis, which is a process from the great bag of the peritonæum, and, remaining open at its upper extremity, forms the sac in a congenital inguinal hernia. *c.* The intercolumnar fibres which bind together the pillars of the external abdominal ring. *d.* The

superior or internal pillar of the ring. *e.* The inferior or external pillar of the ring. *f.f.* The superficial coverings of the hernial sac in the scrotum. *g, g.* A fold of small intestine which, in the congenital inguinal hernia, descends into the cavity of the tunica vaginalis testis, where it frequently lies in apposition with, or is adherent to, the body of the testicle.

The superficial coverings of the sac of a congenital hernia are of the same nature as those of the ordinary scrotal hernia (see page 262), from which it only differs in the circumstance of the hernial sac not being formed, as in the latter case, by a morbid protrusion of a portion of the great bag of the peritonæum, but is constituted by the natural cavity of the tunica vaginalis testis, the superior extremity of which has never been closed. They consist of the skin, the superficial fascia and dartos, the external spermatic fascia, the cremaster muscle, and the funnel-shaped processes of the fascia transversalis and subserous cellular tissue (the *fascia propria*); within these structures is found the tunica vaginalis testis distended by the hernia.

In consequence, no doubt, of the constant disposition with which the processus vaginalis peritonæi is naturally endowed, of contracting itself towards its superior extremity, the seat of the stricture in those cases of strangulated congenital herniæ which have either been examined by dissection, or in which the operation has been performed, has very commonly been found in the neck of the sac, and in the immediate vicinity of the internal abdominal ring. It has, also, been remarked, when strangulation of the contents of the sac of a congenital hernia does occur, that the stricture upon the bowel is much more close than usually happens in the other forms of oblique or external inguinal hernia.

In cases of congenital hernia there is no such distinct line of demarcation or furrow observable between the fundus of the hernial sac and the upper part of the testicle, as is noticed in the ordinary form of scrotal hernia.

When the canal of Nuck still exists in the adult female it is quite possible that a hernia might be formed, which would bear the same relation to the round ligament of the uterus as the congenital hernia does to the spermatic cord in the male; but, the distinction of this from the common form of inguinal hernia of females can be of no practical importance, and, therefore, need not be insisted on.

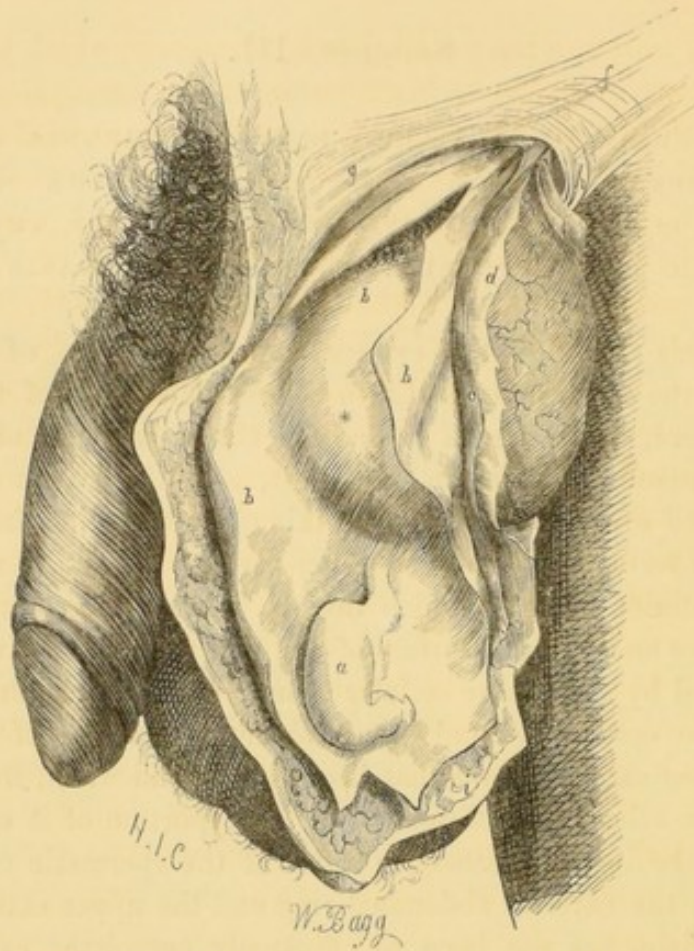
SECTION III.

II. HERNIA INFANTILIS. ENCYSTED HERNIA OF THE TUNICA VAGINALIS. CASE IN WHICH THE HERNIAL SAC IS PROTRUDED INTO THE SHEATH OF THE SPERMATIC CORD, BEHIND THE TUNICA VAGINALIS TESTIS.

In this variety of the external or oblique form of inguinal hernia, the sac is protruded into the cellular sheath of the spermatic cord, and descends behind the tunica vaginalis of the testicle, instead of passing in front of it, as is the case in the common kind of scrotal hernia. In this manner the hernial tumour projects forwards against the upper part of the tunica vaginalis, the posterior layer of which invests, more or less completely, the lower and anterior surface of the sac, from which it is only separated by some loose cellular tissue. This affection is most likely to occur when only the abdominal aperture of the processus vaginalis peritonæi has been closed, and when, from some cause or other, the obliteration of that portion of it which lies within the inguinal canal, in front of the spermatic cord, and between the external abdominal ring and the upper extremity of the testicle, has not been so effectually completed as is ordinarily the case.

The wood-engraving represents, by a side view, the condition of the parts as they have been found upon dissection in cases of infantile hernia. The cavity of the tunica vaginalis of the left side has been laid open, and the hernial sac, with its contents, is seen as it projects behind the posterior layer of that membrane.

a. The body of the testicle, which is covered anteriorly and laterally by the tunica vaginalis testis. *b. b. b.* The tunica vaginalis, the cavity of which is much more extensive than is ordinarily the case;—a free incision has been made into it, so as to show more clearly the relative position of the hernial sac and testicle to one another; and, also, the mode in which the posterior layer of it is projected forwards by the hernial tumour, which is situated immediately behind it. *c.* A portion of the cellular substance, which separates the hernial sac (*d*) from the posterior layer of the tunica vaginalis (*). *d.* The proper hernial sac, which is a fresh production from the great bag of the peritonæum. *e.* A knuckle of small intestine, contained within the hernial sac. *f.* The intercolumnar fibres which bind together the pillars of the ex-



ternal abdominal ring. *g.* The superior and inner pillar of the ring. *h.* The inferior and external pillar of the ring. *i. i.* The superficial investments of the hernia, where it lies in the scrotum.

The late Mr. Hey, of Leeds, was the first to describe this species of inguinal hernia, which he proposed to distinguish by the term *hernia infantilis*, as he considered that it was not likely to be formed at any other time than that of early infancy. It was his opinion, that the intestine, in all such cases, is protruded soon after the aperture by which the tunica vaginalis originally communicates with the abdominal cavity has been closed, and, therefore, that the peritonæum is carried down along with the intestine, and forms the hernial sac. He believed, also, that the hernia must be produced while the original tunica vaginalis remains in the form of a bag as high as the abdominal ring, and is thus able to receive the hernial sac with

its included intestine, and so allow it to come into contact with the testicle.†

Mr. Todd, who has recorded two instances in which he had an opportunity of dissecting large herniæ of this description, differs from Mr. Hey in his opinions as to its nature, and considers that it is by no means peculiar to infancy; but, on the contrary, that it may be formed at any period of life,‡ and, also, that it does occur more frequently than surgeons are aware of. His idea of this species of rupture is, that in it the hernial sac is protruded completely within the cellular sheath of the cord; and, that when it descends near to the point of insertion of the spermatic vessels into the testicle, its fundus comes in contact with the upper part of the tunica vaginalis testis, and receives from it, on its lower surface, a serous covering proportioned to the magnitude of the tumour, or the degree of distension of the sac. Mr. Liston, whose views of the nature of this disorder accord with those entertained by Mr. Todd, operated upon a patient admitted under his care into the hospital of University College some years since, for an inguinal hernia of this kind, the contents of which had become strangulated, and could not be reduced by the taxis. This man did not become the subject of rupture until he had attained the twenty-first year of his age.§

The coverings of the hernial sac in this species of rupture are of the same kind as those which are met with in the common scrotal hernia, with the exception, however, that the upper part of the tunica vaginalis is interposed in front of the tumour, underneath the fascia propria, and hitherto has always been opened by the knife of the surgeon in those instances in which the operation has been performed.||

† *Vide* Practical Observations in Surgery, by W. Hey, F.R.S. Second Edition, 8vo. London, 1810, p. 226.

‡ *Vide* Observations on Hernia, by Charles H. Todd, in the Dublin Hospital Reports, vol. i. p. 237. Mr. Todd relates the case of a man affected with a scrotal hernia of this nature, in which the disease did not occur until the thirty-seventh year of his age.

§ *Vide* A Clinical Lecture on Hernia, by Mr. Liston, in the Lancet of March 21, 1835, page 885. Also Mr. Liston's Operative Surgery. Second Edition, p. 468.

|| Upon this subject see Mr. Liston's Operative Surgery. Second Edition, p. 468, and Sir Astley Cooper on Hernia. Second Edition. Part I. page 79—83.

SECTION IV.

OF INTERNAL OR DIRECT INGUINAL HERNIA.—VENTRO-
INGUINAL HERNIA.

In this form of inguinal hernia the sac is protruded directly through some part of the posterior wall of the inguinal canal, and upon the inner or pubal side of the epigastric artery. (See the wood engraving, No. 9, at p. 287, fig. *r. p.*)

It has already been explained that the peritonæum naturally presents, in the triangular space included between the epigastric artery and the outer edge of the rectus muscle, two deep depressions, or fossæ,† which are separated from one another by the umbilical ligament, and that a direct or internal inguinal hernia may be protruded through the posterior wall of the inguinal canal at either of these points.

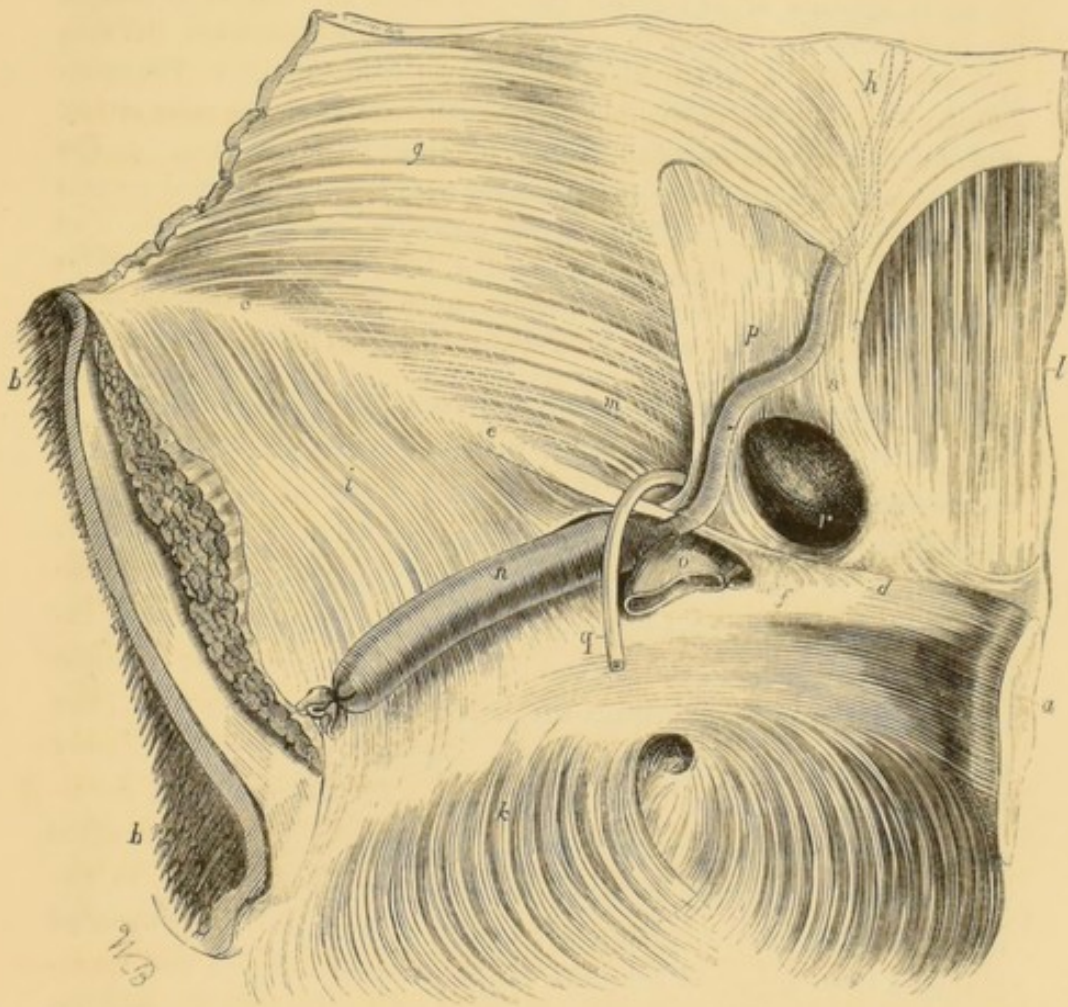
In most persons the conjoined tendons of the internal oblique and transversalis muscles do not extend farther outwards from the margin of the rectus muscle than the umbilical ligament, so that the portion of the posterior wall of the inguinal canal, which is situated opposite the middle fossa of the peritonæum, consists only of the fascia transversalis: if, then, an internal inguinal hernia should commence here,—as is not unfrequently the case,—it will force before it the peritonæum, the subserous cellular tissue, and the fascia transversalis, and, after emerging through the external abdominal ring, will receive additional investments from the external spermatic fascia, the superficial fascia, and skin.

On the other hand, if the hernia commence its descent by being protruded through the third or most internal of the inguinal pouches or fossæ of the peritonæum, the sac—besides being covered by the subserous cellular tissue and the fascia transversalis, as in the foregoing instance—must either break through the conjoined tendons of the internal oblique and transversalis muscles, or it must gradually distend them before it, and so derive an investment from them. In the latter case the hernial

† *Vide* the dissection of the posterior wall of the inguinal canal, at p. 258.

sac will be covered by the skin, the superficial fascia, the external spermatic or intercolumnar fascia, the conjoined tendons of the internal oblique and transversalis muscles, the fascia transversalis, and the subserous cellular tissue: but, in the former, there will be no covering to the sac from the conjoined tendons, whilst the other investments of it remain the same.

No. 9.



The wood-engraving represents a view, from within, of the neck of the sac of a direct or internal inguinal hernia. It will be observed, that the epigastric artery is situated upon the *outer* or *iliac* side of the opening in the posterior wall of the inguinal canal by which the hernia protruded.

a. The cut edge of the symphysis pubis. *b.b.* The ilium sawn across at a little distance from the sacro-iliac symphysis. *c.* The situation of the anterior superior spinous process of the ilium. *d.* The spinous process, or tuberosity of the os pubis. *e.* The posterior surface of the ligament of

Poupart, where the fasciæ iliaca and transversalis unite with each other. *f.* Gimbernat's ligament, which is implanted into the inner part of the iliopectineal line of the os pubis. *g.* The inner surface of the transversalis muscle, partially concealed from view by the fascia transversalis. *h.* A part of the tendon of the transversalis muscle, which forms the posterior division of the sheath of the rectus muscle. *i.* The fascia iliaca, which binds down the iliacus internus and psoas muscles. *k.* The fascia pelvica which is continuous along the brim of the pelvis with the fascia iliaca. *l.* The internal surface of the lower part of the rectus muscle, where the posterior lamina of its tendinous sheath is deficient. *m.* The internal abdominal ring, or upper aperture of the inguinal canal, by which an external or oblique inguinal hernia commences to protrude (see the wood-engraving No. 4, at page 263, fig. *o*). *n.* The trunk of the external iliac artery. *o.* The external iliac vein. *p.* The epigastric artery, which runs along the *outer* or *iliac* side of the neck of the sac of an internal or direct inguinal hernia. *q.* The vas deferens, cut across as it is descending from the inguinal canal towards the side of the bladder. *r.* The internal orifice or mouth of the sac of an internal or direct inguinal hernia. *s.* The line which leads downwards from this letter, marks the proper direction to be given to the incision of the neck of the sac in the operation for a strangulated internal inguinal hernia.

The name of Internal inguinal hernia has been given to this form of rupture by Hesselbach, with the view of indicating the situation which is held by the internal orifice of the hernial sac relatively to the course of the epigastric artery; which vessel, as is seen in the wood-engraving, runs along its *outer* or *iliac* side. By Sir Astley Cooper this affection is named Direct inguinal hernia, because, instead of following the same oblique course as the external form of the complaint, it passes at once through the posterior wall of the inguinal canal, immediately behind the external abdominal ring.† Professor Scarpa considers that it should be regarded as a combination of the *ventral* and *inguinal* forms of hernia; for it approximates itself to the nature of the first, inasmuch as the hernial sac is protruded through the conjoined tendons of the internal oblique and transversalis muscles, opposite the external abdominal ring; and, on the other hand, resembles the more common form of inguinal hernia, in passing in the same manner through the external abdominal ring, along with the spermatic cord.‡

Incomplete internal or direct inguinal hernia.—It sometimes happens that the hernial sac of an internal or direct in-

† *Vide* Sir Astley Cooper on Hernia, 2d edit. Part i. p. 67.

‡ *Vide* Scarpa on Hernia, translated by Wishart, 8vo. p. 82.

guinal hernia, instead of protruding at once through the external abdominal ring, passes into the inguinal canal, where it is closely bound down and compressed by the firm aponeurosis of the external oblique muscle. In this situation the tumour, formed by the hernia, is often exceedingly indistinct externally, especially in corpulent subjects; and is not likely to be recognized, unless a very minute and careful examination be made of the lower part of the abdominal parietes.

Under these circumstances, the existence of a strangulated hernia of this kind has been, on numerous occasions, overlooked; most frequently, however, in females, whose natural modesty induces them to conceal from their medical attendants their knowledge of the fact of there being any swelling or tenderness in the neighbourhood of the groin. So frequently, indeed, has the strangulation of a small knuckle of intestine in this situation passed unnoticed, or only been detected when it had become too late to prevent a fatal termination to the disorder, that it is an established rule of practice with all experienced surgeons, never to undertake the treatment of any case in which there are present any of the rational symptoms which are common to a strangulated hernia, and the several varieties of abdominal inflammation—such as vomiting, constipation, pain and tenderness of the belly, &c.—except they are permitted to institute a strict manual examination of all those regions in which herniæ are most likely to occur.†

Situation of the spermatic cord.—In most instances of direct or internal inguinal hernia the spermatic cord is situated along the external and posterior side of the sac, instead of being placed directly behind it, as is the case in the external or oblique form of inguinal hernia.

A very remarkable exception, however, to this rule was observed by the late Mr. Todd, of Dublin; in which he found, upon making a dissection of the parts, the spermatic cord extended, in an undivided state, across in front of the upper part of the sac to its pubal side, and then descending on that side to the posterior surface of the sac where the testicle was situated. In this case the hernia, in place of passing anterior to the cord,

† For cases where strangulated herniæ of this kind passed unnoticed until after the death of the patient, see Sir Astley Cooper on Hernia, 2d edit. Part I. p. 73.—Lawrence on Hernia, 5th edit. p. 228.

had protruded between it and the inferior pillar of the ring, in such a manner that the cord formed a sort of arch, embracing the neck of the sac for nearly two-thirds of its circumference, close to the external abdominal ring.†

It has been very generally stated by surgical writers, that, inasmuch as the sac of a direct or internal inguinal hernia does not follow, in its descent through the inguinal canal, the same course as the spermatic cord, it is not covered by any of the fibres of the cremaster muscle. This statement, however, is not invariably correct, for in several examples of this species of rupture, which have been met with in the dissecting rooms of University College during the last four winters, it was noticed that the hernial sac derived a partial investment from the cremaster muscle.‡

That direct or internal inguinal herniæ are of much less frequent occurrence than the oblique or external form of rupture, has been remarked by all those who have attentively examined the subject; and, if we adopt the opinion of M. Jules Cloquet, their comparative frequency may be estimated as 1 to 5.

There is no doubt, also, that direct inguinal hernia is much less frequently met with among women than men; indeed, Sir Astley Cooper mentions that he has never witnessed any example of it in a female.§ Professor Cooper, however, once attended a patient, a female, who was the subject of a hernia of this description, the contents of which had been strangulated for three or four days previously: under these circumstances he performed the operation at once, without trying any other means but the taxis, and, in a very short time, the woman perfectly recovered.||

This rarity of the occurrence of direct or internal inguinal hernia amongst females is, in a great measure, attributable to the small size of the external abdominal ring, and to the very limited

† *Vide* Observations on Hernia, by Charles H. Todd, in the Dublin Hospital Reports and Communications, vol. i. p. 231.

‡ Similar cases have been observed by M. Jules Cloquet (*Recherches Anatomiques sur les Hernies de l'Abdomen*, p. 83, Proposition xxxviii.), and by Mr. Todd (Dublin Hospital Reports, vol. i. pp. 230-31).

§ *Vide* Sir Astley Cooper on Hernia, 2d edit. Part I. p. 73.

|| *Vide* The First Lines of the Theory and Practice of Surgery, by Samuel Cooper, 7th edit. p. 560.

dimensions of the inguinal canal in them, as well as to the greater degree of resistance which the several structures composing its posterior wall are capable of affording to the protrusion of the abdominal viscera at any other point than the internal abdominal ring; while, on the other hand, the large size of the crural ring, and the greater laxity of the parts connected with it, necessarily predispose them to become rather the subjects of femoral hernia.

From the observations which have been made by Sir Astley Cooper, it would appear that a direct or internal inguinal hernia is very frequently occasioned in men by the inordinate muscular efforts which are requisite to effect the expulsion of the contents of the urinary bladder, in consequence of old and tight strictures of the urethra.†

The epigastric artery has been observed, in one case, the dissection of which was made by Hesselbach, to run along the inner or pubal side of the neck of the sac of a direct inguinal hernia, instead of taking its usual course along its external or iliac edge. In the subject, a female, in whom this variety in the course of the epigastric artery was noticed, the vessel took its origin from the obturator artery, in place of arising, as is usual, from the trunk of the external iliac artery; and ascended, in a perpendicular direction, upon the inner surface of the abdominal parietes. In such a position the epigastric artery could hardly escape from being wounded, should the operation be performed, and the stricture divided, as has been advised by many, inwards, in the direction of the linea alba.

Since the investments of the sac of an internal or direct inguinal hernia are, in general, rather thinner than those which cover an external or oblique inguinal hernia, a greater degree of caution is required to be observed by the surgeon during the operation, lest the contents of the sac should be exposed unawares, and injured by the edge of his knife.

† *Vide* Sir Astley Cooper on Hernia, 2d edit. Part II. p. 67, and plate x. of the same work.

SECTION V.

Inguinal herniæ containing the cæcum, the sigmoid flexure of the colon, or the urinary bladder.—An inguinal hernia is sometimes formed by the gradual descent of the more fixed portions of the large intestine; as, for example, on the right side, of the cæcum, and, on the left side, of the sigmoid flexure of the colon. The urinary bladder has, also, been observed to descend through the inguinal canal into the scrotum.† These cases are, however, comparatively of rare occurrence.

In these instances the protruded viscus is only partially covered by a peritonæal sac, usually upon its anterior aspect, but now and then only upon one side, generally the inner one; for, in descending from its natural situation, the bowel does not lose the relations which it previously held with the serous membrane, which lines the cavity of the abdomen. These changes are permitted to take place by the lax and extensible property of the cellular substance which is so abundant in the iliac fossæ, and it is owing to the same cause that their progress is so very gradual.

Herniæ of this kind do not admit of being replaced so readily as the more frequent forms of inguinal ruptures, and much caution is required, when they are the subject of strangulation, in the performance of the operation, lest the intestine should be laid open by the surgeon, who is apt to proceed too carelessly in the dissection of the parts as they present themselves under his knife, thinking himself secure because he has not arrived at a sac, which in reality does not exist.

It has just now been stated, that a partial investment from the peritonæum usually covers these herniæ upon their anterior and inner aspects; but it sometimes happens that there is no peritonæal sac at all; as when only the lower and posterior part of the cæcum forms the protrusion, and in some examples of herniæ of the bladder.

Herniæ of this nature are sometimes complicated by the

† Mr. Pott removed a calculus from the bladder of a boy, the subject of this disorder, by cutting into it as it lay in the groin. Pott's Chir. Works, vol. iii. pp. 322—328.

presence of a portion of omentum, or of the small intestine, which renders the case still more difficult.

When it is necessary to operate in order to relieve a rupture of this kind from strangulation, the surgeon must content himself with cutting down upon the seat of the stricture, and having enlarged this, he is, in many instances, obliged to leave the bowel where he finds it; from whence, however, it is sometimes withdrawn by slow degrees into the belly again by the simple efforts of nature.

CHAPTER IV.

OF THE DIAGNOSIS OF INGUINAL HERNIÆ FROM SOME OF THE DISEASES WITH WHICH THEY ARE LIKELY TO BE CONFOUNDED.

THE diseases with which inguinal herniæ are most liable to be confounded, are hydrocele, either of the tunica vaginalis, or of the spermatic cord; hæmatocele; varicocele; chronic abscess, having its seat in the iliac fossa; enlargement of the testicle from various causes; a suppurating inguinal gland; and steatomatous growths upon the spermatic cord within the inguinal canal. In the female, a femoral hernia is occasionally mistaken for a rupture of the inguinal species.

Hydrocele.—It occasionally occurs in practice that considerable difficulty is experienced, even by very distinguished surgeons, in determining the nature of the tumour of a hydrocele; for, when the collection of fluid in the tunica vaginalis is so large as to extend for some way upwards into the inguinal canal, the swelling may have the same form as a scrotal hernia, and, like it, may be very tense and elastic, and receive an impulse whenever the patient is made to cough. If the contents of such an hydrocele should be opaque, then an additional source of doubt is created, and the difficulty of coming to a decisive conclusion greatly increased.

But the sense of fluctuation which may generally be perceived on handling the tumour, its transparency when examined in the usual way with a lighted candle in a darkened room, its light weight as compared with that of a hernia, and the history of its progress, which shows that its first commencement was below, and that it gradually increased in size upwards,—joined with the possibility of feeling a portion of the spermatic cord free, betwixt the summit of the swelling and the abdominal rings,—are signs which, when taken collectively, are quite sufficient, at least in the cases of hydrocele which are ordinarily met

with, to serve as the basis upon which a correct diagnosis may be safely established.

When a hydrocele is combined with a hernia, the former is most commonly situated in front of and below the latter.

By a careless observer a congenital hydrocele, which is most likely to be met with in children, may be mistaken for an inguinal hernia, as the swelling can be easily made to disappear into the abdomen by pressure, but returns again whenever the patient coughs, or assumes the erect position; but its transparency and fluctuation clearly denote its true nature.

The diagnosis, however, of some cases of congenital hernia, where the intestine is adherent to and strangulated by the neck of the sac, may be rendered extremely difficult and obscure, on account of the presence of a large quantity of fluid in the lower part of the sac, which distends it and gives to it all the characters of a hydrocele.†

Hydrocele of the spermatic cord.—When an encysted hydrocele of the spermatic cord is situated below the external abdominal ring, it is easily recognized by its transparency when viewed against the light, by the sense of fluctuation which may be perceived on compressing it between the fingers, and by its mobility upon the cord; but the case is far different when the swelling is placed within the inguinal canal, as it is then concealed from sight, nor can we always distinguish a portion of the cord to be free betwixt it and the internal abdominal ring. I well remember a young man being sent into University College Hospital on account of a swelling of this nature in the inguinal canal, which was said to be a small inguinal hernia, and for which he had been recommended to wear a truss. Mr. Cooper, under whose care the youth was admitted, cut down upon it, and removed a portion of the front of the cyst, after which the lad was quickly discharged cured of his complaint.‡

But the round or ovoid form of the swelling, its constant unvarying size, which is commonly that of a chesnut, and rarely exceeding that of an egg, the ease with which it may be moved upon the cord, and its great tenseness and elasticity, to which

† For the details of two cases in which this difficulty was experienced, see Pott's Works, vol. ii. p. 415, Cases xxxiv and xxxv.

‡ This case is mentioned by Professor Cooper, in his First Lines of Surgery, 7th edit. p. 596.

signs may be added the absence of any disturbance or interruption of the functions of the alimentary canal, will be generally found sufficient to prove that the tumour cannot be an inguinal hernia.†

Hæmatocele.—This disease, which consists in a collection of blood either in the tunica vaginalis testis, within the tunica albuginea, or in the cellular tissue of the scrotum, is distinguished from inguinal hernia by many of the same signs as hydrocele, from which it chiefly differs in not being transparent, nor of so light a weight; while, on the other hand, it may present the same form, the same volume, and be of the same indolent character, accompanied, however, with a more obscure sense of fluctuation. I have, notwithstanding, known a hæmatocele mistaken for a strangulated inguinal hernia, and the operation proposed for its relief, in the case of an elderly person, who, it was afterwards found out, had long laboured under hydrocele of the tunica vaginalis. In this person the complaint was suddenly induced by a violent blow over the region of the inguinal canal, and was quickly followed by pain and tension of the part, accompanied by urgent sickness and vomiting, and constipation of the bowels. The patient was sent into the hospital, to have the operation performed, when a more strict investigation into the history of the case was made, and the conclusion arrived at that it was not a hernia, but a hæmatocele, suddenly supervening upon an old hydrocele; an opinion which was fully confirmed by the subsequent history of the case.

Varicocele.—There are few diseases, perhaps, which have been more frequently mistaken for an inguinal hernia than a varicose enlargement of the veins of the spermatic cord; and yet, to a close observer, it would seem hardly possible to confound the two complaints with one another. This disease more frequently affects the veins of the cord of the left side than those on the right. It presents itself under the form of a soft, indolent, and inelastic swelling, which is, for the most part, situated just above the body of the testicle, but sometimes extends as high as the external abdominal ring; its surface is unequal, and nodulated; it easily yields under the pressure

† For an interesting case where the presence of a small strangulated inguinal hernia was masked by a hydrocele of the cord, and the operation performed, see Liston's Operative Surgery, 3rd edit. p. 538.

of the hand, and, when examined attentively, communicates to the touch the sensation — as it has been very aptly designated — of grasping a bundle of earth-worms. In large varicoceles an impulse may be communicated to the tumour upon coughing; but the essential distinction between this complaint and an inguinal hernia, is drawn from the circumstance, that while the latter, when it has once been reduced, cannot re-descend so long as the inguinal canal is maintained closed by pressure made upon it by the fingers, the former reappears even still more quickly than before; and this happens also, notwithstanding the patient keeps the recumbent position, and avoids the slightest exertion.

Chronic abscess of the iliac fossa, psoas abscess, &c.—Sometimes large deposits of pus are collected in the loose cellular tissue which abounds in the iliac fossæ, and, descending through the inguinal canal, form a prominent tumour in the situation of the external abdominal ring, presenting many of the characters of an oblique inguinal hernia; for example, such as a sudden disappearance of the swelling under pressure, or when the patient lays himself down in the recumbent position, and as quickly reappearing when he raises himself erect, and being always accompanied by a distinct impulse upon coughing. Psoas abscesses occasionally follow the same course, and may cause the same difficulty in establishing a correct diagnosis. Professor Cooper had the kindness to show me a case of this kind, which had been brought to him for his opinion, in which a truss had been previously worn by the patient for a considerable time, under the impression that he laboured under an inguinal hernia.

A careful examination into the whole history of the case, and a strict investigation of all the symptoms, will, however, rarely fail to enable us to steer clear of the error of mistaking either of these complaints for an inguinal hernia.

Enlarged testicle.—If the mistake had not actually occurred, some persons might feel inclined to ridicule the idea of the possibility of any enlargement of the testis being ever mistaken for an inguinal hernia; but several cases of this kind have been recorded by various writers on surgery, in which considerable difficulty was experienced in arriving at a correct diagnosis.

Sir Charles Bell mentions one instance in which he saw the

operation for bubonocoele performed where there was only a tumour of the testicle.† These mistakes have usually occurred where the testicle has not descended completely into the scrotum, but remains within some part of the inguinal canal, and, becoming attacked by inflammation, induces a series of symptoms liable to be confounded with those accompanying a strangulated congenital hernia. An extremely interesting case came under the notice of Professor Cooper, in which the symptoms which accompanied an attack of acute inflammation of the testicle were such as very strongly resembled those usually regarded as pathognomonic of strangulated intestine, and, as Sir Astley Cooper has rightly observed, might have induced a less experienced surgeon to regard the case as one of strangulated hernia.‡ “I once attended,” says Mr. Cooper, “a soldier, with acute inflammation of the testicle, in the Military Hospital of Canterbury, who experienced so much pain in the abdomen on the fifth day of the attack, accompanied by vast swelling of the cord, almost incessant vomiting, complete and obstinate stoppage of the stools, and severe constitutional disturbance, that a suspicion of hernia was raised. The absence of tension in the abdomen, the limitation of the pain to one side of the belly, the inability of feeling any thing like the testicle of its ordinary size below the tumour, as in a bubonocoele, and the history which made it impossible that the case could be a congenital hernia, were circumstances which prevented an erroneous view of the complaint from being adopted.”§ Several instances of a similar nature are related by the justly celebrated Mr. Pott in his excellent treatise upon Hydrocele.||

The solidity and peculiar form of the swelling, and the characteristic pain which is excited by pressure upon the part, added to the previous history of the case, will generally be sufficient to enable us to arrive at a correct diagnosis.

Suppurating inguinal gland.—It sometimes happens that

† *Vide* a System of Operative Surgery, founded on the basis of Anatomy, by Charles Bell, vol. i. 8vo. Lond. 1807, p. 258.

‡ *Vide* Observations on the Structure and Diseases of the Testis, by Sir Astley Cooper, Part II. p. 13.

§ *Vide* a Dictionary of Practical Surgery, by Samuel Cooper, 7th edit. p. 1215.

|| *Vide* the Chirurgical Works of Percivall Pott, F.R.S. 2d edit. vol. ii. pp. 223—31.

a combination of symptoms, such as are commonly looked upon as indicating strangulation of a portion of bowel, accompany the formation of an abscess seated in one of the glands of the inguinal region, and have led hasty and careless observers to form an erroneous opinion as to the nature of the swelling, which is mistaken for a strangulated hernia, requiring the operation to be performed for its relief. Much judgment and discrimination is often required to be exercised in determining the nature of such cases.

On the other hand, the tumour formed by a small hernia, the contents of which are really strangulated, has been mistaken for an abscess, and much valuable time lost in the application of remedies which are incapable of affording the slightest relief. Sir Charles Bell tells us that he has seen four surgeons unanimously of opinion that a bubonocoele was a suppurating gland.†

It is not very many years since I was shown a woman, a patient in a very large hospital, who soon afterwards died in consequence of this error in diagnosis having been committed by one of the dressers of the institution, who laid open a strangulated hernia under the impression that it was a simple abscess in the groin.

Steatomatous tumours upon the spermatic cord.—Large masses of adipose substance are not unfrequently formed in the inguinal canal, upon the spermatic cord and round ligament of the uterus, and form a tumour possessing many of the characters of an inguinal hernia. These steatomatous tumours are occasionally accompanied by a small protrusion of the membrane of the peritonæum, constituting a small hernial sac.

Femoral herniæ.—If close attention were always paid to the situation which is occupied by the neck of the tumour, it would be next to impossible to mistake a femoral for an inguinal hernia; for in the latter it is placed *above* the ligament of Poupart, while in the former it lies *below* it. The mistake is most liable to occur in the female, for the round ligament of the uterus does not afford us the same assistance in making a diagnosis, as the spermatic cord in the male.‡

† *Vide* a System of Operative Surgery, vol. i. p. 259. Also Sir Astley Cooper on Hernia, 2d edit. Note at foot of page 71.

‡ *Vide* Sir Astley Cooper on Hernia, 2d edit. Part I. p. 71.

Whenever a tumour in the groin is accompanied by obstinate constipation, and other symptoms resembling those of strangulated hernia, which are not clearly referrible to other causes, it is to be considered an established rule of practice to cut down upon the swelling, and thus ascertain its precise nature; for many instances have occurred where this rule has been neglected, and the patients permitted to die unrelieved from a small knuckle of intestine being strangulated behind swellings of the nature just described.†

† The reader will find several important cases, illustrating forcibly the propriety of this rule of practice, mentioned in the *Surgical Anatomy of Femoral Hernia*, pp. 138, 139.

CHAPTER V.

OF THE REDUCTION OF INGUINAL HERNIÆ BY THE TAXIS.

ON many occasions the reduction of an inguinal hernia by the taxis is a very easy and safe proceeding, and one which may be undertaken by even the most ignorant persons without any risk being incurred by the patient; as, for example, when the constriction which confines the hernia is of so slight a nature as to yield readily to a very moderate and gentle compression of the tumour. But when the hernia is very tightly girded by the stricture, and has been so for a considerable time, then the nature of the case is very much altered, and it becomes a matter of the greatest importance that the efforts employed to return the contents of the sac by the taxis should be directed by superior judgment and skill. There can be no doubt that much of the danger which so frequently attends upon the operation for strangulated hernia is the result of the force—too often misapplied for an improper length of time—which it is thought requisite to employ before having recourse to the use of the knife. The details of numerous dissections have been recorded by different writers, which satisfactorily prove that the fatal termination of a great number of the cases in which the operation has been performed without success, may be fairly attributed to the extensive bruising and even laceration of the coats of the tender and inflamed intestines, which is caused by the rude force with which they had been compressed against the sharp, resisting edges of the openings through which they had been protruded.†

It is, nevertheless, on many occasions, and more particularly so in hospital practice, exceedingly difficult to decide whether the taxis should be tried any longer; for many examples con-

† *Vide* a very interesting case of strangulated inguinal hernia, in which the bowel was ruptured by the patient in his efforts to return it; with observations, by Benjamin Travers, F.R.S. in 23d vol. of Med. Chir. Trans. Lond. 1840, p. 1.

tinually occur in which an experienced surgeon is able to relieve the patient quickly and safely from a state of imminent danger, even after the most violent and long-continued attempts to effect the same object have been made in vain by others who preceded him in the treatment of the case. But it is, also, equally certain, that the chances of success from the operation which must eventually be had recourse to in all those cases where the taxis—no matter how carefully and skilfully it has been employed—fails to achieve the return of the strangulated parts, are greatly diminished in consequence of the violence which necessarily attends its use. Indeed, many excellent and experienced surgeons have denounced, in very strong terms, the indiscriminate employment of the taxis in all cases of strangulated hernia; and have not hesitated to affirm that it has, upon the whole, been productive of more harm than good, and that the operation is most likely to succeed when no attempts to reduce the hernia have previously been made.†

The principal question to be decided before proceeding to the employment of the taxis is, in the first place, to determine the exact nature of the hernia; whether it is really an inguinal rupture: and, secondly, whether it is of the external and oblique form, or of the internal and direct kind,—for in the former of these varieties the direction of the force which it is necessary to employ is essentially different from that required by the latter.

The other points of importance, which remain to be considered, are,—what is the period of time that has elapsed since the descent of the hernia, and the commencement of the urgent symptoms of strangulated intestine;—the degree of pain and tenderness under pressure of the tumour, but more especially of the belly generally;—and, also, what attempts to reduce the hernia have been made by other surgeons, taking particularly into account their duration, and the amount of force that has been employed, and how far it is probable that these attempts were directed by so much of surgical and anatomical knowledge as would render any further trial of the taxis not only unnecessary, but likely rather to be hurtful than beneficial towards securing the safety of the patient.

In the practice of all large hospitals, the correctness of the

† See the works of Pott, Richter, Petit, Velpeau, Cooper.

foregoing remarks is very strongly illustrated by the history of the cases of strangulated herniæ which are continually admitted into these institutions; for it will be found, upon making the inquiry, that in most of them the patients have undergone, previously to their admission, several long-continued, and, frequently, very violent attempts to reduce the hernia by the taxis, but which have not, however, been followed by success, on account of ignorance or forgetfulness in the operator of the principles by which he should be directed in his endeavours to attain the object sought for.

Before, then, proceeding to employ the taxis, care should be taken to place the patient in such a position in his bed, that all the structures connected with the formation of the inguinal canal may be relaxed to the utmost degree possible. Thus, for example, the thigh of the affected side should be raised and bent upon the pelvis, and, at the same time, rotated inwards, in order that all tension of the lower part of the abdominal parietes, depending upon the connexion between the iliac portion of the fascia lata, and the lower edge of Poupart's ligament, may be completely removed. Some additional benefit, in this respect, is frequently obtained by placing the opposite limb in a similar position. The shoulders and head of the patient should also be elevated as much as possible, by means of pillows introduced underneath them; and he himself should be held engaged in conversation, with the double object of diverting his attention from the operator, whose good intentions he is very likely to frustrate by opposing all his efforts; and of preventing him thereby from diminishing the space of the abdominal cavity by the contraction of the diaphragm, which is necessarily attendant upon the holding of the breath. The surgeon ought, also, to be very careful to obliterate at the first, by drawing the contents of the hernial sac slightly downwards, the angle which is formed by that part of the strangulated bowel which is immediately external to the seat of the stricture, with the portion of it which is embraced within its grasp; for if he should overlook this preliminary step, he is very liable to be foiled altogether in his attempt to reduce the hernia, and, on the other hand, is much more likely to injure the coats of the intestine, by rudely squeezing it against the firm resisting margins of the stricture.

Besides the risk of contusing and lacerating the coats of the prolapsed intestine, which is constantly attendant upon the violent and unskilful performance of the taxis, there is also another danger to be avoided, that of forcing back into the abdominal cavity the hernial sac along with its contents, still closely girt by the stricture, which in these cases commonly depends upon the altered and thickened state of the peritonæum, forming its neck or internal orifice. This reduction of the hernial tumour in a mass, which has been well described by the French writers upon surgery, under the term of *reduction en bloc*, has been frequently observed to happen in the hands of ill-educated practitioners, who are not generally made aware of their error, until the speedy death of the patient affords an opportunity for inspecting the parts, when the sac, with its contents still strangulated, is found rolled up in the loose cellular tissue which lies between the muscular parietes of the iliac fossa and the peritonæum.

The direction of the force which it is necessary to employ for the reduction of an incarcerated inguinal hernia by the taxis, must be varied according to the form of the rupture, whether it be of the oblique external or direct internal kind. In the first case the pressure upon the tumour should be made in the same line as the direction of the inguinal canal; that is to say, obliquely upwards and outwards, towards the centre of the space included between the anterior superior spinous process of the ilium and the symphysis pubis; whilst, in the latter, it should be made more directly backwards, in the course of an imaginary line drawn from the external abdominal ring towards the promontory of the sacrum.

The surgeon, grasping the tumour with one hand, fixes the parts in the vicinity of the neck of the sac with the other, and seeks to return, by a gentle and moderately increasing pressure, that portion of the strangulated intestine which descended the last. Any portion of the bowel that may be thus returned is to be prevented from again descending by making compression of the upper part of the sac with one hand, while with the other a fresh hold is taken of that which still remains down.

If it be thought advisable, the efforts of the surgeon to reduce the hernia by the taxis may be assisted by general bleeding, the use of the hot-bath, and all such other remedies as are

known to possess a powerful influence in diminishing muscular tone and vascular action.

When a judicious trial of the taxis fails to effect the return of the hernia, and there exist no good and sufficient grounds for believing that any benefit is likely to accrue from waiting to make any further attempt, it can be of no use to lose time in the employment of any of those local applications which are too frequently recommended to be tried in such cases; but it will be better for the interests of the patient if the operation be at once proceeded with.

It not unfrequently happens, after the reduction of a strangulated hernia by the taxis, that a certain degree of obscure tumefaction still remains about the parts in the inguinal canal, as well as in the scrotum, and excites a doubt in the operator's mind whether the whole of the protrusion has been effectually returned; but, it should be remembered, that this appearance is very deceptive, and very probably is owing to a serous infiltration of the cellular sheath of the cord, or to an effusion of serum into the interior of the hernial sac; in either case there is no just ground for alarm or anxiety.

It may not be altogether out of place to mention here, that it is only by the knowledge derived from practice, and not from descriptions, however carefully they may be given, that we are taught to estimate correctly the exact amount of force that may be safely used in employing the taxis in different cases of strangulated hernia, and to acquire that tact which is absolutely necessary to make an adroit use of those manœuvres which very frequently prove of essential service in our endeavours to secure a successful result.

CHAPTER VI.

OF THE OPERATION FOR STRANGULATED INGUINAL
HERNIE.

THE patient should be placed upon the table, or on the edge of his bed, in the recumbent position; his shoulders being well supported by pillows, with the view of relaxing, as completely as possible, the abdominal muscles. The hair should be previously removed by shaving the parts.

The first incision — which should comprise in its depth the skin and subjacent adipose layer — ought to be commenced well over the neck of the tumour; at the distance, perhaps, of an inch and a half from the outer angle of the external abdominal ring: the object, in so doing, being to render more easy of execution the future steps of the operation, and, more particularly, the safe division of the stricture, which is most frequently seated near the superior aperture of the inguinal canal. The incisions necessary to expose the contents of the hernial sac should be made upon the centre of the front of the tumour, or rather more towards its inner than its outer side, so as more effectually to avoid the danger of injuring any of the component structures of the spermatic cord, should they happen to be separated from one another in the manner described at pages 276, 277. (See also the wood-engraving No. 6.)

In cases of large scrotal herniæ it is unnecessary to prolong the incisions quite to the fundus of the swelling; as, besides the greater risk which exists in such cases of injuring some of the elements of the spermatic cord, its great length could prove of no advantage to the surgeon; and, on the other hand, would be very likely to expose the patient to the unpleasant circumstances attendant upon making an opening into the cavity of the tunica vaginalis testis.

In small herniæ, however, and especially in incomplete bubonocèles, the external incisions should be carried over the

whole extent of the tumour ; for, unless this were done, sufficient space would not be obtained for the secure and easy completion of the operation.

The first incision may be made, according to the choice of the operator, in one of three ways ; viz. by simply sweeping the knife over the convex surface of the tumour, in the direction of its long diameter ; or by raising the integuments covering the swelling into a thick transverse fold, one half of which is held by an assistant, while the surgeon takes the other in his left hand and cuts it through, either from its surface to its base ; or in the opposite direction, first transfixing it below with the bistoury, the back of which is turned towards the sac, and then cutting outwards. The first of these modes of proceeding is to be preferred when the external investments of the hernia are unusually tense, whilst the other two are more applicable when they are very lax.

In the division of the integuments the external pudic artery is cut across, and, occasionally, also the superficial epigastric artery. If either of these vessels should bleed freely, it is best to secure it immediately with a ligature, before proceeding any further in the operation ; since, if this be omitted, secondary hemorrhage is very likely to occur after the wound has been closed and the dressings applied, and so to give rise to considerable disturbance of the parts.

The several coverings which the hernial sac derives from the intercolumnar fascia, the cremaster muscle, the fascia transversalis, and the subserous cellular tissue, are, in the next place, to be divided either with the knife and dissecting forceps, or by cutting them layer by layer, a director being previously introduced underneath them. It should, however, be clearly understood, that such great variety is continually met with in the appearance, number, and thickness of the several investments of the hernial sac, that it is frequently impossible to recognize them separately in the operation.

It may be of some use to mention here, that the subserous cellular tissue is sometimes very thick, and resembles so closely the omentum, that it may for a moment deceive the surgeon in the operation, especially in cases of direct or internal inguinal herniæ, and lead him to conclude that the sac has been opened before it has been actually exposed.

The hernial sac having been in this manner brought into view, it is to be opened at first upon its lower and anterior part. For this purpose, a small portion of it should be taken up between the blades of the forceps, and an opening carefully made into it, the edge of the knife being directed horizontally. Some surgeons prefer pinching up a small piece of the sac between the finger and thumb of the left hand, and after rubbing it between them, in order to ascertain whether any of the intestine is included, which being decided in the negative, they proceed to open it as before. The aperture which is thus made is to be enlarged to the same extent as the external incisions, by dividing the sac upwards and downwards with the probe-pointed bistoury, guided upon the fore-finger or the director.

The next step in the operation is to seek for the seat of the stricture, by carrying the fore-finger of the left hand upwards, between the sac and the protruded viscera. In the greater number of cases the stricture will be found at the margin of the internal abdominal ring, or in the neck of the sac. Sometimes—but this occurs very rarely—the stricture is situated at the external abdominal ring, or, perhaps, about midway between it and the internal ring, being there produced by the lower edge of the internal oblique and transversalis muscles. It may, on the other hand, exist in a very few instances in some other part of the sac below the inguinal canal.

The sensation which the condensed band of cellulo-fibrous tissue, which commonly forms the stricture, communicates to the finger, strongly resembles what might be supposed would be produced if a piece of strong packthread were drawn so closely around the neck of the sac as to make a defined circular indentation in it, the free border of which projects towards its centre.

In a direct or internal inguinal hernia the stricture is frequently seated in the margins of the lacerated opening in the conjoined fibres of the internal oblique and transversalis muscles, through which the hernial sac has protruded.

The extremity of the common probe-pointed bistoury—guided upon the fore-finger of the left hand, which forms the best director—is now to be cautiously introduced underneath the stricture; which is then to be divided by turning forwards the edge of the instrument, and gently elevating its handle, at the

same time that its point remains steadily fixed in its position within the neck of the sac.

The direction of the incision necessary to divide the stricture should be, in all cases of inguinal herniæ, vertically upwards, parallel to the *linea alba*; since by so doing there can be no chance of doing any injury to the epigastric artery. A very slight cut, not exceeding, perhaps, the eighth part of an inch, will be generally found sufficient to liberate the strangulated bowel.

It is of the utmost importance, during the division of the stricture, that the prolapsed intestines should be completely protected from injury by the knife; which may be done either by the fingers of the operator's left hand being spread over them in such a manner as to prevent them from rising over the edge of the instrument; or, should he be otherwise engaged, then the same object may be fulfilled by the hand of an attentive and intelligent assistant.

It is also very necessary, while endeavouring to reduce the contents of the hernia into the belly, that the sac should be firmly held by its margins; since it has happened, in consequence of neglecting this very advisable precaution, that both it and its contents have been rudely thrust back into the abdomen together in a mass, the bowel remaining still girt by the stricture.

The stricture having been divided, the contents of the hernia must be reduced with great care and gentleness; and, if it should happen that both omentum and intestine have descended, the latter should be replaced before the former. It will facilitate the return of the parts, if the thigh be raised and rotated inwards, as has been already recommended while treating of the taxis.†

The operation being concluded, and the parts safely returned into the abdomen, which is to be ascertained by gently introducing the point of the finger into the mouth of the hernial sac, the edges of the wound should be brought together by a few points of the interrupted suture, and the dressings supported by a thick compress and spica bandage. A copious enema may now be administered by means of the patent syringe; and if this

† *Vide* page 300.

fail, which it seldom does, to produce the desired effects, its action may be promoted by some mild laxative mixture given by the mouth.†

Division of the stricture without opening the hernial sac.—Some very excellent surgeons have strongly recommended the stricture to be divided without opening the hernial sac, and there is no doubt but that this method should be practised whenever it is possible to do so ; yet, at the same time that we acknowledge its superior advantages, we should not forget that it is only applicable to a very small proportion of the cases in which it is requisite to have recourse to the use of the knife. It is done by slipping the director underneath the fascia propria in the vicinity of the lower margin of the transversalis muscle, and dividing both of these structures, with any other tendinous band which may oppose the easy reduction of the contents of the hernia. This plan may also be employed with advantage when the stricture is situated at the external abdominal ring. Notwithstanding that I have seen this mode of operating tried in a great number of cases, I never saw it once succeed.

† For further observations upon the treatment after the operation, and the appearances which are found after death, when a patient dies from a strangulated hernia, the reader is referred to the Surgical Anatomy of Femoral Hernia, pp. 149—152.

THE SURGICAL ANATOMY

OF

THE TESTIS

AND ITS COVERINGS.

AN intimate and accurate acquaintance with the anatomy of the several structures which compose the coverings of the testicle is a subject that demands, in the highest degree, the close attention of all those who are desirous of qualifying themselves to enter upon, with credit and satisfaction to themselves, and with safety to the patients who may be submitted to their care and superintendence, the consideration of the many difficult questions which constantly present themselves for solution by the practitioner, when engaged in the treatment of the numerous and varied diseases to which these organs are liable. Were the anatomy, natural as well as morbid, of this portion of the human frame more diligently studied, we should cease to find those errors in diagnosis so frequently committed by persons who ought to know better; by which an extravasation of urine underneath the dartos is mistaken for an inflammatory swelling of the testicle, hæmatocele for malignant disease of the same organ, and hydrocele and varicocele confounded with scrotal herniæ; with many other serious blunders of a similar nature.

1. *The scrotum.*—The cutaneous investment of the testicle is chiefly remarkable for the thinness of its texture, its deep brown hue, and the numerous rugæ by which its surface is wrinkled. It is partially furnished with some scattered hairs. The scrotum is divided symmetrically by an elevated line or *raphé*, which extends from the under surface of the penis, as far back as the anterior margin of the anus, and corresponds with the mesial line of the body. In hot weather, and in

debilitated persons, the skin of the scrotum becomes very long and lax; while, on the contrary, it is very short and corrugated in persons enjoying robust health, or under the influence of a cold temperature.

A large number of small sebaceous follicles are situated underneath the skin of the scrotum; the secretion from which, under some circumstances, acquires an extraordinary degree of acrimony, and excoriates the neighbouring surfaces in such a manner as to produce great distress to the patient. A strict attention to cleanliness by frequent ablution of the affected parts, and the use of Goulard's lotion, are generally sufficient to effect a speedy cure of the complaint.

The extreme facility with which the skin of the scrotum admits of being extended to an extraordinary degree, is well exemplified in those immense enlargements of this part which are so frequently met with among the inhabitants of eastern climates; and, in this country, is daily witnessed among those who are the subjects of large herniæ, hydroceles, or malignant disease of the testicle.

The extensible quality of the skin of the scrotum allows the surgeon to be less chary of removing large portions of it whenever he conceives it advisable to do so in any of the operations practised upon this part; as, for example, castration, the excision of tumours, fungoid growths, &c.

2. *The dartos.*—This covering of the testis was formerly considered to be of a muscular nature, but at the present day it is looked upon as a transition structure, intermediate betwixt muscular fibre and condensed cellular tissue, and, in many respects, possessing the properties of each. It is composed of numerous reddish-looking fibres, which are disposed longitudinally, following the same direction with each other, being continuous posteriorly with the superficial fascia of the perinæum, and anteriorly with the superficial fascia covering the body of the penis and lower part of the abdominal parietes. The dartos is divided into two separate cavities or compartments, by a process which is sent off from its inner surface, and separates the testicles from one another. This process or membranous partition (*septum scroti*) is not so complete, but that it readily allows of fluids, which may be effused underneath the dartos upon one side, to pass across to the other.

3. *The subdartoic cellular tissue.*—A large quantity of lax cellular tissue, containing in its cellules more or less adipose substance, is situated underneath the dartos, betwixt it and the external spermatic fascia. It is largely supplied with blood from the branches of the superficial perinæal vessels, which freely ramify in its thickness.

This covering of the testicles is deserving of especial notice, since it is into its structure that the copious effusion of serum, which constitutes the common form of anasarca swelling of the scrotum, so frequently met with in patients the subjects of general dropsy, takes place. This structure is also the seat of that insidious and destructive form of diffuse inflammation, which has been denominated by Mr. Liston acute anasarca of the scrotum, as well also as of those devastating extravasations of urine which are liable to occur after any rupture of the urethra in front of the triangular ligament. Large effusions of blood also take place into it in consequence of any contusion of the scrotum, by which some of the branches of the superficial perinæal or pudic vessels are ruptured, or when they have been accidentally punctured in the operation of tapping for the cure of hydrocele of the tunica vaginalis; and the same kind of swelling is sometimes observed to happen after the operation of lithotomy. Violent inflammation of this tissue, followed by sloughing of the greater part of the scrotum, has been frequently occasioned by some of the irritating fluids usually made use of to inject the tunica vaginalis for the cure of hydrocele being permitted to escape into it, either through the awkwardness or carelessness of the surgeon, or some sudden and unforeseen movement of the patient, whereby the end of the cannula is not maintained in its proper position.

It is a question that is sometimes asked in the wards of an hospital, how it happens, while the whole thickness of the scrotum is destroyed by gangrene produced by some of the injuries and diseases just now described, that we see the testicles remain in the midst of the sloughing tissues wholly unaffected by the mischief which is going on around them? The explanation readily suggests itself, when it is recollected that these organs derive their nervous and vascular supply from a distant part of the body, which is far removed from

the influence of those deleterious agents which have caused the destruction of the scrotum.

4. *The external spermatic fascia.*—This covering of the testicle has already been fully described at p. 223; it is the same as the intercolumnar fascia of some writers. Commencing superiorly at the margins of the external abdominal ring, it is prolonged downwards upon the spermatic cord and testis, both of which structures it completely surrounds. It is occasionally found greatly thickened in large and old scrotal herniæ.†

5. *The cremaster muscle.*—As a full description of the cremaster has been given at p. 231, it is wholly unnecessary to repeat it here; suffice it to say, that it is formed by the displacement of the lowermost fibres of the internal oblique muscle, which are drawn downwards by the testicle in its descent through the inguinal canal into the scrotum. The changes which it undergoes in cases of herniæ are mentioned at p. 269.

6. *The funnel-shaped sheath of the fascia transversalis.*—This is the investment which the testis derives from the fascia transversalis, when it descends through the internal abdominal ring. In the natural state of the parts it is extremely thin and delicate. It has been fully described at p. 241, and at p. 268.

7. *The tunica vaginalis communis or cellular sheath of the spermatic cord.*—This is formed by a prolongation from the subserous cellular tissue of the lumbar region, and is capable of being largely distended, as happens in diffused hydrocele of the spermatic cord. It is also frequently the seat of copious extravasations of blood, when secondary hemorrhage takes place from any of the spermatic vessels after the operation of castration, particularly if the upper extremity of the cord has been permitted to be retracted far within the inguinal canal. The blood which is thus effused is liable to cause diffuse inflammation, followed by extensive abscess of the iliac fossa.‡ That part of the tunica communis which invests the spermatic cord is sometimes the seat of large masses of fat, which may form a tumour resembling, in many respects, an irreducible epiplocele. Again, serous fluid may be collected in some of its cellules, and, gradually increasing in quantity, form a species of encysted hydrocele of the spermatic cord.

† Vide p. 223 and p. 270. ‡ Vide also pp. 241 and 250.

8. *The tunica vaginalis testis propria.*—This is a small sac of serous membrane, originally a process from the peritonæal lining of the abdomen, but from any connexion with which, in the normal state of the subject, it is separated by the obliteration of that portion of it which intervenes between the internal abdominal ring and the lower part of the spermatic cord, and which is to be found on dissection lying in front of the spermatic vessels, as a delicate elongated band of condensed fibro-cellular tissue. (See the wood-cut at p. 243, fig. *m*.) Previous to the descent of the testicle, the tunica vaginalis already exists as a small narrow pouch of the figure of the finger of a glove. The tunica vaginalis testis is composed of two parts; one which covers the anterior and lateral surfaces of the testicle and epididymis and lower part of the spermatic cord, whilst the other lines the internal surface of the scrotum. Its internal aspect is smooth, polished, and glistening, being moistened by the serosity which constitutes its natural secretion. Upon the testicle its external surface is intimately adherent to the tunica albuginea, while elsewhere it is in apposition with the fibrous sheath common to the gland and spermatic cord.

In some subjects the tunica vaginalis testis still retains its original connexion with the cavity of the great bag of the peritonæum; and when the communication between them is very free, the intestines readily descend into it, forming a congenital hernia: but sometimes, although the connexion between the two serous membranes still remains open, yet it is through the medium of a very narrow tubular canal, the orifice of which may be suddenly dilated under the influence of any violent muscular effort, by which a portion of intestine is forced down into it, giving rise to a similar kind of hernia as the last, but occurring perhaps at a very late period of life, as happened in the cases observed by M. Velpeau, the details of which will be found in his valuable treatise on Operative Surgery.†

It is occasionally observed, that the portion of the tunica vaginalis, which lies in front of the cord, between the testis and the upper aperture of the inguinal canal, is not obliterated throughout its whole extent, but only at several distinct points,

† *Vide* Nouveaux Eléments de Médecine Opératoire, par A. L. M. Velpeau, 2d edit. tom. iv. p. 182.

and thus forms a series of small isolated sacs of serous membrane, which may become distended with fluid, and constitute another of the varieties of encysted hydrocele of the cord.

Small cartilaginous bodies are occasionally found in the cavity of the tunica vaginalis, either loose and unattached, or connected to the body of the testicle by a delicate pedicle. They are produced by inflammation of a chronic nature.

EXPLANATION OF FIG. 2, PLATE III, opposite p. 237.

The investments of the cord and testicle have been removed, and the cavity of the tunica vaginalis freely exposed by an incision on its anterior surface.

1. The spermatic cord divested of all its coverings, excepting that which it derives from the subserous cellular tissue, and named the *tunica vaginalis communis*.
2. The body of the testicle exposed to view. It is covered anteriorly and laterally by the *tunica vaginalis testis propria*.
3. The upper part of the epididymis, or, as it is termed, the *globus major*, or *caput*.
4. The *globus minor*, or *cauda epididymis*.
5. 5. That portion of the tunica vaginalis reflexa which lines the inner surface of the superficial investments of the testicle. It has been laid open by a free incision upon its anterior surface, and the edges of the opening turned aside.
6. The lower part of the cord, covered by the tunica vaginalis testis, which ascends for a short way upon it in the form of a wide cul-de-sac.

9. *The tunica albuginea*.—This, which is the proper coat of the testicle, and serves to give it its peculiar form, is a strong thick fibrous membrane, which resembles, in many respects, the sclerotic coat of the eye. It invests the whole of the body of the testicle; is of a white colour, opaque, and possesses, moreover, an extremely firm and resisting texture. It, nevertheless, is capable of great distensibility, as is well seen in those sudden and excessive enlargements of the testicle which depend upon an attack of acute inflammation of the gland; but, the causes of its distension being removed, it quickly regains its original dimensions. Externally it is invested upon its anterior and lateral aspects by the tunica vaginalis testis propria, which is very closely united with it; but posteriorly and inferiorly it is pierced by the spermatic vessels

as they enter into the body of the testis, and superiorly by the seminiferous tubes as they emerge to reach the epididymis.

Corpus Highmorianum.—The cavity of the tunica albuginea is divided unequally by a process which is furnished from its inner surface towards its upper and back part; this has been named the *corpus Highmorianum*, or *mediastinum testis*. It is situated nearer the posterior than the anterior surface of the gland. Numerous membranous bands are extended at different points from the front of the corpus Highmorianum to the inner surface of the tunica albuginea. These processes, which are named *sepimenta testis*, serve to separate and support the several masses into which the lobular structure of the gland is divided, and also to preserve the shape of the organ.

10. *The tunica vasculosa.*—This has been described by Sir Astley Cooper as the inner coat or layer of the tunica albuginea; the internal surface of which it not only lines, but it is also extended over the fibrous processes which connect the tunica albuginea with the corpus Highmorianum. It is formed of delicate cellular tissue, in which ramify the ultimate branches of the spermatic artery and vein.

According to Sir Astley Cooper, the outer layer of the tunica vaginalis bears a strong resemblance to the dura mater of the brain—like it, being tendinous and inelastic, and, like it, forming processes internally; whilst the inner membrane of it resembles the pia mater, being reflected inwards upon the lobes of the testis, and forming a bed, on which the branches of the spermatic artery ramify, and supply with vessels the membranes which envelope the tubuli.†

Structure of the testicle.—The glandular structure of the testicle, which is of a yellowish colour, slightly reddened by the vessels of the tunica vasculosa, is chiefly composed of a soft, pulpy, filamentous tissue, formed by the numerous convolutions of the delicate vessels which serve to receive and transmit the seminal secretion.

The tubuli seminiferi.—The seminiferous ducts of the testis are aggregated together into small pyramidal masses or lobules (*lobuli testis*), which are closely invested by the tunica vasculosa or pia mater. They are separated from one another by the membranous processes which have been already described

† Sir Astley Cooper on the Anatomy of the Testis, p. 16.

as connecting the anterior surface of the corpus Highmoranium or mediastinum testis with the interior of the tunica albuginea. The number of the seminiferous tubes is very great, being estimated at three hundred; and each of these is not less than sixteen feet in length, and about $\frac{1}{200}$ th part of an inch in diameter. The extent of the whole, when added together, is said to be near 5000 feet.†

Vasa recta—rete testis.—The seminiferous tubes terminate, after passing through the anterior layer of the mediastinum testis, in another set of vessels, less numerous but larger than themselves, which are named, from the straightness of their course, *vasa recta*. These ascend vertically towards the upper part of the gland, where they emerge to join the epididymis. The portion of the testicle which they occupy is situated at the upper and back part of the gland, and is named the *rete testis*.

Vasa efferentia—coni vasculosi.—The *vasa recta* empty themselves by twelve or fifteen tubes, into the convoluted vessel, of which the epididymis is composed. These are at first straight, but soon assume a very tortuous course, (see the wood-cut No. 10, *b* and *c*,) and thus present a conical figure, whence is derived the name of *coni vasculosi*, which is sometimes given to them. These vessels form the *globus major* of the epididymis.

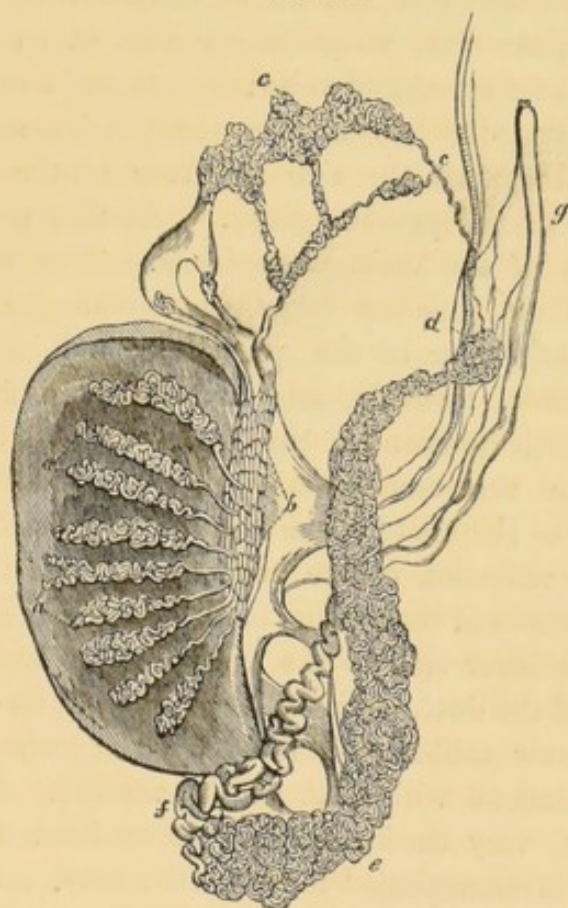
The epididymis.—The epididymis is an oblong, worm-like body, somewhat bent in upon itself at its extremities, which is loosely fixed to the upper and back part of the testicle. (See Plate IV. Fig. 2. 3 and 4.) The superior extremity of the epididymis is larger and more rounded than the inferior, and is named the *globus major*. (Plate III. Fig. 2. 3.) It lies upon the upper part of the testicle, and receives, as has been already described, the *vasa efferentia*. The middle portion of the epididymis has been named the *corpus*; it is but loosely connected to the body of the testicle by the reflexions of the tunica vaginalis testis. The lower extremity of the epididymis, also termed *globus minor*, or *cauda*, is elongated, and tapering in its figure, and gradually terminates in the *vas deferens*. The epididymis is formed by the frequent convolutions of the tube, which results from the union of the *vasa efferentia*; the curves which it forms are pretty firmly fixed

† Manuel d'Anatomie, par I. F. Meckel, tom. iii. p. 627. Paris, 1825.

together by small bands of condensed cellular tissue. Professor Monro has calculated the length of the vessel which forms the epididymis at thirty-two feet. The epididymis is covered in the greater part of its extent by the tunica vaginalis propria testis. The epididymis frequently remains hard and indurated after attacks of acute inflammation of the testicle; but the affection, although not easily removed, is of no serious consequence.

Vas aberrans.—Not unfrequently a long delicate vessel, terminating in a cul-de-sac, is found to extend from the epididymis for a considerable distance upon the cord, and has been named the *vas aberrans*. Sir Astley Cooper possesses a preparation in which is seen three of these tubes in the same testicle, each terminating in a blind extremity.†

No. 10.



The wood-engraving displays the whole of the seminiferous structure of the testicle, as it is seen when injected with mercury and partially unravelled.
a. a. The *tubuli seminiferi*, which compose the lobules of the testicle; the

† *Vide* Sir Astley Cooper on the Anatomy of the Testis, p. 27.

basis of the cone, which they form, is directed towards the front of the gland, the apex towards the corpus Highmorianum. *b.* The *rete testis*, consisting of the *vasa recta*, which are eighteen or twenty in number: they connect the tubuli seminiferi with the vasa efferentia. *c. c.* The *globus major* or *caput epididymis*, which is chiefly formed by the vascular cones of the vasa efferentia. *d.* The *corpus* or body of the epididymis. *e.* The lower extremity (*globus minor*) or *cauda* of the epididymis. *f. g.* The vas deferens: at *f.*, which is the commencement of the tube, it is observed to be larger and more convoluted than higher up, as at *g.*

The vas deferens.—The vas deferens, or excretory duct of the testicle, extends from the lower part of the epididymis—of which it is the continuation—to the prostatic portion of the urethra. Very tortuous, and larger in size at its commencement and termination, the vas deferens follows a straight course in the remaining parts of its extent. It ascends, with the rest of the structures that compose the spermatic cord, as far as the internal abdominal ring, where it separates at an acute angle from the spermatic artery and veins; and then, bending over the epigastric artery, dips down into the pelvis, and becomes closely applied against the side and base of the bladder, as far as the base of the prostate gland. At this point it joins with the duct of the vesicula seminalis. The vessel which results from their junction (*ductus ejaculatorius communis*) traverses the substance of the prostate gland in an oblique direction upwards, forwards, and inwards; and finally opens into the prostatic portion of the urethra, upon the anterior surface of the veru-montanum. In its course along the side and base of the bladder, the vas deferens lies in the angle formed by the reflection of the peritonæum from the posterior and lateral surfaces of that viscus to the side of the pelvis. It also lies on the inner side of the ureter and vesicula seminalis. The interior of the duct,—which, excepting near its extremities, is of very narrow calibre,—is lined by a mucous membrane, which is continuous with that of the urethra. Its external coat is fibrous, very thick, and almost as dense and hard as cartilage. It is accompanied by a small artery, a branch from one of the vesical arteries. The vas deferens may be distinguished from the rest of the constituents of the spermatic cord by its hard wiry feel, and by its position, for it lies behind and to the inner side of the spermatic artery and vein.†

† *Vide* The Surgical Anatomy of the Perinæum, pp. 34-5.

The spermatic cord.—The structures which compose the spermatic cord have been already sufficiently noticed in detail in the preceding pages. They consist of the vas deferens, and the small artery that accompanies it, a branch from the vesical artery; the spermatic artery and veins, with several filaments from the renal plexus of the great sympathetic nerve which accompany these vessels in their course from the loins to the testicle; and the ligamentous cord which remains after the obliteration of the tubular process of the tunica vaginalis in the interspace between the testis and the internal abdominal ring. All these are closely invested by sheaths, derived from the subserous cellular tissue, and the fascia transversalis, opposite the internal abdominal ring.

Towards the lower part of the inguinal canal, the cremaster muscle furnishes a partial investment to the spermatic cord, covering its anterior and lateral surfaces. This muscle is supplied by the cremasteric branch of the epigastric artery, and by the oblique branch of the external pudic or genito-crural nerve.

As the cord emerges through the external abdominal ring, it receives another covering from the external spermatic or intercolumnar fascia; and lastly, from the dartos and integuments of the scrotum. These are freely supplied with blood from the external pudic and superficial perinæal vessels.



CHAPTER II.

OF SOME OF THE MORE FREQUENT DISEASES OF THE
TESTIS AND ITS COVERINGS.

Anasarca of the scrotum.—This affection, when chronic, is usually dependent upon a dropsical habit, and is generally accompanied by other signs of organic disease; as, for example, swelling of the feet and legs, ascites, &c. It is distinguished by its indolent character, and, generally, by the absence of any inflammatory action in the parts affected: the tumour is soft and doughy, readily pitting under the pressure of the finger: its surface is regular, having a pale, glistening, and semi-transparent appearance. In aggravated cases, however, the skin of the scrotum is sometimes affected with an erythematous inflammation.

The complaint usually disappears under the use of such remedies as are generally beneficial in the treatment of the primary affection; but if much uneasiness should be experienced by the patient from the excessive distension of the part, considerable relief may be procured by puncturing the swelling at several points with a fine needle, by which the serosity is permitted to drain off; but, under these circumstances, it is by no means a safe plan to make incisions into the scrotum or to scarify it, as has been recommended by some, for such proceedings are apt to induce gangrene of the part, and even cause the death of the patient.

Acute anasarca—diffuse inflammation.—Sometimes the scrotum is the seat of an acute inflammation of an erysipelatous character, which is attended with excessive redness, swelling, and tension of the part. This disorder is frequently met with in persons whose constitutions have been impaired by habits of intemperance, and in these it may occasionally seem to arise without any obvious cause. On other occasions it would appear to be excited by exposure to wet and cold, or by the irritation

consequent upon the lodgment among the rugæ of the scrotum of some acrimonious fluid, such as the urine, ichorous pus, &c. A similar kind of swelling, though perhaps not quite so acute or violent in its nature, frequently attends upon the spreading of erysipelas to the scrotum from the adjacent surfaces.

Acute anasarca of the scrotum should be treated, in its early stages, by the removal of any exciting causes of a local nature,—should these still exist;—by the application of hot fomentations to the swollen part, which should be well elevated upon a pillow of sufficient size, introduced between the thighs of the patient. If these means, aided by such general treatment as is suited to the character of the complaint, do not succeed in diminishing the inflammation and tension, then free incisions should be practised without delay, if we would prevent the sloughing of the whole of the affected structures.

Sarcomatous tumour.—Enormous enlargements of the scrotum have been frequently observed, but more particularly among the natives of hot climates. These growths are of an innocent character, but may attain an extraordinary magnitude. The only mode of cure which they admit of, is their removal by the knife; nor can this always be done without injury to the penis and testicles.†

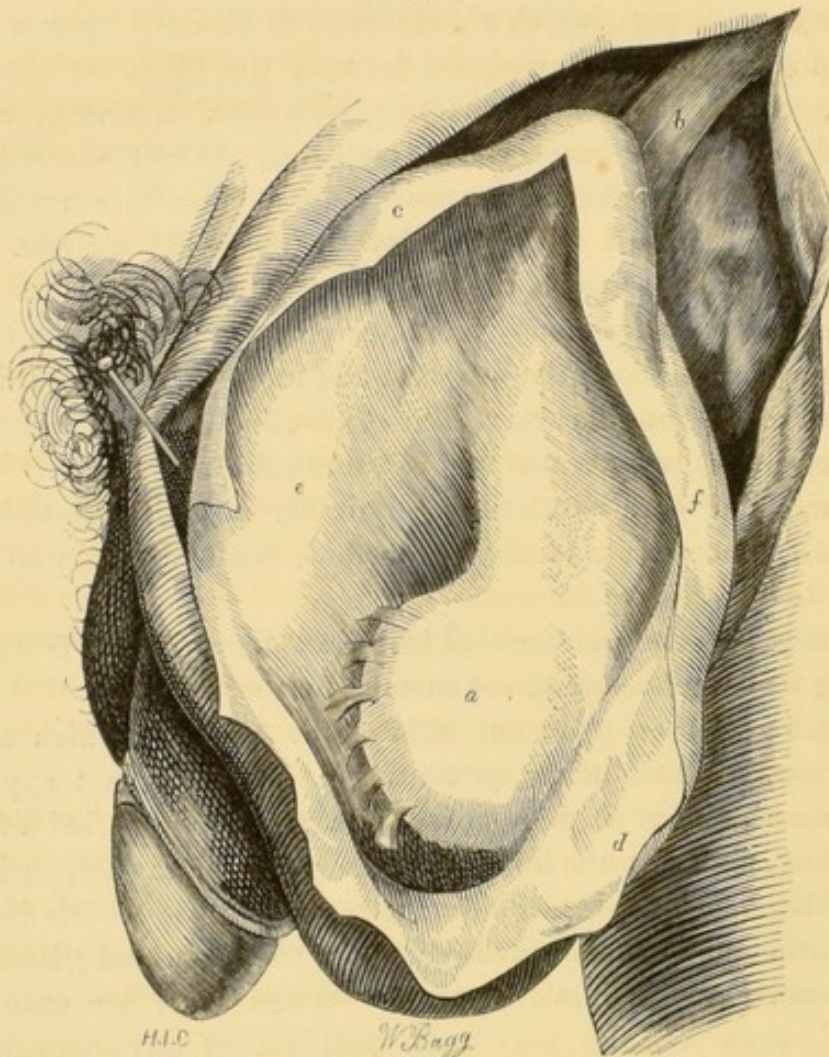
Cancer of the scrotum.—This disease, which is frequent among chimney-sweepers, commences by the formation of hard, warty excrescences upon the skin of the scrotum, which soon break out into foul ulcers, presenting a very malignant appearance; and, except it is removed at a very early period of its existence, either by the knife or some powerful caustic, such as the chloride of zinc, &c. is very apt to involve the testicle itself, and spread along the spermatic cord to the absorbent glands of the lumbar and inguinal regions. When these are once affected, there remains very little prospect of any permanent benefit being derived from an operation.‡

† Dictionary of Practical Surgery, by S. Cooper, 7th edit. p. 1135. Liston's Practical Surgery, 3d edit. pp. 340-1. Titley on Diseases of the Genital Organs, pp. 299—325.

‡ *Vide* the Chirurgical Works of Percivall Pott, F.R.S. Lond. 1779, vol. iii. pp. 225-9. First Lines of the Practice of Surgery, by Samuel Cooper, 6th edit. p. 601. Cases of Diseased Prepuce and Scrotum, by William Wadd, 4to. Lond. 1817, p. 23.

Hydrocele.—The form of this disease, which consists of an accumulation of serous fluid in the cavity of the tunica vaginalis, (*hydrocele of the tunica vaginalis*,) is of the most frequent occurrence. The complaint ordinarily commences without any very obvious cause, though it is highly probable that it is frequently connected with a state approaching to a chronic

No. 11.



The wood-engraving exhibits the cavity of a hydrocele of the tunica vaginalis exposed to view by an incision upon its anterior surface.

a. The body of the testicle, somewhat flattened by the pressure of the effused fluid, and situated at the back part of the swelling, about two-thirds of the way downwards. Small bands of lymph, of old standing, connect it to the sides of the sac. *b.* A portion of the spermatic cord, free betwixt the upper part of the swelling and the external abdominal ring. *c. d. e. f.* The membrane of the tunica vaginalis, forming the parietes of the sac.

inflammation of the membrane of the tunica vaginalis. The swelling is usually of a pyriform shape, and of a very light weight in comparison with its magnitude; it is also free from pain, except when, from its large size, it gives rise to a dragging sensation in the course of the cord towards the lumbar region. The principal diagnostic sign of the disorder is, however, the transparency of the tumour when viewed against the light of a candle in a darkened room; but I have seen many fail in their attempt to observe this sign, because they neglected the necessary precaution of rendering the skin of the scrotum quite tense, by firmly grasping it from behind. The tumour is unaffected, except in very rare instances, by coughing or any other muscular effort on the part of the patient. The growth of the swelling increases gradually from below upwards, and, generally, a portion of the cord may be felt to be free above, between it and the external abdominal ring.

Sometimes the testicle is situated in front of an hydrocele, instead of lying behind it, as is most usually the case. I have witnessed this variety in three instances, which, upon making a dissection of the parts, seemed to depend upon an original transposition of the gland, by which that part of it which is lined by the tunica vaginalis, was turned towards the posterior aspect of the scrotum. Other cases have also been observed, in which this unusual condition of the parts might have been produced by a morbid adhesion of the anterior surface of the testicle to the front of the sac.†

Occasionally it happens that an hydrocele is not transparent when examined with a candle, which circumstance may depend upon the opaque nature of the fluid which it contains, or the great thickness of the tunics of the scrotum, more particularly of the external spermatic fascia and cremaster muscle.

† Sir Astley Cooper mentions the following case in his work on the Anatomy and Diseases of the Testis, which shows the necessity of being acquainted with the possibility of the testicle varying from its usual situation in hydrocele: "A gentleman consulted a surgeon for a swelling in his scrotum, which he pronounced to be hydrocele. He put a trocar into it, no water followed, and he said, "I am mistaken; this is a solid enlargement of the testis, and it must be removed." The patient, excessively alarmed at so severe a sentence, said he should require time to think of it; and another surgeon was consulted, by whom it was injected from the side instead of the fore-part, and the patient perfectly recovered." *Op. cit.* p. 168.

Sometimes an hydrocele of the tunica vaginalis is divided into several compartments, by numerous membranous septa, which spring from the inner surface of the sac. In many cases these cells or sacculi communicate freely with each other, while in others they form separate and distinct cavities.

An hydrocele may attain an immense size. Mr. Gibbon, the celebrated historian, laboured under this complaint, and was tapped for it by Mr. Cline, who drew off six quarts of fluid.† When an hydrocele is very large, it is not advisable to inject it at once, for the irritation of so extensive a surface might be productive of very dangerous consequences: on the contrary, it would be much better to tap it repeatedly, and at short intervals; and when it has been reduced by this means to a moderate size, then the cure of it by injection may be safely undertaken.

Effusion of urine.—Extravasation of urine into the cellular tissue of the scrotum is a frequent consequence of injuries done to the urethra by rude and awkward attempts to introduce a catheter or bougie in cases of retention from stricture: it may, also, ensue upon the bursting of the urethra behind a tight and old stricture, for in this situation the canal is not only greatly dilated, but its coats are weakened by inflammation and ulceration; or it may take place when the urethra has been torn by falls or blows upon the perinæum.

In all these cases the urine generally makes its way from the perinæum into the scrotum with destructive rapidity, being directed in this course by the connections of the superficial fascia with the arch of the pubes and the triangular ligament. The scrotum may be distended to the size of a child's head; it is of a dusky red colour, pits and crepitates on pressure with the finger, and these symptoms are usually accompanied with a burning pain in the affected parts; which soon fall into gangrene if relief be not speedily afforded by incisions of sufficient length and depth.

In neglected cases the urine ascends upon the front and sides of the belly, and may even reach as high as the scapulæ, diffusing itself through the delicate cellular tissue which connects the superficial fascia of the abdomen to the outer surface of the external oblique muscle. In this situation it is usually

† Sir Astley Cooper's Lectures on Surgery, by F. Tyrrell, vol. ii. p. 92.

prevented from extending upon the thighs by the connection between the superficial fascia and the lower edge of Poupart's ligament; but, in one instance, which fell under my notice in the Hôtel Dieu of Paris, it had broken through this barrier, and spread its ravages as far downwards as the knees: the patient, I need hardly add, died exhausted by the excessive discharge attendant upon the separation of the sloughs; which, as will be readily imagined, were of extraordinary extent. The extravasation of a fluid, possessed of such acrimonious qualities as the urine, is necessarily accompanied by constitutional disturbance of a very serious and alarming character, such as frequent rigors — cold clammy perspirations — feeble rapid pulse — dry brown tongue — anxious and haggard countenance — with, frequently, a peculiar dirty yellow hue of the surface of the body.

I have been made acquainted with several instances in which this disorder was mistaken for inflammation of the testicle, and treated as such during several days—a blunder which was followed by the total destruction of the coverings of the scrotum.†

† The subjoined case may serve to exemplify the preceding remarks: T. C. æt. 52, a tinworker, was admitted into University College Hospital in the month of November 1838, on account of extravasation of urine into the scrotum. This man states, that three days since he perceived the right side of the scrotum to swell suddenly while endeavouring to pass his water; to effect which he is obliged to strain considerably, as he has long been the subject of an old inveterate stricture. The part was very red and painful. The next day he was visited by the surgeon of his parish, who said that the swelling of the scrotum was an inflamed testicle, depending upon irritation about the neck of the bladder, for which he prescribed him to take small doses of blue pill and opium at night. As matters, however, got worse, he was brought to the hospital late in the evening of the fourth day. On admission, the right side of the scrotum was tense, shining, and of a dark colour, painful, and crepitating when handled, with evident fluctuation. The house surgeon immediately laid the swelling freely open by an extensive incision, and gave exit to a large quantity of thin, fetid, dirty-coloured pus, mixed with urine. No. 4 catheter was introduced into the bladder with considerable difficulty, and retained there for two days; when it was withdrawn, and changed for No. 7, which, as it passed easily, was not kept in as before.

This man had laboured under stricture of the urethra for the last fifteen years, during which period he has twice suffered from effusion of urine into the scrotum and perinæum; the first time was about six years ago, and the

The treatment which is proper to be pursued in these cases consists chiefly in making free incisions through the integuments and fasciæ which confine the effused fluid; taking care afterwards that too much blood is not lost from any of the vessels that may chance to be divided. If the bladder should be distended, a catheter ought to be introduced, but this is not necessary when the urine flows freely through the wound, until the reparative process is commenced.

Hæmatocele.—Two varieties of this affection are usually recognised in the schools; in one of which the blood, that is effused, escapes into the loose cellular tissue of the scrotum, giving rise to a general and diffused swelling of the part, accompanied by an evident ecchymosis; whilst in the other, — which is the only form of the disease recognised by some surgeons,—the blood is collected in one mass within the cavity of the tunica vaginalis of the testicle.

The treatment of the first case does not differ in any essential respect from that which is adopted in ecchymoses of other parts of the body, for it usually disappears by degrees when the parts are kept at rest, combined with the use of purgative medicines, and the local application of discutient lotions. If, however, in an aggravated case of this nature inflammation should occur in spite of these means, and be followed by suppuration, then a free incision should be made to permit the easy escape of any matter or sloughs that may be formed.†

The second case, or that in which the blood is contained within the cavity of the tunica vaginalis, is not unfrequently the consequence of hydrocele, upon which it may supervene with-

second about a year after the first. On each occasion the complaint was at first treated as an inflammation of the testicle, by leeches and purgative medicine; and his life only saved by going into the hospital, where he was relieved by free incisions, the cicatrices of which are still to be observed upon the scrotum and perinæum.

On account of the thickened and condensed state of the parts consequent upon the destruction of the tissues of the scrotum at the time of the former attacks, the present effusion was neither so rapid or so extensive as it otherwise would have been; but, as it was, the man was restored to health with great difficulty.

For a strange misapprehension in case of rupture of the urethra, see Surgical Observations, by Sir Charles Bell, Part V. p. 25.

† *Vide* the Surgical Anatomy of the Perinæum, p. 69.

out any very apparent existing cause—perhaps, from the rupture of some of the vessels of the tunica vaginalis, which, becoming varicose, burst and pour their contents into the sac. It is, also, frequently produced by wounding one of the vessels of the scrotum or testicle with the point of the lancet or trocar used in tapping a hydrocele; or it may follow a blow upon the scrotum, especially when it is distended by a collection of water in the tunica vaginalis. In this way hydrocele is frequently complicated with hæmatocele; a combination of the two diseases that may render it necessary to lay open freely the tunica vaginalis by incision for its cure.

It is sometimes exceedingly difficult to determine with correctness the nature of the swelling of a hæmatocele, and to distinguish it from disease of the testicle itself; for the tumour in either case possesses the same figure, opacity, and weight; but it would be right, in all cases, where any doubt exists upon this point, to make an opening into the tunica vaginalis before proceeding to perform the operation of castration.

Hæmatocele, depending upon extravasation of blood into the tunica vaginalis, rarely admits of being cured by any milder means than a free incision into the part, by which the coagulated blood may be removed; after which the wound heals by the second intention.

Scrofulous fungus of the testicle.—A peculiar granular protrusion frequently takes place after the bursting of a scrofulous abscess of the testicle, and has often been mistaken for a malignant disease of the gland, requiring its extirpation; but the nature of the affection is quite simple, and is dependent upon much the same causes as a hernia cerebri, which it resembles in the disposition to form an exuberant growth;—the resistance afforded by the containing membranes of the organ affected being impaired at one point by a wound or ulceration.

The fungus may be removed by the application of strong caustics; but the readiest method of curing it consists in slicing it off upon a level with the opening in the tunica albuginea, and then bringing the edges of the wound together by a slip of adhesive plaister, or, if the condition of the integument admit of it, by a few sutures.

No doubt, some cases do now and then occur where the swelling is so large, and the testis so completely involved in it, that it would prove the best practice to remove both.†

† This disease is very accurately and beautifully represented in Plate I. figs. 2 and 3, and Plate II. fig. 1, of Sir Astley Cooper's work on the Anatomy and Diseases of the Testicle, Part II.

THE END.

LONDON:

PRINTED BY SAMUEL BENTLEY,
Bangor House, Shoe Lane.

MORTON'S SURGICAL ANATOMY

OF THE

PRINCIPAL REGIONS OF THE HUMAN BODY.

I.

THE SURGICAL ANATOMY OF THE PERINÆUM; with Four Lithographic Plates and Three Wood-engravings. Royal 8vo. 6s. plain, 7s. 6d. coloured.

"We most cordially recommend Mr. Morton's treatise, as a satisfactory guide in the dissection of the perinæum and pelvis."—*British and Foreign Medical Review*, July, 1839, p. 244.

"Of the plates and wood-cuts which illustrate the work, it is sufficient to say that they are anatomically correct, clear, and beautifully executed. We have no hesitation in recommending this publication as likely to prove useful to students actually engaged in the schools, and to those who, having entered into practice, may find occasion to keep up or refresh their recollections of the anatomy of the perinæum."—*Edin. Med. and Surg. Journal*, 1839, p. 553.

"Mr. Morton's book is a good one. It comprises the recent information, and is likely to be very serviceable to young surgeons."—*Med. Chir. Journ. Lond.* Jan. 1839, p. 175.

"A treatise which contains a variety of useful and solid information."—*Lancet*, Feb. 2, 1839, p. 699.

"To give the student the best information and directions as to his proceedings in the dissection of this region—the most accurate description in the simplest language—the detail in anatomy, as inseparably connected with the practice in surgery; the latter giving importance to the former, and the former decision and safety to the latter, is all that can be looked for, and all to be found here.

"The plates illustrating the letter-press are well drawn, and carefully engraved, and show with great distinctness the parts to be represented; that exhibiting the side view of the pelvis is, we think, clearer and more to the matter than any we have seen before. We can conscientiously recommend the work, and are glad to find that other equally important regions are about to be treated of by Mr. Morton—we hope in the same simple and useful manner."—*Medical Gazette*, May 25, 1839.

II.

THE SURGICAL ANATOMY OF THE GROIN, THE FEMORAL AND POPLITEAL REGIONS. Eight Lithographic Plates and Eleven Wood-engravings. Royal 8vo. 13s. coloured, 9s. plain.

"The production is altogether one which we can conscientiously recommend to the working student. The work will constitute a complete and elaborate treatise, that cannot fail to be highly useful to surgeons in general."—*British and Foreign Medical Review*, Oct. 1839, p. 542.

"The volume does Mr. Morton great credit. We cordially wish his book every success."—*Medical Gazette*, Aug. 10, 1839, p. 728.

"We may say with regard to the present production, that it sustains the good character which we awarded to its predecessor on 'the Perinæum.' Like that volume, as it is equally well and correctly written, it necessarily contains a variety of solid and useful information. The engravings, by Mr. Bagg, afford additional proof of the perfect competency of that artist to represent human anatomy with fidelity on paper."—*Lancet*, Aug. 17, 1839, p. 760.

"The execution of this work is highly creditable to Mr. Morton. So far as we have dipped into them, his descriptions of the anatomy of herniæ are exceedingly correct. The work is well adapted for students, and is calculated to supply them with information of a very valuable character. The plates are extremely well executed. We recommend the work strongly."—*Medico-Chirurgical Journal*, Jan. 1, 1840, p. 167.

"The present part of the work forms a good system of surgical anatomy so far as it goes, and will be highly useful to the surgical student. We trust the author will, in like manner, illustrate the anatomical relations of the neck and its parts."—*Edin. Med. and Surg. Journal*, Jan. 1, 1840, p. 235.

III.

THE SURGICAL ANATOMY OF INGUINAL HERNIÆ, THE TESTIS, AND ITS COVERINGS. Five Plates and Eleven Wood-engravings.

IV.

THE SURGICAL ANATOMY OF THE HEAD AND NECK, THE AXILLA, AND BEND OF THE ELBOW. (*Preparing.*)

UPPER GOWER STREET, DECEMBER, 1840.

NEW AND IMPORTANT WORKS,

PRINTED FOR

TAYLOR & WALTON.

MR. QUAIN'S WORK ON THE ARTERIES.

In Imperial Folio, with an 8vo. Volume of Letterpress,

THE ANATOMY OF THE ARTERIES,

WITH ITS APPLICATIONS TO

PATHOLOGY AND OPERATIVE SURGERY,

IN LITHOGRAPHIC DRAWINGS, THE SIZE OF NATURE,

WITH PRACTICAL COMMENTARIES.

BY RICHARD QUAIN,

Professor of Anatomy in University College, and Surgeon to University College Hospital.

Parts I. to III. each containing Five Plates, 27 by 21½ Inches, and Letterpress. Price 12s. each Part.

The object of this Publication is to lay before the Student and Practitioner, by means of accurate delineations and a record of the peculiarities observed in numerous cases, a correct history of the Blood-vessels, arranged especially with a view to its bearing on Practical Surgery.

PLAN OF THE WORK.

1st. In the Drawings the Arteries are, in the first place, represented according to their most frequent arrangement, without the accompanying veins and nerves.

2dly. They are shown in connexion with the larger veins and nerves.

3dly. The deviations from that which has been taken as the standard condition of the arteries are illustrated in a series of sketches.

4thly. Such peculiarities of the veins, and occasionally of the nerves and muscles, as appeared likely to be of importance in surgical operations are represented on a reduced scale.

5thly. Illustrations of the state of the Arteries after the Operations for Aneurism will be given at the end of the publication.

The letter-press, besides an explanation of, and remarks on the Drawings, will contain—

A Series of Tables showing, in a short space, the condition of each of the larger arteries in about 290 bodies.

And some Practical Commentaries, which will consist for the most part of inferences from the facts previously set forth, and their application in the performance of the operations of Surgery.

PLAN OF PUBLICATION.

The Work will be comprised in about 13 Parts, Imperial Folio, and an Octavo Volume of Letterpress.

A Part containing Five Plates with its accompanying Letterpress will appear on the 1st of every Month. Price 12s. Or packed in a box to send into the country, 13s.

One thick Volume, post 8vo. price 12s.

DEMONSTRATIONS OF ANATOMY,

BEING A

GUIDE TO THE DISSECTION OF THE HUMAN BODY.

BY GEORGE VINER ELLIS,

One of the Demonstrators of Anatomy in University College.

Fourth Edition, revised and enlarged. Illustrated by 140 Engravings on Wood, and four Steel Plates. 1 thick Vol. 8vo. 1l. 2s.

ELEMENTS OF ANATOMY,

FOR THE USE OF STUDENTS,

BY JONES QUAIN, M.D.

Member of the Senate of the University of London.

