

The surgeon's handbook on the treatment of wounded in war : a prize essay / by Friedrich Esmarch ; translated by H.H. Clutton.

Contributors

Clutton, H. H.
Esmarch, Friedrich von, 1823-1908.
Royal College of Physicians of Edinburgh

Publication/Creation

London : Sampson Low, Marston, Searle & Rivington, 1878.

Persistent URL

<https://wellcomecollection.org/works/ygt8xkus>

Provider

Royal College of Physicians Edinburgh

License and attribution

This material has been provided by This material has been provided by the Royal College of Physicians of Edinburgh. The original may be consulted at the Royal College of Physicians of Edinburgh. where the originals may be consulted.

This work has been identified as being free of known restrictions under copyright law, including all related and neighbouring rights and is being made available under the Creative Commons, Public Domain Mark.

You can copy, modify, distribute and perform the work, even for commercial purposes, without asking permission.



Wellcome Collection
183 Euston Road
London NW1 2BE UK
T +44 (0)20 7611 8722
E library@wellcomecollection.org
<https://wellcomecollection.org>

THE
SURGEON'S HAND BOOK
ON THE
TREATMENT OF WOUNDED
IN WAR

Feb 3


R38866



182

THE
SURGEON'S HANDBOOK

PROFESSOR ESMARCH.



THE
SURGEON'S HANDBOOK

ON THE TREATMENT OF WOUNDED IN WAR.

A PRIZE ESSAY

BY

DR. FRIEDRICH ESMARCH,

PROFESSOR OF SURGERY TO THE UNIVERSITY OF KIEL, SURGEON TO THE UNIVERSITY-HOSPITAL KIEL.
SURGEON GENERAL TO THE PRUSSIAN ARMY.

TRANSLATED

BY

H. H. CLUTTON, B.A. CANTAB., F.R.C.S.,

RESIDENT ASSISTANT SURGEON ST. THOMAS' HOSPITAL.

MOTTO: KURZ UND BÜNDIG.



WITH 536 WOOD-CUTS AND 30 COLOURED PLATES.

LONDON:

SAMPSON LOW, MARSTON, SEARLE & RIVINGTON,
CROWN BUILDINGS, 188, FLEET STREET.

1878.

THE
SURGEON'S HANDBOOK

OF THE
ARMY AND NAVY

VOLUME I

GENERAL PRINCIPLES

OF SURGERY

AND
OF THE
DISEASES OF THE
EYE, EAR, NOSE, AND THROAT

ALL RIGHTS RESERVED.


PRINTED BY AUGUST GRIMPE
HANOVER.

TO HER MAJESTY
THE
EMPRESS AND QUEEN
AUGUSTA

THE
NOBLE PATRONESS OF MILITARY SURGERY

THE
ALL-ADMIRER CONDUCTRESS OF PHILANTHROPY
AGAINST THE TERROR OF WAR

DEDICATED
WITH THE DEEPEST VENERATION
BY THE AUTHOR.



To advance the interests of humanity, even in peace, under the symbol of the Red Cross

HER MAJESTY THE GERMAN EMPRESS

on the occasion of the Vienna exhibition, was pleased to offer two valuable prizes, one of which was for the best handbook on surgical appliances and operations for the battle field.

According to the stipulations, on the strict interpretation of which the prizes were made dependant, this handbook was to shew "as shortly as possible the present position of military surgery by a description of the different methods of bandaging and dressing, as well as the surgical operations as they occur on the battle field, in such a manner that it would become an indispensable companion and practical assistance for every military surgeon."

By the prize jury consisting of three members, Professor Dr. B. VON LANGENBECK of Berlin, Professor Dr. BILLROTH of Vienna and Professor Dr. SOCIN of Basle, the first prize was awarded to the author of this handbook.

The book appears now for the first time, as the production of the illustrations has demanded much time and labour.

The author has adhered strictly to the stipulations, and began the work with the idea that such a handbook ought more especially to be employed as an assistance for the memory. This is accomplished better by illustrations than

by words. For on the field no one has time to read much, and a glance at an illustration, which clearly exhibits a dressing, an operation, or an anatomical dissection, can recall in the most rapid manner what has been previously learned, but has escaped the memory under the pressure of military incidents.

The book accordingly contains many illustrations with the shortest possible text.

As the surgeon in time of peace, before an important operation, likes to consult his anatomical handbooks and illustrations, in order to acquaint himself with the relations about the seat of operation, so he must feel the loss of this assistance on the battle field. Therefore for the capital operations the important anatomical relations are clearly shewn by illustrations, some of which are taken from copper-plates of anatomical works; but for the most part they are taken from recent specimens.

Besides the principal object, the author has kept in view the following:

1. The book should serve for the instruction not only of the younger military surgeons, but also of the attendants, as military surgeons are frequently compelled first of all to teach their attendants. By using the illustrations this task can be made easier. For this reason also especial attention has been paid to the impromptu dressings.

2. The book should be a guide for the members of the Red Cross societies in procuring and keeping ready the dressings, appliances, and instruments, as they are principally used in war. It could serve as an illustrated catalogue to the depots of material for volunteer aid in war, and save the

surgeon, who wishes to obtain materials for dressing from the depot, many words, by pointing to the illustrations.

3. This book should assist the surgeon, who has been compelled to erect a hospital in a small village, in making clear to the workmen (joiners, carpenters etc.), by means of the illustrations, his wishes respecting the manufacture of appliances for the treatment of the wounded.

The original drawings for the illustrations have been chiefly executed by the artists Herr JOHN WITTMACK (at present in Strassburg) and Herr H. BRAUNE in Kiel; the wood-cuts in the studios of the successors to the brothers SIMEON and ALBERT PROBST in Brunswick; the coloured plates in the studios of Herr ESCHEBACH and Herr SCHAEFER in Leipzig.

Kiel, June 1877.

FRIEDRICH ESMARCH.

TRANSLATOR'S PREFACE.

The following translation has been made at the request of the author. As strict an adherence to the original, as the technicalities of the English language would allow, has been throughout preserved. The author's preface fully explains the reasons for the short and terse style in which the book is written.


This brevity has increased the difficulties of the translation and will it is hoped serve as an apology for its many deficiencies.

St. Thomas' Hospital.

June 1878.

H. H. CLUTTON.

CONTENTS.



I. THE DRESSING OF WOUNDS.

(BANDAGES AND SPLINTS.)

	Page
A. General rules for the treatment of wounds and injuries	1
B. The covering of wounds	2
C. The cleansing of wounds and their vicinity	4
D. The reduction of heat	8
E. The hermetical sealing of wounds	11
F. LISTER'S antiseptic method of dressing	12
G. The union of wounds	16
H. The bandaging	19
J. The handkerchief-bandages	22
K. Splints	26
1. Wooden splints	26
2. Paste-board splints	29
3. Metal splints	32
4. Temporary splints	34
L. The hardening bandages	39
1. The starch bandage	39
2. The silica bandage	40
3. The guttapercha bandage	41
4. The plaster of Paris bandage	41
M. Dressings for the head	48
A. Bandages	48
B. Handkerchief bandages	50
C. The head-net	52
N. Dressings for the face	52
Bandages and handkerchief bandages	53
O. Dressings for the neck	54
P. Dressings for the upper extremity	54
1. Bandaging	54
2. Handkerchief bandages	54
3. Dressings for injuries of different parts of the upper extremity	58

XII

	Page
Q. Dressings for the lower extremity	81
1. Bandaging the whole leg	81
2. Handkerchief bandages for the leg	82
3. Dressings for injuries of individual parts of the lower extremity . .	83
R. Dressings on the trunk	109

II. OPERATIONS.

A. Chloroform narcosis	112
B. Arrest of haemorrhage	118
1. Temporary arrest of haemorrhage	118
a. The direct compression of the wound	118
b. Compression of the artery above the wound	120
c. The bloodless operation	127
2. Permanent arrest of haemorrhage	136
a. The employment of rest, elevated position of limb, and ice	136
b. Ligature in the wound itself (direct ligature)	137
c. The ligature of the arterial trunks	138
1. General rules for the search and ligature of the chief arterial trunks	138
2. Rules for the ligature of the individual arteries	144
Ligature of the left common carotid artery on a level with the crico-thyroid ligament	144
Ligature of the left common carotid artery between the two heads of the sterno-mastoid muscle	145
Ligature of the lingual artery	146
Ligature of the subclavian artery in the left supra- clavicular fossa	147
Ligature of the subclavian artery in the left infra- clavicular fossa	148
Ligature of the axillary artery in the right axilla	149
Ligature of the brachial artery in the middle of the right arm	150
Ligature of the brachial artery at the right elbow (art. anconeae)	151
Ligature of the radial artery in the upper third of the right forearm	152
Ligature of the ulna artery in the upper third of the right forearm	152
Ligature of the radial artery above the right wrist	153
Ligature of the ulna artery above the right wrist	153


XIII


	Page
Ligature of the common iliac artery (left)	154
Ligature of the external iliac artery (right)	155
Ligature of the femoral artery (common femoral) below Poupart's ligament (right)	156
Ligature of the femoral artery (superficial femoral) below the origin of the profunda at the apex of the ileo- femoral triangle (Scarpa's) (right)	157
Ligature of the femoral artery in the middle of the thigh (HUNTER'S canal) (right)	158
Ligature of the popliteal artery (right)	159
Ligature of the anterior tibial artery above the middle of the leg (left)	160
Ligature of the posterior tibial artery above the middle of the leg (right)	161
Ligature of the anterior tibial artery in the lower third of the leg (left)	162
Ligature of the posterior tibial artery behind the internal malleolus (right)	163
C. Blood-letting	164
D. Transfusion	165
E. Removal of limbs (amputations and disarticulations)	172
I. General rules for amputations	172
a. Preliminary steps	172
b. Division of the soft parts	172
1. The single circular incision (CELSUS)	174
2. The double circular incision (PETIT)	176
3. Amputation by skin flaps (BRÜNNINGHAUSEN)	178
4. Amputation by muscular flaps	180
c. Sawing the bone	182
d. The arrest of haemorrhage	185
e. The closure of the wound	187
f. The dressing of the stump	187
g. The position of the stump	188
II. General rules for the disarticulations	188
III. The amputations and the disarticulations of the upper extremity	189
a. Disarticulation of the terminal phalanx. (By a palmar flap from without inwards)	189
b. Disarticulation at the second phalangeal joint. (By transfixion from within outwards)	190
c. Disarticulations of the fingers at the metacarpo-phalangeal joint .	191
α. The oval incision	191
β. The flap operation	192

XIV

	Page
d. Disarticulation of the thumb at the carpo-metacarpal joint . . .	193
α. By the oval incision	193
β. By lateral flaps (WALTHEB'S)	194
e. Disarticulation of the last four metacarpal bones, preserving the thumb	195
f. Disarticulation at the wrist	197
α. Circular incision	197
β. By the flap amputation	197
γ. Amputation by the radial flap (DUBRUEHL)	198
g. Amputation of the forearm	199
α. By double circular incision	199
β. By skin flaps	199
h. Disarticulation at the elbow	199
α. By circular incision	199
β. By flaps	200
i. Amputation of the arm	201
α. By single circular incision	201
β. By double circular incision	201
γ. By flaps	201
k. Disarticulation at the shoulder joint	201
α. By flaps	201
β. By circular incision	204
IV. Amputations and disarticulations of the lower extremity	205
a. Disarticulation of the toes	205
b. Disarticulation of all the toes together at the metatarso-phalangeal joints	205
c. Amputation of all the metatarsal bones	207
d. Disarticulation of the big toe with its metatarsal bone	207
e. Disarticulation of the fifth toe with its metatarsal bone	208
f. Disarticulation at the tarso-metatarsal joints (LISFRANC)	209
g. Disarticulation through the tarsus (CHOPART)	211
h. Subastragaloid disarticulation (MALGAIGNE)	214
i. Disarticulation of the whole foot (SYME'S)	215
k. PIROGOFF'S amputation of the foot	219
l. GÜNTHER'S modification of PIROGOFF'S operation	220
m. LE FORT'S modification of PIROGOFF'S operation	222
n. Amputation of the leg	224
α. By double circular incision	224
β. By skin flaps	224
o. Disarticulation at the knee by the circular method	225
p. Disarticulation at the knee by the flap operation	227
q. Amputation of the thigh	228
α. By the single circular incision	228
β. By the double circular incision	228
γ. By the flap operation	228

	Page
r. Disarticulation at the hip	229
α. With a large anterior and a small posterior flap (MANEC) by transfixion	229
β. By the circular method	232
s. Reamputation	233
F. Excision of joints	236
I. General rules for excision	236
II. Excision of the lower articular ends of the radius and ulna. By lateral incision	242
III. Complete excision of the wrist. With LANGENBECK'S dorso-radial in- cision	247
IV. Excision of the elbow. With LISTON'S T incision	250
V. Subperiosteal excision of the elbow. With LANGENBECK'S simple straight incision	254
VI. Excision of the elbow. HÜTER'S lateral incision	255
VII. Excision of the shoulder. With LANGENBECK'S anterior vertical incision (older method)	256
VIII. Subperiosteal or subscapular excision of the shoulder. LANGENBECK . . .	259
IX. Excision of the glenoid cavity	261
X. Excision of the ankle. LANGENBECK'S subperiosteal operation	262
XI. Excision of the knee joint	266
XII. Subperiosteal excision of the knee joint. With LANGENBECK'S curved lateral incision	267
XIII. Excision of the hip joint. With posterior curved incision (ANTHONY WHITE)	270
XIV. Subperiosteal excision of the hip joint. With LANGENBECK'S longitudinal incision	272
G. The indications for amputation and excision	277
H. Excision of portions of the calvaria	279
J. Examination and cleansing of gun-shot wounds from foreign bodies and septic matters	284
K. The hypodermic injection	291
L. Tracheotomy	292
M. Paracentesis thoracis	297
N. Sutures for the intestine	299
O. Urethrotomy and lithotomy	301
P. Operations with artificial light	303
Q. Bed-lifts	304
INDEX	307





I. THE DRESSING OF WOUNDS.

(BANDAGES AND SPLINTS.)

A. COMMON RULES FOR THE TREATMENT OF WOUNDS AND INJURIES.

1. The first and most important principle in the treatment of wounds is to keep at a distance all injurious influences, which can hinder or retard their healing. Therefore every method of treatment should be rejected which introduces new noxious influences.

2. *Rest* is the most important condition for rapid healing.

The injured part must be therefore placed at rest (immobilized made immoveable), and absolute rest in bed must be observed in all severe injuries, at any rate at the commencement.


Every unnecessary disturbance (touching, examination, probing, squeezing etc.) of a wound is to be avoided.

3. Venous stasis hinders the healing.

By elevating the limb care is taken, that the escape of venous blood and lymph from the injured part is not impeded; and the removal of any strangulation (such as constricting clothes or bandages) must never be omitted.

4. The retention of the secretions of the wound tends to suppuration, to traumatic fever, and to other accidental complications.

A free escape for the secretions of the wound is therefore always to be considered as one of the most important principles in the treatment of wounds.



There should be no hermetical sealing of wounds, but an escape must be provided for the secretions, by introducing perforated india-rubber tubes (CHASSAIGNAC'S Drainage tubes) (fig. 1) as deeply as possible,

and by an early removal of the sutures. One suture too tightly drawn may result in the death of the patient.

5. Any contamination of a wound may call forth in it decomposition and putrefaction, and with them the accidental complications which retard its healing and endanger the life of the patient.

Care for the most scrupulous cleanliness (of the fingers, instruments, bandages, linen, water, and air) is therefore the first duty of the surgeon, as well as of the attendants.

B. THE COVERING OF WOUNDS.

For protection against injurious influences from without, for the dressing of wounds, there are used:

1. *Compresses* — pieces of old soft linen, moistened with some fluid or ointment which prevents the hermetical closing which would arise from their adhering to the wound.

It is best for this purpose, to make holes through these compresses with a punch, or to change them into so called "Gitter-charpie" by drawing out the threads.

2. *Charpie* — plucked from clean old soft linen with clean fingers, and placed beneath the compress, serves to suck up all the secretions of the wound, and certainly answers for this purpose better than all other substitutes.

As it is always possible that the charpie contains infectious matter, it should be made harmless before its application, by boiling and soaking in disinfecting agents (such as carbolic acid, salicylic acid etc.). Lately too in its place, many of the following materials have been brought into use.

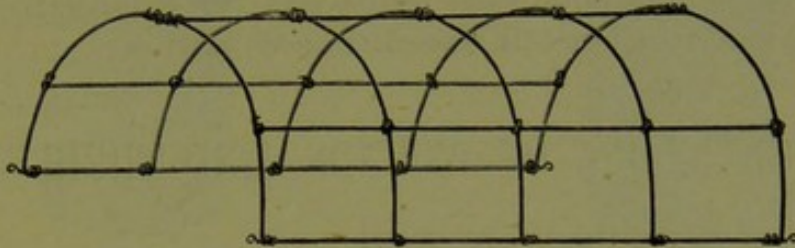3. *Cotton-Wool* — the common wool serves for wrapping up wounded parts; this wool purified and freed from grease by boiling in alkalies (charpie wool, BRUNS' wool dressing) serves for soaking up the secretions of the wound; it is not intended to be applied directly upon the surface of the wound, because the loose fibres of cotton become matted to the granulations.

4. *Lint* — a woven felted cotton, when soaked in water or oil is a good dressing.

5. *Oakum* — plucked from old ships rope thoroughly soaked with tar, acts as a disinfectant and absorptive agent, but is somewhat too hard for irritable wounds. The same may be said of jute (s. p. 15).

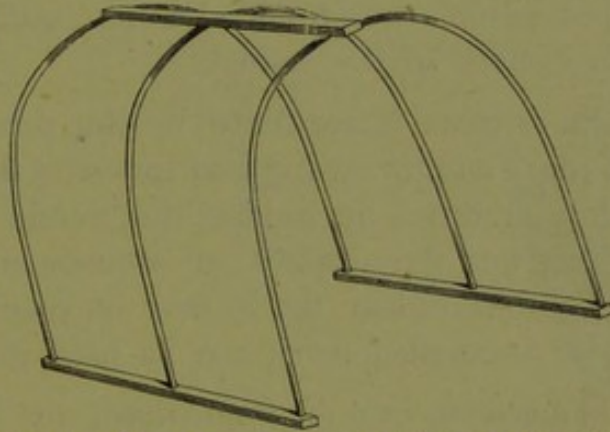
6. *Waterproof materials* — as oil-silk, oil-cloth, gutta-percha tissue, India-rubber material, or varnished silk paper*, serve for covering and keeping moist the dressings, and for the protection of the bed-linen.

Fig. 2.




Cradle of iron-wire, easily made of telegraph wire.

Fig. 3.



Cradle of three copper wires and three wooden rods.

Fig. 4.



The same pressed flat to facilitate its being packed for transport.

* By means of a large brush the silken paper is smeared over with a varnish of linseed oil, to which is added 3 per cent of driers or varnish extract. The varnished smeared sheets are suspended on cords in an airy room for two days, until they are quite dry.

7. *Cradles* — made of bent wire and wood (wire arch) or of barrel hoops, are placed over the injured parts, so as to protect them against the accidental contact and pressure of the bed clothes (fig. 2, 3, 4).

NB. The open treatment of wounds (freeing the wound from any dressing) gives in some cases better results than any other method of treatment, in which the wound is exposed to many injuries.

C. THE CLEANSING OF WOUNDS AND THEIR VICINITY.

For this purpose, there are used:

1. *The wound-douche* (ESMARCH'S Irrigator, fig. 5), by means of which a stream of water (disinfected by the addition of carbolic acid, permanganate of potassium, acetate of alumina, salicylic acid etc.) is conducted over the surface of the wound.

The force of the stream is regulated by the pressure of the two fingers holding the pipe, and by raising and lowering the douche. A tap is unnecessary. It is arrested by sinking the nozzle into the tin-can (fig. 6). For washing out the cavities of wounds and sinuses a soft point of vulcanized india-rubber (fig. 7) may be placed on the pewter point, or a nozzle of decalcified ivory can be used (fig. 8).

An irrigator (THIERSCH) can be improvised, by knocking out the bottom of a wine bottle, placing an india-rubber tube through the perforated cork, and suspending the inverted bottle by a cord (fig. 9).*

Care is taken not to inject the sinuses with too strong a pressure, because in this manner the fluid may be driven into the cellular tissue and produce a violent inflammation. The use of the syringe also is to be discouraged, because less control is obtained over the action of the stream than with the irrigator.

* A cheap Irrigator: Take a bottle, knock a hole in the bottom and place in the mouth a perforated cork with pipe and nozzle, and hang the bottle upside down. For its suspension a pendant of five strings is used. Three of these strings are laid in their entire length upon the bottle, and cross at right angles the other two strings, of which the one is carried transversely round the body, the other round the neck of the bottle. At the point where the strings cross one another they are tied. The three strings placed lengthwise are tied together over the bottom of the bottle at a convenient height and serve for hanging up the bottle. (THIERSCH: *Klinische Ergebnisse*, p. 728.)

Fig. 5.

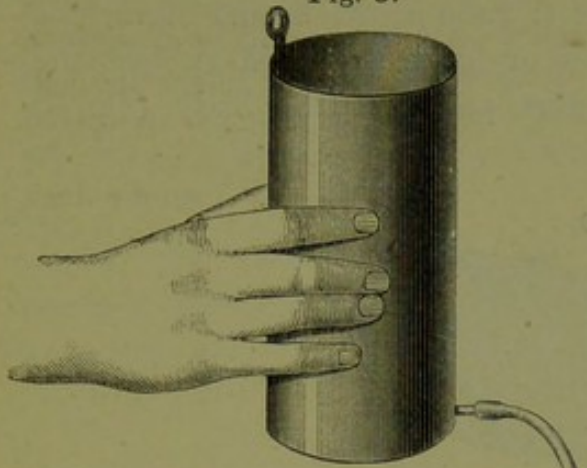
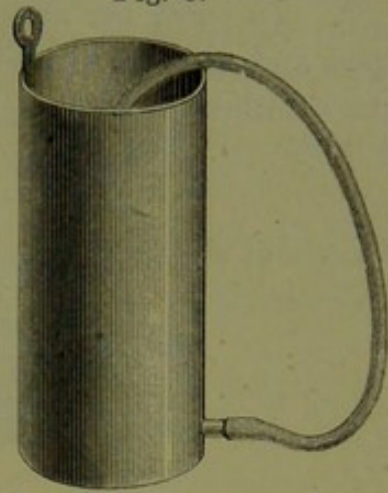
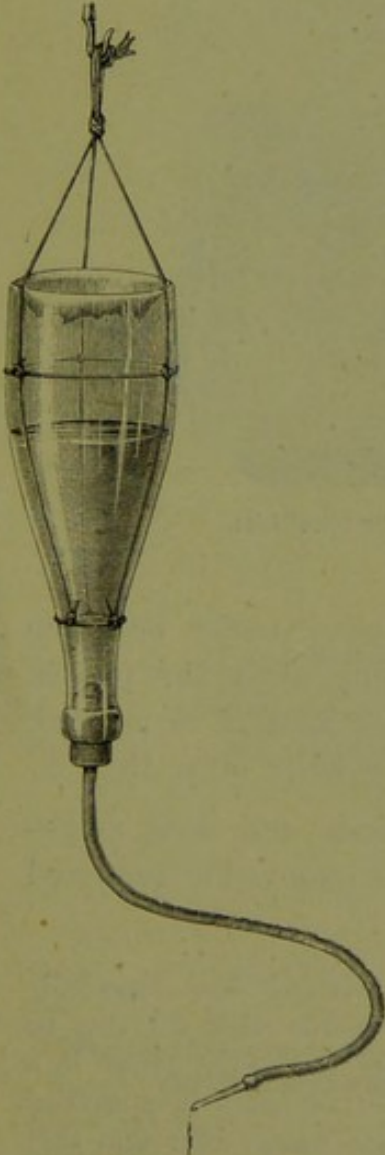


Fig. 6.



Irrigator shut off.

Fig. 9.



Improved Irrigator.

ESMARCH'S Irrigator in action.

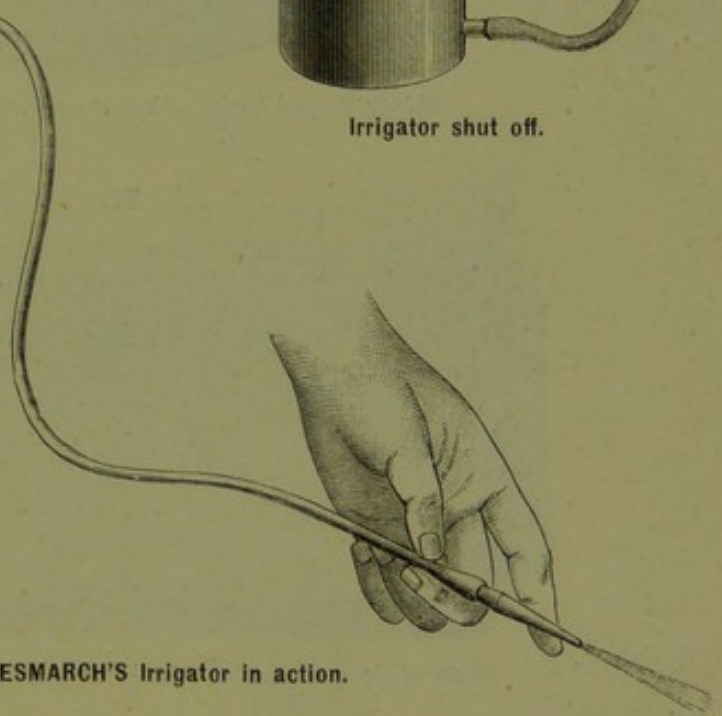



Fig. 7.



Point of vulcanized india-rubber.

Fig. 8.



Nozzle of decalcified ivory.

2. To catch the water and pus as it runs away, basins of various shapes and sizes are used, made of tin or hardened india-rubber, the edges of which accurately fit the various parts of the body (fig. 10 and 11).

Fig. 10.



Kidney shaped basin, either of hardened india-rubber or tin.

Fig. 11.



Basin of tin made like a bath, to be used for washing the extremities.

3. The surface of the wound itself should never under ordinary circumstances be unnecessarily disturbed. For wiping away the pus in the neighbourhood of the wound, charpie-wadding soaked in a weak solution of carbolic acid is used, or the antiseptic balls (s. p. 13).

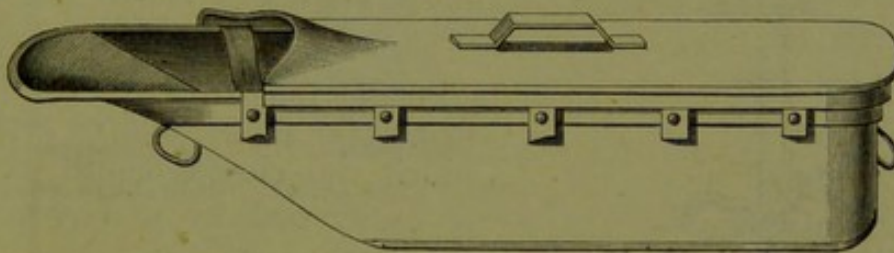
Sponges must only be used for cleaning wounds and their neighbourhood, when all impurities contained in them are removed or rendered harmless.

To thoroughly clean bath-sponges, they must be (KELLER) first repeatedly squeezed out in hot water, then dried, and beaten with a wooden stick till they no longer contain any sand. Sponges which have been used, are freed from grease in a hot concentrated solution of soda. They are then placed for 24 hours in a solution of permanganate of potass (1:500), and again washed in clean water; after that they are soaked in a (1 per cent) solution of the commercial salt of subsulphite of soda to

which is added 8 per cent of the pure concentrated hydrochloric acid, until (in about $\frac{1}{4}$ of an hour) they have become white; and lastly they are again washed in clean water until they are entirely scentless. They must be kept in a strong (5 per cent) solution of carbolic acid. Before being used they are laid in a weak solution ($2\frac{1}{2}$ per cent) of carbolic acid, and while in use they are constantly cleaned in this weak solution.

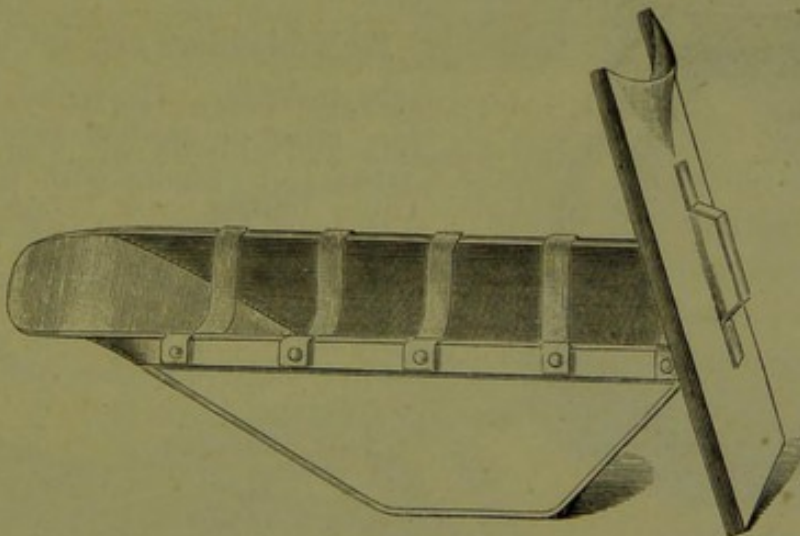
4. *For thoroughly cleaning* the injured parts of the body, the common baths (with the addition of soap, soda, acetate of alumina etc.) are employed, as well as the local-baths (fig. 12 and 13).

Fig. 12.



Arm-bath of zinc.

Fig. 13.



Leg-bath of zinc.

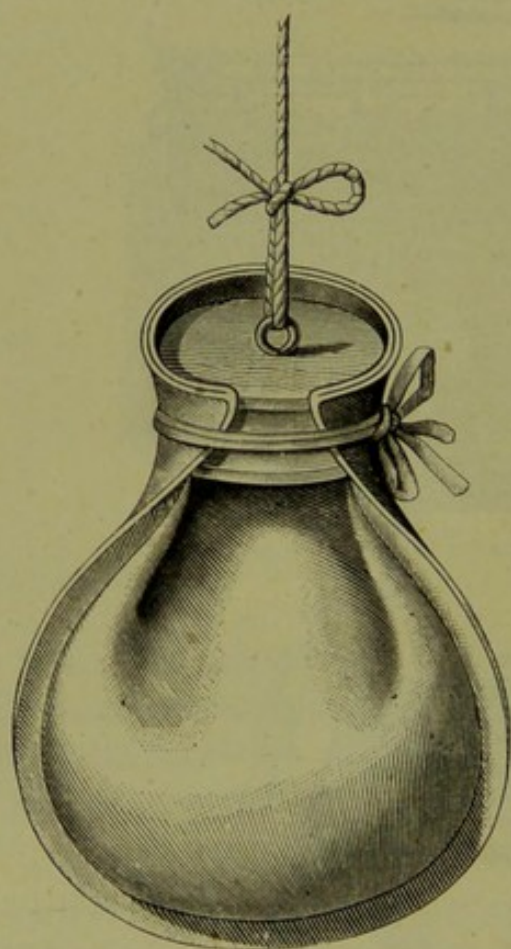The coverlids serve to keep the water in the bath warm; to the buttons on both sides strips of bandages are fastened, which are used for the suspension of the injured limb.

D. THE REDUCTION OF HEAT.

For subduing the inflammation, *cold* by the abstraction of heat, is of service, and this is employed in various ways:

1. In the form of *Cold Wrappings*; they must be very frequently changed, if such heat is really constantly to be abstracted, but this easily disturbs the injured part. If one allows them to remain longer so that they become hot, they act as excitants (PRIESSNITZ'S wrappings).

Fig. 14.



Ice - bag.

2. As *Dry Cold*, by ice in india-rubber bags (ice-bag).

The ice-bags must be securely closed by wooden plugs or large corks, round which the closed mouth of the bag is firmly tied by a narrow bandage (fig. 14).

If the direct application of the ice-bag is too cold, some layers of linen are laid between the ice-bag and the part.

Pig's bladders are apt to leak, and soon putrefy. To avoid the former they must be rubbed before use both inside and outside with lard.

Glass-bottles and tin-boxes filled with ice or cold water abstract the heat more energetically than india-rubber bags, but they are not so well applied to the body.

A very energetic cooling in inflammations of the extremities can be produced by the *Cooling-coil* (s. fig. 15).

This is the name given to a long india-rubber tube, which is wound in serpentine turns round the inflamed part; one end of this tube provided with a perforated tin block is sunk into a pail filled with ice-water, whilst the other end hangs down into an empty pail. By sucking

Fig. 15.

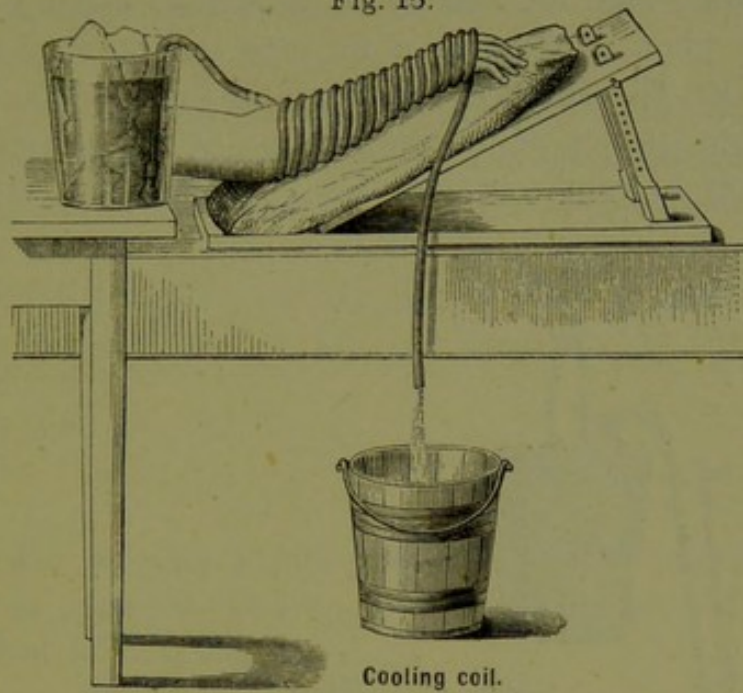
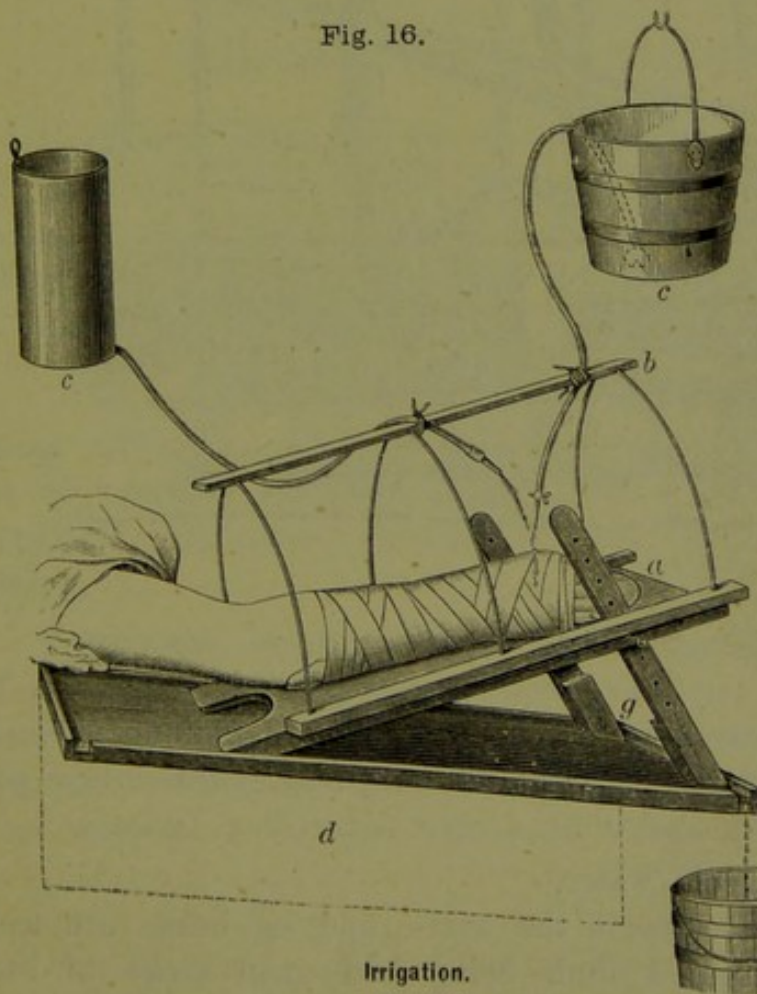


Fig. 16.



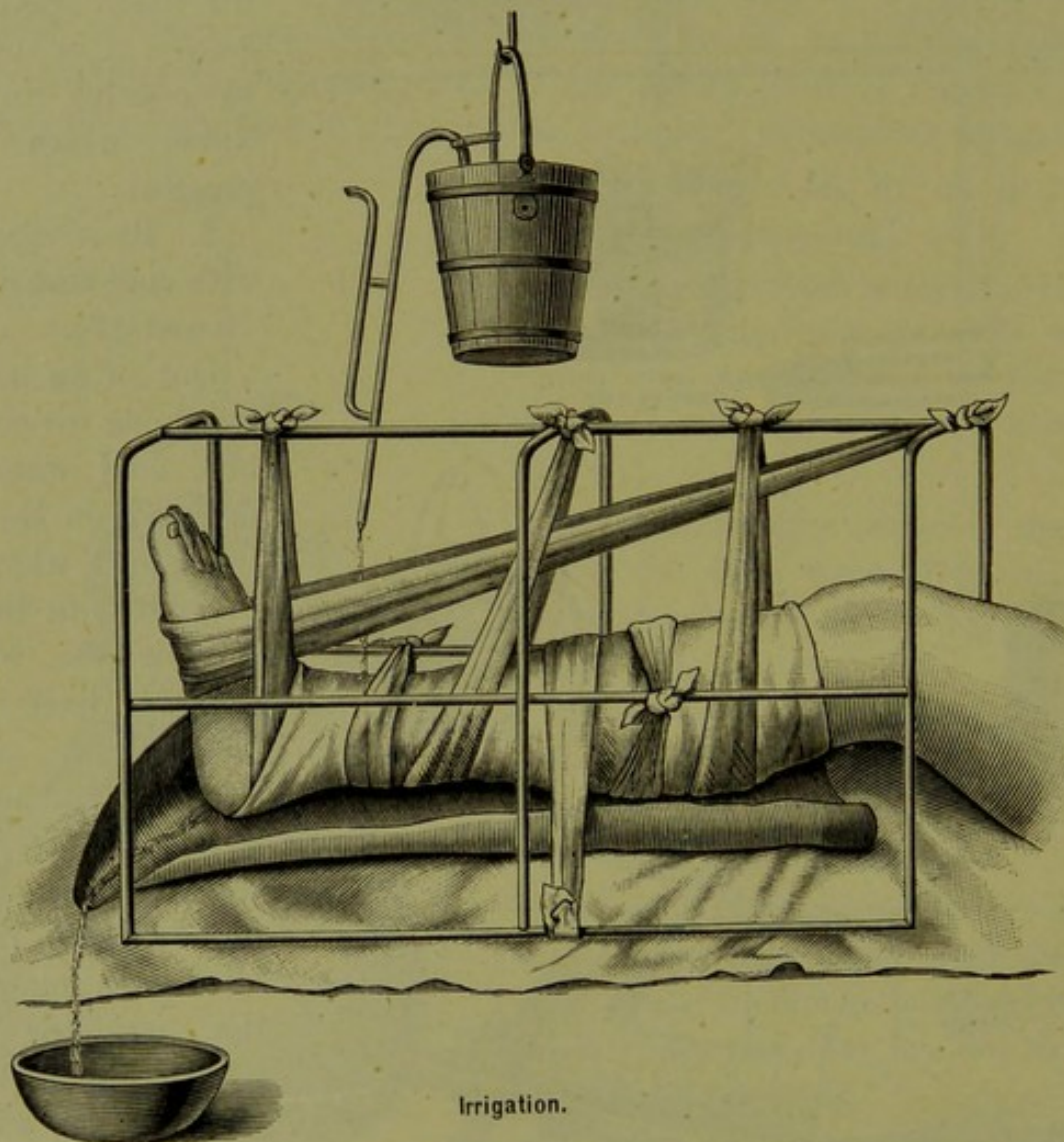
at the latter a current is produced, which can be regulated by the compression of a ligature. When the upper pail becomes empty, it is refilled by pouring in the water which has escaped.

3. By *irrigation* with cold water (fig. 16 and 17).

Out of an irrigator hung over the bed, cold water is dropped on the injured part, which is covered with linen; in this the water diffuses itself. By inserting a straw into the tin-nozzle of the irrigator, the rapidity of the falling drops is regulated. In place of the irrigator an india-rubber tube can be used, which is provided at one end with a tap, at the other end with a perforated block of tin, which is sunk into a bucket filled with water.

The tube acts as a syphon, and must be set in action by sucking. In the same way, a small syphon of glass or a tin pipe can be employed for this purpose (fig. 17). The effect of irrigation in the reduction of heat is very great in consequence of the evaporation of the water. It is not therefore necessary to employ water of a very low temperature.

Fig. 17.



The water as it runs away must be caught upon an oblique plain or upon a waterproof (oil-cloth) beneath the limb, and guided into a pail standing below.

4. By *immersion* in cold water.

To carry out this treatment the arm-, and leg-baths are used (fig. 12 and 13): the injured limb being laid upon strips of ban-

dages, which are fastened to the buttons found on both sides of the bath.

This method of abstracting heat is especially suitable for recent injuries of the hands and feet. It does not require a very low temperature, for the action of the permanent bath is very energetic. Water from 16—18 R. (68—72½ F.), by a long duration in the bath, produces a very perceptible cooling effect. The regulation of the temperature, by pouring in cold water, can generally be left to the patient himself.

For keeping septic matters from the wound, dressings for procuring complete closure are employed, as well as LISTER'S antiseptic method of dressing.

E. THE HERMETICAL SEALING OF WOUNDS.

Hermetical sealing, aims at producing a dry scab upon a recent wound, which remains firmly adherent till cicatrisation ensues. Open wounds can by this treatment heal without suppuration, like subcutaneous ones, and when successful, putrefaction is avoided.

This method is successful:

1. in *superficial injuries*; scratches, burns, abraisons etc., by powdering with flour, charcoal, chalk, potters clay, gum arabic; by drying the surface with a stream of air (from a pair of bellows); by slight corrosion with caustic or carbolic acid; or by covering with cotton wool;

2. in *deeper complicated wounds* (with fracture, injury to a joint etc.); by covering the bloody wound with clean and disinfected wool, teased charpie, lint, or german-tinder, which form with the blood a dry crust. Over this a thick layer of cotton-wool is laid, and over all a water-proof material is fastened with a moistened gauze-bandage.

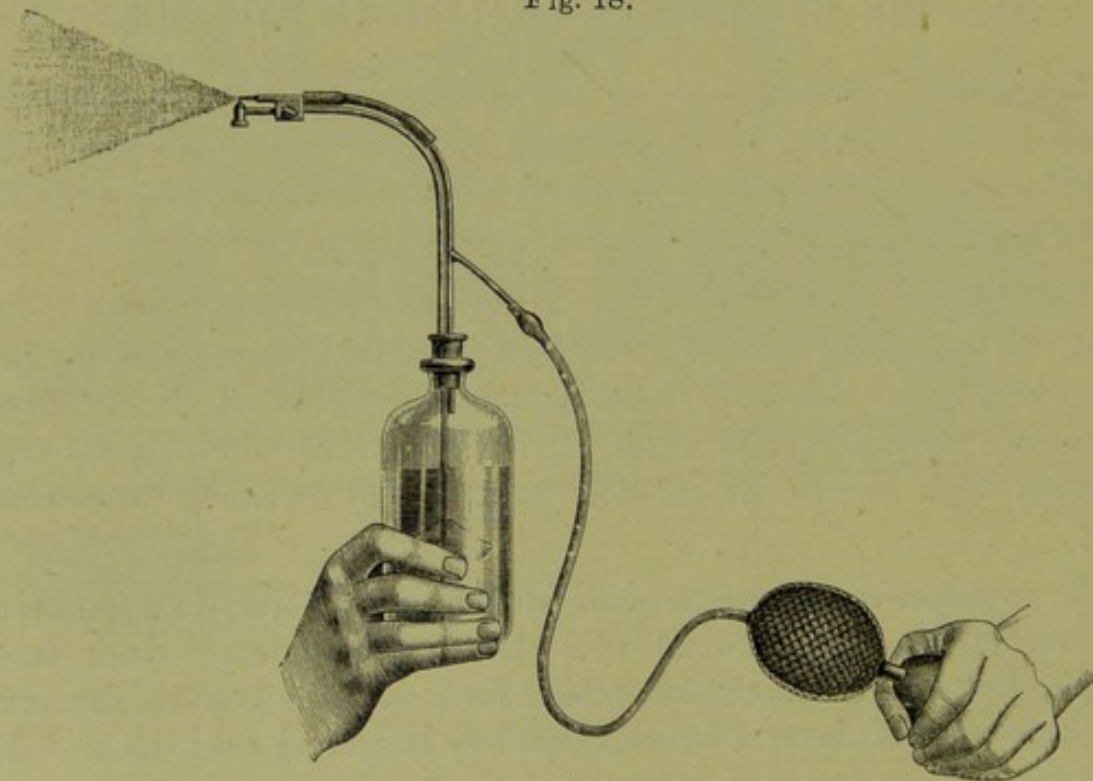
F. LISTER'S METHOD OF ANTISEPTIC DRESSING.

This also aims at keeping from the wound all sources of putrefaction (hovering in the air and clinging to every object), or at rendering them harmless by antiseptic means, which should not however excite the wound to (a septic) suppuration.

1. Firstly for *operations*; the skin around the seat of operation, and everything which comes in contact with the wound (the hands of the operator and of the assistants, the instruments etc.) after previous careful cleaning with soap and brush, is disinfected by washing with a strong (5 per cent) solution of carbolic acid.

2. During the whole operation and at every change of dressing, the air in the neighbourhood of the wound is perpetually filled with a fine mist

Fig. 18.

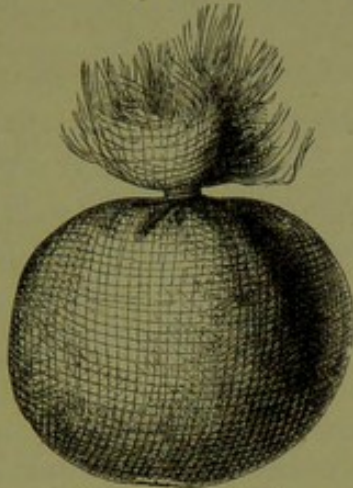


Carbolic - spray.

of a weak solution ($2\frac{1}{2}$ per cent) of carbolic acid. In order to produce this mist the carbolic-spray (RICHARDSON'S spray-producer, fig. 18) is

employed. During lengthy operations and dressings the spray can be momentarily interrupted, if the wound is in the meantime guarded, by being covered with a linen rag soaked in a weak solution of carbolic acid.

Fig. 19.



The antiseptic ball.

The sponges which are used at the operations must, after they are thoroughly cleaned and boiled (s. page 6), be kept in the strong carbolic solution, and before as well as during the operation be squeezed out in the weak solution.

In the place of the sponges the antiseptic balls (fig. 19) can be used. These are balls of salicylic wool, salicylic jute, or salicylic charpie, tied up in salicylic gauze.

3. Wounds which have already been exposed to the air, and operation-wounds which at the operation have come in contact with infectious matter, must before the application of the dressing be disinfected by washing with the strong (5 per cent) solution of carbolic acid; this does not retard healing by first intention; if suppuration has already set in, a stronger disinfection with 8 per cent solution of chloride of zinc is required for thoroughly washing out the wound.

4. *Every bleeding point* is to be carefully ligatured with carbolised catgut, and the ends of the latter cut off close to the knot. After some time they are completely dissolved in the interior of the wound and absorbed.

To render the catgut antiseptic it must lie for at least two months in a carbolic emulsion (1 part of crystallised carbolic acid dissolved in 10 per cent water and 5 parts of olive oil) at a low temperature, and without being shaken. On standing, a part of the watery solution separates from the emulsion, into which the catgut is not allowed to sink. To prevent this a small stone or bead is placed at the bottom of the glass and over this a glass-plate, upon which the catgut rests. The latter begins to swell, becomes opaque soft and slippery, but later it again becomes transparent and as firm as silk.

5. *The wounds are carefully sewn* with silver-wire or carbolised silk.*

* Uncoloured silk which has lain for half an hour in a mixture of melted wax and carbolic acid.

6. *Drainage-tubes* well perforated, and carbolised by being kept in a strong solution of carbolic acid, are pushed into the deepest parts of the wound: and a careful compression is made upon the cavities of the wound by carbolised sponges, or pads of carbolised gauze, wool, salicylic wool, or jute. These are the means used to prevent the retention of the secretions of the wound.

7. *In immediate contact with the surface of the wound* is laid a piece of *protective silk*, steeped in a weak *carbolic* solution, which protects the wound against the direct influence of the carbolic acid, and at the same time when the dressing is changed, it indicates by an alteration in color (dirty-grey, sulphuret of lead) whether decomposition has taken place.

Protective silk is a fine green oiled-silk made waterproof with copal-varnish, (which contains lead), and overlaid with a fine layer of a mixture of 1 part of dextrine, 2 parts of starch and 16 parts of a cold watery solution of 5 per cent carbolic acid. This together with the germs of putrefaction, which perchance are sticking to it, is again washed by dipping it into a weak carbolic solution immediately before its application to the wound.

8. Over the protective a layer of carbolised *gauze in eight folds* is laid, which extends beyond the edges of the wound more than a hand's breadth; between the seventh and eighth fold is placed a piece of mackintosh or varnished silk paper (s. pag. 3), which prevents the secretion from the wound penetrating directly through to the upper surface. The whole is fastened on with gauze bandages.

The antiseptic gauze is prepared in the following manner. Cotton gauze either bleached or unbleached, but containing no starch, is first placed for some time in a double-walled tin vessel, heated by boiling water or steam; then by means of a large syringe it is sprinkled with a hot mixture of 5 parts of resin, 7 parts of paraffine, and 1 part of crystallised carbolic acid, and must remain for 24 hours under a heavy sheet of lead in the hot tin case, so that it may be equally penetrated throughout with the mixture. The gauze is then taken out, and carefully kept till required for application in a wrapping of parchment or varnished paper.

9. *The dressing must be renewed* in the same way, as often as the secretions of the wound appear at the edges of the dressing; at first once or twice a day, later on every two or three days, and at last much less frequently. The dressing is to be changed as quickly as possible. The neighbourhood of the wound is cleansed with the irrigator and cotton wadding soaked in the weak carbolic solution. The cavity of the wound is not needlessly washed out. Only when the silk has

become discoloured must it be disinfected afresh with the strong carbolic solution.

The drainage-tubes are changed after some time, or replaced by thinner ones, and as soon as possible left out altogether.

10. If it is undesirable or impossible to renew the dressing frequently, *the double antiseptic dressing* is applied, the deeper layer of which consists of the "protective" and a compress, soaked in a solution of carbolic acid, which is fixed by a gauze-bandage. Over this come then the dry layers and the sheet of mackintosh. The deeper layer can remain for weeks, and is only moistened at each dressing with the carbolic solution.

11. In default of LISTER'S dry antiseptic gauze, BARDELEBEN'S *moist carbolic dressing* can be used. Over the "protective" are laid many folds of gauze which has first lain for twelve hours in a strong carbolic solution, then been squeezed out and kept in a fresh 1 per cent solution of carbolic acid. As soon as the secretion from the wound penetrates anywhere to the surface, new layers of the moist gauze are put on.

12. *Boracic Acid* also acts as an antiseptic and can be used for superficial wounds, burns, and granulating surfaces either in the form of a watery solution (1 : 30) in which is dipped the lint or gauze, or as an ointment (1 : 2 lard) (CHIENE).

13. *Salicylic Acid*, which has been recommended by THIERSCH and lately so much employed especially in combination with the carbolic dressing, has a similar effect, although not quite so certain an antiseptic as carbolic acid. It can be employed in a watery solution (1 : 300) both for the spray and for impregnating the dressings, for washing the instruments, hands etc. but it is especially used for impregnating the materials for dressing, namely the wool and jute.

Jute (prepared Arrakanian hemp) on account of its permeability is especially fitted for antiseptic dressing.

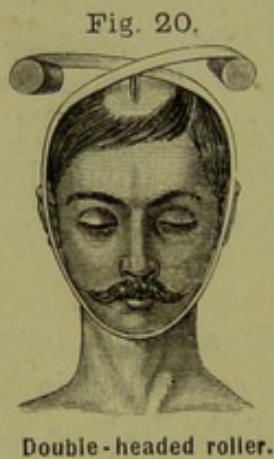
For the description of this dressing s. C. THIERSCH: *Klinische Ergebnisse der Lister'schen Wundbehandlung*. Leipzig 1875, p. 720 u. ff.

G. THE UNION OF WOUNDS.

To unite the edges of wounds, which have no tendency to slough (incisions and incised wounds), we make use of:

1. *Strips of adhesive Plaster*; they are on the whole seldom used, because the plaster easily irritates the skin, producing erythema and eczema, and causes the retention of the secretions of the wound.

2. *Strips of gauze-bandage*, which are fastened on both sides of the wound with collodion (gun-cotton dissolved in ether) or with gutta-percha dissolved in chloroform.

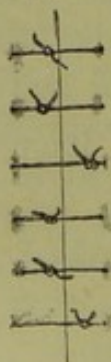


3. *Starch-bandage*, dipped in water and applied over the edges of the wound, which are adapted by the fingers, presses the edges well together without keeping back the secretions of the wound. In many cases it is better to roll up the bandage from both ends, and with it to press the edges of the wound together from both sides (fig. 20).

4. *Sutures.*

a. The interrupted suture (Knopfnaht, fig. 21) is applied by more or less curved needles with waxed or carbolised (s. pag. 14) silk, twine, horse-hair, cat-gut, and silver or iron wire.

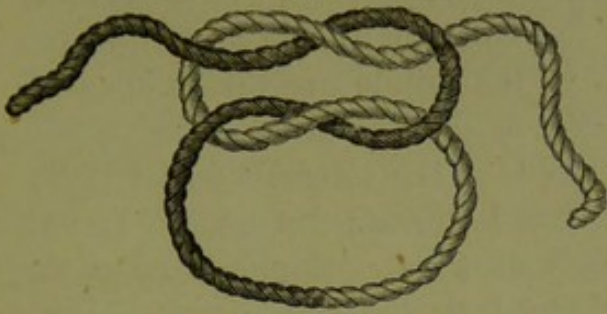
Fig. 21.



The interrupted suture.


It is important to finish the stitch with a safe double knot, which does not of itself become loose. For this purpose the reef knot (fig. 22) is used in which the threads pass respectively beneath and above the corresponding loops, while in the false knot or "granny" (fig. 23) which is not secure, the threads on each side pass one above and the other below the loop.

Fig. 22.



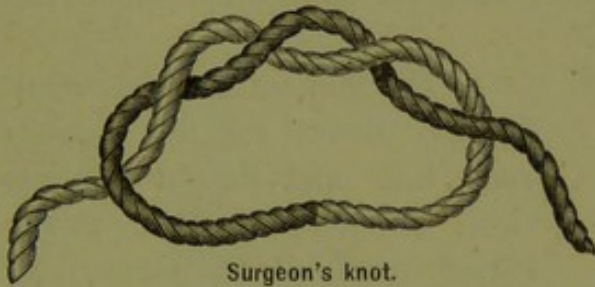
The "Reef" or cross knot.

Fig. 23.



The false knot or "granny".

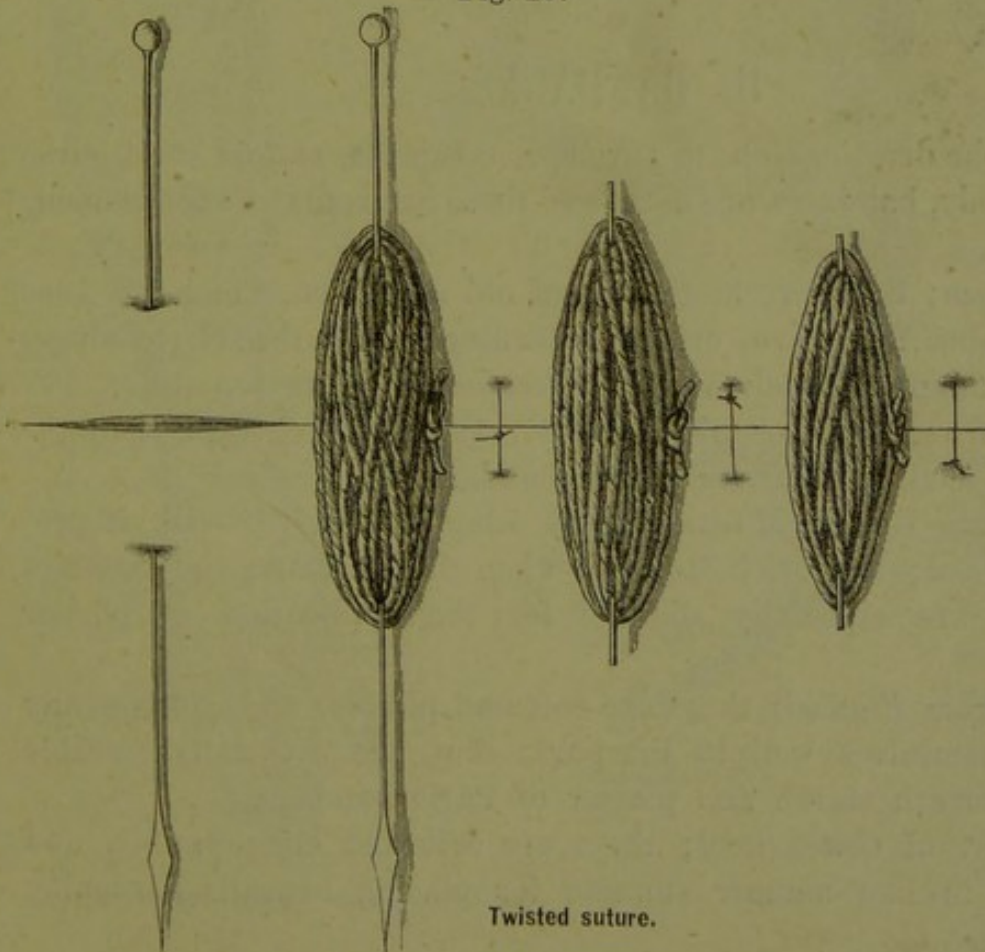
Fig. 24.



Surgeon's knot.

When the edges of the wound are considerably strained, it is best in the first knot to twist the ends of the thread twice round each other (fig. 24, surgeon's knot), and on that to tie the second, as in the reef knot.

Fig. 25.




Twisted suture.

b. The twisted suture (fig. 25) is applied by means of Insect - needles (Carlsbad needles), whose points are beaten flat and sharpened in the form of a lance. When they have been carried through the skin at some distance from the edges of the

wound, they are wrapped round with thick cotton threads in alternating circles and figures of eight, so that the edges of the skin are pressed firmly against each other. The ends of the needle are then nipped off with a pair of pliers. To unite the edges of the wound more accurately, a few fine interrupted sutures are placed in the intervals between the needles. The remains of the needles can be drawn out on the second day, with a twisting motion, by means of a pair of pincers, but the pads of thread, which are generally glued to the skin by the blood, are allowed to remain some days. This suture is especially adapted for large gaping wounds of the face, such as commonly occur after plastic operations.

Fig. 26.



The fold suture.

c. The fold suture (*Faltennaht*, fig. 26) serves for the union of very thin and flaccid edges of skin, which are by this method raised to a fold, and the surfaces in contact increased.

H. BANDAGES.

To keep the dressings on, to envelope, compress, and fix the injured parts of the body, bandages are used, and these are made of the following materials:

a. of *Linen*; these are best made of old soft linen, which has been frequently washed, and torn, or cut according to the thread (bandages of new linen adapt themselves badly, because they are too stiff);

b. torn from *Cotton-stuff* (*Shirting*); these are cheaper than the linen, and especially useful for starch bandages;

c. cut from *Gauze* (*Muslin*); these adapt themselves well, if previously moistened; and stick together when dry, because they contain starch; they are especially suitable for the application of plaster of Paris;

d. torn from *Flannel*; these are soft and pliable, and consequently accomodate themselves well to the part; they are especially suitable for placing beneath starch and plaster of Paris bandages;

e. cut out of *Cotton-wool*; these are soft and compressible, and are therefore in like manner suitable for placing beneath hardening bandages.

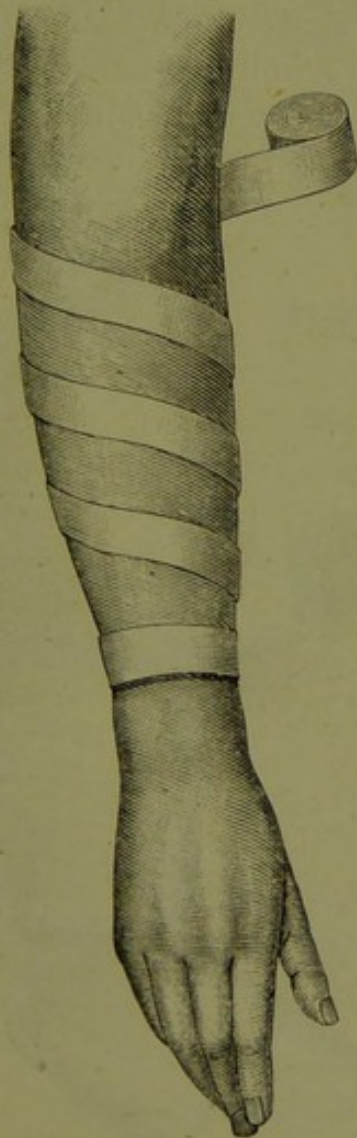
THE BANDAGING

must be done with great accuracy and care, for a badly applied bandage easily gets out of place, and by strangulation may produce considerable mischief.

A bandage too tightly applied soon produces venous stasis; the parts below the seat of strangulation swell, become painful, blue, and cold, and if the cause be not soon removed, gangrene ensues.

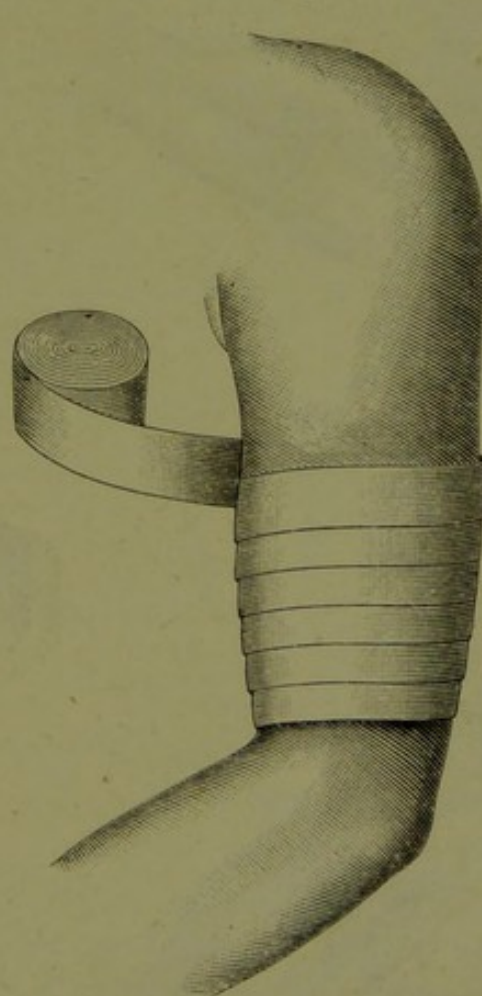
If bandages, applied dry, afterwards become wet (e. g. from cold wrappings) they shrink, and frequently produce strangulation.

Fig. 27.



The circular bandage and rapid spiral.

Fig. 28.



The slow spiral.

In bandaging one distinguishes the following passes or turns:

1. The *circular bandage*, whose turns are applied on one and the same level (fig. 27, infra).

2. The *rapidly ascending spiral* (Schlangentour, dolabra repens) (fig. 27, supra).

3. The *slowly ascending spiral* (Hobelbinde, dolabra ascendens) whose turns partially overlap each other (fig. 28).

Fig. 29.

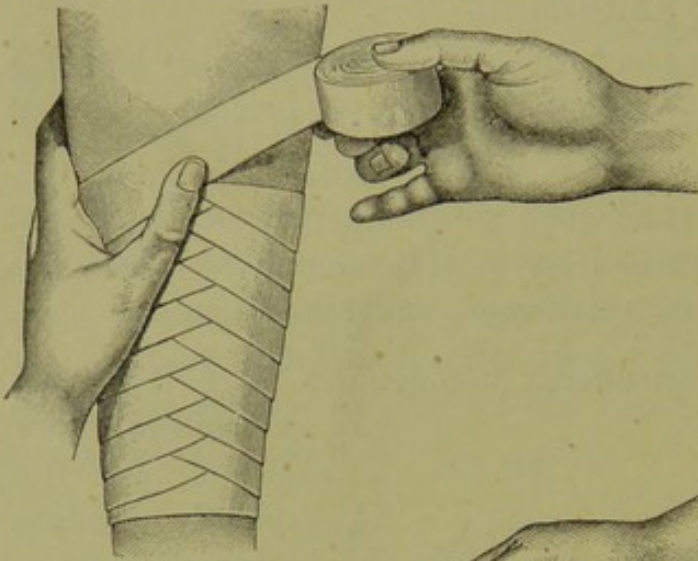


Fig. 30.

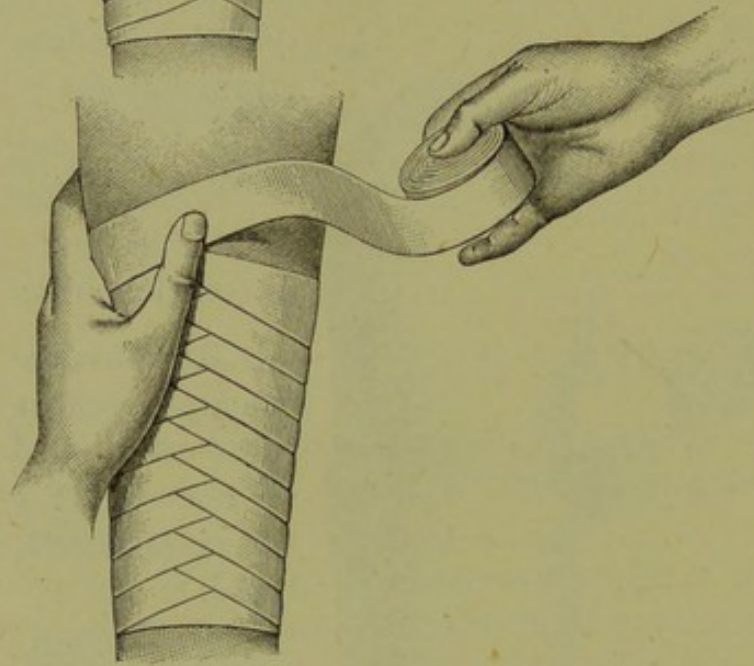
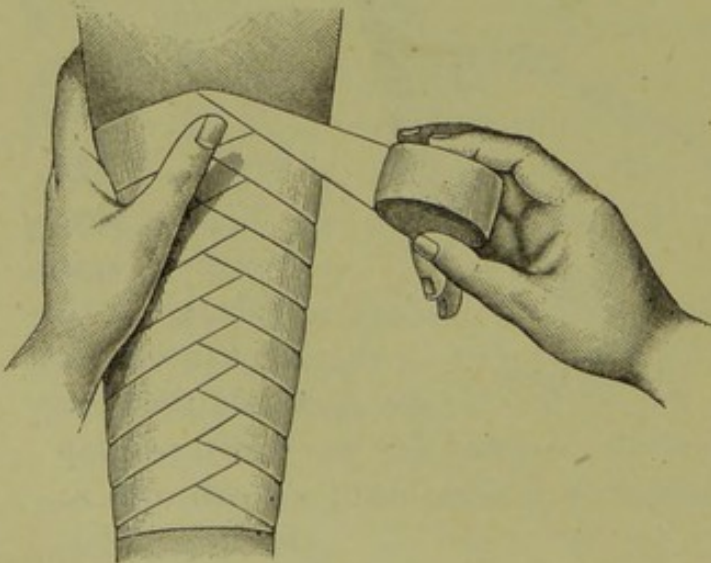


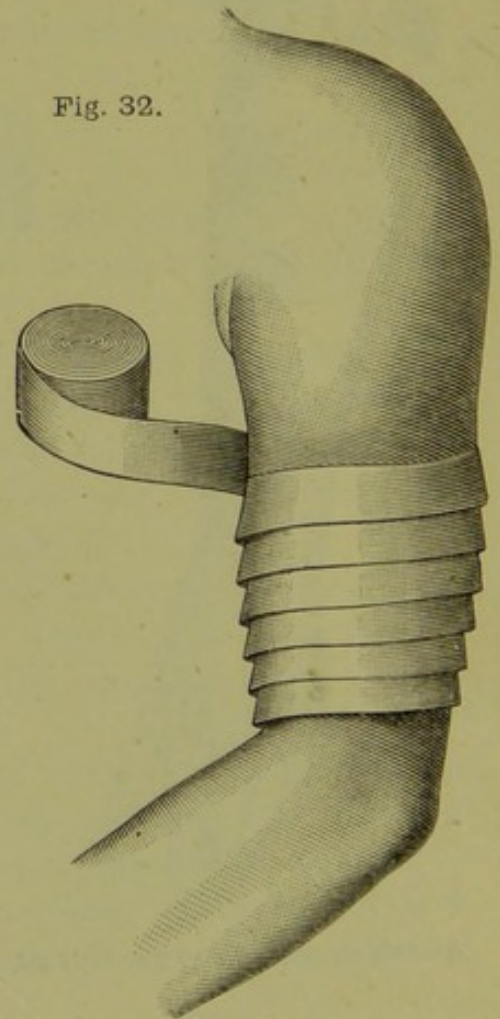
Fig. 31.



The descending spiral is seldom used, on account of its driving back the venous blood.

4. *Bandaging by reverses* (*dolabra reversa, renversée*) (fig. 29—31) must be used, when the circumference of the limb increases or diminishes, so as to avoid the gaping of the turns (fig. 32).

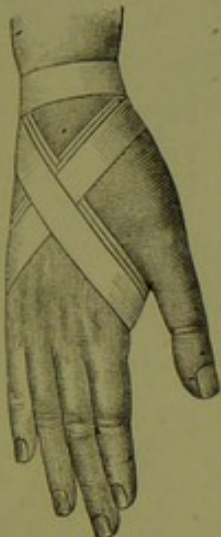Fig. 32.



Gaping bandage.

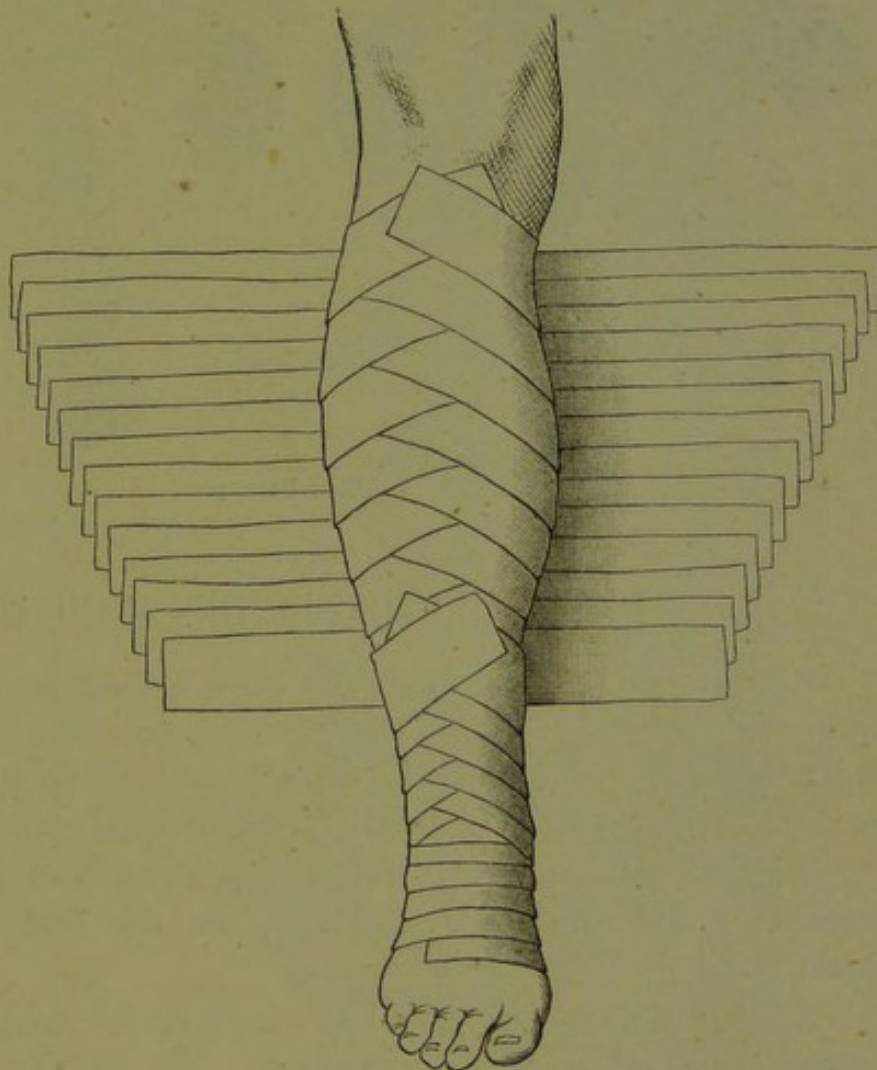
5. The *figure-of-eight* (*spica*) is employed where the bandage passes over a joint (fig. 33).

Fig. 33.



The figure of eight.

Fig. 34.



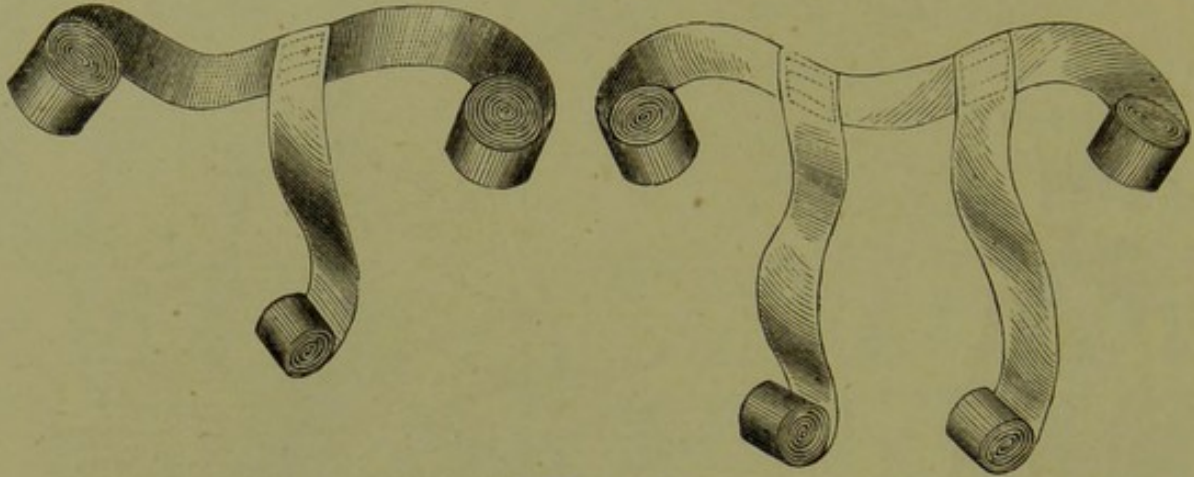
The many-tailed bandage.

6. The *double-headed roller*, a bandage, which is rolled up from both ends, is used especially for the head, and for amputation stumps; it is also employed for drawing together the edges of wounds (s. fig. 20, pag. 16).

7. The *many-tailed bandage*, consisting of many short strips of bandage which overlap each other, is used for compound fractures, and sometimes for the application of plaster of Paris (fig. 34).

8. The **T** bandage, a strip of bandage, to the middle of which another strip is fastened at right angles, is used in some dressings for the pelvis and head (fig. 35).

Fig. 35.

The **T** bandage.

J. THE HANDKERCHIEF BANDAGES.

By means of a linen or cotton cloth, triangular (neck-kerchief) or square (pocket-handkerchief), most of the dressings can be well applied, and many better than with bandages; little or no practice is required for their application, and there is less risk of strangulation.


These bandages are therefore especially well fitted for military practice, and before everything else, for the first assistance on the battle field.

So long as 50 years ago these handkerchief bandages were strongly recommended by MAYOR of Lausanne. But as they have been almost entirely forgotten, the author has endeavoured to procure their re-introduction into field-practice, having illustrations printed on the triangular handkerchiefs, which describe their application for injuries of different parts of the body (fig. 36 and 37).*

As is evident from these drawings, the handkerchiefs can be used for various purposes in different shapes and sizes; as a cloth-bandage folded from apex to base into a long and narrow cravat, as an open

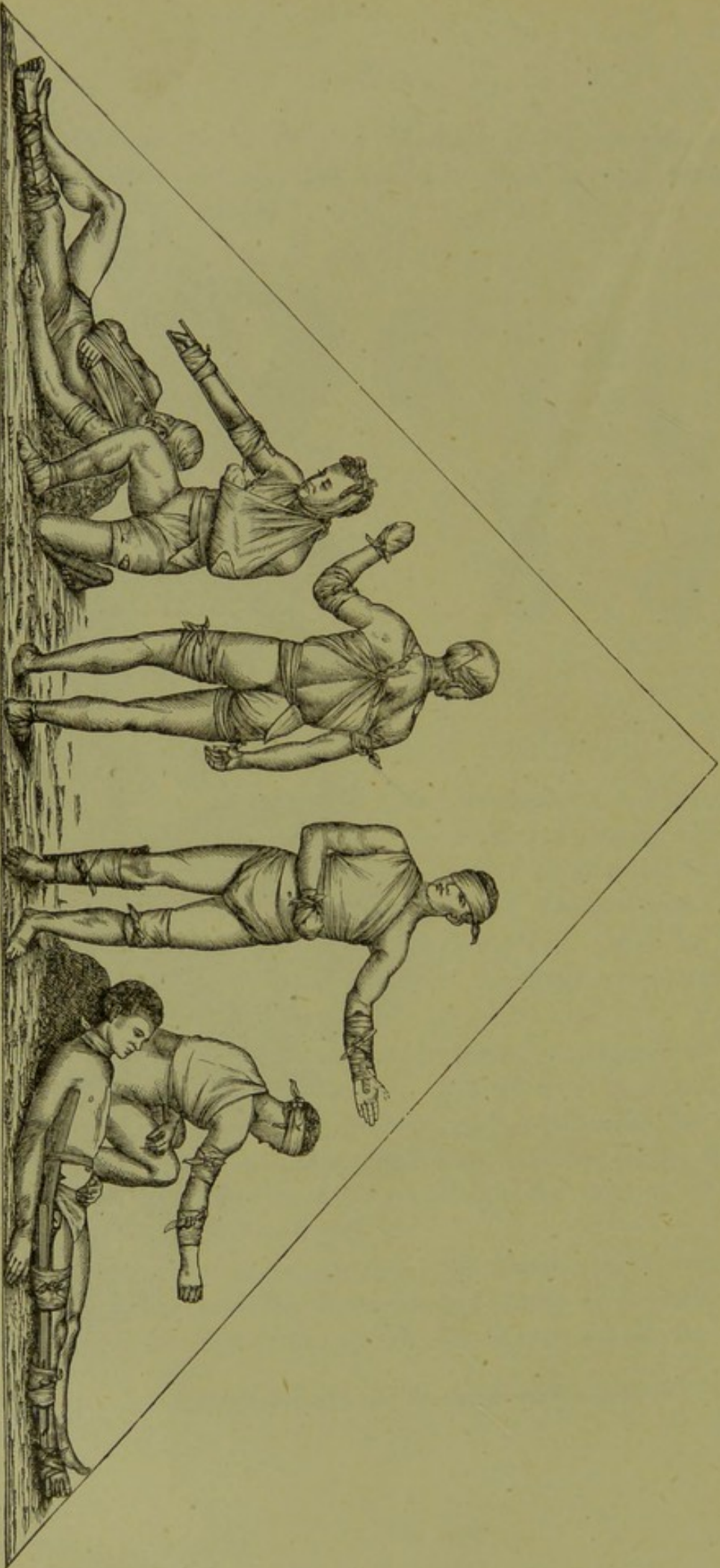
* Vide ESMARCH'S The first dressing on the battle-field translated by DR. THOMAS GUY. Kiel 1869.

Fig. 36.



The first dressing on the battle-field. Kiel 1869.

Fig. 37.

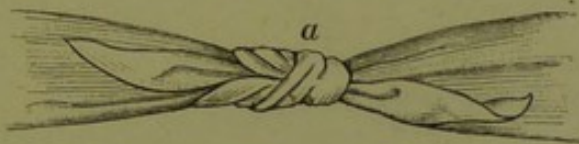

The first dressing. Düsseldorf 1873.

triangle for various applications, by turning-in the separate corners, folding them down, tying them together, or fastening them with pins. (For the individual bandages see later on.)

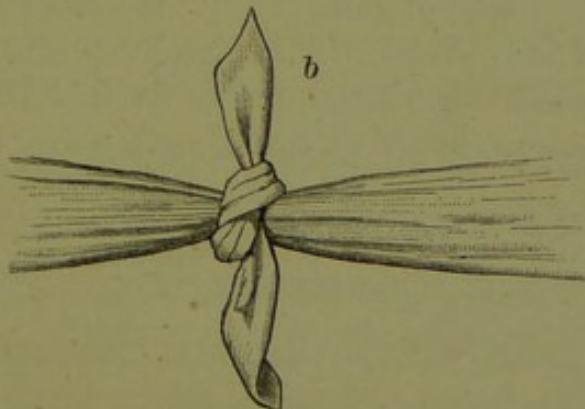
For military practice the three cornered handkerchief should be large enough to serve as a sling for a big man, i. e. the base of the right angled triangle must be at least 130 centimeters long, and the material, of which such handkerchiefs are cut, must be at least 92 centimeters broad. If smaller handkerchiefs are required, the large one can be divided into two equal halves, by cutting it with a pair of scissors from the apex to the middle of the base. To fasten the corners together, the reef-knot (fig. 38) is used, which holds much more securely than the "granny" (fig. 39), or the corners are

Fig. 38.




The reef-knot.

Fig. 39.



The "granny".

Fig. 40.



The safety-pin.

fastened by pins, for which purpose the safety-pins are the most suitable (fig. 40).

K. SPLINTS.

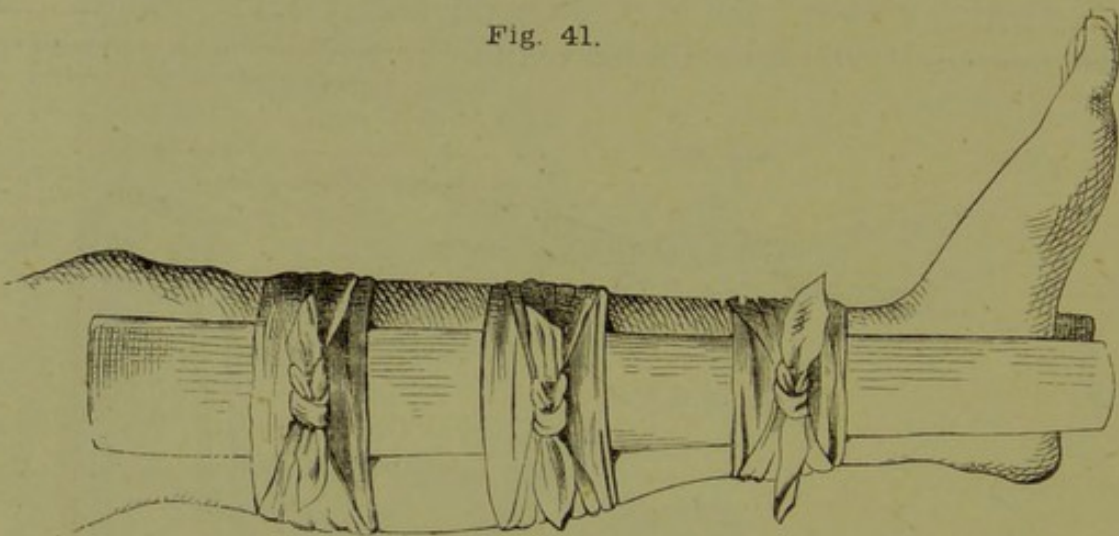
For fixing broken bones, splints are used, which are fastened to the limbs by means of bandages or handkerchiefs. They are made of various materials.

Those most commonly used are the following:

1. WOODEN SPLINTS.

a. Simple thin pieces of *boards*, of different lengths and breadths, flat or concave (fig. 41).


Fig. 41.



Broken leg with splints.

b. *Gooch's flexible split-splints* of thin (6^{mm}) pine boards, which by parallel incisions are cut into strips 1^{cm} in breadth; they do not completely divide the wood, which is pasted on leather or linen. They are perfectly flexible cross-ways, but very firm length-ways (fig. 42).

Fig. 42.




GOOCH'S flexible splint (Spaltschiene).

c. *Schnyder's Cloth splints*, are composed of splints of flexible walnut-wood (Veneer) $2 - 2,5^{\text{cm}}$ broad, and 3^{mm} thick, which are

placed close together and sewn between two pieces of linen or calico (fig. 43).

Fig. 43.




SCHNYDER'S cloth splints.

d. The *Authors splint material*, which can be cut as required, consists of wooden shavings 3^{cm} broad, and 1,5^{mm} thick, which at intervals of 5^{mm} are laid parallel and close to one another between two layers of unbleached calico (stouts), and glued together with (Wasserglas) silica.

Splints of this material are very light, can be cut with scissors, and easily rolled up in considerable quantities to take upon the battle field.

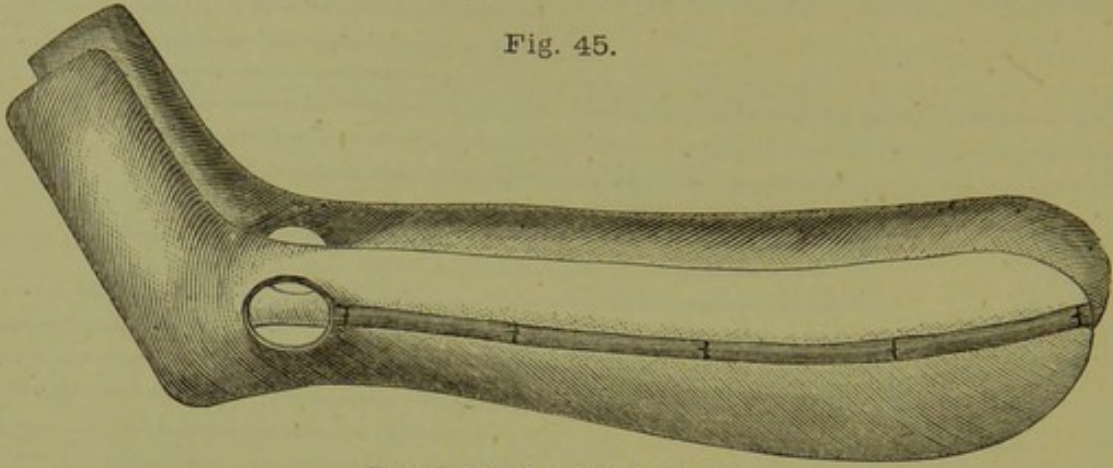
Fig. 44.



ESMARCH'S splint-material.

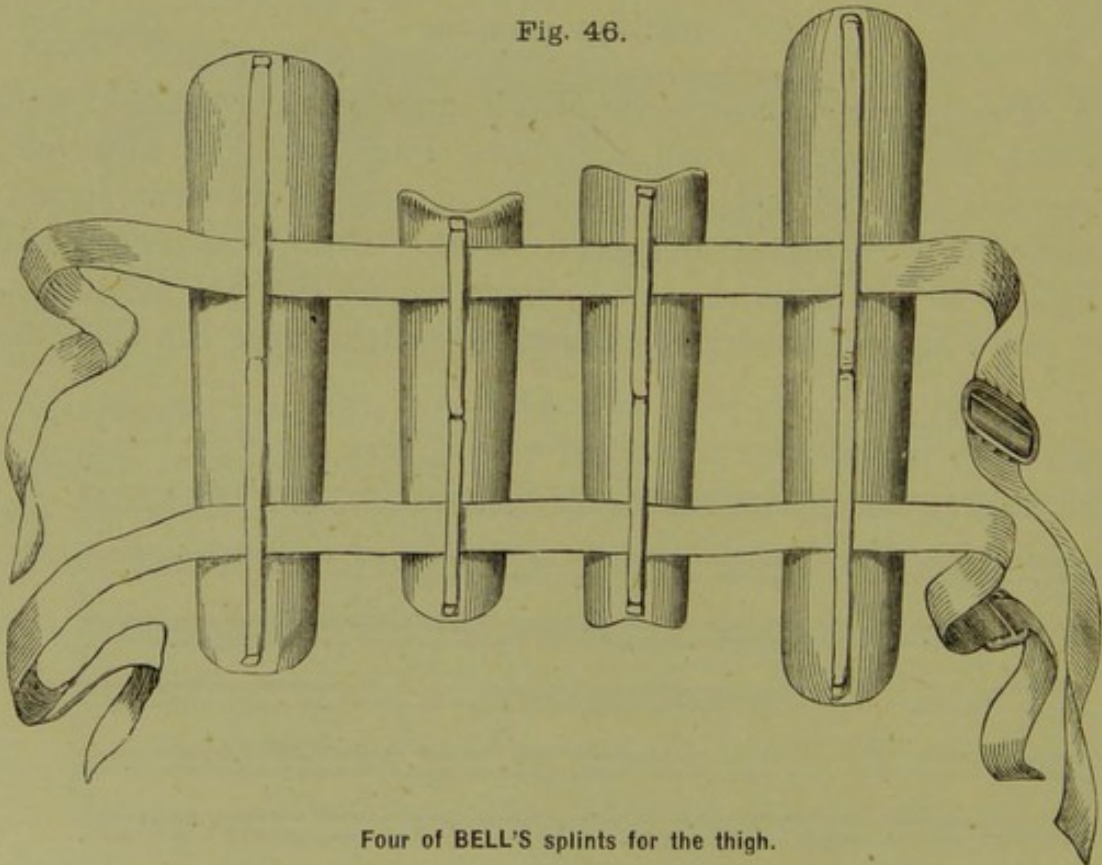
e. *English wooden splints* (after BELL, POTT and CLINE) are neatly cut out of wood to the shape of the limb; to the outer side are fastened strips of leather, beneath which straps provided with buckles can be drawn through (fig. 45 and 46).

Fig. 45.



Two of BELL'S splints for the leg.

Fig. 46.



Four of BELL'S splints for the thigh.

They are padded with cotton wool, and can be very easily applied, loosened, and taken off, especially if the straps are provided with EMMERT'S buckles (fig. 46).

2. PASTE-BOARD SPLINTS.

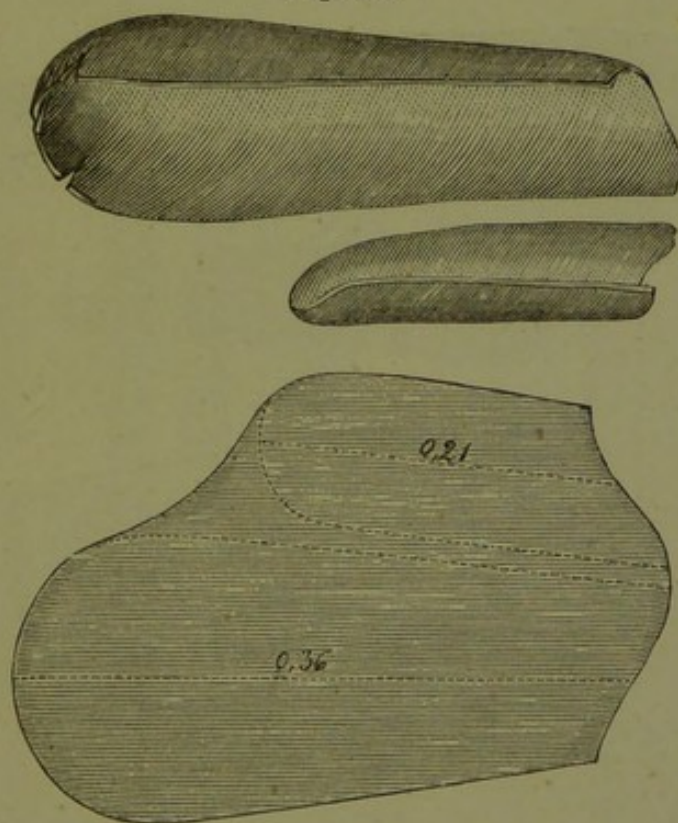
a. Splints of *thick paste-board* can be easily cut to any shape with a sharp knife. They adapt themselves well to the body, when moistened, and bandaged on with a gauze roller, but they give no solid support till they have become dry. They also easily become soft again by contact with blood, secretions from the wound, rain, or any other moisture.

They are especially used in the starch bandage.

b. *Prepared paste-board splints*, made of softened paste-board, which are dried on models of arms and legs and varnished, are light and fit well, i. e. if a sufficient variety of sizes are kept in stock to choose from.

MERCHIE'S double-shelled splints (fig. 47—50) have been introduced into the Belgian army.* PORT'S plaster of Paris splints in three

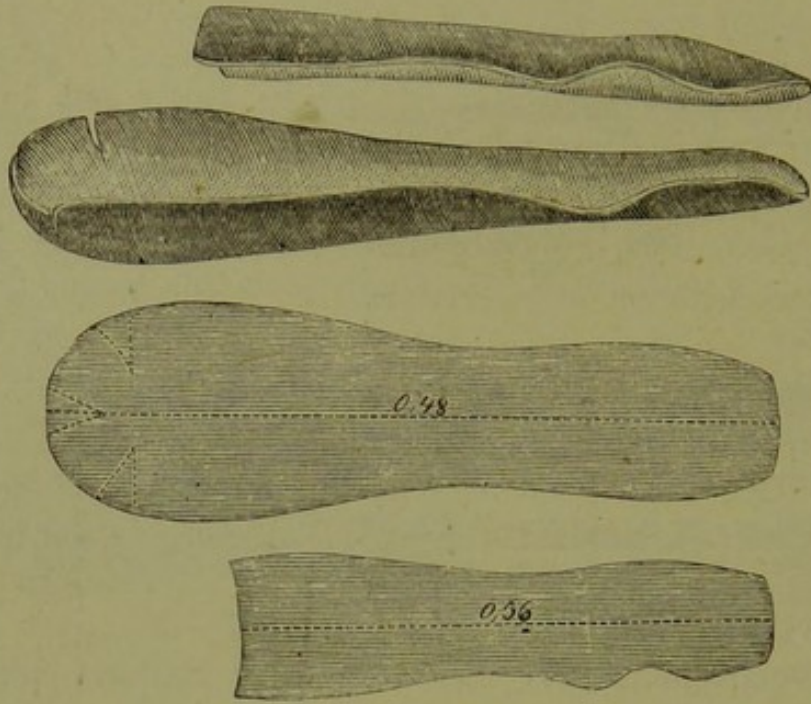
Fig. 47.



MERCHIE'S modelled paste-board splints for the arm, with paste-board pattern.

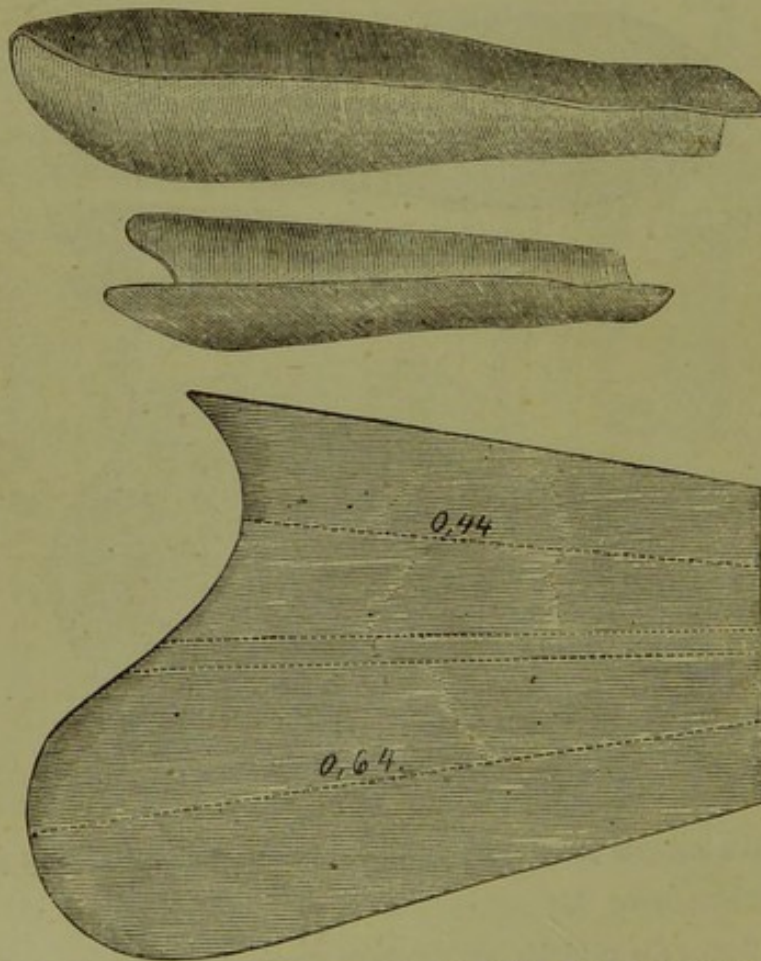
* MERCHIE: *Appareils modelés, ou nouveau système de déligation etc.* Paris 1858.

Fig. 48.



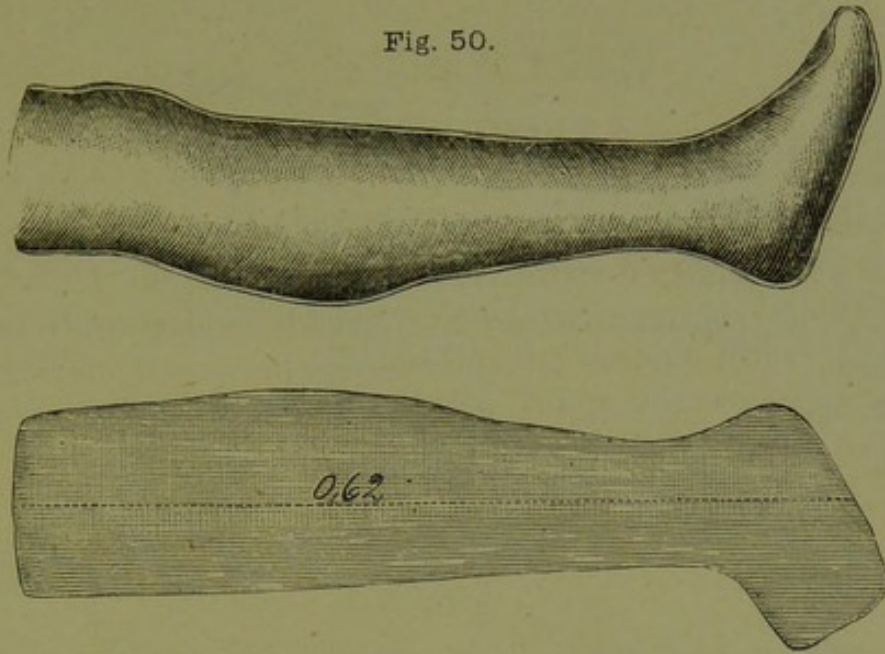
MERCHIE'S modelled paste-board splints for the fore-arm, with paste-board pattern.

Fig. 49.



MERCHIE'S modelled paste-board splints for the thigh, with paste-board pattern.

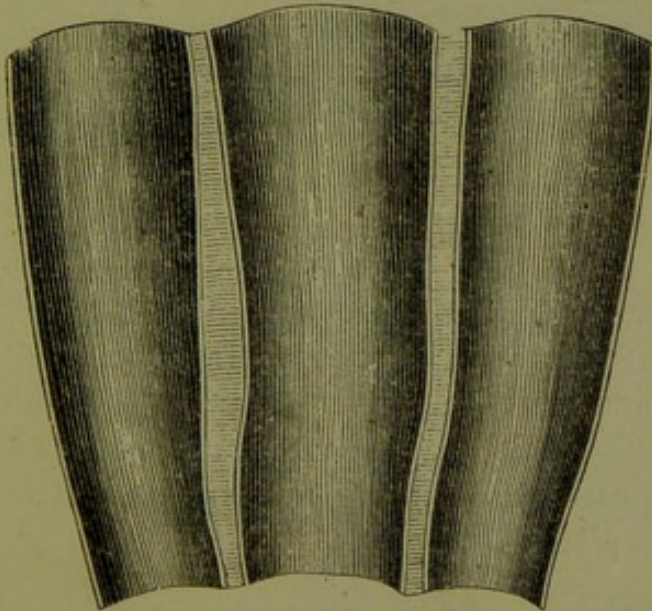
Fig. 50.



MERCHIE'S modelled paste-board splints for the leg, with paste-board pattern.

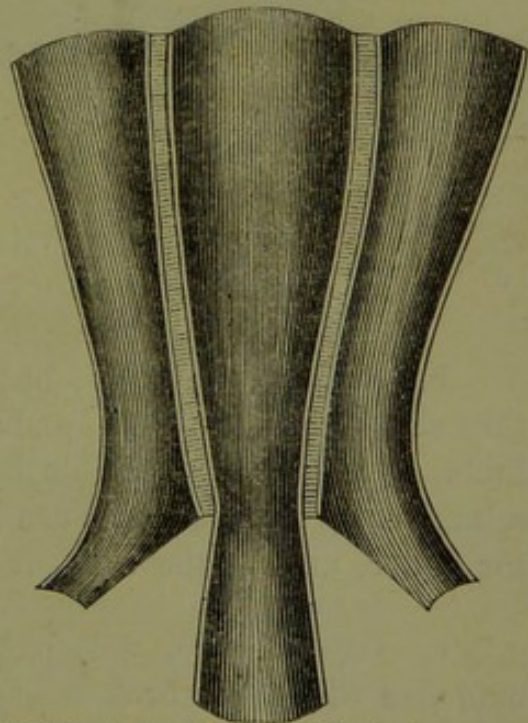
shells (fig. 51 and 52) have been introduced into the Bavarian army, where they are made in time of peace by the army-hospital-corps (Sanitätssoldaten).*

Fig. 51.



PORT'S plaster of Paris splints in three shells for the thigh.

Fig. 52.




PORT'S plaster of Paris splints in three shells for the leg.

* PORT: Studien zur Kriegsverbandlehre. München 1867.

3. METAL SPLINTS.

a. Splints of *tin-plated iron* are especially employed, like the wooden splints, for the temporary disposition of broken limbs on the battle field, and for the first transport. They are quickly and cheaply produced, and can be easily soldered together at angles corresponding to the joints. VOLKMANN'S tin splint for the lower extremity is especially suitable for this purpose.

Fig. 53.

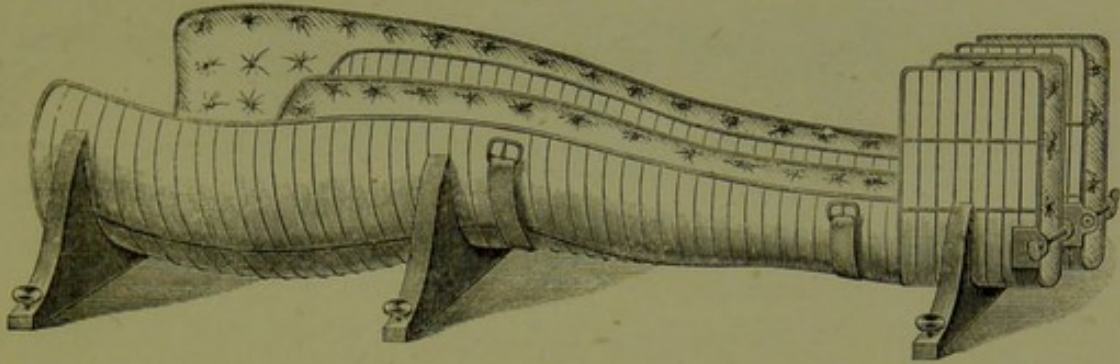


VOLKMANN'S tin splint.

b. Splints can be cut out of *zinc* with a strong pair of scissors: they can be bent with the hands, and nicely adjusted to the shape of the limb. In "Ersatztornistern für den Verbandplatz" the author has described a large chest of zinc, which can be used on the battle field as a receptacle for water, and at the end cut to pieces for splints.

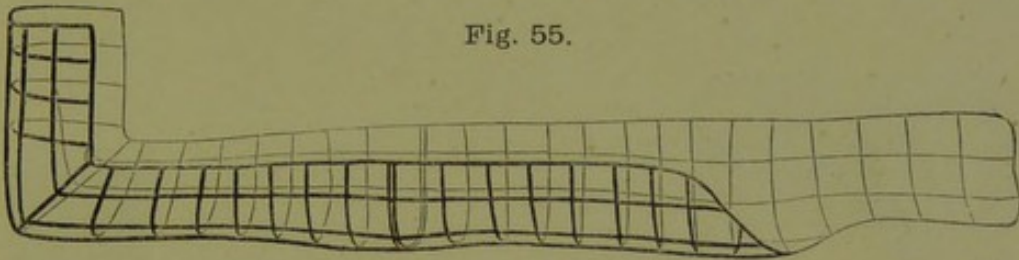
c. Of *iron wire*, well padded wire baskets (MAYOR, BONNET) are made, in which the broken limbs lie comfortably. Flaps or trap-doors can easily be made, so that the wounds can be dressed without taking the limb out of the splint. But they are very expensive, and demand too much room for military practice (fig. 54—56).

Fig. 54.



BONNET'S wire splint.


Fig. 55.



ROSER'S wire splint for the lower extremity.

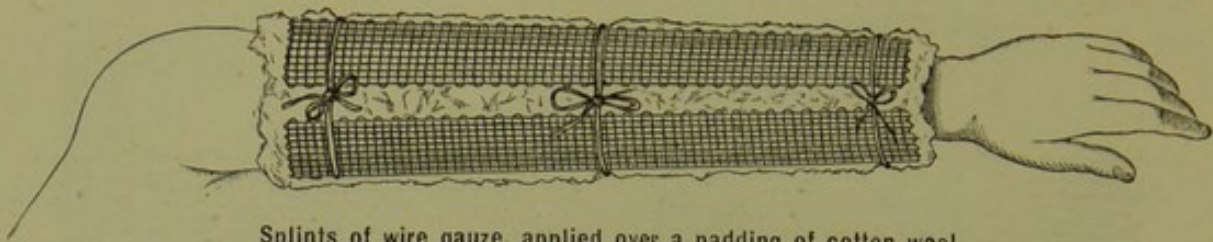
From the *wire gauze*, that is commonly bought, very flexible and airy splints have lately been made, which on account of their lightness and cheapness are especially well fitted for field use (fig. 56 and 57).

Fig. 56.



Three splints of wire gauze, fastened together by cords.

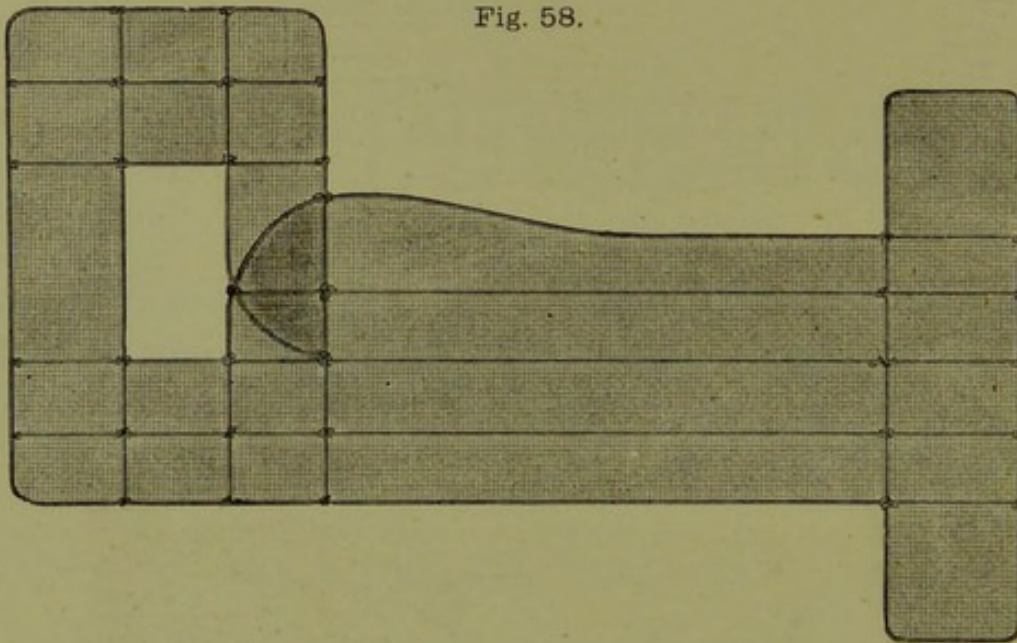
Fig. 57.



Splints of wire gauze, applied over a padding of cotton wool.

Of the same material, wire splints can also be made, which are lighter than BONNET'S wire splints, and so flexible, that they can be spread out flat, and easily taken in great quantities on to the battle field (fig. 58).

Fig. 58.



ESMARCH'S portable wire splint.

4. TEMPORARY SPLINTS

can be improvised out of a great variety of materials, which are found in the open field, in woods, or at the scene of action, e. g.:

- a. out of *branches*, which are bound together into bundles (fig. 59);

Fig. 59.



Splint made from a bundle of branches.


or arranged close to one another, and fastened either by crossbars (fig. 60) or by means of a chain-like moveable twine (fig. 61).

Fig. 60.



Splint of sticks, fastened by cross-bars.

Fig. 61.



Splint of sticks, fastened by twine.

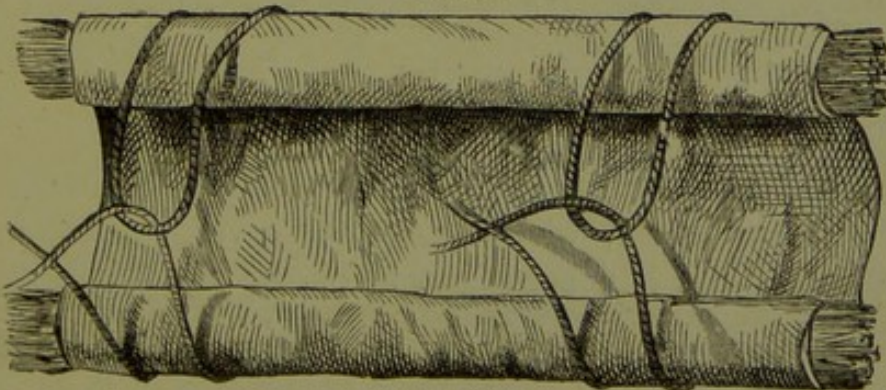
b. out of *straw* and *rushes*, which are formed as much as possible into bundles (fig. 62): a pair of these are rolled in the opposite borders of a cloth, the intervening portion of which is placed beneath the wounded limb: the bundles are thus adjusted, one on each side of the limb, and can be fastened there with cords (fig. 63).

Fig. 62.



Straw splint.

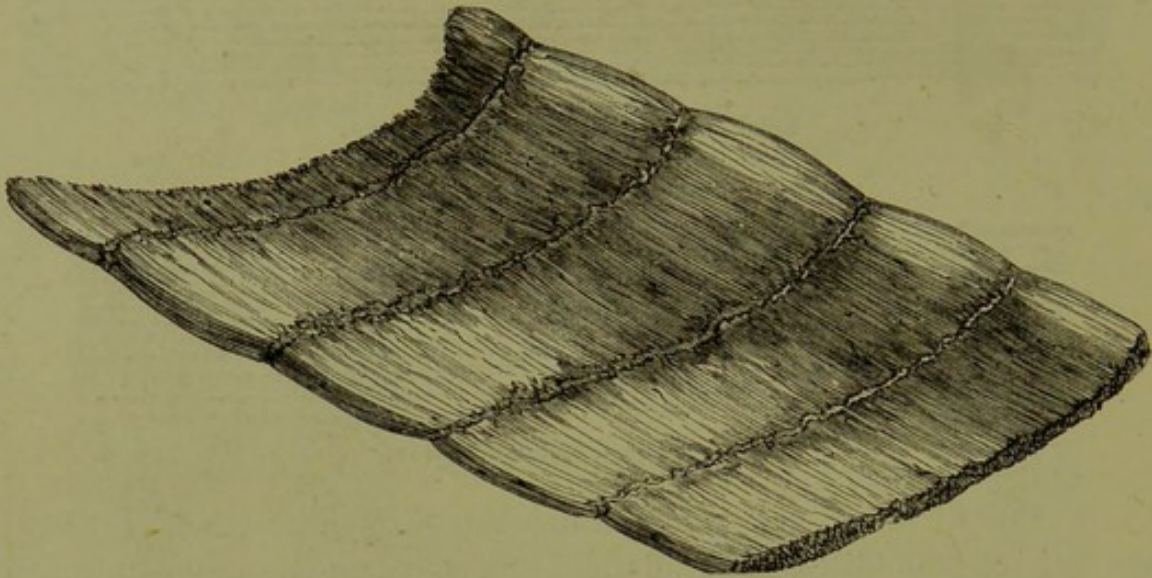
Fig. 63.



Straw casing.

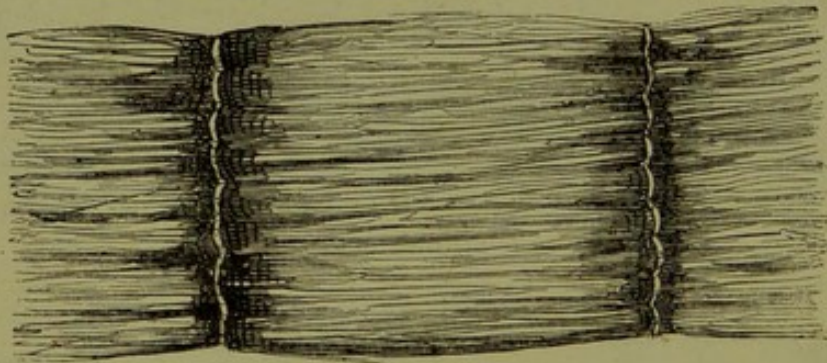
The straw or rushes can also be sewn together into mats (according to BECK), and either employed to wrap round the limb, or they can be rolled up and used as side splints (fig. 64 and 65).

Fig. 64.



Straw mat.

Fig. 65.




Rush mat.

For example, during the siege of Paris the French in their sorties made use of straw mats, which served to cover window frames, as splints for limbs, that had been shot to pieces (fig. 66).

c. out of *weapons* of all kinds, as they are found on the battle field, viz side-arms, sappers' knives, and bayonets with their scabbards,


Fig 66.



French army hospital corps before Paris equipped with straw mats.

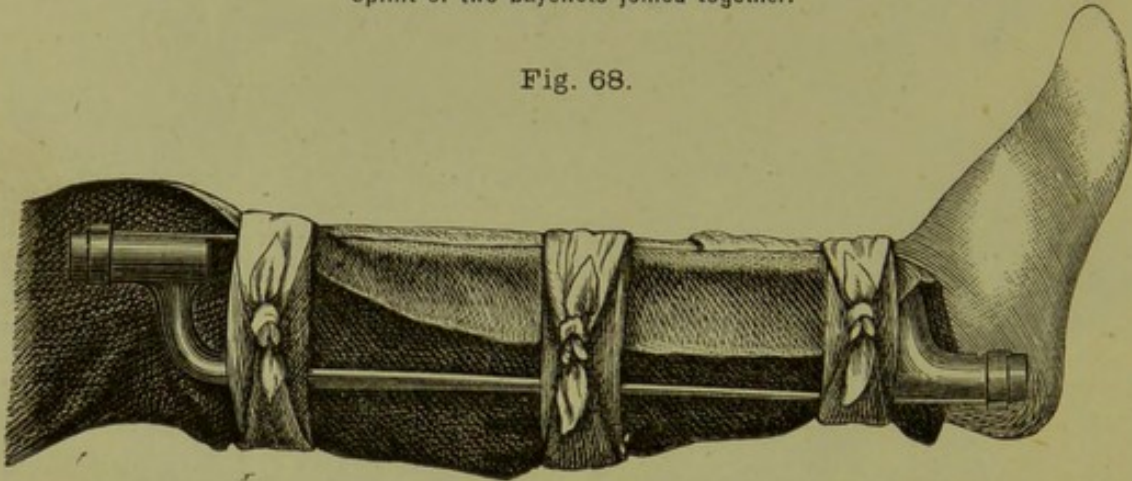
(fig. 67—69), rifles (fig. 70), carbines, ramrods, pieces of lances, spokes of wheels etc. Pieces of uniform too, that have been cut off, should not be

Fig. 67.



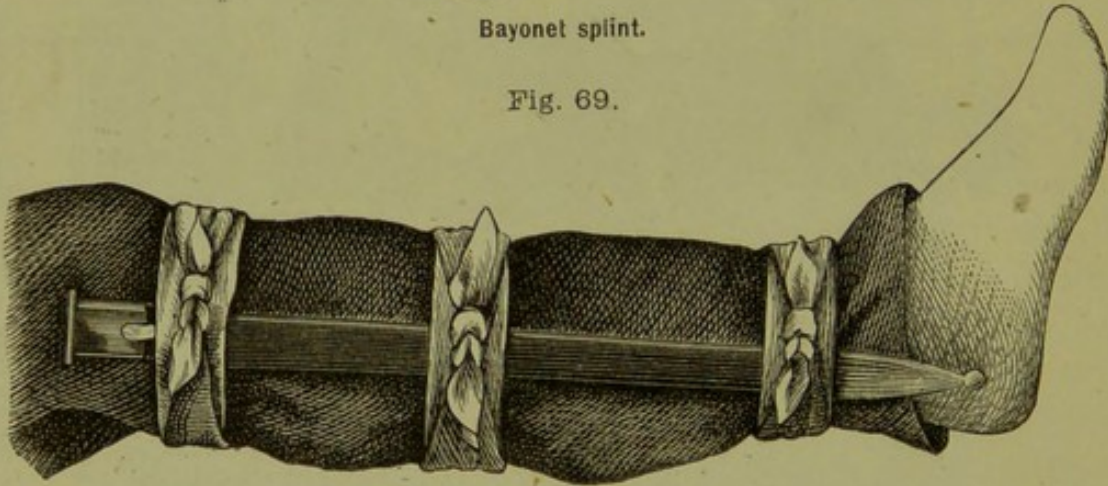
Splint of two bayonets joined together.

Fig. 68.



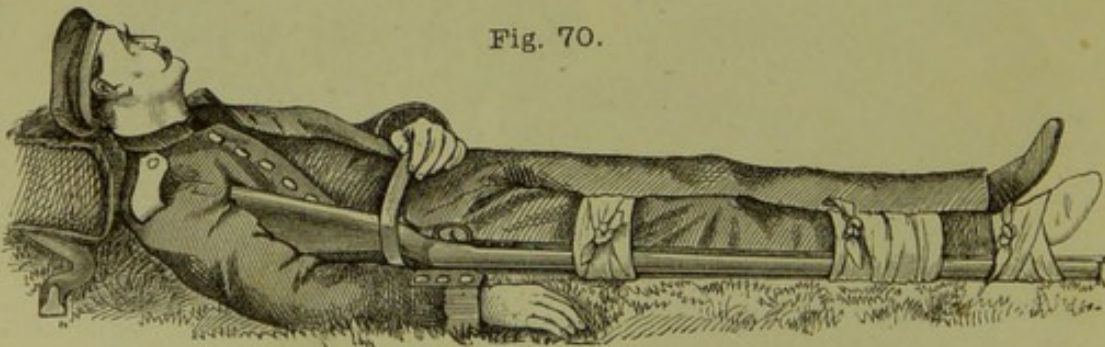Bayonet splint.

Fig. 69.



Scabbard as splint.

Fig. 70.



Gun employed as a splint.

thrown away, but as far as possible turned to account for bandages, e. g. parts of cloaks, coats, trowsers, boot-tops, hats, knapsacks etc.

The men of the army hospital corps must, even in time of peace, be exercised in preparing impromptu splints and employing weapons as their first dressings.

L. THE HARDENING BANDAGES.

1. THE STARCH BANDAGE

was invented by SEUTIN in 1840.

1. *Preparation of starch paste.* Starch is stirred with cold water to a uniform cream like consistence, and then, whilst constantly stirring, as much boiling water is added, as will produce a clear thickish mucilage.

2. *Starch bandages* are strips of shirting, which are drawn through the fresh paste and rolled up into bandages.

3. *Starch splints* are made of strips of paste-board, which are drawn once quickly through hot water, and then thickly smeared on both sides with the paste.

4. *Application of the starch bandage.* The limb is very carefully bandaged with a moist flannel roller, after the recesses about the joints have been padded with cotton wool. A starch bandage is then applied, on which the soft starch splints are laid; and these are firmly bandaged on with a starch roller. Finally the whole is enveloped with a dry calico, cotton, or gauze bandage.

5. *Strips of paper* can be used instead of the bandages: they are drawn through the paste, and applied after the method of SCULTER'S bandage (many-tailed).

6. BURGGRAEVE'S *method* of cotton wool and paste-board is very simple and practical.

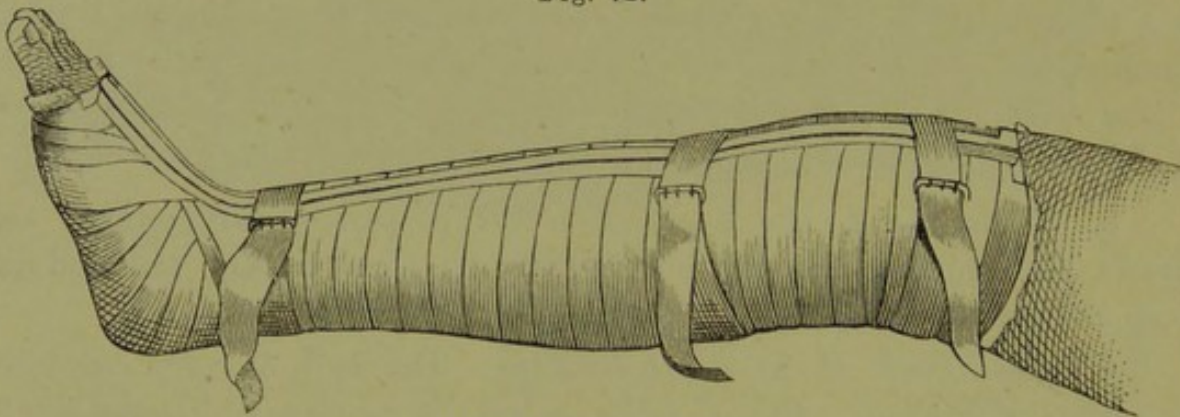
Paste-board splints are cut to the shape of the limb, then covered on one side with paste, and on the other with a layer of cotton wool; the splints are applied with the cotton wool next the limb, and firmly bandaged on with a dry gauze roller; in doing which, one begins with the quickly ascending spiral, in order only first to fix the splints to the limb. Over the gauze bandage is rubbed with the hands, or a large brush an

abundance of starch paste, and lastly the whole is covered with a dry calico bandage.

7. Two or three days elapse before a starch bandage is *quite dry and hard*; by exposing it to the heat of the sun or a stove, its drying can be hastened.

8. To render it *capable of removal* (amovo-inamovibel) the bandage is cut open throughout its whole length with a strong pair of scissors, and the casing bent asunder, while strips of calico bandage are pasted on the edges with starch. The casing is then reappplied and fastened with straps and buckles (fig. 71).

Fig. 71.



Starch bandage cut open.

2. THE SILICA (WASSERGLAS) BANDAGE.

1. If bandages are soaked in a concentrated solution of silicate of potassium (Kali-Wasserglas), which must have a specific gravity of 1.35—1.40 (BÖHM), bandages can be produced, which become perfectly firm and hard, as soon as the water has evaporated.

2. To hasten its stiffening, finely pulverised chalk, or slaked lime and chalk (1:10, BÖHM), magnesite (KÖNIG), or cement (MITSCHERLICH) is stirred in the silica, till a cream-like fluid is produced, of the consistence of honey, in which the bandages are dipped, or with which the bandages are smeared after their application by means of a large brush. Lastly the whole bandage is sprinkled with the dry powder, and well rubbed.

3. THE GUTTAPERCHA BANDAGE.

Splints are cut out of guttapercha 2—3^{mm} thick, and dipped in hot water, at 60° R., till they become quite flexible; they are then applied to the limb, which has been previously enveloped with a wet flannel roller, and firmly bound on with gauze bandages. By pouring cold water over them, they quickly become hard.

4. THE PLASTER OF PARIS BANDAGE

was invented by MATHYSEN in 1852. It has this advantage over all others, that it becomes hard and firm in the shortest time.

1. *Mixing the plaster of Paris* is best done in a porcelain dish, about so much water being poured upon a sufficient quantity of plaster, whilst constantly stirring, as to reduce the paste to the consistence of thick cream. It stiffens in 5—10 minutes to a solid mass.

2. Should it be desirable to *delay the setting* of the plaster, more water is added, or some starch, size, milk, beer, or borax is mixed with the water.

3. If the *setting is to be hastened*, less water, or hot water is used; or some common salt, alum, silica, or cement powder is added to it.

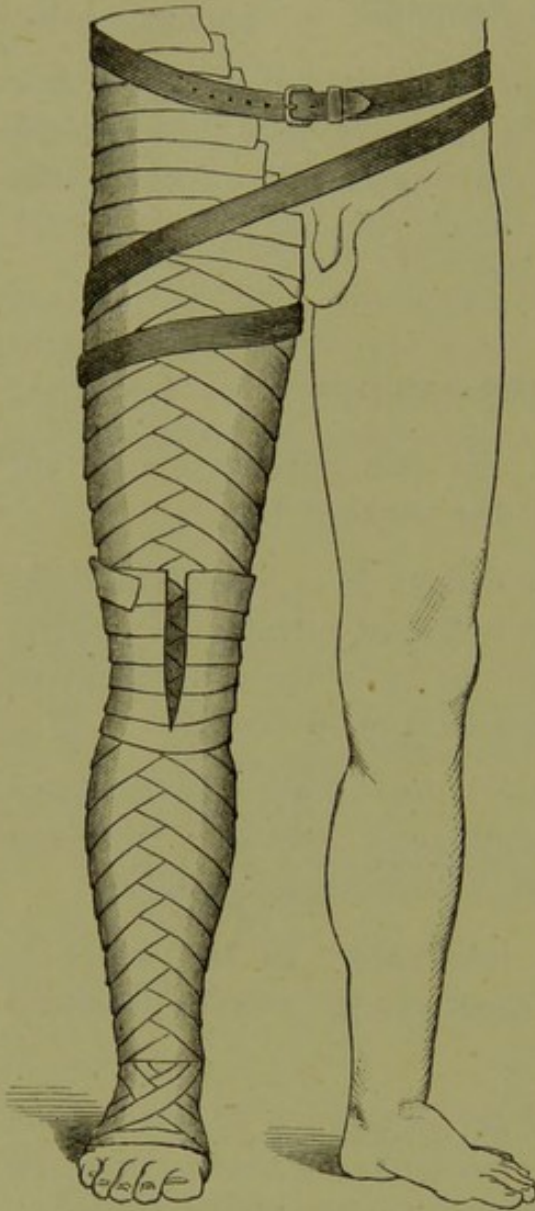
4. If the *plaster has deteriorated* by the absorption of water from the atmosphere, it can be again made serviceable, by heating it in an open pan, till it no longer gives off steam.

5. The *application* of the plaster of Paris bandage can be carried out in various ways.

6. *Strips of bandages* are dipped in the plaster-cream, and placed after SCULTEP'S method (many tailed) round the limb, which has been previously smeared with oil or lard (fig. 72) (ADELMANN).

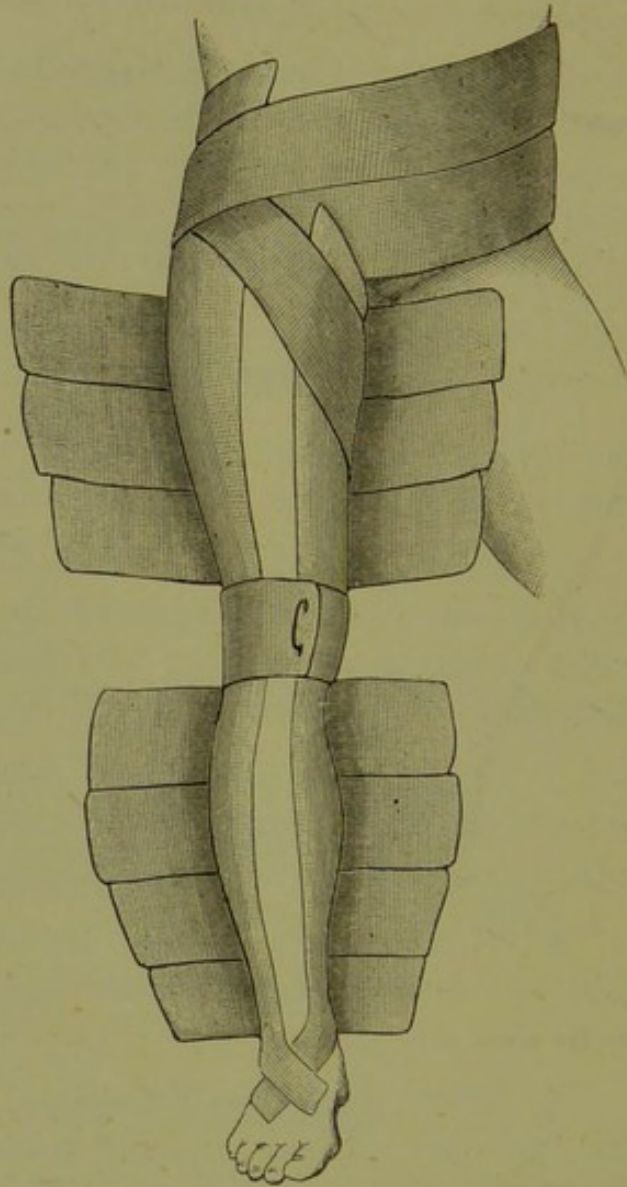
7. *Old clothes* (woollen stockings, drawers, vests etc. or coarse sack-cloth) can be cut up, and used instead of bandages, as they readily absorb the plaster-cream (fig. 73) (PIROGOFF).

Fig. 72.



Plaster of Paris bandage in many-tails.

Fig. 73.

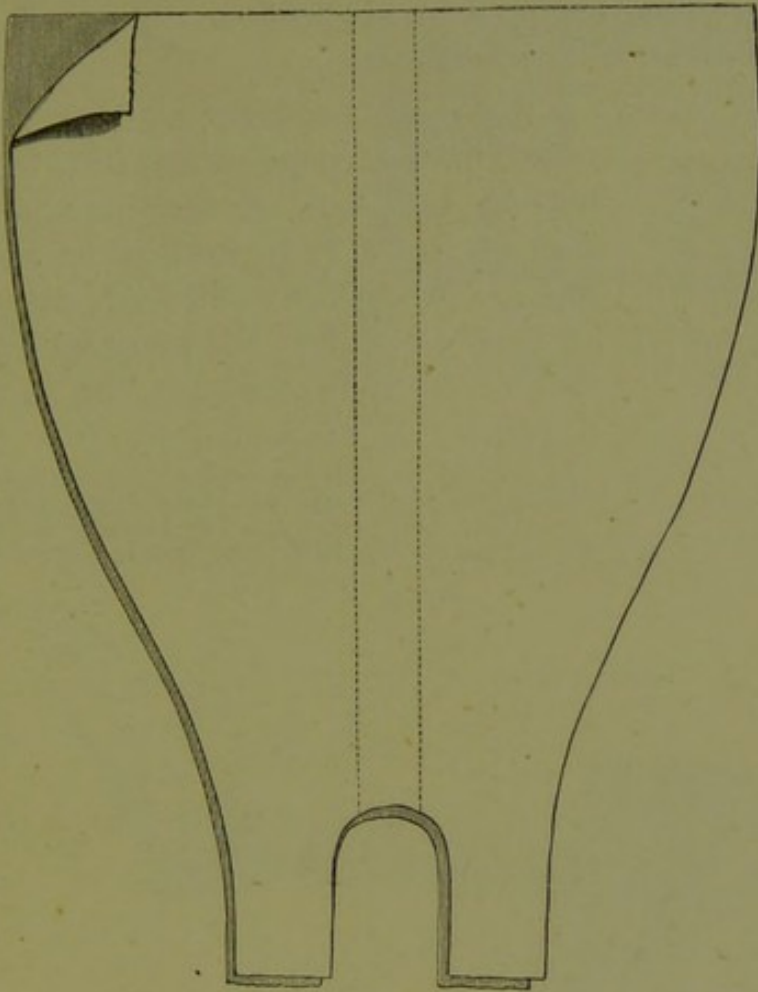


Plaster of Paris bandage of coarse sackcloth.

8. The *Bavarian splint* (fig. 74 and 75). Plaster-cream is poured between two pieces of linen or calico, which is stitched together down the middle, and the limb enveloped in it. As soon as the plaster has set, the two halves, which are connected together by the stitching, can be opened, and the injured parts exposed (*amovo-inamovibel*).

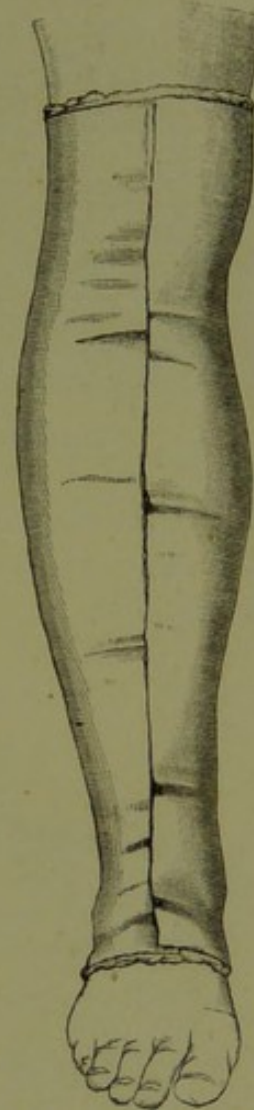
9. Out of *bundles of hemp, flax, or jute*, which are dipped in plaster of Paris, and bandaged to the limb (previously oiled) with flannel rollers, removable plaster splints can be quickly produced (*BEELY*); they are

Fig. 74.



The two pieces of linen used for the leg in the Bavarian splint.

Fig. 75.

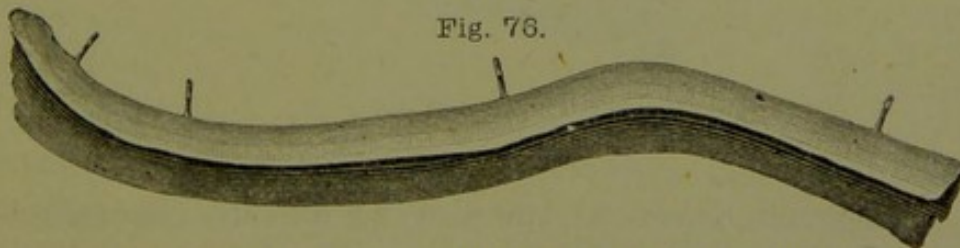

The Bavarian splint applied.

well fitted for fixing compound fractures, which are being treated on the antiseptic method.

If it be desirable to suspend the limb with such a splint, rings or loops of telegraph-wire can be placed in many places between the bundles of hemp, and fixed by the plaster (fig. 76).

Fig. 76.



Dorsal splint of hemp and plaster, for fracture of the leg (BEELY).

10. *Bandages can be impregnated with dry plaster of Paris, and then soaked in water for a short time before their application. The gauze bandages are the most suitable for this treatment.*

Fig. 77.

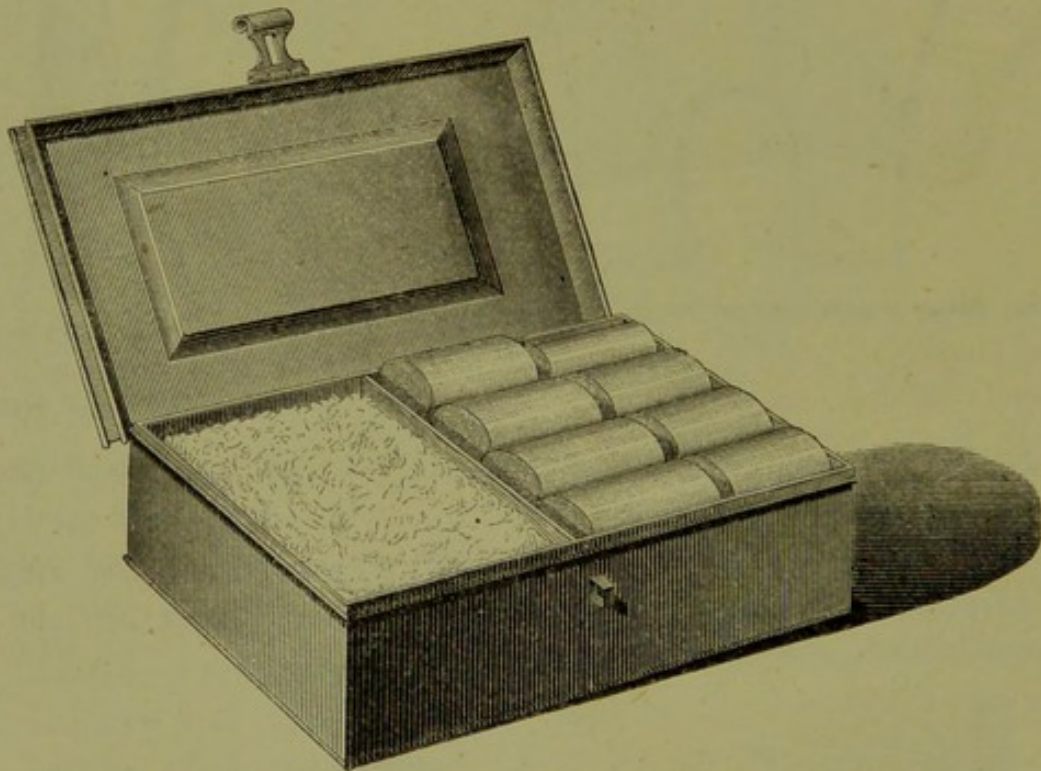


The board.

The gauze bandages are impregnated in the simplest manner, by putting the end of the bandage through a slit in an upright board (fig. 77), in front of which the plaster of Paris is placed; the bandage is then rolled up in this heap with the fingers.

11. The plaster bandages and the powder can be kept together in a tin case, and separated from one another by the board mentioned above (fig. 78).

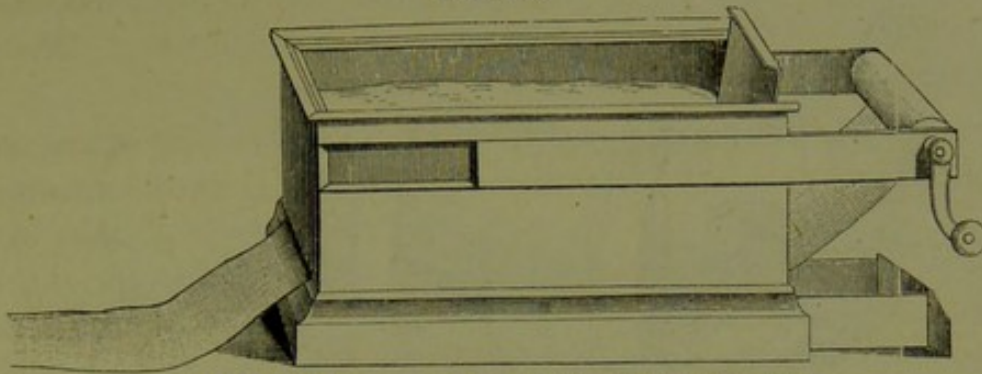
Fig. 78.



Box for plaster of Paris.

12. The gauze bandages can also be quickly impregnated with plaster by means of WYWODZOFF'S *machine* (fig. 79).

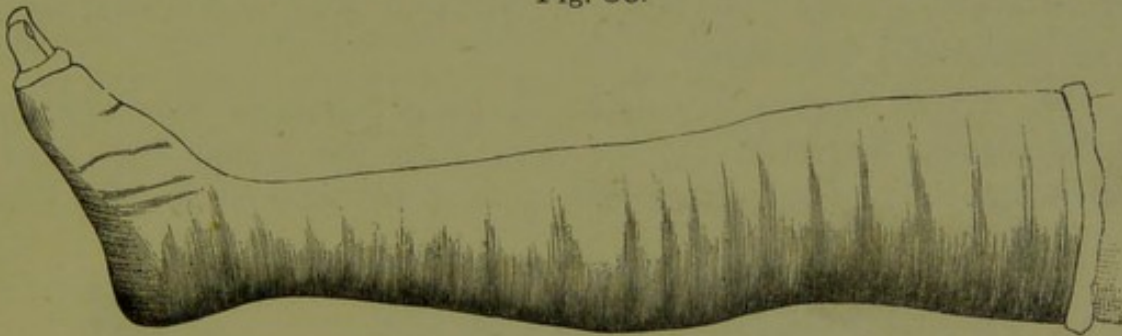
Fig. 79.



WYWODZOFF'S machine for plaster of Paris bandages.

13. As an application beneath the plaster of Paris bandages, *cotton wool* can be suitably employed, as it is the best means of averting pressure and strangulation (fig. 80).

Fig. 80.



The plaster of Paris applied over cotton wool.

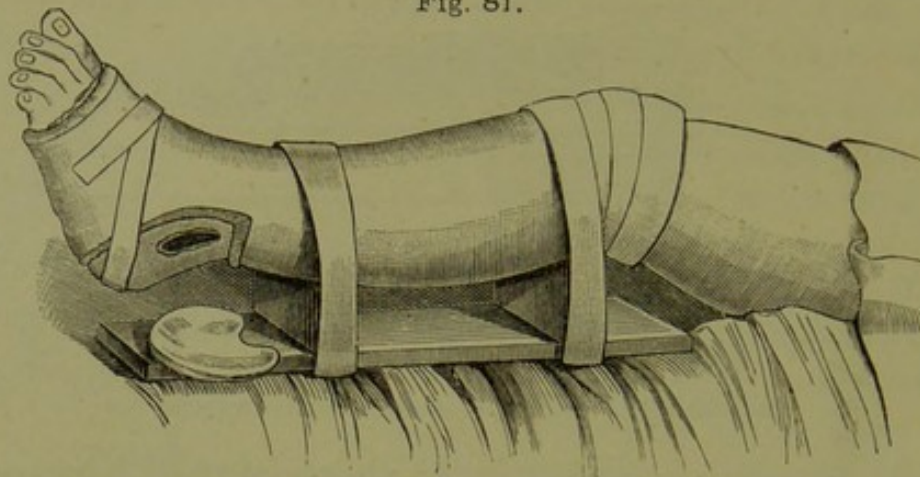
14. Moistened gauze bandages (ROSER), or dry flannel rollers can also be employed for the same purpose in compound fractures, as well as flannel or gauze bandages soaked in carbolic oil (10 per cent): the latter do not easily become impregnated with the secretions from the wound (BARDELEBEN).

15. To make the edges of the plaster of Paris bandage smooth and even, the bandage beneath, which projects somewhat, can be turned over like a frill, and fixed by a turn of the plaster of Paris bandage (fig. 81).

16. To make the plaster of Paris bandage stronger, a layer of the plaster-cream can be smeared over the bandage. But it will thus become very thick and heavy.

17. To give it greater firmness, it is better to introduce *shavings*, *wooden splints*, or *iron wire*, as they last longer and can be easily removed.

Fig. 81.

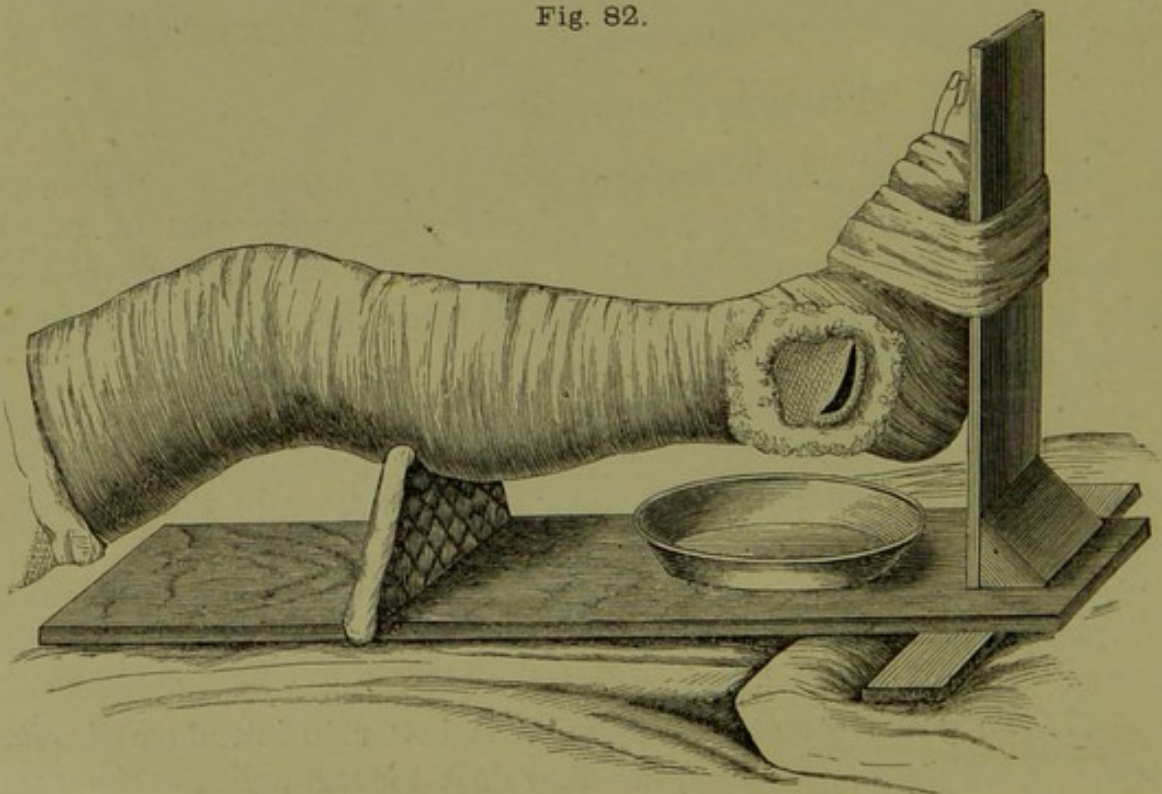


Plaster of Paris bandage with a window and the edges turned over.

18. Lastly should it be desirable to give the bandage a neat and smooth surface, some dry plaster is sprinkled over, and rubbed by the hands moistened with water.

19. Where there are wounds, openings (*windows*) must be made in the plaster, by which the secretion from the wound may have a free escape. These are either left open at the time of the application

Fig. 82.



Windowed plaster of Paris bandage with edges of cotton wool.

of the bandage, or the window is afterwards made with the assistance of a short knife and a pair of scissors.

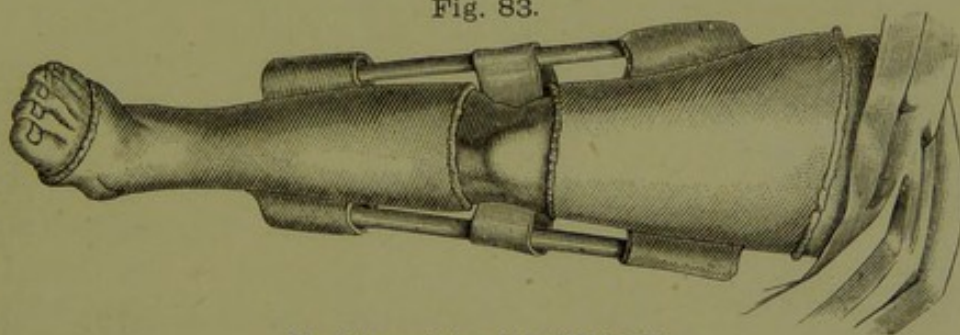
20. In order that the places may be found, where the windows have to be cut, a ball of cotton wool is placed upon the wound: this afterwards forms a nut-like prominence, upon which an incision can be made with confidence.

21. To prevent the entrance of pus between the skin and the plaster bandage, the windows must be smeared all round their edges with carbolised cement, or filled with cotton wool soaked in collodion (fig. 82).

22. If it is necessary to make the plaster of Paris *waterproof*, it must be saturated with a solution of *Damar-resin* in ether [(1:4) Damar-varnish] by means of a brush.

23. For extensive wounds, a plaster of Paris bandage is only applied above and below the injured part, and the two united by means of laths, which are placed upon pads of tow soaked in plaster-cream; these are connected with the apparatus by plaster of Paris bandages (fig. 83).


Fig. 83.



The interrupted splint (PIROGOFF).

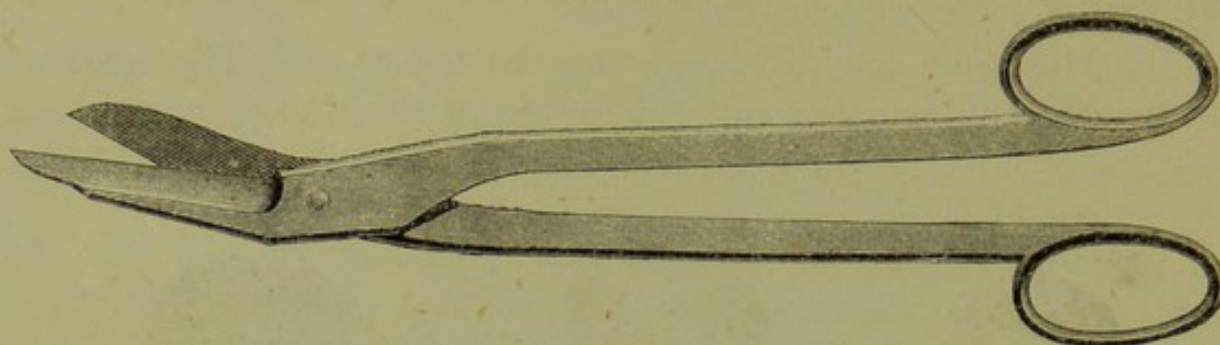
24. The plaster of Paris bandage is most *easily removed*, by cutting a deep groove with a very short thick knife (fig. 84), and then dividing the deeper layers at the bottom with a strong pair of scissors (fig. 85).

Fig. 84.



Plaster of Paris knife.

Fig. 85.

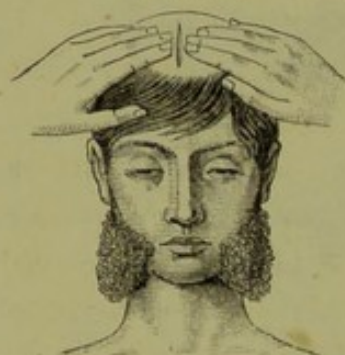

Plaster of Paris scissors.

M. DRESSINGS FOR THE HEAD.

1. In every case of scalp wound, before the application of the dressing, the wound and its neighbourhood must be *carefully cleansed* (by shaving off the hair, washing with disinfectant water by means of the irrigator, and drying with the antiseptic balls).

Fig. 86.



Pushing together the edges of
a scalp wound.

2. For uniting the edges of incised wounds, sutures can as a rule be dispensed with; in large lacerated irregular wounds, a few interrupted sutures may be of use.

It is generally sufficient, to push together (fig. 86) the edges of the wound from both sides; then to press upon the wound a carbolised compress, a piece of carbolised tinder, an antiseptic ball, or a piece of salicylic wool, and to keep it firmly applied by a moistened gauze bandage.

To fasten on the dressings, one makes use of:

A. BANDAGES.

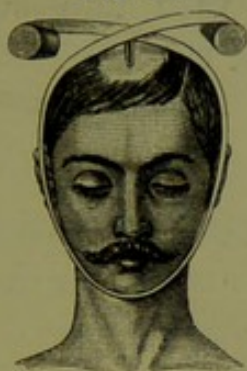a. The *double-headed roller* for obtaining union (*fascia uniens*) (fig. 87).

The centre of the bandage is applied opposite to the seat of injury, and the two heads carried past each other with gradually increasing

traction upon the wound; these turns are then brought back again to the starting point, and the same process repeated several times.

6. The *sagittal bandage* (*fascia sagittalis*) (fig. 88) — a **T** bandage — is especially suitable for transverse wounds of the scalp.

Fig. 87.



Double-headed roller.

Fig. 88.



Sagittal bandage.

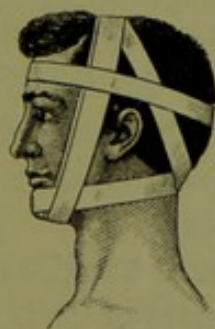Fig. 89.



Knotted bandage.

c. The *knotted bandage* (*fascia nodosa*) (fig. 89) is a double-headed roller, whose turns are crossed at right angles upon the wound, and tightly drawn, as in tying up a parcel (*Packknoten*). It is especially suitable for haemorrhage, where considerable pressure is required. For the same purpose, a tightly stretched cravat or a piece of india-rubber bandage may be used.

Fig. 90.

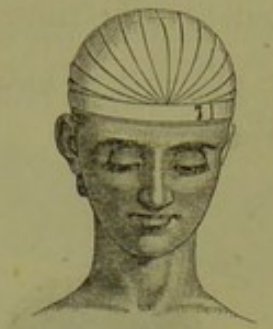

The halter bandage.

d. The *halter bandage* (*capistrum*) (fig. 90). The first turn begins on the top of the head, crosses the cheek by passing under the chin, and returns to the vertex. From here the second turn runs backwards round the occiput: it is then carried from the nape of the neck to the front round the anterior surface of the chin: lastly it returns to the nape of the neck, and ascends again to the vertex. After these have been repeated twice or three times, the third turn brings it to a conclusion by forming a circle from forehead to occiput.

NB. This bandage, as well as the following one, is to be especially recommended as an exercise, for its individual turns can be used for various dressings. Moreover they are both best applied with wet gauze bandages.

Fig. 91.



The capelline bandage.

e. The *capelline* (mitra Hippokratidis) (fig. 91) is a double-headed bandage, one end of which passes round the head from forehead to occiput, and fixes the turns of the other end, which is carried alternately over the right and left parietal bone: each turn overlapping the preceding one.

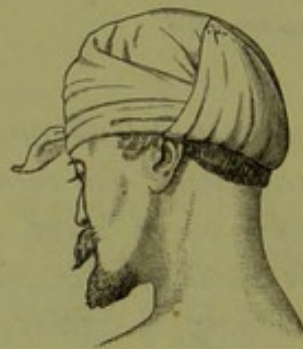B. HANDKERCHIEF BANDAGES.

a. The *triangular handkerchief for the head* (Kopftuch) (capitium parvum triangulare) (fig. 92 and 93). The centre of the triangular hand-

Fig. 92.



Fig. 93.



Triangular handkerchief for the head (from before). Triangular handkerchief for the head (from behind).

kerchief is laid upon the vertex, so that the base passes across in front of the forehead, while the apex hangs down over the nape of the neck. The two corners are then carried backwards above the ears, made to cross one another on the occiput, brought back again to the front, and tied together on the forehead. Finally the point, which hangs down behind, is tightly drawn downwards, then turned upwards over the occiput, and fastened upon the vertex with a safety pin.

b. The *four-tailed cap* (fig. 94 and 95), is a square handkerchief 60^{cm} long, 20^{cm} broad, which is slit from both its narrow ends. If you wish to fix a dressing on the vertex, the two posterior corners or tails are tied together under the chin, and the two anterior on the nape of the neck (fig. 94). But if the dressing is to be kept on the occiput, the anterior corners are tied together under the chin, and the two posterior on the forehead (fig. 95).

Fig. 94.



Four-tailed cap for the vertex.

Fig. 95.



Four-tailed cap for the occiput.

c. The *large square handkerchief for the head* (*capitium magnum quadrangulare*) (fig. 96 and 97) covers the vertex, the ears, the nape,

Fig. 96.

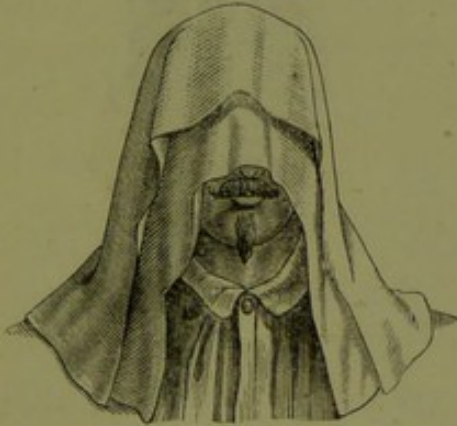

Fig. 97.



The large square handkerchief for the head.

and the entire region of the neck, and is consequently a very practical dressing for bad weather.

A handkerchief, a square metre in size, is so folded that the long border of the upper half lies about 10^{cm} behind the long border of the lower half. A long quadrilateral is thus produced, which is so placed upon the head of the wounded man, that the centre of the handkerchief covers the sagittal suture, whilst the free border of the lower fold hangs down to the tip of the nose, and the border of the upper fold to the eyebrows; the narrow borders lie upon the shoulders.

Of the four corners, which hang down in front upon the chest, the two outer ones are first tied firmly together beneath the chin; the border of the under fold is then turned upward against the fore-

head, and the inner corners, which belong to it, are carried backwards above the ears, and tied together upon the nape of the neck.

C. THE HEAD-NET (fig. 98).

A net, made of coarse cotton thread, adheres firmly, without exercising too much pressure or causing heat. A narrow linen ribbon, which is drawn through the meshes of its lower border, fixes it in a circular manner round the forehead, temples, and occiput. A second ribbon, which

Fig. 98.



Head-net for keeping dressings on a wound.

Fig. 99.



Head-net for fixing on an ice-bag.

is tied beneath the chin, draws the net downwards; and a third contracts the net upon the vertex, like the string of a purse. If an ice-bag is to be placed upon the wound, it is fastened by a ribbon, which is drawn through the meshes of the net (fig. 99).

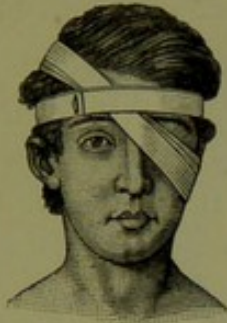N. DRESSINGS FOR THE FACE.

Wounds of the face must be carefully adapted with sutures; the edges of wounds, that are much bruised, are previously removed with the knife. Portions of the nose, lips, and so on, that have been entirely separated, are united, after the bleeding has completely ceased, by fine interrupted sutures (not too tightly); and covered with a material, which keeps off injurious influences from without (e. g. oil-silk, gauze smeared with traumaticin, or salicylic wool). Absolute rest to the part must be procured.

BANDAGES AND HANDKERCHIEF BANDAGES.

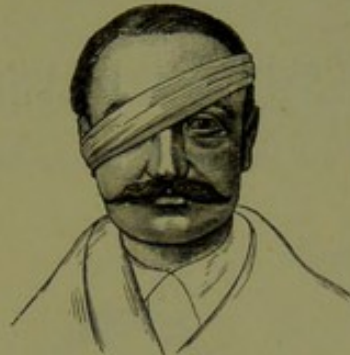a. For injuries of the *temporal region*, and *cheeks*, the turns of the *halter-bandage* are used (s. fig. 90).

Fig. 100.



Eye-bandage.

Fig. 101.



Eye-band.

b. For injuries of the *eye*, the *eye-bandage* (*monoculus*) (fig. 100) is used, or the *eye-band* (fig. 101) which is made from a folded handkerchief.

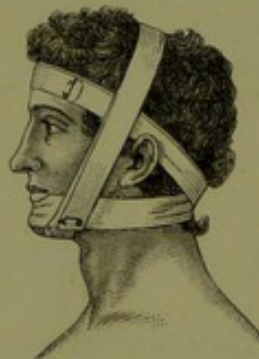c. For injuries of the *nose*, the *nose-bandage* is employed. A broad strip of bandage is folded to the required shape (fig. 102).

Fig. 102.



Nose-bandage.

Fig. 103.



Chin-sling.

d. For injuries of the *lower jaw*, the *chin-sling* (*funda maxillae*) (fig. 103). A bandage 150^{cm} long, and 6^{cm} broad, is slit from both its ends to a central portion 6^{cm} in breadth, so that four equally long tails are produced (*four-tailed bandage*). The central piece is provided with

a slit, and placed upon the chin; the upper tails are carried backwards beyond the occiput, and from thence round the forehead; while the lower tails are carried upwards over the vertex, and down again upon the other side.¹

Fig. 104.



Handkerchiefs as a chin-sling.

A chin-sling can also be made out of two folded handkerchiefs; the centre of one is placed upon the anterior surface of the chin and the ends tied together upon the nape of the neck, whilst the other is carried upwards to the vertex from the under surface of the chin (fig. 104).

For gunshot fractures of the maxillary bones, the buccal cavity must be diligently washed out with the irrigator. The displaced fragments are best reduced by dental splints of vulcanized india-rubber, which must be made by a skilful dentist.

O. DRESSINGS FOR THE NECK.

To fasten dressings on the neck, it is best to make use of:

Fig. 105.



Neckerchief.

Fig. 106.



Neckerchief with paste-board.

1. The *simple neckerchief* (fig. 105), a triangular handkerchief folded like a cravat.

2. For *transverse wounds* of the neck, by introducing a piece of *stiff paste-board* into the neckerchief, the head can be pressed towards the injured side (fig. 106).

P. DRESSINGS FOR THE UPPER EXTREMITY.

1. BANDAGING

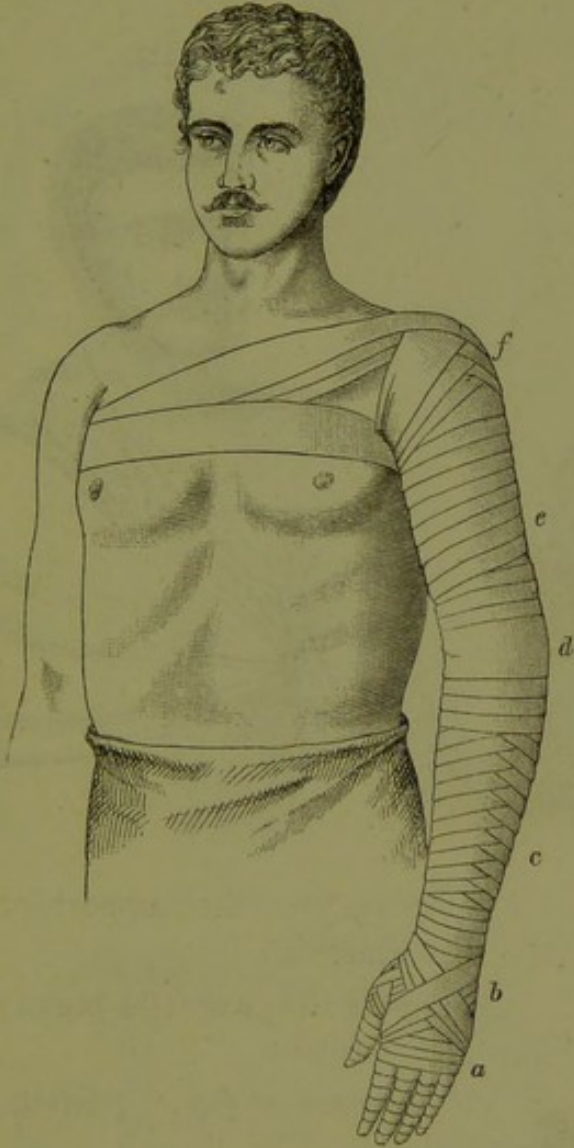
of the whole arm (fig. 107) is commenced, by bandaging every finger and the entire hand with a narrow roller (gauntlet, chirotheka *a, b*), (s. also fig. 33).

The forearm is then bandaged by an ascending spiral with reverses (*c*), the elbow by a figure of eight (Testudo, *d*), the arm by a simple spiral (*e*) and the shoulder by the spica (*f*).

2. HANDKERCHIEF BANDAGES.

- a. *Figure-of-eight for the hand* (fig. 108).
- b. *Covering the whole hand* (fig. 109, left hand).
- c. *Handkerchief for the elbow* (fig. 109, right elbow).

Fig. 107.



Bandaging the arm.

Fig. 108.

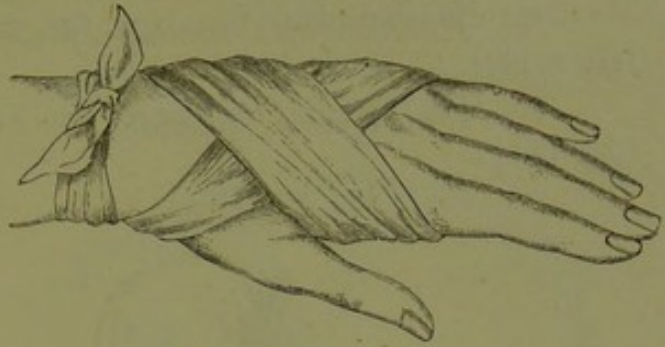



Figure-of-eight for the hand.

Fig. 109.



Handkerchiefs for the shoulder, the hand, and the elbow; and a small sling.

d. *Handkerchief for the shoulder* (fig. 109, left shoulder from the front; and fig. 110, right shoulder from behind).

e. *Handkerchief bandage for an amputation of the arm* (fig. 110, left arm).

f. *Handkerchief bandage for disarticulation at the shoulder-joint* (fig. 111).

Fig. 110.

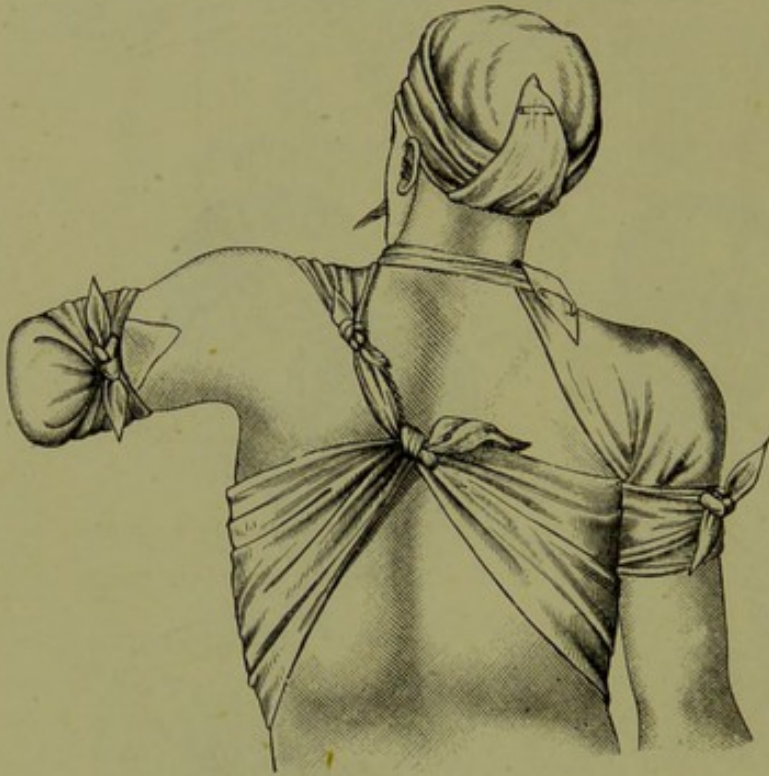


Fig. 111.

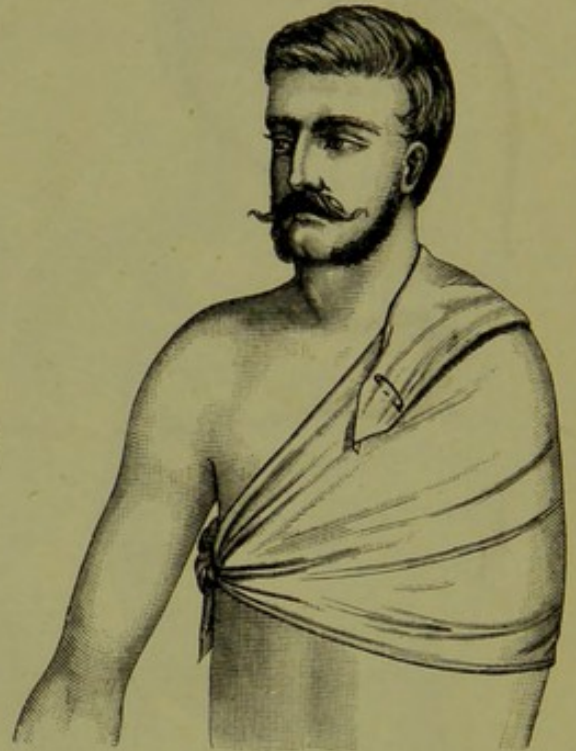
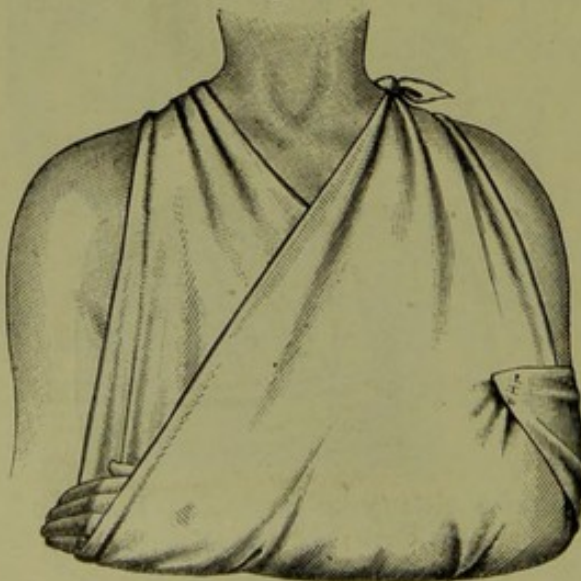

Fig. 112.



g. *Slings for the support of the arm* (mitella):

1) *Small sling* (mitella parva) (fig. 109, left arm).

2) *Triangular sling* (mitella triangularis):

a. The first and common form (fig. 112), where the ends are carried over the shoulders round the neck.

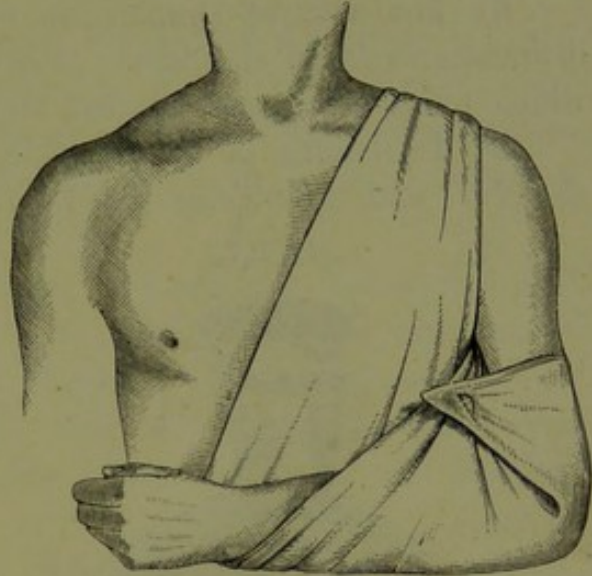
β. The second form (fig. 113), in which, if the shoulder of the injured side can

not bear any pressure, the ends are carried only over the sound shoulder.

Fig. 113.

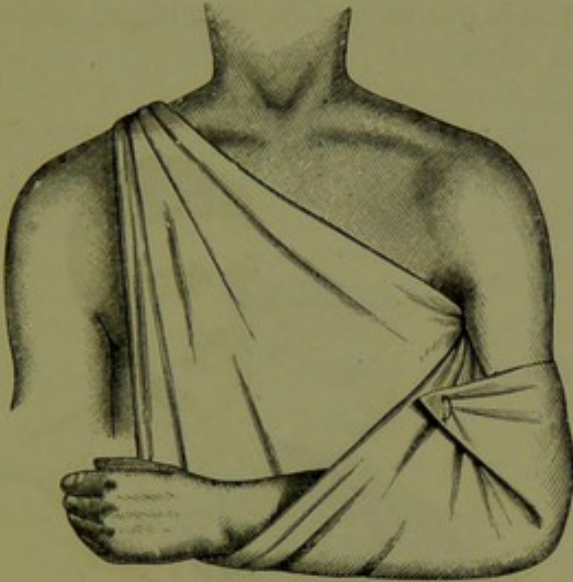

Fig. 114.



- γ. The third form (fig. 114), in which the ends are carried over the shoulder of the injured side, so that the sound arm may remain free for carrying arms etc.

Fig. 115.

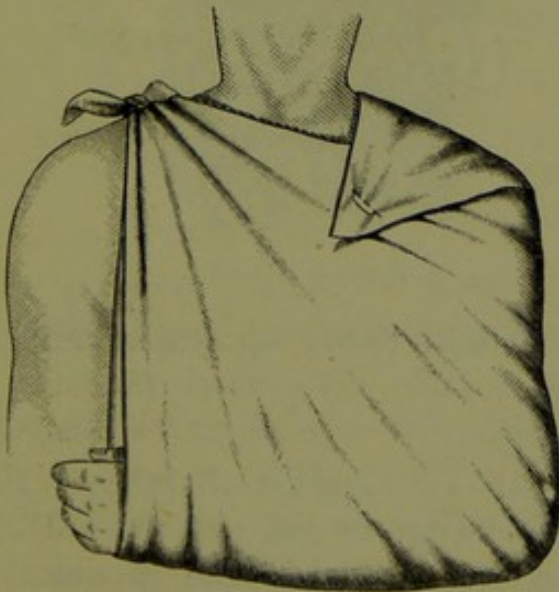
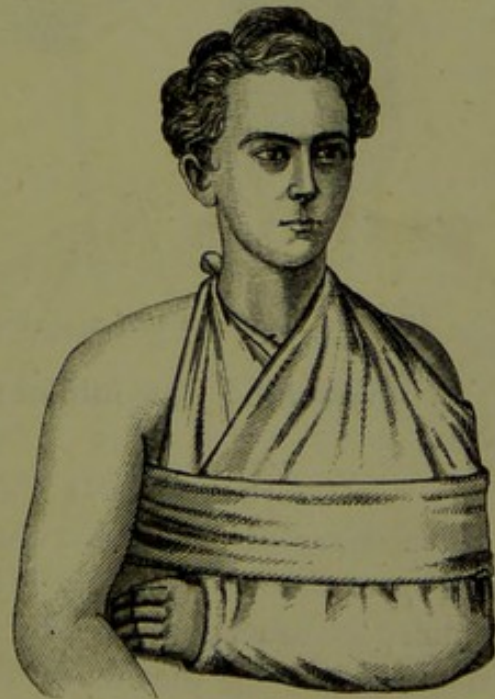


Fig. 116.



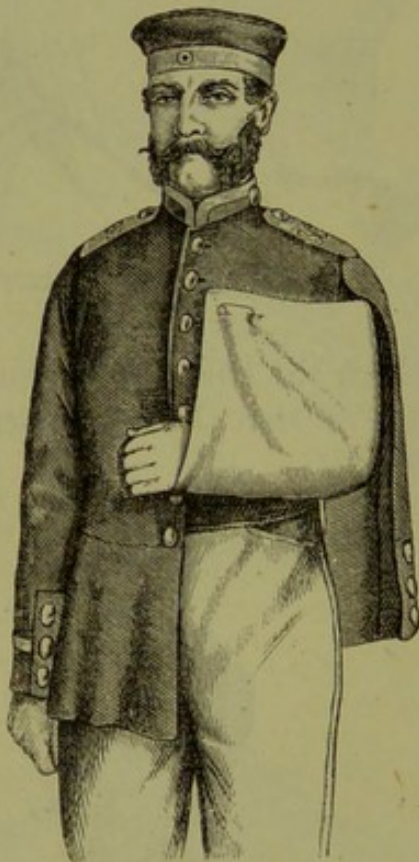3) A *large square sling* (*mitella quadrangularis*) is applied by a large *serviette* (fig. 115).

NB. The corners should be fastened with safety pins, as the knots easily cause discomfort, especially on the neck.

4) For securely fixing the arm (e. g. after the reduction of a dislocation of the shoulder), a *broad cravat* is placed over the sling, which presses the arm against the chest (fig. 116).

5) In default of handkerchiefs, *the skirt of the coat* (fig. 117), or *the coat- and shirt-sleeve* (fig. 118) may be cut up, and used as a sling.

Fig. 117.



The skirt of the coat used as a sling.

Fig. 118.



Coat-sleeve as a sling.

3. DRESSINGS FOR INJURIES OF DIFFERENT PARTS OF THE UPPER EXTREMITY.

a. *Injuries of the hand and fingers.*

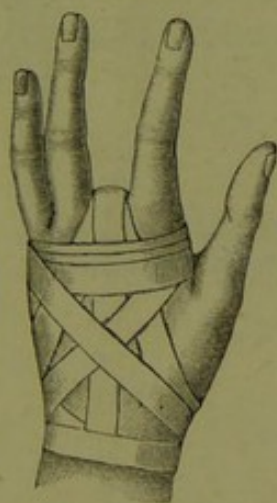
a. *General rules:* No strangulation! To unbutton the shirt! To cut open the sleeves of shirts, and vests up to the axilla! Not to commence bandaging the hand by a circular turn round the wrist! To avoid placing the hand in a dependent position!

β. In *simple and recent wounds*, union is procured by English strapping, sticking plaster, a moist or dry gauze bandage which is smeared with traumaticin or collodion, or by fine sutures (epidermatoraphia, DONDERS). The bleeding is best arrested by pressure (bandaging).

γ. In *contused wounds* of the fingers, bandaging with narrow gauze rollers, which are dipped in weak carbolic or salicylic solution, and from time to time again moistened with the same solution (by immersion or irrigation); and afterwards bandages, dipped in carbolic oil, and surrounded with an air tight covering.

δ. In *fractures of the fingers*, plaster of Paris may be applied with narrow bandages, after the finger has been carefully covered with narrow flannel rollers. Or splints of wooden shavings, wrapped in cotton wool, can be employed: these are fastened with wet gauze bandages, and smeared with starch paste; or with dry gauze bandages, and brushed with traumaticin or collodion.

Fig. 119.



ε. For *fractures of the metacarpal bones*, a large ball of cotton wool is placed in the hollow of the hand; and upon this the hand is firmly bandaged with a flannel roller.

In cases of strong contraction, an extension apparatus is used: two strips of strapping are fastened on to the finger by a plaster spiral, and extension is made by means of an india-rubber ring, attached to a hand board.

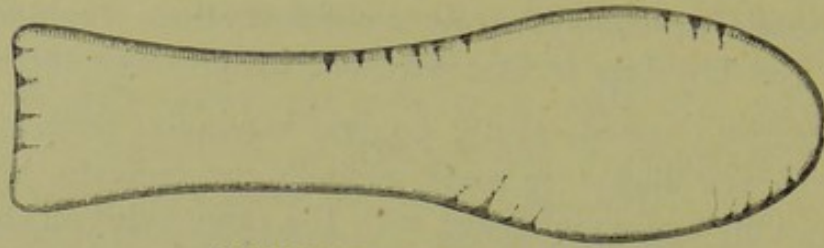
ζ. After *disarticulation of a finger*, a compress can be applied by a narrow figure-of-eight bandage (fig. 119).

η. In *severe injuries of the hand and fingers*, to keep the parts in position, there are used:

1) *Boards* for the hand of thin wood, padded with cotton wool, and lined with linen or waterproof material (fig. 120).

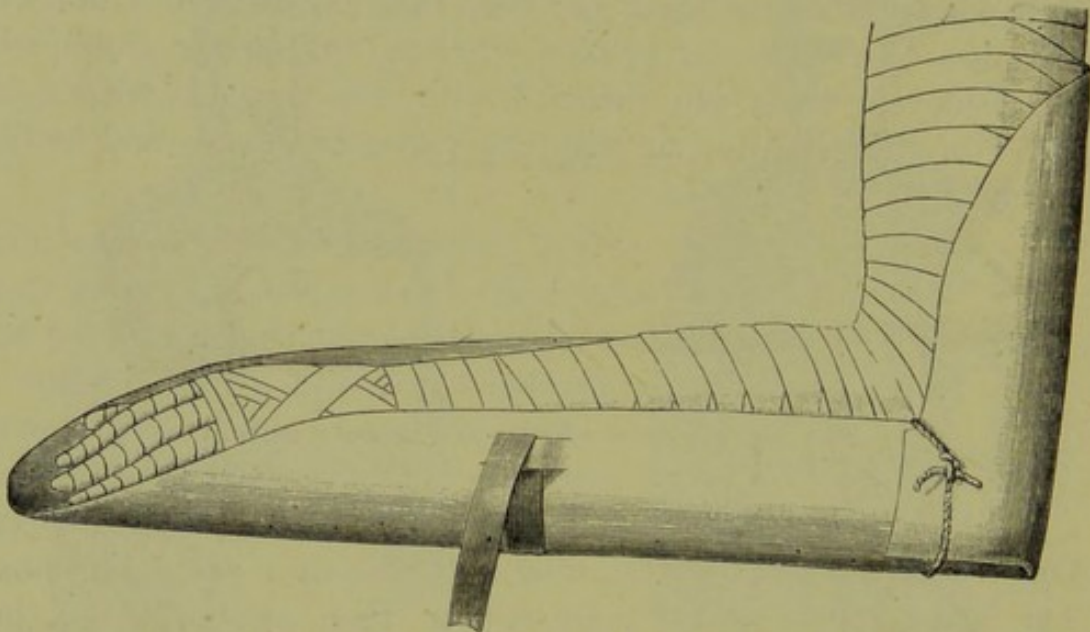
2) *Trough splints* for the arms (fig. 121), lightly made of paste-board, 70^{cm} in length, and 25—30^{cm} in breadth (fig. 122), in which on each side an incision 8—10^{cm} in depth is made, at the junction of one third with the other two thirds of its length.

Fig. 120.




STROMEYER'S padded hand - splint.

Fig. 121.



Paste-board trough for the arm.

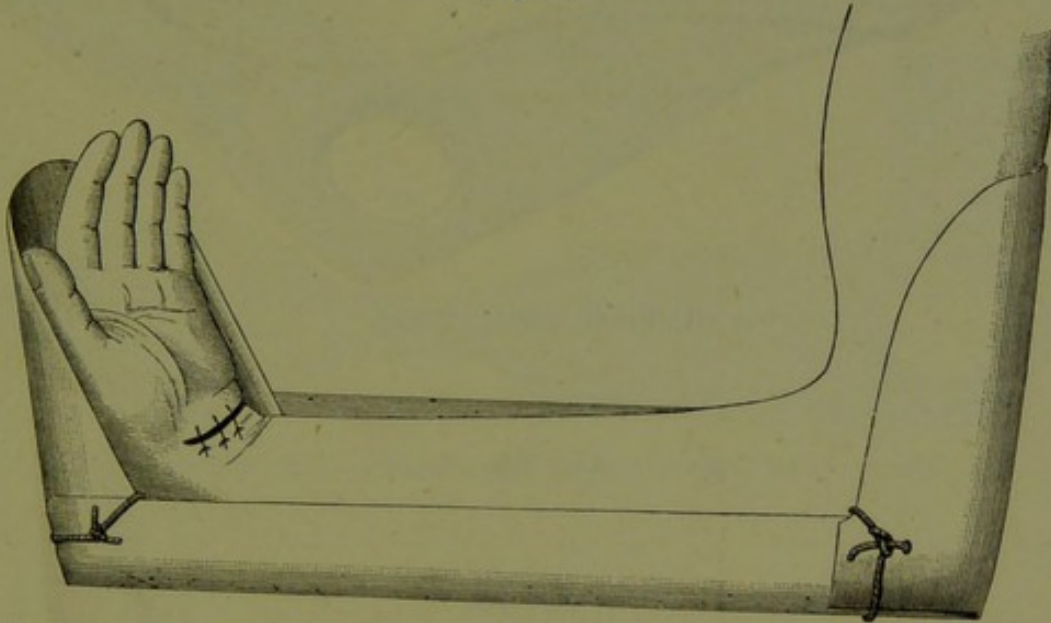
Fig. 122.



Paste - board model for the trough.

In the same way, for injuries on the volar aspect of the hand, a hood-like process can be raised, at the lower end of the paste-board trough, which fixes the hand in the flexed position (fig. 123).

Fig. 123.



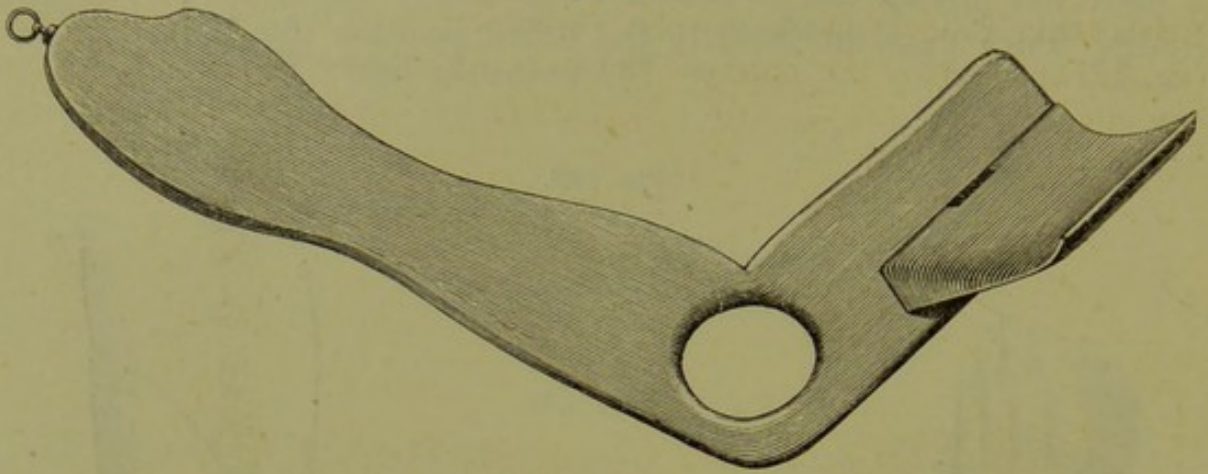
Paste-board trough for injuries on the volar aspect of the wrist.

Arm-troughs can also be made out of tin, wire, wire gauze etc., but they are more expensive, and not so useful as those made of paste-board.

3) To raise the hand, a *sloping board* is used, which can be placed at any angle, and rests upon a table standing by the bed, or upon the bed boards: and this sloping board is at the same time so arranged, that in irrigating, it conducts the water, which runs away, into the bucket (s. fig. 16, pag. 9).

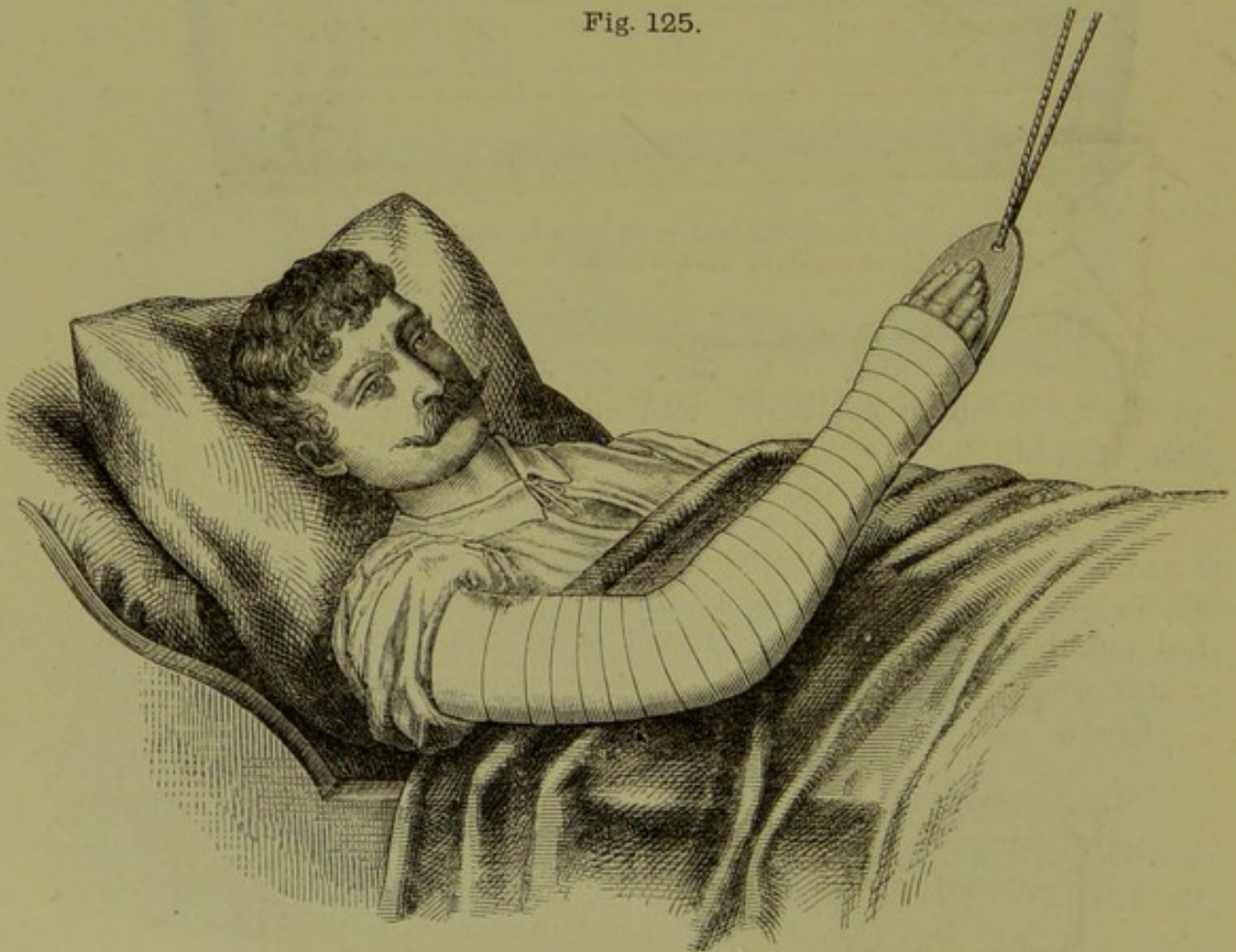
4) To *suspend the hand vertically*, the whole arm is bandaged by spiral turns (not with circular turns) firmly upon a splint, which is used for excision of the wrist (fig. 126), or upon a VOLKMANN'S splint (fig. 124); and this is raised and suspended by a cord, fastened to the lower end (fig. 125).

Fig. 124.



VOLKMANN'S suspension splint.

Fig. 125.

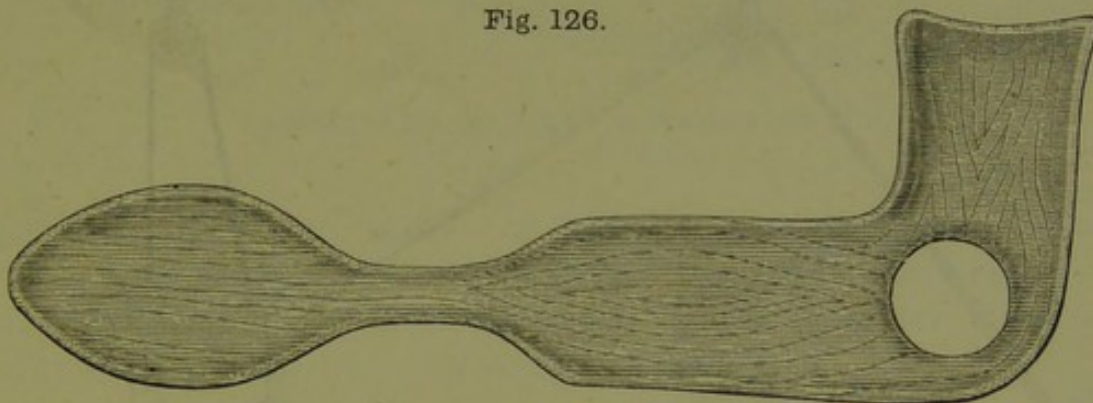


Suspension of the hand after VOLKMANN.

b. For *injuries of the wrist, and after excision of the wrist:*

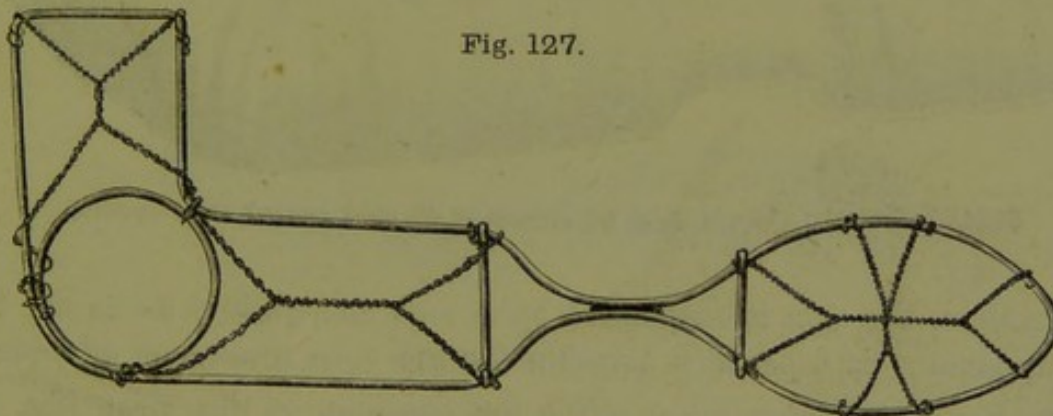
α. ESMARCH'S *plaster of Paris suspension splint*, for excision of the wrist (fig. 126—129), is a splint made of wood or telegraph wire (fig. 127), which is very narrow at the wrist, bent to a right angle at the elbow, and provided with a hole for the internal condyle of the humerus.

Fig. 126.




ESMARCH'S plaster of Paris suspension splint for excision of the wrist.

Fig. 127.



Suspension splint of telegraph wire.

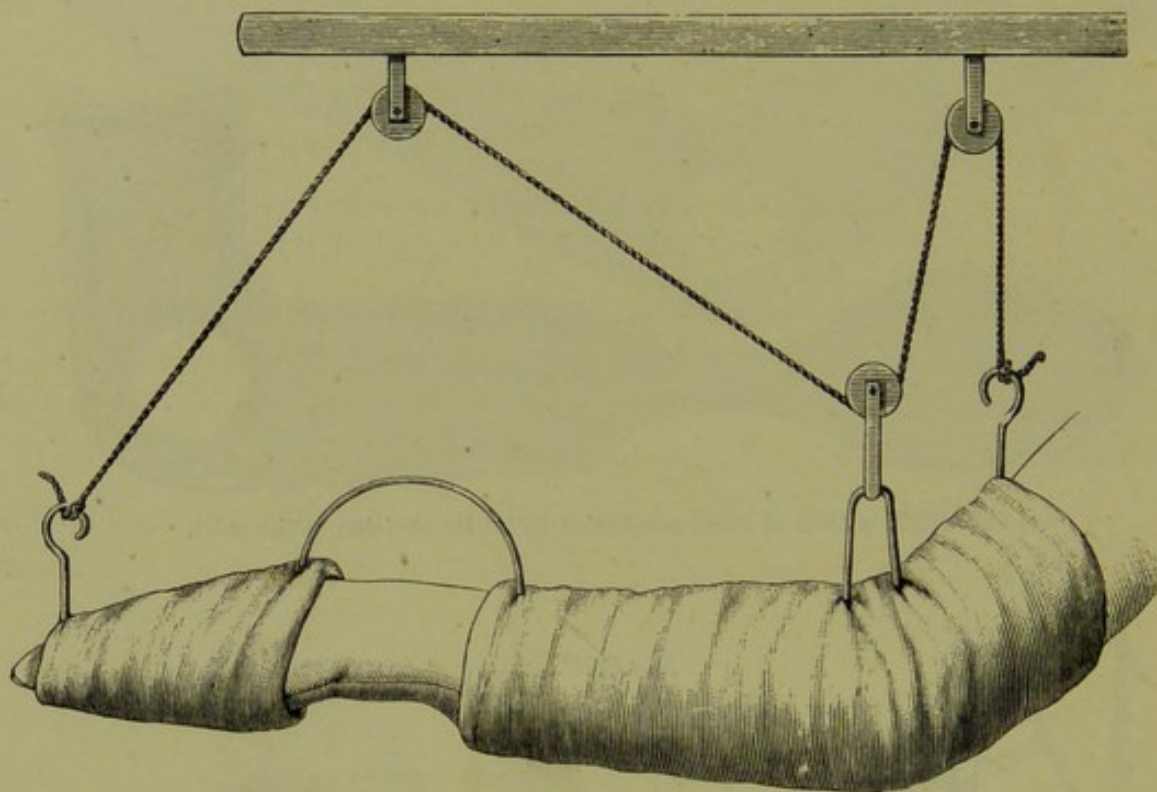
Fig. 128.



Suspension bar.

The arm is placed upon the splint, which is padded with cotton wool, and bandaged with plaster of Paris rollers. Finally, after the suspension bar (fig. 128) has also been bandaged on with plaster of

Fig. 129.

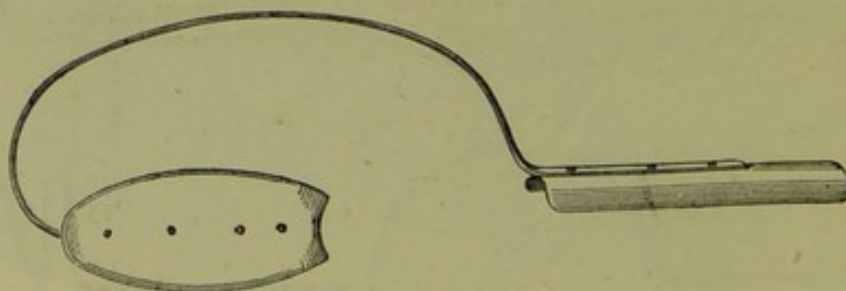


ESMARCH'S Plaster of Paris splint for excision of the wrist (applied and suspended).

Paris rollers, the arm is suspended by a rope and pulleys as in fig. 129. This apparatus is especially suitable for the open treatment of wounds.

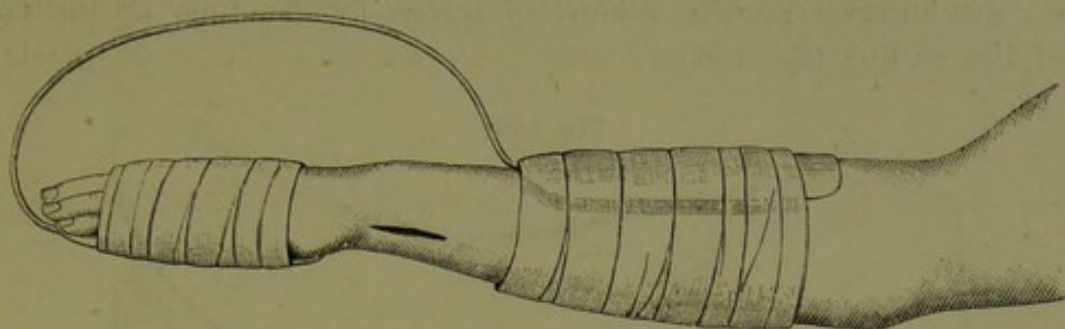
β. ESMARCH'S *interrupted splint* for excision of the wrist (fig. 130 and 131) consists of a piece of sheet iron for the hand, and a tin

Fig. 130.



ESMARCH'S interrupted splint for excision of the wrist.

Fig. 131.



ESMARCH'S interrupted splint for excision of the wrist.

splint for the dorsal surface of the forearm, which are connected with one another by a strong iron bar, shaped like a bow. As the wrist remains exposed for some distance, this apparatus is especially suitable for the antiseptic treatment of wounds.

γ. LISTER'S *splint* for excision of the wrist (fig. 132 and 133), a wooden splint covered with soft leather, upon which the hand and

Fig. 132.

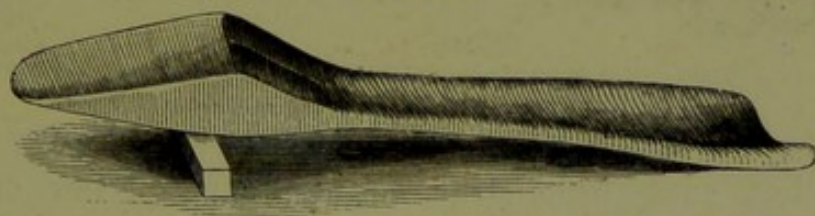
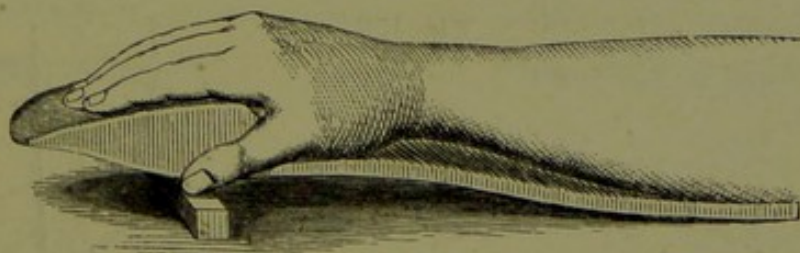


Fig. 133.



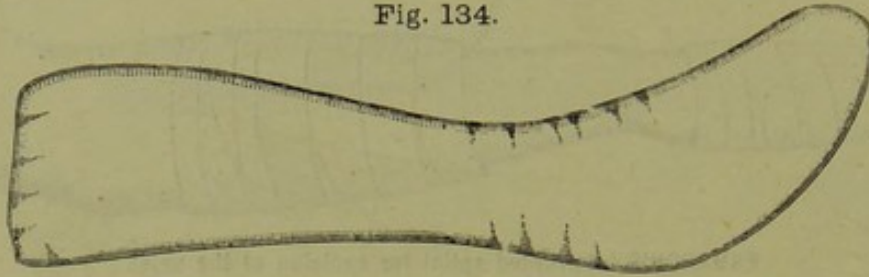
LISTER'S splint for excision of the wrist.

fingers may rest with comfort, is especially suitable for the after-treatment, when frequent passive and active movements of the fingers have to be undertaken.

c. For *Fractures of the forearm*:

α . STROMEYER'S *padded adduction-splint*, for fracture of the lower end of the radius (fig. 134).


Fig. 134.



STROMEYER'S padded adduction splint for fracture of the lower end of the radius.

β . STROMEYER'S *padded forearm splint*, for simple and compound fractures of the forearm (fig. 135).

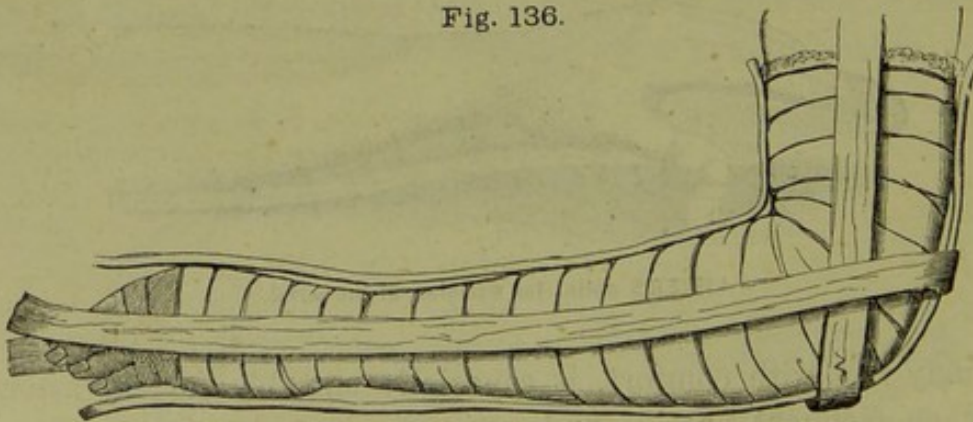
Fig. 135.



STROMEYER'S rectangular padded arm splint.

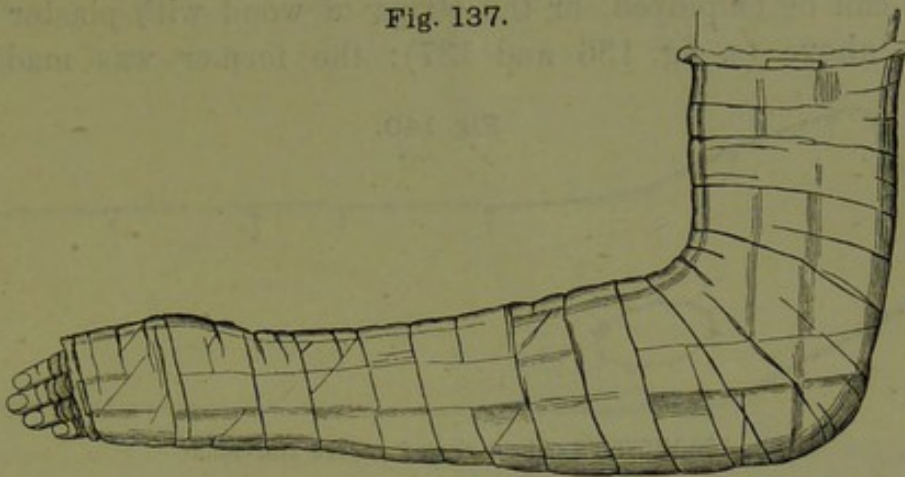
γ . A splint, made from strips of wood and plaster of Paris for fractures of the forearm (fig. 136 and 137), is also used for inflammation of the elbow joint.

Fig. 136.



Strips of wood with plaster of Paris bandage, for the arm flexed at the elbow.
(Application of the strips of wood.)

Fig. 137.




Strips of wood with plaster of Paris bandage, after its application.

Fig. 136 shews the application of strips of wood, after the arm has been enveloped in cotton wool, and bandaged with plaster of Paris rollers. Fig. 137 shews the apparatus finished, after the strips of wood have been fastened on with plaster of Paris bandages, and their projecting ends cut off with scissors.

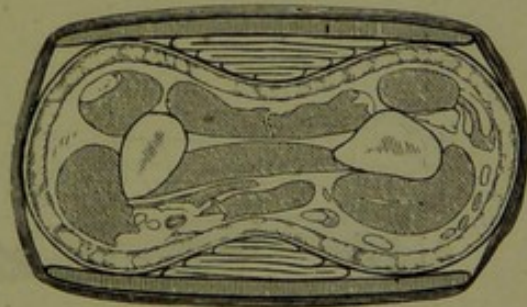
δ. If, in fractures of both bones of the forearm, there is a tendency to displacement of the fragments, *graduated compresses* (fig. 138)

Fig. 138.



Graduated compress.

Fig. 139.



The action of the graduated compresses upon the bones of the forearm.

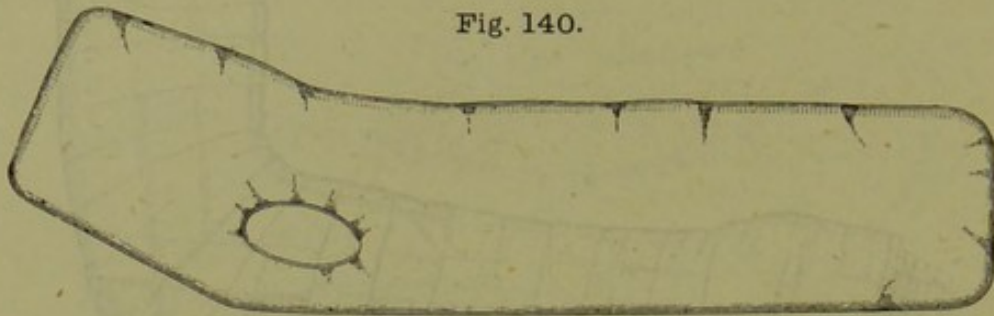
must be placed beneath the splints, which force the bones asunder by pressure against the interosseous space (fig. 139).

d. For *injuries of the elbow joint*:

α. For recent fractures without much displacement, for contusions, sprains, and inflammation of the joint, where an ice-bag is desirable, STROMEYER'S padded arm splint with a hole for the internal condyle

(fig. 140) can be employed, or the strips of wood with plaster of Paris, described above (s. fig. 136 and 137): the former was made use of

Fig. 140.



STROMEYER'S obtuse-angled padded arm-splint.

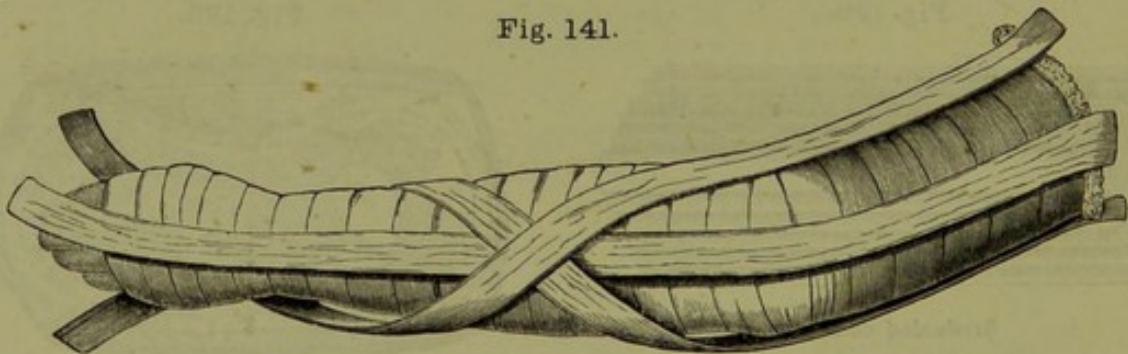
for the after-treatment of excision of the elbow in the Schleswig-Holstein war (1849—50).

If the application of a starch bandage is desirable for chronic inflammation of the joint, the paste board trough (fig. 121), moistened and smeared with starch paste, is very suitable for the reception of the limb.

For *more complicated injuries*, and *after excision of the joint*, there are used

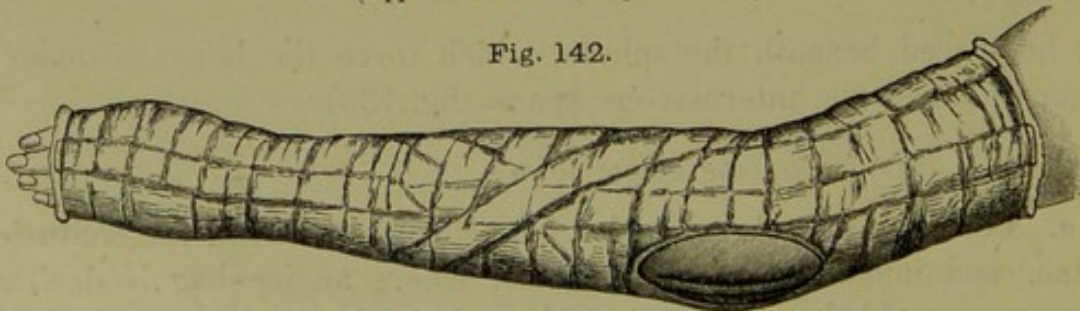
β. The *windowed* plaster of Paris bandage at an obtuse angle (fig. 141 and 142) or

Fig. 141.



Strips of wood with plaster of Paris for excision of the elbow.
(Application of the strips of wood.)

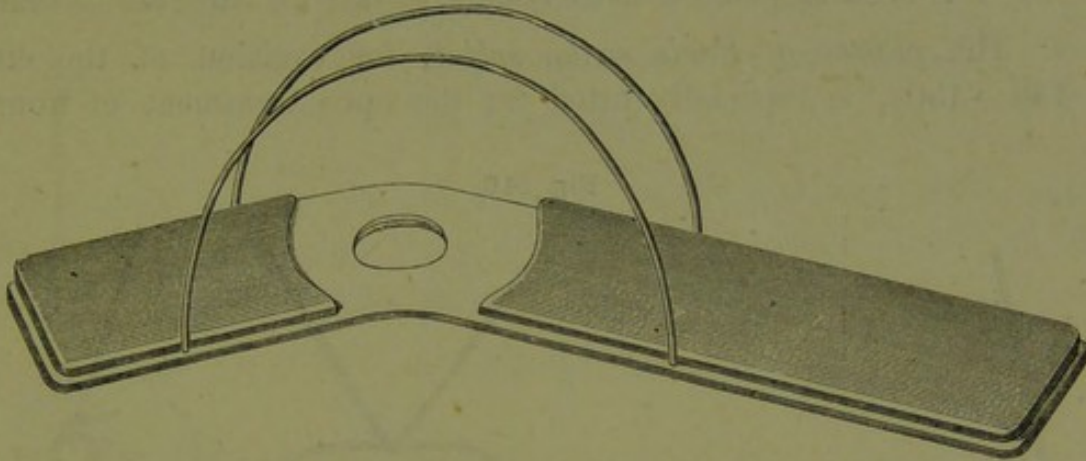
Fig. 142.



Same with window.

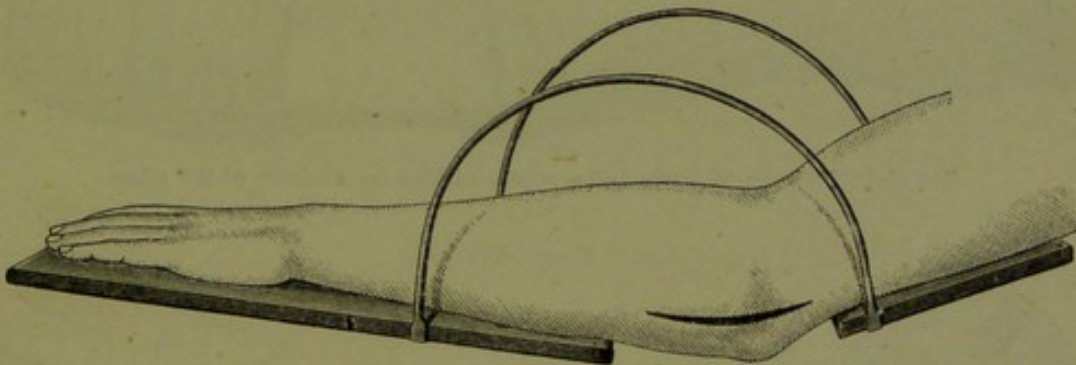
γ. The *double splint* for excision of the elbow (fig. 143, 144 and 145).

Fig. 143.




ESMARCH'S double splint for excision of elbow.

Fig. 144.



The upper padded bracket-splint
with the arm lifted off from the lower wooden splint: the latter gives firmness to the apparatus.

Fig. 145.



The lower wooden splint.

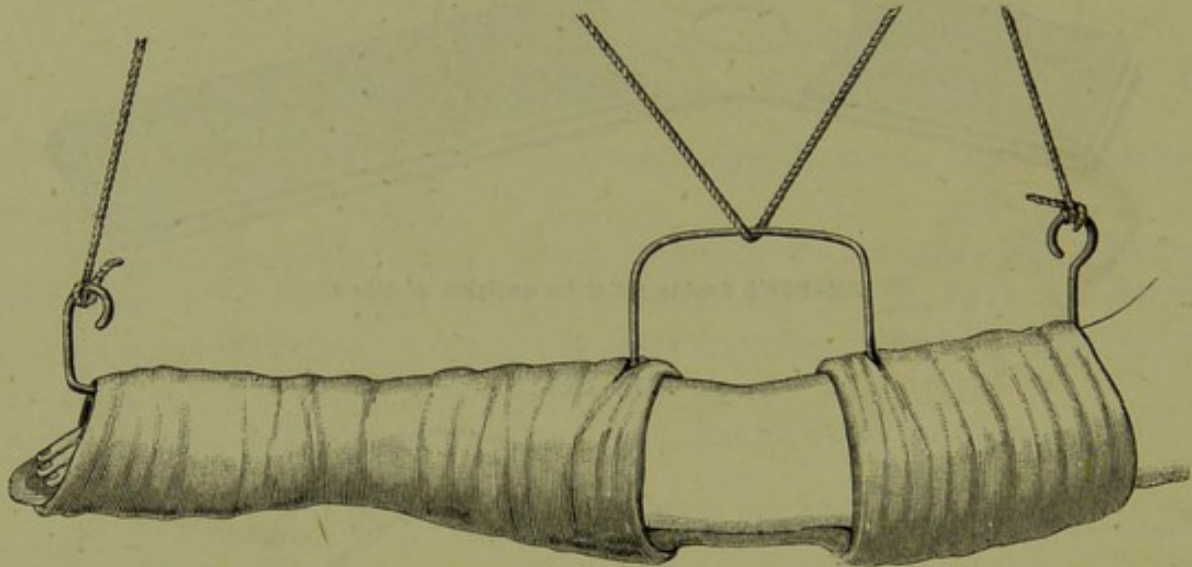
I call it the Langensalza splint, because I made it for the excisions at Langensalza in 1866, when I came from Berlin on a visit to STRO-MEYER.

This splint is very easily made by any joiner, and is as good for the open dressings, as it is for the antiseptic method.

NB. In renewing the dressings, the bracket splint, upon which the arm rests, is lifted off from the splint beneath, so that the latter can be cleansed.

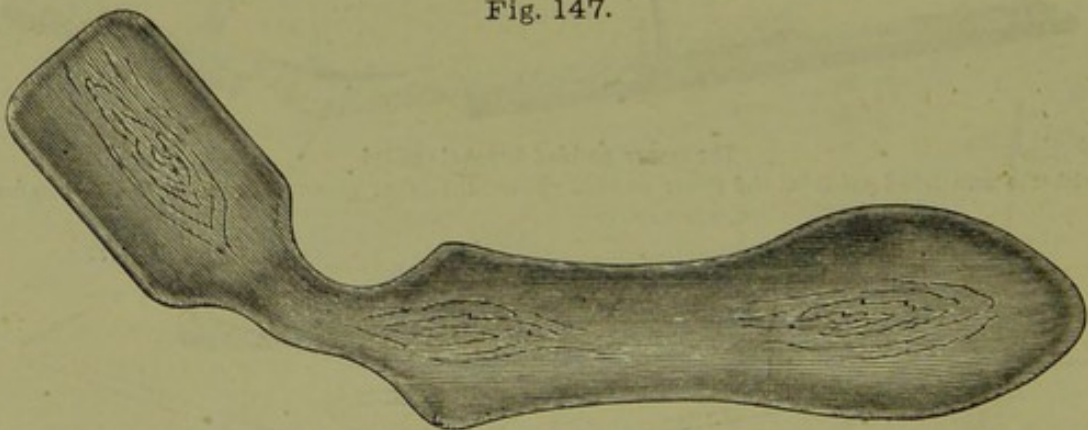
δ. The *plaster of Paris swing splint*, for excision of the elbow (fig. 146—150), is especially fitted for the open treatment of wounds.

Fig. 146.



ESMARCH'S plaster of Paris swing splint, applied for excision of the elbow.

Fig. 147.




The supporting splint of wood, from above.

Fig. 148.



Side view of the wooden splint.

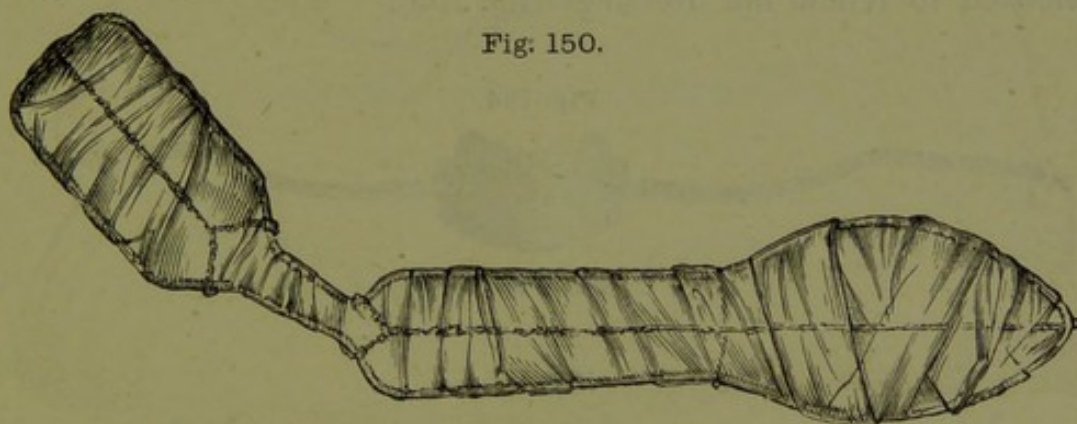
Fig. 149.



The suspension bar.

If wooden splints are not at hand, the supporting splint can be easily made out of telegraph wire. If covered with a plaster of Paris bandage it acquires greater firmness (fig. 150).

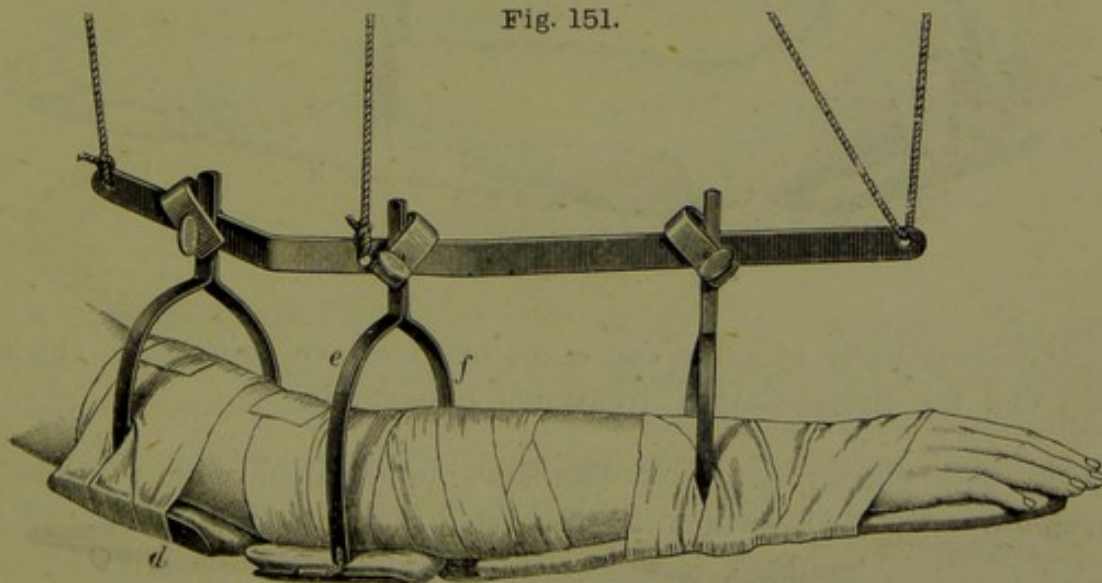
Fig. 150.



The supporting splint of telegraph wire, bandaged with a plaster of Paris roller.

ε. The *interrupted iron swing splint*, for excision of the elbow (fig. 151), consists of three splints, to which are fastened, by means of

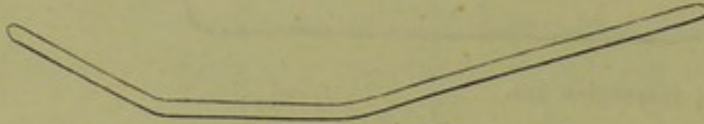
Fig. 151.



ESMARCH'S interrupted swing splint.

joints, moveable arms, which are again attached to a bent supporting rod (fig. 152) by means of screw clamps. The arm rests securely upon

Fig. 152.



Supporting rod.

Fig. 153.



Lower splint for hand and forearm.

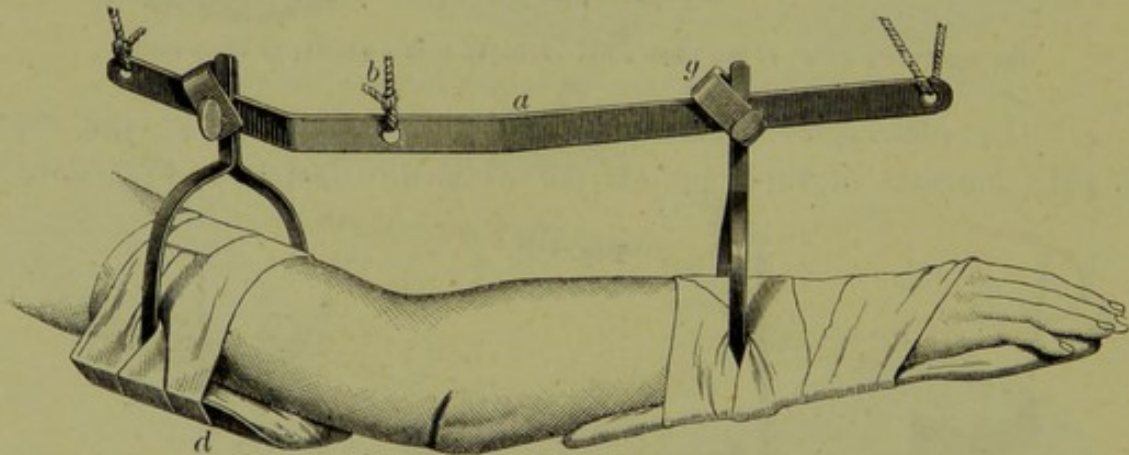
the upper and lower (fig. 153) splints, when the middle splint (fig. 154) is removed to renew the dressings (fig. 155).

Fig. 154.



Middle splint.

Fig. 155.

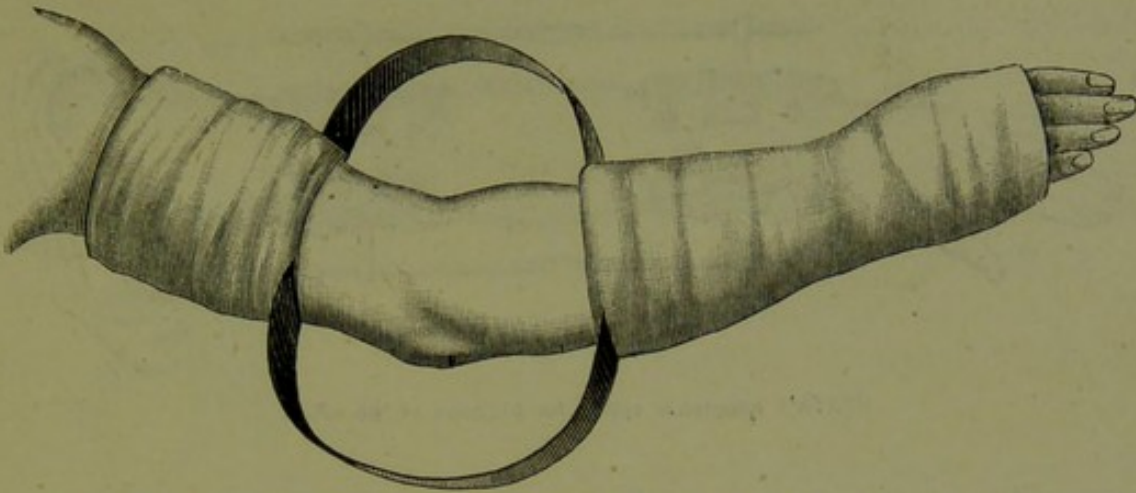


Middle splint removed to renew the dressings.

It is especially suitable for cases of extensive injuries to the soft parts, and for the antiseptic treatment of wounds.

ζ. The plaster of Paris bandage, interrupted with portions of iron hoop (fig. 156), which are inserted between the layers of the plaster of Paris bandage, is especially useful for the practice of antiseptic dressing.

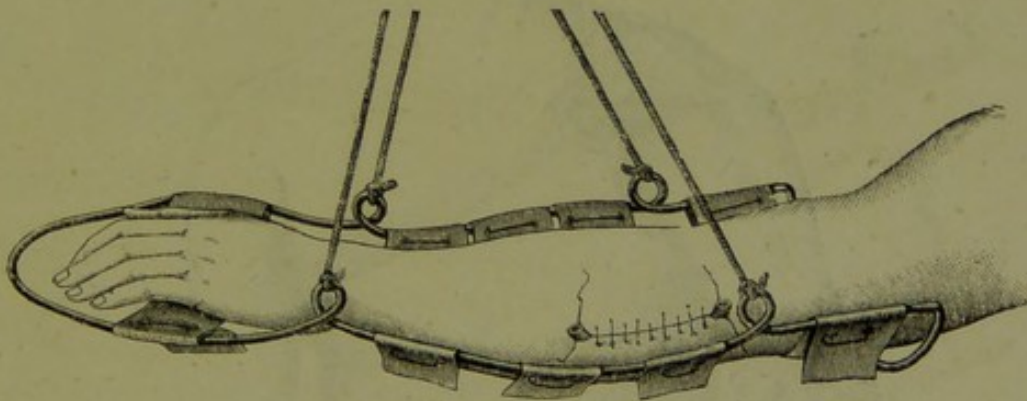
Fig. 156.



Interrupted plaster of Paris bandage with iron hoops.

η. So also is VOLKMANN'S *wire swing* for the arm (fig. 157), in which the excised arm rests upon strips of bandage, which are fastened by safety pins, and can be easily renewed.

Fig. 157.

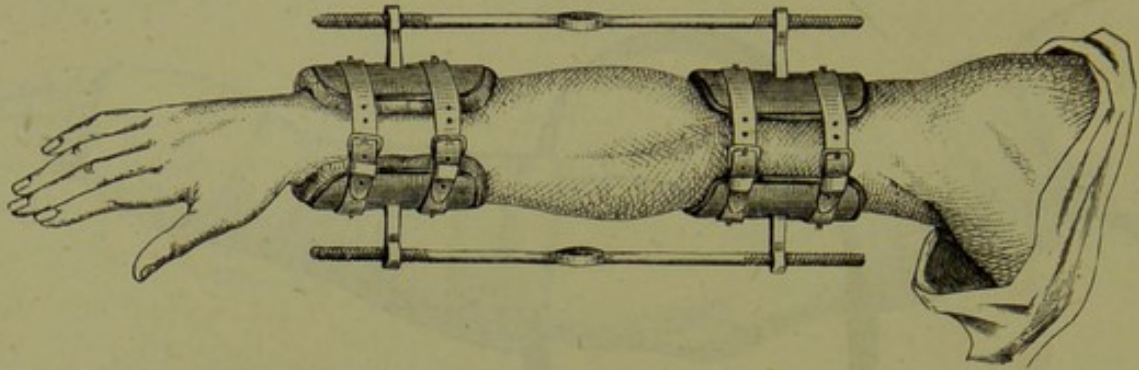


VOLKMANN'S wire swing for the arm.

θ. HEATH'S *adaptable splint*, for excision of the elbow (fig. 158), consists of four padded splints, two for the upper arm and two for the forearm, which they enclose; and connected by bars, which can be bent to the required angle, and lengthened, or shortened, according to the length of the arm under treatment.

ι. If after excision of the elbow a *loose* (flail-like) *joint* remains, the firmness and usefulness of the arm can be restored by SOGIN'S

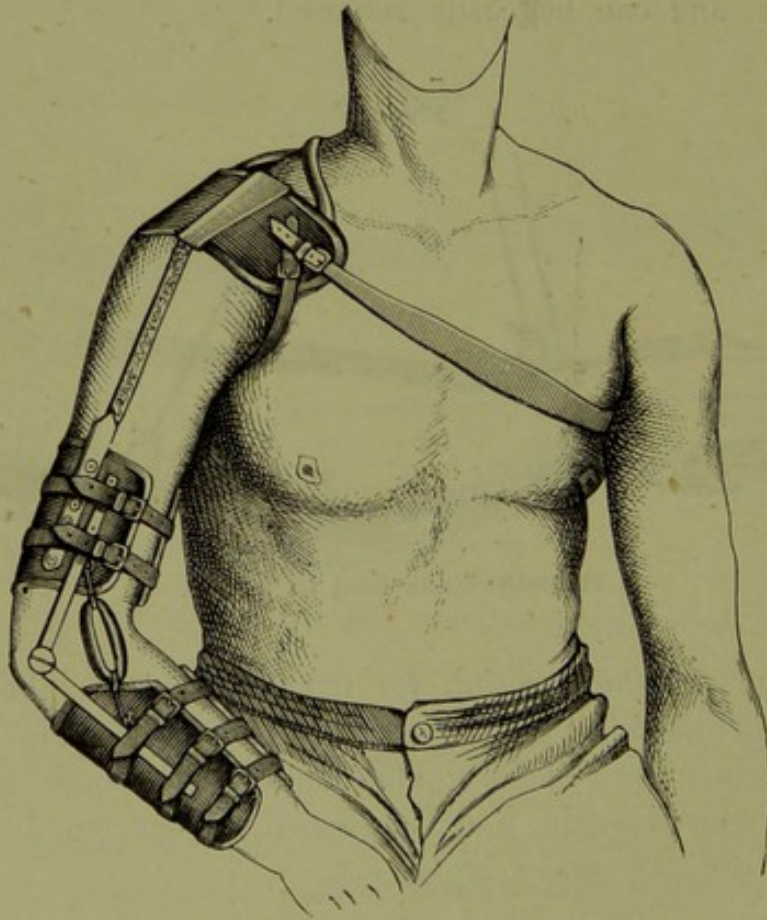
Fig. 158.



HEATH'S adaptable splint, for excision of the elbow.

support (fig. 159), upon which an india-rubber ring is fixed: this contrivance produces the movement of flexion.

Fig. 159.

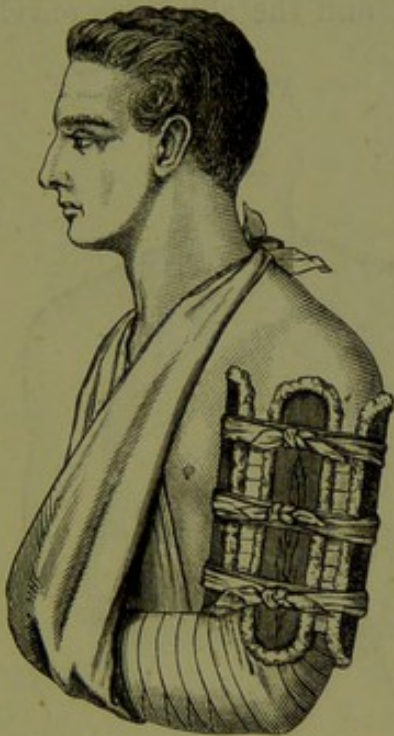

SOCIN'S support for loose (flail-like) joint, after excision of the elbow.

e. For *injuries of the upper arm*, and especially simple fractures:

α. *Four wooden splints*, padded, and applied by means of handkerchiefs (fig. 160), for fracture of the middle of the upper arm. The

Fig. 160.



Splints for fracture of the upper arm.

whole arm must be carefully bandaged, from the tips of the fingers upwards, and supported by a sling. The turns of the bandage must not ascend too high upon the inner side, as they readily produce strangulation in the axilla.

β. For *fractures below the middle*, a paste board trough (s. fig. 121), padded with cotton wool, is sufficient, of which the upper part reaches to the shoulder. A short paste board splint is also laid upon the inner side, and the whole is bandaged with a moistened gauze roller.

γ. The *starch bandage* for fracture of the upper arm is applied as follows: after the whole arm, in the position of abduction, has been very carefully bandaged with moistened flannel rollers, four paste-board splints are applied,

which have been previously moistened, smeared with starch, and padded; a short one is placed on the inner side, and the three longer ones in front, behind, and on the outer side, right up to and over the shoulder; and these are fixed by starch bandages, which also cover the shoulder (*spica*), but leave the axilla free. The arm, flexed at the elbow, is then carefully applied to the thorax and supported by a sling.

δ. The *plaster of Paris bandage* with strips of wood, for fracture of the upper arm, and inflammation of the shoulder joint, is applied as follows. The arm, flexed at the elbow, and abducted at the shoulder, is carefully bandaged with flannel rollers to above the elbow joint; and from that point upwards the upper arm and shoulder are enveloped in cotton wool. The whole arm, from the wrist to the shoulder,

is then quickly bandaged with plaster of Paris rollers, applied against the body, and supported by a sling. The middle of a long strip of wood is placed under the elbow, while the two halves are carried upwards, one in front and the other behind the arm, and the ends made to cross one another upon the shoulder. A second long strip is applied along the outer side of the arm, from the wrist to the side of the neck (fig. 161). Finally the strips, the arm, and the sling are enveloped

Fig. 161.

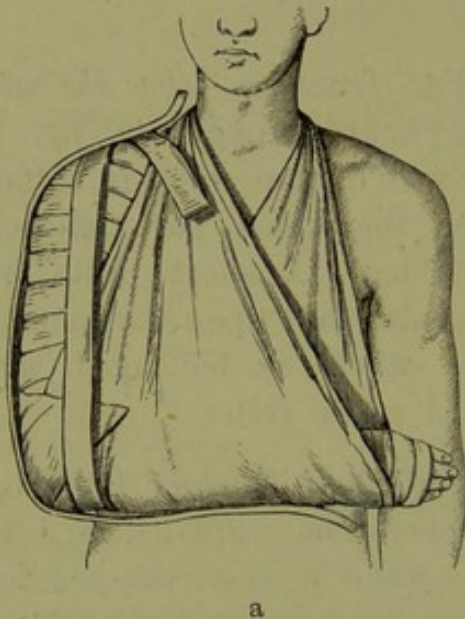
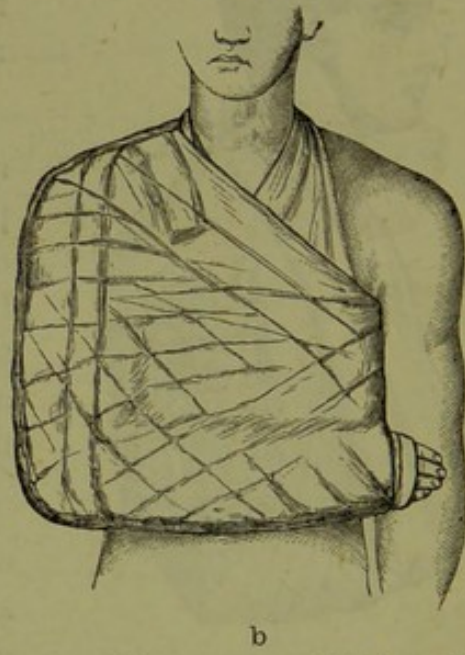
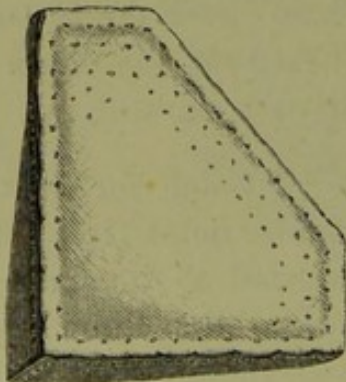
Fig. 162.



Plaster of Paris bandage with strips of wood, for fracture of the upper arm and inflammation of the shoulder joint.

- a. Application of the wooden strips to an arm, which has been covered with plaster of Paris bandages and placed in a sling.
- b. The whole dressing covered and fixed with plaster of Paris bandages.

Fig. 163.



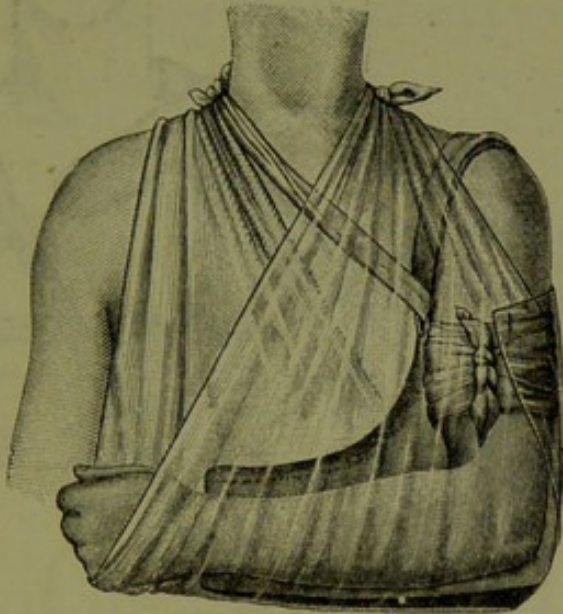STROMEYER'S cushion.

with plaster of Paris rollers, according to DESSAULT'S method of dressing (fig. 162).

e. For *compound fractures* of the upper arm, and for injury to the shoulder joint, STROMEYER'S *cushion* is very useful.

It is a triangular cushion with the angles rounded, softly stuffed with horse-hair, and covered with waterproof material (fig. 163). One of the rounded corners is placed in the axilla, and fastened in front and behind by

Fig. 164.



Application of STROMEYER'S cushion for compound fracture of the arm.

(The sling is represented as transparent.)

safety pins to a bandage, which is carried over the sound shoulder. The flexed arm is then placed upon it and together with the cushion is fixed by a sling (fig. 164).

It secures a position of rest for the arm, whilst it hinders the transmission of the respiratory movements to the seat of fracture.

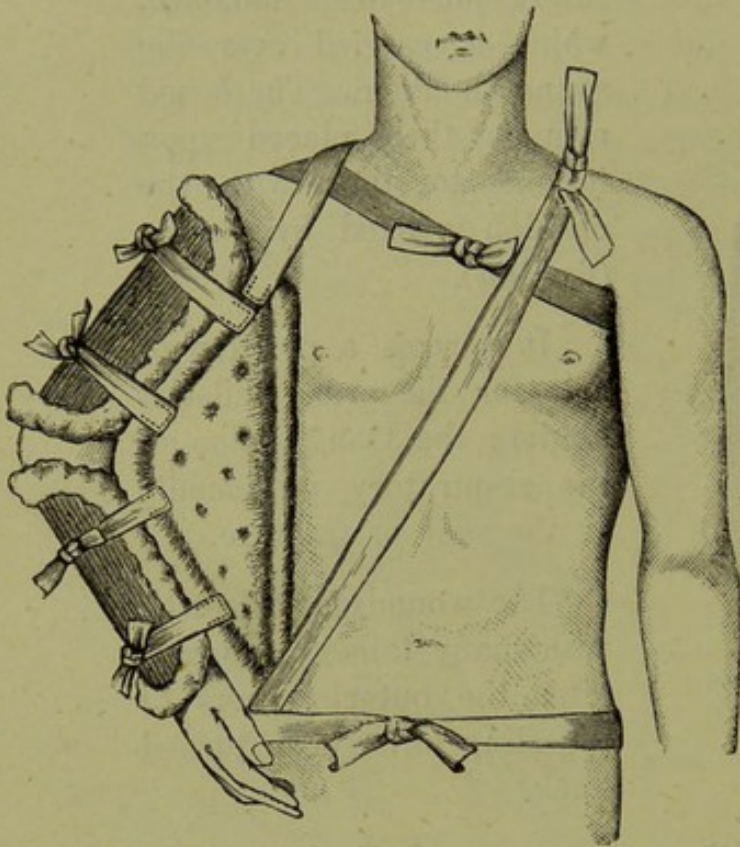
The wounds are dressed with many tailed bandages, after the outer corners of the sling have been turned back.

ζ. If there be *considerable swelling* after severe shattering of the arm, the limb must be first of all raised; and for this purpose it is most conveniently placed upon a padded STROMEYER'S arm-splint with a hole for the internal condyle of the humerus (s. fig. 140).

η. For *fractures of the upper end* of the humerus, with obstinate tilting outwards of the upper fragment, the whole of the upper arm must be placed in the abducted position by MIDDELDORFF'S triangle, a triangular wedge-shaped cushion (fig. 165), or by a double inclined plane (fig. 166), framed out of three boards, whose longest side is fixed to the trunk by straps or handkerchiefs, whilst the arm bent to an obtuse angle is placed upon the two shorter sides, and fixed there by bandages.


As oedema easily arises on account of the dependent position of the arm, the whole arm must be very carefully bandaged from below upwards.

Fig. 165.



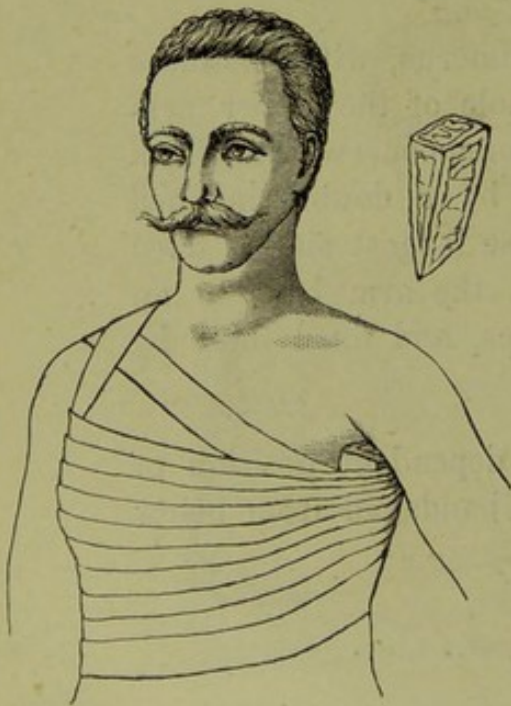MIDDELDORPF'S triangular cushion.

Fig. 166.



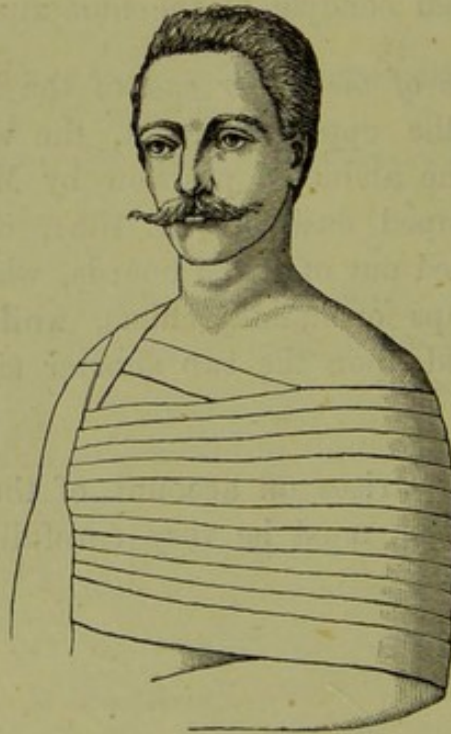
MIDDELDORPF'S triangle.

Fig. 167.



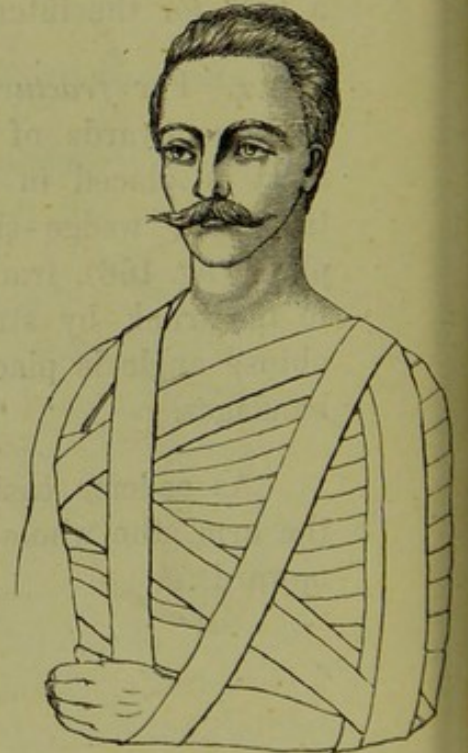
1st part.

Fig. 168.



2nd part.

Fig. 169.



3rd part.

DESAULT'S bandage for fractured clavicle.

f. In *fracture of the clavicle*, the displacement of the fragments can be easily, if not permanently reduced, by

α . *DESAULT'S bandage* for fractured clavicle. It has indeed gone out of fashion, but it is an excellent exercise, in which the individual turns are employed for all shoulder dressings.

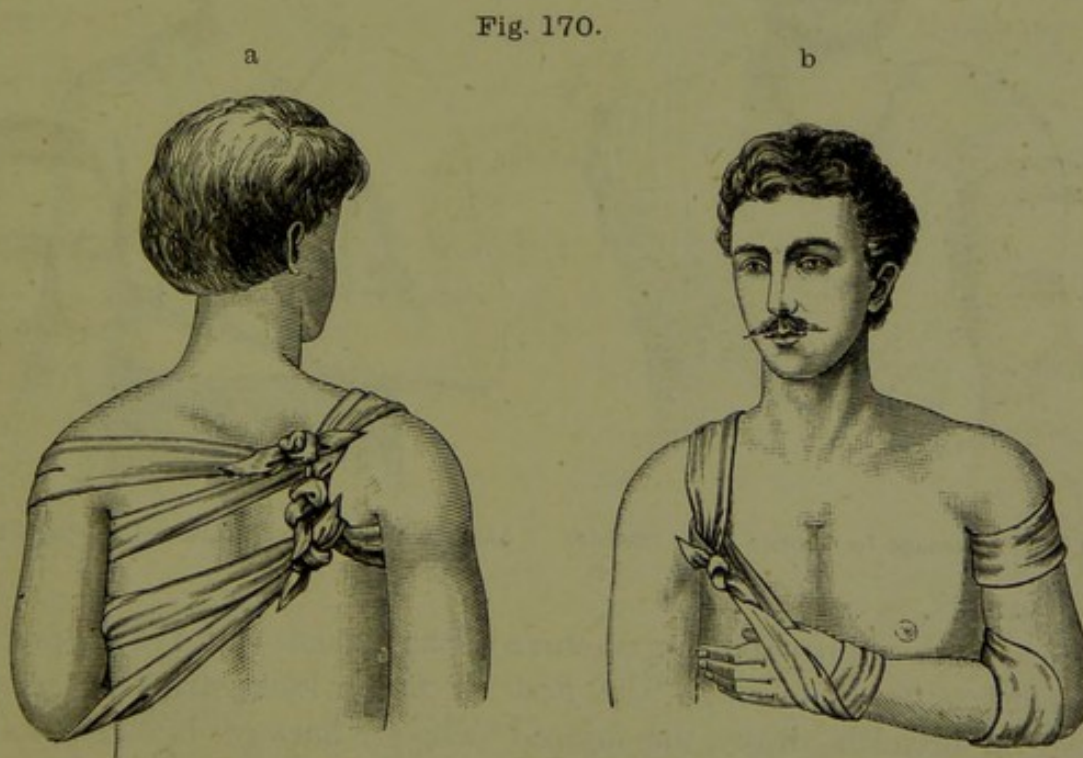
The first bandage fixes a wedge-shaped cushion in the axilla of the abducted arm by turns, which pass round the chest (fig. 167).

After the arm has been lowered and pressed against the cushion, it is fixed by a second bandage to the chest, and at the same time forced backwards (fig. 168).

The third bandage supports the arm in the manner of a sling (fig. 169).

To prevent the turns of the bandage from slipping, they can be smeared with starch, or sewn together in several places with a needle and thread.

β . *SZYMANOWSKY'S handkerchief bandages* for fractured clavicle are very effectual (fig. 170. a, b).



SZYMANOWSKY'S handkerchief bandages for fractured clavicle.

a. From behind.

b. From the front.

Round the sound shoulder is placed a cravat, made into the shape of a ring, towards which the upper part of the arm on the injured side is drawn backwards by a second handkerchief. A third handkerchief draws the lower part of the upper arm backwards, and a fourth supports the forearm after the manner of a sling.

The whole apparatus is fixed by a large linen belt dipped in plaster cream.

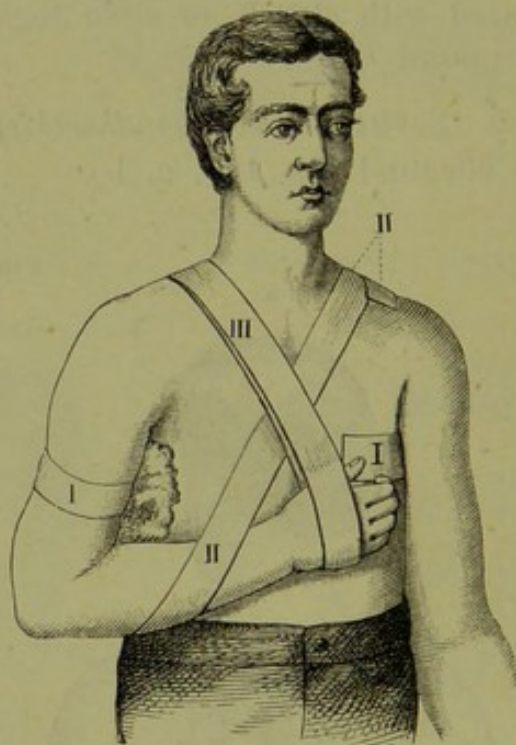
γ. VELPEAU'S *bandage* (fig. 171), which fixes the hand of the injured side upon the sound shoulder, and the elbow in front of the ensiform cartilage, is very useful both for fractures of the clavicle, and for chronic inflammation of the shoulder joint.

Fig. 171.



VELPEAU'S bandage for fracture of the clavicle.

Fig. 172.



SAYRE'S strapping for fracture of the clavicle.

δ. SAYRE'S *strapping* for fracture of the clavicle (fig. 172) is perhaps the most suitable of all. The first of three long strips of plaster, 6–8^{cm} in breadth, draws the injured shoulder backwards and upwards. It commences on the inner side of the injured arm, is carried backwards on its anterior and outer surfaces over the back, and

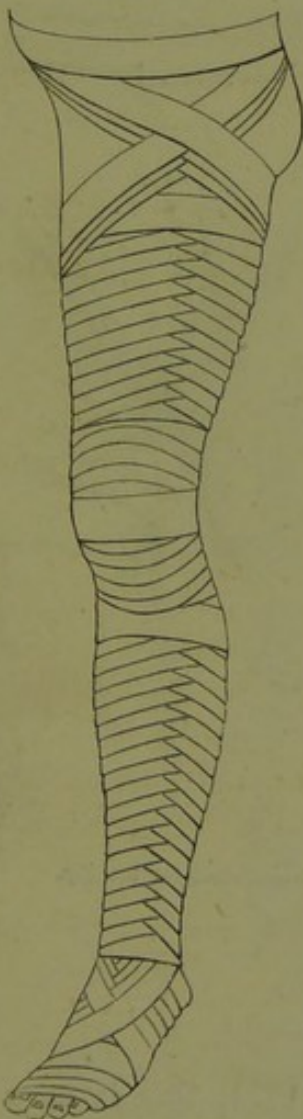
through again to the front under the sound shoulder, as far as the mamma.

The second strip fixes the arm and raises it forwards. It starts from the summit of the sound shoulder, and is carried obliquely downwards over the back, round the elbow of the injured side to the front, and upwards again to the sound shoulder.

The centre of the third strip supports the wrist, while the two ends are carried over the broken clavicle, so that the weight of the arm presses down the fragments of the bone, which are tilted upwards.

A small sling supports the hand.

Fig. 173.



Bandaging the whole leg.

Q. DRESSINGS FOR THE LOWER EXTREMITY.

1. BANDAGING THE WHOLE LEG (fig. 173).

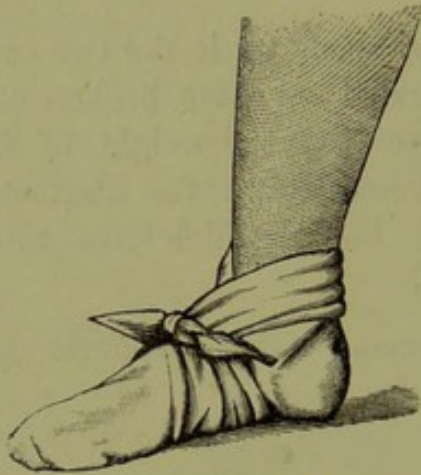This is commenced by bandaging the foot with a (narrow) figure of eight (stirrup, stapes).

The leg is then bandaged by a broader ascending spiral with reverses, the knee by a figure of eight (testudo), the thigh by an ascending spiral with reverses, and the hip by a figure of eight (spica coxae), which is finished off with a few circular turns round the lower part of the abdomen.

2. HANDKERCHIEF BANDAGES FOR THE LEG.

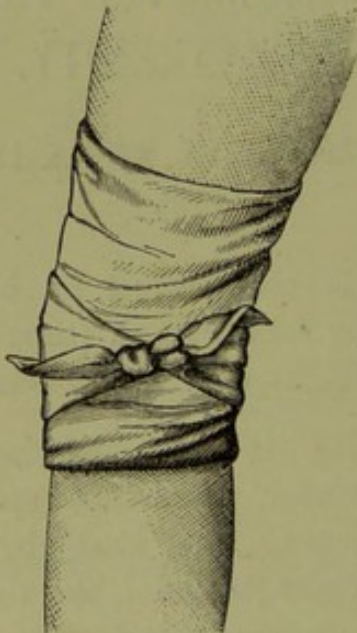
- a. Handkerchief for the foot (fig. 174).
- b. Handkerchief for the knee (fig. 175).
- c. Handkerchief for the hip (fig. 176).

Fig. 174.



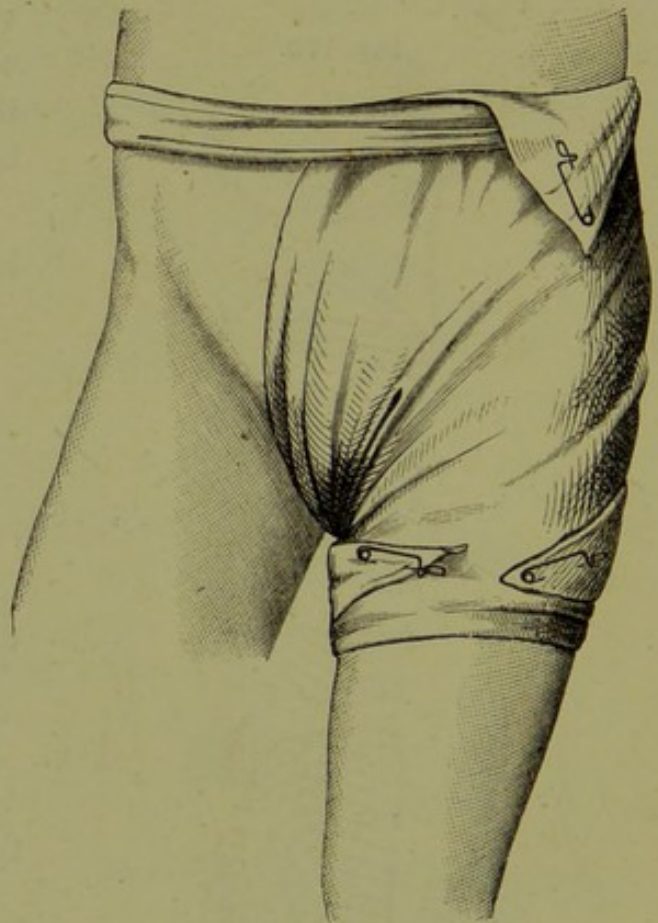
Handkerchief for the foot.

Fig. 175.



Handkerchief for the knee.

Fig. 176.

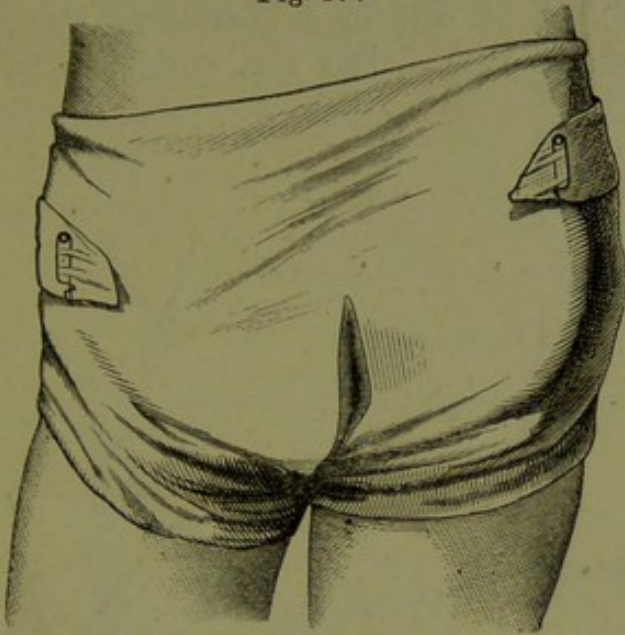


Handkerchief for the hip.

d. Handkerchief for the buttock (fig. 177): this is very useful for bed sores over the sacrum.

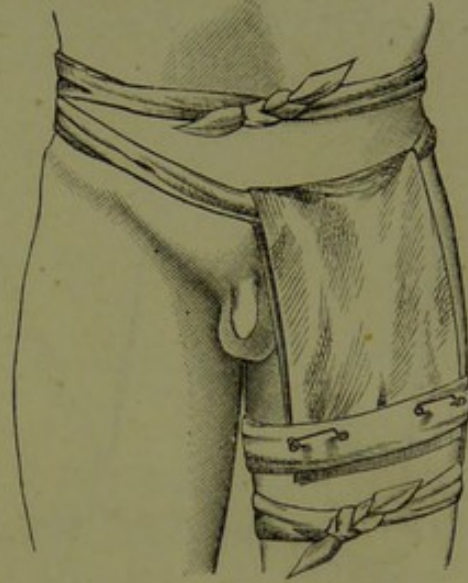
e. Handkerchief in the form of an apron for the groin after ROSER (fig. 178).

Fig. 177.



Handkerchief for the buttock.

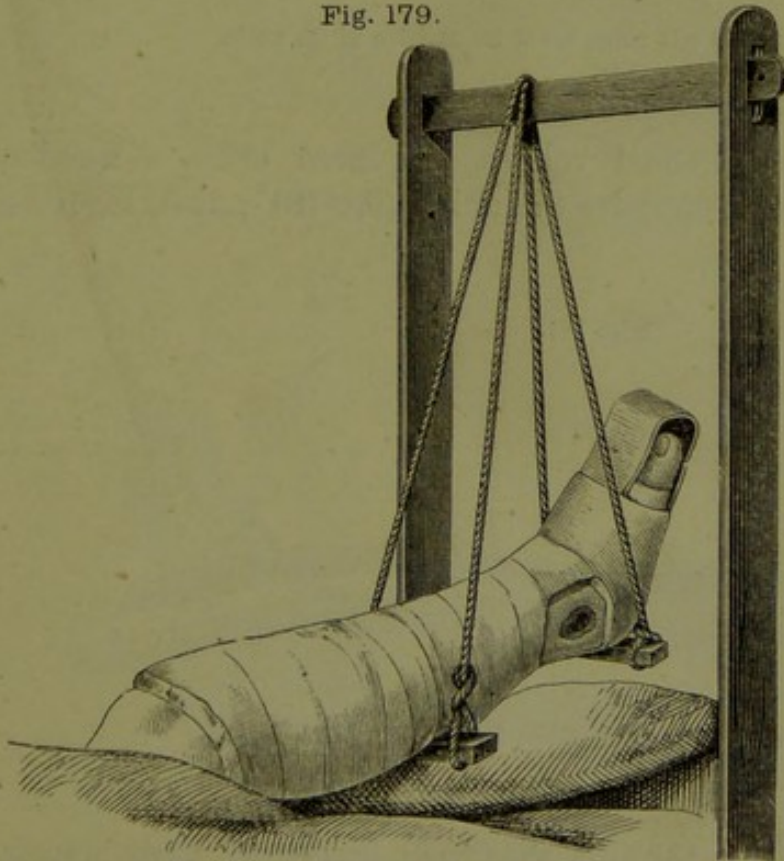
Fig. 178.



Handkerchief in the form of an apron for the groin.

3. DRESSINGS FOR INJURIES OF INDIVIDUAL PARTS OF THE LOWER EXTREMITY.

Fig. 179.



A windowed plaster of Paris suspension bandage for open dressing after excision of the ankle.

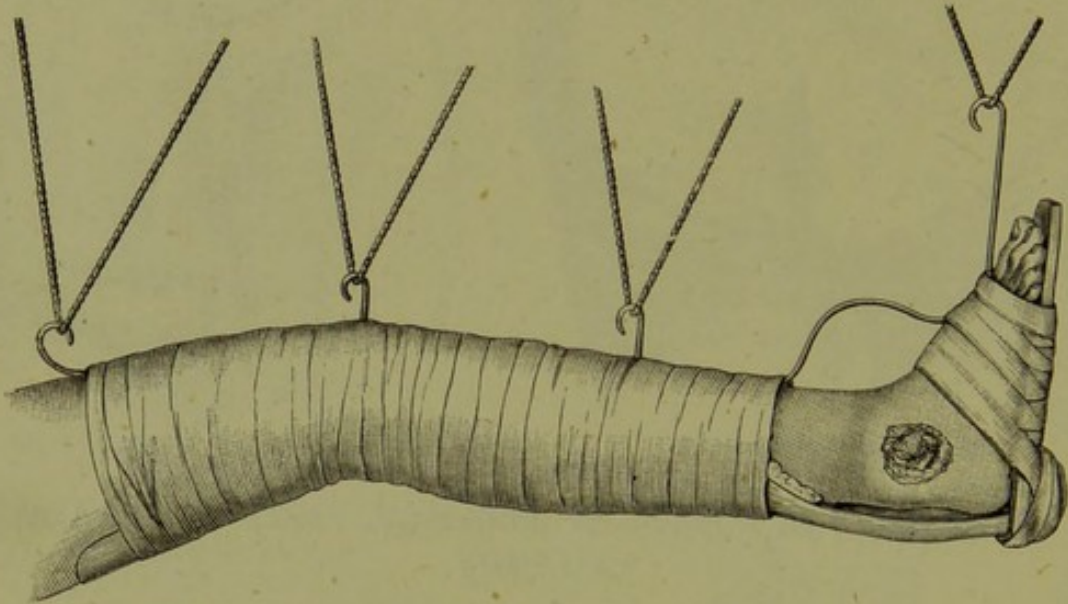
a. For *injuries of the foot* paste-board troughs like those for the arm (fig. 121), tin troughs and wire-baskets (fig. 53 and 55) are used.

b. For *injuries and excisions of the ankle*

a. a *windowed plaster of Paris bandage* can be applied, and swung by means of some cords and wooden laths (fig. 179), or it can be placed firmly upon a frame of boards (fig. 81 and 82).

β. The limb can be safely placed at rest in a *plaster of Paris swing splint*, after WATSON'S plan (fig. 180). The leg, enveloped in

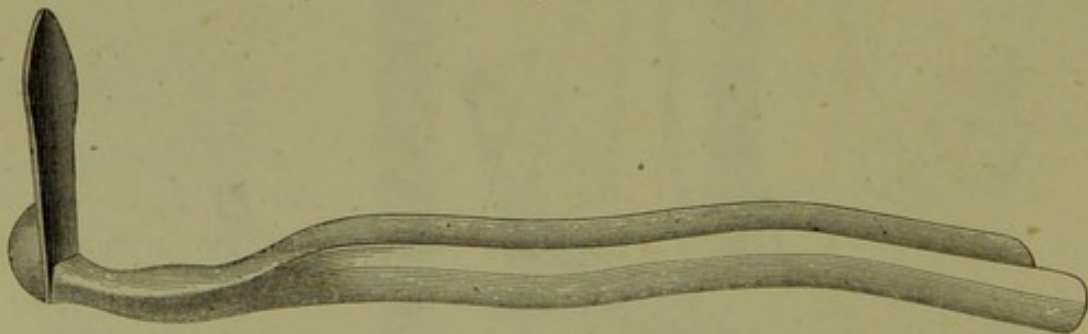
Fig. 180.



ESMARCH'S plaster of Paris swing splint for excision of the ankle.

cotton wool or carbolised flannel rollers, is placed upon a wooden splint, which is very narrow opposite the ankle (fig. 181); this, together

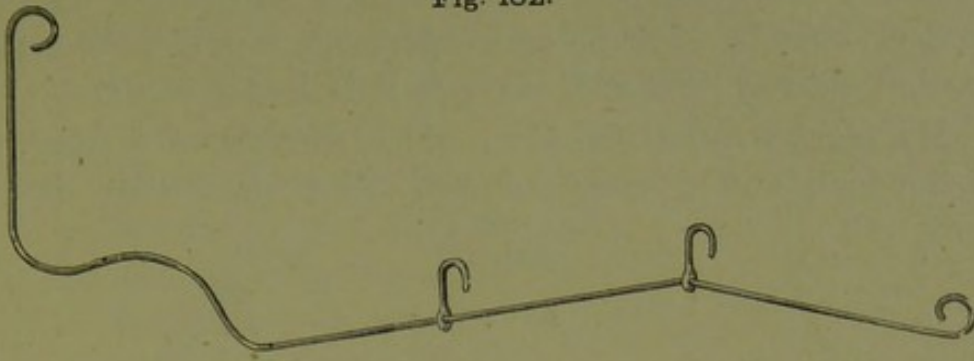
Fig. 181.



ESMARCH'S plaster of Paris swing splint for excision of the ankle.

with the suspension bar (fig. 182), is then well bandaged with plaster of Paris rollers.


Fig. 182.



Suspension-bar to ESMARCH'S plaster of Paris swing splint for excision of the ankle.

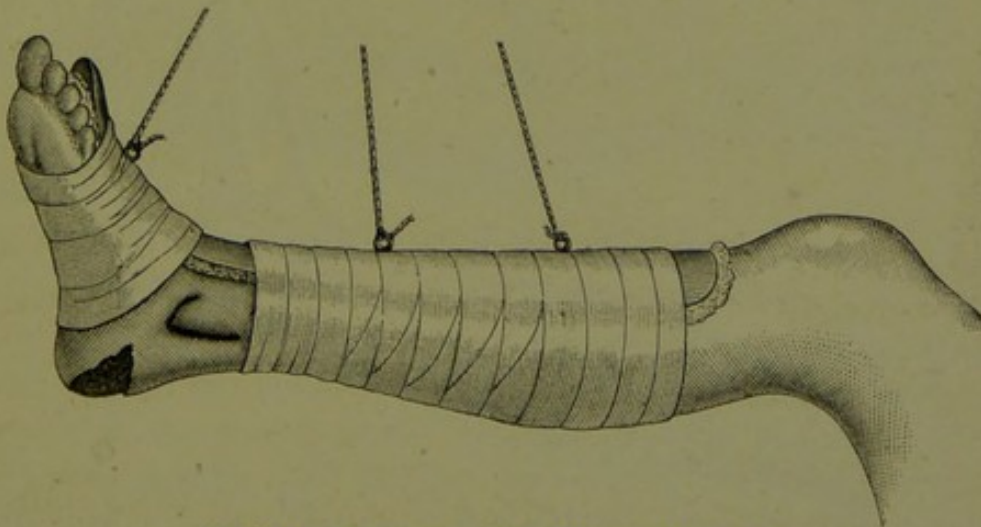
γ. VOLKMANN'S *dorsal splint* of wood (fig. 183), which is fixed to the foot and leg by plaster of Paris bandages, or moist gauze bandages (fig. 184), gives good support to the excised joint.

Fig. 183.



VOLKMANN'S wooden dorsal splint for excision of the ankle.

Fig. 184.

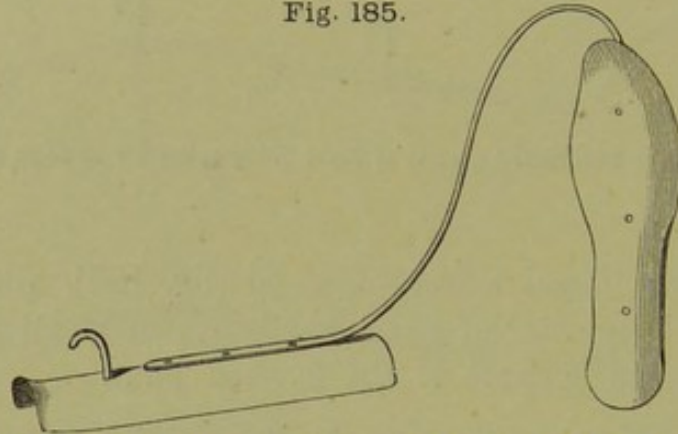


VOLKMANN'S dorsal splint for excision of the ankle.

The three dressings, just mentioned, are well suited for the open treatment of wounds. For LISTER'S treatment, in which the ankle joint must be left entirely free and exposed, it is better to use —

δ. My *bracket splint* (fig. 185), which consists of a splint for the sole of the foot, and a narrow dorsal splint for the leg, both made

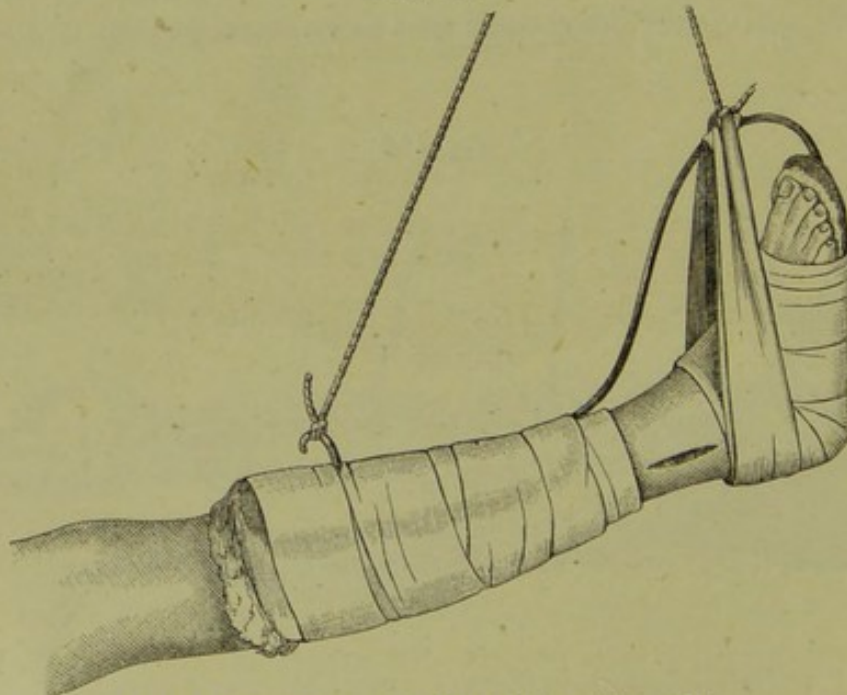
Fig. 185.



ESMARCH'S interrupted iron splint for excision of the ankle.

of tinned iron, and connected with one another by a dorsal wire bracket. The foot is fastened by strapping and a plaster of Paris bandage to the splint for the sole of the foot, and the leg in like manner to the dorsal splint. The heel can be supported by a triangular handkerchief (fig. 186).

Fig. 186.



ESMARCH'S bracket splint for excision of the ankle.

c. For the *immobilisation of fractures of the leg* there are used

- α. Wooden splints (fig. 41 and 45),
- β. Paste-board splints (fig. 50 and 52),
- γ. Tin splints (fig. 53),
- δ. Wire splints (fig. 55),
- ε. Splints of sticks (fig. 59—61),
- ζ. Straw splints (fig. 62—65),
- η. Splints of weapons (fig. 67—69),
- θ. Starch bandages (fig. 71),
- ι. Plaster of Paris bandages (fig. 74, 75, 80).

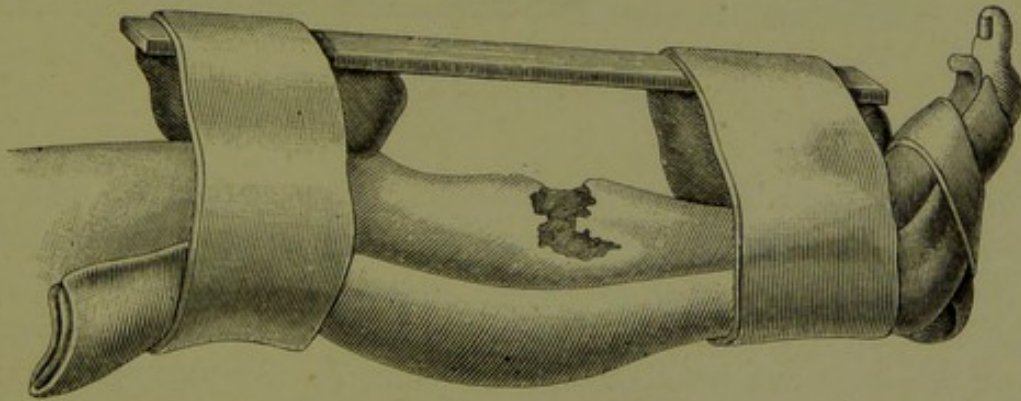
d. For *compound fractures of the leg*

α. the plaster of Paris bandage must either be provided with *windows* (fig. 81 and 82),

β. or *BEELY'S dorsal splints of hemp and plaster of Paris* (fig. 76), are used, if e. g. there are extensive injuries to the soft parts of the calf of the leg.

γ. For *severe shattering of the leg* with extensive injuries to the soft parts *on the anterior surface*, *PIROGOFF'S* interrupted splint with plaster of Paris (fig. 187) is especially suitable.

Fig. 187.

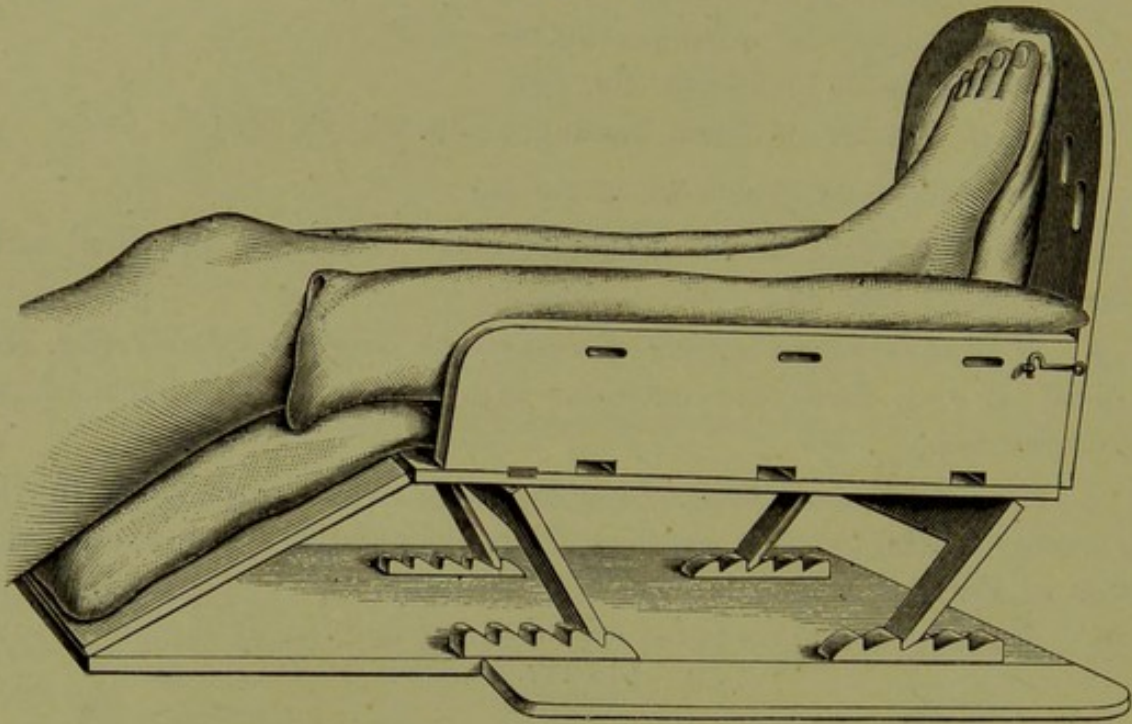


PIROGOFF'S interrupted splint with plaster of Paris.

After a strong plaster of Paris splint of coarse sack-cloth, soaked in plaster cream, has been applied to the calf, two large balls of tow, saturated with the plaster cream, are placed upon the anterior surface of the leg; a wooden lath is then fastened upon the tow with broad strips of linen, which are also impregnated with the plaster cream.

δ. The *box splint* is also very suitable for compound fractures of the leg, and is preferred by many surgeons to the "fixed dressings". PETIT'S box splint, which was introduced into Germany by HEISTER (fig. 188), was always particularly popular.

Fig. 188.

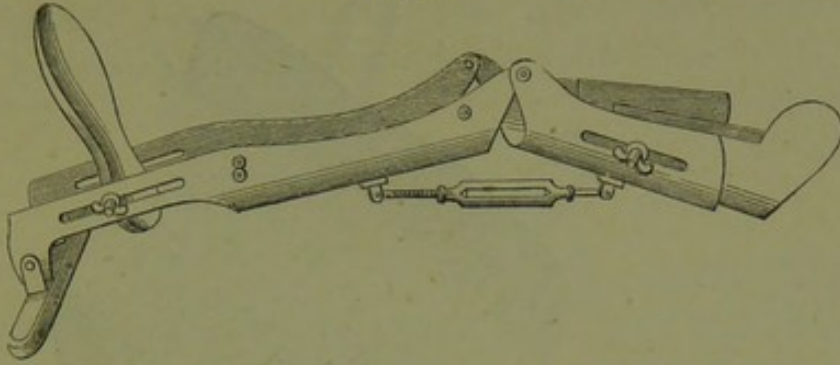


PETIT'S (HEISTER'S) box splint for the leg.

The leg is fixed between the cushions, which are stuffed with chaff, by means of moveable side splints, so that, when the dressing is changed, both sides of the leg can be made accessible one after the other, without altering its position. By means of the moveable support the angle at the knee can be altered at pleasure (cf. STROMEYER'S *Maximen*, pag. 526).

e. LISTON'S *improved* MAC INTYRE of tinned iron is preferred in England for these cases (fig. 189). It has a moveable foot-piece adaptable to various positions, and by a screw at the back the angle of the knee can be very gradually altered. The cross-piece at the lower end gives steadiness to the splint. The thigh-piece can be lengthened or shortened.

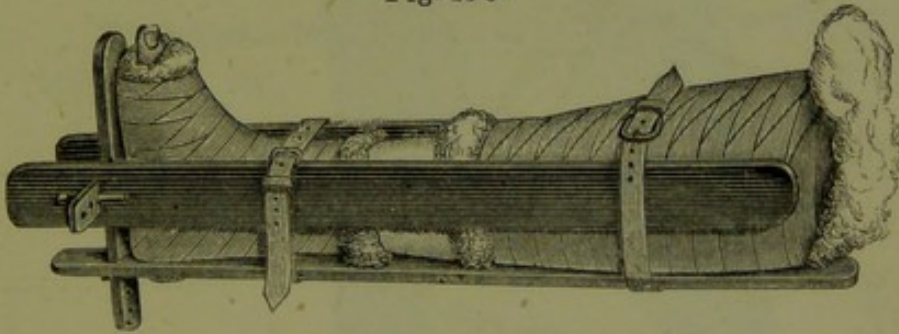
Fig. 189.



LISTON'S improved MAC INTYRE for compound fractures of the leg.

ζ. The *box splint* designed by SCHEUER has this advantage, that it can be very quickly made of wooden laths (fig. 190).

Fig. 190.

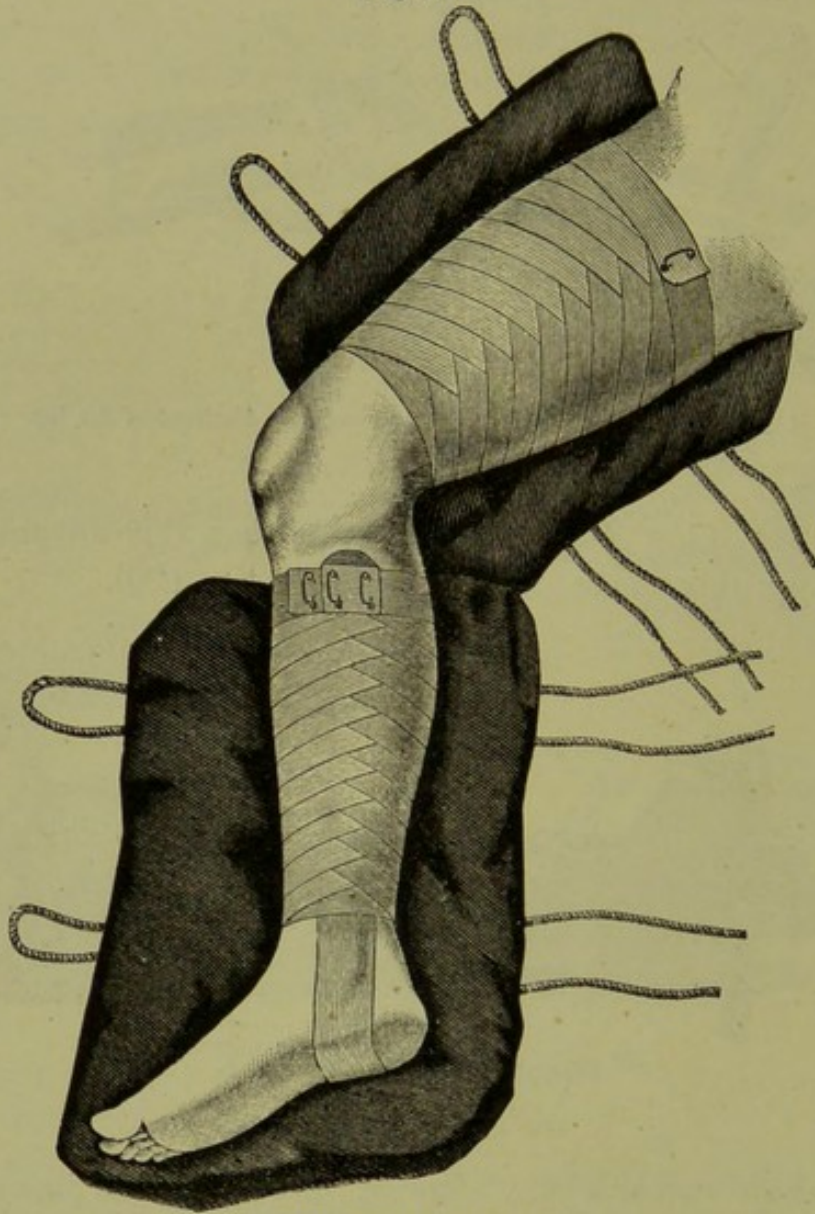


SCHEUER'S box splint for the leg.

η. In those cases, where none of the expedients mentioned above are at hand, or where together with considerable displacement of the fragments, a good deal of inflammatory infiltration of the whole limb has set in, it is recommended to employ POTT'S *lateral position* for a time, i. e., to place the leg upon its outer side, semiflexed at the knee and hip, by which means the muscles are relaxed, and any disturbance of the circulation avoided. If possible, the limb is placed upon cushions in such a manner, that the foot lies higher than the rest of the limb, and the many-tailed bandage is applied to the wound (fig. 191).

θ. If it is desirable to employ *irrigation* for injuries of the leg, the contrivance represented in fig. 17 is recommended for that purpose.

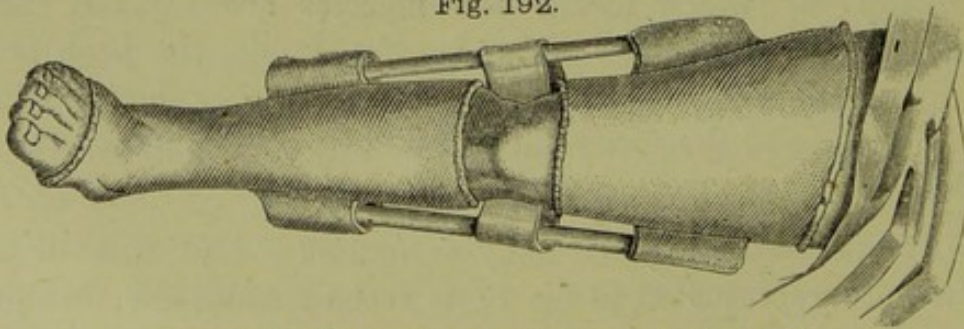
Fig. 191.



POTT'S lateral position.

e. For *injuries and excision of the knee joint*, either
 a. the *plaster of Paris bandage*, interrupted with wooden laths
 (fig. 192), or

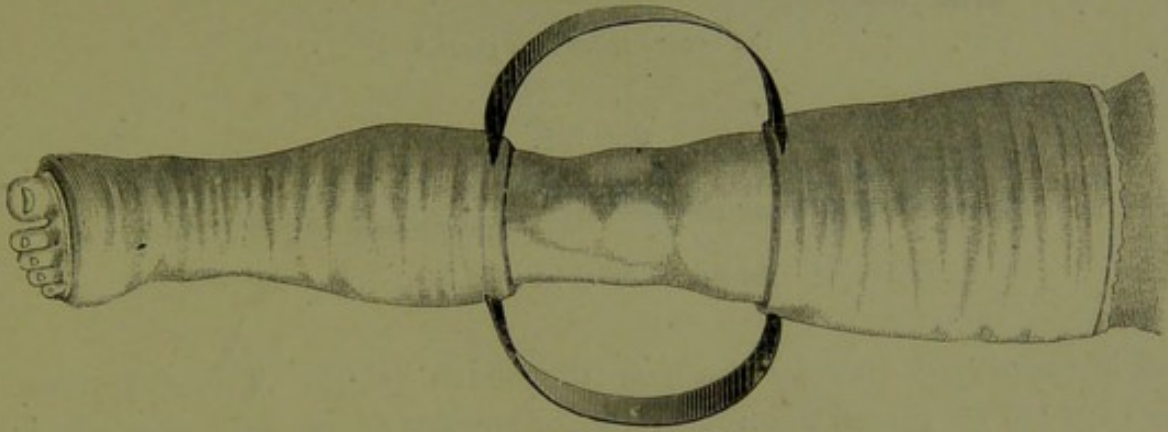
Fig. 192.



Plaster of Paris bandage interrupted with wooden laths.

β. if the knee ought to remain exposed to a greater extent, as in the employment of LISTER'S dressing, the same splint, interrupted with portions of iron hoop, can be applied (fig. 193).

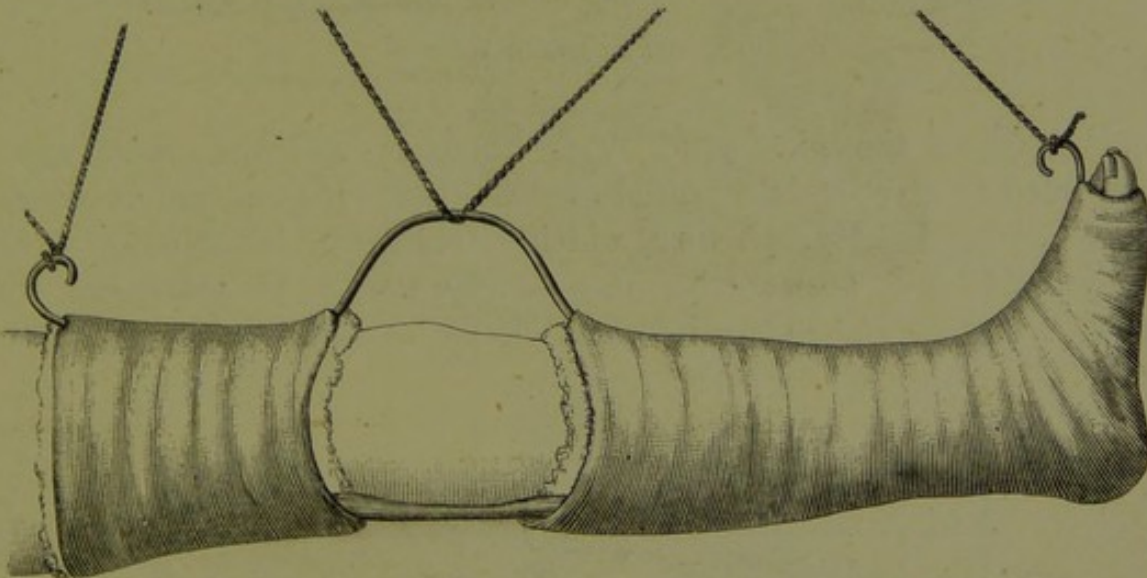
Fig. 193.



Plaster of Paris bandage interrupted with bows of hoop iron, for excision of the knee.

γ. The excised knee rests very comfortably and securely in WATSON'S plaster of Paris swing splint (fig. 194). The leg, enveloped in cotton


Fig. 194.



WATSON'S plaster of Paris swing splint for excision of the knee.

wool, is first placed upon a wooden splint (fig. 195 and 196), which has been rubbed with carbolic oil or ointment, and then bandaged firmly on with plaster of Paris rollers, so that the knee remains exposed,

Fig. 195.



The wooden splint from above.*


Fig. 196.



The wooden splint from the side.

and is supported only by the narrow wooden bridge. The suspension-bar (fig. 197) is placed upon the anterior surface of the limb, beneath the

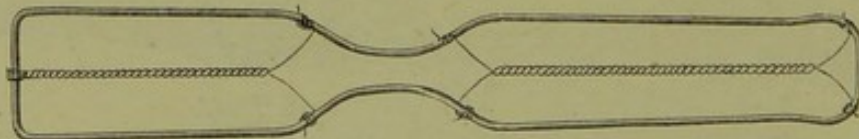Fig. 197.



The suspension-bar.

final turns of the plaster of Paris bandage, and the whole leg is suspended to a cross-bar, placed over the bed. If there are no wooden splints at hand, telegraph wire, which is always to be obtained on the battle field, will answer the purpose (fig. 198). To make the wire splint firmer, it is bandaged with a plaster of Paris roller (fig. 199).

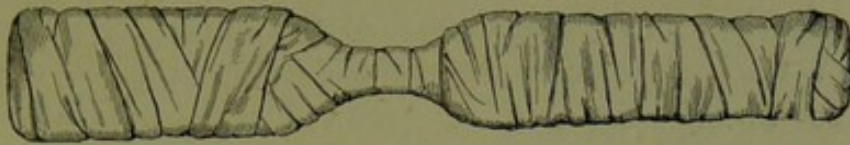Fig. 198.



Swing splint of telegraph wire.

* I have omitted the fork-like lower end, which is found in WATSON'S original splint, because it seems to me to have no special use, and only makes the splint more expensive and fragile.

Fig. 199.



The wire splint bandaged with plaster of Paris roller.

f. For *injuries of the thigh and hip joint* to keep them at rest there are used:

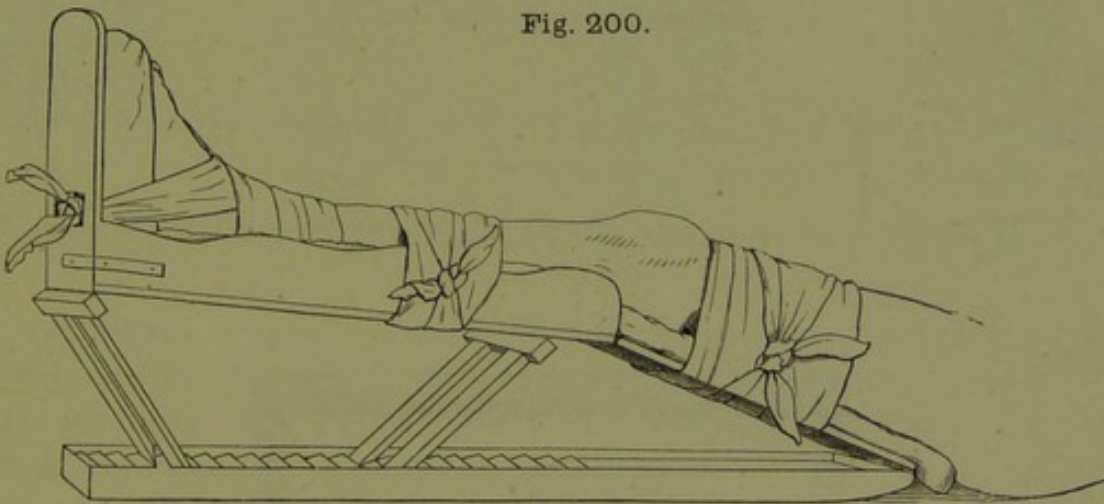
α. BONNET'S wire splints (fig. 54 and 58).

β. SCHNYDER'S cloth splints (fig. 43).

γ. Gun splint as a temporary application (fig. 70).

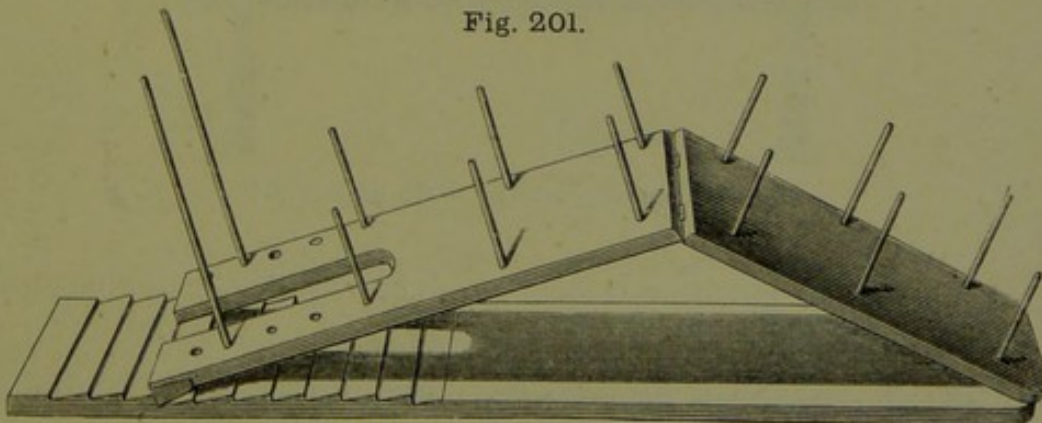
δ. The double inclined plane (*planum inclinatum duplex*), either made as in fig. 200 like a PETIT'S box splint, or a simpler one as in fig. 201, framed out of some boards and provided at the sides with

Fig. 200.



Double inclined plane.

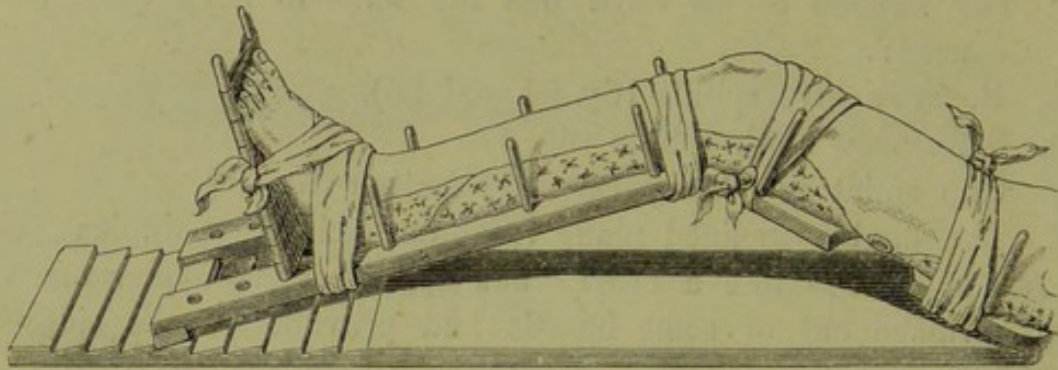
Fig. 201.



ESMARCH'S double inclined plane.

wooden pegs, by which the borders of the quilled horse hair mattress, supporting the leg, are pressed against the limb. Should there be a wound upon the posterior aspect of the limb, a piece of the splint opposite the wound (fig. 202) is removed with the saw. For the

Fig. 202.




ESMARCH'S double inclined plane.

support of the foot two longer wooden pegs are used, between which is stretched a linen bandage in figures of eight.

ε. DOBSON'S *wooden trestle* (fig. 203), which is pushed beneath the

Fig. 203.

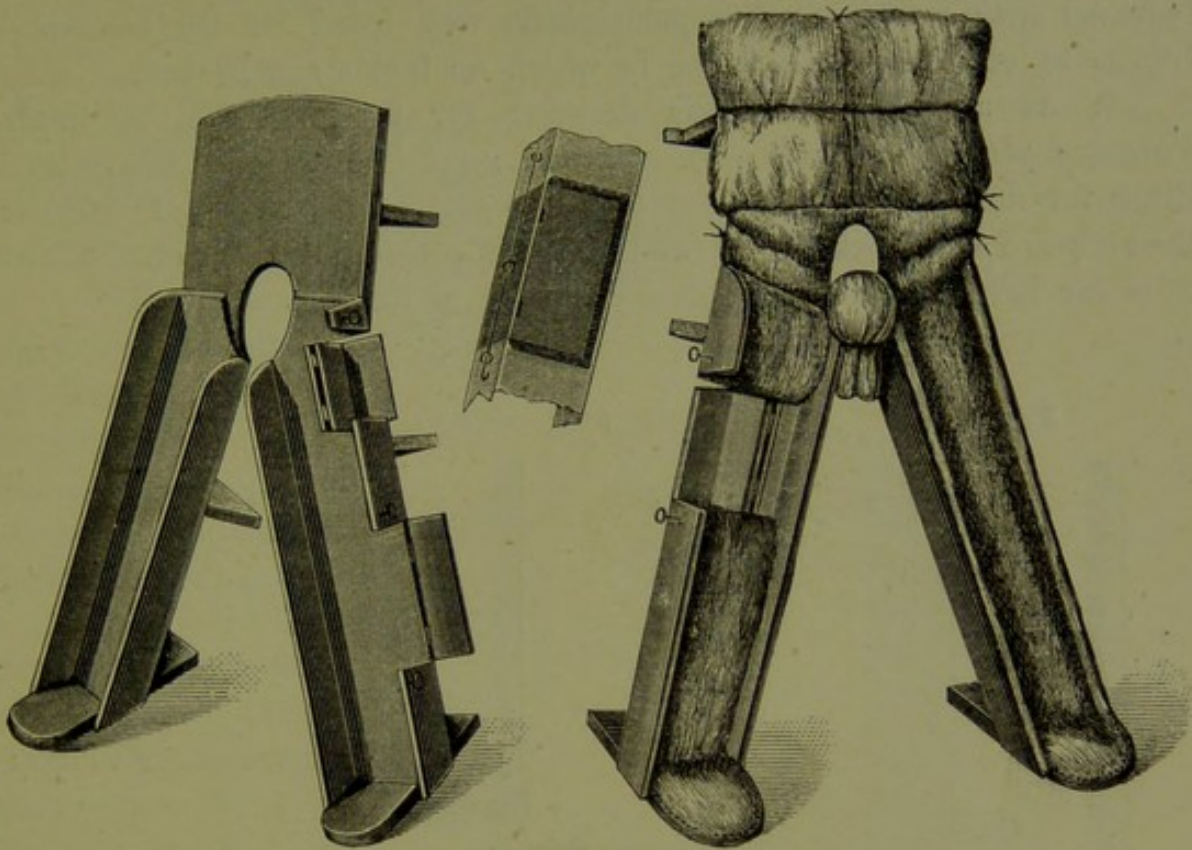


DOBSON'S wooden trestle for lifting the mattress.

mattress under the knees, can also produce a suitable double inclined plane for both legs.

ζ. RENZ'S *double box splint* (Spreizlade) is especially suitable for cases of compound fractures of the thigh, in which the upper fragment

Fig. 204.

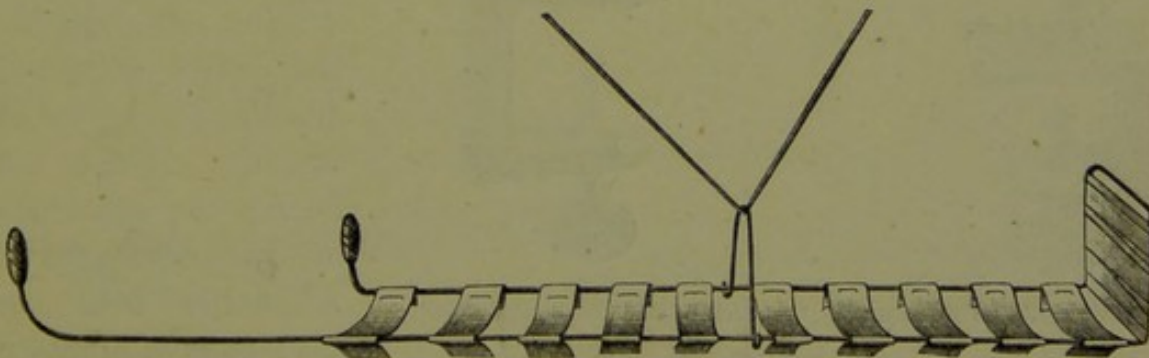


RENZ'S double box splint (Spreizlade).

of the femur is strongly abducted. The boxes can be easily made by any joiner out of boards. Wherever there are wounds, flaps are cut. For defecation the round cushion of cotton wool is removed, which closes the opening made for the perinaeum.

η. BARDELEBEN'S *wire swing* (fig. 205) for the lower extremity, in

Fig. 205.



BARDELEBEN'S wire swing for the lower extremity.

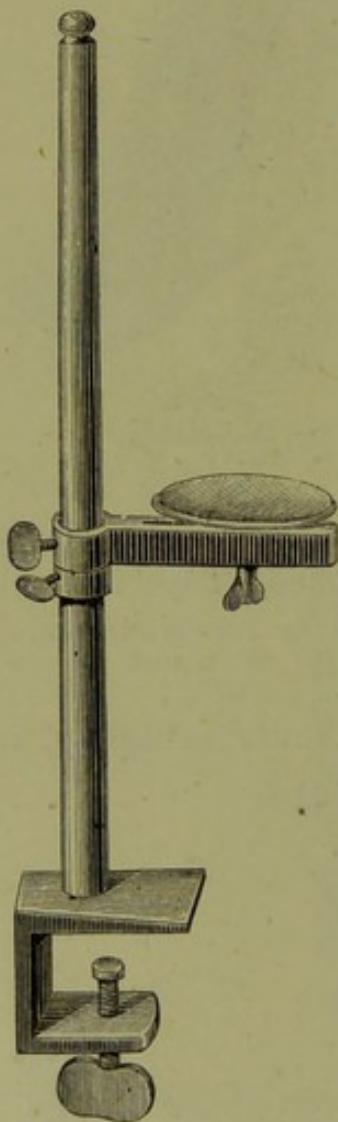
which the leg lies entirely exposed upon separate strips of bandage, fastened with safety pins, is particularly well fitted for the antiseptic treatment of extensive injuries, in which no bones are broken.

0. As a plaster of Paris dressing for fractures of the thigh, VÖLKERS *plaster of Paris with strips of wood* is above all others well fitted for field practice and for the transport of the wounded, because the strips of wood, which are inlaid, give it considerable strength, whilst it is far lighter than the ordinary plaster of Paris bandages.

If the broken thigh ought to be perfectly securely fixed, not only must the whole leg, but also the pelvis be confined in the hardening bandage.


The sacrum is first placed high on a pelvic support (fig. 206, 207, 208), in order that the bandages may be carried above it round the pelvis. Counter-extension is effected by a padded iron pole, against which the patient's perinaeum is drawn by an assistant producing extension from each foot, whilst a third assistant fixes the pelvis with both his hands. For the support of the heel during the application of the bandage, an adaptable heel support can be employed (fig. 209).

Fig. 206.



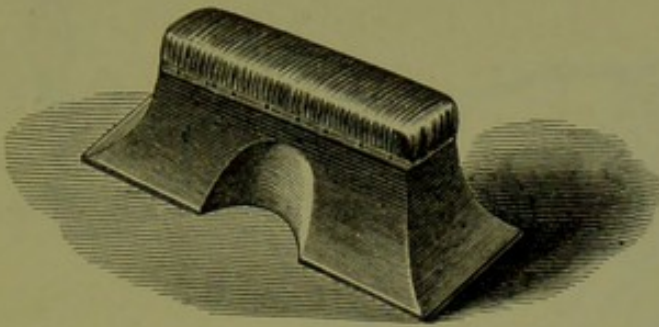
ESMARCH'S pelvic support.

Fig. 207.



BARDELEBEN'S pelvic support.

Fig. 208.

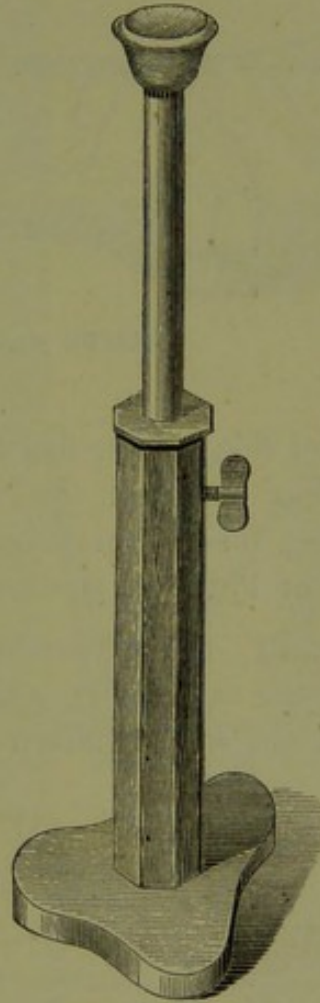


VOLKMANN'S pelvic - support.

First of all the whole leg is enveloped with cotton wool, which is then firmly applied with a plaster of Paris roller.

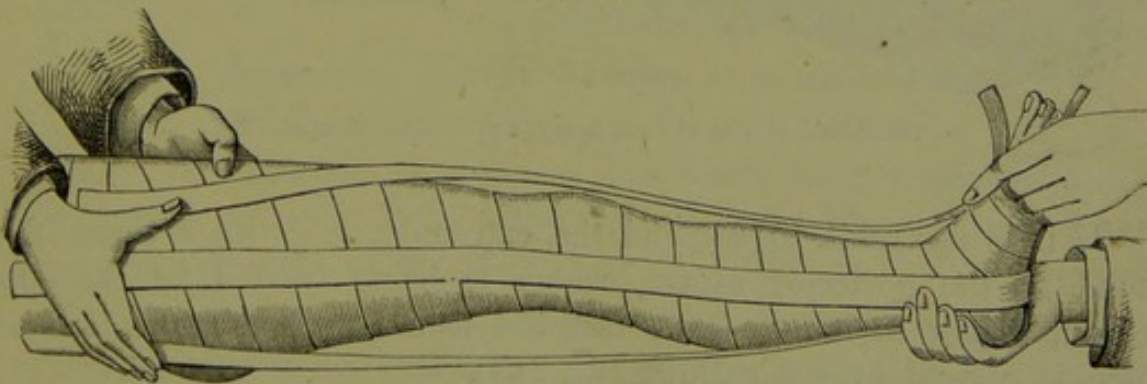
Over this are placed lengthwise in front, behind, and on both sides four strips of wood shavings (fig. 210), which are provisionally fixed, first by the fingers of the assistants, and then by the quickly ascending spiral of a plaster of Paris bandage (fig. 211).

Fig. 209.



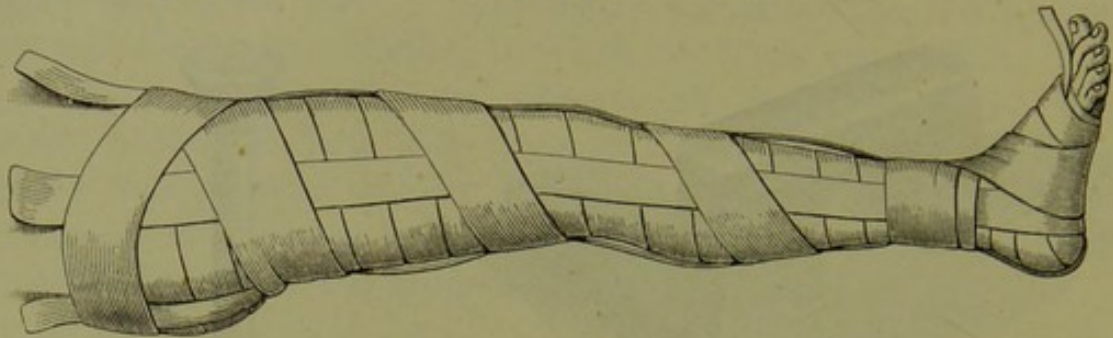
ESMARCH'S heel - support.

Fig. 210.



VÖLCKER'S plaster of Paris bandage with strips of wood. 1.

Fig. 211.

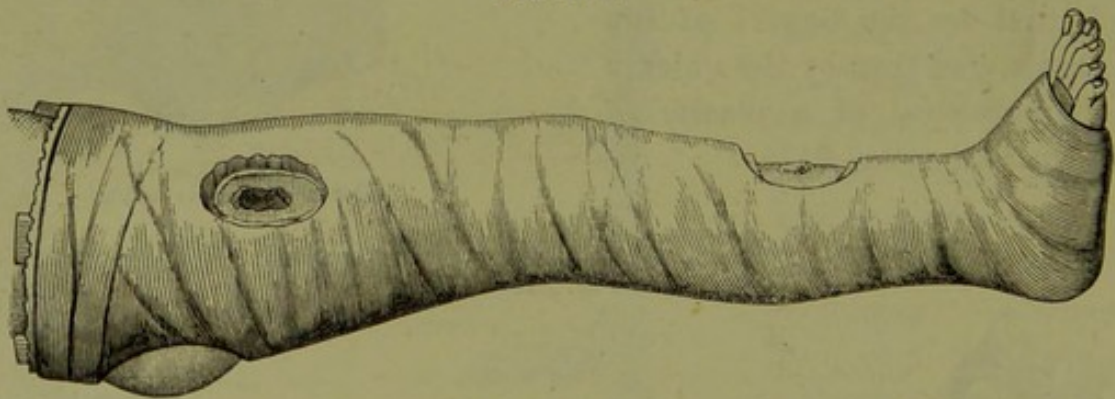


VÖLCKER'S plaster of Paris bandage with strips of wood. 2.

Over this four or five moistened plaster of Paris rollers are bandaged, till it has acquired the necessary strength, which can be increased by laying on a thin layer of plaster cream, or by rubbing in some plaster of Paris in powder with the hands previously moistened.

Finally, the projecting ends of the wooden shavings are removed with a pair of scissors, and at places, where there are wounds, windows are cut out with a sharp knife (fig. 212).

Fig. 212.

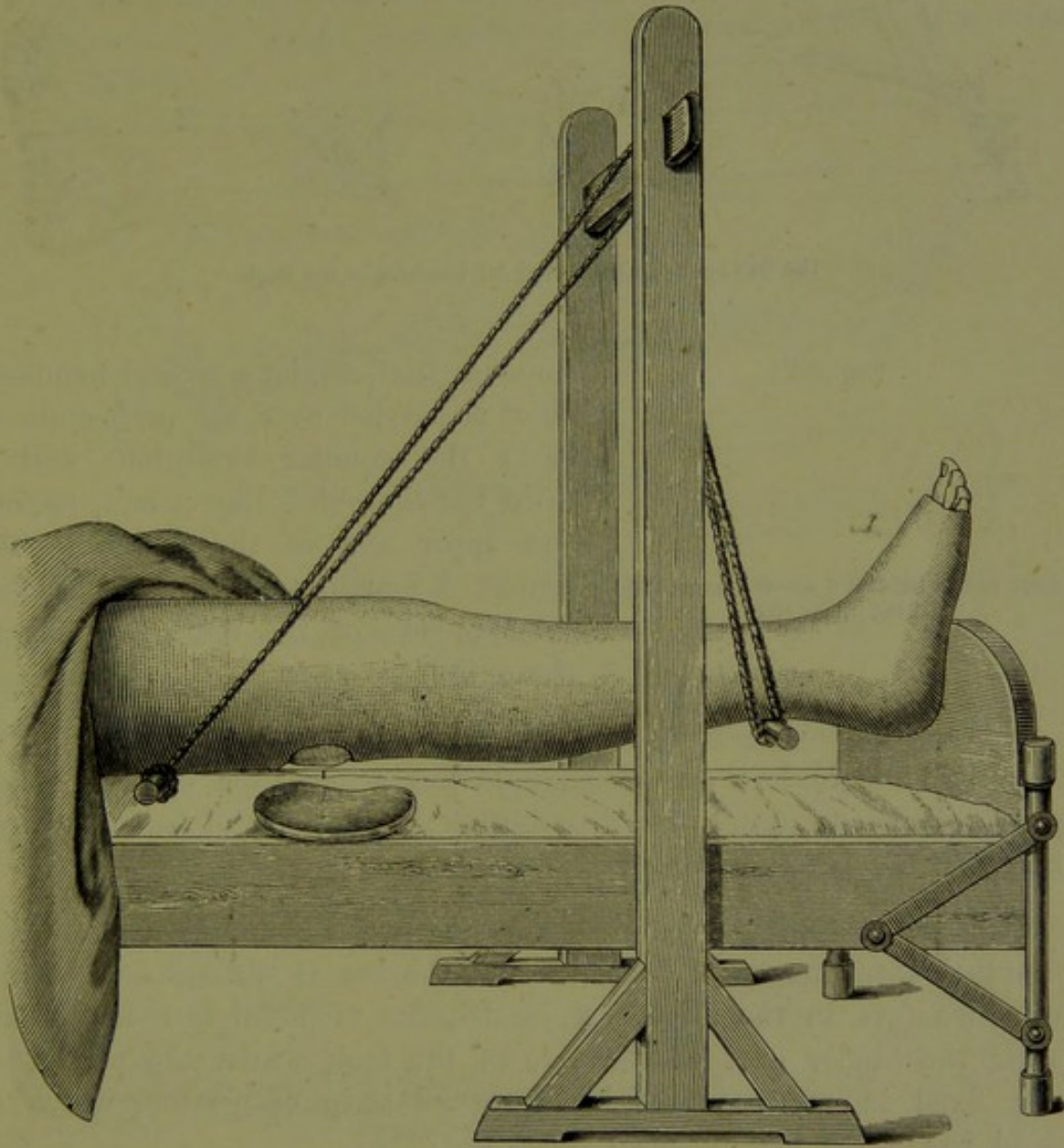


VÖLCKER'S plaster of Paris bandage with strips of wood. 3.

If it is desirable to suspend the extremity, e. g., on account of a wound on the posterior aspect, which is being treated by the open method, a pair of laths can be fastened behind with a cord attached, which is carried over a gallows (fig. 213).

The pelvis must then be placed high upon a pillow, provided with an outlet for the passage of the excreta.

Fig. 213.



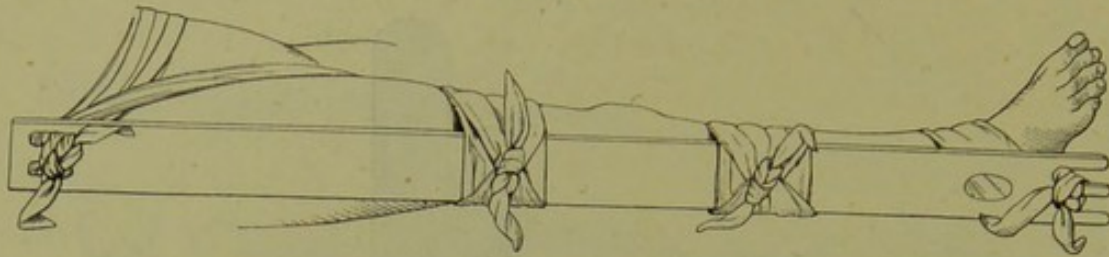
Suspension of a plaster of Paris bandage for the lower extremity.

7. The treatment by extension has lately been employed with the best results, not only in inflammation of joints, but also in simple and compound fractures of the thigh.

Among the imperfect, but simple extensions, which are always useful for the first dressing, belong:


8. The DESAULT-LISTON *splint* (fig. 214) with the lower end improved by HAYNES WALTON (fig. 215): the foot is fastened to it by a

Fig. 214.



The DESAULT-LISTON splint for fractures of the thigh.

Fig. 215.



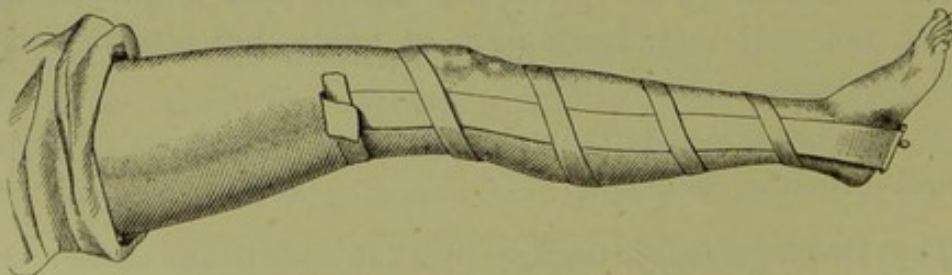
Lower end of LISTON'S splint improved by HAYNES WALTON.

handkerchief, whilst a second handkerchief is carried over the perinaeum to effect the counter-extension: and a third handkerchief, like a belt, fastens the upper end of the splint to the trunk. A fourth, and fifth handkerchief fix the side of the thigh and leg to the splint.

t. But the *treatment by extension* first came into general use, after CROSBY had taught how an extension, lasting a long time, could be made supportable by an appropriate distribution of the point of fastening over a large surface of the skin.

CROSBY'S *strapping* consists of a strong broad strip of plaster, which is applied lengthways on both sides of the leg as far upwards as the seat of fracture in the thigh. A small piece of board is then pressed against the hinder part of the sole of the foot, whilst the plaster is firmly fixed in many places by a second strip of plaster, which is carried round the leg in spiral turns (fig. 216).

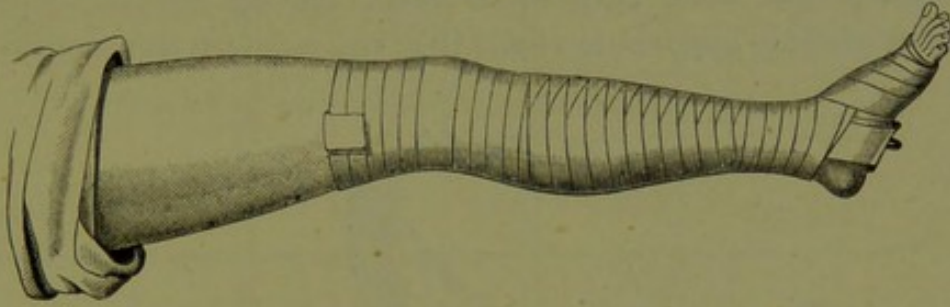
Fig. 216.



CROSBY'S strapping. 1.

The whole leg is again firmly bandaged with a linen roller from the tips of the toes almost to the upper end of the first strip of plaster, which is turned backwards over the highest turn of the bandage (fig. 217).

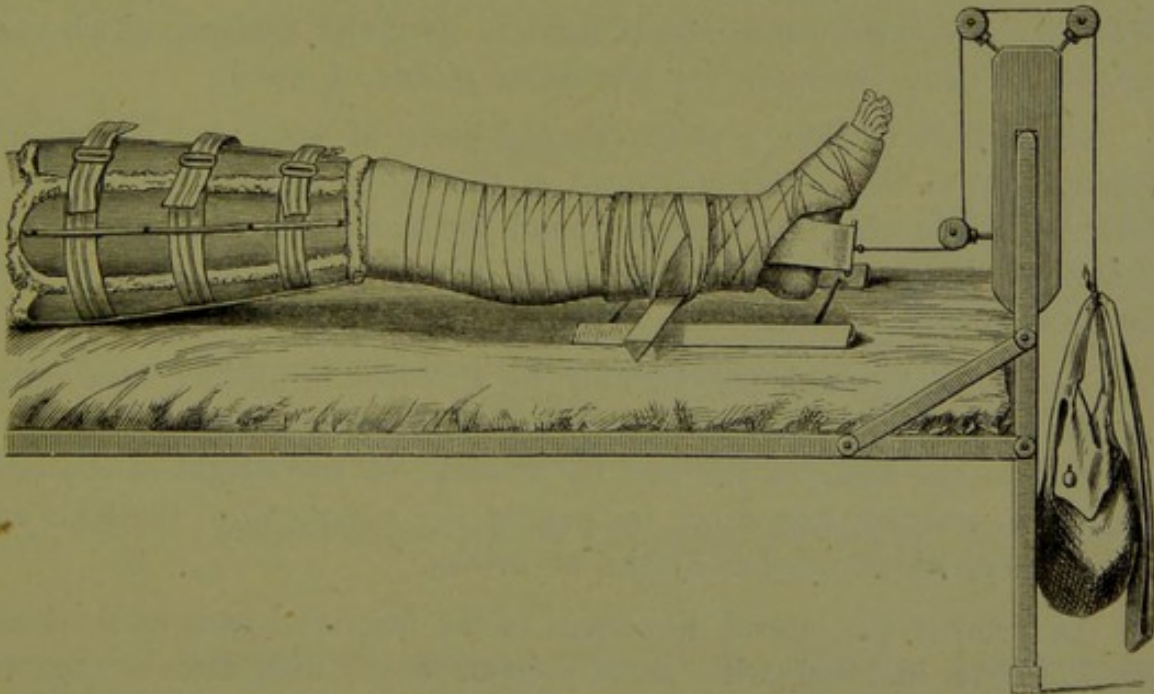
Fig. 217.



CROSBY'S strapping. 2.

A weight is then attached to the ring on the small piece of board by a cord, made to run over pulleys, by which means the leg is drawn down towards the lower end of the bed (fig. 218).

Fig. 218.



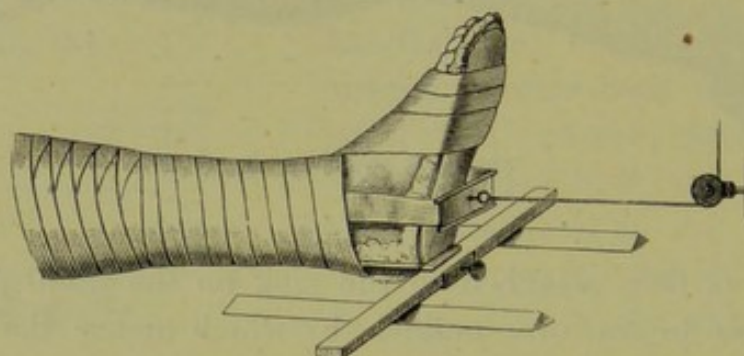
Extension by weight for fractures of the thigh.

(A satchel filled with stones here serves as a weight.)

If the leg were now left without any further support, it would sink into the mattress, and by the friction, the action of the weight would be entirely or partially destroyed. Moreover owing to the foot swinging from side to side, the fragments of the bone suffer rotation.

In order that both may be avoided, the leg should be placed on VOLKMANN'S sliding apparatus (fig. 219), viz, a short iron concave splint

Fig. 219.



VOLKMANN'S sliding apparatus (sliding foot piece).

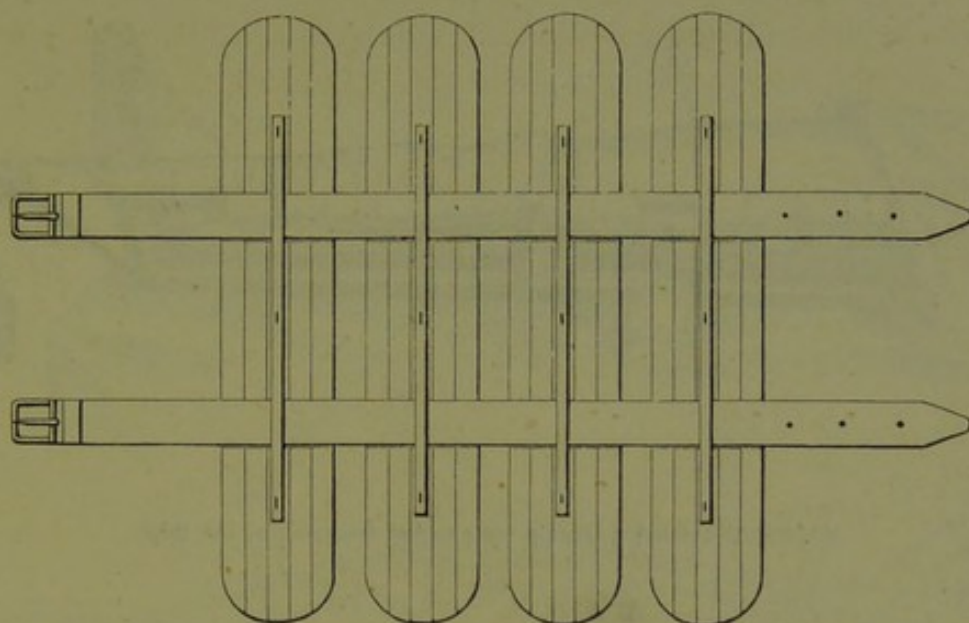
provided with an aperture for the heel, to which a foot-piece is fastened: a narrow cross lath is fixed to its under surface, which rests and slides upon two polished triangular pieces of wood.

In default of this, a prism-shaped piece of wood can be fastened transversely to the posterior aspect of the leg by means of a plaster of Paris bandage, which is carried round the foot; and this is made to slide upon two similar pieces of wood, which are united in a parallel direction to one another by iron wires (fig. 218).

Counter-extension is provided for, by a padded strap (perinaeal band) carried over the perinaeum, or by thick india-rubber tubing, which is fastened to the head of the bed by a hook; or the weight of the body is used as counter-extension, by raising the lower end of the bed, and placing beneath it wooden blocks or bricks.

To prevent the lateral movement of the fractured ends of the bone, the thigh is inclosed with short splints, e. g., with BELL'S (fig. 46) or with GOOCH'S flexible splints, which are fastened together by straps and buckles (fig. 220).


Fig. 220.



GOOCH'S flexible splints with straps and buckles for fracture of the thigh.

x. For the treatment by extension of gunshot fractures of the thigh, HODGEN has also designed a not unsuitable contrivance, which he calls an *extension-cradle* (fig. 221). It consists of a wooden splint with foot-

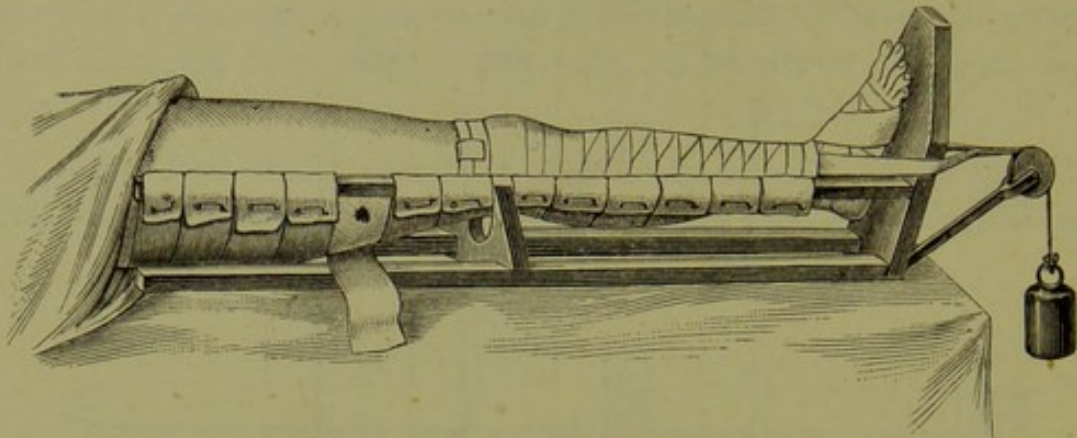
Fig. 221.



HODGEN'S extension-cradle for gunshot fractures of the thigh.

board, and between its side-rods strips of bandage are tightly drawn and fastened, upon which the leg rests, whilst a weight by means of CROSBY'S strapping performs extension (fig. 222).


Fig. 222.



HODGEN'S extension-cradle for gunshot fractures of the thigh.

λ. For simple and compound fractures of the lower extremity (fig. 223), SMITH'S anterior wire splint, which is easily made of telegraph wire,

Fig. 223.

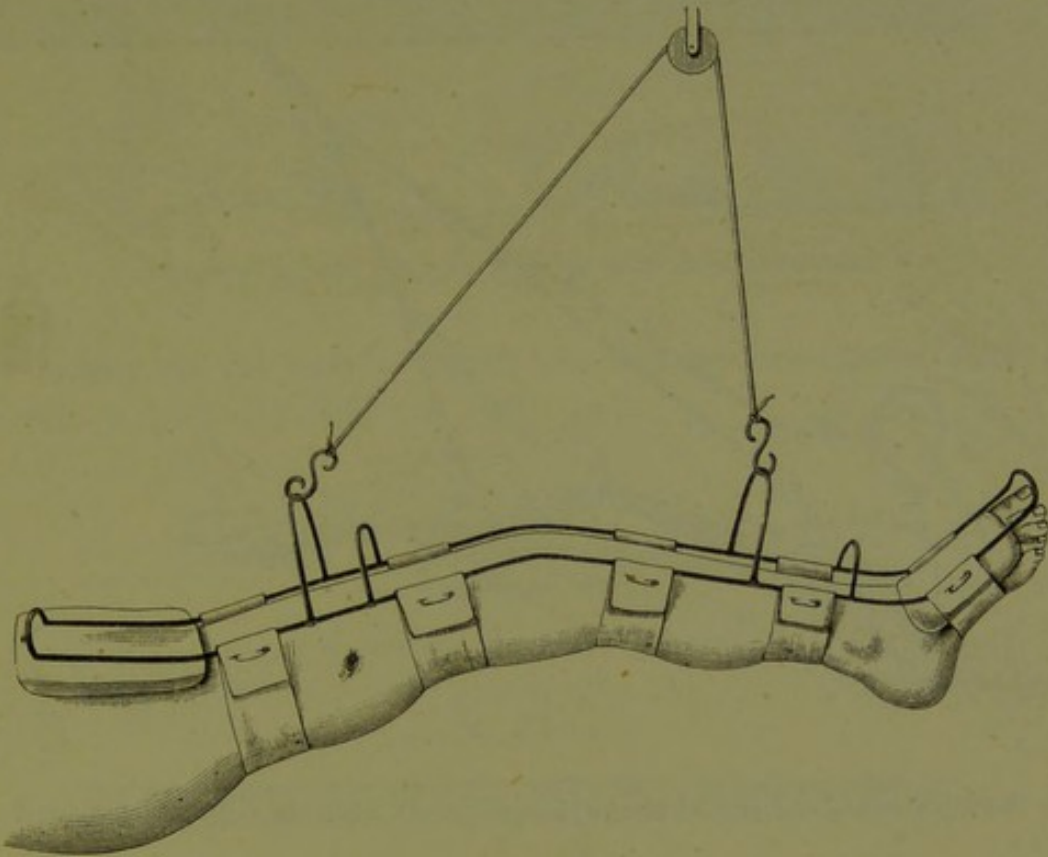


SMITH'S anterior wire splint for suspension. 1.

can also produce traction downwards by suspension from a pulley, which is placed over the leg (tibia). The wire splint is first of all slightly bent in the position of the three joints, placed upon the anterior surface of the leg, provisionally fastened with five moist strips of bandage, and suspended by means of a cord (fig. 224). The dorsum of the foot and the groin are protected from the pressure of the wire splint by small cushions.

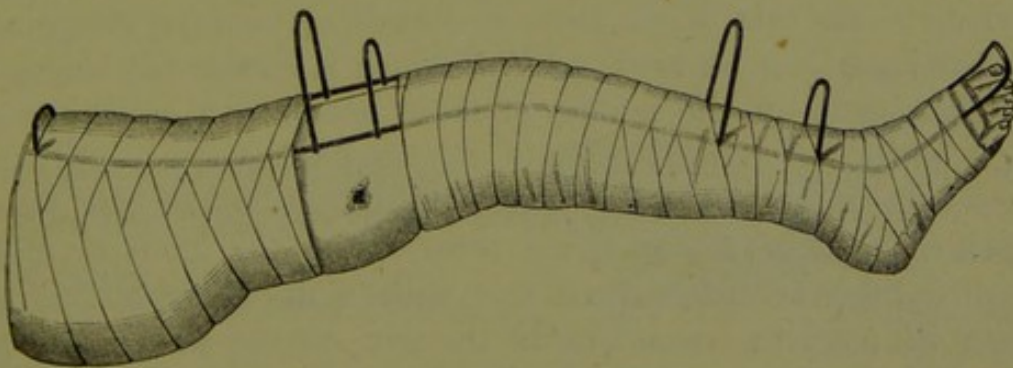
Then the whole leg together with the wire splint is bandaged over, with the exception of the wound. The wound is left exposed, or has a separate bandage (fig. 225).

Fig. 224.



SMITH'S anterior wire splint. 2.

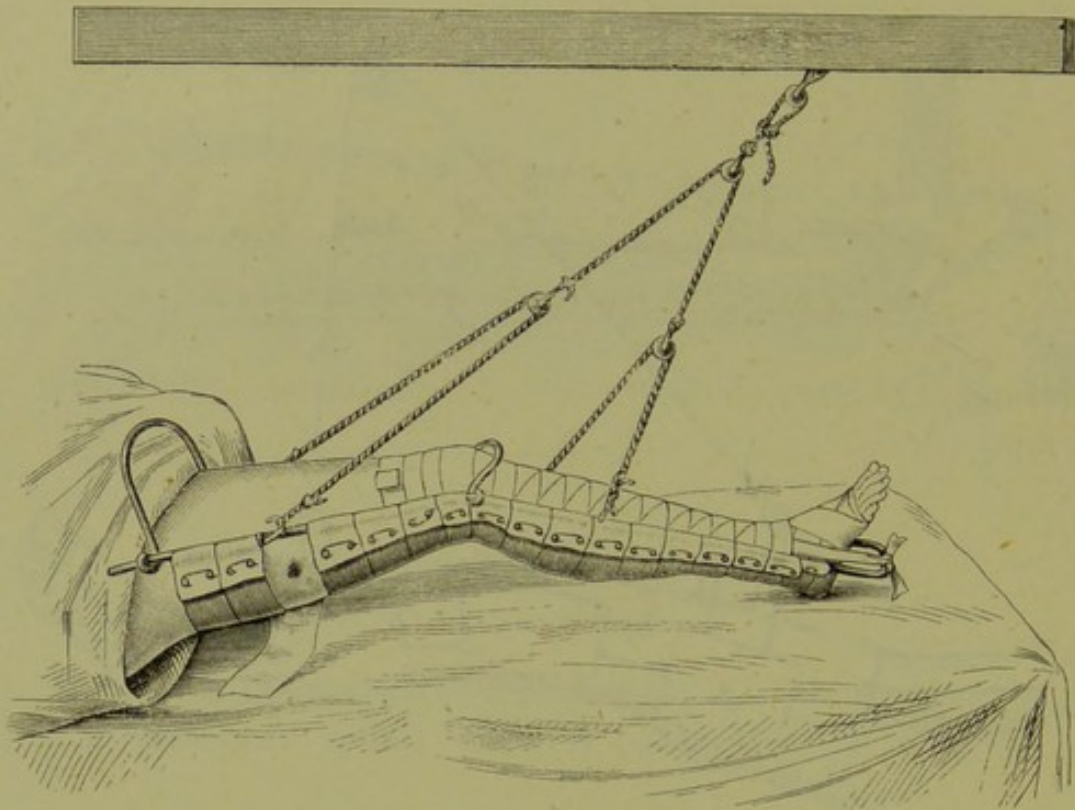
Fig. 225.



SMITH'S anterior wire splint. 3.

μ. HODGEN'S *extension swing* with BLOXAM'S improved suspension is a suitable modification of the preceding apparatus (fig. 226).

Fig. 226.

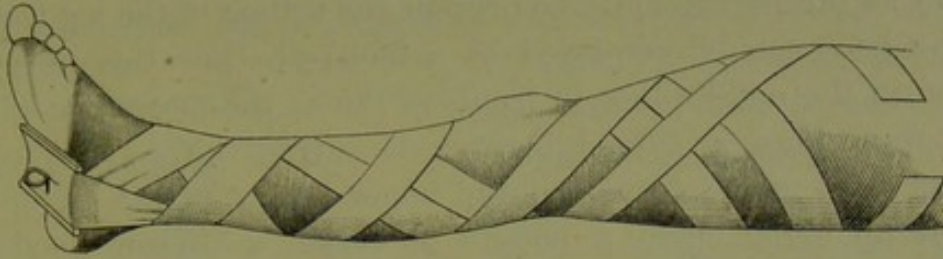


HODGEN'S extension-swing for gunshot fractures of the thigh with BLOXAM'S suspension.

v. Since the extension, either by weight or by suspension, is not well fitted for transport from the battle field, the author has proposed to make use of "*the extension by elastic rings*", which can be made in the following manner. To fasten the small board, used for extension, to the sole of the foot, in default of CROSBY'S strapping, two moist bandages can be used, each of which is double the length of the whole limb: and in the middle of these bandages a small slit is cut, through which is put the ring of the small foot-board. Thus four free ends are attached to the small board, of which two in front and two behind are wound in spiral turns round the limb (fig. 227). If the entire limb is carefully covered with a dry bandage, as far as the seat of fracture, considerable traction on the foot-board can be exercised for weeks, without the bandages slipping. If there is some starch or flour at hand, the fastening can be made more secure by being smeared with either of these materials.

For the elastic extension either the india-rubber rings, which are commonly sold, are used, or in default of these, pieces of india-

Fig. 227.



Fastening the small extension board by moist strips of bandage.

rubber tubing, in the ends of which are tied wooden knobs, each provided with a hook (fig. 228 and 229).

Fig. 228.



Knob and hook for india-rubber tubing.

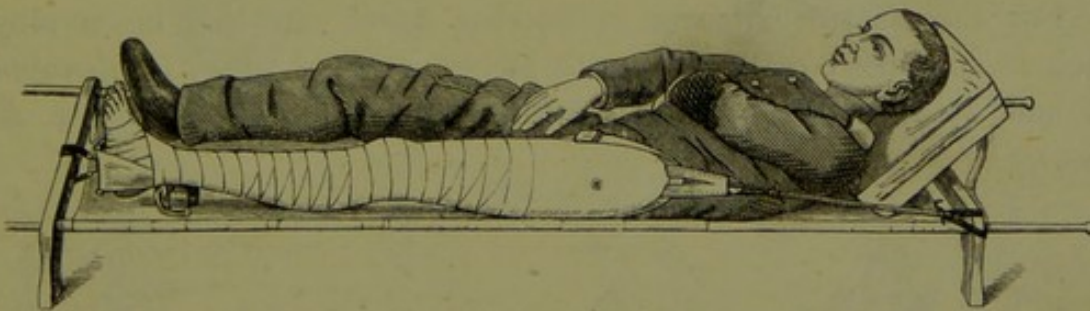
Fig. 229.



India-rubber tube with knobs and hooks for elastic extension.

For the transport of the wounded, the elastic rings can be fastened to the upper and lower end of the stretcher (fig. 230); and as a counter-

Fig. 230.

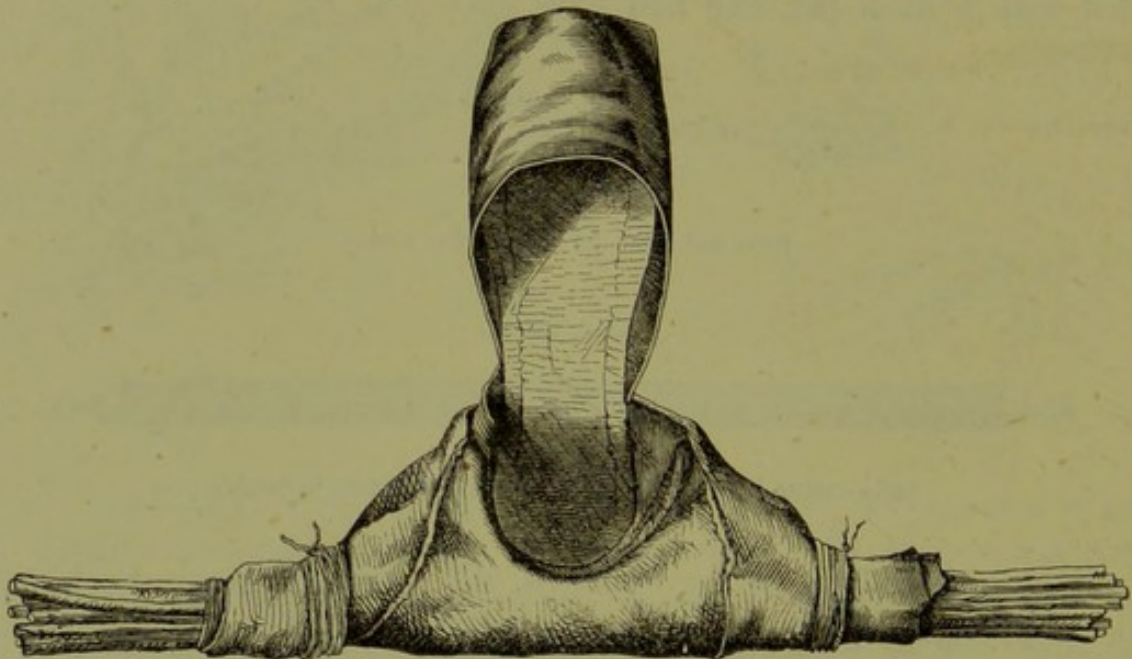


ESMARCH'S stretcher-extension for the transport of gunshot fractures of the thigh.

extension belt, one can use either the patient's waist-belt, or the trouser of the injured leg, which is cut open on the outer side, as high up as

the pelvis, and on the inner side to the middle of the thigh, and rolled up as far as the perinaeum. To prevent the rolling of the leg from side to side, the boot can be employed as a foot-rest. For this purpose it is cut open in the middle line in front, as far as the metatarso-phalangeal joints; from here a curved incision is carried on each side towards the front part of the heel, and the upper border of the leg of the boot is rolled up either upon a bundle of sticks, a narrow wooden splint, or upon the sword or bayonet of the wounded man, and fastened on both sides with some twine (fig. 231).

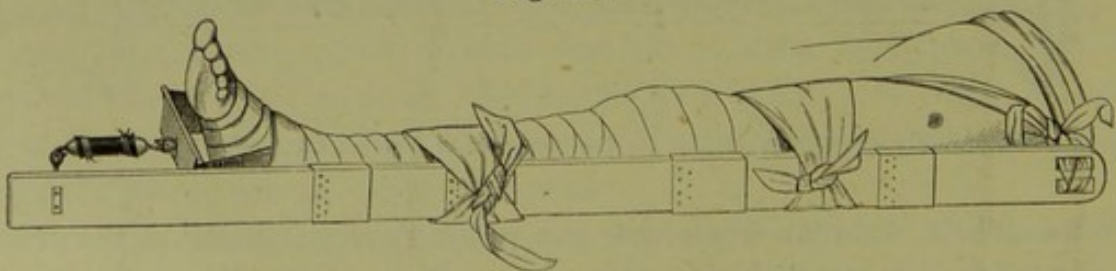
Fig. 231.



Regulation boot cut open and used as a foot-rest.

For the elastic extension a wooden splint can also be employed, which is composed of five separate pieces, each of which is provided at one end with a tin-socket for putting the splint together (fig. 232).

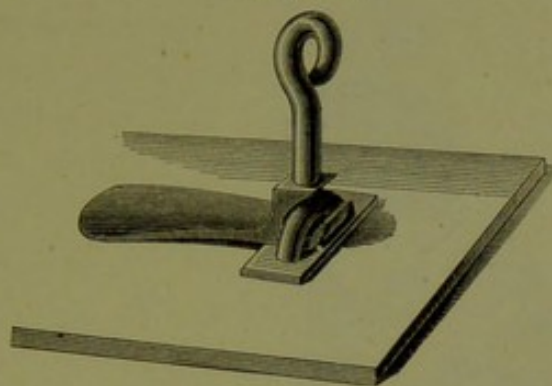
Fig. 232.



Jointed splint for elastic extension of the thigh.

Into the lowest piece, when in use, an iron hook (fig. 233) is fixed, to which the extension ring is attached. In the highest piece there are

Fig. 233.



Removable hook for the jointed extension splint.

two slits, in which the pelvic belt, as well as the perinaeal band, must be fastened by means of the second india-rubber ring. If it is unnecessary to use the trouser of the wounded leg as a belt for counter-extension, it can be folded up, and used as padding between the splint and the leg. The jointed splint with the hook and two india-rubber rings takes so little room, that

several of them can be easily taken on to the battle field in a surgical knapsack.

R. DRESSINGS ON THE TRUNK.

1. Bandaging the chest (fig. 234).
2. Figure of eight for the back (fig. 235).

Fig. 234.

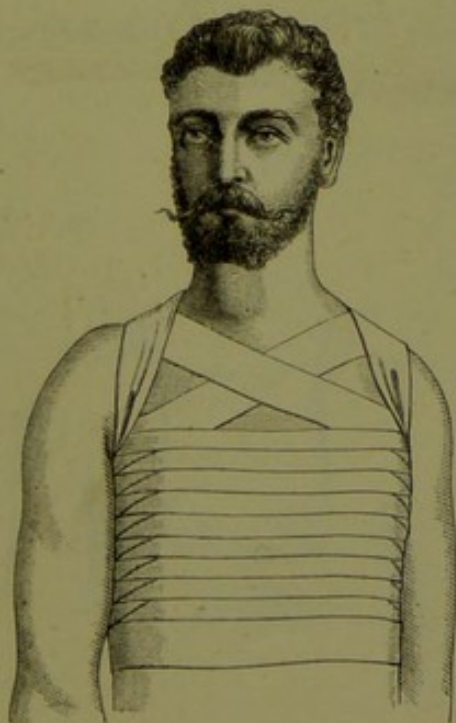
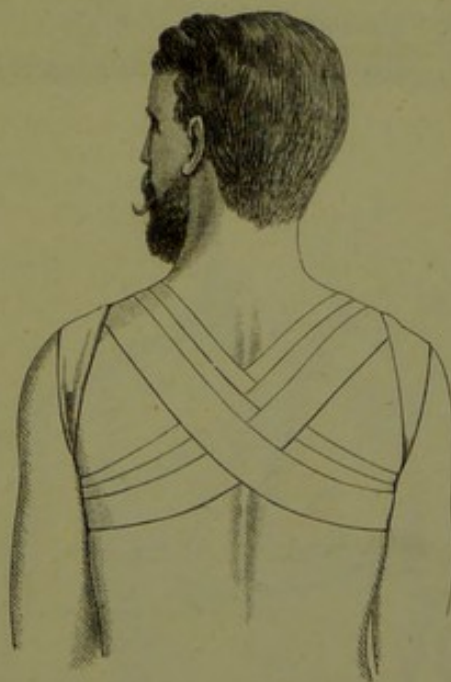

Fig. 235.



3. Belt for the chest (fig. 236).
4. Large handkerchief for the chest, from the front (fig. 237).
5. The same, from behind (fig. 110).

Fig. 236.


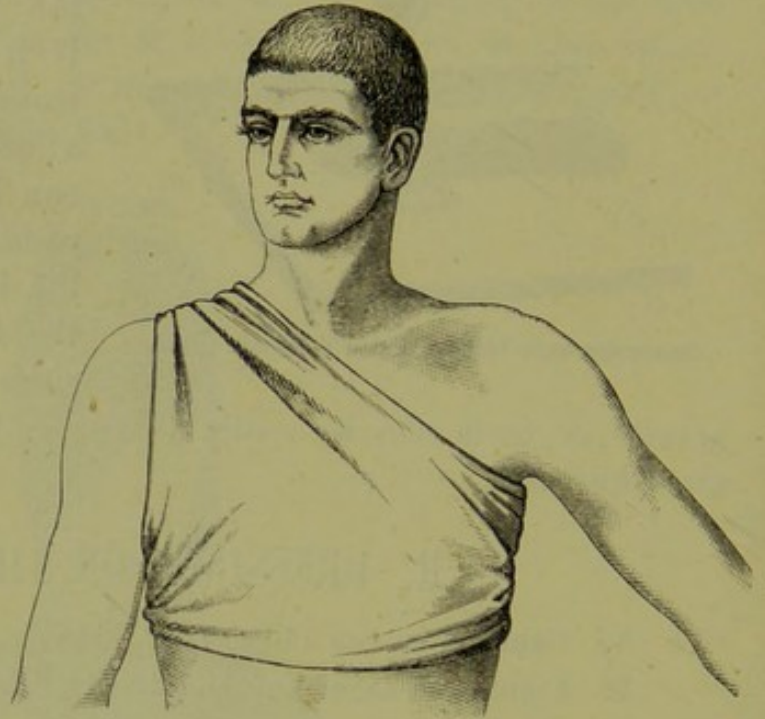


Fig. 237.



6. Handkerchief bandage for the side of the chest (fig. 238).
7. ROSE'S apron bandage for the chest (fig. 239).

Fig. 238.

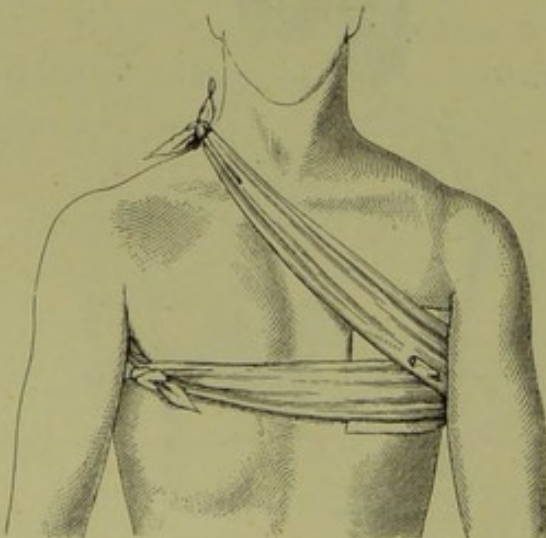


Fig. 239.

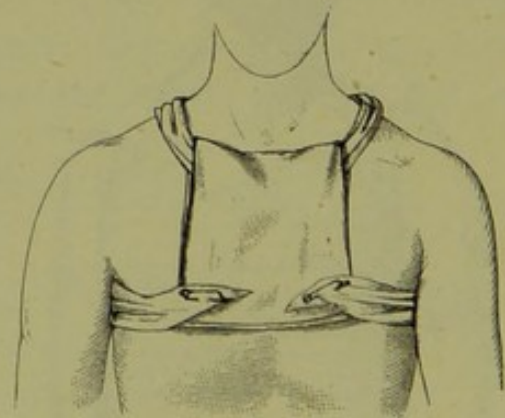
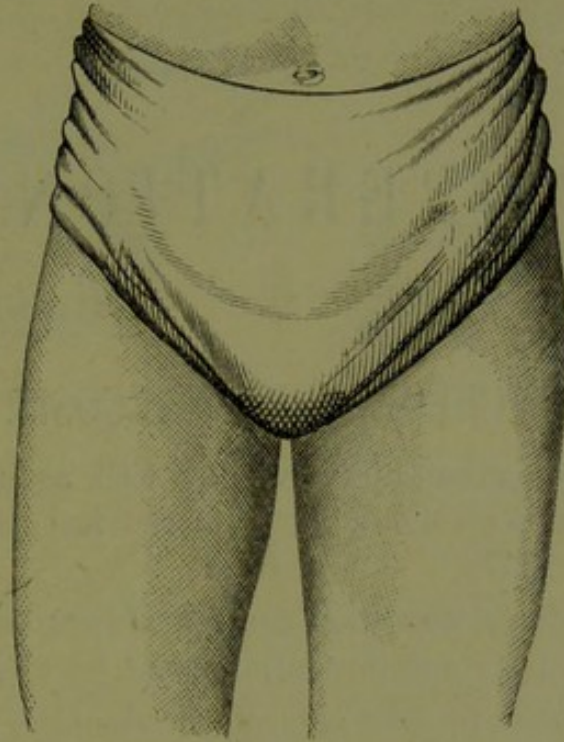


Fig. 240.



8. The large handkerchief for the pelvis (fig. 240).
 9. The handkerchief for the buttock (fig. 177).
 10. The single and double **T** bandage (fig. 35).
-

II. OPERATIONS.

A. CHLOROFORM NARCOSIS.

1. During every great operation, as well as in long and painful examinations, the patient should be rendered insensible by *chloroform inhalation* (SIMPSON 1847).

2. As this wonderful condition can not always be free from danger, *certain precautions* in its administration must be observed.

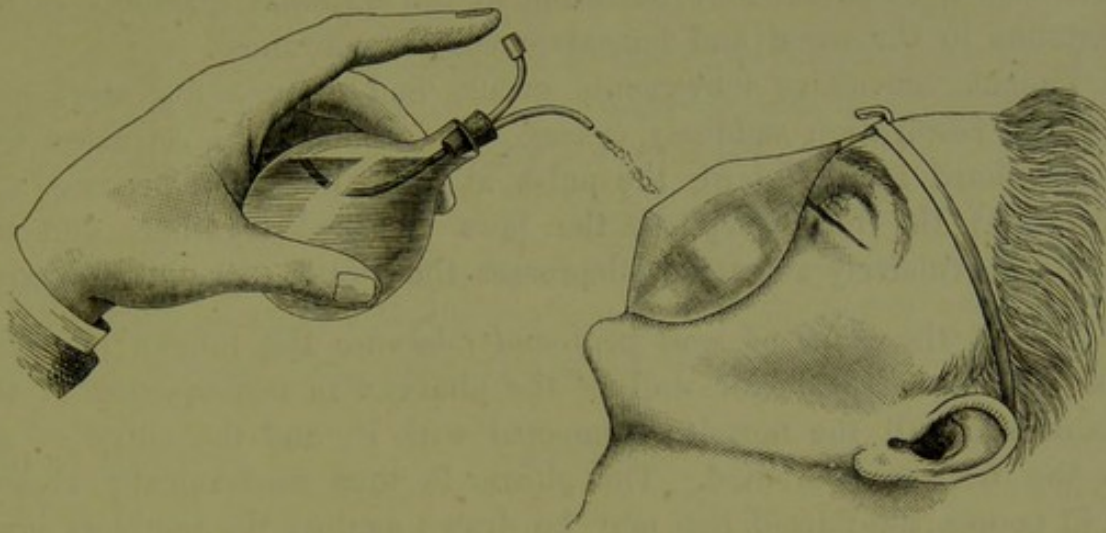
3. A person about to take chloroform *should be fasting* (taking no nourishment for three or four hours previously). During the operation he *should lie on his back or side*, not on the abdomen, because the respiration is thereby interfered with: and he should not sit up, as in this way faintness readily occurs: most of the fatal cases have taken place during trifling operations, in which the patient has been in a sitting posture.

4. *All constriction should be removed* by opening the dress, so that the neck and chest may be exposed, and the abdomen readily accessible.

5. Whilst the chloroform is being administered, *the pulse and respiration* should be under constant observation. (If a sufficient number of assistants be present, the one, who gives the chloroform, should be responsible for the respiration, the two, who hold the arms, should watch the pulse.)

6. The inhaled *vapour of chloroform* should be largely *mixed with air*. Covering the mouth and nose with a sponge or cloth, saturated with chloroform, is dangerous. A wire frame covered with flannel, on which the chloroform is poured drop by drop, is much more convenient, e. g., SKINNER'S apparatus, simplified by the author (fig. 241), can be easily packed in a leather case, together with tongue forceps and drop bottle, and carried in the pocket. With each inhalation

Fig. 241.



ESMARCH'S chloroform apparatus.

a quantity of air is drawn through the flannel. Care must be taken not to pour on too much chloroform at once, as it drops off on to the face, or into the eye, where it may excite severe inflammation.

7. Chloroform commonly produces at first an excitement like that of drunkenness — *the stage of excitement*: this is followed after a longer or shorter time by the *tolerant stage*, in which by degrees the movements cease, and together with consciousness sensibility disappears; in the cornea and nasal mucous membrane last of all. When touching these parts excites no reflex movement, we recognise that the narcosis is profound and complete.

8. Chloroform has also a *paralysing effect* upon the vaso-motor centres of the medulla oblongata, and the motor ganglia of the heart itself. The respiration and the heart's action are both impaired. The respirations are more frequent and superficial, the pulse smaller and weaker. In consequence the blood becomes dark and venous, containing more carbonic acid. The blood pressure diminishes, the temperature of the body falls, and the tissue change is interfered with.

9. If circumstances now arise, which further impede the respiration and the heart's action, the condition becomes one dangerous to life, and demands prompt and efficient assistance.

10. *Sudden arrest of the respiratory and cardiac movements* may take place during the first stage, in consequence of the inhalation of

concentrated chloroform vapour (probably due to the reflex paralysis of the vagus, occasioned by irritation of the terminal filaments of the trigeminus in the nasal and buccal mucous membranes).

Violent convulsive movements occur, and after a few stertorous gasps the respiration suddenly ceases. The abdomen is retracted and becomes hard like a board, the pulse at first slow soon becomes imperceptible, the face purplish, the jaws clenched together, and the tongue, convulsively retracted, depresses the glottis (spastic asphyxia).

11. In the *stage of most profound tolerance* the tongue may fall back against the posterior wall of the pharynx in consequence of the relaxation of all the muscles connected with it, and the entry of air into the trachea prevented. The glottis is thus mechanically closed. In old people the flaccid lips may be drawn against the toothless jaws, and act like valves during inspiration preventing the air entering, and the alae nasi may be drawn against the septum with a similar result. Under these circumstances the respiration is snoring and difficult, the color of the face blue, the blood very dark, and the pulse weak and irregular (paralytic asphyxia).

This accident is the more dangerous, because the symptoms of asphyxia are not so violent, and in a short time the whole blood, already very venous, becomes surcharged with carbonic acid.

12. The most dangerous kind of accident, that may occur during chloroform administration, and which often produces sudden death, is the *sudden arrest of the heart's action* (syncope). The pulse in this case almost immediately becomes imperceptible, whilst the respiration continues for a time, although superficial and irregular: the face becomes deadly blue, the pupils dilated and immovable, and the lower jaw drops. A state of collapse like this may occur at the very commencement of the administration of the chloroform in weakly individuals predisposed to faintness and under the influence of terror. But more frequently it is connected with the acute anaemia of severe injury which is associated with loss of blood, with chronic forms of anaemia and more especially with degeneration of the muscular tissue of the heart (fatty heart, atheroma of aorta, dyscrasia of drunkards), to which it is predisposed by the early exhaustion of its functional power.

With patients of this kind especial care must always be taken, and the heart examined before the chloroform is given. Unfortunately

fatty degeneration of the heart cannot be made out with accuracy in many cases.

13. As soon as an accident of this kind takes place the chloroform apparatus must be at once removed, and an attempt made to restore the halting respiration and heart's action.

14. *In asphyxia* the mouth should be at once opened, and the lower jaw raised with both hands, the index fingers of each being applied behind the ascending ramus, so that the lower range of teeth projects beyond the upper (partial dislocation) (fig. 242). By this

Fig. 242.



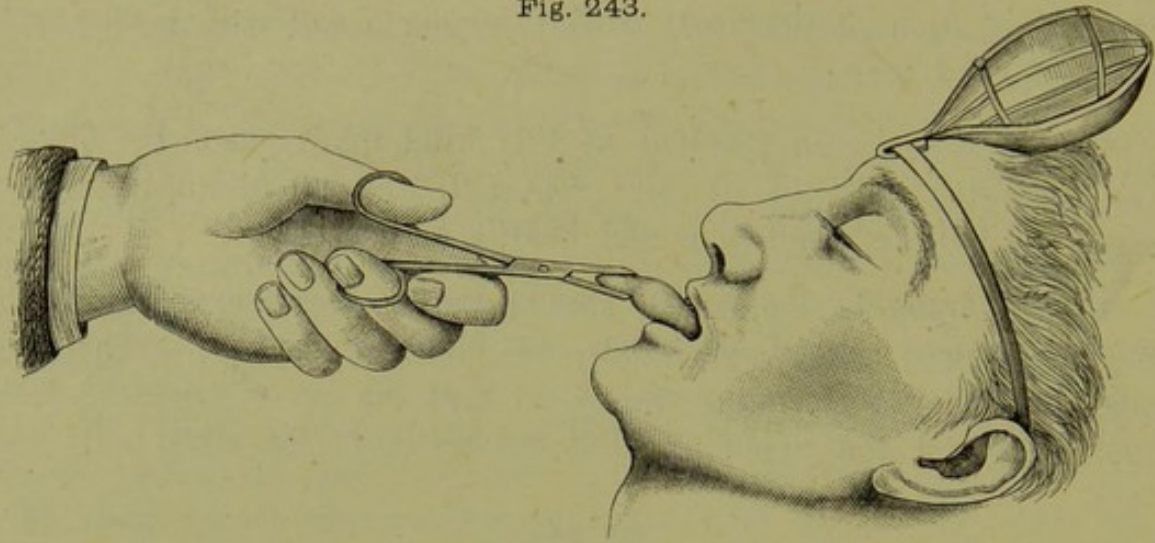
Pushing forward the lower jaw for threatening asphyxia in chloroform narcosis.

manoeuvre, the hyoid bone, the root of the tongue, and the epiglottis are drawn forwards, and the entrance to the larynx rendered free.

15. If muscular contractions prevent this from being accomplished, the teeth should be separated by a dilator, and the tip of the tongue seized with the fingers, or with the tongue forceps (fig. 243), and pulled forwards as far as possible out of the mouth.

16. If the respiration nevertheless continues difficult and is accompanied with coarse râles, it may depend upon blood or mucus in the glottis. This should be removed with a sponge, passed by vulsellum forceps to the larynx.

Fig. 243.



Drawing out the tongue for threatening asphyxia.

17. *If the breathing completely stops*, artificial respiration must be at once resorted to, preferably by SILVESTER'S method. The tongue should be kept drawn out, and standing behind the patient, the operator seizes the two arms below the elbow, pulls them up over the patient's head, and keeps them stretched out for two seconds; the arms are then brought down again, and the elbows pressed gently but firmly against the sides of the chest. These up and down movements must be repeated carefully and quietly about fifteen times to a minute, until spontaneous respiration returns (fig. 244 and 245).

18. *By stimulation of the skin*, the respiratory movements can be excited or assisted in a reflex manner. The following methods are the most effectual: slapping the chest and abdomen with a wet towel, sprinkling the epigastrium with cold water, rubbing the nape of the neck with ice or snow, injecting cold water into the nose, pushing small pieces of ice into the rectum, and exciting the nasal mucous membrane by an electric current.

19. *If syncope occurs*, artificial respiration is to be immediately resorted to. Here it is of importance to lower the head and raise the lower part of the body. This is obtained in the simplest manner by raising the lower end of the table, upon which the patient is lying (fig. 244 and 245) (Inversion after NÉLATON).

The stagnating blood is thereby assisted in its passage from the right side of the heart, and the stream from the left side encouraged

Fig. 244.

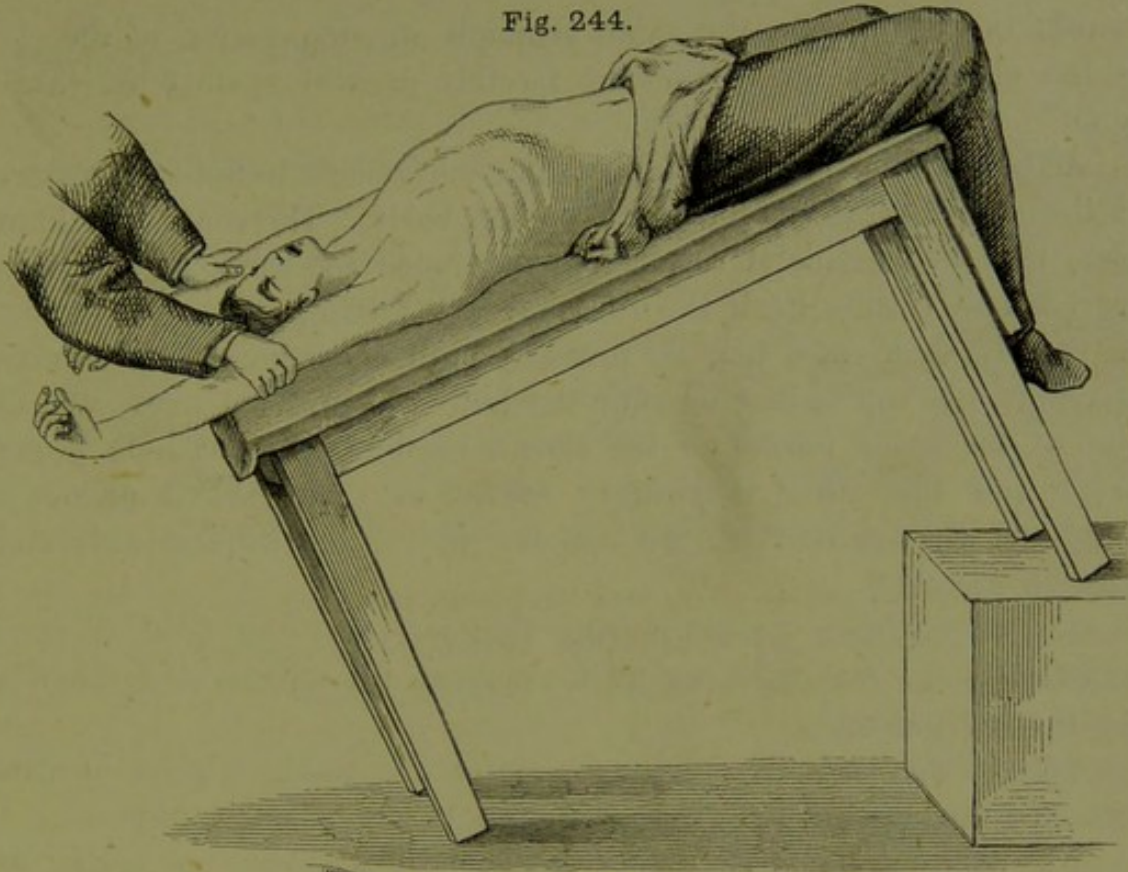
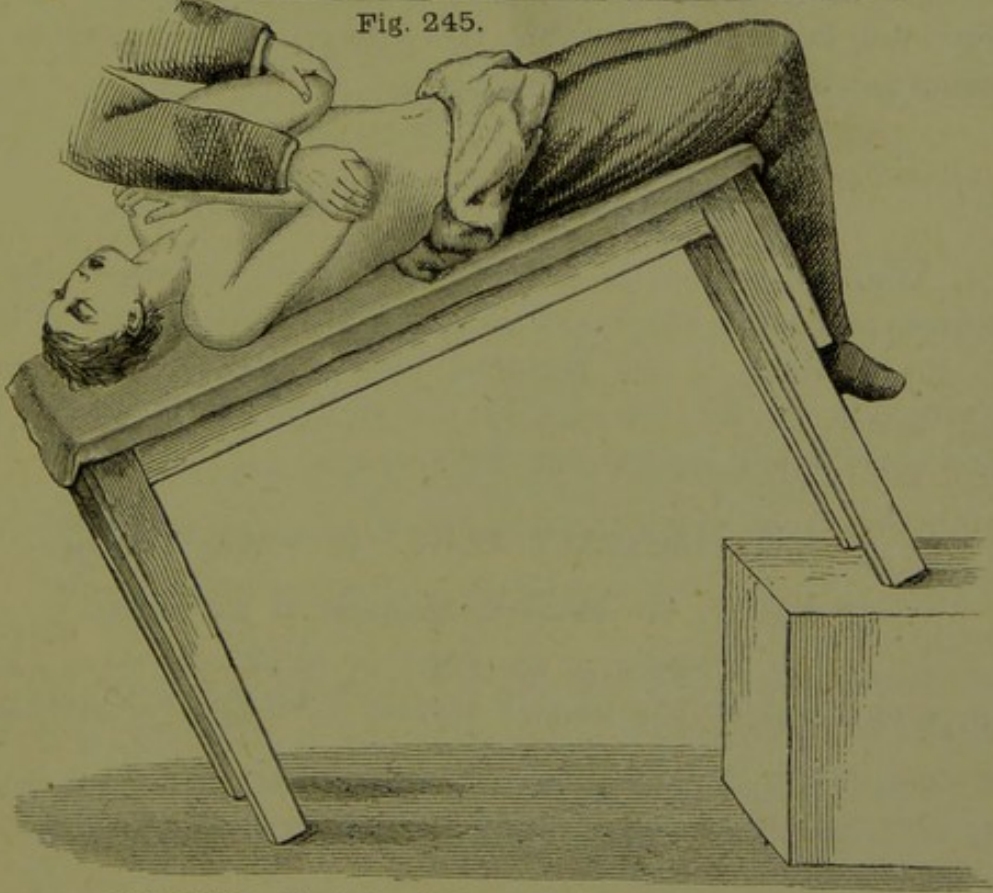


Fig. 245.



SILVESTER'S method of performing artificial respiration.

towards the brain. On the same principle in compression of the chest the left elbow must every time be forcibly pressed against the cardiac region.

Although the respiratory and cardiac movements be not soon restored, yet the efforts must not be given up too early. There are well known cases, in which artificial respiration continued for three or four hours succeeded in calling back the life that was passing away.

20. In such cases too, by pressing both electrodes of an induction apparatus one on each side into the hollow depression above the clavicle at the outer border of the sterno-mastoid, so that both phrenic nerves and the other inspiratory nerves of the brachial plexus are stimulated by the current, we can try to set the inspiratory muscles again in action.*

21. If *vomiting* occurs during the narcosis, the head is turned immediately to one side, so as to prevent the entrance of the vomit into the air passages.

22. If the patient is *much exhausted* and faint, a glass of strong wine is given shortly before the administration of chloroform.

23. If there is *much excitement* in the first stage, too much force must not be used to restrain the patient. It is better to give him a subcutaneous injection of morphia.

B. ARREST OF HAEMORRHAGE.

Violent haemorrhage from recent wounds endangers the life of the patient and must be immediately arrested; this object is best fulfilled by the ligature of the wounded vessel. But if this is not at once practicable, as for instance in the stress of work on the battle field, then some other method can be adopted.

1. TEMPORARY ARREST OF HAEMORRHAGE.

a) Firstly, the **direct compression of the wound.**

α. By the pressure of the finger or hand. In many cases this can be carried out by the patient himself. As however pressure with the

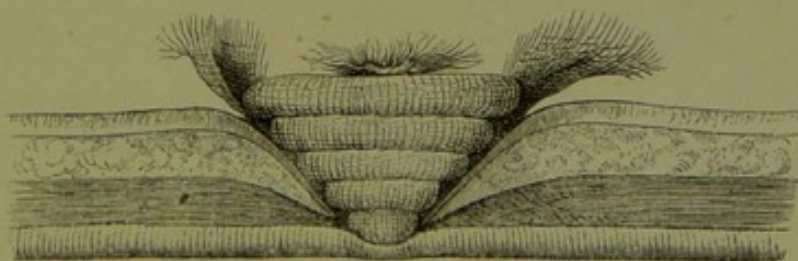
* Electro-puncture of the heart advocated by STEINER is not to be recommended; and would scarcely do more service than the direct compression of the cardiac region during the artificial respiration.

finger cannot well be continued for any length of time, as for example during transport to the hospital, it must be supplied —

β. *By a pad and bandage*, which exercise sufficient pressure upon the wound. But before such a compress is applied, if the part injured be an extremity, the whole limb must first be carefully bandaged (flannel bandage is the best) from below upwards, to prevent the diffuse infiltration of the cellular tissue with blood (bloody infiltration), which is so dangerous. A firm pad is then placed upon the wound, if possible of antiseptic material (antiseptic balls of salicylic jute fig. 19, or carbolic wadding, carbolic jute, carbolic tinder), and pressed firmly upon it by a tightly drawn bandage. A bandage made from some elastic material is the best (india-rubber, or elastic braces).

γ. If the injury in question be that of a large artery, it is safer to apply *the tampon* to the wound itself, i. e., the middle of a piece of LISTER'S gauze, or gauze soaked in carbolic oil is pressed with the finger as deeply as possible into the wound, and the cavity filled, after the finger has been withdrawn, first with small, then with larger antiseptic balls, quickly and firmly, till the last overlaps the edges of the wound (fig. 246). These are kept in position by a tightly drawn bandage, if possible an elastic one. On the arrival of the patient at the hospital, the plug must be removed, and the haemorrhage, if it should recur, is at once permanently arrested.

Fig. 246.





The application of tampon with antiseptic balls.

δ. *Styptics*, i. e., remedies, which promote the coagulation of the blood, and the contraction of the walls of the vessels, and also produce a firmly adherent scab, should only be employed as a last resource, when the haemorrhage can not be controlled by the tampon alone.

For recent wounds are generally violently irritated by these remedies, or even cauterised. In any case they are only effectual in combination with the direct compression. Only such styptics should be employed, which have at the same time an antiseptic action. To these belong, the liquor ferri perchloridi (especially in the form of cotton wool impregnated with the solution), tannin (lately much recommended as antiseptic by GRAF), creosote as Aqua Binelli (1 : 100 water), and oil of turpentine (BAUM, BILLROTH). An endeavour is made to bring these remedies in as direct contact as possible with the bleeding point, by first pressing a tampon soaked in the styptic to the bottom of the wound, and then proceeding as described in the application of the tampon.

ε. *The red-hot iron*, which formerly enjoyed a great reputation as a means of arresting haemorrhage, in no way deserves this confidence, since the eschar produced by it is readily torn off by the iron, unless the latter be at a white heat. It is especially suitable for the arrest of parenchymatous haemorrhage, such for example as is met with in hospital gangrene or in thromboses of veins (STROMEYER'S phlebotatische Blutungen). Should the cauterising irons not be at hand, they can be easily extemporised out of pieces of telegraph wire, by rolling up one end in a spiral form, filing the other end to a point, and pushing it into a piece of wood to serve as a handle (fig. 247 and 248).



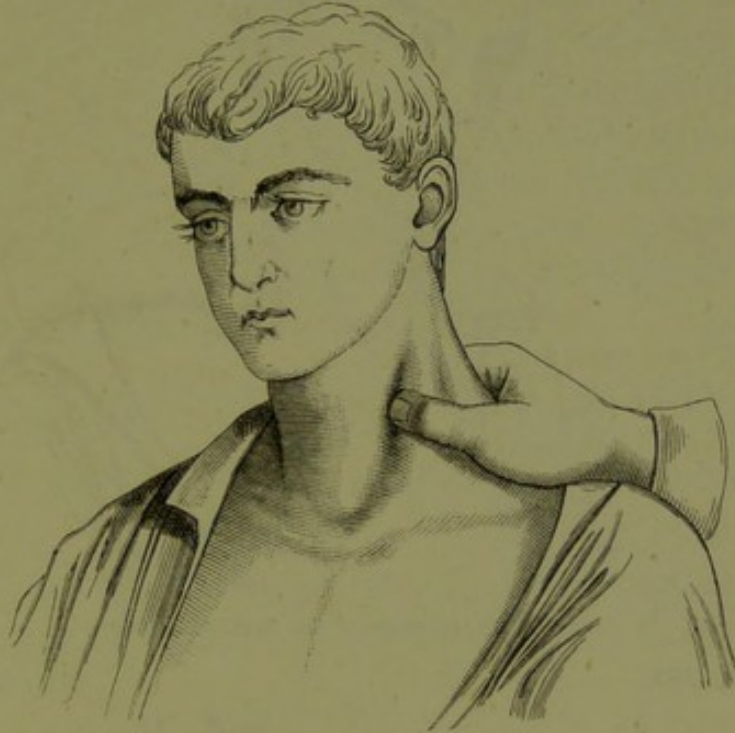
Improvised cautery of telegraph wire after BRANDIS.

b) Compression of the artery above the wound.

α. *Digital compression*. This can only be successfully carried out in those cases, in which a fixed point of resistance is afforded by the bone. The following are the principal places, where digital pressure can be employed:

1) For the *common carotid artery*, the anterior part of the side of the neck, between the larynx and the inner border of the sterno-mastoid muscle, where the finger presses the artery against the vertebrae (fig. 249).

Fig. 249.



Digital compression of the carotid artery.


2) For the *subclavian artery*, the supra-clavicular fossa, where the artery at the outer border of the sterno-mastoid, and issuing from behind the scalenus anticus, is compressed against the first rib. By drawing forwards the shoulder and with it the clavicle, the artery is more easily reached by the finger (fig. 250).

3) For the *axillary artery*, the anterior fold of the axilla, where, when the arm is raised, the artery can be compressed against the head of the humerus.

4) For the *brachial artery*, the centre of the upper-arm, where the artery at the inner border of the biceps can be easily compressed against the humerus (fig. 251).

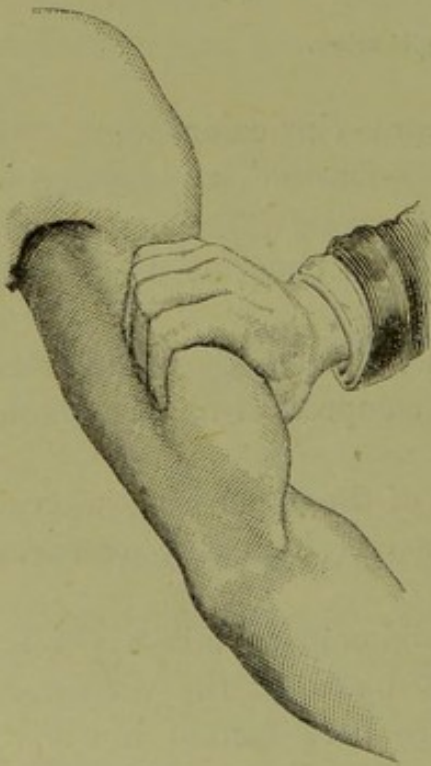
5) The *abdominal aorta*, when the abdominal walls are relaxed and the intestines empty, can be compressed against the vertebrae on a level with the umbilicus. The pressure here cannot however be borne for any length of time without a narcotic being employed.

Fig. 250.



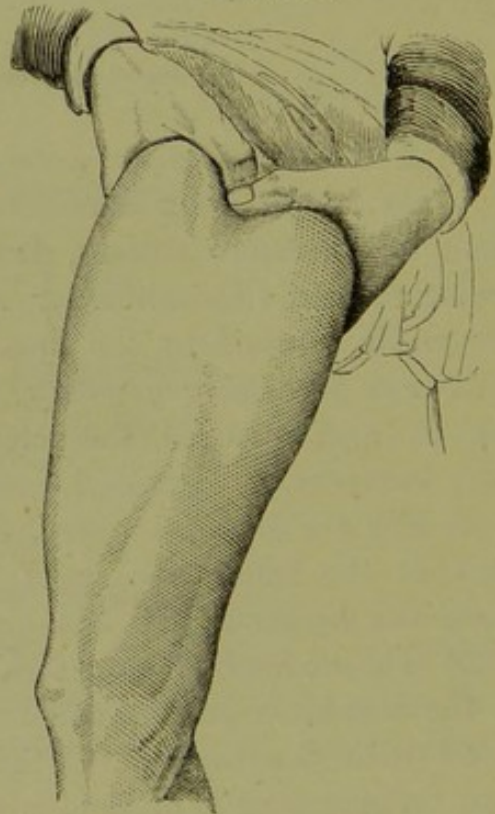
Digital compression of the subclavian artery.

Fig. 251.



Digital compression of the brachial artery.

Fig. 252.



Digital compression of the femoral artery.

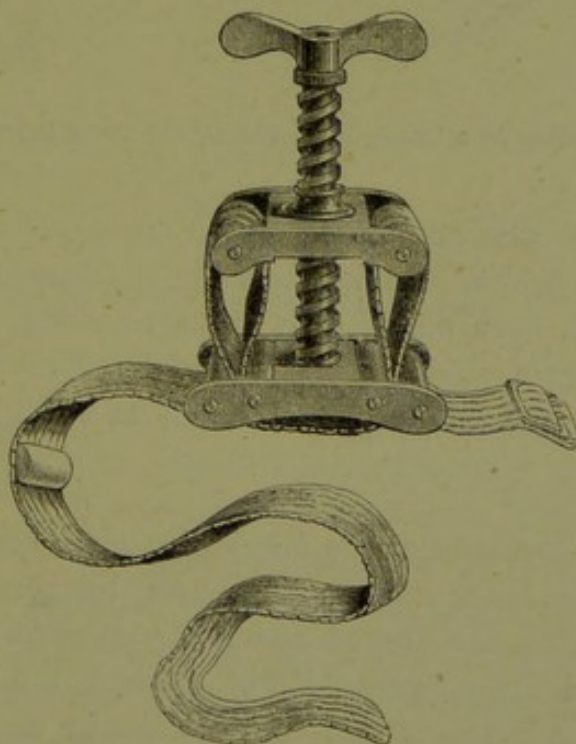
6) The same may be said of the *external iliac artery* in its upper part, where it can be compressed against the brim of the pelvis. It can be compressed more easily and for a longer time against the upper border of the horizontal ramus of the pubes, shortly before its exit from the pelvis above the middle of POUPART'S ligament.

7) The *femoral artery* is most securely compressed just below POUPART'S ligament against ileo-pectineal eminence (fig. 252). It is found in the centre of a line drawn from the anterior superior spine of the ilium to the symphysis pubis. As far as the lower third of the thigh it can be compressed against the femur; but digital compression is difficult and uncertain on account of the thickness of the intervening soft parts, at least in fat or muscular subjects.

As the digital compression for any length of time can only be carried out by a skilled and powerful hand, and as a rule cannot be continued during a long transport, surgeons have attempted to supply its place by various other contrivances. To these belong:

β. *Tourniquets*, amongst which PETIT'S screw tourniquet (fig. 253) is the one most commonly used; by this instrument the pressure, which

Fig. 253.



PETIT'S screw tourniquet.

a pad or roll of bandage exercises upon the artery, can be increased at pleasure (fig. 254 and 255).

Fig. 254.

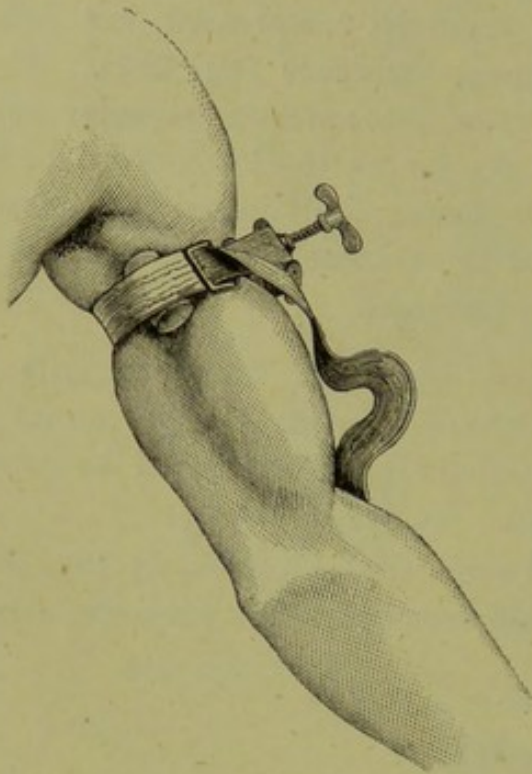
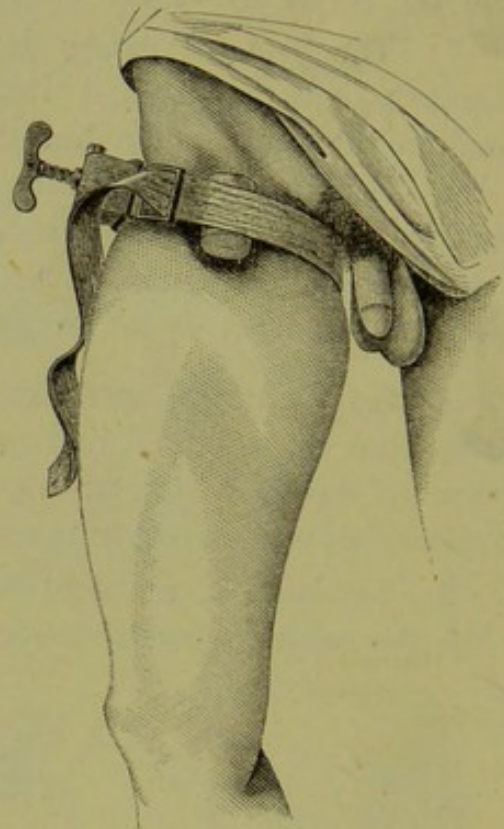


Fig. 255.

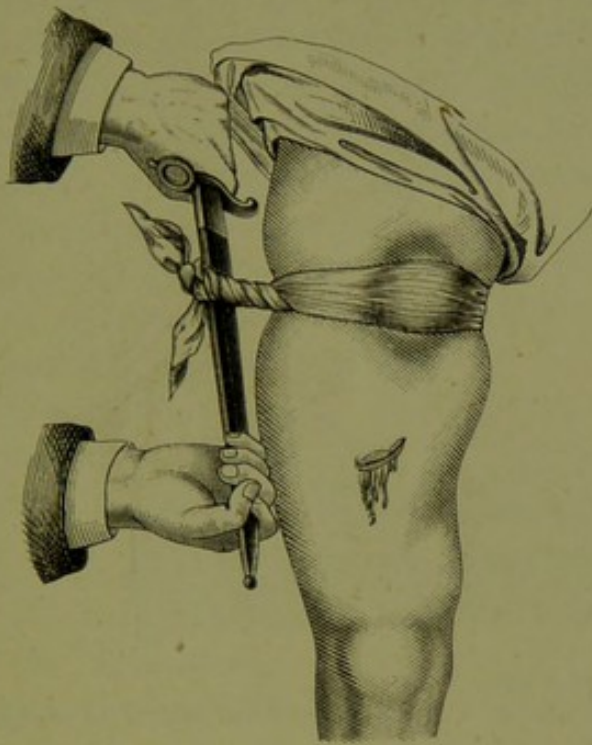


Compression of the brachial artery by a tourniquet. Compression of the femoral artery by a tourniquet.

γ. In default of such an instrument, *a tourniquet can be improvised* in this manner. A pocket handkerchief or a triangular handkerchief, in which a knot has been made, or a stone enfolded, is tied round the limb; and by turning a stick (sword, ramrod, or revolver), which has been pushed beneath the handkerchief, it can be tightly twisted together (fig. 256).

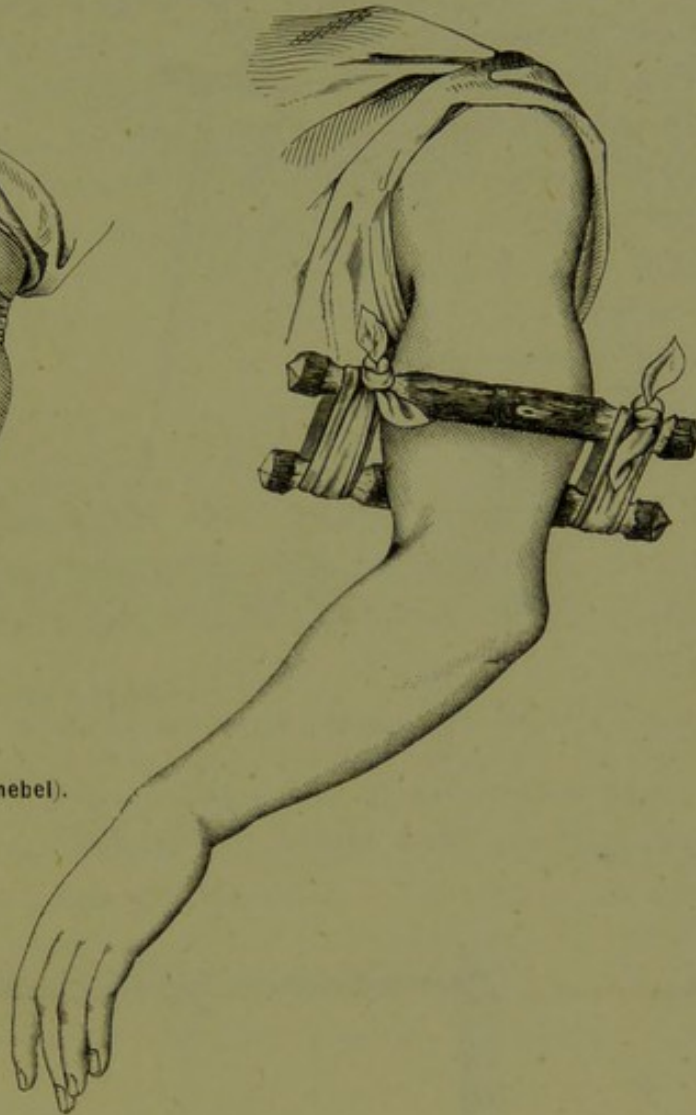
δ. For the compression of the *brachial artery*, comparatively slight pressure against the inner side of the arm by means of a *stick* is sufficient: the muscles are forced asunder partly forwards and partly backwards, and the artery pressed flat against the bone. VÖLCKERS' stick tourniquet, which attains this object, can be easily supplied by a pair of sticks and two handkerchiefs (fig. 257).

Fig. 256.



Improved torsion tourniquet (Knebel).

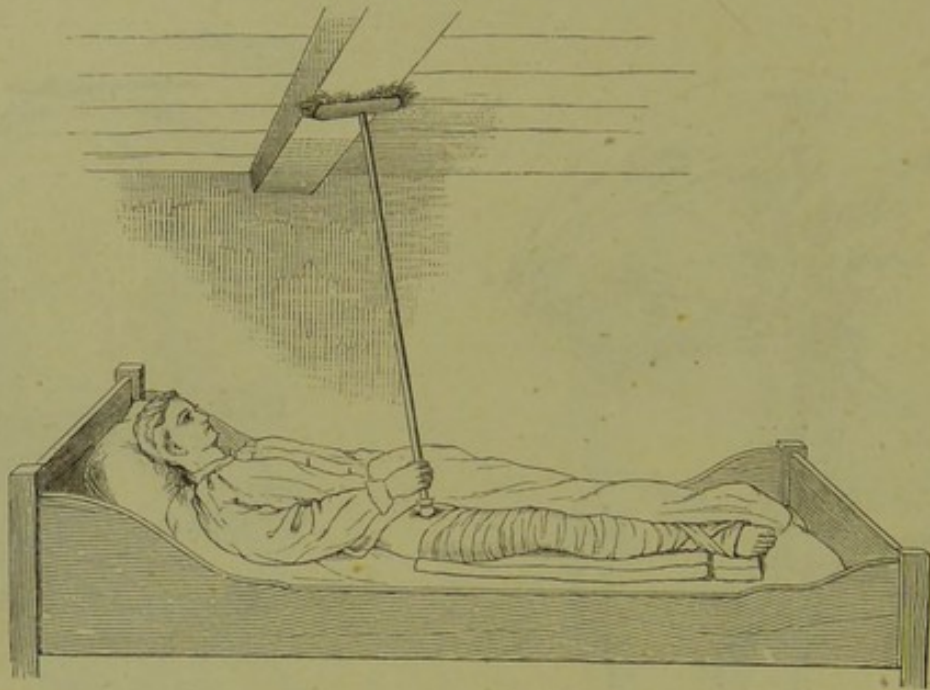Fig. 257.



VÖLKERS' (double) stick tourniquet.

ε. For *patients in bed*, and for those in whom the compression of the femoral artery has to be continued for a lengthened period, *pressure by means of a pole* can be employed. A pole (lath, broomstick, lance etc.) with a pad of linen on its lower end is pressed between the thigh, which is rotated outwards, and the ceiling, so as to exercise sufficient pressure upon the artery. The pole must be a little longer than the perpendicular distance between the ceiling and the point of compression (fig. 258).

Fig. 258.

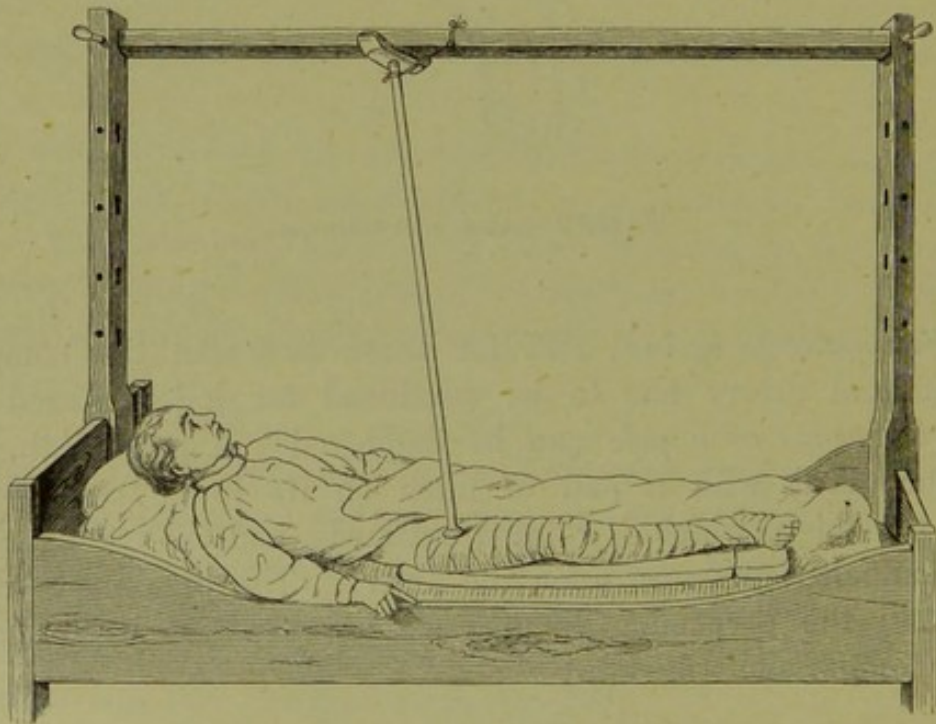


Pressure by a pole.

For the compression of the femoral artery by means of a broom, which is pressed firmly against the ceiling.

If the ceiling is too high, a cross-beam is placed over the bed, and a crutch fixed against it (fig. 259).

Fig. 259.



Pressure with a pole

by means of a crutch, which is fixed against a cross-beam.

ζ. Lastly, *forcible flexion* of the limb (ADELMANN) is to be mentioned as a means of controlling arterial haemorrhage: the trunk of the artery is so much bent, that it prevents the blood from passing through. If for example in arterial haemorrhage from the forearm or hand, the supinated forearm is strongly flexed against the upper arm and firmly tied in that position by means of a bandage or cravat, the pulse immediately ceases at the wrist. In the same way, haemorrhage from the leg and foot can be arrested for a time by forcible flexion of the knee, and haemorrhage from the femoral artery by forcible flexion of the thigh upon the abdomen. This treatment can be successfully practised in cases, where other means of arresting haemorrhage are not at hand. It is however to be observed, that a position sufficiently flexed to completely arrest haemorrhage can not be long tolerated.

η. Tying *an elastic cord* (india-rubber tubing or bandage) round the limb is a simpler and at the same time the safest means of arresting the circulation. If such a cord is wound with strong traction several times round the limb, and the ends fastened by a knot or safety pin, all the soft parts and with them the vessels are so firmly compressed, that not a drop of blood can pass through. It is evident, that an elastic cord produces a lasting effect, while the belt of PERRIN'S tourniquet soon stretches and thereby becomes inefficient. The elastic cord can also be successfully applied in any position you choose; and its employment does not require an intimate knowledge of the part, which is compressed. In urgent cases an elastic brace can be used in its stead.

c) The bloodless operation.

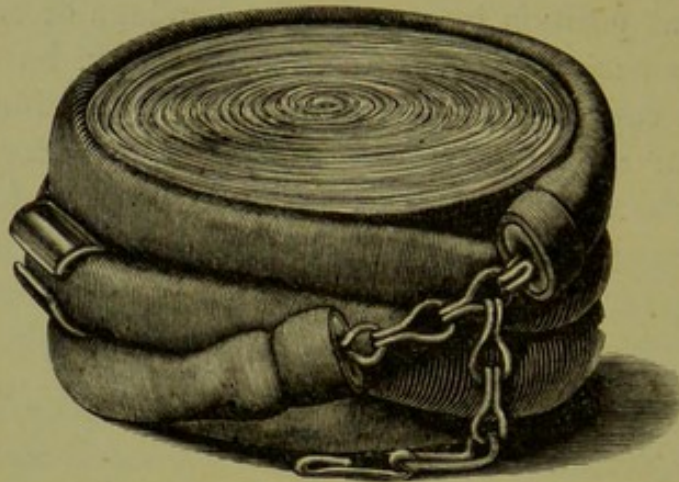
Operations on the extremities can be performed without loss of blood, if they have previously been made bloodless in the following manner:

1. After the wounds or ulcers, which may be present, have been well covered with cotton wool and some waterproof material (varnished paper), the limb is firmly *bandaged with an elastic roller* from the tips of the fingers or toes upwards, till it has reached beyond the site of operation: by this means the blood is completely driven out of the vessels.

2. Where the bandage ends, *an india-rubber tube* (elastic ligature) is wound with moderately strong traction several times round the limb,

so that no more blood can pass through the arteries. The ends of the tube are fastened together by a knot, or by a hook and chain. (Plate I, fig. 2 and fig. 260.)

Fig. 260.



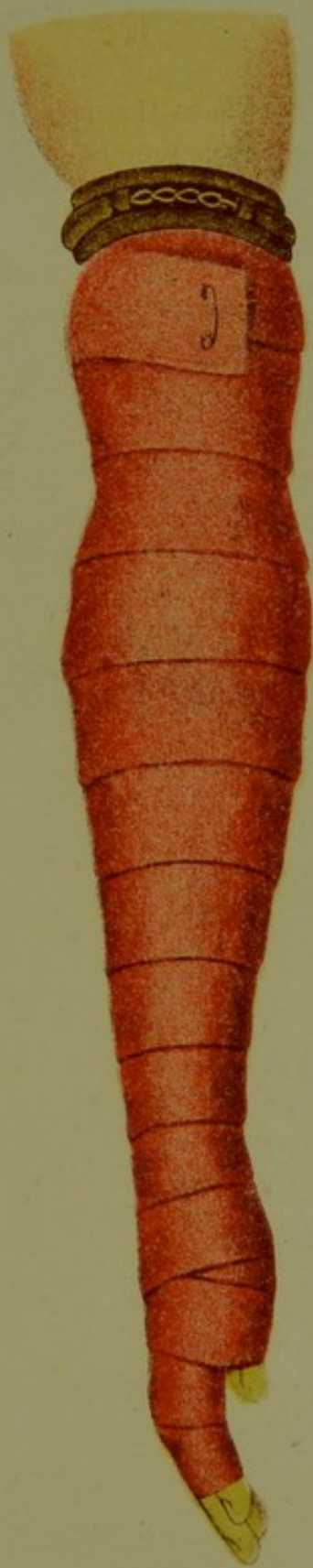
ESMARCH'S apparatus for the bloodless operation.

3. The arteries can also be completely compressed in most cases by an *elastic bandage*, firmly applied in many circular turns, and at the end fastened with a safety pin (v. LANGENBECK'S Schnürbinde). (Plate II, fig. 1.)

4. Then the *first elastic bandage is taken off*. If the circulation has been effectually cut off, the limb exhibits a completely blanched appearance like that of a dead subject, and any operation can be performed without loss of blood just as on the dead subject. (Plate I, fig. 3. Plate II, fig. 1.)

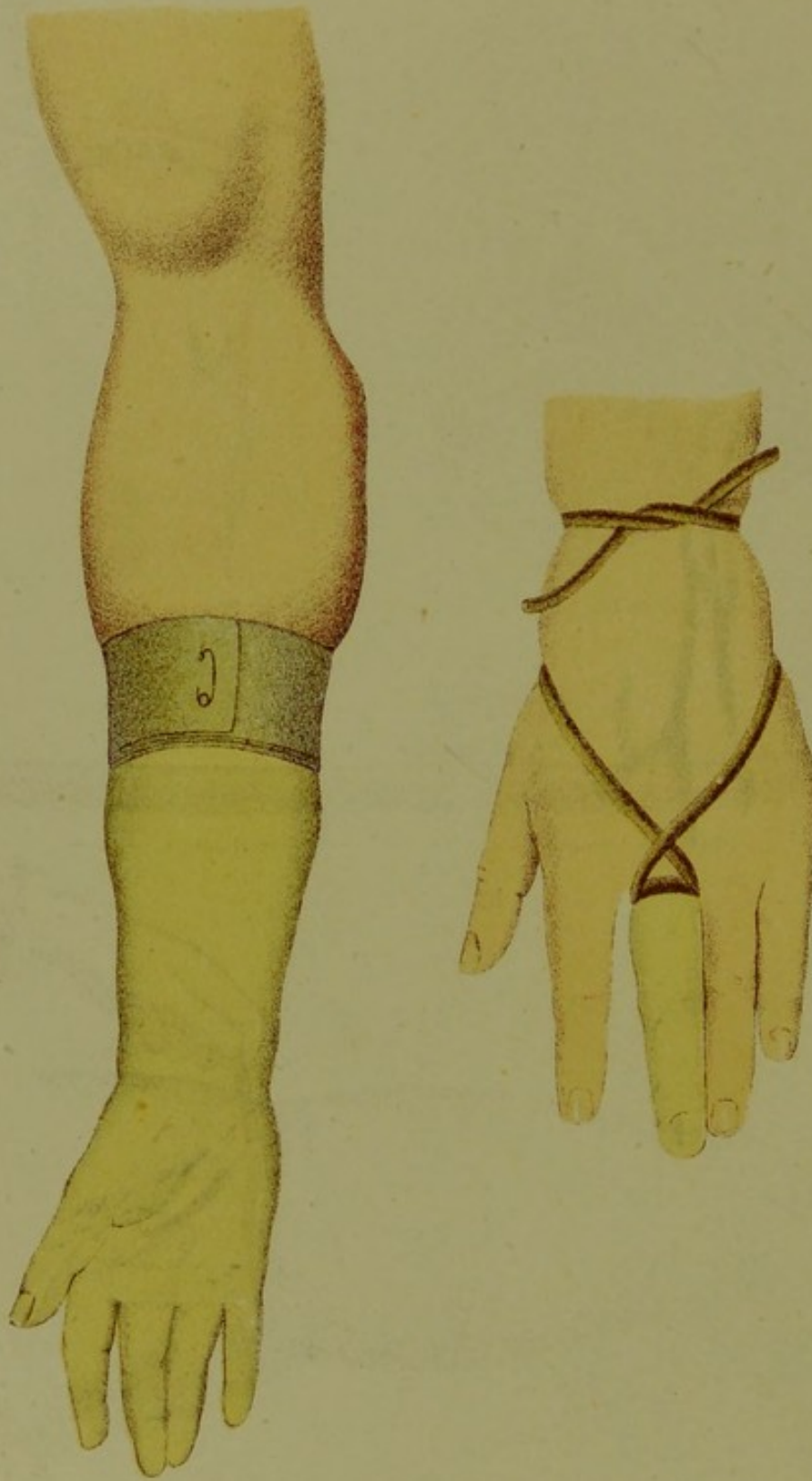
5. Parts which contain *unhealthy pus* must not be firmly bandaged, for infecting matter may thereby be driven upwards into the cellular tissue, and into the lymphatics. In such cases one must be satisfied with raising the limb on high for a few minutes before applying the bandage, so as to diminish the amount of blood in the vessels (LISTER).

6. Instead of the chain and hook a *clasp* can be used for fixing the ends, i. e., a cleft ring of the diameter of the tube or ligature employed, through the cleft of which the stretched ends can be easily pressed.









If after the traction one slightly slackens, both ends of the tube or ligature are firmly squeezed against each other (fig. 261—264).

Fig. 262.

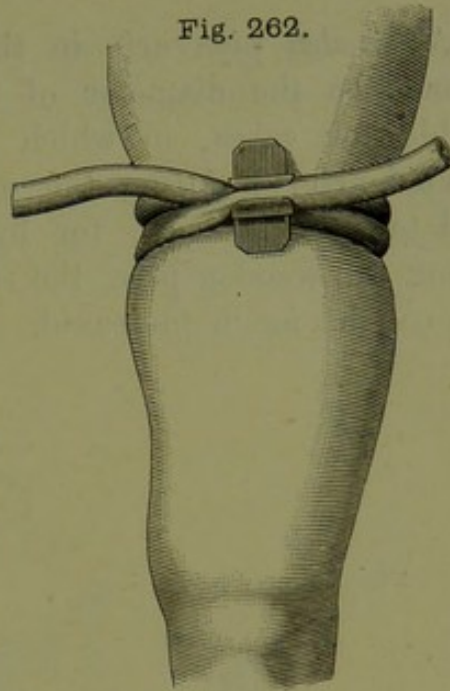

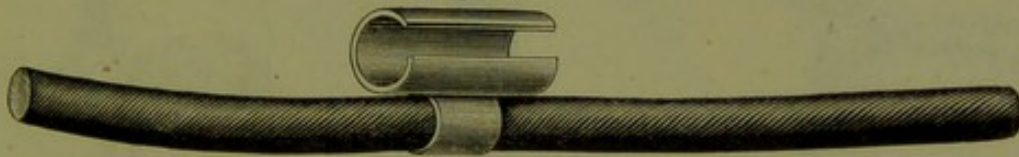


Fig. 261.



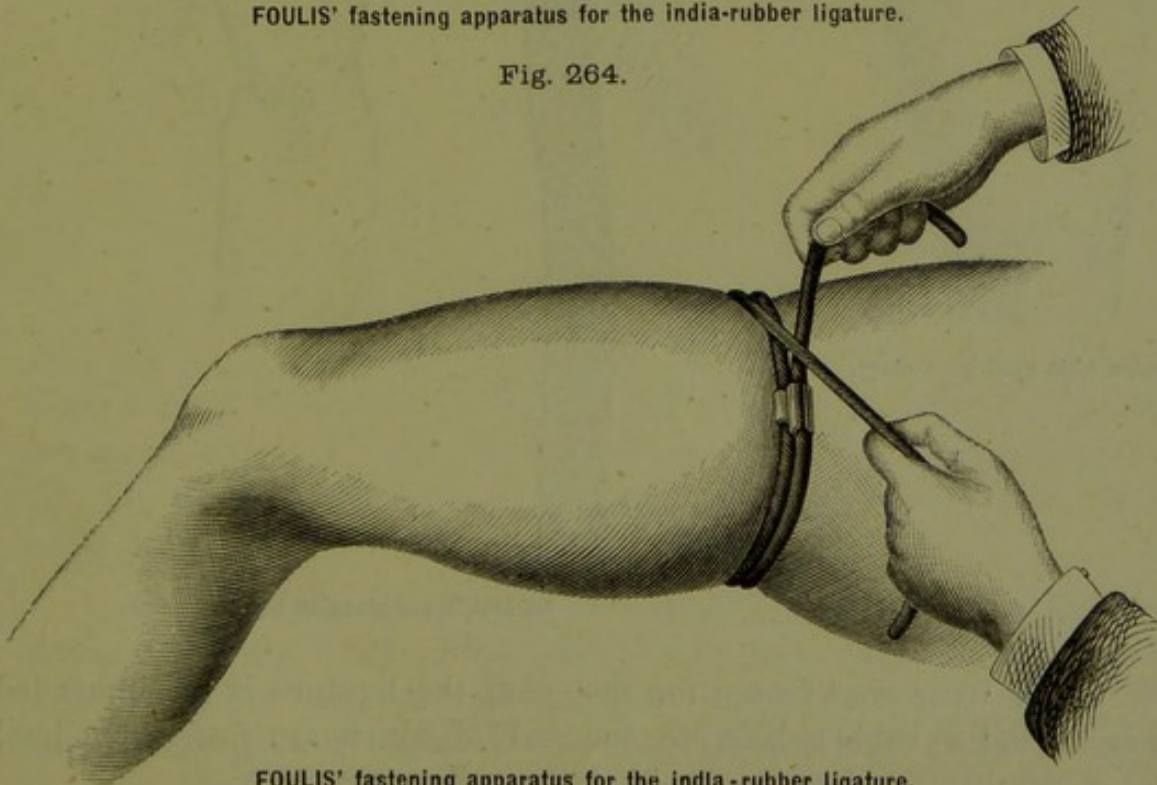
Clasp for the bloodless operation (open brass ring).

Fig. 263.



FOULIS' fastening apparatus for the india-rubber ligature.

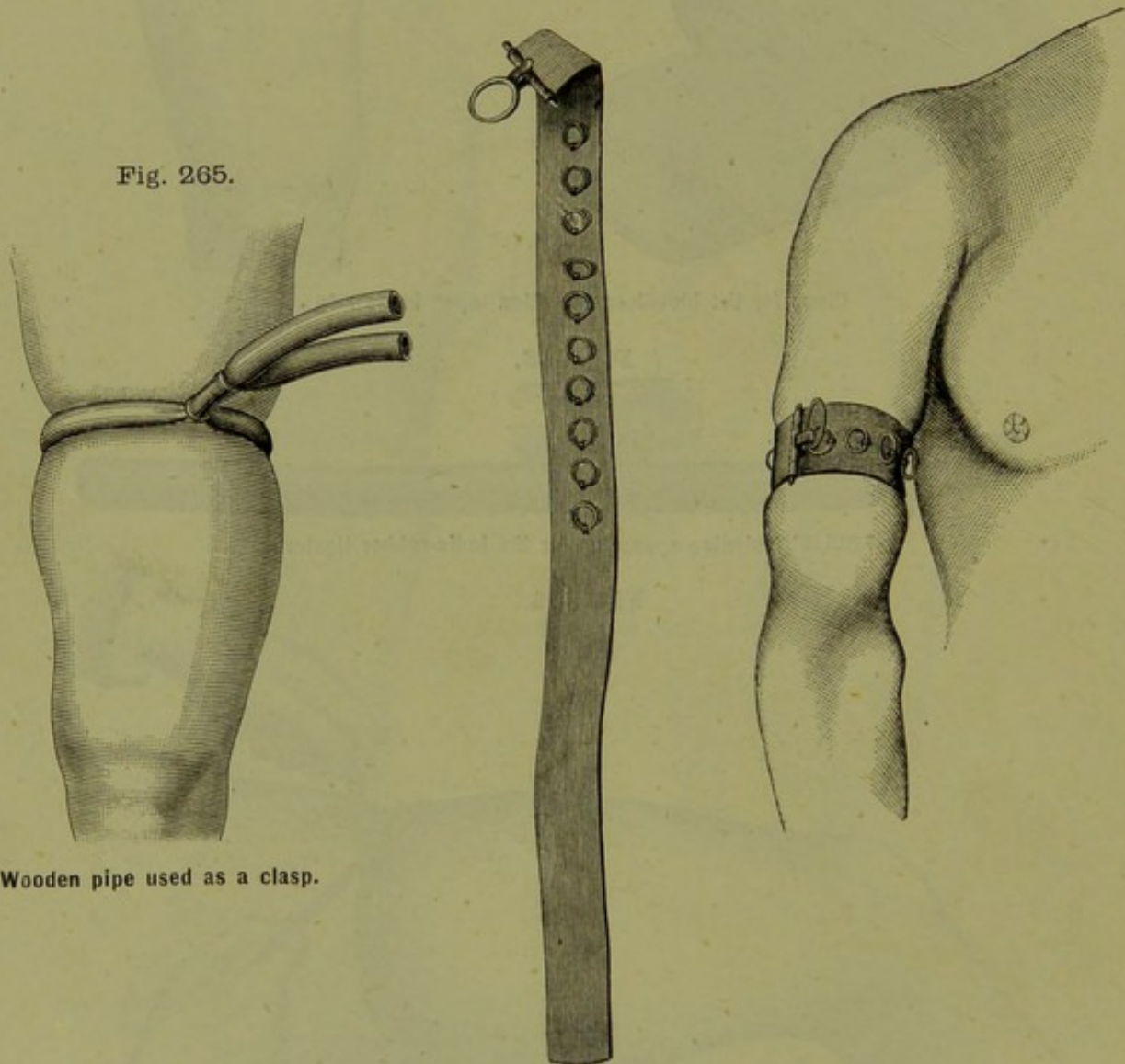
Fig. 264.



FOULIS' fastening apparatus for the india-rubber ligature.

A *wooden pipe* acts in the same way, the lumen of which corresponds to the diameter of the ligature (fig. 265). It is especially suitable for cases, in which (as for example in the ligature of a wounded artery) during the operation it is desirable to allow some blood to pass through, for by drawing on the projecting ends and shifting the wooden pipe, the strangulation can be as easily diminished as it can be again increased.

Fig. 266.



Wooden pipe used as a clasp.

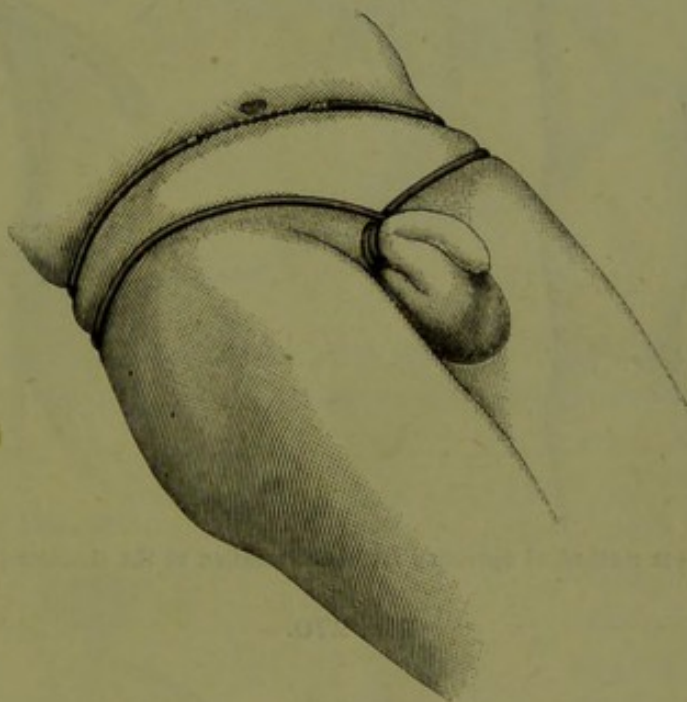
NICAISE'S compression belt.

7) NICAISE'S *contrivance* for fastening the ligature is recommended. It is an india-rubber belt, to one end of which are fastened a hook and a number of rings one behind the other (fig. 266).

8) An india-rubber tube about the size of goose-quill is sufficient to arrest the circulation *in a finger*: it is applied as represented in plate II, fig. 2.

9) A similar tube can be used for *the root of the penis* and scrotum, if an operation is to be performed without loss of blood on the male organs of generation (fig. 267).

Fig. 267.



Elastic ligature for the penis and scrotum.

10) For *disarticulations and excisions of the shoulder* the tube must be fixed by a strong hand over the spine of the scapula, after it has been carried with considerable traction under the axilla to the summit of the shoulder (fig. 268), or it must be fixed by a clasp (fig. 269).

By drawing the ends towards the neck, they are prevented from slipping.

11) For *high amputation of the thigh* the tube is wound once or twice round the thigh immediately below the groin, the ends are crossed over the groin, carried round the posterior aspect of the pelvis, and finally hooked together over the hypogastric region by means of a chain (fig. 270).

Fig. 268.

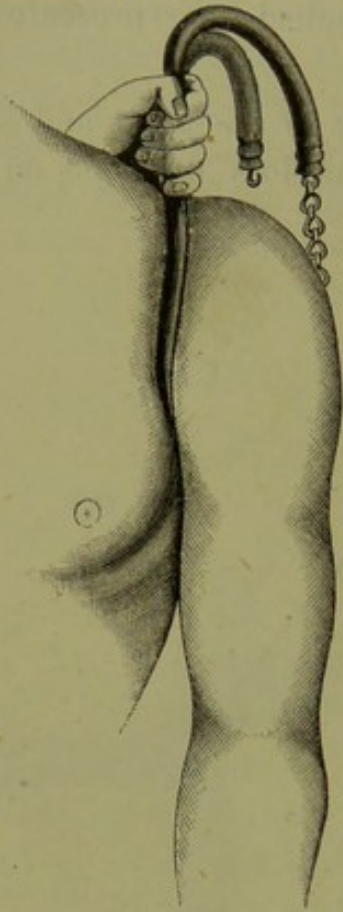
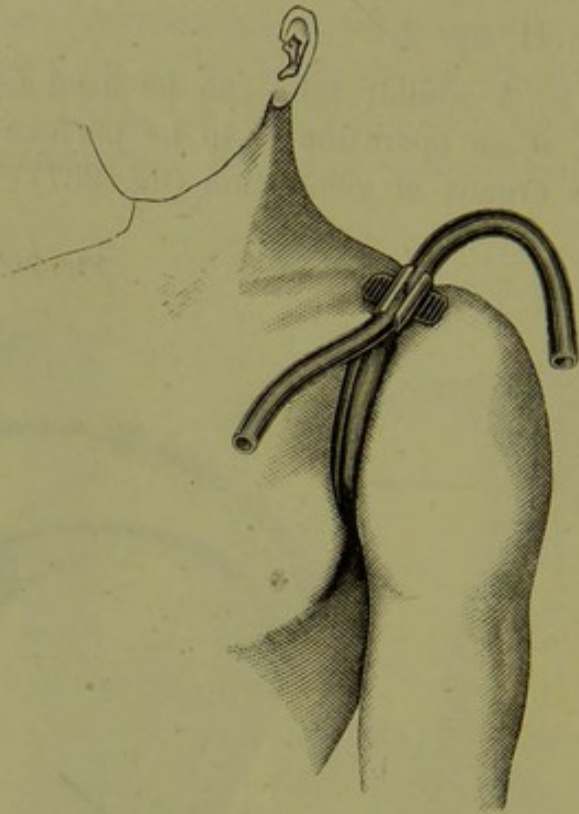
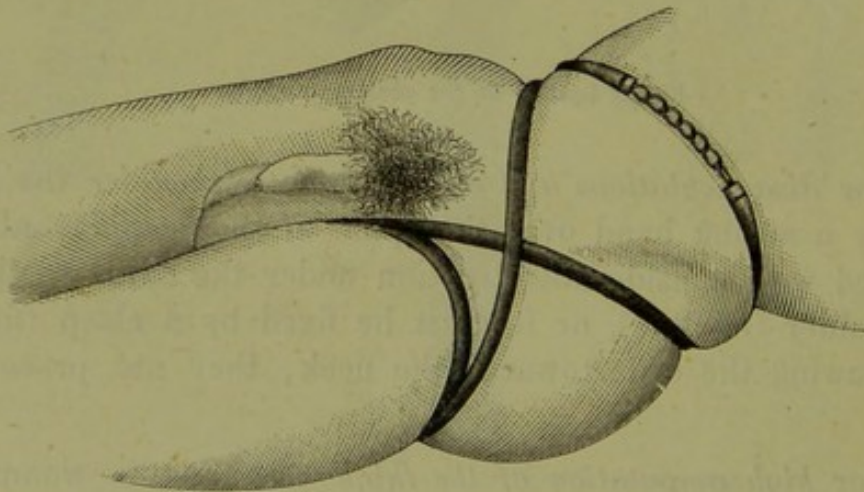


Fig. 269.



Bloodless method of operating for disarticulation at the shoulder joint.

Fig. 270.

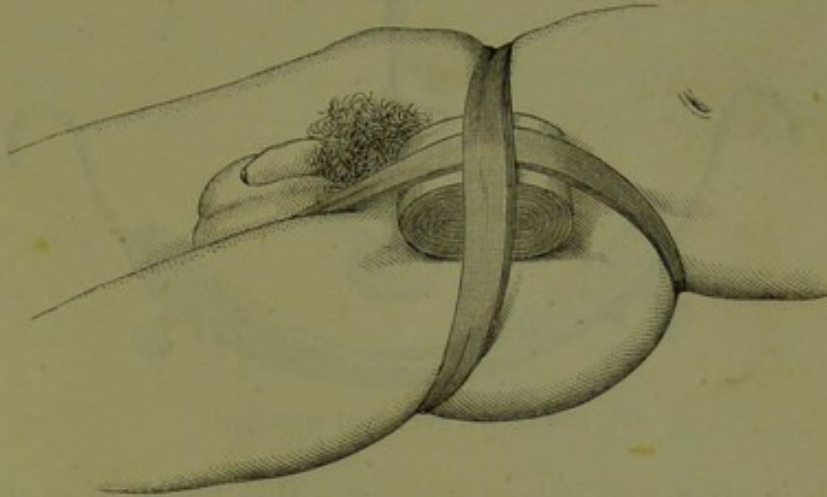


Bloodless method of operating with elastic ligature for high amputation of the thigh.

12) A firmly rolled linen bandage can be placed like a pad upon the *external iliac artery* immediately above Poupart's ligament, and

firmly pressed against the artery by several figure-of-eight turns of a strong india-rubber bandage (fig. 271).


Fig. 271.



Bloodless method of operating for high amputation of the thigh.

(Bandage used as a pad, and an india-rubber bandage.)

Fig. 272.



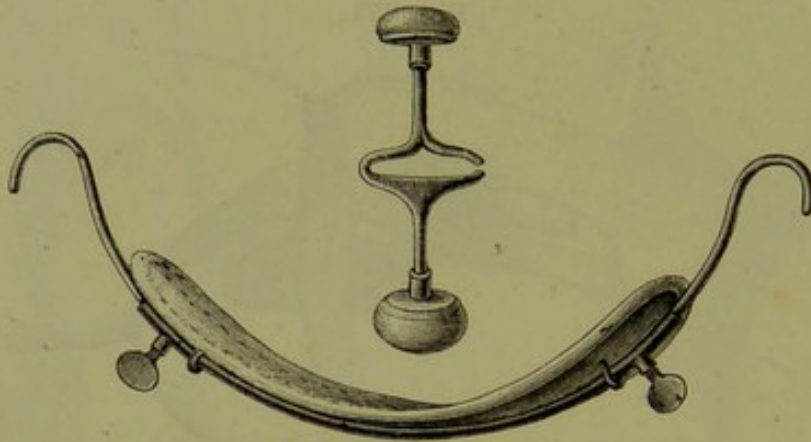
PANCOAST'S abdominal tourniquet.

13. For *disarticulation, and excision of the hip*, the arterial current can be most securely controlled, if the intestines have been previously emptied, by compression of the aorta in the region of the umbilicus.

14. PANCOAST'S *abdominal tourniquet* can be employed for this purpose. The pad is moved by a long screw against the cushion for the back (fig. 272).

15. Or the *author's abdominal tourniquet* may be used (fig. 273). The pad is pressed against the vertebral column by means of an elastic band-

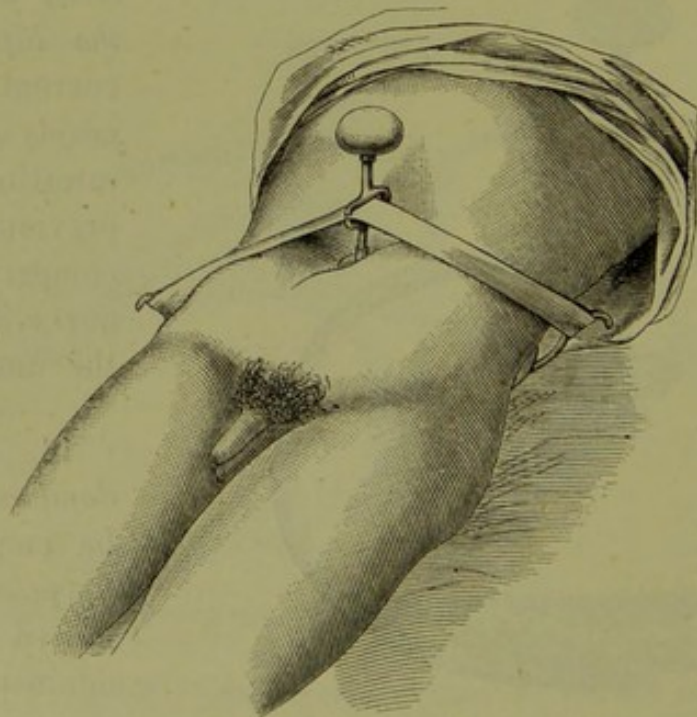
Fig. 273.



ESMARCH'S abdominal tourniquet.

dage, which is stretched between the movable hooks of a cushion fitting the back. The steel rod of the pad is provided with a slit, through which the turns of the india-rubber bandage can be pushed; there are also two pads of different sizes; the upper one is held in its place by an assistant to prevent the lower one from slipping off the aorta (fig. 274).

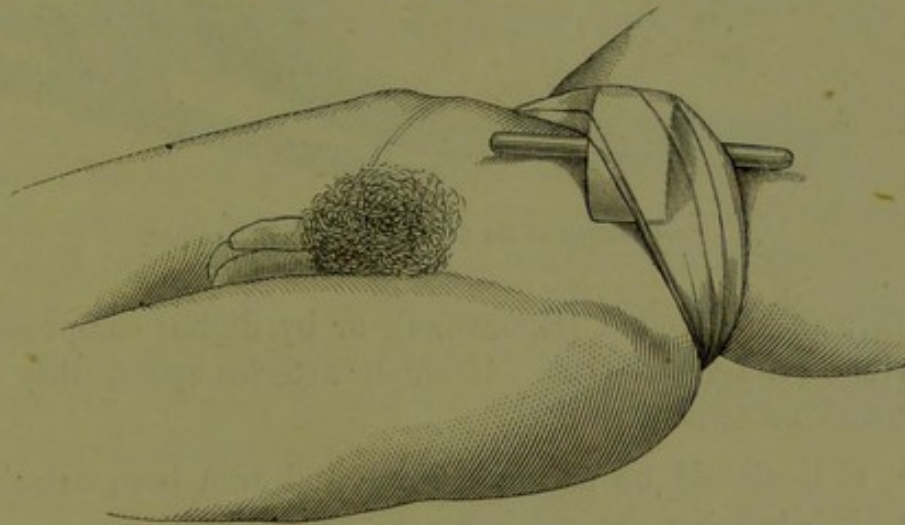
Fig. 274.



ESMARCH'S elastic abdominal tourniquet.

16. If there is not a tourniquet at hand, a pad can be improvised in this way. A linen bandage, 8^m long and 6^{cm} broad, is wound round the middle of a stick, which should be about a foot long, and of the thickness of the thumb. This pad is placed immediately below the umbilicus, and kept in the proper position by an assistant who has charge of the stick. It is then pressed with some force against the vertebral column by the turns of an india-rubber bandage 6^{cm} in breadth, which is carried 5—6 times round the body (fig. 275).

Fig. 275.

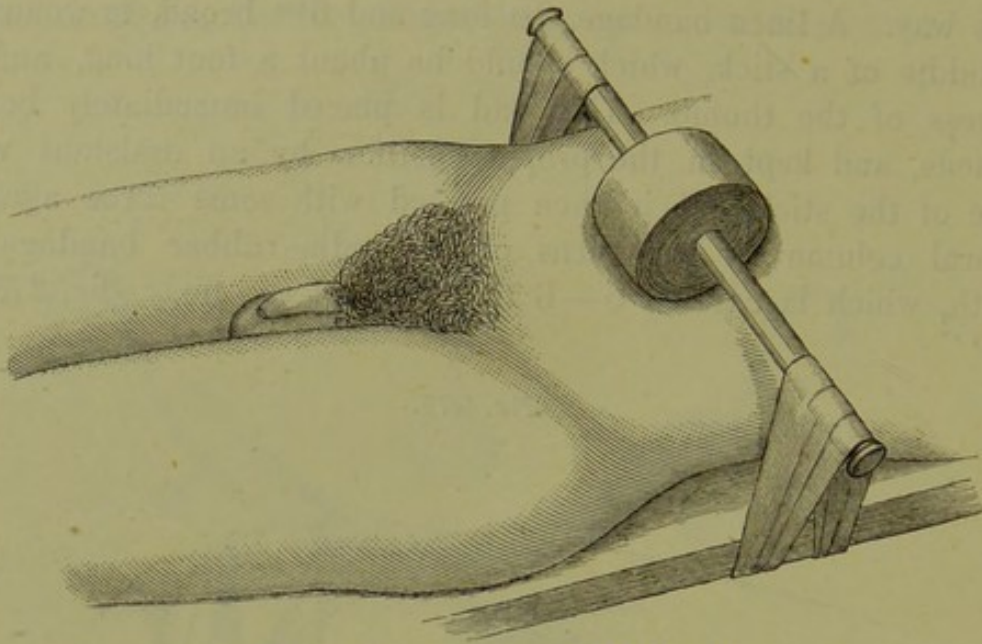


Compression of the aorta with a pad and elastic bandage.

17. If the circular compression of the abdomen is undesirable, the linen bandage is wound upon the middle of a longer stick, and its ends are pressed through the turns of an india-rubber bandage, which is passed beneath the operating table (BRANDIS) (fig. 276).

18. At the conclusion of the operation the ligature must *not be slowly* loosened, but *quickly* removed. The consequent haemorrhage is generally considerable, because the walls of the vessels are paralyzed from the continuous pressure. Haemorrhage must therefore be prevented before the removal of the elastic ligature, either by tying the divided vessel (as in amputations or excisions), or by the application of the tampon to the wound (as in necrosis cases etc.). The parenchymatous haemorrhage, which follows in spite of this treatment, is easily arrested by carbolised ice-water, by the employment of the inducted current to

Fig. 276.



Compression of the aorta after BRANDIS' method.

the surface of the wound (RIEDINGER), or by digital compression of the main artery (v. LANGENBECK). If small arteries spurt, they must also be ligatured or twisted.

19. If it should be necessary, one and even both extremities may be kept bloodless for several hours without injury.

2. FOR THE PERMANENT ARREST OF HAEMORRHAGE

after the arrival of the wounded in hospital, it is sufficient in slight cases:

a. to employ **rest**, an **elevated position** of the limb, and **ice**, avoiding at the same time any strangulation by bandages, tourniquets etc.

Every patient should be unceasingly watched, in whom the injury of one of the larger vessels is to be suspected on account of violent haemorrhage having ensued immediately after the infliction of the wound. The person who watches should also be instructed, what he has to do in case of a sudden recurrence of the haemorrhage.

If the haemorrhage recurs, one must not hesitate to close the bleeding vessel, and if possible by

b) Ligature in the wound itself (direct ligature).

For this purpose the wound must be sufficiently enlarged under the guidance of the fingers, and the blood clots thoroughly cleared out (the so called diffuse traumatic aneurism) with the hand or a carbolised sponge. And while the soft parts are held asunder with retractors, one must, carefully prepared and guided by a good anatomical knowledge, penetrate to the bottom of the wound, till the injured artery has been found. The artery is then separated from its cellular sheath, carefully ligatured above and below the injured spot with carbolised catgut, and divided between the two ligatures, so that both ends of the divided vessel may be able to retract.

If in spite of this double ligature blood still wells up from the bottom, some other vessel must be injured. Not uncommonly it is caused by a branch, which is given off from the posterior wall of the artery at the wounded spot. To recognize this condition of affairs, the injured piece of artery between the two ligatures can be cut out (ROSE). But it may be some other branch, which is injured in the further course of the wound. In any case it must be sought for, and an attempt made to close it with a ligature.

If besides the artery one of the larger veins are injured, it is recognized by the fact, that in spite of the ligature a large quantity of dark blood flows from the wound, especially if pressure is made above the wound. Such venous haemorrhage can as a rule be arrested by a light compress or the tampon; if not, the injured vein must also be ligatured.

These often difficult operations can be essentially made easier by the bloodless method; but to drive out all the blood from the limb is not to be recommended, because one cannot then easily recognize the empty veins, nor avoid injuring them. It is therefore sufficient to apply the elastic bandage above and below the wound (STROMEYER). The circulation is thereby entirely arrested, while the veins remain full and can also be quickly refilled by a momentary removal of the lower bandage, if during the operation the blood should have escaped.

Moreover for the performance of this operation, where the life or death of the patient is at stake, no fear need be entertained of converting a small thrust or gunshot wound into a very large and deep wound.

Concerning the direct ligature of vessels, see the particulars given for amputations.

If the direct ligature is impracticable on account of the depth of the wound, or because it is undesirable again to disturb it (as for example after amputation or excision), the trunk of the artery must be ligatured.

c) **The ligature of the arterial trunks.**

1. **General rules for the search and ligature of the chief arterial trunks.**

α . The operator must before commencing the operation call to mind the exact anatomical relations of the parts at the seat of ligature.

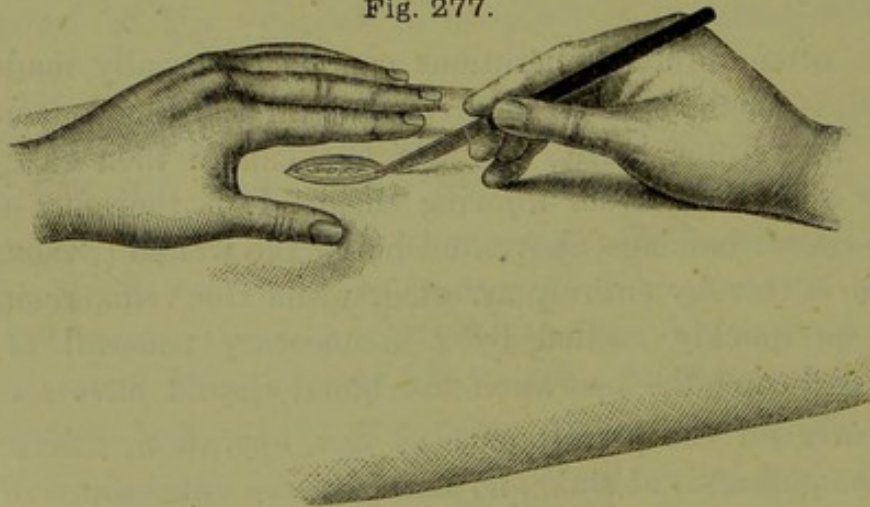
β . The direction and length of the cutaneous incision is then determined. It is expedient to mark it out beforehand upon the skin with indian ink or chalk.

γ . The body is brought into the position most advantageous for the operation, and into the best light.

δ . If an extremity is to be operated on, it is an advantage to make it bloodless, with the modification, which has been given above for the direct ligature. As soon as the time has come for feeling the pulsation of the artery, the upper elastic ligature is loosened.

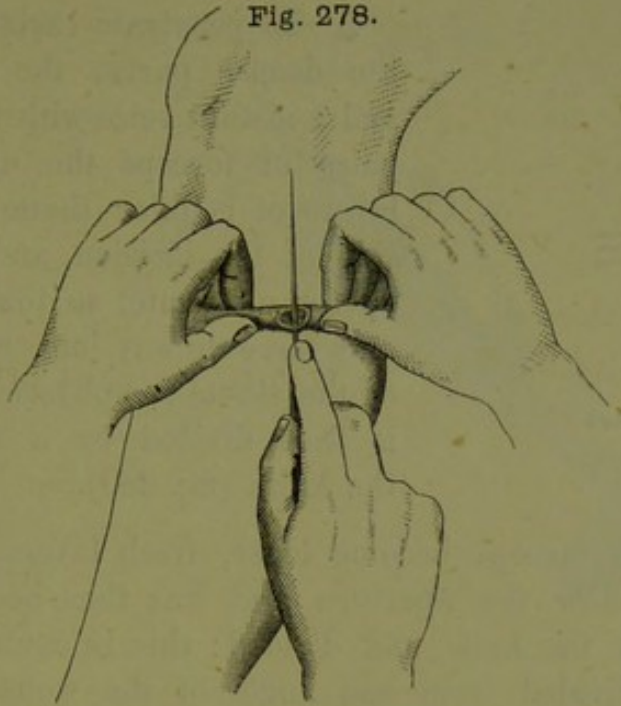
ϵ . The *cutaneous incision* is either made simply by the fingers of the left hand keeping the skin upon the stretch, while the knife cuts through the whole thickness of the skin from end to end (fig. 277), or

Fig. 277.



Simple cutaneous incision.

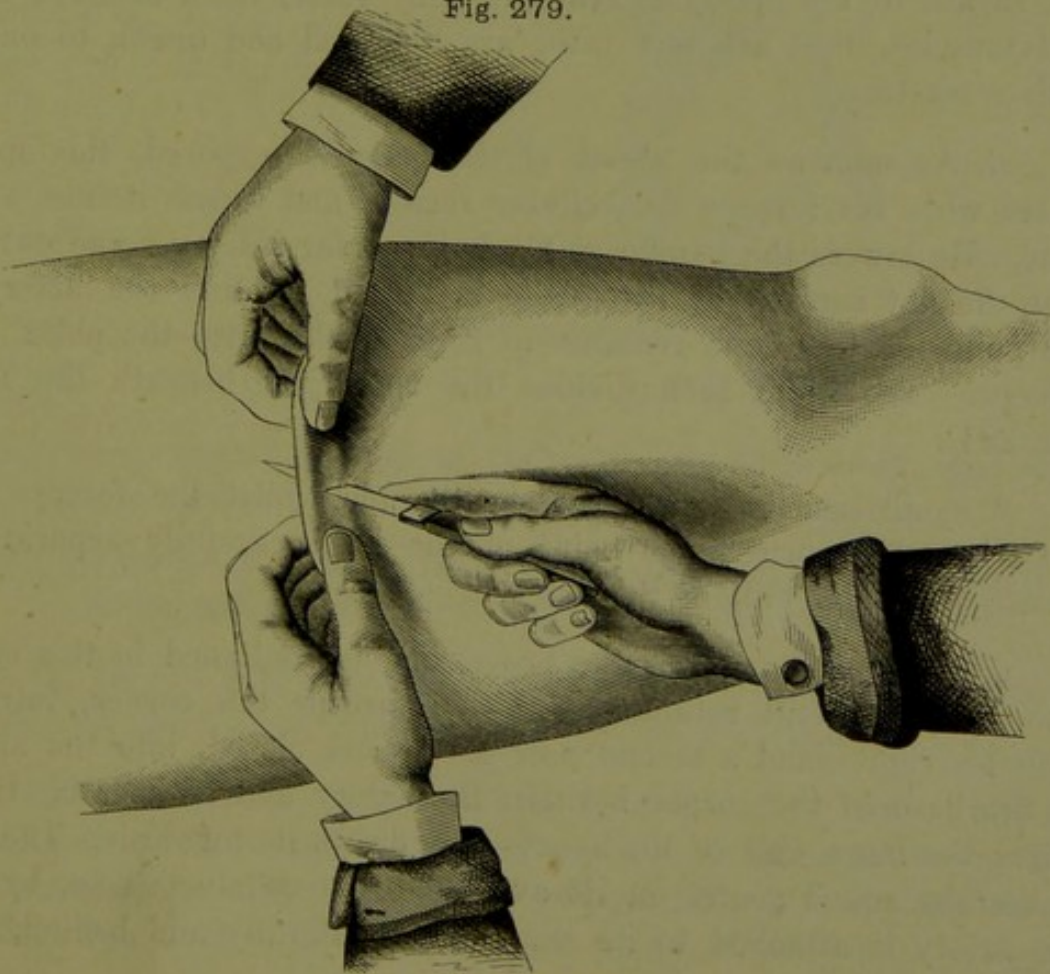
Fig. 278.



Cutaneous incision by pinching up a fold of skin.

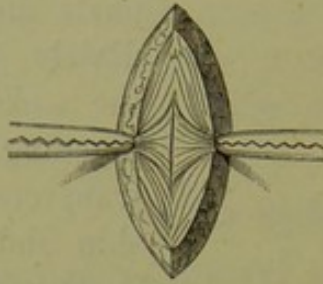
if the artery or other important parts lie immediately beneath the skin, by pinching up a transverse fold of skin and cutting it through with one stroke of the knife, either from without inwards (fig. 278), or by transfixion from within outwards (fig. 279).

Fig. 279.



Transfixion of a fold of skin.

Fig. 280.



Separating the cellular tissue
(between two pairs of forceps).

ζ. To penetrate carefully into the deeper parts, the operator and assistant seize with two good pairs of forceps the uppermost layers of cellular tissue on each side of the incision, and raise it up for a minute, so that the air may force its way into the meshes of the tissue (emphysema). This is then divided by a stroke of the knife (fig. 280).

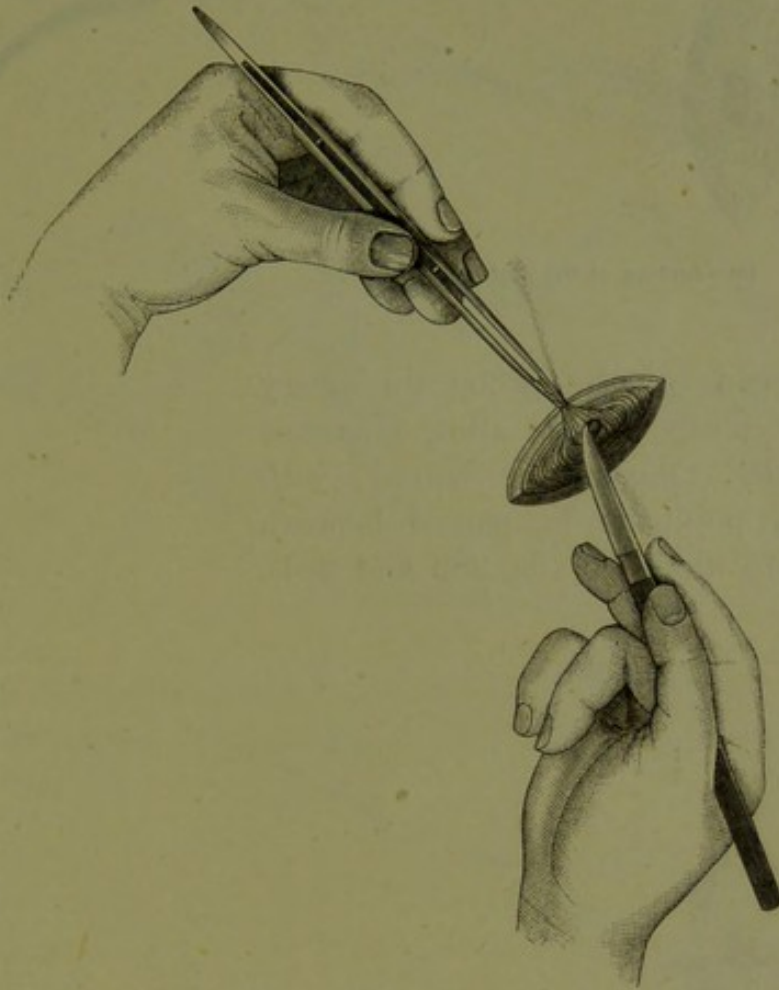
η. As soon as both forceps become loose, fresh layers of tissue are seized above and below the aperture that has thus been made: these are raised towards the knife and divided: this is continued till the layer of tissue is divided from one angle of the wound to the other. The same proceeding is repeated with the following layers, till the sheath of the artery is reached. Any veins, small arteries, nerves, and muscles, that are met with, are liberated and drawn to one side with retractors.

θ. As soon as the *sheath of the artery* is exposed, the operator seizes with his forceps the cellular sheath, and raises it into a small cone. He lowers the handle of his knife so far sideways and outwards, that the flat surface of the blade is turned towards the artery, but the point of the knife remains at right angles with the point of the forceps. The knife then divides the cone just beneath the forceps (fig. 281).

A small incision opens the sheath, and whilst the forceps raises the triangular corner, the point of the knife carefully separates the sheath from the wall of the artery.

ι. For larger arteries the proceeding is continued in this manner. The operator, still retaining with his forceps the corner, introduces with his right hand a second pair of forceps, closed, into the aperture at the base of the corner between the artery and its sheath. He then seizes the inner wall of the sheath and draws it forwards. The artery is thereby rolled gently on its axis, and the cellular tissue, by which the artery is attached to its sheath both laterally and behind, makes

Fig. 281.



Opening the sheath of the artery.

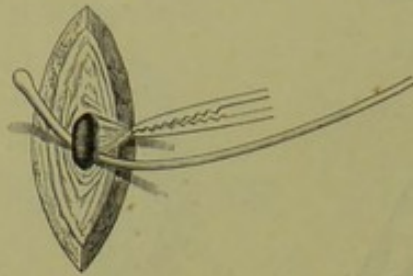
its appearance, and is divided in the same careful manner, and only to the same extent as in the case of the first made opening.

NB. If the artery is detached too far from its sheath, it will be liable to slough, and secondary haemorrhage ensue at the seat of ligature.

In the largest arteries, if one half only of the circumference is liberated, the proceeding must be repeated on the other side.

z. As soon as the artery is loosened all round, a bent probe (or strabismus-hook) is passed carefully round the vessel, and always from the side where the vein lies, whilst a pair of forceps keeps the sheath upon the stretch (fig. 282).

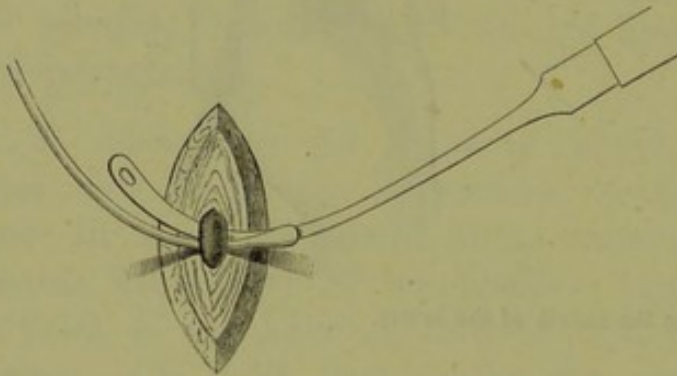
Fig. 282.



Introduction of the probe.

λ. By means of the probe the artery is raised sufficiently high to allow a narrow *aneurism needle* (COOPER'S or SYME'S), with an eye at the point, to be passed beneath in the opposite direction (fig. 283 and 284).

Fig. 283.



Introduction of the aneurism needle.

μ. The probe is removed; through the eye of the needle a strong ligature (of silk or carbolised catgut) is threaded and the needle withdrawn; the middle of the ligature remains lying beneath the artery.

ν. The ends of the ligature are tied together round the artery *with a reef-knot* (fig. 22) [not with a granny (fig. 23)] and without pulling on the artery; the knot

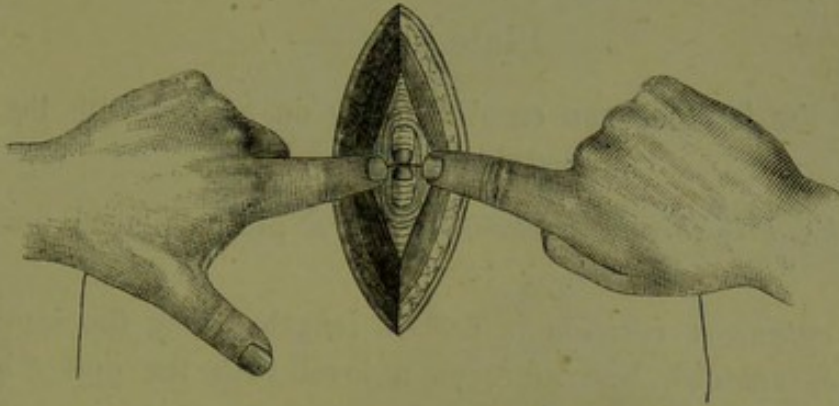
Fig. 284.



SYME'S aneurism needle.

must be drawn together with the tips of both index fingers at the bottom of the wound (fig. 285).

Fig. 285.



Tying the knot.

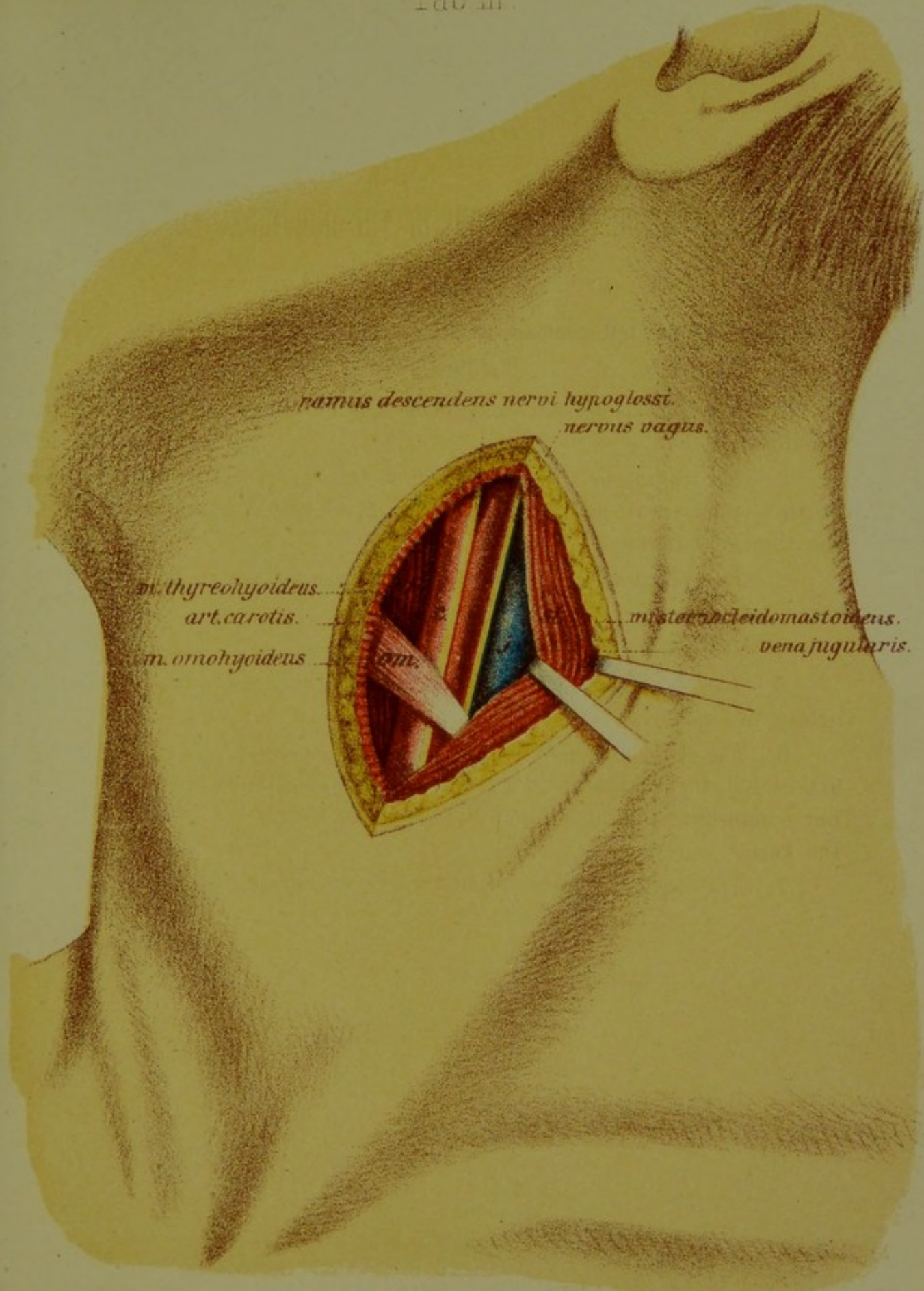
ξ. It is advisable to tie larger arteries with a double ligature, and to divide the vessel between the two, so that both ends may retract within the sheath.

2. RULES FOR THE LIGATURE OF THE INDIVIDUAL ARTERIES.

Plate III.

Ligature of the left common carotid artery on a level with the cricothyroid ligament.

1. *The head is thrown backwards*, by a pillow placed beneath the shoulders.
2. *The cutaneous incision* is 6^{cm} in length, along the inner border of the sterno-mastoid, beginning on a level with the upper border of the thyroid cartilage.
3. *The platysma* and the cellular tissue (avoiding the superficial veins) are divided.
4. *The omohyoid* muscle is drawn downwards.
5. *The descendens noni nerve*, which runs downwards upon the artery, is drawn outwards.
6. *The common sheath* is opened over the middle of the artery. The artery lies to the inner side, the internal jugular vein to the outer side but somewhat superficial, and the vagus nerve lies behind and between the two.
7. *The needle* is passed round from without inwards.



ramus descendens nervi hypoglossi.

nervus vagus.

m. thyrohyoides.

art. carotis.

m. omohyoides.

m. sternocleidomastoideus.

vena jugularis.

am.





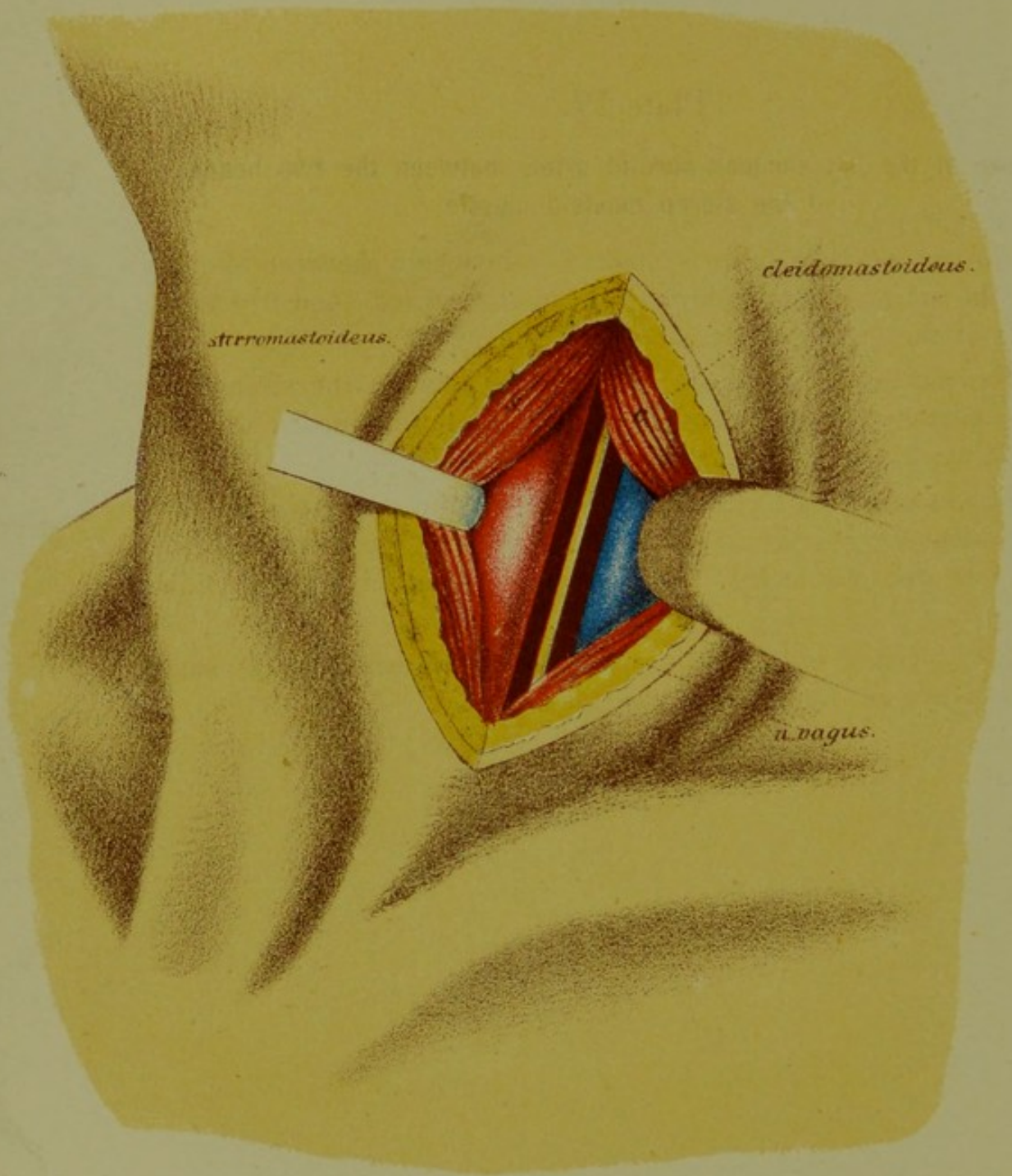


Plate IV.

Ligature of the left common carotid artery between the two heads of the sterno-mastoid muscle.

1. The *cutaneous incision* is made 6^{cm} in length between the two heads of the sterno-mastoid downwards to the clavicle, and 2^{cm} to the outer side of the sterno-clavicular articulation.

2. The *platysma* is divided; the interval between the sternal and clavicular portions of the sterno-mastoid muscle is widened with the fingers, till the internal jugular vein is visible.

3. The *vein* with the clavicular portion of sterno-mastoid is drawn carefully outwards by the finger of an assistant, the sternal portion together with the sterno-hyoid and sterno-thyroid muscles is drawn inwards.

4. To the inner side of the vein appears *the vagus nerve*, somewhat further inwards and deeper lies the artery.

Plate V.

Ligature of the lingual artery.

1. The *cutaneous incision* is 4^{cm} in length along the upper border of the great cornu of the hyoid bone.

2. The *platysma* is divided; the posterior facial vein is drawn outwards.

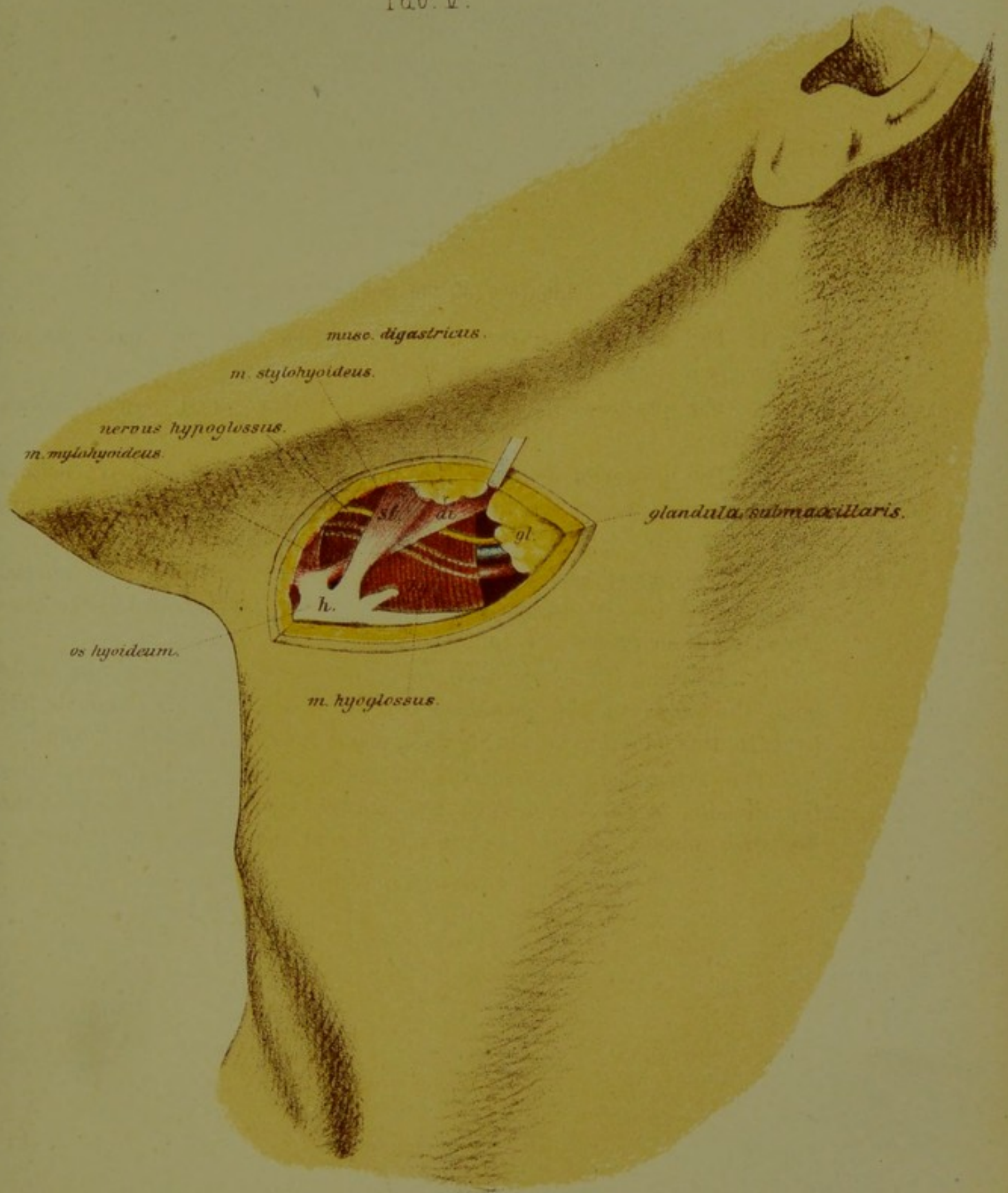
3. The posterior belly of the *digastric muscle* is exposed; behind and below it appears the hypoglossal nerve; the submaxillary gland is drawn upwards.

4. The *hypoglossal nerve* runs in front over the hyoglossus muscle, accompanied by the lingual vein; below the nerve and behind the hyoglossus muscle passes the lingual artery.

5. Between the hypoglossal nerve and the great cornu of the hyoid bone the *fibres of the hyoglossus* are cautiously divided; immediately beneath this muscle lies the lingual artery, accompanied by a vein.

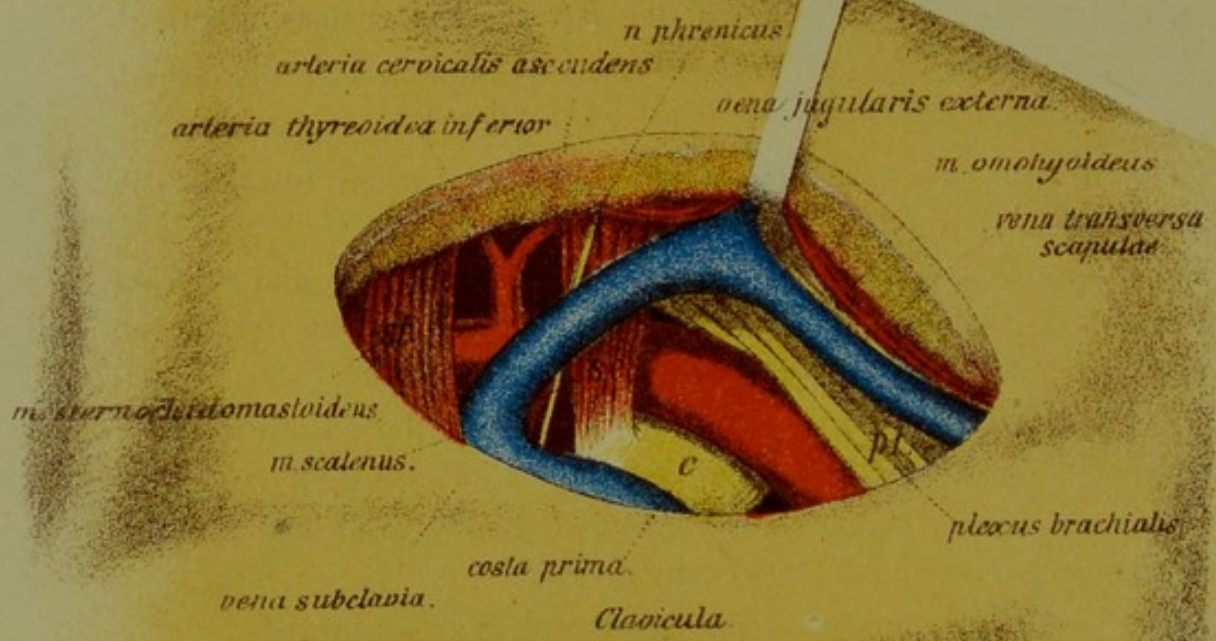
The artery can also be tied in the lingual trigone (Hueter) after the division of the hyoglossus, i. e. between the posterior belly of the digastric muscle and the posterior border of the mylo-hyoid muscle.

Tab. V.









n. phrenicus

arteria cervicalis ascendens

arteria thyreoidæ inferior

vena jugularis externa.

m. omohyoideus

vena transversa scapulae

m. sternocleidomastoideus

m. scalenus.

c

p

plexus brachialis

costa prima.

vena subclavia.

Clavicula.

Plate VI.

Ligature of the subclavian artery in the left supra-clavicular fossa.

(The artery comes forward behind the scalenus anticus, and runs over the first rib downwards and outwards behind the clavicle.)

1. The *arm is drawn downwards*, the head turned towards the opposite side, and a pillow placed beneath the back.

2. The *cutaneous incision* is 6—8^{cm} long, semilunar, and carried obliquely over the supra-clavicular fossa from the outer border of the sterno-mastoid muscle to the outer third of the clavicle.

3. The *platysma* is divided, and the border of the sterno-mastoid muscle exposed; the external jugular vein must not be injured!

4. The superficial layer of the *cervical fascia*, and the adipose tissue in the supra-clavicular fossa are divided.

5. The *omo-hyoid* muscle is detached and drawn upwards.

6. Through the fat and cellular tissue (with veins!), to the *scalenus anticus*, whose tendon can be felt close to the tubercle of the first rib.

7. The inner border of the *brachial plexus* appears, which is drawn upwards and outwards.

8. Between the scalenus anticus and the brachial plexus, but somewhat deeper than the latter, lies the *artery*; it can be seen after dividing the deep layer of the cervical fascia.

9. The *subclavian vein* lies in front and below the tendon of the scalenus anticus, and close behind the clavicle.

NB. Injury of the external jugular vein (at the outer border of the sterno-mastoid), of the supra-scapular artery (near the clavicle), of the transversalis colli artery (upon the brachial plexus), and the phrenic nerve (running downwards upon the scalenus anticus) must be avoided.

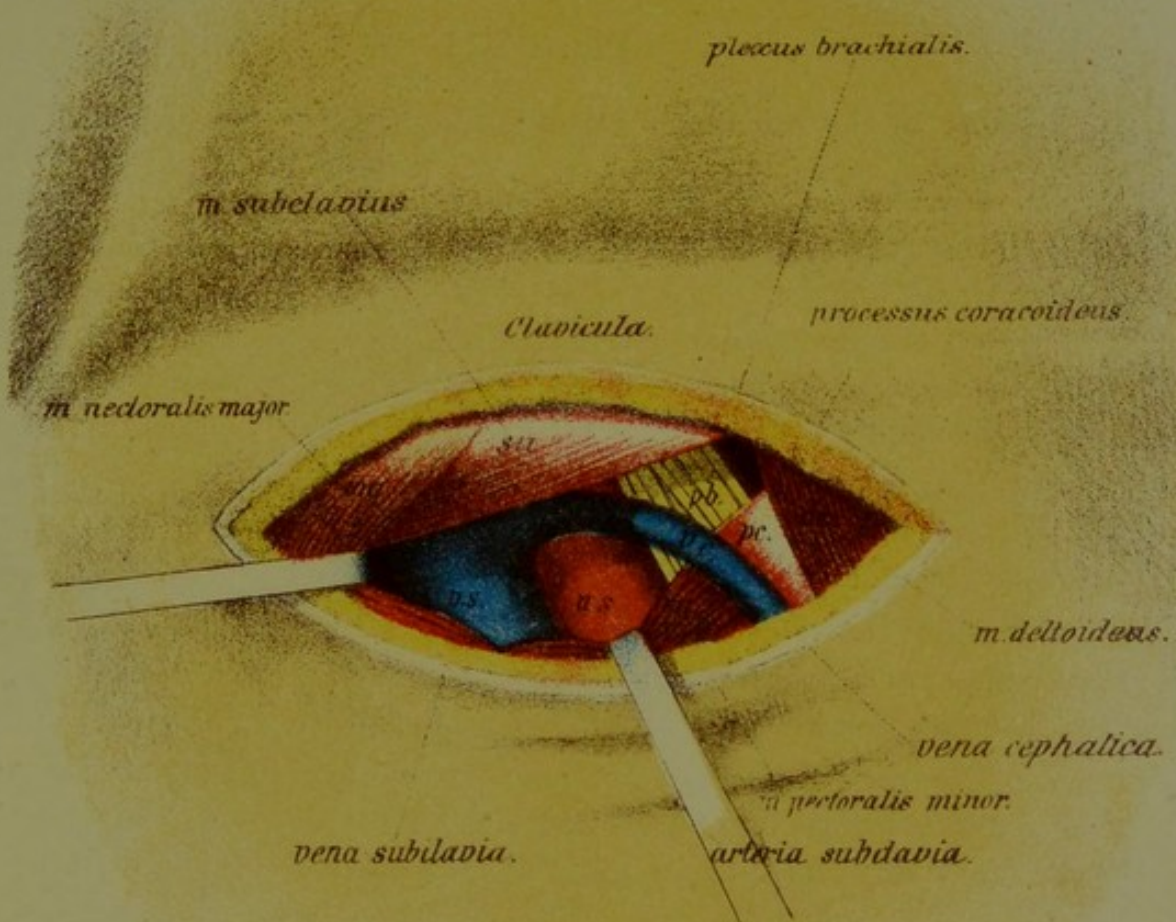
Plate VII.

Ligature of the subclavian artery in the left infra-clavicular fossa.

1. The *shoulder is drawn upwards*.
2. The *cutaneous incision* is 6—8^{cm} long, beginning from the coracoid process and running parallel with the outer half of the clavicle. It exposes the triangular space between the deltoid and pectoralis major muscles, through which the cephalic vein passes to reach the subclavian vein.
3. The *cephalic vein* is drawn outwards with the border of the deltoid muscle, the border of the pectoralis major (which may, if necessary be detached somewhat from the clavicle) is drawn inwards.
4. After the division of some adipose tissue the coraco-clavicular *fascia* appears at the bottom of the wound: this is cautiously divided. The external thoracic artery will generally require a ligature.
5. The *pectoralis minor* is seen, whose inner (upper) border forms with the subclavian muscle an angle open on the inner side. In this angle the artery lies deeply placed between the brachial plexus and the subclavian vein: the vein is to the inner side, and the nerve to the outer side.

NB. If necessary the pectoralis minor can be detached from the coracoid process, and the artery tied further towards the axilla.

Tab. VII



pectus brachialis.

m. subclavius

Clavicula.

processus coracoideus.

m. pectoralis major

m. deltoideus.

vena cephalica.

m. pectoralis minor.

vena subclavia.

arteria subclavia.





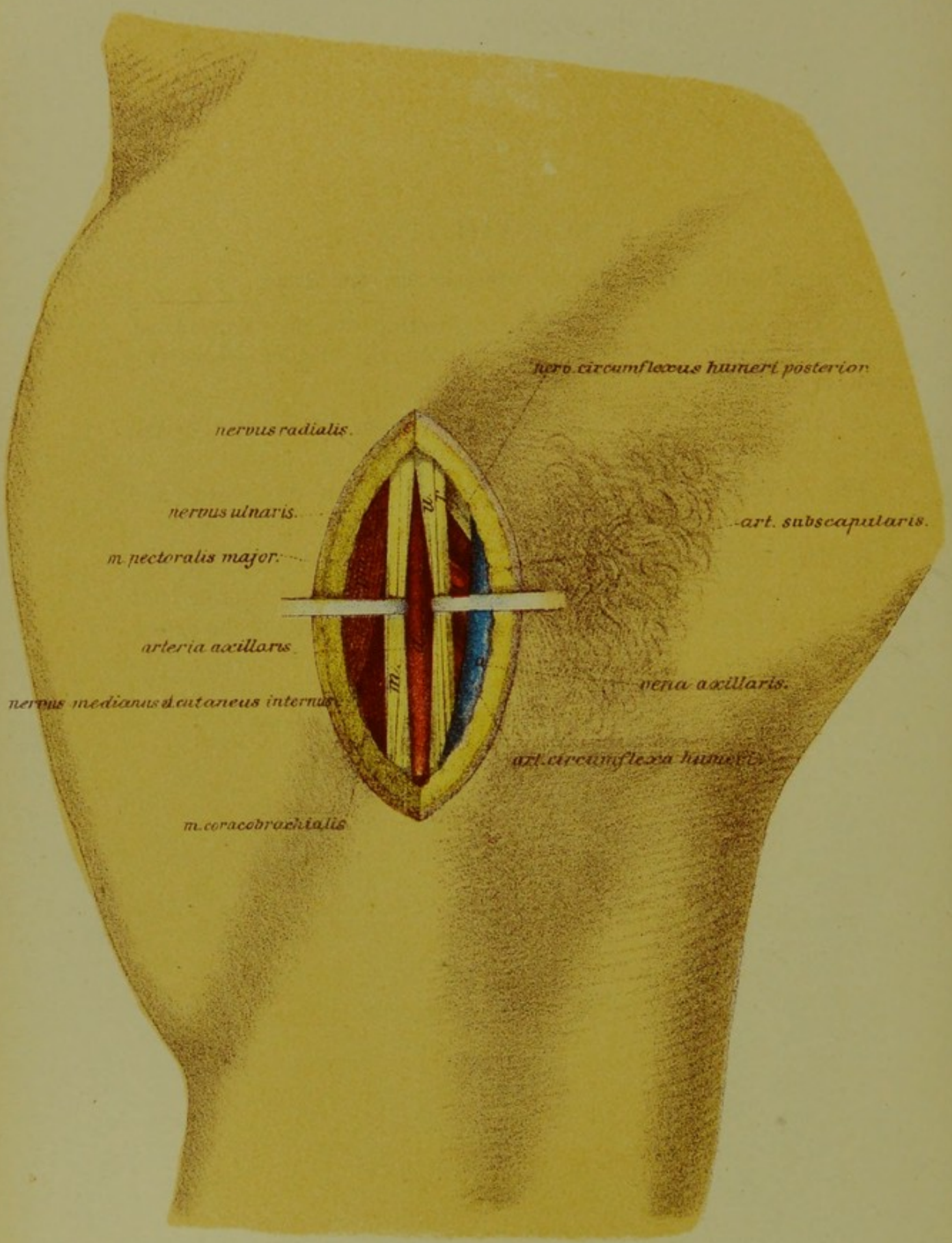


Plate VIII.

Ligature of the axillary artery in the right axilla.

1. The *cutaneous incision*, 5^{cm} in length, with the arm raised, along the inner border of the coraco-brachialis, begins where this muscle is crossed by the pectoralis major.

2. After the division of the fascia *a bundle of nerves* appears, which surrounds the artery.

The *axillary vein* lies at the posterior border of this plexus and somewhat more superficial.

3. The bundle of nerves is separated, the anterior cord (n. medianus et cutaneus medius*) being drawn forwards, the posterior cord (n. ulnaris et radialis) drawn backwards, and the sheath of the artery opened.

* By an oversight it is marked on Plate VIII as cutaneus internus.

Plate IX.

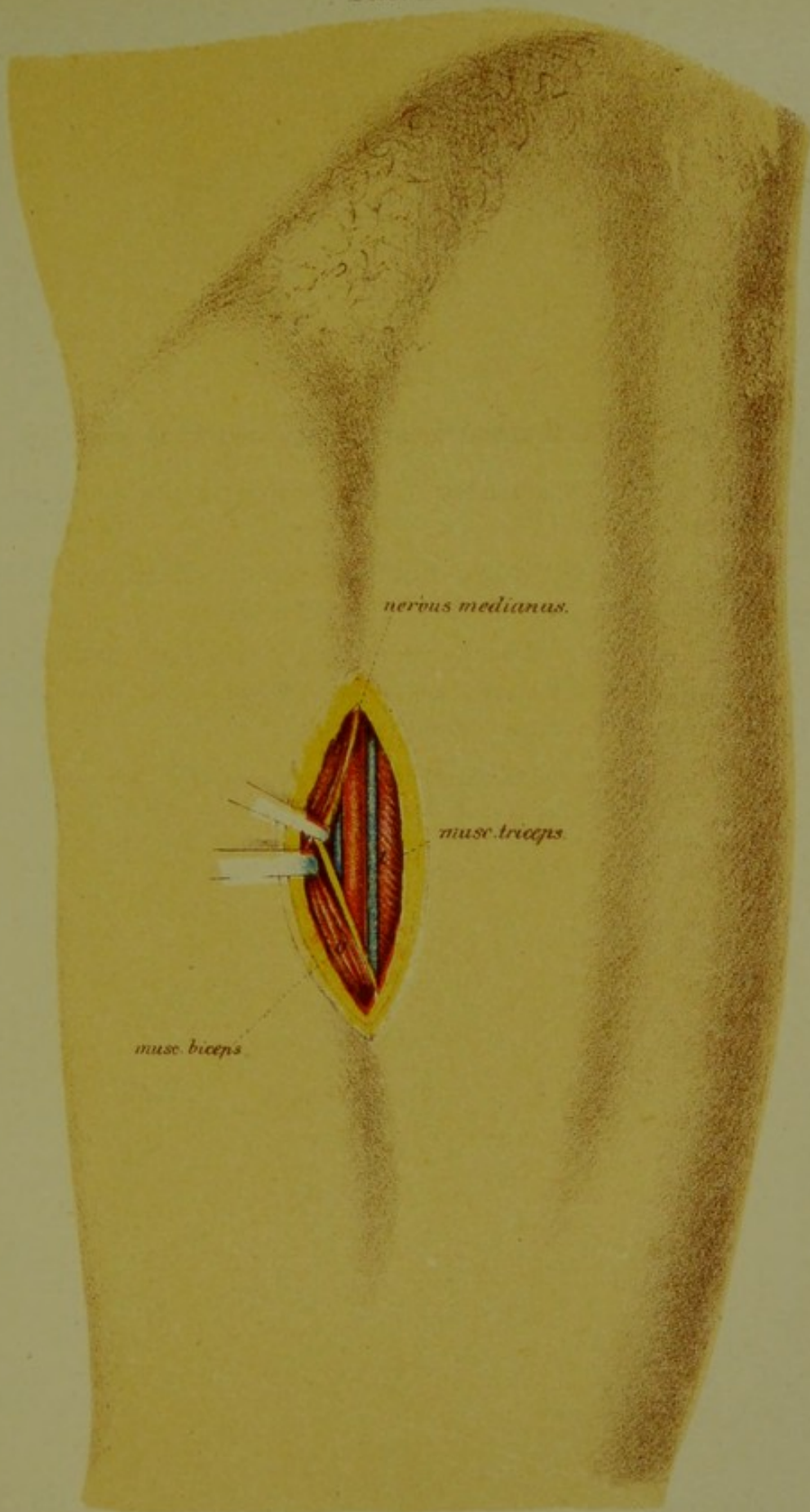
Ligature of the brachial artery in the middle of the right arm.

1. The *cutaneous incision* is 4^{cm} in length along the inner border of the biceps.

2. The *biceps* is drawn outwards with a retractor. The median nerve is seen lying immediately upon the artery.

3. The *median nerve* is detached from the sheath and drawn outwards by a strabismus hook; the *sheath of the artery* is opened: it lies between two veins (*venae comites*).

NB. Sometimes the brachial artery divides into the ulna and radial arteries in the upper third of the arm; the latter in that case commonly runs more superficially and towards the outer side (upon the biceps), while the former then appears conspicuously small.



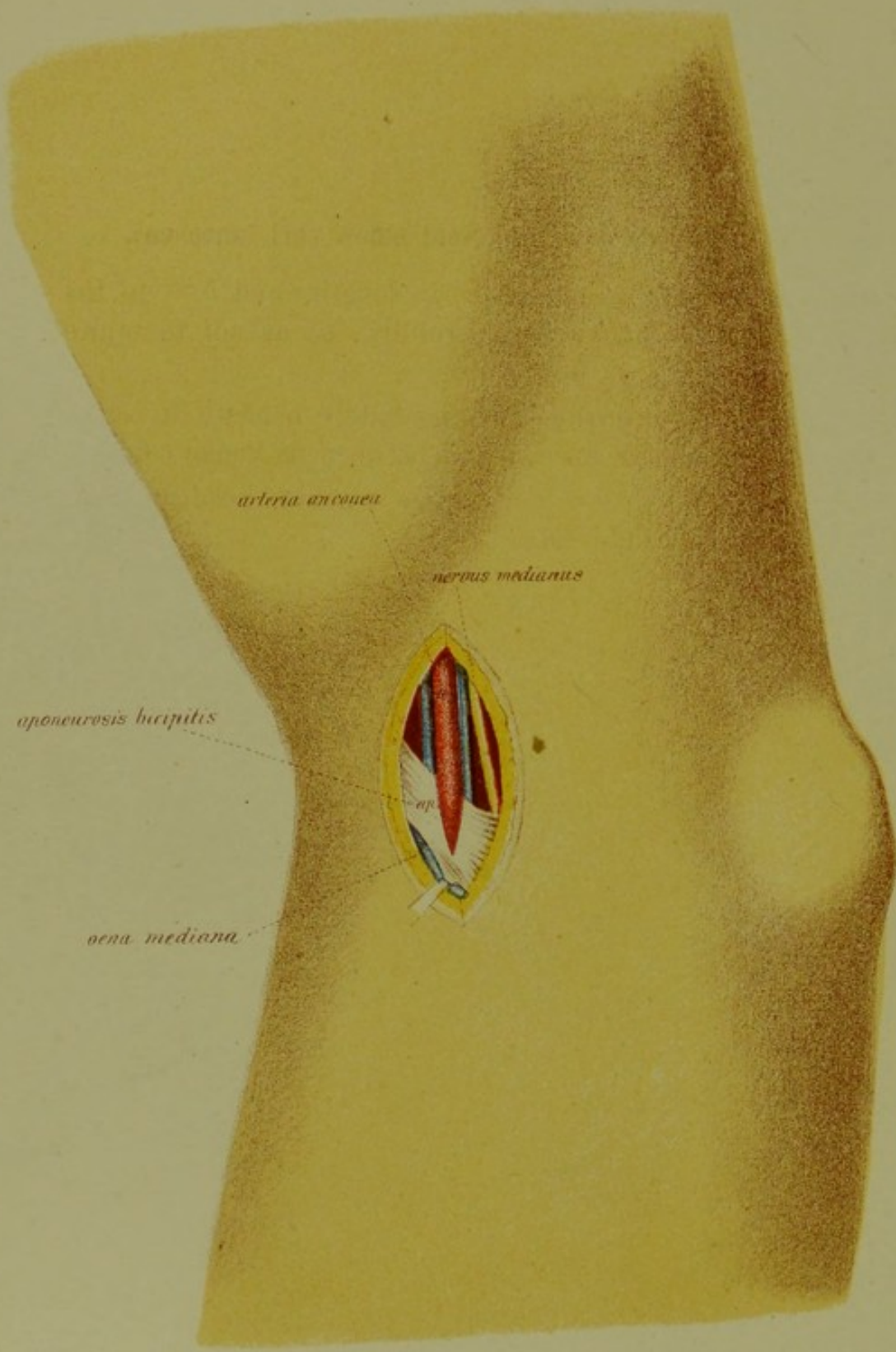
nervus medianus.

musc. triceps.

musc. biceps.







arteria anconeae

nervus medianus

aponeurosis bicipitis

vena mediana

Plate X.

Ligature of the brachial artery at the right elbow (art. anconeae).

1. The *cutaneous incision* is made 3^{cm} in length, and 5^{mm} to the inner side of the tendon of the biceps; carefully, so as not to injure the median vein, which is drawn downwards.

2. The *bicipital fascia* is divided. Immediately beneath it is the artery, lying upon the brachialis anticus and between its venae comites.

The *median nerve* lies a few millimetres further inwards, and passes beneath the pronator radii teres.

Plate XI.

1. Ligature of the radial artery in the upper third of the right forearm.

1. The *cutaneous incision* commences 3^{cm} below the fold of the elbow, and runs for 4^{cm} along a line, which divides in the supine position the radial from the central third of the anterior surface of the forearm.

2. *After the division of the fascia* of the forearm, the interval between the bellies of the supinator longus and the flexor carpi radialis is sought for, and enlarged with the tip of the index finger.

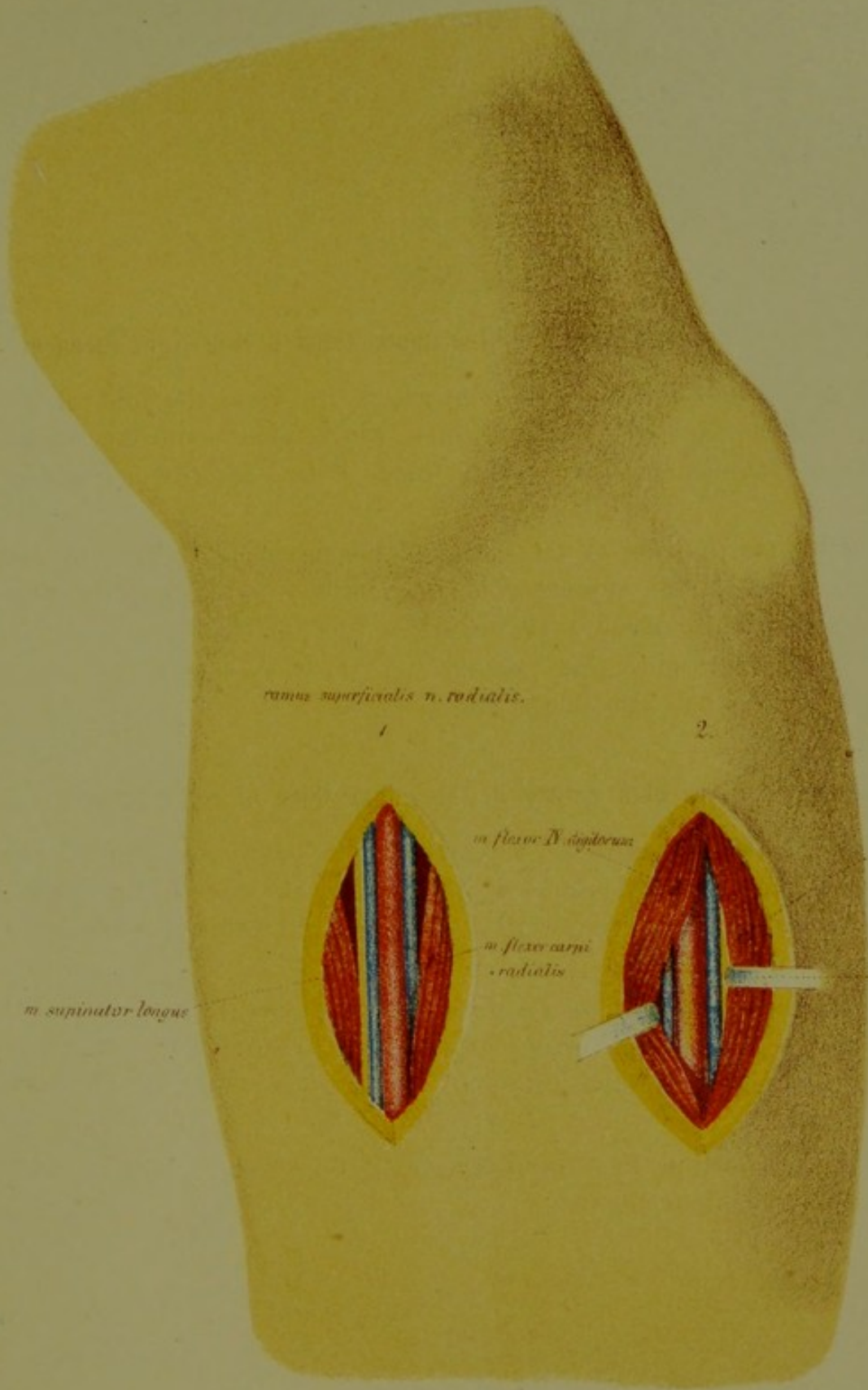
3. At the bottom of the wound lies the *artery* with its *venae comites*; on its radial side is the radial nerve.

2. Ligature of the ulna artery in the upper third of right forearm.

1. The *cutaneous incision* commences 3^{cm} below the fold of the elbow, and runs for 4^{cm} along a line, which divides in the supine position the ulnar from the central third of the anterior surface of the forearm.

2. *After the division of the fascia* of the forearm, the interval between the bellies of the flexor carpi ulnaris and the flexor sublimis digitorum is sought for, and enlarged with the tip of the index finger and blunt hook.

3. At the bottom lies the *artery* with its *venae comites*; on its ulnar side is the ulnar nerve.



ramus superficialis n. radialis.

1

2

m. supinator longus

m. flexor digitorum

m. flexor carpi
radialis

m. flexor carpi
ulnaris

nervus ulnaris





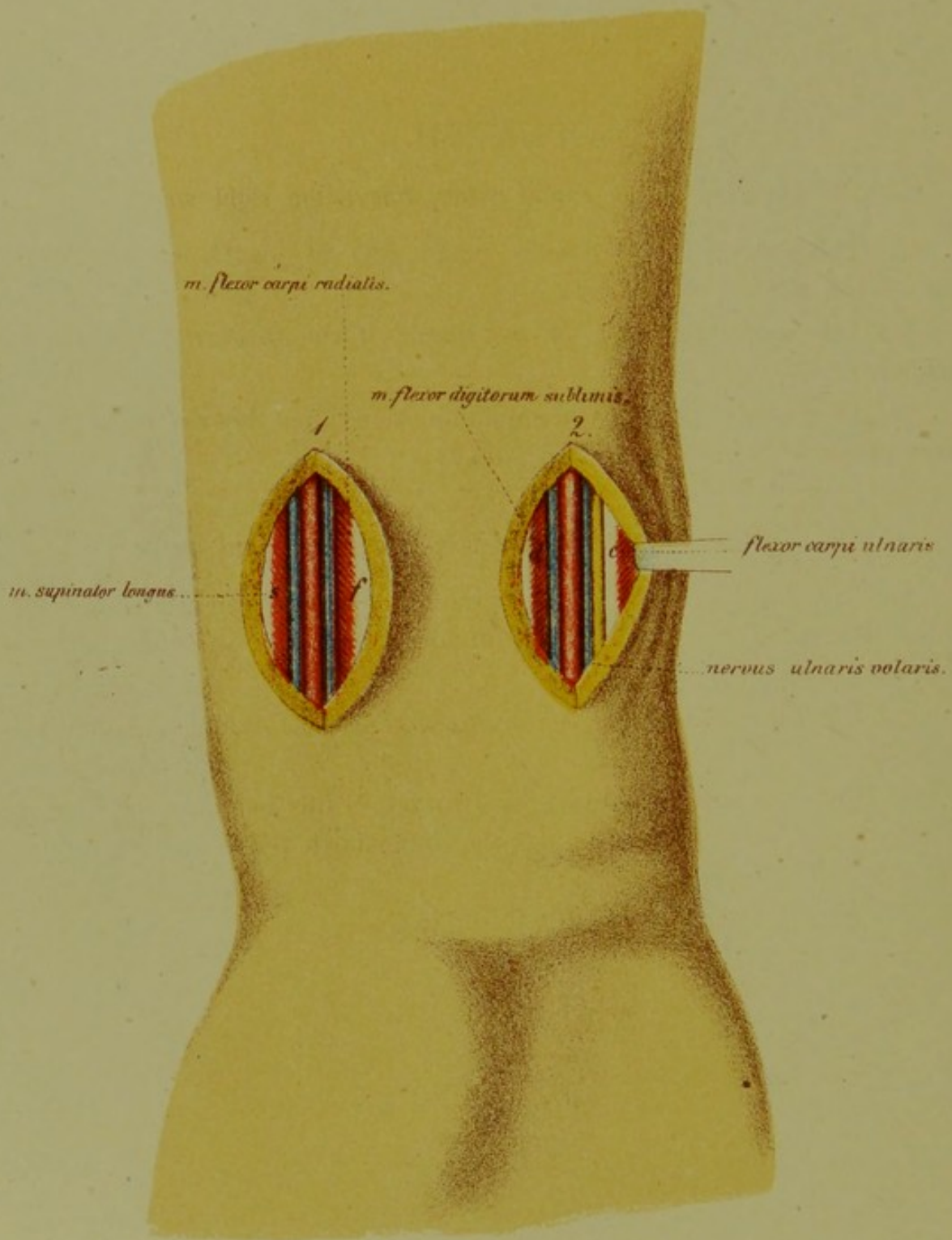


Plate XII.

1. Ligature of the radial artery above the right wrist.

1. The *cutaneous incision* is made 3^{cm} in length on the radial side of the flexor carpi radialis.

2. The *superficial layer of the fascia* of the forearm is cautiously divided.

3. The *artery* with its companion veins lies between the flexor carpi radialis and the supinator longus.

2. Ligature of the ulnar artery above the right wrist.

1. The *cutaneous incision* is made 3^{cm} in length on the radial side of the tendon of the flexor carpi ulnaris, which is inserted into the pisiform bone.

2. The *superficial layer of the fascia* of the forearm is cautiously divided.

3. The *artery* accompanied by two veins, lies between the tendons of the flexor carpi ulnaris, and the innermost tendon of the flexor sublimis digitorum.

On its ulnar side is the ulnar nerve.

Plate XIII.

Ligature of the common iliac artery (left).

1. The *cutaneous incision*, 10—12^{cm} in length, begins 3^{cm} below and to the inner side of the anterior superior spine of the ilium, and ascends vertically, with a slight concavity inwards, almost to the last rib.

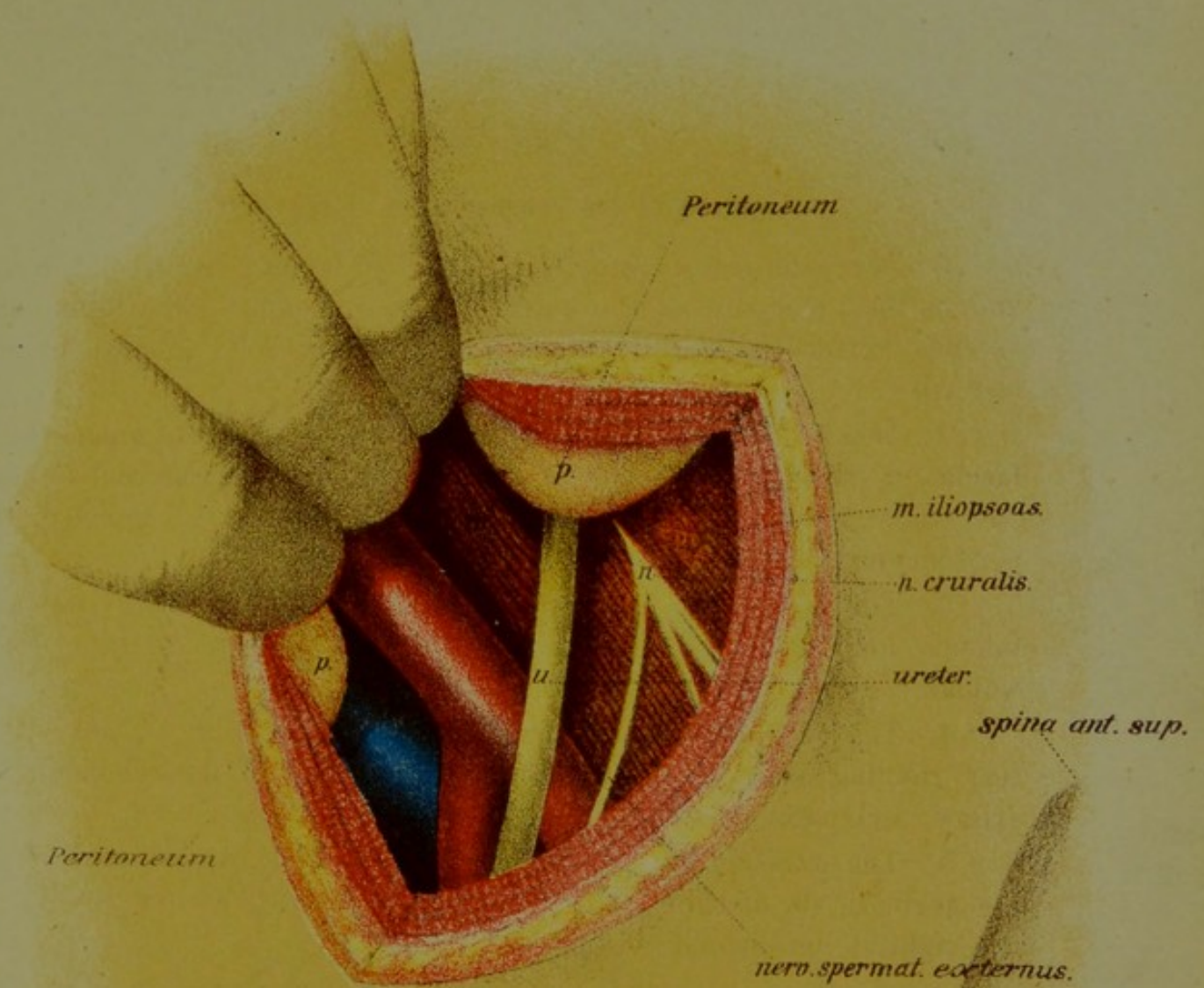
2. When the division of the adipose tissue, of the thin superficial fascia, of *the muscular layers* of the external oblique, internal oblique and transversalis, and of the thin transversalis fascia is completed, the peritoneum is exposed.

3. The *peritoneum* is carefully pressed inwards towards the umbilicus, and drawn with the fingers towards the inner margin of the wound.

4. The *ureter* generally clings to the peritoneum; if not, it is seen running obliquely over the point of division of the common iliac artery, and care must be taken to avoid injuring it.

5. The *whole of the common iliac artery* now lies exposed, from the aorta to its division; on the left the iliac vein lies internally, on the right it lies behind the artery.

NB. The internal iliac artery can also be tied by the same incision.







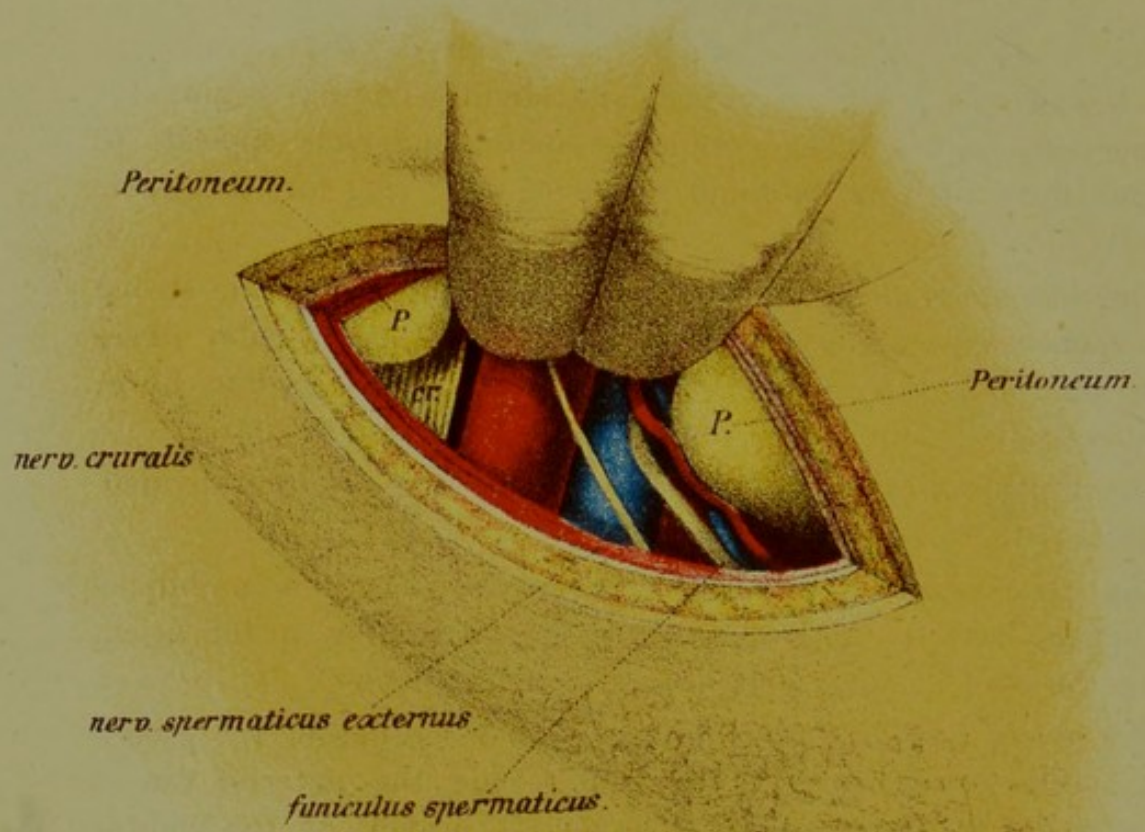


Plate XIV.

Ligature of the external iliac artery (right).

1. The *cutaneous incision*, which is 1^{cm} above and parallel to Poupart's ligament, 8—10^{cm} in length, and slightly convex, begins 3^{cm} to the inner side of the anterior superior spine, and ends opposite to the internal inguinal ring (without exposing the ring or the spermatic cord).

2. The subcutaneous tissue, the thin superficial fascia, the strong tendinous aponeurosis of the *external oblique*, and the muscular fibres of the *internal oblique* are divided; then the horizontal muscular fibres of the transversalis in the outer angle of the wound.

3. The thin subjacent *fascia transversalis* must be carefully divided. (In fat subjects there is still a thin layer of fat.)

4. The *peritoneum* is carefully pressed towards the umbilicus with the fingers bent like a hook (NB. without stripping up the fascia iliaca from the wall of the pelvis and with it the artery).

5. The *artery* lies in contact with the inner border of the psoas; to its inner side is the vein; to the outer side the anterior crural nerve covered by the iliac fascia; the genital branch of the genito-crural nerve crosses the artery obliquely.

Plate XV.

Ligature of the femoral artery (common femoral) below Poupart's ligament (right).

1. The *cutaneous incision* commences at a point midway between the anterior superior spine of the ilium and the symphysis pubis, 2^{mm} above Poupart's ligament, and is carried downwards for 5^{cm}.
2. The *superficial fascia* is divided.
3. The subcutaneous tissue is divided; the lymphatic glands are avoided, by drawing them on one side or by removing them.
4. Division of the *fascia lata*.
5. The *sheath of the vessel* is opened, 1^{cm} below Poupart's ligament (because immediately below it the superficial epigastric and superficial circumflex iliac arteries are given off).
6. The *femoral vein* lies on the inner side of the artery, the anterior crural nerve on the outer side.

ligamentum Poupartii

art. epigastrica inferior.

art. circumflexa ilei.

art. profunda femoris.

fascia lata.

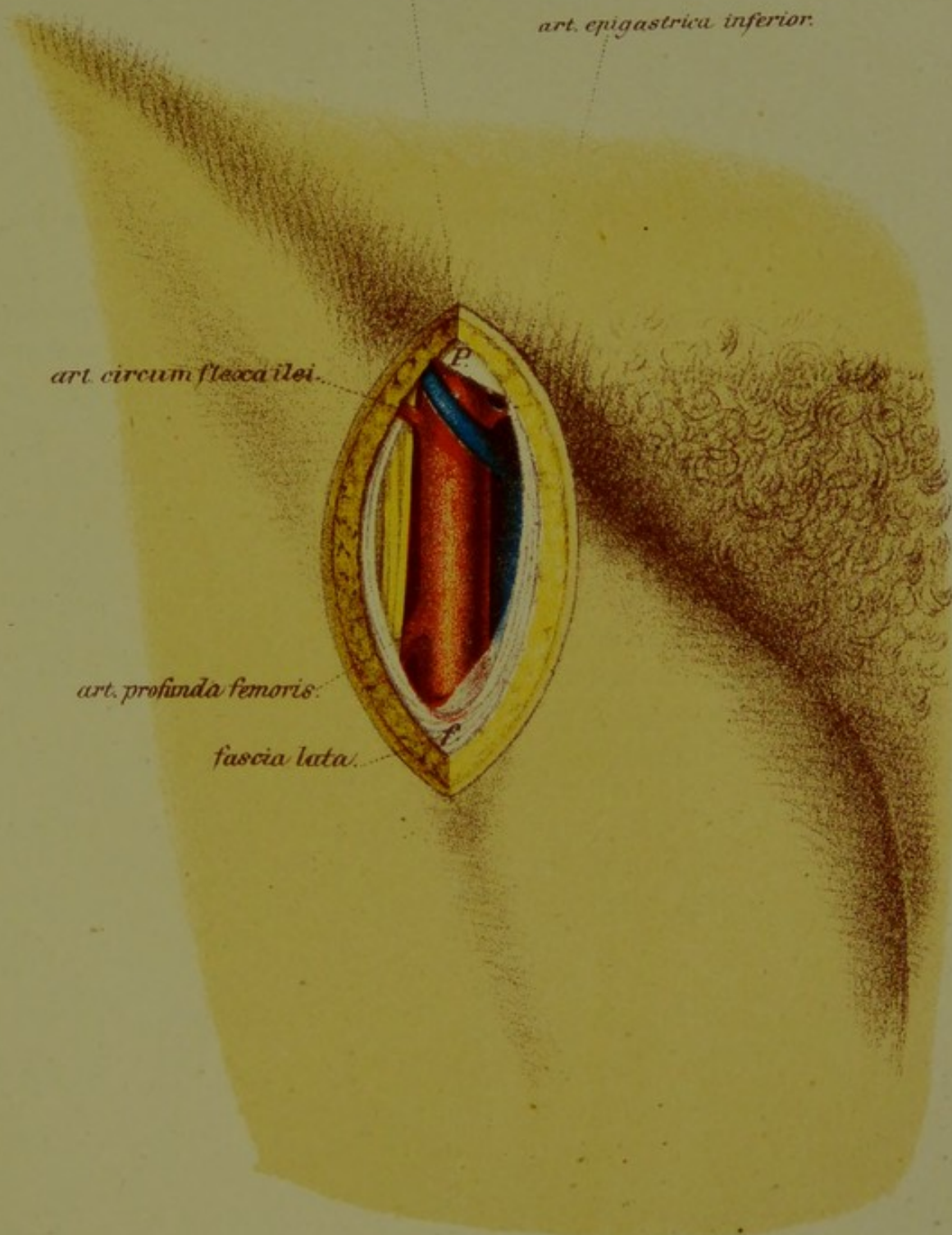





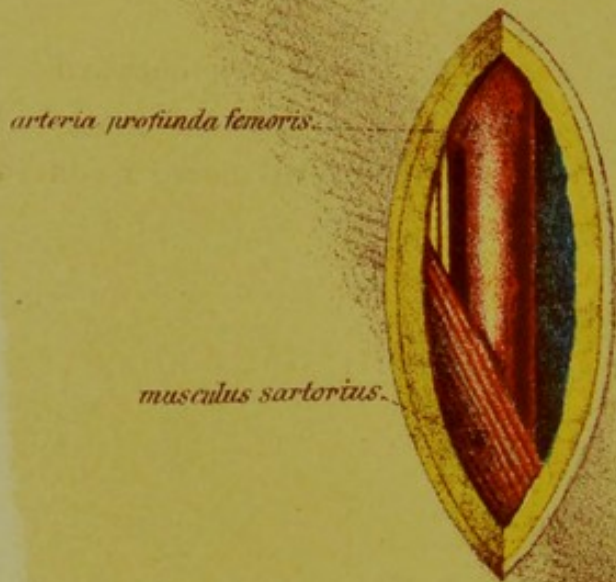


Plate XVI.

Ligature of the femoral artery (superficial femoral) below the origin of the profunda at the apex of the ileo-femoral triangle (Scarpa's) (right).

1. The *cutaneous incision*, 5^{cm} in length at the inner border of the sartorius, commences six fingers breadths (8—10^{cm}) below Poupart's ligament.

2. The *border of the sartorius* is exposed and drawn outwards.

3. The *sheath* is opened. The femoral vein lies to the inner side and somewhat behind the artery; the anterior crural nerve is on the outer side.

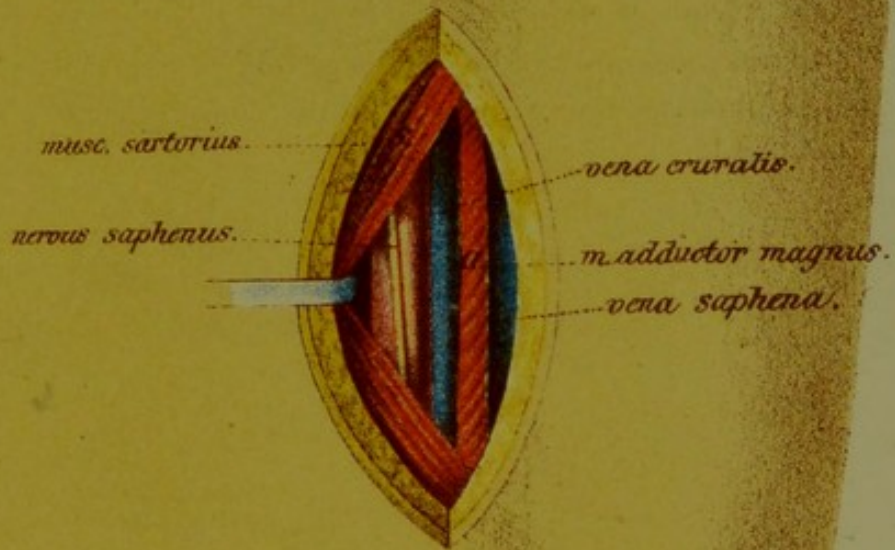
Plate XVII.

**Ligature of the femoral artery in the middle of the thigh
(HUNTER'S canal) (right).**

1. The *cutaneous incision*, 8—10^{cm} in length, is made over the sartorius, in the middle of a line drawn from anterior superior spine of the ilium to the internal condyle of the femur.

2. The *sheath of the sartorius* is opened, the muscle liberated and drawn outwards till the posterior wall of the muscular sheath, which covers the canal, is exposed.

3. After *opening the canal* the artery is exposed; upon it runs the internal saphenous nerve, behind it the femoral vein.

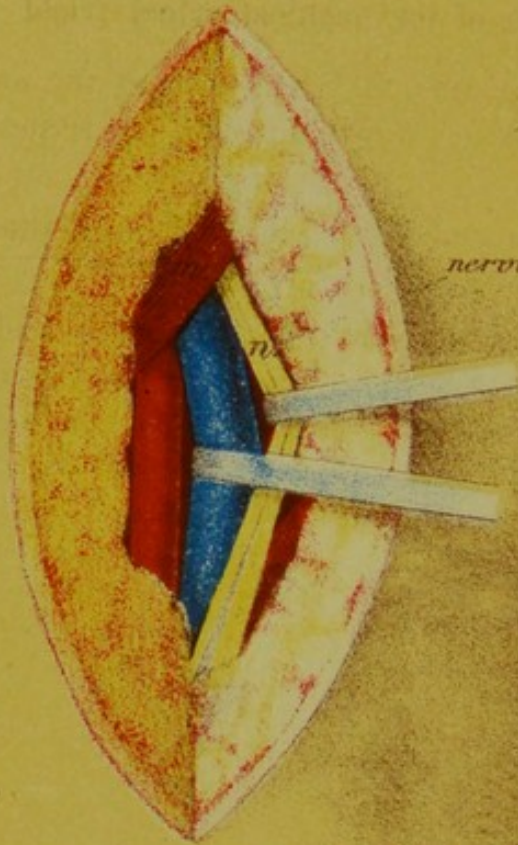






musc. semimembranosus

nervus tibialis



m. gastrocnemius

Plate XVIII.

Ligature of the popliteal artery (right).

1. The *cutaneous incision*, 8^{cm} in length at the outer border of the semimembranosus, is carried down through the tissues of the popliteal space.

2. The dense fascia and fat are divided, until the internal popliteal nerve (nervus tibialis) is visible.

3. The *nerve* is drawn outwards; behind it and somewhat to its inner side lies the *popliteal vein*, which is loosened and drawn outwards; behind the vein and slightly to its inner side lies the artery.

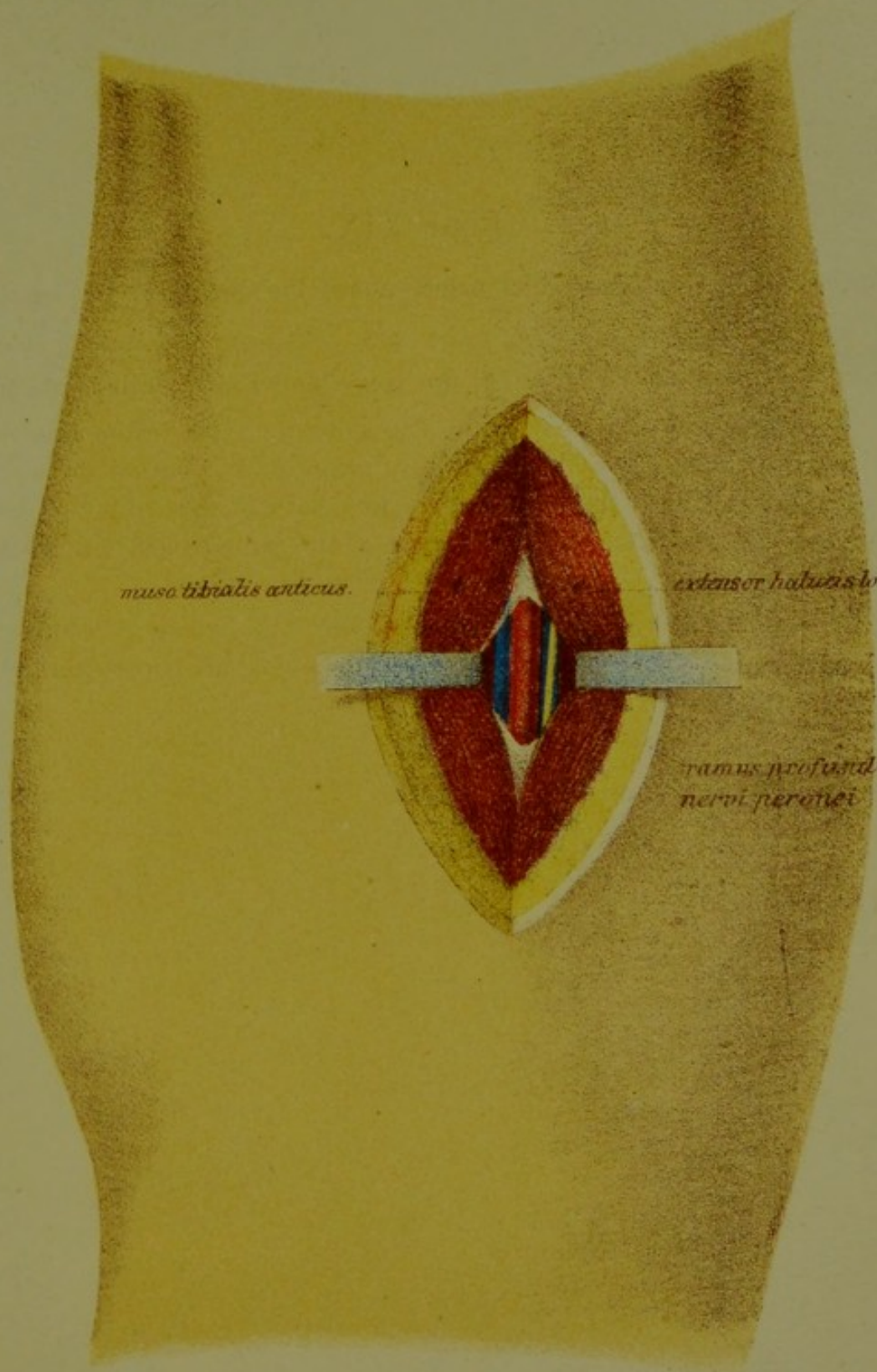
Plate XIX.

Ligature of the anterior tibial artery above the middle of the leg (left).

1. The *cutaneous incision* is 6—8^{cm} in length, and 3^{cm} to the outer side of the crest of the tibia (in the space between the tibia and fibula).

2. The *fascia* is divided in the course of the *white line* nearest the tibia, which will lead to the intermuscular septum between the tibialis anticus and the extensor longus halucis: the interval between these muscles is widened with the tip of the index finger till the sheath is visible.

3. After careful division of the *sheath*, the artery is seen between two veins; on its outer side lies the anterior tibial nerve (*nervus peroneus profundus*).



musculus tibialis anterior.

extensor hallucis longus

*ramus profundus
nervi peronei*





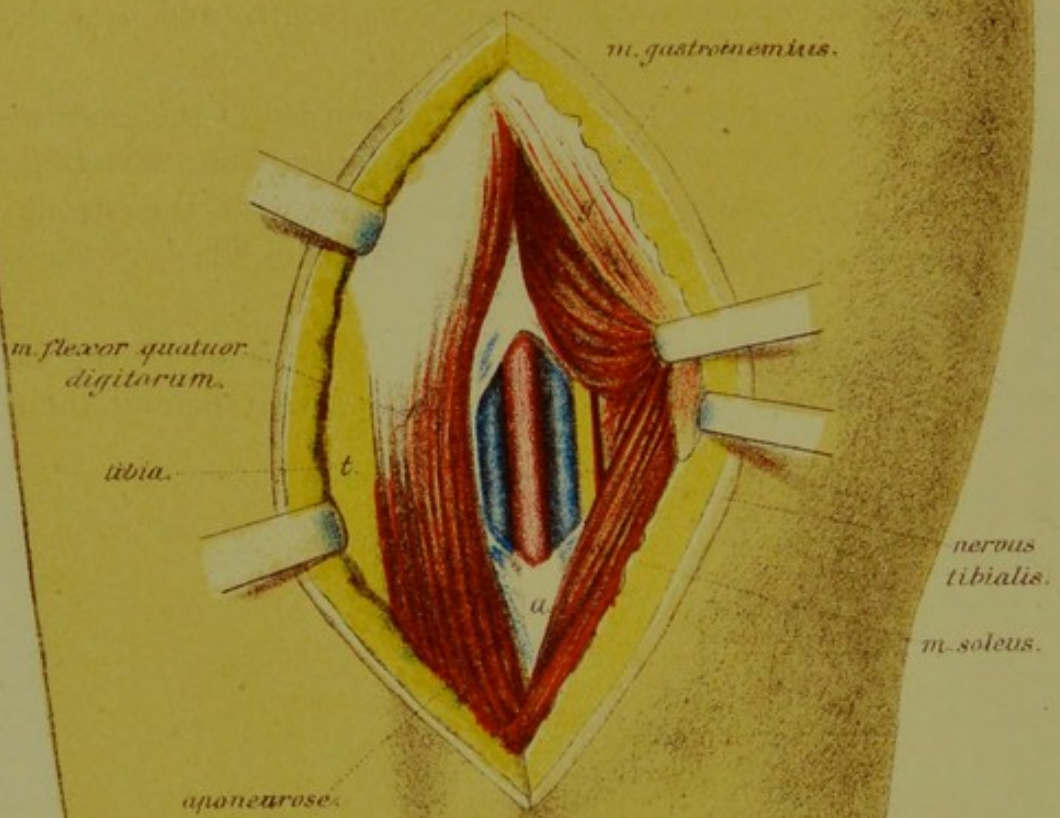


Plate XX.

Ligature of the posterior tibial artery above the middle of the leg (right).

1. The *cutaneous incision* is 8—10^{cm} in length, and at a distance of 1^{cm} from the inner edge of the tibia.

2. After the division of the fascia, the border of the *gastrocnemius* is drawn backwards, and the *soleus* separated from the tibia: the opening is enlarged with the tip of the finger, till the strong deep aponeurosis appears, which consists of the tendinous fibres of the soleus, and the deep fascia of the leg.

3. After the division of this fascia, the *artery* is seen lying between its two veins; the posterior tibial nerve is somewhat behind the artery.

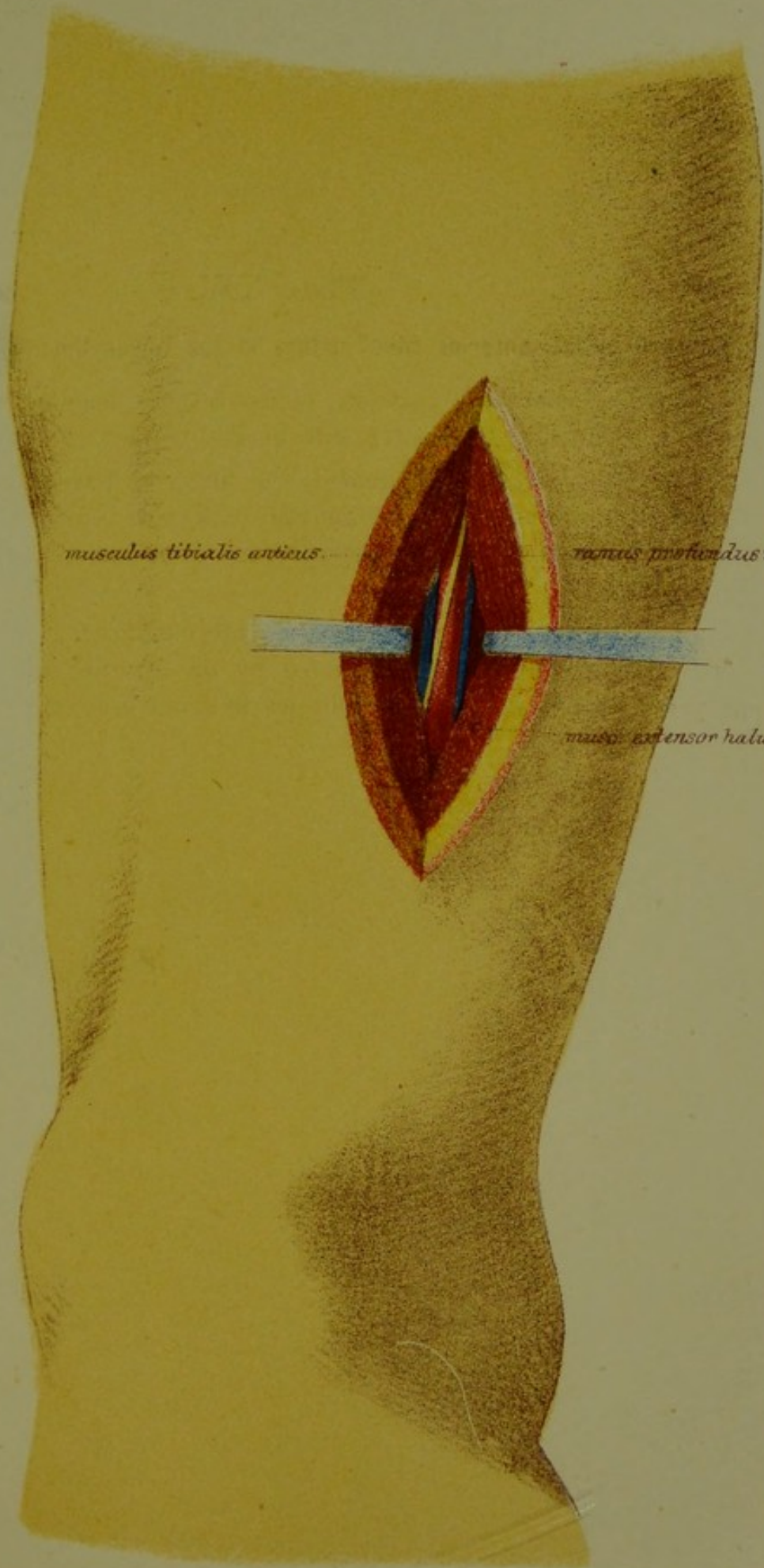
Plate XXI.

Ligature of the anterior tibial artery in the lower third of the leg (left).

1. The *cutaneous incision* is 5—6^{cm} in length, vertical, and a finger's breadth to the outer side of the crest of the tibia.

2. The *fascia being divided*, the finger is pushed into the interval between the tibialis anticus and the extensor longus halucis, and the muscles separated till the interosseous membrane is reached (2—3^{cm} in depth).

3. The *artery* is placed upon the interosseous membrane between its venae comites, and is accompanied by the anterior tibial nerve (ramus profundus nervi peronei), which lies in front and on the inner side.



musculus tibialis anticus.

ramus profundus n. peronei.

muso. extensor halucis longus.





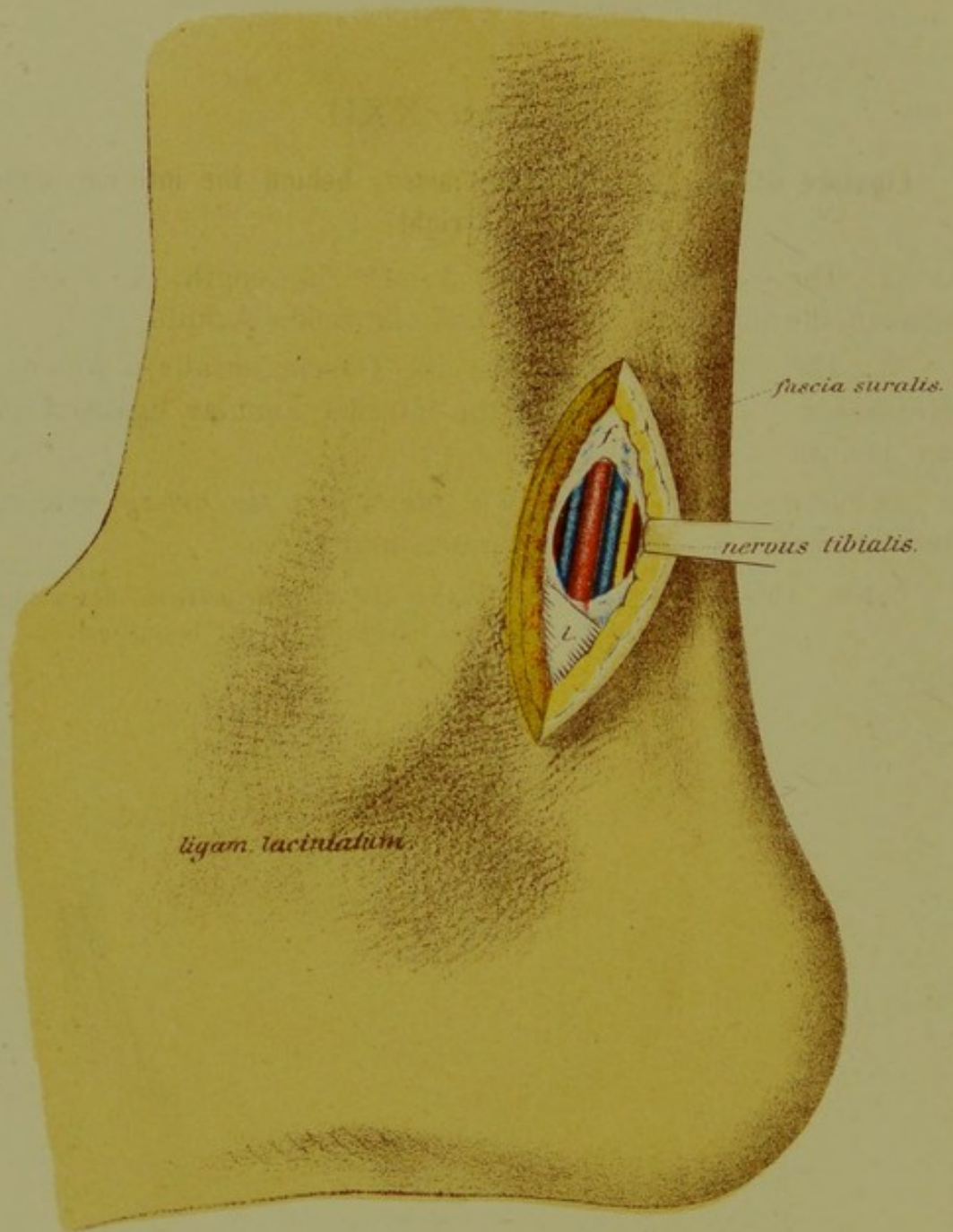


Plate XXII.

**Ligature of the posterior tibial artery behind the internal malleolus
(right).**

1. The *cutaneous incision*, 3—4^{cm} in length, is made midway between the internal malleolus and the tendo Achillis.

2. The *deep fascia* of the leg (*fascia suralis*), which is here strengthened by the fibres of the internal annular ligament (*ligamentum laciniatum*), is divided.

3. Immediately *beneath this fascia lies the artery* with its *venae comites*; behind it is the posterior tibial nerve.

NB. The *sheaths for the tendons* of the *tibialis posticus*, *flexor longus digitorum*, and the *flexor longus halucis* must not be opened.

C. BLOOD-LETTING (VENAESECTIO, PHLEBOTOMIE).

1. As a rule the vein, which projects most prominently at the fold of the elbow, is opened for the abstraction of blood.

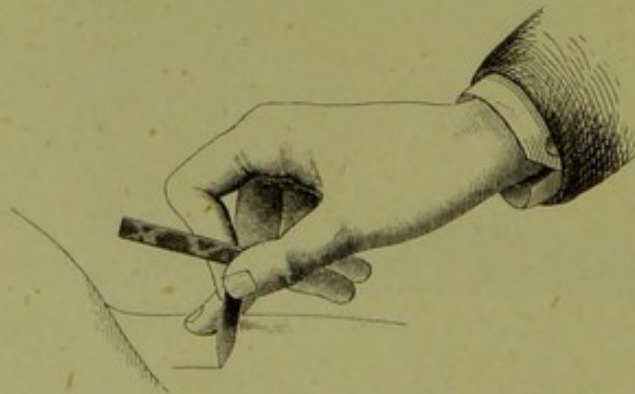
2. In most cases this is the *median basilic vein*. But since it almost always crosses the brachial artery, and is only separated from it by the bicipital fascia, it is advisable, before beginning the operation, to feel for the pulsation of the artery and to make the opening in the vein either above or below the point of crossing.

3. The patient should be *in a recumbent position* and allow the arm to hang, so that the veins may fill.

4. A *bandage* (or a folded handkerchief) is tied round the middle of the upper arm, tightly enough to prevent the return of the venous blood, but not enough to interrupt the arterial current (the radial artery must not cease pulsating). The knot of the bandage is so tied, that it may be loosened by pulling at the end, which hangs down.

5. The operator fixes the arm by clasping it between his own upper arm and his chest, the vein is steadied by the pressure of his thumb below the point of puncture.


Fig. 286.



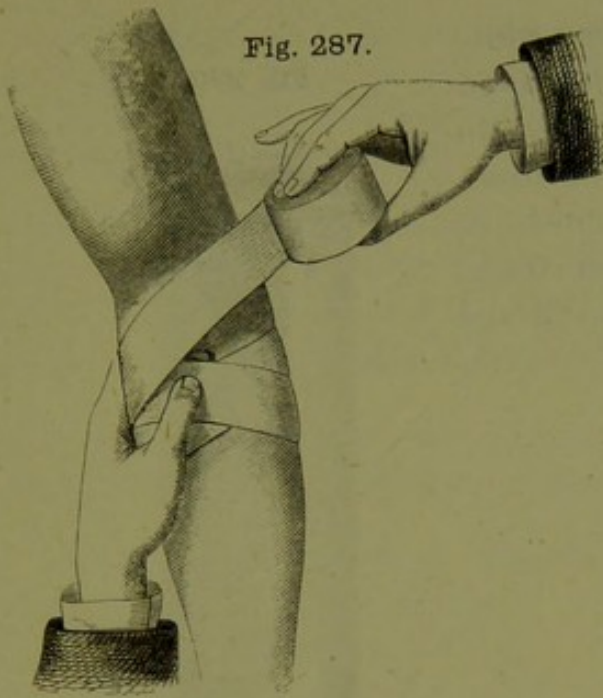
Venesection with the lancet.

6. A *puncture* is made through the skin into the vein with a lancet (fig. 286), or LORINSER'S phlebotome (plate XXIII). This is enlarged by raising the point in such a way, that the anterior wall of the vein is divided in an oblique direction for about 5^{mm}.

7. The blood must issue in a forcible jet; if the stream becomes slow, it can be assisted by alternately opening and shutting the hand.





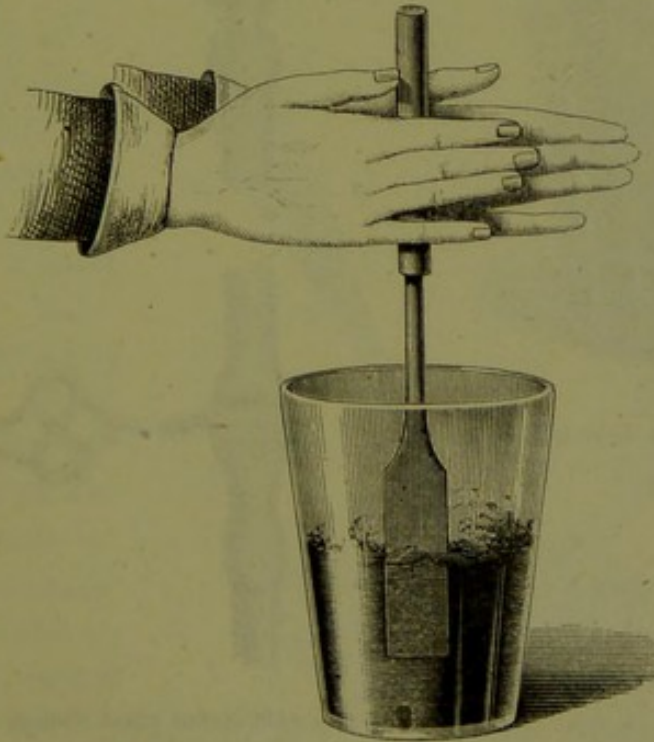


Dressing after venesection.

D. TRANSFUSION.

(TRANSMITTING BLOOD FROM ONE MAN TO ANOTHER.)

Fig. 288.



Defibrinating the blood by twirling a spatula.

8. When a sufficient quantity of blood has been removed, the bandage is taken off, the skin wound pushed somewhat above the opening in the vein, and an antiseptic compress applied. This is fixed, with the forearm slightly flexed, by a figure of eight bandage (fig. 287).

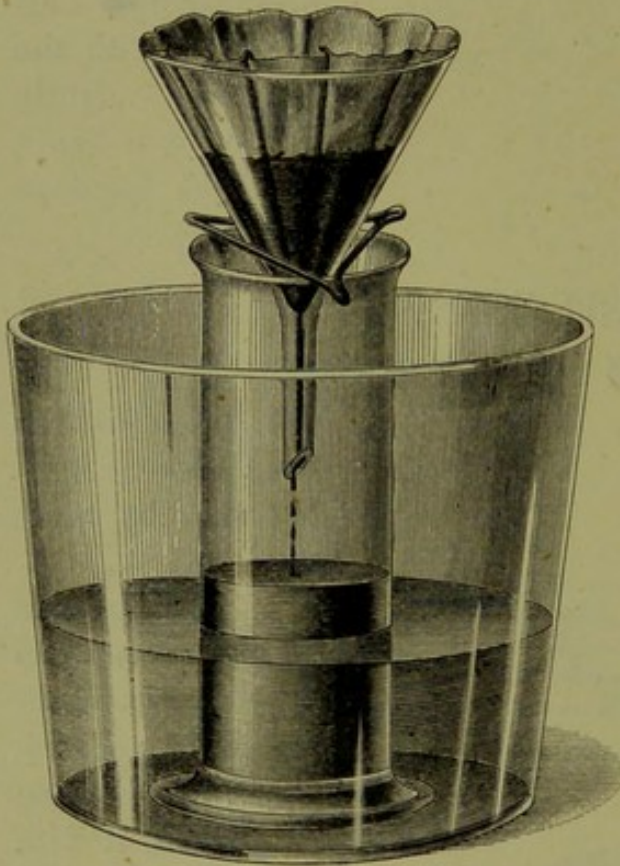
1. Blood is taken from a *strong healthy man* by venesection.

2. The blood is caught in a *clean glass vessel* and immediately *defibrinated*, by whipping or stirring it with a clean rod or spatula, of glass, wood, or vulcanite (fig. 288).

3. The whipped blood is *filtered* through a clean thick linen cloth, then again whipped

and again filtered through clean white satin, the dressing of which has been previously removed by washing in distilled water. The filter can be either placed in a clean glass funnel, or stretched out over a wooden frame provided with small pins (fig. 289 and 290).


Fig. 289.



Filtering defibrinated blood through linen into a glass vessel.

4. The filtered blood flows into a clean dry glass vessel, which is placed in warm water at 40° centigrade (104° Fahrenheit), and remains there till it is required for use.

Fig. 290.



Filtering defibrinated blood through satin into a glass cylinder.

Note. Whipped blood can be kept for 24 hours in a well covered vessel, surrounded with ice, but before the transfusion it must be heated by placing it in warm water at 36° centigrade (97° Fahrenheit), and saturated with oxygen by repeatedly drawing it in and out of a syringe.

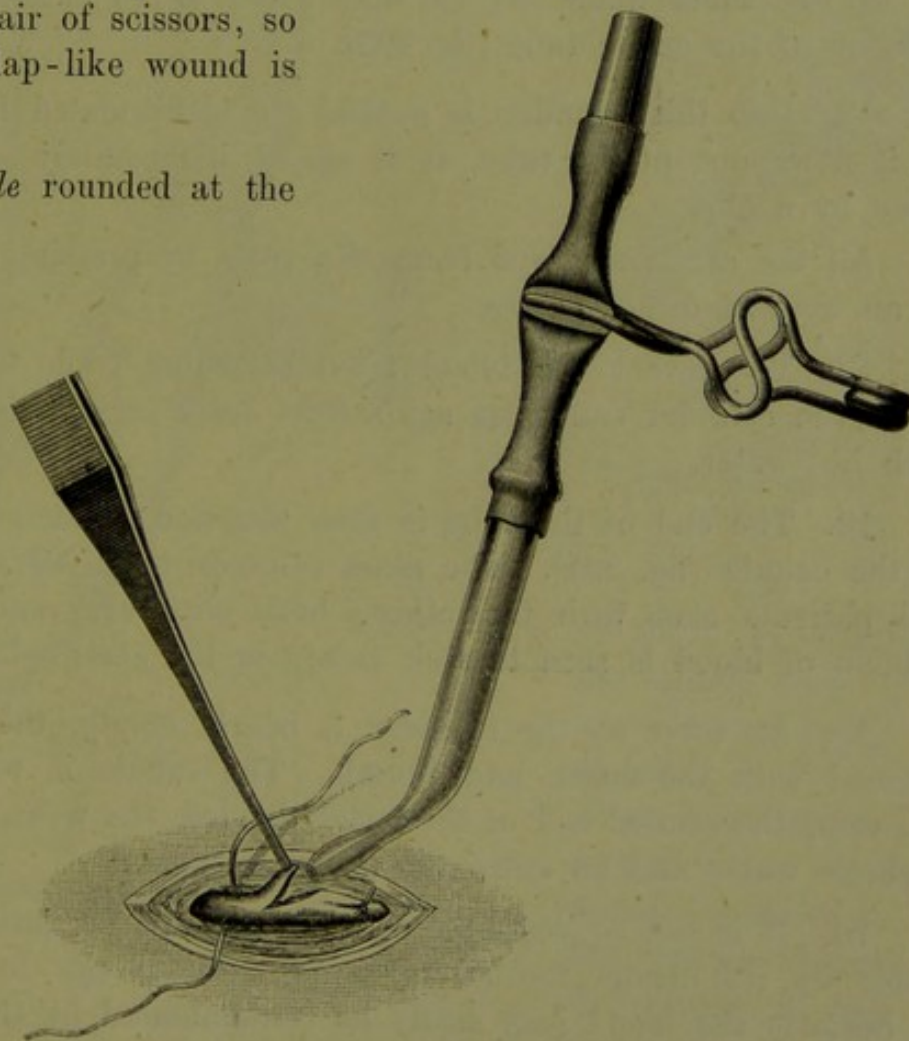
5. Meanwhile on the patient, a subcutaneous vein (e. g. the median basilic at the elbow, or the internal saphenous in front of the internal malleolus) is exposed by incising a fold of skin, and sufficiently isolated to allow two catgut ligatures to be drawn beneath it.

6. The distal part of the vein is tied with one ligature; the other ligature is pushed beneath the proximal portion.

7. The exposed vein is opened by raising the upper wall with a fine pair of toothed forceps, beneath which an oblique slit is made with a pair of scissors, so that a small flap-like wound is produced.

8. A *canule* rounded at the point (of glass, vulcanite or silver) is pushed into the central part of the vein, by raising the flap, and causing the wound in the vein to gape. The canule is fastened with the second catgut thread (fig. 291).

Fig. 291.



Introduction of the canule.

9. The canule and the india-rubber tube fastened to it, together with the connecting piece of vulcanite, are previously completely filled with defibrinated blood (or with a weak solution of carbonate of sodium [$\cdot 3$ per cent], or common salt [$\cdot 5$ per cent]), and closed by means of a clip.

10. The best plan of conveying the defibrinated blood is to employ *hydrostatic pressure* as in the irrigator: for example, in the following manner —

11. A graduated glass cylinder, which holds 3—400 fluid grammes, ends below in a rounded and perforated point, to which is fastened a foot of india-rubber tubing. In the lower end of the latter is put a small perforated connecting piece of vulcanite, which accurately fits the connecting piece of the canule. The calibre of these parts must all be of the same diameter, so that there is no interruption in the interior of the entire tube (fig. 290).

12. Into this cylinder is poured the defibrinated blood; as soon as it flows out of the tube, it is closed immediately above the end-piece by a clip.

All the air is removed from the tube by pressing and squeezing in an upward direction.

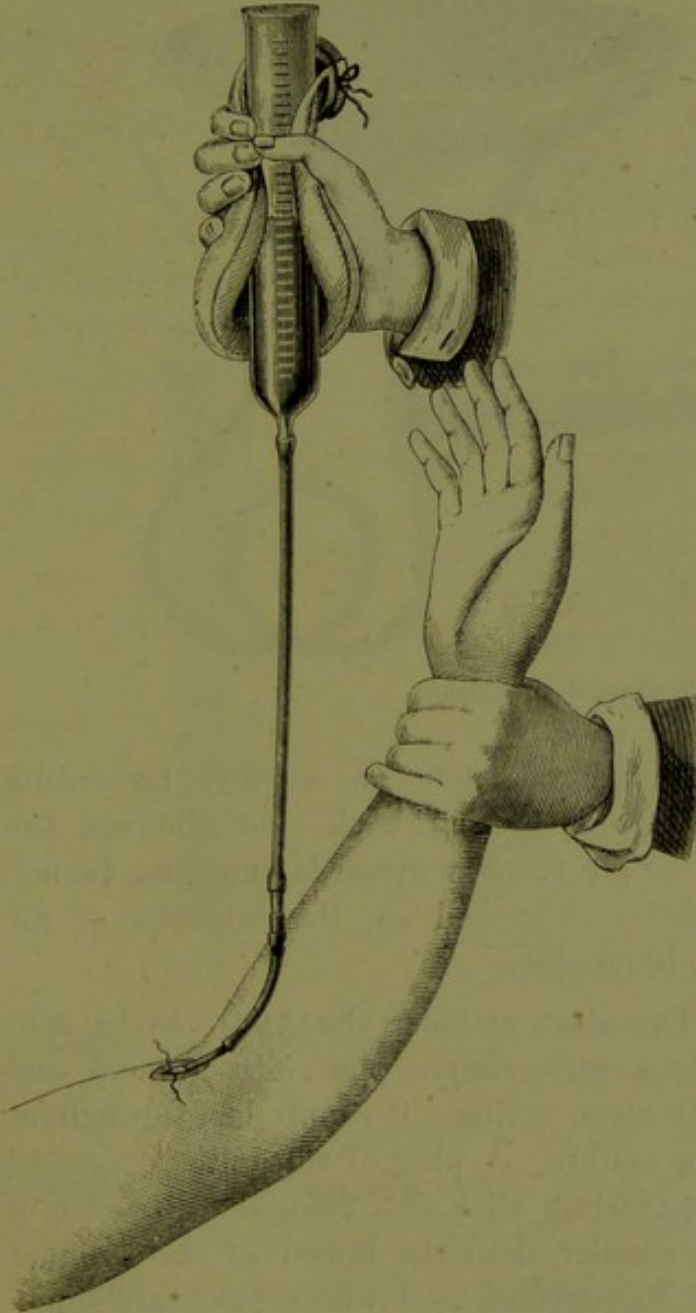
13. To prevent the blood from becoming cool, the hand which holds the cylinder can press against its outer surface an ice-bag filled with hot water.

14. The end of the tube is then attached to the connecting piece of the canule (fig. 291). The glass cylinder is raised with one hand, the patient's arm with the other, both clips are removed, and the column of blood is seen to sink slowly in the glass cylinder (fig. 292).

15. As soon as the cylinder is nearly empty, the tube is compressed with the finger and thumb. The canule is withdrawn from the vein, the central end of the latter divided, the wound cleansed with carbolic water and an antiseptic dressing applied.

16. It is not so desirable to use a syringe for transfusion, 1) because by its means too strong a pressure is apt to be employed, 2) because the blood may easily be contaminated by the piston (from rancid oil, from the dried remains of some previous injection etc.)

Fig. 292.

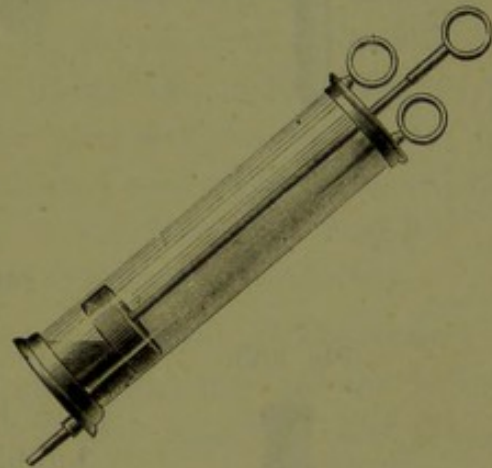


Transfusion by hydrostatic pressure.

and 3) because the risk of the entrance of air into the veins is thereby increased.

17. To avoid this latter complication UTERHART'S *glass syringe* (fig. 293) can

Fig. 293.

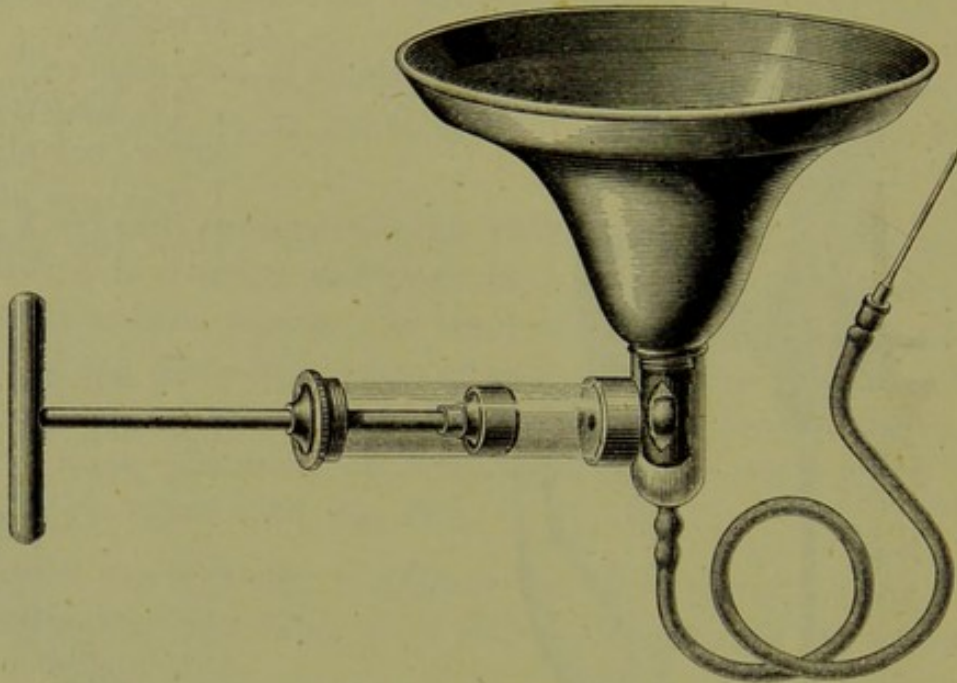


UTERHART'S transfusion syringe.

be used, in which the outlet-tube is placed excentrically, so that any air, which may be present above the fluid, remains behind in the syringe, if only the piston is not pushed to the extreme end.

18. COLLIN'S *transfusion apparatus* (fig. 294) has been introduced into the French army. It is an instrument, in which a light hollow

Fig. 294.



COLLIN'S transfusion apparatus.

Fig. 295.



Twirling stick and piston.

ball of aluminium acts as a valve preventing the blood from flowing back, but allowing the bubbles of air to pass upwards into the funnel. If the piston is pushed on, the injection of air becomes impossible.

19. The glass cylinder (fig. 292) can be converted by a very simple plan into a good and absolutely clean syringe, if it only has throughout a uniform calibre. A plug of vulcanite is screwed on to the twirling stick (fig. 295), the diameter of which is smaller than the lumen of the cylinder by a few millimetres, and whose sides are somewhat concave. Wadding, jute, gauze, or cotton wick is wrapped round, and tied on to it by a piece of protective silk. A piston is thus formed, which is absolutely clean and accurately fills the lumen of the cylinder. If the point is always

held vertically, and the action of the piston interrupted before the blood column has been pressed down to the lower end of the cylinder, no fear need be entertained of injecting air into the vein.

20. When using the syringe it is more especially important, that the piston should be worked *very slowly* and regularly, for fear of over-

Fig. 296.



HASSE'S syringe for transfusion.

filling the right heart. Not more than 25 grammes of blood a minute should ever be injected. In HASSE'S transfusion syringe (fig. 296) the piston is worked by a female screw, whose revolutions permit a very gentle and uniform pressure.

21. The above mentioned danger is most certainly avoided by employing an artery for the injection, as HÜTER does (*arterielle transfusion*). In adults the radial artery above the wrist or the posterior tibial artery behind the internal malleolus is chosen for the purpose, in children the brachial artery at the inner border of the biceps.

22. The artery is exposed as above described, and two catgut ligature passed beneath it. With one the artery is tied at the central end of the incision, and then opened by a small flap-like wound: the point of the syringe is pushed into the opening towards the periphery, and firmly tied in by the second ligature.

23. Since considerable pressure must be employed in arterial transfusion, to drive the blood through the capillaries, a good syringe must be used for this purpose or COLLIN'S apparatus.

24. As soon as the transfusion is finished, the syringe is withdrawn from the artery, and the peripheral end ligatured. The artery is then divided between the two ligatures, and the wound dressed antiseptically.

25. In many cases transfusion can be avoided by temporarily driving the blood out of the extremities, elastic bandages being tightly

applied from below upwards (Autotransfusion, MÜLLER). In others a moribund patient can at any rate be supported by this method till transfusion can be performed.

E. THE REMOVAL OF LIMBS.

(AMPUTATIONS AND DISARTICULATIONS.)

I. GENERAL RULES FOR AMPUTATIONS.

a. Preliminary steps.

1. *Each assistant* has his especial duty and position pointed out to him. The patient is so placed, that the chloroform can be easily administered, and the operator and assistants have sufficient room.

2. The *limb* to be amputated must be turned to the light.

3. The *operator* stands in the most advantageous position, when the amputated limb falls towards his right side (fig. 297).

4. Before commencing the operation, the *skin* in the neighbourhood of the amputation is shaved, most carefully cleaned with soap and brush, and afterwards thoroughly washed with a strong carbolic solution.


5. Narcosis being induced, the extremity is made *bloodless* to a point above the seat of amputation, and after the removal of the bandage again washed with the carbolic solution.

6. During the whole operation all the rules of *antiseptic* surgery are most rigidly followed (page 12).

b. Division of the soft parts.

The *soft parts* must be divided in such a way, that they give a plentiful covering to the sawn surfaces of the bones. The muscles are best cut through perpendicularly to the axis of the limb, for if the muscles are divided obliquely, the vessels are also divided obliquely, and cannot be easily and securely tied. For this reason, of all methods the circular operation and the method by skin-flaps with circular division of the muscles are most to be recommended.

Fig. 297.

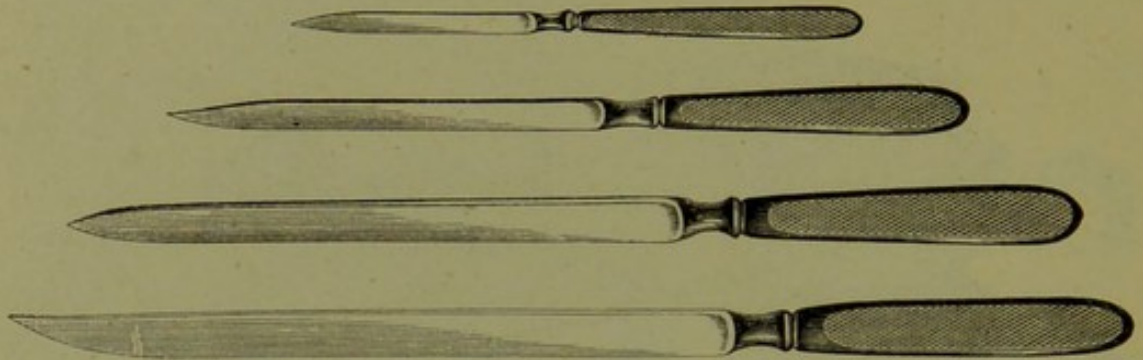


Operator and assistants engaged at an amputation.

1. *The single circular incision (CELSUS).*

With *one stroke* of an amputating knife (fig. 298), the length of which varies in proportion to the thickness of the limb, the soft parts

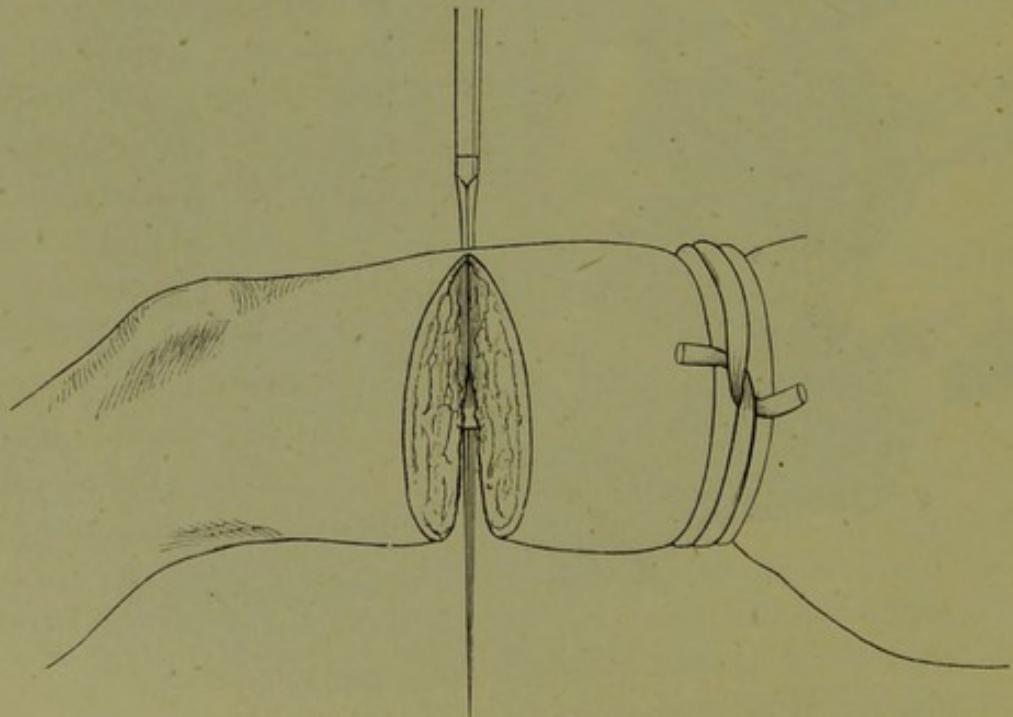
Fig. 298.



Four amputating knives.

are all divided right down to the bone (fig. 299), and the bone immediately sawn through. In order that the soft parts may cover the

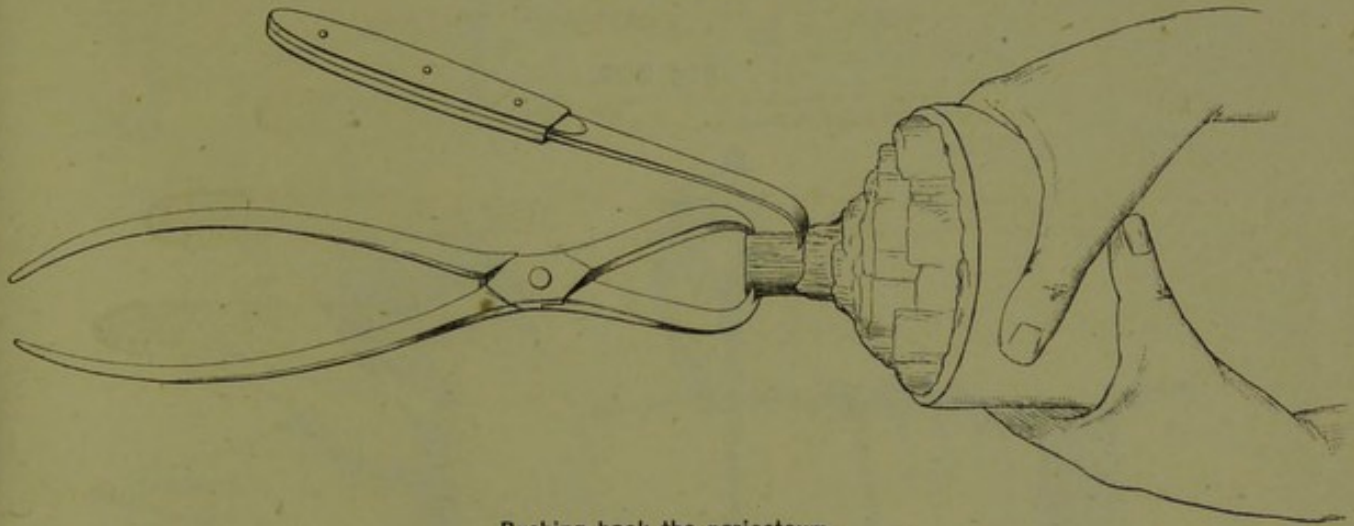
Fig. 299.



Single circular incision.

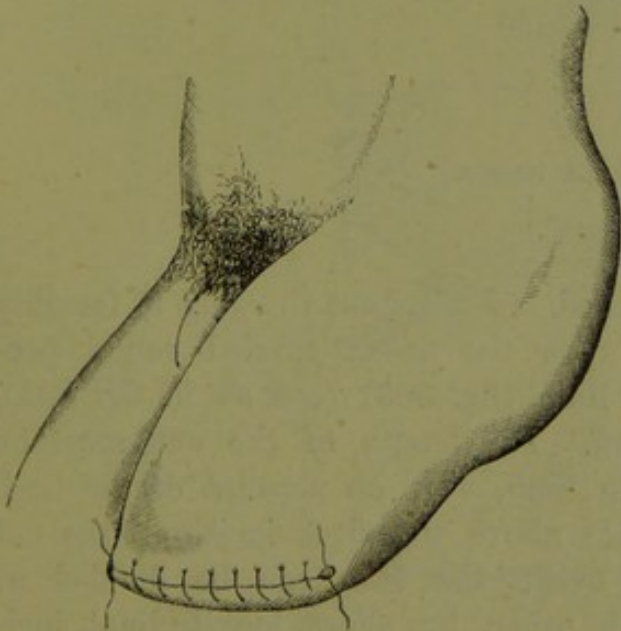
bone without stretching, it must be sawn through again as high up as the diameter of the limb requires. For this purpose the end of the bone is seized with a pair of clutch forceps, and while the soft parts are drawn forcibly upwards, the periosteum is peeled up by a raspator till the bone is uncovered for the required distance.*

Fig. 300.



Pushing back the periosteum.

Fig. 301.



Stump after the single circular incision.

For limbs with one bone this method yields the smallest and most level wound of all. It is not suitable for limbs with a large muscular development, but is particularly good for patients wasted and exhausted with prolonged suppuration.

The wound can be united in any direction by sutures.

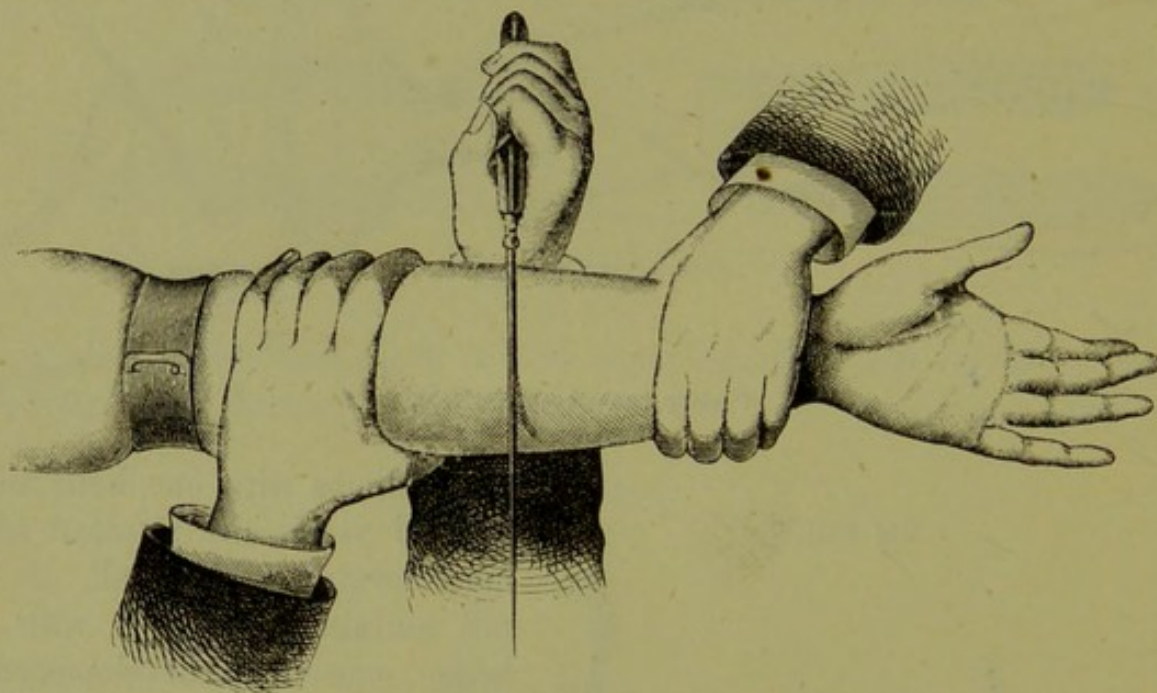
Fig. 301 shows the appearance of a recent stump, after it has been united transversely.

* BRÜNNINGHAUSEN has already recommended this treatment in his "Erfahrungen und Bemerkungen über die Amputation", Bamberg 1818, page 65 and page 76.

2. *The double circular incision (PETIT).*

In the first place the skin is divided down to the fascia by a circular incision round the limb (fig. 302).

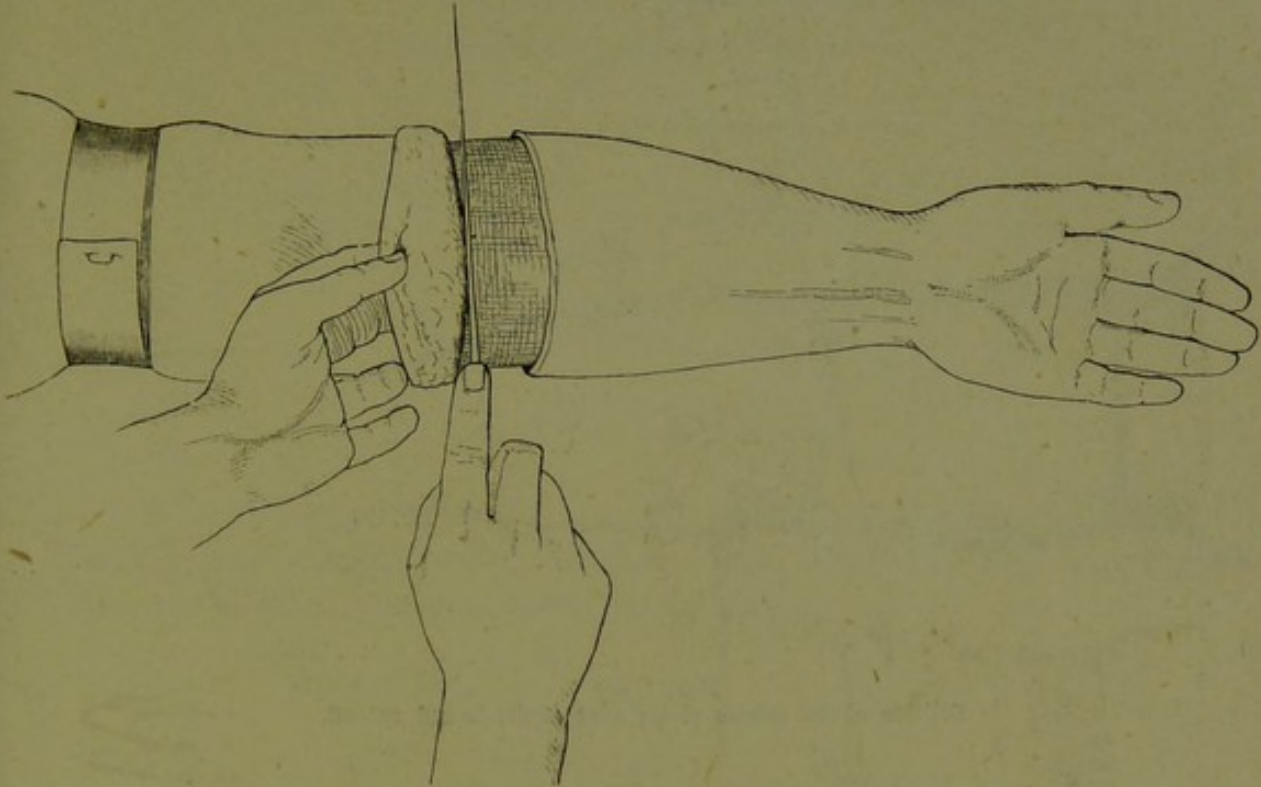
Fig. 302.



Double circular incision.

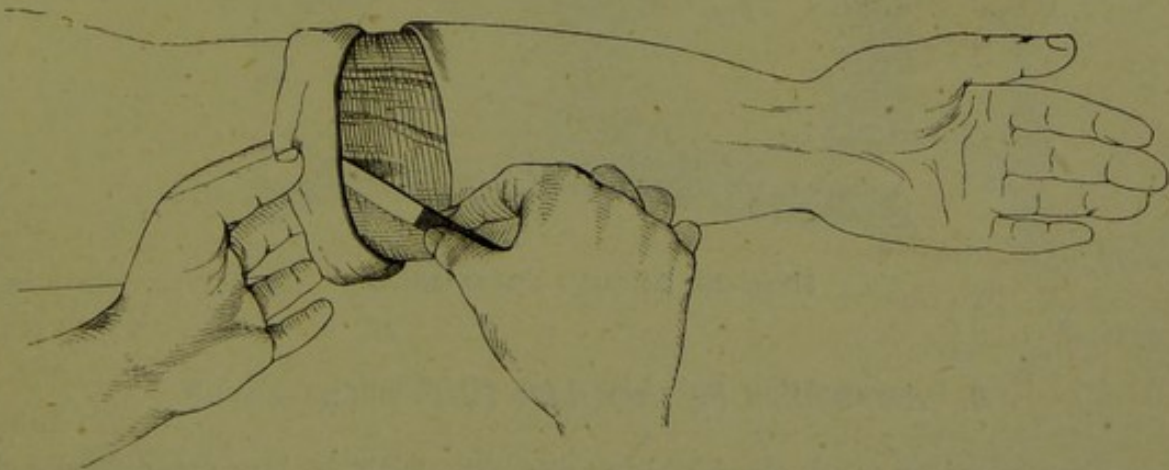
The integument is then detached, an assistant drawing it forcibly upwards, by repeated incisions upon the fascia carried round perpendicularly to the axis of the limb (fig. 303) (not as in fig. 304), till it can be turned up like a cuff. The length of the cuff must be equal to half the diameter of the limb. If, on account of the limb increasing rapidly in circumference above the first incision, the cut border is too narrow to turn over, the skin can be divided at one or two places opposite each other by short longitudinal incisions (see disarticulation at the knee). The muscles are now divided all round close to the line of reflexion by one steady circular

Fig. 303.



Detaching the skin cuff from the fascia.

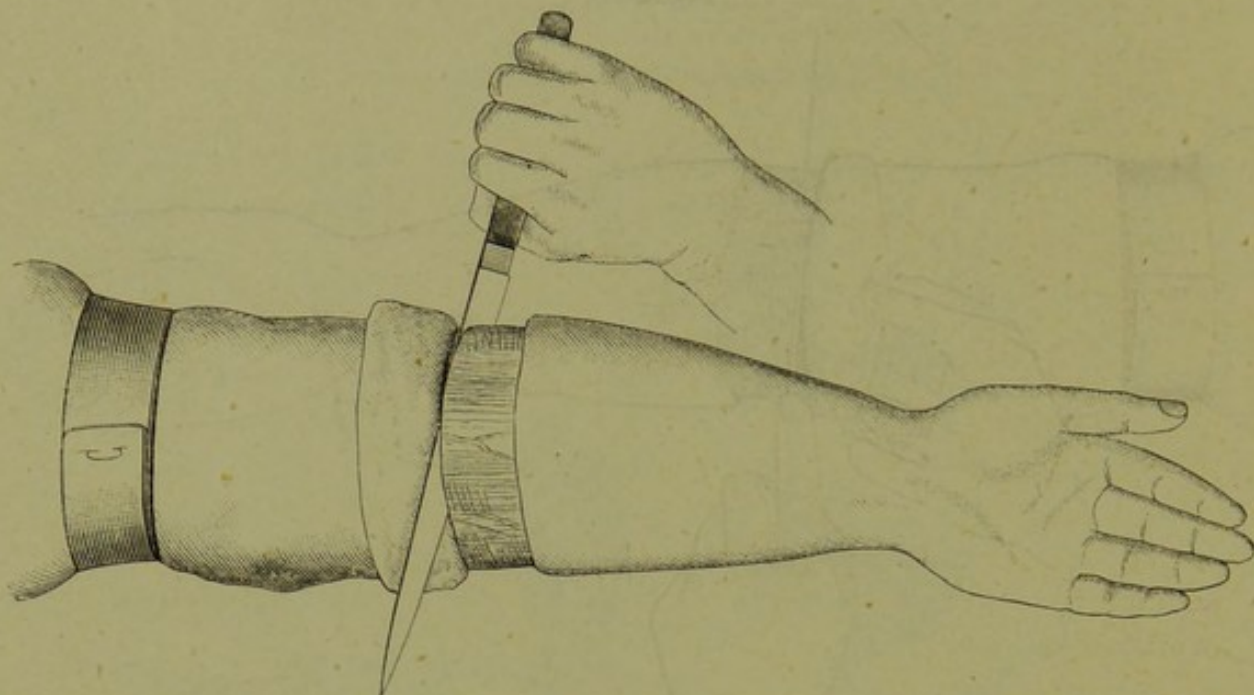
Fig. 304.



Faulty execution of the incision.

sweep of the knife down to the bone (fig. 305), and then the bone
sawn through.

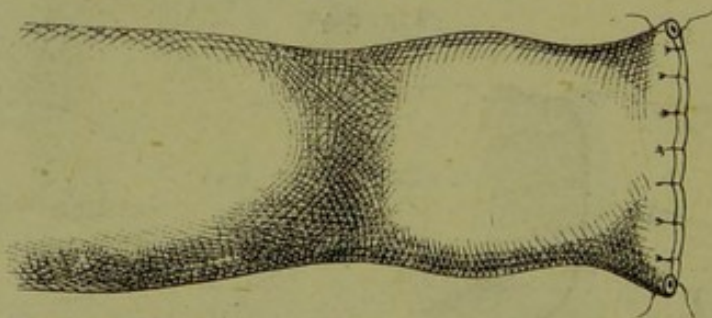
Fig. 305.



Division of the muscle at the edge of the turned up cuff.

Fig. 306 shews the appearance of the recent stump.

Fig. 306.




Stump after the double circular incision.

3. *Amputation by skin flaps* (BRÜNNINGHAUSEN).*

Two semilunar flaps of skin are cut with a large convexedged scalpel (fig. 307): these are detached to their bases from the fascia, and turned upwards (fig. 308).

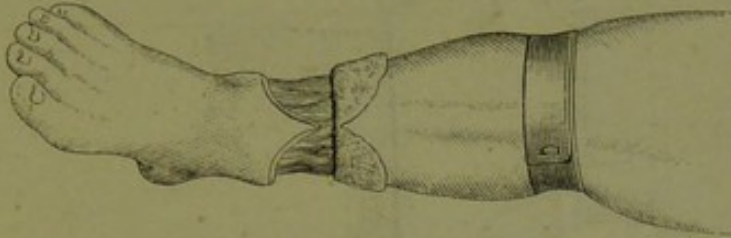
* His book page 81. See also: LISTON'S Practical Surgery. 3 ed. page 378.

Fig. 307.



LANGENBECK'S knife for flap amputation.

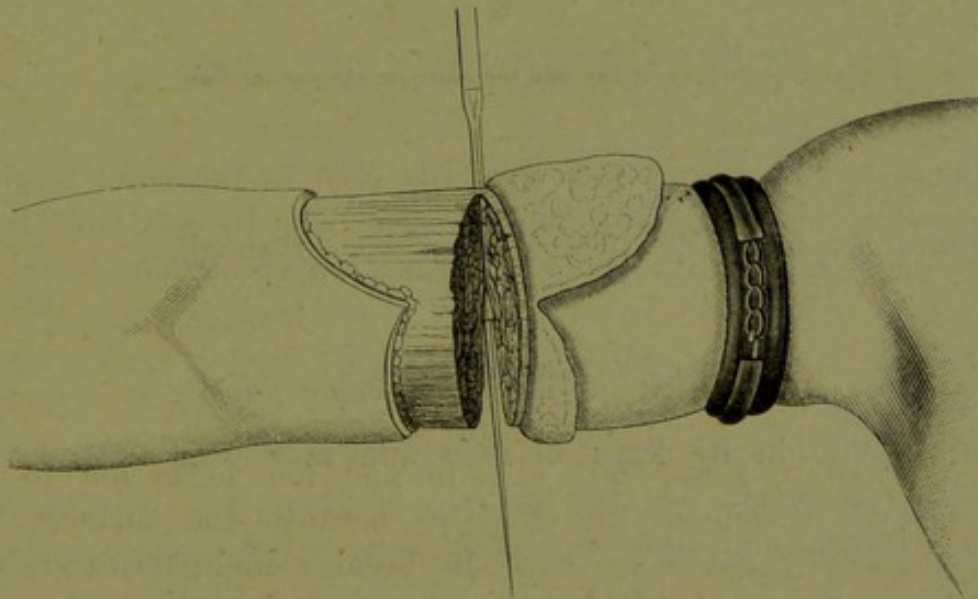
Fig. 308.



Two large skin flaps of equal size.

It is generally most convenient to form a large anterior and a smaller posterior flap (fig. 309), so that the larger flap hangs down over the divided muscles like a curtain.

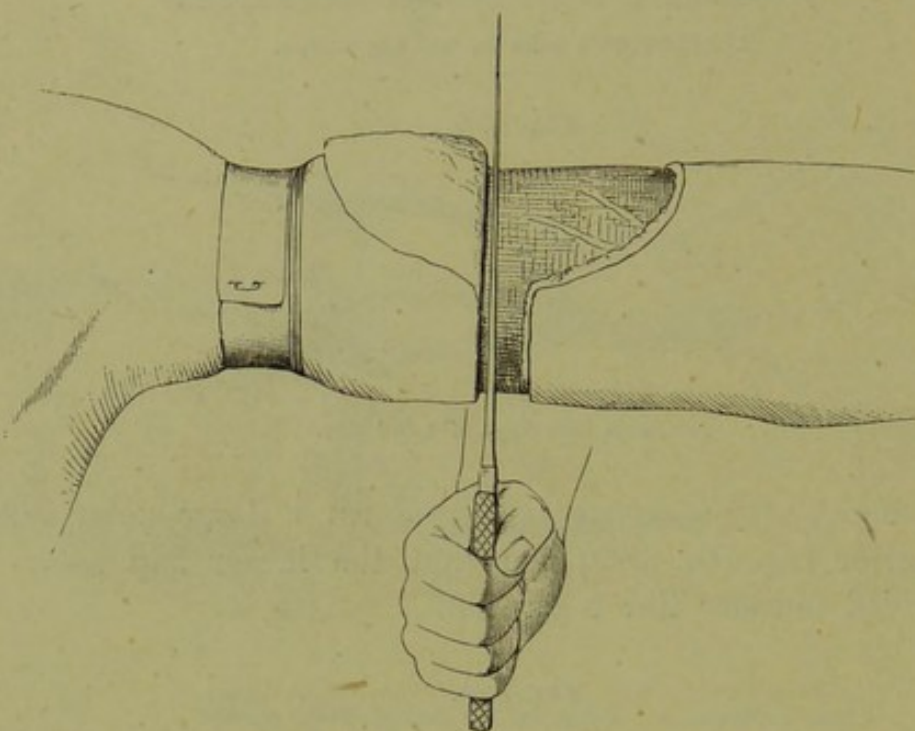
Fig. 309.



Large anterior and small posterior skin flaps.

The skin can also be divided transversely on the posterior aspect by a half-circular incision and reflected slightly upwards (fig. 310). In such a case the base of the large anterior flap must be somewhat smaller than half the circumference of the limb, but its length equal to the diameter of the limb.

Fig. 310.



Anterior skin flap and the posterior circular incision.

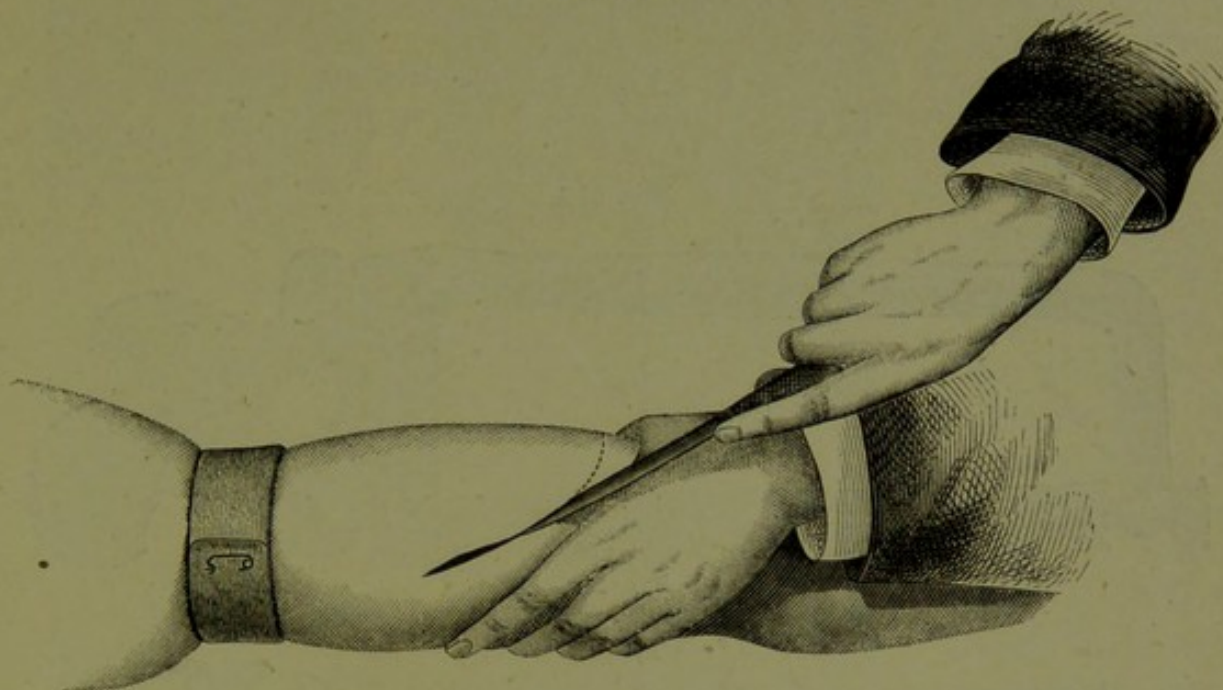
The skin flaps are turned upwards, and at the point of reflexion all the muscles are divided down to the bone by one circular sweep of the knife (fig. 309): the bone is then sawn through.

4. *Amputation by muscular flaps.*

The amputation by flaps of skin and muscle is not to be recommended so much as the former, because the surfaces of the wound are larger, and more especially because the arteries are divided obliquely.

The flaps can be cut either from without inwards (LANGENBECK) (fig. 311), for which purpose a very sharp knife is required, or from within outwards (VERDUIN) by transfixion of the soft parts close to the bone at the bases of the flaps with a double edged knife, which is carried obliquely downwards to the surface in long sawing movements (see disarticulation at the hip joint).

Fig. 311.



Amputation by muscular flaps. LANGENBECK'S method.


Nor is the latter method of amputation so satisfactory for gunshot fractures, because the knife is likely to be arrested by projectiles hidden in the soft parts, or by splinters of bone. A double edged knife is inconvenient, because, if great care be not taken, the vessel may be injured at many places in the flap by the sharp back. In addition to this, the double edged knife is much more difficult to sharpen than the single edged knife. Moreover, with the latter the flaps can be made just as well from within outwards, especially if the point is set like the longest knife in fig. 298.

The *oval incision* (LANGENBECK) is a modification of the flap amputation. In it the two flaps are united at the back by a transverse incision, so that the wound has the appearance of an ace of hearts. It is especially well fitted for disarticulation of the smaller joints (e. g. disarticulation of the fingers and toes). For larger joints it has no advantage over other methods, except the rapidity of execution, which is not of so much importance since the employment of chloroform and the bloodless method of operating. To be correctly executed it requires a large experience and a very sharp knife, which is not always to be had on the battle field.

c. Sawing the bone.


1. After all the soft parts have been divided, the operator exchanges the knife for an amputating saw (fig. 312 and 313), places the

Fig. 312.



Bow-saw.

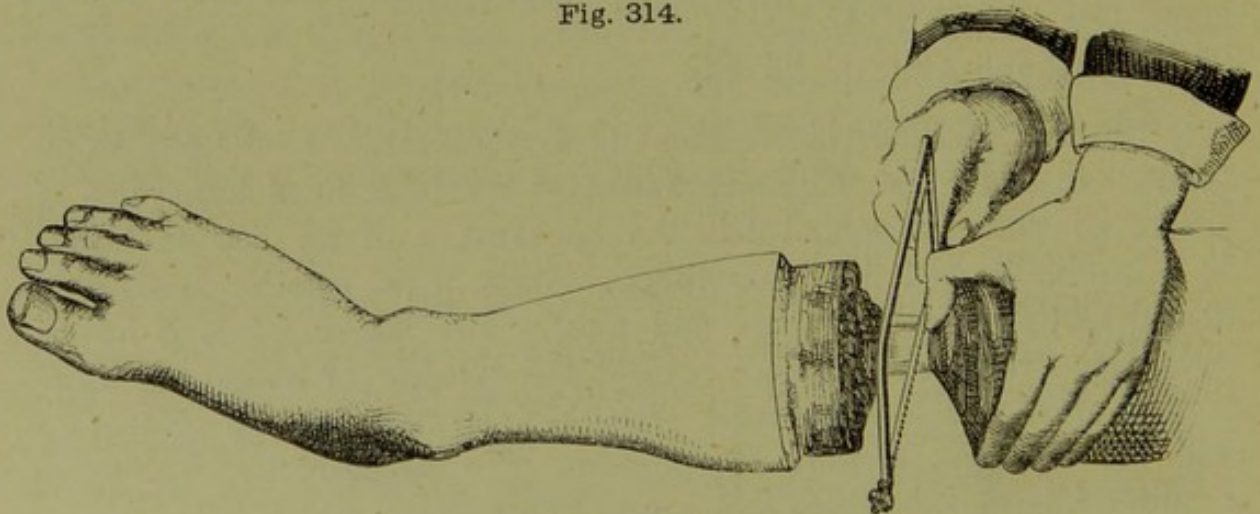
Fig. 313.



Broad-bladed saw.


nail of his left thumb upon the bone to steady the blade (fig. 314) and saws, without pressing, rather quickly through the bone with long steady strokes.

Fig. 314.




Sawing the bone.

Fig. 315.



for one bone.

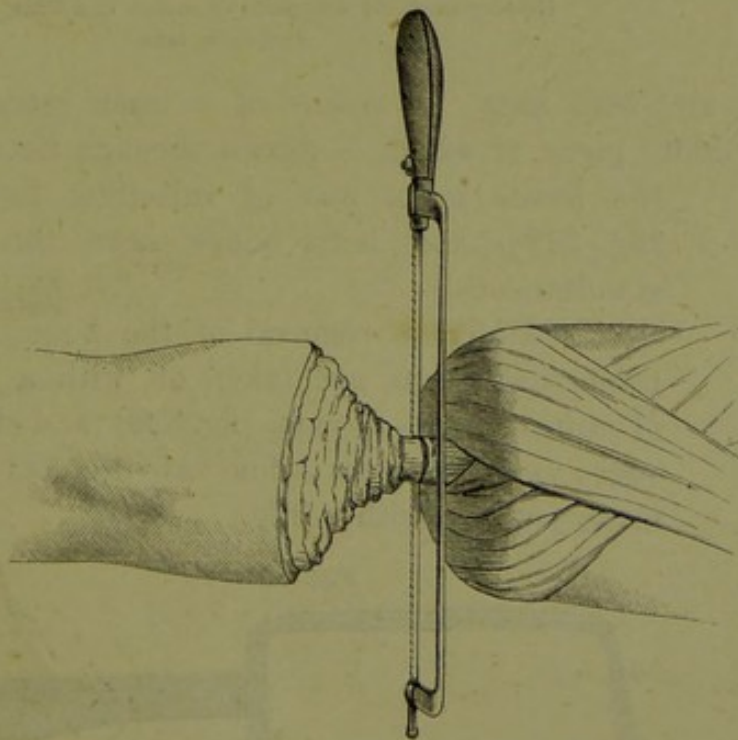
Fig. 316.



for two bones.

Linen retractors

Fig. 317.



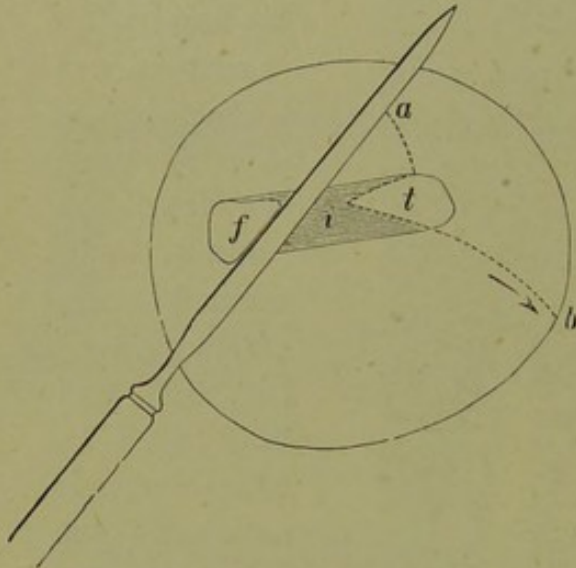
Keeping back the soft parts with the linen retractor.

2. Whilst sawing, the soft parts are drawn forcibly upwards by the hands of an assistant, or by means of a strip of linen slit down the middle and washed in carbolic water (fig. 315 and 316) (fig. 317), while another assistant holds the lower part of the limb firmly and securely, but towards the end sinks a little, to avoid the saw being locked.

3. For limbs with two bones the soft parts in the interval between them must be completely divided before the application of the saw, by pushing a narrow single edged

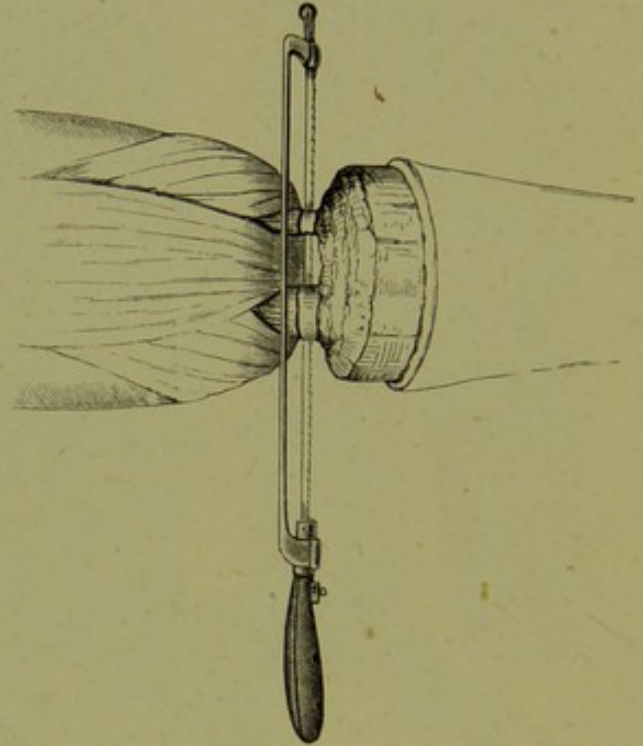
knife (fig. 298) through, and cutting upon one of the bones first from one side then from the other, and making the cutting edge to work as indicated in fig. 318 from *a.* to *b.*

Fig. 318.



The management of the knife between the bones.
f: fibula. *t:* tibia. *i:* interosseous space.

Fig. 319.

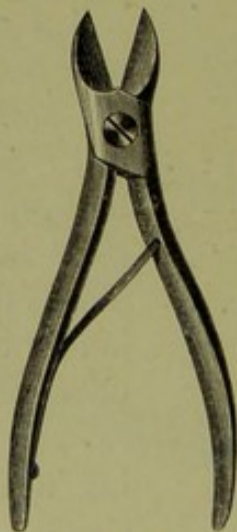


Sawing both bones.

Holding back the soft parts by means of a linen retractor with three tails.

4. The soft parts are held back by means of a linen retractor with three tails, the middle piece of which is drawn through between the bones by a pair of vulsellum forceps (fig. 319), and both bones sawn through simultaneously.


Fig. 320.



Cutting bone-forceps.

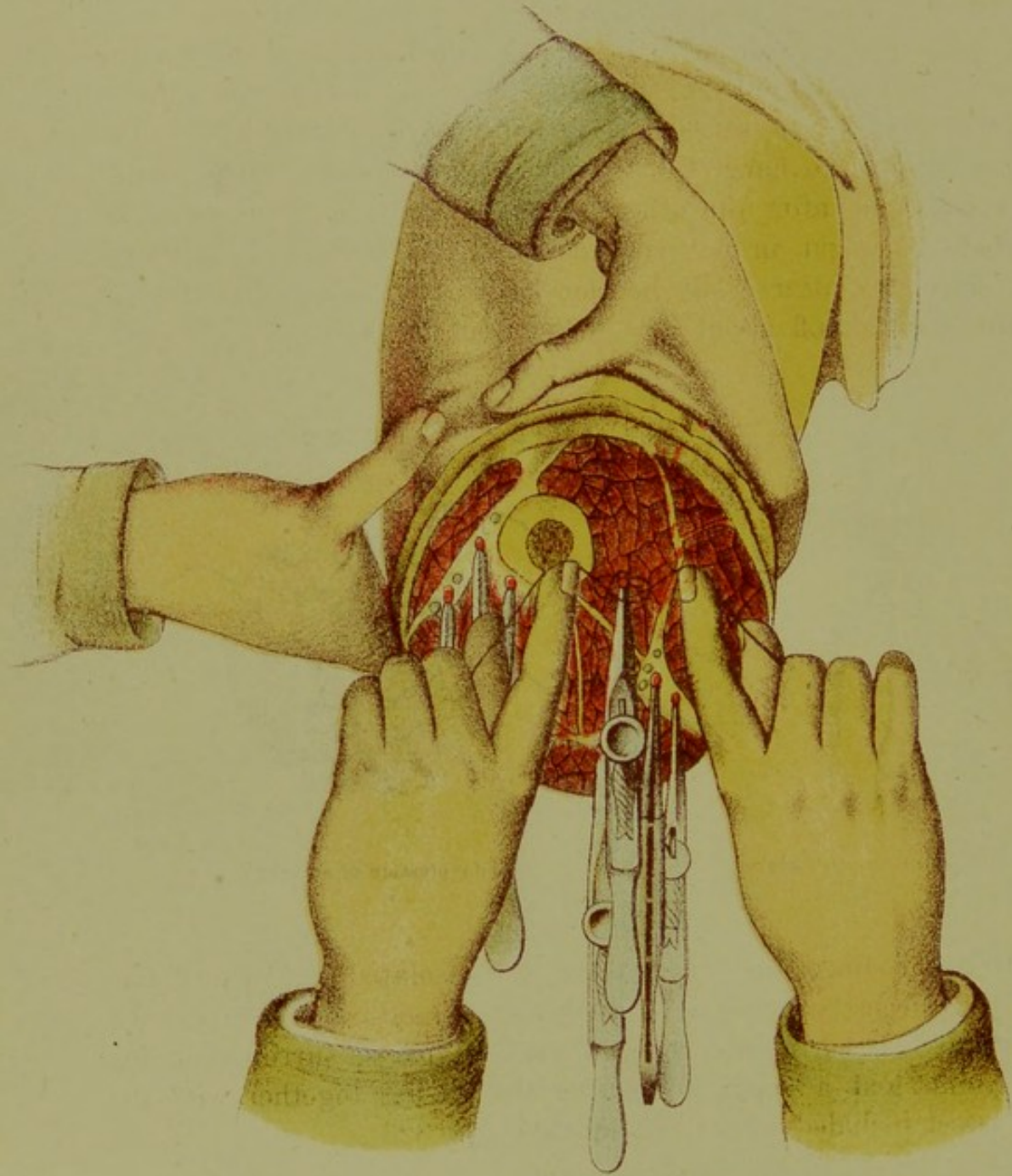
5. After the removal of the bone, any projecting points are taken off with a pair of cutting bone-forceps (fig. 320), and sharp edges removed with a fine saw (fig. 321), or made smooth with a file.

Fig. 321.



Metacarpal saw.

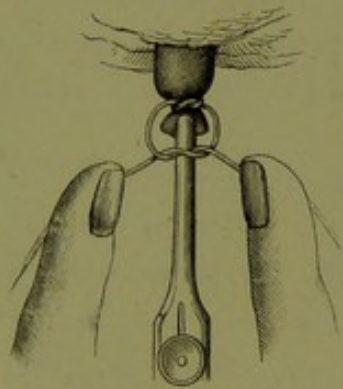




d. The arrest of haemorrhage.

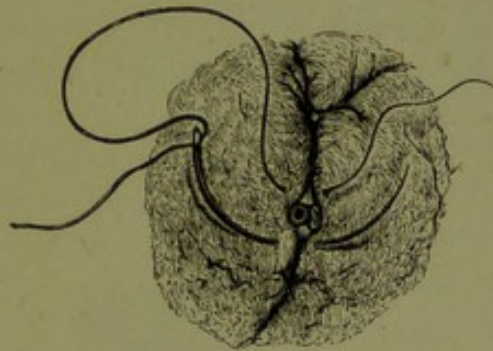
1. All the divided vessels, arteries and veins, which can be recognized, and whose positions have been called to mind before the operation by the assistance of drawings, shewing transverse sections (plates XXVI—XXX), are seized with artery forceps (plate XXIV). The forceps are allowed to hang, till no more gaping vessels can be found; all the vessels one after the other are then tightly and securely tied with carbolised catgut in a "reef knot" (fig. 22), not in a "granny" (fig. 23), since the latter easily becomes loose (fig. 322). The ends of the ligature are cut off about 3^{mm} in front of the knot.

Fig. 322.



Ligature with artery forceps hanging.

Fig. 323.

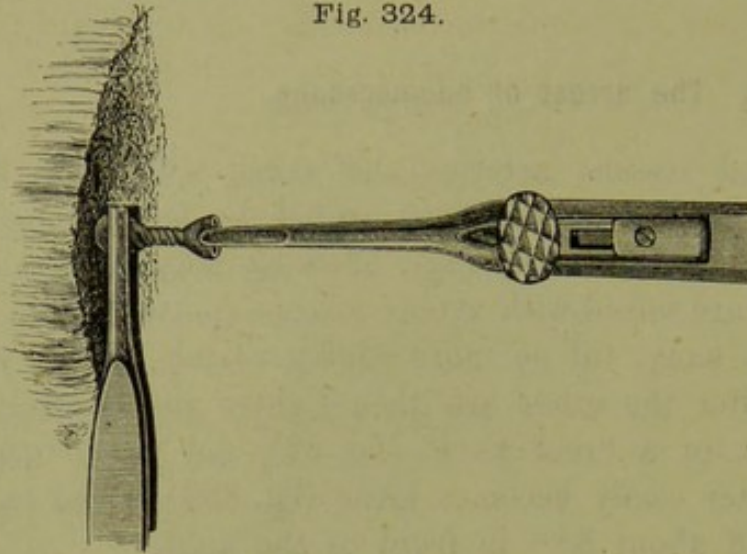


Filo-pressure of an artery.

2. If a bleeding vessel cannot be well isolated and drawn forward for the purpose of applying the ligature, a ligature may be carried by a strongly curved needle through the soft parts, surrounding the bleeding point, and a small portion of the tissues together with the bleeding vessel included within the ligature (fig. 323).

3. If there is no antiseptic material at hand for the ligature, the arteries can be closed by *torsion*. The vessel is seized with a pair of artery forceps, drawn slightly forwards and twisted according to the size of the artery six to eight times upon its axis, while the central part of the piece, that is drawn forward, is fixed by the fingers or better

Fig. 324.



Torsion of an artery.

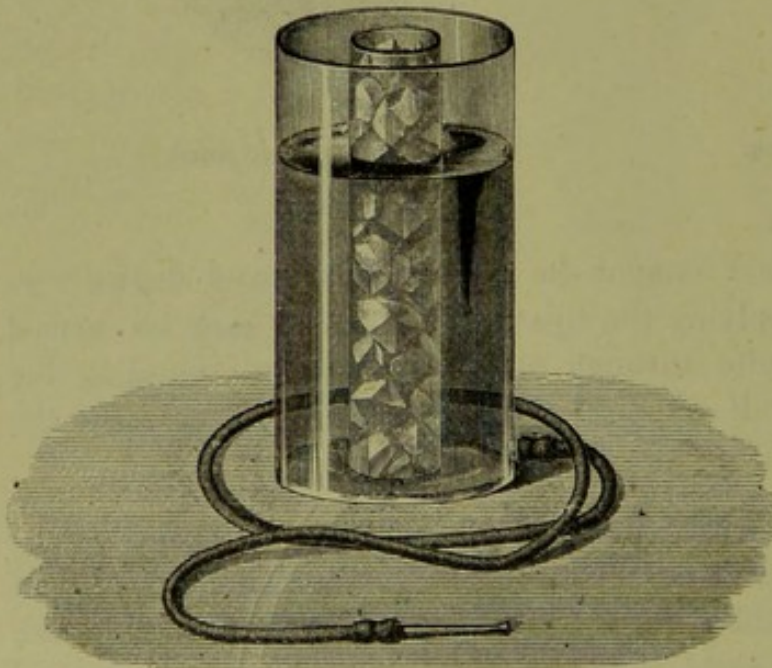
with another pair of forceps (AMUSSAT'S forceps)(fig.324). By this proceeding the inner coat of the artery is curled upwards in the interior, and forms a really safe valve-like means of closing.

4. When all the vessels are tied, which can be seen, the elastic ligature is removed, not gradually but all at once. The cut surfaces at first appear for a few seconds bloodless; the blood then gushes forth first at separate spots, but soon afterwards over the whole surface as out of a sponge.

5. If a cold stream of disinfectant water is conducted over the

entire surface of the wound, with an *ice-douche* (fig. 325), that is, an irrigator, which contains a weak solution of carbolic acid, in the middle of which is placed a tin cylinder, filled with ice and salt, the smaller bleeding vessels are easily recognised, seized with artery forceps, and ligatured, as has been described above.

Fig. 325.



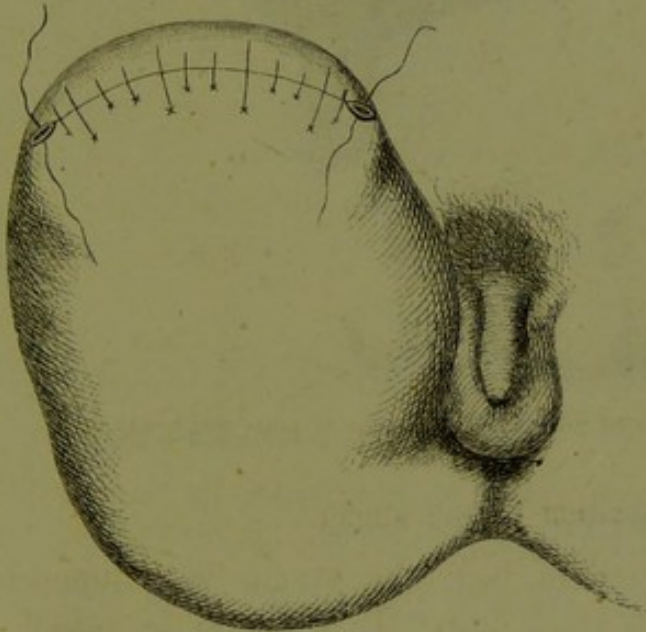
Ice - douche.

6. If in spite of this treatment the parenchymatous haemorrhage continues, it can soon be arrested by raising the stump, by pressure with a large sponge, by digital compression of the arterial trunk (v. LANGENBECK), or by the application of the induced current to the surface of the wound (RIEDINGER).

e. The closure of the wound.

The wound must not be closed before the haemorrhage has entirely ceased. Drainage tubes (s. fig. 1)

Fig. 326.



The amputation wound closed with sutures.

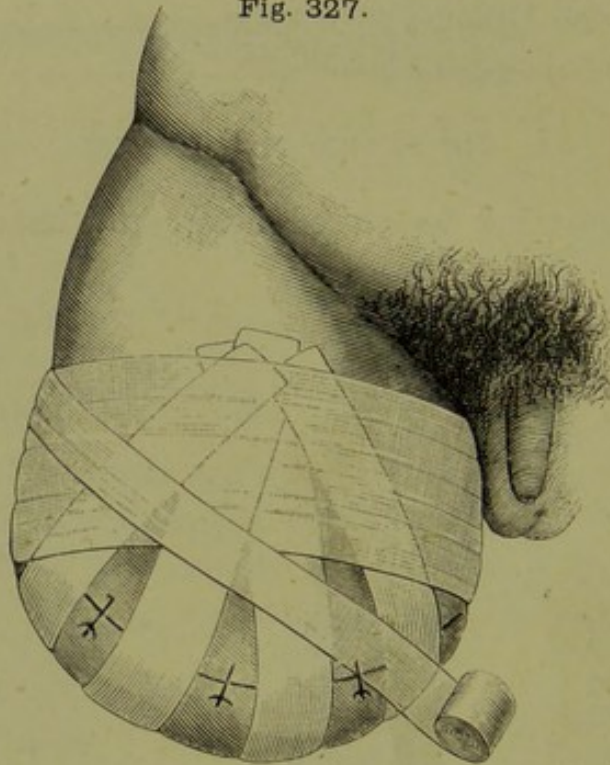
are then placed at the bottom of the wound, with the ends projecting one at each angle. The edges of the wound are carefully adapted to one another, and accurately united with numerous sutures of carbolised silk, silver wire, or catgut, which are alternately passed deeply and superficially through the flaps (fig. 326).

f. The dressing of the stump.

After the ends of the drainage tube have been cut off on a level with the wound, and provided with silk threads to prevent them from slipping in, a narrow strip of "protective" is placed upon the edges of the wound, and over this a broader strip of LISTER'S gauze moistened with the carbolic solution. An uniform compression of the stump is exercised by similar strips, which are placed in all directions upon the wound and then fastened with a LISTER'S gauze bandage (fig. 327).

Finally over this is applied a genuine LISTER'S dressing (page 14. 8), which must reach as high up as possible, and have its upper margin strengthened and secured by an abundant layer of salicylic wool or jute.

Fig. 327.



The dressing of an amputation stump with carbolised strips of gauze and bandages.

g. The position of the stump.

The patient is now placed in bed, the stump well supported, i. e. raised horizontally, not in front only. If it should be raised by muscular spasm (which occurs especially after amputation of the thigh), a folded sheet is placed upon the stump: this keeps it down by its weight.

A cradle is placed over the stump; with this exception it must remain uncovered, so that the occurrence of any secondary haemorrhage may be immediately discovered by the attendant.

II. GENERAL RULES FOR THE DISARTICULATIONS.

1. It is usually most convenient for the operator to stand with his face to the patient, and with his left hand holding the part to be removed.

2. The circular incision is not so suitable as the flap operation for the division of the soft parts. As it is here a question of covering larger surfaces of bone, flaps must be cut proportionately large, either of skin alone, or of skin and the subjacent muscles.

3. In many cases the most advantageous method is by a large anterior and a small posterior flap, as at the knee, shoulder, and hip. In some cases, as at the ankle, and tarsus, the posterior flap must be the larger.

4. The oval incision is especially suitable for small joints, as those of the fingers and toes.

5. After the division of the soft parts, the joint is opened; the bands of tissue, as they present themselves, being put upon the stretch by suitable movements, and then divided with the knife.

6. After the division of the remaining ligaments and the capsule of the joint, the disarticulation is completed; and finally the articular surface is removed with the saw. For the rest of the operation the proceeding is the same as in an amputation.

III. THE AMPUTATIONS AND DISARTICULATIONS OF THE UPPER EXTREMITY.

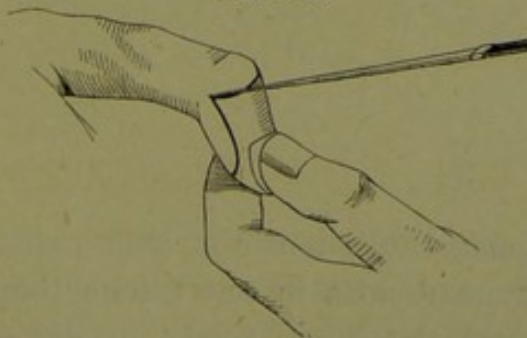
a. Disarticulation of the terminal phalanx.

(By a palmar flap from without inwards.)

1. The hand being held towards him in the prone position, the operator seizes the tip of the finger, and flexes the terminal phalanx.

2. A semilunar incision, 2^{mm} below the top of the joint and carried across the head of the second phalanx, opens the joint (fig. 328).

Fig. 328.



3. The point of the knife divides the lateral ligaments, while the blade with the edge directed downwards, is sunk behind the flexor aspect of the third phalanx (fig. 329), and cuts with a sawing movement a well rounded flap from the tissues on the flexor side (fig. 330).

Fig. 329.

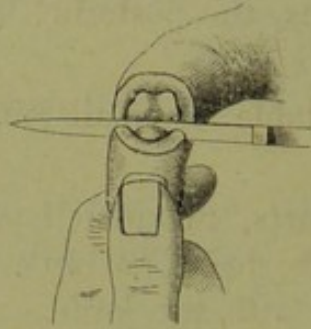
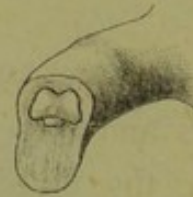

Fig. 330.



b. Disarticulation at the second phalangeal joint.

(By transfixion from within outwards.)

1. The hand being held towards him in the supine position, the operator seizes the tip of the outstretched finger, transfixes with a narrow knife just below the fold of the joint, and carries the blade downwards between the skin and the bone with a sawing movement towards himself, far enough to furnish a well rounded flap (fig. 331).

Fig. 331.

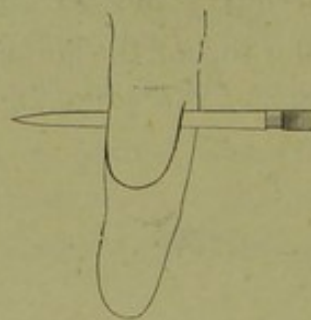
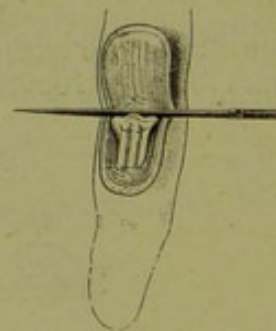


Fig. 332.



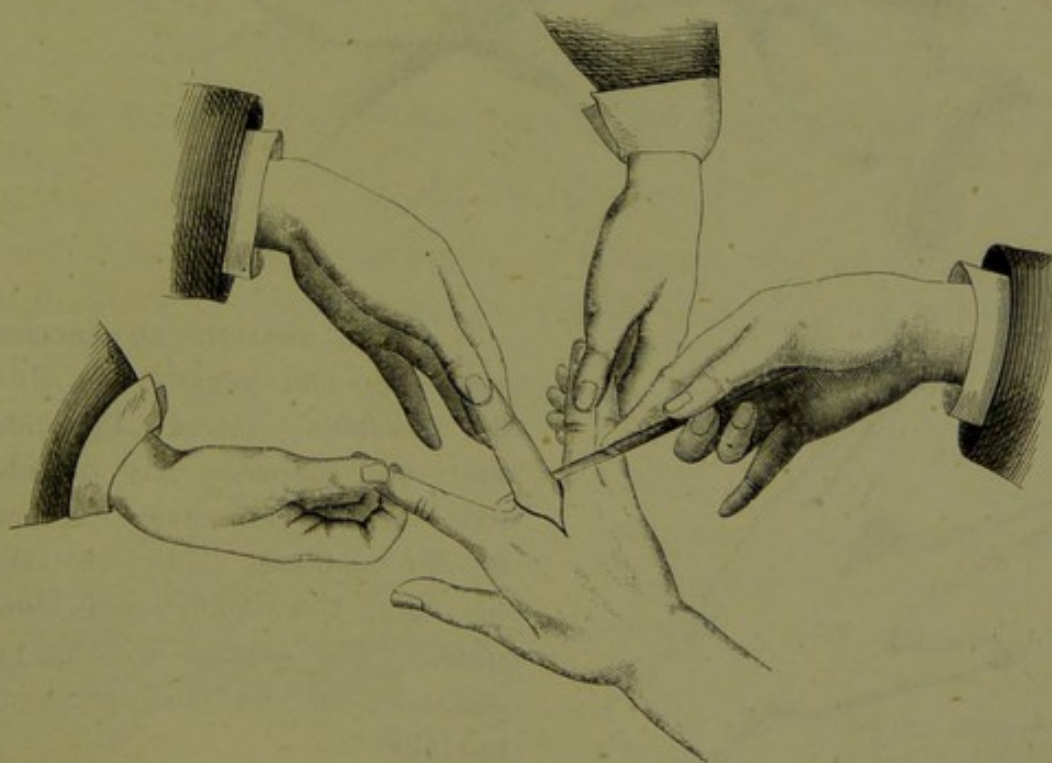2. The flap is turned back, the joint hyperextended, and from the wound outwards the knife divides in one stroke the capsule, the ligaments, and the skin upon the dorsal aspect of the joint (fig. 332).

c. Disarticulation of the fingers at the metacarpo-phalangeal joint.

a. *The oval incision.*

1. An assistant separates the two adjacent fingers, and the operator standing on the left side of the limb, with his back to the patient's face, takes with his left hand the injured finger, and carries it far enough into hyperextension, to see its palmar surface. A narrow knife is then brought from the right side on to the palmar surface of the first phalanx; the soft parts being divided transversely on a level with the extended web, the incision is carried round the right side on to the dorsal surface, and from here upwards in a slight curve on to the head of the metacarpal bone (the position of which has been previously indicated by a mark) (fig. 333).

Fig. 333.



2. The knife is carried under the operator's left hand round the left side of the finger to the commencement of the first incision. Here an incision is made on to the bone, then carried on a level with the

web round the left side of the first phalanx on to the dorsum, and from here upwards in a curve to the end of the first incision (fig. 334).

Fig. 334.

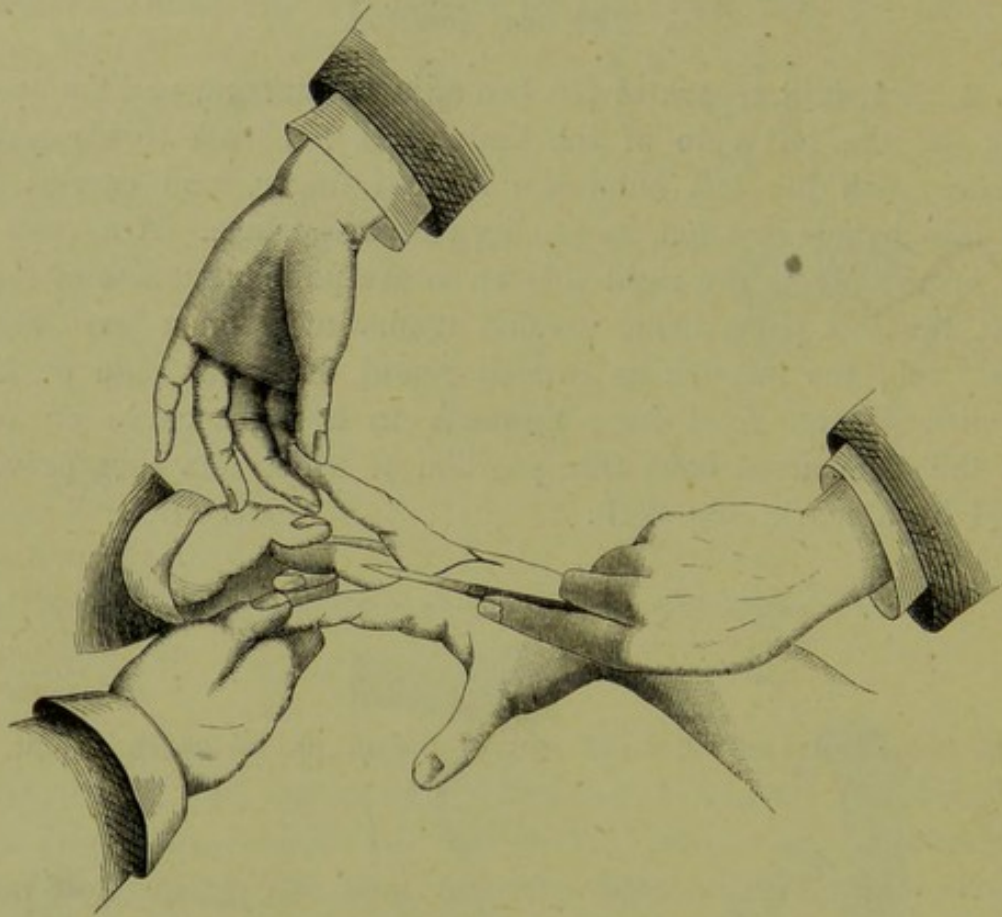
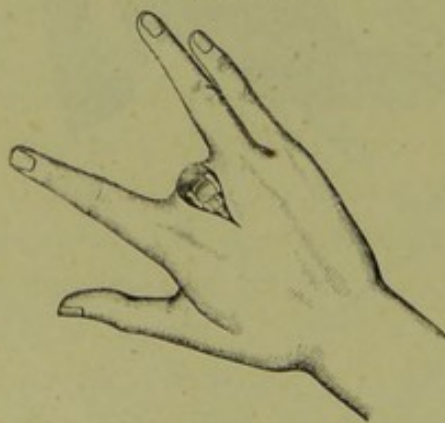


Fig. 335.

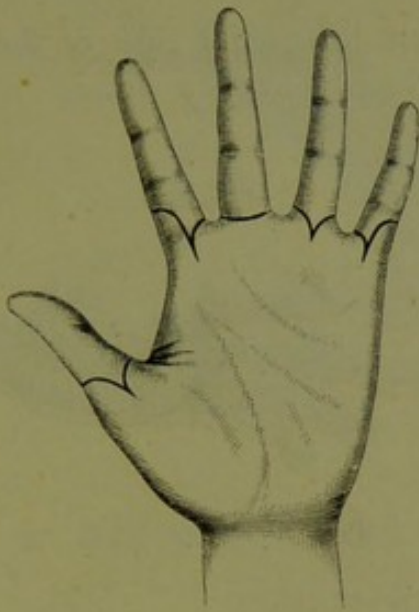


3. Both incisions are successively deepened towards the joint; the tendons, lateral ligaments, and the capsule are divided, with the finger always inclined to the opposite side, to that, on which the incision is being made. The wound has the appearance of an ace of hearts (fig. 335).

β. The flap operation.

1. This incision is the most suitable for the first, second, and fifth fingers, because they are freely accessible on one side.

Fig. 336.



A larger half-oval flap, the base of which is on a level with the joint, is cut from the integuments on the palmar, dorsal, or lateral aspect of the first phalanx, and turned back.

2. A smaller skin flap is then formed on the opposite side, and likewise reflected.

3. Finally the tendons are divided on a level with the joint, which is then freely opened (fig. 336).

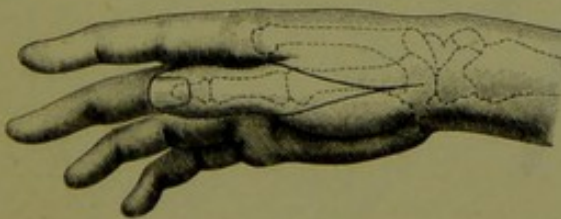
NB. The drawing shews the disarticulation for the ring finger with two lateral flaps, and the oval incision for the middle finger.

d. Disarticulation of the thumb at the carpo-metacarpal joint.

a. *By the oval incision.*

1. The first incision begins on the ulnar side of the first phalanx on a level with the web, and is carried obliquely over the metacarpophalangeal joint as far as the radial side of the metacarpal bone, and is continued along the same side to its base.

Fig. 337.



2. The second incision, starting from the same point, is carried round on to the radial side, and meets with the first at the middle of the metacarpal bone (fig. 337).

3. By repeated incisions on the bone in the same direction it is liberated from the muscles.

4. The joint between the trapezium and the metacarpal bone is opened on the ulnar side, so that the edge of the knife is kept close upon the base of the latter, and thus the joint between the meta-

carpal bone of the index finger and the trapezium, which communicates with the remaining carpal joints, is in no danger of being opened.

5. The division of the ligaments on the radial side of the joint (fig. 338) completes the operation, which leaves a linear cicatrix (fig. 339).

Fig. 338.

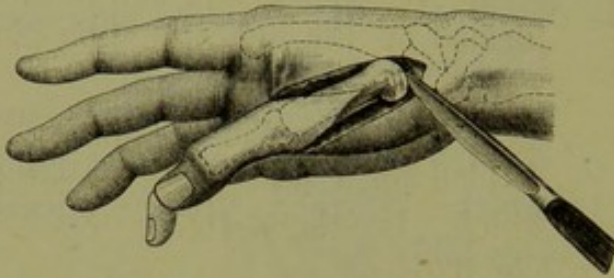
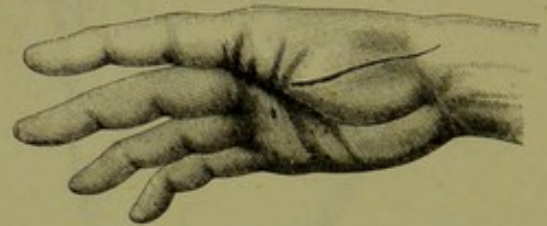


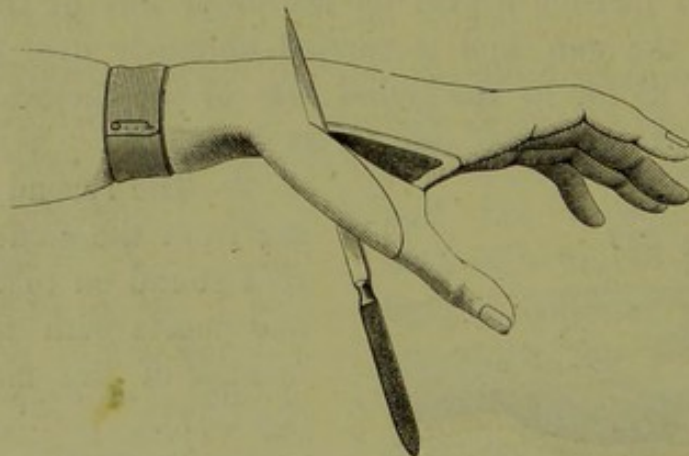
Fig. 339.



β. *By lateral flaps* (WALTHER'S).

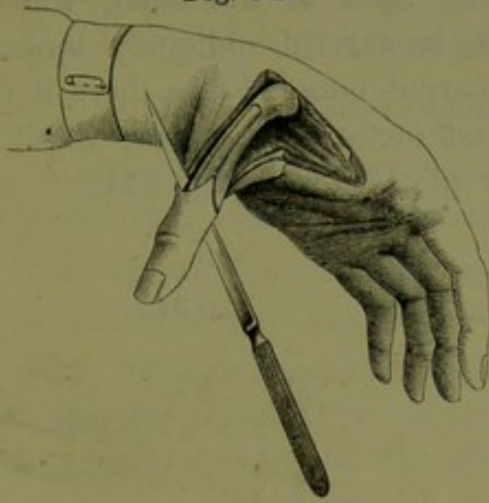
1. The thumb being abducted, the knife is placed upon the middle of the web, and carried upwards with a sawing motion between the first and second metacarpal bones, till it strikes upon the ulnar border of the base of the first metacarpal bone (fig. 340).

Fig. 340.



2. The point of the knife is cautiously inserted under the base of the 1st metacarpal bone, and the carpo-metacarpal joint thus opened. Care however is taken to avoid the joint between the trapezium and the 2nd metacarpal bone.

Fig. 341.

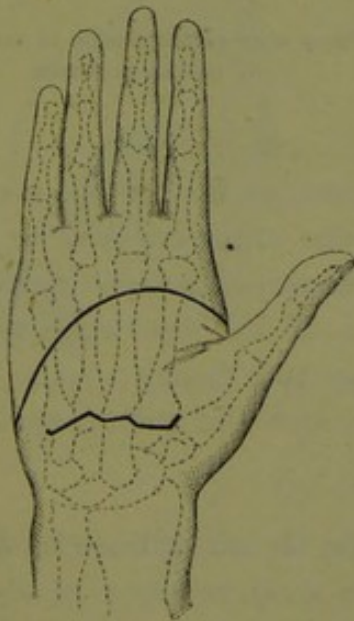


3. The thumb can now be still more strongly abducted. The knife is taken through the joint on to the radial side of the metacarpal bone, and carried downwards again upon it, forming a radial flap, whose rounded point terminates on a level with the web (fig. 341).

e. Disarticulation of the last four metacarpal bones, preserving the thumb.

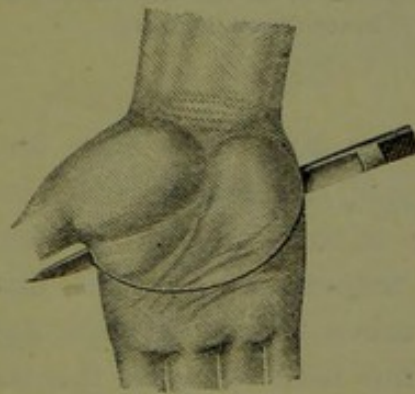
1. A semilunar flap is described upon the palm of the hand by an obliquely curved incision, which begins at the web of the thumb, and terminates at the ulnar border of the base of the fifth metacarpal bone (fig. 342). The flap can also be made from within outwards by transfixion at its base (fig. 343).

Fig. 342.



Palmar incision.

Fig. 343.

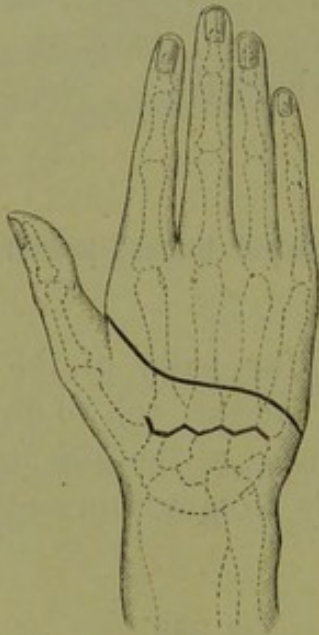


Palmar incision by transfixion.

Disarticulation of the last four metacarpal bones.

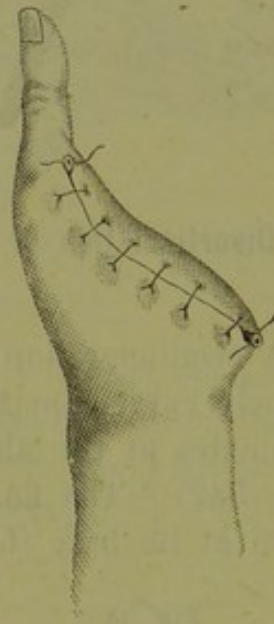
2. An incision is made upon the back of the hand, which, beginning from the web of the thumb, is carried obliquely upwards to the upper third of the second metacarpal bone. From there it is continued transversely over the three last metacarpal bones, till it meets the palmar flap at the ulnar border of the hand (fig. 344).

Fig. 344.



Disarticulation of the last four metacarpal bones (dorsal incision).

Fig. 345.



Stump after disarticulation of the last four metacarpal bones.

3. After both flaps have been reflected as far as the carpo-metacarpal joints, the latter are opened from the ulnar side during a strong abduction of the hand, till the second metacarpal bone is disarticulated from the trapezium. In this latter part of the operation great care must be taken to cut always upon these two bones, so as to avoid injuring the joint between the trapezium and the metacarpal bone of the thumb.

4. The preservation of the thumb is an immense advantage (fig. 345).

f. Disarticulation at the wrist.

a. Circular incision.

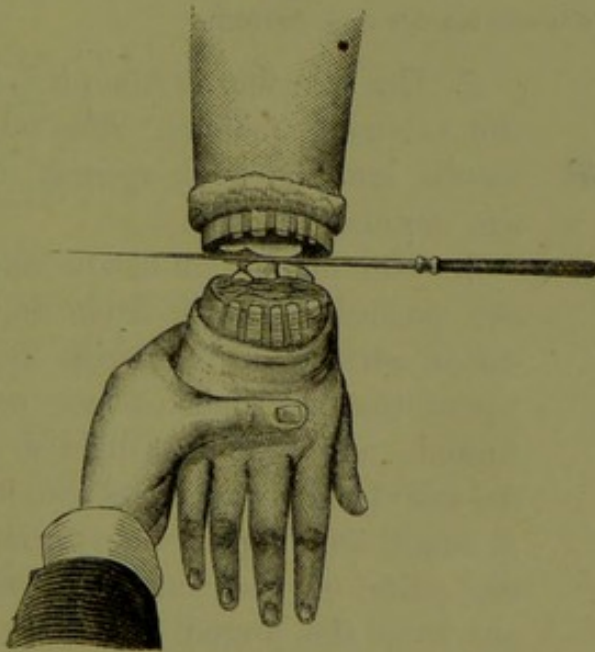
1. A circular incision is carried round the hand over the middle of the metacarpal bones, 4^{cm} below the styloid processes.

2. The skin is liberated all round by perpendicular incisions, till it can be reflected over the styloid processes like a cuff.

3. The hand is pronated and forcibly flexed: the tendons are divided, and the wrist joint opened by an incision over the dorsum from one styloid process to the other with a slight convexity upwards.

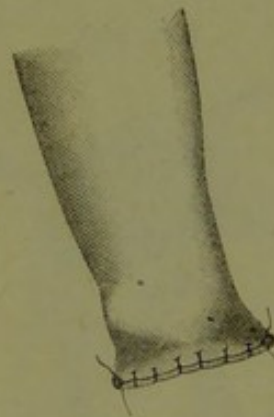
4. The lateral ligaments are divided beneath the styloid processes, and finally the anterior part of the capsule and all the flexor tendons are cut through with one stroke of the knife (fig. 346 and 347).

Fig. 346.



Disarticulation of the hand by the circular incision.

Fig. 347.




Stump after disarticulation at the wrist by the circular incision.

β. By the flap amputation.

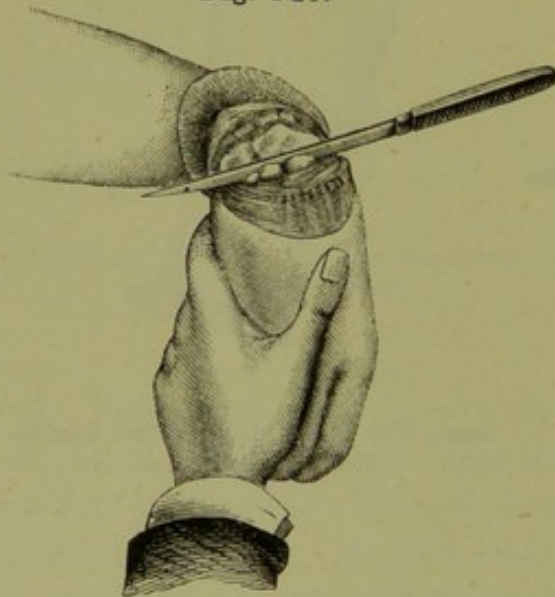
1. The operator takes hold of the lower part of the pronated hand, flexes it, and carries a semilunar incision over the middle of the back of the hand, from the tip of one styloid process to the other (fig. 348).

Fig. 348.



Disarticulation of the hand with two skin flaps (RUYSCH).

Fig. 349.



Forming the palmar flap.

2. The skin flap is liberated from the extended tendons, reflected upwards, and the joint opened, as in the circular incision.

3. The bundle of flexor tendons are pushed forward from the anterior surface of the wrist by the tip of the left index finger in the wound, and carefully divided by a to-and-fro movement of the knife. A small skin flap is then formed in the palm of the hand by cutting out from the wound (fig. 349).

NB. It is convenient to mark out the palmar flap at the commencement of the operation by a cutaneous incision.

γ. Amputation by the radial flap (DUBRUEIL).

1. A semilunar flap is cut from the skin, which covers the metacarpal bone of the thumb. Its base embraces the radial third of the carpus, and its point reaches the base of the first phalanx.



Fig. II.

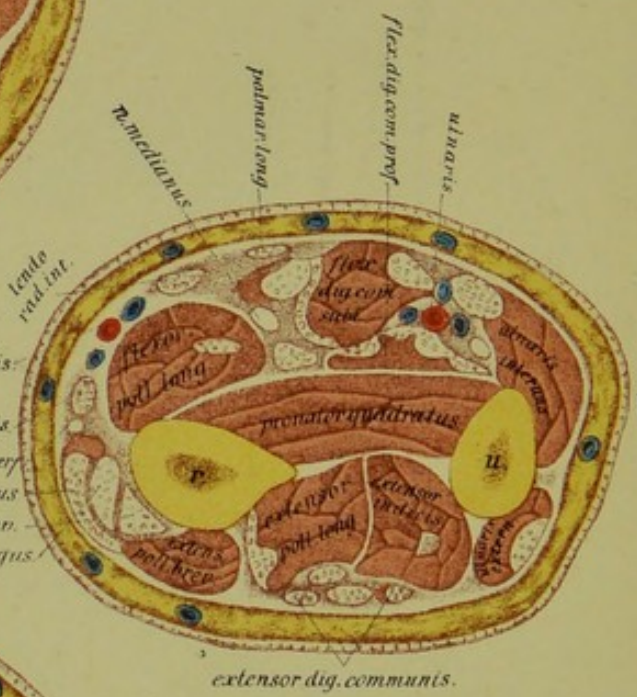
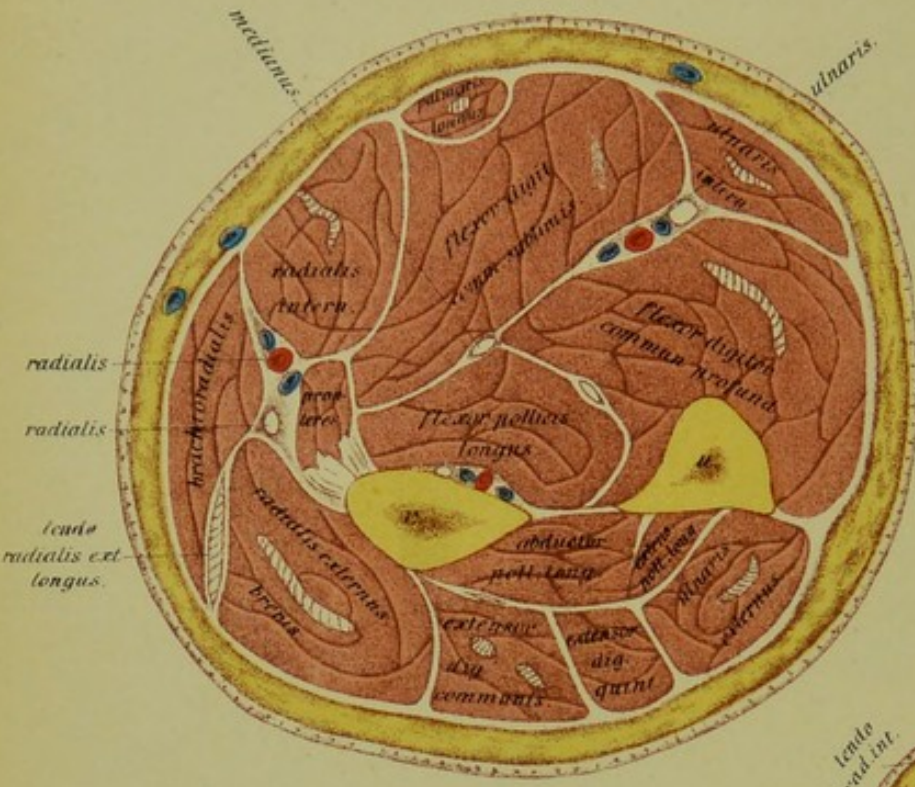
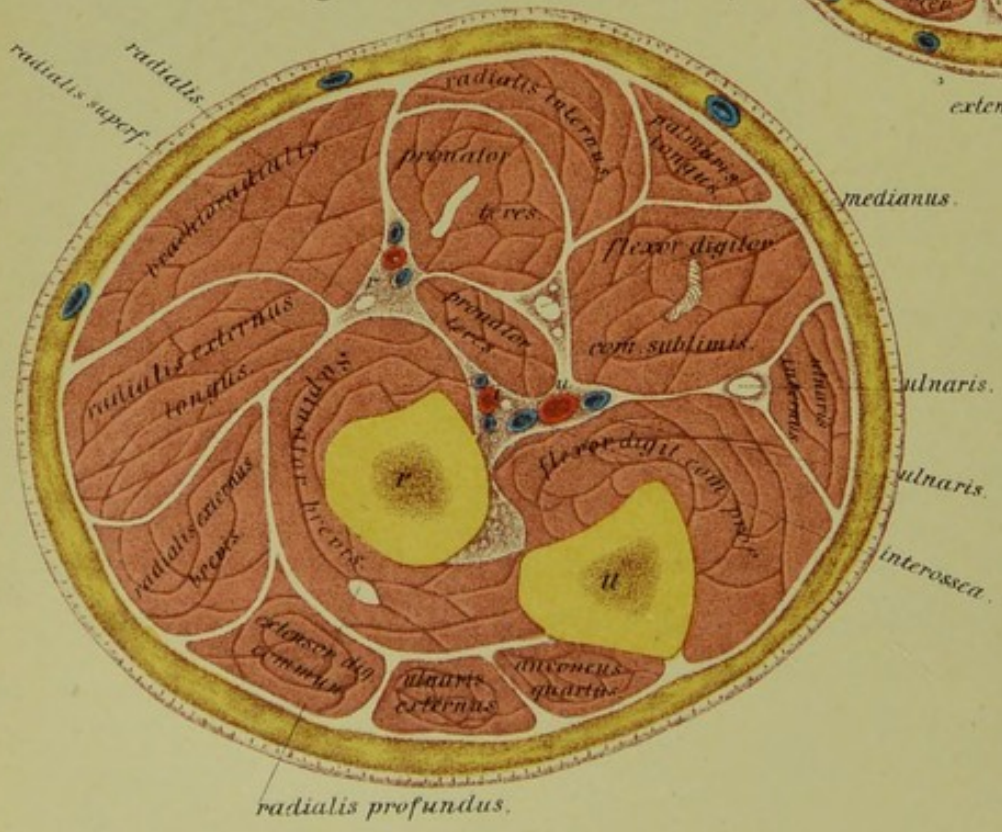


Fig. I.

Fig. III.



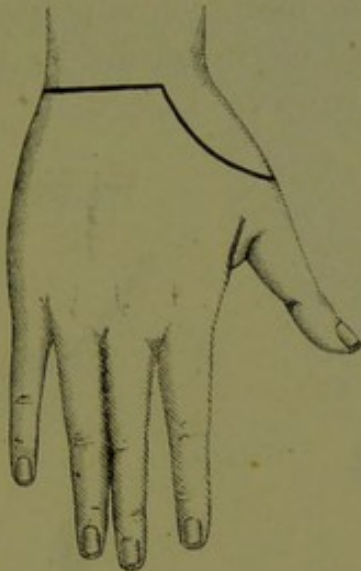tendo rad. int.
 radialis
 brachioradialis
 nerv. radial. superf.
 abd. pol. longus
 rad. ext. brev.
 rad. ext. longus

extensor dig. communis.

radialis profundus.

2. After this flap has been dissected from the muscles of the thumb, and reflected upwards, an incision on the ulnar side is carried transversely round the remaining two thirds of the carpus (fig. 350).

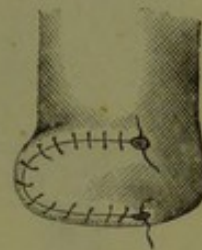Fig. 350.



Disarticulation of the hand (DUBRUEIL).

3. The skin is drawn forcibly upwards and the carpus separated, as above described, from the bones of the forearm (fig. 351).

Fig. 351.



Stump after DUBRUEIL.

g. Amputation of the forearm.

a. By double circular incision

(page 175).

β. By skin-flaps

(page 178).

VOLZ'S transverse sections of the forearm are represented on plate XXV.

Fig. I. Transverse section of the right forearm in the lower third.

Fig. II. Transverse section of the middle of the right forearm.

Fig. III. Transverse section of the right forearm in its upper third.

h. Disarticulation at the elbow.

a. By circular incision.

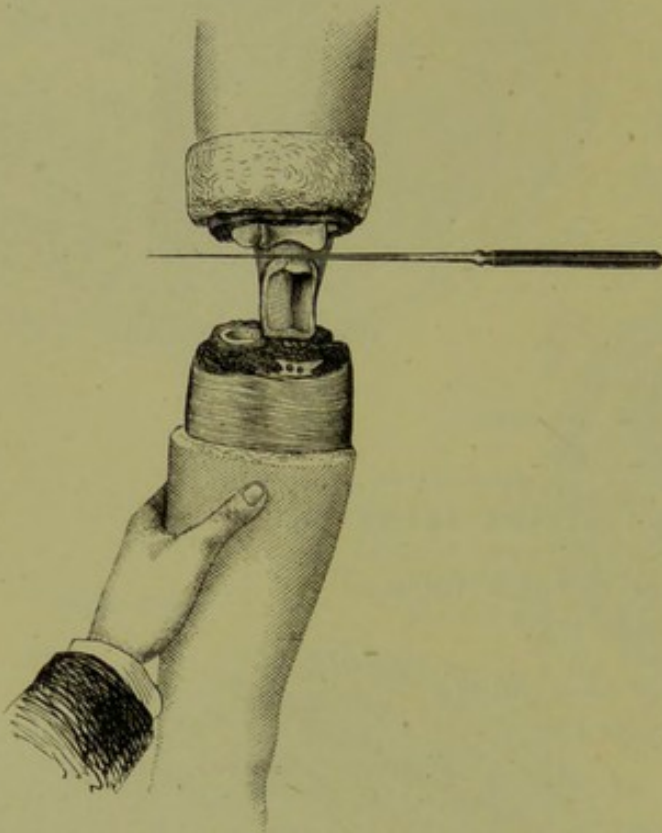
1. A circular incision divides the skin 4^{cm} below the condyles of the humerus; the *cuff* is dissected back and turned over.

2. A transverse incision, across the flexor surface, opens wide the hyperextended joint.

3. An incision above the head of the radius divides the external lateral ligament, and an incision below the internal condyle divides the internal lateral ligament.

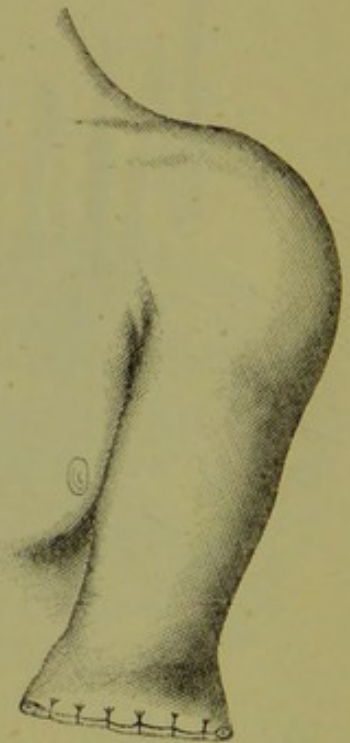
4. The joint is now widely open; the olecranon is pressed into the wound; an incision above the tip of the olecranon divides the tendon of the triceps (fig. 352 and 353).

Fig. 352.



Disarticulation at the elbow by the circular incision.

Fig. 353.



Stump after disarticulation at the elbow by the circular incision.

For a representation of a transverse section through the elbow on a level with the condyles see plate XXVI, fig. 1.

β. By flaps.

1. A curved incision, beginning 2^{cm} below one condyle and ending 2^{cm} below the other condyle, is described on the flexor aspect of the forearm; a large semilunar skin flap is thus liberated from the fascia and turned back.

Fig. II.

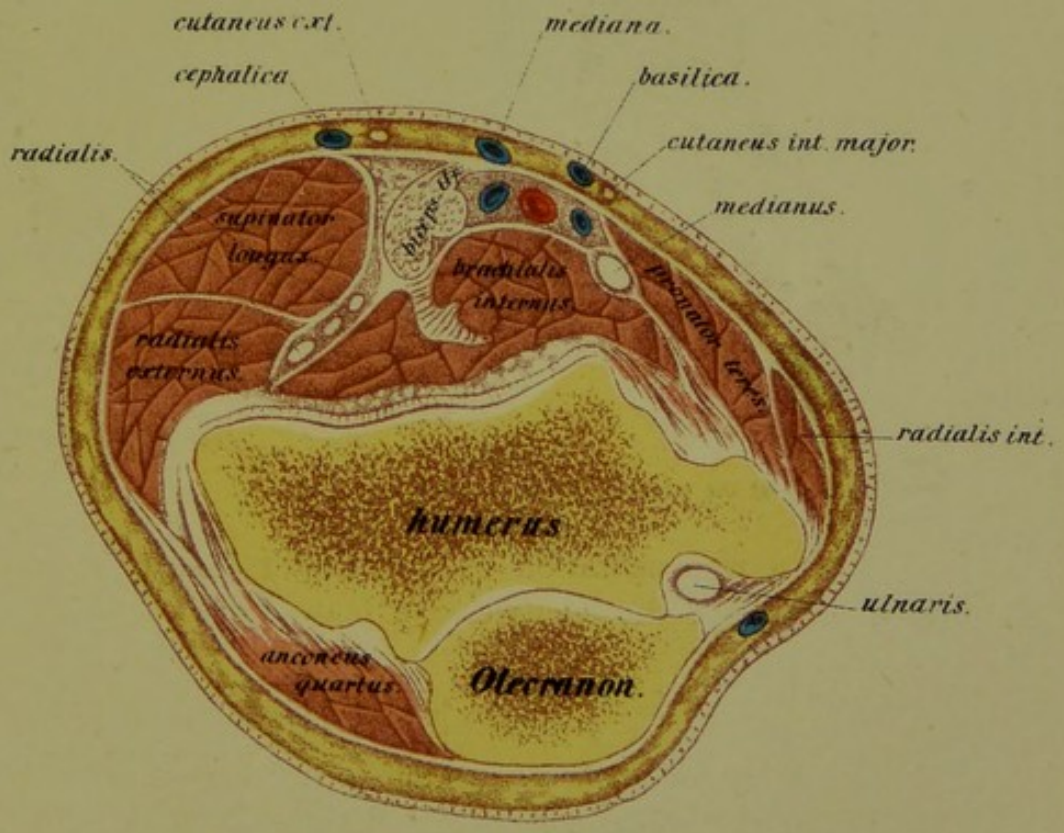
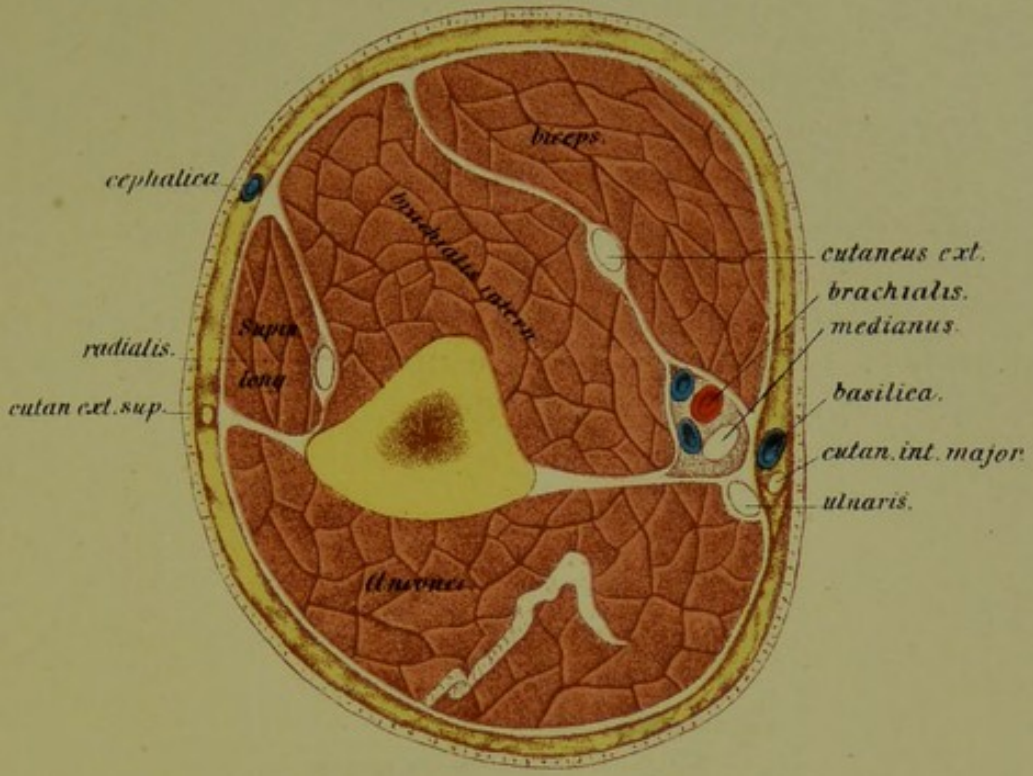


Fig. I.





Fig. I.

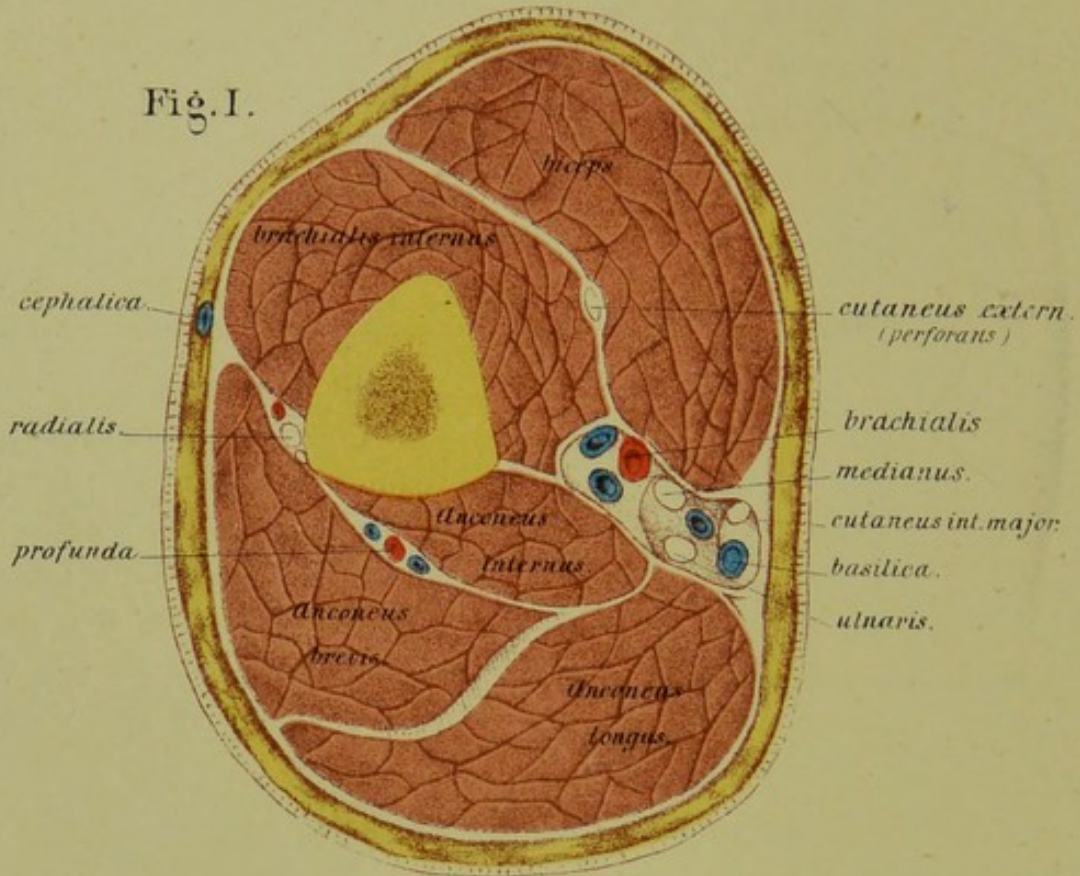


Fig. II.

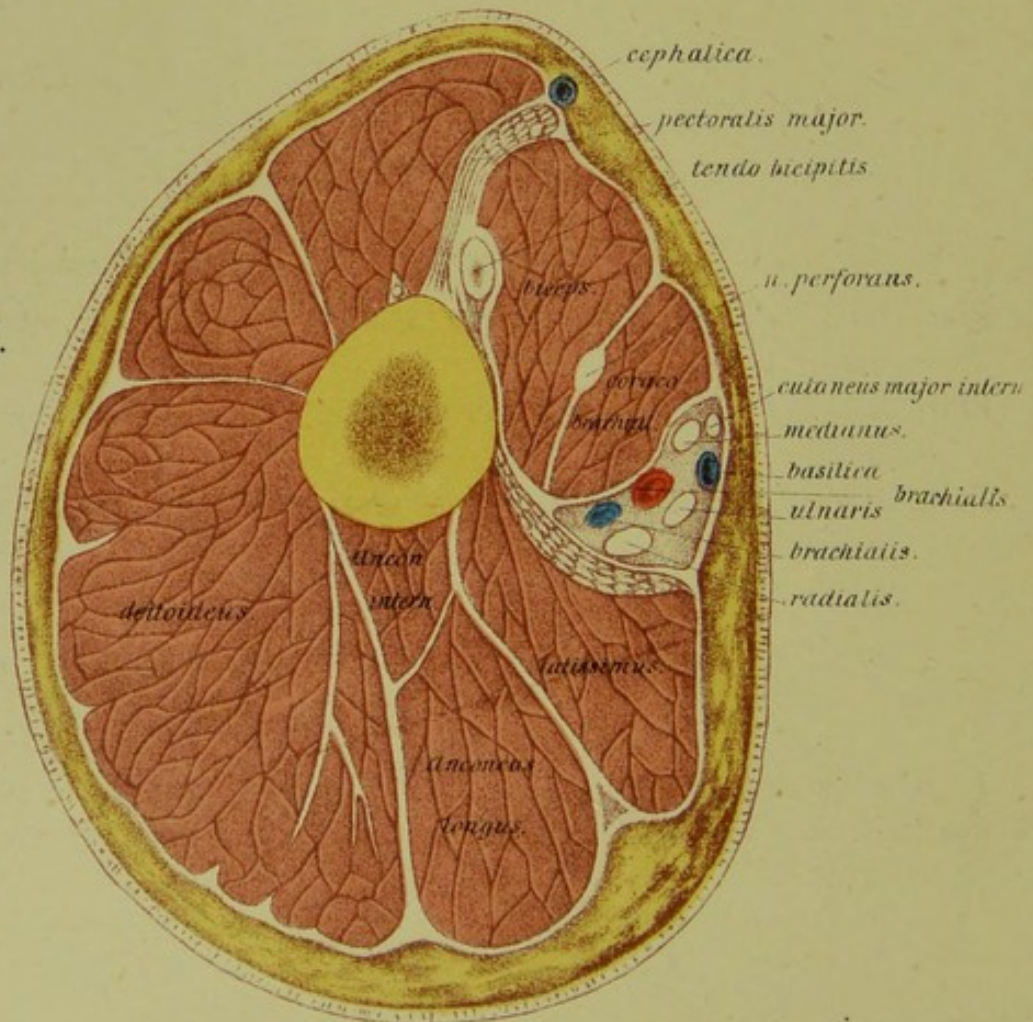
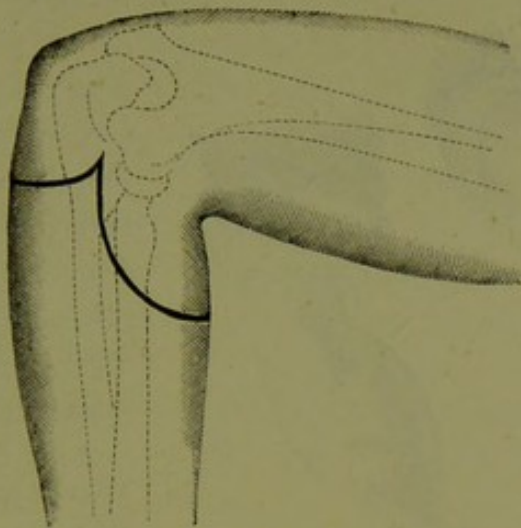


Fig. 354.



Disarticulation at the elbow (by flaps).

2. The arm is forcibly flexed, and twisted in such a way, as to bring the posterior surface of the joint forwards.

3. A convex incision over the olecranon exposes its tip (fig. 354).

4. A transverse incision from one condyle to the other divides the tendon of the triceps and both lateral ligaments; a second divides all the soft parts on the flexor aspect of the joint.

i. Amputation of the arm.

a. By single circular incision
(page 174).

β. By double circular incision
(page 175).

γ. By flaps
(page 178).

VOLZ'S transverse sections of the arm are represented on:

Plate XXVI, fig. II. Transverse section of the right arm in its upper third.

Plate XXVII, fig. I. Transverse section of the right arm in its middle third.

Plate XXVII, fig. II. Transverse section of the right arm just below the axilla.

k. Disarticulation at the shoulder joint.

a. By flaps.

1. The patient lies at the edge of the table, partially turned on his healthy side, and with the upper part of his body raised. The

Disarticulation at the shoulder (by flaps).

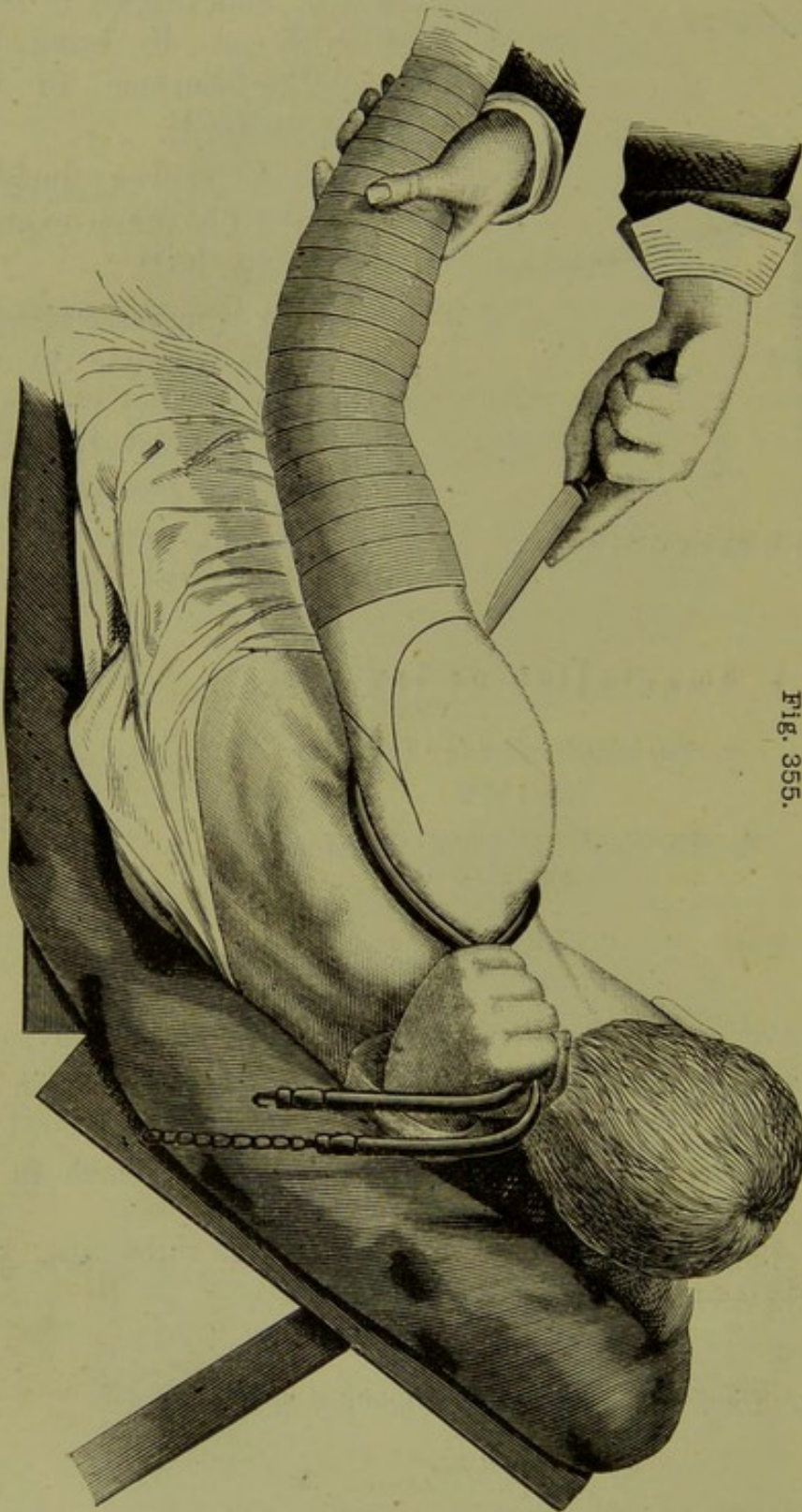


Fig. 355.

more he is brought into the sitting posture, the easier is it for the operator, but more dangerous for the chloroform-narcosis (page 112).

2. A square flap with rounded corners is formed on the outer side of the shoulder, the base of which extends from the coracoid process to the junction of the acromion with the spine of the scapula, and whose lower margin runs over the insertion of the deltoid (fig. 355).

3. With sweeping strokes of the knife, the deltoid flap is raised as far

as the acromion and turned back, so that the capsule of the shoulder joint is exposed.

4. The head of the humerus is pushed upwards; and an incision, made with some force above the two tuberosities, divides the capsule and tendons in front of the joint.

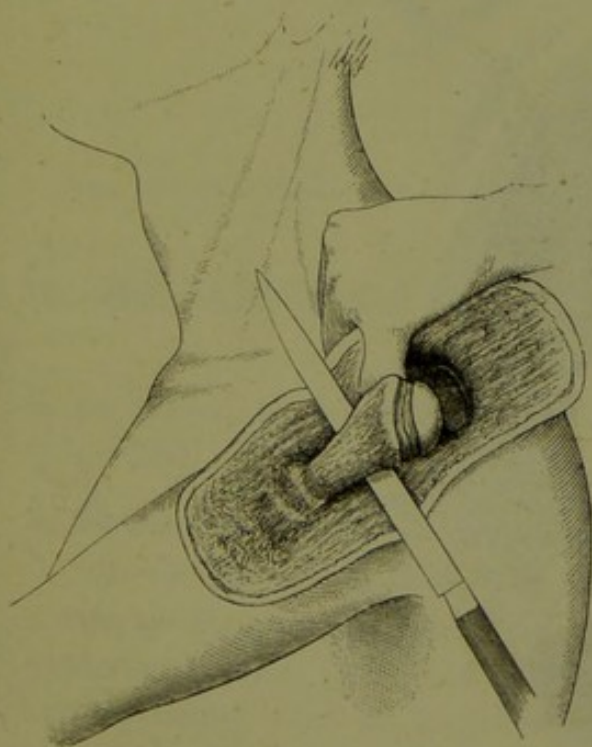
5. The head of the humerus is now tilted forwards, while the knife, placed behind it, divides the capsule on the inner side of the joint.

6. The operator draws the head of the humerus forwards with his left hand, carries the knife with long sweeping strokes down the inner side of the bone, as far as 6^{cm} below the axillary folds. He then turns the edge of the knife inwards (towards the thorax), and divides all the soft parts with one stroke. In this inner flap run the great vessels and nerves.

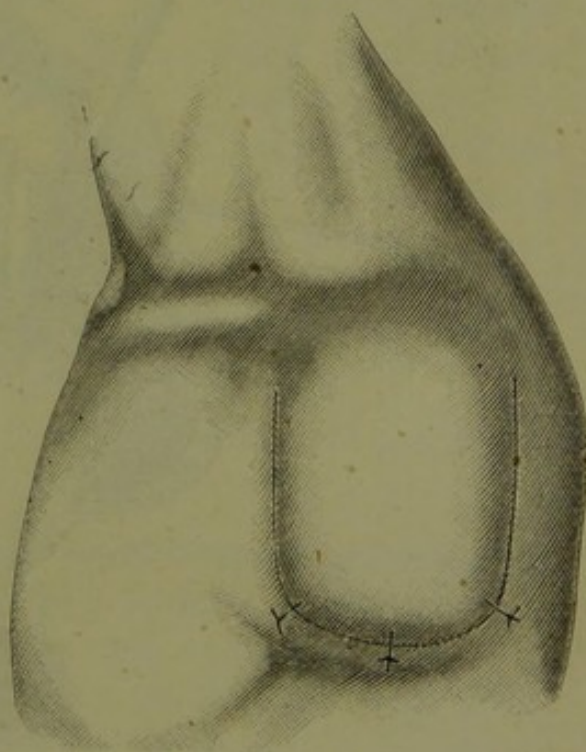
7. When the haemorrhage cannot be completely controlled by compression of the subclavian artery, before the inner flap is completed, an assistant, standing above with his thumb in the wound and his fingers in the axilla, seizes the soft parts on the inside and thoroughly compresses the artery (fig. 356).

Fig. 356.

Fig. 357.



Disarticulation at the shoulder.
Forming the second flap on the inner side.



Stump after disarticulation at the shoulder
by the flap-operation.

8. Fig. 357 shews the appearance of the wound after it has been closed with sutures.

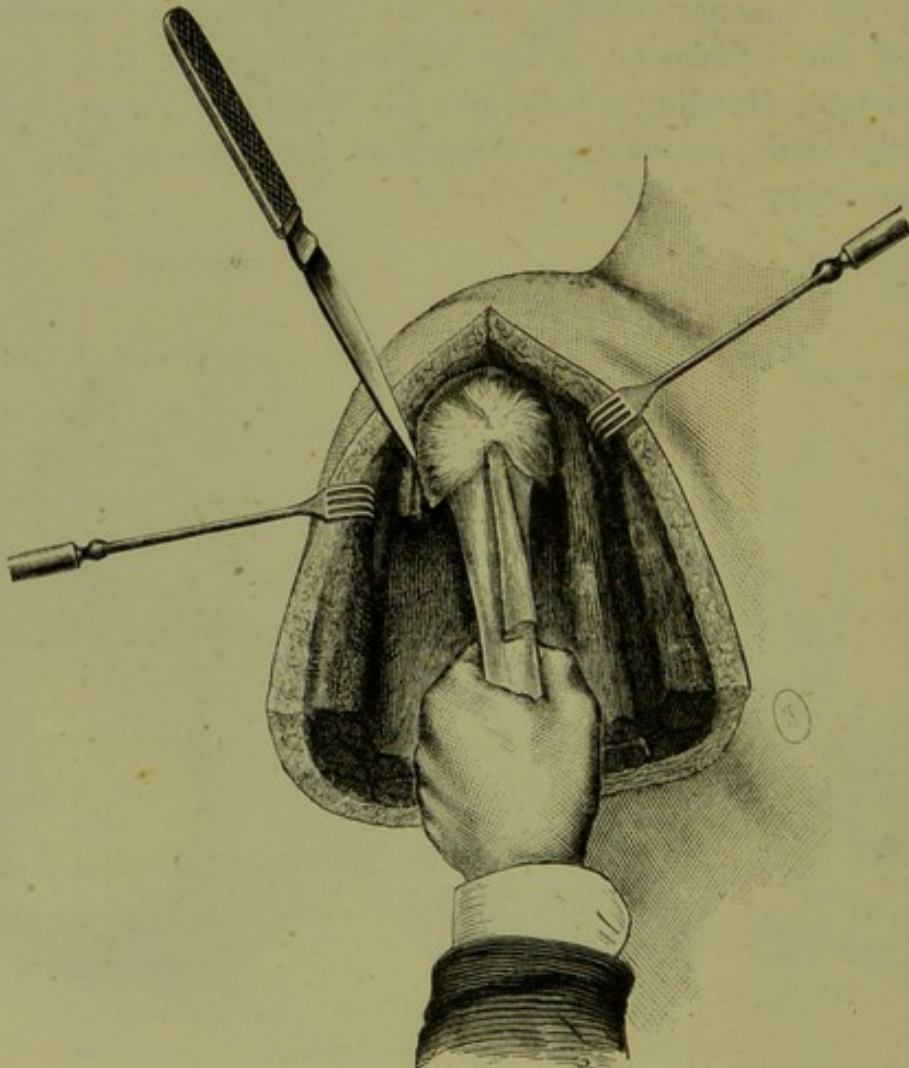
β. By circular incision.

1. The arm is abducted. A circular incision at the lower border of the deltoid divides all the soft parts down to the bone.

2. The bone is sawn through at the same level; and all the gaping vessels are ligatured.

3. A long incision, carried from the anterior border of the acromion to the circular incision, divides all the soft parts down to the bone.

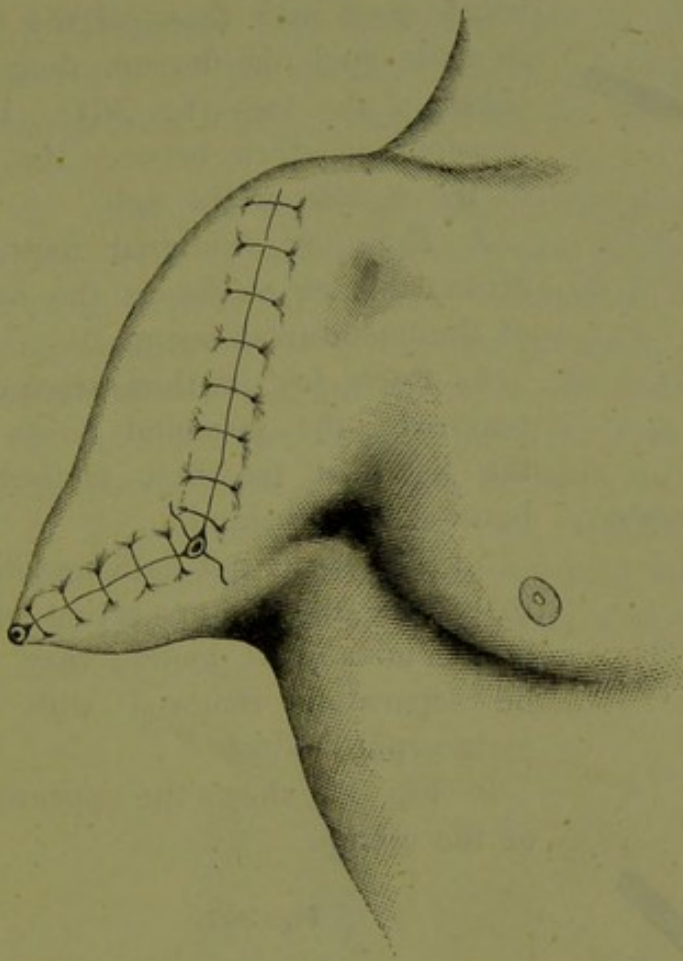
Fig. 358.



Disarticulation at the shoulder joint.

By circular incision combined with vertical division of the soft parts.

Fig. 359.



Stump after disarticulation at the shoulder by the same method.

4. The stump of the humerus is seized with a strong pair of forceps, or with the left hand; and whilst an assistant separates the edges of the vertical incision, the operator liberates the head of the humerus from the joint (fig. 358) by short incisions, directed well against the bone, which is at the same time forcibly rotated; or in suitable cases the operation is performed subperiosteally with elevator and raspatory.

5. Fig. 359 shews the appearance of the stump.

IV. AMPUTATIONS AND DISARTICULATIONS OF THE LOWER EXTREMITY.

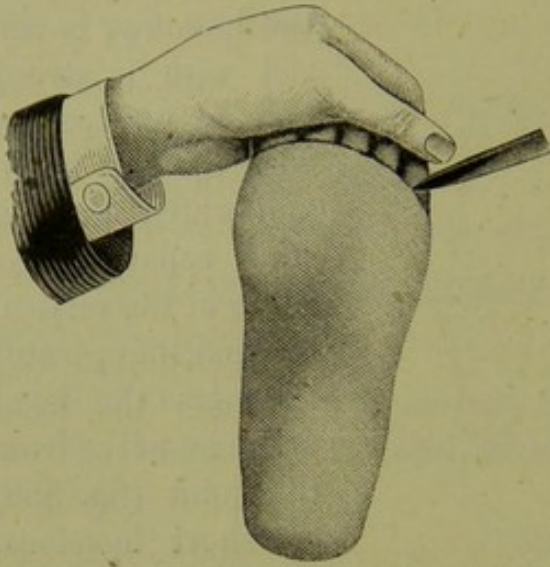
a. Disarticulation of the toes

is performed in the same manner as the disarticulation of the fingers (page 189).

b. Disarticulation of all the toes together at the metatarso-phalangeal joints.

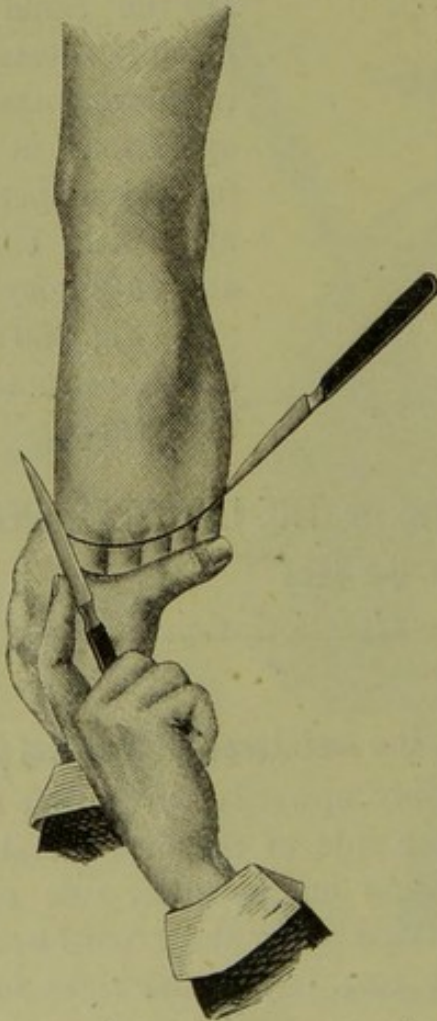
1. While all the toes are bent forcibly upwards by the left hand, a curved incision, beginning on the inner side of the first metatarso-phalangeal joint (left foot) and terminating on the outer side of the corresponding joint of the fifth toe, is carried along the groove between the sole of the foot and the base of the toes. (For the right foot it is reversed.) (Fig. 360).

Fig. 360.



Disarticulation of all the toes (plantar incision).

Fig. 361.



Disarticulation of all the toes (dorsal incision).

2. The toes are forcibly flexed, and a similar incision, the ends of which meet with those of the first, is made upon the dorsum along the bases of the toes (fig. 361). Both incisions penetrate between the toes to the middle of the web.

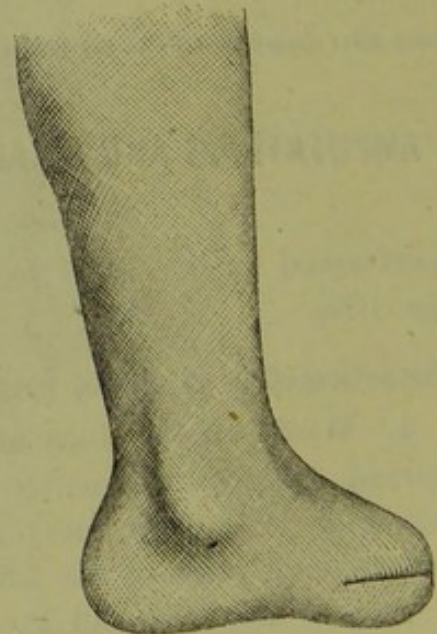
3. Both the semilunar flaps are dissected back as far as the heads of the metatarsal bones.

4. Each toe is then separately removed; the sesamoid bones on the head of the first metatarsal bone are left behind.

5. If there is not sufficient skin, to cover easily the projecting heads of the metatarsal bones, they can be separately removed with the metacarpal saw.

6. Fig. 362 shews the appearance of the stump.

Fig. 362.



Stump after disarticulation of all the toes.

c. Amputation of all the metatarsal bones.

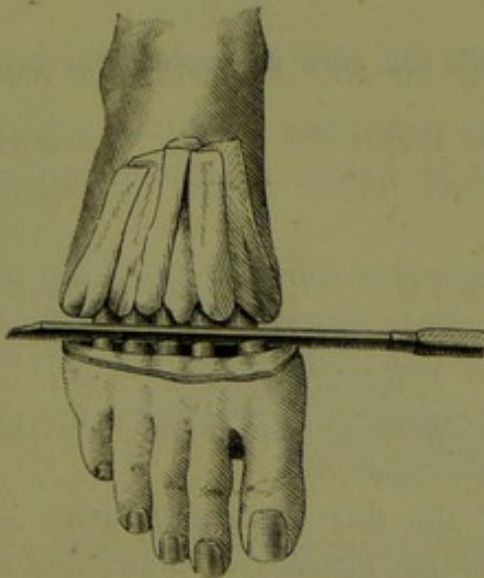
1. From one border of the foot to the other a curved incision is carried along the anterior furrow on the sole of the foot, and the semilunar skin flap is reflected to the spot, where the amputation is required.

2. A smaller semilunar flap is formed upon the dorsum of the foot, the ends of which meet those of the plantar flap at the inner and outer borders of the foot. Instead of the dorsal flap the operation may be completed by a circular incision, if there is sufficient skin from the sole of the foot to cover the ends of the bones.

3. At the bases of both flaps the soft parts are carefully divided with a narrow knife upon and between the separate metatarsal bones.

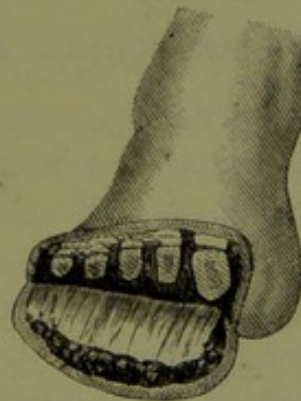4. By means of narrow strips of carbolised gauze or linen, which are drawn through between the separate bones with a pair of forceps, the soft parts are forcibly retracted, and all the bones sawn through (fig. 363 and 364).

Fig. 363.



Amputation of the foot through the metatarsal bones (sawing).

Fig. 364.

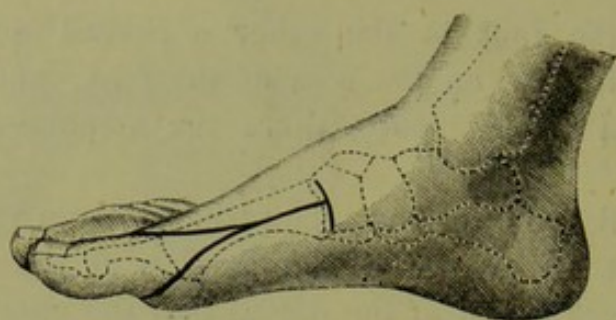


Appearance of the wound after sawing through the metatarsal bones.

d. Disarticulation of the big toe with its metatarsal bone.

1. The oval incision is performed in the same manner as has been described in the disarticulation of the thumb (pag. 193). On account

Fig. 365.



Disarticulation of the big toe with its metatarsal bone.

of the great breadth of the base of the first metatarsal bone, it is advisable to make a transverse incision over the joint at the upper end of the first incision, about 4^{cm} in front of the tubercle of the scaphoid, and to re-

flect the upper and lower flaps thus formed, till the entire bone and the joint are exposed.

2. The tendons of the extensor and flexor longus halucis are divided over the joint, which is opened on the dorsal aspect, and while the bone is steadily twisted round its axis in opposite directions, its connections with the internal cuneiform bone are liberated all round.

e. Disarticulation of the fifth toe with its metatarsal bone.

1. The flap-operation can be performed here in a manner similar to that, which has been described before in the disarticulation of the thumb (pag. 194).

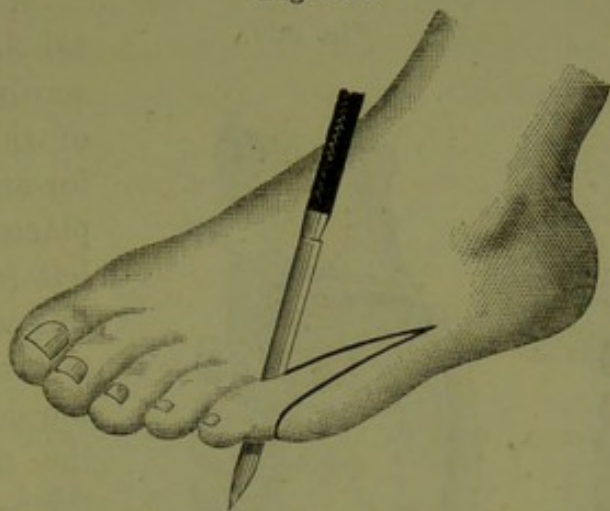
2. The left hand forcibly separates the fifth toe from the fourth, whilst the right carries a narrow knife upwards between the two metatarsal bones from the skin of the web, till it encounters resistance.

3. The end of the cutaneous incision is prolonged upwards about 1^{cm} both on the dorsal and plantar surfaces.

4. By forcible abduction of the fifth metatarsal bone its base is separated first from that of the fourth metatarsal bone, and then from the cuboid.

5. The knife is carried round the projecting tuberosity of the fifth metatarsal bone, and from here downwards along the outer side of the bone. A tongue-shaped outer flap is thus formed, whose rounded point is made to terminate exactly opposite the first incision, which was made in the web between the fourth and fifth toes (fig. 366).

Fig. 366.

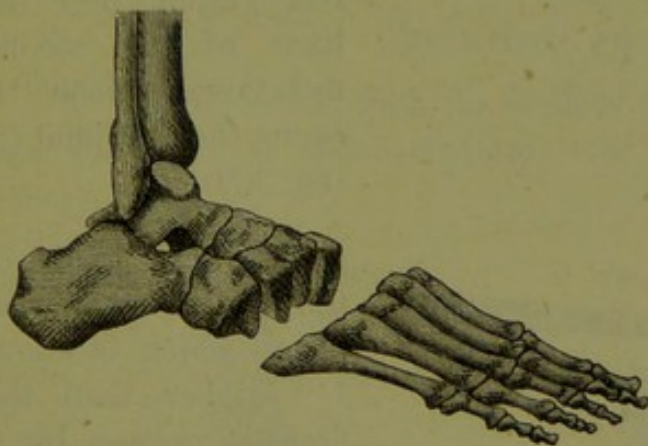


Disarticulation of the fifth toe with its metatarsal bone.

f. Disarticulation at the tarso-metatarsal joints (LISFRANC) (fig. 367).

1. The joint between the cuboid and the fifth metatarsal bone, which lies immediately behind the tuberosity of the latter bone, is sought

Fig. 367.



Disarticulation at the tarso-metatarsal joints (LISFRANC).

for at the outer border of the foot. At the inner border of the foot the joint between the internal cuneiform and the first metatarsal bone, which is 4^{cm} in front of the tuberosity of the scaphoid, is also found. These points are marked with indian ink or by a scratch with the knife.

2. The foot is raised, and from one point to the other (from left to right) a large semilunar flap is

cut upon the sole of the foot, the convexity of which passes over the heads of the metatarsal bones.

3. The foot is brought down, and forcibly extended. The knife is then carried across the dorsum with a slight convexity forwards from one end of the plantar flap to the other (fig. 368).

Fig. 368.

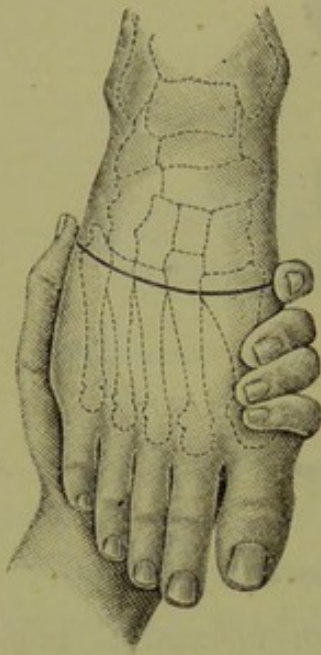


Fig. 369.

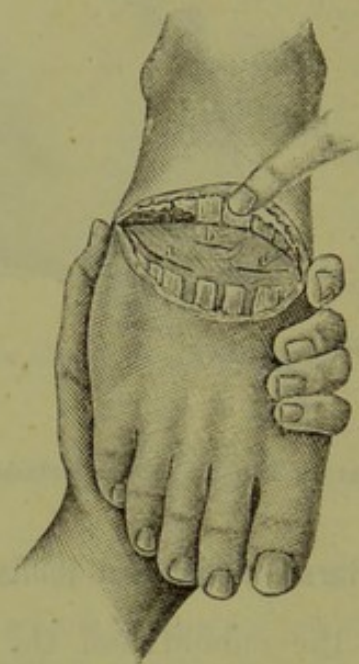
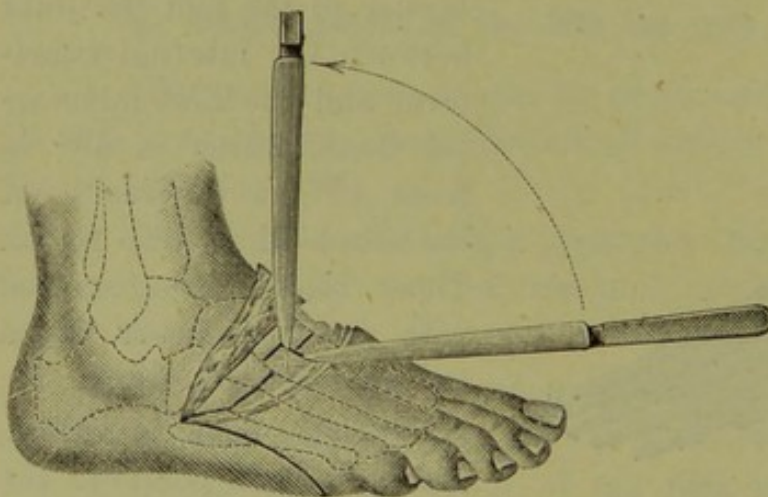


Fig. 370.



attachments of the bone with the internal and external cuneiform, between which its base is inserted, are divided by a puncture of the knife with the edge directed upwards (fig. 370).

7. All the joints being now widely open, the remaining ligaments at the side and in the sole are divided with the knife, and the greater

4. The small dorsal flap is drawn upwards, and the point of the knife searches for and opens the joint placed farthest to the left (on the right foot this would be the fifth metatarsal joint), while the left hand presses the anterior part of the foot forcibly downwards.

5. As soon as the joint is opened, the knife, carried with a slight convexity forwards, opens the fourth and third joints (a). But gliding over the base of the second metatarsal bone it opens the first joint (c) (fig. 369).

6. The joint of the second metatarsal bone, which is about 1^{cm} higher than the first, is opened by a small transverse incision (b); the lateral

part of the muscles in the sole of the foot cut through; the edge is then directed forwards to complete the plantar flap (fig. 371).

Fig. 372 shews its appearance before closing the wound.

Fig. 371.

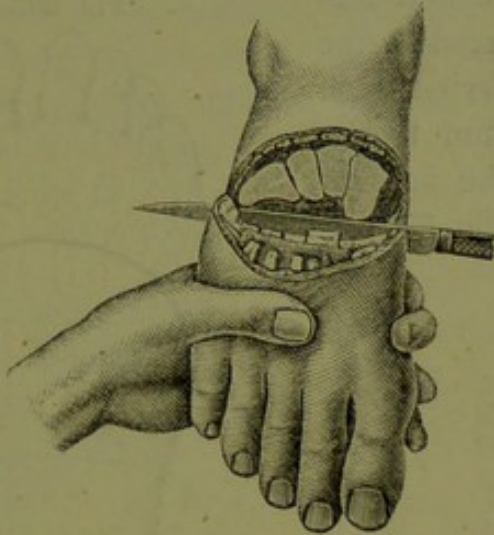
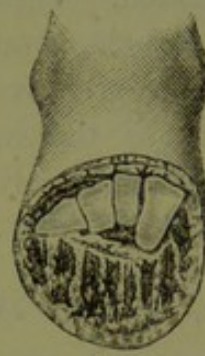

Fig. 372.

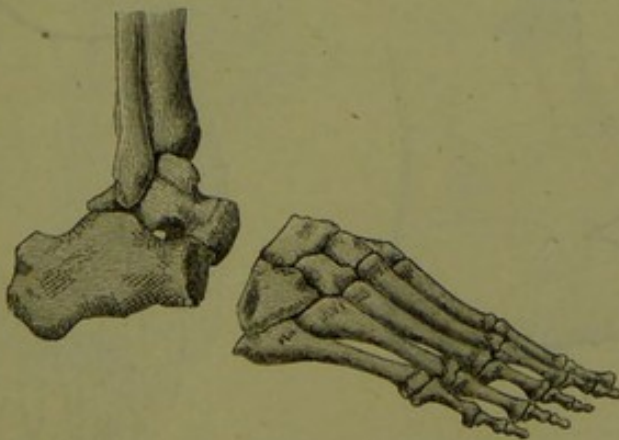


g. Disarticulation through the tarsus (CHOPART).

(Medio-tarsal amputation.)

1. The disarticulation takes place at the joint between the scaphoid and the head of the astragalus, and between the os calcis and the cuboid (fig. 373).

Fig. 373.



Disarticulation through the tarsus (CHOPART).

2. The joint at the inner border of the foot is found 1^{cm} above the tuberosity of the scaphoid, at the outer border of the foot 2^{cm} above the tuberosity of the fifth metatarsal bone. The two points are marked.

3. The foot is raised, and a curved

incision is carried over the sole of the foot, running from the mark on the left border forwards as far as a thumb's breadth behind the heads of the metatarsal bones; then across the sole of the foot, and backwards to the mark on the right border (fig. 374—376).

4. The foot is brought down and forcibly depressed. The knife is placed in the left angle of the wound and carried with a slight convexity over the dorsum to the other angle of the incision in the sole of the foot, dividing only the skin (fig. 377).

Fig. 374.

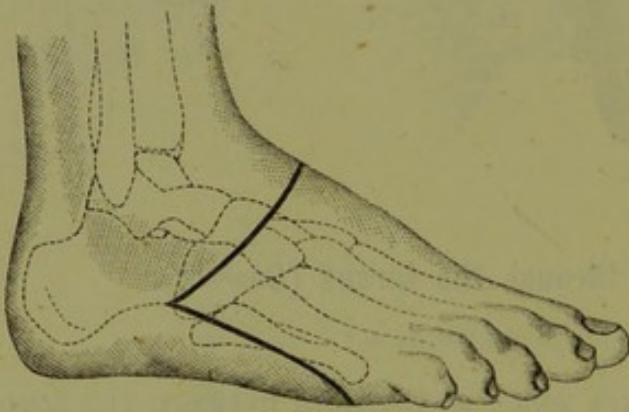

Fig. 376.

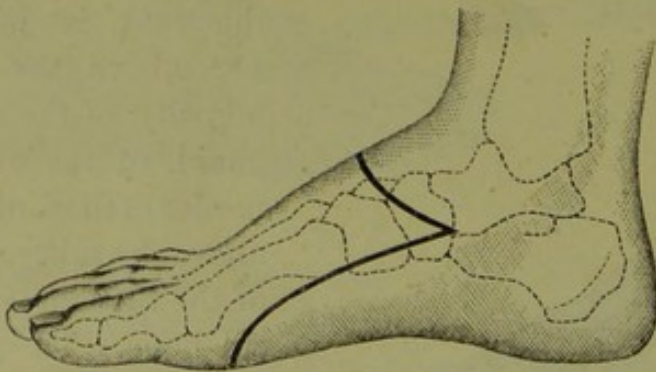


Fig. 375.

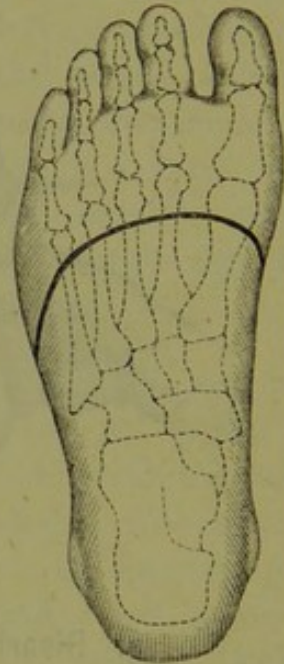
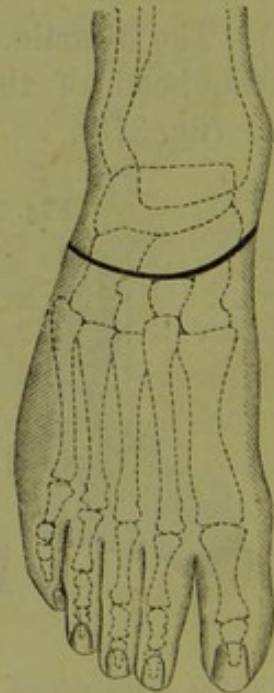


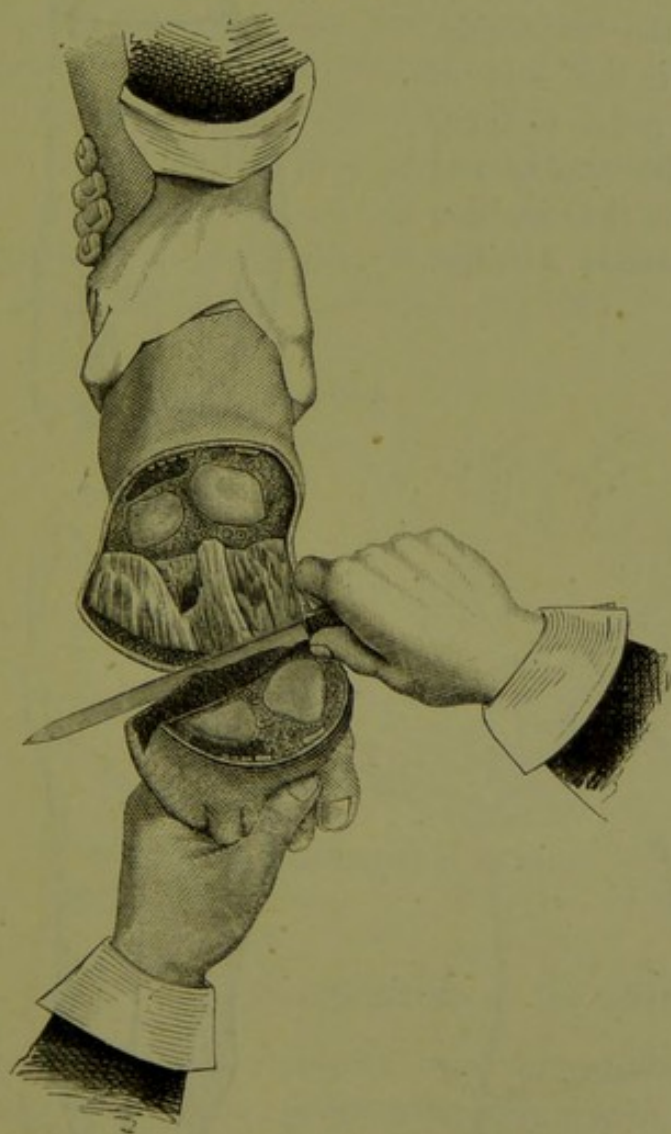
Fig. 377.



5. The small dorsal flap is forcibly retracted, and by one stroke of the knife all the tendons are divided and the joints immediately opened (it is safest to begin over the tuberosity of the scaphoid as it can be plainly felt).

6. With the edge of the knife carried over the line of articulation slightly curved in \sim shape, the joints open with a cracking noise. The point divides every band that is on the stretch, till finally on the plantar aspect the anterior part of the foot can be so completely flexed as to touch the heel.

Fig. 378.

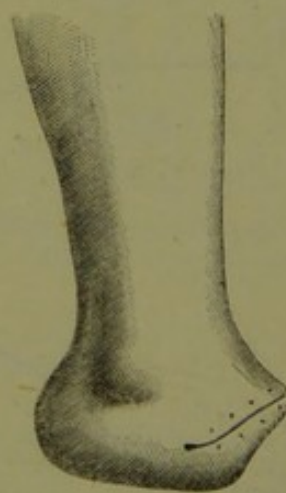

Disarticulation through the tarsus (CHOPART).
(Completing the plantar flap.)

7. After the incision for the plantar flap has been deepened, the blade of the knife with the edge directed forwards is placed beneath the liberated scaphoid and cuboid bones, and carried forwards in a sawing motion, till the plantar flap is completed (fig. 378).

8. Fig. 379 shews the appearance of the stump.

Fig. 379.



Stump after CHOPART'S operation.

h. Subastragaloid disarticulation (MALGAIGNE).

1. Two lateral flaps are formed by an incision, which commences behind immediately above the great tuberosity of the os calcis and divides the tendo Achillis. The incision then runs over the lower half of the os calcis with a wide bend below the external malleolus (fig. 380); from here it ascends transversely over the middle of the cuboid to the dorsum of the foot; it is carried down vertically (fig. 382) over the anterior edge of the scaphoid (fig. 381) to the inner side, till it reaches the centre of the sole of the foot (fig. 383). At this point it turns directly backwards at a right angle, and meets the commencement of the incision at the inner border of the tendo Achillis.

Fig. 381.

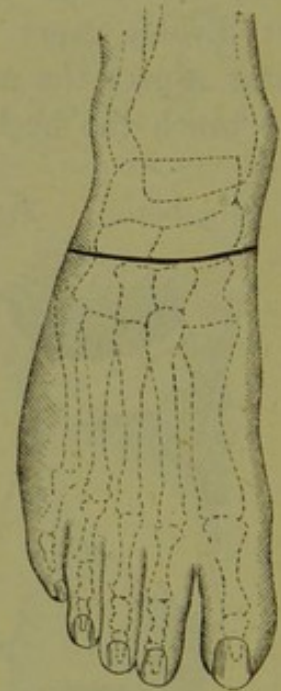


Fig. 383.

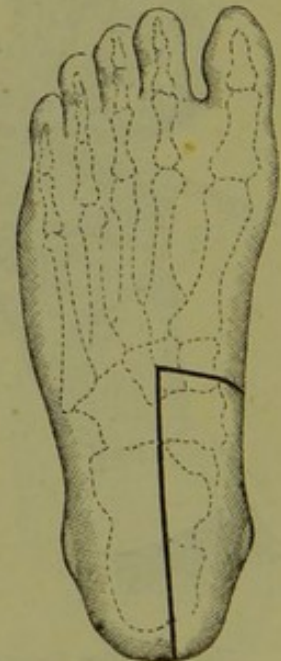
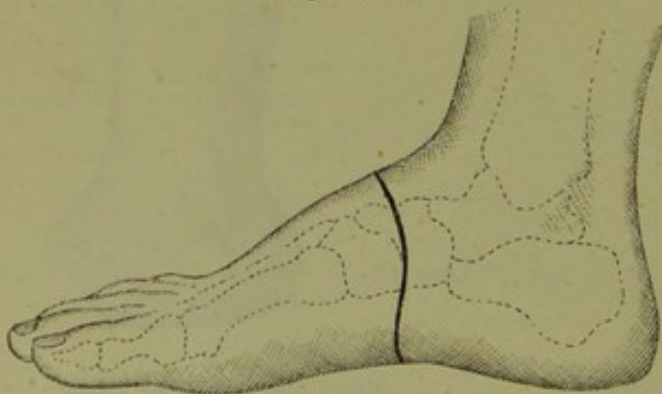


Fig. 380.

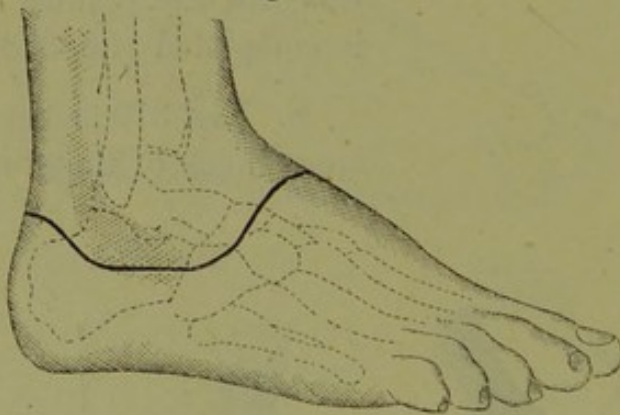

Fig. 382.



Subastragaloid disarticulation (MALGAIGNE).

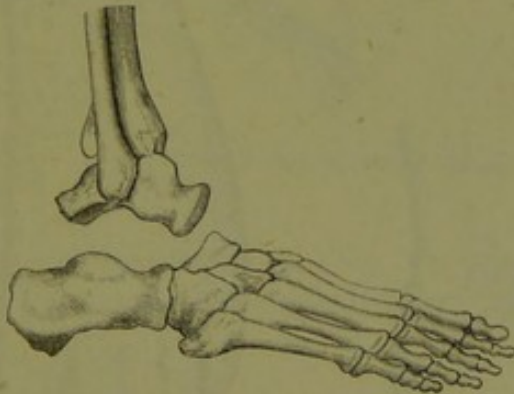
2. Both flaps are liberated from the bones, till both lateral surfaces of the os calcis and the talo-scaphoid joint are exposed. Great care is taken, in approaching the lower end of the malleoli, not to injure the tibio-tarsal joint.

3. The anterior part of the foot is removed by CHOPART'S disarticulation.

4. The anterior end of the os calcis is seized with a pair of bone forceps, and while the bone is being depressed and supinated, the external lateral ligaments are divided with a narrow knife 1^{cm} below the tip of the external malleolus. The same knife then penetrates between the two bones and divides the strong interosseous ligament: and by twisting the bone more and more upon its long axis, the talo-calcaneal ligament is finally divided about 3^{cm} below the inner malleolus. (See the representation of the ligaments for excision of the ankle.)

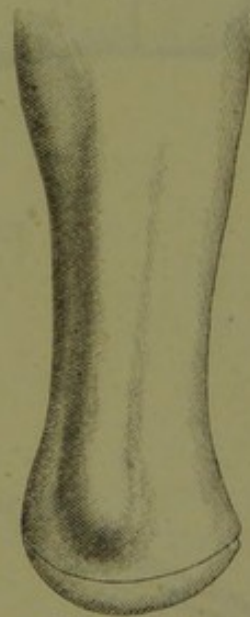5. In spite of the very irregular shape of the under surface of the astragalus (fig. 384), a very useful stump for walking is produced by this operation (fig. 385).

Fig. 384.



Subastragaloid disarticulation of the foot.

Fig. 385.



Stump after subastragaloid disarticulation of the foot.

i. Disarticulation of the whole foot (SYME'S).

1. The foot is placed in an elevated position and flexed to a right angle; an insision, penetrating throughout down to the bone, is carried from the tip of one (left) malleolus transversely across the sole of the foot to the tip of the other (right) malleolus (fig. 386—388).

2. The foot is brought down and forcibly depressed with the left hand, whilst a second incision is carried from the tip of one malleolus to the other across the anterior surface of the tibio-tarsal joint (fig. 389).

Fig. 386.

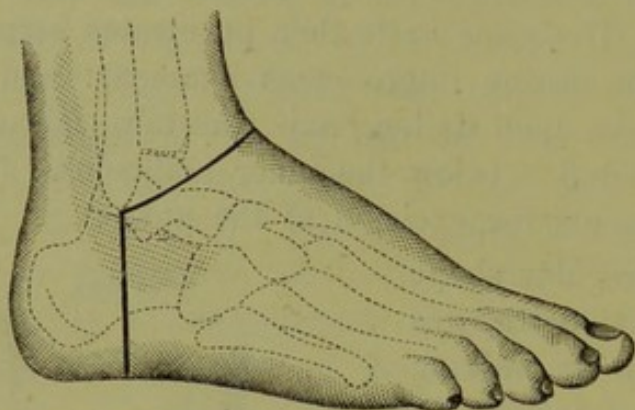


Fig. 388.

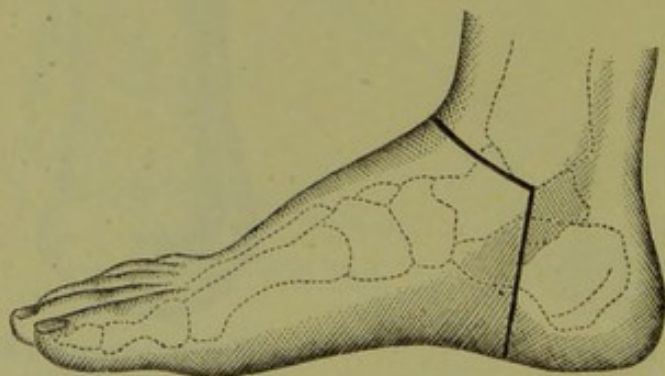


Fig. 387.

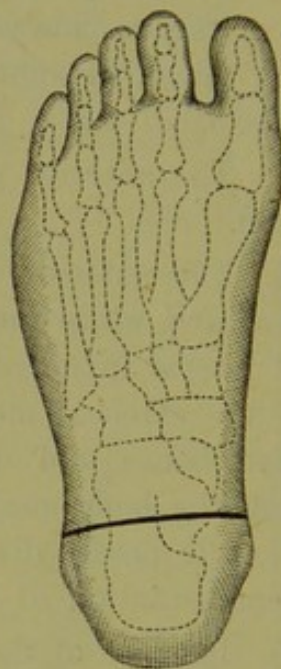
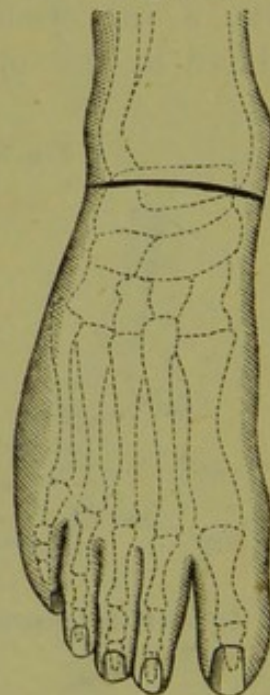


Fig. 389.

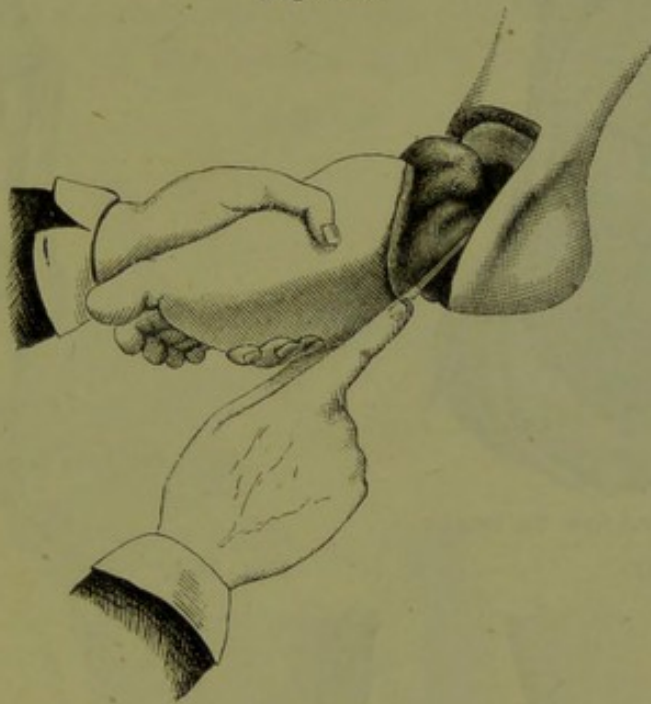


SYME'S disarticulation of the foot.

3. A transverse incision across the articular surface of the astragalus opens the joint in front, and an incision below each malleolus divides the lateral ligaments; the upper articular surface of the astragalus is thus exposed.

4. While the left hand presses the foot more and more against the posterior aspect of the leg, and alternately twists it round its axis to one side or the other, the os calcis is liberated from its heel flap; the tendo Achillis is divided by incisions, which follow closely upon one another, and are made alternately from above, from the side, and finally from behind and below, but always cutting upon the bone (fig. 390).

Fig. 390.



SYME'S disarticulation (dissecting out the os calcis).

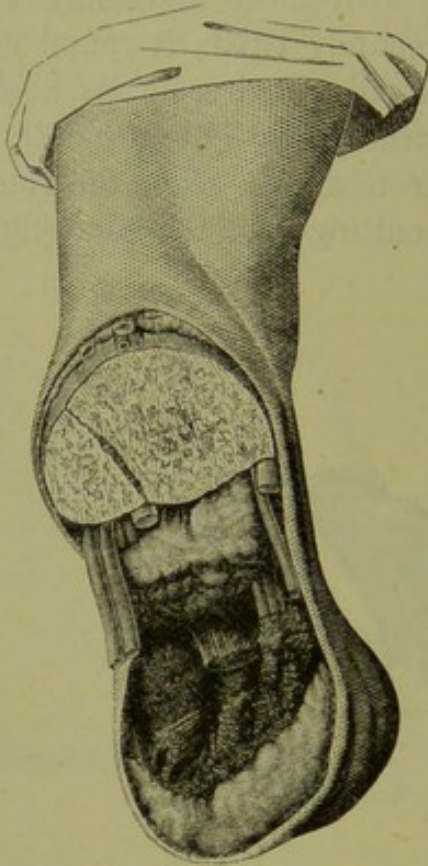
Note. In secondary operations the calcaneus need not be dissected out with the knife, but can be conveniently shelled out from the periosteum with elevator and raspatory.

5. The heel flap is drawn upwards above the malleoli, whilst a circular incision, made just above the articular surface of the tibia, divides the remaining soft parts (tendons and periosteum).

6. The saw is applied to the bones, so as only to remove both malleoli and a thin layer of the articular cartilage of the tibia (fig. 391 and 392).

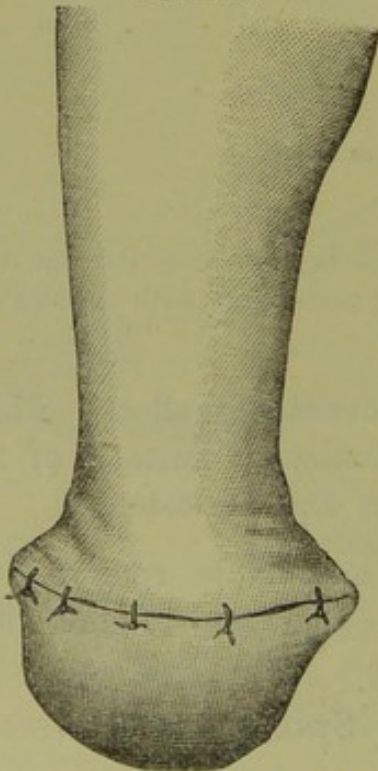The malleoli alone can be removed (as SYME has done several times) with a pair of cutting bone forceps.

Fig. 391.



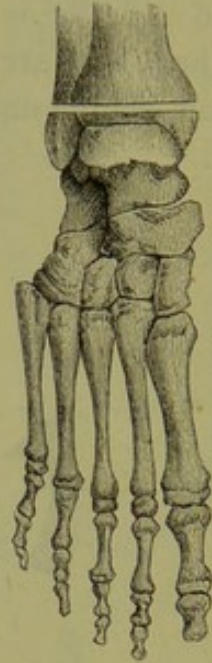Heel-flap seen from the interior.

Fig. 393.



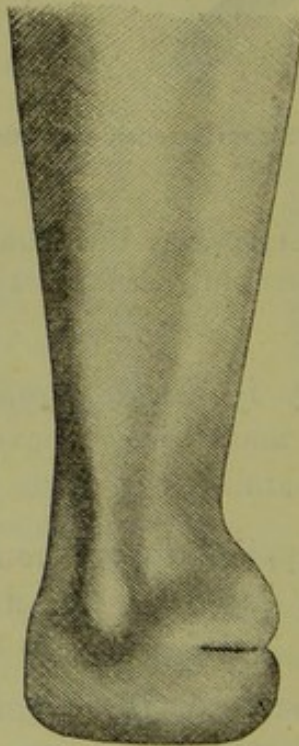
Recent stump after SYME'S operation, from the front.

Fig. 392.



The bone sawn through after SYME'S operation.

Fig. 394.



Healed stump after SYME, from the side.

7. After all the divided vessels have been tied, the skin is perforated behind on the outer side of the tendo Achillis with a narrow knife. Through this aperture a drainage tube is drawn and the wound closed with sutures (fig. 393 and 394).

k. **PIROGOFF'S amputation of the foot.**

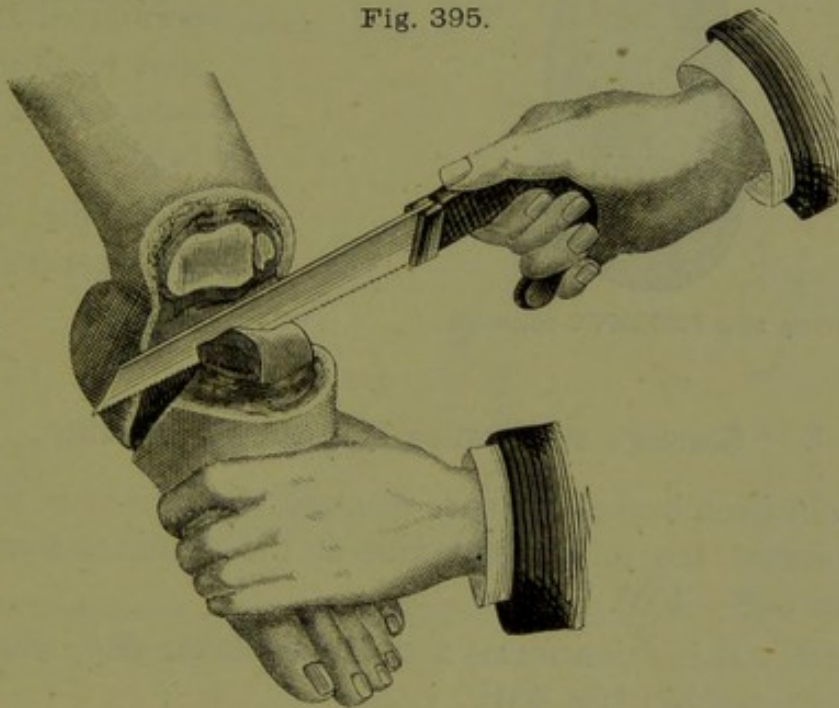
(Calcaneo-tibial osteoplastic amputation.)

1. The same incisions are made in the soft parts as in SYME'S amputation.

2. After opening the joint, the foot is forced downwards till the sustentaculum tali is visible.

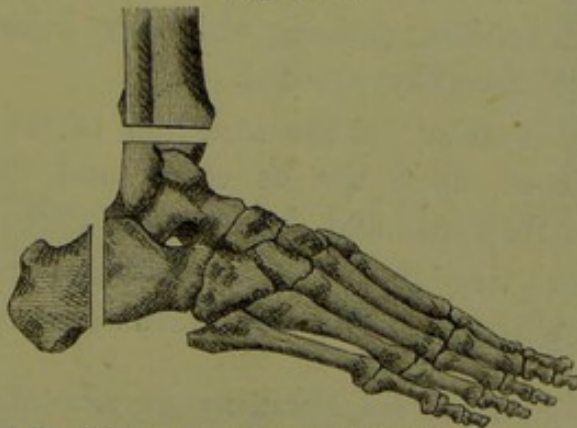
3. The saw is placed upon the upper surface of the os calcis immediately behind the sustentaculum tali, and the bone is sawn through exactly on a level with the incision in the sole of the foot (fig. 395 and 396).

Fig. 395.



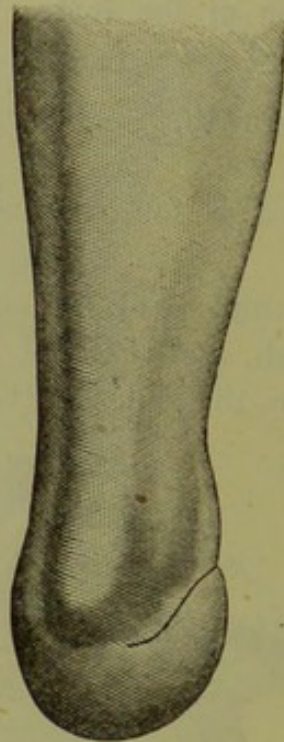
PIROGOFF'S amputation (sawing the os calcis).

Fig. 396.



After the division of the bones in PIROGOFF'S operation.

Fig. 397.



Stump after PIROGOFF'S operation.

4. Both malleoli and a thin slice of the articular surface of the tibia are removed with the saw, as in SYME'S amputation.

5. The tendo Achillis is divided immediately above its insertion, and the skin perforated at the same spot to allow the passage of a drainage tube.

6. Fig. 397 shews the appearance of the stump.

I. * GÜNTHER'S modification of PIROGOFF'S operation.

1. The incision begins and ends immediately in front of the malleoli, and passes across the sole of the foot at the posterior border of the scaphoid (fig. 398—400).

2. The dorsal incision forms a small semilunar flap, which reaches as far as the scaphoid (fig. 401).

3. After the joint has been opened, the soft parts are dissected obliquely backwards on both sides of the os calcis as far as the insertion of the tendo Achillis, in doing which any injury of the posterior tibial artery must be carefully avoided.

4. Immediately in front of the insertion of the tendo Achillis a key-hole saw is placed upon the os calcis and the bone obliquely divided from behind forwards and downwards.

5. In the same way the tibia and fibula are obliquely sawn through from behind forwards and downwards (fig. 402).

* See GÜNTHER'S Leitfaden zu den Operationen am menschlichen Körper. Part I, page 137. Leipzig und Heidelberg 1859.

Fig. 398.

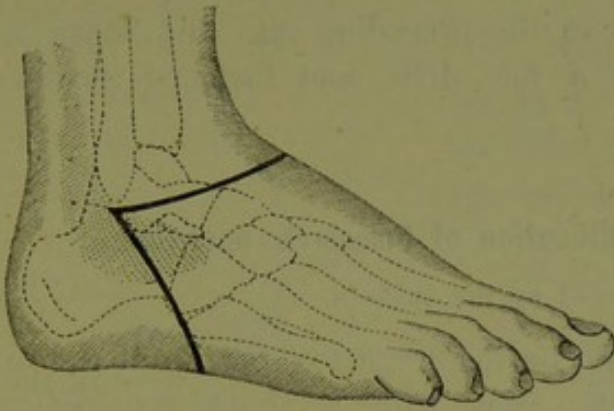


Fig. 399.

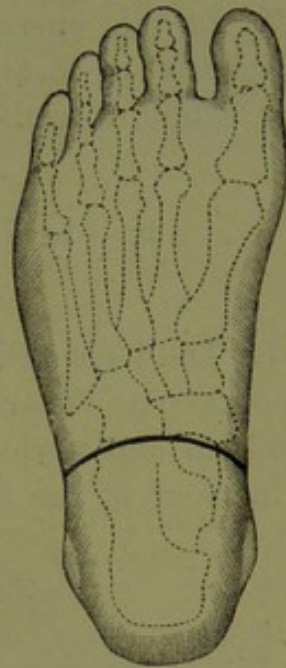
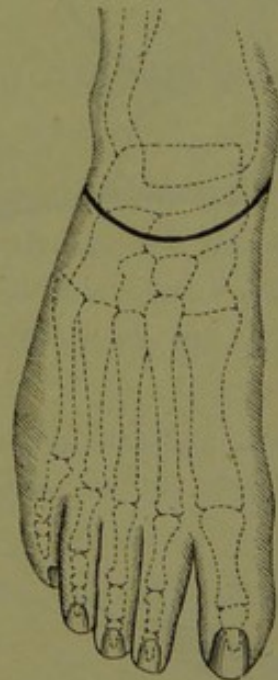


Fig. 400.

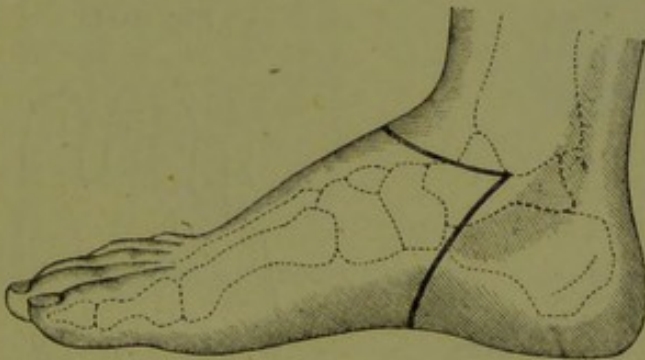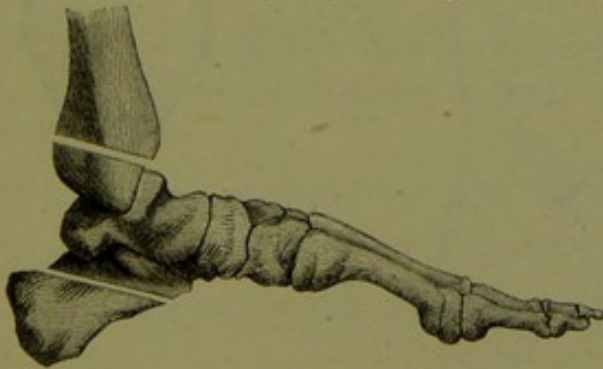


Fig. 401.



GÜNTHER'S modification of PIROGOFF'S operation
(fig. 398—401).

Fig. 402.



The bones sawn through in GÜNTHER'S modification.

6. By this method the sawn surfaces can be easily brought in contact without dividing the tendo Achillis.

7. In this operation, as in the preceding one, the bones may be conveniently perforated with a fine drill, and fastened together with strong catgut threads.

m. *LE FORT'S modification of PIROGOFF'S operation.

(Altered by the author.)

1. The incision in the sole begins 2^{cm} below the tip of the external malleolus (on the right foot), runs with a slight convexity under the cuboid and navicular bones, and ends on the inner side 3^{cm} below and in front of the internal malleolus (fig. 403—405).

Fig. 403.

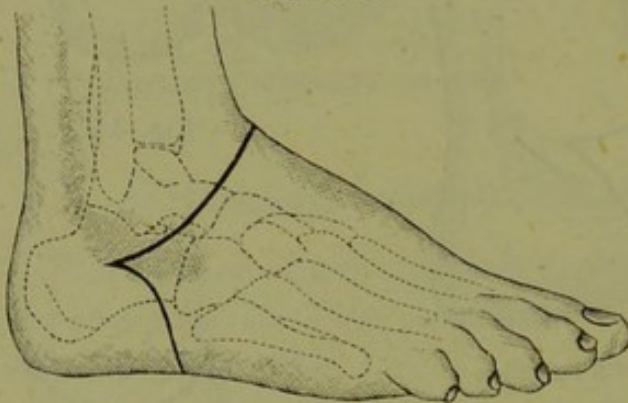

Fig. 404.

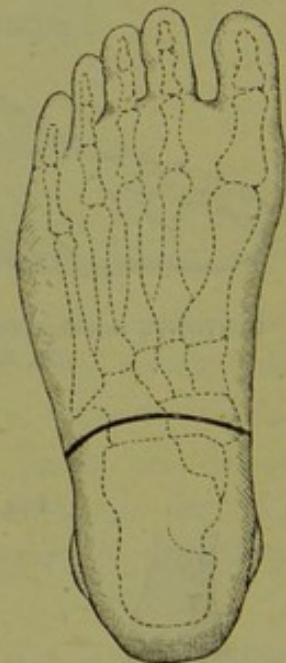
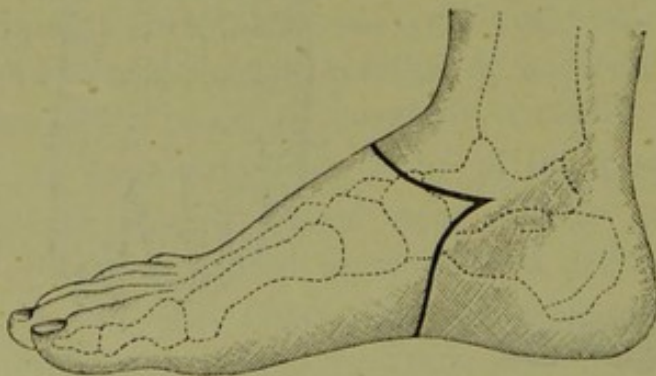


Fig. 405.

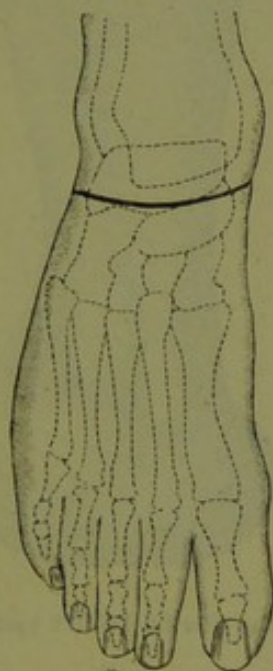


LE FORT'S modification of PIROGOFF'S operation.

* Manuel de médecine opératoire, pag. 618.

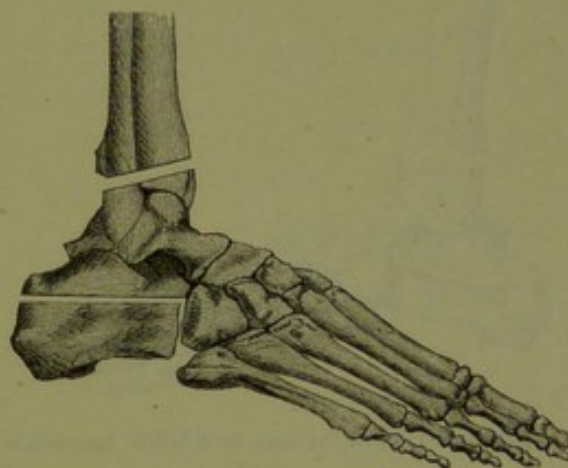
2. The dorsal incision forms from the same points a slightly convex flap, whose anterior margin is the same as in that of CHOPART'S operation (fig. 406).

Fig. 406.



3. The dorsal flap is dissected upwards as far as the tibio-tarsal joint, and the joint opened as in PIROGOFF'S operation.

Fig. 407.



LE FORT'S modification of PIROGOFF'S operation.

The bones sawn through in LE FORT'S operation.

4. The foot is bent backwards, and the upper surface of the os calcis sufficiently exposed to apply a key-hole saw behind the upper margin of the tuberosity of the os calcis. By a horizontal incision from behind forwards the upper third of the bone can be removed with the saw (fig. 407).

5. As soon as the saw has penetrated to the calcaneo-cuboid joint, the cuboid is separated from the os calcis as in CHOPART'S operation.

6. The two malleoli and the articular surface of the tibia are removed with the saw, as in PIROGOFF'S operation.

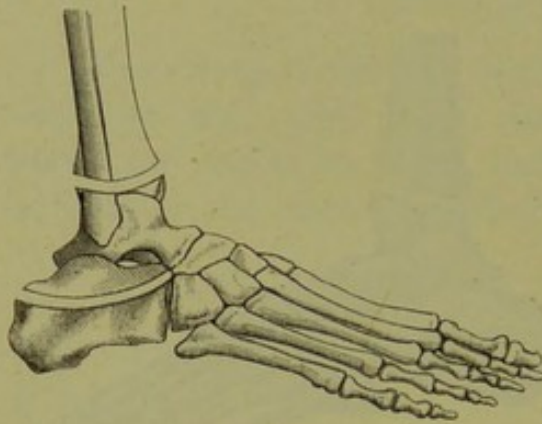
7. The os calcis can also be sawn (BRUNS*) so as to present a

* See P. BRUNS: Klinische Erfahrungen etc. in v. LANGENBECK'S Archiv für klinische Chirurgie. Part XIX. pag. 656.

concave surface, and the bones of the leg a corresponding convexity (fig. 408).

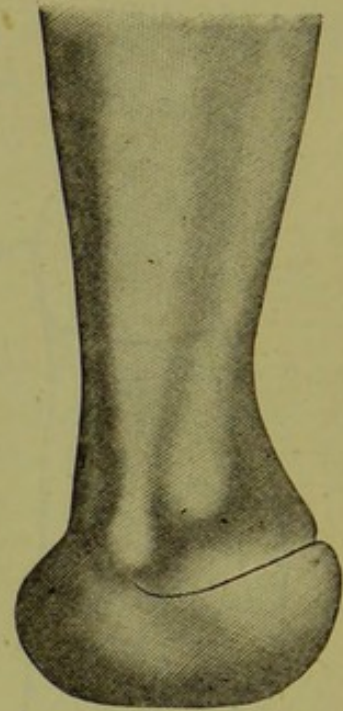
8. By this method the stump receives a very broad basis of support for walking (fig. 409).

Fig. 408.



The bones sawn through in BRUNS' operation.

Fig. 409.



Stump after LE FORT'S operation.

n. Amputations of the leg.

a. *By double circular incision*

(page 175).

β. *By skin flaps*

(page 178).

Amputation by two lateral skin flaps is especially suitable for the lower third of the leg (above the malleoli) (fig. 179).

An anterior skin flap soon suffers from pressure against the sharp edge of the sawn tibia.

A posterior skin flap draws the edges of the wound asunder by its weight.

One lateral flap with a semi-circular incision on the opposite side (LANGENBECK) is a very convenient form of amputation for the upper two thirds of the leg. It is only necessary to recollect, that the base of the skin flap must be somewhat smaller than half the circumference



Fig. III.

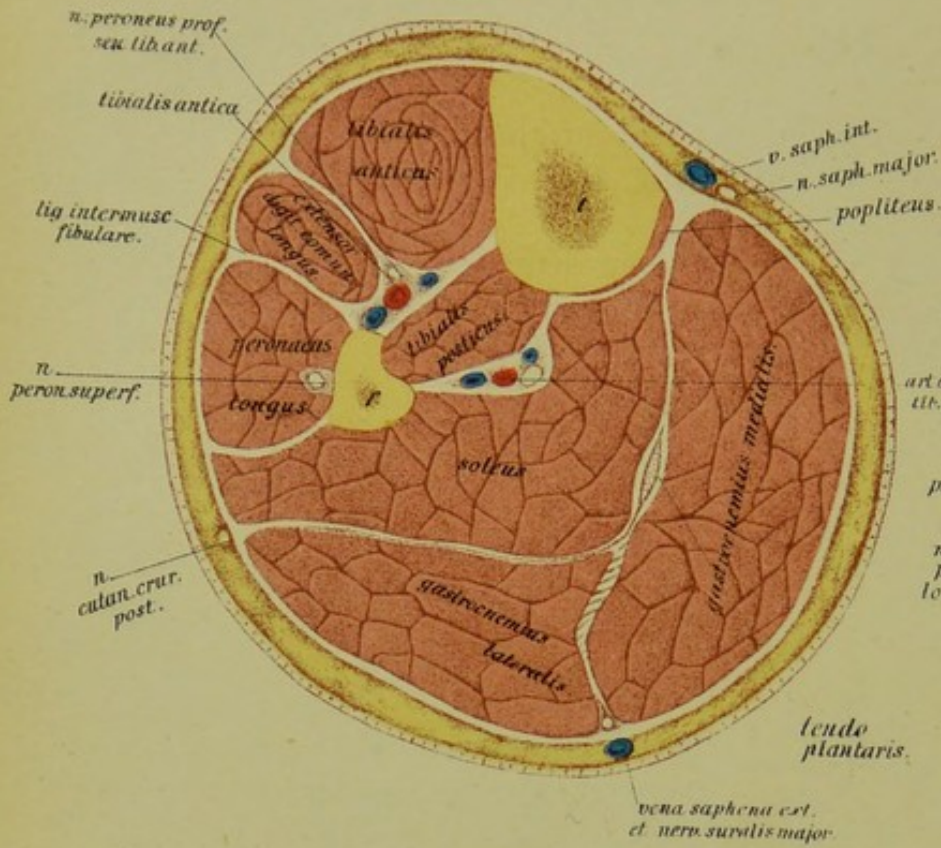


Fig. I.

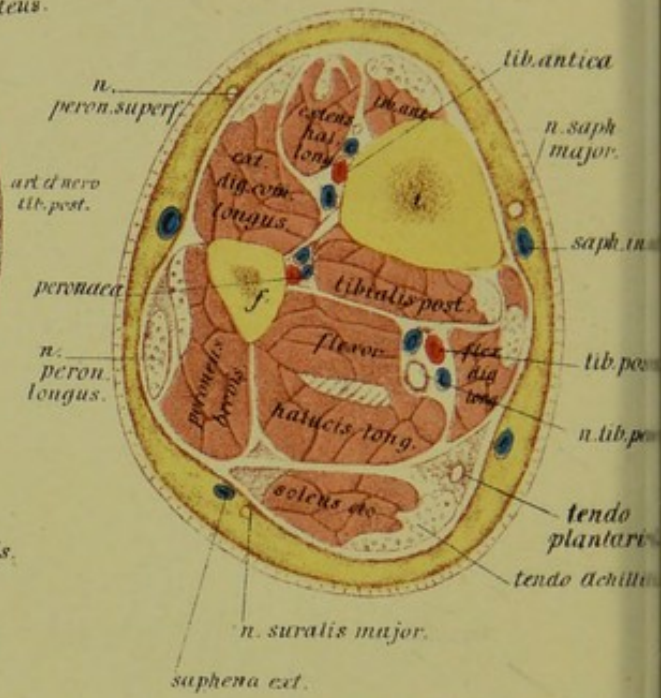


Fig. II.

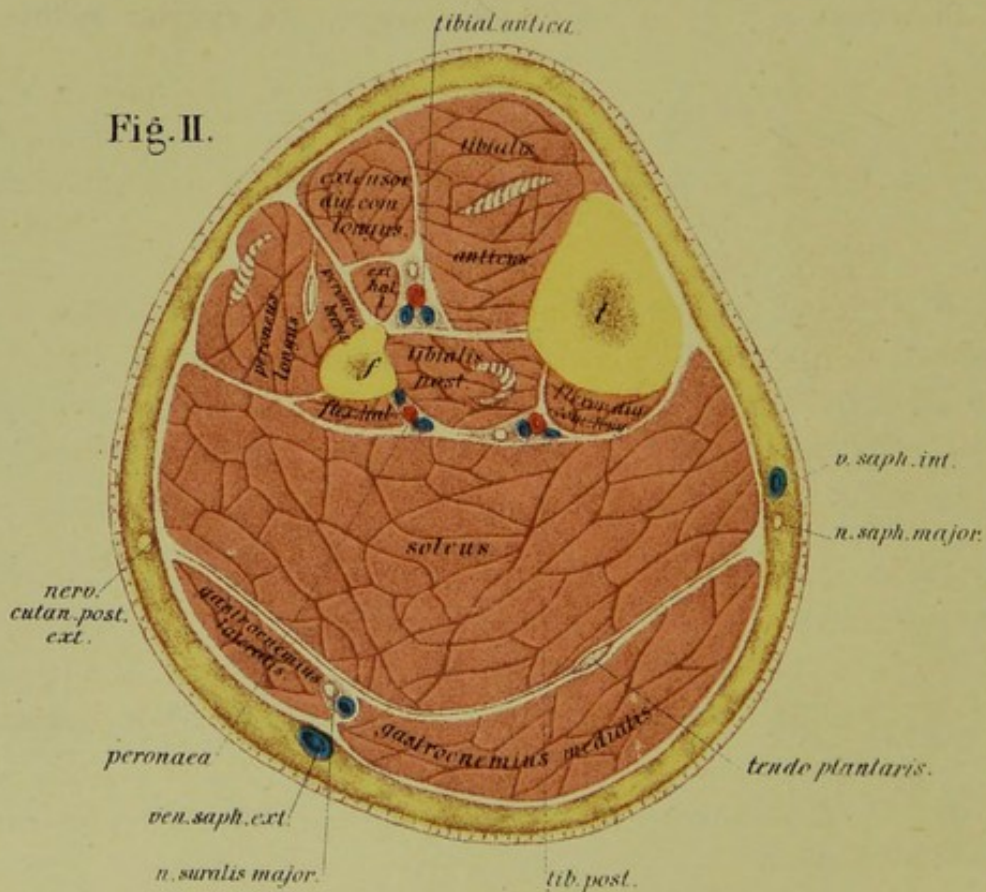
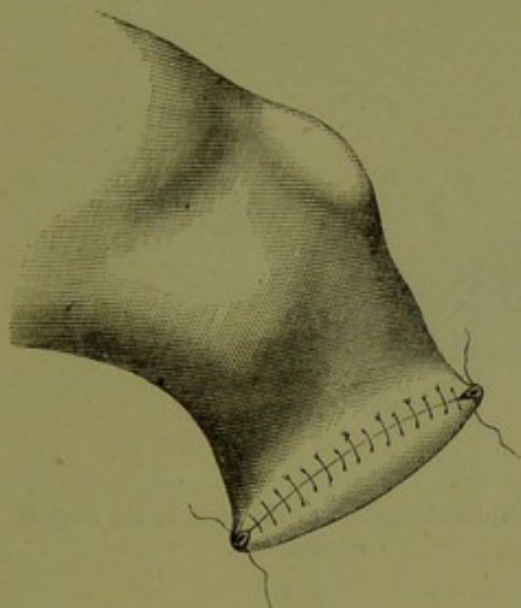


Fig. 410.



Amputation of the leg with lateral flaps.

of the limb at the seat of amputation (fig. 410).

The representations of VOLZ'S transverse sections are found on plate XXVIII, fig. I—III.

Fig. I. Transverse section of the right leg in its lower third.

Fig. II. Transverse section of the right leg in its middle third.

Fig. III. Transverse section of the right leg in its upper third.

o. Disarticulation of the leg at the knee by the circular method.

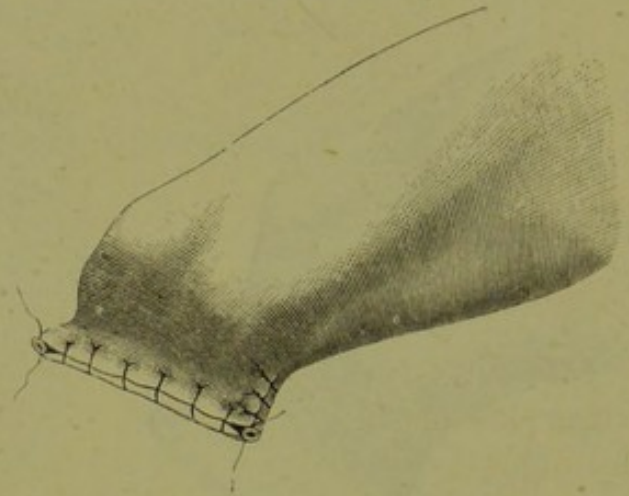
1. With the limb fully extended at the knee, the skin is divided by a circular incision 8^{cm} below the patella. The skin is dissected up circularly as far as the lower border of the patella, and reflected like a cuff.

2. With the knee flexed, the ligamentum patella is first divided immediately below the patella, then the anterior part of the capsule and the lateral ligaments close to the edge of the femur, so that the semilunar cartilages and the greater part of the capsule remain attached to the tibia.

3. After the knee has been still more strongly flexed, the crucial ligaments are separated from the inner surfaces of both condyles. The knee is then again straightened, and the remaining soft tissues at the back of the joint are divided with one sweep of the knife from before backwards (fig. 411).

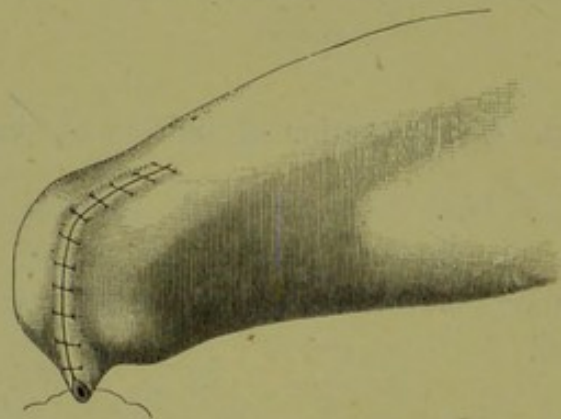
A section of the left thigh through the condyles is represented on plate XXIX, fig. 1.

Fig. 412.



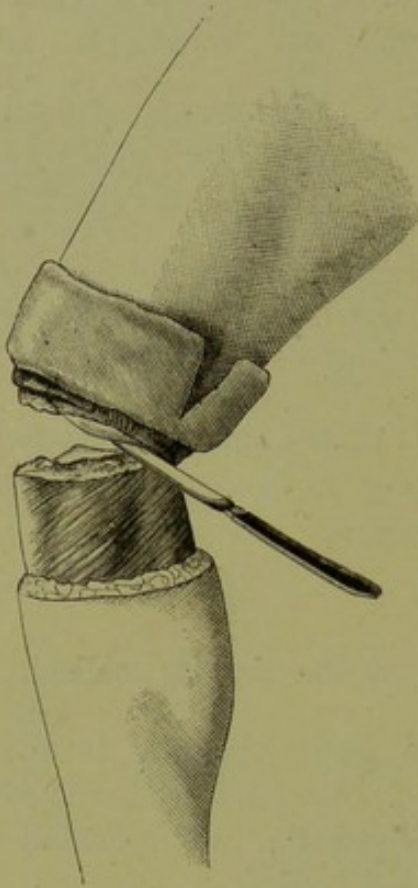
Stump after disarticulation at the knee by the circular method.

Fig. 413.



Stump after disarticulation at the knee by the circular method with anterior vertical incision, and removal of the patella.

Fig. 411.



Disarticulation at the knee (circular method).

4. The wound can be united transversely (fig. 412), or in a direction from before backwards, so that the cicatrix lies between the two condyles (fig. 413).

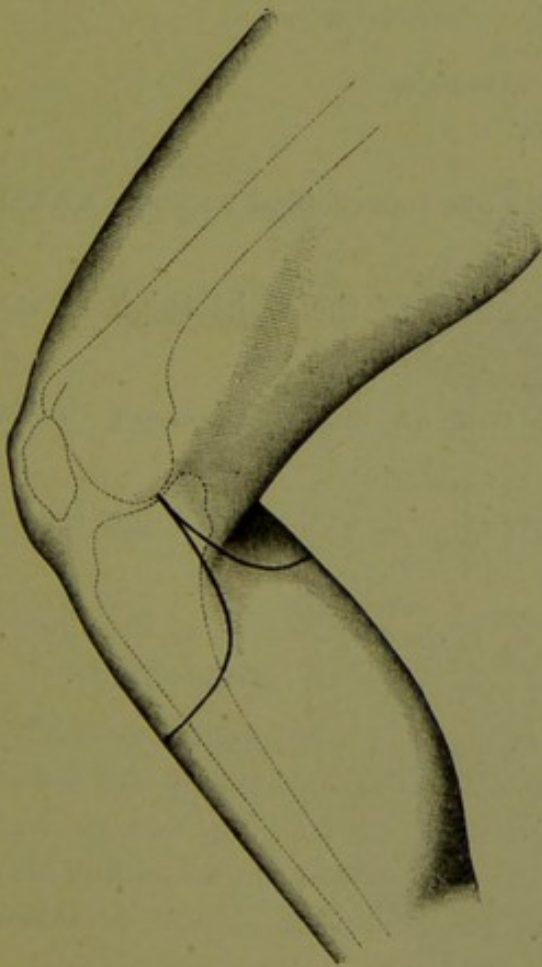
5. If the operator wishes to remove the patella (BILLROTH) and the upper part of the capsule, a vertical incision is made at the end of the circular operation over the middle of the patella, commencing 4^{cm} above it, and the patella separated from the extensor tendon: the latter is then turned upwards, and the part of the capsule lying beneath it is dissected out.

p. Disarticulation at the knee by the flap operation.

1. The leg is raised, and a semilunar flap 8^{cm} in length is formed from the upper part of the calf by a curved incision, beginning 1^{cm} below the middle of the lateral border of one condyle and terminating 1^{cm} below the middle of the other condyle: this is liberated from the fascia as far as its base.

2. The leg is then brought down, and with the knee flexed a larger skin flap, 10—12^{cm} in length, is cut from the same points upon the anterior surface: this is liberated as far as the lower border of the patella, and turned upwards (fig. 414).

Fig. 414.

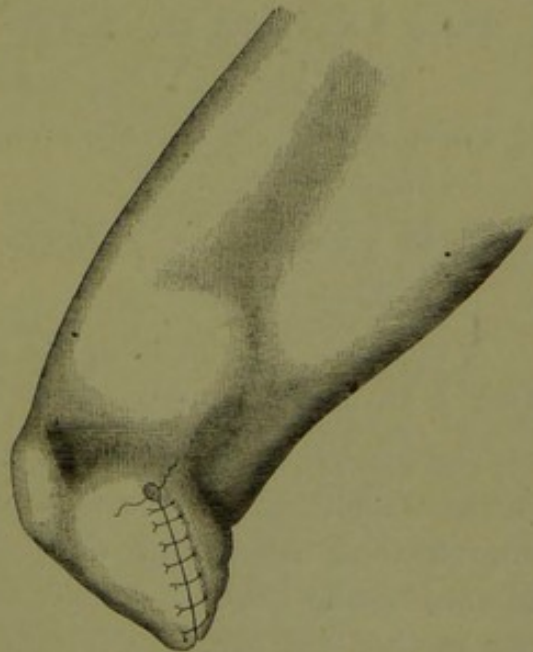


Disarticulation at the knee with two flaps.

3. The disarticulation is effected in the same manner as in the circular method.

Fig. 415 shews the appearance of the stump.

Fig. 415.



Stump after disarticulation at the knee by the flap operation.

4. If there is not enough skin to make the flaps sufficiently large, a piece can be sawn off from the condyles of the femur (CARDEN'S amputation). The sharp edge of the sawn surface must be taken off with the saw or the cutting bone forceps.

5. The method of trying to make the patella, after its articular surface has been removed with the saw, unite with the sawn surface of the condyles (GRITTI), does not appear to have any especial value.

q. Amputation of the thigh.

α. By the single circular incision
(page 174).

β. By the double circular incision
(page 175).

γ. By the flap operation
(page 178).

VOLZ'S transverse sections of the thigh are represented on plate XXIX, fig. II, and plate XXX, fig. I and II.

Plate XXIX, fig. II. Transverse section of the right thigh in its lower third.

Plate XXX, fig. I. Transverse section of the right thigh in its middle third.

Plate XXX, fig. II. Transverse section of the right thigh in its upper third.

A method, for changing the dressing after amputation of the thigh, which I have seen employed by VOLKMANN, is to be recommended.

The patient is raised, and a block of wood or a hard cubical cushion covered with india-rubber is pushed beneath the buttock of the sound side, so that the stump during the change of dressing swings free and need not be held. By this method the back above the sacrum is also free, so that the turns of a spica-bandage, which fix on the dressing, can be easily carried round the body (fig. 416).

Fig. I.

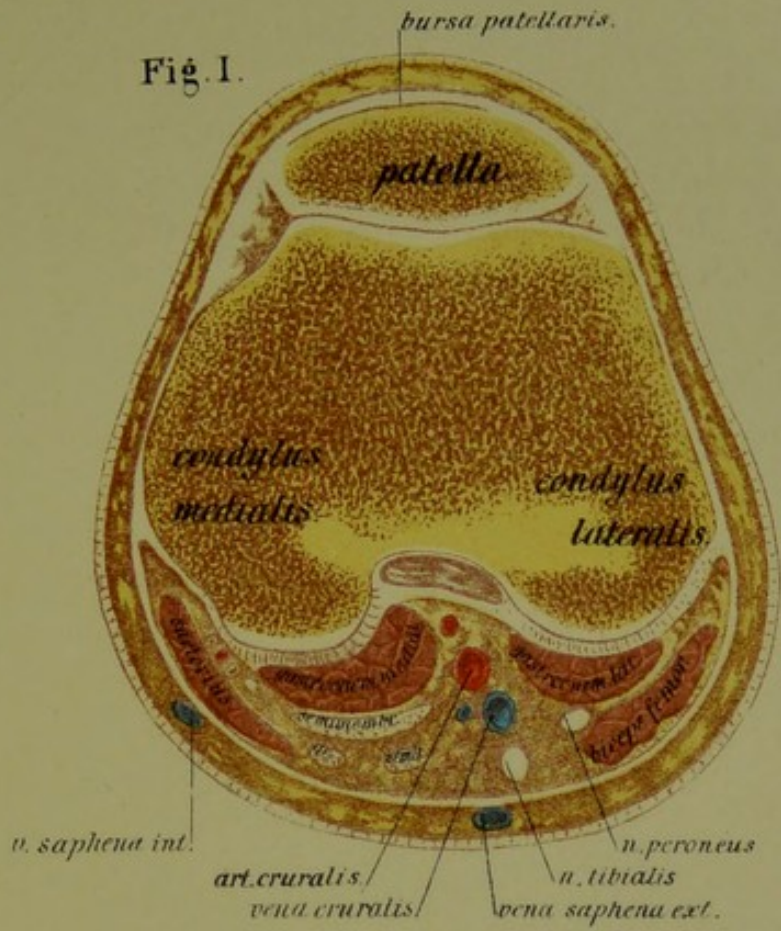


Fig. II.

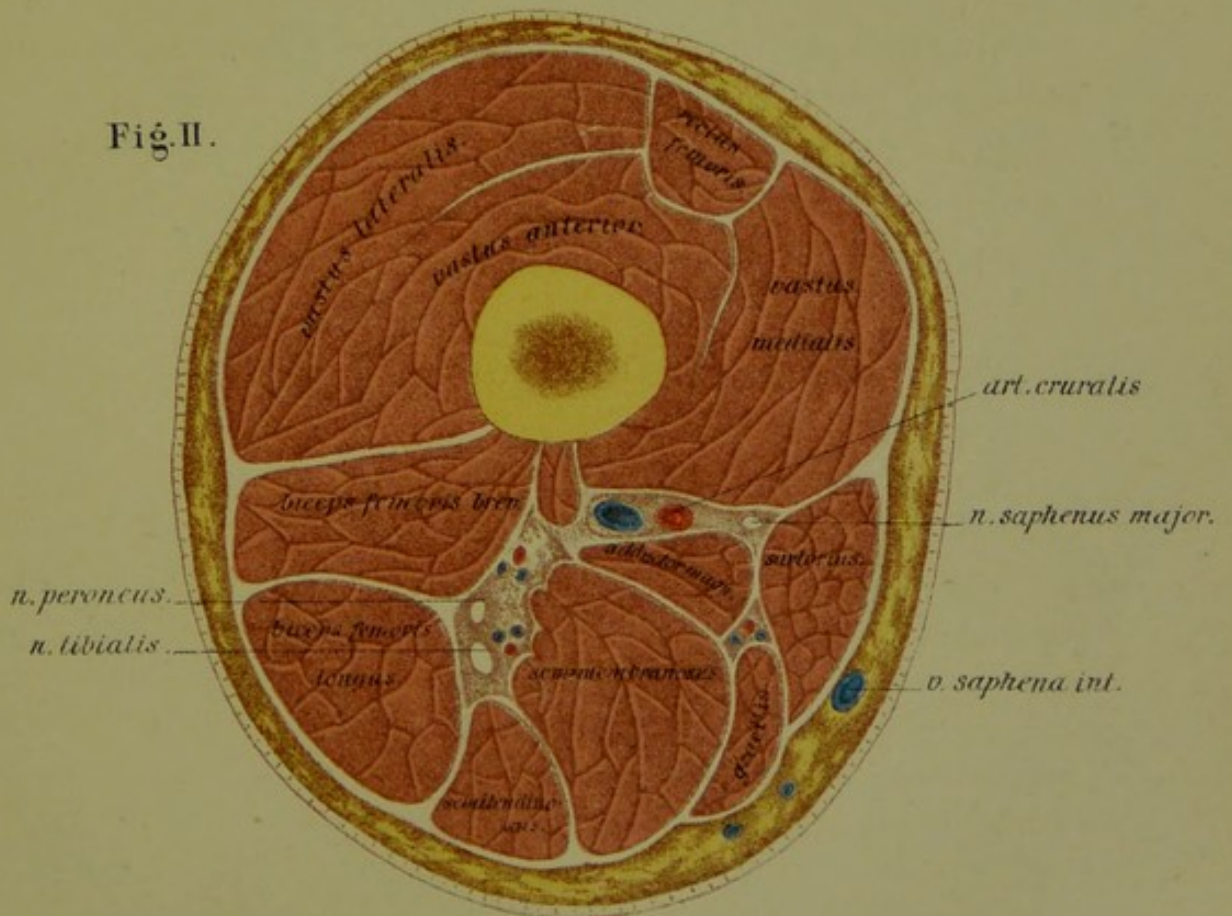






Fig. II.

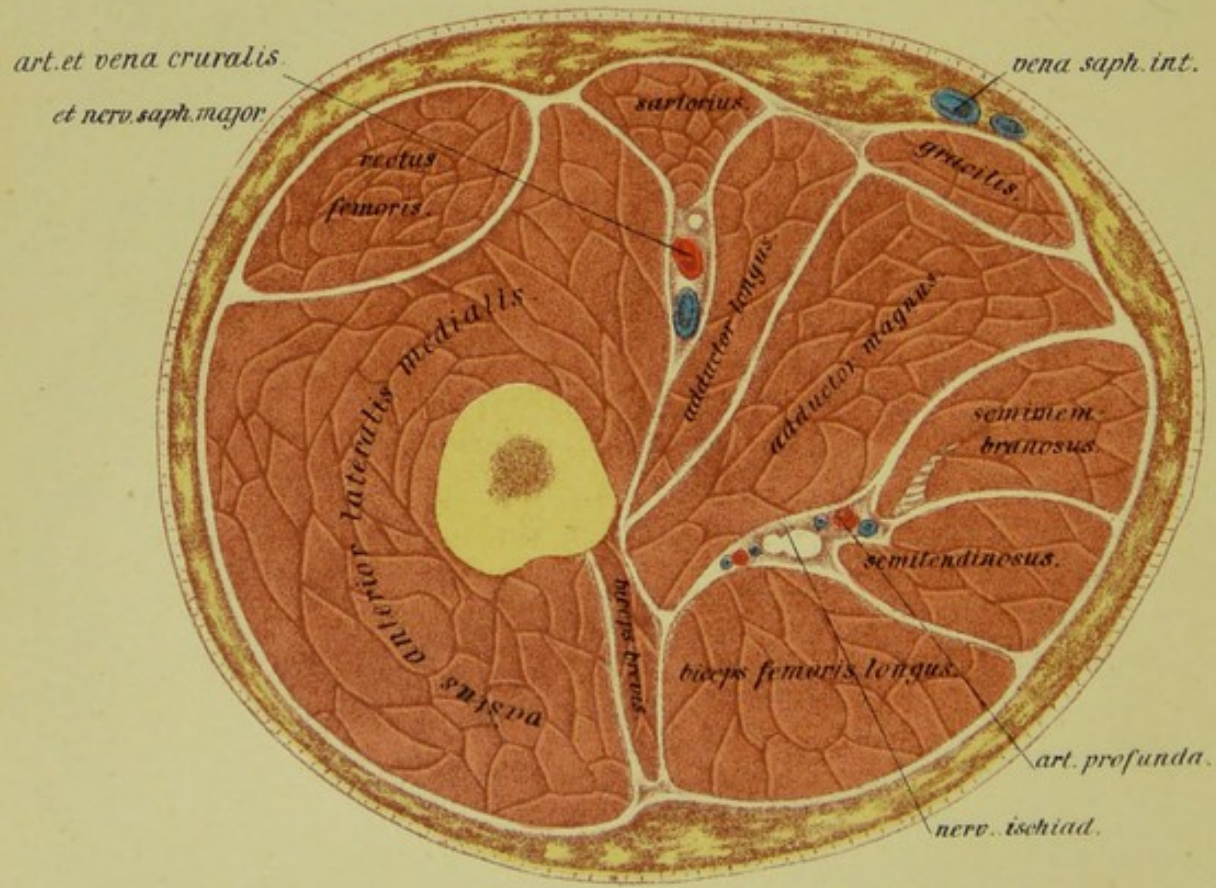
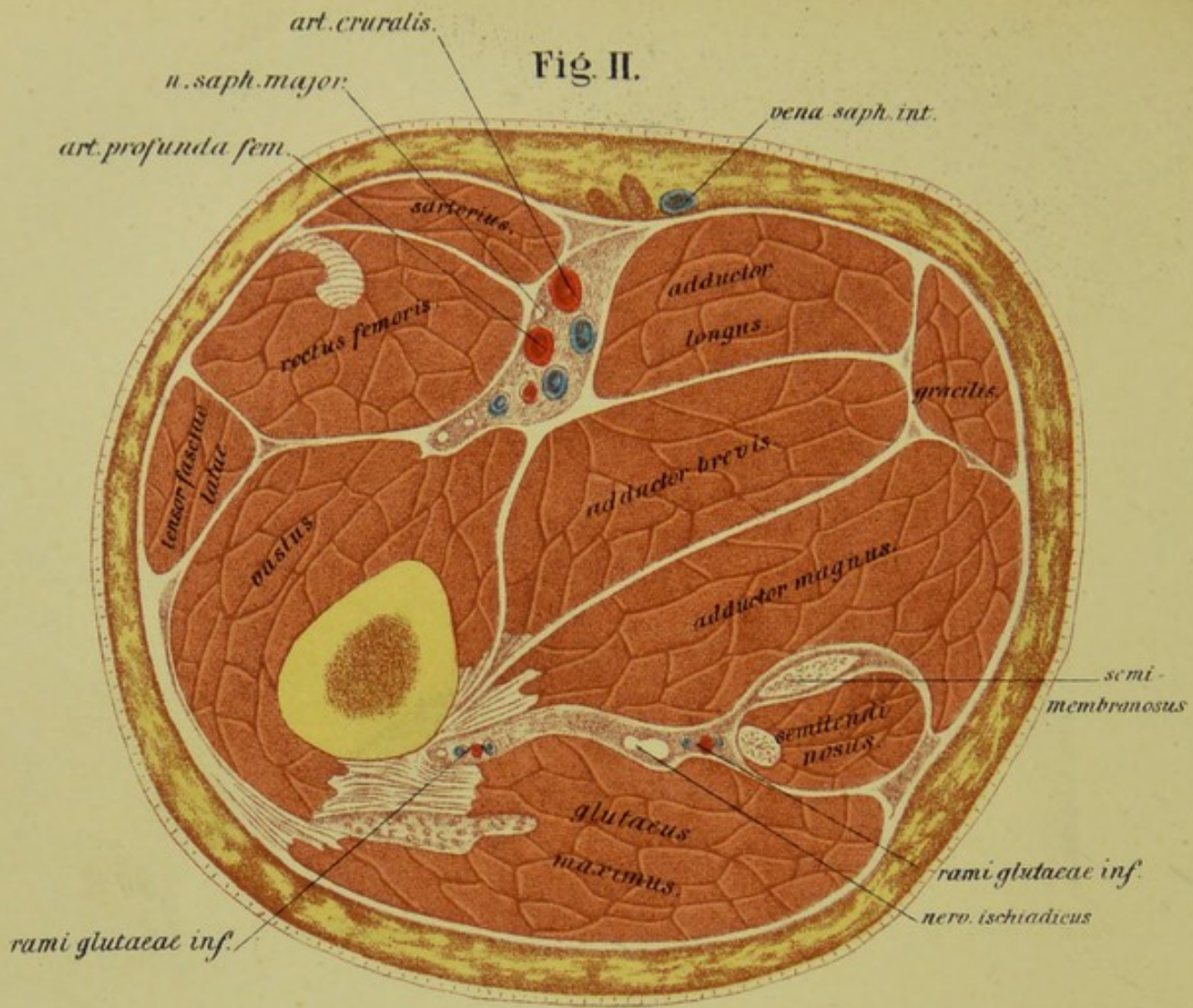
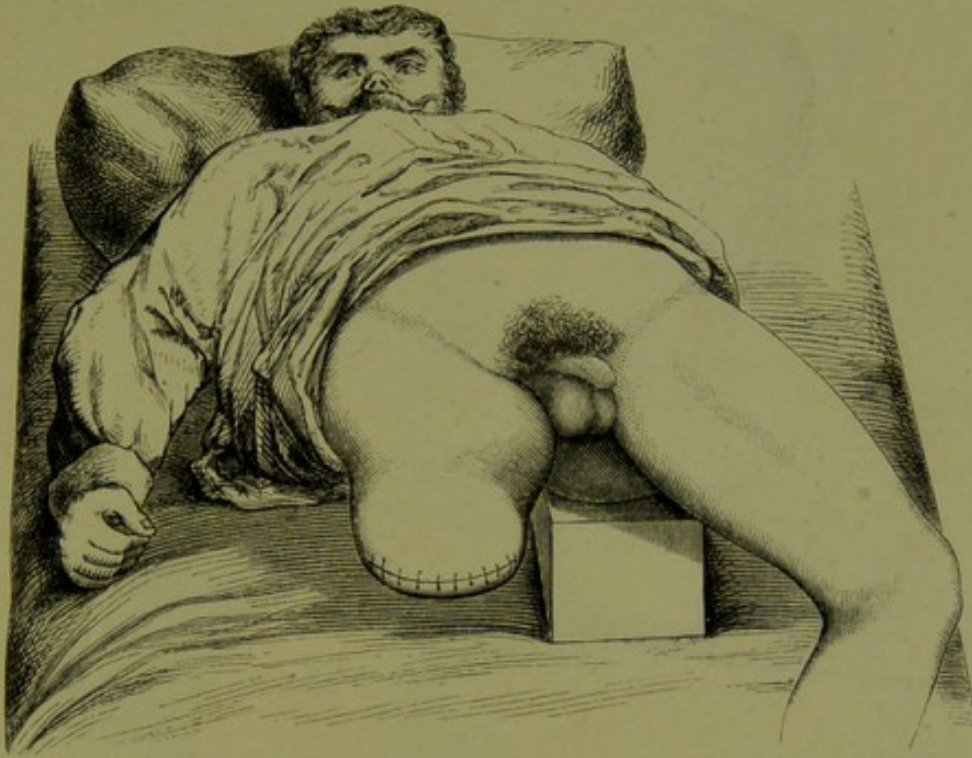

Fig. I.

Fig. 416.



Position of the patient for changing the dressing on a stump after amputation of the thigh.

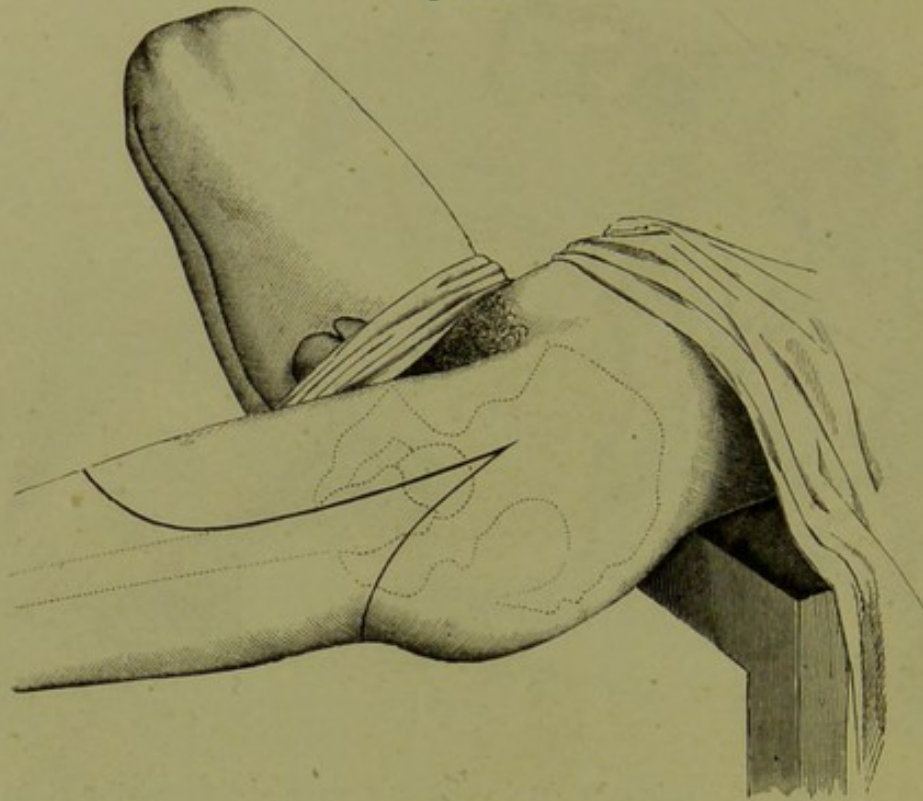
r. Disarticulation at the hip.

a. With a large anterior and a small posterior flap (MANEC) by transfexion.

1. The patient is so placed, that half the pelvis on the injured side projects beyond the lower edge of the table. The upper part of the body must be carefully fixed, and the scrotum drawn upwards towards the opposite side (fig. 417).

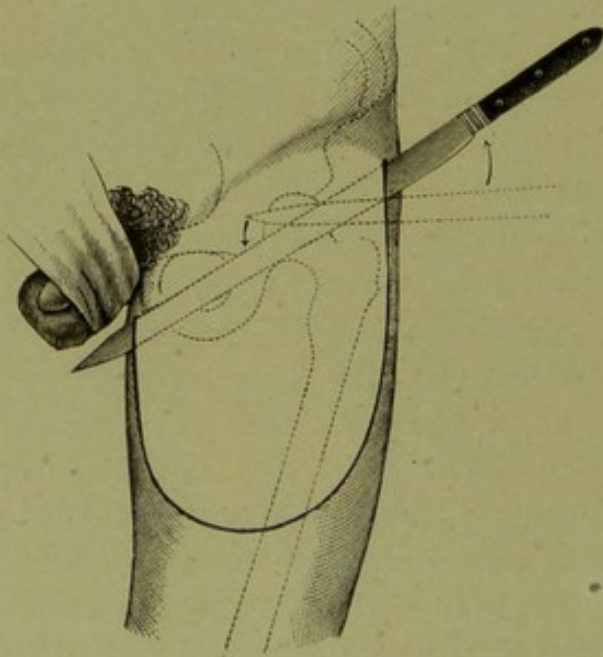
2. After the limb has been made bloodless in the manner described on pages 134—136, a large anterior flap is cut from within outwards in the following manner. The operator enters the point of a long amputating knife (fig. 298) midway between the anterior superior spine of the ilium and the top of the trochanter. The point is carefully glided over the head of the femur (by which the capsule is opened) in a direction parallel with Poupert's ligament: it is then turned downwards and inwards, and made to pass out again on the inner side of the thigh close to the perinaeum (fig. 418). By carrying the knife downwards in long sawing strokes, he cuts a well rounded flap, 18—20^{cm} in length, which is immediately turned upwards and kept in that position.

Fig. 417.



Disarticulation at the hip with anterior and posterior flaps.

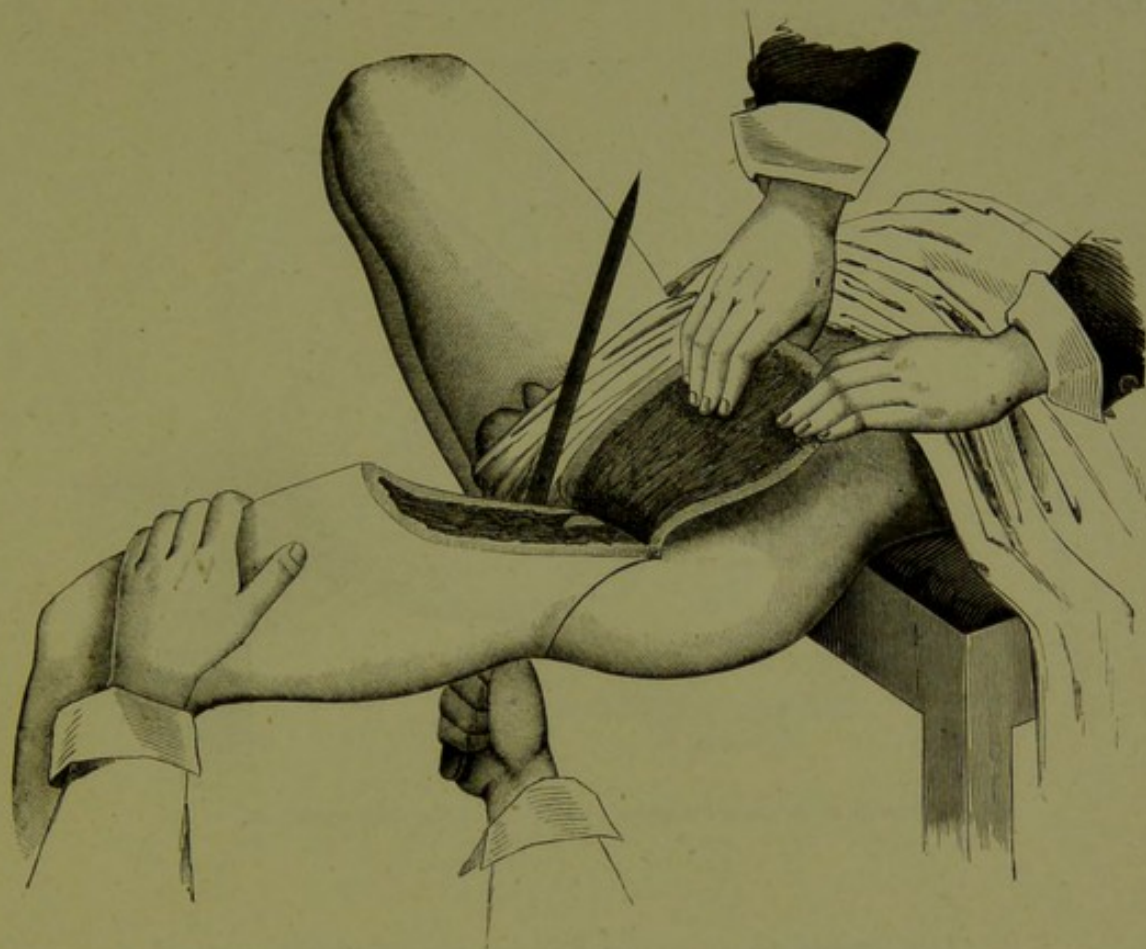
Fig. 418.



Making the anterior flap by transfixion.

3. The knife is carried under the thigh to the inner side, and cuts from without inwards a small posterior flap, the convexity of which extends to just below the gluteal fold, and whose base meets both on the inner and outer side with the base of the anterior flap (fig. 419).

Fig. 419.



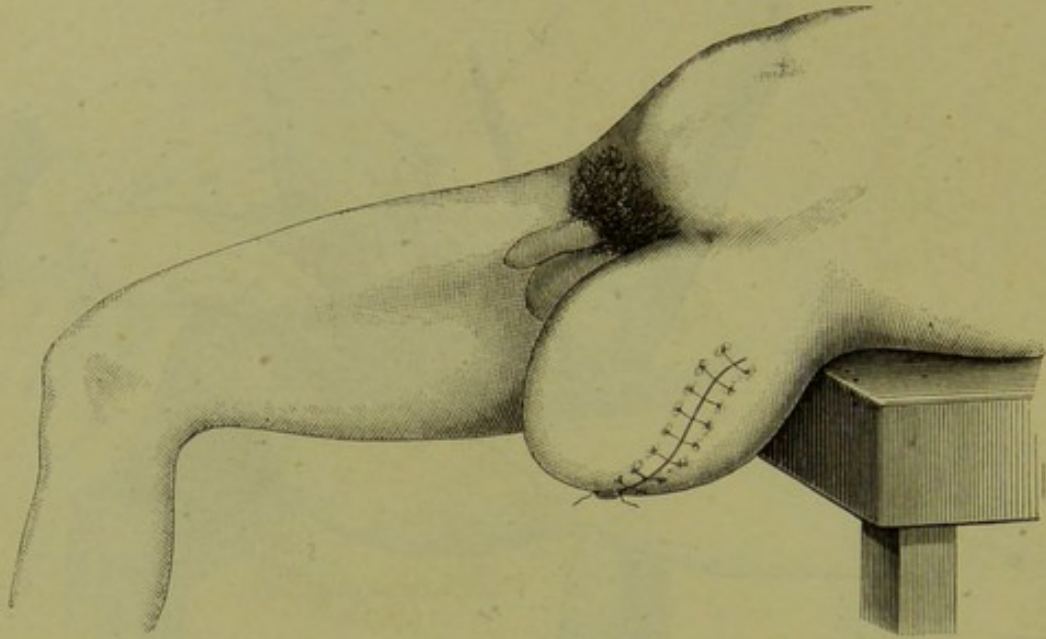
4. The capsule is opened by an incision, which is made with some force by means of a small knife, placed at right angles to the surface upon the head of the femur (as if with the intention of cutting through the head and leaving the upper part in the acetabulum, LISFRANC), while the limb is forcibly carried into hyperextension, and rotated outwards. With a cracking noise the air enters the joint, and the head starts from the acetabulum; an incision upon the ligamentum teres allows it be completely protruded.

5. The operator seizes the head of the femur, draws it forwards, and divides the posterior wall of the capsule, the muscles attached to the great trochanter, and all the soft parts, which have been left till now undivided.

6. One end of a stout drainage tube is placed in the acetabulum, while the other end is brought out through the centre of the wound.

The anterior flap is brought down and adapted to the posterior, as is shewn in fig. 420.

Fig. 420.



Stump after disarticulation at the hip by the flap operation.

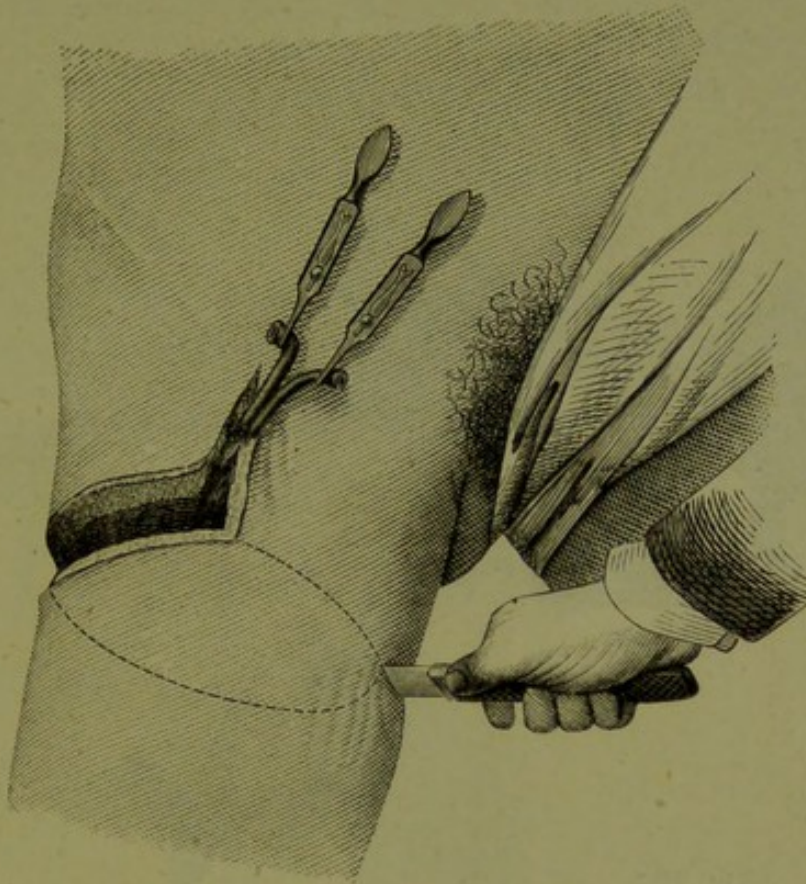
β. *Disarticulation at the hip by the circular method.*

1. By a strong and rapid sweep of the knife a circular incision is made 12^{cm} below the top of the great trochanter, and all the soft parts together divided right down to the bone; the latter is then immediately sawn through.

2. All the vessels — arteries and veins — which can be recognized are seized with artery forceps and tied with catgut (see transverse section of the thigh in its upper third on plate XXX, fig. II).

3. In those cases, in which the bloodless method from some reason or other cannot be safely employed, it is advisable (LARREY), before the circular incision is made, to expose the femoral artery and vein in the iliofemoral triangle by a vertical incision. These are then each secured by two pairs of artery forceps, and the vessels divided between the two: the lower ends are ligatured, but the upper ends are turned upwards, and left till the amputation is finished (fig. 421).

Fig. 421.



Disarticulation at the hip (by the circular method).

4. After the elastic ligature has been removed and all the bleeding arrested, a knife is pushed 5^{cm} above the top of the great trochanter on to the head of the femur, and carried down over the middle of the great trochanter to the circular incision, dividing throughout the soft parts down to the bone (DIEFFENBACH).

5. The operator seizes the stump of the femur with a strong pair of forceps, and while the edges of the vertical incision are separated by an assistant, he strips the periosteum from the bone with the raspatory, till he comes to the attachments of the muscles; these must be separated from the bone with a strong knife.

6. When the bone has been in this manner exposed up to the capsule, the joint is opened as described above, and the head dislocated (fig. 422). The haemorrhage at this part of the operation is generally insignificant.

Fig. 422.

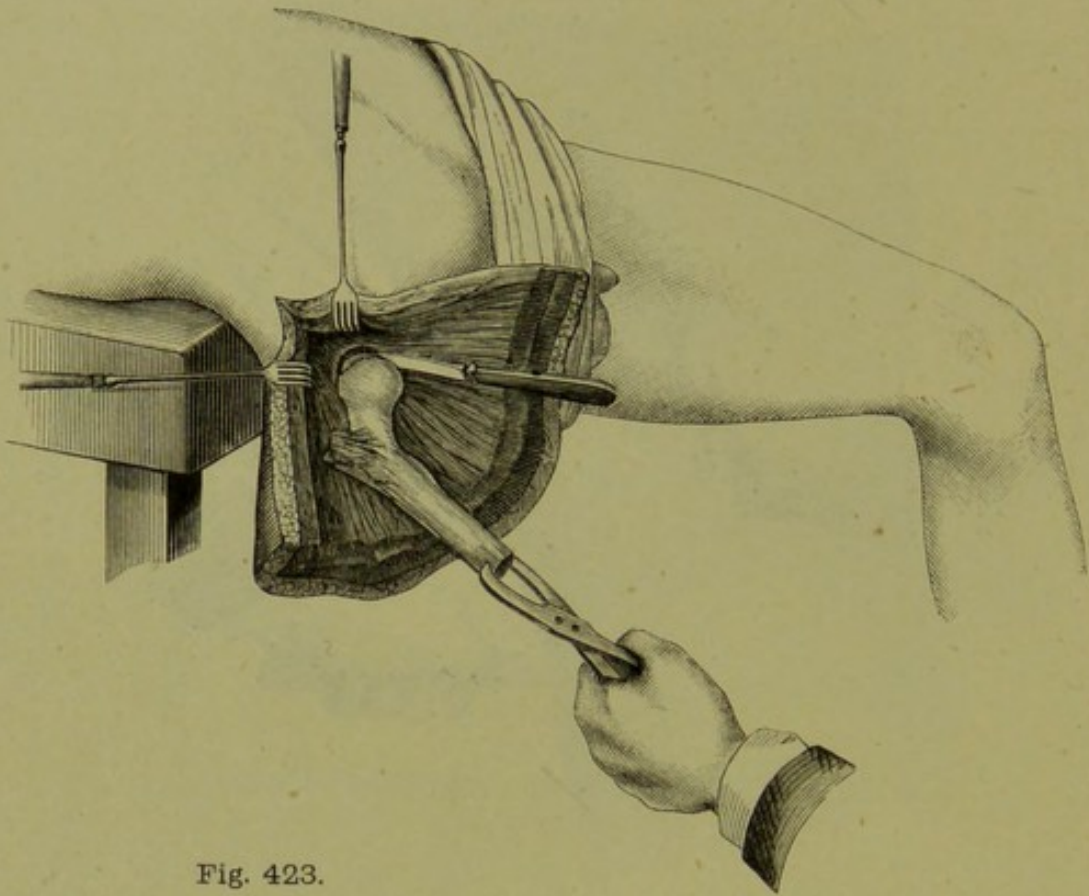
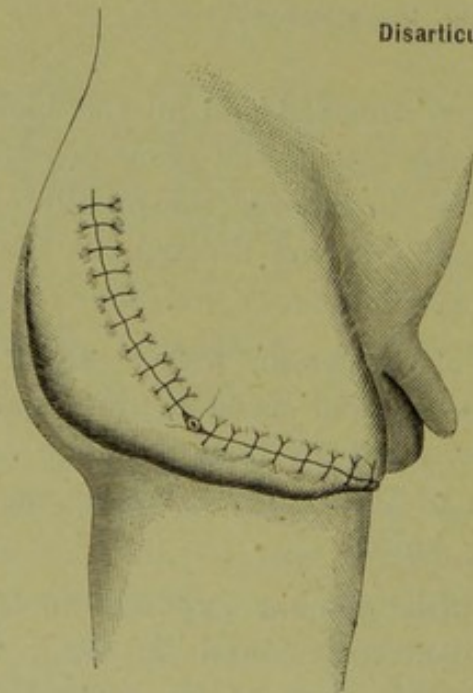


Fig. 423.

Disarticulation at the hip.



Stump after disarticulation at the hip by
DIEFFENBACH'S method.

Fig. 423 shews the appearance of the stump.

7. If the muscles are largely developed, the double circular incision can be employed instead of the single; or a large anterior flap can be formed, and the soft parts divided behind by a circular incision below the gluteal fold.

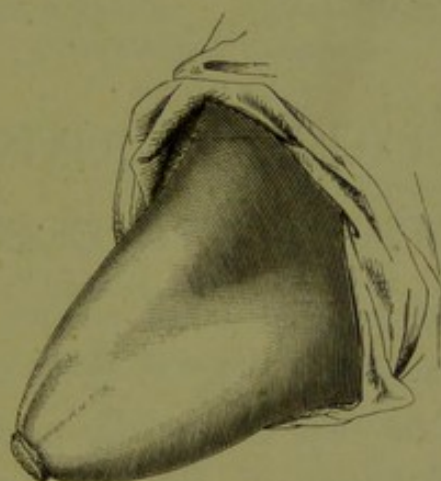
8. If there are not sufficient soft parts on the anterior aspect, a large flap can also be formed

from the tissues behind (VON LANGENBECK), and a transverse incision made in front below Poupart's ligament. But then a stout drainage tube must be pushed in towards the stumps of the divided psoas and iliacus, which retract into the cavity of pelvis, so that there may be no retention of pus.

s. Reamputation.

1. If in an amputation sufficient soft parts have not been preserved (to cover the end of the bone), or the soft parts have retracted during their healing in consequence of an inflammatory swelling (ostitis), or been destroyed by gangrene, a so called conical stump is formed (fig. 424), that is, the end of the bone projects so far forwards, that

Fig. 424.



Conical stump.

cicatrization is never completely accomplished (*ulcus prominens*), or the thin cicatrix, which is at last produced, breaks out again, as soon as the patient begins to use a wooden stump, or an artificial leg. The stumps, which are left after frost bite or a bad burn, are generally in a similar condition.

2. Formerly in such cases the limb was amputated again higher up, or an attempt made to cover the cicatrix by "skin grafting". But the former is generally unnecessary, and as dangerous to the life of the patient as the first amputation; while the latter rarely yields a satisfactory result, because the skin on the extremities is not very suitable for plastic operations.

3. A subperiosteal excision of the end of the bone is much more satisfactory. The cicatrix or ulcerated surface on the projecting bone is freed from the tissues by an incision carried round with a strong knife: the soft tissues are then divided below or laterally (avoiding the part where the large vessels and nerves lie) down to the bone, and the periosteum peeled back from the bone with the raspatory far enough to allow a sufficiently large piece of the bone to be removed with the saw. The haemorrhage is generally very trifling. A drainage tube is introduced as far as the sawn surface of bone and the wound closed with the interrupted suture. It commonly heals by first intention, and the result is a good stump completely covered with soft tissues.

4. If the first amputation has been made in the neighbourhood of a joint, then the subperiosteal disarticulation can be employed in the same manner (cf. fig. 422).

F. EXCISION OF JOINTS.

I. GENERAL RULES FOR EXCISION.

1. The principle of excision is to remove injured or diseased joints with as small a wound of the soft parts as possible.

2. The division of the skin and muscles must therefore be made by preference in the long axis of the limb, and any injury of the larger vessels, nerves, and tendons carefully avoided.

3. The preservation of the periosteum with all the tendons and muscles attached to it in the neighbourhood of the joint (subperiosteal excision, VON LANGENBECK, OLLIER) is of great importance both during the period of healing, and for the subsequent functions of the limb, and must therefore always be attempted. The operation is difficult in recent cases, but easy in older ones. For this reason in the excision of individual joints the older method is here described.

4. To preserve the periosteum, it must be divided in the same direction as the skin, and be peeled off from the bone with the soft parts by means of blunt instruments such as the raspatory (fig. 425) and the elevator (fig. 426).

Fig. 425.



Raspator.

Fig. 426.



Narrow elevator.

Fig. 427.



Broad elevator.

Fig. 428.



Raspator.

LANGENBECK'S instruments.

Fig. 429.



SAYRE'S elevator.

Fig. 430.



ESMARCH'S excision knife.

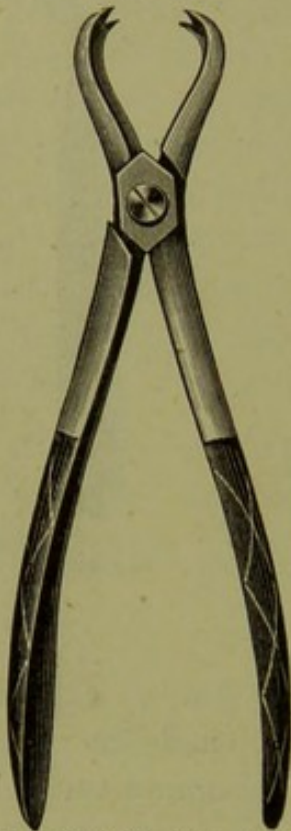
5. The fibrous capsule, the ligaments, and the insertions of muscles cannot thus be liberated from the bone with blunt instruments, but must be divided from them by incisions, carried at right angles to the bone, with strong short-bladed knives (fig. 429). They are however always left connected with the adjoining periosteum.

6. In this operation the knife must therefore be constantly changed for the blunt elevator, and the work done as tenderly as possible so as not to bruise or lacerate the periosteum.

7. After the articular extremities have been thus stripped of their periosteum, they are forced out of the wound, seized with powerful

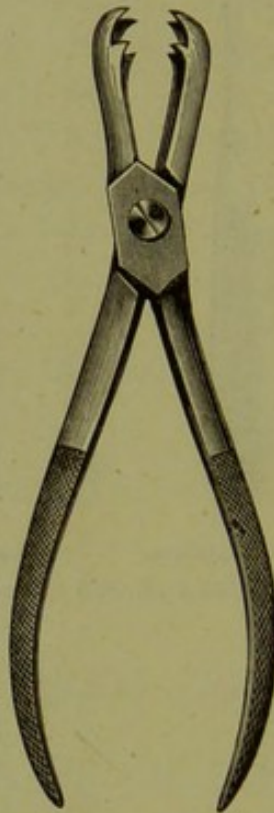
forceps (fig. 431—433), and removed with a saw (fig. 434—439), in

Fig. 431.



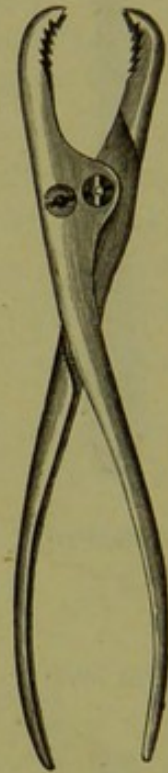LANGENBECK'S clutch forceps.

Fig. 432.



FERGUSSON'S lion forceps.

Fig. 433.



FARABŒUF'S clutch forceps.

Fig. 434.



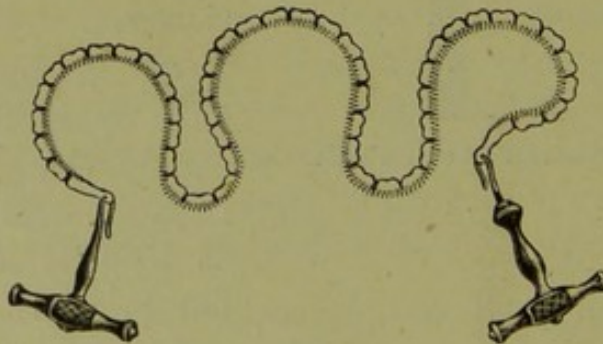
Metacarpal saw with
moveable back.

Fig. 435.



LANGENBECK'S key-hole saw.

Fig. 436.



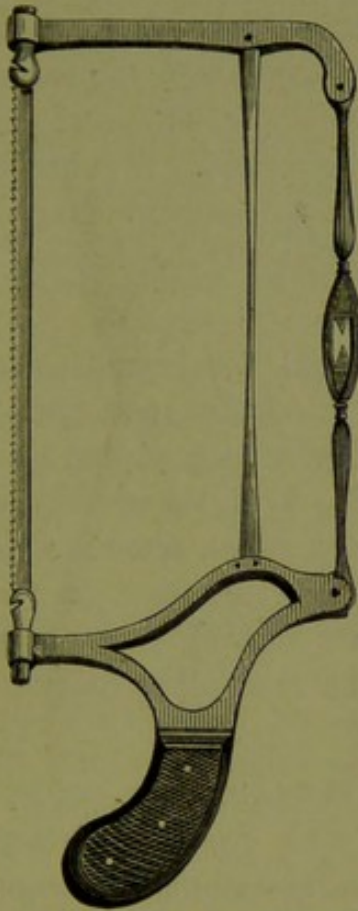
Chain saw.

Fig. 437.



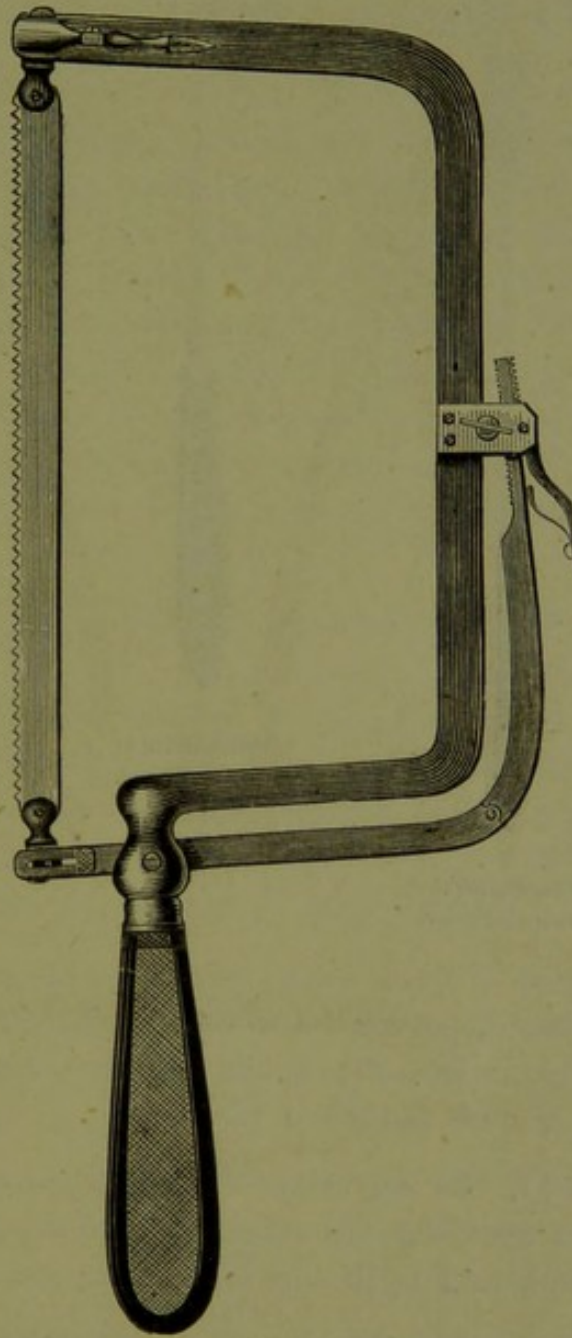
Metacarpal saw with
moveable back.

Fig. 438.



BUTCHER'S excision saw.

Fig. 439.



SZYMANOWSKY'S excision saw.

Fig. 440.



LANGENBECK'S
small retractor.

Fig. 441.



large retractor.

doing which the soft parts must be retracted and protected by means of blunt hooks (fig. 440 and 441), sharp hooks (fig. 442), or by a strip of leather or tin.

Fig. 442.

VOLKMANN'S
sharp retractor.

Fig. 443.

LANGENBECK'S
sharp bone hook.

8. If a portion of an articular extremity has been shot off, it can be seized with LANGENBECK'S sharp hook (fig. 443) and drawn out of the wound. If it has been shattered, the separate fragments are seized with the forceps and extracted.

9. Since the reproduction of a joint is usually most complete, when only a part of the joint is removed, it is advisable, when the injury of an articular extremity is very extensive, to remove only the injured part, and to leave the rest intact (partial excision).

10. Most excisions can be performed with great advantage by the bloodless method. After the operation is finished, all the bleeding vessels must be carefully

ligatured, before the wound is closed: otherwise secondary haemorrhage easily arises, for which the dressing may have to be taken off, and the wound disturbed afresh.

11. In the after-treatment success depends before every thing else upon avoiding the retention and decomposition of the secretions of the wound, and upon the immobilisation of the limb.

12. The rigid rules of antiseptic surgery can in recent cases be employed with the most perfect success. By this treatment the whole wound frequently heals quickly and with exceedingly little suppuration.

13. If the joint is already suppurating, then all the cavities of the wound, before it is closed, must be most carefully washed out with chloride of zink, or strong carbolic solution, or with dilute hydrochloric acid (1 per cent). In every case a free escape must be provided

for the secretions of the wound by the introduction of a sufficiently stout drainage tube to the bottom of the wound. The rest of the wound can then be closed with sutures.

14. The various dressings and appliances which have been described above (vide the dressing of wounds), are used to immobilise the limb. It is to be observed, that in the rigorous antiseptic treatment carried out by LISTER the neighbourhood of the wound must be left exposed for the application of the dressing to a greater extent than in the open method of treatment, which of course can generally only take place at the expense of the immobility: but in the antiseptic treatment a little movement of the excised limb at the change of dressing is usually less injurious, than in other methods of dressing.

15. A windowed plaster of Paris splint is especially suitable for the open treatment of wounds, while in the antiseptic treatment a simple splint (e. g. STROMEYER'S padded wooden splint, VOLKMANN'S tin splint, BEELY'S hempen splint), from which the limb must be raised at the change of dressing, can generally be used without disadvantage; for besides the many layers of LISTER'S stiff gauze, with which the wound is enveloped, the limb is almost sufficiently immobilised.

16. By the time that the excision-wounds have healed, in consequence of the prolonged rest all the joints of the limb have usually become stiff, the ligaments and tendons matted together, and the muscles weak and atrophied (Inaktivitätsparalyse).

To the ignorant the whole limb then appears useless, and remains even later in this unserviceable condition if nothing happens to oppose it.

17. To avoid this result, or to restore the joints to a healthy condition, methodical passive movements should be begun in all the joints of the extremity directly after the cicatrisation of the wound; and at first under chloroform, if there is much pain (NEUDÖRFER'S apolyse).

18. The mobility of the joints of the upper extremity, especially those of the fingers, in which it is desirable to restore their functions as soon as possible, can be preserved by careful movements

practised from the very commencement. This is done by altering the position of the joint at every change of dressing.

19. The activity of the muscles and nerves can soon be restored by warm baths and the employment of electricity. Still more effectual for this purpose is the methodical kneading of limbs (Massage) after the previous application of the cold douche, or the douche combined with subsequent gymnastic exercises.

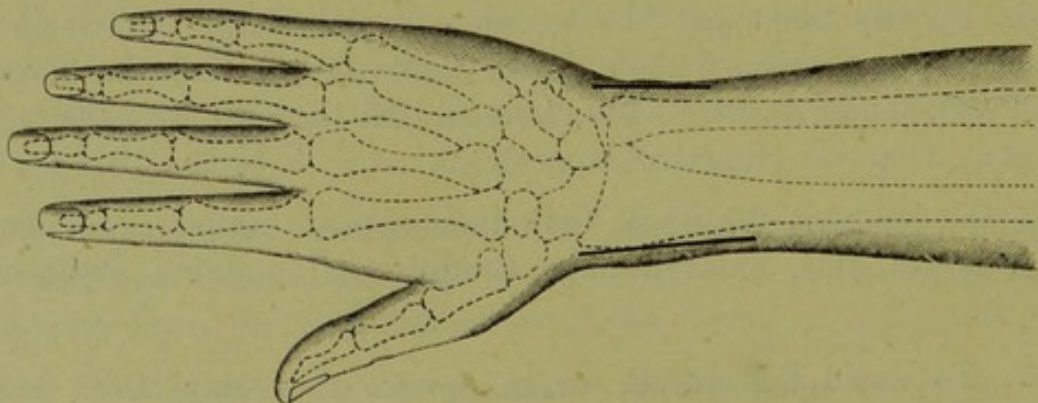
20. If after excision the new joint remains too loose and moveable (like a flail), it can be improved by a supporting apparatus.

II. EXCISION OF THE LOWER ARTICULAR ENDS OF THE RADIUS AND ULNA.

By lateral incisions.

1. A longitudinal incision, dividing the skin and beginning just below the styloid process of the ulna is carried upwards on the inner side of the ulna for 4—5^{cm} (fig. 444).

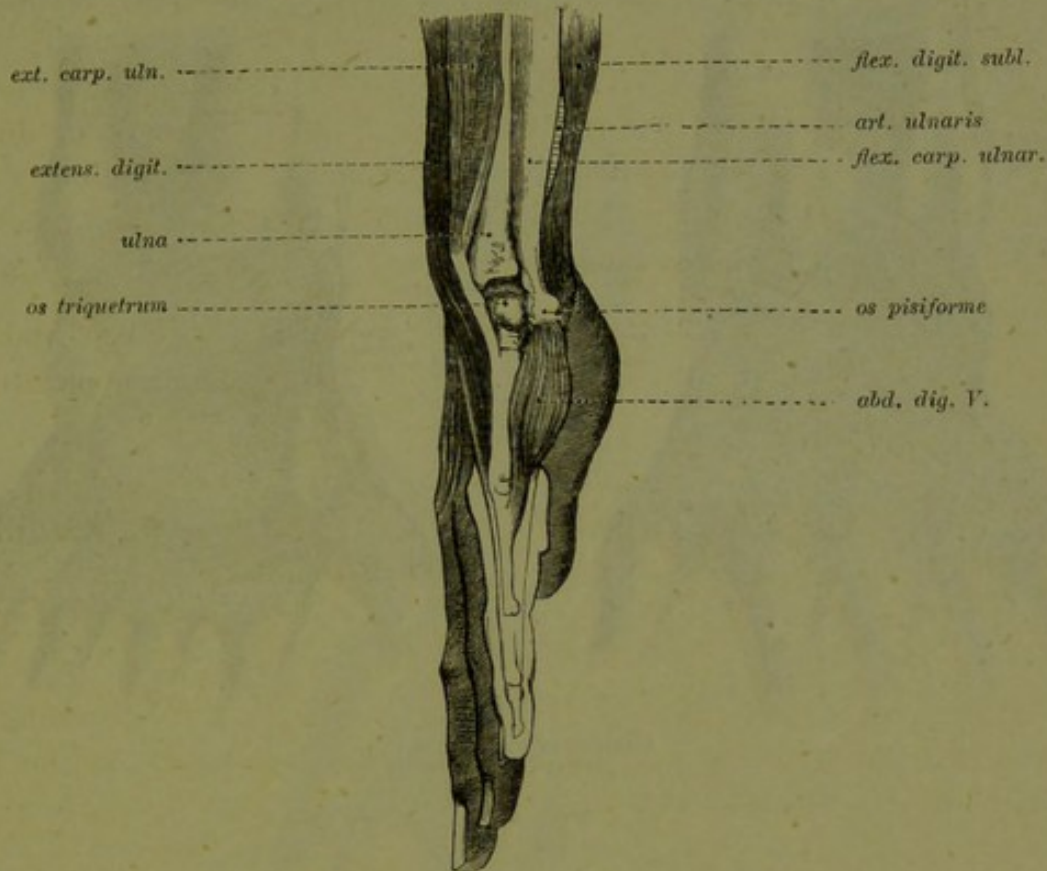
Fig. 444.



Excision of the lower ends of the radius and ulna.
BOURGERY'S lateral incisions.

2. The periosteum is divided in the same direction between the extensor and flexor carpi ulnaris, and reflected with raspatory and elevator first upon the extensor side, then upon the flexor side (pronator quadratus) as far as the interosseous ligament (fig. 445).

Fig. 445.



Muscles and tendons on the ulnar side of the left wrist (HENKE).

3. The portion of ulna thus stripped is divided below the upper angle of the incision by a key-hole saw, or a strong pair of cutting bone forceps.

4. The piece is then seized with a pair of necrosis forceps, twisted out of the wound, and liberated by dividing the lig. laterale ulnare and the lig. accessorium rectum (fig. 446 and 447).

5. A second longitudinal incision, dividing the skin, and beginning just below the styloid process of the radius, is carried upwards for 5—6^{cm} on the outer side of the radius.

6. The tendons of the extensor brevis pollicis (primi internodii pollicis) and abductor longus pollicis (extensor ossis metacarpi pollicis), which run obliquely over the radius, are drawn towards the dorsum, while the hand is forcibly extended upon the forearm (dorsal flexion) (fig. 448).

Fig. 446.

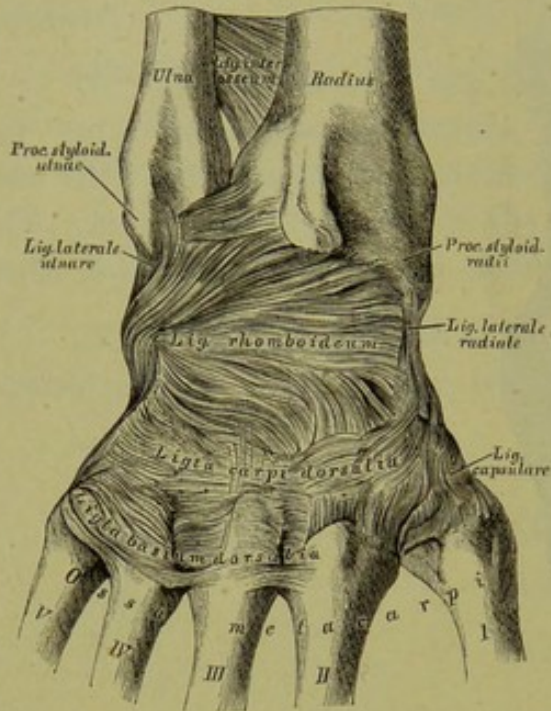
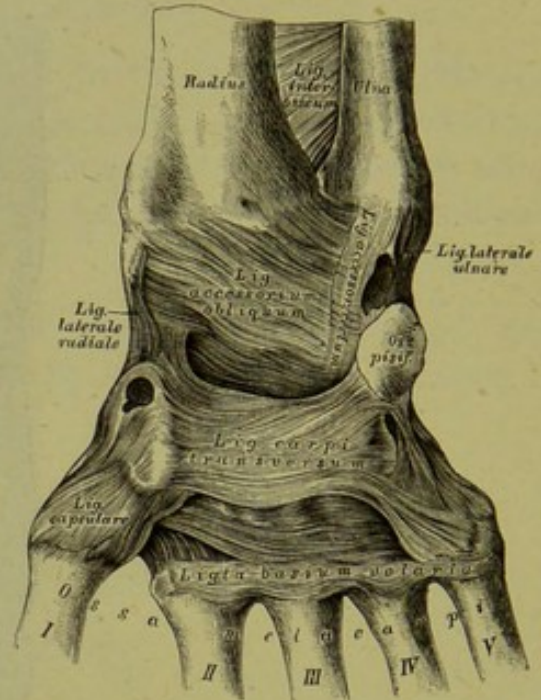
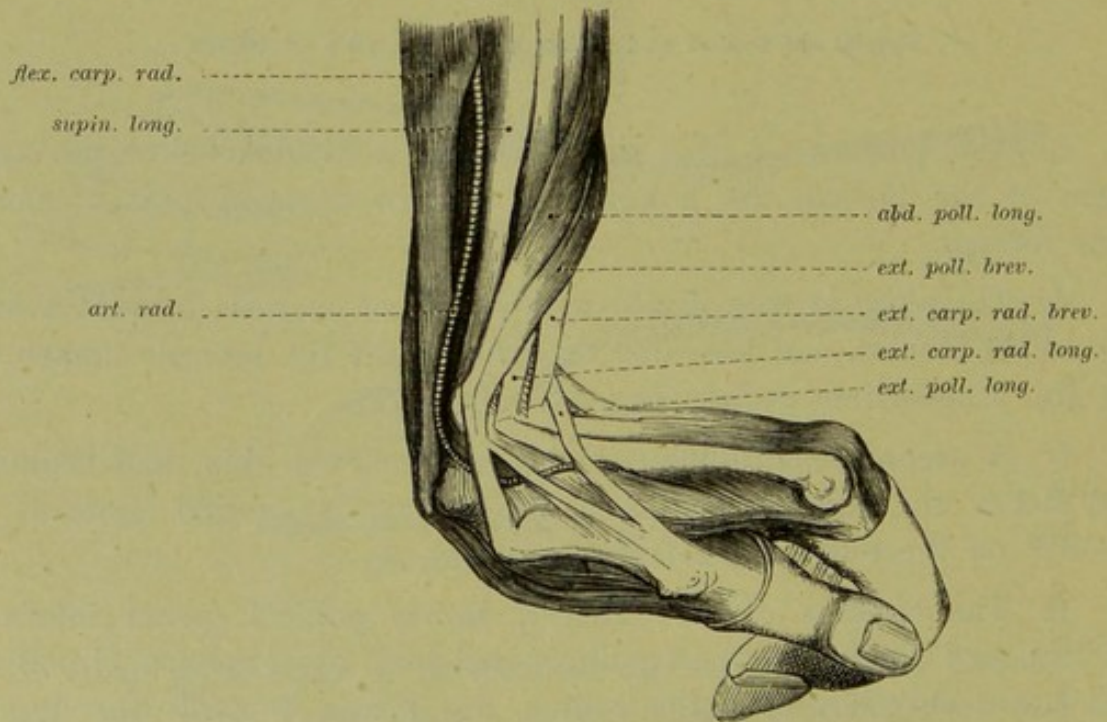


Fig. 447.



Ligaments of the wrist.

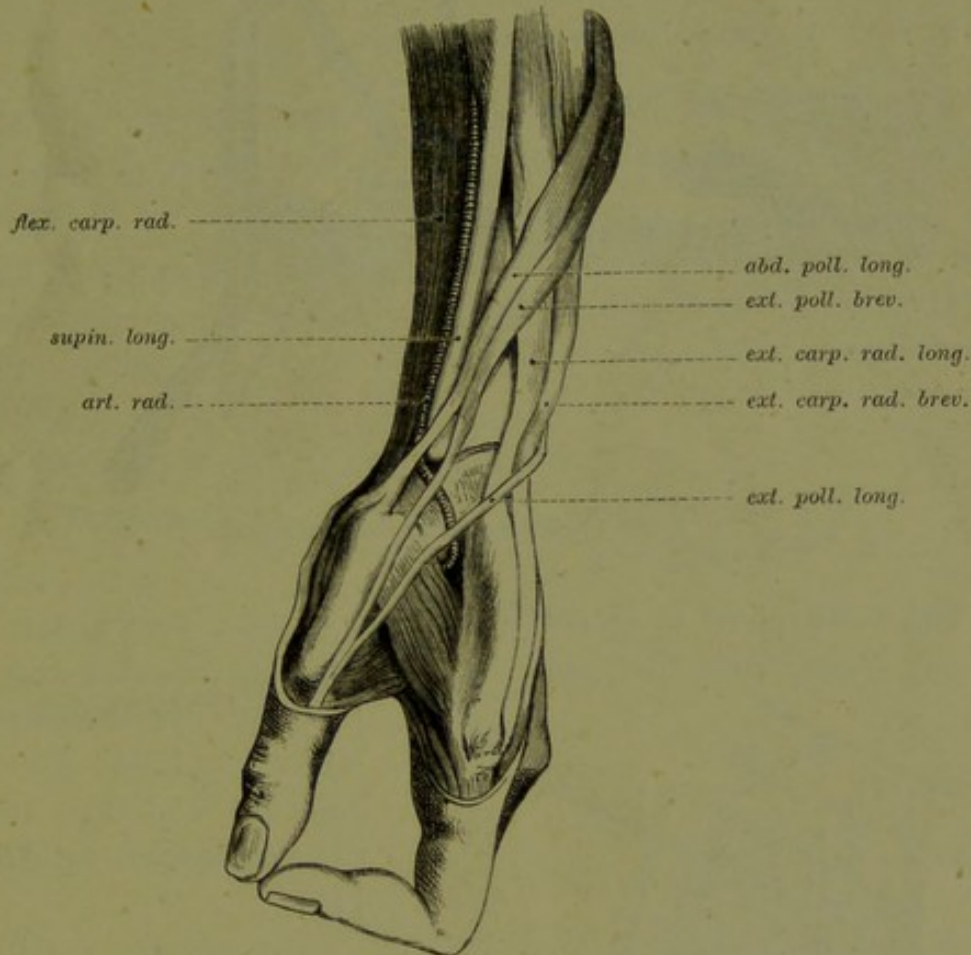
Fig. 448.



Muscles and tendons on the radial side of the left wrist in the position of hyperextension (dorsal flexion) (HENKE).

7. The tendon of the supinator longus (fig. 449) is divided at its attachment from the styloid process of the radius, the periosteum is

Fig. 449.

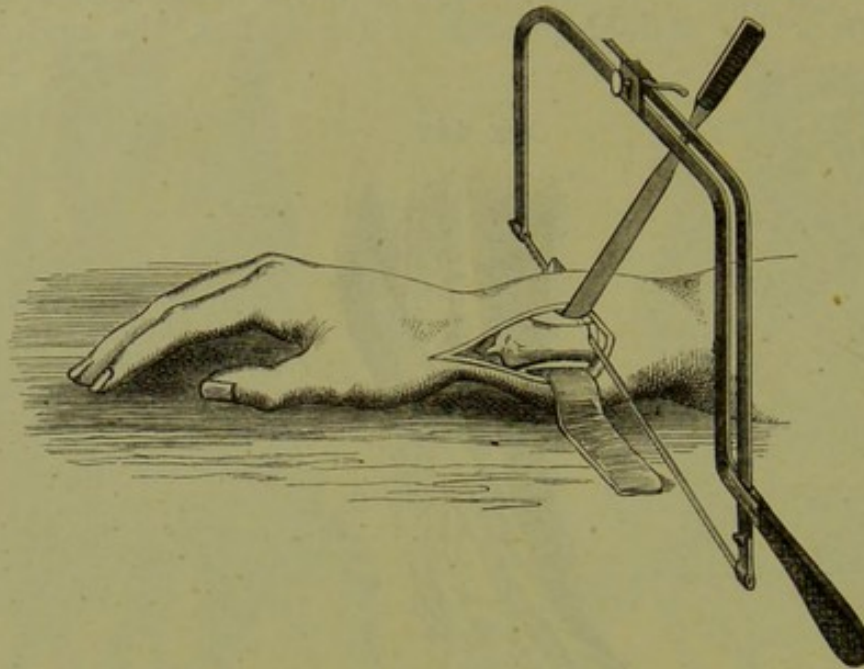


Muscles and tendons on the radial side of the left wrist (extended) (HENKE).

divided in the direction of the wound, and liberated with raspatory, elevator, and knife without separating it from the sheaths of the tendons, first upon the extensor side, then on the flexor side (pronator quadratus), till the soft parts can be lifted all round from the bone for 3—4^{cm} above the articular surface.

8. A broad spatula is placed between the bone and the periosteum on the flexor side, to protect the soft parts; and whilst the periosteum and the soft parts are drawn upwards on the extensor side by a similar spatula, or a retractor, the lower end of the radius is sawn off with a key-hole saw, or a fine excision saw (fig. 450).

Fig. 450.

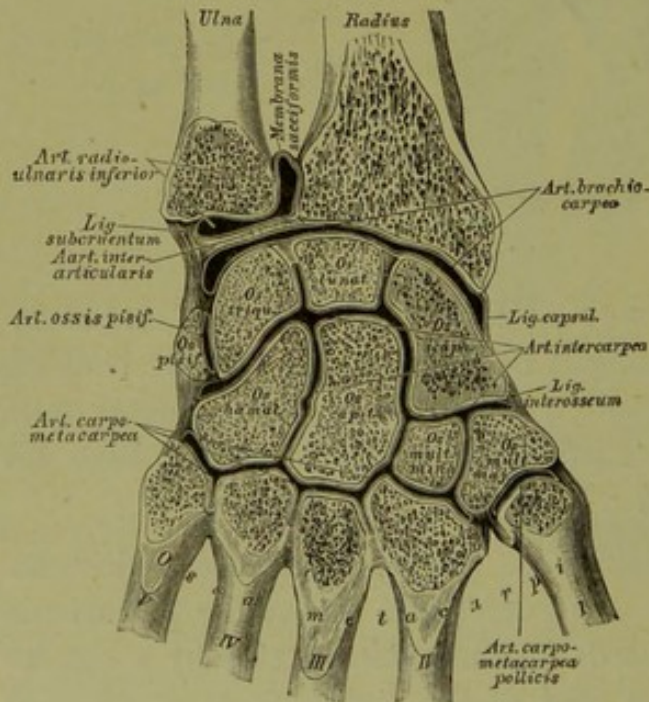


Sawing the radius.

9. The sawn piece is seized with bone forceps, drawn out of the wound, and freed from the hand by dividing the capsular and other

ligaments of the joint (lig. laterale radiale, lig. rhomboideum and lig. accessorium obliquum, fig. 446 and 447).

Fig. 451.



10. If the lower ends of the radius and ulna alone are injured or diseased, the wrist is left entire. But even if only one of the intercarpal joints are opened, all the carpal bones must be removed (with the exception of the trapezium and pisiform bones), because all the joints, which connect the separate carpal bones together and unite

them to the metacarpal bones, communicate with one another (fig. 451). In such a case the following operation is performed.

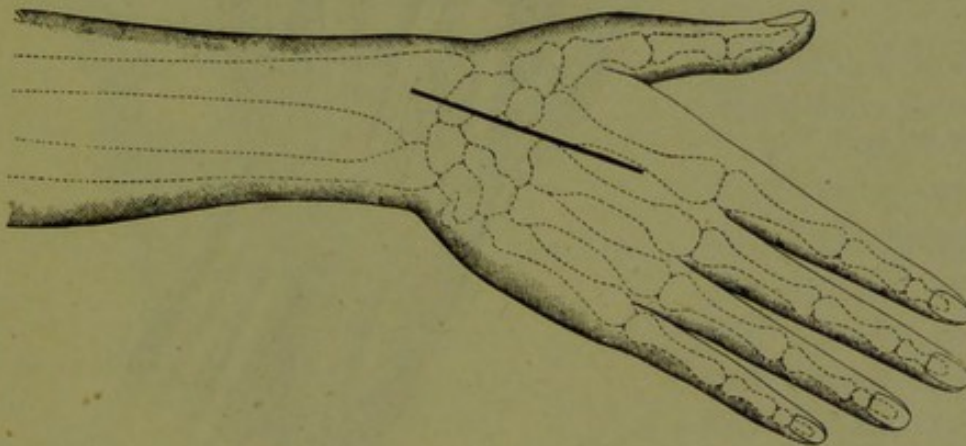
III. COMPLETE EXCISION OF THE WRIST.

With LANGENBECK'S dorso-radial incision.

1. The operator sits at a small table, upon which the hand is placed slightly adducted and with the dorsum uppermost. An assistant sits opposite to him.

2. A cutaneous incision, beginning at the centre of the ulnar border of the metacarpal bone of the index finger is carried upwards for 9^{cm} to the middle of the dorsal surface of the radial epiphysis (fig. 452).

Fig. 452.

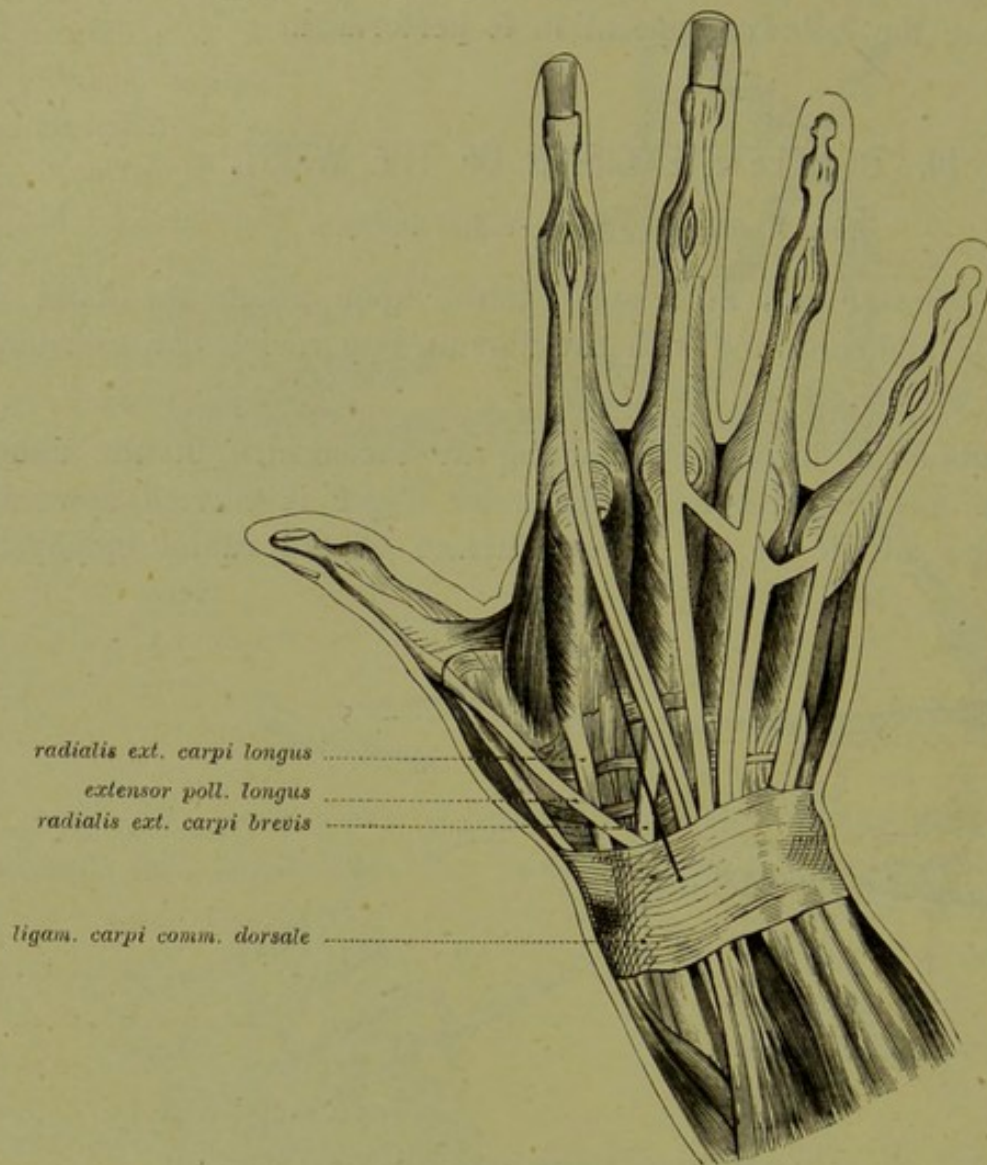


LANGENBECK'S excision of the wrist.

3. The incision is carried deeply on the radial side of the extensor indicis and without injuring its sheath, passing upwards to the ulnar border of the extensor carpi radialis brevis (just at its insertion into the base of the third metacarpal bone). Here it divides the ligamentum carpi dorsalis (posterior annular ligament) between the tendons of the extensor pollicis longus (secundi internodii pollicis) and the extensor indicis as far as the epiphyseal border of the radius (fig. 453).

4. While an assistant draws the soft parts asunder with fine retractors, the capsule is divided longitudinally, and together with the other ligaments separated in the following manner from the bones.

Fig. 453.



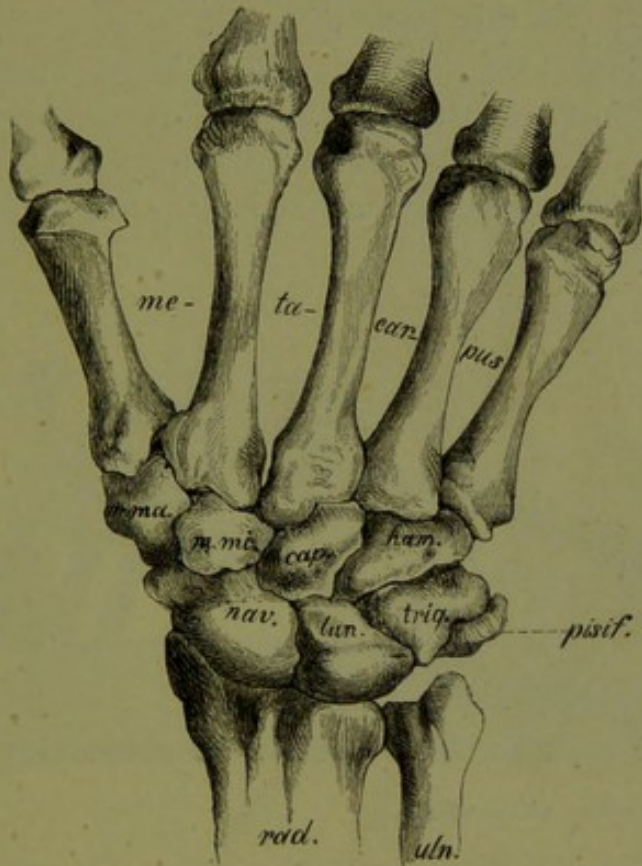
Tendons on the dorsum of the hand.

5. The fibrous sheaths on the radial side, which contain the tendons of the extensor pollicis longus (*secundi internodii pollicis*), the extensor carpi radialis longior and brevior, running in the grooves on the radius, and the tendon of the supinator longus must first of all be separated from the bones, partly with the knife and partly with the elevator.

6. In the same manner on the ulnar side the extensor tendons of the fingers with the posterior annular ligament enclosing them, the periosteum, and the capsular ligament are liberated and drawn inwards.

7. The radio-carpal joint lies open before you. The hand is flexed so that the articular surfaces of the upper row of carpal bones are exposed.

Fig. 454.



The carpal bones.

8. The scaphoid (*nav.*) is liberated from the trapezium (*m. ma.*) and trapezoid (*m. mi.*), the semilunar (*lun.*) and cuneiform (*trig.*) from the os magnum (*cap.*) and unciform (*ham.*) by dividing the intercarpal ligaments, and gently lifted out with a narrow elevator. The trapezium (*m. ma.*) and pisiform bones can be left behind (fig. 454).

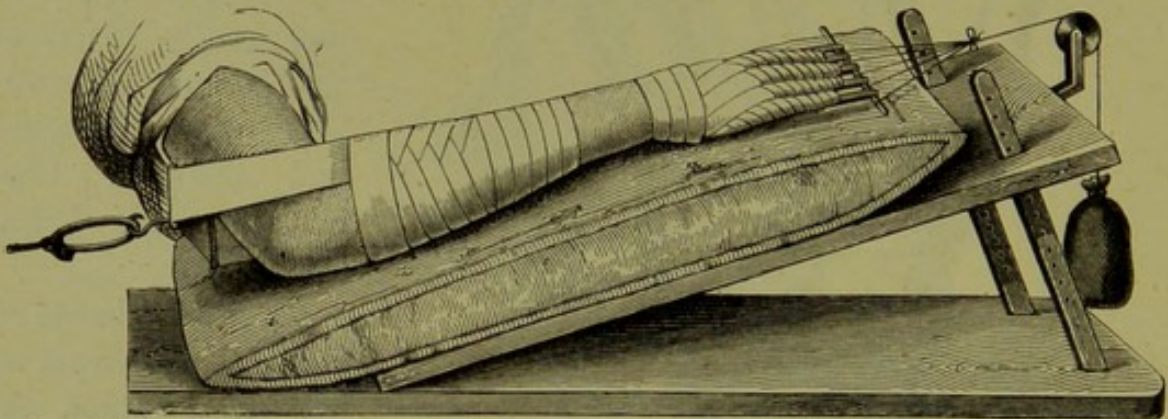
9. The bones of the anterior carpal row are then taken out. The globular articular head of the os magnum (*cap.*) is seized with the fingers of the

left hand or a pair of vulsellum forceps: and while an assistant abducts the thumb the ligaments uniting the trapezium (*m. ma.*) with the trapezoid (*m. mi.*) are divided: the operator then tries to penetrate from here in a direction towards the ulna into the carpo-metacarpal joints by dividing the ligaments on the extensor side of the bases of the metacarpal bones, while an assistant forcibly flexes the latter. The three carpal bones of the anterior row [trapezoid (*m. mi.*), os magnum (*cap.*), and unciform (*ham.*)] can thus be lifted out together.

10. Finally, while the hand is flexed, the epiphyses of the radius and ulna can be forced out of the wound, carefully stripped (as described above), and sawn off. In doing this, care must be taken not to wound the radial artery as it runs over the trapezium (*m. ma.*) to the first interosseous space (fig. 449).

11. During the after-treatment the excised joint must be fixed by one of the methods described on pages 63—65. The treatment by extension is adopted, as soon as possible, by fastening to all the fingers strips of plaster in the form of a gauntlet, through the loops of which a thin wooden stick is placed. To this stick a weight is attached by means of a fine cord, which runs over a pulley. The counter-extension can be effected by a larger form of strapping, which is fastened to both surfaces of the forearm, and drawn backwards by a stretched india-rubber ring. The arm rests upon an inclined plane (fig. 455).

Fig.*455.



Extension of the wrist.

IV. EXCISION OF THE ELBOW.

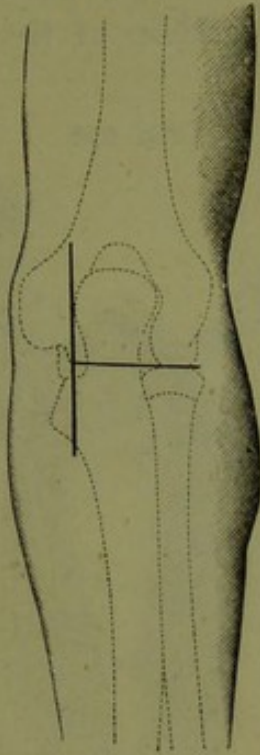
With LISTON'S T incision.

1. The elbow is flexed to an obtuse angle, and its posterior surface presented to the operator by an assistant, who seizes the forearm with one hand and the upper arm with the other (fig. 457).

2. A vertical incision 8^{cm} in length, the centre of which runs along the inner border of the olecranon, opens the capsule between the olecranon and the internal condyle (fig. 456).

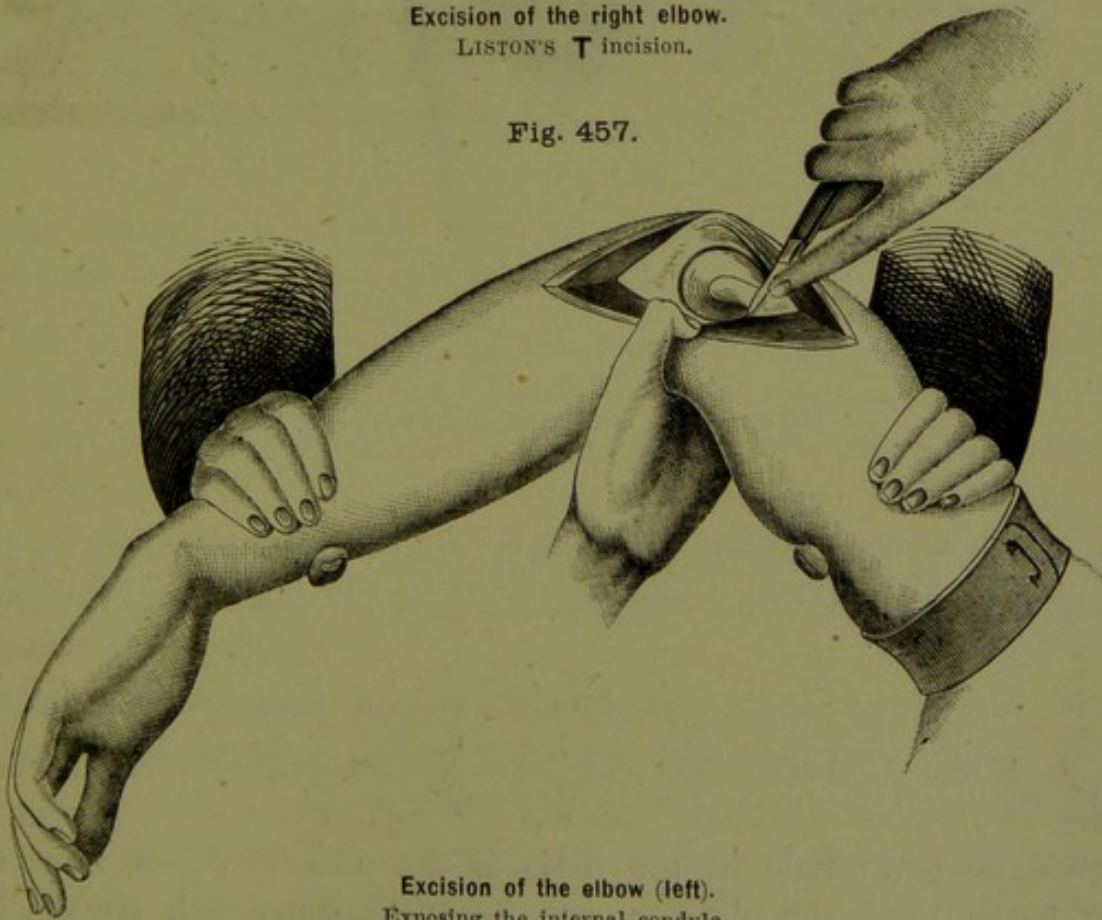
3. While the left thumb-nail draws the soft parts forcibly inwards from the internal condyle, a small knife completes the separation by short incisions at right angles to the bone; till the epicondyle is exposed and projects out of the wound (fig. 457). During this part of the

Fig. 456.



Excision of the right elbow.
LISTON'S T incision.

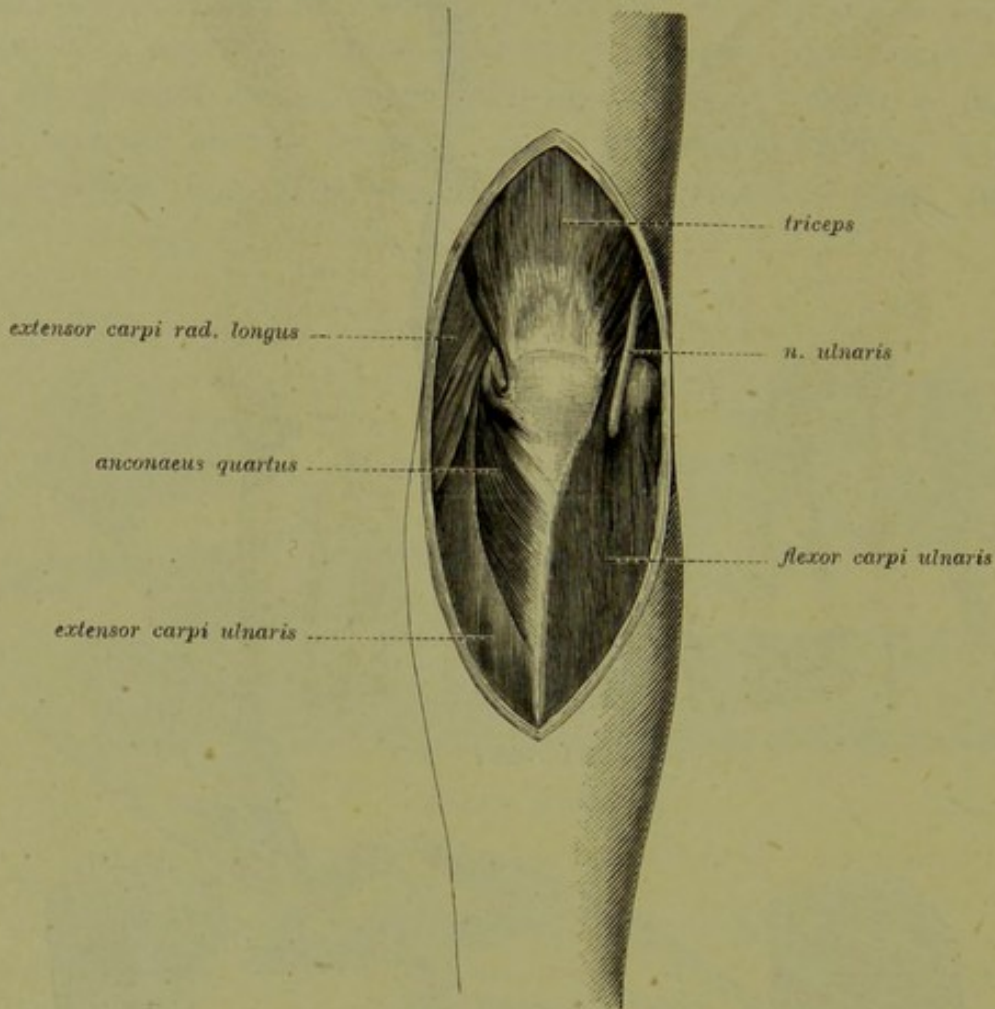
Fig. 457.



Excision of the elbow (left).
Exposing the internal condyle.

operation the forearm must be more and more flexed by the assistant. The ulnar nerve lies in the middle of the reflected soft parts and is not seen (fig. 458).

Fig. 458.



The ulnar nerve at the back of the left elbow.

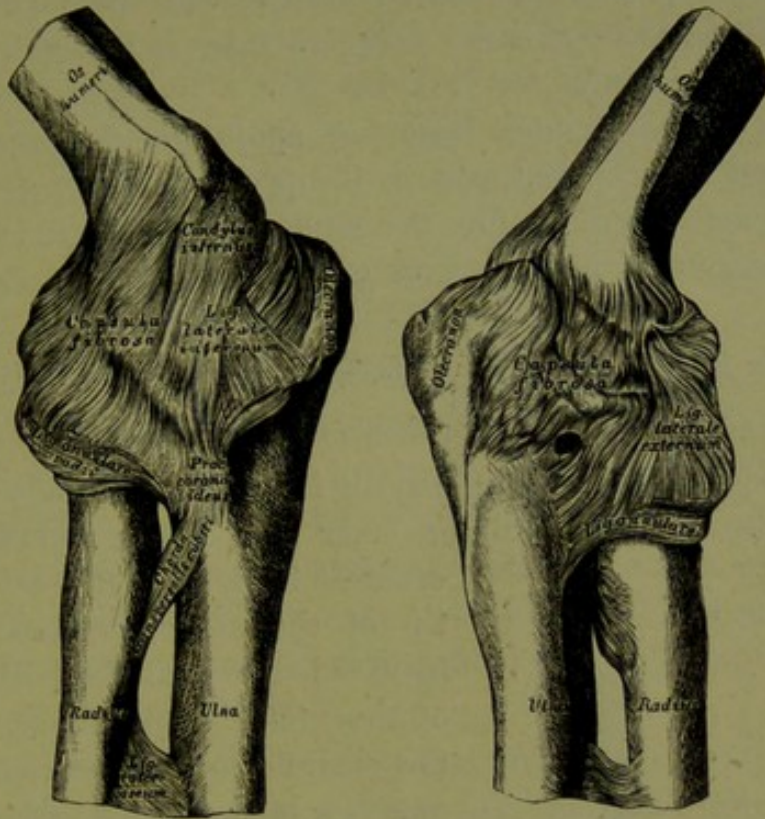
4. By a semicircular incision below the internal condyle the internal lateral ligament is divided close to the origin of the flexor muscles (fig. 459).

5. The arm is again straightened, and an incision carried transversely over the olecranon from the lower border of the external condyle to the centre of the first incision (fig. 456).

6. The periosteum at the back of the ulna is raised from its inner border with the elevator, and left continuous with the tendon

Fig. 459.

Fig. 460.



Ligaments of the right elbow joint.

of the triceps; the latter must be separated from the tip of the olecranon with the knife.

7. Both flaps are pushed outwards over the external condyle, and the joint opened; a few incisions between the head of the radius and the humerus divide the external lateral and orbicular ligaments (fig. 460).

8. The joint gapes widely open; the articular end of the humerus is seized with a pair of bone forceps, and sawn off at the margin of the articular cartilage.

9. By an incision upon the coronoid process of the ulna the upper fibres of the insertion of the brachialis anticus are divided; the olecranon is then seized with the forceps, and the articular surface of the ulna, as far as it is covered with cartilage, removed with the saw.

10. The head of the radius is also sawn off.

11. After the haemorrhage has been arrested, the transverse incision is united by the interrupted suture, but the vertical one only at its two extremities. A stout drainage tube is brought out through the centre of the wound.

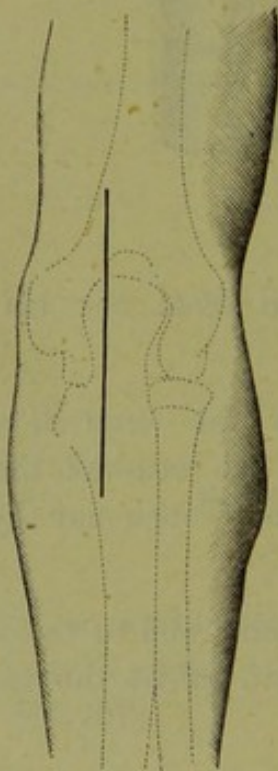
12. One of the various forms of apparatus described on pages 68—74 is used to keep the arm in the proper position. Roser's proposal*, to place the arm for the first few weeks in the extended position, is reasonable and deserves every consideration.

V. SUBPERIOSTEAL EXCISION OF THE ELBOW.

With LANGENBECK'S simple straight incision.

1. An incision 8—10^{cm} in length is made over the extensor surface of the joint somewhat to the inner side of the middle of the olecranon, beginning 3—4^{cm} above the tip of the olecranon and terminating 5—6^{cm} below it at the posterior border of the ulna. It penetrates throughout the length of the incision through muscles, tendons, and periosteum right down to the bone (fig. 461).

Fig. 461.



Excision of the elbow (right).
LANGENBECK'S incision.

2. The periosteum is first of all peeled off with raspatory and elevator towards the inner side, and the inner half of the tendon of the triceps together with the periosteum is divided (by short parallel and longitudinal incisions always directed against the bone).

3. The soft parts, covering the internal condyle and enclosing the ulnar nerve, are drawn by the left thumb-nail towards the tip of the epicondyle, and liberated by curved incisions following closely upon one another and always upon the bone, till the epi-

* Die Ursachen des Schlottergelenkes nach Ellbogenresection im Kriege. A congratulatory address at the celebration of the fiftieth anniversary of Herrn Louis STROMEYER'S doctor's degree, by W. ROSER. April 6. 1876.

condyle is completely exposed. The last incisions are carried round this prominence, and separate the origins of the flexor muscles as well as the internal lateral ligament from the humerus, without however disturbing their connection with the periosteum.

4. After the liberated tissues have been brought back to their former position, the outer part of the tendon of the triceps is drawn outwards, and separated from the olecranon by short incisions, but left connected with the periosteum on the outer side of the ulna, which together with the anconeus is raised from the bone.

5. The fibrous capsule is liberated from the margin of the articular surface of the humerus by incisions following closely upon one another and directed against the bone (first at the trochlea and then at the eminentia capitata), till the external condyle appears.

6. The external lateral ligament and the origin of the extensor muscles are then separated from the external condyle in such a manner, that all these parts remain in connection with one another, and with the periosteum of the humerus.

7. When the external condyle has thus been freely exposed, the joint is forcibly flexed, and the articular surfaces forced out of the wound: these are sawn off one after the other, as described in the preceding chapter.

8. If it is necessary to remove the ulna below the coronoid process, the upper fibres of the insertion of the brachialis anticus must be divided, without destroying the connection of the tendon with the periosteum of the ulna.

VI. EXCISION OF THE ELBOW.

HOTER'S lateral incisions.

1. A longitudinal incision, 2^{cm} in length, exposes the internal condyle: a curved incision below this prominence divides the internal lateral ligament.

2. A longitudinal incision on the outer side of the joint, 8—10^{cm} in length, passes over the external condyle and the head of the radius.

3. The soft parts are retracted, and the external lateral and orbicular ligaments divided.

4. The head of the radius is exposed and removed with the key-hole saw.

5. The insertion of the capsular ligament is liberated in front and behind, first from the border of the capitellum, then from the trochlea.

6. By adduction of the forearm the humerus is forced out of the wound; by this movement the ulnar nerve slips away from its posterior aspect.

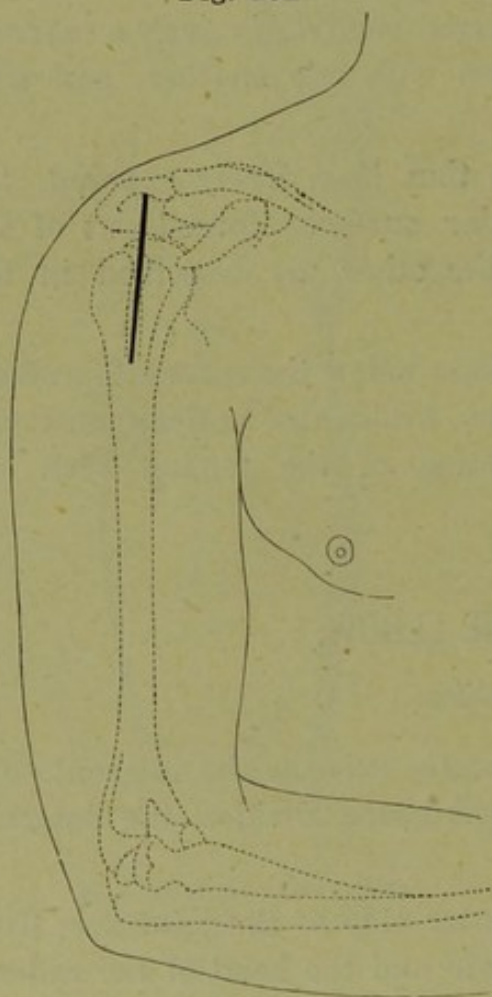
7. The articular surface of the humerus is removed with the saw.

8. The olecranon is exposed and sawn off.

VII. EXCISION OF THE SHOULDER.

With LANGENBECK'S anterior vertical incision (older method).

Fig. 462.



Excision of the shoulder.

With LANGENBECK'S anterior vertical incision.

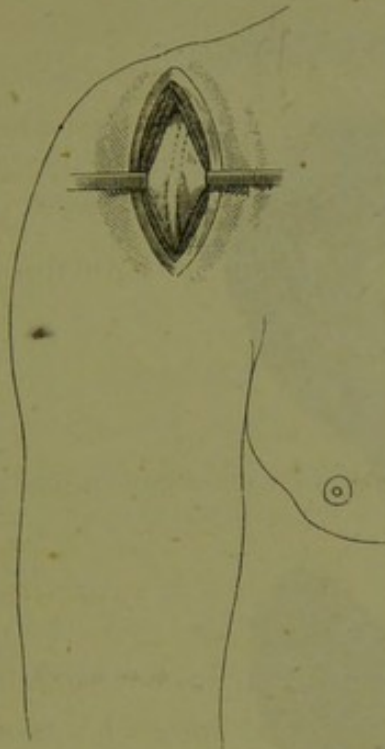1. The patient lies upon his back, with the shoulder raised upon a pillow; the arm is held, so that the external condyle of the humerus is directed forwards.

2. An incision, beginning at the anterior border of the acromion, quite close to its articulation with the clavicle, and running for 6—10^{cm} vertically downwards, divides the deltoid muscle and reaches the capsule of the joint and the periosteum (fig. 462).

3. The muscle is retracted on both sides of the incision: the tendon of the long head of the biceps is seen lying within its sheath (fig. 463).

4. An incision along the outer side of the tendon opens its sheath; the knife is directed upwards with the back of the blade in the bicipital groove, and divides

Fig. 463.



The tendon of the long head of the biceps.

the whole length of the sheath together with the capsular ligament up to the acromion.

5. The tendon of the biceps is lifted out of its groove, and drawn outwards with the blunt retractor.

6. While the assistant rotates the arm outwards, a curved incision, with a strong knife placed at right angles upon the bone, is carried round from the opening in the joint over the lesser tuberosity, dividing the capsular ligament and subscapularis muscle (fig. 464).

Fig. 464.

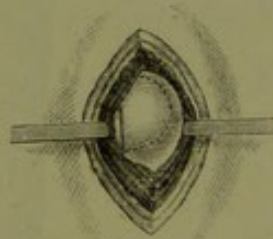
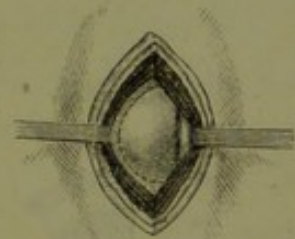


Fig. 465.



7. The arm being again rotated inwards, the tendon of the biceps is also drawn inwards over the head of the bone.

8. The knife is again carried round in a larger circle over the greater tuberosity, and divides the capsule together with the insertions of the supraspinatus, infraspinatus, and teres minor (fig. 465 and 466).

9. The head of the humerus is forced out of the wound by pressure from below, seized with forceps (FARABŒUF'S clutch-forceps are the best) (fig. 433 and 437), and after the posterior insertion of the capsule has been divided, removed with the key-hole saw (fig. 468).

10. When the head of the humerus is separated from the diaphysis by the bullet, it must be drawn forwards and fixed by a sharp bone-hook (fig. 443), or by a bullet-screw (fig. 508). If it is shattered into many pieces, the fragments can be separately seized and removed

Fig. 466.
supraspinatus

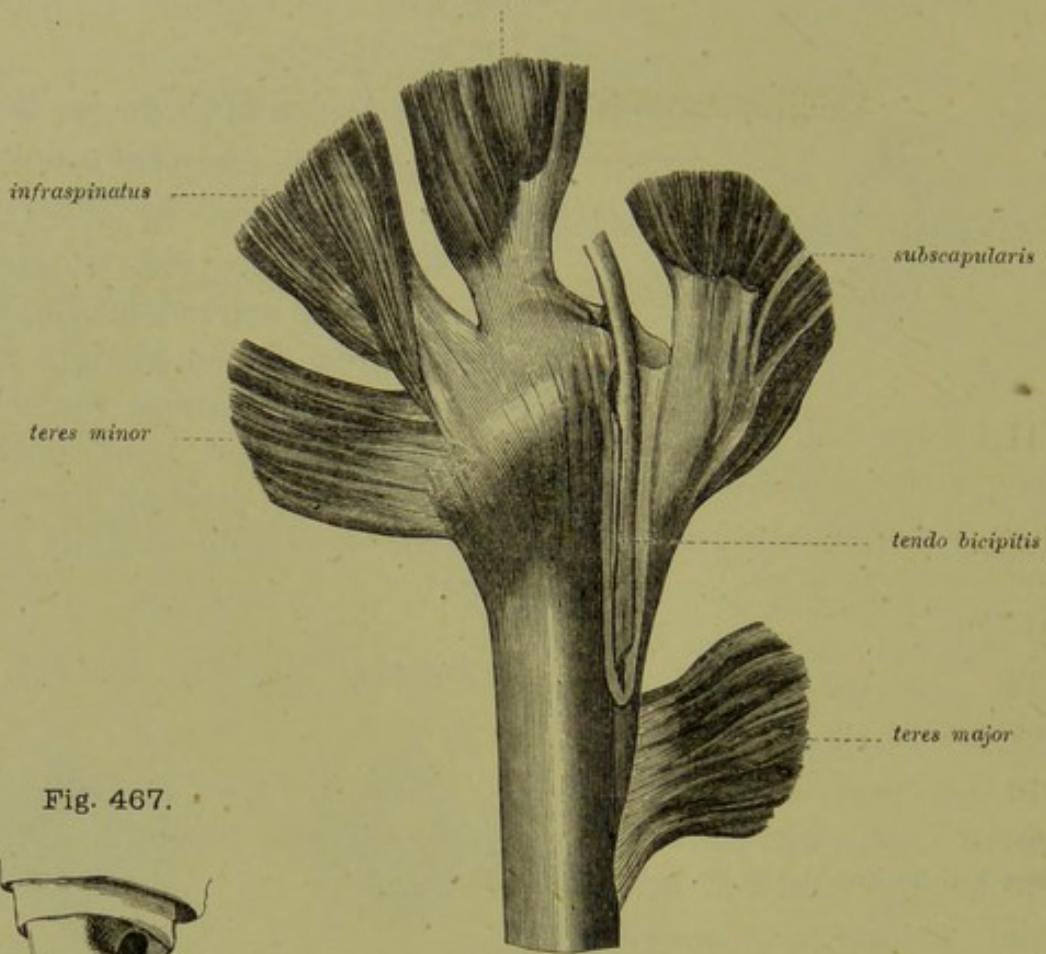
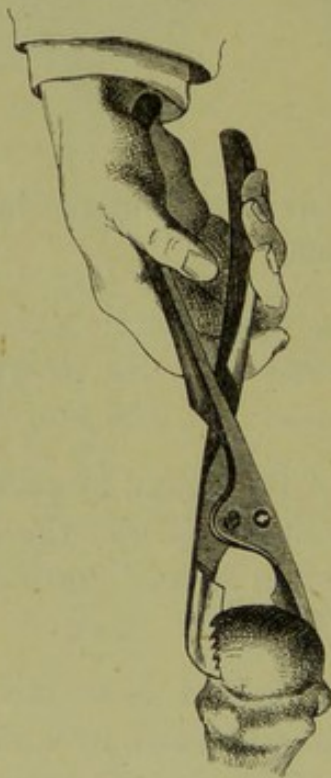

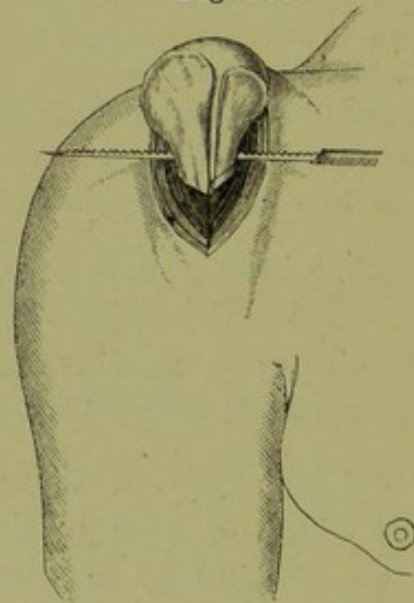
Fig. 467.



Head of the humerus seized with
FARABŒUF'S forceps.

Muscular attachments to the greater and lesser tuberosity.

Fig. 468.



Sawing off the head of the humerus.

with forceps and blunt-pointed (fig. 469) or probe-pointed (fig. 470) bistoury.

Fig. 469.



Blunt-pointed bistoury.

Fig. 470.



Probe-pointed bistoury for excision.

11. After the haemorrhage has been arrested, a stout drainage tube is placed in the glenoid cavity, and the lower end brought out through an opening, which is made in the skin (if there be no gun-shot wound there) behind the wound (on the inner side of the latissimus dorsi).

12. The wound is then closed with sutures, the arm placed in a sling and supported by a STROMEYER'S cushion (fig. 164, page 77).

13. As soon as the healing process commences and the fever has disappeared, the patient may be allowed to walk about and resume a little movement of his hand and elbow.

14. After this method of operating, a loose joint is generally formed, with displacement of the end of the humerus towards the thorax, or a feeble articulation with the coracoid process. A free active movement is produced much sooner, if the connections of all the muscles, surrounding the joint, with the capsular ligament and the periosteum of the shaft are retained. This is the aim of the following method.

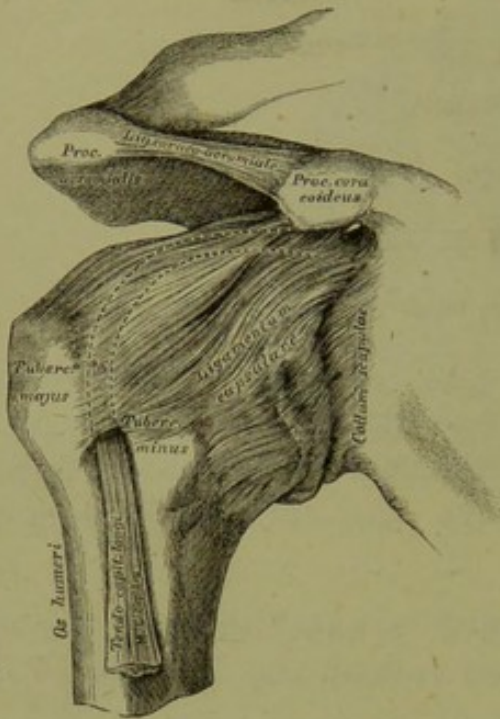
VIII. THE SUBPERIOSTEAL OR SUBSCAPULAR EXCISION OF THE SHOULDER.

LANGENBECK.

1.—4. as in the preceding operation.

5. The periosteum is divided with the bone knife along the inner border of the bicipital groove, and carefully raised with a narrow elevator from the lesser tuberosity.

Fig. 471.



The ligaments of the shoulder joint.

the humerus together with the insertions of the supraspinatus, infraspinatus, and teres minor into the great tuberosity are detached in the same manner as in 6. This preservation of the periosteum is rather difficult in primary excisions, because it is usually so thin.

9. The head of the humerus is forced out of the wound and sawn off as in the preceding operation. If only the head above the tuberosities is to be excised (which always gives the best result), there can be no question about detaching the periosteum. Beginning from the interior of the joint the muscular attachments are peeled off from the bone as far as is requisite: care is taken that they are not divided transversely, but that their connection with the bone below is preserved. But since the head cannot then be forced out of the wound, it must be removed with a fine key-hole saw, or with the chain saw.

10. The remaining steps of the operation are the same as in the preceding.

6. The tendon of the subscapularis is peeled from the bone with knife and toothed-forceps, without separating the fibrous capsular ligament from the liberated periosteum. During this part of the operation the humerus must be slowly rotated outwards, and as it becomes more and more liberated, the knife is frequently changed for the elevator.

7. The arm is rotated inwards again, the tendon of the biceps lifted from its groove, and slipped over the head of the bone to its inner side.

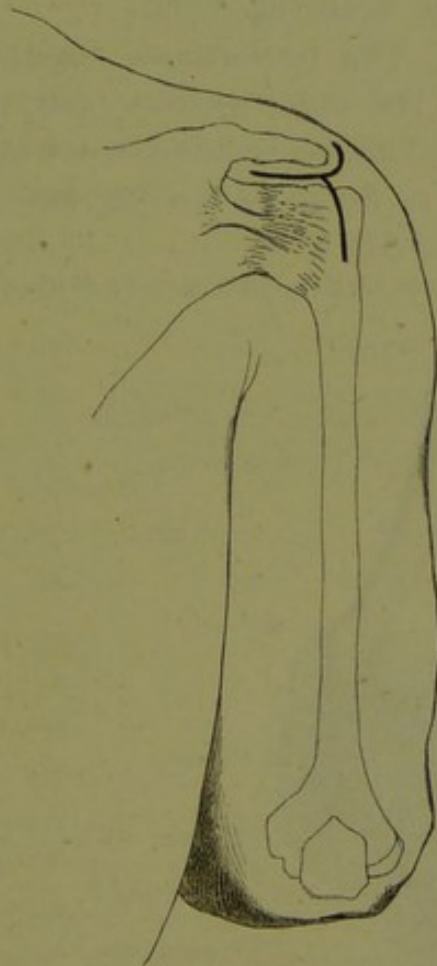8. The periosteum on the outer surface of the neck of

IX. EXCISION OF THE GLENOID CAVITY.

1. Bone is only removed from the scapula in excision of the shoulder, if this bone also has been injured by the bullet. But if the articular surface of the scapula is alone shattered and the head of the humerus is uninjured, then only the former need be sawn off.

2. If there be no gun-shot wound, as there generally is, to indicate the direction, the joint is most conveniently opened by the following method.

Fig. 472.



3. A curved incision, which passes round the posterior border of the acromion and divides the fibres of the deltoid, exposes the posterior and upper surface of the joint (fig. 472).

4. From the centre of this incision the knife is carried down to the posterior and upper margin of the glenoid cavity, dividing the capsular ligament upon the middle of the great tuberosity, in a vertical direction between the tendons of the supraspinatus and infraspinatus, and at the same time dividing the skin and the deltoid muscle in the direction of its fibres.

5. While the soft parts are forcibly separated with retractors, the tendon of the long head of the biceps is liberated from the margin of the glenoid cavity, and the capsular ligament together with the periosteum from the neck of the scapula; the latter is sufficiently exposed to remove the articular surface with the key-hole saw, or to liberate the fragments of shattered bone with the knife.

Excision of the glenoid cavity of the scapula.

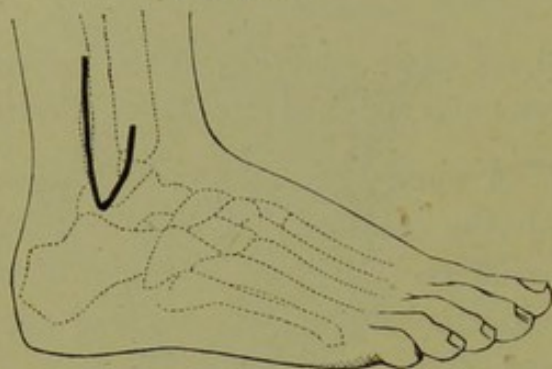6. The after-treatment is the same as in excision of the shoulder.

X. EXCISION OF THE ANKLE.

LANGENBECK'S subperiosteal operation.

1. The foot is placed upon its inner side and a vertical incision, 6^{cm} in length, is carried down along the posterior border of the lower end of the fibula. This incision turns round at the tip of the external malleolus forming a sort of hook, and follows its anterior border for 1.5^{cm}: it penetrates throughout the whole length of the incision right down to the bone (fig. 473).

Fig. 473.

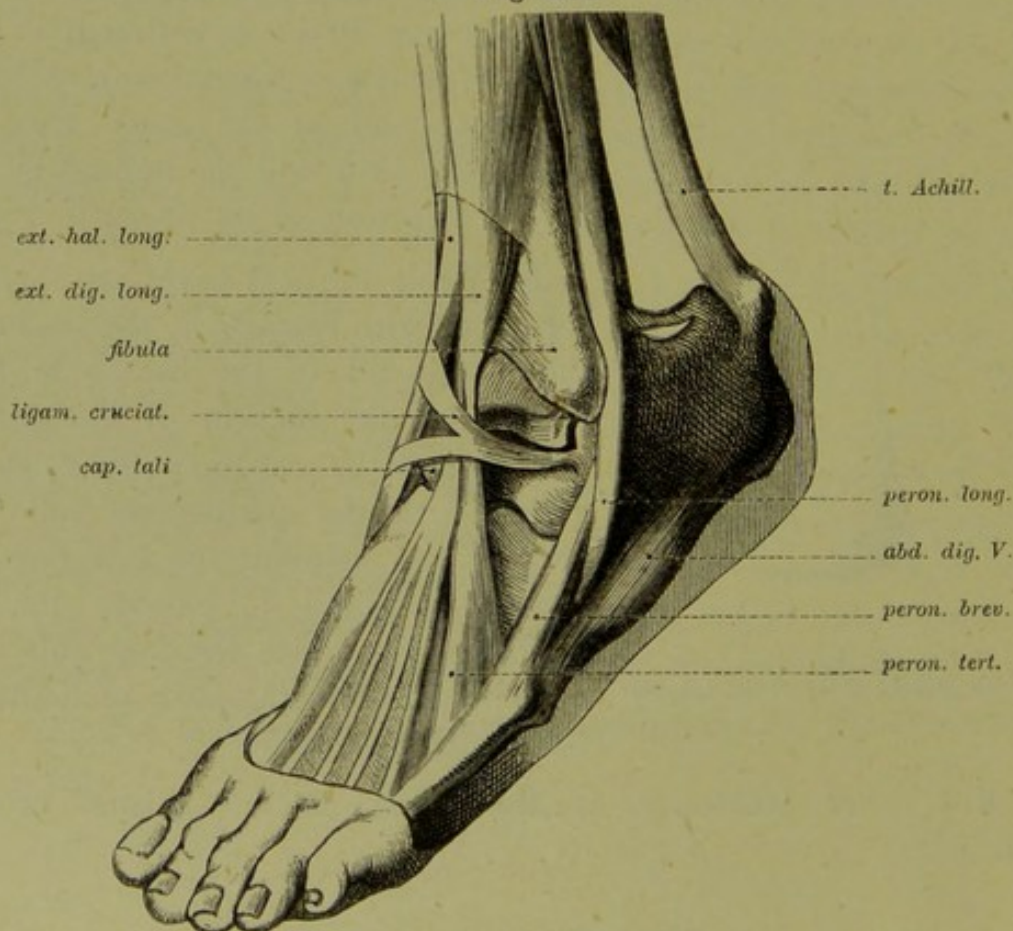


2. The periosteum, together with the skin, muscles, and the sheaths of the tendons upon the anterior and posterior surfaces are liberated from the bone, till at the upper end of the incision a key-hole or chain saw can be carried behind the fibula (fig. 474).

NB. The sheath of the tendon of the peroneus longus must not be injured.

NB. The sheath of the tendon of the peroneus longus must not be injured.

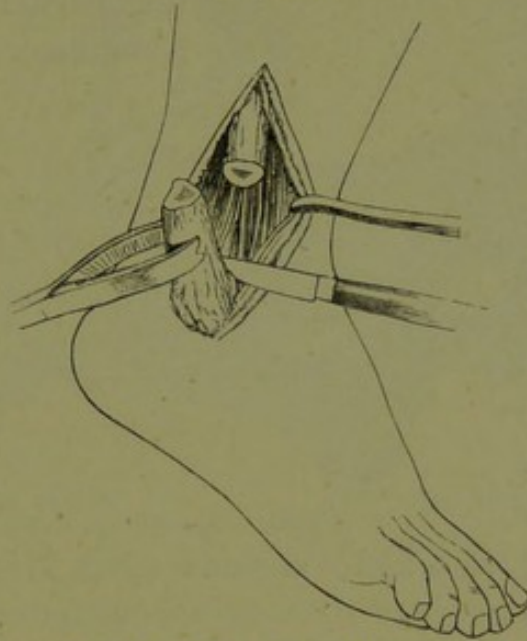
Fig. 474.



Outer side of the left ankle (HENKE).

3. The fibula is sawn through; the piece is then seized with necrosis forceps, drawn slowly but firmly forwards, and separated from the interosseous ligament (fig. 475). Finally from within and from above

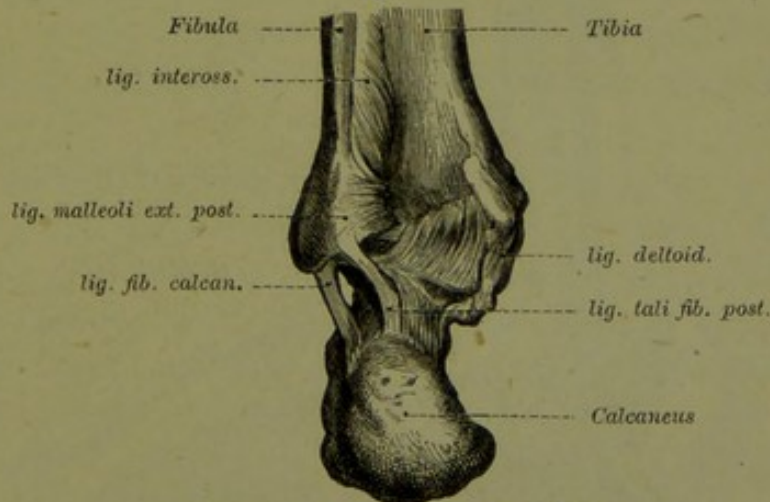
Fig. 475.



Removing the lower end of the fibula.

the lig. malleoli ex. post. (transverse ligament), the lower very firm end of the interosseous ligament (fig. 476), and the three strong liga-

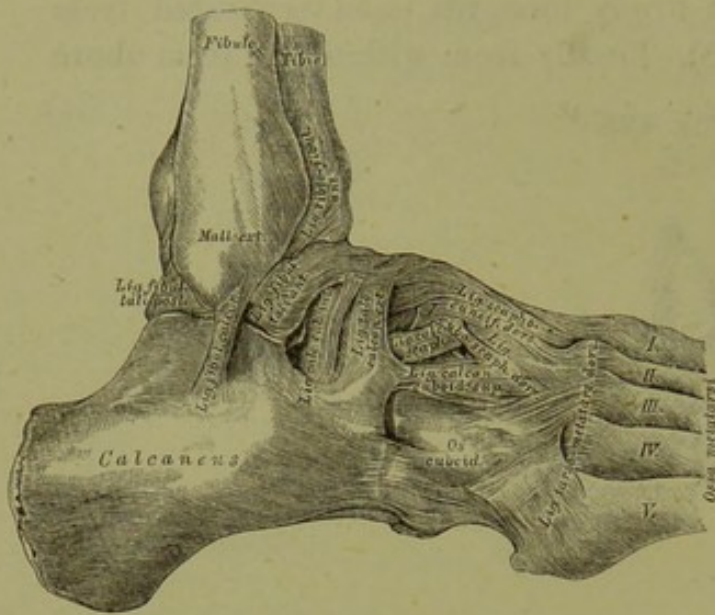
Fig. 476.



Ligaments of the ankle (from behind).

ments (fig. 477) (lig. talo-fibulare anticum and posticum and the external lateral ligament) are divided close to the malleolus.

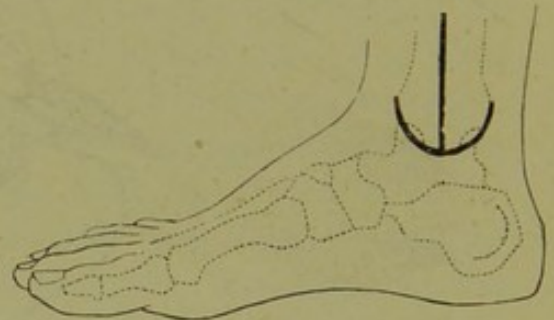Fig. 477.



Ligaments of the ankle joint (outer side).

4. The foot is placed upon its outer side and a semilunar incision, 3—4^{cm} in length, is carried round the lower border of the internal malleolus (fig. 478): from the centre of this wound a

Fig. 478.

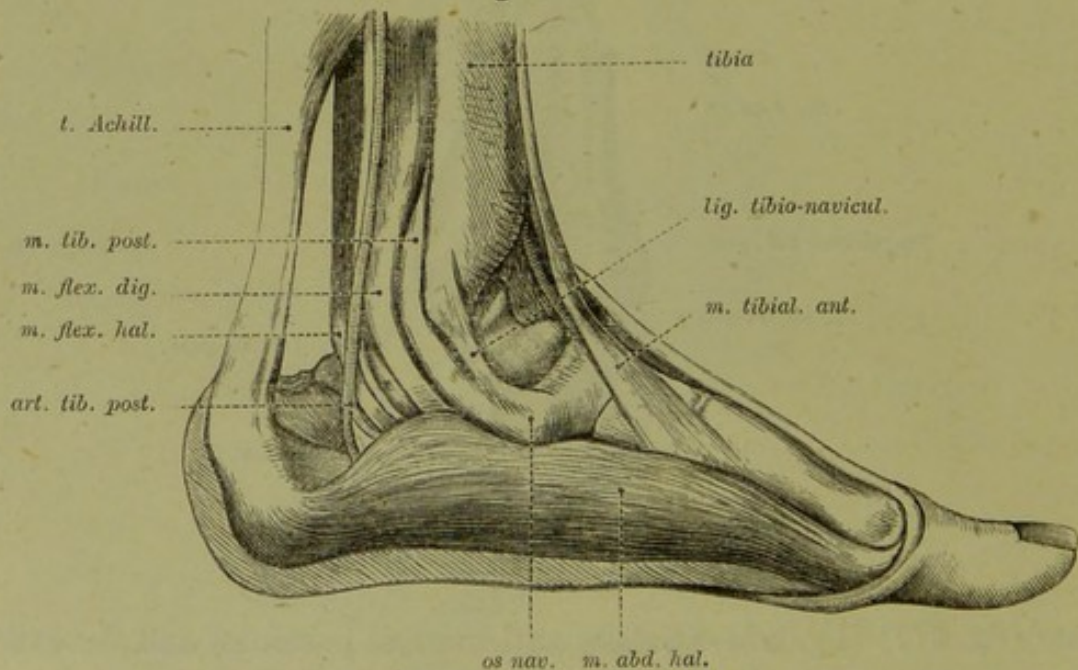


Incision over the internal malleolus.

vertical incision, 5^{cm} in length, ascends upon the inner side of the tibia (anchor incision).

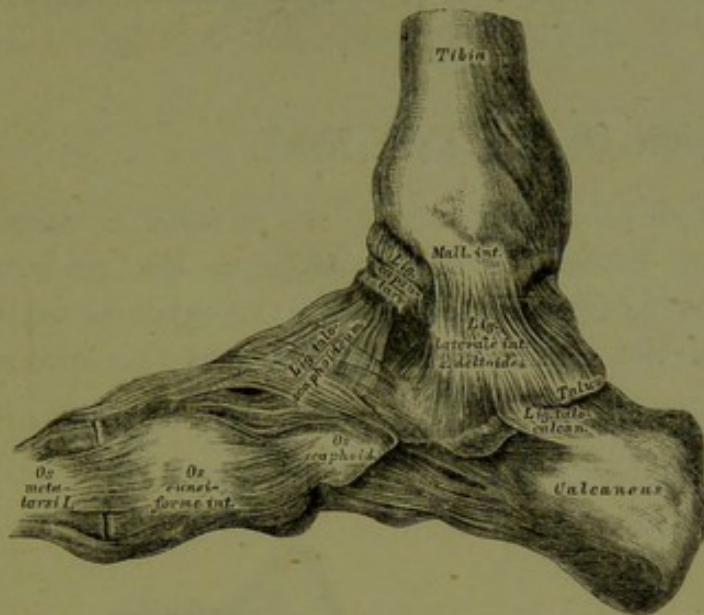
5. The incisions penetrate through the periosteum to the bone. The periosteum is raised in two triangular flaps, with the skin from the inner surface, with the tendinous sheaths of the extensors from

Fig. 479.



Inner side of the ankle joint (HENKE).

Fig. 480.



Ligaments of the ankle joint (inner side).

the anterior surface, and with the tendinous sheaths of the flexors from the posterior surface of the tibia, and finally the internal lateral ligament is divided from the extremity of the malleolus (fig. 480).

6. The tibia is sawn through at the upper end of the vertical incision with a key-hole or chain saw (in an oblique direction on account of the limited

space): the piece is seized with necrosis forceps, and while the elevator from above pushes the periosteal surface of the interosseous ligament away, it is slowly twisted out of the wound.

NB. The preservation of the interosseous membrane is very important for the regeneration of the bone (LANGENBECK).

7. The bone is now only held fast by the anterior and posterior attachments of the capsular ligament. These are divided with the knife; in doing which the tendon of the tibialis posticus must not be injured.

8. If the operator wishes to remove the upper articular surface of the astragalus, it is done with the key-hole saw, which works in the direction of the semilunar incision from before backwards, while the foot is steadied with two hands against the table. LANGENBECK advises the upper articular surface of the astragalus to be sawn immediately after the removal of the fibula from the first incision, but to be taken out only after the removal of the tibia with the elevator.

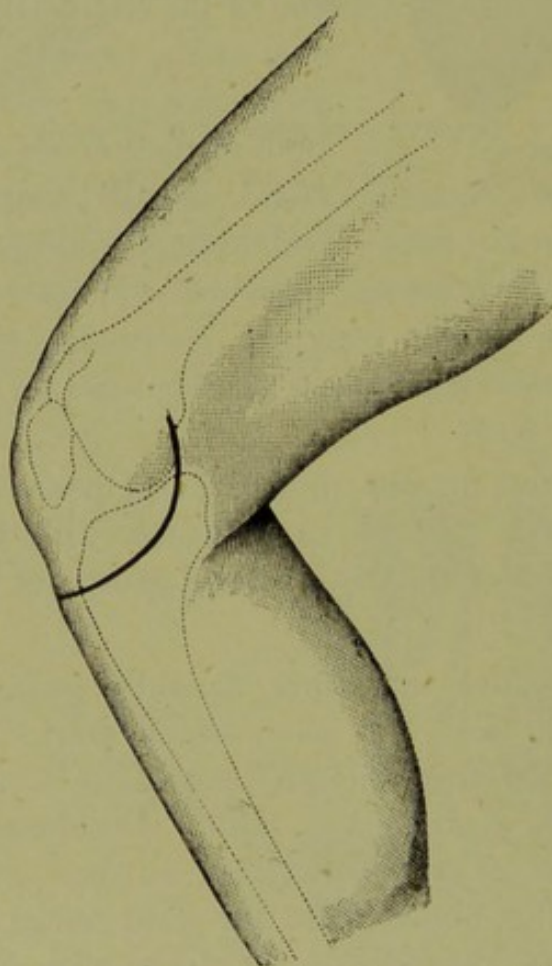
9. After the haemorrhage has been arrested, a stout drainage tube is drawn through the lower part of the wound, which is closed except at this spot with sutures. By one of the methods described

on pages 83—86 the limb is fixed in such a manner, that the foot is kept at right angles with the leg, and the periosteal cylinder stretched out to its natural length.

XI. EXCISION OF THE KNEE JOINT.

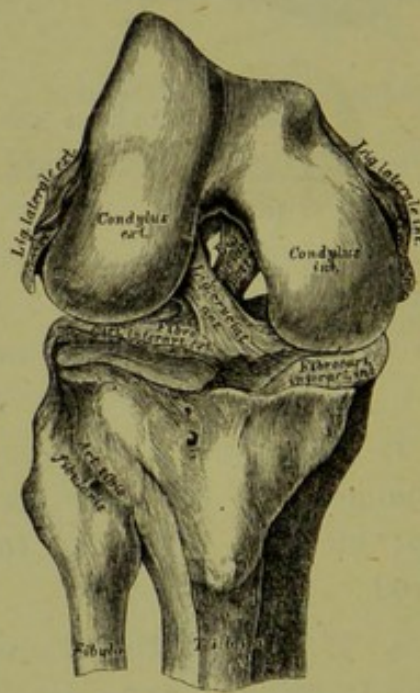
1. With the knee flexed to a right angle, an incision is carried (fig. 481) from the posterior border of one condyle to the posterior border of the other, in a curve immediately above the tubercle of the tibia. This at once divides the ligamentum patellae and the anterior wall of the capsule.

Fig. 481.



Excision of the knee with anterior curved incision.

Fig. 482.



Crucial ligaments.

2. Whilst the leg is still more strongly flexed, the two lateral ligaments and then the crucial ligaments (fig. 482) are separated from the femur; the joint gapes widely open.

3. The posterior part of the capsule is carefully separated from the femur, which is then pressed forward. The whole of the cartilage is sawn off in a direction parallel with its articular surface.

4. In the same manner the articular surface of the tibia is removed with the saw, without injuring the fibular joint, which does not as a rule communicate with the knee joint.

5. The patella is carefully liberated and separated from the quadriceps extensor. The upper synovial pouch must also be dissected out, if it is inflamed or has undergone degeneration.

6. Both articular ends can be conveniently bored (fig. 483) obliquely through in many places by a fine drill with an eye at its point, and

Fig. 483.



Bone-drill.

fastened together by silver wire or strong catgut ligatures.

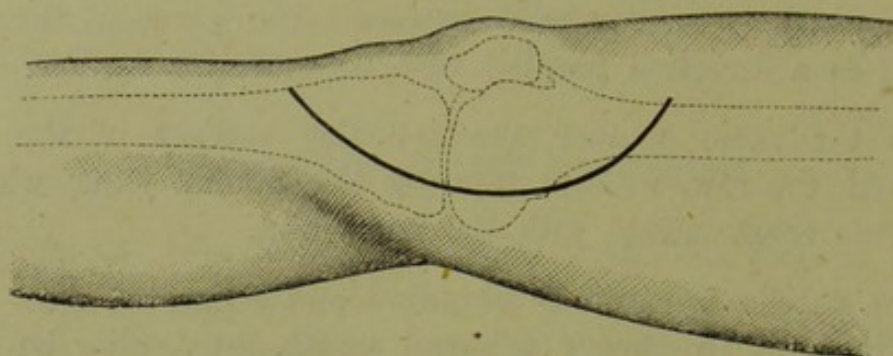
7. After the haemorrhage has been arrested, a stout drainage tube is placed behind the bones across the wound, and brought out at the angles. The rest of the wound is carefully united with sutures, and the limb well adapted and fixed by one of the methods described on pages 90—93.

XII. SUBPERIOSTEAL EXCISION OF THE KNEE JOINT.

With LANGENBECK'S curved lateral incision.

1. On the inner side of the extended joint a curved incision is made, 15—18^{cm} in length, with the convexity backwards over the posterior border of the internal condyle. It commences 5—6^{cm} above the patella at the inner border of the rectus femoris, and terminates 5—6^{cm} below the patella on the inner side of the crest of the tibia (fig. 484).

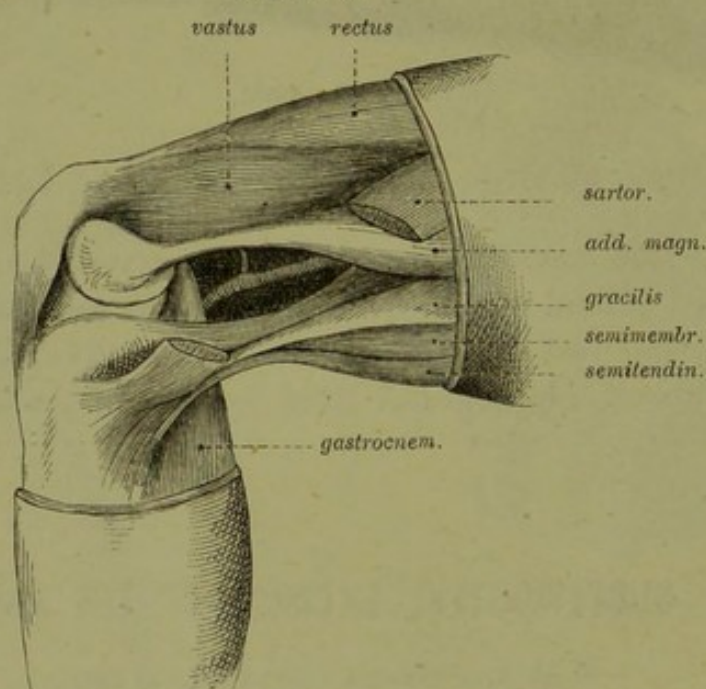
Fig. 484.



LANGENBECK'S curved lateral incision.

2. The vastus internus lies in the upper part of the wound, and below it appears the tendon of the adductor magnus; the tendon of the sartorius is visible at the lower part of the wound: these tendons must not be injured (fig. 485).

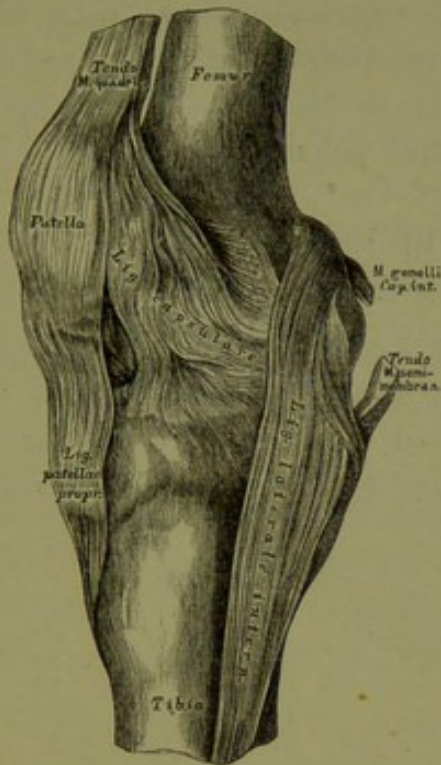
Fig. 485.



Tendons of the knee joint (inner side).

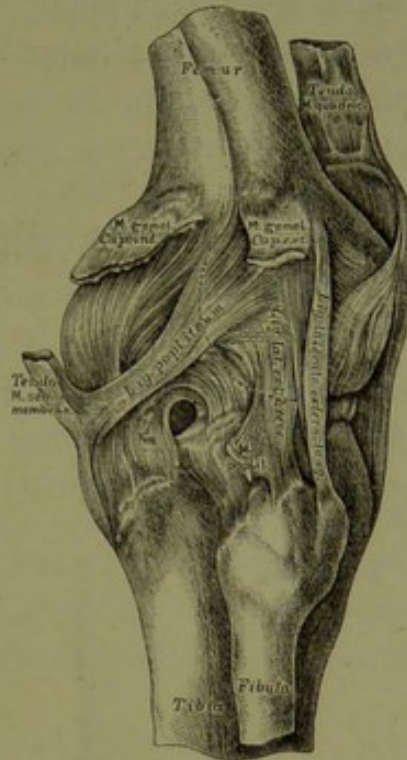3. The internal lateral ligament is divided in the line of the joint, and the insertion of the capsule separated from the anterior surface of the internal condyle as far up as the vastus internus: in a similar manner the internal alar ligament is detached from the anterior border of the tibia as far as the middle line (fig. 486).

Fig. 486.



Inner side.

Fig. 487.



Outer side.

Ligaments of the right knee joint.

4. The knee is flexed, and while it is being again slowly extended, the patella is dislocated outwards by pressure applied with some force.

5. The crucial ligaments are divided: to separate the posterior crucial ligament from the spine of the tibia, the latter must be rotated outwards.

6. The external lateral ligament, with the corresponding part of the capsule, is divided by a semilunar incision, which is carried a few lines below the tip of the external epicondyle (fig. 487).

7. The joint gapes widely open; the posterior part of the capsule is divided; the articular ends of the femur and tibia are forced out of the wound one after the other and sawn off.

8. If the operator wishes to remove the patella, the edge of its cartilaginous surface is cut off all round with the knife, and then liberated with raspatory and elevator from its periosteum, so that the latter may remain connected with the ligamentum patellæ and the extensor tendon.

Before the wound is closed, a strong drainage tube is brought out at the most dependant point. A small counter-opening may be conveniently made on the outer side, from which the other end of the drainage tube is made to project. It is also useful for passing a drainage tube through the upper synovial pouch.

XIII. EXCISION OF THE HIP JOINT.

With posterior curved incision (ANTHONY WHITE).

1. The patient is placed upon the healthy side, and the incision, which commences midway between the anterior superior spine of the ilium and the great trochanter, is carried in a curve round the top of the latter and down the posterior border for about 5^{cm} (fig. 488).

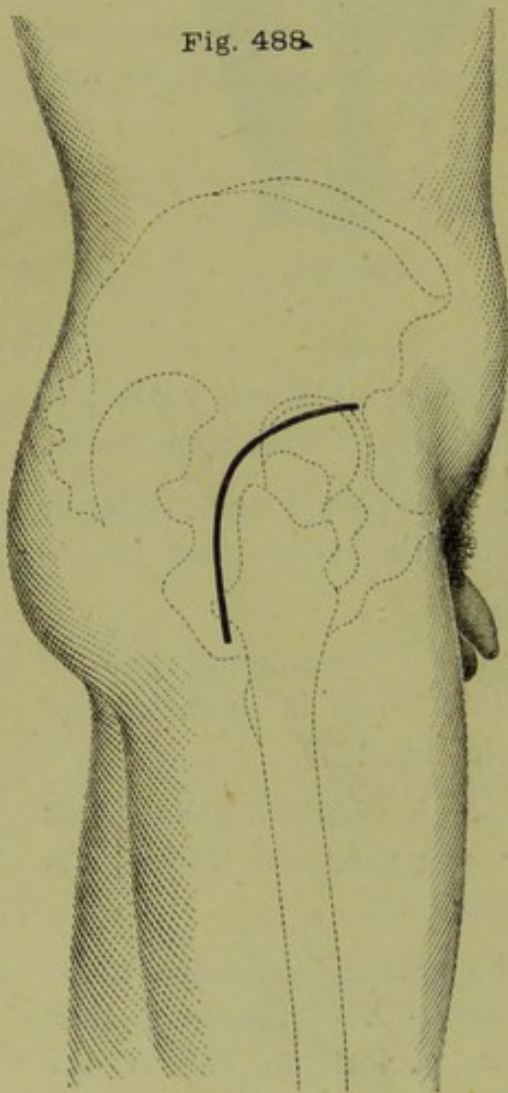


Fig. 488.

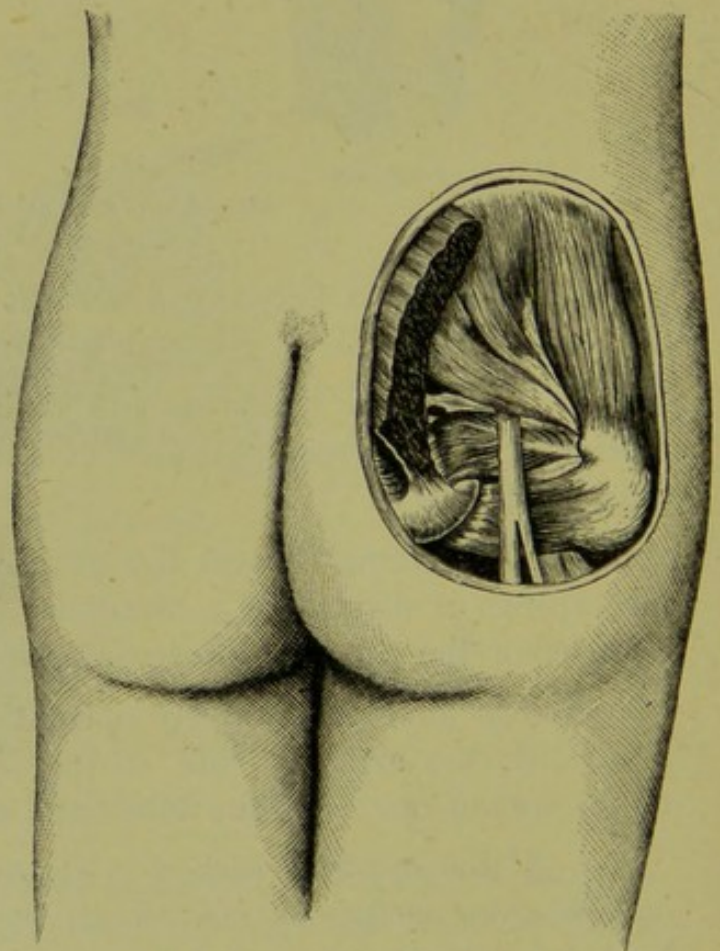


Fig. 489.

Excision of the hip joint.
Posterior curved incision (A. WHITE).

Muscles and great sciatic nerve behind the hip joint.

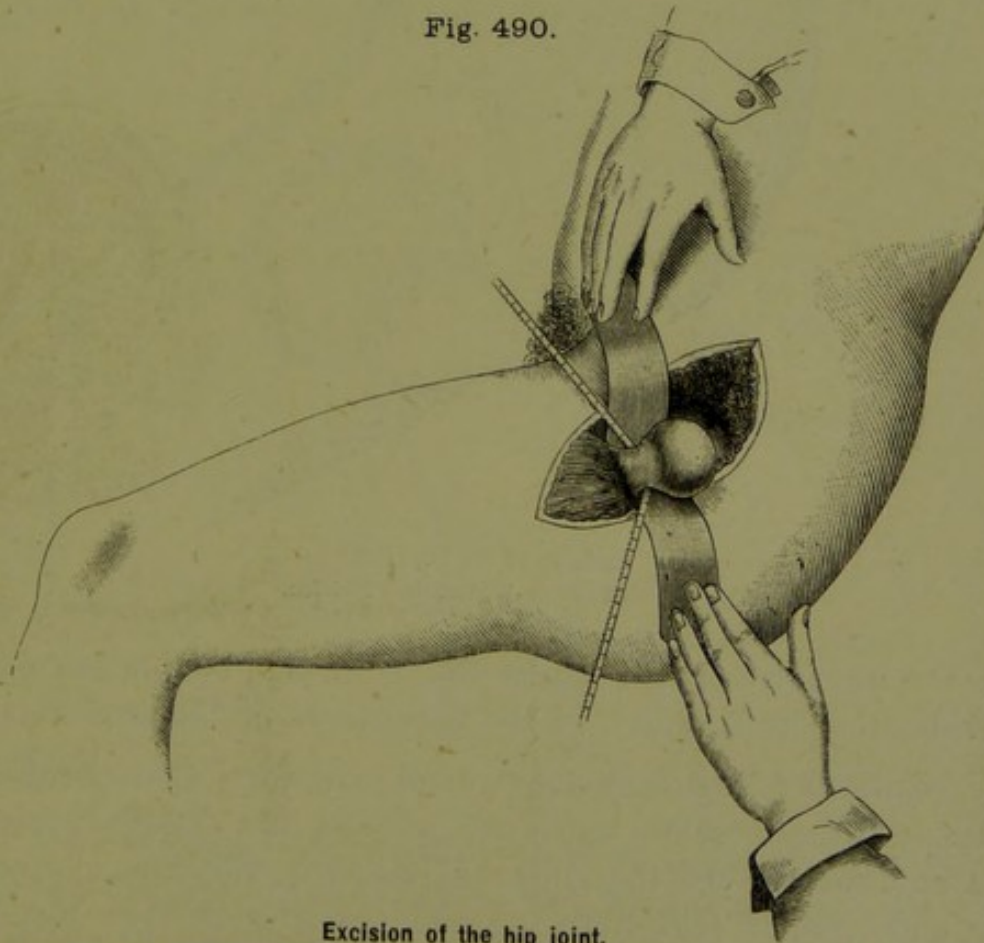
2. With a strong short knife the tendinous attachments of the gluteus medius and minimus, obturator, pyriformis, and quadratus femoris (fig. 489) are separated from the trochanter, and the muscles drawn aside with retractors, till the posterior and upper surface of the neck of the femur and the margin of the acetabulum are visible.

3. The joint is opened by an incision made with some force along the margin of the cartilaginous rim; the thigh is flexed and adducted, and with a cracking noise the head starts from the acetabulum.

4. With a narrow knife, which penetrates from behind and the outer side into the acetabulum, the ligamentum teres is divided against the head of the femur: the latter is then completely freed from the acetabulum.

5. The soft parts are protected by a broad spatula, which is pushed behind the neck of the femur; the neck is sawn through with a key-hole or chain saw, while the head is fixed by necrosis forceps (fig. 490). (See the further particulars in the following operation).

Fig. 490.



Excision of the hip joint.

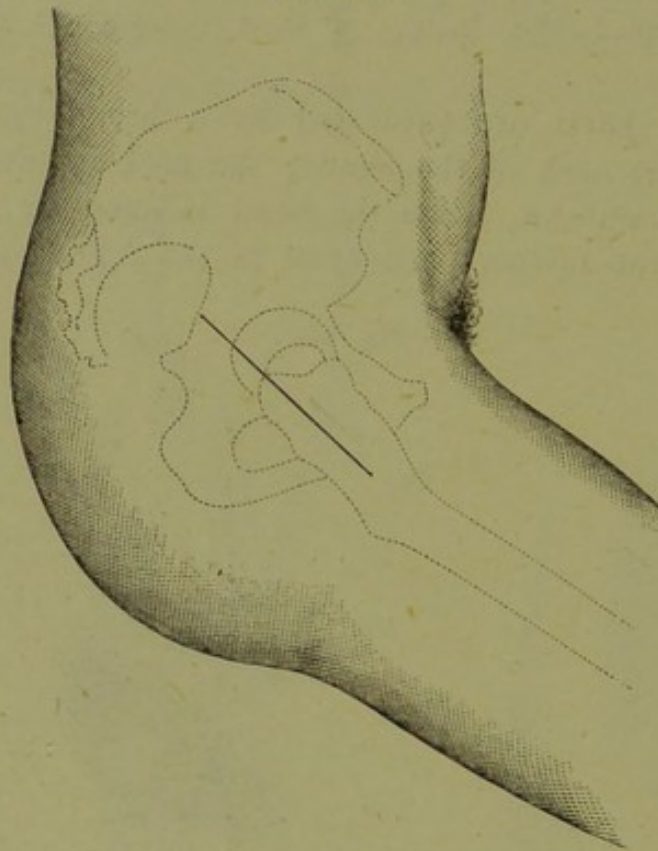
Sawing off the head of the femur with the chain saw. Retraction of the soft parts with a broad tin spatula.

XIV. SUBPERIOSTEAL EXCISION OF THE HIP JOINT.

With LANGENBECK'S longitudinal incision.

1. With the thigh semiflexed (at an angle of 45°) a straight incision is carried from the middle of the trochanter in the long axis of the thigh for about 12^{cm}, in a direction upwards and backwards towards the posterior superior spine of the ilium (fig. 491).

Fig. 491.

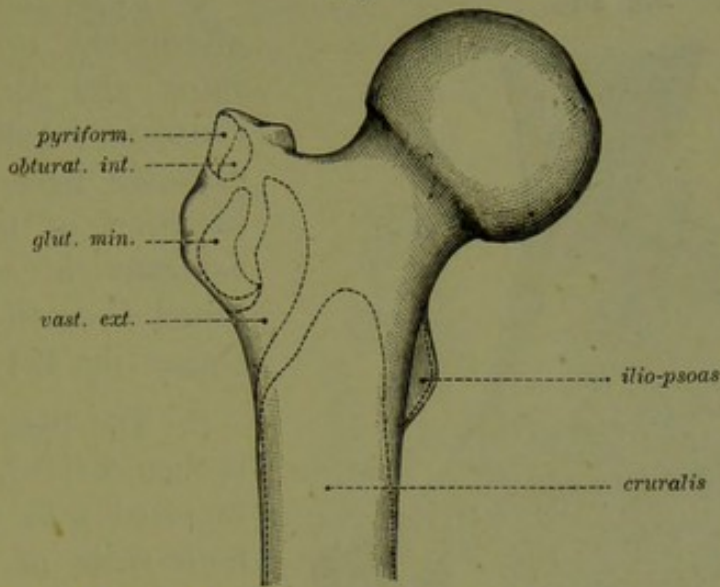


Excision of the hip joint.
LANGENBECK'S longitudinal incision.

2. The incision penetrates between the fibres of the gluteus maximus, and divides the fascia lata and the periosteum of the trochanter.

3. While the edges of the wound are forcibly separated with retractors, all the muscles, which are inserted into the great trochanter [on the anterior surface the gluteus minimus, pyriformis, obturator internus, and gemelli (fig. 492), on the posterior surface the gluteus medius and quadratus femoris (fig. 493)] are liberated from it with the

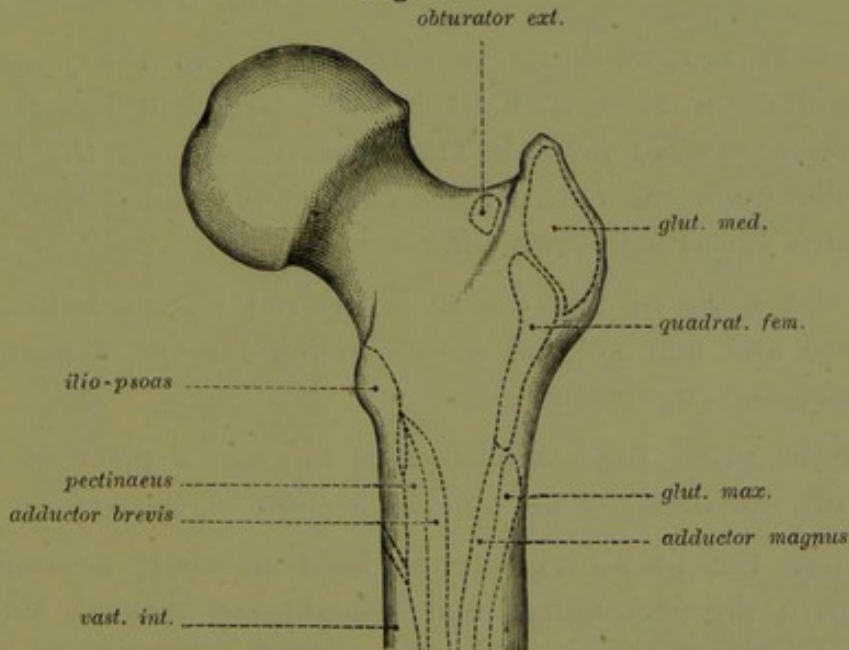
Fig. 492.



Upper end of the right femur with the muscular attachments (from before).

knife; in doing which an endeavour is made carefully to preserve their connection with the fascia lata and the periosteum.

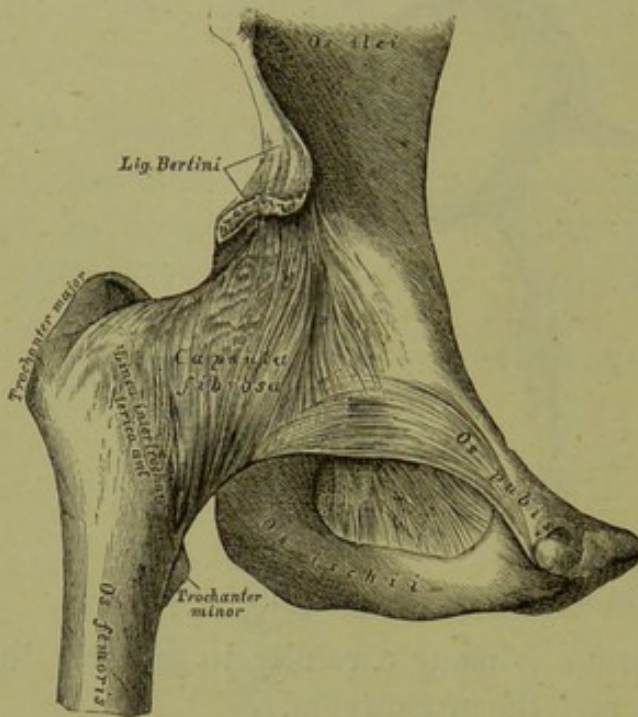
Fig. 493.



Upper end of the right femur with the muscular attachments (from behind).

4. With a strong knife a longitudinal incision is carried with some force upon the neck of the femur, and frequently repeated, till the tough fibres of the capsular ligament and the periosteum are completely divided.

Fig. 494.



Ligaments on the anterior aspect of the hip joint.

5. From this incision, by alternately using the elevator and knife, the periosteum together with the capsular ligament and the insertion of the obturator externus is separated all round from the neck of the femur (fig. 494).

6. The cartilaginous rim is then divided, and a piece removed with the knife on both sides of the incision.

7. The limb being now adducted and rotated inwards, the head of the femur starts from the acetabulum with a cracking sound.

8. A long narrow knife is introduced into the joint from the posterior and outer side, and divides the stretched ligamentum teres by an incision carried inwards and forwards against the head of the femur. Whereupon the entire head can be protruded from the wound and, as above described, sawn off.

9. If the neck of the femur is injured by the bullet, the head must be fixed and manipulated with excision forceps, a sharp hook, or a bullet-extractor (fig. 508).

10. If the great trochanter is also injured, a piece of it must be removed with the neck by an oblique section of the saw.

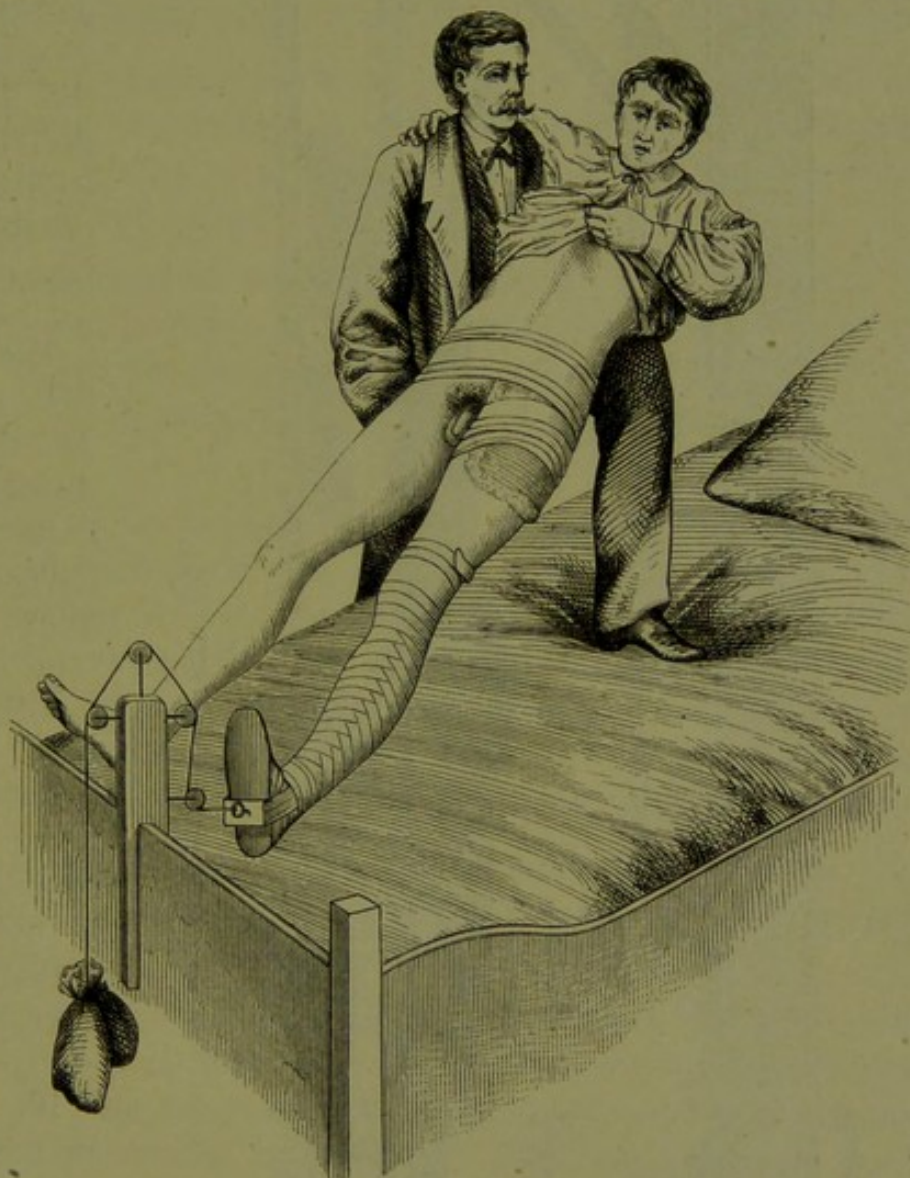11. After the haemorrhage has been arrested, a stout drainage tube is laid in the acetabulum and brought out through the centre of the wound. The rest of the wound is closed with sutures.

12. An extension is then immediately applied (page 101), and the counter-extension effected by raising the end of the bed.

13. In the after-treatment, it is most difficult to change the dressing without putting the extension out of order.

14. This can either be accomplished by a powerful attendant placing his foot upon the bed and allowing the patient's body to rest upon his knee, till the dressing is changed (fig. 495).

Fig. 495.



Raising the patient for change of dressing.

15. Or four broad strips of sailcloth, provided on one side with loops, and on the other with straps and buckles, are placed two beneath the body and two beneath the legs of the patient: one pole of the stretcher is put through the loops, and on the other side the

Stretcher for raising the patient.

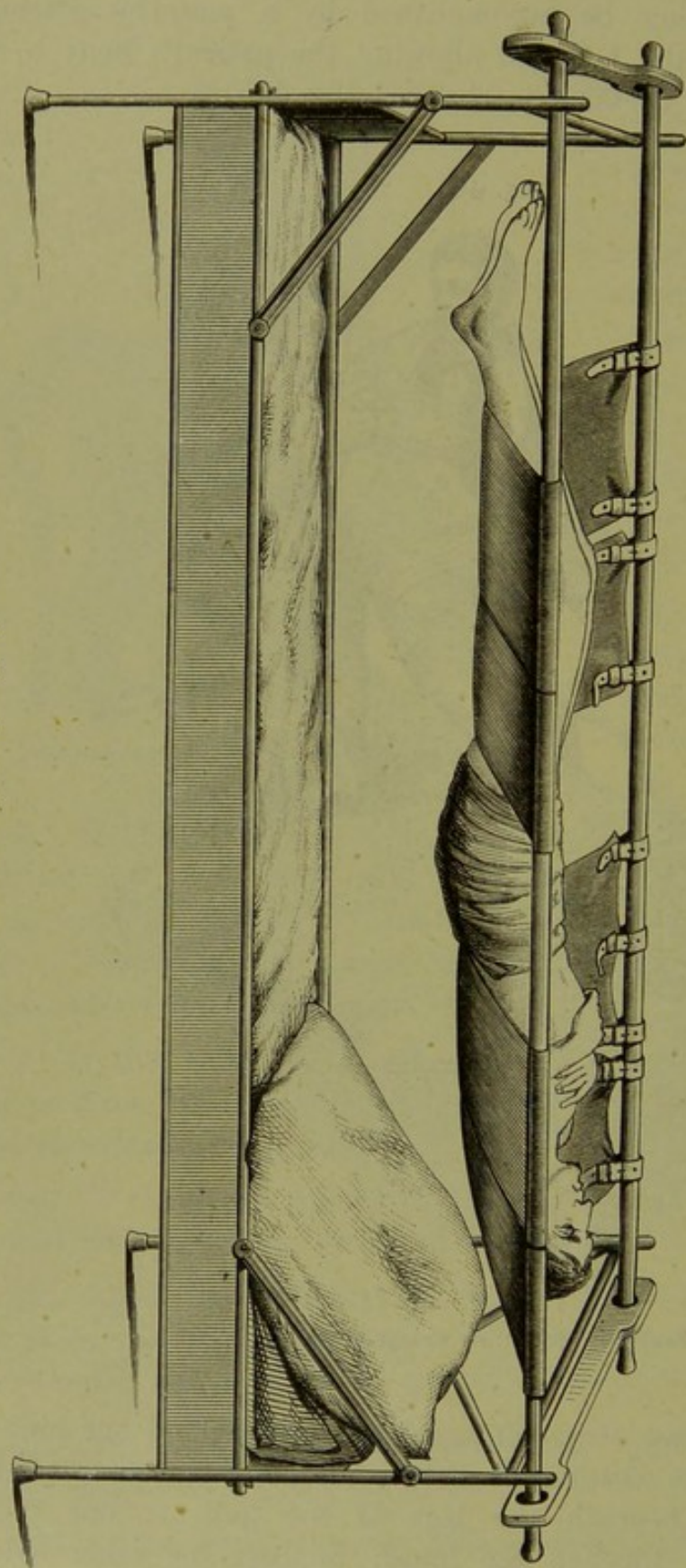


FIG. 496.

cloth is strapped to a second pole: these poles can then be temporarily raised at each end of the bed, and the cloths kept stretched out by two cross-bars.

The hip is left exposed, so that the dressing can be easily changed (fig. 496).

The extension remains in action (to make it less complicated it is not represented in the figure).

16. As soon as the wound has healed, the patient may be allowed to get up and go about with TAYLOR'S apparatus.

G. THE INDICATIONS FOR AMPUTATION AND EXCISION.

The consideration of the indications does not belong strictly speaking to a handbook on surgical appliances and operations.

If then I attempt to describe here in brief outlines the indications for the most important operative procedures on the extremities, I yield to the wishes of the judges and to that of my never-to-be-forgotten father and friend STROMEYER.

I cannot however omit to point out the great difficulty, which this task just now presents. The antiseptic treatment of wounds is beginning to be the common property of all surgeons, while sufficient experience in its employment during a large war does not as yet lie before us.

There can be no question, that antiseptic surgery must have the greatest influence upon the actions of surgeons in their treatment of wounds in time of war, and that the indications for operative treatment are thereby partly restricted, partly extended. But it must never be forgotten, that it has frequently happened in war, that either the antiseptic material is not at hand, or the operating surgeon has not acquired sufficient knowledge or experience in its application.

The removal of a limb is as a rule only indicated, when by so doing the prospect of saving the life of the wounded is rendered essentially better than by the conservative treatment.

When a limb has been torn off by heavy artillery or hopelessly shattered, when a smaller projectile has crushed the bones, and in addition to that has torn the large vessels and nerve-trunks, when gangrene has already set in, which threatens to spread far from the seat of injury, or when an acute purulent infiltration of the cellular tissue begins to extend without interruption towards the trunk, then only a *speedy removal* of the limb above the limit of the dangerous process can save the life of the patient.

And if this indication is clear, then the operation should be undertaken *primarily*, i. e., as soon as possible, and before the onset of inflammatory reaction.

If for some reason this is impossible, then the practice has always been rather to wait, till the violent reaction has passed, because experience has taught, that amputations undertaken at this period (*intermediate*) yield the worst results. By waiting, the statistics of amputations are certainly relatively better; but in reality more wounded men sink by this treatment than would do, if in spite of this violent reaction the amputation were undertaken, i. e., on a healthy subject and with a strict observance of all the rules of antiseptic surgery.

Amputation is not indicated in *gun-shot fractures of the shaft* by small fire arms, if the splintering of the bone has not extended to the joint.

It is the surgeon's duty, to immediately apply an *antiseptic dressing*, and to *immobilise* the injured limb in such a manner, that the shattered bones remain fixed, even during the transport from the battle field to the hospital.

But if a longer and more troublesome transport from the place of injury is unavoidable, and there is no possibility of so fixing the limb, that its condition will not be essentially made worse by the transport, then is there an indication for *immediate amputation*.

This applies especially to gun-shot fractures of the thigh, which are most difficult to fix for transport: but less so to gun-shot fractures of the leg.

In gun-shot fractures of the upper extremity this question is scarcely considered, because they can be much more easily prepared for transport than the lower extremity.

Gun-shot fractures into joints are only an indication for immediate removal of the limb, when the large vessels have also been torn by the shot, because in the latter case gangrene so soon makes its appearance.

The necessity also of exposing a limb, defectively fixed, to a long transport may also be an indication for immediate amputation, as for example after severe shattering, especially of the knee and hip.

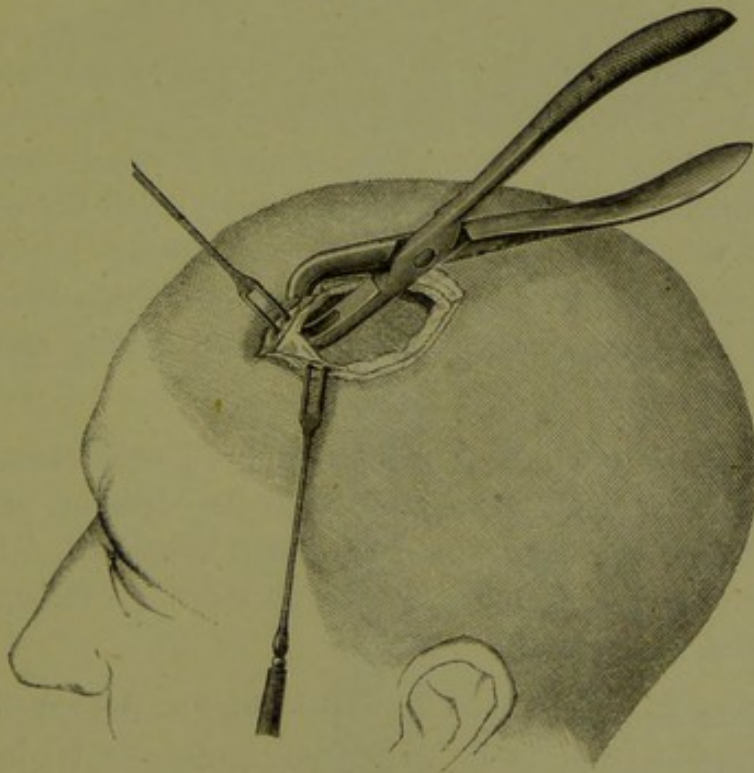
In all other cases the preservation of the limb should be attempted; in slight injuries of joints by a simple *conservative treatment*

(antiseptic dressings, immobilisation, extension, ice), in severe cases by *primary excision*. If in spite of the conservative treatment, a dangerous septic suppuration of the injured joint is developed, then *secondary excision* is indicated, if the suppuration has not already extended so far, that only amputation above the joint concerned can save the life of the patient.

H. EXCISION OF PORTIONS OF THE CALVARIA.

1. Excision of portions of the cranial bones may be necessary to *extract splinters of bone or foreign bodies* (projectiles, the points of broken swords or knives etc.), which have penetrated into the dura mater and brain, to thoroughly cleanse and *render aseptic recent compound fractures* of the skull, and finally to provide an escape for *pus* in the cranial cavity collected either upon or beneath the dura mater.

Fig. 497.



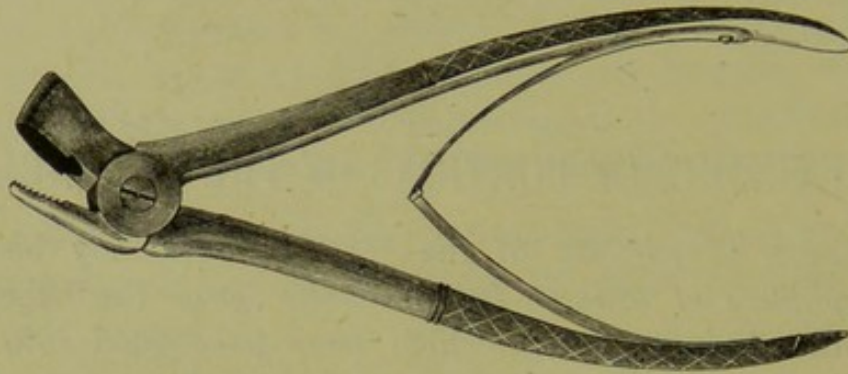
Biting off the edge of bone in a fracture of the skull with LÜER'S gouge-forceps.

2. If there is a *fractured opening* in the skull, and the depressed fragment, as commonly happens, is larger than the outer opening, the latter must be enlarged, for the piece of bone to be raised and extracted.

3. For this purpose LÜER'S (fig. 497) or HOFFMANN'S gouge-forceps

(fig. 498) are most conveniently used, if the outer opening is big enough to push one blade of the forceps beneath the bone. Although only a

Fig. 498.



HOFFMANN'S gouge-forceps.


small piece is ever removed at a time with these instruments from the edge of the fracture, yet the opening can be quickly enlarged in every direction.

4. If there is not a large opening in the skull, but only a *narrow fissure*, which has to be widened, the *gouge* is used; the best instruments for this purpose are the common carpenter's *chisel*, and a wooden *mallet*, with which small sharp blows are dealt upon the chisel obliquely placed upon the bone (fig. 499). If the opening has been carefully widened, in this manner, so that the gouge-forceps can be employed, the opening is enlarged with this instrument in the manner previously described.

5. As soon as the object, which is compressing or penetrates the *dura mater*, is sufficiently exposed, it is raised with the elevator, seized with dressing- or vulsellum-forceps, and carefully extracted. If it clings firmly to the *dura mater*, it must not be torn out by force, but loosened by notching the membrane.


6. If a metal point, firmly wedged into the skull and broken off on a level with the surface, has to be extracted, it can be made accessible on both sides by small cuts with a gouge (fig. 499), and then seized by a strong pair of forceps, or better by a small vice, such as watch-makers use.

Fig. 499.



Gouging out the point of a sword.

Fig. 500.

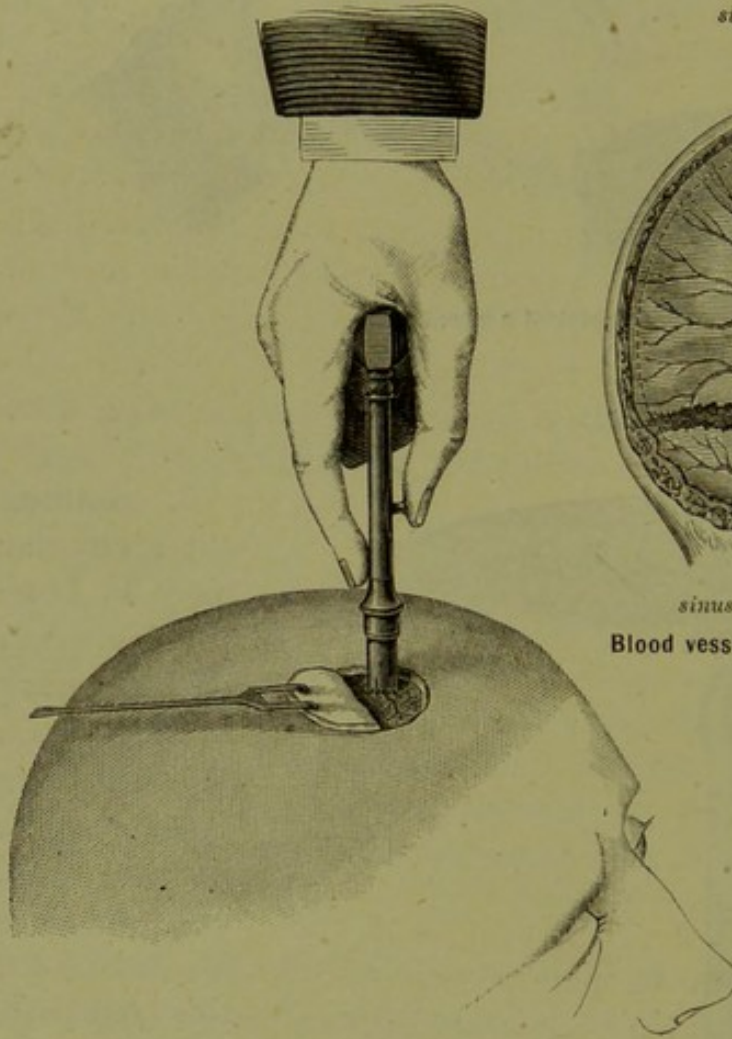


Trephine.

7. Sawing out a circular piece of bone (*trephining*) is only necessary in those cases, in which there is no opening in the skull. The *trephine* is used for this purpose, and the smallest (fig. 500) is usually sufficient: with it a piece of bone the size of a silver groschen can be removed.

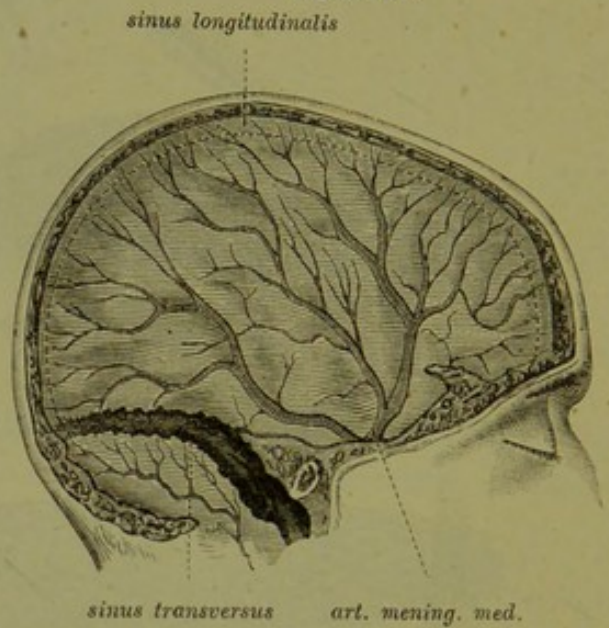
8. If there is already a wound in the scalp, where the trephine is to be applied, it is only enlarged by an incision penetrating to the bone. If there is no wound, it is best to make a semicircular incision down to the bone, and to peel back the periosteum with the flap of the scalp, far enough to apply the trephine (fig. 501).

Fig. 501.



Trephining.

Fig. 502.



Blood vessels on the inner surface of the skull.

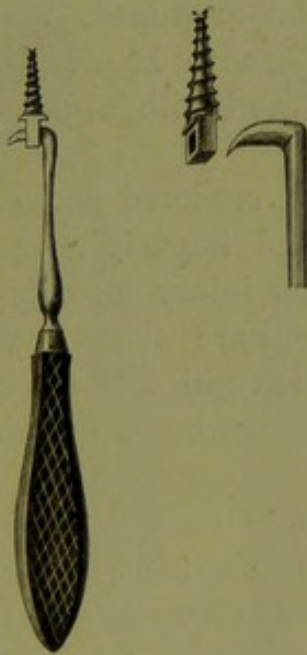
If possible the region of the longitudinal and transverse sinuses is avoided, as well as that of the middle meningeal artery, on account of haemorrhage (fig. 502).

9. To have a perfect control over the direction of the saw, the central pin of the trephine (the pyramid) is first protruded, and made to penetrate the bone: this can be more easily done, if a hole has been previously bored by a tirefond-screw, or a common drill.

As soon as the teeth of the saw have penetrated to the depth of a few millimetres, the pin is withdrawn into the crown of the trephine.

10. The sawing must be interrupted from time to time, partly to examine the depth of the groove made by the saw with the flat end of a probe, or with a quill obliquely sharpened to a point, and partly to free the teeth of the saw from bone dust by brushing and washing with carbolised water.

Fig. 503.



Bone screw with ROSER'S hook.

11. If the bone is completely cut through at one spot, the teeth of the trephine must not here penetrate any deeper, but (by inclining the crown) be made to press only at the place, where the internal table has not yet been divided. A small bone screw is previously introduced into the central bore hole (HEINE'S tirefond) (fig. 503).

12. As soon as the disk of bone is freed all round, it is carefully lifted out by putting a hook, bent to a right angle, into the upper opening of the bone screw. With the same hook the operator also tries whether the depressed fragment can be moved (ROSER), and endeavours to raise it with the same instrument, a stronger lever, or

a pair of forceps, or even entirely to remove it.

13. If during the operation *haemorrhage* should occur from abnormally large veins in the diploe, it is arrested by the pressure of a ball of carbolised wax, softened in hot water, or by the introduction of a piece of catgut (RIEDINGER). Haemorrhage from the middle meningeal artery can also be arrested by the pressure of a ball of wax, if the divided artery cannot possibly be seized and ligatured. Haemorrhage from a wounded sinus usually ceases after the application of a light compress.

14. Before commencing the operation, the scalp must be shaved for some distance round (it is best to shave the whole), and most carefully cleansed with soap and brush, and disinfected with a solution of carbolic acid.

At its conclusion, the wound, the injured dura mater, and the brain itself are washed with strong (5 per cent) carbolic solution, or 8 per cent solution of chloride of zinc, and in the after-treatment all the precautions of LISTER'S antiseptic method are most rigorously employed.

J. EXAMINATION AND CLEANSING OF GUN-SHOT WOUNDS FROM FOREIGN BODIES AND SEPTIC MATTERS.

1. *Recent gun-shot wounds* should only be examined, when the question of immediate operative interference has to be decided. It ought then to be carried out very thoroughly, and with a due observance of all the antiseptic precautions.

2. Such an examination is most frequently rendered necessary in those wounds, in which *projectiles* have remained impacted, or which are complicated with comminution of bones and injury to a joint.

3. But if after such an injury some days have already elapsed, and still no symptoms have appeared of any interruption to the healing process in the interior of the wound (aseptic course), the examination may be omitted, for it might create more harm than good.

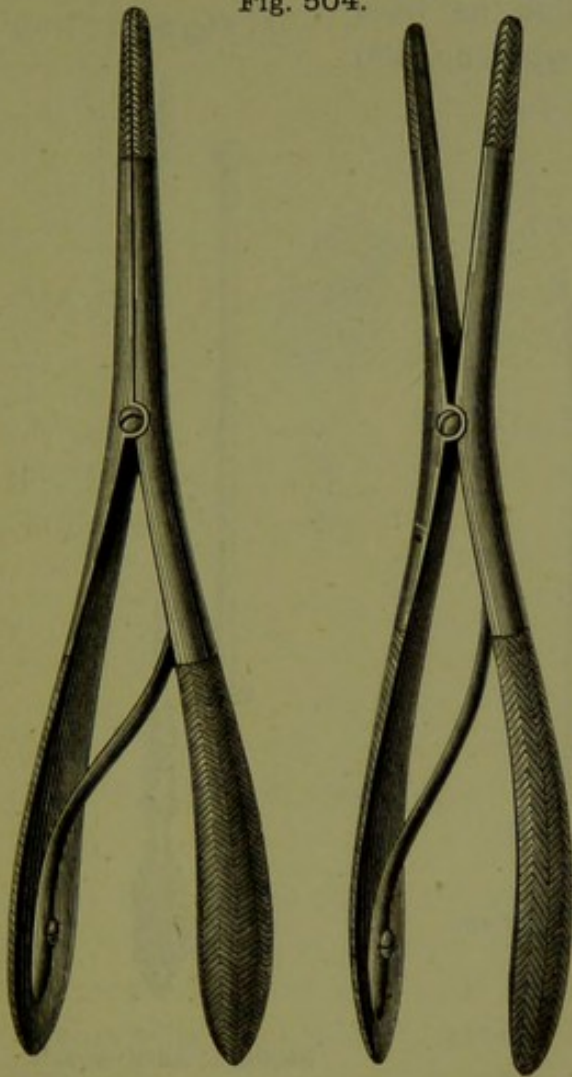
4. Instead of the daily repeated irritation, to which they are usually subjected, by probing, cutting, irrigating, squeezing, removing splinters etc., they are left alone. But as soon as there is any indication, that an active interference has become necessary (such as, high fever, progressive infiltration, unhealthy suppuration, retention of pus, haemorrhage, gangrene etc.), *a thorough examination and cleansing* (revision) of the wound is immediately undertaken, all loose splinters of bone and foreign bodies, which can be found, removed, sufficient outlet provided for the pus, the bleeding vessels ligatured, and an endeavour made, as far as possible, to render the wound aseptic.

5. For this purpose the patient is placed upon the operating table and chloroform administered: and with *the finger* most carefully cleansed and disinfected, the operator then makes his way into the opening of the wound.

6. If the openings in the skin and fascia are too small, they must be enlarged with the blunt pointed bistoury.

7. If the deeper part of the track is too narrow to admit the finger, it is enlarged with blunt instruments, e. g. with dressing forceps,

Fig. 504.



Closed.

Opened.

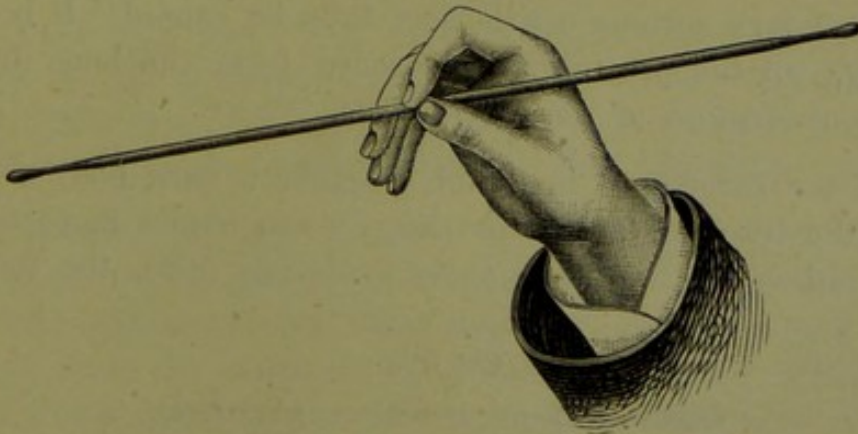
ROSER'S forceps (Sperrzange).

or still better with ROSEK'S forceps (fig. 504), which are introduced closed and then slowly opened. In this manner the inflamed and infiltrated tissue is easily and without haemorrhage forced open.

8. If the wound is so deep, that the finger is unable to reach the end, the common thin probes are not used, for nothing can be accurately felt with them, and their fine points very easily make false passages: but flexible *pewter probes* a foot long and of the thickness of a quill (fig. 505) are employed, with which no injury is done, if the examination is carefully conducted.

NB. It is dangerous to employ catheters, that have been used, for such an examination, as I have sometimes seen done, because some infectious matter may easily have been left behind in its interior from a former use of the instrument.


Fig. 505.



Large pewter probe.

9. If the surgeon feels the bullet, he tries to seize it with a pair of *bullet forceps* (fig. 506 and 507) and draw it carefully out,

Fig. 506.




LANGENBECK'S bullet extractor.

Fig. 507.



American bullet forceps.

Fig. 508.




BAUDENS' bullet extractor.

10. If the ball is impacted in a bone, it can be removed with the help of a *bullet extractor* (fig. 508, Kugelschraube). But if it is found to be firmly wedged in the bone, too much force must not be used, because very serious *ostitis* may thus be caused. It is better to wait quietly, till the projectile is loosened from the bone by the inflammatory absorption of the bony tissue.

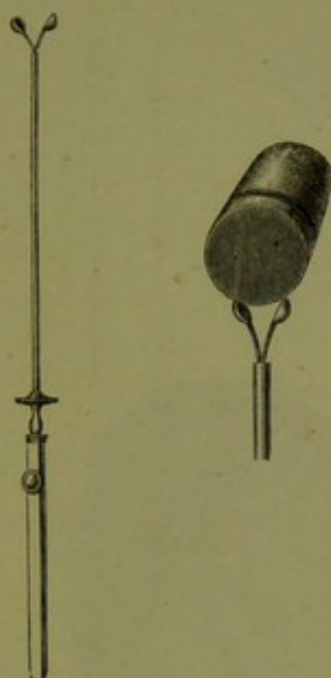
11. If the surgeon is in doubt, whether a hard body felt at the bottom of the track be a ball or not, he can obtain more certain information either by NÉLATON'S *bullet probe* (fig. 509), the small china

Fig. 509.



NÉLATON'S bullet probe with porcelain knob.

Fig. 510.



LECOMTE-LÜER'S bullet detector.

knob of which acquires a black speck by contact with lead, or by LECOMTE-LÜER'S *stylet pince*, with which a small piece of lead can be nipped off from the bullet, or lastly by LIEBREICH'S electrical galvanic bullet probe (fig. 511), which moves the needle of a galvanometer as soon as both points of the insulated probe (a), or of the forceps (c), come in contact with a metallic body.

12. If the bullet can not be felt from the wound, but is *beneath the skin* at a distant part, having been previously well steadied with the fingers, it is cut down upon with a sharp knife; the cellular tissue is pushed aside with a probe or dressing forceps, and the ball extracted with bullet forceps.

If here again there is any doubt as to whether it is a ball or a piece of bone, that is felt, accurate information can be obtained by the introduction of two steel needles provided with handles (acupuncture-needles, fig. 511, b), which are connected with LIEBREICH'S bullet detector.

13. If LIEBREICH'S apparatus is not at hand, a similar one can be improvised (after LONGMORE) out of a copper coin, and a piece of zink folded together, which are separated from one another by a piece of flannel dipped in dilute acid. One of the two insulated copper wires, which end in the acupuncture-needles, is wound several times round a pocket-compass. The needle of the compass moves as soon as the circuit is completed by contact with the ball (fig. 512).

14. Splinters of bone entirely detached, pieces of clothing, and other foreign bodies, which are found during the examination, must be carefully extracted. If there are any abscesses and sinuses, an attempt is made to penetrate into them, and their orifices enlarged with the finger or forceps: counter-openings are also made at convenient places by making the skin project from within with a thick




FIG. 511.

LIEBREICH'S bullet detector.

Fig. 512.

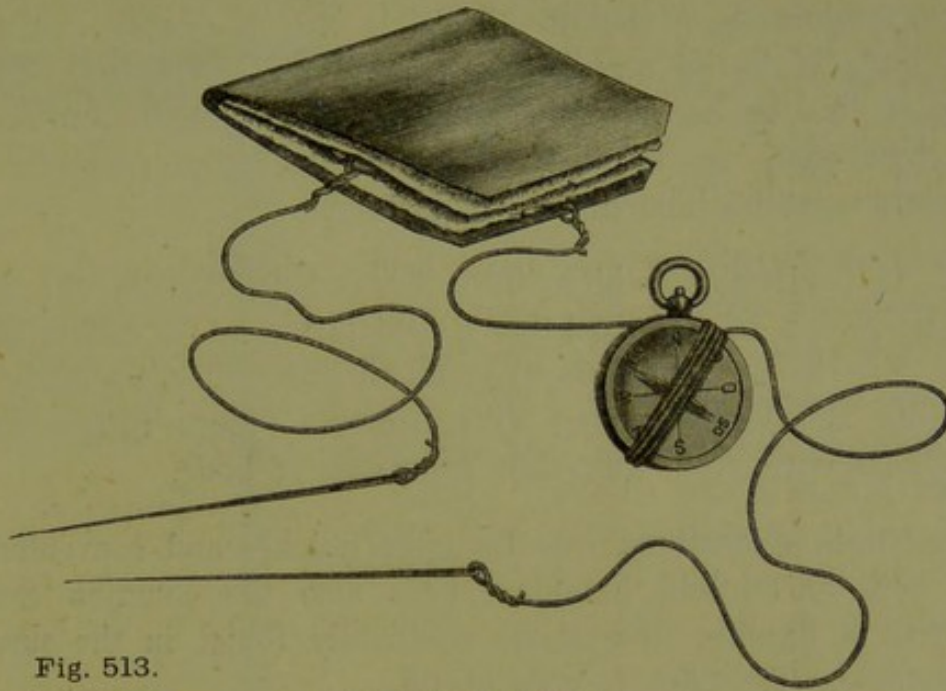


Fig. 513.

LONGMORE'S bullet detector.



Pewter probe with antiseptic balls.

probe, and then cutting down upon it. The whole cavity of the wound with all its sinuses is then thoroughly washed out with strong carbolic or chloride of zinc solution; an irrigator with india-rubber point is the best form of syringe for this purpose.

15. An antiseptic ball (fig. 513) can also in many cases be advantageously tied with strong thread on to the probe; this is dipped in chloride of zinc solution, and drawn backwards and forwards through the sinuses: so that the decomposing secretions of the wound are thoroughly brushed away.

16. Finally, stout drainage tubes are placed through all the sinuses, so that everywhere a free escape is secured for the secretions of the wound: the wound is then either treated on the open method, or according to the rules of antiseptic surgery.

17. If the case be one of gun-shot fracture or injury to a joint, in this examination a definite decision can be made, whether the injured limb is to be any longer treated on conservative principles, whether it has to be fixed in a suitable position by splints or hardening bandages, or whether a capital operation (amputation, excision etc.) must be immediately undertaken.

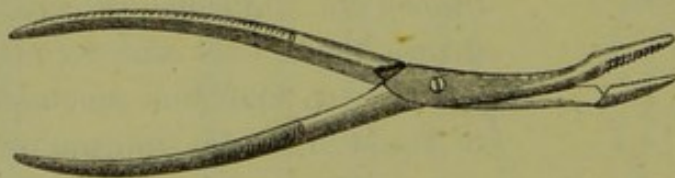
18. If projectiles, which have been imbedded in the bone for years, or pieces of necrosed bone, which lie in so called sequestral cavities, are to be removed, then an opening must be made (*Nekrotomie*) into the bony cavity. This necrosis occurs rather frequently after osteomyelitis from gun-shot contusion of bone.

19. These operations can be most quickly and conveniently performed with chisel and hammer; here also the common carpenter's chisel with a handle, like those commonly found in the surgical instrument cases (fig. 499), is very useful.

At all events, in default of the latter, the necessary instrument can be obtained at the first best joiner's or turner's shop that is met with.

20. The bone in question being exposed by a free incision at a convenient spot, the thickened periosteum is pushed back on both sides with the raspatory, and the sequestral cavity opened by a few sharp blows of the chisel: it is sufficiently enlarged to freely expose the dead bone and to remove it with necrosis forceps (fig. 514).

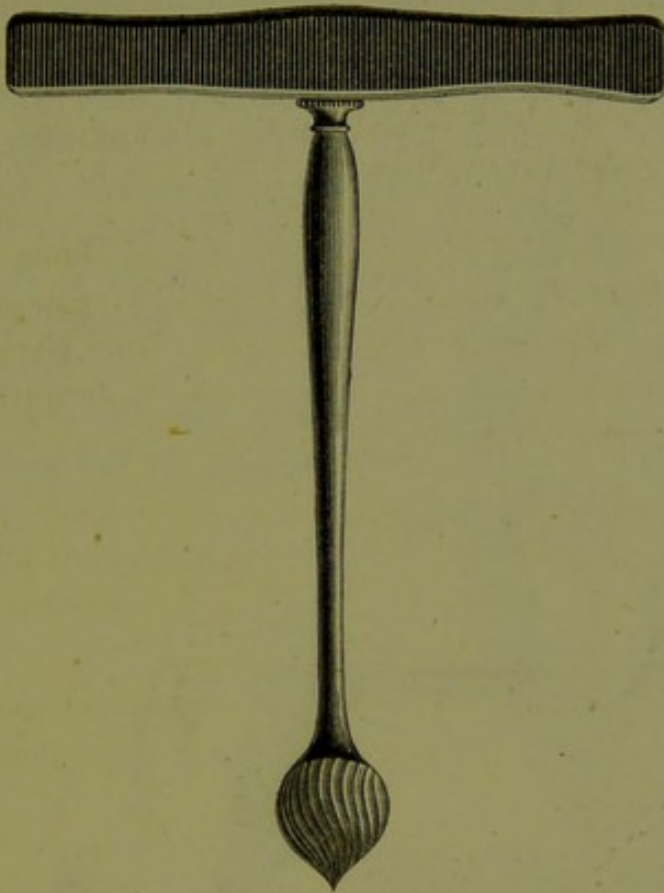
Fig. 514.



Necrosis forceps.

21. If there is only one projectile, lying in a sequestral cavity, to be removed, the cloaca, which leads through the bony wall to the foreign body, can be most quickly enlarged with a *MARSHALL'S osteotribe* (fig. 515).

Fig. 515.



MARSHALL'S osteotribe.

22. In necrosis operations it is not sufficient only to enlarge the cloaca, so that the sequestrum can with difficulty be extracted. There is then never any security against larger or smaller sequestra being left behind in the angles and sinuses of the sequestral cavity, which would render necessary a repetition of the operation.

23. It is much better, to chisel away the entire side of the thickened bone and change the cavity into one large open trough, so that no neighbouring cavities can anywhere be left undiscovered.

24. If before removing the elastic ligature a tampon of antiseptic tinder is applied to the bony trough, the largest operation of this kind can be completed without any loss of blood; the filling up of the cavity with granulations, and the ultimate cicatrisation usually proceed without any especial interruption.

K. THE HYPODERMIC INJECTION.

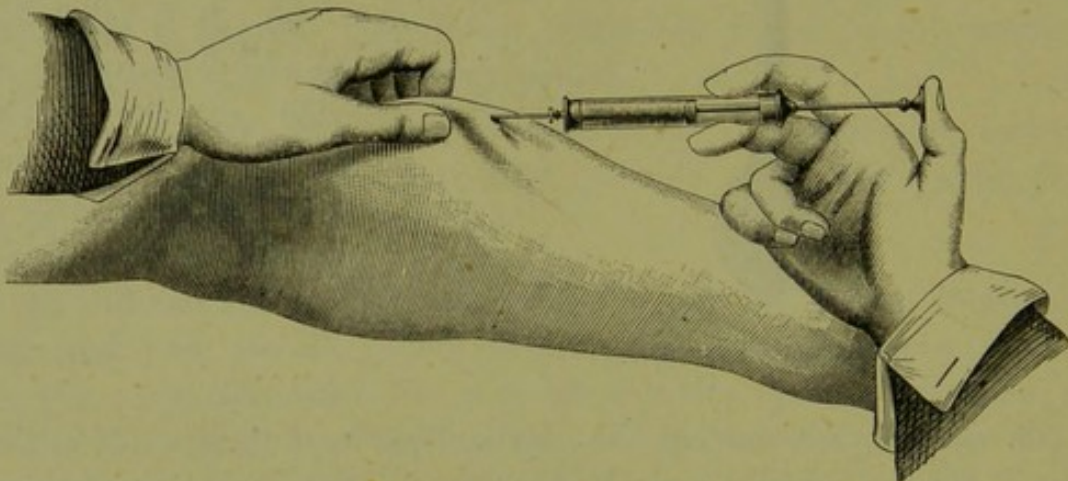
1. The injection of a solution of morphia into the subcutaneous tissue is one of the greatest blessings at the dressing station, as it is in the hospital: and often the only means of alleviating the sufferings of those who are hopelessly wounded.

2. An injection of morphia ($\frac{1}{6}$ — $\frac{1}{3}$ gr. in the adult), given about 10 minutes before the administration of chloroform, usually ensures a gentle and continuous narcosis.

3. Every surgeon should carry with him in war a PRAVAZ'S syringe with a solution of morphia, and be accurately informed, to what dose of morphia each division of his syringe is equivalent.

4. After the prescribed quantity of the solution has been drawn up into the syringe, and the air, which has perhaps entered with it been driven out by pushing on the piston with the point raised, a fold of skin is raised somewhere on the body (e. g. on the back of the forearm, on the outer side of the thigh): the pointed canula is then pushed quickly through the base of the fold into the subcutaneous tissue. The operator, having convinced himself by a few lateral movements, that the point has not penetrated merely into the corium or into a vein, empties the contents by slowly pushing on the piston (fig. 516).

Fig. 516.



Hypodermic injection.

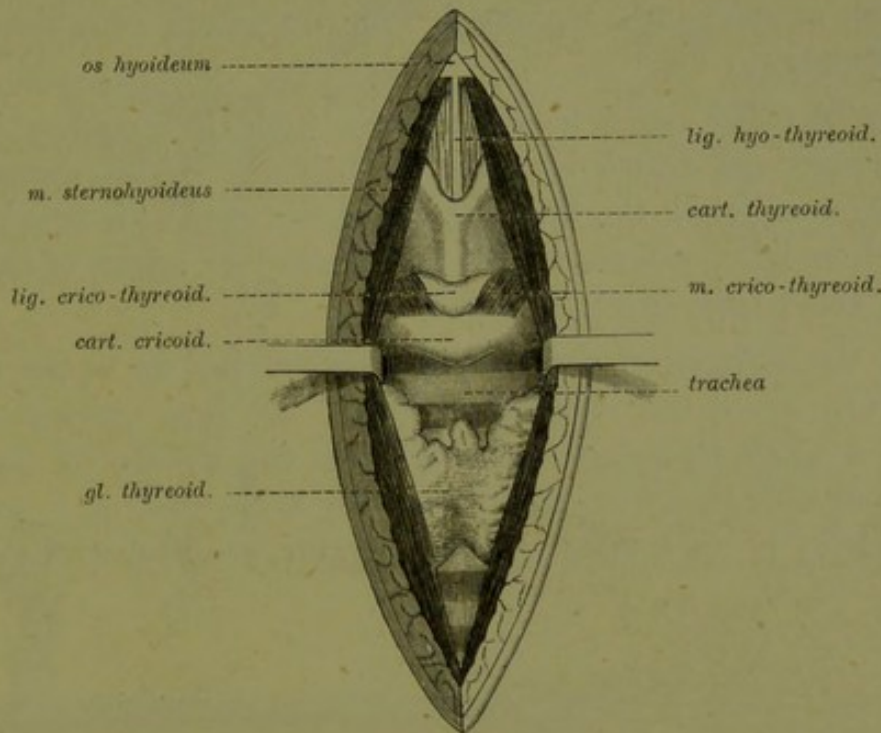
5. The canula is then withdrawn and the forefinger placed for a few minutes upon the puncture, so as to prevent the injected fluid from escaping. At the same time slight pressure and gentle friction, exercised by the middle and ring fingers, promote the distribution and absorption of the solution.

L. TRACHEOTOMY.

1. Opening the wind-pipe artificially is necessary, as soon as the respiration is dangerously impeded from oedema glottidis, which may arise after an injury to the larynx, the trachea, or its immediate vicinity; or in consequence of the entrance of a foreign body into the air passage etc.

2. It is most rapidly and easily performed by division of the crico-thyroid ligament (*laryngotomy*), which is quite sufficient, if it is only required to avert the danger of instantaneous asphyxia (fig. 517).

Fig. 517.



Larynx and trachea.

3. If the opening is not large enough, the cricoid cartilage can be divided (*crico-tracheotomie*).

4. The trachea itself is most conveniently opened above the thyroid body (*tracheotomia superior*).

5. The opening below the thyroid body (*tracheotomia inferior*) is more difficult and dangerous, because the trachea is here much more deeply placed, and large abnormal vessels are frequently found running in front of it (*arteria anonyma, carotis, thyreoidea magna; vena jugularis media, thyreoidea magna*).

6. Chloroform can be administered very safely for this operation, as long as the patient has not become too much asphyxiated. It essentially facilitates the operation, as the movements of the larynx are thereby rendered less violent.


7. With the head well thrown back, a cutaneous incision, 3—4^{cm} in length, is made accurately in the middle line: this can be previously marked out by a coloured line.

8. The cellular tissue in the intermuscular space is raised between two forceps and divided, as described for the ligature (page 140). The sterno-hyoid muscles are separated with retractors (strabismus-hook or eye-speculum).

9. Any bleeding vessel is immediately tied; if necessary, the surrounding tissues are included within the ligature. If the operation has to be rapidly completed, the bleeding vessel is seized with artery forceps, and allowed to hang sideways. By this means the edges of the wound are at the same time drawn asunder.

10. If the isthmus of the thyroid body reaches up to the first ring of the trachea or to the thyroid cartilage, the deep cervical fascia is divided by a small transverse incision upon the middle of the cricoid cartilage, and liberated from the trachea by a director or a strabismus hook (fig. 518): in this manner the operator penetrates without loss

Fig. 518.



Strabismus hook.

of blood *behind* the thyroid body and the plexus of veins (Bose's retro-fasciale Ablösung der Schilddrüse).

11. As soon as the trachea is exposed, it must be well fixed, so that the anterior wall may be accurately and safely divided in the middle line. This is most easily done by a sharp hook (e. g. LANGENBECK'S *double hook*) (fig. 519 and 520), the point of which is fixed into the lower border of the highest cartilage. Whilst the trachea is thus drawn upwards and steadied, the operator places the knife upon the groove of the hook, and pierces the trachea to a depth of 1^{cm}: he then divides the anterior wall as far as it has been exposed. Great care must be taken to avoid cutting into the reflected tissue or the thyroid gland, for a violent haemorrhage might ensue, and the blood enter into the opened trachea. The thyroid body is therefore drawn downwards with a strabismus hook.

Fig. 519.

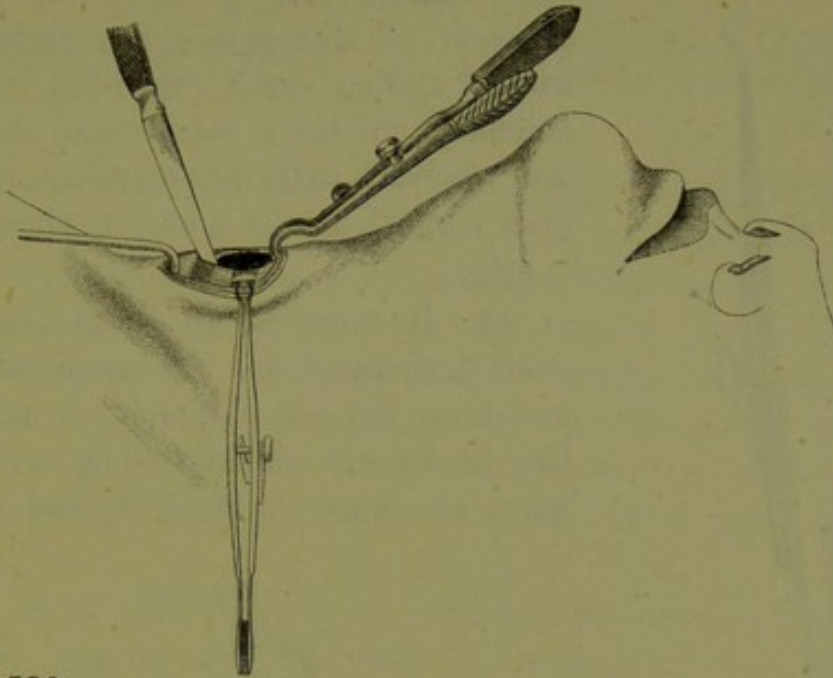
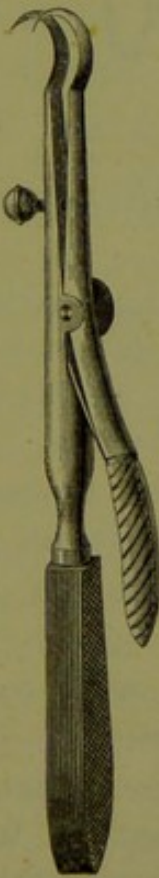

Fig. 520.

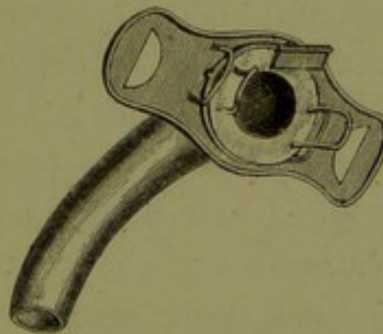
Tracheotomy.

12. The slit in the trachea being made to gape by opening the double hook, a LÜER'S *double canula* (fig. 521) is imme-



LANGENBECK'S double hook.

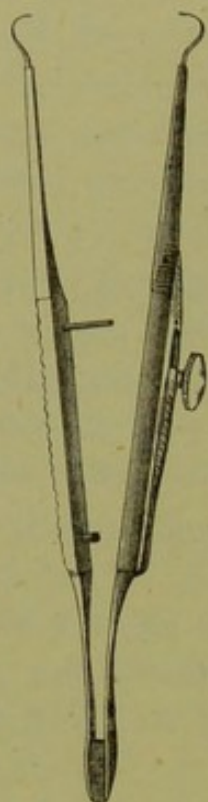
Fig. 521.



LÜER'S double canula.

diately introduced and fastened by an elastic tape round the neck.

Fig. 522.

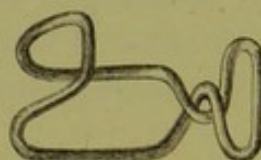


Clutch forceps with sliding catch.

13. Instead of the double hook, two small hooks can be used for fixing the trachea, or still better two clutch forceps with a sliding catch (fig. 522), which are fastened on both sides into the wall of the trachea, and the margins of the cleft drawn apart at the moment when the knife enters.

14. If there is no canula at hand, a stout drainage tube, the lower end of which has been cut off obliquely, is inserted; or two hooks are quickly made out of silver wire, as shewn in fig. 523, and introduced

Fig. 523.



Wire hook.

one on each side into the tracheal opening; these are kept apart by an elastic tape round the neck.

15. If there is nothing of the kind at hand, a ligature or silver wire is drawn through under one of the rings of the trachea with a curved needle; both ligatures are stretched by an elastic tape carried round the neck, so that the wound is kept gaping.

16. Such a makeshift must be replaced as soon as possible by a canula, if the trachea has to be kept open for any length of time.

17. If blood has entered the trachea, it can be sucked out with an elastic catheter.

18. An endeavour is made with forceps to extract bullets or other foreign bodies, which have entered the air passages.

19. The operation being concluded, the anterior surface of the neck is covered with a few layers of moistened gauze, and the inner canula from time to time taken out, and the mucus removed by a soft feather.

M. OPENING THE CAVITY OF THE CHEST. PARACENTESIS THORACIS.

1. When, after penetrating wounds of the chest, an accumulation of air and fluid in the pleural cavity can be diagnosed by physical examination (*pyo-pneumothorax* and *haemo-pneumothorax*), and from the accompanying symptoms (high fever, offensive discharge) an inference drawn, that *decomposition* (septic) of the contents has taken place; or if distressing symptoms of *asphyxia* are produced by the increased intra-thoracic pressure, then there should be no delay in providing a sufficient outlet for the accumulated pus by a *wide opening* from the chest.

2. In many cases the *wound* already existing may first of all be enlarged, by incising the skin from the wound on both sides in the direction of the intercostal space, far enough to allow the finger to enter the cavity of the chest. If there is any difficulty, the intercostal muscles are separated with forceps.

3. If loose splinters of bone, bullets, or other foreign bodies are met with, they are immediately carefully extracted. The wound can undoubtedly be made more accessible by the *subperiosteal excision* of a piece of the fractured rib.

4. When the outlet is sufficiently free, an endeavour is made first of all, by thoroughly washing out the cavity with an irrigator, which is filled with tepid disinfectant water, to clear out the accumulated secretion, and any foreign bodies, that may be present (pieces of cloth etc.).

5. Forcing air in by means of a syringe and rolling the patient on to his side, so that the opening is dependant (both recommended by ROSER), render very essential service.

6. One or more strong drainage tubes are passed into the cavity of the chest, and their ends fastened to the surrounding skin by silk thread or silver wire.

7. The drainage tubes must not be hermetically closed. They are covered either with a large quantity of charpie or jute, in which the secretions are discharged, or the patient is made to assume such a

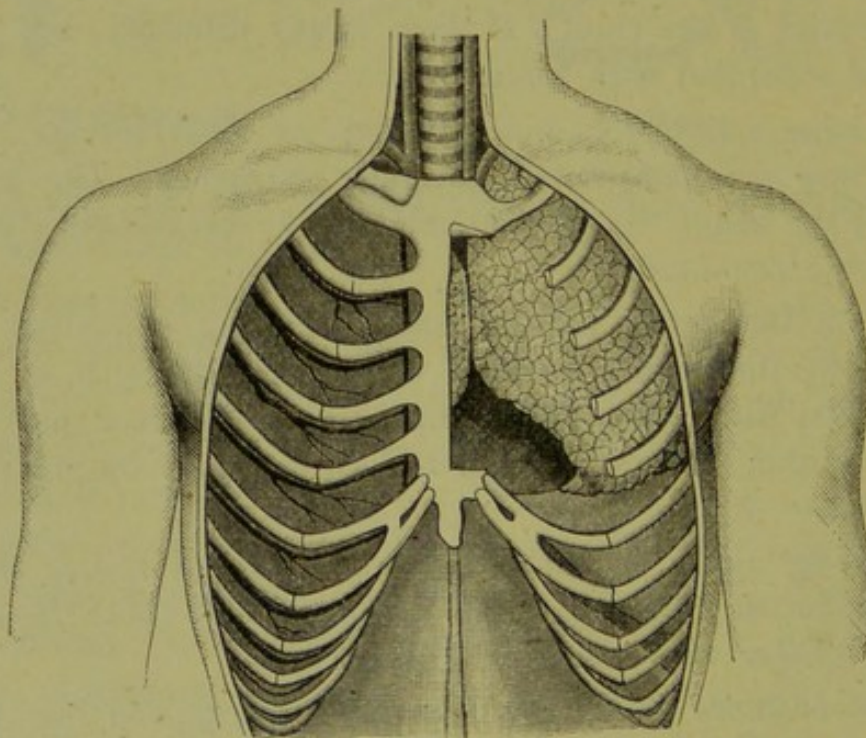
position, that the discharge may have a free escape into a basin placed beneath.

8. Once or more frequently in the day the contents of the cavity of the chest must be as thoroughly as possible emptied and cleansed, by washing it out with a disinfectant solution (carbolic, thymol, salicylic, chloride of zinc, acetate of alumina, spiritus etc.): also by blowing in air and turning the patient on his side.

9. If the outer opening has already healed, or is so placed that it does not allow a free escape for the discharges (e. g. the clavicular or supra-scapular regions), the pleural cavity must be opened at a more suitable place (*paracentesis thoracis*).

10. The fifth or sixth intercostal space midway between the axillary and mammary lines is the most suitable place for this ope-

Fig. 524.



Anterior view of the chest.

ration (fig. 524): it is determined by physical examination, that there is actually a collection of fluid at this spot, and that the lung is not

adherent to the costal pleura. In doubtful cases the diagnosis can be confirmed by aspiration with PRAVAZ'S syringe.

11. At this spot an incision, 3—4^{cm} in length, is made close along the *upper border of the lower rib*, as the intercostal artery and nerve run along the lower border of the upper rib (fig. 524). Here the incisions are carefully carried towards the pleura till the pus makes its appearance. The opening is then enlarged, so that a free outlet is secured.

12. If the intercostal space is too narrow, e. g. from the formation of callus, the periosteum is divided at the upper border of the nearest rib, and raised with a narrow elevator; a sufficiently large piece of the bone is then excised with cutting forceps or chain saw.

13. In the same manner a piece of the sternum can be excised, if it appears necessary for the free escape of the contents of the pleural cavity. But it must not be forgotten, that the *internal mammary artery* runs down behind the costal cartilages at a distance of about 1^{cm} from the margin of the sternum (fig. 524).

N. SUTURES FOR THE INTESTINE.

1. A wound in a piece of intestine, that has been protruded, must be closed by the suture, before an attempt is made to replace it.

2. As it is only the serous surfaces of the intestine that can grow together, they must be brought in contact with one another by the suture.

3. In *simple longitudinal or transverse wounds*, the edges of the wound are turned a little inwards all round, and the folded margins stitched together with a fine round suture-needle and a fine linen or silk thread, by carrying every stitch through the wall of the bowel for about 4^{mm} between the mucous membrane and the muscular layer (LEMBERT'S intestine suture) (fig. 525).

4. The *continuous or glover's suture* can also be used with good results (fig. 526).

Fig. 525.

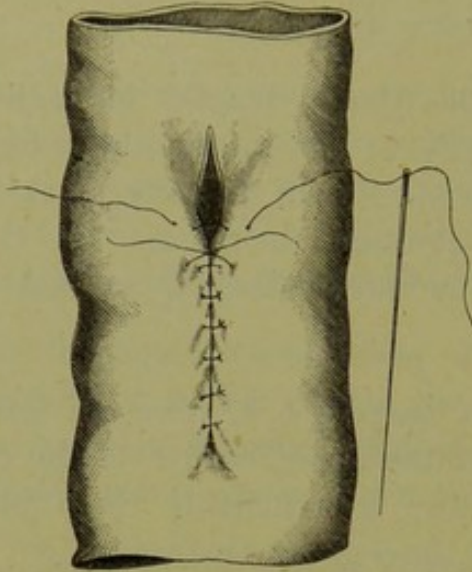
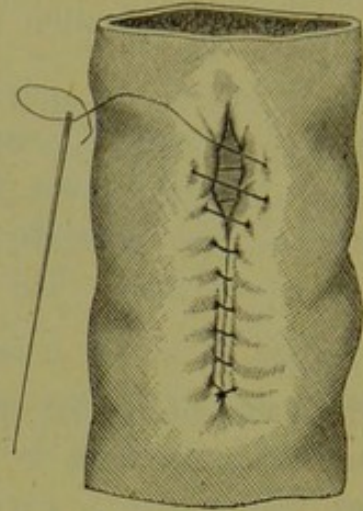
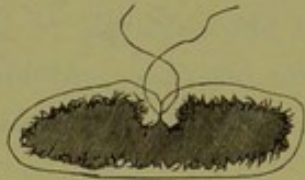


Fig. 526.



Continuous suture.



LEMBERT'S suture for the intestine.

5. When the intestine is *completely divided*, the lower end is turned in, while the upper is simply pushed within the former and united by fine sutures, so that only the serous surfaces are in contact. The

mesentery is previously torn from the intestine for a short distance on both sides (JOBERT) (fig. 527 and 528).

Fig. 527.

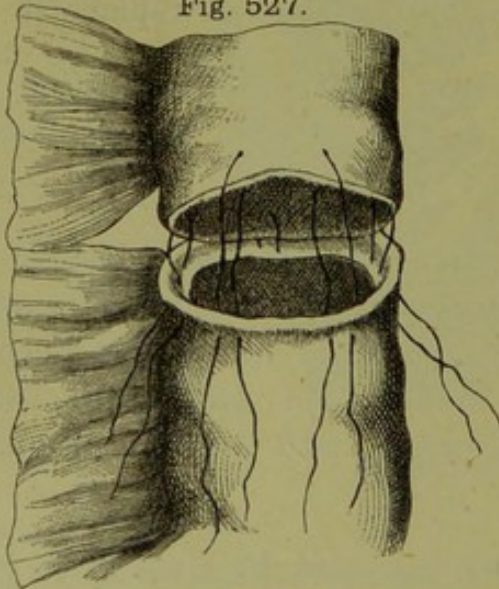
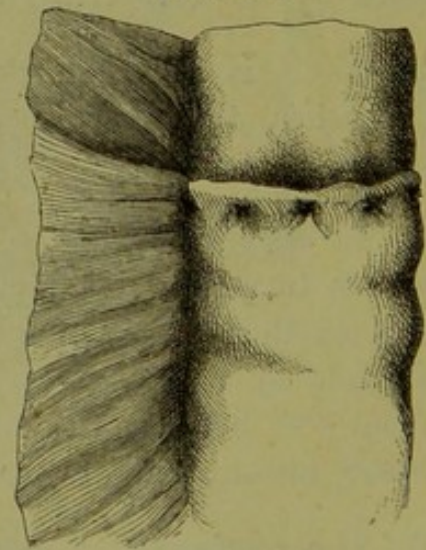


Fig. 528.



JOBERT'S suture for the intestine.

6. The suture being successfully completed, the piece of intestine is replaced within the abdominal cavity, after it has been carefully cleaned and disinfected. The abdominal wound is also closed with sutures.

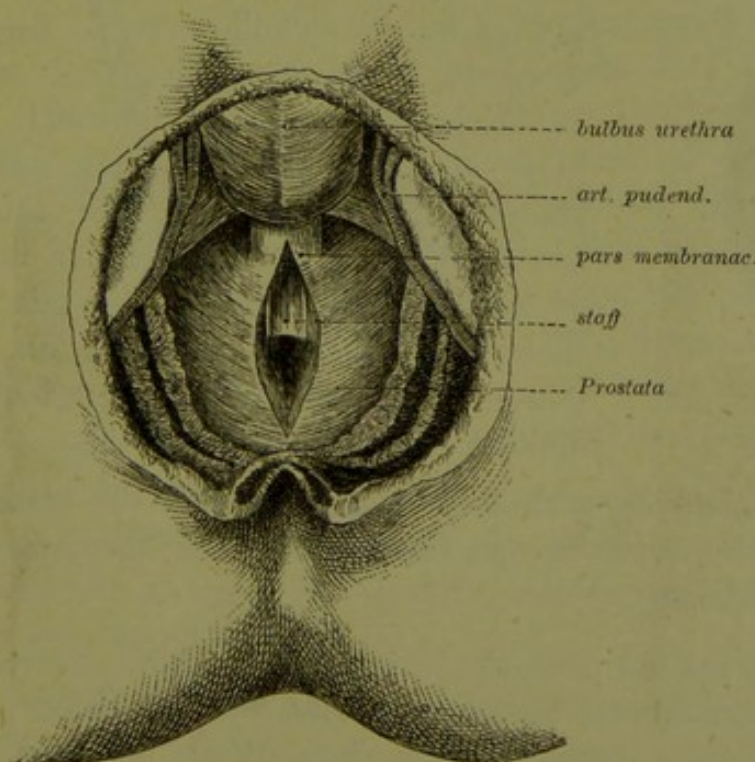
0. URETHROTOMY AND LITHOTOMY.

1. Opening the urethra from the perinaeum is urgently called for (BOUTONNIÈRE, *external urethrotomy*), when the urethra is injured (contused or ruptured), and dangerous urinary extravasation threatens or is already present.

2. A grooved staff or a catheter is passed into the bladder; or if that is impossible it is passed as far as the seat of injury, and held firmly there by an assistant exactly in the middle line.

3. The patient is placed upon his back at the edge of the operating table, with his legs widely separated (*lithotomy position*).

Fig. 529.



4. The scrotum is raised, and the left index finger introduced within the anus to act as a guide; an incision is then made, 3—4^{cm} in length, *accurately in the middle line (raphe)* between the anus and the scrotum.

By carefully repeating the incisions, the deeper structures are reached and the groove of the staff exposed (fig. 529).

5. If the latter has been successfully passed into the bladder, a director curved like \sim is now carried by its side into the bladder, and upon it an elastic catheter, after the sound has been removed. This is left some (two) days in the bladder, till the danger of extravasation is over.

6. But if the staff could not be previously introduced, from the urethra being completely torn across, then it is necessary to find the *vesical end*; this is generally a very difficult operation.

7. While the edges of the wound are held asunder with fine retractors, the operator tries, without employing any force, to penetrate with a probe in a direction towards the neck of the bladder. He succeeds most easily, by allowing the patient to pass water and then pushing the probe against the stream of urine.

8. If this is successful, the operator tries to seize the edges of the torn urethra with fine hooks: he then passes a ligature through the edges on both sides with a small curved needle; the edges can thus be drawn apart.

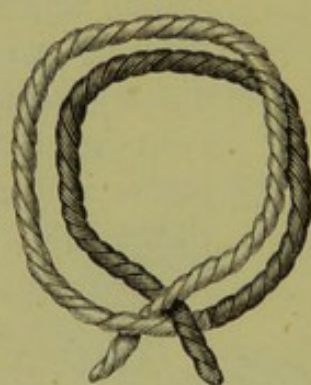


Fig. 530.

Clove-hitch.

9. Now a \sim curved director, and upon it an elastic catheter, can be easily pushed into the bladder. To tie the catheter in, a *clove-hitch* (fig. 530) is made of thick cotton thread, through the loops of which the projecting end is placed. If the ends of the thread are tightly drawn, the knot can never of itself become loose. The ends are then tied either to the hair on the pubes, or to a ring of strapping loosely applied behind the glans penis.

10. If a *foreign body* (e. g. a ball) has penetrated the bladder, it can generally be removed by an incision in the median line (ALLARTON'S *median lithotomy*).

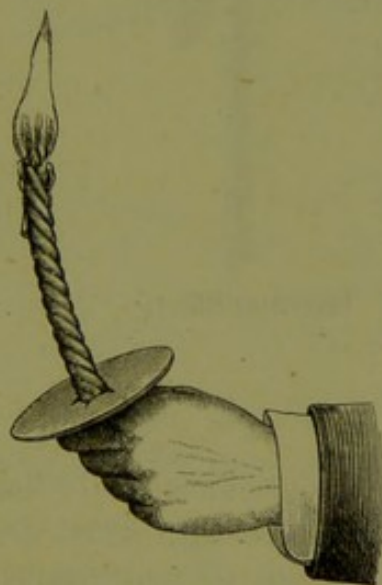
11. The urethra is incised from the perinaeum, as above described, and the prostatic portion dilated by slowly boring with the finger, till a narrow pair of lithotomy forceps can be introduced, and the ball extracted.

12. If the bullet has already remained a long time in the bladder, so that urinary concretions have formed around it, it becomes necessary to choose some other method of lithotomy, by which larger bodies can be removed from the bladder without too much tearing (*lateral lithotomy, supra-pubic lithotomy*).

P. OPERATIONS WITH ARTIFICIAL LIGHT.

1. In war the surgeon has frequently to operate at night; and on board ship during an engagement the necessary operations must according to the rules be performed with artificial light below deck.

Fig. 531.



Wax - torch.

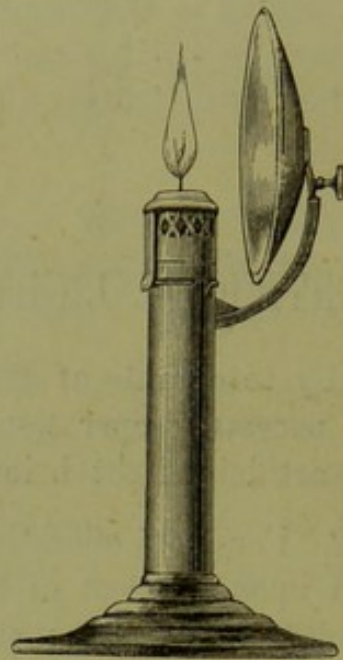
2. For most operations a strong light upon the seat of operation is absolutely necessary; and the surgeon must know what to do, if, as commonly happens, the place itself is only insufficiently lighted.

3. The *wax-torch* is a simple and very good means of obtaining light (fig. 531): it is made out of the common wax-taper, about the thickness of a quill, three or four of which are twisted together like a rope. To protect the hand against the hot wax as it trickles down, the torch is placed through a disk of paste board, which has a hole cut in its centre.

4. RAVOTH'S *operating-candle* (fig. 532) gives a superior light: it is a wax candle, which is placed in a socket provided with a spiral spring; it carries a moveable metallic mirror, which reflects the light upon the seat of operation.

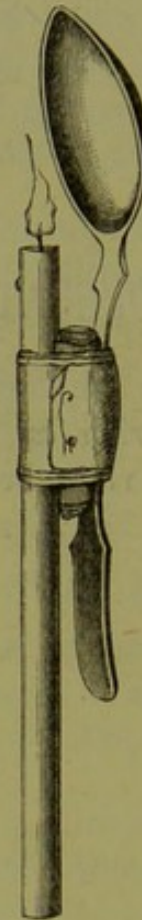
5. In default of this apparatus, a *reflector* can be improvised by fastening a silver spoon to the wax candle by means of a pad and bandage, as is shewn in fig. 533.

Fig. 532.



RAVOTH'S operating light.

Fig. 533.



Improvised reflector.

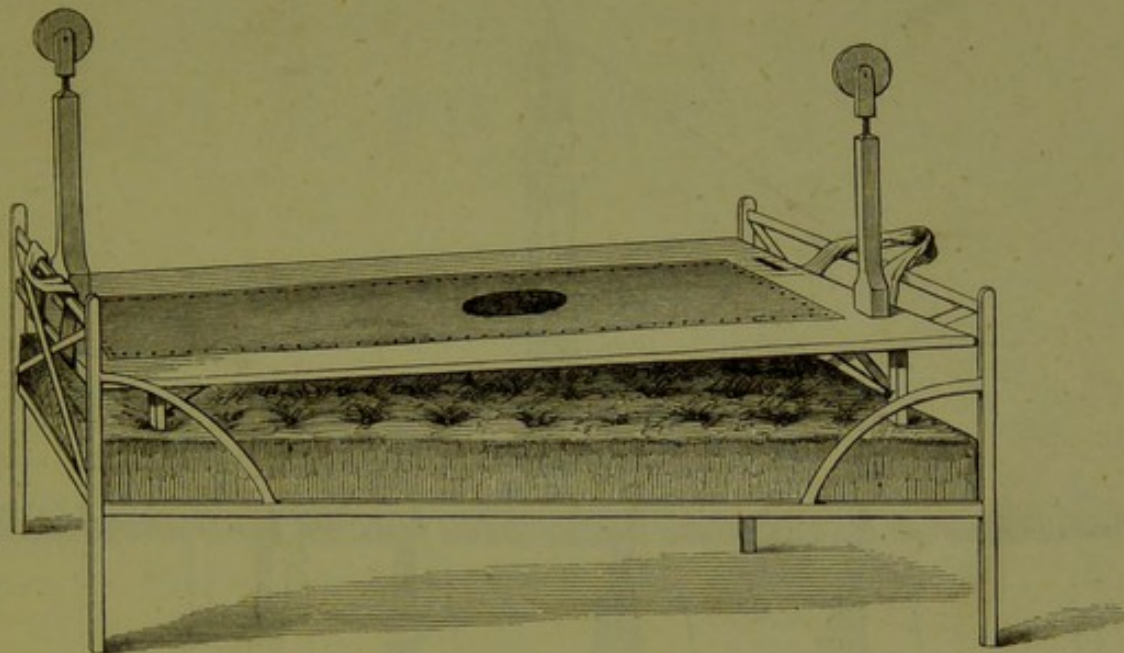
Q. BED-LIFTS.

1. In stationary well-organised hospitals, special means, often complicated and expensive, are kept for raising the patient. They are used, when the patient is severely wounded, for changing and renewing the dressing or the bed-linen, for cleaning the back, for washing, and protecting against a bed sore, and to facilitate defecation without causing the patient much pain, and without injuring the shattered limbs by movements.

2. In war they have often to be quickly improvised, and that with little means at hand.

3. Besides the stretcher for raising, which is represented on page 276 (fig. 496), VOLKMANN'S *bed-lift* is to be especially recommended for its simplicity and usefulness (fig. 534).

Fig. 534.



VOLKMANN'S bed-lift.

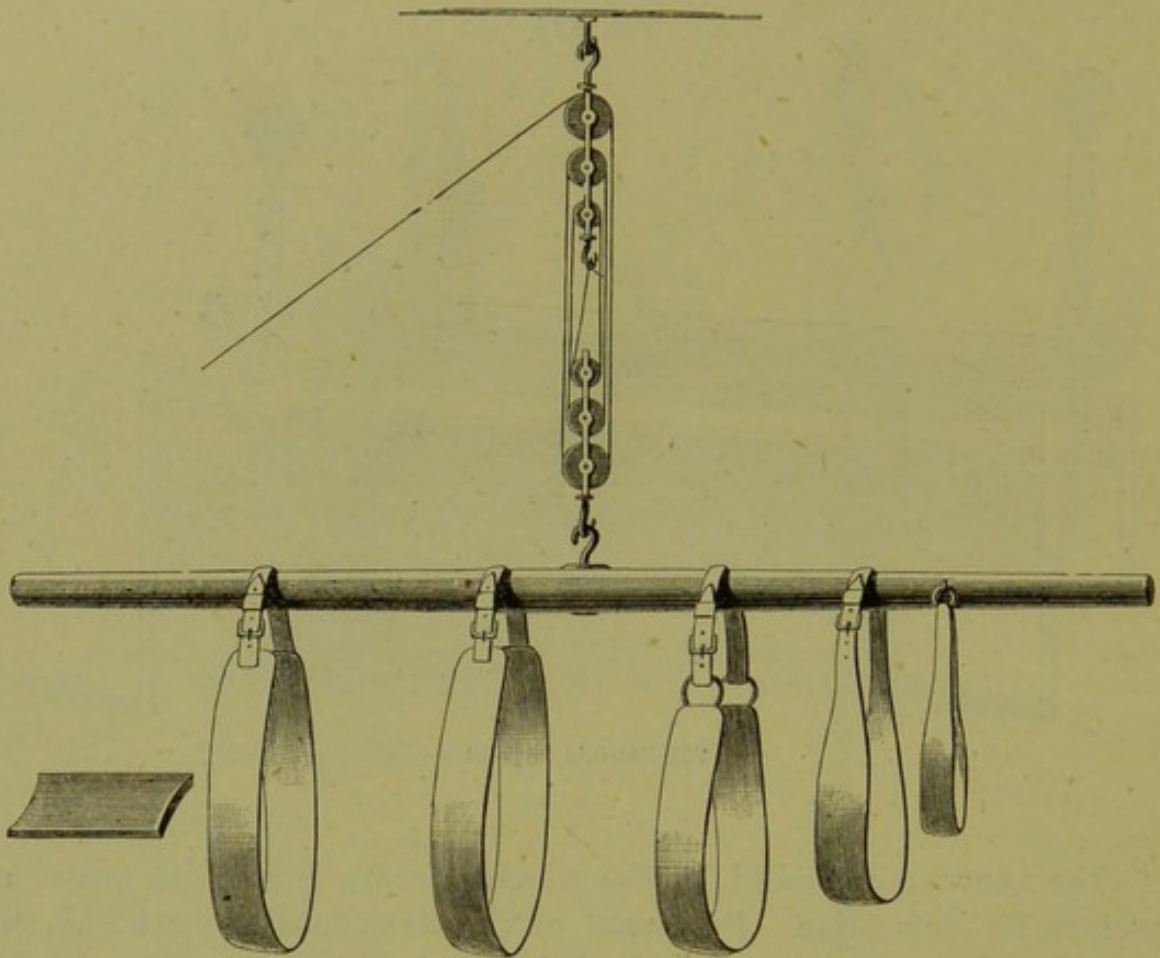
The canvass, stretched by the wooden frame, has in its centre an aperture for defecation. By means of the strap fixed to each end, the frame is raised with the patient, and kept in this position by wooden rests. The pulleys for the extension are fastened to this frame.

4. *SIEBOLD'S apparatus* for raising the patient has also much to recommend it on account of its simplicity (fig. 535).

The strong pole is easily raised by pulleys, which are fastened to the ceiling. Since the belts, in which the patient swings, cling to the body when raised, a board, like the one represented to the left in fig. 535, must be pushed in above the body at the places where this has to be avoided. The board keeps the belts apart.

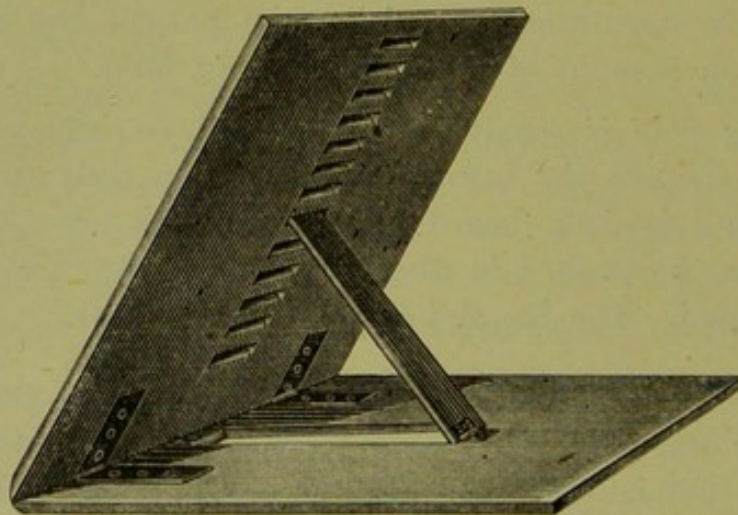
5. *The adaptable bed-rest* is a great comfort to those, who are seriously ill or wounded; it is placed beneath the pillow and permits the patient to assume different positions. They are easily and with little expense made in the form here represented (fig. 536).

Fig. 535.



SIEBOLD'S lifting apparatus.

Fig. 536.



Adaptable bed-rest.

INDEX.

A.	B.
Abdominal tourniquets 133. 134	Balls, antiseptic 13
Actual cautery 120	Bandages 18
Adduction splint, Stromeyer's 66	Bandage, capelline 50
Allarton's median lithotomy 302	— , circular 19
Amputating knives 174	— , double-headed . . . 16. 21. 49
Amputations and disarticulations . . . 172	— , elastic (Langenbeck) 128
Amputation of all the metatarsal bones 207	— , figure of eight 21
— of the arm 201	— , gaping 20
— — forearm 199	— , knotted 49
— — thigh 228	— , many-tailed 21
— — leg 224	— , spiral 19
Amputation, general rules for 172	— , starch 16. 39
Amussat's forceps 186	Bandaging 19
Aneurism, diffuse traumatic 137	— the arm 54
Aneurism-needle 142	— the whole leg 81
Ankle joint, outer side of 262	— the chest 109
— — , inner side of 264	— by reverses 20
Apolyse (Neudörfer) 241	Bardeleben's pelvic support 96
Arm, obtuse-angled splint for the	— moist carbolic dressing 15
(Stromeyer) 68	— wire swing 95
— , rectangular splint for the (Stro-	Basins 6
meyer) 66	Baths 7
— , trough splints for the 59	— for the arm 7
— , wire swing for the (Volkmann) 73	— for the leg 7
Artery, internal mammary 299	Baudens' bullet extractor 286
— , middle meningeal 282	Bayonet-splint 38
— , opening the sheath of 141	Bed-lifts 304
— , torsion of 186	— Volkmann's 305
Artificial light for operations 303	Bed-rest adaptable 306
— respiration, Silvester's 117	Belt for the chest 110
Asphyxia, paralytic 114	Biceps, tendon of the 257
— , spastic 114	Blood, defibrinating the 165
— , drawing out the tongue in	— , filtering defibrinated 166
threatening 116	Bloodless operation (Esmarch's appa-
Auto-transfusion (Müller) 172	ratus) 127

- Bloodless operation for high amputation of the thigh 133
 — — disarticulation at the shoulder 132
 — — amputation of penis and scrotum 131
 Bloxam's suspension 106
 Bone-drill 267
 — forceps, cutting 184
 — screw (Heine's tirefond) 283
 — — with Roser's hook 283
 Bonnet's wire splint 33
 Boot, used as a foot-rest 108
 Boracic Acid 15
 — ointment 15
 Box splint (Petit's) for the leg 88
 — — (Scheuer's) 89
 Brandis' compression of the aorta 136
 — improvised cautery 120
 Brünninghausen's amputation by skin flaps 178
 Bruns' amputation 223
 Buckles, Emmert's 28
 Bullet detector, Lecomte-Lüer's 287
 — — Liebreich's 287. 288
 — — Longmore's 289
 — extractor, Baudens' 286
 — — , Langenbeck's 286
 — forceps, american 286
 — probe, Nélaton's 286
 Butcher's excision saw 239
- C.**
- Capelline bandage, the 50
 Caps for the head 50. 51
 Carbolic-spray 12
 Carbolic dressing, moist 15
 Carpal bones, the 249
 Catgut, carbolised 13
 Cement bandage 40
 Chain saw 238
 Charpie 2
 Chest, anterior view of the 298
 — , opening the cavity of 297
 — , large handkerchief for 110
 Chin-sling 53
 Chloroform apparatus (Esmarch) 113
 Chloroform narcosis 112
 Chopart's amputation 211
 Circular bandage, the 19
 — incision, the single 174
 — — , the double 176
 Cloth splints, Schnyder's 26
 Clasp for bloodless operation 129
 Clasp, wooden pipe used as a 130
 Cleaning bath sponges 6
 Cleansing of wounds 4
 Clove-hitch 302
 Clutch forceps, Langenbeck's 238
 Clutch forceps with sliding catch 296
 Collin's transfusion apparatus 170
 Coat sleeve as a sling 58
 Collodion 16
 Cold applications 8
 Compresses 2
 Compress, graduated 67
 Compression of the artery above the wound 120
 Compression, direct 118
 — by pole, or crutch 126
 Compression belt (Nicaise) 130
 Compression by pad and bandage 119
 Conical stump 235
 Cooling-coil, the 8
 Covering of wounds 2
 Cotton wool 2
 — — styptic 120
 — — and paste board splint 39
 Counter-extension 102
 Cradles 3
 Creosote 120
 Crosby's strapping 100. 101
 Cushion, Stromeyer's 76. 77
 — , Middeldorpf's 78
 Cutaneous incision in ligature of vessels 139
- D.**
- Damar-varnish 47
 Dental splint 54
 Desault's bandage for fractured clavicle 78

- Desault-Liston's splint 100
- Digital compression 120
- — of the brachial artery . . 121
- — — carotid artery . . . 121
- — — femoral artery . . . 121
- — — subclavian 121
- Disarticulations, general rules for . . 188
- Disarticulation of the terminal phalanx of finger 189
- at the second phalangeal joint . 190
- of fingers at metacarpo-phalangeal joint by flaps 192
- — by oval incision 191
- of last four metacarpal bones . 195
- of thumb by oval incision . . . 193
- — by lateral flaps 194
- at wrist by circular incision . . 197
- — by flaps 197
- — by radial flap 198
- at elbow by circular incision . . 199
- — by flaps 200
- at shoulder by flaps 201
- — by circular incision . 204
- of the toes 205
- of the great toe with its metatarsal bone 207
- of the fifth toe with its metatarsal bone 208
- at tarso-metatarsal joints . . . 209
- through tarsus (Chopart) . . . 211
- of foot, Syme's 215
- — , Pirogoff's 219
- subastragaloid, Malgaigne's . . 214
- of leg at knee by flaps 227
- — — by circular 225
- at hip (Manec) by flaps 229
- — (Langenbeck) 235
- — by circular incision . . . 232
- Division of the soft parts in amputations 172
- Dobson's wooden trestle 94
- Dorsal splint for excision of ankle (Volkman) 85
- Dorso-radial incision (Langenbeck) . 247
- Double canula, Luer's 295
- Double hook, Langenbeck's 295
- Double headed bandage . . . 16. 21. 48
- splint for excision of the elbow, Esmarch's 69
- inclined plane 93
- Drainage tube, Chassaignac's 1
- Dressing, the first 23. 24
- amputation stump 187
- Lister's antiseptic method . . . 12
- of wounds (bandages and splints) 1
- for the face 52
- — — head 48
- — — neck 54
- — — upper extremity 54
- — — lower extremity 81
- — — trunk 109
- changing after amputation of the thigh 229
- — after excision of hip 275
- Drop bottle 112
- Dubrueil's disarticulation at the wrist 198
- E.**
- Elastic ligature for bloodless operation 127
- — for the penis and scrotum 131
- — extension by india-rubber rings 106
- Elevators 236
- Elevator, Sayre's 237
- Esmarch's abdominal tourniquet . . 134
- bloodless operation 127
- chloroform apparatus 113
- clasp 129
- double splint 69
- double inclined plane 93
- excision knife 237
- heel support 97
- ice douche 186
- interrupted swing splint 71
- — — for excision of wrist . . 64
- interrupted splint for excision of ankle 86
- jointed splint 108
- pelvic support 96
- plaster of Paris swing splint for excision of ankle 84
- plaster of Paris suspension . . . 63
- pressure by a pole 126

- Esmarch's stretcher extension 107
 — tongue forceps 116
 Examination of guns-hot wounds 284
 Excision of joints 236
 —, general rules for 236
 — of wrist, complete 247
 — — lower ends of radius and ulna 242
 — — elbow, Hüter's 255
 — — —, Langenbeck's subperiosteal 254
 — — —, Liston's 250
 — — shoulder, Langenbeck's 256
 — — —, Langenbeck's subperiosteal 259
 — — glenoid cavity 261
 — — a portion of a rib 297
 — — the cranial bones 279
 — — ankle, Langenbeck's subper. 262
 — — knee with anterior incision 266
 — — — Langenbeck's subper. 267
 — — hip, Langenbeck's subper. 272
 — — —, Anthony White's 270
 — knife, Esmarch's 237
 — saws 239
 Extension, treatment by 100
 Extension-cradle, Hodgen's 103. 104
 Extension by weight for fracture of femur 101
 Eye band 53
 Eye bandage 53
- F.**
- Face, wounds of 52
 Farabœuf's clutch forceps 238
 Femur with muscular attachments 273
 —, splint for fracture of, Desault-Liston's 100
 — — Haynes Walton 100
 Fergusson's lion forceps 238
 Figure of eight-bandage 21
 Filo-pressure 185
 Filtering defibrinated blood 166
 Fingers, contused wounds of 59
 —, fractures of 59
 Flexion (Adelmann). 127
 Fold-suture 18
- Foot, handkerchief for the 82
 Foot-rest, improvised 108
 Forceps, Amussat's 186
 —, Farabœuf's 238
 —, Fergusson's lion 238
 —, Roser's 285
 —, tongue 116
 — with sliding catch 296
 Foulis' fastening apparatus 129
 Fractured clavicle 78—81
- G.**
- Gauntlet 54
 Gauze antiseptic 14
 Gooch's flexible splints 103
 Gouge, the 280
 Gouge forceps, Hoffmann's 280
 — —, Lüer's 279
 Gouging out the point of a sword 281
 Granny, the 17. 25
 Gun-shot wounds, examination of 284
 — —, cleansing of 284
 Gun as a splint 38
 Günther's operation 220
 Guttapercha bandage 41
 Gymnastic exercises 242
- H.**
- Haemorrhage, arrest of 118
 —, permanent arrest of 136
 —, temporary arrest of 118
 —, in amputation 185
 —, parenchymatous 120
 Haemo-pneumothorax 297
 Halter bandage 49
 Hand-board 59
 Hand-splint, Stromeyer's 60
 Handkerchief bandage 22
 Handkerchief, large square, for the head 51
 Handkerchief, small triangular 50
 — for the chest 110
 — — — elbow 55
 — — — hand 55
 — — — shoulder 55
 — — — buttock 83. 111

Handkerchief for the hip	82
— — — knee	82
— — — foot	82
— — — groin	83
Hasse's transfusion syringe	171
Head-net, the	52
Healing under a scab	11
Heath's adaptable splint for excision of the elbow	74
Heel support, Esmarch's	97
Heine's Tirefond	283
Hemp and plaster of Paris splint	43
Hermetical sealing of wounds	11
Hodgen's extension cradle	103. 104
Hoffmann's gouge forceps	280
Hook and knob for india-rubber tubing — , Langenbeck's blunt	107 239
— , removable, for the jointed ex- tension splint	109
— , Langenbeck's sharp bone	240
— , Volkmann's — —	240
Hüter's arterial transfusion	171
— excision of elbow	255

I.

Ice	8
Ice-bag	8
Ice-douche	186
Immersion	10
Inaktivitätsparalyse	241
India-rubber rings for extension	106
— tube with knobs and hooks for elastic extension	107
Indications for amputation and ex- cision	277
Injection, hypodermic	291
Injuries of hands and fingers	58
— of wrist	63
— on volar aspect of hand	61
Interrupted splints	47. 73. 87. 90
Intestine suture	299
— — , continuous	300
— — , Jobert's	300
— — , Lembert's	300
Irrigation	9
Irrigator	4

J.

Jaw, gun-shot fractures of lower	54
— , pushing forward lower, in chloro- form narcosis	115
Jobert's intestine suture	300
Joints, excision of	236
Jute	15

K.

Key-hole saw, Langenbeck's	238
Knee, excision of	266
— , handkerchief for	82
— joint, tendons of (inner side)	268
— — , ligaments of	269
Knife between the bones, carrying the	184
Knives, blunt-pointed	259
Knot, surgeon's	17
— , false	17
— , tying the	143
Knotted bandage, the	49

L.

Langenbeck's bullet extractor	286
— disarticulation at hip	235
— double hook	295
— elastic bandage	128
— elevators	237
— excision of elbow	254
— — — shoulder	256
— — — wrist	247
— key-hole saw	238
— knife for flap amputation	179
— method of amputation by flaps	181
— — — — — oval incision	181
— raspatories	237
— retractors	239
— sharp bone hooks	240
— subperiosteal excision	236
— — — of ankle	262
— — — — hip	272
— — — — shoulder	259
Lateral position, Pott's	90
Laryngotomy	293
Larynx and trachea	293

- Lecomte-Lüer's bullet detector 287
 Le Fort's amputation 222
 Lembert's intestine suture 300
 Liebreich's bullet detector 288
 Lifts, bed 304
 Ligaments of the ankle (outer side) . 264
 — — — — (inner side) . 265
 — — — — (from behind) . 263
 — crucial 266
 — in front of the hip joint . 274
 — of the right elbow 253
 — — — — knee joint . . 269
 — — — — shoulder joint . . 260
 — — — — wrist 244
 Ligature, the 142
 — , direct 137
 — of anterior tibial artery . 160. 162
 — — axillary artery 149
 — — brachial artery . . . 150. 151
 — — common carotid art. . 144. 145
 — — — — iliac artery . . . 154
 — — external iliac artery . . 155
 — — femoral art. . 156. 157. 158
 — — lingual iliac artery . . . 146
 — — popliteal artery 159
 — — posterior tibial art. . 161. 163
 — — radial artery 152. 153
 — — subclavian artery . 147. 148
 — — ulnar artery 152. 153
 Light, artificial 303
 Lint 2
 Lion forceps, Fergusson's 238
 Liquor ferri perchlor 120
 Lisfranc's disarticulation 209
 Lister's splint for excision of wrist . 65
 — method of antiseptic dressing . 12
 Liston's excision of elbow 250
 Lithotomy 301
 — , Allarton's median 302
 — position 301
 Longmore's bullet detector 289
 Lorinser's phlebotome 164
 Lüer's double canula 295
 — gouge forceps 279
- M.**
- Mac Intyre's splint 89
 Mackintosh 14
 Mallet, carpenter's 280
 Manec's amputation by transfixion . . 229
 Marshall's osteotribe 291
 Massage 242
 Mathysen's plaster of Paris bandage . 41
 Mayor 22
 Median lithotomy, Allarton's 302
 Metacarpal bones, fracture of 59
 — saw 184. 238
 Metal splints 32
 Middeldorpf's triangular cushion . . . 78
 Movements, passive 241
 Müller's autotransfusion 172
 Muscles behind the hip joint 270
 Muscular flaps, amputation by 180
- N.**
- Neckerchiefs 54
 — with paste-board 54
 Necrosis forceps 290
 Nekrotomie 290
 Nélaton's bullet probe 286
 Neudörfer's apolyse 241
 Nicaise's compression belt 130
 Nose bandage, the 53
- O.**
- Oakum 2
 Operations 112
 — , artificial light for 303
 Osteotribe, Marshall's 291
 Oval method of amputation (Langenbeck's) 181
- P.**
- Pancoast's abdominal tourniquet . . . 133
 Paracentesis thoracis 297
 Paste-board model for trough 60
 — — for Merchie's splints 29
 — splints 29. 30
 — trough for the arm 60
 Pelvic handkerchief, large 111

Pelvic support Bardeleben's	96
— — Esmarch's	96
— — Volkmann's	97
Petit's box splint for the leg	88
— tourniquet	123
Phlebotome Lorinser's	164
Pig's bladders	8
Pirogoff's amputation	219
— — modified by Günther	220
— interrupted splint	87
Plaster of Paris bandage	41
— — bandages	44
— — — , box for	44
— — — , knife for	47
— — — , machine for	44. 45
— — — , removal of	47
— — — , scissors for	48
— — — , suspension of	83
— — — , waterproof	47
— — — , windowed	46
— — — , with strips of wood	45. 97. 98
Plaster of Paris splints, Port's	31
— — — interrupted with hoops of iron	73
Plaster of Paris interrupted with wooden laths	90
Plaster of Paris interrupted splint, Pirogoff's	47. 87
Plaster of Paris swing splint for excision of the ankle (Esmarch)	84
Plaster of Paris swing splint for excision of the elbow (Esmarch)	70
Plaster of Paris swing splint for excision of the knee (Watson's)	91
Pott's lateral position	90
Porcelain headed probe, Nélaton's	286
Pressure by a pole or broomstick	126
Probe pewter	285
— (Nélaton's)	286
Pravaz's syringe	292
Protective silk	14
Pyo-pneumothorax	297

R.

Raspatory	236
Ravoth's operating light	304
Reamputation	235
Reduction of heat	8
Reef knot, the	17. 25
Reflector, improvised	304
Renz's double box splint	95
Respiration, Silvester's artificial	117
Rest	1
Retractors, linen	183
— — , Langenbeck's small and large	239
Retractors, Langenbeck's sharp	240
— — , Volkmann's —	240
Roser's bone hook	283
— forceps	285
Rush mat	36

S.

Safety-pin, the	25
Sagittal bandage, the	49
Sailor's knot, the	17
Salicylic acid	15
Saw, bow	182
— , broad-bladed	182
— , Butcher's	239
— , chain	238
— , Langenbeck's key-hole	238
— , metacarpal	184. 238
— , Szymanowsky's	239
Sawing the bone	182
— — — , Bruns' method	224
— — — off the head of the humerus	258
— — — — femur	271
Sayre's elevator	237
— strapping for fractured clavicle	80
Scabbard as splint	38
Scalp wounds	48
Scheuer's box splint for the leg	89
Schnyder's cloth splints	26
Scultet's bandage (many-tailed)	21
Seutin's starch bandage	39
Sequestrum forceps	290
Siebold's bed-lift	306

Silica bandage, the	40	Starch bandage	16. 39
Silk carbolised	14	Starch splints	39
— paper, varnished	3	Strabismus hook	294
Silvester's artificial respiration	117	Strapping	16
Sinuses, longitudinal and transverse	282	— Crosby's	100. 101
Skin cuff in circular amputations	177	Straw splints, mat and casing	35. 36
— flaps, amputation by	178	Stretcher for raising patient	276
Sliding apparatus, Volkmann's	102	— extension, Esmarch's	107
Slings	56	Strips of wood with plaster of Paris for fractured forearm	66. 67
— , small	56	Strips of wood with plaster of Paris for fracture of arm and inflam- mation of the shoulder joint	76
— , triangular	56	Strips of wood with plaster of Paris for excision of the elbow	68
— , square	58	Stromeyer's adduction splint	66
Sloping board, the	61	— cushion	76. 77
Smith's anterior wire splint	104. 105	— splint for the arm	66. 68
Socin's apparatus for want of union after excision of elbow	74	Stump, position of	188
Spica bandage, the	21	— , reamputation of	235
Spiral bandage, the	19	Styptics	119
Splints	26	Suspension of plaster of Paris bandage — , Bloxam's	83 106
— , Bell's	28	— , Volkmann's splint	62
— , box, Petit's	88	— of the hand, vertical	61
— , cloth, Schnyder's	26	Sutures	16
— , double box, Renz's	95	— , the interrupted	16
— , English	28	— , the twisted	17
— , flexible	26	Swing splint for elbow, Esmarch's	71
— , for fracture of arm	75	— — of telegraph wire	63. 92
— , Gooch's flexible	26. 103	Syme's amputation	215
— , interrupted for excision of wrist (Esmarch)	64	Syncope	114
— , Langensalza	69	Syphon	10
— , Mac Intyre's	89	Syringe, Pravaz's	292
— , material for	27		
— , Merchie's paste-board	29	T.	
— , metal	32	Tampon	119
— , paste-board	29. 39	T bandage	22
— , plaster of Paris	41	Temporary splints	34
— , — — , interrupted with iron hoops	73	Tendon of biceps	257
Splints, starch	39	Thiersch's salicylic acid dressing	15
— of sticks	35	Tin boxes	8
— , temporary	34	— splint (Volkmann)	32
— , wire gauze	33	Tongue, drawing out, in asphyxia	116
— , wooden	26	Torsion of an artery	186
Spray producer	12	Tourniquets	123
Sponges	6		
Staff, grooved	301		

Tourniquet, Petit's	123
— , abdominal (Esmarch) . . .	134
— , — (Pancoast)	133
— , stick, Völckers'	125
Tracheotomy	292
Transfusion, arterial (Hüter)	171
— by hydrostatic pressure	169
— , Hasse's syringe for	171
— , Collin's apparatus for	170
— with Uterhart's syringe	169
Traumaticin, guttapercha dissolved in chloroform	16
Trephine	281
Trestle for lifting mattress	94
Triangular cloth	22
— cushion, Middeldorpf's	78
Turpentine, oil of	120
Twirling stick and piston	170
— the blood	165

U.

Ulnar nerve, the	252
Union of wounds, the	16
— of flaps after amputation	187
Urethrotomy	301
Urinary extravasation	301
Uterhart's transfusion syringe	169

V.

Velpeau's bandage for fracture of the clavicle	80
Venesection	164
— with the lancet	164
— , dressing after	165
Völckers' plaster of Paris bandage with strips of wood	98
Völckers' (double) stick tourniquet	125
Volkman's bed-lift	306
— dorsal splint for the ankle	85
— pelvic support	97

Volkman's sharp hook	240
— sliding apparatus	102
— suspension splint	62
— wire swing for the arm	73

W.

Walton's splint	100
Wasserglas bandage	40
Waterproof material	3
Watson's swing splint for excision of knee	91
Wax torch	303
White's excision of the hip	270
Wire baskets (Mayor, Bonnet)	32
— gauze, splints of	33. 34
— hook	297
— splint, Bonnet's	33
— — , Esmarch's	34
— — , Roser's	33
— — , Smith's anterior	104. 105
— swing, Bardeleben's, for the lower extremity	95
Wooden splints	26
— strips with plaster of Paris	66. 67. 68
Wound-douche	4
— , improvised	4. 5
Wounds, contused of fingers	59
— of face	52
— , sutures for	16
— , syringe for	4
— , open treatment of	4
— , treatment of	1
— , union of	16
Wrappings, cold	8
— , Priessnitz's	8
Wrist, extension of the	250
— , injuries of the	63
— , ligaments of the	244
— , section through the	246

27

thg





CPA

