Surface anatomy / by Richard J. A. Berry.

Contributors

Berry, Richard J. A. 1867-1962.
Royal College of Physicians of Edinburgh

Publication/Creation

Edinburgh : William Green, 1906.

Persistent URL

https://wellcomecollection.org/works/wy9s9v4m

Provider

Royal College of Physicians Edinburgh

License and attribution

This material has been provided by This material has been provided by the Royal College of Physicians of Edinburgh. The original may be consulted at the Royal College of Physicians of Edinburgh. where the originals may be consulted.
Conditions of use: it is possible this item is protected by copyright and/or related rights. You are free to use this item in any way that is permitted by the copyright and related rights legislation that applies to your use. For other uses you need to obtain permission from the rights-holder(s).

wellcome collection

Wellcome Collection
183 Euston Road
London NW1 2BE UK
T +44 (0)20 7611 8722
E library@wellcomecollection.org
https://wellcomecollection.org

CUIQUE IN SUA ARTE CREDENDUM

U. 6. 24.

R.C.P. EDINBURGH LIBRARY
R28101K0236

SURFACE ANATOMY

CUIQUE·IN·SUA·ARTE·CREDENDUM

SURFACE ANATOMY

BY

RICHARD J. A. BERRY

M D., F.R.C.S.E., F.R.S.E.

PROFESSOR OF ANATOMY IN THE UNIVERSITY OF MELBOURNE

FORMERLY

LECTURER ON ANATOMY IN THE SCHOOL OF MEDICINE OF THE ROYAL COLLEGES, EDINBURGH; AND EXAMINER IN ANATOMY TO THE UNIVERSITY OF ST. ANDREWS, TO THE UNIVERSITY OF ABERDEEN, AND TO THE ROYAL COLLEGE OF SURGEONS, EDINBURGH

ROYAL COLLEGE OF PHYSICIANS, EDINB. LIBRARY.

WITH FORTY-SIX ILLUSTRATIONS

EDINBURGH AND LONDON

WILLIAM GREEN & SONS

1906

TO

PROFESSOR D. J. CUNNINGHAM

IN ACKNOWLEDGMENT

OF

MANY KINDNESSES

PREFACE

In the following work the Author has endeavoured to bridge over the gap which has always seemed to him to exist between Anatomy as studied in the dissecting-room and its practical application in the wards of a hospital; bearing in mind this object, the work will be found to comprise the Surface Anatomy of the Human Body, together with a description of what may be seen by means of special appliances. It need scarcely be said that these descriptions are merely intended to serve as a *preliminary* to hospital practice —not to replace it.

The work having been devised with these practical ends in view, the assistance of competent clinicians became necessary, and the Author desires very cordially to acknowledge the assistance given him in this connection by the following gentlemen:—Dr. Logan Turner has revised all those sections dealing with the Ear, Nose, and Pharynx; Dr. J. S. Fowler has read the entire work from a medical standpoint, and has also rendered invaluable assistance with the proof-sheets; Mr. J. W. Dowden, F.R.C.S.E., has also advised on many points of practical surgical importance; and lastly, Dr. Christopher Addison, of London, has revised the paragraphs dealing with abdominal topography in general, and with his own methods in particular.

The illustrations are not intended to relieve the student from the necessity of mapping out the guiding lines

upon the living subject itself. They are rather designed to facilitate the study of parts of the body not always readily accessible to a student of medicine. Dr. Logan Turner has generously allowed of the reproduction, from his work on *The Accessory Sinuses of the Nose*, of Figures 12, 14, and 15. Nearly all the remaining illustrations have been specially prepared for this work by Mr. E. O. Bowen, or by the Author himself.

To those gentlemen who have so kindly read the proof-sheets, Drs. J. S. Fowler and Thomas Yeates, and Messrs. F. W. Hay and H. M. Spoor, the Author desires to express his cordial thanks.

If the work succeeds in fulfilling the functions for which it has been devised—the study of Anatomy on the living subject and its practical application—the labour of its production will not have been in vain.

EDINBURGH, 1906.

CONTENTS

	PAGE
I. The Head and Neck—	
The Cranium	1
Cranio-Cerebral Topography	5
The Middle Line of the Neck	18
The Triangles of the Neck	21
The Face	29
The Mouth, Tongue, and Fauces	34
The Pharynx	39
The Nose	46
The Eye	55
The Ear	59
II. The Thorax—	
The Thoracic Parietes	71
The Pleuræ	78
The Lungs	80
The Heart	82
The Great Vessels	85
III. The Abdomen—	
The Abdominal Parietes	89
The Abdominal Cavity	97
The Alimentary Canal	103
The Peritoneum	114
The Biliary Apparatus	115
The Pancreas	117
The Spleen	118
The Urinary Apparatus	119
The Great Vessels	122
IV. The Back	125

PAGE

V. The Male Perineum 140
The External Genitals 153

VI. The Male Pelvic Viscera 156

VII. The Female Perineum 164

VIII. The Female Pelvic Viscera 167

IX. The Upper Extremity—
The Shoulder and Axilla 176
The Upper Arm 185
The Elbow 188
The Forearm 192
The Wrist 196
The Hand 200

X. The Lower Extremity—
The Buttock 206
The Back of the Thigh 211
The Popliteal Space 212
The Front of the Thigh 213
The Knee Joint 223
The Leg 226
The Ankle Joint 228
The Foot 230

Index 235

LIST OF ILLUSTRATIONS

FIG.		PAGE
1.	The Skull	2
2.	Cranio-Cerebral Topography. R. W. Reid's method	6
3.	Cranio-Cerebral Topography. Hare and Thane's method	8
4.	Cranio-Cerebral Topography. Chiene's method	12
5.	Cranio-Cerebral Topography. Berry and Shepherd's method	14
6.	The Middle Meningeal Artery, Lateral Sinus, etc.	17
7.	Cutaneous Areas of the Head and Neck	33
8.	The Teeth in a child aged five	35
9.	Mesial Sagittal Section through the Head	41
10.	Posterior Rhinoscopy	43
11.	The Larynx viewed from above	45
12.	Dissection of the outer wall of the Nasal Fossa	49
13.	Anterior Rhinoscopy	50
14.	The Frontal Air Sinuses	52
15.	The Antrum of Highmore	54
16.	The Normal Fundus Oculi	57
17.	The Membrana Tympani	61
18.	The Middle Ear and Mastoid Antrum	63
19.	The Supra-meatal Fossa	70
20.	The Thoracic Lines	74
21.	The Thoracic Regions	76
22.	The Pleuræ and Lungs	79
23.	The Heart	83
24.	Transverse Section through the Thorax	86
25.	The Anterior Abdominal Wall	91
26.	Addison's Method of delimiting the Abdomen	98
27.	Cunningham's Method of delimiting the Abdomen	102
28.	The surface anatomy of the superficial Abdominal Viscera	*Facing page* 104
29.	Traube's Area	106

FIG.		PAGE
30.	The surface anatomy of the deep Abdominal Viscera	*Facing page* 106
31.	Dissection of the superficial Abdominal Viscera	*Facing page* 108
32.	Cast of a Dissection of the deep Abdominal Viscera	111
33.	Dissection of the deep Abdominal Viscera	*Facing page* 118
34.	Morris's Parallelogram for the location of the Kidneys from behind	130
35.	Posterior relations of the Kidney	132
36.	The Kidneys from behind	133
37.	Schematic Sagittal Section through the Male Pelvis	143
38.	Schematic Coronal Section through the Pelvis	145
39.	Attachments of the Fasciæ of Scarpa and Colles	148
40.	Median Section through the Male Pelvis	158
41.	Median Section through the Female Pelvis	168
42.	The Synovial Sheaths of the Hand	204
43.	Bryant's Triangle	209
44.	The Gluteal Sciatic Triangle	210
45.	Schematic Sagittal Section through the Crural Canal	216
46.	The Bones of the Left Foot	231

SURFACE ANATOMY

I.

THE HEAD AND NECK.

THE CRANIUM.

The Fronto-Nasal Suture, or the Nasion.—The fronto-nasal suture, or the nasion, may be felt as a slight depression at the root of the nose. (See Figure 1.) It constitutes an important landmark in almost every method of cranio-cerebral topography.

The Glabella.—The glabella may be felt as a slight prominence above the nasion and between the supra-orbital margins.

The Supra-Orbital Margins.—The supra-orbital margins pass outwards, from the internal angular processes on each side of the fronto-nasal suture, immediately above the eye, to terminate externally in the external angular processes.

At the junction of the inner and middle thirds of the supra-orbital margin is the *supra-orbital notch*, situated about one inch external to the middle line, and which indicates the position of the supra-orbital nerve (sensory) and artery.

The External Angular Process.—The external angular process marks the outer end of the supra-orbital margin.

It forms an easily recognisable landmark, of importance in certain methods of cranio-cerebral topography.

The Fronto-Malar Suture.—The fronto-malar suture may be felt as a slight depression immediately below the

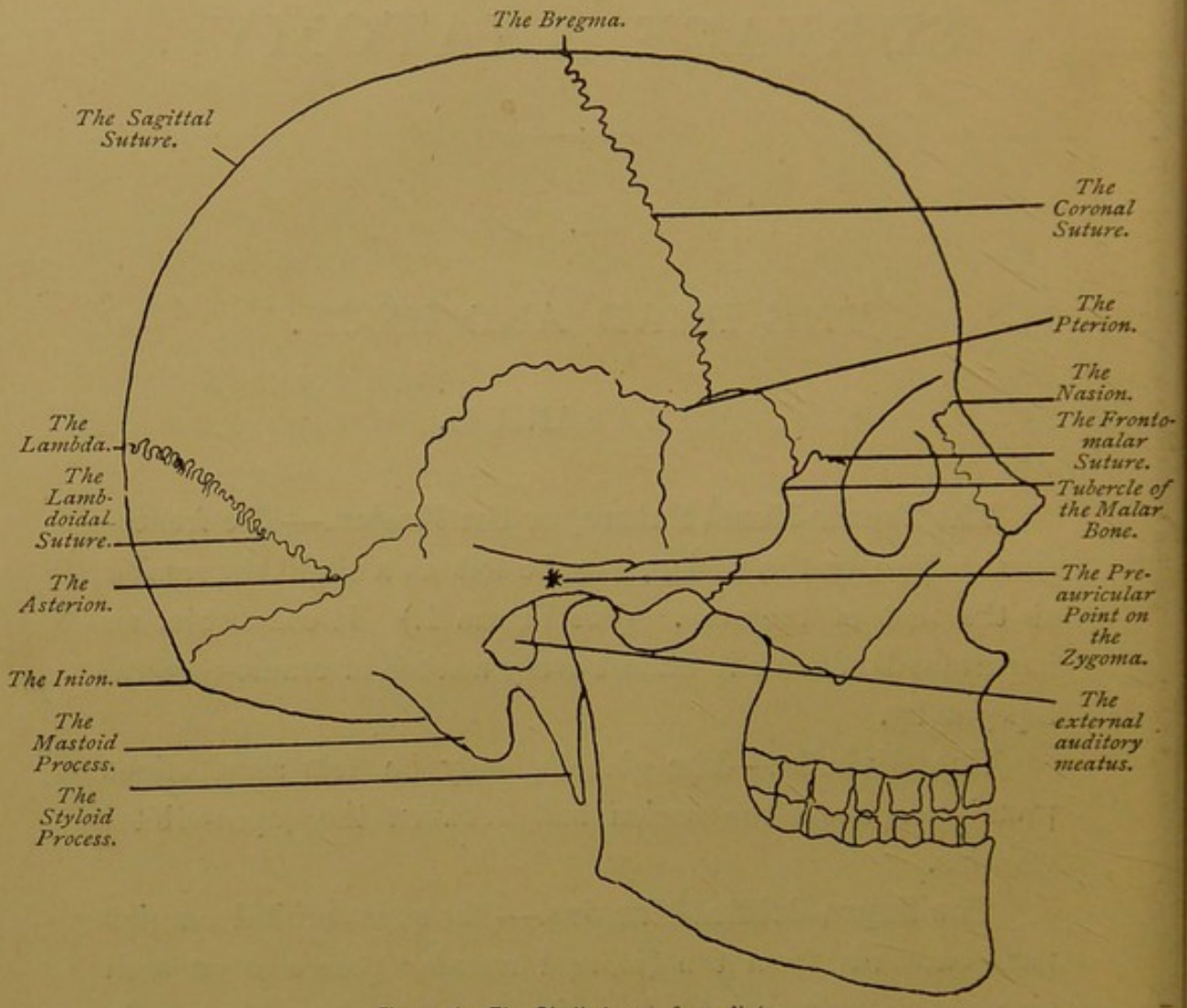

Figure 1.—The Skull drawn from Nature.

external angular process, and just above the level of the external canthus of the eyelid.

The Tubercle of the Malar Bone.—The tubercle of the malar forms a slight projection on the posterior border of the frontal process of that bone. It may be located about half an inch below the fronto-malar suture.

The Zygomatic Arch.—With the head in the natural position the zygomatic arch runs almost horizontally backwards, about on a level with a line drawn through the infra-orbital margin to the external occipital protuberance (the inion). It is therefore on almost the same level as the horizontal part of the lateral sinus. (See Figure 6.)

A point on the upper border of the zygomatic arch immediately in front of the tragus of the ear constitutes the *pre-auricular point.*

The Mastoid Process.—The mastoid process lies immediately behind the ear. The lower part of the anterior border, the apex, the posterior border, and the external surface are all subcutaneous, and can be easily felt on the living subject.

The External Occipital Protuberance, or the Inion.—The external occipital protuberance is easily felt posteriorly in the middle line, about one inch below the posterior pole of the cranium and on the same horizontal level as the zygomatic arch. (See Figure 6.)

The Bregma.—The bregma, or the junction of the sagittal and coronal sutures, lies about one inch behind the junction of the anterior and middle thirds of a line drawn from the nasion to the inion.

The Lambda.—The lambda, or the junction of the sagittal and lambdoidal sutures, is easily felt on the living subject, as a slight depression situated in the middle line of the calvarium about three and a half inches above the inion (external occipital protuberance).

The lambda coincides, fairly accurately, to the position of the external limb of the parieto-occipital fissure of the brain. It also constitutes an important landmark in Berry and Shepherd's method of cranio-cerebral topography.

The Coronal Suture.—The coronal suture may be

indicated on the living subject by a line drawn from the bregma to the middle of the zygomatic arch.

The junction of the middle and lower thirds of this line indicates fairly accurately the position of the *pterion* (that is the antero-inferior angle of the parietal bone), or the meeting-place of the parietal, frontal, sphenoid, and occasionally the temporal bones.

The Sagittal Suture.—The sagittal suture extends, in the middle line of the calvarium, from the bregma to the lambda.

The Lambdoidal Suture.—The position of the lambdoidal suture is indicated, on each side, by the upper two-thirds of a line drawn from the lambda to the apex of the mastoid process.

The junction of the middle and lower thirds of this line indicates the position of the *asterion* (that is the postero-inferior angle of the parietal), or the meeting-place of three sutures—the lambdoidal, parieto-mastoid, and occipito-mastoid.

The Supra-Trochlear Nerve (Fifth) and the Frontal Artery.—The supra-trochlear nerve and the frontal artery pass upwards on to the forehead around the inner end of the supra-orbital margin, a finger's breadth external to the middle line.

The Supra-Orbital Nerve (Fifth) and Artery.—The supra-orbital notch, at the junction of the inner and middle thirds of the supra-orbital margin, is the surface guide to these structures.

The Temporal Branch of the Temporo-Malar or Orbital Nerve (Fifth).—This minute nerve lies immediately behind the tubercle of the malar bone.

The Auriculo-Temporal Nerve (Fifth) and the Superficial Temporal Artery.—These structures cross the zygoma

superficially at the pre-auricular point. The vessel can be seen pulsating.

The Great Occipital Nerve (2nd Cervical) and the Occipital Artery.—These structures cross the superior curved line of the occiput, on their way to the scalp, about one inch external to the inion, the artery being the more external of the two.

CRANIO-CEREBRAL TOPOGRAPHY.

Definition.—By "cranio-cerebral topography" is meant the mapping out of the more important fissures and convolutions of the brain upon the surface, for medical and surgical purposes.

Of the many methods devised for this purpose the four which follow are those most generally employed:—

Reid's method.
Hare and Thane's method.
Chiene's method.
Berry and Shepherd's method.

Reid's Method.—*Reid's Base Line.*—A base line, upon which all perpendiculars are erected, is drawn from the lowest part of the infra-orbital margin through the middle of the external auditory meatus. (See Figure 2.)

The Fissure of Sylvius.—Draw a line from a point one and a quarter inches behind the external angular process to a point three-quarters of an inch below the most prominent part of the parietal eminence.

The *Sylvian point*, that is the point at which the fissure of Sylvius breaks up into its anterior, ascending, and

posterior horizontal limbs, lies on this line three-quarters of an inch behind its anterior extremity.

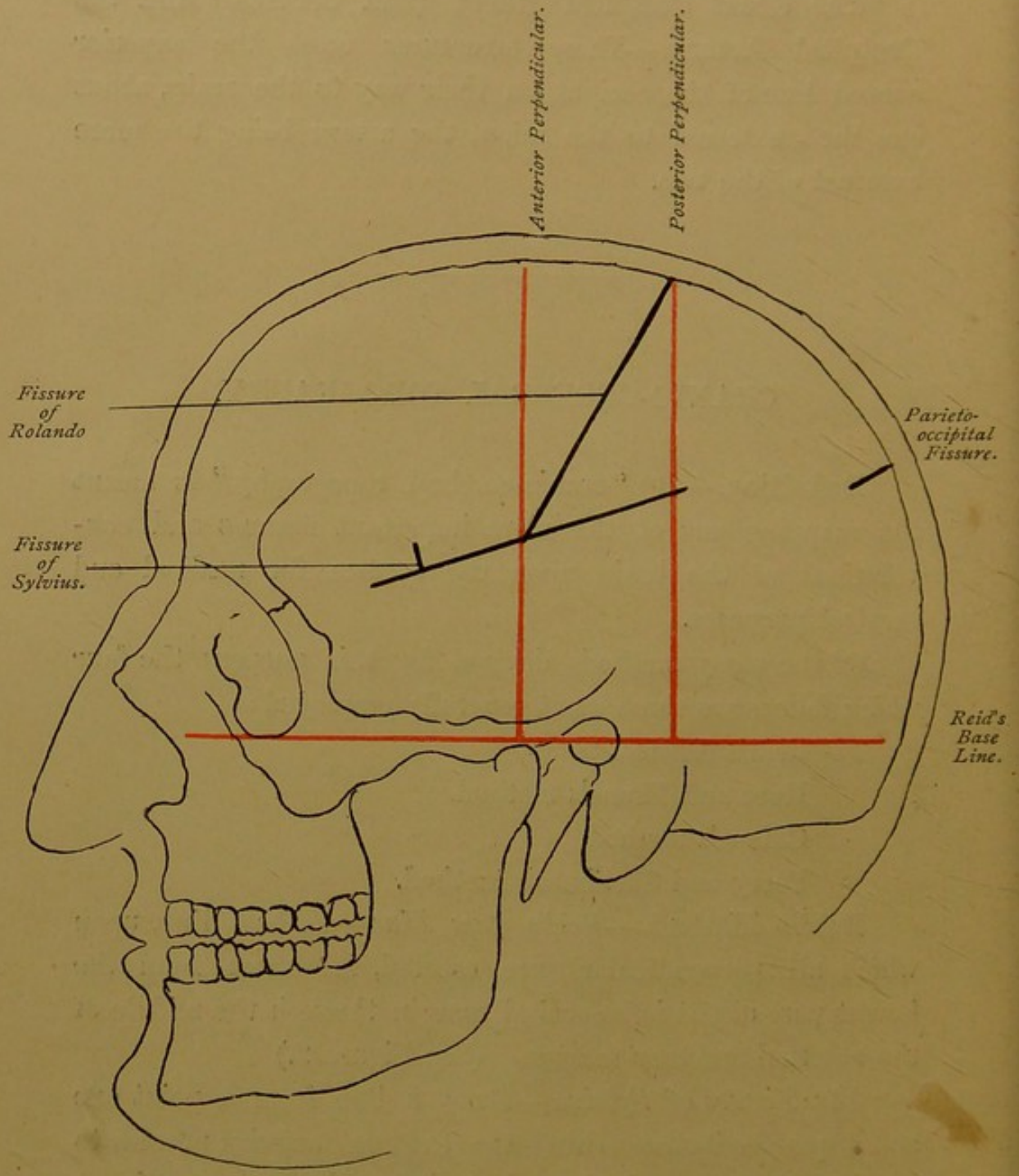

Figure 2.—Cranio-Cerebral Topography. R. W. Reid's Method.

The *posterior horizontal limb of the fissure of Sylvius* is represented by the whole of the line behind the Sylvian point.

The *ascending limb of the fissure of Sylvius* runs vertically upwards from the Sylvian point for a distance of one inch.

The Fissure of Rolando.—From the base line draw two vertical lines upwards, one from the pre-auricular point, and another from the posterior border of the mastoid process at its root. There is thus formed a four-sided figure bounded, in front by the anterior vertical, behind by the posterior vertical, above by the mesial line, and below by the posterior horizontal limb of the fissure of Sylvius.

A diagonal line drawn from the postero-superior angle of this figure to its antero-inferior angle, indicates the position of the fissure of Rolando.

The Parieto-Occipital Fissure.—The parieto-occipital fissure runs outwards and a little forwards for nearly one inch from a point opposite, or a little in front of, the lambda.

Hare and Thane's Method.—*The Superior Rolandic Point.*—If a median line be drawn over the head from the nasion (centre of the naso-frontal suture) to the inion (external occipital protuberance), a point 1 cm. (or half an inch) behind the centre of this line will indicate with sufficient accuracy the spot where the fissure of Rolando meets the upper border of the hemisphere, and may be termed the *Superior Rolandic Point.* (See Figure 3.)

The Inferior Rolandic Point.—The inferior Rolandic point, that is the spot where the fissure of Rolando, if prolonged, would meet the Sylvian line, lies on that line (*q.v.*) 25 mm. behind the Sylvian point.

The Sylvian Point.—From the fronto-malar suture let a line be carried horizontally backwards for 35 mm. (about one inch and a quarter), and from the end of this a vertical line for 12 mm. (about half an inch) upwards; the upper end of the latter line marks the spot where the anterior branches

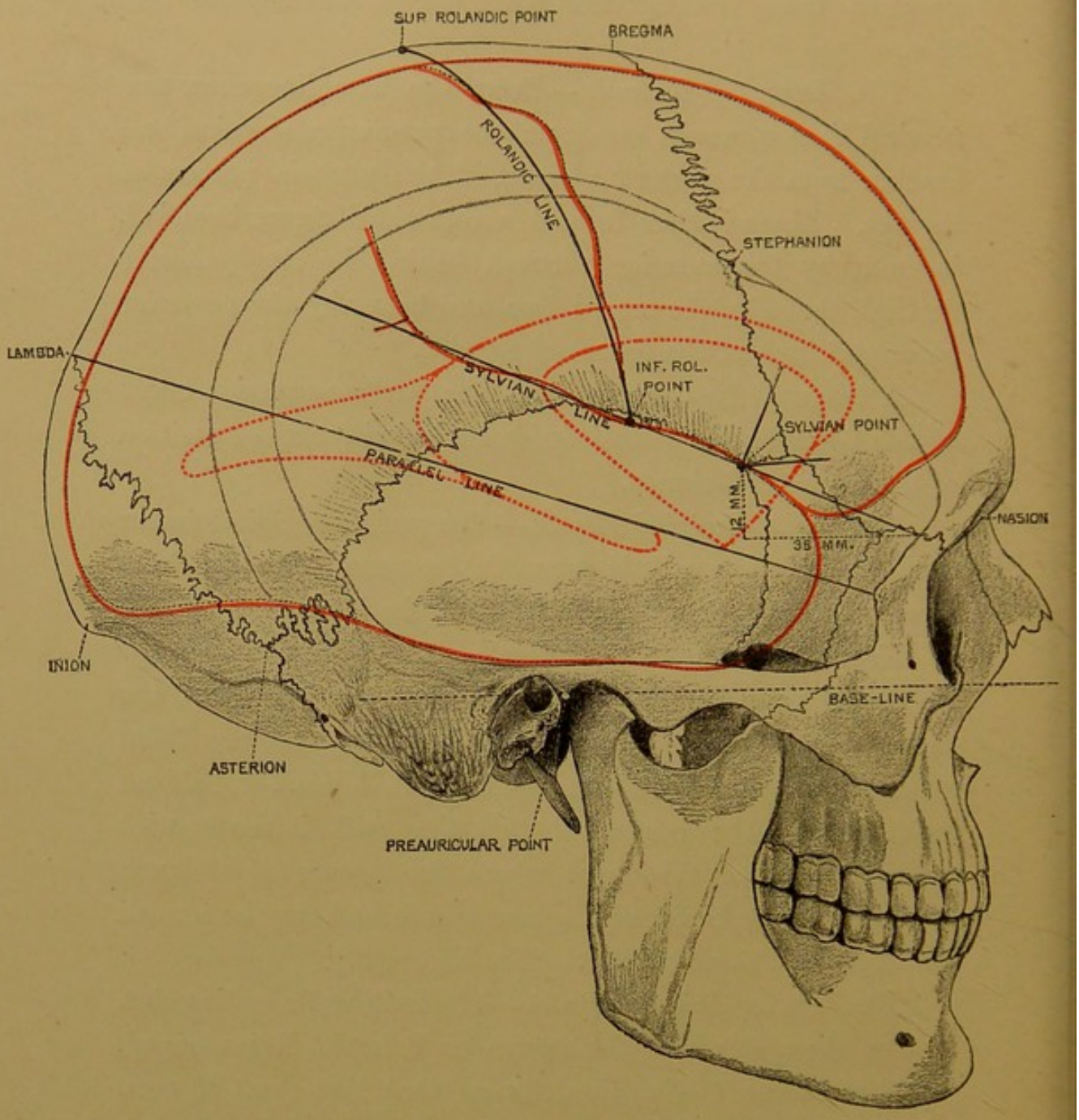

Figure 3.—Side view of a Skull on which the chief points and lines used in Hare and Thane's method of cranio-cerebral topography have been marked.

From "Quain's Anatomy," by permission of Messrs. Longmans, Green, & Co.

The contour of the cerebral hemisphere, with the Rolandic and Sylvian fissures, are marked by continuous red lines, and the outline of the insula and of the lateral ventricle by broken red lines.

are given off from the Sylvian fissure, and may be termed the *Sylvian point.*

The Fissure of Rolando.—The fissure of Rolando is indicated by the *Rolandic line* drawn from the *superior to the inferior Rolandic points*, or more simply by the application of *Hare's angle* of 67½° to the superior Rolandic point, the angle being obtained by Chiene's method of folding any sheet of paper containing a right angle, again folding it, and then taking three of the successive foldings; thus 90° folded gives two angles of 45°, these angles again folded form four angles of 22½°, three of which make up Hare's angle of 67½°. Hare's angle is not the precise angle of the fissure of Rolando, but is usually regarded as being sufficiently accurate for practical purposes.

The Fissure of Sylvius.—A line drawn from the fronto-malar suture through the Sylvian point to the lower part of the parietal eminence will about lie over the posterior horizontal limb of the Sylvian fissure, and may be called the *Sylvian line.*

The ascending and anterior horizontal limbs of the fissure may be marked by lines 2 cm. long starting from the Sylvian point, the one directed upwards and forwards at right angles with the Sylvian line, and the other horizontally forwards.

The External Limb of the Parieto-Occipital Fissure.—This fissure is indicated by a line carried transversely outwards for a distance of 2 cm. from the lambda, or if that cannot be felt, from a point three and a half inches above the inion.

The Frontal Intra-lobar Fissures.—The *superior and inferior precentral sulci* are situated about 15 mm. in front of the fissure of Rolando, with which they are parallel.

The *superior frontal sulcus* may be indicated approximately by a line running forwards from the superior precentral

sulcus slightly internal to the centre of the interval between the temporal crest and the median line of the forehead.

The *inferior frontal sulcus* arches forwards and downwards from the inferior precentral sulcus below the temporal crest of the frontal bone, which can be felt through the skin.

The Parietal Intra-lobar Fissures.—The *postcentral sulci*—upper and lower—lie about 15 mm. behind, and parallel to, the fissure of Rolando.

The *ramus horizontalis*, or the horizontal portion of the intra-parietal sulcus, is indicated by a line drawn from the centre of the Rolandic line to a spot 35 mm. external to the lambda, or 15 mm. from the end of the parieto-occipital line.

The Temporal Intra-lobar Fissures.—The position of the *first temporal or parallel fissure* may be determined by a line drawn from the marginal tubercle of the malar bone to the lambda.

The Island of Reil.—The Sylvian point marks the position of the *pole of the insula*, and a spot on the Sylvian line 35 mm. behind this point will correspond to its *posterior angle*. The *upper limit* of the insula may then be indicated by a line, slightly convex upwards, drawn from its posterior angle to the upper end of the ascending limb of the Sylvian fissure, and continued forwards for a distance of 15 mm. beyond the vertical passing through the Sylvian point; the *lower limit* by a line directed from the posterior angle downwards and forwards to a spot on the parallel line immediately below the Sylvian point; and the *anterior limit* by a line joining the anterior extremities of the two foregoing lines.

The Basal Ganglia.—The area of the island of Reil serves as a guide to the position of the basal ganglia, which extend slightly beyond the limits of the island.

The Lateral Ventricles.—The *anterior horn and body* of the lateral ventricle may be indicated by a line commencing

1 cm. in front of the foremost point of the island of Reil, and passing backwards in an arch an equal distance above the upper limit of the island to a spot 2 cm. behind its posterior extremity.

The *descending horn* runs forwards and downwards, to end about 1 cm. below the level of the parallel fissure and somewhat in advance of the coronal plane passing through the lower Rolandic and pre-auricular points.

The *posterior horn* extends backwards from the body, for a variable distance towards the hindmost point of the hemisphere, which is placed a little higher than the occipital pole, below the occipital point of the skull.

Chiene's Method.—Find in the mesial line of the skull between the nasion (G) and the external occipital protuberance (O) the following points (see Figure 4):—

First, the mid-point (M); second, the three-quarter point (T); third, the seven-eighth point (S).

Find also the external angular process (E) and the pre-auricular point (P). Having found these five points, join EP, PS, and ET. Bisect EP at N and PS at R. Join MN and MR. Bisect also AB at C, and draw CD parallel to AM.

The line MA corresponds to the superior and inferior precentral sulci, and may therefore be termed the *precentral line*. The origins of the superior and inferior frontal sulci may be indicated by trisecting MA at the points K and L, the latter point being at the level of the temporal crest.

The line ET, termed the *oblique or Sylvian line*, intersects the precentral line at the point A, which corresponds to the *Sylvian point*, and to the anterior division of the middle meningeal artery. AC overlies the posterior horizontal limb of the fissure of Sylvius, which terminates at the level of the temporal crest, in the lower part of the triangle HCB. This triangle contains the parietal eminence, and may there-

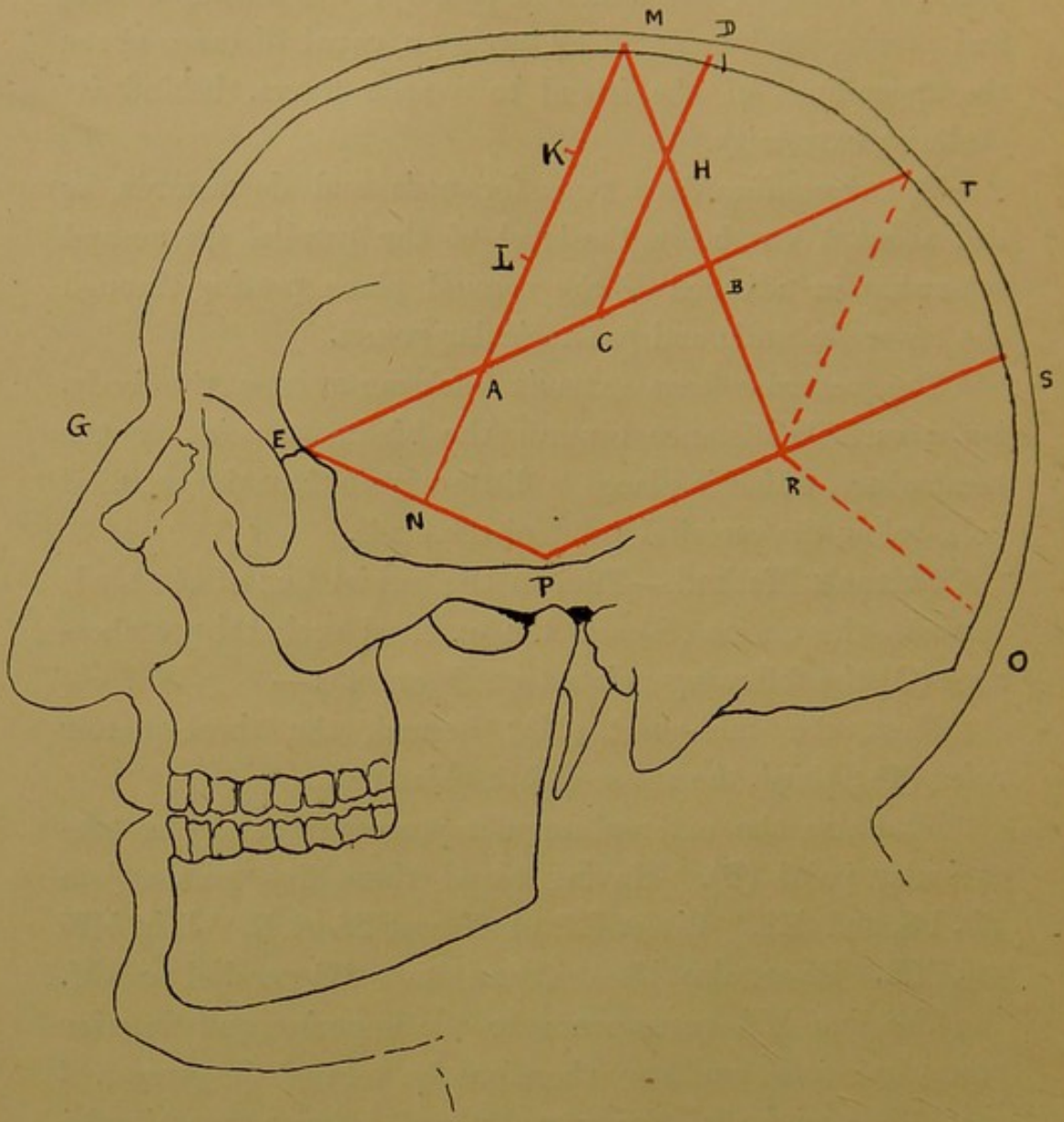

Figure 4.—Cranio-Cerebral Topography. Chiene's Method.

G. *The Nasion.*
M. *The mid point.*
T. *The three-quarter point and the parieto-occipital fissure.*
S. *The seven-eighth point.*
O. *The Inion.*
E. *The external angular process.*
P. *The pre-auricular point.*
K *The superior frontal sulcus.*
L. *The inferior frontal sulcus.*
A *The Sylvian point.*

A C. *The posterior horizontal limb of the fissure of Sylvius.*
M A. *The precentral line.*
E T. *The Sylvian line.*
C D. *The postcentral line.*
T R. *The lambdoidal suture.*
R O. *Tentorium cerebelli and lateral sinus.*
H C B. *The supra-marginal triangle.*
T R O. *The occipital lobe.*
A M D C. *The Rolandic motor area.*
A B R P N. *The temporal lobe.*

fore be termed the *supra-marginal triangle.* The termination of the Sylvian line, at the three-quarter sagittal point T, overlies the parieto-occipital fissure.

By joining TR, RO, a triangle is mapped out which delimits the outer surface of the occipital lobe; the line TR corresponds to the lambdoidal suture, while RO corresponds to, or lies a little above, the tentorium and the upper border of the lateral sinus.

CD, the *postcentral line,* corresponds to the superior postcentral sulcus and lies a little behind the inferior postcentral sulcus.

The parallelogram AMDC overlies the *Rolandic area, i.e.* the ascending frontal and the ascending parietal convolutions, separated by the fissure of Rolando.

The pentagon ABRPN maps out the temporal lobe, with the exception of its apex, which is directed downwards, forwards, and inwards, a finger's breadth in front of the point N.

A finger's breadth below AB is the *parallel sulcus,* the posterior extremity of which turns upwards to terminate at B, the point which indicates, therefore, the position of the angular gyrus.

The *fissure of Rolando* may be mapped out upon the scalp by drawing a line downwards and forwards for a distance of three and three-eighths of an inch from a point half an inch behind the mid-sagittal point M at an angle of $67\frac{1}{2}^{\circ}$ to the sagittal line (Hare).

Berry and Shepherd's Method.—The advantages claimed for this method by its authors are simplicity, accuracy, and the fact that it is the only method which conforms to the recent researches of Sherrington confining the Rolandic motor area to the ascending frontal convolution.

The Superior Precentral and Superior Rolandic Points.—Draw a sagittal line from the nasion (fronto-nasal suture) to

the inion (external occipital protuberance), and bisect it. (See Figure 5.) The point of bisection is the *superior precentral point*, that is the upper end of the precentral sulcus,

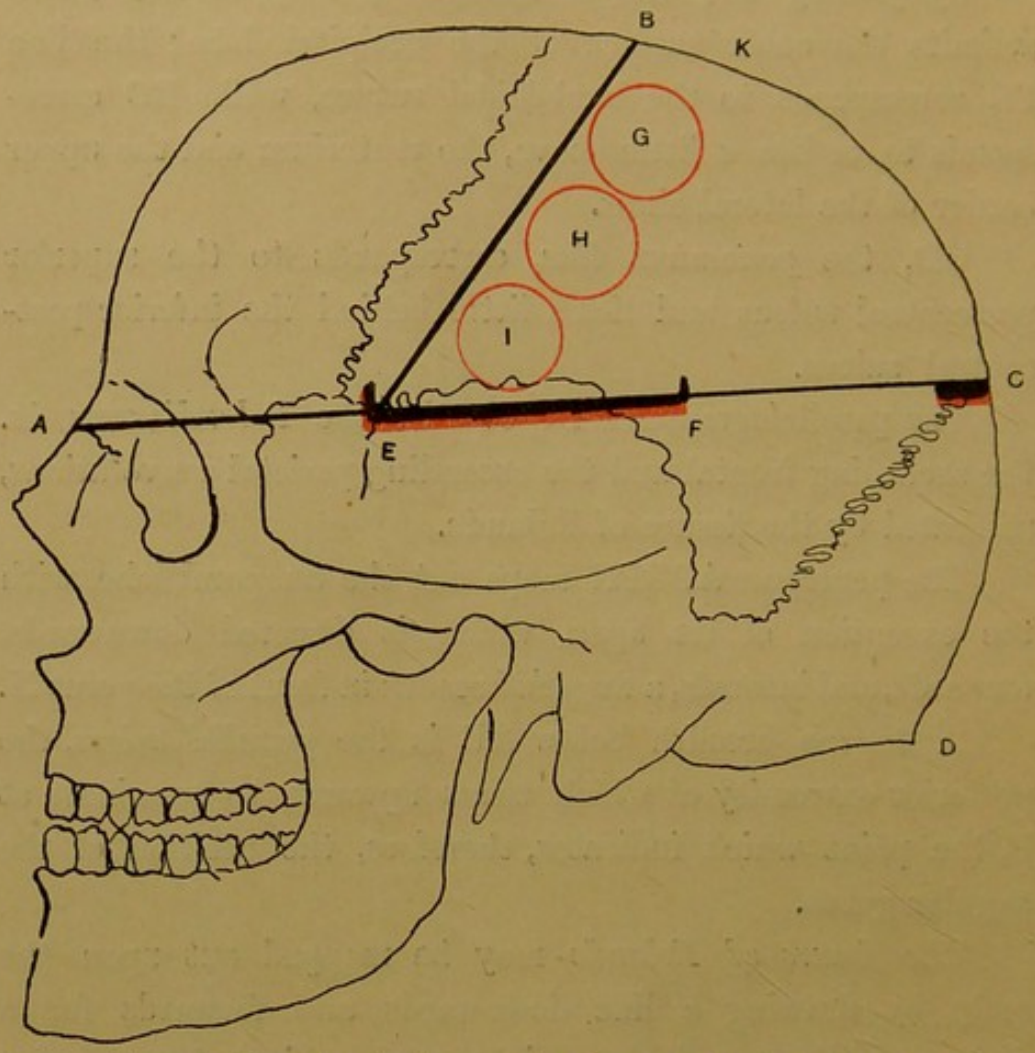

Figure 5.—Cranio-Cerebral Topography. Berry and Shepherd's Method.

A. *The Nasion.*
B. *The superior precentral point.*
K. *The superior Rolandic point.*
C. *The lambda and parieto-occipital fissure.*
D. *The Inion.*
E. *The Sylvian point.*
E F. *The posterior horizontal limb of the fissure of Sylvius.*
B E. *The precentral sulcus.*
G H I. *The Rolandic motor area confined to the ascending frontal convolution.*
A C. *The Sylvian line.*

and a second point, half an inch behind the point of bisection, is the *superior Rolandic point*, that is the upper end of the fissure of Rolando.

The Sylvian Point.—Draw a line—*the Sylvian line*—from the nasion through the external angular process to the lambda. Divide this line into thirds, and the point of junction of the anterior and middle thirds is the *Sylvian point*, that is the point at which the fissure of Sylvius breaks up into its anterior, ascending, and posterior horizontal limbs.

The Fissure of Sylvius.—The *posterior horizontal limb* of the fissure of Sylvius is indicated by the middle third of the Sylvian line. The *ascending limb* by a line three-quarters of an inch in length drawn upwards from the Sylvian point at right angles to the Sylvian line.

The Precentral Sulcus.—The precentral sulcus may be indicated by a line connecting the superior precentral point to the Sylvian point. The *ascending frontal convolution*, which, according to Sherrington, alone contains the Rolandic motor area, lies behind this line.

The Fissure of Rolando.—This fissure may be indicated, if necessary, by a line drawn from the superior Rolandic point downwards and forwards, behind and parallel with the precentral sulcus; or by the application of Hare's angle.

The External Limb of the Parieto-Occipital Fissure.—This fissure is sufficiently accurately indicated by the posterior three-quarters of an inch of the Sylvian line.

The Parallel Fissure.—This fissure lies half an inch below, and parallel with, the posterior horizontal limb of the fissure of Sylvius.

The Postcentral Sulcus.—This fissure lies half an inch behind, and parallel with, the fissure of Rolando.

The Cerebral Lobes.—The cerebral lobes on the external surface of the cerebrum are easily located by remembering that the *frontal lobe* lies in front of the fissure of Rolando; the *parietal lobe* lies between the fissure of Rolando in front, and the external limb of the parieto-occipital fissure and

an imaginary line prolonging that downwards, behind; the *occipital lobe* behind the imaginary line, and the *temporal lobe* below the fissure of Sylvius.

The Anterior Division of the Middle Meningeal Artery.—The anterior division of the middle meningeal artery—the division of the vessel most frequently concerned in extra-dural hæmorrhage—may be indicated by taking three points situated respectively, *the one*, one inch behind the external angular process and one inch above the zygoma; *the second*, one inch and a half from the same points; and *the third*, two inches from these points, and connecting these three points by a line. (See Figure 6.)

The Lateral Sinus.—The *horizontal* portion of the lateral sinus pursues a course slightly convex upwards from the level of the external occipital protuberance to the base of the mastoid process, that is, on almost the same horizontal level as the upper border of the zygomatic arch. (See Figure 6.)

The *vertical* portion of the sinus descends along the mastoid process along a line which roughly corresponds to the line of reflection of the skin of the ear from the mastoid process.

The Cerebellum.—The cerebellum lies below the level of the horizontal portion of the lateral sinus, or, in other words, below the level of a line drawn from the external occipital protuberance to the centre of the external auditory meatus. In operations upon the cerebellum it is advisable to keep the opening in the bone below this level and at the same time to keep behind a point one and a half inches behind the external auditory meatus, for by doing so both the lateral sinus and the occipital artery will be avoided.

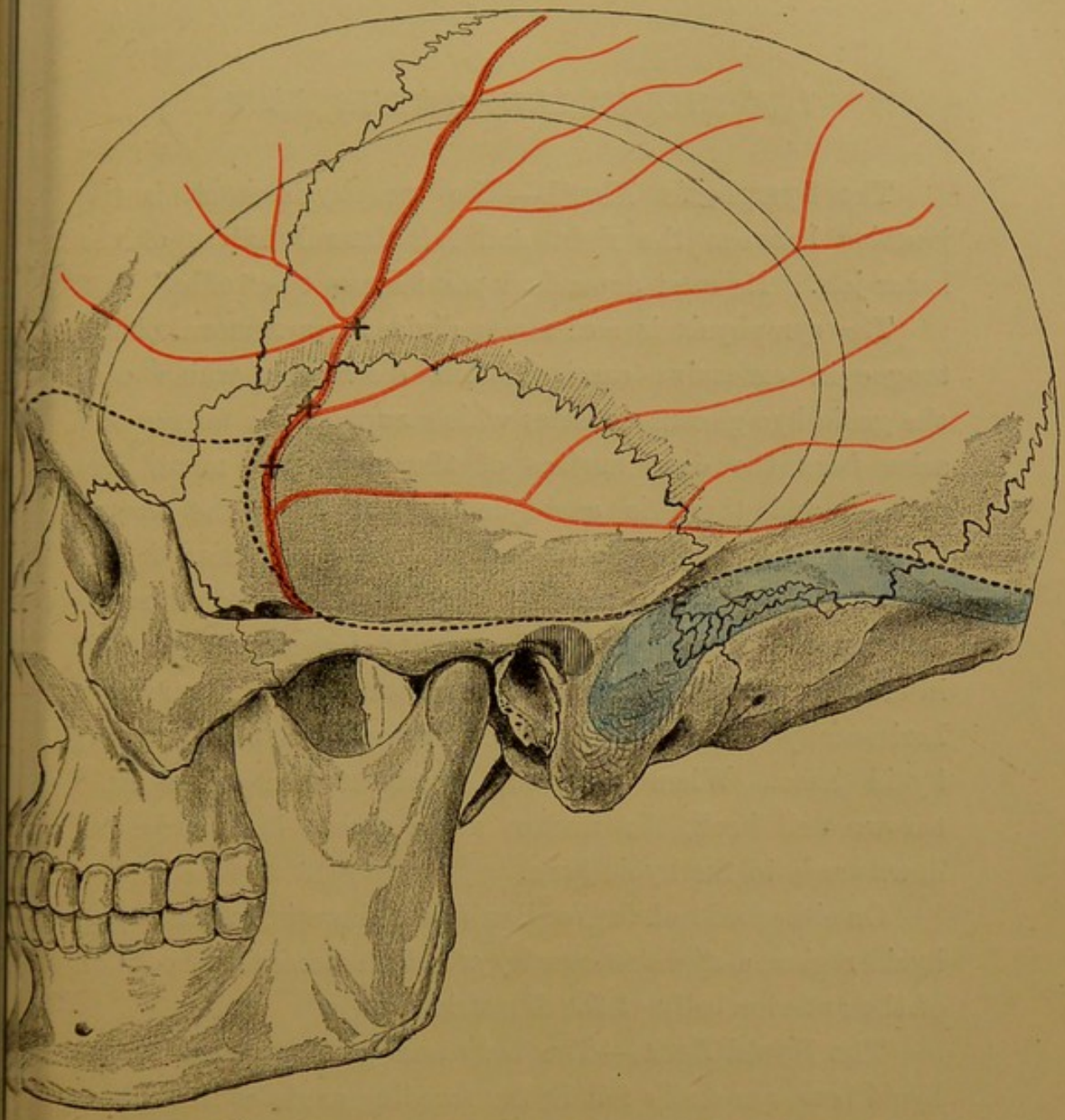

Figure 6.—Side view of Skull, showing the course of the middle meningeal artery, lateral sinus, etc.

From "Quain's Anatomy," by permission of Messrs. Longmans, Green, & Co.

The middle meningeal artery is represented in red, and the lateral sinus in blue.

The shaded area above and behind the external auditory meatus indicates the position of the epitympanic recess and the mastoid antrum.

The dotted line represents the inferior limit of the cerebral hemisphere as traced on the surface of the skull.

+ + + indicate the points of intersection of vertical and horizontal lines situated respectively one inch, one inch and a half, and two inches behind the external angular process of the frontal bone, and above the upper border of the zygoma.

THE MIDDLE LINE OF THE NECK.

The Symphysis Menti.—The symphysis menti is the junction between the right and left lateral halves of the lower jaw. Its most dependent point forms the "chin."

The symphysis is sometimes divided for removal of the tongue in extensive carcinomatous disease, in which case the genio-hyo-glossus muscles which support the tongue and arise from the deep surface of the symphysis menti, are divided, and there is consequently a risk of the tongue falling back upon the glottis and producing asphyxia.

The Mylo-Hyoid Median Raphè.—The median raphè between the two mylo-hyoid muscles forms part of their insertion, and with the head in the natural position stretches horizontally backwards from the symphysis menti to the hyoid bone. When the chin is elevated and the head thrown well back, the median raphè passes backwards and downwards to the hyoid bone.

On either side of the median raphè there is, in the supra-hyoid region, a slight convexity which indicates the position of the anterior belly of the digastric muscle.

The Hyoid Bone.—The body and greater cornua of the hyoid bone are easily felt in the receding angle of the chin.

The position of the hyoid bone varies with the extension or otherwise of the head.

When the head is in an ordinary position, the hyoid bone is on the same level as, or even a little higher than, the most dependent point of the symphysis menti.

When the head is thrown well back, the position of the hyoid is about an inch to an inch and a half below the symphysis menti; hence, in suicide by cut throat, it is most

frequent to find the injury inflicted either just below the hyoid bone, or, almost as commonly, just above it.

Immediately *above* the hyoid bone is the lingual artery and its small supra-hyoid branch, and immediately *below* it the infra-hyoid branch from the superior thyroid.

The hyoid bone lies opposite the fourth cervical vertebra, and the tip of its great cornu is the great central landmark in the carotid triangle.

The Thyro-Hyoid Membrane.—This membrane occupies the narrow interval between the hyoid bone and the thyroid cartilage. It is usually somewhat obscured by the depressor muscles of the hyoid bone, and laterally it is pierced by the sensory internal laryngeal nerve and the superior laryngeal artery.

This membrane is very frequently severed in suicide by cut throat, and in the operation of *sub-hyoid pharyngotomy* the epiglottis and superior aperture of the larynx are reached by passing through the anterior wall of the pharynx at this level.

The Thyroid Cartilage, or Pomum Adami.—The thyroid cartilage is very easily felt about one finger's breadth below the hyoid bone, and is, in fact, the most conspicuous feature in the middle line of the neck. Its *upper border*, opposite which the common carotid artery divides into internal and external carotids, is on the same level as the lower border of the body of the fourth cervical vertebra, whilst the cartilage itself is placed opposite the fifth cervical vertebra.

The *rima glottidis* is placed about opposite the middle of the short anterior margin of the cartilage, or more precisely the anterior extremities of the true vocal cords are attached to the thyroid cartilage, in the male 8·5 mm. below the median notch on the upper border of the cartilage, and, in the female, 6·5 mm. below the same spot.

Division of the thyroid cartilage—thyrotomy—is occasionally performed for the extra-laryngeal removal of tumours of the vocal cords.

The Crico-Thyroid Membrane.—The crico-thyroid membrane occupies the interval between the thyroid and cricoid cartilages. In the emergency operation of *laryngotomy*, which is performed in this space, only the middle portion of the membrane is divided in order to avoid the crico-thyroid muscles. The crico-thyroid branch of the superior thyroid artery crosses the membrane close to the lower border of the thyroid cartilage.

The Cricoid Cartilage.—The cricoid cartilage is easily felt below the thyroid cartilage. It is placed opposite the sixth cervical vertebra a little below the mid-point between the chin and the upper border of the manubrium sterni.

The cricoid cartilage is an important landmark, as it indicates the termination of the pharynx, the commencement of the trachea and œsophagus, and the level at which the omo-hyoid crosses the common carotid artery.

The First Two Rings of the Trachea.—Immediately below the cricoid cartilage, and between it and the isthmus of the thyroid body, the first two rings of the trachea can usually be felt. This portion of the trachea is opened in the operation of *high tracheotomy*.

The Isthmus of the Thyroid Body.—The isthmus of the thyroid body is inconstant in shape and position, but usually lies in front of the third and fourth rings of the trachea. It can usually be felt without difficulty, especially in women.

The Lower Rings of the Trachea.—The fifth, sixth, seventh, and eighth rings of the trachea lie between the isthmus of the thyroid body and the manubrium sterni, but as the trachea rapidly recedes from the surface below the

level of the thyroid isthmus they are not easily distinguished from the surface. At the upper border of the sternum the depth of the trachea from the surface is nearly one inch and a half.

In front of this part of the trachea there are the inferior thyroid veins, the cross communication between the two anterior jugulars, the thyroidea ima artery in 10 per cent. of cases, and not infrequently the left innominate vein or the innominate artery, consequently low tracheotomy is a more difficult operation than high, and pulsation above the sternum does not *necessarily* mean an aneurism.

THE TRIANGLES OF THE NECK.

The Sterno-Mastoid Muscle. — The sterno-mastoid muscle, one of the most important landmarks in the neck, is superficial throughout its whole extent. It may be thrown into great prominence by causing the patient to rotate the chin to the opposite side against opposition.

The *anterior border*, thick and prominent, forms the posterior boundary of the anterior triangle, and leads down to the strongly marked sternal head which arises from the manubrium sterni and assists in bounding the supra-sternal notch. The anterior border of the muscle is the surgical guide to the common and external carotid arteries, and along it are made the incisions for ligating those vessels, as well as those for other operations.

The *posterior border* of the muscle is thin and not very evident in its upper half; its lower half becomes more obvious and leads downwards to the clavicular head of the

muscle. This border of the muscle forms the anterior boundary of the posterior triangle of the neck. From the middle of this border the small occipital, great auricular, superficial cervical, supra-sternal, supra-clavicular, and supra-acromial nerves—cutaneous branches from the cervical plexus—radiate out to their respective distributions, the small occipital running upwards along the upper half of the posterior border of the muscle. The important spinal accessory nerve (*q.v.*) makes its appearance, from under cover of the muscle, at roughly the middle of the posterior border of the sterno-mastoid muscle.

The *superficial surface* of the sterno-mastoid muscle can be palpated throughout its whole extent. It is crossed in a vertical direction by the very obvious external jugular vein.

The *sternal head* of the muscle overlies the carotid sheath and its contents, the chief of which are the common carotid artery, the internal jugular vein, and the vagus or pneumogastric nerve.

The *clavicular head* of the muscle overlies the important scalenus anticus muscle—the key to the subclavian region.

Between the two heads of the sterno-mastoid there is a slight depression bounded below by the prominent sternal end of the clavicle. A needle passed backwards through this depression, immediately above the bone would strike, on the right side, the bifurcation of the innominate artery into right common carotid and right subclavian arteries, and, on the left side, the left common carotid artery as it enters the neck from the thorax.

The *action* of one sterno-mastoid muscle acting alone is very typically exemplified in wry neck or torticollis, where the displacement, like the action, is seen to be threefold; the head is inclined laterally towards the same side, the chin is rotated towards the opposite side, and the neck is slightly

flexed. Both muscles contracting simultaneously, the head is bent forwards.

The sterno-mastoid muscle has a double *innervation*, chiefly from the eleventh cranial or spinal accessory nerve (*q.v.*), and to a less extent from the second cervical spinal nerve.

The Digastric Muscle.—The digastric muscle forms the lower boundary of the digastric triangle. Its posterior belly separates the digastric and carotid triangles.

To map out the *anterior belly* of the digastric muscle, draw a line from the symphysis menti to the anterior part of the hyoid bone, and for the *posterior belly* prolong the line from that point to the upper part of the mastoid process.

The Omo-Hyoid Muscle.—The omo-hyoid—a digastric muscle—crosses both the anterior and posterior triangles of the neck. Its anterior belly lies in the anterior triangle, and separates the carotid and muscular triangles. The posterior belly lies in the posterior triangle, and divides it into an upper or occipital triangle and a lower or supra-clavicular triangle.

To map out the *anterior belly* of the omo-hyoid, draw a line from the fore part of the hyoid bone to the anterior border of the sterno-mastoid just below the level of the cricoid cartilage, and for the *posterior belly* prolong the line from that point to the outer end of the clavicle.

The Scalenus Anticus Muscle.—This important muscle —the surgical "key" to the subclavian region—lies almost directly behind the clavicular head of the sterno-mastoid.

The Subclavian Artery. — The subclavian artery may be mapped out by a line drawn convex upwards from the sterno-clavicular articulation to the middle of the clavicle, the highest part of the curve being half an inch above that bone.

The third part of the subclavian artery, that is the part external to the scalenus anticus, may be compressed against the first rib by making deep pressure downwards and backwards immediately above the clavicle and behind the sterno-mastoid muscle. The compression is most easily applied when the arm is drawn well down.

The Supra-Scapular Artery.—The supra-scapular artery, a branch from the thyroid axis (first part of the subclavian), runs outwards behind the clavicle.

The Transversalis Colli Artery. — The transversalis colli artery, with a similar origin to the supra-scapular, runs transversely outwards, a finger's breadth or more, above the clavicle. Its pulsations can often be felt.

The Common Carotid Artery.—To map out the common carotid artery, draw a line from the sterno-clavicular articulation to a point midway between the angle of the jaw and the tip of the mastoid process. A point on this line, opposite the upper border of the thyroid cartilage, indicates the bifurcation of the vessel into internal and external carotids, and the line itself very nearly coincides with the anterior border of the sterno-mastoid, the deep guide to the artery.

The External Carotid Artery.—The line of the common carotid, if prolonged upwards to a point behind the condyle of the lower jaw, will indicate with sufficient accuracy the line of the external carotid itself. The external carotid artery terminates opposite the neck of the lower jaw by dividing into internal maxillary and superficial temporal arteries after a course of two and a half inches.

The Superior Thyroid Artery.—This vessel arises from the external carotid just below the great cornu of the hyoid bone, and curves downwards and forwards to the thyroid body.

The Lingual Artery.—The lingual artery arises from the external carotid opposite the tip of the great cornu of the hyoid bone, above which it describes a slight arch, on its way to the tongue.

The Facial Artery.—The facial artery, in its *cervical* portion, may be indicated by a line drawn from a point just above the tip of the great cornu of the hyoid bone to the lower jaw just in front of the masseter muscle.

The Occipital Artery.—The occipital, in its first and second parts, follows the lower border of the posterior belly of the digastric.

The Posterior Auricular Artery.—This vessel follows the posterior border of the ear, and is liable to injury in the incision used in trephining the mastoid.

The External Jugular Vein.—The external jugular vein is usually sufficiently obvious descending from a point just behind the angle of the jaw to the middle of the clavicle. It is separated from the surface by the platysma myoides muscle.

The Subclavian Vein.—The subclavian vein lies at a lower level than its artery, and is therefore altogether behind the inner half of the clavicle.

The Internal Jugular Vein.—The internal jugular vein lies immediately external to, and overlaps the internal and common carotid arteries. It receives many tributaries, one of the most superficial and important of which is the common facial vein, which opens into the internal jugular at the level of the hyoid.

The Cervical Spinal Nerves.—THE SIX SUPERFICIAL CERVICAL NERVES.—These nerves are as follows:—

The small occipital nerve . .	}	Second and third cervical spinal nerves.
The great auricular nerve . .		
The superficial cervical nerve . .		

The supra-sternal nerve . .	Third and fourth cervical spinal nerves.
The supra-clavicular nerve . .	
The supra-acromial nerve . .	

The above nerves, which are all cutaneous, may be indicated on the surface by lines radiating from about the middle of the posterior border of the sterno-mastoid in the following directions:—

The *small occipital* runs upwards on to the scalp along the upper half of the posterior border of the sterno-mastoid.

The *great auricular* passes vertically upwards to the ear.

The *superficial cervical* nerve passes forwards at right angles to the long axis of the sterno-mastoid muscle.

The *supra-sternal* nerve crosses the manubrium sterni; the *supra-clavicular* nerve the middle of the clavicle; and the *supra-acromial* the acromial end of the clavicle.

The Phrenic Nerve.—The phrenic nerve—the great motor nerve of the diaphragm—arises mainly from the anterior primary division of the fourth cervical nerve, about the level of the hyoid bone. It descends behind the sterno-mastoid muscle and the sternal end of the clavicle; and below the level of the cricoid cartilage the nerve lies about midway between the anterior and posterior borders of the sterno-mastoid.

The Cervical Plexus.—The cervical plexus, formed by the anterior primary divisions of the first four cervical nerves, lies behind the upper half of the sterno-mastoid muscle. It may be exposed by an incision made along the upper half of the posterior border of the sterno-mastoid.

The Brachial Plexus.—The brachial plexus, formed chiefly by the anterior primary divisions of the fifth, sixth, seventh, and eighth cervical nerves, and by part of the first dorsal or thoracic nerve, occupies the posterior triangle of the neck above and behind the third part of the subclavian

artery. Its upper limits would be represented by a line drawn from a point opposite, and external to, the cricoid cartilage to a point just external to the middle of the clavicle.

The Cranial Nerves.—The Tenth, Pneumogastric or Vagus Nerve.—This nerve descends behind and between the internal jugular vein and the common carotid artery. Its position renders it liable to become included in the ligature, in ligation of the common carotid artery.

The Eleventh or Spinal Accessory Nerve.—This important surgical nerve, which supplies the sterno-mastoid and trapezius muscles, may be mapped out in two ways:—

1. Draw a line from the tip of the mastoid process to the angle of the jaw, and bisect it. A line drawn from the point of bisection at right angles to the guiding line indicates the position of the nerve.

2. Draw a line from a point on the anterior border of the sterno-mastoid one inch below the tip of the mastoid process, through the centre of the posterior border of the same muscle, and prolong it onwards to the trapezius.

The Twelfth or Hypoglossal Nerve.—This nerve crosses the internal and external carotid arteries in the carotid triangle just above the level of the great cornu of the hyoid bone.

The Gangliated Cord of the Cervical Sympathetic.—The gangliated cord of the sympathetic descends behind the carotid vessels. It may be reached through an incision along the posterior border of the sterno-mastoid.

The Submaxillary Gland.—The submaxillary gland can be felt in part, by pressing directly upwards immediately internal to the middle of the lower border of the body of the lower jaw. It is slightly lobulated.

The Cervical Portion of the Œsophagus.—The

œsophagus commences opposite the cricoid cartilage or the sixth cervical vertebra, and in its descent inclines slightly to the left, consequently incisions to open this part of the œsophagus must be made upon the left side along the anterior border of the sterno-mastoid between that muscle and the trachea.

The Lymphatic Glands of the Posterior Triangle.—The lymphatic glands in the neighbourhood of the posterior triangle of the neck are as follows:—

The superficial cervical glands.
The suboccipital glands.
The mastoid glands.

The *superficial cervical glands* are a group of from four to six glands which surround the external jugular vein and lie between the platysma myoides muscle and the deep cervical fascia.

These glands are joined by lymphatic vessels from the external ear, the skin of the neck, and the suboccipital and mastoid glands, and their efferent vessels terminate in the inferior deep cervical glands.

The *suboccipital glands*, one or two in number, are superficially situated at the apex of the posterior triangle. They drain the most posterior part of the scalp, and their efferent vessels terminate in the superficial cervical glands.

The *mastoid glands*, two or three in number, lie superficial to the insertion of the sterno-mastoid muscle. They drain the middle portion of the scalp, and their efferent vessels terminate in the superficial cervical glands.

The Lymphatic Glands of the Anterior Triangle.—The lymphatic glands in the neighbourhood of the anterior triangle of the neck are as follows:—

The superior deep cervical glands.
The inferior deep cervical glands.

The *superior deep cervical glands* accompany the internal jugular vein, and extend from the base of the skull downwards to the bifurcation of the common carotid artery.

They are joined by lymphatic vessels from the following parts:—

From the internal maxillary glands.
From some of the submaxillary glands.
From the cranial cavity.
From the tongue, tonsil, and lower part of the pharynx.
From the larynx and some from the thyroid body.
From the deep muscles.

The efferent vessels from these glands terminate in the inferior deep cervical glands.

The *inferior deep cervical glands* lie along the lower part of the internal jugular vein, and extend outwards into the supra-clavicular triangle. They establish communications with both the glands of the axilla and with the superior mediastinal glands.

These glands are joined, either directly or indirectly, by lymphatic vessels from all the other cervical glands, and hence this group of glands is one of the most important in the head and neck.

Their efferent vessels unite to form a single vessel, which terminates in the right lymphatic duct (right side) or the thoracic duct (left side).

THE FACE.

Bony Landmarks at the Upper Part of the Face.—For the bony landmarks at the upper part of the face, see page 1, and Figures 1 and 6.

The Lower Jaw.—The Condyle.—The condyle of the lower jaw can be explored immediately below the zygoma and in front of the tragus of the ear. (See Figure 6.) On opening the mouth the condyle can be felt moving forwards. Under these conditions a small part of the glenoid fossa immediately behind the condyle can usually be palpated.

The Coronoid Process.—The anterior border of the coronoid process of the lower jaw can be felt on making deep pressure in front of the masseter muscle immediately below the anterior part of the zygomatic arch.

The Ascending Ramus.—The ascending ramus of the lower jaw lies between the masseter muscle externally, and the internal pterygoid muscle internally. Its *posterior border* can be readily explored from the condyle above, to the angle of the jaw below; the *anterior border* is easily felt with the finger in the mouth, and the *external surface* can be explored through the masseter muscle.

The Body.—The body of the lower jaw can be palpated throughout the whole of its extent.

The Malar or Cheek Bone.—The malar bone forms the prominence of the cheek. Its external surface is subcutaneous throughout.

The Infra-Orbital Margin.—The infra-orbital margin, formed internally by the superior maxilla and externally by the malar, is subcutaneous throughout.

The Superior Maxilla.—The facial surface of the superior maxilla is easily palpated, especially the two depressions known as the incisor or myrtiform fossa and the canine fossa, situated respectively internal, and external, to the ridge produced by the root of the canine tooth.

The Nasal Bones.—The nasal bones, forming the bridge of the nose, are subcutaneous throughout.

The Masseter Muscle.—The masseter lies on the outer

surface of the ascending ramus of the lower jaw, and is subcutaneous except posteriorly, where it tends to be overlapped by the parotid gland.

The Buccinator Muscle. — The buccinator muscle occupies the interval between the upper and lower jaws immediately external to the mouth.

The Facial Artery.—The facial artery can be felt, and not infrequently seen pulsating, as it crosses the lower jaw immediately in front of the masseter muscle, about one inch in front of the angle of the jaw.

To map out the *facial* portion of the artery, draw a line from the point where the vessel reaches the face, to the inner angle of the orbit, in such a way that the line lies half an inch behind the angle of the mouth.

The Coronary Arteries.—The coronary arteries run in the upper and lower lips respectively. With the finger in the mouth they can be felt pulsating. In the operation for hare-lip, hæmorrhage from the superior coronary artery may be controlled by compressing the upper lip between the finger and thumb.

The Transverse Facial Artery.—This vessel, a branch of the superficial temporal, runs transversely forwards about a finger's breadth below the zygoma. It is not infrequently ruptured in lacerated wounds of the face.

The Facial Vein.—The facial vein lies behind its artery and pursues an almost straight course from the inner canthus of the eye to the point on the lower jaw immediately in front of the masseter.

Motor Nerve—The Facial Nerve.—The course of the trunk of the facial nerve from its exit from the stylo-mastoid foramen to the posterior border of the ascending ramus of the lower jaw, where it breaks up into its temporo-facial and cervico-facial divisions, is indicated by a line drawn from the

anterior border of the mastoid process at its junction with the ear to the posterior border of the ascending ramus of the lower jaw at the level of the lower margin of the tragus.

The various branches of the facial nerve radiate on to the face from the lower end of the tragus of the ear, incisions in this region must therefore be planned so as to avoid these branches.

Sensory Nerves.—The sensory nerves of the face and anterior half of the scalp are as follows:—

- Fifth cranial nerve.
  - Ophthalmic division.
    - Supra-trochlear.
    - Supra-orbital.
    - Nasal.
    - Infra-trochlear.
    - Palpebral branches of lachrymal.
  - Superior maxillary division.
    - Infra-orbital.
    - Malar.
    - Temporal.
  - Inferior maxillary division.
    - Auriculo-temporal.
    - Long buccal.
    - Mental.

Of these nerves, the supra-orbital, the infra-orbital, and the mental, may be regarded as representing on the face the terminations of the three great divisions of the fifth cranial nerve. (See Figure 7.) A line drawn from the supra-orbital notch to the interval between the two bicuspid teeth of the lower jaw indicates the positions of these three nerves in the following way:—

The *supra-orbital nerve* (ophthalmic division) winds round the supra-orbital notch at the junction of the inner and middle thirds of the supra-orbital margin.

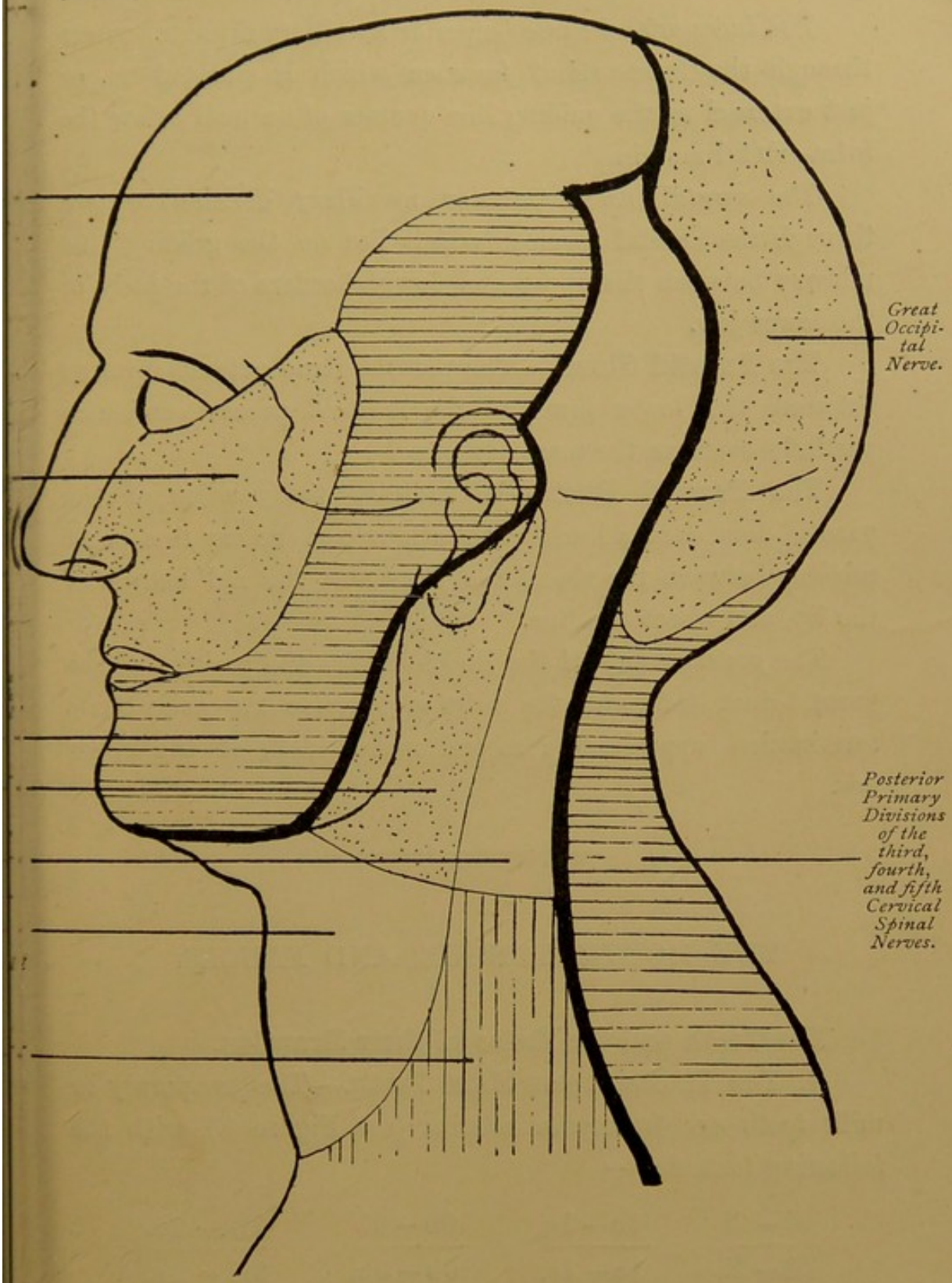

Figure 7.—Scheme designed to illustrate the Cutaneous Areas of the Head and Neck.

The three areas supplied by the fifth cranial nerve are separated from those supplied by the anterior primary divisions of the cervical spinal nerves by a thick black line, whilst the division between the anterior and posterior primary divisions is similarly indicated.

The *infra-orbital nerve* (superior maxillary division) passes through the infra-orbital foramen which is situated on, or just external to, the guiding line quarter of an inch below the infra-orbital margin.

The *mental nerve* (inferior maxillary division) passes through the mental foramen which lies on the guiding line midway between the upper and lower borders of the body of the lower jaw.

The Parotid Gland.—The parotid gland extends inwards between the lower jaw and the mastoid process, and also partially overlaps the masseter muscle.

The Parotid Duct.—To indicate the position of the parotid duct, draw a line from the lobule of the ear to a point midway between the ala of the nose and the red margin of the lip, and bisect the line.

The *posterior half* of the line indicates the position of the parotid duct itself, and the *point of bisection* the point of its termination opposite the second molar tooth of the upper jaw.

THE MOUTH, TONGUE, AND FAUCES.

The Teeth and the Dates of their Eruption.

A. The Temporary or Milk Teeth.—The temporary or milk teeth are twenty in number (see Figure 8), with the following formula :—

$$\frac{2i-2i}{2i-2i,} \quad \frac{1c-1c}{1c-1c,} \quad \frac{0b-0b}{0b-0b,} \quad \frac{2m-2m}{2m-2m.}$$

The order of appearance and dates of eruption of these teeth are as follows :—

1. The lower central incisors . . . . . 6–9 months.
2. The upper incisors, central and lateral . . . 8–10 ,,
3. The lower lateral incisors and the first molars . . 12–14 ,,
4. The canines . . . . . 18–20 ,,
5. The second molars . . . . . 20–28 ,,

B. The Permanent Teeth.—The permanent teeth are thirty-two in number, with the following formula :—

$$\frac{2i-2i}{2i-2i,} \quad \frac{1c-1c}{1c-1c,} \quad \frac{2b-2b}{2b-2b,} \quad \frac{3m-3m}{3m-3m.}$$

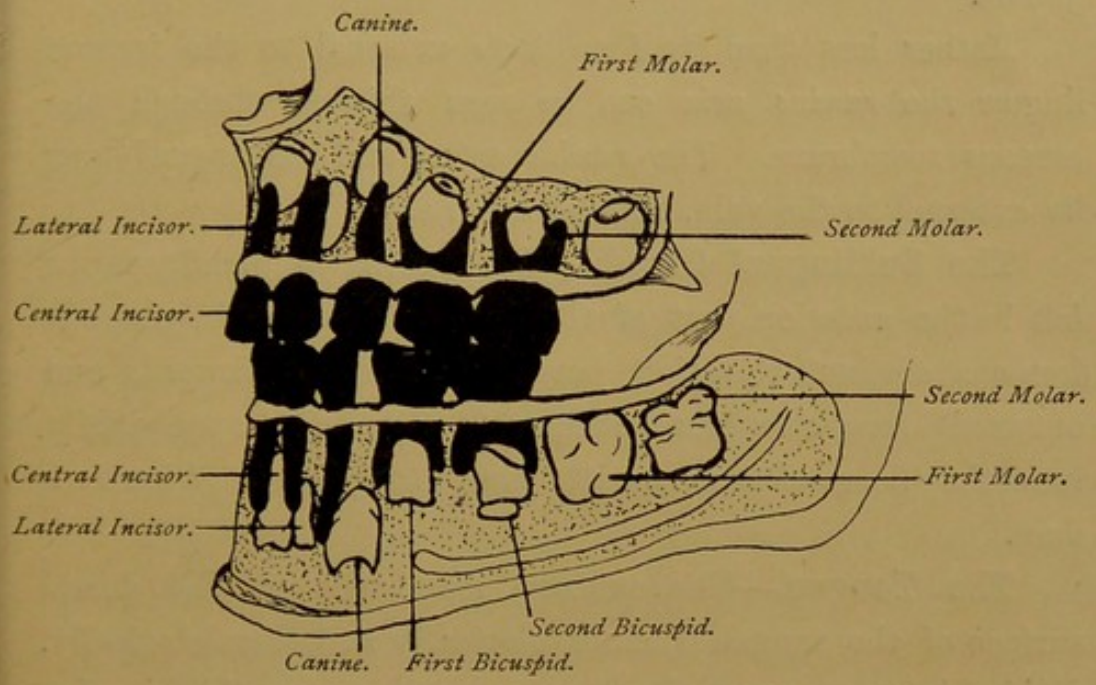

Figure 8.—The teeth in a child aged five. The temporary teeth are shown in black, and the developing permanent Teeth in white.

The order of appearance and dates of eruption of these teeth are, in the case of the *lower jaw*, as appended ; the corresponding teeth of the upper jaw appear somewhat later :—

First molars	6 years
Central incisors	7 ,,
Lateral incisors	8 ,,
First bicuspids	9 ,,
Second bicuspids	10 ,,
Canines or eye teeth	11–12 ,,
Second molars	12–13 ,,
Third molars or wisdom teeth	17–25 ,,

The Frenum Linguæ.—In the middle line of the floor of the mouth passing backwards from the gums to the under surface of the tongue is the frenum linguæ. Immediately below the frenum are the superior borders of the *genio-hyo-glossi muscles*, which pass from the lower jaw backwards to the tongue.

On either side of the frenum linguæ are the minute orifices of *Wharton's ducts*—the ducts of the submaxillary glands.

Rather less than half an inch external to the frenum linguæ the *ranine vein* can be seen shining through the mucous membrane. The *ranine artery* and the *lingual nerve* lie external to the vein, but are not visible.

The Sublingual Gland.—The sublingual gland can be felt in the anterior part of the floor of the mouth, where it forms a distinct elevation, passing obliquely backwards and outwards from the frenum linguæ. Its ducts open partly into the floor of the mouth and partly into Wharton's duct.

The Tongue.—The mucous membrane on the dorsal surface of the tongue is, embryologically and physiologically, divided into two unequal parts—an anterior two-thirds and a posterior third.

The line of demarcation between the two parts is formed by a mesially situated recess, the *foramen cæcum*, and on either side of this by a shallow groove, the *sulcus terminalis* of His, which passes forwards and outwards from the foramen cæcum to the lateral margin of the tongue.

(*a*) The Mucous Membrane over the Anterior Two-Thirds.—In this part of the dorsal surface the mucous membrane is thin, firmly adherent to the subjacent muscles, and is provided with numerous small eminences termed papillæ. Three varieties of these papillæ are described:—

The circumvallate papillæ.
The fungiform papillæ.
The conical and filiform papillæ.

The Circumvallate Papillæ.—The circumvallate papillæ, some seven to twelve in number, almost coincide in position with the sulcus terminalis of His. Each one has the form of a truncated cone, which is situated in a circular depression in the mucous membrane. It is attached to the bottom of this depression by a constricted stem, which is surrounded by a groove; the wider upper end or base projects slightly above the surface of the tongue, and is covered by small simple papillæ.

The Fungiform Papillæ.—The fungiform papillæ are more numerous than the circumvallate papillæ, but are not so large. They are found scattered over the central and anterior portions of the dorsum of the tongue, but are most numerous at the tip and along the lateral borders.

Each fungiform papilla is narrow at its attachment to the tongue, but broadens out as the free extremity is approached. In the living subject the fungiform papillæ may be distinguished by their bright red colour.

The Conical and Filiform Papillæ.—The conical and filiform papillæ are the smallest and the most numerous. They constitute the numerous small projections which are densely set over the dorsal surface of the tongue. These papillæ taper from their bases towards the free extremities, where many of them are provided with smaller secondary papillæ.

(*b*) The Mucous Membrane over the Posterior Third.—The mucous membrane over the posterior third of the dorsal surface of the tongue is thicker, smoother, and less adherent than is that over the anterior two-thirds. It is not covered by papillæ, but is studded all over with numerous glands

and lymphoid follicles, which last are sometimes termed the lingual tonsils.

The Nerves of the Tongue.—The nerves of the tongue are as follows:—

	Anterior Two-Thirds.	Posterior Third.
Ordinary sensation .	The lingual (5th)	Glosso-pharyngeal (9th).
Special sensation (taste)	The chorda tympani (7th)	Glosso-pharyngeal (9th).
Motor nerve . .	The hypoglossal (12th).	

The Isthmus Faucium.—By opening the mouth widely and taking a deep inspiration or by asking the patient to produce the sound "Ah," the soft palate is elevated and the isthmus faucium is easily seen.

The Anterior Pillars of the Fauces.—The anterior pillars of the fauces can be seen to pass from the base of the uvula, downwards and outwards in front of the tonsils, to the posterior extremity of the lateral border of the tongue. They contain the palato-glossus muscles.

The Tonsils.—The tonsils lie in the depression immediately behind the anterior pillars of the fauces, and between those structures and the posterior pillars. They are on the same level as the angle of the jaw, though they cannot be felt from without. When enlarged, the tonsils may almost meet in the middle line below the uvula.

The *Supra-tonsillar Fossa*, a remnant of the second branchial cleft, is a space situated above the tonsil and between the anterior and posterior pillars of the fauces. The space varies considerably in size, and it may extend for some distance into the substance of the soft palate. If the communication between the fossa and the mouth is not sufficiently free, septic material may accumulate in the former,

giving rise to recurring attacks of tonsillitis or peritonsillar abscess. The space may be conveniently explored by means of a probe bent at its distal extremity.

The internal carotid artery lies about four-fifths of an inch behind the tonsil, though the ascending pharyngeal artery is probably a greater source of danger in tonsillectomy.

THE POSTERIOR PILLARS OF THE FAUCES.—The posterior pillars of the fauces pass, from the soft palate, downwards behind the tonsils, to the lateral wall of the pharynx. They contain the palato-pharyngeus muscles.

The Hamular Process.—The hamular process on the internal pterygoid plate of the sphenoid bone can be felt a little behind, and internal to, the last molar tooth. Just in front of the hamular process is the posterior palatine foramen.

The Pterygo-Maxillary Ligament. — The pterygo-maxillary ligament can be felt descending from the hamular process to the lower jaw, in a fold of mucous membrane which passes between the jaws behind the extremities of the dental arches. Just in front of this, and immediately internal to the last molar tooth, the *lingual nerve* passes forward below the mucous membrane—a point of some surgical importance.

THE PHARYNX.

The Pharynx.—The only portion of the pharynx which can be seen through the isthmus faucium without special appliances is the posterior wall of the oro-pharynx. The naso-pharynx may be explored by hooking up the finger behind the soft palate, or by posterior rhinoscopy, whilst

the laryngo-pharynx may be examined both by the finger and by means of the laryngoscopic mirror. The three portions of the pharynx and their methods of examination are therefore as follows:—

The naso-pharynx . .	Digital examination and posterior rhinoscopy.
The oro-pharynx . . .	Digital examination and sight.
The laryngo-pharynx .	Digital examination and laryngoscopy.

The pharynx extends from the base of the skull to the lower border of the sixth cervical vertebra or the cricoid cartilage, where it terminates by becoming directly continuous with the œsophagus. (See Figure 9.)

The pharynx lies *in front* of the basilar process of the occipital bone and the upper six cervical vertebræ; and as it lies *behind* the nose, mouth, and larynx, it is divided into three parts—nasal, oral, and laryngeal.

The Naso-Pharynx.—The naso-pharynx, or the uppermost part of the pharynx, is somewhat irregularly quadrilateral in shape, with four walls—anterior, posterior, and two lateral—none of which are movable. When the soft palate is elevated, a floor may be said to exist, and this then constitutes the only movable portion of the naso-pharynx.

The Anterior Wall.—The anterior wall of the naso-pharynx is entirely occupied by the openings of the two posterior nares, or choanæ, which connect the naso-pharynx with the nasal fossæ.

The posterior nares, or the choanæ, are two oval apertures, about one inch in length by half an inch in breadth, which are separated from each other in the middle line by the posterior free edge of the vomer.

The Posterior Wall. — The mucous membrane of the posterior wall is thickened, and embedded in it there is a quantity of lymphoid tissue, termed *the pharyngeal tonsil, or the tonsil of Luschka.* Immediately below this there is in

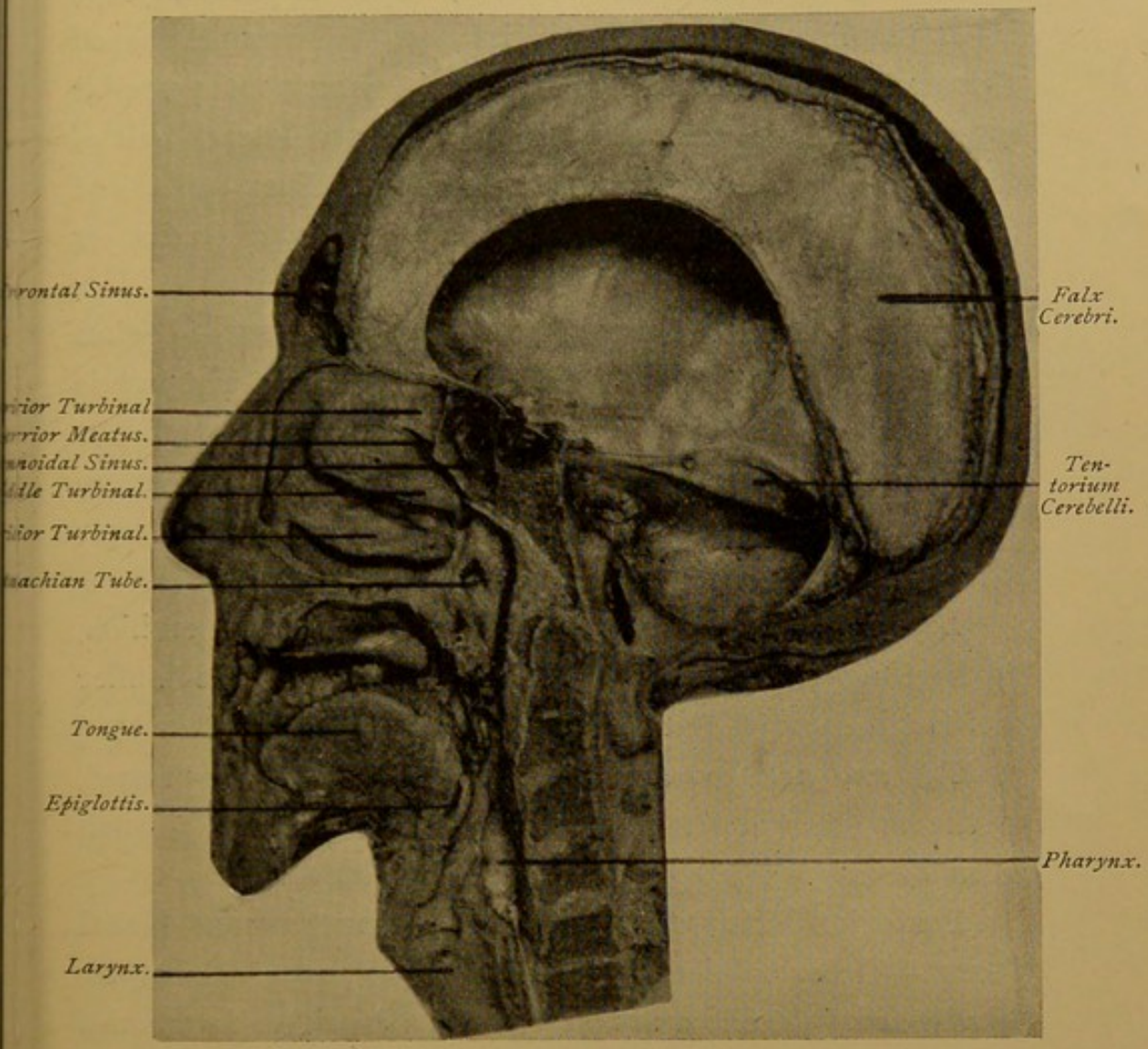

Figure 9.—Mesial Sagittal Section through the head of a formalin hardened subject.

young subjects a recess, known as the *middle pharyngeal recess.*

The Lateral Walls.—The most prominent objects in the lateral walls of the naso-pharynx are the trumpet-shaped extremities of the *Eustachian tubes.* Each tube opens into

the lateral wall of the naso-pharynx on a level with, and half an inch behind, the posterior extremity of the inferior turbinate bone of the nasal fossa.

The pharyngeal orifice of the tube is oval in form and is directed downwards and inwards, whilst its posterior edge is so prominent as to give it its peculiar trumpet-shaped appearance. Immediately behind this prominent posterior edge of the Eustachian tube there is, in the lateral wall of the naso-pharynx, a deep recess passing backwards and outwards. It is termed the *lateral pharyngeal recess, or the fossa of Rosenmüller.*

Digital Examination of the Naso-Pharynx.—Digital examination or posterior palpation of the naso-pharynx is accomplished by rapidly passing the forefinger through the mouth to the posterior wall of the pharynx, and then up behind the soft palate, until the posterior edge of the *vomer* is felt as a thin hard ridge.

Laterally the Eustachian orifice, the Eustachian cushion, the salpingo-pharyngeal fold, and the fossa of Rosenmüller can be felt, in that order from before backwards.

The *roof and posterior wall* of the naso-pharynx present, to the finger, when normal, a smooth hard surface; when adenoids are present, a soft mass is encountered.

Posterior Rhinoscopy of the Naso-Pharynx and Nasal Fossæ.—On examining the posterior nares and naso-pharynx by reflected light and a mirror, there is a considerable amount of foreshortening, but the objects which may be seen are briefly as follows (see Figure 10):—

1. The posterior surface of the uvula surmounted by an eminence—the uvula cushion—on either side of which are two other cushions—the levator cushions.

2. The posterior free margin of the vomer separating the two posterior nares, appears as a pale median ridge.

3. The posterior nares or the choanæ appear on either side of the vomer as two oval openings, through which may be seen from above downwards:—

(*a*) In some cases, the superior turbinal, appearing as a narrow ledge.

(*b*) The middle turbinal of a light red colour, and comparatively smooth surface.

(*c*) The inferior turbinal, appearing as a rounded swelling partially hidden by the soft palate.

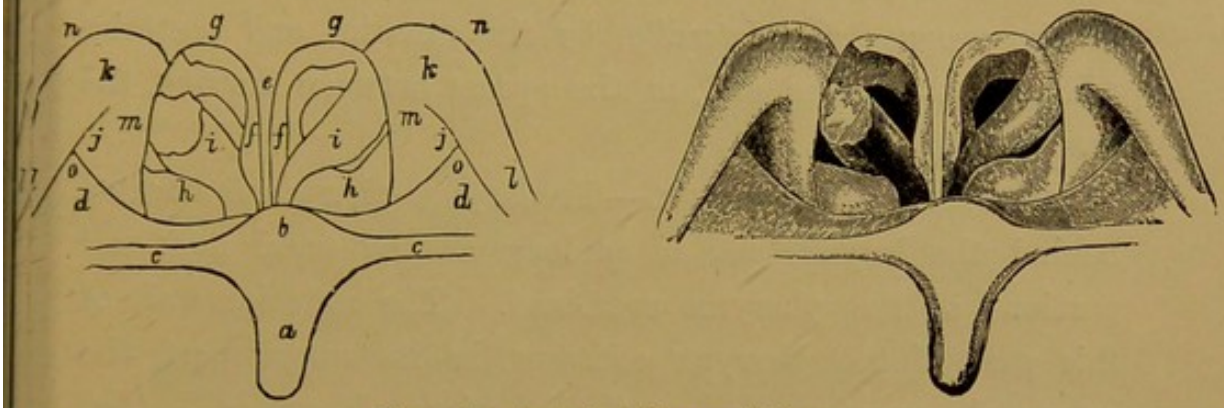

Figure 10.—Posterior Rhinoscopic View.

a. The posterior surface of the uvula.
b. The uvula cushion.
c c. The posterior margin of the soft palate.
d d. The levator cushions.
e. The posterior edge of the vomer.
f f. Swellings upon the septum nasi.
g g. The choanæ or posterior nares.
h h. The inferior turbinals.
i i. The middle turbinals.
j j. The depressions leading to the openings of the Eustachian tubes.
k k. The Eustachian cushions.
l l. The salpingo-pharyngeal folds.
m m. The salpingo-palatine folds.
n n. Positions of the upper parts of the fossæ of Rosenmüller.
o o. The posterior tubal sulci.

4. On the outer side of each choana the depression leading to the Eustachian tube appears as a light triangular area with a dark outline. Above and behind it are the Eustachian cushion and the fossa of Rosenmüller.

5. There is also seen the roof of the naso-pharynx which, when traced backwards, gradually passes into the posterior wall.

The Oro-Pharynx.—The oro-pharynx is situated behind the mouth, below the soft palate, and above the level of the base of the tongue. (See Figure 9.) Its form and size vary, on account of the mobility of its walls. In front it communicates with the mouth by means of the oral aperture of the pharynx, and below that it is bounded anteriorly by the dorsal surface of the tongue.

The oral aperture of the pharynx, or the isthmus faucium, is bounded—*above*, by the soft palate, with the uvula depending downwards from its central part; *below*, by the dorsum of the tongue; and *laterally*, by the anterior and posterior pillars of the fauces, and, in the spaces between the two, the tonsils.

The Laryngo-Pharynx.—The laryngo-pharynx is situated behind the larynx, and is as long as the nasal and oral portions of the pharynx combined. The anterior wall of this part of the pharynx contains, in its upper part, the laryngeal aperture, a vertically situated orifice. (See Figure 9.)

The *laryngeal aperture* is bounded above and in front by the epiglottis; below and behind by the arytenoid cartilages and the interarytenoid fold; and laterally by the aryteno-epiglottidean folds. (See Figure 11.)

Below the level of the laryngeal aperture the anterior and posterior walls of the pharynx are in contact.

At its lowest limit the laryngo-pharynx becomes continuous with the œsophagus by means of the œsophageal aperture. This aperture is the narrowest part of the pharynx, and is situated opposite the cricoid cartilage and the sixth cervical vertebra.

Laryngoscopic Examination of the Laryngo-Pharynx and Larynx.—Such an examination brings into view the parts which surround the superior aperture of the larynx,

its interior, and when the vocal cords are widely separated, the interior of the trachea as low down as its bifurcation. (See Figure 11.)

Between the tongue and the epiglottis can be seen the *middle glosso-epiglottidean fold* and the vallecular fossa on either side of it. Next comes a conspicuous landmark—the arched upper extremity of the *epiglottis* itself—with the prominence formed by the *cushion of the epiglottis* behind and below it.

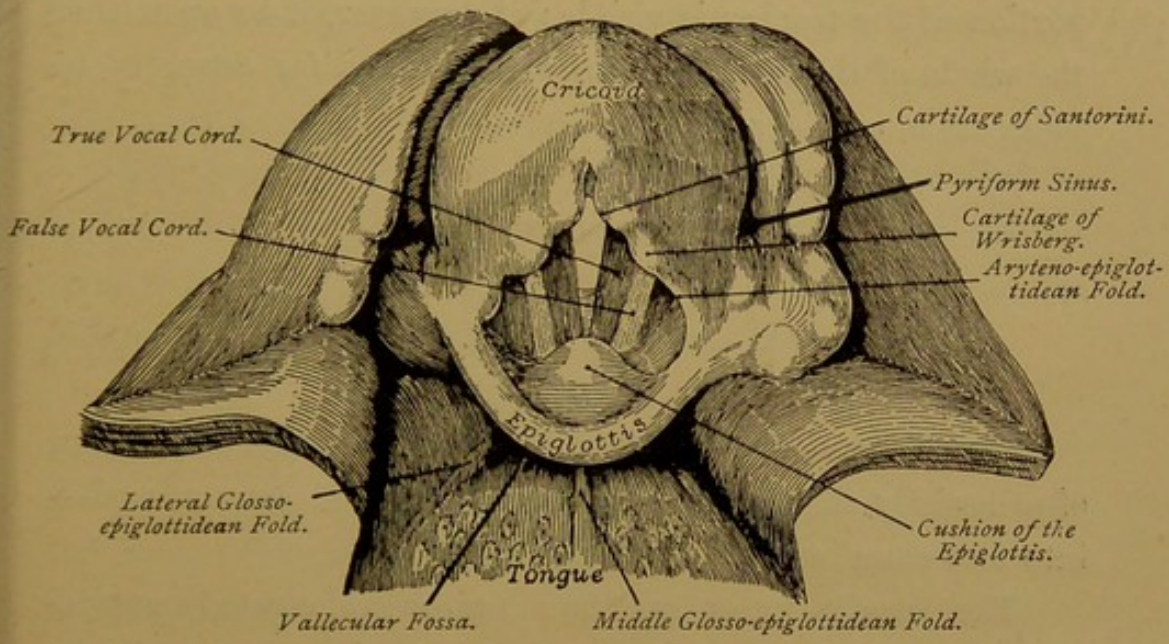

Figure 11.—The Larynx as viewed from above.

Passing from the lateral margins of the epiglottis there are, on either side, the sharp *aryteno-epiglottidean folds*, with, posteriorly, nodular thickenings corresponding to the enclosed cartilages of Wrisberg and the cartilages of Santorini. On the outer side of these cartilages can be seen the recess termed the *pyriform sinus* in which foreign bodies may lodge, whilst behind the cartilages is the *posterior wall of the pharynx.*

In the interior of the larynx the laryngoscope shows from above downwards—

(*a*) The false vocal cords, which are red and fleshy looking.

(*b*) The entrance to the laryngeal sinus appears immediately below the false vocal cord, between it and the true vocal cord, as a dark line on the side wall of the larynx.

(*c*) The true vocal cords, during phonation, appear as two tightly stretched, pearly white bands. If the rima glottidis be closed, these cords are in apposition and no portion of the trachea is visible; if, however, it be open, then the whole of the interior of the trachea, as far down as its bifurcation, can be seen.

THE NOSE.

The Nose.—The cavity of the nose is divided by means of a mesially situated vertical partition—the septum nasi—into two chambers, the nasal fossæ.

The nasal fossæ are two narrow, elongated antero-posterior chambers, which communicate in front with the external air by means of the anterior nares, and behind with the naso-pharynx by the posterior nares or choanæ. They also establish communications with the air sinuses of the surrounding bones.

The dimensions of the nasal fossæ vary in their different parts. The antero-posterior length is greater below than above, and measures near the floor about three inches.

The vertical height of each nasal fossa is greatest in the centre, where it is about one inch and three-quarters, but is rather less than this in front and behind.

The breadth of the fossa is very narrow throughout, but is greater below than above. The upper part of the fossa is very narrow—not more than one-eighth of an inch—and is usually named the *olfactory cleft*. It extends downwards as far as the lower border of the middle turbinate bone. The lower part of the fossa is somewhat wider, its width near the floor being about three-fifths of an inch. This portion of the fossa is termed the *respiratory passage*.

The Floor of the Nasal Fossa.—The floor of each nasal fossa constitutes its widest part. It is almost horizontal from before backwards, and slightly concave from side to side —points to be especially remembered in connection with the passing of a Eustachian catheter.

The Internal Wall of the Nasal Fossa, or the Septum Nasi.—The septum nasi is an osseous and cartilaginous median partition between the two nasal fossæ. It is generally more or less deviated to one or other side.

The External Wall of the Nasal Fossa.—This is the largest and the most uneven of the various nasal boundaries, its unevenness being due to the fact that projecting into the cavity of each nasal fossa from this wall are the three turbinate bones, below each of which is the corresponding meatus.

The Superior Meatus.—The superior meatus, or the ethmoidal fissure, is the smallest and straightest of the three. It is strictly limited to the posterior half of the nasal fossa, and has a blind anterior extremity.

The *posterior ethmoidal air cells* communicate with the superior meatus, commonly at its anterior extremity. Above the superior meatus there is situated the *spheno-ethmoidal recess* into which the orifice of the *sphenoidal air sinus* opens.

The Middle Meatus.—The middle meatus is larger than the superior. It extends from the posterior nares

nearly as far forwards as the anterior extremity of the nasal chamber, and on account of its curvature the middle meatus is open in front as well as below. In this meatus open the frontal, anterior ethmoidal and maxillary air sinuses.

After removal of the middle turbinal, the following parts are brought into view on the outer wall of the middle meatus (see Figure 12):—

(*a*) The *processus uncinatus*, a thin plate of bone covered by mucous membrane, passing downwards and backwards in the form of a sickle-shaped shelf.

(*b*) The *bulla ethmoidalis*, a smooth rounded eminence containing in its interior an ethmoidal cell, and lying immediately above the uncinate process.

(*c*) The *hiatus semilunaris* is the narrow interval bounded above by the ethmoidal bulla and below by the free margin of the uncinate process: it serves as the direct and only communication between the middle meatus of the nose and the infundibulum.

(*d*) The *infundibulum* is a small gutter-like channel bounded superiorly by the ethmoidal bulla and below by the uncinate process.

(*e*) The *ostium maxillare* opens into the most dependent part of the infundibulum.

(*f*) The *ostia* of some of *the anterior ethmoidal cells* open into the infundibulum, while others communicate directly with the middle meatus.

(*g*) The *naso-frontal duct* is a direct continuation of the infundibulum upwards into the frontal sinus. In some cases, however, the frontal sinus opens into the middle meatus independently of the infundibulum.

The Inferior Meatus.—The inferior meatus extends along the whole length of the hard palate. It is the longest and widest of the three.

Opening into its anterior extremity is the termination of the *nasal duct.*

The Anterior Extremity of the Nasal Fossa.—The

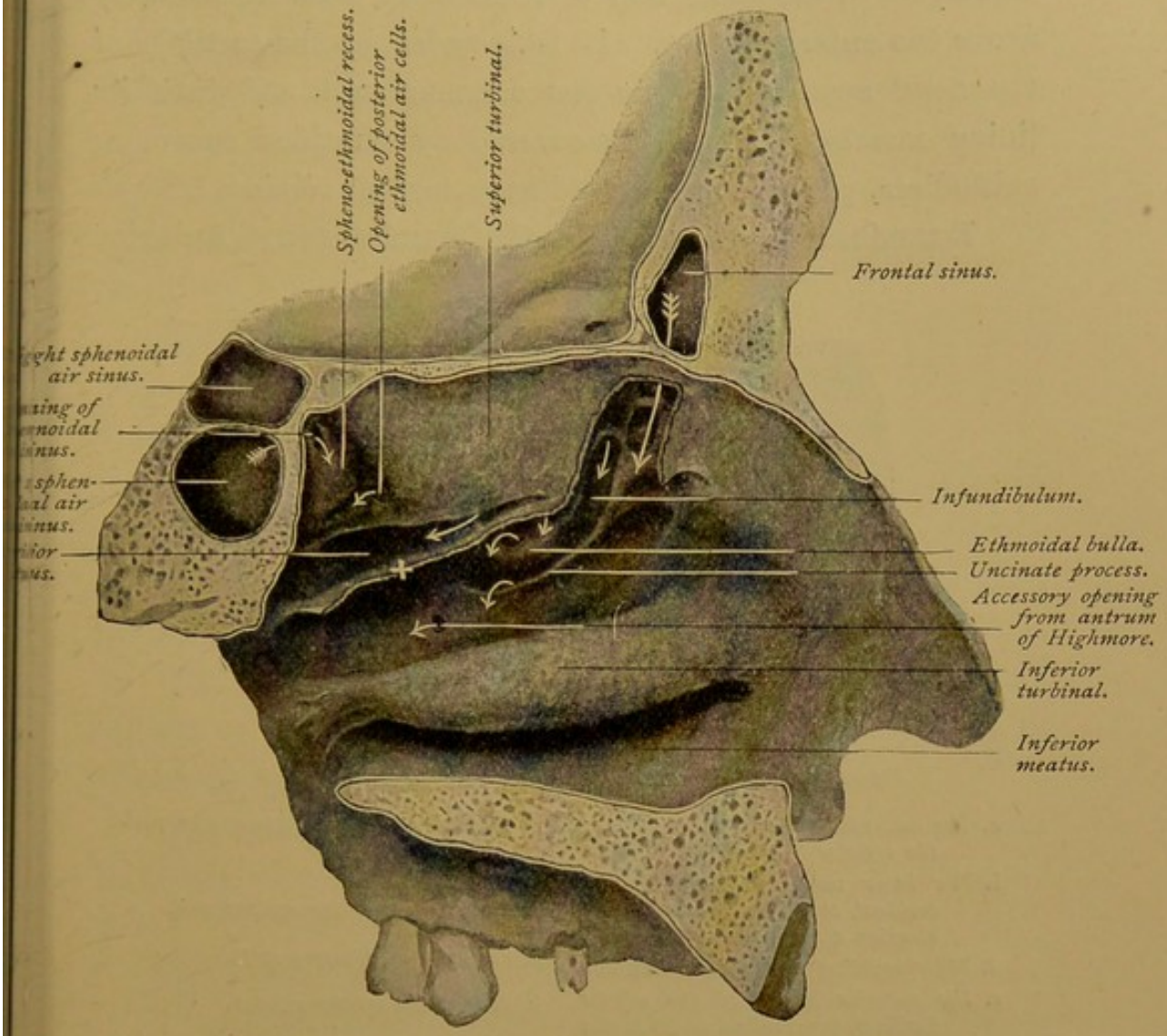

Figure 12.—Dissection showing the outer wall of the left nasal fossa.

From Logan Turner's "Accessory Sinuses of the Nose," by permission of the Author.

The various arrows indicate the positions of the orifices of the sinuses. The middle turbinal has been removed along the line indicated by the cross +.

anterior extremity of each nasal fossa presents for examination—

The anterior nares.

The vestibulum nasi.

The Anterior Nares.—The anterior nares are the anterior openings of the nasal fossæ upon the face.

The Vestibulum Nasi.—The vestibulum nasi is an oval depression in the outer wall of each nasal fossa immediately above the anterior nares. It is bounded by the cartilage of the nasal aperture and by the columna nasi, and from its lining membrane, which is covered by stratified squamous epithelium, project a number of hairs termed *vibrissæ.*

Examination of the Nasal Chambers by Anterior

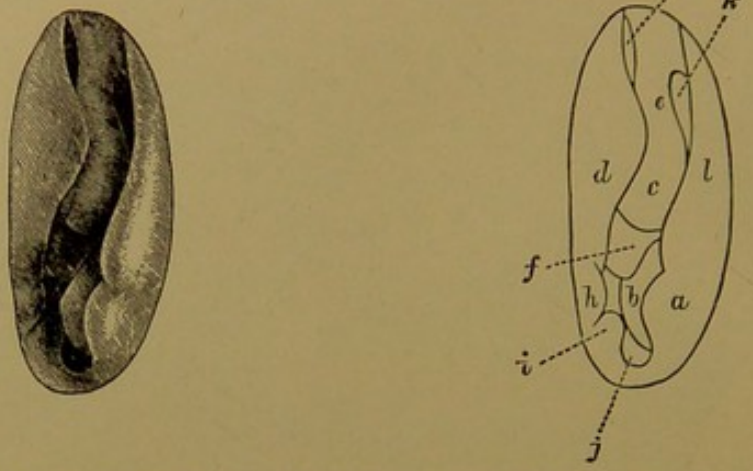

Figure 13.—Left anterior rhinoscopic view in a woman, aged 26.

a. The collapsed anterior extremity of the inferior turbinal.

b. The inner surface of the inferior turbinal, seen in perspective, and showing a rounded swelling.

l. The "neck" of the inferior turbinal.

c. The anterior border of the middle turbinal, terminating at (e) in the "neck" of the body.

f. The lower border of the middle turbinal.

d. The tubercle of the septum nasi.

g. Part of the olfactory cleft.

k. Part of the middle meatus.

hi. Swellings upon the septum nasi.

Rhinoscopy.—On examining the anterior nares by means of anterior rhinoscopy, that is by a mirror and speculum, the anterior extremity of the inferior turbinal appears (see Figure 13), as a round shining eminence with a smooth surface, projecting from the outer wall of the nasal fossa; when turgescent, it is liable to occlude the nostril by coming into contact with the septum nasi.

The inferior meatus can also be examined by bending the patient's head forwards and downwards, but the orifice of the nasal duct is never visible.

By throwing the patient's head well back, the anterior and part of the inferior border of the middle turbinal can be seen, but in actual practice a considerable part of the middle turbinal is often concealed from view by the tubercle of the septum nasi. On the inner side of the middle turbinal a portion of the olfactory cleft is visible, and on its outer side is a depression—part of the middle meatus.

The mucous membrane covering the middle turbinal is normally smooth and shining, and usually paler in colour than that of the inferior turbinal.

The septum nasi can be seen at its lower part only, as an undulating surface passing back to the posterior nares.

The floor of the nasal fossa appears as a somewhat hollow surface greatly foreshortened.

The Accessory Sinuses of the Nose.—The accessory air sinuses of the nose, all of which communicate with the air in the nasal fossæ, are as follows:—

The frontal air sinuses—communicating with the middle meatuses of the nasal fossæ by means of the naso-frontal ducts.

The ethmoidal cell labyrinth—

Anterior ethmoidal air cells—communicating with the middle meatuses of the nasal fossæ.

Posterior ethmoidal air cells—communicating with the superior meatuses of the nasal fossæ.

The sphenoidal air sinuses—communicating with the spheno-ethmoidal recesses above the superior meatuses of the nasal fossæ.

The antra of Highmore—communicating with the middle meatuses of the nasal fossæ.

The Frontal Air Sinuses.—The frontal air sinuses are two cavities situated between the outer and inner tables of the frontal bone above the root of the nose and the inner ends of the eyebrows. (See Figure 14.) They extend upwards and outwards upon the forehead and backwards along the roof of the orbit, and are subject to very considerable

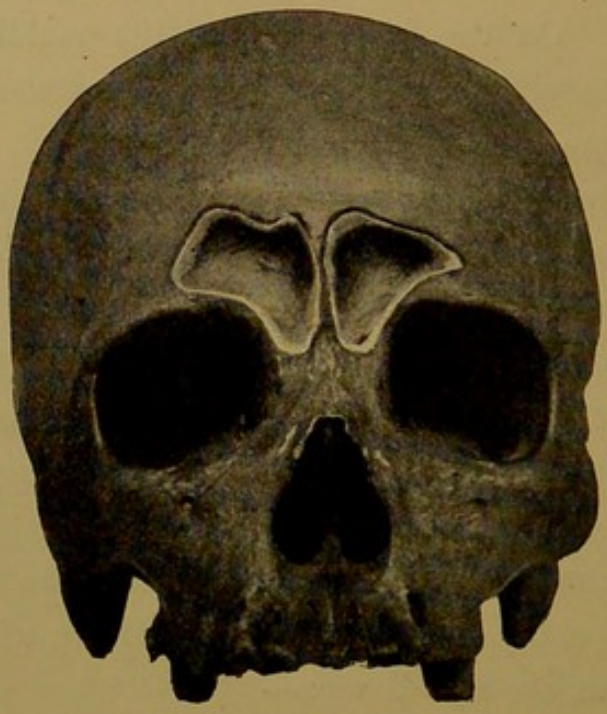

Figure 14.—The Frontal Air Sinuses.

From Logan Turner's "Accessory Sinuses of the Nose," by permission of the Author.

The anterior walls of both frontal sinuses are removed, and the two cavities are of average dimensions. The septum is mesial in position.

variations in size and shape, varying, in different individuals, from a mere recess above the nose, to a cavity of two inches or more; but as a general rule they are larger in the male than in the female, and are absent at birth.

According to Logan Turner, an average-sized frontal air sinus measures one and a quarter inches vertically upwards from the lower end of the fronto-maxillary suture; one inch in breadth from the mesial septum horizontally outwards;

and three-quarters of an inch from the anterior wall of the cavity, backwards along the orbital roof.

Each frontal sinus is separated from its fellow by an osseous septum, which is almost invariably complete, and which may, or may not, be mesial in position.

The lower part of each sinus tapers downwards into the fronto-nasal duct, a narrow passage which leads downwards and backwards through the anterior part of the lateral mass of the ethmoid into the middle meatus of the nose, in which it terminates on about the same horizontal level as the palpebral fissure.

The Ethmoidal Cell Labyrinth.—The ethmoidal cell labyrinth is mainly contained in the lateral mass of the ethmoid bone, but may overflow into the frontal, sphenoid, and superior maxillary bones. It is divided into two groups of air cells—anterior and posterior—which do not usually communicate with each other.

The *anterior ethmoidal air cells* open, some directly into the middle meatus, others into the infundibulum, and thence through the hiatus semilunaris, into the meatus. One of these cells is specially named the ethmoidal bulla and another the frontal bulla.

The *posterior ethmoidal air cells* open into the back part of the superior meatus of the nose.

The Sphenoidal Air Sinuses.—Each sphenoidal air sinus occupies the anterior portion of the body of the sphenoid. The two sinuses are separated by a mesial osseous partition, and communicate anteriorly with the spheno-ethmoidal recess above the superior meatus of the nose.

The Antra of Highmore.—The antra of Highmore, or the maxillary sinuses, are the cavities constantly present in the bodies of each upper jaw. (See Figure 15.) The inner or nasal wall of each antrum is formed by the outer wall of

the nasal fossa, and contains at its upper part the maxillary opening leading into the middle meatus of the nose. The

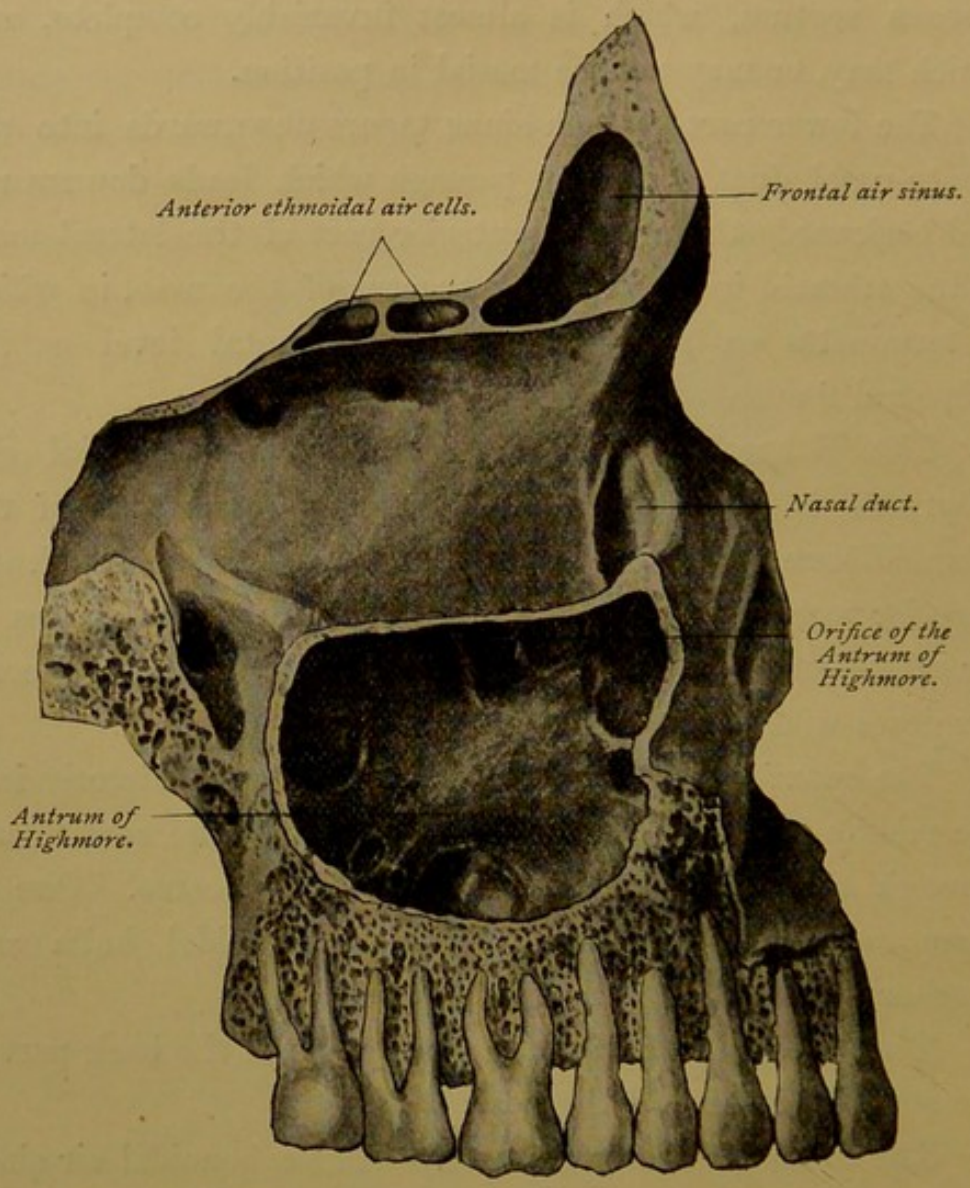

Figure 15.—A dissection showing the right Antrum of Highmore opened upon its outer aspect.

From Logan Turner's "Accessory Sinuses of the Nose," by permission of the Author.

apex is directed towards the malar bone; the floor is very frequently below the level of the floor of the nasal fossa.

The antral or maxillary orifice is situated at the highest part of the inner wall or base of the antrum, and is therefore

most unfavourably situated for natural drainage. It opens into the middle meatus of the nose.

The site of election for the opening and draining of an antral abscess is through the alveolus of the first molar tooth. Other situations are through the canine fossa and the outer wall of the inferior meatus of the nose.

Examination of the Air Sinuses by Transillumination.—The antrum of Highmore may be examined on the living subject by light transmitted from an electric lamp inserted in the patient's mouth. This mode of examination is principally employed clinically as an aid to diagnosis.

The frontal air sinus also may be examined by means of light transmitted through the sinus from a lamp placed against the skin covering the floor of the sinus immediately below the inner third of the supra-orbital margin. When contact is made, the position of the frontal sinus is indicated as an illuminated area, and the osseous septum between the two sinuses by the junction between light and darkness.

THE EYE.

The Eyelids.—At the free margin of each eyelid the skin passes into the palpebral conjunctiva along the line of the eyelashes. Along the anterior or cutaneous border of each eyelid are the eyelashes and the orifices of the sebaceous glands, suppurative inflammation of which produces hordeolum or stye. Along the posterior or conjunctival edge of each eyelid are the minute orifices of the Meibomian glands, obstruction of any one of which produces a tarsal cyst.

The Palpebral Fissure.—The palpebral fissure, or the fissure between the eyelids, is somewhat oval in outline, with an average length of 30 mm., or one inch and a quarter. Externally, the two lids meet at an acute angle, termed the *external canthus*, but internally the palpebral fissure is prolonged downwards and inwards for about a fifth of an inch between portions of the lid margins, which are straight and rounded—the *internal canthus*.

At the inner canthus, at the junction of the curved and straight portions of the palpebral fissure, is a slight elevation, the *papilla lacrimalis*, better marked in the lower lid than the upper, and on the summit of each papilla is the minute opening—the *punctum lacrimale*—of the canaliculus, or canal by means of which the lachrymal fluid is conveyed into the lachrymal sac.

In the neighbourhood of the inner canthus the lids are separated from the eyeball by the *caruncula lacrimalis*, a somewhat red fleshy-looking portion of skin.

The lids can be readily everted, the lower one by simply pulling it downwards, and the upper one by turning it upwards over a probe. This exposes both the palpebral and ocular conjunctivæ, which can thus be readily examined. In health the *palpebral conjunctiva* should be red and velvety, whilst the *ocular conjunctiva* should be transparent, smooth, and contain but few blood vessels. The *Meibomian glands* appear through the palpebral conjunctiva as lines of yellowish granules arranged perpendicularly to the edges of the lids.

On drawing the eyelids forcibly outwards, the *internal tarsal ligament* can be felt as a tense band between the inner canthus and the nasal process of the superior maxilla at the inner margin of the orbit. Behind this ligament and at a slightly higher level is the *lachrymal sac*, into which the

canaliculi from the puncta lacrimalia open. The *canaliculi* pass from the puncta lacrimalia at first vertically, and then almost horizontally, the one above, the other below, the internal tarsal ligament, to their termination in the lachrymal sac.

The *lachrymal sac* lies behind the internal tarsal ligament, and can be opened by an incision made immediately below the latter structure, after which a probe may be passed, downwards and slightly backwards and outwards, along the nasal duct into the inferior meatus of the nose.

Ophthalmoscopic Examination of the Normal Fundus Oculi.—In the examination of the normal fundus oculi

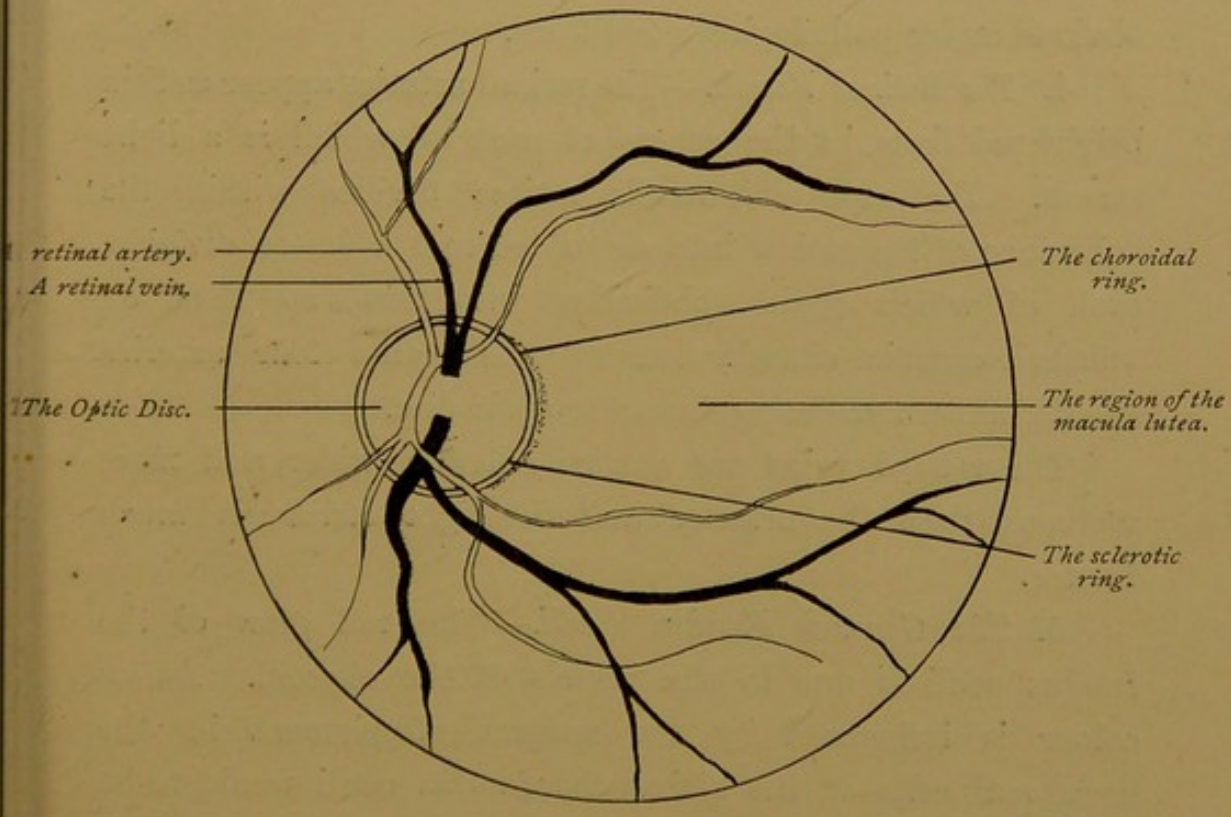

Figure 16.—The Normal Fundus Oculi.

by means of either direct or indirect ophthalmoscopy the structures to be especially examined are as follows (see Figure 16):—

1. *The Papilla or Optic Disc.*—The papilla or optic disc appears as a somewhat pale pink disc, slightly oval in shape, with the long axis vertical. Around the disc is a more or less complete white ring—the sclerotic ring—outside which again there is occasionally a black ring—the choroidal ring.

2. *The Macula Lutea.*—The macula lutea or the yellow spot appears as a bright oval ring, with its long axis horizontal; it is situated on the outer side of the optic disc, in the direct line of vision. In the centre of the macula lutea may sometimes be seen an intensely red point—the fovea centralis.

3. *The Normal Retina.*—The normal retina cannot usually be seen on account of its translucency; it becomes more obvious under pathological conditions.

4. *The Retinal Vessels.*—The retinal arteries appear as thin bright red lines, in the centre of each of which is a light streak. The arteria centralis retinæ divides within the substance of the retina into an upper and a lower division, each of which again subdivides into two, so that on ophthalmoscopic examination of the retina four arteries should be seen radiating from the optic disc.

The retinal veins are normally darker, wider, and more tortuous than the arteries, and the light streak is much fainter.

5. *The General Fundus Oculi.*—The red glow of the fundus oculi is due to the vessels of the choroid. As its colour is influenced by the amount of pigment in the hexagonal cells of the retina, the fundus oculi tends to be darker in dark persons, and lighter in fair persons.

THE EAR.

The Ear. — The portions of the auditory apparatus visible from without are the auricle or pinna, the external auditory meatus, and the membrana tympani—the last by means of a speculum and mirror. Of these the pinna requires no special description.

The External Auditory Meatus.—The external auditory meatus passes generally downwards, forwards, and inwards from the concha to the membrana tympani. Its length from the tragus is nearly one inch and a half. It is not a straight canal but is curved something like the letter S, the most external part inclining inwards, forwards, and slightly upwards, the middle part inwards and backwards, and the innermost part, the longest of all, and the one in which foreign bodies are apt to lodge, passing inwards, forwards, and slightly downwards. To straighten the canal for the introduction of specula and other instruments, the pinna should be drawn upwards and a little outwards.

The external auditory meatus has many relations, some of the more important of which from a practical standpoint are as follows:—

Above, the external auditory meatus is in relation to the cranial cavity, hence abscess or bony disease in this region may be followed by meningitis.

In front of the external auditory meatus are part of the parotid gland and the temporo-maxillary articulation, hence the pain on mastication in acute inflammations of the meatus and middle ear.

Behind the meatus are the mastoid process, some of the mastoid cells, and part of the lateral sinus.

The Membrana Tympani.—The membrana tympani is an elliptical disc which separates the external auditory meatus from the middle ear or tympanum. It is obliquely placed, forming with the horizon an angle of 45° to 55°. It is said to be most oblique in cretins and deaf mutes and most perpendicular in musicians.

Otoscopic Examination of the Membrana Tympani.—The membrana tympani appears in the living and healthy subject of a bluish-grey colour with a somewhat polished surface. At the upper and anterior part of the membrane, close to its periphery, the *short process of the malleus* appears as a whitish knob-like point apparently projecting towards the observer. From this point the *anterior and posterior tympano-malleolar folds* appear as two ridges passing, the one, forwards and upwards, the other, backwards and upwards, to the periphery. (See Figure 17.) They correspond to the line of the chorda tympani nerve, and are caused by the projection of the short process of the malleus, and with it form the lower boundary of that portion of the membrana tympani known as *Shrapnell's membrane*. From the same point, the *handle of the malleus* can be seen as a ridge passing downwards and backwards to the *umbo* or point of maximum concavity of the membrane. From the umbo or lower end of the handle of the malleus, the cone of light extends downwards and forwards to the periphery.

Sometimes in normal conditions the long process of the incus may be seen through the membrane behind the handle of the malleus, and running more or less parallel to it, whilst if the membrane be very transparent or atrophied, other intra-tympanic structures may become visible, such as the incus-stapes joint, or the chorda tympani nerve itself.

For descriptive and clinical purposes it is customary to subdivide the membrane as follows:—

By prolonging the handle of the malleus, by means of an imaginary line, downwards and backwards, to the periphery,

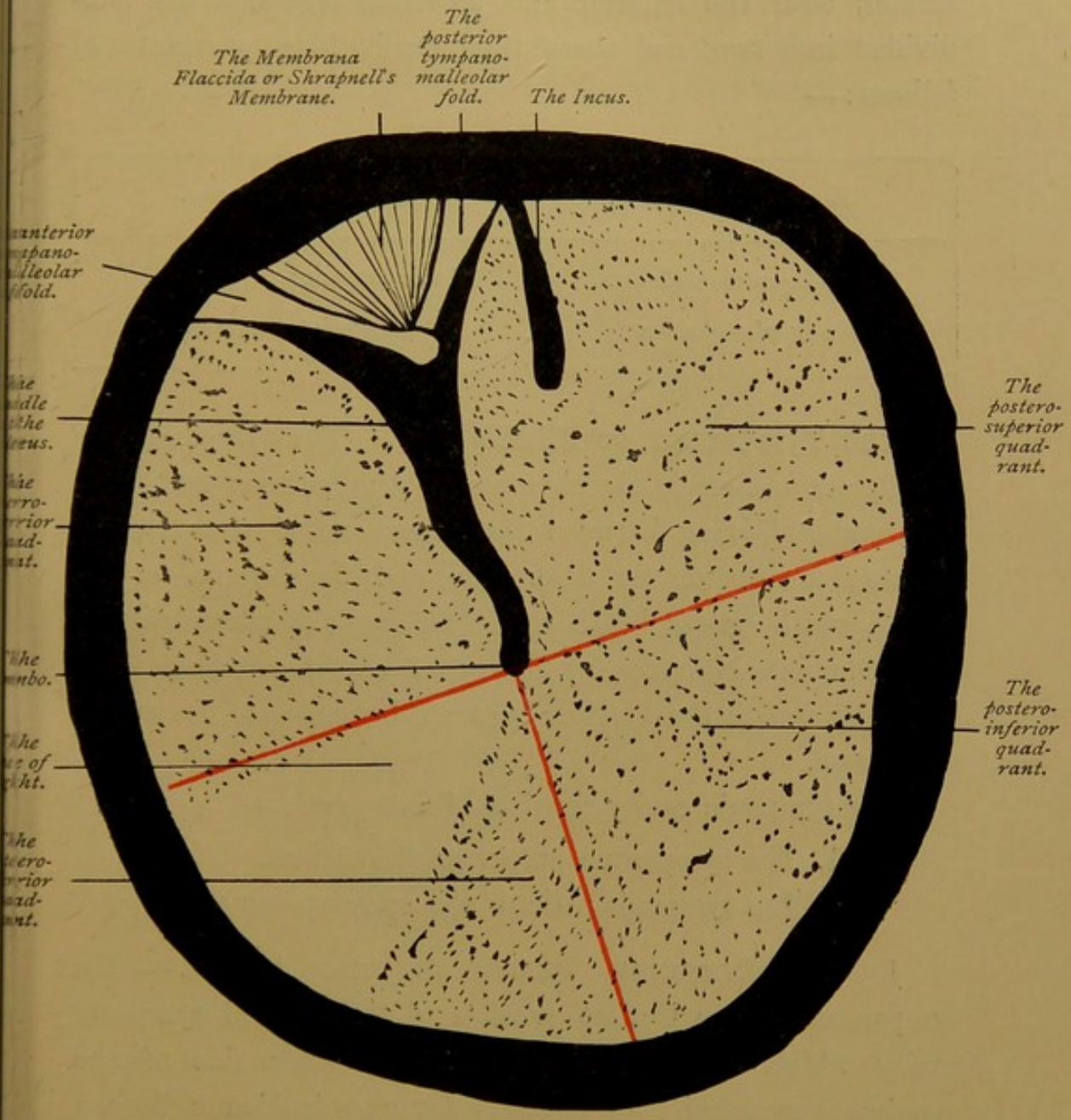

Figure 17.—The external surface of the left Membrana Tympani. (Modified from Hensman.)
The imaginary lines employed clinically to subdivide the membrane into four quadrants are indicated in red.

the membrana tympani is at once subdivided into a small anterior segment and a large posterior segment.

By bisecting the line formed by the handle of the

malleus and its imaginary downward prolongation by means of a second imaginary line drawn at right angles to the former, both the anterior and posterior segments are subdivided into two, and there thus result four quadrants, as follows :—

Posterior Segment.	Anterior Segment.
Postero-superior quadrant.	Antero-superior quadrant.
Postero-inferior quadrant.	Antero-inferior quadrant.

The Tympanum or Middle Ear.—The tympanum or middle ear is a small air chamber in the petrous portion of the temporal, lying between the inner end of the external auditory meatus on its outer side, and the internal ear or the labyrinth on its inner side. In front it communicates with the naso-pharynx by means of the Eustachian tube, and behind with the mastoid antrum by means of the aditus ad antrum.

The tympanic cavity consists of two parts :—

1. The tympanum proper or the atrium.
2. The tympanic attic or the epitympanic space.

1 The Tympanum Proper or the Atrium. — The tympanum proper is that portion of the general tympanic cavity which lies immediately to the inner side of the membrana tympani. It presents for examination a floor, a roof, and four lateral walls. (See Figure 18.)

The Floor.—The floor of the tympanic cavity measures about 4 mm. from without inwards. It is formed by a thin plate of bone which separates it posteriorly from the jugular fossa and the commencement of the internal jugular vein, and anteriorly, from the carotid canal and the internal

carotid artery. These relations are of the utmost practical importance in all cases of otitis media.

The Roof.—The roof of the tympanic cavity measures about 6 mm. from without inwards. It is formed by the thin osseous sheet termed the *tegmen tympani* which separates

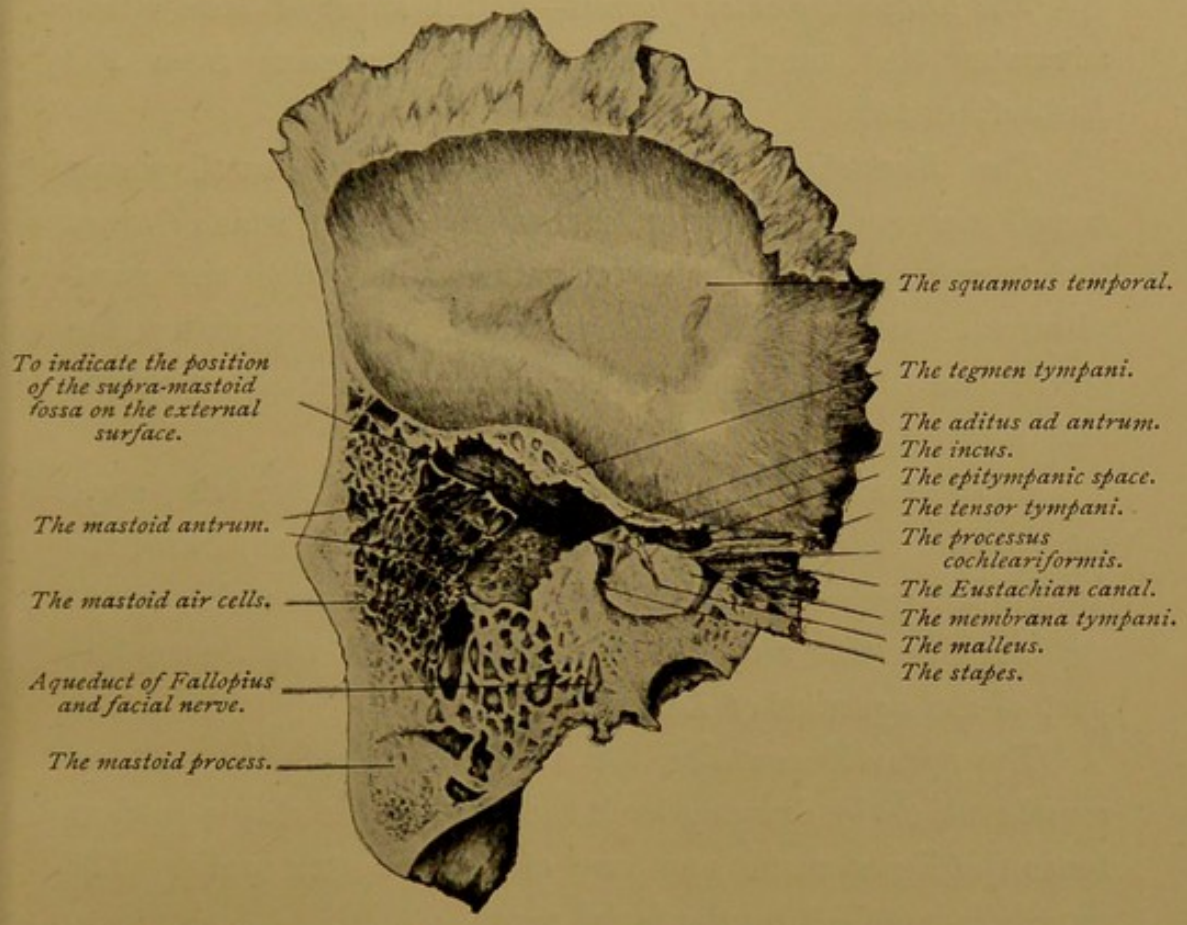

Figure 18.—The outer half of a longitudinal section through the petrous portion of the left temporal bone, drawn from nature by Mr. E. O. Bowen. The preparation is seen from within.

it from the temporal lobe of the brain. This relationship, together with the fact that the petro-squamous suture which limits the tegmen tympani externally, remains unossified for some years after birth, helps to explain the occurrence of abscesses of the temporal lobe of the brain after middle ear disease.

The Anterior Wall.—The narrow anterior wall of the tympanic cavity presents from above downwards—

The *canal for the tensor tympani muscle*—a muscle which renders the membrana tympani tense and is supplied by a branch from the otic ganglion on the inferior maxillary division of the fifth cranial nerve.

The *processus cochleariformis*—a thin sheet of bone which separates the canal for the tensor tympani from the Eustachian tube.

The *Eustachian tube* — an osseous and cartilaginous canal, one and a quarter inches in length, which brings the tympanum into direct communication with the naso-pharynx. It is this communication which explains the occurrence of otitis media after such diseases as scarlatina and measles.

The Posterior Wall.—The posterior wall of the tympanum proper lies below the aditus ad antrum, and separates the middle ear from the mastoid air cells. The most important structures in this wall are the *pyramid* and the descending part of the *aqueduct of Fallopius.*

The pyramid contains the stapedius muscle in part—a muscle which by drawing back the head of the stapes renders tense the ligamentum annulare of the fenestra ovalis. The muscle is supplied by the facial nerve.

The aqueduct of Fallopius contains the seventh cranial or facial nerve.

The External Wall.—The external wall of the tympanum proper is formed by the membrana tympani, and is the only movable wall of the cavity.

The Internal Wall.—The inner wall of the tympanic cavity corresponds to the outer wall of the internal ear or the labyrinth. The chief objects in this wall are as follows :—

The *promontory*—a rounded eminence produced by the first coil of the cochlea.

The *fenestra ovalis*—an oval aperture situated above and behind the promontory, with its long axis directed from before backwards. In the living subject the aperture is closed by the foot of the stapes and the ligament which surrounds it, namely, the ligamentum annulare. In the macerated skull the fenestra ovalis leads into the vestibule of the internal ear.

The *fenestra rotunda*—an irregularly oval aperture below the fenestra ovalis, leading into the cochlea, and closed in the living subject by the membrana tympani secundaria.

2. The Tympanic Attic or the Epitympanic Space.—The tympanic attic or the epitympanic space is that portion of the general tympanic cavity which lies above the level of the upper margin of the membrana tympani. It contains from before backwards the head of the malleus and the body and short process of the incus.

It communicates posteriorly with the mastoid antrum by means of a triangular opening—the aditus ad antrum.

The *aditus ad antrum* has its *base* uppermost, and is there bounded by the tegmen tympani; the *apex* is below, and is formed by the meeting of the inner and outer walls; the *external wall* is formed by the innermost part of the superior and posterior osseous meatal walls, whilst the *internal wall* is formed (1) by an eminence of compact bone, containing the external semicircular canal, below and in front of which is (2) a smaller eminence formed by that portion of the aqueduct of Fallopius (facial nerve) which passes backwards above the fenestra ovalis.

The Mastoid Antrum.—The mastoid antrum is an air

chamber, situated in the interior of the mastoid portion of the temporal bone. It is to be regarded as a backward and upward extension of the tympanic cavity, with the upper part of which—the epitympanic space—it communicates by means of the aditus ad antrum. Surrounding the mastoid antrum and opening into it there are, in the adult, the mastoid air cells. It is thus obvious that the air in the mastoid air cells communicates with the external air by way of the mastoid antrum, the aditus ad antrum, the epitympanic space, the tympanum, the Eustachian tube, the naso-pharynx, and the nasal fossæ.

As a general knowledge of the evolution of the mastoid process, antrum, and air cells is of the utmost practical importance, it is necessary to study these structures at different periods of life.

(*a*) At Birth.—At birth the mastoid antrum is alone present. The mastoid process and the mastoid air cells do not make their appearance until a later period of life.

In the new-born infant the mastoid process, as just stated, has no existence, but in the petro-mastoid segment of the temporal bone there is a single air cell or cavity—the mastoid antrum—which even at this early period communicates quite freely with the epitympanic space in the manner already indicated.

The mastoid antrum is relatively, in the newly born child, almost as large as in the adult, having a vertical measurement of 7–9 mm. and a transverse of 9–11 mm. At this period of life the mastoid antrum is bounded as follows:—

Above, by the tegmen tympani.

Below, by the petro-mastoid.

In front, the antrum communicates with the epitympanic recess by means of the aditus ad antrum.

Behind, by the petro-mastoid and the post-auditory process of the squamo-zygomatic portions of the developing temporal bone, the two portions being united at the masto-squamosal suture.

Externally, by the post-auditory process of the squamo-zygomatic portion of the temporal, this wall having at birth a thickness of only 1–2 mm.

Internally, by the petro-mastoid.

(*b*) At Two Years.—At two years of age the mastoid process makes its appearance as a slight projection from the petro-mastoid. It gradually grows downwards to form a cephalic lever for the sterno-mastoid, splenius capitis, and trachelo-mastoid muscles which are inserted into it. The period of its most active growth coincides with the eruption of the permanent teeth. As the post-auditory process of the squamo-zygomatic forms a considerable part of the developing mastoid process, namely, its anterior border down to its apex, it follows that the adult mastoid process is developed from two portions of the fœtal temporal bone, to wit, the squamo-zygomatic and petro-mastoid.

Coincidently with the appearance and growth of the mastoid process its diploic spaces enlarge to form the mastoid air cells, those around the mastoid antrum coming to open into it, and the more distant ones remaining permanently closed.

(*c*) In the Adult.—In the adult the mastoid process is fully formed; its interior contains the mastoid antrum surrounded by the mastoid air cells.

The Mastoid Antrum.—The mastoid antrum in the adult is liable to considerable variations in size, but its average dimensions are about 10 mm. in the vertical diameter, 10–15 mm. in the antero-posterior diameter, and about 4–6 mm. in the transverse. Its depth from the surface,

that is the thickness of its external wall, varies from 7–14 mm.

The boundaries of the adult mastoid antrum are as follows:—

The Roof.—The roof is formed by the tegmen tympani, a thin layer of bone not more than 1 mm. in thickness, and which alone separates the mastoid antrum from the middle cerebral fossa and the temporal lobe of the brain. The osseous roof not infrequently presents small deficiencies through which the mucous membrane of the antrum and the dura mater become directly continuous, whilst in addition the petro-squamous fissure—the remains of the suture of the same name—is also present in the roof of the antrum, consequently it is easy for inflammatory mischief in the mastoid antrum to spread to the cranial cavity and involve the brain.

The roof of the antrum usually lies on the same level as the supra-mastoid crest, but is, not infrequently, even higher than that.

The Floor.—The floor of the mastoid antrum is on a lower level than the aditus ad antrum—the aperture of communication between the antrum and the epitympanic space—and is therefore very unfavourably placed for natural drainage.

In Front.—In the upper part of the anterior wall of the antrum there is the triangular aperture of communication between it and the epitympanic space — the aditus ad antrum. This opening will usually admit an instrument with a diameter of 0·5 cm. Below the level of the aditus there is, in the anterior wall of the mastoid antrum, a thin sheet of bone which separates it from the most internal part of the posterior wall of the external auditory meatus.

Behind. — Posteriorly the mastoid antrum is only separated from the vertical portion of the lateral sinus by

a lamina of bone 5–10 mm. thick, containing some of the mastoid air cells, consequently thrombosis of the lateral sinus is a possible sequela of middle ear disease.

Externally.—The external wall of the mastoid antrum is formed by the upper portion of the mastoid process, from the surface of which it is separated by about a distance of from 7–14 mm.

Internally.—The inner wall of the mastoid antrum is formed by spongy bone, which separates it from the posterior semicircular canal.

Trephining the Mastoid Antrum. — Trephining the mastoid antrum is an operation undertaken for the evacuation of pus, consequent, most usually, on middle ear disease. The object of the operation is the establishment of free drainage.

The mastoid antrum is reached from the exterior by perforating the mastoid process close to the upper and posterior part of the external auditory process in what is known as *MacEwen's "supra-meatal fossa."* (See Figure 19.) This fossa is bounded as follows :—

Above, by the supra-mastoid crest.

Below and in front, by the postero-superior quadrant of the outer margin of the external auditory meatus.

Behind, by a vertical line tangential to the hindmost point of the external auditory meatus.

In drilling or chiselling through the bone within this area, there are three most important things to be avoided :—

1. The middle cerebral fossa and the brain.

   Avoided by keeping below the supra-mastoid crest.

2. The lateral sinus.

   Avoided by keeping close to the external

auditory meatus, or, in other words, chiselling obliquely to the surface.

3. The facial nerve.

Avoided by not encroaching upon the lower half of the posterior wall of the external auditory meatus.

In order to secure free drainage after trephining the antrum, the operation is extended into the epitympanic space

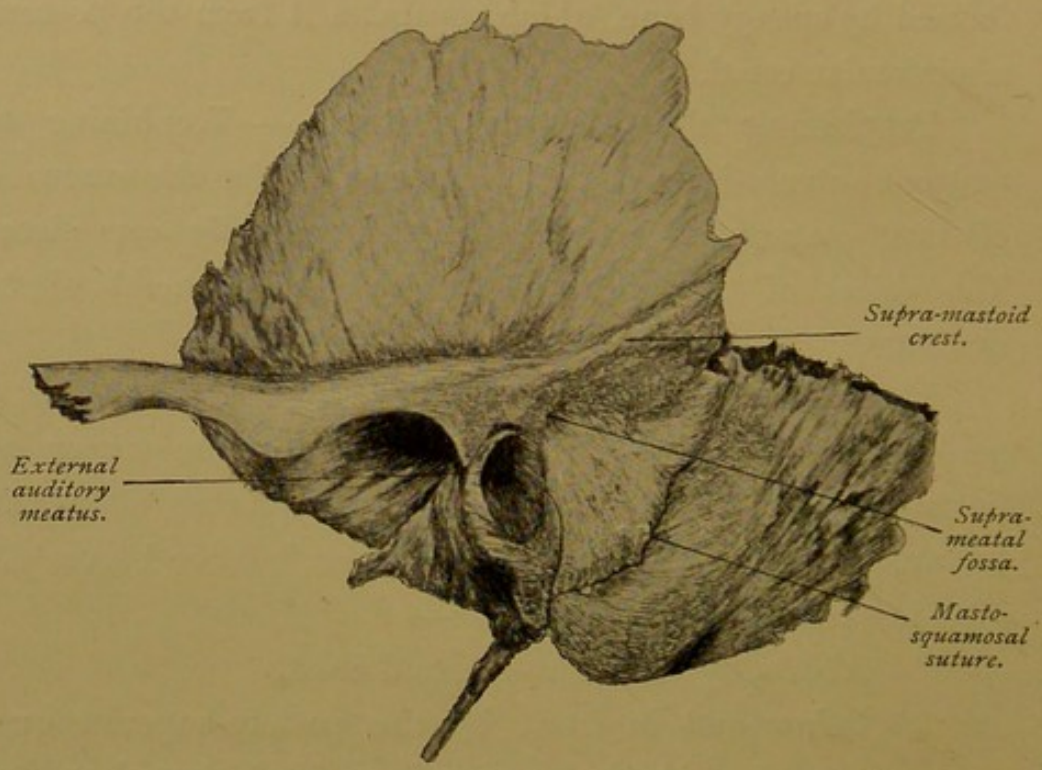

Figure 19.—The outer surface of the left temporal bone, drawn from nature by Mr. E. O. Bowen. To show the supra-meatal fossa.

by cutting away the bone on the outer side of the aditus ad antrum. In doing this the greatest care must be taken to avoid damaging the structures on the inner side of that aperture, namely, the external semicircular canal and the facial nerve in its aqueduct. This is usually done by inserting a Stacke's protector through the aditus, from the antrum to the epitympanic space, and working on the outer side of that instrument.

II.

THE THORAX.

THE THORACIC PARIETES.

The Supra-Sternal Notch.—The supra-sternal notch lies in the middle line between the sternal ends of the clavicles and immediately above the upper border of the manubrium sterni. On either side of the notch are the sternal heads of the sterno-mastoid muscles.

The Sternal Furrow.—The sternal furrow or groove is the slight furrow situated in the anterior mesial line in front of the sternum and between the origins of the two great pectoral muscles. It extends from the supra-sternal notch above to the infra-sternal fossa below.

The Infra-Sternal Fossa.—The infra-sternal fossa is the well-marked though variable depression, situated at the lower end of the sternal furrow in front of the ensiform process and between the seventh costal cartilages and the upper ends of the recti abdominis muscles.

The Sternum.—The sternum lies in the middle line of the body at the bottom of the sternal furrow, and is subcutaneous throughout.

The Manubrium Sterni.—The *upper border* of the manubrium sterni is easily felt at the lower margin of the supra-sternal notch. At the end of the act of expiration it lies opposite the disc between the bodies of the second

and third dorsal vertebræ, and forms the uppermost of the four bony points employed in Addison's method of delimiting the abdomen.

The *lower border* of the manubrium sterni, at its junction with the body of the sternum, forms a well-marked and easily determined transverse ridge, termed the sternal angle or the *angle of Ludwig*. This angle lies exactly opposite the second costal cartilages, and is therefore of the utmost importance in the counting of ribs. It lies opposite the body of the fifth dorsal vertebra.

The *anterior surface* of the manubrium sterni is subcutaneous throughout.

The Body of the Sternum.—The body of the sternum extends from the angle of Ludwig above, to the xiphi-sternal articulation below, and is subcutaneous throughout.

The Ensiform Process or the Xiphi-Sternum.—The xiphi-sternum lies at the bottom of the infra-sternal fossa, opposite the body of the tenth dorsal vertebra, whilst the xiphi-sternal articulation itself is situated about opposite the lower part of the ninth dorsal vertebra.

The Ribs.—The ribs are easily felt and counted in thin individuals, and with difficulty in obese persons.

The first rib being inaccessible, locate the second rib from the angle of Ludwig, and count obliquely downwards and outwards.

The second rib lies opposite the angle of Ludwig.

The fifth rib may be roughly located by tracing the lower border of the pectoralis major inwards to the chest.

The sixth, seventh, and eighth ribs are, under ordinary circumstances, the most exposed, and consequently the most liable to injury.

The seventh rib is the longest.

The ninth rib is the most oblique.

The eleventh and twelfth ribs are floating ribs, their anterior extremities being free and unattached.

The tip of the twelfth rib most usually lies about two inches above the centre of the iliac crest, and is easily felt. This distance is increased on lateral flexion of the vertebral column.

The Costal or Subcostal Angle.—The costal or subcostal angle is the angle formed immediately below the sternum by the lower rib cartilages. It is bounded on each side, and in regular sequence from above downwards, by the seventh, eighth, ninth, and tenth rib cartilages, whilst its apex is occupied by the ensiform process of the sternum. The two sides of the subcostal angle are usually, and normally, inclined towards each other in such a way as to form a right angle (90°).

The Internal Mammary Artery.—The internal mammary artery descends behind the upper six costal cartilages parallel to, and half an inch from, the lateral border of the sternum. At the sixth intercostal space it terminates, by dividing into superior epigastric and musculo-phrenic arteries.

The Intercostal Arteries.—The chief intercostal artery in each space is concealed (from the angle onwards) by the numerically corresponding rib.

Thoracic Lines.—Clinicians employ certain vertical and transverse thoracic lines for convenience in topographical description. (See Figure 20.)

The *vertical thoracic lines*, eight in number, are as follows :—

The mid-sternal line.

The lateral sternal line.

The para-sternal line—drawn midway between the lateral sternal and the mid-clavicular lines—cuts the costal margin opposite the tip of the eighth costal cartilage.

The mid-clavicular or mammillary line—coincides

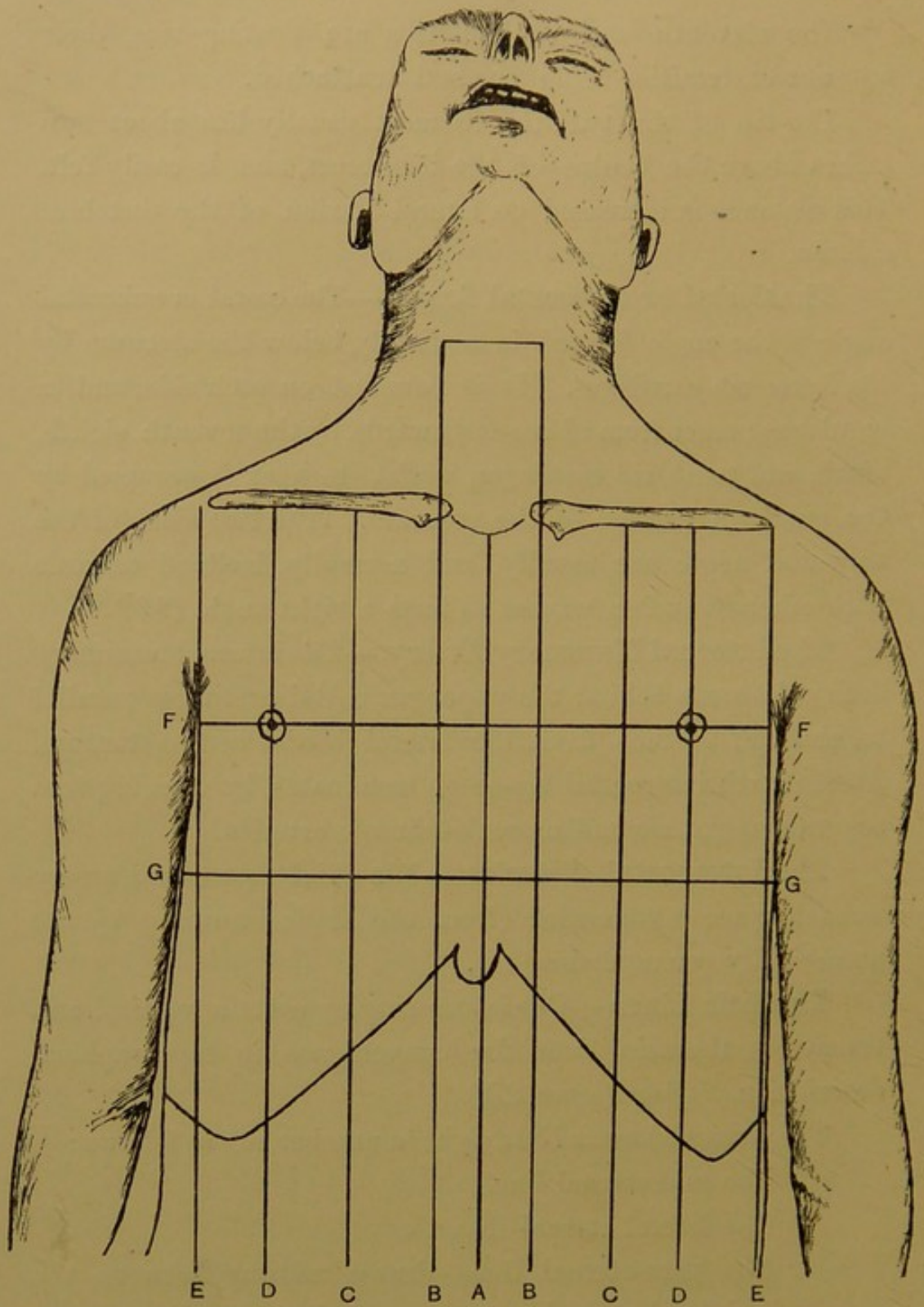

Figure 20.—The Thoracic Lines mapped out on the body. Drawn from nature by Mr. E. O. Bowen.

A. *The mid-sternal line.*
B B. *The right and left lateral sternal lines.*
C C. *The right and left para-sternal lines.*
D D. *The right and left mammillary lines.*
E E. *The right and left anterior axillary lines.*
F F. *The upper transverse thoracic line at the level of the third chondro-sternal articulations.*
G G. *The lower transverse thoracic line at the level of the sixth chondro-sternal articulations.*

almost exactly with the Poupart or lateral line of the abdomen.

The anterior axillary line—drawn vertically from the anterior axillary fold.

The mid-axillary line.

The posterior axillary line—drawn vertically from the posterior axillary fold.

The scapular line—drawn through the inferior angle of the scapula—with the upper limb dependent.

The *transverse thoracic lines*, two in number, are as follows:—

The *upper transverse thoracic line* is drawn through the third chondro-sternal articulation.

The *lower transverse thoracic line* is drawn through the sixth chondro-sternal articulation.

The Thoracic Regions.—For clinical convenience the thorax is subdivided into zones and regions; these are as follows (see Figure 21):—

A. In Front.—1. A *cervical zone* lying above the clavicles and comprising from right to left:—

The right supra-clavicular region.

The supra-sternal region.

The left supra-clavicular region.

The *supra-clavicular regions* are bounded above by an oblique line drawn from the cricoid cartilage to the outer end of the clavicle, below by the clavicle itself, and internally by the upward prolongation of the lateral sternal line.

The *supra-sternal region* comprises that portion of the middle line of the neck which extends from the cricoid cartilage above, to the upper border of the manubrium sterni below. It is bounded on either side by the upward prolongations of the lateral sternal lines.

2. An *upper thoracic zone* bounded above by the clavicles

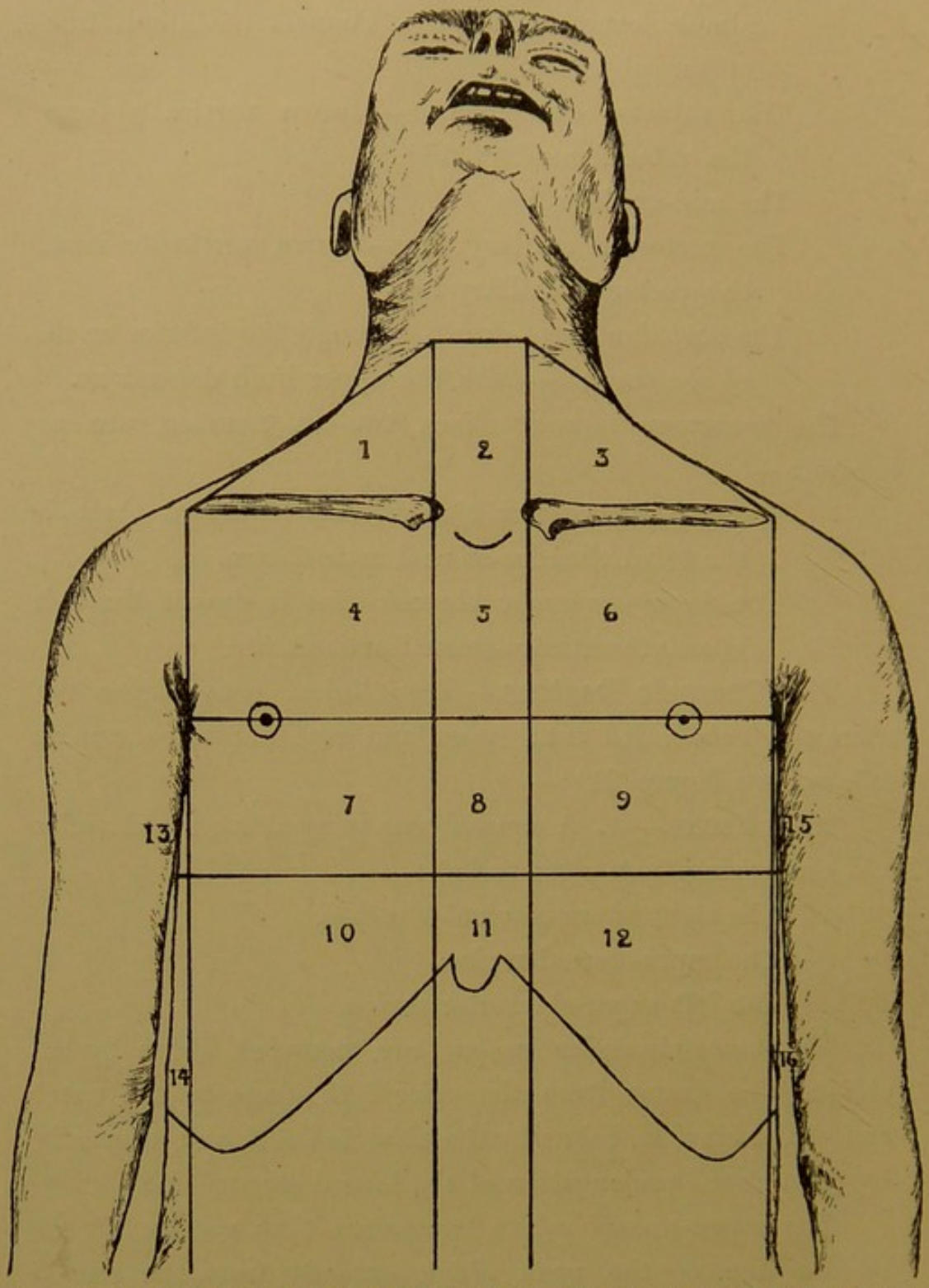

Figure 21.—The Thoracic Regions mapped out on the body. Drawn from nature by Mr. E. O. Bowen.

1. *The right supra-clavicular region.*
2. *The supra-sternal region.*
3. *The left supra-clavicular region.*
4. *The right infra-clavicular region.*
5. *The superior sternal region.*
6. *The left infra-clavicular region.*
7. *The right mammary region.*
8. *The inferior sternal region.*
9. *The left mammary region.*
10. *The right infra-mammary region.*
11. *The infra-sternal fossa.*
12. *The left infra-mammary region.*
13. *The right axillary region.*
14. *The right infra-axillary region.*
15. *The left axillary region.*
16. *The left infra-axillary region.*

and below by the upper transverse thoracic line drawn through the third chondro-sternal articulations. It is divided into three regions by the lateral sternal lines; these are as follows :—

The right infra-clavicular region.

The superior sternal region.

The left infra-clavicular region.

3. A *middle thoracic zone* bounded by the upper and lower transverse thoracic lines drawn through the third and the sixth chondro-sternal articulations respectively. Its three regions are from right to left :—

The right mammary region.

The inferior-sternal region.

The left mammary region.

4. A *lower thoracic zone* lying below the level of the lower transverse thoracic line. Its three regions are from right to left :—

The right infra-mammary region.

The infra-sternal fossa.

The left infra-mammary region.

B. Laterally.—The lateral area of the thorax in the region of the axilla is subdivided into two regions :—

An upper or axillary region lying above the level of the lower transverse thoracic line.

A lower or infra-axillary region lying below the level of the lower transverse thoracic line.

C. Posteriorly.—The posterior area of the thorax is subdivided into four main regions : —

A supra-scapular region above the scapula.

A scapular region opposite the scapula, and often subdivided into a supra- and an infra-spinous area.

An infra-scapular region below the scapula.

An inter-scapular region between the two scapulæ.

The Mamma.—(*See* page 184.)

THE PLEURÆ.

A. The Right Pleural Membrane.—To map out the right pleural membrane, commence at a point half to one and a half inches above, and to the outer side of the sternal end of the right clavicle. From this point the line of junction of the costal and mediastinal portions of the right parietal pleura passes obliquely downwards and inwards, and crossing the middle line comes into contact with, and sometimes overlaps, the left pleura at the level of the second chondro-sternal articulation. (See Figure 22.)

From this point downwards to the level of the fourth, and not infrequently the fifth, chondro-sternal articulation the two pleuræ are either in contact, or are very frequently found overlapping each other in the middle line; below one or other of the articulations just mentioned the left pleura recedes very slightly, whilst the right pleura continues its vertical course downwards to within a quarter of an inch of the xiphi-sternal articulation, or opposite the sixth chondro-sternal articulation.

From this point the *base* of the right pleura—that is the junction of its costal and diaphragmatic parietal portions—follows an oblique line, which passes outwards, behind the seventh costal cartilage until it reaches, in the mid-axillary line, the lower border of the ninth rib, or a point on the same horizontal level as the lowest part of the first lumbar spine, whence it turns almost horizontally inwards, and, clothing the inner or vertebral third of the last rib, reaches the spinal column at the level of the twelfth dorsal spine, or even the first lumbar spine.

From this point it passes upwards to the starting-point

along the side of the vertebral column as high as the neck of the first rib.

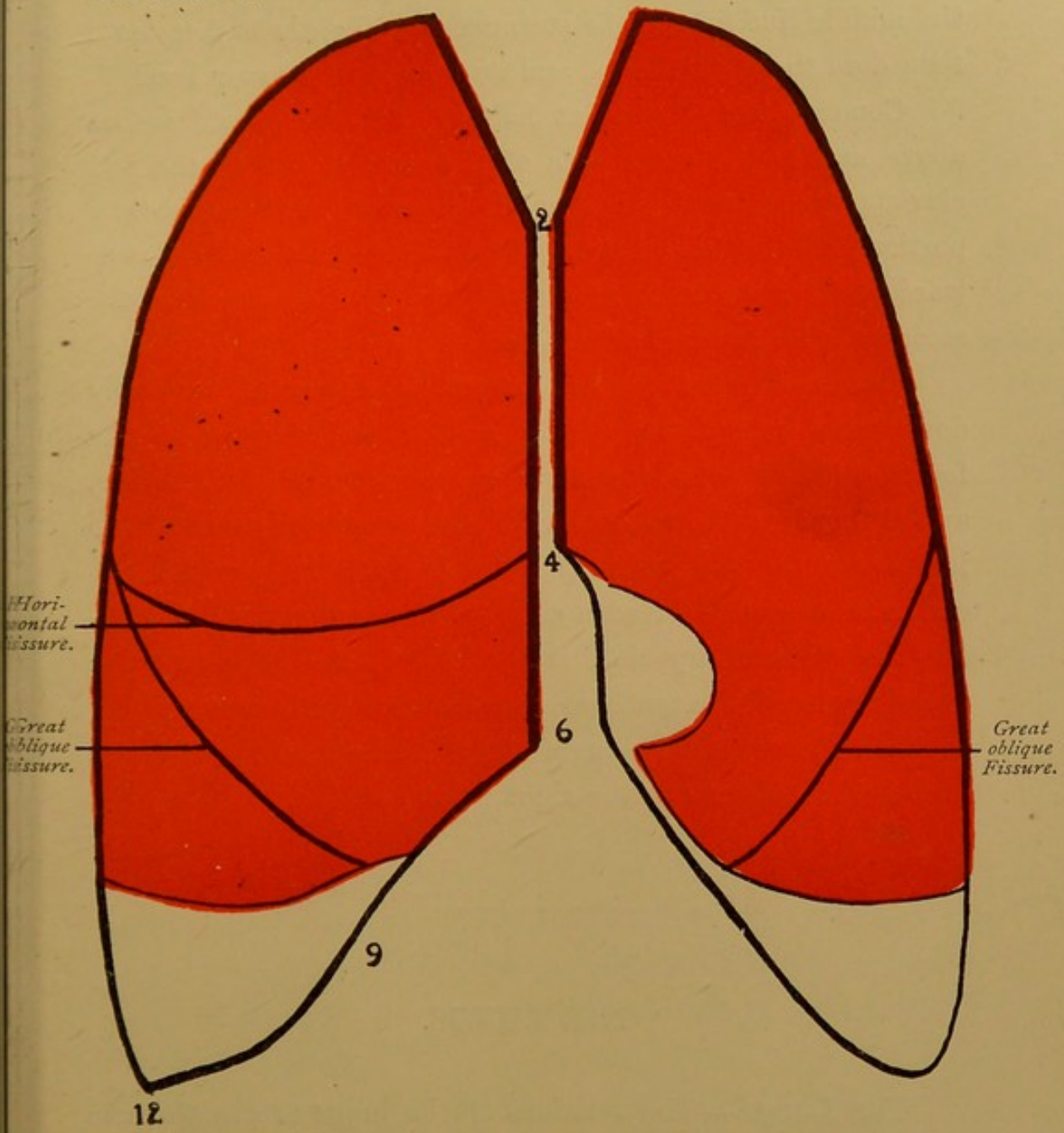

Figure 22.—Diagram of the Surface Anatomy of the Pleuræ and Lungs.

The lungs are indicated in red, and the pleuræ in black.
The numerals refer to the surface markings of the pleuræ.

B. The Left Pleural Membrane.—In mapping out the left pleural membrane it is important to remember that the heart projects more to the left side than the right, and that

the diaphragm does not extend so far upwards on the left side as on the right, consequently the left pleura recedes from the middle line behind the sternum at a slightly higher level than does the right pleura, and its base is at a lower level.

Commencing at a point half to one and a half inches above, and to the outer side of, the sternal end of the left clavicle, the line of junction of the costal and mediastinal portions of the left parietal pleura passes obliquely downwards and inwards to reach the middle line opposite the second chondro-sternal articulation.

From this point the left pleura passes almost vertically downwards behind the middle line of the sternum, to the fourth, fifth, or even the sixth chondro-sternal articulation, and is thence reflected outwards and downwards behind the left border of the sternum to the sixth or seventh rib cartilages, a finger's breadth external to the sternum. Reaching the mid-axillary line, it is there placed opposite the lower border of the tenth rib, and thence ascends very slightly to reach the vertebral column at the corresponding place and in the same manner as the right pleura.

THE LUNGS.

The Lungs.—The relations of the lungs to the thoracic parietes reproduce, with two exceptions, the corresponding relations of the pleuræ. The two exceptions are the bases of both lungs and the incisura cardiaca of the left lung. It is therefore only necessary to indicate these differences. (See Figure 22.)

A. The Base of the Right Lung.—As the lungs do not

extend so far down as the pleuræ, the base of the right lung may be indicated on the living subject by a line drawn, with a slight downward convexity from the sixth chondro-sternal articulation, through the eighth rib in the mid-axillary line, to the tenth dorsal spine posteriorly.

B. The Base of the Left Lung.—The base of the left lung may be indicated in the same way as that of the right, always remembering that the left lung is slightly lower than the right.

C. The Incisura Cardiaca of the Left Lung.—The anterior border of the left lung descends in the middle line as far as the fourth chondro-sternal articulation. It then turns outwards along the lower border of the fourth left costal cartilage to the para-sternal line; crossing the fourth left intercostal space downwards and outwards, it then turns downwards and inwards to reach the sixth left costal cartilage in the para-sternal line internal to the apex beat of the heart.

The Oblique Fissures of the Lungs.—The oblique fissure of the lung, which on the right side separates the lower and middle lobes, and, on the left side, the upper and lower lobes, is indicated by a line drawn from the spine of the second dorsal vertebra to the sixth rib in the mammillary line. With the hand on the opposite shoulder the vertebral border of the scapula very nearly corresponds to the line of the oblique fissure.

The Horizontal Fissure of the Right Lung.—The horizontal fissure of the right lung, which separates the superior and middle lobes, is indicated by a line drawn horizontally outwards from the fourth right chondro-sternal articulation to the middle of the line for the great oblique fissure.

The surface anatomy of the fissures of the lungs thus

shows that on the left side, the upper lobe of the lung, and on the right side, the upper and middle lobes, are confined to the front of the chest; whilst the lower lobe of each lung is confined to the back.

THE HEART.

The Area of Deep Cardiac Dulness.—The area, known clinically as the area of deep cardiac dulness, corresponds to the outline of the heart itself. (See Figure 23.) It may be mapped out as follows:—

The *base*, that is, the region of the heart which gives origin to the great vessels, is indicated on the chest wall by a line drawn from a point situated on the lower border of the second left costal cartilage, one inch to the left of its junction with the sternum, to the upper border of the third right costal cartilage, immediately to the right of its junction with the sternum.

The *right lateral limit* of the heart, that is, the base or right lateral margin of the right auricle, is indicated by a line drawn from the last-mentioned point to the sixth or seventh right chondro-sternal articulations, arching outwards opposite the fourth intercostal space, to a distance of one inch and a half from the middle line of the sternum.

The *margo acutus* of the right ventricle, that is, the lower border of the heart, is indicated by a line drawn slightly convex downwards, from the sixth or seventh right chondro-sternal articulations, across the xiphi-sternal articulation to the apex beat in the fifth left intercostal space.

The *margo obtusus* of the left ventricle is indicated by a line drawn, slightly convex upwards, from the apex beat

to a point situated on the lower border of the second left costal cartilage one inch to the left of its junction with the sternum.

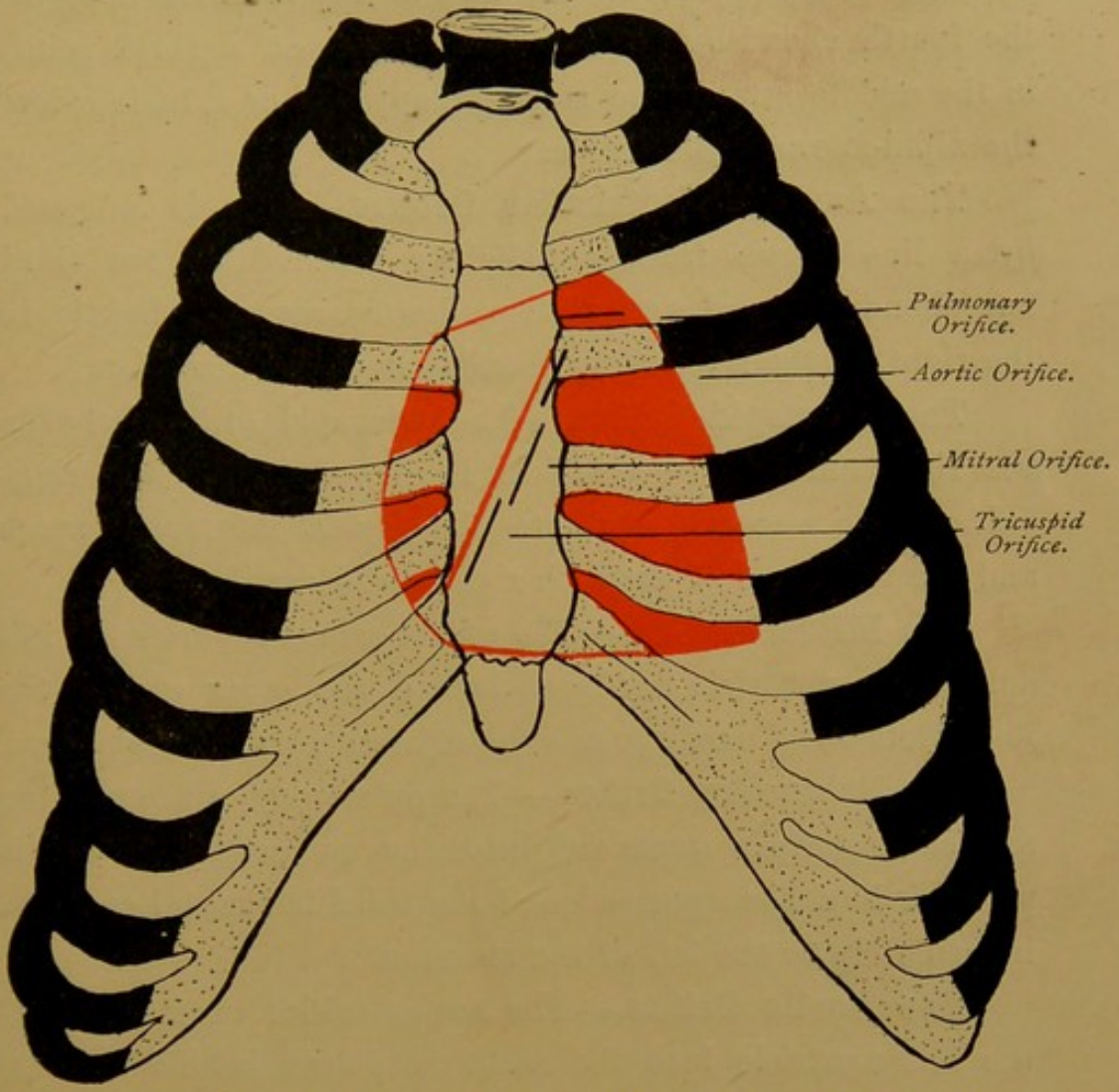

Figure 23.—The area of deep Cardiac Dulness, the valves of the Heart, and the auriculo-ventricular Groove.

The ribs are indicated in black, the costal cartilages are dotted, and the heart is coloured red. The auriculo-ventricular groove is indicated by a red line and the valves by black lines.

The Area of Superficial Cardiac Dulness.—The area, known clinically as the area of superficial cardiac dulness, corresponds to that part of the heart which is uncovered by the lungs.

It may be mapped out by taking three points and joining these together by means of three lines. The three points to be taken are—a point internal to the apex beat; a second point, in the middle line of the sternum opposite the fourth chondro-sternal articulation; and a third point, in the middle line of the sternum, opposite or a little below the xiphi-sternal articulation.

The Auriculo-Ventricular Groove.—This is indicated by a line drawn from, or slightly internal to, the third left chondro-sternal articulation, downwards and slightly to the right, to the sixth right chondro-sternal articulation.

The Tricuspid Orifice.—The tricuspid orifice between the right auricle and ventricle is placed behind the right half of the sternum, opposite the *fourth* intercostal space and the inner end of the fifth right costal cartilage.

The Mitral Orifice.—The mitral orifice between the left auricle and ventricle is placed behind the inner end of the *fourth* left costal cartilage and the adjacent part of the sternum.

The Pulmonary Orifice.—The pulmonary orifice opening out of the right ventricle into the pulmonary artery is placed behind the upper edge of the *third* left costal cartilage immediately to the left of the sternum.

The Aortic Orifice.—The aortic orifice opening out of the left ventricle into the aorta is placed behind the left half of the sternum, opposite the lower border of the *third* left costal cartilage.

All four orifices of the heart lie to the left of the auriculo-ventricular groove in the following order from above downwards:—

Pulmonary.
Aortic. } With these orifices associate the figure three.

Mitral.
Tricuspid. } With these orifices associate the figure four.

The Apex of the Heart.—The cardiac apex, formed entirely by the left ventricle, is situated in the adult in the fifth left intercostal space one and a half inches below the nipple, and three and a half inches to the left of the middle line of the body, or about midway between the para-sternal and mammillary lines of the left side.

The Apex of the Right Auricular Appendix.—The apex of the right auricular appendix is placed behind the middle line of the sternum, opposite the third chondro-sternal articulations.

The Apex of the Left Auricular Appendix.—The apex of the left auricular appendix is placed behind the third left costal cartilage, one inch and a quarter to the left of the sternum.

THE GREAT VESSELS.

The Ascending Aorta.—The ascending aorta extends from the aortic orifice (*q.v.*), upwards, forwards, and to the right to the second right or "aortic" costal cartilage. It may therefore be indicated by a double line drawn from the aortic orifice to a point behind the right lateral margin of the sternum opposite the second right chondro-sternal articulation.

The Arch of the Aorta.—The arch of the aorta extends from the second right costal cartilage, almost directly backwards (see Figure 24) to the lower border of the fourth dorsal vertebra. It lies therefore behind the manubrium sterni, and its highest point would be indicated by a point placed a little above the centre of that bone

The Innominate Artery.—The innominate artery may

be indicated by a double line drawn from about the centre of the manubrium sterni to the upper border of the right sterno-clavicular articulation between the two heads of the right sterno-mastoid muscle, where the vessel terminates by dividing into right common carotid and right subclavian arteries.

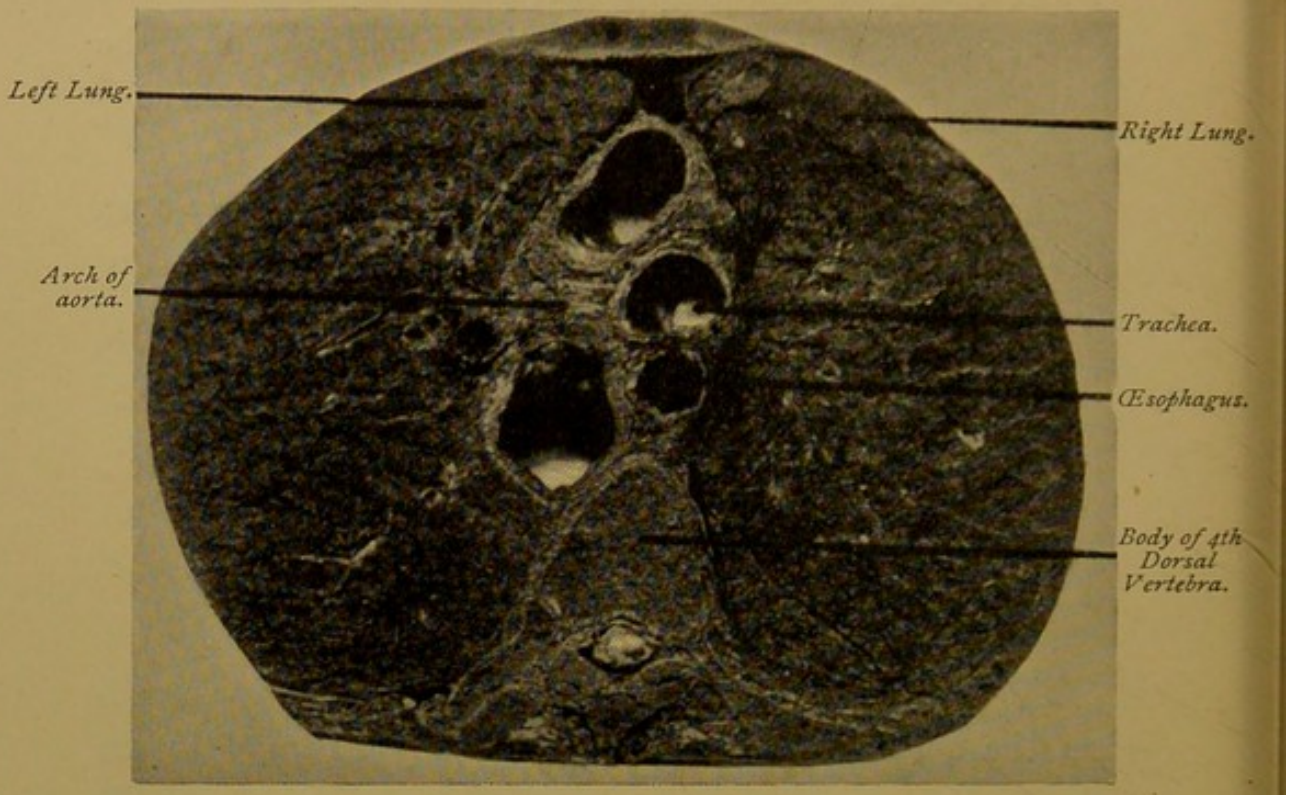

Figure 24.—Transverse Section through the Thorax at the level of the fourth dorsal vertebra. From a formalin hardened male subject aged 66.

Note the antero-posterior direction of the arch of the aorta, the forward projection of the vertebral column, with the resultant antero-posterior narrowing of the thoracic cavity, and the backward projection of the lungs into the costo-vertebral groove.

The Trunk of the Pulmonary Artery.—The trunk of the pulmonary artery may be indicated by a double line drawn from the pulmonary orifice (see page 84) upwards, behind or slightly to the left of the left border of the sternum, to the lower border of the second left costal cartilage.

The Right Innominate Vein.—The right innominate vein extends for a distance of one inch from the upper border of the sternal end of the right clavicle to the first right chondro-sternal articulation. As the latter point cannot be felt upon the living subject, the vessel may be indicated by a double line one inch in length drawn from the upper to the lower border of the sternal end of the right clavicle.

The Left Innominate Vein.—The left innominate vein, three inches in length, extends from the inner end of the left clavicle, obliquely downwards and to the right, to the first right chondro-sternal articulation; it may therefore be mapped out by drawing a double line from the sternal end of the left clavicle to the lower border of the sternal end of the right clavicle, where it unites with the right innominate vein to form the superior vena cava.

The Superior Vena Cava.—The superior vena cava is formed behind the first right chondro-sternal articulation by the junction of the right and left innominate veins. It descends almost vertically for three inches, and terminates behind the upper border of the third right chondro-sternal articulation by opening into the upper angle of the right auricle. This vein will therefore be represented by a double line drawn from the lower border of the sternal end of the right clavicle downwards, behind, or just external to, the right lateral border of the sternum, to the upper border of the third right costal cartilage immediately to the right of its junction with the sternum.

The Trachea.—The trachea extends from the cricoid cartilage or the sixth cervical vertebra to the disc between the fourth and fifth dorsal vertebræ, or, roughly speaking, to the angle of Ludwig, at which point it bifurcates into right and left bronchi after a course of four and a half inches.

The Œsophagus.—The œsophagus extends from the

cricoid cartilage or the sixth cervical vertebra to the body of the tenth dorsal vertebra, where it terminates by opening into the cardia of the stomach. Its length is nine or ten inches, to which, for surgical purposes, must be added six inches for the distance between the incisor teeth and the cricoid cartilage. In the passing of œsophageal instruments for the diagnosis or treatment of strictures of the œsophagus, the following average distances should be remembered:—

Distance from the incisor teeth to—

(*a*) The cricoid cartilage (commencement of œsophagus) . .	6 inches
(*b*) The arch of the aorta . .	9 „
(*c*) The level of the left bronchus .	10 „
(*d*) The œsophageal opening of the diaphragm	14–15 „
(*e*) The cardia (termination of the œsophagus)	15–16 „

Posteriorly the œsophagus extends from the spine of the sixth cervical vertebra to that of the ninth or tenth dorsal vertebræ.

The Semilunar Space of Traube.—(*See* page 106.)

III.

THE ABDOMEN.

THE ABDOMINAL PARIETES.

Bony Landmarks.—The chief bony landmarks of the abdomen, all of which have been described elsewhere, are as follows:—

Above.—The xiphi-sternum and the costal margins. The depression or notch bounded laterally by the sternal ends of the seventh costal cartilages is termed the *infra-sternal fossa.* Below this notch, and bounded on either side by the seventh, eighth, ninth, and tenth costal cartilages, is the *costal* or *sub-costal angle.*

Below.—The iliac crest, tubercle, and spine. The pubic spine, crest, and symphysis.

The Abdominal Furrow.—The abdominal furrow is the median groove between the two recti abdominis muscles. It commences above at the infra-sternal fossa, and continues downwards as far as, or a little beyond, the umbilicus, below which it is obliterated by the approximation of the two recti. It corresponds in position to the linea alba, and varies very considerably in its development in different individuals, being best marked in muscular persons.

The Umbilicus.—The position of the umbilicus is very inconstant, as it varies with the obesity of the subject and the laxity of the abdomen. In the adult it is always situated

above the centre of the body as measured from head to foot, and is always *below* the centre of a line drawn from the xiphi-sternum to the symphysis pubis. As a general rule, the umbilicus is placed opposite the fourth lumbar vertebra, on a level with, or slightly above, a line drawn through the highest points of the iliac crests. The point of bifurcation of the abdominal aorta into right and left common iliacs is a little below and to the left of the umbilicus. (See Figure 25.)

The Lineæ Transversæ.—The lineæ transversæ, produced by the inscriptiones tendineæ of the rectus abdominis muscle, can, in muscular subjects, be seen as slight transverse furrows running outwards from the abdominal furrow, opposite the ensiform cartilage, the umbilicus, and again midway between these two points. Although not always visible on the living subject, they are constantly represented in statuary.

The Linea Semilunaris.—The linea semilunaris, corresponding to the outer edge of the rectus abdominis, is sometimes visible, on the living subject, as a slight furrow, external to the abdominal furrow.

The Fold of the Groin.—The fold of the groin, best marked in obese individuals, is a slight furrow which indicates the position of Poupart's ligament.

The Iliac Furrow.—The iliac furrow is a slight furrow which corresponds to the iliac crest.

The Rectus Abdominis Muscle.—The position of the rectus abdominis is usually sufficiently indicated by the abdominal furrow at its inner border, and the linea semilunaris at its outer border. If the latter cannot be localised, then the outer border of the rectus abdominis may be mapped in by a line drawn from the tip of the ninth costal cartilage to the mid-point of a line drawn from the umbilicus to the anterior superior iliac spine, and thence

to the pubic spine. The muscle itself is subcutaneous throughout.

The Obliquus Abdominis Externus Muscle.—The

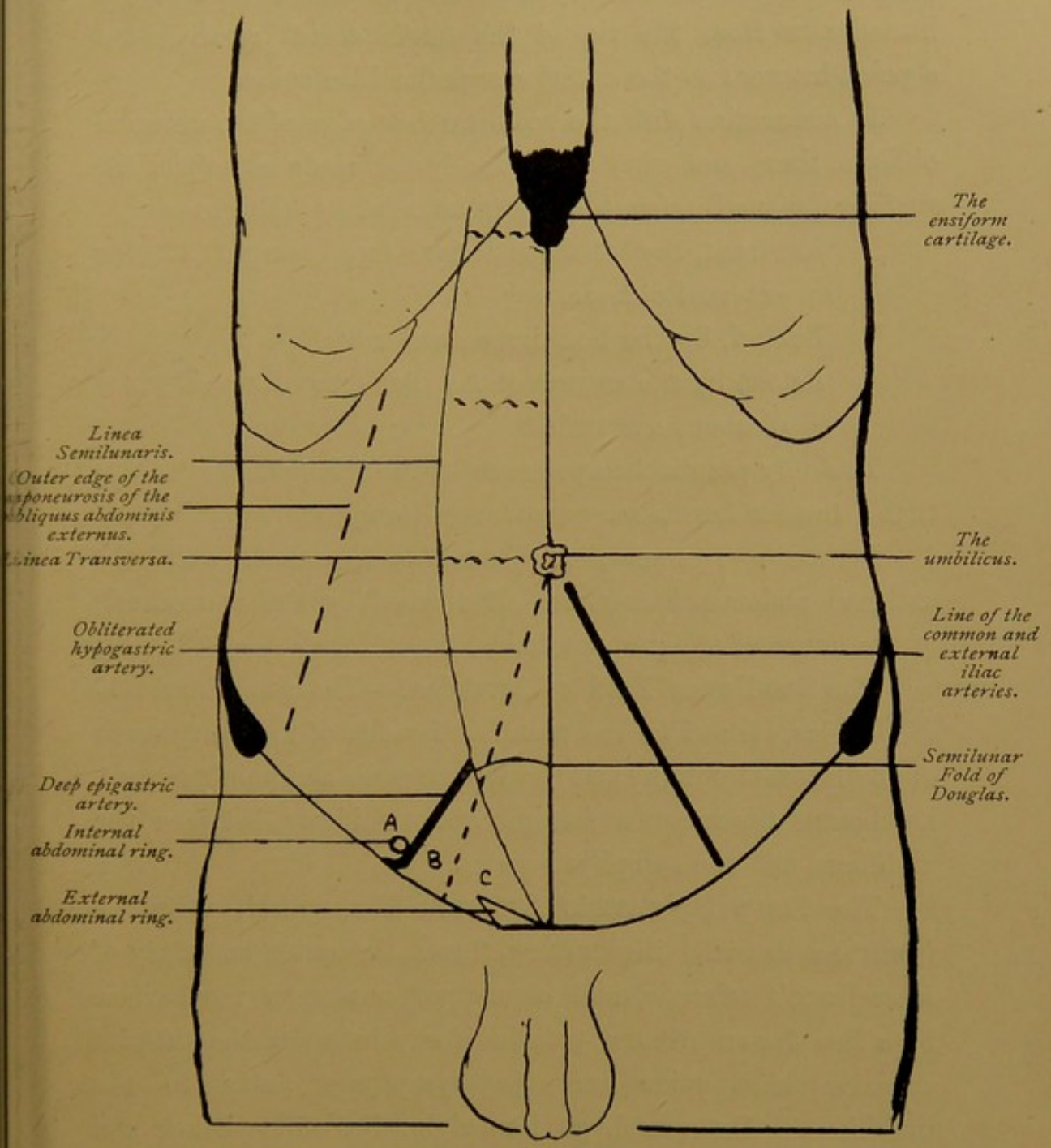

Figure 25.—The Anterior Abdominal Wall.

A. The external inguinal Fossa.
B. The middle inguinal Fossa. } *Hesselbach's Triangle.*
C. The internal inguinal Fossa. }

convex lateral sides of the abdomen are formed by the fleshy parts of the two external oblique muscles. The line of demarcation between the muscular and aponeurotic portions of the muscle is indicated on the surface by a line drawn from the tip of the ninth costal cartilage to a point internal to the anterior superior iliac spine.

In connection with the posterior free edge of the external oblique, there can very occasionally be made out upon the surface the small *triangle of Petit*, bounded as follows:—

In front, by the posterior free margin of the external oblique.

Behind, by the latissimus dorsi muscle.

Below, by the centre of the iliac crest for a distance of about one inch.

The only practical importance of the triangle of Petit is that a lumbar hernia may protrude through it.

Poupart's ligament, Gimbernat's ligament, and the external abdominal ring, are all formed by the aponeurosis of the external oblique muscle.

The Semilunar Fold of Douglas.—The semilunar fold of Douglas, formed by the posterior lamella of the aponeurosis of the internal oblique and the transversalis abdominis muscle, lies behind the rectus abdominis, about midway between the umbilicus and the symphysis pubis.

The Deep Epigastric Artery.—This vessel, a branch from the external iliac artery, forms the outer boundary of Hesselbach's triangle, and is mapped out upon the surface by a line drawn from a point midway between the anterior superior iliac spine and the symphysis pubis to the umbilicus. The vessel, at its origin, lies first below and then to the inner side of the internal or deep abdominal ring,—a relation of great importance in the operation for the relief of a strangulated inguinal hernia.

The Deep Circumflex Iliac Artery.—This vessel, a branch from the external iliac artery, runs outwards behind the outer half of Poupart's ligament. Just about opposite the anterior superior iliac spine it gives off a comparatively large unnamed ascending branch, which passes upwards between the internal oblique and transversalis abdominis muscles. This vessel is liable to be cut in appendicectomies and other operations in this region, but its presence should be remembered, as it affords a valuable index of the depth attained in passing through the abdominal wall.

Nerves.—The anterior primary divisions of the *lower six dorsal or thoracic nerves*, as well as the *ilio-hypogastric* and *ilio-inguinal nerves* from the anterior primary division of the first lumbar nerve, run obliquely round the abdominal wall in regular sequence from above downwards, parallel with a line drawn from the tenth costal cartilage to the umbilicus.

The termination of the *seventh dorsal or thoracic nerve* is situated near the lower end of the ensiform cartilage, that of the *tenth* near the umbilicus, and the *twelfth* a little below a point midway between the umbilicus and the symphysis pubis.

The termination of the *ilio-hypogastric nerve* is just above, and the *ilio-inguinal nerve* opposite, the external abdominal ring.

The Inguinal Canal.—The inguinal canal is the oblique passage formed in the anterior abdominal wall by the testicle in its descent from the abdominal cavity into the scrotum. It presents for examination :—

An entrance, the internal or deep abdominal ring.

A canal, the inguinal canal.

An exit, the external or superficial abdominal ring.

The Internal or Deep Abdominal Ring.—This is the point where the fascia transversalis of the abdomen is evagi-

nated by the descent of the testicle. It is mapped out by taking a point half an inch above Poupart's ligament, and midway between the anterior superior iliac spine and the symphysis pubis. The external iliac artery lies below the ring, separated therefrom by Poupart's ligament, whilst the deep epigastric artery lies first below, and then to the inner side of the ring.

THE INGUINAL CANAL.—The inguinal canal extends from the internal to the external abdominal ring. It is one and a half inches in length, and may be mapped out by a line drawn half an inch above and parallel with the inner half of Poupart's ligament.

Its boundaries are as follows:—

In Front—

The aponeurosis of the external oblique muscle throughout the whole length of the canal, with the internal oblique muscle at its outer end.

Behind—

The fascia transversalis throughout the whole length of the canal, with the conjoined tendon and the triangular fascia at its inner end.

Above—

The arched lower borders of the internal oblique and transversalis abdominis muscles.

Below—

Poupart's and Gimbernat's ligaments.

THE EXTERNAL OR SUPERFICIAL ABDOMINAL RING.—This is the point where the aponeurosis of the external oblique muscle of the abdomen is evaginated by the descent of the testicle. It is mapped out on the living subject by erecting a triangle upon the pubic crest one inch in length by half an inch in breadth, the boundaries of which coincide with those of the ring itself, namely:—

The *base* of the ring is formed by the crest of the pubis, the *external pillar* is formed by the inner end of Poupart's ligament, whilst the *internal pillar* is formed by that part of the aponeurosis of the external oblique which is inserted into the symphysis pubis.

It must be particularly noted that the base of the external or superficial abdominal ring lies internal to the spine of the pubis, consequently an inguinal hernia will descend internal to the pubic spine, whereas a femoral hernia leaves the abdomen external to that point.

Hesselbach's Triangle.—Immediately behind the inguinal canal there is, on the posterior surface of the anterior abdominal wall, a very definite triangular area which is known as Hesselbach's triangle. An oblique or external inguinal hernia, whether congenital, infantile, or acquired, leaves the abdominal cavity at the internal abdominal ring and therefore external to Hesselbach's triangle, whilst a direct or internal inguinal hernia leaves the abdomen through the triangle.

Hesselbach's triangle is easily mapped out on the living subject by noting its boundaries (see Figure 25), which are as follows:—

Below, by the inner half of Poupart's ligament.

Externally, by the deep epigastric artery. (See page 92.)

Internally, by the outer border of the rectus abdominis muscle. (See page 90.)

Summary of the Varieties of Inguinal Hernia.—All forms of inguinal hernia are either oblique and external, or else direct and internal.

An *oblique and external inguinal hernia* is called *oblique* because it traverses the whole length of the inguinal canal and therefore passes through the anterior abdominal wall in

an oblique direction; *external*, because it leaves the abdominal cavity external to the deep epigastric artery. This form includes congenital, infantile or encysted, acquired and funicular herniæ.

A *direct and internal inguinal hernia* is *always* acquired. It is called *direct* because it passes straight forwards or directly into either the middle (rarely) or the inner end of the inguinal canal, and *internal* because it leaves the abdominal cavity internal to the deep epigastric artery.

Coverings of Inguinal Herniæ.—By the coverings of a hernia are simply meant the various strata through which the surgeon must cut in order to reach the intestinal or other contents of the hernial sac. These coverings, as well as the abdominal strata from which they are derived, are shown in the following table:—

Abdominal Wall.	Coverings of Cord.	Coverings of Oblique Hernia.	Coverings of Direct Hernia.
Peritoneum.	Tunica vaginalis.	The sac.	The sac.
Extra-peritoneal fat.	Extra-peritoneal fat.	Extra-peritoneal fat.	Extra-peritoneal fat.
Fascia transversalis.	Internal spermatic or infundibuliform fascia.	Internal spermatic fascia.	Fascia transversalis.
Transversalis abdominis muscle.	Nothing.	Nothing.	Conjoined tendon.
Obliquus abdominis internus muscle.	Cremasteric fascia.	Cremasteric fascia.	
Obliquus abdominis externus muscle.	External spermatic fascia.	External spermatic fascia.	External spermatic fascia.
Integuments.	Integuments.	Integuments.	Integuments.

THE ABDOMINAL CAVITY.

The contents of the abdomen are so numerous and important that it is necessary to subdivide the abdominal cavity into smaller regions for the purpose of simplifying its topography. Of the numerous methods which have been devised for this purpose, Addison's is perhaps the simplest and the most generally useful. It is here appended, as is also that of Cunningham.

Addison's Method of Delimiting the Abdominal Cavity. — Four easily determined bony landmarks — the upper border of the manubrium sterni, the symphysis pubis, and the right and left anterior superior iliac spines—having been located, the abdomen is first "divided vertically by three lines—a median line and two lateral lines." (See Figure 26.)

The Median Line.—The median line is drawn from the upper border of the manubrium sterni to the symphysis pubis.

The Right and Left Lateral Lines.—The right and left lateral lines are drawn vertically upwards, on each side, through a point midway between the anterior superior iliac spine and the median line.

The vertical lines having been thus located, the transverse lines are found by a process of bisection, the body being divided transversely by lines drawn at points a quarter, a half, and three-quarters of the way along the median vertical line. These lines are termed from above downwards :—

The trans-thoracic plane.
The trans-pyloric plane.
The trans-tubercular plane.

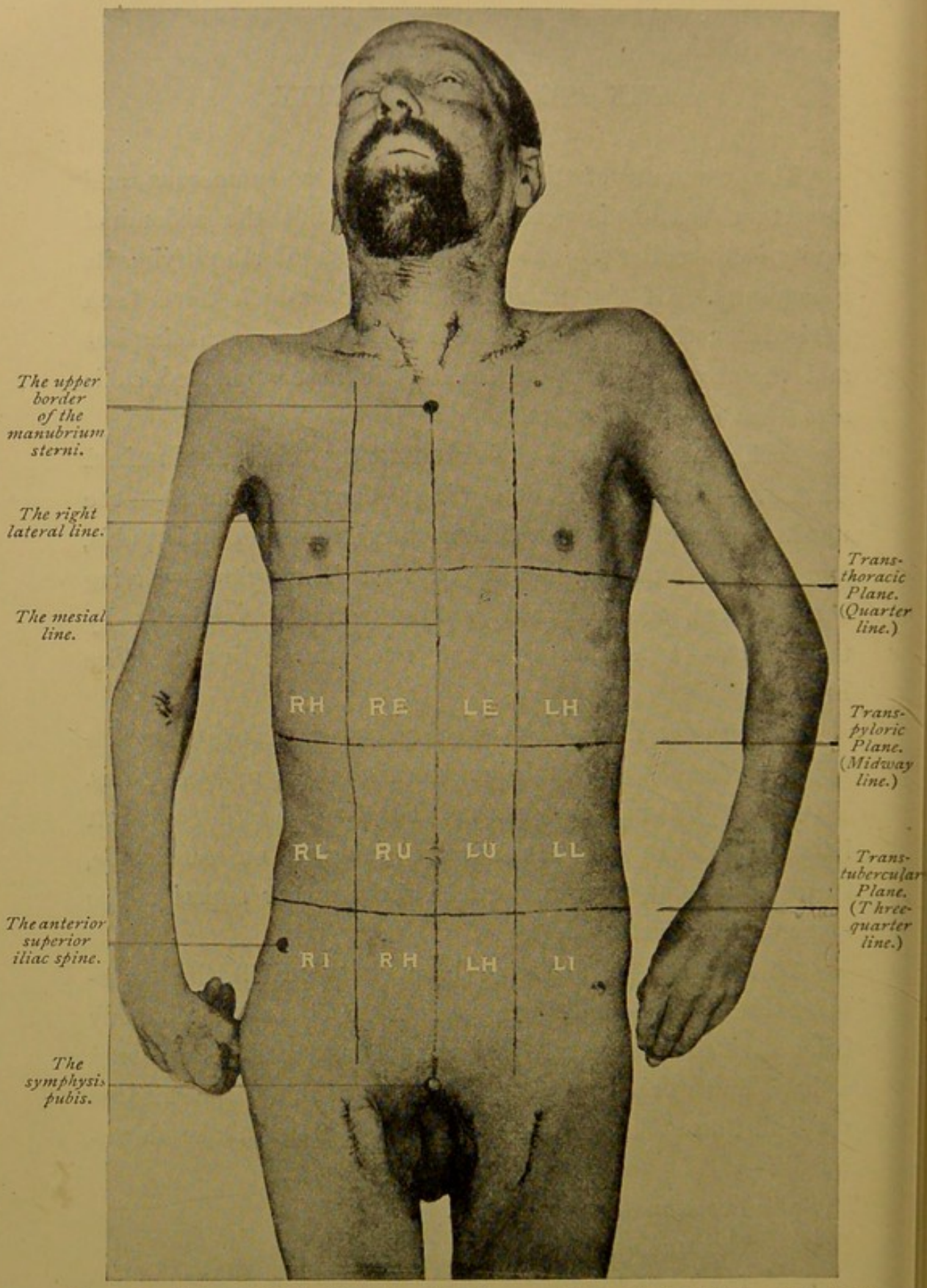

Figure 26.—Addison's Method of delimiting the Abdomen. Photograph from nature. Male, age 50. Distance from manubrium to symphysis 52 cm., and from spine to spine 26 cm.

The Trans-thoracic Plane.—The trans-thoracic plane is a purely thoracic plane, and is of no significance in connection with the subdivision of the abdomen.

The Trans-pyloric Plane.—The trans-pyloric plane passes transversely through a point exactly midway between the upper border of the manubrium sterni and the symphysis pubis, or what is almost the same thing, and is perhaps more useful from a clinical standpoint, through or near the mid-point between the xiphi-sternal articulation and the umbilicus. Posteriorly, this plane strikes the lower border of the body of the first lumbar vertebra, and as it almost invariably passes through the pylorus, it is well named the trans-pyloric plane. As a general rule, this line—the trans-pyloric—intersects the right and left lateral lines exactly opposite the tips of the ninth costal cartilages.

The point of intersection of the trans-pyloric plane with the right lateral line marks out the position of the neck of the gall bladder, the commencement of the second part of the duodenum and the right kidney just above its hilum.

In the middle line the point of intersection is in front of the stomach and the pancreas.

In the left lateral line the point of intersection cuts the anterior border of the pancreas, and the left kidney just outside its hilum. A little to the left of the left lateral line the trans-pyloric plane crosses the basal surface of the spleen.

The Trans-tubercular Plane.—The trans-tubercular plane usually passes through or near the tubercles on the iliac crests, and corresponds therefore almost exactly to the intertubercular plane of Cunningham. This line usually lies about five inches above the symphysis pubis, and its plane cuts the fifth lumbar vertebra. The intersection of the trans-tubercular and right lateral lines marks the upper border of the ileo-cæcal junction.

By Addison's method the abdominal cavity is divided into three zones of equal depth by means of the trans-pyloric and trans-tubercular planes, each zone being sub-divided into four regions of equal size by means of the median and the right and left lateral lines. These zones and regions are as follows:—

The Upper or Costal Zone.

This zone lies between the trans-thoracic and the trans-pyloric planes, and its four regions are from right to left:—

1. The right hypochondriac region.
2. The right epigastric region.
3. The left epigastric region.
4. The left hypochondriac region.

The Middle or Umbilical Zone.

This zone lies between the trans-pyloric and the trans-tubercular planes, and its four regions are from right to left:—

5. The right lumbar region.
6. The right umbilical region.
7. The left umbilical region.
8. The left lumbar region.

The Lower or Hypogastric Zone.

This zone lies below the trans-tubercular plane, and its four regions are from right to left:—

9. The right iliac region.
10. The right hypogastric region.
11. The left hypogastric region.
12. The left iliac region.

Advantages of Addison's Method.—Some of the more important advantages of Addison's method are that it employs fixed and easily determinable osseous landmarks, that the method being a simple process of bisection is easily

remembered, that it employs no variable and obscure rib-cartilages, that the distance between its transverse planes is relatively constant, that it is adaptable to the living subject, and to diagrams and figures of all scales.

Cunningham's Method of Delimiting the Abdominal Cavity.—This method, as now given in its author's text-book of anatomy, is as follows:—

"The abdomen proper is artificially subdivided by two horizontal and two vertical lines drawn on its anterior wall. From these lines imaginary planes are supposed to be continued backwards, which divide up the cavity into nine regions. (See Figure 27.)

"Of the two horizontal lines, one is drawn around the trunk at the level of the lower border of the tenth costal cartilage; this is known as the *subcostal line*, and the imaginary plane corresponding to it, as the subcostal plane—a plane which passes posteriorly through the upper part of the third lumbar vertebra, or the disc between the second and third lumbar vertebræ.

"The second horizontal line is drawn at the level of the highest point of each iliac crest visible from the front; this point corresponds to the tubercle seen on the outer lip of the crest, about two inches behind the anterior superior spine, and can be easily located; the line and plane are consequently known as the *intertubercular line and plane* respectively—the plane cutting posteriorly either the middle or upper part of the fifth lumbar vertebra.

"The vertical lines are drawn, one on each side, perpendicularly upwards from a point on Poupart's ligament midway between the anterior superior spine and the symphysis pubis. These lines and the corresponding planes are known as the *Poupart lines and planes* respectively.

"By the two horizontal lines the abdomen is divided into

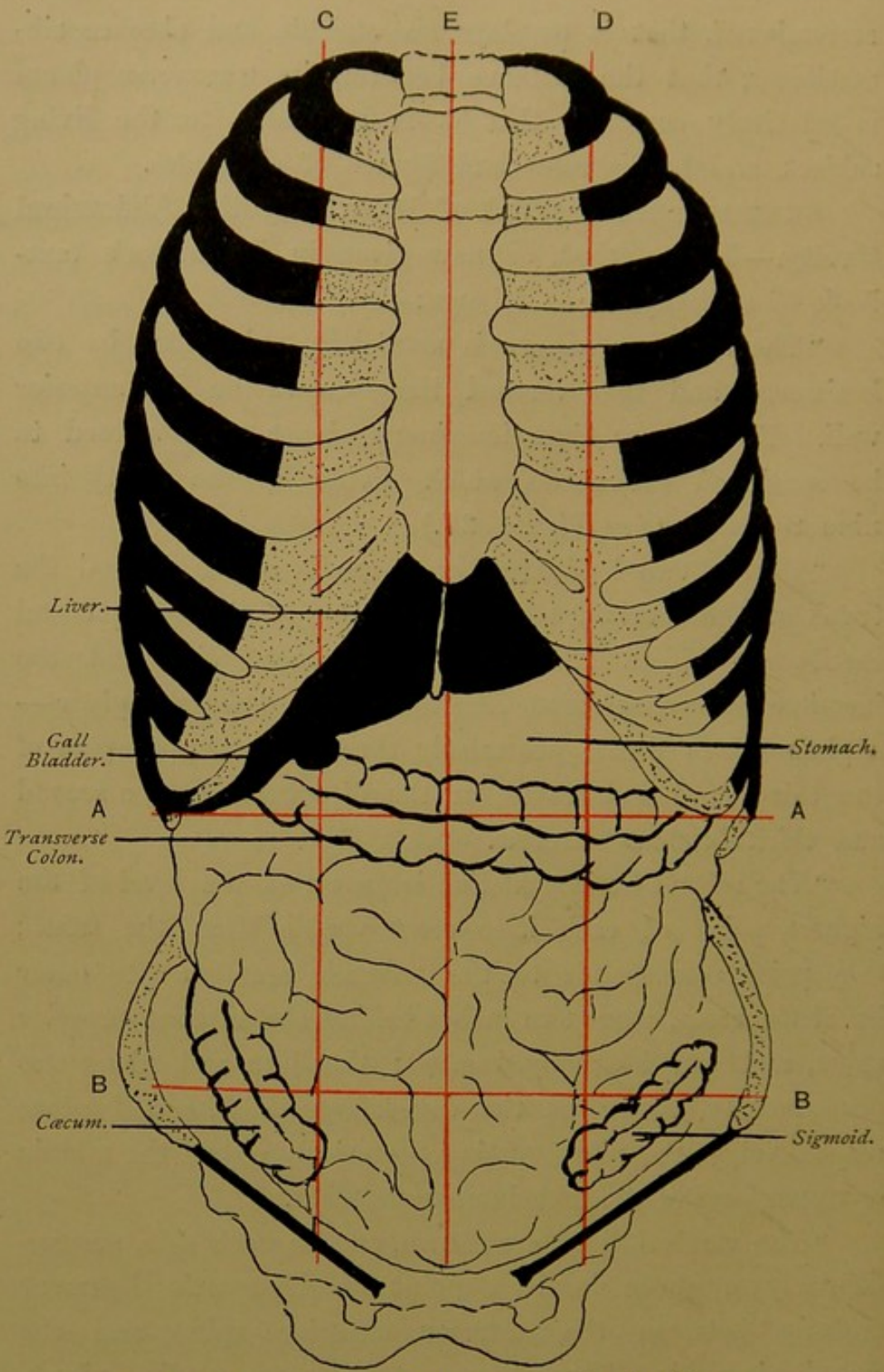

Figure 27.—Cunningham's Method of delimiting the Abdomen.

A A. *The subcostal plane.*
B B. *The intertubercular plane.*
C. *The right lateral line.*
D. *The left lateral line.*
E. *Position of the mesial plane of the body.*

three zones, an upper or costal, a middle or umbilical, and a lower or hypogastric zone. By the two perpendicular lines each of these is subdivided into three parts, a central and two lateral. Thus, in the upper zone, we get a hypochondriac region or hypochondrium on each side, and an epigastric region or epigastrium in the centre. Similarly, the umbilical zone is divided into right and left lumbar regions, with an umbilical region between. And the hypogastric zone has a hypogastric region or hypogastrium in the centre, with right and left iliac regions at the sides.

"In addition, the portion of the abdominal wall above the pubis is known as the pubic region, and that immediately above Poupart's ligaments, as the inguinal region.

"The three central divisions, namely, the epigastric, umbilical, and hypogastric regions, can conveniently be further subdivided by the mesial plane, passing through the middle of the body, into right and left halves."

THE ALIMENTARY CANAL.

The different portions of the alimentary canal within the abdominal cavity are as follows:—

The termination of the œsophagus.

The stomach.

The small intestine.

- The duodenum or fixed intestine.
  - First or superior part.
  - Second or descending part.
  - Third or transverse part.
  - Fourth or ascending part.
- The jejuno-ileum or floating intestine.

The large intestine.

The cæcum.

The vermiform appendix.

The ascending colon.

The hepatic flexure.

The transverse colon.

The splenic flexure.

The descending colon.

The sigmoid colon.

Iliac or fixed part.

Pelvic or movable part.

The rectum.

The anal canal.

The Stomach.—(*a*) THE CARDIA.—The cardia, or the termination of the œsophagus, may be mapped out on the living subject by a point or line placed on the seventh left costal cartilage one inch from its junction with the sternum. The cardia itself lies about four inches behind this point, from which it is separated by the liver. It is the most fixed part of the stomach, and lies opposite the body of the tenth dorsal vertebra, in front of and to the left side of the aorta.

(*b*) THE PYLORUS.—The pylorus, or the gastro-duodenal junction, is the most movable part of the stomach. When that viscus is empty it lies in the trans-pyloric plane, in or to the right of the median line (see Figure 28); but when the stomach is distended the pylorus moves to the right towards or even beyond the right lateral line, and may not infrequently, under these conditions, descend below the level of the trans-pyloric plane. Under all conditions the pylorus is nearer the surface than the cardia, and lies opposite the first lumbar vertebra. When the liver is enlarged, or displaced downwards, the pylorus is pushed downwards and to the left, on to the middle line, or even to the left thereof.

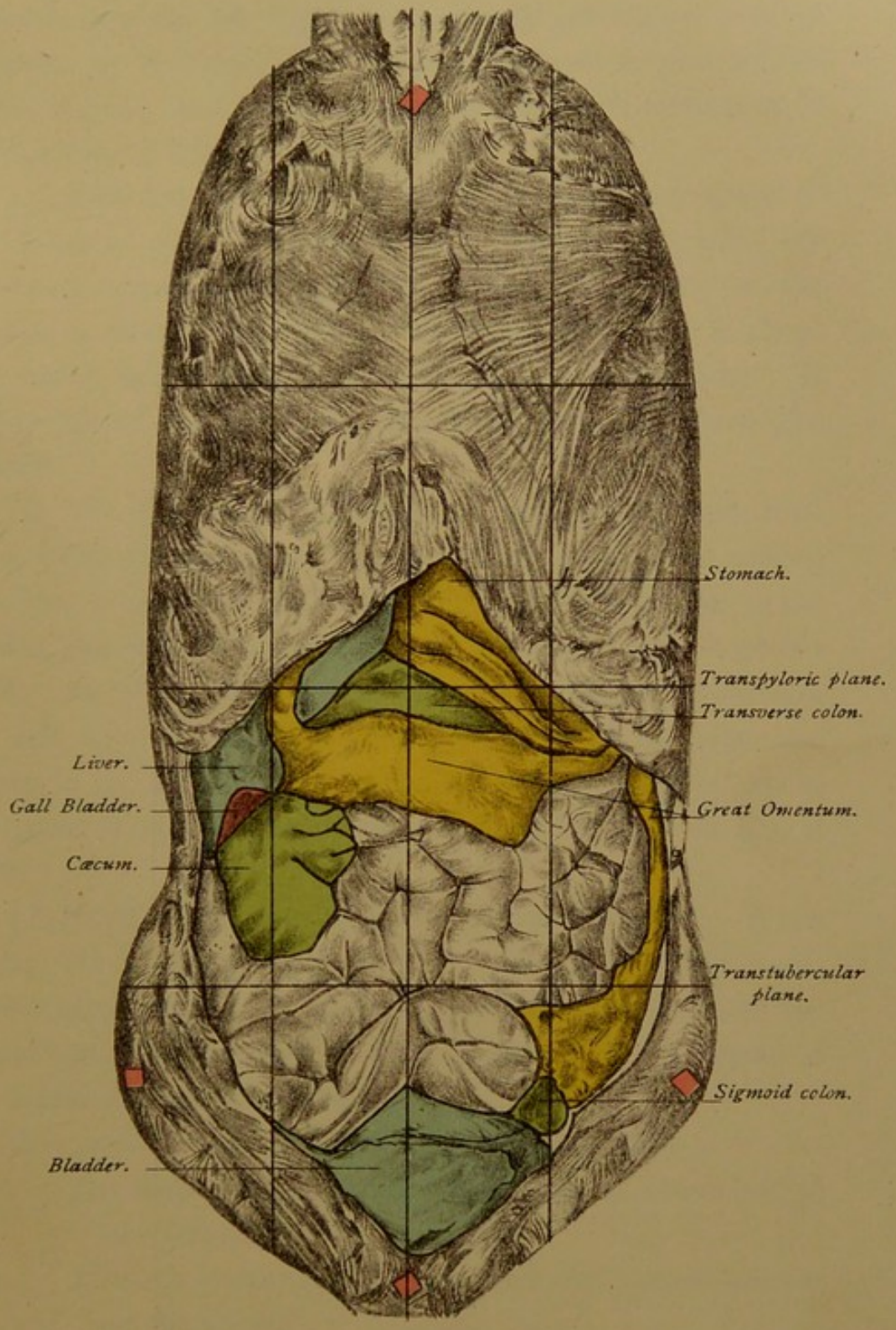

Figure 31.—Male, age 63. Dissection of the superficial abdominal viscera on a formalin hardened subject. Notice the upward displacement of the cæcum due to the distension of the bladder. Distance from manubrium to symphysis 54 cms., and from spine to spine 24 cms.

(*c*) The Fundus.—The fundus of the stomach is directed upwards into the left cupola of the diaphragm, and is roughly indicated by the apex beat of the heart, above and behind which it lies. It extends as high as the fifth interspace in the left lateral line.

(*d*) The Lesser Curvature.—The lesser curvature of the stomach may be indicated by a concave line, with the concavity towards the right, drawn from the cardia to the pylorus in such a way that its maximum curvature is about one and a half inches to the left of the mesial line. It is overlapped by the liver, which separates it from the surface.

(*e*) The Greater Curvature.—The greater curvature, three times as long as the lesser, is indicated on the surface by a line drawn from the cardia upwards and outwards to the fundus, thence outwards, downwards, and to the left, altogether to the left of the left lateral line, then downwards through the left hypochondrium within the curve of the ribs, and thence to the pylorus, cutting the left costal margin at about the point of intersection of the trans-pyloric and left lateral lines.

(*f*) Synopsis of the Relations of the Stomach.—When empty, the stomach may lie altogether behind the liver; when distended it is in contact *anteriorly* with the liver, the diaphragm, and the anterior abdominal wall in the region of the costal or subcostal angle.

The *posterior* surface of the stomach rests upon—

The diaphragm to a very small extent above and to the left of the cardia.

The left suprarenal capsule and the gastric surface of the spleen.

The upper end of the anterior surface of the left kidney.

The splenic artery.

The anterior surface of the body of the pancreas.

The transverse meso-colon, which separates the stomach from the duodeno-jejunal flexure, and from some coils of the small intestine.

(*g*) THE SEMILUNAR SPACE OF TRAUBE.—The semilunar

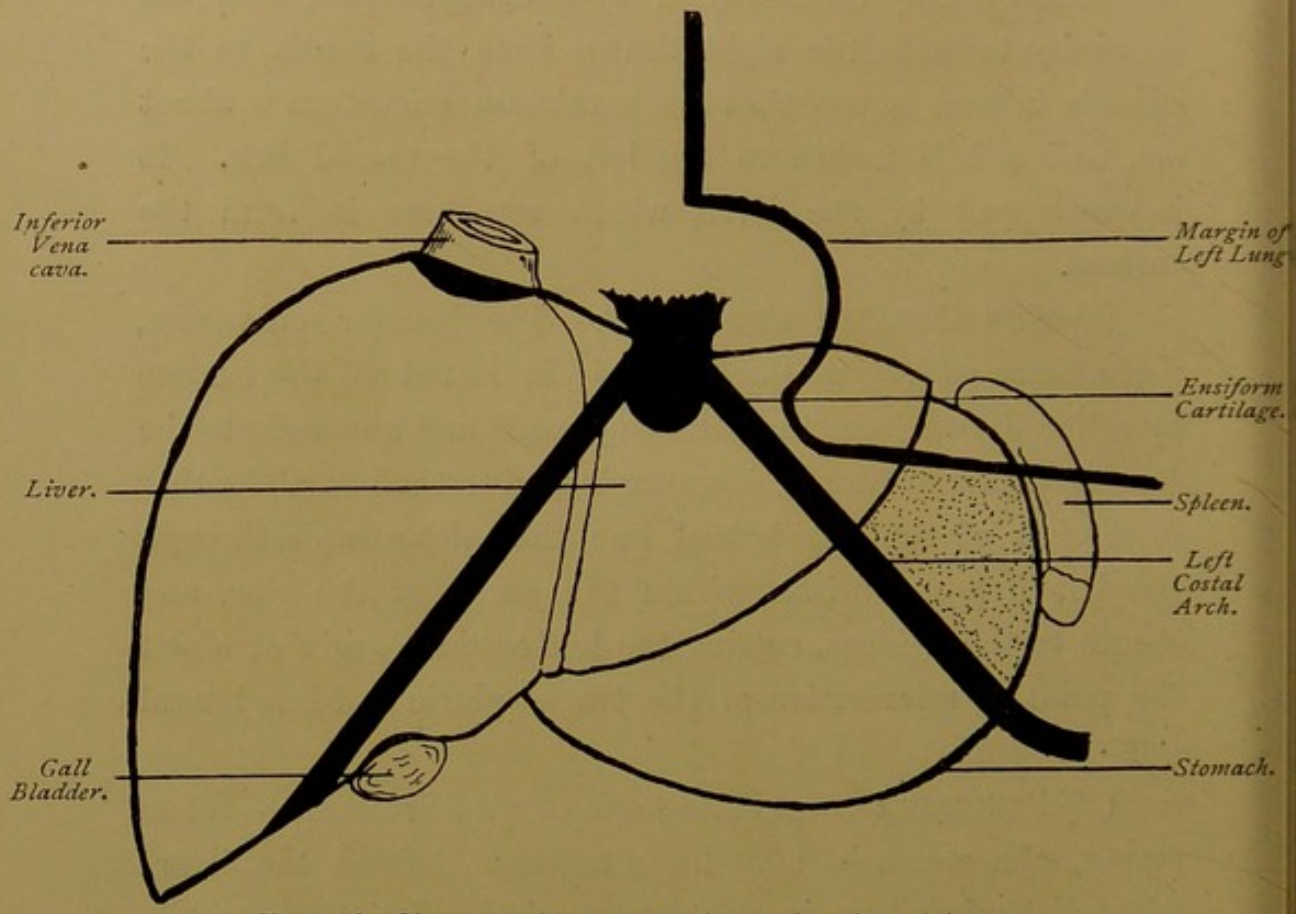

Figure 29.—Diagram to illustrate the boundaries of Traube's area. Traube's area is indicated by the dotted portion.

space of Traube is a term employed by clinicians to denote a certain surface area in front of that part of the stomach which lies behind the left costal arch and the adjacent portions of, roughly, the seventh and eighth costal cartilages, and which on percussion yields a deeply tympanitic note. This area is bounded as follows (see Figure 29):—

Above, by the lower margin of the left lung.

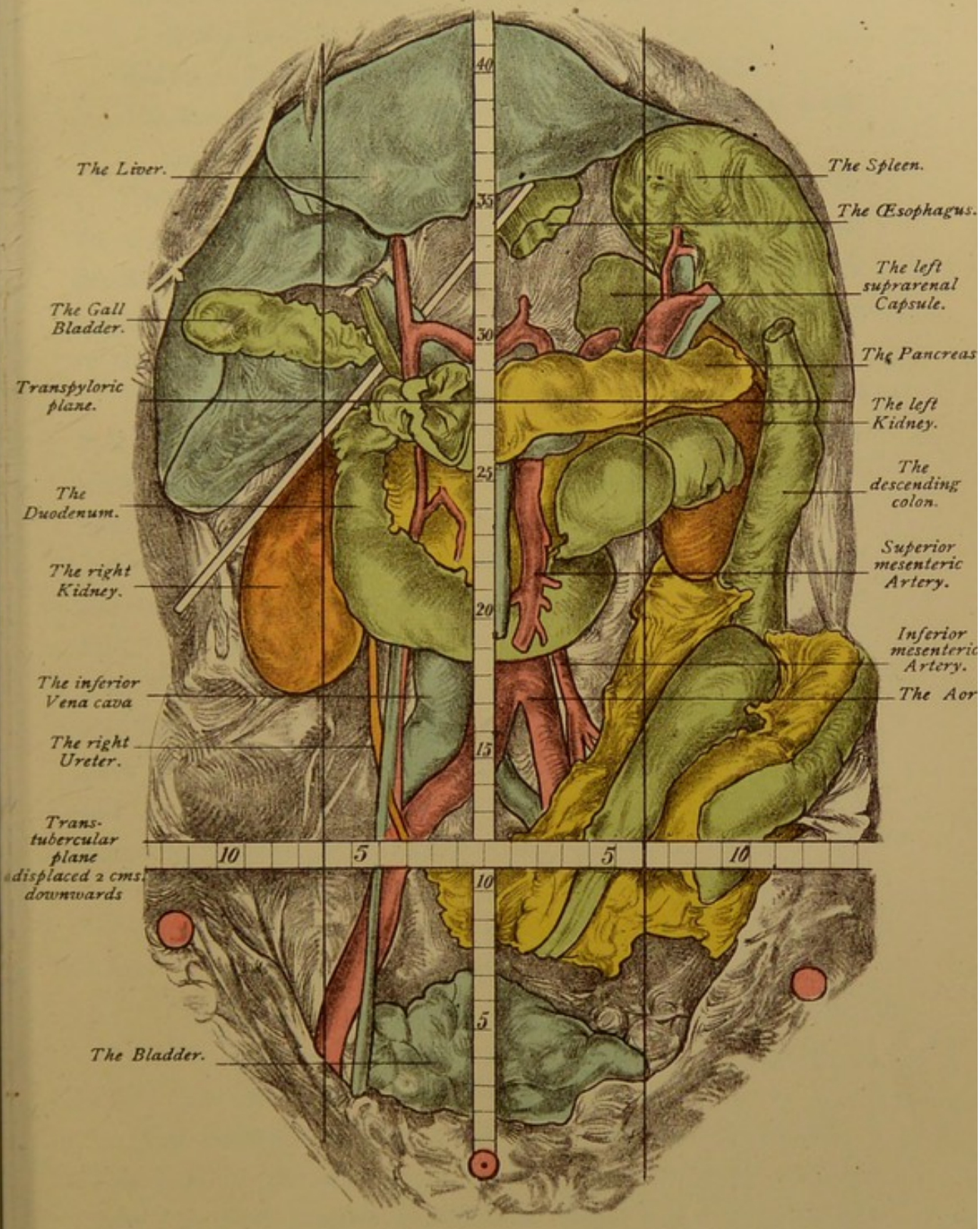

Figure 33.—Male, age 57. Deep dissection from a formalin hardened subject. Berry's frame for locating Addison's lines is seen in situ, marked off in centimetres; the transtubercular line is displaced downwards for 2 cms., in order to display the right ureter crossing the iliac vessels. Distance from manubrium sterni to symphysis 56 cms., and from spine to spine 23·50 cms. The liver is displaced upwards, and the glass rod passes through the foramen of Winslow.

Above and to the right, by the lower edge of the left lobe of the liver.

Below and to the right, by the left costal margin.

On the left, by the anterior border and anterior basal angle of the spleen.

The semilunar space of Traube is crossed, midway between its upper and lower limits, by the line of the base of the left pleura. Clinically the tympanitic area of the space is diminished superiorly by pleuritic effusions, on the right by enlargements of the liver, and on the left by enlargements of the spleen.

The Duodenum.—The duodenum commences at the pylorus opposite the first lumbar vertebra, and terminates, after a course of ten or twelve inches, at the duodeno-jejunal flexure opposite the left side of the upper border of the body of the second lumbar vertebra, immediately below the trans-pyloric plane, one inch to the left of the middle line. It may be divided into three or, better, four parts. (See Figures 30 and 32.)

The First or Superior Part of the Duodenum.—This part of the duodenum, two inches in length, may be mapped out by lines drawn from the pylorus in the trans-pyloric plane, to a point just internal to the right lateral line.

Chief Relations:—

Above and in front—The quadrate lobule of the liver and the gall bladder.

Behind—The portal vein, gastro-duodenal artery, common bile duct, and neck of the pancreas.

Below—The head of the pancreas.

The Second or Descending Part of the Duodenum.—This part of the duodenum, three inches in length, extends from the first lumbar vertebra to the lower border of the body of the third. It may be mapped out by lines drawn from the termination of the first part, downwards in the right

lateral line, to a little below a point midway between the trans-pyloric and trans-tubercular planes.

Chief Relations:—

In front—The liver, transverse meso-colon, and transverse colon, in that order from above downwards.

Behind—The hilum of the right kidney, the right renal vessels, and the inferior vena cava.

Right side—The hepatic flexure of the colon.

Left side—The head of the pancreas.

THE THIRD OR TRANSVERSE PART OF THE DUODENUM.—The third or transverse part of the duodenum crosses the abdomen, most usually, at the level of the third lumbar vertebra, though occasionally at a somewhat lower level. It may be mapped out by lines, three inches long, drawn from the termination of the second part of the duodenum transversely across the abdomen, a little below a point midway between the trans-pyloric and trans-tubercular planes, from the right lateral line to the left of the middle line.

Chief Relations:—

In front—The superior mesenteric vein and the superior mesenteric artery in that order from right to left, with peritoneum elsewhere.

Behind—The inferior vena cava and the abdominal aorta.

Above—The head of the pancreas.

THE FOURTH OR ASCENDING PART OF THE DUODENUM.—The fourth or ascending part of the duodenum, not always clearly differentiated from the third part, passes upwards on the left side of the aorta, as high as the upper border of the second lumbar vertebra, where it terminates abruptly in the duodeno-jejunal flexure by becoming continuous with

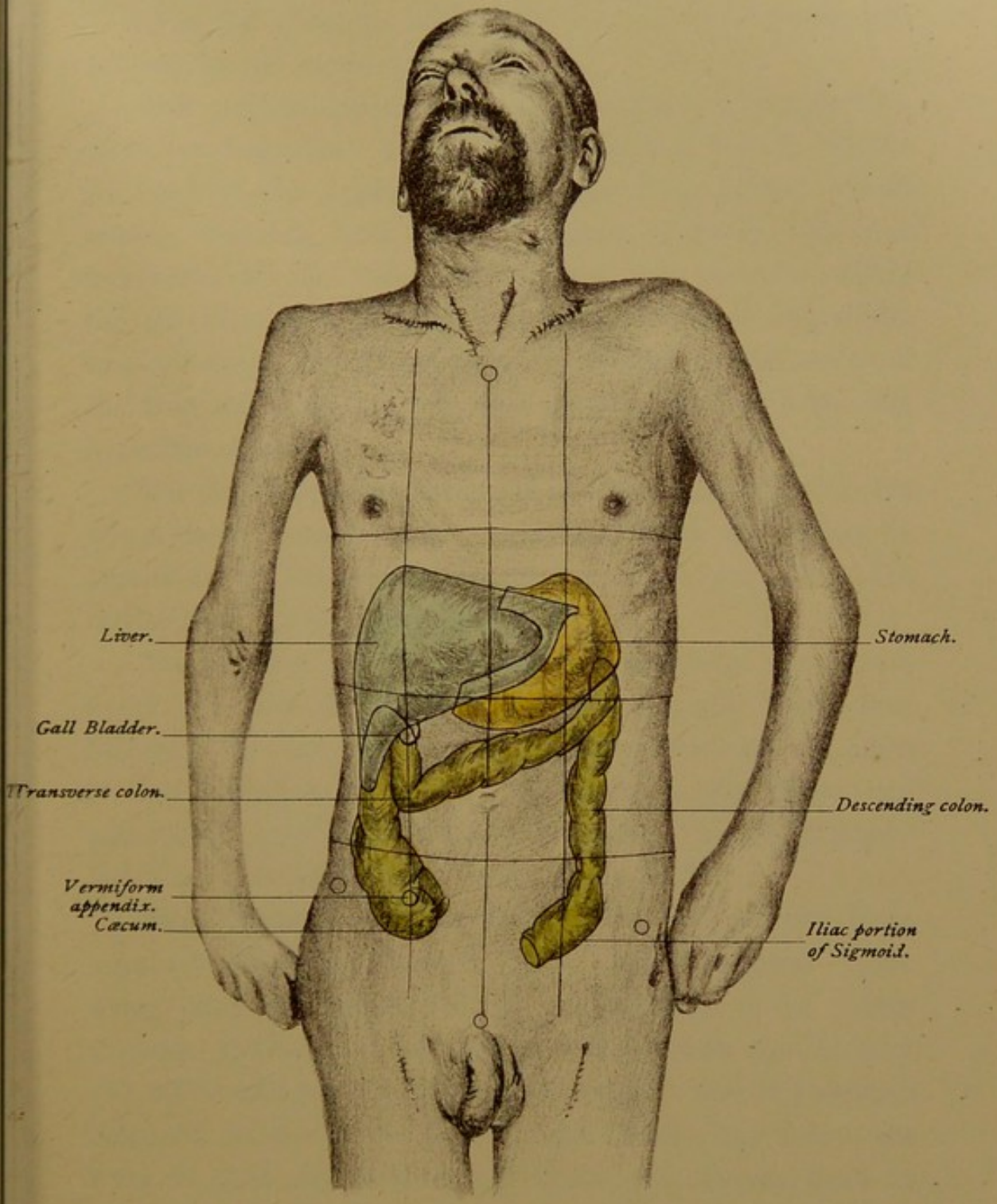

Figure 28.—Male, age 50 years. To illustrate the normal positions of the superficial abdominal viscera as mapped out by Addison's method.

the jejuno-ileum. It may be mapped out by lines drawn upwards, from the termination of the third part on the left of the mesial plane, as high as the trans-pyloric plane, one inch to the left of the mesial line.

The Jejuno-ileum.—The jejuno-ileum, or the floating intestine, commences at the duodeno-jejunal flexure on the left side of the upper border of the body of the second lumbar vertebra, and after a course of twenty-one feet terminates at the ileo-cæcal junction. It occupies chiefly the umbilical and hypogastric zones (see Figure 31), whilst coils of ileum are almost invariably found in the cavity of the true pelvis and a few coils of the jejunum in the left hypochondrium.

The *duodeno-jejunal flexure*, or the commencement of the jejuno-ileum, is most easily mapped out upon the surface by a point in the trans-pyloric plane one inch to the left of the mesial line. (See Figure 30.)

The *ileo-cæcal junction*, or the termination of the jejuno-ileum, lies with its lowest border in the right lateral line, half-way between the trans-tubercular plane and the plane of the interspinous line, or, in other words, below and immediately to the left of the intersection of the right lateral and trans-tubercular lines. (See Figure 28.)

The Cæcum.—The cæcum is that part of the large intestine which is situated below the ileo-cæcal valve. Being entirely surrounded by peritoneum, it is freely movable, but is most usually in contact with the anterior abdominal wall just above the outer third or half of Poupart's ligament, in the plane of the right lateral line below the level of the trans-tubercular line. Its lowest limit is situated in the right lateral line a little below the level of the anterior superior iliac spine, and its most internal point is about the level of the anterior superior iliac spine,

midway between the right lateral and mesial lines. (See Figures 28 and 32.)

The Vermiform Appendix.—The base of the vermiform appendix lies most usually in the right lateral line at, or just below the level of, the anterior superior iliac spine, whilst the appendix itself may occupy any position, but is most frequently found crossing the brim of the pelvis, or occupying a retro-cæcal or retro-colic position. (See Figures 28 and 32.) The surest surgical guide to the vermiform appendix is to follow the anterior longitudinal band of the cæcum downwards to its termination at the true cæcal apex, whence the appendix springs. (Berry.)

The vermiform appendix is a modified lymph gland with all the functions of lymphoid tissue, being most actively functional in the earlier part of life. After thirty years of age the amount of lymphoid tissue within the appendix diminishes in amount *pari passu* with age. (Berry.)

The Ascending Colon.—The ascending colon lies deeply, to the right of the right lateral line, being separated from the anterior abdominal wall by coils of jejuno-ileum. Its external border is just internal to a line drawn vertically upwards from the right anterior superior iliac spine. (See Figures 28 and 32.)

The Hepatic Flexure.—The hepatic flexure is deeply situated in, or to the right of, the right lateral line, in the neighbourhood of the trans-pyloric plane. It is wedged in between the liver in front of it, and the right kidney behind it, lying immediately to the right side of the gall bladder and the second or descending part of the duodenum.

The Transverse Colon.—The transverse colon extends from the hepatic flexure to the splenic flexure. It should form a loop slightly convex downwards crossing the abdomen just above the level of the umbilicus, but whether from

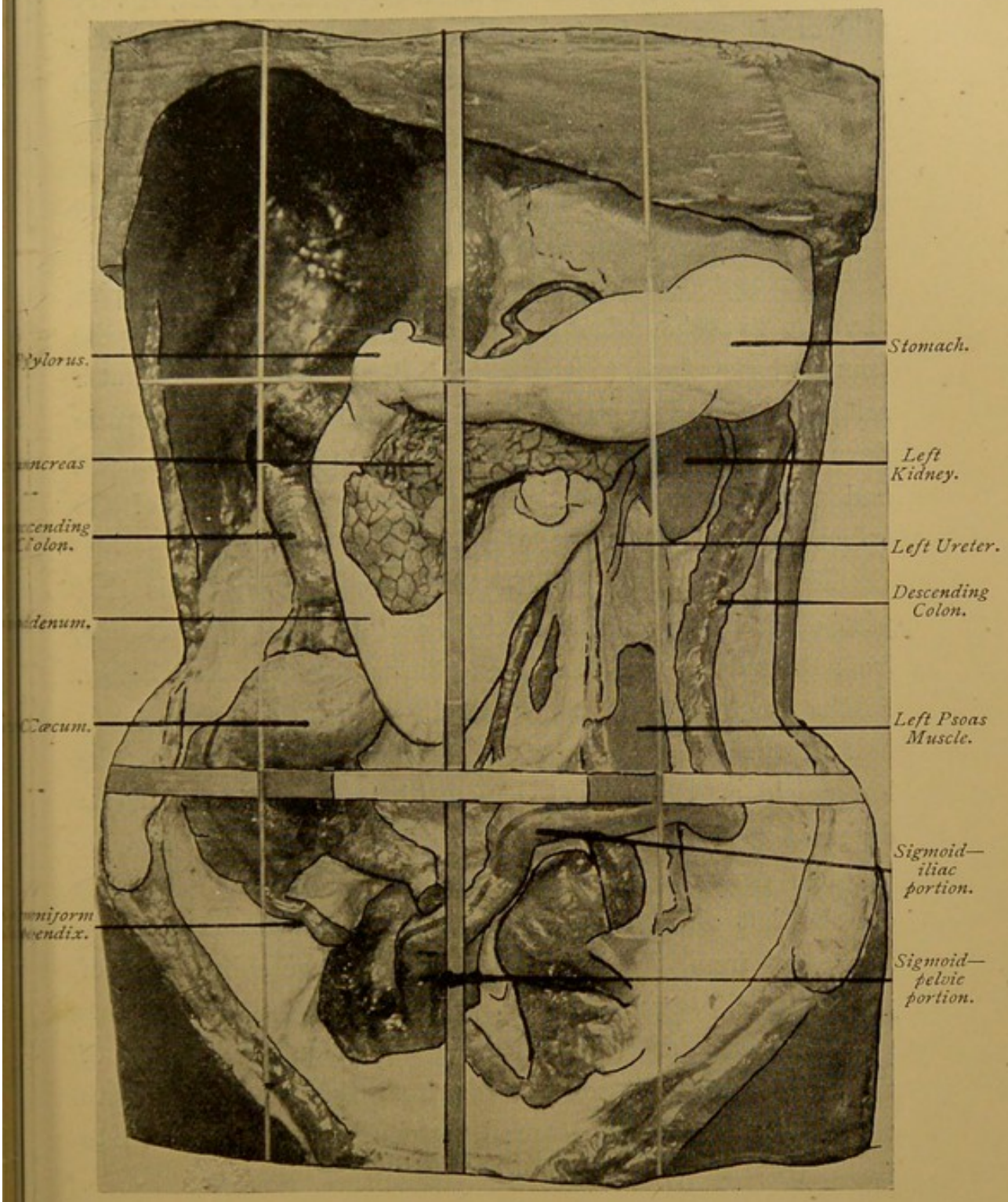

Figure 32.—Photograph of a cast made by the Author from the dissection of the formalin hardened subject seen in Figures 26, 28, and 30. A comparison of these figures will show in how far the viscera coincided in position with the surface markings. The surface lines employed by Addison are here reproduced by Berry's frame. Distance from manubrium to symphysis 52 cm., and from spine to spine 26 cm.

habits of constipation, as has been suggested, or not, it very seldom does so. It is much more common to find the transverse colon forming V- and W-shaped loops which occupy very different regions of the abdomen. In the middle line the upper border of the transverse colon is about one inch below the trans-pyloric plane, and in the left lateral line is in or just below that plane.

The Splenic Flexure.—The splenic flexure occupies the left hypochondriac region, and therefore lies above the trans-pyloric plane, to the left of the left lateral line, at a relatively higher and more posterior plane than the hepatic flexure. It lies behind the greater curvature of the stomach, and is in intimate relation with the basal surface of the spleen and with the tail of the pancreas.

The Descending Colon.—The descending colon is that part of the large intestine which descends, on the left side, from the splenic flexure above, to the crest of the ilium below. In the upper part of its extent it is applied to the lower half of the external border of the left kidney, but at the lower pole of that viscus it turns inwards and then again descends near the outer border of the left psoas muscle.

The descending colon is deeply situated, and descends on the left side of the left lateral line. It is entirely separated from the anterior abdominal wall by coils of jejuno-ileum.

The Sigmoid Colon.—The sigmoid colon is that part of the large intestine which extends from the left iliac crest to the middle of the third sacral vertebra. It is divided into two parts:—

(*a*) An iliac or fixed portion.

(*b*) A pelvic or floating portion.

(*a*) The Iliac or Fixed Portion of the Sigmoid Colon.—The iliac or fixed portion of the sigmoid colon extends from

the left iliac crest to the pelvic brim at the inner border of the left psoas muscle. (See Figure 32.) Its average length is five to six inches and in 90 per cent. of cases it is devoid of a mesentery (Jonnesco), and is therefore tightly bound down to the walls of the false pelvis, and is not in contact with the anterior abdominal wall. This portion of the sigmoid colon terminates in the left lateral line opposite the anterior superior iliac spine, and can generally be felt through the abdominal wall. It is this portion which is most frequently, though by no means always, opened in a sigmoidostomy, as it is obvious that the pelvic portion of the sigmoid may, with much greater ease, being movable, present itself in the incision. To open the sigmoid colon, make an incision above the outer part of Poupart's ligament, the centre of which is to be placed at the junction of the middle and outer thirds of a line drawn from the umbilicus to the left anterior superior iliac spine.

(*b*) The Pelvic or Floating Portion of the Sigmoid Colon.—The pelvic or floating portion of the sigmoid colon extends from the pelvic brim at the inner border of the left psoas muscle, or the level of the anterior superior iliac spine, to the middle of the third sacral vertebra, where it terminates by becoming directly continuous with the rectum. (See Figure 32.) Between these two points it has a well-developed mesentery, and forms a large and variously shaped coil, which usually lies in the cavity of the pelvis. Its length varies from five to thirty-five inches, but averages about sixteen or seventeen inches.

The Rectum.—The rectum is that portion of the large intestine which extends from the middle of the third sacral vertebra to the apex of the prostate, at a point one and a half inches in front of and below the tip of the coccyx. (See also page 156.)

The Anal Canal.—The anal canal is the slit-like passage between the levatores ani muscles which extends from the termination of the rectum to the anus. (See also page 157.)

THE PERITONEUM.

The Great Omentum.—The great omentum is usually described as hanging down in the form of an apron-like fold, from the greater curvature of the stomach and pyloric end of the first part of the duodenum, in front of the transverse colon and jejuno-ileum.

It is, however, much more common to find the great omentum rolled up upon itself and occupying very many diverse positions in the abdomen. It has a strong tendency to incline to the left, which may possibly explain the fact that omental herniæ are commoner on that side; the great omentum also displays a tendency to move towards the site of an intra-abdominal inflammation, with the object, presumably, of bringing an increased number of leucocytes to the protection of the inflamed area.

The great omentum is, from its superficial position, very apt to be wounded; it is also very frequently found in a hernial sac, especially in acquired umbilical herniæ, in which it is almost constant.

The Enteric Mesentery.—The *parietal attachment* of the enteric mesentery or its *root* is six inches in length, and is attached to the posterior abdominal wall along an oblique line, which extends from the left side of the body of the second lumbar vertebra, downwards to the right into the right iliac fossa. In this course the root of the mesentery

successively crosses the third part of the duodenum, the aorta, the inferior vena cava, and the right psoas muscle.

The *intestinal border* of the enteric mesentery is about twenty-one feet long, and is attached to and surrounds the jejuno-ileum.

The parietal attachment of the enteric mesentery to the posterior abdominal wall may be mapped out upon the surface by drawing a line from a point on the trans-pyloric plane, one inch to the left of the median line, to the mid-point of a line drawn horizontally from the right anterior superior iliac spine to the median line.

The Transverse Meso-Colon.—The transverse meso-colon is attached to the posterior abdominal wall along a horizontal line which successively crosses, from right to left, part of the right kidney, the second part of the duodenum, the head of the pancreas, and the anterior border of the body of the pancreas. Its position on the surface is roughly, but not accurately, indicated by the trans-pyloric plane.

THE BILIARY APPARATUS.

The Liver.—As the liver moves with every respiration and is further considerably altered in position by the distension or otherwise of abdominal viscera, such as the stomach, bladder, cæcum, and transverse colon, it follows that any rules for the mapping out of the liver can only be an approximation to the truth. The lower or anterior border of the liver is, as a matter of fact, much more accurately determined upon the surface by percussion applied from below upwards.

THE LOWER BORDER OF THE LIVER.—The lower border of the liver may be approximately indicated upon the surface by a line which commences in the right mid-axillary line below the lowest part of the tenth right costal cartilage, or about two and three-quarter inches below the trans-pyloric plane; it passes thence to the tip of the tenth right costal cartilage, crosses the median line in the trans-pyloric plane, and ascends from that point to the sixth interspace in, or immediately to the left of, the left lateral line, which it crosses about two and three-quarter inches above the trans-pyloric plane. (See Figure 28.)

THE UPPER BORDER OF THE LIVER.—The upper border of the liver may be indicated by a line which, commencing at the left extremity of the lower border, passes to the right, behind the sternum, at the level of the sixth chondro-sternal articulations, and thence to the fifth rib in the right lateral line, that is, almost to the level of the nipple.

The Gall Bladder.—The fundus of the gall bladder, when that viscus is distended, is usually in contact with the anterior abdominal wall in, or immediately external to, the right lateral line one inch below the trans-pyloric plane, and just internal to the ninth right costal cartilage. (See Figure 28.) Its position, however, is, as regards the surface, liable to variation.

The *under* surface of the gall bladder is in contact, from before backwards, with the commencement of the transverse colon and the first part of the duodenum.

The *neck* of the gall bladder gradually becomes constricted and curved like the letter S, and, bending downwards, terminates in the cystic duct near the right end of the transverse fissure of the liver.

The Cystic Duct.—The cystic duct, or the duct of the gall bladder, is about one and a half inches in length.

Bending sharply upon itself close to its origin at the neck of the gall bladder, it turns downwards, backwards, and to the left, and terminates at the mouth of the portal, or transverse, fissure of the liver by uniting with the hepatic duct to form the common bile duct.

The Common Bile Duct.—The common bile duct is formed at the mouth of the portal or transverse fissure of the liver by the junction of the cystic and hepatic ducts. After a course of three inches it terminates by opening into the second or descending part of the duodenum three and a half inches beyond the pylorus, and by an orifice which is common to it and the duct of Wirsung (the main duct of the pancreas).

In its *upper third* the common bile duct lies between the two layers of the small or gastro-hepatic omentum, with the portal vein behind it and the hepatic artery on its left. All these structures lie in the right lateral free margin of the gastro-hepatic omentum, and therefore in front of the foramen of Winslow.

In its *middle third* the common bile duct lies behind the first or superior part of the duodenum, and in its *lower third* behind and between the head of the pancreas and the upper half of the second part of the duodenum.

THE PANCREAS.

The Head of the Pancreas.—The head of the pancreas occupies the curve of the duodenum, and is therefore easily located upon the surface by mapping in the latter viscus. (See Figures 30 and 33.) It lies in front of the bodies of

the second, and upper part of the third, lumbar vertebræ, and therefore lies just below the trans-pyloric plane in the median line.

The Neck of the Pancreas.—The neck of the pancreas lies in the trans-pyloric plane in, or immediately to the right of, the median line, and in front of the disc between the first and second lumbar vertebræ.

The Body of the Pancreas.—The body of the pancreas, four inches in length and one and a quarter inches in depth, runs from the median line towards the left, with its anterior border in, or obliquely across, the trans-pyloric plane. The bulk of the body of the pancreas is above that plane.

The Tail of the Pancreas.—The tail of the pancreas is in contact with the lower portion of the gastric surface, or sometimes with the basal surface of the spleen, in the left hypochondriac region, altogether above the trans-pyloric plane, and to the left of the left lateral line.

THE SPLEEN.

The Spleen. — The spleen occupies the left hypochondriac and left epigastric regions, and the key to its surface anatomy is the fact that its long axis corresponds closely in direction to the posterior half of the tenth left rib.

The upper pole or apex of the spleen is situated on the tenth left rib one and a half inches from the posterior mesial line of the body and about on the same horizontal level as the tip of the ninth dorsal spine, or, in other words, the disc between the tenth and eleventh dorsal vertebræ.

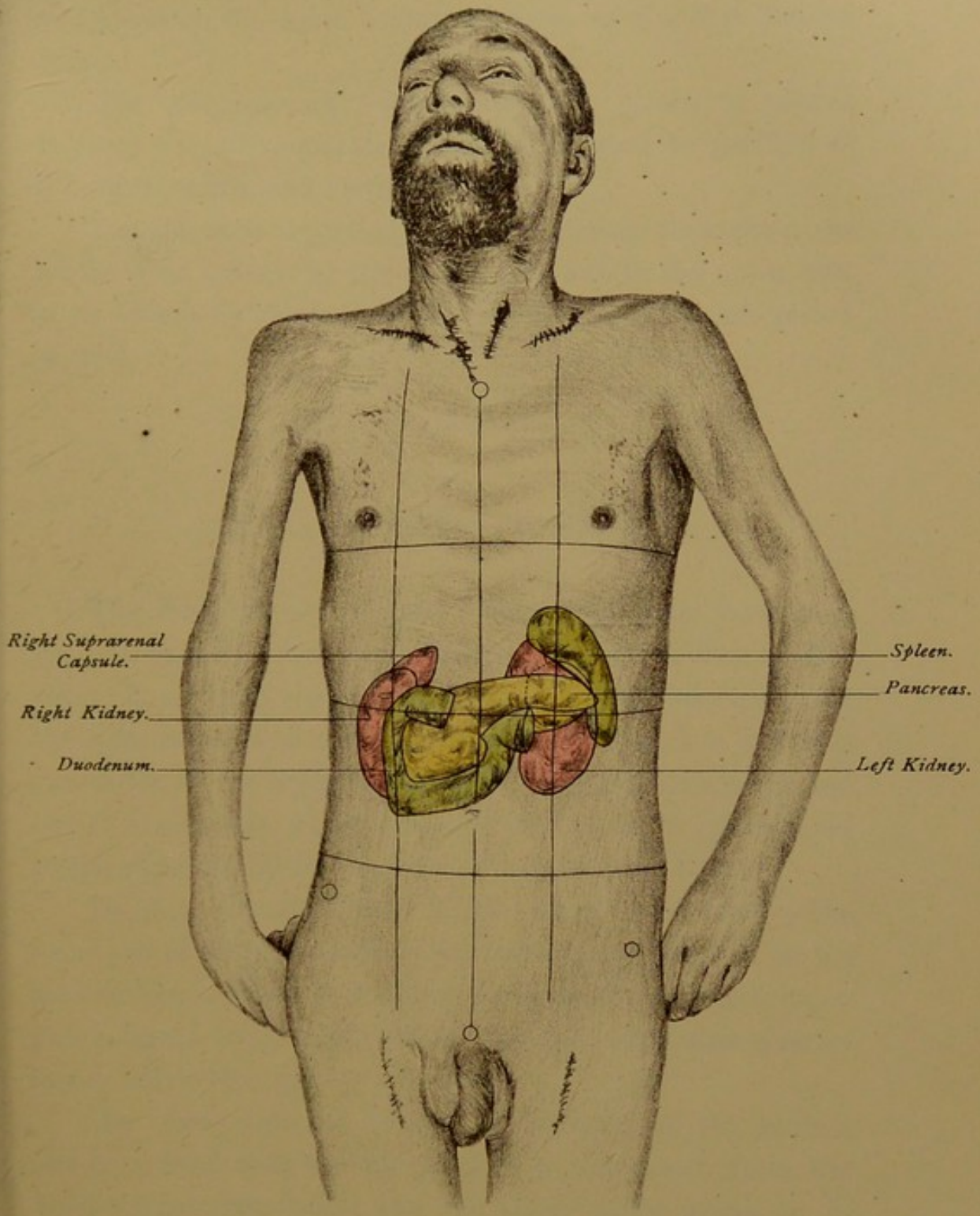

Figure 30.—Male, age 50 years. To illustrate the normal positions of the deep abdominal viscera as mapped out by Addison's method.

The lower pole or inferior border of the spleen is situated on the tenth left rib in, or just behind, the mid-axillary line, and about on the same horizontal level as the first lumbar spine.

The diaphragmatic surface of the spleen is placed between the above-mentioned points internal to portions of the ninth, tenth, and eleventh ribs.

The spleen is separated from the surface throughout the whole of its extent by the diaphragm, and in the upper part of its extent by the base of the left lung and the left pleura as well.

THE URINARY APPARATUS.

The Kidneys.—The right kidney lies a little lower than the left, owing to the greater development of the liver on that side. It occupies the area about the point of intersection of the right lateral and trans-pyloric planes in such a way that two-thirds of the organ lies below the trans-pyloric plane and one-third above it, whilst one-third of the organ lies internal to the right lateral line and two-thirds external to it.

To Map out the Right Kidney from the Front.—The *lower pole* of the right kidney lies three inches external to the median line and one inch above the level of the umbilicus, or just external to the right lateral line two and three-quarter inches below the trans-pyloric plane.

The *upper pole* lies two inches external to the median line on a level with the mid-point of a line drawn from the xiphi-sternal articulation and the trans-pyloric plane, or, in other words, just internal to the right lateral line, and about one and a half inches above the trans-pyloric plane.

The *hilum* of the right kidney lies midway between the upper and lower poles two inches external to the median line, or a finger's breadth internal to the tip of the ninth right costal cartilage. A line joining the hila of the two kidneys should be on about the same level as the trans-pyloric plane.

Each kidney measures about four and a half inches in length by two and a half inches in breadth, the right kidney with one-third of its bulk, and the left kidney with two-fifths of its bulk above the trans-pyloric plane, whilst the right and left lateral lines traverse them longitudinally, and respectively, a little nearer their inner than their outer borders. (See Figures 30 and 32.)

Summary of the Anterior Relations of the Right Kidney.

External Border—The upper two-thirds is in contact with the liver and the lower third with the ascending colon.

Anterior Surface—The upper two-thirds is in contact with the liver, the lower third with the hepatic flexure of the colon, and the lower pole comes into contact with the jejuno-ileum.

Internal Border—The internal border of the right kidney is in contact, in the region of the hilum with the second or descending part of the duodenum.

(For the posterior relations of the right kidney, see page 131.)

THE LEFT KIDNEY.—The left kidney usually, but not invariably, lies about half an inch higher than the right kidney. With this reservation, its surface anatomy is the same as that of the right kidney.

The left kidney occupies the area about the point of intersection of the left lateral and trans-pyloric planes in such a way that three-fifths of the organ lies below the

trans-pyloric plane and two-fifths above it, whilst two-fifths of the organ lies internal to the left lateral line and three-fifths external to it.

Summary of the Anterior Relations of the Left Kidney.

External Border—The upper half of the external border of the left kidney is in contact with the renal surface of the spleen, and the lower half with the upper part of the descending colon.

Anterior Surface—The upper third of the anterior surface of the left kidney is in contact with the stomach, the middle third with the body of the pancreas, and the lower third with the jejuno-ileum.

(For the posterior relations of the left kidney, see page 131.)

It is important to notice that the lower pole of each kidney lies altogether above the umbilicus, and that the body of the kidney is crossed obliquely by the costal margin of the corresponding side.

The Ureters.—The ureter may be mapped out upon the anterior abdominal wall by a line commencing above in the trans-pyloric plane two inches external to the median line, and drawn thence to the pubic spine. (See also page 135.)

The Suprarenal Capsules.—The suprarenal capsules surmount the upper poles of the two kidneys. They lie internal to the right and left lateral lines respectively about two and a quarter inches above the trans-pyloric plane. The left suprarenal capsule is a trifle higher and a little nearer the middle line than the right.

THE GREAT VESSELS.

The Abdominal Aorta. — The abdominal aorta commences in the middle line of the body, at the lower border of the twelfth dorsal vertebra as the direct continuation of the descending thoracic aorta. It is five inches in length, and terminates opposite the middle of the body of the fourth lumbar vertebra, a little to the left of the middle line, by dividing into the two common iliac arteries. (See Figure 33.)

The *upper end* of the abdominal aorta, and consequently the termination of the descending thoracic aorta, is indicated upon the surface by a point in the median line two fingers' breadth above the trans-pyloric plane.

The *bifurcation* of the abdominal aorta into the common iliacs is indicated upon the surface by drawing a horizontal line between the highest points of the two iliac crests, and then taking a point on this line slightly to the left of the median line. Less accurately, on account of the variability in position of the umbilicus, the bifurcation of the abdominal aorta may be indicated by a point three-quarters of an inch below, and to the left of, the umbilicus.

Branches of the Abdominal Aorta.—The branches of the abdominal aorta from above downwards, and the surface anatomy markings of the more important of these, are as follows:—

The inferior phrenics. Paired and parietal.

The cœliac axis. Single and visceral. Two fingers' breadth (approximately) above the trans-pyloric plane.

The middle capsulars. Paired and visceral.

The superior mesenteric. Single and visceral. One finger's breadth above the trans-pyloric plane.

The renals. Paired and visceral. One finger's breadth below the trans-pyloric plane.

The spermatics (male) or ovarians (female). Paired and visceral.

The inferior mesenteric artery. Single and visceral. One and a half inches above the bifurcation of the abdominal aorta.

The common iliacs. Paired and parietal.

The middle sacral. Single and parietal.

The five pairs of lumbar arteries. Paired and parietal.

The Common Iliac Arteries.—The common iliac arteries commence a little to the left side of the middle of the body of the fourth lumbar vertebra by the bifurcation of the abdominal aorta. Each vessel passes downwards and outwards for two inches, and terminates opposite the lumbo-sacral articulation, by dividing into external and internal iliac arteries.

The External Iliac Arteries. — The external iliac artery commences opposite the lumbo-sacral articulation in the manner just indicated, and terminates, after a course of four inches, behind Poupart's ligament by becoming directly continuous with the femoral artery.

The Internal Iliac Arteries.—The internal iliac artery commences opposite the lumbo-sacral articulation, and terminates, after a course of one and a half inches, opposite the upper border of the great sacro-sciatic foramen, by dividing into an anterior and a posterior division, whence arise its parietal and visceral pelvic branches.

The common, and external, iliac arteries may be mapped out by a line drawn from the bifurcation of the abdominal

aorta (*q.v.*) to a point midway between the anterior superior iliac spine and the symphysis pubis. The upper third of the line maps out the common iliac, and the lower two-thirds the external iliac artery.

The Common Iliac Veins.—The common iliac veins lie mainly on the right side of their corresponding arteries, that of the left side also passing behind the right common iliac artery near its commencement. These relations, as well as that of the ureter, must be particularly remembered in ligation of the common iliac arteries.

The Inferior Vena Cava.—The inferior vena cava commences on the right side of the middle of the body of the fifth lumbar vertebra, and terminates in the right auricle of the heart opposite the disc between the eighth and ninth dorsal vertebræ. It lies on the right side of the aorta between it and the right ureter.

Its commencement lies a little to the right of the median line just above the level of a line drawn between the two anterior superior iliac spines. Its termination is just below the level of the nipple behind the right lateral border of the sternum.

IV.

THE BACK.

The Spinal or Nuchal Furrow.—The spinal or nuchal furrow is a median depression which commences above, immediately below the external occipital protuberance. It passes downwards between the prominences formed by the complexus and trapezius muscles of the two sides, and at the bottom of the furrow is the posterior edge of the ligamentum nuchæ of the neck. At the lower part of the neck, about opposite the spines of the seventh cervical and first dorsal vertebræ, the furrow gradually disappears.

In the *dorsal region* the furrow reappears, and as it descends through the lower dorsal and lumbar regions it becomes much better marked, lying between the elevations formed on either side of it by the erectores spinæ muscles, overlapped on each side, above by the trapezius, and below by the latissimus dorsi muscles.

In the *upper sacral region* the spinal furrow, consequent on the flattening of the erectores spinæ, broadens out into a triangular area, the angles of which are about equidistant and are formed by the two posterior superior iliac spines and the third sacral spine. Below this level the spinal furrow merges into the natal cleft. (See page 207.)

The Spines of the Vertebræ.—The spines of the vertebræ lie at the bottom of the spinal furrow, where they can be palpated. They become much more prominent by

causing the patient to flex the spine, and, on the application of friction, stand out as reddened areas.

THE CERVICAL REGION.—The spine of the *second cervical* vertebra, or the axis, lies in the spinal furrow, two inches below the external occipital protuberance, where it can be felt on deep pressure.

The spine of the *seventh cervical* vertebra, or the vertebra prominens, is the next to appear; though occasionally it may be the sixth. It becomes more prominent on bending the head, and must not be mistaken for the spine of the first dorsal vertebra, which is just below it and is usually the more prominent of the two.

THE DORSAL REGION.—The spine of the *first dorsal* vertebra is the most prominent spine visible when the patient bends his head. As just stated, it is more prominent than even that of the so-called vertebra prominens.

The spine of the *third dorsal* vertebra is on the same level as the root of the spine of the scapula, and from it is drawn the line which indicates the great oblique fissures of the lungs.

The spine of the *seventh dorsal* vertebra is on the same level as the inferior angle of the scapula when the upper limb is dependent.

THE LUMBAR REGION.—The spine of the *third lumbar* vertebra is just above the horizontal level of the umbilicus.

The spine of the *fourth lumbar* vertebra is on the same level as the highest portions of the iliac crests, and at this level is performed the simple operation of lumbar puncture.

THE SACRAL REGION.—The spine of the *second sacral* vertebra is on the same level as the posterior superior iliac spines.

The spine of the *third sacral* vertebra indicates the

lowest limit of the meninges of the spinal cord and of the cerebro-spinal fluid.

The Ribs.—The eighth, ninth, tenth, eleventh, and twelfth ribs can be felt posteriorly below the inferior angle of the scapula through the latissimus dorsi muscle and external to the outer edge of the erector spinæ muscle.

The tip of the last rib does not always project beyond the outer edge of the erector spinæ muscle, in which case the lowest rib that can be felt will be the eleventh, hence the necessity of *always* counting ribs from above downwards. Under normal conditions, and with the body erect, the tip of the twelfth rib should lie about two inches vertically above the centre of the iliac crest.

The Scapula.—(See page 176.)

The Trapezius Muscle.—The *lower border* of the trapezius muscle may be indicated by a line drawn from the twelfth dorsal spine to the root of the spine of the scapula. In the latter situation is a distinct depression which indicates the triangular tendon found in the trapezius at the point where it glides over the root of the spine of the scapula.

The *upper border* of the trapezius forms the posterior boundary of the posterior triangle of the neck, and is roughly indicated by a line drawn from a point one inch external to the external occipital protuberance to the junction of the middle and outer thirds of the clavicle.

The Latissimus Dorsi Muscle.—The *upper border* of the latissimus dorsi is indicated by a line drawn from the seventh dorsal spine transversely outwards across the inferior angle of the scapula.

The *lower border* of the muscle may be roughly indicated by a line drawn from the iliac crest, four inches external to the posterior mesial line, to a point in the mid-axillary line

opposite the inferior angle of the scapula. In both cases the upper limb must be dependent.

In connection with both borders of the latissimus dorsi the presence of a triangle must be noted—with the upper border, the *triangle of auscultation*, and with the lower border, the *triangle of Petit.* (See page 92.)

The *triangle of auscultation* lies immediately internal to the inferior angle of the scapula, and overlies the sixth intercostal space. Its boundaries are as follows:—

Below, by the upper border of the latissimus dorsi.

Above and to the inner side, by the lower border of the trapezius.

Above and to the outer side, by the lower border of the rhomboideus major.

In muscular subjects both the triangle of auscultation and the triangle of Petit tend to be obliterated.

The Supra-Scapular Region.—Immediately above the spine of the scapula is a convex surface formed by the supra-spinatus muscle, covered posteriorly or superficially by the thickest part of the trapezius.

Above this again is another convex surface sloping from the upper part of the neck, downwards and outwards, to the upper fourth of the vertebral border of the scapula. It is formed by the levator anguli scapulæ, covered posteriorly or superficially by the upper part of the trapezius.

The Interscapular Region.—Between the two scapulæ lie the rhomboid muscles, covered posteriorly in the greater part of their extent by the trapezius muscles. The rhomboids are thrown into greater prominence by bracing back the shoulders.

The Erector Spinæ Muscles.—The erector spinæ muscles form two, usually very distinct, prominences on each side of the spinal furrow in the lumbar region. The outer

border of the muscle is, as a rule, sufficiently obvious, passing upwards from the iliac crest to the angles of the ribs; but if it cannot be seen it may be indicated by a line drawn from a point on the iliac crest four inches external to the middle line, upwards and slightly outwards to the angles of the ribs.

The Quadratus Lumborum Muscle.—The quadratus lumborum muscle lies deeply in the posterior abdominal wall between the anterior and middle lamellæ of the lumbar aponeurosis. It occupies the interval in the loins between the iliac crest and the last rib, and its *outer border* may be indicated by a line drawn from the iliac crest just external to the line for the erector spinæ, to the twelfth rib internal to the latter muscle.

Viscera.—As the relations of all the viscera to the vertebral column are given in the table of levels (see page 137), it is unnecessary to do more than state the posterior relations of those viscera which are most readily approached from behind. These are all situated in the lumbar region, or the region of the loin, and comprise the kidneys, the descending colon, and the ascending colon.

The Kidneys.—(*a*) SURFACE ANATOMY.—The kidneys may be mapped out posteriorly by Morris's parallelogram (see Figure 34):—

(1) Draw a line parallel with, and one inch external to, the posterior mesial line, with its upper limit opposite the lower edge of the tip of the eleventh dorsal spine, and its lower limit opposite the lower edge of the tip of the third lumbar spine.

(2) and (3) From the upper and lower ends of line (1), draw two lines horizontally outwards for a distance of two and three-quarter inches.

(4) Connect the outer ends of lines (2) and (3) by a

line drawn parallel to line (1). Within the parallelogram thus described the kidney lies.

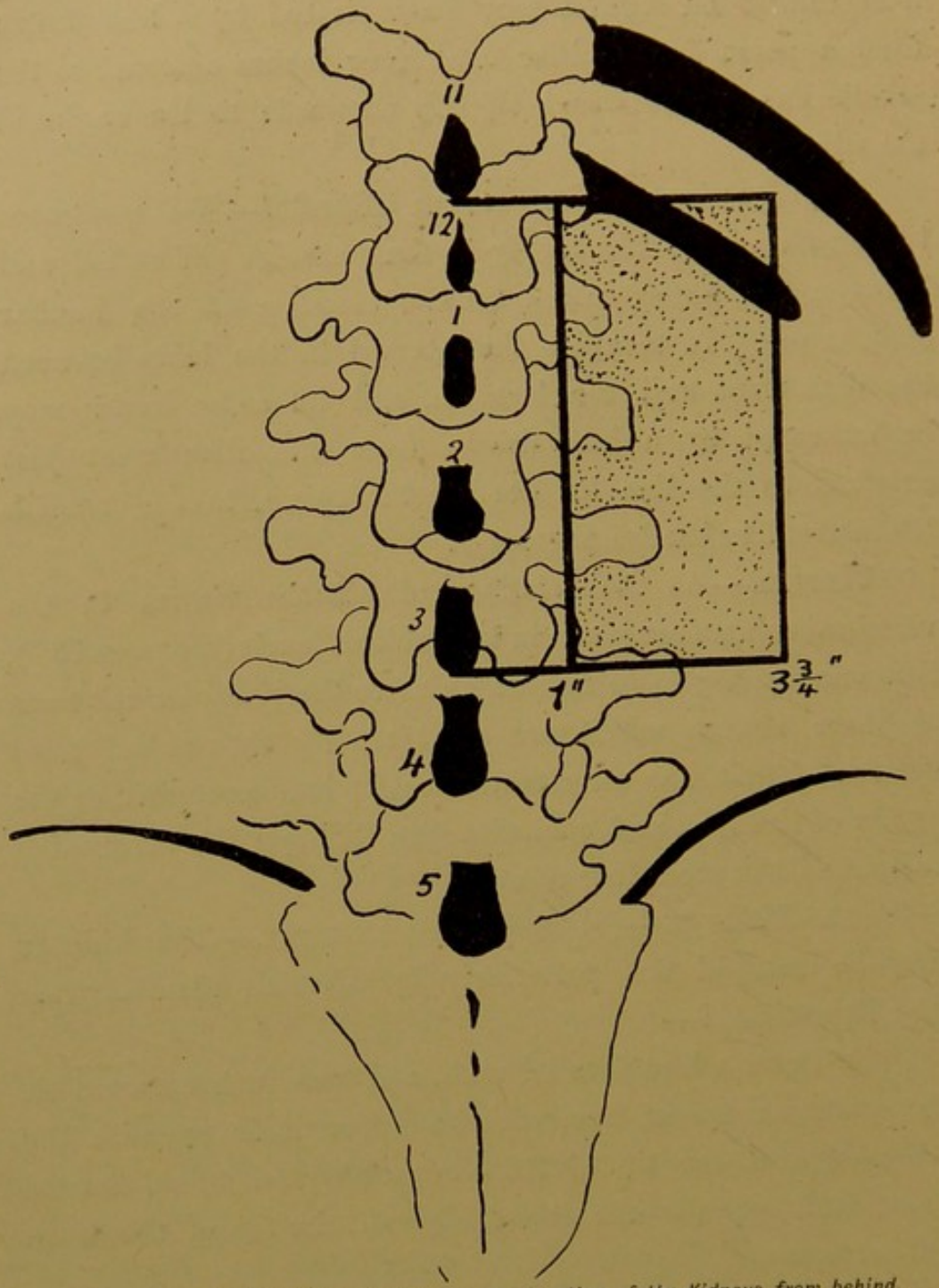

Figure 34.—Morris's Parallelogram for the location of the Kidneys from behind. Indicated by the dotted area.

(*b*) Osseous Relations.—The *upper pole* of the right kidney is usually on the same horizontal level as the

eleventh dorsal spine, and the *lower pole* a little below the second lumbar spine, or about one inch above the iliac crest. The *hilum* lies opposite the first lumbar spine, and is about one and a half to two inches external to it, whilst one-third of the bulk of the organ lies above the lower border of the twelfth rib and has pleura behind it—a very important surgical relation. (See Figure 36.)

The osseous relations of the left kidney are the same as those of the right, always remembering that the left kidney is usually about half an inch higher than the right.

(*c*) Direct Posterior Relations.—The *posterior* surface of each kidney is entirely devoid of peritoneum, and is embedded in areolar and adipose tissue—the perinephric tissue—which separates it from the following structures (see Figure 35):—

The posterior surface of the upper pole of the kidney is in contact with the diaphragm in the region of its vertebral and costal origins—between these two origins there is not infrequently an interval, in which case the kidney is only separated from the pleural cavity by areolar tissue.

Below the diaphragmatic area the kidney is crossed posteriorly and below the twelfth rib, by the last dorsal nerve, accompanied by the abdominal branch of the first lumbar artery, and still lower by the ilio-inguinal and ilio-hypogastric nerves.

The posterior muscular relations of the kidney are, above, as just stated, the diaphragm, below which come from without inwards the transversalis abdominis, the quadratus lumborum separated from the kidney by the anterior lamella of the lumbar aponeurosis, and the psoas, which last separates the kidney from the transverse processes of the first and second lumbar vertebræ. As these three muscles very nearly subdivide the posterior surface of the kidney into three

equal areas, it follows that the outer border of the quadratus

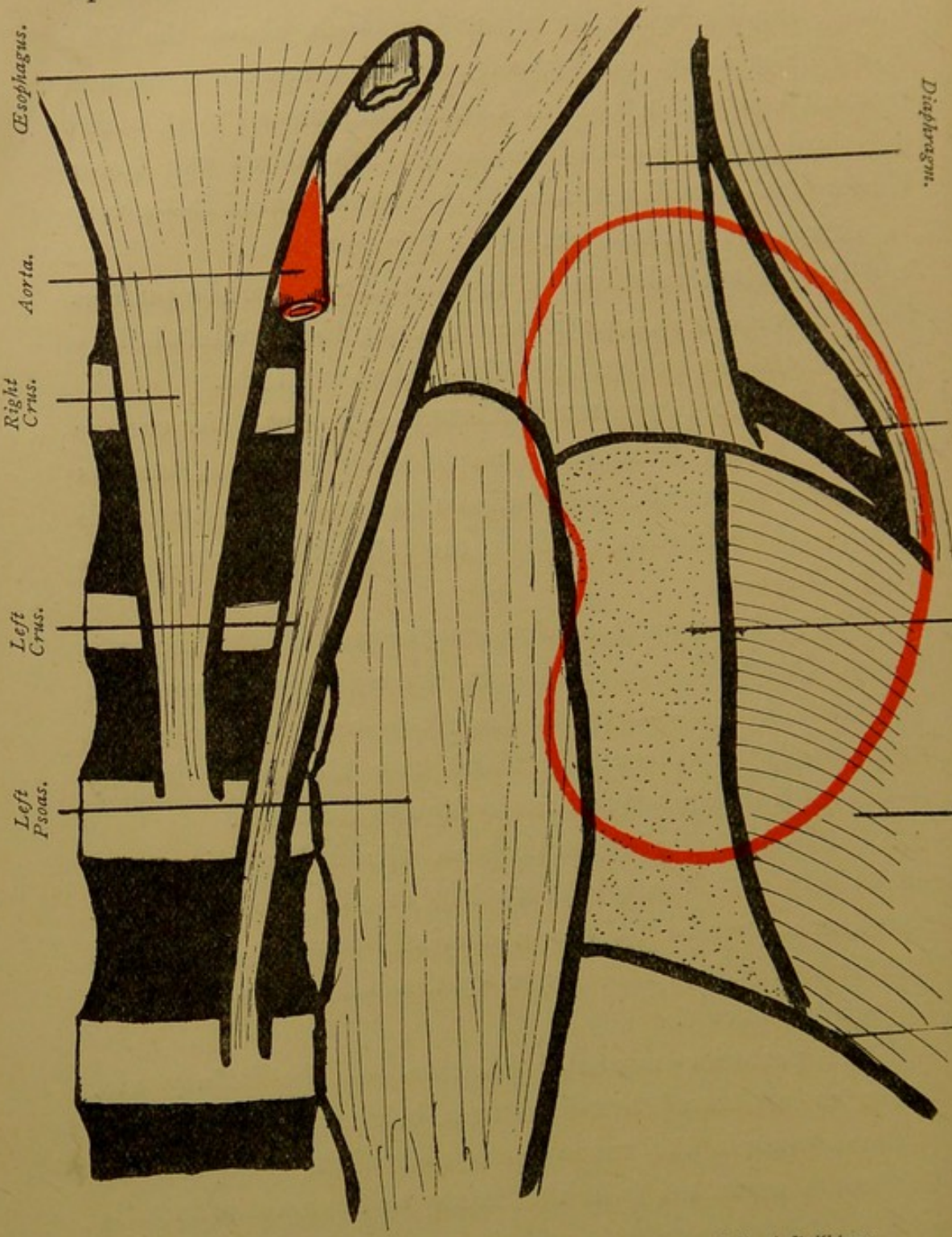

Figure 35.—Diagram to illustrate the posterior relations of the left Kidney.

lumborum muscle crosses the kidney at the junction of its outer and middle thirds.

(*d*) INDIRECT POSTERIOR RELATIONS.—As the lower limit of the pleura is indicated by a line drawn outwards from

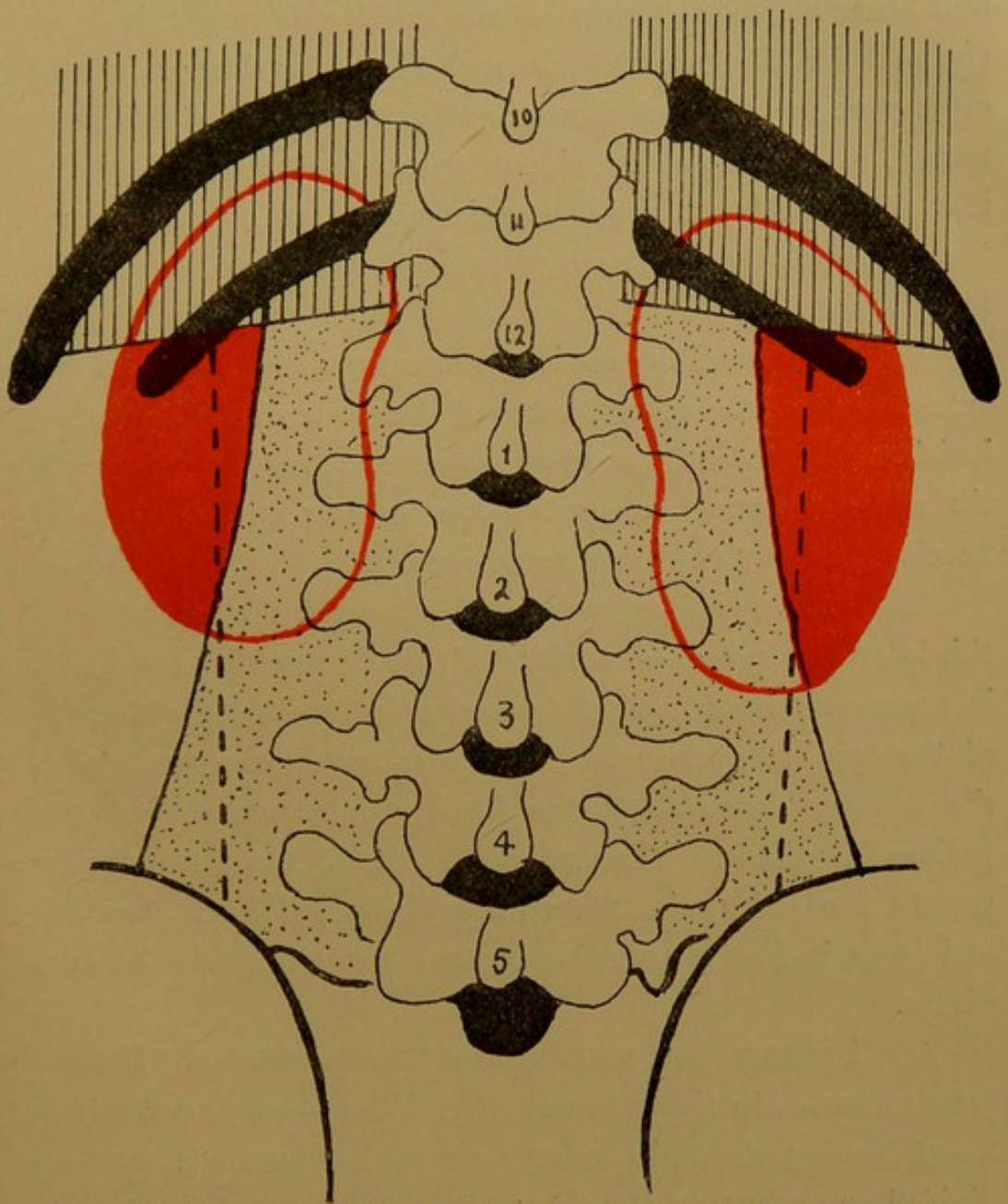

Figure 36.—The posterior relations of the Kidneys, slightly modified from His's Models. The kidneys are indicated in red, the pleuræ by vertical shading, the quadratus lumborum by the dotted area, and the outer edge of the erector spinæ muscle by an interrupted line.

the twelfth dorsal or first lumbar spines, it follows that the upper third, or even more, of the posterior surface of each kidney is clothed posteriorly by the pleural membrane, only separated by diaphragm. (See Figure 36.)

When the twelfth rib is not abnormally short, the pleural membrane crosses it at the outer border of the erector spinæ, and hence an incision may be carried deeply into this angle (formed by the twelfth rib and the outer border of the erector spinæ) without damaging the pleura. For this same reason, all incisions for kidney operations made below the last rib should not commence, internally, at a higher level than a point three-quarters of an inch below the neck of the twelfth rib.

When the twelfth rib is abnormally short and does not extend beyond the outer border of the erector spinæ, then, an incision carried to the apex of the angle between the eleventh rib and the outer border of the erector spinæ must, of necessity, open the pleural membrane.

The erector spinæ muscle lies behind the lower two-thirds of the posterior surface of the kidney from which it is separated, from behind forwards, by the middle lamella of the lumbar aponeurosis, the quadratus lumborum muscle, the anterior lamella of the lumbar aponeurosis, and the perinephric tissue. The external border of the erector spinæ crosses the kidney in the manner indicated in Figure 36, and constitutes a most important surface guide to that viscus.

(*e*) Structures divided or retracted in Kidney Operations.—In the removal of a kidney—nephrectomy—the following strata, in order from behind forwards, must be divided or pushed on one side :—

The integuments. (Divided.)

The posterior lamella of the lumbar aponeurosis with which are fused the latissimus dorsi, serratus posticus inferior, and obliquus abdominis internus muscles. (Divided.)

The erector spinæ muscle. (Retracted inwards.)

The middle lamella of the lumbar aponeurosis. (Divided.)

The quadratus lumborum muscle. (Outermost part divided if necessary.)

The anterior lamella of the lumbar aponeurosis. (Divided.)

The perinephric tissue containing the vessels and nerves previously mentioned. (To be avoided if possible.)

The kidney.

The Suprarenal Capsules. — The suprarenal capsule may be reached from behind by passing a needle through the innermost end of the eleventh intercostal space.

The Ureters.—The abdominal portion of the ureter may be indicated on the surface of the body, by a line drawn vertically upwards from the posterior superior iliac spine, as high as the level of the first or second lumbar spines.

The Descending Colon.—(*a*) SURFACE ANATOMY.—The descending colon may be roughly indicated upon the surface by a line drawn vertically upwards upon the left side from a point half an inch behind the centre of the iliac crest.

(*b*) GENERAL RELATIONS.—The descending colon first descends in direct non-peritoneal contact with the lower half of the external border of the left kidney, lying in this portion of its course immediately in front of the outer border of the quadratus lumborum.

Below the lower end of the left kidney the descending colon inclines somewhat inwards and therefore lies now altogether in front of the quadratus lumborum just external to the outer border of the left psoas.

This portion of the gut is occasionally opened for the purpose of establishing an artificial anus—Amussat's opera-

tion of lumbar colotomy—but the operation of sigmoidostomy is on the whole preferable.

The Spinal Cord.—The spinal cord extends from the foramen magnum to the spine of the second lumbar vertebra —in the child to the third—and is therefore about eighteen inches in length.

The *cervical enlargement* of the spinal cord, which corresponds to the segments of the brachial plexus, extends from the spine of the second cervical vertebra to that of the second dorsal, attaining its maximum breadth opposite the spines of the fifth or sixth cervical vertebræ.

The *lumbar enlargement,* which corresponds to the segments of the lower limb plexus, extends from the spine of the tenth dorsal vertebra to that of the second lumbar, attaining its maximum breadth opposite the spine of the twelfth dorsal vertebra.

The *subdural space*, and therefore the *cerebro-spinal fluid,* extend as low down as the spine of the second sacral vertebra, a point of considerable importance in operations on the rectum from behind.

The *origins of the spinal nerves* from the spinal cord follow certain rules, which are, according to R. W. Reid, as follows:—

The second cervical nerve arises opposite the neural arch of the atlas.

The third cervical nerve opposite the spine of the axis.

The fourth cervical nerve opposite the interval between the second and third cervical spines.

The fifth, sixth, seventh, and eighth cervical nerves each arise opposite the spine of the second vertebra above the place of exit of the nerve from the spinal canal.

The origins of the upper six dorsal nerves are about on a level with the spines of the third vertebra above the place of exit of the nerve from the spinal canal.

The origins of the lower six dorsal nerves are about on a level with the spines of the fourth vertebra above their points of exit from the canal.

The lumbar nerves arise in the neighbourhood of the tenth and eleventh dorsal spines.

The sacral nerves between the eleventh dorsal and first lumbar spines.

TABLE OF HORIZONTAL LEVELS.

Bodies of Vertebræ.	Viscera and Other Structures.	Anterior Aspect of Trunk.
1. Cervical. 2. Cervical.	Soft palate and mouth.	
3. Cervical.	Angle of lower jaw. Upper end of epiglottis.	Angle of lower jaw.
4. Cervical.	Hyoid bone. Bifurcation of common carotid artery.	Hyoid bone.
5. Cervical.	Thyroid cartilage.	Thyroid cartilage.
6. Cervical.	Cricoid cartilage. Lower end of pharynx and larynx. Upper end of œsophagus and trachea. Arch of thoracic duct.	Cricoid cartilage.
7. Cervical.		
1. Dorsal.	Apex of lung. Summit of arch of subclavian artery.	Outer end of clavicle.
2. Dorsal.		Inner end of clavicle. Upper border of manubrium sterni.

TABLE OF HORIZONTAL LEVELS—*continued.*

Bodies of Vertebræ.	Viscera and Other Structures.	Anterior Aspect of Trunk.
3. Dorsal.	Commencement of superior vena cava. Highest part arch of aorta.	
4. Dorsal.	Commencement of descending thoracic aorta. Bifurcation of trachea.	
5. Dorsal.		Angle of Ludwig.
6. Dorsal.	Pulmonary orifice.	
7. Dorsal.	Aortic orifice.	
8. Dorsal.	Mitral and tricuspid orifices. Termination of inferior vena cava.	Nipple.
9. Dorsal.	Fundus of stomach and liver. Central tendon of diaphragm.	Xiphi-sternal articulation.
10. Dorsal.	Cardia of stomach. Upper limit of spleen.	Ensiform process.
11. Dorsal.	Upper end of left kidney and suprarenals. Upper end of right kidney.	
12. Dorsal.	Foramen of Winslow. Splenic flexure of colon. Commencement of abdominal aorta.	
1. Lumbar.	Addison's trans-pyloric plane. Pylorus of stomach, first part of duodenum. Duodeno-jejunal flexure (upper limit). Hepatic flexure of colon. Pancreas. Neck and anterior border of body. Hila of kidneys. Lower end of spleen. Superior mesenteric and renal arteries. End of spinal cord.	

TABLE OF HORIZONTAL LEVELS—*continued.*

Bodies of Vertebræ.	Viscera and Other Structures.	Anterior Aspect of Trunk.
2. Lumbar.	Head of pancreas. Duodeno-jejunal flexure. Lower end left kidney.	
3. Lumbar.	Lower end right kidney. Third part duodenum. Cunningham's subcostal plane.	
4. Lumbar.	Bifurcation of abdominal aorta. Highest parts of iliac crests.	Umbilicus.
5. Lumbar.	Addison's transtubercular plane. Cunningham's intertubercular plane. Commencement of inferior vena cava.	Anterior superior iliac spine.
1. Sacral. Coccyx.		Symphysis pubis.

V.

THE MALE PERINEUM.

Osseous and other Boundaries and their Relations to the Surface.—The perineum, or the outlet of the pelvis, is a somewhat diamond-shaped space, which in the male transmits the urethra and the rectum. It measures from three and a quarter to four inches from before backwards in the middle line, and about three and a half inches from side to side between the two ischial tuberosities.

The boundaries of the region are as follows:—

In Front.—The perineum is bounded in front by the symphysis pubis and the subpubic ligament, structures which are obscured by the presence of the scrotum and penis, and are therefore only located upon the surface with some difficulty.

Laterally.—The lateral boundaries of the perineum are, from before backwards on each side, the ischio-pubic ramus, the ischial tuberosity, and the great sacro-sciatic ligament, the last being overlapped by the inner half of the lower border of the gluteus maximus.

The ischio-pubic ramus can be felt, especially in its posterior part, passing forwards and inwards in front of the ischial tuberosity.

The ischial tuberosity forms an important and easily recognisable landmark which, with the subject in the perineal or lithotomy position, lies about one and a half inches external to the anus.

The great sacro-sciatic ligament being overlapped by the gluteus maximus, cannot be felt, but its position may be indicated upon the surface by a line drawn from the coccyx to the ischial tuberosity.

Behind.—The perineum is bounded behind by the coccyx, which can be readily felt in the deep natal cleft. The apex of the coccyx lies about one inch behind the anus.

Subdivision of the Perineum.—The perineum is subdivided into an anterior or uro-genital triangle and a posterior or rectal triangle, by means of an imaginary line drawn transversely between the two ischial tuberosities and in front of the anus.

The *uro-genital triangle* is still further divided by means of the triangular ligament into two pouches, a *superficial perineal pouch* below the triangular ligament, and a *deep perineal pouch* above it.

The *rectal triangle* is also subdivided, by means of the rectum and anal canal, into *two ischio-rectal fossæ.*

The division and subdivision of the perineum is, therefore, as follows:—

Perineum.
- Uro-genital triangle.
  - Superficial perineal pouch.
  - Deep perineal pouch.
- Rectal triangle.
  - Ischio-rectal fossa.
  - Ischio-rectal fossa.

An accurate knowledge of the position, boundaries, and contents of these four spaces is of paramount importance in connection with the various injuries and diseases of the part, and the operations thereon. These are briefly indicated before giving the surface anatomy of the part.

The Superficial Perineal Pouch. — The superficial perineal pouch is that part of the uro-genital triangle of the perineum which lies below the triangular ligament in the anterior half of the perineum, and consequently its area

coincides with that of the pubic arch. This pouch is open in front, where it communicates freely with the scrotum. (See Figure 37.)

Its boundaries are as follows:[1]—

Below or superficially, by the fascia of Colles.

Above or at its deeper limit, by the triangular ligament.

Laterally, by the ischio-pubic rami and the attachments thereto of both the fascia of Colles and the triangular ligament.

Behind, by the blending of the recurved base of the fascia of Colles with the base of the triangular ligament.

The chief contents of this pouch are the root of the penis, composed of the centrally situated bulb containing the urethra, and clothed by the accelerator urinæ muscle, and the two crura attached to the ischio-pubic rami and clothed by the erector penis muscles, the transverse perineal muscle, and the various perineal nerves and arteries and the termination of the internal pudic artery.

The Deep Perineal Pouch.—The deep perineal pouch is that part of the uro-genital triangle of the perineum which lies above the triangular ligament in the anterior half of the perineum, and consequently its area coincides with that of the pubic arch. Unlike the superficial perineal pouch, it is an absolutely closed space. (See Figures 37 and 38.)

Its boundaries are as follows:—

Below, by the triangular ligament.

Above or at its deeper limit, by the parietal pelvic fascia (*i.e.* the so-called superior layer of the

[1] Note particularly that all terms refer, as they should do, to the body in the erect attitude, and not to the position in which the perineum is operated upon.

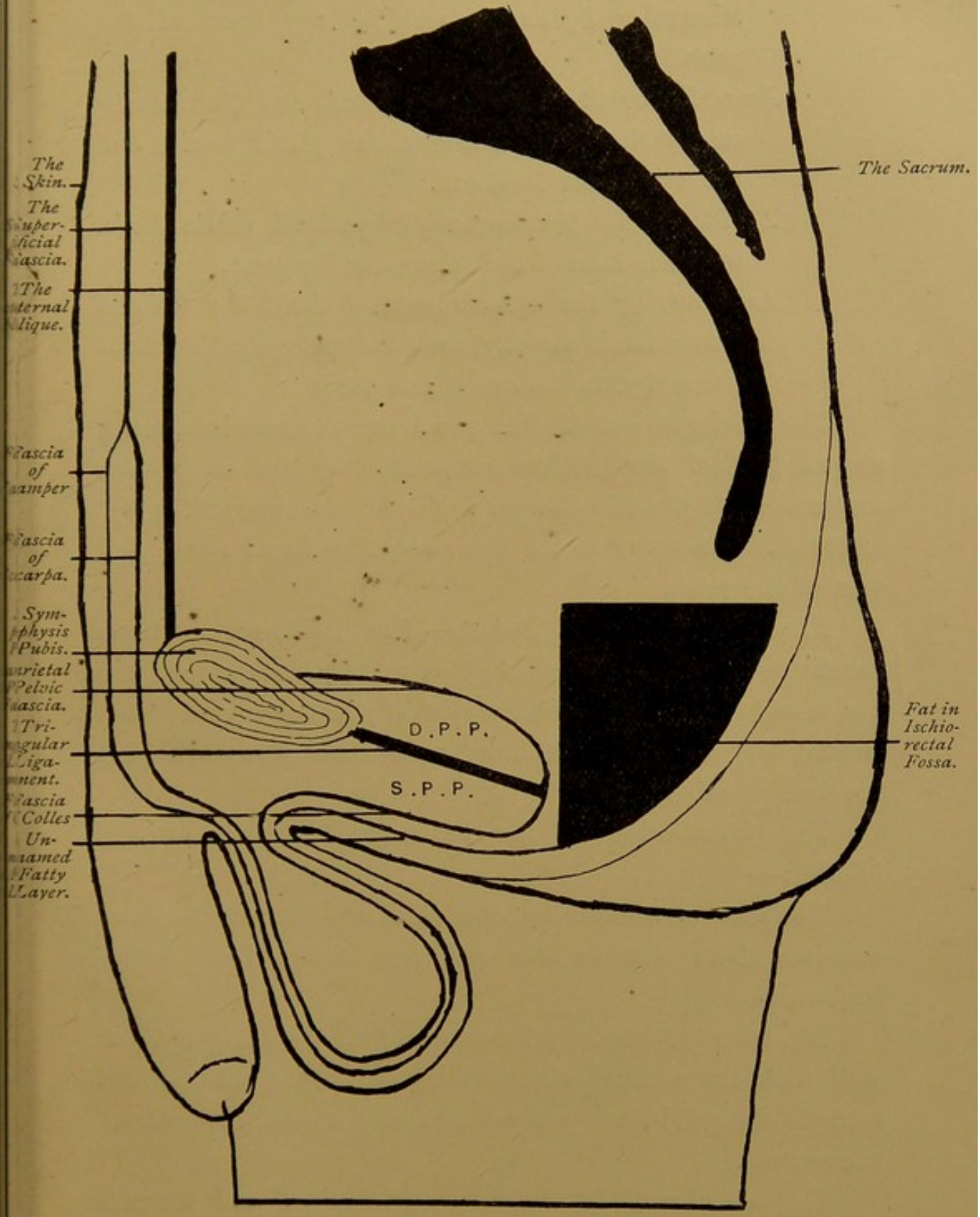

Figure 37.—Schematic Sagittal Section, designed to show the arrangement of the fasciæ in the anterior abdominal wall and perineum, together with the boundaries of the superficial and deep perineal pouches.

S.P.P. *Superficial Perineal Pouch.* D.P.P. *Deep Perineal Pouch.*

triangular ligament), and by the apex of the prostate.

Laterally, by the ischio-pubic rami, and the attachments thereto of the parietal pelvic fascia, and the triangular ligament.

Behind, by the blending of the parietal pelvic fascia with the base of the triangular ligament.

In front, by the attachments of both the parietal pelvic fascia directly, and the triangular ligament indirectly, to the symphysis pubis.

The chief contents of this pouch are the membranous or second part of the urethra surrounded by the compressor urethræ muscle, with Cowper's glands, the internal pudic artery and the artery to the bulb, and the dorsal nerve and vein of the penis.

The Ischio-Rectal Fossæ.—The ischio-rectal fossæ constitute those portions of the rectal triangle of the perineum which lie on either side of the lower end of the rectum and the anal canal, between those structures and the ischial tuberosity.

The boundaries of the ischio-rectal fossa are as follows:—

The *base* is formed by the skin, and measures about one inch from side to side and two inches from before backwards.

The *apex* is formed by the meeting of the oblique inner wall with the vertical outer wall, and is directed upwards towards the pelvis, being about two and a half inches from the surface.

The *outer wall* is almost perpendicular, and extends upwards for about two and a half inches. It is formed by the obturator internus muscle and that portion of the parietal pelvic fascia termed the obturator fascia. Passing

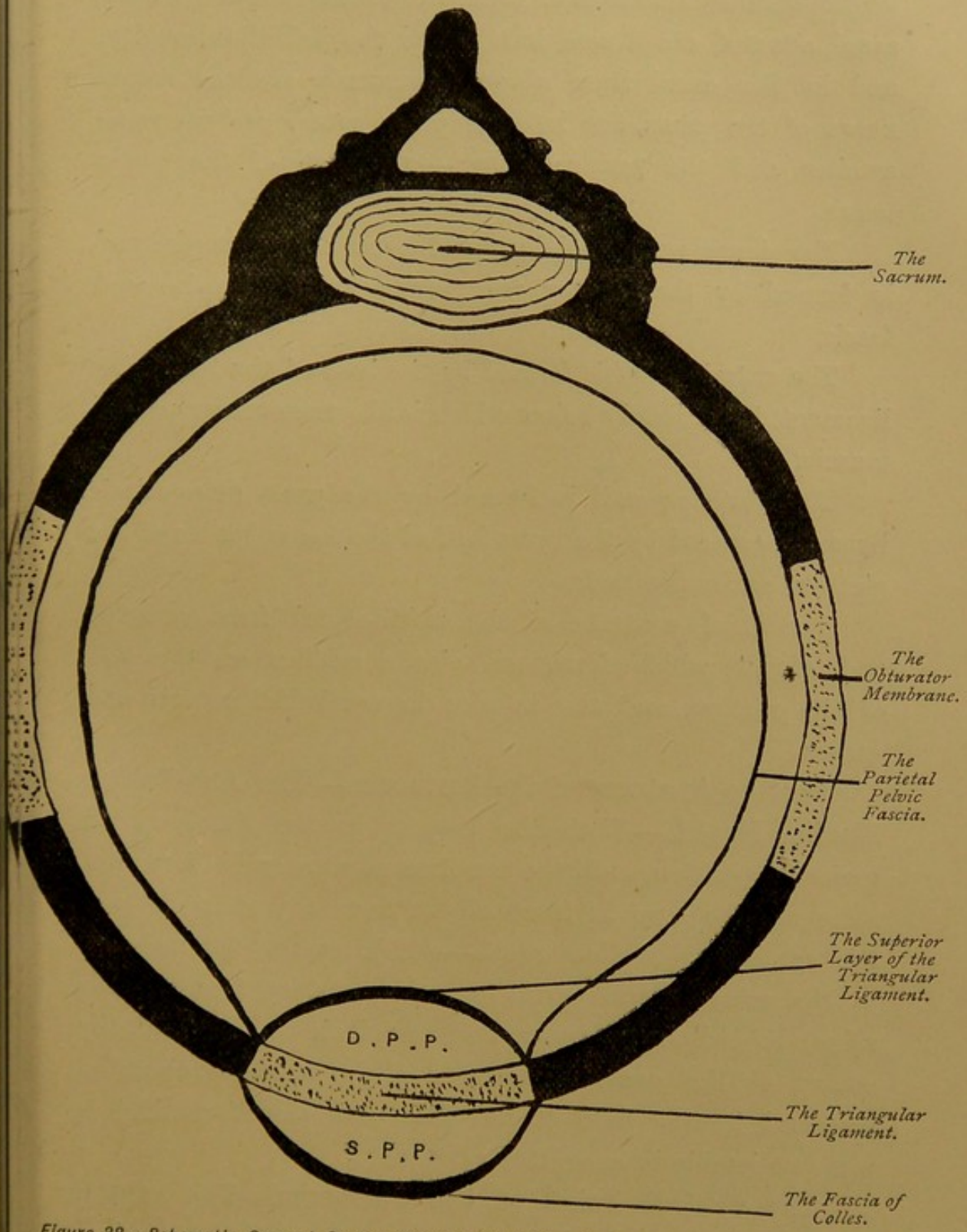

Figure 38.—Schematic Coronal Section through the Pelvis, designed to show how the parietal pelvic fascia roofs in the deep perineal pouch and comes to form the superior layer of the triangular ligament.

S. P. P. *Superficial Perineal Pouch.* D. P. P. *Deep Perineal Pouch.*

forwards in this wall is a tunnel of fascia termed Alcock's canal, situated about one inch above the ischial tuberosity, and in this canal from above downwards are the dorsal nerve of the penis, the internal pudic artery and its venæ comites, and the perineal nerve—a branch of the pudic nerve.

The *inner wall* is oblique and convex downwards, and is formed by the levator ani muscle and the thin anal fascia.

The *anterior wall* is formed by the base of the triangular ligament, immediately below which is the transversus perinei muscle.

The *posterior wall* is formed by the great sacro-sciatic ligament covered by the inner half of the lower border of the gluteus maximus muscle.

The chief contents of the ischio-rectal fossa are the pad of fat which forms an elastic cushion on the side of the rectum, and the inferior hæmorrhoidal vessels and nerves.

Surface Anatomy of the Perineum.—The Ano-Bulbar Median Raphè.—With the subject in the lithotomy or perineal position and the scrotum drawn well forwards, there will be seen in front of the anus a median ridge—the ano-bulbar median raphè—which passes forwards on to the scrotum and penis. In the anterior part of this ridge, behind the scrotum and one inch in front of the centre of the anus, there is a slight median elevation produced by the bulb of the penis—an elevation which is more noticeable in emaciated subjects.

The Central Point of the Perineum.—The central point of the perineum is a point situated on the ano-bulbar median raphè immediately behind the bulb of the penis, and about one inch in front of the centre of the anus.

It corresponds to the centre of the posterior free edge or base of the triangular ligament, and forms the common meeting-point of the perineal muscles.

As the bulb of the penis and the artery to the bulb lie immediately in front of this point, the incision employed in lithotomy should never commence in front of it.

The Anus.—The anus lies in the middle line, about midway between the two ischial tuberosities and one inch and a half below, and in front of, the tip of the coccyx. The skin around it is thrown into puckered folds, which are often rendered even more irregular by the presence of swollen hæmorrhoidal veins.

Around the anus there is a fine white line, which indicates the junction of the skin and mucous membrane, and also corresponds precisely to the line of division between the external and internal sphincter ani muscles.

External hæmorrhoids are developed from the anal folds outside the white line, whilst internal hæmorrhoids are developed from the veins of the mucosa inside the anal canal.

Layers of Fascia.—The Fascia of Colles.—The fascia of Colles is the continuation of the fascia of Scarpa (superficial fascia of the abdomen) into the uro-genital triangle of the perineum. It is therefore sufficiently obvious that the fascia of Scarpa and the fascia of Colles form a single and continuous sheet of superficial fascia found only in the lower part of the abdomen and the uro-genital triangle, and which receives a different name in each of the different regions in which it is found.

As it is the presence of this fascia which determines the peculiar course taken by urine or other fluid extravasated into the superficial perineal pouch, it is of paramount importance to be able to locate its lines of attachments on the surface of the body.

The lowest limit of the fascia of Scarpa is indicated on the surface of the body by a line drawn from the pubic spine horizontally outwards on each side. This line indicates the attachment of the fascia of Scarpa to the inner end of Poupart's ligament and to the fascia lata of the thigh. (See Figure 39.)

Between the two pubic spines the fascia of Scarpa is

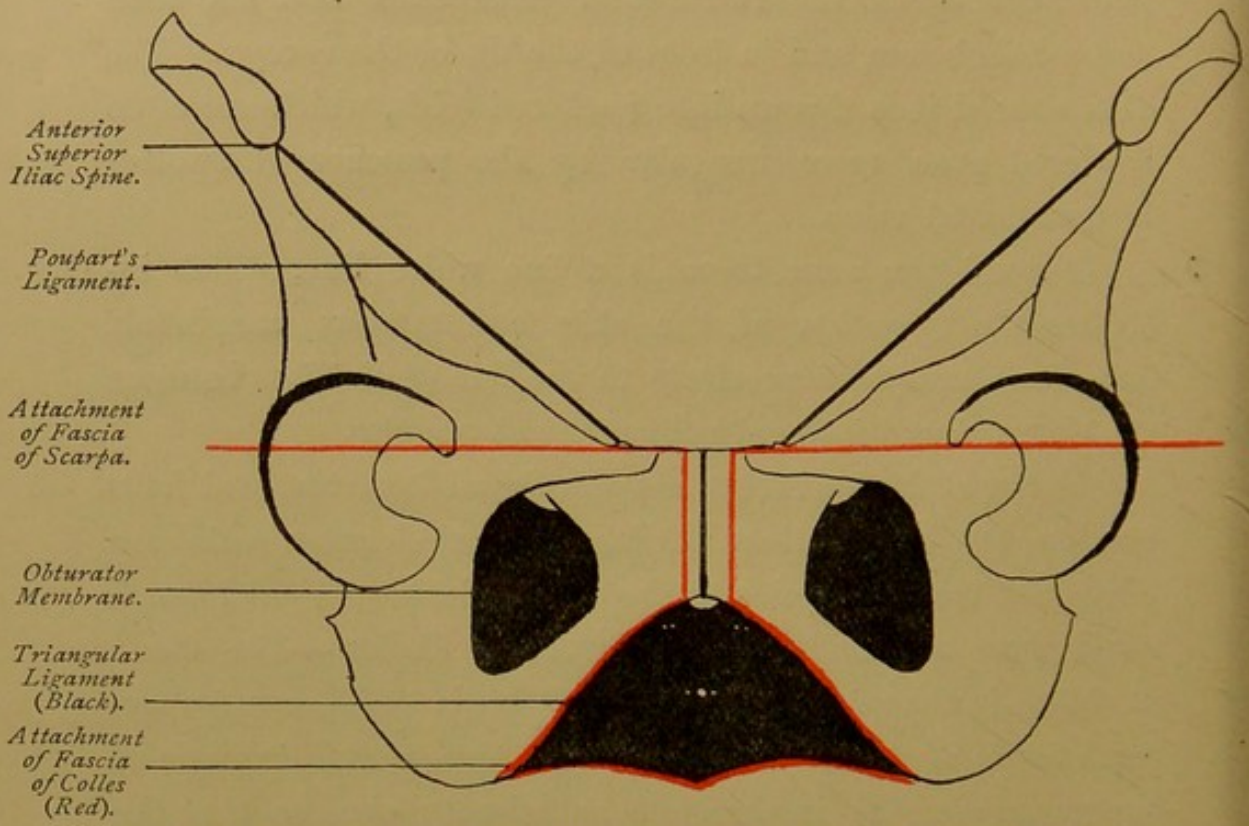

Figure 39.—Scheme designed to illustrate the attachments of the single and continuous sheet of fascia, termed (in the abdomen) the fascia of Scarpa, and (in the uro-genital triangle) the fascia of Colles. Attachments in red.

prolonged downwards through the scrotum as the dartos muscle, and then backwards across the uro-genital triangle as the fascia of Colles, to the base of the triangular ligament, to which it is attached. These attachments may be indicated on the surface by drawing a line from the pubic spine on each side, downwards and backwards, to the upper parts of the ischio-pubic rami, thence along the rami to the anterior

extremities of the ischial tuberosities; whilst lastly, the attachment of the recurved base of the fascia of Colles to the base of the triangular ligament, will be indicated by a line drawn transversely across the perineum between the anterior extremities of the two ischial tuberosities.

In rupture of the penile or spongy portion of the urethra below the triangular ligament, and therefore within the superficial perineal pouch, the urine is extravasated into that pouch, whence it passes into the scrotum and ascends on to the anterior abdominal wall, spreading outwards on each side above, and in front of, Poupart's ligament, without, however, extending downwards into the thigh. Provided the boundaries of the superficial perineal pouch and the attachments of the fasciæ of Scarpa and Colles are understood, the explanation is easy; otherwise difficult, if not actually impossible.

The urine having been extravasated into the superficial perineal pouch, which, it must be remembered, is an open pouch communicating anteriorly with the scrotum, cannot pass *upwards* on account of the triangular ligament, which forms the roof of the pouch, nor *downwards* on account of the fascia of Colles, which forms the floor of the space. *Laterally*, the urine cannot extend beyond the ischio-pubic rami because both the fascia of Colles and the triangular ligament are attached thereto. Its *backward* course towards the anus is rendered impossible by the attachment of the fascia of Colles to the base of the triangular ligament. *Anteriorly*, the superficial perineal pouch communicates with the scrotum, and consequently the urine passes uninterruptedly into the scrotum, which it distends. As the pressure becomes greater, the urine passes upwards on to the abdomen between the symphysis pubis in the middle line and the lateral attachment of the fascia of Colles to the body of the pubis. On the

abdominal wall the urine lies between the fascia of Scarpa in front of it, and the aponeurosis of the external oblique muscle behind it, and spreading outwards, its downward passage into the thigh is prevented by the attachment of the fascia of Scarpa to the inner end of Poupart's ligament and to the fascia lata of the thigh along a line extending horizontally outwards from that point, consequently unless the extravasation be relieved by suitable surgical measures there is now a slight bulging swelling over the uro-genital triangle, within the scrotum, and along the lower part of the abdominal wall, along, and slightly below, the lines of Poupart's ligaments.

The Triangular Ligament.—The triangular ligament—often unnecessarily referred to as the inferior layer of the triangular ligament—is an adventitious sheet of fascia which fills up the pubic arch in the same way that the obturator membrane fills up the obturator foramen. With the body in the erect attitude, it is almost parallel with the ground.

Surface Anatomy.—The lateral margins of the triangular ligament are sufficiently accurately determined by locating the two ischio-pubic rami to which they are attached.

The base may be determined by lines drawn slightly convex forwards from the anterior extremities of the ischial tuberosities to the central point of the perineum.

General Relations.—The superior surface of the triangular ligament forms the floor of the deep perineal pouch, whilst its inferior surface similarly constitutes the roof of the superficial perineal pouch.

It is pierced, in the middle line, about one inch behind the apex of the pubic arch, by the urethra, and on either side of that by the arteries to the bulb. (See Figure 39.)

The Parietal Pelvic Fascia. (Superior Layer of the Triangular Ligament.)—The parietal pelvic fascia lines the interior of the pelvic cavity, and in the vicinity of the pubic

arch, is firmly tacked down around it, thus forming the roof of the deep perineal pouch; it is consequently frequently referred to as the superior layer of the triangular ligament. (See Figure 38.)

The superior layer of the triangular ligament is that portion of the parietal pelvic fascia which crosses the pubic arch and roofs in the deep perineal pouch. In this region it is attached, *in front*, to the pelvic surface of the symphysis pubis; *behind*, to the base of the triangular ligament; on *either side*, to the ischio-pubic rami.

In rupture of the membranous urethra, that is of that portion of the urethra which lies between the parietal pelvic fascia (superior layer of the triangular ligament) and the triangular ligament, the urine is extravasated into an absolutely closed pouch—the deep perineal pouch.

The extravasated urine cannot pass *upwards* on account of the parietal pelvic fascia (superior layer of the triangular ligament), nor *downwards* on account of the triangular ligament. Its course *forwards* is checked by the attachments of both sheets of fascia to the symphysis pubis, and *backwards* by the attachment of the parietal pelvic fascia to the base of the triangular ligament. *Laterally*, the course of the urine is limited by the ischio-pubic rami to which both sheets of fascia are attached.

The deep perineal pouch having been distended to its utmost capacity, the subsequent course of the urine depends upon the rupture of some one or other of the limiting layers of the pouch. It may happen that the extravasated urine bursts through the triangular ligament where the vessels pierce it and so gains access to the superficial perineal pouch, whence it ascends to the anterior abdominal wall, as described on page 149; or it may penetrate the parietal pelvic fascia and so reach the pelvis, where it infiltrates the perivesical connective

tissue, and then ascends through the space of Retzius in front of the bladder, on to the anterior abdominal wall, where it lies between the fascia transversalis in front of it and the parietal peritoneum behind it.

The Internal Pudic Artery.—The regions successively occupied by, and the surface markings of, the internal pudic artery may be summarised as follows :—

Region.	Surface Anatomy.
1. The pelvic cavity.	
2. The buttock (ischial spine).	See page 211.
3. Ischio-rectal fossa (Alcock's canal).	One inch and a half above the lower margin of the ischial tuberosity.
4. The deep perineal pouch.	The ischio-pubic ramus.
5. The superficial perineal pouch.	The apex of the pubic arch.

Of the various branches of the internal pudic artery the two most important are the inferior hæmorrhoidal and the artery to the bulb.

The Inferior Hæmorrhoidal Artery. — The inferior hæmorrhoidal artery is indicated upon the surface by a line drawn from the ischial tuberosity to the anus.

The Artery to the Bulb.—This vessel may be indicated upon the surface by a line drawn transversely across the perineum quarter of an inch in front of the base of the triangular ligament. (See page 150.)

The Root of the Penis.—The root of the penis is composed of the mesially situated bulb of the corpus spongiosum containing the urethra and the laterally placed crura of the corpora cavernosa.

The *bulb* can be felt in the middle line of the uro-genital triangle, its posterior extremity being one inch in front of the anus.

The two *crura* are attached to the ischio-pubic rami.

The Urethra.—The urethra pierces the triangular ligament one inch behind the apex of the pubic arch.

Cowper's Glands.—Cowper's glands lie in the deep perineal pouch just in front of the base of the triangular ligament, one on either side of the mesial line.

THE EXTERNAL GENITALS.

The Penis.—The *anterior extremity* of the penis, composed of the glans penis with the vertical orifice of the meatus urinarius, the corona glandis or projecting border of the glans, the prepuce, and the frænum preputii, are all accessible.

The *body* of the penis is composed of the two dorsally situated corpora cavernosa, and the ventrally situated corpus spongiosum containing the urethra. Upon the dorsal surface there is, in the middle line, the single dorsal vein, immediately external to which are the two dorsal arteries of the penis, and beyond these again the dorsal nerves of the penis.

The *root* of the penis. (See page 152.)

The Scrotum.—The scrotum forms the investment for the testicles and for parts of the spermatic cords. The coverings of the testicle and spermatic cord within the scrotum, and therefore the walls of the scrotum itself, are from without inwards, as follows:—

The skin.

The dartos muscle, derived from the fasciæ of Camper and Scarpa.

The external spermatic fascia, derived from the obliquus abdominis externus muscle.

The cremasteric fascia, derived from the obliquus abdominis internus muscle.

The internal spermatic or infundibuliform fascia, derived from the fascia transversalis.

The parietal layer of the tunica vaginalis, derived developmentally from the peritoneum.

In tapping for a hydrocele, all the above layers are pierced.

The Testicles.—The testicles can be readily felt within the scrotum at its upper and back parts. They are a pair of oval, slightly flattened bodies, measuring about one inch and a half in length, one inch from before backwards, and rather less in thickness. Each testicle is placed within the cavity of the scrotum in such a way that its long axis is directed upwards, slightly forwards, and outwards; the left testicle being somewhat lower than the right.

Along the posterior border of the testicle is the *epididymis* produced by the first convoluted portion of the duct of the gland.

The upper end of the epididymis is termed the *globus major*, and overhangs the upper end of the testicle. Below this is its intermediate portion—the *body of the epididymis*—below which again is the lower and smaller end of the epididymis or the *globus minor*, all of which parts can be made out by digital examination.

The Spermatic Cord.—The spermatic cord extends from the posterior border of the testicle on the inner side of the epididymis to the internal abdominal ring, at which point its constituent parts disperse and separate from each other.

Its contents are as follows:—

The vas deferens, or the duct of the testicle, which extends from the inner side of the globus minor of the epididymis to the base of the prostate, whence, after effecting a junction with the seminal vesicle, it is continued onwards as the common ejacula-

tory duct, through the prostate, into the prostatic urethra.

Arteries—

The spermatic artery from the abdominal aorta.

The cremasteric artery from the deep epigastric artery.

The artery to the vas deferens from the superior vesical artery.

Veins—

The veins accompanying the arteries form the spermatic or pampiniform plexus, whence emerge the spermatic veins—the right to terminate in the inferior vena cava, the left in the left renal vein.

Nerves—

The genital branch of the genito-crural nerve.

Filaments from the sympathetic.

Lymphatics and areolar tissue.

Of these various structures the vas deferens, easily felt by grasping the scrotum, immediately above the testicle, between the finger and thumb, may be recognised by its firm whip-cord-like character.

The spermatic veins are, pathologically, sufficiently obvious in the condition known as varicocele, which is a varicose condition of these veins.

VI.

THE MALE PELVIC VISCERA.

The Rectum.—The rectum extends from the middle of the third sacral vertebra to the apex of the prostate gland, or a point one and a half inches in front of, and below, the level of the tip of the coccyx.

General Relations.—In front of the rectum from above downwards are the recto-vesical peritoneal pouch, the external trigone of the base of the bladder, and the posterior surface of the prostate. (See Figure 40.)

Behind, from above downwards, are the lower two and a half sacral vertebræ, the coccyx, and the ano-coccygeal body.

Laterally, there are the levatores ani and coccygei muscles.

Peritoneal Relations.—A knowledge of the peritoneal relations of the rectum is of paramount importance in all operations for the removal of the rectum.

The *posterior surface* of the rectum is devoid of a peritoneal covering, consequently this wall of the rectum may be removed for a distance of five inches above the anus.

The *anterior surface* of the rectum is covered by peritoneum as low down as the lowest limit of the recto-vesical pouch, that is to say, within three inches of the anus,—one inch for the length of the anal canal, about one inch for the prostate, and one inch for the external trigone of the bladder.

The Anal Canal.—The anal canal, or the terminal portion of the large intestine, is the antero-posterior slit in the pelvic floor by means of which the rectum communicates with the exterior. As the muscles which surround it are normally in a state of tonic contraction, its walls are usually in a state of apposition.

The anal canal is about one inch in length, and extends from the anus, upwards and forwards, to the dilatation of the rectum termed the ampulla.

Digital Examination of the Rectum.—The finger is introduced from the coccyx, that is from behind forwards, and is gently pressed upwards and forwards through the anal canal until it reaches the rectal ampulla at the lower end of the rectum, where the soft mucous membrane of the bowel is felt more or less doubled into transverse folds termed the valves of Houston. These folds, which are sometimes sufficiently large as to be mistaken for pathological conditions, are usually three in number, and are from below upwards, as follows:—

The *first and lowest* is on the left side of the gut about two inches above the anus, and is occasionally absent.

The *second and intermediate* fold, the largest of the three, is situated on the right side of the gut about three inches above the anus, and therefore on the same level as the most dependent point of the recto-vesical peritoneal pouch.

The *third and highest* fold is situated on the left side of the gut four inches above the anus, and therefore beyond the reach of the finger.

Through the *anterior wall* of the rectum can be felt from below upwards—

The bulb of the corpus spongiosum of the penis.

The base of the triangular ligament.

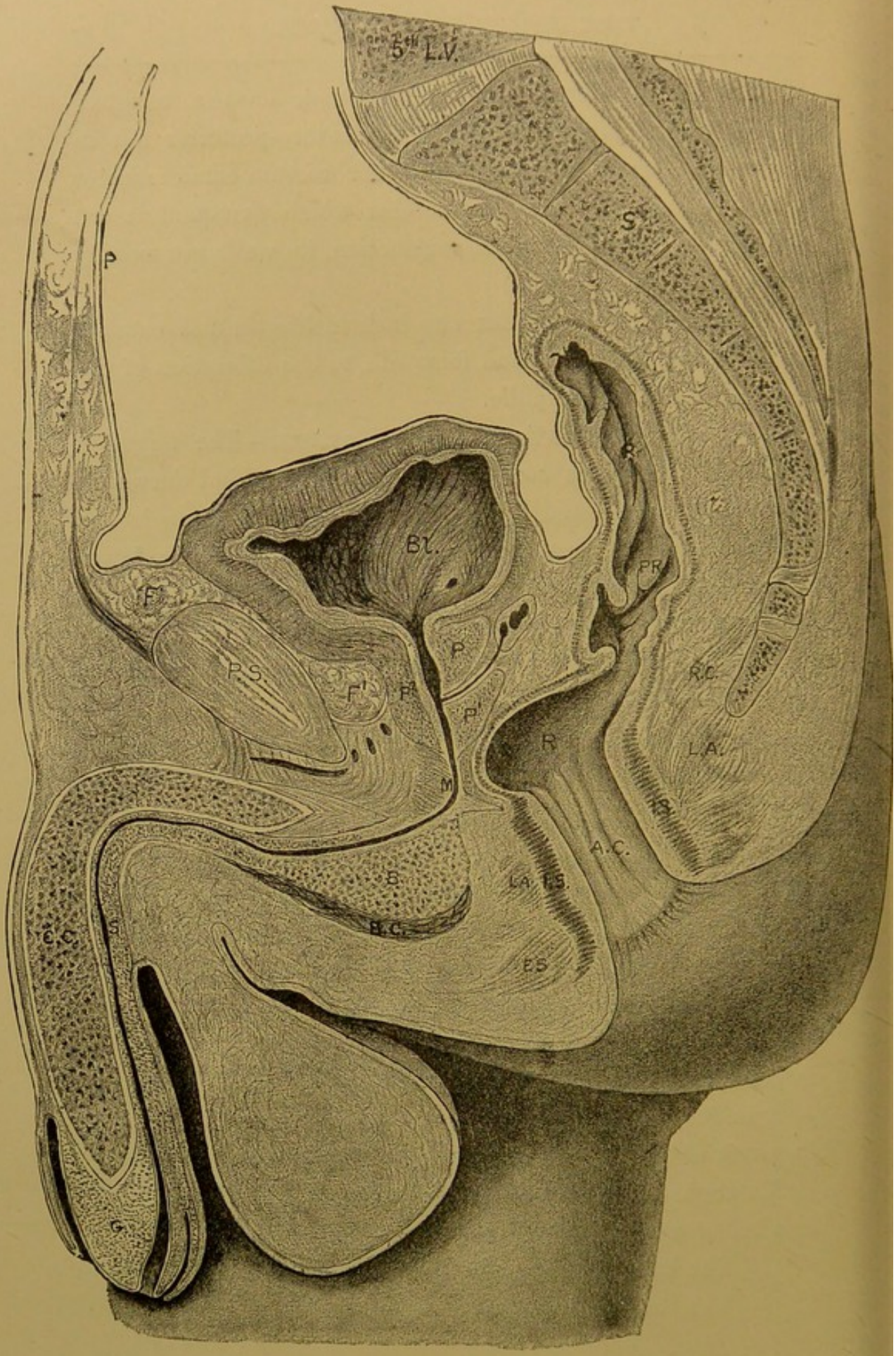
5th L.V.
S
P
Bl.
F
P.S.
F'
P
P'
R
PR
R.C.
L.A.
M
A.C.
B
L.A. F.S.
B.C.
E.S.
C.C.
S
G

Figure 40.—Median Section of the Pelvis and its Viscera of an Adult Male.

From "Quain's Anatomy," by permission of Messrs. Longmans, Green, & Co.

5TH L.V. *Body of fifth lumbar vertebra.*

S. *Body of second sacral vertebra.*

P.S. *Pubic symphysis.*

R.R. *Rectum.*

P.R. *The right valve of Houston.*

A.C. *The anal canal with the columns of Morgagni.*

I.S. *The sphincter ani internus.*

E.S. *The sphincter ani externus.*

L.A. *The levator ani.*

R.C. *The coccygeus muscle.*

BL. *The Bladder.*

P. P^1. P^2. *The prostate gland. Between* P *and* P^1. *is the common ejaculatory duct.*

M. *The membranous urethra.*

S. *The spongy or penile urethra.*

C.C. *One of the corpora cavernosa.*

G. *The glans penis.*

B. *The bulb of the corpus spongiosum.*

B.C. *The accelerator urinæ muscle.*

F. *The supra-pubic pad of fat.*

F^1. *The retro-pubic pad of fat.*

P. *The peritoneum.*

The membranous urethra and Cowper's glands (the latter only when inflamed and enlarged).

The posterior surface of the prostate, the apex of which is normally one inch, and the base two inches, above the anus.

The base of the bladder, upon which the vesiculæ seminales and vasa deferentia can, when enlarged, be felt.

Through the *posterior wall* of the rectum can be felt—

The ano-coccygeal body.

The tip of the coccyx.

The lower part of the ventral surface of the sacrum, and passing out on either side of it the lesser sacro-sciatic ligaments.

Through the *lateral wall* of the rectum can be felt—

The ischio-rectal fossa, external to which is the bony wall of the true pelvis.

The Bladder.—The shape of the bladder, as well as its size, position, and relations, are, in the living subject, subject to perpetual variation according to the degree of distension or otherwise of the viscus.

General Relations.—When moderately distended, the relations of the bladder are as follows (see Figure 40):—

The *base or fundus* is in contact with the rectum; in the upper part the recto-vesical peritoneal pouch intervenes between the two viscera, but in the lower part the bladder and rectum are only separated by the visceral pelvic fascia.

The *superior or abdominal surface* is peritoneal throughout, and has resting upon it coils of jejuno-ileum or other portion of the alimentary canal.

The *antero-inferior or pubic surface*, non-peritoneal throughout, comes successively into contact, as the bladder distends, with—

The retro-pubic pad of fat.
The symphysis pubis.
The anterior abdominal wall.

The *neck* of the bladder is surrounded by the base of the prostate. It lies about one inch behind the middle of the pubic symphysis.

Cystoscopic Examination of the Bladder.—The interior of the bladder may be seen on the living subject by means of the cystoscope.

The normal bladder wall has a pale, pinkish-white colour, with small but distinct blood vessels ramifying on the surface. The pallor varies in degree proportionately to the distension.

Around the *urethral opening* the vesical mucous membrane is somewhat corrugated longitudinally, but in the region of the neck of the bladder it is congested in appearance and prominent.

The orifices of the *ureters* lie about one and a half inches above, and to the outer side of, the urethral orifice. They may be in some instances readily seen, connected by an inter-ureteral bar of mucous membrane, but in other cases they require to be carefully looked for, by judging the distance and proper angle from the urethral orifice. The openings of the ureters are, normally, oblique slits, through which drops of urine are ejected at intervals of a minute or so, and not until this process is actually observed can the observer be certain of having located the ureters.

The triangular area of mucous membrane, bounded by imaginary lines drawn between the two ureters, and between the ureters and the urethral orifice, constitutes the *internal trigone*. The mucous membrane within this area is rather more vascular than elsewhere, and is said to be more sensitive.

The Male Urethra.—The male urethra extends from the vesical orifice to the meatus urinarius, and is about eight inches in length. It is subdivided into three parts—prostatic, membranous, and penile. (See Figure 40.)

The *prostatic* urethra traverses the prostate from above downwards, and is about one inch or more in length.

The *membranous* urethra extends from the apex of the prostate to the triangular ligament. It lies in the deep perineal pouch, and is surrounded by the compressor urethræ muscle.

The *penile* urethra extends from the triangular ligament to the meatus urinarius. It successively traverses the bulb of the penis and thereafter the corpus spongiosum.

The narrowest part of the urethra is at the meatus urinarius, whilst another narrowing occurs at the triangular ligament; hence here are encountered the chief difficulties in the introduction of a catheter, with false passages most frequent in the vicinity of the triangular ligament.

The most dependent point of the urethra is within the bulb immediately below the triangular ligament, hence this is the commonest site for organic stricture, or for rupture of the urethra.

The most muscularly surrounded part of the urethra is its membranous portion, hence this is the commonest site for spasmodic stricture due to spasm of the compressor urethræ muscle.

The most dilatable portion of the urethra is its prostatic portion, hence the immunity of the prostatic urethra from stricture.

The Prostate. — The posterior surface of the prostate can be felt per rectum throughout the whole of its extent. (See page 160.)

Its general dimensions are, in the healthy adult, about

one inch and a quarter from above downwards, one inch and a half from side to side, and about three-quarters of an inch from before backwards.

Its general relations are as follows:—

The *base* is uppermost, and is in contact with the neck of the bladder.

The *apex* is below, and rests upon the superior layer of the triangular ligament. It lies about three-quarters of an inch behind, and a little below the apex of the pubic arch.

The *anterior surface* lies about half an inch behind the symphysis pubis, from which it is separated by a venous plexus and some cellular tissue.

The *posterior surface* is in contact with the rectum.

The *lateral margins* are gripped by the levatores ani muscles.

VII.

THE FEMALE PERINEUM.

General Anatomy of the Female Perineum.—The boundaries, divisions, and subdivisions of the female perineum correspond to those of the male, but the pelvic outlet is rather larger in the female than the male.

The Vulva or Pudendum.—Under this term are included the external organs of generation of the female, that is, all those parts which lie below the hymen. (See Figure 41.) These are as follows:—

The labial folds.
- The mons veneris.
- The labia majora.
- The labia minora.

The vulval cleft, or the uro-genital space.
- The vestibule.
- The meatus urinarius.
- The hymen.

The erectile organs.
- The clitoris.
- The vestibular bulbs.

The Mons Veneris.—The mons veneris is the eminence covered with adipose tissue and hair which lies in front of the symphysis pubis.

The Labia Majora.—The labia majora, which correspond to the male scrotum, are two elongated folds of skin extending

downwards and backwards from the mons veneris to within about one inch of the anus. The *external surface* of each labium is convex and covered with hair; the *internal surface* is in contact with its fellow of the opposite side, and in this way the two labia conceal from view the remaining parts of the vulva. In old persons, the labia minora frequently project beyond the labia majora so as to be visible externally.

The *anterior extremities* of the labia majora unite to form the anterior commissure of the vulva, which is thick and rounded and becomes continuous with the lower part of the mons veneris.

The *posterior extremities* of the labia majora are often connected together across the middle line in front of the anus to form the posterior commissure.

The Labia Minora.—The labia minora, or the nymphæ, lie internal to the labia majora, with their internal surfaces in contact.

The *anterior extremity* of each labium minus divides into two parts, the more anterior and longer of which passes in front of the clitoris and forms the præputium clitoridis. The more posterior and the shorter of the two parts passes to the posterior part of the clitoris, and forms the frænulum clitoridis.

The *posterior extremity* of each labium minus may terminate by blending with the internal surface of the labium majus, but more frequently it becomes continuous with a transverse fold of skin situated at the anterior edge of the perineal body, and termed the fourchette, or the frænulum pudendi. Between the fourchette and the hymen there is a small space termed the fossa navicularis.

The Vestibule.—The vestibule is the anterior part of the uro-genital space. It is somewhat triangular in outline, and has the following boundaries:—

The base is formed by an imaginary line drawn through

the meatus urinarius. The apex is situated at the clitoris, and the two lateral boundaries are formed on either side by the labia minora.

The Meatus Urinarius.—The meatus urinarius—the external orifice of the urethra—lies one inch behind the clitoris near the anterior wall of the vagina, and through it is drawn the imaginary line which forms the base of the vestibule.

The Hymen.—The hymen is a fold of mucous membrane which, in the virgin, partially closes the orifice of the vagina. After coitus, or in women who have borne children, the hymen is usually replaced by some small rounded elevations termed the carunculæ myrtiformes.

In rare cases the hymen forms a complete partition between the vulva and the vagina, giving rise to the condition known as "imperforate hymen," and which usually produces no symptoms until the onset of the menses.

The Clitoris.—The clitoris is an erectile organ—the homologue of the penis—which consists of two dorsally situated corpora cavernosa and a rudimentary glans clitoridis. Unlike the penis, the clitoris is not traversed by the urethra.

The Vestibular Bulbs.—The vestibular bulbs constitute the remaining portion of the erectile tissue in the female. Each bulb is about one inch long, and lies in the lateral walls of the uro-genital cleft below the triangular ligament. They correspond to the corpus spongiosum of the male.

Bartholin's Glands.—Bartholin's glands, the homologues of Cowper's glands, lie in the deep perineal pouch above the triangular ligament, one on either side of the posterior third of the orifice of the vagina.

Each gland is about half an inch in length, and its duct opens into the fossa navicularis between the hymen and the posterior commissure.

VIII.

THE FEMALE PELVIC VISCERA.

The Internal Genital Organs of the Female.—The internal genital organs of the female are those parts which lie above the hymen. They are as follows:—

The vagina.
The uterus.
The Fallopian tubes.
The ovaries.

The Vagina.—The vagina passes from the uro-genital cleft of the vulva, upwards and backwards, to communicate above, with the cavity of the uterus. Its length is about three inches.

The *anterior wall* of the vagina is in contact, from above downwards, with (see Figure 41)—

The base of the bladder, to which the vagina is loosely attached by connective tissue.
The urethra, firmly embedded in the anterior wall of the vagina.

The *posterior wall* of the vagina is an immediate anterior relation of the rectum and anal canal, but intervening between the two viscera are the following important structures:—

Above, the *upper third* of the vagina is separated from the rectum by the lower part of the peritoneal utero-rectal pouch or the pouch of Douglas. This pouch dips downwards between the rectum behind, and the uterus and upper third or

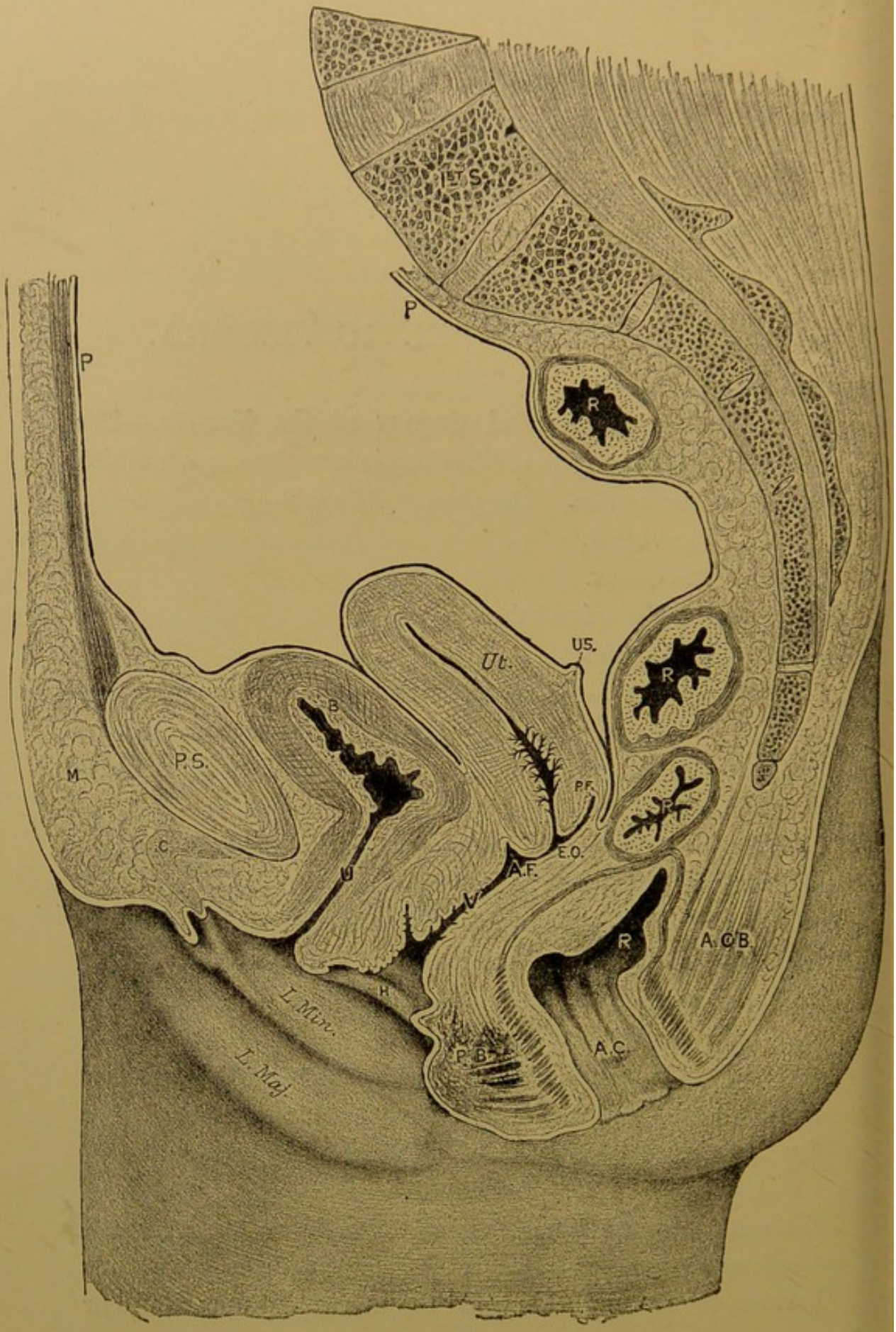
1st S.
P
P
R
US.
Ut.
R
B
P.S.
M
PF.
R
C
U
A.F.
E.O.
R
A.C.B.
H
L. Min.
L. Maj.
P. B.
A.C.

Figure 41.—Median Section of the Pelvis and its viscera of a female aged about 30 years.

From "Quain's Anatomy," by permission of Messrs. Longmans, Green, & Co.

1ST S. *Body of first sacral vertebra.*
P.S. *The pubic symphysis.*
B. *The bladder.*
U. *The urethra.*
Ut. The uterus.
E.O. *The os uteri externum.*
US. *The utero-sacral ligaments.*
V. *The vagina.*
A.F. *The anterior vaginal fornix.*
P.F. *The posterior vaginal fornix.*
H. *The hymen.*
R. *The rectum.*
A.C. *The anal canal.*
L. Min. The labium minus.
L. Maj. The labium majus.
C. *The clitoris.*
M. *The mons veneris.*
P. *The peritoneum.*
P.B. *The perineal body.*
A.C.B. *The ano-coccygeal body.*

fourth of the vagina in front, consequently the posterior wall of the vagina is covered by peritoneum in its upper portion, whilst its anterior wall is altogether devoid of a peritoneal covering.

The *middle third* of the posterior wall of the vagina is only separated from the rectum by a process of the visceral layer of the pelvic fascia.

The *lower third* of the posterior wall of the vagina is altogether separated from the anal canal by the perineal body.

Laterally, the upper part of the vagina is crossed, on each side, by the ureter, below which it is supported by the levatores ani muscles; after piercing the triangular ligament, the vagina comes into lateral relationship with the vestibular bulbs, the glands of Bartholin, and at its termination it is surrounded by the sphincter vaginæ muscle.

Vaginal Examination.—The patient having been placed in a suitable position, the index finger of the right hand is carried along the fold of the buttock towards the middle line until it impinges against the posterior aspect of the vaginal orifice, through which it is turned upwards and backwards into the vagina itself; to render the examination more thorough, the middle finger may now be introduced.

In, or through, the *anterior wall* of the vagina may be felt—

The vaginal portion of the cervix uteri, which projects downwards and backwards through the upper end of the vagina in the form of a knob-like body. Its orifice—the os uteri externum—is, in nulliparous women, felt as a small transverse slit, whereas in multiparous women it is fissured and irregular.

The posterior fornix lies above and behind the cervix,

and through it any abnormal contents of the pouch of Douglas can be felt.

The anterior fornix lies below, and in front of, the cervix, and through it the uterus and bladder can be felt.

The urethra can be felt in the middle line of the lower half of the anterior vaginal wall as a cylindrical cord-like structure which can, not infrequently, be rolled against the symphysis pubis.

In, or through, the *posterior wall* of the vagina may be felt—

The posterior fornix (*q.v.*).

The rectum and its contents.

The perineal body.

In a digital examination of a *virgin*, the entrance of the finger is more or less obstructed by the hymen, the cavity of the vagina is small, its mucous membrane is rugose, and the os uteri externum is a smooth slit; whereas in *women who have borne children* there is no hymen, the cavity of the vagina is larger, the rugæ cannot be felt, and the os uteri externum is fissured and irregular.

By a bimanual examination other of the pelvic viscera, such as the ovaries, can also be located.

Rectal Examination in the Female.—In the female the anus is placed slightly farther forwards than in the male, is not so deeply sunk between the nates, and is surrounded by fewer hairs.

With the finger in the rectum there can be felt through the anterior wall, from below upwards (see Figure 41)—

The perineal body.

The posterior wall of the vagina.

The cervix uteri throughout the whole of its extent.

The posterior fornix of the vagina.

The pouch of Douglas—if abnormal.

The body of the uterus.

The ovaries, but more distinctly, when enlarged.

Posteriorly the same structures as in the male are to be felt. (See page 160.)

The Urethra.—The female urethra extends from the meatus urinarius within the vestibule, upwards and backwards to the neck of the bladder. It is about one and a half inches in length, and is firmly embedded in the anterior wall of the vagina, except just at its upper end. Its vesical orifice is at a slightly lower level than in the male, being about on a level with a line passing from the apex of the pubic arch to the lower end of the sacrum.

The female urethra is capable of considerable distension, so much so that it is possible by means of a speculum to see the interior of the bladder, the appearances presented being as described on page 161.

Structure of the Female Pelvic Floor.—It is important to realise that the female pelvic floor is modified from that of the male type in accordance with the necessities of parturition. In both sexes the pelvic floor must be capable of resisting intra-abdominal pressure and of supporting the weight of certain abdominal viscera, whilst in the female there is the additional complication, that the floor must be sufficiently dilatable as to allow of the passage of the child at birth. The chief anatomical distinction between the male and female pelvic floors is, that the latter is pierced by the vagina and the former is not; the method by which the female pelvic floor adapts itself to its complex functions is, according to Hart, briefly as follows:—

Sagittal mesial sections through the female pelvis clearly show that it is made up of two segments—an anterior or pubic segment, and a posterior or sacral segment.

The *anterior or pubic segment* comprises the bladder and its peritoneum, the urethra and the anterior vaginal wall, and is loosely attached in front to the symphysis pubis by means of the retro-pubic cellular tissue.

The *posterior or sacral segment* comprises the posterior vaginal wall, the rectum and anal canal, the perineal body and the muscles of the pelvic diaphragm.

The two segments differ both anatomically and physiologically, for the anterior or pubic segment is made up of loose tissue, is loosely attached to the pubic symphysis, and is drawn *up* during labour, whilst the posterior or sacral segment is made up of dense tissue, is firmly dovetailed into the sacrum and coccyx, and is driven *down* during labour.

Axial coronal sections show further that the loose retro-pubic tissue which connects the anterior or pubic segment to the symphysis pubis is, in reality, continued right round the pelvis in the following way:—

Commencing as the retro-pubic pad of fat, the ring of loose cellular tissue passes round on the internal surface of the obturator internus muscle and the upper or pelvic surface of the levator ani muscle to the interval between the vagina and rectum, and thence back again to the starting-point.

Within the area circumscribed by this ring of loose cellular tissue are the bladder, urethra, and the vagina, and resting upon it are the uterus and its appendages, the Fallopian tubes and the ovaries. This area is termed by Hart the *entire displaceable portion* of the female pelvic floor.

External to the ring of loose cellular tissue is the *entire fixed portion* of the female pelvic floor composed of the symphysis pubis, the obturator interni muscles, and the anterior rectal wall and the sacrum.

The entire fixed portion of the female pelvic floor thus

supports the entire displaceable portion, and the two combined, that is the pelvic floor, support the pelvic and abdominal viscera.

Summary of the Segments and Fixed and Movable Portions.

Sagittal Mesial Section.		Axial Coronal Section.
Anterior or pubic segment.	Bladder.	Inner ring, or the entire displaceable portion.
	Urethra.	
	Anterior vaginal wall.	
Posterior or sacral segment.	Posterior vaginal wall.	
	Tissue attached to sacrum.	Outer ring, or the entire fixed position.
	Rectum and anal canal.	
	All outside of levator ani.	

Chief Functions of the Female Pelvic Floor. — The chief functions of the female pelvic floor are therefore as follows :—

Support of intra-abdominal pressure.
Vesical and rectal functions.
Parturition.

Support of Intra-Abdominal Pressure.—The abdominal and pelvic viscera rest upon the entire fixed portion of the pelvic floor, which by sloping downwards and inwards on all sides, like a funnel, is enabled, under ordinary conditions, to afford adequate support to the superjacent weight. Failure of this part of the pelvic floor to perform its due functions results in prolapsus uteri.

Vesical and Rectal Functions.—The vesical and rectal functions, that is, the alternate distension and emptying of the bladder and rectum, is efficiently provided for by the

ring of loose cellular tissue which subdivides the pelvic floor into its displaceable and fixed portions.

PARTURITION. — Parturition, the great function of the female pelvic floor, is provided for, structurally, by the subdivision of that floor into an inner displaceable portion and an outer fixed portion, the former being, during childbirth, drawn upwards, and the latter pushed downwards.

IX.

THE UPPER EXTREMITY.

THE SHOULDER AND AXILLA.

The Clavicle. — The collar bone or clavicle is subcutaneous throughout the whole of its extent.

The *inner or sternal end* forms a very obvious prominence on each side of the supra-sternal fossa and between the two heads of the sterno-mastoid muscle.

The *shaft* of the clavicle is subcutaneous throughout. Its inner two-thirds is convex forwards, and its outer third concave forwards.

The *outer or acromial end* of the clavicle is usually at a higher and more posterior plane than the sternal end. Its termination is indicated by a slight elevation, immediately external to which is a depression formed by the acromio-clavicular articulation. This articulation lies in the plane of a sagittal line passing up the centre of the upper arm, and is about one and a quarter inches internal to the outer border of the acromion process.

The Scapula.—The Acromion Process.—The acromion process can be readily felt immediately external to the outer end of the clavicle.

The *tip* of the acromion process looks directly forwards, and is about a finger's breadth external to, and a little in front of, the outer end of the clavicle. From the tip, the

external border of the acromion process can be easily traced backwards, above the shoulder, to the *acromial angle* or the prominent angle of junction of the acromion process with the spine of the scapula. This angle lies on the same level as the third dorsal spine, and is the best spot from which to make comparative measurements of the upper limbs.

The *internal border* of the acromion process can be indistinctly felt through the trapezius. It lies about three-quarters of an inch internal to, and parallel with, the easily located external border.

THE CORACOID PROCESS.—The tip of this important landmark looks almost directly forwards, and tends to be overlapped by the anterior border of the deltoid muscle. It can be felt by exercising deep pressure at a point one inch below the junction of the middle and outer thirds of the clavicle. Immediately internal to it is the infra-clavicular fossa (*q.v.*).

THE SPINOUS PROCESS.—The spinous process of the scapula extends from the acromial angle to the junction of the upper and middle thirds of the vertebral border of the scapula, that is, to the root of the spine of the scapula, situated, when the upper limb is dependent, opposite the interval between the spines of the third and fourth dorsal vertebræ.

THE SUPERIOR ANGLE.—The superior angle of the scapula is somewhat indistinctly felt through the trapezius muscle lying opposite the second rib or the second intercostal space. This level, as well as that of all others quoted in connection with the scapula, refers to the upper limb in a dependent position.

THE VERTEBRAL BORDER.—The vertebral border extends from the superior to the inferior angle of the bone, and is indistinctly felt through the trapezius muscle. With the

upper limb in the position just mentioned, the vertebral border is almost perpendicular and lies just internal to the angles of the ribs.

THE INFERIOR ANGLE.—The inferior angle, overlapped by the latissimus dorsi muscle, is easily felt opposite the seventh dorsal spine.

THE AXILLARY BORDER.—The thick axillary border is overlapped by the teres major and minor muscles, and can therefore only be felt with difficulty.

The examination of the scapula on the living subject is materially assisted by alternately placing the hand on the opposite shoulder, and thereafter the forearm behind the back.

The Humerus.—THE GREATER TUBEROSITY.—The greater tuberosity of the humerus is easily felt through the thickness of the deltoid muscle. It lies below the acromion process, beyond which it projects, and thus comes to form the most external bony landmark of the shoulder. It faces in almost the same direction as the external condyle of the humerus, and rotates on movement.

THE LESSER TUBEROSITY.—The lesser tuberosity, small and conical, can be felt at a point one inch external to, and a little below, the tip of the coracoid process. It faces directly forwards, is explored through the deltoid, and rotates on movement.

THE BICIPITAL GROOVE.—The bicipital groove of the humerus can be felt on making deep pressure between the two tuberosities. It lodges the long head of origin of the biceps flexor cubiti, and its position may be indicated by a line drawn vertically downwards from the tip of the acromion process for a distance of two inches.

These three osseous landmarks are best examined by grasping the two tuberosities with the thumb and middle

finger, which thus leaves the index finger free to explore the bicipital groove; at the same time the flexed elbow of the subject may be rotated with the other hand of the observer.

THE HEAD OF THE HUMERUS.—The lower part of the head of the humerus may be palpated by abducting the arm and pressing deeply in the axilla. In all movements of the limb the head of the humerus faces in the same direction as the internal condyle, and rotates on movement. It is also possible, under the same conditions, to feel the lower margin of the glenoid cavity of the scapula.

The Supra-Sternal Notch.—The supra-sternal notch lies in the middle line between the sternal ends of the clavicles and immediately above the upper border of the manubrium sterni. On either side of the notch are the sternal heads of the sterno-mastoid muscles.

The Sternal Furrow.—The sternal furrow or groove is the slight furrow situated in the anterior mesial line in front of the sternum and between the origins of the two great pectoral muscles. It extends from the supra-sternal notch above to the infra-sternal fossa below.

The Infra-Sternal Fossa.—The infra-sternal fossa is the well-marked though variable depression, situated at the lower end of the sternal furrow in front of the ensiform process and between the seventh costal cartilages and the upper ends of the recti abdominis muscles.

The Sternum.—The sternum lies in the middle line of the body at the bottom of the sternal furrow, and is subcutaneous throughout.

THE MANUBRIUM STERNI.—The *upper border* of the manubrium sterni is easily felt at the lower margin of the supra-sternal notch. At the end of the act of expiration it lies opposite the disc between the bodies of the second and third dorsal vertebræ, and forms the uppermost of the four

bony points employed in Addison's method of delimiting the abdomen.

The *lower border* of the manubrium sterni, at its junction with the body of the sternum, forms a well-marked and easily determined transverse ridge, termed the sternal angle, or the *angle of Ludwig*. This angle lies exactly opposite the second costal cartilages, and is therefore of the utmost importance in the counting of ribs. It lies opposite the body of the fifth dorsal vertebra.

The *anterior surface* of the manubrium sterni is subcutaneous throughout.

The Body of the Sternum.—The body of the sternum extends from the angle of Ludwig above, to the xiphi-sternal articulation below, and is subcutaneous throughout.

The Ensiform Process or the Xiphi-Sternum.—The xiphi-sternum lies at the bottom of the infra-sternal fossa, opposite the body of the tenth dorsal vertebra, whilst the xiphi-sternal articulation itself is situated about opposite the lower part of the ninth dorsal vertebra.

The Ribs.—The ribs, twelve in number on each side, are all accessible to the touch, with the exception of the first, which is concealed by the clavicle. In counting ribs, locate the second rib from the angle of Ludwig and count from above, obliquely downwards and outwards. (See also page 72.)

The Pectoralis Major Muscle.—The pectoralis major muscles cover the anterior part of the chest on each side of the sternum, and are subcutaneous throughout.

The *upper border* of the muscle extends from about the middle of the clavicle to the upper part of the humerus. It forms the innermost boundary of the infra-clavicular fossa.

The *interval* between the clavicular and chondro-sternal

heads of the muscle can often be seen when the muscle is at rest, and always when it is in action.

The *lower border* of the muscle extends from the inner part of the fifth rib to the middle of the anterior border of the deltoid. It forms, as it passes upwards and outwards to the arm, the thick and rounded anterior fold of the axilla.

The Pectoralis Minor Muscle.—The pectoralis minor muscle is deeply situated behind the pectoralis major in the middle third of the anterior wall of the axilla.

Its *upper border* may be indicated upon the surface by a line drawn from the third rib just external to its cartilage to the tip of the coracoid process. The point of intersection of this line with that of the axillary artery indicates the origin of the thoracic axis.

The *lower border* of the pectoralis minor may be indicated by a line drawn from the fifth rib just external to its cartilage to the tip of the coracoid process. The inner half of this line indicates the position of the long thoracic artery.

The Deltoid Muscle.—The triangular deltoid muscle extends from the pectoral girdle to the middle of the shaft of the humerus. It is subcutaneous throughout, and gives to the shoulder its rotundity.

The *anterior border* is easily seen when the muscle is in action. It forms the external boundary of the infra-clavicular fossa.

The *posterior border* of the deltoid is only visible in its lower half, inasmuch as the upper part is closely adherent to the subjacent infra-spinatus muscle.

With the upper limb hanging by the side, the mid-point of the vertical length of the deltoid indicates the level at which the *dorsalis scapulæ vessels* cross the axillary border of the muscle. A point a finger's breadth above the mid-point indicates the level at which the *posterior circumflex vessels* and

the *circumflex nerve* wind round the surgical neck of the humerus.

The Infra-Clavicular Fossa.—The infra-clavicular fossa is a slight depression below the middle third of the clavicle and immediately internal to the tip of the coracoid process.

It is bounded *above* by the middle third of the clavicle, and on *either side* by the converging borders of the deltoid and pectoralis major muscles.

Behind the fossa are the termination of the cephalic vein, the cords of the brachial plexus, the first part of the axillary artery which can here be compressed against the second rib, and the axillary vein, the last three in that order from without inwards.

The Supra- and Infra-Spinatus and Teres Muscles.—The supra- and infra-spinatus muscles lie respectively above and below the spinous process of the scapula. The supra-spinatus is covered posteriorly by the trapezius, whilst the infra-spinatus is continued into the teres minor muscle on the axillary border of the scapula. Below the latter muscle is the thick teres major muscle with the latissimus dorsi winding round it to form the posterior fold of the axilla.

The Coraco-Brachialis Muscle.—This muscle lies in the outer wall of the axilla, and forms a thin fusiform swelling upon the surface when the arm is abducted to a right angle. The third part of the axillary artery can be felt pulsating immediately behind it.

The Serratus Magnus Muscle.—The serratus magnus lies in the inner wall of the axilla on the lateral aspect of the chest. The first digitation visible on the surface is the one attached to the fifth rib at the lower margin of the pectoralis major muscle; the one below it is, however, the largest and most prominent of all the digitations.

The Posterior Fold of the Axilla.—The thick and

prominent posterior fold of the axilla is formed by the latissimus dorsi winding round the teres major. It lies on a lower level than the anterior fold, and leaves the chest a little in front of the inferior angle of the scapula.

The Axillary Artery.—The axillary artery extends from the outer border of the first rib to the lower border of the teres major. To map out its course, abduct the limb to a right angle and draw a line, from the middle of the clavicle to the posterior border of the elevation formed by the coraco-brachialis muscle, as low down as the posterior fold of the axilla.

The subdivision of the artery into its three parts may be indicated by mapping in the pectoralis minor muscle as previously described. The first part of the vessel may be felt pulsating in the infra-clavicular fossa, where it may be compressed against the second rib by exercising deep pressure.

The third part of the vessel may be felt pulsating in the groove behind the coraco-brachialis muscle, and may be there readily compressed against the humerus.

The surface markings of the *thoracic axis* and *long thoracic* arteries are obtained from the pectoralis minor, and the *dorsalis scapulæ* and *posterior circumflex* vessels from the deltoid muscle, as already described.

The Axillary Vein.—The axillary vein extends from the lower border of the teres major muscle to the outer border of the first rib. It lies throughout on the inner side of the artery, and is mapped out accordingly.

The Brachial Plexus.—The three cords of the brachial plexus lie to the outer side of the first part of the axillary artery, and surround it in the second part, where the outer cord lies to the outer side of the artery, the posterior cord behind it, and the inner cord on the inner side of the artery between it and the vein.

The *termination* of the brachial plexus lies opposite the lower border of the pectoralis minor, below which the branches of the plexus completely surround the artery in such a way that it has two nerves on every side.

The Female Mamma.—The mamma, in the female, lies in front of the pectoralis major muscle, extending in a vertical direction from the second rib to the sixth costal cartilage at the angle where it begins to ascend towards the sternum, and in a horizontal direction from just within the lateral border of the sternum, opposite the fourth rib, to the fifth rib in the mid-axillary line.

The *nipple* varies in its position in different individuals, but is most frequently placed opposite the fourth intercostal space, about four inches from the middle line.

The Axillary Lymphatic Glands. — The axillary lymphatic glands vary very considerably both in size and number. They cannot usually be felt in health, but when enlarged many of them become sufficiently obvious.

They are arranged in three main groups—

An *external* group, six or more in number, which accompany the axillary vessels and drain the upper limb.

A *pectoral* group, four or five in number, which accompany the long thoracic vessels and drain the mamma and pectoral region.

A *subscapular* group, four or five in number, which accompany the subscapular vessels and drain the back.

THE UPPER ARM.

The Humerus.—THE SURGICAL NECK.—The surgical neck of the humerus lies immediately below the upper extremity of the bone, and is placed opposite the junction of the upper and middle thirds of the deltoid. It is surrounded by the circumflex nerve and vessels.

THE SHAFT.—The shaft of the humerus is nowhere subcutaneous, but is indistinctly felt on making lateral pressure. Below the insertion of the deltoid the bone comes nearer the surface, and from that point downwards the external supra-condylar ridge is easily felt passing downwards to the external condyle and lying in a furrow, which corresponds to the position of the external inter-muscular septum, between the origin of the brachio-radialis in front of it, and the triceps extensor cubiti behind it. Occupying a similar position on the inner side is the internal supra-condylar ridge, less prominent than the external and not therefore so readily felt.

Behind the middle third of the shaft of the humerus is the musculo-spiral groove lodging the musculo-spiral nerve in part, and the superior profunda vessels.

The Biceps Flexor Cubiti Muscle.—The biceps is subcutaneous, and forms an elongated prominence on the anterior and inner side of the upper arm from the anterior fold of the axilla above, to the elbow below.

At the inner border of the muscle is the *internal bicipital furrow* which, when traced downwards, widens out into an elongated triangle, which becomes continuous with the inner part of the triangle in front of the bend of the elbow. In its upper part the internal bicipital furrow is interrupted by the

prominence formed by the coraco-brachialis muscle, and in its lower part may be seen the basilic vein; the whole length of the furrow roughly indicates the position of the brachial artery.

At the outer border of the biceps is the feebly marked *external bicipital furrow*, along which may usually be seen the cephalic vein.

The Brachialis Anticus Muscle.—The brachialis anticus muscle only comes to the surface in the lower part of the upper arm on either side of the biceps. Between its innermost margin and the triceps may be felt a cord-like band—the internal intermuscular septum—extending upwards from the internal condyle of the humerus. The ulnar nerve is immediately behind it.

The Insertion of the Deltoid.—The insertion of the deltoid into the middle of the outer aspect of the shaft of the humerus is readily seen. It marks the point at which the nutrient artery enters the humerus, and also the level at which the musculo-spiral nerve and superior profunda artery pass behind the bone.

The Triceps Extensor Cubiti Muscle.—The triceps extensor cubiti forms the prominence at the back of the upper arm, the form of which it determines.

The *outer head* of the muscle forms a large prominence immediately below the posterior border of the deltoid.

The *middle, long, or scapular head* can usually be seen emerging from the axillary border of the scapula between the teres major and minor muscles, whence it descends along the middle of the back of the upper arm.

The *inner head* is indistinct and difficult of recognition.

The *tendon of insertion* is represented by a somewhat depressed area immediately above the olecranon process of the ulna.

The Brachial Artery.—The brachial artery extends from the lower border of the teres major muscle to a point a finger's breadth below the bend of the elbow.

To map out the artery, abduct the limb and draw a line from the groove behind the coraco-brachialis muscle opposite the posterior fold of the axilla, to a point half an inch below the middle of the bend of the elbow.

The vessel lies in the internal bicipital furrow, and is usually overlapped by the inner margin of the biceps, but can be felt pulsating throughout.

To compress the vessel in the upper half of the upper arm the pressure must be exercised from within outwards, and in the lower half directly backwards.

The Inferior Profunda Artery.—This vessel may be indicated by a line drawn from the middle of the brachial artery to the back of the internal humeral condyle. It is accompanied by the ulnar nerve.

The Nutrient Artery.—The nutrient artery enters the humerus from above downwards, opposite the insertion of the deltoid.

The Basilic Vein.—The basilic vein is superficial in the lower half or third of its extent, and can therefore be seen upon the surface in the lower part of the internal bicipital furrow.

The Cephalic Vein.—The cephalic vein, superficial throughout, lies in the external bicipital furrow. Above, it is situated in the interval between the pectoralis major and deltoid muscles, where it not infrequently tends to become somewhat deeper in position.

The Median Nerve.—The line of the median nerve in the upper arm practically coincides with that for the brachial artery, which vessel it crosses slightly obliquely from above downwards and from without inwards, lying below at a

point midway between the centre of the bend of the elbow and the internal humeral condyle.

The Ulnar Nerve.—The ulnar nerve lies, in the *upper half* of its extent, immediately to the inner side of the brachial artery, and here therefore the brachial artery line serves for both structures.

The *lower half* of the ulnar nerve may be indicated by a line drawn from the brachial artery opposite the insertion of the coraco-brachialis muscle at about the middle of the inner side of the upper arm, to the interval between the olecranon process and the internal humeral condyle.

The Musculo-Spiral Nerve.—The musculo-spiral is to be indicated by a line drawn from the posterior fold of the axilla, obliquely downwards and outwards across the middle third of the humerus, to the junction of the middle and lower thirds of its outer margin, and thence downwards to the front of the external humeral condyle, where the nerve terminates by dividing into its motor posterior interosseous branch and its sensory radial branch.

THE ELBOW.

The Internal Condyle of the Humerus, or the Epitrochlea.—The internal condyle of the humerus, or the epitrochlea, forms a very distinct and easily recognisable landmark on the inner side of the elbow. It is more prominent than the external condyle, and faces, when the limb is dependent, backwards and inwards, or in almost the same direction as the head of the humerus.

The line of the humeral-ulnar joint lies about one inch

below the tip of the internal condyle, and the ulnar nerve is immediately behind the condyle, in the interval between it and the olecranon process.

The External Condyle of the Humerus, or the Epicondyle.—The external condyle of the humerus is easily felt, but is less prominent than the internal. It normally faces in almost the same direction as the greater tuberosity of the humerus; in front of it is the bifurcation of the musculo-spiral nerve, and the line of the humero-radial joint is about three-quarters of an inch below it.

The Olecranon Process of the Ulna.—The posterior surface of the olecranon process of the ulna is subcutaneous throughout, but its upper extremity is obscured by the triceps, which is inserted into it. The position of the tip of the olecranon process necessarily varies with the position of the joint, as does also the distance between it and the acromial angle of the scapula.

A knowledge of the normal relations of the olecranon process to the humeral condyles is of the greatest practical importance.

In *extension* the tip of the olecranon process is on the same horizontal level as the two condyles, but lies rather nearer the internal than the external one.

In *semi-flexion* the tip of the olecranon process descends and takes up a position below the horizontal level of the condyles.

In *complete flexion* the tip of the olecranon process and the two humeral condyles are about equidistant from one another, and form the three angles of an equilateral triangle.

The Head of the Radius.—The head of the radius lies about one inch below the tip of the external condyle in a pit or depression between the anconeus and the radial extensors

of the wrist. This pit is present in almost every limb, and is particularly noticeable when the forearm is extended.

The head of the radius is best examined from behind, whilst the semi-flexed forearm is being alternately pronated and supinated, during which movements the head of the radius can be felt to rotate.

The Bicipital Tuberosity of the Radius.—It is stated that the bicipital tuberosity of the radius can be felt, but only in extreme pronation, just below the head of the bone.

The Coronoid Process of the Ulna.—The coronoid process of the ulna can occasionally be indistinctly felt by making firm pressure in front of the elbow.

The Brachio-Radialis (Supinator Longus) Muscle.—The brachio-radialis (supinator longus) muscle can be readily demonstrated by placing the forearm in the mid-prone position, and then flexing the elbow against opposition. Under these conditions the brachio-radialis will be seen to form a distinct prominence on the radial side of the elbow and forearm. It forms the external boundary of the anti-cubital fossa.

The Biceps Flexor Cubiti Muscle.—When the elbow is flexed, the tendon of the biceps can be traced vertically downwards across the centre of the bend of the elbow, almost to its insertion into the bicipital tuberosity of the radius.

Immediately to its inner side is the brachial artery, and internal to that again the median nerve.

Under the same conditions—powerful flexion — the bicipital or semilunar fascia can be made to stand out like a razor-edge. It lies on the inner side of the elbow and separates the superficial median-basilic vein from the subjacent brachial artery.

The Pronator-Flexor Muscles.—The five superficial

pronator-flexor muscles all arise from the internal humeral condyle, and form the eminence immediately below it.

The *pronator radii teres*, which forms the ulnar boundary of the anti-cubital fossa, may be mapped out by a line drawn from the internal humeral condyle to the middle of the outer aspect of the forearm—the limb being in the supine position.

The Median Vein.—The median vein, after coursing up the forearm, can usually be seen dividing into the median-cephalic (radial side) and the median-basilic (ulnar side) veins about half an inch below the middle of the bend of the elbow, that is to say, at almost the same spot as the brachial artery bifurcates into its two terminal branches, radial and ulnar.

The Median-Basilic Vein.—The median-basilic, usually larger than the median-cephalic vein, passes obliquely upwards and inwards, across the bicipital or semilunar fascia, to the lower end of the internal bicipital furrow, where it is joined by the subcutaneous anterior and posterior ulnar veins to form the basilic vein.

The Median-Cephalic Vein.—The median-cephalic, smaller and more vertical than the median-basilic vein, passes upwards and outwards, on the outer side of the tendon of the biceps, to the lower end of the external bicipital furrow, where it is joined by the radial vein, to form the cephalic vein.

The Elbow Joint.—The *humero-radial* portion of the elbow joint can be felt externally as a slight depression immediately above the head of the radius and about three-quarters of an inch below the tip of the external humeral condyle.

The *humero-ulnar* portion of the joint may also be felt as a slight depression situated about one inch below the tip of the internal condyle.

The *highest limit* of the elbow joint is about on a level

with a horizontal line drawn between the two humeral condyles; from this point the joint slopes slightly downwards on each side, but more so on the ulnar side.

The Crease of the Elbow Joint.—The crease formed in the skin on slightly flexing the elbow lies, normally, above the line of the elbow joint.

In backward dislocation at the elbow the lower end of the humerus lies about one inch below the crease, but in fractures of the humerus above the condyles the lower end of the upper fragment is on the crease.

Positions of Nerves about the Elbow Joint.—The *median nerve* lies internal to the brachial artery midway between the centre of the front of the elbow joint and the internal humeral condyle.

The *musculo-spiral nerve* divides in front of the external humeral condyle into its posterior interosseous and radial nerves. In this situation it is overlapped by the brachio-radialis muscle.

The *ulnar nerve* descends vertically behind the internal humeral condyle in the interval between that process and the olecranon.

THE FOREARM.

The Shaft of the Radius.—The shaft of the radius is, in its upper half, almost entirely surrounded by muscles, and is therefore practically inaccessible. In its lower half it is, however, nearer the surface, and is easily palpated, especially posteriorly.

The Shaft of the Ulna.—The sinuous posterior border of the shaft of the ulna is subcutaneous throughout, and can

be followed from the olecranon process above, to the styloid process below. It lies in a slight furrow between the flexor carpi ulnaris in front, and the extensor carpi ulnaris behind.

The *shafts of both radius and ulna* are, in all positions of the limb, nearer the posterior or extensor surface than the anterior or flexor surface, and are widest apart in the mid-prone position, hence the setting of fractures in this position.

The Superficial Pronator-Flexor Muscles.—The five superficial pronator-flexor muscles all arise from the internal humeral condyle and form the prominence along the inner and fore part of the forearm.

The *pronator radii teres* can occasionally be seen passing from the internal humeral condyle to the middle of the outer aspect of the forearm. In any case it can always be mapped out.

The muscular mass covering the ulna is formed by the flexor carpi ulnaris and the subjacent flexor profundus digitorum.

The Extensor-Supinator Muscles.—Of the seven superficial extensor-supinator muscles, the *brachio-radialis* has already been described. Immediately internal to it, the *extensores carpi radialis longior and brevior* are occasionally to be made out, becoming tendinous and smaller, below the middle of the forearm.

In the lower third of the forearm there is, on the radial side, a small elongated prominence directed obliquely downwards, outwards, and forwards, which results from the *extensors of the thumb* crossing the radial extensors of the wrist.

The *extensor communis digitorum*, the *extensor carpi ulnaris*, and the *anconeus* can also be recognised in thin persons.

The Posterior Intermuscular Septum.—Between the two radial extensors of the wrist and the extensor communis digitorum there is, on the back of the forearm, an intermuscular septum. This is often sufficiently indicated by a groove upon the surface, but its position may be indicated by a line drawn from the external humeral condyle to Lister's tubercle on the centre of the posterior border of the lower end of the radius.

The upper part of the surface line indicates the position of the *septum* itself.

A spot on this line two inches below the head of the radius indicates the point at which the *posterior interosseous branch of the musculo-spiral nerve* reaches the back of the forearm through the substance of the supinator brevis muscle.

The Radial Artery.—The radial artery extends from the bifurcation of the brachial, into the palm of the hand, which it reaches by winding round the radial side of the wrist to the dorsal side of the first intermetacarpal space, through which it passes into the palm. It is thus divided into three parts—a first part in the forearm, a second part at the wrist, and a third part in the palm.

To map out the radial artery in the forearm, draw a line from a point half an inch below the middle of the bend of the elbow to the interval between the tubercle of the scaphoid and the tendon of the extensor ossis metacarpi pollicis.

The Ulnar Artery.—The ulnar artery extends from the bifurcation of the brachial into the palm of the hand, which it reaches by passing downwards superficial to, or in front of, the anterior annular ligament.

To map out the lower *two-thirds of the ulnar artery* in the forearm, draw a line from the front of the internal humeral condyle to the radial side of the pisiform bone. The whole length of this line maps out the ulnar nerve in

the forearm, and its lower two-thirds corresponds to the lower two-thirds of the artery, the nerve being on the ulnar side of the artery.

To map out the curved *upper third of the ulnar artery* in the forearm, draw a line from a point half an inch below the middle of the bend of the elbow, downwards and inwards to the junction of the upper and middle thirds of the guiding line for the ulnar nerve.

The Median Nerve.—The course of the median nerve in the forearm may be indicated by a line drawn from a point midway between the centre of the elbow and the internal humeral condyle to a point midway between the styloid processes of the radius and ulna, that is, to the outer border of the tendon of the palmaris longus at the wrist.

The Ulnar Nerve.—The course of the ulnar nerve in the forearm may be indicated by a line drawn from the front of the internal humeral condyle to the radial side of the pisiform bone.

The Radial Nerve.—The radial nerve, one of the two terminal branches of the musculo-spiral, may be indicated by a line drawn from the front of the external humeral condyle downwards and inwards to the junction of the upper and middle thirds of the line of the radial artery, thence downwards by the middle third of that line, and from the junction of the middle and lower thirds of the artery, obliquely downwards on to the dorsal surface of the hand.

The Superficial Veins of the Forearm. — Numerous cutaneous veins may be seen on the forearm, chiefly derived from the *dorsal venous plexus* on the back of the hand. From this plexus, two main trunks, the *radial* and *posterior ulnar veins*, ascend along the radial and ulnar borders of the forearm respectively, to terminate in the neighbourhood of the elbow by uniting, the *radial* with the *median cephalic* to

form the *cephalic* vein, and the *posterior ulnar* (joined by the *anterior ulnar*) with the *median basilic* to form the *basilic* vein.

The *median vein* may be seen running up the centre of the forearm or, almost as frequently, arising in the dorsal venous plexus and coursing round the lower part of the radial border of the forearm on to its flexor surface.

THE WRIST.

The Styloid Process of the Radius. — The styloid process of the radius is easily felt. Its *tip* lies a little lower and rather more anteriorly than the tip of the corresponding process of the ulna.

The *external surface* is crossed by the tendons of the extensores ossis metacarpi pollicis and brevis pollicis.

A knife entered horizontally below the tip of the styloid process of the radius would strike the scaphoid.

The Styloid Process of the Ulna.—The styloid process of the ulna is easily felt, when the forearm is supinated, at the inner and posterior part of the wrist, but it must not be confused with the head of the bone.

A knife entered horizontally below the tip of the styloid process of the ulna would enter the radio-carpal articulation.

The Anterior Border of the Lower Extremity of the Radius.—The anterior border of the lower extremity of the radius is easily felt between the flexor tendons as a transverse ridge, situated one inch above the thenar eminence. Immediately below it is the *radio-carpal articulation.*

The Posterior Border of the Lower Extremity of the Radius and Lister's Tubercle.—The posterior border of the

lower extremity of the radius is also easily felt. Upon its middle is *Lister's tubercle*, to the ulnar side of which is the tendon of the extensor longus pollicis.

The Head of the Ulna.—The head of the ulna forms a rounded projection on the dorsal side of the wrist. It is separated from the styloid process of the ulna (with which it must not be confused) by the tendon of the extensor carpi ulnaris. Immediately to its radial side is the tendon of the extensor minimi digiti.

The Tubercle of the Scaphoid.—The tubercle of the scaphoid forms a distinct projection immediately above the thenar eminence and just below and internal to the styloid process of the radius. It lies between the tendon of the extensor ossis metacarpi pollicis on its radial side, and that of the flexor carpi radialis on its ulnar side.

The Pisiform Bone.—The pisiform bone lies immediately above the hypothenar eminence, and is crossed by the crease between the forearm and hand. The tendon of the flexor carpi ulnaris is inserted, in part, into the bone.

The Trapezium.—The ridge on the trapezium may be felt, on deep pressure, through the inner part of the thenar eminence at a spot about half an inch below the tubercle of the scaphoid.

The Hook of the Unciform.—The hook of the unciform can be felt, with difficulty, on deep pressure through the radial side of the hypothenar eminence at a spot about half an inch below, and to the radial side of, the pisiform.

The Bases of the Metacarpals.—The bases of all the metacarpals are easily felt on the dorsal surface, particularly those of the first, third, and fifth.

The *styloid process of the third metacarpal* is readily distinguishable at a point one and three-quarter inches vertically below Lister's tubercle.

The Insertions of Tendons into the Bases of the Metacarpals.—The insertions of the various tendons into the metacarpals, a knowledge of which greatly facilitates their recognition upon the surface, are as follows:—

Metacarpal.	Palmar Surface.	Dorsal Surface.
First.	Nil.	Extensor ossis metacarpi pollicis.
Second.	Flexor carpi radialis.	Extensor carpi radialis longior.
Third.	Flexor carpi radialis.	Extensor carpi radialis brevior.
Fourth.	Nil.	Nil.
Fifth.	Flexor carpi ulnaris (indirectly).	Extensor carpi ulnaris.

Tendons on the Palmar Surface of the Wrist.—The *flexor carpi radialis* tendon, readily seen on flexing the wrist, runs down towards the tubercle of the scaphoid. The radial artery lies on its radial side, where it can be felt pulsating.

The *palmaris longus* is sometimes absent, but when present lies in the centre of the wrist, where it is the most prominent of all the tendons. The median nerve lies behind its outer border.

The *flexor sublimis digitorum* can be felt on the ulnar side of the palmaris longus.

The *flexor carpi ulnaris* is easily felt, and seen, above the pisiform bone, into which it is, in part, inserted. Its position is indicated in extension by a slight groove. The ulnar artery lies between this tendon and the flexor sublimis digitorum, and on deep pressure can be felt pulsating.

Tendons on the Dorsal Surface of the Wrist.—The *extensor ossis metacarpi pollicis* can be seen, and felt, passing to the base of the first metacarpal.

The *extensor brevis pollicis* lies immediately to the ulnar side of the extensor ossis metacarpi pollicis, and can be readily palpated when in action.

The *extensor longus pollicis* may be rendered very prominent by abducting and extending the thumb, when it may be seen passing obliquely from the ulnar side of Lister's tubercle to the base of the terminal phalanx of the thumb.

Its tendon crosses the centre of the lower end of the radius, roughly indicates the position of the interval between the scaphoid and semilunar bones, and forms the ulnar boundary of the depression known as the *tabatière anatomique.*

The *extensor carpi radialis longior* lies immediately above the radial side of the base of the second metacarpal, and is there easily felt on firm pressure.

The *extensor carpi radialis brevior* lies immediately above the radial side of the base of the third metacarpal, and is also easily felt on making firm pressure.

The course of the tendons of the *extensor communis digitorum* to the index, middle, ring, and little fingers can be easily seen on the dorsal surface of the hand.

The tendons of the *extensor indicis* and *extensor minimi digiti* muscles lie on the ulnar sides of the common extensor of their respective digits, and can be palpated when in action.

The *extensor carpi ulnaris* is easily recognised passing down to the fifth metacarpal between the styloid process of the ulna (on its ulnar side) and the head of the ulna on its radial side.

The Radial Artery.—The radial artery can be felt pulsating in the lower third of the front of the forearm midway between the tendons of the brachio-radialis and the flexor carpi radialis.

The *second part* of the radial artery, or the part at the

wrist, crosses the tabatière anatomique, along a line drawn from the front of the styloid process of the radius to the upper end of the first intermetacarpal space.

The Ulnar Artery.—The ulnar artery can be felt pulsating, in the lower third of the front of the forearm, on making deep pressure in the interval between the tendons of the flexor sublimis digitorum and the flexor carpi ulnaris.

Positions of the Chief Nerves at the Wrist.—The *median nerve* lies behind the radial border of the palmaris longus.

The *ulnar nerve* lies to the radial side of the pisiform bone, between it and the ulnar artery.

The Wrist Joint.—The wrist joint may be mapped out by a convex line drawn between the tips of the styloid processes of the radius and ulna, with the convexity upwards, the highest part of the convexity being about half an inch above a line drawn transversely between the two styloid processes.

THE HAND.

The Metacarpal Bones.—The metacarpal bones are all easily felt, especially from the dorsal surface, as are also the lines of the carpo-metacarpal and metacarpo-phalangeal articulations at their upper (bases) and lower (heads) ends respectively.

The Phalanges.—The phalanges, fourteen in all, two for the thumb and three for each finger, are all easily felt, especially from the dorsal surface.

The "Knuckles."—The prominences termed "knuckles" are formed, in every instance, by the bone immediately above

them; thus the *proximal* row of knuckles are formed by the distal ends or heads of the metacarpals; those of the *second* row by the distal ends of the first phalanges, and the *distal* row by the distal ends of the second phalanges.

The Metacarpo-Phalangeal Articulations.—The metacarpo-phalangeal articulations are very easily felt from the dorsal surface. On the palmar surface they lie about three-quarters of an inch above the level of the webs of the fingers.

The Proximal Interphalangeal Articulations.—The proximal row of interphalangeal articulations are easily felt from the dorsal surface. To open into the joints anteriorly, incise along the highest crease in front of the joint.

The Distal Interphalangeal Joints.—These joints can also be easily located from the dorsal surface. To open into the joints anteriorly, incise along the lowest crease in front of the joint.

The Anterior Annular Ligament.—The anterior annular ligament may be easily mapped out from its attachments, all of which can be felt upon the living subject. These attachments are, on the radial side, the tubercle of the scaphoid and the ridge on the trapezium, and on the ulnar side, the pisiform and the hook of the unciform.

The Thenar Eminence.—The thenar eminence, or the "ball of the thumb," is formed by the abductor pollicis on the radial side, the superficial head of the flexor brevis pollicis on the ulnar side, and between the two and resting on the first metacarpal, by the opponens pollicis, all of which are supplied by the median nerve.

The Hypothenar Eminence.—The hypothenar eminence is formed by the abductor minimi digiti, the flexor brevis minimi digiti, and the opponens minimi digiti, all of which are supplied by the ulnar nerve.

The Hollow of the Hand.—The hollow of the hand lies

between the thenar and hypothenar eminences, and owes its grasping strength to the powerful palmar fascia, to the centre of which the skin is tightly adherent, and hence the "hollow."

The Transverse Palmar Furrow.—The transverse palmar furrow, seen on the front of the hand on slightly flexing the fingers, roughly corresponds to—

The upper extremities of the digital synovial sheaths of the index, middle, and ring fingers.

The division of the palmar fascia into its four digital slips.

The metacarpo-phalangeal articulations.

The First Dorsal Interosseous Muscle, or the Abductor Indicis.—This muscle lies between the first and second metacarpals, and on approximating those bones the muscle is seen as a distinct prominence between them on their dorsal aspect.

The Superficial Palmar Arch.—The superficial palmar arch is the continuation of the ulnar artery into the palm of the hand. It is formed by the superficial division of the ulnar artery anastomosing with some one or other of the branches of the radial artery, as, for example, the superficialis volæ from the radial artery in the forearm. The arch supplies the three and a half inner digits.

To map out the vessel, abduct the thumb to its fullest extent and draw a line transversely across the palm at the level of the web of the thumb. The middle third of the line indicates the convexity or the lowest limit of the arch. By connecting its two extremities with the lower ends of the radial and ulnar arteries in the forearm, the whole arch is mapped out.

The Deep Palmar Arch.—The deep palmar arch is the continuation of the radial artery into the palm of the hand, and is completed on the ulnar side by the deep division of the ulnar.

The radial artery in the palm supplies the one and a half outer digits, and its arch forms an alternative blood channel to almost all parts of the hand.

The deep palmar arch rests upon the bases of the metacarpals about quarter of an inch nearer the wrist than the superficial arch, and is mapped out accordingly.

The Median Nerve.—The median nerve enters the palm of the hand behind the anterior annular ligament just internal to the ulnar edge of the upper end of the thenar eminence.

The Ulnar Nerve.—The ulnar nerve enters the palm of the hand in front of the anterior annular ligament immediately to the radial side of the pisiform bone, between it and the ulnar artery.

The Common Flexor Sheath.—This sheath, common to the tendons of the flexor sublimis digitorum, flexor profundus digitorum, and the median nerve, lies behind the anterior annular ligament. It extends upwards into the forearm for one and a half inches above the upper border of the anterior annular ligament and downwards into the palm to a little below its middle. (See Figure 42.)

The Digital Flexor Sheaths of the Index, Middle, and Ring Fingers.—These sheaths, common to the tendons of the flexor sublimis digitorum and flexor profundus digitorum on the index, middle, and ring fingers respectively, extend from the bases of the terminal phalanges upwards into the palm to the necks of the metacarpal bones. Their upper extremities are thus separated from the lowest limit of the common flexor sheath by a distance of not more than half an inch.

The Digital Flexor Sheath of the Little Finger.—This sheath extends from the base of the terminal phalanx of the little finger upwards to the common flexor sheath, *with which it becomes continuous.*

The Digital Flexor Sheath of the Thumb.—This

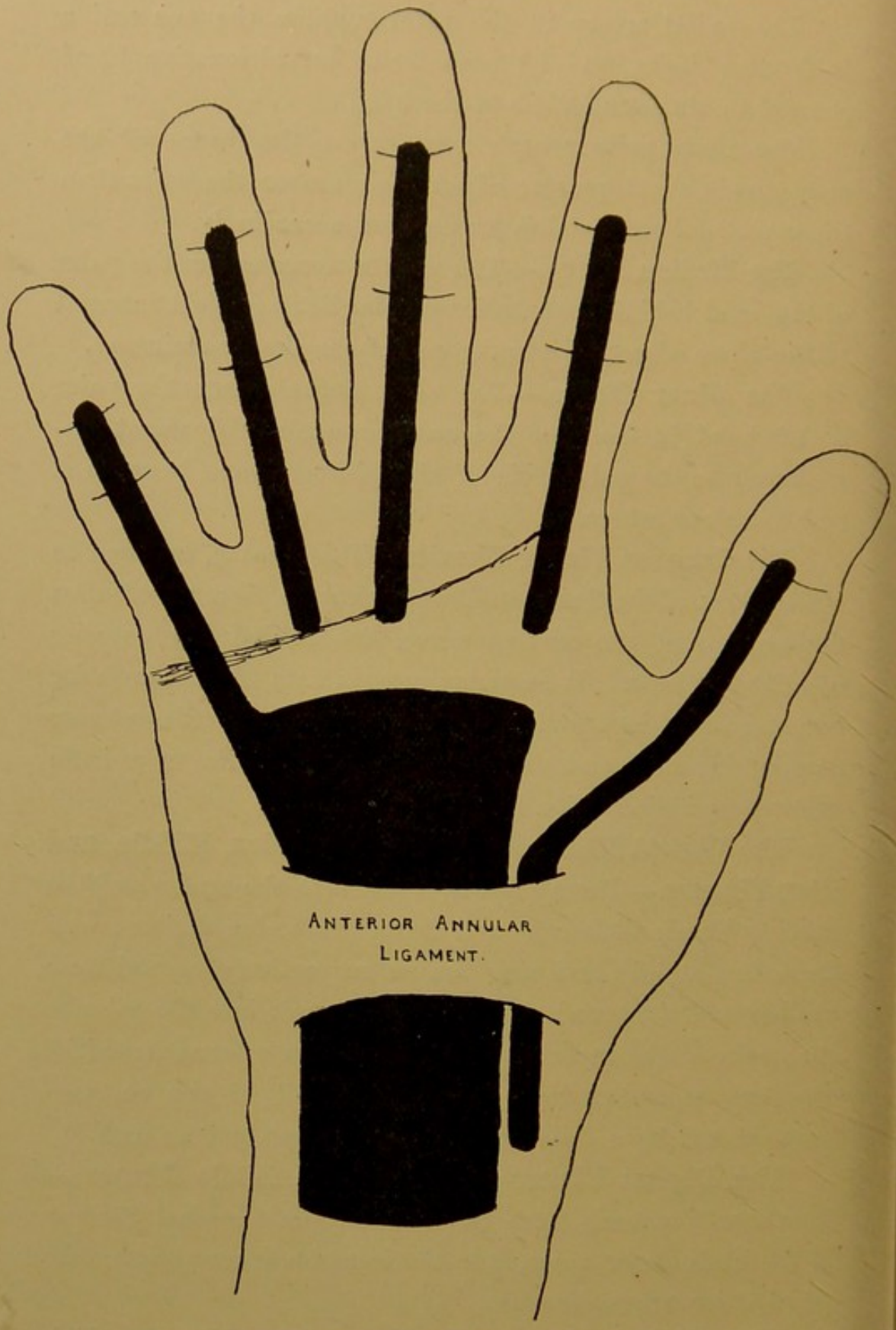

Figure 42.—The Synovial Sheaths of the Hand.

sheath, special to the tendon of the flexor longus pollicis, extends from the base of the terminal phalanx of the thumb, upwards into the forearm for about one inch above the anterior annular ligament. It does not usually communicate with the common flexor sheath, but *occasionally it may do so.*

X.

THE LOWER EXTREMITY.

THE BUTTOCK.

The Crest of the Ilium.—The crest of the ilium is easily determined. It extends from the anterior superior iliac spine to the posterior superior iliac spine, and reaches its highest point a little behind the centre of the entire crest on the same level as the fourth lumbar spine.

The Posterior Superior Iliac Spine.—The posterior superior iliac spine is ill defined. It marks the posterior end of the iliac crest and the centre of the sacro-iliac articulation, and is situated in a dimple or depression opposite the second sacral spine.

The Second Sacral Spine.—The second sacral spine is on the same horizontal level as the posterior superior iliac spine.

The Third Sacral Spine.—The third sacral spine lies just below the second sacral spine, and is about on the same level as the upper border of the great sacro-sciatic foramen. It indicates the lowest limit of the meninges of the spinal cord and of the cerebro-spinal fluid.

The Apex of the Coccyx.—The apex of the coccyx can be located in the depression known as the natal cleft.

The Ischial Tuberosities.—The most prominent parts of the ischial tuberosities are easily felt just above the inner ends of the gluteal folds.

In the erect attitude the ischial tuberosities are overlapped by the gluteus maximus muscles, but in the sitting posture they are only covered by a bursa and some fat.

The Great Trochanter.—The great trochanter of the femur constitutes an important osseous landmark, situated about six inches below the highest part of the iliac crest. It is best explored by slightly abducting the limb and thus relaxing the ilio-tibial band.

The *upper border* of the great trochanter, somewhat obscured by the gluteus medius muscle, is on the same level as the symphysis pubis, and corresponds to the centre of the hip joint.

The prominent *posterior superior angle* of the great trochanter is an important landmark, and is easily recognised.

The Lesser Trochanter.—The lesser trochanter of the femur can be felt on deep palpation above the outer end of the gluteal fold.

The Iliac Furrow.—The iliac furrow is a slight furrow which corresponds to the iliac crest, and which becomes less well marked as it is traced backwards from the anterior superior iliac spine.

The Natal Cleft.—The natal cleft is the deep furrow which runs downwards, in the posterior mesial line, towards the anus, and in which the coccyx can be felt.

The Gluteal Fold.—The gluteal fold is a fold formed during extension of the hip in relationship to the lower border of the gluteus maximus muscle, the oblique lower border of which it crosses horizontally outwards about its middle; thus the lower border of the gluteus maximus lies, internally, a little above the fold, but externally it is below the fold.

Diminution of the fold, due to wasting of the gluteus maximus muscle, is an early sign of hip-joint disease.

Nélaton's Line.—Nélaton's line is a line drawn from the anterior superior iliac spine to the most prominent part of the ischial tuberosity; it should, in health, cross the hip joint at the level of the upper border of the great trochanter.

This line is designed to ascertain the presence or absence of upward displacement of the great trochanter, but is open to the objection that it involves unnecessary movement of the patient.

Chiene's Lines.—Stretch two tapes across the front of the pelvis, the higher one between the two anterior superior iliac spines, and the lower one between the upper borders of the great trochanters.

In health these lines are parallel, but in upward displacement of one trochanter the lower tape converges on the higher one on the injured side. These lines are free from the objection against Nélaton's line.

Bryant's Triangle.—With the patient lying on his back—

1. Drop a perpendicular from the anterior superior iliac spine. (See Figure 43.)
2. From the perpendicular draw a line at right angles to it to the prominent posterior superior angle of the great trochanter.
3. Complete the triangle by a hypotenuse drawn from the anterior superior iliac spine to the prominent posterior superior angle of the great trochanter.

The second line indicates upward displacements of the great trochanter, and the third line displacements in an antero-posterior direction.

The Gluteal-Sciatic Triangle.—This triangle is designed to indicate the points at which the gluteal, sciatic, and internal pudic arteries and the superior gluteal and great sciatic nerves appear in the buttock.

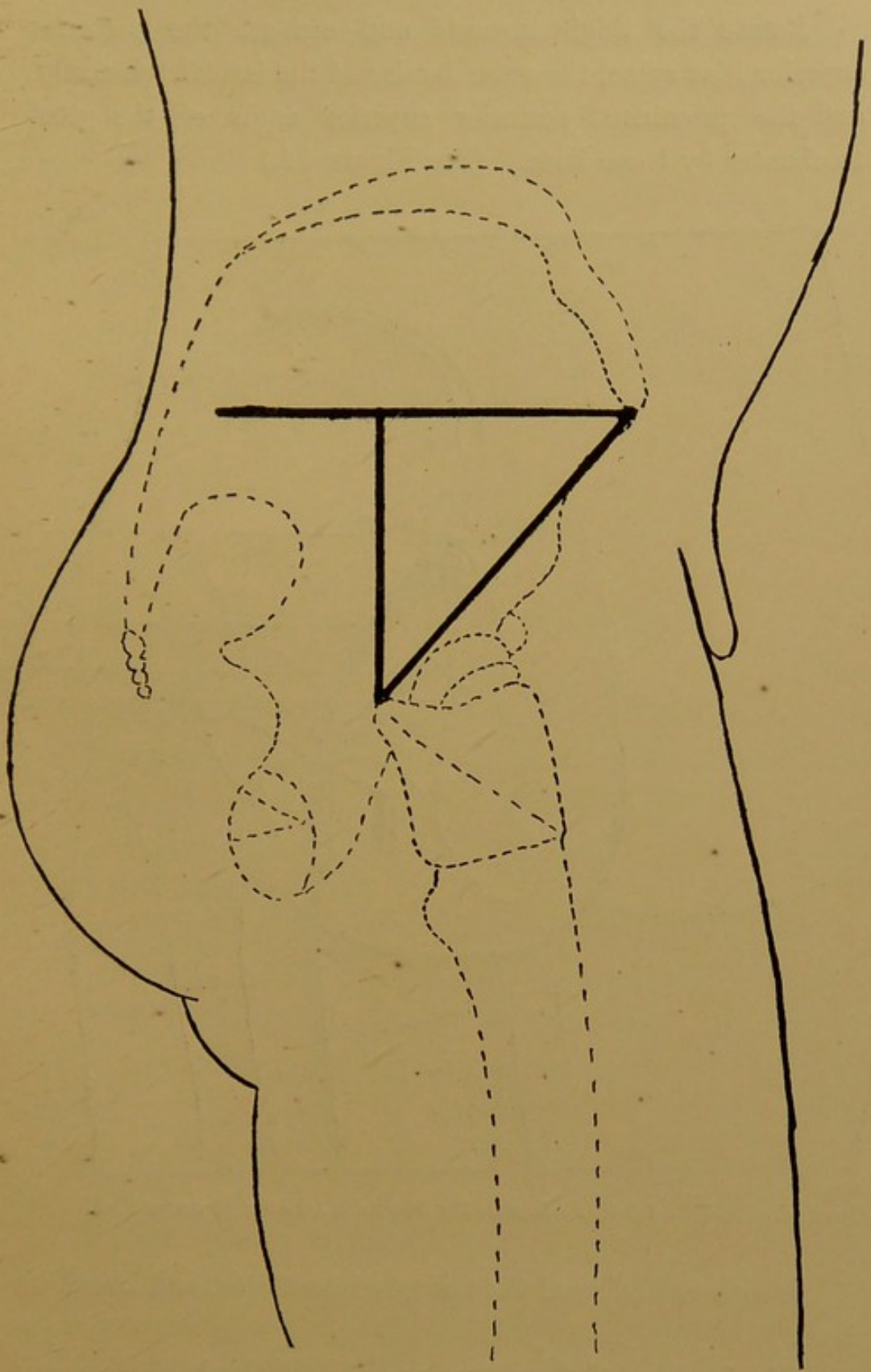

Figure 43.—Bryant's Triangle. The bones are indicated in dotted lines, and the triangle in heavy lines.

Rotate the thigh inwards and connect the posterior superior iliac spine, the outer border of the ischial tuberosity, and the prominent posterior superior angle of the great trochanter by three lines. (See Figure 44.)

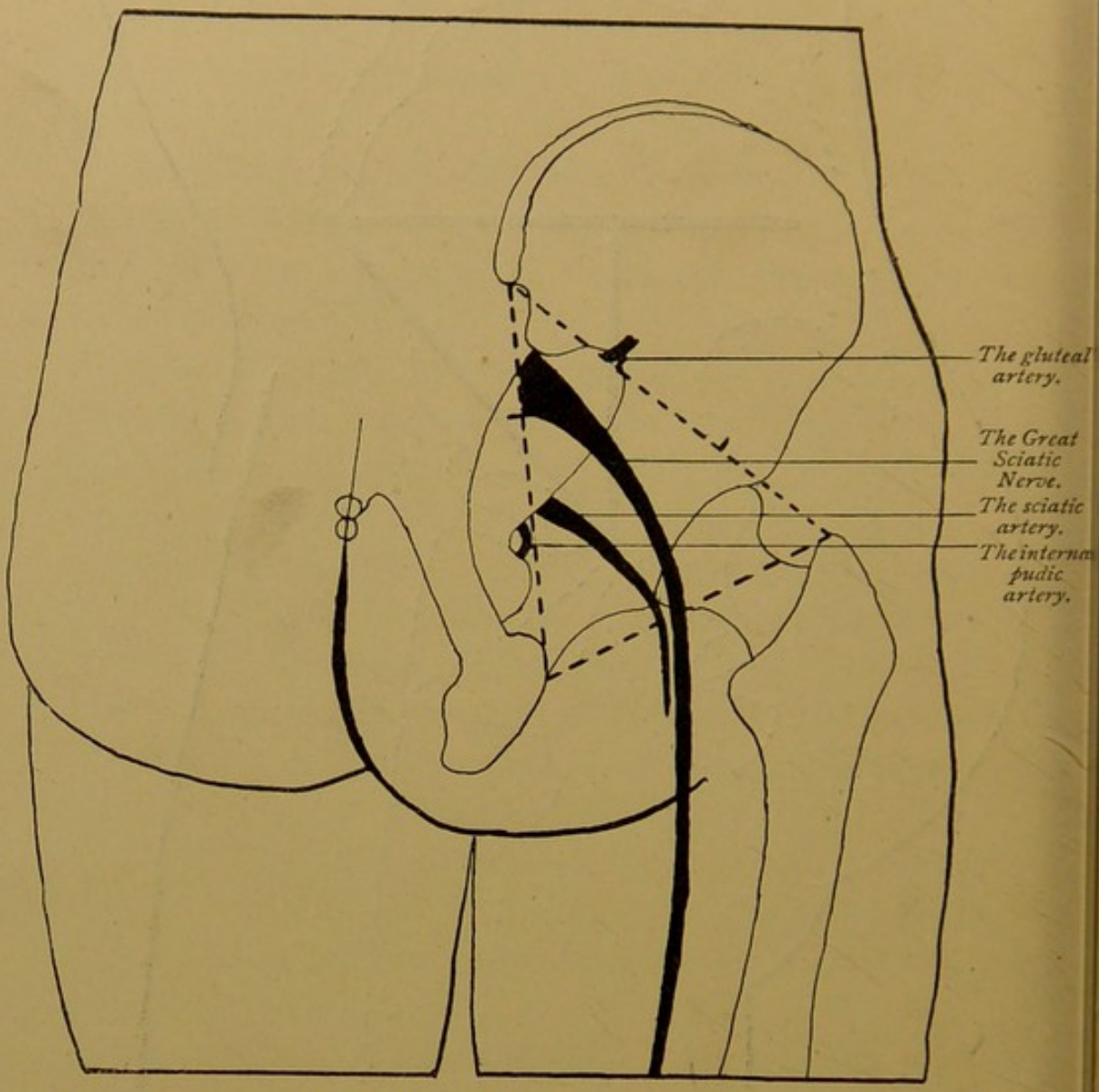

Figure 44.—The Gluteal Sciatic Triangle. The triangle is indicated by dotted lines.

Divide each side of the triangle into thirds, and bisect its base.

The junction of the upper and middle thirds of the outer side of the triangle indicates the spot at which the *gluteal*

artery and the *superior gluteal nerve* make their appearance in the buttock.

The junction of the lower and middle thirds of the inner side of the triangle indicates the spot at which the *sciatic* and *internal pudic arteries* make their appearance in the buttock. It also roughly coincides with the ischial spine.

The *great sciatic nerve* is indicated, in the buttock, by a line drawn slightly convex outwards, from the junction of the upper and middle thirds of the inner side of the triangle, to the point of bisection of its base.

THE BACK OF THE THIGH.

The Hamstring Muscles.—The tendons of the biceps flexor cruris on the outer side, and of the semi-tendinosus and semi-membranosus on the inner side, can be thrown into prominence by causing the subject to stand on tip-toes with the knees slightly flexed.

The external popliteal nerve lies immediately internal to, and is overlapped by, the tendon of the biceps flexor cruris.

The External Intermuscular Septum.—The line of the external intermuscular septum is indicated, when the hamstrings are flexed, by a well-marked furrow situated immediately in front of the biceps flexor cruris, and extending from the insertion of the gluteus maximus above, to the outer side of the knee, below.

Behind the furrow is the biceps flexor cruris, and in front of it the vastus externus overlapped by the ilio-tibial band.

The line of the external intermuscular septum constitutes the best line for incising the shaft of the femur.

The Great Sciatic Nerve.—The femoral portion of the great sciatic nerve is indicated by the *upper half* of a line drawn from a point midway between the outer border of the ischial tuberosity and the prominent posterior superior angle of the great trochanter to the centre of the popliteal space.

The *lower half* of the guiding line indicates the position of the internal popliteal nerve.

THE POPLITEAL SPACE.

Lateral Boundaries.—The lateral boundaries of the popliteal space, all of which may be recognised on the surface by slightly flexing the knee, are as follows:—

Above and to the outer side—

The tendon of the biceps flexor cruris muscle.

Above and to the inner side—

The semi-tendinosus and semi-membranosus tendons.

Below and to the outer side—

The outer head of the gastrocnemius and the plantaris (the latter deeply situated).

Below and to the inner side—

The inner head of the gastrocnemius.

The Popliteal Fascia.—During extension of the knee the popliteal fascia is tense and obliterates the hollow of the popliteal space. To explore the space the knee must therefore be flexed and the popliteal fascia relaxed.

The Popliteal Artery.—This vessel extends from the opening in the adductor magnus muscle to the lower border of the popliteus. Its course may be indicated by a slightly

curved line drawn from a point just internal to the upper angle of the popliteal space to a point midway between the condyles of the femur, and thence vertically downwards to the level of the lower limit of the tubercle of the tibia. The popliteal vein is superficial, that is, posterior to the artery to which it is intimately adherent.

The Internal Popliteal Nerve.—The internal popliteal nerve, which results from the bifurcation of the great sciatic nerve into internal and external popliteals, runs almost vertically through the centre of the popliteal space, crossing the artery superficially from above downwards and from without inwards. (See also p. 212.)

The External Popliteal Nerve.—The external popliteal nerve lies immediately internal to, and is overlapped by, the tendon of the biceps flexor cruris, which it follows downwards to the neck of the fibula, where it may be, not infrequently, rolled under the finger. Its position predisposes the nerve to injuries.

THE FRONT OF THE THIGH.

The Anterior Superior Iliac Spine.—The anterior superior iliac spine looks directly forwards and forms an important and easily recognisable landmark, from which all comparative measurements of the lower limbs are made.

The *inter-spinous line*, that is, a line drawn between the two anterior superior iliac spines, is on the same horizontal level as the sacral promontory.

The two anterior superior iliac spines constitute the lateral osseous landmarks in Addison's method of delimiting the abdomen.

The Iliac Tubercle.—The tubercle on the iliac crest is easily felt about two and a half inches behind the anterior superior iliac spine.

The *inter-tubercular line*, that is, a line drawn between the two iliac tubercles, is on the same horizontal level as the fifth lumbar vertebra. This line is employed by Cunningham in his method of delimiting the abdomen.

The Symphysis Pubis.—The symphysis pubis, easily located, lies in the anterior mesial line, and forms the lower of the two mesial landmarks employed in Addison's method of delimiting the abdomen.

The Crest of the Pubis.—The crest of the pubis forms a rounded, subcutaneous, bony ridge between the symphysis pubis and the pubic spine. It is crossed in the male by the spermatic cord, and in the female by the round ligament of the uterus.

The Pubic Spine.—The pubic spine is very distinct in thin subjects, but in the obese it tends to be obscured by the pubic fat. In any case it is, in the male, readily detected by invaginating the scrotum so as to pass the finger under cover of the fat; and in the female by abducting the thigh, which thus makes the tendon of the adductor longus tense, and so indicates the position of the spine.

A line drawn horizontally outwards from the pubic spine to the great trochanter crosses the front of the hip joint at the level of the lower part of the head of the femur.

The *crural ring* is situated on the above line one inch external to the pubic spine.

The *external abdominal ring* lies immediately internal to the pubic spine.

The centre of the *saphenous opening* lies one and a half inches below and external to the pubic spine.

The tendon of the *adductor longus* lies below the pubic

spine, and tenotomy of the muscle is performed at a point one inch below the bone.

An inguinal hernia descends *internal* to the pubic spine; a femoral hernia *external* to it.

The Head of the Femur.—The head of the femur lies below, and slightly to the outer side of, the centre of Poupart's ligament. It is best located by extending the thigh and rotating outwards.

Poupart's Ligament.—Poupart's ligament can be felt as a tense band, convex downwards, stretching between the anterior superior iliac spine and the pubic spine. Its inner half is almost horizontal, and is more readily palpated than the outer half. In very stout individuals its position is indicated by a furrow—the fold of the groin.

Above and parallel with Poupart's ligament are the *horizontal or inguinal lymphatic glands.* When these are inflamed, examine the buttock and anus as well as the external genitals.

Below and at right angles to Poupart's ligament are the *vertical or femoral lymphatic glands*, which drain the lower limb.

Hernial swellings immediately above Poupart's ligament are usually inguinal; those below femoral.

The Crural or Femoral Ring.—The crural ring is the abdominal entrance into the crural canal, and is therefore the aperture by means of which a femoral hernia leaves the abdomen. It lies immediately to the outer side of the base of Gimbernat's ligament, between that structure and the femoral vein, and is to be mapped out upon the surface at a point behind Poupart's ligament one inch external to the pubic spine. The crural ring has the following boundaries (see Figure 45):—

In front, the superficial and deep crural arches, that is,

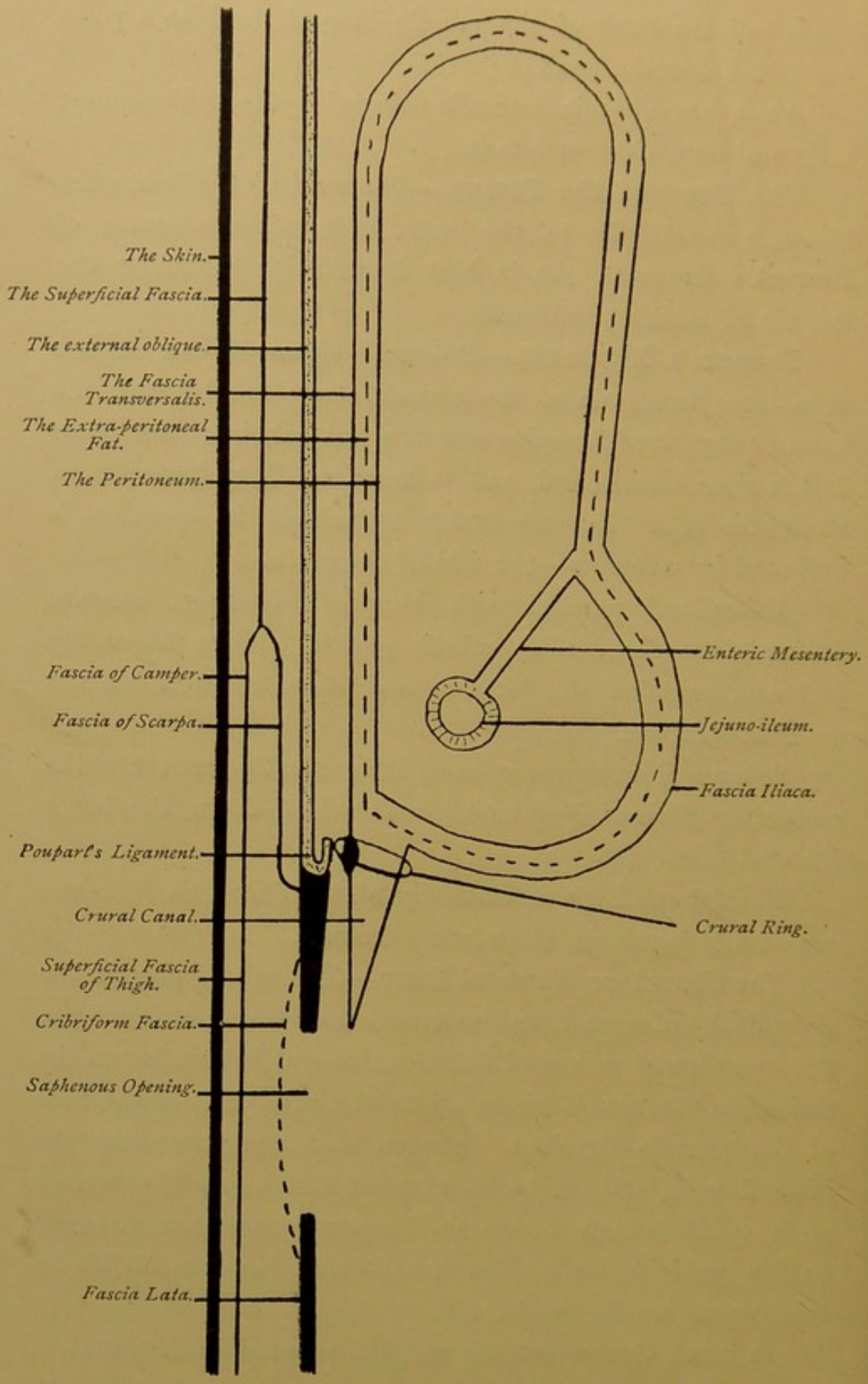

Figure 45.—Schematic Sagittal Section, designed to illustrate the Anatomy of Femoral Hernia.

Poupart's ligament and a specially thickened portion of the fascia transversalis.

Behind, from before backwards, the thickened upper portion of the pectineal fascia, the upper end of the pectineus muscle, and the os pubis.

To the *inner* side there is the lateral free margin, or base, of Gimbernat's ligament.

To the *outer* side, the femoral vein, separated from the crural ring by the more internal of the two antero-posterior septa which divide the femoral sheath into its three compartments.

The crural ring is, therefore, bounded on three sides by dense unyielding structures, and hence the liability of a femoral hernia to become strangulated.

The Crural or Femoral Canal.—The crural or femoral canal is the innermost compartment of the femoral sheath, and extends from the crural ring vertically downwards for a distance of half an inch; it is to be mapped out accordingly.

The *upper end or abdominal entrance* to the canal is the crural ring, which is normally occupied, or plugged, by a portion of the extra-peritoneal fat of the abdomen, to which surgeons usually apply the name septum crurale.

The *lower end* of the canal is situated opposite the superior cornu of the saphenous opening. It is quite closed, and constitutes a blind extremity.

The *anterior boundary* of the canal is formed by the fascia transversalis, which descends from the abdomen to form the anterior wall of the femoral sheath, and therefore of the crural canal.

The *posterior boundary* of the canal is formed by the fascia iliaca of the abdomen fusing with the pectineal fascia of the thigh.

The *external boundary* of the canal is formed by the

femoral vein separated from the canal by the more internal of the two antero-posterior septa which divide the femoral sheath into its three compartments.

The *internal boundary* of the canal is formed by the fusion, on the inner side of the canal, of its anterior and posterior boundaries.

The normal *contents* of the canal are fat and one or two small lymphatic glands, but pathologically it may contain part of the intestine, as in the case of a femoral hernia.

The Saphenous Opening.—The saphenous opening is an aperture in the fascia lata (deep fascia) of the thigh, one and a half inches long and half an inch wide, situated at the upper and inner part of the front of the thigh just below the inner end of Poupart's ligament, with its centre one and a half inches below, and external to, the pubic spine, and its upper end about one inch external to that process.

The *external margin* of the saphenous opening, or its *falciform border*, is sharp, free, and crescentic, and is formed by that portion of the fascia lata which is usually termed its iliac portion. The falciform border lies directly in front of the femoral artery, from which it is only separated by the anterior wall of the femoral sheath.

The falciform border is continued upwards and inwards, in front of the femoral vein and the crural canal, to Gimbernat's ligament as the *superior cornu*, and downwards and inwards as the *inferior cornu*, which lies in the angle between the internal or long saphenous vein and the femoral vein.

The *internal margin* of the saphenous opening is ill-defined and can hardly be said to exist, because on this side of the aperture the fascia recedes from the surface behind the upper ends of the femoral vein and artery, in

order to assist in the formation of the posterior wall of their sheath—the femoral sheath.

The saphenous opening is roofed in by an adventitious sheet of superficial fascia—*the cribriform fascia*—somewhat analogous to a sheet of paper pasted around a hole in a glass window.

In thin subjects the localisation of the saphenous opening upon the surface is facilitated by the long saphenous vein, which can often be seen ascending to, and crossing, its inferior cornu; whilst it also occasionally happens that there is, on the surface, a slight depression, corresponding to the subjacent aperture.

Femoral Hernia.—A femoral hernia leaves the abdomen at the crural ring, descends vertically through the crural canal, turns forwards through the saphenous opening, and finally ascends, in front of the superior cornu of the saphenous opening and the fascia lata of the thigh towards Poupart's ligament.

Such a form of hernia is most common in females, is almost always acquired, displays a marked tendency to strangulation, and is always external to the pubic spine.

Its *coverings*, which are pushed before the hernia in its descent, are, in the order in which they would be operated upon, as follows:—

The skin.

The superficial fascia of the thigh.

The cribriform fascia roofing in the saphenous opening.

The fascia transversalis, or the anterior boundary of the crural canal.

The septum crural, or the extra-peritoneal fat normally plugging the crural ring.

The parietal peritoneum, or the sac of the hernia.

The reason why a femoral hernia turns upwards after passing through the saphenous opening is not altogether understood; it is not, however, due to the fascia of Scarpa, as occasionally taught, because that fascia is attached to the fascia lata of the thigh *above* the saphenous opening.

The Sartorius Muscle.—The sartorius muscle is an important landmark, which may be thrown into greater prominence by raising the leg and foot from the ground and then slightly flexing and rotating outwards the unsupported thigh.

The *upper third* of the muscle forms the outer boundary of Scarpa's triangle; the *middle third* roofs in Hunter's canal; and the *lower third* lies in front of the gracilis and the inner hamstrings.

The relations of the sartorius muscle and femoral vein to the femoral artery are the exact converse of one another; thus at the *base of Scarpa's triangle* the muscle is to the outer side of the artery and the vein to its inner side; at the *apex of Scarpa's triangle* the muscle is in front of the artery and the vein behind; whilst near the *termination of Hunter's canal* the muscle is in front and to the inner side of the artery and the vein behind and to the outer side.

The Tensor Fasciæ Femoris Muscle.—This small muscle forms a distinct prominence immediately external and adjacent to the upper end of the sartorius, the two diverging as they are traced downwards.

When followed downwards the tensor fasciæ femoris becomes continuous with the *ilio-tibial band*, tense in health, and lax in injuries.

The Rectus Femoris Muscle.—The tendon of origin of the rectus femoris may be felt in the angle between the sartorius and the tensor fasciæ femoris muscles, in which position it lies in front of the capsule of the hip joint.

The remainder of the muscle forms the central prominence down the front of the thigh, and is especially noticeable when the muscle is in action.

The Vastus Internus Muscle.—The vastus internus forms a conspicuous mass along the lower half of the thigh, which increases in size towards the knee, and lies between the rectus femoris and the sartorius muscles.

The Vastus Externus Muscle.—The vastus externus muscle forms a broad convex mass on the outer side of the rectus, which extends from the great trochanter above, almost to the knee joint below. It is most conspicuous below, and its external surface is often traversed by a longitudinal groove due to the pressure exerted by the tense ilio-tibial band.

The Adductor Longus Muscle.—The cord-like tendon of the adductor longus running upwards to the pubic spine may be thrown into prominence by abducting the thigh.

The Adductor Magnus Muscle.—The tendon of the adductor magnus may be felt distinctly, when the knee is flexed, extending down to the adductor tubercle on the internal femoral condyle in the interval between the sartorius and vastus internus muscles.

The Femoral Artery.—The femoral artery extends from Poupart's ligament above, to the opening in the adductor magnus muscle below, and covers therefore the upper two-thirds of the thigh. Its upper half lies in Scarpa's triangle, its lower half in Hunter's canal.

The thigh being slightly flexed, abducted, and rotated outwards, the femoral artery may be indicated by a line drawn from a point midway between the anterior superior iliac spine and the symphysis pubis to the adductor tubercle on the upper and back part of the internal femoral condyle. The upper third of this line indicates the position of the

femoral artery in Scarpa's triangle, and the middle third its position in Hunter's canal.

The *common femoral artery* occupies the upper one and a half inches of the line, and the commencements of the *superficial femoral* and *profunda femoris* arteries lie at that distance below Poupart's ligament.

The origin of the *external circumflex artery*, from the profunda femoris, is usually about two inches below Poupart's ligament.

Compression of the common femoral artery is best made directly backwards against the ramus of the pubis immediately below Poupart's ligament.

The seat of election for ligation of the superficial femoral artery is at the apex of Scarpa's triangle, that is, at the junction of the upper and middle thirds of the thigh.

The Femoral Vein.—The course of the femoral vein may be indicated by a line crossing that for the femoral artery obliquely, from below upwards, and from without inwards.

The Internal or Long Saphenous Vein.—This vein, not infrequently visible, may be indicated on the surface by a line drawn from the adductor tubercle to the inferior cornu of the saphenous opening.

The Anterior Crural Nerve.—The anterior crural nerve lies immediately to the outer side of the upper part of the common femoral artery. It terminates about one inch below Poupart's ligament, by breaking up into numerous branches, which supply the skin and muscles on the front of the thigh.

THE KNEE JOINT.

FRONT OF THE JOINT.—**The Patella.**—The patella forms an easily recognisable landmark at the front of the knee joint; it can be moved laterally when the limb is extended and the quadriceps extensor relaxed, but not otherwise. The apex of the patella lies, in complete extension, immediately below the line of the knee joint.

Contraction of the quadriceps extensor cruris draws the patella upwards, firmly fixes it against the femur, and throws into prominence the supra- and infra-patellar tendons.

The relations of the patella to the femur differ according to the degree of flexion or otherwise, thus:—

A. IN COMPLETE EXTENSION.—The patella lies above the knee joint, and its *lowest* pair of articular facets are in contact with the patellar articular surface of the femur.

B. IN SEMI-FLEXION.—The *middle* pair of patellar articular facets are in contact with the femur, and in this position it is of considerable practical importance to notice that the inner margin of the patella, the lower border of the internal femoral condyle, and the upper border of the internal tibial tuberosity bound an easily recognisable triangle, at the bottom of which may be felt the periphery of the *internal semilunar fibro-cartilage.*

C. IN FULL FLEXION.—In this position the patella lies in the inter-condyloid fossa of the femur, rather nearer the external than the internal femoral condyle, and its two *highest* facets are alone in contact with the femur. With the patella in this position the *trochlear or patellar articular surface of the femur* can be easily palpated.

D. IN GREATER FLEXION.—In extreme degrees of

flexion of the knee joint the patella tends to move to the outer side of the joint in such a way that its single *internal and vertical* facet is in contact with the internal condyle of the femur.

The Tubercle of the Tibia.—The tubercle of the tibia lies, in complete extension, about two inches below the apex of the patella. Its lower part gives attachment to the infra-patellar tendon of the quadriceps extensor cruris.

A line drawn transversely round the leg at the level of the lower border of the tubercle indicates posteriorly—

The point of bifurcation of the popliteal artery into anterior and posterior tibials.

The commencement of the popliteal vein.

The termination of the internal popliteal nerve and the commencement of the posterior tibial nerve.

The Supra-Patellar Tendon.—The supra-patellar tendon of the quadriceps extensor cruris lies above the patella, and can be palpated most easily when the muscle is contracted and tense.

The *synovial membrane* of the knee joint extends upwards behind this tendon, and between it and the femur, for a distance of at least one inch above the patella in complete extension of the joint. In this position the synovial membrane not infrequently communicates with the *sub-quadricipital bursa*, which, under similar conditions, extends upwards for another inch.

The Infra-Patellar Tendon, or the Ligamentum Patellæ.—This tendon passes from the patella to the tubercle of the tibia, and is most distinct in the semi-flexed position.

In a normal limb the ligamentum patellæ, the tubercle of the tibia, and the middle of the ankle joint should all be in the same straight line.

The *prepatellar bursa*—affected in housemaid's knee—lies

in front of the upper part of this ligament and of the lower part of the patella.

Posteriorly the ligamentum patellæ is in contact above with the synovial membrane, and below with a pad of fat, and the bursa which separates it from the tubercle of the tibia.

INNER SIDE OF THE JOINT.—**The Adductor Tubercle.**—The adductor tubercle may be felt at the upper and back part of the internal femoral condyle. Its recognition is facilitated by noting that the cord-like tendon of the adductor magnus is inserted into it.

A line drawn from the adductor tubercle to the highest part of the patellar articular surface of the femur indicates fairly accurately the position of the lower epiphysial cartilage of the femur.

The Internal Femoral Condyle.—The internal femoral condyle is prominent and subcutaneous, and forms the chief part of the rounded eminence on this side of the joint. It faces in almost the same direction as the head of the femur.

The Internal Tuberosity of the Tibia.—The internal tuberosity of the tibia forms the prominence immediately below the internal femoral condyle; between the two the depression of the knee joint can be located particularly easily during semi-flexion.

OUTER SIDE OF THE JOINT.—**The External Femoral Condyle.**—The external femoral condyle is easily felt, but is much less prominent than the internal condyle.

The External Tuberosity of the Tibia.—The external tuberosity of the tibia forms a marked prominence on the outer side of the knee joint immediately below the external femoral condyle. Between the two is the line of the knee joint.

The *ilio-tibial band* is attached below to the external

tuberosity of the tibia, and on semi-flexion its posterior border stands out distinctly. Between this structure and the tendon of the biceps flexor cruris is a depression, through which the femur may be incised.

The Head of the Fibula.—The head of the fibula lies on the same horizontal level as the tubercle of the tibia, behind and below the most prominent part of its external tuberosity. It is best seen on semi-flexion.

Inserted into the head of the fibula is the tendon of the biceps flexor cruris, and just below is the point of bifurcation of the external popliteal nerve into anterior tibial and musculo-cutaneous nerves.

THE LEG.

The Anterior Border of the Shaft of the Tibia, or the "Shin."—The anterior border of the shaft of the tibia is subcutaneous throughout, but is best marked in the upper two-thirds of the leg. It pursues a sinuous course from the tubercle above, downwards to the internal malleolus.

The Internal Surface of the Shaft of the Tibia.—The internal surface of the shaft of the tibia is broad, flat, and subcutaneous throughout.

The Posterior Border of the Shaft of the Tibia.—The posterior border of the shaft of the tibia is overlapped by the calf muscles, but can be palpated throughout the whole of its course.

The Fibula.—The only portion of the shaft of the fibula which is subcutaneous is the triangular area immediately above the external malleolus.

The Extensor Muscles.—In muscular limbs, the *tibialis anticus* can, when in action, be seen to lie on the outer side of the shin, with the less conspicuous *extensor longus digitorum* still further to the outer side. Between the two muscles is a groove or depression which constitutes a good guide to the anterior tibial artery.

The Peronei Muscles.—The *peroneus longus* and *peroneus brevis* form two elongated eminences on the outer or fibular side of the leg.

Immediately behind these two muscles is a furrow which extends from the posterior part of the head of the fibula above, to just behind the external malleolus below. This furrow indicates the position of the *posterior peroneal septum*, and in its lower part the shaft of the fibula may be incised.

The Superficial Flexor Muscles.—The prominence on the back of the leg known as the "calf" is formed superficially by the *gastrocnemius*, and more deeply, and on either side of the gastrocnemius, by the *soleus* muscle. These muscles may be rendered more prominent by causing the living subject to raise the body upon the toes.

The Anterior Tibial Artery.—This vessel extends from the lower border of the popliteus muscle to the front of the ankle joint.

A line drawn from a point midway between the external tibial tuberosity and the head of the fibula, to the centre of the front of the ankle joint, indicates the line of the artery and also the external border of the tibialis anticus muscle. The artery reaches the front of the leg on this line at a spot two inches below the tubercle of the tibia.

In the *lower third* of the leg the anterior tibial artery is comparatively superficial, and lies between the tendons of the tibialis anticus on its inner side, and the extensor longus digitorum on its outer side.

The Posterior Tibial Artery.—This vessel may be indicated by a line drawn from the lower angle of the popliteal space opposite the lowest part of the tubercle of the tibia to a point midway between the internal malleolus and the prominence of the heel. At the latter spot the vessel divides into the internal and external plantar arteries.

The Peroneal Artery.—This vessel arises about three inches below the head of the fibula, follows the direction of that bone, and terminates behind the external malleolus.

The Internal or Long Saphenous Vein.—The internal or long saphenous vein ascends in front of the internal malleolus and behind the posterior border of the shaft of the tibia. The vein can often be seen on the surface, and is accompanied by the cutaneous nerve of the same name.

The External or Short Saphenous Vein.—The external or short saphenous vein ascends behind the external malleolus and the middle of the calf to the popliteal space. It is accompanied by the cutaneous nerve of the same name.

THE ANKLE JOINT.

The External Malleolus (Fibula). — The external malleolus is somewhat less prominent than the internal, and its tip descends lower and lies farther back, being usually about three-quarters of an inch nearer the heel than that of the internal malleolus. The tip of the external malleolus constitutes the external guide in Syme's amputation at the ankle.

The Internal Malleolus (Tibia).—The internal malleolus is larger and more prominent than the external malleolus.

The Triangular Subcutaneous Area of the Fibula.—This, the only portion of the shaft of the fibula which is subcutaneous, lies immediately above the external malleolus. Its apex corresponds to the lower end of the groove indicating the anterior peroneal septum. It is in this triangular area that the fibula breaks in Pott's fracture.

The Astragalus.—In complete extension of the ankle joint the most anterior part of the superior articular surface of the astragalus can be seen, and felt, immediately below the anterior border of the lower end of the tibia.

The Ankle Joint.—The line of the ankle joint can usually be felt as a slight depression between the extensor tendons about on a level with a line half an inch above the tip of the internal malleolus.

The Extensor Tendons.—The extensor tendons can usually be palpated in front of the ankle joint, especially when the joint is flexed. The tendons are, from within outwards—

The tibialis anticus, the most internal and the largest.

The extensor proprius hallucis, passing to the great toe.

The extensor longus digitorum, dividing into four slips for the four outer toes.

The peroneus tertius, unimportant and not infrequently absent.

The Peroneal Tendons.—The tendons of the *peroneus longus* and *peroneus brevis* lie immediately behind the external malleolus, the brevis being the one nearest the bone.

The Tendo Achillis.—The large and powerful tendo Achillis forms a very prominent landmark at the back of the ankle. It is formed by the gastrocnemius and soleus, and occasionally by the plantaris as well, and is inserted into

the os calcis. Its narrowest part—cut in tenotomy—lies opposite the bases of the malleoli.

The Flexor Tendons. — The tendon of the *tibialis posticus* descends just behind the internal malleolus. To its outer side is the tendon of the *flexor longus digitorum*, and still further out, that of the *flexor longus hallucis*. Between the last two tendons are the posterior tibial vessels and nerve.

THE FOOT.

THE INTERNAL BORDER.—**The Internal Malleolus.** (See page 228.)

The Sustentaculum Tali of the Os Calcis.—This may be located about a finger's breadth vertically below the tip of the internal malleolus.

Immediately above the sustentaculum tali is the tendon of the *tibialis posticus* passing forwards to the tubercle of the scaphoid, whilst the depression corresponding to the *calcaneo-astragaloid joint* can also be felt.

The Tubercle of the Scaphoid.—The tubercle of the scaphoid is an important and easily recognisable landmark one and a quarter inches in front of the sustentaculum tali and about midway between the plantar and dorsal surfaces of the foot. (See Figure 46.)

Inserted into the tubercle of the scaphoid is the tendon of the tibialis posticus, whilst the tubercle itself constitutes the internal landmark in Chopart's disarticulation at the transverse tarsal articulation. The joint lies immediately behind the tubercle.

The First Tarso-Metatarsal Articulation.—The depres-

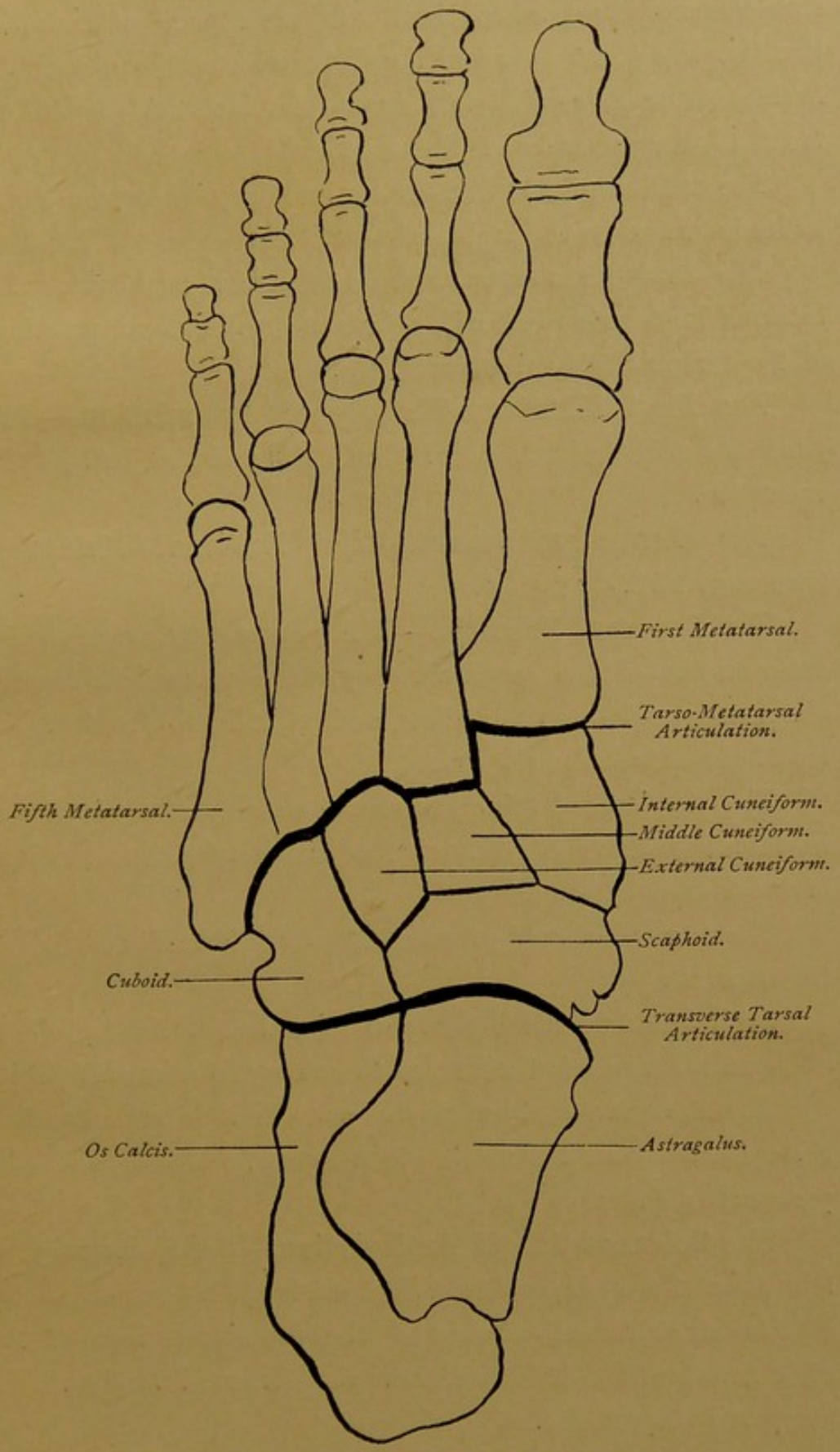

Figure 46.—The Bones of the Left Foot. Dorsal Surface.

sion corresponding to the first tarso-metatarsal articulation, that is, the joint between the internal cuneiform and the first metatarsal, can be felt about one inch and a half in front of the tubercle of the scaphoid.

The tendon of the tibialis anticus may be traced down to its insertion in the region of this joint.

The first tarso-metatarsal articulation constitutes the internal landmark to the Hey-Lisfranc series of amputations at the tarso-metatarsal articulations.

The First Metatarso-Phalangeal Articulation.—This joint lies a little in front of the middle of the ball of the great toe.

The External Border.—**The External Malleolus.** (See page 228.)

The Peroneal Tubercle.—The peroneal tubercle, on the outer surface of the os calcis, may, when present, be located about a finger's breadth below, and a little in front of, the tip of the external malleolus.

The tendon of the *peroneus brevis* passes forwards, immediately above the tubercle, to its insertion into the base of the fifth metatarsal.

The tendon of the *peroneus longus* is immediately below the tubercle.

Midway between the peroneal tubercle and the tip of the external malleolus is the line of the *astragalo-calcanean joint.*

The external surface of the os calcis is subcutaneous throughout almost the whole of its extent, and surrounds the peroneal tubercle.

The Calcaneo-Cuboid Articulation.—This joint may be felt as a slight depression about midway between the tip of the external malleolus and the prominent base of the fifth metatarsal. It constitutes the external landmark in Chopart's amputation.

The Base of the Fifth Metatarsal.—The prominent base of the fifth metatarsal—easily recognisable—forms the external landmark to the Hey-Lisfranc series of operations.

THE DORSAL SURFACE.—**The Tarsals and Metatarsals.**—With the exception of the astragalus, the tarsal bones are not easily distinguished. The metatarsals, on the contrary, can all be recognised and palpated.

The Transverse Tarsal Articulation (Chopart).—This important joint may be indicated on the surface with tolerable accuracy, by a line drawn transversely across the foot, from a point just behind the tubercle of the scaphoid to a little in front of the mid-point between the tip of the external malleolus and the prominent base of the fifth metatarsal. The joint is formed by the os calcis and astragalus behind, and the cuboid and scaphoid in front.

The Tarso-Metatarsal Articulations (Lisfranc).—The guides to these joints are the bases of the first and fifth metatarsals respectively. That portion of the articulation formed by the middle cuneiform and the second metatarsal lies at least quarter of an inch farther back than the first tarso-metatarsal articulation.

The Metatarso-Phalangeal Articulations.—These joints are situated about one inch behind the web of the toes.

The Dorsalis Pedis Artery.—This vessel may be indicated by a line drawn from the centre of the ankle joint to the posterior end of the first inter-metatarsal space.

The guide to the vessel is the external border of the tendon of the extensor proprius hallucis.

THE PLANTAR SURFACE.—**The Plantar Arteries.**—Both the plantar arteries commence at a point midway between the tip of the internal malleolus and the centre of the prominence of the heel, by the bifurcation of the posterior tibial.

The course of the *internal plantar artery* may be indicated by a line drawn from that point to the middle of the plantar surface of the hallux.

The *external plantar artery* may be indicated by a line drawn from the same point to a point just internal to the base of the fifth metatarsal.

The *plantar arch*, formed by the external plantar artery uniting with the dorsalis pedis, may be indicated by a line drawn from the inner side of the base of the fifth metatarsal to the posterior end of the first inter-metatarsal space.

INDEX

	PAGE
ABDOMEN	89
Abdominal aorta	122
,, ,, branches of	122
,, furrow	89
,, glands	215
,, parietes	89
Abductor indicis muscle	202
Accessory sinuses of nose	51
Acromial angle	177
Acromion process	176
Addison's method of delimiting the abdomen	97
Adductor longus muscle	221
,, magnus ,,	221
,, tubercle of femur	225
Adenoids	42
Aditus ad antrum	65
Air sinuses	51
Alcock's canal	146
Alimentary canal	103
Ampulla of rectum	157
Anal canal	114, 157
Anconeus muscle	193
Angle of Ludwig	72, 180
Angular process, external	1
,, ,, internal	1
Ankle joint	228, 229
Ano-bulbar raphè	146
Anterior annular ligament	201
,, axillary line	75
,, crural nerve	222
,, ethmoidal air cells	48, 53
,, nares	50
,, rhinoscopy	50
,, superior iliac spine	213
,, tibial artery	227
,, ulnar vein	196
Antrum mastoid	65
,, maxillary	53
,, ,, orifice of	48, 54
Anus	147
Aorta, abdominal	122
,, ,, branches of	122
Aorta, arch of	85
,, ascending	85
Aortic orifice	84
Apex of antrum	54
,, of auricular appendix	85
,, of heart	85
Appendix, auricular	85
,, vermiformis	110
Aqueduct of Fallopius	64
Arch of aorta	85
,, palmar	202
,, plantar	234
Arm	176
Artery to bulb	152
Aryteno-epiglottidean fold	45
Ascending branch of deep circumflex iliac artery	93
,, branches cervical plexus	25
,, colon	110
,, frontal convolution	15
,, parietal convolution	13
Asterion	4
Astragalo-calcanean joint	232
Astragalus	229
Atrum	62
Attic of tympanum	65
Auricle of ear	59
,, of heart	85
Auriculo-temporal nerve	4
,, ventricular groove	84
Auscultation triangle	128
Axillary artery	183
,, border scapula	178
,, folds	181, 182
,, lymphatic glands	184
,, region	77
,, vein	183
BACK	125
,, of thigh	211
Bartholin's glands	166
Basal ganglia	10
Base line	5

PAGE

Basilic vein . . . 187, 196
Berry and Shepherd's cranio-cerebral topography . 13
,, on appendix vermiformis . 110
Berry's abdominal frame . . 111
Biceps flexor cruris muscle . . 211
,, ,, cubiti ,, . 185, 190
Bicipital fascia 190
,, furrows . . 185, 186
,, groove of humerus . 178
,, tuberosity of radius . 190
Bicuspid teeth 35
Biliary apparatus . . . 115
Bladder, gall 116
,, urinary . . . 160
,, ,, cystoscopic examination of . 161
Body of epididymis . . . 154
,, of pancreas . . . 118
,, of penis 153
,, of sternum . . 72, 180
Brachial artery 187
,, plexus . . . 26, 183
Brachialis anticus muscle . . 186
Brachio-radialis muscle . 190, 193
Bregma 3
Bryant's triangle . . . 208
Buccinator muscle . . . 31
Bulla ethmoidalis . . . 48
Buttock 206

Cæcum 109
Calcaneo-astragaloid joint . . 230
,, cuboid ,, . . 232
Calf 227
Canal, Alcock's 146
,, femoral 217
,, Hunter's . . . 220
,, inguinal . . . 93
,, tensor tympani . . 64
Canaliculi lachrymales . . 57
Canine teeth 35
Canthus of eye 56
Cardia 104
Cardiac dulness, deep . . 82
,, ,, superficial . 83
Carotid artery, common . . 24
,, ,, external . . 24
Carpal bones 197
Cartilage, cricoid . . . 20
Cartilages of Santorini . . 45
,, of Wrisberg . . 45
Cartilaginous rings of trachea . 20
Caruncula lachrymalis . . 56
Cava vena, inferior . . . 124
,, ,, superior . . . 87
Cavum Retzii 152
Cells, ethmoidal air . . . 47
Central point of perineum . . 146

PAGE

Cephalic vein . . . 187, 196
Cerebellum 16
Cerebral lobes 15
Cervical enlargement of spinal cord 136
,, lymphatic glands . . 28
,, nerves 25
,, plexus 26
,, sympathetic cord . . 27
,, zone 75
Chiene's cranio-cerebral topography . . . 11
,, lines 208
Choanæ 43
Chopart's amputation . 230, 232
,, articulation . . 233
Chorda tympani nerve . . 60
Choroidal ring 58
Circumflex nerve . . . 182
,, vessels . . . 181
Circumvallate papillæ . . 37
Clavicle 176
Clitoris 166
Coccyx 206
Cœliac axis artery . . . 122
Colles, fascia of 147
Colon, ascending . . . 110
,, descending . . . 112
,, iliac 112
,, pelvic 113
,, sigmoid 112
,, transverse . . . 110
Common bile duct . . . 117
,, carotid artery . . 24
,, femoral artery . . 222
,, iliac artery . . . 123
,, ,, vein . . . 124
Condyle of femur . . . 225
,, of humerus . . 188, 189
,, of lower jaw . . . 30
Conical papillæ of tongue . . 37
Conjunctiva 56
Coraco-brachialis muscle . . 182
Coracoid process . . . 177
Cord, spermatic 154
,, spinal 136
,, sympathetic . . . 27
Cornua of fascia lata of thigh . 218
,, of hyoid bone . . . 18
,, of lateral ventricles 10, 11
Coronal suture 3
Coronary arteries . . . 31
Coronoid process of lower jaw . 30
,, ,, of ulna . . 190
Costal angle . . . 73, 89
,, zone . . . 100, 103
Cowper's glands 153
Cranial nerves 27
Cranio-cerebral topography . 5
,, Berry and Shepherd . 13

PAGE

Cranio-cerebral topography—
,, Chiene 11
,, Hare and Thane . . 7
,, Reid 5
Cranium 1
Crest of ilium 206
,, supra-mastoid . . 69
Cribriform fascia . . . 219
Crico-thyroid artery . . . 20
,, membrane . . 20
,, muscle . . . 20
Cricoid cartilage . . . 20
Crural arches 215
,, canal 217
,, ring 215
Cunningham's method of delimiting abdomen 101
Cushion of epiglottis . . . 45
Cystic duct 116
Cystoscopic examination of bladder 161

Deep circumflex iliac artery . 93
,, epigastric artery . . 92
,, palmar arch . . . 202
,, perineal pouch . . . 142
Deltoid muscle . . . 181, 186
Dental formula . . . 34, 35
Descending colon . . 112, 135
Digastric muscle . . . 23
Digital examination of naso-pharynx 42
,, ,, of rectum 157, 171
,, ,, of vagina . 170
,, synovial sheaths . . 203
Disc, optic 58
Dorsal interosseous muscles . 202
,, nerves 93
,, ,, last . . 93, 131
,, venous plexus . . . 195
Dorsalis pedis artery . . . 233
,, scapulæ artery . . 181
Douglas, fold of 92
,, pouch of . . . 171
Duct, Bartholin's . . . 166
,, common bile . . . 117
,, cystic 116
,, fronto-nasal . . . 48
,, nasal 57
,, Stenson's 34
,, Wharton's . . . 36
Duodeno-jejunal flexure . . 109
Duodenum 107

Ear 59
,, external 59
,, middle 62
Elbow . . . 188, 191, 192
Eleventh cranial nerve . 22, 27
Eminence, hypothenar . . 201
,, thenar . . . 201

PAGE

Ensiform process . . 72, 180
Enteric mesentery . . . 114
Epicondyle 189
Epididymis 154
Epiglottis 45
Epitrochlea 188
Epitympanic space . . . 65
Erector spinæ muscle . . . 128
Ethmoidal air cells . . . 47
,, bulla . . . 48
,, cell labryinth . . 53
Eustachian cushion . . 42, 43
,, tubes . 41, 42, 43, 64
Extensor brevis pollicis muscle . 199
,, carpi radialis brevior muscle . . 193, 199
,, carpi radialis longior muscle . . 193, 199
,, carpi ulnaris muscle 193, 199
,, communis digitorum muscle . . 193, 199
,, indicis muscle . . 199
,, longus digitorum muscle 227, 229
,, ,, pollicis muscle . 199
,, minimi digiti muscle . 199
,, muscles of leg . 227, 229
,, ,, of thumb 193, 196, 198, 199
,, ossis metacarpi pollicis muscle . . . 199
,, proprius hallucis muscle 229
,, supinator muscles . . 193
External abdominal ring . . 94
,, angular process . . 1
,, auditory meatus . . 59
,, canthus . . . 56
,, carotid artery . . 24
,, circumflex artery . . 222
,, condyle femur . . 225
,, ,, humerus . . 189
,, female genitals . . 164
,, iliac artery . . . 123
,, intermuscular septum of thigh . . . 211
,, jugular vein . . . 25
,, male genitals . . 153
,, malleolus . . . 228
,, occipital protuberance . 3
,, plantar artery . . 234
,, popliteal nerve . . 213
,, saphenous vein . . 228
Extravasation of urine . 149, 151
Eye 55
Eyelids 55

Face 29
Facial artery . . . 25, 31
,, bones 29

PAGE

Facial nerve 31
,, vein 31
Falciform ligament . . . 218
False vocal cords . . . 46
Fascia, Colles 147
,, cribriform . . . 219
,, groin 218
,, lumbar 134
,, perineal 147
,, Scarpa . . . 147, 220
Fauces 34, 38, 39
Female bladder 172
,, genitals . . . 164, 167
,, mamma 184
,, pelvis 167
,, perineum . . . 164
,, rectum 171
,, urethra 172
Femoral artery 221
,, canal 217
,, condyles . . . 225
,, hernia 219
,, lymphatic glands . . 215
,, ring 215
,, vein 222
Femur . . 207, 215, 223, 225
Fenestra ovalis 65
,, rotunda . . . 65
Fibula . . . 226, 228, 229
Fifth cranial nerve . . . 32
Filiform papillæ . . . 37
First temporal fissure . . 10, 13, 15
Fissure of cerebrum . . 5, 6, 7, 9, 10, 13, 15
,, of lung 81
,, parallel . . . 10, 13, 15
,, parieto-occipital . 7, 9, 15
,, precentral . . . 9, 15
,, postcentral . . 10, 13
,, of Rolando . 7, 9, 13, 15
,, of Sylvius . 5, 9, 11, 15
,, temporal . . 10, 13, 15
Flexor carpi radialis muscle . 198
,, ,, ulnaris muscle. 193, 198
,, longus digitorum muscle . 230
,, ,, hallucis muscle . 230
,, profundus digitorum muscle 193
,, sublimis digitorum muscle 198
,, synovial sheaths . . 203
Fold of groin 90
Foot 230
Foramen cæcum 36
Forearm 192
Fossa, canine 30
,, incisor 30
,, ischio-rectal . . . 144
Fourchette 165
Fovea centralis 58
Frænum linguæ 36

PAGE

Frænum præputii . . . 153
Frenulum clitoridis . . . 165
,, pudendi . . . 165
Frontal air sinuses . . . 52
,, artery 4
,, fissures cerebrum . . 9
,, lobe 15
,, processes . . . 1
,, sulci 10
Fronto-malar suture . . . 2
,, -nasal suture . . . 1
,, ,, duct . . . 48
Fundus oculi 58
,, stomach . . . 105
Fungiform papillæ . . . 37

Gall bladder 116
Gangliated cord, sympathetic . 27
Gastrocnemius muscle . . 227
Genio-hyo-glossus muscle . 18, 36
Genitals, female . . . 167
,, male 153
Gimbernat's ligament . 92, 215, 217
Glabella 1
Gland, mammary . . . 184
,, parotid 34
,, sublingual . . . 36
,, submaxillary . . . 27
,, thyroid 20
Glands of Bartholin . . . 166
,, of Cowper . . . 153
Globus major and minor . . 154
Glosso-epiglottidean folds . . 45
Gluteal artery 211
,, fold 207
,, -sciatic triangle . . 208
Great auricular nerve . 25, 26
,, curvature stomach . . 105
,, occipital nerve . . . 5
,, omentum 114
,, sciatic nerve . . 211, 212
,, trochanter . . . 207
,, tuberosity, humerus . . 178

Hamstring muscles . . . 211
Hamular process . . . 39
Hand 200
Handle of malleus . . . 60
Hare and Thane's cranio-cerebral topography 7
Hare's angle 9, 13
Hart on female pelvic floor . 172
Head and neck 1
,, femur 215
,, fibula 226
,, humerus 179
,, pancreas 117
,, radius 189
,, ulna 197

	PAGE
Heart	82
Hepatic flexure	110
Hernia, femoral	219
,, inguinal	95
,, lumbar	92
,, umbilical	114
Hesselbach's triangle	95
Hey-Lisfranc amputations	232, 233
Hiatus semilunaris	48
Hilum of kidney	120, 131
Hordeolum	55
Horizontal fissure, lung	81
,, levels, table of	137
Houston's valves	157
Humerus	178, 185, 188, 189
Hunter's canal	220
Hymen	166
Hyoid bone	18
Hypogastric zone	100, 103
Hypoglossal nerve	27
Hypothenar eminence	201
ILEO-CÆCAL junction	109
Iliac colon	112
,, crest	206
,, furrow	90, 207
,, spine	206, 213
,, tubercle	214
Ilio-hypogastric nerve	93
,, inguinal nerve	93
,, tibial band	225
Ilium	90, 206, 213, 214
Incisor fossa	30
,, teeth	35
Incisura cardiaca	81
Inferior frontal sulcus	10
,, hæmorrhoidal artery	152
,, meatus, nose	48
,, mesenteric artery	123
,, precentral sulcus	9
,, profunda artery	187
,, Rolandic point	7
,, turbinal	43
,, vena cava	124
Infra-axillary region	77
,, clavicular fossa	182
,, ,, region	77
,, hyoid artery	19
,, mammary region	77
,, orbital margin	30
,, ,, nerve	34
,, spinatus muscle	182
,, sternal fossa	71, 77, 89, 179
,, ,, region	77
Infundibulum	48
Inguinal canal	93
,, hernia	95
,, lymphatic glands	215
Inion	3
Innominate artery	22, 85
,, vein	87
Intercostal arteries	73
Internal abdominal ring	93
,, canthus eye	56
,, condyle femur	225
,, ,, humerus	188
,, iliac artery	123
,, jugular vein	25
,, malleolus	228
,, mammary artery	73
,, plantar artery	234
,, popliteal nerve	213
,, pudic artery	152, 211
,, saphenous vein	222, 228
,, tarsal ligament	56
Interphalangeal articulations	201
,, scapular region	77, 128
,, spinous line	213
,, tubercular line	101, 214
,, ,, plane	101
Intra-lobar fissures, frontal lobe	9
,, ,, ,, parietal lobe	10
,, ,, ,, temporal lobe	10
Ischial spine	211
,, tuberosity	206
Ischio-rectal fossa	144
Island of Reil	10
Isthmus faucium	38
,, thyroid body	20
JAW, lower	30
Jejuno-ileum	109
Jugular vein, external	25
,, ,, internal	25
KIDNEY	119, 129
Knee joint	223
Knuckles	200
LABIA majora	164
,, minora	165
Labyrinth, ethmoidal cell	53
Lachrymal canaliculi	57
,, caruncle	56
,, puncta	56
,, sac	56, 57
Lambda	3
Lambdoid suture	4
Laryngeal sinus	46
Laryngo-pharynx	44
Laryngoscopy	44
Laryngotomy	20
Lateral lines	97
,, pharyngeal recess	42
,, sinus	16
,, sternal line	73
,, ventricles	10
Latissimus dorsi muscle	127

PAGE

Leg 226
Lesser curvature, stomach . . 105
,, trochanter . . . 207
,, tuberosity . . . 178
Levator anguli scapulæ muscle . 128
,, cushions . . . 42
Ligamentum patellæ . . . 224
Linea semilunaris . . . 90
Lineæ transversæ . . . 90
Lingual artery . . . 19, 25
,, nerve . . . 36, 39
Lisfranc's amputation . 232, 233
,, articulation . 232, 233
Lister's tubercle 196
Liver 115
Long saphenous vein . . 222, 228
Lower extremity . . . 206
,, jaw 30
,, thoracic zone . . . 77
Lumbar enlargement of cord . 136
,, hernia 92
,, puncture . . . 126
Lung 80
Lymphatic glands, abdomen . 215
,, ,, anterior triangle 28
,, ,, axilla . . 184
,, ,, inguinal region 215
,, ,, posterior triangle 28
,, ,, thigh . . 215

MacEwen's supra-meatal fossa . 69
Macula lutea 58
Malar bone 2, 30
Male genitals 153
,, pelvis 156
,, perineum 140
Malleoli 228
Malleus 60
Mamma, female 184
Mammary artery, internal . . 73
,, region . . . 77
Mammillary line . . . 73
Manubrium sterni . . 71, 179
Margo acutus 82
,, obtusus 82
Masseter muscle 30
Mastoid antrum 65
,, ,, adult . . 67
,, ,, birth . . 66
,, ,, infant . . 67
,, ,, trephining . 69
,, process 3
Maxilla 30
Maxillary antrum . . . 53
Meatus, auditory, external . . 59
,, urinarius . . 162, 166
Meatuses of nose . . 47, 48
Median-basilic vein . . 191, 196
,, -cephalic vein . . 191, 195

PAGE

Median line 97
,, nerve 187, 192, 195, 200, 203
,, vein . . . 191, 196
Meibomian follicles . . 55, 56
Membrana Shrapnelli . . 60
,, tympani . . . 60
Membrane crico-thyroid . . 20
,, thyro-hyoid . . 19
Mental nerve 34
Mesenteric artery, inferior . . 123
,, ,, superior . . 123
Mesentery, enteric . . . 114
Metacarpal bones . . 197, 200
Metacarpo-phalangeal articulations 201
Metatarsal bones . . . 233
Metatarso-phalangeal articulations 232, 233
Mid-axillary line . . . 75
,, -clavicular line . . . 73
,, -sternal line 73
Middle ear 62
,, glosso-epiglottidean fold . 45
,, line neck . . . 18
,, meatus, nose . . . 47
,, meningeal artery . . 16
,, pharyngeal recess . . 41
,, thoracic zone . . . 77
,, turbinal 43
Milk teeth 34
Mitral orifice 84
Molar teeth 35
Mons veneris 164
Morris's parallelogram . . 129
Mouth 34
Musculo-spiral nerve . . 188, 192
Mylo-hyoid median raphè . . 18

Nares, anterior . . . 50
,, posterior . . . 43
Nasal bones 30
,, duct 57
,, fossæ 47
,, nerve 32
Nasion 1
Naso-frontal duct . . . 48
,, -pharynx . . . 40, 42
Natal cleft 207
Neck, cutaneous nerves of . . 25
,, lymphatics of . . . 28
,, pancreas 118
,, triangles of . . . 21
Nélaton's line 208
Nephrectomy 134
Nerves of tongue . . . 38
Nose 46
Nuchal furrow 125
Nutrient artery, humerus . . 187
Nymphæ 165

	PAGE
Oblique line	11
,, fissure, lung	81
Obliquus abdominis externus muscle	91
Occipital artery	5, 25
,, lobe	13, 16
,, nerve, great	5
,, protuberance, external	3
Ocular conjunctiva	56
Œsophagus	27, 87
Olecranon process, ulna	189
Olfactory cleft	47, 51
Omentum, great	114
Omo-hyoid muscle	23
Opening, saphenous	218
Ophthalmoscopy	57
Optic disc	58
Orbital nerve	4
Oro-pharynx	44
Os calcis	230, 232
Ostium maxillare	48, 54
Otitis media	64
Otoscopy	60
Palmar arch, deep	202
,, ,, superficial	202
,, furrow	202
Palmaris longus muscle	198
Palpebral conjunctiva	56
,, fissure	56
Pancreas	117
Papilla lachrimalis	56
Para-sternal line	73
Parallel fissure	10, 13, 15
Parietal intra-lobar fissures	10
,, convolution, ascending	13
,, lobe	15
,, pelvic fascia	150
Parieto-mastoid suture	4
,, -occipital fissure	7, 9, 15
Parotid duct	34
,, gland	34
Patella	223
Pectoralis major muscle	180
,, minor ,,	181
Pelvic colon	113
,, floor	172
,, viscera	156, 167
Penis	152, 153
Perineal fasciæ	147
,, pouches	141, 142
Perineum, central point of	146
,, female	164
,, male	140
Peritoneum	114
Permanent teeth	35
Peroneal artery	228
,, septum	227
,, tubercle	232
Peroneus brevis muscle	227, 229, 232
,, longus ,,	227, 229, 232
,, tertius ,,	229
Petit, triangle of	92
Petro-squamosal suture	68
Phalanges	200
Pharyngeal recess	41, 42
,, tonsil	41
Pharyngotomy	19
Pharynx	39
Phrenic nerve	26
Pillars of external abdominal ring	95
,, of fauces	38
Pisiform bone	197
Plantar arch	234
,, artery, external	233
,, ,, internal	233
Plantaris muscle	229
Pleura	78
Pneumogastric nerve	27
Pomum Adami	19
Popliteal artery	212
,, fascia	212
,, nerves	213
,, space	212
,, vein	213
Popliteus muscle	212
Post-central line	13
,, sulcus	15
Posterior auricular artery	25
,, axillary fold	182
,, ,, line	75
,, circumflex vessels	181
,, ethmoidal air cells	47, 53
,, intermuscular septum, forearm	194
,, interosseou nerve	194
,, nares	43
,, palatine foramen	39
,, peroneal septum	227
,, rhinoscopy	42
,, tibial artery	228
,, ulnar veins	195, 196
Pouch of Douglas	171
Poupart's ligament	215
,, lines	101
,, planes	101
Præputium clitoridis	165
Pre-auricular point	3
Pre-central line	11
,, point, superior	13
,, sulci	9, 15
Pre-patellar bursa	224
Processus cochleariformis	64
,, uncinatus	48
Profunda femoris artery	222
Promontory	65
Pronator-flexor muscles	190, 193
,, radii teres	191, 193

PAGE

Prostate 162
Pterion 4
Pterygo-maxillary ligament . 39
Pubic crest 214
,, spine 214
,, symphysis . . . 214
Pulmonary artery . . . 86
,, orifice . . . 84
Puncta lachrimalia . . . 56
Pylorus 104
Pyramid 64
Pyriform sinus 45

QUADRATUS lumborum muscle . 129
Quadriceps extensor cruris muscle 224

RADIAL artery . . . 194, 199
,, nerve 195
,, vein 195
Radius . . 189, 190, 192, 196
Ramus horizontalis . . . 10
Ranine artery 36
,, vein 36
Rectal ampulla 157
,, examination . . 157, 171
,, triangle 141
Rectum 113, 156
,, examination of . 157, 171
Rectus abdominis muscle . . 90
,, femoris ,, . . 220
Regions, abdomen . . . 100
,, thorax 75
Reid's base line 5
,, cranio-cerebral topography 5
Reil, Island of 10
Renal arteries 123
Respiratory passage . . . 47
Retina 58
Retinal arteries 58
,, veins 58
Rhinoscopy, anterior . . . 50
,, posterior . . 42
Rhomboideus major muscle . 128
,, minor muscle . 128
Ribs 72, 127, 180
Rima glottidis 19
Ring, abdominal external . . 94
,, ,, internal . . 93
,, crural 215
Rings of trachea . . . 20
Rolandic area 13
,, fissure . . 7, 9, 13, 15
,, point, inferior . . 7
,, ,, superior . 7, 13, 14
Root of penis 152
Rosenmüller, fossa of . . 42, 43

SAC, lachrymal . . . 56, 57
Sacral spines 206

PAGE

Sacro-iliac articulation . . 206
Sagittal suture 4
Santorini, cartilages of . . 45
Saphenous opening . . . 218
Sartorius muscle . . . 220
Scalenus anticus muscle . . 23
Scaphoid bone, carpus . . 197
,, ,, tarsus . . 230
Scapula 176
Scapular line 75
,, region 77
Scarpa's triangle . . . 220
Sciatic artery 211
,, nerve, great . . 211, 212
Sclerotic ring 58
Scrotum 153
Semilunar fascia . . . 190
,, fold of Douglas . . 92
,, space of Traube . . 106
Semi-membranosus muscle . . 211
,, -tendinosus ,, . . 211
Septal cartilage 47
Septum nasi . . . 47, 51
Serratus magnus muscle . . 182
Seventh cranial nerve . . 31
Shepherd and Berry's cranio-cerebral topography . . . 13
Short saphenous vein . . 228
Shoulder 176
Shrapnell's membrane . . 60
Sigmoid colon 112
Small occipital nerve . . 25, 26
,, trochanter . . . 207
Soleus muscle 227
Spermatic artery . . 123, 155
,, cord 154
,, vein 155
Sphenoidal air sinus . . 47, 53
Spheno-ethmoidal recess . . 47
Spinal accessory nerve . 22, 27
,, cord 136
,, furrow 125
Spines of vertebræ . . . 125
Spleen 118
Splenic flexure 112
Stapedius muscle . . . 64
Stenson's duct 34
Sternal angle . . . 72, 180
,, furrow . . . 71, 179
Sterno-mastoid muscle . . 21
Sternum 71, 179
Stomach 104
Styloid processes . . . 196
Subclavian artery . . . 23
,, vein 25
Subcostal angle . . . 73, 89
,, line 101
,, plane 101
Subdural space 136

	PAGE
Sublingual gland	36
Submaxillary gland	27
Sulcus terminalis	36
Superficial cervical nerve	25, 26
,, femoral artery	222
,, palmar arch	202
,, perineal pouch	141
,, temporal artery	4
Superior frontal sulcus	9
,, gluteal nerve	211
,, maxilla	30
,, meatus, nose	47
,, mesenteric artery	123
,, precentral point	13
,, ,, sulcus	9
,, Rolandic point	7, 13, 14
,, sternal region	77
,, thyroid artery	24
,, turbinal	43
,, vena cava	87
Supinator longus muscle	190
Supra-acromial nerves	26
,, clavicular ,,	26
,, ,, region	75
,, marginal triangle	13
,, mastoid crest	69
,, orbital arch	1
,, ,, artery	4
,, ,, margin	1
,, ,, nerve	4, 32
,, ,, notch	1
,, patellar tendon	224
,, renal capsule	121, 135
,, scapular artery	24
,, ,, region	77, 128
,, spinatus muscle	182
,, sternal nerve	26
,, ,, notch	71, 179
,, ,, region	75
,, tonsillar fossa	38
,, trochlear nerve	4
Sustentaculum tali os calcis	230
Suture, coronal	3
,, fronto-malar	2
,, fronto-nasal	1
,, interparietal or sagittal	4
,, lambdoidal	4
,, masto-squamosal	67
,, occipito-mastoid	4
,, ,, -parietal or lambdoidal	4
,, parieto-mastoid	4
,, petro-squamous	68
Sylvian fissure	5, 6, 7, 9, 15
,, point	5, 7, 9, 11, 15
Sympathetic nerve	27
Symphysis menti	18
,, pubis	214
Synovial membrane knee joint	224

	PAGE
Tabatière anatomique	199
Tail of pancreas	118
Tarsal bones	233
,, ligament	56
Tarso-metatarsal articulations	230, 233
Teeth, milk	34
,, permanent	35
Tegmen tympani	63
Temporal artery, superficial	4
,, fissures	10
,, lobe of cerebrum	16
Temporo-cervical division, facial nerve	31
,, -facial division, facial nerve	31
,, malar nerve	4
Tendo Achillis	229
Tendons at ankle	229, 230
,, at wrist	198
Tensor tympani muscle	64
,, vaginæ (fasciæ) femoris	220
Tenth cranial nerve	27
Teres major muscle	182
,, minor ,,	182
Testicles	154
Thane and Hare's cranio-cerebral topography	7
Thenar eminence	201
Thoracic lines	73, 75
,, parietes	71
,, regions	75
Thorax	71
Thyro-hyoid membrane	19
Thyroid artery, superior	24
,, body	20
,, cartilage	19
Thyrotomy	20
Tibia	224, 225, 226, 228
Tibial artery, anterior	227
,, ,, posterior	228
Tibialis anticus muscle	227, 229
,, posticus ,,	230
Tongue	36
,, nerves of	38
Tonsils	38
,, of Luschka	41
,, pharyngeal	41
Topography, abdominal	97
,, cranio-cerebral	5
,, thoracic	75
Torticollis	22
Trachea	20, 87
Tracheotomy	20, 21
Trans-illumination	55
,, -pyloric plane	99
,, -thoracic ,,	99
,, -tubercular ,,	99
Transversalis colli artery	24
Transverse colon	110
,, facial artery	31

	PAGE
Transverse meso-colon	115
,, tarsal articulation	233
Trapezium	197
Trapezius muscle	127
Traube's area	106
Triangle, anterior neck	21
,, auscultation	128
,, Bryant's	208
,, carotid	23
,, digastric	23
,, gluteal-sciatic	208
,, Hesselbach's	95
,, muscular	23
,, occipital	23
,, Petit's	92
,, posterior	22
,, rectal	141
,, Scarpa's	220
,, supra-clavicular	23
,, ,, -marginal	13
,, uro-genital	141
Triangular ligament, inferior layer	150
,, ligament, superior layer	150
Triceps extensor cubiti muscle	186
Tricuspid orifice	84
Trigeminal nerve	32
Trigone of bladder	161
Trochanter of femur, great	207
,, ,, small	207
True vocal cords	19, 46
Tuberosity, bicipital	190
,, fifth metatarsal	233
,, humerus	178
,, ilium	214
,, ischium	206
,, scaphoid (carpus)	197
,, ,, (tarsus)	230
,, tibia	224
Tubercle, iliac	214
,, malar	2
Turbinate bone, inferior	43
,, ,, middle	43
,, ,, superior	43
Turner, Logan, on frontal air sinuses	52
Twelfth cranial nerve	27
Tympanic attic	65
Tympano-malleolar folds	60
Tympanum	62

	PAGE
Ulna	189, 190, 192, 196, 197
Ulnar artery	194, 200
,, nerve	188, 192, 195, 200, 203
,, veins	195, 196
Umbilical hernia	114
,, zone	100, 103
Umbilicus	89
Umbo	60
Unciform	197
Uncinate process	48
Upper extremity	176
,, arm	185
,, thoracic zone	75
Ureter	121, 135, 161
Urethra	152, 161, 162, 172
Urinary apparatus	119
,, bladder	160
Uro-genital triangle	141
Uvula cushion	42
Vagina	167
,, examination of	170
Vagus nerve	27
Vallecular fossa	45
Valves of heart	84
Varicocele	155
Vas deferens	154
Vastus externus muscle	221
,, internus ,,	221
Vena cava, inferior	124
,, ,, superior	87
Ventricles, cerebrum	10
,, heart	85
Vermiform appendix	110
Vertebra prominens	126
Vertebræ, spines of	125
Vestibular bulbs	166
Vestibule	165
Vestibulum nasi	50
Vibrissæ	50
Vocal cords	19, 46
Vomer	42
Vulva	164
Wharton's duct	36
Wrisberg cartilages	45
Wrist	196, 200
Wryneck	22
Xiphi-sternum	72, 180
Zygomatic arch	3

Printed by Morrison & Gibb Limited, *Edinburgh.*