

Practical pathology : including morbid anatomy and post-mortem technique / by James Miller.

Contributors

Miller, James, 1875-1958.
Royal College of Physicians of Edinburgh

Publication/Creation

London : A. and C. Black, 1914.

Persistent URL

<https://wellcomecollection.org/works/b9ayyuc4>

Provider

Royal College of Physicians Edinburgh

License and attribution


This material has been provided by This material has been provided by the Royal College of Physicians of Edinburgh. The original may be consulted at the Royal College of Physicians of Edinburgh. where the originals may be consulted.

Conditions of use: it is possible this item is protected by copyright and/or related rights. You are free to use this item in any way that is permitted by the copyright and related rights legislation that applies to your use. For other uses you need to obtain permission from the rights-holder(s).



Wellcome Collection
183 Euston Road
London NW1 2BE UK
T +44 (0)20 7611 8722
E library@wellcomecollection.org
<https://wellcomecollection.org>






PRESS MARK

Press No. **Fc***

Shelf No. **3**

Book No. **45**



7/6 net

R52116

The Edinburgh Medical Series

General Editor—JOHN D. COMRIE,
M.A., B.Sc., M.D., F.R.C.P.E.

PRACTICAL PATHOLOGY
INCLUDING MORBID ANATOMY AND
POST-MORTEM TECHNIQUE


IN THE SAME SERIES.

TEXT-BOOK OF MIDWIFERY. For Students and Practitioners. By R. W. JOHNSTONE, M.A., M.D., F.R.C.S., M.R.C.P.E. Crown 8vo, cloth, with 264 Illustrations (3 coloured). Price 10s. 6d. net.

DISEASES AND INJURIES OF THE EYE. A Text-Book for Students and Practitioners. By WM. GEORGE SYM, M.D., F.R.C.S.E. Containing 25 Full-page Illustrations, 16 of them in colour, and 88 Figures in the Text; also a Type Test-Card at end of Volume. Small crown 8vo, cloth. Price 7s. 6d. net.

AGENTS

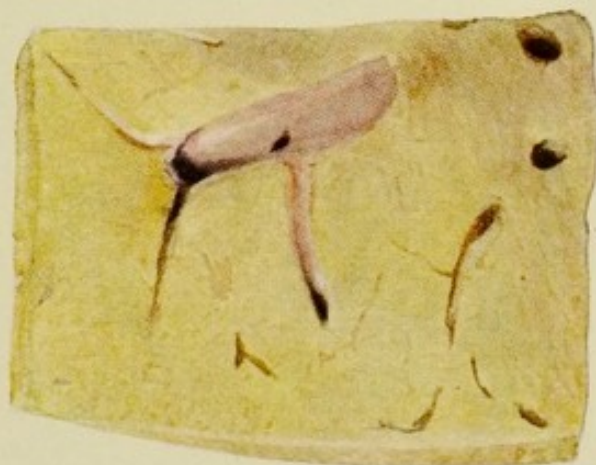- AMERICA . . THE MACMILLAN COMPANY
64 & 66 FIFTH AVENUE, NEW YORK
- AUSTRALASIA THE OXFORD UNIVERSITY PRESS
205 FLINDERS LANE, MELBOURNE
- CANADA . . THE MACMILLAN COMPANY OF CANADA, LTD.
ST. MARTIN'S HOUSE, 70 BOND STREET, TORONTO
- INDIA . . . MACMILLAN & COMPANY, LTD.
MACMILLAN BUILDING, BOMBAY
309 BOW BAZAAR STREET, CALCUTTA




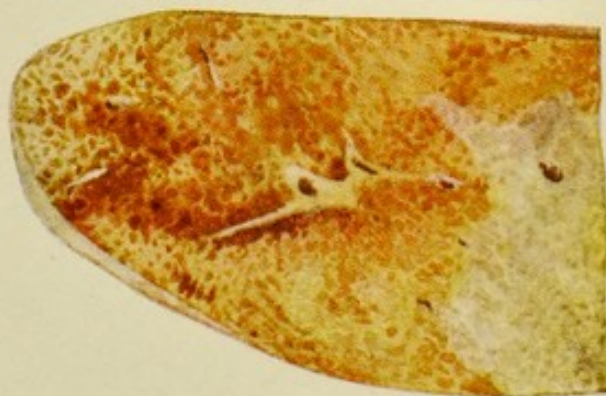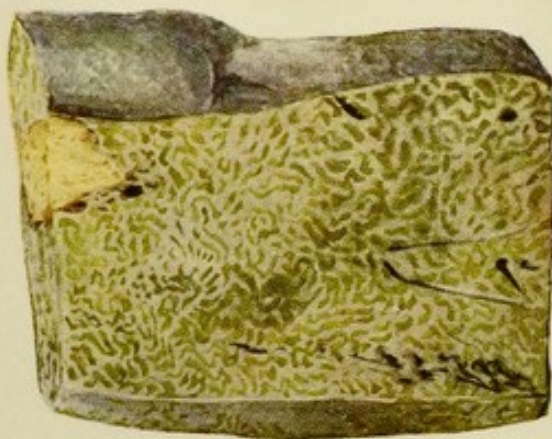
1



2



3



1. Cut surface of liver from case of pernicious anæmia, showing brown coloration from excessive deposit of hæmosiderin. Part has been treated with hydrochloric acid and ferrocyanide of potassium and shows the Prussian blue reaction.
2. Cut surface of liver showing extreme fatty change.
3. Section of liver from case of jaundice showing green coloration of the organ. Nodules of secondary carcinoma are also to be seen.
4. Cut surface of waxy liver the greater part of which has been treated with iodine, the waxy material giving a dark-brown colour with the reagent.
5. Section of liver showing early chronic venous congestion.
6. Section of waxy kidney, part of which has been treated with iodine.

...and
... ..
... ..

... ..
... ..
... ..

... ..
... ..
... ..

... ..
... ..
... ..

... ..
... ..
... ..

... ..
... ..
... ..

... ..
... ..
... ..

... ..
... ..
... ..

... ..
... ..
... ..

... ..
... ..
... ..

PRACTICAL PATHOLOGY

INCLUDING

MORBID ANATOMY

AND

POST-MORTEM TECHNIQUE

BY

JAMES MILLER

M.D., D.Sc., F.R.C.P.E.

LECTURER ON PATHOLOGY AND BACTERIOLOGY, SCHOOL OF MEDICINE OF THE ROYAL COLLEGES, EDINBURGH, AND EDINBURGH SCHOOL OF MEDICINE FOR WOMEN; EXAMINER IN PATHOLOGY, UNIVERSITY OF ABERDEEN AND ROYAL COLLEGE OF PHYSICIANS, EDINBURGH; PATHOLOGIST, ROYAL VICTORIA HOSPITAL, ROYAL HOSPITAL FOR INCURABLES, AND DEACONESS HOSPITAL, EDINBURGH; ASSISTANT PATHOLOGIST, ROYAL INFIRMARY, AND ROYAL MATERNITY HOSPITAL, EDINBURGH; LATE VISITING PATHOLOGIST, GENERAL HOSPITAL, BIRMINGHAM; LECTURER, BIRMINGHAM UNIVERSITY; EXAMINER IN PATHOLOGY, UNIVERSITY OF ST. ANDREWS.

BIBLIOTH
COLL. REG.
MED. EDIN.

LONDON

ADAM AND CHARLES BLACK

1914

PRACICAL PATHOLOGY

AND

POST-MORTEM TECHNOLOGY

BY

JOHN H. BROWN

OF THE UNIVERSITY OF CHICAGO

AND

OF THE UNIVERSITY OF MICHIGAN

AND

OF THE UNIVERSITY OF CALIFORNIA

AND

OF THE UNIVERSITY OF TEXAS

AND

OF THE UNIVERSITY OF ILLINOIS

AND

OF THE UNIVERSITY OF WISCONSIN

AND

OF THE UNIVERSITY OF MINNESOTA

AND

OF THE UNIVERSITY OF NEBRASKA

AND

OF THE UNIVERSITY OF KANSAS

AND

OF THE UNIVERSITY OF OKLAHOMA

AND

OF THE UNIVERSITY OF ARIZONA

AND

OF THE UNIVERSITY OF NEW MEXICO

PREFACE

THE object of this volume is to give the student of medicine and the practitioner, in a handy form, the information required for practical work in relation to Pathology. There will be found short descriptions of the appearances in the more common morbid processes to be met with in the organs and tissues; at the same time these are co-related with the changes in the other organs and tissues of the body in the various diseases. The main points in the microscopic appearances are also given very shortly, merely in order to remind the student what he should look for when going over his slides. In dealing with post-mortem technique, fixing and mounting of preparations, cutting and staining of sections, the endeavour has been to give one reliable method in every case, rather than numerous alternative methods. Hence the book is not one for the specialist. The chapter on Tumours is added to supplement the necessarily short descriptions of neoplasms under the heading of the various organs. For the benefit of the practitioner, a short chapter dealing with the medico-legal aspects of post-mortem work has been included. Owing to the frequent occurrence of cross references, it was decided to bind the illustrations together in the form of an atlas at the end of the book. Illustrations of microscopic preparations have been omitted, as the student has his slides to which he can refer.

The author has made extensive use of volumes such as Sims Woodhead's *Practical Pathology*; Shennan's *Post-Mortems and Morbid Anatomy*; Orth's *Pathologisch-anatomische Diagnostik* and *Erläuterungen zu den Vorschriften für das Verfahren der Gerichtsärzte bei den gerichtlichen Untersuchungen menschlicher Leichen*; Herxheimer's *Grundriss der patho-*

logischen Anatomie and *Technik der pathologisch-histologischen Untersuchung*; Mann's *Physiological Histology*; Mallory and Wright's *Pathological Technique*; Letulle's *La Pratique des autopsies*; Adami's various works; Beattie and Dickson's *Pathology*; Pembrey and Ritchie's *General Pathology*; also Lorrain Smith and Mair's classical work on staining methods for fats in the *Journal of Pathology and Bacteriology*.

To the personal teaching of Professors Greenfield, Muir, and Leith, and of the late Professors Ziegler and Weigert, a deep debt of gratitude is also due.

The author has great pleasure in expressing his indebtedness to Professor Harvey Littlejohn for invaluable help in preparing the chapter on medico-legal post-mortems and for his permission to use two typical post-mortem reports. His thanks are also due to Dr. John Fraser for revising the chapter on diseases of bones; to Dr. James Young for many suggestions in Chapter XII.; to Dr. W. G. Porter for assistance in preparing Figure 12; to Dr. Sidney Smith for the use of his fine preparations illustrating centres of ossification in the infant in connection with the table on p. 309; also to Mr. W. Waldie of the Royal College of Surgeons' Museum, Edinburgh, for his advice as to the fixing and mounting of specimens.

The illustrations have, with one or two exceptions, been made by Mr. Glass from preparations in the author's collection. For the care and trouble taken, the author wishes to express his hearty thanks. If acknowledgment has not in every instance been made to the physician or surgeon who had charge of the case, the author begs to offer his apologies. His thanks are due to Professor Sutherland for the specimen from which Fig. 33 was drawn.

For much useful advice and criticism, I have to thank the Editor of the *Edinburgh Medical Series*—Dr. J. D. Comrie. For reading the proofs and for drawing up the index, I have to express my hearty thanks to my assistant, Dr. Fergus Hewat.

J. M.

SURGEONS' HALL, EDINBURGH,
October 27, 1913.

CONTENTS

CHAPTER I

	PAGE
INTRODUCTORY	I

CHAPTER II

EQUIPMENT OF THE PATHOLOGIST	5
--	---

CHAPTER III

METHOD OF PROCEDURE	13
Removal of Thoracic Contents	22
Removal of Abdominal Contents	28
Removal of the Brain	35
Removal of the Spinal Cord	39

CHAPTER IV

DISEASES OF THE HEART AND PERICARDIUM	46
Malformation of the Heart and Great Vessels	46
Diseases of the Pericardium	48
Diseases of the Myocardium	53
Diseases of the Endocardium	60
Effect on the Heart and Circulation of the Different Types of Chronic Valvular Disease	69

CHAPTER V

	PAGE
DISEASES OF THE VESSELS	77
Diseases of the Arteries	77
Diseases of Veins	87

CHAPTER VI

DISEASES OF THE BLOOD, BONE MARROW, LYMPH GLANDS,	
SPLEEN, AND DUCTLESS GLANDS	91
Diseases of the Blood	91
Hæmorrhagic Diseases	99
Diseases of the Bone Marrow	100
Diseases of Lymph Glands	102
Diseases of the Spleen	105
Diseases of the Thyroid Gland	111
Diseases of the Thymus Gland	113
Diseases of the Suprarenal Glands	113

CHAPTER VII

DISEASES OF THE RESPIRATORY SYSTEM	116
Diseases of the Larynx	116
Diseases of the Bronchi	117
Diseases of the Lungs	119
Diseases of the Pleura	149

CHAPTER VIII

DISEASES OF THE INTESTINAL TRACT AND PERITONEUM	153
Diseases of the Stomach	154
Diseases of the Intestine	159
Diseases of the Peritoneum	172

CONTENTS

ix

CHAPTER IX

	PAGE
DISEASES OF THE LIVER, BILE PASSAGES, AND PANCREAS	175
Diseases of the Liver	175
Diseases of the Gall Bladder and Bile Ducts	194
Diseases of the Pancreas	197

CHAPTER X

DISEASES OF THE KIDNEY AND BLADDER	200
Diseases of the Kidney	200
Diseases of the Pelvis of the Kidney	225
Diseases of the Urinary Bladder	227

CHAPTER XI

DISEASES OF THE BRAIN AND SPINAL CORD AND THEIR MEMBRANES	229
Diseases of the Brain	233
Diseases of the Spinal Cord	244
Diseases of the Cord to which Special Names are given	248
Diseases of the Peripheral Nerves	252

CHAPTER XII

DISEASES OF BONES AND JOINTS	254
Diseases of Bones	254
Diseases of Joints	261

CHAPTER XIII

DISEASES OF THE REPRODUCTIVE ORGANS AND MAMMARY GLAND—DISEASES OF PREGNANCY	264
Diseases of the Ovaries	264
Diseases of the Fallopian Tubes	265
Diseases of the Uterus	266

	PAGE
Diseases of the Placenta	268
Diseases of Pregnancy and the Puerperium	269
Diseases of the Mammary Gland	272
Diseases of the Testicle	273
Diseases of the Prostate	274

CHAPTER XIV

TUMOURS	275
Simple Tumours	277
Malignant Tumours	286
Teratomata	303

CHAPTER XV

POINTS TO BE REMEMBERED IN PERFORMING AUTOPSIES ON CASES WITH A MEDICO-LEGAL ASPECT	306
General Method of Procedure in Medico-Legal Cases	306
Post-Mortems on Newly-Born Infants	308
Post-Mortem Changes produced by Poisons	311
Specimen Post-Mortem Reports	315

APPENDIX

TREATMENT OF SPECIMENS FOR MOUNTING	319
TREATMENT OF TISSUES FOR MICROSCOPIC PURPOSES	324
STAINING METHODS	337
MAKING OF BLOOD FILMS	357
BACTERIOLOGICAL METHODS OF INVESTIGATION	358
EXAMINATION OF SPUTUM, PUS, ETC., FOR THE TUBERCLE BACILLUS	370
THE BACTERIOLOGICAL DIAGNOSIS OF DIPHTHERIA	372
AGGLUTINATION TEST FOR ORGANISMS	374
METHOD OF MAKING PIPETTES	375
EMBALMING	376
INDEX	377

LIST OF ILLUSTRATIONS

FIG.		PAGE
	Sections of liver and kidney (<i>in colour</i>)	<i>Frontispiece</i>
	Plan of the circulation to show the origin and destination of the more common emboli	62
	Plan of the circulation in the kidney	206
1.	Method of opening the abdominal cavity	397
2.	Reflecting the skin and muscles from the sternum and ribs }	
3.	Method of cutting through sterno-clavicular joint	398
4.	Method of cutting through floor of mouth	
5.	Lines of incisions for opening up the cavities of the heart }	399
6.	Method of incising the lung	
7.	Method of opening the coronary arteries	400
8.	Method of testing the competence of the semilunar valves . }	
9.	Method of removing the small intestine	401
10.	Method of opening the bowel after it has been removed . }	
11.	Cutting through tentorium cerebelli in removing the brain }	402
12.	Position of the accessory cavities in relation to the base }	
	of the skull	
13.	Method of incising the kidney	403
14.	Method of stitching up	
15.	Heart, acute pericarditis	404
16.	Acute aneurysm following abscess of left ventricle in }	
	case of osteomyelitis	
17.	Heart, chronic interstitial myocarditis	405
18.	Section through wall of right ventricle, showing increase }	
	of sub-pericardial fat and fatty infiltration of the muscle	
19.	Thrombus in right auricular appendix	

FIG.	PAGE
20. Simple (vegetative) endocarditis in a case of chorea, heart of child	406
21. Simple endocarditis, aortic valve	407
22. Heart, ulcerative endocarditis of mitral valve	
23. Ulcerative endocarditis, aortic valve	408
24. Transverse section of heart, showing hypertrophy of the left ventricle in case of chronic interstitial nephritis	
25. Anterior aspect of heart from case of mitral stenosis, showing dilatation of right auricle and well-marked hypertrophy as well as dilatation of right ventricle	409
26. Same heart from above, showing dilatation of both auricles. The narrowed mitral valve (button-hole) can be seen	
27. Chronic endocarditis of aortic valve, with stenosis	410
28. Portion of descending thoracic aorta, showing atheroma	
29. Arteries at base of brain, showing atheroma	
30. Saccular aneurysm of descending aorta adherent to and eroding the bodies of the vertebræ	411
31. Spleen considerably enlarged from chronic venous congestion, showing infarcts	412
32. Spleen, myelogenous leukæmia and infarction	
33. Spleen, tuberculous masses	
34. Spleen and spleniculus, sago waxy	413
35. Spleen, Hodgkin's disease, showing numerous scattered white masses varying in size	
36. Spleen, Hodgkin's disease, showing white masses arranged in groups	
37. Mass of tuberculous lymphatic glands in section, showing numerous caseous foci	414
38. Lymphatic glands, lymphadenoma (Hodgkin's disease)	
39. Thyroid gland, exophthalmic goitre	415
40. Lung, emphysema	
41. Lung, collapse due to empyema	416
42. Lung, lobar pneumonia	417
43. Lung and bronchi, showing acute bronchitis and septic broncho-pneumonia	418

LIST OF ILLUSTRATIONS

xiii

FIG.	PAGE
44. False membrane in trachea in diphtheria	419
45. Portion of lung, showing two recent infarcts	
46. Lung, gangrene	
47. Lung, silicosis	420
48. Lung, anthracosis	421
49. Lung, acute miliary tuberculosis	
50. Mediastinal glands and lung of infant, showing caseous tuberculosis	
51. Lung, caseous (tuberculous) pneumonia with cavitation	422
52. Lung, chronic tuberculosis, with cavity in which an aneurysm has formed	423
53. Lung, fibro-caseous tuberculosis, with marked tendency to healing	
54. Surface of lung, acute pleurisy	
55. Section of lung, showing large number of nodules of secondary carcinoma	424
56. Lympho-sarcoma of the mediastinal glands invading the root of the lung	
57. Squamous epithelioma of œsophagus, with marked narrowing of lumen	425
58. Peptic ulcer of stomach, with opening into vessel in floor of ulcer	
59. Large duodenal ulcer	
60. Stomach opened up anteriorly to display encephaloid cancer close to cardiac opening	426
61. Intussusception of small intestine and mesentery into large intestine	427
62. Typhoid lesion of small intestine (early stage)	
63. Typhoid lesion of small intestine (later stage)	
64. Tuberculous ulcer of small intestine	
65. Tuberculous ulcer, peritoneal aspect, showing raised tubercles under peritoneum	
66. Large intestine, ulcerative colitis (dysentery)	428
67. Portion of large bowel from case of amœbic dysentery, showing characteristic early lesion	

FIG.	PAGE
68. Acute appendicitis and peritonitis	
69. Pelvic colon, with adeno-carcinoma projecting into interior	429
70. Peritoneal aspect of loop of intestine, showing tuberculous peritonitis	
71. Abscesses of liver, portal pyæmia type	430
72. Liver, large tropical abscess, with much necrotic liver tissue	
73. Liver of child, showing multiple nodular hyperplasia (regeneration of liver substance) following an acute degenerative process	431
74. Liver, common cirrhosis	
75. Liver, showing group of gummata	
76. Liver, cavernous angioma	432
77. Section of liver with secondary deposits of sarcoma	
78. Liver, greatly enlarged, with numerous secondary nodules of carcinoma	
79. Section of liver, with hydatid cyst from which numerous smaller cysts are protruding	433
80. Biliary calculi or gall-stones	
81. Congenital cystic kidney	434
82. Infarcts of the kidney	
83-86. Kidneys illustrating the various types of Bright's Disease	435
87, 88. Kidney, pyæmic abscesses	
89, 90. Kidney, tuberculosis	436
91. Kidney, hydronephrosis	
92. Kidney, hypernephroma	437
93. Coralline calculus in kidney	
94. Brain, showing acute meningitis	
95. Brain, tuberculous meningitis	438
96. Section of brain, showing acquired hydrocephalus	
97. Section of brain, showing hæmorrhages into the basal ganglia on right side	439

LIST OF ILLUSTRATIONS

XV

FIG.

PAGE

98. Cerebellum, with depressed areas from softening of brain substance due to thrombosis in arteries . . .	}	440
99. Vertical section of brain, showing solitary abscess in temporo-sphenoidal lobe		
100. Transverse section of pons, showing hæmorrhages into its substance		
101. Cholesteatoma in frontal lobe	}	441
102. Teratoma (dermoid) of ovary containing sebaceous material and hairs. Solitary cyst above it . . .		
103. Scirrhus cancer of the breast, with indrawing of nipple		
104. Myomata in wall of uterus	}	442
105. Enlargement of costo-chondral junctions (rickety rosary) in rickets		
106. Osteomyelitis of lower end of femur	}	443
107. Lower lumbar vertebræ and sacrum in section, showing tuberculous disease of bodies and psoas abscess . . .		
108. Osteo-sarcoma of shaft of femur	}	444
109. Myeloid sarcoma of jaw		

LIST OF CONTENTS

1. Introduction	1
2. Theoretical Foundations	10
3. Experimental Methods	25
4. Results and Discussion	40
5. Conclusions	55
6. Acknowledgments	60
7. References	65
8. Appendix	75
9. Index	85
10. Glossary	95
11. Bibliography	105
12. List of Figures	115
13. List of Tables	125
14. List of Equations	135
15. List of Symbols	145
16. List of Abbreviations	155
17. List of Acronyms	165
18. List of Initials	175
19. List of Footnotes	185
20. List of Endnotes	195
21. List of References	205
22. List of Bibliography	215
23. List of Appendix	225
24. List of Index	235
25. List of Glossary	245
26. List of Bibliography	255
27. List of Appendix	265
28. List of Index	275
29. List of Glossary	285
30. List of Bibliography	295
31. List of Appendix	305
32. List of Index	315
33. List of Glossary	325
34. List of Bibliography	335
35. List of Appendix	345
36. List of Index	355
37. List of Glossary	365
38. List of Bibliography	375
39. List of Appendix	385
40. List of Index	395
41. List of Glossary	405
42. List of Bibliography	415
43. List of Appendix	425
44. List of Index	435
45. List of Glossary	445
46. List of Bibliography	455
47. List of Appendix	465
48. List of Index	475
49. List of Glossary	485
50. List of Bibliography	495

PRACTICAL PATHOLOGY

CHAPTER I

INTRODUCTORY

THE post-mortem examination, *sectio cadaveris*, or autopsy is an essential part of the scientific investigation of all fatal cases of disease. It is obvious that only by its means can the medical man acquire an accurate knowledge of the nature, extent, distribution, and complications of a morbid condition. It is not too much to say that however plain and simple the diagnosis of a disease may be, some additional light will be thrown upon the case at the post-mortem examination. In a very considerable number of instances, conditions quite unexpected during life will be found, and, in a few, the diagnosis of the clinician will be entirely upset by the pathologist's investigations.

A post-mortem examination should therefore be performed whenever feasible. Further, the examination should be as thorough as possible: should, in other words, include as many parts of the body as possible, and should be followed by microscopic, and, if necessary, bacteriological examination of the diseased organs and tissues. In not a few instances the pathologist's view of a case obtained by naked-eye

examination alone is greatly altered by subsequent microscopic or bacteriological investigation.

For example, in a case which came under the author's notice there was a stricture of the small intestines which, from the clinical history as well as from the naked-eye appearances, was believed to be malignant. Microscopic examination showed the condition to be tuberculous.

In another case, where hæmorrhagic infiltration of the mediastinal tissues was the main post-mortem finding, the true nature of the disease was only found on making cultures, when a pure growth of the anthrax bacillus was obtained, the case proving to be one of "woolsorter's disease."

From another point of view a post-mortem examination may be required, that is the medico-legal. Cases of suspected poisoning may prove to be ordinary diseased conditions, and, *vice versa*, cases where foul play is unsuspected may turn out to be due to poisoning.

To give another example from the author's experience. A well-to-do contractor died suddenly with symptoms of severe jaundice. His will was known to be drawn out in favour of the foreman of his works, with whom he lived. The medical attendant considered phosphorous poisoning a possibility, but post-mortem examination revealed the presence of a large impacted calculus in the common bile duct.

In all cases of sudden death where the cause is unknown, or of violent or suspected violent deaths, notice must be sent at once to the Procurator-Fiscal or Coroner. Such bodies become the property of the Fiscal or Coroner, and cannot be touched without his consent. (For further information on this point see Chapter XV.)

Precautions to be taken.—Before proceeding in any way to carry out a post-mortem examination, it is absolutely necessary that the permission of the nearest relative of the deceased be obtained. In certain hospitals, more happily situated than their fellows, the regulation is, that unless

notice to the contrary be received from the relatives within twenty-four hours of the death of the patient, an autopsy will be performed. This is a far better system than the one under which permission has to be asked for in each case. When not confronted with the choice, the relatives, as a rule, except in the case of certain religious creeds, think little of the matter. When permission is asked for, they at once begin to conjure up visions of mutilation, and it requires in most instances no little tact on the part of the medical man to obtain permission. In every case, however, where leave has to be asked, it should be obtained *in writing* from the *nearest relative*. The absolute necessity for this precaution, if the doctor is to protect himself, has been emphasised on several occasions recently in the law courts. In a case tried before the Court of Session in Edinburgh, the judge, in charging the jury, said that the holding of an unauthorised post-mortem "gave a legal remedy," and that when performed without consent "the case would be treated very smartly"; further, the defender, a medical man who had performed the *sectio*, "would have been well advised had he obtained permission from the father *in writing*."

Medico-legal Cases.—When the case is a medico-legal one, it is necessary to receive permission from the Procurator-Fiscal (Scotland) or the Coroner (England) before a post-mortem examination is performed. This permission having been obtained, none other is required. Although in all cases it is advisable to take full notes at the time, these should be taken with special care in cases which have, or are likely to have, a medico-legal aspect (*e.g.* workmen's compensation cases).

In certain cases with a medico-legal aspect the Coroner or Fiscal will order an autopsy to be performed. When reporting such a case the pathologist should avoid as far as possible the use of technical terms. In Scotland such a

report requires to be drawn up in what is known as the "soul and conscience form" (see Chapter XV.).

Importance of Post-mortem Change.—It is quite obvious that the sooner the post-mortem examination is carried out after the death of the patient the better, but unless there is any special reason to the contrary it is usual to wait for twenty-four hours.

The changes which begin to take place in a body after death tend to mask, and eventually to obliterate entirely, the characteristic appearances of most pathological conditions. Diseased conditions have been found in Egyptian mummies, and caries of teeth and evidence of rickets in the skeletons of prehistoric men, but as a rule the softer parts, and more particularly the hollow viscera and abdominal organs, rapidly lose the characteristic signs of disease through decomposition. The extent and rapidity of this change will, of course, depend upon circumstances. The processes take place much more rapidly in warm weather. Conversely in cold weather, or if, as is possible in some hospitals, the bodies are placed in an apparatus artificially cooled, they will retain their freshness for a much longer period. Another factor bearing upon this is the disease from which the patient has died. In septic conditions, more particularly in the abdominal cavity, decomposition occurs more quickly, and tends to alter the appearance of organs in the neighbourhood.

CHAPTER II

THE EQUIPMENT OF THE PATHOLOGIST

Rubber Gloves.—One of the most important parts of the pathologist's equipment is a good, sound pair of rubber gloves. Fifteen or twenty years ago gloves were seldom worn. In consequence, those carrying out post-mortem work suffered periodically from septic wounds, if not from the more serious infections, such as tuberculosis. Nowadays there is no excuse for such accidents, as gloves are cheap, and with care they last a considerable time. The best type of glove is the thin rubber glove used by the surgeon. The thicker ones naturally last longer, but they are more expensive, more difficult to work with, and are more troublesome to mend.

It is very necessary that the pathologist should care for his gloves, seeing so much depends upon them. During a post-mortem the gloves should be frequently washed under running water to prevent the drying of blood or pus upon their surface. After the operation is finished, they should be washed while on the hands, first with soap and water, and then with water alone, afterwards dried, and while still on the hands moistened all over with biniodide of mercury spirit (biniodide of mercury 1 part, methylated spirit 500) and dried again with a towel. If punctured, the

6 THE EQUIPMENT OF THE PATHOLOGIST

interior of the glove should, of course, be similarly treated. The exact position of a puncture can be found by distending the glove with water. A patch can then be applied, just as one mends a punctured tyre. The gloves should subsequently be folded up and placed in the cardboard box supplied with them.

If long intervals elapse between post-mortems, the gloves may become hard and brittle. A few minutes' immersion in hot water will make them soft again.

Where gloves are not obtainable, the hands may be smeared with carbolic oil.

Post-mortem Wounds.—In the case of a punctured wound obtained at a post-mortem it is well to wash the part thoroughly in warm water, suck it, and then dress it with some weak antiseptic, such as 1 : 40 carbolic. Some recommend the use of pure carbolic or other strong acid in the first instance. If slight, the wound can be covered with a layer of celloidin dissolved in equal parts of alcohol and ether, or with "new skin."

In his movements with knife or needle, the pathologist should always be slow and cautious. When dealing with purulent or other infective fluid, or with fæcal material, great care should be taken *not to splash it about*. Severe eye infections sometimes result in this way, and the author knows of cases in which typhoid infection resulted from the splashing of infected fæces. For this reason it is well to *avoid using a strong stream of water* when washing intestines, or, indeed, at any time.

Eye Infections.—When some foreign material has entered the eye, the conjunctival sac should be washed out with a little warm saline. The method of washing out is to place the individual on a chair with head well thrown back, and to squeeze the saline fluid into the eye with a piece of cotton wool. There is no need to use an antiseptic, as the

conjunctival sac can of itself destroy a considerable amount of infective material. The object of the washing is merely to remove as much of the irritant as possible. In any case the eye should not be rubbed or irritated in any way.

Another source of danger for the pathologist is flies. These are excessively troublesome in warm climates, and are, undoubtedly, a means of conveying infection. Fly-papers will be found useful in reducing the number.

Turning to the question of instruments, these need not be numerous or elaborate. The following are essential :—

Instruments.—1. *A sharp large-bladed knife* for making incisions in the skin and for removing organs. Several of these should be kept.

2. *A long, flat knife* for cutting into the solid organs.

3. *A straight probe-pointed bistoury* for opening the heart, the smaller vessels, such as the coronary arteries, for opening the bronchi, and for incising the dura and cutting nerves in removing the brain.

4. *A pair of dissecting forceps* for finer work.

5. *A pair of fairly large round-ended scissors* for opening the bowel. These may be of the special type commonly used, but an ordinary pair, provided the edges are sharp and the ends blunt, will do almost equally well.

6. *A good saw*, with removable back.

7. *A chisel.*

8. *A wooden or soft metal mallet.*

9. *Several flexible probes.*

10. *A packing needle.*

11. *Strong twine.*

12. *Wooden cones* for measuring the diameter or circumference of the heart valves (*e.g.* those advocated by Shennan) will be found useful.

In addition it is well to have one or more sharp-pointed scalpels for any finer dissection that may be required ; also a

8 THE EQUIPMENT OF THE PATHOLOGIST

pair of small sharp-pointed scissors for fine work, a catheter, sponges, and a wooden block for supporting the head. A screw-driver for coffin lids may also on occasions be found useful.

Knives should, of course, be sharp, and it is advisable to have the means of sharpening them at hand, in the shape of a hone and oil. With a little practice it is possible to put a keen edge on a knife in a very few minutes. Instead of the finer large knives sold by the instrument-makers, butcher's knives will do admirably, and will cost a fourth or fifth of the price.

Another necessary item in the pathologist's equipment is a pair of scales with weights from one gramme to five kilos.

Post-mortem Table and Accessories.—The post-mortem table should be at least 6 feet long and 2 feet broad. It should be either a solid slate slab or wood covered with zinc. The edge should be raised, and runnels arranged so that fluids will pass to a central waste-pipe enclosed in an iron pillar supporting the table, and on which it revolves. There should be a plentiful supply of water ; a tap overhead with hose attached ; a basin with hot and cold supply close by for washing the hands ; a large sink with an ordinary tap, and a tap with rose attached, used for washing organs, the stream from which can be easily controlled by the operator either by the foot or elbow. The operator should frequently cleanse his gloves under running water to prevent blood, pus, or other discharge from drying on them.

It is useful to have accessible a number of bottles containing reagents likely to be required, such as Gram's iodine for testing for waxy disease (see p. 363), dilute hydrochloric acid and ferrocyanide of potassium for testing for hæmosiderin in the organs (see p. 353), 10 per cent formalin, and other fixatives for tissues, and a supply of empty bottles with corks.

A Bunsen burner, a platinum needle, a piece of metal for searing the surface of organs, slides, and culture media should be close at hand. A number of large sponges will be found very useful for mopping out cavities, also a glass measure and a syringe and trocars for injecting specimens with preservatives. A large jar of Pick's or other fixative should be at hand for this purpose, and pots of various sizes for containing specimens.

The post-mortem room of a hospital should be in a detached building. The room itself should be airy and well lighted. It should communicate with a preparation room, and a laboratory for microscopic and bacteriological work.

The operator should, of course, wear a clean overall to protect his clothing. A waterproof apron over or under this is advisable. A pair of spectacles for the protection of the eyes is a good thing.

Note-taking.—Previous to the performance of the *sectio*, a short *résumé* of the main clinical features of the case should be sent to the pathologist. Notes dictated by the operator during the *sectio* should be taken by a competent person. This is absolutely necessary, as the more minute points in the case cannot be put down unless the organs are actually before the operator. Organs change considerably in colour even during the course of the *sectio*, so that it is not safe to trust to the description of a case written up afterwards, even when the more important organs are preserved.

Post-mortems in Private.—In carrying out a *post-mortem in private*, the body should be placed on a kitchen table, with an old sheet and newspapers, or, if possible, a waterproof sheet, underneath. Sometimes the bed is the only place available, in which case the waterproof is very necessary. The head should be supported with a brick, a block of wood, or a suitable box wrapped in newspaper. A slop-pail and basins, with a plentiful supply of water, should

be procured. To mask unpleasant odours, a piece of twisted brown paper lit at one end, the other end being thrust into a jug and left to smoulder, or a handful of ground coffee thrown on a shovelful of burning coals will be found useful. In private, if the spinal cord has to be examined, it is well to begin with that. A number of newspapers, bottles for specimens, sponges, soap and towels should not be forgotten.

Rules to be observed in examining Organs.—A few simple rules should be borne in mind when examining an organ. It is well to have some definite method in order that nothing be passed over. The student should remember, in the first place, to *look before touching*, the former being much the more important process. Note in the first instance the *size* of the organ, and mentally compare it with what, in your experience, is the normal size, remembering always that the age of the subject from which the specimen was taken is an important item in drawing a conclusion as to size. The *general form* of the organ should next be examined, and any deviation from the normal noted, such as swellings or shrinking. Examine next the *surface* of the organ, looking for exudate, which, if recent, is friable and readily scraped away; if organised, it is stringy and difficult to remove. Opaque, white, pearly areas indicate chronic inflammation. *Cicatrices* with indrawing or puckering of the surface indicate old infarcts or healed tuberculous or syphilitic lesions. A *finer roughening*, giving the appearance of morocco leather, is always indicative of fibrosis in the organ.

Next, the organ should be *incised*, and in doing so some idea of its *consistence* may be arrived at. An organ which is the seat of fibrosis will be tougher and more difficult to cut. In incising an organ it is usual to do so from the rounded outer and broader surface towards the root or hilum where the vessels enter and the ducts leave.

The *cut edge* is another point to which attention should be directed, and which bears upon the question of consistence. A rounded edge after a cut indicates soft consistence, and is associated with cloudy swelling and fatty change; a sharp edge is found when the organ is firm. That is the reason for the existence of a sharp edge in organs the seat of amyloid disease—the waxy material gives consistency and firmness to the tissue, unless complicated by other degenerative conditions, such as fatty change.

The student is apt to consider that in diseased conditions associated with fatty change, a *greasy feel* is imparted to the organ. As a matter of fact, adipose tissue and fat generally is greasy to the touch, but it is only comparatively rarely that fatty change (when the change is actually a degenerative one in the parenchymatous cells) gives to the organs which are the seat of the change a greasy sensation when touched.

The next step is to examine the *cut surface*. The *colour* and any irregularity in the distribution of the colouring should be noticed. The presence of *bands of fibrous tissue*, *pigmentations* of various kinds, *opaque spots*. Grey, translucent areas indicate waxy disease or accumulations of cells, such as tubercle foci and leukæmia. Opaque white spots are indicative of degenerative and necrotic foci, such as areas of focal necrosis in the liver in typhoid, eclampsia, etc. Note also the *condition of the vessels* of the organ. If they stand out prominently, it is an indication that their walls are thickened. Their contents should also be noted, whether that is fluid or solid, and the character of the clot if present. The presence of gas in the blood should be looked for.

Use of Knife in making Incisions.—In *incising an organ*, the way in which the knife is used is a matter of no little importance. The knife should, in the first place, be a large one, considerably larger than the organ itself; the larger the better. It must, further, be a sharp knife. As regards the

character of the cut, the knife should be *drawn along* and not *pressed into* the substance of the organ. The cut made by drawing the knife leaves a smooth surface, that made by pressing the knife leaves a rough surface. Further, the cuts must be large and sweeping, not a to-and-fro movement which will leave a series of ridges. If possible, the whole cut should be carried out in a single sweep. As Virchow was accustomed to say to his students, "Smooth, though wrong, incisions are better than correct and uneven ones."

CHAPTER III

METHOD OF PROCEDURE

Object of Post-mortem Examination.—The object of a post-mortem examination is twofold—first, the discovery of the disease condition which has led to a fatal termination in the particular case in point; second, the investigation, as minutely as possible, of that disease condition with a view to advancing medical science in general.

The first object may in some cases be attained by the most cursory examination limited to a single organ or part; in other cases only the closest attention to detail and the investigation of the apparently insignificant will be followed by success; the second object can only be attained after every system has been examined with the greatest care and after minute investigation, assisted by the microscope, and, it may be, by the chemical laboratory. It follows from this that wherever possible a detailed examination should be carried out. There are cases where the cursory investigation will give all the information required, but in a large proportion of cases the pathologist is not doing his duty unless the more detailed examination be resorted to, that is, provided always permission for the extended section be obtained and the time and apparatus be available.

Necessity for definite Plan of Operation.—In order

to carry out this detailed examination some definite plan of operation is necessary. In other words, before starting to carry out the autopsy it is quite essential that the operator should have some idea of how he is going to proceed : of the order in which he is going to examine the various body cavities and their contents. It is by no means necessary to adhere to the same plan invariably. In fact, the experienced pathologist will alter his routine frequently, according to the indications given him by the clinical history as to the parts actually diseased. At the same time it is advisable to have some definite plan, some order in which the various parts are to be examined, so that no detail may be omitted.

It is generally stated that it is better to begin when possible with the head, as otherwise blood may escape from the vessels of the head while the thorax is being examined, and so appearances be altered. This is not a very strong argument. Virchow long ago emphasised the necessity of opening the abdominal cavity before the thoracic, in order that the true position of the diaphragm might be ascertained. As a matter of fact this is usually done, but not for that reason. As a rule, after making an examination of the organs *in situ* and of the large serous sacs—pleura, pericardium, peritoneum—one begins with the more detailed examination first of the thoracic organs.

Different Methods of Procedure.—As Letulle points out, there are really two parts in a complete autopsy. (1) The examination of the cerebro-spinal system. (2) The examination of the viscera. One might add as a third part the examination of bones, muscles, vessels, and nerves. But having admitted that this division exists, it should be realised that the further examination of these parts, more particularly in the case of the viscera, must be carried out *in continuity*. That is to say, taking, for example, the vascular system,

heart, arteries, and veins should be examined before cutting through any large vessel. The alimentary system should be exposed and inspected from pharynx to rectum before it is divided into sections ; more than that, the various canals, such as bile and pancreatic ducts, must be examined while they are in continuity with the alimentary tract. This is the ideal method, and it is the method advocated and carried out by Letulle and others. The whole of the thoracic and abdominal viscera are removed and examined first in continuity, and then the various organs removed and examined by themselves. In practice, however, this method is somewhat tedious, and cannot in many instances be carried out, owing to leave being obtained for the examination only of certain parts of the body.

Two great rules emphasised by Orth should always be kept in view. The first is that *a part should never be removed from its position before its relationship to its surroundings has been established*. Thus the heart should never be removed for examination before the contents of the pulmonary artery and its larger branches have been investigated. Secondly, *no part should be taken away if the removal of it will interfere with the investigation later on of other parts*.

To sum up, it is well for the pathologist to have some routine to which he is accustomed, thus avoiding the danger of omissions, but this plan may be modified according to the exigencies of the case.

Surface Examination.—First there comes the examination of the body, before any incision is made. The following points should be attended to :—

Development of the Body.—Height, breadth, etc., presence or absence of deformities. Any alterations in the shape of the chest should be particularly noted ; the barrel-shaped chest of bronchitis and emphysema, the pigeon breast indicative of rickets in early life are two common malformations.

Nutrition.—Whether the body is well nourished, poorly nourished, or emaciated.

Age and Sex.

Presence and degree of *rigor mortis*. This is observed first in the muscles of the face, and spreads from above downwards, passing off in the same order. *The time of onset of rigor mortis* varies according to the time which has elapsed since death and according to the cause of death. In cases of sudden death due to injury of the spinal cord, in tetanus, in strychnine poisoning, and in wasting diseases, such as tuberculosis and cancer, the condition may come on very early. As a rule it appears in from three to six hours after death. Usually the condition begins to *pass off* in twenty-four to forty-eight hours, the time depending upon the cause of death and the conditions under which the body is kept. In septic conditions and in warm weather rigor mortis passes off rapidly.

Alteration in Colour.—Pallor. Any deepening of the normal colour of the skin or the presence of jaundice.

Lividity.—This naturally occurs after death, owing to the accumulation of blood in the dependent parts. Post-mortem lividity is thus most marked in dependent parts. Where lips or face are livid, some abnormality in the circulation or death from suffocation may be suspected. Lividity may also be due to bruising. Such livid patches, when pressed upon, remain of the same colour, unlike post-mortem lividity, which can be pressed away. When bruised parts are cut into, the blood is found diffused through the tissues. A livid colour along the lines of the superficial vessels may be due to the advance of decomposition, owing to the diffusion of the blood-colouring matter into the surrounding tissues. Green coloration, an indication of the onset of decomposition, should also be noted. It appears first over the abdomen and in the spaces between the lower ribs.

Skin eruptions, superficial tumours, scars, or recent

wounds should be carefully noted, and their extent estimated.

Note the presence of *œdema* and its distribution.

Examine the various *orifices* of the body—mouth, nose, ears—for discharges, foreign bodies, etc. Note the condition of the teeth. Examine for the presence of inguinal or femoral hernia. Note the condition of the external genitals.

Primary Incision.—Standing on the right side of the body, the pathologist grasps his knife firmly with the right hand (Fig. 1). The incision is commenced either immediately under the chin, at the thyroid cartilage, or just above the manubrium sterni in the middle line. It is carried downwards through skin and subcutaneous tissue to left of the umbilicus, as far as the symphysis pubis. Any cicatrices or recent incisions should be avoided. Care must be taken not to go too deeply when incising the abdomen, in order to avoid cutting the liver or bowel. At one point, usually in the epigastric region, the incision is carried through muscle and peritoneum into the cavity. The index and middle finger of the left hand are then inserted into the opening, and separated so as to put the tissue on stretch (Fig. 1). With the knife the incision is prolonged, the two fingers following down, to the pubes. To obtain more room, the rectus muscle on either side should be cut transversely through immediately above the pubic bone without injuring the skin.

In cases where permission is obtained only for the examination of a part of the body—*e.g.* thorax or abdomen—the incision should be correspondingly limited.

Reflection of Skin and Muscles.—The next step in the process is *the dissection of the skin and muscles of the chest from sternum, cartilages, and ribs*, and, at the same time, of the skin of the neck from the subjacent tissue. This should be done by grasping the skin, etc., with the left hand and steadily pulling away from the sternum or ribs. The areolar tissue

and muscles are then touched here and there with the edge of the knife as they are put upon the stretch (Fig. 2). At this stage the operator will be in a position to *determine the amount of subcutaneous fat*, also the *appearance of the muscles*, which in wasting diseases are often abnormally dark and dry, and in toxic conditions such as typhoid fever may show (more especially the recti abdominales) translucent, glassy-looking areas—the so-called vitreous degeneration of Zenker. Also at this stage the *mammæ* may be incised through the pectoral muscles and examined for growths, etc. The *ribs* should also be examined for fractures and enlargement of the costochondral junctions (rickety rosary).

Removal of Sternum.—Before opening the thoracic cavity the *level of the diaphragm* may be noted. Note also the level of the lower border of the liver, and the position of the stomach and other viscera, as regards the lower costal margin. Then, commencing at the second costal cartilage close to its attachment to the rib, and cutting obliquely outwards, so as to avoid injuring the underlying lung, one divides the cartilages on either side.

In many cases of muscular, and more particularly of old men, it will be found impossible to do this with a knife. The saw should then be used, and the cartilages severed, holding the saw perpendicularly to the ribs. Great care should be taken not to splinter the ribs in any way, so to avoid puncture wounds of the hands in subsequent manipulations. An excellent way of avoiding such wounds is to fold the skin which has been dissected from sternum and ribs in over the severed ends of the ribs.

The *sterno-clavicular joint* on either side should then be *disarticulated* by inserting the point of the knife perpendicularly (Fig. 3), the knife being afterwards turned edge outwards, the incision prolonged between clavicle and first rib for half an inch, and the rib cartilage divided external to the

point of disarticulation. If the cartilage of the first rib is ossified it will be necessary to use a pair of bone forceps or a saw to divide it.

The *sternum* and *cartilages* should then be *removed* from below upwards, the diaphragmatic attachment being, in the first instance, cut through. If the sternum be firmly adherent to the mediastinal tissues, great care should be taken not to damage aneurysm or tumour, to which this adherence may be due.

Serous Sacs.—The removal of the sternum opens both pleural cavities, and at this stage of the proceedings the *serous sacs*—peritoneum, pleuræ, and pericardium—should be examined. The *pericardium* is opened by two incisions, commencing at the lower corner on the right side and extending, the one upwards to the aorta, the other outwards to the apex of the heart. In cases where *air embolism* is suspected the pericardial sac should be filled with water, and the right ventricle punctured and pressed, when, if air be present in the right side of the heart, bubbles will appear.

The *general aspect of the thoracic contents* should at this point be noted. The size of the heart and the extent to which it is overlapped by the lungs are points of importance.

In examining the serous sacs look for the presence of *fluid in excess*; note its colour, whether it is clear or turbid or blood-stained. Examine the *surfaces of the viscera*. These ought to be shiny and perfectly smooth. Any dimming of the surfaces indicates inflammatory exudate. Where there are indications of such exudate, films and cultures should be made from the fluid with all necessary precautions. Where *pus* or *fæcal matter* is present *in the abdomen*, careful search should be made for *perforation* of the viscera, more particularly the vermiform appendix, the lower end of the ileum, the stomach, and the duodenum. A careful examination should also be made of the surface of the viscera for any thickening

or adhesions, indicative of ulcerations or tumour formations within.

When *blood* or *blood clot* is present *in the abdomen*, search should be made for a ruptured organ, viscus, or vessel. An area with adherent blood clot is often an indication of the source of the hæmorrhage.

Examine for *adhesions* between visceral and parietal layers of pleura, and note the degree of force required to break down these adhesions.

At this stage, *both lungs* should be *freed* from any *abnormal attachment*. If there are extensive adhesions which cannot readily be broken down, an incision should be made through the parietal pleura, and the latter by means of the fingers torn from the ribs.

Procedure for removing Contents of Thoracic and Abdominal Cavities.—Having examined the serous sacs, the next step is to *remove and examine the contents of the thoracic and abdominal cavities*. The way in which this is done will be determined not infrequently by the nature of the case, the pathologist being guided by the summary of the clinical history, or whatever information is available. To put the matter shortly, there are *two main methods of procedure*: (1) to remove the organs one by one and examine them separate from their surroundings; (2) to remove the contents of the cavities entire or in groups, afterwards to examine canals, vessels, ducts, etc., in continuity with the viscera, and then, and only then, to sever attachments and remove and examine the organs themselves. Unquestionably the latter is the proper method. If the former be adopted, although in many cases no harm will be done, in some instances points will be missed and valuable specimens be ruined. The experienced pathologist can, as a rule, decide whether he may risk adopting the first method, but the tyro ought, if it is at all possible, to make use of the

second. But even if one decide for the second method, certain options present themselves. One may remove the whole contents of both cavities together as Letulle does, but, as already indicated, this has its disadvantages. One may compromise matters somewhat and adopt the method advocated by Shennan, which is excellent, but which necessitates postponing the removal of the thoracic contents (the most important organs in the majority of cases) until all the abdominal organs have been removed.

The method recommended by the author is the removal, in the first instance, of the thoracic contents entire, the examination of the vessels, etc., in continuity, then the separation of the organs and their investigation separately. Subsequently one deals with the abdomen, from which the organs are removed, not en masse, but in groups. This should be the routine method. It has certain disadvantages: œsophagus, aorta, vena cava, and thoracic duct will be cut through. But, as regards the first, the cases in which it is advisable to preserve the continuity of œsophagus with stomach—tumours of œsophagus, cases of poisoning, cases of severe hæmatemesis from varicose veins—are comparatively rare, easily recognised, and special methods can be adopted for the preservation of the continuity. As regards aorta, there is no great disadvantage in examining it in two sections. And as regards the thoracic duct, it is only very rarely (as in cases of acute miliary tuberculosis) that it is advisable to dissect it out and investigate it in its entire length.

(1) *Removal of the Organs one by one.*—Nothing special need be said about the method of procedure in this case. It is usual to begin with the heart, then the lungs, spleen, liver, kidneys, etc. In many cases the pathologist will begin with the organ believed to be mainly affected. As far as possible Orth's rules (p. 15) should be carried out.

(2) *Method of examining the Thoracic and Abdominal Contents by removing them in Groups:—*

EXAMINATION OF THE THORACIC CONTENTS

If not originally begun below the chin, the primary skin incision should be carried upwards to that point. In many cases this may not be necessary, the trachea being cut through at some point above the level of the clavicles. But in some cases it is necessary to have tongue and pharynx attached to trachea. The skin and sterno-mastoid muscles are dissected away from the structures in the neck and beneath the chin. The knife is then passed upwards through the floor of the mouth below the symphysis menti, and by sweeping it round on either side, keeping close to the rami of the lower jaw, the attachments of the muscles are cut through (Fig. 4). The tongue can then be pulled through the opening, and by drawing upon it a view of the pharynx can be obtained. The attachment of soft to hard palate can then be cut through; the posterior wall of the pharynx is incised and dissected down. Care should be taken to include both tonsils in the structures removed. Further traction upon the tongue will then enable the operator to tear through the loose cellular tissue attaching the œsophagus to the prevertebral fascia. At some point the carotids are cut through, also the subclavian vessels. While all this is being done, attention should be paid to any *enlarged glands, thrombosed veins*, etc., which may be met with.

The lungs having been at an earlier stage freed from adhesions, a few touches of the knife will enable the operator, by traction on the trachea in a downward direction, to detach the thoracic contents from the prevertebral fascia as far down as the diaphragm. The œsophagus is then ligatured to prevent the escape of stomach contents. The œsophagus, aorta, and attachment of pericardium to diaphragm are next cut through and the thoracic

viscera are removed and placed upon a table or in the sink.

When it is desired to preserve the continuity of the œsophagus with stomach, and of the thoracic duct and aorta, then the whole of the body contents (thoracic and abdominal) should be removed together, as in Letulle's method.

Æsophagus and Trachea.—The thoracic contents are now placed, anterior aspect downwards, on the table or sink. The œsophagus is slit open with a pair of bowel scissors. The trachea and bronchi are opened in a similar manner. If it is desired to preserve the œsophagus, it can be first removed or turned to the left side. After opening the air passages, *the nature of the contents of bronchi and trachea are noted.*

Aorta.—In the same way the aorta is slit up and examined as far round as the ascending portion. If it be extensively diseased, its continuity with the heart should be preserved. The organs should then be placed anterior aspect upwards, and attention should in the first place be directed to the heart.

Pulmonary Artery.—Incise the pulmonary artery longitudinally, and *examine carefully for the presence of thrombi*, following the branches going to the two lungs as far as possible. Very commonly post-mortem or agonal clots are present, but these are readily distinguished from thrombi (see p. 63).

Superior Vena Cava.—The superior vena cava should then be opened as far as the right auricle. The incision is afterwards carried down to the inferior vena cava.

Heart.—The heart is now separated from the two lungs. For this purpose it is advisable to get an assistant to steady the other viscera. The organ is pulled upwards and over towards the right lung, and the pulmonary veins are cut through as they enter the left auricle. After this the pul-

monary artery and aorta are severed. In cases where the latter is diseased it may be advisable, as already stated, to preserve its continuity with the heart. To do this, a little further dissection is necessary, the aorta being separated from the surrounding structures.

Surface of Heart.—The heart is now taken in the hand and a more careful examination of the *surface* made. Note should be taken of its *shape* and *size*, of any areas of *thickened pericardium* (milk spots), *small hæmorrhages*, *fibrinous exudate*. The amount of *subpericardial fat* should also be noted.

Right Auricle.—Then, attention being turned in the first place to the right auricle, an incision is made from the centre of the previous one joining the two *venæ cavæ* into the auricular appendix, search being made for *thrombi*.

Right Ventricle.—Passing the forefinger of the left hand through the tricuspid valve into the right ventricle and grasping the wall between the finger and thumb, incise the wall of the right ventricle by means of a probe-pointed bistoury, commencing just below the pulmonary artery and carrying the incision down parallel to the interventricular septum and half an inch to the left of it (Fig. 5).

Tricuspid Valve.—Now *test the size* of the tricuspid valve either by means of a suitable cone or with the fingers, the normal orifice admitting three digits. The *segments of the valve* should then be examined. This can be done quite easily from the auricular aspect. One of the segments, the largest as a rule, is situated anteriorly and slightly to the left. It separates the orifice of the valve from the *infundibulum* or *conus arteriosus*, and is therefore known as infundibular segment. The second is situated to the right, corresponding to the free margin of the ventricle; the third lies internally and posteriorly against the ventricular septum, and is known as the septal segment.

Pulmonary Valve. — The *competence* of the pulmonary valve is now tested by allowing a stream of water to fall from a height into the cut end, the sides of the vessel being supported (Fig. 8). The primary incision into the ventricle is then prolonged upwards into the artery, care being taken to cut between the right and left anterior segments. Examine the segments for *thickening* or *vegetations*. Before leaving the right side of the heart examine the *thickness of the muscle* of the right ventricle. Note the *amount of fat* lying over it, and particularly if there is any infiltration of the fat into the muscle.

Left Auricle. — Open the left auricle by an incision joining the two upper pulmonary veins. Continue the incision so as to open the auricular appendix in its entire length (Fig. 5). Examine the interior of the auricle for *thrombi*, *vegetations*, and *thickening of the endocardium*.

Mitral Valve. — A longitudinal incision is now made into the wall of the left ventricle, somewhat anterior to the left border (Fig. 5). The mitral valve is inspected from above and its *diameter measured*. This may be done roughly by the fingers, the valve admitting two digits. Run the knife through the valve and out at the opening in the wall of the ventricle and cut outwards. The segments of the valve are arranged, the larger in front and to the right, between the auricular and aortic openings, the smaller to the left and behind, so that, if done properly, the cut will lie between the segments.

Left Ventricle. — Examine the valve for *thickening*, *calcareous deposits*, *vegetations*, etc., also the *chordæ tendineæ* for *thickening*, *shortening*, *vegetations*, or *rupture*. Note the appearance of the papillary muscles, incising them and examining for *fibrous change*. Note the *colour* and *appearance* of the *muscle* generally, looking for *fatty* and *fibrous* changes. Examine more particularly the state of the muscle towards

the apex of the ventricle where interstitial myocarditis is usually found. Incise the interventricular septum, looking for interstitial change. *Measure the breadth of the wall of the ventricle and test the consistence of the muscle.*

Aortic Valve.—Turn next to the aortic valve. A good way of exposing this valve is to run the probe-pointed bistoury successively into the two coronary arteries, and then to cut upwards and outwards (Fig. 7), thus slitting up the aorta on either side, and at the same time the commencement of the two coronary arteries. Test the *competence of the aortic valve* by a stream of water poured in from above (Fig. 8); *examine the condition of the segments* (there are three—an anterior and a right and left posterior) *and measure the circumference.*

Coronary Arteries.—Next examine carefully the condition of the two coronary arteries, opening up their various branches by slitting with knife or scissors, or, in the case of the finer ones, by cutting them across. *This should be done most carefully in cases of sudden death*, search being made for *impacted emboli or thrombi on atheromatous patches*. If required, the aortic valve may be exposed more fully by cutting between the anterior and the left posterior segment downwards through the anterior wall of the left ventricle until the lateral cut in the ventricular wall is reached.

Certain anatomical points regarding the coronary arteries and their distribution should be remembered. The right vessel, which arises from the anterior sinus of Valsalva, is usually smaller than the left; it supplies the greater part of the wall of the right ventricle, the right auricle, and the greater portion of the left auricle. The left coronary artery, which arises from the left posterior sinus of Valsalva, soon after its commencement divides into two branches. It supplies the outer wall of the left ventricle and the anterior two-thirds of the septum ventriculorum, a small part of the

right ventricle near the septum anteriorly, and the inferior portion of the left auricle. The more important of the two divisions of the left coronary is the descending branch which passes down the anterior interventricular groove. This branch is the one most frequently the seat of atheromatous change. It supplies the apex of the left ventricle and the septum as well as the anterior wall and papillary muscles. Hence it is in these positions that chronic interstitial myocarditis is most frequently met with.

Lungs.—The lungs should now be separated from the mediastinal tissues by cutting through their roots.

Pleural Surface.—Examine, in the first instance, the pleural surfaces, looking for *petechial hæmorrhages*, *fibrinous exudate*, *fibrous thickening*, *puckering*, and *cicatrization*, more particularly at the apices. Note the *colour* of the organs, especially at the posterior and the lower parts. Note also the *consistence*; *feel for any solid areas* or points at apex and along borders. Next *cut into the organs* by a perpendicular incision directed from above downwards, and from its outer, rounded, thick border towards its inner, anterior sharp border (Fig. 6). Other cuts should be made from the original incision forwards to the anterior border in the case of each lobe.

Cut Surface of Lungs.—On the cut surface, note in the first place *alterations in colour*, the presence of *cavities*, *areas of caseation*, etc. Next *feel the lung substance* and *squeeze it*, looking for the *presence or absence of air bubbles* or for the *presence of fluid*; *note the colour and appearance of the fluid expressed*. Examine carefully all *solid areas*, and determine whether the solidity is due to some exudate filling the air cells or to interstitial fibrous change. Suspected solid areas should be placed in a glass beaker of water. *Consolidated areas sink in water*.

Bronchi.—Next open up the bronchi with the probe-pointed bistoury and note the *appearance of any fluid* they contain; also the appearance of their *walls*. *Open up the branches of the pulmonary artery* similarly, *looking for thrombi or emboli*. *Incise the bronchial glands*, noting the *degree of pigmentation*, the *presence of caseous areas* or of *calcification*.

Lastly, the thyroid, parathyroid, and thymus glands should be examined, also the remaining mediastinal tissue.

Thyroid Gland.—The thyroid gland should be examined as regards its *size*. Longitudinal incisions are made into its substance and the *cut surface* examined for *colloid material*, the *presence of cysts*, etc.

Parathyroid Glands.—The average number of parathyroids is four. They are found in close proximity with the thyroid gland, usually posteriorly. They are minute, oval, pink bodies, averaging from 6 to 8 mm. in length.

Thymus Gland.—The thymus gland is situated partly in the neck, partly in the mediastinum immediately behind the manubrium sterni. It is largest during the second year of life ($\frac{3}{4}$ oz. or 20-25 gm.). Until puberty it remains large, thereafter undergoing atrophy, until about the twenty-fifth year it has practically disappeared. Occasionally it may persist throughout life. *An abnormally large thymus gland has been found in certain cases of sudden death, particularly in young children.*

EXAMINATION OF THE ABDOMINAL CONTENTS

Removal of Intestines.—The first step in this procedure is to *remove the intestines, small and large*. The actual examination of these should be deferred to the last moment, in order to avoid the odour of fæcal matter. Before cutting through the mesentery *search should be made for any enlarged*

glands, more particularly caseous or calcareous glands, and the relationship of these glands to the bowel established. Next look for the duodeno-jejunal junction, and having cut through the mesentery at that point, place two ligatures round the bowel and divide it between them. Place a ligature also round the lower end of the rectum and cut it through as low down as possible. Next cut through the mesentery, close to the bowel, from the jejunum to ileo-cæcal valve. This is easily done by pulling upon the bowel with the left hand and merely touching the mesentery with the knife, which, however, cannot be too sharp for the purpose. The knife should be held with its blade perpendicular to the bowel (see Fig. 9).

Having freed the bowel as far as the *cæcum*, the latter *should be removed from its attachments*, along with the ascending colon and appendix. The transverse colon should next be detached from the stomach and removed with the splenic flexure, descending and pelvic colon. In this way the whole of the bowel from jejunum to rectum can be examined in continuity. As previously stated, it is well to defer opening it to a late stage in the post-mortem examination.

Method of opening Bowel.—The *bowel is opened* by means of a pair of bowel or other probe-pointed, sharp-edged scissors, *along its mesenteric attachment* in the case of the *small*, *along one of the longitudinal muscular bands* in the case of the *large intestine* (Fig. 10). The *colour and general appearance of the contents* should, at the same time, be noted.

Examination of Intestine. — Having opened the gut, take it up, piece by piece, commencing with its upper end, and *wash it carefully under a gentle stream of water*. More particular attention should be paid to the lower end of the ileum, where typhoid and tuberculous ulcerations are specially found, and to the large bowel generally. Look for *increase of vascularity, ulcerations, tumours, animal parasites*.

Vermiform Appendix.—The appendix has been looked at during the preliminary investigation of the abdominal cavity. It should now be more carefully examined.

It should always be remembered in connection with the intestinal canal that *post-mortem changes are most marked in the hollow viscera*, and that these changes *tend to mask the appearances in pathological conditions*. Black and greenish-black coloration of the bowel and neighbouring organs is common, and is due to the action of the sulphuretted hydrogen gas from the gut upon the iron pigment of the blood.

Removal of Liver, etc.—In the next place, the *liver*, with the *stomach*, *duodenum*, *pancreas*, and *spleen*, should be removed without disturbing the vascular and duct connections of these organs. This can best be done by standing, in the first instance, on the left side of the body, pulling upon the liver with the left hand and cutting through its connections with diaphragm and posterior abdominal wall. Care should be taken at the start to leave intact the right suprarenal gland, which is in close contact with the liver. The duodenum is then detached by cutting through its peritoneal covering. The liver is then pulled still further over to the left side of the body, and its connection with the large vessels and retroperitoneal tissue cut through. Standing on the right side of the body, the cardiac end of the stomach is cut through, the spleen detached all but its vascular connections, the tail of the pancreas dissected away from left suprarenal, the left lobe of the liver freed from the diaphragm, and the whole group of viscera lifted out. It is more particularly in removing the intestines and other abdominal viscera that an assistant is desirable.

Stomach and Duodenum.—Having placed this group of viscera in the sink or on the table near it, the first procedure is to open the stomach and duodenum. This is usually

done by *cutting with the scissors along the greater curvature of the stomach* and along the anterior wall of the duodenum. Of all organs, the stomach is the one which suffers most from *post-mortem changes*, so that a great deal of what appears to be abnormal in the stomach must be discounted. Look more especially for *ulcers* and *tumours* towards the pyloric end of the stomach, and in the first part of the duodenum. *Press upon the gall bladder* to see if bile can readily be made to flow along the common duct into the duodenum.

Bile and Pancreatic Ducts. — *Incise the common bile duct and pancreatic duct*, pass a probe along them, and if necessary open them up.

Gall Bladder. — Open the gall bladder and note its *contents*, the *colour and consistence of the bile*, and any *gall stones* which may be present. Ascertain whether the cystic duct is patent by passing a probe along it.

Liver. — Attention should next be turned upon the liver. In removing that organ, any *adhesions* between it and the parietes will have been noted. Any *exudate on the surface* of the organ, *thickenings of the capsule*, *cicatrices*, etc., should be searched for. The *size* of the organ should be noted, also any *alteration in shape*, the presence of *perpendicular or horizontal sulci*, such as are caused by tight lacing and the wearing of tight belts.

OUTER SURFACE. — Note *whether the surface is smooth or rough*, also the *colour* of the organ and any irregularity in colouring. *Incise the organ* by means of a number of cuts in a perpendicular direction. Note the *character of the cut edge*, whether rounded or sharp.

CUT SURFACE. — Examine carefully the cut surfaces, noting *colour*, the *outline of the lobules*, *irregularities in colour*, etc. Next test the *consistence* of the liver substance by pushing the finger into it.

Pancreas.—The pancreas is best examined further by a series of transverse cuts. The fat in the neighbourhood of the organ should be examined for areas of fat necrosis.

The *portal and splenic veins should then be opened up* and search made for *thrombi*. The *lymph glands in the neighbourhood of the head of the pancreas* should also be examined.

Spleen.—The spleen, which may be removed by itself or along with stomach and liver, should be *weighed*, its *size* noted, also any *roughening of its surface* or *thickening of its capsule*, also *irregularities in colour* indicating infarcts. Its *consistence* should be noted, and the *organ opened by a longitudinal incision* from its outer surface to its hilum. On the cut surface the *general colour*, the *appearance of the Malpighian bodies*, should they be visible, and the existence of any *tubercle nodules* or *other opaque areas* should be noted.

All the organs have now been removed from the abdomen with the exception of the kidneys, the pelvic organs, and the large vessels.

Removal of Kidneys with Bladder.—Note the position of the kidneys and the courses of the ureters. The kidneys and suprarenals should be removed together. *Where the existence of renal and bladder conditions is suspected, it is well to remove kidneys, ureters, and bladder together.* This can be done by cutting through the blood-vessels of the kidneys and dissecting down the ureters to the brim of the pelvis. A cut is now made through peritoneum round the brim of the pelvis down to the bone, and by means of the fingers the bladder, pelvic colon, and, in the female, the genital organs are all separated from their attachments to the parietes, the vessels, etc. being cut through close to the bone. Grasp these organs with the left hand, pull them upwards and backwards, and cut through the urethra. The point of the knife is then pushed down through the skin of the perineum close to the anus. A circular cut is made round

the anal orifice and the group of organs is removed and placed in the sink.

In the case of the male, when it is desired to retain the continuity between bladder and urethra, as in prostatic disease, cases of rupture of the urethra from fracture of the pelvis, etc., a special method of procedure should be adopted. The pelvic contents are freed from the bony wall as before. The original abdominal incision is then carried downwards for an inch or so along the penis. The penis is then cut through. After freeing the pubic bones from skin and muscular attachments the two rami are sawn through on either side. A little further dissection will enable the operator to remove the whole pelvic contents with the symphysis pubis and root of penis.

If it be desired to remove the female genital organs with bladder and rectum, a cut is made all round the brim of the pelvis through the peritoneum; this is separated as above by means of the fingers from the walls of the pelvis, the knife being used occasionally to divide vessels and nerves. The point of the knife is next pushed down through the skin at one side of the perineum and, by an elliptical cut, the whole floor of the pelvis, including vulva and anus, is cut out. The pelvic organs can now be lifted out from above.

Suprarenals.—Examine the two suprarenals by detaching them from the kidneys and making a series of transverse incisions.

Bladder.—The bladder may now be opened by inserting the probe-pointed bistoury into the urethra and cutting upwards to the fundus. Note any *enlargements of the prostate, ulcerations of the mucous membrane, stone* in the bladder, etc. *Examine the ureters*, and if necessary slit them up.

If there is no obvious reason for keeping the kidneys attached, the ureters are severed at their commencement and the kidneys weighed.

The kidneys may be removed by themselves either after the removal of the intestines, or, in cases where it is not considered

necessary to examine these, before the other viscera are touched. This is done by making a cut through the peritoneum and fascia, inserting the fingers, stripping the organ from its surroundings and pulling it forward. The vessels and ureter are then cut through.

Kidneys.—Note in the first place the *size* of the organs. Examine the *surface* for *irregularities* and *cysts*, the more obvious irregularities of persistent foetal lobulation or old infarction, or the finer markings due to chronic interstitial nephritis. Next *incise the organ* by cutting with the large knife from the outer border to the hilum (Fig. 13); in doing so, note the *consistence* of the organ. *Examine the cortex*, noting its *colour*, its *width*, comparing it with that of the medulla. Look for the *glomeruli*, which may be seen as dark red spots. Note any opaque lines or patches indicating fatty degeneration in the tubules. Look at the large vessels *between cortex and medulla*, and note any *tortuosity* of the *interlobular vessels* which run upwards from them into the cortex. Lastly, note the *amount of fat* which is present between the kidney substance and the pelvis (peripelvic fat) and examine the pelvis itself.

Then, taking the kidney in the right hand, *grasp the capsule* of the organ with a pair of dissecting forceps and *strip it backwards*. In a normal kidney this can be done quite easily, and the surface displayed is perfectly smooth. If the capsule is *thickened* and *adherent*, or if the *surface is rough*, the presence of chronic interstitial nephritis is certain. The appearance of the *small cysts*, so frequently found under the capsule under similar conditions, should also be noted. Note also whether small veins (*venæ stellatæ*) under the capsule are unduly prominent.

Uterus and Appendages.—The uterus is examined by making an incision into it from fundus to cervix, and transverse incisions along the upper border, so as to display the

openings of the Fallopian tubes. The ovaries are incised in their longest diameter.

Testicles.—The testicles may be examined without injuring the scrotum by incising the tissues at the external abdominal ring and pressing the testicle upwards. The gland is opened by an incision in its longest diameter.

Thoracic Duct, etc.—There only remain now for examination the large vessels, the thoracic duct, the retroperitoneal glands, and the cœliac ganglia. The *inferior vena cava*, *aorta*, and *their branches* are slit with scissors along their anterior walls and search made for thrombi and emboli.

The *thoracic duct* will be found behind and to the right of the aorta. In the thorax it lies to the right between the aorta and the azygos vein. It should be examined more especially in cases of *miliary tuberculosis*, and its relation to any caseous lymph gland investigated.

The *semilunar ganglia* will be found on the aorta around the cœliac axis.

EXAMINATION OF THE BRAIN

Scalp Incision.—Place a block under the nape of the neck to support the head. Insert a small knife with its back to the skull under the skin immediately behind the right ear, cut upwards and outwards to the vertex, and from the vertex in the same manner down to a corresponding point behind the left ear. It is advisable to cut outwards in this way in order that the hair may not be cut off. It is well also, in the case of women, to separate the hair along the line of the incision, throwing part forwards and the other part backwards. Raise a portion of the scalp by means of the hair and cut below it with the knife. Then grasp the portion of scalp freed with the left hand, and, pulling forwards

or backwards as the case may be, put the tissues joining scalp to skull and temporal muscle on the stretch, rendering the cutting of them more easy. This should be done forward, nearly to the supraciliary ridges, and backwards to below the occipital protuberance. In carrying this out, *note the presence of any extravasation of blood below the scalp and examine the surface of the skull for fracture.*

Saw-Cuts.—Next, by means of an old knife, mark out the line along which the bone is to be sawn through. In front, this line should run below the frontal eminences, and be carried back on either side, cutting through the temporal muscles to a point just above and behind the ears. Another cut starts from one of these points, and, making an angle of about 160° with the former cut, runs across the back of the skull a little in front of the occipital protuberance to the corresponding point on the other side.

Next, standing on the right side of the body, take a dry towel and throw it over the skull, place the left hand on the towel and through it grasp the calvarium, throwing the anterior portion of the towel over the back of the hand. Take the saw in the right hand and commence to saw through the outer table of the frontal bone, following the previously mentioned lines as closely as possible. The saw-cut should be carried nearly, but not quite, through the inner table, in order to avoid injuring the membranes and brain. When a fracture is suspected, however, it is well to carry the saw-cut through both tables. Then, taking the hammer and chisel, insert the edge of the latter into the saw-cut, and, by a series of sharp taps, crack through the remainder of the inner table. It is well to tilt the chisel slightly, so that the angle of the instrument enters first.

Removal of Calvarium.—The next step is to pull back the calvarium by means of the hook on the cross-piece of the chisel, at the same time separating the dura from the

bone with such an instrument as a periosteum separator. In the case of old people, alcoholics, and also young children the dura may be found too firmly adherent to the bone for this. In such a case the dura should be divided all along the saw cut and removed at the same time as the calvarium. Incise the *superior longitudinal sinus* and examine for clots or thrombi.

Dura Mater.—With a pair of dissecting forceps pick up a portion of the dura mater anteriorly and incise it. Insert a probe-pointed bistoury into the opening and cut round the dura on both sides, at the level at which the skull was sawn through. Insert the knife between the left frontal lobe and the falx cerebri, with the edge towards the falx. Cut through the latter and pull back the dura mater. The dura will usually be found adherent over the vertex by means of vessels and Pacchionian bodies.

Brain Surface.—Examine the exposed surface of the brain, noting its vascularity, any *flattening of the convolutions*, or *filling up of the sulci with exudate* or blood.

Removal of Brain.—Insert two fingers of the left hand under each frontal lobe and gently pull the brain back. Detach the olfactory bulbs from the cribriform plate with the handle of the knife. Cut through the optic nerves and the internal carotid vessels as near the bone as possible. Cut through the 3rd, 4th, 5th, 6th, and 7th nerves. Cut the tentorium cerebelli along its attachment to the petrous portion of the temporal on either side (Fig. 11). Divide the 8th and 9th nerves. Pass the bistoury down the cord and divide it obliquely as low down as possible. Sever the two vertebral arteries and a few nerve roots and the brain will tilt back into the left hand.

Cerebro-spinal Fluid.—During all this process, cerebro-spinal fluid will escape. Note the *amount* and *character* of

this fluid, whether clear or opaque, and, if necessary, secure a specimen for further examination.

Base of Skull.—Either before or after the examination of the brain, the base of the skull should be further investigated. The *lateral and other venous sinuses* should be slit open and their *contents examined*. Where *fracture is suspected*, strip off the dura mater from the bones by means of dissecting forceps.

Examination of Brain.—The brain should now be *weighed* and its *surface further examined*. Note the *condition of the vessels*, more particularly those at the base, looking for *opaque areas of atheroma, thrombi, or small aneurysms*. Note *thickening or opacity* of the pia-arachnoid. Examine for *exudate* in the subarachnoid space, more particularly at the base of the brain. Examine the Sylvian fissures on either side for *small tubercles* along the lines of the vessels. Pass the fingers carefully over the whole surface of the organ, noting the *presence of any area of exceptional softness*.

The method of proceeding further with the examination of the brain depends to a great extent upon the pathological condition present. In a large proportion of cases it is advisable to fix the organ before cutting it up. This is done by injecting 10 per cent formalin, or Pick's or some other preservative, into the larger vessels at the base, placing the whole organ in similar fluid, padding the jar, in which it is suspended by means of a piece of string run through the basilar artery and attached to the lid of the jar, with cotton wool, and leaving it there for some days at least.

Section of Brain.—When it is necessary at once to examine the whole organ, it should be placed vertex downwards and the pons and medulla removed by cutting through the crura cerebri. The cerebrum is then placed upon its

base, and with a large and sharp knife a series of horizontal sections are made at intervals of half an inch, commencing at the vertex, the organ being steadied by means of the left hand placed flat upon it. The pons and medulla are then opened up by means of a series of transverse cuts and the cerebellum examined by an incision from its posterior border to the peduncles. Search is then made on the cut surfaces for *hæmorrhages*, *areas of softening*, *tumours*, etc.

EXAMINATION OF THE SPINAL CORD

Removal of Spinal Cord.—Turn the body over on the face, with the head hanging well down over the end of the table. Make an incision through the skin over the spinous processes from the occiput to the sacrum. Cut the muscles through on either side down to the laminæ, pulling aside the muscles from the spinous processes. Then saw through the laminæ on either side about one half-inch from the middle line, directing the edge of the saw slightly inwards. It is unnecessary to saw below the third or fourth lumbar vertebra, as the cord does not reach farther than the second lumbar. A rough guide for the lower end is the crest of the ilium.

Having partially sawn through the laminæ, complete the process with the hammer and chisel, taking care not to damage the cord. Lift up the spinous processes thus set free at some point, and then, with the bone forceps, proceed to bite through the remainder of the laminæ on either side, lifting up the spinous processes as you proceed. This should be done above as high as the atlas and below as far as the 3rd or 4th lumbar. Free the cord at the lower end by cutting through the nerve-roots and the dura; then, holding dura and cord, cut through the nerve-roots upwards, if necessary removing the ganglia with the roots.

At the upper end of the cord cut through the dura from above, *i.e.* through the foramen magnum, and remove the

whole cord. Next lay the cord on a flat surface, incise the dura anteriorly, and preserve the cord in the first instance in 10 per cent formalin. After two or three days make a series of transverse cuts, dividing the cord into a number of segments which remain attached posteriorly to the dura. Subsequently, thinner portions may be placed in Müller's, Marchi's, or other fixative.

In cases where it is desirable to retain the continuity between brain and cord, as in cases of lesions of the cervical region, the cord should be exposed first and all the nerve-roots severed. The dura mater of the upper portion of the cord is cut through from above, also the upper nerve-roots, and if desired the cord at the level of the foramen magnum may be exposed by taking a wedge-shaped piece of bone from the back of the skull. The cord will now come away with the brain.

Eye and Orbit.—The eye and contents of the orbit may be examined by chipping through the orbital plate of the frontal and removing the pieces of bone with a pair of bone forceps beginning at the optic foramen. The posterior half of the eye can then be removed by making an equatorial cut with a pair of sharp-pointed scissors without damaging the appearance of the face.

Middle Ear.—The middle ear and mastoid antrum can be readily examined after stripping the dura from the base of the skull, by chipping off the upper surface of the petrous portion of the temporal bone with a chisel, or by merely opening through the thin tegmen tympani. For more careful examination it will be necessary to remove the petrous portion of the temporal entire and decalcify it in bulk, afterwards cutting it up (Fig. 12).

Other Accessory Cavities.—The frontal, ethmoidal and sphenoidal sinuses can be opened up by chipping away portions of their bony walls (Fig. 12).

Another method is, after stripping the dura, to make a saw-cut (Harke's) through the base of the skull in its sagittal diameter a little to the right of the middle line (Fig. 12), care having been taken in the first instance to dissect the anterior flap of skin down to the root of the nose, the posterior well down behind the occiput. In making the saw-cut the hard palate and two upper cervical vertebræ must be severed, and great care must be taken not to injure the external surface of the face. The two halves of the skull can then be separated and the right frontal sinus, the ethmoidal labyrinth, and the sphenoidal sinus examined. The *nasal cavities* can be examined at the same time.

In all cases of meningitis careful examination should be made of the cavities in the skull.

The maxillary antrum is best opened by lifting the upper lip, dissecting upwards and subsequently chiselling through the bony wall of the cavity.

Summary of Steps in Method of Procedure.

1. External appearances.
2. Primary incision, reflection of skin and muscles, removal of sternum.
3. Examination of serous sacs — pleuræ, pericardium, peritoneum.
4. Removal of contents of thoracic cavity, examination of
 - (a) Œsophagus.
 - (b) Larynx and trachea.
 - (c) Aorta.
 - (d) Pulmonary artery.
 - (e) Heart.
 - (f) Lungs.
 - (g) Mediastinal contents.
5. Ligature of intestine at junction of duodenum and jejunum, and removal of whole intestinal tract.

6. Removal of stomach and duodenum, liver, spleen and pancreas, and examination of these in detail.

7. Removal of kidneys, suprarenals, ureters, and, if necessary, of the bladder in continuity with these.

8. Removal and examination of pelvic contents and testicles.

9. Examination of abdominal aorta, etc.

10. Opening up skull, removal and examination of brain.

11. Examination of base of skull and accessory cavities.

12. Removal of spinal cord.

13. Examination of peripheral nerves, bones, joints, vessels, etc.

14. Opening and examination of intestine.

LETULLE'S METHOD

After the preliminary incision and the removal of the sternum, the floor of the mouth is cut through close to the jaw, and the tongue, pharynx, tonsils, larynx, œsophagus are dissected down along with the carotid arteries, jugular veins, thyroid and lymphatic glands. The pleuræ are then examined. Should there be no adhesions present, the left lung is drawn over, the operator standing on the right side. The pleura is then cut through longitudinally where it is reflected from the vertebræ on to the lungs and mediastinal contents. The intercostal arteries are then cut through and the œsophagus and other contents of the posterior mediastinum detached from the prevertebral fascia by pulling gently. The same thing is then done for the right pleura, the operator standing on the left side, care being taken in this case not to injure the thoracic duct and the vena azygos major. The brachial plexus and the subclavian arteries and veins are then cut through at the inner margin of the first rib, and the whole contents of neck and thorax are free. In cases where there are extensive firm adhesions between parietal and visceral pleura it is necessary to tear away the parietal pleura from the ribs and intercostal muscles by means of the fingers. The attachments

of the diaphragm are then cut through, taking care not to injure stomach or liver. The whole of the parietal peritoneum is then stripped, along with the abdominal contents, including kidneys, vessels, etc., leaving only the psoas muscles. The iliac vessels are cut through as low down as possible. The peritoneum is stripped from the sides of the pelvis, the skin is cut through round the anal orifice, and the whole of the viscera removed and placed upon a dissecting table.

The examination of the parts in detail commences by placing the viscera with their posterior aspect upwards and opening the venæ azygos major and minor and the thoracic duct. The suprarenal glands are then removed and examined. The ureters are isolated and opened, the kidneys removed and examined. The aorta and the inferior vena cava are then opened throughout their length. The trunk and rootlets of the portal vein are isolated and opened up and the common bile duct examined. The aorta is then dissected away from other structures and the œsophagus and cardiac end of the stomach isolated. The tongue, pharynx, and tonsils are then examined and the œsophagus, trachea, and bronchi opened up. The vagus and other nerves and the lymph glands of the neck are investigated. The viscera being turned over, the thymus and thyroid glands are examined. The superior vena cava and its tributaries are then opened. Next, the pericardium is opened, and the first part of the aorta, the pulmonary artery and veins and their branches outside the lungs are opened up. The heart is next examined externally and removed from its attachments. The lungs are also detached and examined. After examination of the diaphragm, the liver and its bile passages are investigated and detached, also the spleen. Next, the stomach, pancreas, and duodenum are isolated and, along with the œsophagus, removed, opened up, and examined. The intestinal canal is then examined from the outside, detached, opened, and investigated in its various sections. The examination finishes with the genital organs and urinary bladder.

SHENNAN'S METHOD

The organs are removed in the following order:—

- (1) Small intestine,—with or without—
- (2) Large intestine.
- (3) Stomach and duodenum, with liver, bile ducts throughout their whole length, pancreas, spleen, and mesentery.
- (4) Kidneys with suprarenals and ureters.
- (5) Thoracic contents along with the cervical soft structures, the aorta in its whole length, inferior vena cava, crura of the diaphragm with solar plexus and receptaculum chyli.
- (6) Pelvic organs, which in certain cases may be removed in continuity with large intestine, and kidneys.

Stitching up Incisions. Toilet of the Body.—After the completion of the examination it is absolutely essential that the body be restored as nearly as possible to its original condition.

In the first place all fluid should be got rid of by tilting the body or by swabbing out the cavities with sponges. The organs are then replaced and sawdust, wool, tow, or newspapers used to compensate for the loss of fluids, etc. Firm plugs of wool are then placed in the mouth, anus, vagina, etc., in order to prevent the escape of any fluids.

The skin incisions are closed by means of the glover's or blanket stitch, a packing needle and strong twine being used. In carrying out this procedure the needle is always passed from within outwards, the slack of the twine being held firmly between the fingers of the left hand (Fig. 14). The stitches should be about half an inch apart.

Finally, all trace of blood is removed from the surface of the body by sponging.

Cleansing of Gloves and Hands.—After completing all operations in which the hands come in contact with the body or its contents, the gloves, while still on the hand, should be washed in cold running water, at first without, then with soap. Subsequently they are washed in biniodide

of mercury spirit. They are then removed from the hands, and if any leakage of blood or other fluid has occurred the interior should be treated in a similar fashion.

The hands are then thoroughly washed with soap in cold running water.

CHAPTER IV

DISEASES OF THE HEART AND PERICARDIUM

MALFORMATION OF THE HEART AND GREAT VESSELS

THE heart is developed in the first instance as a single tube, with primitive auricle, ventricle, and aortic bulb. The structure later becomes bent upon itself and septa appear in all three divisions, so that eventually there are two auricles, two ventricles, and two vessels—the aorta and pulmonary artery. The commonest congenital malformations of the heart are associated with defects in the formation of these septa.

1. **Defective Interauricular Septum.**—A degree of this, *i.e.* slight patency of the foramen ovale, is a very common occurrence (30-50 per cent of cases). In the vast majority of the cases, owing to the smallness of the aperture and to its oblique direction, there is no interference with the function of the organ. In cases of stenosis of the pulmonary artery or aorta, however, the defect in the septum may be marked.

2. **Defective Interventricular Septum.**—The separation of the ventricle into two begins near the apex. The septum rises towards the base. The last portion to form is the portion represented by the “undefended spot” in the

fully developed heart. It is at this point that defects in the septum most commonly occur. As in the case of defective interauricular septum, patency is usually associated with defects in the vessels, most commonly with stenosis of the pulmonary artery. Complete absence of the septum results in the so-called three-chambered heart.

3. Congenital Stenosis of the Pulmonary Artery.—

This is one of the commonest congenital defects, and its existence leads to a number of others—defective interauricular and interventricular septa and patency of the ductus arteriosus. The narrowing may occur at the valves or in the artery beyond the valve. The cause may be (1) malformation of the septum dividing pulmonary artery from aorta, the septum being found too far to the right. (2) Fœtal endocarditis. All degrees of the condition to complete obliteration or atresia may be found.

4. Congenital Stenosis of the Aorta.—This is much more rare than the preceding condition. Again, it may occur at the valve or in the vessel beyond. When it occurs at the valve there is usually defect of the septa superadded. Stenosis of the vessel beyond, owing to the persistence of the ductus arteriosus, is not of so much importance, the circulation being carried on through the latter vessel. Stenosis is sometimes caused by a circular fibrous band at the point where the ductus arteriosus joins the aorta.

5. Persistence of the Ductus Arteriosus, or, in other words, patency in extrauterine life of the communication between the pulmonary artery and the thoracic aorta accompanies other defects, such as narrowing of the pulmonary or aortic orifices.

6. Abnormalities in the Valves.—These mostly occur in the semilunar valves. (a) There may in the first place be *complete fusion* of the segments leading to stenosis. (b) There

48 DISEASES OF THE HEART AND PERICARDIUM

may be *only two cusps*, a large and a small one, the larger in some cases showing evidence of partial division into two. (c) The *segments may be abnormally numerous*. There may be four instead of three, and all differing in size. (d) The *segments may show fenestrations*. This is a common occurrence, but as the openings are usually close to the free margin, and as the area of contact of the segments extends some distance from the free margin, there is no incompetence of the valve as a result.

Of congenital anomalies of the auriculo-ventricular valves the commonest is *coalescence of the segments of the tricuspid valve*. This may be due to foetal endocarditis. It leads to patency of the foramen ovale.

7. Abnormalities in the Great Vessels.—There may be *transposition* of the aorta and pulmonary artery, so that the latter takes origin from the left ventricle, the former from the right. Occasionally a *double aorta* is met with—a condition found normally in reptiles. Or the *aorta may pass to the right*, the condition found in birds.

The *heart may be situated to the right side of the body*. This may or may not be associated with transposition of the other viscera. Occasionally the *pericardial sac is absent* and the *heart may be situated* in the abdomen (ectopia cordis).

DISEASES OF THE PERICARDIUM

Under the term *pericardium* are included (1) the sac formed of fibrous tissue, triangular in shape, whose base rests upon the diaphragm, and whose sides are attached to the pleuræ laterally, the lower portion of the sternum anteriorly, and the mediastinum posteriorly; (2) the serous endothelial lining of this (parietal pericardium) which is reflected on to the surface of the heart (visceral pericardium or epicardium), and (3) the subserous connective tissue and fat. No hard-and-fast line can, of course, be drawn between diseased conditions of the epicardium and those of the myocardium.

If one is affected, the other of necessity must be. For purposes of classification it is necessary, however, to draw a distinction between them.

After the removal of the sternum and costal cartilages the position of the pericardial sac and its contents as regards the other structures in the thoracic cavity should be noted, also any abnormal distention of the sac. The pericardial sac is, of course, one of the serous sacs or large lymphatic spaces of the body, and as such it is liable to conditions which tend to affect these sacs. Such are œdema or over-filling of these spaces with lymph, inflammatory conditions, more particularly in acute rheumatism.

Hydropericardium, or dropsy of the sac.—There is always a small quantity of clear, straw-coloured fluid in the sac (about $\frac{1}{2}$ oz.). When this is increased to any extent the term *dropsy* is applied. The condition is usually a late manifestation of general dropsy, the cause being commonly kidney or heart disease. Œdema of the tissues of the pericardium themselves may not infrequently be observed, either accompanied by dropsy of the sac or without it.

Hæmopericardium, or blood in the sac.—This is a very rare condition. It may be due to (i.) a *penetrating wound*—bullet wound or stab; (ii.) *rupture of the heart* from (a) degenerative changes in the muscle associated with obstruction to the coronary arteries (common position, the anterior aspect of the left ventricle close to the septum and not far from the apex), (b) abscess of the heart wall communicating with one of the cavities (Fig. 16), (c) injury—a crush (common position, base of heart); (iii.) *rupture of an aneurysm* of the heart itself, of one of the coronary arteries or of the commencement of the aorta; (iv.) *very acute inflammation* of the pericardial sac.

Small extravasations of blood into the substance of the subpericardial tissue (ecchymoses or petechial hæmorrhages) are fairly common. They are found in toxic conditions and

in severe anæmias. They are chiefly situated at the base of the heart, and often on the posterior aspect.

Pneumopericardium, or air in the sac.—A very rare condition, usually associated with purulent pericarditis due to rupture of the œsophagus or stomach into the sac. The gas may be due to the presence of germs, *e.g.* *B. aerogenes capsulatus*.

INFLAMMATION OF THE PERICARDIUM (PERICARDITIS)

Types.

1. Acute pericarditis.
 - (a) Fibrinous, (b) serous, sero-fibrinous, (c) purulent, (d) hæmorrhagic.
2. Chronic pericarditis, (a) following acute, (b) "milk spot."
3. Adherent pericardium.
4. Tuberculous pericarditis.

1. Acute Pericarditis.—This is due invariably to the presence of some germ. Those more commonly found are *micrococcus rheumaticus*, *staphylococci*, *streptococci*, *pneumococci*, etc. The condition occurs in the course of acute rheumatism, pyæmia, pneumonia, kidney disease, the organisms reaching the pericardial sac by the blood or by continuity of tissue from lung, pleura, mediastinum, or heart wall.

The essential point in pericarditis is the presence of an exudate on the surface of the pericardium which coagulates, thus roughening it and causing it to lose its gloss. The amount of this exudate may be very small, forming a mere roughness on the surface, or it may occur as an irregular, thick, opaque, white layer producing a shaggy appearance (*cor villosum*) (Fig. 15). If the pericardial surface is visible the vessels are seen to be injected. The exudate may be

red in colour from hæmorrhage. The amount of fluid in the sac in this condition is variable. Sometimes it is small, forming the so-called "dry," plastic, or *fibrinous* variety, found more especially in kidney disease and in pneumonia. More commonly there is some free fluid with flakes of lymph floating in it. In such a case the term "*serous*" or "*sero-fibrinous*" may be applied. In some cases the fluid is *purulent*, more especially in pyæmia or septicæmia. Occasionally, in intense inflammations, blood in considerable amount is mixed with the exudate (*hæmorrhagic pericarditis*). In the early stages the fibrinous exudate can easily be removed. Later on, when organisation has commenced, it will be found bound down by fine threads which represent penetrating young blood-vessels.

Microscopic Appearances.—The vessels of the subpericardial tissue are dilated. There is a meshwork of fibrin on the surface of the pericardium, and some in the spaces of the tissue itself. Numerous leucocytes (chiefly polymorphonuclear) are found infiltrating the pericardial tissue and caught in the meshes of the fibrin on the surface. In the early stages the endothelial cells are swollen and vacuolated; later they become detached and occur in the fibrin.

Later on, evidence of organisation of the exudate is found. The endothelial cells of the vessels of the subepicardial tissue are swollen and show evidence of proliferation. Small buds can be seen protruding from these vessels and making their way into the fibrinous exudate. At the same time there is swelling and proliferation of the connective-tissue cells generally. The newly formed cells (fibroblasts), which are at first small and rounded, with a fair amount of pale-staining protoplasm and a rounded, relatively small nucleus, accompany the newly formed vessels into the exudate. Where organisation is advanced, the fibroblasts farthest from the pericardium will still be rounded, the deeper ones will be spindle-shaped and arranged parallel with the vessels; still nearer the pericardial surface they tend to lie parallel with that surface and perpendicular to the direction of the new blood-vessels. From the

52 DISEASES OF THE HEART AND PERICARDIUM

protoplasm of these older fibroblasts the collagenous fibres of the new tissue are developed.

In suitably stained specimens micro-organisms may be found.

Results: (1) the exudate may be absorbed, and matters return to the normal.

(2) Organisation with union between heart and pericardial sac may take place (Adherent Pericardium). This union may be partial or complete. If complete, more especially if the surrounding tissues of the mediastinum participate in the inflammatory process, great interference takes place with the action of the heart, with the result that it tends to dilate.

(3) If the exudate be not absorbed it may be the seat of deposit of lime salts, the result being the formation of calcareous plates. This is a rare occurrence.

2. Chronic Pericarditis.—This may follow acute, or it may develop slowly, the result of friction. (a) Following acute, the condition is usually associated with adhesion between visceral and parietal pericardium. (b) A more common variety of it consists in the fibrous thickenings of the pericardium, often called "milk spots" or "soldier's spots." These are white, opaque, well-defined areas, often with a tendinous appearance. They are most frequently found on the anterior surface of the right ventricle. Another common site is the anterior surface of the left ventricle close to the apex. Similar areas are often found thickly covering the surface of the auricles. They are also not infrequently found along the course of the coronary arteries. They are more particularly found in hypertrophied and dilated hearts, and are due to constant friction.

Microscopically all that is to be seen is a thickening of the fibrous tissue under the endothelium.

3. Adherent Pericardium.—This condition not infrequently follows acute fibrinous pericarditis. The layers of

fibrin on visceral and parietal pericardium become organised. Young connective tissue forms between these layers, and the heart is permanently attached to the pericardial sac. This may occur over a limited area, frequently at the apex of the left ventricle. Very often, however, it occurs all over. The inflammatory change may also spread to surrounding structures, such as pleura, mediastinum. The mediastinal glands are enlarged and firm. In this condition the heart is usually enlarged, the cavities being dilated and their walls thickened. There is backward pressure from relative incompetence of the valves, and chronic venous congestion of the organs, such as lung, liver, and spleen. The condition not infrequently causes death from constant excessive strain on the heart.

4. **Tuberculous Pericarditis.**—This may occur as a sub-acute condition associated with the presence of small grey and yellow nodules of tubercle. It is often combined with general miliary tuberculosis. Sometimes the tubercle nodules are found along the course of the coronary vessels without any other evidence of inflammation being present, and sometimes there is excessive distention of the pericardial sac by fluid. Tuberculous pericarditis is, however, a rare condition in the human subject. It is relatively much more frequent in the bovine species.

DISEASES OF THE MYOCARDIUM

DEGENERATIVE CHANGES

Atrophy.—In old age and in wasting diseases, such as tuberculosis and cancer, the heart tends to get smaller, sometimes being reduced to one-third of its usual size. As the process goes on, the epicardium, which does not participate in the shrinkage, becomes wrinkled, the vessels more tortuous,

and the fat under the epicardium reduced in amount. At the same time the muscle substance becomes a darker brown colour. This condition is known as *brown atrophy*. The brown colour is due to the increase of the pigment found normally in the muscle cells, and is probably a coloured fat or lipochrome.

Microscopically the individual fibres of the myocardium are sometimes smaller than normal, but the main change is an increase of the golden yellow granules of pigment which are found in small amount normally at the two poles of the nuclei.

Cloudy Swelling.—This condition is found accompanying infective diseases, more especially those associated with high temperature. The muscle substance is pale, soft, and friable. The friability can be tested by pushing a finger into the muscle.

Microscopically there is often very little alteration to be seen. The individual fibres are somewhat swollen and granular, and there may be some loss of longitudinal and occasionally of transverse striation.

Fatty Changes.—Types.

1. Due to increase in the subpericardial fat.
 - (a) Fatty loading.
 - (b) Fatty infiltration.
2. Due to degenerative changes in the muscle fibres (fatty degeneration).
 - (a) Diffuse form.
 - (b) Patchy form.

1. *Fatty Loading and Fatty Infiltration.*—This condition comes, strictly speaking, under diseases of the pericardium, but for the sake of contrast with fatty degeneration it may be taken here.

There is in all healthy hearts a certain amount of fat in the subpericardial tissue, more especially in that covering

the right ventricle. It occurs particularly along the lines of the vessels and at the base between the auricles and ventricles. In very fat people this adipose tissue is increased in amount, so that not infrequently the whole of the anterior surface of the right ventricle may be covered by it. This is what is known as *fatty loading* of the heart. The increase of fat may also occur in anæmia and in association with atrophy of the heart muscle.

As the fat increases in amount it tends to make its way along the lines of the vessels which penetrate into the muscle substance, leading to indistinctness in the line which separates fat from muscle. When this has occurred, the term *fatty infiltration* is applicable (Fig. 18). The fat in this way tends to separate the bundles of muscle substance from one another, and to cause an atrophy of these by pressure. This fatty infiltration of the heart often accompanies fatty loading, but it may occur where there is relatively little increase in the amount of subpericardial fat.

Microscopically, the rounded fat globules can be seen passing down from the subpericardial fat along the lines of the vessels into the muscle substance. The muscle fibres themselves are compressed and atrophied.

2. *Fatty Degeneration*.—This is a totally different condition from the preceding. It is a degenerative change *in the muscle fibres themselves*. It is found more especially in toxic conditions, such as alcoholic or phosphorus poisoning, bacterial diseases, and in severe anæmias. Two forms of it are distinguished: (1) a *diffuse form*, where the whole muscle substance is uniformly pale, soft, and friable; (2) a *patchy form*, which is usually best seen towards the inner portion of the wall of the left ventricle, more especially in the papillary muscles. In this position the muscle has a mottled appearance, with small transverse parallel patches—the so-called “thrush breast” mottling or “tabby cat” striation.

56 DISEASES OF THE HEART AND PERICARDIUM

Microscopically groups of muscle fibres are found containing numerous small droplets of fat in their protoplasm.

ALTERATIONS OF THE CIRCULATION

Chronic Venous Congestion.—This occurs in conditions where there is backward pressure on the right auricle and therefore on the blood in the coronary sinus. It is accompanied by chronic venous congestion in other organs. The muscle substance is firmer and thicker than usual and is dark in colour.

Microscopically there is distention of the veins and capillaries with blood.

Effects of Obstruction of the Coronary Arteries on the Myocardium.—The branches of the coronary arteries within the heart belong to the group of what were originally called "end" arteries. They are not as a matter of fact entirely devoid of collateral communications, as the name would indicate, but such communications as they have are small, so that when a branch is blocked the circulation cannot be fully restored, and *infarction* occurs. The effect of the obstruction of these branches upon the heart depends to a large extent upon whether it is *sudden* and *complete*, or whether it occurs *slowly*, and is therefore, for some time at any rate, *partial*.

1. *The effect of sudden obstruction* of a large branch of one of the coronary arteries is, as a rule, to produce instant death. When the branch is a small one and the patient survives, infarction occurs. The *cause* of the obstruction is either thrombosis upon an atheromatous patch in the artery or impaction of an embolus. More usually it is the former. *In all cases of unexplained sudden death careful search should be made for such thrombi by slitting up the branches of the coronary vessels.*

The infarcted area is commonly in the anterior wall of the left ventricle, in the part of the myocardium, that is to say,

supplied by the left coronary artery. The area is roughly triangular in shape, with the broad base towards the interior of the ventricle. It may be red or pale. In the early stages it is usually red, becoming pale later on, as necrosis supervenes. Ultimately connective tissue develops, and all that is left is a fibrous scar.

Owing to the weakening of the muscle at the point of infarction, *aneurysmal dilatation* of the wall may occur, or even sudden, complete *rupture*.

Microscopic Appearances.—In the early stages the muscle is found infiltrated with red blood corpuscles. The muscle fibres are swollen, have lost their transverse striation, and stain deeply. The nuclei lose their staining reaction. Later, the area becomes infiltrated with leucocytes and young connective-tissue cells. The degenerated fibres are absorbed and connective tissue takes their place.

2. *Slow Progressive Narrowing of the Coronary Arteries.*—This is due as a rule to *thickening of the intima from atheromatous change*. It leads to degenerative changes of a fatty nature in the muscle fibres of the area supplied, and a gradual replacement of these by well-developed fibrous tissue. As it is the *anterior* or *descending branch* of the left coronary artery which is usually the seat of the most marked change, the fibrosis occurs in the wall of the left ventricle near its apex, in the papillary muscles (Fig. 17), and in the interventricular septum. Owing to the weakening of the heart wall, rupture or aneurysmal dilatation may occur. The change produced is precisely the same as that described under *chronic interstitial myocarditis*. Indeed, slow progressive narrowing of the branches of the coronary artery is the commonest cause of that condition.

Aneurysm of the Heart.—This is most frequently met with towards the apex of the left ventricle. The causation in such cases is usually progressive narrowing of the descending branch of the left coronary artery. The connective tissue

which takes the place of the degenerating muscle is unable to withstand the pressure within the ventricle. The condition may also develop acutely from infarction of the heart muscle or acute myocarditis (Fig. 16). On the inner aspect of such dilatations, thrombosis tends to occur. An aneurysm of one of the sinuses of Valsalva may also penetrate the heart muscle.

INFLAMMATION OF THE MYOCARDIUM (MYOCARDITIS)

Types.

1. Acute myocarditis.

(a) Non-suppurative, (b) suppurative.

2. Chronic interstitial myocarditis.

(a) Following acute, (b) associated with narrowing of the coronary arteries, (c) due to chronic inflammatory conditions (tubercle, syphilis).

1. Acute Myocarditis.—This may be due to (1) *spread of inflammation* from the pericardium or endocardium, or to (2) *blood infection*, as in acute rheumatism, ulcerative endocarditis, pyæmia, etc. The muscle substance may show little alteration from the normal. It is somewhat soft, friable, pale, and mottled. In the special type—*suppurative myocarditis*—small abscesses are seen as minute white points surrounded by zones of congestion and hæmorrhage. Very occasionally large abscesses may form which lead to rupture of the heart (Fig. 16).

Microscopically the muscle substance is found infiltrated with leucocytes, more especially in the neighbourhood of vessels. The leucocytes may be aggregated into large masses, with hæmorrhage around and plugs of cocci in the centre of the abscesses. The muscle fibres themselves show cloudy swelling, or, in the neighbourhood of abscesses, actual necrotic change.

2. Chronic Interstitial Myocarditis.—In this condition there is a *replacement of the muscle substance by fibrous tissue*.

It may (1) *follow acute myocarditis*, (2) *be associated with narrowing or obstruction of the coronary artery or its branches*, (3) *occur in connection with chronic inflammatory diseases*, such as tubercle and syphilis. *The commonest cause is undoubtedly narrowing of branches of the coronary artery.* A slight degree of the condition is often seen in old age due to the same cause.

The condition is usually most marked in the *wall of the left ventricle near the apex*. It should also be sought in the *papillary muscles*. The muscle substance in these areas is partially replaced by white or grey fibrous strands (Fig. 17). The endocardium is often thickened over a corresponding area and thrombosis is frequently associated. The condition may give rise to aneurysmal dilatation of the heart wall.

Microscopically the groups of muscle fibres are found separated from one another by bands of well-developed fibrous tissue. The isolated muscle fibres are often unusually large, with large, dark-staining nuclei.

Syphilis of the myocardium is occasionally met with either as gumma formation or as a diffuse interstitial myocarditis associated with arterial disease.

Tuberculosis of the myocardium is also a very rare condition. It may be met with as small miliary tubercles or as large caseous masses.

HYPERTROPHY OF THE HEART

A general hypertrophy of the heart occurs in those, such as athletes, who constantly over-exert themselves. It also occurs in pregnancy. Hypertrophy of one or more chambers of the heart is usually associated with chronic valvular lesions. Conditions, other than cardiac lesions, associated with hypertrophy of certain cavities are emphysema and

60 DISEASES OF THE HEART AND PERICARDIUM

chronic interstitial disease of the lungs with hypertrophy of the *right* ventricle, chronic kidney disease, and arteriosclerosis with hypertrophy of the *left* ventricle (Fig. 24).

DILATATION OF THE HEART

General dilatation of the heart is found in association with degenerative changes, such as cloudy swelling and fatty degeneration. The dilatation is usually most marked on the right side. In adherent pericardium of any marked degree the heart as a whole tends to dilate.

Dilatation of the right side is found as a rule in cases of death from heart failure. It also occurs in chronic valvular disease involving the mitral or aortic valve. *Dilatation of the left ventricle* associated with hypertrophy occurs in a marked degree in cases of aortic incompetence.

Tumours of the heart are excessively rare. Primary tumours such as fibromata or myomata are described. Secondary tumours—sarcomata and carcinomata—occasionally occur, but may involve the heart very extensively before they result in death.

DISEASES OF THE ENDOCARDIUM

DEGENERATIVE CHANGES

Red staining of the endocardium is found as a result of putrefactive processes, also in septic conditions. It is due to the setting free of hæmoglobin from the red blood cells.

Small hæmorrhages may occur under the endocardium in infective conditions and anæmia.

Areas of **fatty degeneration** occur as white specks or patches, more especially in infective conditions, in anæmias, and in cases of phosphorus and chloroform poisoning. These areas occur chiefly on the valves. Under the microscope the

protoplasm of the endothelial and of the subjacent connective-tissue cells is found filled with fat globules.

Calcareous and **uratic deposits** are found more especially in the valves, and chiefly in association with chronic inflammation. They appear as opaque white or yellow areas of thickening, sometimes with a roughened surface, on which thrombi may be deposited.

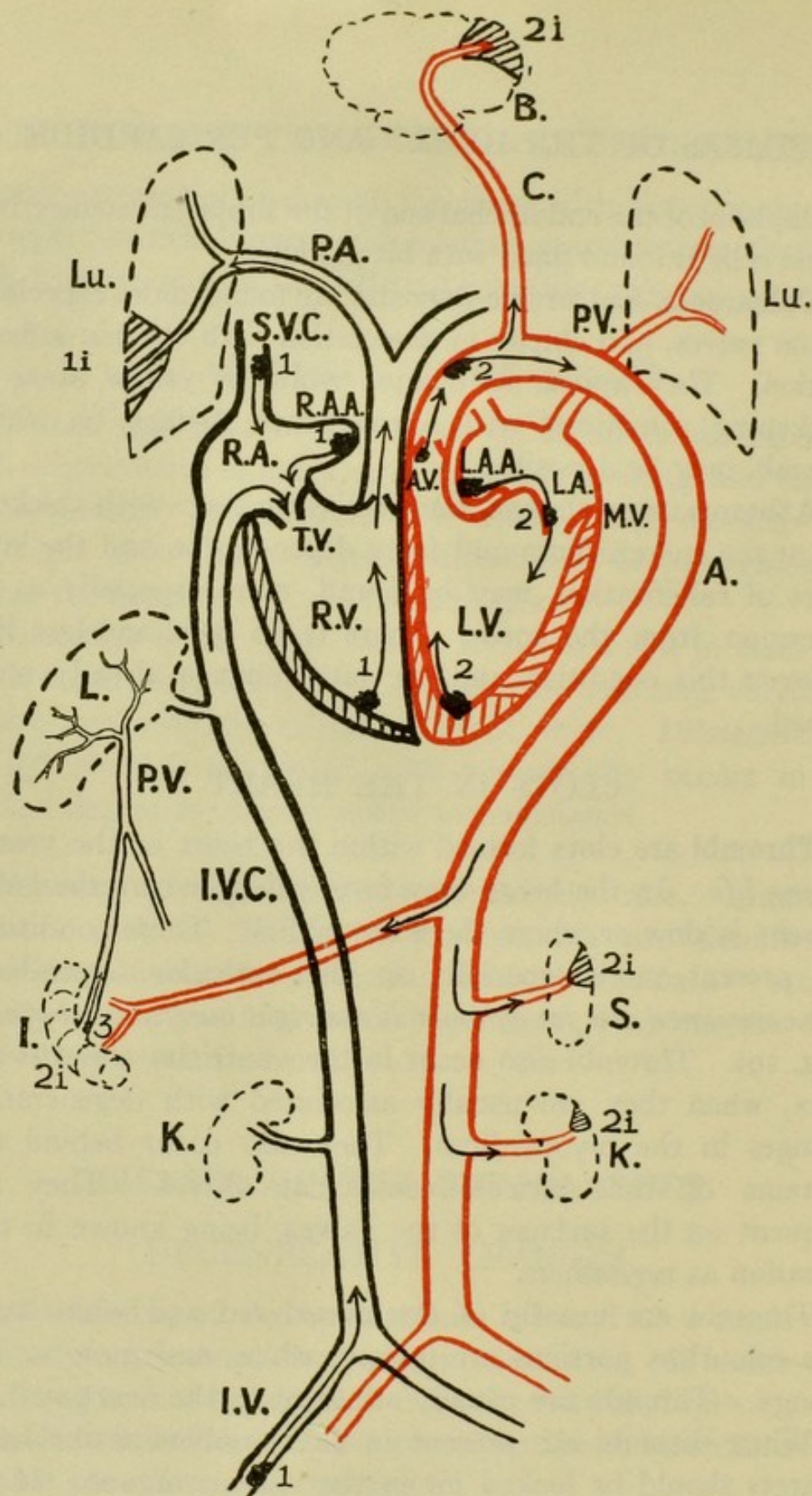
Atheromatous change, both the early stage with thickening of the endocardium and fatty degeneration and the later stage of calcification, may be found, more especially as an extension from the aorta. There is no hard-and-fast line between this condition and the fatty change already mentioned.

CLOTS IN THE HEART

Thrombi are clots formed within the heart or the vessels *during life*. In the heart they form chiefly where the blood current is slow or where there are eddies. These conditions are present more especially in the auricular appendices. *The commonest site for thrombi is the right auricular appendix* (Fig. 19). Thrombi also occur in the ventricles towards the apex, when they are usually associated with degenerative changes in the myocardium. They also occur behind the curtains of the auriculo-ventricular valves. They are frequent on the surfaces of the valves, being known in this situation as *vegetations*.

Thrombi are usually of the mixed red and white type. The colourless portions are opaque white, and more or less stringy. Thrombi are usually adherent to the heart wall.

When thrombi are present in the chambers of the heart infarcts should be looked for in the various organs. If the thrombus is on the right side the infarcts will be found in the lung (except in the rare case of a patent foramen ovale), if on the left side the infarcts may be in brain, spleen, kidney or intestine (see Diagram, p. 62).



Plan of the Circulation to show the Origin and Destination of the more common Emboli.

1, 1, 1 are thrombi in iliac vein (I.V.), or its branches, *e.g.* superficial veins of leg, uterine veins, Superior Vena Cava (S.V.C.), or its branches, *e.g.* cerebral sinuses, right auricular appendix (R.A.A.) and right ventricle (R.V.), which may give rise, by washing away of portions, to infarcts (1i) in the lung (Lu). 2, 2, 2 are thrombi in left auricular appendix (L.A.A.), on mitral valve (M.V.), in left ventricle (L.V.), on aortic valve (A.V.) and on wall of aorta (A), which may give rise, by washing away of particles, to infarcts 2i, 2i, 2i in brain (B), intestine (1), spleen (S), kidney (K). 3 is a thrombus in rootlet of portal vein (P.V.) which might give rise to infarction or, if septic, to abscess-formation in the liver (L).

Post-mortem clots, on the other hand, are red or yellow, translucent or transparent, jelly-like masses which are not adherent. Clots often cling to the columnæ carneæ, but they are not really adherent to the heart wall.

"Agonal" clots occupy a position between the true thrombi and the post-mortem clots. They are more opaque than the clots, they may be stringy, but are not adherent. They are found more particularly on the right side of the heart, extending up into the pulmonary artery. They may completely fill the right auricle and ventricle. They are found especially in pneumonia and other infective conditions.

Rounded thrombi lying free in the auricles, so-called "ball" thrombi, are sometimes found in cases of stenosis of the mitral valve. They, as well as other thrombi in the auricles, often show softening, sometimes liquefaction of their interior (red or simple softening).

(For microscopic appearances of thrombi, see p. 88.)

	Thrombi.	Agonal Clots.	Post-mortem Clots.
Position.	Auricular appendices, valves (vegetations). Apices of ventricles.	Mainly right auricle, ventricle and pulmonary artery.	Anywhere, but chiefly on right side.
Appearances.	Opaque, white, buff-coloured or red.	Semi-opaque. Often fill cavity.	Transparent.
Consistence.	Stringy, friable, sometimes softened in centre.	Soft and gelatinous.	
Relations to heart walls.	Adherent. When broken off, leaving portions behind.	Non-adherent. May cling to columnæ carneæ, hordæ tendinaceæ, etc.	
Associated diseased conditions	Chronic valvular disease of heart. Chronic interstitial myocarditis. Aneurysm of heart wall.	Infective conditions such as acute lobar pneumonia, pyæmia, septicæmia.	

INFLAMMATION OF THE ENDOCARDIUM
(ENDOCARDITIS)

The endocardium possesses no direct blood-supply, nor do the semilunar or auriculo-ventricular valves. This fact in all probability accounts for the rarity of inflammatory phenomena in the ordinary sense of the term in connection with these structures. On the other hand, the intimate connection between endocardium and valves and the circulating blood renders these structures peculiarly susceptible to the action of germs or poisons which may be present in the blood-stream. Once the endocardium is damaged, thrombosis tends to occur upon the injured surface, with the formation of what are called vegetations. Another fact in the production of the more chronic types of endocarditis is strain. Thus the valves of a dilated and powerfully acting heart tend to become thickened.

Types.

1. Acute endocarditis.
 - (a) Simple or vegetative.
 - (b) Ulcerative or malignant.
2. Chronic endocarditis.
 - (a) Following acute.
 - (b) Associated with atheroma.
 - (c) Associated with strain.

1. **Acute Endocarditis.**—This condition is probably invariably due to the presence of germs upon the endocardium. Two sub-varieties are distinguished: (a) *simple* or *vegetative*, and (b) *ulcerative* or *malignant*. *There is no hard-and-fast line between these two.* They are both due to the presence of germs, and may be due to the same germs. The simple type, however, has a very constant relationship to acute rheumatism, and is thus caused probably by the *micrococcus rheumaticus*. The malignant type may be caused by a variety of germs, such as *pneumococcus*, *streptococci*, *staphylococci*, *gonococcus*.

In both varieties the essential change is the presence on the damaged valve of vegetations or thrombi, and, as stated above, no hard-and-fast line can be drawn between the two conditions. In deciding in any case as to which condition is present the following points should be attended to. (1) *Character of vegetations.* These in the ulcerative type tend to be larger and more friable. (2) *Extent.* In simple endocarditis the vegetations are limited to a line close to the free margin of the valve; in ulcerative endocarditis they extend not merely all over the valve but on to the surface of auricle in the case of mitral disease, on to aorta or heart wall in the case of aortic disease; also in the case of the mitral valve they extend on to the chordæ tendineæ. (3) *Effect on valves.* In the case of simple endocarditis beyond swelling of the valve no special change is observed. In the ulcerative type destruction of the valve, aneurysm or rupture of the valve or of the chordæ tendineæ is often met with. As regards the site, both varieties are found much more commonly on the left side of the heart. When endocarditis occurs during foetal life it is found more frequently on the right side.

(a) **Simple Acute Endocarditis.**—This is usually met in connection with the mitral and aortic valves, more rarely on tricuspid or pulmonary valves. It is most commonly associated with acute rheumatism, but may be found in cases of tonsillitis, chorea, scarlet fever, and septicæmia. The valves themselves are somewhat swollen, and on the segments is a fringe consisting of larger or smaller numbers of warty projections (vegetations) (Figs. 20 and 21). These vegetations are found not at the free margin but on a line a short distance from that margin. In the case of the mitral valve they are to be found on the upper or auricular surface, in the case of the aortic valve on the lower or ventricular. The line on which they occur is that of

66 DISEASES OF THE HEART AND PERICARDIUM

maximum pressure of the valves during closure. The vegetations may be soft, friable, and easily removed, or firm and adherent. Infarcts are frequently found in such organs as spleen and kidney.

Microscopic Appearances.—The various cellular and fibrous elements in the valve are separated from one another owing to œdema. There may be fibrin present in the connective-tissue spaces, and usually polymorphonuclear leucocytes and young connective-tissue cells and other wandering cells are found, in addition to the fixed tissue elements. On the surface of the valve there is a mass of granular material staining with acid dyes, and consisting of blood platelets and fibrin. In addition there may be fibrin threads. There are usually numerous white blood corpuscles which are found in groups. Red cells may be present at the free margin, and masses of germs can be demonstrated by suitable methods in some cases. In the later stages evidence of organisation may be found at the junction of valve and thrombus. Spindle-shaped and rounded cells may be seen making their way in from the valve to the vegetation. These are fibroblasts resulting from the division of the connective-tissue cells of the valve.

(b) **Ulcerative Endocarditis.**—In this type the valve may present the same appearance of slight swelling. It is *often thickened* from previous endocarditis. The vegetations tend to be larger and more friable. They are *not limited to the margin of the valve* but extend on to auricle or *chordæ tendineæ* (Fig. 22), ventricle, or aorta. There may be *destruction of the valve substance* with ulceration, *aneurysmal dilation* of a segment, or *complete rupture* (Fig. 23). *Rupture* of such structures as *chordæ tendineæ* also occurs. Owing to the greater friability there is an *increased tendency to embolism and infarction*. Also the infarcts may be septic.

Microscopically, the infiltration of the valve with inflammatory cells is more marked. The other appearances are the same, except that masses of micro-organisms tend to be larger and more numerous. Actual destruction of the valve substance may be found.

DISEASES OF THE HEART AND PERICARDIUM 67

	Simple or Vegetative.	Malignant or Ulcerative.
Character of vegetations.	Small, firm.	Large, friable.
Extent.	Limited to line close to free margin of valve.	Tendency to extend to wall of auricle, and ventricle, to chordæ tendineæ, aorta, etc.
Appearance of valves.	Very little alteration, slight swelling.	Destruction of valve, aneurysm-formation, rupture of valve or chordæ tendineæ. Valve often already thickened from previous acute endocarditis.
Associated conditions.	Chorea, acute rheumatism, scarlet fever, infarcts in spleen, etc.	Pyæmia, greater tendency to formation of infarcts and embolic abscesses.
Causal organism.	<i>Micrococcus rheumaticus</i> , found in many cases.	<i>Pneumococcus</i> , <i>Gonococcus</i> , <i>Staphylococci</i> , <i>Streptococci</i> .

Results of Acute Endocarditis.

(a) The conditions may return to the normal, the inflammatory exudate and vegetations being absorbed.

(b) The proliferated connective-tissue cells may settle down and form new connective tissue, vessels at the same time penetrating the valve from the nearest vascular area. The new connective tissue shrinks and the valve remains permanently thickened and altered. In other words, what is called *chronic endocarditis* supervenes. This very frequently happens with resulting stenosis or incompetence of the valve.

(c) A second attack is not infrequent when a valve has once been the seat of inflammatory change. As already stated, the ulcerative type tends specially to occur in the case of valves already damaged.

68 DISEASES OF THE HEART AND PERICARDIUM

(d) Embolism and infarction due to blocking of branches of the systemic arteries are very commonly met with, more especially in the case of the ulcerative type of the disease.

2. Chronic Endocarditis.—This condition may (1) *follow an acute endocarditis* owing to organisation and subsequent laying down of new connective tissue, (2) *arise slowly* owing to the action of chronically acting poisons, such as lead, alcohol, syphilis, retained products of metabolism (gout), or (3) it may be due to *strain*. Chronic thickening of the endocardium lining the cavities of the heart occurs sometimes when the cavities are the seat of chronic dilatation.

The valve which is the seat of this change is thickened. The thickening may be chiefly at the line of attachment, may be near the margin, or may occur throughout. The valve is thus opaque and white or yellow in colour. The segments are usually shrunken, misshapen, and may be united together so that the orifice is narrowed (Figs. 26 and 27). Such thickened valves are often the seat of calcareous deposits which appear as more opaque, yellow masses in the substance of the valve. Sometimes the endocardium over the calcareous deposit necroses from want of nourishment, and so thrombus formation may take place upon the calcareous surface laid bare.

Microscopically such valves may show little beyond an amount of well-developed fibrous tissue greater than usual. Hyaline degeneration may take place in this connective tissue, also calcareous deposit.

Results of Chronic Endocarditis.—The chief results are : (1) *Narrowing of the valve* from adhesion between its segments, contraction of its fibrous elements, or from both causes (stenosis). (2) *Failure of the valve to perform its function of closure* of the orifice, due to shrinkage and contraction of its segments (incompetence). In consequence of these two results of the changes in the valves themselves an

extensive series of alterations may take place in the various chambers of the heart and in the circulation generally. The diseased condition of the valves, with the accompanying changes in the circulation, is generally known as *chronic valvular disease of the heart*. According to the valve affected and the type of the lesion, different varieties are distinguished.

EFFECT ON THE HEART AND CIRCULATION OF THE DIFFERENT TYPES OF CHRONIC VALVULAR DISEASE

1. **Mitral Stenosis.**—This is perhaps the best defined type of chronic valvular disease. It is found chiefly in women, and is due invariably to the adhesion, shrinking, and contraction of the two segments of the mitral valve following acute endocarditis of the valve, very often of rheumatic origin. The valve is thickened, opaque, the segments are united together, and the opening may be a slit and nearly flush with the attachment of the valve (buttonhole mitral) (Fig. 26), or more or less circular and some distance below the level of the attachment of the segments (funnel-shaped mitral). The amount of narrowing varies in different cases. Occasionally the contraction is so marked that the valve will not admit the tip of the finger, scarcely a crow quill.

The process of narrowing occurs slowly, so that the effect is only gradually felt by the heart. This being the case, the left auricle, upon which the strain falls, gradually dilates and its wall thickens in order to overcome the obstruction. For a time the hypertrophied left auricle may be equal to the task of driving the blood through the narrowed orifice. Eventually, however, the tendency is for the backward pressure to tell upon the pulmonary circulation, so that the lungs show chronic venous congestion. Not infrequently the pulmonary artery exhibits in this condition well-marked

patches of fatty change (atheroma). Through the lungs the pressure tells back upon the right side of the heart, the cavities of which become dilated and their walls thickened (Fig. 25). At the same time the backward pressure tells upon the whole venous system, with the result that chronic venous congestion develops in all the organs and viscera, including the heart, as well as in the tissues and limbs. The degree of this congestion depends upon the capacity of the heart to respond to the demands made upon it. When the heart fails to respond, or, as it is usually expressed, when compensation fails, the congestion becomes extreme, and œdema or dropsy tends to appear, more especially in the tissues of the lower limbs.

The left ventricle in mitral stenosis tends to receive less blood than usual. Its work is not necessarily interfered with. In consequence, it either does not enlarge or it may even become smaller. A degree of incompetence of the valve is usually present in mitral stenosis, especially in advanced cases owing to stiffness of the segments. In cases where the incompetence is marked the left ventricle will tend to dilate.

2. Mitral Incompetence.—This lesion may occur alone, or it may be combined with a degree of narrowing. It may be associated with thickening and contraction of the valves from a previous acute attack of endocarditis, or, on the other hand, the incompetence of the valve may be merely relative, due to a lax or stretched condition of the band of circular muscle fibres which surround the base of the valve and assist in its closure, or due to dilatation of the ventricle carrying outward the attached papillary muscles. In appearance the valves are usually thickened, shrunken, and contracted towards their attachment. Not infrequently the chordæ tendineæ are also thickened and shortened. The lesion is associated with dilatation and hypertrophy of the

left ventricle, then of the left auricle. The lungs become congested, and through the lungs the pressure tells back upon the right side of the heart. Thus the heart in this condition tends to undergo more or less uniform enlargement.

3. **Aortic Incompetence.**—This condition is due to thickening and shrinking of the segments of the aortic valve. It is often associated with a degree of stenosis. The cause may be: (*a*) a previous acute endocarditis of the aortic valve which is not infrequently associated with endocarditis of the mitral valve; (*b*) the spread of disease (atheromatous or syphilitic) from the aorta; (*c*) occasionally it may be due to traumatic rupture of a segment which, however, is usually already the seat of chronic changes; (*d*) very rarely it is caused by congenital malformation or foetal disease. The condition occurs most commonly in men and in later life.

In consequence of the failure of the segments to close the orifice during diastole, blood flows backwards again into the left ventricle from the aorta. The cavity has thus to accommodate this blood in addition to what comes normally through the mitral orifice. The left ventricle therefore dilates. At the same time the wall of the cavity hypertrophies in order to drive on the large quantity of blood. This dilatation and hypertrophy of the left ventricle is often very great. The largest hearts on record are from cases of aortic incompetence. The term *cor bovinum* has been applied to them. Subsequently, owing to the great dilatation of the left ventricle, a relative incompetence of the mitral valve may be brought about. Thus there is backward pressure on the left auricle, then on the lungs and the right heart. Owing to the injection of the blood into the aorta by the powerfully acting left ventricle, aneurysmal dilatation of the aorta may occur, more especially as the vessel is frequently the seat of disease. Owing to the rapid emptying of the arteries, those going to the head are badly supplied

with blood. Hence the marked pallor of individuals suffering from this condition, and hence the tendency to fatal syncope.

4. **Aortic Stenosis.**—This is usually accompanied by more or less incompetence. The cause may be a previous attack of acute endocarditis, or it may be associated with atheroma of the aorta. The segments of the valve are thickened and often the seat of calcareous change. They are usually united together, sometimes leaving only a minute aperture for the passage of the blood (Fig. 27). The effect upon the heart is to cause hypertrophy of the left ventricle, which is usually at the same time dilated, owing to the existence of a certain amount of incompetence.

5. **Tricuspid incompetence** is the commonest valvular lesion on the right side of the heart, and is most commonly merely relative, due to a dilated condition of the right ventricle. It is more rarely due to endocarditis, either during extrauterine or foetal life. It leads to dilatation and some hypertrophy of the right auricle, and is associated with marked venous engorgement, and often with pulsation in the veins of the neck and in the liver.

6. **Tricuspid stenosis** is a rare condition by itself. It is usually associated with stenosis of the mitral valve. It is due to endocarditis occurring either during foetal or extrauterine life.

7. **Lesions of the pulmonary valve** are very rare, and are usually congenital, being due either to malformation or foetal endocarditis.

ŒDEMA OR DROPSY IN CARDIAC DISEASE

When the heart is failing from degenerative changes in its musculature or from dilatation associated with chronic valvular disease, œdema tends to appear. Cardiac œdema is usually distributed about the body in accordance with the

effect of gravity, appearing first and being most marked in the more dependent parts, such as the tissue round the ankles. Later on it spreads to other parts and to the serous sacs—peritoneum, pleura, pericardium. As regards the causation of this type of oedema, increased pressure within the capillaries from venous congestion is certainly an important factor. Experimentally produced venous obstruction is, however, not necessarily followed by dropsy. Another factor must be presupposed. This factor is the damage to the endothelium due to defective nutrition of the cells from mal-oxygenation of the blood and retention of waste products. At the same time there is also obstruction to the lymphatic return owing to the fact that the larger lymph channels open into veins over-distended with blood.

PRIMITIVE MUSCULAR TISSUE OF THE HEART AND ITS RELATION TO "HEART BLOCK"

There are two main portions of primitive muscular tissue which should be examined:—

(1) The *sino-auricular node*, the site of origin of the normal stimuli for the heart's contraction which is situated between the opening of the superior vena cava and the right auricular appendix. It is composed of slender muscle fibres, nerve-cells and fibres. It has been found to show subacute and chronic inflammatory change in cases of arrhythmia.

(2) The *auriculo-ventricular bundle*, which starts from the auriculo-ventricular node, situated on the right side of the inter-auricular septum in front of the opening of the coronary sinus, and above the attachment of the septal cusp of the tricuspid valve. The auriculo-ventricular node consists of tissue similar to the sino-auricular node. From the node the bundle runs forward almost horizontally, but somewhat downwards, and usually to the left in the pars membranacea septi. At the anterior part of the membrane, a little in front of the anterior end of the attachment of the median and septate segments of the tricuspid valve, the bundle divides into two parts. The left division passes downwards and perforates the

74 DISEASES OF THE HEART AND PERICARDIUM

membrane, entering the subendocardial tissue of the left ventricle at a point immediately beneath the union of the anterior and right posterior cusps of the aortic valve. It then spreads out in a fan-shaped fashion under the endocardium of the left side of the septum, going to the papillary muscles of the mitral valve and the ventricular muscle. The right branch runs downwards and enters the moderator band, and subsequently passes to the papillary muscles and wall of right ventricle.

In cases of "heart block" the bundle has been found implicated or destroyed in some part of its course. The lesions found have been : (1) Acute inflammation from spread of ulcerative endocarditis of mitral or aortic valve ; (2) chronic interstitial myocarditis and sometimes calcification associated with arteriosclerosis of the coronary artery ; (3) fibrosis following acute rheumatic inflammation of myocardium ; (4) fatty infiltration ; (5) tumour formation, *e.g.* sarcoma ; (6) gumma of heart wall ; (7) aneurysm of one of the sinuses of Valsalva involving the septum.

GENERAL METHOD OF SETTING ABOUT THE EXAMINATION OF A HEART WHICH HAS BEEN EXCISED AND OPENED UP

Note in the first instance the size of the organ. A rough approximation to the normal size of a heart is obtained by comparing it with the closed fist of the individual. Next note the shape. The normal heart is conical. This shape is retained when the heart is enlarged, if that enlargement be due to uniform increase in size of all the cavities. If, however, the left ventricle be hypertrophied (as in kidney and arterial disease) out of proportion to the rest, although still conical the organ is elongated. In cases where the right side of the heart is enlarged out of proportion to the left, as in mitral stenosis and in chronic pulmonary disease, the organ, instead of being conical, is ovoid (Fig. 15).

Next examine the visceral pericardium for milk spots, petechial hæmorrhages, fibrinous exudate, adhesions to the pericardial sac. Then turn to the right side and examine the right auricle as to its size, the thickness of its walls, its contents (looking more especially for thrombi in the appendix).

DISEASES OF THE HEART AND PERICARDIUM 75

Next examine the right ventricle as to its size, the thickness of the walls, the amount of fat in the subpericardial tissue, and whether this fat is actually invading the muscle substance. Estimate the diameter of the tricuspid valve and examine its segments for thickening and vegetations. The diameter may be measured roughly with the fingers. The opening normally admits three digits. Glance at the pulmonary valve for the presence of thickening and vegetations.

Now turn the heart round and examine the left auricle as to size, thickness of walls, thickening of the endocardium, the presence of vegetations or thrombi (more especially in the auricle). Examine the left ventricle as to its size, the thickness of its walls, the appearance of the cut surface of the muscle. Note the colour of the muscle. Look for fatty change, more especially in the papillary muscles, for fibrous tissue (indicating the existence of chronic interstitial myocarditis), more particularly towards the apex of the ventricle, in the interventricular septum, and in the incised papillary muscles. Estimate the consistence of the muscle by testing its friability.

Now examine the mitral valve as to its diameter. The opening normally admits two digits. Look for thickening of the segments and of the chordæ tendineæ, for vegetations on its surface or fatty change in the endothelium.

Then turn to the aortic valve, estimate its circumference. Look for thickening, calcification, vegetations. Examine the portion of the aorta still attached for atheroma. Lastly, look at both coronary arteries, more especially the left, for the presence of dilatation or narrowing, for fatty or calcareous atheroma, and for thrombosis.

HEART WEIGHTS AND MEASUREMENTS

Weight, 9-13 oz. (250-370 grammes).

Length of left ventricle, $3\frac{1}{4}$ in. (7.6-8.4 cm.).

Thickness of wall of left ventricle, $\frac{1}{4}$ in. (at thinnest) to $\frac{1}{2}$ in. (0.6-1.2 cm.).

Length of right ventricle, $3\frac{1}{8}$ to $3\frac{3}{8}$ in. (7.8-8.6 cm.).

Thickness of wall of right ventricle, $\frac{1}{8}$ in. (0.32 cm.).

DIAMETERS AND CIRCUMFERENCES OF THE HEART VALVES
(Shennan)

				Diameters.	Circumferences.
Tricuspid . . .	ins.			1.5 to 1.8	4.5 to 5.5
	cm.			3.8 to 4.7	11.4 to 14.0
Pulmonary . . .	ins.			1.1 to 1.2	3.4 to 3.7
	cm.			2.8 to 3.0	8.6 to 9.5
Mitral	ins.			1.2 to 1.4	3.7 to 4.4
	cm.			3.0 to 3.5	9.5 to 11.0
Aortic	ins.			0.9 to 1.0	2.8 to 3.2
	cm.			2.3 to 2.5	7.2 to 8.0

CHAPTER V

DISEASES OF THE VESSELS

THESE may be divided into (A) Diseases of the Arteries, (B) Diseases of the Veins.

A. DISEASES OF THE ARTERIES

In all cases of sudden death the arteries of the internal organs should be slit up and carefully examined for the presence of impacted emboli. More particularly is this the case with the pulmonary and coronary arteries.

In cases of senile gangrene the vessels of the affected limb should be opened up and thrombi or impacted emboli sought for.

Amyloid or Waxy Degeneration.—This is a condition which usually starts in the arterioles, particularly those of the internal organs—spleen, kidney, liver, intestine—and spreads forwards to the capillaries and backwards to the larger vessels. In the case of the medium-sized vessels the change occurs in the middle coat, affecting the bands of connective tissue which lie between the circular muscle fibres. The condition is only found on microscopic examination, although by means of iodine, when advanced, it may be made visible to the naked eye. With iodine the affected area gives a mahogany brown colour. Amyloid degeneration

should be looked for especially in (1) advanced tuberculosis, (2) visceral syphilis, (3) chronic suppuration, *e.g.* long-existent empyema, bone disease, etc.

Fatty Degeneration of the Intima.—This may be seen, more particularly in the aorta, in the form of pale yellow streaks or patches often arranged in the long axis of the vessel. It is associated with anæmia and toxæmias.

Microscopically, the fatty change is found in the endothelial cells and in the subendothelial connective tissue.

Calcareous Degeneration of the Media.—This is a change found chiefly in old age. It may be preceded by fatty or hyaline change, and it affects the medium-sized arteries, such as the femoral, brachial, and radial. The arteries which are the seat of the change are hard and brittle and show a transverse striping very noticeable to the naked eye.

Acute Inflammation.—This may occur in the first part of the aorta due to extension of inflammation from aortic endocarditis of the ulcerative form. It may occur in arteries passing through areas which are the seat of acute inflammatory change. More frequently it is caused by the impaction of an embolus containing germs, which sets up inflammation in the wall of the vessel and may lead to the formation of an acute aneurysm, *e.g.* in a branch of the pulmonary artery.

ARTERIOSCLEROSIS

Arteriosclerosis, or hardening of the arteries, is an exceedingly common condition, and as defined includes a number of diseases of somewhat different nature and origin. The calcareous degeneration of the media already mentioned is one type. Another type is endarteritis deformans, atheroma, or, as it has more recently been called, atherosclerosis. Another type is syphilitic disease of arteries.

Lastly, there is hypertrophy of the middle coat of the medium-sized and smaller vessels.

Types of arteriosclerosis.

1. Atheroma, atherosclerosis, endarteritis deformans.
2. Hypertrophy of the media.
3. Endarteritis obliterans.
4. Calcareous degeneration of the media (see above).

Atheroma (Gr. *ἄθῆρη*, porridge), **Atherosclerosis,**
Endarteritis Deformans

A *nodular* and a *diffuse* form of the condition are sometimes distinguished, the former affecting the aorta, the coronary, pulmonary, and cerebral arteries, the latter more associated with the medium-sized and smaller vessels, such as the renal and its branches, the radial, and sometimes the coronary and cerebral. The nodular form is, however, not infrequently found in the smaller vessels mentioned.

In the aorta the condition appears first as streaks or patches of a grey or pearly white appearance, slightly raised above the surface, and due to *thickening of the intima*. These patches occur especially round the openings where smaller branches, such as the intercostals, leave the main trunk, also in the arch of the aorta. Very early in their formation they become opaque and yellow in colour owing to *fatty change*. The patches gradually increase in size, and eventually become the seat of a *calcareous deposit*, thus forming hard brittle plates in the intima of the vessel (Fig. 28). The intima then tends to degenerate and disappear, leaving a cavity, the floor of which is formed of pulpy necrotic material—the *atheromatous ulcer*. *Thrombosis* may occur on the diseased area even before the formation of the ulcer. There is an increased tendency to it after the ulcer has developed. When well marked, the change is often found throughout the entire

length of the aorta—thoracic and abdominal. It tends to be more advanced *in the arch* and in the *lower part of the abdominal aorta* just before it bifurcates. Similar changes are to be seen in the larger branches and in the medium-sized vessels, such as coronaries, cerebrals, etc. The patchy character of the disease is often particularly well seen in the vessels of the brain (Fig. 29), where, owing to their transparency, the yellow areas can be seen even in the smaller branches. In these medium-sized and smaller vessels, such as cerebral and coronary, the thickening of the intima often leads to very marked narrowing of the lumen.

A *special type of atheroma*, termed *syphilitic*, may be distinguished. It is frequently combined with true atheroma. In position, however, it is found especially in the *first part of the aorta*, often spreading to and involving the segments of the aortic valve, thus leading to aortic incompetence. Whereas atheroma is a disease of more advanced age, this type is often found in comparatively young people. It may not always be syphilitic in origin, but in many cases it undoubtedly is so, spirochætes having been found in the lesions in the vessel wall. This type is characterised by the formation of *large, white, raised, semi-transparent or opaque white patches*. *There is not the same tendency to fatty and calcareous change*, so that the patches remain white and there is no formation of atheromatous ulcers. *Puckering* not infrequently occurs in the centres of these areas.

Effects of Atheroma.

(1) Loss of power of the vessel to dilate and contract.

(2) Narrowing of lumen of vessel, with tendency to degenerative changes in organ or tissue supplied, with replacement of functioning cells by fibrous tissue. In kidney—chronic interstitial nephritis; in heart—chronic interstitial myocarditis.

(3) As a result of narrowing of the lumen there is increased

difficulty in driving the blood along, hence hypertrophy of the left ventricle occurs.

(4) Weakening of the vessel wall, with tendency to dilate at some point and form an aneurysm with tendency also to rupture.

(5) Tendency to thrombosis on the diseased areas, with consequent tendency to embolism.

Microscopically, the earliest change is found to be a proliferation of the subendothelial connective-tissue cells. This leads to a thickening of the intima formed of layers of rounded and spindle-shaped connective-tissue cells with intercellular fibrils. Owing to the fact that the nourishment of the intima and of the inner portion of the media is obtained from the blood circulating within the vessel itself, the deeper portions of the thickened intima undergo fatty, and eventually calcareous, change. Fatty globules and crystals of fatty acids are found in the degenerated area, also granules of calcium salts. Changes are also to be observed in the internal elastic lamina. It splits into fine fibrils and becomes fragmented. This damage to the internal elastic lamina is regarded generally as the primary change. The media may also show fatty degeneration, owing to interference with its nourishment. It not infrequently gives way, and the vessel becomes dilated.

In the case of the aorta the changes in the media may be more marked. There may be invasion of vessels from the vasa vasorum into the media, and around these vessels there are numerous round cells.

In the syphilitic type, in addition to the greatly thickened intima composed of layers of well-formed fibrous tissue without fatty or calcareous change, there is marked change in the media. This takes the form of an invasion of the media by vessels accompanied by connective tissue. This results in a replacement of the media by fibrous scar tissue, the contraction of which causes the puckerings.

Causation.—During the first twenty years of life there is a progressive thickening of the coats of the vessels with a progressive development of elastic tissue. For the next twenty years of life approximately things remain stationary.

After that there is a progressive deterioration in the elastic tissue, with consequent weakening of the vessel wall. In certain individuals the elastic tissue of the vessels is congenitally deficient. Atheroma is a disease which develops at the time of life when the vessels are beginning to deteriorate, but the individual is at the height of his physical activities. High blood pressure from bodily exertion, combined with degenerating elastic tissue, are the two main factors in the disease. Sometimes the one, sometimes the other is the more prominent. That high pressure of itself can produce the condition is proved by the experimental work on animals. By the administration of doses of adrenalin over periods of weeks and months, thus causing contraction of the vessels and raising the blood pressure, it has been found possible to produce changes in the vessels of rabbits analogous to atheroma in the human subject. The same thing has been effected by holding the animal up by the hind legs for a few minutes every day for some weeks. In this way well-marked degenerative changes very similar to human atheroma have been produced in the vessels above the diaphragm.

Infective conditions such as syphilis act by causing proliferative changes of an inflammatory nature in the intima. As a result there is malnutrition of the vessel wall subjacent to the thickened area with consequent degenerative changes.

In the human subject toxic conditions associated with high blood pressure, such as renal disease, lead poisoning, gout, alcoholic poisoning, are also factors in the production of the disease. At the same time, infective conditions such as syphilis cannot be ignored.

As to the nature of the primary change, this is generally regarded as being a fragmentation and fibrillation of the internal elastic lamina. Subsequent to this, and with a view to repairing the damage, there is a proliferation of the cells of the intima, with resultant thickening. Owing to the fact that the intima and outer portion of the media obtain their nourishment from the blood flowing in the vessel itself, the deeper portion of this new tissue and the adjacent media undergo degeneration of a fatty nature. The fatty acids which are formed are believed to combine with alkalies to form soaps. Among these soaps are calcium combinations. The fatty acid is rejected by the calcium in favour of carbonic

and phosphoric acid, with resulting deposition of calcium carbonate and phosphate in a granular form.

Summary of Causes of Atheroma.

- (1) Old age.
- (2) Congenital deficiency in elastic tissue of vessels.
- (3) Strain.
- (4) Chronic toxæmias—alcohol, gout.
- (5) Infective conditions—syphilis.

Hypertrophy of the Media.

This is another form of arterio-sclerosis due to contraction under prolonged stimulation by the influence of toxic substances circulating within the vessel. It is very characteristically associated with the subacute and chronic forms of Bright's disease. The condition affects the medium-sized and smaller vessels. The hypertrophy of the muscular coat is followed by a fibrous transformation.

Endarteritis Obliterans or Proliferans

This is a type of arterial disease associated with thickening of the intima in which there is no tendency to degenerative change, as in atheroma. The reason is that the new tissue laid down within the internal elastic lamina carries with it its own blood-vessels. This tissue is, in other words, granulation tissue. The condition is found associated with all types of chronic inflammation, *e.g.* tuberculosis, syphilis, leprosy. It is usually regarded as being specially significant of the presence of syphilitic disease, but it is just as frequent in tuberculosis. It is found in the vessels in the neighbourhood of syphilitic gummata and in vessels in the lung, bones and joints in tuberculosis. Sometimes it occurs in the vessels of the brain in syphilis, thrombosis in these vessels in early life being a not infrequent cause of cerebral paralysis. In the lung in tuberculosis the change is a most beneficial one, as the tendency to rupture of vessels in the neighbourhood of cavities is thereby greatly diminished. It is probable

that the atrophy of limbs in tuberculous joint and bone affections may in part be explained by malnutrition following diminution in size of lumen of the nourishing vessels. As might be anticipated, the change is often accompanied by inflammation of the other coats of the vessel, more especially the adventitia.

Microscopically, the condition is characterised by the laying down of layers of new tissue within the internal elastic lamina. At first the tissue is cellular, later on it becomes well-developed connective tissue. Very often new layers of elastic tissue are formed, and sometimes there are several small vessels within the compass of the original vessel wall. In addition, there are inflammatory changes in media and adventitia, more especially the latter.

Arterial Disease in Syphilis.—Syphilis affects the arteries in several ways. It is one of the infective conditions leading to *atheroma*, more especially to that type called syphilitic, where the aorta is the seat of formation of raised, white, semi-translucent areas with a tendency to puckering.

Another type of lesion found more especially in the smaller arteries is the above-mentioned *endarteritis obliterans*, with accompanying periarteritis.

Syphilitic disease of vessels is a frequent cause of aneurysm formation and of thrombosis.

Arterial Disease in Tuberculosis.—Tuberculous disease has a marked tendency to spread by the perivascular lymphatics, and thus has from the commencement an intimate association with vessels. This condition of periarteritis leads to a thickening of the vessel. The process may spread inwards and produce an *endarteritis*. Sometimes a tuberculous focus may burst its way through a vessel wall, thus giving rise to a general *blood infection*.

This endarteritis is found in a marked degree in all cases of chronic pulmonary tuberculosis. It is also found in the smaller vessels in the neighbourhood of tuberculous

lesions of bones and joints. As in syphilis the thickened intima shows no tendency to degeneration in its deeper parts.

The inflammatory change in the vessel walls in the neighbourhood of cavities may lead to weakening, *aneurysm* formation, or rupture. As previously stated, it more frequently causes more or less complete obliteration.

Aneurysm

An aneurysm is a localised enlargement of the lumen of an artery. The enlargement may involve the whole lumen for a short distance (*fusiform aneurysm*), or it may be a diverticulum from one side of the vessel (*saccular aneurysm*) (Fig. 31).

The term *acute aneurysm* is applied to any rapid dilatation of an artery through an inflammatory process in its wall, usually due to the presence of a septic thrombus within its lumen. A *false aneurysm* is an accumulation of blood communicating with a vessel and surrounded, not by the vessel wall, but by a condensation of tissue in the neighbourhood. A *dissecting aneurysm* is a condition, found usually in the aorta, where the blood finds its way, commonly by a split in a calcareous atheromatous patch, between the intima and media, or between media and adventitia, or again between two layers of media. Sometimes the blood finds its way back again at a different level into the lumen. The term *miliary aneurysm* is applied to minute dilatations, usually of a saccular type, occurring on the course of the smaller cerebral arteries.

The most common *site* for aneurysm is the thoracic aorta—the ascending portion, the arch or descending portion. The next most common site is the abdominal aorta, then come the popliteal and carotid arteries. The special type, miliary aneurysm, is found in the cerebral vessels. Aneurysms also occur in the branches of the pulmonary artery in the neigh-

bourhood of tuberculous cavities (Fig. 52), and as the result of septic embolism.

Aneurysms vary greatly in size and shape. The cavity may be largely filled with white and red thrombus, often with a laminated appearance. This thrombus is seldom the seat of organisation. The wall may be formed of all the coats of the vessel. Usually, however, the intima, if present at all, is in patches. This, no doubt, is the explanation of the non-occurrence of organisation in the thrombus contents. The media may also disappear and the wall be formed only of adventitia and condensed connective tissue surrounding. Occasionally the wall is partly formed of bony structures such as the vertebræ (Fig. 31). The wall of the vessel in the neighbourhood is usually the seat of atheromatous change, frequently of the syphilitic type.

Changes produced in Surrounding Parts.—These depend upon the position of the aneurysm. The dilating vessel presses upon viscera, such as trachea, bronchi, œsophagus, upon nerves and vessels. Thus irritation or paralysis of nerves—recurrent laryngeal, trunks of the brachial plexus—results. Pressure on trachea and bronchi leads to accumulation of secretion, and sometimes to gangrene of the lung, also to erosion and rupture. Pressure on œsophagus similarly causes obstruction, and may result in rupture. Bones such as sternum and vertebræ are eroded, also cartilage, but the softer the tissue the better it resists, so that intervertebral discs may project beyond the harder bone. Pressure upon lung leads to collapse and atrophy.

Smaller vessels arising from the aneurysmal portion of the vessel tend to be contorted, and sometimes their lumen obstructed by thrombus. The heart may be displaced downwards, and may be hypertrophied.

Rupture may occur *through the skin* in thoracic aneurysm, projecting forwards, into the *trachea, bronchi, œsophagus, pericardial sac, pulmonary artery*. In the case of cerebral

aneurysms, into the brain substance or under the membranes ; in phthisical aneurysms, into the lung cavity, with consequent hæmoptysis.

Causation.—Two factors are concerned in the causation.

(1) Conditions which lead to weakening of the vessel wall, (a) injury as from a gunshot wound, (b) disease, such as (i.) acute arteritis from inflammation around the vessel or from impaction of a septic embolus in the vessel, (ii.) chronic arteritis from atheroma, more especially the syphilitic type.

(2) Conditions leading to sudden rise of blood pressure, *e.g.* lifting of heavy weights.

The condition is far more frequent in males than in females (out of 189 cases, 171 males). It occurs as a rule above forty years of age, *i.e.* at the period when the vessels are beginning to degenerate while the individual is still in active work. In something over 50 per cent of cases a history of syphilis may be obtained.

B. DISEASES OF VEINS

Thrombosis occurs in veins where the blood current is slowed from dilatation and varicosity. In all probability in addition there must be some inflammatory condition of the vessel wall leading to damage of the endothelium. The condition may be found in any vein where walls are inflamed. Thus the small venous radicles in the neighbourhood of any inflammatory focus tend to undergo thrombosis. When organisms invade such thrombi and soften and break them down, portions of the thrombus containing germs are apt to be carried away by the blood current and deposited in distant organs. The liver is affected when the rootlets of the portal vein are thrombous ; the lung, in the case of other venous radicles, becomes the seat of septic embolism and abscess formation (see diagram, p. 62).

Thrombosis once started tends to spread. Not infrequently the change begins in the pouch of a valve. The thrombus grows until it blocks the lumen of the vessel. Then the blood current being stopped, thrombosis occurs in the vessel up to the next large branch. Subsequently another slow thrombotic process starts, until again the vessel is blocked. In this way the process initiated in a small rootlet of the femoral vein may pass up as far as the inferior vena cava.

Thrombi in veins may become organised and may lead to obliteration of the vessel. Or they may be the seat of deposit of calcareous material forming so-called phleboliths. Again, sometimes the thrombus in course of organisation may be tunnelled and the circulation re-established.

Two types of thrombi are distinguished according to their colour, (a) red, (b) white. Red thrombi form when the blood is suddenly brought to a standstill, white thrombi are formed when the blood is in motion.

Thrombi in veins not infrequently undergo softening. Two types of softening are distinguished : (a) simple softening ; (b) septic, due to the action of germs.

Microscopically, thrombi consist of the blood elements (red corpuscles, white cells, and blood platelets) in varying proportion, bound together by filaments of fibrin.

(a) In the case of red thrombi the predominant element is the red blood corpuscle. There are a few white cells, and between the cell elements filamentous and granular fibrin. Sometimes the red cells stain well, at other times they have lost their characteristic staining reaction and only their outlines are visible.

(b) In white thrombi leucocytes, platelets, and fibrin predominate. Organisation is frequently seen. The first stage in the process is a covering over of the thrombus with a layer of spindle-shaped endothelial cells from a proliferation of those lining the vessel. Then from the subendothelial and other connective-tissue layers, young connective-tissue cells emigrate

into the thrombus. They appear as rounded mononuclear cells to begin with ; later on they become spindle-shaped. At the same time the endothelial cells of the vasa vasorum proliferate, forming buds of vessels which penetrate the thrombus. Both these processes occur at points where the thrombus is in contact with the vessel wall. Elsewhere the endothelium covering the thrombus develops buds which penetrate the substance of the coagulum and become filled with blood from the original lumen. Subsequently these various blood channels unite with one another, become enlarged, and thus the thrombus becomes tunnelled. During the process of organisation, pigment (hæmatoidin) granules are deposited in large numbers in the cells.

Dilatation and Varicosity.—This is a condition which is found more especially in the superficial veins of the lower limbs, in the veins of the scrotum (varicocele), rectum (hæmorrhoids), and œsophagus.

As regards *causation* there is undoubtedly a tendency to the condition in certain individuals owing to a congenital weakness in the elastic tissue of the vessel wall. The condition is aggravated by gravity. It may also be caused by obstruction to the return of the blood by the wearing of tight garters, by the presence of a tumour or hard fæcal masses pressing on the iliac veins, or by a cirrhotic liver interfering with the flow of blood through the portal veins, and affecting more especially the rootlets from the rectum and œsophagus.

The veins which are the seat of the change are dilated and tortuous. Their walls are thickened and there may be thrombosis within them. Ulceration from skin, œsophagus, or rectum may lead to erosion and consequent hæmorrhage.

Phlebitis, or inflammation of the wall of a vein, may be due to injury, or to an inflammatory focus in the neighbourhood of a vein, as in appendicitis, osteomyelitis, erysipelas. It may also occur in syphilis and in gout. The condition is

always associated with more or less thrombosis or clotting of the blood within the vessel.

Results.—Obliteration of the vein, washing away of portions of thrombi, and so formation of emboli, reabsorption, or tunnelling.

CHAPTER VI

DISEASES OF THE BLOOD, BONE MARROW, LYMPH GLANDS, SPLEEN, AND DUCTLESS GLANDS

DISEASES OF THE BLOOD

ALTHOUGH it is unquestionably better to examine the blood during the life of the patient, it is still possible to do so after death. The ease with which this can be done depends to a great extent upon how far the blood has coagulated within vessels and heart. There is, however, in blood diseases, such as anæmias and leukæmias, a tendency for the blood to remain fluid so that films may often be readily obtained either from heart blood or vessels.

(For the bacteriological examination of the blood, see p. 359).

Septicæmia and Pyæmia. — Micro-organisms enter the blood in many infective conditions. In fact, in most acute infective diseases the causal organism can be cultivated from the blood at some period. Even in the more chronic forms, such as tuberculosis, germs can be detected in the blood in a considerable proportion of cases. Such conditions, in which living organisms are circulating in the blood-stream, are usually known as *septicæmias*. Formerly the term was somewhat restricted in its use; now it may be applied to a large number of acute infective processes

including typhoid fever and pneumonia. In the human subject the germs are almost never present in numbers sufficient for their demonstration readily in stained blood films. Concentration or cultural methods have to be adopted before their presence can be detected. On the other hand, the same germs may, when introduced into one of the lower animals, give rise to a condition in which immense numbers of film organisms can be demonstrated microscopically in the blood. This is notably the case with the *pneumococcus* and the anthrax bacillus.

The organisms may enter the blood, in the case of the smaller blood-vessels, through an intact vessels' wall. In other instances an abscess or similar infective focus (in tuberculosis a caseous focus) may rupture directly into the blood-stream, it may be into a vessel of considerable size, usually a vein. In a majority of instances, in the more acute infective diseases, the actual invasion of the vessel is preceded by a thrombosis within the lumen; the thrombus then becomes infected with germs, and portions of the infected clot are carried to other parts of the body, there to set up metastatic inflammatory foci, or abscesses. This condition of invasion of the blood-stream by organisms *plus* the formation of metastatic abscesses is usually known as *pyæmia*.

The primary focus from which the infection of the blood originates varies very much. It may be the intestine as in typhoid fever, the organism probably reaching the blood by way of the lymphatics. It may be the lung as in acute lobar pneumonia, the organisms passing directly from the alveoli into the pulmonary capillaries. In the conditions more usually characterised by the term septicæmia, it is commonly a suppurative focus in the throat, appendix, bone (in osteomyelitis), or an endocarditis of the malignant or ulcerative type.

When secondary suppurative foci develop these may be found in kidneys, liver, brain, or indeed in any part of the

body in the case of an ulcerative endocarditis, in the lungs most commonly in the case of an osteomyelitis, in the liver in the case of the appendix (portal pyæmic type of liver abscess).

Sometimes a condition may start by being merely a septicæmia. Subsequently it develops into an ulcerative endocarditis and pyæmia. Apparently organisms in the blood-stream have a special tendency to become deposited on the heart valves, especially such as have already been damaged.

Both in miliary tuberculosis and in septicæmia the secondary infective foci invade blood-vessels in their neighbourhood and so further infect the blood-stream with germs.

Pernicious Anæmia.—In performing a post-mortem examination in a case of this disease the following changes will be found with a remarkable degree of constancy.

The *skin* is pale, often with a lemon-yellow tint due to a slight degree of jaundice. The *subcutaneous fat* may be considerable in amount and shows a bright yellow colour. In examining the *serous sacs* minute hæmorrhages will be found, more especially under the visceral pleura and pericardium. The *lungs* are pale and show atrophic emphysema. Not infrequently small hæmorrhages are found in the substance of the lungs as well as under the pleura, and on microscopic examination fatty change may be found in the endothelial cells of the vessels. The *heart* may be dilated, and is very constantly the seat of a fatty degeneration of the muscular substance, which is best seen on the inner aspect of the left ventricle, more especially on the papillary muscle. The change is of the patchy type described as “thrush breast heart.” The *blood* within the heart cavities is often fluid and always pale.

The *liver* is pale and of a yellow-brown colour. It shows fatty degeneration and a marked increase of iron-containing

pigment (hæmosiderin). This can be demonstrated by pouring over the organ ferrocyanide of potassium (2 per cent) and hydrochloric acid (1 per cent), repeating the process several times if the characteristic "Prussian blue" colour does not at once appear. The pigment is present mainly round the outer part of each lobule (frontispiece, Fig. 1).

Microscopic Appearances.—The granules are found within the liver cells mainly in the outer two-thirds of the lobule, and also in the endothelial cells of the vessels. Necrotic areas are sometimes present in the lobules. In the vessels nucleated red cells and endothelial cells containing red corpuscles as well as pigment granules are to be found. Fatty degeneration is present in the central part of the lobule.

The *spleen* is of a dark brownish-red colour. Hæmosiderin may be present in sufficient amount to be demonstrated macroscopically. In any case it will be found microscopically within the endothelial cells of the pulp sinuses, which also show marked phagocytosis for red blood corpuscles.

The *kidney* may show nephritis of a catarrhal or interstitial type. It is very pale in colour and often exhibits the same Prussian blue reaction as is found in liver and spleen.

The *mucous membrane of the stomach and intestine* is pale, petechial hæmorrhages are often present, and there is atrophy of the mucous membrane.

The *bone marrow* in the shafts of the long bones, which is normally of a yellow colour and is composed of fat, is transformed into a bright red marrow with a gelatinous appearance and consistence.

Microscopically, there is a marked erythroblastic reaction, the red cells showing evidence of active proliferation. Many of them are of the large nucleated type known as megaloblasts. There is also evidence of phagocytic activity on the part of large endothelial cells, many of which contain red blood corpuscles.

Occasionally in the *spinal cord* degenerative changes, with consequent sclerosis, are found in the posterior and posterolateral columns.

The chief *blood changes* of pernicious anæmia may be briefly recapitulated. There is marked diminution in the number of red blood corpuscles (average count $1\frac{1}{2}$ millions), with a less marked diminution in hæmoglobin (average 40 per cent), so that the colour index (the ratio of the percentage of hæmoglobin to the percentage number of corpuscles, *e.g.* as above, $\frac{40}{30}$) is greater than unity. On the examination of a film of blood the main change is found to be variation in size of the blood corpuscles (macrocytes and microcytes being present), with marked variation in shape (poikilocytosis). Nucleated red corpuscles are usually to be found, and of these the large variety (megaloblast) predominates over the normoblast. In addition, basophil granules are often found scattered through the corpuscles (punctate basophilia or granular degeneration), and not infrequently the red cell takes on both acid and basic dye, assuming thus a bluish colour (polychromatophilia). The leucocytes are commonly reduced in number, with a slight relative increase of the lymphocytes. The blood plates are also fewer in number.

Splenic Anæmia.—This term is commonly used to characterise cases of severe, unexplained anæmia, in which splenic enlargement is a prominent feature. Undoubtedly a number of different conditions have been included. An adult and an infantile type are described.

Under the adult form the condition known as Banti's disease may be classified. This is characterised by an enlargement of the spleen with cirrhosis of the liver and atheroma of the splenic and portal vessels. Microscopically, the spleen shows a diffuse fibrosis both of the Malpighian bodies and of the reticulum. The Gaucher type of splenic enlargement also comes under this heading. In it the spleen is enormously enlarged and the parenchyma is transformed

into spaces resembling the alveoli of a gland. These spaces are lined by peculiar, large mononuclear cells. The liver is also enlarged and contains groups of these cells. Similar cells are also present in the bone marrow.

The infantile type of splenic anæmia has no constant features. The enlarged spleen shows microscopically a general fibrosis.

The blood pictures in splenic anæmia are not constant or characteristic. The general type is that of a secondary anæmia with a relatively excessive diminution in the percentage of hæmoglobin, hence a low colour index. As a rule the leucocytes are diminished.

Leukæmia (Leucocythemia)

Two main types of this condition are recognised :—

- (1) *Myelocythemia, myelæmia, spleno-medullary leukæmia.*
- (2) *Lymphocythemia, lymphæmia, lymphatic leukæmia.*

(1) **Myelocythemia.**—This is a condition in which there is an enormous proliferation of leucocytes and leucocyte-forming cells, mainly of the granular variety, chiefly in the bone marrow. The result is that fully developed leucocytes and immature forms (myelocytes) overflow into the circulation in large numbers. The disease is probably a tumour formation related to the sarcomata.

The *blood* is often paler than normal. Large greenish-yellow or white clots may be found in the heart and vessels. Films show an enormous preponderance of white blood corpuscles. Instead of the normal proportion of 1 white to 500 reds, there may be 1 to 10, or even 1 to 1. The prevailing types of leucocyte present are the polymorphonuclear and the neutrophil myelocyte. These latter are very large cells, not infrequently 20 μ in diameter, with large, pale nuclei and neutrophil granules in their protoplasm. In addition, there is a marked increase in the number of eosinophils, and eosinophil myelocytes are also present in

large numbers. Mast cells (cells with basophil granules) are present, often in great numbers. There are considerable numbers of lymphocytes and other hyaline cells, but these are relatively greatly diminished. The red cells are reduced in number and nucleated red cells of the normoblast type are usually present.

The *organs generally* tend to be enlarged and have a pale appearance.

The *spleen* is usually greatly enlarged (Fig. 33). It may weigh as much as 18 lbs. The enlargement is uniform, and the shape with the notches is preserved. The organ may reach as far down as the pubis. In consistence the organ is firm. The surface often shows chronic perisplenitis. Infarcts are very commonly present. On section, the cut surface has a uniformly pale pink, flesh-like appearance. The Malpighian bodies are invisible.

Microscopic Appearances.—The sinuses of the pulp are filled with leucocytes of the different types. In addition, there are numerous swollen endothelial cells, in some of which red blood corpuscles can be seen. There is increase of fibrous tissue and pigment, the fibrous tissue spreading from around trabeculæ and vessels. Malpighian bodies are inconspicuous.

The *bone marrow* throughout the body has a pale pink colour. The marrow of the shafts of the long bones, instead of being fatty, has a similar pale pink appearance.

Microscopically, granular cells of all kinds are found present in greatly increased numbers. There is evidence of great rapidity of division (mitotic figures) among all types of myelocytes. Red cells are relatively few in number.

The *liver* (p. 191) and *kidneys* (p. 223) are enlarged and pale, and show microscopically more or less infiltration with leucocytic cells. The lymphatic glands may or may not be enlarged.

(2) **Lymphocythemia.**—In this type of the disease there

is a proliferation of the leucocytes of the non-granular or hyaline type. These overflow into the blood and infiltrate the organs. The condition, like the previous, is probably neoplastic in nature.

The *blood* is pale, and films show usually a marked increase of white corpuscles. This is seldom so marked as in the previous type of the disease. Occasionally there is no increase. The prevailing type of leucocyte is the lymphocyte, large or small. These form from 90 per cent to 99 per cent of the white corpuscles. Granular cells are few and far between. The red blood cells are reduced in numbers, and nucleated corpuscles are usually present.

The appearance of the *bone marrow* is similar to that found in myelocythemia. But on microscopic examination lymphocytes instead of the granular cells predominate.

The *lymphatic glands* are very commonly enlarged, sometimes attaining the size of a hen's egg.

Microscopically, they are found infiltrated with immense numbers of lymphocytes.

The *spleen* is usually enlarged, although it does not attain the size of the organ in well-marked cases of myelocythemia.

Liver and *kidneys* tend also to be enlarged; the latter are usually very pale and show numerous hæmorrhages scattered through them.

Chloroma.—This is a rare condition, found chiefly in male infants. It is characterised by the presence of greenish-coloured tumours, mainly in connection with the periosteum of bones, *e.g.* in the orbit, causing marked protrusion of the eyeballs and on the vertebræ. These, on microscopic examination, show the character of round-cell sarcomata. Deposits with similar characters may be found in the lymphatic glands and bone marrow, and in the liver and kidneys. The coloration of the masses is due to a pigment which occurs in a granular form, and is probably of a fatty nature.

Blood films show appearances similar to those seen in lymphocythemia.

HÆMORRHAGIC DISEASES

Hæmorrhages into the skin, serous and mucous membranes, are characteristic of a number of conditions.

(1) *Infective diseases*, such as pyæmia and ulcerative endocarditis.

(2) *Toxic conditions*, such as jaundice, snake bite, quinine poisoning.

(3) *Cachectic conditions*, as scurvy and severe anæmias.

The term "*purpura*" is often applied when hæmorrhages form a marked feature of a case. The term, however, undoubtedly includes a great many diseases of very different nature.

Scurvy is a disease caused by improper diet—an excess of meat (especially salted meat), and an absence of fresh vegetables. It is characterised by a swollen, spongy condition of the gums which readily bleed, and by hæmorrhages under the skin and into the muscles. The disease is believed to be an acid intoxication with diminished alkalinity of the blood. The coagulation of the blood is slow and incomplete, the other characters being those of a secondary anæmia. Post-mortem, beyond the appearances of cachexia and the hæmorrhages into the skin and muscles, there is little to note.

Infantile Scurvy (Barlow's disease) is a condition which is occasionally seen in infants, not infrequently those of the well-to-do. It is due to improper dieting, especially to an absence of fresh milk and to an excess of proprietary foods. Marked cases are characterised by fusiform swellings of the shafts of the long bones, particularly the tibia and femur. These swellings are due to hæmorrhage beneath the periosteum. The periosteum is always highly vascular. Occasionally the condition is seen also in the upper ex-

tremities. Fracture of the shafts of the long bones is occasionally met with. Microscopically, the bones are abnormally vascular and there is absorption of the bony trabeculæ.

Hæmophilia is a hereditary disease occurring almost exclusively in the males but transmitted exclusively by the females of a family. It is characterised by a tendency to persistent bleeding either spontaneous, or from slight wounds, such as the socket of a tooth. Although sometimes fatal, nothing abnormal is to be found post-mortem. It is stated that there is an unusual thinness of the blood-vessels with fatty change in the intima. This, however, is not always present, and may be merely the result of secondary anæmia. Without doubt the uncontrolled bleedings are to be ascribed to defective coagulability in the blood, in all probability to a deficiency in the amount of prothrombin. Sometimes the large joints, especially the knee, show in this condition appearances not unlike those found in rheumatoid arthritis. There is thickening and fibrillation of the synovial membrane with the formation of fringes which are coloured yellow-red from old hæmorrhages. At the same time there is also destruction of the articular cartilages.

DISEASES OF THE BONE MARROW

The bone marrow should be examined in such a readily accessible position as the ribs by compressing the marrow out by means of bone forceps ; also in the shaft of one of the long bones, such as the femur. In the latter position the marrow consists normally almost entirely of fatty tissue, the red marrow of the long bones being confined in the adult to the cancellous tissue at the ends. The bone (by preference the femur) should be sawn across near the upper end of the shaft. Films should be made on slides or cover-glasses by smearing the marrow over the surface. These can be

stained directly by Leishman's or Jenner's stain. Portions of marrow may also be fixed (best in corrosive sublimate) cut in paraffin and stained by other means.

The marrow should be examined more especially in all cases of anæmia, and in cases where there is enlargement of spleen or lymph glands, also in infective conditions such as pneumonia.

The two main functions of the marrow being the formation of red and white blood corpuscles, two chief alterations are found: (i.) *associated with increased activity in the white cell-forming function (leucoblastic marrow)*; (ii.) *associated with increased activity in the red cell-forming function (erythroblastic marrow)*. Where either of those functions is markedly stimulated, the fatty marrow of the long bones becomes replaced by leucoblastic or erythroblastic marrow, as the case may be.

Leucoblastic Marrow is found in most infective conditions associated with the presence of excess of leucocytes in the circulating blood. It is also found in the two types of leukæmia. Leucoblastic marrow has a pink appearance and soft consistence.

Microscopically, it shows increased proliferative activity as evidenced by presence of mitotic figures in the nuclei of the myelocytes (infective conditions and myelocythemia) or lymphocytes (lymphocythemia), as the case may be. Red blood corpuscles both nucleated and fully formed are relatively diminished in number.

Erythroblastic Marrow is found in cases where there has been a call upon the red cell-forming function, such as anæmias of all kinds. The marrow is redder than normal, and the yellow fatty marrow of the shafts of the long bones is more or less altered into red marrow. In cases of pernicious anæmia this alteration is usually complete, and, in addition, the bony trabeculæ may be absorbed to a certain extent, leaving the interior of the shaft fairly smooth.

Microscopically, this type of marrow is characterised by marked increase in the numbers of the red blood corpuscles, many of which show nuclei in process of division. More especially in pernicious anæmia this is associated with the presence of large numbers of large nucleated red cells or megaloblasts.

Degenerations.—Fibrous and myxomatous transformation of the marrow tend to occur in old age, syphilis, and other debilitating diseases. In old-standing cases of leukæmia and pernicious anæmia degenerative changes may occur.

Pigmentary Changes.—Another function of the marrow, which it shares along with liver and spleen, is destruction of effete red blood corpuscles. In severe anæmias this function may be increased, giving rise in certain cases to a brownish-red coloration, which appears on microscopic examination to be due to the presence of blood pigment.

DISEASES OF LYMPH GLANDS

For pathological purposes the chief groups of lymph glands are :—cervical, axillary, mediastinal, bronchial, mesenteric, retroperitoneal, pelvic, and inguinal.

These groups should be examined carefully as the regions in which they lie are dealt with. Particular attention should always be paid to the condition of the glands in suspected or obvious tuberculosis or malignant disease.

Pigmentary Changes.—These are to be observed, constantly but in varying degree, in the bronchial glands, also in the axillary glands in cases of tattooing of the skin of the arm.

Acute Lymphadenitis.—This is to be seen in the glands through which drain the lymphatics of any area that happens to be the seat of acute inflammatory changes ; the axillary or inguinal glands in cases of poisoned wounds and bubonic

plague; the mesenteric glands in typhoid fever. The gland is enlarged, often congested, fairly firm in consistence, sometimes with areas of hæmorrhage or necrosis, or even softening and suppuration.

Microscopically, there is infiltration with inflammatory exudate, which is sometimes fibrinous; proliferation and throwing-off of the endothelial cells lining the sinuses; areas of hæmorrhage and necrosis, with possibly accumulations of polymorphonuclear leucocytes, and in some cases (plague, typhoid), the causal organism in considerable numbers.

Chronic Lymphadenitis.—This is to be observed in connection with areas where there is chronic inflammation of any kind. The gland is enlarged and firm, the capsule thickened and often adherent to neighbouring glands. On section, the structure is pale.

Microscopically, there is fibrous overgrowth in the capsule and trabeculæ. There is also catarrh and proliferation of the endothelial cells of the sinuses and proliferation of the lymphoid cells.

Tuberculous Lymphadenitis.—This is a very common condition, and should be carefully looked for in all cases. The glands which are the seat of the change are enlarged. In the early stage they are discrete, and, on section, grey and translucent, with, as a rule, areas of opaque white or yellow caseation. In the later stages they tend to be adherent to one another and to surrounding structures, their capsules are thickened, and, on section, the gland substance shows caseous (Fig. 37) and sometimes also calcareous change. Evidence of tuberculosis should be looked for more especially in the cervical, mediastinal, bronchial, mesenteric, and retro-peritoneal groups of glands.

Microscopically, in addition to the changes found in a non-specific chronic inflammation (see above), there are typical tubercle follicles and areas of caseation. Tubercle bacilli are commonly few and scattered. When they occur they are usually

to be found in a zone at the margin of the caseous area. Occasionally they may be found in considerable numbers, and sometimes in the giant and epithelioid cells.

Lymphadenoma or Hodgkin's Disease (also known as **Pseudoleukæmia**).—This is a condition which, on the one hand, resembles malignant growths, and, on the other hand, the chronic inflammatory conditions, such as tuberculosis. Certain cases, with all the characteristic appearances of lymphadenoma, have been proved to be tuberculous by inoculating animals with portions of glands. Other cases resemble very closely the appearance in lymphosarcoma.

The changes in the glands consist of an enlargement, usually greater than that found in tuberculosis, of a group or of several groups, such as the cervical, axillary, mediastinal, abdominal, inguinal. The cervical group is the one most frequently first affected (Fig. 38). The glands while enlarging tend to remain discrete (cf. tuberculosis). They vary in size from a pea up to a hen's egg. They are usually firm. On section, they are grey and somewhat translucent with obvious bands of shining connective tissue, and possibly with yellow areas of necrosis. These areas of necrosis differ from the caseous areas found in tuberculosis in being small and less opaque.

Microscopically, in the earliest stage there is a hyperplasia of the lymphocyte cell elements; later there is a multiplication of the endothelial elements at the expense of the lymphoid cells, which may be relatively few and far between. Many of these endothelial cells have more than one nucleus, but when there are several nuclei these are in a group, not peripherally arranged as in the typical giant cell of tuberculosis. The tissue not infrequently shows infiltration with eosinophil leucocytes. There is always a greater or less amount of connective-tissue fibres, both in connection with the capsule and in the substance of the gland. The fibrous transformation is found most marked in the more advanced cases. Areas of necrosis may be present.

Similar changes are to be found in certain of the internal organs, more particularly the spleen (see p. 110), less frequently the liver (p. 191) and lungs.

Tumours of the Lymph Glands.—*Lymphomata* or tumours of lymphatic tissue, in which the various elements retain their normal proportions, may be found in the mediastinum, tonsils, etc.

Lymphosarcomata or malignant growths arising in connection with, and having the structure of lymphatic tissue, are found not infrequently in the mediastinum invading the roots of the lungs, or in the abdomen. They tend to produce metastases in the other organs. They form a very malignant type of tumour, and usually show microscopically the appearance of a round-cell sarcoma.

Secondary growths in glands are to be looked for in all cases of malignant disease, more especially in carcinoma.

DISEASES OF THE SPLEEN

Atrophy.—This is practically a normal process in extreme old age. The organ becomes smaller, its capsule thickened and shrivelled. On section, there is found an increase of fibrous tissue, the pulp is of a dull, reddish-brown colour and bloodless. The organ is somewhat tough in consistence.

Waxy or Amyloid Degeneration.—This change is to be looked for in all cases of prolonged suppuration, advanced tuberculosis, and visceral syphilis. There are two types of the condition.

(1) *Sago.*—The organ is usually somewhat increased in size, but the increase may not be marked. In consistence it is usually firm, and, when cut into, the edges remain sharp. The cut surface shows numbers of round, translucent areas, uniform in size, but varying in size in different cases, and

regular in distribution (Fig. 34). These give the typical mahogany brown reaction with iodine solution.

Microscopically, the waxy change is found to be chiefly in the Malpighian bodies. The central artery may or may not be affected. Round the artery there is often an area comparatively free from the change. The elements affected are (1) the connective tissue of the capillaries, which run from the central artery to open into the pulp; and (2) the reticulum of the lymphoid tissue. The lymphocytes themselves are pressed upon and disappear. In addition (3) the intermuscular connective tissue of the middle coat of the arterioles running through the pulp will probably show the change.

(2) *Diffuse*.—In this variety the organ is always distinctly enlarged. It is firm, shows a sharp margin on cutting, and its cut surface has a translucent appearance and is of a pinkish-red colour. With iodine a diffuse mahogany brown reaction is given. This type is the one most usually found in syphilitic cases.

Microscopically, the change may be found, as in the previous variety, in the Malpighian bodies, but often it is restricted to the walls (periendothelial connective tissue) of the venous sinuses. Frequently the sinuses are particularly well seen, owing to the organ being the seat of chronic venous congestion. The arterioles of the pulp, and sometimes those of the Malpighian bodies, may show the change.

Hyaline Degeneration of the arterioles of the spleen is found in certain infective fevers, such as diphtheria and scarlatina. The condition gives rise of itself to no obvious alteration.

Microscopically, the change is found chiefly in the intima of the arterioles, which show a homogeneous swelling, partially obliterating the lumen of the vessels.

Pigmentation.—The spleen is specially liable to *post-mortem* pigmentation owing to its position close to the stomach and large bowel. The organ shows a greenish-

black colour, which penetrates for a variable distance into its substance. It is due to the action of the sulphuretted hydrogen escaping from the hollow viscera and acting upon the free iron in the organ, producing black sulphide of iron.

In severe anæmias, in malaria, and in toxic conditions there is *increase of iron-containing pigment* in the organ. This, more particularly in the case of anæmias, may be in such quantity as to be demonstrable to the naked eye. The Prussian blue reaction with dilute hydrochloric acid and potassium ferrocyanide is usually not well seen in the case of the spleen, owing to the large quantity of blood in the pulp.

CIRCULATORY DISTURBANCES

Acute Congestion or Active Hyperæmia.—This is constantly seen in acute toxic conditions, such as pneumonia, septicæmia, acute fevers, etc. The spleen is enlarged, soft as a rule (although in typhoid fever it is often fairly firm), and pale in colour. On section, the pulp is found to be very soft, often capable of being washed away in a stream of water. The colour is a creamy pink. The Malpighian bodies are sometimes prominent, more especially in children. There are not infrequently hæmorrhages.

Microscopically, the sinuses are found to be distended with blood, which shows a larger proportion of white cells than usual. There is swelling of the endothelial cells lining the sinuses, and these can often be seen to contain red blood corpuscles. In typhoid fever, areas of focal necrosis are always found, and often distinct masses of bacilli. In other conditions, organisms may be demonstrable, and even the commencement of abscess formation may be found. True abscess formation in the spleen is rare.

Chronic Venous Congestion or Passive Hyperæmia.—This condition is found in (1) chronic valvular disease of the heart, (2) chronic pulmonary disease, (3) cirrhosis of the liver.

The spleen is uniformly enlarged, retaining its normal shape and notches. There may be opaque areas of chronic perisplenitis. Not infrequently depressed yellow areas (pale infarcts) or dimples or puckerings indicating absorbed infarcts are visible on the surface (Fig. 32). The remainder of the organ is of a dark purple colour. In consistence it is firm. The cut surface is dark purple, with white specks and lines indicating trabeculæ, which may be more prominent than usual. Malpighian bodies are not easily seen.

Microscopically, there may be some increase of the periendothelial connective tissue in the walls of the sinuses. The sinuses themselves are distended with blood. Their endothelial cells are swollen and show increased phagocytosis of red blood corpuscles. Pigment derived from these latter may be seen in the cells. Under the microscope it is exceedingly difficult to distinguish chronic from acute congestion.

Infarction. — This may be due to (1) *embolism*, (2) *thrombosis* occurring in a diseased artery or vein.

The infarcted areas may be red or pale, and in the early stages are raised above the surface (Fig. 31). Later on they become depressed, and eventually form a pucker on the surface and cicatrix in the substance. The larger infarcts may extend right across the surface of the organ. On section, the smaller ones are, as a rule, wedge-shape, and situated superficially. The blocked vessel may be visible at the apex of the wedge, the base being formed by the surface of the organ. In the case of the older infarcts a zone of fibrous tissue forms round the margin. Within this there is frequently a zone of yellow (hæmatoidin) pigment. Rarely the infarcted areas may undergo softening. This softening may be simple or septic.

Microscopic Appearances. — In the earliest stage (red infarct) all that is to be noted is overfilling of the sinuses with blood and the presence of fibrin filaments between the blood cells. Later (pale infarct) the nuclei of the splenic cells are

found to have lost their characteristic staining reaction. The outline of the sinuses and individual cells may still be seen. Still later, all evidence of structure disappears. Round the infarcted area there develops a zone of granulation tissue, consisting of young blood-vessels, leucocytes, and fibroblasts in various stages of development. Within this zone, bunches of yellow acicular crystals of hæmatoidin are frequently to be observed.

INFLAMMATIONS

Acute Perisplenitis is seen in all cases of acute general peritonitis.

Chronic Perisplenitis is very frequently seen as pearly white areas of thickening in the capsule of the organ. The thickening may be considerable and very hard, even like cartilages. It is frequent in cases where the organ is enlarged, as in leukæmia. Adhesions to the parietes are not infrequently associated. In cases of tuberculous peritonitis the capsule of the organ often shows characteristic tubercle granulations.

Acute Inflammation of the Spleen Substance is rare. In cases of septic infarction the commencement of abscess formation may be seen.

Chronic Interstitial Splenitis, or overgrowth of the fibrous tissue of the organ, is to be found in many conditions, lymphadenoma, leukæmia, malaria.

Tuberculosis of the spleen is invariably associated with tubercle elsewhere. Two types of the condition occur. (1) The commonest form is *miliary tuberculosis* associated with generalised infection. The organ is usually not much altered in size. Scattered through it are numerous minute grey, white, or yellow points, which are often difficult to distinguish from Malpighian bodies.

Microscopically, there are found tubercle follicles with giant cells and surrounding epithelioid cells, or centres of commencing caseation.

(2) The other form of tuberculosis in the spleen shows large, rounded, opaque white or yellow caseous masses scattered through the organ, the so-called "hard-bake" spleen, from the resemblance to almond toffee (Fig. 33). This variety is found chiefly in children.

Lymphadenoma or Hodgkin's Disease (also known as **Pseudoleukæmia**). — This is a disease primarily of the lymphatic glands (p. 104). The spleen is, however, very constantly affected, especially in advanced cases. When affected the organ is almost invariably enlarged. The enlargement is uniform, although there may be projections on the surface. On section, numerous opaque, pale bodies, angular in shape and more or less uniformly distributed (Fig. 35), are to be seen. Sometimes they are grouped into masses (Fig. 36). At first grey and somewhat translucent, they become more opaque white in the later stages, and stand out in marked contrast to the general colour of the spleen which is pink to dark red. The whole appearance of the cut surface is compared to masses of suet in a pudding.

Microscopically, the appearances are essentially those seen in the lymphatic glands. The change is primarily in the Malpighian bodies, which in the early stage show merely hyperplasia of the lymphocyte cell elements. Soon the large spindle-shaped endothelial cells appear, many of which are multi-nucleated, while the lymphocytes diminish in numbers. The large endothelial cells tend to pass into the pulp, and as they are actively phagocytic they take up red cells, and later show hæmatoidin pigment. Fibrosis commences at a comparatively early stage, and later the Malpighian body may become entirely transformed into a knot of well-developed fibrous tissue. Not infrequently areas of necrosis occur, as in the lymphatic glands.

Tumours of the spleen are rare.

Angiomata and angiosarcomata, the latter with secondary deposits in the liver, are described.

Secondary tumours are also rare, sarcomata being occasionally found.

EXAMINATION OF THE SPLEEN REMOVED FROM THE BODY

Note in the first instance the size of the spleen. The normal organ measures about 5 inches by 3 (12.5 × 7.5 cm.), and the weight is 5-8 oz. (150-250 gm.). If the spleen is enlarged, note whether this enlargement is uniform, the organ retaining its normal shape, or localised. The spleen is uniformly enlarged in acute congestion, chronic venous congestion, amyloid disease, lymphadenoma, leukæmia, malaria, etc. It is irregularly enlarged in some cases of lymphadenoma, in tumour and cyst formations. It is diminished in size in the atrophy of old age and in wasting diseases.

Examine the surface for thickenings of the capsule, peritoneal tubercles, evidence of infarction, etc. Determine the consistence. The normal organ is moderately firm. In acute congestion it is soft, in chronic venous congestion, waxy disease, lymphadenoma, and leukæmia the consistence is increased. After making a longitudinal incision into the organ, note whether the edge of the cut becomes rounded, as is the case when the consistence is soft, or remains sharp, as is the case when the consistence is increased. Examine the cut surface for the relative prominence of the Malpighian bodies (these are usually much more obvious in children than in adults), for hæmorrhages, infarcts, opacities, etc. Note the general colour of the organ, which normally is brownish purple.

DISEASES OF THE THYROID GLAND

Congenital absence of the thyroid is found in cases of *cretinism*. **Atrophy** of the gland in early life is another cause of the same condition. Atrophy in adult life gives rise to the disease *myxædema*. In this disease the gland is reduced to a mass of fibrous tissue, in which a few gland acini may still be found. Associated with the change in the thyroid is a myxomatous degeneration of the subcutaneous

tissue, with atrophy of the sebaceous glands, hair follicles, and other cutaneous structures.

Waxy Degeneration is sometimes found well marked in the thyroid, the gland being considerably enlarged.

Enlargement of the Thyroid, Goitre, Struma, or Bronchocele.

1. *Simple Goitre*.—A degree of enlargement of the organ is not infrequently found, more especially and markedly in individuals from certain districts, such as Derbyshire. Whether this is a tumour formation, or merely a dilatation of the existing acini, is doubtful. In some cases there is evidence of proliferation of the gland elements, in others none. In certain cases there is marked overgrowth of fibrous tissue.

Microscopic Appearances.—Gland acini are seen, varying in size, some being greatly dilated, lined with cubical cells, and filled with colloid material. There is a variable amount of supporting connective tissue.

2. *Exophthalmic Goitre*.—In the condition often known as Graves's disease there is a uniform enlargement of the thyroid gland (Fig. 39). The gland is pale pink or white, and on section shows no evidence of colloid material. Cysts may be present, but their contents are usually liquid. The cut surface is more like that of the pancreas or of a salivary gland than of the normal thyroid.

Microscopic Appearances.—The most striking thing is the absence, or almost complete absence, of colloid material. The acini are relatively small and vary in shape and size. The cells lining them are columnar instead of being cubical. Papillary ingrowths into the acini may be seen. Shedding of the cells may be found. There is marked vascularity of the interacinous tissue.

Tumours.—Adenomata and cystic adenomata are sometimes found. Carcinomata, and, more rarely, sarcomata

occur. The normal thyroid weighs rather more than an ounce (30-40 gm.).

DISEASES OF THE THYMUS GLAND

This gland is largest about the second year, after which it becomes progressively smaller, and is usually atrophied after the twenty-fifth year of life. It may, however, persist, and may be found enlarged in conditions such as exophthalmic goitre. It is also enlarged, along with the lymph glands of the body generally, in a condition sometimes found in children, where death may occur suddenly under the administration of chloroform, or without any obvious reason. This condition has been called *status lymphaticus* or "lymphatism."

Inflammation of the thymus is found in cases of severe inflammation of the neck, spreading downwards.

Tumours of the gland are rare, although mediastinal sarcomata sometimes take their origin in it.

DISEASES OF THE SUPRARENAL GLANDS

It should be remembered that the suprarenal gland represents a combination of two types of tissue, probably with totally different functions. The *cortical* portion is formed of columns of gland cells with intervening capillary vessels. The cells are polygonal, and, in the fresh condition, contain large quantities of myelin and other fatty bodies; hence the yellow colour of the cortex. The function of the cortical portion has not yet been satisfactorily decided.

The *medullary* portion of the gland is grey to the naked eye, with red spots scattered through it, indicating vessels. Microscopically, it is found to consist of blood spaces lined with endothelium, and between these ganglion cells with a peculiar affinity for neutral salts of chromic acid. These chromaffin or chromophil cells, which are also found in the

pituitary gland, the carotid body, and the coccygeal glands, are believed to be the cells which secrete adrenin. In all cases where the suprarenal is suspected to be at fault the gland, as well as other parts containing chromaffin cells, should be fixed in a chrome salt fixative, such as Müller's fluid, and cut in gum (see p. 354).

Accessory Suprarenals.—These may be found not only in the kidney, liver, and tissue in the immediate neighbourhood of the suprarenal, but also in the broad ligament and ovary. They are known as suprarenal or adrenal rests, and it is believed that they form the starting-point of certain tumours known as *hypernephromata*. These "rests" are formed usually only of the cortical portion of the gland.

Hæmorrhages into the suprarenal are not very infrequent. They occur, more especially in children, in fevers and in wasting conditions. Such hæmorrhages may be the cause of sudden death.

Tuberculosis.—This shows itself in two forms.

1. As a part of a general tuberculosis with small caseous nodules in the gland, as in other organs and tissues.

2. As a fibro-caseous process involving both glands, often the only tuberculous manifestation in the body, causing complete destruction of the organ. This is the type of change commonly *associated with Addison's disease*.

Addison's Disease.—Besides the above-mentioned chronic tuberculosis of the suprarenals, there have been found in cases of Addison's disease fibroid atrophy of the suprarenal and tumour formation. In a few cases the glands have been found normal, but the semilunar ganglia and chromaffin tissue generally have been affected.

Tumours.—*Hypernephromata* or tumours, the cells of which resemble those of the cortex of the normal gland may grow from the suprarenal. They may be simple or malignant (p. 224).

Carcinomata and *sarcomata* may also be found. They are usually secondary, and commonly there are deposits in both organs. The weight of the suprarenals varies considerably. It has been given as 4-7 grammes. The left is slightly the heavier.

CHAPTER VII

DISEASES OF THE RESPIRATORY SYSTEM

DISEASES OF THE LARYNX

Œdema, also called œdema glottidis.—This may be due to the swallowing of boiling water, to acute inflammation in the neighbourhood, *e.g.* acute tonsillitis. It may also occur in association with kidney and heart disease. The parts most affected are the posterior surface of the epiglottis, the aryteno-epiglottic folds, and the false cords. The condition is serious, from its interference with respiration. It shows itself by swelling of the parts affected, which are pale and have a translucent appearance.

Laryngitis.—Acute and chronic catarrhal conditions of the larynx show little that is obvious after death. There may be hyperæmia and collection of mucus.

Membranous Laryngitis.—This is most commonly diphtheritic in origin, although it may be due to streptococcal infection. It may occur in the course of other specific fevers, such as typhoid and smallpox. It occasionally is caused by the presence of foreign bodies, such as fish bones. The membrane usually occurs also over the tonsils and pharynx, and may spread downwards into trachea and bronchi. The membrane is commonly *firmly adherent* in

the pharyngeal region. In trachea and bronchi it is easily removable (Fig. 44). The membrane has a white or grey appearance, and the subjacent tissue and surrounding parts are acutely congested.

Tuberculosis of the Larynx.—This condition is usually secondary to pulmonary tuberculosis. It is characterised by the deposit of tuberculous granulations, with subsequent ulceration. The ulcers are found over the epiglottis, aryteno-epiglottic and inter-arytenoid folds. At first superficial, they tend to extend deeply, eroding the vocal cords, and even the cartilage in the neighbourhood. The margins of the ulcers are raised and nodular.

Syphilis of the Larynx.—This may occur both in hereditary and in acquired syphilis, and both as a secondary and tertiary manifestation. In the secondary stage catarrhal inflammation and mucous patches occur, in the tertiary stage gummata, ulceration, and subsequent cicatrisation and stenosis. Ulceration, when it occurs, tends to destroy cartilage as well as soft parts, such as the base of the tongue and pharynx.

Tumours of the Larynx.—Among simple tumours, papillomata and fibromata occur. Of malignant growths, carcinomata are more common than sarcomata.

DISEASES OF THE BRONCHI

Acute Bronchitis.—Inflammation of the bronchi may be caused by many different organisms, *e.g.* *staphylococci*, *streptococci*, *pneumococcus*, *micrococcus catarrhalis*. In addition, irritating fumes, such as those of ammonia, may produce it. Inflammatory conditions of the smaller bronchi are often accompanied by inflammation in the contiguous portions of lung (broncho-pneumonia).

The appearances in acute bronchitis are swelling and

118 DISEASES OF THE RESPIRATORY SYSTEM

congestion of the mucous membrane, with the presence of a fibrinous or purulent exudate. When the bronchi within the lung substance are affected, squeezing of the lung expresses beads of purulent material.

Microscopic Appearances.—The most striking change is desquamation of the ciliated epithelial cells, which are found lying free in the exudate along with polymorphonuclear leucocytes. The basement membrane upon which the epithelial cells rest is swollen. The underlying vessels are congested, and the surrounding tissue infiltrated with inflammatory cells. The cells of the mucous glands are swollen and granular.

Chronic Bronchitis.—This condition may be organismal, following the acute form, or it may be associated with the occupation, the individual working in an atmosphere in which there are many foreign particles, *e.g.* carbon, stone, steel, etc. In appearance there may be little alteration from the normal. Sometimes the lumen of the tubes is dilated. The mucous membrane may be pale or congested. Occasionally there may be superficial ulceration. There is always a considerable amount of frothy muco-purulent secretion in the tubes, which may show more or less pigmentation from the presence of foreign particles. The condition is usually accompanied by emphysema of the lungs, and often by dilatation of the right side of the heart.

Microscopically, the epithelium, when present, is of a cubical rather than of a columnar type. In places the epithelium may be entirely absent. The basement membrane is often thickened and the subjacent tissue infiltrated with inflammatory cells of a small, round, lymphocyte-like type. There is usually overgrowth of fibrous tissue, and structures such as bronchial muscle and mucous glands may be atrophied. The lumen of the tubes contains desquamated epithelial cells and polymorphonuclear leucocytes, mixed with strings of fibrinous material.

Tuberculous Bronchitis.—Tuberculous lesions of the larger bronchi are not commonly met with, although tubercles

may develop in the mucous membrane and subsequently ulcerate. Lesions of the smaller bronchi within the lung are common in pulmonary tuberculosis. Peribronchial tubercles may break through into the lumen of the tubes and lead to ulceration. The smaller bronchi not infrequently dilate through weakening of their walls by inflammatory change. Such dilatations may form the starting-point of cavities.

Syphilitic Bronchitis.—Gumma formation, with subsequent ulceration, although uncommon, is met in the larger bronchi, usually at their commencement, and in the trachea at its bifurcation.

A number of cases of sudden death from hæmorrhage through erosion of a large vessel (pulmonary artery, left bronchial artery, superior vena cava) by such an ulcer have been recorded.

Bronchiectasis, or dilatation of the bronchi, is usually met with in connection with an interstitial pneumonia (tuberculosis, syphilis). The dilatation may be fusiform or saccular. It is produced by traction on the part of the contracting fibrous tissue in the neighbourhood together with adherence of the lung to the chest wall. A generalised dilatation of the bronchi may follow collapse of a lung.

Bronchiolectasis, or dilatation of the bronchioles, is a common occurrence in broncho-pneumonia, more especially in children. The walls of the tubes, weakened by the inflammatory process and under pressure from within through coughing, distend. As a rule the amount of distention is small, but in certain cases it may go on to such a degree that large cavities are produced in which secretion accumulates. Such a condition has been called "honeycomb lung."

DISEASES OF THE LUNGS

Collapse.—A lung which is not consolidated, and which is not held in position by adhesions between the two layers

of the pleura, the moment that the pleural cavity is opened collapses to about one-third of its bulk. Such lungs are therefore always observed in this semi-collapsed condition. A similar condition, or one which is more complete, may be produced during life by the presence of air in the pleural cavity, or from dropsical or purulent fluid in the sac. In such a case the lung is of a slate-grey colour (Fig. 41), anæmic, tough, and sinks in water. On squeezing, few or no air-bubbles can be expressed from the cut surface. If the collapsed condition have persisted for long, there will be overgrowth of fibrous tissue, and sometimes dilatation of the bronchi. If adhesions bind portions of the lung to the parietal pleura, the collapse will be partial.

Collapse of small portions of lung is often observed *post-mortem*, more particularly in the lower and posterior parts of the organ. These appear as dark purple areas slightly depressed below the general surface. They can be reinflated by pressing air into them from neighbouring parts.

Similar small areas of collapse are found *in cases of broncho-pneumonia*. They are due to blocking of the smaller bronchi with exudate, and the subsequent absorption of the air by the blood.

Localised collapse may also be found in the lung in the neighbourhood of aneurysms or tumours pressing directly upon the lung.

Microscopic Appearances.—The alveolar walls are relaxed and approximated. The vessels are usually dilated. There may be evidence of catarrh in the alveoli. Increase of fibrous tissue may be observed. The elastic tissue appears to be increased, but that is merely because of the relaxation of the lung substance and the condensation of the fibres.

Atelectasis.—This is a condition similar to the above, which may be found in the new-born child, but as it is due to want of expansion, the term “collapse,” although sometimes used, is scarcely applicable. The condition may be

complete or partial. When partial, it is commonest in the lower lobe, especially in its posterior part. The organ which is the seat of the change, instead of being pale pink and crepitant, is dark red, tough, and airless. If the condition is partial, the area affected is depressed below the air-containing portion. The affected portion sinks in water (see p. 310).

Emphysema.—Two varieties of this condition are found in the lung: (1) vesicular emphysema, or over-distention of the air vesicles of the lung; (2) interstitial emphysema, or the escape of air into the fibrous supporting tissue of the lung.

(1) *Vesicular Emphysema.*—This is a condition of over-distention of the lung alveoli caused by (a) forcible distention of the air vesicles from constant coughing, as in chronic bronchitis, or from the blowing of wind instruments; (b) the giving way of the elastic network of alveolar walls before a normal pressure; this may be due to wasting disease, to old age, or to an inherent imperfect development of the tissue. The portions of the lung most affected are the apex, the anterior and lower borders, that is to say, those portions where over-distention can occur most readily. The lung is pale (Fig. 40), light, and has a spongy feel, like the sensation given on pressing a bag of feathers. On section, it is dry and bloodless. There may be areas of very marked distention forming small bladders or bullæ. The condition is usually associated with *chronic bronchitis* and *enlargement of the right side of the heart*. *Hypertrophic* and *atrophic* forms of emphysema are distinguished; in the former the organ is more voluminous, in the latter it is smaller than usual. The hypertrophic type is found in cases where forcible distention from coughing is the cause, the atrophic type in cases of wasting disease in old age, or where the elastic tissue of the organ is naturally imperfectly developed.

Complementary or compensatory emphysema is found in

small areas of lung in close approximation to areas of collapse or to areas of shrinkage from fibrosis. This latter type, found in the neighbourhood of healed tubercle foci, may be called *traction emphysema* (p. 146).

Microscopic Appearances.—There is marked over-distention of the air vesicles and smaller air passages. The smaller vessels have, to a great extent, disappeared. The elastic fibres of the alveolar walls are stretched and widely separated. The bronchi may show evidence of chronic catarrh.

(2) *Interstitial emphysema* is a rare condition when, owing to rupture of the lung from injury (*e.g.* fractured rib, stab, or bullet wound) or disease (*e.g.* gangrene, emphysema), the air escapes into the fibrous supporting tissue. In this position it works its way to the root of the lung, and eventually into the mediastinum and areolar tissue of the neck.

CIRCULATORY CHANGES

Acute Congestion or Hyperæmia.—This condition is usually found preceding or associated with inflammation of the lung. It will be described in connection with pneumonia.

Passive Congestion or Hyperæmia.—Two varieties of this condition may be distinguished.

1. *Hypostatic congestion*, a condition frequently found *post-mortem*, more especially in cases where the circulation has been slowly failing. As the name indicates, it is in the posterior parts of the lung (the parts where gravity has most influence on the blood) that the condition is most marked. The area involved is dark purple in colour, and is often the seat of œdema and inflammatory consolidation.

2. *Chronic Venous Congestion of the Lung.*—This occurs where there is long-standing obstruction to the passage of the blood through the lungs, as in cases of *chronic valvular disease of the left side of the heart*. The organ is of a dark

red, sometimes brick-red colour, and in the later stages it is of firmer consistence, hence the term "brown induration." Not infrequently infarcts are present in such lungs.

Microscopic Appearances.—The vessels generally are dilated, and, in the case of the alveolar capillaries, they project into the interior of the air vesicles and are obviously thickened. Red blood cells may be found free in the spaces, also shed endothelial (catarrhal cells) containing pigment derived from broken-down red corpuscles. Catarrhal changes will also probably be found in the bronchi, and there may be some increase of fibrous tissue, but this is seldom in sufficient amount as to be obvious under the microscope. In the hypostatic variety œdema and more acute inflammatory changes may be present.

Hæmorrhage into the lung substance may occur in the form of minute *petechial hæmorrhages*, usually under the pleura. Such are found in severe anæmias, in cases of death from suffocation, and in infective conditions. Larger hæmorrhages are found in *infarction*, in severe inflammations, and in gangrene; also sometimes in tuberculosis.

Infarction (Pulmonary Apoplexy).—This is a common condition to find in lungs the seat of chronic venous congestion. When the area of lung involved is large, the condition may be the cause of sudden death. The causation of the condition is not quite clear, as it is difficult to produce infarction experimentally by the injection of artificial emboli. In a majority of cases, however, the artery leading to the area will be found plugged with an embolus, and on careful examination a source will be found for the embolus, *e.g.* a thrombus in the right auricular appendix or in a vein (see diagram, p. 62). Another view of the causation is that it is due to thrombosis in the vessel, not to embolism. Another that it is merely due to escape of blood from a burst capillary into the spongy tissue of the lung.

The condition is more frequently found in the *lower lobes*

than in the upper. It occurs specially at the *margins* of the lung (anterior and lower) and towards the *surface*, not in the substance.

The area involved is more or less angular (Fig. 45). It is raised above the general surface of the organ ; that is to say, it remains distended when the neighbouring lung undergoes partial collapse. It is usually dark purple in colour and hard in consistence. Occasionally it may be pale from subsequent decolorisation. Sometimes a zone of fibrous tissue develops around the infarct, and the area may undergo softening or it may cicatrise. Infarcts of the lung, however, seldom show the later changes found in infarcts elsewhere. This is no doubt partly due to the fact of the double blood supply of the lung. It is also due to the fact that many of the infarcts occur shortly before death, and in some instances are the actual cause of death.

Microscopic Appearances.—In the area involved, the alveoli are filled with red blood cells and fibrin, or, in other words, with blood clot. There are also leucocytes present, more especially at the margin. The cells of the alveolar walls show some loss of staining reaction, but necrotic changes are not frequently found in infarcts of the lung. There may also be a development of fibrous tissue round the area.

Œdema.—This is an exceedingly common condition. It is found in cases in which dropsy tends to occur elsewhere, as in *heart disease* and in *Bright's disease*. It is also very commonly present in cases where death has occurred slowly, as in *wasting diseases*, e.g. cancer, anæmia. It is frequently combined with hypostatic congestion, and tends to occur in the more dependent portions of the lung. Thus it is more frequent in the posterior portions of the lower lobe. Occasionally, however, it is most marked in the upper lobe. Œdema frequently occurs in the neighbourhood of pneumonic areas. The organ is pale unless congestion is superadded. It is bulky and feels fairly solid, but, unlike a pneumonic

lung, it pits on pressure. When one cuts into it and presses the lung substance, frothy fluid escapes.

Microscopically, the alveoli are found distended, their contents being finely granular material, which is all that is left of the albuminous exudate after the tissue has been fixed, hardened, and cut. Catarrhal cells and leucocytes are also usually present within the alveoli.

INFLAMMATIONS OF THE LUNG—PNEUMONIA

Types of Pneumonia.

1. Acute lobar pneumonia (croupous pneumonia).
2. Lobular pneumonia (catarrhal pneumonia).
3. Purulent (septic) broncho-pneumonia.
4. Hypostatic pneumonia.
5. Interstitial pneumonia.

1. Acute Lobar Pneumonia

This condition, also called **Croupous Pneumonia**, is so well defined that it may be called a specific disease. It is due in the vast majority of cases to the *diplococcus pneumoniae*. This organism is accompanied not infrequently by *B. pneumoniae*, *streptococci*, *staphylococci*, *B. influenzae*, *B. typhosus*. Occasionally these organisms are present by themselves.

The condition, as its name indicates, is one which usually involves the *whole or the greater part of the lobe of a lung*. The right lung is more frequently the seat of the disease than the left, and the lower lobe than the upper lobe. Not infrequently the whole of one lobe and a portion of another lobe may be affected, and less frequently both lungs may show the change. Orth gives the percentage of involvement of the two lungs as follows:—right, 52; left, 33; both lungs, 15.

The term croupous is applied because of the type of exudate present in the lung alveoli, which is essentially fibrinous.

For reasons of convenience it is customary to divide the process into *four stages*: (1) stage of *active hyperæmia* or acute congestion, (2) stage of *red hepatisation*, (3) stage of *grey hepatisation*, (4) stage of *resolution*. The distinction between these stages is an entirely artificial one. Frequently more than one of them are to be observed in one and the same lung. By themselves the first two are rarely seen, owing to the fact that death does not often occur during the early stages of the disease. They are, however, not infrequently seen in areas of the lung in which the later stages are present in neighbouring parts.

(1) *Stage of Acute Congestion*.—As regards the naked-eye appearances at this stage there is little more to be observed than a bright red colour in the lung substance on section. The lung substance is still crepitant and spongy.

Microscopic Appearances.—The vessels of the lung generally, and the capillaries in the wall of the alveoli in particular, are distended with blood. This condition of the capillaries gives a beaded appearance to the walls of the air vesicles. Within the lumen of the vesicles may be found a few red blood corpuscles, a few catarrhal cells thrown off from the wall, and a minute quantity of exudate. Suitably stained specimens may show germs.

(2) *Stage of Red Hepatisation. Naked-eye Appearances*.—The lung is *distended* and contrasts markedly with the semi-collapsed condition of the ordinary lung. Not infrequently the markings of the ribs may be seen. There is usually some slight amount of *fibrinous exudate* over the area of lung involved. In consistence the organ is *firm*, like a solid organ such as the liver. It cuts readily, quite unlike the soft, yielding, unconsolidated lung. The organ is immensely *increased in weight*. A small portion removed and placed in water at once *sinks*.

The cut surface of that portion of the lung which shows the change has a reddish colour, which, on account of its

being mottled with paler areas and accumulations of black pigment, has been compared with red granite. Usually the cut surface, more especially the paler areas, has a *granular appearance*, owing to the projection of plugs from the alveoli. On squeezing the lung substance, only a little blood and serous fluid, but no air, can be expressed. Those portions of lung not actually consolidated may show congestion, and sometimes œdema.

On opening up the bronchi their mucous membrane is found swollen and injected and their lumen filled with sticky rust-tinged exudate. The bronchial glands are swollen and pink in colour.

Microscopic Appearances.—Instead of the fenestrated appearance of the normal lung section, the lung which is the seat of this change appears like a solid organ. The alveoli are filled with plugs consisting of a network of fibrin threads, sometimes communicating with the coagulum in a neighbouring vesicle through one of the stomata. In the meshes of the fibrin are catarrhal cells, a few red blood corpuscles, and considerable numbers of leucocytes, chiefly of the polymorpho-nuclear type. In suitably stained specimens organisms can usually be found.

In the walls of the alveoli the vessels are still distended with blood. The bronchi show evidence of acute inflammation. The interlobular septa and the supporting fibrous tissue of the lung generally are swollen and infiltrated with fibrin and leucocytes. The pleura shows the changes of acute inflammation. Films made from the bronchial exudate will show leucocytes, fibrin, desquamated epithelium, both flattened and columnar, and characteristic germs. This last is the best source from which to demonstrate the pneumococcus.

(3) *Stage of Grey Hepatisation. Naked-eye Appearance.*—The organ is *distended* as before, shows rib markings and *fibrinous exudate* on the pleura over the affected lobe. As before, it is *firm, heavy*, and a portion removed sinks in water. The cut surface, however, is *pale*, and, with the black mottling of the carbon, is not unlike grey granite in appearance (Fig. 42).

The *granularity* of the cut surface *is more marked*, and, on scraping the surface with a knife, turbid fluid and plugs from the alveoli can be removed. *On squeezing*, similar fluid can be expressed, but *no air-bubbles*. On opening up the bronchi the mucous membrane, as before, is found to be swollen and injected; the contents have a more opaque white appearance.

Microscopic Appearances.—The alveoli and smaller air passages are filled, as before, with plugs, which are, however, at this stage retracted from the walls, this space having been filled during life with fluid. The fibrin threads are not so obvious; they are broken down and granular. In the meshes of the coagulum are vastly more numerous cells, the increase being entirely due to the accumulation of polymorphonuclear leucocytes. Many of these stain badly owing to degenerative changes. Germs are often difficult to find at this stage. The capillaries in the walls of the alveoli are, to a large extent, obliterated by the pressure of the contents of the air vesicles. Bronchi, interlobular septa, and pleura show, as in the earlier stage, evidence of inflammation.

(4) *Stage of Resolution. Naked-eye Appearances.*—The lung is still somewhat distended, but is now much *softer*. From the cut surface *considerable quantities of grey, milky fluid* can be expressed.

Microscopic Appearances.—The alveolar plug is contracted still more, and may be absent altogether. The contents of the alveoli are granular material and degenerated leucocytes. Multiplication in the endothelial cells of the alveoli is often seen, as evidenced by their greatly increased number. These may be found surrounding the remains of the plug. The capillaries of the alveolar walls are again distended with blood.

Other terminations than resolution in the case of lobar pneumonia are: (1) *septic softening*, which may go on to *gangrene*; (2) *fibrosis*, or overgrowth of the fibrous supporting tissue of the lung, producing chronic interstitial pneumonia.

In carrying out a *post-mortem* in a case of acute lobar

pneumonia, the following conditions, more especially, should be looked for in organs other than the lung :—

(1) A leucoblastic condition of the bone marrow associated with the marked polymorphonuclear leucocytosis of the blood in the disease.

(2) Acute congestion of the spleen.

(3) Cloudy swelling of liver, kidneys, and heart muscle.

Other conditions which may complicate the disease are ulcerative endocarditis, pericarditis, meningitis, peritonitis.

2. Lobular Pneumonia

Synonymous terms for this condition are: (1) *broncho-pneumonia*, from the fact that areas of lung in connection with, and around bronchi are involved; (2) *catarrhal pneumonia*, from the character of the exudate most characteristically found in the alveoli.

The etiology of the condition may be said to be the same as in the lobar form of pneumonia. It is *more frequent in children*, and is the form of inflammation of the lung found in the specific fevers. The matter might be put in this way; that pneumococcic infection of the lung in children usually shows the lobular type. When the lobular type occurs in adults, the causal germ is usually some other organism than the *pneumococcus*, e.g. *streptococci*, *staphylococci*.

Naked-eye Appearances.—The lung may be slightly more distended than normal. It has a *mottled*, red surface, with (1) dark purple depressed areas of collapse, (2) red, firm areas of consolidation, and (3) pale areas of compensatory emphysema. On handling it, *irregularly scattered areas of a firmer consistence* than the rest can be felt. On section, the same mottled appearance is visible, with dark purple areas of collapse where a bronchus has become plugged, pink areas of consolidation, more or less rounded (Fig. 43), in the centre of which can often be seen a small bronchus, from

which, on squeezing the lung, a small bead of thick white secretion can be pressed, also paler emphysematous areas. The lung tissue generally is congested. On opening up the bronchi, their mucous membrane is found swollen and congested, with more or less purulent-looking secretion. The bronchial glands are congested and swollen. The smaller bronchi and bronchioles within the lung substance are not infrequently dilated, sometimes to such an extent that a "honeycomb" appearance is produced (see Bronchiolectasis).

Microscopic Appearances.—To realise the true nature of the change, large sections of lung should be cut. The consolidation will then be seen to be patchy in its distribution, the plugged alveoli being usually situated round a small bronchus or bronchiole as their centre. This bronchus shows the appearance of acute bronchitis, and its wall is infiltrated with inflammatory cells. The elastic coat may be ruptured, and not infrequently the lumen is dilated. The alveoli around contain plugs which may be more fibrinous or more leucocytic, the appearances varying considerably in different types of the disease and in different positions. Towards the margin of the area more of the cells filling the alveoli are of the catarrhal type, *i.e.* they are cast off, swollen endothelial cells. Hence the term "catarrhal pneumonia." The walls of the alveoli generally show congestion of their vessels.

Broncho-pneumonia may resolve or may pass into septic pneumonia or gangrene.

The associated changes in spleen, bone marrow, etc., are the same as in lobar pneumonia.

3. Purulent or Septic Broncho-Pneumonia

This condition may occur :—

- (1) As a sequel to broncho-pneumonia, especially when of the so-called *aspiration* type, *e.g.* associated with the inhalation of septic material, as after operations on the mouth.
- (2) Associated with *obstruction to the bronchi*, as by tumour

or aneurysm leading to retention of secretion (so-called "retention" pneumonia).

(3) Associated with the presence of a *foreign body* in the bronchi.

(4) As a *blood infection* due to the deposition of organisms or infective thrombi in the pulmonary vessels (*embolic or metastatic pneumonia*), found specially in such conditions as osteomyelitis and pyæmia. *Septic infarcts* are not infrequently associated. Such infarcts have the same distribution and often very much the same appearance as the non-septic type (see p. 123), but they tend to be paler and often show softening in their centre. Under the microscope such infarcts are characterised by immense numbers of polymorphonuclear leucocytes in addition to red blood cells, also by masses of organisms.

The appearances are the same as in broncho-pneumonia, but the inflammatory changes are more acute, and there is a greater tendency to destruction of pulmonary tissue. The bronchi are filled with purulent material.

Abscess.—This condition is usually associated with *embolic pneumonia* or *septic infarction*. The abscesses are commonly small, but they may extend and pass on to *gangrene*. They are surrounded with a zone of consolidated lung.

Gangrene.—This is usually a *secondary condition*, the result of putrefactive organisms reaching a consolidated or necrosed portion of lung. Thus it may follow *lobar* or *septic pneumonia*, *infarction* or *abscess*. It may also be due to *direct extension*, as from a ruptured ulcer of the *æsophagus*, or from a subphrenic abscess. It may be due to the *presence of foreign bodies* in the bronchi, such as coins or false teeth.

The area involved is at first intensely congested, later it becomes black, and the lung substance breaks down and comes away, leaving a cavity (Fig. 46) lined with black or greenish-black walls, the colour being due to changes in the

effused blood. The contents of these cavities and of the bronchi are usually brown, like prune juice, but may be paler, like pus or putty. The neighbouring portions of lung show pneumonic consolidation. The odour is always most offensive.

4. Hypostatic Pneumonia

This is a type of pneumonia associated with hypostatic congestion and œdema of the lungs, and therefore found in the posterior and lower portions. It is the type of inflammation which supervenes in old age, and in wasting diseases generally.

The distribution of the change allows of immediate recognition. The consolidation is usually partial and associated with œdema.

Microscopically, the appearances differ in different parts—congestion, œdema, with catarrhal, fibrinous, and leucocytic consolidation, all being found in close contact.

5. Interstitial Pneumonias

These are conditions in which there is increase in the fibrous tissue of the lung. They may be divided into three groups:—

- (1) Those *following previous acute pneumonia*.
- (2) Those *due to the inhalation of dust* of various kinds.
- (3) Those *due to chronically acting bacterial poisons*, tuberculosis, syphilis, actinomycosis.

Interstitial Pneumonia following acute lobar or lobular pneumonia is a comparatively rare condition. It usually shows itself as localised areas of thickening of pleura and interlobular septa also of the fibrous tissue at the root of the organ. Sometimes it is more diffuse, involving considerable areas of lung tissue. In this condition, as in other types where there is marked thickening of the alveolar walls, the endothelial cells of the alveoli may become cubical.

Interstitial Pneumonia due to the Inhalation of Dust

(*Pneumokoniosis*).—There are three common varieties of this, according to the type of dust inhaled :—

- (1) *Anthracosis* or coalminer's lung.
- (2) *Silicosis* or stonemason's lung, also known as *Chalicosis*.
- (3) *Siderosis* or needle-grinder's lung.

In all these conditions the foreign particles which are inhaled are absorbed into the lymphatics, partly by the action of phagocytes. They tend to be deposited along the course of the lymphatics, and there to set up irritation and consequent fibrosis. Thus nodules of fibrous tissue develop beneath the pleura, along the interlobular septa, bronchi, and vessels. The lymph glands at the root of the lung are enlarged and indurated. Owing to the irritant action of the foreign particles preparing the way for germs, tuberculosis is a very common accompaniment of all these conditions. They are also frequently complicated by chronic bronchitis and emphysema, and by a degree of catarrhal pneumonia, and occasionally by bronchiectasis. The siliceous particles are more irritating than the carbon, hence the nodules of fibrous tissue tend to be larger in silicosis than in anthracosis ; there are also more catarrhal changes in the alveoli. The steel particles are more irritating than the siliceous, hence the changes are most marked of all in siderosis.

Anthracosis.—There is always a certain amount of pigmentation in the lung of town dwellers, and also in most country dwellers. This is enormously accentuated in those who work in coal mines. When well marked the condition is known as anthracosis. The lung is usually black, or almost black, with small, hard, black nodules scattered under the pleura and in the lung substance (Fig. 48). On squeezing, there exudes an inky-black fluid. The bronchial glands are enlarged, deeply pigmented, and indurated.

Microscopic Appearances. — The nodules are found to consist of well-formed fibrous tissue mixed with carbon

pigment. They occur under the pleura, along the interlobular septa, bronchi, and vessels. The superficial layer of the pleura is, however, free from pigment. There is some degree of catarrhal change in bronchi and alveoli, and some thickening of the vessels.

Silicosis.—The lungs in this condition are grey in appearance, and, scattered through them, are numerous grey nodules, which are hard and gritty to the touch. Similar nodules are present in large numbers under the visceral pleura. They tend to be larger than those in anthracosis (Fig. 47).

The disease is not unlike the more chronic forms of tuberculosis, and, as already pointed out, it is not infrequently complicated by it. The pure condition may be distinguished from tuberculosis by the hard and gritty character of the nodules and by the absence of cavitation.

Microscopic Appearances.—These are the same as in anthracosis but the pigment is not so obvious (although carbon pigment is also present), and there is more catarrhal change in the surrounding lung. There may be endarteritis obliterans of the vessels. Tuberculosis is often superadded.

Siderosis.—The nodules in this type are larger, owing to the greater irritation of the metal particles. The lungs have a grey appearance and may be almost solid. Evidence of tuberculous disease is very frequently present in addition.

Microscopically, in addition to the larger areas of fibrosis, there is more catarrhal change in the alveoli, between the nodules of fibrous tissue.

Syphilitic Disease: (a) *White Pneumonia.*—This is a condition occasionally found in children suffering from congenital syphilis. The lungs are pale and firmer than normal.

Microscopically, there is found an overgrowth of fibrous tissue involving the walls of the individual alveoli. The endothelium lining the alveoli is cubical instead of being flattened.

(b) *Gummata*.—These occur as small caseous foci surrounded by fibrous tissue. They are not infrequently absorbed, leaving puckered cicatrices behind. They are indistinguishable from tuberculous caseous masses.

(c) *Interstitial Pneumonia* in acquired syphilis occurs as areas under the pleura or towards the root of the lung. There is thickening of the pleura, of the interlobular septa, and increase of fibrous tissue around the bronchi and vessels. The last usually show endarteritis obliterans.

Microscopically, there is overgrowth of fibrous tissue, usually catarrh of the alveoli, and often accumulations of small round cells (miliary gummata).

TUBERCULOSIS

Tuberculosis.—The lungs are by far the commonest site for tuberculous disease. In a large proportion of cases the disease does not progress far and soon heals, leaving merely some cicatricial tissue behind. The apex of the lung is the seat of election for the disease. Very often the apices of both the upper and lower lobes are affected. The disease may reach the lung by any of four paths: (1) the *air passages*, (2) the *blood-vessels*, (3) the *lymphatic vessels*, or (4) by *direct extension*. In most cases it is impossible to say by what avenue the disease originally came. Nevertheless, certain statements can be made regarding this question of the path of entrance. (1) Where the tubercle lesions are uniformly scattered through the organ, the disease has been brought by the blood-stream, and search should be made for some older focus of infection in some other part of the body or in the lung itself. This focus is commonly a lymph gland which has become adherent to, and eventually has ruptured into, a vein or a large lymphatic trunk, such as the thoracic duct. Not infrequently the source is a focus in the lung itself which has invaded a branch of the pulmonary

vein. The condition is always associated with disseminated metastatic tuberculosis in other organs, although the areas may not be visible to the naked eye.

(2) Where the lesions are arranged in groups, in a cluster like a bunch of grapes (staphyloid arrangement), the condition has probably been spread by the lymphatics, and a vessel or bronchus will be found in the centre of the group. This arrangement is sometimes found distributed throughout the lung. More often, however, this appearance is seen in areas of the lung where there is an older lesion at some point, and it is always seen at the margin of a spreading lesion of the more chronic type.

(3) Where there is a localised lesion (and commonly, as we have seen, it is at the apex of the upper lobe or at the apex of both upper and lower lobe) the general view is that the infective agent has been inhaled. The reason for the apical position is probably because that portion of the lung receives relatively less blood. Moreover, it is the portion of lung which moves least during respiration. There is great diversity of opinion upon this question. Another view is that the infection has spread from the lymphatics of the neck to the apex of the pleural cavity. There it sets up a localised pleurisy with the formation of adhesions, along which the bacillus passes to the apex of the lung. Again, the spread may be less direct, the infection passing from the cervical glands to the mediastinal and bronchial, and so outward into the lymphatics of the lung itself. In these cases of infection by way of the cervical lymph channels the tonsil is, in all probability, the portal through which the germs enter. A third view is that the infection is by way of the blood-stream, and that, owing to the greater susceptibility of the apex, the disease has progressed at that point and not at others.

(4) Very occasionally the disease may spread directly from a diseased rib or vertebra, or through the diaphragm from the abdominal cavity.

Mode of Spread.—Once started, the tuberculous lesion tends to spread in four ways :—

(1) *By direct continuity*, passing from alveolus to alveolus, and from one part of the lung to another.

(2) *By the Air Passages.*—A focus invades a bronchus, and sets up a tuberculous inflammation. The secretion is inhaled into the areas of lung to which that bronchus passes. Or infected secretion is coughed up for some distance and, in the deep inspiration following a fit of coughing, it is inhaled into the bronchi in other portions of the lung, even into the bronchi of the opposite lung.

(3) *By the Lymphatics.*—Tuberculosis is essentially a disease which spreads by lymphatics. This lymphatic spread shows itself in the occurrence of areas of fibro-caseous change in the lymph channels around a focus of the disease, having the staphyloid arrangement already mentioned. It is also shown by implication of the nearest lymphatic glands.

(4) *By the Blood.*—Chronic tuberculosis leads to thickening of the vessels. Acute tuberculosis tends to invasion of the vessel wall and the infection of the blood. The vessels of the lung are relatively thin walled. Invasion of a branch of the pulmonary artery will lead to further infection of the area of lung supplied by that artery. Invasion of a branch of a pulmonary vein will lead to systemic infection in which the lungs will participate. This is, however, not such a common occurrence as might be expected, owing to the fact that the tuberculous process is accompanied by non-specific inflammatory changes, which tend to obliterate a vessel before invasion with tuberculous material can occur.

According to one authority this is the way in which the lung is infected in most cases. Infection of the bronchial glands occurs first, one of the affected glands becomes adherent to a large branch of the pulmonary artery, and infective material in this way enters the pulmonary circulation.

Characters of the Lesions.—The tuberculous lesions tend to occur in the form of isolated foci. These may be widely separated from one another, or so closely packed that they are practically continuous. They are either grey and more or less translucent when they are formed of cellular elements and fibrous tissue, or opaque white or yellow when these elements have undergone caseation. There is always a certain amount of interstitial change or fibrous tissue formation, both in the lesions and in the lung around.

In the more acute cases this fibrous tissue formation is minimal. In such cases the condition tends to spread diffusely, involving more or less of lung substance and producing a catarrhal consolidation of the alveoli which subsequently undergoes a caseous change (caseous pneumonia).

Microscopically, the tuberculous lesion is characterised by a cell aggregation, the individual cell elements showing three types: (1) large multinucleated or giant cells, the nuclei of which are arranged commonly in a circle, or part of a circle, round a central clear, necrotic area; (2) spindle-shaped and branched cells, with nuclei resembling those of the giant cell, and, arranged round that cell (epithelioid or endothelioid cells); (3) lymphocyte-like cells, with small dark-staining nuclei and little protoplasm.

Polymorphonuclear leucocytes are, except in very acute cases, relatively few in number. The giant cell is not infrequently absent, and its place occupied by an area where the cells are breaking down. This area, as it enlarges, loses all appearance of structure. It is the commencement of the caseous process. In addition, there is always more or less overgrowth of fibrous tissue. In the more acute cases caseation predominates, in the more chronic, fibrous tissue formation. Where this inflammatory process invades the alveoli there is consolidation of the lung, a consolidation characterised by the presence of some exudate, not as a rule fibrinous, with numerous catarrhal cells and leucocytes. This consolidated area of lung also tends to undergo the caseous alteration whereby it becomes apparently structureless, but in this caseous focus the fibrous

tissues, and more especially the elastic fibres, persist for long almost unchanged.

The elastic fibres of the lung undergo some destruction both by fragmentation and solution, in the area where cells and nuclei are breaking down. The fibres which escape this primary destruction may persist in the caseous area for an almost indefinite period. It is largely for this reason that necrotic caseous areas of lung remain firm. When secondary infection with pyogenic and other forms of microbes occurs, complete destruction of the elastic fibres and softening of the caseous area takes place, the softened material is coughed up, and a cavity results. Another way in which cavity formation not infrequently starts is by inflammation of the walls of a bronchus or bronchiole. The wall, weakened by the inflammatory process, next gives way under the increased pressure associated with coughing. Destructive changes then occur, and a cavity results which subsequently extends.

Classification of Tuberculous Affections of the Lungs.—The most satisfactory classification would probably be upon the basis of the path of infection, but, owing to the fact that in most instances it is practically impossible to be certain of the path of entrance of the disease, owing, further, to the fact that even in a case of probable air-passage infection the disease may spread by the lymphatics, and even by the blood-vessels, this method is not entirely satisfactory. Another method of classification is on the basis of the main underlying histological change. As we have seen, there are essentially two such changes in pulmonary tuberculosis: (1) a filling up of the alveoli with exudate and cells (mainly catarrhal); in other words, pneumonia or inflammatory consolidation. The consolidated area subsequently undergoes a necrotic (caseous) change. This type of lesion is characteristic of the more acute conditions, *i.e.* where the virulence of the organism is high or the resistance of the individual low. (2) A laying down of new fibrous tissue usually in relation to pre-existing fibrous tissue (interalveolar, interlobular, etc.), *i.e.* fibrosis, or interstitial pneumonia. This

occurs in cases where the organism possesses a relatively low degree of virulence or where the soil (*i.e.* the individual) is unusually resistant. The two changes are commonly found side by side, but sometimes the one predominates, sometimes the other.

Probably no method of classification is completely satisfactory, but the following has for long been found useful by the author. It has the advantage of describing in general terms the appearance of the lung condition as a whole. It may be regarded as a compromise between the two methods mentioned above.

1. *Miliary or Disseminated Metastatic Tuberculosis* (as suggested by Orth).

2. *Caseous or Tuberculous Broncho-Pneumonia*, or, if diffuse, *Caseous or Tuberculous Pneumonia*. This condition may or may not be accompanied by cavity formation. This includes the conditions which are usually described as acute phthisis.

3. *Fibro-caseous Tuberculosis*, again either with or without cavitation. This includes the condition known as chronic phthisis.

There are objections to the above method of classification, but on the whole it will be found that most types of pulmonary tuberculosis can in this way be satisfactorily described.

The method avoids the use of the term "phthisis," which is really a clinical one, and not infrequently incorrect at that, meaning, as it does, a wasting disease. The terms used merely form a starting-ground from which to detail the more minute changes.

1. Miliary Tuberculosis or Disseminated Metastatic Tuberculosis

This condition is usually *blood-spread*, but may be spread by the *lymphatics*. It is associated with an *older tuberculous*

focus in the lung, bronchial glands, or a lesion in some other part of the body. This primary focus should be sought for. Where the condition is blood-spread, tubercles will be found scattered through other organs and tissues; if not large enough to be seen by the naked eye, they will be found on microscopic examination.

Naked-eye Appearance.—The lung is uniformly congested. Scattered through its substance are immense numbers of grey, white, or yellow foci (Fig. 49), which may vary in size from something just visible to an area one or two millimetres in diameter. Frequently the areas vary in size in different parts of the lung. Sometimes they are found to be larger in the upper portions of the lung. Sometimes the areas are arranged in groups (staphyloid arrangement) round blood-vessels or bronchi, indicating that the spread has been by way of the lymphatics. Where the distribution is uniform throughout, spread by the blood-stream is most probable.

Microscopic Appearances. — Scattered through the lung substance between individual alveoli, around bronchi and blood-vessels and interlobular septa, are rounded areas of cell accumulation. The cells composing these are chiefly mononuclear, of the epithelioid and lymphocyte type with catarrhal cells and a few polymorphs. Sometimes in the centre there are giant cells; at other times the centre is occupied by an area where the cells and their nuclei are breaking down. Not infrequently there is a distinct structureless caseous centre. In specimens stained for elastic fibres there will be found some destruction of these in the central area if they have been included. In other cases (the more chronic type) the fibres are merely pushed aside by the aggregating cells.

There is always a certain amount of involvement of the surrounding lung alveoli. Those alveoli in the immediate neighbourhood are consolidated with exudate, catarrhal cells, and leucocytes. As this area of alveolar involvement enlarges, the condition tends to pass into the second type—caseous broncho-pneumonia. There is usually more or less new formation of fibrous tissue in and around the nodules. In the

more acute type with necrotic centre this is minimal. In suitably stained specimens tubercle bacilli, although few in number, will be found, more particularly in the acute type. Not infrequently bronchi and vessels will be seen in course of invasion by the nodules. It is this secondary invasion of vessels which largely accounts for the great number of the tubercles, and for their variation in size, due to the fact that they are of different ages.

2. Caseous or Tuberculous Broncho-Pneumonia or Caseous Pneumonia

Two types of this condition can be distinguished :—

(1) A type in which there are *areas of consolidation scattered through the lung*, spread by the blood or by the lymphatics. This type is merely an example of the previous condition where there has been fairly extensive spread into the surrounding lung, so that a considerable group of alveoli have become consolidated and have then undergone the caseous change (Fig. 50). This type is found practically exclusively in children. The individual areas may fuse with one another, so that the consolidation may be complete, involving a whole lobe. Occasionally cavity formation may be found.

(2) A type which *commences in one particular portion of the lung*, usually near the apex of the upper lobe, *and spreads from that point*. In such a case the infection is generally believed to have been by way of the air passages. This type is the common one found in progressive acute tuberculosis in the adult. It is only occasionally seen in the early stages, owing to the fact that it does not prove fatal until well advanced. Sometimes, however, the initial stages are met with in cases dying of diabetes or other wasting disease. Usually, as the condition is met with in the post-mortem room, the area of consolidation is extensive and cavitation present (Fig. 51). Sometimes a less advanced type of the disease is found in one lung when in the other a more advanced stage exists.

Naked-eye Appearances.—The lung shows *chronic*, occasionally acute, *pleurisy* on the surface. It is *partially consolidated*, usually the area of consolidation being *towards the apex*. The cut surface shows *areas of a white or slightly yellow, opaque appearance*, not unlike grey hepatisation. These may be isolated and scattered, but there is usually one considerable area which may involve the greater part of a lobe. In these areas are *cavities*, usually small and often numerous, *with ragged walls*. In advance of these areas, and often widely scattered through the lung, are *grey or yellow tubercles in groups*, indicating lymphatic spread (Fig. 51). Besides spread by the lymphatics, spread by the bronchi (aspiration) and by direct continuity of tissue is observed in this condition. The *bronchi* show evidence of *acute bronchitis* and the *lymph glands* at the root of the lung are *enlarged* and show *grey tubercles* and *caseous foci*. There is usually *more or less fibrosis* in connection with this type. As the fibrosis predominates, it passes into the next type.

This type of the disease has to be differentiated from acute lobar and lobular pneumonia and gangrene of the lung, also from growths of the lung. The main points to remember in making this distinction are: 1. Position—tuberculous lesions commonly apical. 2. Extent—tuberculous lesions as a rule involving only a portion of a lobe. 3. Surrounding parts—the presence in the case of tuberculosis of foci of lymph-spread disease in the neighbouring portions of lung. 4. Cavities—characteristic of tuberculosis, present also in gangrene, but in the latter the cavities possessing soft friable black-coloured margins and the other appearances characteristic of tuberculosis (*e.g.* lymphatic-spread nodules) being absent.

Microscopic Appearances.—The two essential processes going on are: (1) a catarrhal consolidation of the lung alveoli which undergoes a caseous change; (2) lymphatic spread of the disease, with formation of caseating tubercles along the lines

of the lymphatics. These tend to spread into surrounding alveoli and bronchi, and so to initiate fresh areas of caseous pneumonia. The elastic tissue of the lung undergoes a certain amount of destruction, but in the caseous areas the network is preserved and tends to persist until cavitation occurs. There is usually a certain amount of increase of fibrous tissue as evidenced by thickening of interalveolar walls, interlobular septa, etc.

Cavities may arise (1) in dilated bronchi or bronchioles; (2) as the result of infection of a caseous area with pyogenic organisms, and so the softening of the area; (3) as the result of the bursting of a caseous area into a bronchus.

The cavities are lined with breaking-down, caseous lung tissue. Suitably stained preparations will demonstrate tubercle bacilli often in very large numbers, both in catarrhal pneumonic areas and in caseous foci or walls of cavities.

The vessels are often involved in the process, and blood infection by invasion of a caseous focus into a vessel is not infrequent.

3. Fibro-caseous Tuberculosis

This is the common condition found in cases of chronic pulmonary tuberculosis. It passes, on the one hand, by insensible gradations into the previous more acute type of the disease. On the other hand, with increase in the fibrous tissue element, it passes into so-called "fibroid phthisis." The term is one which is perhaps not the best possible, but it is descriptive, and is preferable to the purely clinical one of chronic "phthisis."

The condition is usually complicated by *cavitation*. Hence in speaking of this type one would refer to it as fibro-caseous tuberculosis with cavitation.

Naked-eye Appearances.—The lung shows on its surface evidence of *chronic pleurisy*. It is usually *firmly adherent* to the chest wall. For its removal it is advisable to strip the parietal pleura from the ribs in the way described on p. 20. The organ is distended, and on palpation it will be found

partially consolidated. Usually this consolidation is *more marked towards the upper part.*

On cutting into the lung the increase in consistence will be noted. The section will show the following appearances (Fig. 53). Towards the apex of the upper lobe will usually be found one or more *cavities*, one of which commonly is distinctly larger than the other, varying in size from a walnut to a tangerine orange. Indeed, in some cases the cavity may be found to occupy the whole of the upper lobe. The *walls of the cavity* are formed of *fibrous tissue* and are often comparatively smooth. Frequently bronchi and vessels of considerable size can be seen crossing the cavity, the lung tissue having largely disappeared from around these more resistant structures. Occasionally *aneurysms* may be found on the course of such vessels (Fig. 52).

Throughout the remainder of the lung there is a *general increase in the amount of fibrous tissue.* From the thickened pleura, thickened interlobular septa can be seen passing in. The vessels and bronchi are thickened. This thickening is usually more marked towards the root of the lung. The *bronchi* are *not infrequently dilated*, their walls being pulled upon by the contracting tissue around. They show evidence of acute bronchitis and contain more or less muco-purulent secretion.

The *bronchial glands* at the root of the lung are *enlarged* and show *caseous* or *calcareous change.*

Around the cavity, or cavities, the lung substance is *largely consolidated* by a fibro-caseous process. On analysis it will be found to consist of firm nodules, larger and smaller, which are pigmented and show caseous change.

In advance of this more completely consolidated area, *i.e.* in the lower part of the upper lobe and in the lower lobes, will be found *isolated areas of consolidation* of a similar type, having a *staphyloid arrangement* indicating lymphatic spread. In addition, there are often *areas of caseous pneumonia,*

indicating recent acute spread of the disease. The presence of the latter areas suggests "aspiration" spread.

As a rule, in such chronic cases both lungs are affected, one, usually the right, showing the more advanced lesions.

Contraction of the fibrous tissue in the various parts of the lung tends to occur, pulling upon bronchi and air vesicles. Dilation is thus caused, producing bronchiectasis or emphysema (*traction emphysema*), as the case may be.

The above appearances are found mainly in tuberculosis of adults, but similar changes are occasionally met with in children.

This type of the disease requires to be distinguished from the other interstitial pneumonias, more especially from syphilitic disease and from silicosis. Again, the distribution of the disease—apical in the case of tuberculosis, at the root of the lung or under the pleura in the case of syphilis—is the chief means of differentiation. The presence of cavities is characteristic only of tuberculosis, although it should be remembered that silicosis may be accompanied by tuberculosis. Lastly, the nodules in silicosis are much harder and have a characteristic gritty feel.

Microscopic Appearances.—One of the most striking changes is the increase of fibrous tissue—thickening of pleura, of interlobular septa, thickening round vessels and bronchi. The fibrous tissue in these structures often shows a marked new development of elastic-tissue fibres. The lung substance itself shows irregular consolidation due to the presence of numerous fibro-caseous areas, some of which are nodules of tuberculous granulation tissue displacing the lung tissue. Others represent areas of caseous pneumonia, in which the elastic tissue network in suitably stained specimens is still visible, and which are surrounded by zones of fibrous tissue. The blood-vessels generally, more particularly those in the neighbourhood of cavities, show thickening of their intima as well as adventitia. Some have, in this way, their lumen completely obliterated. In others the closure is only partial, and new vessels possessing their own elastic laminae develop within the compass of the

old. The bronchi show evidence of catarrhal inflammation, as also the remaining lung alveoli. The lining cells of the alveoli are often cubical instead of being flat. The cavities are lined with a zone of granulation tissue or of well-formed fibrous tissue. The vessels in the neighbourhood become partially or completely occluded by the occurrence of endarteritis obliterans. In suitably stained specimens, tubercle bacilli may be found, but they are commonly very few and scattered. They occur chiefly in the walls of the cavities and in areas of caseous pneumonia.

Changes in other Organs in Cases of Pulmonary Tuberculosis.—In cases of *miliary tuberculosis*, metastatic foci are found in liver, spleen, and kidneys as in the lung. Acute degenerative changes, such as cloudy swelling and early fatty change, will be seen in the parenchymatous organs, also acute congestion of the spleen. In carrying out post-mortem examinations upon cases of miliary tuberculosis careful search should be made for the site of invasion of the vessel. Attention should be specially directed to the condition of the thoracic duct and the retroperitoneal lymph glands. The various branches of the pulmonary artery within the lung should also be slit up.

In the more usual form of *caseous pneumonia* or *fibro-caseous tuberculosis*, cloudy swelling and fatty change in such organs as heart, liver, and kidneys is constantly present. Not infrequently the liver is greatly enlarged from an extreme degree of fatty infiltration. Waxy disease also should be sought in spleen, liver, kidneys, etc. Very often acute metastatic spread of the disease occurs terminally in these cases also, with the presence of miliary foci in all the internal organs. Intestinal tuberculosis—ulceration of bowel and caseous mesenteric glands—is not uncommon as a secondary manifestation due to the swallowing of infected sputum. In the more chronic forms of pulmonary tuberculosis the right side of the heart will be found hypertrophied and dilated,

and, as a sequel, chronic venous congestion of liver, spleen, etc. Tuberculous meningitis due to spread of the disease to brain or cord is a common termination of the more rapidly progressive cases.

Careful investigation should always be made of the various groups of lymphatic glands—cervical, bronchial, mesenteric—with a view to deciding the point of origin of the disease. The condition of the bones and joints should also be looked into. Finally, in investigating cases of tuberculosis where there are many lesions present, with a view to determining the site of origin of the disease (in other words, the oldest lesion), the following points should be attended to: (1) Nature of lesion—caseous foci are always older than grey, cellular foci; calcareous foci are older than caseous. Fibrosis is also indicative of long-standing disease. (2) Extent of lesion—other things being equal, an extensive lesion is older than a small one.

Tumours of the Lung.—Simple growths of the lung are very rare. Malignant growths are comparatively common, more especially sarcomata, but primary growths of a malignant nature are rare. Straining as they do the whole of the venous blood of the body which has not been strained in the capillaries of the liver, the lungs are apt to be the seat of deposit of metastatic growths which invade the veins. Thus secondary growths are common. Sarcomata are much more frequent in the lungs than carcinomata. The latter occur, but in appearance they are almost indistinguishable from the sarcomata. Another common type of growth in the lung is a sarcoma arising in the glands of the mediastinum and spreading into the lung substance by direct extension (Fig. 56). Occasionally the growth starts in the pleural surface, and either remains limited to it or penetrates the lung.

Naked-eye Appearances.—The growth may occur in the form of white or grey isolated nodules (Fig. 55), or there may

be large areas of lung infiltrated with growth. In both instances the condition is not very easily distinguished from grey hepatisation or tuberculosis, especially as necrosis is common and spread along the lymphatics of vessels and bronchi can be seen. In the case of growth, however, the infiltrated areas have a more translucent appearance, due to the fact that they are formed of cellular tissue. Another point of distinction is that cavitation is not observed in growths. Also it should be remembered that the seat of election in tuberculosis is the apex. There is no particular portion of the lung specially liable to be affected by growth unless it be the root.

DISEASES OF THE PLEURA

Hydrothorax or **Dropsy of the Pleural Cavity**.—A slight amount of free fluid is a common finding at a post-mortem. Where there is any large quantity, a careful note should be made of the appearance, distribution, and approximate amount of the fluid. It is usually pale, clear, and straw-coloured, and has a specific gravity of 1009-1012. On microscopic examination of the centrifugalised deposit, a few endothelial cells and lymphocytes will be found. As a rule the fluid is situated at the most dependent portion of the pleural cavity, but accumulations may occur, limited by adhesions, at other parts. The condition of hydrothorax is found in cases of *chronic heart and kidney disease*, where, as a rule, there is dropsy of other parts.

Hæmatothorax, or blood in the pleural cavity, is a rare occurrence. Free blood is only found in connection with *injuries to the lung or chest wall* and in *malignant disease*. Small extravasations of blood may be found under the visceral pleura in acute infections, in anæmias, and in asphyxia.

Pneumothorax, *i.e.* gas or air in the pleural cavity. This may be due to a *wound of the chest wall or lung, rupture of an*

acute tuberculous cavity, of healthy lung or emphysematous lung in a paroxysm of coughing. It may also be due to the presence of *gas-producing organisms* in the pleura, these organisms coming usually from a ruptured œsophageal or gastric ulcer, or spreading through the diaphragm from a liver abscess or peritonitis. In the last case a purulent inflammation of the cavity is present as well, the condition being known as *pyopneumothorax*.

In all the above conditions, in the absence of adhesions which would bind the lung to the chest wall, complete collapse of the lung occurs.

Acute Pleurisy.—This condition may be primary, due to spread by blood or lymph, or secondary, due to extension from lung, pericardium, mediastinum, peritoneum, etc. Three types of the condition may be distinguished:—

- (1) *Dry* or *fibrinous*, where there is little or no free fluid.
- (2) *Serous* or *sero-fibrinous*, where there is more or less free fluid, in which there are commonly flakes of fibrin floating.
- (3) *Purulent*, where there is purulent fluid.

The last is usually known as **empyema**.

Naked-eye Appearances.—The surface of the lung shows, over a larger or smaller area, a *rough granular* or *thick opaque white* or *yellow deposit* (Fig. 54). This may be adherent or easily removed according to the duration of the inflammatory process. The pleura underneath shows injection of its vessels, and the subjacent lung may show pneumonic consolidation, or sometimes abscess formation. If the fluid be large in amount, and if there are no adhesions binding the lung, the organ shows collapse.

In the case of empyemas which have been in existence for some time, there is usually considerable thickening of both parietal and visceral pleura (Fig. 41).

Microscopic Appearances.—The vessels of the pleura are distended with blood. There is a fibrinous coagulum on the

surface, and also in the interstices of the pleura, in the meshes of which are entangled leucocytes, chiefly of the polymorphonuclear variety in the earlier stages. The endothelial cells of the pleural surface may be swollen but still attached, or they may be thrown off and occur free amongst the fibrin. If the condition has lasted for some time, there is evidence of organisation—young blood-vessels budding out from the pre-existing ones of the pleura, and young connective-tissue cells accompanying these into the exudate. These latter (fibroblasts) are at first rounded, and possess a relatively large amount of protoplasm. Later they tend to become spindle-shaped, and eventually to arrange themselves parallel to the pleural surface. From their protoplasm, fibres are split off which form the intercellular fibres of the new tissue.

In empyemas which have lasted for some time these later changes are more in evidence.

Chronic Pleurisy.—This is a very common condition, either in the form of adhesions between lung and chest wall, or as areas of thickened pleura without adhesions. It is a constant occurrence in subacute or chronic disease of the lung, such as tuberculosis. In this disease the pleura may be very greatly thickened, as much as one inch in certain cases.

Microscopic Appearances.—The thickened pleura consists of spindle-shaped connective tissue cells arranged parallel to the surface with intervening sinuous collagenous fibres. Sometimes these latter are separated more or less widely from one another owing to œdema. Through this tissue are scattered a few wandering (lymphocyte-like) cells. Running at right angles to the surface of the original pleura are vessels which vary in size and thickness.

METHOD OF EXAMINING A LUNG REMOVED FROM THE BODY

Look in the first place at the shape of the organ. The normal lung will become flattened on being placed upon a table, whereas the consolidated lung (whether the consolidation be due to fluid or solid exudate in the alveoli) retains its rounded shape. Note the size of the organ. An organ the seat of

emphysema is usually more voluminous than usual. Weigh the lung. The weight of the normal lung is about 1 lb. 3 oz. to 1 lb. 12 oz. (538-764 grammes), the right being a little heavier than the left, and the lung of the male somewhat heavier than that of the female. Examine the surface of the organ for exudate, fibrous thickening, small hæmorrhages. Note the amount of pigment present at the points where the interlobular septa join the pleura. Examine the margin for evidence of emphysema and look for any puckering of the surface, especially at the apex. Next feel the organ carefully all over, searching specially for any hard areas which would indicate consolidation. Note the distribution of the firm areas, whether discrete or diffuse. Incise the organ longitudinally (see p. 27) and examine the cut surface as to colour. Note the distribution of any congested areas. Feel the surface carefully and squeeze the tissue between the fingers, noting if any fluid escapes and the character of such fluid. Any areas of consolidation should now receive more careful attention as regards colour, distribution, etc. It may be necessary further to incise firm nodules or areas and to remove portions in order to ascertain whether they sink or float in water. Where cavities are present their position, shape, character of contents, wall, and surroundings are all points to note. The large bronchi should then be opened and the character of their contents and appearances of their walls noted. The bronchial and mediastinal glands should be examined as to size, consistence, presence of grey or yellow tubercles, etc. The branches of the pulmonary artery should be slit up and examined for impacted thrombi.

CHAPTER VIII

DISEASES OF THE INTESTINAL TRACT AND PERITONEUM

Diseases of Mouth, Pharynx, etc. — The *condition of the teeth* should always be investigated. The presence of caries should be noted. More particularly in cases of severe anæmia, *suppuration* should be looked for *in the mouth cavity*. Pyorrhœa alveolaris is commonly associated with chronic toxæmia and anæmia. In any case where *enlargement of the cervical glands* is present, the mouth and pharynx should be carefully investigated for tumour formation, suppurative foci, actinomycosis, etc.

In *diphtheria* the tonsils and pharynx should be examined for false membrane. It appears as grey opaque areas surrounded with congestion. The membrane in this position is not easily removed, as it is formed of the covering epithelium infiltrated with fibrinous exudate. In any suspicious case not diagnosed during life, cultures on blood serum as well as films should be made.

Diseases of the Œsophagus. — When any condition affecting the Œsophagus is suspected, as in poisoning, dysphagia, hæmatemesis, care should be taken to remove the viscus entire along with the pharynx and stomach. This can best be done by removing tongue, pharynx, contents of chest and abdomen in one piece as described on p. 23 and then removing the individual organs as required, opening

the œsophagus from behind and examining it in continuity with the stomach.

The œsophagus is not infrequently the seat of *varicose veins* in *cirrhosis of the liver*. This is due to the fact that the veins from the lower part of the œsophagus drain indirectly into the portal vein, which in cirrhosis of the liver is obstructed. The œsophageal veins dilate and become varicose. Such veins may rupture, and severe, even fatal, hæmorrhage result.

The œsophagus suffers along with the stomach in *corrosive poisoning*, and presents much the same appearance as that organ (see p. 312). Rarely it may be the seat of *peptic ulcer* in its lower part. Such an ulcer may rupture into one or other pleural cavity and cause a pyopneumothorax.

Tumours of the œsophagus are occasionally found, by far the most common being squamous epitheliomata. Very infrequently leio-myomata are found. The squamous epithelioma of the œsophagus is found in the form of an ulcer with raised infiltrating margin. It tends to form a ring-shaped area of constriction, and is situated either high up about the level of the cricoid cartilage, low down near the cardiac orifice of the stomach, or at the level of the bifurcation of the trachea (Fig. 57). The ulcer may extend deeply, perforating the trachea, bronchi, one or other pleural cavity, or pericardial sac.

DISEASES OF THE STOMACH

Owing to the action of the digestive juices of the organ itself, and owing to decomposition in its contents and in the contents of the neighbouring viscera, the stomach undergoes considerable changes after death, and the longer the section is delayed the greater will be those changes. Blood tends to accumulate in the vessels of the organ at its more dependent parts, giving the appearance of congestion, and even of hæmorrhage. As the result of decomposition in this

blood, green discoloration takes place. Frequently there is softening of the wall owing to digestion by the gastric juice. This may occur to the extent of causing actual perforation. Obviously, therefore, care must be taken in interpreting changes found in the stomach *post-mortem*. Changes such as softening when they occur before death tend to be diffuse in their distribution, whereas post-mortem softening is found mainly in the more dependent, and therefore posterior, part of the viscus.

Dilatation of the Stomach. — Gastrectasis. — *Acute dilatation* may be due to the ingestion of excessively large quantities of food, or it may be nervous in origin, sometimes following surgical operations.

Chronic dilatation may be due to (1) narrowing of the pylorus from tumour, (2) the presence of abnormal contents from fermentation and atony of the muscular wall associated with chronic catarrh.

Contractions of the Stomach. — Narrowing of the pyloric orifice (*congenital pyloric stenosis*) through thickening of the muscular coat is a somewhat rare condition. Localised contraction of the organ may occur as a sequel to ulceration. It tends to produce the condition of "hour-glass" stomach.

Chronic Venous Congestion. — In chronic valvular disease of the heart, chronic lung and liver disease, passive hyperæmia tends to occur in the stomach as in other organs. It is usually associated with the appearances of chronic catarrh, accompanied by congestion of the vessels of the mucous membrane. Minute hæmorrhages may occur, and these may be followed by small superficial ulcerations (*hæmorrhagic erosions*).

Acute Catarrh of the Stomach may occur as the result of (1) dietetic errors ; (2) the ingestion of irritant or corrosive poisons ; (3) in the course of infective fevers.

Naked-eye Appearances.—In slight cases there may be little or no alteration. In severe cases the walls of the viscus are swollen, the mucous membrane congested, and covered with strings of sticky mucus. Small hæmorrhages may occur. Where the cause has been one of the corrosive poisons there may be necrosis and sloughing of the mucous membrane, sometimes with perforation. In the case of certain poisons characteristic colouring may be present. For further information on the appearances of the stomach in cases of poisoning see pp. 311-13.

Microscopically, the vessels of the wall are dilated. There is shedding of the superficial epithelium, and, in the more severe varieties, necrosis. The wall is infiltrated with inflammatory cells and exudate from the vessels.

Acute Suppurative Gastritis sometimes occurs in the course of specific fevers and pyæmia or as the result of spread of inflammation from neighbouring parts. The portion of the wall affected is thickened, pale yellow in colour, and found, on microscopic examination, to be infiltrated with fibrin and leucocytes. The mucous membrane superficial to the area shows acute catarrh, and sometimes exudate.

Chronic Catarrh.—This may follow acute catarrh or develop independently. It is frequent in chronic alcoholics, and occurs in association with chronic venous congestion, peptic ulcer, and carcinoma.

The stomach is usually dilated. The mucous membrane is pale and atrophied. There may be scattered small hæmorrhages or pigmented black areas following such. The surface of the mucous membrane is covered with thick sticky mucous secretion. Small follicular ulcers may be present. These ulcers are shallow with undermined edges. They may heal, leaving a small puckered scar.

Microscopically, beyond some overgrowth of fibrous tissue, catarrh of the gland cells, and infiltration of the coats with round cells, there is little to be seen.

Peptic, Perforating, or Chronic Ulcer.—This condition is found more frequently in females than in males. It is chiefly found in young, anæmic girls between the ages of twenty and thirty. It may be associated with chronic gastric catarrh.

The ulcer is commonly single, but occasionally there is more than one. It is *situated* usually on the posterior wall near the lesser curvature, and nearer the pylorus than the cardia. About 1 per cent occur on the anterior wall. The ulcer varies in *size*. Usually it is about the size of a sixpence, but it may be much larger. The *margins* of the ulcer are rounded, smooth, and devoid of evidence of inflammation, presenting a punched-out appearance (Fig. 58). The *floor* may be formed by one of the coats of the stomach, but not infrequently it is formed of fibrous tissue, or of one or more of the organs behind the stomach, such as pancreas or liver.

Owing to the fact that the opening in the mucous membrane is larger, the opening in the muscular coat smaller, the ulcer may show a terraced appearance. The associated chronic inflammation in the wall of the viscus causes the formation of adhesions to structures lying posterior; hence with increase of depth these organs become exposed in the floor of the ulcer. Not infrequently, however, before such adhesions can form *perforation* occurs. In the case of the ulcer on the posterior wall this will take place into the lesser sac of the peritoneum. The acute peritonitis resulting is thus, at first, limited. In the case of the anterior ulcer, perforation occurs more rapidly, and takes place directly into the peritoneal cavity, causing a general peritonitis. *Healing* may take place, associated with cicatrization and sometimes the formation of an "hour-glass" stomach. Besides perforation, another accident which may occur is *hæmorrhage* due to erosion of a vessel in the wall of the stomach, or possibly one of the larger vessels lying behind the organ.

A similar type of ulcer is sometimes found in the *duodenum* immediately beyond the pylorus. It resembles the peptic

ulcer of the stomach in every respect except that it is more frequent in the male sex. As a rule the ulcer is small, but it may attain a large size (Fig. 59). As in the case of the stomach ulcer, the floor may be formed by fibrous tissue or by an organ such as the pancreas. Perforation and hæmorrhage are accidents not infrequently met with in this case also.

The causation of both types of ulcer is obscure. Thrombosis occurring in a vessel supplying the mucous membrane, with consequent malnutrition and then digestion by the juices within, has been suggested as an explanation of their occurrence.

Fibromatosis.—Occasionally the stomach is the seat of a diffuse fibrous overgrowth implicating chiefly the sub-mucous and muscular coats, and commonly associated with a chronic ulcer. This condition, which is usually most marked at the pyloric end of the organ, has been called *fibromatosis*. It is sometimes mistaken for malignant new growth.

Tumours.—*Simple tumours* of the stomach are rare. *Fibromata*, *myomata*, *adenomata* are described. *Mucous papillomata* also occur.

Of malignant tumours, sarcomata are uncommon.

Carcinoma.—This is the common stomach tumour. It is most frequently situated at the pyloric end (60 per cent). The next most frequent site is the lesser curvature (20 per cent). About 10 per cent occur at the cardiac orifice (Fig. 60). As regards the type of cancer found, the most common is the encephaloid variety of the adeno-carcinoma. The next most common is the scirrhus, then the colloid, and least frequent is the squamous epithelioma, which is occasionally found at the cardiac end.

The tumour may lead to a localised or diffuse thickening of the stomach wall. More frequently there is an ulcerated surface with a raised, hard, infiltrated margin. Sometimes the growth projects into the interior of the viscus as a cauli-

flower-like mass (Fig. 60). The floor is formed of necrosed tumour substance. Perforation rarely occurs. Secondary deposits are very commonly found in the neighbouring glands and in the liver.

DISEASES OF THE INTESTINE

Malformations.—Meckel's diverticulum is a finger-like *cul-de-sac*, the remains of the omphalo-mesenteric duct, usually 2-3 inches in length, occurring some 2 or 3 feet above the ileo-cæcal valve. It is sometimes attached to the umbilicus. It may become closed and give rise to cyst or abscess formation, or it may become adherent to the parietes, thus forming a band under which a loop of bowel may become strangulated.

Smaller diverticula may be found in connection with other parts of the small intestine, such as the duodenum, and pouches between the layers of the mesentery may be found.

Dilatation of the bowel is found as the result of peritonitis (paralytic distention), constipation, obstruction from strangulation, infarction or tumour formation. When the obstruction is long-continued the wall of the bowel above shows hypertrophy (Fig. 69).

A condition of dilatation of the large intestine, more especially the ascending colon, associated with hypertrophy of the muscular coat, known as *Hirschsprung's disease*, occasionally occurs. It is believed to be congenital.

Stenosis, or narrowing of the bowel, may be due to contraction associated with ulceration (especially tuberculous), tumour formation, or chronic peritonitis.

Volvulus is a condition in which the bowel is obstructed by a loop of intestine becoming twisted upon itself. Half the cases occur in the pelvic colon. An abnormally long mesentery

predisposes to its occurrence. The blood-supply of the portion of gut is interfered with and gangrene tends to occur.

Intussusception is a condition in which a portion of the bowel is invaginated into the section immediately below. It occurs chiefly in infants, and is believed to be caused by violent peristalsis due to active purgation or diarrhœa. The condition may occur in the ileum or the colon, or at the ileo-cæcal valve. The portion of bowel involved forms a sausage-shaped tumour (Fig. 61). Pressure on the mesentery of the intussuscepted portion causes interference with its circulation and a tendency to gangrene.

A similar condition, easily reduced and often multiple, is not infrequently found *post-mortem*. It is believed to develop very shortly before death. In this type there is, of course, no congestion of the intussuscepted portion, and there are no adhesions between the various layers of gut.

Hernia.—A hernia is usually defined as a condition in which there is a protrusion of any of the abdominal contents from the cavity of the abdomen. The term is also used in connection with the rare occurrence of a protrusion of gut through an opening, such as the foramen of Winslow, within the abdomen.

As a rule it is either a *portion of bowel* or a *portion of omentum*, or both, which protrudes. Occasionally it may be a Meckel's diverticulum or an organ such as liver, spleen, or stomach. The *sac* of the hernia is usually lined by peritoneum, although this may disappear.

The condition may be *congenital*, the sac being formed by a diverticulum of the peritoneum such as the processus vaginalis. More usually it is *acquired* through increased abdominal pressure from coughing, crying, straining, or through weakness of the abdominal wall, or from these two factors combined. It may also be due to violence, such as a crush driving some of the abdominal contents through the diaphragm.

The protrusions are found *at points of weakness* in the abdominal wall, usually where vessels enter and leave. The commonest type is the *inguinal hernia* which occurs in the inguinal canal and may be congenital or acquired. The second commonest type is the *femoral hernia*, a projection through the femoral ring. In addition, there is an *umbilical* type found at the umbilicus which may be congenital or acquired. The latter type is found chiefly in very fat women. Certain rarer forms are occasionally met with, such as *obturator hernia*, also herniæ through the abdominal wall at points which have been weakened by scars following operations.

The condition is not of much importance to the morbid anatomist. Herniæ are not infrequently met with by accident at a post-mortem. Strangulation of the hernia, *i.e.* interference with the circulation of blood through the gut with consequent acute congestion and sometimes gangrene, is a cause of acute peritonitis, but it is rarely seen post-mortem. Internal herniæ, *e.g.* herniæ through the diaphragm, are sometimes met with as the result of severe crushing of the abdomen.

Chronic Venous Congestion of the bowel is found in cirrhosis of the liver and in chronic heart and lung disease. There is swelling and congestion of the wall of the gut, especially of the mucous membrane. A degree of catarrhal inflammation is very constantly associated.

Infarction of a portion of bowel, most frequently of that part supplied by the superior mesenteric artery, is sometimes found. It should be looked for in cases which die with symptoms of intestinal obstruction. The portion of gut involved is deep purple in colour, and usually shows peritonitis on its surface. The aorta and its branches should be slit up to find the point where the block occurred. Careful search should be made for a possible source of the embolus,

e.g. a thrombus on an atheromatous patch of the aorta, or in the left side of the heart (see diag. p. 62).

Hæmorrhage occurs into the mucous membrane of the bowel in the form of small extravasations in cases of infective diseases, anæmias, etc.

Large hæmorrhages may occur from ulcerated surfaces, such as duodenal or typhoid ulcers. The blood, mixed with fæcal matter, tends to undergo alteration into a black mass of putty-like consistence which can be seen through the wall of the gut before it is opened.

INFLAMMATION OF THE SMALL INTESTINE— ENTERITIS

Acute Catarrhal Enteritis may be caused by irritating foods, poisons, dust, by normal bacterial inhabitants of the bowel, such as *B. coli* or *streptococci*, or by specific bacteria such as *B. typhosus* and *Vib. cholerae*.

Naked-eye Appearances.—These are often unsatisfactory. The clinical symptoms are frequently out of all proportion to the pathological findings. Usually there is some congestion of the vessels of the mucous membrane, which is more or less swollen. This congestion may be diffuse or patchy. Often it is most marked at the apices of the folds in the mucous membrane. When due to the action of a micro-organism the changes are commonly more marked in the lower part of the ileum. In cases of poisoning, on the other hand, the duodenum and upper part of the jejunum in addition to the stomach are the parts most affected, although it must be noted that irritant poisoning often causes little change (see p. 313). Not infrequently the lymph follicles of the bowel are swollen (*follicular enteritis*) and may ulcerate (*follicular ulcers*). The mucous membrane may be covered with viscid mucus. Sometimes there is a distinct membrane formed of exudate (*membranous enteritis*). Occasionally,

in the more intense forms, the mucous membrane may undergo necrosis, forming a greenish slough. Small embolic abscesses may be found in pyæmia, or there may be a general infiltration of the wall of the gut with pus (*suppurative enteritis*).

Microscopic Appearances.—There is dilatation of the vessels of the bowel, infiltration of the wall with inflammatory cells and exudate; increase of the lymphoid elements and swelling of the endothelial cells in the solitary glands; catarrh of the superficial epithelium. In suppurative enteritis small abscesses and more intense inflammatory infiltration are found.

SPECIAL FORMS OF ENTERITIS

1. **Cholera.**—The changes are most marked in the lower portion of the ileum. There is intense swelling and congestion of the mucous membrane. The lymphoid follicles may be swollen and pale. Small hæmorrhages may be present. Membranous enteritis may occur, due to the exudation of fibrin on the surface of the mucous membrane. The contents of the bowel are pale and watery (rice water).

Microscopically, there is marked catarrh of the epithelium, possibly exudate on the mucous membrane, and infiltration of the wall of the bowel with inflammatory cells. The specific organisms do not penetrate the wall for any distance, but they are found in immense numbers along with desquamated epithelial cells in the rice-water contents of the bowel.

2. **Typhoid.**—In this condition also the change is *most marked in the lowest portion of the ileum*. It consists, in the *early stage*, in a *swelling* of the lymphoid tissue generally, both Peyer's patches and solitary follicles (Fig. 62). These areas are pale, but the bowel between may show congestion. At about the beginning of the second week of the disease, *necrosis* commences in these swollen accumulations of lymphoid tissue (Fig. 63). In this way *sloughs* form which take

on a yellow or green colour from bile staining. These *sloughs* *separate* towards the end of the third week of the disease and *ulcers* are left which have the following characters:—The larger ones, representing as they do an ulcerated Peyer's patch, are usually in the longitudinal direction of the bowel; during the separation of the sloughs *hæmorrhage* tends to occur. The smaller ones, representing the solitary follicles, are rounded. The *edges* of the ulcers are ragged and overhanging. The *floor* is formed of one of the coats of the bowel—the submucous, muscular, or peritoneal. Perforation is not infrequent. The *peritoneal aspect* of the portion of bowel may show evidence of acute inflammation by injection of vessels and even fibrinous exudate.

Occasionally, in cases dying from complications late in the disease, the ulcers may be found in process of *cicatrisation*.

In a case of typhoid fever, in addition to the condition of the intestine, attention should be paid to (1) the mesenteric glands, which are constantly enlarged, congested, and may show hæmorrhages and necrotic foci; (2) the spleen, which shows acute congestion, and, microscopically, areas of focal necrosis; (3) the liver, with cloudy swelling and areas of focal necrosis; (4) the kidneys and heart, which show cloudy swelling; (5) in contrast to most cases of infective disease, the bone marrow, in uncomplicated cases, shows little or no evidence of leucoblastic reaction.

Cultures should be made from the common bile duct, the spleen, or the contents of the small intestine (see p. 360).

Microscopic Appearances.—In the stage of swelling, separation of the cell elements of the Peyer's patch due to œdema is found. There is also swelling and proliferation of the endothelial cells of the lymphoid tissue and catarrh of the mucous membrane generally. Bacilli may be found in groups in the swollen patch. Necrosis begins in areas at the centre of the Peyer's patch and spreads. The typhoid ulcer merely shows

the appearance of an acute ulcer with overhanging edges, floor formed of muscular coat as a rule. Inflammatory changes are present in muscular coat and tissue around. In suitably stained specimens bacilli are found in masses, both superficially and deep in the wall.

The mesenteric glands, in addition to the appearance of an acute lymphadenitis—swelling and loosening of endothelial cells of sinuses, etc.—show areas of necrosis and hæmorrhage, with occasional masses of bacilli.

3. **Tuberculosis.**—This is usually secondary to tuberculosis of the lungs, the intestine becoming infected by the swallowing of sputum containing tubercle bacilli. As a primary condition of the bowel, the disease is comparatively rare, although it has been found in as large a proportion as 12 per cent of all cases of tuberculosis.

Tuberculosis of the mucous membrane of the bowel is, however, by no means necessarily found in cases where the intestine is the path of entrance of the tubercle bacillus. The disease may show itself first in the mesenteric glands or in the peritoneum, no demonstrable lesion of the bowel itself being present.

Naked-eye Appearances.—The part commonly affected is, as in typhoid, the lower portion of the ileum. The earliest lesion consists in a tubercle nodule underneath the mucous membrane. Ulceration occurs over this, and tends, owing to the distribution of the lymphatics of the bowel, to spread laterally, often encircling the bowel, with the exception of that portion over the attachment of the mesentery. The appearances in the fully developed ulcer are as follows (Fig. 64): the *direction* is transverse to that of the bowel, although this character is by no means constant; the *edge* is irregular, nodular, but rounded; the *floor* is formed of tuberculous granulation tissue; the *peritoneal aspect* shows opaque white thickening of the wall, the presence of tubercle nodules (Fig. 65) under the peritoneum, and sometimes white lines of

injected lymphatics radiating from the area. Constriction of the bowel is common, as also is adhesion to surroundings.

Perforation is a comparatively rare occurrence in tuberculous ulceration, as also is hæmorrhage.

The mesenteric glands are constantly enlarged and show caseous areas or grey granulations, occasionally calcification.

Microscopic Appearances.—At the margins of the ulcer, in the floor, often replacing the muscle substance, and under the peritoneal coat, there are tubercle granulations with giant-cell or caseous centres. Tubercle bacilli are not, as a rule, numerous.

TUBERCULOSIS AND TYPHOID ULCERS CONTRASTED AS
REGARDS THEIR NAKED-EYE APPEARANCES

	Tuberculous Ulcer.	Typhoid Ulcer.
Direction .	Typically transverse.	Typically longitudinal.
Margin .	Raised, rounded, nodular.	Overhanging, ragged.
Floor . .	Irregular, formed of tuberculous granulation tissue.	Smooth, formed of one of the coats of the bowel.
Peritoneal aspect	Raised, grey or yellow tubercles. Thickening and sometimes constriction. Perforation rare. Adhesions frequent.	Evidence of acute inflammation, congestion, exudate. Perforation frequent. No adhesions or constriction.
Associated mesenteric glands	Enlarged and firm, caseous. Sometimes calcareous.	Enlarged, congested with necrotic foci, soft.

4. **Syphilis.**—This is a rare condition. It may occur in the form of *gummata*, *ulceration*, or *cicatrization with stenosis*.

5. **Actinomycosis.**—This is also rare. It may affect the intestine or appendix. Secondary abscesses usually occur in the liver.

INFLAMMATION OF THE LARGE INTESTINE

In its slighter forms this condition is known as *colitis*, in its more severe forms as *ulcerative colitis* or *dysentery*.

As regards *causation*, (1) the slighter forms of the disease may be due to indiscretions of diet, chill, germs of various kinds. Of the more severe types, two varieties are distinguished: (2) *Bacterial Dysentery*, with which organisms closely related to *B. coli*, e.g. Shiga's bacillus and Flexner's bacillus, are more especially associated; (3) *Tropical Dysentery*, generally believed to be caused by a protozoon, the *Entamæba histolytica*.

(1) The **milder types** of inflammation show congestion of the mucous membrane, some œdema, swelling of the lymphoid follicles, and, sometimes, slight superficial ulceration.

Microscopically, beyond catarrh of the mucous membrane, congestion of vessels, and infiltration of the coats with inflammatory cells, there is little to be seen.

(2) **Ulcerative Colitis or Bacterial Dysentery.**—The wall of the bowel is usually thickened. On opening the gut there is irregular ulceration with tags of thickened mucous membrane between the ulcers (Fig. 66). These tags often occur in longitudinal ridges. The edges of the ulcers are overhanging, and the floor is usually formed by the submucous or muscular coat. Occasionally, destruction of the muscular coat is found, and sometimes perforation.

Microscopic Appearances.—There is catarrh of the mucous membrane and thickening of the submucous and muscular coats. These are infiltrated with inflammatory cells and exudate, and there is marked swelling of the endothelial cells of the lymphatics and vessels.

The above description holds good more especially for the type of the disease found in Great Britain. In the type

found in Japan, hæmorrhages into the mucous membrane, purulent and fibrinous exudates on to the surface of the mucous membrane are described in addition to ulceration.

(3) **Tropical or Amœbic Dysentery.**—The wall of the bowel is thickened, due largely to a thickening of the submucous coat, partly from fibrous change, partly from inflammatory infiltration. Scattered through the mucous membrane are numerous small raised nodules the size of pin heads or small peas, most of which show a small opening in the mucous membrane through which a whitish slough can be seen (Fig. 67). The bowel between is congested. These minute ulcers tend to run together, forming areas of more extensive ulceration. In the case of the larger ulcers the edges are overhanging and the floor is formed of submucous or muscular coat. Rarely perforation of the bowel may occur.

The seat of the more intense changes varies in different cases. Sometimes it is the cæcum and ascending colon, sometimes the transverse, sometimes the descending or pelvic colon.

The condition is very commonly associated with the tropical form of liver abscess.

Microscopic Appearances.—The wall of the bowel is thickened, more especially the submucous coat. It is also infiltrated with inflammatory exudate and cells. The nodules above mentioned are found to be flask-shaped ulcers in the submucous coat, with overhanging margins and a small opening into the lumen of the bowel. The centre is occupied with a slough consisting of necrotic tissue and leucocytes. Amœbæ are found in the slough and in the submucous coat around. They appear as large rounded cells with vacuolated protoplasm and a relatively small round nucleus. They can be seen in specimens stained with hæmatin and eosin, but are better demonstrated by eosin, methylene blue (p. 243). In the areas of more extensive ulceration the ulcers lose their characteristic appearance, and the changes are more like those found in the other type of dysentery.

Mucous Colitis.—This is a condition in which tubular casts of the bowel or strings and masses of clear mucus are evacuated from time to time. The casts consist of inspissated mucus due to hypersecretion. The condition is frequently of nervous origin aggravated by growth of bacteria and is accompanied by dilatation of the large intestine.

Appendicitis.—The appendix is a *cul de sac* in continuity with the cæcum having the structure of the large intestine, and being subject to inflammatory changes spreading from the large bowel, as well as to such changes originating in itself. Foreign bodies, animal parasites, such as thread worms, and faecal matter may lodge in its lumen, the last, along with inspissated secretion from its own glands, forming the so-called concretions. The actual cause of the inflammation is a micro-organism, usually one derived from the bowel, *e.g.* *B. coli*, *streptococci*, *B. lactis aerogenes*, *B. proteus*, occasionally *B. tuberculosis* and *streptothrix actinomyces*. Three degrees of intensity of inflammatory change may be recognised, viz. (1) Catarrhal, (2) Ulcerative, (3) Gangrenous.

1. *Catarrhal Appendicitis.*—Sometimes there is little alteration from the normal to be observed in this type. As a rule the organ is somewhat swollen and congested.

2. *Ulcerative Appendicitis.*—In this type the inflammatory change is more intense. In addition to swelling and congestion there is destruction of the mucous membrane, sometimes with perforation.

3. *Gangrenous Appendicitis.*—The organ, or parts of it, is of a deep purple colour. There is exudate on the peritoneal surface and ulceration of the mucous membrane, sometimes with abscess formation or perforation (Fig. 68).

Peritonitis, either localised or general, is very commonly associated with appendicitis. When limited by adhesions an abscess may develop, having the appendix as its centre and starting-point. Occasionally such abscesses burrow

behind the cæcum. As the result of inflammation the organ may become obliterated and reduced in whole or part to a fibrous cord. Not infrequently adhesions form between the appendix and neighbouring parts, such as uterus, bowel, or abdominal wall; under the band thus formed, portions of bowel sometimes become strangulated. Phlebitis, with resulting thrombosis, tends to occur in the veins of the appendix as in any acute inflammatory condition of the bowel. Organisms may cause softening of the thrombi, and portions of these may be carried to the liver, where they give rise to the portal pyæmia type of liver abscess.

Microscopically, in the catarrhal type there is distension of the vessels with blood, infiltration of the coats with exudate, which may be fibrinous, also with leucocytes. There is, in addition, catarrh of the mucous membrane, as evidenced by shedding of the gland cells.

In the more severe types of the disease the inflammatory changes are more intense; there is necrosis of the mucous membrane with ulceration. In the floor of the ulcers germs are present in large numbers. There is also more or less marked peritonitis.

Animal Parasites.—The important animal parasites which may be met with in the intestines are:—Protozoa: *Entamæba histolytica* causing the tropical form of dysentery, and amœba coli of little or no importance. Worms: (1) Trematodes—*Bilharzia hæmatobia* which may give rise to polypoid outgrowths of the mucous membrane of the rectum. (2) Cestodes—*Tænia solium*, the cystic stage of which is found in the pig. *Tænia mediocanellata* or *saginata*, the cystic stage of which occurs in the ox. *Bothriocephalus latus*, the cystic stage of which is found in the pike. (3) Nematodes—*Ascaris lumbricoides*, found chiefly in the upper part of the small intestine, occasionally in the bile duct. *Oxyuris vermicularis*, the “thread” or “seat” worm, found in the large bowel in children. *Ankylostoma duodenale*, the “hook,” “tunnel,”

or "miner's" worm, found attached to the mucous membrane of the jejunum. This worm is of more importance than the other round worms, as it may cause a severe type of anæmia. *Trichocephalus dispar*, or "whip" worm, a common inhabitant of the cæcum.

Tumours.—*Simple tumours*, such as *fibromata*, *lipomata*, *myomata*, and *cysts* of various kinds, are occasionally met with. Of malignant tumours, *sarcomata* are rare.

By far the commonest type of growth in the bowel is the *carcinoma*. Of these, all types may be met with: squamous epitheliomata in the rectum, the various types of adenocarcinomata, as columnar-cell carcinoma, colloid cancer, scirrhus cancer. The growth is usually small. It may be a mere ring of infiltration round the wall of the gut, producing a constriction when looked at from the outside, with narrowing of the lumen. In other cases it forms a fungating growth projecting into the interior (Fig. 69). Ulceration of the bowels is very commonly associated, and perforation may occur. There are often adhesions with neighbouring structures, and the nearest lymphatic glands are usually enlarged and infiltrated. Secondary growths in the liver are very commonly present. Diffusion of the growth throughout the peritoneal cavity is sometimes seen.

As regards site, carcinomata may occur at any part of the small or large intestine. They are, however, much more common in the latter, occurring more especially at points of narrowing of the gut, such as the ileo-cæcal valve and the ascending colon immediately above the cæcum; at points where the intestine changes its direction, as, for example, at the hepatic, splenic, and sigmoid flexures. A large proportion of cases show the growth in the lower bowel, usually 2 to 3 inches from the anal orifice.

The appendix is occasionally the seat of a malignant growth of the adeno-carcinoma type. This growth seems

to arise in appendices which have been previously inflamed and are partially obliterated. Such tumours show little tendency to spread, being apparently of low malignancy.

DISEASES OF THE PERITONEUM

Hæmorrhage.—Small petechial hæmorrhages occur into the subperitoneal tissue in infective conditions and in severe anæmias. Free blood and blood-clots in the peritoneal cavity may be due to rupture of an organ (liver or spleen) from injury, acute peritonitis, rupture of a vascular tumour, as, for example, in the spleen, or rupture of an aneurysm.

Dropsy of the Peritoneal Cavity or Ascites.—This condition may be found in diseases which tend to produce dropsy elsewhere, such as *chronic heart* and *renal disease*, or it may be due to *cirrhosis of the liver*. In long-standing cases the peritoneum is frequently opaque and thickened. The fluid is usually clear; when it is milky the turbidity is usually caused by the presence of protein bodies of the nature of globulins. Very rarely milkiness is due to the presence of fat globules (chylous ascites) escaped from an injured lacteal vessel (*e.g.* in filariasis).

Acute Peritonitis.—This may be due to (1) spread of inflammation from structures within the abdomen, such as the appendix and Fallopian tubes or from the pleura; (2) rupture of the gut from injury or perforation associated with ulceration; (3) blood or lymph infection. It may be generalised throughout the peritoneal cavity or localised by adhesions.

Naked-eye Appearances.—There is more or less free fluid in the cavity, more especially in the pelvis and in dependent parts. The fluid may be yellow or brownish and contains flakes of lymph. It is often mixed with fæcal matter or stomach contents, and usually has a foul smell. The omentum is swollen and its vessels injected. There is fibrinous exudate

on the surface of the bowel, more especially between the coils of the intestine (Fig. 68). The coils are thus glued together. Not infrequently on separating the coils small abscesses are opened into.

Microscopic Appearances of the Omentum in Cases of Peritonitis.—There is distension of the vessels, exudation of fibrin on the surface and in the substance, swelling and throwing-off of the endothelial cells. These are found amongst the fibrin threads as large, swollen, and vacuolated cells, often containing germs and polymorphonuclear leucocytes. Numerous polymorphs are found in the fibrin on the surface and infiltrating the tissue generally. There is swelling of the collections of lymphoid tissue along the vessels, and many free lymphocytes are found in the exudate.

Film preparations of the exudate show numerous polymorphonuclear leucocytes in various stages of degeneration, large mononuclear cells often vacuolated and frequently containing leucocytes which they have ingested, lymphocytes, and micro-organisms.

Chronic Peritonitis.—Large or smaller areas of thickening of the peritoneum, or rather of the subendothelial fibrous tissue of the peritoneum, are found frequently, more especially over liver and spleen. They may be associated with adhesions, and are specially frequent in syphilis. A more general thickening of the peritoneum is found in cases of long-standing ascites.

Tuberculous Peritonitis.—This may be associated with tuberculous ulceration of the bowel, but not infrequently no such lesion of the bowel can be found. Usually, however, the mesenteric glands are the seat of tuberculosis. The condition may also occur as a part of a generalised blood infection.

Naked-eye Appearances.—The coils of the intestine are commonly adherent more or less firmly to one another. On separating the coils, if this be possible, there will be found covering the surface of the bowel and mesentery, also the

surface of liver and spleen, as well as the parietal peritoneum, numerous small opaque white or yellow areas, the size of a pin head or larger (Fig. 70). Often the coils of bowel are too firmly adherent to one another to be separated without tearing. The great omentum is thickened, drawn up and infiltrated with grey tubercles. Occasionally free fluid may be present. The matting of the intestines leads to interference with peristalsis. Adhesions may lead to the formation of bands under which loops of bowel may subsequently become strangulated. Occasionally rupture of the bowel may occur as the result of erosion of the wall from the peritoneal aspect.

Microscopically, the appearances are those characteristic of tubercle. Giant cells are often specially numerous and well developed.

Tumours.—Growths primary in the peritoneum are rare. Endotheliomata are met with occasionally growing in the form of multiple polypoid masses. Dissemination of carcinoma sometimes occurs secondary to rupture of a cystic growth of the ovary or the invasion of a bowel tumour into the peritoneal cavity.

CHAPTER IX

DISEASES OF THE LIVER, BILE PASSAGES, AND PANCREAS

DISEASES OF THE LIVER

Deformities.—A transverse sulcus across the lower portion of the right lobe of the organ is frequently seen, due to the wearing of tight corsets. Perpendicular sulci are also met with, due to folding of the liver from a similar cause.

ALTERATIONS IN THE CIRCULATION

1. **Anæmia.**—Yellow or white patches are frequently seen on the surface of the organ. They are due to localised anæmia from pressure.

2. **Chronic Venous Congestion.**—This condition is found in cases of *chronic valvular disease of the heart* and in *chronic pulmonary lesions*. The organ is enlarged in the early stages. In the later stages it may be smaller than normal. It has a dark purple colour with paler areas (Frontispiece, Fig. 5), and is firmer than usual. On section, the cut surface shows a mottled appearance, likened to nutmeg. There are areas of congestion, dark purple in colour, and areas of fatty change, pale yellow. The branches of the hepatic vein are dilated.

Microscopic Appearances.—In the very earliest stage there may be little more than the deposit of yellow pigment in a

zone of liver cells round the central vein. In the later stages there is dilatation of the central veins and the capillaries draining into them, with compression and atrophy of the columns of liver cells between. The liver cells, more particularly those at the margin, may show fatty infiltration. There is some increase of the fibrous tissue of the organ in the more advanced cases.

3. Embolism and Thrombosis in the Portal Vein.—

Thrombosis of the portal vein is sometimes found in connection with cirrhosis of the liver and malignant disease. It may also occur as the result of inflammation round a perforating ulcer of the stomach.

Portions of thrombi from rootlets of the portal vein in the neighbourhood of inflammatory foci, *e.g.* the appendix, are caught in the branches of that vein within the liver. Secondary thrombosis occurs in connection with such emboli, the condition sometimes spreading to large branches of the vein. As the emboli contain organisms, abscess formation is set up.

As regards the effect upon the liver of blocking of a branch of the portal vein, this may be very slight, owing to the fact that the liver lobule is also supplied with blood from the hepatic artery. Sometimes the area supplied assumes a darker brown, even a red colour, but on microscopic examination little is seen in such an area beyond dilatation of the capillaries. The liver cells commonly show no evidence of necrosis. Occasionally, however, in such an area a partial necrosis of the inner two-thirds of the lobule may be seen.

DEGENERATIVE CHANGES

1. **Cloudy Swelling.**—This is found in varying degrees in all infective conditions, and occasionally apart from infections, as in hæmorrhage of the pons where there was a markedly raised temperature during life.

The organ is slightly *enlarged* and has a *pale* appearance. It is soft and *friable*. The last point is tested by the ease with which the finger may be pushed into the substance of the organ. On section, the cut surface has a hazy, misty appearance, described as like the effect of plunging a portion of normal liver into boiling water. The outline of the liver lobules is no longer visible. The condition may be associated with congestion of some of the vessels of the organ. It is also commonly combined with a degree of fatty change.

Microscopic Appearances.—The liver cells are swollen and granular. In the fresh condition the nuclei are obscured by the granules, but these are readily dissolved with dilute acetic acid, when the nucleus is rendered visible again. The cells often show a tendency to separate from one another owing to solution of their cement substance. There may be some infiltration of the portal spaces with inflammatory cells.

The condition is usually complicated with some fatty change in the liver cells. The nucleus in the earlier stages stains more intensely; in the later stages it tends to lose its characteristic staining reaction with basic dyes.

2. Fatty Change.—Two types of this condition are commonly distinguished:—

(a) *Fatty degeneration*, by which is usually meant the breaking down of the chemical constituents, more especially the combinations of proteins with fatty compounds, under the action of some poison, chemical or bacterial.

The organ may not be much altered in size or it may be smaller than normal. It is paler than usual, of a bright yellow colour, soft, and friable. On section, the parts showing more advanced fatty change are seen as opaque yellow areas. These may be in the centre of the lobules, or they may form a zone at the periphery, or the change may be present throughout.

Microscopic Appearances.—Sections should be stained with Sudan III., Scharlach R, or Nile blue sulphate. As

already stated, the change may be at the periphery of the lobule, in the centre or throughout. It is usually described as occurring most characteristically at the centre. The globules of fat in the cells tend to be numerous and small. The nucleus may show degenerative changes : either increased intensity of staining in the early stages, or loss of staining reaction in the more advanced condition.

(*b*) *Fatty infiltration* may be defined as the absorption in excess of fatty material and the deposition of it in a demonstrable form in the protoplasm of the liver cell. A rigid distinction between this and the preceding type cannot, however, be made. The two conditions pass into one another and are frequently combined. Thus there is reason to believe that in the fatty degeneration of phosphorus poisoning the fat in the liver cell is largely derived from outside. Hence in very many cases it is safer to use the term *fatty change*. It is convenient, however, in certain cases to make a distinction into two types, the extremes of which are readily separated from one another.

The organ tends to be larger than normal, in some cases very markedly so. It is pale yellow in colour (Frontispiece, Fig. 2). Its consistence varies in different cases. It may be softer and more friable, or it may be (in cases where there is cirrhosis combined) firmer. On section, the change may appear most marked in the periphery of the lobule, or it may be diffuse.

Microscopic Appearances.—The globules of fat within the liver cells tend to be large, pressing aside the protoplasm and nucleus of the liver cell. The change may be at the periphery of the lobule, *i.e.* merely an exaggeration of a change found normally in the liver during digestion, or it may be diffuse. It is frequently combined with increase of fibrous tissue in the organ.

3. Focal Necrosis.—Areas of focal necrosis are found in the liver in *typhoid fever* and in *eclampsia*. They appear

as opaque white or yellow points scattered through the liver substance, but often they are too minute to be seen with the unaided eye. Cloudy swelling is always associated.

In *eclampsia* the liver shows three characteristic changes, which may not, however, all be present in a given case (see p. 271).

(1) *Hæmorrhage* under the capsule, which may be very extensive; also hæmorrhage into the substance of the organ.

(2) *Fatty change*, usually most marked at the margin of the necrotic areas.

(3) *Areas of focal necrosis*, usually situated at the periphery of the lobules, and often too small to be seen with the naked eye.

4. **Amyloid (Waxy) Degeneration.** — For causation of waxy change see p. 105.

The organ is commonly enlarged, often very much so. It is anæmic and has a translucent appearance if the condition be advanced. It is firm and elastic in consistence like india-rubber. On section, the cut edge remains sharp. The cut surface has the same translucent appearance. The condition is often combined with some degree of fatty change. When the cut surface is treated with a solution of iodine, the waxy areas take on a mahogany brown colour (Frontispiece, Fig. 4).

Microscopic Appearances. — The waxy material has a clear translucent appearance in unstained specimens. In preparations treated with methyl violet it shows a rose-pink to purple colour.

In the early stages the change is limited to the middle coats of the branches of the hepatic arteries and portal veins in the portal tracts. It is the bands of connective tissue between the muscle fibres which show the change. Later on, the peri-endothelial connective tissue of the capillaries in the middle zone of the lobules is affected. Still later, the change becomes diffuse. The capillaries and also the liver cells become compressed by the swollen amyloid material, and

occasionally little or nothing is seen in certain areas but masses of waxy tissue.

5. Pigmentary Changes.—A *black coloration* of those portions of the organ nearest the intestines is often seen, due to the action of the H_2S from the gut upon the iron pigment of the organ. This is, of course, a post-mortem change. *Increase in the amount of iron-containing pigment* in the liver is found in cases where there is an increase in the destruction of the red blood corpuscles within the liver, as in septicæmias and severe anæmias, notably in pernicious anæmia. This increase of hæmosiderin pigment gives a yellow-brown colour to the organ. The pigment may be brought out in a striking fashion by pouring some ferrocyanide of potassium (2 per cent) over the cut surface of the organ, and then some dilute HCl (1 per cent), repeating the process once or twice until the Prussian blue colour appears (Frontispiece, Fig. 1). Microscopic sections of the organ should be treated in a similar way. In chronic venous congestion, also in malaria, there is a deposition of pigment in the liver cells. In cases where there is *obstruction to the outflow of the bile* there is a *yellow coloration* of the organ, which becomes *green* on exposure to the oxygen of the air (Frontispiece, Fig. 3).

ACUTE INFLAMMATIONS OF THE LIVER

1. **Acute Perihepatitis** is found as a part of a general peritonitis. The surface of the liver is covered with more or less fibrinous exudate.

2. **Acute Hepatitis.**—Acute inflammation of the liver substance is found in slight degree in all infective fevers. It is always combined with cloudy swelling, and may be associated with focal necrosis, as in typhoid fever. The evidences of inflammation are usually slight, being confined to infiltration of the portal tracts with inflammatory cells.

3. **Suppurative Hepatitis.**—In discussing the types of liver abscess the paths by which organisms may reach the liver should be called to mind. There are three, (a) *the hepatic artery*, (b) *the portal vein* draining the whole of the abdominal contents, (c) the excretory duct of the organ—*the bile duct*. Thus at once we may distinguish three types of abscess or suppurative hepatitis.

There are, in addition, three other types to which special names are given.

Types of Liver Abscess.

1. Pyæmic.
2. Portal pyæmic.
3. Biliary.
4. Actinomycotic.
5. Tropical.
6. Suppurating hydatid cyst.

(1) *Suppurative Hepatitis of Arterial Origin—Pyæmic Abscess.*—This type is found in cases of pyæmia, septicæmia, and ulcerative endocarditis, where there are organisms circulating in the blood of the body generally. The abscesses in this case are minute and usually numerous. They are scarcely visible to the naked eye, and there are similar abscesses in other organs.

(2) *Suppurative Hepatitis of Portal Origin—Portal Pyæmic Abscess.*—In this type the infective agent comes to the liver by way of the portal vein. It is usually a germ-laden thrombus from a thrombosed vein in the neighbourhood of an inflammatory focus, such as an appendicitis. The abscesses in this case are usually about the size of a pea. They occur in groups or clusters like bunches of grapes (Fig. 71). They form cavities containing yellow or greenish pus, their walls being formed of necrosed liver tissue. Septic thrombi can usually be found in branches of the portal vein (Fig. 71). The condition is sometimes known as portal pyæmia.

(3) *Suppurative Hepatitis of Bile-Duct Origin—Biliary*

Abscess.—This is associated with suppurative cholangitis (suppurative inflammation of the bile ducts), which is commonly caused by obstruction to the bile passages from the presence of gall stones or a tumour. The abscesses are numerous, usually minute and scattered uniformly throughout the organ. The liver is bile stained. Cirrhosis of the liver is not infrequently present in addition.

(4) *Actinomycotic Abscess.*—This type is usually a special variety of the portal pyæmic abscess. It is associated with a focus of infection with the *Streptothrix actinomyces* in some part of the intestinal tract, *e.g.* the vermiform appendix. The affected portion of liver has a worm-eaten appearance owing to the presence of numerous small cavities containing pus, with areas of necrotic liver around, in which there is some fibrosis.

(5) *Tropical Abscess.*—This is usually single and fairly large (Fig. 72). The process is more a necrosis of the liver substance than a true suppurative inflammation. The contents of the abscess have a pink colour and creamy consistence. The condition is commonly associated with tropical dysentery. The *Entamæba histolytica* is found in large numbers in the tissue in the margin of the abscesses, and usually in the pus also.

(6) *Suppuration in a Hydatid Cyst.*—In this case also the abscess cavity is large and may be solitary. Mixed with the pus there will be the ectocyst of the parasite. The cavity is usually limited by fibrous tissue.

ACUTE AND SUBACUTE LIVER ATROPHY

This is a condition which is associated clinically with jaundice, vomiting, a diminishing liver dulness, and eventually coma. It is often connected more or less closely with such diseases as syphilis, tuberculosis, and influenza, and a number of cases have developed in women during the later

months of pregnancy. There is a general consensus of opinion that the condition is a toxic one, but what the nature of the toxin is and where it originates has not yet been determined. It has been suggested that it has its seat in the intestine, and very commonly one finds in these cases evidence of acute inflammation of the duodenum and upper bowel, but this condition has also been ascribed to the action of toxic bile from the necrosed liver.

Two stages in the disease may be recognised, and, as a result, two types of cases are met with *post mortem*.

(1) *Acute cases* in which death occurs within one or two weeks of the onset of the symptoms, and in which *degenerative changes* predominate in the liver. There is usually little evidence of overgrowth of fibrous tissue. To this type the name "acute yellow atrophy" or "acute liver atrophy" is more particularly applicable.

(2) *Subacute cases*, lasting some weeks, or even months, in which there is more or less evidence of the *reformation of functioning liver tissue with overgrowth of fibrous tissue*. For such cases the terms "subacute yellow atrophy," "subacute liver atrophy," and for the cases with marked regeneration "multiple nodular hyperplasia," have been suggested.

(1) **Acute Atrophy**—*Naked-eye Appearances*.—The liver is reduced in size, often markedly so. Its capsule tends to be shrivelled. The organ shows, as a rule, areas of different colours, yellow and red. In the more acute types the yellow areas predominate.

Microscopic Appearances.—In the *yellow areas* the liver cells are usually visible, but they show marked evidence of degenerative changes. They are swollen, granular, frequently contain fatty globules, and their nuclei have to a great extent lost their staining reaction. In addition, there is usually more or less overgrowth of fibrous tissue extending from the portal tracts. This fibrous tissue is vascular and cellular. In the neighbourhood of the portal tracts are small vermiform strings of cells whose nuclei stain deeply. Sometimes these have an

obvious lumen. They represent the remains of pre-existing and of proliferating small bile ducts. In process of degenerating the liver cell undergoes coagulation of its substance, followed by disappearance first of the carbohydrate and fatty elements, second of the albuminous constituents.

In the *red areas* little that is characteristic of liver structure remains. The tissue is a vascular connective tissue with dilated capillaries, and shows large numbers of endothelial cells which may contain pigment, a loose connective-tissue stroma, occasional degenerated liver cells scarcely recognisable as such, and a few leucocytes. In the neighbourhood of the portal tracts the small bile ducts are numerous, and may show evidence of proliferation of their cells (mitotic figures).

(2) **Subacute Atrophy** — *Naked-eye Appearances*.—The organ is of a brownish-red colour, with yellow or greenish nodules varying much in size, sometimes projecting beyond the general surface (Fig. 73). On section, these yellow nodules may be isolated, or may be found scattered through the substance of the liver. Where the nodules are numerous the organ presents the appearance of a coarse cirrhosis, from which condition it is often very difficult to distinguish it.

Microscopic Appearances.—The red-brown portion of the organ consists of a fairly vascular connective tissue with groups of small bile ducts, scattered endothelial cells, and, as a rule, with no liver tissue to be found. The yellow nodules present the appearance of liver tissue. They are composed of masses of liver cells, sometimes arranged in columns, at other times closely packed together. Lobular arrangement is imperfect. Many of the cells are large and multinucleated; some may be found showing mitotic division of their nuclei. The appearances at the margin of these nodules suggest that they are enlarging and pressing aside the surrounding tissue. The fibrous tissue, being newly formed, contains few elastic fibres.

It will thus be seen that the disease is essentially a degeneration of the liver parenchyma under the action of some poison. Complementary to this, there is an overgrowth of fibrous tissue starting from the portal tracts.

The condition may thus be regarded as an acute cirrhosis. It forms a connecting link between the purely degenerative changes, such as occur in phosphorus poisoning, and the chronic interstitial inflammations or cirrhoses.

Following the degenerative changes, attempts, more or less successful, are made to regenerate liver tissue in two ways: (1) By proliferation of the bile ducts. This, although it is an imitation of the way in which the liver lobules are produced in embryonic life, seldom results in the formation of liver parenchyma. (2) By proliferation of liver cells which survive the destructive influence of the poison, with resulting formation of nodules of glandular cells more or less resembling in structure liver lobules, and probably functioning as such.

CHRONIC INFLAMMATION OF THE LIVER

Types.

1. Cirrhosis.

(a) Common.

(b) Biliary.

(c) Syphilitic.

2. Syphilis.

3. Tuberculosis.

Cirrhosis

The term "cirrhosis," introduced by Laennec, simply means "yellow." It has, however, come to be synonymous with fibrosis, and is applied to all conditions of the liver in which there is abnormal development of connective tissue.

The condition is *caused by any slowly acting poison or irritant*. Thus *chronic intoxications*, such as alcohol or lead, produce it. *Infective conditions*, such as syphilis, may also cause it. *Retention of the bile* from obstruction to the bile ducts will produce it; also *inflammatory conditions of the small bile ducts*, which so commonly accompany obstruction.

Lastly, *abnormal accumulation of pigment*, as in malaria and chronic venous congestion, is a factor.

The liver consists of two types of cellular elements: (1) highly differentiated and functioning gland cells very susceptible to the action of poisons, and capable of little in the way of reaction; (2) cells less highly differentiated—connective-tissue cells—not so readily damaged by the action of poisons, and capable of reaction and proliferation in circumstances where the liver cells degenerate. The mere disappearance of the glandular cells is followed by a complementary proliferation of connective tissue. This is well seen in the less acute types of liver atrophy. But where there is an irritant constantly present, as in syphilis, alcoholism, retention of bile, and inflammation of the small bile ducts, another factor comes into play, namely, the proliferative reaction of the connective-tissue cell under irritation. These two factors are, no doubt, both operative in the production of cirrhosis of the liver.

Where there is any great amount of destruction of hepatic gland cells the stimulus to regenerate is felt by the organ, and is answered by the formation of new areas of liver tissue. This is a prominent feature in subacute liver atrophy, and evidence of it is usually present in cirrhosis also.

Classification.—The terms *monolobular* (where the areas of liver cut off by bands of fibrous tissue represent single lobules) and *polylobular* (where such areas represent groups of lobules) are often used to characterise types of cirrhosis. They are practically the same as fine and coarse cirrhosis respectively. They are not very useful as a basis of classification, owing to the fact that the two conditions are usually to be seen alongside one another in the same liver. Another couple of terms used sometimes are “hypertrophic” (meaning an abnormally large liver) and “atrophic” (abnormally small). Owing to the fact that in many instances it is impossible to decide whether a liver is enlarged or not, these terms are

rather to be avoided. The method of classification adopted is as follows :—

A. Common Cirrhosis.—The ordinary type found in association with chronic intoxications, distinguishing (a) an early stage where the liver is large, and (b) a late stage where it is small. This variety is usually polylobular.

1. *Early Stage.*—The liver is *enlarged* and has a *somewhat rough surface*. In some cases it is red, from congestion ; in other cases it is yellow, from fatty change.

The organ is *firmer* and *tougher* than normal, and on section shows *bands of vascular fibrous tissue* running through it. These, as a rule, are not very obvious.

Microscopic Appearances.—Bands of vascular and cellular connective tissue divide up the liver into areas, at one time representing a single lobule, at another time a group of lobules. The liver cells may show little change, or there may be more or less fatty infiltration.

2. *Advanced Stage.*—This is the more common type of the disease, known as “hobnail,” “drunkard’s,” or “gin-drinker’s” liver.

The liver is *distinctly reduced in size*. It has a *roughened surface*, owing to the presence of nodules varying much in size. It usually has a *pale yellow colour*. The *capsule* may be *thickened*. It is distinctly *tougher* and *firmer* than normal. On section, it shows *bands of grey fibrous tissue* passing through the organ in all directions, dividing it up into rounded areas varying much in size (Fig. 74). A number of cases are recorded in which primary carcinoma of the organ was associated with this type of cirrhosis.

Microscopic Appearances.—The most striking change is the overgrowth of fibrous tissue which spreads from the portal tracts, forming bands, thicker or thinner, cutting off individual lobules or groups of lobules. This fibrous tissue is well formed, but it often shows here and there accumulations of small

round cells, indicating that the fibrous proliferation is still progressing. There is considerable development of new elastic fibres in the bands of fibrous tissue. There is a varying number of small bile ducts. These in some cases appear to arise from retrograde changes in columns of liver cells, the latter reverting to their embryonic condition under the pressure of the surrounding fibrous tissue. In other cases the ducts represent an attempt to reform liver tissue, just as in subacute liver atrophy. There is a tendency for the fibrous tissue to invade the liver lobule at its margin to a certain small extent, individual liver cells or groups of them being cut off. The liver cells themselves commonly show more or less fatty infiltration. Not infrequently small nodules of regenerated liver tissue are met with. These are recognised by the evidence of multiplication in the liver cells, some of them having two nuclei, others showing evidence of division. Such nodules also show imperfect lobule formation.

B. Biliary Cirrhosis.—This condition is commonly associated with *obstruction to the bile ducts*. This may be due to congenital obliteration, to gall stones, or to tumour. It is also very commonly associated, as, indeed, obstruction is, with *inflammatory conditions of the bile ducts*.

The organ is sometimes enlarged, sometimes reduced in size. Its surface is not so rough as in common cirrhosis. It is a much finer cirrhosis, corresponding more to the monolobular type. The organ usually has a *deep yellow colour*, turning green on exposure to the air, due to the bile staining which so constantly accompanies it. The organ is firmer and tougher than normal. On section, bands of fibrous tissue can be seen radiating through the liver tissue and dividing it up into small lobules which have a yellow or green colour. Sometimes abscess formation of biliary origin is present.

Microscopic Appearances.—As in the common type, the most striking change is an overgrowth of the fibrous tissue of the organ, extending from the portal tract and tending to

separate individual liver lobules from one another. The fibrous tissue is, on the whole, more cellular than in the common type of cirrhosis, and small bile ducts are a more conspicuous feature. The liver cells show marked degenerative changes, areas of necrosis being frequently met with. Bile pigment may be seen in and between the liver cells. Catarrhal changes in the bile ducts, sometimes with the development of abscesses, is common. In suitably stained specimens germs may be found, especially where abscess formation is present.

C. Syphilitic Cirrhosis (see Syphilis).

Results of Cirrhosis.—Owing to the pressure of the contracting fibrous tissue upon the branches of the portal vein within the liver, there is obstruction to the blood passing through the organ and coming from spleen and bowel, with the following results :—

1. Ascites or dropsy of the abdominal cavity.
2. Chronic venous congestion of œsophagus, stomach, intestine, and spleen, with a tendency to chronic catarrh, varicose veins, hæmorrhage, and, in the case of the spleen, enlargement.

These two changes occur especially in common cirrhosis.

3. Jaundice, which is more characteristic of biliary cirrhosis.

Syphilis of the Liver

(a) *Congenital.*—In this type of the disease a diffuse cirrhotic condition is sometimes met with (congenital syphilitic cirrhosis). The organ is enlarged, commonly bile-stained, firmer than normal, but otherwise little altered.

Microscopic Appearances.—The organ is the seat of a diffuse overgrowth of fibrous tissue. This is more marked in some places than in others. It is not specially restricted to the portal tracts ; on the contrary, it is found within the lobule separating groups of cells and individual cells from one another. In the fibrous tissue are to be found numerous small round cells aggregated in places into small masses, sometimes

with caseous centres (miliary gummata). In suitably treated material, spirochætes may be demonstrated in large numbers.

(b) *Acquired*.—In acquired syphilis the lesions found in the liver are :—

1. *Areas of chronic perihepatitis*, sometimes with adhesions to the abdominal wall and diaphragm.

2. *Gummata*.—These are caseous foci surrounded by a zone of fibrous tissue (Fig. 75), sometimes with cirrhotic change radiating from it into the liver substance. They may occur singly or in groups. They are frequently absorbed, leaving behind scars which show themselves as puckerings on the surface. When these are numerous, sometimes a *coarse cirrhotic condition* is produced, with marked deformity of the organ. Waxy degeneration is sometimes combined with the above.

Tuberculosis of the Liver

Tuberculosis seldom develops to any extent in the liver, that organ apparently not forming a suitable nidus for the growth of the tubercle bacillus. Two types of the disease are found :—

(a) *Miliary Tuberculosis*.—Small scattered foci which may or may not be visible to the naked eye. When visible, they appear as minute white or yellow spots ; sometimes they are bile-stained. Similar areas are found in other organs.

Microscopic Appearance.—Numerous cellular areas are scattered through the organ. They are made up chiefly of large and small mononuclear cells. They may have caseous necrotic centres or may show giant cells.

(b) *Larger caseous nodules*, which may be single or numerous, and are usually bile-stained. This is a rare type, more commonly met with in children than in adults.

Leukæmia of the Liver

The organ is usually enlarged, paler than normal, sometimes with distinct, small, whitish areas scattered through it.

Microscopic Appearances.—There is infiltration of the liver substance with rounded cells, which vary in type according to whether the condition is myelæmia or lymphæmia. These cells are found in the portal tracts and between the columns of liver cells. In the more advanced cases the individual liver cells may be separated from one another. Here and there are cell accumulations without any liver structure. These are the above-mentioned pale areas. The endothelial cells of the capillaries are swollen.

Lymphadenoma (Hodgkin's Disease)

The liver may or may not be affected in this condition. When it is, numerous irregularly shaped pale areas similar to those seen in the spleen are scattered through it. The condition is sometimes indistinguishable from true tumour formation. In most cases, however, the pale areas are more diffusely distributed, smaller, and less well defined.

Microscopically, the appearance of the areas is similar to those found in the spleen in the same disease (see p. 110).

Tumours

A. Simple growths of the liver are not common. The *cavernous angioma* is the one most frequently found. It appears as a dark red area under the capsule of the organ. On section, it is found to be more or less irregularly wedge-shaped. On close inspection, bands of white fibrous tissue may be seen dividing the area up into spaces filled with blood (Fig. 76). Its appearance is suggestive of an infarct, but it should be remembered that true infarction of the liver does not occur.

Adenomata of the liver are occasionally met with. They

appear as circular, well-defined nodules in the substance of the organ, yellow or reddish-brown in colour. They are single or multiple, and microscopically show an approximation to the normal structure of the liver, but without the regular lobular arrangement. Areas of regenerated liver tissue have a somewhat similar appearance.

B. Malignant growths are very common in the liver.

Primary growths are not very frequent, but *secondary growths*, more particularly carcinomata, are very common. The venous blood from the various portions of the bowel passes through the organ, and is naturally strained of any emboli, tumour or otherwise, in it. Inasmuch as the malignant growth of the bowel is almost invariably a carcinoma, the secondary malignant neoplasms of the liver are commonly of this type.

It is seldom possible, with any great amount of certainty, to decide from its appearance whether a tumour is sarcoma or carcinoma, primary or secondary. The growth, or growths, appear as white or yellow areas scattered through the substance of the organ, varying in size, rounded or irregular in shape. The liver is often greatly enlarged (Fig. 78). In the tumour masses, necrotic areas, and hæmorrhages are commonly seen. Owing to sinking in of the necrotic centres the masses on the surface often show crater-like hollows. The intervening liver substance frequently shows bile-staining, and occasionally cirrhosis. The connection between primary cancer and cirrhosis is well recognised.

1. *Primary cancers* of the liver are of two types :—

(1) A type resembling more or less closely the structure of the liver, the tumour cells occurring in columns.

(2) A type arising from the bile ducts and resembling other adeno-carcinomata.

The association between primary cancer and cirrhosis of the liver has already been noted.

2. *Secondary cancers* vary very much in appearance

and in character. All types of adeno-carcinoma of the bowel—columnar cell, scirrhus, encephaloid, colloid occur, also chorionepithelioma.

Of sarcomata (Fig. 77) only the melanotic shows appearances which are distinctive.

Cysts of the Liver

Congenital cystic disease is sometimes met with in the liver, although not so frequently as in the kidney. The cysts are numerous, vary in size, and contain clear fluid.

Hydatid cysts are relatively frequent in the liver. They often attain a very large size, are surrounded with a fibrous capsule, and contain ecto- and endo-cyst, with the characteristic "white of egg" appearance (Fig. 79).

Gas Cysts of small size, caused by the development of bubbles of gas in the liver substance through the action of an organism (*B. ærogenes capsulatus*, also called *B. Welchii*), are occasionally met. They are found in association with supuration in the abdominal cavity. Pressure upon the liver produces a sensation of crackling, such as is normally present in the lungs. Microscopically, spaces representing dilated vessels are found lined with a layer of bacteria. A similar change may be present in other organs, *e.g.* pancreas.

The organism causing this condition is a normal inhabitant of the intestinal tract and is often found in the blood in cases where the section is deferred for some time after death. The blood in such cases has a frothy appearance. Occasionally this invasion of the blood occurs during life when the above appearances are produced in the liver and other organs.

METHOD OF EXAMINING A LIVER REMOVED FROM THE BODY

The general size, colour, and shape of the organ should be noted, also the appearance of the lobules as they shine through the capsule. The capsule is then examined for evidence of

adhesions with the abdominal parietes, for depressions such as are produced by gummata, for the fine or coarse generalised roughening of cirrhosis, also for the fibrinous exudate of acute peritonitis and the caseous foci of tuberculous peritonitis. The organ is weighed, the normal weight of the liver being 45 to 58 oz. (1420-1649 grm.). It is opened up by a series of perpendicular cuts. In so doing the consistence of the organ is noted. Pressure is made upon the cut surface in order further to investigate this point. The cut edge should be looked at in order to see whether it is rounded (indicating soft consistence) or sharp. The cut surface is then investigated as to colour, the presence of abscesses, tumours, etc. Lastly, the gall bladder is opened up, and the amount of bile, also its colour noted. Gall stones should be searched for.

DISEASES OF GALL BLADDER AND BILE DUCTS

Congenital obliteration of the common bile duct is a condition occasionally met with. The exact cause is unknown, but it is believed to be, in some cases, syphilitic in origin. It is associated with a fine cirrhosis of the liver and bile pigmentation of that organ as well as jaundice.

Inflammation of Gall Bladder (Cholecystitis), of Bile Ducts (Cholangitis).

Catarrhal Inflammation.—A mild degree of inflammation of the bile passages is sometimes associated with a catarrhal condition of the stomach, and, owing to the low pressure at which the bile is excreted, blocking of the bile passages from swelling of the walls, with resulting jaundice, may occur. A similar condition is sometimes brought about by the invasion of organisms, such as the *B. typhosus* in typhoid fever. The bacilli, in all probability, reach the bile ducts from the blood by way of the liver, but it is possible that they pass upwards from the duodenum. In the gall

bladder and larger bile ducts a catarrhal inflammation is set up which may persist for months or years after the attack of fever. In many instances this inflammatory change leads to gall-stone formation. When the typhoid bacillus is the cause of this condition the patient suffering from it is constantly voiding with his stools living, virulent organisms, which may contaminate food or drink and lead to the dissemination of the disease. Such individuals are known as "*typhoid carriers*."

Suppurative inflammation of the bile ducts (suppurative cholangitis) is a very common accompaniment of obstruction to the outlet of the bile from gall stones or tumour formation. The organisms found are usually *staphylococci* or *B. coli*. The condition results, not infrequently, in abscesses (biliary) within the liver substance.

Suppurative Inflammation (empyema) *of the gall bladder* is sometimes met with apart from cholangitis. The acute inflammation may pass through the wall of the bladder and give rise to acute peritonitis.

Biliary Concretions or Gall Stones (Cholelithiasis)

Gall stones are much more common in women than in men, something like three-quarters of the cases occurring in the female sex. They usually make themselves felt about the age of forty, although, not infrequently, the stones are found post-mortem without there being in the history of the case anything to indicate their presence. As regards *causation*, tight lacing, good living, and sedentary habits are predisposing factors, but the actual cause of the condition is commonly a catarrhal inflammation of the bile passages associated with the presence of organisms. Aschoff distinguishes two types of gall stones: (1) Those produced by congestion of bile and disturbances of metabolism; the stones belonging to this category consist almost entirely

of cholesterin. (2) Those caused by inflammatory change due to the presence of organisms. The germs which have been separated, in some cases actually from the interior of the stones themselves, are *staphylococci*, *B. coli*, and *B. typhosus*. The mode of formation of the concretions is as follows: a nucleus of *mucus* and *epithelial débris* is formed, and round this are deposited *cholesterin* (largely derived from disintegrated epithelium), *lime and magnesium salts*, and *bile pigment*. Cholesterin is the main constituent, being present usually to the amount of 70-80 per cent; hence the lightness of the stones. Some stones are formed almost entirely of cholesterin. The colour, which varies from pale yellow to black, depends upon the amount of bile pigment present. The concretions vary much in size, from minute particles (gall sand) to masses measuring, it may be, two inches across. Those formed in the bile ducts are usually small; the larger ones develop in the gall bladder. Gall stones are usually multiple, hence commonly faceted (Fig. 80). Sometimes they have a mulberry-like surface and occasionally they are smooth. The smooth stones are, of course, solitary. On section, the concretions often show concentric lamination; sometimes they exhibit radiating lines.

As regards the *effects* of the presence of gall stones, they tend to keep up the chronic irritation which caused their formation. Thus they lead to thickening of the gall bladder and bile ducts and to adhesions to surrounding parts. More acute, suppurative inflammation may be set up. They may ulcerate through into the intestine, and, when very large, have been known to cause intestinal obstruction. They may obstruct the cystic duct, thus leading to atrophy, or, in some cases, to dilatation of the gall bladder. They not infrequently obstruct the common bile duct and give rise to jaundice. Lastly, there is a very definite relationship between cancer of the gall bladder and the presence of gall stones.

Tumours.—The *carcinoma* is the most important tumour of the gall bladder. It is usually a columnar cell adeno-carcinoma, but may be a scirrhous or colloid cancer, or even a squamous epithelioma.

DISEASES OF THE PANCREAS

The pancreas is an organ which *tends to show marked post-mortem changes*, partly because of the action of the digestive juices which it secretes, partly because of its proximity to stomach and intestine, and so to infection with putrefactive germs. Thus, just as in the case of the stomach, so with the pancreas, the pathologist must be careful not to regard as evidence of disease, changes which are merely due to alterations taking place after death.

Where a lesion of the pancreas is suspected, careful search should be made for *areas of fat necrosis*. Conversely, the presence of these areas of fat necrosis is evidence of a lesion of the pancreatic gland. Such areas are found in the fat of the pancreas itself, of the mesentery and omentum, occasionally even of the mediastinum. They appear as opaque white spots the size of pin heads, or even as large as peas. The change in the fat is brought about by a setting free in the peritoneal cavity of the fat-splitting ferment of the pancreas. The neutral fat is at first split into fatty acid and glycerine, the fatty acid probably combining subsequently with a calcium base.

Atrophy of the pancreas is sometimes met in old age and wasting diseases. In diabetes not infrequently the only alteration found is a diminution in the size of this organ.

Fatty infiltration, or penetration of fat into the substance of the gland, with atrophy of the gland tissue, is occasionally seen.

Inflammation

1. *Acute Hæmorrhagic Pancreatitis*.—This is a somewhat rare condition, the etiology of which is not quite clear. The symptoms are those of acute intestinal obstruction. In many instances it is an acute infective process due to the presence of germs, and it is not infrequently found in association with cholangitis and gall stones which may be found blocking the ampulla of Vater. Some regard the hæmorrhage as the primary change, others consider that it is, like the fat necrosis, due to the setting free of the digestive juices of the organ, and the action of these upon the blood-vessels.

As regards appearances, the organ is swollen and dark red in colour, due to infiltration with blood. More or less extensive fat necrosis is always found in the fat in the neighbourhood.

Microscopically, areas of necrosed pancreatic tissue are found, also infiltration of the interacinous tissue with red blood corpuscles, fibrin, and leucocytes. The areas of fat necrosis are well brought out with Nile Blue which stains the necrosed fat blue, the normal fat red.

2. *Suppurative Pancreatitis*.—Organisms may reach the pancreas by way of the blood-stream or by the duct of Wirsung, or again by extension from neighbouring parts. The abscesses may be minute and numerous or large and solitary. Sometimes the change is associated with suppurative cholangitis and gall stones. The abscesses may rupture into the peritoneal cavity and cause peritonitis.

3. *Chronic interstitial pancreatitis* or *cirrhosis of the pancreas* may be met with in association with alcoholism, syphilis, and obstruction to the duct of Wirsung by calculi or tumour formation. In some cases of diabetes a fine fibrosis, involving more especially the islands of Langerhans, has been described.

Tumours.—Primary carcinomata are occasionally met with. By pressure upon the common bile duct such tumours

cause an extreme degree of jaundice. Many of the cases of so-called malignant jaundice are due, not to a neoplasm in the pancreas, but to some secondary deposit in a retroperitoneal gland in the neighbourhood. As a rule carcinomata show microscopically the characters of a columnar cell glandular cancer.

Cysts.—The pancreas, like the liver and kidneys, is sometimes the seat of congenital cystic disease. Such cysts are multiple and small. Large solitary cysts are also met with, due in all probability to obstruction of a duct of the gland.

Relationship between Lesions of the Pancreas and Diabetes.—Since the middle of last century a relationship between changes in the pancreas and the disease diabetes has been recognised. In 1889 it was shown by Minkowski that total extirpation of the organ produced a fatal diabetes. Ligature of the duct was, however, found not to have this effect. It was concluded that the pancreas gave origin to an internal secretion which, in cases of diabetes, was absent. Search was made for some element in the gland which might be the source of such an internal secretion, and the islands of Langerhans, first observed in 1869, were selected as the probable source. Somewhat conflicting statements are at present made regarding the presence of lesions of these structures in diabetes. Some have found fibrosis or hyaline degeneration in a large proportion of cases. There can be no doubt that in many cases no obvious lesion of any structure in the pancreas can be found. The lesions which have been described are simple atrophy, fatty infiltration associated with atrophy, a fine fibrosis, hyaline change in the connective tissue of the islands of Langerhans.

CHAPTER X

DISEASES OF THE KIDNEY AND BLADDER

DISEASES OF THE KIDNEY

CONGENITAL ANOMALIES

Persistence of Fœtal Lobulation is a fairly common finding. It is best seen after stripping the capsule from the organ, and shows itself by a series of intersecting lines dividing the organ into irregularly shaped areas.

Horse-shoe Kidney, a condition in which the two organs are united, usually at their lower end across the vertebral column, is not infrequently found.

Congenital Cystic Kidney.—In this condition, which is always bilateral, the organ is enlarged, often greatly so. The outer surface is studded with projecting cysts, with transparent contents varying in size from something just visible to a walnut. In some cases there is very little kidney tissue left between the cysts. On section, a similar appearance is seen (Fig. 81). The condition is believed to be due to a failure of union between the glomerular and the tubular portions of the kidney tissue, which are developed separately.

Solitary congenital cysts, sometimes of large size, may be met with.

Congenital Hydronephrosis may occur in one kidney owing to defective formation of the ureter.

CIRCULATORY CHANGES

1. **Chronic Venous Congestion.**—This condition is found in cases where there is obstruction to the passage of blood through the heart or lungs.

Naked-eye Appearances.—The organ is somewhat enlarged. It is firm. On section, the medulla has a dark purple appearance, the cortex is paler than the medulla, but shows dark lines and dots indicating vessels and glomeruli. On stripping the capsule, the venæ stellatæ are often very prominent.

Microscopic Appearances.—The vessels generally are dilated, more especially those of the medulla. The glomerular capillaries are distended. Sometimes hæmorrhages into the tubules are seen. Catarrhal and interstitial changes may be superadded.

2. **Infarction.**—Infarcts of the kidney are common. They are almost invariably due to embolism of one of the branches of the renal artery. Occasionally the whole vessel may be blocked. The embolism may be caused by the impaction of portions of thrombi from vegetations on the aortic or mitral valve, thrombi in the left auricle or its appendix, or on atheromatous patches in the aorta. The infarcts are wedge-shaped areas in the cortex, usually white or yellow in appearance, surrounded by a hæmorrhagic zone, more especially where they come in contact with the medulla (Fig. 82). At first the area is level with the rest of the surface. Later on it becomes depressed, and eventually absorbed, leaving a cicatrix.

Very similar irregularly scattered depressed areas are found on the surface of the organ which, on section, prove to be areas where the cortex is narrow and fibrosed. They are due to interstitial change following blocking of vessels owing

to disease. This condition when well marked is usually referred to as arterio-sclerotic kidney (see p. 214).

Microscopic Appearance.—The infarcted portion shows swelling, granularity, and more intense staining of the columnar cells of its tubules. The nuclei usually are broken into masses of chromatin or fail to stain altogether. At the margin the tubules and intertubular tissue are infiltrated with red blood cells, and frequently with leucocytes. The thrombosed vessel can often be seen towards the apex of the wedge. When the embolus contains organisms these may be seen in masses. In such a case polymorphonuclear leucocytes are very numerous.

DEGENERATIONS

1. **Cloudy Swelling.**—This is found in all infective diseases. It is particularly well marked in cases of pneumonia.

The organ is somewhat enlarged, softer, and more friable than normal. On section, the cortex is pale, opaque, and swollen. The cut surface of the cortex protrudes above the level of the medulla.

Microscopic Appearances.—The condition affects most markedly the cells of the convoluted tubules, *i.e.* the largest columnar cells. Such cells are swollen and project into the lumen of the tubule giving a characteristic star-like appearance. Their protoplasm is granular. The nucleus in some cases stains more intensely, in others it is paler than usual. Sections stained for fat will often show a few globules within the cells. There is a tendency to separation of the cells lining the tubules owing to loosening of cement substance, and occasionally cells may be thrown off into the lumen of the tubule. Where this last change is a prominent feature the term catarrhal nephritis is applicable. In fact there is no hard-and-fast line between cloudy swelling and parenchymatous or catarrhal nephritis (see p. 209).

2. **Fatty.**—Two forms of this condition may be distinguished, although no very hard-and-fast line can be drawn between them.

(1) *Primary fatty degeneration* caused by organisms and their products, and therefore found in infective conditions often as a sequel to cloudy swelling ; caused also by chemical poisons such as phosphorus and chloroform.

(2) *Fatty change secondary to catarrh of the tubules*, and found in association with Bright's disease and waxy degeneration.

Naked-eye Appearances.—In the first condition there is usually no great alteration in size in the organ. On section, the cortex is pale opaque-white in appearance, and contrasts with the more vascular medulla.

In the second variety the appearances depend upon the stage of the disease, and will be described in connection with the various types of nephritis and waxy change.

Microscopic Appearances.—In sections stained by ordinary methods, such as hæmatein and eosin, the cells of the convoluted tubules appear swollen and granular, and their nuclei may show degenerative changes. In sections stained with Sudan III. or Scharlach R. the same cells will be found to show numerous fat granules and globules, more especially in the deeper part of their protoplasm. In the collecting and other forms of tubules the same change will be found, but less marked.

3. **Waxy (Amyloid).**—This may be found in association with advanced tuberculosis, visceral syphilis, or chronic suppuration, *e.g.* empyema, bone or joint disease.

The kidney is usually *enlarged*, in the more advanced stages very markedly so, although, when combined with interstitial change, it may be reduced in size. It is *pale* from anæmia and associated fatty change (frontispiece, Fig. 6). As a rule it is *firm*, and shows a sharp edge on section ; occasionally it may be soft. The appearances are very similar to those seen in the subacute form of Bright's disease (large white kidney). In some instances it is possible to distinguish between the two conditions only on testing with iodine. Sometimes the glomeruli can be seen as minute translucent

specks. In the more advanced stages the whole cut surface has a translucent appearance. On treatment with iodine the glomeruli and vessels are brought out as mahogany brown specks and lines. The capsule commonly strips well and leaves a smooth, pale, mottled surface.

Microscopically, the change is observed first in the afferent arterioles (see plan, p. 206); it then spreads to the glomeruli and efferent vessels, and also to the middle coat of the larger arteries. The arteriolæ rectæ in the medulla are early affected. In the advanced stages of the disease the basement membrane of the tubules, the periendothelial connective tissue of the intertubular capillaries, and other strands of supporting fibrous tissue are implicated. The waxy material is homogeneous and translucent when unstained. It appears yellow with transmitted, dark brown, with reflected light after treatment with iodine, and gives a rose pink to purple colour, with methyl violet and subsequent differentiation in dilute acid. There is usually a considerable amount of fatty change, catarrh of the tubules, and, in the later stages, overgrowth of fibrous tissue.

4. Pigmentary Changes.—In pernicious anæmia the kidney, like the liver and spleen, may be the seat of the deposit of hæmosiderin. In jaundice the kidney is the first organ to be affected and shows a yellow tinge which becomes green on exposure to the air.

INFLAMMATION OF THE KIDNEY OR NEPHRITIS

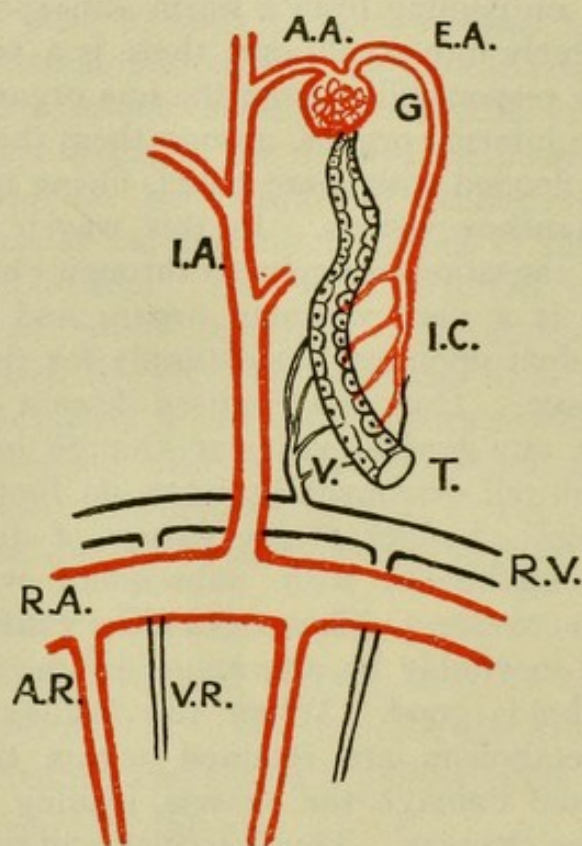
General Facts.—The kidney is an organ essentially concerned with the elimination of waste products of metabolism and poisonous substances. In any condition in which poisons are circulating in the blood, whether these be of chemical nature or bacterial origin, the organ is apt to be damaged. Once this damage has occurred and the eliminating function of the organ interfered with, matters are made worse, for the irritating poison accumulates, as do also waste products of metabolism which further injure the delicate secreting tissue. Thus a vicious circle tends to be set up, which intensifies the action of the poisonous substance.

There are two other eliminating channels for waste products in the body—the lungs and the skin. These to a certain small extent are capable of taking on vicariously the function of the kidney, but only to a very minor extent. Thus in cases of kidney insufficiency the breath and the sweat may contain urea. The converse also holds good, in that when elimination by the skin is interfered with more work is thrown upon the kidney. Thus, on passing from a warm atmosphere where the skin is acting freely into a cold one, there is a sudden change of the excretory responsibility from the one organ to the other. In addition, the internal organs, among them the kidney, tend suddenly to be flooded with more blood, owing to the contraction of the cutaneous vessels. In this way it is possible to understand the causation of nephritis through chill.

The kidney is a very vascular organ, and one which is specially dependent upon its blood-supply for the integrity of its secreting tissue. Thus any localised disease of the vessels of the organ or any general vascular change implicating the renal vessels will tell detrimentally upon its function, and will produce structural changes of the nature of degeneration in the secreting epithelium with subsequent replacement of this by fibrous tissue. Thus, extensive vascular disease is accompanied inevitably by alterations in the kidney. The converse also holds good. When the kidney is damaged, products of metabolism are retained within the circulation which irritate and damage the vessels, leading to thickening and degenerative changes. Thus vascular and renal conditions very frequently coexist, and, inasmuch as the condition of the vessels affects the heart, cardiac disease is eventually super-added.

The vascular supply of the organ is peculiar, and it is well to remember this, as it affords a means of understanding how structural changes may follow alterations in blood-supply. The renal arches which pass between cortex and medulla give off from their cortical aspect branches known as interlobular; from the medullary aspect come the arteriolæ rectæ, which pass downwards into the medulla. The interlobular arteries give off the afferent arterioles which supply the glomeruli. The blood leaves the glomerulus at the same point as it enters it by the efferent vessels. The glomerulus is a bag of coiled capillary

vessels with a narrow neck, through which the blood enters and leaves the structure. But the blood does not at once return to the veins by the efferent channel. The vessel again breaks up into a series of capillaries (see plan), supplying the kidney tubules with blood. Thus any interference with the flow of blood through the glomerulus will inevitably tell upon the tubules leading to degenerative changes in these. Such



Plan of the Circulation in the Kidney.

R.A., branch of renal artery; I.A., interlobular artery; A.A. afferent arteriole; G., glomerulus; E.A., efferent arteriole; I.C., interlobular capillaries; T., tubule; V., venous rootlets; R.V., branch of renal vein; A., arteriæ rectæ; V.R., venæ rectæ.

interference may be rapid in its onset from sudden circulatory disturbances as in "chill," or slowly progressing from a gradual narrowing of the vessel lumen.

Causation.—The causes of nephritis thus are:—

1. *Chemical poisons*, such as alcohol, lead, cantharides, taken into the body; also *poisons formed by the body itself*, such as abnormal products of metabolism or normal products present in excess, as in the disease commonly called gout.

2. *Bacteria and their poisons* in process of excretion, as in the specific fevers, scarlet fever, typhoid, small-pox, etc.

3. *Bacteria multiplying locally*, as in suppurative nephritis and tuberculosis.

4. *Circulatory alterations*, acute congestion associated with "chill," and, to a certain extent, chronic venous congestion.

Classification.—It is customary and convenient to distinguish two primary groups: (1) *Organismal nephritis*, where the germs are actually present and multiplying in the organ. Of this there are two main types: (a) septic nephritis, and (b) tuberculosis of the kidney. (2) *Non-organismal nephritis*, that is to say, where the germs, although they may be present, are not multiplying in the organ. In the commonest type of this disease there may be no germs or bacterial poisons at all, the condition being due to sudden alterations in the circulation of the blood or to toxins. This non-organismal type of nephritis corresponds to what is usually called "Bright's disease."

Bright's disease may be divided, according to the stage of the disease, or rather the degree of acuteness, into three subgroups: (a) *acute nephritis*, (b) *subacute nephritis*, and (c) *chronic nephritis*. Of these subgroups (a) may pass into (b), and (a) and (b) into (c). There is no hard-and-fast line between them, and as a result transitional types are not infrequently met with. The method is, however, useful for purposes of classification and description. As Bright's disease is the most important type of nephritis it will be considered first.

Types.

I. Non-organismal nephritis (Bright's Disease).

1. Acute.

(a) Glomerular.

(b) Tubular or catarrhal.

(c) Interstitial.

2. Subacute (large white kidney).
3. Chronic interstitial (granular contracted).

Sub-group—Arteriosclerotic.

Amyloid degeneration may occur in combination with Nos. 2 and 3.

II. Organismal Nephritis.

1. Acute (septic nephritis).
 - (a) Embolic or pyæmic.
 - (b) Pyelonephritis (surgical kidney).
2. Tuberculosis.
 - (a) Embolic or miliary.
 - (b) Tuberculous pyelonephritis or chronic tuberculosis.
3. Syphilis.

Acute Nephritis

In studying the microscopic changes in the kidney in nephritis, and in describing these changes, it is well to remember that there are three more or less distinct structures or types of tissue in the organ, (a) *the tubules*, (b) *the glomeruli*, (c) *the supporting, interstitial fibrous tissue carrying the vessels*. The poisons which cause nephritis tend to exercise a selective faculty to a certain extent, and one finds that in one case the tubules are more affected, in another the glomeruli, and in a third the interstitial tissue. For example, the poison of scarlet fever has a special tendency to affect the glomeruli. Of course this is true only up to a certain point. These structures are closely related to one another, and it is almost inconceivable that a poison could affect one and not another, and as a matter of fact *they are all affected to a certain degree in all cases*. But in given instances one structure may show such marked changes that one is warranted in taking these changes as a basis for classification. Thus three subgroups of acute nephritis may be distinguished: (a) *glomerular*, (b) *tubular*, (c) *inter-*

stital. As a matter of fact, the naked-eye appearances, never very characteristic in acute nephritis, do not differ to any extent in the three types.

Naked-eye Appearances.—These, as already mentioned, are not very characteristic. In some cases the organ presents very little by way of variation from the normal. In other cases the appearances are merely those of a well-marked cloudy swelling.

As regards size the organ is usually somewhat *swollen*, and in certain cases swelling may be a very marked feature. It is *softer* than usual and may be *paler* or *congested*. On section, in many cases (probably in most) the cortex is swollen, opaque white, or pale yellow, contrasting markedly with the congested medulla (Fig. 83). There may be small hæmorrhages scattered through the cortex. In other cases the whole organ is deeply congested and filled with blood, which drips from the cut surface. The capsule shows no alteration and strips readily from the organ, leaving a smooth surface. Occasionally the Malpighian bodies are prominent.

Microscopic Appearances—(a) *Tubular Changes.*—The cells lining the tubules are swollen and granular. Many of them have become thrown off, and are found lying free within the lumen of the tube. Some of the collecting tubules may be filled up with these desquamated cells. In suitably stained specimens, fat globules in varying amounts will be found within the cells, both those still attached and those lying free. In the more acute types of the condition the nuclei show degenerative changes, as evidenced by pale staining or complete loss of staining reaction. In the less acute types there may be evidence of nuclear division. In many cases there is a granular exudate present within the lumen of the tubules. In all cases the degenerative changes tend to be more marked in the convoluted tubules.

(b) *Glomerular Changes.*—In many instances these are slight. There is swelling, and possibly desquamation of the cells covering the tuft and of those lining Bowman's capsule. There is congestion of the capillaries of the tuft, and increase of the

number of cells in the tuft owing to the presence of leucocytes. In other cases more extensive glomerular changes are present—desquamation and proliferation of the cells covering tuft and lining the capsule. Hæmorrhage into the space between tuft and capsule may be found.

(c) *Interstitial Changes*.—The vessels are distended with blood. There tends to be more or less infiltration of the intertubular supporting tissue with cells, chiefly small, round, lymphocyte-like cells. Where this latter change is a marked feature, the term “acute interstitial nephritis” has been applied.

All the above changes have a tendency to be irregular in their distribution, being often more intense in one part of the cortex than in another.

Changes in the Urine in Acute Nephritis.—The amount secreted is diminished. In colour it is “smoky” to dark red, owing to admixture with blood. On standing it deposits a sediment which contains hyaline, epithelial, and blood tube casts, red blood corpuscles and free epithelial cells. Albumin is usually abundant. The total amount of urea excreted is considerably diminished.

Subacute Nephritis—Large White Kidney

Acute nephritis passes by almost insensible gradations into the subacute type. The latter may follow the acute condition or it may develop insidiously. The causes are the same in the two types. Once degenerative changes have begun in the kidney, products of metabolism are retained. These, accumulating, act themselves as poisons upon the renal cells. Thus a vicious circle is established. It is much more difficult for matters to return to the normal in the case of the kidney once degenerative processes have commenced than it is in the case of any other glandular organ.

Naked-eye Appearances.—The organ is *enlarged* and *pale*. Hence the terms “large pale,” “large white” kidney. This

increase in size may be slight, but in many cases it is very marked. It is *firm* in consistence and the *surface is smooth*. Through the capsule, which is not thickened, the *pallor of the cortex* can be made out, also the superficial veins, which are sometimes prominent. On section, the most striking change is the *swelling of the cortex*, both superficial and interpyramidal (Fig. 84). The cortex may be twice the usual breadth. In other cases there is no great alteration in diameter. It has an *opaque white* appearance, and presents a marked contrast to the medulla, which has the usual dark red colour. Portions of the cortex, representing groups of tubules with more marked fatty change, have a more opaque appearance. Thus there is often a *mottling of the cortex*. The line between cortex and medulla is well defined. The capsule is *not* usually thickened, and on stripping, which is easily carried out, it leaves a *smooth surface* behind.

Microscopic Appearances—(a) *Tubules*.—The epithelium lining the tubules tends to be of a lower type. That is to say, instead of being columnar, it is cubical, or even flattened. It may show evidence of multiplication. Many of the cells are cast off and lying free in the lumen. In suitably stained specimens fat will be found present in many cells, particularly in those which have been thrown off, and especially in the cells of the convoluted tubules. Globules of fat are also to be found in the stroma. Evidence of nuclear degeneration is not so prominently present as in the acute stage. Some of the tubules contain transparent, hyaline, homogeneous casts.

(b) *Glomeruli*.—The changes in the glomeruli are usually well marked, although less marked in some cases than in others. There is multiplication of the cells lining Bowman's capsule, and of those covering the tuft, so that frequently a number of layers of cells are present between the capsule and the capillary tuft. These cells may contain fat. In other cases there is a fibrous change in the glomerulus. Connective tissue is laid down within the structure, with the result that it becomes transformed into a fibrous knot. Both these changes are not infrequently present in the same case.

(c) *Interstitial*.—The intertubular and interglomerular tissue is uniformly increased. This new tissue is fairly cellular, containing considerable numbers of small round cells, scattered and in groups. This is occasionally the predominant change when the term “subacute interstitial nephritis” may be employed to characterise the condition.

The vessels may show a beginning of the thickening which is so prominent a feature of chronic nephritis. This thickening involves both the inner and middle coats.

Waxy disease is not infrequently associated with subacute nephritis.

Changes in the Urine in Subacute Nephritis.—The amount is diminished. The total amount of urea excreted is reduced. Albumin is present, usually in large amount. Blood is sometimes present. The deposit shows large numbers of tube casts (fatty, granular, colloid and hyaline), leucocytes, epithelial cells, and sometimes red blood corpuscles. As the condition becomes more chronic the urine tends to show the characters found in chronic interstitial nephritis.

Chronic Interstitial Nephritis

This condition may follow one or other of the previous types, or it may arise slowly and insidiously as the result of the action of some irritant circulating in the blood-stream. Such irritants are alcohol, lead, and products of metabolism which are not being got rid of, as in gout. There is a *very intimate relationship between this type of nephritis and arterial disease*. It is not always possible to decide which condition is the primary one. Certainly arterial disease may lead to renal changes such as are found in chronic nephritis, but just as certainly arterial changes may be the result of renal inadequacy, products of metabolism not being excreted by the kidney, and leading to arterial degeneration. Or again, the two sets of changes

may advance *pari passu*, being due to one and the same cause.

The causes of chronic nephritis may thus be summed up :—

1. The condition may follow acute or subacute nephritis, and the cause may thus be the same.
2. Chronic toxæmias : alcohol, lead, gout.
3. Arterial disease.

Inasmuch as the main change in this condition is a fibrosis or replacement of the kidney tissue by connective tissue, the term “chronic interstitial nephritis” is generally applicable, and on account of the appearance of the organ the term “granular contracted kidney” is sometimes used.

The essential nature of the process in chronic nephritis, just as in cirrhosis of the liver, is the degeneration and disappearance of the secreting elements, and the replacement of them by fibrous tissue. This may be brought about by chronically acting poison, but is not infrequently secondary to interference with the blood-supply. Thus sclerotic changes in a glomerulus will inevitably lead to interference with the nutrition of the tubules around which its efferent vessel breaks up. Similarly endarteritis in the interlobular arteries will act by causing malnutrition of the area supplied.

Naked-eye Appearances.—The kidney is always *reduced in size*, sometimes very markedly so. It may be adherent to the peri-renal tissue, and thus present some difficulty in removal. It is, of course, *lighter* in weight than normal. Instead of the normal 5 ounces it may weigh 3 or even 2 ounces. The *surface is more or less rough*, and usually shows a varying number of *small cysts under the capsule*. On cutting into it the organ is found to be *tougher* than usual. The cut surface presents great variation in colour in different cases, and the changes are not always uniform, but there are certain fundamental alterations which are commonly present. In the first place *the cortex is narrowed*, more especially the superficial cortex (Fig. 85). In colour, as already stated, the kidney varies.

In some cases there is no great alteration, in others, where congestion of vessels is present, the organ is more intensely red than normal; in other cases, again, where tubular changes of an acute or subacute type are superadded to the chronic process the cortex may be pale. Sometimes the colour of the organ in general, and of the cortex in particular, is employed as a basis of classification; thus the terms *small red* and *small white* kidney are used. Such terms are unnecessary. A striking point is that there is not the usual difference in colour between cortex and medulla, nor is there the usual line of demarcation. The two seem to pass into one another. The *larger vessels* at the line of junction between cortex and medulla *are thickened* and project, and the *lines of the interlobular arteries* passing upwards into the cortex *are tortuous*. This irregularity in the vessel markings is very characteristic. There is in many cases an *increase in the fat around the pelvis* of the kidney. This is due to a shrinkage of the organ away from the pelvis, the place of the kidney tissue being taken by the fat. As a result the organ is, if one may use the expression, smaller than it looks from the outside. The *capsule* of the organ is usually *more or less thickened* and shows *abnormal attachment* to the surface of the kidney, so that in stripping the capsule, portions of the kidney tissue may be removed with it. In other cases this adherence of the capsule is not marked, but *in all cases the surface of the organ when stripped of the capsule shows more or less irregularity* (Fig. 86). This roughening may be slight (morocco-leather appearance) or it may be very marked. The subcapsular cysts, already mentioned, will be obvious on removing the capsule. They contain a clear colourless fluid.

Arterio-sclerotic kidney is the name applied to a special type of chronic nephritis associated with, and believed to be subsequent to, advanced chronic arterial disease. The kidney in this condition is often red and the *roughening of the surface* and the narrowing of the cortex *is irregular in*

its distribution. Thus there are areas of extreme narrowing of the cortex, with marked depression of the surface corresponding to the distribution of those vessels which show most marked narrowing of their lumen. Other areas of the organ are comparatively normal.

Microscopic Appearances.—A striking fact on examining large sections of such kidneys under the microscope is the variation in the appearances seen in one part from those seen in another. Areas will be found in which the alterations are slight, alternating with areas in which they are marked. In the early stage of the condition wedge-shaped areas of interstitial change will be found extending inwards from the cortex. In the more advanced stages this is exaggerated, areas of marked fibrosis alternating with areas more or less normal in appearance. In other cases the interstitial change is diffuse.

(a) *Changes in the Tubules.*—The epithelium lining the tubules is cubical rather than columnar, and shows more or less evidence of catarrhal change. In some cases where an acute or subacute attack has been superimposed upon the chronic process the catarrhal changes are marked. Many of the tubules contain hyaline or colloid casts. In the more condensed areas the tubules are compressed and narrowed. In the intervening portions of the cortex the tubules are more normal in size or, in many instances, dilated, and the cells lining them are often enlarged. Sometimes dilated tubules show papillomatous projections into their lumen.

(b) *Changes in the Glomeruli.*—These consist in a fibroid change, all stages of which may be seen. In the earlier stage the capillaries of the structure are still visible although their walls are thickened. In the later stage the glomerulus is reduced to a knot of fibrous tissue, which may show hyaline alteration, and often contains no cells. Again this change shows irregularity in its distribution. It is more marked in the condensed areas, less marked in the intervening portions.

(c) *Interstitial Changes.*—These consist in an overgrowth of fibrous tissue. In the earliest stage this, as a rule, occurs in wedge-shaped areas extending inwards from the capsule. The fibrous tissue is well formed, although accumulations of small round cells may occur. The vessels show more or less

obvious alteration. As a rule this is most marked in the intima, and consists in a thickening, with narrowing of the lumen. At the same time the middle and outer coats tend to be thickened. These alterations are seen in vessels of all sizes. Sometimes in cases where the organ has a red appearance the intertubular capillaries are dilated.

In the arteriosclerotic type the vascular changes are more marked, otherwise the appearances are very similar.

The overgrowth of fibrous tissue occurs round tubules and glomeruli as well as in the neighbourhood of vessels. Occasionally the fibrous change occurs diffusely throughout the organ.

Changes in the Urine in Chronic Interstitial Nephritis.—The amount tends to be increased. The urine is pale and has a low specific gravity. The amount of urea is diminished. As a rule no blood is present and albumin is scanty; sometimes there is merely a trace. The centrifugalised deposit shows only occasional tube casts. These are chiefly hyaline or granular.

Pathological Conditions associated with Nephritis

Cardiac Changes.—In acute nephritis degenerative changes may be met with in the heart muscle due to the action of the toxic agent which also causes the nephritis. At any stage of the disease pericarditis and endocarditis may occur as complications. The most common alteration in the heart, and one that is specially characteristic of the chronic form of nephritis, is hypertrophy of the left ventricle. This is due largely to the associated arterial sclerosis.

Arterial Changes.—These consist in a thickening of the medium-sized and smaller vessels which in the earlier stages is probably due largely to a contraction and thickening of the media, in the later stages to a fibrous transformation of the media and to a thickening of the intima of an atheromatous type. The frequent association of chronic interstitial nephritis with atheroma is well illustrated by a series of 144

cases recorded by Lorrain-Smith of which 67·6 per cent showed atheroma of one or more groups of vessels. The hypertrophy of the left ventricle and the arterial thickening are both associated with the rise in blood pressure which is so characteristic of the more chronic types of renal disease. In connection with this it may be noted that in cases of cerebral hæmorrhage of the variety found in older people some degree of chronic nephritis as well as arterial disease and hypertrophy of the left ventricle may be confidently looked for.

Blood Changes.—An anæmia of the secondary type occurs in all cases of subacute and in many cases of chronic nephritis.

Lung Changes.—Pneumonia and pleurisy are not uncommon complications of kidney disease. Œdema is also common, and is a not infrequent cause of death.

Dropsy.—Abnormal accumulation of fluid in the lymphatic spaces and in the serous cavities is very constantly met with in nephritis, both in its acute and in its subacute manifestations. In chronic interstitial nephritis, so long as the heart does not fail, œdema is not a prominent feature. The œdema of nephritis is probably due to a combination of a number of factors :—

(1) Damage to the endothelial lining of the vessel from the circulation in it of poisonous waste products.

(2) A watery condition of the blood, due to the anæmia.

(3) Feeble action of the heart.

(4) Retention of salt in the tissues.

The œdema often shows itself in situations, such as round the eye, where the tissue is loose, but it may spread and involve the whole subcutaneous tissue (anasarca), the serous cavities, and lungs. The œdema of nephritis is relatively soft to the touch. In the later stages of chronic nephritis a dropsy having the distribution and character of cardiac dropsy may appear. It is more connected with the failing heart than with the kidney condition.

Changes in Connection with the Nervous System.—In cases

which die with symptoms of uræmia, œdema of the brain is commonly present. In all cases albuminuric retinitis should be looked for. This shows itself in the form of minute hæmorrhages in the retina. As already stated, cerebral hæmorrhage is a frequent cause of death in cases of chronic interstitial nephritis. Of the above-mentioned series of 144 cases 55 died of cerebral hæmorrhage.

Tube Casts

These structures, so characteristic of nephritis in all its stages, are casts of the kidney tubules occurring in these or in the urine. In order to examine for their presence the urine should be centrifugalised or allowed to deposit for some hours. A little of the sediment is then removed with a pipette and placed on a slide under the microscope. In order to see the tube casts properly an ordinary high power lens should be used, and the iris diaphragm of the sub-stage should be shut to a considerable extent. The following varieties of tube casts may be distinguished :—

(1) *Hyaline Casts* are difficult to see owing to their transparency. They may occur in the acute type of nephritis, being formed of an exudation from the blood. They form the basis for other types of casts, such as the cellular variety. In the later subacute or chronic stages, transparent casts with a sharper outline are also met with. They are often spoken of as *colloid* or *waxy casts*. They are due to changes occurring in shed and long retained epithelium.

(2) *Cellular Casts*.—These may consist of (a) red blood corpuscles, (b) leucocytes, (c) desquamated epithelium, or of a mixture of these. They are characteristically present in the acute and subacute stages of the disease.

(3) *Fatty Casts* are produced by fatty change occurring in cellular casts of the epithelial type. They are most characteristic of subacute nephritis.

(4) *Granular Casts*.—These are found mainly in subacute and chronic nephritis. They are due to changes occurring in cellular casts. They may also be produced by the deposit of granules of urates upon hyaline casts.

(5) *Crystalline and Pigmentary Casts* are occasionally met.

TABLE OF COMPARISON BETWEEN THE VARIOUS TYPES OF BRIGHT'S DISEASE.

	Acute Nephritis.	Subacute Nephritis or Large White Kidney.	Chronic Interstitial Nephritis or Granular Contracted Kidney.
Size of organ.	Slight swelling.	Considerable enlargement.	Reduction in size, often very small.
Consistence.	Softer than normal.	Firm.	Tough.
Appearance of cortex.	Varies considerably. Often pale as in cloudy swelling. May be congested.	Greatly increased in breadth, pale and mottled.	Always narrowed, colour varies, pale or red.
Capsule.	Non-adherent.		Thickened and often adherent.
Surface after stripping.	Smooth.		Always rough, usually with small cysts.
Vessels.	Not as a rule altered.		Thickened, cut ends prominent.
Peripelvic fat.	Not altered.		Increased.
Associated Conditions.	Œdema of brain, other forms of dropsy; inflammatory conditions, <i>e.g.</i> pneumonia, pericarditis, etc.		Arteriosclerosis; hypertrophy of left ventricle; cerebral hæmorrhage.

Suppurative Nephritis

This is a form of nephritis in which germs themselves are present and are multiplying in the kidney tissue. It is associated with more or less obvious suppurative foci or abscesses.

There are clearly two paths by which bacteria may reach the kidney tissue—the blood-stream and the ureter. Thus there are two types of suppurative nephritis.

1. *Hæmatogenous Suppurative Nephritis — Pyæmic or Embolic Abscesses of the Kidney.*—This condition is associated with the presence of organisms in the circulating blood—with pyæmia, ulcerative endocarditis, etc. The suppurative foci are usually numerous and irregularly scattered through both kidneys. Occasionally the abscesses may occur in groups, or even one group, and the condition may be limited to one organ. The germs found are those associated with pyæmia and ulcerative endocarditis (see p. 64).

Naked-eye Appearances.—The organ may be slightly enlarged, and is somewhat softer than normal. On section, opaque yellow foci are found scattered through cortex and medulla quite irregularly or in groups (Fig. 87). These foci vary in size, but are usually minute, and are surrounded by a zone of congestion and hæmorrhage. The intervening portions of cortical substance are pale. The capsule strips well and the abscesses are often particularly well seen (Fig. 88) from the outer aspect. Infarcts are not infrequently associated.

Microscopic Appearances.—All the appearances of an acute nephritis are present. There is marked cloudy swelling and catarrhal change in the tubules, and, in the neighbourhood of suppurative foci, actual necrosis. The most striking change, however, is an acute interstitial change, the fibrous structures being infiltrated with numbers of cells, chiefly polymorpho-nuclear leucocytes. This change is intensified in parts so

that the kidney tissue disappears, and its place is taken by a mass of leucocytes—in other words, there is an abscess. In the centre of this area masses of germs are not infrequently found, and around the mass of leucocytes a zone of hæmorrhage occurs. The vessels generally are congested. Leucocytes may also be found within the lumen of tubules.

2. *Suppurative Pyelonephritis or Surgical Kidney*.—In this type the infective agent arrives by way of the ureter. It is thus associated with inflammation of the bladder, ureter, and pelvis of the kidney. It is usually bilateral, but is often more marked on one side than on the other. It may occur in cases of cystitis due to infection by the passing of a catheter. It is thus found in connection with obstruction to the urinary passages from stricture or enlarged prostate. It not infrequently follows lesions of the spinal cord where there is loss of control of the bladder and the urine dribbles away. Organisms readily pass up the tract under these conditions and infect first the bladder, then the ureter, the pelvis of the kidney, and kidney itself. The organisms found are very frequently inhabitants of the lower bowel; thus *B. coli* is very commonly present, also *streptococci*, *staphylococci*, etc.

Naked-eye Appearances.—The organ is often enlarged, soft, and pale. It may, however, be abnormally small from pre-existing chronic nephritis. On section, *pus is found in the pelvis*, which may show thickening, injection of vessels, fibrinous exudation, or hæmorrhage, but which frequently shows no very obvious alteration. Running up into the medulla are *yellow lines* representing spread of the suppurative process into the pyramids. In the cortex are similar but more rounded areas (abscesses) with a zone of hæmorrhage surrounding them. The intervening portions of cortex are pale. The capsule may or may not strip easily according as chronic interstitial changes are present or not. The abscesses are often well seen from the outer surface.

Microscopically, the changes are precisely similar to those found in the previous type.

Tuberculosis of the Kidney

Two types of tuberculosis of the kidney may be distinguished.

1. A type *associated with blood infection*, and therefore with miliary tuberculosis of other organs. In this type there are small, scattered white or yellow foci, usually minute, and mainly in the cortex.

Microscopically, these are found to be typical tubercle follicles with giant cells or caseous centres (see p. 138).

2. *Tuberculous Pyelonephritis or Chronic Tuberculosis*.—This type may be associated with tuberculosis of the lung or other organs. Not infrequently, however, the lesions, in the renal tract, are the most striking manifestation of the disease. The condition of the kidney is very frequently associated with tuberculosis in other parts of the uro-genital tract, with tuberculosis of testicle, vesiculæ seminales, vas deferens, bladder, and ureter. Undoubtedly in some cases the infection is an ascending one, but in many cases the bladder may be infected from the kidney.

Naked-eye Appearances.—The appearances vary much according to the stage of the disease. The condition may be limited to one kidney; in most cases it is more advanced in one organ than in the other. The organ may be enlarged and is usually pale. The change begins in the pelvis in most cases, and spreads backwards into the substance of the organ. The pelvis is thus *lined with caseous necrotic material*, and scattered through the kidney substance are fibro-caseous foci (Fig. 89). Destruction of the kidney substance proceeds with the formation of cavities or excavations (Fig. 90). In advanced cases the organ may be transformed into a bag containing structureless caseous material.

The condition is sometimes, in its more acute manifestations, difficult to distinguish from suppurative nephritis. The foci in tuberculosis tend, however, to be firmer, more yellow, and to stand out more from the surrounding kidney tissue.

Microscopically, the changes are those usually associated with the more chronic types of tuberculosis—fibrosis, tubercle follicles, and caseous foci.

Syphilis of the Kidney.—In some cases of syphilis a *diffuse interstitial nephritis* may be met with. This may or may not be combined with amyloid disease. *Gummata* of the kidney occasionally occur.

Leukæmia of the Kidney.—In some cases of leukæmia the kidney undergoes little or no alteration. In other cases, more especially in the lymphatic type, the changes may be extreme.

In a well-marked case of leukæmia kidney the organ is *enlarged* and *pale* (one type of large white kidney) and through it and under its capsule are scattered *numerous hæmorrhages*. The characteristic appearance of the cut surface of the organ is to a great extent lost.

Microscopically, there is a marked infiltration of the organ with round cells, lymphocytes, or myelocytes, as the case may be, with a separation of the kidney structures—glomeruli and tubules—from one another. Areas of infiltration with red blood corpuscles are also met with.

Tumours.

Simple tumours are infrequent, with the exception of small fibromata of the medulla of the kidney, which are very common and appear as small white rounded areas. Adenomata occasionally occur.

Of *malignant growths* sarcomata are more common than cancers. They are specially frequent in children.

Rhabdomyomata or striped muscle tumours of sarcomatous nature are occasionally met with.

Hypernephromata are among the commonest type of kidney growth. They occupy a position by themselves. They are believed to arise from suprarenal rests. Such rests are not infrequently found under the capsule of the kidney as small yellow spots. The hypernephroma varies very much in size and appearance. It usually has opaque yellow areas resembling the cortex of the suprarenal in appearance, mixed often with hæmorrhagic areas and brownish areas of necrosis (Fig. 92). The tumour is undoubtedly simple in many cases, but in others, where it attains a very large size, it shows malignant characters.

Microscopically, the appearances of the hypernephroma vary a good deal, but, as a rule, the cells contain a large amount of fat, myelin, etc., are vacuolated, and generally show some approximation to the appearance of the cells in the cortex of the suprarenal.

METHOD OF EXAMINING A KIDNEY REMOVED FROM THE BODY

Having removed all adherent fat which, except in cases of chronic interstitial nephritis, is easily done, note, in the first instance, the size of the organ and its weight. The normal kidney measures about $4\frac{1}{2}$ inches (11-12 cm.) in length, 2 inches (5-6 cm.) in breadth, and $1\frac{1}{2}$ inches (3-4 cm.) in thickness. The average weight is $5\frac{1}{3}$ ounces (150 gm.). Next examine the surface for any gross irregularities, yellow areas under capsule indicating suprarenal rests and cysts or cicatrices. Holding the organ in the left hand, with the hilum towards the palm, cut it longitudinally with a large knife from its convexity to the pelvis, taking care not to injure the glove or the hand which is holding the organ (see Fig. 13). While cutting, note the consistence of the kidney tissue. Examine the cut surface, attending to the following points:—

(1) The cortex, its breadth relative to that of the medulla. This should be as one to three, the cortex measuring about

one-fifth of an inch (5-6 mm.) in width. Its colour, which should be reddish-brown, somewhat paler than the medulla. The lines of the vessels running through it for any tortuosity or unusual distinctness from congestion. The glomeruli for unusual prominence and alteration of colour on treatment with iodine.

(2) The line between cortex and medulla, which should be fairly distinct, forming a series of arches. In cases of interstitial nephritis this line is indistinct and irregular. Note also the appearance of the larger vessels (renal arches) running between cortex and medulla.

(3) The medulla for its colour, any opaque lines indicating deposits of urates, the presence of small grey nodules—fibromata.

(4) The pelvis for thickening, hæmorrhage, calculus or exudate indicating inflammation.

(5) The peripelvic fat for its relative amount. In the normal organ there is only a very small amount of this. In chronic interstitial nephritis, on the other hand, where there has been a more or less marked shrinkage of the organ, it is often greatly increased.

(6) With a pair of dissecting forceps take hold of the capsule of the organ, ensuring that the whole capsule is grasped by crushing through a small portion of the most superficial cortex with the instrument. Strip the capsule from the cortex, noting the relative ease with which this is done, *i.e.* whether portions of cortex are removed along with the capsule. Then note the appearance of the outer surface of the organ, whether it is smooth or rough. If rough, whether the roughness is uniform or irregular. Look for subcapsular cysts, cicatrices indicating old infarcts or the more regular markings of foetal lobulation. Note lastly the thickness of the capsule.

DISEASES OF THE PELVIS OF THE KIDNEY

Hydronephrosis, or dilatation of the pelvis of the kidney, is due to obstruction to the outflow of the urine. The condition may be bilateral or unilateral.

(1) *Bilateral hydronephrosis* is due, as a rule, to some obstruction to the passage of urine through the urethra, *e.g.* stricture, enlarged prostate, calculus in the bladder.

Occasionally it is produced by a large tumour in the pelvis pressing upon both ureters. The ureters in this type are dilated throughout as well as the pelves.

(2) *Unilateral hydronephrosis* is due to some obstruction to the flow of urine through one of the ureters. This may be (a) something blocking the lumen of the ureter, usually a calculus; (b) kinking of the ureter from cicatricial changes following injury, with the formation often of one or more S-shaped bends (Fig. 91); (c) a tumour pressing upon the ureter from the outside.

As the result of the increased pressure within the pelvis, the calyces become distended and the pyramids flattened. Gradually the pressure causes atrophy of the kidney substance, until eventually it may disappear altogether, leaving a fibrous bag containing a fluid which shows only traces of urea and urinary salts. This distention occurs only if the obstruction is incomplete. Complete obstruction to the outflow of urine leads, not to hydronephrosis, but to atrophy of the kidney.

Pyonephrosis is a precisely similar condition to the preceding, in which the fluid in the dilated pelvis is pus. Infection may occur from the bladder or by way of the blood.

Pyelitis, or inflammation of the pelvis of the kidney, may be associated with the irritation due to the presence of a calculus. More often it is caused by an organism such as *B. coli* or one of the pyogenic cocci. Occasionally it may be due to the presence of animal parasites such as filariæ. In the organismal type, infection may come from the bladder or from the kidney.

In many cases there is very little alteration. In well-marked cases there is congestion of the vessels, minute hæmorrhages and exudate.

The inflammatory process tends to spread to the kidney itself, giving rise to suppurative pyelonephritis (surgical kidney).

Turbid fluid in the pelvis of the kidney should be examined microscopically in doubtful cases, as phosphates in the urine give an appearance very similar to that of pus.

DISEASES OF THE URINARY BLADDER

Inflammation (*Cystitis*). — Organisms may reach the bladder (1) from the blood, often by way of the kidney, or (2) from without by the urethra. The latter is the commoner path of infection, the organisms being introduced by means of a catheter or finding their own way up in cases where there is incontinence of urine. The commonest germ found in cases of cystitis is *B. coli*, but *B. proteus* and cocci of various types are met with. Cystitis may also be associated with inflammation in neighbouring organs, such as the rectum. A degree of inflammation is usually present along with calculi, but the calculus may be a sequel of cystitis.

In slight degrees of the disease there may be merely an increased vascularity of the mucous membrane of the organ. In more severe types there is ulceration and in some cases necrosis of the mucous membrane with slough formation.

The urine in cystitis may be acid when voided, but it tends rapidly to become alkaline. In some cases this change occurs within the bladder. There is usually a copious deposit consisting, in addition to phosphates, of transitional epithelial cells from the bladder wall, pus cells and micro-organisms.

Tuberculosis of the bladder is usually associated with tuberculosis of the kidney. It appears first as small tubercles under the mucous membrane. These are found either grouped thickly round the orifices of the ureters (descending infection) or at the trigone and neck of the bladder (ascending infection). Later, ulceration occurs, due to coalescence of the small tubercles and destruction of the mucous membrane. As in other types of bladder ulceration urinary salts are frequently deposited upon the floor of the ulcer.

Tumours.—The common tumours of the bladder are the *villous papilloma* and the *carcinoma*.

The former occurs as a soft, friable, “sea-anemone”-like outgrowth, usually from the base of the bladder. Filaments from the growth not infrequently break away and are found along with isolated epithelial cells in the urine. Hæmorrhage is very common in such cases. Very frequently these papillomata are multiple.

Carcinoma of the bladder is usually of the squamous epithelioma type. It appears as an ulcerated area with raised hard margins.

Calculi in the Urinary Tract.—These are found in the pelvis of the kidney or in the bladder, also occasionally in process of passing down the ureter or urethra. Stones which originate in the pelvis of the kidney may in this way be found in the bladder. Urinary calculi are rarely found in the post-mortem room. They are usually solitary, but may attain a very large size and may show branching as in the so-called “coralline” calculus of the kidney (Fig. 93).

Those which form in the pelvis of the kidney are usually composed of uric acid, urates or oxalate of lime, or a combination of these with phosphates. Those which arise in the bladder are usually composed of phosphates.

By blocking the pelvis of the kidney, calculi not infrequently cause hydronephrosis. The presence of a stone in the bladder leads to hypertrophy of the wall of the viscus and to a degree of cystitis.

Parasites.—*Bilharzia hæmatobia* is sometimes found in the bladder. The adult worms occur in the vesical veins. The ova, which show a characteristic terminal spine, are found in the submucosa, where they cause thickenings and papular elevations. They also occur in the urine along with red blood corpuscles.

CHAPTER XI

DISEASES OF THE BRAIN AND SPINAL CORD AND THEIR MEMBRANES

INFLAMMATION OF THE MEMBRANES OF THE BRAIN (MENINGITIS)

TYPES.

1. Pachymeningitis.

(1) Acute.

(2) Chronic.

(3) Pachymeningitis hæmorrhagica.

2. Leptomeningitis.

(1) Acute, due to various pyogenic organisms.

(2) Tuberculous.

(3) Syphilitic.

(4) Serous.

Two main types of this may be distinguished, although the two very frequently occur together. (1) Pachymeningitis, or inflammation of the dura mater. (2) Leptomeningitis, or inflammation of the pia-arachnoid.

1. **Pachymeningitis**, or inflammation of the dura mater, is usually secondary to *suppurative inflammation in one of the cavities in the bone, such as middle ear and mastoid disease*, or to a *penetrating wound of the skull*. It may be accompanied by septic thrombosis in the venous sinuses in the neighbourhood of the inflammatory focus, or by abscess of the brain

or leptomeningitis. The membrane is somewhat swollen, the vessels are injected, and there is exudate on the surface. The pia-arachnoid may adhere to the affected area.

Chronic pachymeningitis may occur in connection with fractures or with chronic bone disease.

A rare condition known as *pachymeningitis hæmorrhagica* is sometimes found in cases of insanity, such as general paralysis and senile dementia, and in alcoholism and scurvy. On the inner aspect of the dura mater which covers the vertex, as a rule close to the *falx cerebri*, laminated blood clot is found. Some regard the condition as being merely a hæmorrhage due to rupture of a degenerated vessel, others consider it to be inflammatory. Under the latter supposition the primary change is believed to be a fibrinous exudate on the surface of the membrane. This becomes organised. Some of the young blood-vessels in this granulation tissue give way from time to time and so layer upon layer of blood clot is formed. Those who hold the view that the condition is purely hæmorrhagic see in the granulation tissue merely an attempt to organise the blood clot.

2. *Leptomeningitis, or inflammation of the pia-arachnoid.*

—This may be due to:—

(1) Infection passing from a *fracture or a penetrating wound of the skull* or from a *fracture of the base* by way of the ear or nose.

(2) *Spread of inflammation through the bone* from a suppurative focus in middle ear, mastoid antrum, or other space.

(3) *Infection from the Blood.*—In cases where organisms are circulating in the blood the germs may settle down in the membranes of the brain, because for some reason these form a favourable site for their growth.

As regards the organisms found: inasmuch as *pneumococci* in children and *streptococci* in adults are common causes of middle-ear disease, such germs are very frequently

found either by themselves or in combination with others. *Staphylococci* and *B. pyocyaneus* occasionally occur. *B. influenzae* may be met with sometimes as a bacillus or in the form of filaments. The *Diplococcus intracellularis meningitidis* is found in cases of epidemic cerebro-spinal meningitis (spotted fever). *B. tuberculosis* is responsible for a large number of cases. Rarer organisms are *B. anthracis* and *Streptothrix actinomyces*. In tuberculous meningitis, and, more rarely, in other forms, infection may be due to spread from diseased vertebræ.

Naked-eye Appearances.—There is *congestion of the meningeal vessels*, and vessels normally invisible can be seen. In some cases of rapidly fatal cerebro-spinal meningitis this is all that can be noted. After one or two days there is usually *more or less exudate*. This exudate may be fibrinous or purulent. It may be very obvious, yellow and creamy, or thin and inconspicuous. It tends to accumulate in the spaces between arachnoid and pia (Fig. 94), more especially in the interpeduncular space and in the sulci along the lines of the vessels. The *distribution* of the change varies in different types. In most types, notably in cerebro-spinal meningitis and in the tuberculous type, the condition is most marked at the base, the exudate occurring in the interpeduncular space and spreading up on either side along the Sylvian fissure, also on to the surface of pons, cerebellum and occipital lobes. In other cases the change is most marked on the vertex or over the frontal lobes (pneumococcal cases). The *convolutions* tend to be *flattened*. There is usually an *excess of cerebro-spinal fluid*, which is turbid and may be purulent. The inflammatory change may extend to the ventricles, and in many cases these spaces show more or less distention with fluid (hydrocephalus).

The membranes of the spinal cord are very constantly affected to a greater or less extent. When this is the case the term *cerebro-spinal meningitis* may be applied.

Microscopic Appearances.—These are similar to those found in inflammations of other serous surfaces. There is dilatation of blood-vessels, exudation of fibrinous material on the surface and in the substance of the membranes, and emigration of leucocytes, chiefly of the polymorphonuclear type. Organisms may be found in suitably stained specimens. There is usually more or less inflammation of the underlying cerebral substance (encephalitis), as indicated by cellular infiltration around vessels dipping into the brain substance.

Microscopic examination of the cerebro-spinal fluid obtained during life by lumbar puncture shows polymorphonuclear leucocytes in greater or less abundance, and sometimes germs.

Tuberculous meningitis requires special mention.

It is essentially a basal inflammation and is usually associated with a similar inflammation of the spinal meninges. A more or less marked increase of cerebro-spinal fluid is found, which is often fairly clear. In the sub-arachnoid space at the base of the brain and spreading up the sylvian fissures there may be an opalescent exudate. Sometimes it is conspicuous and creamy, at other times it is difficult to make out at all. The smaller vessels appear thickened, owing to perivascular infiltration, and at the spreading margin, along the vessels of the Sylvian fissure, or upper surface of cerebellum, etc., *minute grey or yellow tubercles* are found (Fig. 95). Sometimes these are only discovered on stripping the membranes and examining them most carefully by floating them out in water. The ventricles are more or less distended with fluid which may be clear or slightly turbid.

Microscopic Appearances.—The cells in the exudate tend to be of the mononuclear type, but in the more acute cases polymorphs are often abundant. Here and there, especially round vessels, are follicular aggregations of cells with giant cells or necrotic centres. Tubercle bacilli may be numerous, but are often difficult to find.

Microscopic examination of the fluid obtained by lumbar puncture shows cells which tend to be of a mononuclear type,

but polymorphs are not infrequently present in considerable numbers. On careful search tubercle bacilli are generally to be found, but it is necessary, in most cases, to centrifugalise the fluid, and to make several films from the deposit.

Syphilitic Meningitis.—This may be acute associated with an infiltration of the pia-arachnoid with small round cells. It may be accompanied by gummata in the shape of small foci with yellow caseous centres which show a tendency to infiltrate the brain substance. Or it may be chronic, associated with fibrous thickening at the base of the brain and leading to compression of the cranial nerves.

Serous meningitis is a condition comparatively recently recognised which is characterised by congestion and œdema of the meninges with production of a serous and cellular exudate. It is most frequently found in children and is associated with infective diseases, *e.g.* measles and scarlet fever; in adults it is sometimes found in relation to alcoholism and kidney disease. The appearances are sometimes more marked at the base of the brain, sometimes at the convexity. The causal factor is not always clear.

DISEASES OF THE BRAIN

CIRCULATORY CHANGES

1. **Congestion** of the cerebral vessels may be due to active hyperæmia in inflammations such as lepto-meningitis or to chronic venous congestion, the result of valvular disease of the heart.

2. **Anæmia** may be part of a general want of blood, as in pernicious or other type of anæmia or severe hæmorrhage, or it may be local, due to accumulation of blood elsewhere or to the pressure of a tumour.

3. **œdema** is a common condition which may occur as part of a more general dropsy or may be localised to the

cerebral substance. The causes are those of œdema in general, such as renal and heart disease. Alcoholism is a not uncommon cause. Chronic alcoholics not infrequently die, apparently from this cause alone. Clinically such cases may simulate, as regards their symptoms, many different types of cerebral lesion,—hæmorrhage, thrombosis, etc.—and at the post-mortem the only brain condition found is œdema.

On section the brain in œdema has a *moist shiny appearance*. The grey matter is often rather more obvious than usual from congestion of minute vessels. A small amount of fluid may be squeezed from the cerebral substance, and the ventricles are usually distended with fluid.

4. **Hydrocephalus**, or excess of fluid in the lateral ventricles, may be *congenital* or *acquired*.

In the *congenital* form the head may attain an enormous size. The cranial bones are thinned and separated from one another. There is great distention of the lateral ventricles and narrowing of the cerebral substance. The large size of the head leads to difficulty at parturition. The cause of the condition is obscure, but it is probably mainly due to obstruction to the outflow of fluid from the ventricles into the meningeal spaces.

Acquired hydrocephalus follows sometimes from basal meningitis or tumour formation at the base of the brain. It is due to the matting of the meninges and consequent obstruction to lymph-flow, following on the inflammatory condition (Fig. 96), or to direct pressure of the neoplasm on the vessels.

Excess of cerebro-spinal fluid in subdural and subarachnoid spaces is met with in a large variety of diseases. It may occur as part of a general œdema; it may be due to inflammation of the meninges; or may accompany atrophy of the cerebral substance in chronic alcoholism and in various forms of mental disease.

5. **Arterial Obstruction.**—This may be due either to *thrombosis* or *embolism*. *Thrombosis* is usually secondary to disease of the arterial wall, either atheroma or syphilitic disease (endarteritis obliterans). It also occurs secondary to embolism. It is met with more commonly in the branches of the posterior cerebral and basilar arteries and in the small superficial cortical branches. *Embolism* is brought about by the impaction of an embolus, usually a portion of a thrombus, in a vessel the lumen of which is too small for its passage. The portion of thrombus may come from (1) a vegetation on the mitral or aortic valve; (2) a thrombus in the auricle or ventricle; (3) a thrombus on a patch of atheroma in the ascending aorta; or (4) from a thrombus in an aneurysm of the ascending aorta or aortic arch (see diagram, p. 62). The arteries at the base of the brain are specially apt to be involved. The commonest vessel to be blocked, because it offers the most direct route for the embolus, is the middle cerebral (usually the left) or its branches. Then, in order of frequency, come the posterior cerebral, the vertebral, the anterior cerebral, the cerebellar and basilar. As a result of the presence of the embolus blocking the vessel, thrombosis occurs to a varying extent.

Results of Arterial Obstruction.—The cerebral arteries, more especially those branches going to the ganglia at the base of the brain, belong to the group of "end arteries," *i.e.* arteries whose collateral anastomosis is not equal to the re-establishment of the circulation after blocking of the vessel. Infarction therefore occurs, and the type of infarct which develops is the pale infarct. The reason for this is that, owing to swelling of the nerve elements in the primary stages of degeneration, the return of blood by way of minute collaterals cannot occur or occurs only to a very small extent. In contrast to other organs such as kidney and spleen, where pale infarcts also occur, the necrotic change which takes place results in progressive **softening** (colliquative necrosis),

instead of, as in kidney and spleen, coagulation necrosis. Such a pale, softened area is often called an area of *white softening*. Sometimes there is a certain amount of return of blood which escapes from the degenerating vessels with resulting numerous small hæmorrhages (*red softening*). Later on, as liquefaction proceeds and changes occur in the blood-pigment, the area tends to become yellow (*yellow softening*). Ultimately, removal of the degenerated material occurs with the formation of a cyst, the walls and sometimes the contents of which show yellow pigmentation (Fig. 98).

In the later stages such areas are, of course, easily recognised. Sometimes, when death occurs rapidly owing to the area involved being large or including some vital centre, the recognition is somewhat difficult. There may be nothing more than a very slight softening of the cerebral substance. Thus *in all cases where arterial obstruction is suspected the consistence of the brain substance should be estimated by careful palpation*; suspected areas being compared as regards their consistence with the corresponding areas on the other side as well as with surrounding parts of the brain.

Microscopic Appearances.—These are the changes usually found in degenerations of the central nervous system:—

Ganglion cells show loss of staining of their Nissl bodies and nuclei. The nucleus loses its central position and is eventually extruded. The cell processes become fragmented.

Myelin substance absorbs water, swells and breaks up into fatty material, which may be demonstrated by fat stains, cholesterin, lecithin, etc. The fat globules are taken up to a certain extent by phagocytes, thus forming granular-looking cells sometimes called compound granular corpuscles.

In the later stages the *neuroglia and other connective tissue elements* proliferate, the young mononuclear cells which are thus produced acting as phagocytes for fat, blood corpuscles and blood pigment. The area is invaded by leucocytes, mainly mononuclear, which also act as phagocytes. Hæmatoidin crystals are often found at the margin of the area, also in the fluid contents of the cysts.

6. **Cerebral Hæmorrhage.**—Although capable of considerable resistance to strain, the arteries of the brain are much thinner-walled than those of any other organ or part. More especially are they deficient as regards muscular substance. Moreover, they are less well supported owing to the relative softness of the brain substance. For these reasons, rupture of vessels and consequent hæmorrhage is more common in the brain than in any other organ.

There are *two main factors* operative in cerebral hæmorrhage :—(1) *degenerative changes in the vessel wall* ; (2) *increased blood pressure*. As regards the *degenerative changes*, these may be relatively acute as in the vessels of an infarcted area or in the inflammation following septic embolism (*e.g.* in ulcerative endocarditis), or slowly progressive as in atheroma or syphilitic disease. Not infrequently the vessel, previous to rupture, undergoes localised dilatation with the formation of an aneurysm. *Increased blood pressure* is either sudden from strain, or chronic, as met with in cases of generalised thickening of the vessels and in kidney disease, which is so frequently accompanied by chronic vascular disease. Thus the two factors often occur together, and *in all cases of cerebral hæmorrhage careful examination of the vascular system and of the kidneys should be made*.

Types.

1. Small capillary (petechial) hæmorrhages.
2. Large hæmorrhages which may be into
 - (a) Basal ganglia sometimes extending into the lateral ventricle.
 - (b) Pons Varolii.
 - (c) Pia-arachnoid on cerebral cortex.
 - (d) Cerebellum.
 - (e) Other parts of the brain.
3. Hæmorrhage due to laceration of brain.

As regards *hæmorrhage caused by disease*, one may distinguish, (1) *small capillary hæmorrhages*, which are found in

acute inflammation of the cerebral substance, infective diseases, cerebral softenings, blood diseases such as purpura and pernicious anæmia, or in tumours ; (2) *large, extensive hæmorrhages*, which are usually due to chronic disease of the vessels, much less frequently due to septic embolism in cases of acute (usually ulcerative) endocarditis, and may occasionally be due to rupture of a vessel in a tumour such as a glioma. The first type of cause is met with most commonly in individuals past the prime of life, the second and third types may be met with at any age. It is stated that in something like one-third to a half of the cases of the first type the point of actual rupture is a small aneurysm. Some of these aneurysms, more especially those in the vessels at the base of the brain, are easily visible with the naked-eye. Others, which are usually in connection with the more minute vessels inside the cerebral substance, are only visible under a low power of the microscope. Such aneurysms have been called miliary. Some of these miliary aneurysms are in reality false aneurysms.

The most common *site* for cerebral hæmorrhage is the *region of the basal ganglia* (Fig. 97). Something like 75 per cent of cases occur in this position. The vessel which ruptures is usually the lenticulo-striate branch of the middle cerebral artery, which supplies the outer segment of the lenticular nucleus and the external capsule. It then perforates the internal capsule and ends in the caudate nucleus. So frequently is this vessel the site of origin of the hæmorrhage that it has been called the artery of cerebral hæmorrhage.

The next most frequent site for hæmorrhage is the *pons Varolii* (12 per cent) (Fig. 100). In something like 12 per cent the hæmorrhage commences in one of the *superficial vessels*, *i.e.* one of the cerebral arteries which has not yet penetrated the brain substance. A rare situation for hæmorrhage is the *cerebellum* and other parts of the cerebrum, such as the frontal lobe. When the cause of the hæmorrhage

is a septic embolus or one of the hæmorrhagic diseases such as purpura, the site may be almost anywhere, *e.g.* the frontal lobe. In the case of a hæmorrhage into the basal ganglia or internal capsule, if there is much tearing up of the brain substance the blood may escape into the *lateral ventricles* and from there extend under the pia-arachnoid. Hæmorrhage under the pia mater is also observed when the ruptured vessel is outside the brain substance.

Naked-eye Appearances.—On removing the skull cap and reflecting the dura mater, a general *flattening of the convolutions* is usually observed. Sometimes the flattening is more marked on one side (the side of the hæmorrhage) than the other. In the case of hæmorrhage into the lateral ventricles, or hæmorrhage from one of the larger vessels before it enters the brain substance, or from an aneurysm of a large vessel, extravasated *blood may be seen in the subarachnoid space* sometimes extending on to the vertex, but usually more marked at the base of the brain.

On section of the brain, a larger or smaller area of *cerebral substance is found torn up and the space occupied by blood clot*. In older hæmorrhages the clot becomes brownish in colour, and the surrounding tissue is stained yellow.

In all cases of cerebral hæmorrhage, as already stated, careful examination should be made of the vascular system—vessels and heart—and of the kidneys. The vessels as a rule show more or less marked arterio-sclerosis, the heart shows hypertrophy of the left ventricle and in some rare cases acute endocarditis. The kidneys very constantly show more or less marked chronic interstitial nephritis, which may be of the arterio-sclerotic type.

Following on a hæmorrhage there is always, if the patient survive, more or less *secondary degenerative change in the nerve tracts which have been interrupted*. Thus when the hæmorrhage occurs into one internal capsule there will be descending degeneration in the direct pyramidal tract of the

same side and in the crossed pyramidal tract of the opposite side in the spinal cord.

Superficial hæmorrhage may also be caused by *laceration of the brain substance* due to injury. If the patient survive some time, red or yellow softening occurs (see p. 236).

Microscopically, there is little to be seen beyond the extravasation of red blood-cells. In older hæmorrhages there is more or less pigmentation from deposit of hæmatoidin in the parts around. There tends also to be an increase of connective tissue (neuroglia and fibrous tissue) around the clot.

INFLAMMATION OF THE BRAIN (ENCEPHALITIS)

In the brain substance subjacent to inflamed meninges, in the neighbourhood of injuries, blood clots, areas of softening and tumours there is always more or less marked inflammatory change, showing itself in degenerative changes in the ganglion cells and nerve processes, proliferation of neuroglia, infiltration with mononuclear cells, particularly around vessels.

Types.

1. Simple encephalitis following injuries, etc. (see above).
2. Suppurative encephalitis (abscess).
 - (a) Pyæmic type.
 - (b) Solitary abscess.
3. Tuberculosis.
4. Syphilis.

Suppurative Encephalitis (Cerebral Abscess). — Two types may be distinguished: (1) *Pyæmic*, (2) *Solitary*.

The *pyæmic type* is usually minute, and consists of numerous abscesses scattered irregularly through the brain substance. There is usually hæmorrhage around the abscesses owing to the vessels damaged by the inflammatory process giving way.

The *solitary abscess* is commonly due to extension of inflammation from neighbouring parts, as a rule to *middle*

ear disease (suppurative otitis media) or *suppuration in the mastoid antrum*. Thus the common sites of abscess of the brain are the *temporo-sphenoidal lobe* (Fig. 99) and the *cerebellum*, the two portions of the brain nearest to this suppurative focus. Occasionally such abscesses are due to injuries. The size of the abscess varies much. It may be the size of a walnut or even a tangerine orange. The wall may be formed of softened, ragged cerebral tissue, or of a layer of granulation tissue, depending upon the age of the abscess. The contents consist of pus, which may be white, yellow or greenish, and is often very foul-smelling. The organisms found are many and various—*streptococci*, *staphylococci*, *B. pyocyaneus*, etc.

There is a rare and unexplained association between solitary abscess of the brain and pulmonary diseases such as bronchiectasis and empyema.

Microscopically, the appearances are those usually seen in abscess formations—accumulations of polymorphonuclear leucocytes with necrotic debris and germs of various kinds. In the brain substance around are seen hæmorrhages, infiltration of the cerebral substance with inflammatory cells of various types, particularly round the vessels, and degenerative changes in the ganglion cells and other nerve elements.

Tuberculosis.—*Miliary tuberculosis*, when it occurs in the brain, shows a more marked tendency to affect the meninges than the cerebral substance. In tuberculous meningitis, however, there is always a tendency for the inflammatory change to pass downwards into the brain substance. Occasionally one meets with *multiple caseous foci* in the brain substance, but a more common manifestation is the *solitary nodule* which is found specially in relation to the cerebellum and more commonly in children. Such nodules often act like tumours, producing pressure symptoms.

Syphilis, like tuberculosis, when it occurs in the brain, shows a tendency to affect the meninges and vessels. In the

latter case, *periarteritis* and *endarteritis* are not uncommon. Occasionally, *gummata* are met with, which, like the solitary tubercle nodules, act as tumour formations. Such gummata consist of a caseous centre with surrounding granulation tissue.

General Paralysis.—This is a disease which is found chiefly in males, between the ages of thirty and fifty. Like locomotor ataxia, it has a very close relationship to syphilis; in fact, quite recently, spirochætes have been found in the brain in cases of general paralysis.

If death occur during the early stages, little more than swelling and congestion of the brain substance is found. In the later, paralytic stages there is found thickening of the membranes of the brain, which are very adherent to the cerebral substance. Sometimes pachymeningitis hæmorrhagica (see p. 230) is present. There is a general atrophy of the brain substance. On section, œdema of the cerebral tissue is often found, the lateral ventricles are dilated and their ependyma shows minute granulations. In advanced cases the calvarium is usually more or less thickened and condensed.

Microscopically, there are found degenerative changes in the ganglion cells and wasting of their dendritic processes, proliferation of neuroglia, thickening of the blood-vessels, and infiltration of the perivascular lymph sheath with lymphocyte-like cells.

TUMOURS

The brain substance is formed of (1) nerve cells and their processes, which are epiblastic in origin and practically never give rise to tumour formations; (2) neuroglia or binding connective tissue of the brain, also epiblastic in origin, which is the source of a majority of the primary growths of the brain; (3) vessels, endothelium of meninges and ordinary connective tissue, mesoblastic in origin, which may

be the origin of sarcomata and angiosarcomata; (4) the ependyma lining the ventricles from which carcinomatous tumours may arise.

Types.

A. Primary Tumours.

1. Gliomata.
2. Sarcomata, endotheliomata, angiosarcomata, psammomata, etc.
3. Carcinomata.
4. Cholesteatomata.

B. Secondary Tumours.

1. Granulomata.
 - (a) Tuberculous nodules.
 - (b) Gummata.
2. Sarcomata.
3. Carcinomata.

Primary Tumours of the Brain.—The commonest of these is the *glioma*. This may occur in any part of the brain. The tumour varies in size, and has a grey, pink or white appearance, and is not well defined. Sometimes it is translucent, at other times opaque. Hæmorrhages frequently occur in it. The tumour may be simple, but often is malignant, and is then called *glio-sarcoma*.

Microscopically, the simple type shows branching cells with small round nuclei and long "spider-leg" processes which interlace with one another, forming a felted network between the cells. In the malignant types the cells are more numerous, larger and more irregular, and the intercellular material is correspondingly reduced in amount.

Other forms of *sarcomata* found in the brain are *angio-sarcomata*, characterised by marked vascularity and tendency to hæmorrhage; *endotheliomata*, with the sub-variety *psammoma*, which occur mainly in connection with the meninges (see pp. 292-93).

As already mentioned, primary *carcinomata* are occasionally met in the brain, arising from the ependyma of the ventricles.

A curious and rare but interesting tumour is the *cholesteatoma* (Fig. 101), also known as the "pearl" tumour from the mother-of-pearl appearance of the surface. It is a solitary tumour, well defined from the brain substance, occurring in connection with the meninges chiefly towards the middle line. On section it is soft and has a white, laminated appearance. On microscopic examination it shows layers of what appear to be epithelial cells, with a small amount of subjacent connective tissue and a large amount of laminated dead epithelium. Some regard the tumour as arising from the pia mater, and therefore as being an endothelioma; others consider it to be formed of skin epithelium and therefore a teratoma.

Secondary tumours are relatively common in the brain. Both sarcomata and carcinomata are met with. The growths may be single and large or numerous and small.

Under this heading may be included the so-called "granulomata" or nodules composed of chronic inflammatory tissue usually with caseous centres, and either tuberculous or syphilitic in origin. In no other part of the body are such nodules regarded as tumours. In the brain, however, not only because of their appearance but also on account of the effects which they produce, the term tumour may be applied to them.

DISEASES OF THE SPINAL CORD

CONGENITAL ABNORMALITIES

Spina Bifida.—This is a congenital malformation due to incomplete closure of the coverings of the spinal cord, as a rule, in its lower part. Various degrees of the condition are met with, from one where the only superficial indication of

the presence of an abnormality is a tuft of hair over the lower lumbar region (*spina bifida occulta*) to one where skin in addition to the posterior bony wall of the spinal canal is absent. The common type is one where there is incomplete closure of the bony canal posteriorly associated with a tumour in the lumbar region which may contain meninges only (*meningocele*), or nerve elements in addition to meninges (*meningo-myelocele*). Cases of spina bifida, if at all marked, do not live long. Infection occurs sooner or later through the skin and spinal meningitis results.

Syringomyelia is a rare condition of the spinal cord in which there is a tumour-like overgrowth of the neuroglia (*gliosis*) in or near the centre of the cord. The overgrowth is in a longitudinal direction and is found in the cervical, sometimes in the cervical and dorsal regions of the cord. Usually, either throughout the affected part or in some portions of it, there is a cavity in the centre of the area of gliosis. This condition of gliosis associated with cavitation is known as syringomyelia. The cavity is larger than and distinct from the central canal. The proper nerve structures of the cord are atrophied in consequence of the pressure of this mass of connective tissue. In outward appearance the cord may be unaltered or may be enlarged.

Microscopically, in the affected area tissue consisting entirely of neuroglia is found. In this tissue there is a space or cavity which may or may not be lined with epithelium.

Hydromyelia.—This is a condition corresponding to hydrocephalus, in which there is an over-distention of the central canal with fluid.

INFLAMMATION OF THE MEMBRANES OF THE CORD (SPINAL MENINGITIS)

As in the case of the brain, two primary types may be distinguished: (1) pachymeningitis or inflammation of the

dura mater; (2) leptomeningitis or inflammation of the pia-arachnoid. It is unnecessary to discuss the causation and the various forms of the condition, as these have already been considered under cerebral meningitis. The two conditions are commonly combined, the term cerebro-spinal meningitis being employed. Sometimes the inflammatory change commences in the brain and spreads secondarily to the cord; at other times the reverse is the case. In addition to spread from the brain, infection may reach the spinal meninges from an inflammatory focus in one of the vertebræ, from the blood or from the skin surface in cases of spina bifida and bed sores.

INFLAMMATION OF THE CORD (MYELITIS)

Under this heading are included a number of conditions of very various origin. Myelitis may be due to the action of irritants and organisms, or it may be due merely to pressure or alterations of circulation. The causes may be classified as follows: (1) *Extension of inflammation* from vertebræ or meninges. (2) *Organisms and toxins brought by the blood stream*, such as the viruses of tetanus, hydrophobia, influenza, acute poliomyelitis, etc. (3) *Pressure of dislocated vertebræ or tumour*. (4) *Circulatory disturbances—thrombosis* in sunstroke, *embolism* in "Caisson" disease. Probably under this heading may also be included the cases due to "chill."

As regards the *distribution* of the change, the part involved may be mainly the grey matter, when the name **poliomyelitis** has been applied. Or it may be that the white matter is chiefly affected. As a rule, both are implicated. When the whole diameter of a section of cord is affected, the term **transverse myelitis** is used. If the change is irregularly scattered up and down the cord, the term **disseminated** is employed.

The *morbid anatomy* of the condition varies according to

the rapidity of the change and the stage at which it is observed. In the early stages all types are characterised by a *softening of the cord substance*. In testing for the presence of the condition, the finger should be gently passed down the cord and any alteration in consistence noted.

On section of the cord, in addition to the softening, there may be *increased vascularity*, which gives a pink appearance to the grey matter more especially. Sometimes *small hæmorrhages* are present, and occasionally the cord is so softened that the line of demarcation between grey and white matter is rendered indistinct.

The *later stages* are accompanied by an *overgrowth of neuroglia* replacing the degenerated nerve elements. This may manifest itself by atrophy and contraction and by the appearance of grey translucent areas with variable distribution, a condition often characterised by the term *sclerosis*. Degenerative changes occur in the tracts running upwards and downwards from the area or areas involved.

Microscopic changes.—These are similar to those found in encephalitis.

(i.) *Changes in the nerve cells.*—These consist in a disappearance of the Nissl spindles, loss of staining capacity in the nuclei with margination and eventual extrusion.

(ii.) *Changes in the processes of the cells.*—Swelling, beading and fragmentation of axis cylinders and other processes. Degenerative changes in the myelin sheath associated with setting free of fat in a demonstrable form.

(iii.) *Changes in the neuroglia.*—Swelling and proliferation of the cells, many of which become free and act as phagocytes taking up fat globules and appearing as large vacuolated cells (compound granular corpuscles). In the later stages the proliferated glia cells settle down to form more or less extensive areas of gliosis, replacing the nerve elements.

(iv.) *Vascular changes.*—Hæmorrhage or thrombosis may be met with. Exudation of fluid and of leucocytes occurs to a greater or less marked extent, depending upon the acuteness of the inflammatory change. A very constant appearance is

a filling of the lymph space which surrounds the vessels of the cord (perivascular lymph space) with cells which may be polymorphonuclear leucocytes, lymphocytes or vacuolated phagocytic cells of uncertain origin, according to the type and the acuteness of the change.

In the areas of secondary degeneration above and below the level of the lesion there is disappearance of the nerve elements—axis cylinders and myelin sheaths—and a replacement of these by an overgrowth of neuroglia.

DISEASES OF THE SPINAL CORD TO WHICH SPECIAL NAMES ARE GIVEN

There is a number of diseases which affect mainly the spinal cord to which special names are given. Some of these are inflammatory in origin, due to the action of poisons upon cells and their processes, others are degenerative. No hard and fast line can be drawn between these two sets of causes, however. No system of classification is attempted, because in many cases the site of the primary change, whether in nerve cell, nerve process or nerve ending, is uncertain. Only the more important conditions are included.

Acute Poliomyelitis.—This condition was originally known as *acute anterior poliomyelitis* and, in its later stages, as *infantile paralysis*. At first thought to be circulatory in origin, due to blocking of the anterior spinal artery by embolus or thrombus, it is now regarded as organismal in nature, due to a specific virus the exact nature of which has not yet been shown. The virus passes through a porcelain filter and is infectious for monkeys. The disease may be epidemic or sporadic. It occurs mainly in young children, usually in the late summer and autumn months. It is associated with more or less marked fever, and later on with the development of paralysis in muscles.

The condition may be met by the pathologist in the

early, acute stage, or in the later stage, when there is atrophy and contracture of limbs.

In the *early stage* the condition has the appearance of a myelitis affecting the whole of the substance of the cord, not merely the grey matter, although the change may be most intense in the latter. As regards distribution the change may be met with in the cervical or lumbar portions of the cord. Usually there are alterations to be found throughout the cord, sometimes also in the medulla and cerebrum. The site of the most intense change may or may not show softening. Sometimes there is a slight degree of inflammation of the meninges. On section of the cord there is usually congestion of the grey matter, and sometimes there are scattered hæmorrhages.

Microscopically, all the changes described in connection with myelitis may be met with. There are degenerative changes in the anterior horn cells, infiltration of the grey matter with cells, partly leucocytes, more especially lymphocytes, partly multiplied neuroglia and connective tissue cells. Small hæmorrhages may be present. Degenerative changes may also be found in the white matter, but the most obvious change is an infiltration of the perivascular lymph sheath of the vessels with cells, chiefly lymphocytes. There is usually a varying amount of inflammatory change in the meninges.

The *later stage of the disease* is connected pathologically with atrophy of the grey matter, more especially of the anterior horn, sometimes unilateral, at other times bilateral. This shrinkage is associated microscopically with a disappearance of the nerve elements and overgrowth of neuroglia. There is also present a descending degeneration in the motor tracts and nerves.

Progressive Muscular Atrophy (chronic anterior poliomyelitis).—This is a condition which develops in middle life, usually in males. Overstrain, injury, exposure to severe cold and infective disease have been put down as causes. It is

characterised by a progressive atrophy of the muscles, usually beginning in hand and arm, especially the right hand.

The primary pathological change is a degeneration with atrophy in the anterior horn cells of the grey matter in the lower cervical region.

In the disease known as *amyotrophic lateral sclerosis*, which is believed by many to be the same condition, in addition to the degenerative change in the motor cells, there is sclerosis in the crossed pyramidal tracts.

Disseminated or Insular Sclerosis.—This is a disease which usually commences in early adult life. Nothing definite is known as regards its etiology, although in some cases an association with acute infective disease has been established. It is characterised clinically by (1) a spastic condition of the limbs associated with weakness; (2) tremors; (3) alterations of speech; (4) nystagmus.

As regards the pathological anatomy, the lesions are usually found in the spinal cord, less frequently in brain, pons and medulla, and consist in scattered, grey, transparent areas of sclerosis, varying much in size and shape, and having no relation to any structures or tracts of nerves.

The patches occur in grey and white matter alike and are sharply defined from the surrounding healthy tissue. As a rule, ascending and descending degenerations are absent.

Microscopically, in the sclerosed areas the medullary sheath is found to have disappeared entirely, although sometimes the axis cylinder is still present. The place of the degenerated nerve elements has been taken by proliferated neuroglia. Ganglion cells persist for long in diseased patches. In the earlier stages and at the margin of older areas numerous granular cells containing fat globules are found. The vessels in relation to the patches often show alteration, such as peri- and endarteritis.

Locomotor Ataxia (*Tabes Dorsalis*).—This disease has a very definite relationship to syphilis. It is characterised

clinically by a peculiar stamping gait, absence of knee-jerks, loss of sense of position, Argyll-Robertson pupil, optic atrophy, various paralyses, etc.

The changes found in fatal cases of the disease are most marked in the spinal cord, which shows a sclerosis of the posterior columns. To the naked eye these columns are translucent and shrunken. There is often thickening of the membranes over the posterior portion of the cord. On more careful examination the distribution of the sclerosis is found to vary according to the level examined. In the common variety, where the change commences in the lumbar region, examination of the cord at that level shows degeneration in the postero-external column. Sometimes, in the more advanced cases, both postero-external and postero-internal are sclerosed. In such cases the upper dorsal and the cervical segments show the degeneration mainly in the postero-internal tract. This is due to the fact that the sensory fibres which run in the posterior columns do so first in the postero-external tract and then gradually pass into the postero-internal on their way to the ganglia in the medulla. In cases of cervical tabes, on the other hand, the change is found in the postero-external tract in the cervical region. In combined cervical and lumbar cases, the whole of the posterior columns is affected. Occasionally other ascending tracts, such as the direct cerebellar and antero-lateral-ascending, are implicated.

Microscopically, in the sclerosed areas there is found a disappearance more or less complete of the axis cylinders and medullary sheaths, and a replacement of these by neuroglia.

In addition, degenerative changes are found in the cells of the spinal ganglia in some cases (see changes in nerve cells, p. 247), also in the peripheral portions of the sensory nerves.

Thus there is in tabes a progressive degenerative change in the sensory neurons of the cord, most marked in the intra-medullary fibres of the posterior sensory neuron, followed by

a proliferation of the neuroglia. As regards the primary change there is great uncertainty and considerable difference of opinion. Some regard it as being the sclerosis of the posterior columns, others a local meningitis implicating the posterior roots as they pass through the meninges and so cutting them off from their trophic centres. Others again say that the degeneration of the cells in the posterior root ganglion is the first lesion.

Hereditary Spinal Ataxia (*Friedreich's Ataxia*).—This is a disease which usually affects several members of the same family. The lesion in the spinal cord is similar to that found in locomotor ataxia, but in addition to the sclerosis of the posterior columns there is a similar change in the lateral parts of the cord affecting the crossed pyramidal tracts, sometimes also the direct cerebellar and antero-lateral-ascending tracts.

Tumours

Tumours of the cord or its membranes are rare. Apart from tubercle nodules and gummata, the commonest growth is the glioma; next comes the sarcoma. Secondary growths, both sarcomata and carcinomata, are occasionally met with.

More common are tumours in the vertebræ—sarcomata and carcinomata—pressing upon the cord and leading to myelitis.

DISEASES OF THE PERIPHERAL NERVES

Neuritis, or inflammation of the nerves, may be due to (1) bacterial poisons such as in diphtheria, (2) chemical poisons such as alcohol, arsenic, lead and gout, (3) trauma, (4) extension of inflammation from adjacent parts.

It is customary to distinguish two types: (*a*) parenchymatous neuritis, in which the degenerative change in the axis cylinders and medullary sheath is the main thing. (*b*) Interstitial

neuritis, in which the overgrowth of the fibrous tissue elements of the nerve is the chief process. There is in reality no hard and fast line between the two types. When the poison is, as in diphtheria, rapid in its action, the degenerative change predominates ; when the poison is, like tuberculosis or leprosy, slow in its effect, the interstitial process is in the ascendant.

In the more acute cases, beyond some swelling and increased vascularity of the nerve, there is little to be seen with the naked eye. In the more chronic types, nodules of granulation tissue and fibrous thickening are met with.

Microscopically, specimens treated with osmic-acid will show black colouration of the myelin sheath. There is infiltration of the connective tissue with inflammatory cells, more marked in the chronic cases.

Tumours.—The commonest growth is the fibroma (so-called neuro-fibroma). Such tumours are often multiple. Occasionally they undergo a sarcomatous change.

Microscopically, the swellings are found to consist entirely of fibrous tissue, the nerve fibres running through them.

CHAPTER XII

DISEASES OF BONES AND JOINTS

DISEASES OF BONES

RICKETS

THIS is essentially a disease of infancy, although the results of it tend to persist throughout life. The underlying factor in its production is a deficiency of calcareous material in the newly-formed bone.

The causation of the disease is still obscure, but deficient amount of lime salts in the food or failure to make use of the lime salts already present is, in all probability, the explanation of the relative absence of these salts in the bones. Some ascribe the condition to defective action of ductless glands, which produce an internal secretion, such as the pituitary and suprarenal.

The changes found in the body in cases of rickets are as follows :—

1. *Enlargement of the head* with prominence of the protuberances of the skull and thinning of the remainder of the bony walls (craniotabes). The fontanelles remain open for an unusually long period.

2. *Enlargement of the epiphyses of the long bones and of the costo-chondral junctions.* The latter condition results in the formation of a double row of nodules, the so-called

"rickety-rosary" (Fig. 105). On section of one of these nodules the line of junction between bone and cartilage, which should be more or less straight, is very irregular and vascular.

3. *Deformation of the bony skeleton* as a result of the softening associated with the absence of lime salts.

(a) Prominence of the sternum.

(b) Curvature of the spine (kyphosis and scoliosis).

(c) Curvature (occasionally fracture) of the long bones such as the femur. Sometimes, consequent on the bending, a new formation of bone takes place along the concavity of the tibia or femur (buttressing).

(d) Narrowing of the pelvis antero-posteriorly, resulting in difficulty during parturition. Also throwing out of the iliac bones.

In addition, there is often abnormal prominence of the abdomen, and dentition is usually delayed.

Microscopically, there is found at the epiphyses of the bones and at the costo-chondral junctions (a) a broadening of the zone where the cartilage cells are undergoing multiplication; at the same time there is irregularity in the arrangement of the cartilage cells.

(b) Irregular calcification of the cartilage.

(c) Penetration of blood-vessels into the cartilage.

(d) Formation of a spongy osteoid tissue with deposition of lime salts which can be demonstrated as granular material, rather than a combination of the lime salts with connective tissue to form true bone.

At the same time there is a laying down of a layer of vascular tissue under the periosteum, which later undergoes ossification.

OSTEOMALACIA

This is a rare disease, found especially in certain localities, *e.g.* the Rhine Valley and Flanders. It is more frequent in females and has a definite relationship to pregnancy.

It is stated to have been cured by the removal of the ovaries.

The condition is essentially a decalcification of the bony trabeculæ, beginning at the surface of the bones, with, at the same time, a tendency to the formation of new bone which remains imperfectly calcified. As the result of the process of softening and under the influence of pressure, the bones become deformed and sometimes fractured.

The pelvic bones, owing to the great pressure to which they are subjected, are usually the most deformed, with the result that there is a crumpling of the bony wall of the pelvis, so that the cavity is greatly narrowed. Other bones, such as the vertebræ, clavicles, and femur, undergo a similar process of bending.

INFLAMMATION OF BONE

The inflammatory process as it occurs in relation to bone shows certain peculiarities due in great measure to the physical characters of the tissue and to the anatomical arrangement of its constituents.

From the point of view of inflammation, three different parts of a bone may be distinguished—(1) *the periosteum*, a vascular connective tissue structure which covers the exterior of the bone and from which the nourishing vessels enter the bone. When the periosteum is stripped from the underlying bone, as it may be artificially or by the accumulation of exudate, the more superficial parts of that bone tend to undergo necrosis. Further, the periosteum has the capacity of forming new bone, and under the influence of chronically acting poisons this function is stimulated. (2) *The bone itself* is a rigid non-expansile tissue, dependent for its nourishment upon the vessels which pass into it from periosteum and medulla. When it is the seat of the more acute types of inflammation, the exudate from the vessels, unable to infiltrate the rigid tissue around, accumulates and presses upon the vessels, thus leading to necrosis of the bone. In the less acute types of inflammation, probably in order that there

may be space for the inflammatory reaction, the hard resisting bone is excavated by means of large cells (osteoclasts). This rarefaction of the bone is known variously as osteo-porosis or caries. (3) *The medulla or bone marrow*, also a vascular tissue, having as its function the nourishment of the bone and also the formation and destruction of blood.

When inflammation attacks bones the process usually commences in one or other of the vascular structures—periosteum or medulla; by far most commonly in the latter. As the process extends, it tends to involve the other structures, so that periostitis usually accompanies osteomyelitis and *vice versa*.

The causation of the inflammatory process may be (1) injury; (2) organisms such as the pyogenic cocci, *B. typhosus*, *B. tuberculosis*, the organism of syphilis, etc.

Three processes are found going on, often side by side, in inflammation of bone: (1) *Necrosis or death of bone*; (2) *New formation of bone* which is often hard (sclerosis) but may be porous; (3) *Rarefaction* of the pre-existing or newly-formed bone (osteo-porosis or caries). In the case of the *more acutely acting irritants* the necrotic process tends to predominate, owing to the tendency for exudate to accumulate and to obliterate vessels and separate periosteum. In the case of the *more chronically acting poisons*—prolonged coccal infection, tuberculosis and syphilis—the rarefying process is met with along with new formation of bone. This laying down of new bone is merely a modification of fibrosis or interstitial inflammation due to the fact that the new connective tissue contains bone-forming elements.

Acute Osteomyelitis.—This condition sometimes occurs during the course of specific fevers, but often occurs spontaneously. Young children are particularly susceptible. Sometimes there is a history of an injury to the bone, at other times the disease arises without any such predisposing cause.

The condition is an organismal one, *staphylococcus pyogenes aureus* being very commonly present, but other *staphylococci*, *streptococci* and *B. typhosus* are occasionally found. The organism reaches the bone marrow by way of the blood-stream, having been absorbed from the throat or intestinal tract or other focus of infection. The area of marrow involved shows congestion of its vessels, purulent infiltration and hæmorrhages. Sometimes localised areas of suppuration (abscesses) develop in the bone. The periosteum is very commonly involved and pus may accumulate under that membrane. In this way *necrosis*, more or less extensive, may occur in the shaft of the bone with formation of *sequestra*. Sometimes the epiphyses and joints are involved.

Owing to the occurrence of thrombosis in the veins in the neighbourhood and subsequent infective softening of the thrombi, *metastatic abscesses* and *septic infarcts* may form in other parts and organs, especially in the lungs. *Pericarditis* is not an uncommon accompaniment of acute osteomyelitis, the infection being carried by the blood.

The bones which are most frequently affected are the femur and tibia, although other bones may be the seat of the change by extension of inflammation from neighbouring parts, *e.g.* the bones of the skull or finger in cases of septic wounds. Rarely the vertebræ may be affected.

Chronic Osteomyelitis.—Healing of the inflamed focus may occur spontaneously, or, as is most usually the case, the diseased area may be removed by the surgeon, and healing result. At other times the inflammatory change persists. Organisms remain in portions of dead bone (*sequestra*), and the irritation is kept up. From such foci a purulent discharge is constantly flowing, which finds its way to the surface by openings in the bone (*cloacæ*) and sinuses in the soft parts. At the same time the periosteum, kept in a constant state of proliferation, forms new bone which may enclose the

sequestra or dead areas, forming what is called a "new case." This new bone usually has a spongy character but may be dense (Fig. 106).

Waxy disease is not infrequently found in relation to chronic suppurative conditions of bone.

Tuberculosis of Bone.—Tuberculous disease of bones is met with more especially in young children, *i.e.* in growing bones, although the results of such disease are often seen in the adult. A large percentage of cases are due to infection with the bovine type of the tubercle bacillus. The organism may reach the bone by the blood-stream or by the lymphatics. In the latter instance the primary focus is usually the synovial membrane of a neighbouring joint. The bones most frequently involved are the vertebræ (Fig. 107), femora, the tarsal and carpal bones, and the ribs.

The condition may begin in the interior of the bone, usually in the cancellous tissue at the ends (in the case of the long bones) or, much less frequently, in the periosteum. It appears first as a grey translucent area surrounded by a vascular zone. This area spreads, gradually absorbing the bone, and so producing rarefaction or caries. At the same time, owing to the irritation of the focus, new bone may be laid down in the neighbourhood, particularly under the periosteum. In rapidly progressive cases, largely owing to obliterative changes in the vessels, but also due to the action of the tubercle poison, necrosis of larger or smaller areas of bone occurs, with formation of sequestra.

The change may spread to the surrounding parts and a tuberculous (so-called "cold") abscess develop in the tissues. This is particularly the case in tuberculosis of the vertebræ; retropharyngeal abscess occurring in connection with cervical disease, psoas abscess in relation to lumbar disease (Fig. 107). Sometimes the focus infects the spinal cord, setting up a meningitis.

Deformity of bone frequently follows tuberculous disease. This is more especially seen in tuberculosis of the spine.

Syphilis of Bone.—Bone may be the seat of disease both in congenital and acquired syphilis.

In congenital syphilis the disease shows itself chiefly at the ends of the long bones in the part where ossification is taking place (*syphilitic epiphysitis*). The line of calcification is broader and more irregular than normal. The result of this is an interference with growth leading to a form of dwarfing.

In the acquired form of the disease the lesion is essentially gummatous. Such gummata may occur in the periosteum or in the medulla of the bone. The process may be found in any part of the skeleton, but it is commonest in the tibia, ulna, sternum and calvarium. Underneath the gumma there is erosion of the bone which has, in the case of the calvarium, a characteristic circular appearance (*corona veneris*).

Sometimes thickenings occur in the bones (long and flat) leading to the formation of raised areas (syphilitic nodes). The newly-formed bone is in these cases very dense.

Osteitis Deformans (Paget's disease of bone).—This is a rare disease of advanced life.

There is a general thickening of such bones as the tibiæ clavicles, skull, and vertebræ. The bones are at the same time spongy and relatively light, although the medullary cavity is narrowed from the formation of new bone. Owing to the softness of the bones deformity occurs, particularly in bones, such as the lower extremities, spine and clavicles, which are subjected to pressure.

Acromegaly, a condition caused by disease of the pituitary gland, is associated with an enlargement of certain bones, e.g. the lower jaw, bones of the face, hands and feet. The enlargement is due to a laying down of new bone as well as to a thickening of the periosteum.

Tumours of Bone.—Of simple tumours, *osteomata*, *chondromata* and *fibromata* are met with.

Of malignant growths, sarcomata of various kinds occur primarily—*Osteo-sarcomata* (Fig. 108), *chondro sarcomata*, *myeloid sarcomata* (Fig. 109), and *myelomata*.

Secondary deposits of carcinoma are occasionally met, particularly in carcinoma of the breast and prostate.

DISEASES OF JOINTS

INFLAMMATION (ARTHRITIS)

Acute Arthritis.

1. *Non-suppurative*.—This is found following injury and in connection with acute rheumatism. In the latter instance, the synovial membrane is swollen and shows irregularly scattered areas of congestion. There is excess of a thin yellowish fluid in the joint. From the inflamed synovial membrane (not from the fluid as a rule) *micrococcus rheumaticus* can in some cases be cultivated.

2. *Suppurative Arthritis*.—This may occur in the course of a pyæmia, the organisms being conveyed by the blood, or infection may take place directly, due to a penetrating wound or inflammation in bone or neighbouring tissues. The germs found are the pyogenic cocci, more especially *streptococci* and *gonococci*.

The synovial membrane is swollen and its vessels injected. The joint contains more or less purulent fluid, often mixed with blood. In the more severe forms, particularly the gonococcal, there is destruction of the cartilages of the bones.

Tuberculous Disease.—Tuberculosis may commence in the synovial membrane of the joint or it may spread from the adjacent bone.

In a well-marked case of joint disease there is a general pallor of the tissues in the neighbourhood. There is some

increase of synovial fluid which is serofibrinous and occasionally purulent. The synovial membrane is thickened, sometimes with the formation of fringes. The cartilage is eroded through the invasion of granulation tissue from the margins of the bones. There may be caries or sequestrum formation in the exposed bone. In advanced cases the tendons and ligaments in connection with the joint are infiltrated with tubercle. The joints most commonly affected are hip, knee, elbow and ankle. The condition may heal, with the result that ankylosis frequently occurs.

Rheumatoid Arthritis.—This is a disease which is found most frequently in females. The small joints of the hands and feet are usually first affected. Later on those of the elbow and knee are involved. The joints show a fusiform swelling and contain excess of clear synovial fluid. The synovial membrane is swollen and congested, and, even in the early stage, there may be some fibrillation and destruction of cartilage. The condition is not often found in the post-mortem room in the early stage.

In the later stages of the disease, erosion of cartilage with eburnation or polishing of the bone laid bare, also new formation of bone at the margins of the joint (lipping), are characteristically present. At the same time there is marked deformity as well as restriction of movement, due both to the lipping of the bones and to the formation of fibrous tissue between them.

Gout.—This condition should be looked for specially in the metatarsophalangeal joint of the great toe. It shows itself by deposits of opaque white material (salts of uric acid) in the cartilage and in advanced cases in ligaments and soft tissues. There is chronic inflammation in the tissues around.

Charcot's Disease of Joints.—This is a rare condition, found sometimes in individuals suffering from locomotor

ataxia and syringomyelia. There is a great enlargement of the joint due to the accumulation of fluid in it, also increased mobility. There is later destruction of the cartilage, bones and ligaments, the condition being, however, painless. The synovial membrane is thickened, and may show villous outgrowths.

CHAPTER XIII

DISEASES OF THE REPRODUCTIVE ORGANS AND MAMMARY GLAND—DISEASES OF PREGNANCY

DISEASES OF THE OVARIES

THE appearances of the ovary in menstruating women should be carefully differentiated from those seen in disease.

The organ is swollen and vascular, and hæmorrhagic areas occur in it. Occasionally severe hæmorrhage may occur into the peritoneal cavity. Similarly *corpora lutea*, with their yellow colour and characteristic wavy outline, should be distinguished from tumours.

In acute inflammations of the peritoneum the ovaries and tubes participate in the inflammatory condition, and often show marked vascularity. This should not be mistaken for evidence of primary inflammation in these organs. In old age the organs undergo atrophy. The capsule becomes thickened and shrivelled.

Tumours.—The ovary is one of the organs in which tumours are exceedingly common. As a rule such tumours are cystic.

Single cysts occasionally occur from dilatation of a Graafian follicle. Solitary cysts also develop sometimes from the parovarium.

Compound Cystic Adenoma.—This is a common tumour which may attain an enormous size. It consists of a number

of rounded or irregularly shaped spaces enclosing a translucent or transparent gelatinous or semi-solid material containing various mucinous constituents. Not infrequently small papillomatous ingrowths are found within the cysts which divide and subdivide. When such are present the term *papilliferous cystadenoma* is applied. Such a tumour, like the similar one found in the breast, may undergo a malignant transformation. When these cystic tumours of the ovary rupture they sometimes give rise to the formation of immense numbers of secondary growths scattered through the peritoneum.

For microscopic appearances see pp. 285, 286.

Dermoid Cysts (Teratomata).—The ovary is the commonest site for this type of tumour. They vary much in size. They are recognised by the soapy-looking contents mixed with hair and containing often teeth, cartilage, bone, etc. (Fig. 102).

Fibromata occasionally occur in the ovary, also *fibrosarcomata* which may attain a large size.

DISEASES OF THE FALLOPIAN TUBES

Salpingitis.—Two types of this condition are met with, viz. *gonococcal* and *tuberculous*. In the former the tubes are thickened and dilated, and contain creamy or cheesy-looking pus, which in many cases is found to be sterile.

In the *tuberculous* type there is a similar dilatation, thickening and tortuosity. Minute grey tubercles may be visible in the walls; the contents are often caseous. These two conditions are sometimes to be differentiated only on microscopic examination.

Both give rise to localised peritonitis with adhesions, and both may be the starting-point of a generalised inflammation of the peritoneum.

The Fallopian tube is the commonest site for the occur-

rence of **ectopic gestation**. Death occurs from rupture and hæmorrhage into the peritoneal cavity.

DISEASES OF THE UTERUS

The *size of the uterus* should in all cases be measured and its cavity investigated for developing ovum or foetus.

Thrombosis in the uterine veins is a constant occurrence after parturition. Occasionally portions of such thrombi are carried away, and produce fatal pulmonary embolism.

Sometimes, after operations on the uterus or ovaries, a similar accident may occur. In such cases the emboli may originate from vessels in the neighbourhood of the removed growth or organ or from the abdominal wound.

Acute Endometritis.—This condition is a not uncommon cause of death in puerperal cases. The disease is an infective one, due as a rule to a *streptococcus*. A gram-negative coccus not unlike the gonococcus has been recently described as occurring in the uterus in such cases.

The organ is of course enlarged. The interior has a grey appearance, owing to the presence of septic sloughs in the wall. There is usually a foul odour. Films from the soft necrotic interior show immense numbers of organisms, among them *streptococci*. The uterine veins are filled with thrombi, which may be undergoing septic softening. Septic infarcts are not uncommonly present in the lungs.

Organs such as liver, kidneys, and heart show extreme cloudy swelling. Acute peritonitis localised to the neighbourhood of the uterus or generalised throughout the peritoneum may be present.

Microscopically, the innermost portion of the uterine wall shows necrosis. Numerous germs of various kinds are present. Further from the lumen the uterine muscle is infiltrated with inflammatory cells, and thrombi are found in the vessels; in

this position in suitably stained specimens *streptococci* are usually the only organisms seen.

Chronic Endometritis.—Two types of this condition are commonly distinguished: (1) glandular endometritis, (2) interstitial endometritis.

1. *Glandular endometritis* is also called glandular hyperplasia. It is questionable whether this condition is in reality an inflammatory one. There is little or no evidence of inflammation from the microscopic point of view. The main change is a hyperplasia of the gland elements of the endometrium. Many regard it as neoplastic in nature, *i.e.* an adenoma.

The uterus is enlarged and its mucous membrane thickened, vascular and spongy. Polypoid outgrowths may be associated.

Microscopic Appearances.—Sections of the uterine wall show gland acini more or less regularly arranged, but often tortuous and sometimes dilated, between which is a delicate stroma of connective tissue. The gland acini may often be seen penetrating the muscular wall for some distance, so that the condition may be confused with an adeno-carcinoma of the uterine wall. The gland cells are, however, only a single layer in thickness, and are arranged regularly upon a basement membrane, although there is sometimes shedding of the cells.

Sections of curettings from a case of this kind present a similar appearance.

2. *Interstitial endometritis* is often combined with chronic metritis. It has been called fibrosis uteri. The uterus is larger, firmer, and heavier than normal.

Microscopically, curettings show a dense fibrous stroma, in which the vessels are thickened. The gland acini are usually few in number and widely separated from one another.

Tuberculosis of the uterus is a rare condition. It may occur as an endometritis with the development of ragged

caseous walls, or fibro-caseous nodules may occur in the wall of the uterus which is usually considerably thickened.

Tumours.—Of simple growths the *fibro-myoma* (leiomyoma), or tumour composed of non-striped muscle and fibrous tissue, is the commonest (Fig. 104). A full description is found under Tumours, p. 280.

Of malignant growths the carcinoma is very common. Two main types are found :—

1. Squamous epithelioma occurring in the cervix.
2. Columnar cell carcinoma occurring in the body or cervix.

DISEASES OF THE PLACENTA

Infarcts, *i.e.* areas of necrosis in the placenta, are not uncommon. They are best developed in cases of eclampsia. They appear as opaque white or pale yellow areas, more or less wedge shaped, and towards the maternal surface. They are caused by thrombosis in the intervillous blood spaces.

Fibrosis.—Under the influence of the syphilitic virus the placenta becomes larger, firmer, and paler, and may present a dull, greasy appearance.

Microscopically, the chorionic villi are found to be thicker and show a marked decrease in the number of vessels. In the thickened stroma are numerous round and spindle-shaped cells.

Tumours.—*Hydatid mole or myxoma of the chorion* is a condition in which chorionic villi become greatly enlarged and œdematous. The tumour shows immense numbers of translucent globular masses like white currants, varying much in size, strung upon thin filaments. The condition occurs after an abortion. It may become malignant, passing into the condition known as chorion-epithelioma (p. 304).

Microscopically, the globular masses show the structure of myxomatous tissue, hence the term myxoma of the chorion.

There is at the same time proliferation of the covering epithelial layers—syncytium and Langhan's layer.

Chorion epithelioma or Deciduoma malignum is a tumour formation which, like the preceding, has a distinct relationship to pregnancy and abortion. Its appearance and nature are discussed under Tumours (p. 304). It is associated with the development of secondary growths, particularly in the lung.

DISEASES OF PREGNANCY AND THE PUERPERIUM WHICH MAY BE FATAL

It is convenient to discuss here some of the diseases of pregnancy and the puerperium which may be seen in the *post-mortem* room. Pregnant and puerperal women may, of course, die of intercurrent diseases of various kinds. Thus, heart disease and kidney disease are not uncommonly a cause of death under such circumstances. There are, however, certain conditions more directly associated with the pregnant state which may prove fatal.

In the first place there is **ectopic gestation**. When an ovum develops in a situation other than the uterus, such as the Fallopian tubes or ovary, death not infrequently occurs from hæmorrhage into the peritoneal cavity.

Rupture of the uterus may occur during pregnancy or during labour, with resulting fatal hæmorrhage.

Pulmonary embolism has already been alluded to as a cause of sudden death after labour.

Chorea gravidarum may prove fatal. In a case which came under the author's notice recently there was present—what is usually found in any fatal case of chorea—acute simple endocarditis of the mitral valve.

Puerperal fever, one of the commonest causes of death after labour, has already been dealt with under Diseases of the Uterus (acute endometritis) (p. 266).

Hyperemesis Gravidarum or Pernicious Vomiting of Pregnancy.—This condition of severe and sometimes fatal vomiting developing during pregnancy is believed by authorities to be toxæmic in origin, and probably allied to such diseases as eclampsia and acute liver atrophy. In many cases lesions of the liver, similar to those occurring in the latter disease, are found. In some cases the liver shows a fatty degeneration of an extreme degree; in others there are areas of necrosis similar to those found in eclampsia, but instead of being situated at the periphery of the lobule, as in that disease, they occur in the centre. Degenerative changes of a type similar to those in eclampsia are found in the kidney. The condition is associated with a high ammonia co-efficient in the urine, and there is a corresponding marked reduction in the output of urea.

Acute Liver Atrophy.—As already stated, there is a distinct relationship between this condition and the pregnant state. For a description of the lesions found in the liver see p. 183.

Eclampsia.—This is perhaps the commonest cause of death in such cases. The disease may prove fatal either during pregnancy or after the birth of the child. It is associated clinically with more or less marked albuminuria (sometimes also blood and casts) and with the occurrence of fits.

The *cause* of the condition is at present uncertain.

As regards the *post-mortem findings* in fatal cases of the disease, these vary considerably in different cases. There are, however, certain appearances found with considerable constancy. *Post-mortem changes* are often specially well marked. There is often a general *icteric tint* of the skin. Œdema of the subcutaneous tissues may be present. Excess of fluid in the peritoneal, pleural, and pericardial sacs is also a fairly constant finding. The heart muscle is pale

and soft. The organs which show the most constant changes are the liver and kidneys.

The *appearances in the liver* when well marked are exceedingly characteristic. The organ is usually somewhat enlarged. The surface has a dark red appearance, either in whole or in part from the occurrence of more or less extensive subcapsular hæmorrhage. In consistence it is usually soft. The cut surface shows a yellow appearance, with hæmorrhages scattered through the substance, chiefly in the portal spaces. The necrotic areas, so characteristically present when sections are examined under the microscope, are, as a rule, too small to be seen by the naked eye. Occasionally the liver may show the appearances of cloudy swelling and early fatty change without the occurrence of hæmorrhages.

Microscopically, there are found (1) changes in the liver cells characteristic of cloudy swelling; (2) more or less marked fatty change intensified round the necrotic foci; (3) areas of focal necrosis somewhat similar to those found in typhoid fever in which the liver cells have undergone extreme degenerative changes. They are swollen and vacuolated, or have broken down and disappeared. Fatty change is not as a rule present in the cells within such foci. Endothelial cells and leucocytes are present along with red blood corpuscles. These necrotic foci are found chiefly at the margin of the lobules; (4) areas of hæmorrhage in which the tissue is infiltrated with red blood corpuscles.

Changes in the Kidney.—As previously stated, there is in the urine distinct evidence that the kidney is damaged, that, in other words, a degree of acute nephritis is present. But even in cases where the urine shows most indications of disease comparatively little change may be found in the kidney itself, more especially microscopically. The organ is somewhat enlarged and pale. On section, the cortex is swollen and tends to stand up above the level of the medulla (Fig. 83). The colour of the cortex is a pale yellow,

272 DISEASES OF THE REPRODUCTIVE ORGANS

occasionally with hæmorrhages scattered through it. In consistence the organ is softer than usual. Unless the case is complicated with chronic renal disease, the capsule strips perfectly, leaving a smooth, pale surface.

Microscopically, as already indicated, the changes are less marked than one would have expected from the examination of the urine. There is (1) always more or less evidence of cloudy swelling of the renal epithelial cells, especially of the cells lining the convoluted tubules. (2) There is more or less fatty change in these cells, but this is never very marked. (3) There is a certain amount of shedding (catarrh) of these cells with a massing of the shed cells in the collecting tubules. (4) There may be escape of red cells into the tubules.

The appearances are, in short, those of marked cloudy swelling or of an acute catarrhal nephritis, and, as already stated, between these two conditions there is no very hard and fast line.

It should be remembered in connection with the microscopic appearances of the kidneys that a degree of cloudy swelling (toxic change) is practically constantly found in pregnancy.

As already mentioned, infarcts in the placenta are specially frequent in cases of eclampsia.

DISEASES OF THE MAMMARY GLAND

Little need be said in such a treatise about diseases of the mammary gland. Owing to their being readily removable, growths of the gland are seldom seen post mortem.

Acute inflammatory conditions (*acute mastitis*) with abscess formation are not uncommon.

Chronic inflammation (*chronic interstitial mastitis*) is difficult to distinguish clinically and by the naked eye from carcinoma. It occurs as a hard mass, ill defined, in the substance of the gland. On section it appears as white-looking tissue radiating through the fatty tissue of the breast.

Microscopically, the condition is characterised by the development of a large amount of well-formed fibrous tissue with isolated islands of gland tissue scattered through it. Cysts formed by dilated gland acini are often present.

Tuberculosis is occasionally met with in the form of multiple caseous foci surrounded with fibrous tissue scattered through the gland substance.

Tumours.—The mammary gland is one of the organs in which tumour formation is most common. No doubt this is due to the fact that the breast is periodically undergoing hypertrophy and involution and also to the irritation to which it is subjected from trauma and acute inflammatory processes.

Simple tumours, such as adenoma and cystic adenoma, are dealt with among tumours under these headings (p. 285).

Carcinomata are dealt with under adeno-carcinomata.

Although primary carcinomata of the breast are seldom met with in the post-mortem room, the secondary deposits are frequently seen. They may occur in the lungs (Fig. 55), or disseminated through the body, often showing a marked preference for bone.

DISEASES OF THE TESTICLE

Such diseases do not often come under the notice of the pathologist.

Tuberculosis of the testicle is not infrequently associated with generalised tubercle and with tubercle of the genito-urinary tract. The condition tends to develop first in the epididymis and may remain localised there.

Syphilis.—Two chief types of syphilis are found in the testicle.

1. *Gummata.*—These are firm white or yellow caseous-looking masses which have to be distinguished from sarcomata.

2. *Interstitial Inflammation or Fibrosis.*—A slight degree

of this is not uncommonly met with even in cases which show few other manifestations of the disease. Bands of white fibrous tissue are seen running through the characteristic slightly brownish tinged, soft testicular substance.

Tumours.—*Sarcoma* is the commonest tumour of the testicle. It is often of the large round cell type, and in appearance (owing to accompanying necrosis) sometimes resembles a gumma. Such tumours are rarely seen in the post-mortem room, but the recurrences in the retroperitoneal glands may be met. Such recurrent sarcomata may attain a large size.

DISEASES OF THE PROSTATE

Hypertrophy.—Simple enlargement of the prostate is a common condition in men of sixty years of age and upwards. It leads to obstruction of the urethra and to dilatation and hypertrophy of the bladder. A fibrous and a glandular variety are distinguished, the former being hard and the latter soft.

Microscopically, sections show the structure of the normal prostate-gland spaces and intervening fibro-muscular tissues. In some cases the former, in others the latter, predominate.

Corpora amylacea are commonly present in the gland spaces in this condition. They are produced by a transformation occurring in desquamated epithelial cells and appear as rounded or oval bodies showing concentric lamination not unlike starch grains.

Acute Prostatitis, with abscess formation, is occasionally met with following the formation of a false passage in catheterisation of the urinary bladder.

Tumours.—Carcinoma of the prostate is the commonest tumour. It has a special tendency to show secondary deposits in bone. The types met with are: columnar-celled, scirrhus, and encephaloid.

CHAPTER XIV

TUMOURS

TUMOURS may be primarily divided into (1) Simple and (2) Malignant. There is actually no very hard and fast line between the two varieties, certain tumours being less malignant than others. Moreover, a simple tumour may become malignant. On the whole, however, the distinction is sufficiently well marked to serve as a basis for classification.

The main morphological difference between the two types is that the simple tumour is *encapsuled*, *i.e.* is more or less sharply defined from the tissues in its immediate neighbourhood, while the malignant tumour *infiltrates* surrounding tissues and erodes structures such as blood-vessels. The tendency to recur when removed, and to produce *metastases* or secondary growths, both characters belonging to malignant tumours, are explained by this character of infiltration.

In deciding in a given instance whether a tumour is **simple or malignant**, certain points should be attended to.

1. *Position*.—Tumours of the intestine are usually malignant, while in the case of the uterus the commonest tumour is the simple myoma.

2. *Size*.—On the whole a large tumour is more likely to be malignant than a small one, although there are notable exceptions to this.

3. *Ulceration*.—An ulcerating tumour is much more likely to be malignant than simple.

4. *Necrosis*.—Necrotic changes are more frequently met with in malignant growths, owing to their tendency to overgrow their blood-supply and from other causes.

5. *Hæmorrhage* is much more frequently met with around and in malignant growths, owing to their capacity to erode blood-vessels, and owing to the fact that their own blood-vessels are thin walled and badly supported.

6. *Infiltration* of the surrounding parts, as already indicated, is characteristic of malignant growths, while the simple tumour is, as a rule, well defined.

7. *Occurrence of Metastases*.—If such are present the tumour is malignant. It should be borne in mind, however, that simple tumours, such as the myoma of the uterus, may be multiple.

Microscopic points of distinction between the two groups are as follows :

1. *Resemblance to Homologous Normal Tissue*.—This is much more characteristic of simple growths. Malignant growths deviate more or less markedly from the normal tissues which they represent. They tend to resemble more closely the embryonic equivalent of the tissue.

2. *Character of Cells*.—The cells of malignant growths tend to be larger and to vary in size and shape. Their nuclei also are larger and often multiple. Mitotic figures are frequently numerous in malignant growths and may show aberrant types, such as multipolar division.

3. *Infiltration* of surrounding tissues is again a microscopic character of malignant growths, while simple tumours are encapsuled. Associated with this character is the tendency to erode blood-vessels and other normal structures.

4. *Inflammatory changes in the tissues around* are found in connection with malignant growths, while simple tumours excite little reaction.

5. *Necrosis* is again more characteristic of the malignant type than of the simple.

6. *Hæmorrhage* more or less extensive is very characteristic of malignant growths and is due as a rule to escape of red blood cells from thin-walled, imperfectly-developed blood-vessels, but may also be due to erosion of vessels by cancer cells.

7. *Relation of epithelial cells to stroma*.—In glandular tumours of the simple type a basement membrane is usually present. In malignant growths this is absent.

In the following description of the common tumour formations no elaborate system of classification is adopted. Any such system of classification must of necessity be tentative, pending the discovery of the cause of tumour growth. Further, exceptions to rules are so frequently met with in relation to neoplasms that the most elaborate system breaks down at many points unless each tumour be placed in a category by itself.

A. SIMPLE TUMOURS

Tumours composed of Fibrous Tissue

Fibroma.—This is a tumour composed of connective tissue cells and fibres. Two types, *soft* and *hard*, are distinguished, according as the cells or the fibres predominate.

Sites.—They may arise anywhere where there is connective tissue,—cutis, fascia, periosteum, dura mater, submucous tissue, pharynx and nose (polypi). They are also common as minute growths in the medulla of the kidney. Sometimes they occur in connection with scars (cheloids). A special type, the neurofibroma, occurs in relation to nerves.

Appearance.—Usually a well-defined rounded or lobulated and encapsuled nodule, soft or hard, firm in consistence, pink or white, the softer type tending to be pink from its greater vascularity. The cut surface sometimes has a watered silk

appearance. Degenerative changes, such as myxomatous, œdematous, calcareous, are sometimes met with.

Microscopically, the appearances are those of ordinary connective tissue. Sometimes the cells predominate, at other times the intercellular material, according as the tumour is of the hard or soft variety. The cells are usually spindle-shaped, but in the more cellular types may be rounded. The intercellular material consists of wavy collagenous fibres, staining deep red with eosin and with acid fuchsin.

Tumours composed of Myxomatous Tissue

Myxoma.—This is a somewhat rare tumour composed of mucoid or myxomatous tissue, an embryonic form of connective tissue. The umbilical cord is largely composed of such tissue. Certain connective tissue tumours—fibromata, fibro-myomata, chondromata—are not infrequently in part composed of myxomatous tissue. When occurring in relation to tumours composed of more adult tissue, the change is regarded as a degenerative one.

Sites.—Such tumours may be found in any of the sites in which fibromata occur; most commonly in subcutaneous and submucous tissue. Not infrequently such growths show a tendency to diffuse themselves and invade surrounding structures; such are to be regarded as sarcomata. The placental or hydatid mole is often classified as a myxoma (myxoma of the chorion, p. 268).

Appearance.—Very soft and gelatinous, not infrequently the material when manipulated forming long strings. Translucent, sometimes with minute hæmorrhages.

Microscopically, the growth is found to be made up of rounded, spindle-shaped and branching cells, widely separated from one another. The material between the cells is homogeneous or slightly fibrillated, and usually stains very faintly. Vessels are of course present and hæmorrhages may be found.

Tumours composed of Fatty Tissue

Lipoma.—*Sites.*—Subcutaneous tissue, especially parts liable to pressure, *e.g.* shoulders, buttocks, wall of large bowel, kidney, rarely brain.

Appearance.—Such tumours vary much in size, may be very minute, occasionally very large, are usually lobulated, and resemble fatty tissue.

Microscopically, they consist of adipose tissue with bands of supporting fibrous tissue carrying blood-vessels. All stages in development of fat cell are found from fibrous tissue cell, with minute globule of fat, up to cell with merely thin rim of protoplasm and nucleus pressed aside by large fat globule. Crystals of fatty acids are often present in the cells.

Tumours composed of Cartilage

Chondroma.—A tumour composed of cartilage either hyaline or fibro-cartilage.

Sites.—It is occasionally found growing from cartilage of rib or larynx (ecchondroma) more usually in relation to bone or in the interior of glands such as parotid, testicle (enchondroma). One of the commonest sites is the periosteum of long bones, especially at the ends of the metacarpals and phalanges.

Appearance.—It is a rounded or lobulated tumour, firm and elastic, surrounded with a fibrous capsule which sends in trabeculae between the lobules. Not infrequently it shows calcification or soft areas of myxomatous degeneration.

Microscopically, the tumour is found to consist of lobules of cartilaginous material composed of rounded or branched cartilage cells lying in spaces between which is a matrix, sometimes homogeneous, at other times fibrillated, occasionally myxomatous. Calcified areas which take on the hæmatoxylin stain deeply are not infrequently met with. The tumour is surrounded with a connective tissue capsule carrying blood-vessels, prolongations of which dip down between the lobules.

Tumours composed of Bone

Osteoma.—Two varieties are distinguished : (1) the compact or eburnated ivory exostosis found in connection with the bones of the skull ; (2) the spongy osteoma, in which the bony trabeculæ are thinner and more widely separated. The exostoses found in connection with the attachment of muscles are probably not true tumours. They are more of the nature of hypertrophies of bony tissue, *i.e.* ossification following trauma or irritation.

Tumours composed of Muscle

Myoma.—Two varieties are distinguished : (1) the *rhabdomyoma* or tumour composed of striped muscle fibres, which is very rare, usually congenital and commonly malignant (sarcomatous). It is found in the kidney and testicle, and is due to inclusion of portions of the lumbar muscles. (2) *Leiomyoma*, a very common tumour composed of non-striped muscle fibres.

Sites.—Leiomyomata are found by far most frequently growing in the wall of the uterus. They may also occur in other positions where non-striped muscle is found, such as the alimentary tract, more especially the œsophagus, also bladder and prostate.

Appearance.—In the uterus the tumours are frequently multiple. They vary greatly in size, from something just visible by the unaided eye to a tumour the size of a foetal head. They are most frequent in the body of the uterus but also occur in the cervix.

Three varieties are distinguished according to the position in the uterine wall, viz. (1) intramural ; (2) subserous, when projecting into the peritoneal cavity and covered with peritoneum over the greater part of its surface ; (3) submucous, when projecting into the cavity of the uterus (Fig. 104).

The tumours are rounded and well defined from the neighbouring muscle. On the cut surface they are usually pink in colour and show an appearance like watered silk or balls of cotton. Degenerative changes are common in myomata, *e.g.* myxomatous change, calcification and a necrotic change known as "red softening."

Microscopic Appearance.—The tumour does not differ in any essential respect from the normal uterine-wall tissue. It is composed of bundles of (1) non-striped muscle fibres running in all directions and therefore in sections cut sometimes longitudinally, sometimes obliquely, sometimes transversely; (2) fibrous tissue running between the bundles and between the individual fibres. So markedly does this fibrous element enter into the composition of the tumour that the term "fibromyoma" is often employed. In the myomata found in the œsophagus the amount of fibrous tissue is much less. The individual muscle fibres when cut longitudinally are elongated, often sinuous structures with similarly elongated nuclei. The fibrous tissue often shows degenerative changes: (1) myxomatous, (2) hyaline, (3) calcareous. Blood-vessels with well-developed walls are always present. Sometimes gland acini are scattered through the fibro-muscular tumour (adeno-myoma).

Tumours composed of Vascular Tissue

Angioma.—Two primary varieties may be distinguished, *viz.* (1) hæmangioma, (2) lymphangioma; a further subdivision of each variety into (*a*) plexiform or capillary, and (*b*) cavernous may be made.

Sites and Appearance.—*Hæmangiomata* are most usually found in relation to skin or mucous membrane. They may be merely areas of purple colour, the so-called "port wine stains," or they may project and may even be pendulous. They are always dark red in colour and are often pulsatile. These cutaneous angiomata most usually belong to the plexiform variety, but may be cavernous. The cavernous type is most common in the liver, but may occur in relation to the

membranes of the brain and in the skin. It appears as a dark purple area, more or less wedge shaped, immediately under the capsule of the organ (Fig. 76). The condition is much more common in the ox than in man. *Lymphangiomata* are found in relation to skin and tongue. They are probably always congenital and mostly belong to the cavernous type.

Microscopic Appearances.—(1) *Capillary Angioma.*—Instead of the dense fibrous tissue of the cutis, great numbers of minute spaces lined with fairly large endothelial cells are found. Some of these spaces contain blood, others are empty. Between the capillaries there is more or less loose connective tissue.

(2) *Cavernous Angioma.*—In this type, large spaces are found lined with spindle-shaped endothelial cells and filled with blood, sometimes with thrombi. The walls of the spaces are formed of well-developed fibrous tissue.

Tumours composed of Lymphoid Tissue

Lymphoma.—A simple lymphoma is a rare tumour, usually small and solitary. Microscopically, it has the appearance of normal lymphoid tissue, having a capsule, a reticulum in which are large numbers of lymphocytes also endothelial cells. The condition is very difficult to distinguish from mere hypertrophy of lymphoid tissue. The malignant type, lymphosarcoma, is more common and much more important.

Tumours composed of Neuroglia

Glioma.—Such tumours, arising as they do from the neuroblast, are epiblastic in origin.

Sites.—They are found in the brain, retina and spinal cord.

Appearance.—As a rule they are not well defined, but merge into the surrounding brain substance. They vary much in size, may be opaque or translucent, white or pink.

A slow-growing, simple type is recognised, but many of them have the characters of malignant growths and may be called glio-sarcomata (see p. 243). Hæmorrhages frequently occur into their substance.

Microscopically, such tumours are formed of small round cells with branching prolongations (spider cells), the latter forming a felted meshwork between the cells. In the case of the retinal glioma, the branching processes may be absent. Vessels are present which are often thin walled and may rupture, leading to hæmorrhages.

Epithelial Tumours

Such tumours, in addition to their epithelial elements, always possess a greater or smaller amount of supporting fibrous tissue stroma.

1. **Papilloma**.—This is a tumour projecting from an epithelium-covered surface, composed of connective tissue and epithelial cells. Two types, (*a*) squamous papilloma and (*b*) mucous papilloma, may be distinguished according to the type of epithelial surface from which the tumour grows.

(*a*) *Squamous papillomata*.—*Sites*.—These are found in relation to skin, mouth, larynx, pharynx, œsophagus or vagina.

Appearance.—They consist of a series of projections composed of a connective tissue core carrying blood-vessels and a covering of squamous epithelium. The epithelium is frequently much thickened and the dead material tends to accumulate between the prolongations. The skin papilloma or ordinary wart is sometimes congenital. It is commonest in childhood and is often infective, being probably due to some micro-organism. One of the infective papillomata, the venereal wart, is found in relation to the genitals. Some are due to the irritation of chemicals, such as paraffin. *Molluscum contagiosum* is a condition appearing as small red elevations, affecting more especially the skin

of the head, face and hands. The elevations break down in the centre and discharge a cheesy material. The disease is regarded as being due to some germ not yet discovered.

Microscopic Appearances.—The connective tissue core containing vessels is seen in places in connection with the cutis. In other places there are isolated rounded areas of fibrous tissue produced by the cutting transversely of one of the finger-like processes. Upon this connective tissue is placed the epithelium which corresponds to the stratified epithelium of the skin and like it shows differentiation into layers. The epithelium shows a sharp line of demarkation from the subjacent connective tissue. Occasionally whorl-like masses of cornified epithelium are seen simulating the "cell-nests" of cancers, but these are buried in the thick layer of epithelium and do not penetrate the fibrous stroma.

(b) *Mucous papillomata.*—*Sites.*—These may grow from any mucous membrane—alimentary canal, bile ducts, bladder, pelvis of kidney. Some of these are undoubtedly due to organisms, viz. the condition known as coccidiosis, which is a papillomatous condition of the bile ducts, found specially in the rabbit, due to a protozoon—the coccidium oviforme. A somewhat similar condition in the stomach of the rat is due to the presence of a small nematode.

Appearance.—In structure the mucous papilloma consists of a slender connective tissue core carrying blood-vessels, and covered by a layer of epithelium which may be columnar, cubical or transitional, according to the site. One of the commonest sites for this type is the bladder, where the growth consists of numerous delicate processes forming a sea-anemone-like mass.

Microscopic Appearances.—A connective tissue core of great delicacy, carrying blood-vessels, dividing and again dividing, is seen in connection with the submucous coat of the viscus if the section be accurately through the root of the tumour. Many of the branches are, however, cut transversely. Upon this connective tissue core is placed the epithelium

which may be transitional (in the case of the bladder) showing numerous layers of elongated epithelial cells tending to become loosened and to separate in the more superficial layers. In the case of the intestinal and bile duct papilloma the epithelial cells are columnar. Mitotic figures are often numerous in the cells of the villous papilloma of the bladder.

2. **Adenoma** is the term applied to a *simple tumour composed of gland elements*. Such tumours contain, in addition to the epithelial gland cells, a larger or smaller amount of supporting fibrous tissue. In this connective tissue the nutrient vessels run. When the fibrous tissue is large in amount, the term *fibro-adenoma* is used. Often the gland acini in the tumour become dilated (*cystic adenoma*). Occasionally (breast and ovarian adenomata) within the cysts there is a papillomatous development of the epithelial elements supported by fibrous tissue (*papilliferous cystic adenoma*). Such tumours are generally regarded as being of doubtful simplicity.

Sites.—Any gland may be the site of origin of an adenoma. The commonest site for such tumours is undoubtedly the mammary gland. The prostate, thyroid, liver and other glands may be the seats of similar tumours.

Appearance.—Such tumours are round or lobulated, vary much in size, and are surrounded by a fibrous capsule so that they are readily shelled out. The colour is white or pink, and on section minute clear foci representing groups of gland acini may be seen. Cysts are often present. Another common site for adenomata is the ovary, forming the so-called compound cystic adenoma. The cysts are often very large and contain mucinous material.

Microscopically, the essential parts of the tumour are (1) gland acini lined with epithelium, resembling that of the gland from which the tumour arises, set upon a basement membrane. Secretion may be present, colloid material in the case of tumours of the thyroid gland, mucinous material in the

compound cystic ovarian tumour. The acini are not infrequently dilated, forming cysts of various size. Intracystic papillomatous projections also covered with epithelium may be found, and in the case of the breast tumours small rounded masses of fibrous tissue, the so-called intracanalicular fibromata. The epithelium in the case of the ovarian tumours is markedly columnar in type.

(2) Fibrous supporting tissue, which varies much in amount, sometimes, in the case of the fibro-adenomata, occurring in large bands which separate the groups of gland acini widely from one another. Running in this connective tissue stroma are the blood-vessels of the tumour, as a rule, well developed.

B. MALIGNANT TUMOURS

The general characters of malignant growths and the points wherein they differ from the simple tumour have already been discussed. The chief characteristic of such growths is the tendency to *invade* normal structures, so that they *infiltrate* the tissues in which they arise and tend to erode blood- and lymph-vessels, and to pass by these in the form of tumour emboli to other parts of the body.

The term cancer is sometimes used generically for such growths, but the pathologist usually reserves that term for the epithelial type of malignant growth.

Microscopically, the malignant tumour is characterised by an imperfect repetition of the normal tissues. Whereas the simple growth resembles, in many cases very closely, the normal adult tissue from which it arises, the malignant tumour shows considerable deviation from the homologous normal tissue. It tends to resemble in many instances the embryonic type of the tissue. Hence the use of the term "atypical" in relation to them.

Just as simple tumours may be divided primarily into (1) those arising from and composed of connective tissue and (2) those arising from and partly composed of epithelial tissue, so in the case of the malignant growths we may distinguish

a connective tissue and an epithelial group. The former are *sarcomata*, the latter *carcinomata* or true cancers.

SARCOMATA

These are tumours which are *essentially cellular, i.e. contain a minimal amount of intercellular material*. The cells are of the connective tissue type and are embryonic, *i.e. imperfectly differentiated*. So that what appears to be the most advanced stage of development of which the tumour cells are capable corresponds with an early stage in the development of a fibrous tissue cell from the primitive round connective tissue corpuscle.

Under normal circumstances, either during development or in the course of the laying down of new tissue in the process of healing, the connective tissue corpuscle passes from a small round cell with small round, relatively large, nucleus and small amount of protoplasm to the large round cell with abundant protoplasm. The cell then becomes oval and eventually spindle shaped. Subsequently from the protoplasm there are split off collagenous fibrils which form the intercellular material.

In this type of growth the cell which has taken on tumour characters may stop at any one of these stages and subsequently reproduce cells of a similar stage of development and no other type. Seldom does it occur that the fully-developed type of connective tissue cell is found in the sarcomata. It is usually the more primitive types which are found. Occasionally a tumour which shows a high degree of differentiation may on recurring exhibit a differentiation of a less high degree. Thus a tumour with the characters of a fibroma may on recurring (recurrent fibroid) assume the characters of a sarcoma.

As the name *sarcoma* indicates, such tumours are flesh-like. As a rule they form large masses of opaque white or

faintly pink material. Necrotic areas are not infrequently present, and hæmorrhages are very common. Certain types are very vascular (angiosarcomata) and some develop pigment (melanotic sarcomata).

In consistence sarcomata are commonly soft, sometimes diffuent, and often show areas of more marked softening. They are, however, sometimes firm and may even be hard. Like other forms of malignant growth, they show a marked tendency to infiltrate and thus are seldom encapsuled.

Although, as already stated, they tend to stop short of the fully-developed form of the connective tissue from which they arise, such tumours not infrequently reach a fair degree of differentiation of tissue. Thus those arising from cartilage tend to produce cartilage, those arising from bone produce bone-like tissue, those arising from muscle may produce muscle cells, and so on. This differentiation forms a basis for classification. Hence we speak of chondro-sarcomata, osteo-sarcomata, etc. A majority of these tumours, however, merely exhibit the various stages of development of the connective tissue cell. In order to classify them we use such terms as small round cell sarcoma, large round cell sarcoma, small spindle cell sarcoma, large spindle cell, fibro-sarcoma, mixed cell sarcoma.

As a rule, the less differentiated the type of cell composing the tumour the more malignant it is. Thus the small round cell sarcoma is one of the most malignant types. Sometimes a tumour starts by being simple but becomes malignant, either a portion of the growth assuming the malignant type, or the whole tumour, as in the so-called recurrent fibroid, becoming more and more malignant at each recurrence. This prepares one for the fact that *there are degrees of malignancy*.

Sarcomata very commonly produce metastases. Such metastatic growths are found not so frequently in lymph glands as in the internal organs. Hence the statement that these tumours spread more by the blood than by the lymph

channels. This is true up to a certain point ; but there are exceptions, particularly in the case of the melanotic tumour which often spreads by the lymphatics.

As regards *sites of origin*, such growths may arise in any part of the body in which connective tissue is found, and this means anywhere at all. There are, however, certain parts and tissues more commonly affected than others. Thus, subcutaneous tissue, intermuscular septa, fasciae, periosteum, bone, lymph glands are common sites of origin. As regards the secondary deposits, these occur more commonly in the lung than in any other organ (see p. 148).

Types of Sarcomata

Small Round-Cell Sarcoma.—This is a white, grey or pink, soft, sometimes diffuent tumour, found primarily in connection with subcutaneous tissue, bone, muscles, brain testicle, and secondarily anywhere, but most commonly in the lungs. Hæmorrhages and areas of necrosis are frequent. The tumour is one of the most malignant types known.

Microscopically, such tumours are composed of small round cells closely packed, with scanty protoplasm and small dark-staining nuclei. The cells resemble very closely the lymphocyte of the blood and lymph glands. The intercellular material is scanty, granular or slightly fibrillated. The vessels are thin walled, often consisting of a single layer of cells. Hæmorrhages and areas of necrosis are frequent.

The so-called **Lymphosarcoma** may be regarded as a sub-variety of the above. It originates in lymphoid tissue, very commonly the lymphatic glands of the mediastinum, and is very malignant. In appearance it resembles other types of sarcoma (Fig. 56).

Microscopically, such tumours are composed in large part of small round lymphocyte-like cells with rather more intercellular material than in the case of the ordinary type of small round-

cell sarcoma. There is often a fair number of larger flattened or polygonal cells, representing the endothelial elements of lymphoid tissue. Occasionally this larger type of cell is the predominant one (endothelioma).

Large Round-Cell Sarcoma.—These tumours have much the same appearance as the above, but tend to be on the whole firmer in consistence. The sites of origin are also much the same, but the testicle, pharynx and posterior nares and muscle are perhaps more commonly affected.

Microscopically, as in the previous type, the tumour is composed essentially of cells, but there is more intercellular material, and the fibrils of which it is composed are thicker. The cells are of course larger, rounded or polygonal, with more abundant protoplasm and a nucleus with a wider-meshed network, hence staining less deeply. Areas of necrosis and hæmorrhages are common. The vessels are better developed. Sometimes the cells have an alveolar arrangement.

Small Spindle-Cell Sarcoma.—Such tumours resemble the preceding but are more benign.

Microscopically, the tumour is composed of small oat-shaped cells arranged irregularly in bundles. The cells represent a further stage in the development of the connective tissue corpuscle. The vessels are, however, still very imperfectly formed.

Large Spindle-Cell Sarcoma.—In this type the fasciculation may be visible to the naked eye. The tumour bears considerable resemblance to a fibroma. It is, moreover, firmer than most other types. Such tumours occur in relation to periosteum, muscles, mamma, or ovary.

Microscopically, the cells are arranged in bundles. There is a considerable amount of intercellular fibrillated material, and the vessels are fairly well supported. It is difficult in many instances to differentiate such growths from cellular fibromata. The cells tend, however, to be larger and to vary more in size, and mitotic figures are often present.

From the microscopic point of view it is *a matter of great difficulty* in many instances, especially when only a minute portion of tissue is available, *to differentiate such tumours from granulation tissue*. Nothing less than long experience will enable the pathologist to do this in many cases. The point to attend to is: the uniformity of type in the cells. In the case of granulation tissue all stages of development of the fibrous tissue cell will be met with, whereas in the case of the sarcoma the cells tend to be all of one type, round or spindle, as the case may be.

Mixed Cell Sarcomata are met with occasionally. In such, in addition to round and spindle cells, giant cells (multinucleated masses of protoplasm) are often found.

To this type belongs the **myeloid or giant cell sarcoma** found in relation to bone.

Sites.—Such tumours occur in young subjects, chiefly in the upper end of the tibia and fibula, the lower end of the femur and in the lower jaw (malignant epulis, Fig. 109).

Appearance.—These tumours are slow growing and show generally a low degree of malignancy. They do not tend to produce metastasis and rarely recur when removed. They grow from the interior of the bone, distending and thinning the overlying bony tissue. They show the appearances of sarcomata generally, but hæmorrhages are specially frequent.

Microscopically, myeloid sarcomata are usually composed of spindle-shaped cells with large multinucleated masses of protoplasm scattered more or less regularly through them. These giant cells are sometimes absent over considerable areas. They may be differentiated from the giant cells of tuberculosis by their nuclei occurring all through the cell, especially in the centre, whereas the tubercle giant cell has its nuclei arranged in a zone at the margin. Hæmorrhages are frequent.

Glio-sarcoma is a type found in the central nervous system and retina. It is the malignant analogue of the glioma and resembles it in appearance (see p. 243).

Sarcomata sometimes show a greater amount of differentiation of tissue. Those arising in connection with bone may show a tendency to form cartilage (**chondro-sarcoma**) or bone (**osteo-sarcoma**) or a mixture of the two. Such tissue only imperfectly reproduces the structure of its normal homologue. The cartilage is very irregular and has a marked tendency to undergo myxomatous change. The bony tissue is only imperfectly formed, the calcareous material being deposited in rather than combined with the intercellular tissue. Necrosis and hæmorrhage are prominent features of such tumours.

Endothelioma.—*Sites.*—This is a term of somewhat indefinite significance applied to tumours occurring in connection with serous membranes such as the pleura, peritoneum and dura mater, but also in other parts of the body in relation to lymph and blood channels and lymph glands. Apparently they may originate in any position where connective tissue tends to assume a flattened character in consequence of forming a lining to a channel, space or cavity.

Appearance.—Such tumours have the characters and appearances of sarcomata in general.

Microscopically, the chief characteristic is a tendency for the cells to group themselves so as to form rounded or irregularly shaped spaces into which the flattened or polygonal cells project. Owing to the above-mentioned microscopic appearances the term **alveolar sarcoma** is often applied to these tumours.

Perithelioma is a term applied to a neoplasm in which there is whorl-like arrangement of the constituent cells round a central blood or lymph space, the cells being of a flattened or polygonal shape. Such tumours are found, specially in the central nervous system, growing from the membranes of the brain or cord. Sometimes in the centres of these whorls of cells instead of a space there may be a mass of calcareous material. Such tumours have been

called *Psammomata* or "brain sand tumours." They occur in relation to the cerebral meninges and ventricles.

Angiosarcoma.—Closely related to the above are malignant growths in which spaces containing blood are the principal feature. The spaces are lined with endothelial-like cells. Such tumours have of course a very vascular appearance. They are not uncommon in the brain, and are found occasionally in the spleen.

Myelomata are tumours which arise from one or other of the blood-forming elements in the bone marrow. The cells composing them are rounded or polygonal and may resemble the myelocyte, lymphocyte, nucleated red cell or plasma cell. They occur as multiple white masses in the interior of bones such as sternum, ribs, spinal column, skull, femur, humerus. They destroy and distend the bone, leading sometimes to spontaneous fracture. In the urine a peculiar form of albumose (Bence-Jones albumose) is sometimes found in such cases.

Malignant Melanotic Tumours

Melanin pigment occurs normally in the deeper cells of the *stratum Malpighii*. Subjacent to these, in the cutis vera, are certain spindle-shaped cells which may contain pigment and which are known as *chromatophore cells*. Whether these cells elaborate the pigment from the blood or bear it to other destinations from the epithelial cells is uncertain. Similar pigment is also found in the choroid and in the iris. The chemical characters of the pigment vary somewhat according to the site, but as a rule it contains a considerable quantity of sulphur and little or no iron. In colour, under the microscope, the pigment varies from yellow to dark brown. To the naked eye it usually appears black.

The exact position from the point of view of classification

of many of these melanotic tumours is uncertain. Some have the microscopic characters of sarcomata of the spindle-cell type. In others the cells are polygonal and others again have the appearance of epitheliomata. Pigmented mesoblastic cells are found in the choroid and iris, and, as we have seen, cells resembling connective tissue corpuscles (chromatophore cells) are found in the cutis, but whether these latter form the origin of melanotic tumours is uncertain. The pigment-containing cells in the pigmented moles are also of uncertain nature. Many of these melanotic tumours probably arise from the cells in the deeper layers of the stratum Malpighii, and are therefore of epithelial origin and should be classified with the carcinomata.

Sites.—Tumours which contain melanin are met with primarily in connection with the *skin* (particularly in relation to pigmented moles) and with the *eye*. Secondary deposits occur specially in *lymphatic glands* and in the *liver*. Such tumours, as a rule, are exceedingly malignant in the sense that secondary growths may occur early when the primary tumour is minute.

Appearance.—The appearance of such tumours is very characteristic owing to the presence of the melanin, which imparts a dark-brown to black colour to the growth. The pigment may, however, be present only in parts, the pigment-free areas having the appearance of an ordinary sarcoma. The student should be careful not to fall into the error of calling a neoplasm in the lung, where carbon pigment is normally present, melanotic.

Microscopically, such tumours, as already stated, vary considerably. The cells may be spindle shaped, polygonal or epithelioid. The pigment is present within the cells and in masses outside. Considerable areas of the tumour may have no pigment present at all. The pigment is yellow to dark brown in colour and is exceedingly resistant to reagents of all kinds. For its demonstration sections of the tumour should

be stained in the nuclear dye (*e.g.* hæmatein) only. The cells often have an alveolar arrangement.

CARCINOMATA OR CANCERS

These are malignant tumours, the essential constituent of which is epithelium. In addition to the epithelium there is always a greater or smaller amount of *connective tissue stroma*, which supports the epithelial elements and in which run the nutrient vessels. This stroma is derived in part from the pre-existing tissue of the area in which the tumour occurs; to a much greater extent it is a new development from the fibrous tissue of the host. It is this occurrence of two distinct types of tissue—epithelial elements and supporting connective tissue scaffolding—which distinguishes this type of malignant growth from the sarcomata. In the case of the latter the cells tend to be all of one type and are diffusely arranged.

Inasmuch as there are two main types of epithelium—(1) the stratified squamous type, covering skin and lining mouth and œsophagus; (2) the glandular type, covering the intestine and forming the secreting elements of glands—so there are two main types of carcinomata: (1) Squamous epitheliomata; (2) Adeno-carcinomata.

The characters of these tumours are those of malignant growths in general. The main underlying property is that of *invasion of the normal tissues*. Sometimes, in the case of a tumour of a surface such as the skin or of a lining membrane of a viscus such as the bowel, enlargement may take place mainly by projection of the growth. Such an appearance often receives the name “fungating” tumour (Fig. 69). As a rule, however, the tumour grows chiefly by penetrating the healthy tissues around.

When growing on one of the surfaces—skin or bowel—*ulceration* of the growth very soon occurs. This leads to

invasion of organisms and absorption of toxins, an important factor in the production of the cachexia of cancer.

The erosion of the tissues by the cancer cell elements leads to *invasion of lymph- and blood-vessels*. It is chiefly by the former that carcinomata spread, so that the secondary deposits are to be sought for first of all in the nearest lymphatic glands. Spread may also occur *by way of the blood-stream*, secondary foci occurring in the internal organs such as liver and lungs.

This invasion by the cancer cells is resented by the normal tissues, with the result that an *inflammatory reaction of a subacute type occurs in the tissues at the growing margins* of such growths. This inflammatory reaction manifests itself by an infiltration of the tissues with small round cells, similar in appearance to the lymphocytes of the blood but in reality of diverse origin.

The *metastases resemble as a rule the primary growth fairly closely*. They show the same division into epithelial elements and supporting fibrous tissue. The tendency is, however, for the epithelial elements to show less marked differentiation. Thus in squamous epitheliomata the secondary deposits may show little or no tendency to cornification and formation of cell nests.

The *cancer cells* themselves vary greatly in shape and appearance. As a rule they tend to be larger than their normal homologues. They may show evidence of secretory activity when they arise from glandular epithelium. This is indicated by vacuolation of the cells and by the accumulation of mucinous or colloid material in the gland spaces. *They do not preserve the normal relationship with their surroundings*. Thus the groups of gland cells have no basement membrane. Instead of the normal single layer of cells forming an acinus there are often several layers.

Mitotic figures are often numerous, their number being taken as a measure of the rapidity of the growth of the tumour.

The figures are frequently abnormal, showing multipolar division. The chromosomes are more often heterotypical (*i.e.* rounded instead of V-shaped—a condition characteristic of the stage of maturation of the sexual cells) than is the case in the cell dividing normally.

Various forms of *inclusions* are commonly met with in the cancer cells. These are known as “cancer bodies,” and have from time to time been taken as representing parasites of various types. They are produced by the phagocytic activity of the cells taking up leucocytes, other cancer cells, red blood corpuscles, etc. They appear as rounded bodies, usually with a distinct space surrounding them. Other bodies occurring mainly between the cells, usually in groups, are found. They are known as Russell’s fuchsin bodies, and probably represent hyaline degenerations of cells or segregations of albuminous material.

Carcinomata occur (1) at or near the orifices of the body—lip, tongue, rectum, vagina; (2) at points where normally there is narrowing of a canal—pylorus, ileo-cæcal valve; (3) at points where a canal changes its direction—hepatic, splenic, simoid flexures of large intestine; (4) in glands such as the mammary, and in organs such as the uterus, which are periodically undergoing hypertrophy and involution. In other words, there is a marked association of cancer with chronic irritation of various kinds.

The tumours commonly grow from a single centre. The various prolongations of the growth will be found all to radiate from a single point.

As previously indicated, carcinomata may be divided into two main groups—(1) *Squamous epitheliomata*; (2) *Adeno-carcinomata* or *glandular cancers*.

I. Squamous Epitheliomata

Sites.—These grow from (a) *the skin*; (b) *mucous membranes covered with stratified squamous epithelium, such as mouth,*

œsophagus, vagina, cervix uteri; (c) *embryonic epithelial canals, such as the thyro-glossal duct*. Occasionally they occur where no squamous epithelium is found normally, *e.g.* in stomach and gall-bladder.

Appearances.—Such tumours occasionally project beyond the general surface, forming a fungating mass. More commonly they appear as *ulcerated areas, the margins of the ulcer being raised and hard* (Fig. 57). On cutting down through the floor of the ulcer so that the relationship with the subjacent tissues is displayed, the opaque white epithelium will be found penetrating the tissue for a variable distance.

Microscopically, such tumours are found to be formed of tongue-like prolongations of epithelium. Sometimes these can be traced in continuity with the original mass, at other times they are cut transversely and appear as isolated rounded masses. At the spreading margin and in the early stage of the condition these columns of epithelial cells, being only a few cells thick, show no differentiation into layers. In the larger masses the central cells become flattened and undergo a change similar to the keratinisation of the stratum corneum. When the columns are cut transversely the appearance is that of a central whorl of flattened cells concentrically arranged, representing the stratum corneum and surrounded by the polygonal epithelial cells representing the cells of the stratum Malpighii, and like them showing intercellular bridges. This appearance is known as a “cell nest.” These cell nests must be distinguished from hair follicles and other normal structures.

The cells forming these epithelial down-growths resemble the normal cells found in the deeper layers of the stratum Malpighii. They tend, however, to be somewhat larger than their normal homologue. Mitotic figures are usually to be found amongst their nuclei, sometimes in large numbers.

Between these columns of epithelial cells are the tissues—muscle, connective tissue, glandular structures—which have been invaded by the growth. These are infiltrated by small round cells. These cells are specially well seen at the growing margin of the tumour, the appearance being known as small round-cell infiltration. Such small round cells may be

lymphocytes from the blood or young connective tissue cells. Hæmorrhages are not uncommonly met with in the marginal portions of the growth. In addition to the pre-existing tissues of the part there are strands of newly-formed connective tissue between the masses of epithelium. These constitute the scaffolding of the new growth, and are composed of granulation tissue, with a large proportion of small round cells.

Rodent Ulcer.—This is a variety of squamous epithelioma with a low degree of malignancy.

Site.—The condition occurs in old people on any part of the skin, but most frequently on the upper part of the face, about the root of the nose, the external angle of orbit, the side of the cheek and the forehead.

Appearance.—It appears as an ulcerated area with raised margins, which erodes down to the bone and may destroy the nose or ear, but which does not produce metastases and is very amenable to treatment. The tumour is believed to originate from the hair follicles or sweat glands, rather than from the epithelium proper.

Microscopically, the condition is characterised by the presence of masses of epithelial cells penetrating the subjacent tissues. There are certain points of distinction between this and the ordinary squamous epithelioma. (1) The cells are cylindrical or spindle shaped, and are as a rule smaller than those found in the epithelioma. (2) There are no cell nests or only imperfect attempts at keratinisation in the centres of the epithelial masses. (3) There is little or no evidence of cell reaction (round-cell infiltration) in the tissues which are being invaded. (4) The line between epithelial masses and fibrous stroma is sharply marked.

II. Adeno-Carcinomata, Malignant Adenomata, or Glandular Cancers

These tumours are composed of gland cells arranged in alveoli or in solid masses and of intervening supporting fibrous

tissue. This stroma is often absent at the spreading margin of the growth, the gland cells occurring in and between the tissue elements of the part.

As stated above, the epithelial elements show two fairly well-marked types of arrangement. They may occur *in acini*, *i.e.* with an arrangement of the cells similar to what is found in most normal glands, the epithelial elements lining a space; or, on the other hand, they may occur *in solid masses*. In the first type the cells tend to be columnar; in the second type from mutual pressure they assume a rounded or spheroidal form. This difference in the shape of the cancer cells is usually taken as a basis for further division into two types, *viz.*: (1) *Columnar cell carcinoma*, and (2) *Spheroidal cell carcinoma*. By some authorities the term adeno-carcinoma is reserved exclusively for the first type.

There are other types of carcinomata occurring in certain glandular organs, the cells of which are arranged not in acini but in columns. This arrangement obtains in the liver, and in glandular cancer of the liver the columnar structure may be reproduced.

Occasionally a tumour may show an acinous arrangement in one part and in another the cells may be massed together. At the same time the tumours of the two types preserve their characters with a fair degree of constancy.

1. Columnar Cell Carcinoma.—*Sites.*—These tumours are found most frequently in the stomach and the intestinal tract. They are also found in the liver, pancreas, uterus, mammary gland, etc.

Appearance.—They may occur as projecting fungating masses (Fig. 69), or merely as ulcerated surfaces with infiltration and thickening of the walls of the gut. There is commonly annular contraction of the gut at the affected point. Secondary deposits are common in the nearest

lymph glands and in the liver. Such secondary growths have a very variable appearance.

Microscopically, these tumours are mainly characterised by a downward growth of the gland elements into the wall of the viscus, so that gland acini are present in the submucous and muscular layers. At the same time the cancerous epithelium differs from the normal. The cells tend to be larger; they vary somewhat in size and shape. They possess no basement membrane. Mitotic figures may be found in considerable numbers. There is a tendency to form several layers of epithelium instead of one, and sometimes there is no lumen present owing to the multiplication of the gland cells. There is an inflammatory infiltration of the normal tissues at the spreading margin of the growth. Where the tumour is projecting into the lumen of the gut, also when it occurs as large solid masses in organs such as the liver, also in the secondary deposits in glands, a stroma of connective tissue forms which carries the nutrient blood-vessels.

2. Spheroidal Cell Carcinomata.—These tumours are commoner in certain situations, *e.g.* breast, but they may occur anywhere. It has been customary for long to distinguish them according to their physical characters into *Scirrhus* or *hard cancers*, and *Encephaloid* or *soft cancers*. Such names are still in use, and although the distinction depends merely upon the relative preponderance of fibrous tissue and cancer cells, it is convenient to describe them under these headings.

(a) **Scirrhus Cancer.**—*Sites.*—This is found most typically in the breast, although it also occurs in stomach, intestine, pleura, ovary.

Appearance.—Such tumours are opaque white, tendinous-looking masses radiating into the surrounding parts (Fig. 103). They are very hard, and creak on being cut. Opaque yellow areas of necrotic change are sometimes visible, although these are not nearly so numerous as in the encephaloid type. In the case of the breast there is very commonly indrawing

of the nipple. The cut surface often becomes depressed and cup shaped.

Microscopically, the tumour shows a large preponderance of the fibrous stroma element. This connective tissue in the more central parts is well developed and shows few cells. At the growing margin it is more cellular. In this fibrous stroma are elliptical spaces filled with cancer cells. The cancer cells themselves are spheroidal from mutual pressure, and there is often a space (artificially produced by shrinkage) between them and the fibrous stroma. Mitotic figures may be found. No basement membrane is present. In the centre of the growth the groups of cancer cells may be few and far between. At the growing margin they are more numerous. Occasionally there may be attempts at the formation of a lumen.

(b) **Encephaloid, Medullary or Soft Cancer.**—*Sites.*—They occur in sites such as the breast, stomach and pancreas.

Appearance.—The tumours in this type tend to be larger, softer, more vascular, and there are more often areas of necrosis.

Microscopically, they are characterised by a smaller proportion of fibrous stroma and a larger proportion of glandular epithelium. The cancer cells vary in size, but they occur in much larger masses than in the scirrhous type. Further, necrotic changes are very commonly present amongst them.

3. Colloid Cancer is a special type of Adeno-carcinoma, characterised by the accumulation of mucinous material in the spaces, which becomes inspissated and hence gum-like in consistence.

Sites.—The stomach, large intestine and mammary gland are the common sites for such growths.

Appearance.—It appears as gelatinous translucent material, in greater or less amount, in the tumour and its secondary deposits. Otherwise the growth has the appearance of a columnar cell carcinoma.

Microscopically, these tumours often show in parts the characters of the ordinary columnar cell carcinoma. In other parts, the gland acini are dilated and the lumen filled with homogeneous or slightly fibrillated material. The cells are often vacuolated from the presence of secretion. They become detached from the fibrous stroma and eventually disappear altogether, fusing with the mucinous contents of the spaces.

C. TERATOMATA

There remains for consideration a number of tumour formations traceable to some defect in the development of the individual, also others due to the grafting of the embryo's tissues upon the maternal organism.

To the first group belongs the **Teratoma** properly so called *or* **Dermoid Cyst**.

Such tumours are, as their name indicates, usually found in the form of cysts. The cyst wall is developed from the tissues of the host. The wall is lined by skin epithelium and encloses chiefly soapy-looking material and hairs, frequently also teeth, skin, bone, cartilage, muscle, nerve elements it may be, and rudimentary viscera. The causation of the condition is, in most cases, the inclusion of the elements of one individual within the body of another. The growth is simple in nature.

Site.—The site of such tumours is commonly in or near the ovary (Fig. 102), but they may also occur in the testicle, the neighbourhood of the sacrum, the side of the neck and face; also very occasionally in the brain.

Appearance.—The tumour varies much in size. Occasionally it may be as large as a foetal head. As a rule there is a point, the so-called "protuberance," which represents the head and from which arises a tuft of long hairs.

Microscopically, dermoid cysts show a great variety of types of tissue—stratified squamous epithelium, sweat glands, hair

follicles, cartilage, bone, gland acini lined by epithelium of various kinds, etc.

To the second group (those due to the grafting of embryo tissues upon the maternal organism) belong (*a*) the **placental mole**, or myxoma of the chorion, already described on p. 268 ; and (*b*) the **chorion-epithelioma** or deciduoma malignum.

Chorion-Epithelioma

This is an exceedingly malignant condition which may follow an abortion or full-time pregnancy, also its simple analogue the placental mole.

The outer surface of the chorionic villi consists of the layers of foetal epiderm. The most external (syncytium) is formed of multinucleated masses of protoplasm (giant cells). These possess normally intense phagocytic properties, whereby the villi are enabled to penetrate the maternal tissue and come to lie within the blood sinuses of the uterus. Underneath this layer is a second, in which the cells are separate and do not stain so deeply. This is what is known as the Langhans layer.

After an abortion or full-time pregnancy the layers of cells covering the chorionic villi may take on abnormal growth ; developing into a tumour which is essentially cellular (having no intercellular material), which shows no arrangement of its elements and possesses no blood-vessels.

Sites.—The usual site for such tumours is the uterus, following abortion or full-time pregnancy. Occasionally they occur independently of pregnancy, as for example in the testicle. Such are probably due to germ cells taking on active development and producing a trophoblast (the two layers of cells covering the villi are known as trophoblast) from which the tumour arises.

Appearance.—Such a tumour appears as a soft spongy vascular mass in the wall of the uterus. Necrosis and hæmorrhage are characteristic features of it. Metastatic growths

develop very early and are found especially in the lungs, but also in the liver and kidneys.

Microscopically, two types of cells are found in the parts of the tumour which are not necrosed: (1) large plasmodial masses, mostly multinucleated, derived from the syncytium, the nuclei of which are in rapid division and show all varieties of abnormal mitoses; (2) groups of smaller, polyhedral cells derived from the Langhans layer. Both types of cell are found in the uterine wall penetrating the tissues and eroding blood-vessels.

TABLE OF TUMOURS

A. SIMPLE TUMOURS—

Fibroma, Myxoma, Lipoma, Chondroma, Osteoma, Myoma, Angioma, Lymphoma, Glioma, Papilloma, Adenoma.

B. MALIGNANT TUMOURS—

(a) *Sarcomata*—

Small round-celled, Lymphosarcoma, Large round-celled, Small spindle-celled, Large spindle-celled, Mixed celled, Myeloid, Chondro-sarcoma, Osteo-sarcoma, Endothelioma, Alveolar, Perithelioma, Angiosarcoma, Myeloma, Melanotic.

(b) *Carcinomata*—

I. Squamous Epitheliomata.
Rodent ulcer.

II. Adeno-Carcinomata.

1. Columnar Cell Carcinoma.
2. Spheroidal Cell Carcinomata.
Scirrhus, Encephaloid.
3. Colloid Cancer.

C. TERATOMATA—

I. Dermoid Cyst.

II. Embryomata.

Myxoma of Chorion (simple).

Chorion-Epithelioma (malignant).

CHAPTER XV

POINTS TO BE REMEMBERED IN PERFORMING AUTOPSIES ON CASES WITH A MEDICO-LEGAL ASPECT

GENERAL METHOD OF PROCEDURE IN MEDICO-LEGAL CASES

It must be remembered that all cases of death which have occurred suddenly or unexpectedly, and cases of death where no medical man has been in attendance, as well as all cases of death from violence whether the result of accident, suicide or homicide, are the subject of inquiry by the authorities—in Scotland the Procurator-fiscal and in England the Coroner—and that in all cases of the above nature a post-mortem should not be made without instruction from the authorities.

It must also be noted that *in cases of accidental injury to work-people*, in which death ensues either at the time, or, it may be, months afterwards, a public inquiry may be held by the authorities, and that therefore *a post-mortem should not be made until the authorities have been communicated with.*

In performing a medico-legal post-mortem, the following precautions should be exercised.

1. The body should, if possible, *be identified by relations or the police in the presence of the doctor before the post-mortem is commenced.*

2. Under *all* circumstances, such a post-mortem must be *complete, i.e.* every cavity and organ must be examined.

Note.—Unless there are special circumstances indicating its necessity, it is not usual to examine the spinal cord.

3. *If there is any suspicion of poisoning, the following tissues should be preserved :—*

- (1) Stomach and its contents.
- (2) Intestines and their contents.
- (3) Liver (at least half).
- (4) Kidney and spleen.
- (5) Some blood.
- (6) Urine.

In special cases it may be advisable to remove other organs, such as the brain, lungs, etc.

4. *All tissues, etc., removed must be placed in glass vessels which are chemically clean, which should then be made airtight, sealed and labelled.* The label should bear on it the nature of its contents, and the date of the post-mortem, and should be signed by the doctor.

Each tissue or organ should be preserved in a separate vessel, and no preservative of any sort should be used.

In Scotland the medical examiner must write a report of the examination in "*soul and conscience*" form.

This medical report must contain the following :—

- (1) Date and place.
- (2) State by whom body has been identified.
- (3) Where the examination was performed.
- (4) An account of the external appearances.
- (5) An account of the internal appearances.
- (6) Conclusion from above as to the cause of death.

It is essential that *any alterations should be initialled*, but it is better to rewrite the report if additions or alterations have to be made.

No opinions other than the conclusion as to the cause of death *should be given* in the report.

No technical terms should be employed in writing the

report. The language used should be, as far as possible, popular.

The report should be signed by the medical man or men, their medical qualifications being appended.

The report is sent to the Procurator-Fiscal of the district.

In England a written report is not as a rule sent to the Coroner. The doctor gives his evidence usually at the Coroner's inquest, and *should have his notes of the post-mortem examination with him*. His evidence at the inquest is given *on oath*, and it should be remembered that all statements made there are written down, forming his "deposition," and that this deposition is produced in any subsequent proceedings.

POST-MORTEMS ON NEWLY-BORN INFANTS

In performing sections upon newly-born children the questions which require answering are :—

1. Was the child viable ? *i.e.* was development sufficiently far advanced for the child to be able to live apart from the mother ?
2. Did the child actually live (*i.e.* breathe) either during or after birth ?
3. If the child lived, what was the cause of its death ?

In order to be able to answer these questions the points of chief importance to note are :—

External Examination.—Note the length of body, weight, the condition of the finger-nails, the presence of the testicles in the scrotum ; the presence or absence of a *caput succedaneum* (the presence of such indicating that the blood was circulating during birth) and head moulding.

The condition of the umbilical cord, whether cut or torn, and whether any evidence of a line of separation having formed.

TABLE SHOWING THE PRINCIPAL DEVELOPMENTAL CHANGES IN THE FŒTUS
(LUFF, SLIGHTLY MODIFIED).

Month.	Length in Inches.	Weight in Pounds.	Eyelids.	Pupillary Membrane.	Nails.	Testicles.	Centres of Ossification present.
6th	9-12	1-2	Adherent.	Present.	Just forming.	In abdominal cavity immediately below kidney.	Manubrium. Os calcis. Bodies and laminae of sacral vertebrae.
7th	12-15	2-4	Non-adherent.	Beginning to disappear.	Finger nails not reached extremities of fingers.	Near abdominal rings.	First piece of body of sternum. Astragalus.
8th	15-18	4-5	Non-adherent.	Disappeared.	Reached extremities of fingers and nearly extremities of toes.	In inguinal canals or upper part of scrotum, especially left testicle.	Second piece of body of sternum.
9th	18-20	5-8 Average 6½	Non-adherent.	Disappeared.	Project beyond tips of fingers and reach ends of toes.	In scrotum.	Lower epiphysis of femur. Third and fourth piece of body of sternum. Cuboid. First coccygeal vertebra.

The presence of *vernix caseosa*, blood and injuries to the skin.

The neck should especially be observed for abrasions.

The mouth and nostrils should be inspected for the presence of froth or any obstructing body.

Internal Examination.—Attention should be first concentrated upon the air-passages and lungs in order to determine the question, *Has the child breathed?*

The trachea should be opened and carefully examined for the presence of froth. Some authorities recommend the tying of the trachea before opening the thorax. This is not necessary.

After opening the thorax, the contents of the thoracic cavity—lungs, heart and thymus gland—are removed and placed entire in a pail of water. If the whole mass floats, there can be no further doubt about the question of the child having breathed. Should the organs sink, then the individual lungs should be carefully examined as to the presence of any mottled areas that would indicate partial aeration. The organs should then be cut up and the separate portions tested as to their capacity to float. It may be advisable in some cases to examine portions of the organs microscopically. (For the appearance of the non-aerated lung, see Atelectasis, p. 120.)

Thereafter the examination proceeds in the usual manner, attention being, however, specially directed to *the presence of air in the stomach and small intestine* as conclusive evidence of breathing; also to *the presence of food in the stomach* as evidence of the child having survived its birth for some time.

In all cases *the presence or absence of an ossific node at the lower end of the femur must be determined* in connection with the conclusion as to the stage of maturity attained (see table, p. 309). For this purpose the cartilage of the epiphysis should be cut away in thin layers. This should be done until

the diaphysis is reached in order to be quite certain as to the presence or absence of such a node. Another important centre of ossification for purposes of determining the stage of maturity reached by the child is that of the cuboid (see table, p. 309).

The common causes of death in the new-born child are as follows :—

1. Compression of the umbilical cord.
2. Protracted delivery.
3. Malnutrition and immaturity.
4. Hæmorrhage from the cord.
5. Fracture, usually of bones of skull.
6. Accidental asphyxia.
7. Congenital malformation or disease.

Among the modes by which death may be caused in cases of infanticide are the following :—

1. Suffocation.
2. Strangulation.
3. Drowning.
4. Fracture of skull.
5. Exposure and neglect.
6. Hæmorrhage from the cord.

POST-MORTEM CHANGES PRODUCED BY POISONS

As stated elsewhere (p. 21), in cases of poisoning or suspected poisoning, after examination of the lips and mouth, the tongue, together with the fauces, œsophagus, stomach, and duodenum, should be removed and examined *in continuity*.

It should be carefully borne in mind that with certain exceptions the appearances in cases of poisoning are by no means characteristic. There may be nothing at all in the alimentary tract to suggest poisoning. Hence the necessity in all suspicious

cases for the preservation of the organs and stomach contents for subsequent chemical analysis.

Appearances in Poisoning with Corrosives.—In all such cases there is *softening of the tissues of the upper alimentary tract*—lips, mouth, œsophagus and stomach. Sometimes there is *necrosis of the superficial layers of viscera*. The stomach shows *swelling and contraction of its walls, extravasation of blood, which under the influence of the acid becomes black, ulceration, and sometimes perforation*. The lining shows in some cases a *characteristic colouring, e.g. in the case of nitric acid a yellow colour*. The appearances in *sulphuric and hydrochloric acid* poisoning are *very similar* and cannot in many cases be differentiated. The only point of distinction is that *sulphuric is a stronger acid* than hydrochloric, hence the corrosion is more intense and there is a greater tendency to perforation; the appearances varying, however, according to the dilution of the poison. The mucous membrane may be charred to a dark brown or black colour, or the appearances may be merely those of an intense gastritis. In poisoning with *carbolic*, if the acid has been taken in a concentrated form, there is *necrosis of the mucous membrane* particularly of the stomach with the formation of a *putty-like layer*. If the acid has been dilute, the interior of the stomach is dusky red from hyperæmia.

In the case of *oxalic acid* there are as a rule no external appearances. When the acid has been taken *in the concentrated form* there is a *whitish appearance of the mucous membrane inside the mouth*. When dilute, the appearances are those of irritation, viz. congestion.

In poisoning with *caustic alkalies* the appearances are somewhat similar to those found in the case of acids, but *the tissues have a characteristic soapy feel*. In *ammonia poisoning*, in addition to the appearances of corrosion in the alimentary tract, there is generally *acute inflammation in the air-passages*.

Appearances in Irritant Poisoning.—*The common irritant poisons, such as arsenic, antimony, mercury, produce changes which do not differ to any extent from one another. By the mere naked-eye examination of the parts, beyond the fact that the appearances may be those of acute gastritis and enteritis, there is little that is characteristic.* In some instances, even when the poison has been taken in a concentrated form, there may be little to suggest that the case is one of poisoning. As a rule, however, *the mucous membrane of the alimentary canal in its upper part is swollen and in parts hyperæmic.* In other words, the appearances are those of gastro-enteritis. Occasionally there is ulceration.

In the case of *phosphorus poisoning*, in addition to the evidence of irritation in the alimentary tract, there is *extreme fatty change in the liver* (which is of a bright yellow colour), also in the kidney and heart. Such cases have to be distinguished from acute yellow atrophy of the liver (see p. 183), severe anæmias, and toxæmias. The distinction can, of course, be readily made on carrying out a chemical analysis of the organs.

Appearances in Poisoning with Gases.—In poisoning with *carbon dioxide* the appearances are merely those of suffocation. The face, lips, and ears have a dark purple colour.

The appearances in *carbon monoxide* (carbonic oxide) poisoning are as a rule typical. *Externally*, the post-mortem lividity is of a pink or light red colour, and the same colour can often be seen in the lips, conjunctivæ, and nails. *Internally*, while the blood in bulk may show no change yet wherever it is in a thin layer, e.g. the mesentery, etc., the pink or light red colour is most striking. The liver, spleen, kidneys and other organs frequently show the same change of colour.

A simple but effective test can be carried out as follows:—
Take two test-tubes partly filled with tap water; add to one

a few drops of normal blood and to the other a few drops of blood from the body which is being examined. Normal blood when diluted in this way will always give a *yellow* colour. Blood containing carbonic oxide, on the other hand, however much it is diluted, will always be *pink*.

A conclusive diagnosis can be made chemically as follows :— A small quantity of normal blood is placed in a test-tube and diluted with three or four times the amount of tap water. A small quantity of blood from the case under investigation is similarly treated. A small amount of tannic acid is dissolved in three times its bulk of water. Add some of this solution to both test-tubes and shake. In the case of the normal blood a *chocolate brown precipitate* will form. Should the blood from the case contain carbon monoxide the precipitate will be a *rose red*.

In poisoning with *ammonia gas* there is intense inflammation in the respiratory passages.

In **poisoning with alkaloids**, such as *morphine*, *strychnine*, etc., there is usually absolutely no abnormality visible. Occasionally tablets of the poison are found in the stomach.

In **cyanide poisoning** the characteristic odour may be observed by those with a trained sense of smell. Similarly in poisoning with chloral, sulphonal and chloroform.

The appearances in cases of **vegetable poisoning** are in no case very characteristic. Search should be made in the intestinal tract for the presence of seeds, leaves, or other evidence of vegetable tissue.

In cases of **meat poisoning**, cultures should be made from the intestinal contents and from the spleen. Blood should be removed in order to test the serum against various micro-organisms for the presence of specific agglutinins (see p. 374).

SPECIMEN POST-MORTEM REPORTS

The following are typical post-mortem reports in the form in which they should be sent to the Procurator-Fiscal:—

A

EDINBURGH, *4th June 1909.*

WE hereby certify on soul and conscience, that by instructions of the Procurator-Fiscal of the County of Midlothian, on

SATURDAY, *3rd June 1909,*

in the Mortuary of Edinburgh Castle, we examined the body of a man which was identified in our presence by

Sergeant JOHN SMITH,

and by one of us,

Captain JONES, R.A.M.C.,

as that of

Private JAMES SCOTT.

The body was that of a well-built muscular man, $70\frac{3}{4}$ inches in height, and apparently about thirty-five years of age. The body showed no signs of putrefaction, and the usual post-mortem rigidity and lividity were present.

Situated on the right side of the chest, and in a line drawn between the junction of the collar bone and breast bone above and the right nipple below, there was a linear wound one and a half inches in length, the edges of which had been brought together by means of three stitches. The upper extremity of this wound was distant one and a half inches and the lower end two and a quarter inches from the middle line of the body. This wound was found, in the first instance, by means of a blunt probe, and subsequently, during the course of the dissection, to proceed obliquely through the second intercostal space downwards, backwards, and towards the left side, and to pass through the upper lobe of the right lung near its anterior

margin, into the pericardium, and finally to enter the right auricle of the heart above the auricular appendage and close to the junction of the superior vena cava with the auricle. The length of the wounds in the lung and pericardium was one inch, and that in the auricle half an inch.

With the exception of the injury above described, the body presented no marks of external violence.

The right pleural cavity was full of coagulated blood. The right lung was collapsed and bloodless. The left lung was healthy. The heart contained some coagulated blood, and with the exception of the wound in the right auricle, was normal.

The liver, spleen, kidneys, and other abdominal organs presented normal appearances.

The stomach contained a quantity of green bilious fluid. Its mucous membrane was in the condition of chronic catarrh.

The mouth, upper air-passages and trachea were healthy.

The brain and its membranes were congested, but otherwise they were normal.

From the foregoing examination we are of opinion that death was due to loss of blood from a wound of the heart produced by a sharp, pointed instrument.

Signed by the two medical men
present at the post-mortem.

B

EDINBURGH, *20th May 1897.*

WE hereby certify upon soul and conscience, that we
yesterday,

THURSDAY, *20th May 1897,*

examined, in the Royal Infirmary, the body of a man, which
was identified in our presence by

the Wife of the deceased,
by a Police Constable, and by the
House Surgeon attending the case,
as that of

THOMAS ROBINSON.

Deceased was an able-bodied person, apparently about sixty years of age. The only mark of violence observable was a lacerated wound of the nose, situated on the prominence, and about a quarter of an inch in length. Its edges were somewhat swollen and gaping. It was partially covered with a soft scab. The root of the nose was also somewhat swollen.

The various cavities and their contents were carefully examined; but with the exception of marked congestion of the spinal cord, and the effects of the wear and tear of life, nothing unusual was detected.

Portions of the heart, liver, and kidneys were subjected to examination by the microscope. They were all more or less fatty, but not to a great extent.

We are of opinion that the cause of death in this case was acute congestion of the spinal cord, such as we are conversant with in fatal cases of Tetanus.

Signed by the two medical men
present at the post-mortem.

APPENDIX A

TREATMENT OF SPECIMENS FOR MOUNTING

Fixatives.—In many cases the pathologist will meet with specimens which he wishes to preserve for purposes of further examination, reference, or teaching. It is his object to keep, as far as possible, the form of the organ or part and its natural colour. For this purpose the tissue must be fixed. The best all-round fixative is certainly formalin, but by itself it does not penetrate well, and the colour is not well preserved. Salts of various kinds should be mixed with it. The resulting fluids are variously known as Pick's, Jores's, and Kaiserling's solutions. The formulæ for making up these are given on pp. 322-3. Of the three, probably Pick's solution costs least to prepare. There is, however, little to choose between them as regards results. The explanation underlying the preservation of the colour of the organ in the case of all three is as follows: the oxyhæmoglobin is transformed by the formalin into acid hæmatin which has a brown colour; this, under the influence of the alcohol, becomes alkaline hæmatin, which has a bright red colour so like the original oxyhæmoglobin that the natural colour appears to have returned.

Method of preparing Specimens.—The specimen is placed in this fluid after having been cut open, or after having the fluid injected into it, the object being to secure the penetration of the organ or part by the fluid so as to prevent subsequent shrinkage or deformity. Specimens are treated differently according to their nature and consistence. It should always be remembered that a large excess of fluid is necessary for proper fixation.

Solid Organs.—There are two ways of dealing with solid organs, such as liver and spleen, if it is desired to preserve the organ whole. Fixative must either be injected into the main vessel—in the case of the liver, the portal vein—or the fluid is injected here and there into the substance of the organ with a syringe.

In most cases it is not necessary to preserve the whole organ, in which case the best way is to cut it into a series of parallel slices about an inch thick. In the case of the kidney it is sufficient to open up the organ in the usual way. The brain is best injected through the large arteries at the base. In the case of superficial exudates in the meninges or elsewhere some stronger formalin may be smeared over the surface so as at once to fix the material. When dealing with large tumours, it is well to inject fluid with a syringe here and there, more especially in the softer parts.

Groups of Organs.—When dealing with a group of organs, it may be necessary to fix them prior to removal. This can be done by injecting fixative into the circulation through one of the carotids or into a main vessel going to the part.

Lungs.—In the case of the lungs, it is best to inject the fluid into the bronchi, and, in addition, into any cavity or area of softening, before opening up the organs. If they have already been opened, it is usually sufficient to immerse each half in fixative.

Cysts.—When dealing with cysts, such as hydronephrosis, pyonephrosis, hydatid cysts, etc., the greater part of the fluid in the cyst should be removed with a syringe and replaced by fixative.

Intestine.—Portions of the intestine should either be opened up, washed, laid flat or pinned out flat, and immersed in fixative; or they may be washed out by running water through them, then, having tied one end, fixative is poured in at the upper end, the upper end tied, and the whole immersed in fluid. This latter method is more especially adapted to the preservation of tumours, the bowel being subsequently slit up into two halves, as has been done in the case of Fig. 69.

Time necessary for Fixation.—As regards the time during which specimens should remain in the fixative, this depends upon their size and consistence. Thin tissues, such as

intestines treated as above, are fixed in twenty-four hours. Lungs injected through the bronchi, and brains injected through their vessels, will be fixed sufficiently for cutting in forty-eight hours. It is necessary, however, to leave the slices some time longer in the fixative. For more solid organs, such as liver, kidney, spleen, or heart, ten days to three weeks will usually suffice, but the specimens take no harm from remaining considerably longer. A good test as to whether or no an organ is fixed is to squeeze it. If red blood exude, it is well to leave the specimen some time longer. Another test is, of course, the consistence of the organ. As a rule, so long as it is soft, further fixation is required.

Mounting Fluid.—When properly fixed, the organ is washed in clean water for some minutes and placed overnight in methylated spirit, which may have been previously used. It is then placed in fresh, clean spirit, until the colour has returned; a few hours is usually sufficient. The specimen is then washed again in running water for a few minutes, and placed in the following fluid:—

Glycerine (pure)	.	.	.	1 part.
Water	.	.	.	2 parts.

To each Winchester quart of the above, 1 fluid oz. of formalin (40 per cent) is added, also 1 oz. of a saturated solution of pure potassium acetate. The object of the formalin is to prevent the growth of mould. This fluid should be changed once or twice, and when the specimen is finally mounted in a glass jar, the same fluid should be filtered in. In such a fluid a specimen will remain soft and retain its natural colour for many years. Care should, however, be taken not to expose the specimen to direct sunlight, otherwise fading of the colour will occur.

Mounting.—When selecting a jar for permanent mounting, the nature and size of the specimen will, of course, be taken into consideration. As a rule, the rectangular glass jars are the best, the specimen being fixed to one side of the jar by means of a little gelatine, or secured to a plate of glass with strong thread. Whole hearts and spleens are best suspended in round jars. Portions of intestine laid open can

be stretched upon sheets of glass or mica, or within a frame formed of a bent glass rod. The interior of cavities and the surfaces of organs are best coated with gelatine fluid, which is prepared as follows, in order to prevent portions coming away and producing turbidity :—

100 grains pure gelatine
800 c.c. thymol water (saturated in the cold)
200 c.c. glycerine.

This is gently heated until the gelatine melts. A few drops of acetic acid are added, and the whole is clarified with white of egg. The gelatine is poured upon the specimen while warm and fluid and allowed to solidify before the specimen is mounted. For fixing on the cover of the jar the best medium is a mixture of litharge and Archangel tar in quantities sufficient to make a thick paste. A band of Berlin black should then be painted round the margin of the cover.

*Summary of Steps in Treatment of Specimens
for Mounting*

1. Place in Pick's, Jores's, or Kaiserling's fixative (for composition see below) for a variable period depending upon size, consistence, etc., of specimen.
2. Wash in clean water for some minutes.
3. Place overnight in methylated spirit which has been previously used.
4. Transfer to fresh spirit for a few hours until colour returns.
5. Wash in running water for a few minutes.
6. Place in glycerine and water (one part of the former to two of the latter), to which potassium acetate (1 ounce sat. sol. to Winchester quart) is added, also formalin to prevent the growth of moulds.
7. Mount in fresh fluid of similar composition.

Pick's Fixative

Formalin (pure, <i>i.e.</i> 40 per cent)	.	.	50 c.c.
Artificial Carlsbad salt	.	.	50 grm.
Distilled water	.	.	1 litre.

The Carlsbad salt is prepared by mixing Sod. sulphate 22 parts, Sod. bicarb. 18 parts, Sod. chloride 9 parts, Pot. sulphate 1 part. The last ingredient is not essential.

Kaiserling's Fixative

Formalin	100-200 c.c.
Pot. nitrate	15 gm.
Pot. acetate	30 gm.
Water	1 litre.

Jores's Fixative

Formalin	50-100 c.c.
Mag. sulph.	20 gm.
Sod. sulph.	20 gm.
Sod. chloride	10 gm.
Water	1 litre.

In each case to obtain the best results the formalin used should be Schering's. It costs about twice the price of the ordinary commercial formalin, but it is greatly superior in quality.

The salts for the various fixatives may be made up in packets and mixed with the water and formalin as required.

In the case of each of the methods, after fixation is complete the specimen is transferred to methylated spirit in which the acid hæmatin becomes alkaline and the colour thus returns to the blood in the tissue.

After twenty-four hours in spirit the specimen is placed in a preservative which in each instance contains glycerine as its principal ingredient. As a rule the glycerine is diluted with double the quantity of water to which potassium acetate (in the case of Pick's and Kaiserling's method) is added.

Recently Mr. R. Frost of Sheffield (Proc. Path. Soc. Great Britain and Ireland, Jan. 1912) has proposed the following as a preserving medium :—

Sod. fluoride	80 gm.
Chloral hydrate	80 gm.
Pot. acetate	160 gm.
Cane sugar (Tate's cube)	3500 gm.
Thymol water (saturated)	8 litres.

The chief advantage of this medium is its cheapness.

TREATMENT OF TISSUES FOR MICROSCOPIC PURPOSES

Necessity for Routine Microscopic Examinations

For a complete investigation of a fatal case of disease, it is necessary not only to examine as many parts of the body as possible with the unaided eye, but to investigate them further by means of the microscope. This routine examination of the organs microscopically cannot be too strongly insisted upon. Where only specimens of exceptional interest are put through and cut, the pathologist will never be able to acquire skill in differentiating the finer shades of pathological change. Further, diseased tissues do not always bear their secrets stamped upon them plainly, and unless a microscopic examination is carried out as a matter of routine, much that is of exceptional interest will be lost.

Selection of Portions of Organs or Tissues

As regards selection of a portion of a diseased organ, no definite rules can be laid down. It is well not to be satisfied with a single portion, but to take several pieces from different parts. Where one is dealing with a tumour, one section should include the capsule or a portion of any invaded tissue. If the tumour be in the bowel, along with the portion should be taken a piece of the normal gut wall. In the case of such organs as kidney, liver, and spleen, one section at any rate should include the capsule. Sections of the kidney should of course include both cortex and medulla.

It is not at all a bad plan to cut the different organs in different ways, or at any rate to pare them down to different shapes after they have been passed into spirit. Thus, kidney may be cut as a triangle, the base being the capsule, liver cut in squares, and spleen in the form of a rectangle. The advantage of this method is that afterwards, when the tissues are being passed through the various reagents and also when in paraffin, they may be recognised at a glance.

In any case, the section of the organ should be thin. It

cannot well be too thin. A good average thickness, except for certain purposes, is $\frac{1}{8}$ inch. In the case of tissue which is to be fixed in such mixtures as Flemming's or Marchi's still thinner sections are required. This does not mean that the pieces of tissue must not be large. As a matter of fact, it is most advantageous to have large sections, although they are much more difficult to cut with the microtome. In the case of lung preparations, it may be safely said that the sections cannot be too large. It is exceedingly difficult, if not impossible, to judge of the nature and distribution of pulmonary diseases from a minute portion of lung taken out at random.

These statements do not apply to sections for all purposes. When examining minute changes by serial sections, it is well to have small pieces for cutting, because it is obviously much more easy to find corresponding areas in the sections above and below any given point if the portion of tissue is minute.

When dealing with portions of the bowel, it is well to pin out a fairly large area of intestine upon a small block of wood and immerse both in the fixative. Subsequently, smaller portions may be cut or snipped out. For any of the above purposes a sharp scalpel or razor is required. In certain cases it may be advisable to fix the specimen entire before cutting away any portion for microscopic examination. This particularly applies to tumours of the stomach and bowel. In any case, it never spoils a specimen neatly to cut out a small piece for microscopic purposes.

It is well at the same time as one takes the sections to make a note of any matter of importance upon the label of the bottle in which the tissues are to be placed, such as the part of the organ from which the specimen was taken. Instead of pasting it on the bottle, the label written in pencil may be placed inside the bottle along with the specimens.

Fixation of Tissue

It is impossible to cut in the fresh condition sections of organs thin enough for microscopic purposes. Parenchymatous cells and softer parts fall out, leaving a mere skeleton of fibrous tissue. It is necessary therefore, in the

first place, to fix the tissue. There are many fixatives for tissues, but for ordinary purposes 10 per cent formalin (*i.e.* 10 per cent of the commercial 40 per cent formaldehyde) is probably the best. It is readily procured and made up, penetrates well, and gives excellent results. For this purpose undoubtedly Schering's formalin is the best. With other brands, costing less, precipitates are very apt to form, especially in tissues containing much blood. For certain purposes other fixatives may be employed, and as a matter of fact, when dealing with cases of special interest, it is well to use more than one fixative. One of the advantages of formalin is that other methods of fixation can be employed subsequently, such as bichromate of potash and osmic acid; another is that sections can be placed in gum, frozen, and cut directly from the formalin solution. As in all methods of fixation, it is essential to have plenty of fluid—at least twenty volumes of fluid to one of tissue.

Treatment of Tissue for cutting in Gum

Suitable portions of tissue are placed in the 10 per cent formalin, and are left for twenty-four hours. In the case of thick pieces, it is well to leave them longer. At the end of that time, if a rapid diagnosis is required or if it is necessary to stain for the presence of fat, pieces of the organs can be transferred directly from the formalin to a gum solution made up as follows :—

Gum Arabic	.	.	1 part,
Water	.	.	3 parts,
Thymol,			a few crystals,

and subsequently frozen and cut.

Although good results are obtained by cutting directly after fixation in formalin it is better to harden in spirit for 24 hours or longer, to wash out the spirit in running water overnight, and subsequently to place in gum solution for some hours.

Other Methods of Fixation

1. For the brain, cord, or other portion of the nervous system, where it is desired to preserve the myelin sheath of

the nerve elements, it is necessary to fix the myelin substance by bichromate of potassium or other similar salt. For this purpose, *Müller's fluid* is as good as many others of more recent introduction. It is made up as follows:—

Bichromate of potassium	.	.	2.5	gram.
Sulphate of sodium	.	.	1	gram.
Water	.	.	100	c.c.

The sodium sulphate of the Müller's fluid may, according to Mann, be omitted without the solution suffering as a fixative.

Portions of brain or cord may be placed in this direct or, better, transferred to it from formalin. They should be left in the fluid for six to eight weeks, washed thoroughly in running water for some hours, and transferred first to 50 per cent spirit, then 75 per cent, lastly pure spirit. The bichromate fluid should be *changed frequently* during the process of fixation. The process can be hastened considerably by placing the fixative containing the pieces of cord in the incubator at 37° C.

Although tedious, the above method gives very good results, even with specimens which have to be stained with ordinary methods. Müller's fluid also forms the basis of a number of other fixation methods, so that it is advisable to keep it in considerable quantity in stock.

2. *Zenker's Fluid*.—This can be made from Müller's fluid by adding corrosive sublimate, 5 grams, and glacial acetic acid, 5 c.c. to every 100 c.c. It is advisable to add the acetic acid as required to the quantity of stock solution used, as it readily evaporates if kept. The tissues should be fixed in the above for twelve to twenty-four hours. At the end of that time wash in running water for some hours and place in methylated spirit till required.

This is an exceedingly good method of fixation for most purposes. The solution penetrates well and preserves nuclear structure admirably. One objection which it has in common with all mercury fixatives is that the mercury becomes precipitated in the tissues. This can be removed by means of iodine, which forms with it a colourless soluble compound. The iodine may be added to the spirit in which the tissues are

preserved, or, what is a better way, the sections may be treated with Lugol's fluid (see p. 350) or a 1 per cent alcoholic solution of iodine for ten to twenty minutes before staining, followed by treatment with spirit to remove the iodine.

3. *Orth's Fluid*.—This is simply Müller's fluid in which 10 c.c. pure commercial formalin is added to the 100 c.c. The formaldehyde should be added immediately before the fixative is used. Fixation is complete in three to four days. The specimens are afterwards washed in running water, and placed in methylated spirit. Mallory states that the addition of 5 per cent acetic acid improves the fluid. The fluid is an excellent fixative for most purposes.

4. *Marchi's Fluid*.—This is Müller's fluid two parts, to osmic acid (1 per cent aqueous solution) one part. As in the case of all osmic acid fixatives the sections should be very thin. They should remain in the fluid three days protected from light. They are afterwards washed in running water and hardened in spirit. The method is specially applicable to the demonstration of recent areas and tracts of degeneration in the spinal cord and brain (see p. 356).

5. *Flemming's solution* is made up as follows :—

Osmic acid 2 per cent aqueous solution	.	4 parts.
Chromic acid 1 per cent „ „	.	15 „
Glacial acetic acid	1 part.

The portions of tissue should be exceedingly thin, as the osmic acid penetrates badly. They are left in the fluid for one to three days in the dark, subsequently washed in water, and hardened in spirit. The method is specially applicable to the study of nuclear changes, and to the demonstration of olein fats.

6. *Corrosive sublimate*, a saturated solution in normal saline with, if desired, the addition of 5 per cent glacial acetic acid. The tissues are fixed for twelve to twenty-four hours, washed thoroughly in water and hardened in spirit. This is an exceedingly good all-round fixative. More especially is it applicable to the fixation of tissues when it is desired to demonstrate granules in the leucocytes and other cells. The same objection as in the case of Zenker's fluid holds good with corrosive sublimate. The sections must be treated with iodine before staining in order to dissolve the mercury.

7. *Absolute alcohol* and *methylated spirit* are both fixatives as well as hardening agents. Under their influence, however, the tissues and cell elements tend to shrink considerably. They are said to be specially good for tissues in which it is desired to demonstrate bacteria. But as a matter of fact formalin and corrosive sublimate are equally as good.

It is always desirable to place a little cotton-wool in the bottle in which the fixation is carried out, in order to prevent sections adhering to the bottom. It is also desirable, particularly when dealing with unconsolidated lung, to place some at the top, in order to prevent the pieces of tissue from floating. Remember always to have a large excess of fluid present.

Sending Material to a Distance

The practitioner not infrequently desires to send pathological material to some institute or hospital where expert opinion can be obtained. For this purpose the best fluid in which to place the tissue is 10 per cent formalin. The pieces of tissue should be small, and at least ten times as much fluid as tissue should be present in the bottle, otherwise penetration of the fixative will be incomplete and putrefactive processes will progress. In the absence of formalin, methylated spirit or absolute alcohol may be used.

Treatment after Fixation

After fixation is complete, as a rule it is advisable to wash the tissue in running water. This is absolutely necessary when fixatives, such as Zenker's, Orth's fluid, corrosive sublimate, Flemming's, have been used. It is not necessary in the case of formalin-fixed tissue. The latter may be placed directly in methylated spirit.

Hardening.—After fixation, or if necessary after fixation and washing, the tissue is placed in methylated spirit. This can be done by placing directly in commercial methylated spirit or by passing through dilutions (50 per cent and 70 per cent) first. For ordinary purposes the dilutions may be omitted, especially when one is dealing with material removed from the body twenty-four or forty-eight hours after death. When

it is desired to preserve the finer details, more especially when one is dealing with the central nervous system, then passage through the dilutions is advisable, as there will probably be somewhat less shrinkage in the cell elements. In addition to hardening the specimen, the passage through spirit also to a certain extent dehydrates.

Dehydration.—The next process is dehydration, or the removal of all water from the tissue. Some tissues are more difficult to dehydrate than others. As a rule the denser the tissue the more difficult it is to dehydrate. For this reason any specimen containing well-formed connective tissue requires longer than a specimen such as, for example, normal liver. For purposes of dehydration it is well to use two changes of absolute alcohol. As a rule, a few hours in the first alcohol and twenty-four hours in the second is sufficient. The alcohol must be replaced by fresh after being used for a succession of specimens during a few days.

Embedding

The further treatment of the specimen depends upon whether one wishes to cut the sections in paraffin or celloidin. In the case of most organs and tissues, it is necessary to impregnate with some substance which will hold together the cellular elements during the process of cutting and staining. For this purpose, paraffin or celloidin is commonly employed. Each has its own special advantages, each therefore has its supporters. Probably paraffin is more generally used, so we shall consider it first.

Embedding in Paraffin.—From the absolute alcohol, the sections are placed in a clearing fluid, which may be chloroform, benzol, xylol or some such chemical substance, benzol being the cheapest of those mentioned. All these have this in common that they readily mix with alcohol on the one hand, and with paraffin on the other. At least twenty-four hours should be allowed for this clearing process, and it is well to use two changes of the clearing medium.

The sections should then be transferred to benzol, or whatever clearing agent is employed, to which some pieces of paraffin have been previously added, and the bottle placed on

the top of the paraffin oven, or inside the incubator. At this temperature, which will be about 37° - 40° C., benzol will, of course, take up much more paraffin. From this mixture, at the end of twenty-four hours, the pieces of tissue are placed in a shallow uncovered dish containing pure paraffin, in the interior of the paraffin oven. Here they remain until all the benzol has been driven off. If the sections are not too thick or if they are turned over at intervals, a few hours will suffice. It is important on the one hand not to leave the specimens too long, because the heat of the oven shrivels them. On the other hand, it is necessary to drive off all the benzol, else the tissue will shrivel afterwards and will not cut well. As a rule, if they are placed in the pure paraffin (melting-point 50° - 53° C.) the first thing in the morning, they may be cast the same day, some time during the afternoon. The criterion for the whole of the benzol having been driven off is the absence of the characteristic odour on shaking the dish containing the pieces of tissue.

To cast the specimens, two L-shaped moulds are placed upon a porcelain slab, so as to shut in a space the size of which will vary with the number and size of the specimens. Melted paraffin from a large dish is then poured in, to the depth of about 1 centimetre, the specimens are transferred by means of a warm pair of forceps, and placed, according to the direction in which it is desired to cut them, in the fluid paraffin upon the porcelain slab. When the surface of the paraffin has solidified, slab, paraffin and moulds may be placed in cold water and the blocks removed when solidification is complete.

The above periods for dehydration, clearing, etc., may be considerably shortened if the specimens be small and thin. Various abridged methods are in use, of which the following is a reliable one. At the same time, it must be remembered that leisurely methods give the best results.

Quick Method for embedding in Paraffin (Mallory and Wright).—Small pieces of tissue or organ are placed in two changes of acetone for half to two hours. The acetone must be in large excess. From this they are transferred to xylol or chloroform for fifteen to thirty minutes. They are then placed in pure melted paraffin for half an hour to an hour and a half at 57° C. Embed in paraffin.

Summary of Method of embedding in Paraffin

Fixation in formalin for	24	hours.
Hardening in spirit for at least	24	„
Absolute alcohol, two changes	24-48	„
Benzol, xylol, or chloroform, two changes	24	„
Benzol, etc., saturated with paraffin at 37° C.	24	„
Pure paraffin, melting-point 50°-53° C.	6-12	„

Cutting Preparations embedded in Paraffin.—For cutting sections embedded in paraffin, one of the improved rocking microtomes made by the Cambridge Scientific Instrument Company is probably the best. No special knife is required. Suitable razors are supplied by Hilliard, Edinburgh, for 3s. They must be kept in good order by frequent stropping and occasional setting on a Canadian hone. The block of paraffin, in which the specimen has been cast, is pared down to a convenient size with a penknife. It is fixed to one of the dies, which screws on to the arm of the microtome, by means of a heated piece of metal—the end of a copper section-lifter will do admirably. The screw regulating the thickness of the section is adjusted to the desired position (about 10 microns), and a number of sections are cut. These can be lifted by means of a fine-pointed pair of forceps and a small brush, and placed in warm water about 44° C. When the sections have flattened out they are mounted singly, or, if desired, in a series, on a clean slide. Slides previously smeared with albumin (egg albumin in water) have this advantage, that the sections adhere to them more firmly. The slide, or series of slides, is then placed in a slanting position till dry. They are then placed on the top of, or in, the paraffin bath, or in an incubator at 37° C.

Embedding in Celloidin.—The sections are taken from absolute alcohol and placed for twenty-four hours in a mixture of equal parts of absolute alcohol and ether. From this they are transferred to a dilute solution (2 per cent) of celloidin (Schering's granular) in equal parts of alcohol and ether.

They may be left in this for twenty-four hours or longer, and at the end of that time are transferred to a 6 per cent solution of the same material. Here they remain for twenty-four hours more.

To cast the specimens, take a cube of wood of a suitable size. Pour a little celloidin over the cross-grained surface, then place the specimen on it and pour a little more over. Allow the whole to dry till it is of a firm consistence, then place in 85 per cent methylated spirit.

The celloidin method of embedding is more especially used for sections of the brain, spinal cord, bone, and skin, but it is applicable to all types of tissue. Its chief advantage is, that during the process of impregnating the specimen with the celloidin no heat is applied. Another advantage which it has over the paraffin method is that the sections are floated in the staining fluids and not fixed to slide or cover-glass. This allows of the stain acting from two surfaces, and undoubtedly has the result of giving a more natural appearance to the tissue elements.

Cutting Preparations embedded in Celloidin.—For cutting such preparations a number of microtomes are available. Among them the Schanze, Minot, and, for large sections, the Bruce microtome are the best known. Special knives are always supplied with these, which require great care in order to keep sharp.

While cutting, the specimen and the knife are always kept moist with 80 per cent spirit, applied one or two drops at a time by means of a large brush. Serial sections may be obtained by placing the sections as they are cut upon tissue paper moistened with spirit. The sections are lifted with a brush, and placed in 80 per cent spirit until they must be stained. From this they are taken and either washed first or placed directly in the staining fluid.

Cutting Sections in Gum.—As previously stated, it is advisable to fix specimens before cutting them. It is possible, however, to obtain sections good enough for making a diagnosis, as, for instance, *at an operation while the surgeon is waiting*, by placing a small piece of tissue in gum and immediately cutting it. When such rapidity is not demanded, twenty-four hours' fixation in 10 per cent formalin is sufficient, but where time permits, and when it is not desired subsequently

to stain for fat, it is well in addition to harden the tissue in spirit for a day or two. This should not, of course, be done with sections which are subsequently to be stained for fat. At the end of that time the spirit should be washed out in running water over night, and the specimen placed in gum for some hours. It is absolutely necessary to wash out the spirit thoroughly, and to allow sufficient time for the gum to penetrate. Sections cut in this way give as good results as any when suitably stained. For many tissues, notably lung, the results are as good as those obtained with the best celloidin sections, and the tissues are less subjected to the influence of chemicals, and in consequence are less shrunken. Further, very large sections can be obtained by freezing, the size only being limited by the size of the freezing stage, and this, as has been already emphasised, is a matter of supreme importance in studying lung disease. Formerly, when ice and salt had to be used for freezing, the method was clumsy. Later, the introduction of ether simplified the process; but in these days of liquid CO_2 no method of cutting sections is more simple or effective.

With regard to the type of microtome, the Cathcart, with ether freezing, is a useful little instrument, particularly for travelling purposes, when the pathologist accompanies the surgeon to an operation.

For laboratory purposes undoubtedly one of the numerous CO_2 freezers is preferable, owing to its more rapid and more powerful action. Of the more elaborate CO_2 microtomes, the Aschoff-Becker is very good. A simple one is that introduced by Dr. Mixer, and used largely in America.

The piece of tissue is placed upon the stage of the microtome, and some gum poured on the top and round it. The carbonic acid gas is then turned on and off a number of times till the specimen is opaque, white, and hard. In this condition the knife will not cut it, but when it is just commencing to thaw the best sections will be obtained. To prevent the deeper portions from thawing, the gas should be turned on every now and then. A razor, the blade of a carpenter's smoothing-plane, or one of the special knives supplied with the microtomes is used for cutting. The sections are removed with a brush and placed in a basin of

cold water, where they will gradually flatten out. The sections may be stained at once, or preserved in formalin water, or better, in spirit, for future use. When it is desired to stain fat, spirit cannot of course be used.

Decalcification

Tissues which contain bone or calcium salts, such as atheromatous patches in the aorta, calcareous tuberculous glands, etc., require to be decalcified before being cut, otherwise the razor or knife employed will be ruined. Before decalcifying, the portion of bone or tissue is fixed, having been previously sawn or cut to the desired size. As fixative, formalin 10 per cent, Zenker's or Orth's fluid may be used. After washing, the specimen is placed in methylated spirit for at least twenty-four hours.

There are many decalcifying fluids, the chief constituent being, in all cases, *some acid*. In order to ensure the penetration of the acid, the fluid should be frequently changed, and should be used in large quantity. Unfortunately, nuclei are always damaged by such acids, so that the sections require to be stained for longer periods and never give quite such good results as tissues which are not so treated.

Nitric acid is one of the most effective decalcifying agents. It is used in a 5 per cent aqueous solution. For rapidity of action Perenny's solution can be strongly recommended. It is made up as follows :—

Nitric acid, 10 per cent	400 c.c.
Absolute alcohol	300 c.c.
Chromic acid, $\frac{1}{2}$ per cent	300 c.c.

In the above solution decalcification is usually complete, if moderately thin pieces of tissue are used, in from ten to fourteen days.

Apparatus required in Staining

As regards apparatus required, this depends upon the way in which the sections have been cut. Slides 3 in. \times 1 in. for ordinary sections, and 3 in. \times 1 $\frac{1}{2}$ in. for larger sections, as well as cover-

glasses (No. 1 and No. 2) will always be required. For sections cut frozen or in celloidin, a series of watch-glasses to hold the staining fluids and reagents, a bowl of water for washing between the processes, needles for lifting the sections, drop-bottles containing absolute alcohol and xylol, and a bottle of Canada balsam, also glycerine jelly or Farrant's medium, are all that is required. In the case of sections cut in paraffin, these may have been mounted either upon cover-glasses or on slides. In the former case, a series of drop-bottles containing the reagents and a pair of Cornet's forceps to hold the specimen are all that is necessary. In the latter case it is well to have a series of stoppered jars, of a size suitable for holding at least two slides, back to back, for stains and reagents. A tap for cold water and a sink should be at hand, also a jar containing distilled water. A pair of scales for weighing out stains is also necessary.

For sections cut in celloidin, watch-glasses or other small glass dishes for the stains and reagents, and needles for lifting the sections, are required.

Slides and cover-glasses should always be clean; more especially they should be free from grease. The best way of securing this is to place them in strong hydrochloric acid for a short time, then wash in running water, and finally put them into a jar with a properly fitting top containing methylated spirit. From this spirit they are taken and dried with a *clean* cloth as they are required.

Mounting Media

Canada Balsam.—This is prepared by dissolving the balsam either in benzol or xylol. The solvent is added in sufficient quantity to give a yellow fluid with a syrupy consistence. The balsam should be kept in one of the specially prepared stoppered bottles. It is necessary to add a little of the solvent from time to time to replace that which evaporates.

In the case of tissues treated with osmic acid, chloroform should take the place of the benzol or xylol.

Sections which have been stained in anilin dyes such as thionin tend to become discoloured when mounted in ordinary balsam. This is due to the fact that ordinary balsam is acid

as a result of oxidation. In neutral balsam, which may be obtained from Grüber, Leipzig, the colour is preserved for a much longer period. Another way of getting over the difficulty is to mount the section in *Colophonium* dissolved in terpentine oil.

Glycerine Jelly.—This is specially useful in mounting sections which have been stained for fat or waxy material. It contains—

Gelatine (Coignet's)	.	.	30 parts.
Distilled water	.	.	70 „
Glycerine	.	.	100 „
Alcoholic solution of camphor			5 „

After standing overnight in the distilled water the gelatine and water are boiled and subsequently strained through a warm filter. The glycerine and camphor are added and mixed thoroughly. Before use the medium should be liquefied by being placed in warm water.

Farrant's Medium.—Equal parts of water, glycerine and a saturated watery solution of arsenious acid (saturated by boiling) are mixed together thoroughly. To this is added about half its bulk of gum-arabic. The mixture is stirred from time to time until solution is complete. It is then filtered and a little carbolic (1 : 20) added.

STAINING METHODS

Treatment of Sections cut in Paraffin before Staining.—Before staining, sections which have been cut in paraffin require to be treated with some solvent for paraffin, such as benzol or xylol. The reagent is dropped on to the section and the slide or cover-glass gently tilted backwards and forwards for some seconds. The benzol is then poured off and replaced by fresh. The process of solution of the paraffin may be hastened by warming the slide or cover-glass *very gently* well above the flame of a bunsen until the paraffin is seen to melt. The benzol is then poured on and allowed to remain for a few seconds.

The benzol must now be washed off by means of a few drops of methylated spirit, the slide being inclined so as to

allow the fluid to run away. The section is now gently immersed in water and left for a few minutes before staining. The stain is then dropped or filtered on to the section, or the section and slide are placed in a suitable jar containing the stain.

Treatment of Sections cut in Celloidin and Gum.—Sections cut in gum or in celloidin are taken direct from water by means of a needle and placed in the staining fluid, usually in a watch-glass or similar hollow dish. Such sections stain much more rapidly than those cut in paraffin, by reason of the fact that the stain acting upon the tissue from both sides penetrates more readily.

Picro-Carmine

This is a combined nuclear and protoplasmic stain. It also has the advantage of differentiating between various types of tissues and cells. The nuclei of cells and fibrous tissue are stained brilliant crimson. Epithelial cells, necrotic material, fibrin and elastic tissue are stained yellow. The stain is prepared as follows :—

Pure carmine	1 part.
Liq. ammoniae fort.	3 parts.
Dist. water	3 „

Dissolve the stain in a test tube in the ammonia and water and add 200 parts of a cold, saturated, and filtered solution of picric acid, and mix thoroughly. Place the fluid in a basin covered with glass and allow to ripen in direct sunlight, testing its powers of staining from time to time. To prevent the picric acid crystallising out, add 10 to 20 per cent of distilled water to the fluid that remains. Add also 2 to 6 drops of 1 to 20 carbolic to prevent the growth of fungi.

Method.

Spread the section out on a cover-glass, drain off superfluous water. Run several drops of staining fluid over and allow to stand for fifteen to twenty minutes. Drain off excess of stain. Do not wash. Mount in Farrant's medium.

The method is specially useful for sections cut in gum,

Hæmatoxylin (Hæmatein), Eosin

Hæmatoxylin is obtained from the wood of *Hæmatoxylon campechianum* by extraction with ether. It is not in itself a dye but becomes one on oxidation. In its oxidised form it is known as hæmatein. Neither the original substance nor the oxidation product is capable of staining directly. Each requires a mordant added to it or used separately. As mordants, alum and iron are very commonly used.

There are many useful methods for staining with hæmatoxylin and hæmatein. They all give very similar results, the nuclei staining a dark blue or purple colour.

Of the hæmatoxylin methods probably the best, both as regards ease of preparation of the stain and rapidity of action, is Weigert's iron-hæmatoxylin.

Weigert's Iron-Hæmatoxylin.—Two solutions are prepared, No. 1 containing the hæmatoxylin, No. 2 the mordant (iron). These solutions keep well separately. For use, equal parts of the two are mixed together. The mixture will stain at once, but is better after twenty-four hours. It will keep good for eight to fourteen days.

The solutions are made up as follows :—

Solution 1

Hæmatoxylin	1 grm.
Alcohol 96 per cent	100 c.c.

Solution 2

Liq. ferri perchlor. (S.G. 1.124)	4 c.c.
Dist. water	100 c.c.
Hydrochloric acid (conc.)	1 c.c.

The mixture, which has a brownish-black colour, is dropped on to the section and allowed to remain from one to five minutes. Better results are obtained by differentiation for one or two seconds in acid alcohol (1 per cent hydrochloric acid in methylated spirit). The section is then thoroughly well washed in tap water and counterstained with eosin or picro-fuchsin (van Gieson's stain).

An excellent hæmatein is that recommended by Mayer. It is prepared as follows :—

Hæmatein	1 gm.
90 per cent alcohol	50 c.c.
Alum	50 gm.
Water	1 litre.

A crystal of thymol is added to prevent the growth of moulds. The hæmatein should be dissolved first in the alcohol by the aid of warmth, and then added to the water in which the alum has been already dissolved.

The stain improves on keeping. The ripening process is more rapid if the stain be exposed to sunlight. At first it may require half an hour or even longer to stain ; later, ten to fifteen minutes is sufficient. If the stain is too deep or too diffuse a few seconds in acid alcohol (hydrochloric acid 1 per cent in methylated spirit) will differentiate. The section is then washed thoroughly in tap water until the blue colour returns.

Method.

1. Stain in hæmatoxylin for two to five minutes or hæmatein ten to thirty minutes.
- (2. Differentiate in acid alcohol if necessary.)
3. Wash thoroughly in water.
4. Counterstain in $\frac{1}{2}$ per cent watery eosin for one to four minutes.
5. Wash in water.
6. Dehydrate, and at the same time take out some of the eosin in absolute alcohol.
7. Clear in benzol.
8. Mount in balsam.

In the case of sections cut in gum or in celloidin a much shorter period is required for staining in the hæmatein and eosin solutions.

Hæmatoxylin combined with Picro-fuchsin (van Gieson's stain)

For this combination the hæmatoxylin or hæmatein may be any of those in common use, such as the above mentioned, but it is necessary when using these with picro-fuchsin to stain

for a longer period than when eosin is used, as the picric acid tends to decolourise the hæmatein. Another alternative is to use a stronger nuclear stain, and for this purpose Weigert's iron-hæmatoxylin has no rival.

Van Gieson's Solution.—It is best to prepare a stock solution as follows :—

Acid fuchsin	1.5 grm.
Saturated watery solution of picric acid (about 0.6 per cent)	150 c.c.

This solution keeps well. For use, mix 1 c.c. of the stock solution with 10 c.c. saturated watery solution of picric acid. This solution will also keep for some weeks.

Method.

1. Stain in iron-hæmatoxylin for two to five minutes or in hæmatein for fifteen to thirty minutes.

2. Wash in water.

3. Stain in picro-fuchsin ten to thirty seconds.

4. Wash rapidly in water.

5. Dehydrate rapidly in absolute alcohol.

6. Clear in carbol-xylol (or carbol-benzol).

The advantages of the carbol-xylol is that dehydration need not be very complete if it is used. This is of importance because prolonged treatment in alcohol extracts the stain. The mixture consists of three parts xylol (or benzol) to one of melted crystalline carbolic acid.

7. Clear again in xylol (in order to get rid of the carbolic).

8. Mount in Canada balsam.

The special advantage of the van Gieson method is that a differentiation is effected between certain types of cells and tissues. Red blood corpuscles are stained a bright yellow colour, connective tissue fibres red, and muscle fibres yellow or brownish-yellow.

In staining sections cut in gum or in celloidin with picro-fuchsin a longer period of washing in water is required.

Eosin, Methylene Blue Staining Method

This is a method of very general applicability. In some schools in America it is used as the routine staining method.

It has many advantages. It is a fairly sharp nuclear stain, but its chief advantage is as a stain for protoplasm. The structure of the protoplasm, more particularly any granules which it may contain, are brought out with the characteristic reaction to the acid (eosin) and basic (methylene blue) dyes. The outline of the individual cells will be brought out very clearly and their relative size thus more easily estimated. Moreover, any bacteria present will be stained with the methylene blue.

In order to get the best results the tissue should be fixed in Zenker's fluid or in saturated corrosive sublimate. Fairly good results will, however, be obtained with formalin-fixed tissue.

Method.—A simple method of using the stains is as follows :—

1. Stain in eosin (1 per cent aq. solution) five to ten minutes.
2. Wash in water.
3. Stain in methylene blue (1 per cent aq. solution) half minute.
4. Wash in water.
5. Differentiate and dehydrate in absolute alcohol.
6. Clear in xylol or benzol and mount in balsam.

After staining with the eosin, Potas. Alum (sat. sol.) may be used for fixing the stain.

The differentiation should be carefully carried out and controlled by putting the section under a low power of the microscope, and noting the point at which the nuclei of the cells become sufficiently clear. The method requires some practice before the best results are obtained.

Mallory and Wright recommend the following :—

1. Stain in eosin (5 per cent aq. sol.) for twenty minutes or longer.
2. Wash in water.
3. Stain in Unna's alkaline methylene blue (one part in five of water) for ten to fifteen minutes.

Unna's Alkaline Methylene Blue

Methylene blue	1	gram.
Carbonate of potassium	1	gram.
Water	100	c.c.

4. Wash in water.
5. Differentiate in alcohol, clear and mount.

According to Mallory and Wright the success of the method depends upon the presence of colophonium in the alcohol used for differentiation. This is usually present in alcohol, but it may be necessary to add it in such quantity as to make a 10 per cent solution.

A stain which gives very similar results is prepared by diluting Leishman's stain with nine parts of water. The sections are allowed to remain in this stain for twenty-four hours. They are then differentiated in a very dilute solution of acetic acid (1:1000), washed in water, dehydrated, cleared and mounted in balsam. This makes an excellent counterstain instead of methylene blue after using Ziehl-Neelsen's carbol-fuchsin for staining tubercle bacilli.

Pyronin-Methylgreen Method (Unna-Pappenheim)

This is a useful method for differentiating the various types of cells in inflammatory tissue, more especially for demonstrating "plasma cells." The staining mixture (pyronin-methylgreen) is best obtained ready made from Grüber.

1. Fix in alcohol, formalin, or Orth's fixative.
2. Stain in pyronin-methylgreen mixture for 10-15 minutes, warming the slide slightly.
3. Wash in water for several minutes.
4. Differentiate in 70 per cent alcohol.
5. Dehydrate rapidly, clear, mount.

By the above method the protoplasm of the "plasma cells" is deep red, the nucleus green.

Elastic Tissue Stain

Elastic fibres enter into the formation of many tissues and organs in the body. More especially is this the case with the lungs and testicle and with vessels (other than capillaries) and skin. In studying pathological changes in these tissues it is therefore absolutely necessary to employ some method for the demonstration of the elastic fibres. A number of

staining methods will show elastic fibres, but for the study of changes in these fibres special selective methods must be employed. Of these selective methods, undoubtedly the best is Weigert's resorcin-fuchsin method.

The stain may be obtained in the form of powder or fluid, but it is easily prepared as follows :—

Resorcin	.	.	.	4	gram.
Fuchsin (Grübler)	.	.	.	2	gram.
Water	.	.	.	200	c.c.

Bring the mixture to the boil in a porcelain dish, and add 25 c.c. of the liquor ferri sesquichloridi (Pharm. Germ. S.G. 1.1). Boil for five minutes, stirring at the same time. A precipitate forms which after cooling is filtered. This precipitate is dissolved in 200 c.c. of 94 per cent alcohol, heat being applied till the alcohol boils. The solution is then allowed to cool, made up to 200 c.c. with alcohol, and 4 c.c. of hydrochloric acid added.

Method.

1. Tissues are fixed in formalin or corrosive, hardened in alcohol and cut in paraffin, celloidin, or better, in gum with the freezing microtome. It is well to cut the sections fairly thick (20-40 μ) in order that the sinuosities of the fibres may be followed. Tissue hardened in alcohol must of course be washed thoroughly in water (twenty-four hours) before being placed in gum.

2. Stain sections in lithium carmine one to five minutes (paraffin sections twenty-four hours).

Orth's Lithium Carmine

Carmine	5	gram.
Sat. aq. sol. of lithium carbonate	100	c.c.
Thymol, a few crystals.							

3. Differentiate in acid alcohol (p. 339) for one to twenty-four hours. The longer the sections are left in this the better the result.

4. Place direct in resorcin-fuchsin mixture for ten minutes (gum sections) to one hour (paraffin sections). The stain

tends to become less active on keeping, but the differentiation is better.

5. Differentiate and dehydrate in absolute alcohol. In the case of gum sections, this is best done in a "Petri dish" so that the section can be spread out on the slide while in the alcohol.

6. Clear in carbol-xylol or carbol-benzol.

7. Afterwards in xylol or benzol and mount in balsam.

By this method the elastic fibres are stained dark blue, the cell nuclei red. The elastic tissue stain can be used along with other staining methods. A very good combination is the following :—

Stain in iron-hæmatoxylin, then in Weigert's resorcin-fuchsin, and finish up with picro-fuchsin.

Fibrin Staining Method

Weigert's fibrin method is merely a modification of the Weigert-Gram method for staining bacteria, and sections stained with it will also show gram positive organisms. The method is particularly adapted for demonstrating the exudate in acute inflammations of pleura, pericardium and lung, also for the fibrin network in thrombi.

Method.

1. Fix in formalin or corrosive sublimate, but not in Müller's or Orth's fluid.

2. Cut in gum, paraffin or celloidin.

3. Stain in lithium carmine (see p. 344), in the case of paraffin sections for some hours, in the case of gum or celloidin sections for one to five minutes.

4. Differentiate in acid alcohol for some time, best twenty-four hours.

5. Wash well in water.

6. Stain in anilin gentian violet (p. 363) five to ten minutes.

7. Pour off excess and blot carefully.

8. Mordant in iodine solution for two minutes.

Potassium iodide	.	.	.	5 grm.
Water	.	.	.	100 c.c.
Iodine in excess.				

9. Pour off excess and blot firmly.

10. Differentiate in anilin-xylol (equal parts of anilin oil and xylol).

11. Clear in xylol, mount.

By this method the fibrin is stained blue while the nuclei of cells are stained red.

Staining of Fat in the Tissues¹

Fat occurs in the tissues as (1) neutral fats (combinations of fatty acid and glycerine); (2) fatty acids (palmitic, stearic, or oleic); (3) soaps (combinations of fatty acids and alkalies—potassium, sodium, or calcium); (4) combinations of fat with protein (albumin soaps). All the first three varieties are demonstrable by microchemical means, the last only by chemical analysis.

In order to demonstrate fat by staining methods it is necessary to cut sections of the tissues fresh or, better, after fixation with formalin. The portion of tissue is taken direct from the formalin and frozen, or it is placed for some hours in gum (p. 326) and then cut. Tissues passed through the usual reagents and cut in paraffin or celloidin have all their fat removed, unless they have been fixed previously in osmic acid, which stains certain fats black, or in a chrome salt such as bichromate of potash.

Basic anilin dyes will stain fats in the form of free fatty acid by combining with them to form coloured soaps. As a rule fatty acids occur in small amount in the fat of tissues, although in some morbid conditions (*e.g.* fat necrosis) they are present in large amount. The neutral fats, which are the predominant form, are, however, readily hydrolysed by the action of acids and so split into fatty acid and glycerine. The carbonic acid of the atmosphere will act in this way. This hydrolysed fat will take on the basic anilin dye. In this way the fat in sections stained with such a dye and exposed to the air or to the action of an acid such as sulphurous acid gradually combines with the dye and so becomes coloured. In

¹ Lorrain-Smith and Mair, *Journal of Pathology and Bacteriology*, 1906, vol. xi. p. 415; *ibid.*, 1908, vol. xii. pp. 1, 126, 134; *ibid.*, 1908, vol. xiii. pp. 14, 345; *ibid.*, 1911, vol. xv. pp. 53, 180.

other words, globules of acid fat are stained immediately with basic anilin dyes, while globules of neutral fat remain unstained until they have been hydrolysed and the fat has become acid.

Demonstration of Fat by Hæmatoxylin.—Fat in the tissues will stain with *hæmatoxylin*, in a similar way to myelin in Weigert's method, after partial oxidation by fixation in bichromate of potash or in chromic acid. The fat, however, takes considerably longer than the myelin to reach the stage of oxidation at which it will "lake" hæmatoxylin.

In order to stain sections of fatty liver in this way the piece of tissue, after rapid fixation in formalin, should be cut in gum and the sections placed in a saturated solution of potassium bichromate at 37° C. for a fortnight. At the end of this time they are stained in Kultschitzky's hæmatoxylin, and differentiated as on p. 355, or by means of Weigert's borax-ferricyanide mixture prepared as follows:—

Borax	2	gram.
Pot. ferricyanide	2.5	gram.
Water	100	c.c.

Demonstration of Fat by Osmic Acid.—For this purpose osmic acid 1 per cent solution in water or any of the fixatives containing osmic acid, such as Flemming's (p. 328) or Marchi's (p. 328) solutions, may be used. The action depends upon the reduction of the osmium peroxide to osmium oxide. Only certain fats are blackened in this way, more especially olein and oleic acid. The pieces of tissue treated should be very thin as the osmic acid does not penetrate well.

One advantage of the method is that the tissue can afterwards be embedded in paraffin or celloidin, although in the case of paraffin embedding xylol should not be used. Subsequent staining with safranin (1 per cent) gives very good results.

The staining with osmic acid can also be carried out with sections cut in gum. The sections are placed in $\frac{1}{6}$ per cent solution of perosmic acid for 12 hours in the dark, washed well in water, and mounted in Farrant's solution.

Lorrain-Smith's Nile Blue Sulphate Method.—Nile blue sulphate (A) is a dye of the oxazine series, and, like other basic

anilin dyes, it combines with fatty acid forming a coloured soap. When sections of tissue containing fat are stained with it, the larger proportion of the fat globules are found stained a brilliant red, others are stained a deep blue, while others are purple. The explanation of this is that the dye in watery solution contains a red substance (oxazone base), which is derived from the blue dye (oxazine base) by a process of oxidation. This transformation can be carried out more rapidly by heating the blue stain for some hours in the presence of acid. This red oxazone base is readily soluble in both fatty acids and neutral fats, and in virtue of this leaves the stain and concentrates in the fat. This solution of the dye in the fat is a rapid process. Hence the great proportion of the fat in the tissue will be coloured red. The blue stained globules represent the fatty acid portion of the fat which has combined with the basic dye (oxazine base) to form a soap. This process is a relatively slow one.

When both neutral fat and fatty acid are present in a globule, both stains act, thus giving a purple colour.

Method.

1. Fix in formalin.
2. Cut in gum with freezing microtome.
3. Place the sections in a concentrated watery solution of Nile blue sulphate for ten minutes.
4. Wash in water.
5. Differentiate in 1 per cent acetic acid.
6. Wash thoroughly.
7. Mount in Farrant or in glycerine jelly.

Method of staining Fats with Sudan III. and Scharlach R.—Sudan III. and Scharlach R. are two anilin dyes belonging to the azo group, closely allied to one another, the latter being richer by two methyl groups than the former, and in consequence being the stronger stain. Both dyes are readily soluble in alcohol and in fat, but not in water. It is in virtue of their solubility in fat that the colouration takes place. Both stains are capable of colouring all types of fat—fatty acid, neutral fat, and soaps. This fact, in conjunction with the ease of staining, renders them the best all-round dyes for fatty changes. Because of its more intense staining, Scharlach R. is to be preferred to Sudan III.

Method.

1. Formalin fixed tissue.
2. Cut in gum with freezing microtome.
3. Place sections in 70 per cent spirit for a few seconds.
4. Then in a saturated solution of Scharlach R. in 70 per cent alcohol, previously filtered, for ten minutes to twenty-four hours in covered dish. (The longer the sections remain in the solution, the more intense is the staining.)
5. Transfer to 70 per cent spirit.
6. Wash in water.
7. Counterstain for five minutes in alum hæmatein.
8. Mount in Farrant or in glycerine jelly.

Owing to the fact that the stains are not very soluble in 70 per cent alcohol, a relatively long period is necessary for perfect staining. The time can be shortened considerably by using one of Herxheimer's methods, of which the following is the best :—

70 per cent alcohol	.	.	.	50 c.c.
Pure acetone	.	.	.	50 c.c.
Scharlach R.	.	.	.	excess.

In the mixture of alcohol and acetone the Scharlach R. is much more soluble than in the alcohol alone. Hence two to five minutes suffices for staining. Care should be taken to filter the stain before use and to keep the dish covered in which the staining is carried out as otherwise precipitates may occur.

Demonstration of Glycogen in the Tissues

Glycogen is a carbohydrate which occurs in cells, *e.g.* liver, muscle, kidney, and, more rarely, in intercellular substance. It is readily soluble in water but insoluble in alcohol, therefore the tissue under examination must not be treated with water or watery stains. It gives a dark brown colour with iodine. For ordinary purposes **Ehrlich's method** is quite good.

Method.

1. Place tissue at once in absolute alcohol.
2. Embed in paraffin.
3. Stretch the cut sections in 50 per cent alcohol.

4. Place a drop of the following mixture on the slide :—

Gum-arabic	100 parts.
Lugol's iodine solution (see below)	1 part.

Lugol's Solution

Iodine	1 grm.
Pot. iodide	2 grm.
Water	300 c.c.

Place a cover-glass on the specimen and investigate.

In order to obtain permanent preparations, more elaborate methods, such as Lubarsch's and Best's, must be adopted.

Lubarsch's Method

1. Fix tissue in absolute alcohol, embed in paraffin, cut, stretching sections in 50 per cent alcohol.
2. Stain in Mayer's alcoholic carmine for several minutes.

Carmine	4 grm.
Water	15 c.c.
Hydrochloric acid	30 drops.

Dissolve by boiling, add 95 c.c. of 85 per cent alcohol ; filter in warm condition and neutralise with ammonia until a permanent precipitate forms, then filter in the cold.

3. Differentiate in acid alcohol (see p. 339).
4. Wash in absolute alcohol.
5. Stain in methylanilin violet solution as for Weigert's fibrin method (p. 345), warming slightly for two minutes.
6. Wash very rapidly in water.
7. Pour on Lugol's solution (see above), and leave for 10 seconds.
8. Dry with filter paper.
9. Differentiate in—

Anilin oil	2 parts.
Xylol	1 part.

10. Clear in xylol and mount in balsam.

By this method the glycogen is coloured blue-violet and the nuclei of the cells red.

Best's Method

1. Fix in absolute alcohol, embed in celloidin and cut.
2. Stain in Weigert's iron-haematoxylin (p. 339).
3. Differentiate in acid alcohol.
4. Wash rapidly in water.
5. Stain in ammonia carmine prepared as follows :—

Carmine	2	gram.
Pot. carbonate	1	„
Pot. chloride	5	„
Dist. water	60	c.c.

Boil for a few minutes, and after cooling add ammonia 20 c.c. For use take—

Carmine solution	20	parts.
Ammonia	30	„
Methyl alcohol	30	„

Stain in this for 5 minutes to 24 hours.

6. Place in differentiating fluid for several minutes until the section is again blue. Differentiating fluid—

Abs. alcohol	40	parts.
Methyl alcohol	20	„
Dist. water	50	„

7. Wash in 80 per cent alcohol.
8. Dehydrate in alcohol, clear in xylol, mount in balsam.

In the above method the haematoxylin may of course be omitted. Paraffin sections may be treated similarly if, after dissolving out the paraffin with xylol and washing off the xylol with alcohol, the sections are placed in thin celloidin for 3 to 4 hours. At the end of that time they are placed upon a slide and stained in Best's carmine. The glycogen by this method is stained red.

Demonstration of Calcareous Material in the Tissues

Hæmatoxylin and hæmatein stain calcareous material dark blue.

Von Kossa's Silver Method.

1. Fix in formalin for a short period, and cut with freezing microtome.
2. Lay the sections in 5 per cent silver nitrate in the light for 10 minutes to 1 hour.
3. Wash in distilled water.
4. Transfer to a 5 per cent solution of sodium hyposulphite in order to remove excess of silver nitrate.
5. Wash thoroughly in water.
6. As a counterstain safranin (1 per cent watery solution) may be used.
7. Dehydrate, clear, mount.

In carrying out the above method phosphate of silver is formed by interaction between the silver nitrate and the phosphates of calcium and magnesium. Under the influence of light the silver salt is reduced to metallic silver which appears in the section black.

Stains for Amyloid or Waxy Substance

Amyloid or waxy degeneration is a change which affects connective tissue, chiefly that in relation to blood-vessels.

The tissue becomes swollen, transparent, and homogeneous. The material of which this degenerated tissue is composed is an albuminous body combined with chondroitin sulphuric acid.

Tissues containing waxy substance should be fixed in formalin and hardened in spirit, but should not be kept too long in either fluid, as the amyloid material tends to lose its characteristic staining properties in these fluids. It is possible, however, to stain sections successfully which have been kept for years in spirit.

Sections are best cut in gum after the spirit has been thoroughly washed out with water. The waxy material is well demonstrated by such ordinary methods as hæmatoxylin and picro-fuchsin, by which means it is stained a yellow-brown

colour. There are two selective methods for waxy material—(a) iodine, (b) anilin stains.

(a) **Iodine Method.**—The sections cut in gum are placed in an iodine solution—Gram's or Weigert's (p. 363) solutions are both suitable—and left there for two to five minutes. They are then mounted in glycerine jelly without washing.

By this means the waxy material appears, by transmitted light, a golden yellow, by reflected light a mahogany brown.

(b) **Anilin Stains.**—A number of anilin dyes, which are mixtures of several different chemical compounds, such as methyl violet (a mixture of tetra, penta, and hexamethyl-rosanilin), gentian violet (a mixture of the chloride of penta and hexamethyl-pararosanilin), polychrome methylene blue (formed by boiling methylene blue with an alkali and containing methylene violet), show characteristic staining with tissues containing waxy material. In other words, such tissues when stained by one of these dyes show the waxy material a pink or purple colour while the rest of the tissue is stained blue. Methyl violet is probably the best-known stain.

Method—

1. Stain sections in a 1 per cent solution of methyl violet in water for several minutes.
2. Differentiate in acetic acid, 1 per cent in water.
3. Wash thoroughly in water. Best for twenty-four hours in several changes.
4. Mount in glycerine jelly or a watery solution of levulose.

Demonstration of Iron-containing Pigment in the Tissues

The sections may be fixed in formalin and cut in paraffin or in gum. The latter is best for the purpose.

Method—

1. Lay the sections in a 2 per cent watery solution of ferrocyanide of potassium for a few minutes.
2. Transfer to hydrochloric acid 1 per cent in water (acid alcohol may be used), and leave for one to two hours.
3. Wash in water.

The sections may be counterstained in eosin or, better, in alum carmine prepared as follows:—

Carminc	.	.	.	2 grm.
Alum	.	.	.	5 grm.
Water	.	.	.	100 c.c.

Boil for one hour, allow to cool, and filter.

Sections should be stained for ten minutes (gum or celloidin sections) to twenty-four hours (paraffin sections).

Demonstration of Chromaffin Cells

In cases which had symptoms suggestive of Addison's disease during life it is necessary (p. 114) to investigate the chromaffin tissue of the body. Chromaffin cells (cells, *i.e.*, which have an affinity for chrome salts) are found in the medullary portion of the suprarenals, in the carotid body, etc. For the demonstration of such cells the tissues should be fixed in Müller's or Orth's fluids, cut in gum, and stained in some nuclear stain, *e.g.* polychrome methylene blue, to bring out the nuclei of the cells. After such treatment the chromaffin cells assume a grass-green colour.

Weigert's Method for staining the Medullary Sheath of Nerves

Methods for staining the medullary sheath of nerves are all founded upon Weigert's method, which consists in fixing the tissue in potassium bichromate, fluor chrome, or some such mordant, subsequently staining in hæmatoxylin and differentiating. Under the action of the bichromate, the myelin substance of the medullary sheath becomes partially oxidised. Lorrain Smith and Mair¹ bring forward evidence to show that it is probably cholesterin in the form of a loose combination with a fatty acid which becomes oxidised during bichromating. The oxidation, if not too prolonged, is only partial. There is still an unsaturated grouping. On treatment with hæmatoxylin further oxidation occurs. The oxide of chromium present in the myelin combines with the hæmatoxylin, so that "laking" of the hæmatoxylin, and therefore staining of the myelin sheath takes place. It is possible to prolong the treatment with the bichromate to such an extent that there is

¹ *Journal of Pathology and Bacteriology*, 1909, vol. xiii. p. 14.

complete oxidation of the myelin substance, when no staining occurs on placing the tissue in hæmatoxylin.

By this method the myelin sheath is stained a dark blue-black. Any area of brain, cord, or nerve, where the myelin substance has disappeared, will remain unstained. The method is adapted for demonstrating such degenerated areas. They may be brought into greater prominence by counter-staining in picro-fuchsin (van Gieson's stain) when the degenerated area appears bright red.

The tissue having been mordanted in potassium bichromate, *e.g.* in Müller's fluid (see p. 327), for some six weeks, hardened in alcohol, embedded in celloidin, and cut, sections are placed in some preparation of hæmatoxylin, of which one of the best is Kultschitzky and Wolter's, prepared as follows:—

Hæmatoxylin	1 grm.
Absolute alcohol	10 c.c.
Acetic acid (2 per cent)	90 c.c.

This solution should be prepared at least a week previous to using. It keeps well, and indeed improves on keeping.

Method—

1. Stain in hæmatoxylin twelve hours at 37° C.
2. Wash in water.
3. Place in $\frac{1}{4}$ per cent watery solution of potassium permanganate for twenty to thirty seconds.
4. Wash in water.
5. Differentiate in equal parts of sulphurous acid and water for a few minutes, *i.e.* until the grey matter is colourless.
6. Wash thoroughly in water.
7. If desired, counterstain in picro-fuchsin (p. 341).
8. Wash in methylated spirit.
9. Dehydrate in absolute alcohol.
10. Clear in benzol.
11. Mount in balsam.

After washing with water (2) and (6), it is advisable to leave the sections for some time (one to two hours) in water to which a small quantity of a solution of lithium carbonate has been added.

Marchi's Method for demonstrating Degenerated Myelin

In *areas of degeneration* in brain, cord, or nerve, as the result of disintegration of the myelin sheath, globules of fatty substance are set free. These fatty globules will blacken on treatment with perosmic acid, because the fatty substances, having an unsaturated grouping, are oxidised at the expense of the perosmic acid, which is reduced to black oxide of osmium. The *normal* myelin substance of nerve tissue will act in the same way if sections are placed in perosmic acid, directly or after fixation in formalin. On the other hand, if the nerve tissue containing the degenerated focus be exposed for a short time to the action of bichromate, the normal myelin sheath will not blacken, because oxidation of the myelin substance occurs. The globules of fat in the *degenerated* area are only slowly oxidised by the bichromate, thus reduction of perosmic acid and blackening of the globules results. As stated elsewhere (p. 347), only the olein compounds react in this way.

In order to demonstrate degenerating myelin in this way a portion of spinal cord, brain, or nerve is placed in formalin for twenty-four hours. At the end of that time very thin portions are removed from the larger piece and placed in Marchi's fluid (see p. 328) for three days. They are then washed thoroughly in running water and cut in celloidin. In order to show the nuclei of the cells safranin (1 per cent) may be used.

Method of demonstrating Ganglion Cells and their Nissl Bodies

For fixation, any of the fixatives may be used. Nissl recommends absolute alcohol. Small portions only of the tissue (brain or cord) should be taken. Fixation and hardening is complete in the alcohol in two to three days. Nissl cuts the tissue embedded in gum arabic hardened by alcohol, but embedding in celloidin or paraffin gives quite good results.

Method—

1. Stain sections in Unna's polychrome methylene blue (Grübler) for ten minutes.
2. Wash in distilled water for some minutes.

3. Rinse in methylated spirit, and then in
4. Absolute alcohol to which one or two drops of acetic acid have been added, and afterwards in pure abs. alc.

Differentiation may also be carried out in Unna's glycerin-ether mixture (Grübler's) diluted with water.

5. Clear.
6. Mount. (Colophonium dissolved in xylol is recommended for this purpose.)

Instead of the polychrome methylene blue, thionin or toluidin blue may be used.

MAKING OF BLOOD FILMS

(a) Take some perfectly clean slides. Knock off the corner of one of them (so that the end measures a little less than one inch) by making a small scratch with a glass cutter. Place a small drop of blood at the end of another slide and with the broken end of the first guide the drop along the surface. In this way a thin film of blood will be obtained which reaches not quite to the margins of the slide on either side.

(b) Take a number of perfectly clean square No. 2 cover-glasses. Place them on filter paper. Lift one of them with a pair of small forceps and remove from the pricked finger or ear a very small drop of blood. (The size of the drop required depends upon the size of the cover-glass; only experience will teach the operator.) Allow this cover-glass to rest upon another, the drop of blood being between and the angles of the slips not coinciding. The weight of the upper cover-glass will spread the blood, and if both slips be clean an even film will be obtained. The lower cover-glass is then lifted by means of the forceps by one of the projecting angles and grasped between finger and thumb by two opposite angles. The upper cover-glass is then grasped at a projecting angle by the forceps and gently slid off the lower.

Each film is then allowed to dry in the air. The forceps used should be preferably non-serrated at the points.

Staining of Blood Films.—For ordinary purposes this is best done by Jenner's, Leishman's, or Wright's stains. In each case the stain is an eosinated methylene blue dissolved in pure methylic alcohol. The stains may be bought ready made

up, or tabloids prepared by Burroughs, Wellcome, & Co. may be used. These should be dissolved in 10 c.c. of methylic alcohol. *No preliminary fixation is required as the methylic alcohol acts as a fixative.* The action of the stain can be limited by drawing two lines across the slide with a grease pencil.

Leishman's and Wright's Stains—

1. The stain is poured on to the film and allowed to remain for one to two minutes.

2. Add an equal quantity (*circa*) of distilled water by means of a glass pipette. Mix by gently rocking, and leave for three to five minutes.

3. Pour off the stain and add from time to time distilled water, rocking the specimen to and fro until the thinner portions become pink.

4. Pour off the water and allow the film to dry in the air.

These stains are also excellent for demonstrating parasites, such as malaria, trypanosomes, etc.

Jenner's Stain—

1. Pour on stain and leave for two to four minutes.

2. Wash off with distilled water, controlling the differentiation by examining under the microscope.

3. Dry in the air, placing in a sloping position.

BACTERIOLOGICAL METHODS OF INVESTIGATION

Requisites

A bunsen burner or, in the absence of gas, a spirit lamp should be close at hand. A number of sterile pipettes made by drawing out suitable glass tubing in a blow pipe, and rubber teats; a looped platinum needle; a flat piece of metal for searing organs; a rack with culture tubes (broth and agar and blood-agar slopes), and a number of clean slides should be within reach. When culture tubes are not available, several sterile test-tubes, or, better, sterile swabs in test-tubes for removing samples of exudate, will serve the purpose. In his laboratory the pathologist should, of course, have an incubator, dyes for staining, etc., etc. A pencil for writing on glass will be found useful.

Method of inoculating Culture Tubes

Sterilise the platinum needle by holding it obliquely in the flame. Turn round the cotton wool plug of the culture tube to be inoculated so as to ensure its easy removal. Holding the platinum needle in the right hand like a pen and the culture tube in the left, remove some of the exudate or pus, an assistant holding open with forceps the incision previously made into the serous sac, abscess, or organ. Grasp the cotton wool plug between the right ring and little fingers and remove it. Smear the surface of the agar tube with the exudate. In the case of the broth tube, rub the loop of the needle against the side of the tube at the upper level of the fluid.

Owing to the fact that bacteria of all kinds rapidly invade the body after death, chiefly from the alimentary canal, bacteriological investigations carried out upon the cadaver are not nearly so reliable as those performed during the life of the patient. Pathogenic microbes tend to die out and their place to be taken by the unimportant saprophytic forms which have invaded the tissues. At the same time, where cultural investigations have not been made during life, or where the affected focus is in a part of the body which ordinary clinical methods could not reach, it becomes necessary for the pathologist to elucidate as far as he can the bacteriological aspect of the diseased condition. Although, as we have seen, it is advisable to carry out the examination as soon as possible after the death of the patient for ordinary purposes, it is doubly so when the pathologist has in view any bacteriological investigation. The bacteria which invade the tissues multiply and spread at such a rapid rate that ultimately any exact bacteriological observations become impossible.

Examination of the Blood

This is, of course, best done during the life of the patient by drawing off 1-5 c.c. of blood from one of the arm veins. In cases of bacteraemia, when this has been omitted during life, it is still possible to carry out the observation after death. Unfortunately the blood is the tissue of the body most rapidly

invaded by the saprophytic germs. Nevertheless, when carefully done, the investigation is undoubtedly useful.

It has been shown by Canon¹ that it is the blood in the peripheral veins which gives the most reliable results, much more reliable than in the case of the heart.

A large vein in the arm should be exposed by cutting through the skin, incised with a sterile knife, and by pressing down from above, a fair amount of blood or blood serum can be collected in a syringe or pipette. The fluid is then added to one or more broth tubes, or smeared over an agar slope, and incubated.

The blood may also be obtained from the heart or from the interior of one of the solid organs, such as the spleen, as will be detailed later.

Examination of the Solid Organs

The spleen in typhoid fever, the lung in pneumonia, the liver in cases of abscess formation, the brain in meningitis may be examined in this way.

The surface of the organ is seared by means of a red-hot flat piece of metal. A useful instrument for this purpose is a copper section lifter. A knife is sterilised either in the flame or by boiling, and a cut is made into the substance of the organ through the seared portion of the surface. A platinum loop is then inserted through the opening, pushed further in if that is possible, withdrawn, and then smeared over the surface of an agar slope or shaken in a broth tube.

Smears on slides may also be made from the solid organs, more especially spleen or lung, and stained to demonstrate bacteria.

Examination of Contents of Hollow Viscera

Bacteriological examination of the intestinal canal is seldom of much use, owing to the multiplication of the organisms of putrefaction. In certain cases, however, useful information may be obtained. In typhoid fever, for example, pure cultures of the bacillus typhosus may be obtained from the upper part of the

¹ *Die Bakteriologie des Blutes bei Infektionskrankheiten*, Jena, 1905.

jejunum as well as from the urinary bladder and gall bladder. In opening these viscera for such a purpose, it is well to sear the surface, incise with a sterile knife, and remove a sample of the contents with platinum loop or pipette.

Examination of the Contents of Serous Sacs

This is usually the first and the commonest bacteriological problem which the pathologist encounters. Where the presence of pus is suspected in one of the serous sacs, it is necessary to open the sac with certain precautions.

Having dissected down to the lining membrane—pleura, pericardium, peritoneum, as the case may be—a clean knife (bistoury) and pair of dissecting forceps are taken, the membrane is raised with the forceps and a small incision made. Through this a sterile platinum loop or a pipette is inserted, a small quantity of the fluid removed and inoculated into a series of culture tubes.

As a rule, the media employed will be broth or agar slope, and where the presence of one of the more delicate germs is suspected, such as the streptococcus, pneumococcus, or influenza bacillus, blood agar or blood serum. Subsequently, a number of films from the fluid should be made and stained.

Where the cavity has been already opened into, that is, before its infected nature was realised, pressure should be exerted upon the deeper parts so that some fresh fluid appears, and as this flows over the edge of the opening a sample for inoculation may be obtained by means of a platinum loop or pipette.

Blood agar culture media may be readily obtained from ordinary agar slopes by smearing with a platinum loop a little blood from the finger over the surface. The finger should be first rubbed at the root of the nail with a little methylated spirit which is allowed to dry. A sharp stab is then made by means of a sharp-pointed knife similarly sterilised, a cloth being wrapped round the finger to congest it.

Method of making Films from Pus and Sputum

When the pus or sputum is thick, an excellent method is to place a drop of the fluid on a clean slide, place another

on the top until the pus has spread between the two, then slide them rapidly apart. In this way two good films are obtained. Another method is to spread the fluid with the platinum needle laid flat on the glass.

The film is then dried by moving it to and fro well above the bunsen flame, and ultimately fixed by passing it thrice through the flame. Another method of fixation is by means of absolute alcohol. The alcohol is dropped on and left for some minutes, after which it is washed off in water. Still another fixative for films is the following mixture :—

Methylated spirit . . .	9 parts.
Formaldehyde . . .	1 part.

This is dropped on and left for thirty seconds to a minute, and then washed off with water.

Staining Methods for Bacteria

Bacteria are composed to a large extent of nuclear material. Thus when it is desired to demonstrate them microscopically, they are stained with nuclear dyes. Hæmatoxylin and similar dyes, however, only stain organisms faintly. It is the basic anilin dyes which are most commonly used for this purpose, such as methylene blue, gentian violet, basic fuchsin.

As a rule, bacteria do not take up these dyes nearly so readily as the nuclei of cells. In consequence, it is necessary to enforce their action by (*a*) allowing the stain to act for a prolonged period, (*b*) by heating, or (*c*) by the addition of some mordant to the stain, such as carbolic acid, caustic potash, anilin oil. Once stained, however, the bacteria retain the dye with much more persistence than the nuclei of cells amongst which they may lie. Hence it is possible by the use of a decolourising or differentiating agent, such as alcohol or some dilute acid, to bring the bacteria into greater prominence and differentiate them from the surrounding cells. This resistance to decolourising agents is more marked in a group of bacteria which includes the tubercle bacillus. In consequence, the term "acid-fast" is applied to them. The tubercle bacillus, after having been stained, resists also the decolourising action of alcohol as well as of acid.

Gram's Method and Weigert's Modification

1. Fix film.
2. Filter on to film or section anilin or carbol-gentian violet made up as follows :—

Saturated solution of anilin oil in water or
 carbolic acid 1 to 40 9 parts.
 Saturated alcoholic solution of methyl or gentian
 violet 1 part.

For films of bacteria or pus this should be left on for two minutes.

For sections of tissue it should remain five minutes.

3. Wash in water.
4. Pour on Gram's or Weigert's iodine solution. The latter is three times the strength of the former and is better for this reason. It is prepared as follows :—

Iodine excess.
 Potassium iodide 5 grm.
 Water 100 c.c.

The iodine is left on for one minute in the case of films, for two minutes in the case of sections.

5. Differentiate in methylated spirit.

Some experience is required before this can be done successfully. A few seconds is usually all that is required for films. In the case of sections, not quite all the blue should be removed.

A better method with sections is to blot the section firmly but carefully with filter paper after the iodine. Then drop on anilin xylol (equal parts of anilin oil and xylol). This may be allowed to act until all the blue has been removed. Rapidly treat with spirit to remove the anilin xylol.

6. Wash in water.
7. Counterstain for half a minute in some red or brown stain, such as fuchsin, safranin, Bismarck brown, or lithium carmine considerably diluted.
8. Wash in water.
9. In the case of films, dry them well above the flame. In

the case of sections, dehydrate, clear, and mount in Canada balsam.

Carbol-Thionin Blue

1. Filter on staining solution consisting of 1 gramme thionin blue dissolved in 100 c.c. carbolic (1 to 40). The author has found this stronger solution preferable to the dilution of the above, in the proportion of 1 of the stain to 3 of water, recommended by Muir and Ritchie.

Films should be stained for three to five minutes, sections from five to ten minutes.

2. Wash in water.

In the case of films, blot, dry, and, if necessary, mount.

In the case of sections and thick films of pus

3. Decolourise very rapidly in 1 per cent acetic acid in water.

4. Wash in water.

5. Dehydrate, clear, and mount.

The above is an excellent method for demonstrating the ordinary bacteria in films from cultures, in pus and in tissues. It is specially suitable for showing up masses of typhoid bacilli in spleen and mesenteric glands, *bacillus coli* in liver, *bacillus pestis* in spleen or bubo, *entamæba hystolytica* in dysentery, etc. The organisms stain a deeper purple than the nuclei of the cells. Red blood corpuscles in properly stained specimens are yellow.

Where the organisms are too readily decolourised, as in the case of *bacillus pestis* sometimes, after staining, instead of washing in water and decolourising, blot the specimen and pour on some anilin oil and rock the slide to and fro until the greater portion of the stain has come out, then use xylol and mount in balsam.

This staining method may also be used for demonstrating mucus which takes on a red or purple colour with Thionin blue.

Eosin Methylene Blue

This method is given above (p. 342). It is well adapted for demonstrating masses of cocci in vegetations, diphtheria

bacilli in false membrane, abscesses, etc., also entamœbæ in the large bowel or liver.

Both this method and the previous one have this advantage over Gram's method that the cells and intercellular fibres of the tissues and bacteria are stained more naturally. In Gram's method the organisms appear often abnormally large, and the tissues tend to be altered by the iodine.

Staining Methods for the Tubercle Bacillus

A. Ziehl-Neelsen Method

1. Filter on the following stain usually known as Ziehl-Neelsen's carbol-fuchsin stain :—

Basic fuchsin	1 part.
Absolute alcohol	10 parts.
Carbolic acid in water (1 : 20)	100 parts.

Instead of the carbolic (1 : 20) a saturated solution of anilin oil in water may be used. This should of course be filtered previous to making up.

The best way is to keep in a stock bottle absolute alcohol saturated with basic fuchsin. This is added to the carbolic water as required.

In the case of films, hold over flame or place upon hot metal slab or coin while steam rises. Remove the specimen and repeat the process twice, the staining occupying three to five minutes.

In the case of sections, the above method may be used, the staining process occupying at least five minutes.

The author has, however, found that placing the sections in the carbol- or anilin-fuchsin in a jar in the paraffin bath at 50-55° C. gives much better results, the tissues being less damaged by the heating.

2. Wash in water.

3. Differentiate in 1 per cent hydrochloric acid in methylated spirit. This the author has found very much better than the usual 25 per cent H_2SO_4 in water. The advantages

are that there is no danger of decolourising ; the alcohol test is applied to the organism at the same time as the acid, and, in the case of sections, the tissues are not damaged as they certainly are by the stronger acid. Differentiation should be carried out until there is just a slight pink tinge in the film or section. Thick portions of the film will probably be still red, but in any case, in searching for tubercle bacilli, such thick areas should be avoided.

4. Wash in water.

5. Counterstain in a 1 per cent watery solution of methylene blue for half a minute.

With sections, diluted Leishman's stain gives excellent results. One part of Leishman's stain is added to 10 of ordinary tap water ; the section is left in this in a jar over night. It is then differentiated rapidly in acetic acid (1 : 1000), dehydrated, cleared, and mounted.

6. In the case of films, wash in water, blot, dry, and mount.

In the case of sections, dehydrate thoroughly, thus removing excess of methylene blue, clear in xylol or benzol, and mount in balsam.

B. Much-Gram Method

1. Stain film in the following mixture, either heating above the flame for a few minutes till steam rises or leaving in the incubator at 37° C. for twenty-four to forty-eight hours :—

Saturated alcoholic solution of methyl violet B.N.	10 c.c.
2 per cent water solution of carbolic acid.	100 c.c.

2. Apply Gram's iodine for one to five minutes.

3. Drop on 5 per cent nitric acid and leave for one minute.

4. Drop on 3 per cent hydrochloric acid and leave for ten seconds.

5. Differentiate in acetone and alcohol equal parts.

6. Wash in water.

7. Counterstain in dilute fuchsin if required.

8. Wash, dry.

More recently Much has used instead of 2, 3, and 4 the following mixture :—

Potassium iodide	5 gm.
2 per cent hydrogen peroxide	100 c.c.

The film is then differentiated in absolute alcohol.

By either of the above methods, in addition to the ordinary form of the tubercle bacillus which is demonstrated by methods such as Ziehl-Neelsen's, a granular form of the organism which appears as minute blue-black granules is shown. This form is believed by many to be a resting stage or spore form of the bacillus. The granules may occur in a bacillary form or may be found free.

C. Method combining Ziehl-Neelsen with Much-Gram (Much-Weiss)

1. Stain in the following mixture for twenty-four to forty-eight hours.

Much's carbol methyl violet solution	1 part.
Carbol-fuchsin	3 parts.

Subsequently treat with iodine, nitric acid, etc., as in the Much-Gram method.

Method of demonstrating the Club Form of Streptothrix Actinomyces

These bodies are exceedingly variable in their staining reactions. They are sometimes demonstrable by means of Gram's method, but they are more often decolourised. The author has introduced the following method, which has the advantage of bringing the bodies out in striking contrast to their surroundings.

The tissues may be fixed in either 10 per cent formalin or in saturated corrosive sublimate. The section is placed in the following mixture, which is known as Mann's methyl-blue and eosin stain :—

1.	1 per cent methyl-blue in distilled water	35 c.c.
	1 per cent eosin in distilled water	45 c.c.
	Distilled water	100 c.c.

The section should be left in this for twenty-four hours. A few hours would suffice, but in order to obtain the best results, the longer period is necessary.

2. Wash in water.

3. Dehydrate in absolute alcohol to which a few drops of a 1 per cent solution of caustic potash in absolute alcohol has been added.

Treat the specimen with the above reagent until it becomes a bright pink colour.

4. Wash in 1 per cent acetic acid in water. The section will now become bright blue.

5. Wash in water.

Examine under microscope, and if necessary repeat 3 and 4.

6. Dehydrate, clear, and mount.

The above method is a slight modification of Mann's methyl-blue and eosin stain. By means of it the clubs will be stained a bright red colour, while the cells surrounding them, as well as the mycelium on the fungus, stain blue. The stain is not absolutely specific, as red blood corpuscles and inflammatory exudate as well as the granules of eosinophil leucocytes and pancreatic cells react in a similar fashion.

Method for staining the Capsules of Bacteria

The following is a slight modification of Muir's capsule method, suggested by Dr. F. E. Reynolds. It is useful for staining the capsule of the pneumococcus or pneumobacillus in blood, sputum, or pus films :—

1. Stain in Carbol-fuchsin, steaming, for one minute.

2. Wash well in water.

3. Apply Muir's mordant for one to two minutes.

Muir's mordant is prepared as follows :—

Saturated solution of corrosive sublimate	2 parts.
Tannic acid (20 per cent solution)	2 parts.
Saturated solution of potash alum	5 parts.

4. Wash well in water.
5. Differentiate in methylated spirit for one minute.
6. Wash well in water.
7. Stain in methylene blue for one to two minutes.
8. Wash in water.
9. Dehydrate quickly in absolute alcohol.
10. Clear in xylol or benzol for five minutes.
11. Mount in Canada balsam.

By this method the organisms are stained red, while the capsules of the bacteria, the pus cells, etc., are stained blue.

Hiss's Method

1. Stain in the following mixture, heating for a few seconds over the flame until steam rises.

Saturated alcoholic solution of acid fuchsin	. 1 part.
Distilled water	. 19 parts.

2. Wash off the staining fluid with a 20 per cent solution of copper sulphate.

3. Without washing in water dry with filter paper.

By this method the capsules of organisms growing in both as well as these in blood and pus films can be demonstrated.

Methods for demonstrating Spirochætes

In Films—

(1) *Giemsa's Method.*

1. Make a thin film of the fluid to be examined.
2. Fix it in absolute alcohol for fifteen minutes.
3. Dilute Giemsa's stain by adding 10 drops to 10 c.c. distilled water and pour over film, leaving for ten to thirty minutes.

4. Wash well in a stream of water and dry.

(2) *Burri's Ink Method.*

For this purpose a little "Chin-chin, Pelican" ink is mixed with an equal quantity of distilled water. This mixture should be sterilised in the autoclave and allowed to sediment for some time (two weeks). It is then decanted off the

sediment. With a platinum needle a small quantity of the fluid to be investigated is mixed with a little of the ink on a clean slide and a film made. This is allowed to dry and is then examined with the oil immersion lens.

In Tissues—

For this purpose Levaditi's method gives excellent results.

1. Thin pieces of the tissues are placed in 10 per cent formalin for twenty-four hours.
2. Transfer to 96 per cent alcohol for twenty-four hours.
3. Place in distilled water until they sink.
4. Transfer to $1\frac{1}{2}$ -3 per cent solution of silver nitrate in distilled water and leave there for three days in the incubator at 37° C.
5. Wash rapidly in distilled water.
6. Reduce by placing for twenty-four to forty-eight hours at room temperature in the dark in

Pyrogallie acid	4	gram.
Formalin (40 per cent)	5	c.c.
Distilled water	100	c.c.

7. Wash in water.
8. Embed in paraffin or celloidin.

After cutting, the paraffin sections merely require solution of the paraffin and mounting in balsam.

By this method the spirochætes appear black, from the silver which is precipitated in their substance.

EXAMINATION OF SPUTUM, PUS, ETC., FOR THE TUBERCLE BACILLUS

The sputum should be poured into a Petri dish, and by means of sharp-pointed forceps and scissors a suitable portion is removed and placed upon a clean slide. A second slide is placed upon the top of the first and the sputum spread out by pressing the slides together. The two slides are then slid apart and the two films dried and fixed in the flame. Suitable portions for examination are any rounded yellow or white

masses, or, in the absence of these, opaque white streaky material. Both slides are then stained with carbol-fuchsin for three to five minutes, the stain being heated until the steam rises. A convenient way of doing this is to heat a penny in the flame and then place the slide covered with carbol-fuchsin upon the coin. Where a number of slides have to be stained at once a useful method is to place two pieces of glass tubing across a sink; the slides are then placed across these, the stain is filtered on, and the slides heated by playing a bunsen flame on them from below. Having been stained, the films are washed in water and differentiated in a 1 per cent mixture of hydrochloric acid and methylated spirit. This medium for differentiating has the advantage that the alcohol and acid test are applied at one and the same time. The slide is then washed in water, counter-stained in methylene blue (1 per cent watery), washed again in water, dried, and examined under the oil immersion. It is well to examine both slides systematically from one end to the other.

Pus or caseous material may be examined in a similar way.

The reason for differentiating with acid is because a majority of organisms, after staining in carbol-fuchsin and heating, are readily decolourised with dilute acid. The tubercle bacillus and other germs, such as the bacillus of leprosy, the smegma bacillus, the Timothy-grass bacillus, the butter bacillus, etc., are not decolourised with dilute acid. They thus form a group of acid-fast bacilli. Spirit or alcohol forms another differentiating medium, because the tubercle bacillus resists it, whereas the smegma bacillus is decolourised.

Concentration Method for Sputum, Pus, etc.

Add to the sputum, pus, etc. an equal quantity of 50 per cent antiformin.

Antiformin may be made up as follows :—

Solution 1

Sod. carb.	10 grm.
Calx chlorinata (bleaching powder)	50 grm.
Dist. water	100 c.c.

Solution 2

Sod. hydrate	.	.	.	15	gram.
Dist. water.	.	.	.	100	c.c.

For use mix equal parts of 1 and 2, and dilute with equal quantity of water.

The mixture is then shaken thoroughly and allowed to remain for two to twenty-four hours. At the end of that time it will form a more or less homogeneous fluid. This may be centrifugalised at once and the deposit examined by staining, or Eurich's method may be employed as follows:—Acetone and ether (equal parts) are shaken up with the antiformin mixture in a narrow glass vessel. The fluids will then separate into two layers, the acetone and ether being above, and at the point of junction a white precipitate, which contains the larger proportion of any cellular debris in the sputum, also the micro-organisms and among these the tubercle bacilli. The precipitate is easily removed (after pipetting off the ether) by means of a glass pipette and rubber teat. Films are made from this, stained, and examined. In cases where no precipitate forms at the junction of the fluids, the acetone and ether should be decanted off, and some of the antiformin mixture centrifugalised. Films are made from the deposit. Should such deposit be found difficult to spread on a slide, a little of the original sputum mixed with it will assist matters.

Caseous tissue should be cut up into thin shreds by sectioning with the freezing microtome and the resulting pulp treated with antiformin and centrifugalised. The deposit is then smeared on slides and stained by the Ziehl-Neelsen or Much-Gram method.

Care should always be taken to see that any distilled or tap water used in carrying out these processes is itself free from acid-fast organisms.

THE BACTERIOLOGICAL DIAGNOSIS OF DIPHTHERIA

It may be necessary in some fatal cases of disease to ascertain whether or not diphtheria bacilli are present in the

fauces, tonsils, or mucous membrane of the air passages. The method of diagnosis is the same as in the case of the living subject, and should be carried out as follows :—

(a) Films should be made from suspicious exudate in any of the above situations and stained by (i.) Gram's method ; (ii.) carbol-thionin blue ; (iii.) Neisser's method (see below). Characteristic organisms may or may not be found. If none are seen, cultures should be made.

(b) A sterile swab or platinum needle is rubbed over the surface of any exudate which may be present. If no exudate is present, the secretion covering the tonsil is removed and smeared over the surface of a tube of blood serum or blood agar. This is incubated at blood heat for 12 to 24 hours. Films are then made from the growth which develops, and stained by the above methods.

Neisser's Staining Method for the Diphtheria Bacillus

Solutions

- A. Methylene blue (Grübler), 1 grm., dissolved in 20 c.c. of 96 per cent alcohol.
Add to this 950 c.c. of distilled water and 50 c.c. glacial acetic acid.
- B. Bismarck-brown (Vesuvium) . . . 2 grm.
Distilled water 1 litre.

Method.

Stain films for one to three seconds in A, pour off the excess of stain and blot. Drop on B and leave for three to nine minutes. Wash, dry, and examine.

By this method the body of the diphtheria organism is stained brown while the granules are dark blue.

A modification of the method is as follows :—

Prepare two staining fluids :

- A. Methylene blue 1 grm.
96 per cent Alc. 20 c.c.
Glacial acetic acid 50 c.c.
Distilled water 1 litre.

B. Crystal violet (Höchst).	. 1	gram.
Abs. alc. 10	c.c.
Distilled water 300	c.c.

Mix two parts of A with one of B.

Method.

1. Stain in mixture for about ten seconds.
2. Wash in water.
3. Stain in cresoidin (2 gram. in 300 c.c. water) for about ten seconds (the stain should be dissolved in hot water and filtered).
4. Wash, dry, and mount.

The appearance of the organism is the same as with the first method.

AGGLUTINATION TEST FOR ORGANISMS

It is sometimes necessary to carry out an agglutination test in the case of an organismal condition such as typhoid fever (Widal reaction), or in cases of suspected meat poisoning (see p. 314); the serum of the individual being tested as regards its agglutinating power against the germ or germs cultivated from the lesion or from intestinal contents or against stock cultures of known organisms.

The method of carrying out the test is as follows:—

1. The *serum* of the case is secured by centrifugalising a quantity of blood or blood-clot obtained from the heart and pipetting off the supernatant fluid. This is mixed with normal saline solution by means of a graduated pipette so as to make dilutions of 1 in 5, 1 in 20, and 1 in 40, etc.

Another method is to prepare a capillary pipette (see below), make a mark upon it with a grease pencil, and draw up, by means of a rubber teat, to the mark one portion of the serum and subsequently four portions of the normal saline solution, allowing a bubble of air to intervene between the various portions. These are then blown out and mixed in a watch glass, thus forming a dilution of one in five. From this the other dilutions can be made in a similar fashion.

2. A *pure culture* on solid medium, *e.g.* agar slope, of the organism against which it is desired to test the serum is obtained. An emulsion is made by mixing some of the growth,

removed by a platinum needle, in normal saline, thus making a solution with a distinctly opalescent, but not too turbid, appearance. This is allowed to settle for an hour, or centrifugalised for a few minutes, in order to get rid of any clumps of bacteria.

A slide with a hollow in the centre is then taken and smeared round the margin of the hollow with vaseline. A cover slip is cleaned, and by means of a platinum loop a minute spot of the serum (1 in five) and one of the emulsion are placed side by side on the cover glass, and, after heating the loop in order to dry it and allowing it to cool, the two are mixed together. The cover slip is then lifted with a pair of forceps, turned over, and placed upon the slide so that the drop hangs in the hollow. The slide is examined under a $\frac{1}{6}$ objective, care being taken to cut off the greater part of the light coming from the mirror of the microscope, by means of the iris diaphragm. The organisms will usually be seen as minute highly refractile bodies, darting hither and thither. Similar hanging-drop preparations should be made with the other dilutions of the serum. Dilutions of 1 in 10, 1 in 40, and 1 in 80 are thus obtained. Control preparations may also be made with a normal serum.

After examining the slides under the microscope to see that the bacteria are visible and motile they should be placed in the incubator and again examined after one-half to one hour. The presence of clumps of motionless bacteria is indicative of a positive reaction. At the same time a positive result with a dilution of 1 in 10 should be neglected unless there is agglutination in the higher dilutions as well.

In the absence of the hollow slides, ordinary slides may be used.

METHOD OF MAKING PIPETTES FOR REMOVING FLUIDS, ETC.

Mark off a section, 6-8 inches long, of soft glass tubing ($\frac{1}{4}$ inch bore) with a file and break it across. This is held in the hands so that the centre lies in the flame of a blow-pipe or an ordinary Bunsen burner, the tubing being constantly turned between the fingers so that the flame plays upon all sides of it. No attempt should be made to draw the two ends

apart until the central portion is quite soft. When this has been effected, the tube is withdrawn from the flame, and very slowly the two ends are separated, until a capillary tube of at least 12 inches long has been made. The tubing should be held in the same position until it has cooled sufficiently to prevent it bending. It is then broken across in the centre, thus forming two pipettes. The end of the pipette should be passed through the flame before using for the removal of exudate, blood, etc. A rubber teat attached at the broad end will enable the operator to withdraw a considerable quantity of fluid.

APPENDIX B

EMBALMING

In cases where bodies have to be sent long distances, it may be necessary to inject a preservative into the circulation in order to stay the progress of putrefaction. The simplest fluid for the purpose is made up as follows :—

Formalin	4 pints.
Acid-carbolic (cryst.)	1 lb.
Water	2 gallons.

This fluid, to the amount of two gallons (in the case of an adult male), should be introduced by means of a cannula into the femoral artery or abdominal aorta. The time selected for the operation should be at least twenty-four hours after death, *i.e.* at a time when rigor mortis has just passed off. If the femoral artery is selected, the injection should be made in Scarpa's triangle, and the nozzle of the injector directed upwards towards the heart.

If a post-mortem examination has to be performed in addition, this should be carried out at least twenty-four hours after the injection.

Preservative fluid should also be introduced into the stomach, intestines, bladder, pleura, and other spaces.

The surface of the body may, in addition, be washed with a saturated solution of corrosive sublimate in methylated spirit mixed with five times the amount of glycerine. (C. R. Box, *Post-Mortem Manual*.)

INDEX

- Abdominal contents, examination
of, 28
- Abscess, cerebral, 240
 - actinomycotic, 182
 - association with pulmonary
disease, 241
 - of liver, 181
 - of lung, 131
 - tropical, 182
- Absolute alcohol, as fixative, 329
- Acid alcohol, 339
- Acromegaly, 260
- Actinomycosis of liver, 182
 - of intestine, 166
 - of mouth, 153
- Acute yellow atrophy of liver,
182, 183, 270
- Addison's disease, 114
- Adeno-carcinoma, 299
 - of breast, 273
 - of intestine, 171
 - of liver, 192
 - of stomach, 158
- Adenoma, 285
 - malignant, 300
 - of breast, 273
 - of thyroid, 112
- Agglutination test for organisms,
374
- Agonal thrombi, 63
- Albumose, Bence-Jones, 293
- Alimentary tract, parasites of, 170
- Alveolar sarcoma, 292
- Ammonia carmine, 351
- Ammonia gas, poisoning from, 314
- Amœbic dysentery, 168
- Amyloid, stains for, 352
- Amyotrophic lateral sclerosis, 250
- Anæmia, pernicious, 93
- Anasarca, 217
- Aneurysm, causes of, 87
 - dissecting, 85
 - effects on surrounding parts, 86
 - false, 85
 - fusiform, 85
 - miliary, 85
 - rupture of, 86
 - saccular, 85
 - sites of, 85
 - types of, 85
- Angio-sarcoma, 293
- Angioma, cavernous, 281
 - lymph, 282
 - plexiform, 281
- Anilin stains for waxy material,
353
- Anthracosis of lung, 133
- Anthrax, 2
- Antiformin, 371
- Antrum, maxillary, examination
of, 41
- Aorta, abnormalities of, 48
 - atheroma of, 79
 - congenital stenosis of, 47
 - examination of, 23
- Aortic valve, diseases of, 71, 72
 - effects of disease of, 71
- Apoplexy, cerebral, 237
 - pulmonary, 123
- Appendicitis, 169
- Arteries, calcareous degeneration
of, 78

- Arteries, diseases of, 77
 fatty degeneration of intima of, 78
 hypertrophy of media of, 80
 inflammation of, 78
 waxy degeneration of, 78
 Arteries in nephritis, 216
 in syphilis, 84
 in tuberculosis, 84
 Arteriosclerosis, 78
 Arteriosclerotic kidney, 214
 Artery, pulmonary, congenital stenosis of, 47
 pulmonary, examination of, 23
 Arthritis, acute, 261
 rheumatoid, 262
 suppurative, 261
 tuberculous, 261
 Aschoff-Becker microtome, 334
 Aschoff on gall stones, 195
 Ascites, 172
 chylous, 172
 Atelectasis of lung, 120
 Atheroma, 79
 aneurysm from, 81
 calcareous deposit in, 79
 causes of, 82
 diffuse, 79
 effects of, 81
 interstitial nephritis in, 81
 nodular, 79
 syphilitic, 80
 thrombosis in, 81
 Atherosclerosis, 79
 Atrophy, brown, of heart, 54
 yellow, of liver, 182, 183
 progressive muscular, 249
 Auriculo-ventricular bundle, 73
 Autopsy, 1
 B. diphtheria, stain for, 373
 B. pestis, staining of, 364
 Bacteria, acid-fast, 362
 stain for (acid-fast), 365
 carbol-thionin blue stain for, 364
 eosin methylene blue stain for, 364
 Gram's stain for, 363
 Bacteria, Gram-Weigert's stain, 363
 methods of staining, 362
 staining of capsules, 368
 Bacteriological investigation, methods of, 358
 capillary pipettes, 375
 for diphtheria, 372
 of blood, 359
 of hollow viscera, 360
 of serous sacs, 361
 of solid organs, 360
 requisites for, 358
 Ball thrombus, 63
 Banti's disease, 95
 Barlow's disease, 99
 Base of skull, Harke's saw-cut for, 41
 Bence-Jones albumose, 293
 Best's method of demonstrating glycogen, 351
 Bile ducts, diseases of, 194
 inflammation of, 194
 obliteration of, 194
 obliteration of in fine cirrhosis, 194
 suppuration of, 195
 Bile and pancreatic ducts, examination of, 31
 Biliary concretions, 195
 Bladder, urinary, diseases of, 227
 tumours of, 228
 calculi of, 228
 Bladder and urethra, examination of, 33
 removal of, 33
 Blood, bacteriological examination of, 359
 diseases of, 91
 in carbon monoxide poisoning, 313
 in nephritis, 217
 post-mortem examination of, 91, 358
 test for carbon monoxide in, 314
 Blood-film, making of, 357
 Blood-vessels, diseases of, 77
 Body, external examination of, 13
 identification of, 307
 toilet of, 44

- Bone, osteitis deformans, 260
 syphilis of, 260
 tuberculosis of, 259
 tumours of, 260
- Bone marrow, degeneration of, 102
 diseases of, 100
 erythroblastic, 101
 examination of, 100
 functions of, 101
 in pneumonia, 129
 leucoblastic, 101
 pigmentary changes in, 102
- Bowels, examination of, 28
 diseases of, 159
- Brain, circulatory disturbances, 233
 diseases of, 229, 233
 embolism of, 235
 examination of, 38
 gumma of, 242
 hydrocephalus of, 234
 inflammation of, 240
 œdema of, 233
 removal of, 35, 37
 syphilis of, 241
 thrombosis of, 235
 tuberculosis of, 241
 tumours of, 242
- Breast, diseases of, 272
- Bright's disease, 207
- Bronchi, dilatation of, 119
 diseases of, 117
 examination of, 28
- Bronchiectasis, 119
- Bronchiolectasis, 119
- Bronchitis, acute, 117
 chronic, 118
 syphilitic, 119
 tuberculous, 118
- Bronchocele, 112
- Broncho-pneumonia, 129, 130
- Broncho-pneumonia, purulent, 130
- "Brown atrophy" of heart, 54
- "Brown induration" of lung, 123
- Bruce microtome, 333
- Burri's ink stain for spirochætes, 369
- "Button-hole," mitral, 69
- Caisson disease, 246
- Calcareous degeneration of media, 78
- Calcareous material, staining of, 352
 Von Kossa silver stain for, 352
- Calculus, biliary, 195
 urinary, 228
- Calvarium, removal of, 36
- Canada balsam, 336
- Cancer, general use of term, 286
 "Cancer bodies," 297
- Cancers, 295
- Canon on bacteria in peripheral veins, 360
- Capsule stains for bacteria, 368
- Carbol-fuchsin stain, 365
- Carbol-thionin blue stain for bacteria, 364
- Carbolic oil in place of rubber gloves, 6
- Carbon monoxide poisoning, 313
- Carcinoma, adeno-, 299
 colloid, 302
 columnar cell, 300
 differences from sarcomata, 295
 encephaloid, 302
 general characteristics of, 295
 glandular, general characteristics of, 300
 inclusions, 297
 medullary, 302
 metastases, 296
 of bladder, 228
 of bone, 261
 of brain, 224
 of breast, 273
 of gall bladder, 197
 of heart, 60
 of intestine, 171
 of kidney, 223
 of larynx, 117
 of liver, 192
 of lung, 148
 of lymph glands, 105
 of pancreas, 198
 of prostate, 274
 of spinal cord, 252
 of stomach, 158
 of suprarenal, 115

- Carcinoma of thyroid, 112
 of uterus, 268
 scirrhus, 301
 sites of, 295, **297**
 soft, 302
 spheroidal cell, 301
 spread to glands, 296
 types, 295
 ulceration of, 295
 Capsules, staining of, 368
 Cathcart, freezing microtome, 334
 Cavernous angioma, 281
 "Cell nest," 298
 Celloidin, embedding in, 332
 sections, cutting, 333
 staining of, 338
 Cerebral hæmorrhage, 237
 artery of, 238
 causes of, 237
 site of, 238
 types of, 237
 Cerebro-spinal fluid, excess of, 234
 Cerebro-spinal meningitis, 231
 Chalicosis of lung, 133
 Charcot's joint, 262
 Cheloids, 277
 Chest, barrel-shaped, 15
 pigeon, 15
 Chloroform poisoning, 314
 Chloroma, 98
 blood in, 99
 Cholangitis, 194
 suppurative, 181
 Cholecystitis, 194
 Cholelithiasis, 195
 Cholera, 163
 Cholesteatoma, 244
 Chondroma, 279
 Chondro-sarcoma, 292
 Chorea gravidarum, 269
 Chorionepithelioma, 268, **304**
 Chromaffin cells, staining of, 354
 Chromatophore cells in melanotic
 tumours, 294
 Chronic venous congestion, of
 intestine, 161
 of kidney, 201
 of liver, 175
 of lung, 122
 of myocardium, 56
 of spleen, 107
 of stomach, 155
 in valvular disease, 70
 Cirrhosis, acute, 183, **185**
 atrophic, 186
 biliary, 188
 common, 187
 hypertrophic, 186
 monolobular, 186
 of liver, 185
 results of, 189
 polylobular, 186
 syphilitic, 189
 Clots, agonal, in pulmonary artery,
 23
 post-mortem, **61**, 62
 Cloudy swelling of heart, 54
 of kidney, 202
 of liver, 176
 CO₂ for freezing, 334
 Coal-gas poisoning, 313
 "Coal miner's lung," 133
 Colitis, 167
 mucous, 169
 Collapse of lung, **119**, 120
 medico-legal, 310
 Colliquative necrosis, 235
 Colloid cancer, 302
 Colophonium as mountant, 337
 Colour, preservation of in mount-
 ing specimens, 319
 Columnar cell carcinoma, 300
 Compound cystic adenoma, 264
 Concentration method of examin-
 ing pus and sputum, 371
 Congenital cystic kidney, 200
 Cornet's forceps, 336
 Coronary arteries, anatomy of, 26
 effects of obstruction, 56
 narrowing of, 57
 "Corona veneris," 260
 Coroner, 2, **3**, **307**
 Corpora amylacea in prostate, 274
 Corpus luteum, 264
 Corrosive sublimate, as fixative,
 328
 Cover glasses, cleaning of, 336
 Cretinism, 111
 Cuboid, ossific node in, 310

- Culture tubes, inoculation of, 359
- Cutting paraffin sections, 332
- Cutting sections in celloidin, 333
- Cutting sections in gum, 333
- Cyanide poisoning, 314
- Cystic adenoma, 285
- Cysts of pancreas, 199
- Death, causes of in infanticide, 311
causes of in new-born, 311
sudden, 26, 28, 77, 114
- Decalcification of tissues, 335
- Decalcifying fluid, 335
- Deciduoma malignum, 268
- Degeneration, fatty, of endocardium, 60
fatty, of heart, 55, 60
fatty, of kidney, 202
fatty, of liver, 177
fatty, of myocardium, 55
Zenker's, 18
waxy, of liver, 179
waxy, of kidney, 203
waxy, of spleen, 105
- Dehydration of tissue for microscopic sections, 330
- "Deposition," medico-legal, 308
- Dermoid cyst, 265, 303
- Developmental changes in foetus, 309
- Dextrocardia, 48
- Diabetes, pancreas in, 199
- Diffuse-waxy spleen, 106
- Digestion, post-mortem, 155
- Dilatation of heart, 60
- Diphtheria of mouth, 153
method of examination, 372
- Disseminated sclerosis, 250
- Dropsy, 217
in cardiac disease, 72
of peritoneum, 172
of pleura, 149
renal, 217
- Ductus arteriosus, persistence of, 47
- Duodenum, examination of, 30
ulcer of, 157
- "Dust diseases," 133
- Dysentery, amœbic, 167, 168
bacterial, 167
- Eclampsia, 270
kidney in, 271
liver in, 179, 271
- Ectopic gestation, 265, 269
- Egyptian mummies, 4
- Ehrlich's stain for glycogen, 349
- Elastic tissue stain, 343
- Embalming, 376
- Embedding in celloidin, 332
in gum, 326
in paraffin, 330
quick method, 331
summary of, 332
- Emboli, septic, of lung, 131
- Embolism from acute endocarditis, 68
of brain, 235
of intestine, 161
of kidney, 201
of liver, 176
of lung, 123
of portal vein, 176
of spleen, 108
of uterine veins, 266
pulmonary, 123, 269
- Emphysema of lung, 121
- Empyema, 150
of gall bladder, 195
- Encephalitis, suppurative, 240
- Encephaloid cancer, 302
- Endarteritis, in brain syphilis, 242
deformans, 79
obliterans, 83
proliferans, 83
- Endocarditis, acute, 64
acute results of, 67
chronic, 68
difference between simple and ulcerative, table of, 67
results of chronic, 68
simple acute, 65
ulcerative, 66
in pneumonia, 129
results of, 66
- Endocardium, atheromatous, 61
calcareous deposits in, 61
diseases of, 60

- Endocardium, fatty degeneration
of, 60
red staining of, 60
- Endometritis, acute, 266
chronic, 267
tuberculosis, 267
- Endotheliomata, 292
- Entamœba hystolytica, stain for, 364
dysentery due to, 167
- Enteritis, 162
acute, 162
tuberculous, 165
typhoid, 165
- Eosin, 339
methylene blue, Mallory and Wright's method, 342
stain for bacteria, 364
staining method, 341
- Epithelioma, squamous, 297
of gall bladder, 197
of intestine, 171
of œsophagus, 154
of stomach, 158
of uterus, 268
- Epulis, malignant, 291
- Equipment of pathologist, 5
- Ether for freezing, 334
- Examination of abdominal contents, 28
of aorta, 23
of bile and pancreatic ducts, 31
of bladder and urethra, 33
of brain, 35, 38
of bronchi, 28
of duodenum, 30
of eye and orbit, 40
of gall bladder, 31
of heart, 23
of intestines, 29
of kidneys, 34
of liver, 31
of lungs, 27
of maxillary antrum, 41
of middle ear, 40
of pancreas, 32
of plural cavities, 19
of sinuses of head, 40
of spinal cord, 39
of spleen, 32
- Examination of stomach, 30
of suprarenals, 33
of surface of heart, 24
of testicles, 35
of thoracic contents, 23
of thoracic duct, 35
of thyroid gland, 28
of uterus, 34
of valves of heart, 24, 25, 26
of venæ cavæ, 23
of vermiform appendix, 30
- Exostosis, 280
- Eye and orbit, examination of, 40
- Fallopian tubes, diseases of, 265
- Farrant's medium for mounting, 337
- Fat necrosis, 197
Nile blue sulphate stain for, 347
osmic acid stain for, 347
Scharlach R., stain for, 348
staining by hæmatoxylin, 347
Sudan III. stain for, 348
- Fat in tissues, staining of, 346
- Fatty change in phosphorous poisoning, 313
degeneration of endocardium, 60
of heart, 54
of intima, 78
of kidney, 202
of liver, 177
of myocardium, 55
infiltration of heart, 54
of liver, 178
loading of heart, 54
- Femur, ossific node in, 310
- Fever, puerperal, 269
- Fibrin staining method, 345
- Fibro-adenoma, 285
- Fibro-myoma, 280
of uterus, 268
- Fibroid phthisis, 144
- Fibroid, recurrent, 287
- Fibroma, 277
in ovary, 265
- Fibromatosis of stomach, 158
- Fibrosis of lung, 146
- Fixation of nervous tissue for microscopic sections, 325, 327

- Fixative, absolute alcohol, 329
 corrosive sublimate, 328
 Flemming's, 325, 328
 Jores's, 323
 Kaiserling's, 323
 Marchi's, 325, 328
 methylated spirit, 329
 Müller's, 327
 Orth's, 328
 Pick's, 322
 Zenker, 327
 Fixing paraffin sections on slides, 332
 Flemming's fixative, 325
 solution, 328
 Flies at post-mortem, 7
 Focal necrosis, 178
 Fœtus, table of, developmental changes in, 309
 Formalin, Schering's, 323
 Fracture of skull, examination for, 35
 Freezing gum sections, 334
 Friedreich's ataxia, 252
 Frost's preservative, 323
 "Fuchsin bodies," 297
- Gall bladder, diseases of, 194
 empyema of, 195
 examination of, 31
 inflammation of, 194
 suppuration of, 195
 tumours of, 197
 Gall stones, types of, 195
 Ganglion cells, staining of, 356
 Gangrene of lung, 131
 Gastrectasis, 155
 Gastritis, suppurative, 156
 Gelatine fluid for mounting specimens, 322
 General paralysis of insane, 242
 Gention violet stain, 353
 Giant cell sarcoma, 291
 Giemsa's stain for spirochætes, 369
 "Gin-drinker's" liver, 187
 Glioma, 282
 Gliosarcoma, 243, 283, 292
 Gliosis of spinal cord, 245
 Gloves, rubber, cleansing of, 44
 care of, 15
- Glycerine jelly, 337
 Glycogen, Best's method of staining, 351
 Lubarsch's method of demonstrating, 350
 in tissues, demonstration of, 349
 Ehrlich method of staining, 349
 Goitre, 112
 exophthalmic, 112
 simple, 112
 Gout, 262
 Gram's method of staining, 363
 Grave's disease, 112
 Grey hepatization of lung, 127
 Gum, cutting sections in, 333
 sections, staining of, 338
 Gumma, of bone, 260
 of brain, 242
 of heart, 59
 of liver, 190
 of lung, 135
 of spinal cord, 252
 of testicle, 273
- Hæmangioma, 281
 Hæmatein, eosin stain, 339
 Hæmatothorax, 149
 Hæmatoxylin, Kultschitzky and Wolter's, 355
 stain for fat, 347
 eosin, method of staining, 340
 stain, 339
 Weigert's iron, 339
 Hæmophilia, 100
 clotting in, 100
 Hæmorrhage, cerebral, 239
 into pericardium, 49
 Hæmorrhagic diseases, 99
 Hæmosiderin in liver, 180
 method of demonstrating in tissues, 353
 Hands, cleansing of, 44
 Hardening tissue for microscopic sections, 329
 Harke's saw-cut for base of skull, 41

- Heart and great vessels, malformations of, 46
 and pericardium, disease of, 46
 aneurysm of, 57
 auriculo-ventricular bundle of, 73
 brown atrophy of, 54
 cloudy swelling of, 54
 congenital abnormalities of, 46
 development of, 46
 dilatation of, 60
 "ectopia cordis," 48
 examination of, 23
 examination of excised, 74
 fatty infiltration of, 54
 fatty loading, 54
 gumma of, 59
 hypertrophy of, 59
 in nephritis, 216
 in pneumonia, 129
 primitive muscular tissue of, 73
 surface of examination of, 24
 syphilis of, 59
 tumours of, 60
 valves, table of diameter and circumference of, 76
 weight and measurement of, 75
- Heart-block, causes of, 74
- Hepatitis, acute, 180
 chronic interstitial, 185
 suppurative, 181
- Hereditary spinal ataxia, 252
- Hernia, 160
 strangulated, 161
- Herxheimer's method of Scharlach R. staining, 349
- Hirschsprung's disease, 159
- Hiss's capsule stain, 369
- "Hobnailed" liver, 187
- Hodgkin's disease, 104
- "Honey-comb" lung, 119
- Hydatid cyst of liver, 193
 suppurative in, 182
- Hydatid mole, 268, 278
- Hydrocephalus, 234
- Hydromyelia, 245
- Hydronephrosis, 275
 congenital, 201
- Hydropericardium, 49
- Hydrothorax, 149
- Hyperemesis gravidarum, 269
- Hypernephroma, 114, 224
- Hypertrophy of heart, 60
- Incising organ, use of knife in, 11
- Indian ink method, Burri's, 369
- Infant, signs of maturity in, 309
- Infanticide, causes of death in, 311
- Infarction from acute endocarditis, 68
 of brain, 235
 of intestine, 161
 of kidney, 201
 of liver, 176
 of lung, 123
 of placenta, 268
 septic, of lung, 131
 of spleen, 108
- Infections of eye, 6
- Infiltration, fatty, of liver, 178
 of heart, 54
- Ink method of demonstrating spirochætes, 369
- Instruments for post-mortem, 7
- Insular sclerosis, 250
- Intestine, actinomycosis of, 166
 chronic venous congestion, 161
 dilation of, 159
 diseases of, 159
 examination of, 29
 hæmorrhage of, 162
 hernia of, 160
 infarction of, 161
 inflammation of large, 167
 inflammation of small, 162
 intussusception of, 160
 malformations of, 159
 parasites of, 170
 removal of, 28
 stenosis of, 159
 syphilis of, 166
 tuberculosis of, 165
 tuberculous ulceration of, 165
 table of differences from typhoid ulceration, 166
 tumours of, 171
 typhoid of, 163
 typhoid ulceration of, 164
 volvulus of, 159

- Interauricular septum, defective, 46
- Interventricular septum, defective, 46
- Intussusception, 160
- Iodine stain for waxy material, 352
test in waxy disease of arteries, 77
- Iron-containing pigment, demonstration of, 353
- Iron-hæmatoxylin, 339
- Irritant poisoning, appearances, 313
- Jaundice, obstructive, from pancreatic tumours, 199
- Jenner's stain, 358
- Joint, Charcot's, 262
gouty, 262
- Joints, diseases of, 261
rheumatoid arthritis of, 262
tuberculosis of, 261
- Jores's fixative, 323
- Kaiserling's fixative, 323
- Kidney, arterio-sclerotic, 214
Bright's disease, 207
chronic venous congestion, 201
cloudy swelling of, 202
congenital anomalies of, 200
congenital cystic, 200
congenital cysts of, 200
degenerations of, 202
diseases of, 200
examination of, 35, **224**
fatty degeneration associated with Bright's, 203
fatty degeneration of, 202
hydronephrosis, 225
in eclampsia, 271
infarction of, 201
inflammation of, 204
large white, 210
leukæmia of, 223
pigmentary changes of, 204
pyelitis of, 226
removal of, with bladder, 32
suppuration of, 221
syphilis of, 223
- Kidney, tube casts of, 218
tuberculosis of, 222
tumours of, 223
waxy disease of, 203
waxy, in tuberculosis, 147
- Kultschitzky's hæmatoxylin, 347,
- Laryngitis, 116
diphtheritic, 116
- Larynx, diseases of, 116
syphilis of, 117
tuberculosis of, 117
tumours of, 117
- Leiomyoma, 280
- Leishman's stain, 358
- Leptomeningitis, **230**, 231
cerebral, 230
spinal, 246
- Letulle's method of making post-mortem, 14, **42**
- Leucocythæmia, 96
- Leukæmia, 96
liver in, **191**, 97
kidney in, 223
pseudo-, 104
- Levaditi's stain for spirochætes, 370
- Lipoma, 279
- Lithium carmine, 344
- Liver, abscess of, 181
actinomycosis, 182
acute yellow atrophy of, **182**, 183, 270
amyloid degeneration, 179
chronic venous congestion of, 175
circulatory disturbances of, 175
cirrhosis of, 185
cloudy swelling of, 176
congenital syphilis, 189
deformities of, 175
degenerations of, 176
diseases of, 175
examination of, 31, **193**
fatty degeneration of, 177
fatty infiltration of, 178
focal necrosis in, 178
gumma of, 190
in eclampsia, 179, **271**
inflammation of, 180

- Liver, leukæmia of, 191
 lymphadenoma of, 191
 nutmeg, 175
 pigmentary changes in, 180
 pigment in chronic venous congestion, 180
 regeneration of, 185
 results of cirrhosis of, 189
 subacute yellow atrophy, 184
 syphilis of, 190
 tropical abscess of, 182
 tuberculosis of, 190
 tumours of, 192
 waxy degeneration of, 179
 waxy, in tuberculosis, 147
 Lobar pneumonia, 125
 Lobular pneumonia, 129
 Locomotor ataxia, 251
 Lorrain-Smith's Nile blue sulphate stain for fat, 347
 Lubarsch's method of demonstrating glycogen, 350
 Lugol's iodine, 350
 Lung, abscess of, 131
 acute congestion of, 122
 anthracosis, 133
 atelectasis of, 120
 brown induration of, 123
 caseous tuberculosis, differences from lobular pneumonia, etc., 143
 caseous tuberculosis of, 142
 coal-miner's, 133
 collapse in new born, medico-legal, 310
 collapse of, 119
 chronic venous congestion of, 122
 chronic venous congestion with tuberculosis, 148
 diseases of, 119
 emphysema of, 121
 examination of, 27, **151**
 fibro-caseous tuberculosis with cavitation, 146
 fibrosis, 146
 gangrene of, 131
 gumma of, 135
 hæmorrhage of, 123
 hypostatic congestion of, 122
 Lung, hypostatic pneumonia, 132
 infarction of, 123
 inflammation of, 125
 in nephritis, 217
 interstitial pneumonia of, 132, 133
 miliary tuberculosis of, 140
 œdema of, 124
 passive congestion of, 122
 pneumokoniosis of, 133
 pneumonia of, 125
 septic pneumonia, 131
 siderosis of, 134
 silicosis of, 134
 stone mason's, 134
 syphilis of, 134
 tuberculosis of, 135
 classification, 139
 metastasis, 147
 mode of spread, 137
 paths of entry of infection, 135
 "seat of election," 135
 tumours of, 148
 water test, medico-legal in infant, 310
 water test, in pneumonia, 120
 Lymphadenitis, 102
 tuberculous, 103
 Lymphadenoma, 104
 glands in, 104
 liver in, 105, **191**
 lungs in, 105
 spleen in, 105, **110**
 Lymphangioma, 281
 Lymphatic leukæmia, 97
 Lymph glands, diseases of, 102
 examination of, 102
 pigmentary changes in, 102
 tumours of, 105
 Lymphocythæmia, 97
 blood in, 98
 bone marrow in, 98
 kidney in, 98
 liver in, 98
 lymph gland in, 98
 spleen in, 98
 Lymphoma, 282
 Lympho-sarcoma, 282, **289**

- Mallory and Wright's eosin, methylene blue stain, 342
 Mammary gland, tuberculosis of, 273
 inflammation of, 272
 tumours of, 273
 Mann's methylene blue stain, 367
 modification of Müller's fluid, 327
 Marchi's fixative, 328
 staining method, 356
 Mastitis, 272
 Maturity, table of signs in new born of, 309
 Mayer's hæmatein, 340
 Meckel's diverticulum, 159
 Medico-legal post-mortem, 2, 306
 preservation of organs in, 311
 procedure in, 306
 report in England, 308
 report in Scotland, 307
 typical reports, 215, 216
 Medullary cancer, 302
 sheaths, staining of, 354
 Melanotic tumours, 294
 Meninges of brain, diseases of, 229
 Meningitis, cerebral, 229
 cerebro-spinal, 231
 serous, 233
 spinal, 245
 syphilitic, 233
 tuberculous, 232
 Meningocele, 245
 Meningo-myelocele, 245
 Methylated spirit as fixative, 329
 Methylene blue, eosin stain, 341
 Methyl-violet stain, 353
 in Much's method, 366
 Microscopic examination, routine of, 324
 selection of urine for, 324
 Microscopic sections, cutting in gum, 333
 cutting in celloidin, 333
 cutting in paraffin, 332
 decalcification, 335
 dehydration, 330
 embedding in celloidin, 332
 embedding in gum, 326
 embedding in paraffin, 330
 Microscopic sections, quick method, 331
 fixation of tissue, 325
 freezing of, 334
 hardening of tissues, 329
 mounting media, 336
 preparation of, 324
 staining methods, 337
 Microtome, Aschoff-Becker, 334
 Bruce, 333
 Cathcart, 334
 Minot, 333
 Mixer, 334
 making use of, 332
 Schanze, 333
 Middle ear, examination of, 40
 association with meningitis, 227
 "Milk spots," 52
 Miller's method of staining clubs of actinomyces, 368
 Minot, microtome, 333
 Mitral valve, disease of, 69, 70
 effects of disease of, 70
 Mixed cell, sarcoma, 291
 Mixer, microtome, 334
 Mole, placental, 304
 Molluscum contagiosum, 283
 Mordant, alum, 339
 iron, 339
 Morphia poisoning, 314
 Mounting, fluid for specimens, 321
 media for sections, 336
 of specimens, 319
 Mouth, diseases of, 153
 tumours of, 153
 Much-Gram stain combined with Ziehl Neelsen stain, 366, 367
 Much's peroxide of hydrogen method, 367
 Mucous colitis, 169
 Muir's capsule stain, 368
 Müller's fixative, 327
 Muscles, vitreous degeneration of Zenker of, 18
 Muscular atrophy, progressive, 249
 Myelæmia, 96

- Myelin, degenerated staining of, 356
 Myelitis, 246, 247
 Myelocythæmia, 96
 blood in, 96
 bone marrow in, 97
 kidney in, 97
 liver in, 97
 spleen in, 97
 Myeloid sarcoma, 261, 291
 Myeloma, 261, 293
 Myocarditis, 58
 chronic interstitial, 58
 Myocardium, chronic venous congestion of, 53
 degeneration of, 53
 diseases of, 53, 55
 fatty degeneration of, 55
 syphilis of, 59
 tuberculosis of, 59
 Myoma, 280
 Myxœdema, 111
 Myxoma, 278
 Myxoma of chorion, 268, 278, 304
 Neisser's stain for diphtheria, 373
 Nephritis, 204
 acute, 208
 table of comparison, 219
 blood in, 217
 cardio-vascular changes in, 216
 causes, 208
 chronic interstitial, 212
 chronic interstitial urine in, 216
 classification, 207
 dropsy in, 217
 hæmatogenous, 220
 heart in, 216
 lungs in, 217
 changes in nervous system in, 218
 subacute, 210
 suppurative, 220
 Nerve sheaths, staining of, 354
 Nerves, diseases of, 252
 tumours of, 253
 Nervous system in nephritis, 218
 tissue embedding in celloidin, 333
 Neuritis, 252
 interstitial, 253
 parenchymatous, 252
 Neuro-fibroma, 253
 New-born, causes of death of, 311
 infants, post-mortem in, 308
 table of signs of maturity in, 309
 Nile blue sulphate stain for fat, 347
 Nissl bodies, staining of, 356
 Nitric acid as decalcifying fluid, 335
 "Nutmeg" liver, 175
 Oedema in cardiac disease, 72
 of brain, 233
 of glottis, 116
 of lung, 124
 renal, 217
 subcutaneous, 217
 Œsophagus, corrosive poisoning of, 154
 examination of, 23
 peptic ulcer of, 154
 removal of, in suspected poisoning, 153
 tumours of, 154
 varicose veins of, 153
 Omphalo-mesenteric duct, 159
 Orbit, examination of, 40
 Organs, bacteriological investigation of, 360
 Orth's fixative, 328
 lithium carmine, 344
 rules for making post-mortem, 15
 Osmic acid, stain for fat, 347
 Ossific node in cuboid, 309, 311
 in femur, 309, 310
 Osteitis deformans, 260
 Osteoma, 280
 Osteo-sarcoma, 292
 Ovaritis, 264
 Ovary, tumours of, 264
 Pachymeningitis, cerebral, 229
 acute, 229
 chronic, 230
 hæmorrhagica, 230
 spinal, 245
 Paget's disease of bone, 260
 Pancreas, cysts of, 199
 diseases of, 197

- Pancreas, examination of, 32
 fatty infiltration of, 197
 relation to diabetes, 199
 tumours of, 198
 Pancreatic duct, examination of, 31
 Pancreatitis, acute hæmorrhagic, 198
 chronic interstitial, 198
 fat necrosis in, 197
 suppurative, 198
 Papilliferous, cystic adenoma, 265, **285**
 Papilloma, 284
 of larynx, 117
 Papilloma, mucous, 283
 of bladder, 228
 squamous, 283
 Pappenheim's stain, 343
 Paraffin, embedding in, 330
 quick method, 331
 Paraffin sections, cutting of, 332
 fixing on slides, 332
 staining for bacteria, 363
 treatment before staining, 337
 Paralysis, general, of insane, 242
 infantile, 248
 Parasites of alimentary tract, 170
 of bladder, 228
 Parathyroids, 28
 Pathologist, equipment of, 5
 infection of eye, 6
 wound of finger of, 6
 Perenny's decalcifying fluid, 335
 Pericarditis, acute, 50
 chronic, 52
 classification of, 51
 results of, 52
 tuberculous, 53
 Pericardium, adherent, 52
 air in, 50
 anatomy of, 48
 blood in, 49
 diseases of, 46, **48**
 dropsy of, 49
 incision of, 19
 tuberculosis of, 53
 Perihepatitis, 180
 Perithelioma, 292
 Peritoneum, ascites of, 172
 diseases of, 172
 hæmorrhage of, 172
 tuberculosis of, 173
 tumours of, 174
 Peritonitis, acute, 172
 chronic, 173
 tuberculous, 173
 Pernicious anæmia, 93
 bone marrow in, 94
 colour index, 95
 heart in, 93
 intestines in, 94
 kidney in, 94
 liver in, 93
 lungs in, 93
 red blood corpuscles in, 95
 skin in, 93
 spinal cord in, 95
 spleen in, 94
 stomach in, 94
 subcutaneous fat in, 93
 white blood corpuscles in, 95
 Phlebitis, 89
 results of, 90
 Phosphorus poisoning, 313
 Phthisis, 140
 fibroid, 144
 Pick's fixative, 322
 Picro-carmin, 340
 methods of staining with, 338
 Picro-fuchsin, 340, **341**
 Pipettes, method of making, 375
 Placenta, diseases of, 268
 Plasma cells, staining of, 343
 Pleura, diseases of, 149
 Pleural cavities, examination of, 19
 Pleural cavity, dropsy of, 149
 gas in, 150
 Pleurisy, 150
 chronic, 151
 classification, 150
 in tuberculosis, 151
 Plexiform angioma, 281
 Pneumokoniosis, 133
 Pneumonia, 125
 broncho, 129
 catarrhal, 129
 congestion of spleen in, 129

- Pneumonia, croupous, 125
 grey hepatisation, 127
 heart in, 129
 hypostatic, 132
 interstitial, 132, 133
 leucoblastic marrow in, 129
 lobar, acute congestion in, 126
 lobar, causes of, 125
 lobular, 129
 other organs in, 129
 red hepatization, 126
 resolution in, 128
 septic, 131
 syphilitic, 135
 tuberculous, 142
 types of, 125
 white, 134
- Pneumopericardium, 50
- Pneumothorax, 150
- Poisoning, ammonia gas, 314
 carbon monoxide, 313
 chloroform, 314
 cyanide, 314
 irritant, 313
 morphia, 314
 phosphorus, 313
 ptomaine, 314
 strychnine, 314
 vegetable, 314
- Poisons, post-mortem changes in
 organs from, 311
- Poliomyelitis, 248
- Polychrome methylene blue, 353
- Polypi, 277
- Portal pyæmia, 181
- Portal vein, embolus of, 176
 thrombosis of, 176
- Post-mortem, 1
 hospital regulations for, 2
 importance of changes, 4
 in private, 9
 instruments for, 7
 Letulle's method, 14, 42
 medico-legal, 2, 3
 procedure in, 306
 notes of, 9
 object of, 13
 permission for, 2
 primary incision, 17
 procedure in making, 13
- Post-mortem, reflection of
 muscles, etc., 17
 rules for examining organ at, 10
 Shennan's method of, 43, 21
 surface examination, 15
 table and accessories, 8
 wounds, treatment of, 6
- Post-mortem report, medico-legal,
 in England, 308
 in Scotland, 307
- Post-mortem medico-legal, speci-
 men reports, 215, 216
- Post-mortem room, equipment of,
 9
 solutions, etc., for, 8
- Pregnancy, diseases of, 269
- Preparation of tissue for dispatch,
 329
- Preservative, Frost's, 323
- Primary incision at post-mortem,
 17
- Procurator-fiscal, 2, 3, 307
- Progressive muscular atrophy, 250
- Prostate, diseases of, 274
 hypertrophy of, 274
 tumours of, 274
- Prostatitis, acute, 274
- Prussian blue reaction, 94
- Psammoma, 293
- Ptomaine poisoning, 314
- Puerperium, diseases of, 269
- "Pulmonary apoplexy," 123
 artery, congenital stenosis of,
 47
 examination of, 23
 tuberculosis, 135
 valve, lesions of, 72
- Purpura, 99
- Pus, examination for tubercle
 bacillus, 371
 making of films from, 362
- Pyelonephritis, 221
- Pyloric stenosis, congenital, 155
- Pyopneumothorax, 150
- Pyorrhœa alveolaris, 153
- Pyronin-methylgreen stain, 343
- Red hepatization of lung, 126
- Redressing of body, 44
- "Red softening," 281

- "Red staining of intima," 60
Removal of organs from thorax
and abdomen, 20
Shennan's method, 21
Resolution of lung, 128
Resorcin-fuchsin stain, 344
Respiratory system, diseases of,
116
Reynold's capsule stain, 368
Rhabdomyoma, 280
"Rice water stools," 163
Rickety rosary, 18, 255
Rigor mortis, 16
Rodent ulcer, 299
Round cell sarcoma, large, 290
small, 289
Rules for examination of an organ
at a post-mortem, 10
Russell's "fuchsin bodies," 297
- Sago-waxy spleen, 105
Salpingitis, 265
Sarcoma, 287
alveolar, 292
angio-, 293
characteristics of, 287
chondro-, 292
classification of, 288
difference from granulation
tissue, 291
large round cell, 290
large spindle cell, 290
lympho-, 289
melanotic, 294
mixed cell, 291
myeloid, 291
of bone, 260
of brain 243
of heart, 60
of intestine, 171
of kidney, 223
of larynx, 117
of liver, 193
of lymphatic glands, 105
of nerve, 253
of ovary, 265
of spleen, 110
of stomach, 158
of testicle, 274
of vertebræ, 252
- Sarcoma, osteo-, 292
small round cell, 289
small spindle cell, 290
sites of origin of, 289
Schanze microtome, 333
Scharlach R. stain for fat, 348
Schering's celloidin, 332
formalin, 323
Scirrhus cancer, 301
Sclerosis of spinal cord, 247
disseminated, 250
Scurvy, 99
infantile, 99
Sectio cadaveris, 1
Serous sacs, bacteriological in-
vestigation of, 361
examination of, 19
Shennan's method of post-
mortems, 21, 43
Siderosis of lung, 134
Silicosis of lung, 134
Sino-auricular node, 73
Sinuses, accessory, of head, ex-
amination of, 40
Skull, fracture of, examination
for, 35
Slides, cleaning of, 336
Soft cancer, 302
"Soldier's spots," 52
"Soul and Conscience," form of
report, 4, 307
Specimens, method of mounting,
321
mounting of, 319, 321
preparation for transmission,
329
preservation of, 319
preservation of, in medico-legal
work, 307
Spina bifida, 244
occulta, 245
Spinal cord, congenital abnor-
malities of, 244
diseases of, 244
examination of, 39
gumma of, 252
inflammation of, 246
named diseases of, 248
tuberculosis of, 252
tumours of, 252

- Spindle cell sarcoma, large, 290
small, 290
- Spirochætes in atheroma lesion, 80
in tissues, staining of, 370
methods of staining, 369
in brain, 242
- Spleen, acute congestion, 107
atrophy of, 105
chronic venous congestion of, 107
circulatory disturbances, 107
diseases of, 105
examination of, 30, **32**, **111**
iron pigment in, 107
hyaline degeneration of, 106
in Banti's disease, 95
infarction of, 108
inflammation of, 109
in pneumonia, 129
lymphadenoma of, 105, **110**
miliary tuberculosis of, 109
pigmentation of, **106**, 107
tuberculosis of, 109
tumours of, 110
waxy degeneration of, **105**, 147
- Splenic anæmia, 95
- Splenomedullary leukæmia, 96
- Sputum, examination for tubercle bacillus, 370
making of films from, 361
- Squamous epithelioma (see Epithelioma), 297
papilloma, 283
- Staining methods, 337
sections, apparatus required, 335
- Sterno-clavicular joint, disarticulation of, 18
- Sternum, removal of, **18**, 19
- Stomach, acute catarrh of, 155
chronic catarrh of, 156
chronic venous congestion of, 155
congenital pyloric stenosis, 155
dilatation of, 155
diseases of, 154
effect of acids on, 156
examination of, 30
fibromatosis of, 158
- Stomach, hæmorrhagic erosions of, 155
hour-glass contraction of, 155
post-mortem digestion in, 155
suppurative catarrh of, 156
tumours of, 158
ulcer of, 157
- Stone in bladder, 228
"Stone-mason's lung," 134
- Streptothrix actinomyces, staining of club forms, 268
- Strychnine poisoning, 314
- Struma, 112
- Subacute nephritis, 210
urine in, 212
- Subacute atrophy of liver, 184
- Sudan III. stain for fat, 348
- Sudden death, arteries in, 77
examination of coronary arteries in, 26
in relation to hæmorrhage into supra-renals, 114
thymus gland in, 28
- Supra-renals, accessory, 114
diseases of, 113
examination of, 33
hæmorrhage into, 114
hypernephroma, 114
removal of, 33
structure of, 113
tuberculosis of, 114
tumours of, 114
- Surgical kidney, 221
- Syphilis, congenital, of liver, 189
of arteries, **80**, 84
of bone, 260
of brain, 241
of bronchi, 119
of heart, 59
of intestine, 106
of kidney, 223
of larynx, 117
of liver, **189**, 190
waxy degeneration in, 190
of lung, 134
of meninges, 233
of testicle, 273
- Syringomyelia, 245

- "Tabby cat" heart, 55
- Tabes dorsalis, 251
- Tabloids for making stains, 358
- Teratoma, 303
 - of ovary, 265
- Test for carbon monoxide in blood, 314
- Testicle, chorionepithelioma of, 304
 - diseases of, 273
 - examination of, 35
 - fibrosis, 273
 - gumma of, 273
 - removal of, 35
 - syphilis of, 273
 - tuberculosis of, 273
 - tumours of, 274
- Thoracic contents, examination of, 22, 23
- Thoracic duct, examination of, 35
- Thrombi, 61, 88
- Thrombosis, in vessels of brain, 235
 - of portal vein, 176
 - of uterine veins, 266
 - of veins, 87
- Thrombus, red, 88
 - septic, softening of, 88
 - simple, 88
 - white, 88
- "Thrush breast" heart, 55
- Thymus gland, 28
- Thyroid gland, diseases of, 111
 - examination of, 28, 113
 - tumours of, 112
 - waxy degeneration of, 112
- Tissues, preparation of, for microscopic examination, 324
- Tricuspid valve, diseases of, 72
- Tropical abscess of liver, 182
 - associated with dysentery, 182
- "Tube casts," 218
- Tubercle bacillus, concentration method of examining for, 371
 - extraction with acetone and ether, 372
 - in sections, staining of, 366
 - in sputum, examination for, 370
- Tubercle bacillus, Mùch - Gram stain, 366
 - Ziehl-Neelsen method, 365
 - staining for, 365
- Tuberculosis, arteries in, 84
 - miliary, of lung, 140
 - of bladder, 227
 - of bone, 259
 - of brain, 241
 - of breast, 273
 - of epididymis, 273
 - of Fallopian tubes, 265
 - of heart, 59
 - of intestine, 165
 - of joints, 261
 - of kidney, 222
 - of larynx, 117
 - of liver, 190
 - of lung, 135
 - broncho-pneumonic, 142
 - caseous, 142
 - changes in other organs, 147
 - classification of, 139
 - fibro-caseous, 144, 147
 - hypertrophy of heart in, 147
 - interstitial, 147
 - mode of spread, 137
 - paths of entry of infection, 135
 - "seat of election," 135
 - waxy disease in, 147
 - of myocardium, 59
 - of pericardium, 53
 - of peritoneum, 173
 - of spinal cord, 252
 - of spleen, 109
 - of suprarenal, 114
 - of testicle, 273
 - pleurisy in, 151
- Tuberculous enteritis, 165
 - lymphadenitis, 103
 - meningitis, 232
 - pneumonia, 142
 - ulceration of intestine, 164
- Tumours, difference between simple and malignant, 275
 - epithelial, 283
 - malignant, 286

- Tumours, myxoma of chorion, 304
 neuroglial, 282
 of bladder, 228
 of bone, 260, **280**
 of brain, 242
 of cartilage, 279
 of fatty tissue, 279
 of gall bladder, 197
 of heart, 60
 of intestine, 171
 of kidney, 223
 of larynx, 117
 of liver, 192
 of lung, 148
 of lymph gland, 105
 of lymphoid tissue, 282
 of mammary gland, 273
 of mouth, 153
 of muscle, 280
 of myxomatous tissue, 278
 of myocardium, 60
 of nerves, 253
 of œsophagus, 154
 of ovaries, 264
 of pancreas, 198
 of peritoneum, 174
 of placenta, 268
 of prostate, 274
 of spinal cord, 252
 of stomach, 158
 of suprarenal, 114
 of testicle, 274
 of uterus, 268
 of vascular tissue, 281
 of vertebræ, 252
 simple, 277
 types, 275
 Typhoid carriers, 195
 fever, 163
 kidney in, 164
 liver in, 164
 spleen in, 164
 ulcers compared with tuberculous ulcers of intestine, 166
 Ulcer, rodent, 299
 Unna's alkaline methylene blue, 343
 Unna-Pappenheim stain, 343
 Urine in acute nephritis, 210
 in chronic interstitial nephritis, 216
 in subacute nephritis, 212
 Uterus, diseases of, 266
 examination of, 34
 rupture of, 269
 tuberculosis of, 267
 tumours of, 268
 Valves of heart, abnormalities of, 47
 diameter and circumference of, 76
 examination of, 24, 25, 26
 Van Gieson stain, method of use, 341
 Varicose veins, 89
 Veins, diseases of, 87
 thrombosis of, 87
 varicose, 89
 Venæ Cavæ, examination of, 23, 35
 Vermiform appendix, examination of, 30
 Vertebræ, tumours of, 252
 Virchow, opening of abdominal cavity, 14
 Viscera (hollow) bacteriological investigation of, 360
 Volvulus, 159
 Von Kossa silver stain, 352
 Water test for lungs, 310
 Waxy degeneration in tuberculosis, 147
 of arteries, 78
 of liver, 179
 disease of kidney, 203
 of spleen, 105
 material, anilin stains for, 353
 iodine stain for, 353
 methyl-violet stain for, 353
 stains for, 352
 Weigert's borax - ferricyanide differentiating mixture, 347
 elastic stain, 344
 fibrin stain, 345
 iron-hæmatoxylin stain, 339

- | | |
|---|---|
| Weigert's medullary sheath stain,
354
modification of Gram's stain, 363 | Zenker's degeneration of muscle,
18
fixative, 327 |
| White softening, 236 | Ziehl-Neelsen stain for tubercle
bacillus, 365 |
| Widal reaction, 374 | Ziehl-Neelsen with Much-Gram
stain, 369 |
| Woolsorter's disease, 2 | |
| Wright's stain, 358 | |

THE END

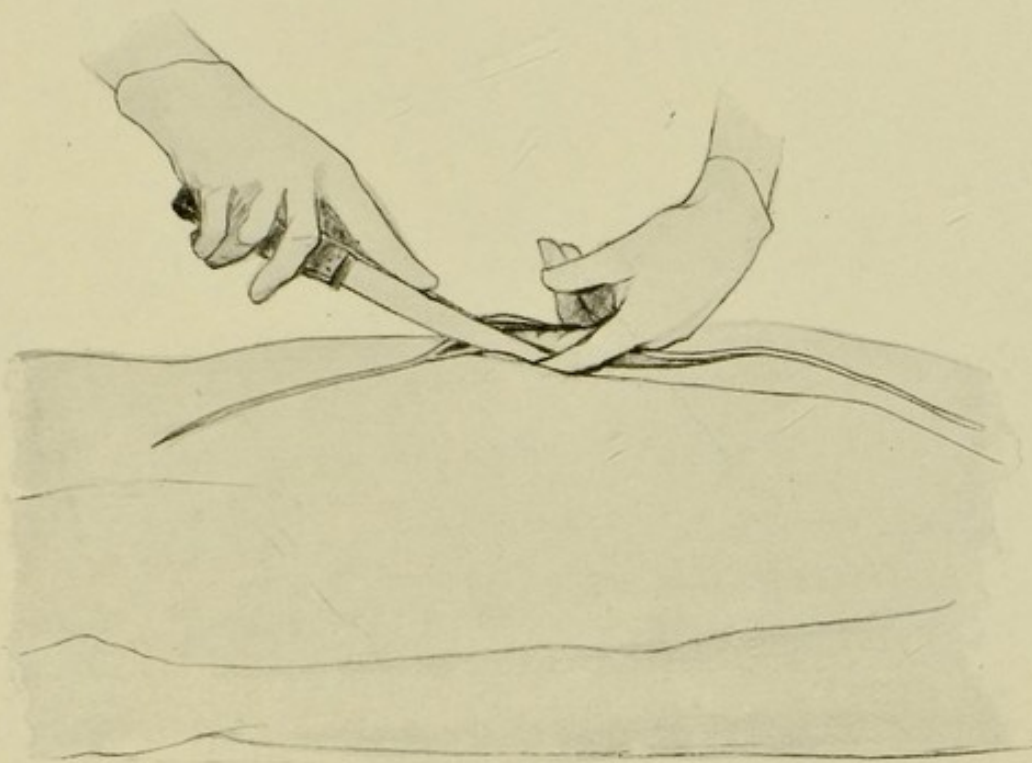


FIG. 1.—Method of opening the abdominal cavity.

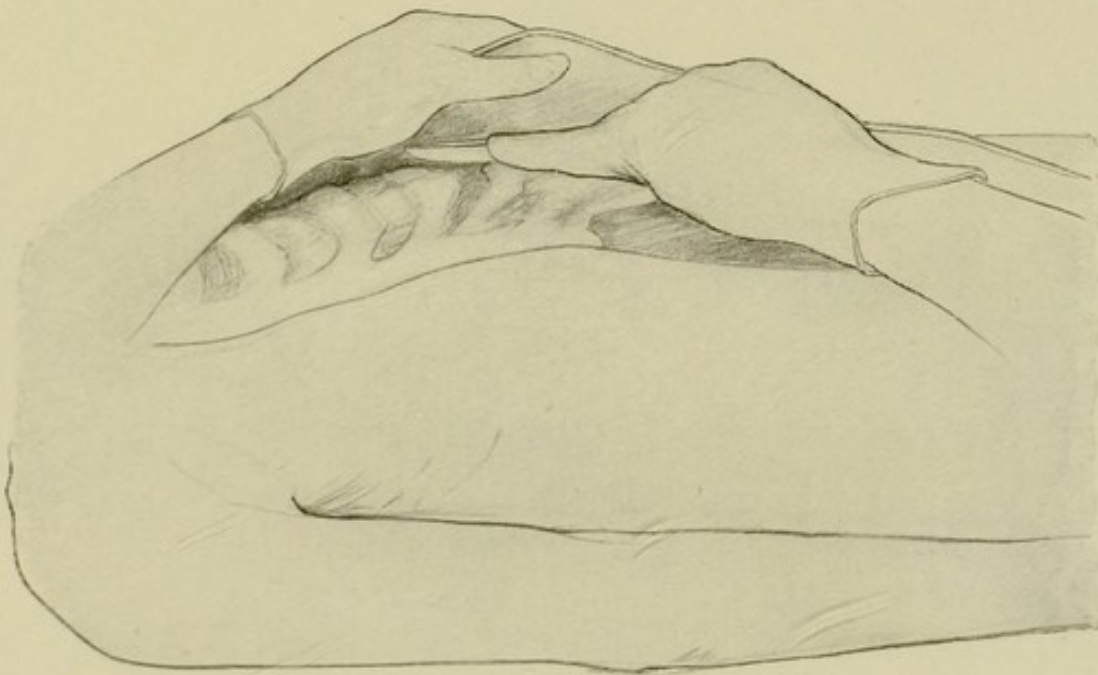


FIG. 2.—Reflecting the skin and muscles from the sternum and ribs.

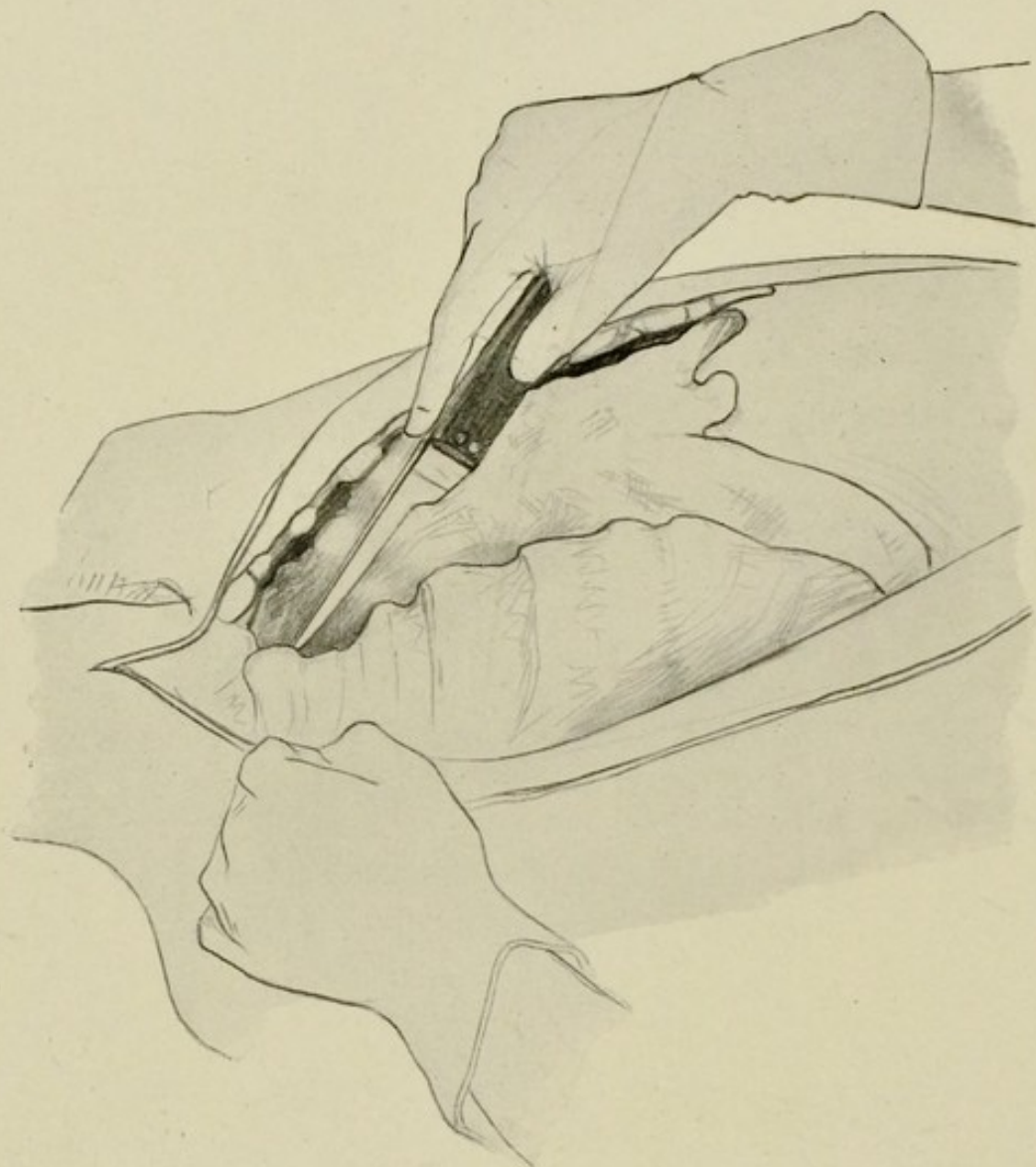


FIG. 3.—Method of cutting through sterno-clavicular joint.

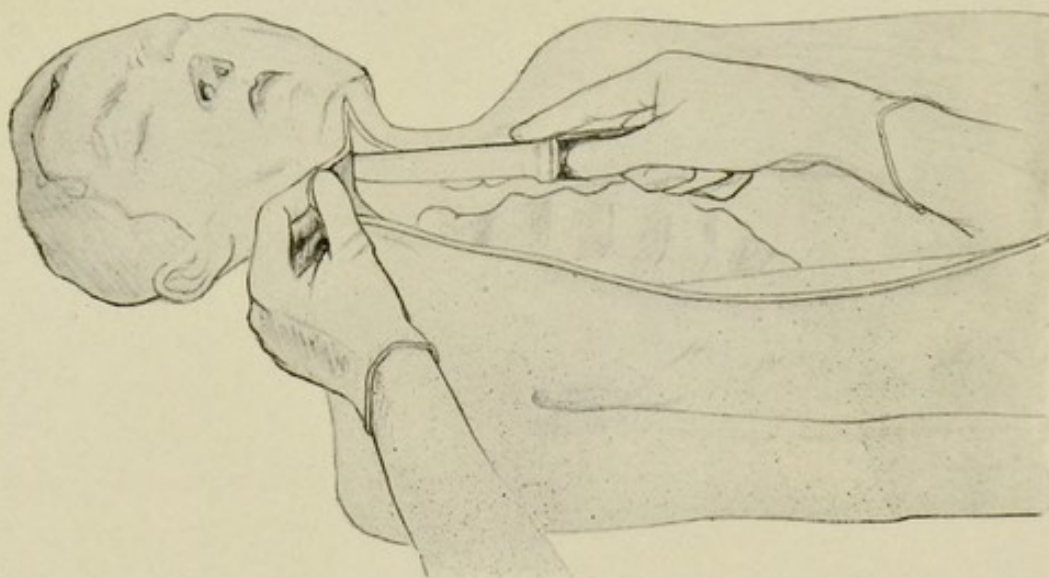


FIG. 4.—Method of cutting through floor of mouth.

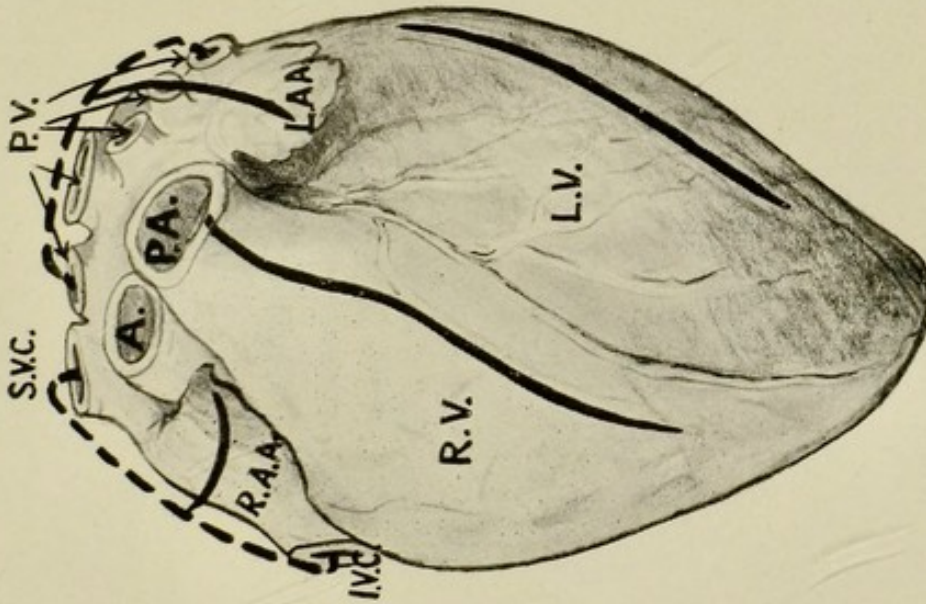


FIG. 5.—Lines of incisions for opening up the cavities of the heart.

I.V.C., inferior vena cava. S.V.C., superior vena cava. R.A.A., right auricular appendix. R.V., right ventricle. P.A., pulmonary artery. P.V., pulmonary veins. L.A.A., left auricular appendix. L.V., left ventricle.

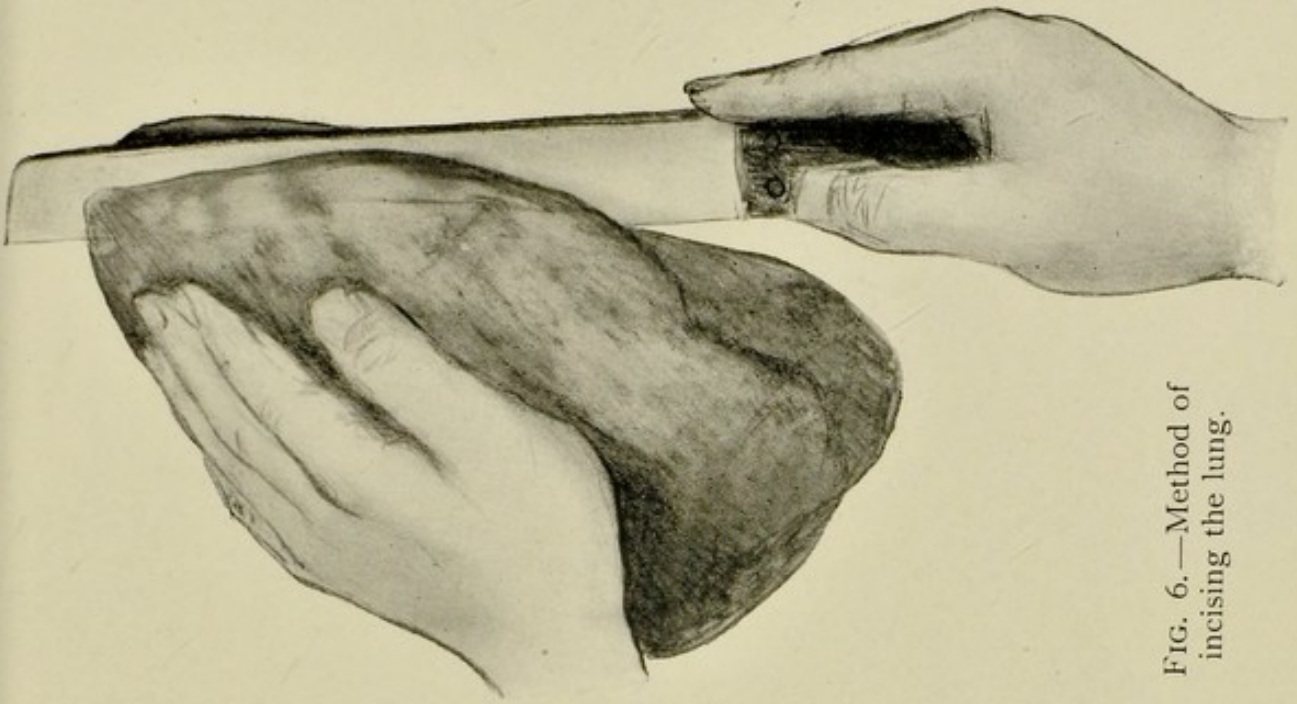


FIG. 6.—Method of incising the lung.

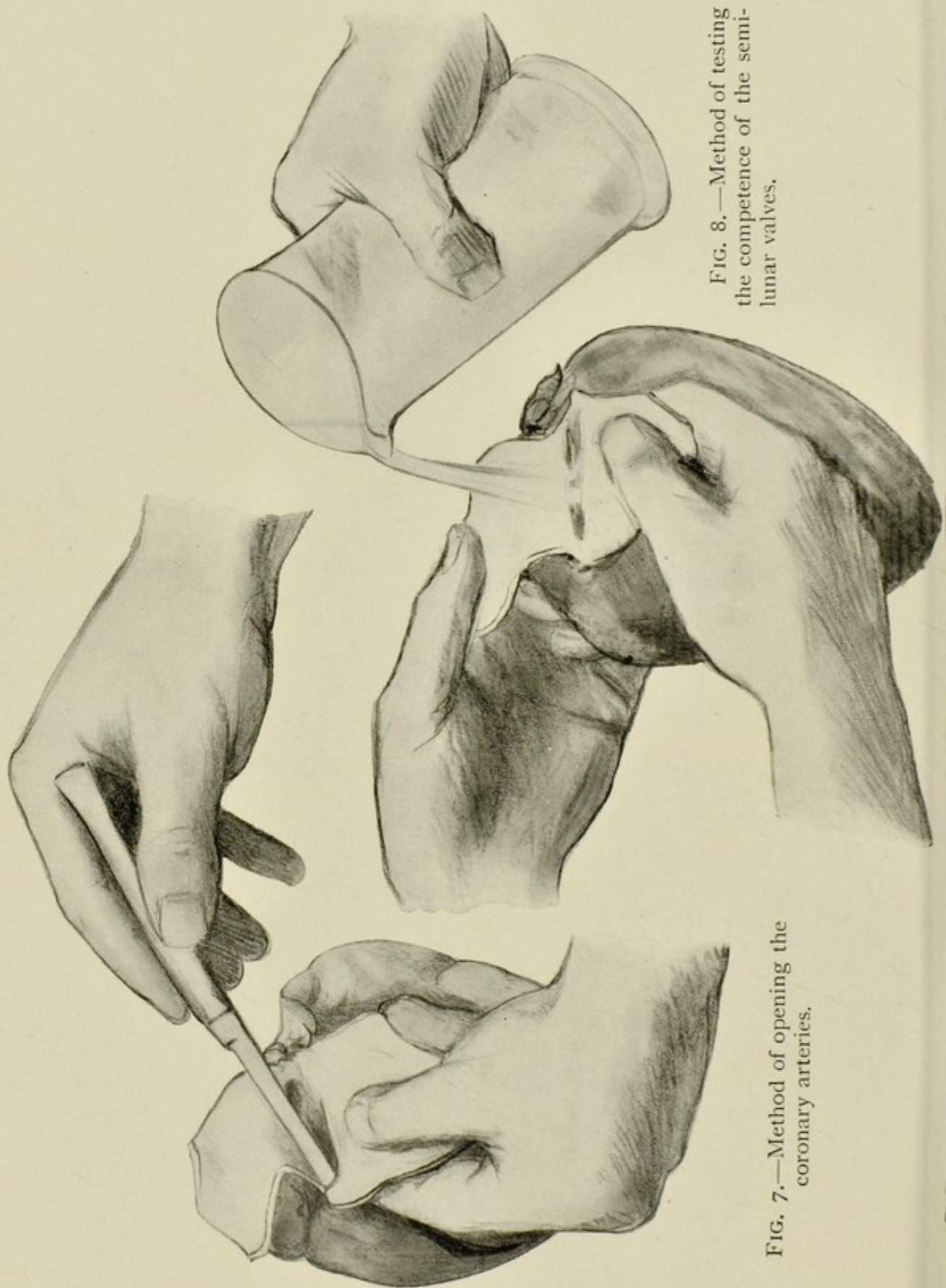


FIG. 8.—Method of testing the competence of the semi-lunar valves.

FIG. 7.—Method of opening the coronary arteries.

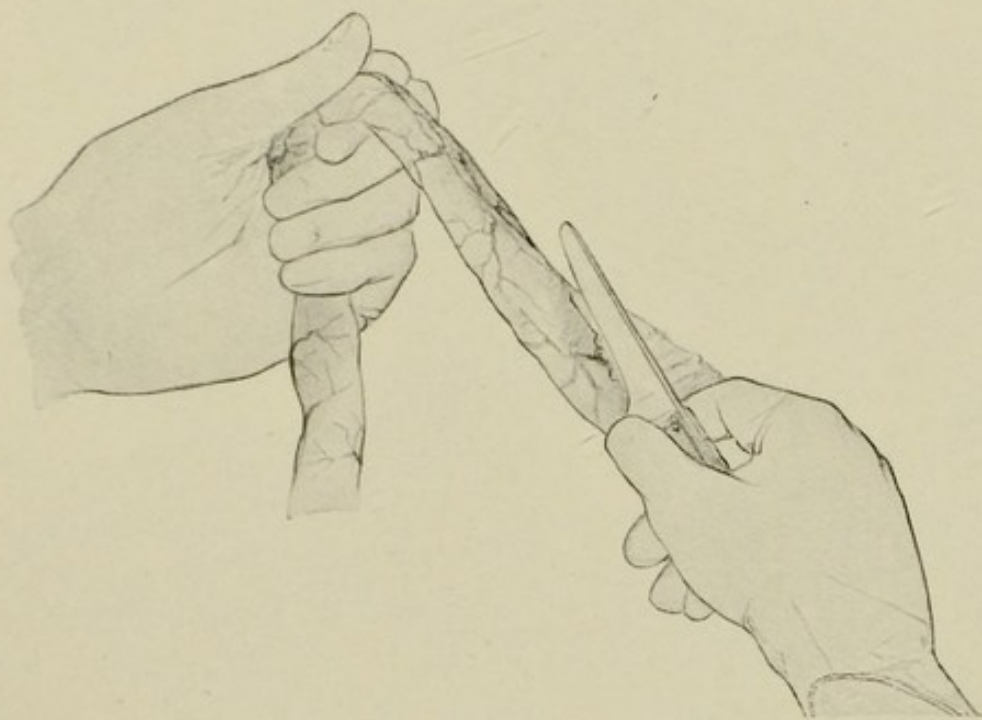


FIG. 9.—Method of removing the small intestine.

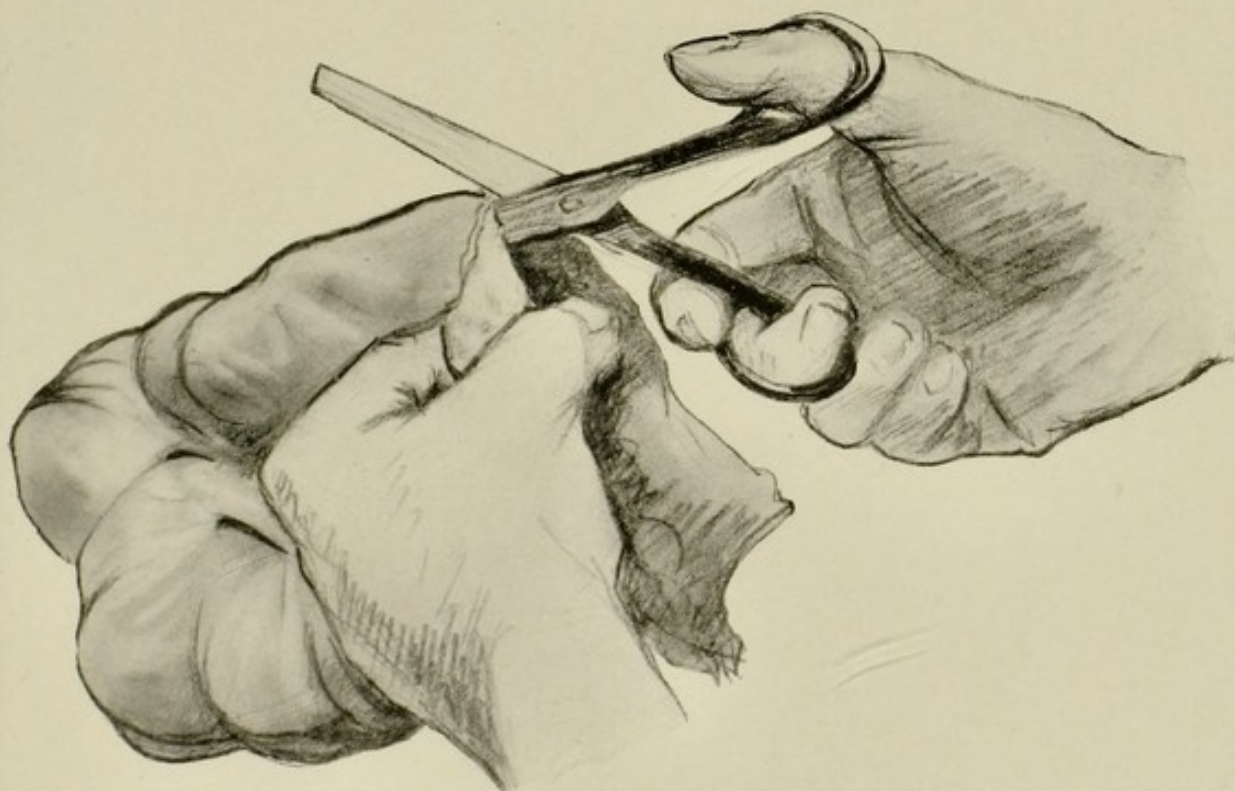


FIG. 10.—Method of opening the bowel after it has been removed.

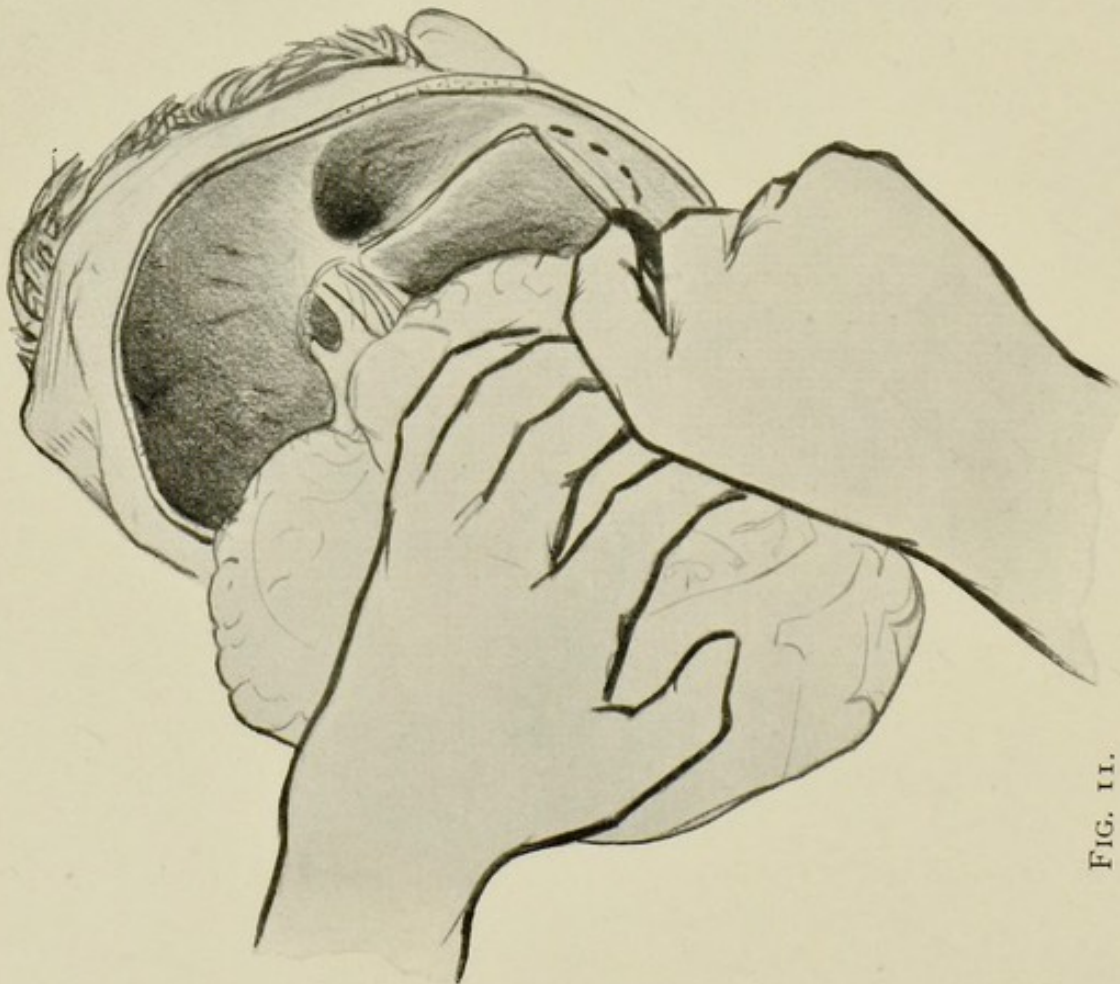


FIG. 11.

FIG. 11.—Cutting through tentorium cerebelli.

FIG. 12.—Position of the accessory cavities in relation to the base of the skull.

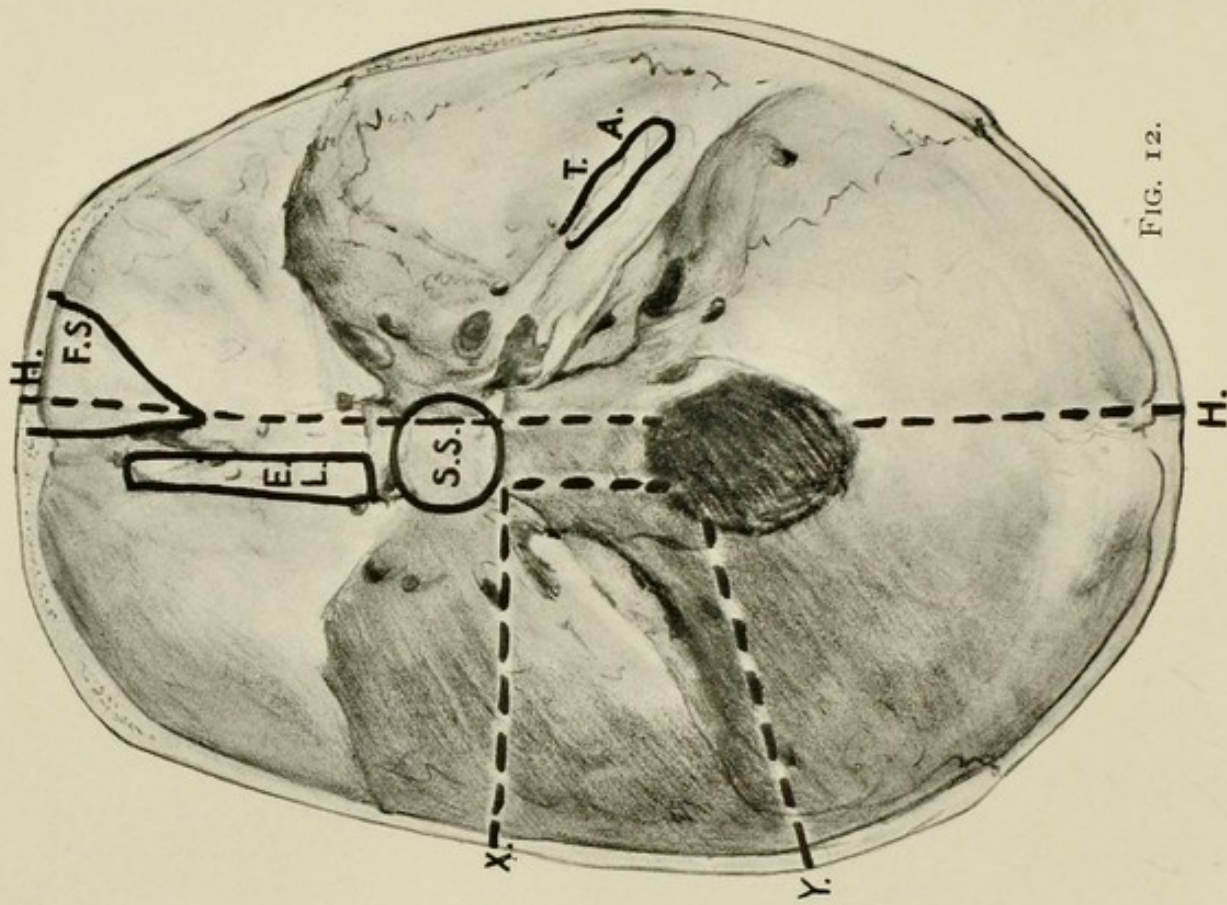


FIG. 12.

F.S., frontal sinus. E.L., ethmoidal labyrinth. S.S., sphenoidal sinus. T., tympanum. A., mastoid antrum.
H.H., saw-line for splitting base of skull according to Harke's method. X. Y. saw-lines for removing temporal bone.

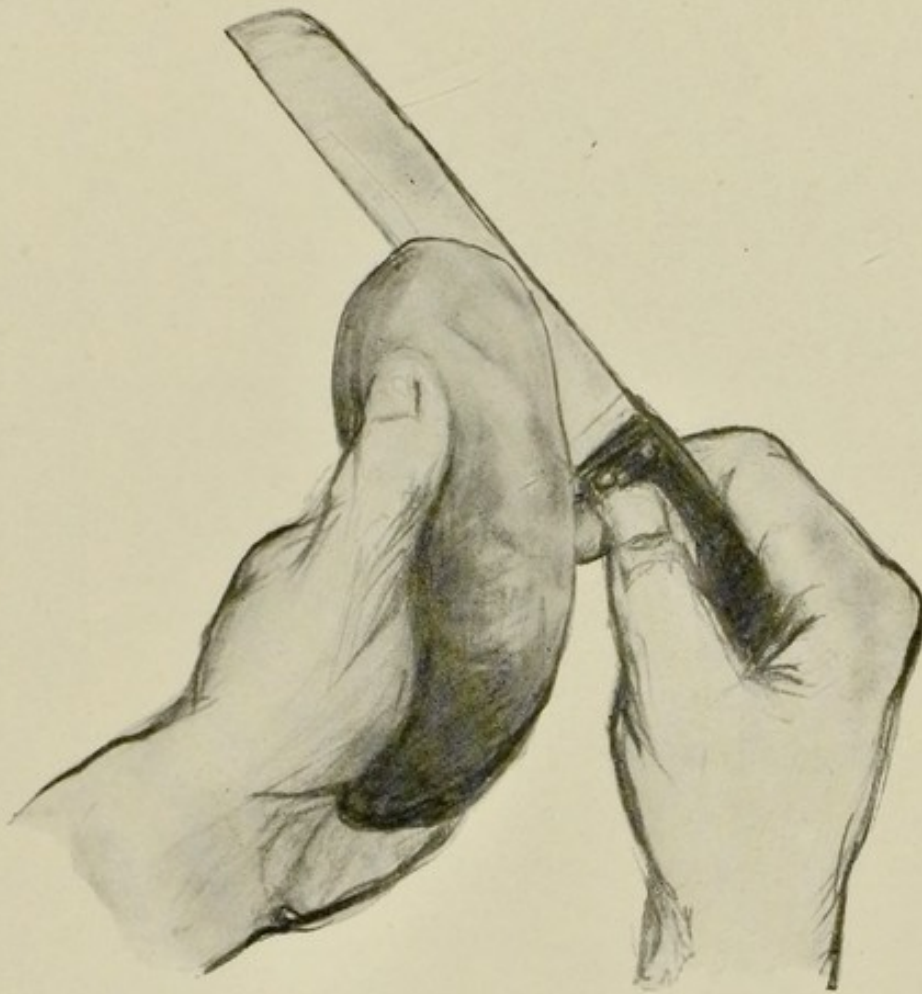


FIG. 13.—Method of incising the kidney.

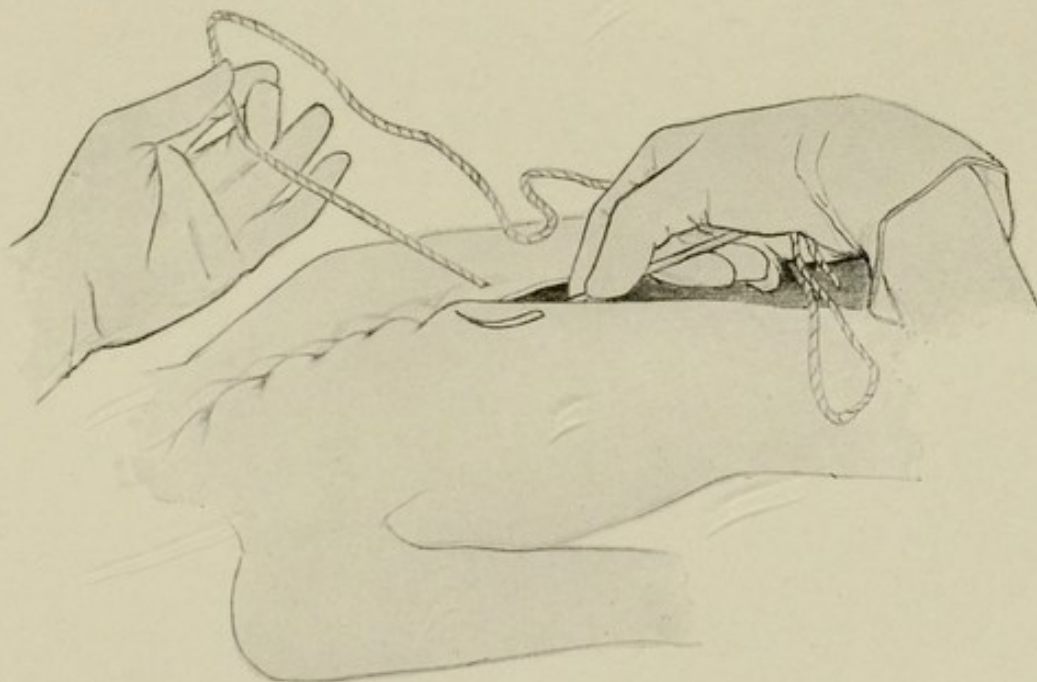


FIG. 14.—Method of stitching up.

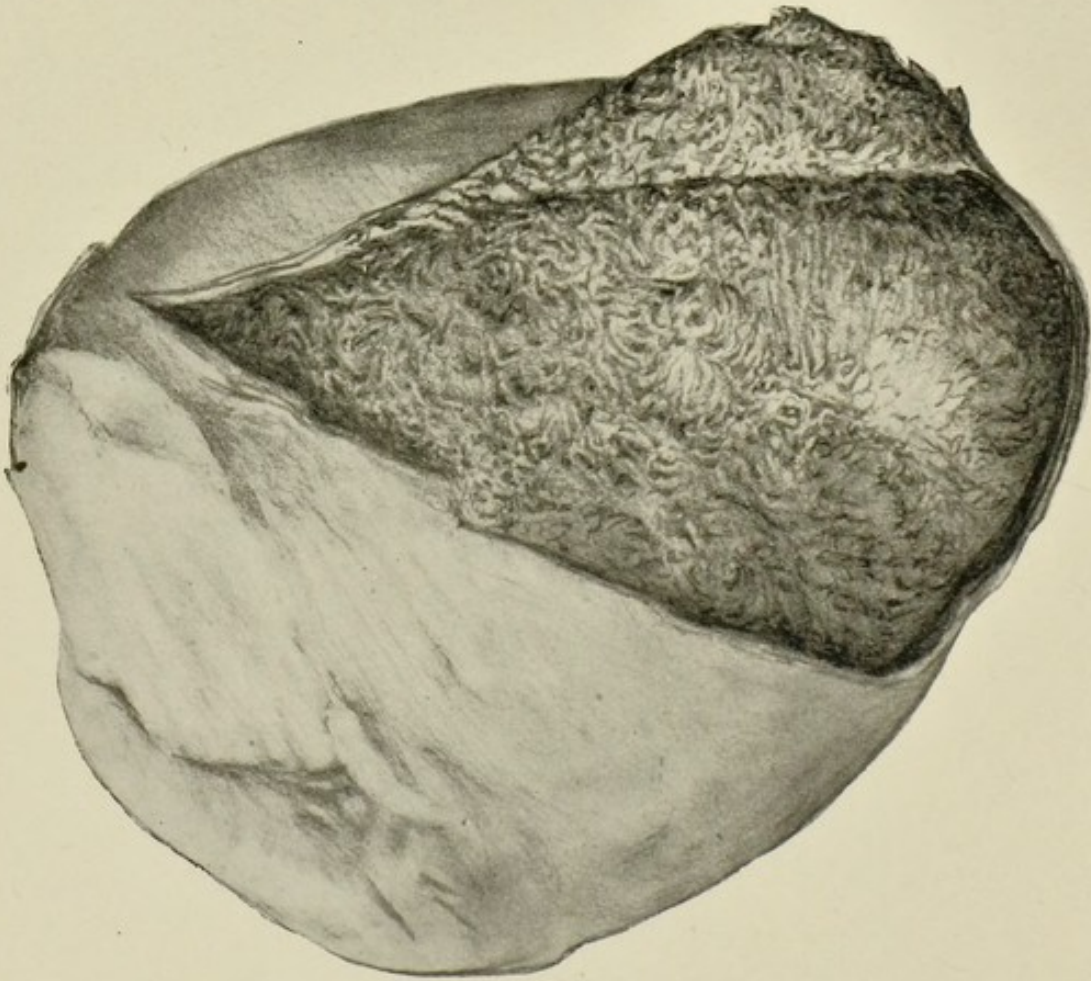


FIG. 15.—Heart, acute pericarditis. $\frac{1}{3}$.
Pericardial sac opened and turned aside, showing thick layer of fibrinous exudate covering heart ("villous" appearance).

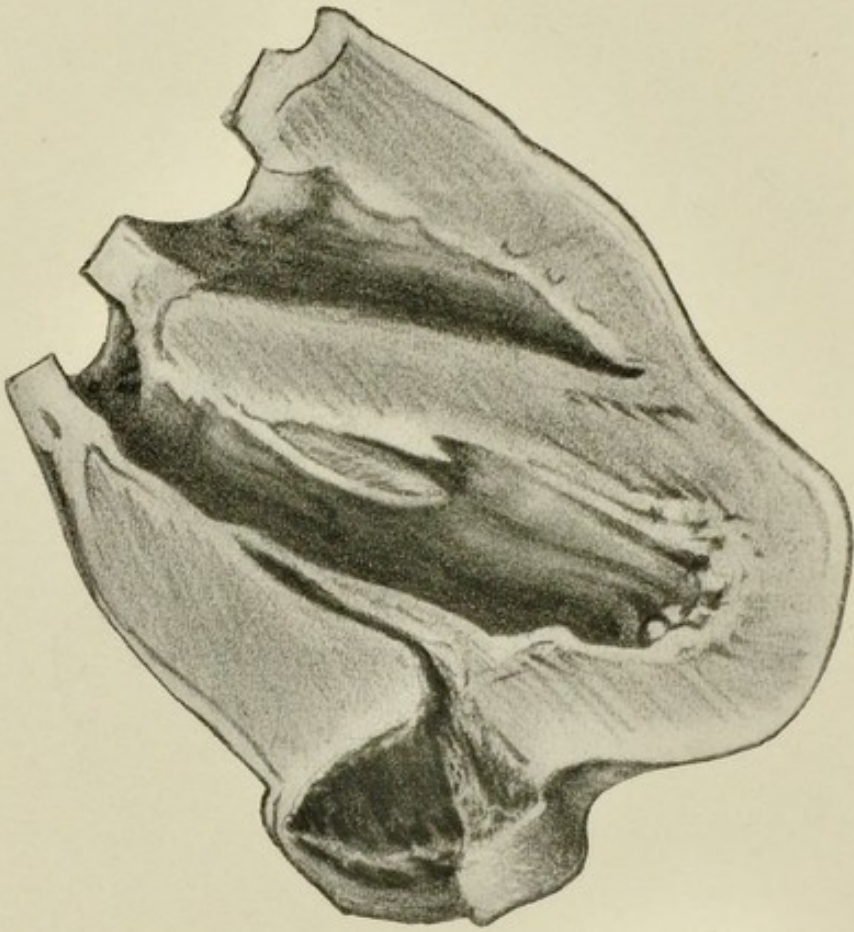


FIG. 16.—Acute aneurysm following abscess of left ventricle in case of osteomyelitis. Posterior view. $\frac{1}{3}$.

The abscess established a communication with the left ventricle, became distended with blood, and then burst into the pericardial sac. The aneurysm is partly filled with blood-clot.

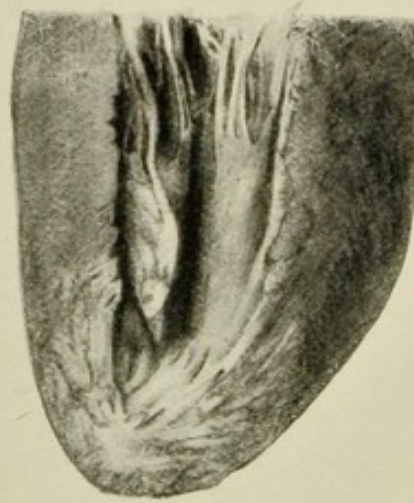

FIG. 17.—Heart, chronic interstitial myocarditis. $\frac{1}{2}$.

Apical portion of left ventricle showing white patches of fibrous tissue replacing the muscle substance. The change is most marked at the apex and in the right papillary muscle, which has been cut open.

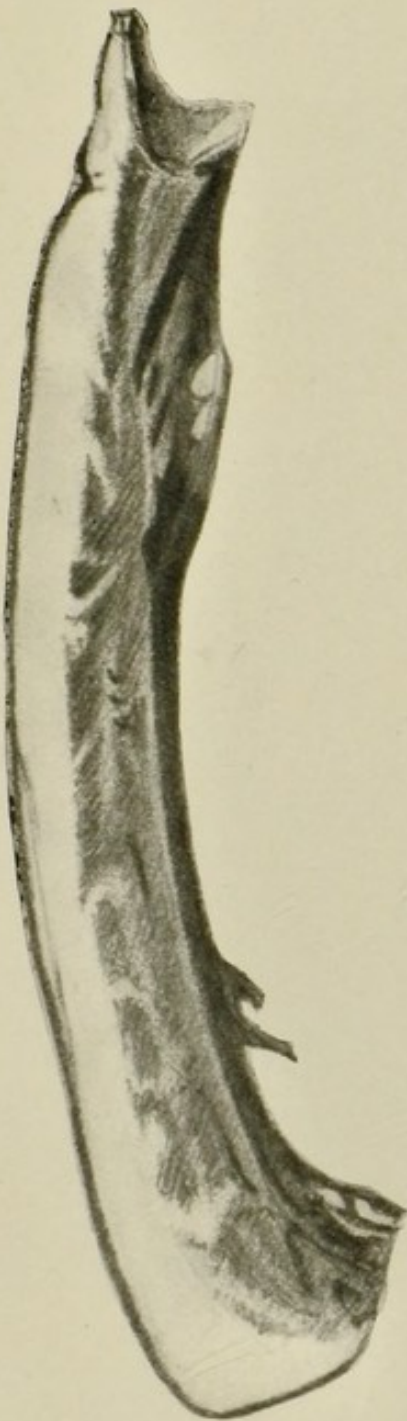


FIG. 18.—Section through wall of right ventricle, showing increase of sub-pericardial fat and fatty infiltration of the muscle. $\frac{1}{4}$.

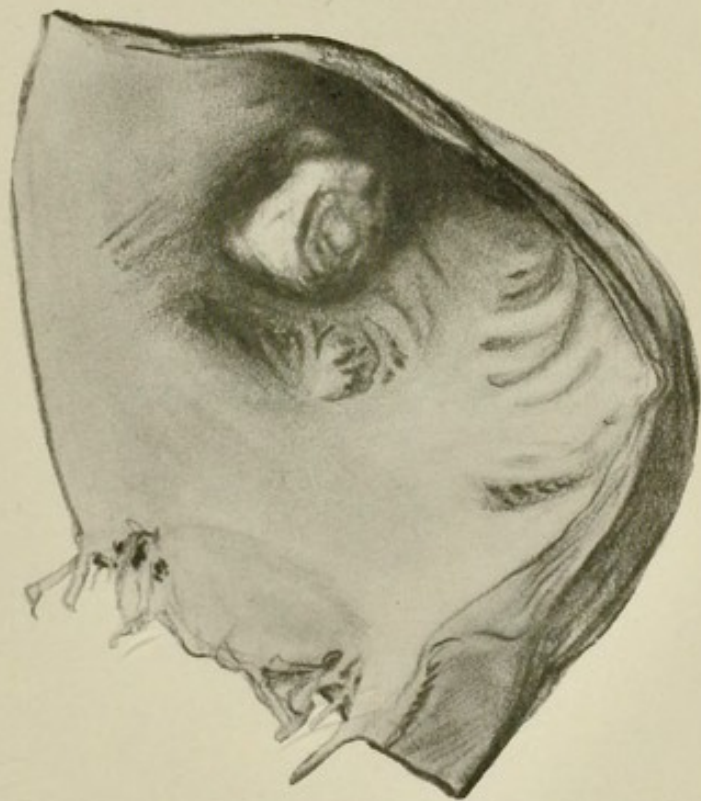


FIG. 19.—Thrombus in right auricular appendix. $\frac{3}{4}$.

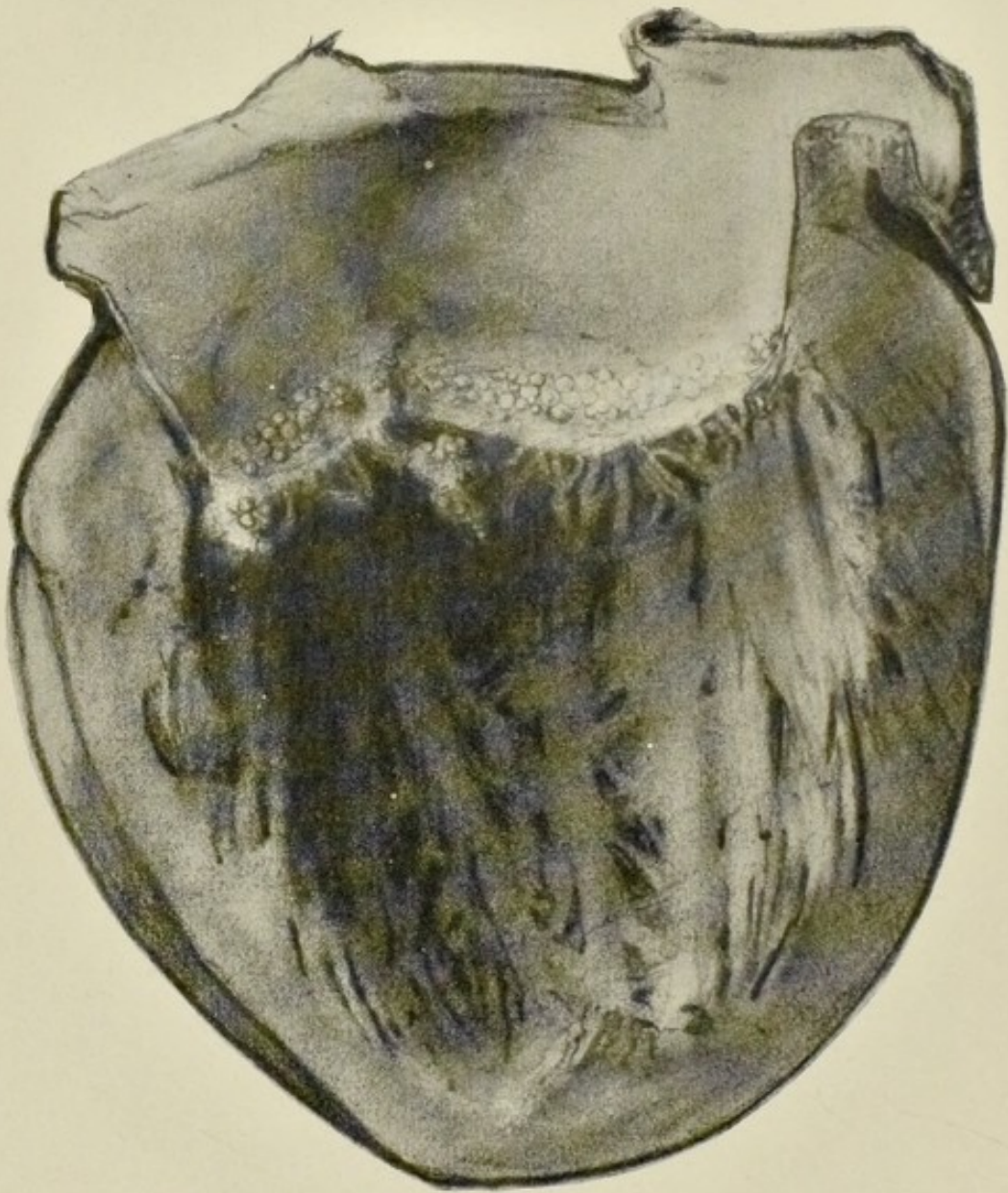


FIG. 20. —Heart of child, simple (vegetative) endocarditis
in a case of chorea. $\frac{1}{4}$.

Minute rounded vegetations covering mitral valve close to free margin.

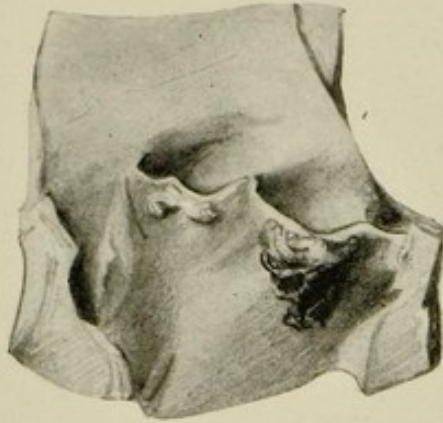


FIG. 21.—Aortic valve, simple endocarditis. $\frac{1}{2}$.
Vegetations along margin of two segments, with red thrombus
attached to one of the vegetations.

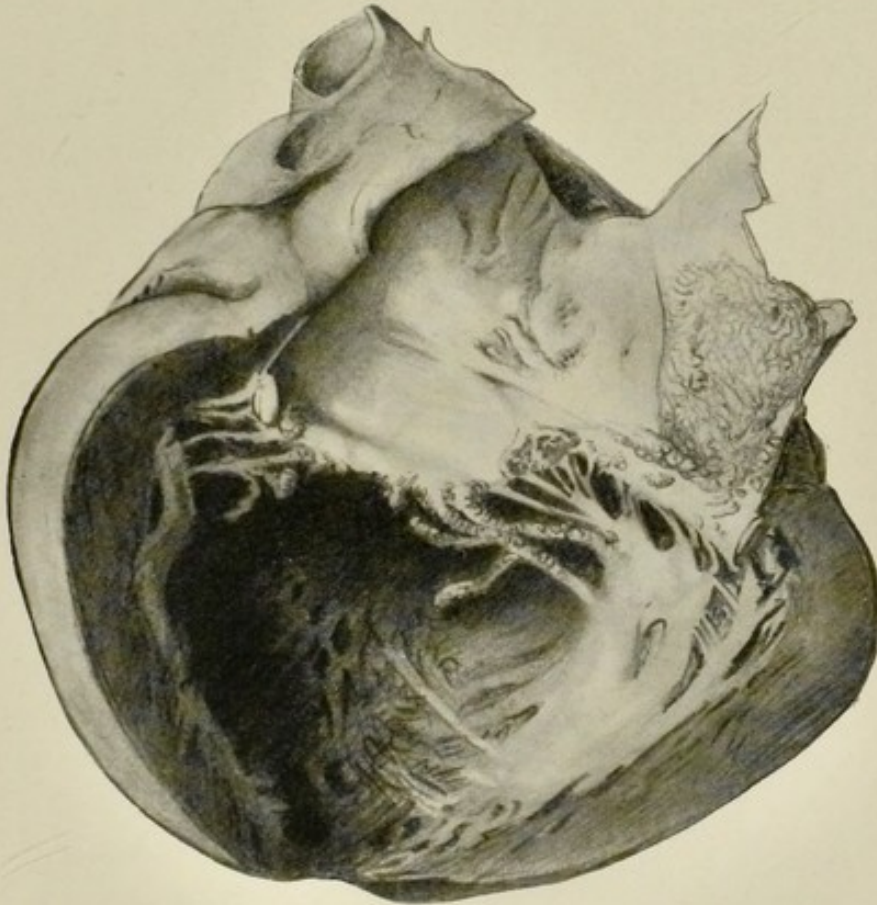


FIG. 22.—Heart, ulcerative endocarditis of mitral valve. $\frac{1}{2}$.

The valve has been the seat of a previous endocarditis as evidenced by the thickening of the segments and of the chordæ tendineæ. Both sets of structures are covered with vegetations, which also extend on to the wall of the left auricle and chordæ tendineæ. The wall of the left ventricle is thickened, and the cavity dilated, due to the incompetence of the mitral valve which existed previous to the ulcerative endocarditis. One or two of the chordæ tendineæ have ruptured.

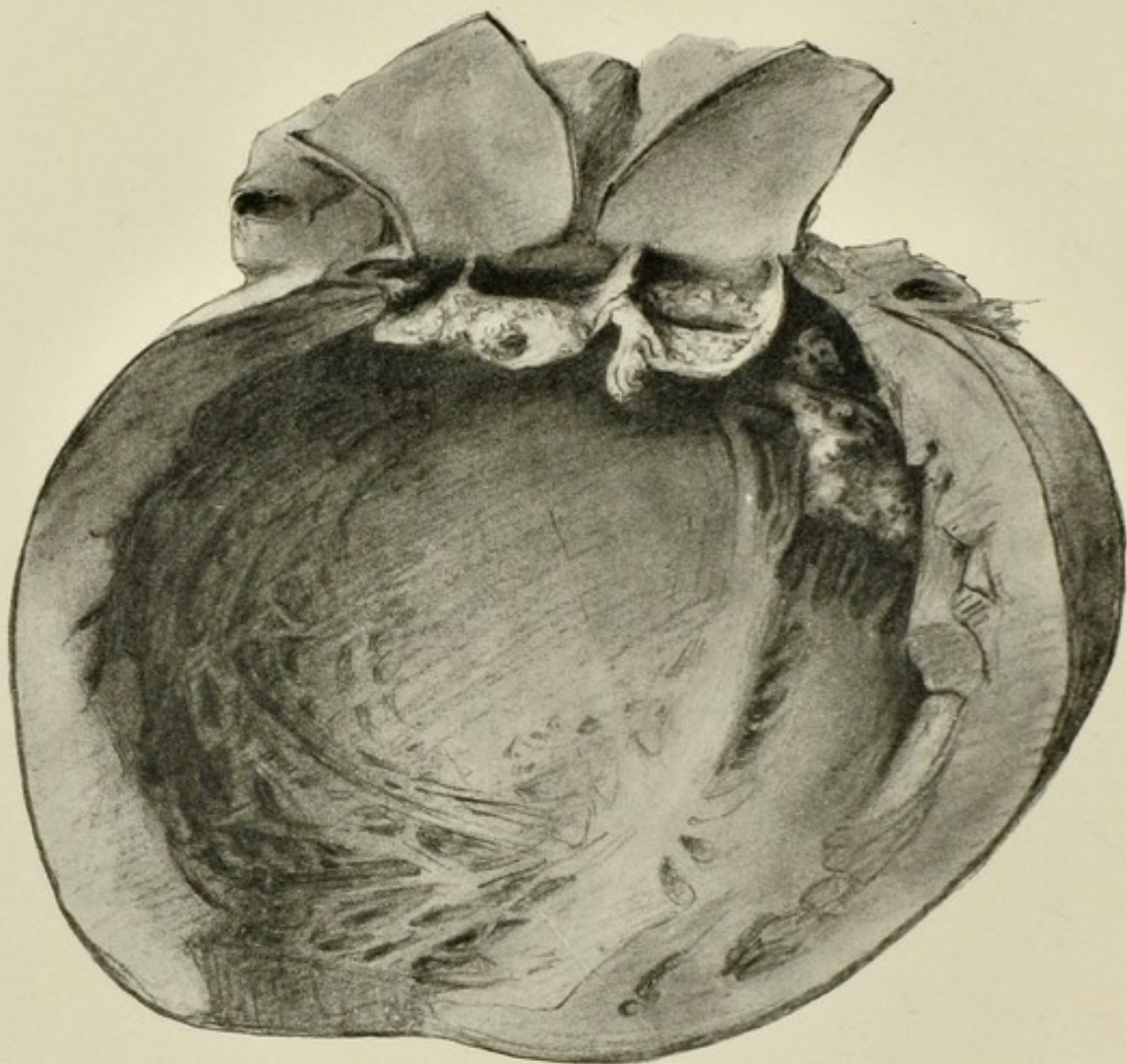


FIG. 23.—Ulcerative endocarditis, aortic valve. $\frac{1}{2}$.

The segments had been thickened previously. They are covered with vegetations. One of the segments has ruptured. There are also vegetations visible on the mitral valve to the right. There is marked dilatation of the left ventricle, largely due to the incompetence of the previously thickened valve.

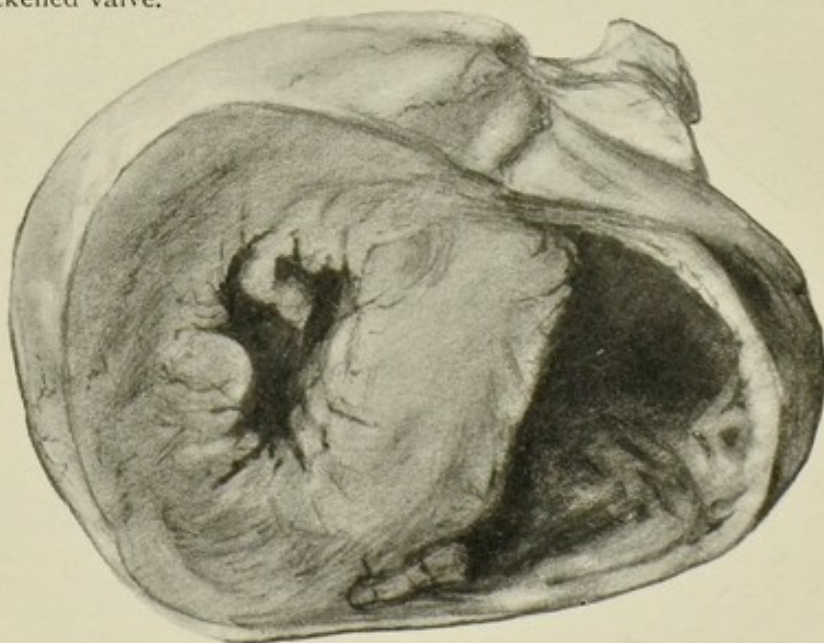


FIG. 24.—Transverse section of heart. $\frac{1}{2}$.

Marked hypertrophy of left ventricle in case of chronic nephritis. Right ventricle dilated.

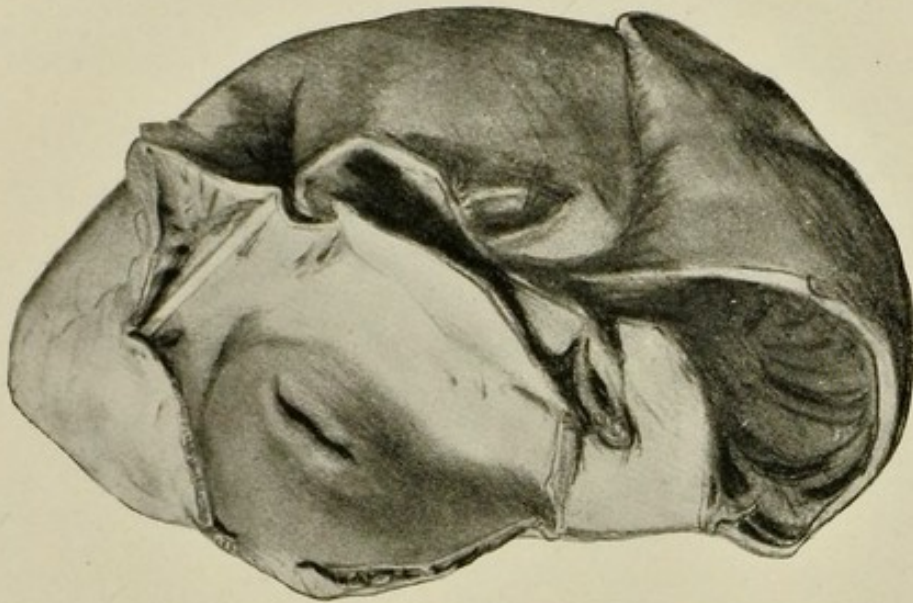


FIG. 26.

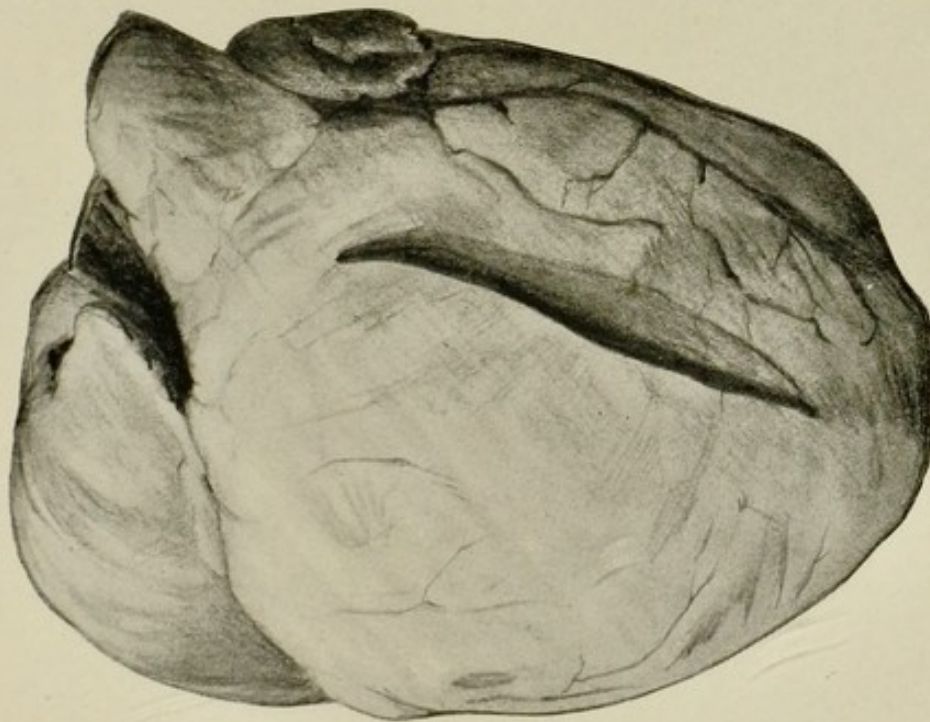


FIG. 25.

FIG. 25.—Anterior aspect of heart from case of mitral stenosis, showing dilatation of right auricle and well-marked hypertrophy as well as dilatation of right ventricle. $\frac{1}{2}$.

FIG. 26.—Same heart from above, showing dilatation of both auricles. The narrowed mitral valve (button-hole) can be seen. $\frac{1}{2}$.

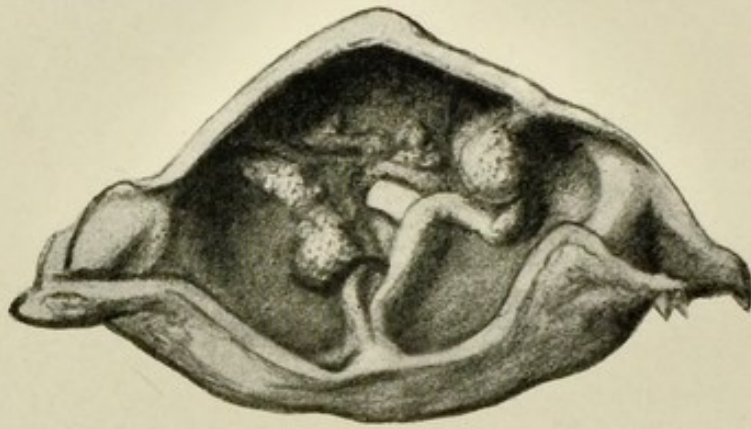

FIG. 27.—Chronic endocarditis of aortic valve. $\frac{1}{4}$.
Calcareous deposits in the thickened cusps, also union of the segments with consequent stenosis.



FIG. 28.—Portion of descending thoracic aorta. $\frac{1}{2}$.
Showing advanced atheroma. Thrombi have formed in one or two places.

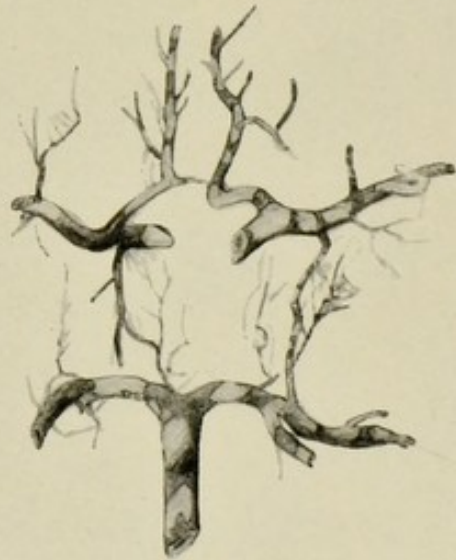


FIG. 29.—Arteries at base of brain. $\frac{1}{2}$.
Showing white patches of atheromatous change.

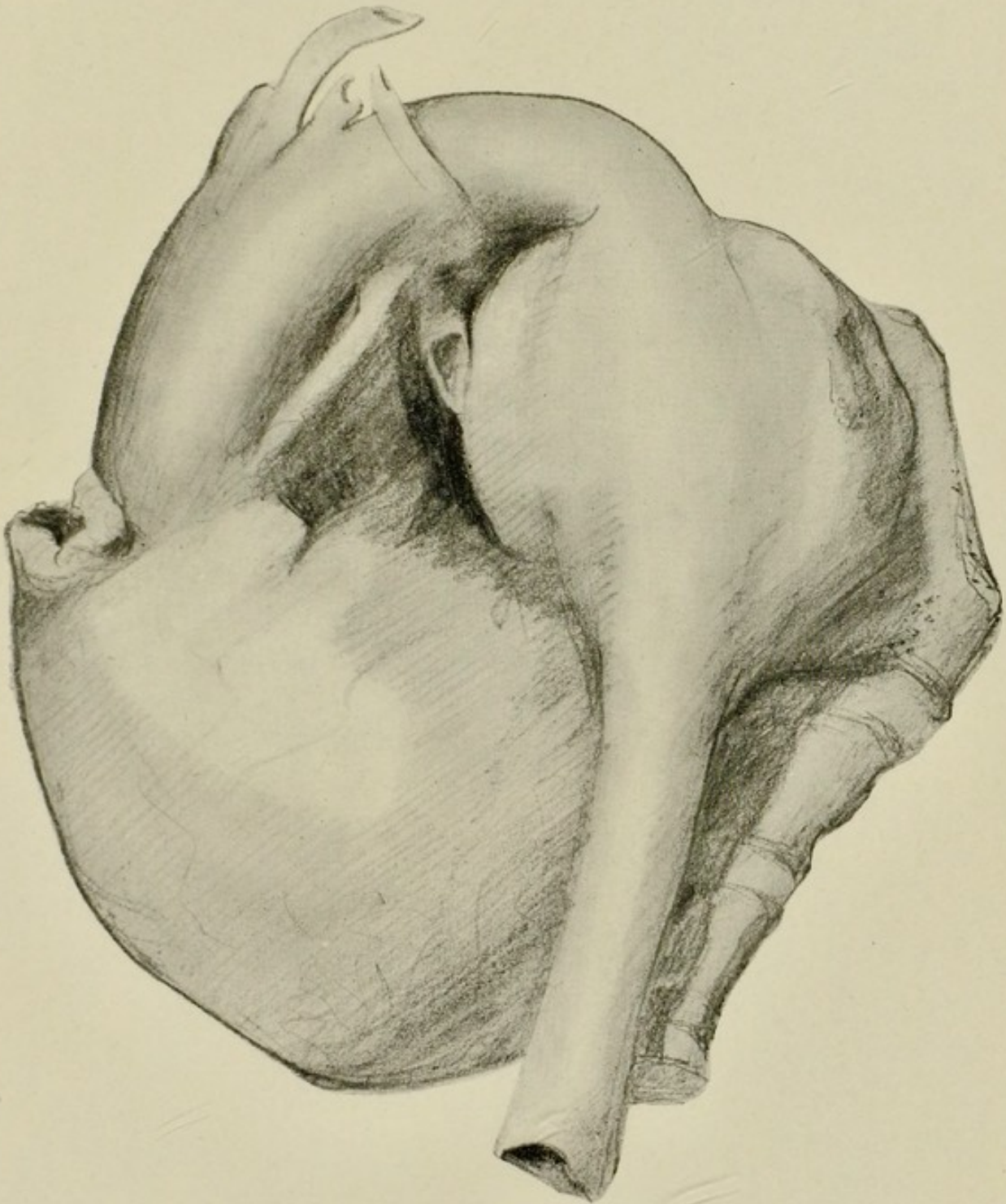


FIG. 30.—Saccular aneurysm of descending aorta adherent to and eroding the bodies of the vertebræ. $\frac{1}{2}$.

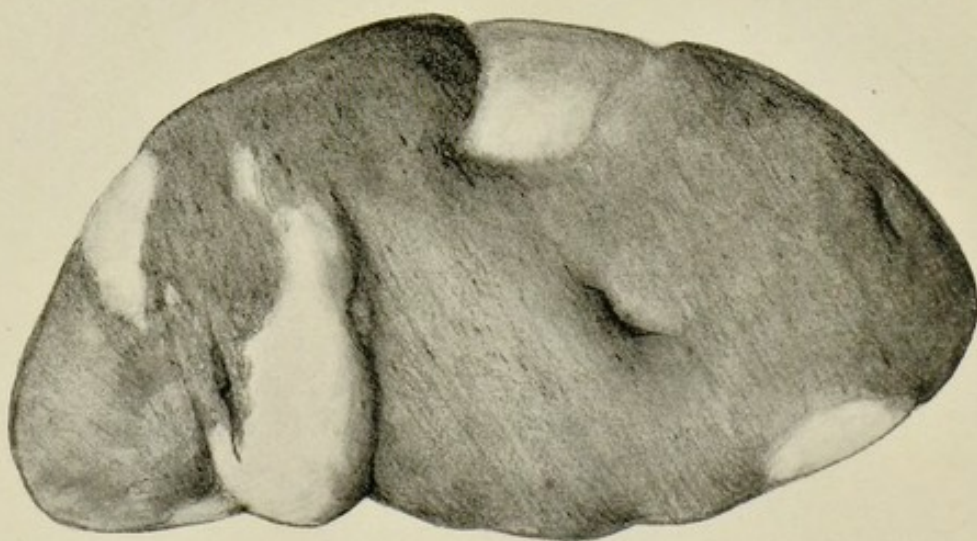


FIG. 31.—Spleen considerably enlarged from chronic venous congestion. $\frac{1}{2}$.

Shows several large infarcts, some projecting above surface, others depressed and in process of absorption.

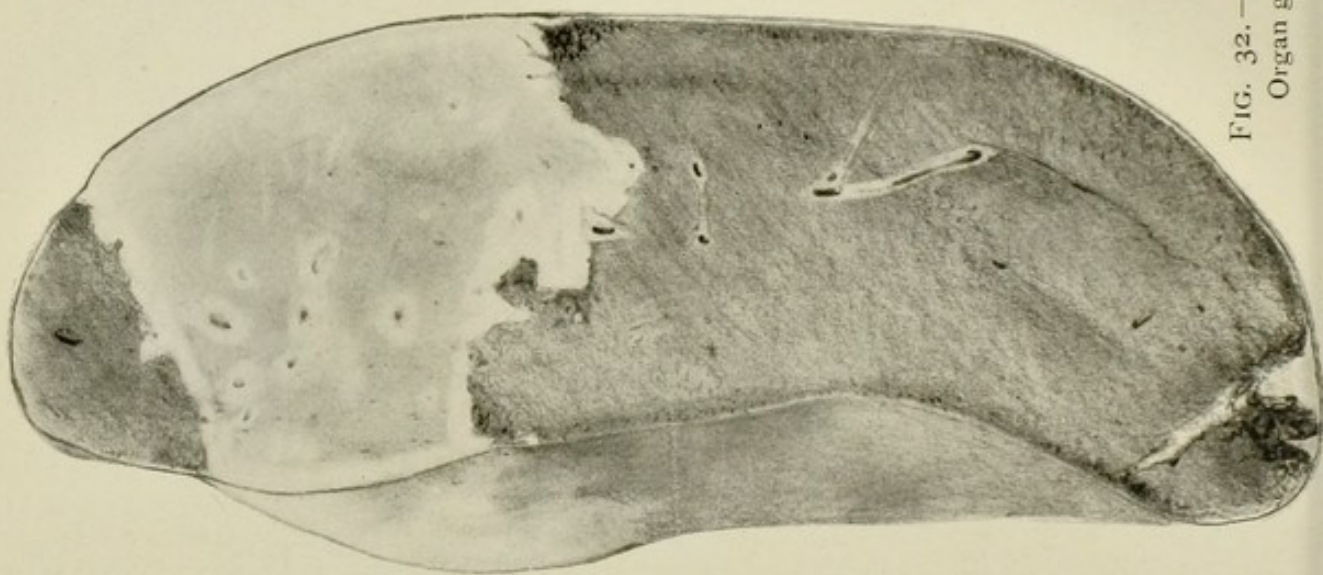


FIG. 32.—Spleen, myelogenous leukaemia. $\frac{1}{2}$.
Organ greatly enlarged. One very large and one smaller pale infarct.

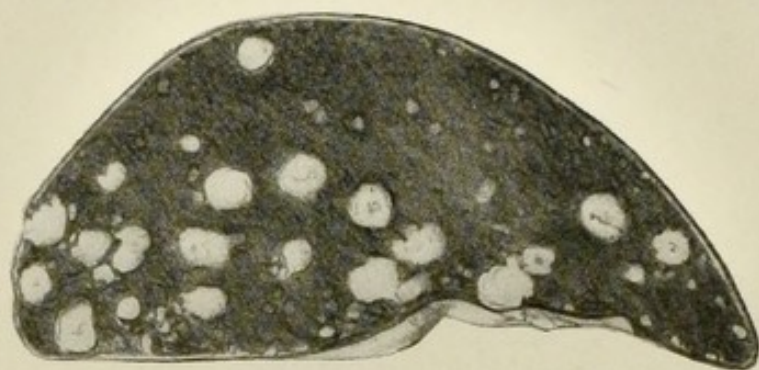

FIG. 33.—Spleen, tuberculous masses. (Museum of University College, Dundee.) $\frac{1}{2}$.

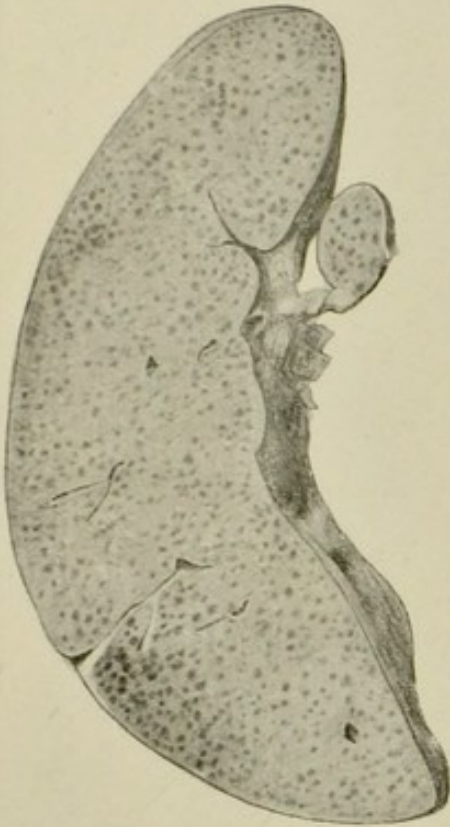


FIG. 34.—Spleen and spleniculus,
sago waxy. $\frac{1}{2}$.

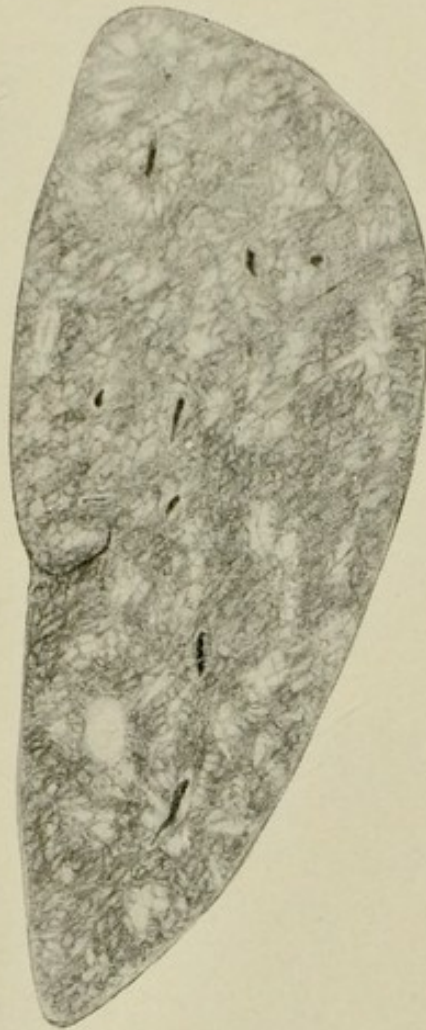

FIG. 35.—Spleen, Hodgkin's disease, showing numerous
scattered white masses varying in size. $\frac{1}{2}$.
The organ is considerably enlarged.

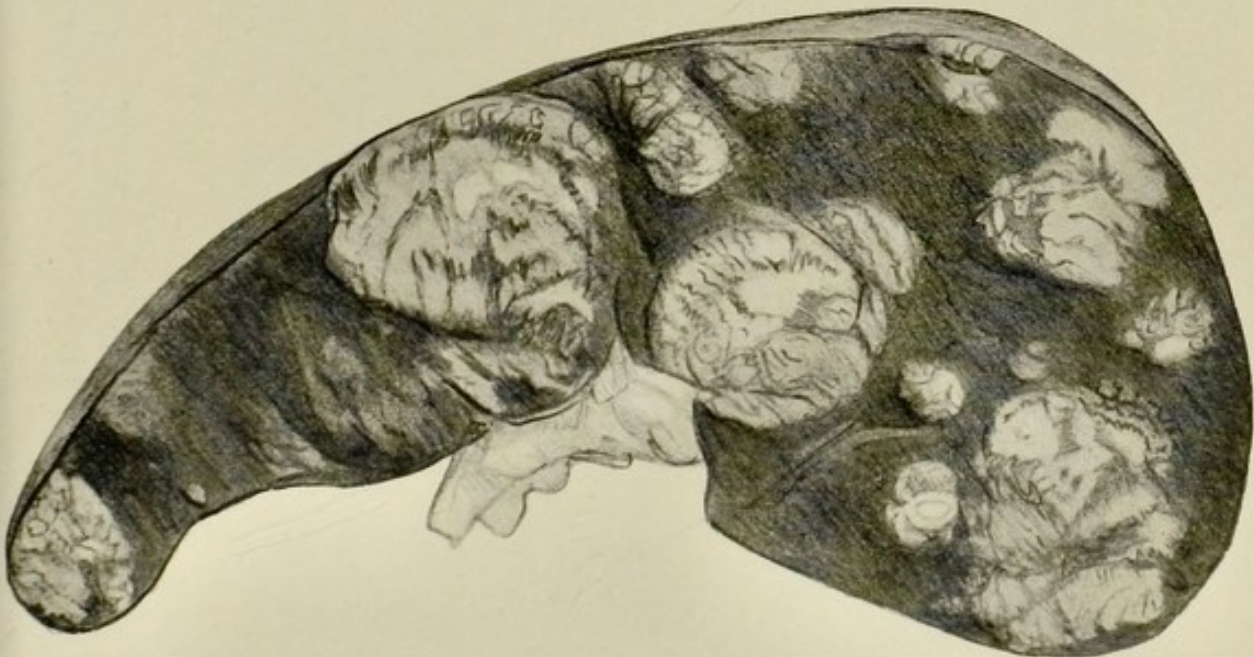


FIG. 36.—Spleen, Hodgkin's disease. (Dr. Byrom Bramwell's case.) $\frac{1}{2}$.
Suet-like areas forming large tumour-like masses.

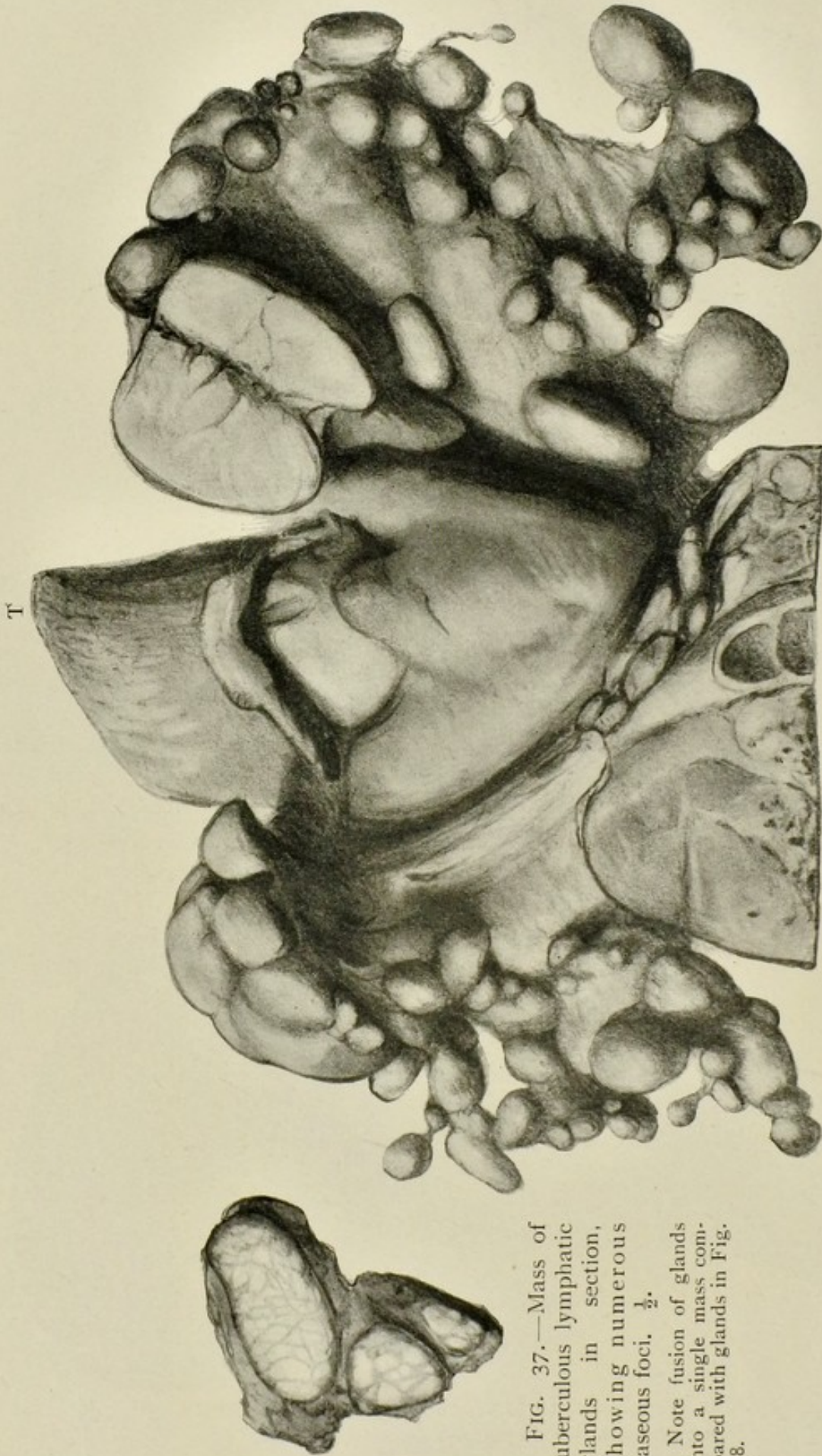

FIG. 37.—Mass of tuberculous lymphatic glands in section, showing numerous caseous foci. $\frac{1}{2}$.

Note fusion of glands into a single mass compared with glands in Fig. 38.

FIG. 38.—Lymphatic glands, lymphadenoma (Hodgkin's disease). (Dr. Byrom Bramwell's case.) $\frac{1}{2}$. Great enlargement of cervical and mediastinal glands. Thyroid gland also somewhat enlarged. T, point of tongue.

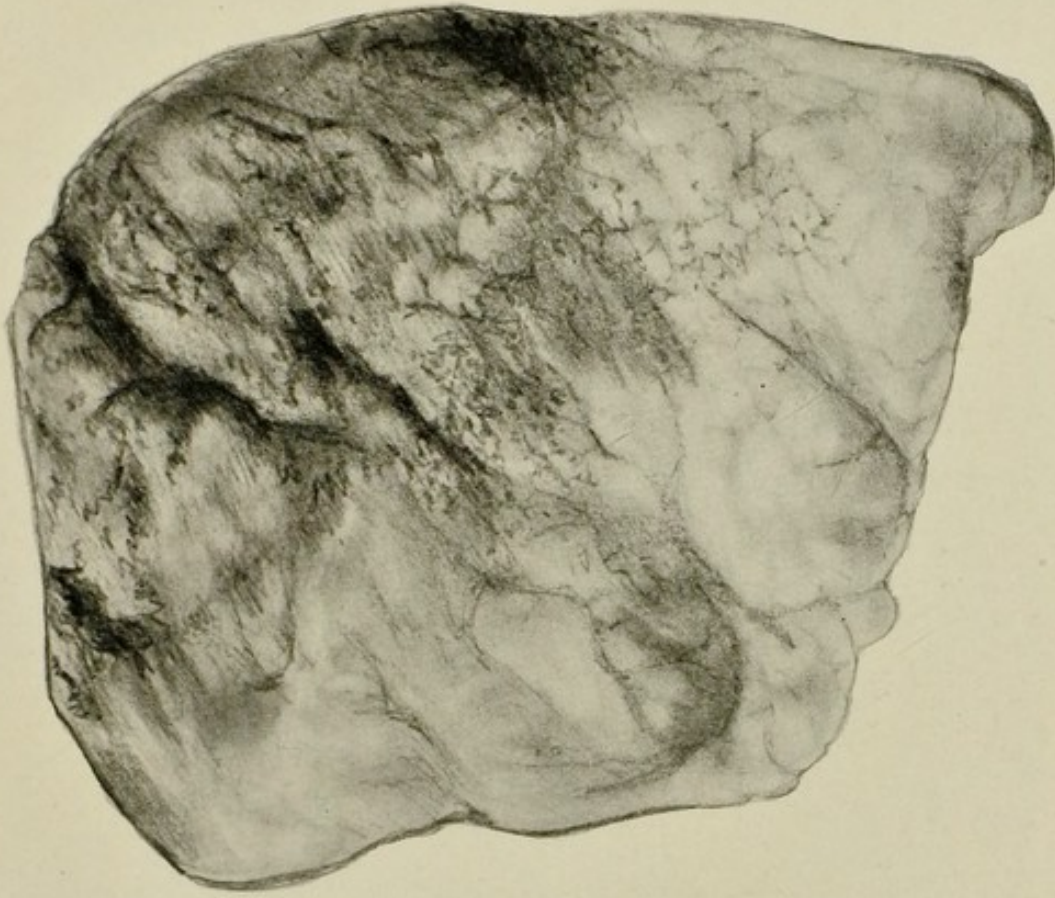


FIG. 40.—Lung, emphysema. $\frac{1}{2}$.
Most marked along anterior and lower border.

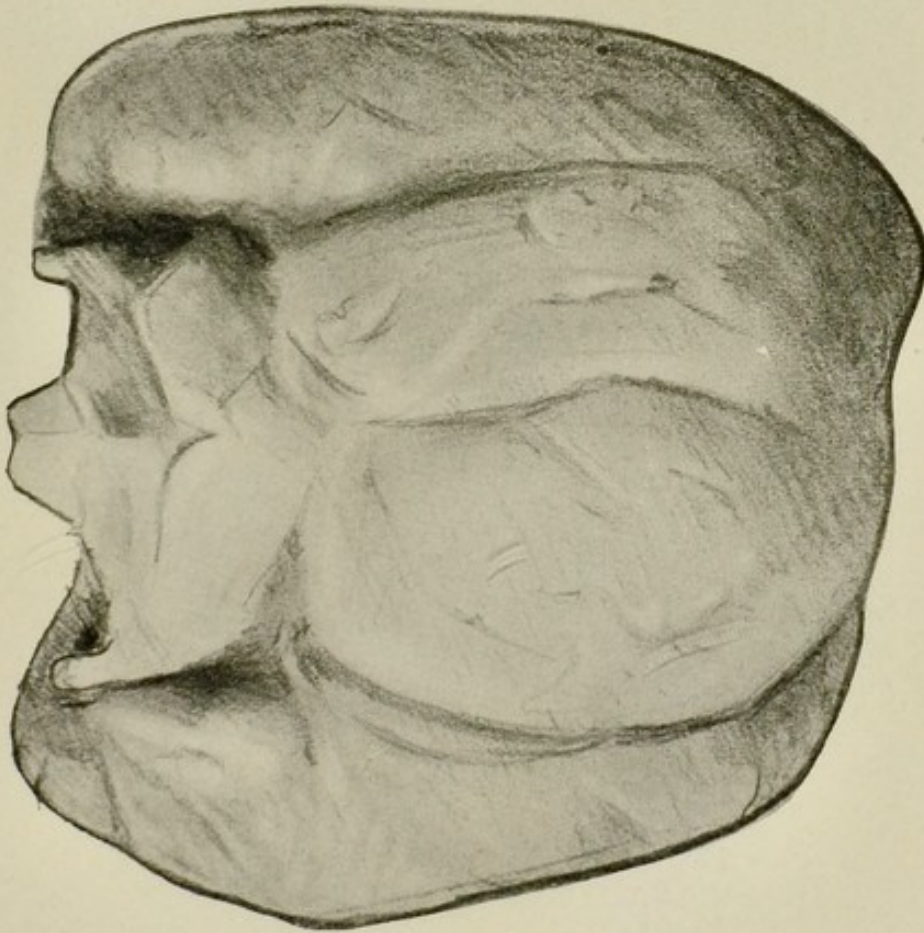


FIG. 39.—Thyroid gland, exophthalmic goitre. $\frac{3}{4}$.

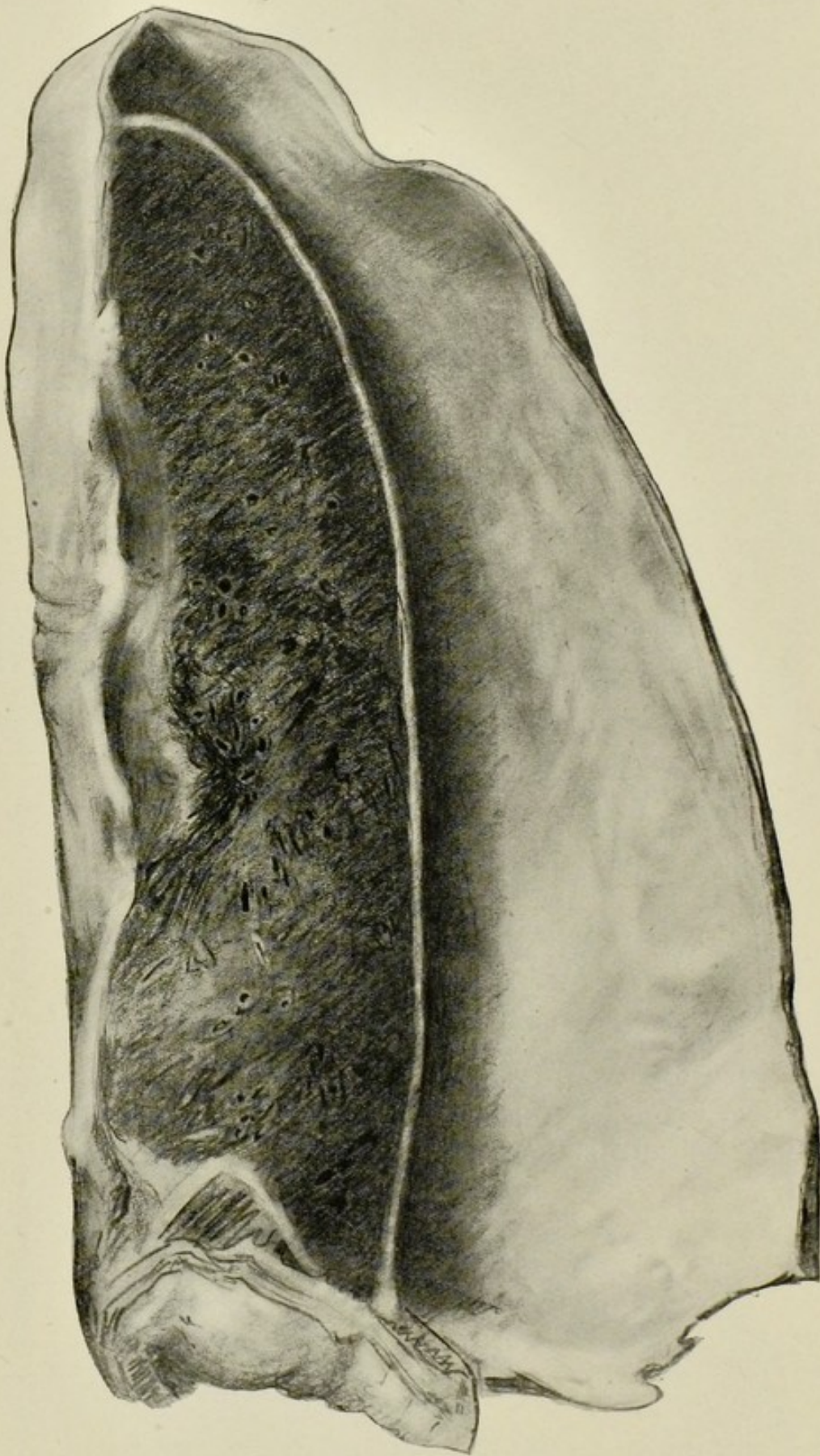


FIG. 41.—Lung, collapse due to empyema. $\frac{1}{2}$.
Thickening of parietal and visceral pleura.

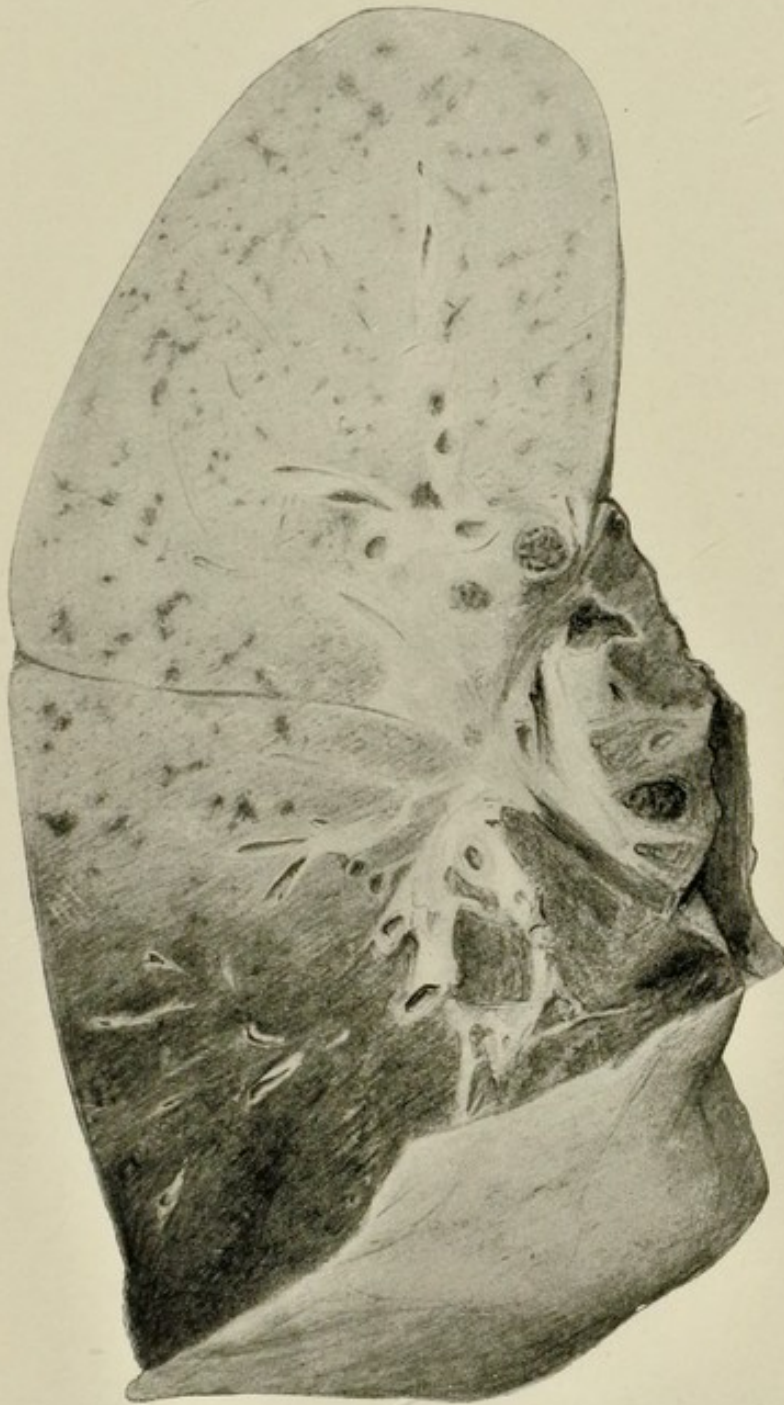


FIG. 42.—Lung, lobar pneumonia. $\frac{1}{2}$.

The whole of the upper lobe and the upper portion of the lower lobe are consolidated and in the stage of grey hepatisation. The lower portion of the lower lobe is congested.

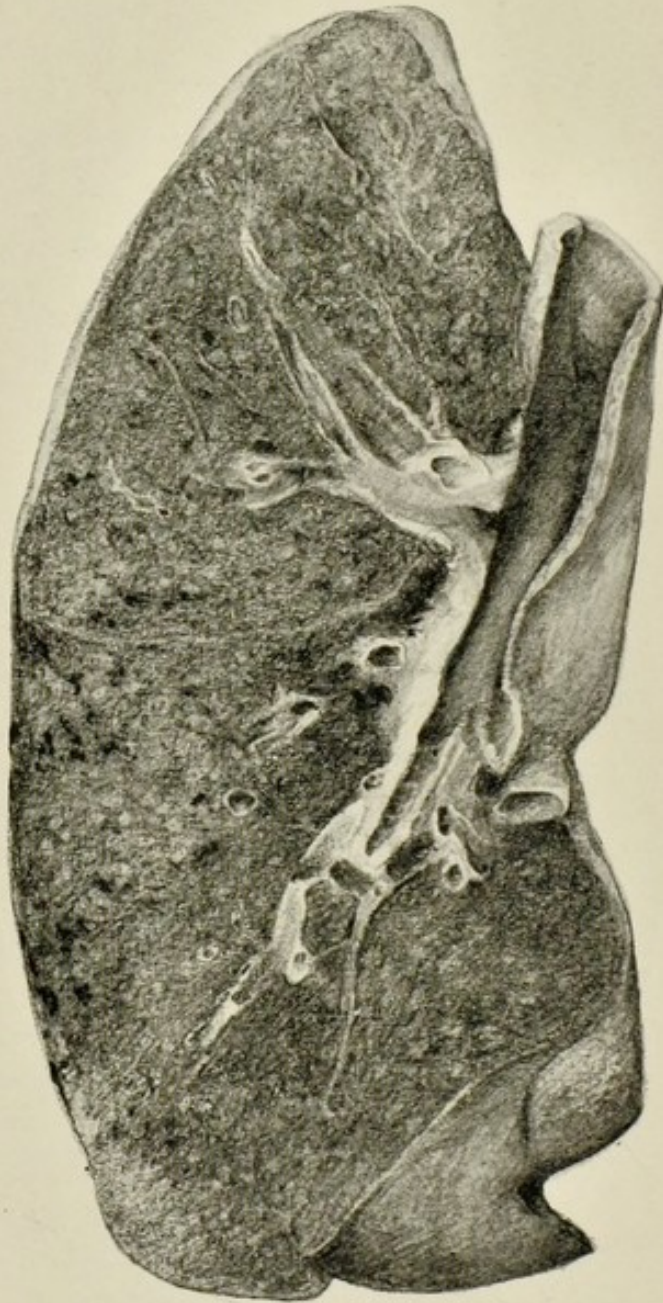

FIG. 43.—Lung and bronchi, showing acute bronchitis and septic broncho-pneumonia. $\frac{1}{2}$.

The bronchitis is indicated by the congested mucous membrane of the bronchi, the broncho-pneumonia by the ill-defined pale areas of consolidation scattered through the lung.

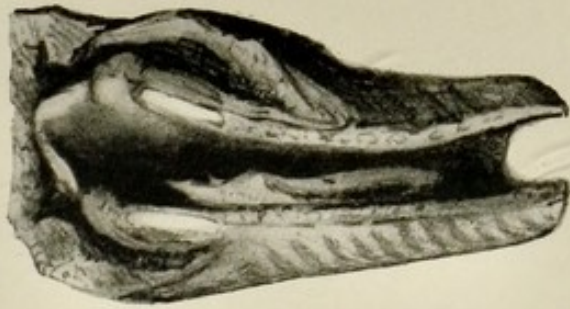


FIG. 44.—False membrane in trachea in diphtheria. $\frac{1}{2}$.

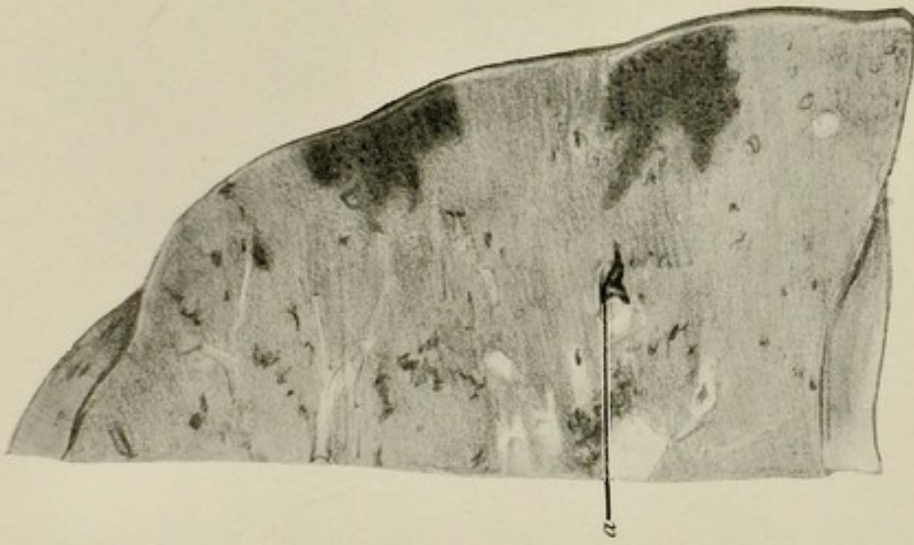


FIG. 45.—Portion of lung showing two recent infarcts. $\frac{1}{2}$.

(a) Thrombus projecting from branch of pulmonary artery.

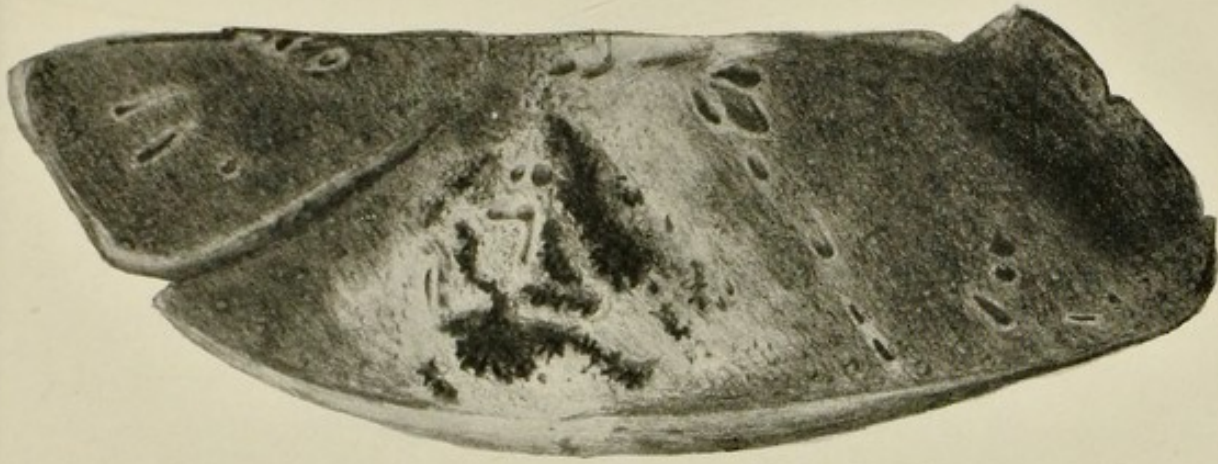

FIG. 46.—Lung, gangrene. $\frac{1}{2}$.

The dark areas in the centre are gangrenous cavities. The pale zone around is due to pneumonic consolidation.

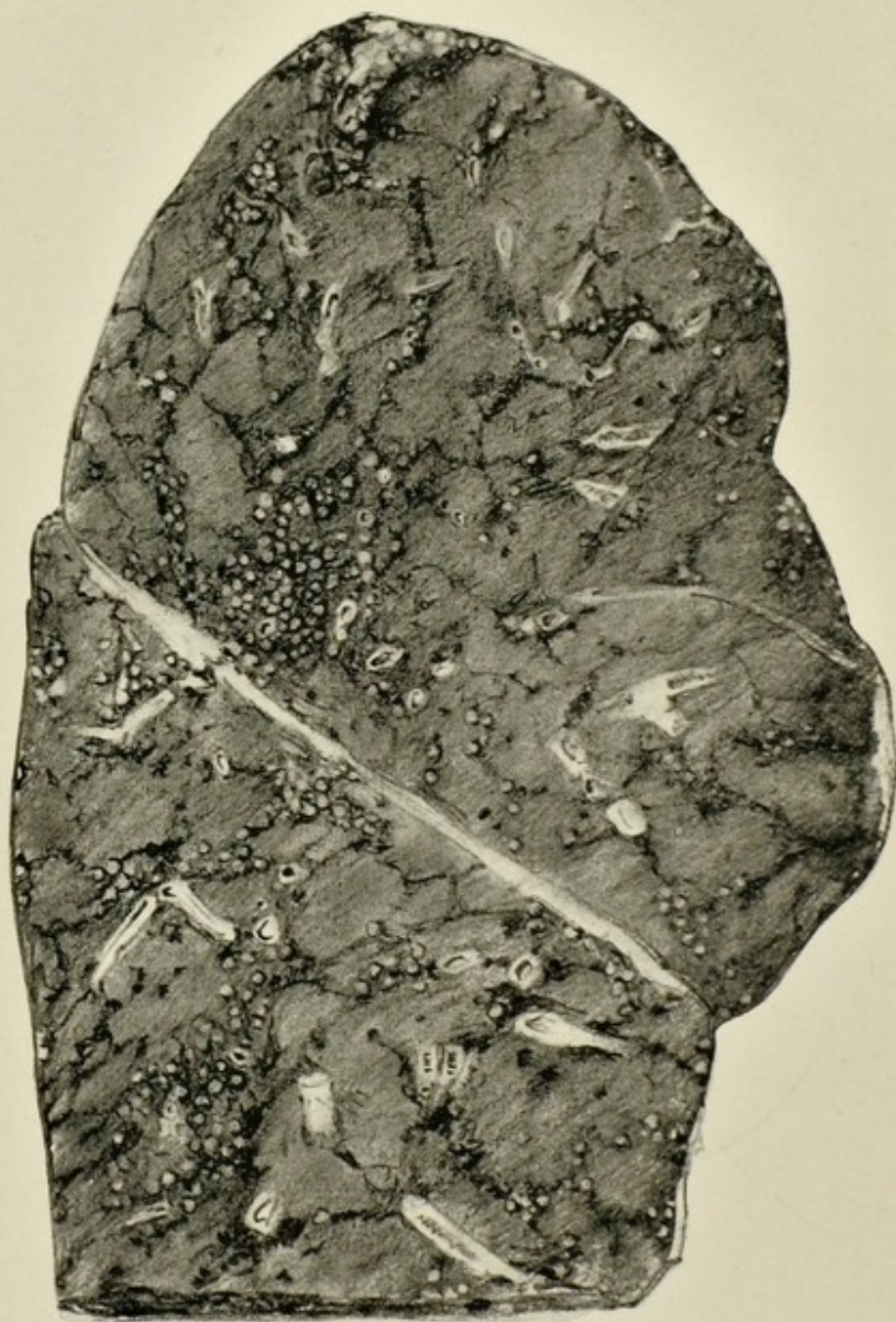


FIG. 47.—Lung, silicosis. (Dr. J. D. Comrie's collection.) $\frac{1}{2}$.

Raised, hard, grey areas, surrounded with black pigment, scattered in groups under pleura, around vessels and bronchi, and along interlobular septa.

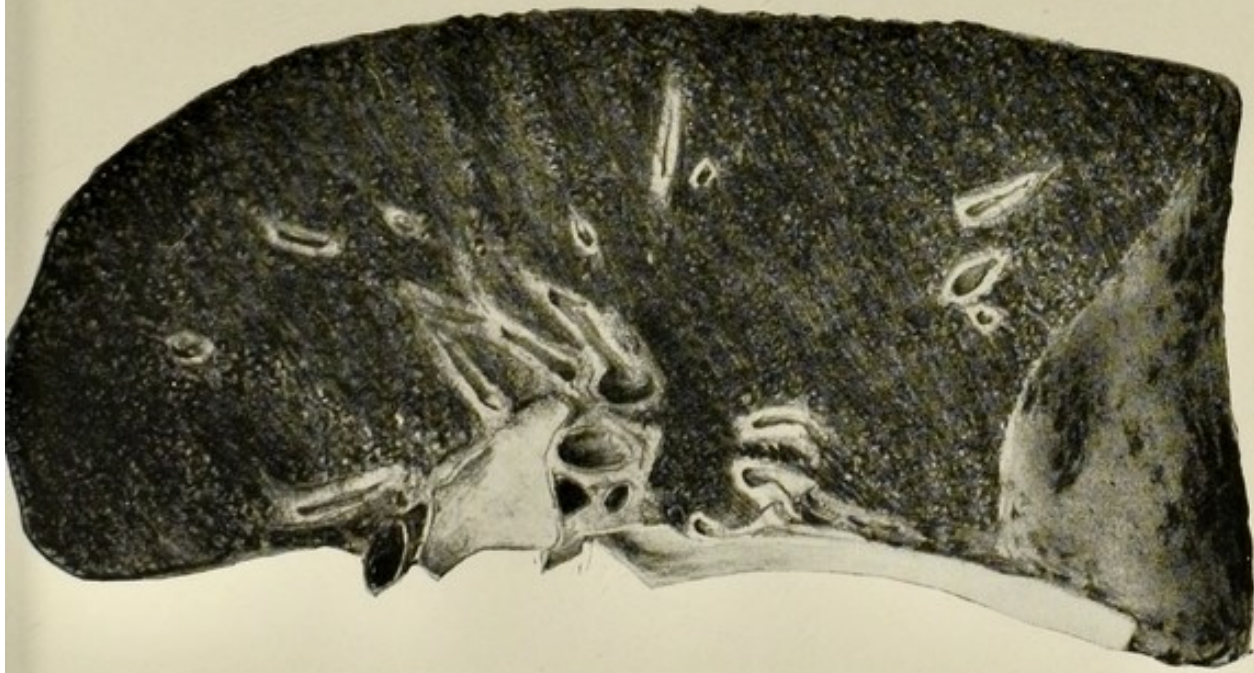


FIG. 48.—Lung, anthracosis. $\frac{1}{2}$.

Note the uniform dark colour of the organ, the raised areas of fibrous tissue formation and pigmentation scattered through the lung, also the foci of pigmentation on the diaphragmatic surface.

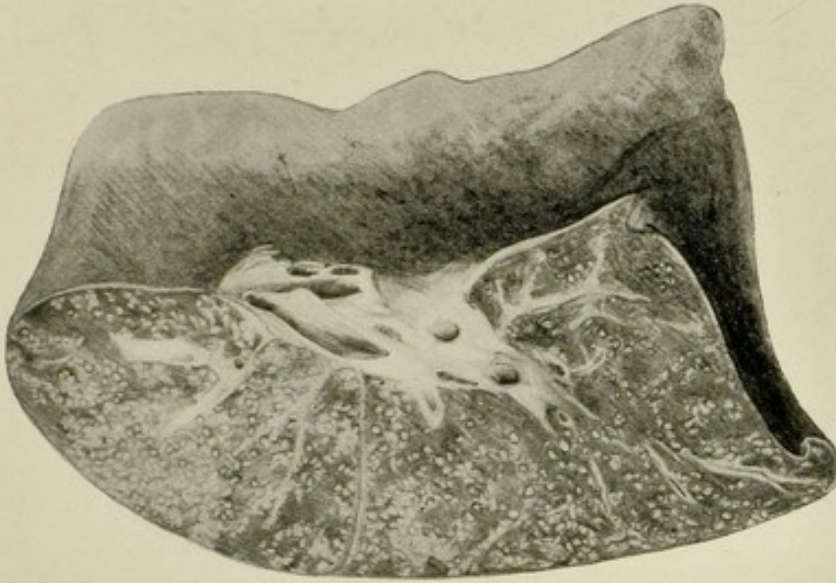


FIG. 49.—Lung, acute miliary tuberculosis. $\frac{1}{2}$.

Minute grey tuberculous foci irregularly scattered through the lung.

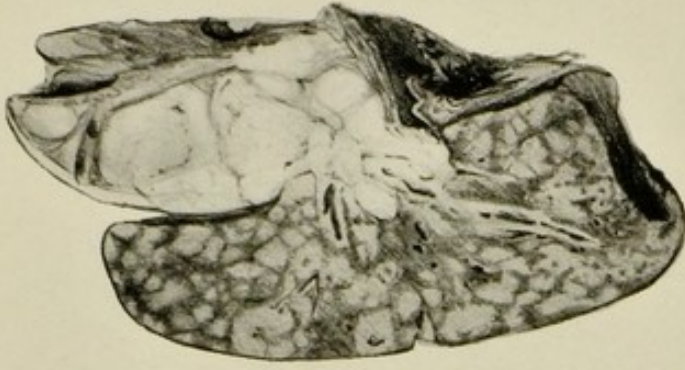

FIG. 50.—Mediastinal glands and lung of infant. $\frac{1}{2}$.

The former shows marked enlargement due to tuberculosis, the latter caseous (tuberculous) broncho-pneumonia.

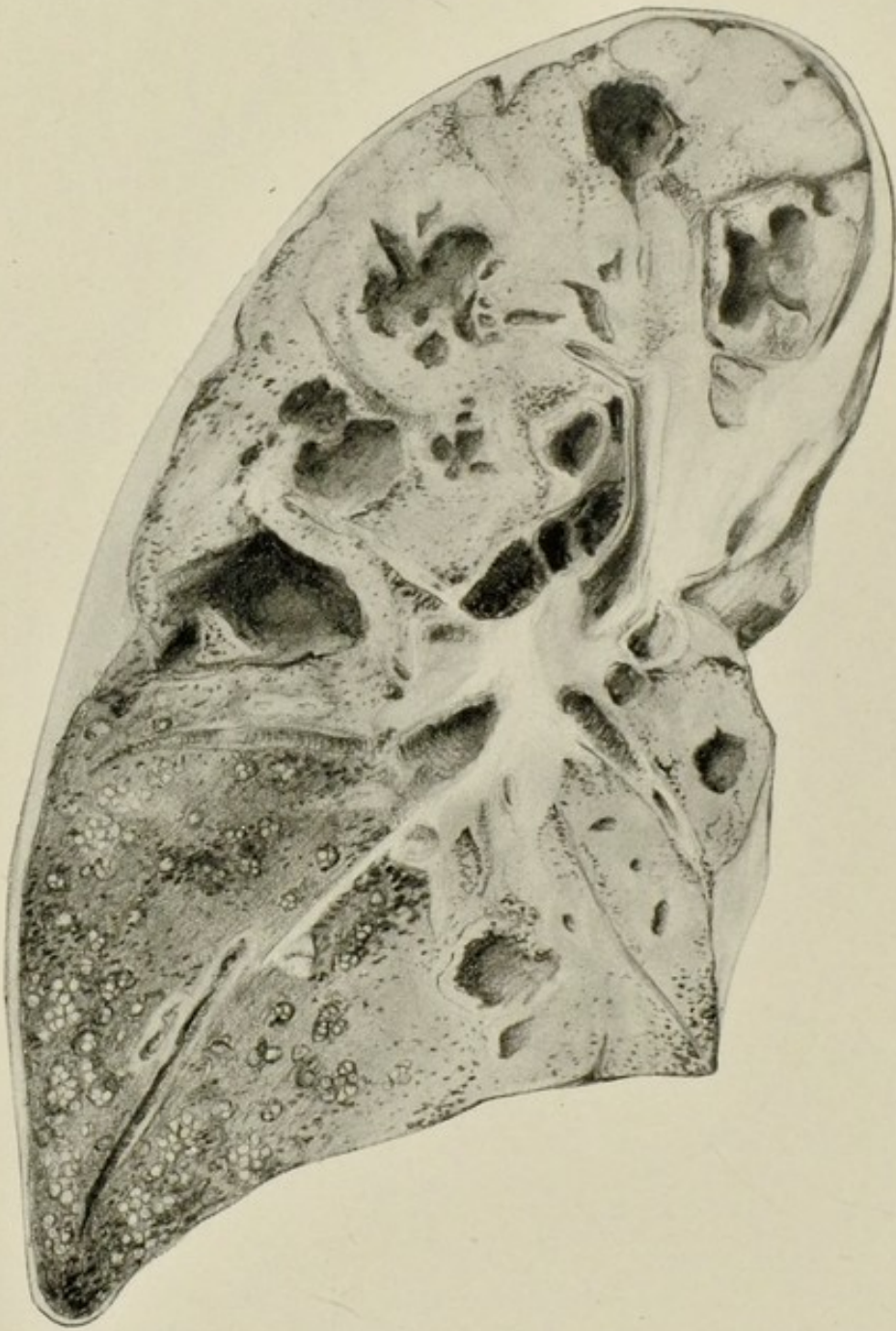


FIG. 51.—Lung, caseous (tuberculous) pneumonia with cavitation. $\frac{1}{2}$.

There is caseous consolidation of the upper portion, with numerous acute cavities. In the lower portion there are groups of tubercles arranged in a staphyloid manner indicating lymphatic spread. The pleura is thickened.

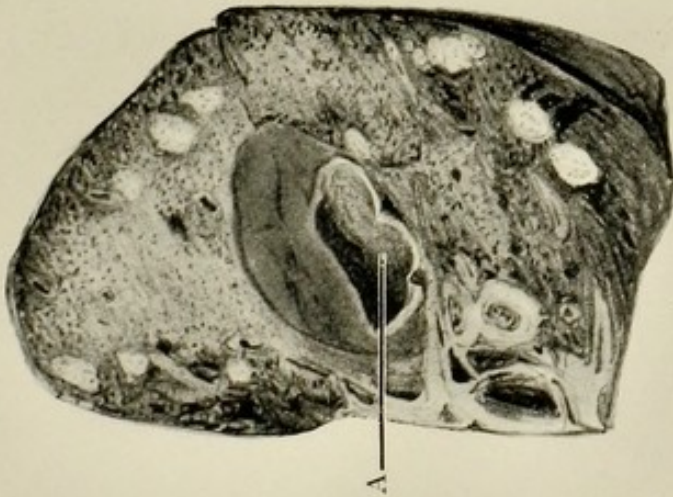


FIG. 52.—Lung, chronic tuberculosis with cavity in which an aneurysm (A) has formed. $\frac{1}{2}$.

The space between the aneurysmal sac and the wall of the cavity is filled with blood-clot. There are caseous areas scattered through the lung.

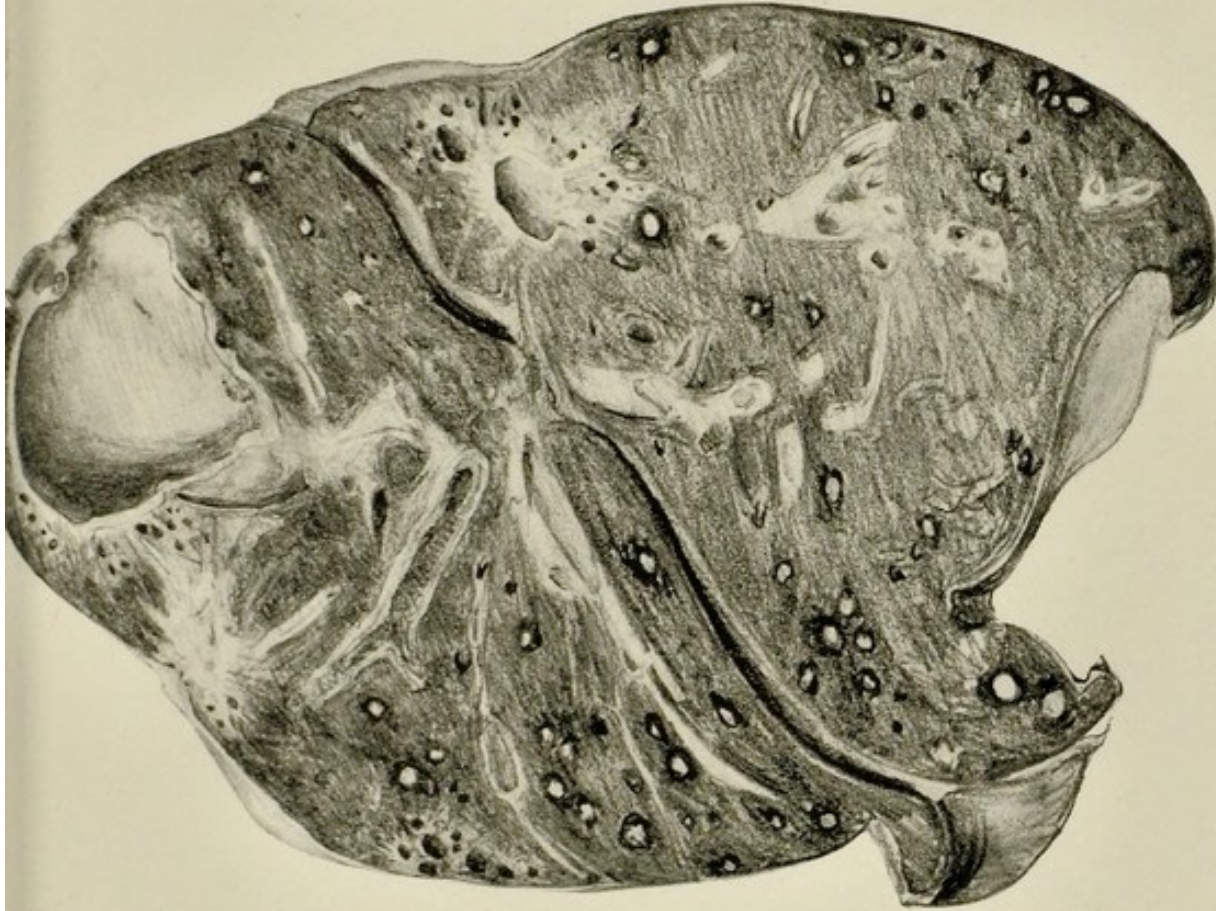

FIG. 53.—Lung, fibro-caseous tuberculosis, with marked tendency to healing. $\frac{1}{2}$.

Two chronic cavities, one in apex of upper lobe, the other in apex of lower lobe, surrounded by fibrous tissue and showing tendency to contract and pull upon surrounding lung, causing "traction emphysema." Nodules of chronic fibro-caseous tubercle surrounded with pigment are scattered irregularly through the remainder of the organ.

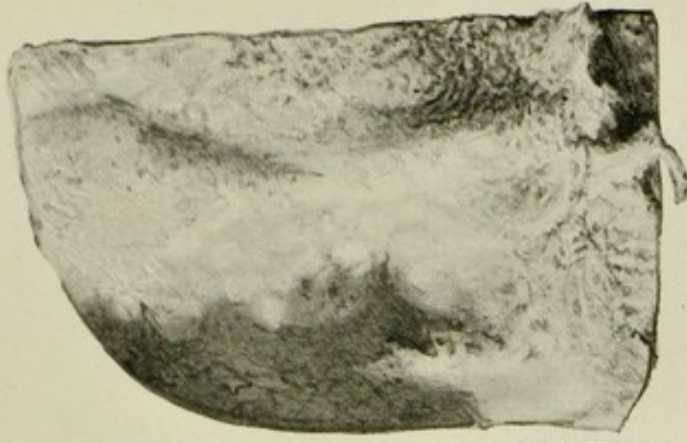


FIG. 54.—Surface of lung, acute pleurisy. $\frac{1}{2}$.

Congestion of vessels and thick fibrinous exudate.

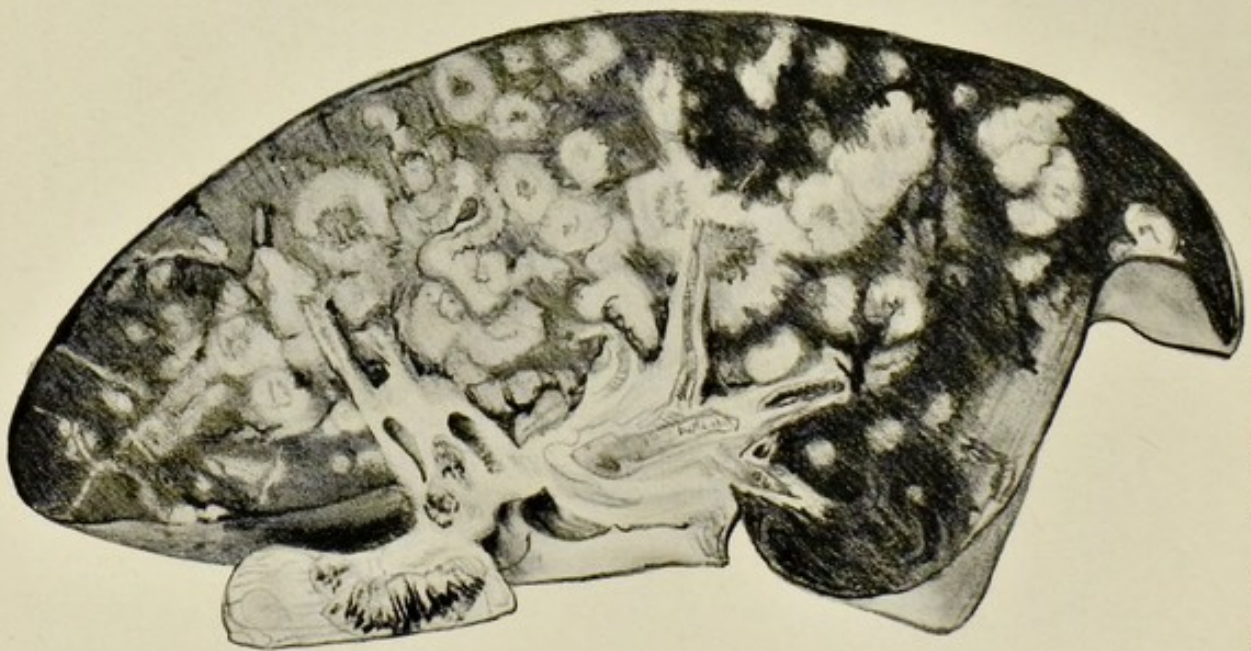

FIG. 55.—Section of lung showing large number of nodules of secondary carcinoma. $\frac{1}{4}$.

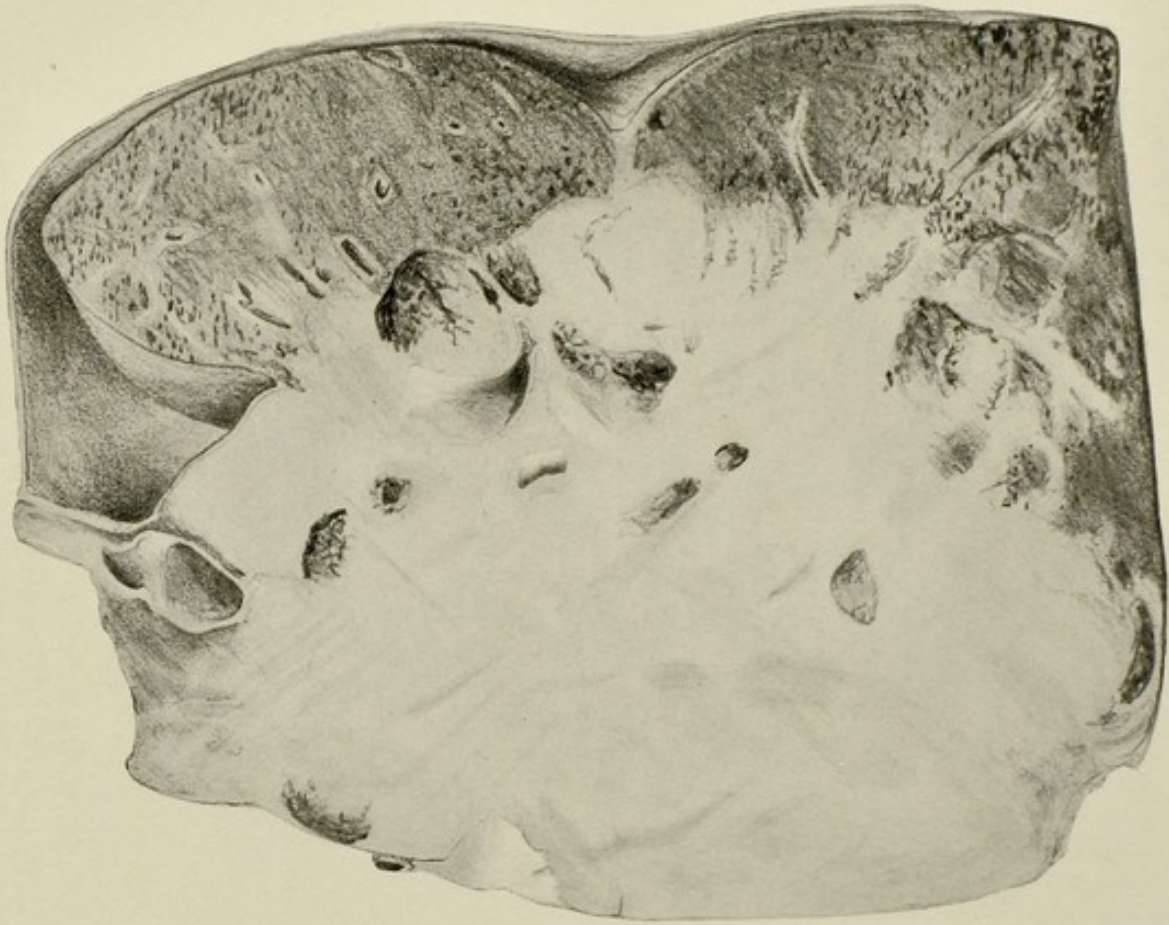


FIG. 56.—Lympho-sarcoma of the mediastinal glands invading the root of the lung. (Dr. Edwin Bramwell's case.) $\frac{1}{2}$.

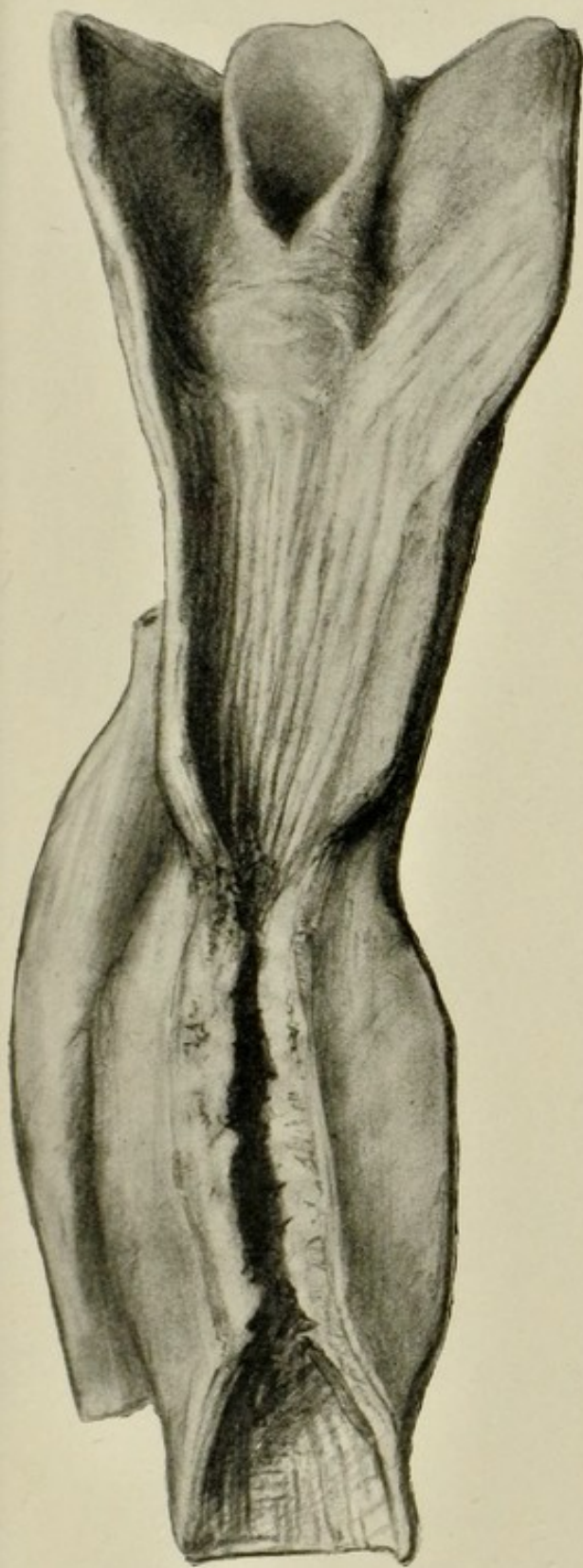

FIG. 57.—Squamous epithelioma of œsophagus, with marked narrowing of lumen. $\frac{1}{2}$.

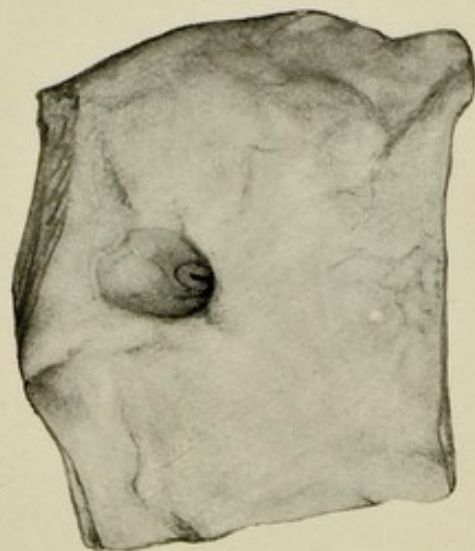


FIG. 58.—Peptic ulcer of stomach, with opening into vessel in floor of ulcer. $\frac{1}{2}$.

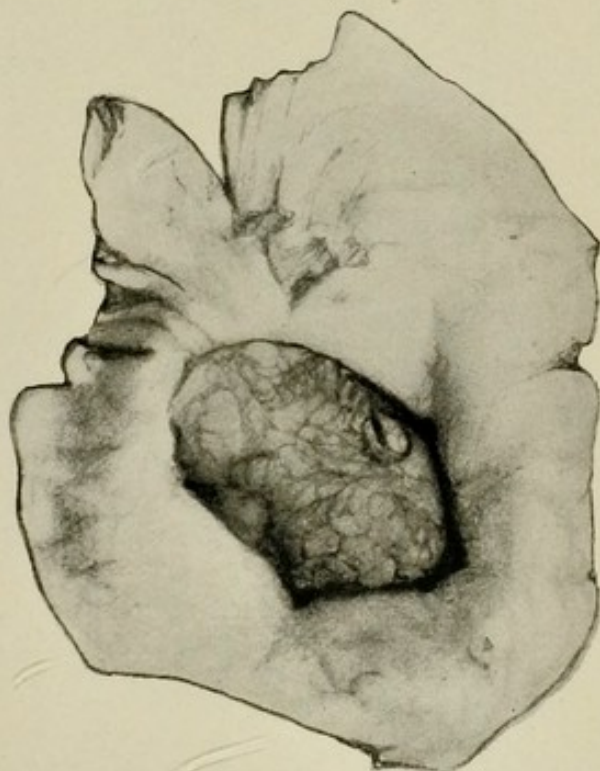


FIG. 59.—Large duodenal ulcer.
(Dr. Cattenach's case.) $\frac{1}{2}$.

Pancreas forming floor. Opening into large vessel at one point, from which fatal hæmorrhage occurred.

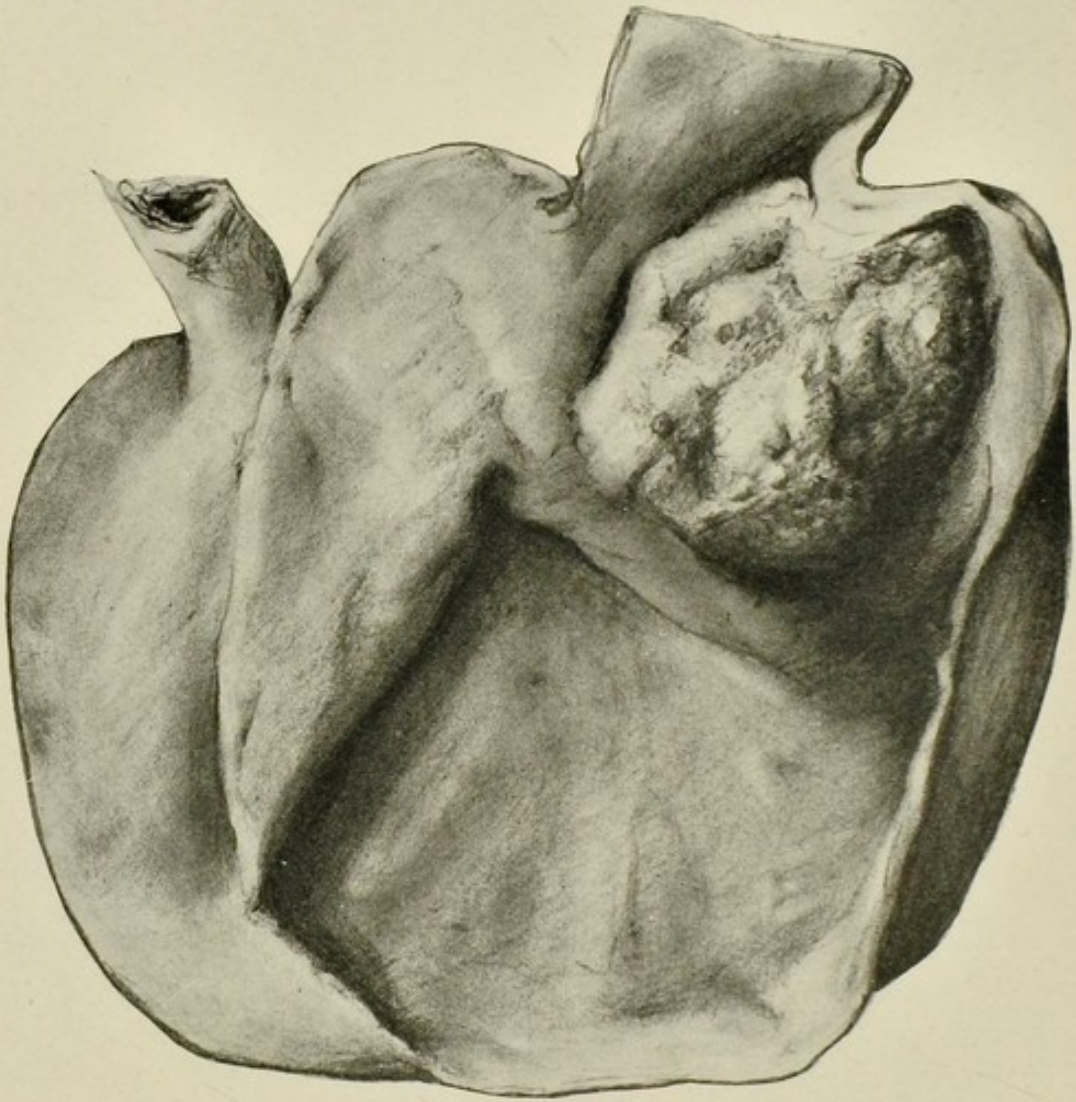

FIG. 60.—Stomach opened up anteriorly to display encephaloid cancer close to cardiac opening. $\frac{1}{2}$.

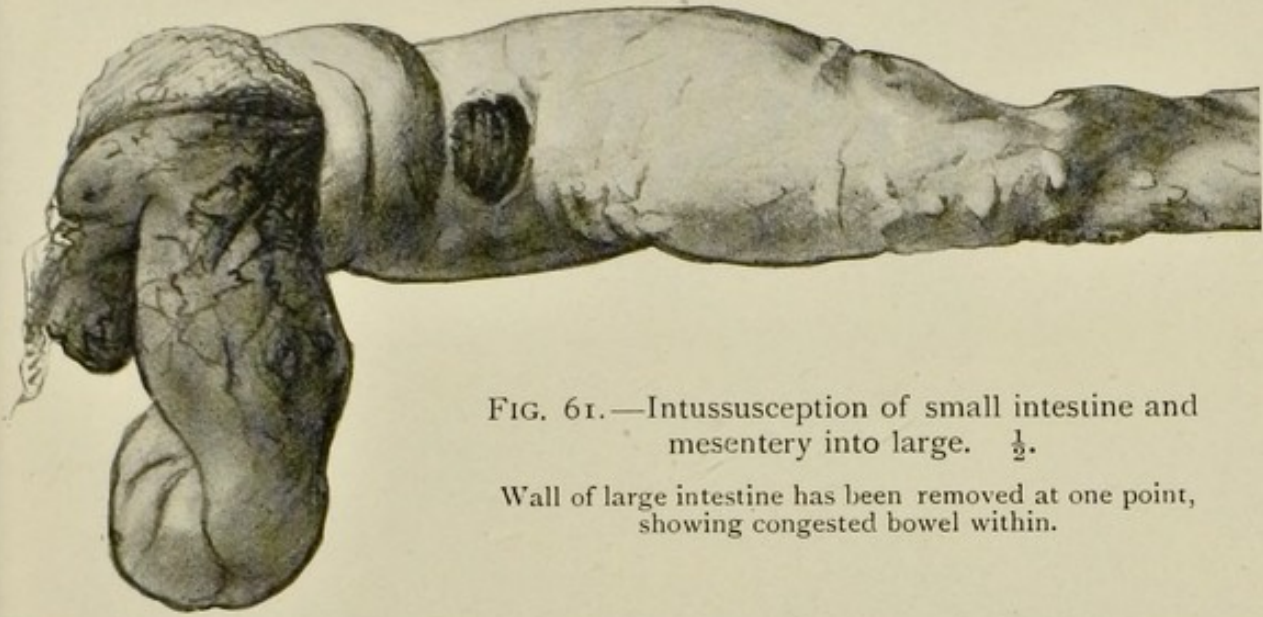


FIG. 61.—Intussusception of small intestine and mesentery into large. $\frac{1}{2}$.

Wall of large intestine has been removed at one point, showing congested bowel within.

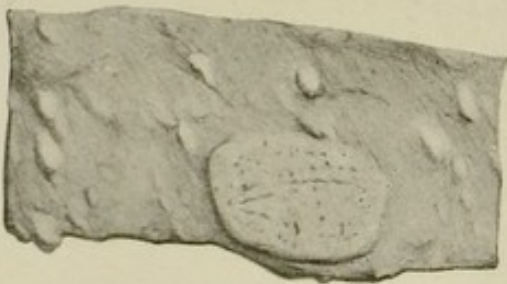


FIG. 62.—Typhoid lesion of small intestine. $\frac{1}{2}$.

Early stage, showing swelling of Peyer's patch and solitary follicles.

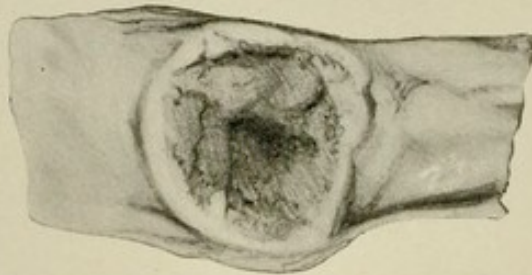


FIG. 63.—Typhoid lesion of small intestine. $\frac{1}{2}$.

Later stage, with necrosis of swollen patch and formation of slough.

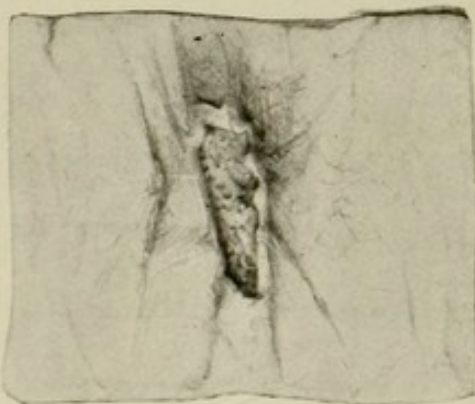

FIG. 64.—Tuberculous ulcer, lower portion of ileum. $\frac{1}{2}$.

Note transverse direction, raised margin, and irregular floor.

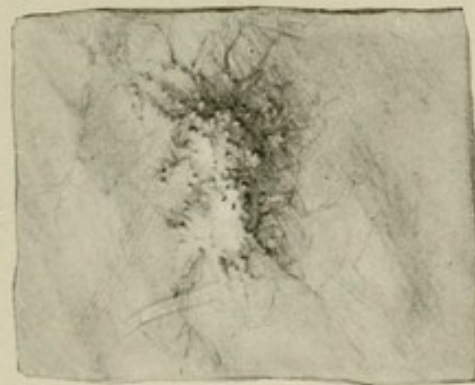

FIG. 65.—Tuberculous ulcer, peritoneal aspect, showing raised tubercles under peritoneum. $\frac{1}{2}$.

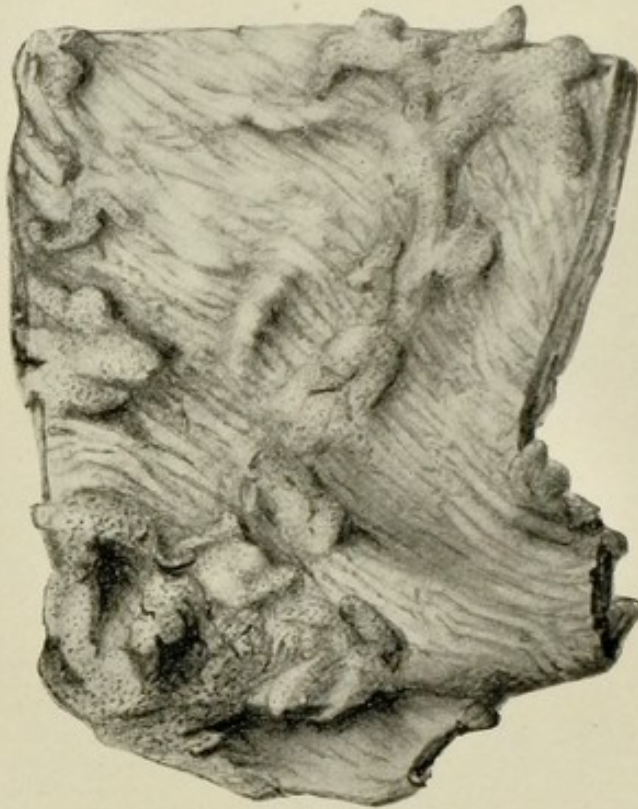

FIG. 66.—Large intestine, ulcerative colitis (dysentery). $\frac{1}{2}$.
Lines of hypertrophied mucous membrane with ulcerated surfaces between,
in which the muscular coat is laid bare.

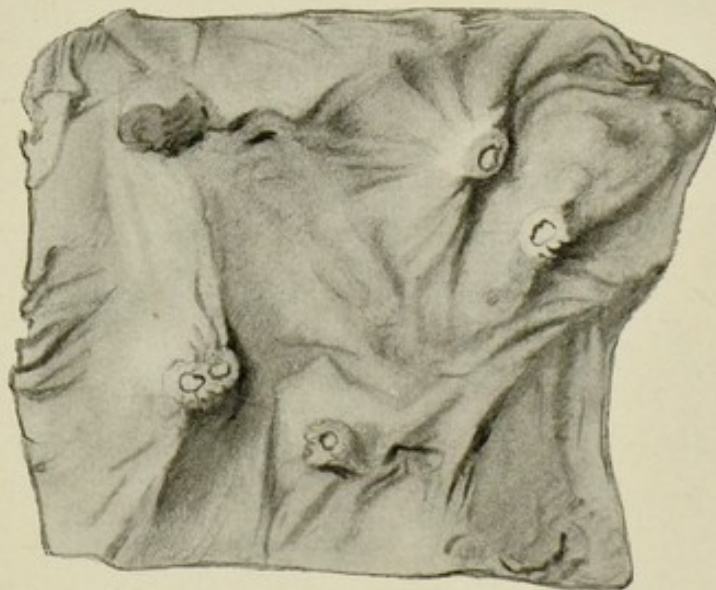


FIG. 67.—Portion of large bowel from case of amœbic dysentery,
showing characteristic early lesion. $\frac{1}{2}$.
Minute crater-like ulcers with central slough.

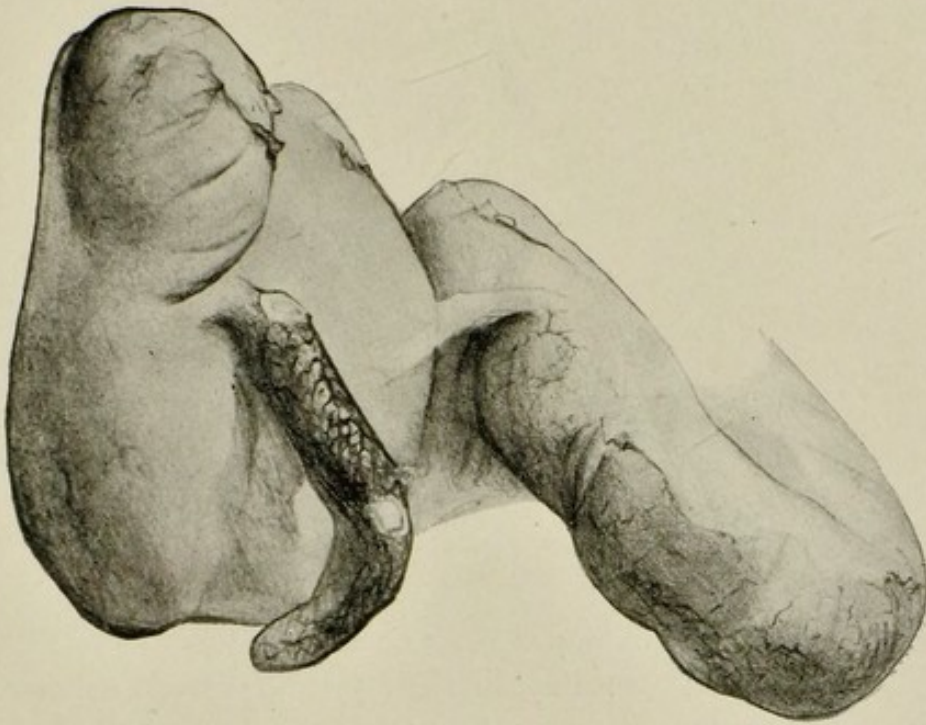


FIG. 68.—Acute appendicitis and peritonitis. $\frac{1}{2}$.

The appendix is swollen and congested, and has ruptured at two points. The portion of small intestine seen is covered in part with a thick layer of fibrinous exudate.

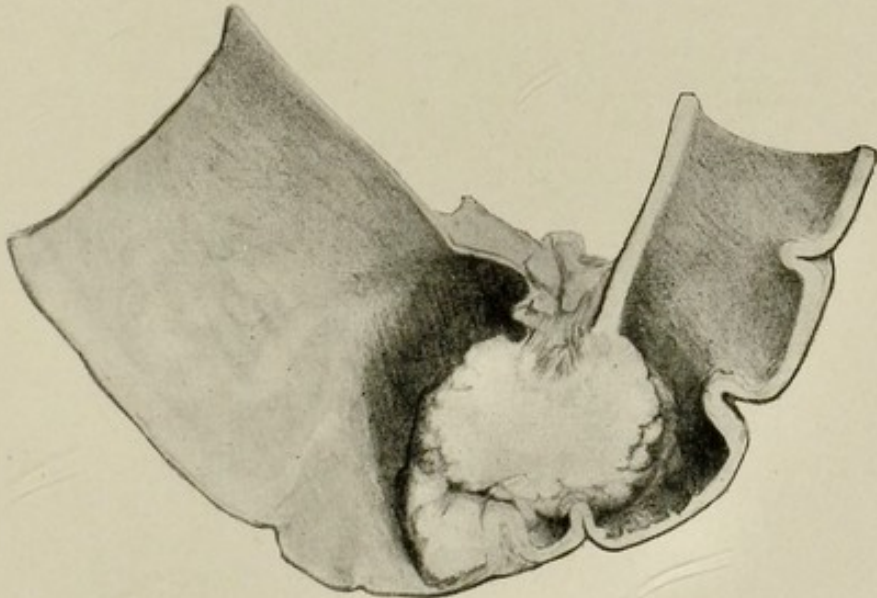


FIG. 69.—Pelvic colon with adeno-carcinoma projecting into interior. $\frac{1}{2}$.

The wall of the gut is hypertrophied above.

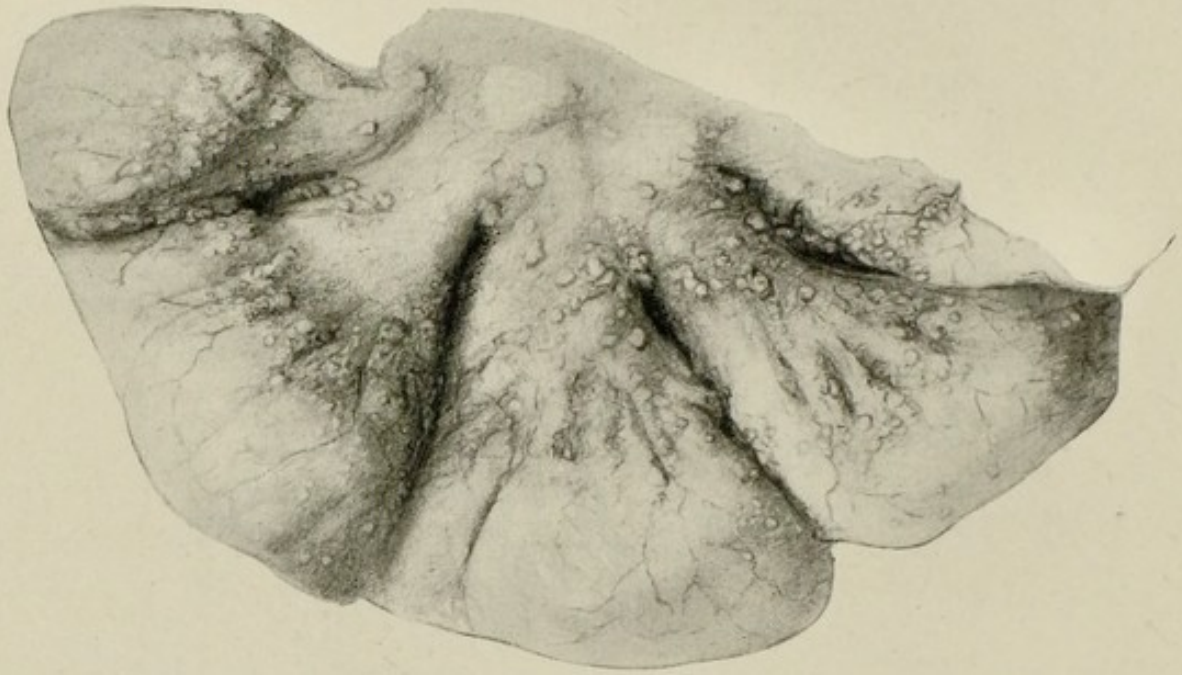


FIG. 70.—Peritoneal aspect of loop of intestine showing tuberculous peritonitis. $\frac{1}{2}$.
There are also swellings in the mesentery from enlarged mesenteric glands.

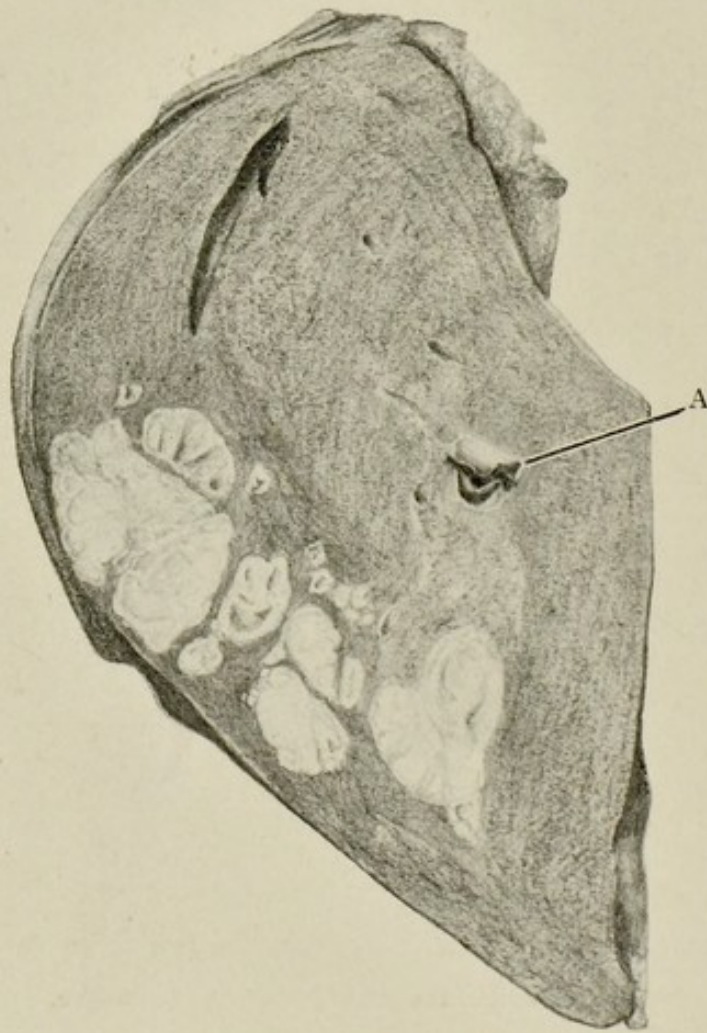


FIG. 71.—Abscesses of liver, portal pyæmia type. $\frac{1}{2}$.
A thrombus is seen projecting from one of the branches of the portal vein (A)

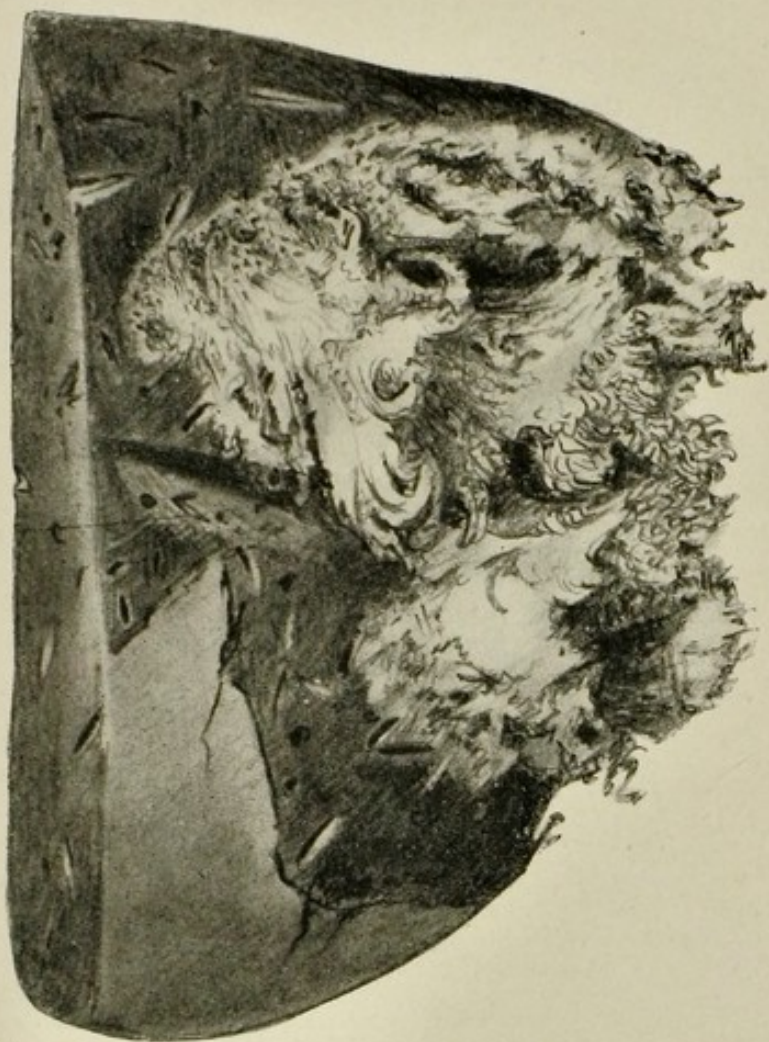

FIG. 72.—Liver, large tropical abscess with much necrotic liver tissue. $\frac{1}{2}$.

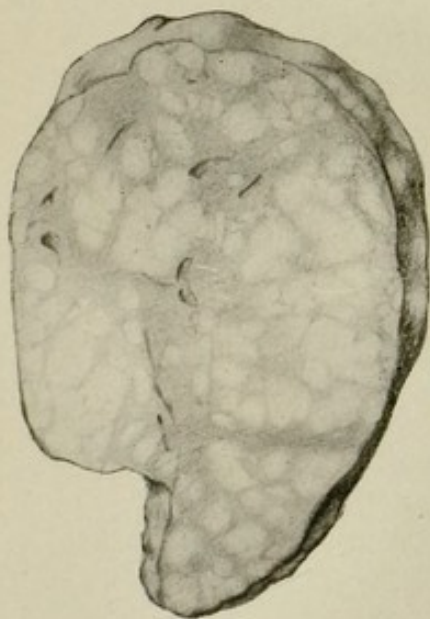


FIG. 73.—Liver of child showing multiple nodular hyperplasia (regeneration of liver substance) following an acute degenerative process. (Dr. Byrom Bramwell's case.) $\frac{1}{2}$.

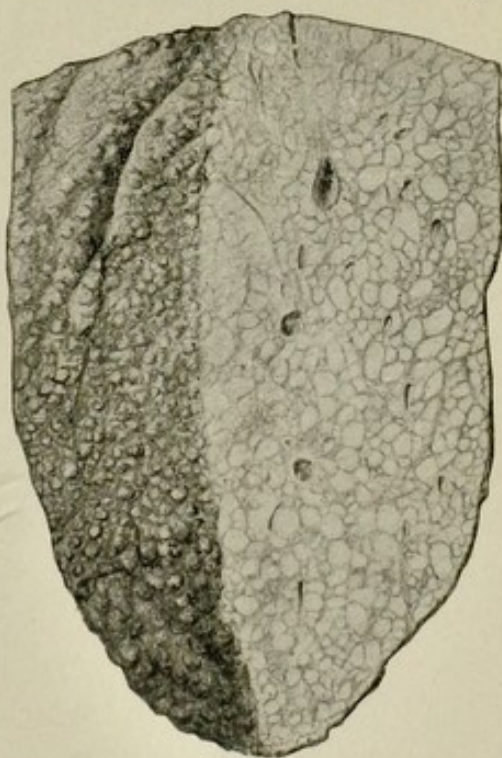


FIG. 74.—Liver, common cirrhosis. $\frac{1}{2}$.
Surface of organ shows "hob-nail" projections. Section shows areas of liver tissue varying in size, separated from one another by bands of connective tissue.

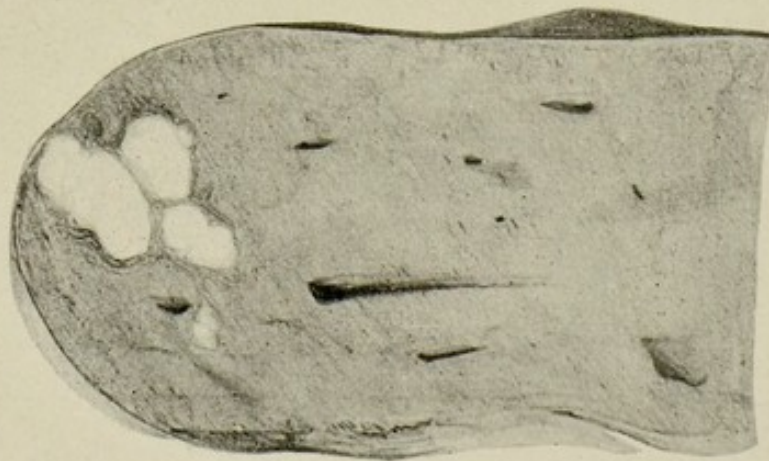


FIG. 75.—Liver showing group of gummata. $\frac{1}{2}$.

Caseous foci surrounded by a zone of connective tissue.

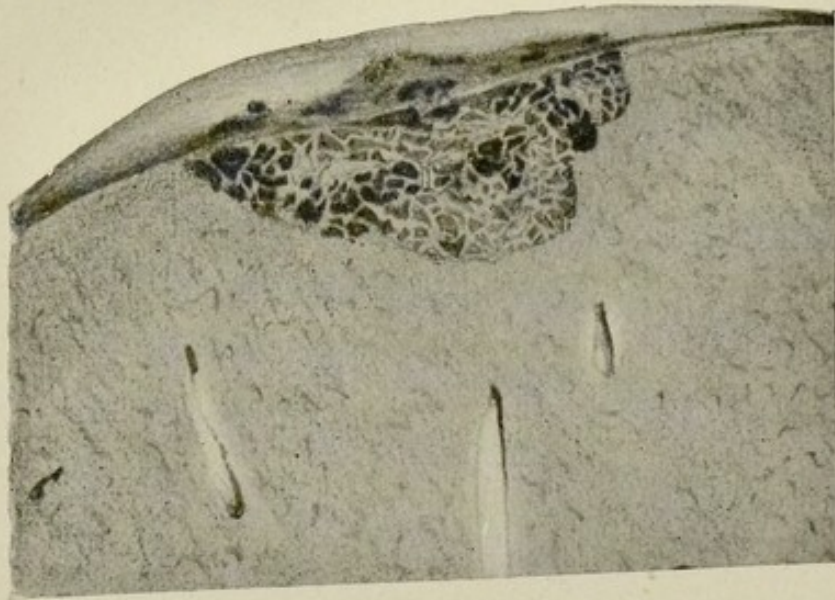


FIG. 76.—Liver, cavernous angioma. $\frac{1}{2}$.

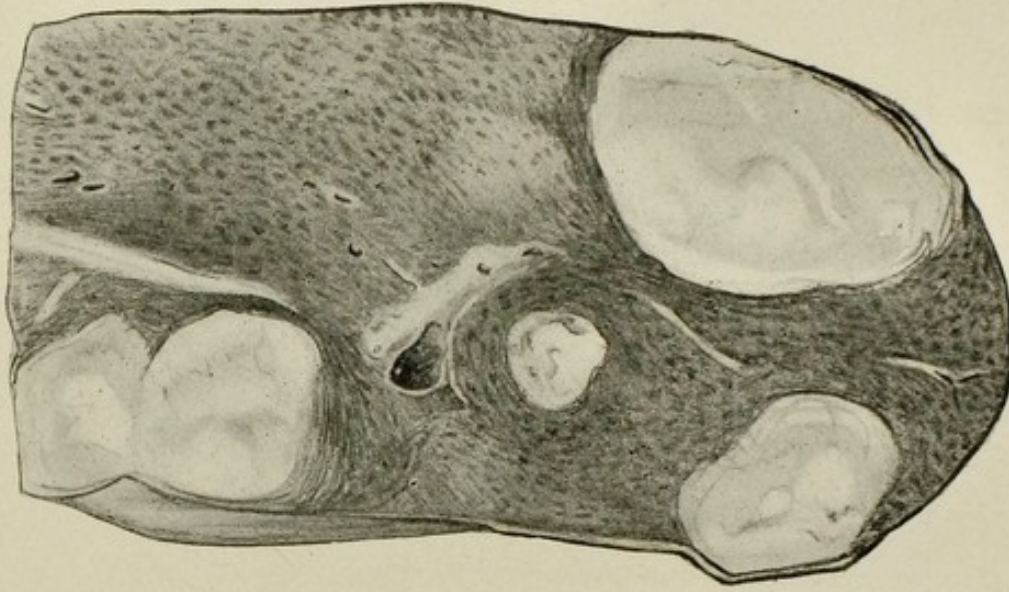


FIG. 77.—Section of liver with secondary deposits of sarcoma. $\frac{1}{2}$.

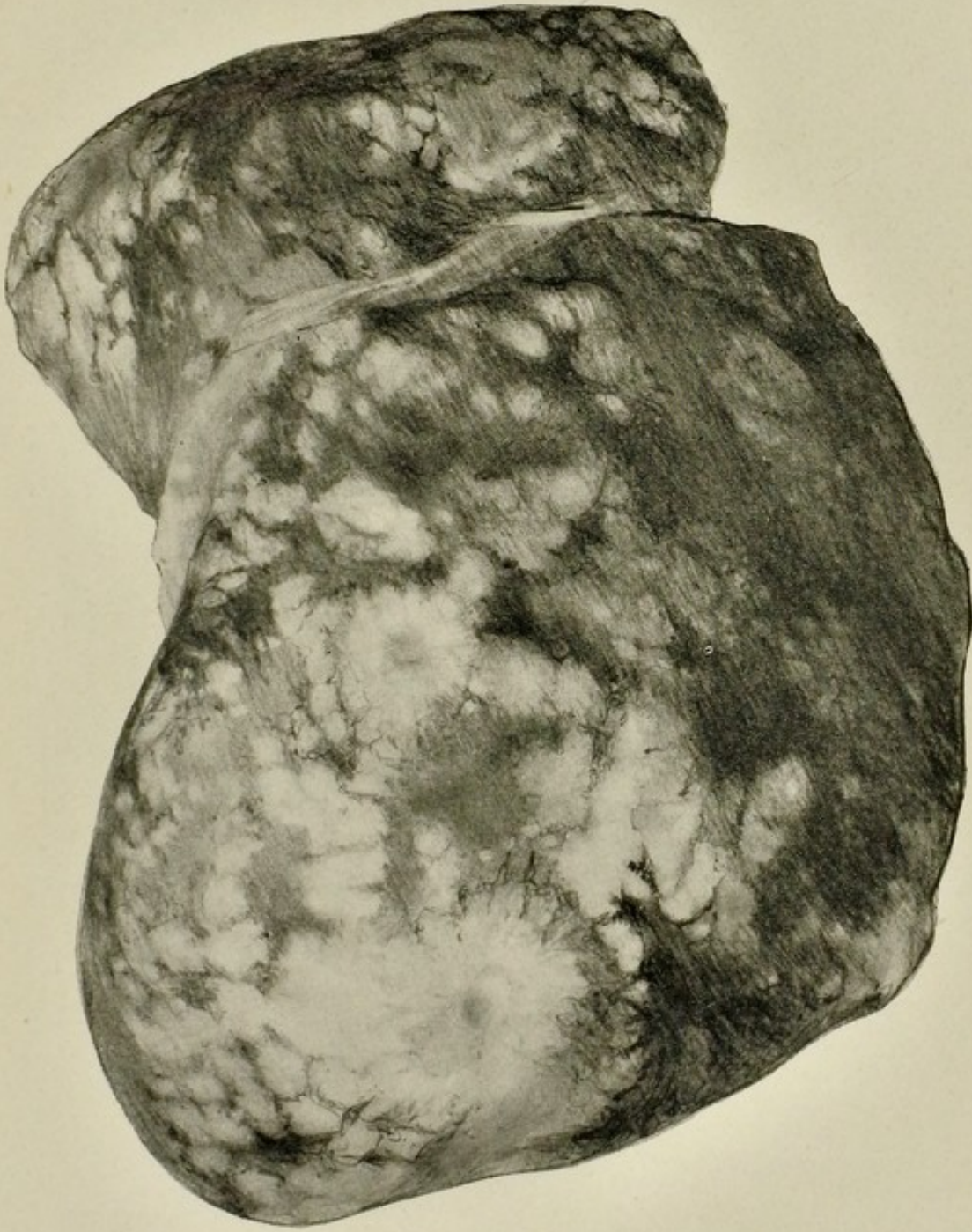


FIG. 78.—Liver, greatly enlarged with numerous secondary nodules of carcinoma. $\frac{1}{3}$.

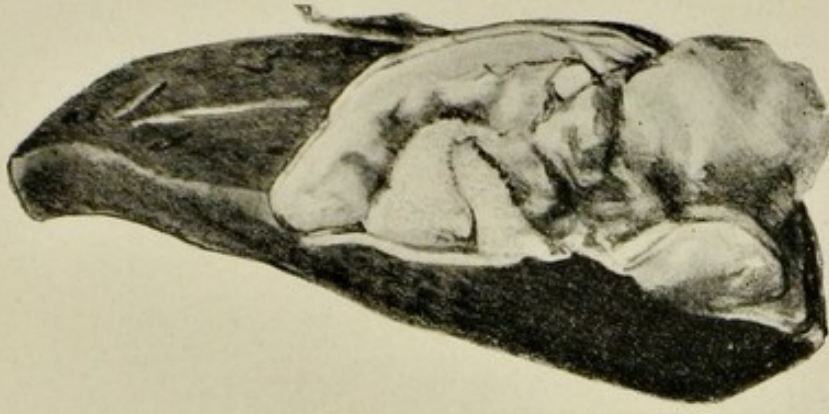

FIG. 79.—Section of liver with hydatid cyst from which numerous smaller cysts are protruding. $\frac{1}{2}$.

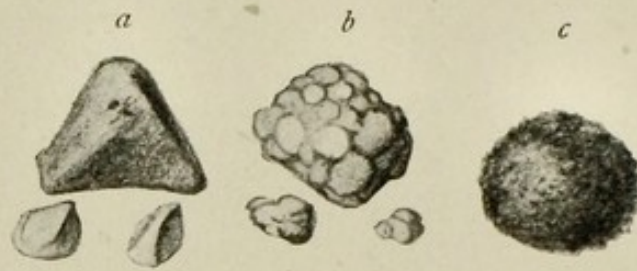


FIG. 80.—Biliary calculi or gall-stones. $\frac{1}{4}$.

a, common faceted type.

b, mulberry type.

c, rounded, solitary stone composed of pure cholesterin.

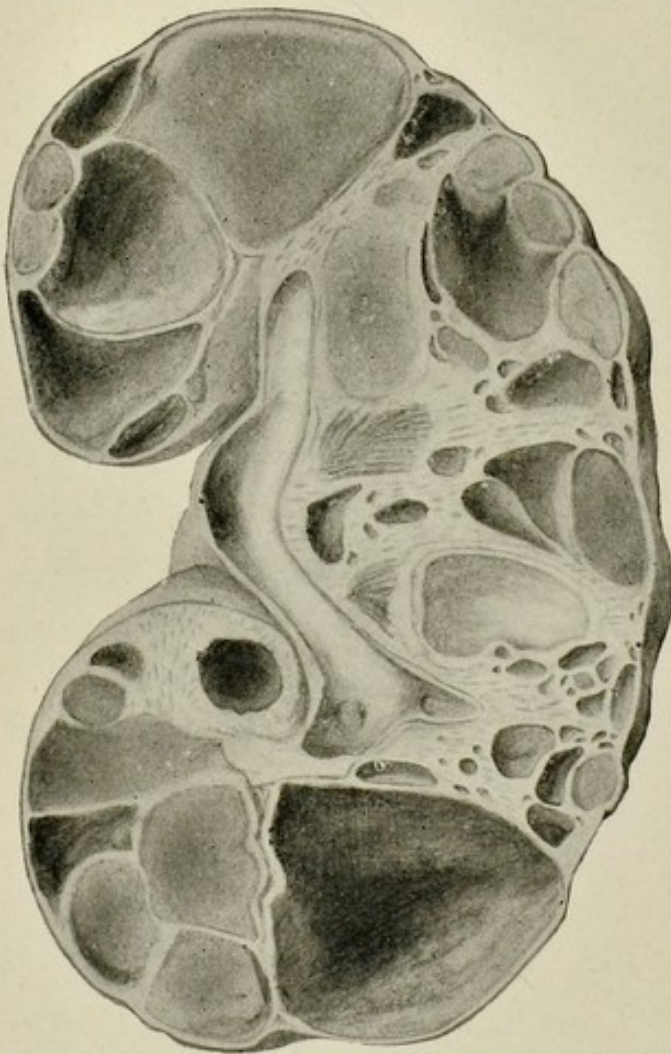


FIG. 81.—Congenital cystic kidney. $\frac{1}{2}$.

Rounded spaces, varying greatly in size, some empty, others containing translucent gelatinous material.

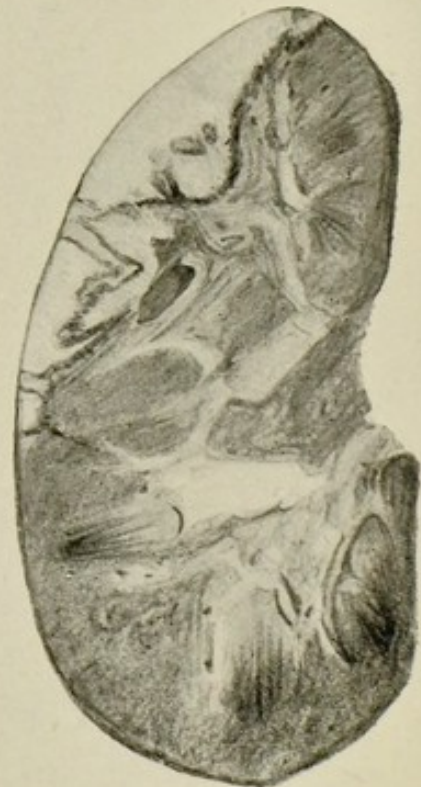

FIG. 82.—Infarcts of the kidney. $\frac{1}{2}$.

Three infarcts varying in size are seen in the upper part of the organ.

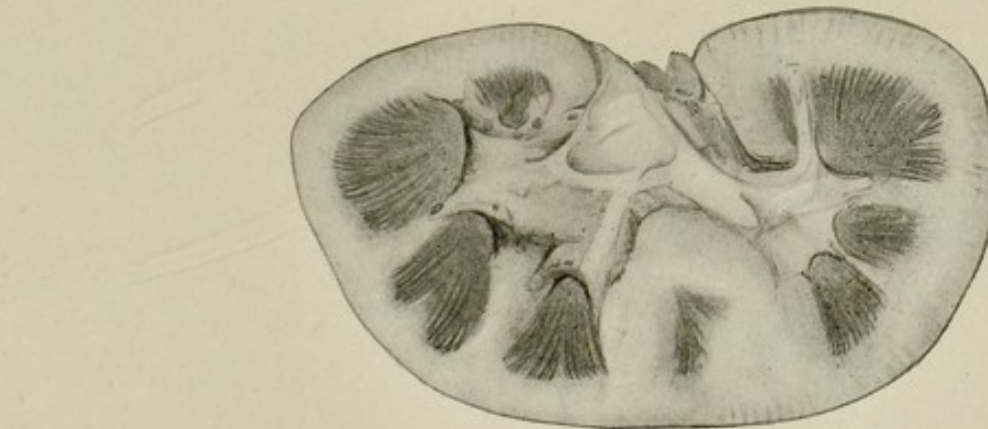


FIG. 83.

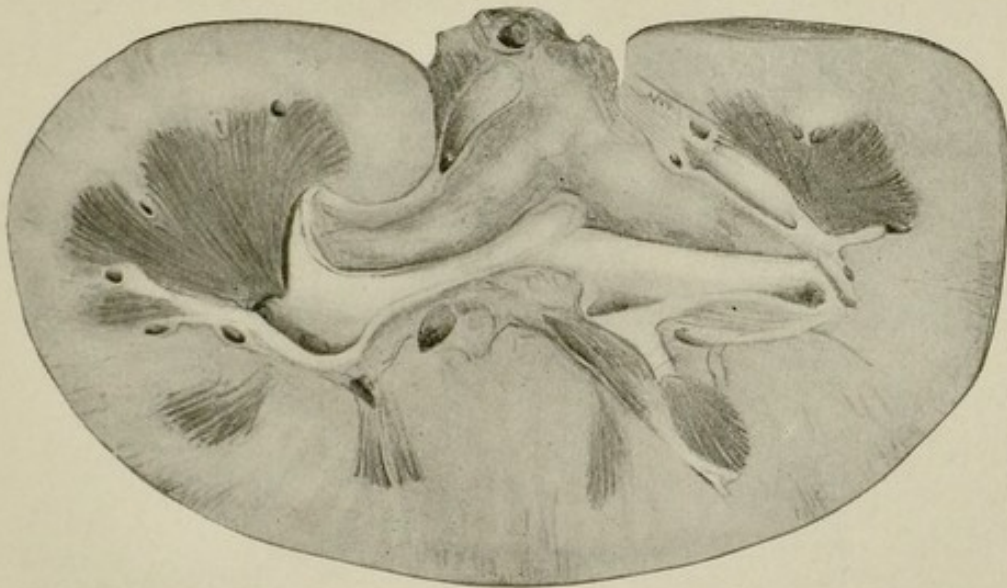


FIG. 84.

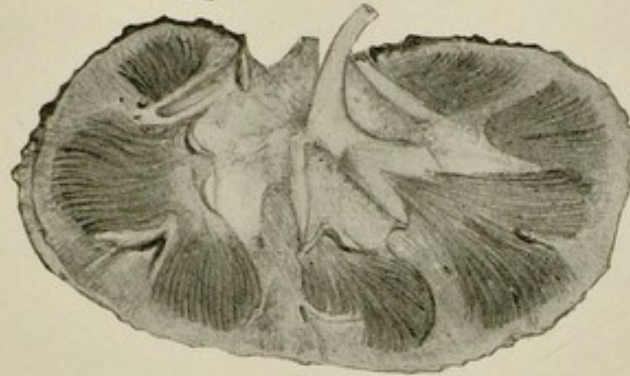


FIG. 85.

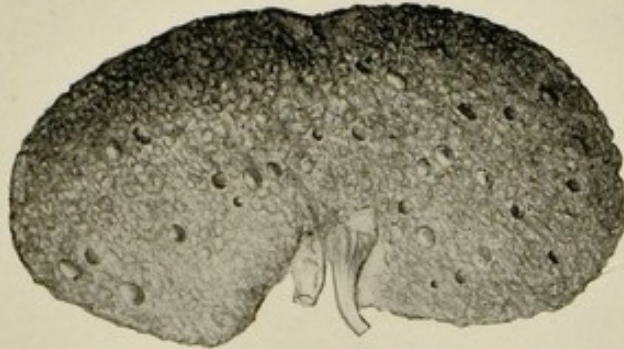


FIG. 86.

Kidneys illustrating the main types of Bright's disease. $\frac{1}{2}$.

FIG. 83.—Acute nephritis. Organ very slightly enlarged, marked pallor and some swelling of cortex.

FIG. 84.—Subacute nephritis. Organ greatly enlarged. Cortex, more especially interpyramidal portions, greatly swollen and pale.

FIG. 85.—Chronic interstitial nephritis. Organ diminished in size. Section showing narrowed cortex.

FIG. 86.—The same, surface view after stripping capsule, showing roughening of surface and presence of subcapsular cysts.

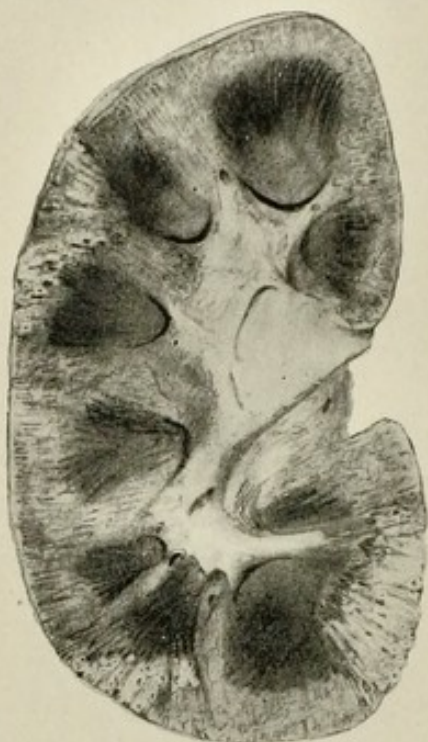

FIG. 87.—Kidney, pyæmic abscesses. $\frac{1}{2}$.
Cut surface.

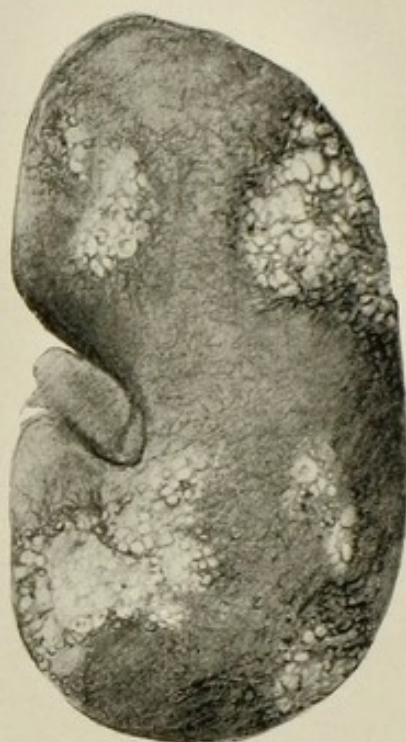

FIG. 88.—Kidney, pyæmic abscesses. $\frac{1}{2}$.
Surface with capsule stripped.

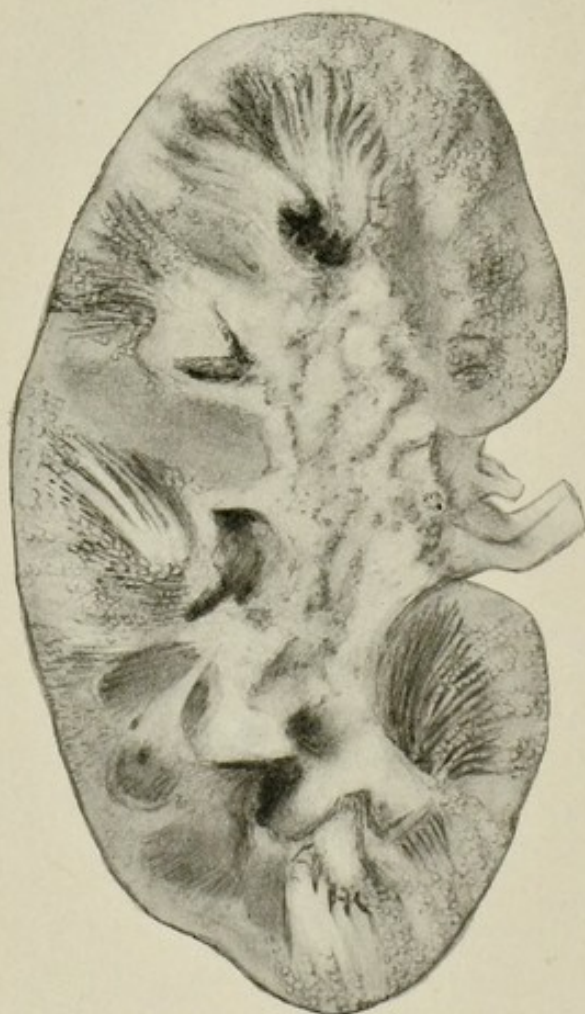


FIG. 89.—Kidney, tuberculosis. $\frac{1}{2}$.
Acute type of the disease. Large masses of tuberculous foci scattered, mainly in groups, through organ. Pelvis lined with zone of caseous tissue.

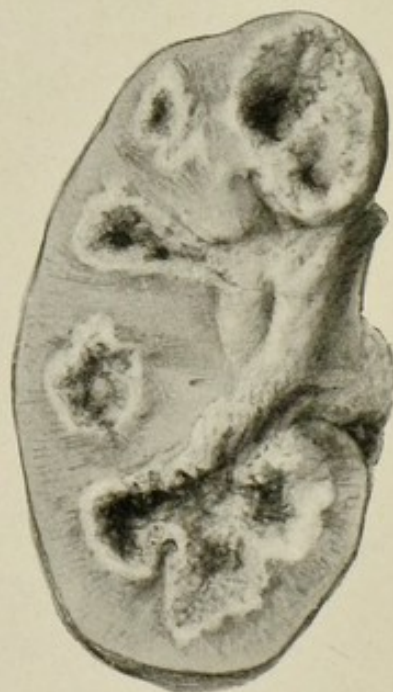

FIG. 90.—Kidney, tuberculosis. $\frac{1}{2}$.
Partial destruction of renal tissue forming cavities with ragged walls, and with a zone of caseous tissue around.

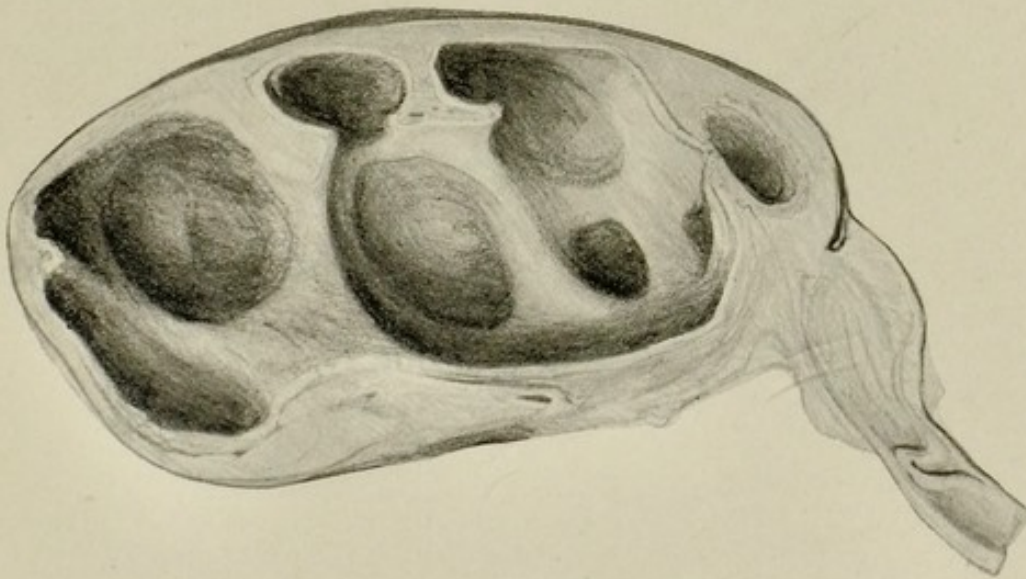


FIG. 91.—Kidney, hydronephrosis. $\frac{1}{2}$.
An S-shaped bend in the ureter following an injury.

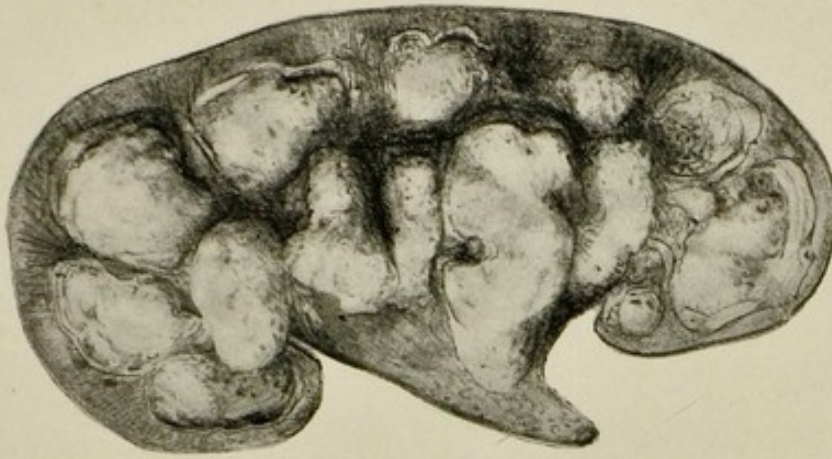


FIG. 93.—Coralline calculus in kidney. $\frac{1}{2}$.

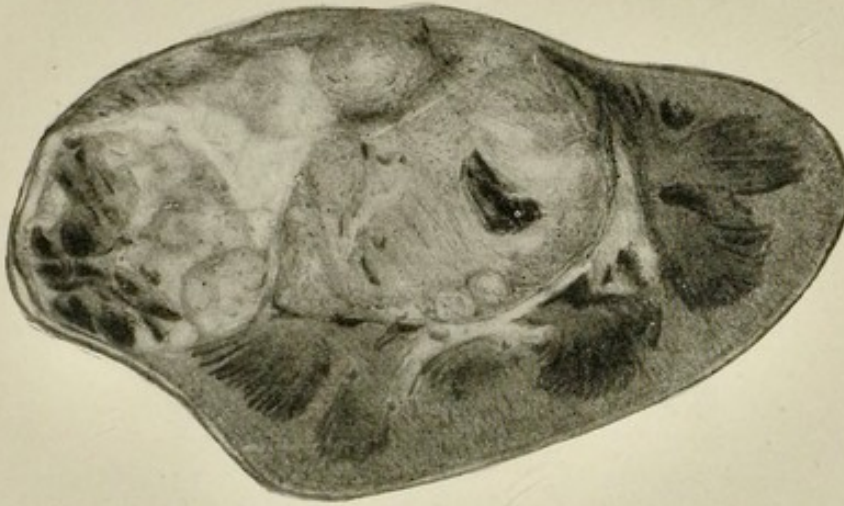

FIG. 92.—Kidney, hypernephroma and chronic venous congestion. $\frac{1}{2}$

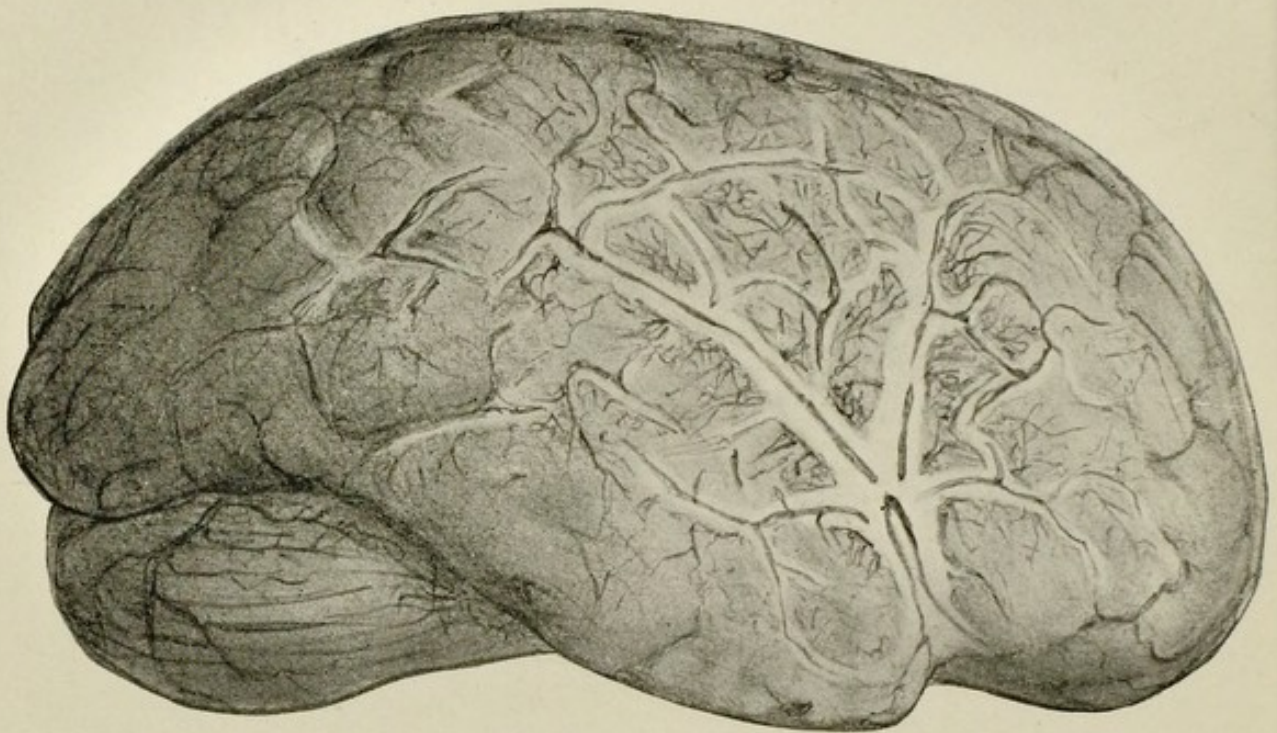


FIG. 94.—Brain, showing acute meningitis. $\frac{1}{2}$.

There is general prominence of the vessels and exudate in the sulci and fissures, especially the Sylvian fissure.

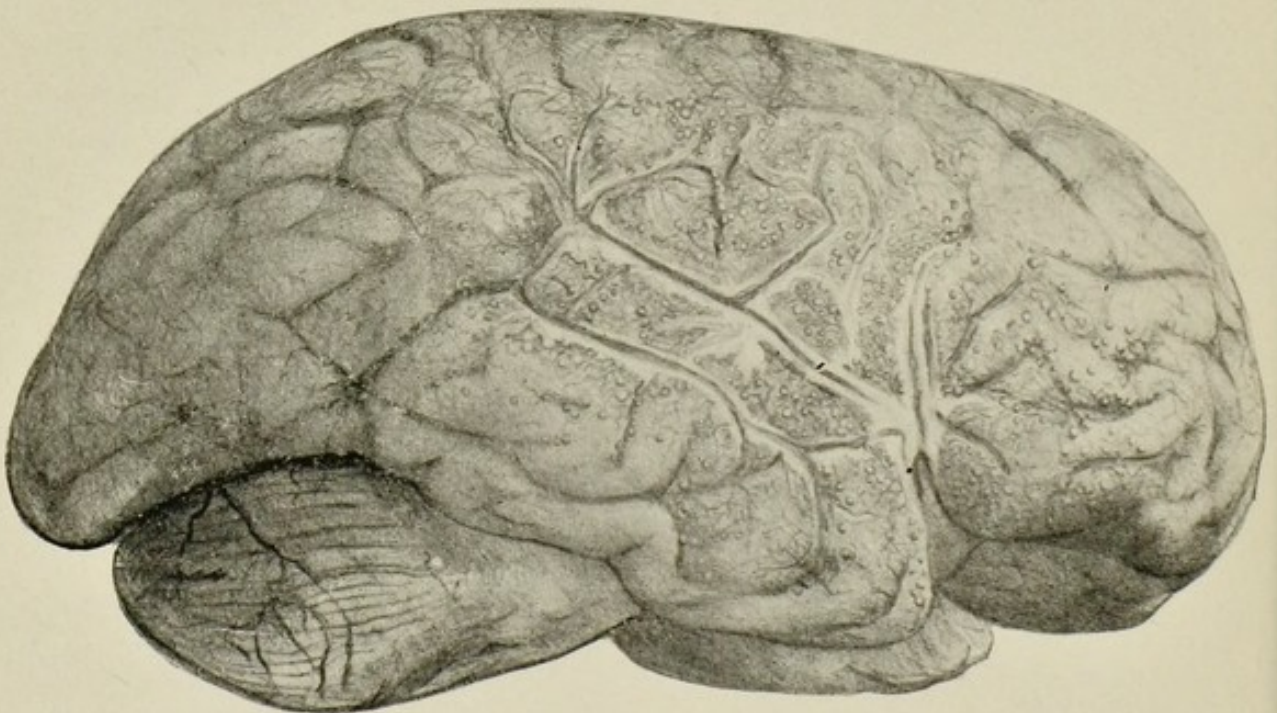


FIG. 95.—Brain, tuberculous meningitis. $\frac{1}{2}$.

Exudate extending up the Sylvian fissure and breaking up into discrete foci (tubercles) along the distribution of the smaller arteries in the sulci and over the convolutions.

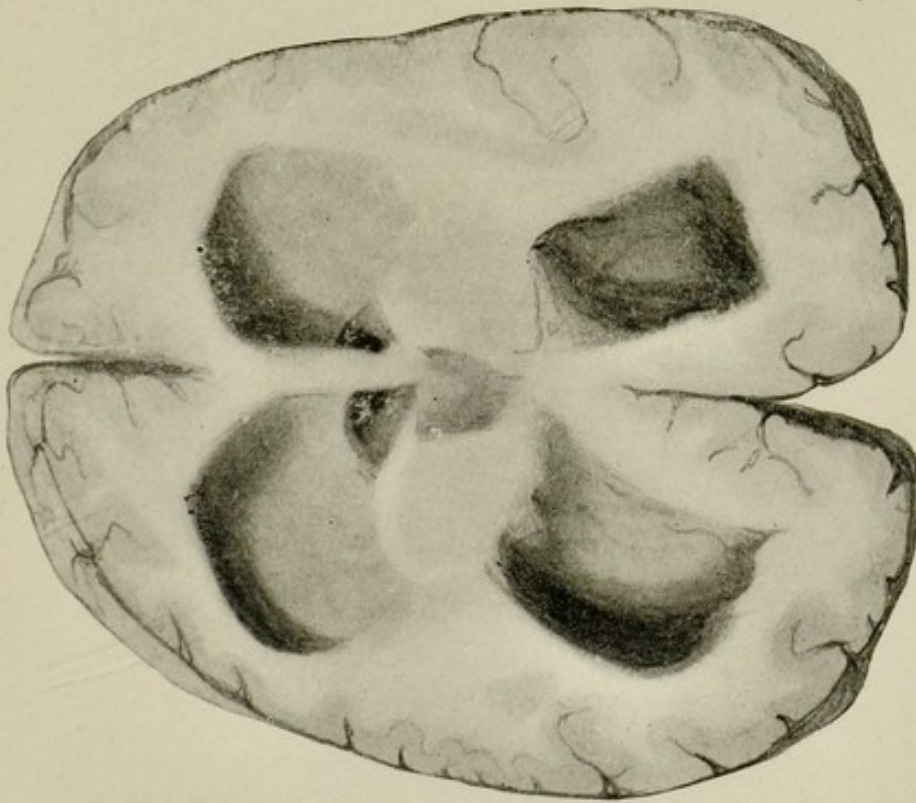


FIG. 96.—Section of brain, showing acquired hydrocephalus. $\frac{1}{2}$.
Distension of lateral ventricles secondary to basal meningitis.

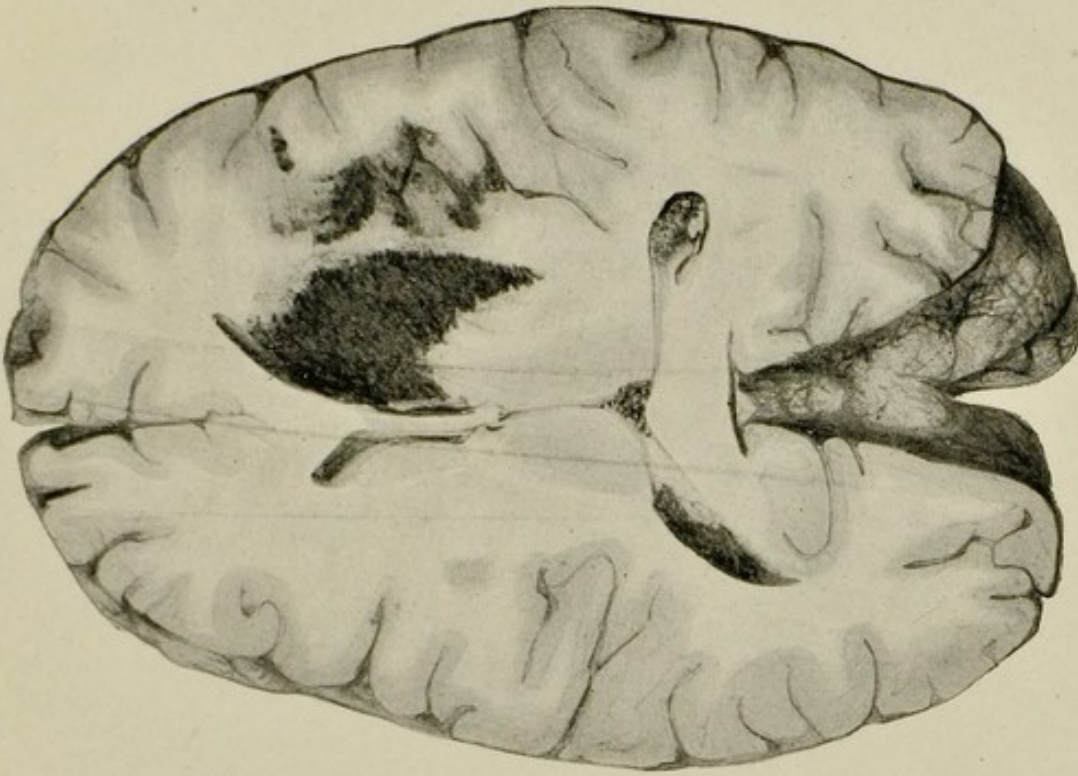


FIG. 97.—Section of brain, showing hæmorrhages into the basal ganglia on right side. $\frac{1}{2}$.

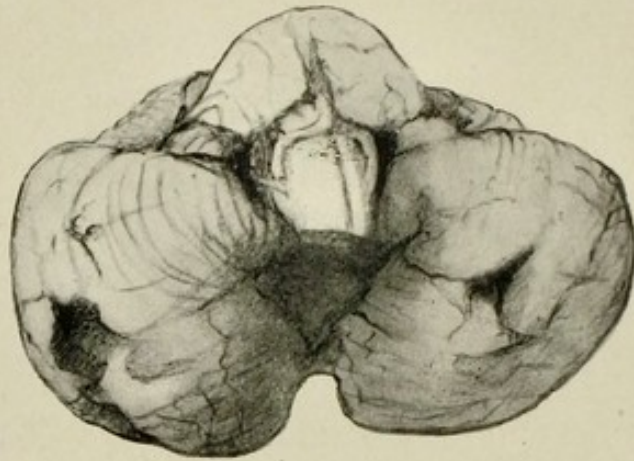


FIG. 98.—Cerebellum with depressed areas from softening of brain substance due to thrombosis in arteries. $\frac{1}{2}$.

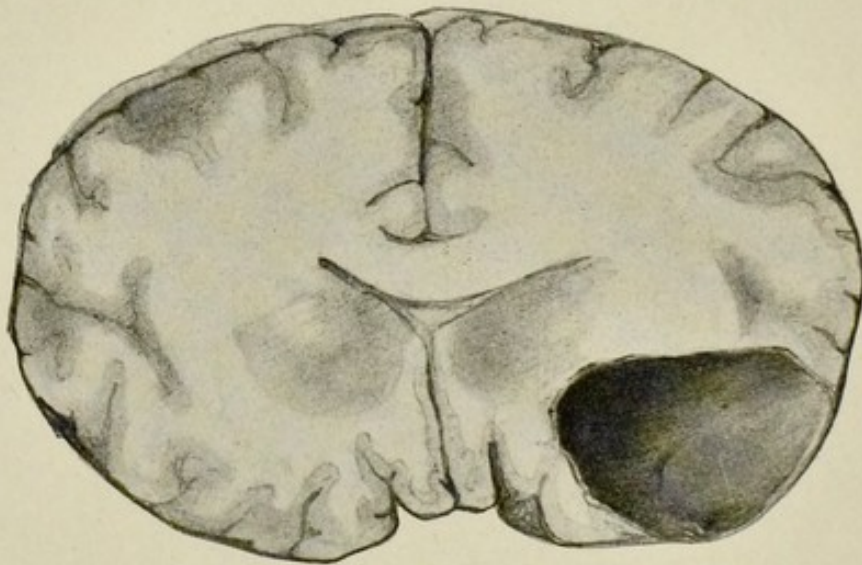


FIG. 99.—Vertical section of brain, showing large solitary abscess in temporo-sphenoidal lobe. $\frac{1}{2}$.



FIG. 100.—Transverse section of pons, showing hæmorrhages into its substance. $\frac{1}{4}$.

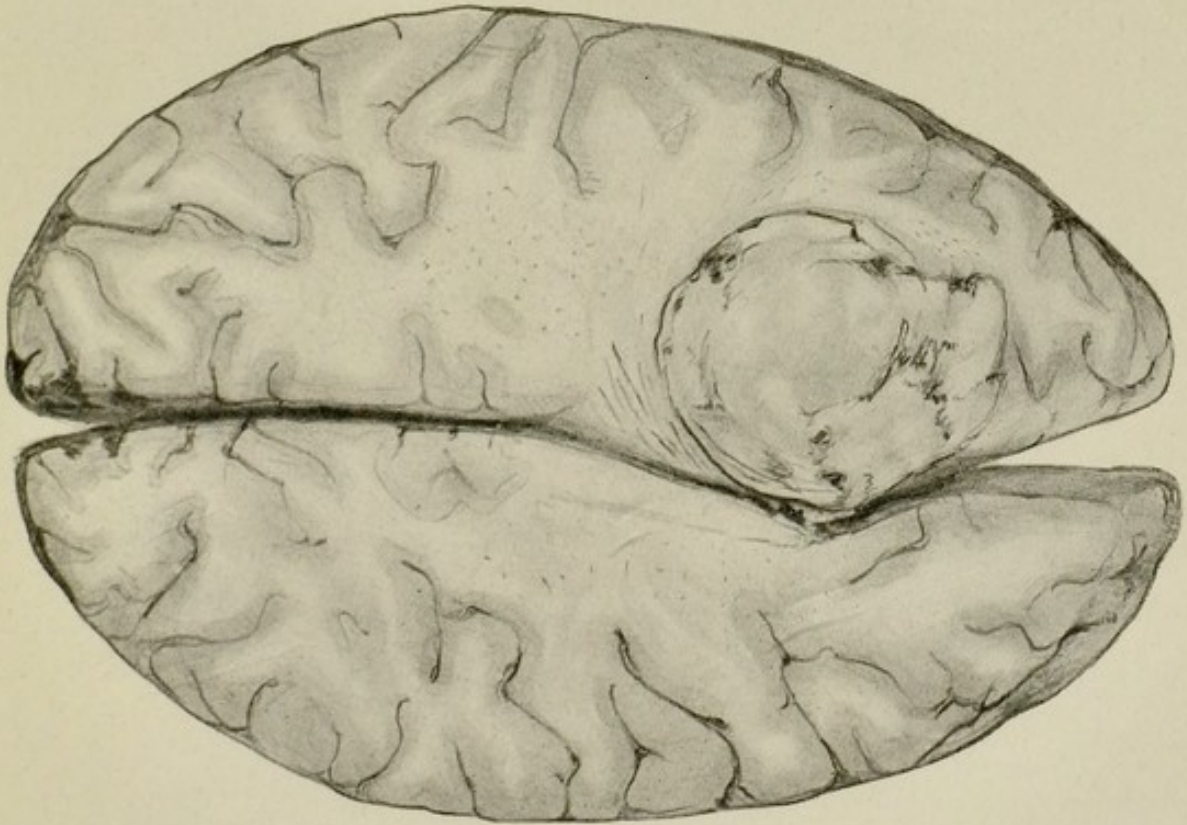


FIG. 101.—Cholesteatoma in frontal lobe.
(Sir Halliday Croom's case.) $\frac{1}{2}$.

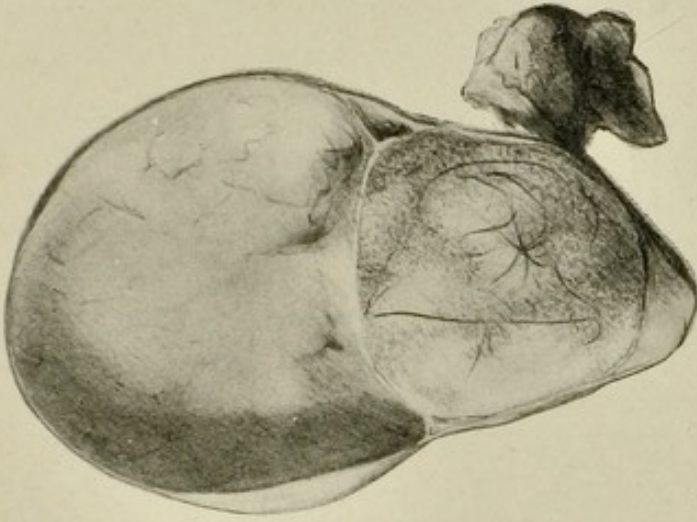


FIG. 102.—Teratoma (dermoid) of
ovary containing sebaceous material
and hairs. Solitary cyst above it.
(Dr. W. Fordyce's case.) $\frac{1}{2}$.

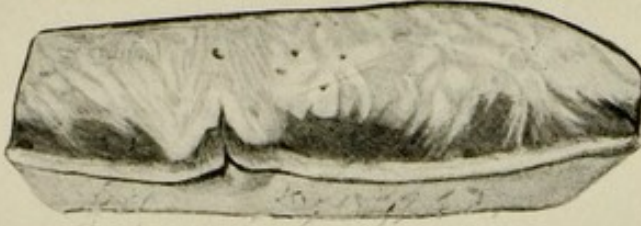

FIG. 103.—Scirrhus
cancer of the breast, with
indrawing of nipple. $\frac{1}{2}$.

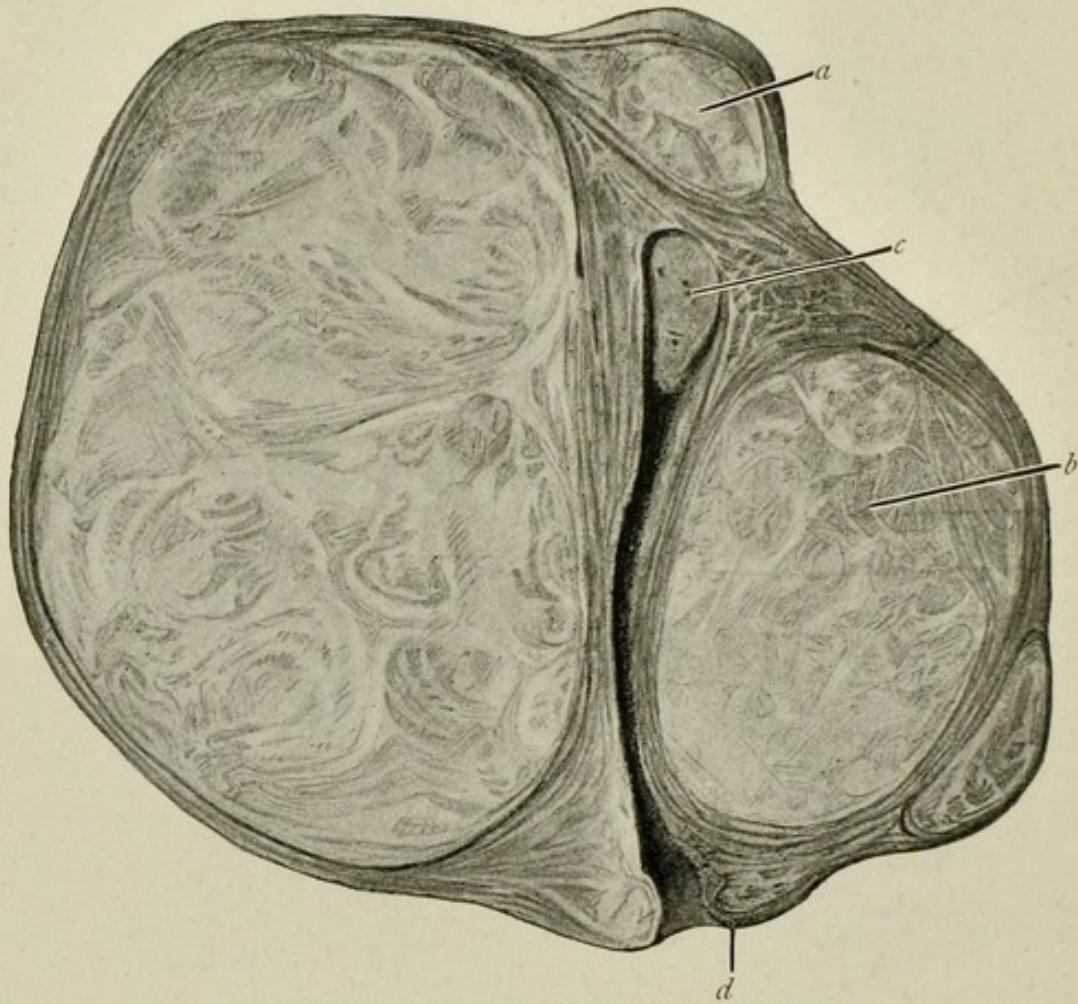


FIG. 104.—Myomata in wall of uterus. $\frac{1}{2}$.
a, subserous type. *b*, intramural type. *c*, submucous type. *d* indicates position of os uteri.

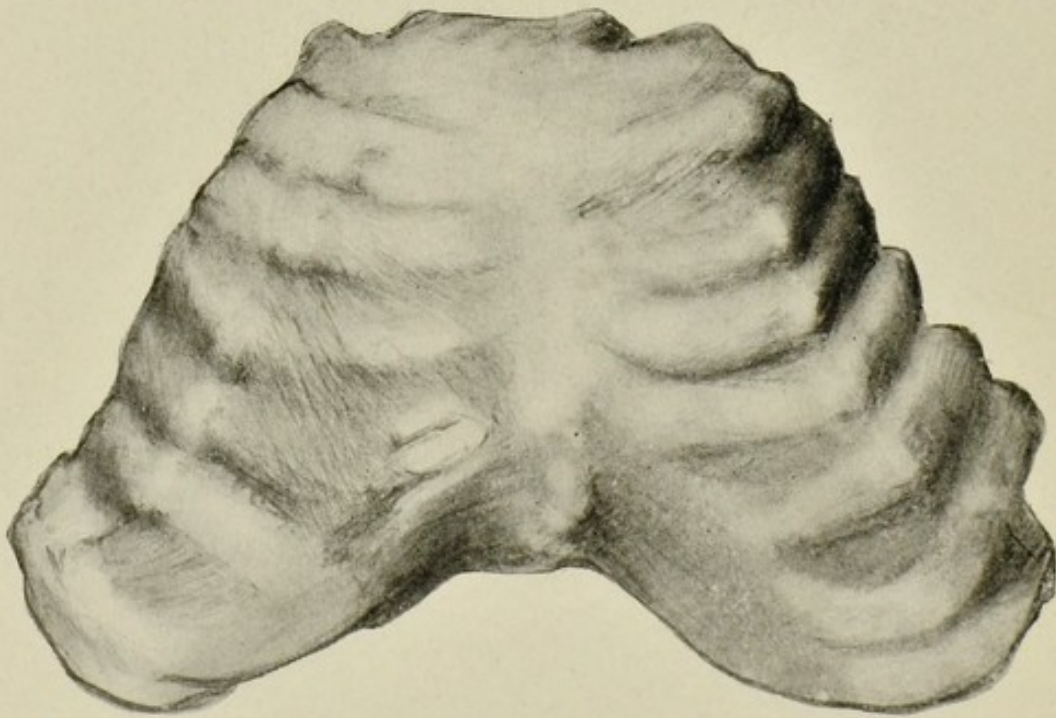


FIG. 105.—Enlargement of costo-chondral junctions (rickety rosary) in rickets. $\frac{1}{2}$.

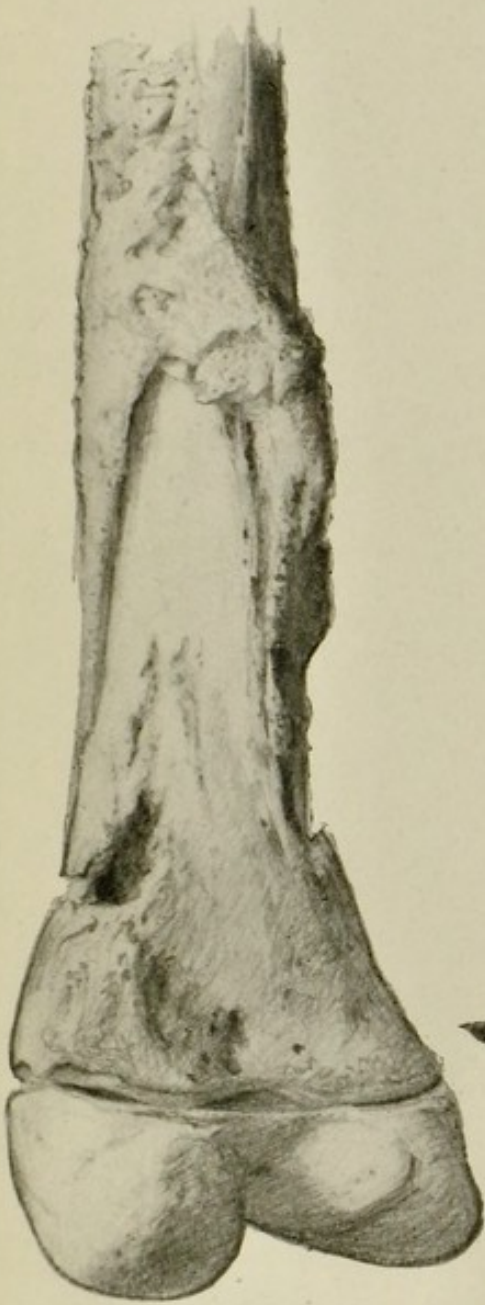

FIG. 106.—Chronic osteomyelitis of lower end of femur. $\frac{1}{2}$.

A new casing of bone is seen above, below is necrosed bone with openings (cloacæ).

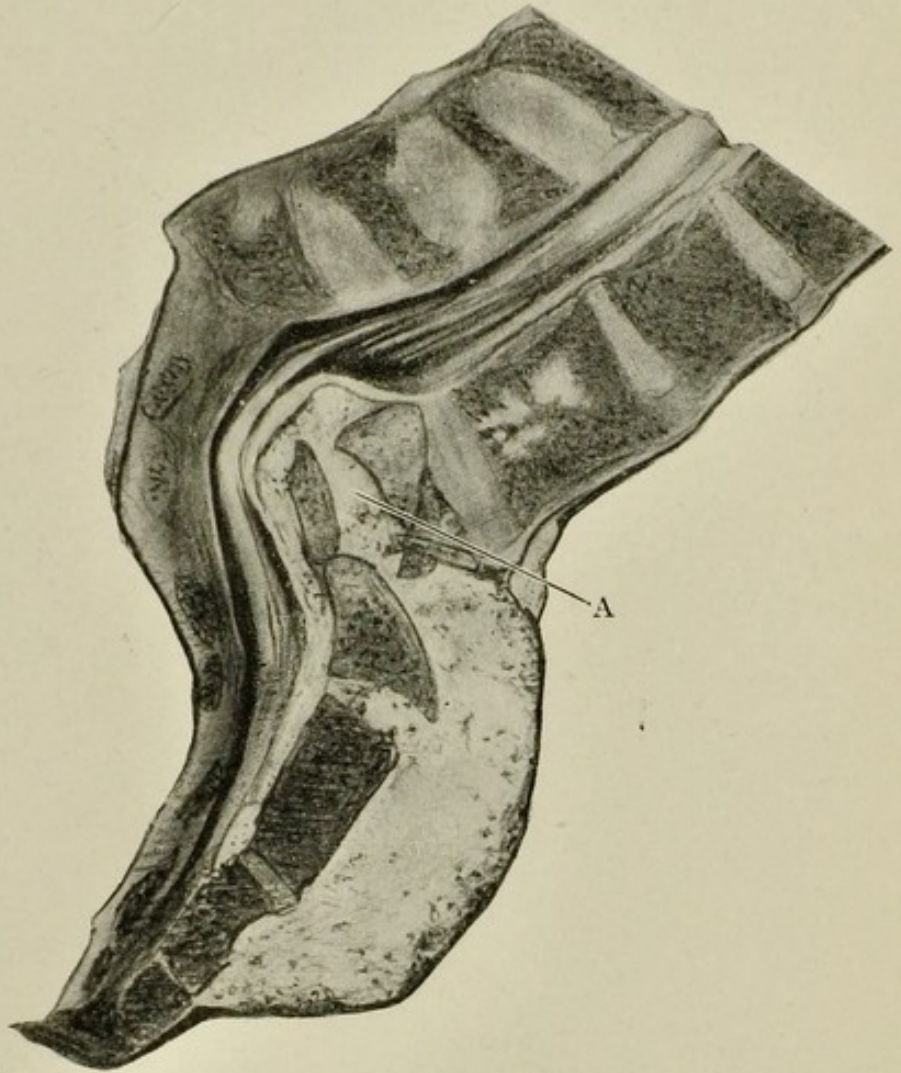


FIG. 107.—Lower lumbar vertebræ and sacrum in section. $\frac{1}{2}$.

Showing destruction of the body of one vertebra (A), with abscess containing caseous material extending from it anteriorly, the cauda equina being pressed upon behind. The body of the vertebra above shows infiltration with tuberculous foci.

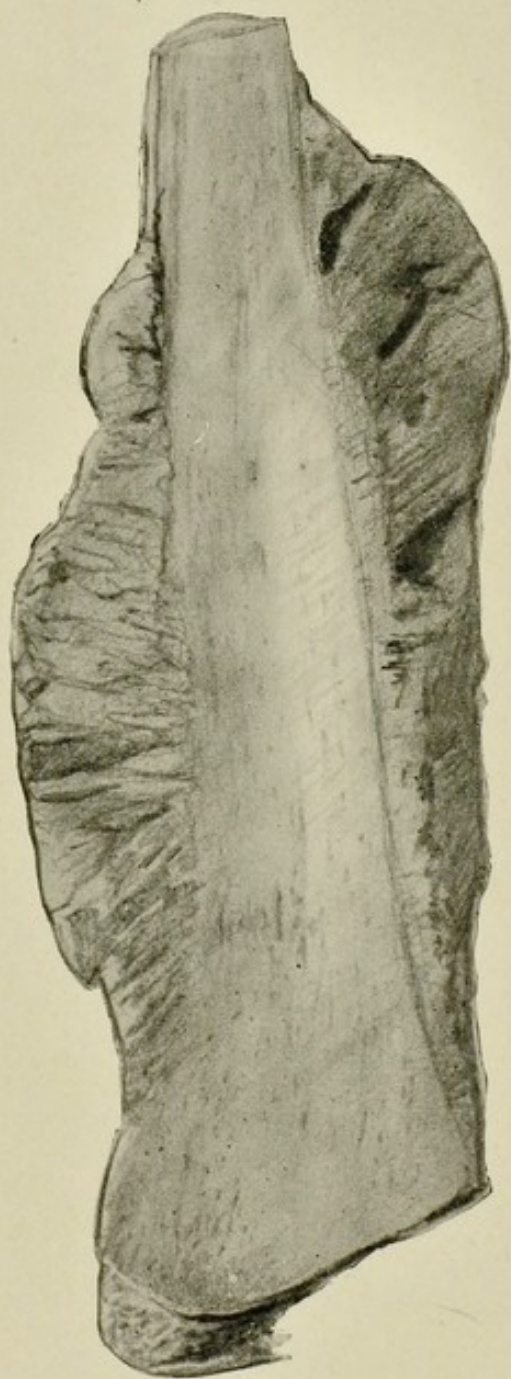

FIG. 108.—Osteo-sarcoma of shaft
of femur. $\frac{1}{2}$.

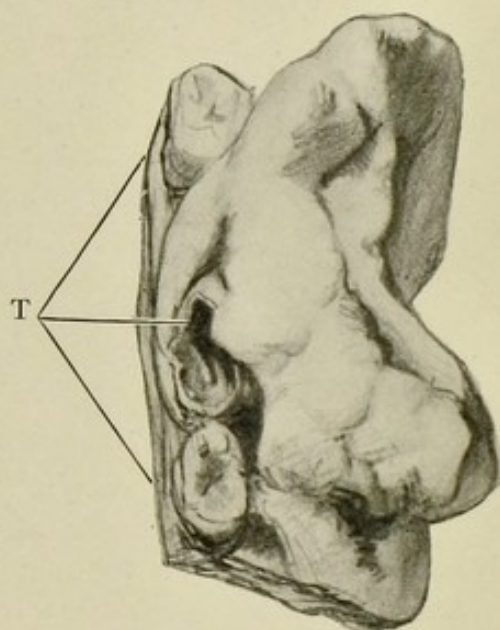


FIG. 109.—Myeloid sarcoma
of jaw. $\frac{3}{4}$.

T indicates three teeth.

OTHER MEDICAL BOOKS.

DISEASES & INJURIES OF THE EYE

A TEXT-BOOK FOR STUDENTS AND PRACTITIONERS

BY WILLIAM GEORGE SYM

M.D., F.R.C.S.E.

Ophthalmic Surgeon, Edinburgh Royal Infirmary; Lecturer on Diseases of the Eye
in the University of Edinburgh.

*Crown 8vo, cloth, containing 25 full-page Illustrations, 16 of them in colour, and
88 figures in the text; also a Type Test-Card at end of volume.*

By Post,
7s. 11d.

PRICE **7s. 6d.** NET.

By Post,
7s. 11d.

SOME PRESS OPINIONS.

"We may say at once that the book is a useful introduction to the subject to those for whom it is intended, as was only to be expected from one of wide experience obtained in as important a centre as Edinburgh."—*Lancet*.

"The text is excellent, and the various chapters deal efficiently with the subjects on which they treat."—*British Medical Journal*.

"This book is an excellent up-to-date presentation of the subject written for the student and practitioner."—*British Journal of Surgery*.

"The book . . . is extremely good, is most practical, and is full of useful information. . . . We can with confidence recommend it to medical students and practitioners."—*Medical Times*.

"Amongst the small text-books on the eye, already numerous, this deserves a prominent place."—*Practitioner*.

A TEXT-BOOK OF MIDWIFERY

FOR STUDENTS AND PRACTITIONERS

BY R. W. JOHNSTONE

M.A., M.D., F.R.C.S., M.R.C.P.E.

Assistant to the Professor of Midwifery and to the Lecturer on Gynæcology in the University of Edinburgh; Extern Assistant Physician, Royal Maternity Hospital; Obstetric Physician, New Town Dispensary; University Clinical Tutor in Gynæcology, Royal Infirmary; Gynæcologist, Livingstone Dispensary, Edinburgh.

Crown 8vo, cloth, containing 264 Illustrations.

By Post,
10s. 11d.

PRICE **10s. 6d.** NET.

By Post,
10s. 11d.

SOME PRESS OPINIONS.

"This excellent and clearly written text-book is published opportunely, and supplies just what is wanted in a convenient size for the student who desires an up-to-date compendium on the art of obstetrics."—*Edinburgh Medical Journal*.

"This is an excellent little manual. . . . We can recommend the book with confidence as a reliable and up-to-date text-book on the subject."—*Indian Medical Record*.

"Should become popular with medical students."—*Hospital*.

"To take the chapter on 'Normal Labour,' we have seldom read such a practical and satisfactory account of this important subject. The chapter on 'The Toxæmias of Pregnancy' is attractively written, and the best methods of treating the hæmorrhages of pregnancy—accidental and unavoidable—are very fully discussed."—*Prescriber*.

ADAM & CHARLES BLACK, 4, 5 & 6 SOHO SQUARE, LONDON, W.

OTHER MEDICAL BOOKS.

A MANUAL OF MEDICAL JURISPRUDENCE, TOXI- COLOGY, AND PUBLIC HEALTH

BY W. G. AITCHISON ROBERTSON

M.D., D.Sc., F.R.C.P.E., F.R.S.E.

Second Edition. Crown 8vo. Cloth. With 39 Illustrations.

By Post,
8s. 4d.

PRICE **8s.** NET.

By Post,
8s. 4d.

Dr. Aitchison Robertson has been long and well known as a teacher of Forensic Medicine and Public Health in the Edinburgh School of Medicine. He has written this manual expressly for the use of students who are preparing for examination in these subjects. The volume is not large, yet it includes all that the average student may be expected to know. It is written in a popular and interesting style, yet it is fully up-to-date in scientific matter. As the author has had large experience both as a teacher and as an examiner, it may be taken for granted that all the subjects are adequately and succinctly treated. The method of quoting specific cases to illustrate various points is well suited to assist students in mastering the subjects dealt with.

A HANDBOOK OF MEDICAL TREATMENT

A GUIDE TO THERAPEUTICS FOR
STUDENTS AND PRACTITIONERS

WITH AN APPENDIX ON DIET

BY JAMES BURNET

M.A., M.D., M.R.C.P. (Edin.)

Foolscap 8vo. Cloth.

By Post,
3s. 10d.

PRICE **3s. 6d.** NET.

By Post,
3s. 10d.

The author of this handbook is well known for his contributions on Therapeutics. As a teacher and examiner he has had abundant experience of the needs of the profession in the way of guidance as to the treatment of medical diseases. This volume is an unambitious attempt to supply the main facts of medical treatment within the compass of a small work, which is not only convenient to handle but also to carry about. Purely surgical and gynaecological affections have been entirely omitted. The arrangement of diseases followed by the author is an alphabetical one, so that the book is extremely convenient for rapid reference. The doses of drugs recommended are always fully stated, and throughout the book there are scattered quite a number of practical and useful prescriptions.

ADAM & CHARLES BLACK, 4, 5 & 6 SOHO SQUARE, LONDON, W.

OTHER MEDICAL BOOKS.

THE POCKET PRESCRIBER

BY JAMES BURNET

M.A., M.D., M.R.C.P.E.

Third Edition. Foolscape 16mo. (4½ by 2¾ inches.) Cloth.

By Post,
1s. 2d.

PRICE **1s. NET.**

By Post,
1s. 2d.

Although there are numerous books of prescriptions on the market, there is none which is quite comparable with this dainty little volume. The prescriptions given have been actually tested by the author, and were only included after careful observation and repeated trial. In fact, each one is a model of perfection which it would be very hard indeed to imitate, and quite impossible to improve upon. The diseases are arranged alphabetically, and for each one or two typical formulæ are given. The fact that two large editions of this book were rapidly exhausted shows that it has been widely appreciated. It differs from the voluminous collections of prescriptions which have from time to time been published, in that none of those given by the author are obsolete or useless. Nor is there a bewildering collection of formulæ for each disease such as confronts those who refer to more pretentious books on the subject. In short, this is a real aid to the student and practitioner which, once he possesses, he will never be without.

THE POCKET CLINICAL GUIDE

BY JAMES BURNET

M.A., M.D., M.R.C.P.E.

Foolscape 16mo. (4½ by 2¾ inches.) Cloth.

By Post,
1s. 8d.

PRICE **1s. 6d. NET.**

By Post,
1s. 8d.

This small work is intended to be a companion volume to *The Pocket Prescriber*, by the same author. There are many students and practitioners who at times need a really small work of reference on clinical methods such as they can readily carry in the waistcoat pocket. This volume exactly meets this requirement. It contains five chapters which deal respectively with the examination of the urine, the blood, the sputum, the stomach contents, and the fæces. The section on the examination of the urine deals with its naked-eye inspection and with its chemical and microscopic investigation, while a useful table is given showing the urinary changes met with in various kidney diseases.

The chapter on the blood includes an account of Widal's reaction and of the opsonic index. The blood changes met with in certain diseases are fully detailed. A very clear account is given of the microscopic examination of the sputum. The sections on the stomach contents and the fæces are extremely practical. This guide will be found absolutely indispensable for all who wish to know the essentials of clinical methods without being burdened with unnecessary and too elaborate details.

ADAM & CHARLES BLACK, 4, 5 & 6 SOHO SQUARE, LONDON, W.

OTHER MEDICAL BOOKS.

BLACK'S MEDICAL DICTIONARY

BY JOHN D. COMRIE

M.A., B.Sc., M.B., F.R.C.P.E.

Fifth Edition, completing 27,000 Copies, containing 425 Illustrations, 12 being full-page in Colour. Demy 8vo.

By Post, 8s.

PRICE **7s. 6d.** NET.

By Post, 8s.

SOME PRESS OPINIONS.

"No one could read it through without acquiring a large amount of sound information, not only in regard to the organs of the human body, their functions and the diseases to which they are liable, but also a good deal of learning in regard to such important matters as clothing, diet, exercise, sanitation, and ventilation. It is a thoroughly practical, useful book, singularly complete, which should be welcome in many households."—*Scotsman*.

"This is a book which would prove useful from time to time in any household, and is, moreover, so well written—its prime merit that of clearness—as to furnish reading of an interesting character quite apart from the idea of turning the information to immediate use."—*Guardian*.

"The book should be of great service to such classes as ship captains, nurses, and those in the country who live some distance from a doctor."—*Liverpool Courier*.

"The best manual for its purpose that we have seen."—*Observer*.

TEXT-BOOK OF OPERATIVE SURGERY

BY DR. TH. KOCHER

Third English Edition, greatly increased. Translated by HAROLD J. STILES, M.B., F.R.C.S. (Edin.) from the 5th German Edition. Containing 415 Illustrations, many with Colour introduced. Super Royal 8vo. Cloth.

By Post,
30s. 8d.

PRICE **30s.** NET.

By Post,
30s. 8d.

SOME PRESS OPINIONS.

"We can heartily recommend the book to all members of the profession interested in surgery, but more especially to those who are daily called upon to operate. . . . It is a book which is unsurpassed in its particular line for originality, and is founded on the experience of a surgeon whose methods are known throughout the world for their ingenuity and resource. . . . The best book on operative surgery—for operating surgeons—in the English language. . . . For those who can appreciate the writings of a practical man there is no book which will give them greater satisfaction."—*British Medical Journal*.

"It should be in the hands of every practising surgeon."—*North of England Clinical Journal*.

"Deserves a place in the surgeon's library."—*Guy's Hospital Gazette*.

"The most modern, the most original, and indeed the standard work on operative surgery."—*Student*.

ADVICE TO CONSUMPTIVES

Home Treatment, After Care and Prevention

BY NOEL DEAN BARDSWELL, M.D.

Crown 8vo.
Cloth.

PRICE **1s. 6d.** NET.

By Post,
1s. 9d.

SOME PRESS OPINIONS.

"One of the most valuable books on the home life of consumptives that has ever been written, and derives its value from the fact that it is based on extensive practical experience."—*Daily Telegraph*.

ADAM & CHARLES BLACK, 4, 5 & 6 SOHO SQUARE, LONDON, W.

2/8

