

**Post-mortem pathology : a manual of post-mortem examinations and the interpretations to be drawn therefrom : a practical treatise for students and practioners / by Henry W. Cattell.**

**Contributors**

Cattell, Henry W. 1862-1936.  
Royal College of Physicians of Edinburgh

**Publication/Creation**

Philadelphia; London : J.B. Lippincott, 1903.

**Persistent URL**

<https://wellcomecollection.org/works/njg6pxxj>

**Provider**


Royal College of Physicians Edinburgh

**License and attribution**

This material has been provided by This material has been provided by the Royal College of Physicians of Edinburgh. The original may be consulted at the Royal College of Physicians of Edinburgh. where the originals may be consulted.

Conditions of use: it is possible this item is protected by copyright and/or related rights. You are free to use this item in any way that is permitted by the copyright and related rights legislation that applies to your use. For other uses you need to obtain permission from the rights-holder(s).









Fb<sup>x</sup>10.8  
Presented by Dr Welsh

R50110



Ra. Welch  
1904.







# POST-MORTEM PATHOLOGY

A MANUAL OF POST-MORTEM EXAMINATIONS  
AND THE INTERPRETATIONS TO BE  
DRAWN THEREFROM

*A PRACTICAL TREATISE FOR STUDENTS AND PRACTITIONERS*

BY

HENRY W. CATTELL, A.M., M.D.

PATHOLOGIST TO THE PHILADELPHIA HOSPITAL AND THE WEST PHILADELPHIA HOSPITAL FOR WOMEN,  
AND SOMETIME DIRECTOR OF THE JOSEPHINE M. AYER CLINICAL LABORATORY OF THE PENNSYLVANIA HOSPITAL; SENIOR CORONER'S PHYSICIAN OF PHILADELPHIA; PATHOLOGIST TO THE PRESBYTERIAN HOSPITAL; PROSECTOR OF THE AMERICAN ANTHROPOMETRIC SOCIETY; DEMONSTRATOR OF MORBID ANATOMY IN THE UNIVERSITY OF PENNSYLVANIA, ETC.

WITH 162 ILLUSTRATIONS

"Rotto dal mento insin dove si trulla.  
Tra le gambe pendevan le minugia;  
La corata pareva, e il tristo sacco  
Che merda fa di quel che si trangugia."

—DANTE

PHILADELPHIA AND LONDON  
J. B. LIPPINCOTT COMPANY

1903



COPYRIGHT, 1903  
By J. B. LIPPINCOTT COMPANY

ROYAL COLLEGE OF PHYSICIANS EDINBURGH	
INV	ACC 75178
CAT ✓	REFS
SI REFS	INDEX
CLASS	

PRINTED BY J. B. LIPPINCOTT COMPANY, PHILADELPHIA, U.S.A.

TO THE MEMORY OF  
MY FRIEND

DR. THOMAS S. KIRKBRIDE, JR.

WHOSE EARLY DEATH WAS A  
SAD LOSS TO

AMERICAN PATHOLOGY





## PREFACE



THIS book has been written for those who ought to make autopsies but do not and for those of whom such investigations are required, as medical students, hospital interns, and coroner's physicians. While it would seem to be quite needless to urge upon a practitioner the importance of performing post-mortem examinations, it is a fact that extremely few are made outside of hospitals, and even there necropsies are usually conducted by the untrained resident or the substitute of the pathologist. It cannot be questioned, however, that the physician who improves his opportunities for pathological study on the cadaver will be a better diagnostician and safer therapist, will have a more enduring reputation, and will receive a greater pecuniary return than he who neglects such means of investigating morbid processes.

While the author has mainly relied upon his personal experiences in the preparation of the subject-matter of this manual, he has freely used classifications and material derived from ORTH's *Pathologisch-Anatomische Diagnostik*, OSLER's *Practice of Medicine*, NAUWERCK'S *Sections-Technik*, and other publications mentioned in the foot-notes and in the text. He is, therefore, much indebted to these authorities, as well as to Dr. GEORGE ROBINSON and Mr. LOUIS SCHMIDT for most of the drawings, all of which were prepared under the writer's direction, to his friends and former students Drs. WILLIAM S. WADSWORTH, MARY E. LAPHAM, E. D. BURKHARD, and EDWARD LODHOLZ for suggestions in the preparation of the book, and to that excellent proof-reader Mr. T. GROW TAYLOR for seeing the work through the press.

HENRY W. CATTELL.

3709 SPRUCE STREET, PHILADELPHIA, March 31, 1903.





# CONTENTS



CHAPTER	PAGE
I. GENERAL CONSIDERATIONS .....	1
II. POST-MORTEM RECORDS AND NOTE-TAKING .....	14
III. POST-MORTEM INSTRUMENTS AND HOW TO USE THEM .....	24
IV. THE CARE OF THE HANDS AND THE TREATMENT OF POST-MORTEM WOUNDS .....	40
V. EXAMINATION OF THE EXTERIOR OF THE BODY .....	46
VI. TECHNIC OF EXPOSING THE ABDOMINAL CAVITY AND THE SUPERFI- CIAL EXAMINATION OF THE PARTS CONTAINED THEREIN .....	54
VII. TECHNIC OF EXPOSING THE THORACIC CAVITY AND THE EXAMINATION OF THE PARTS CONTAINED THEREIN .....	64
VIII. LESIONS OF THE HEART, BLOOD, AND BLOOD-VESSELS .....	76
IX. EXAMINATION OF THE PLEURÆ, LUNGS, AND UPPER AIR-PASSAGES ....	93
X. DISEASES OF THE LUNGS, PLEURÆ, AND ACCESSORY PARTS .....	97
XI. CRITICAL EXAMINATION OF THE ORGANS OF THE ABDOMINAL CAVITY ...	112
XII. DISEASES OF THE KIDNEY .....	145
XIII. DISEASES OF THE BLADDER, FALLOPIAN TUBES, OVARIES, UTERUS, VAGINA, AND TESTICLES .....	151
XIV. DISEASES OF THE LIVER AND GALL-DUCTS .....	157
XV. EXAMINATION OF THE SKULL AND BRAIN .....	164
XVI. THE SPINAL CANAL AND CORD .....	180
XVII. DISEASES OF THE BRAIN AND CORD .....	183
XVIII. EXAMINATION OF THE NASOPHARYNX, EYES, AND EARS .....	193
XIX. POST-MORTEM EXAMINATIONS OF THE NEW-BORN .....	197
XX. RESTRICTED POST-MORTEM EXAMINATIONS .....	200
XXI. RESTORATION AND PRESERVATION OF THE BODY .....	203
XXII. DISEASES DUE TO MICRO-ORGANISMS, PARASITES, AND HÆMATOZOA ....	209
XXIII. THE PRESERVATION OF TISSUES FOR MACROSCOPIC AND MICROSCOPIC PURPOSES .....	244
XXIV. BACTERIOLOGICAL INVESTIGATIONS .....	263
XXV. WEIGHTS AND MEASURES .....	267
XXVI. COMPARATIVE POSTMORTEMS .....	281
XXVII. MEDICOLEGAL SUGGESTIONS .....	305
XXVIII. THE PRUSSIAN REGULATIONS FOR THE PERFORMANCE OF AUTOPSIES IN MEDICOLEGAL CASES .....	336
XXIX. USUAL CAUSES OF DEATH; THEIR NOMENCLATURE, COMPLICATIONS, AND SYNONYMS .....	348





## LIST OF ILLUSTRATIONS

FIG.	PAGE
1. Post-mortem room of Ayer Clinical Laboratory, Pennsylvania Hospital ..	8
2. Plans for post-mortem table .....	8
3 and 4. Refrigerator box with scales arranged to weigh body while in it ....	9
5 and 6. Plans for refrigerator box for storage of bodies .....	10
7 and 8. Plan for a combination electric, gas, and water fixture above post-mortem table .....	11
9. Combination electric, gas, and water fixture for post-mortem table.....	12
10. Section- or cartilage-knife .....	24
11. Cartilage-knife with projection on back .....	25
12. Post-mortem knife with faulty point and improper belly .....	25
13. Brain-knife marked as a measuring rule .....	25
14. Bread-knife for incising large organs .....	25
15. Valentine's knife .....	26
16. Pick's myelotome .....	26
17. Saw for post-mortem work .....	26
18. Butcher's saw for post-mortem work .....	27
19. Hey's saw .....	27
20. Metacarpal saw .....	27
21. Luer's double rhachiotome .....	27
22. Cryer's electrical surgical engine .....	28
23. Strong scissors with short blades .....	29
24. Scissors with one dull point and with bent handles .....	29
25. Proper form of enterotome .....	30
26. Improper form of enterotome .....	30
27. Proper form of costotome .....	30
28. Improper form of costotome .....	31
29. Steel hammer with proper handle .....	31
30. Steel side chisel .....	32
31. Curved chisel .....	32
32. Brunetti's curved spinal chisel.....	32
33. Satterthwaite's calvarium clamp .....	33
34. Iron clamp for attachment to skull before removing brain .....	34
35. Bigelow clamp .....	34
36. Folding iron head-rest .....	34
37. Cornell folding clamp .....	34
38. Cones for measuring orifices .....	34
39. Glass balls for measuring orifices .....	35
40. Hemp twine ready for use .....	37
41. Formad's pocket-case for post-mortem instruments .....	38



FIG.	PAGE
42. Method of holding cartilage-knife .....	35
43, 44, and 45. Scheme showing various forms of incisions for examining thorax and abdomen .....	54
46 and 47. Initial incision over sternum (vertical and lateral views) .....	54
48 and 49. Right thoracic flap made in opening body (vertical and lateral views) .....	54
50. Opening of abdominal cavity .....	55
51. Method of severing costal cartilages .....	55
52. Method of separating sternoclavicular attachment .....	64
53. Incision of first left rib .....	64
54. Incising first rib and sternoclavicular articulation with costotome .....	65
55. Severing diaphragmatic attachments of sternum .....	65
56 and 57. Final steps in removal of sternum .....	65
58. Breastplate after its removal from the body .....	70
59. Method of covering ribs with skin-flap for protection of operator's hands, and methods of enlarging abdominal opening .....	70
60. Opening of pericardium .....	71
61. Primary incisions for opening heart .....	71
62. Secondary incisions for opening heart .....	71
63. Completed incisions for opening heart .....	71
64. Opening of right auricle .....	72
65. Opening of left ventricle .....	72
66. Removal of heart from body .....	72
67. Incision of pulmonary veins .....	72
68. Examination of right ventricle and of pulmonary artery .....	73
69. Examination of left auricle and ventricle .....	73
70. Reconstruction of heart after completed incisions .....	73
71. Opening of lung .....	94
72. Lung laid open for minute inspection .....	94
73. Minute examination of pulmonary vein .....	95
74. Examination of bronchi .....	95
75. Method of removing tongue, tonsils, œsophagus, bronchus, etc., in a single piece .....	96
76. Method of examining œsophagus .....	96
77. Examination of organs of neck .....	97
78. Method of opening trachea .....	97
79. Examination of trachea and vocal cords .....	97
80. Method of removing intestines .....	114
81. Method of passing string through mesentery previous to tying the same ..	116
82. Bucket method of opening and cleansing intestines .....	116
83. Removal of small intestines .....	116
84. Opening of small intestine after its removal .....	116
85. Incision of the kidney with its ureter still attached .....	116
86 and 87. Method of opening kidney .....	127
88. Relations of pancreas, kidney, ureter, adrenal, and solar plexus .....	131
89. Preparation of body for post-mortem examination of rectovaginal region ..	117
90 to 97. Removal of bladder, rectum, uterus, and its adnexa <i>en masse</i> and restoration of the parts .....	117
98. Lines for opening uterus .....	132
99. Uterus and adnexa after opening .....	132



## LIST OF ILLUSTRATIONS

xi

FIG.	PAGE
100, 101, and 102. Examination of testicles, epididymis, spermatic cord, etc., without disfigurement .....	136
103. Examination of seminal vesicles .....	136
104. Removal of liver .....	136
105. Examination of biliary ducts and vessels .....	137
106. Method of incising liver .....	137
107. Examination of gall-bladder and hepatic and pancreatic ducts .....	138
108. Examination of stomach .....	137
109. Preliminary skin incision for opening skull .....	164
110. Parting of hair so as to prevent its injury in incising scalp .....	164
111 and 112. Angular method of sawing skullcap .....	164
113. Method of breaking up inner table of skull .....	165
114. Method of drawing off skullcap .....	165
115. Appearance of dura mater after removal of calvarium .....	165
116. Appearance of brain after removal of dura .....	172
117. Removal of brain from skull .....	172
118. Dissection of brain; commencement of initial incision .....	173
119. End of initial incision .....	173
120. Exposure of central portions of brain .....	173
121. Central portion of brain, with cerebellum, pons Varolii, and medulla oblongata still attached .....	173
122. Segmented brain .....	174
123. Separation of cerebellar lobes from pons Varolii and medulla oblongata ..	174
124. Method of sectioning cerebellum .....	174
125. The whole brain after it has been sectioned .....	174
126. Sectioning of brain without separation of individual parts .....	175
127. Basal ganglia, with cerebellum, pons Varolii, and medulla oblongata still attached .....	174
128. Sectioning the brain according to Flechsig, Brissaud, and Dejerine .....	175
129. Dejerine's incisions of brain in cortical lesions .....	175
130. Lines for removing spinal cord and brain through a small triangular occipital incision .....	180
131. Position of body in removal of spinal cord .....	180
132. Removal of spinal cord; primary incisions .....	180
133. Completion of sawing .....	181
134. Opening of spinal canal .....	181
135. Severance of atlas and axis .....	181
136. Final steps in removal of spinal cord.....	181
137. Methods of examining nasopharynx, eyes, and ears .....	194
138 and 139. Harke's method of examining nasopharynx .....	194
140. Examination of umbilical vessels .....	195
141. Examination of ductus arteriosus .....	195
142. Removal of spinal cord of a child .....	195
143 and 144. Method of examining for syphilitic osteochondritis of the femur	202
145 and 146. Method of examining nasal cavities, antrum of Highmore, etc. ..	202
147 and 148. Method of sewing up body .....	203
149. Slee's method of fixing skullcap .....	203
150. Author's method of holding skullcap in place .....	203
151 and 152. Refrigerator plant for preservation of bodies, University of Pennsylvania .....	208



FIG.		PAGE
153.	Guinea-pig upon which a post-mortem examination has been made in a Ravenel pan.....	209
154.	Post-mortem examination of animals; equine viscera.....	285
155.	Further dissection of Fig. 154.....	286
156.	Further dissection of Fig. 155.....	288
157.	Lines for opening cephalic cavities of a horse.....	295
158.	Lines for opening cranial cavity of a horse.....	295
159.	Lines for exposing cranial and nasal cavities in ruminants.....	298
160.	Appearances of cranial cavity of a cow.....	298
161.	Post-mortem examination of dog.....	300
162.	Exposure of oral and pharyngeal cavities in a dog.....	301

# POST-MORTEM EXAMINATIONS



## CHAPTER I

### GENERAL CONSIDERATIONS

POSTMORTEM, autopsy, and necropsy<sup>1</sup> are synonymous terms applied to the systematic exposure and critical examination of the cadaver with the object of determining the cause of death or of studying morbid anatomy in any of its various aspects. In no other department of medical science are the faculties of observation and discrimination more vigorously called into play, and in none other are sound knowledge and accurate work so indispensable.

As the purpose of a post-mortem examination is the acquisition of exact data to be employed either for the promotion of the ends of justice or for scientific use, the information acquired should be obtained in a regular and systematic manner. This is especially important in medicolegal cases, which frequently involve not only the reputation and liberty, but even the life of a human being. If the examination is conducted in a perfunctory or desultory way, some detail of the greatest importance may be overlooked, or the information obtained may be so undigested as to be practically valueless for statistical or demonstrative purposes.

Relying upon one's memory for records is a treacherous device, and appearances which seem to be of no importance while the organ is before you are often of value to others who for various reasons may be called upon to read the protocol of the autopsy, but who have not had the opportunity of examining the parts in which they are interested.

---

<sup>1</sup> Other synonyms are necroscopy, mortopsy, obduction, section, sectio, and post (colloquial). German, *Autopsie, Section, Selbstsehen, Leichenöffnung, Obduction, Necropsie*, and *Nekroscopie*; French, *autopsie, obduction, necropsie*, and *necroscopie*; Italian, *autopsia, autossia*; Spanish, *autopsia*; Greek, *αὐτοψία*; Latin, *autopsia, necropsia, necropsis, necroscopia, sectio cadaveris*, and *sectio anatomica*. The German word *Obduction* is correctly applied only to a medicolegal postmortem.



All notes should, therefore, be dictated while the autopsy is in progress, and should consist exclusively of descriptions of the conditions then and there observed. Names of diseases should be omitted in the notes themselves, but are to be inserted under the heading of "Pathological Diagnoses" at the head of the report. The record of morbid changes present ought to be full, clear, and exact, so that from it alone the pathological lesions can be made out by another pathologist as well as by the one who performed the necropsy. One well-worded description of an autopsy dictated to a reliable amanuensis during the progress of the work is of much more value than scores written from memory after their completion. Drawings, photographs, skiagraphs, kromskopic pictures,<sup>1</sup> casts, microscopic slides, properly mounted museum specimens, and cultures of micro-organisms make valuable additions to a well-written account of a postmortem.

If the ascertainment of the cause of death be the object in view, the line of inquiry should be based upon a hypothetical or tentative diagnosis suggested by the clinical history or special circumstances of the case. This may subsequently be corrected, modified, or abandoned as the autopsy proceeds; but the final diagnosis should, of course, not be made until the autopsy shall have been completed.

A lesion found in one portion of the body may indicate the existence of pathological conditions in another, perhaps remote, part. For example, multiple melanotic sarcomata of the liver are frequently secondary to a primary growth in the eye; an embolism in the brain often arises from malignant endocarditis; hæmatomata of the ears will suggest chronic meningo-encephalitis, with thickening of the cranial meninges; and the presence of miliary tuberculosis should lead one to an examination of the pulmonary arteries for tuberculous thrombi arising from caseous tuberculous glands. Again, particles of coal-dust embedded in the hands demand a careful inspection of the lungs for anthracosis, while bronzing of the skin will suggest the careful examination of the adrenals and of the sympathetic ganglia (Addison's disease).

There are cases in which it is impossible to state positively the cause of death, even on the completion of the autopsy, after a most thorough and painstaking examination. In such instances, as in all others, the accuracy of the conclusions drawn will depend upon the

---

<sup>1</sup> CATTELL, *International Clinics*, Vol. ii., Tenth Series, 1900.



care exercised in the observation of details. Fortunately for those having to do with cases coming under the notice of the coroner, sudden death is nearly always attended with well-marked pathological lesions. When no such cause of death is found, chemical or early bacillary poisoning should be suspected. Any epidemic disease, such as smallpox, which is now (1903) so widely distributed throughout America, should always be thought of during the time of its prevalence, as death may occur before the characteristic rash or symptoms have made their appearance.

The opportunities for the study of the appearances and characteristics of normal structures offered by postmortems upon the remains of healthy persons killed by accident should not be neglected, as a thorough knowledge of normal conditions is necessary in order that morbid changes or slight variations from health may be recognized. Such subjects also often afford favorable opportunities to study disease in its earliest manifestations; this is especially true of tumors and the infective granulomata. New combinations of anomalies may also be found. As the science of medicine advances, new discoveries require a constant revision of the statistics of even the most common diseases.

Autopsies likewise present exceptional opportunities for reviewing the study of anatomy and even for acquiring dexterity in the practice of surgery,—a method much practised by Agnew, Keen, and other celebrated surgeons. To this end, it is permissible in suitable cases to perform surgical operations that entail no disfigurement or mutilation of the body. Thus, in females an Alexander's operation, oöphorectomy, symphysectomy, or hysterectomy may be performed, and on subjects of either sex the operator may practise a preliminary laparotomy, a laminectomy, and lumbar puncture for diagnostic purposes or for spinal anæsthesia, or study the technique of stretching the sciatic nerve, or of removing the ear-ossicles, the Gasserian ganglion, or the vermiform appendix. Some of the newer surgical devices, such as decapsulization of the kidney, mechanical irritation of the hepatic peritoneum, the Lorenz operation for congenital dislocation of the hip, the formation of an anterior and posterior cusp in the cervical os to prevent conception, but still permitting the outflow of the menstrual fluid, etc., will at once suggest themselves as being worthy of practice upon the cadaver as the opportunity offers itself.

In every instance the first step is to secure a legal right to make



the examination. When the postmortem is not to be performed by order of the coroner or of the court, consent (preferably in writing) should be obtained from the next of kin to the deceased, or, in the absence of relatives, from the person in charge of the funeral. The feelings of friends and relatives must be fully respected, and it should be remembered that scientific zeal is no excuse for any procedure that may shock those who were intimately associated with the deceased. In a recent suit for damages against a Philadelphia hospital where a postmortem was made without the consent of the nearest relative, the judge severely deprecated the procedure, but held that no damages could be recovered from the hospital, it being founded for charitable purposes.

The method to be pursued in gaining permission will depend on the nature of the case, but the exercise of tact will nearly always secure consent, except where religious bigotry stands in the way. Thus, one resident in a hospital will obtain an autopsy upon almost every patient dying in the wards during his term of service, while another interne of the same institution will, for one reason or another, meet refusal in the great majority of his cases. The curiosity of relatives and friends may be aroused, or the humane plea of doing no harm to the dead and possibly much good to the living will often appeal to the better judgment of those from whom the permission is to be obtained. The laity should be encouraged to ask for the making of an autopsy, which when carefully performed may win ready consent to, or even a voluntary request for, other postmortems in the vicinity in which the physician resides. The blank forms which accompany insurance papers often contain the query, "Was an autopsy made?" and an affirmative answer greatly strengthens the holder's claim. The offer of a small sum of money will often secure permission to make a necropsy among the indigent foreigners who are so numerous in our large cities, but the threat to refer the case to the coroner unless permission is voluntarily granted should never be employed.

Dead bodies may have a pecuniary value, and thus give rise to legal difficulties. The Supreme Court of California has recently decided that a man cannot by will dispose of his own corpse. A man left to the managers of a medical college, in the hospital of which he had been treated, his body to be used for scientific purposes. When he died, the nearest of kin claimed the body, and applied to the courts



for an injunction restraining the medical college from taking the cadaver. The kinsfolk won; the court holding that the custody of the corpse and the right of burial belong to the next of kin.<sup>1</sup> There are several societies in America, the members of which sign cards granting permission for the performance of postmortems on their bodies: it would, therefore, seem best on account of this decision to have the card endorsed by the legal heirs. And yet circumstances may readily occur, even in such cases, to prevent the autopsy. Thus in the case of Phillips Brooks, who was a member of the American Anthropometric Society, I, as the prosector of the society, on reaching Boston could not perform the postmortem, as the body had been placed in an hermetically sealed coffin owing to his death having been caused by diphtheria, and a public funeral was desired by his many admirers. There should be a law that all persons dying in our public institutions shall be posted. Such a rule exists in the hospitals in Germany and has recently been adopted, with practically no opposition, in Blockley here in Philadelphia. In those cases going to the anatomical board care should be taken to preserve the arteries for future injection. If in the course of an autopsy conditions are found which indicate foul play, as injuries, or the presence of poisons, the postmortem should be immediately suspended and steps at once taken to have the coroner or other legal officer take charge of the case. If properly authorized by the coroner or the person who is legally acting as such, the examination may be proceeded with in the manner usual in performing medicolegal postmortems.

When portions of the body are desired for preservation or for future study, permission to remove them should be obtained from some one connected with the household, though not necessarily from the nearest relative, as in gaining consent for the performance of the autopsy. It is, of course, unnecessary to tell how much of the body is to be taken away! Should, however, the person authorizing the autopsy forbid the removal of any portion of the body from the house, no specimens should be secured. Consent can nearly always be obtained for the removal of small pieces of tissue for microscopic purposes, even in those cases in which permission to take away larger specimens is refused. Thus, in the postmortem on President McKinley, the bullet causing the fatal wound was not found, owing to

---

<sup>1</sup> *American Medicine*, April 6, 1901.



Mrs. McKinley objecting—though without legal right so to do—to the search being longer continued, and it was only with the greatest difficulty that permission was obtained to remove portions of the body for microscopic study.

Professional friends should be invited to be present at an autopsy; under the scrutiny of critical eyes better work is undoubtedly done. Besides, in medicolegal cases the responsibility of making an autopsy in which the evidence obtained may be sufficient to convict or acquit a person of the gravest of crimes is often too great to be borne alone.

Those present are frequently prone to make suggestions, many of which are worse than useless; but it should not be forgotten that often two heads are better than one. On the other hand, courtesy demands that a guest should not be too forward in offering advice, but should be ever ready to render such assistance to the operator as he may need or request.

The interval allowed to elapse after death before an autopsy should be performed depends upon the circumstances governing each case, and may vary from a few minutes to several days or even months. In no case should the examination be deferred longer than is absolutely necessary, as the entire cadaver is soon invaded by bacteria, and nuclear figures and cellular elements quickly lose much of their value for microscopic study. The feeling of warmth, however, imparted to the hands of the operator while making a necropsy upon the cadaver of one who has just died, especially if there has been much elevation of temperature, as in a case of heat exhaustion or of atropine-poisoning, is so repugnant to one's sensibilities that sufficient time should always be allowed for the corpse to reach a temperature inconsistent with suspended animation. In New York State a postmortem must immediately follow an electrocution inflicted for capital punishment. It is popularly believed that in at least one case the man was not positively killed by the electric current. The case of Bishop, the so-called mind-reader, will also be recalled in this connection, where the post-mortem on a cataleptic was made immediately after death. In Germany at least twenty-four hours must elapse after death before the performance of the autopsy.

The time required for the completion of a postmortem depends, of course, upon the conditions under which it is performed, upon the nature of the case, and upon the skill of the operator. In favorable cases I have removed the brain in less than three minutes from the



time of making the preliminary incision, and have made an entire postmortem, including the removal of the cord, in a few seconds over eighteen minutes. On the other hand, eight hours of uninterrupted work have been consumed in the actual performance of one of my autopsies. In a hospital the usual time required for a post-mortem examination is about an hour and a half. It is stated that Rokitansky<sup>1</sup> performed over thirty thousand autopsies, which would hardly allow an average of an hour for each. I have known Kolisko to make five or six autopsies in a morning, and have myself performed ten in one day. Owing to lack of time, the surgeon or clinician often wishes the necropsy to be done with more celerity than is consistent with thoroughness, as he merely desires to ascertain a certain fact or to observe a single organ. He can generally be accommodated in a few minutes and the necropsy afterwards completed in the routine manner.

The place at which a post-mortem examination is to be made is rarely a matter of choice, especially in private practice, but it should always be where the best light is obtainable. Daylight from the north, such as is used by artists, should be preferred. If the autopsy must be made after dark, a combination of the electric and Welsbach lights is the most satisfactory artificial illuminant. Orth suggests that a good substitute for daylight may be obtained by filling a glass flask with water slightly colored with methylene blue. Such a flask may be used as a condenser so that the rays of light are concentrated upon the surface to be examined. One should, however, early become accustomed to the changes of color produced by artificial light, as shown in one of my autopsies made by gaslight on a subject of poisoning by battery fluid: I was much struck next morning on observing how different those tissues stained with bichromate of potassium appeared by daylight. In Manchester, England, where the days are so often dark, textile workers adopt a number of methods to get true color values; one of these consists in passing the light through a specially colored glass.

Time and labor will be saved by making the autopsy before the body is dressed for interment, and the undertaker should be directed not to inject the body until after its completion. The argument may

---

<sup>1</sup> Preface to New Sydenham Society's translation of ROKITANSKY's *Pathologischen Anatomie*. Quoted from BROCKHAUS's *Conversations Lexicon*, 1854.



be used to the undertaker that much blood is removed at the autopsy, and the appearance of the exposed parts is improved by the gravitation of the blood into the larger cavities of the body. Fortunately, the formalin injecting fluid now most generally employed for embalming purposes does not interfere with the microscopical study of tissues as did the old arsenic injection. Indeed, one of the special methods for the hardening of the brain is based on its previous injection with formalin through a cannula inserted in the orbit or nasal cavities.

The amount of preparation necessary for an autopsy will depend somewhat on whether the autopsy is to be made (I.) in a private house or at an undertaker's establishment, (II.) in a hospital or morgue.

I. In the former case a table on which to lay the body is rarely available, and a substitute must be provided. If the postmortem be not performed as the body lies in the coffin, the coffin-lid or, still better, the bottom of the inverted coffin, the wooden slab usually found in the coffin, or a door taken from its hinges and placed upon two kitchen chairs affords a good substitute for a table. For the body of a child the marble slab from the top of a bureau may be used.<sup>1</sup> In order that the necessary manipulations may conveniently be made, the body must not lie too low, and a piece of oil-cloth, mackintosh, or old carpet should be placed under the table or its substitute, to prevent soiling the floor. In addition to the articles brought by the operator (see page 36), two buckets half filled with lukewarm water, an empty basin, and several newspapers should be provided. Before work is begun, the relatives and friends should be tactfully requested to leave the room. The undertaker or his assistant should remain, as he can often render valuable aid in the performance of the autopsy.

Scrupulous cleanliness in the performance of an autopsy is of the greatest importance. The reasons for this are apparent. We owe a duty to our fellow-men not to leave behind malignant organisms in the place where a postmortem has been performed. You can see better and feel better if the organs and fingers are not besmeared.

---

<sup>1</sup> A portable post-mortem table has been invented by Dr. KLEY, of Rahden, Kreis Lübbecke, Germany (Orth). There are in the market many portable operating tables which may also be used for this purpose, as the one described by SHERMAN, *American Medicine*, October 26, 1901.






FIG. 1.—Post-mortem room of the Ayer Clinical Laboratory of the Pennsylvania Hospital.



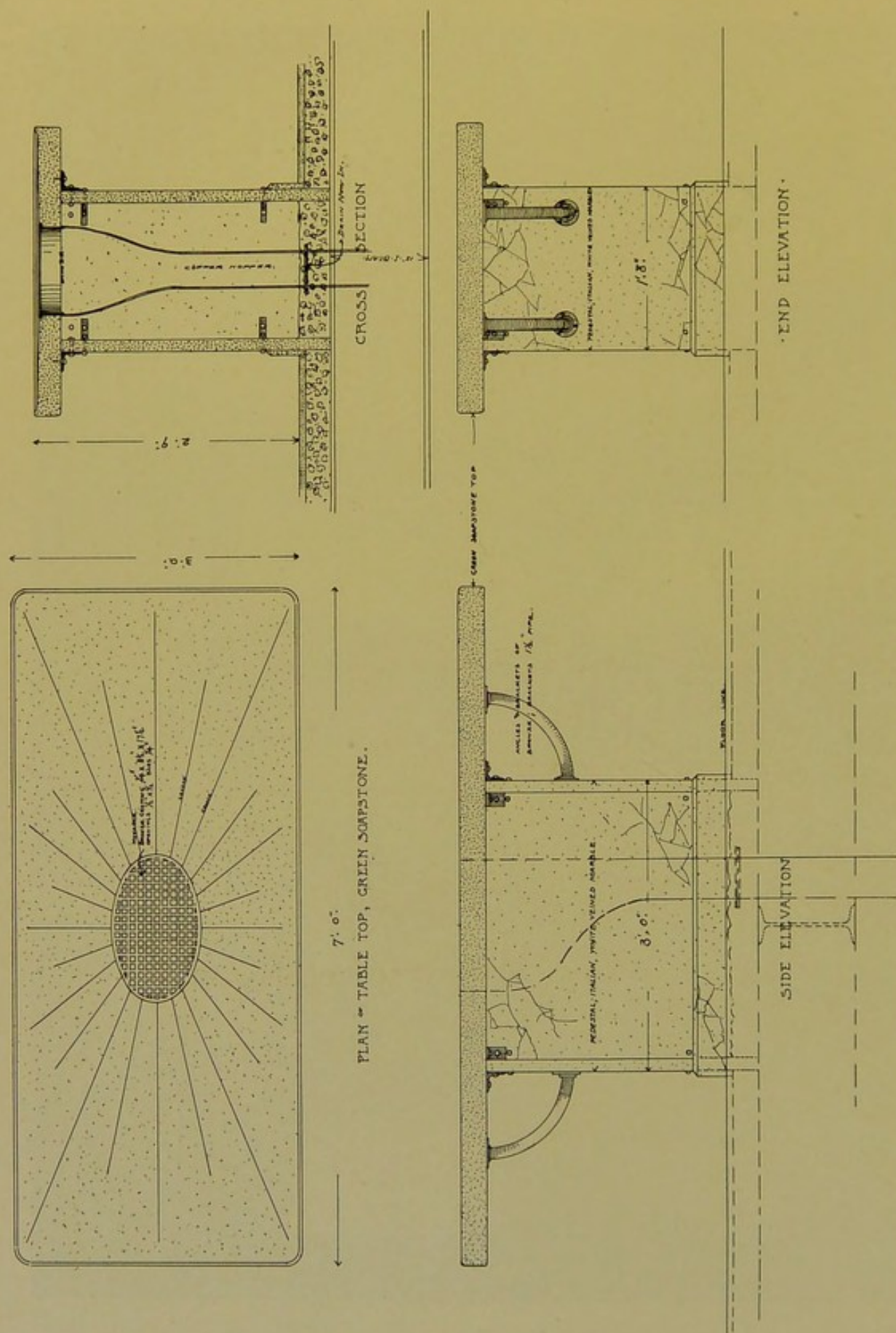


FIG. 2.—Plans prepared for the writer by Mr. Addison Hutton for a post-mortem table at the Ayer Clinical Laboratory. (See also Fig. 3.)



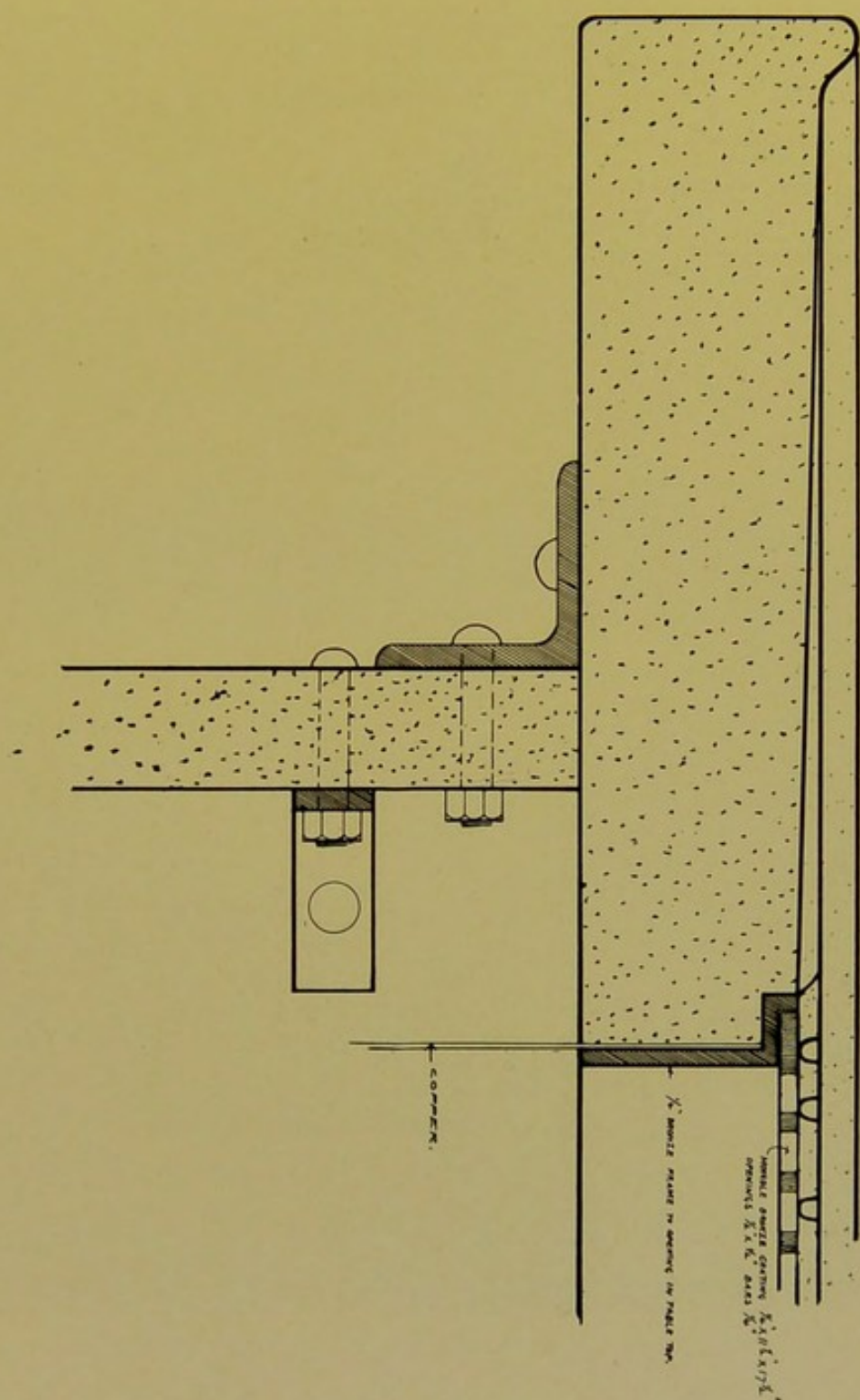


FIG. 3.—Plans for a post-mortem table. (See also Fig. 2.)




FIG. 4.—Refrigerator box for the preservation of nine bodies, with scales so arranged as to weigh a body while it is in the refrigerator, in the lower compartment next to the scales.



If the operator be careful not to soil his own person, the surrounding objects will escape contamination. For this reason he may accustom himself in private work to make postmortems without any protection to his own clothes. To keep clean there should be a bountiful supply of water, a basin for the hands, a board on which to arrange the instruments in a regular and constant position, and a frequent use of the sponge, except on mucous and serous surfaces, where an examination should be made previous to the application of water, and when the water is applied it should be allowed to flow upon the surface without bringing the sponge in contact with it.

In private work the laity are likely to estimate the skill of the pathologist by the neatness displayed in sewing up the body and the appearance of the room after the autopsy is completed. The greatest care should be exercised that no blood-stains are left behind. Incense or cascarilla bark may be burnt, or ground coffee may be strewn on red-hot coals, to remove the odor from the room where the autopsy was held, after which the apartment should be thoroughly aired.

II. In a hospital or morgue the facilities for making an autopsy are much more complete. A well-appointed mortuary room, like the one at the Ayer Clinical Laboratory of the Pennsylvania Hospital (Fig. 1), should contain an operating table, which should be strongly built, about seven feet long, two feet nine inches high, and three feet six inches wide. The top may be of either slate, zinc, or copper, and should slope gently towards a central perforated depression connected with a drain and a ventilating shaft worked with an electric fan. Sunken grooves radiating towards the centre should also be provided. (Figs. 2 and 3.) The side upon which the body rests should be divided into feet and fractional parts of an inch or into centimetres. The markings may be made directly on the top of the table, or, if slate be used, a metal rule may be sunk into the slate, taking care that no edges be exposed. For class instruction, a revolving table is required, and by an ingenious arrangement of a fulcrum and lever attachment the body can be weighed on the table. Several additional tables upon which to place instruments, scales, plates, and other requisites should be provided.

The refrigerator box should be provided with scales so arranged that the body can be weighed within it. At my suggestion the Fairbanks Scale Company prepared one of their scales to combine with a Ridgeway refrigerator for the Ayer Clinical Laboratory (Fig. 4).



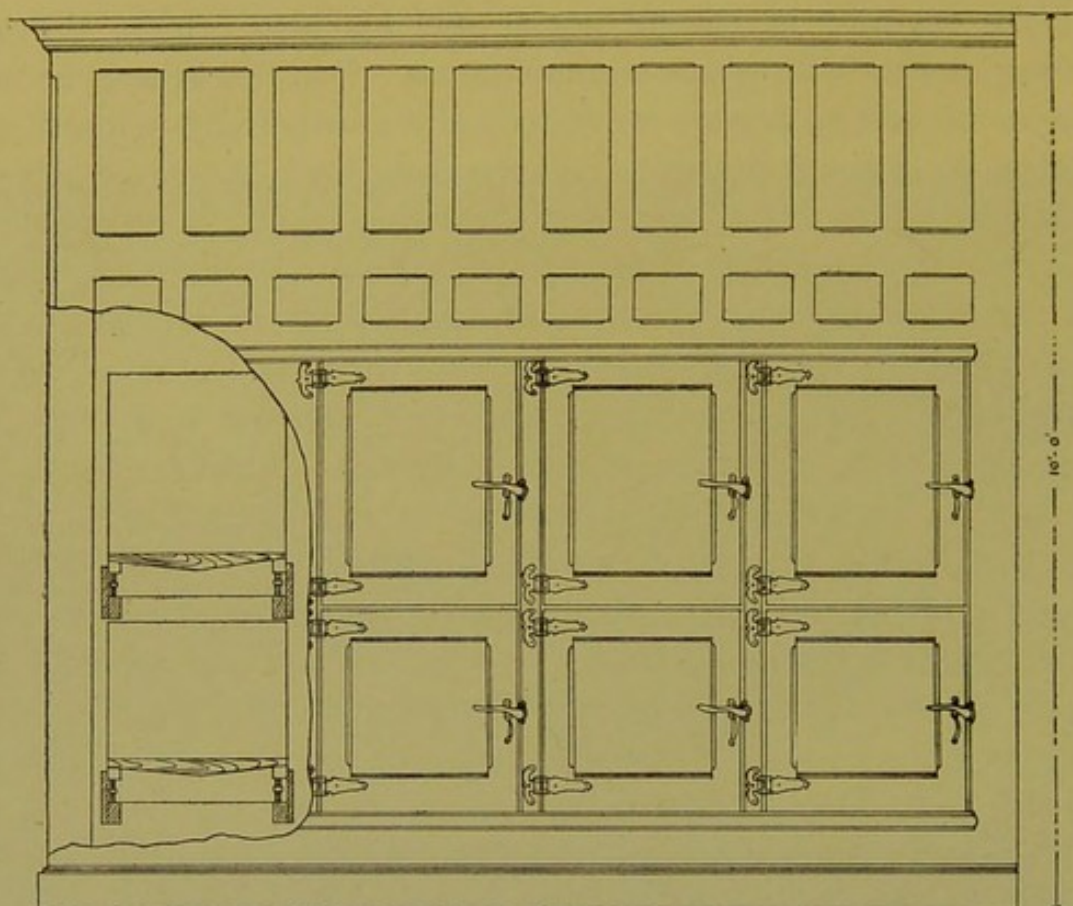


FIG. 5.—Working plans for preparing refrigerator with eight compartments for the storage of bodies preparatory to their removal for burial. Front view.




FIG. 6.—a, guide; b, track.

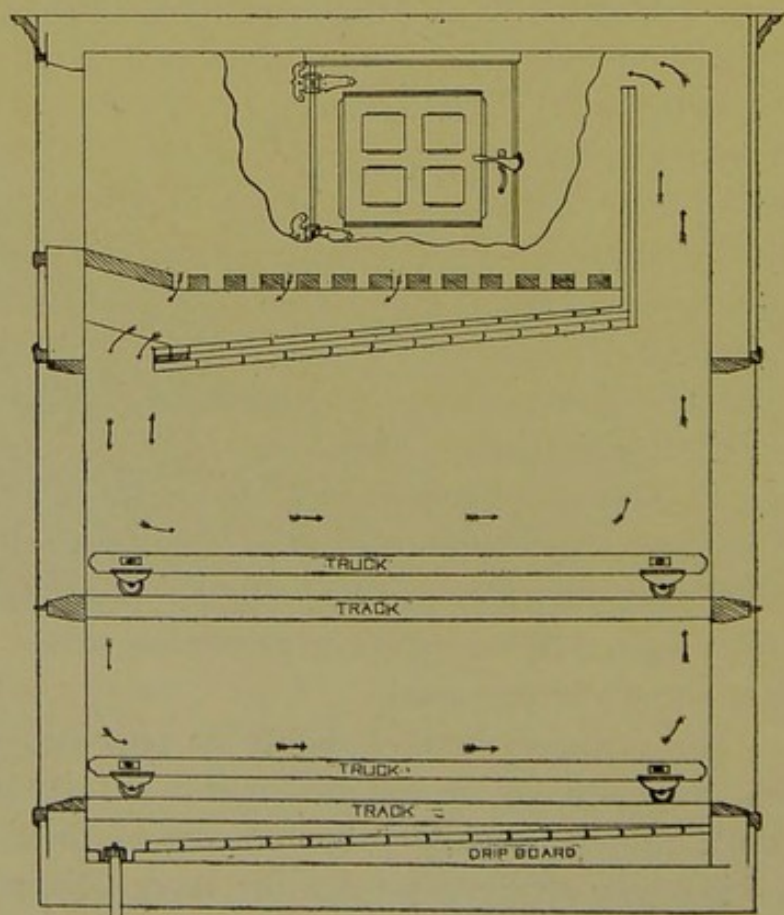


FIG. 7.—Lateral view.



The scales are at one side, against but outside of the refrigerator box, so that the body can be weighed while it is in the ice-chest, and

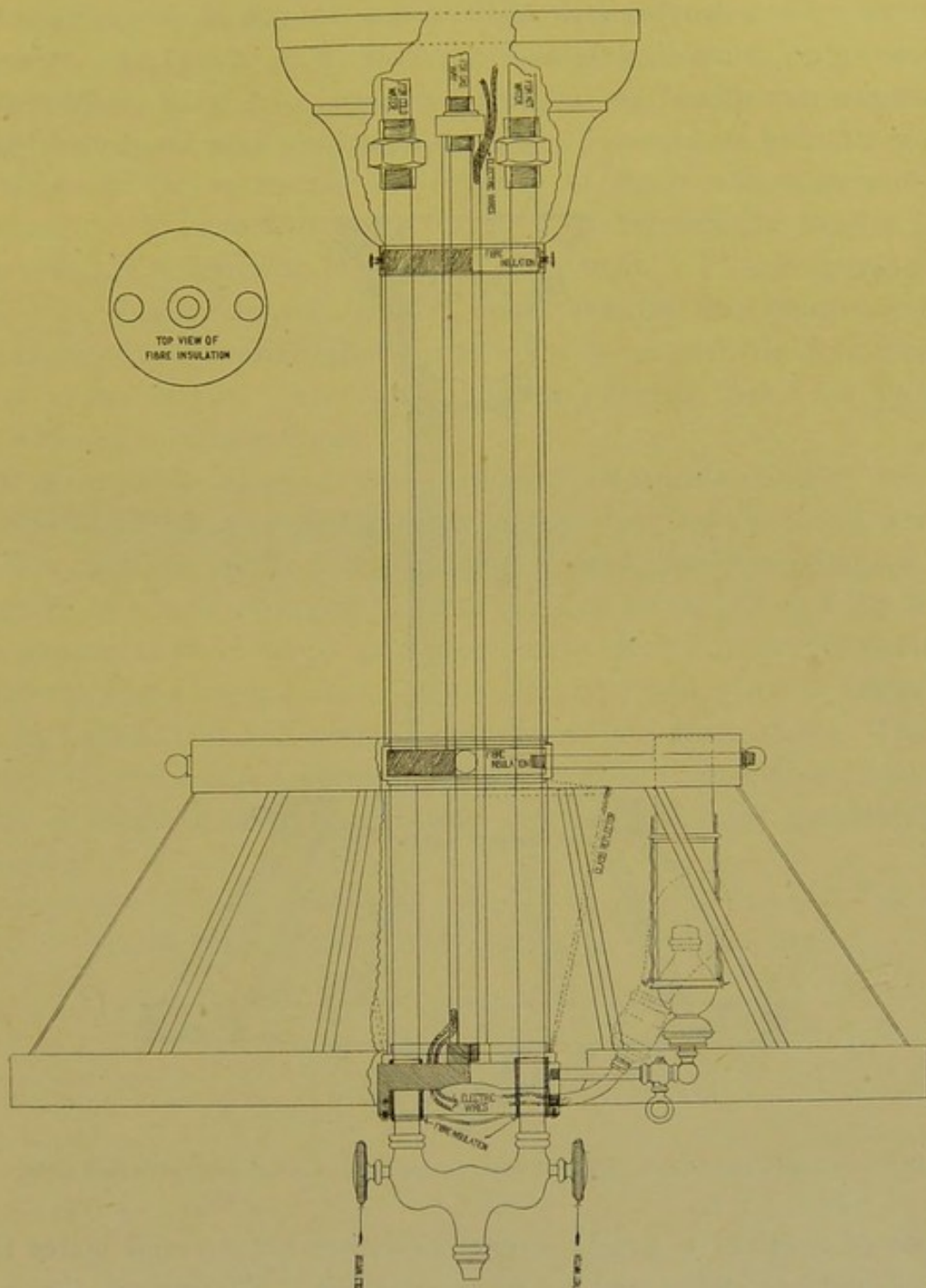


FIG. 8.—Working plan, prepared by Dr. Drysdale at the request of the writer, for combination electric, gas, and water fixture above post-mortem table at the Ayer Clinical Laboratory; constructed by Horn & Brannen, of Philadelphia.

with its doors closed. Each box should have two doors, one opening into the post-mortem room, and another on the opposite side, through

which the body may be viewed by friends and removed by the undertaker. (For working plan see Figs. 5, 6, and 7.)

Illumination for both day and night work should be provided, preferably by a northern skylight and a combination gas-light and electric-light fixture directly over the table (Figs. 8 and 9). Plenty of running water should be supplied by means of a spigot with rubber tubing attached and brought from above within easy reach, so that by

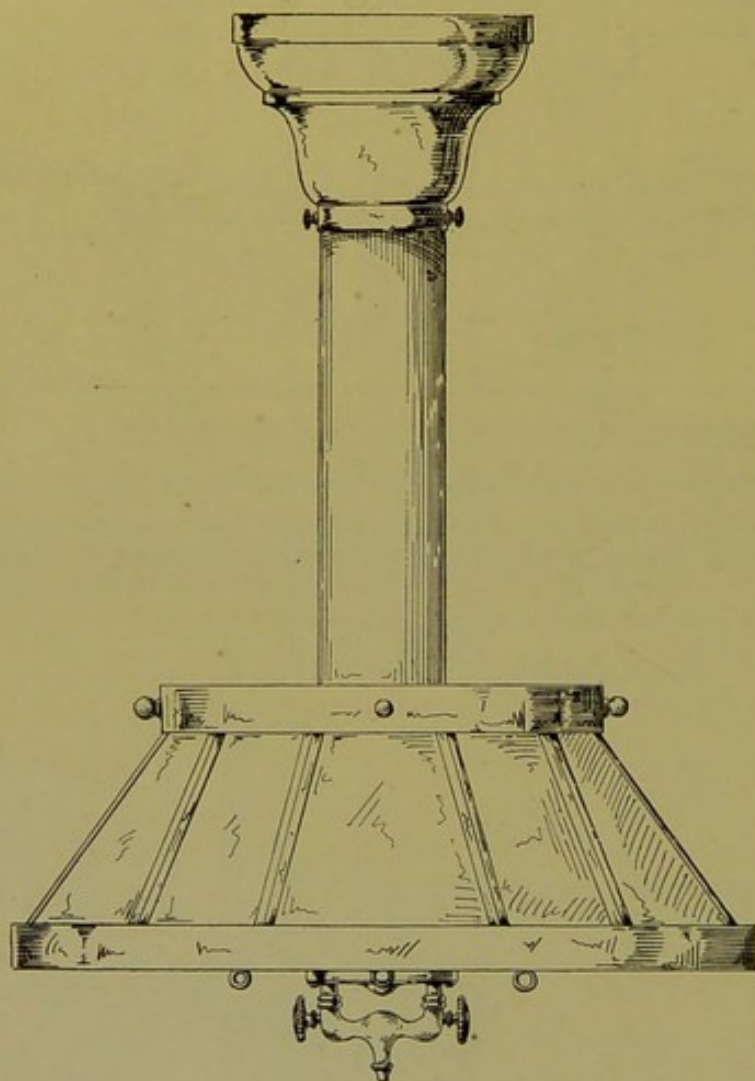


FIG. 9.—Combination electric, gas, and water fixture to be placed above post-mortem table.

the use of a mixer a steady stream of either hot or cold water may be had without delay and wherever desired. To support the head there should be a solid block or a rest such as is used by undertakers. This block should be thirty centimetres long, twenty centimetres high, and six centimetres broad. (For children smaller sizes are to be employed.) It is hollowed out on top for the nape of the neck to rest upon. Some of the various shapes in common use are



shown later on in Figs. 46, 47, and 109. A board upon which organs may be placed after their removal, for convenience in making sections, etc., should also be at hand, as the slate slab becomes slippery from the fluid exuded and the organs are held with difficulty when incisions are made into them. It is the custom abroad to set a stool over the upper ends of the thighs, and upon this the instruments are arranged within easy reach of the operator.

To avoid the spattering or dripping of fluids when opening the cranium, it will be well to place on the floor beneath the head a piece of previously moistened horse-blanket or mop. If the operator be subject to rheumatism, he should, while making the autopsy, stand on a piece of dry board rather than on the cement or tile floor usually found in mortuaries. The latticed wood flooring found on ships is well adapted to this purpose.

A work-table supplied with ordinary chemicals, a desk for the post-mortem book, a revolving chair, a slop-sink, a wash-stand, several cabinets, and an outfit for preparing frozen sections complete the furniture of a well-equipped mortuary. The preparation of the latter adds greatly to the interest as well as value of an autopsy by enabling the operator to compare the microscopic and macroscopic appearances of a part while it is still under examination in a fresh state. The use of ethyl chlorid as the freezing agent, where the more elaborate carbon dioxid or ether freezing apparatus is not at hand, may sometimes be advisable.<sup>1</sup>

---

<sup>1</sup> CATTELL, *International Medical Magazine*, December, 1896.



## CHAPTER II

### POST-MORTEM RECORDS AND NOTE-TAKING

THE three following rules are to be rigidly observed in making post-mortem examinations.

I. Never disturb any part or organ until its position relative to adjacent tissues and organs has been accurately determined.

II. Never unnecessarily remove a part or organ if the proper inspection of remaining parts or organs will thereby be rendered difficult or impossible.

III. When it is necessary to cut open an organ in order to examine its cavities, walls, or component parts, make the requisite incisions in such a way as to permit, as far as possible, the reconstruction of the organ in its original shape and condition.

In the fulfilment of these conditions it is, therefore, best to begin by making a preliminary topographical (superficial) examination of the cavity and the contents about to be examined. In the case of the trunk, the abdominal cavity is inspected first, the thoracic cavity next, and the pericardial last, whereas the removal of the organs contained in these cavities and their description should be made in the reverse order. The abdomen should be examined before the thorax is opened in order that the position of the diaphragm and the relative situations of the various abdominal organs can be determined before the entrance of air into the thoracic cavity has altered the normal relationship and the escape of blood and other liquids has obscured the appearances of the parts under consideration. If the postmortem is rewritten, any descriptions given in the superficial examination may be combined with the detailed description of the parts removed from the abdominal cavity, thus permitting of the omission of any possible repetitions. The following characteristics of each organ are to be noted.

1. Situation and relations to other parts.
2. Size and weight.
3. Shape, contour, borders, and coverings (capsule, serosa, etc.).
4. Color.
5. Consistency.
6. Anomalies and malformations.



7. Cut surfaces and liquid exuded.
8. Odor.
9. Pathological conditions.

1. *Situation and Relations to other Parts.*—This takes into account any change in the normal position or attachments of the organ. There are a number of regional landmarks frequently used; thus, in the case of the diaphragm we speak of its height in relation to the ribs or the intercostal spaces; of the stomach as extending so many inches below the umbilicus; and of the heart in its relation to the left nipple and the xiphoid cartilage.

2. *Size and Weight.*—Various means are employed for determining size besides actual measurement. Virchow had, in the old Charité dead-house before its recent destruction by fire, a cabinet containing specimens of various familiar objects, such as beans, peas, lentils, etc., with which pathological lesions could be compared. Later on, recognizing the relation of specific gravity to size and weight, he estimated the size by noting the quantity of water displaced by the organ in a flask of known capacity. A number of familiar objects at once suggest themselves, which may be used for comparison in describing the size of a lesion or part. In the writer's experience, persons have, as a rule, but a vague idea as to the actual size of familiar objects, such as the head of a horse (usually underestimated) or the height from the ground of a stationary washstand (usually overestimated).

For tables of weights and measures of the body, see Chapter XXV. Whenever possible, it is advisable to give the dimensions in centimetres and the weight in grammes. It should be remembered that a large organ is not necessarily a heavy one. Atrophy and hypertrophy may be present in the same part, as seen in those cases of hypertrophic cirrhosis of the liver in which acute yellow atrophy has supervened.

3. *Shape, Contour, Borders, and Coverings (Capsule, Serosa, etc.).*—Here are noted any deviations from the normal. It is often advisable to use the name of some familiar object in order to convey the idea as to the configuration,—e.g., cauliflower growth, hobnail liver, etc. Descriptions of the surface include the external appearance of solid organs. The surfaces may be smooth, granular, nodular, shrivelled, puckered, etc. Here we also describe the capsules of the kidney, spleen, etc., and the serous coverings of the lungs, heart, uterus, bladder, etc. The borders of organs that have undergone infiltration are



usually rounded and filled out; in the degenerations they are generally flatter, thinner, and sharper than normal. Thus, in fatty infiltration the edges of the liver are rounded, while in cirrhosis its margins, often so largely composed of connective tissue as to contain practically no liver-cells, are sharply defined. The general contour of the blood-vessel may be markedly changed, as in aneurisms.

4. *Color*.—It is most difficult to describe colors or to reproduce them satisfactorily. Various shades of red are the most common colors found in the body; there is no such thing as pure white, even the conjunctivæ being a pearl-grayish pink. In pathology the word "pale" means a minor degree of color. Note the color of the organ as soon as possible after exposure, as air, light, and water tend to alter it considerably, though naturally more or less change brought about by death has already occurred. Thus, the transparent living pericardium at autopsy is only translucent. An organ should not be washed before its color is described, as water washes away part of the coloring matter present, acts on the proteids, and modifies the original consistence of the organ; these changes may readily be demonstrated by placing the thymus gland with the surrounding areolar tissue in running water for five minutes. Air oxidizes the blood, so that a bluish stain may in a short time change to bright red. In the case of a congested lung it is often well to note its appearance both before and after the blood has become oxidized. Certain abdominal organs are frequently discolored by sulphid of iron produced through the precipitation of the iron from the hæmoglobin by the hydrogen sulphid arising from decomposition. In a case of ammonium hydrate poisoning observed by the author, although the body was well preserved, the characteristic discoloration had penetrated the substance of the liver to a considerable extent (three-quarters of an inch).

5. *Consistency*.—This is learned only by experience, and is determined by pinching the organ between the thumb and the index-finger. It should be remembered that the consistency is affected by the season of the year in which the body is examined, by the temperature of the body and of the place where the postmortem is held, by the length of the interval between death and the making of the autopsy, by the manner of death, and by the method adopted for the preservation of the body.

6. *Anomalies and Malformations (Congenital and Acquired)*.—Each part or organ has its own peculiar anomalies and malformations,



and an entire chapter might readily be written upon the various altered conditions revealed by autopsies. Thus, the writer has seen perforation of a typhoid ulcer in a Meckel's diverticulum; free calcified bodies in the abdominal cavity; peculiar curvatures of the iliac arteries; the left kidney shaped like the spleen; the tip of the vermiform appendix resting near the pyloric end of the stomach; an artificial anus made by the rupture of a typhoid ulcer; the vermiform appendix in a *left* femoral hernia and the sigmoid in a *right* inguinal hernia; a fish-bone in the omentum; etc.

7. *Cut Surfaces and Liquid exuded.*—When an organ is incised, describe first that which is most striking, as, for example, the presence of a hydatid cyst that is exposed on section of the spleen. Note the color of the exposed surface; whether it is smooth or granular; the amount, character, and chemical reaction of the fluid that is spontaneously exuded or is obtained by scraping with a knife; and the condition of the blood-vessels, especially as to atheroma and thrombosis. Numerous incisions may lead to the discovery of new lesions or afford an opportunity of studying the morbid process in its various stages.

Under the term "liquid exuded" is included not only blood, transudates, and exudates that follow on incising the part, but also any fluid that may be contained in the cavity of a hollow organ or in a cyst present, and the juice that appears on scraping or squeezing.

Œdema of an organ may be detected by squeezing it. In the lungs a frothy œdema shows the absence of a pneumonic infiltration. Surfaces should be scraped and the material thus obtained examined with the microscope.

In describing cavities pay especial attention to the lining membranes, noting their color, lustre, smoothness or roughness, and the presence of any adhesions; also the quantity, color, consistence, odor, and reaction of their contents and any sediments found therein.

8. *Odor.*—It is safe to predict that twenty years hence more attention than at present will be given to the significance of odor. The organ of smell is poorly developed, and varies greatly in different individuals and in the same individual at different times. The peculiar odor that accompanies the growth of certain bacteria, such as the *Bacillus coli communis*, is well known. Smallpox and measles have their peculiar stench. We may also mention the acetone odor of diabetes, the pus-like odor in leucocythæmia, the butyric-acid-like or alcoholic odor from the brains of those who have drunk heavily before



death, the uræmic odor, the odor in cases of carbolic or hydrocyanic acid poisoning, etc. Great care must be exercised to draw a correct inference from the odor. Too often a case of apoplexy is taken to a police-station and the diagnosis is there recorded as one of alcoholism, simply because the odor of alcohol is found on the person arrested.

9. *Pathological Conditions.*—From the sum of the characteristics previously given we arrive at our diagnosis, which in many if not all cases will have to be confirmed by microscopical examination.

Finally, while it may be easy to distinguish from which side an organ has been taken when there are no marked changes in shape, the author has found that much time is saved and confusion avoided by marking each of the double organs as it is removed from the body,—one nick for the left and two nicks for the right-sided organs.

In order that nothing of importance shall be missed in the examination the pathologist must have a definite plan of survey that he follows at each autopsy. The following order of examination has given me most excellent results:

1. Examination of the exterior of the body.
2. Topographical examination of the abdominal cavity.<sup>1</sup>
3. Topographical examination of thoracic cavities.<sup>1</sup>
4. Pericardium.
5. Arch of the aorta.
6. Heart.<sup>2</sup>
7. Lungs. (a) Left. (b) Right.<sup>3</sup>
8. Larynx and trachea; external examination of the œsophagus.
9. Mesentery and peritoneum.
10. Spleen.
11. Intestines, except the duodenum.
12. (a) Left adrenal body and semilunar ganglion. (b) Left kidney. (c) Right adrenal body and semilunar ganglion. (d) Right kidney.
13. Ureters and bladder.
14. (a) In the male: Prostate gland, spermatic cord, urethra, testicles, etc. (b) In the female: Uterus, tubes, ovaries, broad ligaments, etc.
15. Duodenum and its ducts.
16. Stomach and œsophagus.
17. Liver.
18. Pancreas.

---

<sup>1</sup> At this stage of the examination the organs are not to be incised nor are their relations to be markedly disturbed.

<sup>2</sup> While the heart is being examined time may be saved by having an assistant undertake the opening of the skull, as, theoretically, the heart should be exposed before the head is opened and the brain inspected before the heart is incised.

<sup>3</sup> The pleural cavities, already superficially examined, are to be most carefully inspected after the removal of each lung.



19. Retroperitoneal glands, the diaphragm, psoas muscle, thoracic duct, thoracic and abdominal aortæ, venæ cavæ, abdominal sympathetics, abdominal portion of the spermatic duct, etc.
20. Head. (a) Scalp and skull. (b) Meninges. (c) Encephalon. (d) Eye. (e) Ear. (f) Nasopharyngeal cavities.
21. Spinal cord.
22. Bones, peripheral nerves, arterial trunks of the extremities, muscles, etc.
23. Portions preserved, and the character of fluid employed.
24. Microscopical, chemical, and bacteriological examinations.

Post-mortem records may be kept in a book specially prepared for that purpose, or on sheets to be filed away with the clinical history of the case under consideration. In my own practice I have endeavored to give each autopsy performed by myself a specific number, and lately have preserved my records on sheets kept in a flat-opening note cover-book, until they are ready to be filed away and indexed in properly made manila covers. The interchangeable sheets in the note-book measure seven by eight and one-half inches. By means of an ingenious clasp opening in the centre, one end being fixed and the other movable, the leaves are held in place by passing the clasp through two small circular openings on the left-hand side of the page. When the clasps are closed, the leaves can be turned like a book; when open, one or more sheets may readily be removed or others inserted. This method I find superior to the one of keeping the records in special books or on the large index cards which are used by many physicians in preserving their private case records.<sup>1</sup>

In post-mortem books prepared for hospital records it is advantageous to have some memoranda printed at the top of each page if the book be a large one or at the top of the left-hand page alone if the book be less than ten by fifteen inches, so as to afford ample room for notes. In my service at the Pennsylvania Hospital I used the following:

---

<sup>1</sup> *International Clinics*, Vol. iv., Eleventh Series, 1902.

# PENNSYLVANIA HOSPITAL.

## POST-MORTEM RECORDS OF THE AYER CLINICAL LABORATORY.

Autopsy number,	Date,				
Hospital number,					
Name,	Ward,	Bed,	Sex,	Age,	Color,
Occupation,	Nationality,		Weight,	Height,	feet, inches.
Died,	Commenced autopsy		hours after death, and finished same at		
Weather,	Clinical diagnosis of				
Permission given by	Performed by				

REMARKS.

PATHOLOGICAL DIAGNOSES.



The routine order of examination employed in the making of the autopsy may then follow, or a card showing this order may be displayed in such a manner as readily to be seen by the one making the autopsy and the person to whom the notes are being dictated.

Figures corresponding to the numbers of the divisions in the list can be placed just before the notes describing the lesions to be found in the parts under examination. It is important, especially in medico-legal cases, to write "examined" or "normal"<sup>1</sup> after the number referring to the part under study, even if no lesion exists, as this shows that an actual examination of this portion of the body has been made.

As a general rule, the order above suggested will be found convenient and practical. It must, of necessity, be subject to more or less variation, depending on the circumstances of the case. Thus, in coroner's work it is often advantageous to examine the seat of the suspected fatal lesion at once, and afterwards resume the order given above as nearly as possible. Again, in autopsies on the remains of those who have died from nervous diseases it is often best to remove the brain and cord before opening the body.

Many writers advise the use of more or less elaborate printed descriptions of the various anatomical regions and organs, with blank spaces to be filled in at the time of making the autopsy. This method of keeping notes has not in my hands yielded as satisfactory results as the one described at the beginning of this chapter. I give, however, the following example of a post-mortem record, which was prepared in 1890 by Dr. Formad and myself and was in use for a number of years at the Philadelphia Hospital. The opposite (right-hand) page contained no printed matter, and could be used for more extensive descriptions or for the dictated record of the entire autopsy.

There are on the market, especially in England, a number of printed books and forms for this purpose.

---

<sup>1</sup> Objection to the use of the word "normal" may properly be raised, for what one person may consider normal another would class as abnormal, while its use by an inexperienced person might lead to the omission of certain data which might be of use in the future. It is, therefore, well to describe the part in detail. This will not only impress upon the obducent the normal appearances, but also lead him to make a more critical examination than he otherwise would be likely to do. The comparison of one organ with its fellow or of one part of the organ with another is often of value in this connection.



BLOCKLEY ALMSHOUSE,  
PHILADELPHIA HOSPITAL—POST-MORTEM RECORD.

No. of Autopsy, Name, Ward, Admitted History of { Alcoholism, Syphilis, Consumption, Injury,	No. Bed, 189	Age, Bed, 189	Nationality, 189	Sex, Autopsy, Clinical Diagnosis, Mode of Death, { Sudden, Slow,	Occupation, Autopsy, Clinical Diagnosis, Mode of Death, { Sudden, Slow,	Color, Autopsy, Clinical Diagnosis, Mode of Death, { Sudden, Slow,	Date of Autopsy, Address, { Married, { Single, hours after death. Attending Physician, Resident Physician, Performed by	Weather, { Cold, Mild, Hot,
Cause of Death,								
I. EXTERNAL APPEARANCES.—Condition of Nutrition, Appearance of Skin, Deformities, Rigor Mortis, HEAD.—Scalp, Skull—size, Fluid in Cranium, amount, Dura Mater.— Sinuses, quantity of blood, Pia Mater.— Surface of Hemispheres, Brain.—Weight, Ventricles,—Size, Softening, Base of Skull after removing Dura, SPINE.—Deformities of Spinal Column, THORAX and Neck.— Tongue, Larynx, Lungs.— Left Lung, Right Lung, Lesion,								
Weight of Body, lbs., Height, { Wounds, Bruises, Other Peculiarities, P. M. Lividity, Eyes, Hair, { Color, Quantity, Soft and thin, Hard and thick, Adherent to Calvarium,								
Fluid, Vessels at Base, Condition of Convolutions, { Flattened, Asymmetrical, Puncta Vasculosa, 4th Ventricle, Other Lesions, Areas of Degeneration, Membranes, Thyroid, Tonsils, Pharynx, { Mediastinal Glands, Bronchial Pleural Cavities.— Left, Adhesions, Effusion, Right, Adhesions, Effusion, Blood,								
Thymus.								







## CHAPTER III

### POST-MORTEM INSTRUMENTS AND HOW TO USE THEM

VARIOUS combinations of post-mortem instruments are found in the sets catalogued by dealers, but these, except for the systematic work possible only in hospitals and morgues, are more luxurious than necessary. In fact, the instruments that are really indispensable are very few in number, as a complete autopsy may be performed with a penknife and an ordinary wood-saw. Of course, in this field, as in surgery, ample opportunity has been offered for the exercise of mechanical ingenuity, and many instruments have been devised for facilitating post-mortem work that save much time and render greater neatness and exactitude possible.

The following list contains the instruments, apparatus, and chemicals most commonly used in the performance of an autopsy.

**KNIVES.**—*Section- or Cartilage-Knives.*—These should be made very strong, with a broad back, blunt rounded ends, and a bulge or belly at the outer third (Fig. 10), and should be narrower at the



FIG. 10.—Section- or cartilage-knife, with rounded end. (One-half natural size.)

attachment of the blade to the handle. For general purposes the length of the entire knife should be from seven to seven and a half inches (about eighteen centimetres), the handle measuring about four inches. The Germans use knives even as long as eleven inches (twenty-eight centimetres). A separate rounded expansion for the index-finger found on the back of some section-knives is unnecessary (Fig. 11). The sharp-pointed knife should emphatically be condemned (Fig. 12). When the knives are sent to be sharpened, the instrument-maker should be cautioned not to grind them to a point. *Scalpels*, such as are used in dissecting. Those made of a single piece—*i.e.*, without wooden, bone, or ivory handles—are to be preferred. The *brain-knife* (Fig. 86) should have a thin blade about ten inches (twenty-five centimetres) long, one and a half inches (four centi-



metres) broad, and blunt at the end like a table-knife. This instrument may also be used for incising the large organs and in opening

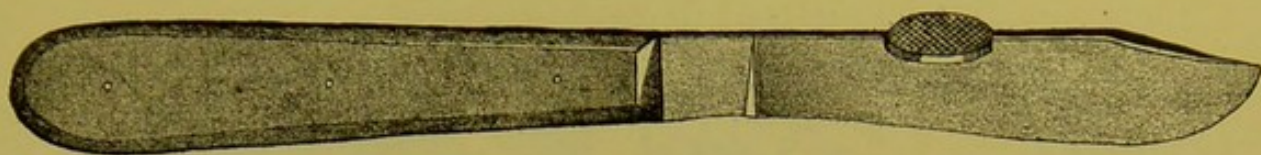


FIG. 11.—Cartilage-knife with projection on back upon which the index-finger rests when making incisions. (Two-thirds natural size.)

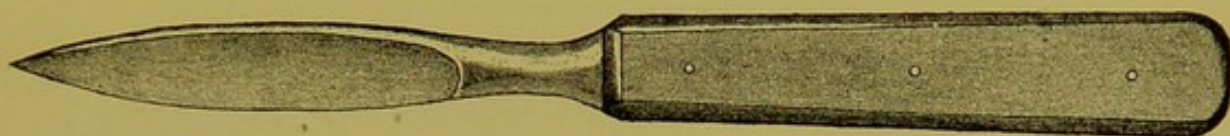

FIG. 12.—Post-mortem knife with faulty point and without proper belly. (Two-thirds natural size.)

the cavities of the heart. The brain-knife may be marked in the form of a rule and thus serve a double purpose (Fig. 13). An *amputation-*




FIG. 13.—Coplin's brain-knife marked in centimetres on one side and in inches on the other. (Reduced.)

*knife* may be employed in place of a brain-knife, or in removing the brain through a trephine opening made in the skull. A *Waring bread-knife* (Fig. 14), which also does good work, may be used for incis-




FIG. 14.—Bread-knife, useful in incising large organs, as the brain, the liver, etc. It comes in two forms,—with both sides meeting at the cutting edge like an ordinary knife, or with one side perpendicular and the other slanting for about three-eighths of an inch above the sharp edge, as shown near the handle in the illustration. (One-third natural size.)

ing the larger organs. A *Valentine knife* (Fig. 15), which has two parallel blades adjustable by screws to keep them the desired distance apart in order to cut at will thick or thin sections, is now rarely seen, but was much employed before the freezing microtome came into common use. Pick's *myelotome* (Fig. 16) is an instrument with a short blade bent nearly at right angles to the shaft, for cutting the spinal



cord squarely across instead of in an oblique direction. A *curved probe-pointed bistoury* is used in cutting the dura mater, spinal cord,

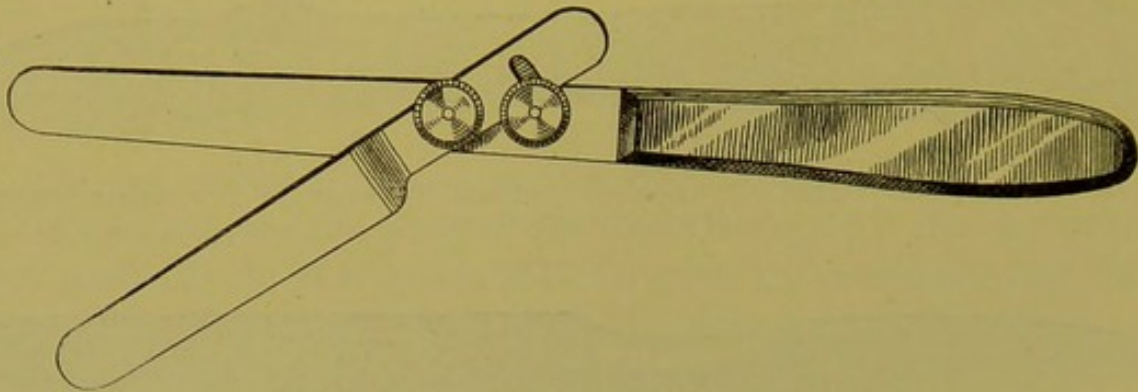


FIG. 15.—Valentine's knife. (One-half natural size.)



FIG. 16.—Pick's myelotome. This little instrument is useful for severing the spinal cord in the removal of the brain. (One-half natural size.)

etc. A razor was formerly included in all lists of post-mortem instruments, but is now discarded.

**SAWS.**—The *saw* should possess a strong blade solidly attached to the handle (Fig. 17), as the two-piece jointed ones, kept in place by a screw, are very liable to become loosened. A butcher's meat-saw,




FIG. 17.—A very desirable saw for post-mortem work; it is solidly constructed, and the teeth on the curved end are useful in sawing out the angles in the removal of the skullcap by the angular method described on page 166. (Slightly less than one-half natural size.)

which is arranged like a scroll-saw (Fig. 18) with its teeth pointed towards the front, its cutting surface measuring from ten to fourteen inches (twenty-five to thirty centimetres) for an adult and six inches (fifteen centimetres) for a babe, or a large cross-cut carpenter's saw, does the quickest work in removing the calvaria. *Hey's saw* (Fig. 19) is useful in sawing the angles when opening the skull. A *metacarpal saw* (Fig. 20) is often of service, especially in examining the femur



of a babe for syphilitic osteochondritis. *Luer's double rhachiotome* (Fig. 21), used for opening the spinal column, consists of two parallel




FIG. 18.—Butcher's saw, very useful for quick work in opening the calvarium. (One-quarter natural size.)

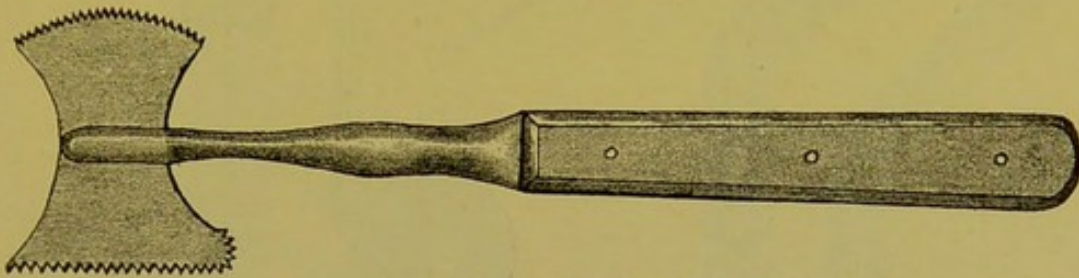


FIG. 19.—Hey's saw. (Two-thirds natural size.)



FIG. 20.—Metacarpal saw. (Slightly less than two-thirds natural size.)

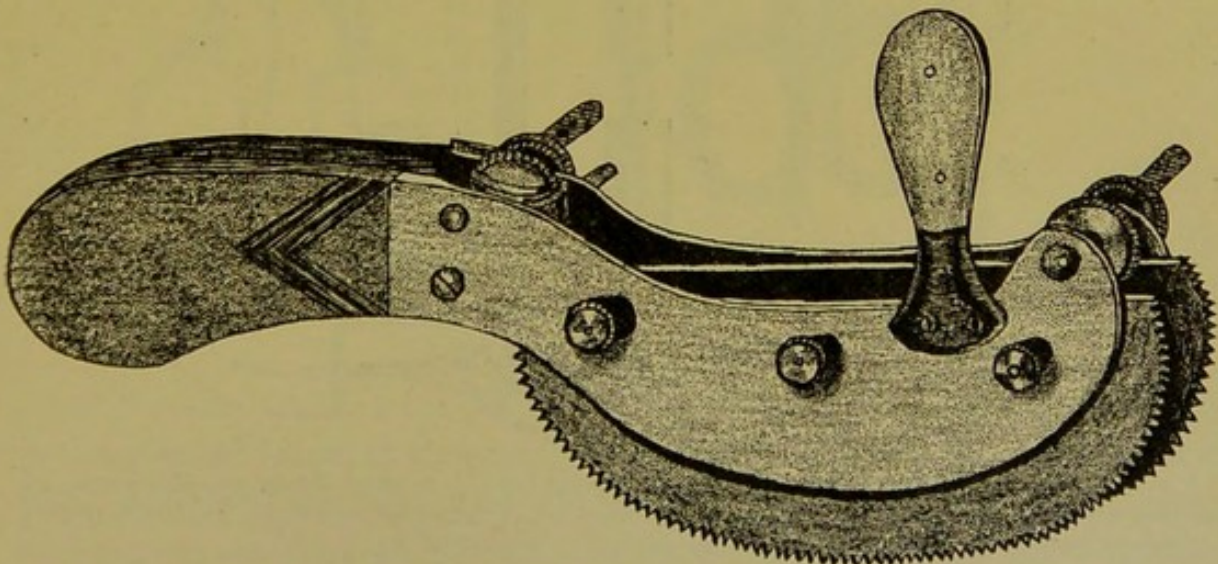


FIG. 21.—Luer's double rhachiotome. This instrument is held in the right hand and steadied by means of the handle attached to the fixed blade, the other blade being movable by clamps, so that the distance between the parallel blades may be varied at the will of the operator.

saws with curved blades, the distance between which can be regulated by screws, and a very firm handle with a strong central support.

Various forms of *dental and trephining engines*, usually driven by electricity, have recently been introduced and are useful in saving time

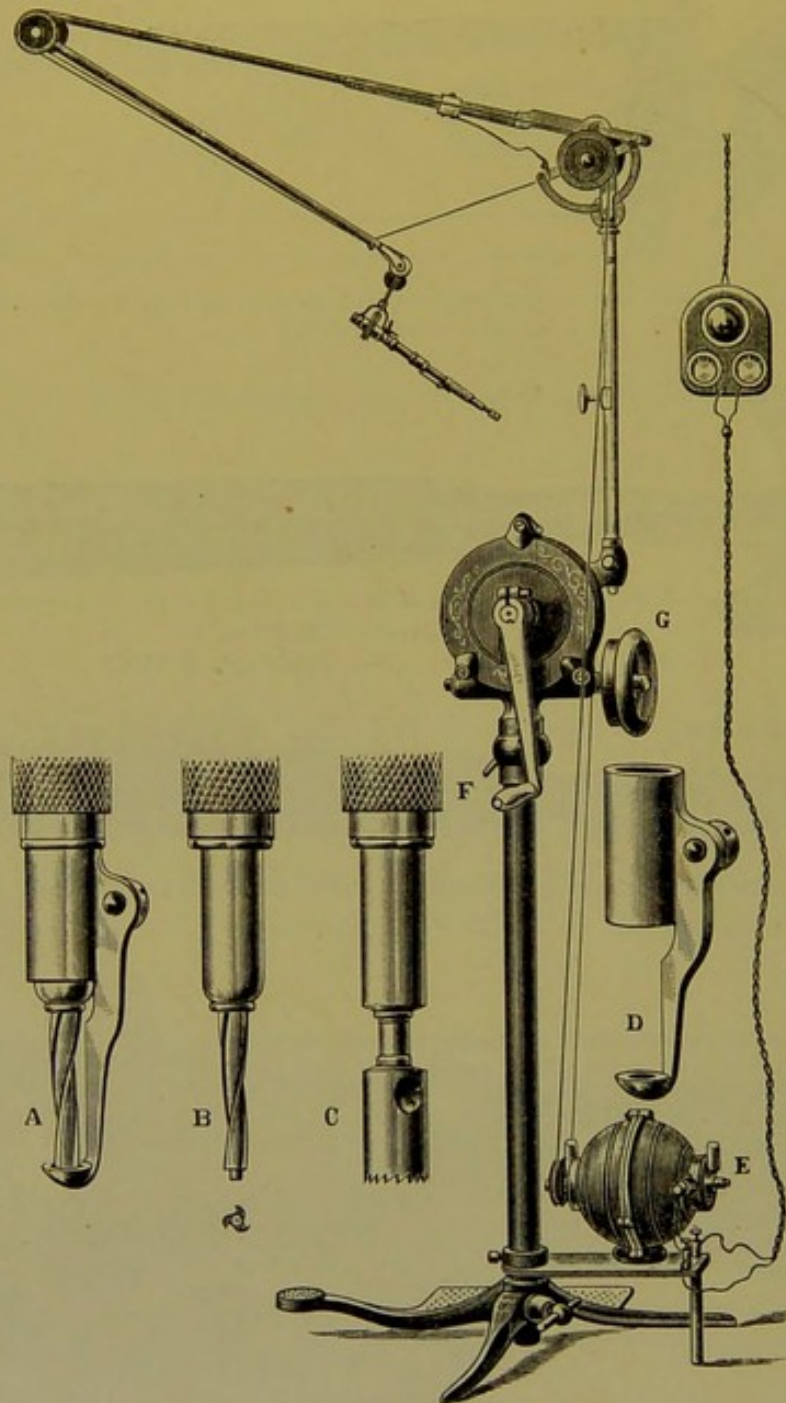


FIG. 22.—Cryer's electrical surgical engine for cutting bone. *A*, spiral osteotome, with guard, for removing section of skull; *B*, spiral osteotome; *C*, trephine; *D*, guard for osteotome; *E*, electric motor; *F*, crank for hand propulsion; *G*, driving wheel for hand propulsion.

and labor. Among such engines may be mentioned those of Cryer<sup>1</sup> (Fig. 22), de Vilbiss, Wright, etc. These instruments are high-priced

<sup>1</sup> *Medical News*, January 30, 1897.



(from one hundred to three hundred dollars), on account of the infrequent demand for them. Hand-driven instruments may be purchased for twenty-five dollars and upward.

SCISSORS.—One pair of scissors should be large and strong, with long handles and short, stout blades (Fig. 23); the other pair should

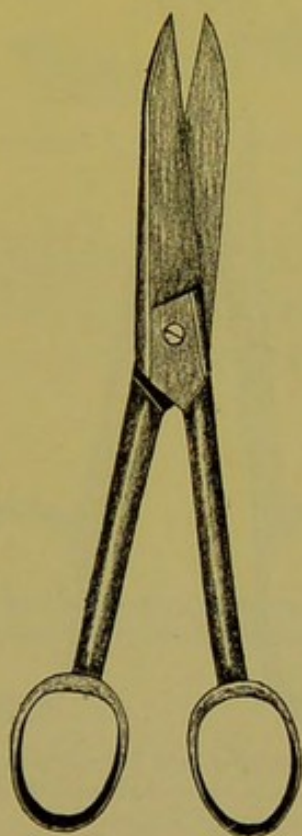


FIG. 23.—Strong scissors with short blades. (One-half natural size.)

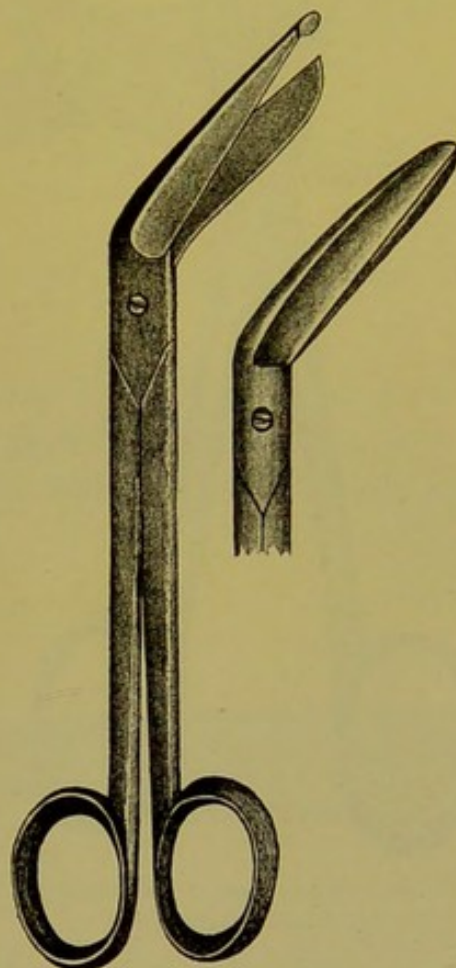


FIG. 24.—Scissors with one rounded blade and with bent handles. (One-half natural size.)

have rounded ends with bent handles (Fig. 24). A pair with one probe-pointed blade is frequently useful. The *enterotome* is a scissors with one short and one long blade (Fig. 25), the latter being blunt and curved on itself at the end. Be sure that there is no sharp-pointed end, as this is the form usually supplied (Fig. 26). The *costotome* (Fig. 27) is an expensive instrument, with short, thick blades, the under one being curved and having a strong spring between the handles. Dangerous blood-blisters are sometimes produced by pinching the skin with the ends of the handles, which usually meet and

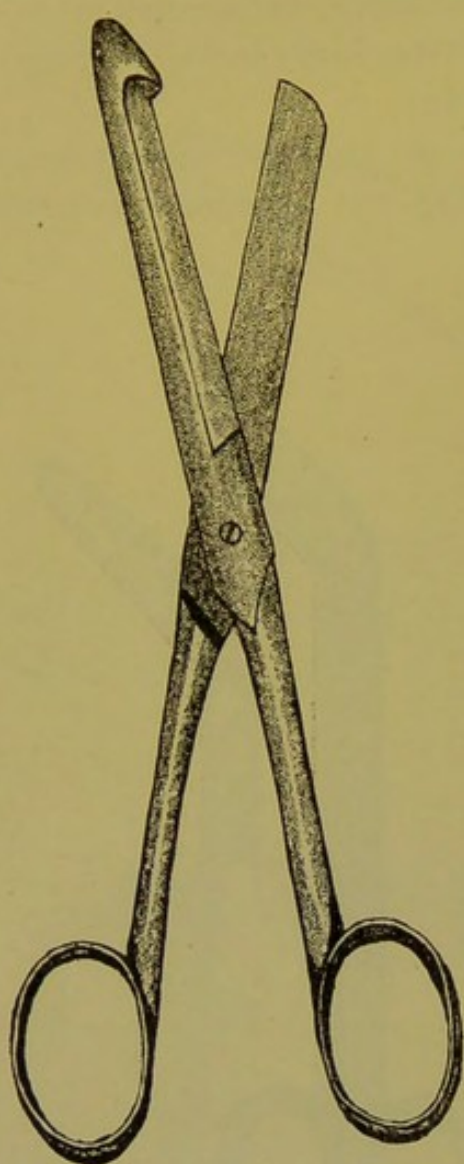


FIG. 25.—Proper form of enterotome.  
(One-half natural size.)

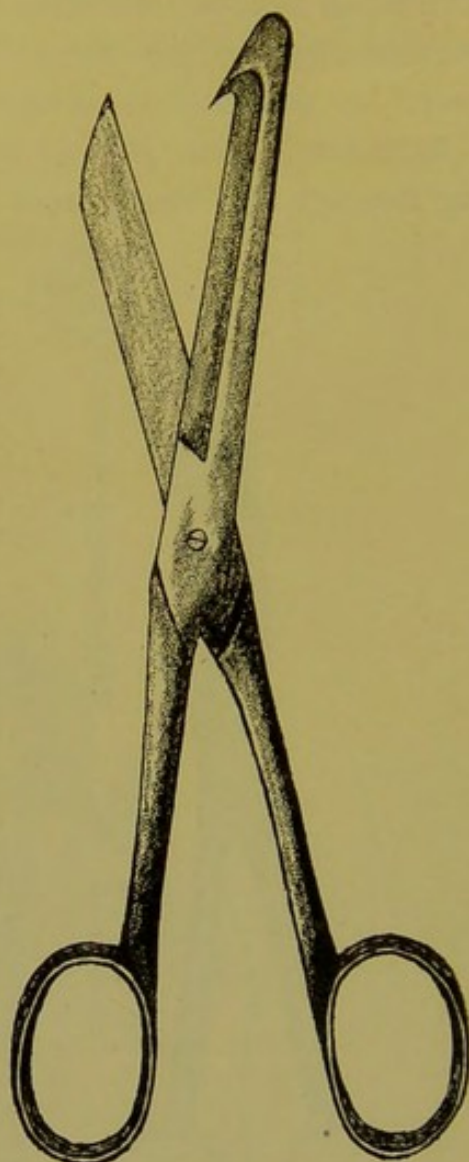


FIG. 26.—Improper form of enterotome, with  
pointed ends. (One-half natural size.)

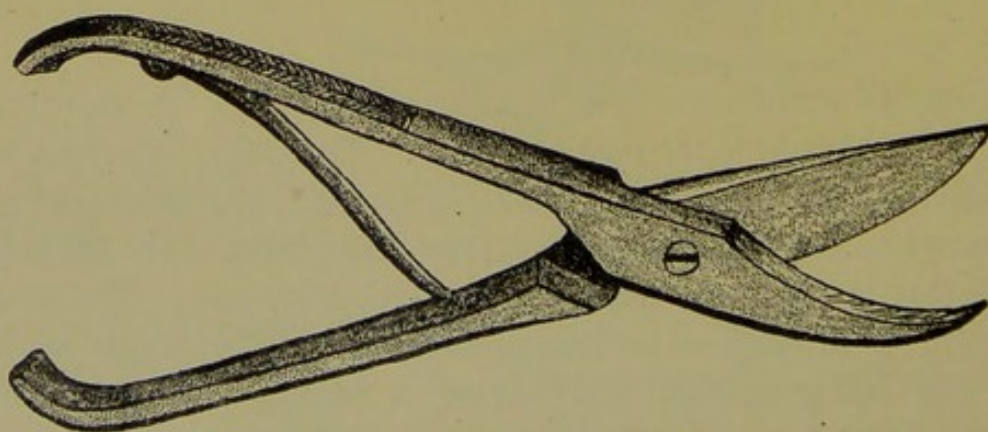


FIG. 27.—Proper form of costotome; the handles do not meet by one-quarter of an inch and the ends are not pointed, but rounded. (One-half natural size.)



fasten with a catch (Fig. 28). The ends should not meet and there is no necessity for the catch.

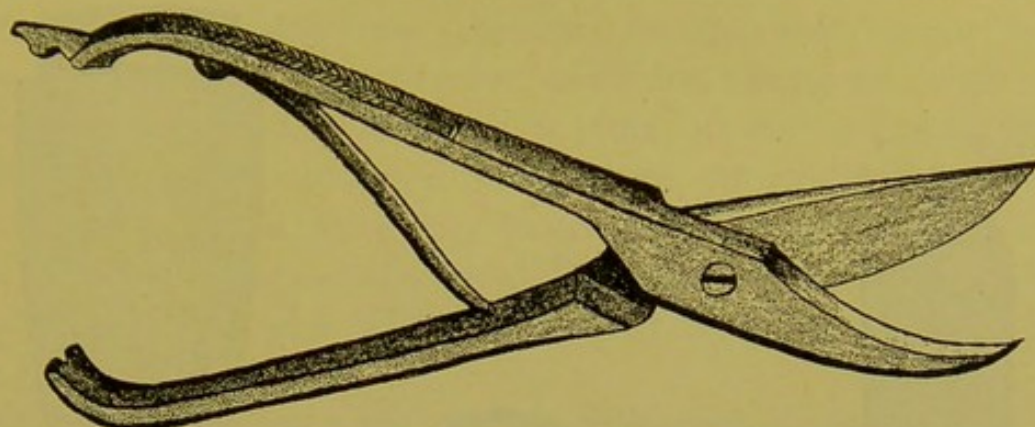


FIG. 28.—Improper form of costotome, with pointed blades and a catch, the handles meeting when they are closed. (One-half natural size.)

**HAMMERS.**—The most useful hammer is made of solid steel (Fig. 29). One end of the head or striking portion is cuneiform, and there may be a hook on the end of the handle which is of service in spring-

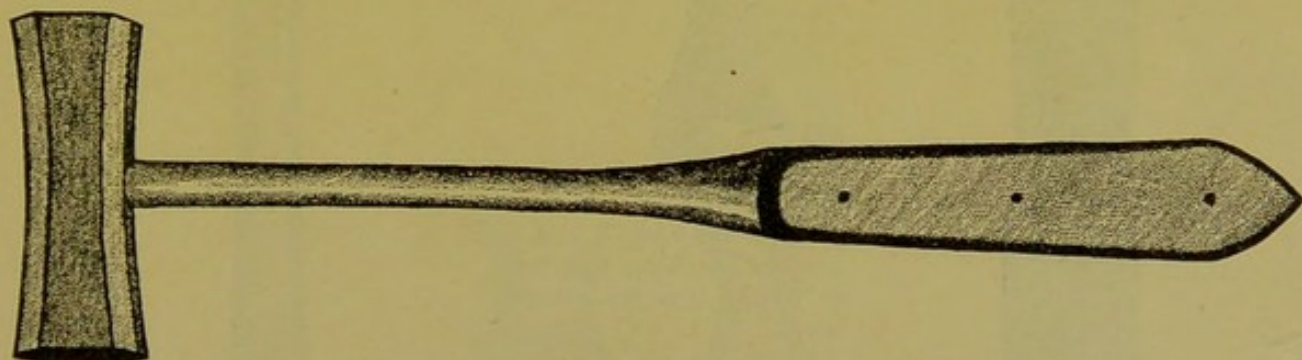


FIG. 29.—Steel hammer with proper handle. (One-half natural size.)

ing off the calvarium. Lead filling in a hammer muffles the sound of its impact and prevents rebounding. A wooden mallet is preferred by some pathologists.

**CHISELS.**—There are chisels of various patterns devised for use in different regions. The *straight chisel* is the most serviceable, as it can be used in any region. The T-shaped chisel is also generally useful; it has one arm placed perpendicular to the other, and the arm which serves as a handle has one sharp and one blunt end so that it can be hammered upon. The chief use of the T-shaped chisel is in springing off the calvarium and in elevating the periosteum from it. Guarded, hatchet-shaped, and other chisels (Figs. 30 and 31) and spinal



chisels (Fig. 32) are useful in opening the spinal canal, and a chisel with a guard about half an inch, or 1.25 centimetres, from the edge



FIG. 30.—Solid steel side chisel for breaking through any unsawed portions of bone in removing the calvarium. The pointed end is used as a pry and retractor for pulling out the sawed-off portion of the skull. (One-half natural size.)

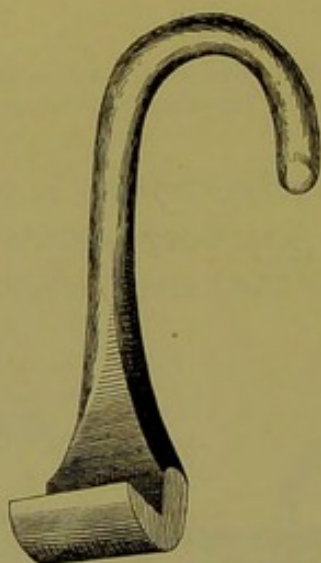

FIG. 31.—Curved chisel, used for the same purposes as Fig. 30. (One-half natural size.)

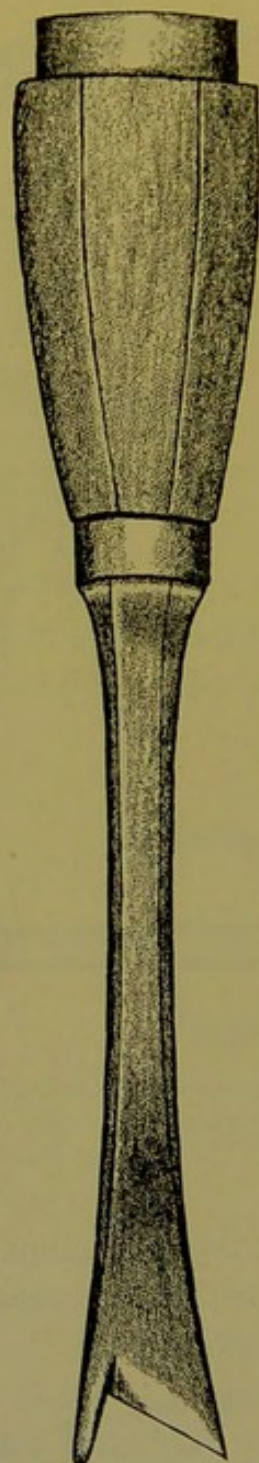


FIG. 32.—Brunetti's curved spinal chisel, of use in opening the vertebræ. (One-half natural size.)

will not injure the brain while springing off the calvarium from the dura mater. The *raspatory* of Chiara has a broad, spoon-shaped end, four centimetres wide, with which the periosteum from a large surface



can easily be removed; the other end is of the shape of a lance, one inch (2.5 centimetres) long, and is used for deep separation.

**FORCEPS.**—Dissecting forceps are indispensable when it is necessary to trace small structures; pointed, straight and curved forceps are the forms in use. *Bone-forceps*, large and strong and with rough handles, are necessary. One blade is blunt, so that it can be shoved against soft tissues without injuring them, as in cutting the ribs. *Lion-forceps* of special type may be used when removing the bodies of the vertebræ. *Dura-tongs*, for pulling the dura mater away from the calvarium when it is adherent, may save the fingers from being injured by the bone.

Grooved and curved **DIRECTORS** are frequently necessary.

**CHAIN HOOKS** and a **TENACULUM** may be of use, but they are dangerous instruments. **HOOKE**D **RETRACTORS** are more desirable than a tenaculum or chain hooks.

**VARIOUS INSTRUMENTS.**—A metal *catheter* and several flexible catheters, all of size number 8, may be needed for withdrawing urine.

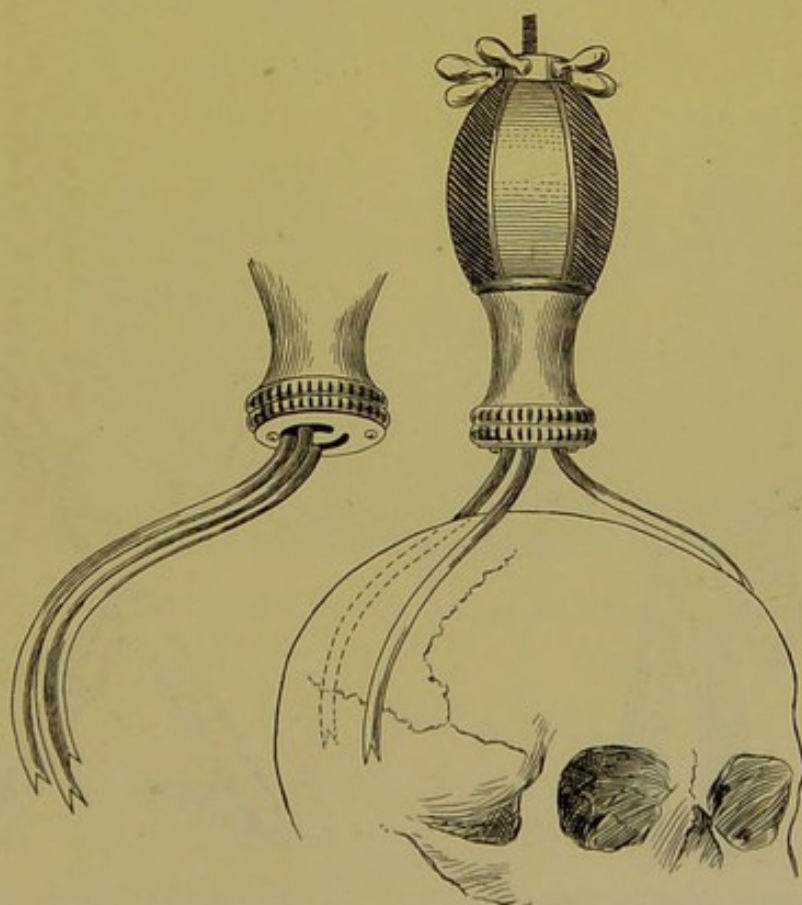


FIG. 33.—Satterthwaite's calvarium clamp, closed and in use.

A *blow-pipe* with a stop or valve, a *trocar and cannula*, *probes*, some of which have eyes, and some form of *injecting syringe* are also

useful. A *vise* is serviceable in firmly holding bone preparations in course of dissection, and in fixing a saw that is being sharpened. A *skull clamp* is considered by some to be of use in removing the calva-

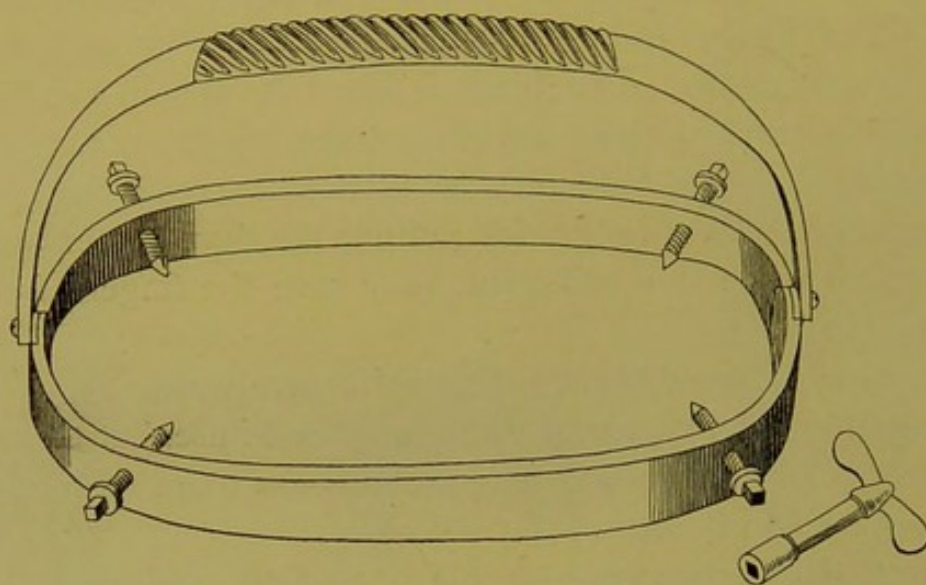


FIG. 34.—Iron clamp to be applied to the skull before the removal of the brain; especially used in dissecting rooms.

rium (Figs. 33, 34, and 35). *Iron tripods* and other special devices for holding the head are shown in Figs. 36 and 37.

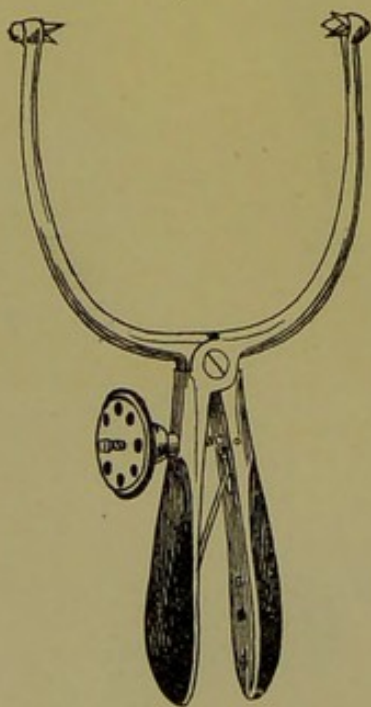


FIG. 35.—Bigelow clamp for holding the head in the removal of the brain.

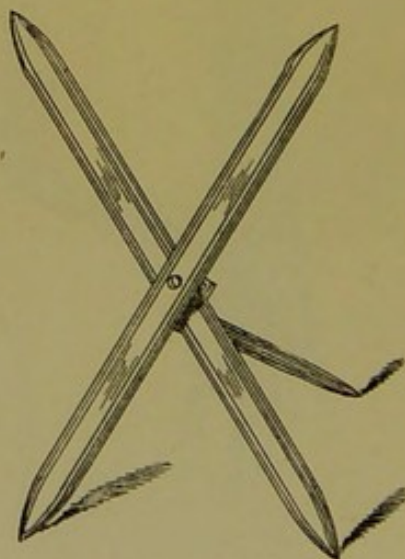


FIG. 36.—Folding iron head-rest.

*Weights and measures* of various kinds are frequently found to be indispensable. These should include scales, a steel tape measure, grad-






FIG. 37.—Cornell folding clamp for the secure holding of the head in the removal of the calvarium.

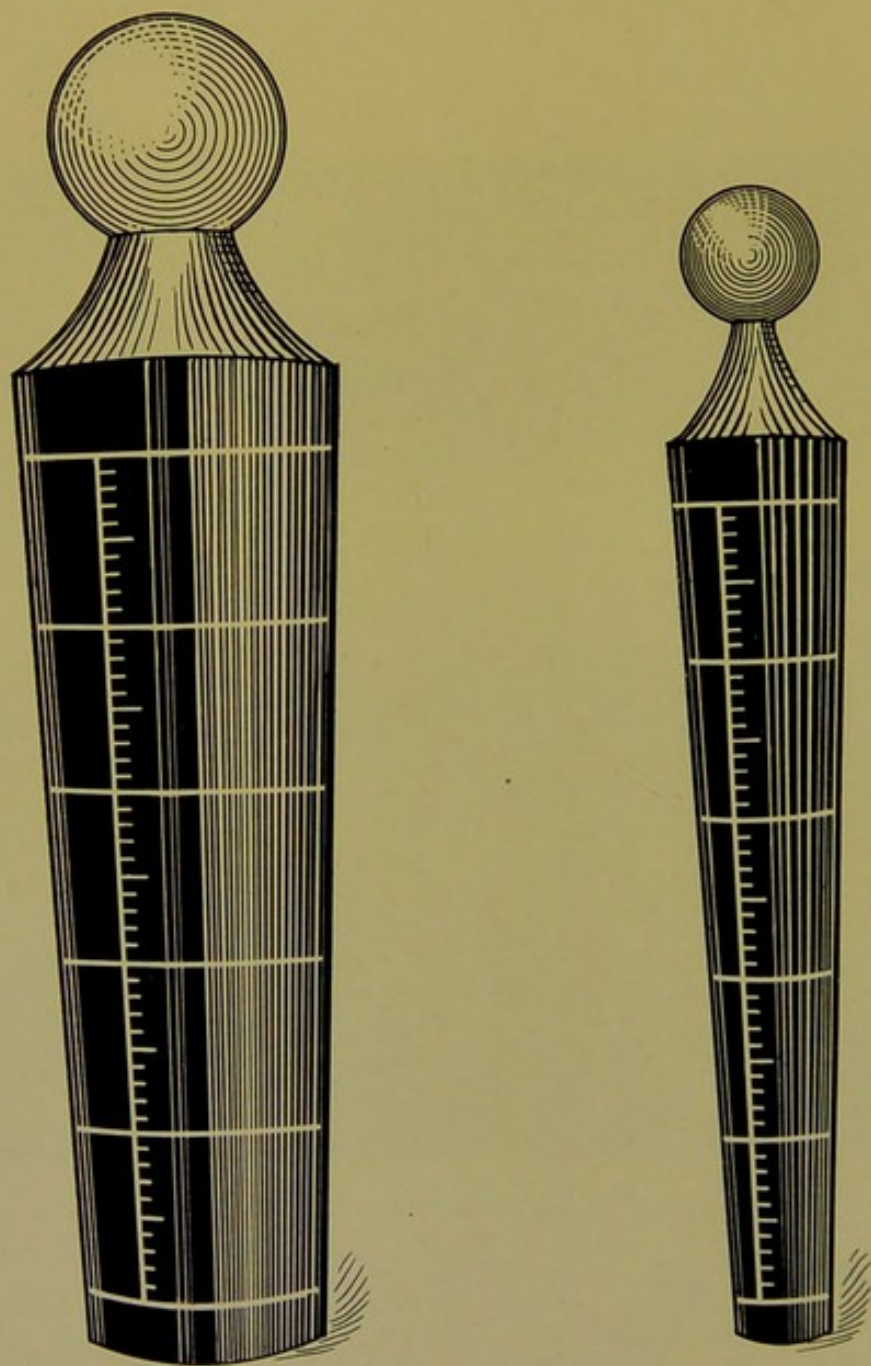


FIG. 38.—Cones for measuring orifices. (Actual size.)






FIG. 39.—Glass balls to which handles are attached, for measuring orifices.

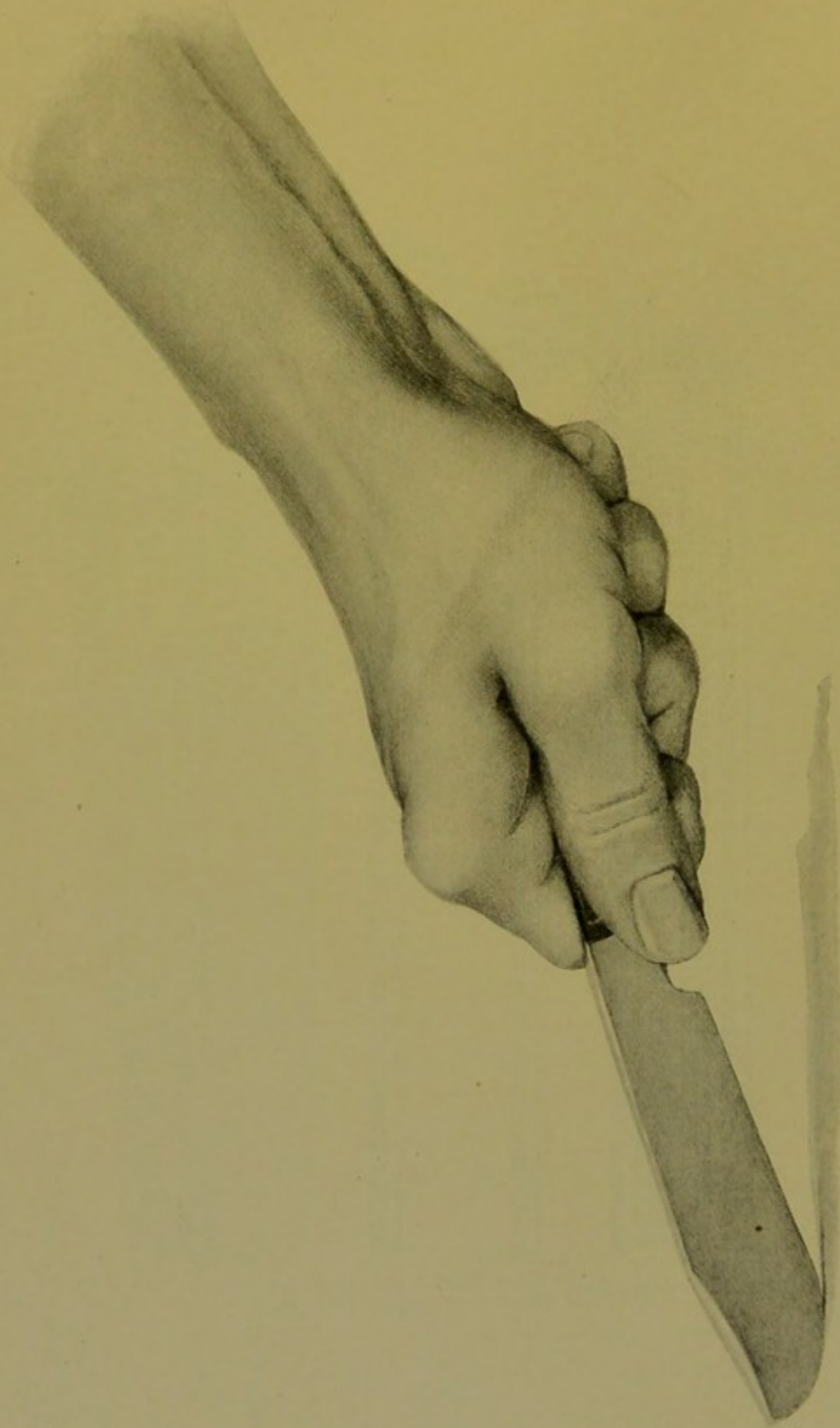


FIG. 42.—Method of holding cartilage-knife. The hand firmly grasps the knife, and the cutting is done with the belly of the blade.



uated calipers, graduated glass cones, glass balls, and graduated measuring vessels of glass. The *scales* should have a capacity of twenty pounds, or ten kilogrammes, and be supplied with weights from a gramme upward. They are needed in weighing organs. The *steel tape measure* and the *two-feet rule* are marked in both centimetres and inches. *Graduated calipers* are useful in determining diameters. *Graduated wooden cones* are used in measuring orifices (Fig. 38). *Glass balls* are serviceable in determining the size of apertures and canals (Fig. 39). *Graduated measuring vessels* of glass are desirable. The larger vessels should be marked at every hundred cubic centimetres up to one or two litres, and the smaller for every two cubic centimetres up to a hundred. A *stomach-pump* is especially useful in withdrawing fluids from cavities. *Ladles* with a lip or spout, made of enamelled or agate ware, and with a capacity of half a pint, or two hundred and fifty cubic centimetres, are needed in dipping fluid from cavities.

A *magnifying-glass* that enlarges at least ten diameters should be in the hands of every one making postmortems.

OTHER SUPPLIES.—*Enamelled trays* or *basins* are useful for receiving removed organs, and the basins are also required in cleansing the hands and instruments. *Blocks of wood* are required to support the body. Some of these should be prismatic in form, others excavated to fit under the neck during removal of the brain. All wooden utensils should be finished with oil so as to be non-absorbent. *Earthenware plates* or *wooden boards* are useful during the dissection of organs. *Needles and coarse flax thread* or *fine twine* are needed in closing incisions made through the skin. The thread is also required in ligating the intestines before removing them. *Sponges* are a necessity readily procured, and should always be moist when in use. *Pins* are useful in fixing small structures in course of dissection. Special *tables* of zinc-covered wood, slate, iron, or glass are desirable in a pathological department. Rotating tables are convenient, but weighing tables are expensive. The table should be constructed so as to carry off all fluids into a receptacle provided for them.

*Rubber gloves* that reach well up the wrist and *finger-cots* afford protection to the pathologist, particularly in cases where the danger of infection is great; but the operator can work more swiftly with bare hands, the abrasions upon which have been protected with flexible colloidion containing two per cent. of iodoform. It is also an advantage



to introduce cosmoline into the crevices around the finger-nails. The gloves are more readily put on and are preserved by dusting them freely with *ground soapstone* kept in a dusting bottle. Quart *museum jars* are useful for holding specimens to be preserved, and two-ounce, *wide-mouth bottles*, for microscopic specimens. A clean *glass bottle* with a glass stopper and *sealing-wax* to keep it closed are needed to receive the contents of the stomach in a case of poisoning. *Bromin* in a strong bottle with a ground-glass stopper that fits well serves a good purpose in disinfecting fresh wounds.

*Pails* are needed as containers for water and to receive fluid removed from the body. *Cotton wool*, *sawdust*, or *tow* placed in the large cavities of the body before they are closed prevents the escape of fluid from them. *Plaster of Paris* and *sand* serve a similar purpose in the cranial cavity. *Disinfectants* and *deodorants* should not be forgotten, as it is desirable to destroy or neutralize odors emanating from the body, and to disinfect and deodorize the hands of the pathologist after the examination has been completed. *Bellows* are occasionally useful in inflating hollow viscera. A *hand-bag* which can be cleansed is required in carrying instruments to and from private houses.

The *chemical*, *bacteriological*, and *microscopic supplies* required in the work of the pathologist at the postmortem are red and blue litmus paper, turmeric paper, Lugol's solution, solution of sulphid of ammonium for detection of free iron derived from bile pigment, as in pernicious anæmia, Gabbett's solution, carbol-fuchsin, Loeffler's alkaline blue, absolute and commercial alcohol, ethyl chlorid or methyl chlorid, culture-tubes containing blood-serum, agar, and gelatin (bouillon is troublesome to carry), an alcohol-lamp, glass slides and covers for microscopic specimens, filter-papers three or four inches in diameter, an old scalpel which can be heated, a platinum wire three inches (or eight centimetres) long, set in a solid glass rod six inches (or fifteen centimetres) long, for making cultures (called an öse), a microscope, a freezing microtome, and easy access to an incubator.

In my own experience it has been found desirable or convenient to discard one instrument after another until now my satchel for private work weighs with its contents but nine pounds, and contains the following articles: two section-knives *in good condition*; a scalpel; a pair of medium-sized, strong scissors; a pair of bone-forceps; a dissecting forceps; a saw; an enterotome; a hammer with a hook on its handle; a pelvimeter; a new rubber catheter;



gummed labels; various kinds of litmus paper; sealing-wax; a dissecting-apron and sleeves; a pair of rubber gloves, with plenty of ground soapstone in an iodoform dusting bottle; finger-stalls; a piece of thin rubber sheeting forty-five by thirty inches; a piece of oiled silk, or a rubber bag (sixteen by ten by four inches) from which fluid will not escape; two medium-sized bath-sponges; a quart museum jar graduated into ounces or cubic centimetres, into which some of the smaller articles are placed and which can be used for the removal of gross specimens later, if desired; a large needle and flax twine, cut and wrapped (Fig. 40) into three lengths, for sewing the

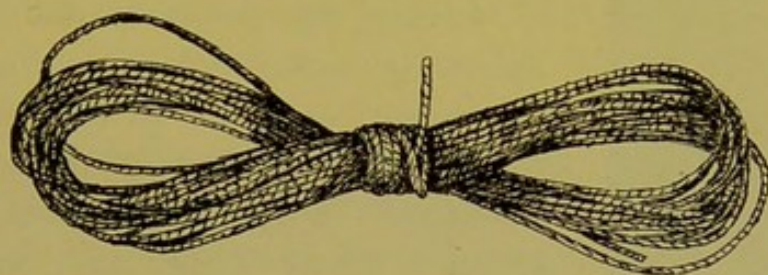


FIG. 40.—Hemp twine cut of the proper length and ready for use.

body with single thread (forty-five inches), for sewing the head (twenty-five inches), and for tying the intestines (ten inches); some bromine in a strong bottle with a well-fitting ground-glass stopper; two per cent. iodoform celloidin solution; a small roll of cotton; four two-ounce, wide-mouth bottles for microscopic specimens, one of which should be filled with seventy per cent. alcohol, one with ten per cent. formalin, one with Müller's fluid, and the fourth with a saturated solution of mercuric bichlorid; two ounces of creolin; a cake of one per cent. bichlorid of mercury soap; an öse; an alcohol-lamp; several culture-tubes properly packed; incense powders; matches; pins, safety and ordinary; a steel tape-measure marked in inches and centimetres; a hand lens magnifying about ten diameters; a pair of spring scales weighing up to fifteen pounds; and last, but not least, a notebook and several pencils, one of which will write on glass. To this list may be added other articles as the necessities of the case may demand.

For the private use of the general practitioner, a large section-knife, a scalpel, an enterotome, a saw, a chisel, a mallet, a pair of scissors, and a large needle may be purchased for about five dollars. These should be kept rolled up in a piece of chamois-skin, preferably made with pockets into which the instruments fit, and if the latter be



put away clean after use they are always ready for service; or a leather case (Fig. 41) may be employed.

The proper handling of post-mortem instruments is not acquired in a day, and the beginner will find that experience teaches many lessons which are not likely to be forgotten. A well-ground, keen-edged knife is a great desideratum, the advantages of a dull knife being simply that it is less likely to injure a beginner or careless operator and to disfigure the exposed portions of the body.<sup>1</sup>




FIG. 41. — Formad's leather pocket-case, holding the instruments usually employed in making a postmortem. (One-half natural size.)

In opening the body the free incisions should be made by an easy, untrammelled movement, executed by the muscles of the shoulder rather than by those of the arm or hand. It is essential that the knife be grasped firmly (Fig. 42), and not held like a pen, as is a scalpel in the act of dissecting. Virchow says that the knife should be held in the whole hand, so that when the arm is stretched out the blade extends with it. The fingers and hands are fixed, if not absolutely, at least relatively, and execute the motion with the whole arm, so that the movement is principally in the shoulder-joint and secondarily in the elbow-joint. Thus the whole strength of the arm and shoulder muscles is brought into play, and long, smooth incisions, so essential to proper inspection, are made. In cutting, pressure should be uniform, and the greater the pressure the quicker will the knife pass through the tissues. A clean cut made in the wrong place does less harm than a

ragged one in the right place (Virchow). The portion of the blade near the handle should be used for work which dulls a knife, as cutting

<sup>1</sup> The method of holding and using the instruments will be seen illustrated by reference to the pages treating of the examination of the various organs.



the ribs. This also applies to scissors, the part near the pivot being employed in all cases in which considerable force is required. When held as shown in Figs. 47 or 49, but preferably as in Fig. 47, the operator is sure to have a firm grasp of the knife-handle, so that there will be little likelihood of a dangerous slip. The actual cutting is properly and mainly done with the belly of the knife about one inch from its end, for which reason this part of the blade is always the thickest. The direction of the incision should invariably be *from* the operator, especial care being taken not to wound the left hand, and *from* those portions of the subject in which disfigurement would be most likely to be noticed. Care must also be taken not to injure the assistants or those standing near. When the resistance of a tissue is unexpectedly overcome, the knife will sometimes travel a considerable distance before it can be stopped by an effort of the will.

The blade of the knife must be kept free from blood by frequent washing. This is especially necessary when incising organs, as the brain, in which incisions are made with much more satisfaction if the knife-blade be previously moistened. A pointed knife may be used for the removal of the tongue and the larynx, and a scalpel for fine dissection, as in tracing the spermatic or thoracic duct.



## CHAPTER IV

### THE CARE OF THE HANDS AND THE TREATMENT OF POST-MORTEM WOUNDS

BEFORE beginning the autopsy, especially in a purulent case, the pathologist should carefully examine his hands; if these be not in good condition, the notes may be dictated by him while some one else can usually be found to do the actual cutting.

For the protection of their patients, residents during their term of service in the surgical and gynæcological wards of our hospitals should be forbidden to make autopsies, and they should not be tempted to break this rule by a request to assist at a postmortem, even though no one else be available to do the routine work of opening the body.

Slight wounds on the hands may be protected before beginning the necropsy by placing a small piece of absorbent cotton upon them and then applying the ordinary thick celloidin used in bacteriological work, or the iodoform celloidin referred to on page 37.

Before starting work upon the body, many pathologists anoint their hands with some antiseptic salve, such as vaseline containing boric acid, ten grains to the ounce, a ten per cent. carbolic acid ointment, or a solution of the balsam of Peru. If these be used, they should be renewed several times during the progress of the autopsy. It is, however, doubtful whether the advantages gained by their employment are not more than offset by the fact that the hold upon the instruments is thereby rendered less secure. This can to a certain extent be avoided by anointing the entire left hand (which comes in contact with the tissues of the body) and only the back of the right hand (the instruments being held by the palm of this hand) with the ointment, as it is here that infection usually takes place when no mechanical injury to the hand is inflicted. Frequent washing of the hands in clean water is regarded by many as decidedly better. Of course, when digital examinations are necessary, as in exploring fistulous tracts, examining the vagina and os, and in certain cases of peritonitis, antiseptic unguents are desirable; in such cases it is necessary to anoint only that portion of the hand which comes in contact with the tissues under examination.



An equally efficient and in many respects a much better safeguard against infection is the use of rubber gloves. Post-mortem gloves made of *thin* gum elastic and provided with long sleeves may be found in the rubber stores and at instrument-makers'. They fit snugly, and are especially desirable in opening the stomach and intestines, as it is most frequently the intestinal contents which impart the odor that adheres so persistently to the hands. They do not prevent, though they to a certain extent hinder, the production of post-mortem wounds. Rubber finger-stalls, especially the variety known as the seamless rolled finger-cot, which unrolls as it is placed on the finger, are useful if the operator have any hangnails or other abrasions of the fingers. Blood, pus, or other cadaveric fluid should not be allowed to dry upon the instruments used nor upon the hands, for it not only impairs the delicacy of touch so desirable in this work, but it also may cause unsightly stains upon the skin, which are difficult to remove, especially when certain preservatives have been employed in embalming the body.

Odor can usually be removed from the hands by applying to them, while still wet, either a few drops of turpentine, formic aldehyde, from one to three per cent., aromatic spirit of ammonia, listerine, paregoric, or mustard, and then washing them thoroughly with a good glycerin soap. Neelsen (quoted by Nauwerck) states that, if the odor can be removed in no other way, equal parts of fuming hydrochloric acid and glycerin should be used. The employment of equal parts of hypobromite solution (used in the quantitative estimation of urea) and of water, while severe, is also very effective for this purpose.

For disinfection of the hands after the postmortem one may use creolin water, made by placing about an ounce of creolin in a basin of tepid water,<sup>1</sup> or a concentrated solution of potassium permanganate, and the removal of the brownish discoloration can be accomplished with oxalic acid or an antiseptic soap. Of the latter, I prefer the one per cent. bichlorid of mercury soap.

A post-mortem wound as usually referred to means not only a cut or injury received at a postmortem, but the additional inoculation of any break in the continuity of the skin by means of which pathogenic bacteria derived from the dead bodies of human beings or of animals gain entrance to the system and there multiply. Wounds presenting similar appearances may, of course, be derived from many sources, as

---

<sup>1</sup> Or, more exactly, a two per cent. creolin solution.



from surgical operations and from other post-mortem wounds. The intact skin of the hand is a perfect protection against the invasion of bacteria. In order that the organisms may infect the body, there must be both a point of entrance and a predisposition of the individual. While any of the infectious diseases may be contracted in making a postmortem, those most to be feared are tuberculous warts, syphilis, gonorrhœal ophthalmia, tetanus, anthrax, glanders, plague, actinomycosis, typhus fever, diphtheria, yellow fever, cholera, and smallpox.

Inoculations from serous surfaces are especially to be guarded against, as from some of the varieties of peritonitis due to criminal abortion, and other forms of septic peritonitis, meningitis, or pleurisy. Among other virulent forms of post-mortem wounds may be mentioned those derived from cases of pyæmia, of septicæmia, of puerperal fever, of malignant œdema and diffuse cellulitis, of erysipelas, and of gangrene. Personally, I have the most wholesome respect for the *Bacillus pyocyaneus*, with which I became inoculated from a case of cancer of the gall-bladder with secondary infection by this organism. For a number of days my temperature was above 105° F.

It is often asked why post-mortem wounds and injuries received in the performance of similar operations are more dangerous than those which are otherwise inflicted. Their greater virulence may in part be due to the fact that they are usually punctured wounds, and thus afford a favorable opportunity for the deep implantation of pyogenic organisms. Again, it is a well-known bacteriological fact that many organisms become more virulent by passing through successive animals, and finally, an organism which has overcome the resistance of the tissues and killed them is naturally more destructive than one which has not had such favorable opportunities for growth.

Post-mortem wounds are generally caused in one or other of four ways: first, by cuts from instruments used in the making of the autopsy, especially sharp-pointed knives and the saw; second, by scratches or punctures from ragged bones or calcified tissues, as the ribs or atheromatous patches of the aorta which have undergone calcareous infiltration; third, by inoculation of pre-existing wounds, abrasions, small eruptions, especially at the roots of the hair-follicles, hangnails, blisters, fissures in chapped hands, etc.; and, fourth, by cuts and scratches accidentally inflicted by the operator on his assistant, as in opening the head. Indeed, so frequently does the latter occur that I always dispense with a helper to steady the head unless his hands



be thoroughly protected by some covering, such as a towel. Ragged wounds, such as those caused by the saw or by bones, are especially to be dreaded, for, being both punctured and lacerated, they are particularly prone to become infected.

Then, too, it has been shown experimentally that bone marrow possesses marked bactericidal properties. Hence wounds produced by sharp spicules of bone are usually severe, for the reason that they introduce into the wounded tissues large numbers of bacteria by which this resistance of the bone marrow has already been overcome. The micro-organisms found at a postmortem made several days after death are apt to be less virulent than those encountered soon after dissolution, the saprophytes having now gained the upper hand. Other things being equal, the more quickly the patient died after infection, the more severe will be the post-mortem wound; but the character of this lesion and the nature of the organism must always be considered. Undoubtedly, persons making many postmortems become immune to inoculation by the ordinary *Staphylococci* and *Streptococci*. When toxins are introduced along with the bacteria, the constitutional symptoms are apt to be more severe, as the toxins overcome a certain amount of reserved force of the tissues which might otherwise be used in combating the organisms themselves.

Some of the usual ways of producing wounds which are especially worthy of mention are: by the operator cutting towards instead of away from himself or his assistant; by leaving the knife in one of the cavities and forgetting its presence; by placing his instruments in a dangerous position on the body, the table, or the ice-box; by the use of sharp-pointed knives; by punctures from the needle, made during the sewing up of the body; and by the too rapid passage of thread through the hands producing a sort of brush-burn.

The great protection afforded by the bleeding of a wound is well known; hence the immediate closing of the latter by the application of caustics or of cellöidin is worse than useless. If the finger be wounded, it should be wrapped with a miniature Esmarch bandage and then allowed to bleed freely under *running water for at least five minutes*. Sucking of the wound may then be practised, and, if a caustic be required, there is probably nothing better than glacial acetic acid or pure formalin. The use of the actual cautery is advisable in some cases, but must be so thoroughly applied that no organisms are left behind, as otherwise the necrosed tissue may afford a favorable



medium for their growth. An antiseptic dressing may then be applied, which should be renewed every twelve hours. On the slightest indication of pus or a deadish-gray appearance of the wound, it should be *freely* incised, thoroughly cleansed with hydrogen peroxide, bromine, or formalin, and dressed with iodoform and a wet bichloride bandage; or a solution of silver nitrate may be applied with benefit. I have seen no good effect from the local use of the unguentum Credé (ointment of soluble metallic silver). The injection of formalin in cases of septicæmia is well spoken of. The frequent application of hot flaxseed poultices containing a teaspoonful of Labarraque's solution is most grateful when the wound is discharging. Several inches above the wound a ring of iodine should be plentifully painted.

Involvement of the lymphatics, as seen by red lines running up the arm, usually on the inner surface, and tenderness in the axilla, indicates danger. Inflammation of the lymph-glands of the axilla may cause the glands in this region to become tender and swollen, so that an incision is necessary; and in cases of axillary cellulitis, even though the wound of inoculation be small, early incision should be employed. Quinine is useful in these cases, and iron may be prescribed later. The affected arm should be carried in a sling, tonic treatment with changes of air instituted, and a surgeon consulted, who will treat the case according to the character of the wound, the nature of the infection, and the constitution of the patient. When healing has commenced, massage has made many a useful finger or hand out of what would otherwise have been a stiff and useless one.

The general health has much to do with the severity of the wound, and, other things being equal, severer symptoms and slower convalescence may be expected in those who are habituated to the use of alcohol.

The anatomical wart is a local tuberculous lesion, often multiple, and situated on the back of the hand or at the flexor joints of the fingers. There is a warty thickening of the papilla of the skin, accompanied by a discharge of thin serous pus, but with no true ulceration. The sensation produced is similar to that caused by a splinter, which, however, subsides for several days after the removal of the fluid contents. The lesion sometimes heals spontaneously, but may give rise, as in one of my cases, to general tuberculosis. Wet dressings, combined with an application of equal parts of glycerin and extract of belladonna, may be employed, or the following mixture applied:



R Salicylic acid, 10 parts;  
Extract of cannabis indica,  
Cocaine hydrochlorate, of each 1 part;  
Oil of turpentine, 5 parts;  
Glacial acetic acid, 2 parts;  
Collodion, 100 parts.

It would be interesting to try the hypodermic injection of tuberculin, or some of the newer forms of treatment for lupus of the face, as that recommended by Dr. Finsen.<sup>1</sup> In one of my cases I thought that an anatomical wart was rendered worse by the use of the X-rays.

One of my patients evidently contracted a tuberculous wart from a cow, thus adding another case against Koch's dictum which he announced at the meeting of the Tuberculosis Congress in 1901.

When tuberculous warts have lasted several months, surgical treatment should be instituted, care being taken not to open them into the circulation, and that sufficient healthy tissue be removed to make a good cicatrix. Guinea-pigs injected with such material linger a long time, and in one of my cases over six months elapsed before the animal died from general tuberculosis.

Suppuration of the matrix of the nails can often be cured only by the removal of the nail, though frequent soaking of the finger in a hot saturated solution of boric acid or a strong solution of lead subacetate may be tried. Diffuse cellulitis should be treated by early and free incision and the application of cold compresses. When the hand itself is involved in spreading gangrene, amputation should usually be practised. I have seen septicæmia, pyæmia, general tuberculosis, ulcerated endocarditis, purulent meningitis, boils, whitlows, etc., follow post-mortem wounds.

If the knives used in post-mortem work were thoroughly sterilized after each necropsy, there would be fewer infected wounds. The making of autopsies is undoubtedly dangerous, and therefore those who are in the habit of doing so should insure themselves in one or other of the accident companies which contain a clause giving a claim for benefits in case of wound-infection. As these companies show a disposition to dispute claims, any injury, no matter how slight it may be, should be reported to them as soon as possible after its occurrence.

---

<sup>1</sup> BIE, *International Clinics*, Vol. iii., Eleventh Series, 1902.



## CHAPTER V

### EXAMINATION OF THE EXTERIOR OF THE BODY

AFTER carefully considering the clinical history and weighing the evidence derived from an examination of the surroundings and from questioning the persons who have been brought in contact with the corpse, the nude body should be minutely inspected, first as a whole and then with regard to its component parts.<sup>1</sup> This external examination is of especial value in medicolegal cases or when the postmortem is about to be performed upon an unidentified body. The noting of certain details, such as moles, birth-marks, angioma, tattoo markings, scars, condition of the teeth, and anomalies of the ear and eye, may be of great importance, and may even later on be the sole means of identifying the body. Should the clothes be preserved for any reason, as for purposes of identification or for showing the entrance of a bullet, camphor or tar camphor should be added previous to their being securely wrapt up and properly labelled, in order to prevent their destruction by moths. In handing them over to the proper legal officers it is well to get a receipt for such articles and to have the transaction take place in the presence of a witness. The knowledge acquired by inspection of the surroundings and the exterior of the body must, however, in no way bias the examiner in his internal examination, as the unexpected happens here as elsewhere.

The sex, the race, and the apparent age<sup>2</sup> are first carefully noted. The height is now determined by measuring in a straight line from the vertex of the head to the centre of the external arch of the instep. If a scale is not marked on the table and no other means of measuring is at hand, a piece of inelastic string or tape may be employed for this

---

<sup>1</sup> It would be well if the living body were more frequently made the subject of careful study in the nude state, as the information thus obtained is often of great value to the clinician or surgeon.

<sup>2</sup> By *apparent age* is meant the age of the body as it appears to the judgment of the observer at the time of making the postmortem. Thus, a person may look younger or older than his or her *real* age, suffering, mental depression, etc., often making the body seem many years older than it really is. *Per contra*, the signs of suffering may pass away and the features become relaxed and appear in better condition than for years before death.



purpose and measured later. The writer would suggest the use of a measuring apparatus modelled on a shoe-measure. A simpler form can readily be made by taking two one-foot rulers, or other sticks of about the same size, and attaching, one inch from one end, a seventy-eight inch tape-measure,<sup>1</sup> which is made to run through a transverse slit one inch from the top of the other ruler. The first ruler is held close to the foot, which is placed in a vertical position, and the other stick is held parallel to the first stick by an assistant at the head and the tape drawn until it is taut. When not in use the tape-measure is wound around the sticks. Next measure the circumference of the head and shoulders. Should there be shortening of a limb, or atrophy, as in infantile paralysis, full measurements of both limbs are to be made. *Right*-handed adults can commonly be told by the fact that the *left* hand is more apt to show the presence of scars and other signs of traumatic injury. Note the development of the skeleton, also any deformities and peculiarities, such as rickets, pigeon-breast, Pott's disease, etc.

Estimate the weight and observe particularly the state of nutrition of the body; if emaciation be present, note whether it is due to deficiency in fat (*panniculus adiposus*), to muscular atrophy, or to a combination of both. This can usually be readily determined by picking up a fold of skin over a muscle and rolling it between the thumb and fingers. One may practise this on himself, noting the differences in thickness found in the front, the back, and the sides of the neck.

Post-mortem lividity, or hypostatic congestion, produces a bluish-red discoloration of the skin in the dependent parts of the body. This condition may resemble a bruise made during life, but the discoloration in post-mortem lividity disappears on pressure while that due to a bruise does not. Ante-mortem bruises and post-mortem lividity may also be differentiated by incising them. From a patch of post-mortem lividity blood will flow quite freely, because the vessels in the dependent parts are engorged with blood, while from a bruise there is little or no oozing, as the original hemorrhage is circumscribed and the discoloration is due mainly to staining of the tissues and not to the presence of blood. If the part be washed with running water, blood will appear again and again in hypostatic congestion. Should the two conditions

---

<sup>1</sup> If a tape-measure of this length is not at hand, forty-two inches of double inelastic tape may be sewed together and this attached to a measure of the ordinary length.



be combined, it is well to free the area from the hypostatic congestion before describing the bruise. Thus, if the lesion be situated on the back, it is well to let the body rest on the stomach for a time. As a rule, the more fluid the blood, as in cases of death from suffocation, the acute infectious fevers, poisoning by hydrocyanic acid, etc., the more marked will be the post-mortem lividity. In the latter case, as well as in poisoning by illuminating gas, the lividity may be of a characteristic rose-red color.

It is important to distinguish between post-mortem lividity and the greenish discoloration of commencing decomposition, usually first seen over the abdomen. The greenish color is due to the precipitation of the iron of the hæmoglobin by the hydrogen sulphid arising from the decomposition of the tissues under the influence of bacteria. In one of my cases such discoloration was mistaken for a bruise, and serious allegations based upon this error were made against the husband of the deceased.

Bodies which have been kept for a long time (or a shorter time under unfavorable conditions) after death, especially during cold weather, present another form of cadaveric lividity which is characterized by a uniform reddish tint. This is caused by the diffusion of hæmoglobin from the blood-vessels into the surrounding tissues (imbibition). This form of lividity is most conspicuous along the course of the superficial veins and is not affected by pressure.

Much discussion has arisen in regard to the means at our command for distinguishing wounds made before and after death, and which is the fatal wound in case there are more than one injury. On these and similar questions I have heard experts testify in court in a manner utterly unsupported by the facts of the case. Great caution should, therefore, be used in the expression of dogmatic statements in regard to such findings.

Post-mortem rigidity commences in the muscles of the jaw and spreads downward, disappearing in the same order. In ordinary cases it begins about two hours after death, is complete in from seven to nine hours, and ends in three or four days. The stronger the individual and the shorter the duration of the fatal disease, the more prompt and marked will be the rigidity. The bodies of soldiers killed by being shot in battle after forced marches sometimes retain the position they occupied when they were hit, in certain instances even remaining erect when standing. Rigidity often sets in very early in



those who die suddenly, as while reading or while at table. It is very marked, especially in the abdominal muscles, after death from cholera. The body of one who has just died from tetanus or strychnine poisoning may lie supported only by the head and heels, or when placed upright may stand erect with little or no support. It should be remembered that in the preparation of the body by the undertaker the rigidity may have been overcome by force; this is especially true of the elbows. Be careful, on the other hand, not to be deceived by previously existing ankylosis.

Rigidity disappears more quickly in cachectic subjects, and is sometimes almost entirely absent in heat-stroke. It may be overcome by the use of hot applications, but when it has once disappeared it seldom returns and is never again so pronounced as at first. Strychnine and other spinal poisons, as *veratrum viride*, and suffocation cause long-continued post-mortem rigidity. In one of my cases of strychnine poisoning rigor mortis was present on disinterment twenty-four days after death.

The color of the skin varies: it rarely possesses the rosy hue of health, but is rather of a light grayish white, most conspicuous in cases of poisoning by the chlorate of potassium. The skin on those parts which have been exposed to the sun is generally more or less tanned. The color in jaundice varies from the faintest tinge of yellow to a dark yellowish brown. The pallor due to loss of blood is often so marked as to suggest the possibility of internal hemorrhage, as from the rupture of an aneurism or of the sac in extra-uterine pregnancy. The cachexiæ of cancer, argyria, etc., are at times peculiarly conspicuous in the dead body. The color of the integument in argyria is similar to that of living persons when they are exposed to the light produced by burning a solution of salt and alcohol in a dark room. The patches of bronzed skin, alternating with affected areas, seen in Addison's disease, may be scattered over the entire body, but are especially well marked on the abdomen; they are also sometimes found upon the mucous membrane of the mouth. This bronzing may occur when the suprarenal bodies are still apparently normal. Moles, tattoo-marks, and certain cutaneous diseases, such as vitiligo, leucoderma, etc., cause discolorations of the integument peculiar to themselves. Redness of the skin may be due to the wearing of red underclothes.

Parchment-like spots are often seen on the body where the epidermis has been robbed of its protecting epithelium. Such areas are



due to drying of the part, and if produced during life there will usually be found some ecchymotic spots surrounding them. When seen around the mouth, they suggest the possibility of the previous introduction of such agents as strong acids (including carbolic) and alkalies. The drawn-up and wrinkled appearance of the skin known as "goose-flesh," or *cutis anserina*, is especially conspicuous after drowning. The scrotum here is markedly contracted and the testicles are drawn up.

Note the presence of bed-sores, blisters (remember that blisters found on dead bodies are sometimes due to carelessness in the use of hot-water bags or bottles during the final illness), the marks of saline injections (dermatolysis), hypodermatic injections, and cupping. In a recent case posted by me the trocar had penetrated the lung and given rise to abscesses, which resulted in the death of the patient. In another case the exploratory needle used in searching for a right-sided pleural fluid penetrated the liver and gave rise to a fatal hemorrhage. Scars made by the hypodermic needle in persons addicted to the use of morphine are usually found on the arms and thighs,—*i.e.*, in those situations which are hidden by the clothes and yet are easily accessible to the individual. Small abscesses containing pus are often present in these cases. Hypodermic injections by physicians shortly before death are usually made over the deltoid muscles or the breast, this region being selected owing to the quickness with which the drug is here absorbed into the general circulation. The punctures may be surrounded by an elevated white or reddish area similar to that produced by the application of cups.

Many signs of inflammation, especially of the mucous membranes, disappear soon after death. Enlargement of the superficial lymph glands (especially in the inguinal region as found in syphilis) should be noted. Even an extreme eruption of measles may disappear after death. If it is desired to study such lesions, or others which disappear *post mortem*, it will be necessary to mark their location during life with a dermographic or anilin pencil or by the use of silver nitrate.

General or local œdema is noted, especially as to its extent and the character of the pitting on pressure.

Ask if the eyes and mouth were open or closed when death occurred, and find out if the expression was peaceful or the countenance distorted. Note the color of the eyes. Look at the pupils, corneæ, and conjunctivæ, taking care to close the eyes after they have been examined. Jaundice, especially in the negro, may best be seen in the con-



junctivæ. Examine the eyes for arcus senilis. The size of the pupils is best estimated in millimetres. In death from chloroform the pupils may remain enlarged; in opium poisoning the pupils often expand shortly before or after death.

Note the color, length, quality, amount, distribution, etc., of the hair on various parts of the body, as the scalp, eyebrows, eyelashes, axillæ, pubes, breasts in the male, etc. Pass your fingers through the hair, if it be at all thick, to discover injuries, tumors, etc., which it may conceal. Should these be discovered the hair may be parted so as to examine them more carefully, or it may be cut or partly shaved off; in injuries to the head, however, it will usually be found that this has already been done by the surgeon. The region of the neck should be carefully inspected for finger markings, scratches, rope markings, etc. The neck should be rotated so as to see if a fracture or a dislocation exists.

The condition of the teeth and gums should next be determined. Hutchinson's teeth may be discovered.

Look for lineæ albicantes, and always examine the breasts of women and note the presence of fluid or tumors. The character of the fluid in abortion is especially to be noted. Supernumerary nipples are not uncommon, and a well-formed breast with its nipple may be found in the axilla.

In cases of death by electricity the points of entrance and exit of the current ought to be carefully sought for, and the shoes should be examined for the burns which are usually seen near the nails in the heels.

Examine the skin for any abnormal marks, such as eruptions, scars, wounds, bruises, blood, dirt, etc.; it is possible for a wagon or even a street-car to pass over the body without leaving any trace on the skin other than a brush-burn.

Discharges from the ear, nose, mouth, vagina, urethra, or rectum should not be overlooked, and foreign bodies found in any of these orifices should be noted.<sup>1</sup> See if the secretion is fluid or dried, watery or purulent. Note its color and odor. In rape any vaginal secretion should be examined microscopically for spermatozoa and *Gonococci* and the condition of the hymen noted.

---

<sup>1</sup> The creation of the office of coroner in England was due to the pouring of molten lead into the ear with homicidal intent.



Do not neglect the examination of the back, which may readily be made by turning the body on one side. The anal region should be inspected for fissures, fistulæ, eruptions, etc. The part is often distorted by the previous introduction of cotton by those who have had charge of the body.

Examine for scars on the genitalia (when on the glans penis or prepuce they are usually of syphilitic origin) and on the mucous membrane of the mouth. Look for herniæ, hydrocele, etc., and for external parasites, such as pediculi. Lice upon the body or head are often associated with alcoholism; pediculi crack with a loud noise when thrown into a hot fire. These annoying parasites may be quickly and effectually disposed of by saturating a towel with chloroform<sup>1</sup> or kerosene and placing it upon the head for a few moments preparatory to removing the brain.

See if the penis is erected; it is often found in this condition after death by hanging. Injuries to the spinal cord may give rise to similar conditions. I have often seen after drowning erection of the penis due to the formation and collection of gases from decomposition in the loose areolar tissue. Note if the prepuce is moist from the escape of urine; if the discharge is purulent, search for the *Gonococcus*.

Observe the condition of the extremities, especially as regards the presence of injuries, dislocations or fractures, deformities, gouty deposits, etc., and the lobes of the ear for tophi. Examine the tibiæ for thickening of its periosteum, etc.

After the body has been carefully inspected it should be examined by palpation and percussion, but in handling it care should be taken not to disturb the relations of the contained viscera. Consolidation of the lungs, enlargement of the spleen, liver, etc., may be revealed by palpation or percussion even when the organs are not in their normal positions.

The odors of many drugs, such as carbolic acid, oil of bitter almonds, etc., may be detected from the mouth. The odor of alcoholic beverages can best be noted from the brain. Certain diseases, as small-pox, have characteristic odors. In one of my cases of poisoning by ammonium hydrate a rod dipped in hydrochloric acid when held near the mouth gave off fumes of ammonium chlorid.

---

<sup>1</sup> Formalin may be used if it can be applied several hours previous to the post-mortem, but its fumes are so irritating as to forbid its application when the autopsy is to be made immediately afterwards.



In a male infant observe whether the testicles have descended. In a female child see if the ovary lies in the canal of Nuck. Examine the regions where hernia is apt to occur. In a new-born babe look for vernix caseosa and pay special attention to the umbilicus and its vessels.

An entire chapter might easily be written on the significance and value of scars induced by various means. Those made by the surgeon are often from their location self-explanatory.<sup>1</sup> It would, however, certainly facilitate matters, in this age of numerous hospitals and frequent operations, if the absence of organs removed by operation were indicated by some method which would be generally understood. Thus, the first letter of the Latin name of the part excised followed by the sign minus might be tattooed on the skin near the initial incision; *e.g.*, A— would show that the appendix had been removed, R— that nephrectomy had been performed, etc. The presence of scars may lead the obducent to think of herpes zoster, cupping, smallpox, chicken-pox, various skin diseases, as acne and syphilis, explosions, setons, certain occupations, etc.

---

<sup>1</sup> The writer once desired to secure for a friend some fresh testicular tissue, and hurried to a recent suicide for the purpose of obtaining the testes. Finding scars on the scrotum, but no testicles, it was learned on investigation that these organs had been removed several years previously, and the young man had committed suicide because for this reason he was unable to marry.



## CHAPTER VI

### TECHNIC OF EXPOSING THE ABDOMINAL CAVITY AND THE TOPOGRAPHICAL EXAMINATION OF THE PARTS CONTAINED THEREIN

AFTER the completion of the preliminary examination of the exterior of the body, having placed all necessary instruments in order upon a board or tray,<sup>1</sup> and having plenty of basins and water, with sponges and towels, the operative part of the autopsy may be begun.

The operator should stand so that when facing the body the incisions from the head towards the feet can be made with the greatest ease. Thus, it is best for right-handed operators to stand on the right side of the supine subject. The body should be drawn well to the side of the table nearest the operator, the head resting at the top of the table and the shoulders supported by a block.

With the knife held in the manner previously described (page 38), as nearly horizontal as possible, a clean incision (Fig. 43) should be made by a single sweep from the interclavicular notch (*A*) to the symphysis pubis (*B*), passing to the left of the umbilicus (*C*) in order to avoid the round ligament and any vessels going to and from the navel, care being taken not to penetrate the abdominal cavity and thus injure the contained viscera, or extend the incision to the external genitalia (Figs. 46 and 47). On the chest this primary incision goes down to the bone, whereas on the abdomen it penetrates only to the muscle-sheath. In Europe the initial incision is usually made at the middle of the chin,—*i.e.*, starting at the symphysis menti and ending at the symphysis pubis; for there, as a rule, only those who die in the hospitals reach the post-mortem table, autopsies being seldom performed on the bodies of persons belonging to the upper classes, who would naturally object to the disfigurement entailed by this method. In this country the longer incision should be used only when great haste is necessary, as in cases of contagious diseases, such as diphtheria, or when the body is not to be seen again by relatives or friends.

---

<sup>1</sup> A towel may be laid over the external genital organs and the upper parts of the thighs, upon which the instruments to be used in the performance of the autopsy are placed with their handles towards the obducent.



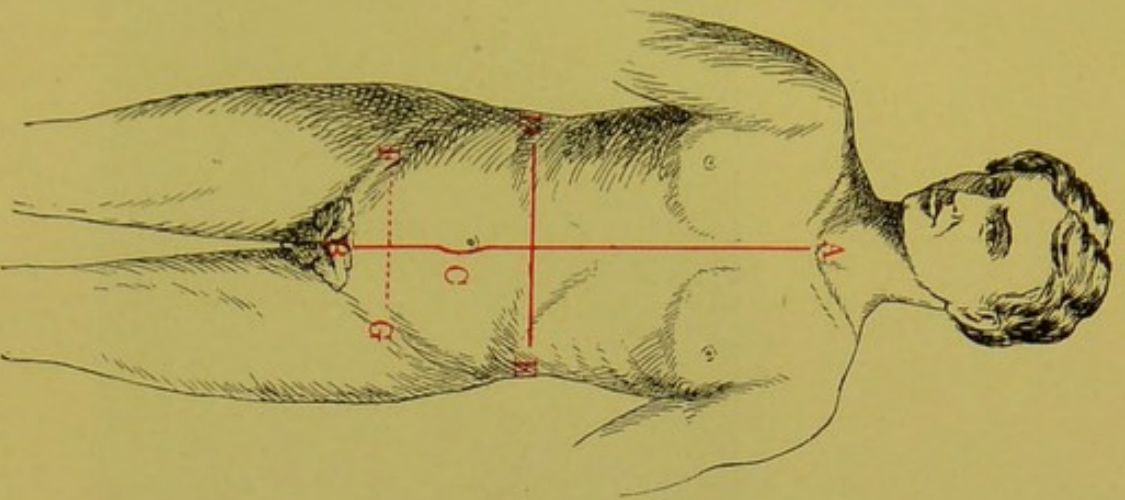


FIG. 43.—Scheme to show the lines for incising the trunk and exposing more fully the abdominal cavity. The primary incision, *A B*, from the interclavicular notch to the symphysis pubis, goes to the left of the umbilicus at *C*. The transverse incision, *D E*, and the cutting of the rectus muscles at *F G*, are for the purpose of enlarging the abdominal opening.

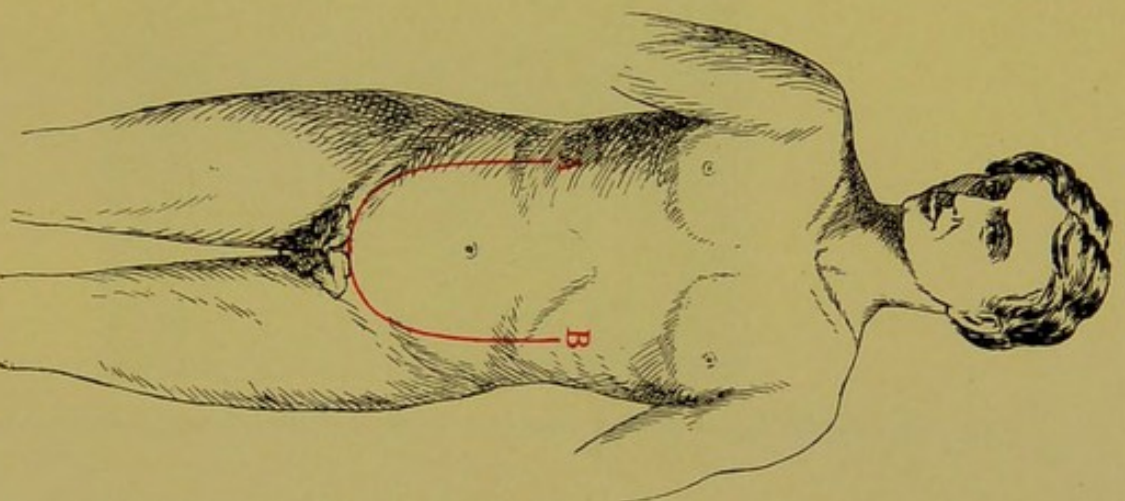


FIG. 44.—Elliptical incision for examination of the abdominal cavity; sometimes useful after abdominal operations and in infants who died from inflammatory conditions of the umbilical vessels.

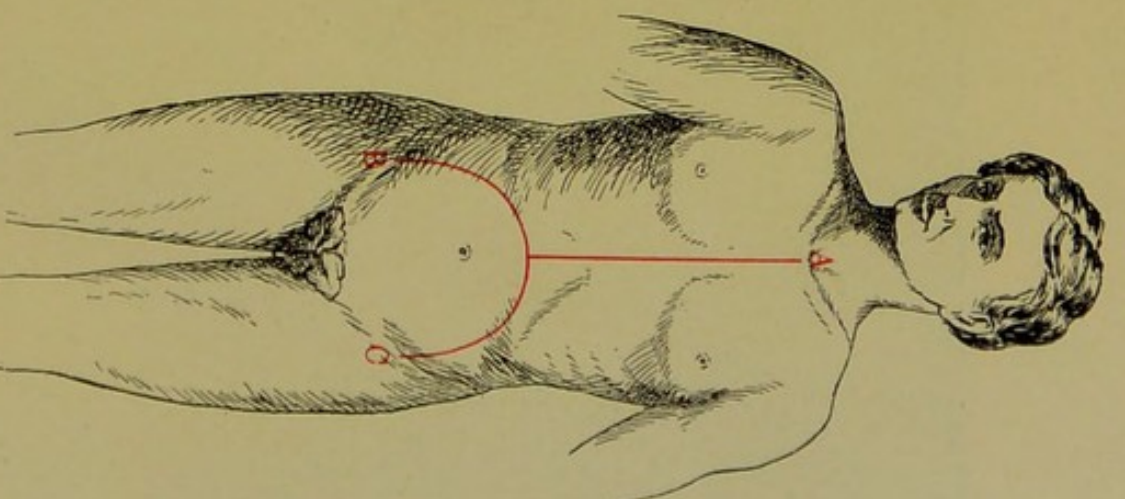


FIG. 45.—Incision sometimes useful after death following operation in the abdominal cavity.



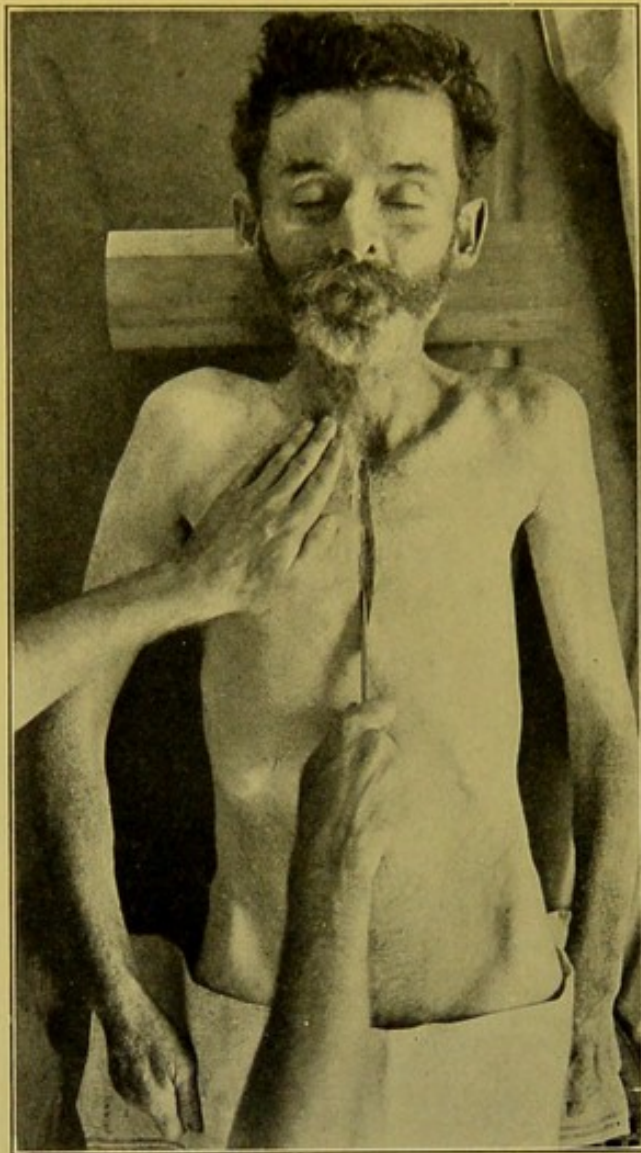


FIG. 46.—Method of making the initial incision over the sternum, as seen from above.

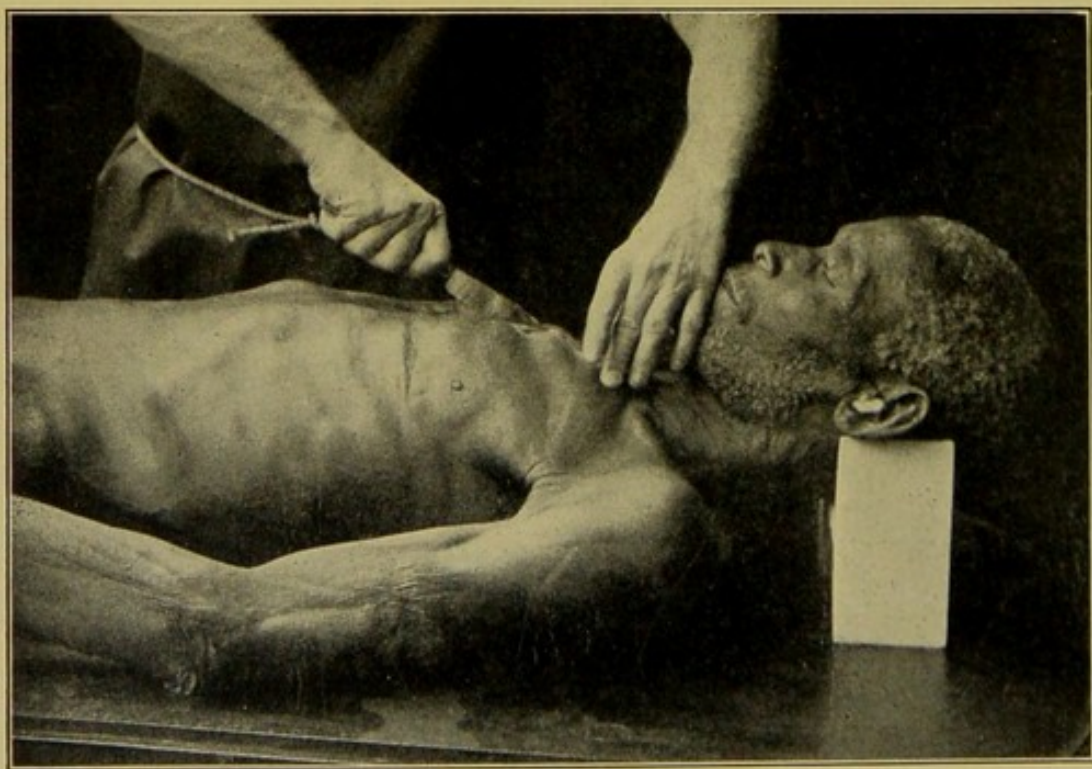


FIG. 47.—The same incision as in Fig. 46 somewhat extended, as seen from the side.



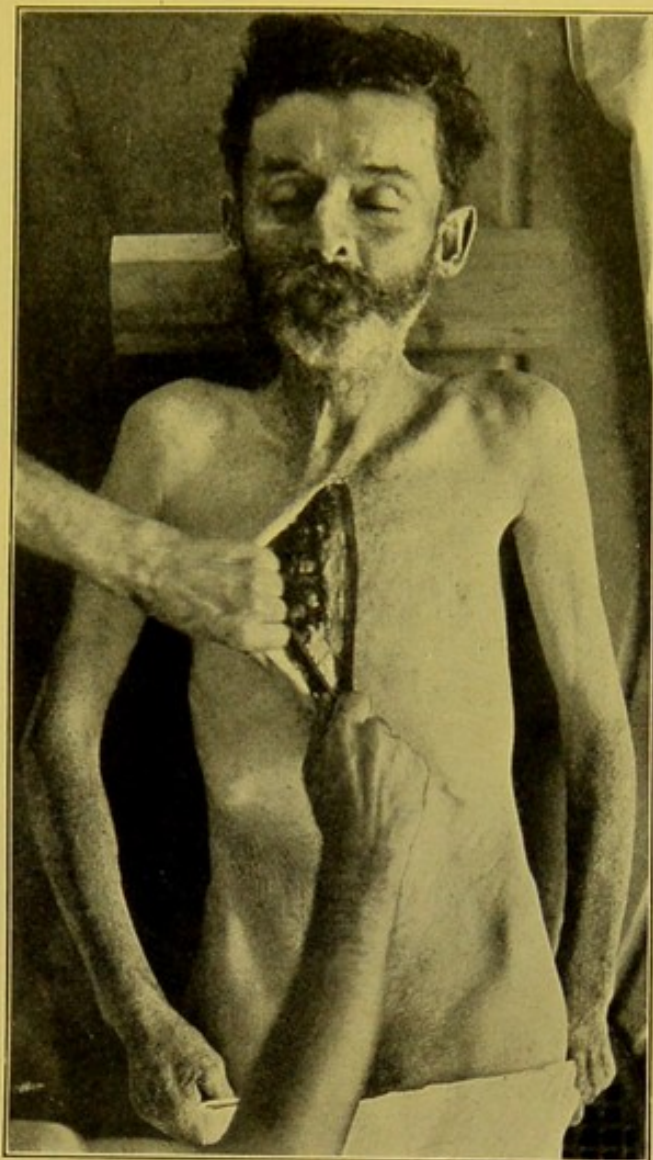


FIG. 48.—Method of raising flap on right side so as to expose sternum and ribs, as seen from above.

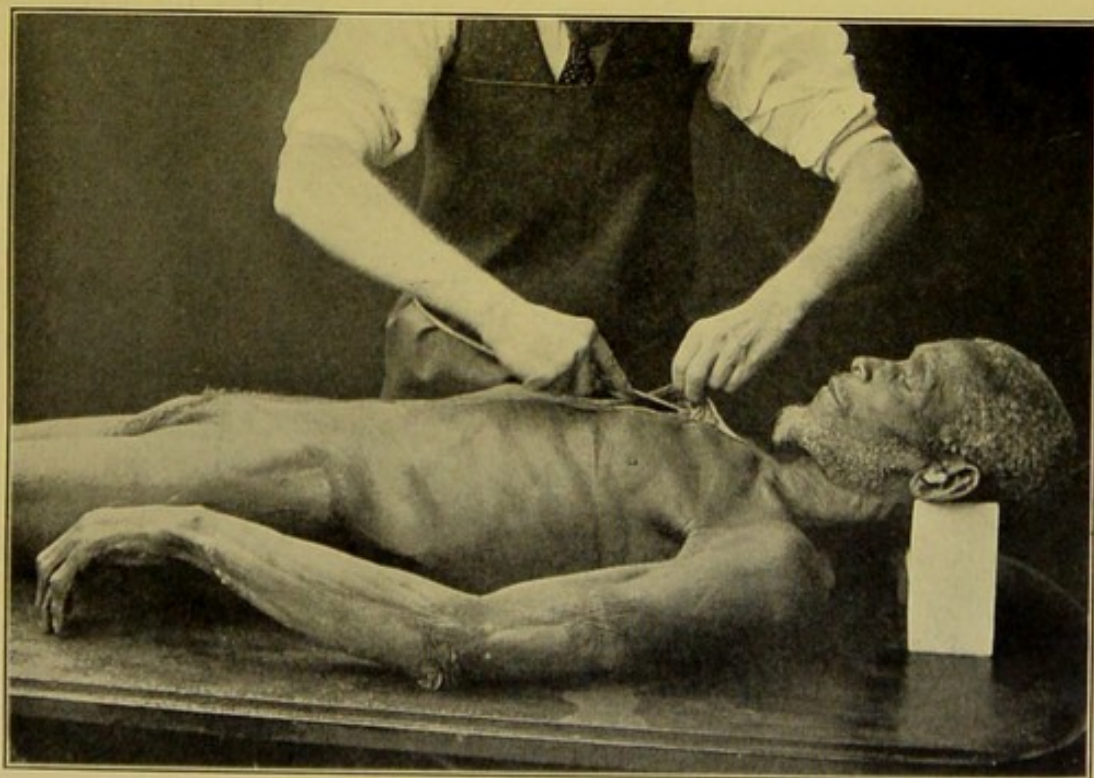


FIG. 49.—Same incision as in Fig. 48 somewhat extended, seen from the side.



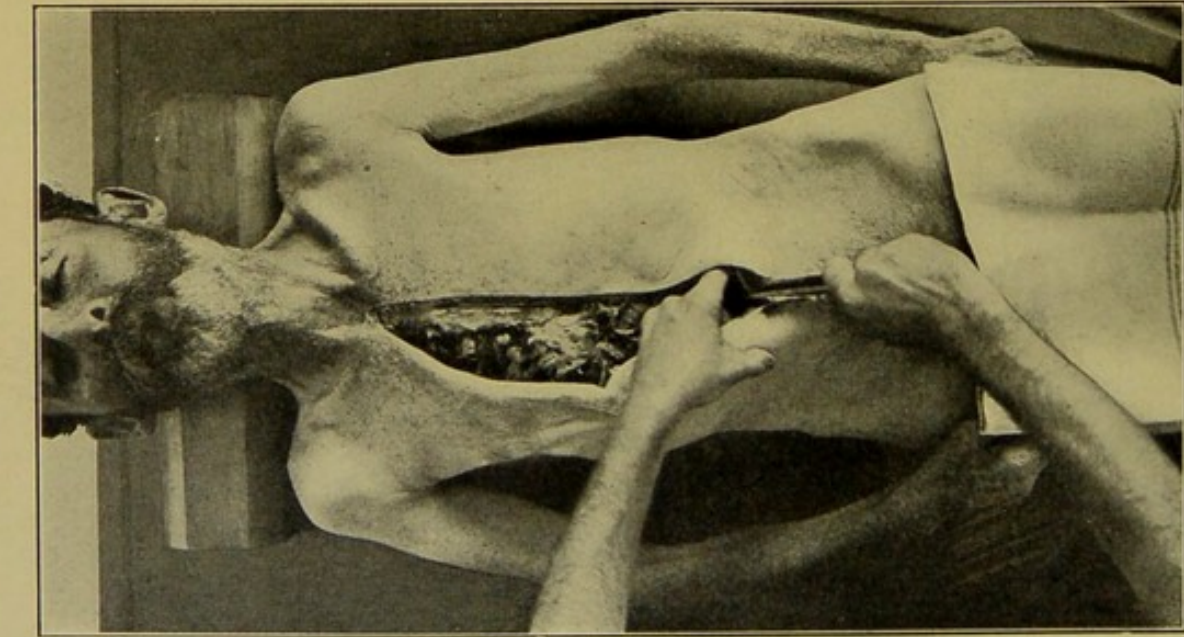


FIG. 50.—Method of opening the abdominal cavity. The index and middle fingers being stretched apart, the abdominal wall is lifted off the viscera so that the cutting may safely be done from above downward.

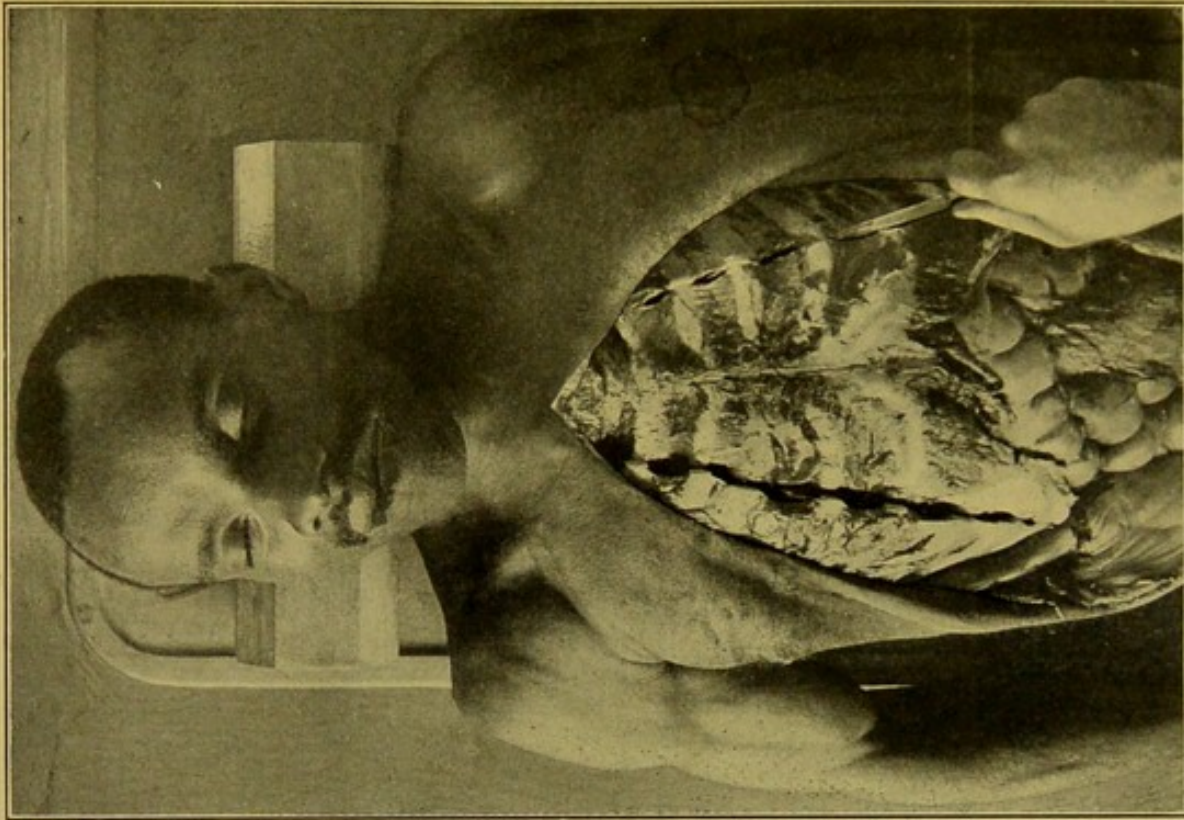


FIG. 51.—On the right side the cartilages have been cut through near their junction with the osseous portions of the ribs. On the left side the fifth rib is about to be cut through, the knife being introduced below it and the cutting done upward, using the sixth rib as a fulcrum.



The initial incision over the thorax is now carried down to the sternum, and the layers of skin, fascia, and muscles of the right side are quickly dissected away close to the ribs, freely exposing the costo-cartilaginous articulation and some three inches of the sternal end of the clavicle. To do this the attachments of the soft tissues are made tense by drawing them from the median line (Figs. 48 and 49), making long sweeping incisions downward and laterally with the large section-knife. The left side may next be similarly treated, though in practice this is more frequently done after the abdominal incision has been completed.

Should a pneumothorax have been diagnosed during life, the thoracic pocket made by elevating the skin flap on the side of the pneumothorax is filled with water and a puncture made at the bottom through the costal pleura between the sixth and seventh intercostal spaces at the axillary line. If a pneumothorax be present, bubbles of air will escape. If the head be lowered and the supply of water be sufficient, this will finally escape from the mouth. It should be remembered that a cavity in the lung opened by the initial incision would give the same result as that found in a pneumothorax.

A note is now made as to the situation and character of any blood which may escape. The character of the fat (*panniculus adiposus*) is considered, and its thickness noted at the nipple-line below the xiphoid and again three inches below the navel. In atrophy the color of the fat becomes darker, changing to orange or reddish yellow. The tissues here are often œdematous, as in general dropsy or erysipelas. As a rule, the older the individual the darker in color is the fat, varying from straw-color in children to dark yellow later on in life. Different species of animals have different colored fat, depending upon the difference in its chemical composition. The mammary glands may now be examined from behind, and, if desired, the glands of the axillæ may be exposed by continuing the dissection of the pectoral muscles from beneath.

The muscles here included are those of the neck, chest, and abdomen. Both a transverse and a longitudinal section are necessary to a complete study, and the following general characteristics should be observed in all muscles.

(a) *Size*.—The external examination has already noted any marked changes in bulk. The muscles may be atrophic or hypertrophic.



(b) *Color*.—Normally this is a bright red, but in anæmia it becomes paler, at times a grayish red. In typhoid fever a dark red color is often found; at other times in typhoid, as well as in diseases where the muscles have long been inactive, a grayish translucent appearance is observed,—waxy degeneration. In general it may be said that the color and consistence of the muscles bear a distinct relation to each other: pale muscles are usually soft, while the darker muscles are more firm. The muscles are dry when much fluid has been carried off by the alimentary canal, as in typhus and cholera, and moist in disturbances of the circulation.

(c) *Cut Surface*.—The usual moist glistening appearance may be lost in typhoid, while in œdematous conditions considerable fluid may ooze out.

These general characteristics having been observed, the pathological conditions to which these muscles are subject are not liable to escape detection. The important pathological conditions are:

1. *Hemorrhages*.—These may result from trauma, wet cups, etc. A special form of bleeding into the rectus may occur in typhoid fever,—“*hæmatoma recti abdominis*.”

2. *Inflammations*.—Under these are included:

(a) *Acute Interstitial Myositis*.—This is suppurative, and may be primary, from trauma, or secondary, in the muscles of the chest, to pleural affections, or, in the muscles of the abdomen, to pelvic suppuration. This inflammation does not, as a rule, produce true abscesses, but infiltrates the muscle and separates the fibres, which undergo a fatty or hyaline degeneration.

(b) *Chronic Interstitial Myositis*.—The interstitial connective tissue is increased so that at times it is visible to the naked eye, the muscle-fibres are atrophied, the color becomes a grayish red, and the muscles feel hard. This condition is generally associated with diseased states of the neighboring parts,—*e.g.*, affections of the ribs, pleuræ, cervical glands, etc.

(c) *Parenchymatous Myositis*.—The muscle is paler than normal. Microscopical examination is necessary in order to determine whether the change is cloudy swelling, hyaline, or fatty degeneration.

3. *Parasites*.—The most important parasite is the *Trichina spiralis*, which, especially when calcified, may be seen with the naked eye. These organisms are found most frequently in the muscles of the neck and in the intercostals near the attachment of the diaphragm. In the



muscle itself the site of election is close to the portion where the tendon unites with the muscle proper. In old cases the calcified capsules are easily recognized as small, white, oval bodies, which when present in large numbers look like grains of white sand. In order to see the parasite the capsule must be dissolved with hydrochloric acid. In earlier stages the animal is less readily seen, and its detection is made easier by pressing a teased portion of muscle between two glass slides and observing it by transmitted light. Non-encapsulated trichinæ cannot readily be seen without the aid of the microscope.

A series of light incisions over the abdominal cut is made between the umbilicus and the xiphoid cartilage until a small portion of the peritoneum is exposed.<sup>1</sup> The peritoneum should then be carefully opened and a note made of the presence or absence of gas or fluid.

If it be desired to determine the presence and the character of gas in the abdominal cavity, the incision is made down to the peritoneum, either two inches above or the same distance below the umbilicus, and the abdominal walls are elevated with the fingers or a tenaculum so as to form a pouch, into which water is poured. A test-tube is then filled with water and inverted, and a small incision is made through the peritoneum under the mouth of the test-tube so as to allow the escape of gas into it. The test-tube is then tightly closed by pressing a thumb or finger up against its mouth, and placed in a shallow dish containing sufficient water to seal the open end of the tube. If a lighted match is held close to the point where a knife is pushed into the chest, any gas escaping deflects the flame. It should be remembered that certain gas-forming organisms may be the cause of the collection of gas in the serous cavities. The recent discovery of hitherto unknown elements in the air makes the study of aggregation of gases here an extremely interesting one. If the gas has an acid odor, a perforation in the wall of the stomach is to be suspected.

If fluid be present, as in ascites, just enough should be removed to facilitate the determination of the height of the diaphragm. The height and location of this muscle may be determined by introducing the hand, palm upward, or a steel sound into the abdominal cavity and following the under surface of the diaphragm as far as possible. The

---

<sup>1</sup> Should a bacteriological examination be required, a portion of the peritoneum is seared with a hot knife before opening it and the abdominal cavity is incised with a sterilized knife.



tips of the fingers or the end of the sound should be carried to the point of least resistance and this spot sought for with the other hand from without. The vault of the diaphragm extends to the fifth rib on the left side and to the fourth rib or fourth interspace on the right. Both sides are measured in the line of junction of the ribs with the costal cartilages. The greater height on the right is due to the liver, which forces the diaphragm upward. Increase in the abdominal contents, as by tumors, pregnancy, hypertrophy of the spleen, etc., pushes the diaphragm upward. On the right side by hypertrophy of the liver it may reach the level of the second rib. Increase in the thoracic contents naturally presses the diaphragm downward. Along with the depression is a sense of fluctuation in cases of hydrothorax. The position of the diaphragm in a new-born child helps to determine whether or not it has breathed. Before respiration has occurred the summit is found on a level with the fourth rib on the right side, and on a level with the fifth rib or the fourth intercostal space on the left. After full expansion of the lungs has taken place, the summit is found at the fifth or sixth rib on the right, and at the sixth rib on the left (Orth).

The opening may now be somewhat enlarged and additional fluid removed with a syringe, cup, or large pipette, measured, and its character noted. The remaining portion may afterwards be removed from the various folds and pouches in the peritoneum by a sponge or small cup. The amount of fluid normally present is very small, not usually exceeding a teaspoonful; it may be lemon-yellow, red, or brown; icteroid or milky; watery, thick, gruel-like or even semisolid. The removal of liquid at this stage of the operation prevents its admixture with blood, as from an accidental incision made in the liver while cutting the costal cartilages, or with other fluids of the body, such as those from the pericardium, the pleura, the bladder, or various portions of the intestinal tract.

In cases of increased amount of fluid it is of importance to distinguish between a serous transudate and an inflammatory exudate. When large amounts of pus and fibrin are present, the differentiation is easy, as a transudate contains neither. Difficulty arises when a clear watery fluid is found in which minute flocculi are seen, as these may be either small flakes of fibrin and pus-cells or small collections of washed-off endothelial cells. The differential points may be tabulated as follows:



## TRANSUDATE.

Fluid clear and watery.  
 Alkaline reaction.  
 Flocculi are thin, veil-like, and of a transparent gray color.  
 Specific gravity usually below 1016.  
 Albumin usually below three per cent.  
 Microscope shows the flocculi to consist of flat cells with large nuclei and lymphocytes.

## EXUDATE.

Fluid thick and ropy.  
 Acid reaction.  
 Flocculi are thick, opaque, and of a grayish-white color.  
 Specific gravity usually over 1016.  
 Albumin usually above three per cent.  
 Microscope shows the flocculi to consist of fine threads and polynuclear leucocytes, the nuclei of which appear more distinctly on the addition of acetic acid.

Milky exudates are of two kinds, fatty and chylous. The former excretion has been found in connection with peritoneal and mesenteric cancer, and is recognized by the fat-globules seen on microscopical examination. Mild cases may be due to the fact that the patient was on a milk diet and had a lipæmia, a dyscrasia also found in diabetes (Osler). A chylous exudate results from the perforation of the thoracic duct or the receptaculum chyli.

Suppurative exudates are thick, yellowish, and contain much fibrin, which is deposited on the peritoneum and bowel in layers. The odor, which is peculiarly nauseating, is due to the *Bacillus coli communis* or to fecal masses, as in perforation; this process is usually an acute one.

A hemorrhagic exudate or fluid may be non-inflammatory, as from trauma (rupture of the liver or spleen or extra-uterine pregnancy) and from some cases of cirrhosis of the liver, or inflammatory, as in cancerous and tuberculous peritonitis. Pure bile, most frequently mixed with blood, may be found in the abdominal cavity from injury of the gall-bladder or the bile-ducts.

A single finger is now introduced into the opening previously made in the abdominal cavity, the flap of skin is elevated, and the incision is somewhat lengthened. Then the index and middle fingers of the left hand, held V-shaped (Fig. 50), palm upward, are thrust under the abdominal wall in order to raise it above the intestines so as to prevent injury to them in the subsequent incision, the fingers acting as a director while the cut is continued to the pubes. If there be much meteorism, the index-finger of the left hand can be introduced and held against the parietal peritoneum. If scissors be used, the lower blade may be guarded by the fingers of the left hand when the cut is made. Another method is to make strong traction on the right



abdominal flap in the direction of the operator's head and when the part is well elevated above the intestine cut from without inward. The cutting should preferably be done from within outward, great care being taken not to puncture or injure any of the abdominal viscera. It is well to break up adhesions with the index-finger. Should the intestinal tube be accidentally opened, it is best to stop at once and tie both above and below the opening in order to prevent the escape of the contents of the bowel into the peritoneal cavity.

If it be desirable to enlarge the opening in the abdominal wall (Fig. 43), a second incision (*D E*) may be made, at right angles to the first one and about three inches above the umbilicus, or the rectus muscles on one or both sides of the body may be divided subcutaneously a little above Poupart's ligament (*F* and *G*). Should there be a penetrating wound of the abdomen, as from a dagger or a previous coeliotomy, the abdominal incision may be changed at will (Figs. 44 and 45). When the contents of the stomach are found in the peritoneal cavity, care must be taken to determine whether their escape was due to post-mortem digestion, to erosion of the coats of the stomach, or to perforation from a gastric ulcer. In the first case the gastric contents are found in the immediate neighborhood of the perforation and the rent is large; while in the latter cases the opening is small and circular, the ingesta are usually widely distributed throughout the abdominal cavity, and signs of peritonitis are present.

Undigested food in the peritoneal cavity points to its exit from the stomach; when digested food or fæces are present, the seat of injury is the bowel or duodenum, and, if the latter, the material is usually stained with bile. The presence of such material, when not escaping through a traumatic opening, is usually due to the perforation of a round ulcer, to autodigestion, or to putrefaction. Autodigestion is especially frequent in cachectic children. In perforation from this cause the loss of tissue is greater and the opening more irregular than in one caused by round ulcer, the walls are soft and slimy, blood and peritonitis are absent, and the intestines have a blistered appearance due to the corrosive action of the gastric juice. From the fact that the autopsy is usually performed some time after death, the appearances presented by a round ulcer are slightly different from those seen at an operation during life, for the serous wall of a gastric ulcer may undergo post-mortem digestion and its true appearance be thus altered. Foreign bodies, which may be calcified, are sometimes found free in



the abdominal cavity; they are derived from torn-off appendices epiploicæ or polypoid tumors. Intestinal worms may escape into the peritoneal cavity through openings produced by the perforation of ulcers. Surgical instruments and appliances may be discovered in the abdomen after the performance of operations.

The abdominal cavity now being thoroughly exposed, the most striking abnormalities contained therein are to be noted. Transposition of the viscera would at once be noticed. The most marked displacements of abdominal organs which I have ever seen have been in Pott's disease and diaphragmatic herniæ.

The situation of the omentum usually comes first under observation. Normally it is non-adherent to the intestines except at its point of attachment; in purulent peritonitis it may be markedly adherent to the peritoneum covering the intestinal tract, creamy or plastic lymph appearing in streaks throughout its structure. The omentum may form a part of all varieties of hernia found in the abdomen; it may be present alone in the hernial sac, or the intestines may become strangulated by passing through an opening in it. The amount of fat deposited within its layers varies considerably, being in some cases practically absent and in others as much as half an inch in thickness. During health the omentum is rich in fat, which disappears early and rapidly in emaciation. By atrophy of the connective tissue, openings, some of which may be of large size, are produced. Normally the layers are readily separable, and when spread out form a beautiful picture of a delicate, thin, transparent membrane, with irregular deposits of fat, and showing the blood-vessels partly filled with blood. It is a favorite seat of fat necrosis, tuberculosis, and generalized cancer; in the last two conditions it may be so contracted upon the transverse colon as to be hardly visible and only separable therefrom with the greatest care. Enlarged glands, encysted parasites, infarcts, supernumerary spleens, etc., may be found. It may, even when normal, be rolled upon itself, forming an integral part of the transverse colon or the greater curvature of the stomach.

The transverse colon may be U-shaped, extending to the bladder; it may or may not drag down the stomach. In some cases it forms peculiar S-shaped curves; in others the hepatic and splenic flexures may be markedly deficient.

Note if the gall-bladder extends below the liver, and if so to what extent. Follow with the hand the upper surface, first of the right lobe



and then of the left, in order to determine their extent, noting the height and the distance to which they extend below the ribs. The tips of the right and left lobes of a large liver sometimes almost meet at the vertebral column. The left lobe may extend downward like a beaver's tail, and from tight lacing the whole organ may be divided into an upper and a lower portion by bands of connective tissue containing the biliary vessels and a few liver-cells. Extra lobes are very common; some of them even take the form of supernumerary livers. This condition may be congenital, but is more frequently due to syphilis. In one of my syphilitic cases the liver was made up of more than thirty lobes, in shape resembling a bunch of flattened and distorted hydatid cysts. The liver should next be slightly raised, the pylorus examined, and the tips of the fingers used to determine the presence of calculi in the bile-ducts and gall-bladder.

The stomach is subject to marked changes in size and in situation, as from hour-glass contracture, tumors, ulcerations, etc. In the babe its situation is nearly vertical.

All the openings in which herniæ are apt to occur are next to be examined, the order of frequency being inguinal hernia in the male and femoral and umbilical herniæ in the female. Other forms of hernia are those through the canal of Nuck, the obturator foramen, or the sciatic notch; into the various fossæ about the cæcum or the fossa jejunalis; into new fossæ formed by bands of adhesion, as from extra-uterine pregnancy; from solutions of continuity in the mesentery; crural; diaphragmatic, which is often congenital, but may be due to traumatism; between the rectus muscles and through Petit's triangle; after operations, especially those on the appendix, etc.

Volvulus and invagination are not infrequently seen. True invagination is distinguished from a form which often occurs in children just previous to death, by the presence of adhesions; in the latter case these are produced in the agonal period and are multiple, sometimes as many as fifteen or twenty being found. There is a peculiar form of invagination in which the ileocæcal valve draws the ileum down into the caput coli; this condition when extreme may even cause the ileocæcal valve to appear at the anus.

The serous covering of the intestines should be minutely inspected, as the play of colors is very varied and the information gained from this examination is often of great importance. In thrombosis of the mesenteric vessels the gut may be gangrenous for ten feet or more.



Miliary tubercles are found opposite tuberculous ulcers and extend along the lymphatics; they are also seen on all the other portions of the peritoneum, often being wide-spread in tuberculous peritonitis. Small yellowish, creamy collections of lymph, with dilated lymphatics, are seen if death occurred several hours after eating; these are physiological and not pathological products, but I have known them to be mistaken for miliary tubercles and even for carcinomatous growths. The presence of typhoid ulcers may be recognized by a congested area running along the length of the intestine. The location of the vermiform appendix should always be noted, and Virchow's dictum (published in 1875, though long put in practice) should be remembered: "At least in every case of inflammation of the peritoneum the appendix is to be carefully examined." In the female an examination should be made of the uterus and its adnexa. The mesenteric glands, especially those near the ileocaecal valves, are to be carefully looked at; they are greatly enlarged in typhoid fever, where they sometimes undergo suppuration, and in children dying from inanition, where they appear as red nodes, often running together into conglomerate masses.

Cotton which has been inserted in the rectum or vagina by the nurse or undertaker to prevent the escape of fecal or other matter may be mistaken for a foreign body and may possibly have caused displacement of neighboring parts. When no extensive pathological lesions exist, the situation of the pancreas may readily be determined by remembering its connection with the concavity of the duodenum.

During this superficial examination of the abdominal cavity any needful departure from the ordinary routine may be planned. Thus, in a case of cancer of the head of the pancreas it may be advisable later on to remove this organ along with the stomach, the duodenum, or even the liver. Again, in the case of a child or when there is not time for a careful dissection, all the organs of the abdominal cavity may be removed *en masse*.

To repeat, the relative positions of all the tissues should be observed and any departure from the normal noted, and a careful search made for foreign growths, anomalies, etc., none of the parts being at this time removed from the body or their relations disturbed for further examination.



## CHAPTER VII

### TECHNIC OF EXPOSING THE THORACIC CAVITY AND THE EXAMINATION OF THE PARTS CONTAINED THEREIN

AFTER a superficial examination of the abdominal cavity (without the use of the knife) is complete, the thorax should be exposed to view in the following manner. The costal cartilages on the right side, from the second to the tenth, are cut through, one by one, from above downward, at a point a few millimetres to the sternal side of their attachments to the osseous portions of the ribs. For this purpose a heavy cartilage-knife is employed, which should be held as nearly parallel to the chest surface as possible, so that as the blade cuts through one cartilage it strikes the next one, thus preventing injury to the organs beneath. Or the knife may be introduced in the intercostal space beneath the rib that is about to be cut, using the next lower rib as a fulcrum and cutting from within outward (Fig. 51). Each lower rib is incised more and more towards the axillary line and away from the median line of the body, making the opening in the chest larger and larger as the incisions proceed down the chest. In cases where the cartilages are calcified it may be necessary to use a costotome or a saw for their division, in which event the ribs are cut outside the costochondral junction in order to allow more room for the subsequent manipulations. The second to the tenth ribs on the left side are now severed.

The right clavicle is next separated from the sternum. As its head articulates with the sternum and the cartilage of the first rib, the clavicle is grasped with the left hand and the sternal end of the bone is moved to and fro, or an assistant can produce the same result by moving the whole arm. In this way the line of articulation is easily made out and permits the part to be disarticulated by cutting downward and slightly outward, until the first rib is reached (Fig. 52), thence continuing outward along the under border of the clavicle for at least two inches. The first rib, which is generally calcified, is next cut through with a knife from below and outward or from above and inward (Fig. 53). Or, the costotome may be employed for this purpose (Fig. 54). The next procedure is accomplished by making



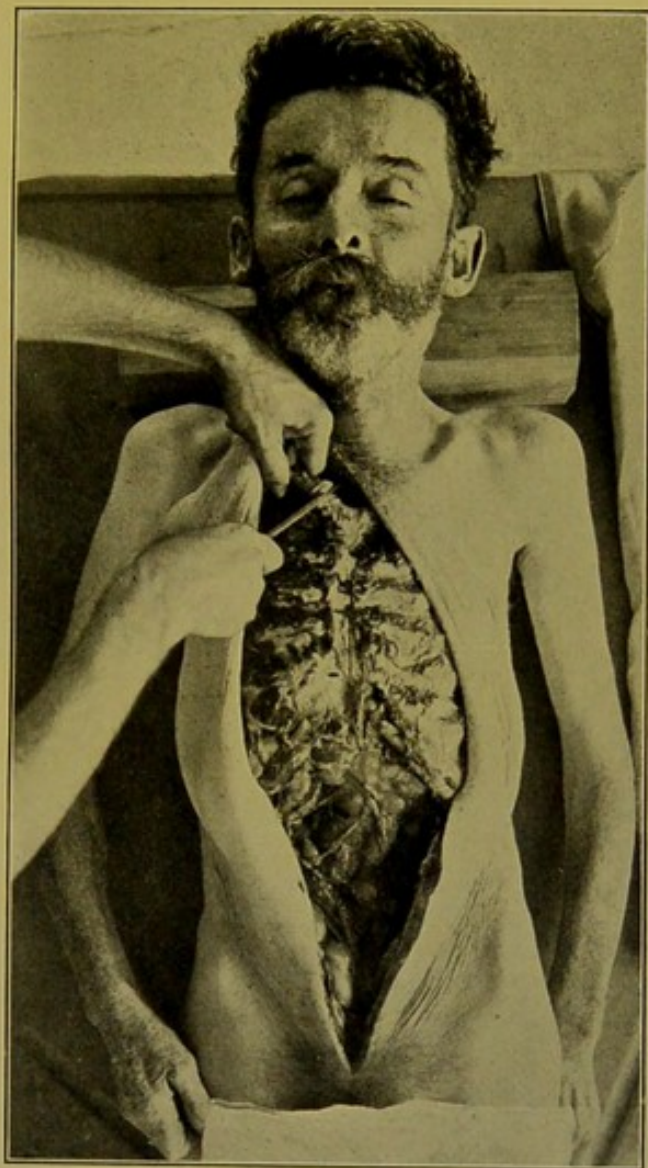


FIG. 52.—Method of separating the sternoclavicular attachment. The articulation is discovered by steadying the sternum with the right hand and moving the clavicle in opposite directions with the left hand. Unless marked ankylosis exists, incision with the knife is easy after the discovery of the articulation.



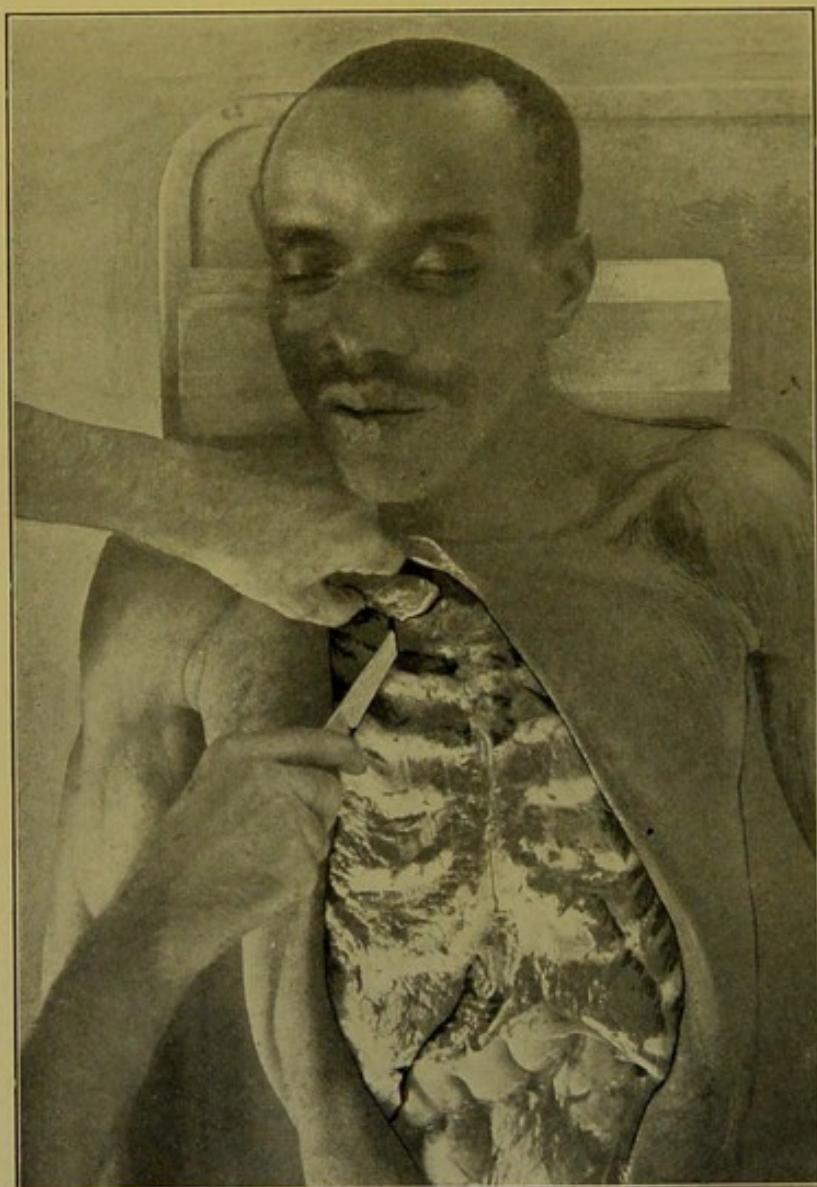


FIG. 53.—The incision through the first rib is here shown. The previous incision seen in Fig. 52 has been carried almost to the thumb, the clavicle elevated, and the incision made through the first rib.



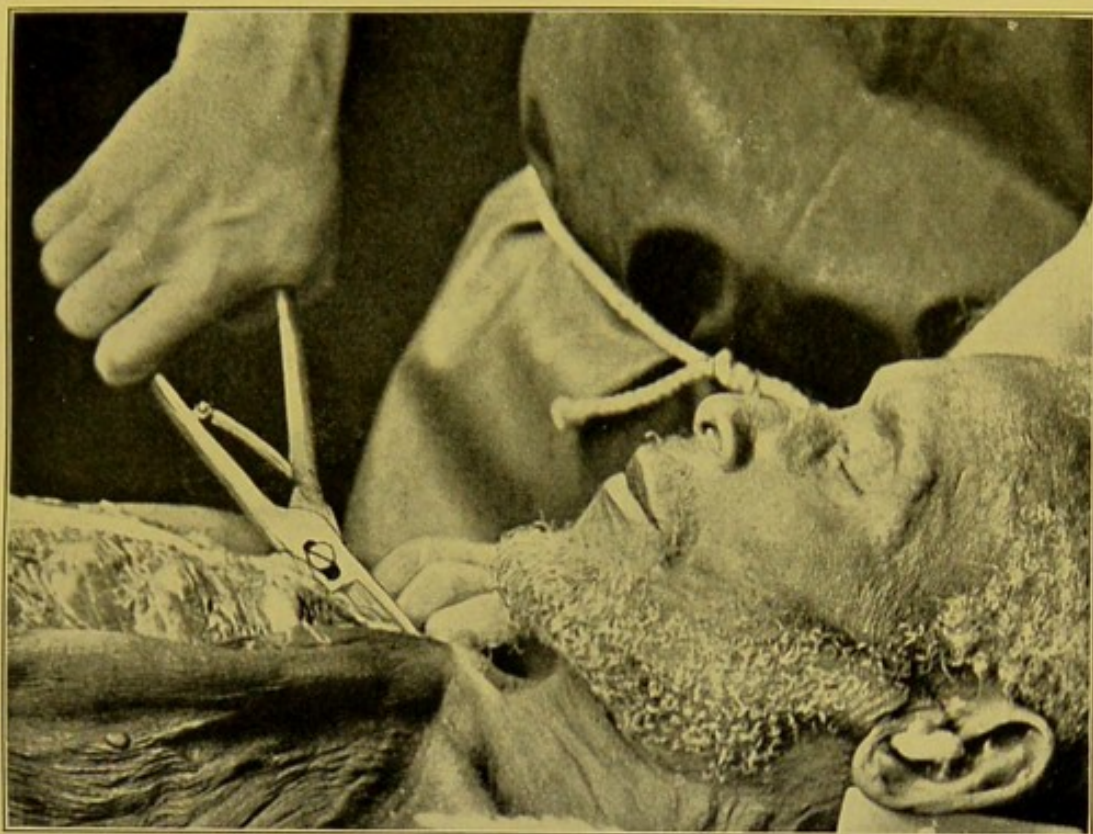

FIG. 54.—Method of incising the first rib and the sternoclavicular articulation with the costotome.

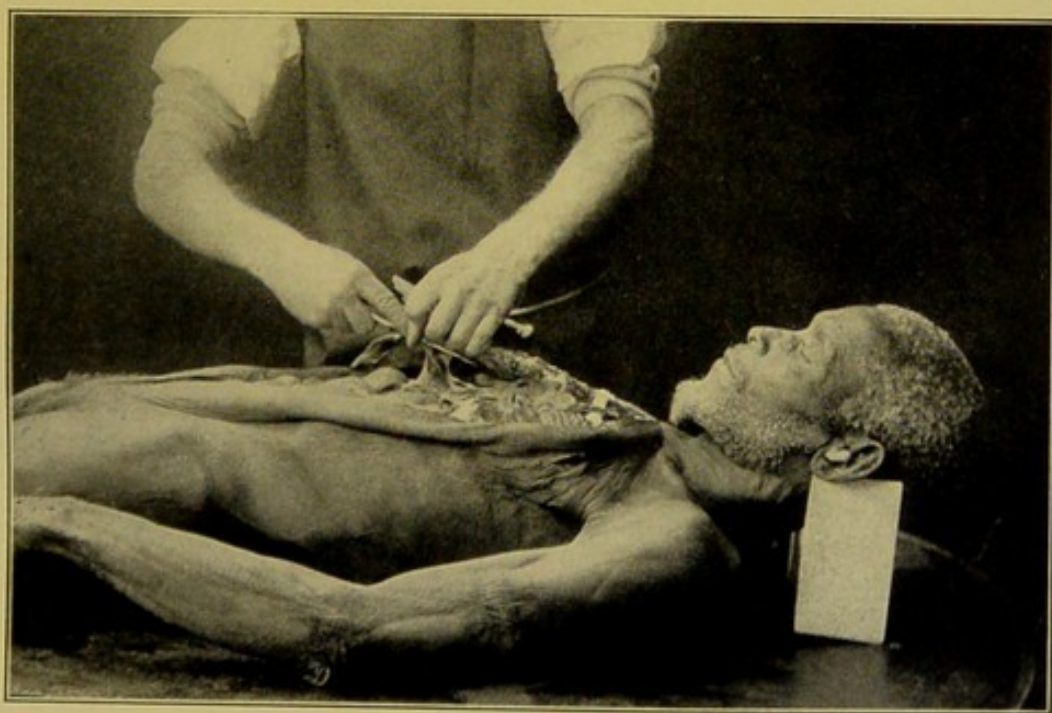


FIG. 55.—All the ribs of the right side have been severed, the sternoclavicular attachment to the first rib remaining intact on the left side. The lower portion of the sternum is elevated and traction made on the diaphragm, which is cut as close as possible to the lower border of the sternum.



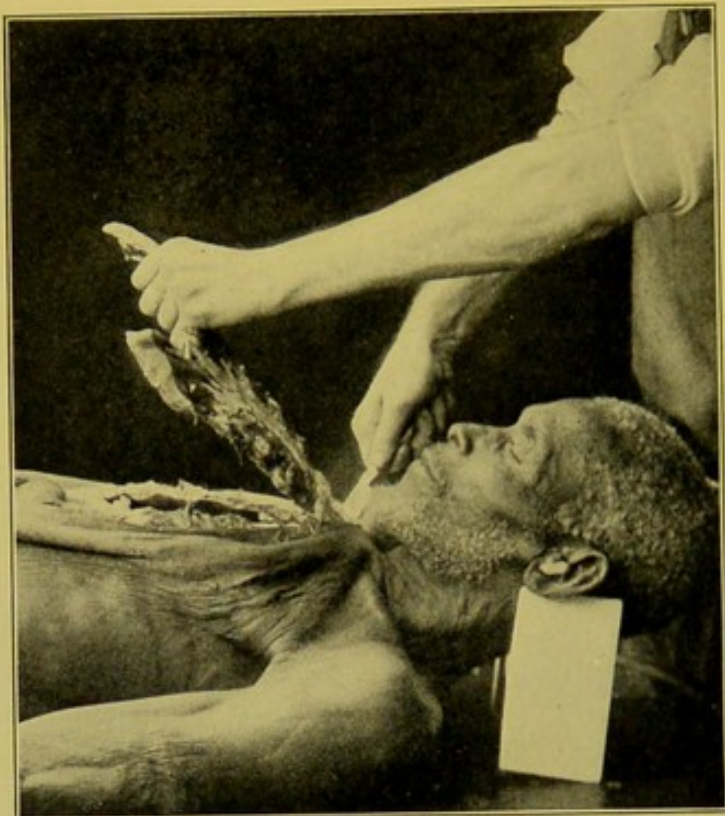


FIG. 56.—The lower border of the sternum having been freed, the breastplate is elevated and pulled upward and towards the left. The left sternoclavicular attachment is thus easily discovered, and is cut through, as well as the first rib.

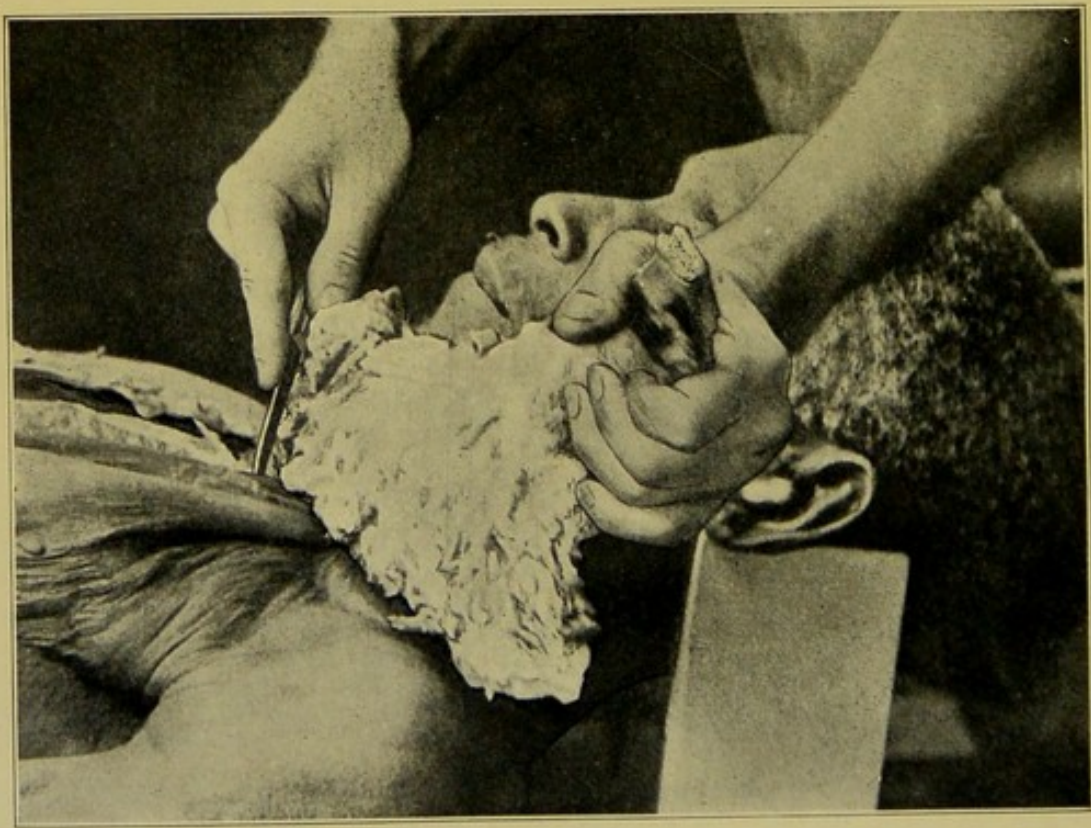


FIG. 57.—In this illustration the sternum is practically ready to be removed from the body. The knife is cutting any attachments which may not previously have been severed.



traction on the breastplate upward and towards the right. Beginning below on the left side and keeping close to the bone, the tissues are cut through with short transverse cuts of the knife (Fig. 55). All of the lower attachments having been cut, the breastplate is now elevated and any uncut tissues of the mediastinum and of the right side are incised; the sternum is pulled towards the left; the sternoclavicular attachment on this side, having been made tense, is easily discovered, and this part along with the left clavicle is severed from below (Fig. 56). The sternum is next severed, as seen in Fig. 57. The breastplate, after its removal, is shown in Fig. 58. If an aneurism or tumor be found attached to the ribs or sternum, this point of attachment is preserved by sawing through the bone some distance away. In order to protect the hands of the operator from injury, the skin flaps are now wound around and beneath the exposed clavicle and ribs (Fig. 59).

In the performance of the operation for the removal of the sternum great care is necessary in order to avoid cutting the innominate or internal mammary veins which lie beneath the clavicle and the upper part of the sternum. In Bavaria and Württemberg, in order that these vessels may not be injured, the regulations for the performance of medicolegal autopsies direct that, after cutting the cartilages from the second to the tenth in the manner described, the soft parts attached to the lower border of the sternum be divided, the mediastinal tissues separated, the lower end of the sternum strongly elevated, and the sternoclavicular connection and the first rib cut from the under side, or the sternum may be sawn through below the attachment of the first rib, leaving it and the sternoclavicular articulation intact. I do not approve of the method often used after cutting the ribs, of breaking the sternum by turning it backward just below the clavicular attachment. Though it avoids injuring the veins, it leaves an ugly place from which to receive scratches and does not give the same amount of room for the examination of the thoracic cavity and neck. Some careless operators do not even remove the bone, but while still attached turn it back over the face.

The examination of the sternum and ribs may now be undertaken. Their shape is often altered, as in Pott's disease, pigeon-breast, emphysema, perforated sternum, etc. Tuberculous caries of the sternum, often secondary to caseation of the mediastinal lymph glands, may be present, or an aneurism may cause pressure atrophy (erosion) or even perforation of this bone. A form of internal pressure atrophy is seen



in the shoemaker who holds the shoe against his breast. Fracture is not common, but may occur between the second and third costal cartilages,—*i.e.*, near the junction of the manubrium with the gladiolus. The ensiform appendix of the sternum is sometimes curled upward and outward, like a hook, in cases of hypertrophy or of tumor of the liver. When this condition is present in atrophic cirrhosis of the liver, it indicates a previous enlargement of that organ (Suchard). The marrow of the sternum, which may be exposed by a longitudinal section of the bone, is normally a slightly reddish, lymphoid bone-marrow, and may present the changes characteristic of leukæmia, anæmia, tuberculosis, etc. The ribs may show evidence of rhachitis in the presence of the rhachitic rosary, in which case a section of the rounded enlargements, especially where the cartilage joins the bones, will show the changes peculiar to rickets. In old persons the entire cartilage may be calcified or even ossified. The central substance of the ribs sometimes undergoes atrophy and absorption, leaving a large canal filled with blood. The cartilage may contain cystic cavities.

The sternoclavicular articulation may be inspected to discover a possible chronic inflammation, and the clavicle examined for recent or old fractures, tumors, etc.

Note the condition of the mediastinum, especially as to emphysema and tumors, the ductus arteriosus, and the thymus and the peribronchial and other lymphatic glands. The latter are often pigmented, and for this reason are not infrequently mistaken by students for melanotic sarcoma. They are often tuberculous, and may be cancerous. Emphysema is sometimes produced artificially by the removal of the sternum at the time of the postmortem or by decomposition. When the lung is actually lacerated, the emphysema is more extensive and may extend even into the neck.

*Thymus Gland.*—This weighs about 13.75 grammes at birth, and increases in size until the end of the second year, when it weighs about 26.2 grammes. It then gradually diminishes and after puberty is normally absent, though it has been observed in acromegaly, myxœdema, and many other pathological conditions. Hemorrhages are often found in the thymus of stillborn babes. Pus may occasionally be present. Mistakes have been caused by the altered appearance of the normal secretion after it has undergone post-mortem change; hence great care is necessary in making the diagnosis of suppuration.

Hemorrhage into the mediastinum may be due to trauma, to



phosphorus poisoning, or to acute yellow atrophy of the liver. An abscess may be found, or a chronic mediastinitis, marked by fibrous thickening and density of the connective tissue. The latter usually occurs in conjunction with a fibrous pericarditis (mediastino-pericarditis), and is of importance on account of its influence upon the heart action (Orth).

The thyroid gland may at this time be examined *in situ*, or, if preferred, it, together with the tongue, epiglottis, œsophagus, trachea, parathyroids, carotids, etc., may be removed *en masse* and studied subsequently. Note the position of the pericardium, whether or not it is distended with fluid, and to what extent it is covered by the lungs.

Observe the appearance of the presenting portions of the lungs. The normal color of the lungs at birth is a pinkish-white; in adult life, a dark slate-color, mottled in patches; and as age advances this mottling becomes nearly or quite black, owing to the deposit of carbonaceous material. Changes in color may be due to the amount of blood present or to some pathological process.

When the thorax is opened, the normal lung retracts on account of its own elasticity. This contraction of the lung may not occur, because of the absence of elasticity, because of emphysema, because of pleural adhesions, because the alveoli are full of solids or fluids, the result of inflammation, or because stenosis of the larynx, trachea, etc., may prevent the egress of air. In cases of alcoholic intoxication and suffocation the lungs are very markedly expanded (Orth).

If for any reason a pneumothorax is suspected, after having carefully removed any opaque fluid present, fill the pleural cavity with water and inflate the lungs with air by means of an intubation tube connected with a pump by a piece of rubber tubing. The rising air bubbles will reveal the situation of the laceration in the lung. In examining the pleural cavities inspect first the left and afterwards the right. Note the amount of contained fluid, whether or not it is bloody or of an inflammatory nature, and whether or not adhesions are present. The remarks made upon the peritoneal fluid apply with equal force to that found here and in the pericardium.

The pericardium should be grasped near its centre by the fingers or a tenaculum, and a longitudinal fold elevated before it is incised, in order to prevent injury to the heart or the escape of fluid. A small incision is then made at the highest point, under the strictest precautions if a bacteriological examination is to be made, and any fluid pres-



ent should be drawn off with a syringe or pipette into a graduated glass and its quantity noted. When there is much distention of the pericardial sac, the direction and length of its principal diameters—which, it should be remembered, are anatomically the reverse of those of the heart—should be noted before any fluid is allowed to escape. The opening in the pericardial sac may be enlarged sufficiently to admit two fingers, which are then spread apart and protect the heart while allowing the pathologist to cut between them. With a knife or a pair of scissors two downward cuts are made—one downward and to the right, the other downward and to the left—as far as the diaphragmatic attachment. The right flap is then drawn strongly forward away from the heart and another cut is made in an upward direction to the point where the pericardium is reflected around the vessels coming off from the heart (Fig. 60).

About half an ounce of clear serous liquid is normally present in the pericardial sac. Normal pericardial fluid does not contain any fibrinous flocculi, though it may coagulate on standing. In hydropericardium there is an increase in the amount of the pericardial fluid; this condition may follow passive congestion of the lungs or appear as a part of a general anasarca. The presence of blood in the pericardial sac, or hæmopericardium, may be a sequence of rupture of the heart or of an aneurism of the aorta, pulmonary artery, or coronary arteries; or, when the blood is part of an exudate, may have resulted from an inflammatory process. Blood derived from the rupture of an aneurism, from trauma, etc., is always clotted, while that which is intimately mixed with a fluid exudate is derived from newly formed vessels of inflammatory tissue. Pneumopericardium may be due to rupture of the stomach or œsophagus or of the lungs, into the pericardial sac; or may be consequent upon the decomposition of an inflammatory exudate. Foreign bodies, also cysticerci, echinococci, and trichinæ, have been found in the pericardium.

The signs of pericarditis are to be looked for.

The normally transparent glistening membrane may have lost its lustre, or may be hyperæmic, thus indicating a dry fibrinous pericarditis. An abundant serofibrinous exudate is the result of a pericarditis serofibrinosa. In this condition, when there is much fibrinous exudate and little fluid, on account of the movement of the heart, the exudate is thrown into villoid projections and the characteristic *cor villosum* may be found. Newly formed granulation tissue may accompany a



fibrinous exudate, with the formation of a productive pericarditis. Suppurative pericarditis shows pus in the sac, the result of trauma, or secondary to suppurative mediastinitis, cancer of the ribs, gangrene of the lung, or a general infection. A chronic process may leave many extensive adhesions between the two layers of the pericardium, or a fibrous or adhesive pericarditis may cause a complete obliteration of the sac.

Tuberculosis of the pericardium, most often associated with a fibrino-hemorrhagic exudate, may show tubercles along the course of the vessels, or old cheesy tuberculous foci may be found in chronic cases. Gummatous inflammation and metastatic carcinoma or sarcoma of the pericardium may occur.

If an aneurism has been discovered, it is usually best not to separate the aorta from the heart, but to remove the aneurismal sac and the heart together. The aorta is not to be opened until the heart has been examined. In endocarditis vegetations are sometimes present in the arch of the aorta, and might easily be overlooked if not especially searched for.

#### THE HEART.

The heart is to be carefully observed before it is touched. Its normal position may be altered by fluid in the pericardium or in the pleuræ, by cardiac hypertrophy, in which case the apex may reach to the anterior axillary line, or by tumors of the mediastinum. The heart is about as large as the right fist. It measures from base to apex about 85 to 90 millimetres in men and 80 to 85 millimetres in women between the ages of twenty and sixty years; its greatest transverse diameter varies from 92 to 105 millimetres in men and 85 to 92 millimetres in women; it is about 35 or 36 millimetres thick in men, and from 30 to 35 millimetres in women. Any displacement is determined by the situation of the apex and the base, which are anatomically described especially in relation to the ribs, sternum, nipples, and median line of the body. Cardiac enlargement may be due to heart disease or secondary to disorders of the lungs, kidneys, aorta, etc. The color of the surface of the heart depends very much upon the condition of the epicardium and the underlying fat. The auricles, especially when well filled, are dark blue, while the color of the ventricles differs with the condition of the muscle. The consistence of the various portions of the heart depends upon the degree of contraction of its muscular tissue, as well as upon the amount and composition of its contents (Orth).



The contraction (systole) and the relaxation (diastole) of the two auricles and the two ventricles are considered in relation to the amount of blood contained within them. The amount of blood, especially if it be fluid, does not afford a criterion of the quantity therein during life, owing to the free communication of the vessels and cavities of the heart. For example, after death by asphyxia the right side of the heart is distended with dark fluid blood, while after death from digitalis the left ventricle is contracted. Overfilling of the left ventricle is found when death was caused by cardiac paralysis. For bacteriological examination or chemical analysis the blood is usually taken from the cavity which is most distended with it, unless, of course, for some reason blood from a special cavity or side is desired.

The epicardium and the amount of subepicardial fat are to be carefully observed, as well as milk spots. In cachexia the subpericardial fat may be transformed into a soft, transparent, gelatinous mass, which becomes whitish on the addition of acetic acid. This is the so-called mucoid change of the subepicardial fat. Small lipomata may be found near the apex; and small subpericardial ecchymoses—so-called spots of Tardieu—are of medicolegal importance, as they are frequent in cases of death due to suffocation, particularly in the new-born, but may occur in the infectious fevers, as in diphtheria.

The situation of the coronary arteries should be noted, and the anterior one should be felt, to learn whether or not it is "pipe-stem" in character. The interior is to be examined when they are opened later on. The coronary veins are easily distinguished from the arteries by the relative thinness of their walls as well as by their course. Overfilling of the larger veins indicates an obstruction to the outflow of blood from the right auricle (suffocation, etc.), unless it be confined to the posterior wall, in which case it is due to hypostasis.

The interior of the heart is now to be examined, and here again, to secure the best results, it is necessary to adhere to a definite plan of procedure. There are several so-called "methods" of opening the heart, but all have the same object and all accomplish it more or less completely,—viz., that of exposing the cavities and valves with the least possible interference with the septa and the parts subsequently to be examined, and in such a way as to permit of the organs being reconstructed, or returned to their original shape and relations. The method adopted and described by Virchow for use in the Berlin Charité is undoubtedly the best, although the others may, if thoroughly understood and properly executed, yield very satisfactory results.



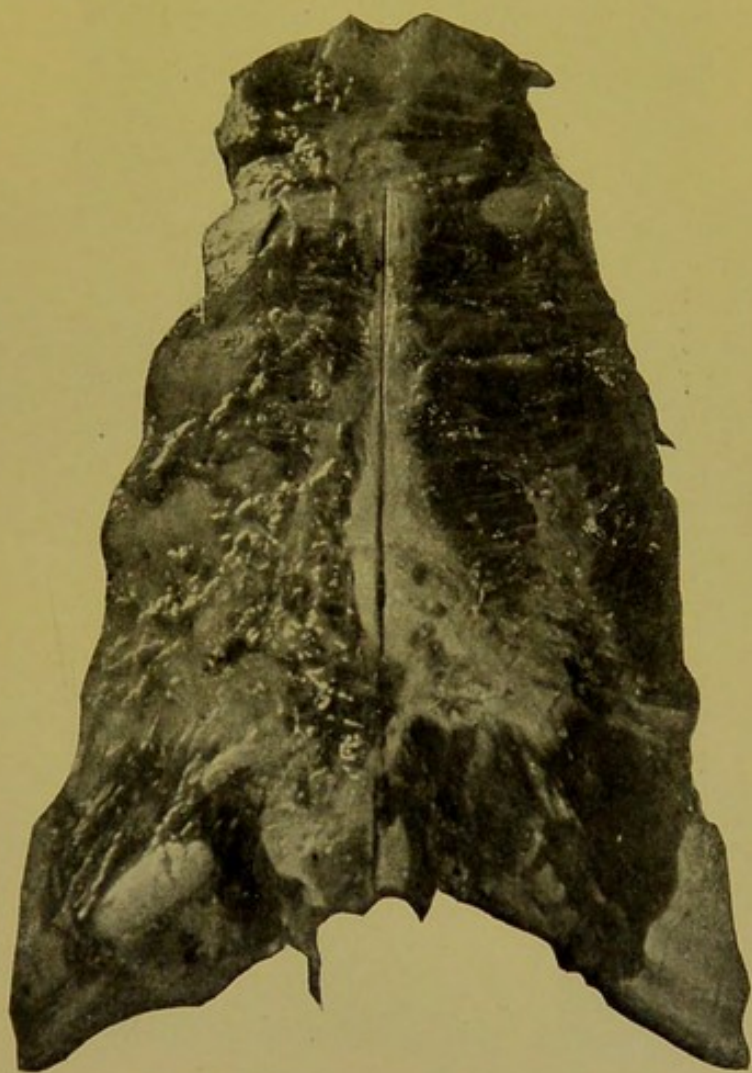


FIG. 58.—Shows the breastplate after its removal from the body.



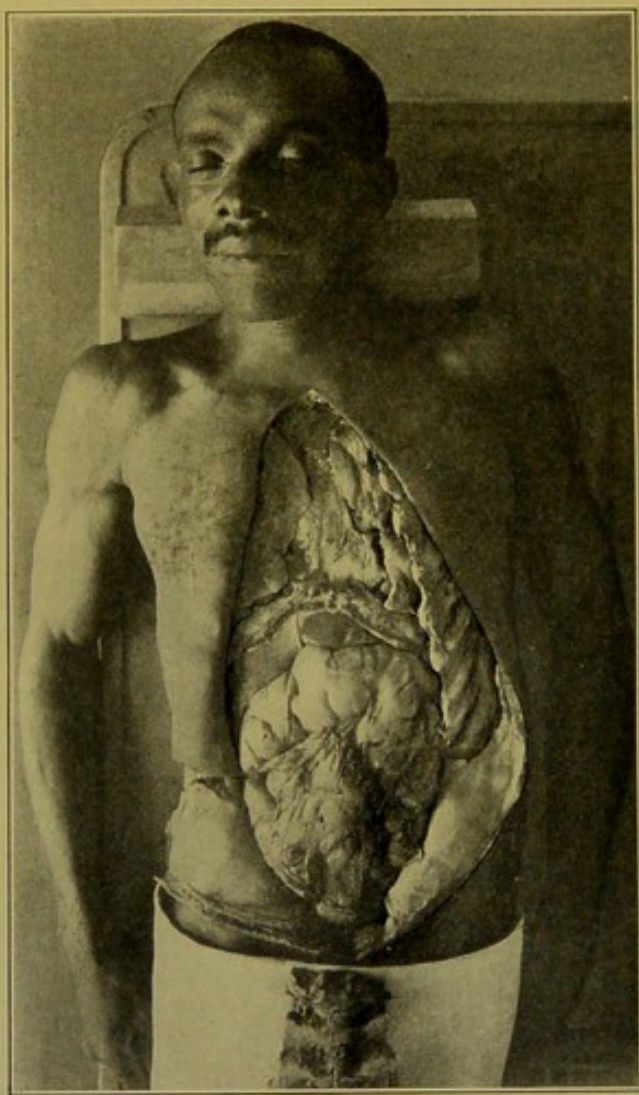


FIG. 59.—The skin flap is placed over the projecting margins of the right clavicle and ribs in order to protect the operator's hands from injury. On the left side this has not been done. On the right side a transverse incision, Fig. 43, *D*, has been made, while on the left side the rectus muscle has been incised as in *G* of the same figure.



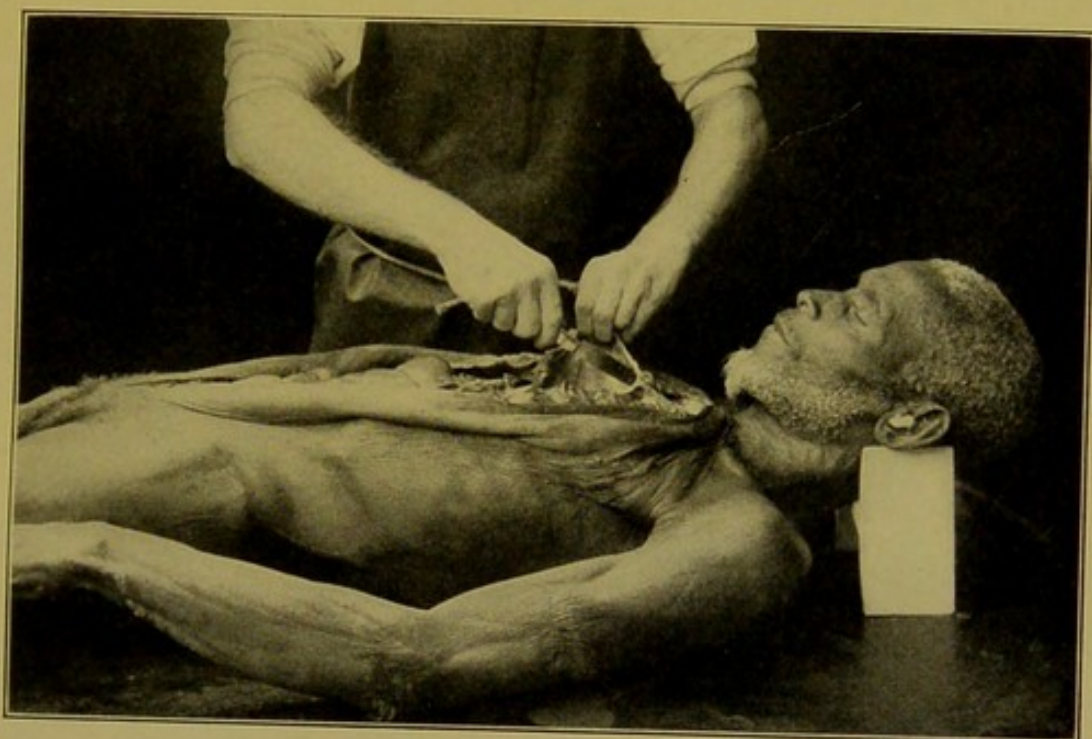


FIG. 60.—Method of opening pericardium. The left hand supports the right flap of the pericardial sac, while the knife cuts the pericardium up to its attachment to the great vessels coming off from the heart.



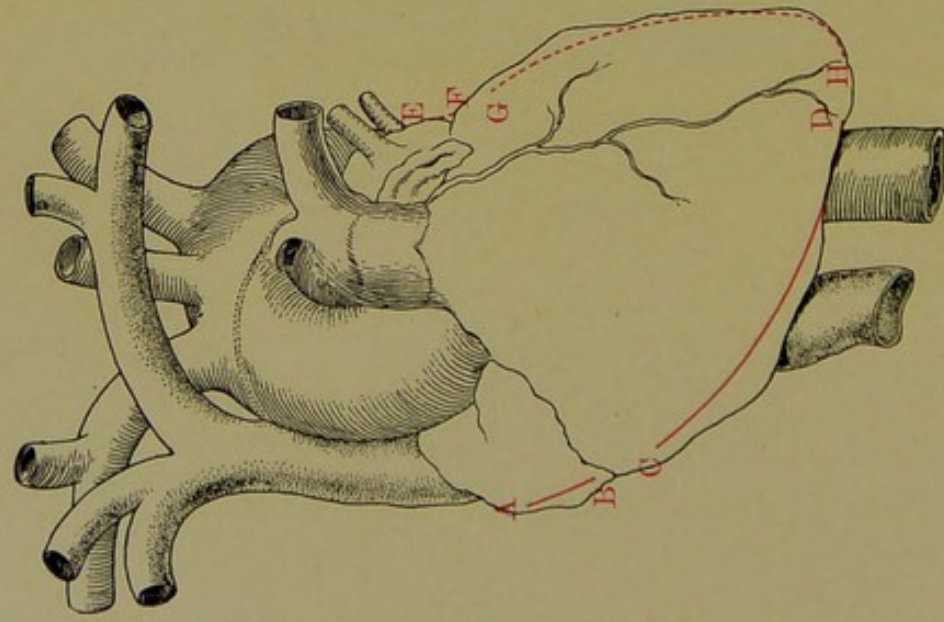


FIG. 61.—Primary incisions for opening the heart usually made while this organ is still in the body.

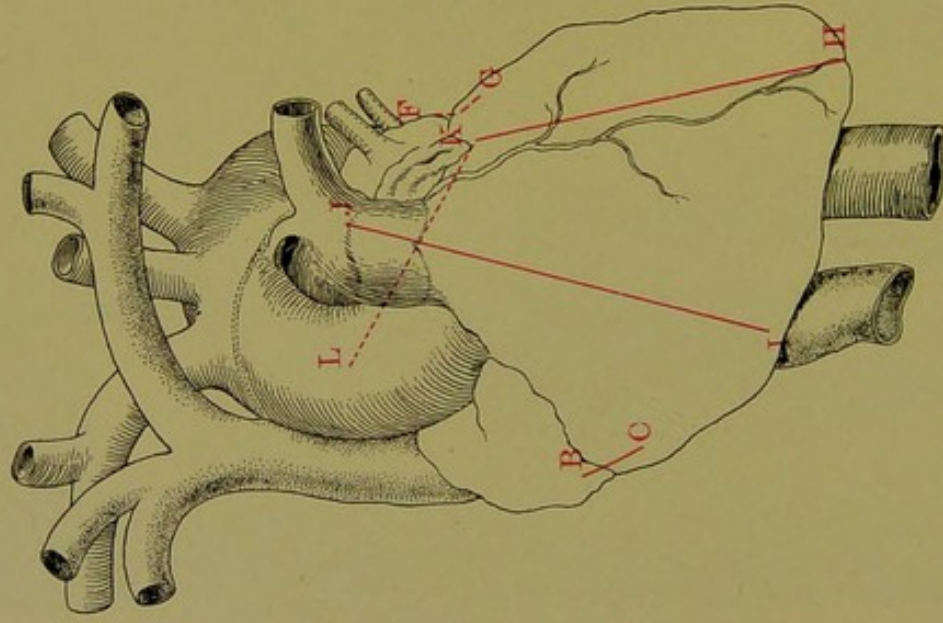


FIG. 62.—Secondary incisions for opening the heart.

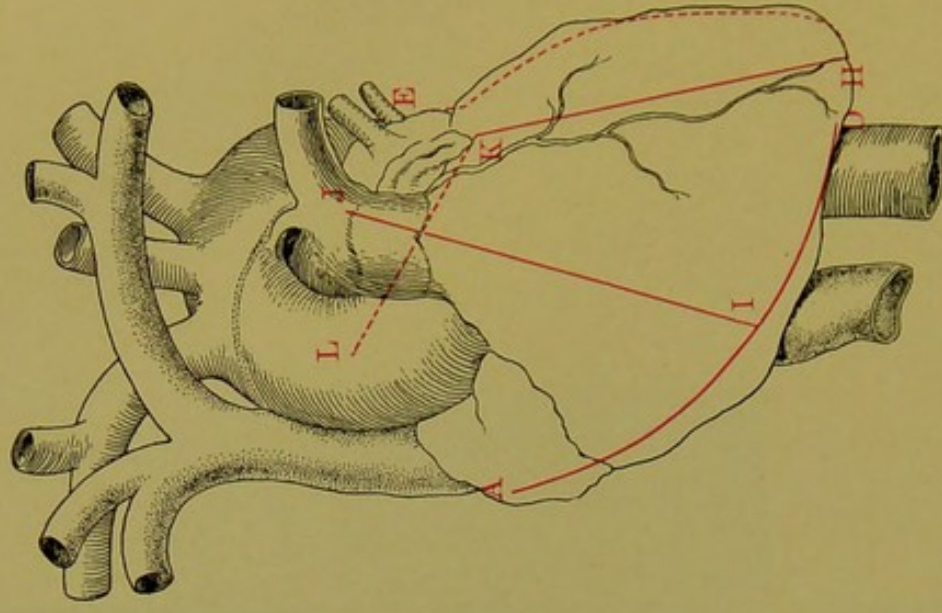


FIG. 63.—The completed incisions for opening the heart.



Ordinarily it is advisable that certain incisions be begun while the organ is still *in situ* and completed after it has been removed from the body. As each cavity is opened, careful note should be made of the quantity, color, and consistence of the contained blood and of the size and character of any clots that may be present. If the opening is occupied by a clot, this should be at once removed.

Bacteriological examinations may be made while the heart is *in situ*, or in some cases may be facilitated by removing the heart before incising it.

*Primary Incisions.*—After breaking up pericarditic adhesions, if present, the heart should be gently rotated on its long axis by slight pressure between the index-finger and thumb of the left hand, at the same time that slight traction is made downward and to the left of the body. This will bring the points of entrance of the superior and inferior venæ cavæ into view; midway between which the first incision is begun and then carried downward in the direction of the right ventricular ridge until the right auriculoventricular septum is reached (Fig. 61, *AB*, and Fig. 64). Next make an incision in the right ventricle, just below the auriculoventricular septum, passing down the right ventricular ridge to the interventricular septum, which is a little to the right of the apex (Fig. 61, *CD*). On the left side make an incision in the auricle, beginning in or slightly below the lowermost pulmonary vein and continuing in the direction of the left ventricular ridge as far as the auriculoventricular septum (*EF*). Open the left ventricle along the entire length of the left ventricular ridge, and, as this ventricle normally forms the apex of the heart, the incision will be carried to and through that point before the ventricular septum is reached (Fig. 61, *GH*, and Fig. 65). This incision must not join that of the other ventricle, but should be separated by an interval of about one-half inch. From the fact that these incisions are made while the heart is still *in situ*, they may be called primary incisions.

In cases of sudden death in which an embolus of the pulmonary artery is suspected, it is best to open that blood-vessel before removing the heart. This assures the finding of the embolus, which might otherwise be obscured in cutting the pulmonary artery for removal of the heart. By this method, also, the ductus arteriosus and congenital heart lesions in infants may be investigated.

*Removal of the Heart from the Body.*—To remove the heart, introduce the index-finger and thumb of the left hand into the left



and right ventricles respectively, grasp the ventricular septum near the apex, and elevate the heart sufficiently to make slight traction on the great blood-vessels (Fig. 66). Then, if no aneurism be present, sever all the normal attachments as near their point of passage through the pericardium as possible, and in the following order,—viz., the inferior vena cava, the superior vena cava, the pulmonary artery, the aorta, and lastly the pulmonary veins. Avoid injury to the œsophagus during the removal of the heart from the body. Or, the heart is drawn outward preparatory to severing the vessels, as seen in Fig. 67.

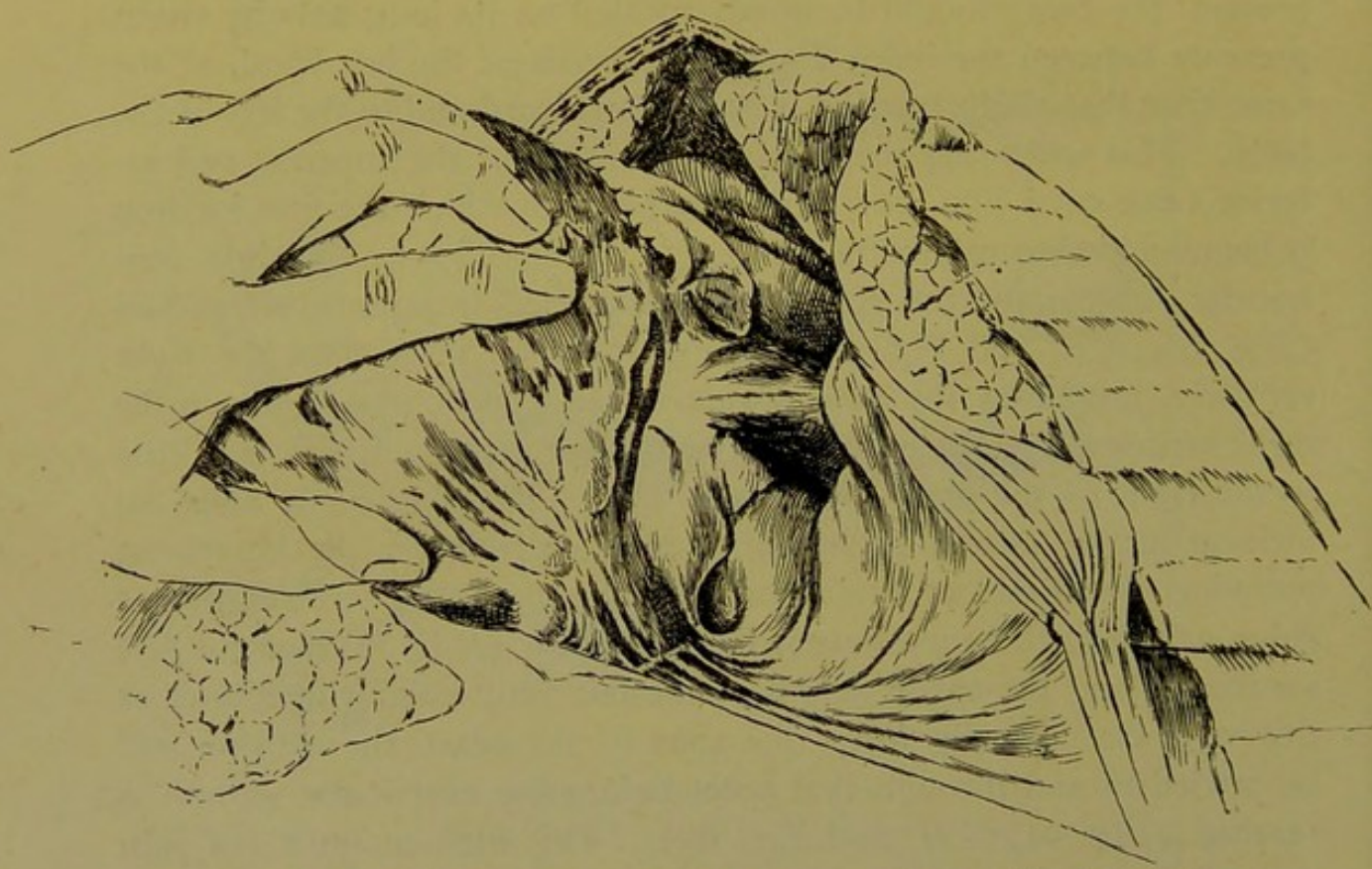


FIG. 67.—The pulmonary veins are placed on a stretch, and are ready to be incised.

*Measuring and Testing the Valves.*—Immediately upon the removal of the heart from the body, the blood and clots should be carefully removed from about the valves. The valvular openings are then to be measured. Their size is usually estimated by the number of fingers that the ostium will admit. Normally the mitral ostium will admit the index and middle finger, whereas through the tricuspid opening the index and middle finger of one hand and the index-finger of the other hand can be introduced. This method is, of course, convenient, but is very unscientific and inaccurate and should be superseded by the



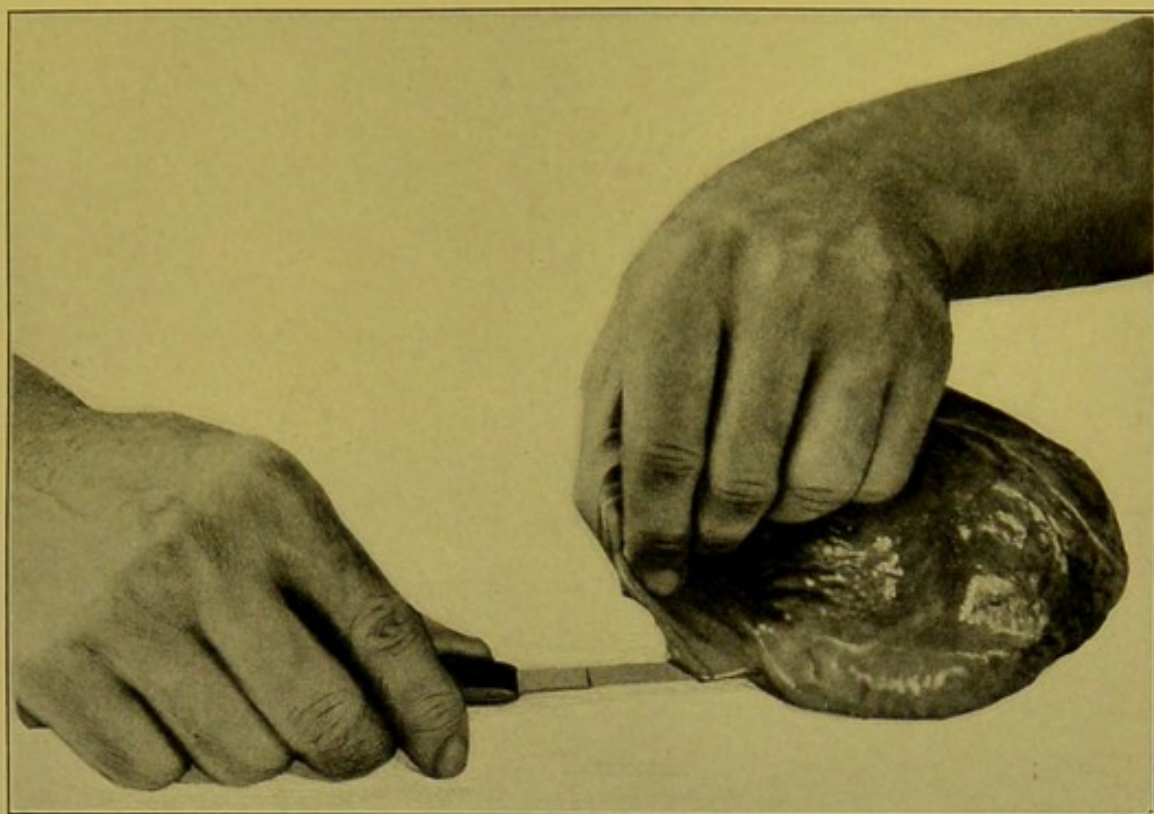


FIG. 64.—Method of opening the right auricle; incision is made down to the auriculoventricular septum of the right side. This incision is usually made while the heart is *in situ*, but for the sake of clearness is here shown as being made outside of the body.

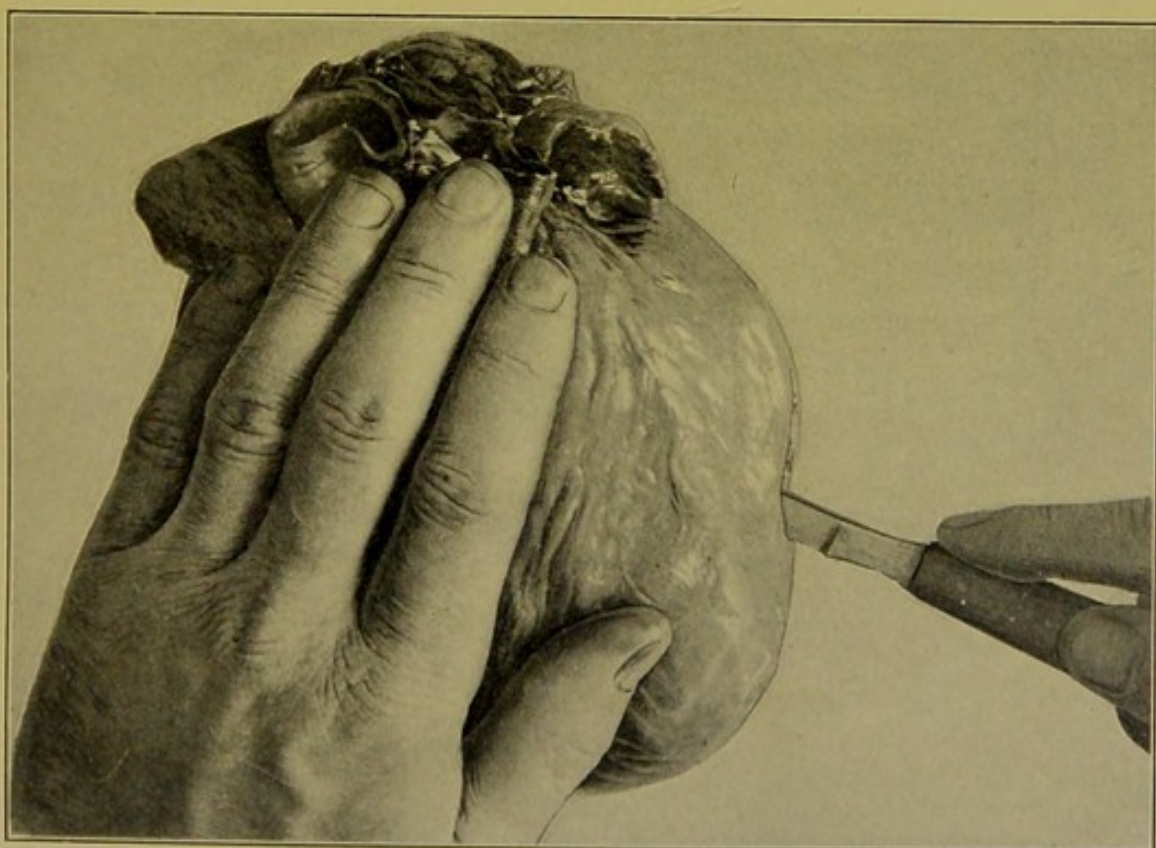


FIG. 65.—Method of opening left ventricle. The heart is being opened outside of the body. The left hand steadies the heart while the knife cuts along the left ventricular ridge, starting just below the auriculoventricular septum and ending at the apex.



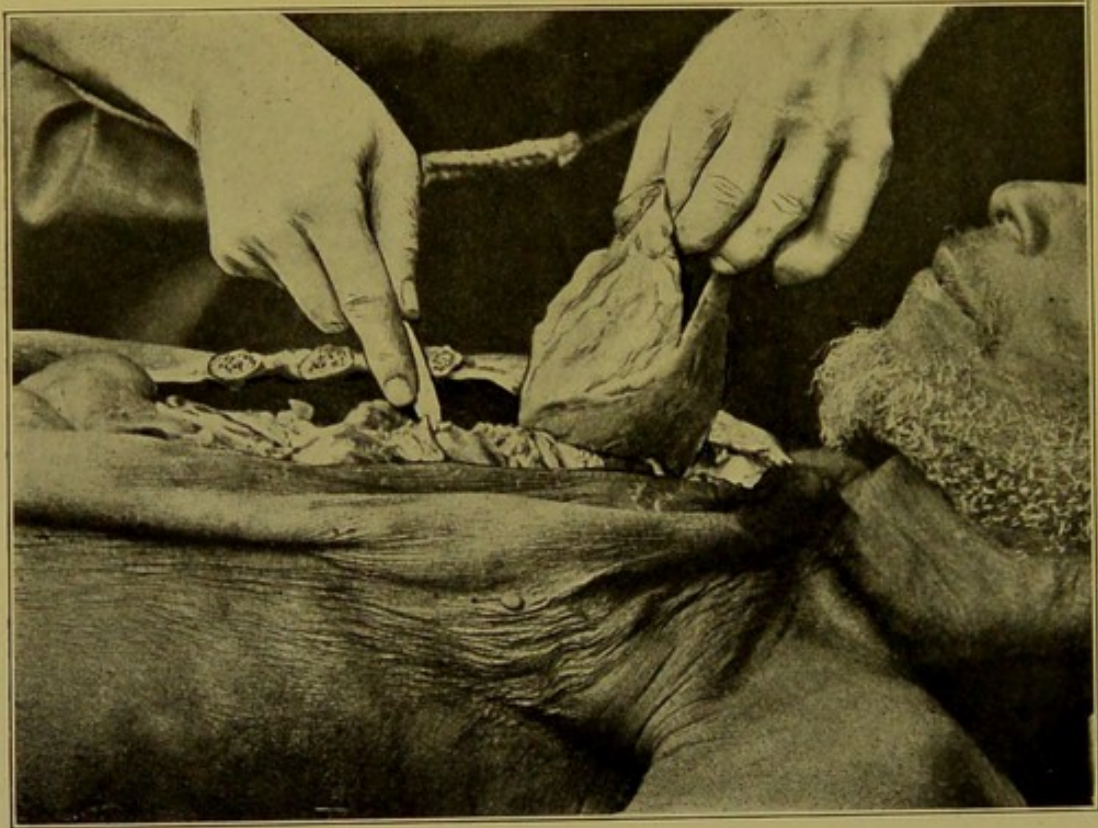


FIG. 66.—Method of removing the heart from the body. The index-finger is placed in the left ventricle and the thumb in the right ventricle, and the ventricular septum is grasped. The heart is then raised upward and towards the chin, placing on a stretch the blood-vessels which enter the heart. These are cut, starting with the lower pulmonary vein and going from left to right in a circular direction until the upper pulmonary veins are reached, or the initial incision may be made at the inferior vena cava and end with the pulmonary veins.



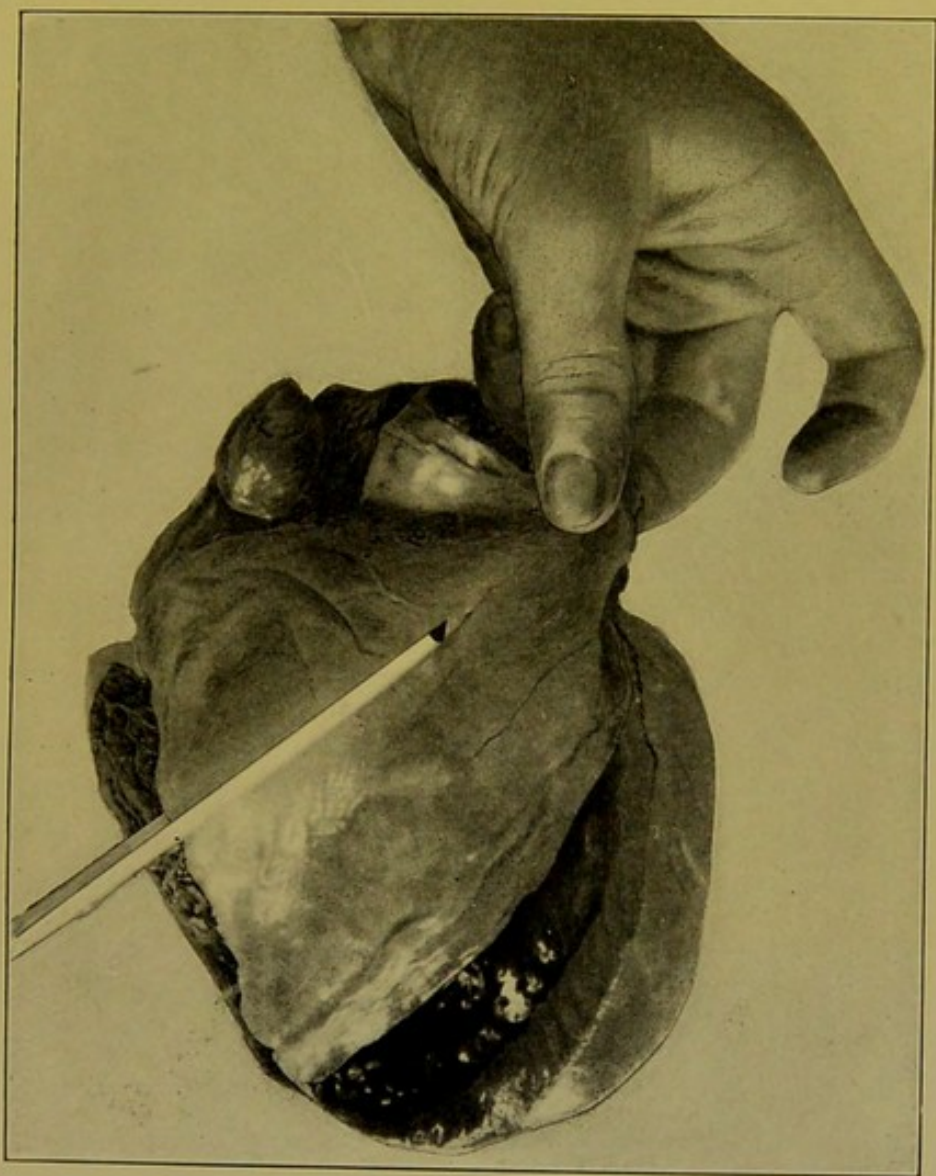


FIG. 68.—The pulmonary artery is made tense with the left hand, while from the centre of the right ventricular incision the anterior portion of the right ventricle is cut in the direction of the thumb and middle finger which mark the junction of the two anterior pulmonary semilunar cusps.



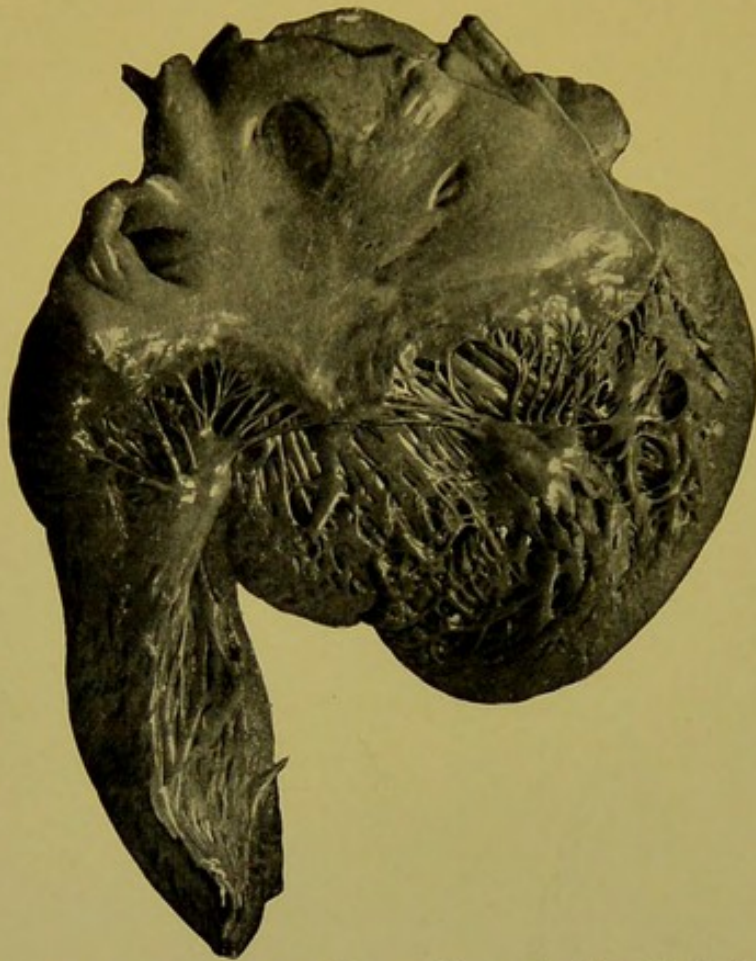


FIG. 69.—The left auricle and ventricle are fully opened, exposing the mitral valve, chordæ tendineæ, papillary muscles, endocardium, etc.

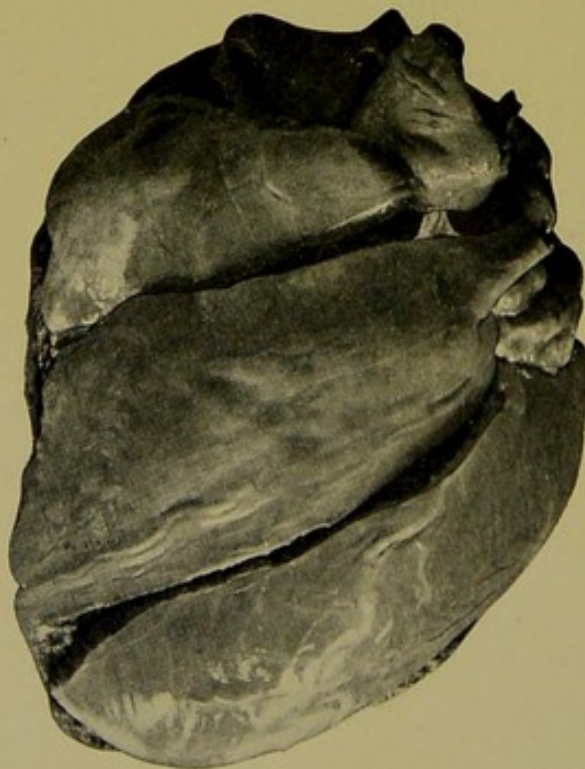

FIG. 70.—Completed incisions of the heart, the organ having been reconstructed after the examination of all its cavities and parts.



use of a constant unit of measure. Graduated cones, or balls of definite sizes (Figs. 38 and 39), placed on rods, answer the purpose very well. They are gently inserted in the direction of the blood-current, and the exact size of the opening can then be given in millimetres or inches. Vegetations upon the valves may be injured by their careless use. An equally scientific method is to measure the attached margins and to determine the diameter by dividing by 3.14 ( $\pi$ ).

The competency of the valves should now be tested. To do this, trim the great vessels down so that the valves may be seen. The heart is then evenly supported by each of the vessels in turn,—*i.e.*, held in air and in such a way that the semilunar valves will be as nearly horizontal as possible, at the same time receiving no unnatural support from beneath. Water or mercury is then gently poured in by a second person until the vessel is filled, and note is made of the action of the valve. In case no one else is present, the heart is to be held under water and then quickly taken out, and the valve being tested observed. If there is any leakage from the aorta, make sure that it is not from a branch of one of the coronary arteries. The best result of the water-test is seen in the semilunar valves, the competency of the auriculo-ventricular valves not being accurately determined by this method, which has of late rather fallen into disuse.

Should it be necessary or desirable to ascertain the competency of the auriculoventricular valves, the primary incisions above described are not made until the heart has been removed from the body, and the test is begun by cutting a transverse slice from the apex and exposing the ventricles. The heart is now everted and each ventricle is filled separately with liquid. This method of removing the organ before opening is also useful in examining the heart of a child or when it is desired to make a bacteriological examination of the valves. In the latter event no water should be used, lest some of the vegetations be washed out or other bacteria than those present be introduced, thus creating more or less serious confusion.

Hamilton advises the use of air for testing the competency of the valves, and gives the method as follows:<sup>1</sup> "An incision is first made into the left auricle, and any post-mortem clots are carefully removed from the left chambers through it. Another incision large enough to admit the nozzle of a half-inch tube is made into the ventricle near its

---

<sup>1</sup> HAMILTON, *Text-book of Pathology*, vol. i. p. 9.



apex and in the line of that required for laying it fully open. The tube is joined to a bellows, and air is driven intermittently into the ventricle by means of it, the aorta having been meanwhile closed. The valve will be seen to open and close, according as the air is aspirated or driven out of the bellows. A like procedure is adopted for the demonstration of the tricuspid. To test the aortic valve, the incision before described as necessary to lay open the left ventricle is continued up as close to the valve as possible without injuring it. The tube is tied into the aorta, and the action of the valve is watched from below. The same method is used to test the competency of the pulmonary artery valve. As a matter of fact the tricuspid, in the human heart, will always be found more or less incompetent."

*Secondary Incisions.*—Place or hold the heart with its posterior surface downward. This can be told by the situation of the pulmonary artery, which is situated anteriorly. Insert a pair of probe-pointed scissors or the blade of the enterotome (now a cardiotome) in the incision in the right ventricle, and cut from the centre of that incision through the centre of the attachment of the two anterior leaflets of the pulmonary artery (Fig. 62, *I J*, and Fig. 68). The point of junction of the anterior leaflets can usually be seen from the outside, but, if not, it can very easily be determined by looking into the vessel or feeling it with the index-finger. This incision is to be continued until it opens up the entire portion of the pulmonary artery which has been removed from the body. Some pathologists advise making this incision towards the left of the pulmonary artery, so as to cut between the left anterior and posterior cusps. The right ventricle is now exposed so that the condition of the pulmonary valves, endocardium, myocardium, chordæ tendineæ, etc., of this side of the heart may be noted. Now dissect away the connective tissue binding together the pulmonary artery and the aorta.

In opening the left ventricle, cut the anterior wall as near the ventricular septum as possible, starting from the apical extremity (*H*) and stopping at the point overlapped by the left auricular appendix (*K*). Then, using the cardiotome, the incision is completed (either from the aorta or from the ventricle) by cutting between two leaflets (*L K*). In the aorta there is but one anterior leaflet, consequently the incision should be to either one or the other side, but preferably as close as possible to the curves of the pulmonary artery. After examining the valves, myocardium, aortic intima, etc., dissect out the coronary arteries with probe-pointed scissors.



Lastly, unite the auricular and the ventricular incisions of each side by cutting through the auriculoventricular septa (Fig. 63). In Fig. 69 is shown how well the auricle and ventricle of the left side may be examined after the completion of the incisions.

The heart now freed from blood and clots is to be weighed. The valves will not be injured by this method and the entire heart can be folded together so as to show its original contour (Fig. 70). In extreme mitral stenosis it is often advisable not to complete the left auriculoventricular incision.

The simplest method of opening the heart, and one which yields fair results, is to place two fingers on the anterior ventricular septum, which is recognized by the situation of the anterior coronary artery, and make two parallel incisions into each ventricle. Incisions may then be made through the pulmonary artery and the aorta. If it be desired to follow out the subclavian vessels, the entire clavicle of that side should be removed by careful dissection.

The situation of the mitral and pulmonary valves can be easily remembered by the mnemonic *Martin Luther, The Reformer*,—*mitral* on the *left* side, *tricuspid* on the *right*. There is but one *posterior* cusp to the *pulmonary* and one *anterior* cusp to the *aorta*, which fact affords an easy way to recall this oft-forgotten point.



## CHAPTER VIII

### LESIONS OF THE HEART, BLOOD, AND BLOOD-VESSELS

**CHARACTERISTICS.**—The gross appearance of the heart, as well as the thickness, color, and consistence of the various parts of the cardiac muscle, can now be observed. The wall of the right ventricle is normally from 2 to 3 millimetres thick (in women slightly less than in men) and may pathologically be from 7 to 10 millimetres thick. The thickness of the wall of the left ventricle is from 7 to 10 millimetres, and may be increased to 25 millimetres or more by pathological changes. The estimation of the weight of the heart is one of the means of determining whether or not a true hypertrophy is present. The normal heart weighs about 250 grammes in women and about 300 grammes in men; but when hypertrophied it may weigh over a kilogramme. The color of the heart muscle varies according to the amount of blood it contains, but is always lighter and more grayish red than the skeletal muscles. The heart muscle may be of a brownish red or even brown, as in anæmia and brown atrophy of the heart, where, with its tortuous vessels and mucoid covering, in some cases it varies from yellowish to a distinct yellow, which color is usually not uniform, but scattered in patches throughout the muscle, or in bands making a sort of net-work (wren's breast or tiger markings). This yellow streaking is often most conspicuous on the papillary muscles of the left ventricle. In septic conditions the heart is of a dirty-red color. Light-gray spots or streaks indicate the formation of fibrous tissue. The consistence of the heart muscle varies with the color: brown hearts are hard and dense, while those of a yellowish tinge are soft and flabby. After dilatation of an hypertrophied heart sets in, the muscle becomes softer by the process of fatty degeneration. The heart muscle is very soft in sepsis, also in cases of heart weakness developing after an infectious disease, especially after typhoid fever and diphtheria.

**ANOMALIES.**—Abnormalities in the development of the heart vary exceedingly. Dextrocardia may be the only abnormality of the chest, or a part of a general situs inversus confined to the thoracic organs. An increase or decrease in the number of the semilunar leaflets may



be met with, and a circumscribed thickening of the muscle may occur, and may cause a stenosis of the aorta if there situated. There may be an insufficient development of the whole heart, hypoplasia, found in cases of chlorosis; or a patulous foramen ovale. In the examination of the auricles an aperture in the foramen ovale may be overlooked if the heart is so held as to put the auricular wall on the stretch. As the openings most frequently come off from the sides, this method of holding the heart will very often prevent their discovery. All suspicious cracks or orifices should be searched for with a pointed probe while the heart is relaxed, care being taken not to tear or puncture the tissues or to mistake the mouths of veins for pathological openings. With a defect or an opening in the interventricular septum is often associated a stenosis of the conus pulmonalis, with a narrowing of the pulmonary valve. In these cases the ductus arteriosus may be patulous. Atresia of the mitral or tricuspid valves may be due to faulty development or to inflammation. Fenestration of the semilunar leaflets is of frequent occurrence and has no particular significance.

**BLOOD.**—Many of the changes which the blood undergoes are macroscopical and can be studied at this point, especially if the innominate veins be opened.<sup>1</sup> There may be observed all degrees of coagulation, from an almost absolutely fluid condition of the blood to a hard and dense fibrinous clot,—the so-called heart polyp,—which contains almost no red blood-corpuscles. The firm, yellowish “chicken-fat” clots may adhere to the walls of the heart, and indicate slow death, with gradual paralysis of the heart’s action. When all the coagula are rich in fibrin, some acute inflammatory process has caused an increase in the leucocytes and blood-plaques, the generators of fibrin. Normally the clots in the beginning of the aorta and of the pulmonary artery contain a large percentage of fibrin. In the left auricle they at times assume polypoid or ball shapes. The ordinary post-mortem coagulum is the red clot, the so-called currant-jelly clot, which is not attached to the endocardium, though it may adhere to the interstices of the heart. Hyperinosis, or increased capability for fibrin formation in the blood, is met with at times, in certain anæmic affections and infectious diseases. Hypinosis, or decreased capability for fibrin formation, occurs in leukæmia, in hydræmia, and when the

---

<sup>1</sup> A small spectroscope and a Tallqvist hæmoglobin scale are very useful for studying the blood at the postmortem.



blood is overladen with carbonic acid, as in cases of suffocation, or intoxication with gases, and in many of the infections. Blood saturated with carbon dioxide is very dark in color; in cases of poisoning by that gas the blood when exposed to the air quickly oxidizes. Methæmoglobin, found in cases of poisoning by chlorates, nitrites, toadstools, etc., gives a brownish tinge to the blood. The blood in cholera, where anhydræmia is present, is very thick, while in diseases of the heart, lungs, kidneys, and liver in which hydræmia is present the blood is thin and watery (Orth). In chlorosis and pernicious anæmia the blood is pale, particularly so in the latter, where it is even raspberry red, while in lipæmia, in which fat occurs free in the blood-plasma, and leukæmia a milky appearance of the blood may be noted. In putrefaction if the blood be left standing the clear serum separates and the sediment is yellowish green. Under the microscope shadows of red cells are seen.

*Pathological Conditions.* — (a) *Plethora Vera*. — A condition in which all the elements of the blood are proportionately increased. (b) *Plethora Serosa*. — A marked increase in the watery constituents. (c) *Olygæmia*. — A diminished amount of blood; occurs only as a temporary condition. (d) *Hydræmia, Anhydræmia*. — Abnormal increase or decrease in the watery portion of the blood. In anhydræmia the blood becomes thick and even tarry, as in cholera. In hydræmic plethora there is an absolute increase of serum. If relative it is an oligocythæmia. (e) *Hæmolysis*. — Destruction of red corpuscles; occurs after burns, certain poisons, infectious fevers, etc. (f) *Polycythæmia rubra* is an absolute increase in the reds. (g) *Anæmia*. — A diminution in one or more of the constituents of the blood. (h) *Primary, Essential, or Idiopathic Anæmia*. — An anæmia, the cause not definitely known, usually attributed to the blood-making organs, and characterized by a *disproportionate* reduction in the elements of the blood. (i) *Secondary, Simple, or Symptomatic Anæmia*. — An anæmia due to a definite cause, as an infectious fever, and characterized by a *proportionate* reduction in the elements of the blood. (j) *Poikilocytosis*. — Alteration in the shape of red corpuscles (crenated, reniform, and pyriform are most common). (k) *Leucocytosis*. — Increase in the number of white blood-cells without alteration of the relative numbers of each variety. (l) *Leucopenia*. — A diminution in number of white blood-cells; seen most characteristically in typhoid fever. (m) *Lipæmia*. — Fat in the blood. Diabetes. (n) *Uræmia*. — The presence in the blood of an excess of chemical com-



pounds, as urea, which should be eliminated by the kidneys or other excretory organs. There may be an increase in blood-plaques, as is supposed to occur in purpura.

*Abnormal Constituents of the Blood.*—(a) Tumor cells, as in renal sarcoma, the cells growing into the veins. (b) Pigment particles, as in malaria. (c) Hæmatoidin crystals. (d) Bilirubin crystals. These may be so considerable as to produce to the naked eye an orange-red color, or when the buffy coat of a clot or when a clot well washed in water is seen microscopically, usually in the shape of needles. Occur in icterus neonatorum, in pernicious anæmia, acute yellow atrophy, pyæmia, but not in ordinary icterus. (e) Gas bubbles,—due to putrefaction, to air-producing bacteria which develop very rapidly after death. In fresh blood air bubbles, particularly when seen in the right heart and surrounded by a clot, are due to the entrance of air into the veins during life. (f) Charcot-Leyden crystals,—leukæmia. (g) Lower organisms, — 1. Spirochætæ of relapsing fever (not always found after death). 2. Anthrax. 3. Cocci,—micro-, strepto-, diplo-, etc. 4. Plasmodia. 5. *Filaria sanguinis hominis*. 6. *Distoma hæmatobium*. 7. Trypanosoma.

Many names have been given to such conditions, as septicæmia, where there are pyogenic micro-organisms in the blood and tissues, without areas of suppuration; pyæmia, where metastatic or pyæmic abscesses are found in the tissues and organs of the body, and sapræmia, where the symptom-complex is produced by the presence in the blood and tissues of the vital chemical products known as toxins. These toxins may be formed by the action of pyogenic or saprophytic micro-organisms.

BLOOD-DISEASES. — *Anæmia, Progressive Pernicious.* — An idiopathic, chronic anæmia characterized by definite blood-changes, by a lemon-yellow coloration of the skin, and by progressively developing weakness without corresponding emaciation. *Etiology:* (a) Most common in the male sex. (b) Overwork. (c) Bad hygiene, especially poor teeth and unclean mouth. (d) Adult life, though the disease may occur in children. (e) Intestinal parasites. (f) Pregnancy and parturition. (g) Atrophy of the gastric tubules. I. *Blood.*—(1) Marked reduction in number of red corpuscles (to one million or less per cubic millimetre). (2) Alteration in their shape, — poikilocytosis. (3) Alteration in size, — microcytes, macrocytes, megalocytes. (4) Nucleated reds, — normoblasts, megaloblasts. (5) Increase of neutro-



philic whites. (6) Hæmoglobin markedly decreased, but color-index usually high. II. *Miscellaneous Lesions found Post Mortem.*—(1) Muscles resemble horse-flesh. Heart usually large, flabby, empty, and tawny-brown. (2) Spinal cord may show posterior sclerosis with hemorrhagic foci. (3) Skin and serous membranes commonly reveal hemorrhages; these may, however, be present only in the retina. (4) All organs exhibit fatty changes. (5) Iron is deposited in excess in the lobules of the liver, especially in the outer and middle zones. (6) The bone-marrow—best seen in the humerus or femur, though also found in the clavicle—is red (lymphoid) in character.

*Chlorosis.*—Chlorosis is a primary anæmia which occurs usually in girls, and is characterized by marked diminution of hæmoglobin and sometimes by hypoplasia of the circulatory and generative organs. (a) Female sex. (b) Age from fifteen to twenty. (c) Bad hygiene and overwork. (d) Shock or fright. (e) Absorption of intestinal poison. Cases of simple chlorosis rarely come to autopsy. The blood shows marked diminution of hæmoglobin. In severe cases there may be great alterations in the number, shape, and size of the red corpuscles. The white rarely show much variation. The flesh is usually well preserved. The skin is pale and of a greenish hue, and there may be other evidences of anæmia. The internal organs will be found pale and flabby. The heart and larger blood-vessels and the generative organs show hypoplasia.

*Leucocythæmia (or Leukæmia).*—A form of primary anæmia characterized by great increase of the white corpuscles and by marked structural changes in the lymphatic glands. Cause: Not definitely known; usually ascribed to changes in the blood-making organs. *Classification.*—(a) Splenic. (b) Medullary. (c) Lymphatic. (d) Combinations of the three forms. As a rule, the patient is apparently well preserved, but in some cases emaciation may be extreme. The skin has a peculiar lemon-yellow color. The mucous membranes are blanched. The amount of adipose tissue is frequently increased and of a peculiar punctate appearance, owing to the presence of petechial hemorrhages. The blood is pale in color,—often milk-white. It rarely clots with any rapidity. The organs in general are pale; the liver, spleen, and lymphatic glands are usually markedly enlarged. The heart is pale, flabby, and frequently fatty in appearance. (a) In splenic anæmia, which is a comparatively rare form of the disease, the spleen is markedly enlarged, somewhat firm in consistency, and of a reddish-



brown color. The Malpighian bodies are frequently obliterated, their place often being taken by grayish-white, circumscribed tumors throughout the organ. The hyperæmia in some cases is excessive, and rupture of the spleen is said to have occurred from this cause. Dropsy from pressure on the abdominal viscera may result. As in other forms of leukæmia, the bone-marrow may show decided changes, especially in the long bones. Instead of fatty tissue there may be splenization, or it may resemble the consistent matter which forms the core of an abscess. Microscopical examination of the blood shows that the increased white corpuscles are largely myelocytes. (b) Medullary leukæmia very seldom occurs as an inflammatory process. Where the marrow changes are excessive, the flat bones—as, *e.g.*, the sternum—undergo alterations similar to those occurring in the long bones. (c) In lymphatic leukæmia the lymphatic glands throughout the body, especially those of the neck, the axillary and inguinal regions, and the glands of the mesentery and the intestines, show marked involvement. The liver, as well as the spleen, is enlarged and may exhibit marked structural changes. The lymphatic glands in general are swollen, pale in color, firm to the touch, and seldom suppurate or show any tendency to run together. The spleen, liver, and other lymphatic glands often show marked thickening of their capsules. On section the glands are somewhat resistant, and often exhibit nodule-like bodies, which are firm in consistence and largely composed of proliferating leucocytes and connective tissue. Microscopical examination of the blood shows that the marked increase of the leucocytes is in the lymphocytes. (d) The blood in leukæmia in general shows somewhat marked diminution of the amount of hæmoglobin; it is light raspberry-red in color and may in the severest cases be yellow; small balls of corpuscles, especially in the pulmonary artery, are sometimes seen; the red corpuscles are reduced in number, sometimes markedly so. The white corpuscles are enormously and permanently increased, so that one white to twenty red, or even one to one, is not uncommonly found. The characteristic feature of leukæmic blood is the alteration of the relative proportions of the various white corpuscles the one to the other.

*Hæmophilia.* — An hereditary constitutional disease characterized by a marked tendency to excessive hemorrhage from very slight causes. It is transmitted through the females of a family to the males. Little regarding the morbid anatomy is definitely known. The vessel-walls are unusually thin, brittle, and do not readily retract. In some cases



the blood itself presents marked alterations. Hemorrhages have been found about the capsules of joints, with inflammation of the synovial membrane.

*Purpura*.—A disease characterized by the appearance on the skin of numerous blotches of extravasated blood and by great debility. Very little is known of its origin. It is apparently more common in males than in females and more frequent in the young than in the old. *Classification*.—The forms are (*a*) *Purpura simplex*, (*b*) *purpura hæmorrhagica*, (*c*) *purpura rheumatica*, (*d*) *iodic purpura*, (*e*) *Henoch's purpura*. Among the points revealed by autopsy are: (1) The existence and extent of hemorrhagic effusions with evidences of anæmia. (2) Occasionally the skin presents erosions or ulcerations. (3) The hollow viscera and serous cavities may contain considerable quantities of blood-stained serum. (4) The serous membranes and solid organs, as well as the skin, may reveal hemorrhages varying in size from a pin's head to the palm of the hand. (5) Congestion and œdema of the lungs are frequently present. (6) Slight degrees of acute diffuse nephritis may occur. (7) Ulcerations of the intestines with enlargement of the solitary and agminated glands are sometimes present. In one of my cases the husband was accused of beating his wife and thus causing her death.

*Scurvy*. — Caused by: (*a*) Deficiency of fresh vegetables. (*b*) Bad hygienic surroundings. (1) After death decomposition sets in rapidly. The hemorrhagic patches observed in the skin during life are soon obscured by post-mortem lividity. (2) The subcutaneous tissues, especially those of the lower extremities, contain a blood-stained fluid with here and there discolored patches, some black and others of a pale color. (3) About the back of the thigh and knee the muscles and tendons may be embedded in a thick, firm clot, and themselves contain numerous hemorrhagic foci. (4) The blood is dark and fluid. Hemorrhages may be present in any of the serous membranes or internal organs. (5) The gums are swollen, sometimes ulcerated, and the teeth may have fallen out. (6) Hemorrhages in the mucous membranes are extremely common. Rarely there may be ulcers in the intestines. (7) The spleen is enlarged and soft, while fatty changes are constant in the liver, kidneys, and heart. (8) There is very little wasting of the subcutaneous fat of the muscles. This disease is by no means so frequent as formerly, owing to better hygienic conditions and to the proper feeding of those in ships, prisons, work-houses, etc.



*Scurvy, Infantile.*—Usually associated with improper food, such as malted or condensed milk. Cases, however, have been reported in breast-fed children. (1) The most important lesions are increased vascularity and extravasation of blood affecting the periosteum and bones, especially those of the lower limbs. Extensive hemorrhages are frequently found between the periosteum and the bone. They may also occur in the cavity of long bones, forming masses of blood-clots. (2) These deep-seated extravasations may give rise to muscular swellings and in some cases to extravasations in the joints. (3) Smaller extravasations have been observed in the pleura, lungs, spleen, intestines, and kidneys. (4) Fractures are not uncommon. In fact, in the majority of cases there are bone changes analogous to those of rickets. (5) The gums are spongy, sodden, distended with serum, and sometimes covered with blood. (6) One of the most characteristic lesions is extravasation of blood into the orbital cavity, causing displacement of the eyeball downward and forward. The report of the American Pediatric Society on this condition is of a most interesting character.

*Diabetes Insipidus.*—A constitutional condition characterized by the passage of large amounts of pale urine, of low specific gravity, containing neither albumen nor sugar. It occurs more often in the male sex and during early life. Heredity may be a causal factor. The urinary system may merely show the signs of the passage of an abnormal amount of liquid,—enlarged and congested kidneys, dilated pelves, dilated ureters, and an hypertrophied bladder.

*Diabetes Mellitus.*—A constitutional disease characterized by the passage of large amounts of pale urine, of high specific gravity, containing sugar. It occurs most frequently in adult males, Hebrews being specially predisposed. Mental strain or worry may be a cause. There are no constant lesions of the nervous system, but tumors of the medulla, injury of the floor of the fourth ventricle, or sclerosis in various areas have been found. The sympathetic ganglia may be enlarged and sclerosed and a secondary multiple neuritis is not rare. The celiac ganglion is atrophic in this disease (Orth). Neuroretinitis is very common, and there may be hemorrhages in the retina and opacities in the vitreous. The most usual change is thickening and congestion of the membrane. Croupous pneumonia, bronchopneumonia, and tuberculosis are common complications; any of them may terminate in gangrene. Fat embolism of the pulmonary vessels has been described. The lung may soften (malacia) and, becoming mixed with stomach secre-



tions *post mortem*, forms the so-called *pneumomalacia acida*. It has a sour but not a gangrenous odor. The pancreas is often diseased, especially the islands of Langerhans. There may be simple atrophy, pigmentary cirrhosis, cancer, calculi, cystic disease, or fat necrosis. The spleen is usually small, pale, and soft, but may be enlarged and congested. Diffuse nephritis with fatty degeneration occurs frequently, also glycogen degeneration, most marked in pyramids. Boils, carbuncles, onychia, eczema, and gangrene of the extremities are common. The blood generally appears normal, but may be loaded with finely divided fat which floats on the surface in a cream-like layer. The liver is usually enlarged, often congested, abnormally firm to the touch, and gives the glycogen reaction; fatty degeneration is common. The myocardium is pale and soft; rarely it may be hypertrophied. Advanced fatty degeneration of the muscular fibres is the characteristic change in long-standing cases of diabetes. The urine is of high specific gravity, of a pale, somewhat cloudy appearance, always containing sugar and sometimes acetone and diacetic acid. Do not mistake for alkaptonuria.

*Gout*.—A constitutional disease characterized by deposits of uric acid or its salts in the joints of the extremities. Predisposing causes are: (a) Male sex. (b) English race. (c) Heredity. (d) High living. Anatomical changes are found most frequently in the great toe, though the disease shows a marked tendency to involve the smaller joints, both of the feet and the hands. In acute stages there are notable hyperæmia and round-celled infiltration and diffusion into the joint. Macroscopically the joint is swollen, tense to the touch, of a purplish color, and glazed. In the chronic form the ligaments and fibrocartilages of the joint become infiltrated with chalky deposits (tophi). These consist of sodium urate in the form of crystalline needles or rhombs. The addition of hydrochloric acid causes their immediate disappearance, but later whetstone crystals of uric acid make their appearance. Necrosis in the cartilage always precedes the formation of tophi (Ebstein). These deposits may be slight or may lead to enormous distortion of the joint. In some cases the skin may ulcerate and the tophi be extruded. The deposits may be found in the cartilages of the ear, the nose, the eyelids, and occasionally the larynx. The kidneys usually show chronic interstitial inflammation with deposits of urates in the form of small flakes or stripes, chiefly in the pyramids. Arteriosclerosis, with hypertrophy of the left ventricle, is very common. Cutaneous affections, such as eczema, are not infrequent.



**HEMORRHAGES.**—Disturbances of the circulation of the endocardium are rare, as this membrane possesses no blood-vessels of its own. A diffuse redness in this situation may, however, be the result of imbibition, and in the case of long-diseased valves, in which there are newly formed blood-vessels, reddish streaks and spots may be observed, which are due to small hemorrhages. In the myocardium larger hemorrhages may be met with, as a result of the rupture of small aneurisms of branches of the coronary arteries or as a hemorrhagic infarct. Anæmic infarct is also found as a result of a partially obstructing embolus or the formation of a thrombus. The condition of softening of the heart, or myomalacia cordis, is most frequently situated in the anterior wall of the left ventricle, near the apex. The degenerated tissue may form a scar, but more frequently leads to an aneurismal dilatation, which may subsequently rupture. Aneurisms of the sinus of Valsalva may form and rupture in unexpected places; I have seen, for example, an aneurism of an aortic sinus ruptured in the right ventricle.

*Varieties of Hemorrhage.*—The following terms are applied to hemorrhages from various parts of the body: Epistaxis, hemorrhage from the nose; hæmoptysis, pulmonary hemorrhage; hæmatemesis, or gastrorrhagia, hemorrhage from the stomach; metrorrhagia, uterine hemorrhage not occurring during the regular menses; menorrhagia, excessive menstrual flow; post-partum, hemorrhage from uterus after delivery; complementary, hemorrhage occurring in some place other than that in which the original bleeding occurred; consecutive or secondary hemorrhages; extrameningeal, a hemorrhage external to the cerebrospinal meninges; hemorrhage per diapedesis; hemorrhage per rhexis.

*Hemorrhages, Causes of.*—(a) Traumatism. (b) Acute inflammation. (c) Passive congestion. (d) Corrosive poisons. (e) Malignant growths. (f) Diseases of the vessels. (g) Rupture of an aneurism. (h) Cachectic disease. (i) Dyscrasias. (j) Nervous disturbances. (k) Vicarious menstruation.

**HYPERTROPHY AND DILATATION.**—These conditions are usually associated with each other. In concentric hypertrophy the walls are thickened and the cavities are smaller than normal. As this condition is often due to post-mortem contraction or to marked systole, the heart should be soaked in tepid water before the measurements are taken. One may also distinguish simple hypertrophy, where overgrowth of



the walls is found associated with normal cavities; eccentric hypertrophy, or hypertrophy with dilatation; and pure dilatation without hypertrophy. The highest degrees of hypertrophy occur in cases of double aortic disease, where, too, moderator bands are sometimes found.

INFILTRATIONS AND DEGENERATIONS.—In fatty infiltration, or *obesitas cordis*, there is an increase of fat in those places where it is normally deposited; it starts from the outside and goes inward along the trabeculae of connective tissue; while in fatty degeneration the change originates from within. In fatty infiltration the heart may be embedded within such an enormous deposit of fat as to leave no muscle exposed to view. Hyaline and amyloid degeneration may also occur, as well as calcareous infiltration, fragmentation, and segmentation.

MYOCARDITIS.—Parenchymatous myocarditis may be diffuse or limited. When the inflammatory process involves all of the musculature of the heart, as is frequent in the infectious diseases, it is characterized at first by the flabbiness and the turbid grayish-red color of the heart muscle. In the later stages there is much fatty degeneration. Segmentary parenchymatous myocarditis is marked by a cloudy appearance of the heart muscle, which is flabby and friable. (Orth.) Acute circumscribed interstitial myocarditis, or abscess of the heart, is usually a part of a general pyæmic disease, with infection through the coronary circulation. These metastatic abscesses occur in cases of puerperal sepsis, in osteomyelitis, and other intensely septic diseases, but particularly in cases of malignant endocarditis. There may be only a few abscesses or the heart substance may be studded with innumerable suppurating points. In size the abscesses vary from the merest dots to cavities of the size of a cherry. Acute diffuse interstitial myocarditis occurs in various forms of infectious fevers. The affected heart muscle is soft and often distinctly friable; there may be spots of hemorrhagic infiltration, but, as a rule, the color is rather lighter than that of the normal organ. The cavities of the heart are frequently dilated, particularly the left ventricle. Chronic interstitial myocarditis or fibrous myocarditis may also be diffuse or localized, though the circumscribed form is the most common. This fibroid overgrowth is very commonly met with at the tips of the papillary muscles, on the trabeculae, or in the substance of the heart muscle, and often at the apex of the left ventricle, where it may lead to such a degree of atrophy



that a chronic localized aneurism of the heart may be formed by the constant pressure of the blood upon this thinned area. The process is usually secondary, and is dependent upon primary disease of the coronary arteries, or disturbances of the circulation in the coronary arteries, consequent perhaps upon old age, alcohol, gout, syphilis, and the like. The characteristic change is the formation of dense, grayish sclerotic areas, which appear either as more or less irregular spots or as streaks or lines running in the direction of the fibres of the heart. The entire substance of the heart may be involved and thickening of the walls may result. (Stengel.)

ENDOCARDITIS.—In the foetus endocarditis is usually situated in the right side of the heart; during extra-uterine life the lesion is most common in the left side. In the great majority of adult patients acute endocarditis affects the endocardium of the valves,—the mitral, the aortic, and the pulmonary valve in order of frequency; but it is sometimes found in the endocardium of the cavities of the heart,—in the left ventricle, the left auricle, and the right ventricle. Various names have been applied to these conditions, as simple, or verrucose, benign, ulcerative, septic, mycotic, rheumatic, syphilitic, diphtheritic, or malignant endocarditis. Such cases differ much in their appearance, even when produced by the same organisms. Endocarditis starts on the endocardium as a minute, roughened area, which is red in color and slightly elevated. This can easily be scraped off, but, if the spot where it was found is carefully examined, a small ulcer will be seen. More and more fibrin is deposited, and the corpuscular elements are caught in its meshes; the organisms multiply, and the clot undergoes a liquefaction necrosis, the process not stopping in the newly formed tissue but often penetrating the valves or even the walls of the heart. Endocarditis is frequently a secondary affection, dependent upon inflammatory disorders in other organs, such as suppurating wounds, purulent peritonitis, and pneumonia. Sometimes, however, the endocarditis forms the first local manifestation of an infection, the exciting agent of which has left no recognizable traces at the seat of its entrance into the body. Embolic occlusion of certain vessels and metastatic inflammations in other organs, especially the kidneys, spleen, brain, and skin, are not infrequently associated with endocarditis (Ziegler). Such hemorrhagic areas are to be sought for in the palpebral conjunctiva; their discovery therein during the external examination of the body has more than once led me to suspect ulcerative endocarditis,



even where there was no clinical history of its existence. This observation is of special value when a bacteriological examination of the heart is desired. These ulcerative areas on healing are replaced by scar tissue, which, by contraction and by various degenerative changes, such as necrosis, fatty degeneration, and calcification, gives rise to the most fantastic shapes and appearances of the parts affected.

VALVULAR DISEASES.—An extreme degree of mitral stenosis is seen in the so-called buttonhole mitral, which causes hypertrophy of the left auricle, followed by dilatation. Brown induration of the lungs, cyanotic induration of other viscera, and dropsical effusions may follow mitral incompetence. In aortic stenosis the valves are usually thickened, rigid, and cartilaginous; later they become calcified and the division between the different cusps is lost. First there is ventricular hypertrophy, later right-sided enlargement, and finally dilatation with pulmonary congestion. In aortic incompetency arteriosclerotic changes are marked, being seen not only in the valves but also in the aorta.

SYPHILIS, TUBERCULOSIS, ACTINOMYCOSIS, TUMORS, ETC.—Syphilitic gummata appear in the heart as rather large yellow foci surrounded by fibrous tissue; they may also be found in the arch of the aorta. Miliary tubercles, when present, are usually subendocardial or situated in the large vessels coming off the heart. At a postmortem in Ziegler's mortuary I once saw where a caseating peribronchial gland had eaten its way through the pulmonary artery and given rise to a most marked local and general miliary tuberculosis. Actinomycosis has been observed. Tumors are rare; myxomata, lipomata, fibromata, sarcomata, and rhabdomyomata may be met with as primary tumors of the heart, while, as secondary, carcinomata, sarcomata, and especially multiple melanotic sarcomata may be observed. Foreign bodies, as needles, pieces of bone, etc., have been found in the cardiac wall and even in the cavities of the heart. Cysticerci, echinococci, and very rarely pentastomata are sometimes discovered in the various parts of the heart.

ARTERIES, MORBID CHANGES IN.—*Arteriosclerosis*.—A hardening of the arteries, characterized by a diminution in elasticity of the vessels and marked alterations in blood-pressure. It may be local or general. Due to: (a) Old age. (b) Chronic disease,—e.g., gout, rheumatism, syphilis, etc. (c) Overwork, especially early in life. (d) Chronic poisoning,—by lead, arsenic, alcohol, etc. (e) Infectious diseases, etc. The



arch of the aorta is the most common seat. In the *first stage* there is a loss of elasticity, due to hyaline or other changes in the subendothelial coat, and the intima is thickened. The *second stage* is characterized by a thickening of the media, atrophy of muscular and elastic tissue, with proliferative changes in all the coats; this increase of new tissue gives rise to pressure on the vasa vasorum, with interference of nutrition, which leads to the *third stage*. This consists of more or less marked macroscopic changes. The vessels are hardened, firm to the touch, do not retract or close when cut, and their lumina may be smaller or larger than normal. On the intima may be seen milk-white or yellowish patches, calcareous plates, abscesses (which consist of fat, cholesterin, and detritus), or ulceration. There may be a marked tendency to dilatation with the formation of an aneurism or to contraction with obliteration. *Special Forms*.—(a) Senile. Affects larger arteries most; they are dilated, tortuous, thin but stiff; often show atheromatous changes in intima. Cyanotic induration of heart, liver, and kidneys is common. (b) Nodular. Knob-like yellowish-white projections are seen in the aorta and its branches, particularly about the orifices; sudden dilatation or aneurism may result. (c) Diffuse. The lesion is wide-spread and more uniform; the intima, as a rule, does not show marked naked-eye changes. Cardiac hypertrophy is constant; the kidneys are sclerosed, their capsule is adherent, cortex irregular and often cystic. (d) Endarteritis obliterans. There is particularly a thickening of the intima. It is not uncommon at the base of the brain.

*Amyloid Degeneration*.—Usually microscopic, and best brought out by staining. *Atrophy*.—A general diminution in the size of arteries, best seen in stumps after operations. *Calcareous Infiltration*.—In the media of the arteries of the old, particularly involving those of the extremities, calcification of the media occurs. It interferes with the blood stream, predisposes to thrombosis, and may be the cause of senile gangrene. Seen as a diffuse or circumscribed process, usually in connection with atheroma. *Fatty Degeneration*.—In fatty degeneration the affected areas of the intima have a white or a citron-yellow appearance. These areas occur in the form of points, stripes, regular or irregular or net-shaped figures. A frequent location is the posterior wall of the aorta around the origin of the intercostals. For more careful macroscopic study the surface of the fatty area should be removed with a fine forceps and in the centre a shallow incision should be made. Here small and large fat droplets can be seen. When placed in Flem-



ming's solution these droplets become black. The fatty degeneration may involve the media and even be the cause of rupture. *Hyaline Degeneration*.—Almost always microscopic; affects mostly the elastic coat and is often the beginning of an arteriosclerosis. It most frequently involves the small arteries. *Hypertrophy*.—There is hypertrophy of the muscular layer in some diseases of the kidney, and hypertrophy of this layer in arteries of medium size in aortic insufficiency. A general enlargement, best seen in the collateral circulation after ligation of a large vessel. *Hypoplasia*.—Hypoplasia of the aorta is congenital and is the result of stenosis, most commonly situated near the insertion of the ductus arteriosus Botalli. It usually soon causes death; if not, the aorta is contracted, thinner, but very much more elastic. Virchow attributes chlorosis to it. *Inflammations*.—I. Acute endarteritis (proliferative or obstructive endarteritis, thrombo-arteritis). This starts with an injury to the endothelium, proliferation occurs, and an obstruction is formed in the vessel-wall, on which a thrombus forms, partially or completely obstructing the vessel. This may terminate in absorption, suppuration, ulceration, or fibroid change. II. Chronic endarteritis. This usually follows the acute form, but is sometimes primary. It may be local (organization of a thrombus) or general (arthritis deformans). *Syphilis*.—Numerous small foci of cell infiltration, necrosis, and particularly induration, with small thickenings of the inner surface, are said by Heller, quoted by Orth, to be characteristic differences between syphilis and chronic aortitis. Gumata are rare. May be local or general sclerosis; is usually a diffuse process, affecting all the coats, especially the intima. *Tuberculosis*.—Tuberculous lesions are less common in the arteries than in the veins. The small arteries are most frequently affected, and the pia, the brain, the kidneys, and particularly the lungs are the usual locations of such a lesion. Commonly a local process; it may arise as an internal tubercle (gray nodule) of hæmatogenous origin starting in the intima or as an extension from a neighboring tubercular process. Cheesy peribronchial glands may ulcerate through the pulmonary artery and thus give rise to miliary tuberculosis. Thrombosis and embolism, especially in the brain, are of extreme importance. In embolism air, fat, portions of tumors, micro-organisms, etc., are brought to a smaller vessel from a larger one, though the converse may occur, and there set up characteristic changes, as infarcts, softening, abscesses, etc.

**ANEURISM**.—An aneurism is a circumscribed, tumor-like dilatation



of an artery, containing blood in direct connection with the blood-current. A true aneurism has a sac composed of one or more of the arterial coats. A false aneurism is one in which some of the walls are formed by the tissues surrounding an opening in the artery; these sometimes attain an enormous size. Aneurisms may be caused by: (a) Arteriosclerosis. (b) Strain or traumatism. (c) Embolic and mycotic processes. The elastic coat is now believed to be the starting-point of aneurismal changes. *Varieties*: Cylindrical, when there is widening in all directions; saccular, when one side is affected; cirroid, when a large extent, or even the whole ramification, of an artery becomes dilated and tortuous; this form most often occurs in the frontal, occipital, or iliac arteries; arteriovenous, when there is communication between an arterial aneurism and a vein; varicose, when an artery and a vein communicate through a false aneurism lying between them; dissecting, when blood circulates between the coats of an artery. Extensive degeneration must precede this form. I have seen such an aneurism, which began at the transverse arch of the aorta, open again into the blood-stream just above the aortic bifurcation. Mycotic aneurisms are multiple and are micro-organismal in origin. This variety is often seen in connection with malignant endocarditis. The mesenteric arteries of the horse sometimes become dilated with considerable numbers of the *Strongylus annatus*. Miliary aneurisms are usually multiple and consist of small dilatations; they are found especially in the brain and lungs, and often antedate a hemorrhage in these regions. They are best seen in the brain by excising the middle cerebral artery and floating it out in a white dish partially filled with water. These aneurisms may be due to emboli. They are mostly sac-shaped and may attain the size of a cherry-stone.

The walls of the blood-vessels may be present or altogether absent; they may be thickened and opaque or almost transparent. If the aneurism be large, the cavity has a roughened wall, often lined with endothelium, and frequently contains clots which are white, red, organized, or softening. They frequently show lamination. I have seen a fibrinous clot of an aneurism of the carotid mistaken for a sarcoma of the neck, a gluteal aneurism opened for an abscess, and a femoral aneurism mistaken for a hernia. Rupture of an aneurism, usually from the aorta into the pericardium, is a most frequent cause of death in cases brought to the notice of the coroner. The rupture often occurs during the act of defecation. Three cases of aneurism of the sinus of Valsalva have



come under my notice. The direction of the increase in size of a forming aneurism depends on its location. Constant pressure of the sac may overcome the resistance and cause absorption of the densest tissue, even bone. Hence aneurisms of the arch of the aorta may rupture externally or erode the vertebral column.

The question as to the etiology of aneurism is much debated. My own statistics on this subject confirm the opinion that syphilis is a frequent cause, especially in the early stages before marked arteriosclerotic changes have taken place in the arteries. This view is also supported by the fact that animals are rarely affected with aneurism. The experimental production of aneurism in animals by alcohol, trauma, etc., affords an interesting field for future investigators.



## CHAPTER IX

### EXAMINATION OF THE PLEURÆ, LUNGS, AND UPPER AIR-PASSAGES

THE general condition of the pleuræ and the exterior of the lungs having been noted when the thorax was opened, a minute examination of the serous surfaces and of the lung tissue is next made. As a practical point it is well to remember that serous membrane when normal is barely visible to the naked eye, being smooth and glistening, but when inflamed its appearance depends upon the nature of the inflammation; the membrane will then be found roughened and more or less opaque, especially if examined by an oblique light. The extent of this condition should be noted as well as the character of the exudates.

To remove the lung the left hand, palm inward, is introduced along the costal curve until the upper lobe can be elevated without undue pressure upon the pulmonary tissue. Should there have been no antecedent inflammation, this procedure is readily accomplished, but sometimes, when the adhesions are very strong and cannot be broken down by the hand, it may be necessary to dissect away the costal pleura and even the ribs and remove them along with the lung. When this condition is found in the performance of routine postmortems, the examination of the affected lung may be accomplished by making the incisions while the organ is still in the body. The upper lobe is now carried away from the median line of the body, anteriorly and downward, thus exposing the structures forming the root. Then, separating the index and middle finger of the left hand, the root of the lung is surrounded so that the upper lobe rests on the palm. In this way pressure can be made downward and away from the spinal column. Next, a perpendicular incision should be made in the direction of the spinal column and the bronchus severed. The advantage of this procedure is that it enables the operator to observe the character of the fluid in the bronchus, avoiding its (otherwise very probable) contamination with blood. When the character of the fluid is noted, the rest of the structures may be severed with a few horizontal incisions, care being taken to avoid cutting the aorta and the œsophagus. It is well to remember when cutting these vessels that the left bronchus, which is considerably longer than the right, is situated below the pulmonary artery, while the right



undivided bronchus is entirely above the right pulmonary artery. The left lung should be removed first, and, as it has usually two lobes while the right has three (I have seen this condition reversed but twice), there is no necessity of adopting any method of distinguishing them after they have been removed from the body. Then, too, the left lung has a depression in its anterior border for the apex of the heart, it is longer and narrower than the right, not quite so heavy, and, as already stated, the arrangement of the bronchus and artery is different on the two sides. If, however, it is deemed necessary to do this, a single cut in the apex or bronchus of the left lung and two in the right will afford a ready means of distinguishing the one from the other. Examine the visceral pleura for fibrinous deposits, exudates, adhesions, etc.; note the color, which varies with the age, the quantity of contained blood and air, minute hemorrhages, excessive pigmentation, cicatrices, spicules of bone, emphysematous spots, miliary tubercles, calcified tubercles with cheesy interiors, nodules, patches of consolidation, hemorrhagic and anæmic infarcts, tumors, etc. The lungs should be weighed at this time, before they are opened for further study.

Placing the lungs upon their posterior surface on a board, rather than upon the more slippery stone table, the lower lobe of one lung is grasped with the thumb, the remaining fingers seizing the upper lobe;<sup>1</sup> in this way the organ is firmly held (Fig. 71). With a single stroke an incision should be made from apex to base, commencing at the lateral convexity and passing to the entrance of the large vessels in the direction of the bronchi, the lung being laid open like a book (Fig. 72). In the case of the left lung the base will be turned towards the operator, while in the right it will be the apex, requiring an extra incision to open the middle lobe. Immediately note the color of the cut surface. The normal color without blood is light gray, while with different quantities of blood the shade ranges from light red or brick-red to dark, black, or blue-red. In heart disease the color of the pulmonary tissue is brown; in anthracosis it is black. The amount of hypostatic congestion and the character of the fluid which exudes on squeezing are now determined. A microscopic examination of the scraping may be made. Next it is necessary to examine the substance of the lung for cavities, to observe the shape and position of areas of consolidation, and to ascertain the

---

<sup>1</sup> If the index-finger is introduced into the fissure between the lobes (and this method holds the lung very securely), care must be taken not to cut the finger in the subsequent procedures.



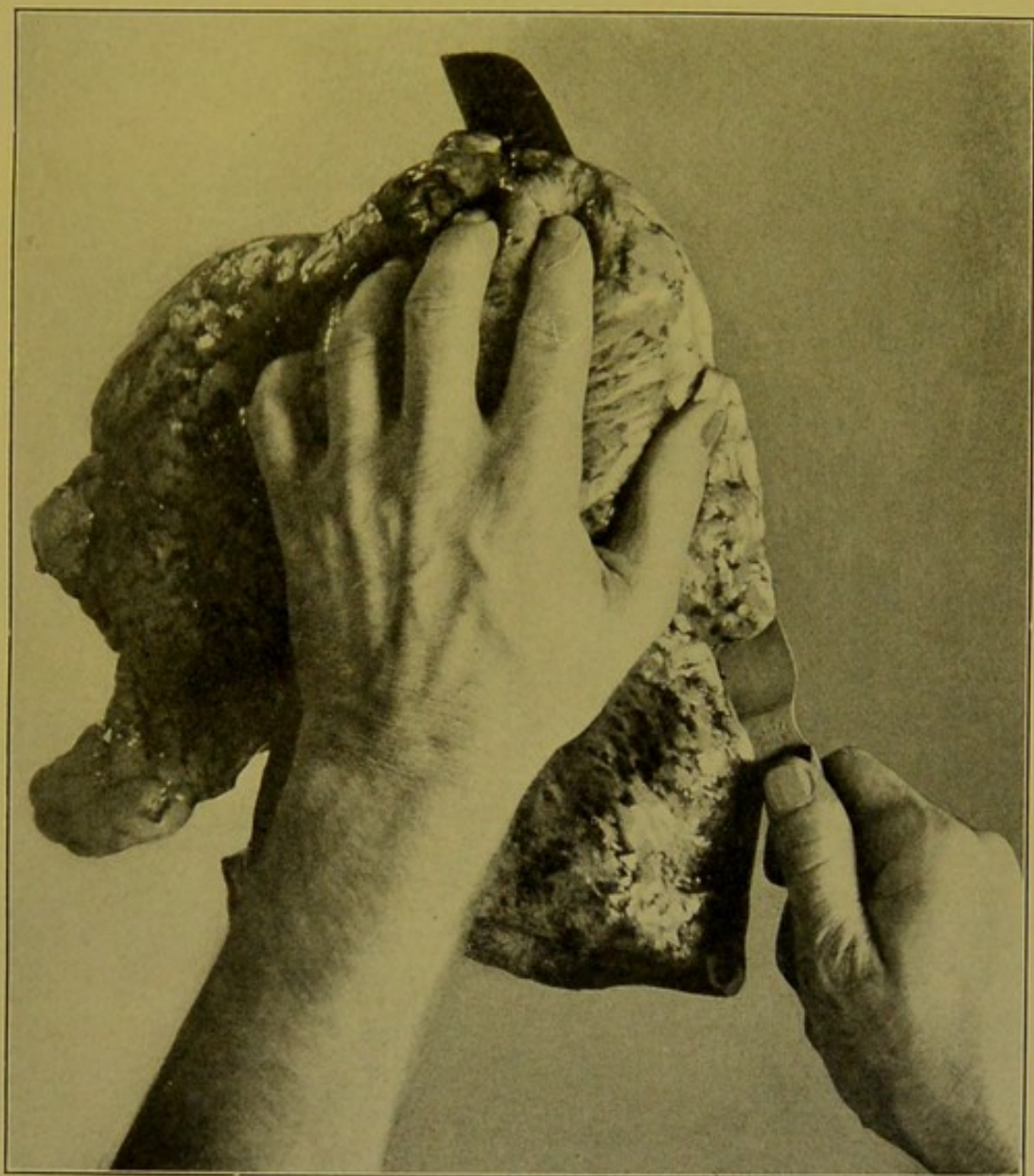


FIG. 71.—Method of opening the lung. The organ, lying on its posterior surface, is held steady by slight pressure with the left hand on its upper portion, while a long, clean cut is made from the apex to the base of the lower lobe.



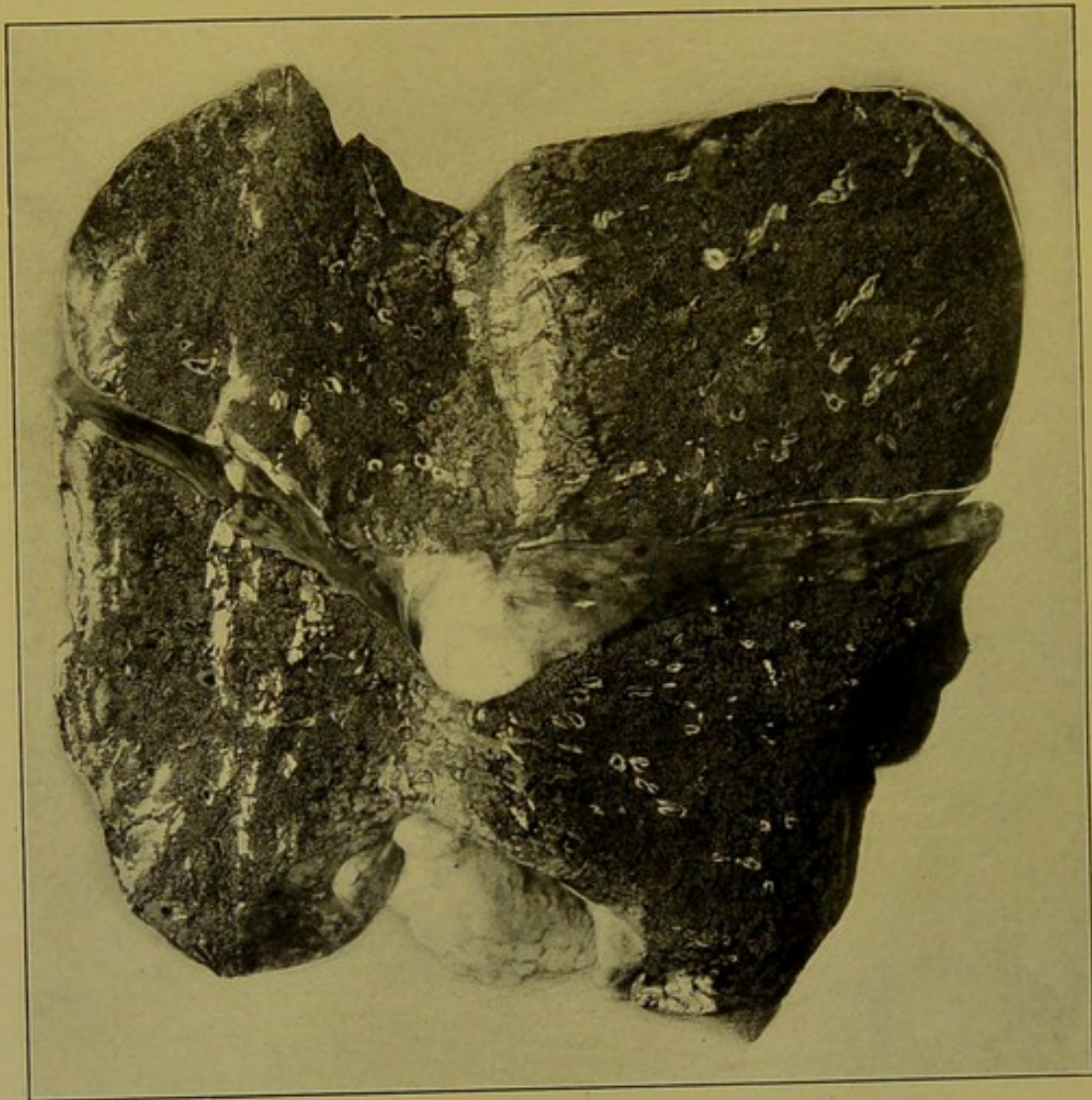

FIG. 72.—Lung laid open for minute inspection. The lung from this case was emphysematous and showed bronchiectasis.



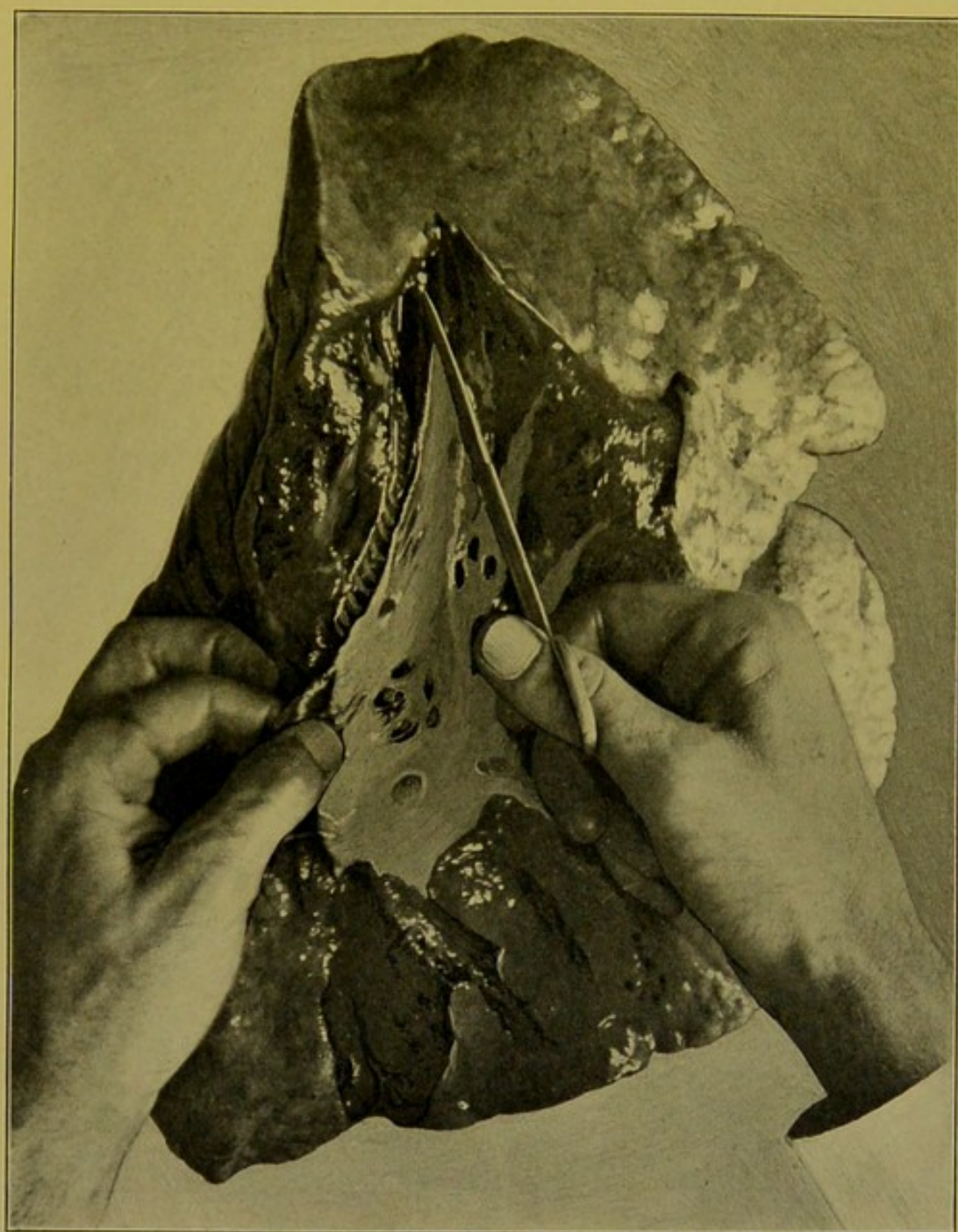


FIG. 73.—Method of opening the pulmonary blood-vessels.



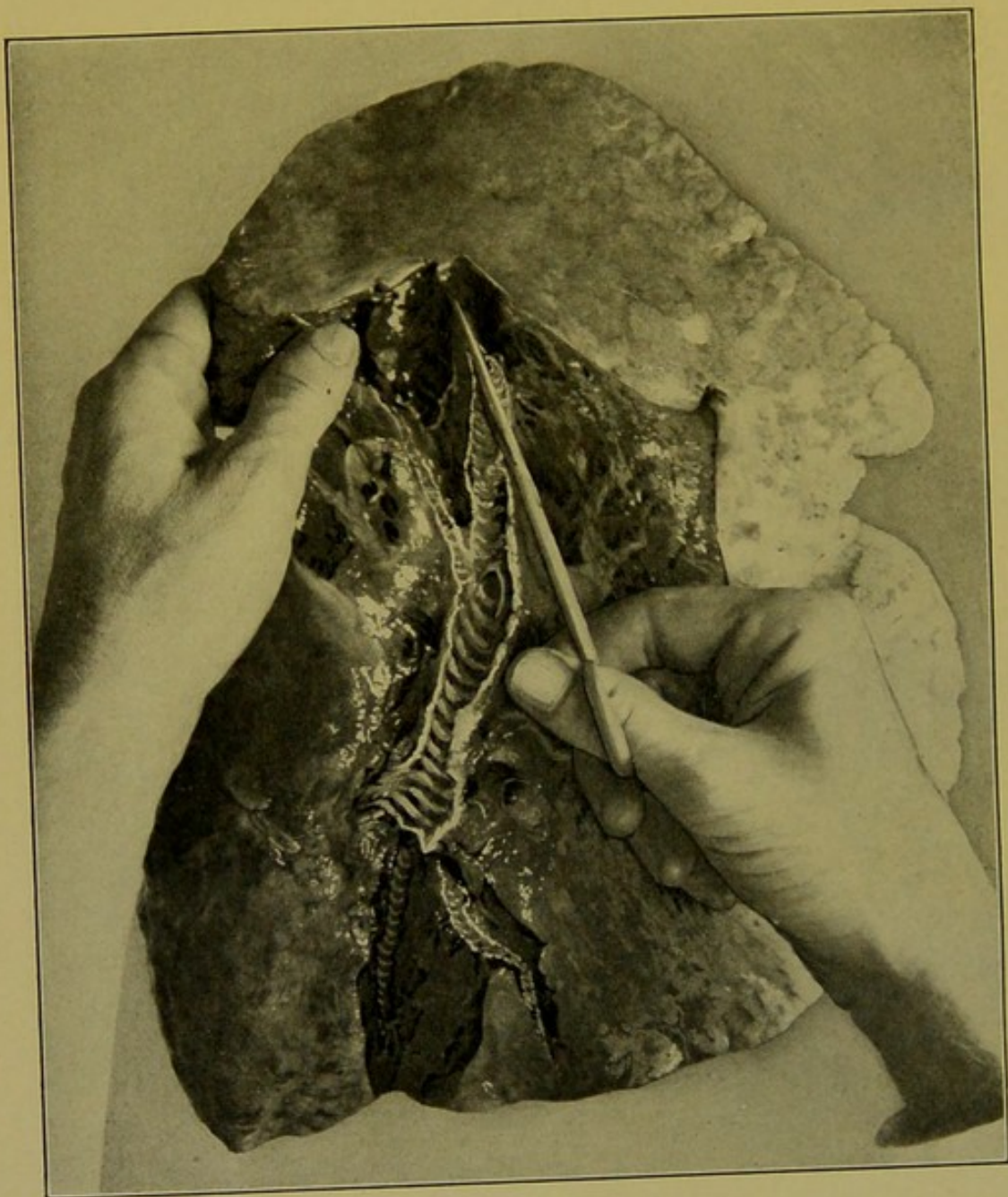


FIG. 74.—Method of opening the bronchi.



specific gravity of consolidated areas in cold water. In pneumonic cases the entire lung may be placed in water to determine the portions containing air. A hemorrhagic infarct or a portion of apoplectic lung will sink in water, as well as the lung of croupous pneumonia.

Now is the time to open the pulmonary vein (Fig. 73), artery, and bronchus (Fig. 74) with scissors. Parallel or transverse incisions may be made, but care should be taken not to make them so deep as to detach any portions of the lung.

In order to obtain more room for the examination of the abdominal cavity, the attachments of the diaphragm to the ribs on the right side may now be severed, and the liver rolled over into the thorax. This gives the additional advantage of supplying a more favorable opportunity for the subsequent inspection of the gall-bladder, biliary ducts, and portal vessels.

It is frequently advisable to excise as one piece the tongue, œsophagus, thyroid gland, trachea, epiglottis, etc., so that a minute examination of these parts may be made while they are exposed to good light in a convenient situation. For this purpose, in those cases where disfigurement of the body is of no importance, the primary incision over the thorax may be extended up to the symphysis mentis and the parts dissected out with ease. Orth's method of doing this is as follows: Having made the primary incision to the chin early in the operation, the skin is reflected. Then by the use of the cartilage-knife an incision is made into the mouth at one angle of the jaw, cutting with a sawing motion to the chin and then back on the other side to the angle of the jaw, severing the geniohyoglossus muscle. The tongue, after being separated from the jaw, is pulled down with the forceps; after which the soft palate should be separated from the hard by the use of a knife, including in the operation the tonsils. A cut should now be made as high up as possible to remove the pharynx, tongue, and œsophagus from the spinal column and the deep pharyngeal muscles. This should be done with small perpendicular incisions on the spinal column through the retropharyngeal and retro-œsophageal tissue. These parts may be removed, however, without the incision being extended to the chin, as by careful manipulation the hand can tear the skin anteriorly away from its attachments by working from beneath, and a knife may be introduced into the centre of the tongue (through the geniohyoglossus muscle) posterior to its frænum, thus leaving the tip *in situ* in case an examination of the mouth is to be made. (Fig. 75.) By a circular



incision of the muscles, fasciæ, etc., with the knife beneath the skin, keeping as close as possible to the bony walls of the jaw, to the carotids, the bodies of the vertebræ, pharynx, and larynx, the trachea and œsophagus may be separated, drawn forward and downward, and removed. The tonsils are either torn out bodily with the fingers from below, or else incised while in the body and examined from above or below by reflected light. The edges of the tongue may be examined for injuries, such as wounds made by the teeth during a fatal convulsion. The mucous membrane is flattened in syphilis, and the tongue may be the seat of lymphangioma. The vessels of the arm should now be cut and the arch of the aorta severed from the œsophagus and bronchi. The whole aorta may be examined later or, if it is deemed better, this vessel as far as the diaphragm can be removed with the œsophagus. The latter procedure is particularly useful when disease of the œsophagus is suspected. The aorta is from seven to eight centimetres in diameter at its commencement and gradually narrows to forty-five or even thirty-five millimetres in the abdominal cavity. The œsophagus and the trachea are preferably opened up posteriorly throughout their entire extent. (Figs. 76, 77, 78, and 79.) Carefully examine the vocal cords; see if there are any tumors, syphilitic or tubercular ulcerations, inflammation, malformations, foreign bodies, diphtheritic membrane, etc. The œsophageal veins frequently carry on a large part of the collateral circulation in cirrhosis of the liver, and the rupture of one of these veins may cause death from hemorrhage, much blood being found in the intestinal tract.

The examination of the vessels of the neck in cases of strangulation, as by hanging or otherwise, is of great importance. For this purpose the incision behind the ear made for the removal of the brain may be extended down the neck and the skin, fat, and superficial fascia of the face dissected away, thus making easy the exposure of the jugulars, carotids, etc. The tearing of the intima of the carotid indicates hanging or strangulation; marks produced by pressure of the rope in the form of parchment-like skin at the sides of the neck and hemorrhages into the tissues are also found in hanging. Emboli of the carotid may cause sudden death, and thrombophlebitis of the jugular in cases of thrombosis of the lateral sinus is to be searched for. Aneurisms are sometimes seen. Hemorrhage into the sympathetic may occur in cases of fever with delirium and of heat-stroke; pigmentation and fatty changes take place in the cachexias and in fevers.



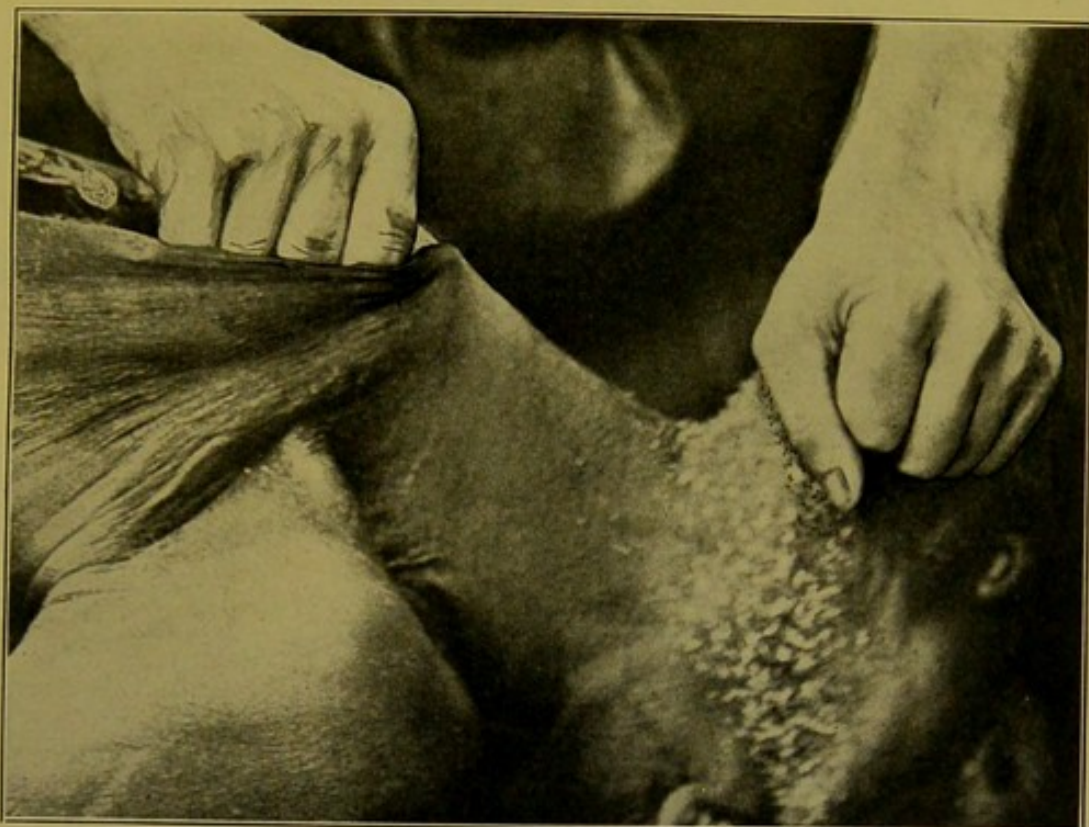


FIG. 75.—Method of removing tongue, tonsils, œsophagus, bronchus, etc., in a single piece, without incising the skin more than is done in the primary cut.



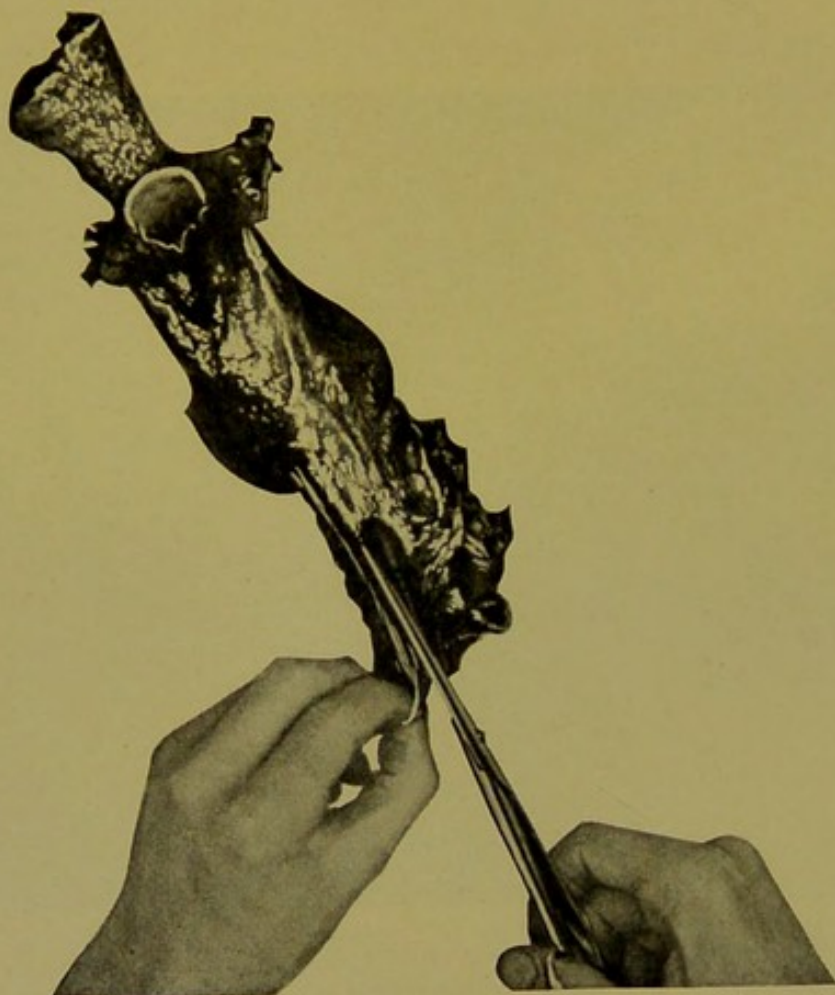


FIG. 76.—Method of opening the œsophagus. The incision starts from below and extends upward



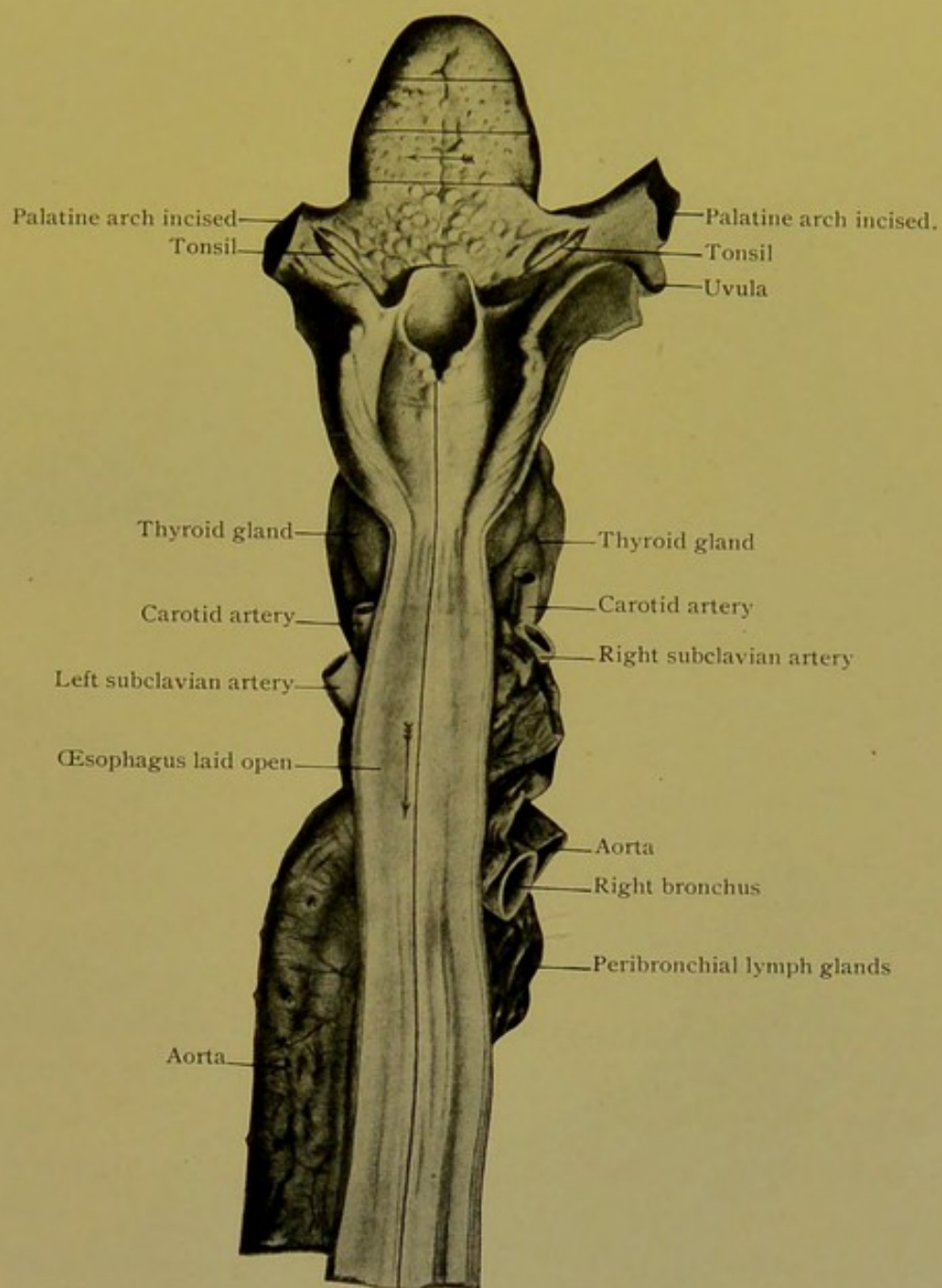


FIG. 77.—Examination of the organs of the neck. The arrows show the direction in which the incisions in the tongue and in the posterior wall of the œsophagus are to be made. (After Nauwerck.)



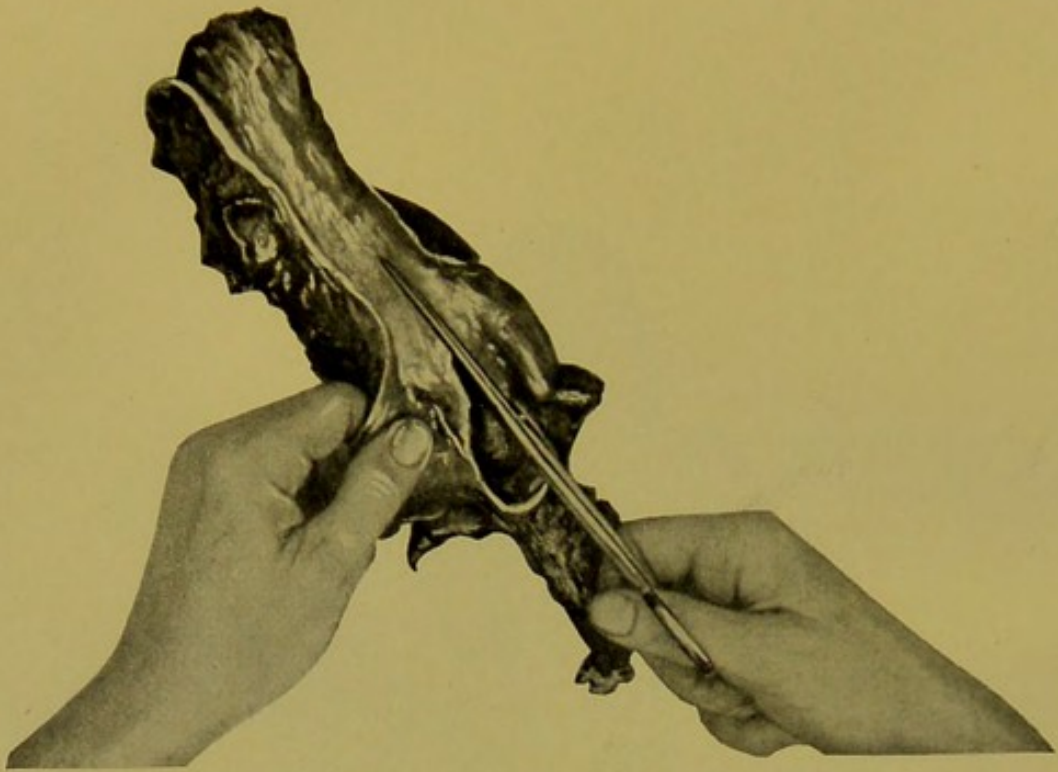


FIG. 78.—Method of opening trachea. The incision starts from above and extends downwards.

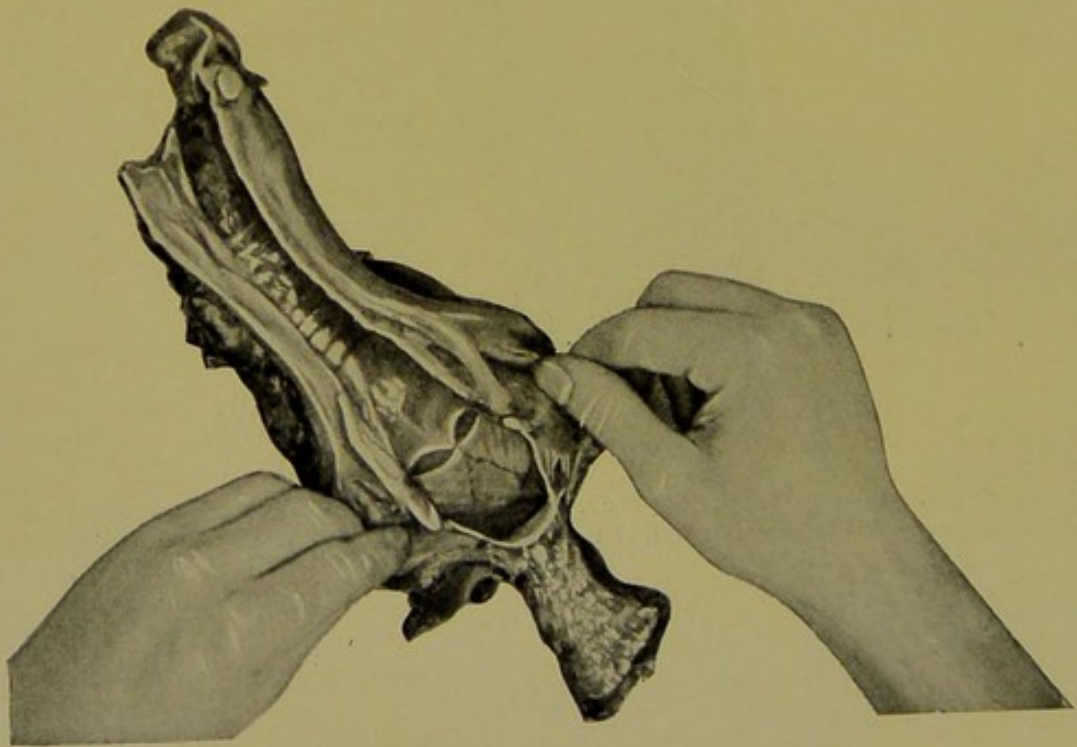


FIG. 79.—Examination of trachea and vocal cords.



## CHAPTER X

### DISEASES OF THE LUNGS, PLEURÆ, AND ACCESSORY PARTS

**ABSCESSSES.**—Many varieties of bacteria have been found in pulmonary abscesses, such as pneumococci, tubercle bacilli, gonococci, actinomyces, and various pyogenic micro-organisms. (*a*) Solitary abscesses of the lung are comparatively rare. They are usually the result of extension from neighboring parts, as the pleura, liver, or mediastinum. The abscess is encapsulated and contains a greenish-yellow pus, which often has an offensive odor. (*b*) Multiple abscesses are common in pyæmia. They are generally superficial, frequently wedge-shaped, and rarely encapsulated. They are at first firm, grayish red in color, and surrounded by a zone of hyperæmia. Later they become distinctly purulent. The pleura is usually covered with a greenish lymph. Perforation of the pleura, causing pyæmia, may occur. Septic pleuritis may be found associated. I have often seen such abscesses having their origin in a septic condition following criminal abortion.

**ASTHMA AND HAY FEVER.**—Conditions characterized by attacks of dyspnœa, due to spasmodic contractions of bronchial tubes and air-vesicles. They are more frequent in males, and are due to spasm of the bronchial muscles and hyperæmia of the bronchial mucous membrane. Attacks are induced by certain localities, odors, pollen of flowers, dust, etc. Lesions are not marked. There are hypertrophy and widening of the bronchial tubes, with thickened mucous membranes. Emphysema of air-vesicles. Chest is barrel-shaped; dorsal spine may be curved. Charcot-Leyden crystals and Curschmann's spirals are often found in the sputum.

**ATELECTASIS.**—Collapse of the lung may be partial or total. It may exist in the fœtus at birth or be caused by closure of the bronchi, capillary bronchitis, compression as from tumor, diaphragmatic hernia, pleuritic transudates and exudates, and marantic conditions, which latter state of affairs is due to weakness, is most marked in the smaller ramifications of the lower and posterior bronchi, and often ends by subsequent œdema in pulmonary splenization. Any air remaining in the shut-off portion is absorbed, and the airless portion on section is dark red or bluish red.



**BRONCHIECTASIS.**—Dilatation of the bronchi, the result of various diseases of the lungs and bronchi. *Etiology.*—(a) Neighboring bronchus may not be patulous or its own alveoli may be closed (includes atelectatic bronchiectasis). (b) Puckering of the peribronchial or interstitial fibrous tissue. (c) Parenchymatous change, as after chronic bronchitis. (d) Circumscribed narrowing, as from tumors, etc. *Classification.*—(a) Cylindrical or uniform. (b) Saccular, spherical, or ovoid. (1) Dilatation of the bronchial tubes may be local or general. A number of sacculi are found opening one into another; these vary considerably in size; they have smooth walls covered with epithelium (mucous membrane), but may in dependent portions show ulceration which is prone to set up a fatal gangrene or a tuberculous lesion may develop. Sometimes the sacs are large and situated immediately beneath the pleura. Putrefaction frequently follows the retention of material in them, causing a putrid bronchitis. (2) The lungs usually show marked fibroid changes, though these may be slight. The air-vesicles are sometimes emphysematous or condensed by pressure. (3) Adhesive pericarditis may follow extension of inflammation from pleura. (4) The liver usually shows chronic congestion; it may be fatty.

**BRONCHITIS.**—Inflammation, acute or chronic, affecting the bronchial tubes, but not involving the terminal bronchi. I. *Acute.*—(a) Infectious fevers. (b) Exposure. (c) Irritant gases and vapors. (d) Extension of inflammation from neighboring organs. II. *Chronic.*—(a) Certain occupations (stone-cutters, etc.). (b) Old age. (c) Saprophytic and other micro-organisms. (d) Repeated attacks of acute bronchitis. *Classification.*—I. *Acute.*—(a) Catarrhal. (b) Suppurative. (c) Croupous. II. *Chronic.*—(a) Hypertrophic. (b) Atrophic or senile. (c) Putrid. (d) Plastic. (e) Tuberculous. I. *Acute.*—(1) In catarrhal inflammations the mucous membrane is thickened, swollen, may be hemorrhagic, and in early stages is covered with tenacious exudate. Later the exudate becomes thinner and purulent, and may be in quantities large enough to fill the large bronchi. If it extends to the small bronchioles it is called capillary bronchitis or preferably catarrhal pneumonia. Lobular atelectasis surrounds the affected areas. (2) In suppurative bronchitis small abscesses, the result of septic embolism, are found in bronchial tubes. (3) Croupous bronchitis is characterized by the formation of a diphtheritic membrane, which sometimes forms complete casts of the smaller bronchi, but is not, as a rule, associated



with the Klebs-Löffler bacillus. Bronchopneumonia is a frequent complication. II. *Chronic*.—(1) Hypertrophic. The whole lung is larger, firmer, and darker in color. The mucous membrane is thickened and often shows petechial hemorrhages. The whole bronchus is thicker and more fibrous; its lumen is sometimes narrowed and may cause stenosis, sometimes dilated. The surrounding lung is usually emphysematous and shows increase of fibrous tissue. (2) Atrophic. Often the lung appears smaller, also lighter in weight and color. Its elasticity is impaired, and it feels "cottony" to the touch. There may be increase of connective tissue, but the mucous membrane is smooth, atrophied, and the lumen of the tubules may be widened. (3) Putrid. This is practically a bronchiectasis. The bronchi are dilated; their walls are usually smooth, but frequently show ulcerations, with fatty plugs and purulent masses such as are found in the sputum during life. Purulent œdema of lung is more or less general. (4) Plastic (fibrous). A chronic form of "croupous," occurs only rarely and is paroxysmal. The membrane is a fibrous, fairly consistent pseudomembrane about two millimetres thick. There is no epithelium under it. The mucous surface is hyperæmic and infiltrated with cells. The thick ducts of the glands push the fibrous tissue off and it is coughed up. The smaller bronchi show catarrhal inflammation, but no membrane. (5) Tuberculous. This may be acute, but usually manifests itself as a part of a diffuse caseous process or as tuberculous ulcerations resembling those of the larynx. The right ventricle is hypertrophied in chronic bronchitis. (6) Cheesy bronchitis. The catarrhal secretion remains in the lumen, becomes thicker, and caseates. The mucous membrane becomes infiltrated with cells and these subsequently undergo caseation. (7) Gangrenous. Often associated with bronchiectasis.

CIRCULATORY DISTURBANCES. — Anæmia, brown induration, œdema, hemorrhages, infarcts, fat embolism, or even air embolism of the lungs may be associated with a similar condition in the right heart. A number of fatal cases of pulmonary embolism have followed intramuscular injections of calomel for syphilis. Fat embolism should always be thought of in cases of fractures or of extensive injuries to the subcutaneous fatty tissues. Hæmoptysis may occur from hemorrhagic infarcts, brown induration, tuberculosis, an aneurism rupturing in the trachea or bronchi, acute inflammations, purpura, scurvy, etc. It is interesting to note that a pulmonary hemorrhage in tuberculosis may be the beginning of an attack or precede a fatal termination.



CONGESTION, PASSIVE.—This condition occurs where there is obstruction of the circulation, especially in chronic illness requiring the recumbent position and in diseases of the central nervous system. (a) In mechanical congestion there is obstruction to the return of the blood to the heart. The lungs are voluminous, russet-brown in color, and cut and tear with difficulty. On section they are of a maroon tinge, which soon gives place to a vivid red on exposure to the air. (b) In hypostatic congestion the bases of the lungs are deeply cyanosed, the posterior parts particularly are engorged with blood and serum, and in some instances portions of the tissue will sink in water. In prolonged coma the hypostatic congestion may be associated with patches of consolidation due to the aspiration of food into the air-passages. (c) In cerebral apoplexy the bases of the lungs are deeply engorged and heavy and on section exude a bloody serum. This congestion is most marked in, and may be confined to, the paralyzed side.

EMPHYSEMA.—The dilatation of the air-vesicles is due to some weakening of the lung structure and a dilating force, usually expiration. It may follow chronic cough, certain occupations, as glass-blowing, senile changes, traumatism, albinism, congenital absence of elastic tissue, and atrophy of the diaphragm. The thorax is increased in its anteroposterior diameter and barrel-shaped. The clavicles are prominent, as are also the sternum and the costal cartilages. The intercostal spaces are enlarged and the sternal fossa is deep. The neck appears to be shortened. Dilated veins may be seen along the line of the attachment of the diaphragm. The back is rounded and the curve of the spine increased. On removing the sternum, the anterior mediastinum is found to be completely occupied by pulmonary tissue and the pericardial sac may be entirely covered by the lungs. The latter are large, light in color, and only slightly pigmented. They are inelastic and do not collapse, but pit readily on pressure. The edges are distinctly rounded and obtuse. Beneath the pleura, especially about the anterior margins and the inner surface of the lobe near the right, enlarged air-vesicles of a delicate bladder-like appearance may be seen, varying in size from that of a pea to a hen's egg (bullous emphysema). To the touch the sensation is soft like that of feathers, and when the air is removed a crackling sound is made and a paper-thin tissue is all that remains. The chief seats are at the edges and the apices. The mucous membrane of the large bronchi may be rough and thickened; bronchiectasis may also be present. The right heart is



dilated and hypertrophied; the pulmonary artery may be enlarged and show atheromatous changes. Emphysema may be vesicular, where the air is confined within the dilated alveolar spaces, or it may be interstitial, the alveolar walls being broken. The latter condition is seen especially beneath the visceral pleura and may be produced *post mortem* by decomposition.

**GANGRENE.** — Gangrene may be circumscribed or diffuse. The lower lobe is usually affected, the peripheral portions rather than the central. The gangrenous part is larger, heavier, and of an ash-gray to greenish-black color. The outer tissues are intensely œdematous, next is an area of deep congestion, and then a cavity with shreddy, irregular walls containing a greenish fluid. The pleura may be simply inflamed and contain an abnormal amount of exudate, or it may be perforated, causing a pyopneumothorax. The gangrenous material gives rise to an intense bronchitis, the bronchial tubes containing a thin, highly offensive pus. The elastic threads disintegrate later than the remaining tissue and this fact is of considerable diagnostic value. Embolic processes are common, abscesses of the various organs, especially the brain, being the result. The odor accompanying the softening and death of pulmonary tissue is seldom absent and is usually most offensive. This condition is called pneumomalacia and may be due to emboli. The mucus in the bronchial tubes may contain fatty acids, tyrosin, and leucin. A bacillus is supposed by some to be the cause of the gangrene.

**GOITER.**—Hypertrophy of the thyroid gland. The etiology is unknown, but certain countries and localities seem to predispose. The glandular involvement may be local or general, the disease being characterized pathologically by the variety of the morbid changes. In the same gland may be found cystic disease, with mucoid, fatty, and colloid degenerations. The gelatinous or colloid change is the most important. On section the gland appears as a yellow or brownish mass, through which are scattered areas of colloid, in size from a pin-head to a millet-seed or even larger. In cystic goiter there is a distinct limiting membrane, brownish red if the cyst be due to hemorrhage. If slender masses of tissue project from this membrane, the condition is known as papillary cystadenoma. In some cases the enlargement of the gland may be due to marked vascular dilatation without the formation of new gland-tissue. When the arteries only are dilated, Orth calls it *struma aneurysmatica*; if the veins only, *struma varicosa*. Fibroid and calcareous changes are also common.



**GOITER, EXOPHTHALMIC (BASEDOW'S OR GRAVES'S DISEASE).—**A disease of doubtful origin, characterized by symptoms referable to the eye, the thyroid gland, the heart, and the nervous system. It is more common in females and during early adult or middle life. Hypertrophy of the thyroid gland is rarely as great as in ordinary goiter. It may be diffuse or unilateral. There is a marked increase in the number and size of the blood-vessels and an absorption of the colloid material, which is replaced by a more mucinous fluid. One or both eyes show undue prominence, probably due to increase of the orbital fat. The thymus gland is persistent and enlarged, and there is an increased amount of connective tissue in the neck. Pigmentation of the skin may be marked and simulate Addison's disease. Myxœdema may develop in the later stages. Emaciation may be extreme. Glycosuria and albuminuria are not infrequent. The heart is usually hypertrophied; it may be dilated or even normal in appearance.

**HEMORRHAGE, PULMONARY, OR APOPLEXY.—**This is a condition in which there is hemorrhage into the air-cells and lung-tissue. The lung is large, firm in consistency, dark in color, and heavy. On section there is extravasation of considerable amounts of fluid blood, usually more or less frothy. The extent of lung involved differs very greatly. The hemorrhage may be due to thrombosis or aneurism of the pulmonary artery or to aspiration, as in gangrene and tuberculosis, and may occur in the hemorrhagic diathesis.

**INFARCTS.—**Notwithstanding its ample collateral circulation, the lung is frequently the seat of small or larger infarcts, especially of the hemorrhagic variety. They are usually associated with brown induration. The embolus may come from a marantic clot in the right heart, and in some cases may be infected with pyogenic organisms.

**LARYNGITIS, ŒDEMATOUS.—**(a) Septic infection. (b) Traumatism. (c) Certain drugs. (d) Chronic visceral diseases, — *e.g.*, Bright's disease. *Classification.*—(a) Inflammatory, which may be septic or non-septic. (b) Non-inflammatory or dropsical. (1) The aryepiglottic folds and the ventricular bands are the parts chiefly affected. The vocal cords are seldom included, but the œdema may go below them. (2) The exudation may be serous, seropurulent, or purulent, and may or may not be blood-stained. (3) In very severe cases the larynx may be entirely closed.

**PLEURISY.—**This condition is due to exposure to cold and wet, traumatism, extension of inflammation from neighboring organs, pyo-



genic micro-organisms, many infectious fevers, infectious granulomata, or malignant tumors. *Classification.* — I. Acute. (a) Serous, serofibrinous, fibrinous. (b) Purulent. (c) Hemorrhagic. II. Chronic. (a) Pleurisy with effusion. (b) Dry pleurisy. (c) Primitive dry pleurisy.

I. (a) In acute pleurisy the serous, serofibrinous, and fibrinous differ in the character of the exudate. In all three the serous membrane is at first red, sticky, and lustreless; later it becomes somewhat pale, thickened, and roughened. The pleural cavity may contain a liquid inflammatory exudate varying in amount from a few cubic centimetres to one or more litres. Its specific gravity is above 1017; it is rich in fibrin and contains many leucocytes and some red corpuscles and swollen endothelial cells. The serofibrinous exudate contains more fibrin and less fluid. The characteristic of the fibrinous exudate is the so-called bread-and-butter appearance. The fibrinous deposit varies in thickness from a millimetre to a centimetre or more. (b) Purulent pleurisy may follow the other acute forms or may be primary. The serous membranes are covered with a creamy exudate and the pleural cavity contains from a few cubic centimetres to a litre or more of pus. This is of a greenish-yellow color, often has an offensive odor, and is frequently associated with tuberculosis of the membranes. (c) Hemorrhagic pleurisy may be due to asthenic conditions—tuberculosis, cancer—or may occur in perfectly healthy individuals. In the latter case it must be remembered that during aspiration the lung may be wounded and any fluid present may thus become mixed with blood. The pleural cavity contains blood, which is usually in a fluid condition varying considerably in density. The serous membranes are generally inflamed and stained with blood-coloring matter. II. (a) Chronic pleurisy with effusion may persist for months without undergoing alteration. The post-mortem appearances are very similar to those of an acute pleurisy. (b) Chronic dry pleurisy is the result of an acute pleuritis in which the exudate is partially absorbed and the material remaining undergoes organization. This occurs usually at the base and may cause marked flattening of the chest. Small pockets of fluid are often found. The lung itself is compressed, airless, and fibroid. It is frequently impossible to separate the layers of pleura. (c) Primitive dry pleurisy may be limited in extent or universal. The layers of pleura are firmly adherent to one another and, especially about the lower lobe, are much thickened. In cases of tuberculous origin they present fibroid masses



and small tubercles, and between the layers is a reddish-gray fibroid tissue, sometimes infiltrated with serum. Dry pleuritis may be unilateral or bilateral, and may be accompanied by a similar condition of the pericardium and peritoneum. The bronchi may present marked dilations and the lung tissue is more or less sclerosed. In diaphragmatic, encysted, and interlobar pleurisy the morbid anatomy is similar.

PNEUMONIA.—We may distinguish various forms of pneumonia as catarrhal (bronchopneumonia), chronic interstitial, and lobar (croupous or fibrinous). In cattle there is also found a very infectious variety known as pleuropneumonia. Catarrhal pneumonia is an acute (and also chronic) inflammation of the lungs, involving both bronchial tubes and air-vesicles, due to aspiration of irritants. It arises from: (a) Micro-organisms, — *e.g.*, *Diplococcus pneumoniae*, staphylococci, streptococci, the diphtheria bacillus, and the bacillus of pneumonia. (b) Inhalation of irritant gases and vapors. (c) Infectious fevers. (d) Extension of inflammation from neighboring parts. Macroscopically the lung is larger, heavier, and firmer to the touch. On section the surface is somewhat dark red in color, but distinctly mottled, and may drip blood. On palpation nodular bodies can be felt, surrounded by crepitant areas. The nodules may resemble gray hepatization; typical ones contain a central bronchiole surrounded by a grayish-red elevated area of consolidation and filled with tenacious purulent mucus which can be pressed out. Minute hemorrhages are common in the lung and on the pleural surfaces. Emphysema is seen on the anterior and upper portions of the lung, especially within the inflamed areas. Fibroid changes seldom follow bronchopneumonia.

Chronic interstitial pneumonia may be due to: (a) Various acute inflammations (rare). (b) Tuberculosis. (c) Chronic pleurisy. (d) Chronic poisoning. (e) Syphilis. The disease is usually unilateral; the chest on the affected side is sunken, deformed, and the shoulder depressed. The opposite side is usually emphysematous. On opening the chest the affected lung is seen to be airless, firm, hard, and very resistant to the knife. On section grayish fibroid tissue of variable amount, through which pass the blood-vessels and bronchi, is found. The latter may be more or less dilated. The unaffected lung is much enlarged and occupies the greater portion of the mediastinum. The heart is drawn over to the affected side. It is hypertrophied and there may be atheromatous changes in the pulmonary artery. Amyloid changes in the other viscera may be found.



Lobar pneumonia occurs in adult life, in males, in infectious diseases, in alcoholism, after exposure to cold and wet. The *Diplococcus pneumoniae* of Fränkel, or *Streptococcus lanceolatus*, is found in a large proportion of cases. It occurs in pairs surrounded by a lanceolate capsule. The organism is readily demonstrated in cover-glass preparations stained by Gram's method. It is found in the bronchial secretions and in sections of the affected lung. The disease is divided into three distinct stages,—hyperæmia, red hepatization, and gray hepatization. (a) In the stage of engorgement, which lasts about twenty-four hours, the lung is heavier, more solid, firmer, and redder than normal. The surface of section exudes fluid and serum. The lung still crepitates, though not so distinctly as the healthy tissue. The excised portions partially float. (b) In cases of red hepatization, which lasts from one to four days, the lung is still larger, heavier, firmer, and of a deep-red color. It is airless, does not collapse on exposure to the atmosphere, and excised portions sink in water. The surface of the lung is covered with a more or less extensive layer of fibrin, which forms a false membrane that contrasts markedly with the smooth shiny appearance of the unaffected portions of the lung. The surface may retain impressions of the ribs. On section the lung is dry and reddish brown. It is exceedingly friable. Careful inspection shows that the surface is distinctly granular, the granules being due to fibrinous plugs, which can be scraped off with a knife together with a reddish viscid serum. The plugs of exudate are lighter in color than the intensely red tissue. The smaller bronchi often contain fibrinous clots, which may also be found filling the blood-vessels at the root of the lung. The microscope reveals fibrinous threads, in the meshes of which are seen alveolar epithelial cells which have undergone hyaline and necrotic changes, leucocytes, red blood-cells, micro-organisms, etc. Sections taken from the central portion of the lung show more cellular elements, while those from the surface are richer in fibrin, showing that infection probably takes place from the bronchi. In this connection it is well to remember that there is a pneumonic form of plague and of several of the other infectious fevers. (c) In gray hepatization the color varies from a reddish brown to a grayish white. The surface is more moist, the exudate more turbid. The granules are less distinct and the lung-tissue is still more friable. The exudate is softened and the pneumococcus is usually no longer to be demonstrated. The cell-elements are disintegrated and prepared for absorption. Gray and red hepatization may coexist in the



same lobe. In advanced stages we may also have a purulent infiltration. Carnification may result. This is a productive inflammation, and the lung is an airless, firm, regular, gray or red mass. It is probable that in these stages resolution could not take place. Abscesses of varying sizes, however, may develop, and if found should always be searched for the detection of tubercle bacilli.

*Other Lesions in Croupous Pneumonia.*—(a) Usually the right lung is affected, the process being confined to the lower lobe. The unaffected portions are congested and œdematous. (b) At the time of death the bronchi contain, as a rule, a mucous secretion tinged with blood, more rarely the tenacious mucus so characteristic of pneumonic sputum. The mucous membrane is reddened, but not usually swollen. The affected areas and small bronchi contain fibrinous plugs, which may extend into the larger tubes and form perfect casts. The bronchial glands are swollen, soft, and hemorrhagic. (c) The pleural surface over the inflamed area shows a more or less extensive exudate, which may be serous or fibrinous.

*Lesions in Other Organs.*—(a) The distention of the right heart is marked. The cavities are often distended with firm tenacious coagula. (b) In many cases the spleen is enlarged. (c) The kidneys show cloudy swelling and often acute parenchymatous changes. (d) Pericarditis is not infrequent; it is often associated with pneumonia of the left side or with double pneumonia. (e) Endocarditis is more common; it may be of a malignant type. (f) Meningitis, usually cortical, is not infrequent and is often associated with malignant endocarditis. (g) The liver shows parenchymatous changes and often extreme engorgement of the hepatic veins.

*Complications.*—(a) Pleurisy. (b) Empyema. (c) Pericarditis, most common in children. (d) Endocarditis is more frequent than pericarditis. (e) Myocarditis is rare. (f) Meningitis is perhaps the most serious complication. (g) Otitis media is not unusual in children. (h) Abscesses or gangrene in the lung occasionally occur. (i) Severe and often fatal toxæmia may develop with a comparatively slight lesion in the lung. (j) Also in conjunctivitis, arthritis, etc.

*Terminations.*—(a) Liquefaction, absorption, and resolution. (b) Suppuration. (c) Abscesses or gangrene. (d) Fibroid changes or carnification. (e) Lymphangitis and perilymphangitis may occur.



TABLE SHOWING DIFFERENCES BETWEEN CROUPOUS AND CATARRHAL PNEUMONIA.

CROUPOUS PNEUMONIA.	CATARRHAL PNEUMONIA.
1. Whole lobe usually affected; hence the name lobar pneumonia.	1. Lobules affected; hence the name lobular pneumonia.
2. No areas of healthy lung tissue in affected lobe; other lobes healthy, but may be congested, especially those near the affected lobe.	2. Irregular areas of lung tissue in various stages of degeneration intermingled with normal lobules.
3. Lung weighs much more than normal. An entire lobe may sink in water.	3. Lung weighs but slightly more than normal. An entire lobe will float on water, though small portions may sink.
4. Microscopical appearance varies according to stage. Much fibrin; hence the name fibrinous pneumonia for this condition.	4. Microscope reveals three zones: central, a small bronchus; middle, a desquamative area containing many cells, but little or no fibrin; outer, a zone of congestion. Hence, the synonym, bronchopneumonia.
5. An extensive fibrinous exudate on the pleura covering the affected area; hence the name pleuropneumonia for this affection.	5. Exudate slight, if present.
6. Pneumococcus found in nearly all cases.	6. Pneumococcus rarely found.
7. Usually at base and posteriorly.	7. Usually at the termination of the smaller bronchioles and anywhere in the lung.
8. Usually one-sided.	8. Usually on both sides and associated with other diseases.
9. On section the lung varies according to stage, the marbled appearance being especially striking in the third stage. Notice the fibrinous plugs.	9. On section the lung is congested. Small angular irregular patches, the central portion being the oldest, are seen.
10. Sputum, so-called rusty sputum.	10. Sputum more purulent.
11. Lung lesions of same age.	11. Diseased portion of the lung varies; some spots are old, some are new, the oldest being around the bronchioles; healthy tissue between affected areas. Caseous pneumonia, really a form of catarrhal pneumonia, is due to the action of a toxin, as from the tubercle bacilli. In phthisis there may be small areas of croupous pneumonia.
	12. Capillary bronchitis and catarrhal pneumonia are, pathologically, practically the same.



**PNEUMONOCONIOSIS.**—This is a fibroid condition of the lung often associated with tuberculosis, produced by the inhalation of particles of mineral or metallic substances. Various names have been applied to it, depending upon the nature of the inspired dust,—*e.g.*, anthracosis, siderosis, calcicosis, lithosis, silicosis, etc. Occupations such as coal-mining, the manufacture of pottery, steel-grinding, grindstone-making, tobacco-sorting, needle-grinding, etc., are conducive to this condition. Unless, as is frequently the case, emphysema coexists, the affected lungs are harder, firmer, and often smaller than normal. They are usually of a blue-black or a yellowish or buff color, and afford a striking contrast to the lung of a child. Even when the inspired dust is pale, the lungs are apt to be of a dark color. In advanced stages of anthracosis an ink-like juice may exude from the cut surface. In siderosis, caused by oxide of iron, the lung is of a reddish color. On section condensed portions of highly fibroid tissue are seen. The surface of section commonly exhibits numerous raised points, which give it a coarse granular appearance. These raised points are found to be small, thickened, fibroid bronchial tubes protruding above the surface. The deposits are found microscopically everywhere along the course of the lymphatics. The signs of chronic bronchitis are present, though the mucous membrane of the bronchi remains unpigmented. The bronchial and peribronchial glands as well as the peribronchial lymph-nodes are frequently intensely pigmented; usually pigmentation may be found also in the pleura, liver, and spleen. True osseous formations, coral-like in shape, may be found in the lungs.

**PNEUMOTHORAX.**—This condition may be due to traumatism, tuberculosis of the lung rupturing into the pleura, other infectious granulomata, and malignant growths. The thorax is usually distended; the intercostal spaces may be obliterated. The introduction of a trocar allows the escape of air. The pericardium and heart are pushed or drawn to the opposite side. The serous membranes are inflamed and a serous or purulent fluid is present. The lung is usually compressed and carnified and may be adherent to the chest wall at the apex. It is frequently the site of caseous nodules or cavities at the apex.

**STOMATITIS.**—(a) Extremes of life. (b) Most common in nursing children. (c) Irritant foods and poisons. (d) Extension of inflammation from the intestinal tract. (e) The infectious diseases (scurvy). *Classification.*—I. Acute. (a) Catarrhal. (b) Aphthous. (c) Vesicular (herpetic). (d) Ulcerative. (e) Gangrenous. (f) Infectious.



II. Chronic. (1) Catarrhal. The mucous membranes are swollen, hemorrhagic, and glazy in appearance. The follicles are often very prominent. There is desquamation of epithelium and sometimes small ulcers form. The submucous tissue may be involved. (2) In aphthous stomatitis the tongue, the cheeks, and the tonsils are principally affected. The mucous membrane is covered with small whitish pinpoint elevations, which frequently undergo necrotic changes and show more or less superficial ulcerations. The lesion always starts as a vesicle. The surrounding mucous membranes usually show evidences of acute inflammation, although they may appear normal. (3) In ulcerative stomatitis the points of election are the gums, the lips, and the cheek in the line of the teeth. The ulcers are gray and linear, with sharply defined, red edges. In strumous children they show a marked tendency to affect the deeper structures, sometimes causing necrosis and suppuration of portions of the jaw. In severe cases where the alveoli are involved, the teeth may loosen and fall out. (4) Gangrenous stomatitis (noma) occurs between the ages of two and twelve years, is more common in girls than in boys, and follows infectious fevers (fifty per cent. of the cases occur after measles). It is characterized by the formation of a fungoid ulcer, beginning on the inner aspect of the cheek, usually with distinctly circumscribed, deeply congested edges, the surrounding tissues being markedly œdematous. The outer surface of the cheek is reddened, brawny, and indurated. The gangrenous ulcer has a decided tendency to spread, frequently involving the gums, cheek, tongue, and bones of the neighboring structures. Pneumonia not infrequently develops and is one of the causes of a fatal termination. Some recent investigators have found true diphtheria bacilli in the diseased area. That these organisms have an etiological connection with noma is confirmed by reports of cures after the use of the anti-toxin of diphtheria.

SYPHILIS.—(a) In white pneumonia of the foetus the affected lung is heavy and airless. On section it presents a grayish-white appearance. (b) Hereditary gummata are small in size, grayish in color, firm, and more or less symmetrically distributed throughout the lung. (c) Acquired gummata vary in size from a pea to a goose's egg. They are grayish yellow in color and are embedded in connective tissue. The parts around them are hard and brawny and of a glossy lustre. (d) There may be a fibrous interstitial pneumonia in which the lesions are hard, large, and pale or dark grayish red in color. The middle of



the right lung or either apex is the part most frequently involved. (e) The pleura is thickened. (f) Endocarditis may extend to the hepatic artery and portal vein. The usual seat is at the hilum. Some of the cases described as being of syphilitic origin are nothing more nor less than a chronic interstitial tuberculous pneumonia.

TUBERCULOSIS. — I. Acute. (a) Miliary tuberculosis. (b) Phthisis florida. II. Chronic. (a) Ulcerative phthisis. (b) Fibroid phthisis.

I. *Acute*.—(a) In acute miliary tuberculosis the lesions are usually present in both lungs, having been propagated by the pulmonary blood-vessels. They are frequently so small and transparent that they may be overlooked on macroscopic examination. At other times they are exaggerated in localized spots or even become diffuse. In the latter case the lung is increased in size, is firm in consistence, in color is a darker shade of red, is heavier, and crepitates. (b) Phthisis florida, or acute phthisis with formation of cavities, presents a varied appearance. One lobe or more or less of the whole lung may be affected. The organ is heavy; the implicated portions do not collapse and are firm and airless. The pleura is covered with a thin exudate. On section the condition may resemble red or gray hepatization or an intermediate stage between them. In other instances the lung presents a mottled appearance, some areas being intensely congested, others exhibiting a characteristic pale-gray gelatinous exudate, others caseous degeneration and not infrequently cavity formation. Recently affected areas of pulmonary tissue with croupous pneumonia are often seen. Such lungs readily caseate and produce ulcerative excavations of considerable size.

II. *Chronic*.—(a) In ulcerative tuberculosis apical involvement in relation to implication at the base exists in the proportion of five hundred to one, according to Kidd. There are various lesions. First, there are caseous nodules, which are grayish, white, or yellow in color. Second, cavities may exist, which, if the case is acute, have walls made up of soft caseous masses. In the more chronic cases these walls are replaced by pyogenic membranes of greater or less density. Frequently trabeculæ are seen in the walls; these are the blood-vessels which have resisted the tuberculous process. Third, pneumonic areas and evidences of chronic bronchitis are seen. Fourth, some thickening of the pleura is constant. This may be merely an acutely inflamed area rubbing against a corresponding area on the parietal pleura or it may be tightly adherent to it. Not infrequently perforation causes a pyopneumo-



thorax. Fifth, enlarged bronchial glands are discovered which are caseous and often pigmented. Lastly, the bronchi are thickened and the lumina of the smaller ones often obliterated. The larger tubes show caseous deposits in the submucous and fibrous coats. (*b*) In fibroid phthisis the organ is permeated with interstitial overgrowth. In some cases the interstitial change is most prominent; in others the tuberculous process is slightly more marked. The unaffected portions of the lung are very emphysematous and pigmentation is considerable. The right ventricle and sometimes the whole heart are hypertrophied.

TUMORS.—The benign tumors, fibroma, adenoma, and chondroma, and the malignant growths, both primary and secondary, are found in the lung, the first being rare, while the second are comparatively common. Carcinoma may originate in the epithelium of the alveoli, the bronchi, or the mucous glands. Endothelioma starts from the lymphatic apparatus. In primary growths one lung only is involved; in secondary growths, both lungs. Secondary cancer is more frequent in women than in men. These secondary growths may be scirrhus, encephaloid, epitheliomatous, or colloid cancer, or melanosarcoma. In malignant diseases of the lungs pleurisy, generally of a hemorrhagic type, is commonly present. The tracheal or bronchial glands are usually the seat of metastatic growths. The condition is most common in middle life. Dermoid cysts are found, but very rarely.



## CHAPTER XI

### CRITICAL EXAMINATION OF THE ORGANS OF THE ABDOMINAL CAVITY

#### THE OMENTUM AND PERITONEUM.

HAVING thoroughly examined the omentum during the general inspection of the abdominal cavity, it may now be removed therefrom and any abnormalities or pathological lesions studied and described, though, as a rule, I prefer to make this examination in the body, and to remove the omentum afterwards along with the transverse colon.

Cancer of the peritoneum is found: (a) Female sex. (b) Age from forty to sixty years. (c) Heredity. (d) Secondary to cancer of stomach or ovaries most often. It is almost always secondary. Often spoken of as "miliary carcinosis," because nodules are small, spherical, and diffuse. The serous membranes are pale, thickened, with marked fibrinous deposits, which form adhesions to neighboring viscera; the omentum is indurated and forms a mass transversely across the abdomen; the bowels are often firmly matted together. Ascites is usually present; the amount of fluid may be only a few ounces or several pints. In some cases of colloid cancer the masses are of large size.

Acute general peritonitis is due to: (a) Exposure to cold and wet. (b) The following micro-organisms have been found: *Streptococcus pyogenes*, *Bacillus coli communis*, *Staphylococcus aureus*, *Streptococcus lanceolatus*, *Bacillus proteus*, and *B. pyocyaneus*; rarely, the gonococcus in the female and anthrax and typhoid bacilli. (c) Perforation of the bowel. *Classification.* — (a) Serous. (b) Serofibrinous. (c) Fibrinous. (d) Purulent. (e) Putrid. (f) Hemorrhagic. (g) Ulcerative. In acute general peritonitis the peritoneum has lost its lustre, is opaque, and is covered with an exudate varying with the type of the disease. The intestinal coils are distended and glued together with lymph. They are more or less displaced and compressed and their walls are easily torn. The serous membrane may be easily separated from the muscular coat. In peritonitis due to perforation the peritoneum and its contents are discolored by the fæces, while the peritoneal cavity contains gas, which escapes with a hissing noise when it is opened.

Chronic peritonitis: (a) Follows acute. (b) Tuberculosis. (c)



Extension of inflammation from the abdominal organs. (*d*) Cancer. *Classification*.—(*a*) Local adhesive. (*b*) Diffusive adhesive. (*c*) Proliferative. (*d*) Hemorrhagic. (1) Localized peritonitis occurs about the spleen, liver, intestines, mesentery, and pelvic organs. Bands of connective tissue more or less firmly organized bind the various organs together, producing marked alterations in appearance and position of the parts. The peritoneum is thickened and puckered. (2) Diffuse adhesive peritonitis follows acute inflammation, either simple or tuberculous. The abdominal cavity is often obliterated; the intestinal coils are firmly matted together by the plastic exudate, which becomes eventually converted into bands of fibrous tissue. The liver and spleen are usually involved in the adhesions. (3) In the proliferative form there is great thickening of the peritoneum, which is opaque and white in color. The omentum is usually rolled into a thick mass between the stomach and the colon. The liver and spleen are the subjects of a chronic capsular inflammation; both are usually smaller in size, with thickened, wrinkled capsules. There are seldom many adhesions, and serous effusion may be present in the abdominal cavity. The intestinal wall is greatly thickened and the mucous membrane of the ileum is thrown into folds. Nodular thickenings may be present and be mistaken for tubercles. (4) The hemorrhagic form occurs particularly in cancerous and tuberculous conditions. Layers of new connective tissue form on the surface of the peritoneum; they contain large blood-vessels, from which the bleeding occurs. It is commonly a circumscribed process. Orth compares it to chronic internal hemorrhagic pachymeningitis.

#### THE SPLEEN.

The spleen varies greatly in size and weight, even during health and in the same individual at different times. I have removed a spleen which weighed only one hundred and eighty-six and one-half grains (senile atrophy) and another weighing over seven pounds (malarial enlargement). The normal weight is about five ounces and the measurements are five by three by one and one-fourth inches. The spleen may now be removed from the abdominal cavity, though some pathologists recommend its excision later in connection with the pancreas. It is easily found by passing the hand along the left under surface of the diaphragm from the eighth to the eleventh rib, well towards the side and beneath the cardiac end of the stomach. Usually but little



force is necessary to bring it into view, with the gastrosplenic omentum and splenic artery and vein still intact. These parts are then cut or torn with a sort of twisting movement. In some cases the spleen is so soft that lacerations may be made in its substance by the fingers. These should not be mistaken for traumatic rupture of the organ or for the rupture that sometimes, though rarely, results from disease. Occasionally the spleen is absent. Before detaching it examine the course of the splenic artery for aneurisms, supernumerary spleens, enlarged glands, etc. When this has been done the artery may be divided and the organ removed from the body. Notice whether or not the capsule is normal or thickened; it should be thin, smooth, and transparent.

Lay the spleen on the table, fix it with the left fingers, and with one stroke incise it in its longest diameter. Other incisions transverse to the primary one may be made for further investigation. The color of the normal spleen is dark red, somewhat darker and of a bluish tinge in children; it may be brownish, from the presence of hæmosiderin; or yellow, as in jaundice (or in the new-born, due to bilirubin crystals); or streaked with blue, owing to the presence of melanin. Coal dust may be found in the spleen, having probably entered the circulation through the peribronchial glands. Hyperplasia of the fibrous stroma in cases of chronic enlargement of the organ, as in malaria and leukæmia, may give to the spleen a grayish tinge.

The structure of the splenic tissue may then be examined, and the changes in the splenic pulp, the Malpighian bodies, and the connective-tissue trabeculæ noted. A disturbance of the local circulation may lead to various changes. Oligæmia is marked by the pale light-red or grayish-red color of the spleen, with wrinkling of the capsule and prominence of the trabeculæ. Hyperæmia due to congestion is characterized by an enlarged, hard, dark-red splenic pulp, with smooth surface on section and thickening of the capsule, trabeculæ, and vessel walls. Infarcts of the spleen are common, and are usually wedge-shaped, with the apex towards the hilum. They vary in size from that of a pea to that of a cherry and may at times include half of the spleen. Anæmic infarcts are of a cloudy-yellow color, while the less common hemorrhagic infarcts are very dark red, and later become yellowish red, and even whitish yellow as the coloring matter of the blood disappears. Acute splenitis, resulting in the formation of pus, is not frequent. An acute productive splenitis, the cause of the so-called splenic



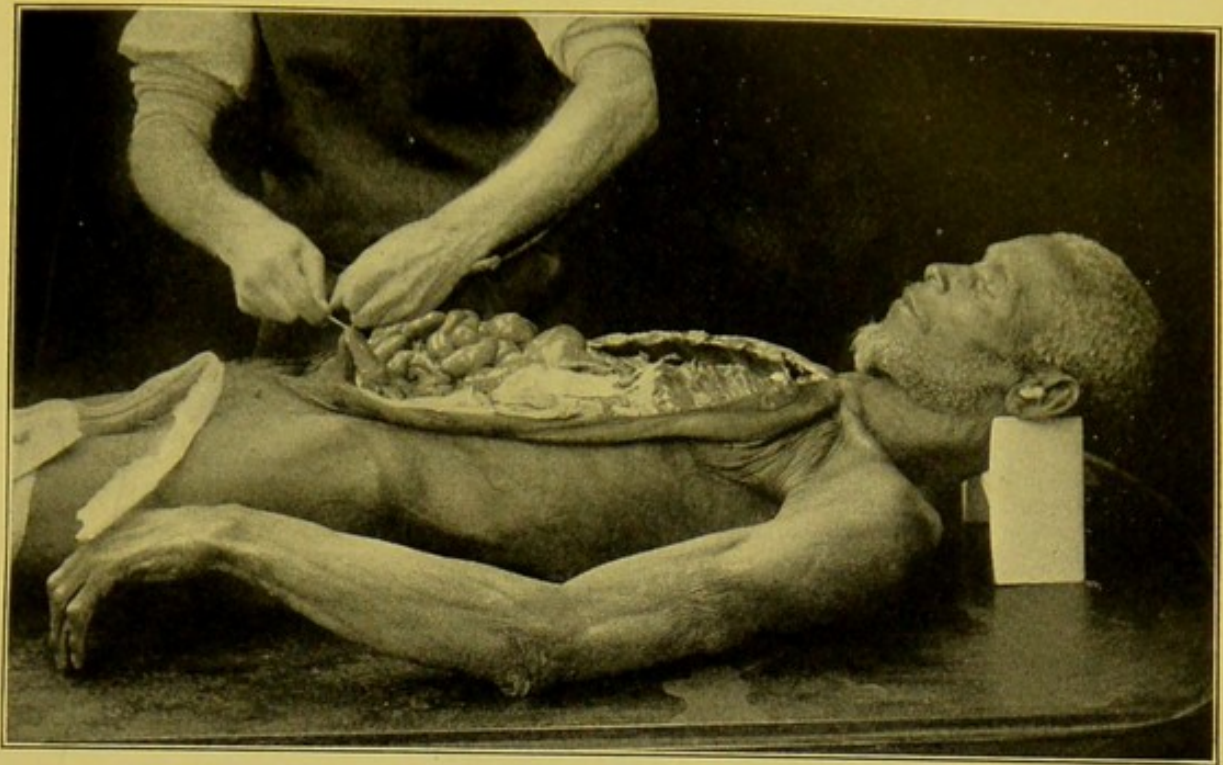


FIG. 81.—Method of removing the intestines. They are first tied in two places, a foot or so above the ileocaecal valve.




FIG. 82.—Bucket method of opening and cleansing intestines.



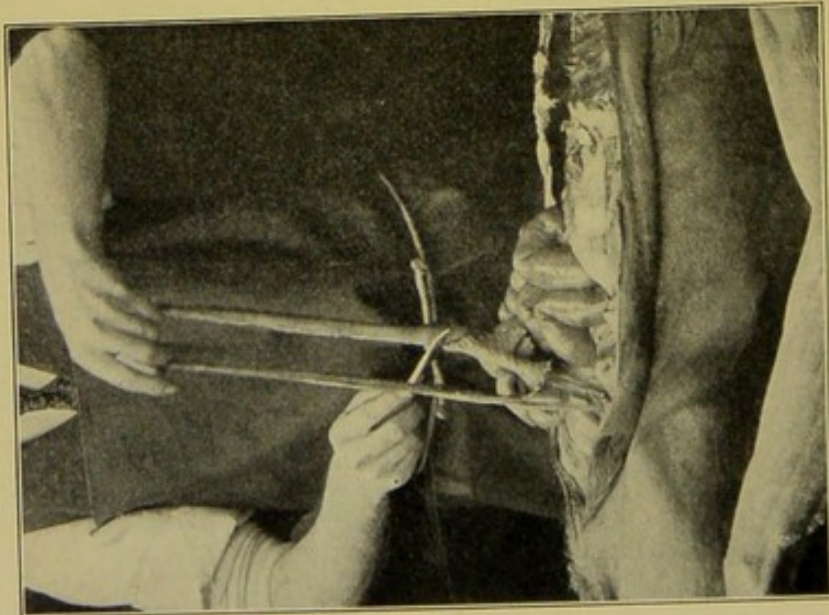


FIG. 83.—Method of removing the small intestines. They are elevated and traction is made on the mesentery, which is cut as close as possible to its attachment to the bowel.

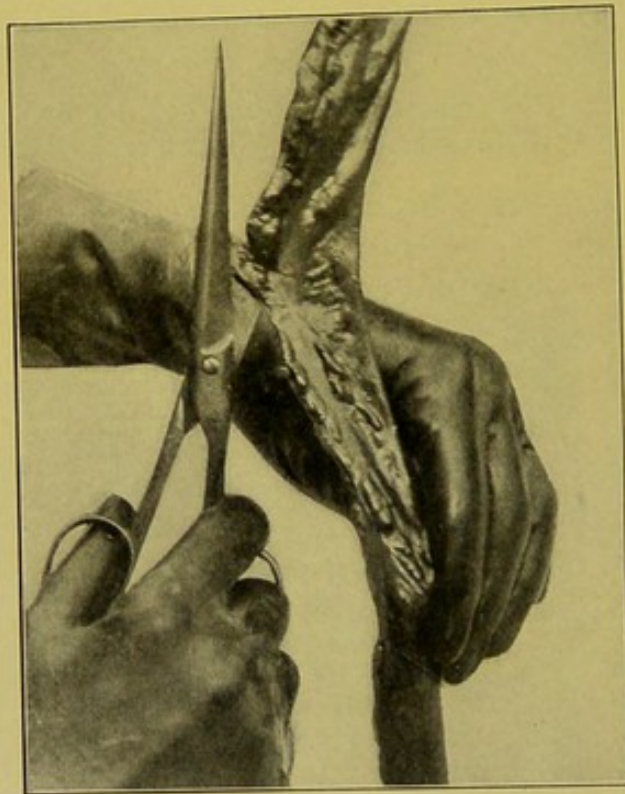

FIG. 84.—Opening of the small intestine after its removal from the body, incision being made with enterotome along mesenteric attachment.

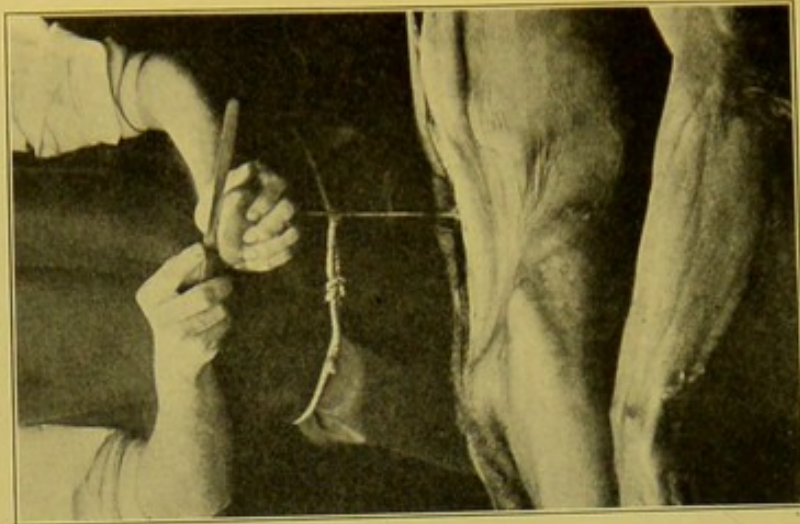


FIG. 85.—Method of incising the kidney with its ureter still attached.



tumor, is characterized by enlargement of the spleen, with the capsule markedly on the stretch, and the pulp on section being of a vivid red, at first darkish and later somewhat lighter. The pulp is soft and exudes so as to conceal the Malpighian bodies. Fibrous productive or chronic inflammation of the spleen causes the chronic splenic tumor, recognized by the large size of the organ, which is hard, of a light or dark brownish hue, with thickened trabeculæ, that may appear as streaks through the splenic substance. A leukæmic spleen is very hard and of a reddish-gray color; it sometimes weighs over twenty pounds. Miliary tubercles, with caseation, and various tumors of the spleen should be noted. In the colored race miliary tubercles at times do not undergo caseation and may attain the largest size of any developing in the body. I have frequently seen them as large as wild cherries. The most important of all the forms of retrogressive disturbances of nutrition of the spleen is amyloid degeneration. In this disease the spleen is firm and inelastic, so that the pressure of the finger leaves a decided mark. Amyloid degeneration of the pulp is characterized by the smooth, shining, almost transparent appearance of the cut surface, while the so-called sago spleen—the amyloid degeneration of the Malpighian bodies—is recognized by the enlargement of the lymph-nodules, which on section appear somewhat transparent and scattered over the cut surface. The amyloid reaction would be more frequently demonstrated if Lugol's solution were applied as a routine practice. Echinococcic cysts of the spleen are sometimes found.

#### THE INTESTINES.

When the exudation in the peritoneal cavity is fibrinopurulent and has a fetid odor, its source should be sought in a perforation of the intestine, although it may originate elsewhere, as from the uterus and adnexa. The entire intestinal tract should be very carefully inspected, starting from below and going upward, and areas of adhesions very gently broken down, care being taken not to make an artificial opening, an accident quite apt to occur in certain diseased conditions of the bowels. A proper examination of the intestines can be made only after they have been removed from the body. For this purpose an opening is made in the mesorectum near the point of attachment of the gut, and with a loop of string carried under the nail of the index-finger (Fig. 80) the intestine is ligated in two places far enough apart to allow it to be divided between them (Fig. 81). According to Orth,



the lower end of the colon is used as the starting-point, and, according to Nauwerck, the transverse colon. After the bowel is cut, its proximal extremity is grasped and the mesentery is severed by a sawing or

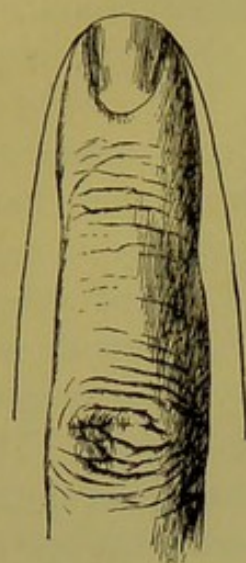


FIG. 80. — Method of passing the string through an opening in the mesentery previous to tying it.

fiddle-bow movement close to its intestinal attachment along the whole extent of the colon and about a foot along the ileum. Here two more ligatures are applied and the intestine is severed between them; this portion is then removed to the sink or bucket and washed out, but the ileocæcal region and its contents are to be examined before washing. If a spigot is at hand, the upper end of the tube may be drawn over it and the water allowed to run through until clean. After examination of the matter washed out, the intestine is opened along its mesenteric border and the mucous membrane inspected. The intestines are opened either by pushing them into the open blades of the scissors or, better, by thrusting the enterotome or scissors

through the bowels along the line of the mesenteric attachment. In some cases it may be advantageous to tie and divide the upper sigmoid, after which the rectum and pelvic viscera may be removed together. In cases where haste is a matter of importance, the intestines need not be removed from the body, but at the end of the autopsy the region of the ileocæcal valve is opened as well as the sigmoid and rectum, and, if no lesions are discovered here, the remaining portion remains unopened, unless palpation or inspection in the preliminary examination of the abdominal cavity has led one to suspect a lesion in other situations. If a competent dead-house assistant is at hand, the opening of the bowel may be entrusted to him, as it saves the operator's time and prevents his hands from becoming impregnated with the disagreeable fetid odor of the gut. The assistant is instructed to call attention at once to any abnormalities observed and, after washing it, to arrange the entire bowel, mucous surface upward, upon the post-mortem table, so that the pathologist may at a glance examine the intestines throughout their entire extent. The bucket method of opening and cleansing the intestines—a very useful method in private cases—is illustrated in Fig. 82. In warm weather these viscera are particularly liable to undergo rapid decomposition after exposure to the air. If for any reason a perforation of the lower bowel is sus-



pected, it should be examined under water before the ligatures are loosened; pressure on the intestine will cause bubbles of gas to appear.

The small intestine is removed in a similar manner (Fig. 83) and opened with the enterotome along its mesenteric attachment (Fig. 84). If the peritoneal fluid has suggested perforation, the gut may be examined under water. The site of perforation is usually marked by an area of fibrinous exudation, which may be so dense as to occlude the opening, or there may be several perforations, as in a case of typhoid fever. In duodenal ulcer the contents will be stained with bile. Erysipelas is an occasional though rare cause of intestinal ulcer.

When the intestines are extensively agglutinated, as in appendicitis, tuberculous peritonitis, etc., the parts may be better studied by first carefully noting their relations and then removing them *en masse*.

Observe whether there be distention or contraction of the bowels. Distention is marked in cases of stenosis or cholera and when a large amount of fæces is contained within the intestines. Contraction is noted in enteritis and after starvation. Localized constrictions may be due to bands of peritoneal adhesions. A Meckel's diverticulum should not be overlooked, and its omphalomesenteric attachment going to the umbilicus should be searched for. The duct sometimes remains patulous until puberty or even later. The greater the distention of the bowel the more pale is the grayish shade of the mucous surface, and if the contents of the gut are bloody the walls are dark red. This diffused color is to be distinguished from the redness due to hyperæmia, occurring in inflammations, congestions, etc., by the marked injection of the capillary blood-vessels which is seen in the latter case. Even the vessels of the submucosa and the mucosa are observed to be over-filled. The lymph follicles may be injected, and are noted as irregular whitish lines which, when pricked, exude a drop of milky fluid,—chyle. The color of the normal mucous membrane is light gray, varying according to the amount of blood present and the contents of the bowel. Congestion of the small capillaries causes a general redness, while injection of the larger vessels produces the appearance of red streaks; the two conditions may occur together. Thickening of the walls as well as partial thickening of the mucous membrane, often in the form of small polyps, may be observed in many of the chronic inflammations of the intestines. Enlarged villi, individually made out with the naked eye, may be noted in some cases of inflammation. (Orth.) Tuberculous and typhoid ulcers are to be differentiated.



DIFFERENCES BETWEEN TUBERCULOUS AND TYPHOID ULCERS.<sup>1</sup>

## TYPHOID ULCERS.

1. Direction often longitudinal, involving the Peyer's patches, which are larger in size; actual amount of surface involved greater.
2. Edges undermined, ragged, and can be floated out on water; thin, vascular, and composed of mucosa and submucosa; red.
3. Floor smooth and vascular.
4. Peritoneal surface unaltered, except that it may be inflamed. No thickening and no gray or yellow patches.
5. Mesentery unaltered; glands enlarged, vascular, pink, and softened.
6. Perforation more common both by separation of slough and by direct extension of the ulcerative process. Small opening by which the fæces may escape. Peritonitis. Hemorrhage may occur during either of these processes.
7. Microscopically: A specific inflammation affecting the adenoid tissue; blood-vessels distended, and increased vascularity of the mucosa and the submucosa. Dense masses of small round cells—lymphoid cells and leucocytes—with some large multinucleated cells, the latter of which are derived directly from endothelioid cells. A line of demarcation is formed and abscess results, beginning in the solitary glands and other lymphoid tissue of the mucosa and submucosa. Widal test positive.
8. Extension takes place laterally or in depth.

## TUBERCULOUS ULCERS.

1. Direction transverse (frequently). This distinction is not so characteristic as is sometimes held. The ulcers are smaller and may be very numerous.
2. Edges not undermined; thick, prominent, nodulated, terraced, or sloping; pale or red; composed of tissue infiltrated with tuberculous nodules.
3. Floor nodular, irregular, thickened, vascular, with pale or yellow points or areas.
4. Peritoneum thickened; small yellow or gray points in the floor of the ulcer running along the lines of the lymphatics.
5. Mesentery thickened at its attachment to the bowel; glands enlarged, firm and gelatinous on section, or caseous.
6. Perforation, peritonitis, and hemorrhage are all rare.
7. Microscopically: A specific inflammatory affection of the adenoid tissue and the mucous membrane, ending in caseation and connective-tissue formation; vascularity of the mucosa and submucosa; increase of the connective-tissue cells and lymphoid cells; tubular nodules, typical or caseating. It begins in the mucous membrane, and, like the typhoid lesion, is due to direct contagion or infection. Widal test negative.
8. Extension usually takes places laterally.

<sup>1</sup> After WOODHEAD, *Practical Pathology*, 3d edition, p. 455.



- |   |  |
|---|--|
| <p>9. Heals by granulation, the thin edges falling on to and uniting with the granulating floor of the ulcer.</p> <p>10. Leaves a smooth, often depressed, pale, anæmic, or pigmented cicatrix, covered by a layer of epithelium, but no gland tissue. Seldom breaks out afresh, relapses being due to the affection of adenoid patches previously little damaged.</p> <p>11. Presence of typhoid bacilli, which are also found in the enlarged mesenteric glands and in the spleen.</p> <p>12. Spleen enlarged and soft.</p> | <p>9. Very rarely heals.</p> <p>10. Leaves a puckered cicatrix in which are gray or white nodules; often breaks out afresh.</p> <p>11. Presence of tubercle bacilli easily demonstrated.</p> <p>12. Evidence of tuberculosis elsewhere, especially in the lungs.</p> |
|---|--|

Cases of paratyphoid fever explain the failure of the Widal test in a certain number of cases. A most careful study of all clinical typhoid cases should be made where the Widal reaction was not obtainable during life. I have elsewhere<sup>1</sup> suggested the possible value of the agglutinative test as a means of diagnosing human blood and its probable source. None of the lower animals suffer except experimentally from typhoid fever, and it is possible to conceive of a case in which blood taken from an instrument would give the Widal reaction and the measurements of the corpuscles be found consistent with the view that they were of human origin, thus showing the presence of human blood. The new blood test will be considered in Chapter XXVII., on medicolegal suggestions.

Whether during life a rectal enema may by reversed peristalsis be carried to the stomach and then vomited is an interesting but debated question which I believe should be answered in the affirmative. It is very difficult by pressure to force liquid past the ileocæcal valve, but in relaxed conditions, as in cholera, this is perfectly possible. The problem is interesting as bearing on the possibility of a gastrocolic fistula and reversed agonal invaginations.

An abundance of fæces in the large intestine indicates constipation, which occurs in an extreme form in partakers of opium, where I have found scybalous masses lying in pouches in the transverse colon as hard and dry as if they had been retained there for many weeks or even months. Distention of the small intestines shows that considerable

<sup>1</sup> CATTELL, *International Medical Magazine*, April, 1897.



food has recently been taken. When the lacteals are well dilated, some three and a half hours have elapsed since the taking of food which has reached this portion of the intestine. Pavlof finds that psychical secretion of the intestinal juices varies markedly according to the character of the food ingested. When the fæces are light in color, an absence of bile is shown; when dark or light red, blood is probably present, though it must be remembered that medicines, such as hæmatoxylin, may give a similar appearance. When dark or black, the presence of iron or bismuth may be suspected; if yellow, the possible administration of rhubarb should be considered.

Gall-stones may be found anywhere in the intestinal tract, but most frequently above the ileocæcal valve and lower rectum. Tapeworms are seen, if present. In one of my cases I found two *Tæniæ medio-canellatæ*, their heads being strongly attached to the mucous membrane beneath a fold of the valvulæ conniventes at the end of the duodenum and not far apart. Ascarides may occur anywhere in the intestinal tract; a specimen in the Wistar and Horner museum of Philadelphia shows where one of them had penetrated the bile ducts. Seat-worms are found in the lower rectum. Packard removed *post mortem* a specimen of *Tænia nana* at the Pennsylvania Hospital. Of course any of the varieties of intestinal worms seen in man may be found here, but it is surprising how few cases are described in post-mortem notes of our hospitals. The foulest odors arise in icterus and dysentery, while in cholera the odor may be hardly perceptible. True intestinal sand may be found.

In hemorrhage of the bowel the bleeding may be localied or diffuse. In the former variety petechial spots or ecchymoses are found on the mucous membrane. The mucous membrane surrounding the hemorrhages may be normal in appearance or show the results of active or passive congestion. In diffuse hemorrhages the blood is free in the bowel or may be extravasated into the mucous membrane. In the former case it is brownish black or black in color and usually semi-liquid or tarry. In the latter case the extravasated blood is in slate-colored or black patches.

Appendicitis is most common in males and in early adult life, and is favored by fecal concretions and rarely by foreign bodies. The theory has recently been advanced that influenza is the cause of many cases of appendicitis. Metschnikoff thinks that the condition is often associated with worms of various sorts. The principal micro-organisms



are the *Bacillus coli* (most common), *Streptococcus pyogenes*, *Staphylococcus pyogenes*, *B. tuberculosis*, *B. typhosus*, *B. influenzae*, *Proteus vulgaris*, *B. pyocyaneus*, *Actinomyces*, etc. Mixed infection is often present. Of the acute forms the following are noted: Catarrhal, follicular, suppurative, and gangrenous. Of the chronic: Catarrhal, obliterative, and chronic infective. In acute forms the organ is reddish brown, black, or greenish yellow in color. The mucous membrane is swollen, reddened, and presents hypertrophied follicles, ulcerations, or a false membrane. The whole appendix is thickened, the serous membrane red and lustreless. In the suppurative form the abscess may be small and limited to the appendix; when large the pus frequently invades the peritoneal cavity, the sac being formed by peritoneum, fibrinous exudate, and fibrous adhesions. It should be remembered that abscess formation may start outside of the appendix and there be no perforation in cases of appendicitis. In severe cases following ulcerative or obliterative conditions the abscess-cavity may contain the whole or a portion of the appendix which has been sloughed off. The abscess-cavity may become limited and remain so and be subsequently absorbed, or it may later open into the general peritoneal cavity. Rarely it breaks through the skin. It may rupture into surrounding organs or structures, as the vagina and rectum.

Ulceration following typhoid is often seen, and perforation is not unknown. In obliterative appendicitis the entire tube is thickened, firm, and stiff; the peritoneal surface is smooth or injected and may be adherent or free. It may become cystic, the contents being clear fluid or pus. The situation of the appendix varies greatly; rarely it may be found on the left side, as in transposition of the viscera, or it may be entirely absent. I have seen the tip of the appendix resting beneath a distended gall-bladder, entering into the formation of a left femoral hernia, or lying in the sigmoid flexure in a case of ileocaecal intussusception. On microscopic examination the lymph follicles are numerous and close together, but as age advances they become separated and smaller. Late in life the appendix undergoes marked fibrous change, which must be distinguished from obliterative appendicitis. Primary cancer of the appendix has been found in several cases.

The mesentery may be shortened by contraction, as by granulation of the tissue, or lengthened, as by traction upon the bowel in a strangulated hernia. Hemorrhage takes place into this tissue in phosphorus poisoning and in acute yellow atrophy of the liver. The glands are red



and swollen in enteritis, especially in typhoid fever, where they may be very numerous and break down. They afford a most favorable spot from which to secure cultures for the different varieties of colon and typhoid bacilli. When the glands become tuberculous, they often caseate and may reach a large size. In *tabes mesenterica* in children they are usually enlarged even in non-tuberculous cases. All statistics bearing upon tuberculous infection of these glands is extremely useful at the present time, in order to place upon a sound scientific basis the relation of tuberculous milk to infant mortality. We also find enlarged glands in leukæmia and Hodgkin's disease. By the stopping up of the vessels, the mesentery may become gangrenous. It may be wholly converted into a mass of fat. Search should be made for calcified tubercles, tumors, chylocysts, etc. Thrombosis and embolism of the mesenteric vessels should also be thought of. Hemorrhagic infarcts are sometimes seen. Parasites of various kinds have been described and aneurisms have been noted.

More people die from dysentery than from plague, cholera, and yellow fever. Found especially in warm climates and after eating improper food. I. *Acute*.—(a) Catarrhal. (b) Amœbic. (c) Gangrenous. II. *Chronic*. In the early stages the bacillus of Chantemasse<sup>1</sup> is found, and in the later stages, especially where abscess develops, the amœba coli is seen. The blood of patients affected with tropical dysentery has an agglutinative reaction with the bacillus of dysentery. Summer diarrhœa of children has also recently been shown to be due to the same organism. All the lesions of dysentery have certain points of election for the starting of the inflammatory process,—viz., the large bowel, the flexures of the large bowel, and the course of the valvulæ conniventes. (1) *Acute Catarrhal Dysentery*.—The mucous membrane is enlarged, swollen, and covered with tenacious blood-stained mucus. The solitary follicles stand out prominently and in protracted cases often show necrotic or suppurative change. In some cases numerous ulcers appear throughout the large bowel. In children the picture is that of an acute follicular colitis. At first glance the mucous membrane seems to be universally congested; on closer examination it is found to be more or less streaky, with bright-red pin-point areas of intense congestion. The peritoneal surface is enlarged, lustre-

---

<sup>1</sup> Commonly spoken of as the bacillus of Shiga, though described by CHANTEMASSE and WIDAL in 1888. *Presse méd.*, July 23, 1902.



less, and sticky. (2) *Amœbic Dysentery*.—In this form the amœbæ, of which there are several kinds, both pathogenic and non-pathogenic, are almost always present. These are unicellular protoplasmic motile organisms, five or six times the size of a white blood-corpuscle. They contain a nucleus and one or more vacuoles. The characteristic lesion is an ulcer, which has a small external opening, with extensive undermined infiltrated edges. Sometimes these ulcers run together, forming deep sinuous tracts bridged over by apparently healthy mucous membrane. There is a progressive infiltration of the connective-tissue layers of the intestine, causing pressure upon the blood-vessels and subsequent necrotic changes in the overlying structures, so that the mucosa or the muscularis may be sloughed off *en masse* in certain parts of the bowel. In severe cases the whole of the intestine may be much thickened and riddled with ulcers, with only here and there islands of intact mucous membrane. More rarely these ulcers have but slightly undermined edges, the borders being more or less cleanly cut. In some cases there is a tendency to purulent formations. (3) *Gangrenous Dysentery*.—This form is characterized by the formation of a diphtheritic membrane, which is more or less irregularly distributed; it is at first yellowish brown, in later stages becoming black or ashen-gray; in the latter case it appears as sloughs more or less easily detachable. There is thickening of all the coats of the intestine, with great interference with the blood-supply, so that in severe cases whole portions of the bowel may become gangrenous. (4) *Chronic Dysentery*.—In this form the anatomical changes are variable. Deeply pigmented ulcers are often present or there may be cicatrizations; again, no trace of ulceration may appear, but the entire mucous membrane presents a rough, irregular, figured appearance, in places slate-gray or blackish in color. Certain parts of the mucosa are greatly thickened and the muscular coat is hypertrophied. In some cases the solitary follicles are enlarged and pigmented. At times the outlets of tubules of the glands are closed, thus forming "slime cysts" (Orth), varying in size from a pin-head to a pea. The condition is called chronic cystic enteritis. The calibre of the bowel may be reduced, but stricture is very rare. *Complications*.—(a) In all cases dysentery may be complicated by peritonitis, pleurisy, pericarditis, or pyæmic manifestations. (b) In amœbic dysentery the characteristic complication is the abscess of the liver, which is usually single and occupies the right lobe. It may be multiple, when it is apt to be distributed superficially in any or all of the lobes. It



is a large solitary abscess, the wall of which is made up of broken-down, rough, shaggy liver-tissue, without any of the ordinary pyogenic membrane. The contents of this abscess vary. The outer portions are gelatinous and composed of broken-down liver-tissue, blood-pigments, pus-cells, amœbæ coli, etc. The interior is usually of an almost watery consistency, and of a brownish or reddish color. In some cases cultures made from these abscesses are sterile. In hot climates the amœbæ coli can almost always be found on microscopical examination.

In colitis, or inflammation of the large bowel, consider: (a) Early life. (b) Summer weather. (c) Improper foods. (d) Certain micro-organisms. (e) Poisons. (f) Some infectious diseases. *Classification*.—(a) Simple. (b) Membranous. (c) Ulcerative. (d) Chronic. (1) In simple colitis the mucous membrane is much thickened and reddened, the rugæ are prominent, and petechial hemorrhages are common. In ordinary inflammation the follicles are inflamed and œdematous and on section they appear like pearls. When there is a marked cell increase, they are white or gray and more prominent. These follicles may become confluent. (2) Membranous colitis is characterized by the formation of a more or less complete cast of the intestine, usually from one inch to six inches in length, but it may extend a distance of several feet. The membrane usually appears homogeneous, but may be distinctly laminated and show deposits of fecal matter between the layers. The end of the cast may be well defined, but often shades off into a transparent gelatinous material. Associated are swelling and œdema of the submucosa. The mucous membrane not involved is very much inflamed and there may be hemorrhagic infiltration. The intestine may show that perforation has occurred and gangrene may sometimes supervene. (3) In ulcerative colitis the appearances vary greatly: the ulcers may be small and numerous or they may be large in size and few in number. They may be perfectly regular in outline, but are usually irregular, with slightly undermined edges. The floor of the ulcer generally shows a somewhat sloughing bowel. The ulcers may communicate by separation of layers of the intestines. In long-standing cases they are often intensely congested and tend to become transverse. Sometimes the floor of the ulcer becomes so thin as to be pushed out and form pouches. In very acute cases the mucous membrane is much reddened, highly vascular, and the surface is soft. The peritoneal coat of the bowel may be normal in appearance, but is usually red, somewhat sticky, and shows many dilated blood-vessels. Small hemor-



rhages are common. (4) In chronic colitis the bowel is often much thickened in all its coats. It may be larger in diameter. It is firm, even leathery, to the touch. The mucous membrane is hypertrophied, often much pigmented, and shows many small hemorrhages. The follicles are swollen and have a slaty appearance. There may or may not be ulceration.

There are four forms of dilatation of the colon: (*a*) Distention from gas. (*b*) Distention due to some solid substance within the bowel. (*c*) Distention caused by an organic obstruction in front of the dilated bowel. (*d*) The so-called idiopathic dilatation.

Malignant disease of the colon is generally a cylindrical-celled epithelioma, usually confined to a small area, where its contraction sets up an annular stricture.

#### THE KIDNEYS AND ADRENALS.

The spleen and intestines having been removed and the liver turned over into the thoracic cavity, as described on page 95, the kidneys and suprarenal bodies yet remain behind the peritoneum, deeply embedded in the perinephrial fat. Of course, in anomalous cases, in certain diseases and deformities (notably Pott's disease), and in floating kidney they may be considerably displaced. In any event it is best and simplest first to find the ureters as they descend on the psoas muscles and enter the pelvis. The exact situation of the ureters is as follows: Each ureter at first passes obliquely downward and inward to enter the cavity of the true pelvis and then curves forward and inward to reach the base of the bladder. In its whole course it lies close behind the peritoneum and is connected to neighboring parts by loose areolar tissue. Superiorly it rests upon the psoas muscle and is crossed very obliquely from within outward by the spermatic vessels, which descend in front of it. The right ureter is close to the inferior vena cava. Lower down the ureter passes either over the common or the external iliac vessels, behind the termination of the ileum on the right side and the sigmoid flexure of the colon on the left. Descending into the pelvis it enters the fold of the peritoneum forming the corresponding posterior false ligament of the bladder, and, reaching the side of the bladder near its base, runs downward and forward in contact with it, below the obliterated hypogastric artery, and in the male is crossed upon its inner side by the vas deferens, which passes down between the ureter and the bladder. In the female the ureters run along the sides of the cervix



uteri and the upper part of the vagina before reaching the bladder. (Quain's Anatomy.)

Incise the peritoneum on the left side first, then on the right over and in the direction of the brim of the pelvis, and follow up each ureter, gently tearing away the loose connective tissue, but being careful not to disturb seriously the relationship of the kidney and adrenal and their vessels until they have been noted. If this method be adopted, there is no need of making an incision in the peritoneum directly over the kidney, as is recommended by most pathologists. The organs may next be "shelled out" of their bed of cellular tissue and fat and the vessels severed, thus permitting their removal from the body. The adrenal<sup>1</sup> is then separated from the kidney, weighed, measured, and incised in its greatest plane. Should disease of the bladder or ureters be present, the kidneys may be removed from the body with the ureters attached. This is always better in those very common cases where double ureters are found. One nick is then put in the left kidney at its upper or lower border, and the kidney and adrenal are removed, or the kidney may first be dissected. Another method of distinguishing the right kidney from its fellow is to make a uniform rule as to which ureter shall be left the longer by several inches on the separation of the kidneys from the body. The kidney is then cleaned and weighed, and any peculiarities are noted.

To remove the kidney while the intestines are still in the body, first hold aside the left sigmoid flexure and pull away the fundus of the stomach and the tail of the pancreas. Then make a long incision in the convex border of the kidney. Next separate it from the surrounding tissue and cut it out along with the suprarenal. The right kidney lies under the liver, and in removing this suprarenal be careful not to cut the inferior vena cava. If you remove the ureters with it (Fig. 85), on the right side a long incision must be made through the peritoneum that goes from the abdominal wall to the cæcum and colon. (Orth.) Nauwerck recommends a more complicated method. He cuts the descending colon from the mesocolon first. His primary incision is vertical and between the hilum and the spinal column, a second one being made in the convex border of the kidney.

Holding the kidney longitudinally in the hand, the hilum towards

---

<sup>1</sup> The right adrenal is more difficult to find than the left, and may be permitted to remain in the body until *after* the removal of the stomach, duodenum, and pancreas, but should be sought for *before* the removal of the liver.



the palm and the convexity upward, a clean brain-knife or large cartilage-knife is used to divide it through its middle parallel to its greatest

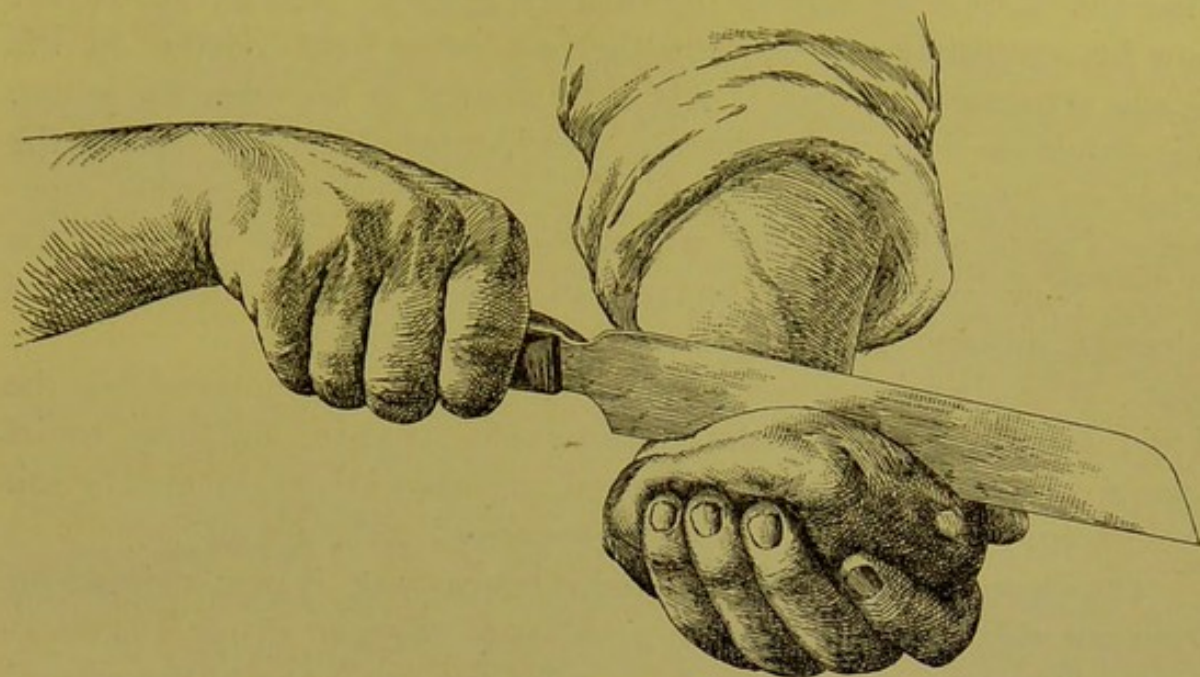


FIG. 86.—Method of opening the kidney. The organ is held in the left hand with its hilum downward, and an incision is made with a brain-knife along its upper convex border and more than half through the renal substance. It is then reversed (Fig. 87), and the incision continued until the gland is nearly, but not quite, divided. In this manner there is no danger of cutting the hand.

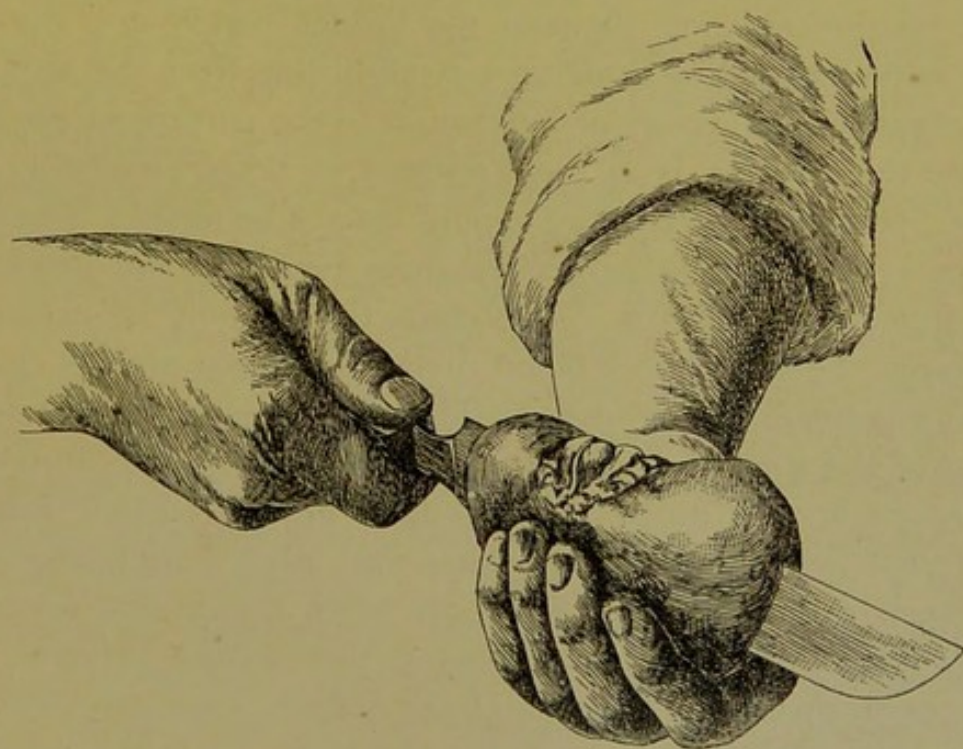


FIG. 87.—Method of opening kidney in such a manner as not to injure the hands of the operator.

surface. The knife must be so sharp that it will cut without tearing, and care should be taken not to extend the incision through to the hand



(Fig. 86). The wisest precaution for this purpose is first to bisect the kidney only to its centre, then reverse the organ in the hand and complete the incision by cutting outward (Fig. 87). The pyramids will now be completely exposed and the two halves held together by the tissues composing the pelvis. If it be desired to lay open the hilum, this should be done with scissors. Precipitates of urinary salts in the pelvis are often mistaken for pus. A microscopical examination, especially if acetic acid be added, will at once reveal the true nature of the fluid. Now examine the surface for cysts, stellate veins, aberrant adrenals, miliary tubercles, tumors, etc. Large cysts can readily be seen. When incising a cystic kidney it should be remembered that the liquid therein is often under considerable pressure, and may squirt several feet when the cavity is opened, and thus injure the eyes or soil the clothing of the operator or of those present at the autopsy.

The capsule, which when normal is transparent, is next stripped off from one side, and its condition noted as to whether or not it is thickened, adherent or non-adherent. If adherent, see if any of the cortical substance is removed with it,—*i.e.*, whether the inner surface is smooth or rough. The normal color of the surface of the kidney after removal of the capsule is brownish red.

The relation existing between the lighter cortex and the darker medulla is determined by drawing a straight line from the apex of one of the largest central cones of a pyramid to the surface of the kidney. Normally this relation is as one (cortex) to three (medulla); it is, however, frequently altered and should always be noted. The cortical substance is increased in parenchymatous nephritis and decreased in chronic interstitial nephritis. Also study the color of the external and cut surfaces, the quantity of blood or fluid exuding and its character, and the consistence of the organ. Thus, in parenchymatous nephritis the color of the cortex is a grayish white or light yellow, in poisoning by hydrocyanic acid much blood exudes, and in chronic interstitial nephritis the nephritic tissue is dense and hard. Both anæmic and hemorrhagic infarcts occur. Scars are often found, and may be due to many different causes, as gummata, thromboses, infarcts, stones, former operations, etc. Tumors of the kidney, especially fibroid, are quite common. With atheromatous and granular kidneys, suspect apoplexy, especially if there has been a clinical history of flushing of the face. As a routine practice in the examination of the kidney, the amyloid reaction should be tried. A thin slice about one inch square,



including both cortex and medulla, is removed from the organ and placed in Lugol's solution (which is preferably diluted four or five times) for several minutes and then examined with a hand glass in a good light.

Where decapsulation as an operative therapeutic measure has been practised, also after the scraping of the hepatic peritoneum for ascites, the post-mortem examination should be very thorough, as any information concerning such cases is most important at the present time.

The adrenals are best removed attached to the kidneys, though, as already stated, the ablation of the right adrenal with the kidney is more difficult than that of its fellow, and for this reason it is often left in the body and examined at the time of the removal of the pancreas. The adrenals are very delicate and care must be exercised lest they be injured in their excision. Normally the adrenals consist of three layers, which differ more or less in the young and the old. The outer or cortical layer is light yellow in adults and grayish red in children. This tissue somewhat resembles that found in the thyroid gland. It is composed of radiating follicles whose cells are undergoing fatty degeneration. It will be seen in the new-born that the adrenals are relatively of large size in comparison with the kidneys and when examined microscopically no fatty metamorphosis is discovered. The inner or medullary substance is composed of neuroglia and ganglionic cells connected with a rich vascular supply. The middle zone, or intermediary substance, is brown, owing to pigmentation of the follicles. The amount of intermediary substance is subject to considerable variation (Langerhans). Later on in life there is a tendency for the central part to become separated from the intermediary portion, and in atrophy of this organ when it takes place unevenly (as it frequently does) nodes are left on the surface which are not unfrequently mistaken for tubercles. These organs are subject to numerous pathological changes and are hyperplastic in many varieties of congenital deformities in which other nerve tissue is affected. We may have here hæmatoma, melanoma, cysts, hypertrophy, glioma, primary cancer, echinococcic cysts, hæmatoid degeneration, tuberculosis, purulent infiltration, and internal proliferations. The recent discovery of the marked action of adrenalin would seem to show the presence of an internal secretion acting directly upon the vascular apparatus. It by no means follows that the adrenals will be found affected either macroscopically or microscopically in all cases of Addison's disease. Exquisite miliary tubercles



are seen in the adrenals, and the caseating mass in advanced tuberculosis may reach the size of a walnut.

Addison's disease is most frequently seen in laborers between the ages of twenty and forty years. It may be due to: (a) Tuberculosis, simple atrophy, cirrhosis, hemorrhage, or tumors of the adrenals. (b) Inflammation or pressure of structures bordering the adrenals. (c) Changes in the semilunar ganglia and the sympathetic system. The adrenals are most frequently tuberculous, and there is always a deficiency of the internal secretion of these organs. The brownish pigmentation (bronze disease) is most marked on the chest. The spleen may be enlarged, as may also the thymus, if the latter organ persists. The stomach and intestines may show hypertrophied lymphoid follicles. No specific blood-changes have been observed. One of the most marked cases of pigmentation of the abdomen which I ever saw was that of a girl who had undergone an operation for the removal of a large dermoid cyst of the ovary. It is possible that in this case the semilunar ganglia or the adrenals were affected by pressure or otherwise. In two cases of primary sarcoma of the adrenal, and in one of general tuberculosis with marked involvement by caseous tubercles of both adrenals, I observed no pigmentation of the skin at the time of the autopsy.

#### SEMILUNAR GANGLIA.

The semilunar ganglion or cœliac plexus, which receives the great splanchnic nerve and the pneumogastric, is situated behind the stomach and in front of the crura of the diaphragm, by the side of the cœliac axis and the root of the superior mesenteric artery, and close to the suprarenal body (Fig. 88). The ganglia should be carefully studied microscopically in all cases where lesions are suspected in the adrenals or in the sympathetic system. The color and vascularity as well as the condition of the surrounding connective tissue should be noted. In cholera and typhus fever the ganglia are hyperæmic and may show evidence of the occurrence of hemorrhage (Rokitansky).

#### THE URETERS.

The ureters may be distended with urine, as from an impacted stone, from cancer of the uterus, and from overfilling of the bladder. They are often double, most frequently uniting in their middle third, more rarely in the structure of the bladder, but may enter this viscus by separate papillæ. The ureters being slit open throughout their entire



extent, the appearance of the mucosa is described, taking into account the color and character of any catarrhal exudate, should it be present. Many microscopists teach methods of diagnosing the situation of a lesion in the urinary tract from the shape of the epithelial cells. A most interesting experiment is to take at a postmortem scrapings from the pelvis of the kidney, the ureter, bladder, and urethra, examine them

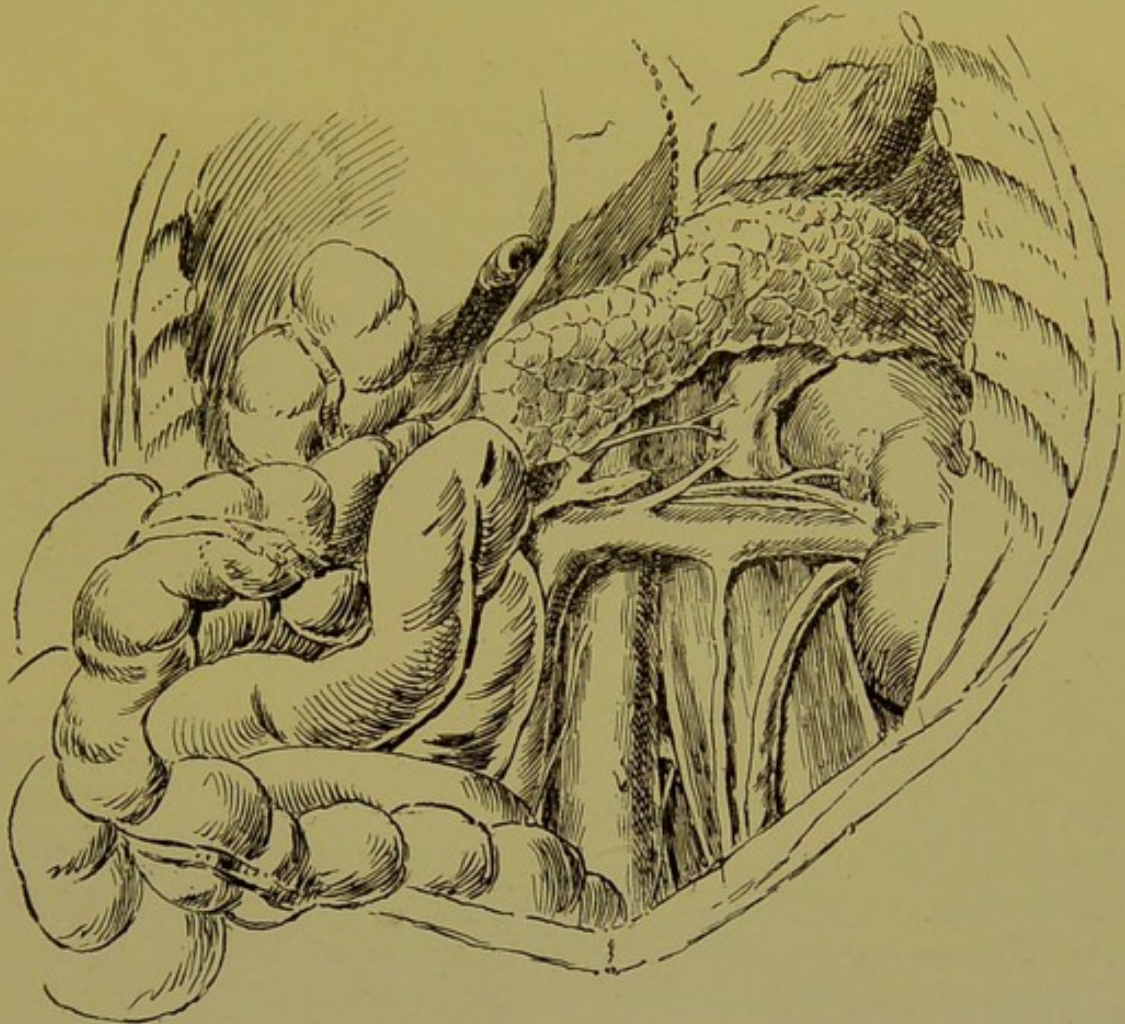


FIG. 88.—The relations of the pancreas, kidney, ureter, adrenal, and solar plexus are shown, the liver having been turned upward and the intestines shoved over to the right.

under the microscope, and determine whether or not such a diagnosis is possible. Hemorrhages, abscesses, papillary fibromata, the *Distoma hæmatobium*, calcified bodies, etc., are found in the ureter. Miliary tubercles of the mucous membrane are seen, often of typical shape and large size.

In some three hundred autopsies performed in one year, I met with three cases in which the ureter had been tied during abdominal operations on the uterus and its adnexa. The right ureter seems to be ligatured oftener than the left.



If it be desired to collect the urine for microscopical, chemical, or medicolegal examination, it should be drawn off into a sterilized vessel with a new catheter. Should strychnine poisoning be suspected, place a live frog in the urine, and if strychnine is present in any amount the frog will show the typical strychnine convulsions. Unfortunately, however, in strychnine poisoning the alkaloid is not always secreted in the urine, the quantity of which is often very small.

#### PELVIC ORGANS.

REMOVAL OF THE FEMALE GENITALIA.—By means of a circular incision, starting and ending at the symphysis pubis and including the anterior portion of the sacrum, the parietal peritoneum is freed around the entire brim of the true pelvis. Orth begins the incision between the rectum and the sacrum, while Schottelius recommends the ending of the incision at the posterior superior spine of the ilium. The body is then placed in the position seen in Fig. 89, and the thighs are separated. An oval incision is next made, starting above the external genitalia, below the symphysis pubis, and ending behind the anus near the coccyx (which may be examined at this time), passing to the outside of the labia on each side. Traction is then made upon the soft parts towards the median line and the incision deepened, keeping as close as possible to the pelvic bones and taking care that the knife or scissors cutting in the direction of the long axis of the body does not injure the rectum, bladder, or external genitalia. It is now possible to remove the external genitals, bladder, and rectum through the abdominal cavity, or the internal parts through the oval incision exteriorly. (Figs. 90 to 97 inclusive.) Whichever method is adopted, the muscles, fatty tissue, and fascia holding the parts in place are to be severed without injury to the tissues desired to be preserved. Or an internal or external hysterectomy may be performed, if for any reason the external incisions should be avoided. If the ureters and kidneys have been left connected, they may be removed at the same time. After the pelvic organs have been excised they are placed on a board upon the table in the same relative position that they occupied while they were in the body. The bladder is then opened anteriorly with the scissors on the median line from the fundus to the urethra, not neglecting to open this (and in the male to observe the prostate).<sup>1</sup> The rectum is slit up along its posterior wall,

---

<sup>1</sup> Many obducent's partially open the bladder while it is still attached to the body; indeed the entire examination of the pelvic organs can be made with the parts *in situ*.



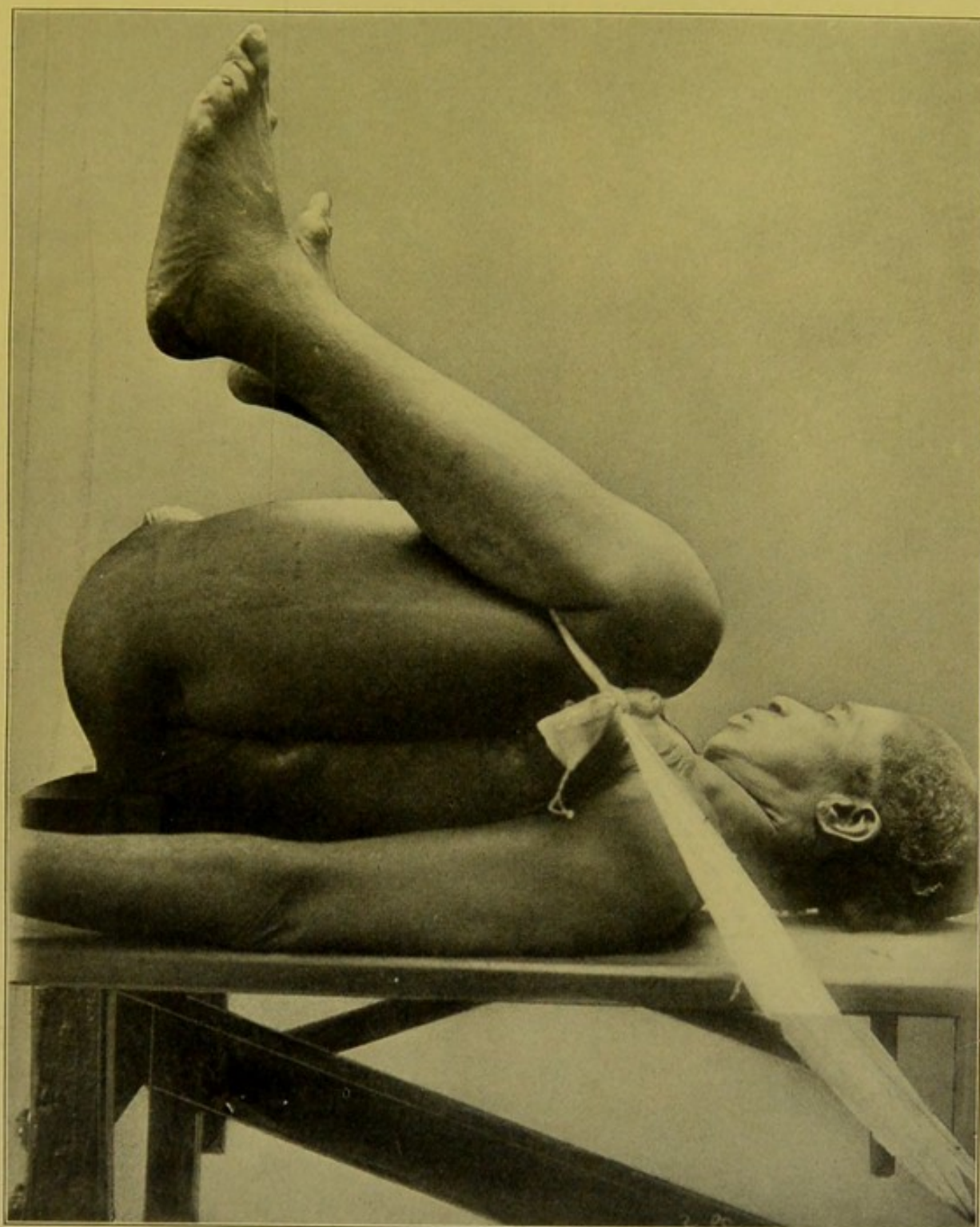
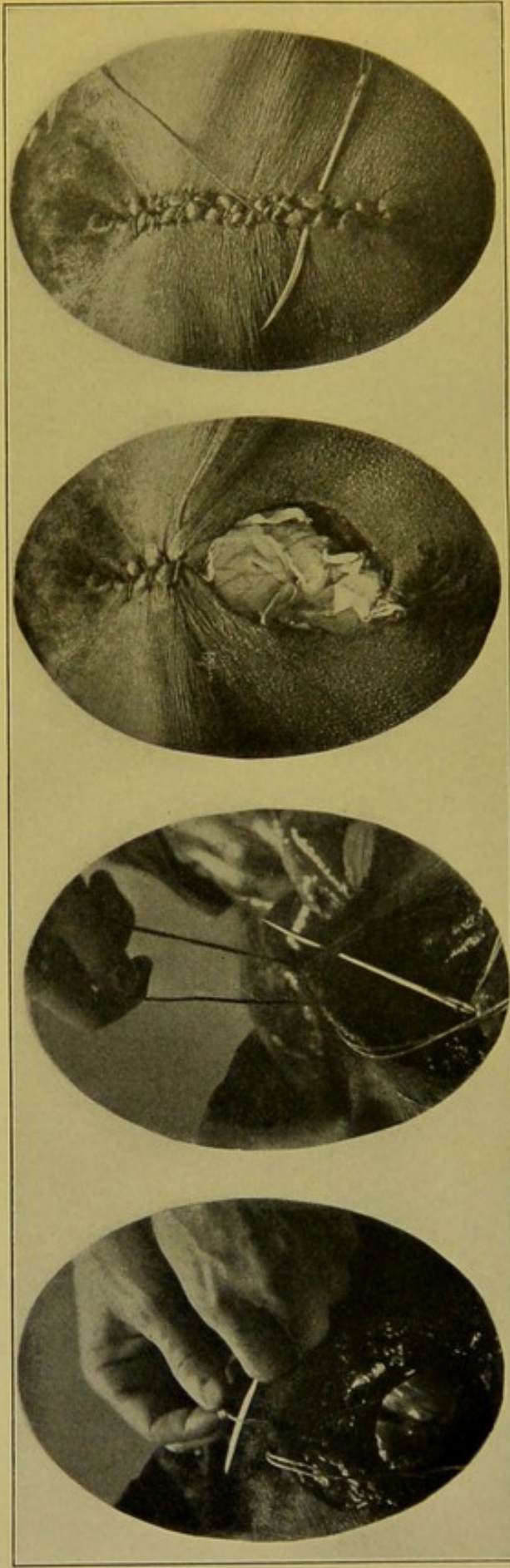
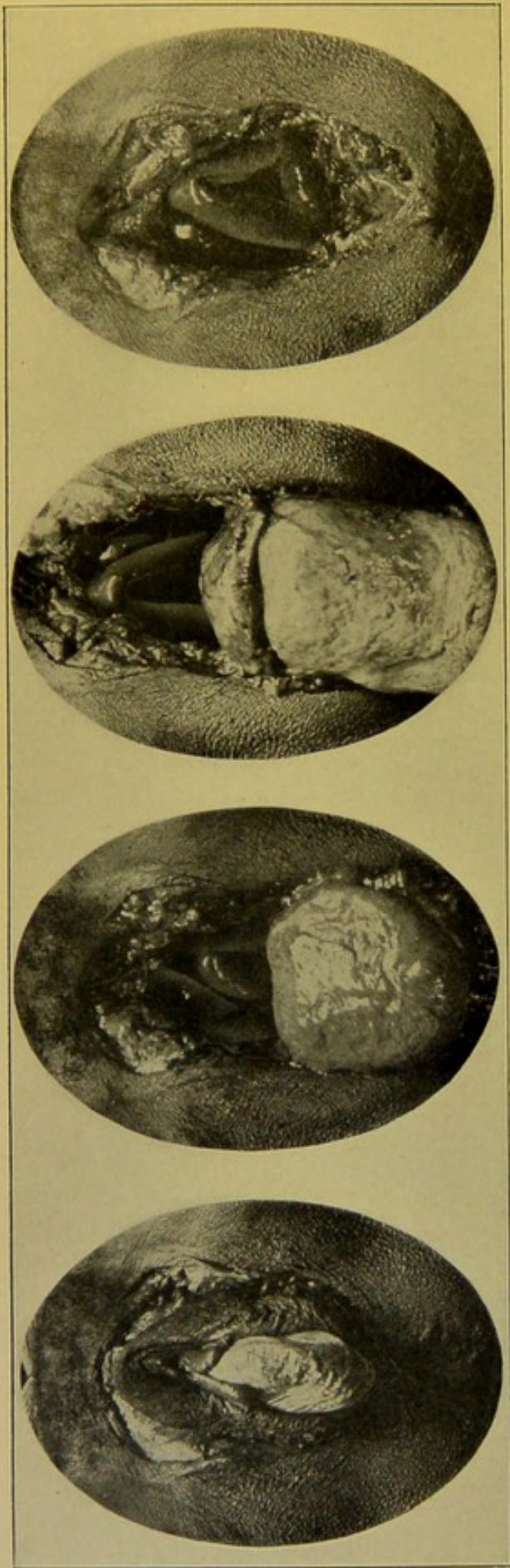


FIG. 89.—Position in which the body is advantageously placed for examination of the rectovaginal region and for the performance of a postmortem *per vaginam* or *per rectum*. The body is drawn down towards the end of the table and the hips are elevated with a block. The thighs are then strongly flexed and held securely in place by a bandage fastened beneath the table.





FIGS. 90-97.—Method of performing a post-mortem extirpation of bladder, uterus, and adnexa through the vagina and the restoration of the parts afterwards. An ovoidal incision, Fig. 90, is made through the skin about an inch from the external genitalia; this is then enlarged and deepened until the pelvic cavity is reached, when with the hand the bladder is loosened and the parts desired brought through the opening. Figs. 91 and 92 show the parts *in situ*; Fig. 93, after their removal. In sewing up the part afterwards to prevent leakage double thread is used. It is introduced at the upper or lower portion of the wound and the needle passed through the two threads so that when it is pulled tight there will be no chance of the thread slipping. (Fig. 94.) Figs. 95, 96, and 97 show method of sewing. (In this case there was a prolapse of the uterus, which is well seen in Figs. 89 and 90. The figures are numbered from left to right.)



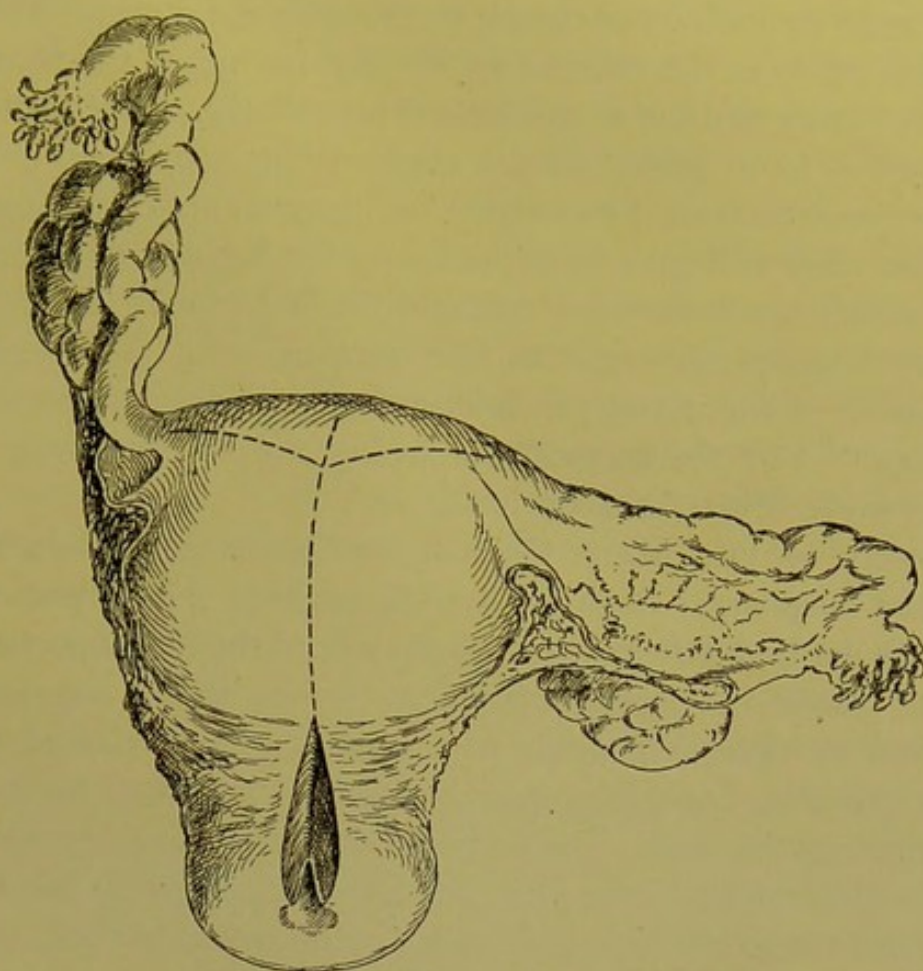


FIG. 98.—Method of opening the uterus; the lines show the places for the incisions, one of which has already been started at the cervix.

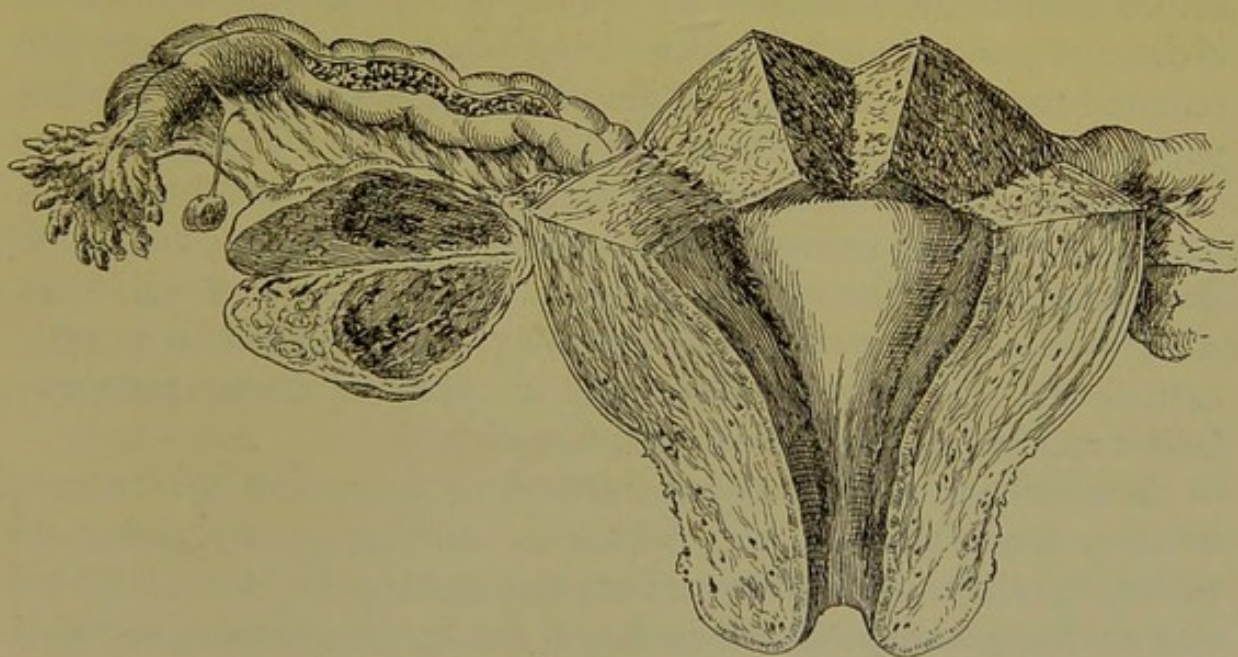


FIG. 99.—The uterus has been incised in the manner called for in Fig. 98. The ovary and the tube are opened. The fimbriated extremity, the hydatid of Morgagni, and a corpus luteum are well shown in the illustration.



while an anterior incision is chosen to examine the uterus. When it is desirable to preserve the exterior of the bladder intact, the rectum may be dissected away and the womb incised posteriorly, or the bladder may be removed so as to permit of the uterus being opened up anteriorly. A transverse incision in the uterus from the entrance of one oviduct to that of the other will give an opportunity for a study of their uterine termini, which are sometimes rather difficult to find. Each ovary is completely bisected through its free surface, with the exception of enough tissue at the bottom to hold the two halves together. (Figs. 98 and 99.) For the method of closing the external opening, see directions under Figs. 94 to 97 inclusive.

REMOVAL OF THE MALE ORGANS OF GENERATION.—In the male the bladder is pressed downward well towards the rectum, and the tissues thus put on a stretch are incised close to the under portion of the symphysis pubis. A circular incision is then made anterior to the rectum and as close as possible to the parts to be removed (seminal vesicles, prostate, Cowper's gland, bulbus, etc.) without injuring them or buttonholing the skin. The soft tissues of the penis (cavernous and membranous portions of the urethra) are dissected away from the skin from *within* the pelvis, traction being made to draw these parts into the pelvic cavity as fast as those above are loosened. The corpora cavernosa and corpus spongiosum being now fully exposed, they are incised transversely near the attachment of the prepuce, just below the corona glandis and frænum. By pulling on the spermatic cords from above and pushing up the testicles from below, these organs are then removed together. The skin of the penis and scrotum is well stuffed with cotton, so as to conform as nearly as possible to the original shape of the parts, or, if desired, after dissection of the testes and their appendages, they may be returned to their normal situations. Unless by an accidental perforation of the skin,—as the knife is working in the dark,—there need be no visible deformity if this method be properly carried out. The rectum and the bladder and its component parts may be left attached or can be separated, as preferred.

The technic of my external method of examining the testicles, urethra, spermatic cord, etc., without mutilating or disfiguring the external genitals, is as follows: The penis is grasped with the left hand and drawn upward and backward over the symphysis pubis in such a manner as to expose its under surface and the scrotum. With the thumb and forefinger of the same hand a fold of skin is taken up at



the point where the integument of the penis merges into that of the scrotum. This fold, which should be in the line of the long axis of the penis, having been drawn taut, incision is made across it at right angles to the line of the penis. If this transverse incision be not carried too far, it will leave an oval gap about an inch and a half in diameter when the fold of skin is allowed to fall back. This will be quite large enough to permit the proper execution of the subsequent steps of the operation, though the wound after being sewed is so small that it is entirely concealed by the penis when replaced in its normal pendent position. The finger is next introduced into the scrotum and swept around so as to break up the delicate areolar connective tissue that forms the septum scroti and unites the dartos with the testes; then by slightly dilating the external wound the testicles can be removed from the scrotal sac. Next the root of the penis is grasped from within, and the extremely loose bands of connective tissue that unite the body of the organ to the integument are broken up, still using only the finger. These connections having been severed, the body of the penis can be drawn from its cutaneous sheath as far as the point of union of the prepuce with the tissues at the cervix, so that now the testes and the penis as far as the glans are exposed denuded of their cutaneous investment. In severing the body of the penis from the glans and the tissue included in the inverted sheath of skin, great care must be exercised not to "bottonhole" the delicate structure of the prepuce. This accident can be avoided by amputating the glans at a point one-fourth of an inch from the corona (which can be plainly seen and felt through the delicate skin covering it), and carrying the incision parallel to its plane. The direction of the incision will be downward and forward, for in the position in which the integument attached to the cervix now holds the penis the frænum is in front. The amputation of the glans is most conveniently performed with scissors, the body of the penis being supported by the thumb and first finger of the left hand. (Figs. 100, 101, and 102.)

Nauwerck describes the following method of finding the seminal vesicles: They lie as long flattened organs on the lateral side of the spermatic duct immediately above the prostate and the posterior wall of the bladder. The fundus of the rectovesical excavation is held up, and the index-finger is placed in the incision in the prostate, the middle finger in the posterior wall of the bladder, and the thumb on the rectum, which on being pulled downward exposes the back part of the



neck of the bladder, upon which rest the seminal vesicles. Or, cut through the peritoneum in the depth of the excavatio rectovesicalis and dissect up the spermatic cord until the vesicles are reached. They are then to be incised and the duct opened up with a fine pair of scissors. (Fig. 103.)

#### THE LIVER AND GALL-BLADDER.

The liver is removed from the body by severing its attachments to the diaphragm, falciform ligament, blood-vessels, and ducts, and breaking up any existing adhesions. For this purpose traction is made by introducing the left hand behind the right lobe and raising the liver so that it hangs over the ribs of the right side (Fig. 104). Nauwerck removes the organ by finding the hepatoduodenal ligament and then, introducing the index-finger into the foramen of Winslow, pulling it somewhat towards the duodenum and cutting from right to left over the finger the ductus choledochus to the right, the hepatic artery on the left, and lastly the portal vein which lies between the two posteriorly (Fig. 105). The liver is then weighed and measured, and the color and condition of the surface are noted. After examination of the serous surface of the gall-bladder and duct, the sac should be laid open by a longitudinal incision carried through the duct.

The liver is laid on its posterior surface and a series of parallel incisions about half an inch apart, which do not completely pass through the organ, are made, either longitudinally or, still better, transversely (Fig. 106).

In pernicious anæmia the presence of free iron may be shown by placing a thin strip of hepatic tissue in a ten per cent. solution of potassium ferrocyanide for several minutes and then washing it thoroughly with a two per cent. solution of hydrochloric acid. The production of a blue color (Prussian blue) indicates the presence of iron.

Observe: Bile ducts: (*a*) caliber,—normally that of a thin goose-quill, may be closed, or may be of the size of a finger; (*b*) gall-stones; (*c*) ulcers. Portal vein: (*a*) color of blood; (*b*) thrombosis; (*c*) caliber,—may be thin as result of old inflammation; (*d*) periphlebitis. Gall-bladder: (*a*) size; (*b*) adhesions; (*c*) tumors; (*d*) contents,—1, bile (note its color,—light or dark yellow, reddish yellow, greenish yellow,—quantity, quality, etc.); 2, foreign bodies,—gall-stones; 3, mucous membrane,—thickening, change in color, and inflammations. Liver: (*a*) position; (*b*) size,—increased in parenchymatous inflam-



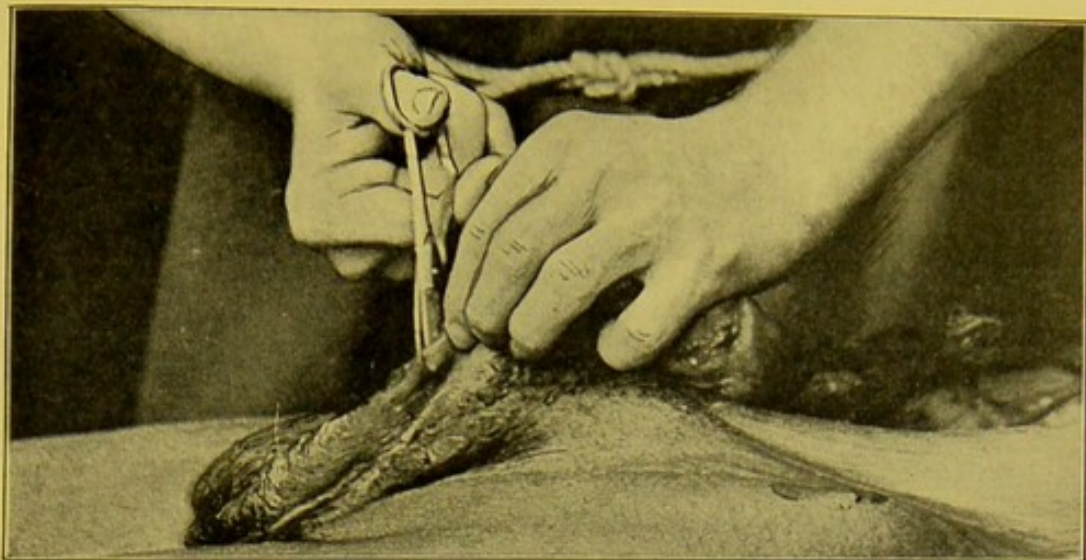


FIG. 100.—Method of examining testicles, epididymis, spermatic cord, etc., without disfigurement. The primary incision is made in the median raphe in such a manner as to be covered when the penis is returned to its normal situation.

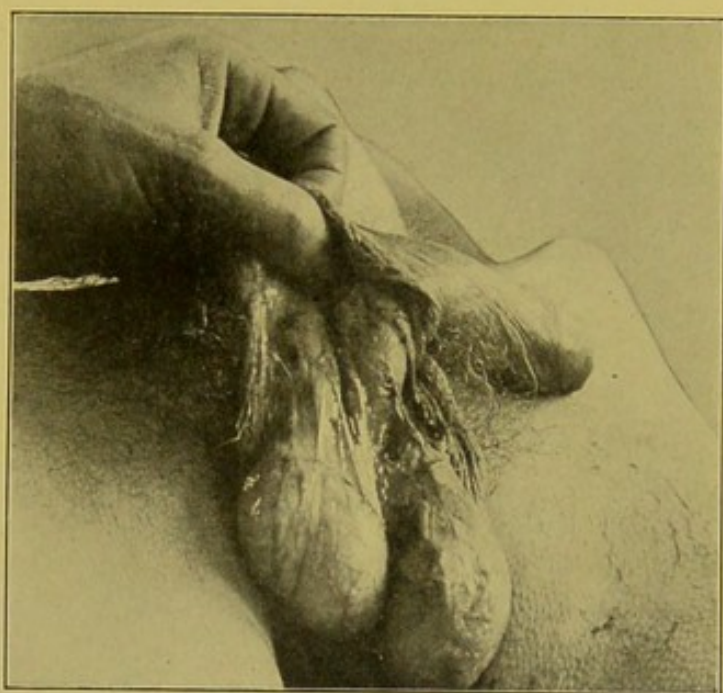


FIG. 101.—Testicles shelled out of the scrotum through the opening made in Fig. 100.

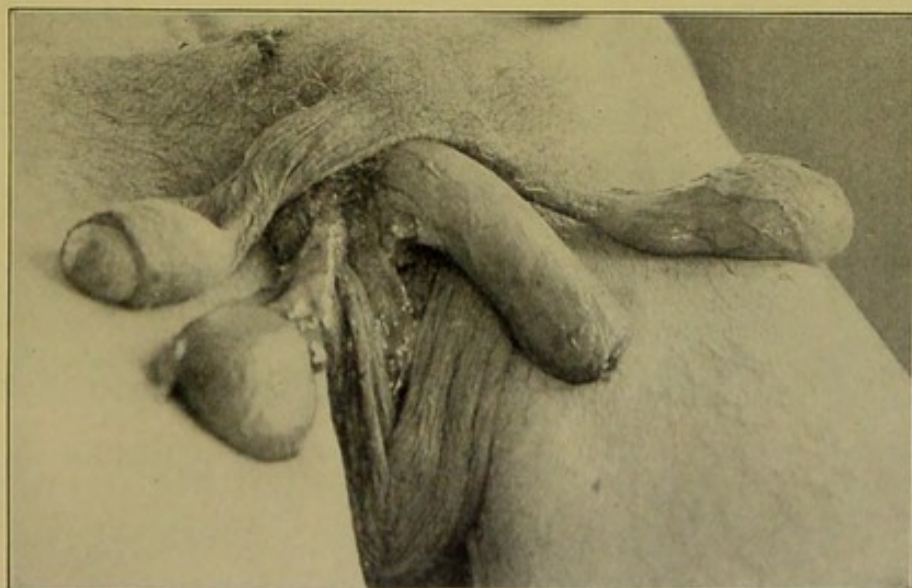


FIG. 102.—Appearance of the male external genitalia preparatory to minute examination in the author's method of exposing them without disfigurement.



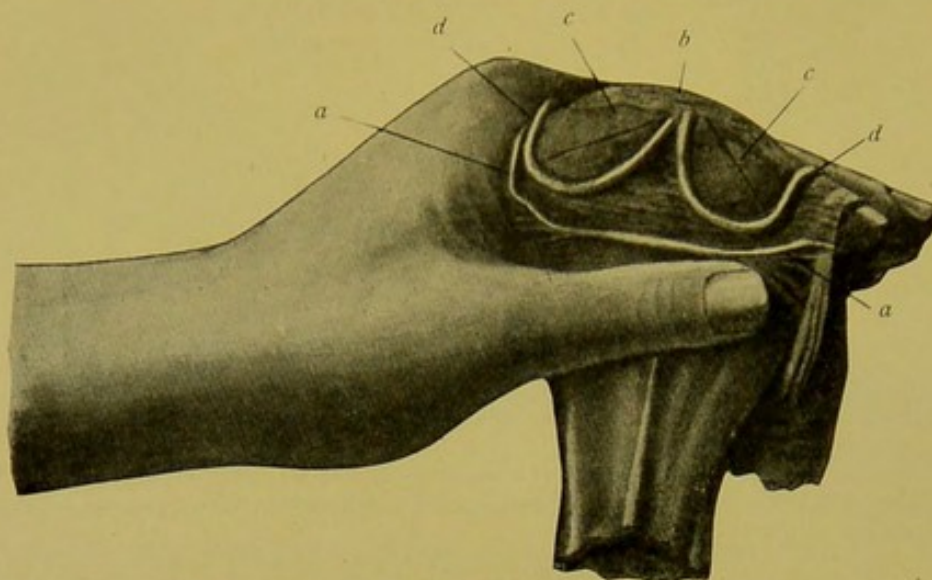


FIG. 103.—Method of opening the seminal vesicles. The lines above the seminal ducts show the places of incision used to examine the seminal vesicles. *a, a*, edge of severed portion of peritoneum; *b*, urinary bladder; *c, c*, seminal vesicles; *d, d*, spermatic ducts.

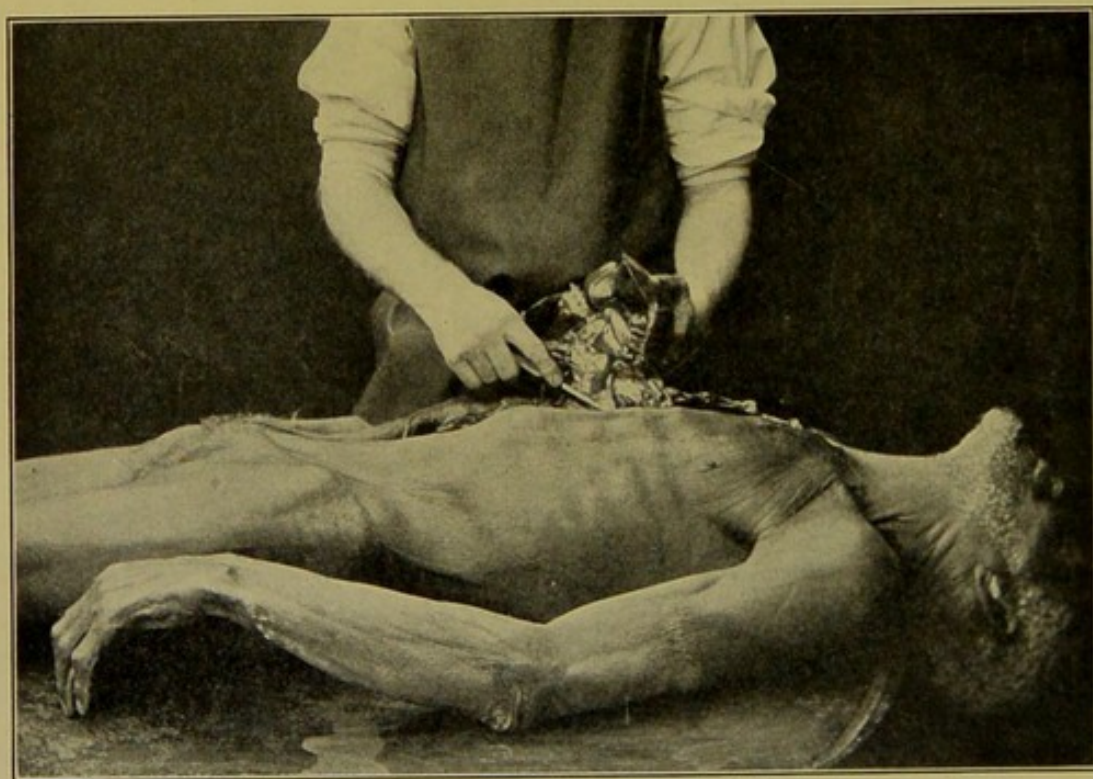


FIG. 104.—Removal of the liver from the body. It is held in the left hand and incision is made towards the operator. This stretches the diaphragmatic attachments of the large blood-vessels, so that they may readily be incised.



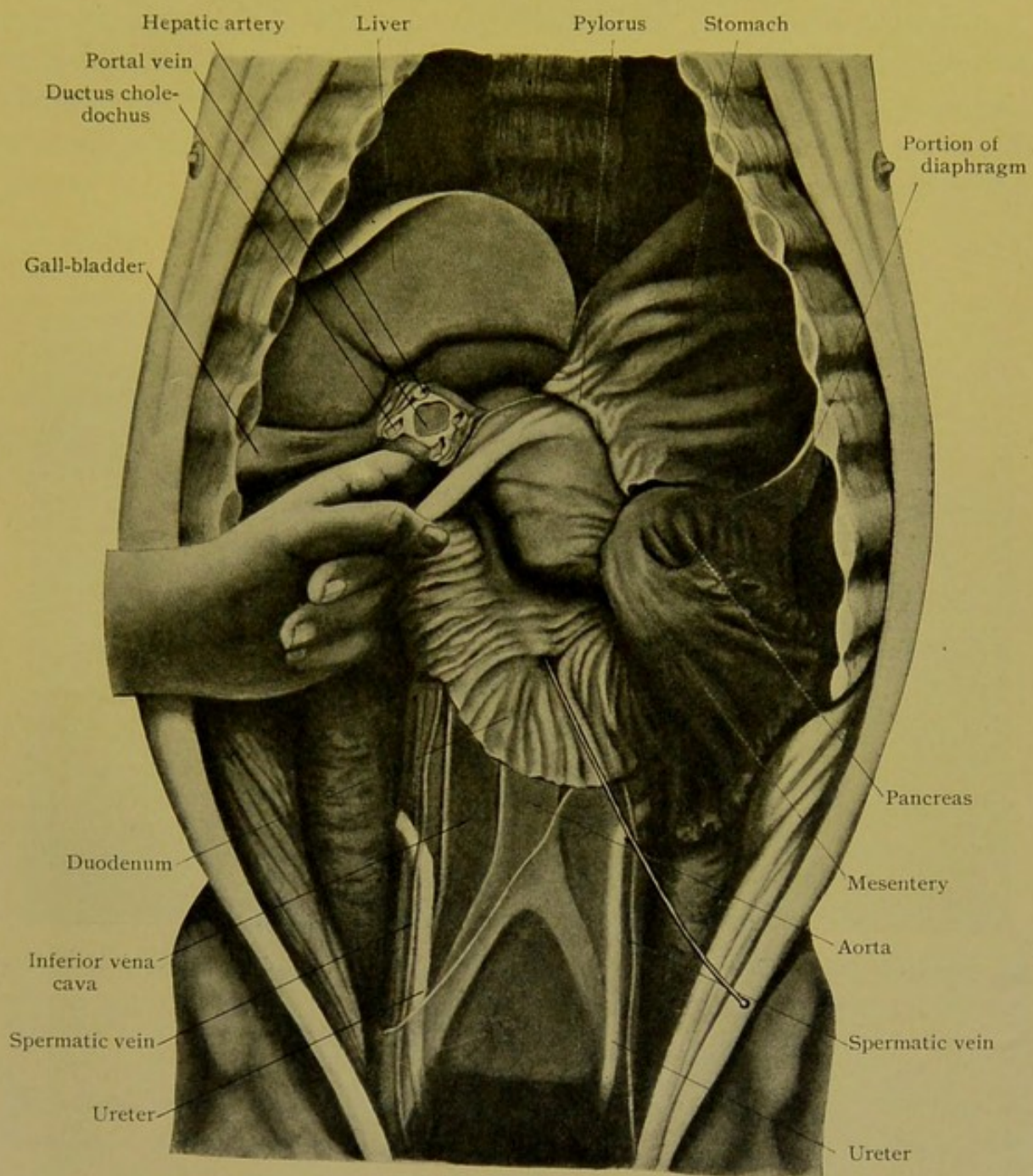


FIG. 105.—Examining the bile ducts. The left index-finger is introduced into the foramen of Winslow, and supports the hepatic artery, the portal vein, and the ductus choledochus, into the latter of which a sound has been introduced and is seen coming out of the opening in the duodenum. (After Nauwerck.)



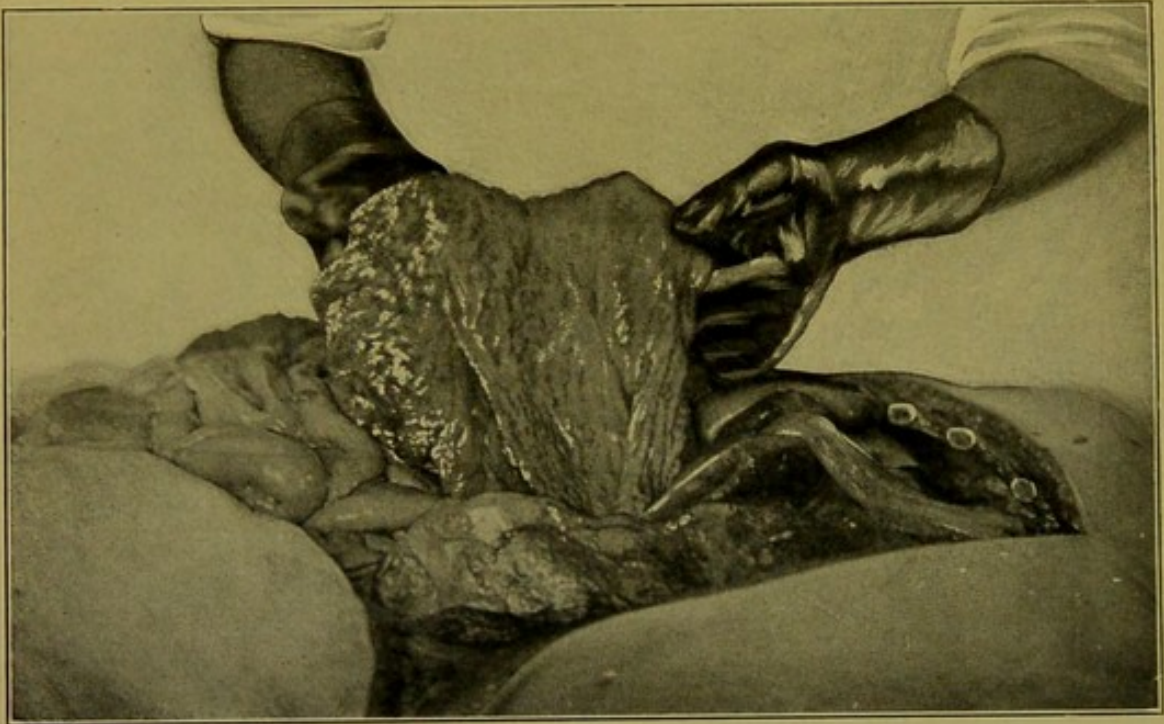


FIG. 108.—Method of examining the stomach, which in this case was markedly hypertrophied. Rubber gloves are very useful for this purpose.



mation, decreased in atrophy; (*c*) form,—fissures or granular distortion of surface; (*d*) color,—brown or brownish red normally, yellow in fatty infiltration, dark brown in atrophy, gray in amyloid and interstitial overgrowth, ochre-yellow in acute yellow atrophy, green in icterus, or dirty green when decomposition sets in; (*e*) consistence,—normally rather hard (pitting soon disappears), increased in amyloid disease, the pitting remaining for some time, softer in parenchymatous affections and early stages of acute yellow atrophy, fluctuates in echinococcus cysts and abscesses; (*f*) capsules,—normally transparent, but

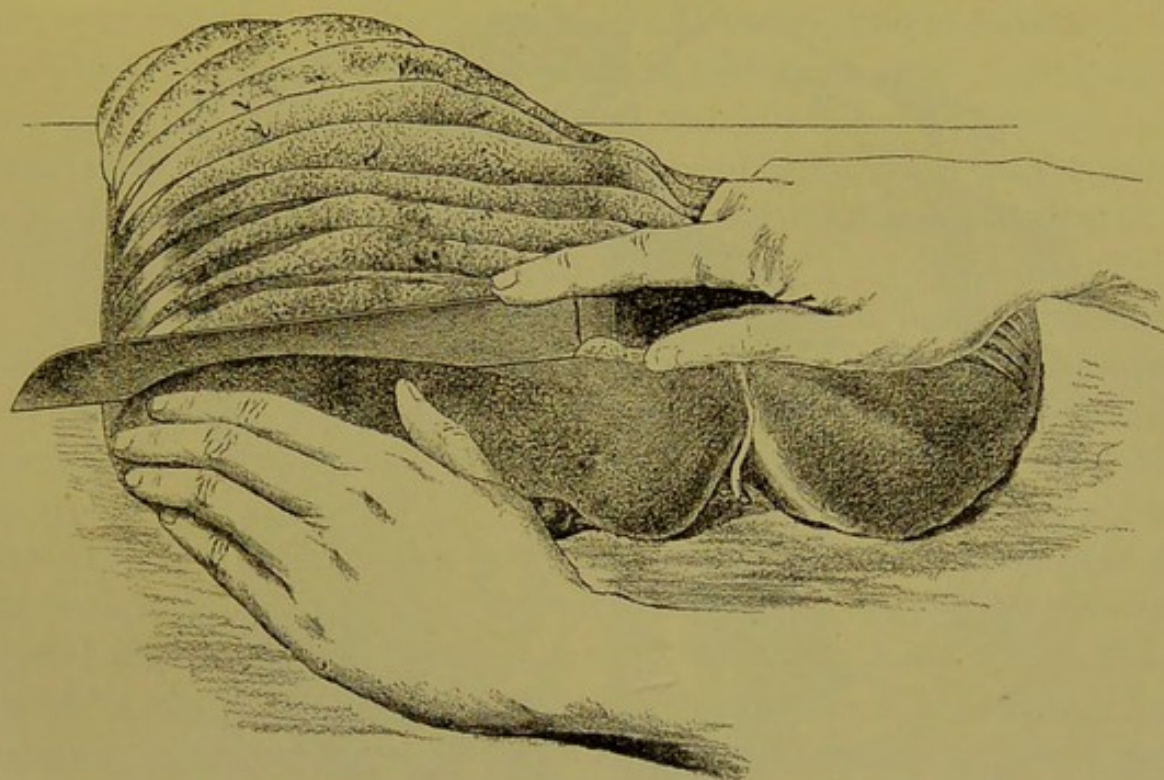


FIG. 106.—Method of incising the liver. Long parallel incisions are made from the right lobe to the left, care being taken not to cut through the organ, which would prevent reconstructing it in its normal state, nor to extend the incisions so deeply as to injure the gall-bladder. The structures of the under surface of the liver have been previously dissected.

thickened in chronic inflammation, syphilis, etc.; (*g*) section,—smooth, uneven, rough, or granular; (*h*) lobules,—notice that they are separated by connective tissue, more distinct in cirrhosis, less so in acute yellow atrophy. It is well to remember that in man the separation of the lobules by the connective tissue of Glisson's capsule is not at all well marked. Observe whether the lobules are larger or smaller than normal. Notice that the color is darker in the centre of the lobule than at its periphery (cyanotic induration). See if the periphery is yellow (fatty infiltration). On section note whether the tissues retract



as in high-grade cyanotic atrophy, or project as in fatty liver. Amyloid degeneration affects especially the middle zone.

#### DUODENUM, OUTLET OF THE COMMON BILE DUCT, STOMACH, AND ŒSOPHAGUS.

The duodenum may be slit while still *in situ*, or it can be excised together with the stomach, liver, and pancreas, and the whole dissected after removal from the body. The gut is best opened with a knife, starting at the tied end about the centre of its anterior surface and with

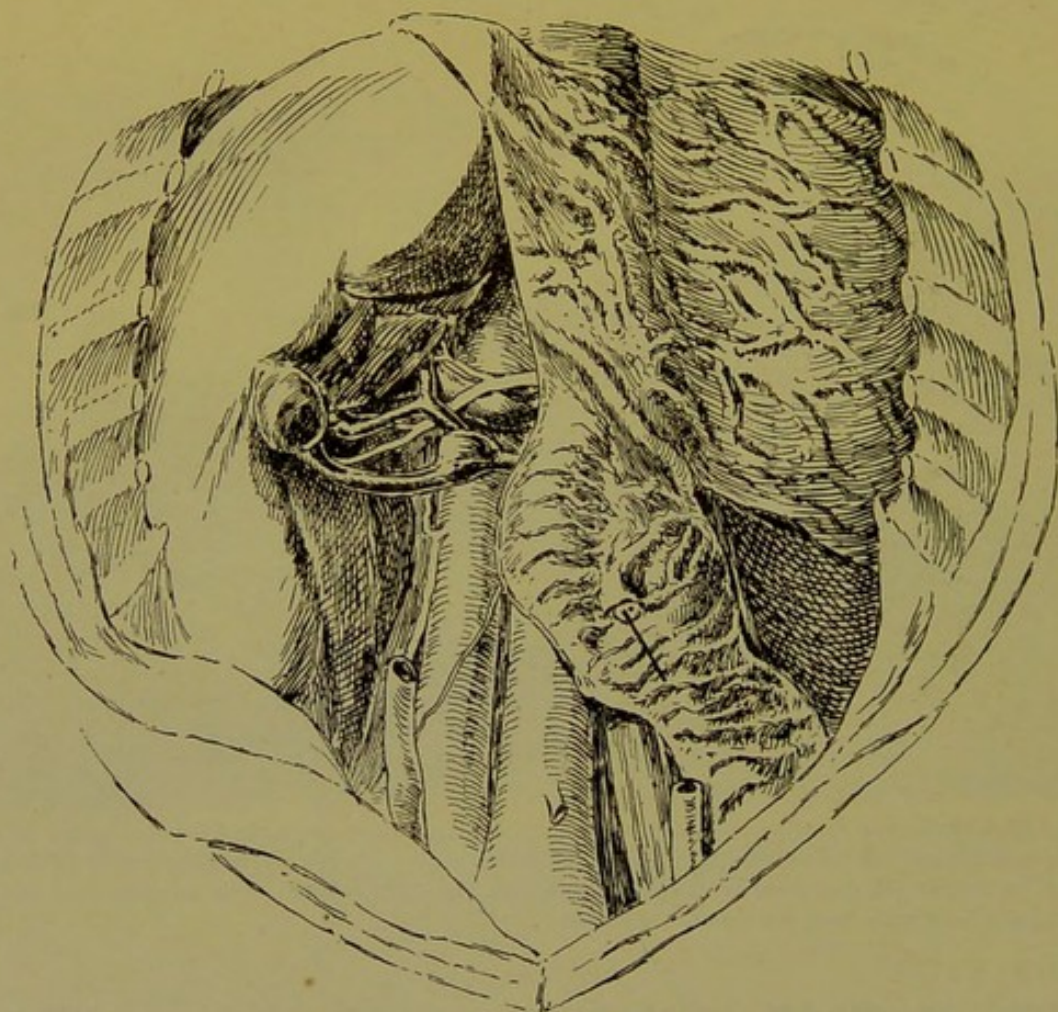


FIG. 107.—Relations of the gall-ducts and duodenum. The gall-bladder in this case was packed with stones, and one large one was found in the common bile duct. In this case the pancreatic duct communicated with the duodenum by a separate outlet, and a probe is seen emerging from the opening through which the bile normally finds its way into the duodenum.

the enterotome cutting more and more to the right until at the pylorus the incision almost reaches the posterior surface of the duodenum. (Fig. 107.) The papilla, the outlet of the ductus choledochus communis, can usually be discovered if it be remembered that it appears as an elevation of the mucosa near the junction of the second (descend-



ing) portion and the third (transverse or oblique) portion of the duodenum, about three and one-half inches from the pylorus, just below the head of the pancreas, and towards the inner and back part of the duodenum. The duct runs for three-quarters of an inch in the muscular coat of the bowel, where it is usually joined by the pancreatic duct. A small magnifying-glass will often enable one to distinguish the papilla from the *valvulæ conniventes*. Pressure upon the gall-bladder, as suggested by Virchow, will cause bile to flow out (but care must be taken not to dislodge a gall-stone, either here or in the cystic duct) and thus reveal the opening of the duct. Another way is to follow down the cystic duct, make a transverse incision in it, introduce downward a small probe or piece of broom until this emerges through the opening in the papilla, and then slit it with a knife or scissors. Orth says that if after finding the head of the pancreas the intestines are stretched transversely the outlet will readily be discovered a little below the middle of the head.

Unless poisoning is suspected (see pages 325 and 342) the stomach is incised along the greater curvature, a *little below* the cardiac orifice and a *little above* the pyloric, the contents are removed and the openings examined, when the incision is extended in both directions until the entire viscus is laid open. The mucous membrane may be washed by allowing a gentle stream of water, as from a sponge, to flow over it, but it should never be rubbed with the sponge. The organ may be opened and examined without removal from the body (Fig. 108). Should it be desired to find the artery from which a hemorrhage has occurred in a gastric ulcer, water is injected into the gastric artery supplying this area, and it will be seen to exude from the open part.

The contents of the stomach should be examined as to their quantity, consistency, reaction, odor, gas formation, foreign bodies, color, inflammation, and infectious granulomata. Blood coming from the lungs is apt to be mixed with air, frothy in character, and redder than blood issuing from the œsophagus or the stomach itself, where, if the vessel be of good size, large, compact, blackish-red lumps appear. The blood from cancer is blackish brown (the so-called coffee-grounds appearance); that from diapedesis, cirrhosis of the liver, and inflammations is a brownish homogeneous mixture combined with mucus. The biliary pigments often impart to it a yellowish or greenish hue. In peritonitis and in obstruction to the bowel the gastric contents may be fecal in character.



The œsophagus is opened up along its anterior surface throughout its entire median extent either while *in situ* or after its removal from the body (Fig. 76). Its caliber may be directly determined by graduated cones, or may be calculated by dividing by 3.14 its linear measurements made after it has been laid open.

In cancer consider heredity, sex (more common in the male), age (average about fifty years), previous history of a gastric ulcer, and place of origin, inquiring particularly whether or not other cases have occurred in the same house. Cylindrical-celled cancers are found especially at the pylorus, while squamous epitheliomata occur mostly at the cardiac end of the stomach. The tumor may be hard (scirrhus), soft (medullary), or colloid. (a) *Scirrhus*.—The growth starts as a small nodule, usually at the pylorus, often sharply defined, and very hard. It is whitish on section and no cancer-juice exudes from the cut surface. Stricture of the pylorus with hypertrophy and dilatation of the stomach is common. Connective tissue is very abundant and cancer-cells are few. Ulceration occurs late in the disease. (b) *Medullary*.—This tumor tends to become larger than the previous one. It contains much less connective tissue and is therefore softer. It involves all the coats and is not circumscribed. It ulcerates very early and hemorrhages are frequent. As in the previous instance, metastasis is very common. (c) *Colloid*.—This variety usually consists of gelatinous cancer-cells in a condition of colloid degeneration. It extends over the entire stomach and metastasis is very rapid. Metastasis in all the forms affects the various tissues and organs in the following order: lymphatic glands, liver, peritoneum, omentum and intestine, pancreas, pleura, lung, and spleen. The squamous variety is a somewhat flat tubular swelling involving the superficial layers. It may constrict the œsophageal orifice and cause atrophy of the stomach. Cases in which a cancerous stomach has been removed entire during life demand special attention at the postmortem.

Gastrectasis, or dilatation of the stomach, is due to: I. *Pyloric Stenosis*.—(a) Carcinoma. (b) Congenital conditions. (c) Hypertrophy of the pyloric sphincter. (d) Cicatrix of an ulcer. (e) Peritoneal adhesions. (f) Cancer of the head of the pancreas or other structure pressing on the duodenum. (g) Spasm of the sphincter. II. *Atony of the Gastric Walls*.—(a) From chronic gastritis. (b) Excessive ingestion of solids and liquids. (c) Traumatism. (d) Surgical intervention. (e) Serious infectious diseases. (f) Neurasthe-



nia. (Hemmeter.) At first there is hypertrophy of the muscular walls. Soon, however, interstitial sclerosis comes on, the stomach may become either pyriform or hour-glass in shape, and the mucous coat is thrown into exaggerated folds. As atrophy advances all the layers of the stomach become thinner; the bundles of muscles are separated by connective tissue; the surface may show evidences of pigmentation and petechial hemorrhage; and while the serous surface sometimes remains unaltered, it is usually thick, pale, and opaque.

Gastritis, or inflammation of the stomach: I. *Acute*.—(a) Errors in diet both as regards quantity and quality. (b) Irritant poisons. (c) Mechanical: external (severe injury to the epigastrium); local (fish-bone, etc.). (d) Thermal (hot or cold ingesta). (e) Infectious diseases. (f) Psychic shock (grief, sorrow, etc.). (g) Extension of inflammation. II. *Chronic*.—(a) Follows repeated acute attacks. (b) Slow poisons (alcohol, tobacco, gout, rheumatism). (c) Diet. (d) Anæmia and chlorosis.

I. (a) In simple gastritis the mucous membrane is hyperæmic, swollen, and covered with profuse thick mucus. There are localized areas of ecchymosis and often small erosions. In severe cases there is considerable denudation of epithelium, with perhaps an exudate of grumous blood. (b) Phlegmonous or suppurative gastritis may exist in two forms: the abscesses may be small, multiple, and miliary, or they may be diffuse. The pyloric end is most commonly involved. The submucous layer is most extensively altered. It is swollen, œdematous, purulent, and sometimes even bloody. The mucous membrane overlying the abscess may be normal in appearance, it may slough off, or, again, it may be swollen and hemorrhagic. On the other hand, the surface is sometimes studded with numerous areas of focal necrosis of a yellowish appearance, and, on section, may discharge pus. Diphtheritic gastritis sometimes follows laryngeal or pharyngeal diphtheria, and frequently accompanies pyæmia, scarlet fever, variola, and malignant endocarditis. In this form of gastritis we find a variable number of circumscribed areas of false membrane firmly adherent to the underlying structures and leaving a raw surface when removed. It is apt to attack particularly the crests of the rugæ. The diphtheritic patches are usually surrounded by areas of more or less pronounced congestion. (c) In toxic gastritis the appearance of the viscus depends upon the amount of contained food at the time of ingestion and the concentration and kind of poison. If the latter is diluted, the mucous membrane



alone suffers; if concentrated, all the coats may be involved. Alkalies appear to be more destructive than acids, the lesions produced resembling those of an intense congestion, more or less localized. In very severe cases perforation may follow. Sloughs or ulcers are almost invariably found where the poison has been concentrated. Mycotic gastritis may be due to: (a) Anthrax. (b) Favus. (c) Thrush.

II. *Chronic*.—(a) *Hypertrophic*.—Virchow calls a condition of the mucosa when there are swelling, cloudiness, and a yellow color, gastritis parenchymatosa or glandularis; it is due to poisons, as arsenic and phosphorus, to acute infectious diseases, to acute atrophy of liver, etc. This may be localized or diffuse. In the former case numerous mucous polyps can be seen over the affected area. This variety occurs in drunkards. These warty elevations show considerable cystic degeneration. In the diffuse variety the stomach is almost invariably enlarged and the walls are thickened, particularly the mucous coat, which is decidedly velvety both to sight and touch. Besides being swollen, rugæ are often present in exaggerated folds. Petechial hemorrhages and areas of pigmentation are common. There are often evidences of previous ulcerations (cicatrices). The stomach frequently contains a variable quantity of thick, tenacious, sour-smelling, greenish mucus.

(b) *Atrophic*.—When this variety of the disease exists the walls of the stomach become thinner. There is connective-tissue overgrowth, which by its contraction causes the epithelial cells to undergo degeneration and disappear. The mucous membrane is thin, smooth, and pigmented.

In hemorrhage from the stomach, if the blood come from without, as from a rupture of an aneurism, the stomach presents but few changes. The blood may be fluid or clotted; it may be bright red or dark in color. When the hemorrhage is due to actual disease of the stomach, this blood is apt to be coffee-brown. Petechial hemorrhages in the mucous membranes are common. Extensive hemorrhage from the wall of the stomach is usually associated with gastric ulcer.

#### PANCREAS.

The position of the pancreas having been determined in the preliminary examination of the abdominal cavity, its isolation and detachment are attended by no difficulty unless there be disease of neighboring parts, in which case its removal may necessitate taking an adjacent viscus with it. Many students are singularly unfamiliar with the nor-



mal anatomy of the pancreas, the splenic artery often being mistaken for the pancreatic duct and the sensation of hardness which this gland normally imparts to the touch being regarded as an evidence of sclerosis; the head and tail of the pancreas, too, are not infrequently left in the body and thus escape examination. Disease may extend from the pancreas to the portal vein, bile ducts, pylorus, or duodenum, or from these organs to the pancreas. Hemorrhages, tumors, degenerations, calculi, atrophic changes, cysts, etc., may be found in this organ. The possible presence of fat necrosis—a not infrequent cause of sudden death—should be borne in mind.

The etiology of pancreatitis is practically unknown, though it is probably of a chemical nature. In the lower animals acute pancreatitis can be produced experimentally by the injection of an artificial gastric juice, but it is impossible to foretell which form of the disease will result. I. Acute. (a) Hemorrhagic. (b) Suppurative. (c) Gangrenous. II. Chronic. (a) In hemorrhagic pancreatitis the organ is enlarged, thin, irregular in outline, and intensely congested, coagulated blood often appearing on the surface of the pancreas while other areas may be comparatively normal. The gland is somewhat harder than normal, but may be almost diffuent. There may be adhesions to the surrounding structures. The omentum and mesentery sometimes show focal areas of fat necrosis, whereas the serous membranes and the subcutaneous tissue are often the seat of various-sized hemorrhagic extravasations. The stomach may contain grumous blood and present the evidences of an acute gastritis. (b) Suppurative pancreatitis may follow the hemorrhagic variety or may be the result of septic infection from a distant focus. The pancreas appears swollen, is softer in consistence, and may be the seat of a single abscess or of numerous ones. It forms adhesions to surrounding structures, from which it can be separated only with much difficulty. There may be numerous metastatic abscesses in other organs. (c) In gangrenous pancreatitis the gland may present a dry, necrotic appearance, but, as a rule, it is a dark slate-colored, diffuent mass, surrounded by more or less dense adhesions with the adjacent viscera. In some cases it has been found that the organ has entirely disappeared, its place being taken by an abscess-cavity containing a foul-smelling mass. II. A chronic interstitial pancreatitis exists in congenital syphilis. The pancreas is quite firm. The capsule is of firm consistence and gray in color. On section it crackles. The pancreas is diseased in fifty per cent. of the cases of diabetes



mellitus. There may be simple atrophy, pigmentary cirrhosis, cancer, calculi, cystic disease, or fat necrosis. The islands of Langerhans are peculiarly liable to be affected.

Retroperitoneal lymph-glands, best exposed by dividing the vertebral attachments of the mesentery at its roots, may be thickened from inflammation (as in syphilis) or be the seat of primary tumors (especially sarcoma and lipoma), secondary cancer, amyloid degeneration, and tuberculosis, or may have undergone changes due to various other inflammatory, cystic, and systemic affections.

Examination of the diaphragm may reveal the existence of hernia, abscess on the under surface, perforation (as in echinococcus cysts or amœbic abscess of the liver), trichina spiralis, inflammation of its serous investment, fatty degeneration and brown atrophy, hypertrophy (as in obstruction to normal respiration), atrophy (as in pseudohypertrophic muscular atrophy), etc.

The vena cava and the aorta should be inspected for signs of inflammation, thrombosis, etc. To remove the aorta it should be grasped as high up as possible, drawn forcibly forward, and cut obliquely from within and above outward and downward. In order to secure a firmer hold one finger may be inserted in its lumen. (Orth.)

The thoracic duct, with its three- to eight-millimetre caliber, is situated behind and to the right of the aorta, and may be most readily found near the diaphragm. It can be opened by slitting with a pair of fine scissors.

Abscesses in the psoas muscles may be secondary to Pott's disease, coxitis, perforation of the intestine, tumors, etc. Examine the spinal column for kyphosis, lordosis, and scoliosis.

In death from fright and chloroform narcosis, a large amount of blood is collected in the abdominal veins as the result of vasomotor paralysis.



## CHAPTER XII

### DISEASES OF THE KIDNEY

No little confusion exists in the description of the pathological lesions of the kidney owing to the multiplicity of terms employed. I have long been in favor of the following classification of renal diseases, which depends upon the structure affected: 1, epithelial (parenchymatous) nephritis; 2, fibrous (interstitial) nephritis; 3, vascular nephritis. It should be borne in mind that there is no such thing as a perfectly pure form of nephritis and that the condition which predominates gives the name to the lesion. For example, when we speak of parenchymatous nephritis, we do not mean that the epithelial cells alone are affected without involvement of the connective tissue, for it is entirely proper to describe a case as chronic parenchymatous nephritis in which the interstitial changes are beginning to predominate. The epithelial cells of any portion of the kidney may be affected primarily, hence the name glomerulo-nephritis, etc.

AMYLOID CHANGES.—These may be due to (*a*) prolonged suppuration (tuberculous or syphilitic), (*b*) chronic disease of the kidney, or (*c*) lack of cardiac compensation. The amyloid kidney is usually enlarged (the condition occasionally occurs in a contracted kidney), pale in color, and firm in consistency. The capsule is adherent in places and shows petechial hemorrhages beneath it. The cortex is increased in size. The glomeruli are first affected and usually prominent, although the cortex is pale in contrast to the somewhat reddish color of the pyramids. The organ has a bacony or waxy appearance. The urine contains albumin. The tube-casts are hyaline, waxy, or finely granular. Œdema of the extremities is common.

CONGENITAL DEFECTS.—(1) Total absence. (2) Absence of one, with hypertrophy of the other. (3) Rudimentary, cystic. (4) Duplication. (5) Partial coalition, usually lower end (horseshoe).

CONGESTION.—(*a*) In traumatism the kidney is large; the capsule is tense; the color is dark red. On opening the capsule the contents are found to be soft and bulge out and blood drips freely from the surface of the section. The dependent portions are more congested than the cortex. In passive congestion the organ is enlarged and firm; the capsule strips off readily; the cortex is wider than normal; the surface



on section looks coarse and connective tissue is plainly visible; the cortex is of a deep-red color and the pyramids are of a purple-red. Congestion may be due to (*b*) drugs, as cantharides or turpentine, (*c*) infectious fevers, (*d*) alterations of the circulation in the kidney itself or in the vena cava (rare), (*e*) valvular lesions of the heart, (*f*) diseases of the liver, or (*g*) diseases of the lungs.

**CYSTIC DISEASE.**—(*a*) Congenital cystic kidneys are greatly enlarged, so much so at times as to impede labor. There may be a conglomeration of cysts varying in size from that of a pea to a small apple. In some cases no renal tissue can be seen without the aid of a microscope. The cysts are lined with flattened epithelium and contain a fluid in which are found albumin, blood-crystals, cholesterin, triple phosphates, and fat-drops. (*b*) Chronic nephritis (which see). (*c*) Adenocystomata, of similar origin as the corresponding cysts in the ovary. (*d*) Concretions block up the uriniferous tubules and press upon the still intact epithelial cells, which later become flattened and disappear. The stroma and vascular supply are next affected and a cystic condition is produced, or the disease may go on to the formation of large concretions.

**HYDRONEPHROSIS.**—The outflow of liquid from the pelvis of a kidney may be obstructed by (*a*) congenital deformities, as when the pelvis comes off too high up on the kidney, (*b*) twists of the ureter, (*c*) calculi, (*d*) morbid growths, or (*e*) cicatricial bands. There is an accumulation of non-purulent fluid, which by steady pressure produces an atrophy of the organ and a gradual distention of its pelvis. The papillæ become more flattened and disappear, and their place is taken by concave recesses in the medulla, which becomes narrower. In extreme cases the kidney may be converted into a large cyst with some imperfect septa. There may be an enormous quantity of the contained fluid or only a few ounces. It is yellowish in color and contains urea, uric acid, and sometimes albumin and sugar. There is usually compensatory hypertrophy of the opposite kidney.

**INFARCTS.**—(*a*) Calcareous infarcts extend through the tips of the papillæ as stripes through one-half or more of the medulla, mainly along the canals, but also in interstitial tissue. There is effervescence on the application of hydrochloric acid. (*b*) Uric acid—found as acid ammonium urates in very young children and as acid sodium urates in mature years in cases of gout—may be deposited within the kidneys in the form of flakes (uric acid nephritis or gouty kidneys). In babes



they appear as yellow radiations from papillæ into medulla, and show that the child was born alive, as they occur only after breathing has taken place. Sodium hydrate dissolves the acid ammonium urates. (c) Hæmoglobin occurs in hæmoglobinuria. It exists in the canals first as lumpy brown, later as granular, and seldom as crystalline masses. Hæmatoidin crystals are seen where old hemorrhages were (Virchow). (d) Bilirubin infarct gives the bile reactions. It occurs in the icterous new-born, in acute atrophy of the liver, and in progressive pernicious anæmia. (e) Infarcts caused by salts of silver are very rare.

INTERSTITIAL NEPHRITIS.—In acute interstitial nephritis the whole kidney is increased in size; the color is uniform, making it hard to distinguish the border line between the cortex (which is swollen) and the medulla. The process is essentially a productive one. There is a marked migration of the leucocytes and the connective tissue undergoes proliferation. The cells increase in number and the intercellular substance disappears. The pus-cells get between the epithelial cells and the lumina of the canals can no longer be followed. Such areas may be found anywhere in the kidney substance. The process is essentially due to pyogenic bacteria brought from the heart, as in malignant endocarditis, or the uterus, as in puerperal sepsis. The process ends in abscess formation, often affecting the perinephric tissues. (Langerhans.) A similar condition may start from without the kidney or extend up from the pelvis or further down the urinary tract.

Chronic interstitial nephritis may start as an acute form, but most frequently affects alone the connective tissue of its stroma, the blood-vessels not being involved. The process naturally ends in contraction. The canals are freed from their epithelial cells and the glomeruli may be brought so close together as to touch each other. The capsule is adherent and the surface lumpy or granular and grayish red in color. The cortex is much smaller and may measure only a few millimetres in thickness, but its consistence is markedly increased. Compensatory hypertrophy may occur. If the canals are fatty they appear as yellow stripes or points. Cysts are common and are most marked at the junction of the cortex and medulla. The vessel walls are thickened. Localized interstitial nephritis is usually syphilitic, while the diffuse form is due to gout, lithæmia, lead, over-indulgence, etc. In the latter form we have granular atrophy, the so-called red granular kidney, in which, as contraction takes place, cysts are found.



MOVABLE KIDNEY.—(a) Female sex. (b) Absorption of perinephric fat. (c) Repeated pregnancies. (d) Traumatism. (e) Displacement by tumors. As a rule, the displacement is not great. The kidney usually moves downward or upward and inward, generally rotating so that the outer border and upper end move forward and the hilum is directed inward and backward. Nearly all cases are associated with a medial displacement of the colon. The right kidney is the one most frequently affected.

PARASITES.—Of the parasites the following are found: (a) *Distoma hæmatobium* (*Bilharzia hæmatobia*). (b) *Filaria sanguinis hominis*. (c) Echinococci. (d) Cysticerci. (e) Pentastoma. (f) *Strongylus gigas*. All are rare in this country.

PARENCHYMATOUS NEPHRITIS.—Acute diffuse inflammation of the kidney is due to: (a) Acute infectious fevers. (b) Poisons,—e.g., turpentine, arsenic, etc. (c) Traumatism. (d) Exposure to cold and wet. Macroscopically the organ is swollen, tense to the touch as the capsule is stretched, but the substance of the kidney is softer than normal, the color is gray to yellowish, and the stellate veins on the surface are prominent. The capsule strips off easily and is somewhat thinner than normal. On slitting the capsule the contents of the kidney bulge out. The cortex, which is increased in amount, is somewhat pale, swollen, and soft; the glomeruli appear as minute red dots. The pyramids are distinct and striated. The radiations in the medulla may be gray or transparent, gelatinous or watery. The larger blood-vessels are overfilled and prominent.

PARENCHYMATOUS NEPHRITIS, SUBACUTE.—The large white kidney is more swollen than in the acute form and the tissue itself is of greater consistency. The cortex may be increased, therefore, before contraction commences. Yellow spots where the degenerative changes are most marked are found in the gray glossy substance. Cysts are absent, unless interstitial changes are associated. The kidney is dry on section, and the pyramids of the medulla show reddened stripes pointing towards a papilla. This condition may be associated with amyloid degeneration, most marked in the glomeruli. The mucous membrane of the pelvis is frequently swollen and of a pinkish color. Microscopically the changes are those of an acute diffuse inflammation, including cloudy swelling, proliferation, desquamation, and a granular change in the cells lining the tubules. The straight connecting tubules may entirely escape, though there is a form of catarrhal nephritis,



usually of an ascending variety, in which this part of the kidney is alone affected. In the surgical kidney there is an acute parenchymatous nephritis with abscess formations. Each individual cell is larger, the transverse diameter of the tubule increased, and the lumen diminished or even obliterated. Death most frequently takes place before the degenerative changes are complete; otherwise resorption and contraction follow, and on the surface there are slight indentations, often associated with a hemorrhagic condition, hence bloody casts, as in poisoning by cantharides and potassium chlorate, where even pigmentary infarcts may be found. The urine is scanty, high colored, albuminous, and contains casts and free blood. There may be extensive œdema, with effusions into the serous cavities.

**PARENCHYMATOUS NEPHRITIS, CHRONIC.**—This process is latent and runs a slow course, often of years; not all of the kidney is affected at once, some portions showing normal parenchyma while at other places degenerative changes are going on and at still others degeneration is complete and the parts are already in an atrophic condition. The cortex contracts irregularly, and has not the regular granular appearance seen in the kidney affected with interstitial nephritis (Langerhans), nor is there much increase in the stroma except at those places where contraction has taken place.

**PERINEPHRITIC ABSCESS.**—(a) Traumatism. (b) Extension of inflammation from the kidney or from neighboring organs. (c) Perforation of the bowel. (d) Infectious fevers, particularly in children. The kidney is surrounded by pus, especially posteriorly. The abscess-cavity is usually extensive. The pus is often offensive and may have a distinctly fecal odor. It may burrow and discharge into the lung, bowel, peritoneum, or bladder, or it may follow the psoas muscle and appear in the groin.

**PYELITIS AND PYELONEPHRITIS.**—(a) Tuberculosis. (b) Infectious fevers. (c) Calculi. (d) Cystitis. (e) Tumors. (f) Drugs. (g) Cold and wet. *Classification.*—(a) Simple catarrhal. (b) Purulent. (c) Hemorrhagic. (d) Calculous. In simple acute pyelitis the mucous membrane of the pelvis is swollen, hemorrhagic, and turbid. In the purulent form the mucous membrane is swollen and covered with a cream-like exudate of a yellowish or yellowish-green color. Ecchymoses are common. The kidney itself is enlarged, softened, œdematous, grayish in color, and shows little distinction between cortex and medulla. Areas of necrosis or miliary abscesses are distributed through



the kidney substance. The kidney may attain the size of a human head. It is usually firmly adherent to the adjacent organs, tissues, and vessels. A quart of pus may be contained in the cavity; in these extreme cases all appearance of the gland substance may be lost. The hemorrhagic variety occurs in anthrax, sepsis, and leukæmia. In calculous pyelitis the mucosa is roughened, grayish in color, and thickened. There are also more or less dilatation of the calyces and flattening of the papillæ. These may be covered by a gray membrane. After the renal substance has been destroyed, if the pelvic orifice is still obstructed, the pus may become inspissated and ultimately impregnated with lime salts.

STONES.—The following varieties of stone may be found in the kidney or its pelvis: (a) Oxalate. This is very hard, dark, brownish yellow or gray in color, with rough surface and mulberry shaped. (b) Uric acid. This is usually smooth or a little rough, light brownish yellow in color and often striped, and of medium consistence. (c) Phosphate stones are white, crumbling, and chalky. (d) Cystin and xanthin stones are rare.

TUMORS.—(a) Fibromata are the most common of benign tumors. (b) Lipomata. (c) Myxomata. (d) Myomata. (e) Angiomata. (f) Lymphadenomata (or lymphomata). (g) Rhabdomyomata. (h) Carcinoma may be primary or secondary; it is comparatively rare. The cancer may infiltrate the whole cortex or may be knotty and separated sharply from the surrounding tissue. (i) Sarcoma may be primary or secondary. It is more common than cancer, usually occurs in children, and may attain to an enormous size. Here it exists as a myosarcoma. (j) Carcinoma sarcomatodes. (k) Patches of adrenal tissue may start growing and give rise to large tumors, the so-called hypernephroma heterotopes. Such growths are by no means rare.



## CHAPTER XIII

### DISEASES OF THE BLADDER, FALLOPIAN TUBES, OVARIES, UTERUS, VAGINA, AND TESTICLES

BLADDER.—The color of the mucous membrane is normally a pale gray, but is red in recent inflammation and blackish red if the inflammation be very severe. The mucous membrane may be œdematous and especially hyperæmic after the ingestion of certain poisons, as phosphorus and cantharides. It is also subject to necrosis, abscess, gangrene, and tuberculosis. The veins may be distended, especially when hemorrhoids exist and venous thrombosis occurs. The mucosa affords a favorite location for the growth of various organisms and a great many of the pathogenic bacteria are found. Thus, typhoid bacilli may frequently be detected in the urine of patients suffering from typhoid fever. Cystitis caused by the colon bacillus may give the agglutinative reaction in a dilution of one to fifty of the blood of a patient suffering therefrom. Cystitis is due to: (a) Irritants in the urine. (b) Extension of inflammation from adjacent parts. (c) Traumatism. (d) Septic infection through the blood or the urethra. (e) Infectious diseases. (f) Stricture of the urethra. (g) Enlarged prostate. (h) Diseases of the cord (myelitis). In acute cases the mucous membrane is swollen, reddened, and covered with a thin film of mucus or pus. When hemorrhage has occurred, the surface of the membrane is of a universal gray tint, or mottled with gray, black, or reddish-brown patches. In severe cases necrosis, abscess, or even perforation may occur. In the diphtheritic form of the disease necrotic patches are seen and small hemorrhages in the region of the trigone and the surrounding fundus. These increase in size. There is submucous swelling, which subsequently becomes infiltrated with pus. The whole mucous membrane over it degenerates and can easily be removed from the muscular coat. In chronic cystitis the bladder may be enlarged, but it is often smaller than normal. The various coats are much thickened and there may be true hypertrophy of the muscular coat. This condition is best seen in cases of long-standing chronic cystitis, where the inner surface may be thrown into folds and roughened so that the picture resembles that of the interior of a heart, and shows how difficult it is for injections into the bladder thoroughly to cleanse



the walls in cases of inflammation. In severe cases the inner coats often feel rough and sandy to the touch from encrusted salts. There is a considerable variety of tumors in the bladder; they frequently assume the form of polyps and villi. Cavernous angiomata are met with, also dermoid or echinococcic cysts. Pockets (diverticula) may develop in the walls of the bladder, sometimes being covered only by the peritoneum. Their openings may be very small, though the size of each diverticulum may reach that of a hen's egg. These pockets are at times produced by and may contain stones. In exstrophy the inner surface of the bladder is exposed externally above the pubes through a hiatus in the median abdominal wall. Professor Guit  ras once related to me an interesting case of primary diphtheria upon this exposed mucous membrane. In hypertrophy dilatation of the cavity exists along with increase in the thickness of the wall, which may reach an inch or more. The female bladder may become inverted and appear through the urethra. It may also take part in herni   of various forms. The bladder may be ruptured by external violence without any sign thereof being visible. In overdistention from hemorrhage the bladder may reach to the umbilicus or may open into the rectum or vagina (vesicorectal or vesicovaginal fistula).

In the interesting condition called trichosis vesic  e the hair is usually referable to the breaking of a dermoid cyst into the bladder or to the growing of hair from the mucosa itself. In one case—an autopsy on a female—I could not see where the dermoid had arisen unless in the walls of the bladder itself. In a body examined at the Pennsylvania Hospital a bundle of hair was found which had become encrusted with salts and formed a calculus.

Vesical calculi may contain any of the normal or abnormal constituents of the urine. If this liquid be allowed to stand, precipitation occurs, the character of which depends upon the acidity or alkalinity of the urine. Bacteria in the body may cause an alkaline decomposition, with the formation from urea of carbon dioxide and ammonia, which uniting with the uric acid forms ammonium urates and triple phosphates. The most important sediments are uric acid, sodium urate, ammonium urate,—all of which give the murexide test,—calcium oxalate, calcium carbonate, calcium diphosphate, calcium triphosphate, and triple phosphate. Concretions may be found in the form of sand or as calculi. They are held together by an albuminous or cement-like substance, to which may be added cast-off epithelial



cells, shreds of tissue, blood, mucus, etc. Primary stone formation may take place in urine which has not undergone decomposition; such calculi are composed of uric acid and urates. Secondary stone formation occurs in an alkaline urine, the starting-point being a foreign body introduced through the urethra from without or a small calculus which has found its way down from the kidney; these stones are composed of ammonium urates and phosphates. They often consist of different substances concentrically arranged. Metamorphosed stones are produced where, for example, a primary stone has been partially dissolved by the action of an alkaline menstruum and the remainder covered by secondary deposits. Calculi assume a large number of shapes and differ much in their size. (Schmaus.) In addition to those named above, cystin and xanthin stones exist. Parasites in the bladder are rare. The following have been found: (a) *Distoma hæmatobium* (*Bilharzia hæmatobia*). (b) *Filaria sanguinis hominis*. (c) Echinococci. (d) Cysticerci. (e) Pentastoma. (f) *Eustrongylus gigas*.

FALLOPIAN TUBES.—I have seen the oviduct lengthened to over ten inches by the growth of a uterine fibroid, and have observed in the tube extra openings supplied with fimbriæ, the presence of which might at times have an important bearing upon the question of ectopic pregnancy. This dangerous condition may occur anywhere within the tube, or the fecundated ovum may escape into the abdominal cavity or become caught in a corpus luteum of either ovary. It is doubtful whether a pure form of ovarian extra-uterine pregnancy exists; in cases so diagnosed which have been brought to me for examination careful study showed that fecundation occurred near the ostium, and the fimbriated extremities became attached to the ovary just as in a case of ovarian abscess, making it to appear as if the pregnancy had started in the ovary. An interesting abnormality is lithopædion, where a foetus may remain in the abdominal cavity for thirty or forty years with certain of its tissues still in a condition to be readily recognized. The convoluted interior of the oviduct offers a favorable place for the growth of various organisms, and the tube itself may be affected with many kinds of benign and malignant tumors, the latter being primary or metastatic. It is subject to hemorrhages and different forms of inflammation. In catarrhal conditions the tube may rupture and give rise to general peritonitis. It is very apt to be bound down to the adjacent parts by adhesions.



In salpingitis the *Gonococcus*, the *Streptococcus*, the *Bacillus coli communis*, etc., are found. *Classification*.—(a) Hydrosalpinx. (b) Pyosalpinx. (c) Hæmatosalpinx. (d) Proliferous salpingitis. (1) In acute salpingitis the Fallopian tubes are swollen. The neighboring blood-vessels are dilated, tortuous, and overfilled with blood. There is often considerable exudate on the serous surfaces, causing adhesions of the tubes to the surrounding structures. On section the lumen of the tubule is found to contain serous, mucopurulent, or hemorrhagic fluid. The mucous membrane is thickened, swollen, and often intensely congested. To show the ciliated cells, though these may have been shed by the inflammatory process, care must be taken to harden the tissue at once after removal and in the same manner as to show karyokinesis. (2) In chronic (proliferous) salpingitis the tubes become enormously thickened, hard, and resistant to the touch. The adhesions to surrounding tissues are very marked and more or less completely organized. The new connective tissue contracts, throwing the organs out of their proper relation and often obliterating the normal appearance of these parts.

OVARIES.—These show perhaps more pathological changes than any other part of the body. The ovary may be divided into lobes by bands of connective tissue, or actual duplications of the parts may occur. It may form part of a hernia, and in a child I have found it in the canal of Nuck. As the opportunity arises, study the differences between a true and a false corpus luteum and a corpus hæmorrhagicum. The ovaries are subject to various forms of inflammation, an entire organ at times being converted into a pus sac. They are often bound down by adhesions and in later life undergo senile atrophy and may even become calcareous. Among the tumors here found may be mentioned adenomata, dermoid cysts, which are of an almost endless variety, enchondromata, endotheliomata, fibromata, fibromyomata, myomata, cancers, cystomata, sarcomata, psammocarcinomata, etc. Ovarian cysts may grow to an enormous size and contain even a hundred pounds of fluid.

UTERUS.—In examining the womb notice any abnormalities on the exterior and be sure to search every portion of the interior for any lesions which may exist. The situation of the organ may be markedly altered, both as a whole and as to its individual parts. Thus, we may discover anteflexion, anteversion, retroflexion, retroversion, prolapse, inversion, dilatations, elongations, bendings, or even find it forming part of an inguinal or a crural hernia. The chief congenital malforma-



tions are uterus bicornis, bicornis duplex, bilocularis, subseptus, and bipartitus. The uterus is subject to atrophy, hypoplasia, atresia, and hypertrophy. Uterine tumors are of great variety,—adenoma, adenocystoma, cancer, deciduoma malignum, hæmatoma polyposum, fibroma, myoma, myofibroma, myosarcoma, etc. A placental polyp may assume destructive characteristics. Hemorrhages are common, and, besides those due to menstrual disturbances, are found associated with polyps, cancer, etc. After parturition and after the menopause marked changes take place in the blood-vessels, which may undergo amyloid degeneration. Infarcts are seen. Many varieties of endometritis exist, such as gonorrhœal, tuberculous, diphtheritic, decidual, fibrous, gangrenous, glandular, interstitial, catarrhal, purulent, mycotic, villous, etc. Langerhans describes an interesting case of an old woman in which the uterus was so enlarged by a solid mass of thrush fungi and other bacteria that it measured some two inches in diameter. The uterus may rupture, as from childbirth, trauma, etc.

In acute forms of endometritis the mucous membrane is red, swollen, and sodden; the discharge is profuse, stringy, and often purulent; in severe cases blood is present. As the result of contusion during labor, plus infection, there may develop a suppurative process which transforms the parts into a soft, stinking, grayish-green or brown mass that tends to become gangrenous. The cervix is the most often involved. In diphtheritic endometritis there is formed a thick grayish-yellow or white membrane, the decidua lying loosely on the surface. This process may begin and remain at the placental insertion or may involve the cervical portion of the uterus. The infection may spread through the lymph stream or blood-vessels. Acute (ulcerative) endocarditis is a frequent complication of puerperal infection. In hemorrhagic endometritis the mucous membrane is red from engorgement of blood-vessels and numerous punctiform hemorrhages. It is distinguished from a similar appearance in menstruation by the condition of the ovaries.

In chronic hypertrophic endometritis there is a hyperplasia of the mucosa with softening and congestion, forming polypoid excrescences; the glandular structures also hypertrophy, become occluded, and form cysts of various sizes. In the cervix enlarged Nabothian cysts should be looked for. In atrophic endometritis the mucous membrane becomes thin and pigmented and the glandular structures disappear. Follicular erosion of the cervix occurs after lacerations.



VAGINA.—The vagina may be wholly or partially divided by a longitudinal septum. It may be entirely closed or so small that if coitus be attempted it takes place through the urethra, which thus becomes markedly dilated. The normal flora is considerable, and of pathogenic organisms the *Gonococcus*, *Bacillus diphtheriæ*, and *Oidium albicans* (thrush) are of importance. It is well to remember that diplococci other than the *Gonococci* are frequently found in the vagina. Severe inflammation may exist, and even gangrene may supervene. It is subject to numerous tumors, and malignant neoplasms of the cervix uteri may by extension of the growth involve the vaginal walls, which should, therefore, always be examined in such cases.

TESTICLES.—The testes are subject to many lesions, but the exposed situation and extremely specialized character of these organs are sufficient to account therefor. The testicles may be found undescended, and in such cases are peculiarly liable to injury and the subsequent development of tumors. They may be malformed or duplicated, and when one is removed the other may undergo compensatory hypertrophy. They may be affected by syphilis, tuberculosis, leprosy, etc. In guinea-pigs infected with glanders the testes are especially apt to become diseased. It is often impossible to tell whether a tumor originating in these organs is a sarcoma or a cancer. Dermoids and mixed neoplasms containing cartilage are not uncommon. Hemorrhage may take place into the tunica vaginalis and the testicle may atrophy owing to pressure from the fluid in a hydrocele. In typhoid fever the condition of the testes should always be noted, as they may become infected with the typhoid bacillus. True abscesses are found in them, and they may undergo brown atrophy, glycogenic infiltration, pigmentary or amyloid changes. In elephantiasis they may show hypertrophy. The cords sometimes rupture, and varix is common. I have seen the duct tortuous and calcified.



## CHAPTER XIV

### DISEASES OF THE LIVER AND GALL-DUCTS

**ACUTE YELLOW ATROPHY.**—This is an acute disease of the liver, presumably of infectious origin, characterized by a rapid fatty degeneration of the organ, with invariably fatal termination. Due to: (*a*) A specific micro-organism(?). (*b*) The ordinary micro-organisms of suppuration and infectious diseases have been found in this condition. (*c*) Certain poisons,—*e.g.*, phosphorus. (*d*) Female sex. (*e*) Pregnancy or the puerperium. The liver is greatly reduced in size,—one-half to one-third; in one of my cases, however, the condition had been preceded by hypertrophic cirrhosis and the organ weighed over five pounds. The liver is thin, flattened, and flabby, the capsule is wrinkled, and the gland is of a pale-yellow color. Both on the surface and on section may be seen a number of orange-yellow patches, in the centre of which are usually marked hemorrhagic areas. The remainder of the liver is of a yellowish-brown or mottled color. The outlines of the lobules are very indistinct. The bile ducts and gall-bladder are empty. Bilirubin crystals may be seen under the microscope. If a section of the liver be allowed to remain in the air for some time, a thin, white coating appears on its surface, which on examination is found to consist of crystals of leucin and tyrosin. The adjacent organs are usually stained with bile and present numerous hemorrhages, especially on the surface. The spleen is enlarged and the heart and kidney show marked granular change. The color of the liver in acute yellow atrophy depends on the time at which death took place: in the earlier stages the organ is ochre-yellow, in the later stages it is mottled, and if much blood be present it is grayish red.

**AMYLOID DEGENERATION.**—Found in cases of: (*a*) Prolonged suppuration, tuberculous or syphilitic. (*b*) Infectious fevers. (*c*) Chronic visceral diseases with cachexia. The liver is large in size, smooth in outline, and pale in color. The edges are distinctly rounded; small hemorrhages are common on the surface. On section the surface is anæmic, semi-transparent, and infiltrated. It presents the characteristic lardaceous or waxy appearance. The process may be a localized or a generalized one; in either case staining by Lugol's solution is



never uniform, as the diseased brown spots appear only in certain areas. The characteristic coloration may be seen upon the lining of both hepatic and portal vessels. Early in the disease this reaction is hard to detect, except by special stains under the microscope. Very thin pieces of the liver should be sectioned with a scalpel and put in a small glass dish. Add a solution of iodine and then wash out with water. Put something white under the dish and the characteristic coloration can be more readily seen.

CANCER.—I. *Secondary Cancer*.—Most common. Histologically shows same structure as primary growth, which is usually in the stomach, bowel, or pancreas. The liver is enormously enlarged, irregular, and nodular. The nodules are usually symmetrical, often superficial, flattened, discrete, and umbilicated; they may be more or less evenly distributed throughout the liver. On section whitish masses of varying size are seen, contrasting with the red color of hepatic tissue, the yellow staining of bile, pigmentation due to blood, and the light-yellow areas of fatty degeneration. The cancerous masses may undergo fatty degeneration, suppuration, or fibroid change. II. *Primary Cancer*.—Rare. (a) Massive. Causes great enlargement. On section the mass is uniform grayish white in color, somewhat firm, and distinctly outlined from the liver substance. (b) Nodular. Large and small nodules are scattered throughout the organ. These usually consist of a primary growth and numerous secondary nodules. (c) Cancer with cirrhosis is rare. Liver not much enlarged. Surface of section is grayish yellow, studded with nodular yellowish masses. In one of my cases of primary cancer of the gall-bladder the cancerous portions and the liver had become infected by the *Bacillus pyocyaneus*.

CHOLECYSTITIS, ACUTE INFECTIOUS.—There exists an acute inflammation of the gall-bladder due to: (a) The introduction of pyogenic micro-organisms,—for example, the *Bacillus coli communis* and the typhoid bacillus, pneumococcus, staphylococcus, and streptococcus. (b) Gall-stones. (c) Extension of inflammation from the bile ducts. The gall-bladder is distended; its walls are thickened and tense. The mucous membrane is swollen, hyperæmic, and may be covered with a purulent exudate. The submucosa may also be involved. The contents of this sac are cloudy and dark in color, and may be mucopurulent or hemorrhagic. Orth states that the inflammation is usually of a necrotic character. The tissue is of a dirty yellow-brown color and sometimes is rotten and easily torn. Gall-stones are frequently present. The



cystic duct is often obliterated. There may be adhesions with the bile duct or omentum.

**CHOLELITHIASIS.**—Gall-stones may be formed within the gall-bladder or in the ducts leading to or from it. Consider: (a) Most frequent in females. (b) Age, fifty per cent. over forty years old. (c) Sedentary habits. (d) Overeating. (e) Carcinoma(?). (1) The calculi are usually multiple, rarely single. They vary in size as well as in number. When multiple they are faceted, sometimes mulberry-shaped. They are of a dark bluish or greenish color. On section there is a nucleus consisting of epithelium, rarely a foreign body, then comes a layer of inspissated bile-salts, the outer covering being cholesterin. There may also be bile-acids, fatty acids, salts of calcium and magnesium, with a trace of iron and copper. When the stones consist of pigment exclusively, they are very easily broken and vary from yellowish brown to black in color. When composed of cholesterin entirely, they are softer, easily indented with the finger-nail, but not brittle, and are crystalline, the crystals forming layers. They are colorless and more or less transparent, but turn blue when iodine and sulphuric acid are added. They generally consist of both pigment and cholesterin, which may be combined or may be separated by layers. These stones are usually firm in consistence, rarely friable. (2) The gall-stones may lead to impaction of the gall-bladder or to obstruction of the cystic and common ducts or even of the bile duct alone. There may be formation of a fistula, external or internal, with escape of bile. The bladder itself is much thickened, sometimes dilated, sometimes smaller than normal through chronic inflammation.

**CIRRHOSIS.**—Under this heading are classified various forms of disease of the liver characterized by a marked increase of its connective tissue, which may be capsular, interlobular, or intralobular, with or without increase or decrease in the size of the organ. Causes: (a) Alcohol. (b) Certain infectious diseases,—*e.g.*, syphilis, tuberculosis, malaria, scarlet fever. (c) Micro-organismal infection. (d) Mechanical obstruction to the onward flow of the blood. (e) Rickets. (f) Anthracosis. (g) Poisons, as phosphorus and cantharides. *Classification.*—(a) Alcoholic. (b) Fatty. (c) Hypertrophic. (d) Capsular. (e) Syphilitic. (f) Cyanotic. (g) Malarial. (h) Scarlatinal. (i) Tuberculous. (j) Rhachitic. (k) Anthracotic. (1) In the atrophic cirrhosis of Laennec the organ is greatly reduced in size, although in the beginning it may be slightly enlarged, and later is



altered in shape. The surface is irregular and nodular and the capsule thickened. The nodules are usually small, but in some cases they may be greatly increased in size. The tissue is firm, hard, and resistant to the knife. The surface of section presents a mottled appearance, the lobules being divided by bands of connective tissue. The liver substance itself is of a yellowish or greenish-yellow color. The areas of connective tissue which are periportal are gray. (2) In fatty cirrhosis, found usually in drunkards, the organ is enlarged, somewhat smooth, although often slightly granular. It is paler than normal and of a yellowish-white color. It is firm and resistant to the knife. The capsule is opaque and often much thickened. The peritoneal cavity usually contains ascitic fluid. The membrane is opaque and thickened. Chronic involvement of the stomach and small intestine is always present. The spleen is enlarged; the kidneys are often cirrhotic. Owing to interference with the portal circulation by the cirrhotic liver, extensive compensatory circulation is formed. The abdominal vessels above and below the umbilicus are markedly enlarged. Around the umbilicus is found the caput of Medusa. Acute tuberculosis of the peritoneal cavity is not infrequently associated. (3) Hypertrophic cirrhosis is most common in young men. Ackerman compares it to elephantiasis. The organ is enlarged, but the outline is normal. The surface is usually smooth and its color an olive-green; the consistency of the organ is increased and the capsule is thickened. The surface of section is uniformly greenish yellow and the lobules may be separated by distinct bands of connective tissue. The spleen is greatly enlarged. Jaundice is a marked symptom of this disease. Ascites is usually absent. (4) In capsular cirrhosis there is enormous thickening of the capsule, which is irregular and somewhat wrinkled, producing great contraction of the liver. The organ itself is rarely markedly cirrhotic, its tissue being usually soft. Chronic capsulitis of the spleen, chronic perisplenitis, and ascites are often present. The kidneys usually show granular change. (5) In syphilitic cirrhosis the liver is markedly irregular in shape, being divided into peculiarly shaped lobes by extensive bands of fibrous tissue traversing the organ in indefinite directions. In one of my cases over forty distinct lobulations were present. The cut surface is mottled, often fatty in appearance, and shows the presence of gummata or of syphilitic scars. The connective-tissue bands are of a gray or reddish-gray color. (6) For cyanotic cirrhosis see Passive Congestion of the Liver. (7) In malarial cirrhosis the liver is markedly enlarged, com-



monly extending to the level of the umbilicus. It is firm in consistence, of a dark-red color, smooth in outline, and bleeds freely on section. (8) Klein has pointed out that chronic interstitial hepatitis may follow an attack of scarlet fever, which may account for some cases of cirrhosis of the liver in children. (9) Rhachitic cirrhosis is a form of the disease in which there is a marked increase of connective tissue around the individual lobules. (10) Anthracotic cirrhosis occurs in coal-miners, in whom the coal-dust may occasionally reach the liver in sufficient quantities to cause a marked connective-tissue formation about the portal canal. (Welch.)

CONGESTION.—(a) Acute infectious diseases. (b) Traumatism. (c) Extension of inflammation,—*e.g.*, from the intestines. (d) Valvular heart-disease. (e) Pressure of tumors. (f) Other mechanical obstructions to the circulation. The condition is most marked when the veins of the liver are closed, as in periphlebitis or Chiari's endophlebitis. (1) The post-mortem appearances of active congestion are not characteristic. The liver is swollen, dark in color, and full of blood; the hyperæmia is not limited to any one portion of the liver substance. (2) In passive congestion the liver is large in size, smooth or slightly granular in outline, and of a distinctly mottled hue. The surface of section presents the characteristic nutmeg appearance (the centre of the lobule being deeper), due to a marked congestion occurring in the central veins, the congested tissues being of a reddish-brown color. This is surrounded by a large area of a pale-yellowish color (fatty infiltration), with a third zone of cellular infiltration and new connective tissue. In rare cases this order is reversed, the congested area occurring at the periphery of the lobe and the lighter or fatty parts towards the centre. In chronic and well-marked cases there may be considerable induration and shrinkage of the liver substance, with irregular surface, so that the hypertrophy gives place to an atrophy, called cyanotic atrophy or Virchow's red atrophy.

EMPHYSEMA.—Portions of the liver when squeezed under water show the escape of bubbles. This condition may be due to putrefaction or to the growth of gas-forming organisms during life.

FATTY CHANGES.—(a) Middle life. (b) Alcohol. (c) Sedentary habits. (d) Infectious fevers. (e) Certain poisons. (f) Cachexias. (g) Interference with local or general circulation. *Classification*.—(a) Fatty degeneration. (b) Fatty infiltration. (1) The liver may be increased or diminished in size. The capsule may be



smooth or wrinkled. The consistence is usually somewhat decreased; the organ is paler than normal and somewhat mottled in appearance. Periphery of lobule is first involved. The surface of section is smooth, usually bloodless, and imparts a greasy stain to the knife. The general color is a dull gray or grayish yellow. (2) In fatty infiltration the liver is often markedly enlarged, normal in outline, smooth to the touch, and of a somewhat pale, excessively fatty color. Globules of fat may be readily expressed with a knife. Hyperæmia may obscure the characteristic appearance.

HEPATITIS, SUPPURATIVE.—Abscess of the liver may be due to: (a) Traumatism. (b) Extension from neighboring organs,—*e.g.*, the bowel and the pleura. (c) Pyæmia. (d) Amœbic dysentery. (e) Malignant emboli. (f) Diseases of veins, as periphlebitis, thrombophlebitis, and thrombo-umbilicalis. (g) Stoppage of bile, as from gall-stone or dead ascarides. (h) Idiopathic tropical disorders. *Classification*.—(a) Pyæmic hepatitis. (b) Portal pyæmia. (c) Pyo-septicæmia or multiple abscess. (d) Tropical or endemic hepatitis. (e) Suppurative cholangitis. (1) In multiple abscess the change in the liver depends upon the number of the abscesses. If these be few, the liver walls may be comparatively little altered; if they are very many, the liver is apt to be enlarged, softened, and friable. The abscesses themselves appear as minute foci which are non-encapsulated, the centre containing a thick white, yellow, or greenish pus surrounded by a zone of congestion. The abscesses may number from five to ten, or many hundreds. These multiple abscesses frequently arise from pyæmic embolism of the portal vein or hepatic artery or vein, or they may result from a cholangitis. They may be generally distributed or appear in clusters. If from a malignant endocarditis, they are usually situated under the capsule. (2) Large abscesses occur in two forms,—the large chronic encapsulated abscess surrounded by a pyogenic membrane and the tropical or amœbic abscess. (See Dysentery.) The large abscess is usually single; there may be two or more. The right lobe is usually affected. There is a distinct limiting membrane. The pus is usually of a greenish-yellow color and often of a disagreeable odor. The surrounding substances often show but few changes, except as the result of pressure.

SARCOMA.—This may be primary (very rare) or secondary. The most frequent variety is the secondary melanosarcoma following sarcoma of the eye, of the skin, or of the penis. In these cases the liver



is greatly enlarged, weighing as much as fifteen pounds, and the secondary nodules, which are of a black or slate color, are usually uniformly distributed throughout the gland. In primary sarcoma of the liver there are but few nodules, and these reach a large size, measuring at times five or six inches in diameter. Metastases to other organs often occur, though other portions of the liver may escape.

OTHER TUMORS.—In addition to carcinomata and sarcomata, the liver is the seat of adenomata, adenocystomata, angiomas, fibromata, and aberrant adrenal tumors similar to those found in the kidney. The cavernous angiomas are usually small in size and, when found, are usually seen on the surface of the liver in elderly persons. They may be injected with colored material by means of any of the hepatic blood-vessels, and then form excellent microscopic specimens for future study.



## CHAPTER XV

### EXAMINATION OF THE SKULL AND BRAIN

THE body is placed in the supine position on the side of the table nearest the operator, the head, elevated by a block placed under the neck and occiput, projecting slightly beyond the end of the table. If the cadaver be in a coffin or box, it may be drawn to the upper end thereof, the head being raised and placed upon a board laid across the top, the back supported by a head-rest, a block of ice, or any convenient bundle of rags or paper. Of the various forms of support employed, the Cornell head-rest (Fig. 37) is peculiarly well adapted for holding the head steady.

Note any anomaly in the size or shape of the head. (See page 270.) The scalp should be subjected to the same careful preliminary scrutiny for evidences of disease or injury, remote or recent, as the other parts of the body. It is then divided by an incision extending from one mastoid process to the other (Fig. 109), passing over the vertex when the hair is abundant and about midway between the vertex and the external occipital protuberance when it is thin. If the hair be long, it should be parted along the proposed line of incision, in order that as little of it as possible may be cut (Fig. 110). For the same reason and to guard against damage to the knife, the cutting edge of the scalpel or cartilage-knife should be directed from the skull when the scalp is being cut. When all the tissues overlying the skull have been separated by force, the scalp is reflected backward and forward; the calvarium may be exposed from the occiput to or slightly beyond the frontal eminences. The eyes and nose should be protected by pledgets of cotton placed beneath the anterior flap. Care should be taken to avoid tearing the scalp at the extremities of the incision behind the ears, especially if the posterior incision with a large anterior flap be made. Indeed, it is for this reason that the incision should begin and end behind and not in front of the ears, for a tear behind the ear would hardly be noticed, while one in front would cause considerable disfigurement. The scalp may be so adherent to the cranium as to necessitate its removal by dissection with the knife or scraping with a chisel. Whatever instrument is used, guard against its slipping, lest



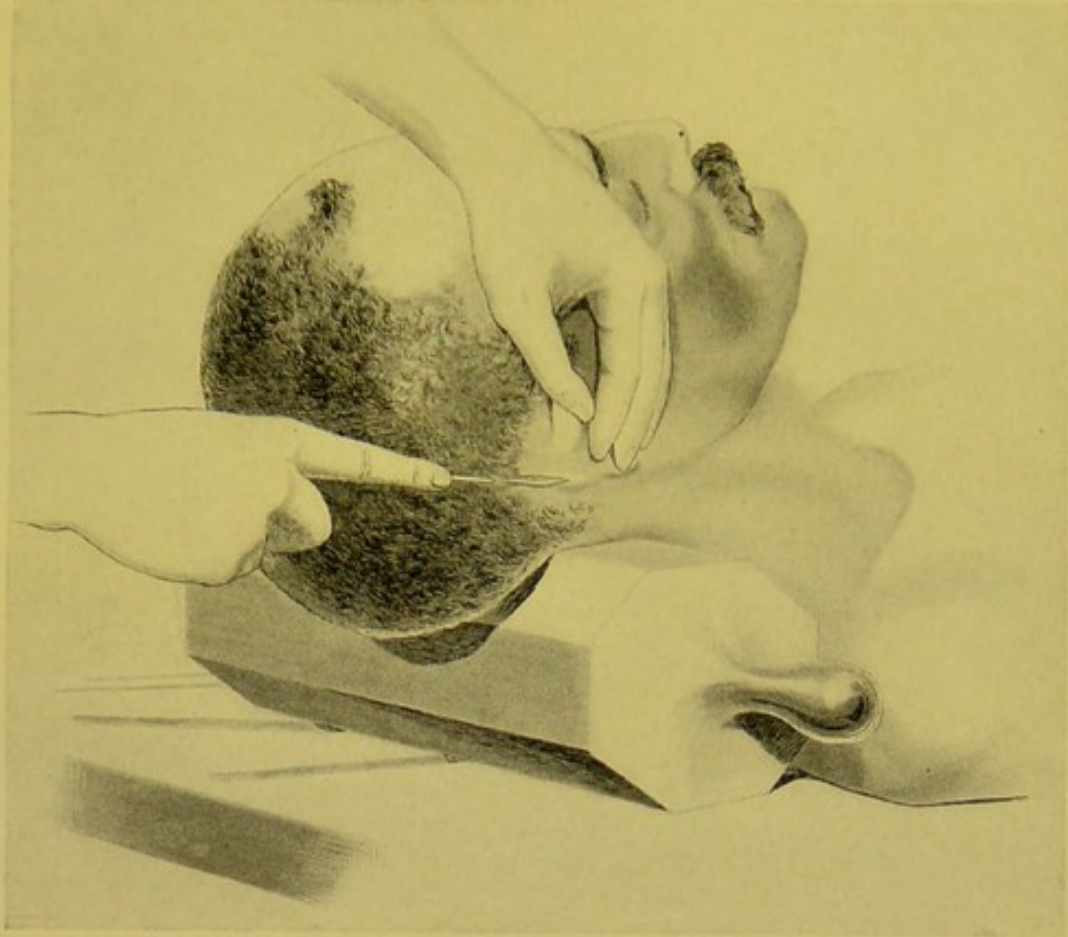


FIG. 109.—While the right ear is held back with the left hand an incision is started directly over the mastoid process. The remainder of the incision over the vertex will be made from within outward, thus avoiding dulling the knife and cutting the hair.

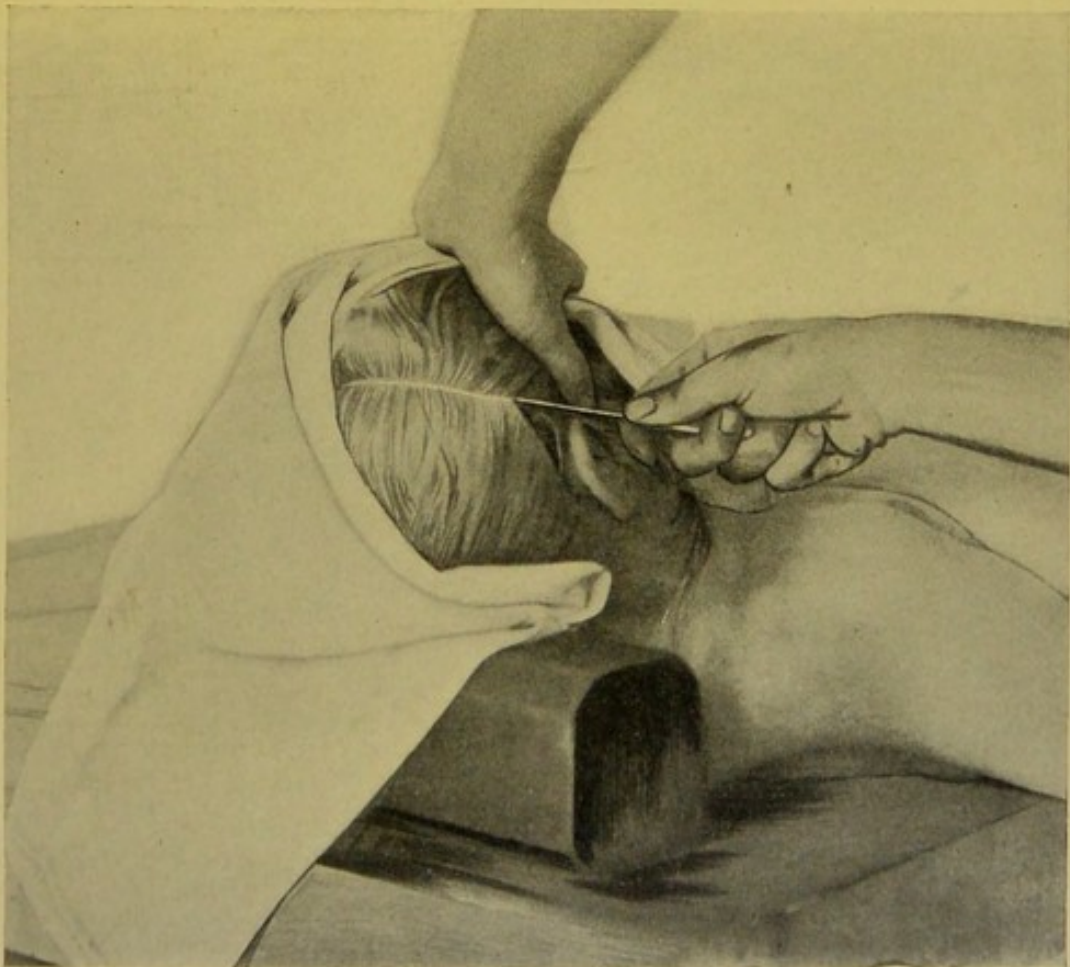

FIG. 110.—After the initial incision behind the ear, the hair is parted when it is long, so as not to injure it.



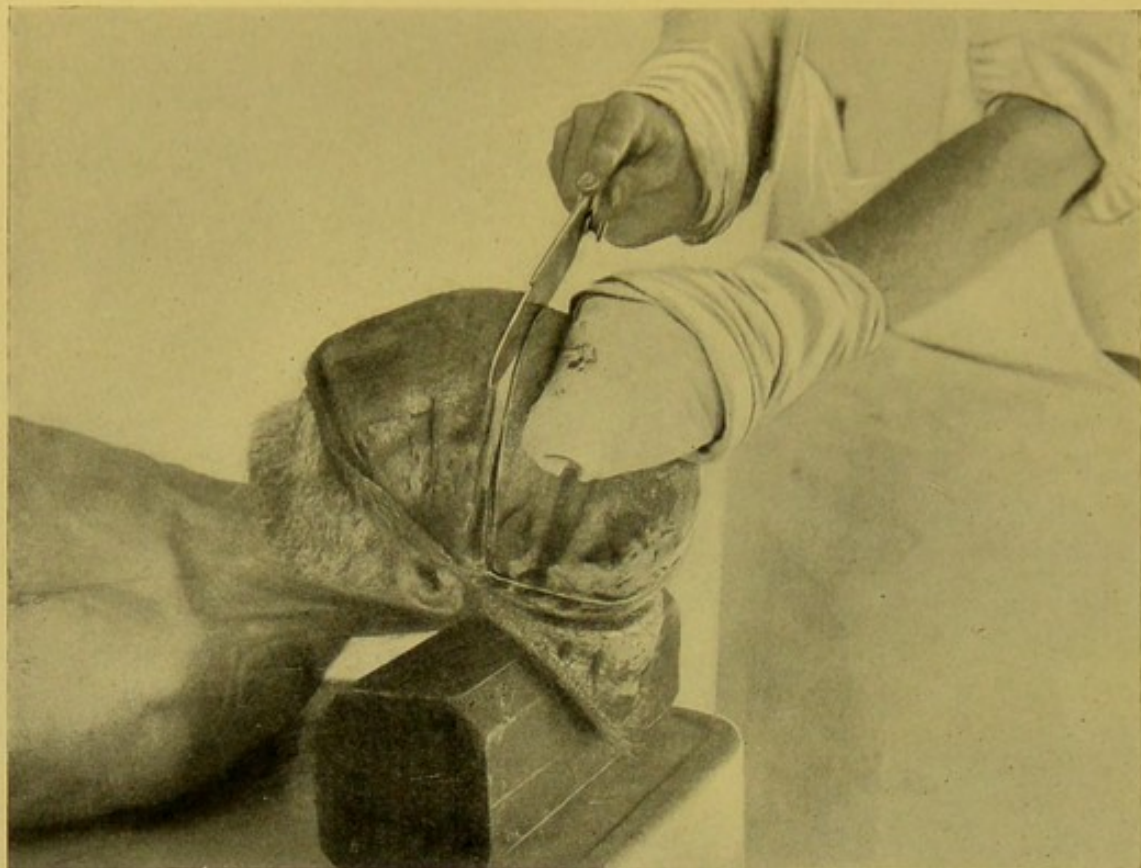


FIG. 111.—Method of sawing the skullcap. The temporal muscle has been cut through with a knife in the direction of the future sawing, and a pencil mark shows the posterior line along which to saw. The hand is protected with a towel.

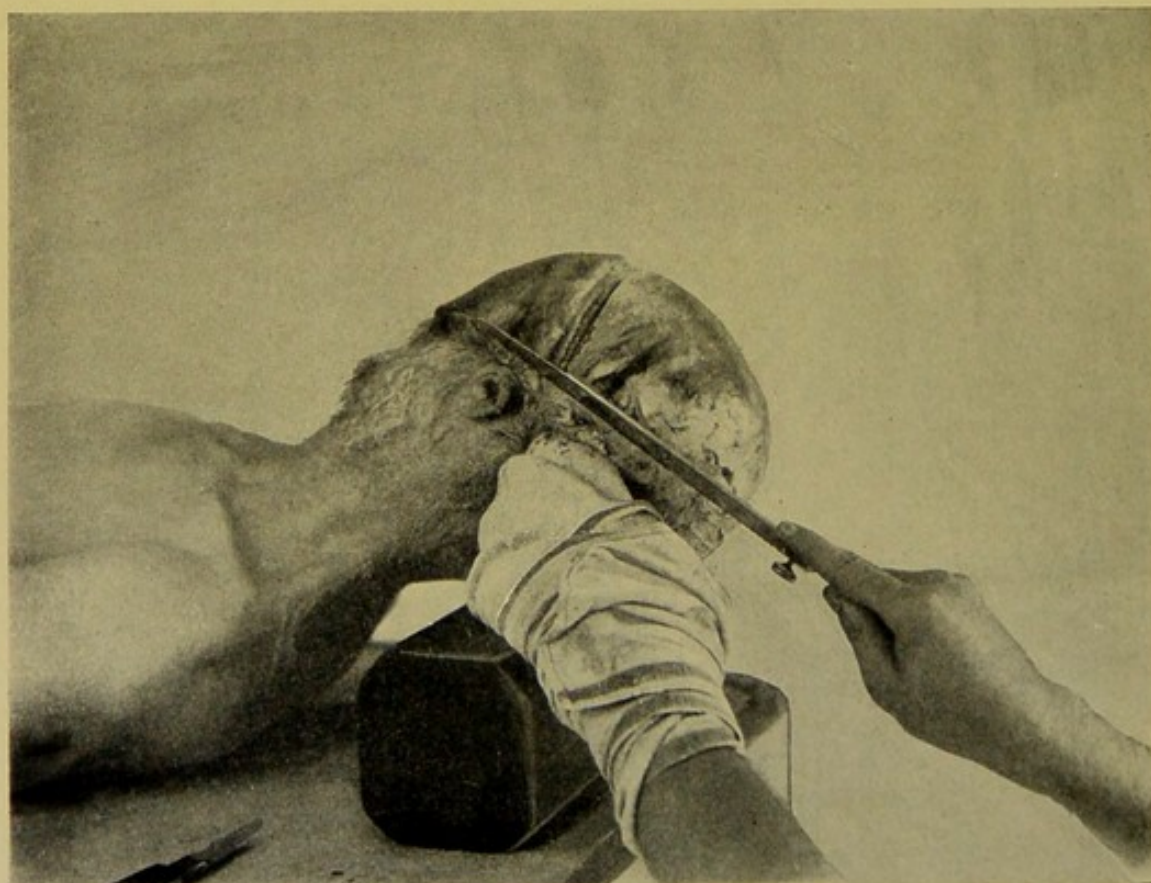


FIG. 112.—Angular method of removing the brain. The saw markings in each case pass close to the ear and meet an inch or so above it. The left hand is covered with a towel to protect it from injury.



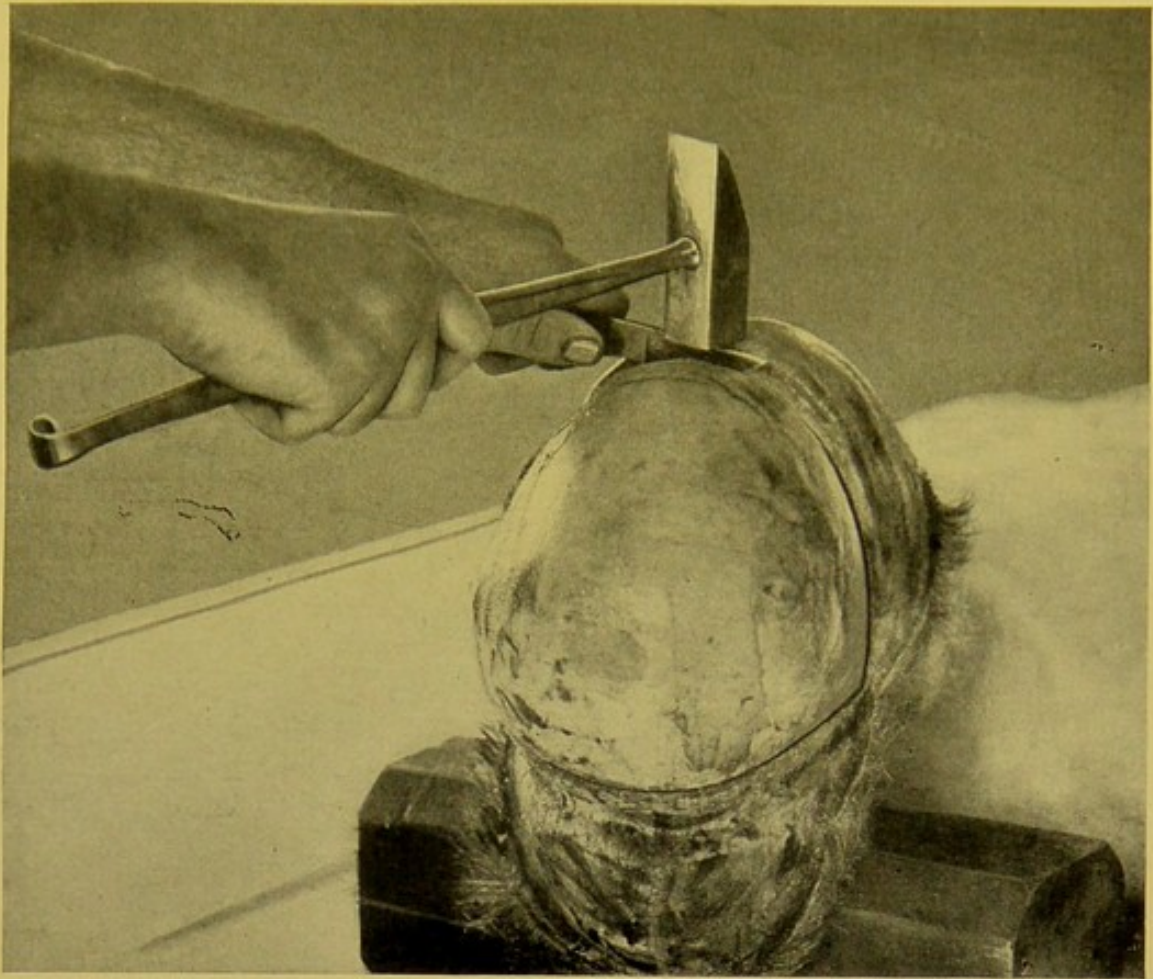


FIG. 113.—Method of breaking up the inner table with an old knife after sawing. (There are also various forms of chisels made especially for this purpose.)

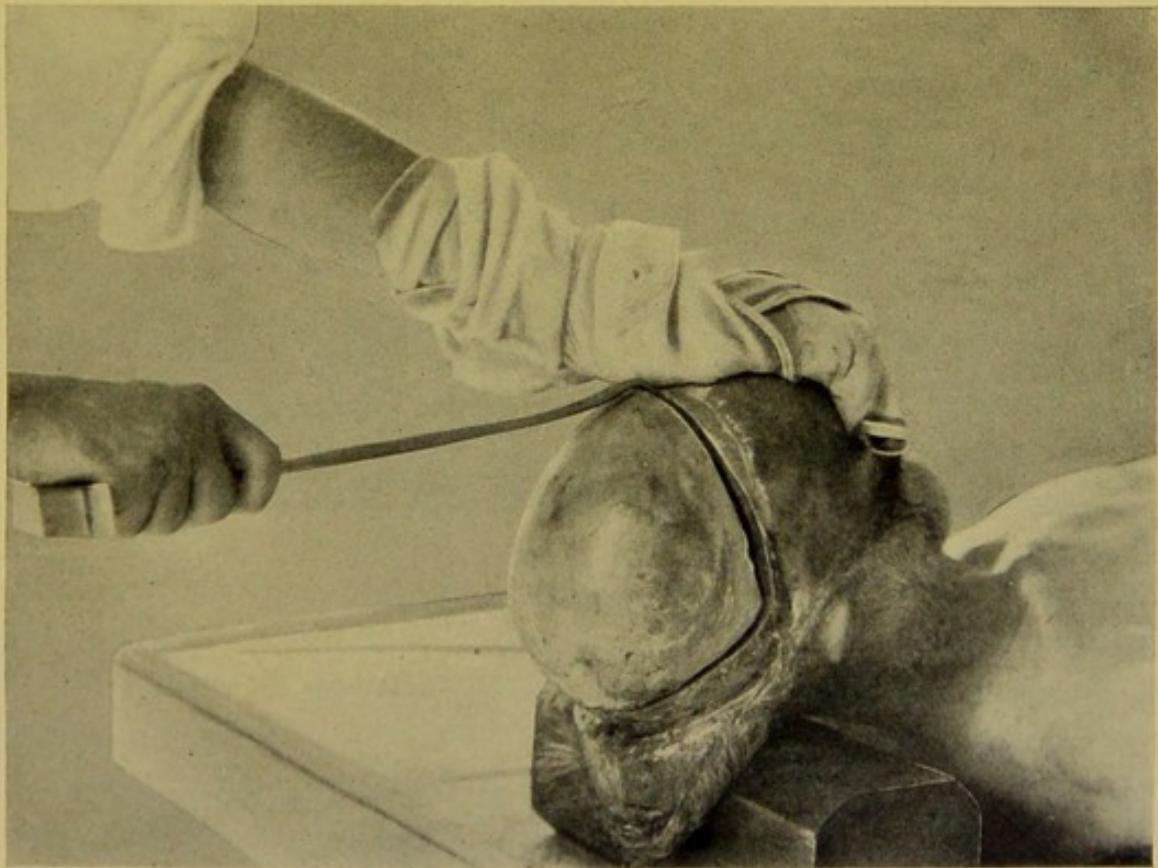


FIG. 114.—Method of drawing off the skullcap with a retractor after the sawing is completed.



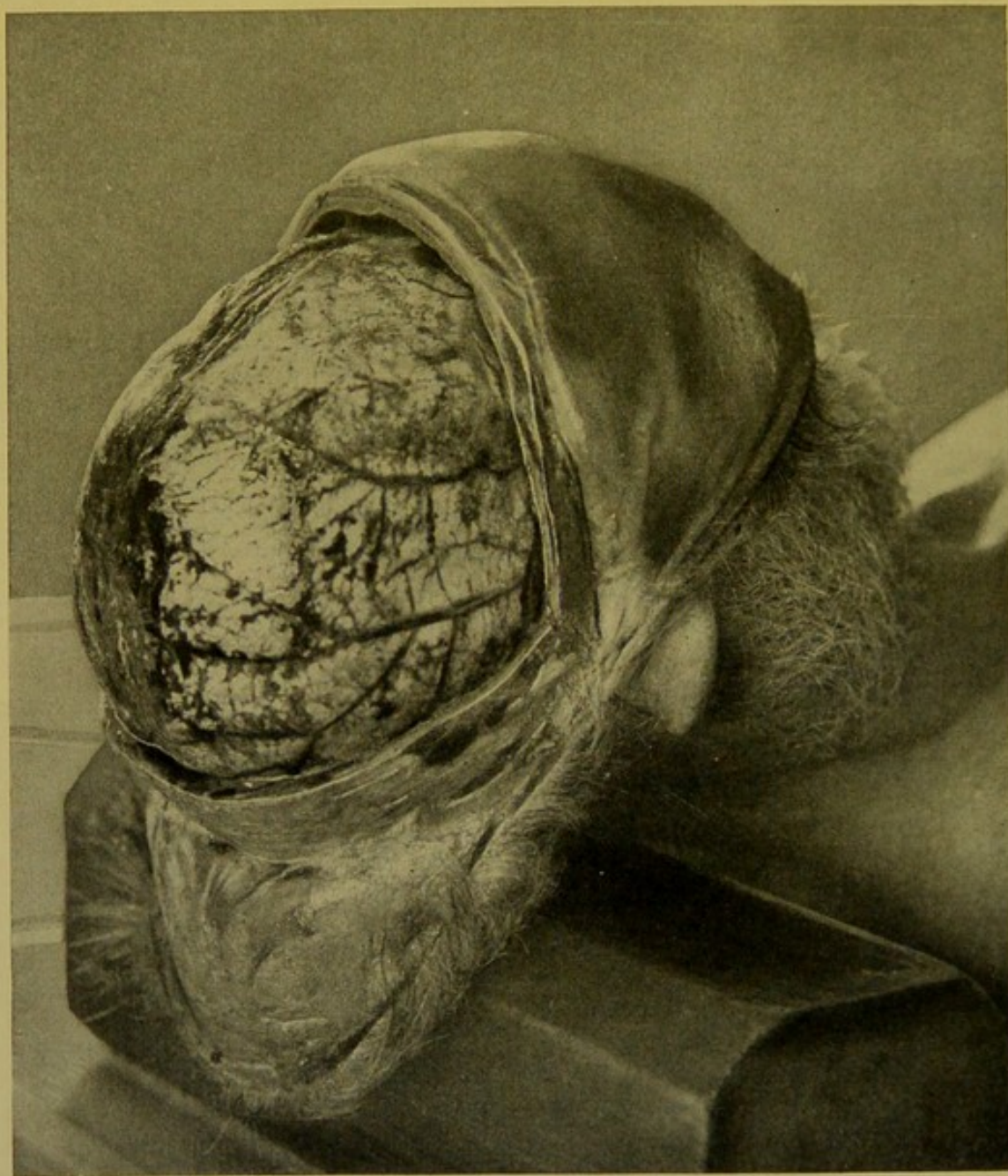


FIG. 115.—Appearance of the dura mater after removal of the calvarium, showing the superior longitudinal sinus and the meningeal vessels.



injury be done to the operator or to the subject. Avoid undue traction of the scalp, which would cause it to present a baggy appearance when replaced.

The skull should next be examined in detail. Fractures and other evidences of injury may now be revealed which could scarcely have been discovered in the preliminary examination. Note should be made of the presence of atrophy, hypertrophy, or softening of the bone, of premature or delayed synostosis and supernumerary bones, of tumors, syphilitic or tuberculous abrasions or openings, marks of previous trephining, of asymmetry and abnormal coloration, the "greenish-yellow" discoloration due to osteomyelitis or the "citron-yellow" due to tertiary syphilitic lesions, etc. (For cranial measurements and pathological types of skull see page 270.)

There are two methods of removing the calvarium,—the angular, in which the skullcap is sawed in two intersecting planes meeting behind the ear, and the circular, in which the bone is divided in a single plane. The former method is usually to be preferred, as it permits more secure reposition of the skullcap, but the latter is easier of application and will, therefore, be considered first.

**THE CIRCULAR METHOD.**—The path of the saw, which may be marked with a pencil or the point of a knife, traverses a plane cutting the skull from half an inch to an inch above the glabella anteriorly, an inch or an inch and a half above the external auditory meatus laterally, and passing just above the inion posteriorly. This line will cross the temporal muscles obliquely, and they and their fascia should be divided with a knife instead of the saw, in order that their edges may be accurately approximated for suturing when the skullcap is replaced.

Sawing the skull is no easy task; it may be greatly facilitated by the employment of an electric or dental engine. For this part of the operation it is a decided advantage to be ambidextrous. While the sawing is being done with one hand, the head must be steadied with the other, placed either on the vertex or on the face and protected by a towel, for the saw is liable to slip, especially when first applied. The scalp, especially of a female, should be protected from "sawdust" by wrapping towels about it. Proffered assistance should be declined, because, while it is natural to look out for one's own fingers, it is impossible effectively to guard another's. The reason I often give for not accepting aid is that "I am reasonably supposed to know



where my hand is, but not where yours may be." The saw may be carried entirely through the bone or, better, only to the inner table, this being divided with chisel and hammer. In no case, however, where it is suspected that the skull may have been fractured should the latter procedure be adopted, as the force of the blow required might be sufficient to split the bone. While a post-mortem fracture may be recognized by the absence of extravasated blood, the enlargement of a pre-existing fracture is more difficult to differentiate. A receptacle should be placed beneath the head to catch the cerebro-spinal fluid and the blood that escape when the skullcap is removed and the meninges are opened, and care must be taken to prevent spattering. The calvarium is loosened by twisting a chisel or the sharp end of a hammer in the kerf, and removed with a blunt hook. If instead of an instrument the fingers be used for the purpose, they must be well protected, as they are liable to slip and be abraded by the sharp edges of the bone. Traction should be made steadily and not in jerks, lest from a sudden giving way the calvarium be damaged by falling on the floor or surrounding objects be soiled by being splattered with blood or other fluid. When, as is sometimes the case, the calvarium does not readily yield to traction applied in front, it may often be easily detached by inserting the hook posteriorly. If the dura be adherent, as not infrequently happens in cases of chronic alcoholism, old injuries, or sunstroke, it may be loosened with a blunt instrument, or it may be divided along its margin with a pair of blunt-pointed scissors or a curved, probe-pointed bistoury cutting from within outward, the falx cerebri being incised close to the corpus callosum. In children under seven years of age this must always be done, as up to this time of life the dura is normally adherent to the osseous structures of the skull.

THE ANGULAR METHOD.—In this method the skull is sawed in two planes which by their intersection form an obtuse angle at a point a little below and slightly posterior to the apex of the ear. Always try to saw above the line of the hair in front. Although this makes the anterior fossa deeper and consequently the removal of the brain more difficult, it obviates the ugly ridge on the brow so liable to be made by the inexperienced. It is necessary too that the angles be well sawed through and carefully broken, because if spicules of bone remain the brain may be caught and injured during its removal. (For this method of opening see Figs. 111 to 114 inclusive.)



In the French method of opening the adult skull with a hammer,<sup>1</sup> the anterior and posterior flaps are made in the usual manner. A line one centimetre above the soft tissue is drawn around the skull, the temporal muscles being cut through with a knife; by means of blows with the hammer the skull is then fractured along this line. This method is much employed in France and in the hands of experienced operators gives good results. It must not be used in children, in cases of fractures, bone lesions, etc. The dura is opened along the circular incision, or, more frequently, crucial incisions are made on either side of the longitudinal sinus and each side is incised by a perpendicular cut running from the vertex down to the upper margin of the bone. The four pieces are then turned down and the falx cerebri is cut anteriorly just behind the crista galli and pulled backward.

The thickness of the skull is next noted. It varies much, being usually greater in negroes and, at times, in syphilitic subjects. It also varies in different parts of the same skull, being thinnest in the temporal region and thickest at the occiput, and is often unequal in corresponding points of the opposite sides. Thin spots are readily detected by holding the calvarium to the light. The diploe may be entirely absent in some places, in which case the bone-dust will lack the reddish color commonly observed in recently sawed bone. The skull is usually from two to six millimetres thick. In rare cases the frontal sinus may extend high up and be of unusual thickness; in one of my subjects it measured half an inch across at the top after removal of the calvarium in the usual manner. Note the relations of the external table, internal table, and diploe. Pay especial attention to the amount of blood in the latter; if abundant, suspect fracture. At times it is entirely bloodless. The skullcap should be held up to the light so that any inequality in its thickness may be perceived. The Pacchionian granulations often give rise to small nodular depressions in the inner table, which are of course perfectly normal and should not be mistaken for pressure atrophy. They sometimes cause perforation of the bone.

The grooves of the middle meningeal artery must be looked for on each side. In one of my cases of acromegaly the inner table resembled worm-eaten wood; the bone was soft and pliable and offered no resistance to the saw. It is necessary to be familiar with the normal

---

<sup>1</sup> J. DEJERINE, *Anatomie des centres nerveux*, 1895.



yellowish-gray color of the inner table in order that changes in it may be readily detected. Whenever blood is found between the inner table and the dura, careful search must be made not only in its vicinity but also on the opposite side for a fracture by *contrecoup*. In the examination of the dura mater note its thickness, the degree of distention, its color, which is normally gray and never very red, and the amount of blood contained within it. As all liquid naturally gravitates downward, those portions of the dura which cover the most dependent parts will be most distended, unless, as often happens, an injury of this membrane has allowed the fluid to escape.

The arteries lie between the two veins. The larger arteries usually contain more blood than the veins. The dura is supplied with but few capillaries and these rarely become inflamed.

In the examination of the outer surface of the dura mater (Fig. 115) note alterations in color and gloss. The latter is often lost in consequence of tumors, hemorrhage, hydrops, abscess, and other conditions that cause increase of intracranial pressure. Search for hemorrhages (which at times are profuse and depress the brain) and their points of origin, Pacchionian bodies (which must not be mistaken for tubercles), bulging tumors, and external pachymeningitis (ossified, purulent, syphilitic, or tuberculous), etc. The degree of tension due to fluid, etc., may be determined by puncture or by pinching up the dura.

The brain may be exposed, but not dissected, before the heart is incised, as the quantity of blood in the cerebrum may be modified by venous oozing during the examination of the thorax. If the brain is to be injected, it is best not to remove the dura, as by its detachment usually some of the veins entering the longitudinal sinus are torn, and this permits the escape of the injecting fluid when under pressure. It has been shown that this operation can be performed without external disfigurement while the brain is *in situ* by forcing the fluid through a cannula introduced by way of the nostrils or the orbits.

The longitudinal sinus is opened throughout its entire length with a pair of probe-pointed scissors, and the condition and quantity of the contained blood are noted.

The dura is divided parallel with and slightly above the sawed edge of the skull, with a pair of blunt-pointed scissors, which may be introduced through a chance nick made by the saw or through an opening made with a knife for the purpose. The incision is carried completely



around the skull except at the poles of its anteroposterior diameter, where it is necessary to sever the falx cerebri. The arachnoid surface of the two lateral flaps of the dura may be examined by reflecting them to one side. The character of the blood in the membranes of the brain and in its cortex, the fluid in the subarachnoid space, the character of the sulci and convolutions, and the presence of lymph are all to be noted.

To detach the falx grasp both folds of the frontal dura with the left hand, and with the right insinuate the blade of a knife along the outer face of the left fold of the dura to its attachment to the ethmoid bone. This is severed by turning the cutting edge of the blade inward towards the falx and detaching it along the line of its insertion from before backward, as near the crista galli as possible without injury to the olfactory bulbs. As the knife reaches to the anterior genu of the corpus callosum, the index-finger may be gently introduced into the longitudinal fissure so that a view may be had of the portion to be cut. It is no unusual thing to leave behind a thin strip of the dura just above the corpus callosum, which mistake may cause annoyance to the operator or injury to the brain during its removal.

The dura may now be drawn backward and cut off posteriorly or left *in situ* (Fig. 116). The portion of the pia mater dipping down to the genu and splenium of the corpus callosum may be detached with forceps, and that overlying the surface of the cerebrum with the fingers. The handling of this delicate membrane can be greatly facilitated by allowing a stream of water to flow gently over it during its removal. The pia is colorless when normal, but may be gray or grayish white when thickened, yellow when pus is present, or red from hyperæmia or hemorrhage.

The anterior extremities of the frontal lobes are gently raised with the tips of the fingers of the left hand, and any remaining shreds of dura are severed to prevent injury to the cerebral tissue in the frontal region or corpus callosum. With the handle of a scalpel the olfactory bulbs are now shelled from the grooves in the cribriform plate of the ethmoid bone in which they lie, and the entire brain is gently turned outward while supported by the left hand. The various nerves and vessels are then divided, as near as possible to their respective foramina, with a sharp, narrow-pointed scalpel, always cutting towards the bone. First the ophthalmic artery and optic nerve are severed close to the optic foramen. Then the dura enclosing the pituitary body is cut



with a sharp knife near to the bone (*sella turcica*) at all points except posteriorly near the *infundibulum*, great care being taken not to injure the delicate *hypophysis*, which then may be shelled out and the remaining portion of the *dura* behind be excised with scissors. The internal carotids are cut long, especially if the brain is to be injected. As the *temporosphenoidal* lobe leaves the middle fossa of the skull, the *tentorium cerebelli* is divided with blunt-pointed scissors, or a knife with a broad flat back made especially for this purpose, along the superior border of the petrous portion of the temporal bone, preferably passing from the median line towards the sides. In making this incision care must be taken not to injure the *cerebellum*.

The brain mass being now supported on the left hand, cut the cord as low down as possible by a transverse incision. *Pick's myelotome* is a very convenient instrument for this purpose. *Orth* thrusts the knife through the centre of the cord and severs first one side and then the other. Any attachments of the spinal cord and medulla can readily be loosened by introducing the forefinger into the cavity of the spinal column and through the *foramen magnum*. Of course, if the cord has already been removed, it remains only to cut the vertebral vessels.

The brain is now entirely free, but the *cerebellum* still remains in the posterior fossa, from which it is best removed by holding it firmly to the cerebrum with the fingers of the right hand and turning the brain first to one side and then to the other (Fig. 117). A towel previously rolled up into the form of a turban makes an excellent temporary resting-place for the inverted brain.

During this entire procedure, which has taken longer to describe than it does to perform, the secant has been searching the exposed parts for any lesions or abnormalities, as their presence may modify subsequent processes.

Examine the external surface of the brain, the adherence of the *pia-arachnoid* being tested in several places, not forgetting the fourth ventricle, the circle of *Willis*, and the course of the middle cerebral artery lying in the fissure of *Sylvius*. With the latter the island of *Reil* and the *retroinsular* convolutions are also exposed.

#### INTERNAL EXAMINATION OF THE BRAIN.

The brain may be sectioned either immediately upon its removal or after first being hardened, each method having its advantages. If an immediate diagnosis is required or colleagues are present to give



unusual interest to a discussion of the findings, the sectioning will probably be done at once. If any hemorrhagic lesion is suspected, it is more conspicuous in the recent state, and a wholly unexpected bacteriological investigation might be demanded by the revelations of the incisions. If none of these considerations prevail, the brain is hardened in a medium which will not interfere with any microscopical work that may be desired after the sectioning. Since hardening in certain fluids is necessary for certain stains and entirely precludes others, we must first of all decide what staining methods will be used before a choice of hardening fluids can be made. A two and one-half per cent. solution of bichromate of potassium or Müller's fluid will develop color contrasts between the white and gray matter and furnish material for Weigert and Golgi work, but the later methods for ganglion cells and neuroglia are precluded. Formalin is suitable for all special staining methods, including Nissl's, though the best results are obtained when the tissues are hardened in alcohol.

The brain may be hardened entire in a ten per cent. solution of formalin in a week or ten days and be suited for general topographical work. For finer histological methods the parts should be serially incised, the sections being not more than three millimetres thick and remaining *in situ*, or, if the material to be studied is not superficial, the brain may be incised according to the methods herein to be given and then hardened. The advantages of hardening the brain in most pathological cases are so obvious that they do not require mention. It should always be done unless contraindicated, and when the fresh brain is sectioned and examined, the incisions should be so made that all the segments will fold together like the leaves of a book,—uninjured, undisturbed in their structural relationship, and fit for the most exhaustive microscopical examination.

Whether the brain is sectioned first or after hardening, the choice of a method will be somewhat determined by the situation of the lesion and the desire to preserve intact all its structural relations. Morbid changes in the cortex which we might wish to trace down through the internal capsule would be studied only with the greatest difficulty after sectioning by Meynert's method, whereas if the lesions were bulbar or situated anywhere in the brain-axis this method would be very advantageous, since it permits of examining the whole of the brain-axis by serial sections.

The centrum ovale is well studied by Pitres's method, but future



microscopical investigation is impossible. The same is true of Nothnagel's method, and to examine lesions of the internal capsule we must have horizontal sections. For exposing suspected or unsuspected lesions, for gaining a good idea of the general condition of the brain, and for ease and rapidity of routine work, probably no method is more useful than that of Virchow. Unfortunately, it does not favor microscopical examination and therefore is rather sweepingly condemned by some authors.

Dejerine makes a special effort so to section the brain that it may be sufficiently exposed without in any way interfering with future investigation.

**VIRCHOW'S METHOD.**—A long, sharp knife should be used in the dissection, which should be kept clean and moist by frequent washing, so that the cut surfaces will be even and smooth. A dull knife tears the brain substance more or less, thus distorting the delicate structures. Virchow insisted strongly upon the necessity of a long, clean, smooth incision being made at one stroke, and said that he would rather have a wrong incision rightly made than a right incision wrongly performed.

The brain is placed on its base with its occipital lobe towards the operator. Laying the left hand upon the left hemisphere, with the thumb in the longitudinal fissure and the fingers upon the convexity, raise this hemisphere slightly and pull it away from the median line so as to expose the corpus callosum. Insert the point of a thin narrow knife into the roof of the lateral ventricle, which lies immediately below the corpus callosum, well forward and two or three millimetres externally to the median raphe of the corpus callosum (Fig. 118). Make a concave incision—concavity directed outward—through the roof back to the posterior cornu, being careful not to injure the floor of the lateral ventricle. Note the character and quantity of fluid present, which normally is perfectly clear and about three cubic centimetres in amount. Connect the two extremities of the first incision by a second and third incision meeting at an angle of 45 degrees just outside the basal ganglia. In this manner the greater portion of the cerebral cortex on the left side will be removed away from the basal ganglia for future sectioning (Fig. 119). The right hemisphere may be turned half around and sectioned in the same way.

The knife is then introduced into the foramen of Monro and the anterior fornix is brought forward, exposing the vela interposita and



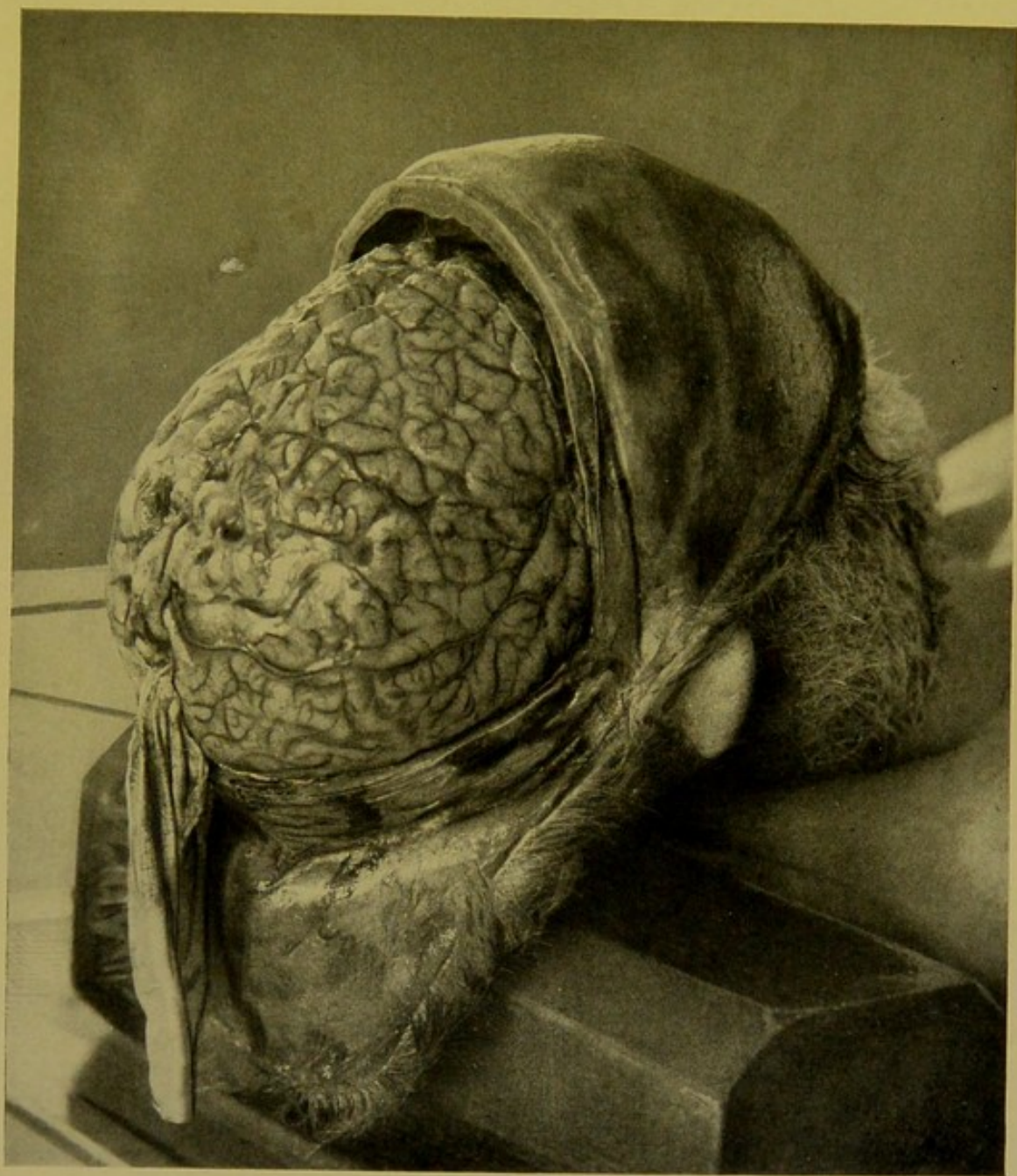


FIG. 116.—Appearance of the brain after removal of the dura, which has been left attached to its posterior extremity.



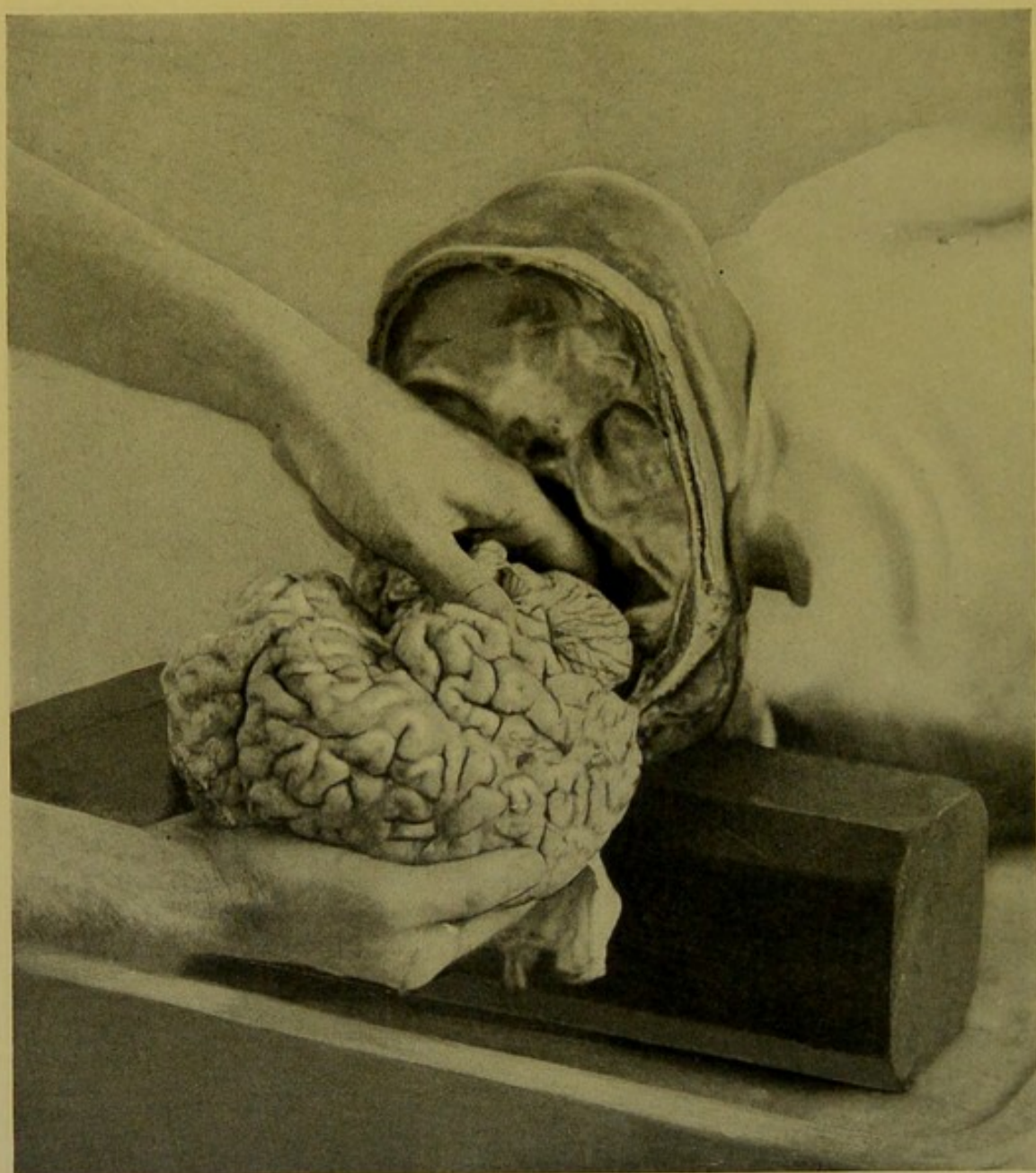


FIG. 117.—Method of removing the brain after it is severed from the body.



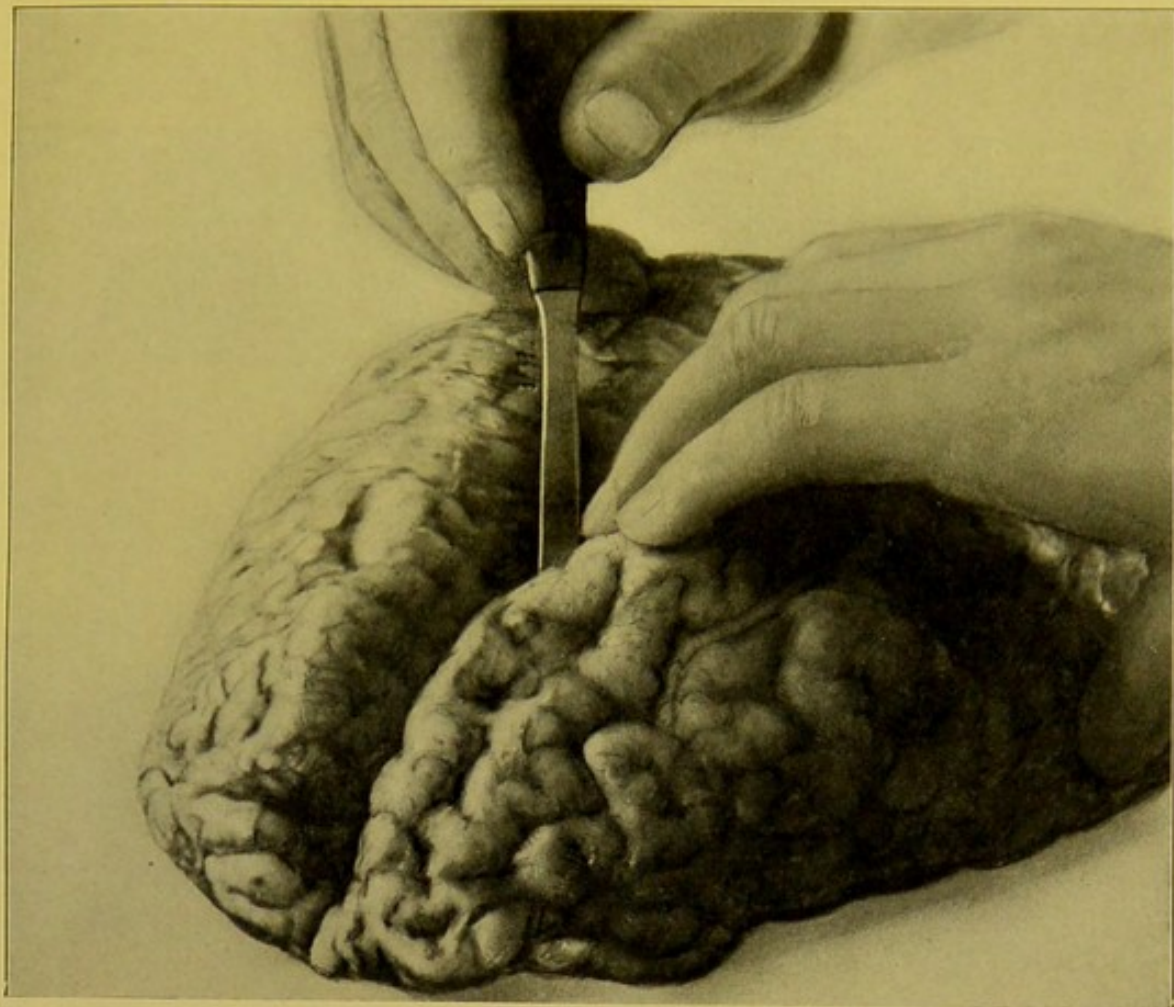


FIG. 118.—Dissection of the brain; commencement of initial incision.

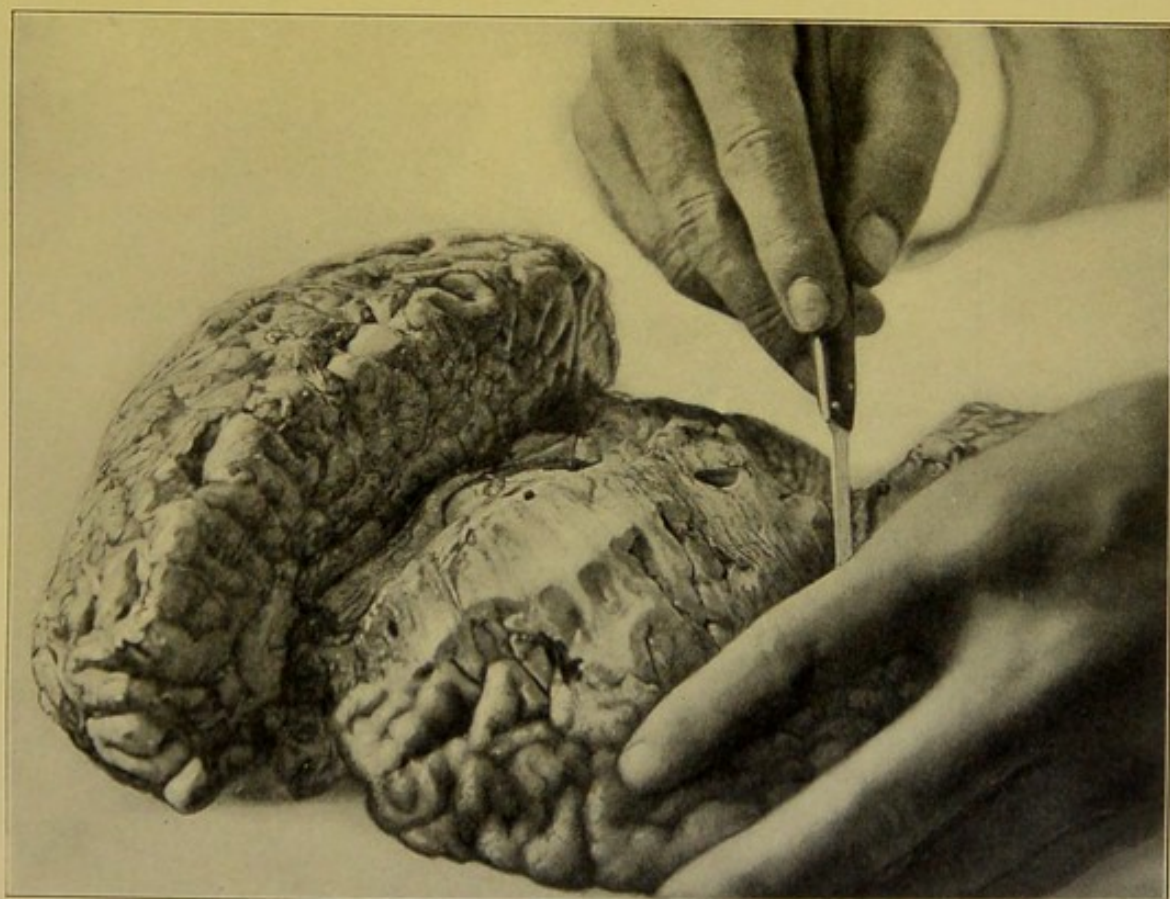


FIG. 119.—End of initial incision.



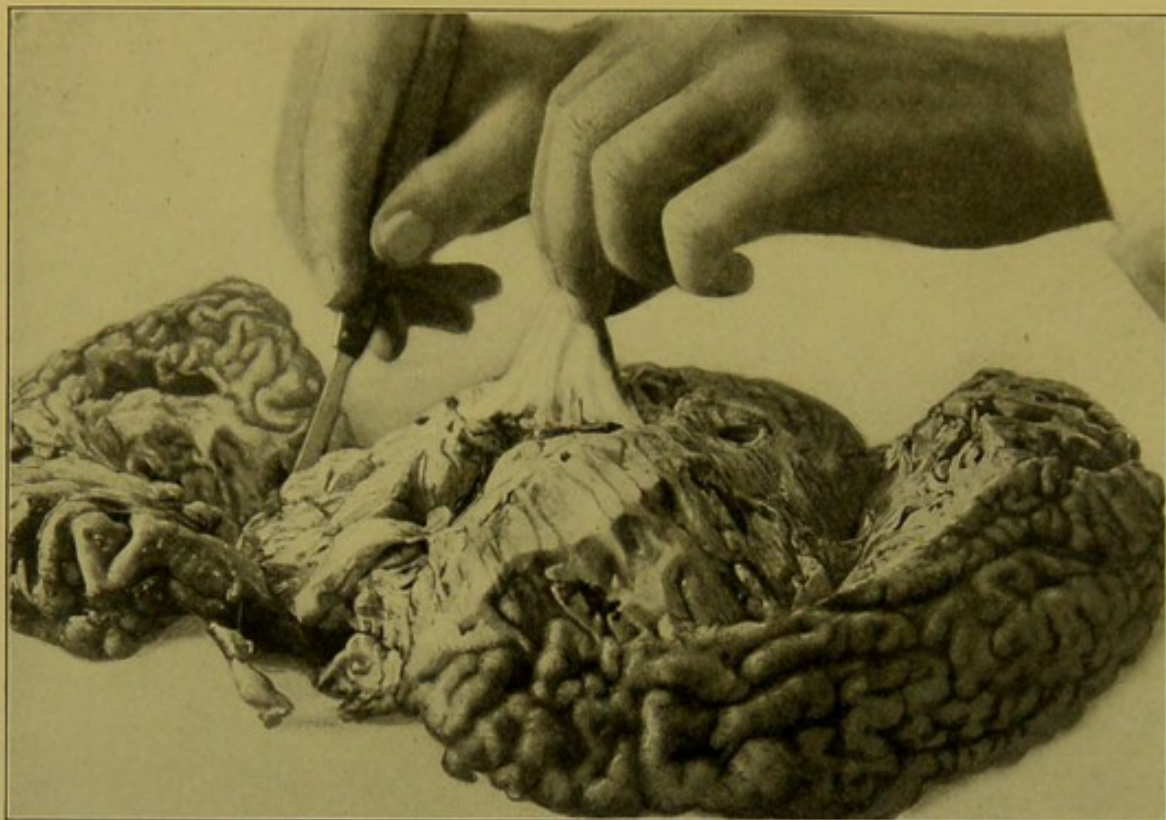


FIG. 120.—Exposure of the central portions of the brain.

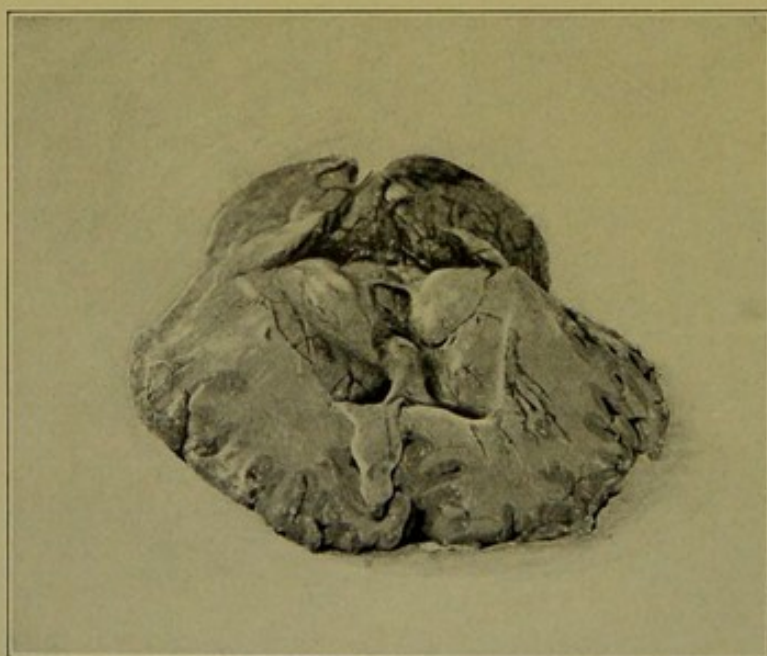


FIG. 121.—Central portion of the brain with the cerebellum, pons Varolii, and medulla oblongata still attached.



the choroid plexuses, which with the body of the fornix are carried back, thus exposing the third ventricle (Fig. 120). Then examine the corpus fimbriatum, the lyra, the anterior, posterior, and middle commissures, the corpora quadrigemina, the pineal body, and the commencement and lumen of the *iter a tertio ad quartum ventriculum*. If it be desired to examine the fifth ventricle, an incision is made directly in the median line into the septum lucidum, parallel to the corpus callosum, the anterior fornix being elevated by the left hand and thus put on a stretch.

The crura are then severed by transverse incisions joining at about a right angle in the median line. The cerebellum, the medulla oblongata, and the pons Varolii are next to be removed. After examining for dilated veins, tumors, and cysticerci, transverse incisions are made in the cerebellum on one side through the centre of the arbor vitæ, and then on the other side. The cerebellum may, however, be removed before these incisions are made by severing the medulla oblongata and the pons Varolii, and dividing the cerebellar hemispheres in the median line into two parts. The pons, the medulla, and the commencement of the spinal cord may now be cut transversely, by incisions one-fourth to three-eighths of an inch apart, and all pathological changes carefully noted, but these portions are preferably hardened previous to examination, which is best accomplished by the preparation of serial sections. (Figs. 121 to 126 inclusive.)

Both Nauwerck and Orth, before making transverse sections of the pons and medulla, fold the sections of the brain together as you would the pages of a book in order that it may be turned. Then, pushing the fingers of the left hand under the pons and medulla, the transverse cuts may be made. In case of tumors or metastatic conditions simpler methods may be used; thus, only one longitudinal or one transverse section may be made through the diseased as well as the healthy tissue, while the arachnoid is left intact.

MEYNERT'S METHOD, SLIGHTLY MODIFIED BY BLACKBURN.—The brain is placed with its base upward and the cerebellar end towards the operator. The cerebellum is elevated and the pia mater cut through above the corpora quadrigemina, around the crura, and along the inner margins of the temporal lobes until the middle cerebral arteries are reached. The Sylvian fissures are opened to their entire extent, the opercula are raised, and the insular lobes exposed to their limiting furrows.



The apices of the temporal lobes are now elevated, and, with the knife held nearly horizontal, their junction with the base is cut through until the anterior extremities of the descending cornua are opened. The knife is inserted in the descending horn, and the incision is carried backward as far as the posterior angle of the insula, or even some distance beyond it, severing some of the convolutions at the posterior extremity of the Sylvian fissure.

The next incision is made to separate the basal piece from the posterior extremities of the frontal lobes. It connects the anterior

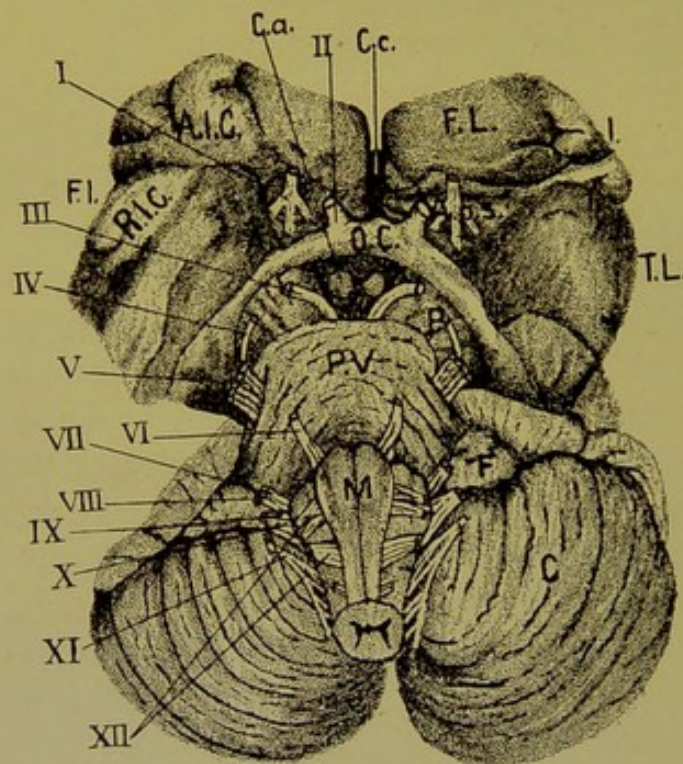


FIG. 127.—Basal ganglia, with cerebellum, pons Varolii, and medulla oblongata attached, in Meynert's method of dissecting the brain. The twelve cranial nerves are shown. *C*, cerebellum; *F*, flocculus; *M*, medulla; *P.V.*, pons Varolii; *T.L.*, temporal lobe; *F.L.*, frontal lobe; *P*, peduncles; *C.a.*, corpora albicantes; *C.c.*, central commissura; *R.I.C.*, retroinsular convolution; *O.C.*, optic commissura; *P.S.*, posterior roots of olfactory; *I*, insula. (After Dejerine.)

boundaries of the islands and opens the anterior horns of the ventricles. The incision may be a slightly curved, transverse one, connecting the anterior border of the islands; or, by a little care and a double crescentic cut, the exact boundaries of the convolutions may be followed.

The cerebellum is now raised, the knife entered at the posterior angle of the island, and the incision carried along the outer limiting furrow until it meets the cut previously made through the anterior border. Care must be taken to keep the knife in the angle between the



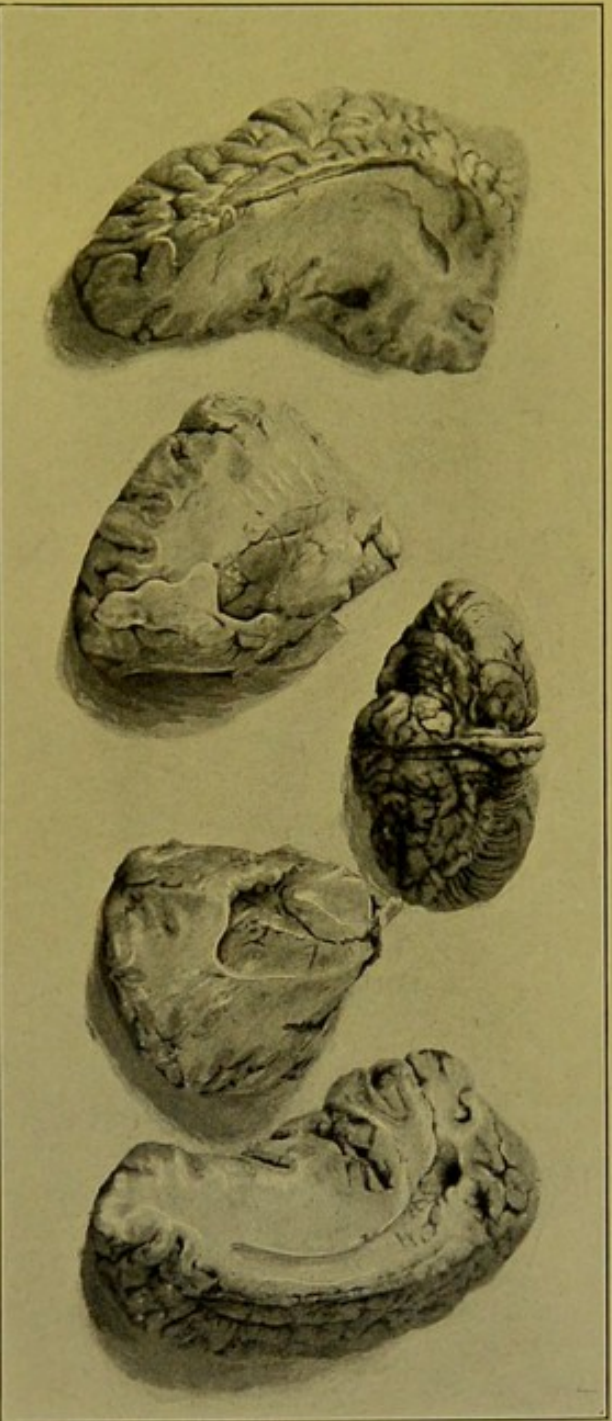


FIG. 122.—Segmented brain. The central portion has been divided into two parts. The cerebellum, pons Varolii, and medulla have been everted with the right and left cortical portions.



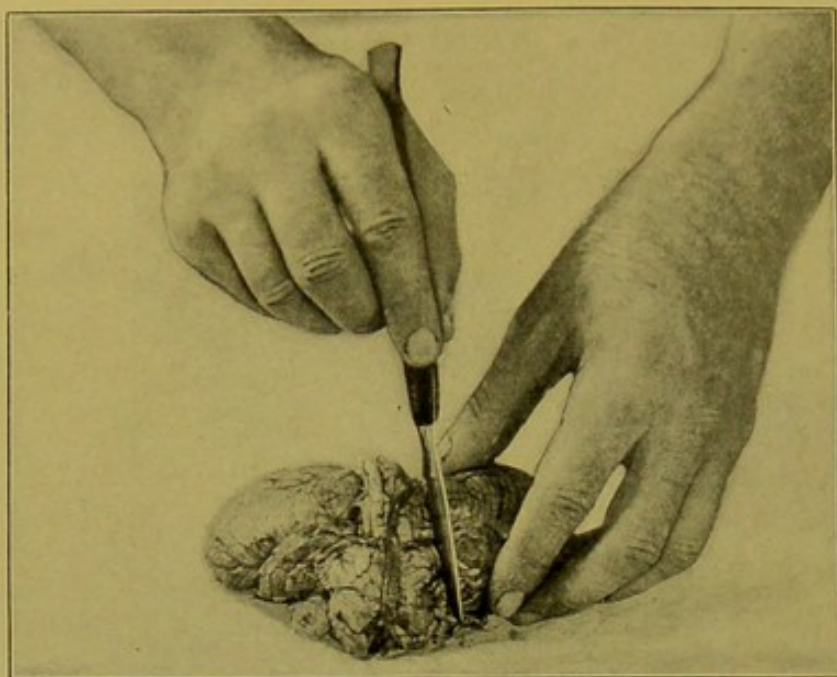


FIG. 123.—Method of removing the cerebellar lobes from the pons Varolii and the medulla oblongata.

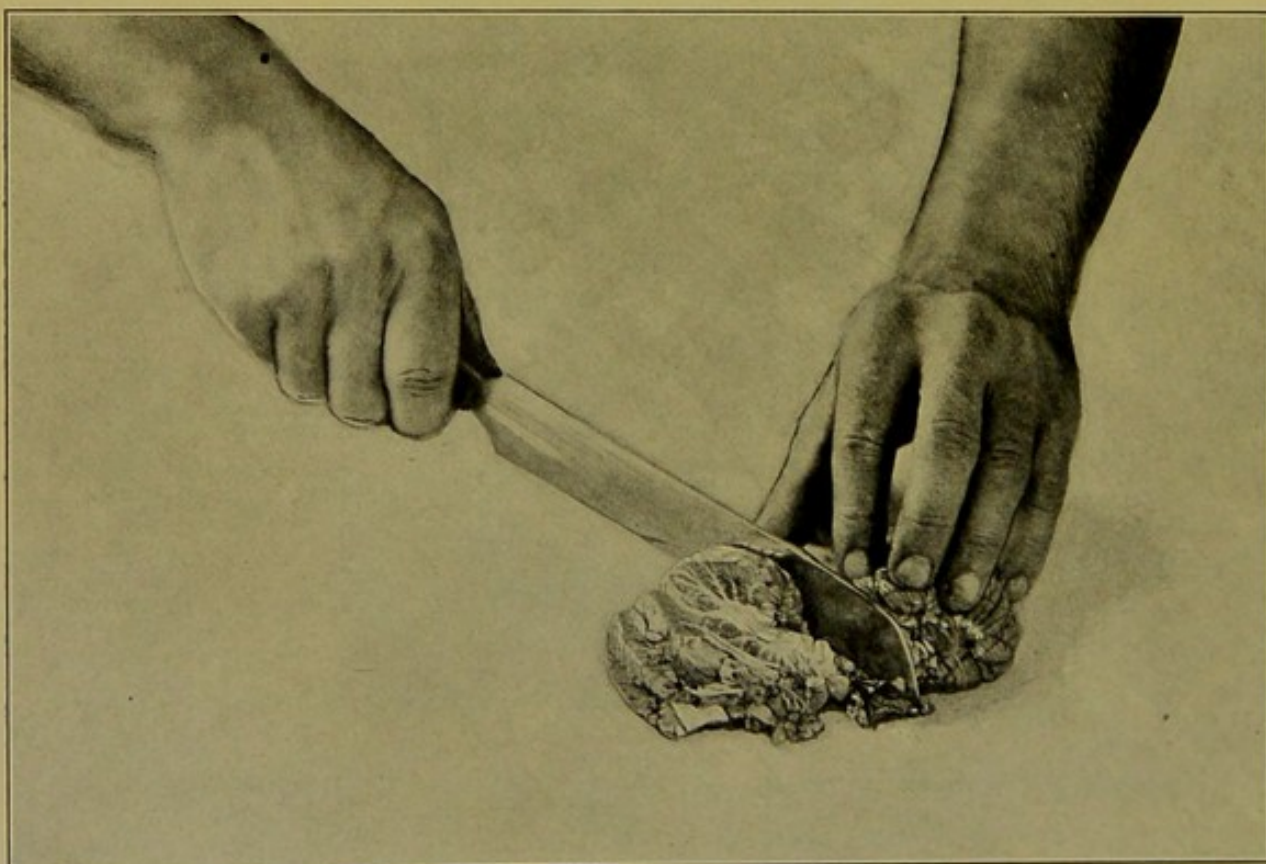


FIG. 124.—Method of sectioning the cerebellum.



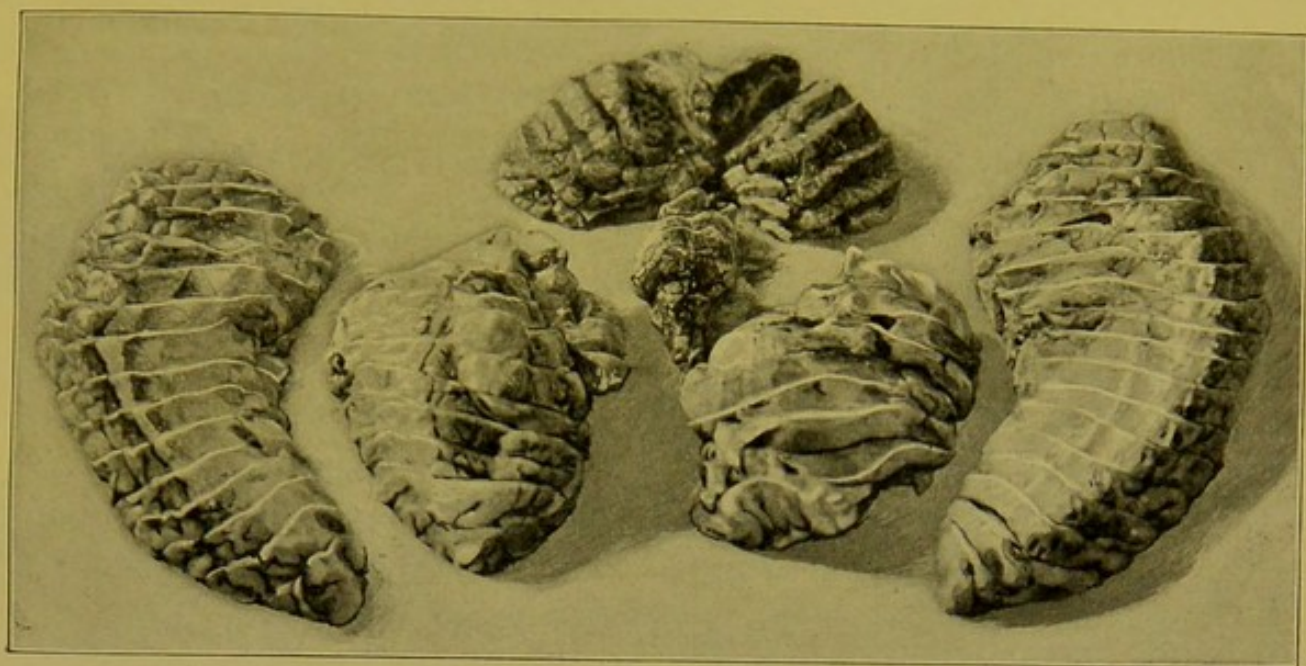


FIG. 125.—The whole brain after it has been sectioned.

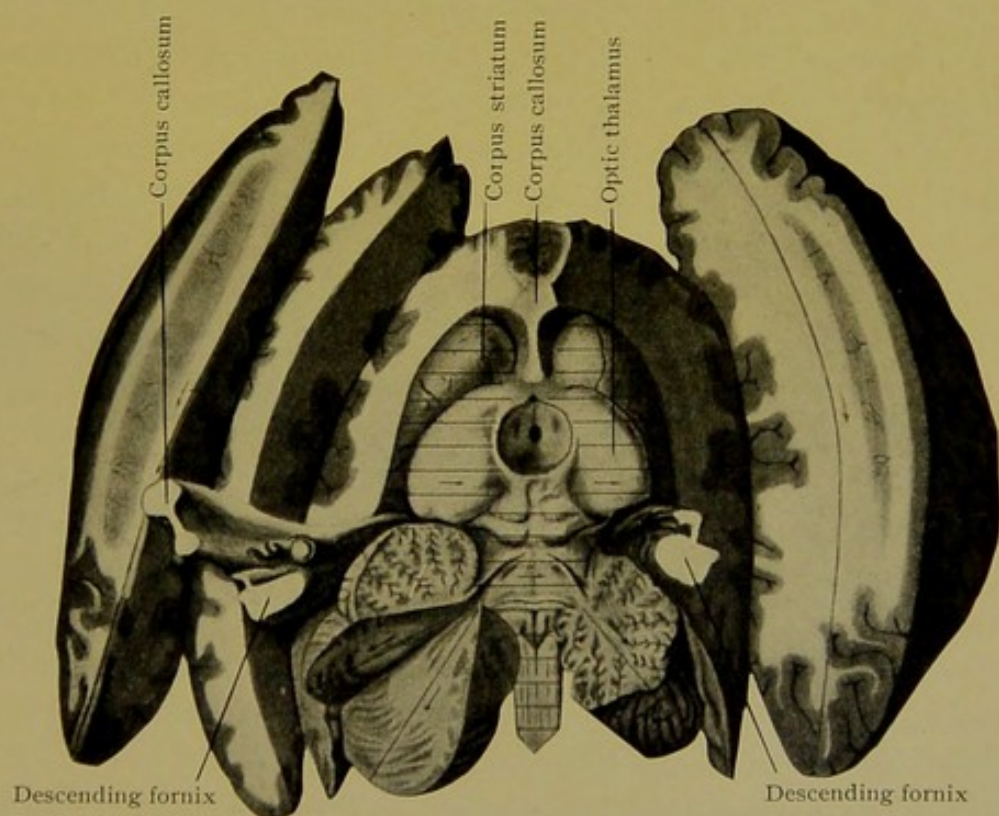


FIG. 126.—Section of the brain. The lines and arrows show the position and direction of the various incisions. (After Nauwerck.)



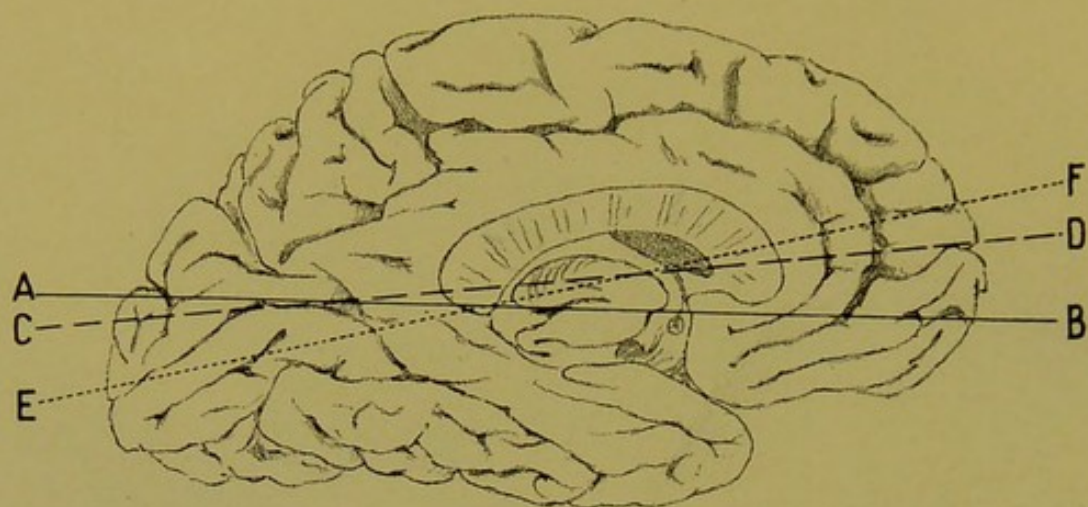


FIG. 128.—Sectioning of the brain. *AB*, incision practised by Flechsig; *CD*, that of Brissaud; *EF*, that of Dejerine. (After Dejerine.)

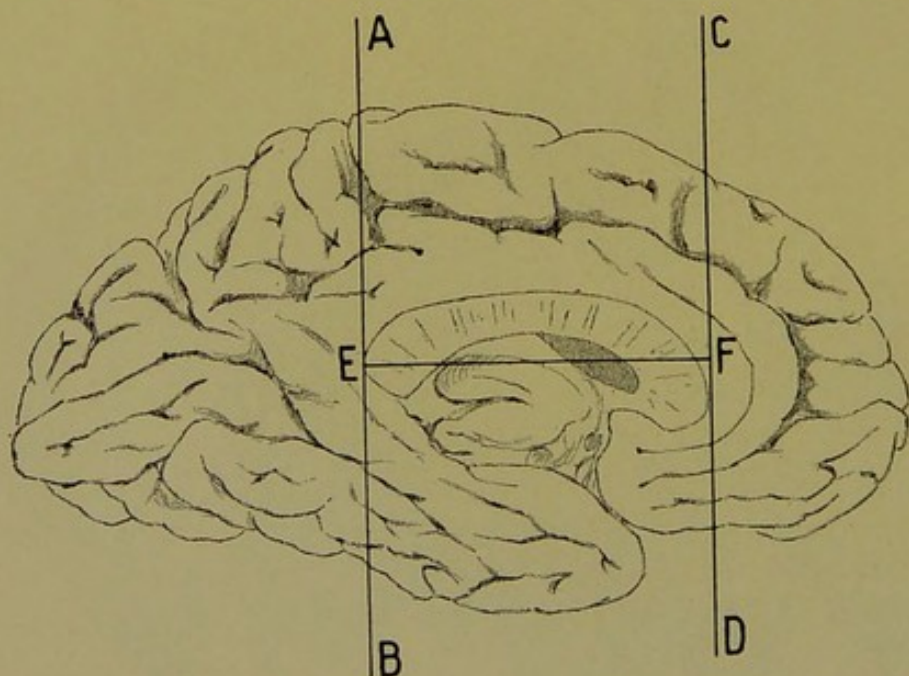


FIG. 129.—Incisions made by Dejerine in a case of cortical lesion previous to hardening. (After Dejerine.)



roof of the ventricle and the basal ganglia, to avoid injuring the latter. The basal piece is now lifted until the anterior crura of the fornix and the septum lucidum may be severed, and the basal section thereby completed.

The basal piece thus separated includes the island of Reil, the basal ganglia, the crura, pons, medulla, and cerebellum. (Fig. 127.)

PITRES'S METHOD.—The lateral ventricles are exposed as in Virchow's method. The hemisphere lies on its internal surface and a series of transverse vertical sections are made parallel to the fissure of Rolando. Pitres's method is very useful for localizing lesions in the centrum ovale, but not at all adapted to studying the internal capsule nor for subsequent microscopical work. The same is true of the closely similar method of Nothnagel.

Some operators do not even take the trouble to remove the brain from the skull, but merely make a number of transverse incisions across the cerebral structures. This method is only mentioned to be condemned, though it may diagnose a hemorrhage, a tumor, or an abscess. The next method to be described, that of Dejerine, gives the best results of any of the methods now in vogue.

METHOD OF DEJERINE.<sup>1</sup>—The brain is examined upon all its surfaces to see if there be any cortical lesion. The inferior surfaces of the crura are carefully inspected for secondary degenerations. The cerebrum is separated from the cerebellum by sectioning the pons horizontally in a plane directly parallel with the inferior surface of the hemispheres and passing just above the great root of the trifacial. Fig. 128 shows the direction of the incisions adopted for this purpose by Flechsig, Brissaud, and Dejerine. This divides the brain into two portions. The upper one contains the two hemispheres, the cerebral peduncles, and the superior portion of the pons, while the corpora quadrigemina is preserved intact by the obliquity of the incision. The lower portion contains the rest of the pons, the cerebellum, and the medulla. The surfaces of the section through the pons are carefully examined for degenerations in the pyramidal tracts, and the two hemispheres are separated after determining in which one the lesion is situated, which is often decided by the appearance of degenerations in the cut surfaces of the pons. While Dejerine regards this as important to determine, because the corpus callosum should be sectioned as closely

---

<sup>1</sup> *Anatomie des centres nerveux*, pp. 22 et seq.



as possible to the normal hemispheres, and the incision should not pass through the interpeduncular space but encroach at least a centimetre upon the sound peduncle and corresponding portion of the pons, other neuropathologists object to this mode of procedure as being apt to cause disfigurement of the parts.

The method of examining the hemispheres is determined by the situation of the lesion,—whether it is central or cortical. If central the only degenerations that are of importance are those of the tracts of the internal capsule and in the region of the tegmentum (dorsal portion of the crus cerebri). Divide each hemisphere by a horizontal incision passing through the superior third of the optic thalamus, harden, prepare a drawing of the part, and section with a microtome.

If the lesion is cortical the brain is sectioned by (1) a vertical transverse incision (Fig. 129, *C D*) passing just posterior to the splenium of the corpus callosum, and (2) a vertical transverse incision (*A B*) just anterior to the knee of the corpus callosum. In this way the hemisphere is divided into three segments. The posterior segment is composed of the occipital lobe and part of the parietal. The anterior is the forepart of the frontal lobe. The central is the largest and contains the regions adjacent to the fissure of Rolando, the middle portion of the temporal convolutions, the posterior portion of the frontal convolutions, the basal ganglia, the cerebral peduncle, and the corresponding part of the pons. The anterior and posterior segments are hardened as they are, and the central segment also if the cortical lesion is extensive and deep so that the fluid can penetrate easily; if not, a horizontal section (*E F*) is made through the superior third of the optic thalamus. In either event the pieces are hardened and cut with a microtome, preferably of the Gudden type. The anterior and posterior segments are cut vertically transverse and numbered. The central segment or segments are incised horizontally. In this way a cortical lesion can be localized with great precision not only, but traces of degenerating fibres may be studied throughout their whole extent, which is not practicable by any other method.

**HAMILTON'S METHOD.**—Hamilton injects the vessels of the brain<sup>1</sup> as follows: The brain is freed from the dura, but not from the pia and arachnoid, weighed, and injected through the vessels at the base with Müller's fluid or any other hardening fluid desired. It is well to

---

<sup>1</sup> *Text-book of Pathology*, 1889, vol. i. p. 56.



have a round stoneware jar with a lid of sufficient size, three fair-sized cannulas, several feet of good rubber tubing of a caliber to receive the ends of the cannulas, and a three-tubed "distributer." A piece of the rubber tubing about eighteen inches long having been firmly tied on one end of a cannula, its other end is tied into an artery,—viz., one into each carotid and one into one of the vertebrals, the opposite vertebral being securely ligated. The brain, with its attached tubes, is now placed in the jar, which is partly filled with the hardening fluid. The weight of the cannulas and tubes is taken off the vessels by suspending the tubes over the edge of the jar. Tie the other ends of the rubber tubes to the three arms of the distributer, and connect the common tube with the stopcock of a tank filled with the preservative fluid, which can be conveniently raised or lowered at will, and is now placed about four feet above the brain in the jar.

When certain that all attachments are secure, the stopcock is gradually opened, allowing the tubes to become filled and the fluid to percolate slowly through the brain. Care should be taken that the cannulas do not bend the arteries short upon themselves, thus occluding their lumina. The first fluid which passes through will be mixed with blood and should not be used again, but when it has become clear it may be used over and over. It usually runs through very quickly, and the tank should be refilled at least every day for the first week, and oftener if convenient. The brain should always be in an excess of the fluid and a vessel provided for the overflow. For refilling the tank it is best to draw some of the liquid out of the jar with a siphon, which will not disturb the brain or the position of the cannulas.

A week or two will suffice in urgent cases, but the longer the brain remains in the fluid the better will be the hardening. Some of my most beautiful specimens are those which were kept in Müller's fluid for five or six months. Haste and thoroughness are incompatible in this process. No padding should be used to keep the organ in position, the best and surest agent for this purpose being a plentiful excess of the liquid and an occasional change in its position.

If it seems unnecessary to inject the vessels, the following method may more easily be carried out and gives most excellent results. An open jar, bucket, or wash-basin is one-quarter filled with absorbent cotton, and Müller's fluid—to which one per cent. of formalin may be added with great benefit—is poured in until the vessel is about half full. The brain, after being weighed, is carefully placed in the centre of



the vessel and more fluid is added until the organ is well covered, when it is placed in a refrigerator. If this be done, even though the arteries have not been injected nor any incision made into the ventricles, there is no danger that the brain will decompose, even in summer. On the next day the position of the brain is altered and the fluid changed. The renewal of the fluid can best be accomplished with a siphon, only a part of it being removed at one time.

The fluid is changed again on the third day, then every other day for three times, twice a week for the next three weeks, and once a week for the final three weeks. Remember that the jar is uncovered, and this allows of the evaporation of the fluid and possible spoiling of the specimen. The brain can then be thoroughly washed and put in 80 per cent. alcohol, or the Müller's fluid can after the fifth or sixth week be diluted with one-fifth alcohol, then with one-quarter, one-third, one-half, and finally three-quarters alcohol, where the brain can be kept for several months until it is transferred to the alcohol of 80 per cent. strength. Instead of Müller's fluid a 2.5 per cent. solution of bichromate of potassium may be employed. It is important to remember that nervous tissue preserved for the purpose of study by the Nissl method should not be placed in Müller's fluid, but in alcohol or formalin. About two thousand cubic centimetres of a 10 per cent. formalin solution are used and changed every third day. The solution must be kept in a tightly closed jar.

GIACOMINI'S METHOD.—This is well adapted for the macroscopical study of the brain, but, on account of the zinc chlorid used, the tissue is rendered unfit for microscopical work. If the specimen is a brain tumor, a small portion of it may be placed in a hardening fluid for microscopic study and the remainder then treated by this process.

The brain, in as fresh a state as possible, is put into the *Liquor zinci chloridi* (U. S. P.). It will be found to float at first and should be turned several times the first day. On the second day the pia and arachnoid, which until now have been useful in keeping the brain intact, are removed while the organ is under water or floating in the fluid; if allowed to remain longer, they become so adherent to the cortex as to be separated with difficulty and more or less damage to the cortical substance. The brain is left in the fluid for from six to ten days, then removed, well washed with water, and put in 95 per cent. alcohol for ten days or two weeks and next in glycerin for another ten days or more. After this it is placed in absorbent cotton and



exposed to the air in a dark place free from dust. Any exudation should be carefully removed, and when no more appears (which may be in from several weeks to as many months) the surface is to be well coated with the best mastic varnish applied with a soft camel's-hair brush. To prevent flattening of the surface upon which it rests, it must be well packed in absorbent cotton and its position frequently changed.

KAISERLING METHOD.—See page 261 for the preparation of brains with the object of preserving their natural coloration.

In the coroner's work it is often necessary to make a diagnosis between heart-disease and apoplexy, when, because of baldness of the individual or for lack of time, it is impracticable to open the head. In such cases I have found it feasible to trephine just above the ear and from this point tap the ventricles and other situations liable to be the seat of hemorrhage, using an instrument resembling an apple-corer to remove brain substance for examination, though enough clotted blood may be brought out attached to a long thin brain-knife passed into the places where hemorrhage usually occurs—*i.e.*, the ventricles and the cerebellar lobes—for the purpose of establishing a diagnosis.

The base of the skull and its sinuses are next to be examined. Study the dura at its base for (1) inflammation resulting from fracture or caries, (2) tubercles, (3) gummata, (4) thrombosis of lateral sinus, (5) pachymeningitis and leptomeningitis, and (6) tumors. A fracture may be hid by the dura, but its situation will usually be shown by the presence of hemorrhage. The dura must be stripped off, though this often consumes considerable time, so that the surface of the bone may be exposed. Unless this is done, a linear fracture—one near the foramen magnum, for example—might readily be overlooked. Special examinations should now be made of the orbit, internal ear, and nasopharyngeal cavities.



## CHAPTER XVI

### THE SPINAL CANAL AND CORD

THE spinal cord may be removed either anteriorly or posteriorly,—*i.e.*, by excising the bodies of the vertebræ through the thorax and abdomen freed from their viscera or by severing the laminae and spinous processes of the vertebræ through an incision posteriorly. The latter route is decidedly the more convenient and is used whenever possible. Generally it is best to remove the cord before the abdomen is opened, this being a much cleaner operation, an important factor in private practice.

The cadaver is placed prone upon the table, with the head hanging over the end or, better, with a block under the chest and neck and, if desired, one under the lumbar region. Beginning at the external occipital protuberance, an incision is carried along the spinous processes to about the fourth lumbar vertebra, dividing all the tissues down to the bone. (Figs. 130, *A B*, and 131.) The superficial and deep structures are then dissected from the bones, exposing the vertebral groove on either side of the spinous processes. Or, after incising the skin over the spinous processes, insert the knife, with its back down, at the lower end of the incision and cut upward along the column, keeping the blade pressed against the spinous processes. In this way the fibrous attachments are cut close and the vertebral groove is clean and free from troublesome soft tissues. The soft parts should be very thoroughly removed, as they would interfere considerably with the subsequent sawing. This can be quite well done by scraping with a chisel or an old knife.

In cases of luxation, fracture, Pott's disease, etc., it may be desirable to remove portions of the vertebral column *en masse*. This can readily be done by the proper use of a saw after severing the intervertebral cartilages above and below the lesion. The space is then filled by inserting a stick and pouring plaster upon it.

The canal is easily opened with Luer's rhachiotome, an adjustable, double-bladed saw devised for the purpose (Fig. 21). It does the work more quickly, but has the serious fault that it is liable to become impacted and injure the cord in its release. The same object may be



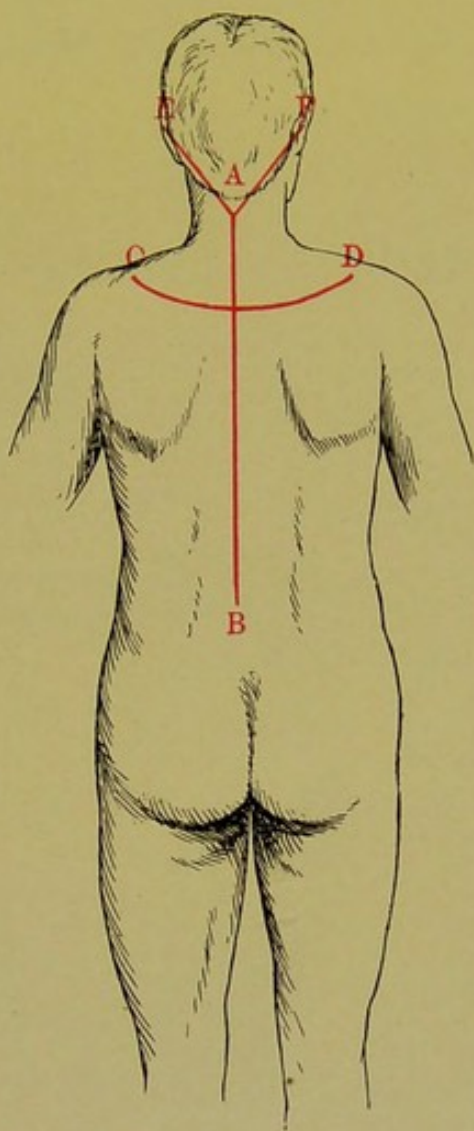


FIG. 130.—Lines for removing the spinal cord and the brain through a small triangular occipital incision. *AB*, initial incision for removal of the cord; *CD*, curved incision for the purpose of avoiding division of the skin above the dressed portion of the body; *EAF*, angular incision in the occipital bone through which to remove the brain without elsewhere opening the skull.



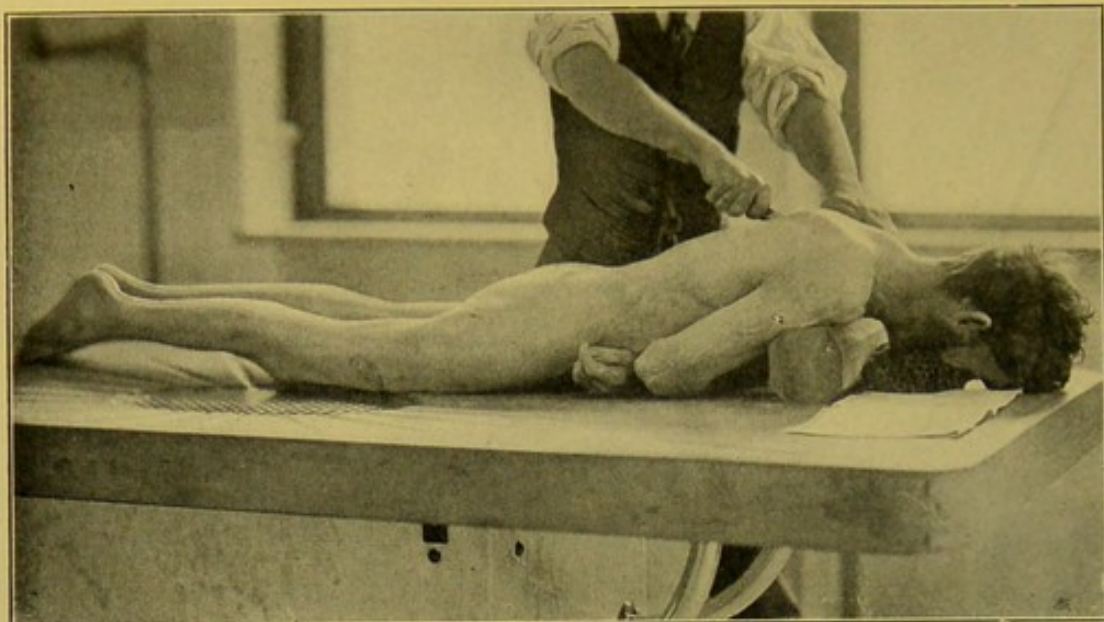


FIG. 131.—Position of the body in removal of the spinal cord. The primary incision is being made.

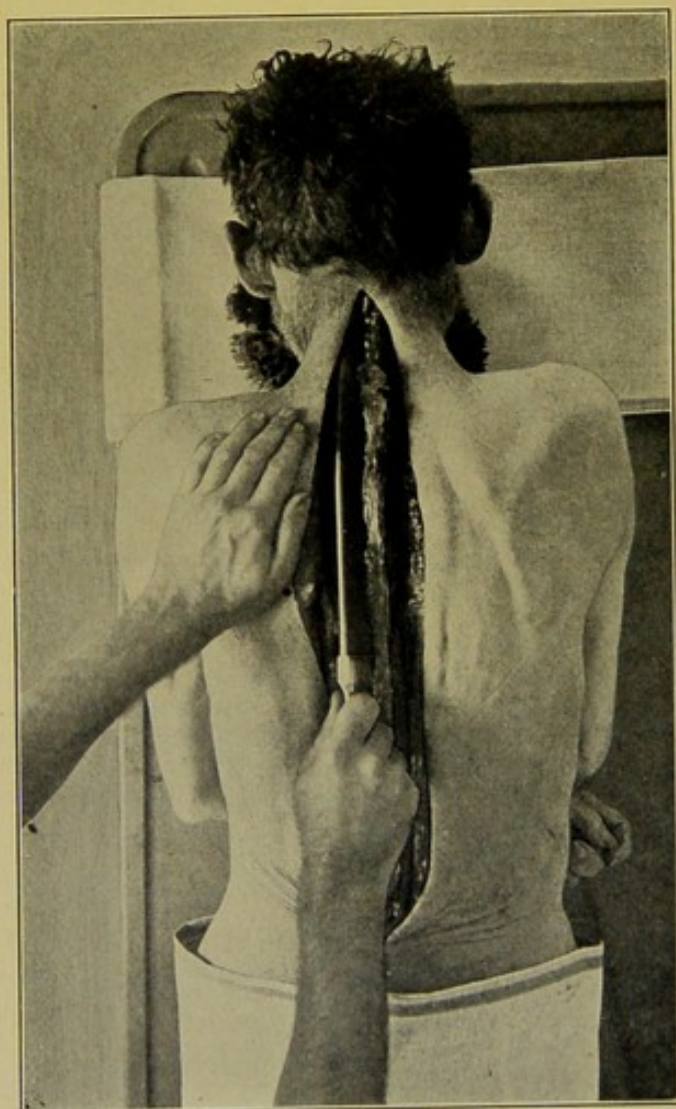

FIG. 132.—Removal of spinal cord. The primary incision has been made and the vertebral column freed from muscle, fascia, etc. The angle at which the saw should be held is well shown.



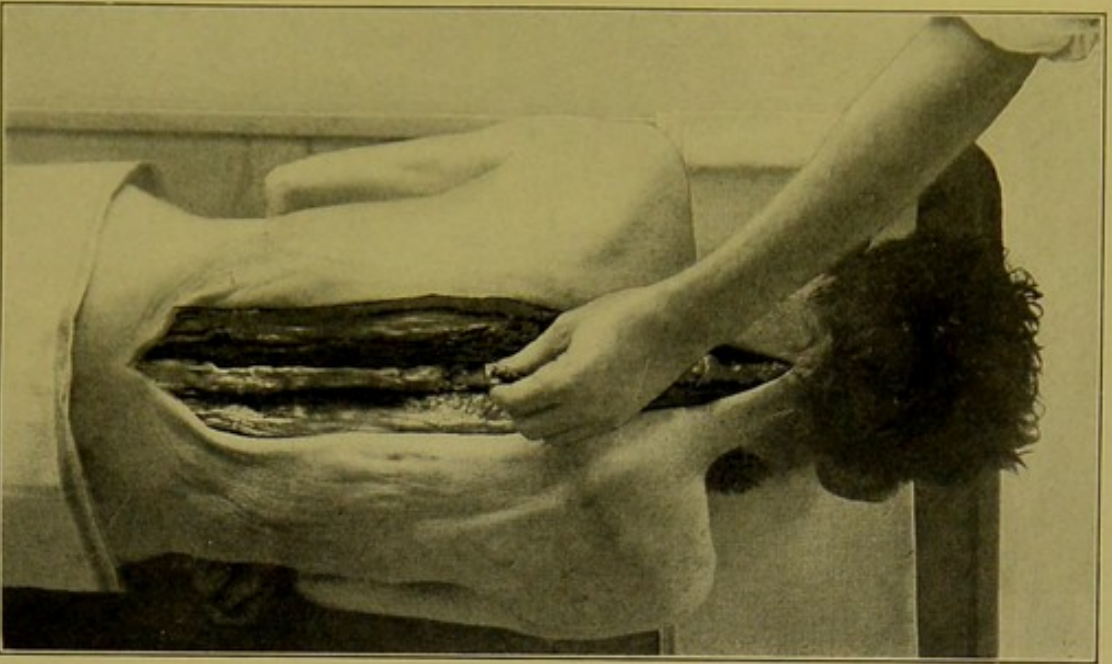


FIG. 133.—Removal of spinal cord. The sawing having been completed at a convenient point in the dorsal vertebrae, the sawed bone is elevated with the fingers or, if strongly attached, with the forceps.

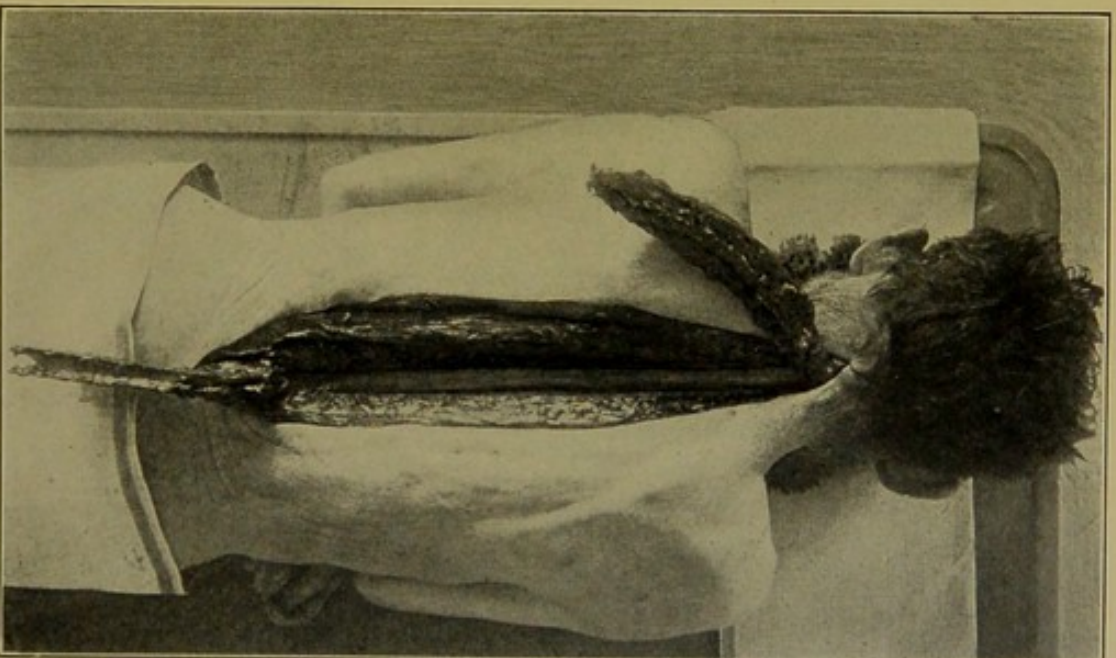


FIG. 134.—Removal of spinal cord. The spinal canal is well shown with the dura mater still intact. The sawed portions of bone both above and below are left attached.



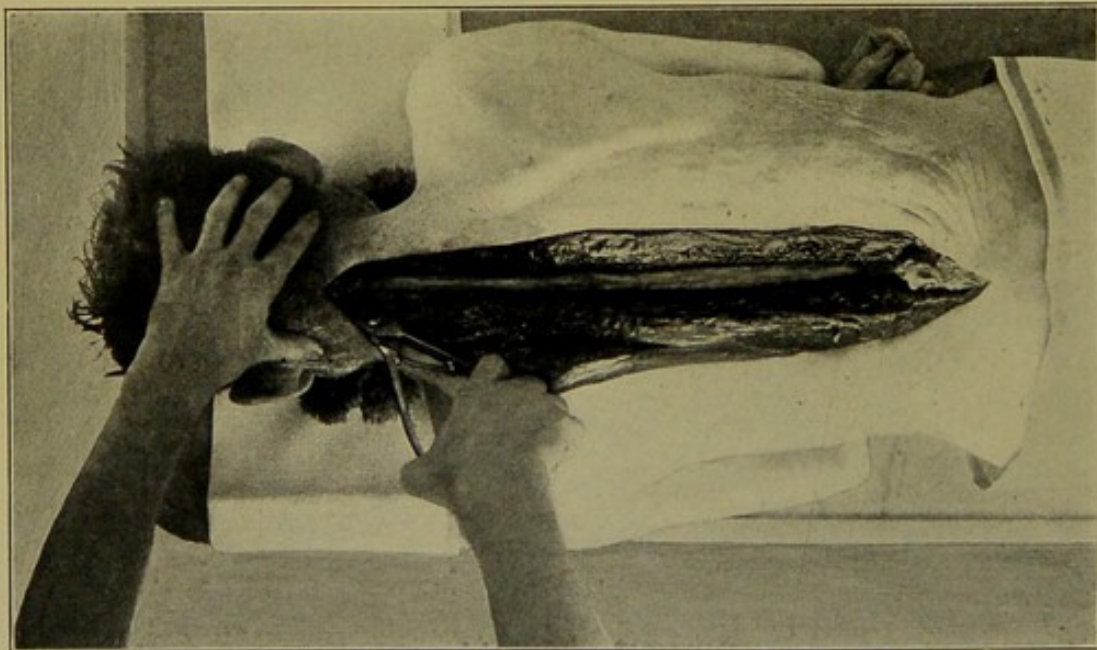


FIG. 135.—Removal of spinal cord. The atlas and the axis are being severed with the costotome.

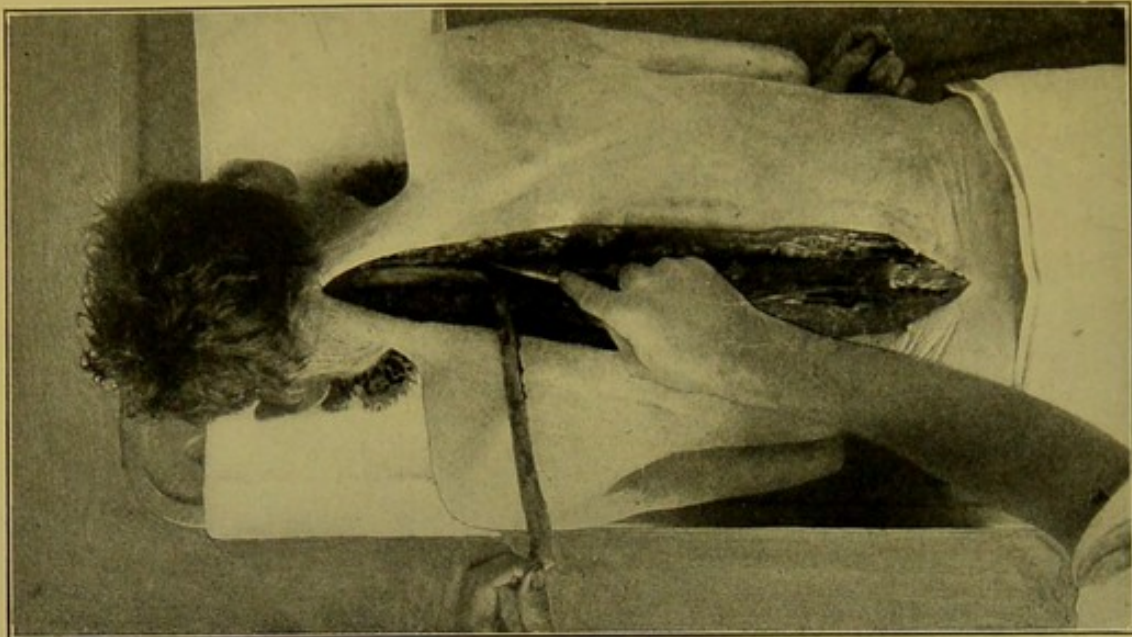


FIG. 136.—Removal of the spinal cord with its dura. The lower end is held with the left hand while the nerves are being severed. Figs. 132 to 136, inclusive, are from photographs taken directly from above.



accomplished with a single-bladed saw having curved ends (Fig. 17). The lamina should be sawed close to the transverse process, with the saw teeth held away from the spine at an angle of about thirty degrees (Fig. 132). Unless this direction is taken there is some danger that the canal will be missed or that the blade may enter it and the cord be injured. Orth calls attention to the fact that one can tell when sufficient sawing has been done by the mobility of the spinous processes. Other instruments which may be used are the double chisel of Esquirol, the knife-shaped chisel of Brunetti, and the rhachiotome and hammer of Amussat, the latter being much preferred in France to Luer's rhachiotome, which is not approved of. After the canal has been opened in the dorsal region with the saw, a pair of bone-nippers is used to pry up the portions of vertebra thus loosened, and the dura is exposed (Figs. 133, 134). The sawing can then be continued in both directions until the entire canal is opened, except the atlas and axis, which had better be cut with bone-forceps (Fig. 135). In using either bone-forceps or pliers be very careful not to produce artefacts of the cord. The cord at the first dorsal vertebra is then tied with a string, so as to have the situation accurately determined, or the first dorsal nerve may be dissected out and left attached to the cord.

The spinal cord covered with its membranes may now be studied *in situ*, after which the dura and the spinal nerves are divided *below* the cauda equina. The dura being elevated with the fingers or forceps and pushed to one or the other side, the spinal nerves are cut, with a long, thin, narrow-pointed, sharp knife, close to their points of entrance into the intervertebral foramina. (Fig. 136.) The dura at the foramen magnum can best be severed from the bony margin above after the brain has been removed. The cord may be taken away with the brain attached if so desired. The spinal ganglia may be extracted with the nerves and cord by cutting away the articular processes and gently pulling the cord, by the dura, to the opposite side and severing the nerve as far in the foramen as possible.

By making a median incision in the dura mater the cord is exposed, and can, of course, be removed. This procedure, however, is more liable to cause injury to the cord than the method given above.

After freeing all points of attachment the cord must be very gently transferred to the table or tray for further examination. Study the dura for (1) thickness, (2) color, (3) blood, the cerebrospinal fluid for (1) pus, (2) blood, and the pia for (1) expansion, (2) thick-



ness, (3) contained blood, and (4) color. Gentle palpation may reveal areas of softening or sclerosis. The further manipulation of the part will depend upon the extent of the examination required. If the cord is to be preserved for future study, the dura is opened in the median line throughout its entire extent, the blade being inserted at the lower end, and transverse incisions about one inch apart down to the pia are made in the cord. It may be hardened at the same time and in the same jar as the brain by curling it around that organ; but it is better to suspend it by the dura, with a small weight attached, in a long jar, or it may be kept in such a jar lying upon its side. In summer the jar should be placed in the refrigerator.

If the examination is to be completed immediately, the cord is laid out on the table and the dura opened throughout its entire length as already directed. Note is made of the conditions observed. Much valuable information can be obtained by the macroscopic examination, especially if a hand-glass be used and diagrams made at the time. Then, with a sharp, thin knife, which should be moistened with water after each incision, transverse sections about an inch apart are made through the cord and membranes; the under surface of the dura, however, is left uncut, in order that the cord may be replaced in its entirety. Areas of softening should not be incised, because of the inevitable disturbance thus produced in the relations of component parts.

Where the avoidance of disfigurement above the parts covered by clothing is a matter of great importance, sufficient room for opening the cervical canal can be obtained by making a crescentic incision from the centre of one shoulder to the other, with the concavity towards the head, and dissecting up the skin. (Fig. 130, *C D*.)

Sometimes it is advantageous to open the canal by removing the vertebral bodies through the long anterior incision. Brunetti's chisels were devised for this purpose. After removal of the thoracic and abdominal viscera, the pointed guard is inserted in the vertebral canal, and the instrument, held parallel with the long axis of the spinal column, is driven forward with a mallet, thus severing the pedicles and removing the bodies or anterior wall. By this method the spinal ganglia are said to be rendered more easily accessible. The remaining steps are about the same as those described for the posterior incision.



## CHAPTER XVII

### DISEASES OF THE BRAIN AND CORD

**ABSCESS OF THE BRAIN.**—There is a circumscribed collection of pus in or upon the brain substance, with or without a pyogenic membrane. (a) Micro-organisms,—*e.g.*, *Staphylococcus pyogenes*, *Streptococcus*, the diplococci of pneumonia, gonorrhœa, and cerebrospinal fever, *Bacillus coli communis*, the bacillus of typhoid, influenza, etc. (b) Traumatism. (c) Extension of disease from the middle ear or mastoid cells and cranial bones. (d) Septic emboli from distant foci,—*e.g.*, abscess of the liver, ulcerative endocarditis, putrid bronchitis, localized bone-disease, etc. (e) Actinomycosis and other mycotic germs (rare). *Classification.*—(a) Primary (rare) or secondary (common). (b) Single (from extension) or multiple (metastatic). (c) Large (size of a walnut or an orange) or minute (then usually multiple). *Seats.*—(a) Cerebrum, usually in the temporo-sphenoidal lobe (most common). (b) Cerebellum, especially in middle-ear disease. (1) Acute abscesses, usually about blood-vessels; are minute, with no definite wall; contain pus mixed with reddish *débris* and softened brain matter. (2) Chronic abscesses, may be superficial or deep; have a pyogenic membrane, which develops in from three to five weeks; pus has a greenish tint, an acid reaction, and may have a peculiar odor depending on micro-organisms. It may undergo fatty degeneration, but cystic formation is doubtful.

**ACROMEGALY.**—A chronic disease of nervous origin, occurring most frequently in adults, and characterized by an overgrowth of the bones, especially those of the face and extremities, by malnutrition, and by impairment of the senses. Morbid changes are always found in the pituitary body (hypertrophy, colloid degeneration, tumors, etc.) and usually in the thyroid and thymus glands. There are marked hypertrophy of the bones of the face (especially the maxillæ) and osteophytic growths on the bones of the hands and feet, with exaggeration of the normal ridges and tubercles. The thorax is enlarged and kyphosis may be present. The sternum is thickened, lengthened, and widened, as are also the ribs and clavicles. There may be hypertrophy of the pharynx and larynx, leading to marked dyspnœa. In



one of my cases there was found after death a sarcoma of the pituitary body; in another, all of the glands of the body appeared to be hypertrophied. I have removed *post mortem* the pituitary body through the orbit. Under acromegaly may also be classed OSTEITIS DEFORMANS, an affection which causes softening and distortion of the long bones of the body; HYPERTROPHIC PULMONARY OSTEO-ARTHROPATHY, where there is antecedent lung disease and the bones of the skull are not involved, and LEONTIASIS OSSEA, an overgrowth of the bones of the cranium. In MICROMEALY the condition is the reverse of that found in acromegaly.

ANÆMIA CEREBRI.—A condition in which the brain is temporarily or permanently deprived of part of its blood-supply. Due to: (a) Mechanical obstruction to the circulation,—*e.g.*, valvular heart-lesions, thrombosis, embolism, or ligation of a vessel. (b) Hemorrhage. *Classification*.—(a) General or local. (b) Acute, subacute, or chronic. (c) Partial or complete. The membranes are pale; small arteries over the gyri are empty, though large veins are full. The brain substance is anæmic, the surface moist, few puncta vasculosa are seen, and the cerebrospinal fluid is increased.

ANEURISM OF CEREBRAL ARTERIES.—*Classification*.—(a) Single or multiple. (b) Large or minute. *Seats*.—(a) Most frequent in branches of the middle cerebral artery, especially those of anterior perforated spaces. (b) May be cortical. The aneurisms are usually very small, varying in size from that of a pea to a cherry-stone (seldom larger), multiple, and may resemble bunches of grapes. If hemorrhage occurs in basal aneurisms, the internal capsule and basal ganglia are injured, the lesion usually being extensive. On the cortex the result of hemorrhage is much less grave.

APOPLEXIA NEONATORUM.—A form of hemorrhage of the brain occurring in the new-born, usually the result of traumatism. (a) Accidents during labor, from forceps, etc. (b) Congenital defects in blood-vessels, brain, or skull. (c) May result from prolonged and severe normal labor. *Seats*.—(a) Meninges (piaarachnoid) most frequently, often bilateral, and usually at the base. (b) May be between dura mater and skull; is accompanied by cephalæmatoma. (c) May occupy the ventricles. (d) May occur in brain substance about basal ganglia. (e) Sometimes found in parietal region and Sylvian fissure. (1) Generally the hemorrhage is meningeal primarily, producing brain-lesions secondarily, such as atrophy and softening, by pressure.



(2) Cortical hemorrhage is represented by a clot, which may be encysted, softened, or organized, causing more or less injury to the brain. (3) When the hemorrhage is between dura and skull, fracture is said to be always present.

ATAXIA, HEREDITARY (FRIEDREICH'S).—A form of ataxic paraplegia occurring in children and congenital in origin. (a) Hereditary, not common. (b) More common in males than in females. (c) Early life. (d) A specific lesion of the cord. (1) There is a gliosis of the posterior column of the spinal cord, due to developmental errors (Osler). (2) Talipes equinus occurs in both feet. (3) Lateral curvature is common.

ATAXIA, LOCOMOTOR (TABES DORSALIS).—A chronic disease of the nervous system, characterized by sclerosis of the cord and brain, and by incoördination, with motor, sensory, and trophic disturbances. (a) Male sex. (b) Adult life. (c) Syphilis. (d) Wet and cold. (e) Sexual excesses, etc. (1) *Spinal Cord*.—Externally the meninges are thickened and adherent. Posterior roots are atrophic and of a grayish tint. Internally sclerosis of the cord begins in the posterior-root zone, involving the outer layers of posterior columns in the lumbar region. The sclerosis gradually extends inward, involving successively the columns of Burdach and Goll; when the process reaches the upper dorsal region, it is confined to the column of Goll. The cord presents a flattened appearance posteriorly, the sides being somewhat contracted. The diseased areas are firm, grayish or grayish red in color, and the whole cord is often firmer in consistency. (2) *Brain*.—Changes of less consequence than in the cord may be sclerosis in restiform bodies, inferior peduncles of cerebellum, and certain cranial nerves,—the oculomotor, optic, and auditory. Atrophy of the optic nerve and hemiplegia may occur. Some recent writers consider paralytic dementia to be such a disease of the brain as locomotor ataxia is of the cord. (3) Peripheral nerves may show degeneration or even neuritis. (4) In later stages occur dermopathies and arthropathies,—e.g., perforating ulcer of foot, herpes, etc., Charcot's joint, etc. There may be evidences of loss of control of sphincters.

CAISSON DISEASE.—A peculiar nervous affection, the result of a sudden reduction of atmospheric pressure. Occurs in bridge-builders, divers, etc., who, after working for hours under a pressure of two or three atmospheres, have suddenly returned to air of normal density. In fatal cases there is a marked destruction of nerve tissue in the pos-



terior columns and the posterior portions of the lateral columns, forming fatty detritus and compound granular cells.

CHOREA, ACUTE.—(a) Female sex. (b) Early life (before the fifteenth year). (c) Heredity. (d) Bad hygiene. (e) Fright. (f) Bad habits. No constant lesions are found. Vascular changes, such as hyaline degeneration, leucocytic infiltration, minute hemorrhages, and thrombosis of small arteries, have been described.

CONGENITAL ANOMALIES. — Cranioschisis, rhachioschisis, hydro-meningocele, encephalocele, myelomeningocele, hypoplasia of different parts, as of the cerebellum, micrencephaly, hydrocephalus, internal and external porencephaly, idiocy, cretinism, micromyelia, total absence of parts, and anomalies of distribution.

CRETINISM.—A low form of idiocy, either congenital or acquired during the early years of life, and associated with anatomic changes in the thyroid gland, as absence, hypoplasia, atrophy, or goiter. It is endemic in certain localities, notably Switzerland, where goiter is prevalent. Heredity bears a causative relation. The condition usually appears at birth. The child is stunted and dwarfish in appearance. The trunk is large in proportion to the development of the head, hands, and feet. The head is flat, the face broad and expressionless, the eyes are dull and stupid, the nose is flat and depressed, the lips are thick, and the tongue is large and usually protrudes. The teeth are carious; the hair is thin, brittle, and harsh to the touch; the skin about the hair is dry and scurfy. The abdomen is prominent; the legs are short and thick, the hands and feet undeveloped. The skin is yellow, leathery, and rough to the touch.

DELIRIUM, ACUTE.—The post-mortem findings are usually negative. There may be great venous engorgement of the meninges, and the cortex and blood-vessels may show exudation and leucocytic infiltration into the lymph-spaces and sheaths. Careful examination of the lungs and ileum should be made in fatal cases.

ENCEPHALITIS, ACUTE.—Due to: (a) Acute infectious disease. (b) Traumatism. (c) Intoxications. The minutest foci of inflammation are not recognizable by the unaided eye; later stages have a pinkish appearance or are represented by clusters of small dark-red hemorrhagic foci. When suppuration follows, these areas take the form of yellowish-white patches whose tissue soon liquefies and becomes purulent.



HÆMATOMYELIA.—Hemorrhage into the cord. (a) Traumatism. (b) Exposure. (c) Convulsions. (d) Tumor. (e) Syringomyelia. (f) Myelitis. (g) Male sex. (h) Middle life. The cord is usually enlarged, occasionally lacerated. The blood is generally confined to the gray matter, but may escape beneath the membranes.

HEMIPLEGIA IN CHILDREN.—Causes: (a) First or second year. (b) Traumatism. (c) Embolism or thrombosis. (d) Congenital defect. *Classification*.—(a) Embolism, thrombosis, or hemorrhage. (b) Atrophy and sclerosis. (c) Porencephalon. (1) The results of embolism, thrombosis, or hemorrhage depend on the extent and rapidity of the formation and on location. When the process is an acute one and extensive, it is either immediately fatal or leads to more or less extensive destruction of the brain substance; there is a tendency to softening or suppurative change. (2) Atrophy and sclerosis may involve a group of convolutions, an entire lobe, or even a whole hemisphere. The affected gyri are firm, hard, and atrophied, contrasting sharply with the normal tissue. They may be uniform in appearance or there may be nodular projections. In porencephalon there is loss of substance, with the formation of cavities or cysts at the surface of the brain.

HEMORRHAGE, CEREBRAL.—The most common cause (sixty per cent.) is rupture of the lenticulostriate artery. *Classification*.—(a) Basilar. (b) Cortical. In basilar hemorrhage section of the brain substance frequently shows miliary aneurisms, which are seen as small dark bodies along the course of the blood-vessels penetrating the anterior perforated spaces. Aneurism of a branch of the circle of Willis may be found. Endarteritis and periarteritis are found in the cerebral vessels. At the seat of a recent hemorrhage the brain has a dark-red, softened appearance, the tissue being reduced to a coagulated or pulpy mass of detritus. When the hemorrhage has been extensive, the remainder of the brain is anæmic. The gyri are more or less flattened, from extravasated blood, and the sulci are indistinct. Hemorrhages are most common near the corpus striatum towards the outer section of the lenticular nucleus. They may be small and limited to the lenticular body and internal capsule or may break into the lateral ventricle. Ventricular hemorrhage is rare. It is usually bilateral. Meningeal hemorrhage is usually caused by fracture of the skull or rupture of a blood-vessel. The hemorrhage may be small or large. It may be above or below the dura or between the pia and the arachnoid.



HEMORRHAGE INTO THE SPINAL MEMBRANES.—Extrameningeal hemorrhage may be extensive, without compression of the cord. Rupture of an aneurism into the spinal canal may produce profuse and rapidly fatal loss of blood. There may be little demonstrable morbid change. Intrameningeal hemorrhage usually occurs in scattered areas as the result of acute infectious fevers. More extensive hemorrhages result from epilepsy, tetanus, and strychnine poisoning. Occasionally hemorrhage into the spinal meninges may ascend to the brain.

HYPERÆMIA, CEREBRAL.—This may be: (a) Active. (b) Passive. (1) The cerebrum is congested, the blood-vessels are somewhat distended, and petechial hemorrhages are numerous. On section the gray substance contrasts very markedly with the white; the former is of a brick-dust color; the latter shows many punctate hemorrhages. (2) In passive congestion the veins of the cortex are distended; the gray matter has a deeper color and its vessels are full. The gray matter shows distention of the smaller veins, which on section allow their contents to exude as drops of blood of various sizes. Excessive passive hyperæmia may result in cerebral œdema.

LEPTOMENINGITIS, ACUTE CEREBROSPINAL.—Acute inflammation of the pia and arachnoid of the brain and spinal cord. Causes: (a) Acute infectious fevers. (b) Injury or disease of the base of the skull. (c) Extension of disease from nose, ear, or Eustachian tube. (d) Pyæmia. The organisms most commonly found are the meningococcus, the pneumococcus, the tubercle bacillus, and the cocci of inflammation; more rarely, the bacilli of influenza and of typhoid, the colon bacillus, and the gonococcus. *Classification*.—(a) Simple or traumatic. (b) Purulent. (c) Tuberculous. (1) In simple or purulent meningitis the membranes are thickened, the blood-vessels dilated, and there is more or less exudation, which may be serous, serofibrinous, or purulent. The exudation may be so extensive as to cover up the convolutions. The inflammatory process is most marked in the basilar portions. It may be unilateral or bilateral. In the former the condition is due to extension from neighboring parts. (2) The tuberculous form of the disease is usually cortical as well as basilar. It begins as a miliary tuberculosis, and in the early stages exudate is not extensive. The ventricles also may be involved and present considerable distention and softening; they seldom suffer in other forms of the disease.



MENINGITIS, ACUTE CEREBROSPINAL.—An acute infectious disease, especially of early life, characterized by inflammation of the membranes of the brain, with an exudation of fibrinopurulent material, chiefly towards the base, and due to the *Diplococcus intracellularis*. (1) *Membranes of the Brain*.—In acute fatal cases there is intense injection of the pia and arachnoid, with a little exudate. In more chronic cases there is a formation of fibrin or of pus, or of both; this is most marked at the base of the brain. The meninges are much thickened and opaque. The larger blood-vessels are overfilled and many of the smaller ones are obliterated. Sometimes the entire cortex is covered with a thick purulent exudate, and there may be much lymph along the larger fissures and in the sulci. In acute cases the ventricles are dilated, the ependymæ are inflamed, and the cavity may contain pure pus. (2) *Cranial Nerves*.—The nerves usually involved are the second, fifth, seventh, and eighth. They are often embedded in the exudate. Micro-organisms may be found in the fibrin. (3) *Brain Substance*.—This is softer than normal, has a pinkish color, with foci of hemorrhage and of brain softening. (4) *Lungs*.—Pneumonia and pleurisy may occur. The lungs are often congested, with evidences of bronchitis. (5) *Abdominal Organs*.—The liver is rarely altered. Acute nephritis is sometimes present, and the intestines may show swelling of the follicles. (6) *Skin*.—There may be rose-colored, hyperæmic spots, resembling the typhoid rash, urticaria or pemphigus, and in rare instances gangrene. (7) *Eye*.—Neuritis is common, and there may be acute papillitis. Purulent chorioido-iritis or even keratitis sometimes occurs. (8) *Ear*.—Otitis media develops from direct extension, and frequently leads to abscesses. In one of my cases the bacillus of tuberculosis was found associated with the meningococcus. In two fatal cases examined by me there was a history of traumatism, though no sign of this was found at the postmortem. During an epidemic domestic animals, as the goat, should be watched for signs of disease.

MENIGO-ENCEPHALITIS; CHRONIC DIFFUSE OR DEEP CHRONIC LEPTOMENINGITIS.—(a) Male sex. (b) Early adult or middle life. (c) Syphilis. (d) Alcoholism. (e) Certain occupations, as those of artists, navy and army officers, etc. The membranes of the brain are thickened and opaque and more or less extensively adherent to the cortex, which is torn on attempting to remove them. The convolutions of the brain are atrophied, especially in the frontal and parietal



regions. The gray matter may be obscurely outlined. The white matter is firm in consistency. The ventricles are dilated and the ependymæ granular; frequently there are areas of hemorrhage or softening associated with chronic arteriosclerosis. There is an increase in the cerebrospinal fluid. Usually sclerosis of the posterior columns, with involvement of the lateral, is found. There may be an extraordinary development in the lymph connective system of the brain, with a parallel degeneration and disappearance of the nerve-elements and the axis-cylinders, and finally shrinking and extreme atrophy of the parts involved.

MUSCULAR ATROPHY, PROGRESSIVE (SPINAL).—(a) Male sex. (b) After the thirtieth year. (1) Macroscopically there is great muscular wasting, beginning usually in the thenar and hypothenar eminences and thence extending to the general muscular system. In marked cases the subject may be reduced "to skin and bone." Deformities and contractures result and lordosis is almost always present. (2) Microscopically the muscles undergo fatty and sclerotic change and the terminal ends of the motor nerves are degenerated. (3) Examination of the cord shows the anterior roots corresponding to the diseased muscles to be atrophied. Neuroglial tissues show marked increase, most conspicuous in the anterolateral tracts. The degeneration of the gray matter extends to the medulla. Large ganglion-cells in the motor cortex may be wasted. In a case at Elwyn which I examined *post mortem* the diaphragm was easily seen through when held up to the light.

MYELITIS, ACUTE.—(a) Traumatism. (b) Exposure. (c) Certain infections. (d) Disease of the spine. (e) Disease of the cord. (1) The cord is swollen and soft and the pia injected. On incision a diffuent fluid may escape. The distinction between gray and white matter is often lost. Hemorrhages are frequent. (2) Histologically the nerve-fibres are swollen, the axis-cylinders beaded, myelin droplets abundant, and corpora amylacea may be seen. The ganglion-cells are swollen, irregular in outline, and exceedingly granular and vacuolated. In the removal of the cord in these cases great care must be taken not to produce artefacts.

MYELITIS FROM COMPRESSION.—(a) Caries of the spine. (b) New growths. (c) Aneurism. (d) Parasites. (e) Distention of central canal with inflammatory liquid or blood. Changes appear first



in the white matter, the fibres of which may within six hours swell up and disintegrate.

**POLIOMYELITIS, ACUTE ANTERIOR.**—(a) Early life. (b) Boys more susceptible than girls. (c) Acute infectious fevers. (d) Probably a specific micro-organism. (1) The seat of the lesion is in the part supplied by the anterior median branch of the anterior spinal artery. Cervical or lumbar portions of the cord are most often affected. (2) In the early stages the lesion is an acute hemorrhagic myelitis, with rapid destruction of the large ganglion-cells. (3) The nerve-fibres of the anterior roots corresponding to the ganglion-cells destroyed break down and disappear. (4) Certain anterior nerve-roots are atrophied, and the muscles innervated by them waste and become fatty and sclerotic.

**RAYNAUD'S DISEASE.**—A form of symmetrical gangrene, affecting especially the fingers and toes, caused by spasm and constriction of the small blood-vessels.

**SCLEROSIS, INSULAR (DISSEMINATED SCLEROSIS).**—Its cause is not definitely known. Is more common in the young than in the old. Sclerotic areas are usually small, of a grayish or whitish color, widely distributed in the brain and cord and in the gray and white matter. They are more abundant about the ventricles, the central canal, the pons, the cerebellum, and the basal ganglia. The patches are firm, dry, and sharply defined from the surrounding tissue; in some cases they may be less firm and not so well defined. Microscopically there is a marked increase of neuroglia, the medulla of the nerves is destroyed, and the axis-cylinders persist.

**SYRINGOMYELIA.**—Syringomyelia is a chronic affection of the spinal cord characterized anatomically by the pathological formation of cavities in its gray matter, and clinically by peculiar disturbances of sensibility associated with trophic disorders. Causes: (a) Embryological malformations. (b) A gliosis. (c) Traumatism. (d) Development of embryonal neuroglial tissue in which hemorrhage or degeneration takes place with the formation of cavities. (1) The characteristic lesion is a cavity which forms in the cord in or near the central canal and extends into the gray matter of the anterior, or more frequently the posterior horns. It is most often situated in the cervical and thoracic portions of the cord. (2) On transverse section the cavity may be oval, circular, or narrow and fissure-like, or it may present the appearance of two or more cavities independent of each other or inter-



communicating. (3) The contents of the cavity are usually a colorless liquid. Occasionally it may be a yellow or brown gelatinous substance, or it may consist of blood and the products of its degeneration. The white matter of the cord in moderate cases is unaffected, but where the cavity is large and pressure from the sclerotic tissue has become great, the white matter is in its turn involved, being crowded to the periphery and more or less unable to carry on its functions.



## CHAPTER XVIII

### EXAMINATION OF THE NASOPHARYNX, EYES, AND EARS

#### EXAMINATION OF THE NASOPHARYNX.

IN order to expose to view the upper air-passages, nasal, pharyngeal, laryngeal, and accessory cavities, epiglottis, etc., Harke's <sup>1</sup> method has come into general use. If the procedure is properly carried out, the parts when returned to their normal position present no noticeable deformity, though during the examination such a result seemed almost impossible.

**HARKE'S METHOD.**—The brain having been removed and the examination of the skull completed, the anterior skin flap is dissected away from the frontal bone down to the root of the nose, while the posterior flap is dissected away some distance below the foramen magnum. It is not necessary that the primary incision of the scalp behind the ears be made lower than the mastoid process on each side. Next, directly in the median line, the skull is cleft with a small saw into two lateral portions. For the sake of convenience the saw markings may be divided into two sets (Fig. 137), the first starting from the front in the frontal bone, extending down to the nasal bone, and continuing to the foramen magnum (*AB*), and the other starting at the occipital bone and extending to the foramen magnum (*CD*). The atlas and axis are sawed through if much room be desired. The sawed portions are now separated by means of a chisel and hammer, any portions of mucous membrane that may appear being severed with a knife or scissors. By means of strong lateral traction the two segments may be pulled apart, and the entire region down to the vocal cords will thus be exposed. Usually the incision passes to one or the other side of the nasal septum. The walls of the accessory cavities are readily cut away with strong scissors, and a plain view is obtained of the maxillary sinuses as well as the frontal, sphenoid, and ethmoid. Even the epiglottis and vocal cords can be examined by this method (Fig. 138). In order to view the parts better, light may be thrown in by means of a mirror.

Another method is to drill holes just in front of the sphenoid and a little behind and to the right and left of the crista galli, and then with a

<sup>1</sup> *Berliner klin. Wochenschrift*, 1892, No. 30; *Virchow's Archiv*, 1891, Vol. 125.



saw or a chisel make an ovoid incision extending almost to the foramen magnum, and remove the portion of bone which hides the nasopharyngeal cavities. (Fig. 137, *P Q*.) The two lateral halves are then brought together and wired as in Fig. 139.

#### EXAMINATION OF THE EYES.

For this purpose a triangular piece of the orbital plate of the frontal bone is broken through with a hammer or chisel, care being taken not to injure the optic nerve in the optic foramen, the remaining portion of the eye and the nerve being well protected. (Fig. 137, *E* and *F*.) The direction of the nerve can be determined by observing the situation of its exposed portion, and the chiselling done a small distance on either side of its normal position. The pieces of bone are removed with the nippers and the optic nerve is carefully dissected out, its cut end being held with the fingers or forceps. The capsule of Tenon and the fat are removed, and the entire eye is excised or, if this is not permitted, an incision is made in the sclerotica posterior to the conjunctival attachment. This requires a very sharp knife, as the tissue is extremely tough. A circular incision is made around the entire eye, and the fundus is exposed. A piece of dark cloth or cotton dipped in ink is placed in the remaining portion of the eye and the cavity is packed with cotton.

If only a macroscopic examination of the retina and other structures is desired, the retina may be floated out in normal salt solution and then separated from the choroid. If the retina is to be fixed for microscopic examination, the incision should be as nearly equatorial as possible and the fundus placed immediately in Orth's or Müller's fluid or ten per cent. formalin, or fixed by exposing for three minutes to the fumes from a one per cent. osmic acid solution heated just to the boiling point. The eye is then put for twelve hours into Lindsay Johnson's mixture:

Potassium bichromate, two and one-half per cent.....	70 parts.
Osmic acid, two per cent.....	10 parts.
Platinic chlorid, one per cent.....	15 parts.
Acetic or formic acid (to be added just before using)....	5 parts.

The gloss of the cornea disappears as soon as death comes on. After twenty-four or thirty hours, and often earlier, the bulbus softens and the cornea and retina become dull. The conjunctiva is now removed more easily from the cornea, and the sclera which is not covered



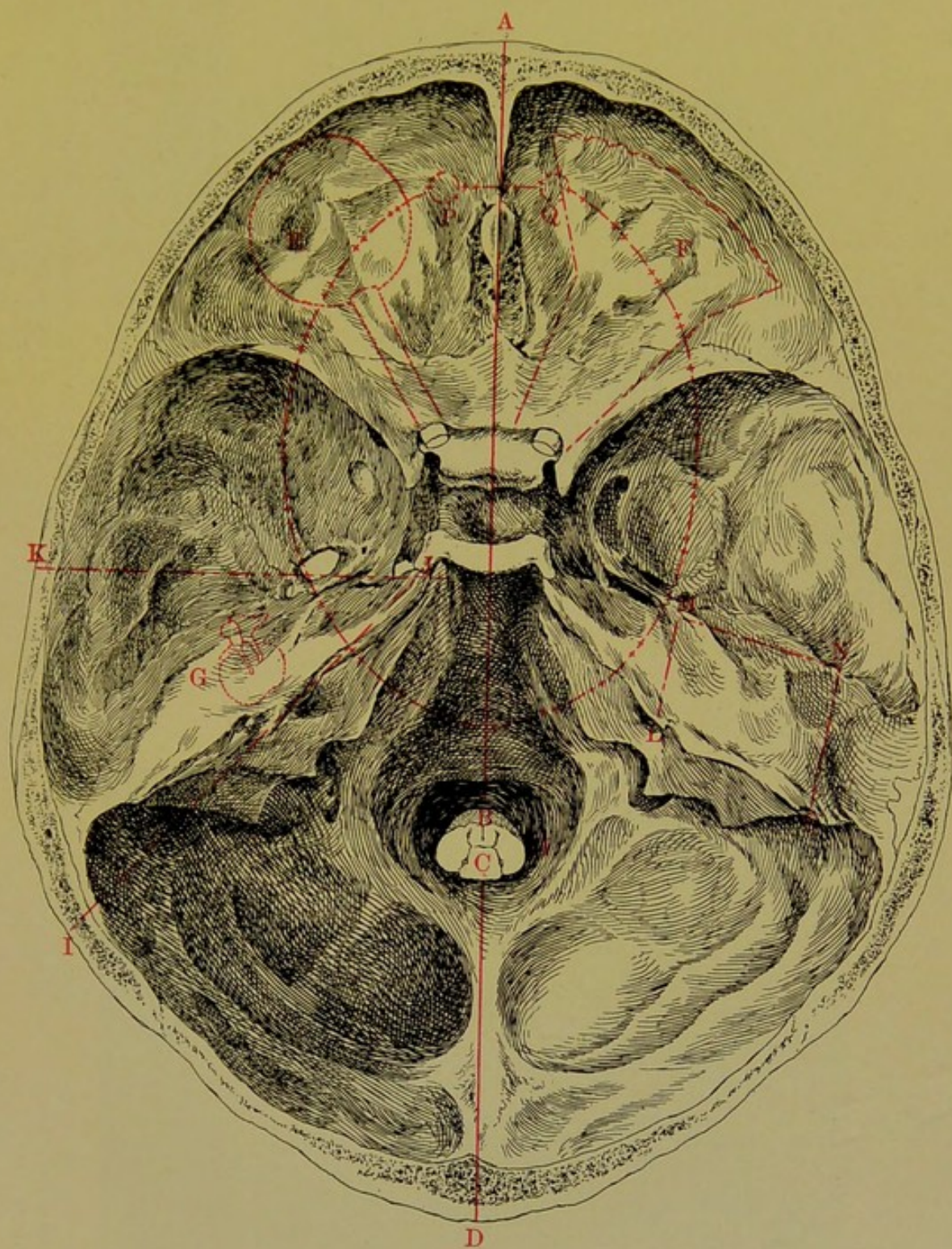


FIG. 137.—Method of examining nasopharynx, eyes, and ears. The sawing for opening the nasopharynx is done in the median line from the frontal bone, *A*, to the anterior portion of the foramen magnum, *B*, and from the occipital bone, *D*, to the posterior portion of the foramen magnum, *C*. The sawing can best be accomplished by standing on the table directly over the head, the finger-saw being especially useful at the beginning and the end of the operation. *E* and *F*, lines of incisions for the removal of the eyes; *G*, situation of the ear-ossicles; *KJI* and *LMNO*, lines for removal of the ear-ossicles; *P* and *Q*, drill-holes for saw-markings in the oval method of examining the nasopharynx.



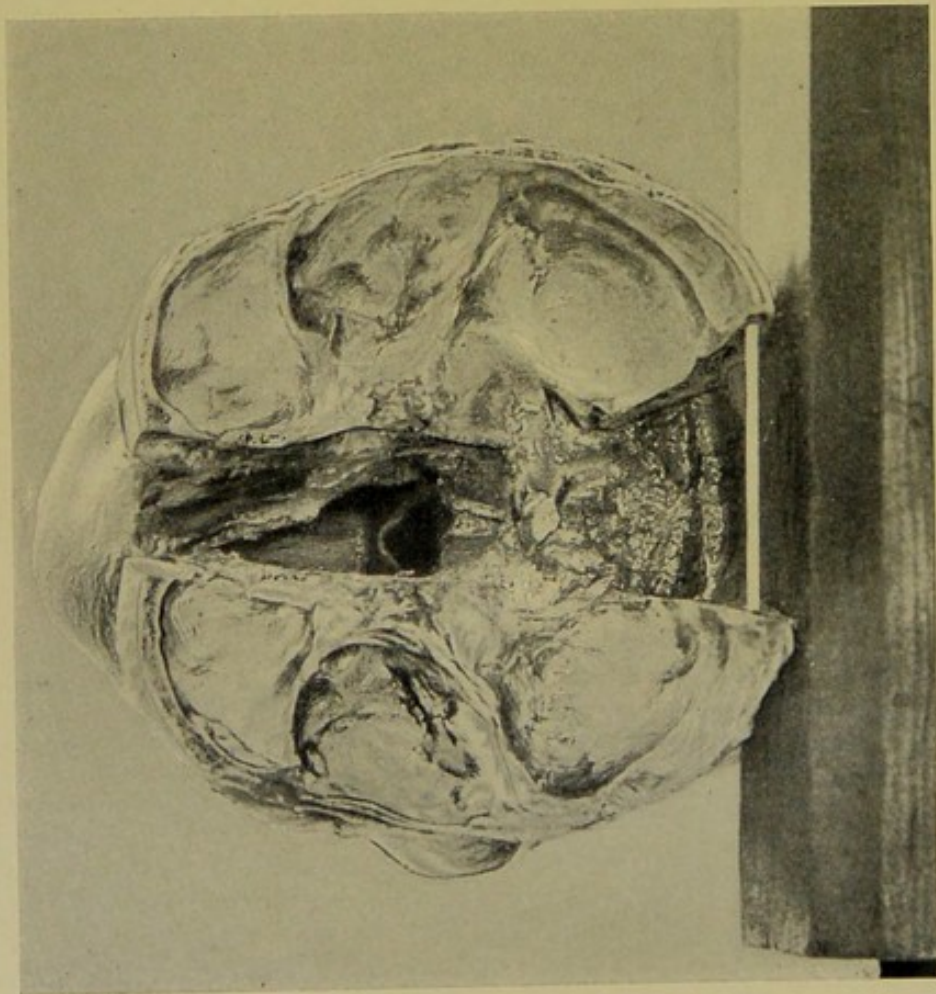


FIG. 138.—Harke's method of examining the nasopharynx. Appearance of the parts after the sawing has been completed and the lateral halves have been pried apart. The tip of the epiglottis is plainly seen in the photograph.

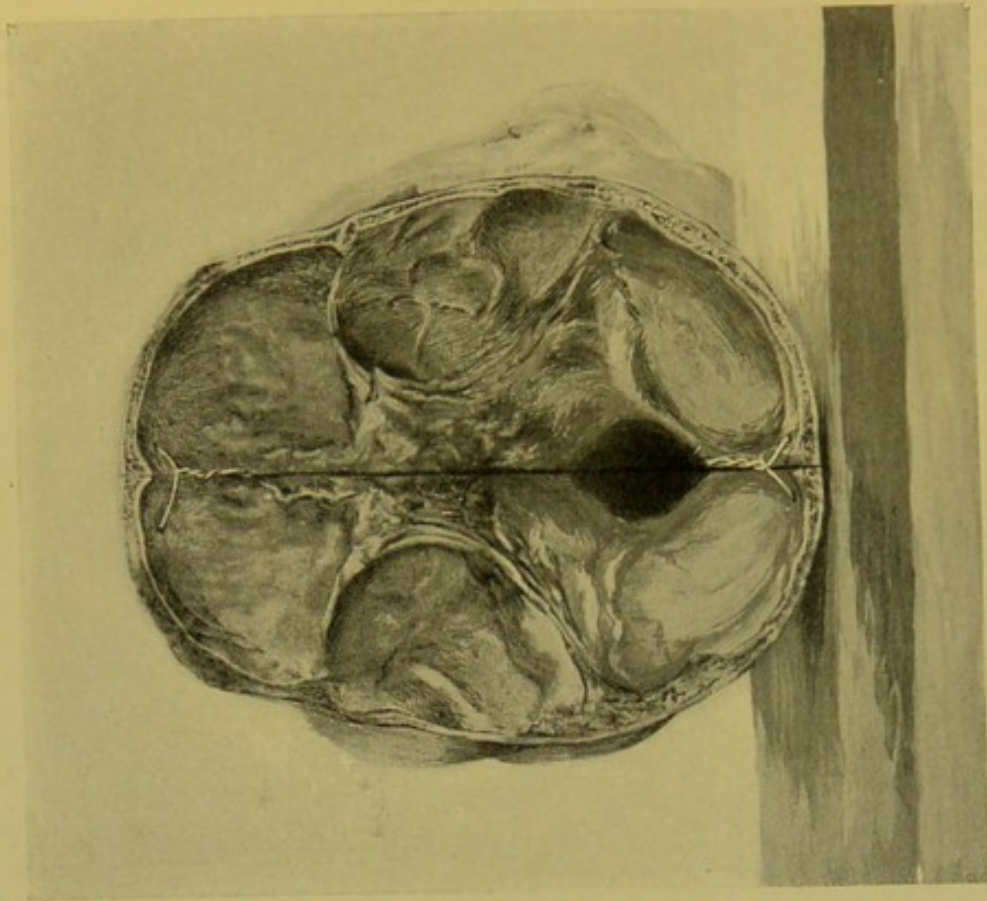


FIG. 139.—Appearance of the parts after wiring of the lateral halves in Harke's method of examining the nasopharynx.



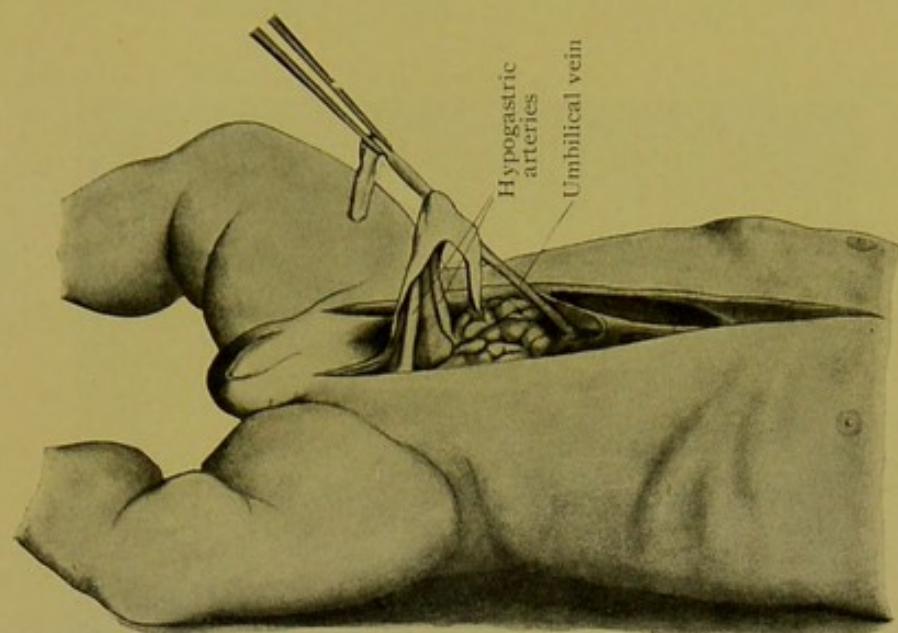


FIG. 140.—Examination of the umbilical vessels. (After Nauwerck.)

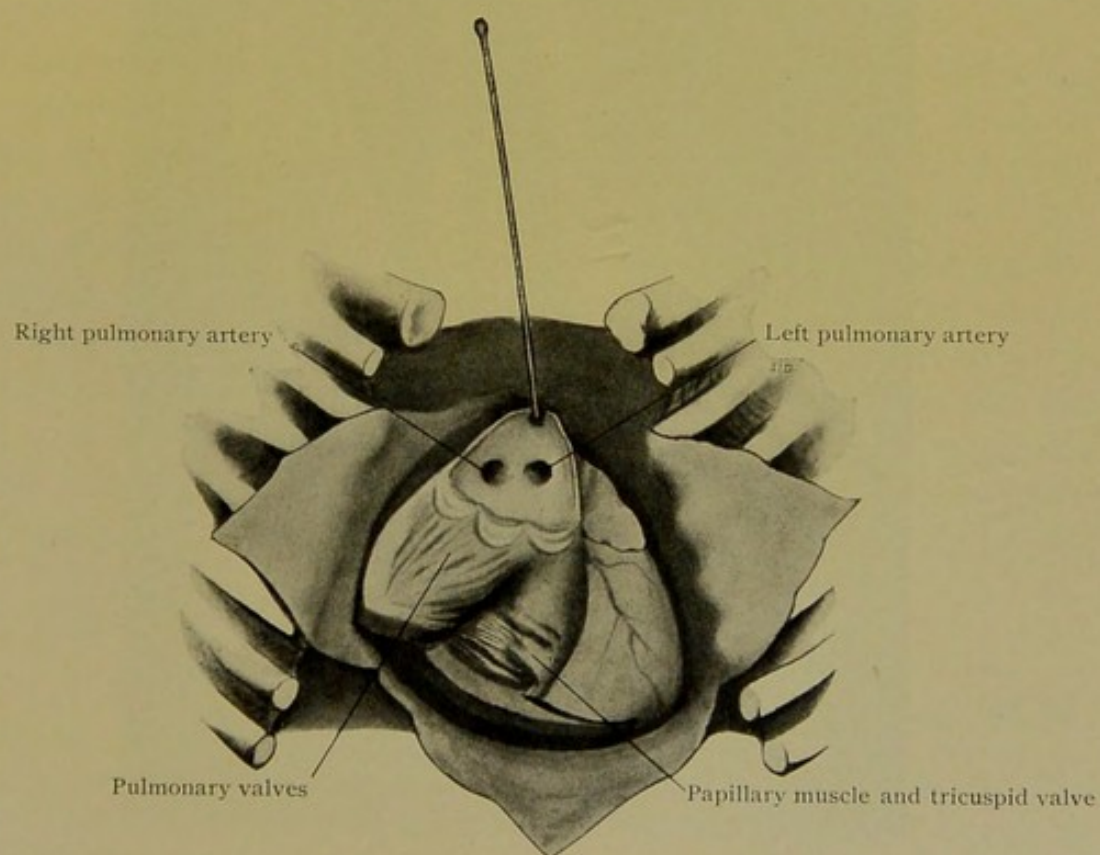


FIG. 141.—Examination of the ductus arteriosus. The sound is represented as introduced into the ductus arteriosus Botalli; this duct usually closes about the fourth day after birth. (After Nauwerck.)



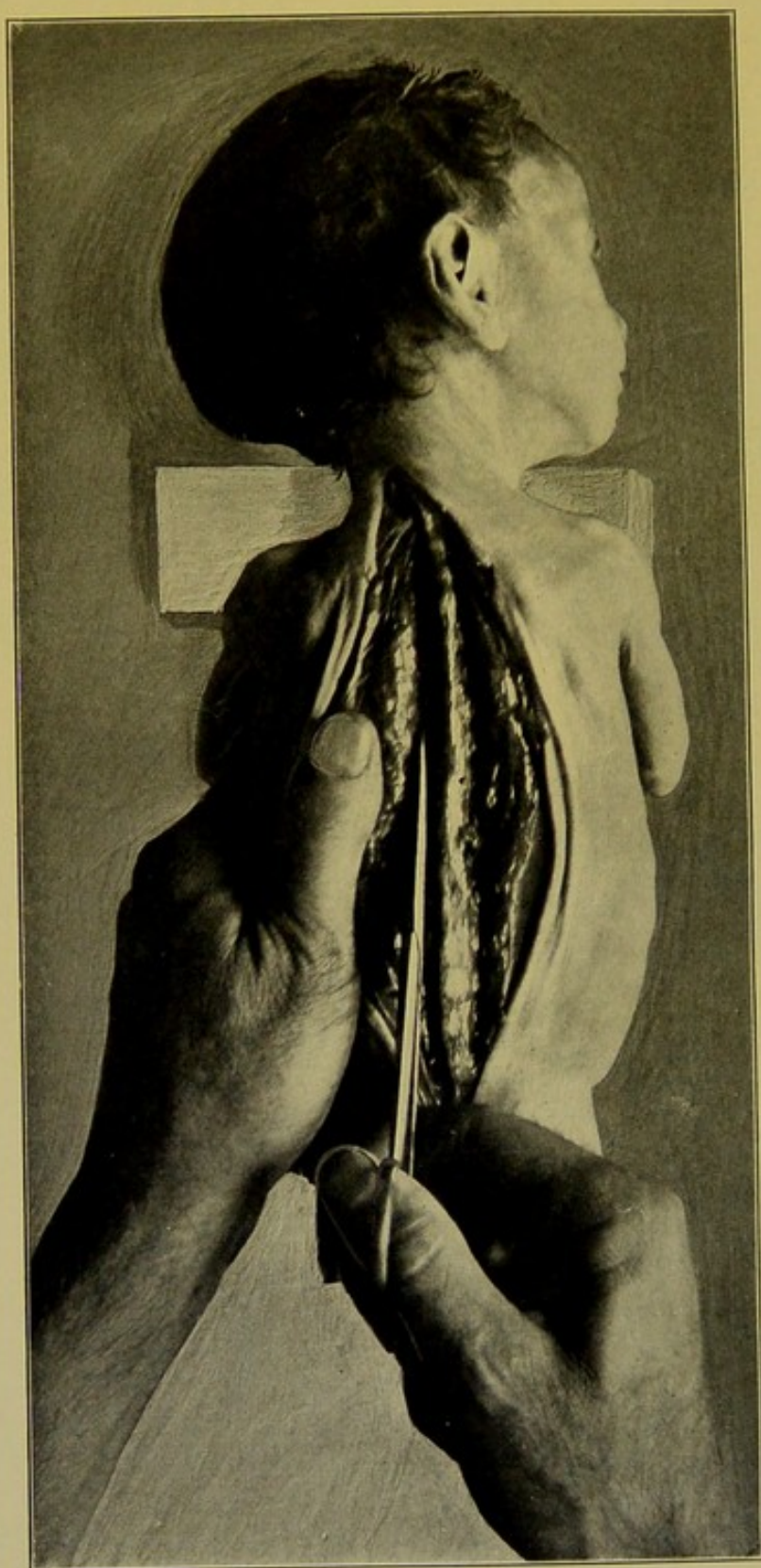

FIG. 142.—Removal of the spinal cord of a child.



by lids becomes brownish black and dry. (Orth.) According to Runge, several days after death a diffuse redness occurs in the transparent media of the eyes of a foetus that has died *in utero*. The redness affects first the cornea and then the lens,—extending from without inward,—in this way indicating approximately the date of death.

The position of the eye may be altered. Exophthalmus, or protrusion of the eye, may be caused by a retrobulbar tumor, œdema, hypertrophy of fat, collection of blood from hemorrhages, emphysema, inflammatory exudates, Basedow's disease, etc. Enophthalmus, or retraction of the eye, may take place in atrophy of the fat, loss of liquid, as in cholera, deformity from scars, etc. The consistency of the eye varies, being increased in glaucoma and diminished in certain forms of degeneration.

#### EXAMINATION OF THE EARS.

A fair idea of the condition of the middle ear may be obtained simply by chipping away the roof with a chisel or biting it off with bone-forceps, but if a closer inspection is desired the petrous portion of the temporal bone and the mastoid process had better be removed together.

Carry the incision from its original point back of the ear and along the anterior border of the trapezius about half-way down the neck. Reflect the flaps with their soft tissues so as to leave the bone clear. Begin at the apex of the petrous portion of the temporal bone and with a chisel laid flat break through the petrobasilar suture to the jugular foramen, and chisel or saw through the skull on a line from the jugular process of the occipital to a point about five centimetres posterior to the base of the mastoid process. Anteriorly chisel or saw through the skull on a line from the apex passing posterior to the spinous process of the sphenoid; or between the foramen ovale and the foramen spinosum and well anterior to the external meatus, just cutting off the root of the zygoma.

Woodhead<sup>1</sup> uses the following method:

“The temporal bone, with its petrous portion containing the internal ear, may be taken out and examined after removal of the brain, by stripping off the dura mater from the base, dissecting off the skin and muscle, detaching the external ear from the bone, and disarticulating the jaw; then, taking the margins of the temporal bone as the

<sup>1</sup> *Practical Pathology*, p. 28, 1892.



base of a pyramid, the apex of which is a little beyond the inner extremity of the petrous portion, two saw-cuts are carried almost vertically downward so as to bound the pyramid, and then with a bone-chisel and mallet the whole temporal bone may be removed, after which it may be softened in a decalcifying fluid; or the internal ear may be dissected out with a small saw, a pair of sharp well-fitting bone-forceps, and a sharp gouge and chisel. The internal ear or tympanic cavity and mastoid cells may also be opened up with the aid of the above instruments."

By sawing or chiselling as in Fig. 137, *K J I* or *L M N O*, the ear-ossicles and internal ear may readily be reached.



## CHAPTER XIX

### POST-MORTEM EXAMINATIONS OF THE NEW-BORN <sup>1</sup>

IN performing a postmortem on a child it is sometimes advantageous to remove the viscera *en masse*. To practise evisceration the trachea and œsophagus are divided as high up as practicable and then elevated with the free hand. All the posterior attachments are cut as close as possible to the vertebral column until the diaphragm is reached. This is excised laterally and posteriorly, adhesions being severed with the knife as before. The crura being cut loose, the diaphragm is free. Two ligatures are now applied to the rectum, which is then divided between them. When everything which holds the abdominal organs in place has been loosened with the hand, the organs of both the thorax and the abdomen can readily be removed, leaving only the bladder and organs of generation *in situ*; these may be excised later, in the same manner as that described for the adult on page 132. By this method the viscera can be more conveniently examined both anteriorly and posteriorly, and, as they are all attached, their normal relations are preserved.

The body of a child thus disembowelled can be kept for a long time, especially if the abdominal cavity be packed with a mixture of equal parts of bran and salt, to which a little white arsenic may advantageously be added. The cadaver should then be surrounded with cotton and a circular bandage applied to the chest and thorax. Parental consent to the performance of an autopsy may sometimes be obtained by suggesting the employment of this method of preserving the body. The methods of examining the umbilical vessels and the ductus arteriosus are readily seen by referring to Figs. 140 and 141 respectively.

The removal of a child's brain is more difficult than that of an adult, because, first, it is much softer, and, second, the dura is normally adherent to the cranium. But it is easier in one thing,—the fact that the bones and sutures are not ossified. In a new-born child the brain

---

<sup>1</sup> For the sake of convenience, references are here added to other portions of this work which may be consulted when making postmortems in the new-born. To ascertain the intra-uterine age of a stillborn child see page 313. To determine whether the child was dead or alive see page 312. For weights and measurements of the child at birth see page 269.



is so soft that its removal without injury is almost impossible. In such cases it is advisable to lay the body for a short time on ice sprinkled with salt, in order that the brain may become hardened by the cold. Another method, and one in which I have obtained the best results, is to place the child in a large basin or tub containing a strong solution of common salt (about half a bucketful to four or five times this amount of water) and conduct the final operation of removing the brain beneath the surface of the liquid, where the body is held by an assistant. Brine of the above strength has a specific gravity slightly greater than that of the brain substance, thus affording more general and even support and lessening the liability of damage.

The method is as follows: The scalp is incised across the vertex and the flaps are turned forward and backward as in the adult. With scissors having well-rounded points cut through the sutures and dura well down to the floor. The five flaps thus formed are pulled outward and if necessary cut partly across their base by strong scissors. While the brain is being removed the body should preferably be held in the salt solution. Begin by removing the falx cerebri and longitudinal sinus, then the frontal lobes, olfactory bulbs, etc., in the usual order. When the tentorium and falx are cut through, the brain can be pushed out into the solution, where it will float. If it is desired to harden the brain, it will be well to place a jar of Müller's or other hardening fluid under it, the transfer being made from the salt solution to the preservative fluid without much of the solution passing into the jar, though the fluid should afterwards be changed for a fresh supply.

The spinal cord may be removed from the body of a baby with scissors alone, as the parts are easily cut through. The lines for the incisions through the skin and the vertebræ are made in the same manner as in the adult, but neither knife nor saw is required, the scissors being strong enough easily to penetrate the soft bony structures of the vertebral column in a child under fifteen months of age. (Fig. 142.) In babes the spinal cord is relatively much more firm than the brain.

In autopsies on babes suspected of being the victims of hereditary syphilis it is often important to look for the fatty changes produced by that disease at the junction of the cartilage and the bone in the femur. For this purpose a longitudinal incision is made directly over the head of the os femoris and the soft parts are dissected until the bone is reached. The ligaments are then incised and the head is disarticulated. The shaft is held by the left hand securely wrapped in a towel



while a perpendicular incision through the cartilaginous head is made down to the bone; should this be much ossified, the incision may be continued with a saw. After sawing for about two inches, a knife is introduced and one segment is broken off. The presence of a yellowish area of fatty degeneration, more conspicuous in the osseous portion than in the cartilage, shows an interference in the nutrition of the part which is quite characteristic of hereditary syphilis. (Figs. 143 and 144.)



## CHAPTER XX

### RESTRICTED POST-MORTEM EXAMINATIONS

IN case permission to open the thorax is refused, the diaphragm may be severed from its anterior attachments, and the lungs, the heart, and even the tongue and adjacent parts may be removed *en masse* through an abdominal incision or a laparotomy wound.

Should the avoidance of visible mutilation be imperative, it is possible to examine and, if necessary, to remove both the abdominal and thoracic viscera through the rectum or perineum in males or through the vagina in females. In the male this procedure is performed in the following manner: <sup>1</sup>

The body is placed on the back, with the buttocks very near the end of the table and the thighs widely separated and flexed upon the body. The scrotum is then well drawn up, and an incision is made from the perineo-scrotal junction to the margin of the anus and down to the bulb. The knife is carried around this and through the subjacent tissue to the pelvic fascia underlying the vesicorectal pouch, without injuring the bladder or rectum. The left arm being bared to the shoulder, the hand is introduced through the incision, and gradually forced up between the parietal peritoneum and the rectus muscles to the diaphragm. The peritoneum may be opened, but the intestines will invest the hand like a tightly fitting glove and make the manipulation more difficult. If unable to perforate the diaphragm with the fingers, a scalpel may be carried up, with the blade flat against the index-finger, and a nick made in the muscle, the knife being then withdrawn and the opening enlarged with the fingers. The lungs may be examined by palpation, any adhesions broken up, and the organs dragged into the abdominal cavity, the roots being severed with a knife, after which they may be removed. The heart can be examined in a similar manner, except that, before it can be moved very far, scissors or a knife will be necessary to sever the large vessels. The kidneys, adrenals, spleen, stomach, etc., may be removed in this manner, but the liver must generally be divided into its lobes in order to get it through the incision. The organs are examined in the usual manner and returned to the body; some wads of oakum may then be pushed into the abdominal cavity and the perineal incision very carefully closed by hidden sutures.

---

<sup>1</sup> H. A. KELLY, *Medical News*, June 30, 1883.



It is also possible to make the examination through the rectum, but the sphincter is left dilated and gaping, presenting a much more conspicuous and unsightly appearance than the perineal incision.

This method is most difficult of accomplishment when the operator's arm measures more than ten or eleven inches around the biceps, especially in subjects of only average size. The work is very arduous, because of the strained and cramped position which the hand and arm must assume in order to pass the promontory of the sacrum. Coplin suggests the use of the photographer's thimble in tearing the tissues within the abdominal cavity.

Access to the interior of the trunk may readily be had from the dorsum by making a longitudinal incision to one side of the spinal column and sawing the ribs close to their vertebral attachments. When the examination is made through the vagina, an oval incision such as is described on page 132 may be made, or a vaginal hysterectomy may first be performed (Figs. 89 to 93 inclusive).

The brain may be removed almost intact (in two or three pieces) by making a transverse four-inch incision across the fifth cervical vertebra, dissecting up the soft tissues, and cutting a V-shaped segment out of the occipital bone by introducing a saw through the foramen magnum and sawing towards the ears and then across transversely. (Fig. 130, *E A F*.) My rapid method of diagnosing hemorrhage also permits of the removal of the brain in small pieces. (See page 179.)

An examination of the bones of the face is sometimes desirable, but the circumstances and conditions under which it may be required are so variable that the method must be left entirely to the judgment of the operator. Disfigurement is so readily noticed that nothing further than a superficial examination should be attempted without the permission of those interested. The simplest and most unobjectionable method of procedure is to introduce the knife through an incision previously made from the ear to the neck and dissect subcutaneously the tissue investing the bony structures. If the bones of the face are to be removed, it may be necessary to make a transverse incision, the point of election being the furrow between the inferior maxilla and the neck.

If the oral cavity must be examined through the orifice of the mouth after rigor mortis has set in, the rigidity may be overcome by placing towels soaked with hot water over the muscles of the jaw. Such appli-



cations repeated for about five minutes usually suffice. Do not use a chisel to pry the jaws apart, as is sometimes recommended, because of the danger of breaking the teeth or knocking them out. As the rigidity rarely returns, it is advisable at the end of the examination to close the mouth with a few sutures through the mucous membrane of the upper and lower lips.

The nasal cavity may be exposed and examined by detaching with a knife the upper lip from the maxilla from within and then removing with a saw such portions of the superior jaw-bone as will afford room for inspection of the parts under consideration (Figs. 145, 146). By the removal of the eye the pituitary body, Gasserian ganglion, etc., are rendered easily accessible. Indeed, it is surprising what extensive dissections may be made in the region of the face and neck in the ways just mentioned, thus affording an opportunity for thorough digital examination of areas not open to ocular inspection.



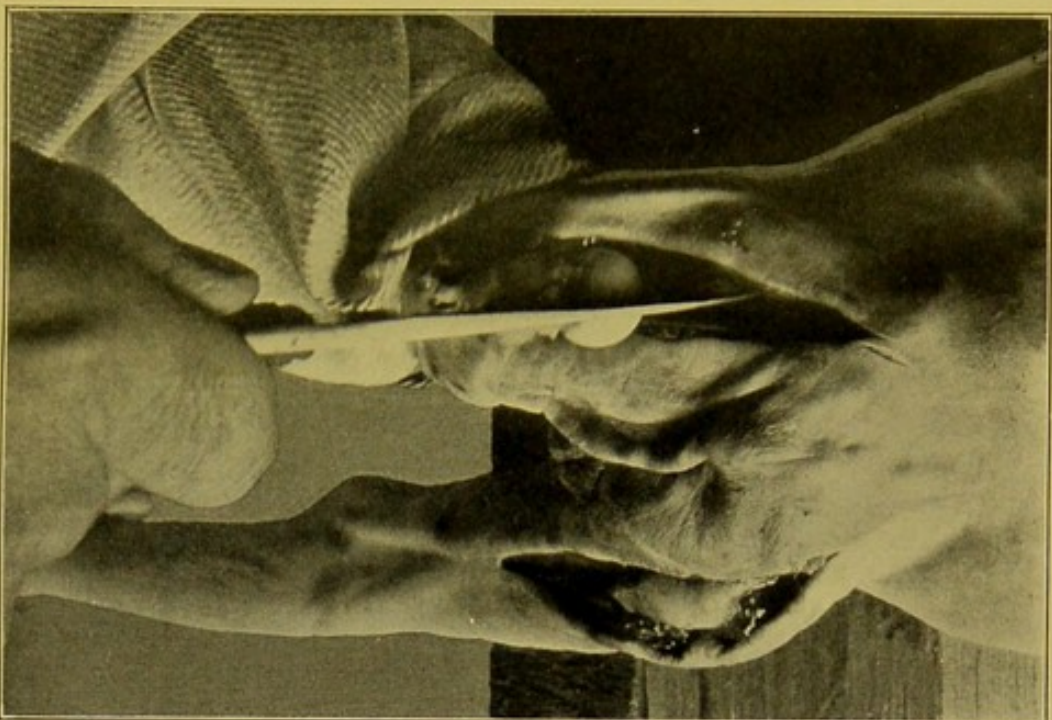


FIG. 143.—Method of examining for syphilitic osteochondritis of the femur. The initial skin incision is seen over the femur on the right side; in the left limb the bone has been disarticulated. The left hand, holding the bone, is well wrapped in a towel. The longitudinal incision is made with a strong cartilage-knife. Usually this is sufficient even to cut the bone; if not, a small saw may be used.

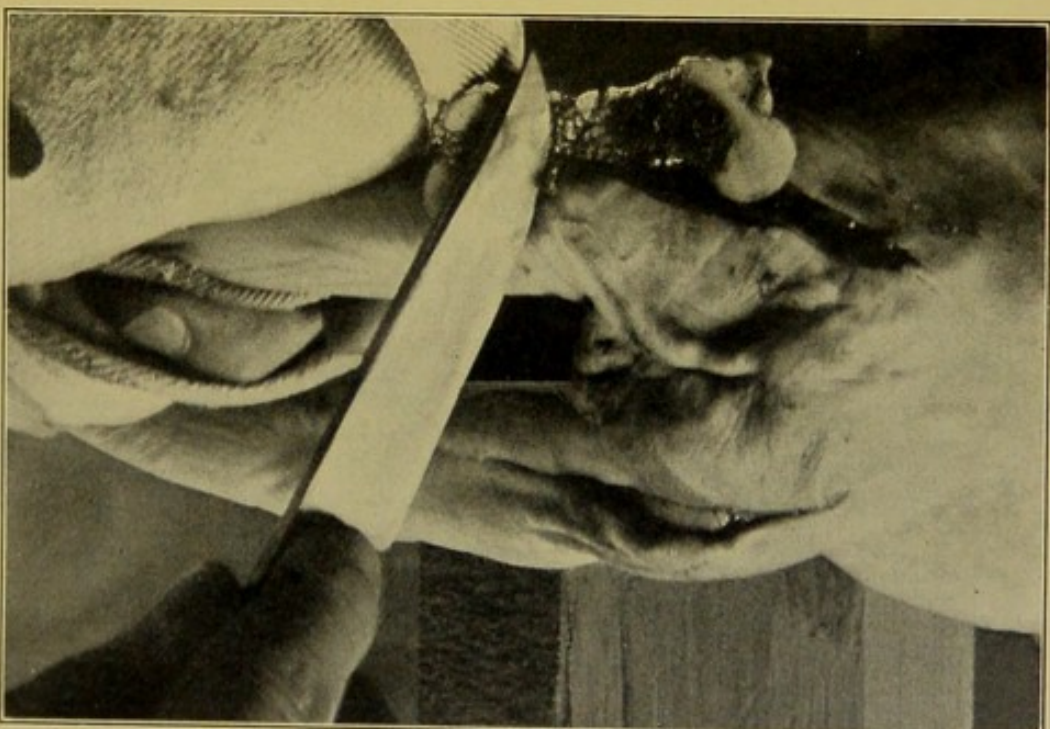


FIG. 144.—Examination for syphilitic osteochondritis of the femur. After the sawing is completed, one portion of the cut bone is bent back and the osteochondral line is well shown.



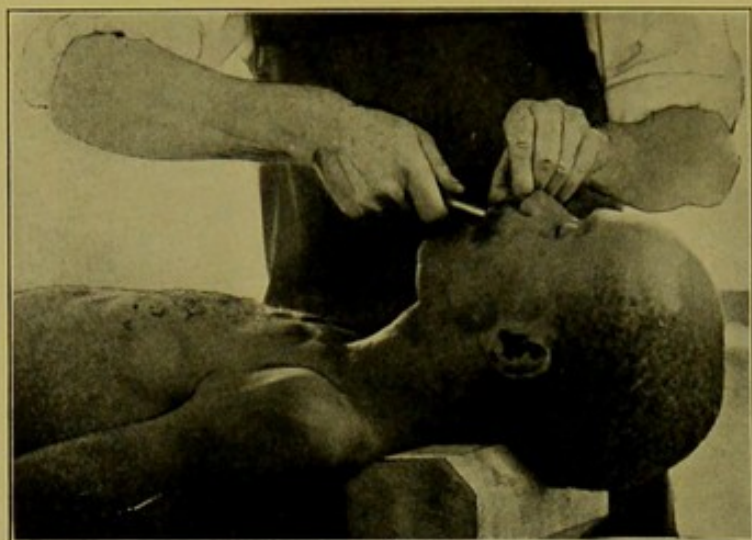


FIG. 145.—Method of examining nasal cavities, antrum of Highmore, etc. By means of a knife the uppermost mucous membrane between the lip and the superior maxilla is incised, the upper lip being elevated with the left hand during the incision. Vertical sawing is now done in the median line, and the tooth extracted at the point where the lateral sawing is to take place. The bone-forceps readily bring the desired portion of bone away, or it can be loosened by means of a chisel.

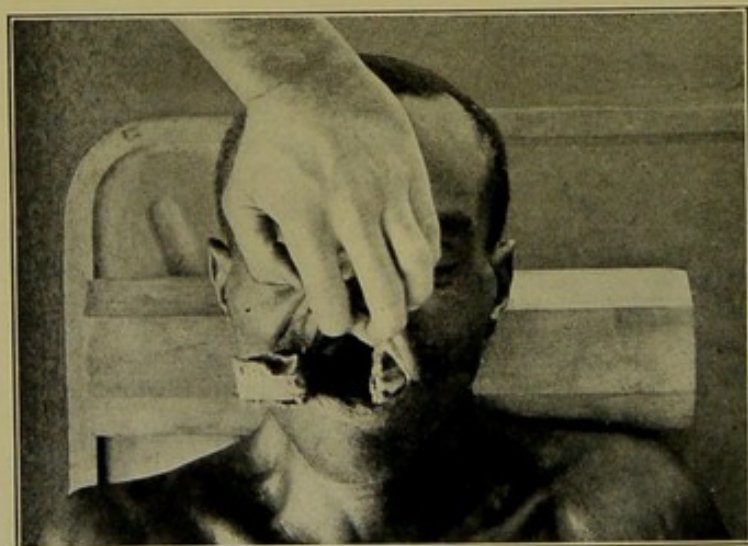


FIG. 146.—Appearance of the part after removal of a portion of the superior maxilla for the purpose of examining the nasal cavities, antrum of Highmore, etc.



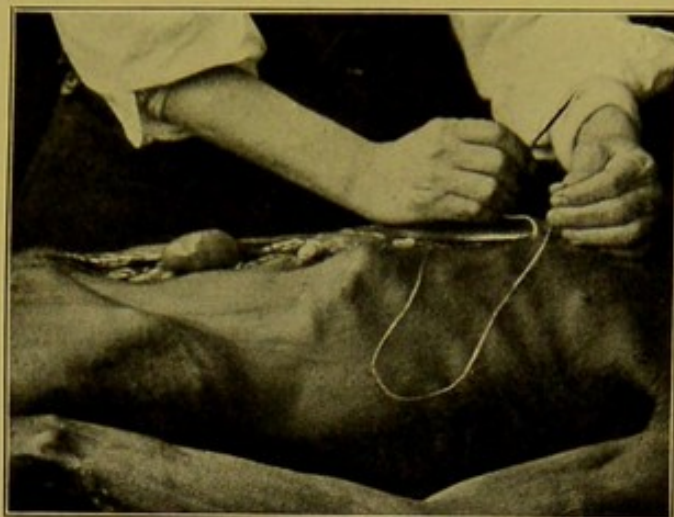


FIG. 147.—Method of sewing up the body.

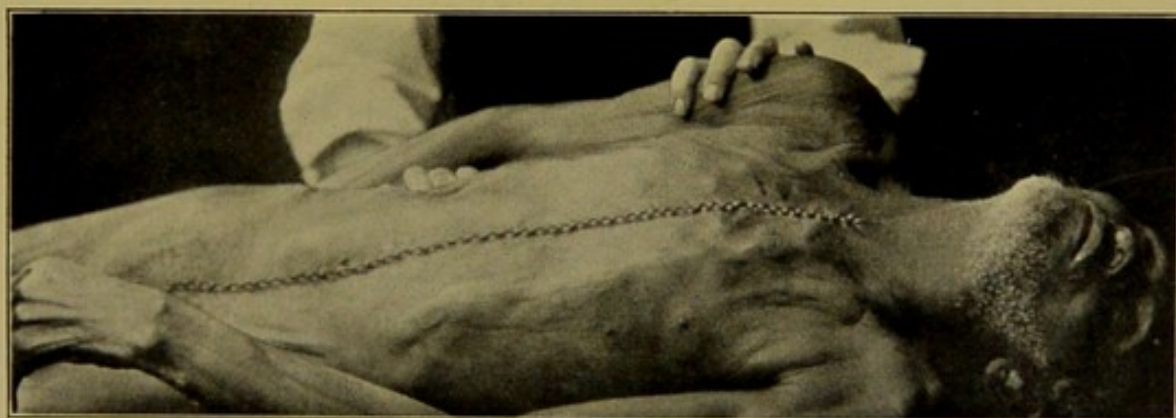


FIG. 148.—Appearance of body after it has been sewed with base-ball stitch. The sewing has been done from above downward, and there is no puckering at the point of starting.



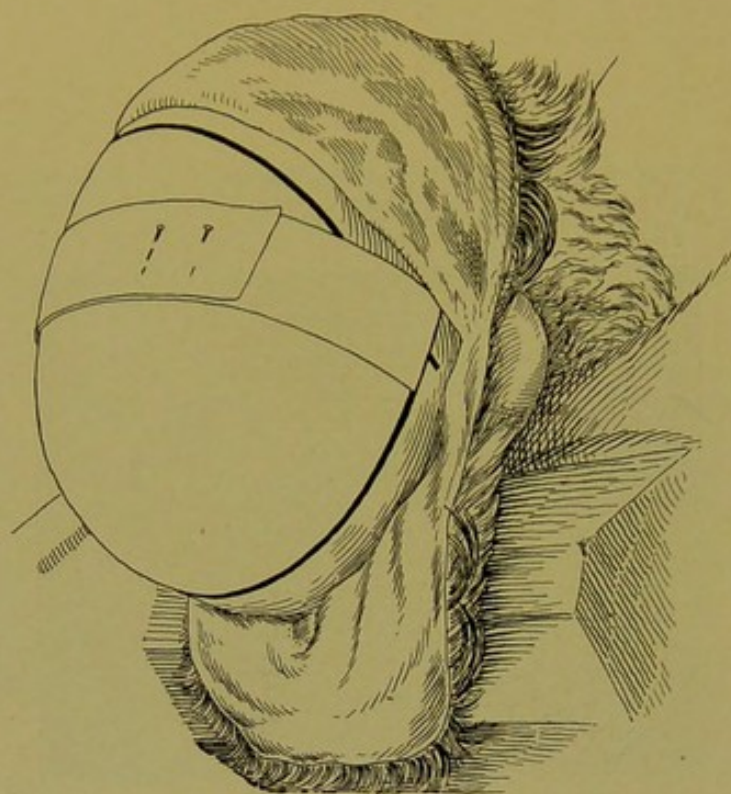


FIG. 149.—Slee's method of fixing the skullcap.

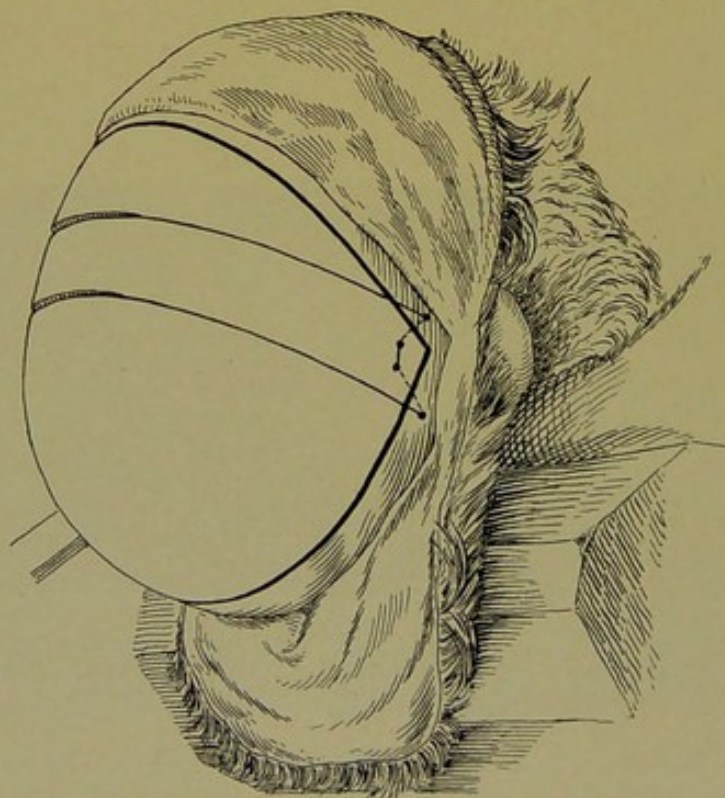


FIG. 150.—Author's method of holding skullcap in place. Four holes are drilled in the bones on each side, two to the right and left of the angle in the temporal bone and two in the skullcap just above the angle. Saw-cuts to hold the wire or string are made in the vertex, the string being thrust in and out of the openings and tied at any convenient spot.



## CHAPTER XXI

### RESTORATION AND PRESERVATION OF THE BODY

WHEN the examination has been completed, the cavities of the body should be thoroughly sponged out, all blood and other fluids removed, and bleeding vessels tied to prevent leakage. The organs should then, as nearly as possible, be returned to their respective positions, and the cavities filled with dry bran, absorbent cotton, sawdust, sea-weed, or shavings, in sufficient quantity to restore the original contour of the body, covering the abdominal contents with old cloth or papers to protect the under surface of the seam. The brain is generally put into the abdominal or thoracic cavity, owing to the great difficulty in returning it to the skull. If several postmortems be made at the same time and place, care should be taken to return the organs to the proper body, nor should a cadaver be used as a convenient receptacle for the disposal of specimens which are no longer of any use. The late Dr. Formad told me of a case where three livers were found in a body previously posted in one of our Philadelphia hospitals and disinterred for suspected poisoning. In the case of a child a small bag may be packed with sand or sawdust so as to assume the shape of the brain and placed inside the calvarium; the brain itself, after dissection, is placed in the abdominal or thoracic cavity.

In all private cases it is important to secure the skullcap in position, to prevent the unsightly disfigurement produced when it slips after the scalp has been sutured. A number of efficient methods have been devised, but the one selected usually depends upon circumstances or upon ingenuity. The fossæ of the skull as well as the calvarium may be filled with plaster of Paris, and while the plaster is still soft a short, stout stick of wood is pushed through into the foramen magnum, the upper end extending to the skullcap, which is then adjusted. When the plaster hardens, the calvarium is well fastened in good position. If in removing the calvaria the precaution is taken to crack at least a part of the inner table with the chisel and hammer, projecting pieces of bone are usually left, which interlock and hold the calvaria snugly in position when it is replaced.<sup>1</sup> If the edges of the temporalis have not been too badly lacerated, sutures may be passed through the muscle and fascia

---

<sup>1</sup> MALLORY and WRIGHT, *Pathological Technique*.



with very satisfactory results. Small holes may be drilled in the skull and sutures passed through them, or a wide staple (or double-pointed carpet-tack) may be used for the same purpose. Another method is to drive a small wire pin, or a wire nail with its head cut off, about half an inch long, half-way into the diploe of the skull and insert the other end in a hole, made to correspond, in the calvarium. Two of these pins should be enough. Still another method is that described by Slee.<sup>1</sup> The posterior line of sawing, instead of stopping at the angle, is continued an inch or more into the temporal bone; a piece of ordinary roller bandage is then stretched across the skull and inserted in the saw-cut; the calvarium is replaced, the ends of the bandage are brought together over the vault and securely sewed, pinned, or tied (Fig. 149). A ready and efficient method of my own for fixing the skullcap is to make in two or three places on the thickest portions of the skull vertical pencil-marks across the line of sawing and extending an inch above and below it, saw these for three-quarters of an inch or so, and into each pair of saw-cuts insert the ends of a thin double-wedge-shaped piece of iron or steel so made that it will be tightly pushed into place when the skullcap is affixed. Any portion projecting beyond the bone is hammered down. For another method see Fig. 150.

If the vault of the cranium is to be retained by the physician and a substitute cannot be found, take a square piece of pasteboard about three millimetres thick (thinner for children) and soak it in warm water for a quarter of an hour, or until it is soft enough to be easily moulded over the skullcap. Having done this, cut the pasteboard parallel to the edges of the saw-cuts and overriding them from ten to fifteen millimetres. Then fill the skull cavity with wadding or plaster of Paris. Remove the pasteboard from the skullcap just as soon as it becomes so dry that when it is applied to the base of the skull the edges will adapt themselves to the border thereof. With a knife the edges of the pasteboard are cut obliquely, any folds which are formed therein are incised along their crests, one edge is tucked in under the other, and the surface smoothed by the use of the knife. Strong twine is bound twice around and the pasteboard thus securely fastened to the base of the skull. The temporal muscle is drawn upward and the skin stitched over the whole as in the usual way. (Nauwerck.)

---

<sup>1</sup> *Medical News*, December 31, 1892, p. 737.



The skullcap being secured, the scalp is replaced and sutured with glover's or base-ball stitches,—*i.e.*, those made by repeatedly passing the needle from within outward. By careful use of black or dark thread the incision may be so neatly closed as to escape even fairly close inspection. It sometimes happens that by stretching the skin becomes baggy. A small portion of the hairy scalp may then be removed previous to the sewing.

After the organs are returned, the sternum should be supported by paper, or, still better, by old linen. Bran and fine sawdust are very useful to fill in with, as they absorb the moisture. Oakum makes the sewing difficult. Formad used to tell of a disastrous though amusing result which occurred from the use of a large quantity of self-raising buckwheat flour for this purpose.

If the organs have been removed through the vagina or rectum, these outlets should be doubly sewed, some absorbent material having first been introduced to prevent leakage.

A round stick or a piece of gas-pipe may be placed in the spinal canal after the removal of the cord, with the upper end pushed through the foramen magnum, especially if any of the vertebræ have been taken away, and plaster of Paris may be poured in until the cavity is well filled. An old cloth or some paper is then placed on top and the whole sewed together. The line of the incision may be covered with a strip of adhesive plaster.

The abdominal incision is closed by sewing from the pubes to the sternum, passing the stitches from within outward, about three-eighths of an inch from the cut edges and about half an inch apart, alternating on the two sides so that each needle-hole on one side will be midway between two on the opposite side. The twine should be about half a millimetre thick. Both ends of the suture should be securely tied. For the closing stitch it is well to cut the thread near the needle, withdraw one end, and tie in a surgeon's knot. Roughly estimated, the thread required is twice the length of the incision to be closed. Carefully crowd in any extruding fascia and avoid puckering of the part. (Figs. 147, 148.)

If the mouth has been opened, or any of the tongue removed with the structures of the neck, the lips may be held together by a few sutures passed through the oral mucous membrane.

If any portions of bone have been excised, their place may be sup-



plied by using a properly shaped piece of wood, which is held in position with sutures, wire, or strong cord, or by plaster of Paris.

Lastly the body should be very carefully cleaned and returned to the place and position in which it was found.

The characteristic "post-mortem odor" is very persistent and defies all kinds of soap. It usually results from handling the intestines, and can best be removed by washing the hands with aromatic spirit of ammonia or, in the absence of that, by rubbing them with dry mustard and then washing with soap and water, or, still better, with some of the newer liquid antiseptic soaps.

Ammonia or the aromatic spirit thereof will remove iodine stains, while carbol-fuchsin and other aniline stains yield to a weak solution of sodium hypobromite.

#### EMBALMED AND FROZEN BODIES.

It has become an almost universal custom to preserve bodies by embalming or freezing very soon after death, a process which often interferes with the work of the pathologist as well as with that of the toxicologist. The appearance of the body in such cases will, of course, depend very largely upon the fluid used. Fortunately, the old zinc, mercurial, and arsenical combinations have been very largely superseded by formalin, a much more desirable preparation, although it may irritate the eyes, deaden the sensibility of the finger tips, and even produce an eczema of the hands.

If it is impossible to make the autopsy at once, preservatives may be injected into the body to keep it until such time as convenient. For this purpose, about three hundred cubic centimetres of a five per cent. solution of formalin are sufficient. The fluid may be introduced through the arteries (arterial embalming), or a coarse trocar and cannula may be driven deeply into the tissues and the cavities and organs injected (cavity embalming).

The former method is usually practised by opening one of the large superficial arteries, as the femoral, and forcing the fluid through the vessels. Nauwerck uses the following instruments: an injection-syringe with a capacity of five hundred cubic centimetres; long cannulae of different calibers, with pear-shaped ends and with stopcocks or, preferably, with double stopcocks; strong twine; scalpels, scissors, forceps, grooved director, hæmostats, an aneurism-needle, and ordinary needles; basins and buckets; several packages of absorbent



cotton; cloths and sponges; and ten litres of a one per cent. watery solution of corrosive sublimate, which may be kept in one-litre bottles. His method of embalming is begun by exposing the lower part of the abdominal aorta and the two iliac arteries. Two ligatures are placed beneath the aorta, about two finger-breadths apart, and the aorta is obliquely incised to allow the entrance of the cannula, which is secured by tying the distal ligature over it. The injection into the upper part of the body is then begun carefully and slowly, pausing occasionally when the counter-pressure becomes too great. About three litres are injected, more or less, depending upon the appearance of swelling of the face, seen first about the eyes and chin. The cannula is removed, both proximal and distal ligatures are tied, and the aorta is cut through. In like manner a litre of the solution is injected into each leg through the common iliac artery. A cannula with a double stopcock can be used to inject both the upper and lower parts of the body at the same time. The mesentery is ligated, and the intestines, from the beginning of the jejunum to the end of the sigmoid flexure, are removed, opened, washed out, and put in a one per cent. solution of bichloride of mercury, and later replaced in the abdominal cavity, wrapped in sublimated cotton, or, where practicable, disposed of by cremation. The stomach, duodenum, and rectum are cleaned out with sublimate solution and packed with sublimated cotton. The bladder, vagina, external ear, and nose are similarly treated. The abdominal cavity is carefully wiped with a cloth wrung out of the bichloride solution and dried, and the abdominal incision is sewed. The surface of the body, with the exception of the hair, is also wiped with the solution and dried. If this method fails, Nauwerck injects into the carotid and axillary arteries.

Hewson<sup>1</sup> recommends the following preservative injection for the embalming of human bodies:

R Sodium arsenate .....	2 kilogrammes.
Boiling water.....	7850 cubic centimetres.
Boil until complete solution, then add	
Glycerin .....	2000 cubic centimetres.
Formalin.....	100 to 150 cubic centimetres.

About two and one-half gallons of this fluid are introduced into an artery—say the common carotid—by gravity, openings having pre-

---

<sup>1</sup> *Philadelphia Medical Journal*, October 27, 1900.



viously been made in the toes or in several of the veins if they be distended with blood. After injection the body is thoroughly greased, covered with paper, bandaged, and placed in cold storage until wanted for dissection.

Frozen bodies should not be thawed hastily by the addition of warm objects, but should be allowed to remain in a warm room for some twelve hours previous to the post-mortem examination. Figs. 151 and 152 show the refrigeration room of the Medical Department of the University of Pennsylvania, planned by Dr. Holmes, in which when teaching in that institution I kept the cadavers used in illustrating my lectures. The bodies were removed during the afternoon preceding the performance of the autopsy the next morning.

In cavity embalming the instrument is thrust preferably through the umbilicus, so that the wound of entrance will not be conspicuous, and efforts are made to puncture the intestines in as many places as possible and to penetrate the heart, lungs, and liver; blood is then withdrawn, the gas escapes, and the fluid is injected. The disadvantages of this method are: first, in cases of abortion with peritonitis there may be considerable difficulty in determining whether the markings were made before or after death; secondly, such punctures may also complicate matters by opening up abscess-cavities, cysts, aneurisms, etc.; and thirdly, in cases of poisoning, besides allowing the stomach contents to escape, the fluid may contain the same substance as that which caused death. Even when formalin has been employed, as in the recent Haines case in New Jersey, the syringe may have been previously used for injecting an arsenical preparation.





FIG. 151.—Refrigerating room. *A*, recording thermometer and middle tier of shelving; *B* and *D*, tiers of shelving; *C*, brine tank; *E*, pipes of refrigeration apparatus.

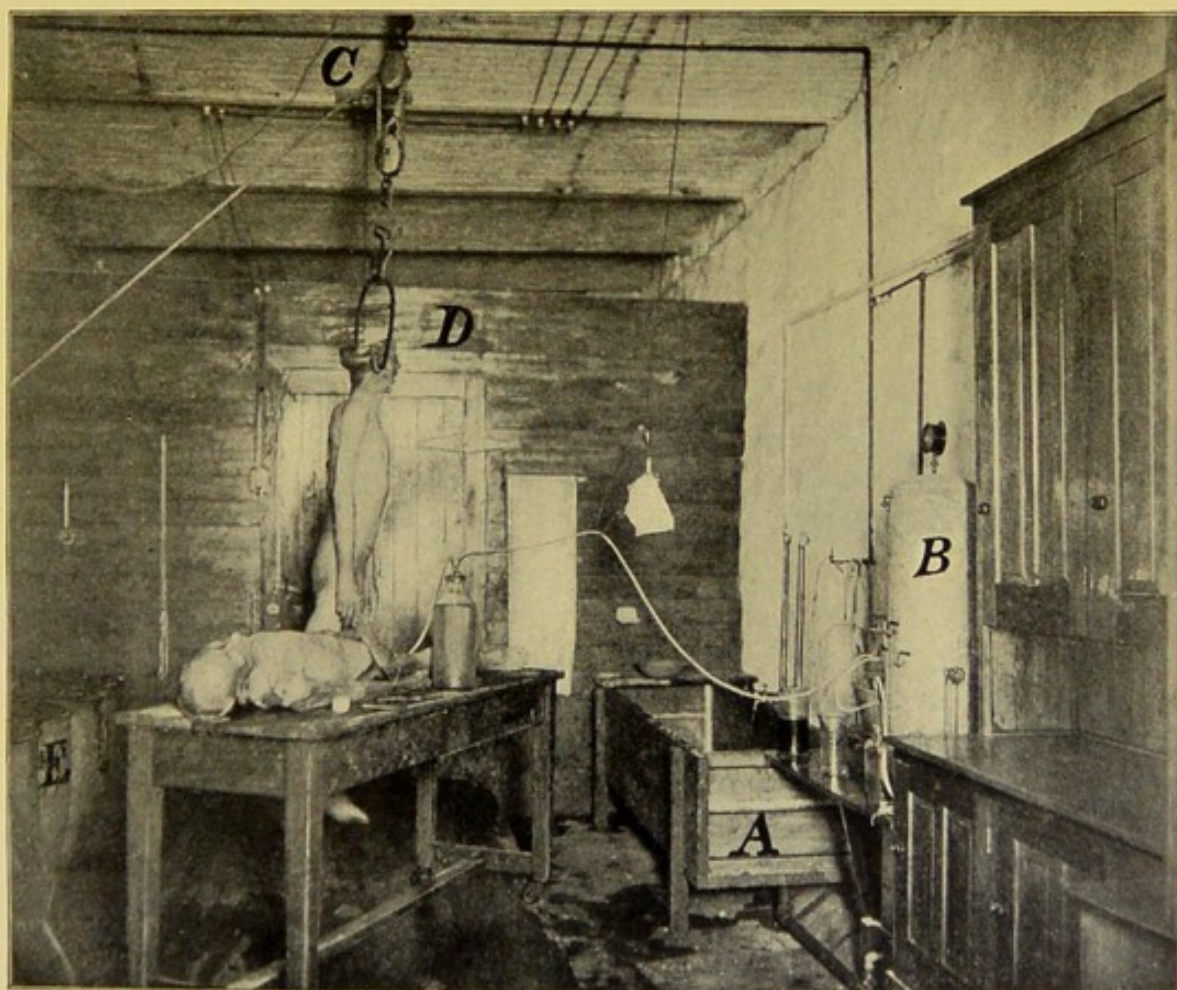


FIG. 152.—Preparation of bodies after removal from refrigerating room. *A*, bath; *B*, air-condenser and injecting apparatus; *C*, pulley suspension apparatus; *D*, exterior of refrigerator box; *E*, odorless excavator barrels.





FIG. 153.—Post-mortem examination of guinea-pig, made in Ravenel pan. Near the four corners (not seen in the illustration) are hooks upon which the chains are fastened in order to hold the animal in position.



## CHAPTER XXII

### DISEASES DUE TO MICRO-ORGANISMS, PARASITES, AND HÆMATOZOA

THE number of diseases known to be due to vegetable and animal parasites is constantly on the increase, the study of tropical diseases especially having in recent years received marked attention and added much to our knowledge on this subject. The lesions which are produced by these agencies and found *post mortem* are varied, though rarely characteristic, and require special bacteriological and histological training for their study and elucidation.

ACTINOMYCOSIS.—A chronic, infectious disease, which occurs most frequently in cattle (as “lumpy jaw” or “wooden tongue”), but is found also in man; it is characterized by the formation of small nodules, which break down and infiltrate the surrounding tissue. The exciting cause, the *Streptothrix actinomyces* (ray-fungus), is found in the form of yellowish opaque granules,—called sulphur balls,—which measure from one-half to two millimetres in diameter. When these masses are crushed and placed under the microscope, they give the appearance so beautifully depicted (in 1856) by Lebert in his Atlas. The organism is introduced into the body with food, often through the medium of carious teeth. In one case reported the patient had been accustomed to pick his teeth with a straw. The most common locations of the lesions are: I. Alimentary canal. II. Lungs (lesions are usually unilateral). (a) Chronic bronchitis. (b) Miliary nodules formed by masses of fungi surrounded by granulation tissue. (c) These nodules may fuse, forming abscesses and finally cavities. (d) Bronchopneumonia. III. Heart, emboli and localized parenchymatous myocarditis. IV. Thorax. (a) Erosion of vertebræ. (b) Necrosis of ribs and sternum. V. Skin. (a) Subcutaneous abscesses. (b) Chronic ulceration, which may last for years. VI. Primary infections of the brain, liver, and vermiform appendix have been described. The characteristic primary lesion is a small nodule resembling that seen in an anatomical wart. Later there occurs, especially in the lower jaw, proliferation of cells into surrounding tissues similar to those seen in osteosarcoma; this is followed by suppuration. The abscesses are at first multiple, spherical, and discrete; later they coalesce and give a



reticulated and honeycombed appearance to the part affected. Metastases may occur.

**ANTHRAX.**—An acute, infectious, contagious disease, more common in the lower animals than it is in man, caused by the *Bacillus anthracis*, and having for its characteristic lesion a pustule. Certain animals are predisposed, especially sheep and goats, though the Angora sheep is apparently immune. In man the disease is contracted in certain occupations, as wool-sorting, tanning, etc., and by the ingestion of the flesh or milk of an infected animal. The *Bacillus anthracis* is a rod-shaped micro-organism, from two to twenty-five microns in length, non-motile (thus distinguished from the similarly shaped but motile *Bacillus subtilis*), often united, and grows with great rapidity. Characteristic cultures may be made on gelatin plates at ordinary temperatures. The bacillus is easily killed, but the spores are very resistant. For seven successive years Ziegler was able to produce anthrax in mice by inoculations from similarly prepared pieces of dry catgut which contained the spores. Two sets of lesions are found, depending upon the method of invasion,—by skin or mucous membranes. I. *External Anthrax.*—(1) Malignant pustule. At the site of inoculation appears a papule which rapidly becomes a vesicle; later a brown eschar is formed, surrounded by small vesicles and an extensive area of brawny induration. The neighboring lymphatics are swollen, tender, and hard. (2) Malignant anthrax œdema. This is an extensive œdema affecting the eyelids, the head, arm, and often the entire upper extremity. It may terminate in gangrene, enteritis, peritonitis, or endocarditis. II. *Internal Anthrax.*—(1) Thorax. Very soon after death the upper extremities, both anteriorly and posteriorly, become dark purple, the nails are blackish blue, and dark chocolate-colored fluids issue from the mouth and nose. The cellular tissues of the upper part of the chest are emphysematous and crackle on pressure. On opening the thorax these tissues are often found infiltrated with blood and a gelatinous effusion. The pleuræ contain much serum (two or three pints), the right more than the left. The pericardial fluid is also increased (six or eight ounces). The lungs are engorged with dark-colored blood. Some portions are œdematous, others harder than normal and of a darker-red color. The bronchial glands are swollen, hemorrhagic, and friable. The heart-muscle is dark colored, soft and flabby; the heart may be empty or contain dark, semifluid blood in all its cavities. The lining membranes of the heart and larger blood-vessels are stained a



color varying from cherry-red to dark chocolate, according to the time which has elapsed since death. The serous membranes throughout show extravasations of blood. (2) Abdomen. The intestines show lesions consisting of dark infiltrated spots (phlegmonous inflammation), about the size of a dime, with a greenish or grayish slough in the centre, which are composed mainly of anthrax bacilli situated chiefly in the lumen of the blood-vessels (Strümpell). The cavity contains considerable serum or there may be gelatinous œdema; hemorrhages appear in the serous membrane. The liver shows less change than any other organ; it may be normal. The spleen may be larger than natural or normal in size and appearance. (3) Kidneys. The parenchyma is gorged with dark blood, and hemorrhages appear in the capsule. (4) Brain and spinal cord. Extravasations of blood are discovered between the membranes and sometimes small infarcts are found. In a recent case which I had the opportunity of studying with Dr. Morton, the pustule was on the palm of the hand. The disease was probably contracted from a bone fertilizer while working with a trowel in the garden. Early excision of the pustule, with the application of carbolic acid to the wound, was followed by recovery. (5) Retropharyngeal abscess may be of this origin.

**BERIBERI.**—An infectious disease of tropical and subtropical countries, characterized by muscular pains and weakness, disseminated neuritis, cardiac failure, and general anasarca. Little regarding its origin is definitely known. Various micro-organisms have been suggested. Overcrowding and a fish diet may predispose. Two types, the œdematous and the paralytic, are recognized. The special lesion appears to be in the peripheral nerves. They are swollen and hemorrhagic, but at times appear normal. The lesion is a parenchymatous neuritis. Atrophy of striated muscles may appear, in which case they are dry and shining, or the affected muscles, including the heart, are pale, flabby, and fatty. Evidences of general anasarca, affecting the upper extremities most, are present.

**CHOLERA ASIATICA.**—An acute infectious disease originating in Eastern countries, characterized by the presence of spirochæta and by a profound inflammation of the bowel. The comma bacillus of Koch is a motile, screw-shaped micro-organism about half the length of a tubercle bacillus, but thicker. The bacilli are found in large numbers in the rice-water stools, but rarely in the vomit. The position of the body is characteristic, the extremities being flexed, the fists



closed, and the abdomen scaphoid. There is cyanosis of the skin. (1) In very acute cases the intestinal lesions are not characteristic, but the bowel contains large quantities of "rice-water." In more protracted cases the bowel presents a mapped appearance, — some areas hyperæmic and some anæmic, some hypertrophic and others ulcerated. The inflammation is well marked in the Peyer's patches. The serous membrane is sticky and of a rosy color. The blood-vessels are prominent and the body looks thin and shrunken. The mesenteric glands are swollen, soft, and of a reddish color. (2) The stools are largely serous and contain masses of columnar epithelial cells and almost pure cultures of the micro-organism. (3) The kidney is swollen, of a violet hue, and shows the changes of acute diffuse nephritis. (4) The liver shows little alteration except cloudy swelling, with minute areas of focal necrosis. (5) The heart is flabby. Its right side is usually distended with tarry blood. The left heart is usually empty. (6) The lungs are collapsed and show marked congestion at their bases. Pneumonia and pleurisy may develop, and abscesses are not uncommon. (7) There is a decided tendency to the formation of diphtheritic exudate on mucous membranes, particularly in the throat. (8) The celiac ganglion is hyperæmic or even hemorrhagic (Rokitansky). (9) All the abdominal organs are very dry.

DENGUE.—An acute infectious disease, prevalent in our Southern States, and generally known as "break-bone fever." It is bacterial in its origin; a therapeutic serum being now made like the antitoxin of diphtheria. The large and small joints become red and swollen. There is commonly a rash, but this has no distinctive character. General enlargement of the lymphatic glands is not uncommon. Being rarely fatal, no detailed observations have been made regarding the pathological anatomy of this disease.

DIPHTHERIA. — An acute infectious, contagious disease, characterized by the presence of the Klebs-Löffler bacillus and of a false membrane. This bacillus is a non-motile micro-organism which, when grown on blood-serum, assumes a great variety of shapes. It is easily cultivated on albuminous media in from twelve to sixteen hours. The bacillus is fairly resistant, and will live for months under favorable conditions. Many other organisms produce a similar membrane, and the identity of this organism with the pseudobacillus of diphtheria, the bacillus of scleroderma, and the organism of ozæna is believed by many, but the subject is still *sub judice*. The presence of the organism



in well persons is a fact of great interest. The forms of the disease are nasal, pharyngeal, laryngeal, and cutaneous. The characteristic lesion of diphtheria is a false membrane, beginning early as a slightly raised, opaque, whitish-yellow spot on the mucous membrane. As a rule, it grows rapidly, becoming thicker, of a grayish or greenish hue, and firmly adherent to the underlying tissues. In the early stages if an attempt be made to remove it, there is left behind a raw bleeding surface. In the later stages the membrane becomes less firmly adherent, soft, shreddy, and somewhat easily detached. The diphtheritic patches may become hemorrhagic, the color being then dirty brown or grayish green. The blood not only infiltrates the submucous layer but also the pseudomembrane. When the submucous layer and the surrounding connective tissue become markedly infiltrated, the inflammation is said to be phlegmonous. There is great swelling and pus soon forms. A retropharyngeal abscess may be of diphtheritic origin. In nasal diphtheria the membrane may be slight in extent or may entirely block up the nasopharynx. It is apt to lead to extension of inflammation to the membranes of the brain. In the pharyngeal form the exudate is usually first seen on the tonsils. It is apt to be very extensive and extend into the mouth, the œsophagus, and even the stomach. In the laryngeal form the amount of exudate is often very great: it may entirely occlude the air-passages and extend to the lungs and the bronchial tubes, even to those of the third and fourth dimensions, but as it extends it gets softer and thinner. In this form the pharynx may be entirely free from membrane. The cutaneous form is somewhat less common; it is apt to occur about wounds, the false membrane being seldom extensive. In nearly all cases of diphtheria there is marked inflammation of the neighboring lymphatic glands and often of the salivary glands. There is apt to be a bronchopneumonia. There are small atelectatic patches surrounded by areas of inflammation. Should the diphtheritic membrane become gangrenous, the process is liable to extend to the lung. Klebs-Löffler bacilli are usually not found, but cocci of various kinds are numerous. Endocarditis is extremely rare, but changes in the fibres of the heart-muscle are comparatively common. The serous membrane often shows ecchymoses. The kidneys always show more or less diffuse inflammation, which may be hemorrhagic, and albuminuria is a constant symptom of the disease. The other organs show the ordinary febrile changes. In malignant cases the micro-organisms may be found in the bladder and the internal



organs. As a rule they do not penetrate below the submucosa at the site of the lesion. Orth describes an enteritis nodularis in which the follicles and Peyer's patches are markedly swollen and hyperæmic. Growths may occur in various mucous membranes, as in the eye, the œsophagus, the vagina, in exstrophy of the bladder, etc.

**ERYSIPELAS.**—An acute contagious disease, characterized by a rash, and due to the *Streptococcus* or *Diplococcus erysipelatis*. The micro-organisms gain entrance through a wound or abrasion of the skin or mucous membrane. Three types of erysipelas are noted,—simplex, ambulans, and phlegmonosum. In uncomplicated forms little more than an inflamed œdema is seen. The micro-organisms can be found *post mortem* in the lymph-spaces and in the zone of spreading inflammation. In severe forms the face is enormously swollen, the eyes are closed, the lips œdematous, the ears thickened, and the scalp swollen. Blebs and vesicles often appear upon the eyelids, ears, and forehead. Small cutaneous abscesses about the cheeks, forehead, and neck are common, while beneath the scalp large quantities of pus may accumulate. There is enlargement of the cervical glands, but this is masked by the œdema. Erysipelas of the phlegmonous type may extend to the intermuscular fascia. It is then likely to be gangrenous, particularly when following hemorrhagic contusions. This form, besides being the cause of acute purulent œdema, may result in emphysematous inflammation when gas-producing germs are associated. Infarcts often occur in the lungs, spleen, and kidneys; these are usually septic in character. Endocarditis ulcerosa is particularly common. Albuminuria is a constant complication, but true nephritis is only occasionally seen. Septicæmia, septic pericarditis, and pleuritis are of comparatively frequent occurrence. Acute atrophy of the liver sometimes occurs.

**FEVER, GLANDULAR.**—An infectious disease of childhood, characterized by marked enlargement of the cervical glands. It is bacterial in origin and occurs between the ages of one and ten years. The disease is rarely fatal. The cervical glands are swollen and softened; they seldom suppurate, and the adjacent skin and mucous membrane show no marked changes.

**FOOT-AND-MOUTH DISEASE.**—Stomatitis aphthosa epizootica is an acute contagious disease, occurring most frequently in cattle and sheep, but found also in persons who come in contact with the disease in animals. It begins as a small vesicle (which is at first clear, later grayish)



on the lips, cheeks, or pharyngeal mucous membrane. When the vesicle reaches a diameter of from one and a half to three centimetres, it bursts, leaving a shallow ulcer, with oval, circular, or irregular edges. The affected mucous membranes are inflamed, swollen, and œdematous, and there is considerable exudate. The lesions are also found on the udder and feet, usually appearing after the eruption in the mouth. The post-mortem appearances are most varied, consisting in œdema, hemorrhagic infiltrations, fatty changes in the parenchymatous organs, etc. Löffler and Frosch consider the disease to be due to an organism so minute that it passes through the finest filters and is even not visible with the best of our present microscopes. A colored illustration of the lesion is seen in Kitt's *Atlas der Thierkrankheiten*, 1896.

FRAMBÆSIA.—Yaws is a contagious disease of the skin, characterized by an indefinite period of incubation and the presence of dirty or bright red-raspberry-like tubercles. It is presumably of microbic origin. The eruption begins as a papule, usually at the site of an old wound. In a few days the papules are scattered over the body; they rapidly enlarge and become tubercles, which are generally circular in shape, and vary in size from that of a pin's head to a small apple. The epidermis splits or cracks, exposing a raw granulating surface, which rarely ulcerates. The disease is by some supposed to be a modified form of syphilis. In his excellent work on *Tropical Diseases*, Manson states that the question of their identity is certain to be debated until the respective germs of yaws and syphilis have been separated, cultivated, and inoculated, though he considers them to be specifically distinct diseases.

GLANDERS.—A contagious disease occurring most frequently in horses and asses, the exciting cause being the *Bacillus mallei*. Two forms are recognized: (a) Glanders proper. (b) Farcy. (1) Glanders proper is an acute disease, essentially a necrotic alteration (Unna), occurring most frequently on the mucous membrane of the nose and upper respiratory tract. Its characteristic lesion is a node or tubercle, which is at first spherical, later becomes flattened, then breaks down and presents more or less extensive ulcerations which tend to run together. The mucous membrane is swollen, is of a purplish or dark-red color, and there is considerable exudate from the ulcerating surfaces. The process may extend to the lungs, the most prominent lesion being a catarrhal pneumonia, in which the diseased areas show a marked tendency to break down, with the formation of abscesses. An



eruption of papules, which soon become pustular, frequently appears upon the face and about the joints. The cervical glands are usually much enlarged. A dirty-yellow pasty mass of pus in the gastrocnemii is probably due to glanders. Chronic glanders usually occurs in the nose and is often mistaken for a chronic coryza. There are frequently ulcers about the turbinated bones. (2) Farcy may be acute or chronic. The acute form is of the nature of a phlegmonous inflammation at the point of inoculation. The process may be very extensive and lead to rapid suppuration of the surrounding parts. Metastasis to the surrounding tissues is common, accompanied by the formation of abscesses in the muscles. In chronic farcy localized tumors are found, usually in the skin, the subcutaneous tissue, and the muscles. These tumors result in abscesses and may form deep ulcers. The disease in man has been described as a chronic specific pyæmia, characterized by eruptions on the skin and nasal mucous membranes, with frequent intramuscular abscesses.

GONORRHOËAL INFECTION. — Lesions due to the presence of the gonococcus. That organism has been found in the blood, which after death may be fluid or semiliquid and tarry-black in color. Manifestations of the infection include: (1) *Arthritis*.—The inflammation is acute, periarticular, and extends along the sheaths of the tendons. It is a synovitis which rarely becomes purulent. (2) *Conjunctivitis*.—This occurs most frequently in the new-born. It leads to thickening and ulceration of the conjunctivæ; erosions or entire destruction of the cornea may result. The skin of the lids may be destroyed. (3) *Endocarditis*.—An acute form of simple or ulcerative endocarditis, from which pure cultures of the gonococcus have been made. (4) The results of gonorrhœal infection are periurethral abscess, prostatitis, vaginitis, salpingitis, iritis, pericarditis, pleurisy, etc. All these lesions show a marked tendency to suppurative change.

HYDROPHOBIA. — Rabies is a convulsive disease due to the action of the toxins of the bacillus of hydrophobia on the higher nervous centres. The cerebrospinal system shows congestion of the blood-vessels. There are minute hemorrhages, most numerous in the medulla. The mucous membrane of the pharynx is congested and not infrequently covered with blood-stained mucus. This is true of the larynx, trachea, and larger bronchi, also of the lungs, œsophagus, and stomach. Experiments have shown abundant virus in the spinal cord, brain, and peripheral nerves, but it has not been found in the liver, spleen, or kidneys.



When a dog that is supposed to be mad has bitten a human being, the animal should not be at once killed, but permitted to live and kept under close observation until it shows unmistakable signs of rabies. It should then be killed and its body sent to a competent bacteriologist for microscopic study and inoculation experiments on rabbits. While the recent so-called rapid method of diagnosing rabies is not absolutely characteristic of the disease, it affords a most valuable and early means of tentative diagnosis, to be confirmed or disproved by subsequent animal inoculation. The method employed is that of Babès, van Gehuchten, and Nélis, and is as follows:<sup>1</sup> Several intervertebral ganglia or a portion of the bulb are put at once into absolute alcohol, in which they are left for twenty-four hours. They are then transferred for one hour to a mixture of absolute alcohol and chloroform, next put for one hour into pure chloroform, then for one hour into a mixture of chloroform and paraffin, and lastly for an hour into pure paraffin. The sections are put in the oven for a few minutes, then passed through xylol, absolute alcohol, and ninety per cent. alcohol, after which they are stained for five minutes in methylene-blue, according to Nissl's formula, differentiated in ninety per cent. alcohol, dehydrated in absolute alcohol, and cleared in essence of cajuput and xylol. Other methods of preparing the tissues may be used, as the rapid fixation with ten per cent. formalin, subsequent freezing, and staining with hæmatoxylin and eosin. The microscopical changes are chromatolytic and capsular. The "rabie tubercle" of Babès consists in the pericellular accumulations of the embryonal cells described by Kolesnikoff. The prolongations of the cells of the bulbar nuclei are shortened, the nuclei are altered or even obliterated, and the nerve-cells are invaded by the embryonal cells and small corpuscular elements. Atrophy, invasion, and destruction of the nerve-cells of the intervertebral and plexiform ganglia of the pneumogastric take place by cells newly formed from the capsule, which appear between the cell body and its endothelial capsule, in advanced cases the field even resembling an alveolar sarcoma.

INFLUENZA.—The grippe is an acute, epidemic, contagious disease, due to Pfeiffer's bacillus, and characterized by abrupt onset, great depression, and many sequelæ. The bacillus is found in the nasal and bronchial secretions. It is one of the smallest organisms known, non-

---

<sup>1</sup> RAVENEL AND MCCARTHY, *Proceedings of the Pathological Society of Philadelphia*, 1901, p. 93.



motile, and stains well with Löffler's methylene-blue. On culture media it grows best in the presence of hæmoglobin. (1) Lesions of the respiratory form are those of an acute inflammation of the mucous membrane of the upper respiratory tract and bronchial tubes. Lobular pneumonia is common, and is probably due to a mixed infection. Pleurisy is more rare, but may lead to empyema. Tuberculosis is apt to be exaggerated by an attack of influenza. (2) In the gastro-intestinal form the inflammation extends to the mucous membrane of the stomach and the intestines. It is seldom of a severe type. The spleen is usually enlarged in this form. The recent large number of cases of appendicitis is attributed by some to the wide-spread prevalence of this disorder. (3) In the nervous form mild degrees of meningitis and encephalitis are not uncommon. Abscesses of the brain have occurred in severe acute cases. In some epidemics accumulations of pus in the nasopharynx are exceedingly common. *Complications.*—Acute diffuse nephritis is quite frequent. Endocarditis, pericarditis, and thrombosis have been reported. Occasionally purpura is seen and also catarrhal conjunctivitis and iritis. In an autopsy on a child dying from meningitis following the grippe Dr. Kneass isolated for me the influenza bacillus.

LEPROSY.—Leprosy is an infectious disease characterized by the formation of a node or nodule, and due to the leprosy bacillus. The *Bacillus lepræ* has many points of resemblance to the bacillus of tuberculosis. It, however, stains more readily, is more easily decolorized, and is present in far greater numbers in the lesions which it causes. (1) The tubercular form starts as a small red spot in the corium, which either disappears or gives rise to the formation of inflammatory nodules of a brownish-red color, somewhat soft in consistency, and resembling a strawberry. The primary lesion is found most frequently in the skin of the face and on the surfaces of the knees, the elbows, the hands, and the feet. It may also involve the conjunctiva and the mucous membrane (particularly the nasal), the cornea, and the larynx. This form of the disease is apt to be exceedingly chronic, the surrounding tissues showing marked fibroid changes. The tubercles at times undergo fatty disintegration and in this way become swollen. (2) In the anæsthetic form the leprous process gradually involves the peripheral nerves, first causing a perineuritis, then obliterating them and producing marked trophic changes, consisting in necrosis and ulceration with extensive loss of substance, as of fingers, toes, and even



limbs. There is great loss of hair and the face often shows marked ravages of the disease. Death results not infrequently from laryngeal complication or aspiration pneumonia. That leprosy may be cured in the sense of the lesions not advancing is now an established fact. Van Houtum<sup>1</sup> claims to have cultivated successfully the *Bacillus lepræ*, while several investigators have recently given promising reports of the discovery of a curative serum.

**MALTA FEVER.**—Mediterranean fever is a chronic disease, resembling in its clinical course typhoid fever and malaria, occurring most frequently in the Mediterranean region, and due to the *Micrococcus melitensis*. It is often followed by swellings of the joints, profuse diaphoresis, anæmia, orchitis, and neuralgia. Young and previously healthy adults who are unacclimated are most frequently attacked, and it is a serious disease in the British garrisons. The micrococcus is found in large numbers in the spleen. The visceral changes are those common to all infectious diseases with high temperature. The small intestine is usually anæmic except in the upper part, where it may be intensely congested. The mesenteric glands show little change. The spleen is much enlarged and dark in color; its pulp is soft and friable, and sections show an increase in the lymphoid elements. The average weight is eighteen ounces. The liver is congested and its surface on section is pigmented. The kidneys are usually congested and may be slightly hemorrhagic. The agglutinative reaction can be obtained with the micrococcus and the blood of a patient affected with Malta fever. It should be remembered that this disease occurs in our new possessions, and that soldiers on their return home may bring the affection with them.

**MEASLES.**—Morbilli or rubeola is a markedly contagious disease, attended with a skin eruption and catarrh of the mucous membranes, and due to a micro-organism the identity of which is not yet definitely settled. This affection, as well as scarlet fever and German measles, must be distinguished from Duke's fourth disease, a malady having characteristics in common with all three disorders. Lesage, Canon and Pielicke, Czajkowski, and others have described organisms as causes of the disease. The post-mortem appearances in measles are chiefly those of its complications and sequelæ. The skin, especially about the face, may be swollen and slightly œdematous, and may show

---

<sup>1</sup> *Journal of Pathology and Bacteriology*, September, 1902.



the remains of the characteristic rash, especially in the hemorrhagic type. Desquamation, when present, is in the form of fine branny scales. The gastro-intestinal mucosa is usually hyperæmic; Peyer's patches are frequently swollen, sometimes markedly so. The lungs invariably show evidence of bronchitis, and almost invariably lesions of broncho-pneumonia with areas of collapse; less frequently lobar pneumonia may be found. The bronchial glands are invariably swollen. Pleurisy is less common. In debilitated infants severe stomatitis, cancrum oris, or ulcerative vulvitis may develop. In the middle ear catarrhal inflammation, which may go on to abscess formation, is not uncommon. Of the sequelæ tuberculosis is the most important; it is either miliary or a caseous pneumonia. Severe forms of conjunctivitis and ulcer of the cornea are not uncommon. Nephritis is exceedingly rare. There is cloudy swelling of the organs.

MUMPS.—An acute, infectious, contagious disease, characterized by a marked cellular infiltration of the parotid glands, which do not tend to suppurate or to become fibroid, and frequently complicated with metastases to the ovaries and mammary glands in females, and the testicles in males. (a) Probably due to a coccus infection. (b) Childhood and adolescence. Very young infants and adults are seldom attacked. Uncomplicated mumps is rarely fatal. Of the complications meningitis, acute mania, endocarditis, gangrene, and optic atrophy are the most important.

PLAGUE.—An acute, infectious, contagious, epidemic disease, due to the *Bacillus pestis*, occurring usually in the far East, but at present (1903) widely distributed over the earth's surface, and characterized by marked glandular enlargements which tend to suppuration and by a general septic condition. The bacillus was discovered by Kitasato and Yersin. It is a short rod with rounded ends, and is found in the blood, glands, and viscera. Hossack found no buboes in thirty per cent. of his cases in Calcutta in 1900. *Varieties*.—(a) Bubonic. (b) Pneumonic. (c) Septic. (d) Intestinal. (e) Meningeal. (f) Carbuncular. Lesions: (1) At the point of inoculation, which usually occurs on the lower extremities, there appears a small spot (plague-corpuscle) which soon becomes a vesicle and then a pustule. (2) Following primary inoculation, the inguinal glands become swollen, succeeded in order by the axillary, cervical, popliteal, and then any of the glands in the body may become affected. The diseased glands swell rapidly and are at first tense and firm to the touch, but soon undergo a



suppurative change, and in rare cases gangrene ensues. It may be stated that it is the periglandular tissue which becomes œdematous and undergoes septic inflammation. (3) Carbuncles may develop in the skin of the legs, hips, and back. Subcutaneous hemorrhages are very common and may also occur in the mucous membranes. (4) The central nervous system, especially the brain, is deeply congested. The brain substance may become softened and the blood-vessels, especially the veins, are engorged. (5) The lungs are deeply congested, especially posteriorly, and are at times the primary seat of the disease. (6) The pericardium contains an excess of blood-stained fluid. The right heart is dilated with black, imperfectly coagulated blood, and the whole venous system is engorged. The heart-muscle is pale and somewhat softened. (7) The stomach and small intestine contain blood or blood-stained fluid. There may be ulceration, but Peyer's patches are not affected. The spleen is greatly enlarged in all cases. (8) The dorsum of the tongue is coated, but the edges, the tip, and often the median raphe remain pink and clean; sometimes, however, becoming red and dry (Hossack). The disease must be distinguished from puerperal fever, septicæmia, pyæmia, smallpox, influenza, cerebrospinal meningitis, diphtheria, erysipelas, measles, gonorrhœa, syphilis, mumps, malaria, scrofulous glands, Hodgkin's disease, etc. In a recent case of a Chinaman suspected of having the plague, the writer found almost complete occlusion of the prepuce, with a discharge containing the gonococcus, and in the suppurating bubo a fat diplo-bacillus which did not stain by Gram's method.

RELAPSING FEVER.—An acute, epidemic, contagious disease, not found at the present time in America unless imported, occurring in the same class of persons as typhus fever, giving rise to a fever which lasts from five to seven days, followed by relapses, and due to the *Spirochæta* of Obermeier, which are found in the blood only during the paroxysms of fever. Due to a specific, motile organism, which is rarely discovered *post mortem*. No characteristic or constant lesions are found after death. The following are sometimes present. (1) If death occurs during the paroxysm, the spleen is large and soft; the pulp is purple. The follicles are enlarged and often obliterated, though they may be gray or whitish yellow in color. Infarcts are not uncommon. (2) The heart is flabby, of a pale dirty-gray color, and very friable. (3) The liver is more enlarged in this than in any other infectious fever. Its color is uniform gray-red. Fatty degeneration



may be marked. (4) The kidneys may retain their normal weight. The renal parenchyma is soft and flabby; the cortical substance is increased and shows cloudy swelling. Hemorrhagic spots or lines radiating to the pyramids are often observed. (5) The lungs may be the seat of pneumonic infiltration, bronchitis, or bronchiectasis. (6) Hyperplasia of the bone marrow has been found. *Complications.*—(a) Pneumonia is frequent. (b) Rupture of the spleen. (c) Nephritis and hæmaturia. (d) Ophthalmia in certain epidemics. (e) Abortion usually takes place. (Osler.)

**RHEUMATIC FEVER.**—(a) Follows exposure to cold and wet. (b) Usually regarded as a coccus infection, though a bacillus has also been described as the etiologic factor. (1) The affected joints are swollen, tense to the touch, and somewhat hyperæmic. The fluid in the joint is turbid, and contains albumin, leucocytes, and a few flakes of fibrin, but rarely pus. There may be slight erosion of the cartilages. (2) Endocarditis occurs in about sixty per cent. of all cases. The verrucose variety is most common. The mitral valve is most frequently involved. (3) Pericarditis may occur, with or without endocarditis. It may be fibrinous, serofibrinous, or, in children, purulent. (4) Myocarditis occurs most frequently in association with endopericarditis. It leads to weakening and dilatation of the heart-muscle, and is the most common cause of sudden death in rheumatic fever. (5) Pleurisy and pneumonia occur in about ten per cent. of all cases. (6) Rheumatic nodules, varying in size from a small shot to a large pea, are found on the fingers, hands, and wrists. They may also occur about the elbows, knees, spines of the vertebræ, and scapulæ. (7) Meningitis is extremely rare. (8) Purpura may be present.

**RHEUMATISM, CHRONIC.**—(1) The synovial membranes are injected. There is usually not much effusion. The capsules, ligaments, and sheaths of the tendons are thickened. There may be erosion of the cartilages. As a result of these changes, the joints are often deformed and ankylosis may occur. (2) Muscular atrophy, especially about the joints, frequently follows. (3) Valvular heart-lesions, due to sclerotic changes, are of common occurrence.

**RUBELLA (RÖTHELN, GERMAN MEASLES).**—This disease is rarely fatal in uncomplicated cases. There is no distinctive lesion other than the rash, which may fade entirely after death.

**SCARLET FEVER.**—(a) The majority of cases occur before the tenth year. (b) Infants and adults are usually exempt. (c) Cocci are fre-



quently found in the throat-lesions and in the blood. Class, of Chicago, claims to have isolated a specific coccus, which has also been described by Baginsky. (1) Rigor mortis is usually well marked. Decomposition may set in early and develops with exceptional rapidity, cadaveric lividity usually appearing before death. (2) The blood is dark in color, thin, and coagulates imperfectly. The vessel-walls are usually stained. (3) Except in the hemorrhagic form the skin after death rarely shows a trace of the rash. (4) In the throat follicular tonsillitis, diphtheritic membrane, or suppuration may be present. Punctate hemorrhages, especially about the mouth, are always observed. (5) Catarrhal inflammation of the gastro-intestinal mucous membrane is not uncommon. The follicles of the small intestines are swollen, red, and may even be hemorrhagic. (6) In severe cases an intense lymphadenitis, with much inflammatory œdema, is found in the neck. This may lead to suppuration or even gangrene, and in rare cases to ulceration of the carotid artery and fatal hemorrhage. (7) The kidney lesions are most important. Acute diffuse nephritis is present in a majority of cases. It is frequently of the glomerular type and may be hemorrhagic. This lesion is not infrequently followed by the changes observed in chronic parenchymatous nephritis. (8) Endocarditis, which may be either simple or malignant, is not infrequent. Pericarditis and myocardial changes are less common. (9) The spleen is often enlarged, and shows the changes which characterize acute splenic tumor. (10) Hemorrhages into the subserous tissues beneath the pericardium, endocardium, and pleura are quite frequent. There is more or less cloudy swelling of all the organs.

*Complications.*—(a) The most important is nephritis. The urine is small in quantity, of a high specific gravity, cloudy, and of a dark blood-color. It contains large amounts of albumin, free blood, and epithelial cells, with hyaline and epithelial tube-casts. Œdema may be slight or marked; in a few cases œdema of the glottis has caused sudden death. (b) Heart complications are next in importance. There may be endocarditis, pericarditis, or myocarditis. (c) Catarrhal pneumonia, more rarely croupous pneumonia or pleurisy, may occur. (d) Involvement of the middle ear may lead to thrombosis of the lateral sinus, meningitis, abscess of the brain, or necrosis *en masse* of the middle ear. (e) Adenitis may result. The glands of the neck are those most frequently involved. There may be great destruction and loss of tissue. (f) Arthritis of a rheumatic type or more closely resembling



the gonorrhœal variety may be found. In the latter affection only one joint is involved and suppuration may supervene. The toxin seems to act especially on the epithelial cells. In one of my cases death occurred in convulsions twenty-four hours after the onset of vomiting and without the appearance of any rash. The diagnosis was confirmed by a sister being attacked with the disease later on.

**SCLERODERMA (HIDE-BOUND SKIN).**—(1) *Circumscribed Form.*—On the skin are found patches varying in size and of a waxy or dead-white appearance. They are brawny, hard, and inelastic. (2) *Diffuse Form.*—This form usually occurs in the extremities or on the face. Gradually a diffuse brawny induration develops. The skin becomes firm, hard, and so closely united to the subcutaneous tissue that it cannot be picked up or pinched. The color may be natural. The skin is commonly glossy, drier than normal, and unusually smooth.

**SMALLPOX.**—(a) Overcrowding. (b) Improper food. (c) Season, fall or winter. (d) Streptococci are found in the characteristic lesions. Councilman<sup>1</sup> has announced the discovery of a protozoön. (1) The characteristic lesion of smallpox is a rash. On the skin may be seen papules, umbilicated vesicles, pustules, and crusts. A shot-like feel of the papules upon the forehead and wrist is quite characteristic. (2) The rash may also be found upon the mucous membranes from the mouth to the rectum, but on account of the moisture the pocks are not quite so characteristic in these situations as upon the skin. In some cases there is deep ulceration, especially in the larynx, which may be followed by necrosis of the cartilages. (3) Swelling of Peyer's patches is not uncommon. (4) In the hemorrhagic form of smallpox extravasations of blood are found on the serous and mucous surfaces, in the parenchyma of the organs, in the connective tissue, and about the nerve-sheaths. They have also been observed in the bone-marrow and in the muscles. (5) As a rule, the spleen is markedly enlarged, but it may be small, very dark, and firm. The liver shows evidences of parenchymatous inflammation. (6) The heart is flabby and pale. The myocardium shows cloudy swelling and fatty degeneration. It is often dark brown in color and may be firm to the touch. The cavities contain little or no clotted blood, and the arterial trunks are nearly

---

<sup>1</sup> See ZIEGLER's *General Pathology*, translation by CATTELL, 1895, p. 39: "It is not impossible that other infectious diseases—for instance, smallpox—are caused by parasites that belong among the protozoa."



empty. (7) Lesions of the kidney are not common. It may show cloudy swelling and areas of focal necrosis, or the pelvis may be blocked with dark clots which sometimes extend into the ureters. (8) Absence of the scar resulting from vaccination is very often noted. (9) The epidermis of the hands and feet may be shed entire. The skin is sometimes plum-colored. (10) The face may be swollen. In black smallpox there may be found hemorrhages in all the numerous membranes and in joints. The cornea may be sunken. *Complications.*—(a) Bronchopneumonia is almost invariably present in fatal cases; lobar pneumonia and pleurisy less commonly. (b) Albuminuria is frequent, but true nephritis rare. (c) Purulent changes in the arteries, bones, conjunctiva, and middle ear are common. (d) Ulcerative laryngitis with œdema sometimes causes death. (e) Myocarditis, endocarditis, and pericarditis are comparatively common. At the postmortem the odor is so characteristic that the disease may be recognized by this means alone. The physician should always vaccinate himself both before and after making an autopsy on a smallpox case.

**SPRUE (PSILOSIS).**—A chronic remittent inflammation of the whole or part of the mucous membrane of the alimentary canal, occurring principally in persons residing, or who have resided, in tropical or subtropical climates. Apparently nothing is known of its origin. At postmortem the thoracic organs, the abdominal viscera, and the tissues generally are found to be much wasted, giving the body a mummified appearance. The bowel is exceedingly thin, and on opening it a thick layer of dirty viscid gray, tenacious mucus is seen. On removing this, areas of congestion, ulceration, pigmentation, or thickening may be found. The mesenteric glands are generally enlarged.

**SYPHILIS.**—Lustgarten and van Niessen have described specific organisms, neither of which has been definitely accepted. *Classification.*—I. *Acquired Form.*—(a) Primary. (b) Secondary. (c) Intermediate period. (d) Tertiary. II. *Hereditary Form.*—(a) Primary. (b) Secondary. The following lesions should be looked for in making a postmortem: (1) The initial lesion or its scar. (2) Lymphatic enlargement, especially of the groin, neck, and elbow. (3) Various skin lesions and thinness of the hair. (4) Mucous patches. (5) Onychia and dactylitis. (6) Gumma in the viscera, skin, subcutaneous tissues, muscles, etc. (7) Parotitis. (8) The bones for periostitis or osteomyelitis. (9) The eye for iritis or choroiditis. (10) The bowels for stricture, especially the rectum. (11) The nervous system for tabes,



dementia paralytica, and other forms of sclerosis. I. The lesions found in the *primary stage* are: (1) The chancre. This begins as a small red papule, usually situated at the junction of the skin and mucous membrane. It gradually enlarges and breaks in the centre, leaving a small ulcer with indurated edges and base. (2) The neighboring lymphatic glands are enlarged and hard. II. *Secondary Stage*.—(1) Cutaneous eruptions of all forms. As a rule, the syphilide is polymorphous, varying in form from an erythema to a pustular eruption. It is symmetrically distributed and of a reddish-brown or copper color. It appears most frequently on the chest, abdomen, and flexor surfaces of the arms. (2) The mucous patch is a softened and macerated epithelium, and appears on the mucous membrane or on the moist regions of the skin. It is most frequently found in the mouth, in the throat, and about the anus. The mucous patch is irregularly shaped, non-inflammatory, and does not discharge pus. (3) The hair of the scalp is decidedly thin. (4) Ulcers may be seen on the tonsils and larynx. (5) There may be warts about the vulva and anus. (6) Iritis is common; retinitis rare. (7) The finger-nails may be diseased, forming dry or moist onychia. (8) Periostitis may be present. III. In the *intermediate stage* there are but few lesions: (1) Gumma of the testicles and (2) choroiditis are the only ones found. IV. *Tertiary Stage*.—(1) The late syphilides show a tendency to ulcerate and destroy the deeper layers of the skin, leaving scars. Rupia may develop. (2) The gummata are the characteristic lesions, and may be hard or soft. The former develop in the internal organs and in the mucous membranes. They most frequently terminate in cicatrization, forming stellate scars which often cause marked deformities. Soft gummata are found in bones, skin, etc. They tend to break down and ulcerate, leaving chronic indolent, often serpiginous, sores. (3) When there has been prolonged suppuration, amyloid degeneration of the liver, spleen, and kidneys often occurs. This is especially true with regard to rectal syphilis in women. (4) *Circulatory System*.—The heart frequently shows sclerotic changes of the valves, especially about the aorta. (5) The blood-vessels present arteriosclerosis or atheromatous changes. (6) In the central nervous system sclerosis of the brain and cord and gummata are common. V. *Congenital Syphilis*.—(1) At birth the infant is usually apparently healthy, but it may present well-marked lesions. (2) There is wasting, and pemphigus is noticed on the hands and feet. (3) The lips may be ulcerated and



the mouth and anus fissured. (4) There is inflammation of the nasal mucous membrane; hyperæmia with papillary infiltration is present and necrosis of the bone may occur. (5) The spleen and liver are enlarged. (6) The lungs may present the lesions of white pneumonia or miliary gummata. (7) The long bones usually show characteristic changes, and the epiphysis may be separated. (8) Later the child looks prematurely old. The teeth are wedge-shaped and the cutting edges notched (Hutchinson's teeth). (9) Eye lesions may be seen as interstitial keratitis. (10) Dactylitis is not uncommon.

*Syphilis of the Brain and Cord.*—(1) Gummata are usually multiple, varying in size from a pea to a walnut. In the cerebrum they occur along the sulci. Heubner describes two forms. In the first variety they are grayish or grayish red in color, soft, and not sharply defined. On section they are moist and exude a small amount of juice. In the second form they are quite hard and dry. Their outline is distinct. On section they may be cheesy and look not unlike tubercular growths. An enarteritis around them exists and causes softening. (2) Gummatous arteritis and sclerosis of both arteries and nerve tissue may exist. (3) There may be softening due to obstruction of the blood-vessels. Recently in Philadelphia a man was condemned to death for killing a person in cold blood. A commission of experts pronounced him sane. The man committed suicide by hanging, and I found at the postmortem numerous gummata of the brain, situated especially in the right temporal and frontal regions.

*Syphilis of the Circulatory System.*—(1) Gummata are rare. (2) Fibrosis of the heart-muscle is common. (3) Sclerosis of the valve is frequent. (4) Arteriosclerosis, aneurism, and endarteritis obliterans are common.

*Syphilis of the Gastro-Intestinal Tract.*—(1) The œsophagus is rarely affected. Ulceration or stenosis may be present. (2) Ulcers, phlegmonous inflammations, or abscesses may be found in the pharynx. (3) Ulcers may occur in the small intestine and cæcum. (4) The rectum is not infrequently the seat of cicatricial contraction. This lesion is most frequently seen in women. The lesions that syphilis produces in the gastro-intestinal tract are (a) chancre, (b) ulcers, (c) localized fibrous patches, (d) gummata, (e) miliary nodules, (f) condylomatous masses.

*Syphilis of the Kidneys.*—(1) Gummata are not infrequent. (2) Acute syphilitic nephritis may occur. (3) Chronic interstitial nephri-



tis is more common. This is a localized nephritis caused by the resultant shrinking and marked irregularity of the surface of the kidney. It is sometimes hard to distinguish it from old infarcts, but the change in color, which in syphilis is gray, in infarcts is brown, is a pretty certain point of differentiation.

*Syphilis of the Larynx.*—(a) Congenital. (b) Acquired, which may be secondary or tertiary. (1) In the secondary form there is erythema, with symmetrical, superficial, whitish ulcers on the cords or ventricular bands. (2) Mucous patches are occasionally seen. (3) In the tertiary form true gummata may appear towards the base of the epiglottis. These break down, producing deep flask-shaped ulcerations, which may heal by connective tissue that shrinks and produces stenosis. (4) Islands of connective tissue commonly appear between the cicatrices and form inflammatory excrescences. (5) The neighboring cartilages may show necrotic changes. (6) A fatal termination may result from perforation of an artery.

*Syphilis of the Liver.*—(1) In diffuse syphilitic hepatitis there is marked fibrous change. The organ is hard, firm, and resistant. The disease usually begins with a perihepatitis, which frequently causes adhesions to the surrounding structures. With contraction of the fibrous tissue great deformities of the liver become manifest. Capillary bile ducts may be present in abundance in the cirrhotic portion. (2) The smaller gummata are pale-grayish nodules, the larger ones pale yellowish in color. Usually they are multiple (miliary). Although they may be present in any part of the organ, the most common situation is at the junction of the right and left lobes. Great deformity results from healing and contraction.

*Syphilis of the Lung.*—(1) In white pneumonia of the foetus the affected lung is heavy and airless. On section it presents a grayish-white appearance (white hepatization). (2) Hereditary gummata are small in size, grayish in color, firm in consistence, and more or less symmetrically distributed throughout the lung. (3) Acquired gummata vary in size from a pea to a goose's egg. They are grayish yellow in color and are embedded in connective tissue. The parts around them are hard and brawny and of a glossy lustre. These gummata may break down and form cavities. This condition is called syphilitic phthisis. (4) There may be a fibrous interstitial pneumonia in which the lesions are hard, large, and pale or dark grayish red in color. The middle of the right lung or either apex is the part most frequently



involved. (5) The pleura is thickened. (6) Endocarditis may extend to the hepatic artery and portal vein.

*Syphilis of the Testes*.—(1) Gummatous growths usually involve the epididymis, which becomes a hard mass, from the size of a bean to that of a walnut. It affects the head more commonly than the body of the epididymis. (2) In interstitial orchitis the progress of the disease is slow. The organ is larger than normal and distinctly harder to the touch. The overlying skin is not adherent and there is no tendency to suppuration.

**TETANUS**.—The bacillus of tetanus is a slender rod usually growing in long threads. It is motile, grows on ordinary media at ordinary temperatures, and is anaërobic. It stains readily, but does not retain the stain very well. (1) The bacilli develop at the site of the wound, which is usually of a penetrating character, and do not invade the blood or organs, except very rarely late in the course of the disease. (2) No characteristic lesions have been found. (3) The condition of the wound depends upon the kind and extent of the injury. (4) The central nervous system shows congestion, with perivascular exudations and granular change in the nerve-cells. Some investigators have found swelling and areas of disintegration in the gray matter of the cord, with exudation of a finely granular material and disintegrated blood. (5) In tetanus neonatorum the umbilicus may be inflamed. (6) The rectus muscle has been found ruptured as the result of a spasm. (7) Death may occur from heart-failure or asphyxia.

**THRUSH**.—This disease is due to the *Oïdium albicans*, or thrush fungus. Parts affected: (1) The mouth, tongue, cheeks, etc., are more or less densely covered with minute, slightly raised, white spots, which are quite firm and adherent to the mucous membrane. When scraped off and examined microscopically, the characteristic fungus is seen. (2) Occasionally the fungus invades the œsophagus and grows to such an extent as seriously to obstruct its lumen.

**TUBERCULOSIS**.—Any morbid lesion produced by or through the agency of the tubercle bacillus, which is a rod-shaped micro-organism, measuring in length about one-half the diameter of a red corpuscle and in width two-tenths of a micron. It is bent upon itself, grows best on agar containing glycerin, stains with difficulty, but retains the stain tenaciously. The best method of staining is by carbol-fuchsin and Gabbett's solution. When stained it often has a beaded appearance. It is morphologically similar to the bacillus of leprosy and the



smegma bacillus. Tuberculous lesions are: I. *Acute*.—(a) Miliary tuberculosis. (b) Caseous pneumonia or phthisis florida. (c) Tuberculous ulcerations. II. *Chronic*.—(a) Diffuse tuberculosis, ulcerative phthisis, or caseous tuberculosis. (b) Fibroid phthisis. (c) Cold abscesses. III. *Modes of Invasion*.—(a) Aërogenous. (b) Lymphogenous. (c) Hæmatogenous. IV. *Characteristic Lesions of Tuberculosis*.—(a) Miliary tubercle. (b) Caseation. (c) Cold abscesses. (d) Ulceration. *Characteristics of Tuberculous Lesions*.—(1) Miliary tubercle is a small nodule about the size of a millet-seed, grayish white in color, semi-translucent, raised above the surface, and primarily adherent to the surrounding structures. (2) In caseation or diffuse tuberculosis two or more miliary tubercles agglutinate, isolating the intervening healthy tissue and cutting off its blood-supply. The necrosed area loses symmetry of shape and arrangement and undergoes fatty degeneration. The area is yellowish in color, soft or firm in consistence, and is surrounded by an inflammatory zone. There is an almost complete absence of blood-vessels. (3) Cold abscess is most frequently found in association with tuberculosis of the vertebræ. It is frequently seen as a "psoas" abscess. The capsule of this abscess is more or less imperfect. It does not present the ordinary characteristics of a pyogenic membrane, the limiting wall being composed mainly of broken-down tuberculous tissue with more or less perfectly formed tubercles. The contents of the abscess are pale and of a somewhat watery consistence, composed mainly of broken-down cells, fatty *débris*, and water. Bacteriologically the contents of the abscess are usually sterile. V. *Distribution of Tubercles in the Body*.—(a) The lungs are most commonly affected. In two hundred and seventy-five cases out of a thousand autopsies, the lungs were, with two or three exceptions, involved in all. Other organs were affected as follows: (b) Intestines in sixty-five cases, (c) peritoneum in thirty-six, (d) kidneys in thirty-two, (e) brain in thirty-one, (f) spleen in twenty-three, (g) generative organs in twenty, (h) liver in twelve, (i) pericardium in seven, and (j) heart in four. (Osler.) VI. *Fate of Tuberculous Lesions*.—Tuberculous lesions may terminate: (a) In resolution, which is rare. (b) In fibroid changes. This sometimes occurs in the small intestine and may cause stenosis. (c) In caseation or supuration. (d) In calcification. (1) Resolution sometimes takes place when the area of tuberculosis is small, the blood-supply good, and the patient under favorable conditions, especially when leading an out-door



existence. (2) In healing by fibroid change the area affected is first encapsulated and then by gradual pressure and absorption the affected area is removed, leaving a scar. (3) Caseation is by far the most common result of all tuberculous lesions. The process has been already described. Suppuration in tuberculous lesions is the result of the introduction of pyogenic organisms. (4) Calcification is the most fortunate ending of the tuberculous process, and it is estimated by careful observers that seventy-five per cent. of all persons who die after the age of forty years show this form of tuberculosis in their lungs or pulmonary glands.

*Tuberculosis of the Alimentary Tract.*—This form may be: (a) Primary in the mucous membranes. (b) Secondary to disease of the lungs or eating infected food. (c) It occurs rarely through extension from the peritoneum. I. *Mouth.*—(1) Primary tuberculosis, which is usually miliary. The tonsils are more often affected primarily than was formerly supposed. (2) Secondary to tuberculosis of the face, larynx, or lung. It may attack the tongue or cheeks and be miliary or caseous. II. *Æsophagus.*—(1) Primary tuberculosis is very rare. (2) Secondary tuberculosis through extension from the lungs or larynx is comparatively common. (3) The lesions may be miliary, caseous, or ulcerative. III. *Stomach.*—Tuberculosis of the stomach is comparatively rare; Orth never saw a case. IV. *Intestines.*—The lesions occur in the ileum, cæcum, colon, and rectum. The most frequent seat is in the ileum, just above the ileocæcal valve, as it is here that stasis of the intestinal contents occurs and a favorable opportunity is given for the growth of the tubercle bacillus. (1) The large bowel is less frequently involved than the small bowel. (2) Small, firm, gray nodules develop, which soon soften and become yellow in the centre. If cut into at this stage, pus does not exude as in an ordinary abscess, but a thick caseous material may be pressed out. The mucous membrane over these nodules finally breaks down and the cheesy material is erupted. There remains an ulcer with swollen cheesy base and edges (primary tuberculous ulcer of Rokitsansky), which soon combines with others and enlarges irregularly (secondary tuberculous ulcer of Rokitsansky). Miliary tubercles in the form of small gray nodules now appear at the base and edges of the ulcer and its immediate vicinity. Through the caseation of these, the ulcer enlarges both downward and laterally. The round ulcer becomes a long one, with its longer axis usually at right angles to the long axis of the intestine; it may



extend around the bowel. Hemorrhages may occur, particularly at the edges. The submucosa and muscularis are usually involved, and colonies of young tubercles may be scattered over the serous membrane. Perforation is rare. Gangrene may occur in a very rapidly developing ulcer. Healing sometimes takes place. (3) There may be solitary or multiple areas of cicatricial tissue. (4) *Fistula in ano* is quite common. V. (1) The liver is constantly involved in general tuberculosis. It is pale in color, often fatty, and presenting miliary tubercles or caseous masses which may break down into numerous small abscesses, especially about the smaller bile-ducts. (2) There may be a slight increase in the connective tissues, leading to tubercular cirrhosis.

*Tuberculosis of the Brain and Cord.*—(a) Acute miliary infection. (b) Chronic meningo-encephalitis. (c) Solitary tubercles. I. *Acute Miliary Tuberculosis.*—(1) This is usually secondary to tuberculosis of the lungs, bronchial glands, or bones. (2) Miliary tubercles occur most frequently in the pia and arachnoid of the cerebellum, next in the cerebrum, then in the pons. They follow the direction of the blood-vessels. They are apt to lead to obliteration of the vessels and thus cause softening and necrotic changes. Serous, seropurulent, or sero-fibrinous exudate is also present. (3) This acute process may result in acute inflammation of the meninges, principally the pia and arachnoid. It is spoken of usually as acute hydrocephalus. This is most pronounced towards the base of the brain and occurs most frequently in children. I have found tubercle bacilli in fluid removed by Quincke's lumbar puncture. II. *Chronic Meningo-Encephalitis.*—The membranes at the base of the brain are most often involved, next in frequency the optic chiasm, the Sylvian fissure, and the interpeduncular space. The membranes are thickened, firmly adherent, and covered with a fibrinous, purulent exudate. The convolutions are flattened and the sulci obliterated. The cerebral substance is more or less cedematous. The lateral ventricles are dilated and contain a turbid fluid. III. *Tuberculous Tumors of the Brain.*—(1) Solitary tubercles are found most usually about the cerebellum. As a rule, they are attached to the meninges, often to the pia mater. (2) Cerebral softening from pressure is not uncommon. The tubercles vary in size from a pea to a small orange. They are grayish yellow in color, caseous, and usually firm and hard, but the centre may be semi-fluid. They may be surrounded by submiliary tubercles, but are, as a rule, surrounded by a soft translucent tissue. (3) They may calcify.



*Tuberculosis of the Circulatory System.*—(1) Primary tuberculosis of the larger vessels is unknown; secondary lesions are not infrequently found if carefully searched for. (2) In the lungs, brain, and other organs the smaller arteries are usually involved in acute infiltration which leads to thrombosis. (3) Tubercles may develop in the walls of the vessels, particularly the muscularis, and undergo softening, which may result in hemorrhage or a wide-spread distribution of the tuberculous infection.

*Tuberculosis of the Genito-Urinary System.*—(a) Most common in males. (b) Age from twenty to forty years. I. *The Kidneys.*—(1) These organs are frequently the seat of an acute miliary infection, which may be primary or secondary. The disease is most marked in the cortex. It may be limited to the areas supplied by a single blood-vessel. Necrosis and caseation rapidly follow. The miliary tubercles may be seen in a row in the direction of the vasa interlobularia. One or both organs may be affected, but at autopsy both are found to be enlarged. (2) Not infrequently one kidney may be completely destroyed and converted into a series of cysts; these contain a cheesy substance, and lime salts may be deposited in their walls. This is a chronic form of the disease and frequently starts at the apices of the pyramids. (3) The walls of the pelvis may be thickened and cheesy, and the mucous membrane converted into a necrotic ulcerating mass. The ureters are usually thickened, caseous, or ulcerated. II. *The Bladder.*—Tuberculosis here is most common in men. (1) Infection of this organ is nearly always secondary to infection elsewhere, particularly in the pelvis of the kidney. The bladder is small, shrunken, thickened, and surrounded by sclerosed tissue. Ulcer formation is most common. It is lenticular in shape and is surrounded with red mucous membrane. Its seat of predilection is the trigone and fundus. Minute gray tubercles may be seen. In advanced cases ulcers are found. (2) To find tubercle bacilli in the urine centrifugation should be employed, and the precipitate stained in the usual manner for showing these organisms. Care must be taken not to get the smegma bacillus; it is, therefore, advisable that the urine be collected with the strictest precautions. III. *The Testes.*—Infection may occur before the second year. It may be secondary to peritoneal tuberculosis. At times the greater part of the testis is destroyed, its stroma being replaced by a softened or still firm caseous deposit, which may be softened in the centre. IV. Tuberculosis of the *ureters* is very rare. V. *Salpingitis.*—



The oviducts are enlarged, the walls thickened and infiltrated, and the contents cheesy. It is usually bilateral.

*Tuberculosis of the Larynx.*—The lesions may be primary or secondary, usually the latter. The lesions found are: (1) Miliary tuberculosis. (2) Diffuse tuberculosis. (3) Ulceration. In early cases the epithelium is intact, the tubercle starting in the mucosa or submucosa.

*Tuberculosis of the Lung.*—I. *Acute.*—(a) Miliary tuberculosis. (b) Phthisis florida, showing itself as bronchopneumonic tubercles, as lobar-pneumonic tubercles, or as a combination of both. II. *Chronic.*—(a) Ulcerative phthisis. (b) Fibroid phthisis. I. *Acute.*—(1) In acute miliary tuberculosis the lesions are usually present in both lungs. They are frequently so small and transparent that they may be overlooked on macroscopic examination. At other times they are aggregated in localized spots or even become diffuse. In the latter case the lung is increased in size, is firm in consistence, in color is a darker shade of red, is heavier, and crepitates. The pulmonary vessels should be opened with the scissors, and seldom in the pulmonary arteries but often in the veins miliary tubercles can be seen, the infection having been brought through the circulation. Such tubercles may, however, be localized near an old caseous mass, the lymphatic system then being the transmitter. Local spots of emphysema are seen if the condition is not very acute. The tubercles may be peribronchial, perivascular, or in the parenchyma. There is a chronic miliary tuberculosis which presents a combination of lesions of both acute miliary tuberculosis and phthisis and is the connecting link between the two. (2) Phthisis florida, or acute phthisis with formation of cavities, presents a varied appearance. One lobe only, or more or less of the whole lung, may be affected. The organ is heavy; the implicated portions do not collapse and are firm and airless. The pleura is covered with a thin exudate. On section the condition may resemble red or gray hepatization or an intermediate stage between them. In other instances the lung presents a mottled appearance, some areas being intensely congested, others exhibiting a characteristic pale-gray gelatinous exudate, others caseous degeneration and not infrequently cavity formation. Recently affected areas of pulmonary tissue with croupous pneumonia are often seen. II. *Chronic.*—(1) In ulcerative tuberculosis apical involvement in relation to implication at the base exists in the proportion of five hundred to one, according to Kidd.



There are varied lesions. First, there are caseous nodules, which are grayish, white, or yellow in color. Second, cavities may exist, which, if the case is acute, have walls made up of soft caseous masses. In the more chronic cases these walls are replaced by pyogenic membranes of greater or less density, at times covered with granulations. Frequently trabeculae are seen in the walls; these are the blood-vessels, branches of the lung artery, which have resisted the tuberculous process. The arteries sometimes become aneurismal. Their rupture may be followed by hemorrhage severe enough to cause death. Frequently they are contracted and empty, due to a previous endarteritis or thrombosis. Third, pneumonic areas and evidences of chronic bronchitis are seen. Fourth, some thickening of the pleura is constant. This may be merely an acutely inflamed area rubbing against a corresponding area on the parietal pleura or it may be tightly adherent to it. Not infrequently perforation causes a pyopneumothorax. Fifth, enlarged bronchial glands are discovered which are caseous and often pigmented. Lastly, the bronchi are thickened and the lumina of the smaller ones frequently obliterated. The larger tubes show caseous deposits in the submucous and fibrous coats. (2) In fibroid phthisis the organ is permeated with interstitial overgrowth. In some cases the interstitial change is most prominent; in others the tuberculous process is slightly more marked. The unaffected portions of the lung are largely emphysematous and pigmentation is considerable. The right ventricle and sometimes the whole heart are hypertrophied.

*Tuberculosis of the Lymphatic Glands.*—(1) Location, most frequent in the cervical chain. (2) Extension opposite that of the lymphatic stream. (Treves.) I. *Chronic Form.*—(1) Hard. (2) Non-adherent. (3) Yellowish white in color. (4) Little tendency to break down and suppurate. (5) Tendency to be localized. (6) Overgrowth of connective tissue considerable. In tabes Virchow compared them to a sectioned potato. II. *Less Chronic Form.*—(1) Not as dense. (2) Tendency to become adherent. (3) Gray or grayish white in color. (4) Tendency to liquefy and suppurate. (5) Connective tissue less in amount. (6) Tubercle bacilli more abundant. When tuberculous lymphatic glands are associated with phthisis, they are sometimes found to have opened into a bronchus and caused the disease. This is particularly common in children, and especially when the middle and lower lobes are involved.



*Tuberculosis of the Mammary Gland.*—(a) Female sex. (b) Strumous temperament. (c) Age from the fortieth to the sixtieth year. The seat of predilection is the gland duct. (1) Induration is at first small and very slowly increases in size. (2) The nipple may be retracted. (3) The skin over the gland becomes riddled with sinuses with indurated edges. (4) Associated with lymphatic enlargement, tuberculosis of bone, or other tubercular involvement near the gland.

*Tuberculosis of the Peritoneum.*—I. *Miliary Form.*—(1) On opening the abdominal cavity the serous membranes seem to be covered to a greater or less extent with miliary tubercles, which are present in the mesentery and the omentum also. Frequently the gray nodules follow the distribution of the blood-vessels. (2) In many cases there is little or no inflammatory exudate, although petechial hemorrhages are common. (3) The peritoneum, however, has not its normal shining surface, but is usually pale, somewhat sticky, and lustreless. (4) In many cases there is an effusion of straw-colored or bloody fluid which may amount to a litre or more. It contains a considerable amount of albumin and some cells. The exudate is rarely purulent. II. *Chronic Diffuse Form.*—(1) The abdominal viscera and peritoneum are bound together by tough, firm, membranous bands of organized exudate and the peritoneal cavity is obliterated. (2) The intestinal coils are shortened and contracted, while the mesenteries and omentum are enormously thickened. (3) The capsules of the liver and spleen undergo extreme thickening, varying from a few millimetres to several centimetres. The organs are rough and irregular in outline. III. *Ulcerative Form.*—(1) There is a formation of caseous masses that vary in size from a pea to a marble, and which tend to run together and break down, forming more or less extensive ulcerating surfaces. (2) Adhesions are formed of a serofibrinous or seropurulent character. (3) The new tissues are apt to become pigmented and of a gray or almost black color. (4) The intestinal walls are very friable. (5) *Fistulæ*, opening at various points, are not infrequent.

*Tuberculosis of Serous Membranes.*—There are three groups of cases: (1) Acute miliary tuberculosis, which may develop very rapidly and is accompanied by more or less serous but turbid exudate. (2) A chronic form characterized by exudation, the formation of cheesy masses, and a tendency to suppuration. (3) Cases in which



the tubercles are hard and fibroid, the membranes much thickened, but with little or no fluid exudate. In these cases there may be no visceral tubercles.

*Tuberculosis of the Skin.*—Anatomical warts are small papillary outgrowths frequently seen on the hands of those who make many autopsies. The process is chronic, and, as in the case of one of my helpers in the post-mortem room at Blockley, may give rise to general tuberculosis. The bacilli are few, and are best demonstrated by inoculation of some of the secretion into a guinea-pig. The animal lives for a longer period of time than is usual when it is inoculated with tuberculous material taken from other sources. *Lupus vulgaris* is a cutaneous form of tuberculosis, characterized by the formation of nodules, which tend to break down, producing more or less ulceration. The tubercle bacillus is found in very few numbers. (1) The lesion begins as a small nodule, reddish brown in color and of soft consistence. These nodules vary in size from a pin-head to a cherry and quickly break down and ulcerate. The ulcers are more or less rounded and have a red base covered with granulations. The intervening tissues show diffuse infiltration and fibrous hyperplasia. Warty excrescences may develop in the epidermis or in the floor of the ulcers. The face is the most common seat of the disease. (2) In lupus of the larynx the lesion is surrounded by hyperæmic, œdematous tissue. In the course of time smooth, hard nodules appear, causing great deformity of the parts. Softening and ulceration give the larynx a worm-eaten appearance. The disease follows the lymphatic channels.

**TYPHOID FEVER.**—The intestinal lesions are: First week, intense catarrhal inflammation of the mucous membrane of the intestines and in the first few days only moderate swelling of the follicles. Towards the end of this week, however, there is more decided medullary swelling. Second week, the medullary swelling goes on to resolution or formation of eschar or, third week, ulcer formation. In the fourth week there is beginning cicatrization. The lesions are most marked in the lower ileum, but they also exist in the cæcum and large intestines, rarely in the jejunum. Hyperplasia of the mesenteric lymphatic glands and the spleen develops early in the disease. Cloudy swelling and fatty degeneration of the heart, liver, and kidneys may be present. Waxy degeneration and bleeding in the voluntary muscles should be looked for. Other lesions are lymphoma of the liver, acute nephritis, bleeding of the skin, hypostatic or catarrhal pneumonia,



purulent bronchitis, perforation, and peritonitis. The Widal test and the diazzo-reaction may be determined *post mortem*. Paratyphoid or paracolon infections are more common than was formerly supposed, and furnish most interesting cases for thorough study.

YELLOW FEVER.—The chief lesions are: (1) Bleeding from the mucous membranes. (2) Tarry blood. (3) High-grade fatty degeneration of the liver. (4) Acute hemorrhagic inflammation of the stomach and intestinal mucous membrane. (5) Icterus. The interesting work done by Reed, Carroll, and Agramonte in Havana, in showing that this disease is dependent on the *Stegomyia*, a variety of mosquito, is one of the most important contributions to medical literature of the past decade. The bacillus X of Sternberg and the bacillus icteroides of Sanarelli are by some supposed to be identical, by others not to be the cause of yellow fever. There is an interesting illustrated article on this subject in the *New Orleans Medical and Surgical Journal* for January, 1902.

#### PARASITES.

PEDICULI.—(a) *Pediculus capitis*.—The female louse measures from one and eight-tenths millimetres to two millimetres in length, the male being somewhat smaller. The darker the skin of the person infested the darker is the color of the parasites. So marked is this peculiarity that some writers are of the opinion that different species affect different races. The ova are grayish glistening specks enclosed in a membrane firmly adherent to the shaft of a hair not far from its root, and coming off at an acute angle, with the opening away from the scalp after the exit of this parasite. Considerable irritation is caused by these animals, and when this is severe the hair on the back of the head may be found matted with soft yellow crusts. The scalp is covered with moist red granulations. The cervical lymphatic glands posteriorly are enlarged. This condition is most frequently seen in children. (b) *Pediculus pubis*.—It differs slightly from the above in that it is smaller and infests regions, as the axillary, the pubic, and the periocular, where the hair is short. (c) *Pediculus corporis* is the largest form of the parasite. It lives in the clothing, when not in search of food on the body. By its constant irritation it causes dermatitis, and if present for a long time, pigmentation and thickening of the skin. (d) *Cimex lectularius* (common bedbug). (e) *Pulex irritans* (the common flea). (f) *Pulex penetrans* (sand-flea, jigger). The latter



is common in tropical and subtropical countries. It is smaller than the common flea. It burrows under the skin and produces a pustular swelling. (g) *Sarcoptes (Acarus) scabiei*.—The female itch-mite is .45 of a millimetre long and .35 of a millimetre broad; the male is about one-half the size. Its color is pearly white. The burrow in the skin, wherein may be found the excrement and the eggs of the parasites, is about one centimetre in length, and is present where the skin is moist, as in the webs of the fingers and toes. Cutaneous lesions result from the scratching instigated by the irritation caused by the parasite.

CESTODES.—*Intestinal Cestodes*.—(a) *Tænia solium* in the mature form may reach to twelve feet or even more in length. It is composed of numerous segments about one-third of an inch long and averaging a fourth of an inch wide. The head is very minute, being no larger than the head of a pin. In front is a rostellum and at the base of this is a fringe of hooklets. It has four suckers. The worm is hermaphroditic. When mature thousands of ova are passed by the rectum. The embryo has six hooklets. It penetrates the walls of the stomach and burrows into the tissues of the animal that has swallowed it. (b) *Tænia saginata* is larger, longer, and of more frequent occurrence than the preceding. The head is nearly square and measures more than two millimetres in breadth, but has no hooklets. The segments are larger than those of the *Tænia solium*. The reproductive organs are on the ventral aspects of the segments in the median lines. (c) The *Bothriocephalus latus* is larger and longer than any of the flat worms. In the mature state it is twenty-five feet or more in length. It has no hooklets, but is furnished with slit-like fossæ on the head, which act like suckers. The larvæ develop in the peritoneum of fish. (d) *Tænia flavopunctata* is very rare. It is about sixteen centimetres long. (e) The *Cysticercus cellulosæ* is the larval form of the *Tænia solium*. It is found in the muscles, brain, cord, peritoneum, or almost any other tissue of the affected animal. The surrounding capsule is frequently calcified. In the making of many autopsies it is surprising how few tænia are found in the intestinal tract. My experience is limited to but two cases. One of these was that of a man who committed suicide with opium. Two *Tæniæ saginatæ* were found, the head of the first one being firmly attached beneath a fold of one of the valvulæ conniventes high up in the jejunum and the other five or six feet farther down the intestine, the segments of both worms then continuing on down to near the ileocæcal valve.



NEMATODES. — (a) *Ascaris Lumbricoides*. — It is a cylindrical worm with both ends pointed. The female is from ten to sixteen inches in length, the male considerably smaller. It is brownish yellow, reddish, or white in color. The head ends in three lips. (b) The *Oxyurus vermicularis* (seat-worm) is a very small round worm, about ten millimetres long. (c) The *Trichina spiralis* in the mature state lives in the intestine; in the immature state in the muscles. The embryo is surrounded by a capsule, which quickly calcifies. Under the microscope the embryo can be seen coiled up in its capsule; it is less than a millimetre in length. (d) The *Anchylostomum duodenale* lives in the upper part of the intestine. The female is the larger, and varies from ten to sixteen millimetres in length. At the anterior portion of its head are hooklets, with which it attaches itself to the intestinal walls. It is frequently associated with Egyptian chlorosis. Stiles and Harris have recently called attention to the wide distribution of uncinariasis in the South; the disease may be readily recognized by finding the ova in the fæces. (e) The embryo of the *Filaria sanguinis hominis* is a round worm one-seventy-fifth to one-one-hundredth of an inch long. It is enclosed in a delicate sac. It circulates freely in the blood, but only at night. The adult parasite is located in the lymphatic vessels and is three or four inches in length. According to Manson, it is introduced into the body by the mosquito.

DISTOMIASIS. — (a) Liver-flukes. (b) Blood-flukes. These worms are lanceolate in shape, quite flat, and possess a distinct head and neck. They are three-fourths of an inch long and about half an inch broad. The color is dull brown. The female blood-fluke has a grooved channel posteriorly for the reception of the male. They have two suckers, one near the mouth and the other near the ventral portion of the body. The liver-fluke infests the upper intestine and the bile-ducts. It causes the "liver-rot" in sheep. The blood-fluke is found chiefly in the portal system and the veins of the bladder. The ova may be seen in the urine as elongated ovoid bodies, sharply pointed at one extremity, and containing black pigment. They can easily be seen with a low power of the microscope. Parasitic hæmoptysis now occurs in America as well as in Asia, and is due to the *Paragonimus Westermanii*. The eggs are found in the sputum, the fluke measuring from eight to sixteen millimetres long by four to eight millimetres across.

MYIASIS.—By this term is meant a condition in which a diseased



part becomes "living," as it is called. It is caused by the larvæ of certain flesh-flies, of common house-flies, or of the bot-flies of oxen or sheep. The ova of these flies may be deposited in the nostrils, ears, conjunctiva, open wounds, or even in the vagina during the puerperium.

**ECHINOCOCCUS DISEASE.**—A parasitic disease, found most frequently in those countries, as Iceland and Australia, where the dog lives in intimate association with man; it is characterized by the formation of endogenous or exogenous multilocular cysts in various portions of the body. The *Tænia echinococcus* is a very small, thread-like tape-worm (length from three to six millimetres), having only three segments. The head has four suckers, a rostellum, and a double row of hooklets. The adult worm is found in the dog. The embryos (scolices) are found in the ox, hog, sheep, horse, and man. *Distribution in Man.*—(a) Liver (most common). (b) Lung and pleura. (c) Intestinal tract. (d) Kidney, brain, etc. The embryo, freed from the cyst by digestion in the stomach, burrows through the intestinal wall and is carried to the various organs; it then loses its hooklets and is gradually converted into a cyst (hyatid) having two walls, external laminated, internal granular or parenchymatous, containing blood-vessels and muscle-fibres. The interior is filled with a clear non-albuminous fluid, specific gravity 1005-1009, usually containing sugar and hooklets. From irritation of surrounding tissues a fibrous capsule generally develops on the outside. The cysts vary in size from that of a small pea to that of a child's head. From the inner (parenchymatous) layer may develop brood capsules, which in their turn produce numerous scolices. The cysts grow slowly; when the embryo dies, the whole becomes calcified. Sometimes the cysts suppurate; occasionally they rupture into adjacent structures.

#### HÆMATOZOA.

**MALARIA.**—This widely distributed and much-studied disease is due to a true hæmatozoon, transmitted to man by the bite of the *anopheles* mosquitoes. Three varieties have been described: (a) Tertian. (b) Quartan. (c) *Æstivo-autumnal*. *Classification.*—(a) Acute malarial fever, which may be quotidian, tertian, or quartan. (b) Pernicious malaria. (c) Chronic malarial cachexia. In the blood of the cadaver the plasmodium is seldom visible, but it may be found in sections of the brain, liver, and spleen. (1) Cases of simple malarial fever



are rarely fatal. The blood shows disintegration of red corpuscles and an accumulation of pigment is thereby formed. The spleen is enlarged, dark in color, and may show pigmentary deposits. (2) In pernicious malaria the blood contains enormous numbers of the parasites. The red corpuscles are in all stages of destruction and the serum is tinged with hæmoglobin. The spleen is moderately enlarged. The pulp is soft, chocolate-colored, and turbid; it contains large numbers of red corpuscles and parasites and the amount of pigment is greatly increased. The liver is swollen and presents areas of focal necrosis and capillary thrombosis. Pigmentary deposits are also common. The kidneys present more or less parenchymatous change with only moderate pigmentation. (3) In malarial cachexia the blood presents all the characteristics of an advanced anæmia, often distinguishable from pernicious anæmia only by the presence of the parasite and icterus. The spleen is greatly enlarged: it may weigh from seven to ten pounds. The organ is firm and resistant to the knife. The capsule is thickened and the parenchyma brownish or slate-colored, with areas of pigmentation. The kidneys are enlarged and of a grayish-red color. The peritoneum is thickened, opaque, and of a deep slate-color; the gastric and intestinal mucous membrane may have the same hue. The gray matter of the brain is of a deep reddish-gray color or in very chronic cases a chocolate-brown. The meninges are congested. (4) Among accidental and late lesions is cirrhosis of the liver. Very extensive pigmentation may occur. Pneumonia is believed to be common; moderate albuminuria is frequent; acute nephritis is not uncommon; chronic nephritis may follow long-continued or repeated infection. Rupture of the capsule of the spleen may occur, followed by bleeding into the peritoneum and even peritonitis. In pernicious malaria the brain may show thrombosis, due to the parasites, with secondary softening of the surrounding tissue. The same thing may be found in the gastro-intestinal mucosa and be followed by superficial ulceration. There may be advanced fatty degeneration of the heart.

**PSOROSPERMIASIS.**—A condition produced by the presence of oval, transparent bodies belonging to the coccidia, to which class the malarial organism also belongs. I. (1) In the majority of cases of the internal form the psorosperms have been found in the liver. (2) Whitish growths resembling tubercles and containing the coccidia have been found upon the peritoneum, omentum, and pericardium. (3) Similar masses are sometimes seen in the ileum, liver, spleen, and



kidneys. The liver may be enlarged and contain caseous foci which are surrounded by areas of congestion. (4) The spleen may be similarly affected. II. (1) In cutaneous affections the lesions closely resemble those of tuberculosis of the skin. They occur in Paget's disease of the nipple and by some are believed to be its cause. (2) A case has been reported in which at autopsy nodules were found in the lungs, adrenals, testicle, spleen, on the surface of the liver, and on the pleuræ. Great numbers of psorozoa were found in the lesions. (3) Successful inoculations were made into rabbits and dogs.

TRYPANOSOMA.—Four animal diseases are caused by varieties of trypanosomes, nagana, surra, *mal de caderas*, and dourine. Recently Nepveu, Dutton, and others have found them in man.



## CHAPTER XXIII

### THE PRESERVATION OF TISSUES FOR MICROSCOPIC AND MACROSCOPIC PURPOSES<sup>1</sup>

WHEN tissues are to be preserved for microscopical study, the method of fixing and hardening them should be decided upon at the time of their removal from the body. The objects of fixation and hardening are permanently to solidify the structural elements of a part as nearly as possible in their original form and situation. All our present methods, however, fail to give an accurate picture of the living cell, and not enough attention is now paid to the microscopical examination of unstained fresh scrapings removed during the performance of the autopsy. The best slides are secured by the use of different processes for various purposes. The use of perfectly fresh tissues is essential, for many structural details disappear on molecular death. Fortunately, this does not occur until several hours after molar death, so that it is often possible to obtain tissues still living.<sup>2</sup> Our choice of reagents also is constantly being enlarged. The method of wrapping tissues in paper or cloth and transporting them to a distance is only to be regarded as a last resort. When this is done, pieces of sufficient size to insure preservation of their interior intact are enveloped in an abundant supply of clean cotton (antiseptic gauze causes markings on them), moistened very slightly with a bichloride-tablet solution, and thoroughly protected from pressure; these segments are cut down to a proper size before they are put into the fixing agent in the laboratory. The careless wrapping of tissues in cloth or paper is mentioned only to be condemned.

Bottles containing the more common fixatives should be ready, and as soon as the tissues are exposed and described—before the part

---

<sup>1</sup> Based on the works of LEE, *The Microtometist's Vade Mecum*; MALLORY AND WRIGHT, *Pathological Technique*; APÁTHY, *Die Mikrotechnik der thierischen Morphologie*; FISCHER, *Fixirung, Färbung, und Bau des Protoplasmas*; SZYMONOWICZ, *Lehrbuch der Histologie*; STÖHR, *Text-book of Histology*; BÖHM AND VON DAVIDOFF, *Text-book of Histology*, and the *Encyklopädie der mikroskopischen Technik*, 1903.

<sup>2</sup> A most inviting field of investigation is opened up by the experimental staining of tissues during life and their fixation while the animal is still living.



becomes distorted, fluids escape, or surfaces dry—they should be cut with a clean, sharp knife into pieces about two centimetres in length and breadth and one centimetre thick. Sections of organs should include their characteristic structures,—cortex, capsule, hilum, endocardium, etc. Sections of tumors should be taken from the centre, where degenerative changes are most marked, and from the growing peripheral margin, if possible including some normal tissue; this is of especial importance in the case of malignant tumors. Mucous and serous membranes are pinned out on cork, or wood that will give no stain when soaked in the preservative fluid to be used, with their secreting surfaces uppermost. Muscle-fibres are best preserved by being tightly stretched upon and tied at the ends of a piece of wood. The segments of tissue, without being touched by either fingers or forceps, are lifted on the blade of the scalpel and dropped immediately into a bottle containing an amount of fixing fluid far in excess of their bulk. Of energetic fixatives, such as Flemming's or Hermann's, about fifteen times the volume of the object introduced will suffice, while of milder fluids, like the bichromate of potassium or picric acid solutions, one hundred times such volume will be required.

If the different tissues are distinguishable macroscopically, they may be placed in the same jar; if not, separate bottles are better. Tags may be attached, the writing being done with a lead-pencil, as they are not acted upon by the usual preservatives. The jars are labelled with the date, the number or name of the autopsy, and the fixative used. It is often of importance to add the exact locality from which the pieces have been removed and the plane on which they are to be cut when placed in the microtome.

The fluid should always be changed after it becomes turbid; or in the case of alcohol or formalin, preferably after three hours, whether it is turbid or not. If the specimens are to be sent away, they should not go until the fluid remains clear; if the time necessary for transportation exceeds that of the proper action of the fixative, they should be worked on up to 80 per cent. alcohol and shipped in that fluid, firmly packed in absorbent cotton.

The choice of a fixing agent is determined by the nature of the object to be preserved and the purpose for which the investigation is undertaken. The characteristics of different pathological conditions are better preserved in some fixatives than in others. Thus, fatty degenerations are well preserved by an osmic acid, bichromate, or



formalin solution; œdematous and parenchymatous changes, by corrosive sublimate; fibrin and hemorrhagic conditions, by absolute alcohol, etc. Moreover, different tissues require different treatment; the fixation of a lymph-node is quite a different matter from that of a retina. Then the purpose for which the examination is made will largely influence the choice. If it be simply a question of general diagnosis, Orth's fluid and alcohol will answer every purpose; by the use of alcohol we can preserve the specific staining properties of micro-organisms and hæmoglobin and various important chemical reactions, and by the use of Orth's fluid colloid and mucoid material retain their transparency, fat is preserved, etc. If we undertake the investigation of pathological processes and the comparison of abnormal with normal cellular anatomy, then special fixatives must be used.

The advantages and disadvantages of the fixing solutions most in use will first be given, next a list of pathological conditions and the solutions best calculated to preserve their characteristics, and finally a list of staining solutions requiring certain fixatives for their use.

**FIXATIVES; INSOLUBILITY.**—To preserve soluble cell contents they must first be rendered insoluble, and the transformation must be equable throughout. The colloid or fluid material must harden homogeneously and enclose the more solid structures without loss of former relationship: there must be no shrinkage, no condensation, no expansion; but everything should be precisely as it was when manifesting vital activities, except this change into a compound that will remain undissolved and persist through subsequent necessary manipulations. This insolubility is supposed to be due in some cases to a sort of clotting process; and if the coagulating property be stronger in absolute alcohol than its dehydrating power and less in alcohol of lower percentage, this fact explains why more shrinkage is caused by 96 per cent. than by absolute alcohol, and why the shrinkage increases with the lowering of the alcoholic strength. Other fixing agents, such as osmic acid, chromic acid, potassium bichromate, and corrosive sublimate solutions, seem to form a chemical union with the cell contents and so produce an extremely durable insolubility. Others, such as picric acid and nitric acid, harden well, but form such unstable compounds that the fixation is easily removed by washing in water and must be preserved by placing the specimens in alcohol. It is evident that any solvent action by the reagent—*e.g.*, the action of alcohol on fat and that of acetic acid on protoplasm—forbids its use.



**OPTICAL DIFFERENTIATION.**—Some agents in producing insolubility effect another change which is equally valuable and which is known as optical differentiation. The various cell structures respond differently to the fixative. Their indices of refraction are altered; some are raised, some lowered, and marked contrasts in refractive properties are developed throughout the cell. In this way structures become visible that were before unseen. Bichromate of potassium stiffens very equably, with neither shrinkage nor expansion, but has no power of optical differentiation; while osmic acid possesses this in a high degree. Since observation with the microscope is directly dependent upon differences in refraction, it is evident that this is a most valuable property of a fixative.

**PENETRATION.**—The ability to reach all points of the tissue at the same time is another important characteristic of a fixing agent and one clearly connected with securing optical differentiation. Osmic acid has but little penetration. If pieces placed in its solutions are too thick or remain therein too long, the superficial layers become over-exposed, the indices of refraction are all equally raised, and differentiation disappears. This is true not only of cells in mass, but also of intracellular structures. Prompt and uniform action, the sharp fixation of tissues at the precise moment, insures good optical differentiation; slow, unequal action results in loss of definition.

**FIXING FLUIDS.**—All acids apparently possess fixing properties, and every fixing fluid should be acid, with possibly the exception of alcohol. Of the organic acids acetic and formic are those most used; of the inorganic, nitric, sulphuric, picric, hydrochloric, osmic, and chromic.

*Acetic Acid.*—By this term is always meant glacial acetic acid, which has very great penetrating power and aids in optical differentiation. It causes swelling and solution of protoplasm, and hence is not used alone, but with fixatives such as osmic acid to aid in penetration and prevent excessive blackening, with alcohol and corrosive sublimate to prevent shrinkage, and with chrome salts to aid in optical differentiation. It is usually added to these various solutions in strengths varying from 0.5 to 5 per cent. All liquids containing a large percentage of acetic acid should be allowed to act only for a short time. Acetic acid should not be used for connective tissue.

*Alcohol* (95 per cent. or absolute; 2-24 hours; 5 mm. thick).—Alcohol has certain important advantages. It can be readily procured,



does not have to be made up, tissues are hardened as well as fixed by it, and, since it represents one of the last stages preparatory to embedding, its use saves much time and trouble, and the material for a general diagnosis is easily and promptly prepared, which is often a great convenience. It penetrates well, preserves the specific staining properties of micro-organisms and various important chemical reactions, permits the use of most stains and is demanded by others,—*e.g.*, Nissl's, Lenhossék's, Weigert's, Ribbert's phosphomolybdic hæmatoxylin, Unna's orcein, etc. It is especially good for glands, skin, and blood-vessels, mast-cells, plasma cells, fibrin, and hyperæmic conditions, since it preserves the color-reactions of hæmoglobin. On the other hand, it sometimes causes shrinkage and exerts a bad solvent action, so that the cells come out lean and empty, with foamy, vacuolated protoplasm and with distortion or loss of original structure.

Tissues should not remain too long in absolute alcohol, as they sometimes stain very poorly after as short a time as twenty-four hours. Alcohol is not a good fixative for van Gieson's stain. Alcohol of lower percentage than 95 causes excessive shrinkage.

The shrinkage of alcohol is corrected by the use of acetic acid.

Carnoy's fluids (for nuclear structures) :

- |                             |          |
|-----------------------------|----------|
| 1. Glacial acetic acid..... | 1 part.  |
| Absolute alcohol.....       | 3 parts. |
| 2. Glacial acetic acid..... | 1 part.  |
| Absolute alcohol.....       | 6 parts. |
| Chloroform .....            | 3 parts. |

Leave pieces in for from fifteen to thirty minutes; wash out in alcohol. Avoid aqueous liquids.

(For acetic alcohol with sublimate see "Gilson's solution" and "Ohlmacher's solution" under *Corrosive Sublimate*.)

After the use of alcohol as a fixing agent, tissues must either be embedded in celloidin or paraffin as soon as hardened or left in cedar oil, or put through 95 per cent. alcohol and finally preserved in 80 per cent.

*Chromic Acid*.—Chromic acid is a powerful and rapid coagulating agent, but, on account of its lack of penetration and tendency to cause shrinkage and make tissues brittle, it is seldom used alone. Its defects are remedied by adding acetic, formic, osmic, or nitric acid to its solutions. All tissues fixed by chromic acid solutions are to be washed in running water and hardened in graded alcohols in the dark.



## Chromo-acetic acid (Rabl) :

Acetic acid, 0.1 per cent. in water.....	1 part.
Chromic acid, from 0.2 to 0.25 per cent.....	1 part.

## Chromo-formic acid (Rabl) :

Chromic acid, 0.33 per cent.....	200 cc.
Formic acid, concentrated.....	from 4 to 5 drops.

Use at once, fix for from twelve to twenty-four hours.

## Chromo-nitric acid (Perenyi) (4-5 hours) :

Nitric acid, 10 per cent.....	4 parts.
Alcohol .....	3 parts.
Chromic acid, 0.5 per cent.....	3 parts.

Transfer directly to 70 per cent. alcohol for twenty-four hours, to 95 per cent. for some days, and to absolute alcohol from four to five days.

Chromo-osmic acid has been superseded by

## Chromo-aceto-osmic acid (Flemming) :

Chromic acid, 1 per cent.....	45 cc.
Osmic acid, 2 per cent.....	12 cc.
Glacial acetic acid.....	3 cc.

Objects may stay in this solution for hours or even several days. The pieces should be perfectly fresh and not thicker than 4 mm.

It should be made up shortly before using. When all the conditions are fulfilled, it is unequalled as a fixative and in producing optical differentiation. The most delicate structural details are brilliantly shown. Especially used for mitotic figures.

*Bichromate of Potassium*.—The simple aqueous solution is used in gradually increasing strengths from 2 to 5 per cent. for hardening purposes, for which it is excellent, but, on account of its lack of penetration and tendency to cause the chromatin to swell, it is not suitable for a nuclear fixing agent without being reinforced. The addition of glacial acetic acid gives a fluid which acts nearly as well as Zenker's and is much more convenient to use. The excess of bichromate is to be well washed out in running water and the tissues hardened in alcohols in the dark.

## Acetic bichromate (Tellyesniczky) (1-2 days) :

Bichromate of potassium.....	3 grammes.
Glacial acetic acid.....	5 cc.
Water .....	100 cc.

Begin hardening with 15 per cent. alcohol.



Osmic, bichromate, and platinum chlorid (2 hours) (Dr. Lindsay Johnson) :

Potassium bichromate, 2.5 per cent.....	70 parts.
Osmic acid, 2 per cent.....	10 parts.
Platinic chlorid, 1 per cent.....	15 parts.
Acetic or formic acid (just before using).....	5 parts.

A fine fixative for delicate objects, such as a retina. Leave objects in for two hours. Wash in running water. Harden in alcohol.

The slow, mixed, and rapid methods of Golgi stain the cells with their prolongations, the nerve-fibres with their terminal ramifications, and the neuroglia cells.

Golgi's slow method: Harden pieces of tissue in a 2 per cent. solution of bichromate of potassium from two to six weeks. Keep in the dark and change often. Transfer to a 0.75 per cent. aqueous solution of silver nitrate.

Golgi's mixed method: Harden small pieces of tissue for from three to five days, or longer, in a 2 per cent. solution of potassium bichromate at 25° C. in the dark. Place in the following solution for from three to eight days.

Osmic acid, 1 per cent.....	2 parts.
Bichromate of potassium.....	8 parts.

Then into a 0.75 per cent. silver nitrate solution.

Golgi's quick method: Tissues should be absolutely fresh, and the pieces not more than three millimetres thick.

Osmic acid, 1 per cent.....	1 part.
Bichromate of potassium, 3.5 per cent.....	4 parts.

Leave pieces of neuroglia in the solution for two or three days, nerve-cells from three to five days, nerve-fibres and collaterals from five to seven days. Then place in 0.75 per cent. silver nitrate solution.

Müller's fluid (6-8 weeks) :

Bichromate of potassium.....	2.5 grammes.
Sulphate of sodium.....	1. gramme.
Water .....	100. cc.

This fluid, once so universally used, is now largely replaced by better fixatives. It has all the faults of the plain bichromate solution and the same need of being reinforced. (For acetic acid and sub-



limate additions see "Zenker's fluid" under *Corrosive Sublimate*; for formalin see "Orth's fluid" under *Formalin*.) It hardens evenly without shrinkage and gives very good consistency to tissues, but it is in no way a nuclear fixative. As a hardening agent for nervous tissue it has been almost entirely replaced by formalin.

Pieces of tissue not larger than two centimetres are hardened in from six to eight weeks. Change daily for seven days, then once a week. Wash in running water twenty-four hours. Nervous tissue is placed directly in alcohol.

*Erlicki's Solution*.—

Potassium bichromate.....	2.5 grammes.
Copper sulphate .....	0.5 to 1. gramme.
Water .....	100. cc.

This is an extremely good agent for hardening voluminous objects. Its action is much more rapid than that of Müller's fluid. For microscopical work, however, it gives precipitates likely to be misleading and difficult to remove. It is used as a fixative for Freud's gold stain for nerve-fibres.

*Chlorid of Iron (Mallory)* (3-5 days).—For peripheral nerve-fibres.

Chlorid of iron.....	1 part.
Distilled water.....	4 parts.

Wash out thoroughly in water. Transfer to a saturated solution of dinitroresorcin in 75 per cent. alcohol for several weeks. Wash, dehydrate, etc.

This stain may be used after Flemming or Müller.

*Corrosive Sublimate (Bichlorid of Mercury)*.—This is a very active penetrating and hardening agent, and since tissues are sufficiently affected by it in from three minutes to two hours and are then placed directly into alcohol, the process is a quick and convenient one. Carmin and van Gieson stains are particularly brilliant after it. The Heidenhain-Biondi triple stain requires its use. It is an especially good fixative for the alimentary tract; for oedematous tissues and albuminous degenerations, since it coagulates nearly as well as boiling water; it is used for connective-tissue fibrillæ with Mallory's anilin-blue stain. Its disadvantages are that it causes shrinkage and the formation of precipitates which must be removed. If tissues are too long exposed to its action they become brittle, and if



kept too long in alcohol they are very difficult to cut. Unless corrected by the addition of some other agent, poor optical differentiation is obtained, so that corrosive sublimate should be used only for general and not for cytological work. Pieces of tissue should not be larger than five millimetres, and must be removed as soon as they become thoroughly opaque, otherwise they will be too brittle. All solutions containing this salt act much better when freshly made, as they deteriorate by standing.

Sodium chlorid and bichlorid of mercury (Heidenhain's solution): A saturated solution of bichlorid of mercury in 0.5 per cent. solution of sodium chlorid.

Acetic sublimate: A saturated solution of corrosive sublimate in 5 per cent. glacial acetic acid.

Gilson's solution:

Absolute alcohol.....	1 part.
Glacial acetic acid.....	1 part.
Chloroform .....	1 part.
Sublimate to saturation.	

This liquid is one of the most penetrating and rapidly acting of any, if not *the* most. Wash out with alcohol containing tincture of iodine.

Ohlmacher's solution (15-30 minutes):

Absolute alcohol.....	80 parts.
Chloroform .....	15 parts.
Glacial acetic acid.....	5 parts.
Sublimate to saturation (about 20 per cent.).	

A cerebral hemisphere sectioned by Meynert's method is hardened in from eighteen to twenty-four hours.

Zenker's fluid:

Corrosive sublimate.....	5 grammes.
Glacial acetic acid.....	5 cc.
Müller's fluid.....	95 cc.

Add the sublimate and acetic acid just before using. Leave tissues in from twenty-four to forty-eight hours.

This fluid is comparable to that of Flemming in perfect fixation. It has better penetration, over-fixation is not so likely to occur, it gives better staining results, and is much cheaper. It is altogether most satisfactory. Eosin stains are especially brilliant after its use. Its one disadvantage is that the sublimate must be removed by placing



sections in 70 per cent. alcohol containing enough tincture of iodine to give it the color of a dark sherry wine; but this is true of all sublimate solutions.

Bensley's solution ( $\frac{1}{2}$ -2 hours) :

Potassium bichromate, 1 to 2 per cent. solution in water... 1 part.

Corrosive sublimate, saturated solution in alcohol..... 1 part.

Mix the two solutions just before use. Leave tissues in from one-half hour to two hours. Wash well in water.

This solution is especially useful for the gastro-intestinal tract.

*Formalin*.—This agent acts very rapidly; it causes no shrinkage. Cytoplasm and nuclei are well preserved. Mitotic figures are fixed. Hæmoglobin and micro-organisms retain their specific staining reactions. Fat is not dissolved; mucin is not precipitated, but remains transparent. Formalin is an especially valuable fixative for nervous tissues: an entire brain may be hardened in a 10 per cent. solution in from a week to ten days. It gives great toughness and elasticity to tissues, and is required for many methods of staining nerve-fibres. Pieces of nerve tissue ten millimetres thick may first be fixed in formalin and then subjected to the action of any mordant desired.

It is used in a standard solution of ten cubic centimetres of formalin to ninety cubic centimetres of distilled water. Change after three hours. Tissues are fixed in from one to two days, but may remain in the fluid indefinitely if the percentage of formalin is maintained.

Orth's fluid (1-2 days) :

Potassium bichromate..... 2.5 parts.

Sodium sulphate..... 1. part.

Water ..... 100. cc.

Formalin ..... 10. cc.

Add the formalin just before using.

This is Müller's fluid with 10 per cent. formalin. It is one of the best general fixatives in use.

*Nitric Acid* (3 per cent.; 6 hours; 70 per cent. alcohol).—It gives toughness to tissues and is especially suitable for organs rich in connective tissue. Bichromate of potassium may be used after fixation in nitric acid.

*Osmic Acid*.—This is one of the finest fixatives known, especially for cytoplasm. It has great power of rendering cell constituents in-



soluble and of developing optical differentiation, thus bringing to view structures previously unknown. As it has very little penetration, superficial cells may be overfixed and homogeneous. Carmin stains badly after its use, but hæmatoxylin is not affected. It is seldom used alone except for fixation by vapors. Very delicate objects are pinned out on the well-fitting cork of a wide-mouthed bottle and exposed to the vapors of a small quantity of a 1 per cent. solution poured into the bottle. A retina needs an exposure of some hours and is more equally fixed than when placed in the solution. Osmic acid solutions do not keep well and must be carefully protected from dust. Lee recommends a 2 per cent. solution in 1 per cent. chromic acid. This serves for vapor fixation and Flemming's solution. It may also be kept as a 1 per cent. solution in distilled water. (For Flemming's solution see "Chromo-aceto-osmic acid.") In making osmic acid solutions the capsule containing this acid is broken within the bottle containing the solution. Tellyesniczky<sup>1</sup> suggests as the best substitute for osmic acid the following:

Potassium bichromate .....	3 grammes.
Acidi aceti .....	5 cc.
Aquæ .....	100 grammes.

Platinico-acetico-osmic-acid solution (Hermann's solution; 1-8 days): This celebrated reagent is Flemming's solution with platinic chlorid instead of chromic acid.

Platinic chlorid, 1 per cent.....	15 parts.
Glacial acetic acid.....	1 part.
Osmic acid, 2 per cent.....	2 to 4 parts.

Its action is comparable to that of Flemming's solution. The most delicate structures are faithfully preserved and well shown.

Pianese's solution (36 hours):

Chlorid of platinum and sodium, 1 per cent. aqueous solution .....	15 cc.
Chromic acid, 0.25 per cent. aqueous solution.....	5 cc.
Osmic acid, 2 per cent. aqueous solution.....	5 cc.
Formic acid, C. P.....	1 drop.

For karyokinesis and the so-called cancer bodies. Pieces of tissue

<sup>1</sup> *Arch. f. mikrosk. Anat.*, 1898, vol. lii. p. 202.



must not be more than two millimetres thick. It gives very interesting results histologically.

*Picric Acid* (2-24 hours).—Picric acid is an extremely penetrating and delicate fixative. It hardens very slightly, and the insolubility caused by its action may be easily removed by washing in water; hence its preparations should always be placed in alcohol. It is used as a saturated aqueous solution and in large quantity,—about one hundred times the bulk of the object. It is an excellent fixative for delicate serous membranes, which may be floated in it without retraction or distortion. The omentum and peritoneum are well fixed in it.

Picro-acetic acid: A saturated solution of picric acid in one per cent. acetic acid; a very good fixative.

Picro-sulphuric acid (Kleinenberg): Add 1 cc. of concentrated sulphuric acid to 100 cc. of a saturated aqueous picric acid solution. Let stand for nearly four hours; filter; add double its volume of distilled water. This is an excellent fixative for delicate embryos.

Picro-nitric and picro-hydrochloric acid solutions are also used, but their action is essentially the same as that of picro-sulphuric.

The advantages of picric acid solutions are that they give a very delicate fixative with excellent cutting qualities, and delicate membranes are not thickened excessively as with stronger reagents.

HARDENING.—To give to tissues a proper cutting consistency they are gradually hardened by being passed through a series of graded alcohols. For general diagnosis tissues may go from water into 70 per cent. alcohol, then 95 per cent., and finally absolute alcohol, usually remaining twenty-four hours in each grade. Corrosive sublimate and Golgi tissues are to be placed for only a few hours in 95 per cent. and absolute alcohols, without passing through the lower grades. For finer work begin with 30 per cent. or even 15 per cent. alcohol, then use 50, 70, 80, 95, and absolute. When the tissues are passed from a lower to a higher grade of alcohol, surplus moisture should be removed with blotting-paper to avoid lowering the percentage of the next grade.

PRESERVATION.—After being fixed and hardened, tissues are usually preserved in 80 per cent. alcohol. Those fixed by formalin may remain in a 10 per cent. solution thereof. Golgi preparations keep indefinitely in the silver nitrate solution. Corrosive sublimate tissues will not cut well if kept too long in any kind of alcohol; they had better be kept in cedar oil.



*Pathological Conditions suggesting Certain Fixatives.*—Acute infectious processes: Alcohol.

Acute inflammatory exudates: The fibrin, leucocytes, and red blood-corpuscles of hemorrhagic conditions are preserved especially well in Zenker's fluid.

Albuminous degenerations: Corrosive sublimate, Zenker, or boiling water.

*Amœbæ coli*: Stain especially well with Mallory's chlorid of iron hæmatoxylin; any fixative may be used except perhaps formalin. *Amœbæ coli* may be studied either in the fæces or in the tissues. Collect the fæces in a perfectly clean dry vessel, warmed in cold weather, and keep them at the temperature of the room. Add a drop of a weak solution of toluidin blue to a particle of the fæces, make a cover-slip preparation, and preserve in Farrant's medium. For the tissues fix in Heidenhain's or Bensley's solution, stain with iron hæmatoxylin or with a weak solution of toluidin blue. If a contrast stain is desired, stain first with eosin or benzo-purpurin, then for fifteen or twenty minutes with a weak solution of toluidin blue; differentiate with alcohol.

Amyloid degenerations: Corrosive sublimate, Zenker, alcohol.

Blood: Make thin films on cover-glasses; dry in air; then place in absolute alcohol and ether, equal parts, for half an hour.

Bone: For infectious processes, alcohol; for histological purposes, Zenker, Orth. Bone must always be fixed before decalcifying.

Bone marrow: Make smears on cover-slips. Fix pieces of bone marrow in Zenker or formalin.

Cartilage: Alcohol, Zenker, Orth.

Central nervous system: A whole brain may be hardened in about three thousand cubic centimetres of Müller's fluid. Change every day for a week, then every week for four weeks, and every two weeks thereafter; it takes about three months to complete the hardening. Keep in a refrigerator if the weather be very warm. Erlicki's fluid hardens better and its action is more rapid, hardening being accomplished in about four weeks.

In a 10 per cent. solution of formalin a whole brain may be hardened in from ten days to two weeks. Change the solution every day for three days, then every third day. Cerebral hemispheres may be sectioned by Meynert's method and hardened in twenty-four hours in Ohlmacher's solution. These methods are not recommended for fine work. Pieces not larger than one centimetre may be hardened



in formalin and then subjected to any bichromate or osmic acid mordant, including Golgi's methods.

Ganglion cells: For Nissl's method fix in 96 per cent. alcohol. For Lenhossék fix in 90 per cent. alcohol (or 10 per cent. formalin) and follow with 96 per cent. alcohol. For Golgi methods use Golgi fixatives.

Myelin sheaths: For Weigert fix with 5 per cent. bichromate until "ripe,"—that is, until color contrasts between white and gray matter are well developed. For Marchi use Müller's fluid. Use formalin for Busch-Mallory, Weigert, Weigert-Pal, and Heller. For Exner use 1 per cent. osmic acid; change second day; leave pieces in for five or six days.

Neuroglia fibres: These are not well preserved by chromates. For Weigert methods fix in formalin. For Mallory fix in ten per cent. formalin in a saturated aqueous solution of picric acid.

Medulla, pons, and basal ganglia: They may be removed together *en masse* and hardened entire in formalin for from one to two weeks, then cut into parallel slices not over one centimetre thick, and mordanted by Weigert's quick method or Mallory's or in any way desired. Golgi stains are not very applicable to the medulla.

Axis-cylinders and their terminal processes: For Freud's or Stroebe's gold stain fix in Erlicki or Müller. For Gerlach's method harden in 0.5 per cent. solution of bichromate of ammonium for from one to three weeks. (For Golgi see "Golgi methods" under *Bichromate of Potassium*.)

Degenerated nerve-fibres: Harden in Müller or Erlicki for Marchi or Algeri methods, or harden in 10 per cent. formalin followed by Müller and Erlicki.

Peripheral nerve-fibres: Fix in chlorid of iron.

Retina: The retina may be fixed in a 10 per cent. solution of formalin; in Zenker's, Orth's, or Lindsay Johnson's solution, as given under *Bichromate of Potassium*; in equal parts of glacial acetic acid and osmic acid (2 per cent.); in equal parts of chromic acid and platinic chlorid (each 1.4 per cent.); or it may be pinned out on a cork and exposed to the vapor of a 1 per cent. solution of osmic acid.

Colloid material: Formalin or Orth.

Connective tissue: For Ribbert's phosphomolybdic hæmatoxylin stain for fibrillæ fix in alcohol. For Mallory's anilin-blue stain fix in corrosive sublimate or Zenker.



Elastic fibres: For Unna's orcein method fix in alcohol. For Weigert fix in alcohol or formalin.

Fatty changes: Flemming, Orth, Müller, Erlicki, or formalin.

Fibrin: For eosin hæmatoxylin, methylene blue, and Mallory's anilin-blue stain fix in Zenker or corrosive sublimate. For infectious processes and Weigert's method fix in absolute alcohol.

Glands: Fix in absolute alcohol.

Granulation tissue: Fix in Zenker, Flemming, or Pianese for attendant degenerations.

Hyaline degenerations: Zenker, corrosive sublimate, Orth.

Liver: For pernicious anæmia and amyloid degenerations fix in alcohol. For bile capillaries use Golgi method.

Mast-cells: For Ehrlich's or Unna's methods fix in alcohol.

Mucoid material: For Mallory's anilin-blue stain fix in Zenker or corrosive sublimate. For other stains use Orth or 10 per cent. formalin.

Myxomas: Zenker or corrosive sublimate.

Œdematous conditions: Throw small pieces of tissue into boiling water for a minute or two, or fix in corrosive sublimate.

Ovaries: For follicular degenerations use Flemming or Hermann if tissues are fresh, if not use Zenker, Orth, Carnoy, or Ohlmacher.

Pancreas: For Altmann's granules fix in equal parts of a 5 per cent. solution of bichromate of potassium and a 2 per cent. solution of osmic acid.

Plasma cells: Zenker is especially favorable for showing eosinophiles.

Pus or purulent conditions: Orth, Zenker, or corrosive sublimate. Skin is best fixed in alcohol.

Spleen: For Heidenhain Biondi triple stain fix in corrosive sublimate. For eosinophiles or Ehrlich's triacid use Zenker or alcohol.

Suprarenal: If fresh fix in Flemming or Hermann; if not, in Ohlmacher, Zenker, or Orth.

Thyroid: For colloid degeneration fix in Orth or 10 per cent. formalin.

*Fixatives.*—The following list gives the fixatives used for the various stains.

Alum hæmatoxylin: Stains very slowly after chromic solutions.

Anilin blue (Mallory): Succeeds best after Zenker or corrosive sublimate. It may be used after formalin.



Biondi Heidenhain (see "Heidenhain Biondi").

Eosin and methylene blue: Best after Zenker.

Freud's gold stain: For axis-cylinders and nerve terminals; used after Müller or Erlicki.

Gold stains: Freud's, Stroebe's, after Müller or Erlicki; Gerlach after 0.5 per cent. bichromate of ammonium for from one to three weeks.

Golgi chrome silver preparation: After Golgi fixing solutions.

Heidenhain Biondi triple stain: Only after corrosive sublimate.

Lenhossék: For ganglion cells 90 per cent. alcohol or 10 per cent. formalin, both followed by 96 per cent. alcohol.

Nissl: For ganglion cells 96 per cent. alcohol.

Orcein (see "Unna's orcein stain").

Phosphomolybdic acid hæmatoxylin: Best after alcohol.

Phosphotungstic acid hæmatoxylin: After 10 per cent. formalin.

Thionin (Lenhossék's ganglion-cell stain): 90 per cent. alcohol followed by 96 per cent. or formalin 10 per cent.

Triple staining: Heidenhain Biondi only after corrosive sublimate.

Unna's alkaline methylene blue: Alcohol.

Unna's orcein stain: For elastic fibres, alcohol.

Weigert's stain: For fibrin and elastic fibres, absolute alcohol.

*Macroscopical Specimens.*—If a microscopical examination of the organ to be preserved is desirable, portions of tissue therefor should be removed before anything is done towards preparing it as a gross specimen.

If for any reason it be desirable to keep the specimen for a short time, it should be kept moist by being wrapped in cloths wet with a 10 per cent. formalin solution. If the specimen is to be shipped, wrap it in a cloth wet with such solution and pack it in parchment-paper, rubber cloth, or sawdust. Parenchymatous organs of slaughtered animals will keep for a week packed in this way and, when sectioned, the tissues appear fresh. The organs of deceased animals do not keep as well. If the specimen is to serve for a bacteriological investigation and for inoculations, it should not be wrapped in any disinfecting agent, but simply packed in parchment-paper or rubber cloth.

By a percentage solution of formalin is meant such a dilution of the commercial 40 per cent. (which is sold as formalin) as will reduce it to the desired strength. For instance, ten cubic centimetres of



commercial formalin added to ninety cubic centimetres of water produce a 10 per cent. solution of formalin or a 4 per cent. solution of formaldehyde. The percentage of formalin must be maintained, as it is quickly exhausted; when there is no odor of formalin, the fluid should be renewed.

It is not always necessary to save the entire organ to be examined, but enough should be preserved to show its relationship to the lesion.

GENERAL CONSIDERATIONS.—*Washing*.—If alcohol be used as the preserving solution, blood and other impurities may be removed by a thorough washing with water. In other cases the parts should be carefully sponged with the preservative to be employed.

Cavities should be distended with tow or absorbent cotton. The lungs should be placed in a jar and the jar filled by pouring the fluid through the trachea. Mucous and serous membranes should be protected from the distortion caused by shrinkage by being pinned out on cork or on wood which will impart no color in soaking. A more elegant method is to sew the membranes over the edges of frames made of glass rods. The secreting surfaces of these membranes should always be uppermost.

Compression of any part of the specimen should be avoided by the use of a soft cushion of absorbent cotton placed in the bottom of the jar. Jars made especially for museum preparations are preferable, but if necessary they may be replaced by such as are used by grocers and druggists for candy, etc.

*Preserving Fluids*.—Alcohol is a convenient and efficient agent. It preserves form relationships very well, as in tumors, typhoid ulcers, invagination of the intestine, etc.; but it destroys all contrasts in a pathological organ, such as a diseased lung or kidney, and makes recognition of the lesion very difficult. It bleaches the tissues and causes much shrinkage, so that natural appearances are not retained. The specimen is to be washed in water, then immersed in 60 per cent. alcohol (which is changed every day until it remains clear), and finally kept in 80 per cent. alcohol. To preserve the natural appearance of tissues, formalin followed by alcohol is used, and the specimen is finally placed in glycerin solution containing some salt of acetic acid, usually potassium. Formalin converts the hæmoglobin into methæmoglobin and a brown color is developed; alcohol changes the methæmoglobin into a red pigment, so that the flesh-color is restored. The tissues are so thoroughly hardened that they may be kept in the



glycerin solution without being thereby softened. The principles involved are simple, but their application requires experience and ingenuity. All tissues do not respond equally to the treatment, and to retain some color peculiar to a certain pathological condition—such as prevails in icterus, for example—requires careful management. There are various formulæ and different methods of applying them, but the two following are perhaps as simple and useful as any. It must always be remembered that if the tissues are placed in too strong formalin, or remain too long even in a weak solution, the alcohol will fail to transform the brown or gray pigment back into red.

1. Place the fresh organ or a segment as large as the hand for from twenty-four to forty-eight hours in one of the following solutions.

Kaiserling fluid:

Formalin .....	200 cc.
Water .....	1000 cc.
Potassium nitrate.....	15 grammes.
Potassium acetate.....	30 grammes.

Melnikow-Raswedenkow:

Formalin .....	10. parts.
Sodium acetate.....	3. parts.
Potassium chlorate.....	0.5 part.
Distilled water.....	100. parts.

It is well to wrap the specimen in wadding and pour the fluid over it. The wadding protects the organ from distortion due to compression. If the organs are very thick, incise them or inject the blood-vessels, ureters, etc., with the fluid. This should be done very gently, in order not to wash out the blood.

Formalin is very injurious to the respiratory tract and the skin. Hence it is better when using it to wear rubber gloves and to keep the jars covered.

2. After two days place the specimen in 60 per cent. alcohol, first removing the wadding. Two or three days later change to 80 per cent. alcohol, then to 90 or 93 per cent.

3. The specimen is finally placed in the preserving fluid:

Glycerin .....	400 grammes.
Potassium acetate.....	200 grammes.
Water .....	2000 grammes.



The solutions may be used several times, but a fresh preserving fluid is better, and it is even advisable to change it occasionally.

Pick adds at once to the formalin solution 5 per cent. of Carlsbad salts, which prevents the formation of acid hæmatin, while Marpmann uses fluorsodium both in the formalin solution and in the glycerin. The use of ten parts of an 0.8 per cent. salt solution with one part of the 40 volume strength formalin is also recommended.

Littlejohn<sup>1</sup> recommends that fresh specimens or those preserved by any well-known method be kept in glass jars made air-tight by sealing their covers with gold size and putty. The one objection to this method is the vapor which collects in the jars. To avoid this the preparations are soaked for several weeks in glycerin and water and afterwards placed on wool to which some formalin glycerin is added. Perfectly washed stomachs from cases of poisoning, such as carbolic acid and the corrosive acids, require no preservative whatever, and when prepared in this manner retain their natural and characteristic coloring for many years.

---

<sup>1</sup> *Journal of Pathology and Bacteriology*, September, 1902.



## CHAPTER XXIV

### BACTERIOLOGICAL INVESTIGATIONS

It frequently happens that the bacteriological investigation is a most important factor in the ultimate value of a post-mortem examination, but, because of the lack of facilities or of knowledge of technic, it is neglected. In the first place, the cost of equipment, as in post-mortem sets, is very largely limited by the *conveniences*, rather than the *necessities*. Culture-tubes can be obtained from the larger pharmaceutical manufacturing companies and their agencies quickly and at reasonable rates. In the second place, the technic is not so complicated as to require especial skill, except in the finer manipulations and diagnoses. It is not unreasonable to expect the general practitioner who is not within easy reach of a pathological laboratory or of a board of health to be sufficiently equipped with apparatus and adequately trained to make cultures and even inoculations for diagnostic purposes. Of course, it is impossible under such circumstances to do the work of well-endowed laboratories and skilled bacteriologists, but the material can at least be studied until the time arrives for placing it in the hands of those devoting their especial attention to the study of bacteriology.

As stated elsewhere, every operator should go to the autopsy prepared not only to save and to preserve morbid specimens, but also to provide for proper bacteriological investigation.

The important factor in the technic of a bacteriological examination is that all instruments shall be scrupulously clean and absolutely sterile, and all sources of contamination carefully guarded against in every possible manner.

The fluid contents and accumulations in abscess and serous cavities, especially meningeal, pericardial, peritoneal, and pleural, the blood, endocardial vegetations, ulcerated surfaces, and the cut surface of solid organs may present foci of bacterial invasion which are examined by "smear preparations" and cultures.

**SMEAR PREPARATIONS.**—These are made in the following manner: Having a number of carefully cleaned and dried cover-slips in



readiness,<sup>1</sup> with a platinum wire, which has just been sterilized by heating to a red glow in an alcohol flame or the upper (hottest) part of a Bunsen burner, a drop of the fluid is put in the centre of one slip and another slip is placed upon it; the two are very gently pressed together and then separated by sliding one over the other until they come apart, thus leaving the material thinly and quite evenly distributed over both slips. The same result may be accomplished, though not so satisfactorily, by placing the drop near the edge of the slip and spreading it out by drawing a smooth-edged slide broad-side over it. Or the fluid may be spread with the platinum wire zigzag over the slide, instead of the cover-slip, because the former is easier of manipulation, not so readily broken by subsequent handling, and allows a larger field of observation. Should there not be sufficient fluid to make a satisfactory smear preparation, a little distilled water or physiological salt solution may be added to the glass, before performing the above manipulations.

The cover-slip or slide may be touched directly to a freshly cut surface of the solid organ, which has been incised with a scalpel sterilized by heat, or the material may be removed by a specially contrived platinum spear having a hole in its end or in the ordinary manner with the öse.

The "smear" being dried with *very little* or no heat, there yet remains to "fix" it on the glass. This is done by the routine method of passing the glass three times through a flame, with the smeared surface upward to avoid burning the material. In this way the albuminous organic matter is dried or coagulated and the bacteria are thus caused to adhere to the glass surface. In "fixing" very great care must be used to avoid the application of too high a temperature,—shown by a brownish coloration,—which would seriously distort the bacteria, especially if the film had not been thoroughly dried previously. Such a preparation will keep for a considerable length of time, and can be safely and easily protected by gumming the clean surface to a piece of card-board cut to the size of the ordinary glass slide, on which also may be written all necessary data. The cards may then be packed in an ordinary pill box, care being exer-

---

<sup>1</sup> It is well to use new cover-slips which have been cleansed in strong nitric acid, washed in distilled water, and kept in alcohol to which a few drops of ammonia have been added. When wanted for use, they must be wiped dry between the fingers with a clean handkerchief.



cised that the films do not come in contact with anything that will be liable to rub or scratch them.

A diagnosis made from the study of smear preparations must often be corroborated by cultures, though such study will frequently offer valuable suggestions as to the kind of culture-media to employ. The negative value of a slide from a suspected syphilitic sore may be considerable and is not sufficiently appreciated.

**INOCULATING CULTURE-MEDIA.**—For the formulæ and methods of preparing culture-media and tubes the reader is referred to any standard work on bacteriology.

Test-tubes containing any of the solid or liquid media may be inoculated at the place where the autopsy is performed when it is not so far from the laboratory as to endanger the growth of the culture by exposure to extremes of temperature. Sufficient heat is secured, however, by placing the tubes after inoculation, securely wrapped, in an inside coat-pocket.

The culture-tube is held in the left hand, in an almost horizontal position, if the medium be liquid, between the thumb and index-finger. Should the tube contain a solid medium, such as blood-serum or agar, it is inverted. The öse, held in the right hand, is now sterilized by heat and cooled, while the cotton plug is removed from the test-tube by a cork-screw motion and held, inner part outward, between the index and middle fingers of the left hand in such a manner that it does not come in contact with any portion of the hand. With the tip of the platinum wire a small portion of the substance to be inoculated is now placed on the surface of the medium; if this surface is slanting the fluid is rubbed gently over it, thus making a "smear" or "stroke" culture, while the needle is thrust deep down into the medium if a "stab" culture is to be made. The öse is then withdrawn, the cotton plug reinserted, the needle sterilized, and the tube labelled and put in a warm place until it can be sent to the laboratory.

If the culture is to be made from the surface of a solid organ, the method is the same, except that the organ is incised with a very sharp and absolutely sterile knife, and in addition it is well, as a precautionary measure, to sterilize the surface again before plunging the needle deep into the tissue.

Post-mortem examination of animals dying from diseases produced by experimental inoculation should always be made as soon as possible, so as to prevent the invasion of the tissue by other bacteria



than those causing the fatal malady; it may usually be done within twelve hours after death. Fig. 153 shows the position generally adopted for the performance of necropsies upon the smaller animals, such as the guinea-pig. It will there be seen that the body is placed on a board in the same position as in crucifixion and securely held there by nails driven through the feet and the tip of the nose. An external examination is first carefully made, the weight determined, temperature taken, etc., especial attention being paid to the wound of inoculation.

Numerous smears and cultures are produced from cutaneous lesions and from the initial incisions, which are usually made with sterilized scissors, the parts having previously been moistened with alcohol or with a 1 to 500 solution of the bichloride of mercury. The skin is then dissected away and tacked to the board, so as not later on to contaminate the field of operation. After the strictest precautions—heat being the agent employed for the sterilization of the instruments—the thorax and abdomen are opened. This is done by heating a knife to a red heat and bringing it in contact with the portion of the body or organ in which the culture is to be made. Nuttall's platinum spear may be used, instead of the platinum wire, for the purpose of removing the material.

Every precaution should be taken to prevent dispersion of the bacteria; as, *e.g.*, by the dropping of cover-glasses, which on becoming broken might cause infection later on.

Portions to be preserved for microscopic study are put in fixing solutions, such as those mentioned in Chapter XXIII.

When the postmortem is completed, the animal should be placed in a cloth wrung out with formalin and immediately cremated. The pan and all implements employed should be thoroughly sterilized by heat, and nothing should be left behind which in any way has come in contact with the blood or other portions of the body in which the pathogenic germs are to be found.



## CHAPTER XXV

### WEIGHTS AND MEASURES

It is customary in this country and in England to give the weights of the organs in avoirdupois ounces, their dimensions in inches, and their capacity in cubic inches, though the metric system has more to commend it and is fast gaining favor in English-speaking countries. Troy weight is sometimes used and may give rise to much confusion.

The grain is the same in both Troy and avoirdupois weights. The ounce avoirdupois is 437.5 grains, or 28.34 grammes. The ounce Troy is 480 grains, or 31.1 grammes. To convert grammes into avoirdupois ounces divide by 28.34, into Troy ounces divide by 31.1. Conversely, to convert ounces avoirdupois into grammes multiply by 28.34; Troy ounces multiply by 31.1.

A kilogramme equals one thousand grammes, or 2.2 pounds. A gramme equals one thousand milligrammes, or 15.433 grains. A metre equals one thousand millimetres, or 39.37 inches. A litre equals one thousand cubic centimetres, or 61.027 cubic inches, and is equivalent to 2.113 American pints or 1.76 English pints.

#### I. Average height (European standard) :

Adult male .....	172 centimetres, or 5 feet 7.7 inches.
Adult female .....	160 centimetres, or 5 feet 3 inches.
New-born male .....	47.4 centimetres, or 18.66 inches.
New-born female.....	46.75 centimetres, or 18.4 inches.

When a child is two years old, it is about one-half as tall as it will be when fully grown.

#### II. Average weight (European standard) :

Adult male.....	65 kilogrammes, or 143 pounds (av.).
Adult female .....	55 kilogrammes, or 121 pounds.
New-born child.....	3250 grammes, or 7.15 pounds.

#### The American Insurance standard :<sup>1</sup>

A man of five feet and one inch should weigh.....	120 pounds.
A man of five feet and three inches should weigh.....	130 pounds.
A man of five feet and six inches should weigh.....	143 pounds.
A man of five feet and nine inches should weigh.....	155 pounds.
A man of five feet and eleven inches should weigh....	165 pounds.

---

<sup>1</sup> From FINLAYSON'S *Clinical Manual*.



A child may be born weighing less than a pound and live. The greatest recorded weight attained by man is some 1000 pounds.

According to Orth, the mean length of a full-term, sound child is between fifty and fifty-one centimetres, the male being slightly longer than the female. The average weight of a full-term boy at birth is thirty-six hundred grammes, that of a girl thirty-two hundred and fifty grammes. For the last five lunar months of fetal life, if the height expressed in centimetres be divided by five, the approximate age of the child in lunar months will be obtained. For example, if the child measures thirty-five centimetres, we divide this by five, and we have seven, which is the number of months which the child has passed *in utero*. The fetal age of the child in the first five months about equals the square root of the height expressed in centimetres. For example, if the height is sixteen centimetres, the child is four lunar months old.

In terms of the English system the length of the new-born child is twenty inches, which divided by two will give approximately the number of lunar months the child has passed *in utero*.

According to Hirst, the following are the dimensions of a full-term, healthy child: Length of hair, from two to three centimetres; anterior fontanel, from two to two and one-half centimetres; occipito-frontal circumference, thirty-four and one-half centimetres; occipito-frontal diameter, eleven and three-fourths centimetres; occipitomenal diameter, thirteen and one-half centimetres; bisacromial diameter, twelve centimetres; intertrochanteric diameter, nine or ten centimetres.

Lambinon<sup>1</sup> gives the following figures, obtained at the Liège Maternity, as to the weight of the placenta in cases of miscarriage. The average weight of the placenta at six weeks was 20 grammes (about 5 drachms); at ninety days, 67 grammes ( $17\frac{1}{3}$  drachms); at one hundred and twenty days, 111 grammes ( $28\frac{2}{3}$  drachms); at one hundred and sixty-five days, 262 grammes ( $67\frac{2}{3}$  drachms); and at two hundred and thirty-five days, 330 grammes ( $85\frac{1}{4}$  drachms).

Nauwerck gives the following measurements and weights of the healthy infant at full time: Average length, from fifty to fifty-one centimetres (boys generally larger than girls); maximal length, fifty-

---

<sup>1</sup> *De la détermination de l'âge du fœtus d'après le poids du placenta dans les cas de fausse couche.* Paris, 1898.



eight centimetres; minimal length, forty-eight centimetres; average weight (v. Hecker), thirty-two hundred and seventy-five grammes (boys thirty-three hundred and ten grammes, girls thirty-two hundred and thirty grammes); maximal weight, fifty-five hundred grammes; minimal weight, twenty-five hundred grammes.

Weight of the different organs and measurements of various parts:

Brain.....	380 grammes (Bischoff).
Brain.....	348 grammes (Meynert).
Thymus.....	14 grammes (Friedleben).
Heart.....	20.6 grammes (Thoma).
Lungs.....	58 grammes.
Width of the large fontanel.....	2-2.5 centimetres.
Head: circumference.....	34.5 centimetres.
Occipitofrontal diameter.....	11.5 centimetres.
Biparietal diameter.....	9.0 centimetres.
Bitemporal diameter.....	8.0 centimetres.
Occipitomenal diameter.....	13.5 centimetres.
Trachelobregmatic diameter.....	9.5 centimetres.
Spleen.....	11.1 grammes.
Kidneys (together).....	23.6 grammes (Thoma).
Testicles.....	0.8 gramme.
Liver.....	118 grammes.

The rule<sup>1</sup> that a child has usually attained double its birth weight at the fifth month and triple at from the twelfth to the fourteenth month is convenient and useful in estimating an infant's probable age.

### III. Table of approximate weight of the internal organs:<sup>2</sup>

	Adult, grammes.	New-born, grammes.		Adult, grammes.	New-born, grammes.
Brain.....	1397	385	Left kidney.....	150	
Heart.....	304	24	Both kidneys.....	299	23.6
Lungs.....	1172	58	Testicles.....	48	0.8
Liver.....	1612	118	Muscles.....	29,880	625
Pancreas.....	201	11.1	Skeleton.....	11,560	445
Right kidney.....	141				

### IV. The body weight by percentage:

	Adult, per cent.	New-born, per cent.		Adult, per cent.	New-born <sup>1</sup> per cent.
Heart.....	0.52	0.89	Liver.....	2.77	4.39
Lungs.....	2.01	2.16	Brain.....	2.37	14.34
Stomach and alimen- tary canal.....	2.34	2.53	Thymus gland.....	0.0086	0.54
Pancreas.....	0.346	0.41	Skeleton.....	15.35	16.70
			Muscles.....	43.09	23.40

<sup>1</sup> GRAHAM, *Archives of Pediatrics*, January, 1899.

<sup>2</sup> Tables are from VIERORDT, quoted by ZIEGLER, 7th German ed., vol. i. p. 181.



In measuring an organ its length, breadth, and thickness may often be more quickly and accurately ascertained by thrusting the steel rule through it than in any other manner.

#### THE SKULL AND ITS CONTENTS.

*Shape.*—Even in members of the same race the form of the skull is subject to marked variations, and these are still greater when individuals of different races are compared. The characteristic measurements of the cranium are its length, height, and breadth. The cephalic index is the ratio of its length (taken as one hundred units) to its breadth. The altitudinal index is the ratio of its length to its height. The accepted horizontal plane is that passing through the upper edges of the external auditory meatus and the lower orbital margin.

According to the variations of the cephalic index, we distinguish the *dolichocephalic* (index less than 75) and the *brachycephalic* (index more than 80) types. Intermediate forms are called *mesocephalic*. If the ratio of the breadth to the height is less than 70, the skull is *platycephalic*; if between 70 and 75, *orthocephalic*; if above 75, *hypsi-cephalic*. The character of the facial profile is indicated by the *facial angle* of Camper,—namely, the angle between a line on the level of the external auditory meatus and the floor of the nasal cavity and a line touching the middle of the forehead and the anterior portion of the alveolar process of the superior maxilla. If this angle be 80 degrees or more, the skull is called *orthognathous*; if it is between 80 degrees and 65 degrees, *prognathous* (Gegenbaur).

Pathological types of skull are due in part to premature synostosis. Among them we distinguish the *hydrocephalic* type (from dropsy of the ventricles), the *cephalonic* (or big head), the *microcephalic* (or small head), the *dolichocephalic* (or long head), the *sphenocephalic* (or wedge-shaped head, due to compensatory development of the anterior fontanel), the *leptocephalic* (or narrow head), the *clinocephalic* (or saddle-shaped head), the *trigonocephalic* (or triangular head, due to narrowing of the frontal bone from fetal synostosis of the frontal suture), the *brachycephalic* (or short head), the *pachycephalic* (in which the bones of the cranium are thickened), the *oxycephalic* (or pointed head), the *platycephalic* (or flat head), the *trochocephalic* (or round head), and the *plagiocephalic* (or unsymmetrical oblique head).<sup>1</sup>

<sup>1</sup> ZIEGLER'S *Text-Book of Special Pathological Anatomy*, English Translation by MACALISTER and CATTELL, vol. i. pp. 206, 207.



*Weight.*—The maximum weight of the adult male encephalon is about 2222 grammes, or 74 ounces, and the minimum is about 960 grammes, or 34 ounces. The average is about 1400 grammes, or 49.5 ounces. The maximum weight of the adult female encephalon is about 1585 grammes, or 56 ounces, and the minimum is 880 grammes, or 31 ounces. The average is from 1230 to 1245 grammes, or from 43½ to 44 ounces. Thus it will be seen that the adult male brain is on an average four or five ounces, or about nine per cent., heavier than that of the female. See also *American Medicine*, May 17, 1902, p. 830.

Table showing in grammes the mean weights of the brain at different ages in the two sexes:

	Male.	Female.
Children stillborn at term .....	393	347
Children born alive at term .....	330	283
Under three months of age.....	493	451
From three to six months .....	602	560
From six to twelve months .....	776	727
From one to two years.....	941	843
From two to four years .....	1,095	990
From four to seven years.....	1,138	1,135
From seven to fourteen years....	1,301	1,154
From fourteen to twenty years.....	1,374	1,244
From twenty to thirty years.....	1,333	1,237
From thirty to forty years .....	1,364	1,220
From forty to fifty years.....	1,351	1,212
From fifty to sixty years.....	1,343	1,220
From sixty to seventy years .....	1,313	1,208
From seventy to eighty years.....	1,288	1,168
Over eighty years.....	1,283	1,125

By the above table it appears that the brain is relatively heavier between fourteen and twenty years of age than at any other period; but according to Broca, and also Peacock, the maximum is attained between the ages of twenty-five and thirty-five.

Orth quotes Meynert, whose results were obtained from the investigation of 157 cases in the Vienna insane asylum. He gives the mean weight of the brain, in men between the ages of twenty and sixty-nine years, as 1296 grammes; in women, 1169 grammes. He says the maximal weight is attained during the fourth decade in men and the fifth decade in women. The average weight of the cerebrum is 1018 grammes in men and 917 grammes in women; of the brain stem, 143 grammes in men and 129 grammes in women; of the cerebellum, 135 grammes in men and 123 grammes in women. Weisbach found that



in sane German-Austrians the brain weighed 1314.5 grammes in men and 1179.52 grammes in women, while the cerebrum weighed 1154.97 grammes in men and 1038.90 grammes in women, the cerebellum 142.2 grammes in men and 125.56 grammes in women, and the pons 17.33 grammes in men and 15.06 grammes in women. Bischoff found the weight of the pia and arachnoid to be from 25 to 40 grammes. Nauwerck quotes Vierordt, who found the mean weight of the brain in men within the ages of twenty and eighty years to be 1359 grammes, in women 1235 grammes.

The weight of the encephalon relative to that of the body is subject to great variation, but may approximately be put down as 1 to 36.5 in the adult male and 1 to 35.2 or 1 to 36.46 in the female. These figures are based on observations upon persons dying from more or less prolonged disease, but in the cases of a few individuals who died suddenly from disease or accident the average ratio was found to be 1 to 41. The proportion to body weight is much greater at birth than at any other period of extra-uterine life, being about 1 to 5.85 in the male and 1 to 6.5 in the female.

The weight of the human cerebrum also bears a somewhat definite relation to the stature of the individual. The weight in ounces may be obtained for a male by dividing the height in inches by 1.6, and for a female by multiplying the quotient thus obtained by  $\frac{30}{31}$ . The weight in grammes may be obtained by multiplying the height in centimetres by 7 for a male, and the product again by  $\frac{30}{31}$  for a female. Thus,

$$\begin{aligned}\text{Weight in ounces of the mean cerebrum} & \dots\dots\dots = \frac{\text{height in inches}}{1.6} \\ \text{Weight in ounces of the mean female cerebrum} & \dots\dots = \frac{\text{height in inches}}{1.6} \times \frac{30}{31} \\ \text{Weight in grammes of the mean male cerebrum} & \dots\dots = \text{height in centimetres} \times 7 \\ \text{Weight in grammes of the mean female cerebrum} & = \text{height in centimetres} \times 7 \times \frac{30}{31}\end{aligned}$$

These proportions are slightly deficient for the higher and excessive for the lower statures.

*Dimensions.*—The mean cubic capacity of the male cranium is 1450 cubic centimetres; that of the female is 1300 cubic centimetres (Welcker). The length of the male brain is from 160 to 170 millimetres, or from  $6\frac{2}{5}$  to  $6\frac{4}{5}$  inches, and that of the female brain is from 150 to 160 millimetres, or from 6 to  $6\frac{2}{5}$  inches. The greatest transverse diameter is 140 millimetres, or  $5\frac{3}{5}$  inches, and the greatest ver-



tical diameter is 125 millimetres, or 5 inches. The volume is about 1330 cubic centimetres, or 81 cubic inches.

The specific gravity of the brain is from 1035 to 1040.

#### THE HEART.

*Weight.*—The mean weight of the heart in the adult male is about 310 grammes, or 11 ounces; its proportion to the body weight is 1 to 169. That of the adult female is about 255 grammes, or 9 ounces; proportion to body weight, 1 to 149. According to Krause, the proportion of the heart weight to the body weight is as 1 to 169 in men and as 1 to 162 in women.

The weight of the heart increases with the body weight, but in a gradually decreasing ratio, until the seventieth year, when it begins to diminish. At birth it is about 24 grammes; proportion, 1 to 130 (Quain).

*Dimensions.*—The heart is generally of about the same size as the right fist of the individual. Its extreme length is about 125 millimetres, or 5 inches; width, 87 millimetres, or 3 inches; thickness, 62 millimetres, or  $2\frac{1}{2}$  inches. The thickness of the wall of the right ventricle is from 2 to 3 millimetres, or  $\frac{1}{18}$  to  $\frac{1}{8}$  of an inch; of the left ventricle, from 7 to 10 millimetres, or  $\frac{1}{4}$  to  $\frac{2}{5}$  of an inch. Pathologically these measurements may be increased threefold.

Nauwerck and Orth quote Bizot as follows: The weight of the heart is 300 grammes in men and 250 grammes in women. The length in men is from 85 to 90 millimetres, in women from 80 to 85 millimetres; the breadth in men is from 92 to 105 millimetres, in women from 85 to 92 millimetres; the thickness in men is from 35 to 36 millimetres, in women from 30 to 35 millimetres. The thickness of the right ventricle without the trabeculæ is from 2 to 3 millimetres in men and slightly less in women; the left ventricle is from 7 to 10 millimetres thick.

The dimensions of the orifices of the heart are shown in the following tabular statement.

Orifices.	Diameter.	Circumference.		Area.	
		Male.	Female.	Male.	Female.
Aortic.....	24 to 25 mm., or 0.9 to 1 in.	81 mm.	76 mm.	530 sq. mm.	452 sq. mm.
Mitral .....	30 to 35 mm., or 1.2 to 1.4 in.	103 mm.	101 mm.	855 sq. mm.	804 sq. mm.
Pulmonary .....	27 to 30 mm., or 1.1 to 1.2 in.	91 mm.	89 mm.	660 sq. mm.	615 sq. mm.
Tricuspid.....	37 to 45 mm., or 1.5 to 1.8 in.	122 mm.	115 mm.	1194 sq. mm.	1017 sq. mm.



*Volume.*—In the new-born this is about 22 cubic centimetres, which is increased to 250 centimetres at twenty years and about 280 centimetres at fifty years, after which it gradually decreases. Up to the age of puberty it is about the same in both sexes, but after that it is from twenty-five to thirty centimetres larger in the male. Because of obvious difficulties, these figures can only be regarded as approximate.

#### THE LUNGS.

*Weight.*—Obviously the lungs are subject to great variation in weight, depending upon the amount of blood or other liquid and of air in their cavities. Their combined weight ranges from 850 to 1370 grammes, or from 30 to 48 ounces, the average being from 1020 to 1190 grammes, or from 36 to 42 ounces (1300 grammes in the male and 1023 grammes in the female.—Krause). The right is generally 2 ounces heavier than the left. The weight of the right lung is from 360 to 570 grammes; that of the left lung, from 325 to 480 grammes (Schmaus quoted by Nauwerck). The lungs are absolutely heavier in the male and also appear to be heavier in proportion to the body weight.

*Dimensions.*—The extreme length of the right lung in the male is 271 millimetres, or  $10\frac{4}{5}$  inches, and that of the left is 298 millimetres, or 12 inches; and in the female, 216 millimetres, or  $8\frac{3}{8}$  inches, and 230 millimetres, or  $9\frac{1}{8}$  inches, respectively. The extreme outer and posterior diameters in the male are, of the right, 203 millimetres, or  $8\frac{1}{8}$  inches, and of the left, 176 millimetres, or 7 inches; and in the female, 176 millimetres, or 7 inches, and 162 millimetres, or  $6\frac{1}{2}$  inches, respectively. The transverse diameter at the base is, in the male, 135 millimetres, or  $5\frac{2}{5}$  inches, for the right, and 129 millimetres, or  $5\frac{1}{6}$  inches, for the left. In the female the measurements are 122 millimetres, or  $4\frac{7}{8}$  inches, and 108 millimetres, or  $4\frac{1}{8}$  inches, respectively. (Krause, quoted by Vierordt.)

The specific gravity of the healthy adult lung varies from 345 to 746. When fully distended with air it is about 126, while that of the lung tissue itself, entirely deprived of air, is about 1056.

#### THE LIVER.

*Weight.*—The liver weighs from 50 to 60 ounces in males, a little less in females. Its mean weight is 1600 grammes,—from a minimum of 1247 grammes to a maximum of 1981 grammes,—according to



Vierordt, quoted by Nauwerck. In a four-months foetus it is about one-tenth of the body weight; at birth it is one-twentieth; in the adult male it is one-fortieth; in the adult female it is one-thirty-sixth.

*Dimensions.*—(Quain.) The transverse diameter is from 150 to 200 millimetres, or 6 to 8 inches; vertical diameter, from 125 to 175 millimetres, or 5 to 7 inches; and anteroposterior, from 100 to 150 millimetres, or 4 to 6 inches.

(Morris.) Transverse, from 175 to 250 millimetres, or 7 to 10 inches; vertical, from 150 to 175 millimetres, or 6 to 7 inches; and anteroposterior, from 75 to 150 millimetres, or 3 to 6 inches.

(Gray.) Transverse, from 250 to 300 millimetres, or 10 to 12 inches; vertical, 75 millimetres, or 3 inches; and anteroposterior, from 150 to 175 millimetres, or 6 to 7 inches.

Right lobe, from 18 to 20 centimetres. Left lobe, from 8 to 10 centimetres. Longitudinal diameter: right, from 20 to 22 centimetres; left, 15 or 16 centimetres.

According to Orth, the transverse diameter is from 25 to 30 centimetres, that of the right lobe being from 18 to 20 centimetres and that of the left from 8 to 10 centimetres. The anteroposterior diameter averages from 19 to 21 centimetres,—from 20 to 22 centimetres for the right lobe and 15 or 16 centimetres for the left. The greatest vertical diameter is from 6 to 9 centimetres.

*Volume.*—This varies from 1475 to 1638 cubic centimetres, or from 90 to 100 cubic inches. The mean volume is 1574 cubic centimetres.

The specific gravity is between 1050 and 1060, which in fatty degeneration may be reduced to 1030 or even less.

Supernumerary livers may weigh an ounce or more.

#### THE KIDNEYS.

*Weight.*—Each kidney weighs from about 127.5 to 170 grammes, or  $4\frac{1}{2}$  to 6 ounces, in the male, and from 113 to 156 grammes, 4 to  $5\frac{1}{2}$  ounces, in the female. The left kidney is usually a little heavier than the right,—from 5 to 7 grammes heavier, according to Orth, who states that one kidney weighs about 150 grammes, while both kidneys after the removal of the connective tissue of the hilum weigh 320 grammes in men and 293 grammes in women. At the end of the first year the kidneys together weigh 62 grammes. The ratio of the weight of the kidneys to the body weight is as 1 to 200. The mean proportion



of the weight of the heart to the weight of the kidneys between the ages of twenty and thirty-five years is as 1 to 1.1 (Thoma).

*Dimensions.*—Length about 100 millimetres,  $2\frac{1}{2}$  inches; breadth and thickness, from 30 to 35 millimetres,  $1\frac{1}{4}$  to  $1\frac{1}{2}$  inches; or in the proportions of about 1 to  $\frac{1}{2}$  to  $\frac{1}{3}$ . The left kidney is usually a little longer and narrower than the right. Nauwerck states that the kidneys are from 11 to 12 centimetres long, 5 or 6 centimetres wide, and 3 or 4 centimetres thick.

*Specific Gravity.*—About 1050.

The following points serve to distinguish between the right and left kidneys.

RIGHT KIDNEY.	LEFT KIDNEY.
Impression from liver.	No impression from spleen.
Shorter and broader.	Longer and narrower.
From five to seven grammes lighter.	About five to seven grammes heavier.
The spermatic or ovarian vein empties into the inferior vena cava.	The spermatic or ovarian vein empties into the renal.

In both kidneys the posterior surface is the flatter, the external border is convex, the internal border concave, and the upper portion is more expanded than the lower. At the hilum the attachment of vessels and ureter is, from above downward, the body being in the erect posture, artery, vein, ureter (AVU); and from before backward, vein, artery, ureter (VAU). Place the organ on the table, with its posterior surface down, the lower extremity (the ureter pointing downward) being towards the observer. The ureter is then behind and below the other vessels, and the hilum will be directed towards the side of the operator to which the kidney belongs,—*i.e.*, towards the left hand if it is the left kidney, and towards the right hand if it is the right kidney.

#### SUPRARENAL BODIES.

*Weight.*—Each suprarenal weighs about 4 grammes, or 1 drachm, the left being slightly the heavier. They are nearly as large at birth as in adult life. Orth gives the weight in adults as from 4.8 to 7.3 grammes.

*Dimensions.*—Vertical length is from 30 to 50 millimetres, or  $1\frac{1}{4}$  to 2 inches; breadth, from side to side, about 30 millimetres,  $1\frac{1}{4}$  inches; thickness, from 5 to 6 millimetres,  $\frac{1}{8}$  to  $\frac{1}{4}$  inch. Nauwerck states that the mean diameters are from 4 to 5 centimetres, 2.5 to 3.5 centimetres, and 0.5 centimetre.



## THE SPLEEN.

*Weight.*—This organ varies within wide limits in both size and weight. Ordinarily its weight is between 100 and 300 grammes, or  $3\frac{1}{2}$  and 10 ounces, with the average at about 170 grammes, or 6 ounces. In intermittent and some other fevers it may weigh 18 or 20 pounds. Orth states that the normal weight varies between 150 and 250 grammes. Its weight in proportion to the body weight is at birth about 1 to 350; in the adult, 1 to from 320 to 400; and in old age, 1 to 700.

*Dimensions.*—Generally the spleen is from 125 to 150 millimetres, or 5 to 6 inches, in length; from 75 to 90 millimetres, or 3 to  $3\frac{1}{2}$  inches, in breadth; and from 25 to 40 millimetres, or 1 to  $1\frac{1}{2}$  inches, in thickness. According to Orth, the length is from 12 to 14 centimetres, the breadth 8 or 9 centimetres, and the thickness 3 or 4 centimetres.

*Volume.*—This does not usually exceed from 200 to 300 cubic centimetres, or 12 to 18 cubic inches. Orth gives 221.5 cubic centimetres as the mean volume.

## THE PANCREAS.

*Weight.*—The weight is very variable,—from 30 to 100 grammes, or 2 to  $3\frac{1}{2}$  ounces, and may even be 170 grammes, or 6 ounces; in adults, from 90 to 120 grammes (Orth).

*Dimensions.*—From 120 to 150 millimetres, or 5 to 6 inches, in length; and from 12 to 25 millimetres, or  $\frac{1}{2}$  to 1 inch, in thickness. Length 23 centimetres, breadth 4.5 centimetres, thickness 3.8 centimetres (Orth).

*Specific Gravity.*—1046.

## THE THYMUS GLAND.

*Weight.*—At birth this gland weighs about half an ounce. In twenty adult cases it was found to average 5 grammes (Quain). Nauwerck quotes Friedleben, who says that the thymus weighs at birth 14 grammes and at nine months of age 20 grammes. Up to the second year it weighs a little more than 6 grammes, and from the third to the fourteenth year a little less than 26 grammes.

*Dimensions.*—At birth the length is about 60 millimetres, or 2 inches; width, 37 millimetres, or  $1\frac{1}{2}$  inches; and thickness, from 6



to 8 millimetres, or  $\frac{1}{4}$  to  $\frac{1}{3}$  of an inch. From birth to the ninth month the length is 5.91 centimetres (Friedleben); from the ninth month to the second year, 6.96 centimetres, and from the third to the fourteenth year, 8.44 centimetres. The breadth across the middle is from 2.7 to 4.1 centimetres; above and below, from 0.7 to 0.9 centimetre (Nauwerck).

#### THE THYROID GLAND.

*Weight.*—From 28 to 56 grammes, or 1 to 2 ounces, being larger in the female. Orth gives the weight as from 30 to 60 grammes.

*Dimensions.*—Each lateral lobe is about 50 millimetres, or 2 inches, in length; from 18 to 30 millimetres, or  $\frac{3}{4}$  inch to  $1\frac{1}{4}$  inches, in breadth; and from 18 to 25 millimetres, or  $\frac{3}{4}$  to 1 inch, in thickness. The right lobe is usually the larger. The isthmus is nearly 12 millimetres, or  $\frac{1}{2}$  inch, in breadth, and from 6 to 18 millimetres, or  $\frac{1}{4}$  to  $\frac{3}{4}$  inch, in depth. According to Orth, each lateral lobe is from 5 to 7 centimetres long, from 3 to 4 centimetres broad, and from 1.5 to 2.5 centimetres thick.

#### THE TESTES.

*Weight.*—Each testicle weighs from 18 to 25 grammes, or 6 to 8 drachms, the left being slightly the heavier. Orth gives 18 to 26 grammes as the weight; Nauwerck says the testicle and epididymis weigh from 15 to 24.5 grammes.

*Dimensions.*—Length, about 37 millimetres, or  $1\frac{1}{2}$  inches; breadth, anteroposterior, 30 millimetres, or  $1\frac{1}{4}$  inches; thickness, from side to side, 24 millimetres, or 1 inch.

#### THE OVARIES.

*Weight.*—From 4 to 8 grammes, or 1 to 2 drachms. Orth gives 5 to 7 for the weight, and Nauwerck quotes Puech, who puts the mean weight at 7.0 (from 5 to 10) grammes.

*Dimensions.*—Length, usually about 37 millimetres, or  $1\frac{1}{2}$  inches; breadth, 18 millimetres, or  $\frac{3}{4}$  inch; thickness, 12 millimetres, or  $\frac{1}{2}$  inch. The right is usually a little larger than the left. According to Orth, the ovary is from 2.5 to 5 centimetres long, from 2 to 3 centimetres broad, and from 7 to 12 millimetres thick. Nauwerck gives the following dimensions, quoted from Puech.



Length, maidens .....	from 4.1 to 5.2 centimetres.
Length, women .....	from 2.7 to 4.1 centimetres.
Breadth, maidens .....	from 2.0 to 2.7 centimetres.
Breadth, women .....	from 1.4 to 1.6 centimetres.
Thickness, maidens .....	from 1.0 to 1.1 centimetres.
Thickness, women .....	from 0.7 to 0.9 centimetre.

## THE UTERUS.

*Weight.*—Generally from 28 to 42 grammes, or 1 to 1½ ounces. Orth quotes Huschke, who gives from 33 to 41 grammes as the weight of the uterus in virgins and 105 to 120 grammes as the weight in multiparæ. Nauwerck gives 33 to 41 grammes as the weight in virgins, and 102 to 117 grammes as the weight in multiparæ.

*Dimensions.*—Length, about 75 millimetres, or 3 inches; breadth, 50 millimetres, or 2 inches; thickness, nearly 25 millimetres, or 1 inch. The virgin uterus is from 5.5 to 8 centimetres long, from 3.5 to 4 centimetres broad, and from 2 to 2.5 centimetres thick; in multiparæ the womb is from 9 to 9.5 centimetres long, from 5.5 to 6 centimetres broad, and from 3 to 3.5 centimetres thick. The walls of the virgin uterus are from 1 to 1.5 centimetres thick; of the cervix, from 0.7 to 0.8 centimetre thick. In multiparæ the uterine walls may be as thick as 2 centimetres, and the cervix is from 0.8 to 0.9 centimetre thick. (Orth.)

The length of the virgin uterus, from the fundus to the external os, is from 7.8 to 8.1 centimetres and the breadth of the fundus is from 3.4 to 4.5 centimetres; the thickness below the fundus is from 1.8 to 2.7 centimetres; the length of the cervix is from 2.9 to 3.4 centimetres; the breadth of the cervix is 2.5 centimetres; the thickness of the cervix is from 1.6 to 2 centimetres. In multiparæ the length of the uterus is from 8.7 to 9.4 centimetres, the breadth 5.4 to 6.1, and the thickness 3.2 to 3.6 centimetres. The length of the uterine cavity in virgins is 5.2 centimetres, after the menopause 5.6 centimetres; in multiparæ 5.7 centimetres, after the menopause 6.2 centimetres. (Nauwerck.)

## THE PROSTATE.

*Weight.*—Average, from 18 to 20 grammes, or 4½ to 4¾ drachms. Orth gives 17 to 18.5 grammes as the weight; and Nauwerck quotes Krause and Bischoff, who give 19 to 20.5 grammes as the weight.

*Dimensions.*—Transverse diameter, about 37 millimetres, or 1½ inches; vertical, 30 millimetres, or 1¼ inches; anteroposterior, nearly



18 millimetres, or  $\frac{3}{4}$  inch. These measurements are subject to great variation, according to the fulness of the rectum and bladder. According to Orth, the prostate measures from 32 to 45 millimetres in its transverse diameter, 14 to 22 millimetres in thickness, and 25 to 35 millimetres from apex to base. Nauwerck gives the following dimensions: Transverse diameter (breadth), from 3.2 to 4.7 centimetres (mean, 4.5 centimetres); sagittal diameter (thickness), from 1.4 to 2.3 centimetres (mean, 2 centimetres); from apex to base (height), from 2.3 to 3.4 (mean, 2.7 centimetres).

Embryos<sup>1</sup> about one millimetre long are about twelve days old; 2.5 mm., fourteen days old; 4.5 mm., nineteen days old; seven mm., twenty-six days old; 11.5 mm., thirty-four days old; seventeen mm., forty-one days old. For all embryos from one to one hundred mm. long, multiply the length of the embryo from the vertex to the breech in millimetres by one hundred and extract the square root; the result will be the age in days. For embryos from one hundred to two hundred millimetres long, measure from vertex to breech; this length in millimetres will equal the age expressed in days.

---

<sup>1</sup> MALL, *Bull. Johns Hopkins Hosp.*, vol. xiv., No. 143, February, 1903; abstracted in *Medicine*, vol. 9, No. 3, 1903, p. 240.



## CHAPTER XXVI

### COMPARATIVE POSTMORTEMS <sup>1</sup>

THE great number, importance, and variety of diseases which human beings may contract from the lower animals are more and more coming to be recognized. Our domestic animals suffer from nearly all the contagious maladies found in man, and impart to him various disorders from which he would otherwise be exempt, such as glanders, actinomycosis, anthrax, hydrophobia, foot-and-mouth disease, echinococcus cysts, trypanosomiasis, etc. The rat disseminates bubonic plague, the mosquito malaria, yellow fever, and dengue, and the pig trichinosis, and were it not for the rat, the mosquito, and the pig these diseases would probably cease to exist.

Many of the suggestions made in the previous chapters apply with equal force to the performance of necropsies upon the lower animals. Such comparative examinations are of two distinct classes,—veterinary postmortems and laboratory postmortems. For laboratory study small animals, such as the guinea-pig, rabbit, mouse, and rat, are generally chosen, while in veterinary investigation the subject is usually a dog, a horse, a cow, or a cat. So intense is the interest now taken in comparative pathology that all classes of animals come to section, even reptiles (especially snakes) receiving no small amount of attention.

**INSTRUMENTS.**—In post-mortem examinations of the large domestic animals (cow, horse, mule, etc.) the instruments used must necessarily be larger than those employed in human autopsies. The following is a partial list. (1) Large butcher's knife, to expose the thorax and abdomen and remove the skin; (2) large cleaver; (3) large butcher's saw, to open the thoracic and cranial cavities, expose the nasal septum, etc.; (4) large chisel, to remove the cord; (5) hammer, for the same purpose; (6) bone-forceps (costotome); (7) enterotome; (8) scissors; (9) brain-knife; (10) dissecting forceps; (11) large needle; (12) strong twine, etc.

**UTENSILS.**—Buckets, pitchers, large and small enamelled plates,

---

<sup>1</sup> Much of the material and all the illustrations except Figs. 163 and 164 in this chapter are taken from Kitt's *Lehrbuch der pathologischen Anatomie der Haustiere*, 1900, vol. ii. pp. 1-54.



sponges, soap, towels, and disinfectants, and green soap or lysol are especially useful.

**CLOTHING.**—An operator's apron may be drawn over the clothes or an ordinary rain-coat worn, but a special suit for operating is better.

**GENERAL SUGGESTIONS.**—In many cases the necropsy must be made at the place where death occurred, be this in the fields, stable, slaughter-house, or veterinary morgue. The procedure will vary with the conditions and conveniences, but the end in view should be carefully considered and certain general rules observed. If the animal is alive, the method of killing to prepare for the desired investigation should be one that will not injure the organs involved. In cerebral trouble the animal should not be killed by a blow upon the head, but by poison or chloroform; in inflammatory conditions all loss of blood should be avoided; if the trouble is in the digestive system, no poison should be used; and in pulmonary affections the animal must not be shot through the heart (Csokor).

The skin, extremities, joints, excessive functionation of the mammary gland, and the frequency of parasitic lesions in the muscular tissue, are so often subject to pathological conditions that they present a rich field in post-mortem examinations of lower animals. Malformations are also quite common.

There has recently taken place an interesting discussion as to Koch's statements that human tuberculosis differs from bovine and cannot be transmitted to cattle, and that man does not, except possibly in the rarest instances, contract tuberculosis from the cow. Both sides admit, however, that there is a great difference between the virulence of various forms of the tubercle bacilli. From a careful study of the work of Koch, Schutz, Ravenel, Jong, Chippolina, and others, it would seem that bovine and human tuberculosis may be intercommunicated and cannot always be distinguished the one from the other, and that man may, and children often do, contract tuberculosis from the cow. In Switzerland and in this country the writer has been struck with the freedom from tuberculosis of districts in which cow's milk is not used.

**OPERATIVE TECHNIC.**—In opening the cadaver the normal position of the intestines should be retained as far as possible, and they should be carefully examined to see that they are uninjured and are sufficiently exposed. Horses, large and small ruminants, and the larger swine are usually placed upon the left side of the body so that the right side may be opened. A dorsal position may be chosen for dogs and



cats, and even for swine or larger animals if sufficient assistance be present, as it gives a better view of the abdominal cavity.

The postmortem is begun by removing the hide, which has a market value and must not be injured. As scalpels and straight-edged knives are apt to button-hole the skin, a butcher-knife with rough cutting edge is to be preferred. Beginning at the angle of the chin a longitudinal incision is made down the median line the whole length of the body, avoiding the udder, prepuce, and scrotum, and the navel in the case of young animals. A transverse incision is made perpendicular to the first along the median surface of the foreleg and the skin is drawn back from the edges up over the dorsal surface. A similar cut is made upon the median surface of the thigh and leg down to the tuberosity of the os calcis. On both the limbs and the body the hair-seams will serve as a useful guide for the knife. A circular incision is made around the head from angle to angle at the lips. If the head is to be preserved, as in the case of a deer, the circular incision is made at the manubrium. The skin may be detached either with the hands or with the handle of a chisel.

REMOVAL OF THE EXTREMITIES.—After the animal has been skinned, it is placed on its side, and the uppermost limbs are removed in order to secure more room for subsequent manipulation. First the foreleg is held up by an assistant and the shoulder-joint disarticulated. The mass of common muscle is cut through in the median portion by a butcher-knife grasped firmly by the whole hand. During the execution the extremity should be constantly raised by an assistant and the blade of the knife should be held somewhat towards the thorax so as to cut obliquely to the ribs.

To remove the posterior extremity make a deep circular incision through the hip muscles, beginning with the broad crural fascia and above the large trochanter, passing up over and through the musculature of the croup and downward and outward into the ischiatic fossa, but not behind the tuberosity of the ischium; raise the foot; cut through the adductors in a line with the acetabulum, open its capsular ligament, and section the round ligament. The incision of the capsular ligament is accompanied by a snapping sound, due to the entrance of air into the joint. The limb can now be drawn backward, the remaining fascia and muscles sectioned, and the whole removed.

EXPOSURE OF THE ABDOMINAL CAVITY.—Before opening the abdominal cavity of a filly the udder should be entirely removed from the



abdominal wall, and in geldings and stallions the scrotum and the penis should be isolated and thrown back. It should be remembered that in herbivora meteorism occurs soon after death, so that the intestines are pressed up closely against the abdominal wall and may easily be injured.

The operator should stand in the space between the remaining extremities with his face towards the breast of the animal. An incision is made through the median line of the body, beginning with the ensiform cartilage of the sternum, extending as far as the pubic region, cutting through the muscles and fascia only and not injuring the peritoneum. This will not be difficult if the blade of the knife be held flat and the ball of the thumb placed near the edge and close to the point. As the peritoneum is carefully torn through with the fingers, the exit of gases, liquids, or abnormal contents of the abdominal cavity should be noted, as well as the position of the intestines. The index and middle finger are then separated so as to form a V-shaped space, in which the knife is placed and its point thrust through the abdominal wall along the line of the linea alba, the fingers following. At the posterior end of the longitudinal incision a second incision is made, perpendicular to the first, extending from the pubic region to the lumbar. The right upper half of the abdominal wall is held up by its edges with the left hand. The assistant pulls on the lower ribs in order to make the abdomen tense, and its covering is cut through with sawing strokes of the knife as far as the costal processes. The knife is so held by the whole hand that the point is shoved away from the operator towards the lumbar region and the lower part of the blade is used instead of the point.

We have now a large anterior and a small posterior segment of the abdominal wall. They may easily be drawn back and a view of the abdominal organs obtained. The ribs of the horse extend so low down that a sufficiently extensive view for pathological purposes cannot be obtained; therefore, before removing the abdominal contents the thoracic cavity is exposed. Then, by thrusting the hand well up under the lower ribs, we notice whether the diaphragm is tightly vaulted forward or is more or less relaxed.

**EXPOSURE OF THE THORACIC CAVITY.**—A small incision is made between two of the true ribs and note is taken whether or not air enters the thoracic cavity and the diaphragm becomes relaxed. If the abdominal examination showed the diaphragm drawn down posteriorly,



the incision should receive special attention; instead of air entering, there may be an exit of gas from the pleural cavity, indicating some essentially pathological condition.

The direction for cutting the ribs is through the costal angles following the course of the iliocostal muscle. An incision is made

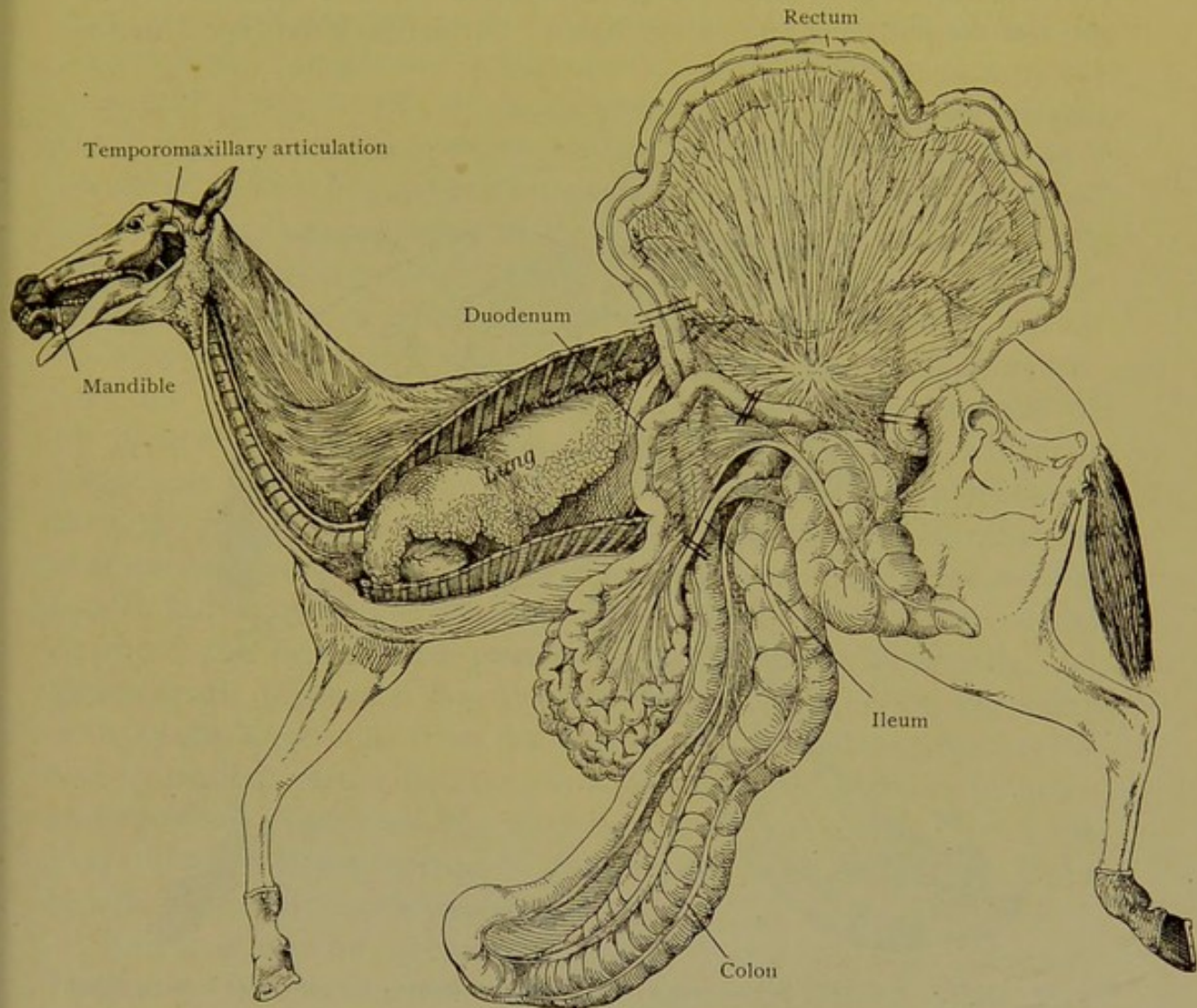


FIG. 154.—Equine viscera, the animal resting on its right side, the anterior and posterior left limbs having been removed, and the abdominal, thoracic, oral, and pharyngeal cavities opened. The double lines show the places in the intestines which are to be tied previous to being cut.

between the true ribs and the blade of the saw introduced, an assistant making the breast tense while the sawing is done; very little pressure should be used or the bone will splinter. When the ribs have been sawed through, they are turned over towards the median line and removed by severing the costal cartilages. The situation of the organs and the pathological contents should be carefully noted. (Fig. 154.)



REMOVAL OF THE ABDOMINAL CONTENTS IN THE RIGHT LATERAL POSITION.—After exposing the abdominal cavity by the longitudinal and transverse incisions, pull the two left coils of the colon either up over the thorax or out across the body on the right side, so that the sigmoid flexure looks towards the head or lies on the ground and the body and tip of the cæcum come into view. Spread the mesorectum out over the left flank and pelvic region. Stroke back the fæces, doubly

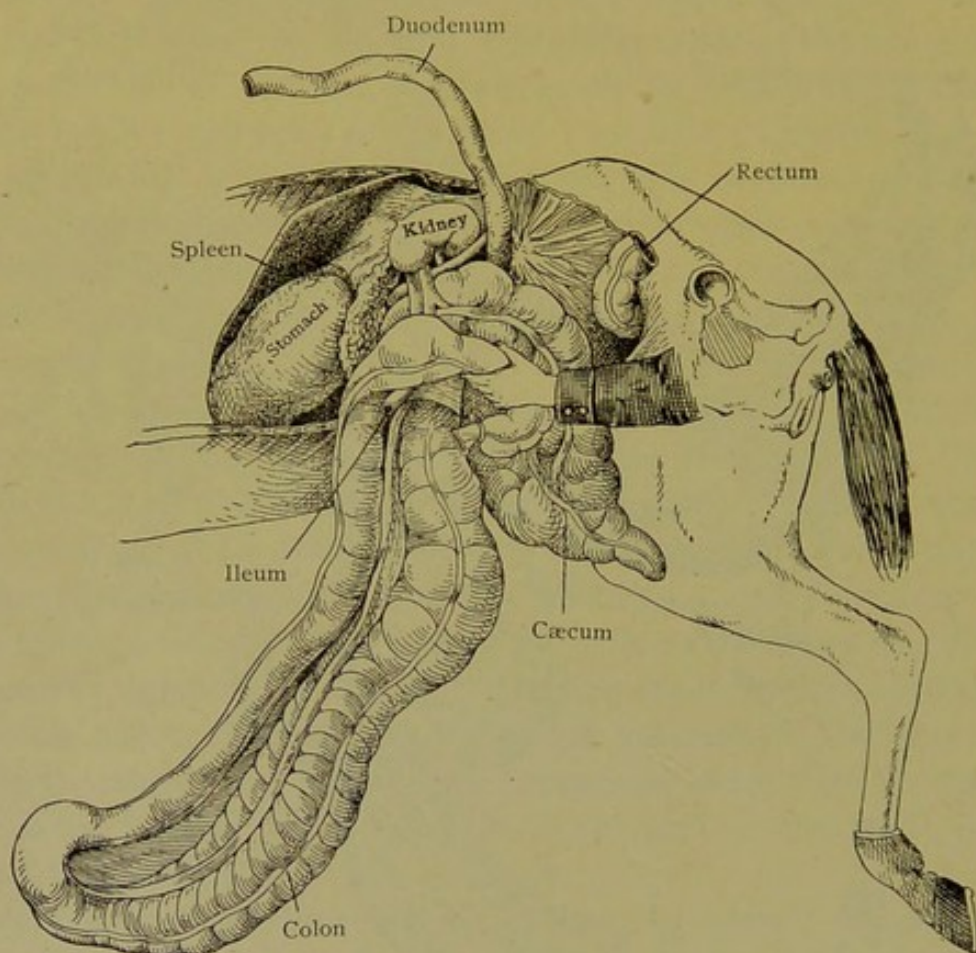


FIG. 155.—Further dissection of animal seen in Fig. 154. Appearance of the parts after removal of the rectum, ileum, and jejunum.

ligate the rectum at its entrance into the pelvis, and section. Cut away the mesorectum up to its origin at the rectoduodenal ligament, doubly ligate the rectum, section, and remove.

The ileum is easily recognized by its thicker walls and its entrance into the cæcum. Apply a double ligature, section, and, holding the intestine in the hand, cut away all the mesentery from the whole of the small intestine as far as the rectoduodenal ligament, divide this, doubly ligate the duodenum, and section. The junction of the colon



with the rectum is now exposed,—the so-called stomach-like or gastroid dilatation,—under which lies the anterior root of the mesentery. Grasping the dilatation with the left hand (Fig. 155), pull it towards the cæcum, and with the right hand work loose or cut partly away the connections between the gastroid dilatation and cæcum and the omental sac, kidney, and pancreas. In this way better access to the portal vein and anterior root of the mesentery is obtained. With the fingers work through the cellular tissue surrounding the root of the mesentery, grasp it with the hand, and together with the portal vein cut it away close to the intestine, leaving as much of it as possible with the aorta. The colon and cæcum are now drawn out of the cavity, all the remaining sections being easily torn or cut away, while the right branch of the pancreas which lies upon the cæcum and the root of the mesentery must be carefully dissected away. Grasp the spleen, section the suspensory (gastrosplenic) ligament and the gastrosplenic omentum, and free the spleen from the stomach. Separate the branches of the pancreas from the larger blood-vessels and the kidneys, so that it hangs only by its body from the liver, and leave it in this position or, after examining its excretory duct, cut it away. Next remove the stomach and duodenum by cutting along the sigmoid curvature and the smaller curvature of the stomach and by sectioning the duodenorenal ligament, the hepatic and pancreatic ducts, the diaphragmatic and gastrohepatic ligaments, and the œsophagus, after pulling the latter down as far as possible from the diaphragm. Excision of the liver is an easy matter: section first the left lateral ligament, then the coronary and suspensory ligaments, the vena cava on the anterior surface of the liver, the right lateral portion of the coronary ligament, and the right hepatic and renal hepatic ligaments.

REMOVAL OF THE ABDOMINAL CONTENTS IN THE LEFT LATERAL POSITION.—The rectum is sectioned at its entrance into the pelvis after pressing back the fæces with the fingers, applying a double ligature, and cutting between them. Seize the colon at its anterior curvature and pull it carefully out of the abdominal cavity as far as possible. The left folds of the colon will fall out with very little assistance. (Fig. 156.)

In the region of the kidney will be seen the arch of the duodenum lying between the anterior and posterior roots of the mesentery and covered by the ribs. Cut through this arch and its mesentery, after applying a double ligature, and remove. The cellular tissue lying



between the cæcum and psoas muscle and the right kidney should be carefully worked loose and the pancreas separated from the cæcum and the colon; this is done by tearing or cutting through the peritoneum covering the intestine and pancreas, getting the hand in under the pancreas, and working it loose. Beginning posteriorly, cut away the mesorectum from behind forward and any connections that may remain between the cæcum and colon and the region of the kidney,

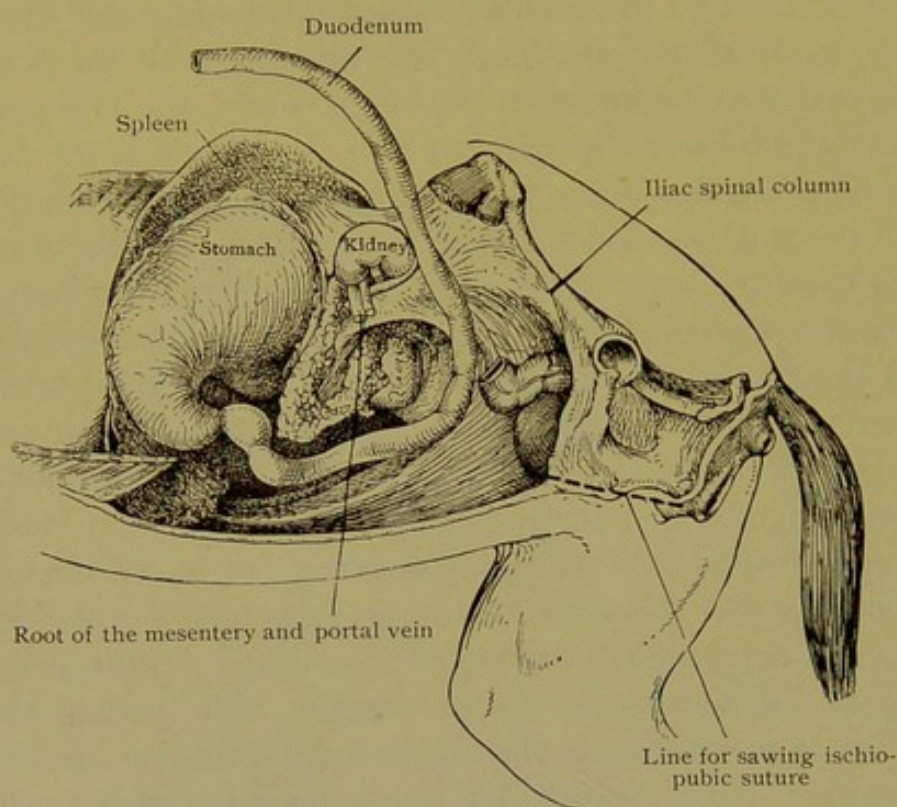


FIG. 156.—Further dissection of animal seen in Fig. 155. Appearance of the parts after removal of the large intestine.

grasp as much as possible of the attachment of the mesentery, pull the intestine back away from the kidney, and section the root of the mesentery in front of the left hand, as far from the aorta as possible. With the exception of a small portion of the duodenum and the pelvic portion of the rectum the large and small intestines can be drawn out from the abdominal cavity by cutting or tearing away any attachments which may remain; the operator stands alternately at the back and in front of the cadaver while removing these portions.

**REMOVAL OF THE KIDNEYS, STOMACH, LIVER, AND SPLEEN.**—The removal of the kidneys leaves a freer field for the stomach, spleen, and liver. With the hand and fingers separate first the right and then the left kidney and the suprarenal capsules from the surrounding cellular



tissue. If the ureters and kidneys are intact the kidneys may at once be cut away together with their vessels. In case of any abnormalities they should be left hanging or a sufficient length of the ureters removed with them, together with the surrounding tissues, or they may remain attached to their ureters and placed in the pelvic region.

The pancreas, spleen, and stomach are freed from the mesentery and sectioned. The assistant pulls on the right side of the diaphragm, and the inferior vena cava between it and the liver is cut through together with the œsophagus. The stomach is turned backward. The left and right hepatic ligaments are sectioned and all the three organs removed together in a mass.

If the kidneys are left in place, the exenteration of the stomach, pancreas, and liver is more difficult and demands more caution, especially if the animal has not been bled, because the field is obscured by blood and other impurities. Dissect away carefully the attachments of the right kidney to the suprarenal capsule and left branch of the pancreas, which lies deep down, covered by the branches of the mesenteric arteries; next the adrenals, then the fundus of the stomach from the cruræ of the diaphragm, the suspensory ligament of the spleen, the splenorenal ligament, the right coronary and lateral ligaments of the liver, the hepatic renal ligament, the vena cava, with the falciform ligament, the œsophagus, and the left lateral and coronary ligaments of the liver.

All these organs may be removed with the diaphragm, and, when there are adhesions to its posterior surface, this is the preferable method. The right lobe of the liver is first separated from the kidney; the pancreas, spleen, and stomach are worked loose from the spinal column in the thorax; the posterior vena cava, the œsophagus, and the pulmonary attachments to the diaphragm are sectioned; the diaphragm is freed from the thoracic wall by a circular excision, and the whole mass removed together. Finally, the aorta and the venæ cavæ with their branches are dissected off the spinal column from the diaphragm to the pelvis.

EXENTERATION IN THE DORSAL POSITION.—The body may be kept on its back by tying the feet to rings in the wall or to posts or poles. The extremities remain attached to the body, of course, and the broad muscles of the chest are only to be sufficiently incised to permit the anterior extremities to spring out a little and give access to the chest. If during the postmortem the extremities are released too



much, the body will fall to one side and make the exenteration more difficult.

A longitudinal median incision is first made, then a bilateral transverse incision just posterior to the last ribs. The two left folds of the colon are drawn up over the right side of the body. The rectum is pulled out and spread over the left thigh and left ventral wall and the small intestine spread out over the region of the lower ribs. The ileum is found at its insertion into the cæcum; it is thicker than the rest of the small intestine. It is tied off and sectioned, remaining in the hand after its mesentery is severed close up to the intestine. In this way the whole of the right lateral small intestine is removed from the abdominal cavity and its mesentery left hanging by its root. When it passes into the duodenum between the two roots of the mesentery, doubly ligate and section. Doubly ligate and section the rectum at its entrance into the pelvis and again at its junction with the colon.

The pancreas and first part of the duodenum are dissected away from the colon as in the first method. The roots of the mesentery and both the branches going to the large intestine are sectioned close up and the large intestine is removed.

The stomach, spleen, etc., are removed as in the first method. Many operators prefer to excise the spleen and open the stomach along its greater curvature and the duodenum on its inferior surface, whereupon the pathway of the bile ducts may be determined and then the empty organs cut away.

In the dorsal position the thoracic organs may be ablated by drawing them down towards the abdominal cavity. An incision is made between the rings of the trachea, two fingers are inserted, the trachea is grasped firmly, and the larger vessels are sectioned at the thoracic inlet; the aorta is dissected away from the vertebræ and the posterior vena cava and œsophagus are sectioned. If it be desired to remove the thoracic viscera together with the trachea and cervical organs, the first rib is sawed through and excised; the cervical organs are then ablated according to the method to be described later.

VIENNA METHOD OF EXENTERATION IN THE LEFT LATERAL POSITION.—Csokor's quick method for removing the thoracic and abdominal contents is as follows: The extremities are removed and the abdominal cavity is exposed by a longitudinal and a transverse incision as in the first method; then the muscles of the back are cleared away and the sectioned abdominal wall is drawn up by a hook. With a



hatchet each rib is cut away from the spinal column and then from the breast-bone. The whole right wall of the thorax and abdomen is now drawn up over the head of the animal and the contents of both cavities are exposed. The right kidney is next removed and then the thoracic contents. After their ablation the cardiac end of the stomach is freed from the diaphragm and the duodenum is detached from the liver and its surroundings and excised together with the stomach and spleen. The abdominal aorta is separated from the spinal column, the rectum sectioned, and all the intestines removed. The remaining organs are extirpated as in the other methods. This modification permits a very rapid necropsy, but the removal of the stomach and spleen is somewhat difficult.

DISCUSSION OF THE ABDOMINAL CONTENTS.—To ascertain the macroscopical conditions of the abdominal contents it is necessary to make a few special incisions. The aorta is first examined and its dorsal wall slit up with the shears to expose the entrances into its branches, which are then cut open. On account of its great frequency, close search is to be made for an aneurism in the root of the mesentery. It is usually felt externally as a thick, cystic expansion. The branches to the small intestine—the duodenal, jejunal, and iliac arteries—are first given off from the short trunk of the artery lying in the root of the mesentery (the anterior mesenteric artery); next a large vessel, the ileocolic artery, which gives off a large branch, the inferior colic, and the ileocæcal artery with its three branches. The superior colic comes off above the root of the mesentery on a level with the anterior rectal artery. After examining these branches slit the inferior and superior colic arteries in the mesocolon from their origin to the sigmoid flexure. If it seems necessary, examine the arteries of the small intestine in the same way and observe the mesenteric lymph-nodes. The bowel is opened with the shears along the line of the attachment of the mesentery so as to get a good view of Peyer's patches; keep the intestine lying flat, for if held up the contents run down into the lower portions, which is a nuisance.

If the stomach is sufficiently full, cut it open with a knife along its greater curvature. If the duodenal portion remains with the stomach and liver, open it with the shears on its inferior surface in such a way that the termini of the hepatic and pancreatic ducts will not be injured and their patency may be demonstrated. Press and push along the course of the ducts so as to force out their contents. If there is any



suspicion of abnormalities in these ducts, it is better to leave the stomach and duodenum in place and to open them before removal.

REMOVAL OF THE THORACIC CONTENTS.—First carefully examine for sharp points of bone and excise them with cutting forceps. The pericardium should then be examined and worked free with the hands. The posterior vena cava is tied off and divided between the ligature and the diaphragm; the attachments of the liver and heart to the diaphragm are sectioned and an incision is made obliquely through the aorta down to the vertebral column. Thrust the finger into the posterior aorta, pull it up, and cut along the spinal column in the line of the vena azygos and the attachment of the longus colli. Now make an oblique section through the œsophagus, trachea, anterior aorta, and anterior vena cava along the line of the first rib, so that the thoracic organs may be removed. This avoids cutting the large veins, which bleed so freely as greatly to obstruct the view of the parts under observation.

SECTION OF THE ORAL CAVITY AND CERVICAL ORGANS.—This is begun by removing the ramus of the lower jaw on one side. Cut the buccal parietes and the cheek at the angle of the lips up to the zygomatic arch, between the molar teeth and the space between the lower jaw and the large maxillary swelling, dividing the masseter and sawing through the bones. The ramus of the jaw may now be worked up and down, its muscular connections severed by a knife introduced along its median surface, and an incision made between the parotid gland and the posterior border of the bone. The temporal muscle is cut through above the coronoid process and the ligaments and capsule of the joint are sectioned, the jaw being moved up and down to find the joint. After examining the local conditions, sever the left connections of the tongue with the jaw and the soft palate; saw through both to the large branches of the hyoid bone. The larynx, trachea, and œsophagus are easily freed from their loose cellular tissue by cutting into the channel of the external jugular vein, between the longus colli muscle and the œsophagus, so that the thyroid gland is not injured.

DISSECTION OF THE THORACIC AND CERVICAL ORGANS.—In order more closely to inspect these organs, cut through the vault of the velum palati with the shears and continue down into the œsophagus, sectioning it dorsally. With the knife grasped firmly incise the larynx in the median dorsal line between the arytenoids. Pushing the œsophagus



aside, cut the posterior muscular ligament of the trachea with shears throughout its whole length and thrust the cartilages apart to get a good view of the interior. The lobes of the lungs are laid open with long, deep, bisecting strokes, and portions of each lobe are tested by throwing them into water to see whether they contain air and will float or will sink because of collapse or the presence of an exudate. The lymph-nodules around the roots of the bronchi must always be examined and sectioned.

If the heart is hacked into or improperly opened, the distinctive appearance of any abnormality that may be present is destroyed, and these anomalies are of great importance to the whole organism. First make an incision into the right ventricle along the septum, insert the shears, and cut up into the pulmonalis. Holding the heart by this flap, lengthen the incisions towards the apex and the flap so as to get a better view of the ventricle. In the same way incise the left ventricle close to the septum and on the anterior surface; insert a finger through the opening, find the entrance into the aorta, and with the shears cut down between the pulmonalis and the left auricle. It is true that in this way both semilunar valves are sectioned, but the auriculoventricular valves are spared and they are much more likely to present abnormalities than the semilunar. The size of the openings can be tested by inserting a finger, and the thickness of the walls measured, after which each auricle is cut through up into its vessels and a good view of their openings obtained.

EXENTERATION OF THE PELVIS.—The removal of the pelvic organs is preceded by the previously described excision of the kidneys and ureters and in males by the exposure of the testicles and the external genitalia. The scrotum and penis were then turned back, and now their dorsal suspensory ligament and surroundings are divided as far as the ischiatic notch and all the flesh lying ventrad to the ischiatic suture is carefully cleaned away. The scrotum and the right and left inguinal canals are split open and the testicles together with the spermatic vessels pulled up into the abdomen. It is especially necessary to cut the tendinous ligament which binds the corpora cavernosa to the ischium close to the bone, as well as the strong ischiopenile muscle. Two sections made by sawing will remove the right wall of the pelvis. The first one is made through the ischiopubic suture over the acetabulum to the iliac spinal column; the second, through the thin part of the iliac bone, after cutting away the flesh that lies over the acetabulum



on the iliac column. By cutting the bone loose from the pelvic cellular tissue, it is easily pulled away.

The lateral wall of the pelvis being removed and a good view of the organs obtained, divide the connective tissue between the rectum and the superior pelvic wall; free the uterus and ovaries, the neck of the bladder, the vagina, and the accessory sexual glands; cut through the strong rectococcygei and the skin between the tail and the anus; and make a circular incision around the anus and the vulva (or the region of the penis). Remove the whole mass and section the organs dorsally.

EXENTERATION OF THE CRANIAL CAVITY.—To remove the head from the trunk we may either cut around the joint as if the throat were being cut or puncture the capsule ventrally and amputate between the condyles and the atlas. It is best to remove the whole of the lower jaw and let the skull, wrapped in a cloth, rest on its base and the molar teeth; it may then be held much more steadily than if the inferior maxillæ had been left in place. The cranial attachments of the cervical and temporal muscles are next cut away and the soft parts removed from the roof of the skull.

There are three lines for sectioning the cranium. The first lies transversely across the forehead about a thumb's breadth above the upper border of both superciliary ridges. The two other lines begin at the ends of the frontal incision, pass backward across the temples and petrous bones, and converge to the condyloid apophyses (Figs. 157, 158). The first section can be made continuously, but the second and third will have to be done in several portions on account of the convexity of the cranium.

The walls of the cranial vault are not equally thick, and care must be taken not to penetrate too deeply into the middle of the parietal bones and the squamous portion of the temporal bones. The frontal section passes through the frontal sinuses, so that there is very little danger here; and the same is true of the vertex and the pyramidal region above the condyles. The plates are not usually sawed clear through along the whole line, but the connections are broken with a chisel. Rest the palm of the hand upon the skull, grasp the chisel firmly near its edge so that it cannot enter too deeply, and tap gently with the hammer. When the bones are completely severed, pry the piece off by rocking the chisel backward and forward, first in the frontal and then in the condylar region. A sudden strong pull on the



pericranium, grasping it at the edge of the frontal section, will generally separate it from the other parts of the head; sometimes the

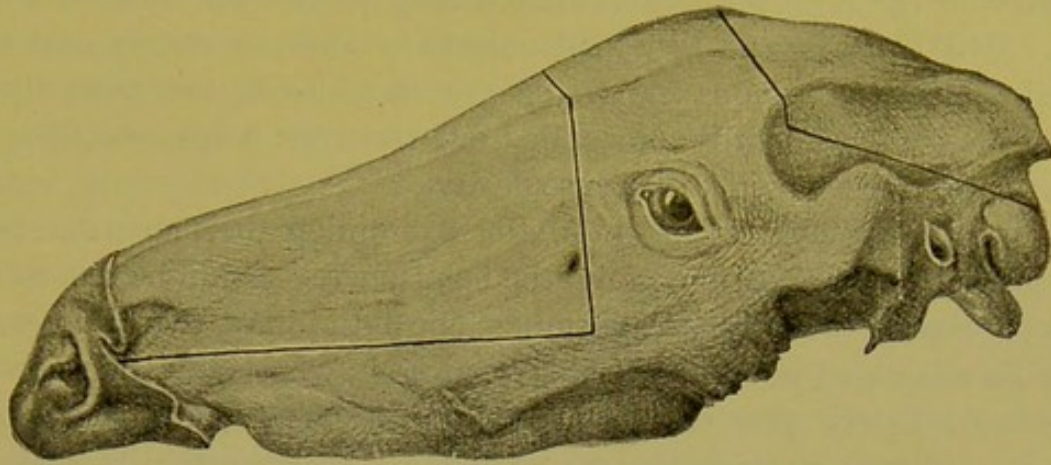


FIG. 157.—Lines to guide the saw in opening the cephalic cavities of a horse.

whole brain will come away at one jerk, together with the root of the skull.

If the dura is too closely held or is adherent to the inner table of

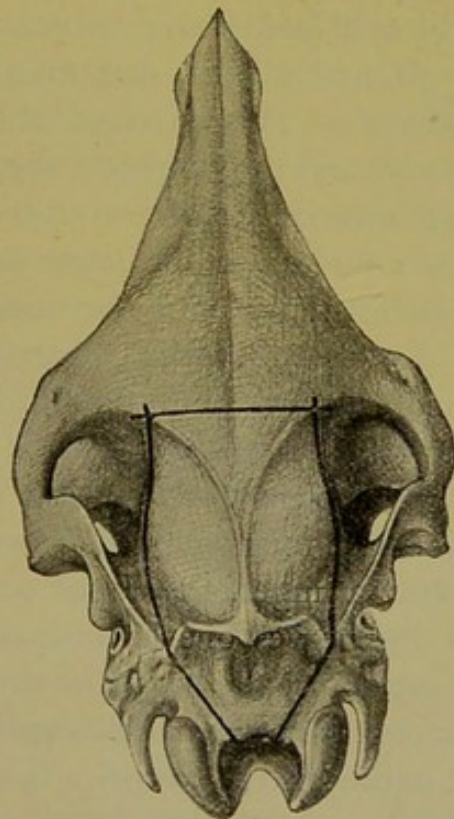


FIG. 158.—Lines of sawing for opening the cranial cavity of a horse.

the skull, with the shears incise it in the line of the section in such a manner that the dorsal portion will come away with the calvarium.



Next excise the longitudinal and transverse blood-vessels in the duras. That part of the dura lying over the hemispheres is held up with forceps and cut with scissors so that it may be thrown back on both sides. The tentorium is sectioned anteriorly and posteriorly and removed. The membranous transverse septum which is torn away from the falx is incised laterally and pulled out from the transverse fissure, due attention being paid to its vascularity.

**DISSECTION OF THE BRAIN.**—After examining the pia mater and the superficial surface of the brain, the hemispheres should be separated so as to expose the corpus callosum. The interior of the brain may either be examined now or after its removal. A horizontal incision is made immediately over the corpus callosum, starting at the median surface, and using preferably the so-called "brain-knife" or a long, flat scalpel. If the incision is not quite deep enough to enter the lateral ventricle, you will come first to the so-called "egg-shaped middle point" (*centrum semiovale Vieussenii*); press this gently with the finger and you will find a yielding point which, when incised, opens into the lateral ventricle. Follow the finger with the knife and slit open the roof anteriorly and posteriorly. Look for a collection of fluid, and examine the choroid plexus, corpora striata, horns of the ventricle, and median septum. This is seized in the middle, raised a little, sectioned transversely, and thrown back, the connections holding it to the peduncles being severed. Now carefully insert four fingers into the transverse fissure and raise the posterior lobes in order to expose the corpora quadrigemina, optic thalami, pineal gland, and middle choroid plexus. By separating the two thalami a little, you can divide the commissura mollis and see into the third ventricle.

To remove the brain, support the skull upon the incisors in such a position that the condyles look upward and the brain would fall out if it were free. Into the space thus obtained between the medulla and the base of the skull, insert a finger, the closed scissors, or the handle of a scalpel, and sever the nerves one by one as they appear. The olfactory bulbs, which are unusually large in comparison with those of man, are worked out from the ethmoidal depressions by a circular thrusting motion of the handle of the scalpel. When they are all separated, the brain will fall into the waiting hand, which must steady it constantly or the olfactory bulbs would be torn away by its falling out too soon.

After the brain is removed, the inferior surface is first examined,



then, turning the brain over, the cerebellum is cut into halves. Expose the fourth ventricle and incise the floor longitudinally. With a thin-bladed knife cut radially to the cortex and transversely to the cruræ, making numerous narrow incisions to detect the presence of any small hemorrhage or other lesion.

REMOVAL OF THE SPINAL CORD.—This requires much time and labor when properly done, but is managed in various ways. But little time is spent in routine work when you have a butcher to assist you. The animal is suspended and the vertebræ are split off from their bodies by a hatchet; when this is cleverly done, the line of cleavage being kept a little to one side, the cord is but slightly injured. It is better, however, to proceed as follows: Saw off the ribs at their angles, separate the ilium from the sacrum, and clean off all the flesh. Laying the spine upon the table, begin at the pelvis and chisel off the vertebral arches, remembering that two chisels are necessary, one for each side, as the two instruments have different curves (Fig. 32). If an ordinary chisel is used, the arches should be partially sawed through to make their division easier. The hand holding the chisel supports itself on the spine, and the chisel is held as flat as possible while an assistant grasps the spinous processes and springs the arch apart. You may also expose the spinal canal ventrally by sawing through the vertebral bodies and arches on one side only. Section the nerves at their points of exit laterally to the intervertebral ganglia and lift out the cord enclosed in its membranes. Cut open the dura with the scissors and section the cord transversely with a sharp, thin knife.

EXPOSURE OF THE ACCESSORY SINUSES.—To expose the nasal fossæ saw the head in two, after removing the brain, a little to one side of the median line so as not to injure the septum on either side. These fossæ may be sectioned transversely or their walls chiselled away to show the accessory sinuses. Csokor saws through the osseous structure of the nose transversely from the level of the malar or lachrymal bone to the roots of the molars; a section is then made horizontally beginning at the anterior nares and joining at the first section (Fig. 157). On raising this cap you have the maxillary, nasal, and frontal fossæ well exposed.

One or two long bones should be sawed through to judge of the condition of the bone marrow.

POSTMORTEMS ON RUMINANTS.—There are certain peculiarities in the skulls of ruminants which must be remembered when exposing



the cranial cavity. It is only in very young animals that the cranial bones possess diploe, and in necropsies on hornless cattle the incisions are the same as for horses. On account of the prominent crests, which fall away very abruptly, and because a calf's head is somewhat rounder,

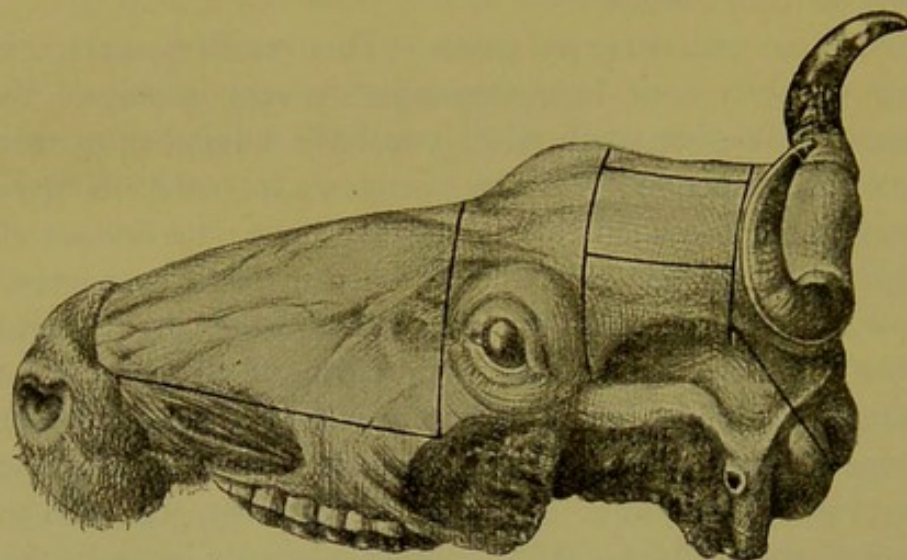


FIG. 159.—Lines used in sawing in order to expose the cranial and nasal cavities in a ruminant.

the sawing will have to be done in more segments, and great pains must be taken on account of the thinness of the bones. The older the animal the larger are the hollow places between the internal and external plates; the diploe disappears and only a few crusts and plates

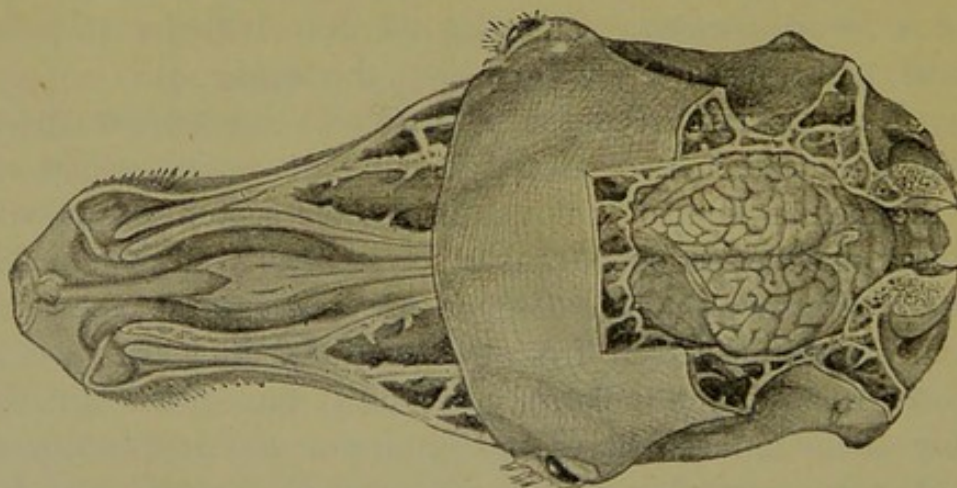


FIG. 160.—Appearances of cranial cavity of a cow after removal of the bony vault.

of bone interrupt the hollow spaces. The lateral and posterior portions of the skull are very prominent because of two large crests. The transverse section is nearly coincident with the posterior border of the superciliary ridges. The lateral sections are made in two segments,



beginning at the ends of the transverse frontal incision and passing back over the temples to the foramen magnum. Clement has devised a better method (Figs. 159 and 160). First clear away all that part of the calvarium formed by the frontal eminence and the lateral depressions by sawing through the skull in a line passing from just in front of the horns obliquely backward and downward to the condyles or foramen magnum. After removing this plate of bone the whole of the posterior portion of the brain is exposed. Next make a transverse incision on a level with the superciliary ridges across the anterior end of the cranial cavity. Finally make two short longitudinal incisions, one on each side, about three centimetres from the median line; with mallet and chisel remove the oblong piece enclosed, and the whole brain is exposed. The curved horns of a sheep or a goat serve as convenient handles for removing the calvarium and may very well be left on, while the horns of neat cattle should be knocked off.

POSTMORTEMS ON SWINE.—With the body lying on its left side, the right extremities are removed, the abdomen is exposed by longitudinal and transverse incisions, the diaphragm observed, and the lateral thoracic wall divided by cutting with the bone-shears or sawing through the angles of the ribs and severing the cartilages close to the sternum. To remove the abdominal contents, first find where the duodenum is attached to the rectum; sever the duodenorectal ligament, separate the pancreas from the mesentery, and section the duodenum. The anterior root of the mesentery is loosened by working it free with the hand and pulling on it, then sectioned, the whole of the mesentery excised from before backward, and the rectum divided. Now cut away the spleen from the stomach, examine the opening of the bile duct, section it and the œsophagus, and separate the stomach from the diaphragm, leaving the liver freed from its suspensory ligament. The thoracic and cervical organs are removed as with other animals.

In old quadrupeds the brain lies very deep, because of the immense air-spaces in the cranial bones which surround the brain on all sides except the temporal region. The transverse section is made a full thumb's breadth above the superciliary ridges (the eyes being first removed) and the lateral sections run back to the occipital foramen. Instead of a transverse section we may make two oblique ones, beginning at the posterior border of the frontal process and joining each other and the lateral incisions in the anterior frontal region.



POSTMORTEMS ON DOGS AND CATS.—The necropsy of a dog is easily and quickly made in either the dorsal or the left lateral position. The procedure is the same as for the horse, but it is not necessary to remove the extremities entirely or to take off the hide; simply cut through the muscles enough to allow the limbs to fall away a little and the body will be sufficiently steady. (Figs. 161, 162.) The thick-

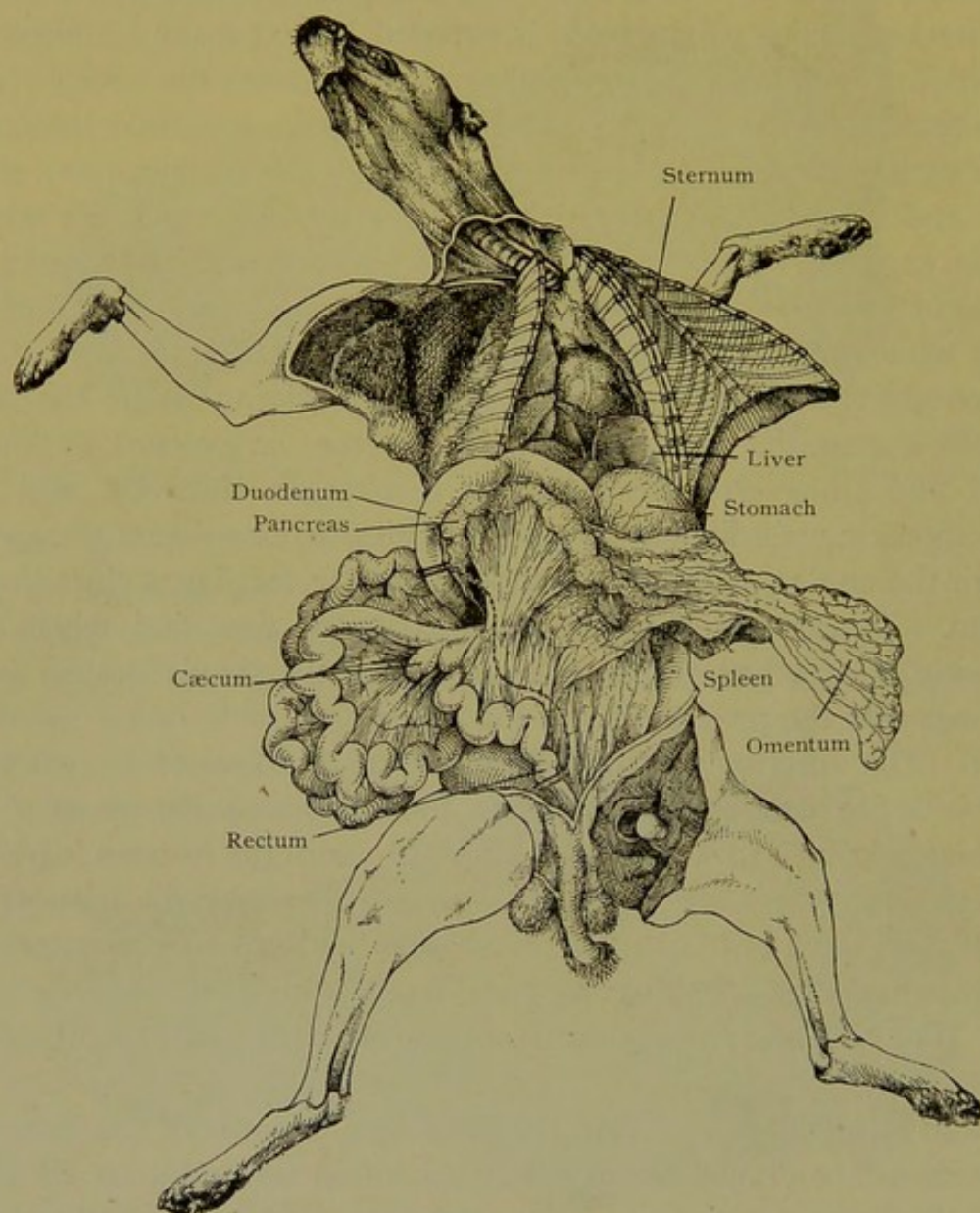


FIG. 161.—Postmortem of the dog. Double lines show places at which the intestines are to be tied; the dotted line indicates the direction for incising the mesentery.

ening at the junction of the cartilages with the ribs is easily felt, the articulations are cut, and the sternum is pushed upward and forward after freeing the pericardium and the pleura. Section the tracheal



vessels and œsophagus at their entrance into the thorax and remove the thoracic organs.

The removal of the abdominal contents of a dog is easy. Divide the rectum at the pelvis and the two mesenteric roots, and the abdominal aorta and inferior vena cava behind the liver; thrust the hand in between the liver and the diaphragm, and with scissors section the suspensory ligament of the liver, the vena cava, and the œsophagus after it is pulled down from the diaphragm and tied off or compressed with the fingers. All the abdominal contents may now be removed together. Spread them out, examine each again, test the patency of the bile ducts, and straighten out the bowels. It is, however, better first to remove the intestine, which is sectioned through the duodenum

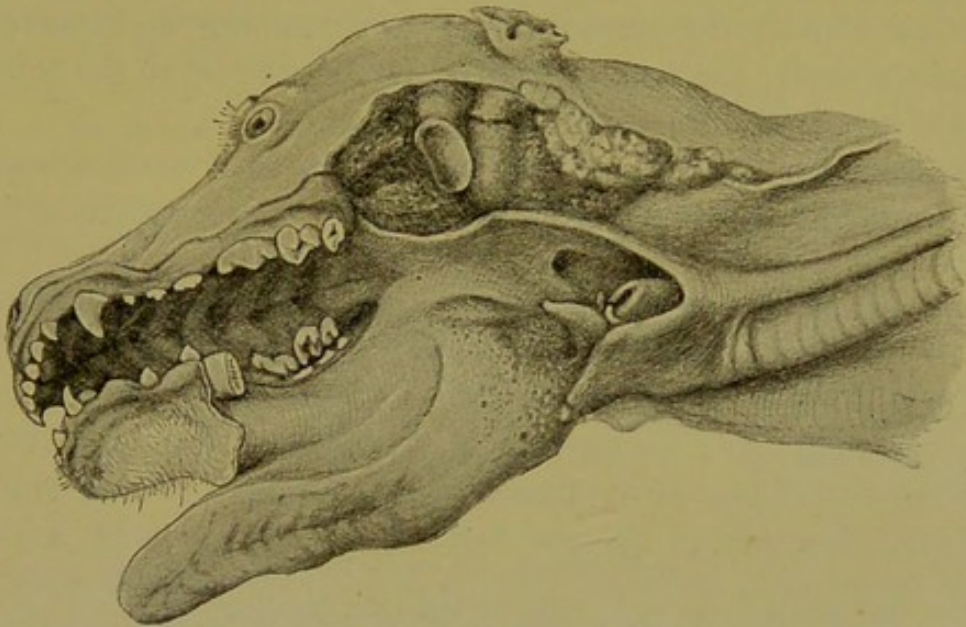


FIG. 162.—The left ramus of the mandible has been removed and the tongue pulled outward and downward, thus exposing the oral and pharyngeal cavities in a dog.

at the pancreas and through the rectum at the pelvis. You may next either remove the liver with the stomach, or after inspecting the bile ducts you may cut away the stomach from the œsophagus and duodenum and then remove the liver.

To expose the cranial cavity we have the same three lines as usual, the transverse section lying directly posterior to the rudimentary superciliary ridge, crossing the frontal sinuses and the anterior lobes of the brain. The anterior temporal and the parietal bones are not thick and contain diploe, so that the sawing must be carefully done. Since the petrous portion of the temporal bone has deep impressions upon its internal surface, in which convolutions of the cerebellum lie, and since



the bony processes project from the adjacent bones, great care must be taken not to tear the cerebellum. In small dogs with round heads the line for sectioning is more nearly a circular one.

The postmortem of a cat is made in the same way.

**POST-MORTEM EXAMINATION OF BIRDS.**—Plug up the nostrils, mouth, and vent with cotton; make an incision from the point of the breast-bone, or a little above, backward to and through the anterior portion of the anus, leaving the uropygium (pope's nose). Loosen each leg to the knee (above the femur) by tearing the soft parts with your thumb and fingers, then cut with a knife until they meet around the pelvis at the rump. With your thumb-nail work the wings loose, hold the skin firmly, and, pressing your nail towards the body, cut off the wings at the elbow. Make a V-shaped slit with its apex towards the median line at the foramen magnum, running up towards the centre of the skull; the brain is thus removed attached to the body and the skin is kept whole for taxidermic preservation.

**POST-MORTEM RECORDS.**—Kitt suggests the following scheme for the more intelligible recording of the findings in postmortems on the lower animals.

#### RECORD OF NECROPSY.

Species	Gender	Age	Color of hair	Owner
Clinical history		Treatment	Mode of death	Date of death
Necropsy performed by			Where performed	Date
Order of			Persons present	

#### A.—EXTERNAL EXAMINATION.

Position of the cadaver (on back, right or left side, hanging)  
 Nutritional condition (weight)  
 Removal or absence of parts  
 Rigor mortis  
 Condition of the skin and its appendages (the skin around the head, trunk, and extremities; the horns, claws, hoofs, ears, scrotum, prepuce, udder)  
 The natural body openings and visible mucous membranes (the discharge of foam, fluids, and excrements; the color of the lips, nasal mucous membranes, conjunctivæ, anal and vaginal mucosæ)

#### B.—INTERNAL EXAMINATION.

Facts obtained in removing the hide  
 Condition of subcutaneous tissues, fat, lymph-nodules, vessels, extravasated blood, muscles, ligaments, tendons, and bones  
 Abdominal and thoracic data  
 Condition of diaphragm, position of organs, appearance of peritoneum, mediastinal and costal pleuræ, and pericardium



The\* oral cavity, tongue, soft palate, salivary glands, pharynx, Eustachian tubes, œsophagus, retropharyngeal and laryngeal lymph-nodules  
 The larynx, trachea, thyroid, and surroundings  
 The lungs, bronchi, bronchial lymph-nodes  
 The pericardial sac, heart, and thoracic vessels  
 The liver and bile ducts, portal vein, and periportal lymph-nodules  
 The spleen (capsule, pulp, trabeculæ, Malpighian bodies, and vessels)  
 The stomach and crop  
 The pancreas; the large and small intestines  
 The mesentery, omentum, posterior aorta and its branches, and vena cava  
 The kidneys, adrenals, ureters, capsule and pelvis of the kidney, and its half section  
 The urinary bladder, urethra, and accessory sexual glands  
 The pelvic portion of the rectum  
 The genitalia: uterus, vagina (pregnancy, foetal membranes, embryo), and the male genitals  
 The cranial cavity and the brain: calvarium, sinuses, cavities at the base of the skull, dura, cerebral superficies, ventricles, gray and white matter  
 The eyes; the middle and internal ears  
 The fourth ventricle and the spinal cord with its membranes  
 The nasal fossæ and accessory sinuses  
 The udder and supramammary lymphatic nodules  
 The bone marrow  
 The microscopical report

INSPECTION OF SPECIAL ORGANS.—The essentials for diagnosis which are to be looked for and recorded are about as follows: 1. Name of the organ; from what animal; whether it died or was killed; whether the organ was entire or fragmented; whether parts, lobes, etc., have been amputated; and if there are any adhesions to adjacent parts. 2. Weight. 3. Length and breadth of the part. In the absence of a tape measure we may ascertain these dimensions approximately by comparison with the breadth of the hand and the length of the finger. Every person should know the length of his index-finger, which is usually about ten centimetres and may be used to measure organs, pathological spots, streaks, canals, etc. 4. Surfaces: whether smooth, even, wavy, granular, corrugated, rough, transparent, or cloudy. Color of the surface: general and primary color, special deviations and shades. The external contour of the organ and any prominences, with especial reference to their size as compared with grains of sand, millet-seeds, lentils, peas, beans, hazel-nuts (or filberts), a pigeon's, a hen's, or a goose's egg, the fist, the thickness of a child's arm, a child's head, a man's head, etc. 5. The consistence as determined by palpation: soft, elastic (like the lungs), doughy, splenified, hepatized, tough, inelastic, carnified, indurated, leathery, like the kid-



neys and skin, as hard as wood, cartilage, bone, or stone. 6. Sectioning of special parts: through the compact, so-called parenchymatous organs (muscles, liver, kidneys, lungs) large dissecting incisions are made. Through the brain and heart sections must be made in a certain way in order properly to expose certain cavities. On sectioning notice the resistance of the tissue, whether it cuts easily or is tough and pulls, whether the knife creaks as it goes through, whether the tissue is so hard that a saw is necessary, and observe if any fluid follows the section or if there are any abnormal contents. The surfaces of the section must be noted, their color, thickness, consistence, fluidity, and vascularity, as well as any other peculiarities which may be present. The pathological diagnosis is made by considering the details gained in this way, which lead to one conclusion and exclude another. A gross anatomical diagnosis is often only provisional and dependent upon microscopical and chemical confirmation.



## CHAPTER XXVII

### MEDICOLEGAL SUGGESTIONS

ALTHOUGH a physician is not expected to have a profound knowledge of legal matters pertaining to his profession, yet every doctor should be more or less familiar with the medical laws of the State or county in which he is practising. He should be well acquainted with the regulations of the board of health, of the coroner's office,<sup>1</sup> of the criminal court, etc., and do all in his power to aid in their rigid enforcement. A synopsis of such laws and regulations is usually readily obtainable in book form, and nearly every physician has among his patients or friends a lawyer who is glad to discuss legal questions in return for medical information. Some of the salient points relating to medicolegal investigations and autopsies will here be briefly considered, though many references to these matters will be found elsewhere throughout this work, especially in Chapter XXVIII.

OBLIGATIONS OF PHYSICIANS TO THEIR PATIENTS.—The obligation of a physician to society in the practice of medicine is in a certain sense voluntary. His is the right to refuse any and all cases that may apply to him for treatment or advice. Services once begun, however, he must, after giving notice of his intention to discontinue them, allow his patient reasonable time to fill his place, as otherwise he renders himself liable for damages. This obligation is equally binding in the case of charity patients. Contracts between a physician and a patient may be either implied or express. In the former neither party specially promises anything. An express contract may specify anything not contrary to public policy. Contracts making the payment contingent upon successful treatment are valid, but, should the patient fail to follow the doctor's directions or to give him sufficient opportunity for treatment, the Court would probably allow the latter reasonable compensation. If the physician fail to exercise ordinary skill,

---

<sup>1</sup> The office of coroner is an old and important one. It was established during the reign of King Athelstan, 925 A.D., and more clearly defined after the Norman conquest. The institution was brought to America by the colonists. The authority of the coroner to hold an inquest is not confined to the body of a person who may have died within his jurisdiction, but extends to all bodies brought within his territory, no matter where death may have taken place. (Witthaus.)



he renders himself liable for malpractice. In law malpractice consists in wilful or negligent acts or acts which are expressly forbidden by statute and by which a person suffers injury or death. It is a criminal offence to practise medicine or surgery while intoxicated.

EXPERT TESTIMONY.—Applying these principles pertaining to medical practice to our subject, no Court can compel a physician to give expert testimony, to make autopsies, or to conduct laboratory investigations without his consent, but any knowledge which the doctor may possess pertaining to an individual criminal case must be given to the Court in the same manner as if he were an ordinary witness. His scientific training is, however, his own personal property, the result of many years' study, careful research, and expenditure of money, and he is entitled to commensurate remuneration for the expert use of his knowledge. For the good of society, any facts pertaining to a given criminal case which are known to him should be freely and willingly given to the Court, though he thereby may be put to considerable loss of time and money.

Whether the Court may compel him to divulge professional secrets is a debatable question. In some states and countries such confidences of the patient are held sacred, as are the confessions to a priest; while in other places such confidences (wrongly, we believe, in civil cases, but rightly in first-degree criminal cases) must be divulged to the Court should questions be asked the physician pertaining to the same while on the witness stand.

An expert is one who, by reason of his peculiar experience, special study, or performance of certain duties, is in a position to form an opinion or judgment such as could not be expected from the judge or jury. No regular witness is permitted to express a mere opinion, as this is supposed to be the province of the members of the jury. Thus, in one of my cases, where infanticide was suspected, an iceman had found the dead body of the baby in an ash-barrel, and the judge would not permit the iceman to act as an expert in giving the approximate weight of the child, though it would seem that, on account of his frequent weighing of ice, he would be more fitted to give a correct estimate of the weight than an ordinary person. The weight of the child (nine pounds) was desired in order to show that it was born at or near full term.

A medical man should refuse to testify as an expert unless he is thoroughly qualified. In no case should he go on the witness stand



without being as fully informed as is possible on the subjects on which he is to be examined, nor should he allow himself to be questioned on subjects on which he is not prepared. He should be honest and candid with those securing his services before the trial, and, no matter what may be the consequences, his answers while on the witness stand must be made with absolute impartiality.

The medical expert should at all times confine himself to purely medical topics and never become involved with matters that will place him in the light of an ordinary witness, of a detective, or of an attorney, and he should carefully avoid acting as a champion of the parties who are paying for his services or attempting to plead one side of the case.

His language should be as free as possible from technicalities and such as can readily be followed by the least educated of the twelve jurymen, many of whom are, unfortunately, unfit for the performance of their duties. Some judges carry this plainness of language to an extreme. Thus, while acting as an expert in a murder trial, the writer was once requested by the judge not to use the word "hemorrhage" in testifying, as this term was too technical for the jury to understand. I at once substituted "bleeding" for the objectionable word and proceeded with my testimony. When not positively certain of a point he should unhesitatingly acknowledge the fact; thus harm and the possible endangering of a human life will be avoided. But when sure of his ground he should undeviatingly adhere to it. At the close of his testimony, especially if long and exacting, an opportunity is almost always given him to correct any misstatements which he may inadvertently have made, and to make clear the meaning of any dubious points of his original testimony which may have been clouded by the cross-examination of the opposing counsel.

Too much is often expected from the expert, as the following instance shows. While testifying as an expert in a country town on a case where the postmortem revealed beneath the left eye a small incision closed with two stitches, ecchymosis about the eyeball, and a fracture of the skull, the district attorney and the judge criticized me severely because I would only state that the man had died from hemorrhage of the brain due to fracture of the skull. They desired me to say that the man had been knocked down with the fist of a person who had a ring upon his ring-finger, and that in this manner the fracture had been produced. I was naturally willing to say that it



could have been produced in this manner, but would not say, much to their apparent disappointment, that it was so caused.

IDENTIFICATION OF THE BODY.—Before a postmortem is begun, the remains should, if practicable, be positively identified to the obducent by one or more persons who knew the individual during life. If this is impossible, the one finding the dead body or those having seen it in its original situation after death and those removing the cadaver from one place to another may act as identifiers. Persons who have gone under several names should be recorded under their legally correct name, any other aliases which had been used being also recorded.

That the place where an unidentified body is found should be carefully stated is shown by one of my cases. A colored woman confessed the placing of the corpse of a new-born male bastard wrapped in a shawl in an ash-barrel on the corner of A—— Street, Philadelphia, Pennsylvania, in which State the concealment of the death of an illegitimate child is a penal offence. The body identified at the postmortem was that of a new-born colored babe wrapped in a shawl, but found in an ash-barrel situated at the corner of B—— Street, some two blocks away. On the plea of the lawyer for the defence that there was no *corpus delicti*, as the body found at B—— Street was not shown definitely to be the body left at A—— Street, the judge decided that the trial should not proceed and ordered the jury to acquit. This was at once done, and, though new evidence might later be secured, it could not be used, as the woman could not have her life put in jeopardy a second time, though, as in the Mollineux trial, a man might once be condemned but on a new trial be acquitted.

Should personal identification be impossible, a cast of the face, a photograph, an accurate description of the body, with a full and clear statement of any peculiarities, should be made. Clothing alone is not sufficient for purposes of identification, as bodies have been substituted and clothed in the wearing apparel of the alleged deceased, such substitutions being made in order to defraud life insurance companies or change succession to titles and estates.

As the person whose body is being examined may have been a criminal and thus during life have had the Bertillon system applied for purposes of future identification, these measurements and finger-impressions should be secured in important cases. Skiagraphs of old osseous lesions might also lead to identification.



CARE OF CLOTHING AND OF SURROUNDINGS.—Where the clothing has not been already removed by responsible persons, as is done in certain places (though this is scarcely justifiable), the examiner should observe the condition of the articles and their position, whether torn or soiled, displaced or reversed. If any irregularity is observed, he must determine, if possible, any significance that may be attached thereto. For example, singeing about a small recent bullet hole, with the powder markings pointing upward, would indicate that the powder used was black and not smokeless, that the weapon was discharged at close range, and that the trigger was held in the opposite direction,—*i.e.*, down.<sup>1</sup> Again, recent seminal stains on or marked disarrangement or tearing of the clothing of a female would strongly suggest—at least an attempt to commit—rape. When he has satisfied himself by this examination, the obducent may remove the clothing, which, where necessary, should be disinfected and preserved from destruction by moths or other injuries agencies. Thus, in a suit of clothes preserved to show the entrance and the exit of a bullet, it is disappointing at or just before the trial to find the material so badly moth-eaten as to be useless for demonstrative purposes. As one's memory is treacherous, spots to be remembered, such as those showing blood, should be marked with thread or ink and a careful note made as to their exact location.

The desire of the police to be on friendly terms with the reporters often renders the study of the surroundings impossible or misleading. In one of my cases, a brutal murder by violence, the scene had been visited by dozens of persons and the body removed to an undertaker's before the writer was summoned to perform the autopsy. The importance of ascertaining the nature of the substance upon which the body rested is shown by my finding at the postmortem in the rectum of a four-year-old boy "needles" from a Christmas-tree, and the later securing of a similar "needle" in the hat of the murderer and sodomist many blocks from the place where the crime was committed.

THE CORPUS DELICTI.—In many cases where homicide has been committed and the murderer has attempted to destroy the evidence of his guilt, or in destructive accidents, the *corpus delicti* has been proved by the finding of a part or member of the body or a portion of the clothing, as a piece of charred bone, a tooth, a ring, or a button.

---

<sup>1</sup> BRINTON, *International Clinics*, October, 1902.



On the other hand, instances are on record where deluded individuals made confessions of murder which were proved to have been unfounded by the subsequent appearance in life of the person said to have been killed. So important is this point that time and time again juries have failed to convict where the moral evidence was wellnigh conclusive. It is only upon irrefutable evidence that the fundamental principle concerning the corpus delicti is disregarded.

Where only a part of the body is available for examination, considerable difficulty is apt to arise as to the best method of procedure. The examiner will then need to possess a wide knowledge of comparative and pathological anatomy and to exercise great ingenuity in order satisfactorily to demonstrate the identity of the parts submitted. Should the only proof of the corpus delicti be a skeleton or a portion of one, the expert will be asked to determine the age, race, and sex of the person and the probable date at which death took place,—whether the bones are old or recent. Thus, in the case of Wakefield Gaines the trunk alone was found, the head and limbs having been severed from the body. With limitations, the age would be known by the condition of the epiphyses, whether or not united; by the cranial sutures, whether or not closed; and by the state of dentition. Race would be indicated by the different racial characteristics and peculiarities: thus, the negro by his splay-foot, projecting heel, and prognathous jaw; the Caucasian by his higher forehead, wider facial angle, and larger cranial capacity. Evidence of this character is not, however, absolutely conclusive. The determining of sex, after the age of puberty, presents less difficulty. In man the size of the cranium is greater and all the bony points are heavier and more prominent, the angle of the neck of the femur with the shaft is greater, and the lower jaw is heavier; in woman the ribs are lighter and more compressed, the patella is smaller, and the articular surface of the femur and tibia is narrower. The characteristic differences are, however, found in the broad female pelvis, the diameters of which are all greater with the exception of the vertical; the sacrum and coccyx are more curved and there is greater spread of the arches of the pubes.

The probable age of the bones would be indicated by their condition and appearance. The presence of the marrow and the periosteum is the most conclusive evidence of a recent state. The soft parts are usually destroyed within two years. Under ordinary conditions the body skeletonizes in about ten years, although this period is subject



to wide variations, depending upon the cause of death, the chemical properties of the soil in which the body was found, and whether or not preservatives were used.

MEDICOLEGAL POSTMORTEM.—The objects of a medicolegal post-mortem include the finding out of the cause and mode of death, the establishment of a *corpus delicti*, the determination as to whether a crime has been committed, and if so the discovery of a motive therefor and the exact nature of the process employed therein. In such legal investigations the pathologist should protect his reputation in every possible manner, and he should hesitate to make a postmortem without the presence of a witness, who should, if possible, be a professional brother. Never forget that the findings of the autopsy should be dictated to an amanuensis during its progress, verified at its completion, and the record signed.

In general the medicolegal post-mortem examination does not differ materially from the pathological, except that in the former greater precautions are necessary in order to avoid sources of error or confusion, and that the cranial contents are examined before opening the large blood-vessels, as signs of congestion disappear after the severance of the aorta and venæ cavæ. The importance of examining the vertebræ in all autopsies was illustrated recently by an article in the *Lancet*. Two cases were reported of fracture of the cervical vertebræ without external signs of violence, and in each case there was present a lesion of the heart which would have been assigned as the cause of death had not the real cause been demonstrated in the inspection of the vertebral column. In some cases after a most rigid and painstaking inspection no cause of death can be ascertained, but with care and systematic examination mistakes and inaccuracies will be reduced to a minimum.

In case of suspected poisoning the primæ viæ should be tied at each end and removed. Double ligatures should then be applied at the junction of the duodenum and the ileum and at the end of the small intestine, dividing the viscera into three portions. The contents of the stomach and those of the intestines should be emptied into separate jars. Many poisons are extremely volatile and without great care traces of them may be lost and justice defeated.

Each organ should be received in a separate receptacle, and each receptacle should be marked, sealed, dated, and deposited where tampering with it would be impossible.



The form of report used by the writer in medicolegal cases is as follows: "I made a post-mortem examination of the body of Walter Foster on April 10, 1898, at St. Agnes Hospital, Philadelphia. The body was identified by George Bell, 636 Siegel Street, and Michael A. Bruder, 1847 Sartain Street, both of Philadelphia. I find that death was caused by shock and hemorrhage from stab-wound of the heart."

While acting as coroner's physician I rarely volunteered more than this, but waited for the district attorney to ask questions in regard to the nature of the wound and as to other facts of interest. By this method the jury is not confused by an enormous amount of irrelevant testimony, though the expert must be prepared to give, under cross-examination by counsel for the defence, the minutest details as to how the postmortem was performed.

**AUTOPSIES ON INFANTS.**—The first question to determine in the examination of a babe is, was it born alive? If so, was it a full-term child or a premature birth? If born dead, how many months of uterine gestation caused it to reach its present development, and after attaining its maximum growth was it carried as a foreign body in the uterus?

**DETERMINATION OF THE VIABILITY OF A CHILD FROM THE POST-MORTEM APPEARANCES.**—The reader is advised carefully to read Paragraphs 23 and 24 of Virchow's regulations for the performance of medicolegal postmortems. To discover the ductus arteriosus remove the thymus gland, incise the right ventricle along its septum, and extend the incision into the pulmonary artery along the middle portion of its anterior wall. The orifice is situated between and beyond the two openings of the right and left pulmonary branches. If the duct is open, a sound will readily pass into the aorta.

If in the hydrostatic test the lungs float on top of the water, they have been completely aerated, a strong proof of breathing at or after birth; if they float beneath the surface, aeration is incomplete; and if they sink, no respiration has occurred. Decomposition of the lung tissue may cause it to float. A very valuable sign of the viability of the child is the presence of uric acid crystals in the kidneys.

Ante-natal rigor mortis may be met with, and does not prove, as has sometimes been asserted, that the infant was born alive in the legal acceptation of this phrase. Rigidity of the foetus may unduly prolong labor by interfering with delivery.<sup>1</sup>

---

<sup>1</sup> *Lancet*, February 14, 1903, p. 460.



The *Lancet* of April 26, 1902, raises the query whether the dead body does not possess properties akin to radio-activity, and alludes to the photographs taken by Vignon and exhibited by him, with the winding sheet preserved at Turin and traditionally said to be that of Christ, which seem to justify the belief that the human body is either radio-active or that it gives off vapors which exhibit a similar action to light upon sensitive surfaces. Peroxide of hydrogen may be the main factor concerned.

PERIOD OF INTRA-UTERINE GESTATION.—In deciding the age or period of development of the infant the external evidences of value are: (1) Length and weight of the child (for tables of dimensions and weights of the new-born see page 268). (2) Conditions of the skin and its appendages. In the healthy babe at full term the skin is white and covers the body smoothly; woolly hairs are present in perceptible numbers only on the shoulders; the hair of the head is from two to three centimetres long; the nails are hard and horny, extending beyond the ends of the fingers, but not of the toes. (3) Condition of the umbilical cord, which at term is fifty centimetres in length and is inserted somewhat below the middle of the abdomen, falling off by inflammatory demarcation on the fifth or sixth day. (4) State of the cartilages of the nose and ear, being hard in the mature infant. (5) Presence or absence of the membrana pupillaris, which disappears after the eighth month. (6) Condition of the genitals in both sexes; as descensus begins at the seventh month, the testicles of the full-term male should be in the scrotum; in the female the labia are generally found closed. (7) The measurement of the fontanel, of the cranium, and of the transverse diameter of the body at the shoulders and hips. (8) The size of the centre of ossification (Béclard's) in the lower epiphysis of the femur. To reach this the leg is flexed on the thigh, a transverse incision is made below the patella, which is removed, and the femur is then exposed. Thin, transverse sections of the cartilage are made until the greatest diameter of the centre of ossification, if present, is reached. The centre is absent before the thirty-seventh week, and in the child at full term has a diameter of from two to three lines, though it may even then be absent. If the diameter is more than three lines, the child has very likely lived for a certain length of time. (Reese.) The osteochondral line is also to be examined for syphilitic changes.

From the internal examination important evidence as to the age



of the child and especially as to respiration is secured. Upon exposing the abdominal cavity, which is to be done before opening the thorax or cranium, the position of the diaphragm in its relation to the ribs is immediately noted, as especially urged by Virchow. If the lungs do not contain air or are but partially distended, the diaphragm reaches to the fourth rib; when the lungs are fully distended, the diaphragm is at the fifth or sixth rib on the right, and at the sixth rib or intercostal space on the left.

To facilitate the examination of the umbilical vessels, Nauwerck recommends a division of the usual abdominal incision, shortly before reaching the navel, into two diverging incisions extending to the pubes. The abdomen is opened, and the umbilical vein, made prominent by traction on the triangular flap, is traced along its course, opened with small scissors, ligated, and divided. Turning down the flap over the pubes exposes for examination the umbilical arteries to either side of the remains of the urachus. (Fig. 140.)

CRIMINAL ABORTION.—Formerly abortion was not legally a crime if performed with the consent of the mother prior to the viability of the foetus. It was at one time not regarded as murder even to take the life of a child at any period of uterine gestation. The barbarousness and danger to society of this view were early recognized, both abroad and in this country, and various laws with different penalties attached thereto were enacted making it a criminal offence to practise abortion at any period of gestation, unless for the express purpose of saving life. (Witthaus and Becker.)

There is no other class of cases so trying to the patience, ingenuity, and skill of the pathologist as those of abortion, which is accomplished by numerous methods. Many respectable women expose themselves to cold, falls, and douches with the hope of relieving themselves of their offspring apparently by accident. Many pills and potions are sold to induce a resumption of the menstrual discharge, and one often finds them on sale in drug-stores of the first rank. These nostrums are sometimes composed of poisons that may cause the death of the mother. The use of instruments, especially the spiral douche advertised in so many papers, is a very common method of procedure. Indeed, the most successful criminal abortionists operate so that, unless through accident, no evidence of the operation is left. Usually all that can be found is evidence of a recent pregnancy.



When violence is done to the child, the nature of the injuries must be carefully noted. When violence is done to the uterus, some form of infection usually follows. Care must be taken in examination to exclude the possibility of previous disease of the uterus or adnexa as a cause of the infection or possibly as a cause of abortion. In former days, when curettage was more used than it is now in the treatment of abortion, an additional factor was added, making it difficult and often impossible to distinguish dilatations of the os due to the instrument producing the abortion and to the passage of the foetus from those induced by the introduction of the curette and the subsequent packing with iodoform gauze. Care should be taken to compare the vital history of the foetus with the physical condition of the mother, the history of sexual life of the parents, specific disease, etc.

**SIGNS OF DEATH.**—Space permits only brief mention of the signs of death; the reader interested in this subject is referred to Brouardel's work on death and sudden death.

The positive signs of death in an unmutilated body are decomposition, complete loss of temperature, and cadaveric lividity and rigidity. The negative signs are: (1) Cessation of respiration, determined by holding before the nostrils a down feather, a small flame, or a cooled mirror, or by placing a glass containing water on the epigastrium. (2) Cessation of circulation, ascertained by observation, palpation, section of a small artery, transmitted light through web of fingers, loss of vasomotor constrictors, acupuncture of the apex of the heart, emptiness of the arteries, etc. (3) Cessation of nervous and muscular irritability, determined by application of light to eye, or of cold, heat, force, electricity, irritants, etc., to skin. (4) Cessation of tissue vitality, abolition of reflexes, etc.

Respirations usually cease by a moment before the heart-beats stop, but sooner in the new-born than in others. In the last agony or shortly after death the pupils dilate, but within an hour contraction sets in, which lasts from three to four days, the contractions of the pupils often being unequal. Spermatzoic movements may be found in those dying suddenly more than twenty-four hours after death in suitable cases. Lowering of temperature occurs first on the surface, requiring, according to good authority, twenty-three hours to become complete.

**PREMATURE BURIALS.**—That premature interment has occurred is undoubted. In Munich the popular belief in such instances is so great that the body is placed in a specially prepared room, with a



bell in the hand of the corpse ready for use in case of an emergency! Such notions usually originate from careless handling of the coffin, from the expulsion of a foetus by the formation of gases in the body of a pregnant woman, from real or apparent growth of hair, from conversion of bodies into adipocere, etc.

USUAL CAUSES OF DEATH.—In Chapter XXIX. will be found a list of all the recognized causes of death, and it is recommended that this classification be used by every one in order that uniformity of nomenclature may be secured throughout the world. Sudden death is usually due to failure of the circulatory apparatus, to cessation of respiration, to disturbance of the nervous system, to deficient nutrition, to poisons either produced within the body or introduced from without, or to violence by physical or chemical forces, heat or cold, electricity, wounds, missiles, etc.

Many conditions that have existed a long time may cause sudden death by breaking the balance of life. Thus, in chronic nephritis uræmia may develop suddenly and cause death after only a very slight illness. Again, an aneurism may rupture without sudden increase in the symptoms or any violence, simply by a natural slow progress of the lesion. All mortal diseases and many that by themselves do not end fatally may contribute to the causing of sudden death as well as to the slower dissolution.

No disease causing severe disturbance of heart, kidney, lung, nerve, or digestion can be ignored in estimating the factors that brought about the death of the patient. Certain maladies of common occurrence should be in our minds in making examinations, though never so prominently as to prevent a proper search for other conditions. Thus, in children think of pneumonia, enteritis, bronchitis, meningitis, congenital syphilis and other hereditary diseases, infectious fevers, malformations, etc.; in young adults, infections, local and general, violence, typhoid fever, and tuberculosis; in middle life, diseases of the lungs, kidneys, heart, and blood-vessels, hepatic and gastro-intestinal conditions, infections, violence, occupation neuroses, pneumonia, tuberculosis, cancer, etc.; in old age, nephritis, carcinoma, sarcoma, aneurism, cerebral hemorrhage, embolus, thrombosis, tumor or abscess, arteriosclerosis and obstruction of the coronary arteries, heart lesions, etc.

In coroner's cases death very commonly results from heart exhaustion, due, as the case may be, to intrinsic disease, to excitement,



or to poisons. Care should be taken to determine the cause of this exhaustion, whether it was due wholly to heart disease, such as a valvular lesion, or to one of the exciting causes. In kidney congestions consider whether death was due to failing heart causing passive congestion, to poisons, or to inflammatory congestion, such as would be part of an acute nephritis. Ascertain if the œdema of the lungs is dependent upon cardiac, renal, or cephalic lesions or primarily upon a lung condition principally.

DECOMPOSITION.—The bodies of infants decompose more quickly than those of adults. The process begins earlier in plethoric and fat adult bodies than in thin aged persons. It is more rapid after muscular activity and in those dead of acute diseases, fevers, heat-stroke, sepsis, suffocation by gases, etc., while it is longer delayed in cases where the system is exhausted and muscular irritability retarded, and in the bodies of those fatally poisoned by hydrocyanic acid, carbonic acid, sulphuric acid, etc. Arsenic may or may not prevent decomposition. At the same temperature a body which has been for one week in the air, one which has been two weeks in water, and one which has been eight weeks buried will show similar degrees of decomposition. (Brown-Séguard.)

Hofmann recommends in cases where decomposition is much advanced the removal of the brain in the ordinary manner, the making of some openings in the skin, the washing of the entire body in running water for twelve hours, and the further bathing of the corpse in a concentrated alcoholic sublimate solution or chlorid of zinc for an equal period. The green coloration due to decomposition disappears to a marked degree under this treatment.

The length of time which has elapsed since death has to be determined by the circumstances peculiar to each case. So many considerations may apply that in many instances it is dangerous to be too dogmatic.

VIOLENT DEATH.—When there is doubt as to homicide, all the precautions necessary for such cases must be strictly observed. The sort of violence, its mode of application, and something of an estimate as to the amount, direction, and conditions of application of force can usually be made from post-mortem examination. In the inspection of wounds the condition of the tissues and the position and direction of all lesions discovered are to be very carefully noted, as sometimes the instrument with which they were inflicted may safely be



inferred therefrom, and at times the findings will point to the circumstances under which the injuries were received. A minute description of the injuries is absolutely necessary, so that if called upon in court an exact account of them can be given. The amount of contusion, laceration, extravasation of fluids, and damage to any vessels must be carefully noted. In gunshot wounds the projectile should be found: this is imperative. About the wound of entrance look for powder marks, singeing, and smudge. If the projectile struck a bone, a splinter may have been detached and caused injuries not along the line of the main wound. Death is frequently due to shock, which may result from a blow that leaves no mark visible at the post-mortem. This is quite uncommon. Injuries to the head make it necessary to estimate the structural and tensile strength of the skull in each case. When a fracture of the skull is found or suspected, the skullcap must be cut away with the saw only, not using the chisel. Contrecoup must always be considered in hunting for fractures and lacerations of blood-vessels.

**BURNS AND SCALDS.**—Burns are produced by dry heat and show when fresh no maceration of the tissues. When inflicted by intense heat or by flame, there will be found scorching or singeing of clothing and hair, and possibly of flesh. When resulting from contact with a hot surface, note especially the shape of the burn, and, if the supposed hot object is to be obtained, a corresponding mark may be found upon it. In burning the hair often reddens.

Scalds are produced by vapor, steam, or a liquid, and usually show some trace of the action of the fluid on the mucous membrane or skin. In plain scalds singeing is absent, but where fire has followed an explosion both scalds and burns may be found. In such cases the mucous membrane of the air-passages should always be examined.

In cases of scalds and burns the extent of the injuries must be determined both in breadth and in depth, with a careful observation of secondary changes, such as sepsis, internal congestions, and inflammations. There is probably produced by these means a product poisonous to the organism, which acts as in other forms of auto-intoxication.

**DEATH BY ELECTRICITY.**—There are no absolute and constant indications. In some cases the point of entrance or of exit can easily be made out by the change in tissues or in clothes. Frequently there



is marked burning of the skin. In many instances the only evidence is an unnatural rigidity of the muscles, sometimes with distortion, due to a coagulation of the muscle substance by the current, which, if found in one part and not in another of the same body, may be of significance. There may be evidence of electrolytic action in the blood and organs, as in the brain and cord. There may be livid areas, even hemorrhages, though after sudden death they are not usual.

The face is sometimes distorted. The heart is usually flaccid, although the left side may be hard or tense. On the right side dark fluid blood is often found distending both auricle and ventricle. The same condition exists in the left auricle, but the ventricle is almost empty. The pupils are invariably widely dilated immediately after death. The blood is usually fluid, but clots have been found in the heart and large veins.

Jellinek<sup>1</sup> finds that the anatomical changes in the tissues resulting from the passage of a powerful electric current diminish the resistance of future currents. Mice are killed with a weak current, but pigs show the greatest resistance. Death by electricity occurs more quickly after administration of morphine or cocaine, but is retarded by chloroform anæsthesia. A dose of morphine might therefore be administered with benefit before an electrocution. Microscopically, degenerations are found in the gray matter of the spinal cord along with dilatation of the central canal and hemorrhages.

DEATH FROM HEAT OR COLD.—After fatal heat-stroke the body is often very hot for hours and decomposition may be uncommonly rapid. There may be general internal congestion. It is usually necessary to know somewhat of the history of the case before a verdict can be rendered of heat-exhaustion, sunstroke, or thermic fever. In cases of death from cold we often find pallor or dislocation of the skin and a congestion of the viscera with blood of rather bright color. No single characteristic lesion results from exposure to moderate excess of either heat or cold. When no pathological lesions can be found, death is probably due to shock. Any chronic disease of viscera tends to reduce the power to resist severe temperature changes. There is no significance in the freezing of the body beyond showing that considerable time may have elapsed since death. The

---

<sup>1</sup> *Wiener klin. Wchnschr.*, Nos. 16 and 17, 1902.



frozen flesh of the mastodon sometimes found in the Siberian plains is good eating, though it must be thousands of years old.

There are no characteristic changes in sunstroke. Rigor mortis comes on early. Lividity and putrefactive changes develop rapidly after and even before death. Venous engorgement is extreme, particularly in the cerebrum. The left ventricle of the heart is contracted; the right is dilated and may be full of blood imperfectly coagulated and deficient in oxygen. The blood is fluid, dark in color, acid in reaction, and probably contains, as in burns, a poisonous substance which acts on the more highly specialized cells of the body. Petechial patches may appear in the subcutaneous and subserous tissues. The elevation of temperature is often remarkable, and it is extremely disagreeable to make an autopsy in these cases, as I have done, soon after death, with a temperature of  $106^{\circ}$  F. In a case of mine of stramonium poisoning, with a temperature of nearly  $110^{\circ}$  F., the clinician had diagnosed sunstroke.

INFANTICIDE.—Many methods have been resorted to, as exposure to cold, smothering in various ways, strangulation either by the hands or by a ligature around the neck, and wounding with various instruments, sometimes accompanied by efforts to conceal the act. The child may be intentionally drowned in a vessel containing fluids discharged from the vagina at the time of birth. Gross violence or poisons may be employed.

DEATH BY STARVATION.—There is usually extreme emaciation, which is shown especially by a sinking of the eyes and an unfilled condition of the skin. It is sometimes necessary to determine whether starvation resulted from disease or neglect, especially in cases of those children which have been reared in foundling homes and hospitals.

SUFFOCATION; STRANGULATION; HANGING; DROWNING.—All these produce death by asphyxia, or carbon-dioxid poisoning, combined with oxygen starvation, the signs of which are more or less marked. In death from asphyxia there are usually hemorrhages into the thymus gland, as well as Tardieu ecchymoses in the pleura and pericardium.

Plain suffocation may show no marks of violence. The dark fluid blood, possibly hemorrhages from increased blood pressure, general congestion of the lungs, frequently congestion of viscera, often blue nails and lips, occasionally suffusion of the face with dark venous blood, and an absence of other pathologic conditions, give a general



type of finding that is not easily mistaken when clearly marked but is difficult to recognize when not conspicuous.

Strangulation adds the factor of mechanical arrest of respiration, and may result from the presence of food, some foreign substance, or a growth or swelling in the throat. When due to throttling the marks about the neck are of great importance. There may be compression of veins.

Hanging may cause death by injury to the spinal cord as well as by compression of the blood-vessels and air-passages. The parchment-like appearance of the skin on the sides of the neck and the rupture of the intima of the carotids afford valuable evidence.

Wachholz<sup>1</sup> has shown experimentally that in acute suffocation there may be found, along with the soft currant-jelly clots in the heart, solid white clots embedded in the meshes of the cardiac muscle. La Casagne and Martin have described a method, called *docimasie hépatique*, of diagnosing sudden death by a marked increase in the sugar contents of the liver of persons who have died suddenly. Wachholz finds from his experiments that no such relation exists.

Reuter, working with Kolisko,<sup>2</sup> from a study of twenty-two cases of throttling and two hundred cases of hanging, thinks that these two very similar modes of death may be differentiated from each other. In throttling there is (1) cyanosis of the face, with ecchymoses of the eyelids and conjunctiva. (2) The scalp, the coverings of the brain, and its membranes are always rich in blood. (3) As a rule, hemorrhages in the soft tissues of the neck, especially in the muscles, occur. (4) There is marked injection of the upper air-passages, combined with numerous small hemorrhages. (5) Injuries to the larynx and hyoid are rare. (6) Rupture of the intima of the carotid is never noted; in only three cases were there suffusions into the adventitia. In hanging (1) cyanosis of the face is usually not noted; ecchymoses are seen in twenty per cent. of typical and in thirty per cent. of atypical strangulations. (2) The amount of blood contained in the organs in the skull varies, but usually consists only of that which was present in these parts at the time the circulation was interrupted. (3) Hemorrhages in the muscles are rare,—two per cent. in typical and fourteen per cent. in atypical cases. (4) Injuries to the laryngeal and hyoid structures are com-

---

<sup>1</sup> *Vrtljschr. f. gerichtl. Med.*, 1902, p. 34.

<sup>2</sup> *Zeitschr. f. Heilk.*, 1902, vol. xxii.



mon,—sixty per cent. in typical and thirty per cent. in atypical cases. (5) Rupture of the intima of the carotids occurs in five per cent. of typical and four per cent. of atypical hangings. The external markings on the neck are also often different.

In a case of drowning water or foreign substances may be found in the openings of the body, in the respiratory organs, or in the stomach, or death may be due to spasmodic arrest of respiration. The froth from the air-passages is coarser than that seen in cases of œdema. Very soon after death we often find watery fluid in the pleura. The spongy condition of the lungs is found only where there has been inhalation of water, which does not always happen. After decomposition has set in, the evidence of drowning gradually disappears until it is impossible to make the diagnosis.

**BLOOD-STAINS.**—When any suspicion of violence occurs, look carefully for blood-stains. If possible, determine whether any stains found are blood. If in doubt, treat them as if they were, unless some special reason exists for not doing so. Such stains should be most critically examined in the privacy of the laboratory. Try to ascertain: (1) Their connection with the person examined. (2) Their source. (3) Their extent, using great care in determining the nature of the substance stained and whether there has been flowing or running, to be judged partly by shape and direction of the stains. (4) Conditions,—whether fluid or clotted, wet or dry, cracked or caked, etc. (5) How made,—whether by smear, by splash, by flow, by soaking up as in cloths, etc. (6) Connect, if possible, the amount, shape, and condition of the stains with their probable source and note any peculiarities. When practicable, preserve parts or all of stains. It is often well to saw off an entire step or remove a panel, in order to produce the same as evidence in court. In the present state of our knowledge it is not safe to state from what part of the body the blood came and the age of the stain, though the more recent, the more soluble.

Two illustrations from my case-book will show the importance of this line of research. A man committed rape on a child, and blood was seen on the fly of his trousers by his room-mate. In order to divert suspicion from himself, he accused his room-mate of the crime. The trousers of both men were sent to me for examination. In the pair of pants belonging to the perpetrator of the crime the lining of the fly had been cut away and neatly sewed, but there remained a



few telltale threads containing blood, which was found to possess the characteristics of human blood. On the trousers of the other man was found a red substance, which examination showed to be lumberman's red chalk, the crime having been perpetrated in the backwoods. In the second case blood splashes on a white curtain were stated by a murderer to be red paint which one of his children had put there with a paint-brush.

The presence or absence of blood is determined by the (1) physical examination; (2) chemical tests; (3) spectroscopical examination; (4) microscopical examination; and (5) the hæmolytic serum test. One of the most recent and valuable books on this and kindred medicolegal subjects is that of Glaister.<sup>1</sup>

I am unaware as yet of any murder trial in which the new agglutinative reaction for the diagnosis of human blood has been applied. It will certainly be a feature of all such trials in the future, as when used in conjunction with the other tests it would seem to afford positive proof of the presence of human blood. Uhlenhuth<sup>2</sup> was put to a severe test by the German Department of Justice. Various objects stained with the blood of man and of different animals were sent to him, the nature of the blood being known to the Department of Justice, but not to him. When the blood was furnished in sufficient quantities, his results in each case were positive. One method of applying the test is as follows:

Ten cubic centimetres of defibrinated human blood are injected into the peritoneal cavity of a rabbit at intervals of six days, and after five such injections an effective serum should be obtained. The blood to be tested is then diluted with water, one to one hundred, and filtered. Of this clear, slightly red solution, two cubic centimetres are placed in a small tube and mixed with an equal quantity of 1.6 per cent. salt solution; six to eight drops of the serum of the rabbit are then added to each tube about to be tested, but all will remain perfectly clear except the tube containing human blood. The reaction is extremely delicate and can be obtained with very slight traces of even old dried blood. Deutsch,<sup>3</sup> Wassermann and Schultze,<sup>4</sup> and Dieudonne<sup>5</sup> describe prac-

<sup>1</sup> *A Text-book of Medical Jurisprudence, Toxicology and Public Health*, 1902.

<sup>2</sup> *Deutsche med. Wchnschr.*, September 11 and 18, 1902.

<sup>3</sup> *Orvosik Lapja*, 1901, No. 11.

<sup>4</sup> *Berl. klin. Wchnschr.*, 1901, vol. xxxviii., No. 7.

<sup>5</sup> *München. med. Wchnschr.*, 1901, No. 14.



tically the same method as Uhlenhuth and have obtained the same results. The first of these claims to have been the first to use this method of differentiating human blood, while the last found that the same result could be obtained with human urine and human pleural exudate, although to a less degree.

Corin<sup>1</sup> believes that the active principle of the serum in the biological differential diagnosis of the blood is paraglobulin, for not only may blood-serum be used for this purpose, but also transudates containing globulin. The paraglobulin in an ascitic fluid was precipitated by magnesium sulphate, dried, and injected into animals in an aqueous solution. In like manner the paraglobulin can be precipitated from the blood of the animal experimented upon and preserved in pulverized form. This powder when wanted for use is dissolved in water and employed in testing the blood under examination. Biondi<sup>2</sup> finds that the reaction occurs with the semen, so that human and animal spermatic fluid can be differentiated. The reaction was also secured from many of the normal and abnormal secretions and excretions of the body.

Butza<sup>3</sup> prepares the animal by injecting from ten to twenty cubic centimetres of a centrifugated human pleural exudate intraperitoneally into a rabbit for five or six successive days.

The Bremer-Williamson reaction of diabetic blood may be obtained a considerable time after death;<sup>4</sup> the procedure is as follows: Forty cubic millimetres of water are placed in a small, narrow test-tube; to this are added twenty cubic millimetres of blood, one cubic millimetre of a one to six thousand aqueous solution of methylene blue, and forty cubic millimetres of liquor potassæ. The test-tube is placed in boiling water for four minutes, at the end of which time, if the blood is diabetic, the blue color will have disappeared and a dirty-green color will have taken its place. Williamson obtained the reaction in forty-three cases of diabetes tested and thinks it is due to an increase of glucose in the blood. The reaction is of especial value in coma where urine cannot be obtained.

CRYOSCOPY.—The determination of the osmotic pressure of liquids at their freezing-points is being studied extensively. The lowering of

<sup>1</sup> *Vrtljschr. f. gerichtl. Med.*, 1902, p. 61.

<sup>2</sup> *Ibid.*, *Suppl.-Heft*, 1902, p. 1.

<sup>3</sup> *Spitalul.*, 1902, xxiii. p. 377.

<sup>4</sup> T. R. BROWN, *International Clinics*, January, 1903.



the freezing-point is directly proportionable to the osmotic pressure of the liquid. Cryoscopy is a method introduced by Raoult, of Grenoble, for the purpose of measuring the urinary toxicity as well as furnishing enlightenment upon the metabolic changes in the blood, cerebrospinal fluid, and other fluids of the body. It has been found that the freezing-points of these fluids of the body present certain appreciable differences in certain diseases. The method has a wide field of usefulness both in experimental research and in diagnosis and prognosis of disease. Those interested in the clinical applications of cryoscopy and their possible application to pathology are referred to Widal and Lesné's admirable paper in Vol. vi. of Cornil's *Traité de pathologie générale*, p. 661. Space permits but a single example of the possible use of this method. Revenstorf<sup>1</sup> determines the freezing-point of the blood from both sides of the heart, as more or less of the fluid in which an animal is drowned usually passes through the capillaries of the lungs and dilutes the venous blood. He concludes that the method, when positive,—i.e., when it can be shown that the freezing-point of the blood from the right side of the heart is higher than that of the blood from the left side,—is valuable as additional evidence of drowning, and is very easily carried out; but decomposition rapidly removes any difference which may have existed, and the blood is not necessarily diluted during death by drowning.

CYTOLOGY.—The different kinds of cells found under various conditions in the serous cavities form a most inviting field of study. Thus, in syphilitic hydrocele we have endothelium, in gonorrhœal hydrocele, marked polymorphonuclear leukocytosis, in tuberculous hydrocele, lymphocytosis, in mechanical hydrocele, few or no leukocytes. Naturally, the age of the process has much to do with the number and variety of the cells.

TOXICOLOGY.<sup>2</sup>—The presence of poisons in the animal economy may be recognized by clinical, chemical, pharmacological, and pathological methods. While we have chiefly to do with the latter method, the success of the chemist and the pharmacologist depends largely upon the procedures adopted for the preservation of material by the pathologist at the time of the performance of the autopsy. There are certain poisons which may kill without leaving in the tissues any

<sup>1</sup> *München. med. Wchnschr.*, No. 45, 1902, p. 1880.

<sup>2</sup> Much of the material in this section is taken from ROBERT'S *Lehrbuch der Intoxikationen*, Stuttgart, 1902, and GLAISTER'S *Medical Jurisprudence*, 1903.



specific alterations to be found *post mortem*, especially when the examination is postponed for several days.

A poison is any substance which, when taken into the system and either being absorbed or by its direct chemical action upon the parts with which in contact, or when applied externally and entering the circulation, is capable of producing deleterious results. (Wormley.) Poisoning commonly results from alcohol, morphine, lead, arsenic, phosphorus, oxalic acid, carbolic acid, etc.; from food (bromatotoxismus); from meat (kreotoxismus); from milk products (galactotoxismus); from fish and shell-fish (ichthyotoxismus, mytilotoxismus); and from grain (sitotoxismus); of the latter poisoning there are three kinds,—ergotism, lathyrism, and pellagra.

It should always be remembered that conditions which we are apt to regard as being alone produced by strictly pathological processes are often due to poisons. Thus, toxic inanition may be produced by chronic poisoning with mercury, lead, arsenic, etc.; fatty degeneration, by phosphorus, alcohol, *Amanita phalloides*, etc.; calcification of the renal epithelium, by corrosive sublimate; and amyloid degeneration, by repeated injections of turpentine.

Suspicious undissolved foreign bodies may be found in the vomit and in the contents of the alimentary tract, as arsenic (white, metallic, and various salts), antimony, sulphide of antimony, mercury and its preparations, as calomel, oxid, and bichlorid, chrome salts, oxalates, cantharides, nux vomica beans, heads of matches, and parts of poisonous plants. In one of my cases diagnosed as a heat-stroke, with a temperature of over 110° F., the finding of leaves of datura stramonium in the stomach led to the correct diagnosis. Morphine even when given hypodermically may be found in the stomach contents. Certain chemicals may be detected by odors coming from the body or from the various cavities when opened, as alcohol, ether, chloroform, aromatic oils, formalin, phosphorus, turpentine, nitrobenzol, benzene, wood alcohol, hydrocyanic acid, paraldehyde, camphor, chloral, carbolic acid, nicotine, bromin, chlorin, iodine, ammonia, hydrochloric acid, oxalic acid, opium, sulphuretted hydrogen, etc.

When the acidity or alkalinity of the gastric contents is abnormally increased, certain reagents are to be suspected, such as acids, alkalies, and potassium cyanid. The liver especially shows poisoning by phosphorus, antimony, arsenic, and toxins, while the kidney is affected by hæmolytic and methæmoglobinic poisons, by oxalic acid.



oxamid, mercury, silver salts, preparations of cantharides, etc. The spectroscopic picture of the blood should always be obtained as soon after death or removal from the body as possible. The addition of a little distilled water is admissible in methæmoglobinæmia, but even here it is better at once to seal hermetically in glass tubes with exclusion of air as far as practicable. If the blood coming from veins is fluid and scarlet, suspect carbon monoxid poisoning; if a laky purple fluid, not changing on the exposure to oxygen, suspect cyanid. If the muscles of the abdominal walls are drawn and contracted spirally, we may suspect any of the instant poisons, as strychnine or potassium cyanid. I have for a long time had a bottle of blood from a case of cyanid poisoning, and have many times exposed it to the air by removing the cork, yet it is apparently still in a perfect state of preservation.

The left heart is found markedly contracted in death from overdoses of members of the digitalis group, veratrine, and barium salts. As already stated, the odor of the poison may sometimes be detected on exposing the brain. In one of my cases of ammonia poisoning a rod dipped in hydrochloric acid gave off fumes when introduced into the cranial cavity after removal of the brain. Much attention has been paid to the actions of poisons on the central nervous system, and the rapid diagnosis of hydrophobia by this method should not be forgotten. The joints are alleged to be inflamed after poisoning by colchicum. Testicular atrophy is said to be induced by the long-continued use of capsicum, solanus pseudocapsicum, and conium maculatum.

The mucous membrane of the stomach is irritated and stained by many poisons, as sulphuric acid (black), nitric acid (yellow), oxalic acid (white), bromin (red), iodin (purple), and by a large number of metallic salts, as sulphid of arsenic (yellow), chromate of potassium (red), etc. I have, however, seen several cases of arsenical poisoning with but little inflammation of the gastric mucosa.

Among the questions to be answered in every case of suspected poisoning are: Was death caused by a poison originating within or without the body? What poison caused death? Is the substance found by the chemist the poison which killed the person in whose body it was found? Might not the poison have been administered as a medicine? Is the poison present in such quantity as always causes death? Were there attendant circumstances which conduced to the



fatal result? Was more than one poison given? How and when was the toxic substance administered? Could poison have been given and yet not be discovered? Was the fatal dose taken for purposes of suicide? Was it administered with the object of killing? Was it administered accidentally? Did the person for whom it was intended receive the poison? Could the toxic symptoms be simulated? Was cremation practised in order to destroy evidences of poisoning? Was there any motive for homicide? Are there any accomplices? What became of the vehicle in which the poison was administered? Was there any poison found? Was any poison destroyed?

Nearly every toxicologist has his own classification of poisons. Thus, one divides them into mineral, vegetable, animal, and mechanical groups, another into irritants, narcotics, and narcotic irritants, a third into chemical and vital poisons, etc. All such divisions are arbitrary, as quickly becomes evident on attempting to place the various poisons in their proper subclasses.

#### SCHEME FOR THE DIVISION OF POISONS.

INORGANIC	{ Irrespirable gases : carbon monoxid, coal gas, chlorin, bromin, hydrofluoric acid, sulphur dioxid, etc.	
	{ Chemical : sodium hydrate, sulphuric acid, etc.	
	{ Irritant : arsenic, antimony, mercury, phosphorus, etc.	
ORGANIC	{ Irrespirable gases : chloroform, ether, formalin, etc.	
	{ Chemical : carbolic acid, acetic acid, pyrogallallic acid, etc.	
	Irritant	{ Vegetable : gamboge, colchicum, squill, etc.
		{ Animal : cantharides, etc.
	Alkaloidal	{ Narcotic : opium, hyoscyamus, belladonna, cannabis indica, etc.
		{ Sedative : digitalis, hydrocyanic acid, aconite, conium, etc.
		{ Excitomotor : strychnine, ergot, etc.
	Synthetical	{ Antiseptics : creolin, lysol, etc.
		{ Antipyretics : antipyrin, acetanilid, etc.
		{ Hypnotics : sulphonal, trional.
	Toxic	{ Bacterial : toxins, hæmolysins, cytolytins.
		{ Animal : snakes, scorpions, ptomaines, etc.
		{ Vegetable : ricine, abrine, etc.

ACIDS. — Poisoning may be produced by mineral and vegetable acids, the corrosive action depending largely upon the strength of the acid at the time of its introduction into the body. Naturally, those parts are most affected which remain longest in contact with the acid.



The mucous membrane of the lips rarely escapes, and often the skin of the lower lip is discolored. The mucous membranes of the mouth, œsophagus, and stomach are acted upon, and œdema of the glottis is common. The tissues are softened; sometimes there is actual destruction followed by necrosis, which may lead to perforation. Around these areas of corrosion is a more or less marked hemorrhagic inflammation. If the acid were diluted, this inflammation is more marked and the corrosion less so. The blood in the external veins of the stomach is usually black. In all cases where death does not occur quickly, changes are seen in the parenchymatous organs, especially the kidneys. The color produced by different acids is somewhat characteristic. In carbolic acid poisoning the œsophagus is of a silver-gray color, the stomach is thrown into rugæ, and the mucosa is of a rough, brownish, cracked appearance. The urine may be dark in color and smell strongly of phenol. In poisoning by sulphuric acid the mucous membrane of the upper intestinal tract is brownish or even black, due to the extraction of water from the tissues and the action of this acid on the coloring matter of the blood. It is often difficult or impossible to say whether perforation occurred during life or after death. The effects of hydrochloric acid are similar to those of sulphuric acid, but less marked, corrosive action on the skin being almost absent. Nitric acid imparts to the skin and mucosa a yellowish tinge, owing to the formation of picric acid. In oxalic acid and oxalate of potassium poisoning white to grayish corrosion of the upper intestinal tract occurs, crystals of oxalates of lime being found in the blood and kidneys. Concentrated acetic acid may also cause death.

**ACONITE.**—In aconite poisoning the physiological test should always be applied. No characteristic lesions are found *post mortem*.

**ALCOHOLISM.**—There are no really characteristic lesions. I. *Gastro-intestinal Tract.*—(1) Chronic hypertrophic gastritis may be followed by (2) atrophic gastritis with dilatation. (3) Hypertrophic or atrophic cirrhosis of the liver. Orth says, "Most drinkers have no cirrhosis of the liver, but a fat liver, and many with liver cirrhosis are not drinkers of alcohol." II. *Vascular System.*—(1) The heart is usually enlarged and its muscle often thin, fatty, and friable. (2) The blood-vessels are frequently sclerosed, especially those arteries exposed to much strain. (3) The venules of the cheek and nose are often distended. III. *Central and Peripheral Nervous System.*—(1) The pia-rachnoid is thickened, with wasting of its convolutions. (2) The blood-



vessels are thickened, tortuous, and may show miliary aneurisms. (3) The motor nerves of the muscles are sometimes altered (multiple neuritis). IV. *Genito-urinary Tract*.—(1) The kidneys are enlarged, cyanotic, and indurated. (2) The bladder is thickened and often shows signs of chronic cystitis.

ALKALIES AND CAUSTIC SALTS.—Alkalies, potash, soda, and ammonium hydrate act much the same as acids except that the involved areas are brown and less brittle. The epithelium is shed in threads and there are ecchymotic folds of the mucosa. Capillary bronchitis is common; so is stricture of the œsophagus in patients who recover. In one of my cases cancer followed at the seat of stricture due to the accidental drinking of lye.

ANTIMONY.—Poisoning is usually due to tartar emetic. The mucous membrane from the mouth to the duodenum inclusive is usually inflamed, and often ulcerated and covered with stringy mucus. In chronic cases there is considerable emaciation; chemical tests will determine its true character.

ARSENICAL POISONING.—This may be: (a) Acute. (b) Subacute. (c) Chronic. In acute arsenical poisoning there is generally a marked gastro-enteritis, which differs in severity according to the amount taken. The mucous membranes are intensely swollen, œdematous, and present small emphysematous bullæ or diphtheritic exudate. Petechial eruptions may occur in both the stomach and intestines. The contents of the stomach are usually of a brownish color. In subacute arsenical poisoning or where large doses have been taken, patches varying in size from a dime to a silver dollar, consisting of an opaque white, yellowish, or even violet coagulated lymph mixed with arsenous acid and firmly fixed to the mucous membrane, with signs of intense inflammation around them, may be found in the bowels. White spots of arsenic are sometimes discovered between the rugæ, and fatty degeneration of the intestinal epithelium and of the viscera is also present. Chronic arsenical poisoning is characterized by wide-spread fatty degeneration, affecting especially the heart, liver, spleen, and kidneys. Marked changes are also found in the voluntary muscles, which show wasting, fatty degeneration, and often cirrhosis. Trophic changes are common, such as overgrowth of hair and nails, both of which are harsh and brittle. The skin is harsh, dry, and frequently shows eruptions. Although arsenic is rapidly eliminated from the body, enough usually remains for purposes of identification. The urine should always be saved. The white



material should be examined microscopically for the octahedral crystals, and in England for soot and indigo, as the law there requires the retailing pharmacist to mix his arsenic previous to selling with one or the other of these substances. There are no characteristic lesions *post mortem*. It is a disputed question as to whether bodies keep a longer time after death in arsenical cases. The manifold ways in which arsenic may accidentally get into the system and thus cause death should always be remembered. From wall-paper it enters the system as diethylarsin. In England there were recently thousands of cases of arsenical poisoning, with many deaths, due to the drinking of beer made from glucose containing arsenic. Gautier, a celebrated French chemist, claims, contrary to general belief, that arsenic is a normal weighable constituent of the thyroid gland. Rough-on-rats and Paris green are favorite preparations for use by would-be suicides.

**ATROPINE.**—Fatal cases of atropine poisoning, either suicidal or homicidal, are rare, though accidental poisoning by the *Datura stramonium* is common. Death is caused by asphyxiation, the symptoms resembling those seen in heat-exhaustion. Careful search should be made in the stomach for any seeds, leaves, or berries.

**CHLORAL HYDRATE.**—Urine should always be preserved for chemical examination. Chloral is often taken with other drugs, as morphine, and after a debauch; this renders it difficult or even impossible to tell just what the effect of the chloral on the system actually is.

**CHLOROFORM AND ETHER POISONING.**—The saying of Tait, that the coroner has to do with chloroform death while the physician signs the death certificate in ether cases, is well known. Fright may have something to do with death in these cases. Signs of asphyxia are usually present and the characteristic odor is capable of determination. But then the ether may have been given, yet death be due to other causes.

**COCAINE POISONING.**—At postmortem the heart is found in diastole and the nerve-centres are said to be congested. Cocaine should be tested for before making the diagnosis.

**COPPER.**—The lining walls of the stomach often have a bluish or greenish tinge. On the application of ammonia the coloration deepens into a darker shade of blue, or the green is converted into this color. Part of the toxic effect of the arsenite of copper is due to the copper. Zinc, tin, and barium salts may also cause death in an overdose.

**ERGOT POISONING.**—After death from ergot poisoning the arteries are found contracted and the abdominal viscera inflamed. In the



chronic form the posterior columns of the cord are sclerosed and microscopical sections resemble those characteristic of locomotor ataxia.

FORMALDEHYD.—Bock<sup>1</sup> reports a case of poisoning by formalin in an imbecile twenty-six years of age. From one to three ounces of a four per cent. solution were taken. Death occurred thirty-two hours later. The stomach was necrotic, dark, tough, and cut like leather. Klüber<sup>2</sup> and Zorn<sup>3</sup> have also reported cases of poisoning by formalin.

HYDROCYANIC ACID AND CYANID OF POTASSIUM POISONING.—The mucous membrane of the stomach is markedly and uniformly injected and congested. The odor of bitter almonds is detected at once on opening the abdomen. It should always be remembered that, if the post-mortem is not made for thirty-six hours after death, all the hydrocyanic acid may be converted into formic acid. The blood is dark and fluid and keeps for a long time without undergoing decomposition.

ILLUMINATING GAS AND CARBON MONOXID POISONING.—These two poisons are not quite alike in their action, though the poisonous properties of illuminating gas are largely due to the considerable amount of carbon monoxid which it contains, especially if of the variety known as "water gas." The body may appear quite life-like, with even a rosy hue upon the cheeks. After death the blood retains its bright cherry-color for some time, seen especially in the brain, and when shaken forms a froth of a violet color. All color reactions should be studied at once, before giving time for the oxygen of the air to act upon the blood. The skin and internal organs, as also the patches of post-mortem congestion, are bright red. The lungs are frequently congested. Carbon-monoxid hæmoglobin produces two absorption bands near *D* and *E* like oxyhæmoglobin, the latter, however, being reduced by the addition of the sulphid of ammonium. The blood should not be taken from the heart for this purpose, but from the smaller vessels in the muscles. It is well to remember that the spectroscopic test may even be secured several months after death in favorable circumstances. To detect a small quantity of carbon monoxid in the air of a room fresh normal blood is added to distilled water until the latter is faintly tinged; about five cubic centimetres are placed in a flask of some one hundred and fifty cubic centimetres' capacity and agitated several

---

<sup>1</sup> *Fort Wayne Medical Journal Magazine*, July, 1899, p. 249.

<sup>2</sup> *München. med. Wchnschr.*, October 9, 1900.

<sup>3</sup> *Ibid.*, November 13, 1900.



minutes in the suspected atmosphere; if the noxious gas be present, the liquid assumes a rose tint and gives the characteristic spectrum. In cases which live a day or so and then die bilateral softening may occur in the region of the inner capsule and the caudate and lenticular nuclei. The victim may die from a dose of some other poison taken with suicidal intent before turning on the gas.

**LEAD POISONING.**—In acute lead poisoning there is marked gastroenteritis, and the bowels usually contain a large amount of blackish fluid. The kidneys show evidence of acute diffuse nephritis. In chronic lead poisoning the distinctive features are a marked fatty degeneration affecting the muscles, kidneys, spleen, and liver. There is often marked cirrhosis with atrophy of these organs. Arteriosclerosis with hypertrophy of the heart is also marked. Distinct gouty deposits are often found, particularly about the big toe. The brain is sometimes shrunk and dry, the blood-vessels being constricted; or these organs may be pale and extremely firm, or pale and œdematous, as in cases of uræmia. The small intestines may show areas of extreme contraction.

**MERCURIAL POISONING.**—The mucous membranes of the gastrointestinal tract, especially the small intestine and cæcum, show extensive desquamation, with hyperæmia, ecchymoses, and grayish-white eschars. The bowel generally contains large quantities of liquid of a yellowish-brown or blood-stained character. The macroscopic appearances are those of dysentery. In some acute cases decalcification of the bones occurs, with a deposit of lime elsewhere in the body, especially in the kidneys. The number of mercurial salts is legion, many forming with albumin an insoluble albuminate of mercury. Chronic cases of poisoning occur, ulcerative stomatitis being one of the chief lesions.

**METHYL ALCOHOL.**—Blindness or impairment of vision may occur not only from the ingestion of wood alcohol, but also from inhalation of its fumes, as methyl alcohol seems to have a predilection for the retina and the optic nerve. A number of cases of poisoning from this source have recently occurred in New Orleans from the use of a proprietary medicine.

**NITROBENZOL POISONING.**—Besides the odor of the artificial oil of bitter almonds, the blood and muscles are of a brownish color and the mucous membrane of the stomach is ecchymotic and injected. The body is cyanosed and of a leaden hue.

**OPIUM POISONING.**—In acute poisoning there is nothing to distinguish the condition of the brain from that in other cases of cerebral



congestion. Extreme passive congestion of the bases of the lungs may take place, as in cerebral apoplexy (Osler). Cases of uncomplicated chronic poisoning are rare. The most important lesion is fatty degeneration of the heart. The liver may show similar changes. If laudanum has been used, the characteristic odor may be determined. I know of no drug which is more apt to escape detection at the postmortem than morphine, as there are absolutely no characteristic lesions and chemical analyses are difficult and at times inaccurate. It seems strange that one of the most common and easily accessible poisons is thus so hard to detect. The pupillary reaction is of no value after death, and the clotting of blood in the right heart is by no means constant.

**PELLAGRA POISONING.**—The lesions found are in the posterior columns and the crossed pyramidal tract. The cells in the anterior horn are deeply pigmented, and pigment is found in the internal organs and the skin. The brain presents general wasting; the ventricles are somewhat distended and contain an excess of fluid.

**PHOSPHORUS POISONING.**—In acute phosphorus poisoning the gastro-intestinal tract, especially in the stomach, shows an intense degree of inflammation. Hemorrhages are common and the stomach may contain grumous (coffee-ground) blood. The mucous membrane is the seat of numerous ecchymoses as well as more or less extensive necroses. The skin, the serous membranes, the muscles, and the adipose tissues all show numerous small hemorrhages. The blood is liquid and dark. The skin is jaundiced. The liver, in the early stages increased in size, soon—in from ten to fourteen days—becomes small (from one-half to one-third of the normal bulk), the capsule is wrinkled and shrunken, the color is pale yellowish, and on section the organ presents yellowish patches in the midst of which are areas of deep congestion. Drops of fat are seen upon the knife. The kidneys are large, their cortex pale, and the medullary portions congested. The epithelium often shows marked granular degeneration. As a rule, the spleen is not markedly altered. In chronic poisoning by phosphorus wide-spread fatty degeneration is the rule. In cases of workers in phosphorus having defective teeth, necrosis of the jaw is not uncommon. It is the yellow phosphorus that is poisonous and not the red variety. Bug exterminators often contain phosphorus. The coating from the ends of matches is often taken with suicidal intent.

**POTASSIUM CHLORATE POISONING.**—The blood has the color and consistence of chocolate, the oxyhæmoglobin having been reduced to



methæmoglobin. There is usually a hemorrhagic nephritis, especially of the glomeruli.

PTOMAIN AND TOADSTOOL POISONING.—Such cases are of especial interest to the toxicologist, as the symptoms produced and the lesions found at the postmortem are similar to those caused by many alkaloidal and irritant poisons, and the possibility of the case under consideration in a trial being due to one or other of these substances is always suggested by the defence.

SILVER NITRATE POISONING.—I have been fortunate enough to see one case of this rare form of poisoning. The darkening of the necrosed mucous membrane on exposure to light was the chief diagnostic point. The child had an inspiration pneumonia.

SNAKE POISONING.—After death caused by cobra bite rigor mortis occurs as usual. The areolar tissue in the region of the bite is infiltrated with a pinkish fluid and the vessels are injected. The blood presents no demonstrable change. The veins of the pia mater are usually engorged, and the ventricles often contain turbid fluid. The lungs are generally congested and the lining of the bronchi injected. The appearance of the kidneys varies from normal to one of intense congestion. After death following the bite of an Australian snake the appearances are much the same as those just described. The blood may contain soft coagula, the lungs are sometimes the seat of hemorrhages, and the mucous membranes may be intensely congested and hemorrhagic. The central nervous system shows engorgement of the blood-vessels. At autopsy, after the bite of a viperine snake, the region of the wound is seen to be the seat of intense œdema and extravasation of blood, and the underlying muscles are frequently disorganized and even diffuent from the latter cause. Hemorrhages may also be found in any of the organs and along the alimentary tract. The kidneys are acutely congested or hemorrhagic. The blood is fluid.

STRYCHNINE POISONING.—Rigor mortis is intense and persistent and the blood is dark and fluid as in asphyxia. Be sure to save the urine if any be present; a frog placed in it will have convulsions, even if but a small amount of strychnine be present.



## CHAPTER XXVIII

### THE PRUSSIAN REGULATIONS FOR THE PERFORMANCE OF AUTOPSIES IN MEDICOLEGAL CASES

THE Prussian regulations governing the performance of postmortems by the legally appointed officers of the court are of great historic interest, as they bear the imprint of Virchow, and, though put in force February 13, 1875, are still observed throughout Prussia. These regulations also form the basis of similar statutes in other German states and in many countries throughout the world; indeed they are so well defined that it is advisable, though one may chafe under their apparently unnecessary restrictions, to depart from them only in exceptional instances. This is especially the case if the one performing the autopsy is a beginner in medicolegal work.

#### I. GENERAL CONSIDERATIONS.

The Physicians making the Autopsy, and their Duties      § 1. According to the present law, an examination of a corpse for medicolegal purposes may be made only in the presence of a magistrate by two practitioners, one of whom should be a state-appointed physician and the other a district surgeon. Those performing the autopsy are empowered with the duties of medicolegal experts. If doubt should arise in the technical performance of the autopsy, the physician or his deputy decides the question under consideration conditionally upon the right of the surgeon to state upon the protocol his dissenting opinion.

Substitutes      § 2. The medical officers are permitted to appoint substitutes only when unavoidably detained from the performance of their medicolegal duties. If possible, the deputy chosen is to be a physician who has passed his *pro physicatu* examination.

Time after Death at which the Post-mortem is to be performed      § 3. As a rule, postmortems should not be performed until twenty-four hours after death; the mere inspection of a corpse, however, may be made earlier than this.

The Examination of Decomposed Bodies      § 4. As a rule, post-mortem examinations must not be neglected nor their performance refused by the legally appointed physicians because of the presence of decomposition, for even in a badly decomposed cadaver abnormalities and injuries to the bones may still be detected; many facts of value in the identification of a body may be ascertained, such as the color and appearance of the hair, the absence of limbs, etc.; and substances which have entered the body from without may be discovered, as well as unsuspected pregnancy or poisoning. On the same grounds, when for one reason or another the advisability of disinterring a body is under consideration, the physicians are to approve of such exhumation without regard to the time which has elapsed since death.



§ 5. The legally appointed physicians are to be careful to have the following instruments in readiness and in good condition: Instruments  
 from four to six scalpels, of which two are to possess a straight and two a rounded cutting edge; one razor; two strong cartilage-knives; two forceps; two double hooks; two pairs of scissors,—the stronger pair should have one blade pointed and the other rounded, while the smaller pair should possess one probe-pointed and one sharp-pointed blade; one enterotome; one injecting nozzle with stopcock; one coarse and two fine sounds; one saw; one chisel and one hammer; one costotome; six curved needles of different sizes; one pelvimeter; a one-metre rule divided into centimetres; one measuring-glass divided into one hundred, fifty, and twenty-five cubic centimetres; one pair of scales capable of weighing up to ten pounds; one good magnifying-glass; blue and red litmus paper. The cutting instruments must be perfectly sharp. Those performing the postmortem are recommended to have ready for use a microscope with two objectives, so as to be able to magnify at least four hundred diameters, and the required instruments, glassware, and reagents necessary for the preparation of microscopical slides.

§ 6. A sufficiently large well-lighted room is to be chosen for the autopsy, and all possible care is to be taken in the selection of Place for the Autopsy  
and its Lighting  
 a suitable place on which to lay the body and in the avoidance of all disturbing surroundings. Post-mortem examination by artificial light, except where postponement is impracticable, is not allowed; should it be done, the reason therefor must be expressly stated in the protocol (§ 27).

§ 7. If the body be frozen, it must be brought into a heated Frozen Bodies  
 place and the autopsy postponed until the cadaver has sufficiently thawed; the employment of warm water or other warm articles to hasten the thawing process is forbidden.

§ 8. If possible, when for any reason the body is moved, especially if transported from one place to another, there is to Transportation  
of Corpses  
 be no excessive pressure made upon any of the individual parts, nor any marked departure from the horizontal position of the organs in the larger cavities.

## II. TECHNIC OF THE POSTMORTEM.

§ 9. Those performing the postmortem must hold steadfastly to the object in view, which is to make the investigation with Medicolegal Aspects  
of the Postmortem  
 accuracy and completeness. All important findings must be shown to the magistrate by the obducent before they are entered in the protocol.

§ 10. In those cases in which this appears to be necessary, the Duties of the Obdu-  
cients in regard to  
the Ascertainment  
of Special Circum-  
stances connected  
with the Case  
under Investigation  
 examiners are required, as early as feasible before the performance of the autopsy, to ask the magistrate for permission to visit the place where the body was found, and they are to ascertain the position in which the body was discovered and be given an opportunity to examine the clothing which the deceased wore at the time of his or her death. As a rule, however, it is sufficient for them to await the solicitation of the magistrate to undertake these investigations. They are also obliged to ask for information from the magistrate in regard to any disclosures which might be of use to them in the performance of the autopsy or in helping them to make up their deductions therefrom.



Microscopical  
Examinations      § 11. In cases in which a doubtful finding is to be quickly and definitely settled,—as, for example, the differentiation between a fluid containing blood and one which is merely stained with hæmatin,—a microscopical examination is to be then and there undertaken. When circumstances render this impossible or when difficult microscopical investigations which cannot be made at once are required,—as, for example, of certain tissues of the body,—portions of such tissue are to be preserved under legal protection and as quickly as possible thereafter to be thoroughly examined. It is to be distinctly stated in the report of such findings when the examinations were performed.

The Postmortem: its  
two main divisions      § 12. The postmortem is divided into two main parts: A. External examination (inspection). B. Internal examination (section).

External  
Examination      § 13. In the external inspection of the body its appearance in general and that of its individual parts in particular are to be noted. In this general examination of the body the following points, if possible, are to be brought out and recorded. 1. Age; sex; size; development; general condition of nutrition; any signs of previous illnesses,—e.g., ulcers of the foot; special abnormalities,—e.g., moles, scars, tattoo markings; increase or absence of limbs. 2. The signs of death and the changes that have already taken place from decomposition.

After removal by washing of any contaminations of the body in the way of blood, fæces, dirt, etc., record is to be made of the presence or absence of post-mortem rigidity; the general color of the skin of the corpse; the manner and degree of coloration and discoloration brought about by putrefaction; and the color, situation, and extent of any areas of hypostatic congestion, which are to be incised and then examined and described, in order to prevent their being mistaken for extravasations of blood.

The following particulars are to be considered in the study of the individual parts. 1. In unidentified persons, the color and other appearances of the hair (head and beard), as well as the color of the eyes. 2. The possible presence of foreign substances in the normal openings of the head, the arrangement of the teeth, and the situation and appearance of the tongue. 3. An examination is next to be made of the neck, the breast, the abdomen, the back, the anus, the external genitalia, and finally of the limbs.

If an injury is found in any of these parts, its shape, situation, and direction with relation to fixed points of the body are to be described and the length and breadth of the injury given in the metric system. In solution of continuity of tissue, probing is, as a rule, to be avoided in the external inspection, because after the internal examination of the body and of the injured spot the extent of the injury is to be described. Should the obducent decide that the introduction of a sound is necessary, this procedure is to be done with great care and special mention of the reason therefor is to be made in the protocol (§ 27). When wounds are present, a description of their borders and the adjacent tissues is to be given, and after such an examination and description of the lesions in their original condition the same are to be enlarged in order that the appearance of the borders and of the bottom may be disclosed. As to wounds and injuries which clearly did not conduce to, originate from, or have any connection with death,—for example, markings produced in the endeavor to restore life, gnawing by animals, and the like,—a summary description of the findings is sufficient.



§ 14. In the internal examination the three main cavities of the body—the cranial, the thoracic, and the abdominal—are to be opened. Opening of the vertebral column or of the individual joints is not to be omitted in cases where important findings might be secured thereby. When there is a definite suspicion as to the cause of death, the postmortem is to be commenced with that cavity in which the chief changes are suspected. Otherwise the head is to be examined first, the thorax next, and the abdominal cavity last.<sup>1</sup> The situation of the organs found in each of the above-named cavities is first to be determined, then the color and the appearance of the exposed surfaces. The presence is to be noted of any unusual contents, such as foreign bodies, gases, fluids, or clots, and in the last two cases measured and weighed, and finally each individual organ is to be examined externally and internally.

Internal Examination;  
General Considerations

§ 15. When no injuries are present, the opening of the cranial cavity is accomplished by making an incision from one ear to the other directly over the skull, after which the skin-flaps are displaced forward and backward. (In case such injuries are found, they should be as much as possible circumvented by the knife, thus giving rise to a different procedure.) As soon as the appearance of the soft parts and the surface of the bony cranium has been described, the latter is cut through with a saw by a circular incision, and the calvarium, the inner table, and the part removed are described. The external surface of the dura mater is next examined, the longitudinal sinus opened, and its contents estimated. The dura mater is then to be separated on one side and laid back, and the internal surface of the same described, as well as the appearance of the exposed pia mater. After this has been done on the opposite side, the brain is to be removed in as perfect a condition as possible, and the presence of abnormal contents in the skull is to be noted, and the appearance of the dura and pia mater at the base and sides of the skull and the condition of the large arteries are to be described. After the opening of the transverse sinuses (and, in case reason therefor exists, of the remaining sinuses), the size and shape of the brain are noted and an examination is made of its individual parts by means of a series of well-ordered incisions. Such parts include both cerebral hemispheres, the large ganglia (optic thalamus and corpus striatum), the corpora quadrigemina, the cerebellum, the pons Varolii, and the medulla oblongata, in the description of which are to be included especially the color, the fulness of the vessels, the consistency, and the structure. In addition, the tissue and the vessels of the choroid plexus are always to be described. The size and the contents of the different ventricles as well as the appearance and fulness of the different vascular plexuses in the individual sections of the brain are constantly to be kept in mind, and especial note is to be made of the presence of any clotted blood outside of the blood-vessels. The dura mater over the base of the skull and the sides is then to be removed and the condition of the bones in these regions described.

Cranial Cavity

§ 16. When it is required to open the internal portions of the face, to examine the parotid gland, or to inspect the auditory apparatus, the initial incision extending over the skull is continued behind the ear and down the neck, and the skin, for appearances' sake, is dissected

Face, Parotid Gland, and Ear

<sup>1</sup> As to autopsies on the new-born see §§ 23 and 24.



away from beneath towards the part to be investigated. In this examination special attention is to be paid to the condition of the large arteries and veins.

Spinal Column  
and Cord

§ 17. The opening of the spinal column (§ 14) is usually made from behind, the skin and the subcutaneous fatty tissue being cut directly over the spinous processes and the musculature dissected away from the side of the latter and from the vertebral arches. During this examination hemorrhages, lacerations, and similar changes, especially fractures of bones, are to be carefully searched for. Then a chisel, or, if one is at hand, a vertebral saw (rhachiotome) is used for the purpose of separating the spinous processes with the adjacent portions of the arches throughout their entire extent. When they are removed, the external surface of the dura mater, which is now brought into view, is examined. It is next to be carefully opened by means of a longitudinal incision, and any abnormal contents, especially fluid or extravasated blood, are to be described, also the color, appearance, and similar characteristics of posterior portions of the pia mater, and by means of a gentle passage of the fingers over the spinal cord its degree of consistency is to be determined. Next, on both sides, by means of a longitudinal incision the nerve-roots are cut through; then with one hand the lower end of the spinal cord is carefully grasped, and, after dividing the anterior attachments one after another, its upper end is finally drawn out of the occipital foramen. In all these proceedings special care should be taken not to make pressure on the spinal cord or to bend it. When the cord has been removed, the anterior surface of the pia mater is to be examined; next the external appearance of the cord as to size and color is to be described, and finally, by a considerable number of transverse incisions with a sharp and thin knife, the internal appearance of the spinal cord, both as to its white and its gray matter, is to be noted. Finally the dura mater of the vertebral bodies is to be removed, and they are to be examined in order to determine if there have been any hemorrhages, injuries, or changes in the bones or in the intervertebral discs.

Neck, Thoracic and  
Abdominal Cavities;  
General Considera-  
tions

§ 18. The neck and the thoracic and abdominal cavities usually are opened by means of a single long incision from the chin to the pubic symphysis, passing to the left of the navel. Most commonly the incision in the abdomen is made deep enough to penetrate the abdominal cavity, care being taken to avoid injuring the organs contained therein. This is best begun by cutting a small nick in the peritoneum, at the same time observing whether any gas or fluid escapes. One finger is introduced into the opening and then another, the abdominal wall is elevated from the intestines, and the further opening of the peritoneum is made between the two fingers. The situation, the color, and other appearances of the intestines are to be immediately observed, as well as any abnormal contents within them, and the condition of the diaphragm is to be determined by palpation of its under surface.

The examination of the abdominal organs is to be proceeded with at this time only where a strong suspicion exists that the cause of death may be found within the abdomen (§ 14). As a general rule, the thorax is to be opened and inspected before any further scrutiny of the abdominal cavity.

Thoracic Cavity

§ 19. In opening the thoracic cavity the soft parts of the breast are dissected slightly beyond the junction of the osseous and cartilaginous portions of the ribs. Next with a strong knife



the cartilages are incised a few millimetres within their attachment to the ribs, care being taken to avoid cutting the lungs or the heart. If the cartilages be ossified, the ribs are to be separated with a saw or a costotome somewhat beyond the cartilaginous junction. The attachments of both clavicles to the sternum are then separated by vertical semicircular sections, and the junction of the first rib, be it cartilaginous or ossified, is loosened with the knife or costotome, great care being taken to avoid injuring the vessels which lie beneath. The diaphragmatic attachments along the line of incision are severed close to the false cartilages and the ensiform process. The sternum is turned upward and the mediastinum is cut through, with careful avoidance of any injury to the pericardium or the large blood-vessels. When the sternum has been separated, the condition of the pleural cavity is to be determined, especially as to any abnormal contents, which are to be measured and their characteristics described; also the extent and the appearance of any portions of the lung which are in view. If any vessels have been injured in the removal of the breast-bone, they are to be tied or a sponge is to be placed beneath the bleeding points to catch the blood which if it were allowed to enter the pleura would later obscure the observation of the parts therein. The condition of the mediastinum and especially that of the thymus gland are to be noted, as well as the appearance of the large blood-vessels lying outside of the pericardium, which are not yet incised. The pericardium is next to be opened and examined and the exterior of the heart inspected. Before the heart is incised or removed from the body its size, the filling of the coronary vessels and its individual cavities (auricles and ventricles), its color, and its consistency (rigor mortis) are to be estimated. While the organ is still in its natural position, the ventricles and auricles are to be separately opened and the contents of each chamber determined as to their amount, condition, coagulation, and appearance, and the dimensions of the auriculo-ventricular openings are to be ascertained by the introduction of two fingers through the auricle. The heart is then to be removed from the body and the condition of the arterial vessels tested, first by filling them with water and next by incising their walls. Finally the color and exact appearance of the heart muscle are to be described. In every case wherein it is suspected that extensive changes—*e.g.*, fatty degeneration—have occurred in the muscular tissue a microscopical investigation is to be made. To this examination belongs that of the large vessels, with the single exception of the descending aorta, which is to be examined after the lungs have been excised. A minute inspection of the latter is not undertaken until they have been removed from the thoracic cavity. During this procedure great care is to be taken to avoid tearing or pressing upon the tissues. Should there be any extensive, especially old, adhesions, these are not to be broken down, but the attached pleura at this point is to be excised at the same time. When the lungs have been removed, their surface is again to be carefully examined for recent changes, so that nothing shall be overlooked,—for example, the commencement of inflammatory exudations; then the air contents, color, and consistency of the individual lobes are to be given. Finally large, smooth sections are to be made in order to determine the appearance of the cut surface and the air, blood, and fluid contents, as well as any solid contents of the air-vesicles, the condition of the bronchi and the pulmonary arteries, the latter being examined with special care to detect any obstructions, etc. For this purpose the air-passages and the large pulmonary vessels are to be opened with scissors and their finer ramifications followed out. When the suspicion arises that foreign materials are present in the air-passages or substances are therein found the nature of which cannot with certainty be determined by the naked eye, a microscopical examination is to be made.



Neck                    § 20. The examination of the neck may, according to the nature of the case, be made either before or after the opening of the thorax or the removal of the lungs. The obducents may also sever the larynx and the bronchus before the further inspection of the remaining parts when it seems to them especially desirable so to do, as is the case in drowning or hanging. As a rule, it is wise next to examine the large vessels and the nerve-trunks, then the larynx and trachea, by means of an anterior incision, and note their contents. If this observation should appear to be of especial importance, it is to be made before the removal of the lungs, which are at the same time to be carefully pressed upon to see if any fluid, etc., arises in the trachea. The larynx, the tongue, the velum palati, the pharynx, and the œsophagus are to be removed together; the individual parts are to be carefully opened and their contents and the mucosa thoroughly examined. At the same time the thyroid, the tonsils, the salivary glands, and the lymph glands of the neck are to be observed. In every case where injuries of the larynx or of the bronchus have been found or important changes therein are suspected, the air-passages are to be opened after their removal from the body and they are then to be examined from their posterior aspect. In cases of hanging or in suspicious cases of strangulation the carotids are to be opened in order to ascertain whether or not their inner coats have been injured. This examination is to be undertaken while the vessels are still in their natural situation. Finally the condition of the cervical vertebræ and of the deep musculature is to be determined.

Abdominal Cavity    § 21. The abdominal cavity and its viscera are now to be critically inspected in such order that the removal of one organ does not prevent the exact determination of its relations to another. Thus, the duodenum and the gall-ducts are to be examined before the scrutiny of the liver. As a rule, the following order of examination commends itself: 1. Omentum. 2. Spleen. 3. Kidneys and adrenals. 4. Bladder. 5. Organs of generation: in the male, prostate, seminal vesicles, testicles, and penis with the urethra; in the female, ovaries, Fallopian tubes, uterus, and vagina. 6. Rectum. 7. Duodenum and stomach. 8. Gall-ducts. 9. Liver. 10. Pancreas. 11. Mesentery. 12. Small intestine. 13. Large intestine. 14. The large blood-vessels in front of the vertebral column, whose condition as to blood contents is to be ascertained and noted.

Spleen                In every case the spleen is examined in regard to its length, breadth, and thickness, not while held in the hand, but when placed on a solid surface and without pressure by the instrument used in measuring. It is to be divided throughout its entire length, more incisions being made in different directions if diseased areas are suspected.

Kidneys              Each of the kidneys is to be removed after cutting vertically through the peritoneum externally and behind the ascending or descending colon, which is shoved back. The capsule is then incised longitudinally through its convex border and slowly peeled off, and the exposed surface of the kidney is examined in regard to size, form, color, condition of blood, and other appearances. Next a longitudinal incision is made through the entire kidney to its pelvis, and the cut surfaces are washed with water and described, in which description medullary and cortical substances, vessels, and parenchyma are to be distinguished.

Pelvic Organs        The pelvic organs (bladder, rectum, and genitalia in connection therewith) are removed *en masse*, but preferably the bladder is opened and its contents are examined while it is in its natural situation. After their removal these organs are again inspected, the reproductives



being examined and opened last. The slitting of the vagina is to precede that of the uterus. In puerperæ the venous and lymphatic vessels both in the internal surface of the uterus and in its walls and adnexa require special attention as to their width and contents.

When their external condition has been determined, the stomach and duodenum are with a pair of scissors opened in their natural situation, the duodenum on its anterior surface and the stomach along its greater curvature. After a careful inspection of their contents, the permeability and the presence of any matter in the opening of the gall-passages are determined and these parts are then removed for further examination.

Stomach and  
Duodenum

The liver is first described externally in its natural situation, and after its secretory ducts have been examined (as mentioned in the preceding paragraph) the gland is excised. Smooth incisions are now made through the entire length of the organ and its capacity for blood and the condition of the parenchyma determined. In the description a short account is always to be given of the general relations of the individual lobes, noting especially the relations of the inner and outer portions.

Liver

The small and large intestines, after their individual portions have been examined externally as to dimensions, color, and other peculiarities worthy of mention, are removed together, their mesenteric attachments being severed with a knife close to the bowels, which are then opened with a pair of scissors at the place where the mesentery was attached. During these incisions the contents of the several parts are observed and described. Next the intestines are cleansed and the condition of the individual portions, especially of the small intestine, is inspected with special regard to the Peyer's patches, the solitary follicles, the villi, and the intestinal folds. At least in every case of inflammation of the peritoneum the appendix is to be carefully examined.

Small and Large  
Intestines

§ 22. In those cases in which poisoning is suspected the internal examination is to begin with the abdominal cavity. Before anything else is done the external appearance of the upper abdominal viscera, their situation and extent, the filling of their vessels, and the presence of any odor are to be determined. In regard to the vessels, here as in other important organs, we are to ascertain whether we are dealing with arteries or veins, whether the smaller ramifications or both the main trunks and their branches are filled to a given degree, and whether the extent of the vascular thinning is considerable or otherwise. Then to the portion of the œsophagus just above its entrance into the stomach and to the duodenum just below the entrance of the gall-duct double ligatures are to be applied and both parts incised between them. Next the stomach with the duodenum attached is carefully removed from the body and opened in the manner described in § 21. The contents are immediately examined as to their amount, consistency, color, composition, reaction, and odor, and placed in a clean porcelain or glass vessel. Then the mucosa is washed and its thickness, color, surface, and condition are determined, the state of the blood-vessels and the structure of the mucous membrane being particularly noted and each individual portion separately described. Of especial importance is it to ascertain whether the blood which is present lies within the vessels or is exuded therefrom, whether it is fresh or changed by decomposition or by digestion, and whether in these conditions the neighboring tissues are permeated therewith. If such imbibition has occurred, its location is to be determined, also whether upon the surface or in the tissue, whether

Cases of Poisoning



it is coagulated or not, etc. Finally it is of especial importance to decide, in the inspection of the surface, whether loss of substance, erosions, and ulcers are present. The question whether these changes might not have resulted from natural processes of decomposition after death, especially from the action of the fermentative juices of the stomach, is always to be considered. After the completion of this examination, the stomach and duodenum are to be placed in the same vessel with the gastric contents (see above) and given to the magistrate for further investigation. An anatomical examination having been made of the œsophagus, it is tied high up in the neck, severed above the ligature, and placed in the same vessel. In those cases in which but a small amount of stomach contents is present the contents of the jejunum are also to be preserved. Finally other substances and portions of organs, as blood, urine, pieces of the liver and of the kidney, etc., are to be removed from the body and given to the magistrate for further examination. The urine is to be placed in a separate vessel, and the blood is to be preserved separately only in those cases where spectroscopic examination might disclose facts of interest. All of the remaining portions are to be placed together in a single receptacle. Each of these vessels is closed, sealed, and labelled. In every case where the macroscopical examination shows special alteration and swelling of the mucous membrane of the stomach, a microscopical examination thereof is to be made as soon as possible, especial attention being given to the condition of the peptic glands. Whenever suspicious bodies are found in the stomach contents, as portions of leaves or other parts of plants, remnants of animal food, etc., these also are to be viewed with a microscope. Where trichinosis is suspected, not only a microscopical examination of the contents of the stomach and of the upper portion of the small intestine is to be made, but portions of muscular tissue from the diaphragm, the neck, and the thorax are also to be laid aside for future study.

The New-born;  
Determination of the  
Maturity and Period  
of Intra-uterine  
Gestation

§ 23. In postmortems on the new-born, besides the points previously given, there are to be determined, first of all, the data upon which the maturity and the intra-uterine developmental period of the child depend. For these purposes consider the length and weight of the body, condition of the general coverings and of the umbilical cord, length and appearance of the hair of the head, size of the fontanels, longitudinal, transverse, and diagonal measurements of the head, appearance of the eyes (pupillary membrane), condition of the nasal and auricular cartilage, length and characteristics of the nails, transverse diameter of the shoulders and hips; in boys the situation of the testicles and the appearance of the scrotum, and in girls any peculiarities of the external genitalia. It still remains to be noted whether there be present, and if so to what extent, an ossifying centre in the inferior epiphysis of the femur. To determine this the patella is removed through a horizontal incision made just below it while the knee-joint is strongly flexed, and thin transverse sections are made continuously through the cartilage until the greatest transverse diameters of any centres of ossification which may there be present are found, which are then to be measured in millimetres. When from an examination of the offspring it seems to have been born before the thirtieth week, the postmortem may be discontinued unless a special request is given by the magistrate for its completion.

The Determination  
as to whether or not  
the Child has  
breathed

§ 24. If it be determined that the child was born after the thirtieth week, the following data must be obtained in order to decide whether it breathed during or after birth. For this purpose the respiratory tests are to be applied in the following order:  
(a) Immediately after the opening of the abdominal cavity the



condition of the diaphragm in relation to the corresponding ribs is to be determined. Hence in every case of examination of the new-born the abdominal cavity is to be opened first and afterwards the thoracic and cranial cavities.<sup>1</sup> (b) Before opening the thoracic cavity the trachea is to be once ligatured above the sternum. (c) The thoracic cavity is next to be opened and the extent and the degree of the overhanging portions of the lungs, the latter especially in regard to the pericardium, determined both as to the color and as to consistency. (d) The pericardium is to be incised and both its condition and the external appearance of the heart are to be described. (e) The individual cavities of the heart must be laid open, their contents noted, and other appearances determined. (f) The larynx and the portion of the trachea above the ligature are to be slit, and their contents as well as the appearance of their walls determined. (g) The trachea is to be cut through above the ligature and removed in connection with the other organs of the thorax. (h) After the removal of the thymus gland and the heart, the lungs are to be tested as to whether or not they float in a large vessel filled with pure cold water. (i) The lower portion of the bronchus and its branches are to be opened and their contents specially examined. (j) Incisions are to be made into both lungs, the presence or absence of crepitation being carefully noted as well as the amount and appearance of any blood which may exude under slight pressure upon the cut surfaces. (k) The lungs are also to be incised under water in order to determine if any air-bubbles arise from the cut surfaces. (l) The lobes of both lungs are next to be cut apart, each lobe subdivided, and every separate portion tested as to its sinking or floating in water. (m) The œsophagus is to be opened and its condition ascertained. (n) Finally, in those cases where it is suspected that the pulmonary tissues may have been filled with the products of disease (hepatization) or with foreign bodies (vernix caseosa and meconium), so as not to permit of the entrance of air, the same are to be examined microscopically.

§ 25. Lastly, it is the duty of the obducent to examine all organs not mentioned in these regulations in case injuries or other abnormalities are discovered. Further  
Examinations

§ 26. The district surgeon, with the second physician acting as a consultant, is required, after the ending of the autopsy and as far as possible the removal of waste, to undertake the proper closure of those cavities of the body which have been opened. Closure of the Body

### III. THE DRAWING UP OF THE PROTOCOL OF THE POSTMORTEM AND THE FINAL REPORT OF THE SAME.

§ 27. A post-mortem protocol is to be made by the magistrate, at the time and place of performing the autopsy, concerning all matters relating thereto. The medical officer must, therefore, be careful that the technical findings which have been determined at the examination are faithfully recorded in the protocol. In order to accomplish this, it is recommended to the magistrate that the description and findings of each individual organ be written down before another part is examined. The Post-mortem  
Protocol

<sup>1</sup> But in no case shall section of the organs of the abdominal cavity be undertaken before the opening and examination of those of the thorax.



Arrangement and Form of the Protocol      § 28. The technical findings given in the post-mortem protocol by the medical officer must be stated clearly, definitely, and in such a manner as to be understood by one who is not a physician; for this purpose the use of foreign expressions is to be avoided except where these may be needed to make clear the description of the findings. Both chief divisions, the external and internal examinations, are to be designated with capital letters (A and B). The findings for the openings in the cavities are to be given, in the order in which they were examined, with Roman numerals (I, II.); but the organs in the thorax and abdominal cavity are to be entered under a single number. The descriptions of the organs of the thorax and abdominal cavity, named in § 18, are to be designated by the letters a and b. The results of the examination of each individual part are to be designated with Arabic numerals, such numbers running consecutively from the beginning to the end of the protocol. The record of the examination must be given in the protocol with special reference to the actual observations, and not in the form of mere statements,—as, for example, inflamed, gangrenous, healthy, normal, wound, ulcer, and the like. The obducent has the option, however, in those cases in which it seems necessary for clearness, to add such observations, inclosed in parentheses. In every case a note must be made of the blood contents of each important part, and a short description thereof must be given, and not simply a name,—as considerable, moderate, middling amount, much reddened, rich in blood, poor in blood. Before any part is incised its size, form, color, and consistency are to be noted, in the order here named.

Provisional Opinion      § 29. At the close of the postmortem the obducent is to give in the protocol their provisional opinion of the case, without stating their reasons therefor. If anything be known by means of which the diagnosis is influenced, in the way of previous history or the like, this must be briefly noted. Should the magistrate ask any special questions, the answers should be distinctly entered in the protocol, with the statement that they are given at his request. In every case the opinion as to the cause of death is to be stated, first with special reference to the facts bearing on the objective findings and then as to the question of criminal motive. If the cause of death is not determined, this fact must be recorded. It is never sufficient to say that death resulted from internal causes or from disease. The latter, whatever it is, must be specifically named. Special mention is to be made, with the reason therefor, in cases where further technical examinations are needed or where doubtful conditions exist.

Supplemental Observations on Instruments      § 30. Should injuries be found on the body which were presumably the cause of death, and if suspicion be aroused that a specially discovered instrument might have inflicted such injuries, the obducent, at the request of the magistrate, are obliged to investigate and to express an opinion as to which and what injuries might have been caused by the instrument, and what conclusions from the situation and appearance of the wound are to be drawn as to the manner in which the one performing the act might have committed the deed, and also as to the strength with which it was performed. When definite weapons are not found, the obducent, as far as it is possible from the conditions present, are to give their opinion as to how the injuries were caused and especially as to what instruments might possibly have been used.



§ 31. If the obducent be requested to present a report, this should give, without useless details, a condensed but exact review of the case, with the conclusion reached by them and the facts on which it is based. So much of the post-mortem protocol as they think necessary for the explanation of the case is to be given verbatim, with the number of the protocol. Any change made therein must be expressly stated. The style of the post-mortem report must be plain and concise, and the proof which led to the formation of the opinion therein expressed so set forth as to be understood by and convincing to one not a physician; for this purpose, the obducent is to use, as far as possible, German expressions and ordinarily accepted meanings. Especial attention to literary sources of knowledge is, as a rule, to be avoided. When as medical experts the obducent is asked certain questions by the magistrate, these are to be answered fully but as concisely as possible, or, if this cannot be done, the reasons therefor are to be given.

Both obducent must sign their report, which must also bear the official seal of the district physician if he has taken part in the autopsy. When such a post-mortem account is requested, it must be delivered by the obducent within four weeks at the latest.



## CHAPTER XXIX

### USUAL CAUSES OF DEATH; THEIR NOMENCLATURE, COMPLICATIONS, AND SYNONYMS

As morbidity and mortuary statistics are intimately associated the one with the other, uniformity in their nomenclature throughout the world is greatly to be desired. At the Eighth International Congress of Hygiene and Demography, held in Paris, August 18 to 21, 1900, a modification of the old Bertillon classification was adopted and called the "International System of Nomenclature of Diseases and Causes of Death."<sup>1</sup> It is here added complete as to its essential parts and but slightly altered in a few minor particulars.

#### I. GENERAL DISEASES.

1. TYPHOID FEVER (Abdominal Typhus). *Include:* Dothienenteritis; mucous, continued, enteric, ataxic, or adynamic fever; abdominal typhus.—*Do not include:* Adynamia (179); ataxo-adynamia (179).—*Frequent complications:* Pneumonia; pulmonary congestion; intestinal perforation; peritonitis; intestinal hemorrhage; sloughing; albuminuria.
2. EXANTHEMATOUS TYPHUS.<sup>2</sup> *Include:* Petechial fever; petechial typhus.—*Do not include:* Abdominal typhus.
3. RECURRENT FEVER. *Include:* Relapsing fever; recurrent typhus.
4. INTERMITTENT FEVER AND MALARIAL CACHEXIA. *Include:* Paludal fever; pernicious fever; accesso pernicioso; remittent fever; malaria.
- 4a. MALARIAL CACHEXIA. *Include:* Paludism; pernicious cachexia; paludal anæmia.
5. VARIOLA. *Include:* Smallpox, varioloid.—*Do not include:* Varicella (19).—*Frequent complications:* Meningitis; endocarditis; suppuration; albuminuria.
6. MEASLES. *Include:* Eruption of measles.—*Do not include:* Rubeola (19).—*Frequent complications:* Bronchitis; bronchopneumonia.
7. SCARLATINA. *Include:* Puerperal scarlatina; scarlatinous angina.—*Frequent complications:* Albuminuria; eclampsia; œdema of the glottis; hemorrhage; endocarditis; pericarditis; paralysis; convulsions.
8. WHOOPING COUGH. *Frequent complications:* Bronchitis; convulsions.
9. DIPHTHERIA AND CROUP. *Include:* Diphtheritic, buffy, pseudomembranous, infectious, malignant, or toxic angina. Diphtheria under all its forms, especially diphtheria of wounds, cutaneous diphtheria; conjunctival diphtheria;

<sup>1</sup> Supplement to Public Health Reports, vol. xv., No. 49. Translated by Passed Assistant Surgeon H. D. Geddings.

<sup>2</sup> The word "typhus," without qualification, will be taken in the sense which is usual to it in each country,—viz., in the sense of "abdominal typhus" in German-speaking countries, or as "exanthematous typhus" in French-speaking ones.



buccal diphtheria. Pseudomembranous bronchitis; pseudomembranous laryngitis; malignant laryngitis; diphtheritic paralysis.—*Do not include*: Stridulous croup (88); spasmodic croup (88).—*Frequent complications*: Pneumonia; albuminuria; paralysis.

9a. DIPHTHERIA.

10. GRIPPE. *Include*: Influenza; grippe pneumonia; grippe bronchitis, and grippe bronchopneumonia.
11. SWEATING OR MILIARY FEVER.
12. ASIATIC CHOLERA. *Include*: Indian cholera; cholera (without qualification); epidemic cholera.
13. CHOLERA NOSTRAS.<sup>1</sup> *Include*: Sporadic cholera; cholerine; choleriform enteritis or diarrhœa.—*Do not include*: Cholera infantum; antimony cholera (175); hernial cholera (108).
14. DYSENTERY. *Include*: Choleriform dysentery; Chinese dysentery; dysentery of tropical countries.
- 14a. EPIDEMIC DYSENTERY.
15. PEST (Plague or Bubonic Plague).
16. YELLOW FEVER. *Include*: Vomito negro; fiebre amarilla.
17. LEPROSY. *Include*: Elephantiasis Græcorum.—*Do not include*: Elephantiasis Arabum (145d); Morvan's disease (63); syringomyelitis (63).
18. ERYSIPELAS. *Include*: All surgical erysipelas or medical erysipelas, without regard to seat.—*Do not include*: Gangrenous or phlegmonous erysipelas (144); erysipelatous phlegmon (144).
19. OTHER EPIDEMIC AFFECTIONS.<sup>2</sup> *Include*: Mumps; rubeola; acrodynia; varicella; beriberi; and any other epidemic affections which may not be included in this nomenclature.—*Do not include*: Epidemic dysentery (14a); epidemic cerebrospinal meningitis.
20. PURULENT AND SEPTICÆMIC INFECTION.<sup>3</sup> *Include*: Pyohæmia; purulent absorption; putrid absorption; putrid infection; putrid fever; anatomical wounds; streptococchæmia.—*Do not include*: Puerperal septicæmia (137); infectious fever (55).
21. GLANDERS AND FARCY.
22. MALIGNANT PUSTULE AND CHARBON (Anthrax).
23. RABIES. *Include*: Hydrophobia.—*Do not include*: Sitiophobia (68).
24. ACTINOMYCOSIS, TRICHINOSIS, ETC. *Include*: Dystoma hepaticum; cysticerci.—*Do not include*: Cyst or hydatid tumor of the liver (111) or of the lungs (99); intestinal parasites (107).
25. PELLAGRA.
26. TUBERCLE OF THE LARYNX. *Include*: Tuberculous laryngitis; laryngeal phthisis.
27. TUBERCLE OF THE LUNGS.<sup>4</sup> *Include*: Pulmonary tuberculosis; pulmonary phthisis; phthisis (without qualification); phymia; phymatosis; pneumonophyma; acute, galloping, or miliary phthisis or tuberculosis; granulia; pulmonary cavities; consumption; caseous pneumonia; tuberculous, bacil-

<sup>1</sup> The word "cholera morbus" will be taken in its ordinary signification in each country, as in the sense of "cholera nostras" in North America, and as "Asiatic cholera" in France and in other countries.

<sup>2</sup> In cases where epidemics arise, it will be necessary here to adopt a special provisional title.

<sup>3</sup> When an adult female is returned as having been stricken with "septicæmia," send the report back in order that the physician may state whether or not the disease was puerperal.

<sup>4</sup> See observation on No. 93, relative to "apical pneumonia."



- lary, specific, granular, neoplastic, or heteroplastic bronchitis or pneumonia; bacillosis; tuberculous pleurisy; tuberculous hæmoptysis; tuberculosis (without qualification).—*Do not include*: Hæmoptysis (without qualification) (99); pulmonary hemorrhage (99); bronchorrhagia (without qualification) (99); apical pneumonia (93); laryngeal phthisis (26); pulmonary anthracosis (99).—*Frequent complications*: Hemorrhage; pneumonia; pleurisy; incontrollable diarrhœa.
28. TUBERCLE OF THE MENINGES. *Include*: Meningeal tuberculosis; tuberculous meningitis; granular, miliary, caseous, bacillary, specific, neoplastic or heteroplastic meningitis.—*Do not include*: Meningitis (without qualification), even for children of tender age.
  29. ABDOMINAL TUBERCLE. *Include*: Tuberculous, granular, bacillary, or specific peritonitis; peritoneal tuberculosis; tuberculous enteritis.
  30. POTT'S DISEASE. *Include*: Vertebral caries; vertebral disease; vertebral polyarthritis.—*Frequent complications*: Cold abscess, or abscess by congestion.
  31. COLD ABSCESS AND ABSCESS BY CONGESTION. *Include*: Ossifluent abscess.
  32. WHITE SWELLING. *Include*: Fungous growths of joints; coxalgia; scapulargia.
  33. OTHER TUBERCULOUS AFFECTIONS. *Include*: Tuberculosis of the skin; tuberculous nephritis; lupus; esthiomene; bacillary abscess; tuberculous ulcer; osseous tuberculosis.—*Do not include*: Pott's disease (30).
  34. GENERALIZED TUBERCULOSIS. *Include*: Tuberculosis showing itself simultaneously in any two or more organs.
  35. SCROFULA. *Include*: Lymphatism; scrofulides.—*Do not include*: Blepharitis; or conjunctivitis, or scrofulous keratitis, or lymphatic keratitis (75).
  36. SYPHILIS. Of which are recognized: (1) Primary, (2) secondary, (3) tertiary, (4) hereditary. These divisions are intended for mortuary statistics alone. *Include*: (1) Indurated or infecting chancre; chancre of the mouth or face; primary accident or infection; (2) Secondary manifestations—mucous plaques; syphilitic amygdalitis; angina or laryngitis; (3) Tertiary manifestations—specific manifestations; gummata; ulcerations; exostoses, etc. Osteocopic pains; all these diseases to be specified as "syphilitic."—*Do not include*: Soft, simple, or phagedenic chancre (36a).
  - 36a. SOFT CHANCRE. *Include*: Chancroid; chancrelle; simple chancre; phagedenic chancre or bubo; bubo of soft chancre; venereal, virulent, or absorption buboes.—*Do not include*: Infecting or syphilitic chancre or bubo (36, 1); chancre of the mouth (36, 1); scrofulous bubo (35); suppurating bubo (144); plague bubo (15); bubo without qualification (144). (Morbidity statistics only.)
  37. BLENNORRHAGIA OF THE ADULT. *Include*: Blennorrhœa; gonorrhœa; ardor urinæ; urethritis; military drop; balanitis; balanorrhagia; balanoposthitis; vaginitis; gonorrhœal cystitis, orchitis, buboes, arthritis, rheumatism, or conjunctivitis of the adult; or gonorrhœal or blennorrhagic ophthalmia of the adult.—*Do not include*: Vaginismus (132); vaginalitis (126).—*Frequent complications*: Bubo; adenitis; cystitis; orchitis.
  38. GONORRHŒAL AFFECTIONS OF THE CHILD.<sup>1</sup> *Include*: Blennorrhagic or gonorrhœal conjunctivitis of the child (under five years of age); gonorrhœal vulvitis (of the child under five years).

<sup>1</sup> This title takes no account of children over five years of age.



39. CANCER AND OTHER MALIGNANT TUMORS OF THE BUCCAL CAVITY. *Include:* Cancer of the mouth or lips, or of the tongue, or the roof of the mouth, or the velum of the palate; cancer of the maxilla; epithelioma, or carcinoma, or cancrroid of these organs; smokers' cancer.
40. CANCER AND OTHER MALIGNANT TUMORS OF THE STOMACH AND LIVER.<sup>1</sup> *Include:* Cancer of the œsophagus; cancer of the cardia; cancer of the pylorus; carcinoma or scirrhus, or colloid or encephaloid tumor of these organs; gastrocanceroma; tumor of the stomach.—*Do not include:* Hæmatemesia (104).
41. CANCER AND OTHER MALIGNANT TUMORS OF THE PERITONEUM, INTESTINES, AND RECTUM. *Include:* Cancer of the colon; cancer of the anus; carcinoma, or scirrhus, or encephaloid, or cancrroid, or epithelioma of these organs.
42. CANCER AND OTHER MALIGNANT TUMORS OF THE FEMALE GENITAL ORGANS. *Include:* Cancer of the uterus; cancer of the womb; cancer of the vagina; cancer of the vulva; carcinoma, or encephaloid, or colloid tumor, or heteromorphous or neoplastic growth, or cancrroid, or sarcoma, or epithelioma of these organs.
43. CANCER AND OTHER MALIGNANT TUMORS OF THE BREAST. *Include:* Carcinoma, or scirrhus, or encephaloid, or heteromorphous or neoplastic growth, or cancrroid, or epithelioma of the breast or nipple.
44. CANCER AND OTHER MALIGNANT TUMORS OF THE SKIN. *Include:* Cancrroid (without qualification); epithelioma or epitheliomatous tumor (without qualification); cancer of the ear, of the face, or cervicofacial; "noli me tangere."—*Do not include:* Esthiomene (33); lupus (33).
45. CANCER AND OTHER MALIGNANT TUMORS OF OTHER ORGANS, AND OF ORGANS NOT CLASSIFIED. *Include:* Abdominal cancer; pelvic cancer; cancer of the lung, of the kidney, of the bladder, and of the prostate; cancerous goitre; thyrosarcoma; sarcohydrocele; cancer of the bone; osteosarcoma; cancerous or sarcomatous tumor of the neck; carcinoma, or scirrhus, or encephaloid, or cancerous ulcer, or malignant tumor, or sarcoma, or malignant fungus of these organs, or of other organs not specified.—*Do not include:* Cancer of the œsophagus (40); cancer of the anus (41); cancer of the ovary, vagina, or vulva (42).
46. OTHER TUMORS (Tumors of the Female Genital Organs excepted). *Include:* Tumor (without qualification); abdominal tumor; intestinal tumor; vascular or erectile tumor; angioma; lymphoma; lymphadenoma; lymphatocele; adenoma; chondroma; osteoma; myoma; lipoma; wen; grub; sebaceous tumor; cystoma.—*Do not include:* Cancer and its synonyms (40-45); tumor of the stomach (40); stercoraceous tumor (108); tumor of the uterus (129); hydatid tumor (111); cyst of the ovary (131); aneurismal tumor (81); varicose tumor (83); polyp of the ear (76); polyp of the nasal or nasopharyngeal fossæ (87); uterine polyp (129).
47. ACUTE ARTICULAR RHEUMATISM. *Include:* Rheumatic arthritis; rheumatic meningitis; abdominal or cerebral rheumatism; rheumatic vertigo; rheumatic endocarditis, pericarditis, pleurisy, or peritonitis.—*Do not include:* Organic diseases of rheumatic origin (79, etc.); rheumatic iritis (75); arthritis deformans (48); gonorrhœal rheumatism (37).

<sup>1</sup> In countries where the words "organic lesion of the stomach" always signify "cancer of the stomach" classify these diagnoses under No. 40. In countries where, on the contrary, this is not always so, classify them under No. 104.



48. CHRONIC RHEUMATISM AND GOUT. *Include:* Arthritis deformans.
49. SCORBUTUS. *Include:* Werlhoff's disease.
50. DIABETES. *Include:* Glycosuria.—*Frequent complications:* Pneumonia; anthrax; gangrene; cerebral hemorrhage and cerebral softening; tuberculosis.
51. EXOPHTHALMIC GOITRE. *Include:* Exophthalmia; Basedow's disease; Graves's disease; exophthalmic cachexia.—*Frequent complications:* Hypertrophy of the heart; cachexia.
52. ADDISON'S DISEASE. *Frequent complications:* Cachexia; ascites.
53. LEUKÆMIA. *Include:* Adenoleukæmia; leucocythæmia; Hodgkin's disease; pseudoleukæmia.—*Frequent complications:* Hemorrhage; ascites; apoplexy; cachexia.
54. ANÆMIA; CHLOROSIS. *Include:* Pernicious anæmia.—*Do not include:* Cerebral anæmia (74b).
55. OTHER GENERAL DISEASES. *Include:* Autointoxication; infectious fever; virulent disease (without explanation); visceral steatosis; acromegalia; amyloid or generalized fatty degeneration.
56. ALCOHOLISM, ACUTE OR CHRONIC. *Include:* Drunkenness; ethylism; alcoholic intoxication; alcoholic delirium; alcoholic dementia; delirium tremens; absinthism; absinthæmia; dipsomania.—*Do not include:* Alcoholic cirrhosis (112); general alcoholic paralysis (67); atheroma (81); or any other disease attributable to alcohol; intoxication amblyopia (75).
57. SATURNISM. *Include:* Saturnine colic; lead colic; painters' colic; lead encephalopathia; lead paralysis; chronic lead poisoning; all conditions characterized as "saturnine."
58. OTHER TRADE OR OCCUPATION INTOXICATIONS. *Include:* Mercurial (hydrargyrisim); phosphorus, arsenical, or other intoxication, when special mention by the physician makes it clear that the intoxication is the result of a trade. Failing in this specific declaration, it should be classed in one of the conditions under No. 59.
59. OTHER CHRONIC POISONINGS.<sup>1</sup> *Include:* Morphinism; cocainism; chronic ergotism.—*Do not include:* Amblyopia by intoxication (75).

## II. DISEASES OF THE NERVOUS SYSTEM AND OF THE ORGANS OF SPECIAL SENSE.

60. ENCEPHALITIS. *Include:* Cerebral fever.
61. SIMPLE MENINGITIS. *Include:* Meningitis (without qualification); meningoencephalitis; pachymeningitis.
- 61a. EPIDEMIC CEREBROSPINAL MENINGITIS. *Do not include:* Tuberculous meningitis (or other synonym) (28); rheumatic meningitis (47).
62. PROGRESSIVE LOCOMOTOR ATAXIA. *Include:* Duchenne's disease.
63. OTHER DISEASES OF THE SPINAL CORD. *Include:* Disease of the cord; sclerosis in plaques; symmetrical sclerosis; lateral sclerosis; sclerosis (without qualification); Charcot's disease; Morvan's disease; syringomyelitis; spasmodic tabes dorsalis; hemorrhage into the spinal cord; hæmatomyelitis; hæmatorrhachia; myelitis; medullary congestion; affections of the bulb; bulbar paralysis; spinal paralysis; paralysis agitans; trembling paralysis;

<sup>1</sup> Note the observation under the preceding title.



- ascending paralysis; essential paralysis of infancy; fatty or amyloid degeneration of the cord; Parkinson's disease; Friedreich's disease; medullary compression or compression of the cord; progressive muscular atrophy; fatty degeneration of muscles; atrophic muscular paralysis; amyotrophia; amyotrophic paralysis; atrophic paralysis; pseudohypertrophic paralysis.
64. CEREBRAL CONGESTION AND HEMORRHAGE. *Include:* Apoplexy; cerebral apoplexy; meningeal apoplexy; serous apoplexy; cerebral atheroma; oedema of the brain; cerebral effusion; cerebellar hemorrhage; meningeal hemorrhage; cataplexia; apoplectic dementia.—*Frequent complications:* Hemiplegia; paralysis.
65. CEREBRAL SOFTENING. *Do not include:* Senile dementia.—*Frequent complications:* Hemiplegia; paralysis; pulmonary congestion.
66. PARALYSIS WITHOUT SPECIFIED CAUSE. *Include:* Paralysis (without qualification); hemiplegia; facial paralysis; generalized paralysis (not to be confounded with general paralysis).—*Do not include:* Diphtheritic paralysis (9); atrophic muscular paralysis (63); general paralysis (67); paralytic cachexia or marasmus (67); paralytic dementia or idiocy (67); shaking or trembling paralysis (63); bulbar paralysis (63); ascending paralysis (63); essential paralysis of infancy (63); labioglossolaryngeal paralysis (74b); paralysis of the velum palati (101); paralysis of the muscles of the eye (53).
67. GENERAL PARALYSIS. *Include:* Paralytic lunacy; paralytic dementia; paralytic cachexia; paralytic marasmus; diffuse meningo-encephalitis; diffuse peri-encephalitis.—*Do not include:* Generalized paralysis (66).
68. OTHER FORMS OF MENTAL ALIENATION. *Include:* Dementia; lunacy; unsoundness of mind; hallucinations; mania; megalomania; monomania; delusions of persecution; melancholia; lypomania; nostalgia; spleen; nosophobia; necrophobia; sitiophobia; lycanthropy; homesickness; andromania; nymphomania; priapism; satyriasis; mental disease.—*Do not include:* Alcoholic dementia or delirium (56); delirium tremens (56); delirium (179); uræmic delirium (120); apoplectic dementia (64); paralytic dementia (67); choreic dementia (73); senile dementia (154); hysteria (74a).
69. EPILEPSY. *Include:* "Haut mal;" disease of Hercules.—*Do not include:* Epileptiform convulsions (70).
70. ECLAMPSIA (Non-puerperal).<sup>1</sup> *Include:* Epileptiform convulsions (of adults).—*Do not include:* Scarlatinous eclampsia (7); uræmic eclampsia (120); eclampsia of young infants (71).
71. CONVULSIONS OF CHILDREN.<sup>2</sup> *Include:* Eclampsia of young children; contractures of children.—*Do not include:* Trismus nascentium.
72. TETANUS. *Include:* Opisthotonos; emprosthotonos; pleurosthotonos; trismus nascentium.
73. CHOREA. *Include:* Choreic dementia; Bergeron's disease.
74. HYSTERIA. *Include:* Hysterical anorexia; hysterical colic; all diseases classified as "hysterical." (Morbidity statistics alone.)
- 74a. NEURALGIA. *Include:* Tic douloureux; sciatica. (Morbidity statistics alone.)
- 74b. OTHER DISEASES OF THE NERVOUS SYSTEM. *Include:* Cerebral compression, cerebral tumor; acquired hydrocephalus; neuroma; encephalopathia (with-

<sup>1</sup> When a female of child-bearing age is designated as having been stricken with "eclampsia," return the report to have the physician state whether or not the disease was puerperal.

<sup>2</sup> This title only applies to children under five years of age.



out qualification); idiocy; imbecility; cretinism; gatism (?); amnesia; paramnesia; loss of speech; aphasia; nervous or cerebral accidents; cerebral anæmia; neurosis; tic; convulsive tic; contracture; anæsthesia; neurasthenia; migraine; vertigo; somnambulism; catalepsy; boulimia; Landry's disease; symptomatic or Jacksonian epilepsy; athetosis; labioglossolaryngeal paralysis; amyloid or fatty degeneration of the nervous system.—*Do not include:* Senile dementia, imbecility or gatism (?) (154); syringomyelitis (63); myxœdema (89); congenital or undescribed hydrocephalus (150).

75. DISEASES OF THE EYE AND ITS ADNEXA. *Include:* Ophthalmia; foreign bodies; conjunctivitis (not including diphtheritic conjunctivitis); xerophthalmia; xerosis; pterygion; pinguecula; keratitis of every description; staphyloma; diseases of the cornea; arcus senilis; diseases of the sclerotic; diseases of the iris; iritis; diseases of the choroid; choroiditis; iridochoroiditis; sclerochoroiditis; glaucoma; diseases of the retina; retinitis; optic neuritis; amaurosis; amblyopia; amblyopia by intoxication; hemiopia; hemeralopia; nyctalopia; diseases of the lens; cataract; aphacia; parasites of the eye; ophthalmozoa; coloboma; strabismus; strabotomy; paralysis of the muscles of the eye; nystagmus; styas; chalazion; blepharitis; blepharoconjunctivitis; scrofulous blepharitis; blepharophimosis; blepharoplastia; ectropion; entropion; trichiasis; dacryoadenitis; diseases of the lachrymal gland and lachrymal sac; dacryocystitis; dacryolithiasis; dacryoma; lachrymal fistula; diseases and tumors of the orbit (cancer excepted).—*Do not include:* Diphtheritic conjunctivitis (9); cancer of the eye (45); ocular tuberculosis (33); exophthalmic goitre (51); exophthalmia (51).
- 75a. FOLLICULAR CONJUNCTIVITIS. (Morbidity statistics alone.)
- 75b. TRACHOMA. (Morbidity statistics alone.)
76. DISEASES OF THE EAR. *Include:* Otitis; otorrhœa; catarrh of the ear; hydro-titis; foreign body in the auditory canal; obstruction of the auditory canal; polyp of the ear; inflammation of the tympanum; "vertigo ab aure læso;" Ménière's disease, or vertigo; caries of the labyrinth (?); deafness; deaf-mutism.—*Do not include:* Mumps.

### III. DISEASES OF THE CIRCULATORY APPARATUS.

77. PERICARDITIS. *Include:* Cardiopericarditis; hydropericarditis; hydropneumopericarditis; pericardial adhesions.—*Do not include:* Rheumatic pericarditis (47); endopericarditis (78); pleuropericarditis (94); pneumopericarditis (93).
78. ACUTE ENDOCARDITIS. *Include:* Endocarditis (without qualification); myocarditis, acute or without qualification; endopericarditis.—*Do not include:* Rheumatic endocarditis, or the other cardiac accidents which may supervene in the course of an attack of rheumatism.
79. ORGANIC DISEASES OF THE HEART. *Include:* Aortic, mitral, tricuspid, or cardiac affection or lesion; cardiac or valvular insufficiency or stenosis of the valves of the heart; cardiac cachexia; hypertrophy of the heart; dilatation of the heart; cardiectasis; steatosis of the heart; degeneration of the heart; cardiopathy; cardiosclerosis; cardiovascular sclerosis; cardiomalacia; cardiostenosis; labored heart; tachycardia; rupture of the heart; cardior-



- rhexia; cardiac palpitations; asystole; cardiac asthma.—*Do not include:* Cardiac accidents (undetermined) (86); persistence or patency of the foramen of Botallo (150).—*Frequent complications:* Dropsy; bronchitis and pneumonia; albuminuria; embolism; thrombosis.
80. **ANGINA PECTORIS.** *Include:* Cardialgia; sternalgia; neuralgia of the heart.
81. **AFFECTIONS OF THE ARTERIES, ATHEROMA, ANEURISM, ETC.** *Include:* Arteritis; fatty degeneration of arteries; arteriosclerosis; atheroma of arteries; arteriectasis; aortic ectasis; Hodgson's disease; atresia of the pulmonary artery; aortitis; aneurismal tumor.—*Do not include:* Aortic affection (79).
82. **THROMBOSIS AND EMBOLISM.** *Include:* Thrombosis (non-puerperal); phlegmasia alba dolens (non-puerperal).—*Do not include:* Embolism (puerperal) (140).
83. **AFFECTIONS OF VEINS (Varices, Hemorrhoids, Phlebitis, etc.).** *Include:* Pneumophlebitis; varicose ulcer; varicocele.—*Do not include:* Puerperal phlebitis (137); vascular or erectile tumor (46); angioma (46).
84. **AFFECTIONS OF THE LYMPHATIC SYSTEM.** *Include:* Angioleucitis; adenopathy; lymphangitis.—*Do not include:* Suppurative adenitis (144); adenophlegmon (144); leucæmic adenitis (53); lymphatism (36a); bubo (36a); adenoma (46); lymphoma (46); lymphadenoma (46).
85. **HEMORRHAGES.** *Include:* Hemorrhage (without qualification); internal hemorrhage; hæmophilia; epistaxis; stomatorrhagia; cutaneous hemorrhage; purpura hæmorrhagica.—*Do not include:* Cerebral hemorrhage (64); cerebellar hemorrhage (64); meningeal hemorrhage (64); pulmonary hemorrhage (99); hæmoptysis (99); hæmatemesis (104); intestinal hemorrhage (109); hæmaturia (121); uterine hemorrhage (135 or 128, depending on whether it is or is not puerperal); metrorrhagia (128 or 135); umbilical hemorrhage (152); traumatic hemorrhage (166).
86. **OTHER AFFECTIONS OF THE CIRCULATORY APPARATUS.** *Include:* Cardiac accidents (undetermined); angiectasis; angiectopia; affections of the great vessels; permanently slow pulse.—*Do not include:* Vascular nævus (150).

#### IV. DISEASES OF THE RESPIRATORY APPARATUS.

87. **DISEASES OF THE NASAL FOSSÆ.** *Include:* Coryza; cold; polypus of the nasal or nasopharyngeal fossa; ozæna; abscess of the nasal fossa; adenoid vegetations.—*Do not include:* Epistaxis (85); syphilitic coryza (36).
88. **AFFECTIONS OF THE LARYNX.** *Include:* Acute, chronic, erysipelatous, œdematous, phlegmonous, or stridulous laryngitis; aphonia; loss of voice; false croup; spasmodic croup; stridulous croup; œdema of the glottis; spasm of the glottis; polypus of the larynx; stricture of the larynx; laryngotomy.—*Do not include:* Tuberculous laryngitis (26); laryngeal tuberculosis (26); croup (9); diphtheritic laryngitis and its synonyms (8); foreign bodies in the larynx (176).
89. **AFFECTIONS OF THE THYROID BODY.** *Include:* Goitre; pulsating thyrocele; myxœdema; pachydermic cachexia.
90. **BRONCHITIS, ACUTE.<sup>1</sup>** *Include:* Capillary bronchitis; tracheitis; tracheobronchitis; broncho-alveolitis.—*Do not include:* Bronchopneumonia (92); specific bronchitis or other synonym of pulmonary tuberculosis (see No. 27); fetid bronchitis (96); summer bronchitis (99).

<sup>1</sup> See note on No. 91.



91. BRONCHITIS, CHRONIC.<sup>1</sup> *Include:* Mucous bronchitis (pituitous); catarrh (without qualification); bronchial, pituitous, pulmonary, or suffocating bronchitis; bronchorrhœa; dilatation of the bronchi; bronchiectasis.—*Do not include:* Fetid bronchitis (96); tuberculous bronchitis (27).
92. BRONCHOPNEUMONIA. *Include:* Catarrhal pneumonia.—*Do not include:* Capillary bronchitis.
93. PNEUMONIA.<sup>2</sup> *Include:* Croupous pneumonia; fluxion of the lung; pleuropneumonia; pneumopleurisy; splenopneumonia; apical pneumonia; peripneumonia; pneumopericarditis; typhoid pneumonia.—*Do not include:* Caseous pneumonia (27); specific, bacillary, or any synonym of pulmonary tuberculosis (27); pulmonary congestion (95).
94. PLEURISY. *Include:* Pleuropericarditis; pleuritic or thoracic effusion; pneumothorax; hydropneumothorax; pyothorax; pleural vomica; pneumopyothorax; hæmothorax; thoracentesis; empyema; pleural adhesions.—*Do not include:* Pleurodynia (99).
95. PULMONARY CONGESTION AND PULMONARY APOPLEXY. *Include:* Œdema of the lungs.
96. GANGRENE OF THE LUNG. *Include:* Fetid bronchitis.
97. ASTHMA. *Do not include:* Cardiac asthma (79); suffocating catarrh (91); hay fever (99).
98. EMPHYSEMA OF THE LUNGS. *Include:* Emphysema (without qualification).—*Do not include:* Subcutaneous emphysema.
99. OTHER DISEASES OF THE RESPIRATORY APPARATUS (Phthisis excepted). *Include:* Tracheostenosis; pleurodynia; pneumopathy; hydatids of the lung; pulmonary calculus; abscess of the lung; pulmonary anthracosis; interstitial pneumonia; cirrhosis of the lung; secondary sclerosis; hay fever (summer bronchitis or catarrh). To be also included when their nature is not indicated: Organic lesion of the lung; pulmonary accidents; hæmoptysis; spitting of blood; pulmonary hemorrhage; pneumorrhagia; bronchorrhagia; tracheotomy.—*Do not include:* Cancer of the lung (45).

## V. DISEASES OF THE DIGESTIVE APPARATUS.

100. AFFECTIONS OF THE MOUTH AND ITS ADNEXA. *Include:* Diseases of the gums; epulis; gingivitis; ulorrhagia; glossitis; diseases of the tongue (except cancer); parotid tumor; parotiditis; salivary fistula; ranula; thrush; diseases of the teeth; odontalgia; dental caries; staphylitis; staphyloplasty; staphylorrhaphy.—*Do not include:* Cancer of the lips or tongue (39); chancre of the mouth (36a); noma (142); mumps (19); gangrene of the mouth (142); diseases of the palate (146 or 36); fracture of the maxilla (164); necrosis of the maxilla (146); paralysis of the velum palati (101).
101. AFFECTIONS OF THE PHARYNX. *Include:* Angina or Ludwig's disease; anginas of all descriptions (except diphtheritic angina and its symptoms; see Diphtheria, No. 9); amygdalitis; quinsy; abscess of the fauces, throat, or

<sup>1</sup> Return to the physician the reports given in as "bronchitis," in order that he may specify acute or chronic. When the physician fails thus to answer, classify under No. 90 all reports of children under five years of age, and under No. 91 all reports of those of greater age.

<sup>2</sup> In countries where "apical pneumonia" is always synonymous with "phthisis," class this diagnosis under No. 27. In countries, on the contrary, where this is not constant, class under No. 93.



- retropharynx; paralysis of the velum palati; elongation of the uvula; pharyngitis.—*Do not include:* Angina pectoris (80); cardiac angina (80); scarlatinal angina (7).
102. AFFECTIONS OF THE ŒSOPHAGUS. *Include:* Foreign bodies in the Œsophagus; wound of the Œsophagus; stricture of the Œsophagus (except from cancer); spasm of the Œsophagus; Œsophagotomy.—*Do not include:* Cancer of the Œsophagus (40); stricture of the Œsophagus, syphilitic (36).
103. ULCER OF THE STOMACH. *Include:* Round ulcer.—*Frequent complications:* Hæmatemesis; perforations of the stomach; peritonitis.
104. OTHER AFFECTIONS OF THE STOMACH (Cancer excepted).<sup>1</sup> *Include:* Dilatation of the stomach; paresis of the stomach; dyspepsia; apepsia; gastritis; gastrohepatitis; foreign body in the stomach; gastrotomy; perforation of the stomach (non-traumatic); gastralgia; "vertigo a stomacho læso;" catarrh of the stomach; indigestion. To be also included when their nature is not indicated: Gastrorrhagia; hæmatemesis; gastric hemorrhage.—*Do not include:* Gastro-enteritis (105 or 106, according to age).
105. DIARRHŒA AND ENTERITIS (under two years). *Include:* Gastro-enteritis or gastrocolitis of children; infantile enteritis; cholera infantum; athrepsia. This title only considers these ailments in children under two years.
- 105a. DIARRHŒA AND ENTERITIS, CHRONIC. *Include:* Athrepsia.
106. DIARRHŒA AND ENTERITIS (two years and over). *Include:* Gastro-enteritis or gastrocolitis of adults; enteritis of adults; diarrhœa of adults; lien-enteritis; intestinal ulcerations; colitis; intestinal colic; flatulent colic; inflammatory colic. *Do not include:* Tuberculous enteritis.
107. INTESTINAL PARASITES. *Include:* Helminthæ; oxyuri; tænia; solitary worm; ascaris lumbricoides; trematodes; trichocephalus; ankylostomes; colic from worms.
108. HERNIAS AND INTESTINAL OBSTRUCTIONS. *Include:* Internal strangulation; intestinal invagination; stercoral tumors; ileus; intestinal occlusion; volvulus; hernial colic; hernial gangrene. The following to be included when their nature is not specified: Merocele; sarco-epiplocele; sarco-epiplophalitis; kelotomy; herniotomy; artificial anus; stercoraceous vomiting.—*Do not include:* Laparotomy (without other qualification) (46).—*Frequent complication:* Peritonitis.
109. OTHER AFFECTIONS OF THE INTESTINES. *Include:* Paralysis or paresis of the intestine; enteroptosis; constipation; stercoræmia; intestinal calculi; intestinal perforation; foreign bodies in the intestine or rectum; rectitis. Include also the following diseases when their nature is not indicated, and these operations when their cause is not specified: Enterotomy; artificial anus; enterorrhagia; intestinal hemorrhage; melæna; prolapsus of the rectum; stricture of the rectum.—*Do not include:* Stercoral tumor (108); intestinal invagination and its synonyms (108); typhlitis (118); perityphlitis (118).
- 109a. DISEASES OF THE ANUS AND FECAL FISTULAS. *Include:* Proctitis; periproctitis; proctocèle; proctoptosis; fissure of the anus; abscess of the margin of the anus; fistula of the anus, either fecal or rectovaginal.—*Do not include:* Urinary fistulæ, even when these involve the rectum (124); artificial anus (108) (morbidity statistics alone); unnatural anus (108); imperforate anus (150). (For morbidity statistics alone.)

<sup>1</sup> See observation under No. 40 as to "organic lesion of the stomach."



110. **ICTERUS, GRAVE.** *Include:* Pernicious icterus; acute yellow atrophy of the liver; parenchymatous hepatitis; Weil's disease.—*Do not include:* Icterus (without qualification) (114); chronic icterus; icterus of the new-born (151).
111. **HYDATID TUMORS OF THE LIVER.** *Include:* Hydatid cyst; hydatids; echinococci.
112. **CIRRHOSIS OF THE LIVER.** *Include:* Cirrhosis (without qualification); alcoholic cirrhosis; interstitial cirrhosis; biliary cirrhosis; amyloid or fatty degeneration of the liver; slow atrophy of the liver; steatosis of the liver; alcoholic, interstitial, or chronic hepatitis.—*Do not include:* Organic lesion of the liver (114); hypertrophy of the liver (114).—*Frequent complications:* Dropsy; hemorrhage; pneumonia; tuberculosis.
113. **BILIARY CALCULI.** *Include:* Hepatic calculi; biliary lithiasis; hepatic colic.
114. **OTHER AFFECTIONS OF THE LIVER.** *Include:* Abscess of the liver; hepatitis; hepatitis, acute; angiocholitis; cholecystitis; hepatocystitis; choluria. To be also included when their precise nature is not indicated: Organic lesion of the liver; tumor of the liver; hypertrophy of the liver; acholia; cholæmia; icterus; chronic icterus; jaundice; hepatic congestion.—*Do not include:* Grave icterus (110); icterus of the new-born (151).
115. **AFFECTIONS OF THE SPLEEN.** *Include:* Splenitis; splenopathia; megalosplenism; splenocele.—*Do not include:* The affections of the spleen due to leukæmia or malaria.
116. **PERITONITIS, SIMPLE (Puerperal excepted).<sup>1</sup>** *Include:* Peritonitis (without qualification); peritonitis, chronic; peritoneal adhesions; epiploitis; metroperitonitis, pelvipерitonitis.—*Do not include:* Tuberculous peritonitis (29); cancer of the peritoneum (41); puerperal peritonitis (137); rheumatic peritonitis (47).
117. **OTHER AFFECTIONS OF THE DIGESTIVE APPARATUS (Cancer and Tubercle excepted).** *Include:* Diseases of the pancreas (cancer excepted).
118. **APPENDICITIS AND PHLEGMON OF THE ILIAC FOSSA.** *Include:* Iliac phlegmon or abscess; typhlitis; perityphlitis; typhlodiditis; appendicitis.—*Do not include:* Pelvic abscess (130); periuterine abscess (130); pelvic suppuration (130).

## VI. DISEASES OF THE GENITO-URINARY APPARATUS AND ITS ADNEXA.

119. **NEPHRITIS, ACUTE.** *Do not include:* Scarlatinous nephritis (7); chronic nephritis (120); tuberculous nephritis (33); nephritis of pregnancy (138).
120. **BRIGHT'S DISEASE.** *Include:* Chronic, albuminous, interstitial, or parenchymatous nephritis; albuminuria; amyloid or fatty degeneration of the kidney; amyloid kidney; steatosis of the kidney; renal sclerosis. To be included when their precise nature is not indicated: Uræmia; uræmic eclampsia; uræmic delirium; uræmic coma.—*Do not include:* Organic lesion of the kidney (121); puerperal uræmia (138); cardiac albuminuria (79).—*Frequent complications:* Anasarca; dropsy; convulsions; hemorrhages; cerebral apoplexy; pneumonia.

<sup>1</sup> When an adult female is returned as having been stricken with "peritonitis," without other explanation, the report should be returned in order that the physician may specify whether or not the condition was puerperal.



121. OTHER DISEASES OF THE KIDNEYS AND THEIR ADNEXA. *Include:* Pyelitis; anuria; renal congestion; renal ectopia; nephroptosis; floating, motile, or displaced kidney; movable kidney; renal cysts; polycystic kidney; hydro-nephrosis; hæmaturia; perinephritis; perinephritic abscess; pyelonephritis; nephropyosis. To be also included when their nature is not specified: Organic lesion of the kidney; nephrorrhagia.
122. CALCULI OF THE URINARY TRACT. *Include:* Renal, ureteral, nephritic, vesical, or urinary calculus; nephritic colics; nephrolithiasis; gravel; stone; calculary affections; urinary lithiasis; lithotritry; lithoclasty.—*Do not include:* Prostatic calculus (125).
123. DISEASES OF THE BLADDER. *Include:* Cystitis, acute or chronic; vesical or ureteral catarrh; cystorrhagia; tumor of the bladder; cystocele; cystop-tosis; foreign body in the bladder; section; cystotomy; retention of urine; dysuria; paralysis of the bladder; vesical inertia; incontinence of urine; tenesmus of the bladder.—*Do not include:* Hæmaturia (121); urinary fistulæ, even when they involve the bladder (124); cystosarcoma (45).
124. DISEASES OF THE URETHRA. *Include:* Urinary abscess, etc.; ankylurethria; foreign bodies; urethrotomy; urinary fistula (urethral, urethrorectal, vesico-rectal, or vesicometrorectal); urinary infiltration; urinary intoxication; urethralgia; urethrorrhagia; urinæmia; stricture of the urethra; urethrostenosis; urethroplasty; urethrorrhaphy.—*Do not include:* Urethral catarrh (123); retention of urine (123).
125. DISEASES OF THE PROSTATE. *Include:* Hypertrophy of the prostate; prostatitis; abscess of the prostate; prostatic calculus.—*Do not include:* Cancer of the prostate (45); tubercle of the prostate (33).
126. NON-VEREAL DISEASES OF THE GENITAL ORGANS OF THE MALE. *Include:* Phimosis; paraphimosis; amputation of the penis; seminal losses; spermatorrhœa; orchitis; epididymitis; funiculitis; hydrocele; hæmatocele of the testicle, cord, or scrotum; castration (in man); Malassez's disease.—*Do not include:* Cancer of the testicle (45); tubercle of the testicle (33); sarcohydrocele (45); syphilitic sarcocele (36); varicocele (83).
127. METRITIS. *Include:* Ulcer of the uterus; ulceration of the neck (of the womb).
128. UTERINE HEMORRHAGE, NON-PUERPERAL. *Include:* Metrorrhagia; menorrhagia; tamponage of the vagina or uterus.
129. UTERINE TUMOR (not cancerous). *Include:* Fibroid tumor, or fibroid body of the uterus; hysteromyoma; uterine polypus; fungus or fungoid tumors of the uterus.
130. OTHER DISEASES OF THE UTERUS. *Include:* Ulcerations of the neck; uterine or vaginal catarrh; deviation, anteflexion, retroflexion, anteversion, falling or prolapse of the uterus; prolapse of the vagina; uterine prolongation; amenorrhœa; hypertrophy of the neck of the uterus; dysmenorrhœa; organic lesion of the uterus; hysterectomy; hysterotomy; metrotony; ablation of the uterus; abscess of the pelvis; periuterine or retro-uterine abscess or phlegmon; pelvic suppuration; Huguier's disease; leucorrhœa; fluor albus (whites; vaginal flow; white flux).—*Do not include:* Puerperal diseases; abscess of the iliac fossa (95).
131. CYSTS AND OTHER TUMORS OF THE OVARY. *Include:* Ovariectomy; castration (in the female).



132. OTHER DISEASES OF THE GENITAL ORGANS OF THE FEMALE. *Include:* Vaginitis; tumors of the vagina; ovaritis; salpingitis; salpinx; metrosalpingitis; hæmatosalpinx; pyosalpinx; abscess and tumors of the vulvovaginal glands; vulvitis; periuterine or retro-uterine hæmatocele.—*Do not include:* Urinary fistulæ (124); stercoral fistulæ (109a); even when they involve the genital organs.
133. NON-PUERPERAL DISEASES OF THE BREAST (Cancer excepted). *Include:* Mammitis; abscess of the breast (non-puerperal); cyst of the breast; cystic diseases of Reclus; tumor of the breast (without qualification, or non-cancerous); amputation of the breast.—*Do not include:* Fistula of the breast (puerperal, or without qualification) (43).

## VII. THE PUERPERAL STATE.

REMARKS.—It often happens that physicians neglect to note the puerperal character of the disease; hence the following rule for the guidance of those whose duty it is to collect statistics. "Whenever an adult female is noted as having been affected with a disease which *may* be puerperal, the report should be returned to the reporter, in order that he may state explicitly whether or not the disease was puerperal." The following are these diseases: Peritonitis; pelviperitonitis; metropéritonitis; septicæmia; hemorrhage; metrorrhagia; eclampsia; phlegmasia alba dolens; phlebitis; lymphangitis; embolism; sudden death; abscess of the breast.

134. ACCIDENTS OF PREGNANCY. *Include:* Miscarriage (death of mother); abortion (death of mother); hemorrhage of pregnancy; incoercible vomiting; rupture of tubal pregnancy; ablation of the pregnant tube; difficulties and fatigues supervening in the course of pregnancy.
- 134a. LABOR, NORMAL. (Morbidity statistics only.)
135. PUERPERAL HEMORRHAGE. *Include:* Metrorrhagia, puerperal.
136. OTHER ACCIDENTS OF LABOR. *Include:* Dystocia; Cæsarean section; rupture of the uterus; metrorrhæxia; laceration or rupture of the perineum; perineorrhaphy; placenta prævia; malposition, retention, detachment, or apoplexy of the placenta; cephalotripsy; embryotomy (adult); symphyseotomy; version; application of forceps; uterine inversion.
137. PUERPERAL SEPTICÆMIA. *Include:* Puerperal fever; puerperal infection; puerperal endometritis; puerperal salpingitis; perimetrosalpingitis, or phlegmon of the broad ligament, or diffuse pelvic puerperal cellulitis; puerperal peritonitis, metropéritonitis, phlebitis, lymphangitis, or pyohæmia.—*Do not include:* Septicæmia (without qualification) (20).
138. ALBUMINURIA AND PUERPERAL ECLAMPSIA. *Include:* Puerperal uræmia; nephritis of pregnancy; eclampsia of women in labor; epileptiform convulsions of women in labor; puerperal tetanus.
139. PHLEGMASIA ALBA DOLENS, PUERPERAL. *Do not include:* Phlegmasia alba dolens, non-puerperal (82).—*Frequent complications:* Gangrene; embolism.
140. OTHER PUERPERAL ACCIDENTS; SUDDEN DEATH. *Include:* Puerperal embolism; puerperal thrombus; sudden death in the puerperium; consequence of labor (without other explanation).—*Do not include:* Sudden death, non-puerperal (178); puerperal scarlatina (7).
141. PUERPERAL DISEASES OF THE BREAST. *Include:* Fissure of the nipple (puerperal); circumscribed abscess; abscess of the breast (puerperal); fistula of the breast (puerperal or without further indication).



## VIII. DISEASES OF THE SKIN AND CELLULAR TISSUE.

142. GANGRENE. *Include*: Eschar; sphacelus; gangrene, dry; gangrene, senile; gangrene of the extremities; gangrene of the mouth; gangrene of the vulva, etc.; noma; Raynaud's disease.—*Do not include*: Gangrene of the lung (96); hernial gangrene (108); gangrenous erysipelas (144).
143. FURUNCLE (Carbuncle).<sup>1</sup> *Do not include*: Biskra, Aleppo, or Medina button.
144. PHLEGMON; WARM ABSCESS. *Include*: Abscess (without qualification); phlegmonous tumor; adenophlegmon; suppurative adenitis; bubo (without qualification); suppurating bubo; diffuse phlegmon; phlegmonous or gangrenous erysipelas; panaris; whitlow; abscess of the mediastinum; vomica (without any other indication).—*Do not include*: Bacillary abscess (33); abscess of the fauces, throat, or retropharynx (101); of the liver (114); of the iliac fossa (118); of the pelvis (130); of the prostate (125); urinary (124); periuterine (14); of the breast, non-puerperal (130); cold (31); by congestion (31); ossifluent (31); angioleucitis (84).
145. TINEA FAVUS. (Morbidity statistics alone.)
- 145a. TINEA TONSURANS, TRICHOPHYTON. *Include*: Tinea (without qualification). (Morbidity statistics alone.)
- 145b. PELADES. (Morbidity statistics alone.)
- 145c. ITCH. (Morbidity statistics alone.)
- 145d. OTHER DISEASES OF THE SKIN AND ITS ADNEXA. *Include*: Erythema; urticaria; prurigo; pityriasis; lichen; psoriasis; dermatitis; eczema; impetigo; aphtha; herpes; ecthyma; elephantiasis Arabum; pachydermatitis; polysarcia; scleroderma; cheloids; fungoid mycosis; seborrhœa; trophoneuroses; zona; Wardrop's disease; Biskra, Aleppo, or Medina button; Pendine ulcer; Cochin-China ulcer; pemphigus; myiasis.—*Do not include*: Pachydermatous cachexia (89); elephantiasis Græcorum (17).

## IX. DISEASES OF THE ORGANS OF LOCOMOTION.

146. AFFECTIONS OF THE BONES (Non-tuberculous). *Include*: Periostitis; periostosis; osteitis; osteoperiostitis; osteomyelitis; caries; necrosis; sequestrum; perforation of the palatine vault; necrosis of the maxilla (non-phosphoric or without qualification); exostosis (without qualification); osteoma; osseous tumor; cranial tumor; foreign bodies in the frontal or other sinuses; mastoiditis; abscess of the frontal or maxillary sinus; osteomalacia; softening of bone; rhachitis; scoliosis; lordosis; kyphosis.—*Do not include*: Caries of the petrous bone (76); dental caries (100); osteocopic pains (36c); osteosarcoma (45); phosphorus necrosis (58).
147. ARTHRITIS AND OTHER DISEASES OF THE JOINTS (Tuberculosis and Rheumatism excepted). *Include*: Arthritis; polyarthritis (non-vertebral); hydrarthrosis; foreign bodies in joints; arthrodynia; arthropyosis; arthrophytis; ankylosis; arthralgia; arthrocele; genu valgum.—*Do not include*: Rheumatic arthritis (47).
148. AMPUTATION. *Include*: Only those cases in which the lesion, the cause for amputation, is not specified.—*Do not include*: Amputation of the breast

<sup>1</sup> The word "anthrax" will be taken in the sense in which it is ordinarily employed in each country, as for example: in French-speaking countries, as "an aggregation of furuncles" (143); and as "malignant pustule" (22) in Russia.



(133); amputation of the penis (126).—*Frequent complications:* Septicæmia; erysipelas; tetanus; hemorrhage.

149. OTHER AFFECTIONS OF THE ORGANS OF LOCOMOTION. *Include:* Hygroma; perichondritis; disarticulation; tarsalgia; painful talipes valgus; retraction of the fingers or of the palmar aponeurosis; Dupuytren's disease; non-traumatic muscular rupture; muscular diastasis; myodiastasis; non-traumatic rupture of a tendon; diseases of tendons; tenophytes; tenosynovitis; tenotomy; tenorrhaphy; torticollis; lumbago; curvature.

### X. MALFORMATIONS.

150. MALFORMATIONS (Stillbirths not included). *Include:* Malformation; monstrosity; anomaly; arrest of development; congenital hydrocephalus; hydrocephalus (without qualification); megaloccephalus; hydrorachia; spina bifida; encephalocele; podencephalia; congenital eventration; omphalocele; exomphalos; ectopia; imperforate anus, etc.; hare-lip; cleft palate; anaspadias; hypospadias; cryptorchid; vascular nævus; polydactylia; syndactylia; congenital club-foot; talipes valgus, varus, or equinus, congenital; congenital deafness or blindness; persistence of the foramen of Botallo (foramen ovale).—*Do not include:* Coloboma (75); painful flat-foot (149); acquired hydrocephalus (74b).

### XI. EARLY INFANCY.

- 150a. THE NEW-BORN AND NURSINGS DEPARTING FROM HOSPITALS WITHOUT HAVING BEEN SICK. (Morbidity statistics alone.)
151. CONGENITAL DEBILITY, ICTERUS, AND SCLEREMA.<sup>1</sup> *Include:* Premature birth; atrophy (infantile); icterus or hepatitis of the new-born; atelectasis of the lungs in the new-born; œdema of the new-born.
152. OTHER DISEASES OF EARLY INFANCY. *Include:* Umbilical hemorrhage; inflammation of the umbilicus; cyanosis of the new-born. (This title has reference to children not more than three months old.)
153. LACK OF CARE.

### XII. OLD AGE.

154. SENILE DEBILITY. *Include:* Senility; old age; cachexia (of the old); senile exhaustion; senile dementia.—*Do not include:* Senile gangrene (142).

### XIII. AFFECTIONS PRODUCED BY EXTERNAL CAUSES.

Among suicides there should only be classed those in whom suicide or attempted suicide is clearly demonstrated. In collective suicides there should only be counted those who have attained their majority. Minors ought to be regarded as the victims of assassination.

155. SUICIDE BY POISON. *Include:* Voluntary poisoning; voluntary absorption of sulphuric acid (or any other corrosive substance).
156. SUICIDE BY ASPHYXIA. *Include:* Suicide by the vapor of charcoal.
157. SUICIDE BY HANGING OR STRANGULATION. *Include:* Hanging.
158. SUICIDE BY DROWNING.
159. SUICIDE BY FIREARMS.
160. SUICIDE BY CUTTING INSTRUMENTS.



- 161. SUICIDE BY JUMPING FROM HIGH PLACES.
- 162. SUICIDE BY CRUSHING.
- 163. OTHER SUICIDES.
- 164. FRACTURES. *Include:* Separation of the epiphyses; fracture of the cranium.
- 165. SPRAINS. *Include:* Strains; stretching of ligaments. (Morbidity statistics alone.)
- 165a. LUXATIONS. *Include:* Subluxations.
- 166. OTHER ACCIDENTAL TRAUMATISMS. *Include:* Stabs; contusion; bites (non-venomous, non-virulent); crushing; railroad accidents (suicide excepted); wounds by cutting instruments (suicide not demonstrated); accidental falls; concussion of the brain; perforation of the cranium; traumatic hemorrhage; traumatic fever; traumatic eventration; perforation of the abdomen or chest; all acute affections designated as "traumatic;" wounds by firearms.
- 167. BURNS AND SCALDS. *Include:* Burns and scalds; burns from steam; from petroleum.—*Do not include:* Conflagration.
- 168. BURNS FROM CORROSIVE SUBSTANCES. *Include:* Burns by vitriol.
- 169. INSOLATION. *Include:* Sunstroke.
- 170. FREEZING. *Do not include:* Effects of cold (new-born) (153).
- 171. ELECTRICAL DISTURBANCES. *Include:* Death from lightning.
- 172. ACCIDENTAL SUBMERSION. *Include:* Drowning (non-suicidal).
- 173. PROSTRATION. *Include:* Fatigue. (Morbidity statistics alone.)
- 173a. INANITION. *Include:* Hunger; insufficient food (new-born excepted); misery.—*Do not include:* Lack of care (new-born) (153); lack of nutrition (new-born) (153); sitiophobia (68); hysterical anorexia (74a).
- 174. ABSORPTION OF DELETERIOUS GASES (Suicide excepted). *Include:* Asphyxia, accidental (pathological asphyxia and suicidal asphyxia excepted); asphyxia by illuminating gas; asphyxia by stoves (fixed or portable); absorption of carbonic oxid; conflagration; absorption of ammonium sulphid; asphyxia by night-soil; absorption of chloroform; absorption of nitrous oxid.—*Do not include:* Asphyxia of the adult (without qualification) (179).
- 175. OTHER ACUTE POISONINGS. *Include:* Every acute poisoning (suicide excepted); antimony cholera; acute ergotism; absorption of venom; bite of serpent; accidental absorption of sulphuric acid or other corrosive substances.—*Do not include:* Saturnism (57); hydrargyrisms, etc. (58 or 59); morphinism, chronic ergotism, etc. (59).
- 176. OTHER EXTERNAL VIOLENCE. *Include:* Accident (without other qualification); bad treatment (upon a child); capital punishment; foreign body in the larynx; foreign body in the trachea.

#### XIV. ILL-DEFINED DISEASES.

The following titles will include only those conditions ill-defined by the physician, whether from lack of sufficient data, or because the disease was ill-defined, or because the physician was negligent in making a complete diagnosis.

- 177. DROPSY. *Include:* Anasarca; ascites; œdema of the extremities or generalized œdema; organic lesion (not defined).—*Do not include:* Œdema of the new-born (151); œdema of the glottis (88); œdema of the lungs (95); œdema of the brain (64).



178. **SUDDEN DEATH.** *Include:* Syncope (followed by death).—*Do not include:* Puerperal sudden death (140), nor sudden death followed by an explanation, as "diabetic" (30) or "apoplectic" (64).
179. **ILL-DEFINED OR UNSPECIFIED CAUSES OF DEATH.** *Include:* Exhaustion or cachexia or debility (of adults); asthenia; adynamia; ataxo-adynamia; coma; asthenic, hectic, colliquative, synochal, gastric, bilious, or pituitary fever; gastric involvement; fever of detention; paralysis of the heart (in German "herzlahmung" or "herzschlag," in English "heart failure"); cyanotic asphyxia (without indicated cause, the new-born excepted); or any other insufficient diagnosis.—*Do not include:* Exhaustion, cachexia or debility of the old (154); fever, ataxo-adynamic, continued, summer, or hay (99); asphyxia by external cause (156 or 174); cyanosis of the new-born (152).

An endeavor is now being made to adopt the following death certificate throughout America.

## RETURN OF A DEATH IN THE CITY OF PHILADELPHIA.

### Physician's Certificate.

1. Full Name of Deceased, .....
  2. Color, ..... State if { Chinese,  
Japanese,  
Indian.
  3. Sex, .....
  4. Single, Married, ..... State if { Widow,  
Widower,  
Divorced.
  5. Age, { Years, .....  
Months, .....  
Days, ..... 6. Date of Death. { Year, .....  
Month, .....  
Day, .....
- (If age is less than one day, give hours.....)
7. Cause of Death, { Chief, .....  
Contributing, .....

No Certificate will be accepted which is **MUTILATED, ILLEGIBLE, INACCURATE**, or any portion of which has been **ERASED, INTERLINED, CORRECTED**, or **ALTERED**, as all such changes impair its value as a Public Record.

*This Certificate must not be issued for any other purpose than as a report to the Board of Health. Should the Physician issue a duplicate, it must be distinctly marked "Duplicate," and state why issued.*

.....M.D.

Residence, .....



# INDEX



(The Roman numeral letters refer to chapters ; the Arabic numeral figures to pages.)

## A

Abdominal cavity, diseases of organs of,  
vi, xi, xii, xiii, xiv, xxii, xxvii,  
xxviii, xxix  
exposure of, vi  
removal of organs of, xi, xix, xx  
superficial examination of organs  
of, vi  
Abortion, criminal, 314  
Abscess of brain, 183  
liver, 162  
lung, 97  
perinephric, 149  
subdiaphragmatic, 144  
Acarus scabiei, 239  
Acromegaly, 183  
Actinomyces, 209  
Addison's disease, 130  
Adrenalin, 129  
Adrenals, diseases of, 129  
examination of, 129  
measurements of, 276  
removal of, 129  
situation of, 124  
weight of, 276  
Air-embolism, 99  
Air-passages, upper, examination of, 93,  
193  
Amyloid kidneys, 145  
liver, 157  
Anæmia cerebri, 184  
of brain, 184  
lungs, 99  
progressive pernicious, 79  
Anatomical wart, 44, 237  
Anchylostomum duodenale, 240  
Aneurisms, 90, 184  
Angular method of removing skullcap,  
166  
Anomalies of brain, congenital, 186  
cord, congenital, 186  
Anopheles, 241

Anthrax, 210  
Aorta, 144  
Apoplexia neonatorum, 184  
Apoplexy, cerebral, 187  
of lungs, 102  
Appendicitis, 120  
Arachnoid, 169  
Arteries, morbid changes in, 88  
Arteriosclerosis, 88  
Asthma, 97  
Ataxia, hereditary, 185  
locomotor, 185  
Atelectasis, 97  
Atrophy, acute yellow, of liver, 157  
progressive spinal muscular, 190  
Autopsy, see Postmortem

## B

Bacteriological investigations, xxiv  
Basedow's disease, 102  
Beriberi, 211  
Bertillon classification, 348  
Bile ducts, 136, 138  
Biologic blood-test, 323  
Bladder, diseases of, xiii  
Blood-diseases, 79  
Blood, lesions of, viii  
Blood-stains, 322  
Blood-tests, 323  
Blood-vessels, lesions of, viii  
Bodies, examination of exterior of, v  
frozen, 207  
identification of, 308  
pecuniary value of, 4  
preservation of, 206  
removal of portions of, 5  
restoration of, 203  
right to dispose by will of, 4  
Bothriocephalus latus, 239  
Bowel, inflammation of large, 124  
Brain, abscess of, 183



- Brain, anæmia of, 184  
 diseases of, xvii  
 examination of, xv  
     Dejerine's method, 173  
     Giacomini's method, 178  
     Hamilton's method, 176  
     Meynert's method, 173  
     Pitres's method, 175  
     Virchow's method, 172  
 hyperæmia of, 188  
 preservation of, Kaiserling's method, 178  
 removal of, 169  
     in child, 198  
 syphilis of, 227  
 tuberculosis of, 232  
 weight of, 271  
 Bronchiectasis, 98  
 Bronchitis, 98  
 Brown atrophy of heart, 76  
     induration of lungs, 99  
 Brunetti's chisels, 32  
 Bucket method of opening intestines, 116  
 Burials, premature, 315  
 Burns, 320

## C

- Caisson disease, 185  
 Calcicosis, 108  
 Calculi, renal, 150  
     vesical, 152  
 Calvarium, clamps for holding, 34  
     removal of, 166  
 Capsule of kidney, removal of, 128  
 Cephalic cavity, inspection of, xv  
 Chantemasse, bacillus of, 122  
 Charcot-Leyden crystals, 97  
 Chisels, 31  
 Chloroform narcosis, 144, 331  
 Chlorosis, 80  
 Cholecystitis, acute infectious, 158  
 Cholelithiasis, 159  
 Cholera Asiatica, 211  
 Chorea, acute, 186  
 Cimex, 238  
 Circular method of removing skullcap, 165  
 Circulatory system, syphilis of, 227  
     tuberculosis of, 233  
 Cirrhosis of liver, 159  
 Clamps for holding calvarium, 34

- Clothing, care of, 309  
 Cœliac plexus, 130  
 Cold, death from, 319  
 Colitis, 124  
 Colon, dilatation of, 125  
 Color of parts, 16  
 Common bile duct, 138  
 Comparative postmortems, xxvi  
 Complications of diseases causing death, xxix  
 Congenital defects of kidneys, 145  
 Congestion of kidneys, 145  
     liver, 161  
     passive, of lungs, 100  
 Considerations, general, i  
 Cord, diseases of, xvii  
     examination of, xvi  
     removal of, xvi  
     syphilis of, 227  
     tuberculosis of, 232  
 Cornell head-rest, 34, 164  
 Coronary arteries, 70  
 Coroner's cases, 5  
     office, establishment of, 305  
 Corpus delicti, 309  
 Cretinism, 186  
 Cryoscopy, 324  
 Culture media, inoculating, 265  
 Curschmann's spirals, 97  
 Cystic disease of kidneys, 146  
 Cysticercus cellulosæ, 239  
 Cystitis, 151  
 Cytology, 325

## D

- Death, ascertainment of the cause of, 2  
     no cause found for, 2  
     signs of, 315  
     usual causes of, 316, xxix  
     violent, 317  
 Decomposition, post-mortem, 48, 317  
 Delirium, acute, 186  
 Dengue, 212  
 Diabetes insipidus, 83  
     mellitus, 83  
 Diabetic blood, reaction for, 324  
 Diaphragm, 144  
 Diarrhœa, summer, cause of, 122  
 Differentiation, optical, 247  
 Diphtheria, 212  
 Diseases, nomenclature of, 348



## Diseases of adrenals, 129

aorta, 144  
 arachnoid, 169  
 bile ducts, 136  
 bladder, xiii  
 brain, xvii  
 common bile ducts, 138  
 cord, xvii  
 coronary arteries, 70  
 diaphragm, 144  
 duodenum, 138  
 dura, 168  
 ears, xviii  
 eyes, xviii  
 Fallopian tubes, 153  
 gall-bladder, 136  
 gall-ducts, 157, xiv  
 heart, viii  
 intestines, xi  
 kidneys, 145  
 larynx, 95, 228, 234  
 liver, 157  
 lungs, x  
 meninges, 189  
 mesentery, 121  
 nasal cavities, xviii  
 new-born, xix  
 œsophagus, 140  
 omentum, 112  
 orbits, 194  
 ovary, 154  
 oviducts, 153  
 pancreas, 142  
 pericardium, 67  
 peritoneum, 112  
 pharynx, 95  
 portal vein, 136  
 prostate, 134  
 psoas muscle, 144  
 retroperitoneal glands, 144  
 semilunar ganglia, 130  
 spermatic vessels, 134  
 spinal canal and cord, xvi  
 spleen, 114  
 stomach, 140  
 testicles, 156  
 ureter, 130  
 urethra, 134  
 uterus, 154  
 vagina, 156

## Dissecting wounds, iv

## Disseminated sclerosis, 191

Distomiasis, 240  
 Dourine, 243  
 Duke's disease, 219  
 Duodenum, 138  
 Dura mater, 168  
 Drowning, 320  
 Dysentery, 122  
   acute catarrhal, 122  
   amœbic, 123  
   chronic, 123  
   complications of, 123  
   gangrenous, 123

**E**

Ears, examination of, xviii  
 Echinococcus disease, 241  
 Electricity, death by, 318  
 Embalmed bodies, 206  
 Embolism, air, 99  
   fat, 99  
 Embryos, length of, at different ages, 268,  
   280  
 Emphysema of liver, 161  
   lungs, 100  
 Encephalitis, 186  
 Encephalon, examination of, xv  
 Endarteritis obliterans, 89  
 Endocarditis, 87  
 Engines, dental and trephining, 28  
 Enterotome, 29  
 Epiglottis, examination of, 95  
 Erysipelas, 214  
 Expert testimony, 306  
 Exterior of body, examination of, v  
 Extra-uterine pregnancy, 153  
 Exudate, 59  
 Eyes, examination of, xviii

**F**

Face, examination of, xx  
 Fallopian tubes, diseases of, xiii  
 Fat embolism, 99  
 Fatty changes in liver, 161  
 Fever, glandular, 214  
   paratyphoid, 119  
   typhoid, 118  
 Filaria sanguinis hominis, 240  
 Fixatives, 246, 256  
 Foot-and-mouth disease, 214  
 Formad pocket-case, 38



Framboesia, 215  
 Friedreich's ataxia, 185  
 Fright, 144  
 Frozen bodies, 206

**G**

Gall-bladder, 136  
 Gall-ducts, diseases of, xiv  
 Gall-stones, 159  
 Gangrene of lungs, 101  
 Gastritis, 141  
 Gastro-intestinal tract, syphilis of, 227  
 General considerations, i  
 Genitalia, female, removal of, 132  
     male, removal of, 134  
 Genito-urinary system, tuberculosis of, 233  
 German measles, 222  
 Glanders, 214  
 Goitre, 101  
     exophthalmic, 102  
 Gonorrhœal infection, 216  
 Gout, 84  
 Graduated cones, 35  
 Graves's disease, 102

**H**

Hæmatomyelia, 187  
 Hæmatozoa, diseases due to, xxii  
 Hæmophilia, 81  
 Hæmoptysis, causes of, 99  
 Hammers, 31  
 Hands, care of, iv  
 Hanging, 320  
 Hardening, 255  
 Harke's method, 193  
 Hay fever, 97  
 Heart, actinomycosis of, 88  
     amyloid degeneration of, 89  
     anomalies of, 76  
     characteristics of, 76  
     degeneration of, 86  
     dilatation of, 85  
     dimensions of, 273  
     diseases of, viii  
     examination of, 69  
     hypertrophy of, 85  
     infiltration of, 86  
     lesions of, viii  
     removal of, 71  
     syphilis of, 88  
     tuberculosis of, 88

Heart, tumors of, 88  
     valvular diseases of, 88  
     volume of, 274  
     weight of, 273  
 Heat, death from, 319  
 Height, 267  
 Hemiplegia in children, 187  
 Hemorrhages, 85  
     cerebral, 187  
     into spinal membranes, 188  
     of lungs, 102  
     pulmonary, 102  
 Hepatitis, suppurative, 162  
 Hereditary ataxia, 185  
 Hey's saw, 26  
 Hide-bound skin, 224  
 Hydronephrosis, 146  
 Hydrophobia, 216  
 Hydrostatic lung test, 345  
 Hyperæmia, cerebral, 188

**I**

Identification of the body, 308  
 Illumination, 12  
 Infanticide, 320  
 Infants, autopsies on, 312  
 Infarcts of kidney, 146  
     lungs, 99, 102  
 Influenza, 217  
 Injection, preservative, 207  
 Instruments, proper and improper, iii  
     to be taken to postmortem, 36  
     use of, iii, 24  
 Insular sclerosis, 191  
 International system of nomenclature of  
     diseases and causes of death, 348  
 Interstitial nephritis, 147  
 Intestines, diseases of, 116  
     gall-stones in, 120  
     hemorrhage of, 120  
     removal of, 115  
     worms in, 120  
 Intra-uterine gestation, period of, 313

**K**

Kaiserling method, 261  
 Kidneys, 125  
     amyloid changes in, 145  
     congenital defects of, 145  
     congestion of, 145  
     cystic disease of, 146



Kidneys, diseases of, xii  
 examination of, 128  
 hydronephrosis of, 146  
 infarcts of, 146  
 movable, 148  
 opening of, 127  
 parasites of, 148  
 removal of, 126  
 stones of, 150  
 syphilis of, 227  
 tuberculosis of, 233  
 tumors of, 150  
 weights and measures of, 275  
 Knife, method of holding, 38  
 Knives, 24  
 Koch controversy, 282  
 Kromskopic pictures, 2

L

Large bowel, 125  
 Laryngitis, cedematous, 102  
 Larynx, removal of, 95  
 syphilis of, 228  
 tuberculosis of, 234  
 Leontiasis ossea, 184  
 Leprosy, 218  
 Leptomenigitis, acute, cerebrospinal, 188  
 chronic diffuse, 189  
 deep chronic, 189  
 Leucocythæmia, 80  
 Leukæmia, 80  
 Light, artificial, 7  
 Lithosis, 108  
 Liver, 136  
 abscess of, 162  
 acute yellow atrophy of, 157  
 amœbic abscess of, 123  
 amyloid degeneration of, 157  
 cancer of, 158  
 cirrhosis of, 159  
 congestion of, 161  
 dimensions of, 275  
 disease of, xiv  
 emphysema of, 161  
 fatty changes in, 161  
 sarcoma of, 162  
 syphilis of, 228  
 tumors of, besides cancer and sarcoma, 163  
 volume of, 275  
 weight of, 274

Lividity, post-mortem, 48  
 Longitudinal sinus, 168  
 Luer's rhachiotome, 27  
 Lungs, abscesses of, 97  
 air-embolism of, 99  
 anæmia of, 99  
 apoplexy of, 102  
 atelectasis of, 97  
 brown induration of, 99  
 circulatory disturbances of, 99  
 dimensions of, 274  
 diseases of, x  
 emphysema of, 100  
 examination of, ix  
 fat embolism of, 99  
 gangrene of, 101  
 hemorrhage of, 102  
 infarcts of, 99, 102  
 œdema of, 99  
 passive congestion of, 100  
 removal of, 93  
 syphilis of, 109, 228  
 tuberculosis of, 109, 234  
 tumors of, 110  
 volume of, 274  
 weight of, 274  
 Lupus vulgaris, 237  
 Lymphatic glands, tuberculosis of, 235  
 Lymph-glands, retroperitoneal, 144

M

Malaria, 241  
 Mal de caderas, 243  
 Malta fever, 219  
 Mammary gland, tuberculosis of, 236  
 Measles, 219  
 German, 222  
 Measures, xxv  
 Medicolegal postmortems, 311, xxviii  
 suggestions, xxvii  
 Meningitis, acute cerebrospinal, 189  
 Meningo-encephalitis, 189  
 Mesentery, disease of, 121  
 Micromegaly, 184  
 Micro-organisms, diseases due to, xxii  
 Miliary tuberculosis of the lungs, 110  
 Morbilli, 219  
 Movable kidney, 148  
 Müller's fluid, 250  
 Mumps, 220  
 Muscular atrophy, progressive spinal, 190



Myelitis, acute, 190  
     from compression, 190  
 Myelotome, 25  
 Myiasis, 240  
 Myocarditis, 86

## N

Nagana, 243  
 Narcosis, 144, 331  
 Nasal cavity, examination of, 201  
 Nasopharynx, examination of, xviii  
 Necropsy, see Postmortem  
 Nematodes, 240  
 Nephritis, interstitial, 147  
     parenchymatous, 148  
 New-born, examination of, xix  
 Noma, 109  
 Nomenclature of causes of death, xxix  
 Notes, taking of, 1, 2, 14

## O

Obligations of physicians to their patients, 305  
 Odor of parts, 17  
 Œdema of lungs, 99  
 Œsophagus, 140  
     examination of, 95  
 Omentum, 112  
 Oral cavity, examination of, 201  
 Orbits, examination of, 194  
 Organs, characteristics of, 14  
 Osmic acid, 253  
 Osteitis deformans, 184  
 Osteo-arthritis, hypertrophic pulmonary, 184  
 Ovaries, diseases of, xiii  
     weight and measures of, 278  
 Oviducts, 134, 153  
 Oxyurus vermicularis, 240

## P

Pancreas, 142  
     weight and measures of, 277  
 Pancreatitis, 143  
 Parasites, 148, 238  
     diseases due to, xxii  
 Paratyphoid fever, 119  
 Parenchymatous nephritis, 148  
 Pediculi, 238  
 Pelvic organs, 132  
 Penetration, 247  
 Pericarditis, 68

Pericardium, 67  
 Perinephric abscess, 149  
 Peristalsis, reversed, 119  
 Peritoneum, 112  
     cancer of, 112  
     tuberculosis of, 236  
 Peritonitis, 112  
 Permission to perform postmortem, 4  
     method of obtaining, 4  
 Pharynx, 95  
 Phthisis, 110  
 Pia mater, removal of, 169  
 Pick's myelotome, 25  
 Placenta, weight of, at different ages, 268  
 Plague, 220  
 Pleuræ, diseases of, x  
     examination of, ix  
 Pleurisy, 102  
 Pneumonia, 104  
     catarrhal, 107  
     and croupous, differences between, 107  
     chronic interstitial, 104  
     croupous and catarrhal, differences between, 107  
     complications of, 105  
     lesions of, 105  
     terminations of, 105  
     lobar, 105  
 Pneumonoconiosis, 108  
 Pneumothorax, 108  
 Poison, definition of, 326  
 Poisoning by acids, 328  
     aconite, 329  
     alcohol, 329  
     alkalies and caustic salts, 330  
     antimony, 330  
     arsenic, 330  
     atropine, 331  
     carbon monoxid, 332  
     chloral hydrate, 331  
     cocaine, 331  
     copper, 331  
     cyanide of potassium, 332  
     ergot, 331  
     formaldehyd, 332  
     hydrocyanic acid, 332  
     illuminating gas, 332  
     lead, 333  
     mercury, 333  
     methyl alcohol, 333



- Poisoning by nitrobenzol, 333  
 opium, 333  
 pellagra, 334  
 phosphorus, 334  
 potassium chlorate, 334  
 ptomain, 335  
 silver nitrate, 335  
 snakes, 335  
 strychnine, 335  
 suspected, 311  
 toadstool, 335
- Poisons, classification of, 328
- Poliomyelitis, acute anterior, 191
- Portal vein, 136
- Postmortems, additions to account of, 2  
 cleanliness at, 8  
 comparative, xxvi  
 definition of, 1  
 general considerations of, 1  
 in hospital, 8  
   morgues, 8  
   private house, 8  
 instruments for, 36  
 interval to elapse before performance  
   of, 6  
 legal right to perform, 3  
 made before dressing, 7  
   by artificial light, 7  
 medicolegal, 311  
 on anatomical cases, 5  
 operations at, 3  
 order of examination, 18  
 permission for, 4  
   method of obtaining, 4  
 place of making, 7  
 preparation for, 8  
 Prussian regulations for the perform-  
   ance of medicolegal, 336  
 purpose of, 1  
 record books, forms for, 20, 22  
 restricted, xx  
 room, furnishings of, 9  
 study anatomy at, 3  
 synonyms of, 1  
 time of making, 6  
 treatment of wounds at, 40
- Post-mortem decomposition, 48  
 instruments, i  
 lividity, 48  
 note-taking, i  
 records, i, 14
- Post-mortem rigidity, 48  
 table, 8  
 wounds, iv
- Potassium bichromate, 249
- Preservation of bodies, xxi  
 tissues, xxiii
- Prostate, 134  
 weight and measures of, 279
- Prussian regulations, 336
- Psilosis, 225
- Psoas muscles, 144
- Psorospermiasis, 242
- Pulex, 238
- Purpura, 82
- Pyelitis, 149
- Pyelonephritis, 149
- R**
- Rabic tubercle, 217
- Radio-activity of dead bodies, 313
- Raspatory, 32
- Raynaud's disease, 191
- Records of postmortems, 14
- Rectal enema, reversed peristalsis after,  
 119
- Rectum, 115, 132
- Regulations, Prussian, 336
- Relapsing fever, 221
- Restoration of body, xxi
- Retroperitoneal lymph-glands, 144
- Reversed peristalsis, 119
- Rhachiotome, 27
- Rheumatic fever, 222
- Rheumatism, chronic, 222
- Rigidity, post-mortem, 148
- Rigor mortis, ante-natal, 312
- Rötheln, 222
- Rubber gloves, 35
- Rubella, 222
- Rubeola, 219
- S**
- Salpingitis, 154
- Sarcoma of the liver, 162
- Sarcoptes scabiei, 239
- Satterthwaite's calvarium clamp, 33
- Saws, 26
- Scalds, 320
- Scalp, 164
- Scarlet fever, 222
- Scissors, 29



- Scleroderma, 224  
 Sclerosis, disseminated, 191  
     insular, 191  
 Scurvy, 82  
     infantile, 83  
 Semilunar ganglia, 130  
 Serous membranes, tuberculosis of, 236  
 Serum blood-test, 323  
 Shiga, bacillus of, 122  
 Siderosis, 108  
 Silicosis, 108  
 Skin, tuberculosis of, 237  
 Skull and brain, examination of, xv  
     examination of, 165  
     shape of, 270  
     thickness of, 166  
     types of, 270  
 Smallpox, 224  
 Smear preparations, 263  
 Spermatic vessels, 134  
 Spinal canal and cord, xvi  
 Spine, 225  
 Spleen, diseases of, 114  
     removal of, 113  
     weight and measures of, 277  
 Starvation, death by, 320  
 Statistics, morbidity and mortuary, 348  
 Stegomyia, 238  
 Stomach, 140  
     contents of, 139  
     hemorrhage of, 142  
     removal of, in cases of poisoning, 139  
 Stomatitis, 108  
 Stones of kidney, 150  
 Strangulation, 320  
 Suffocation, 320  
 Suggestions, medicolegal, xxvii  
 Suprarenals, see Adrenals  
 Surra, 243  
 Syphilis, 225  
 Strygomyelia, 191
- T**
- Tabes dorsalis, 185  
 Tænia flavopunctata, 239  
     saginata, 239  
     solium, 239  
 Testes, syphilis of, 229  
     weight and measures of, 278  
 Testicles, diseases of, xiii  
 Tetanus, 229
- Thoracic cavity, examination of, vii, 64  
     inspection of, 65  
     duct, 144  
 Thrush, 229  
 Thymus gland, weight and measures of, 277  
 Thyroid gland, arsenic in, 331  
     examination of, 95  
     weight and measures of, 278  
 Tissues, preservation of, 244  
 Tongue, removal of, 95  
 Tonsils, removal of, 95  
 Toxicology, 325  
 Trachea, examination of, 95  
 Transudate, 59  
 Trichina spiralis, 240  
 Trichosis vesicæ, 151  
 Trypanosoma, 243  
 Tuberculosis, 229  
 Tuberculous ulcers, 118  
 Typhoid fever, 237  
     ulcers, 118
- U**
- Ulcers of intestine, typhoid, 118  
     tuberculous, 118  
 Uncinariasis, 240  
 Ureters, 130  
     situation of, 125  
     tying of, in operations, 130  
 Urethra, 134  
 Urine, collection of, 132  
 Use of post-mortem instruments, i  
 Uterus, diseases of, xiii  
     opening of, 133  
     weight and measures of, 279
- V**
- Vagina, diseases of, xiii  
 Valentine knife, 25  
 Vena cava, 144  
 Vesical calculi, 152  
 Viability, determination of, 312
- W**
- Wart, anatomical, 44, 237  
 Weights, xxv  
 Wounds, treatment of post-mortem, 40
- Y**
- Yellow fever, 238















