

Outlines of gynaecological diagnosis : for the use of students and practitioners in making examinations / by N.T. Brewis.

Contributors

Brewis, N. T.
Royal College of Physicians of Edinburgh

Publication/Creation

Edinburgh : W.F. Clay, 1894.

Persistent URL

<https://wellcomecollection.org/works/rwvt4e3g>

Provider

Royal College of Physicians Edinburgh

License and attribution


This material has been provided by This material has been provided by the Royal College of Physicians of Edinburgh. The original may be consulted at the Royal College of Physicians of Edinburgh. where the originals may be consulted.

This work has been identified as being free of known restrictions under copyright law, including all related and neighbouring rights and is being made available under the Creative Commons, Public Domain Mark.

You can copy, modify, distribute and perform the work, even for commercial purposes, without asking permission.



Wellcome Collection
183 Euston Road
London NW1 2BE UK
T +44 (0)20 7611 8722
E library@wellcomecollection.org
<https://wellcomecollection.org>



x⁴ Feb 3. 58

R37845




Digitized by the Internet Archive
in 2015

<https://archive.org/details/b21958506>



OUTLINES OF
GYNÆCOLOGICAL DIAGNOSIS.



OUTLINES
OF
GYNÆCOLOGICAL
DIAGNOSIS.

*FOR THE USE OF STUDENTS AND PRACTITIONERS
IN MAKING EXAMINATIONS.*

BY

N. T. BREWIS, M.B., C.M., F.R.C.P.E.,

LECTURER ON GYNÆCOLOGY, EDINBURGH SCHOOL OF MEDICINE; GYNÆCOLOGIST TO THE
NEW TOWN DISPENSARY; FORMERLY ASSISTANT TO THE LATE GYNÆCOLOGICAL
PHYSICIAN, EDINBURGH ROYAL INFIRMARY.



WITH ILLUSTRATIONS.

EDINBURGH: WILLIAM F. CLAY,

18 TEVIOT PLACE.

1894.

EDINBURGH: PRINTED FOR WILLIAM F. CLAY,
18 TEVIOT PLACE

LONDON: SIMPKIN, MARSHALL, HAMILTON, KENT AND CO., LIMITED.

[*All Rights Reserved.*]

THIS BOOK

IS

DEDICATED TO THE MEMORY OF

MY LATE MASTER,


DR. ANGUS MACDONALD,

TO WHOSE THOROUGHNESS AS AN INSTRUCTOR,

AND KINDNESS AS A FRIEND,

I AM UNDER A LIFELONG DEBT OF

OBLIGATION.



PREFACE.

DIAGNOSTIC skill in disease of the female pelvic organs is more difficult to acquire than in that of any other branch of medicine.

This difficulty is due to the concealed position of these organs which, for the recognition of disordered conditions, require an experience not easily obtained, owing to reluctance on the part of the patient to submit to examination, and to the inevitable want of opportunities of investigation on the part of the student. In like manner the teacher has scanty material at his disposal, and finds it no easy task to give the thorough instruction which the importance of the subject deserves.

The following pages contain the outlines of the course of instruction in practical Gynæcology I have given during the last seven years, and are published to supply the want I have felt of a simple handbook to aid those who wish to be able to examine a gynæcological case in a systematic and intelligent manner.

I must express my indebtedness to Professor Schultze for kindly allowing me to reproduce several illustrations from his book on "Displacements of the Uterus."

N. T. BREWIS.

23 RUTLAND STREET,
EDINBURGH, *January 1894.*

CONTENTS.

CHAPTER I.

HISTORY.

	PAGE
<i>History of</i> —Present Illness—Menstruation—Intermenstrual Discharge—Pregnancies—Miscarriages—Parturition—Puerperia—Lactation—Pareunia—Micturition—Defæcation. General Health, Previous Illnesses, and Family Health,	1-6

CHAPTER II.

PHYSICAL EXAMINATION.

General Appearance—State of Mammæ—The Abdomen—Inspection, Palpation, Percussion, Auscultation and Mensuration of the Abdomen—Inspection of the External Genitals,	7-16
---	------

CHAPTER III.

PHYSICAL EXAMINATION—*continued.*

The Vagina—The Vaginal Portion of the Cervix—The Fornices,	17-28
--	-------

CHAPTER IV.

PHYSICAL EXAMINATION—*continued.*

Bimanual Examination—The Double Bimanual—Abdomino-Vaginal Examination—Palpation of the Uterus, The Ovaries, The Fallopian Tubes, The Broad Ligaments, The Utero-Sacral Ligaments, The Round Ligaments, The Ovarian Ligaments, and The Pouch of Douglas—Rectal and Abdomino-Rectal Examination,	29-43
--	-------

CONTENTS.

CHAPTER V.

PHYSICAL EXAMINATION—*continued.**Instrumental Aids to Diagnosis.*

	PAGE
Vaginal Specula—Sim's, Trelat's, Cusco's, Ferguson's—Anal Specula—The Volsella—The Uterine Sound—Cervical Dilators—The Curette—The Aspirator—Exploratory Incision,	44-58

CHAPTER VI.

PHYSICAL EXAMINATION—*continued.*


The Urethra—Palpation, Exploration—The Bladder—Passing the Catheter—Inspection and Palpation of the Bladder—Exploration of the Interior of the Bladder, by Sound, by Finger, by means of Specula, by Electric Illumination—The Ureters—Inspection, Palpation, and Catheterisation of,	59-68
---	-------

PHYSICAL EXAMINATION OF OTHER SYSTEMS.

DIAGNOSIS.

LIST OF ILLUSTRATIONS.

FIG.	PAGE
1. Bimanual palpation of the uterus in the position it normally occupies when bladder and rectum are empty. (SCHULTZE),	19
2. Retro-position of the uterus from peritoneal adhesions. (SCHULTZE),	20
3. Pathological anteversion. (SCHULTZE),	21
4. Retro-uterine hæmatocele. (SCHROEDER),	22
5. Retroflexion of the uterus. Relaxation of utero-sacral ligaments. (SCHULTZE),	23
6. Lateral version of the uterus. (SCHULTZE),	27
7. Prolapse of the uterus. (SCHULTZE),	33
8. Pelvic inlet, showing position of ovary. (Modified from SCHULTZE),	35
9. Right ovary at side of uterus. Left ovary in pouch of Douglas. (SCHULTZE),	37
10. Sim's speculum,	45
11. Trélat's speculum,	47
12. Cusco's speculum,	48
13. Ferguson's speculum,	48
14. Brewis' volsella,	50
15. Prof. A. R. Simpson's sound,	53
16. Sim's dilator,	54
17. Hegar's dilator,	55
18. Tupelo tent,	56
19. Martin's curette,	57
20. Passing the catheter,	61



OUTLINES
OF
GYNÆCOLOGICAL DIAGNOSIS.

CHAPTER I.

HISTORY.

To diagnose disease of the female genital organs in a given case, one must consider the information obtained—1st, from the History; 2nd, from the Physical Examination.

The former is told by the patient, and its exactness depends on her intelligence and veracity; while the latter is made by the examiner, its accuracy depending on his skill.

It is essential that every case be investigated systematically. For this purpose we recommend the following scheme:—

Name and Address of Patient.

Age.—Age is of special importance in connection with the accession of menstruation and of the menopause. Certain growths are prevalent at certain ages.

Occupation.—Women of the working-class, whose household or other duties are laborious, and who do

not get sufficient rest at their confinements, are prone to suffer from displacements and inflammations of the pelvic organs.

Married, Single, or Widow.—In the married the diseases we have to investigate are usually those following childbirth or abortion. In the single, disordered menstruation is generally the complaint. When the patient is a widow we must ascertain whether her illness began during widowhood or married life.

Length of time married.

Number of children—Number of miscarriages—Date of last birth or miscarriage.—The date of the last birth or miscarriage is all-important, being frequently the starting point of disease.

Complaint.—This should be taken down as nearly as possible in the patient's own words, provided they convey an intelligible meaning.

History of Present Illness.

Note when and how the illness commenced, and trace its course down to the present time. Obtain history, and record carefully any abnormality in—

MENSTRUATION.

Age at commencement.—In this country it usually appears for the first time about the age of fourteen; it may begin earlier in girls who are accustomed to an in-door and indolent life. It is delayed in the anæmic, and in those whose pelvic organs are defectively developed.

Periodicity.—Menstruation most frequently recurs every twenty-eight days; it is then called the twenty-eight day type. It may recur every twenty-one or thirty days, forming respectively the twenty-one and the thirty day types.

Duration is from two to eight days—if less than two or more than eight days, disease is indicated.

Amount.—The amount of discharge is estimated at from two to nine ounces. If fewer than six or more than eighteen napkins are soiled, the amount may be considered abnormal.

Character.—At the commencement of the period the discharge is slight in quantity and pale in colour. On the second or third day it is more copious and is bright red, but non-coagulable, owing to the admixture of mucus. After the third or fourth day it gradually ceases, again becoming lighter in colour. The presence of clot or membrane in the discharge must be noted.

Pain before, during, or after the flow.—Premenstrual pain is said to point to disease of the uterine appendages. Pain during the flow indicates uterine affection.

Date of last period.—This must always be obtained. Pregnancy is the first thing to be thought of when a patient has missed a period.

Date of Menopause.—The menopause usually takes place about the age of forty-five. It may be premature, as in defective development and in superinvolution of the uterus; or delayed, as when fibroid disease is present.

INTERMENSTRUAL DISCHARGE.

Amount.—A certain amount of white discharge is physiological; when it occurs in quantity sufficient to necessitate the use of napkins it is pathological.

Colour.—It may be white, yellow, yellow streaked with red, or red.

Odour.—Fœtid in malignant disease.

Consistence.—Thin and watery in corporeal endometritis and chlorosis; sticky in endocervicitis; thick and creamy in vaginitis.

Persistence.—Ascertain whether the discharge is present during a part or the whole of the intermenstrual period.

PREGNANCIES.

Note the number of pregnancies, the length of the interval between each, and whether the number is, as it should be, in direct proportion to the duration of the patient's married life. A woman who has had several children in rapid succession is said to be liable to malignant disease of the cervix. The health of the patient during her pregnancies, especially the last, should also be inquired into.

MISCARRIAGES.

The patient must be questioned regarding the number she has had, their ages—*i.e.*, the months or weeks to which pregnancy had advanced when they took place, the dates of their occurrence, their apparent cause, and the influence which they exerted

on her subsequent health. There is no more frequent source of pelvic disease than a miscarriage, consequently the history of such must always be carefully gone into.

PARTURITION.

Note the character of the labours, their duration and severity, and whether instrumental or other operative interference was necessary.

PUERPERIA.

Health during recovery from labours, especially the last. As displacements and inflammation of the uterus and surrounding parts frequently originate during the puerperium, it is important to discover if any symptoms were complained of, such as rigor (weed), feverishness, or pain.

LACTATION.

Inquire whether patient suckled her children or not. Ascertain the state of her general health, whether menstruation occurred, and if pelvic pain was present during lactation. The duration of lactation should also be recorded.

PAREUNIA.

In some cases it is necessary to find out if there is pain during coitus (dyspareunia).

MICTURITION.

Frequency.—In acute cystitis a patient may micturate every quarter of an hour.

Pain.—Pain during micturition points to urethritis, urethral caruncle, &c. Pain after the act is generally due to cystitis.

Dribbling away of urine occurs as a symptom of retention when there is incarceration of the retroflexed gravid uterus; also in uterine prolapse. A constant involuntary flow of urine indicates a vesical or urethral fistula. In enuresis the patient micturates involuntarily from time to time.

Character of urine.—Note the quantity secreted, its reaction, specific gravity, and appearance. Examine it chemically and microscopically.

DEFÆCATION.

Make inquiries about the state of the bowels as to constipation, diarrhœa, pain during or after the act, bleeding, &c. When the perineal body and anal sphincter are torn through the patient may suffer from incontinence of fæces.

General Health, Previous Illnesses, and Family Health.

Obtain a short history of the general health of the patient; of her former illnesses, especially those bearing on the present complaint. Inquire into the health of the various members of her family.

CHAPTER II.

PHYSICAL EXAMINATION.

In conducting a gynæcological examination there are some considerations which it is well to bear in mind:—

1. Respect the sensibility of your patient. Remember that in submitting to an examination the patient in many cases has to exercise a great amount of courage. Let there be as little exposure as is consistent with an accurate diagnosis.

2. Avoid inflicting physical pain. Your touch must be gentle and light. Perfect development of the sense of touch is what the gynæcologist requires most. A perfect touch is a light one, and is the only one by which information can be obtained. The more pressure used in an examination the more the patient resists, and the more difficult is it to recognise the structures aimed at.

3. Examine with clean hands, the finger-nails of which must be short.

4. Do not examine a young unmarried girl unless the symptoms are urgent. If no anæsthetic be used, examine per rectum.

5. Before an examination is made the rectum and bladder should be emptied. The time for conducting

such is in the intermenstrual period, but it may be necessary to examine during a period which is abnormally prolonged.

General Appearance.

Note the size of the patient, her configuration, expression, complexion, and diathesis.

State of Mammæ.

Development.—The size of the breast depends chiefly on the amount of adipose tissue.

Consistence.—The glandular tissue is recognised by its firmness. Where there is much fat the breasts are soft and flabby. Note change of consistence produced by tumours, &c.

The Presence of Secretion in the breast, and of striæ in the skin covering it, are valuable signs of pregnancy.

State of Nipples.—Normally the nipple forms a conical projection on the surface of the mamma. It is frequently depressed. Mark the presence of fissures, ulcers, eczema, psoriasis, &c.

Areola.—In virgins the areola is pink in colour, the surface being studded over with tubercles. During gestation the areola darkens and the tubercles hypertrophy.

The Abdomen.

The Abdomen is examined by means of Inspection, Palpation, Percussion, Auscultation, and Mensuration.

INSPECTION.

During inspection the patient lies on her back with the lower limbs extended.

The Contour.—In a well-nourished woman the contour is convex or rounded. This convexity is regularly increased in obesity, flatulent distension, or when the pregnant uterus, uterine ovarian or other tumour, uniformly distends the abdomen. It is irregularly increased by swellings, rendering prominent some portion of the normally convex surface. In a woman of more spare habit, the lower part of the abdomen may be flat and the upper part rounded. In the emaciated, the surface may be depressed as a whole, *e.g.*, as occurs in stricture of the pylorus. A localised swelling may make some part of a depressed surface prominent.

The Position of a swelling is noted in regard to the abdominal region it occupies. The regions are made by drawing vertical lines upwards from the middle of Poupart's ligament to the eighth costal cartilage on each side, and by transverse lines at the level of the ninth costal cartilages and the anterior superior iliac spines respectively. These lines divide the abdomen into nine regions, which are well known to every student. Their names and contents are as follows:—

Right hypochondriac.—Right lobe of liver, gall-bladder, first part of duodenum, hepatic flexure of colon, right suprarenal capsule, part of right kidney.

Epigastric.—Stomach (centre and pylorus), liver, pancreas.

Left hypochondriac.—Stomach (cardiac end), spleen, tail of pancreas, splenic flexure of colon, left suprarenal capsule, part of left kidney.

Right lumbar.—Ascending colon, small intestine, second part of duodenum, part of right kidney.

Umbilical.—Great omentum, transverse colon, third part of duodenum, small intestines.

Left lumbar.—Descending colon, small intestine, part of left kidney.

Right iliac.—Cæcum, vermiform appendix, right broad ligament, ovary, Fallopian tube.

Hypogastric.—Small intestines, bladder in distension and in children, fundus uteri when bladder is distended.

Left iliac.—Sigmoid flexure of colon, left broad ligament, ovary, Fallopian tube.

Size of any swelling.—When a swelling is present, causing increased convexity, its size may be estimated by comparing it to the pregnant uterus at a certain month, or by the distance that its upper margin reaches above or below the umbilicus. It is perhaps, however, more exact to ascertain its size by mensuration.

Shape of any swelling.—The shape of any swelling or of the uniformly distended abdomen may be noted—as the somewhat ovoid shape of the pregnant uterus, or an ovarian cyst, the flat surface with bulging flanks of ascites.

The condition of the umbilicus is to be observed, whether it is retracted or projected; also the *appearance of the skin*, if smooth or streaked, pigmented or covered by eruptions. Streaks are either white or purplish red, and show that the fibrils of the rete Malpighii have been ruptured. White streaks indicate remote, while purplish red denote recent stretching. These streaks are not pathognomonic of pregnancy, as any condition distending the abdomen may produce them. Further points to be noticed are herniæ, enlarged veins, the separability of the recti muscles, the movements of respiration, of peristalsis, and of the fœtus; also the pulsations of the aorta.

PALPATION.

By palpation we feel the abdominal contents through the anterior abdominal wall. The patient now lies with her knees drawn up. The localisation of the organs contained within the abdominal cavity must be kept in mind. It is well also to remember one or two topographical facts, *e.g.*, that when a patient lies on her back the anterior abdominal wall almost touches the spine; that the umbilicus lies over the second last lumbar vertebra, and that the aortic bifurcation is one inch, and the promontory of the sacrum two inches, lower down.

In order that the abdominal contents may be felt, the resistance offered by the abdominal wall should be abolished. To accomplish this the examiner asks the patient to breathe deeply, and diverts her atten-

tion by conversation. Deep respiration and the act of speaking prevent rigidity of the abdominal muscles, but this rigidity can be mastered by palpation itself if performed with a gentle touch and warm hands. Cold hands or forcible palpation cause the muscles to contract and harden, while warm hands and a gentle touch are agreeable to the patient, and the resistance that is at first experienced is soon overcome by pawing the surface. In palpating the whole of the palmar surface is laid on the abdomen, and by alternately depressing and raising the hands over different parts of the surface the resistance disappears, and, in a normal case, the contents communicate to the fingers the sensation of kneaded dough. Thick abdominal walls render palpation difficult, and inflammatory conditions of the abdominal contents make it impossible from the pain caused by the pressure of the hands.

Palpation is specially useful in diagnosing tumours. When there is a swelling the examiner must bear in mind the possibility of its being functional, and not pathological.

The hypogastrium may be distended by an oval swelling, which the catheter will prove to be an over-filled bladder. A movable tumour of doughy consistence, easily indented by the finger, may be felt in any part of the abdomen, and be made to disappear by a brisk purgative. The physiological enlargement of the uterus by pregnancy must first be thought of in all cases of abdominal swelling.

By palpation we endeavour to make out the position, dimensions, connections, mobility, shape, condition of the surface, and the consistence of any swelling. A tumour may occupy the whole or a part of the abdomen. In the latter case the position and dimensions are noted by referring to the regions before mentioned. In many instances we are able to get the greater part of a tumour between our hands, but it should be remembered that, in a number of cases, we can only feel the more superficial parts of the swelling, for, the deeper parts being out of reach, their extent cannot be estimated. The connections of a swelling to adjacent structures can often be felt with considerable distinctness. The pedicle connecting a subperitoneal fibroid with the body of the uterus, the pedicle of an ovarian or other tumour, peritoneal bands, &c., are sometimes easily palpated through the abdominal wall. Such connections, however, are usually better made out by combined internal and external examination, and frequently become more apparent to the fingers in the vagina when the tumour is pulled on from above.

Palpation tells us whether a tumour is movable or fixed, and gives an idea of its shape. The condition of the surface of a tumour, whether smooth, rough, nodular, or corrugated is easily recognised by the finger tips. Palpation reveals the consistence of a tumour—if hard, soft, elastic, solid, semi-solid, or fluid. By it we detect fluctuation and fluid thrill. If there

is fluctuation the examiner must elicit if it is confined to parts of the swelling, as in multilocular cysts, or if free to travel from one side of the tumour to the other, as in monolocular growths. In practising fluid thrill one hand is placed on a particular part of the swelling, and when a point opposite is smartly tapped with the fingers of the other hand a sharp impulse is communicated to the one held against the tumour. Fluid thrill differs from fluctuation in that the wave travels quicker. It is well marked in parovarian tumours. Pain on pressure, friction, pulsations, foetal, and intestinal movements can also be determined by palpation.

PERCUSSION.

Percussion gives information concerning the relations of the hollow viscera to intra-abdominal swellings, and to free fluid in the peritoneal cavity. Tumours usually grow towards the anterior abdominal wall; free fluid seeks the lowest point, and when a patient lies on her back gravitates towards the loins. In the case of the former a dull note is elicited in front, while in the flanks the note is resonant. Change of position does not alter the percussion note. When free fluid is present the note is dull in the flanks, while in front it is tympanitic, because the intestines rise towards the anterior abdominal wall. Change of attitude alters the note. A tumour and free fluid may co-exist. Then the note is dull in the flanks as well as over the surface of the tumour.

In percussing the abdomen it is best to do so along definite lines. Percuss along a line from the symphysis to the ensiform cartilage; along lines from the umbilicus to the anterior superior iliac spines (ilio-umbilical lines); along lines from the umbilicus to each flank; and along lines from the umbilicus to the eighth costal cartilage on each side. By this method we can map out with exactitude the position of any dull area.

AUSCULTATION.

Auscultation is of most importance in the diagnosis of pregnancy and of fibroid tumours. In both conditions the uterine souffle is heard, whilst in the former the foetal heart sounds may be detected after gestation has advanced to four and a-half months. Other sounds heard are the aortic beat, intestinal murmurs, and friction.

MENSURATION.

Mensuration is of value in noting the size, the rapidity, and direction of growth of abdominal tumours.

The chief measurements are:—

1. The circumference of the abdomen at the umbilicus.
2. The greatest circumference of the abdomen.
3. The distance from the symphysis to the umbilicus, and to the ensiform cartilage.

4. The distance from the umbilicus to the right and left anterior superior iliac spines respectively.

Inspection of the External Genitals.

This is resorted to whenever the examiner suspects specific disease, and when the symptoms complained of point to a vulvar affection.

CHAPTER III.

VAGINAL EXAMINATION.

It is usual in this country to make this examination in the *left lateral position*. This method possesses one advantage—namely, that the patient, lying on her side with her face directed away from her examiner, feels her situation less keenly than if on her back; and for this reason it may be more politic to make the first vaginal exploration in such a position. But as the bi-manual succeeds the vaginal examination, and requires the patient to be in the dorsal decubitus, and as the fornices are best explored in that position, the *dorsal is to be preferred to the lateral*.

In this examination we use one or two fingers of one hand, and explore the parts from the vulvar orifice to the vaginal roof. The structures lying above the vault of the vagina cannot be palpated with the fingers of one hand alone. To feel them both hands are necessary.

In conducting the vaginal examination, it is best to describe the parts in order from below upwards. If you are going to examine with your right hand, stand at the right side of the patient, ask her to raise her knees, pass your hand under her right thigh to the buttock, flex all your fingers on the palm, make

the fore-finger prominent, place it between the folds of the buttock, and pass it from behind forwards over the anus, perineum, between the labia, until it comes against the pubic arch, then straighten the finger, and it will pass into the vagina. The advantages of this method are that, as the bent finger is broad and blunt, it cannot enter the anus, but slips easily between the labia, and, being arrested at the pubic arch, the sensitive parts—clitoris and vestibule—are not touched. After the fore-finger is introduced into the vagina, the middle finger is slipped in beside it, the thumb abducted, while the ring and little fingers remain flexed on the palm.

VAGINAL ORIFICE.

The examining fingers ascertain the *size* of the vaginal orifice. This is estimated by the number of fingers admitted. Two fingers should pass easily in every married woman, whether she has borne children or not. In the unmarried one finger can generally be inserted without injury to the hymen. Where the perineum is deficient or absent, the orifice may admit three or even four fingers.

Sensitiveness.—The passage of the finger should be painless. In abnormal cases, as in vaginismus, the slightest contact causes great pain, and renders further manual examination impossible without an anæsthetic. In painful conditions inspection must be resorted to to discover the cause.

THE LENGTH OF THE VAGINA.

Roughly speaking, the vagina may be called of normal length when the lower end of the vaginal portion of the cervix is about a finger's length from the vulva (Fig. 1). If the external os uteri is more

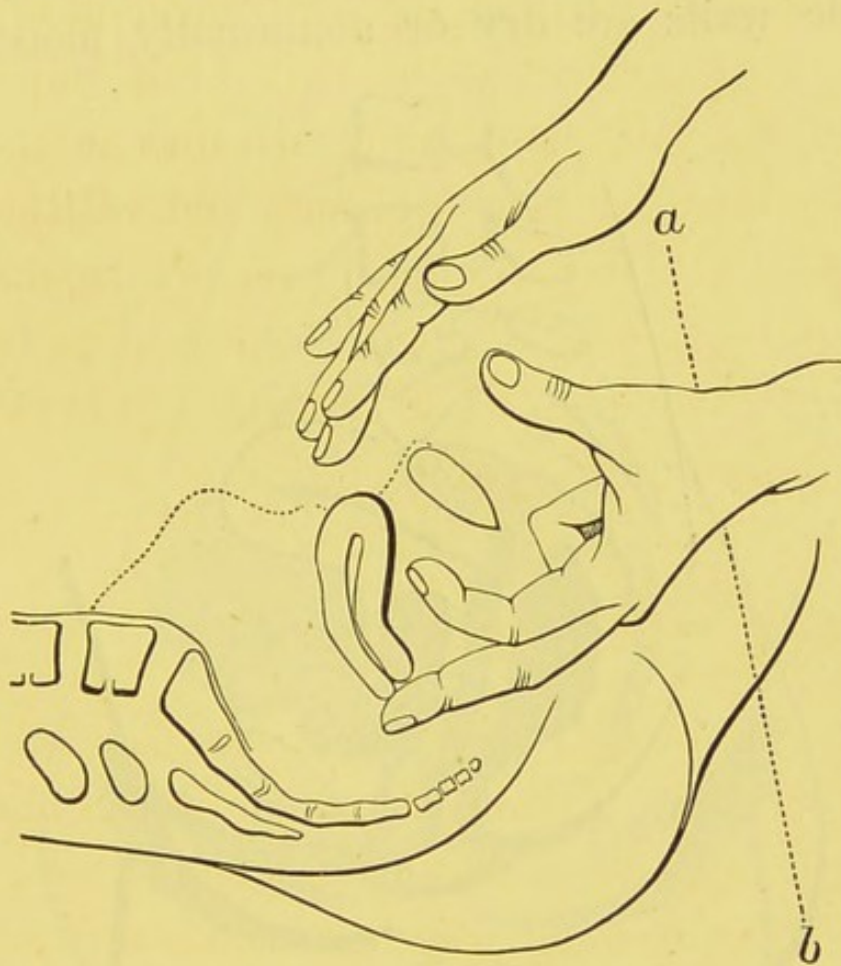


FIG. 1.—Bimanual palpation of the uterus in the position it normally occupies when bladder and rectum are empty. The line *a b* would be horizontal in the upright position. (SCHULTZE.)

than a finger's length distant, the vagina is long; if less, it is short.

The vagina is *long* in retroposition (Fig. 2), pathological anteversion (Fig. 3) of the uterus, and when retro-uterine hæmatocele (Fig. 4) or other tumours elevate the uterus.

It is *short* in retroversion and retroflexion (Fig. 5), in partial prolapse of the uterus, and in hypertrophy of the vaginal portion of the cervix.

THE VAGINAL WALLS.

The fingers feel if the normal *moisture* is present or if the walls are dry or abnormally moist from

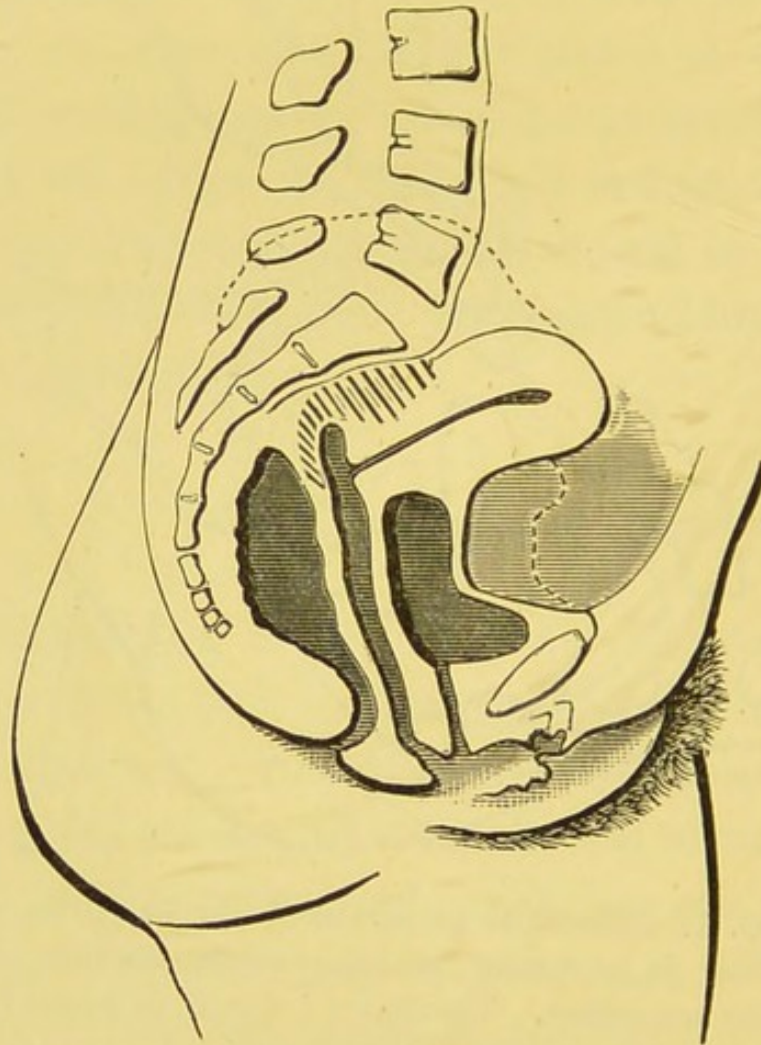


FIG. 2.—Retro-position of the uterus from peritoneal adhesions. (SCHULTZE.)

hypersecretion. *Increased heat* is felt in acute inflammatory conditions, such as vaginitis, metritis, peritonitis, and cellulitis. *Rugosity* is usually well marked in the unmarried, and in those who have not borne children, whilst in parous women the walls,

particularly the posterior, are generally smooth. *Laxity* of the walls occurs in partial prolapse, and in retroversion and retroflexion of the uterus. In these positions the uterus occupies a low place in the pelvis, and in consequence the vaginal walls, particu-

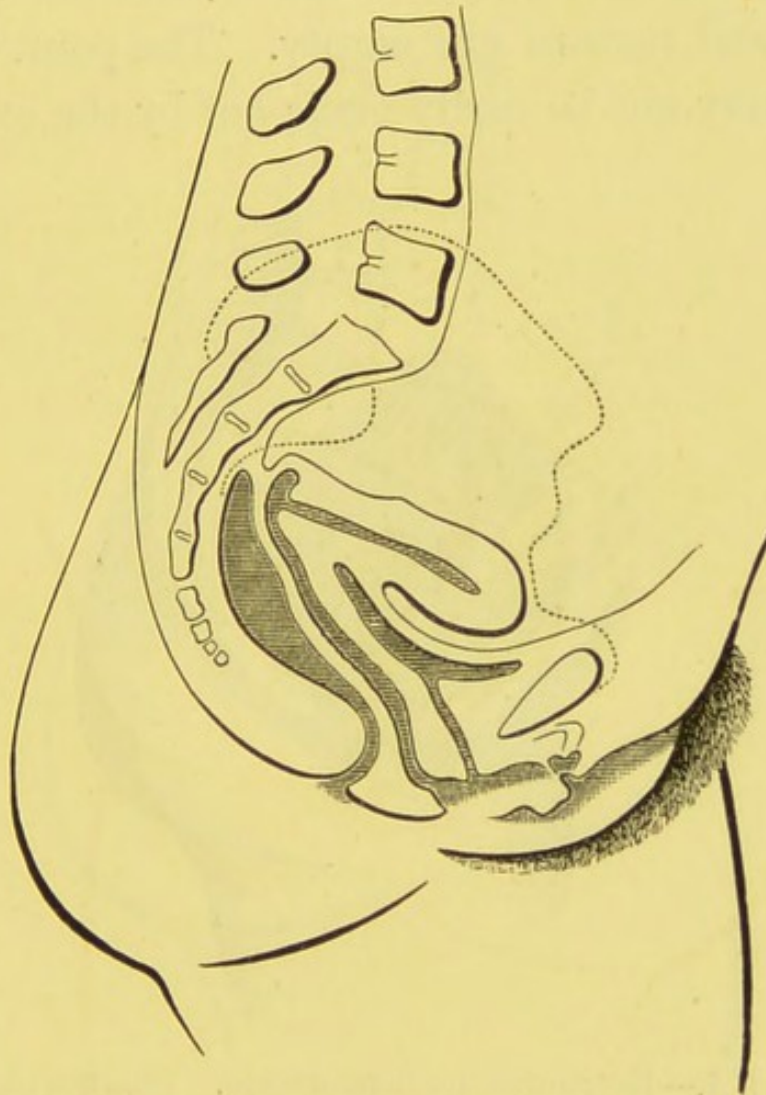


FIG. 3.—Pathological anteversion. (SCHULTZE.)

larly the anterior, are thrown into lax folds. *Abnormal openings*, such as urethro, vesico, and recto vaginal fistulae, if of any size, can be readily recognized by the examining finger. *Growths* from the walls, viz., cystoma, fibroma, carcinoma, sarcoma, will be felt, if present.

THE VAGINAL PORTION OF THE CERVIX.

The examiner notes its *position* in regard to (1.) *The height* it occupies in the pelvis. A line joining the ischial spines intersects the lower end of the vaginal portion in the position it assumes when the bladder and rectum are empty. The point of intersection may not be easily made out by the examining

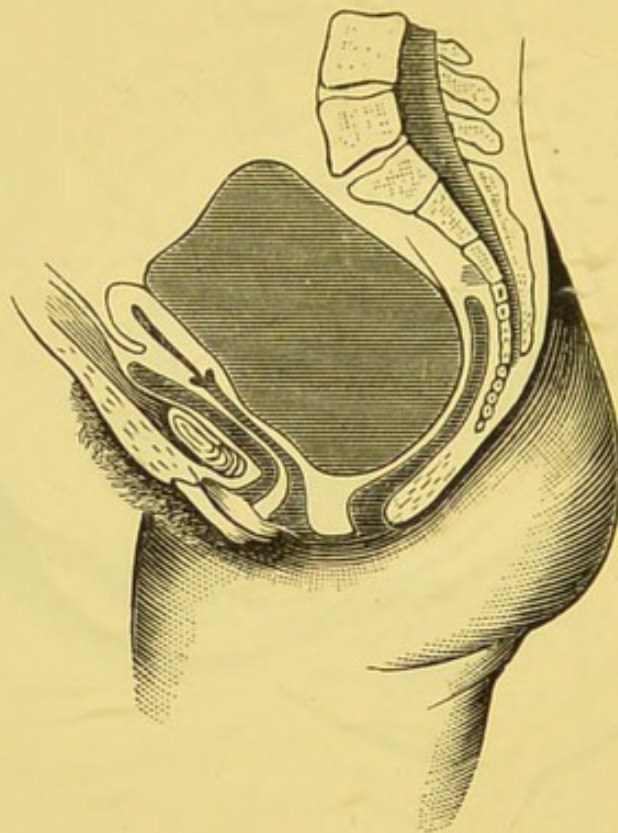


FIG. 4.—Retro-uterine hæmatocele. (SCHROEDER.)

finger, but for all practical purposes we may consider the external os uteri normal in height when distant a finger's length from the vaginal orifice (see length of vagina).

(2.) *Its relation to the antero-posterior plane of the pelvis.*—Normally the vaginal portion should be *median*, or a little to the left. Frequently we find it

to one or other side, drawn out of its place by cicatricial contraction of the broad ligament, by peritoneal bands (Fig. 6), or pushed over to one side by tumours.

(3.) *Its relation to the pubes and sacrum.*—It should be nearer the latter (Fig 1). Inflammation behind the cervix frequently draws the vaginal portion

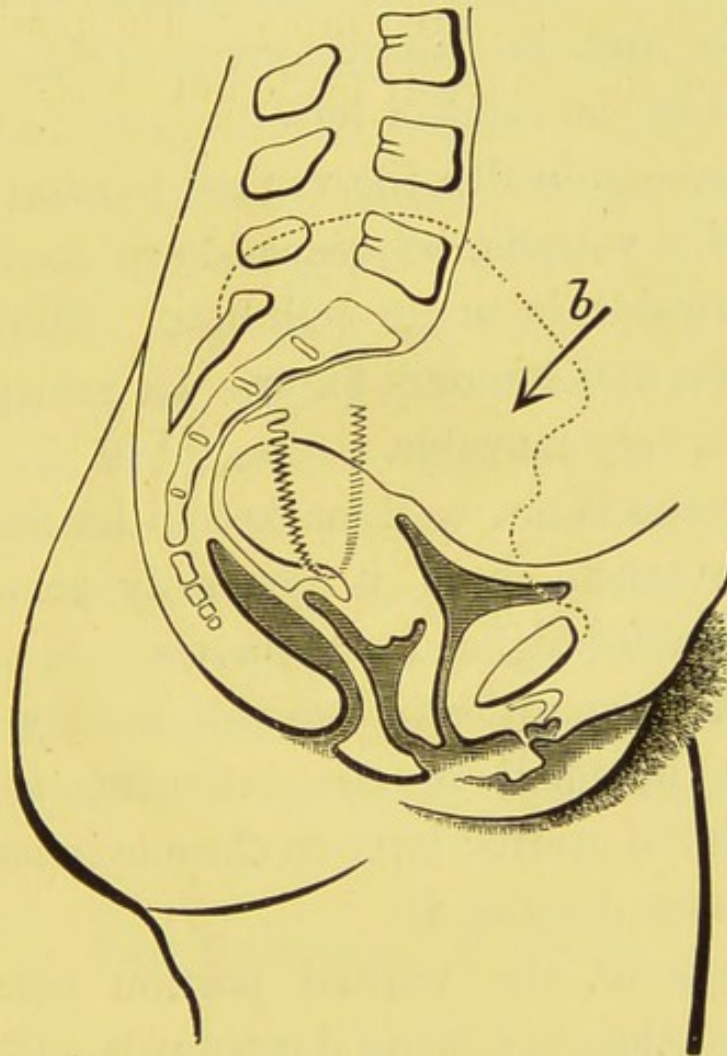


FIG. 5.—Retroflexion of the uterus. Relaxation of utero-sacral ligaments. (SCHULTZE.)

upwards and backwards nearer the sacrum than normal (Figs. 2, 3), whilst retro-uterine haematocele (Fig. 4) and tumours push it towards the pubes. In retroversion and retroflexion (Fig. 5) it approaches the pubes.

The direction of the vaginal portion should be downwards and backwards, corresponding to a line drawn from umbilicus to coccyx. Change of direction is very common. For example, in retroversion or retroflexion the direction may be downwards, downwards and forwards, or forwards (Fig. 5). In pathological anteversion (Fig. 3) it is upwards and backwards, and in lateral version (Fig. 6) downwards and to the right or left.

Mobility.—In health the vaginal portion can, with the aid of a volsella, be drawn down to the vulva. It is immovable in acute cellulitis. Old cellulitic contractions and tumours fix it. In prolapse of the uterus it is very movable.

Sensitiveness is not well marked in health. When painful to touch there is generally some inflammatory mischief higher in the pelvis.

Size.—Abnormalities in size will readily be recognised. It is small in the infantile, senile and superinvolved uterus; large in chronic inflammation, carcinomatous disease, &c.

The shape of the vaginal portion resembles a blunt cone—the apex being downwards. Changes in shape are caused by laceration, inflammatory thickening, Nabothian follicles, carcinoma, &c.

The consistence normally is firm with some elasticity. It is softer than natural in pregnancy, and harder in inflammatory thickening and in early carcinoma.

Presence and Direction of Lacerations.—A slight tear in the left side is normally present in parous

women. When deep, approaching the fornix, it is abnormal. Bilateral lacerations are frequently met with, less common are those in an antero-posterior direction. Sometimes a number of tears more or less deep are found surrounding the outer os, giving rise to the stellate form.

Presence of Ectropion.—Sometimes some ectropion exists when the uterus is retroflexed, but usually well marked laceration is necessary to produce it. It most commonly accompanies bilateral tear; then the lower end of the vaginal portion is divided into an anterior and a posterior lip, and when ectropion is established the anterior lip is turned forwards and upwards, and the posterior backwards and upwards.

The condition of the mucous membrane is felt by the finger. It should be smooth over the whole surface. The smooth character is altered where there are erosions, ulcerations, &c. Erosions feel either abnormally soft and velvety, or rough and granular.

THE EXTERNAL OS UTERI.

Size.—When not enlarged the tip of the fore-finger should be able to cover it. In *shape* it normally is a transverse slit.

Lacerations increase the size and alter the shape, which may be oval, irregularly oval, crescentic, &c. The external os of the infantile uterus is small and round (pin-hole).

Protrusions, such as portions of abortion, polypi,

the inverted body of the uterus, may be felt coming through the outer os.

Secretions from the cervical canal can be observed by withdrawing the fingers and noting the character of the discharge which adheres to them.

THE FORNICES.

We next proceed to explore the fornices. The vaginal roof,* for purposes of description, is divided into four parts—the fornices. The space in front of the vaginal portion is called the *anterior fornix*, that behind is the *posterior fornix*, while at the sides are the *right* and *left lateral fornices*.

The fornices possess width and depth. The *width* is the distance from the vaginal portion to the pelvic walls. The *depth* is the distance from the external os uteri to the highest point of the fornix. Normally the lateral fornices are of equal width and depth, or the left may be the narrower, as the vaginal portion in health frequently lies towards the left. The anterior is wide and shallow; the posterior is narrow and deep. The difference in the two latter is due to the vaginal portion being placed nearer the sacrum than the pubes. (Fig. 1.)

Width.—The examiner first compares the width of the lateral fornices, which are often unequal. When one is increased in width the opposite one is corres-

* Anatomically speaking, there is no vaginal roof. The vagina being a slit, the vaginal walls are in apposition throughout, except where the vaginal portion separates them. We make fornices by introducing the fingers.

pondingly narrowed, and *vice versa*. Conditions which push or draw the cervix, or uterus as a whole, to one side cause the irregularity. For example, tumours on the left side of the uterus push that organ over to the right, and cause widening of the left lateral fornix and narrowing of the right. Conversely, such conditions as old cellulitis in the left broad ligament which draw the uterus over to the left side narrow the left lateral fornix and widen the right. (Fig. 6.)

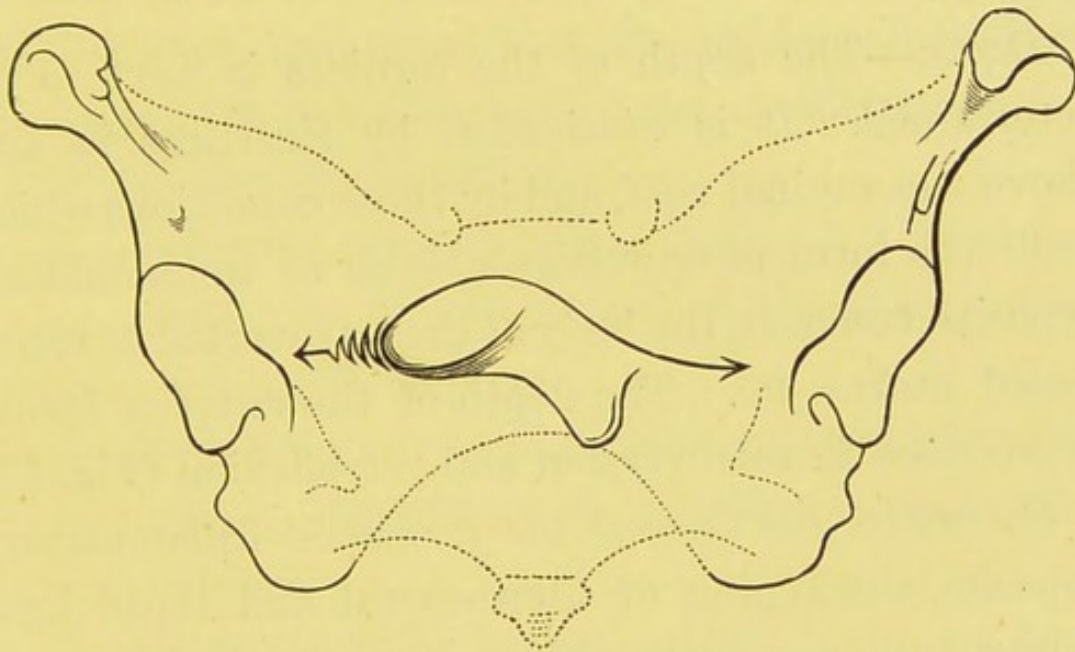


FIG. 6.—Lateral version of the uterus. (SCHULTZE.)

The width of the anterior fornix is diminished, and that of the posterior correspondingly increased by conditions which cause the vaginal portion to approach the pubes. The vaginal portion may be drawn forwards by inflammatory bands, pushed forwards by swellings situated behind the uterus, such as ovarian or fibroid tumours, extra uterine gestation, retro-uterine hæmatocele (Fig. 4); or it may move forwards in the partial rotation which takes place in

retroversion and in retroflexion, when the utero-sacral ligaments have become elongated. (Fig. 5.)

The width of the posterior fornix is lessened and that of the anterior proportionately increased by those conditions which draw the cervix, or the entire uterus, towards the sacrum. This is usually brought about by the contraction which follows inflammation posterior to the uterus, as is well seen in pathological anteversion (Fig. 3), and in retroposition of the uterus (Fig. 2).

Depth.—The depth of the fornices is next to be determined. It is *diminished* by cicatrices in and above the vaginal roof, and by those conditions which push the fornices downwards, such as inflammatory deposits, tumours, the body of the retroverted or retroflexed uterus, &c. The depth of the anterior fornix is *increased* in retroversion and retroflexion (Fig. 5).

Structures felt through the fornices.—Inflammatory deposits, thickening of utero-sacral and broad ligaments, tumours, prolapsed ovaries, the body of the uterus, &c. &c., may be felt through the roof with the fingers in the vagina.

The examiner finishes the vaginal examination by feeling, usually through the anterior fornix, what he takes to be the body of the uterus. He is unable to diagnose it with certainty at this stage, but it is probably the uterine body if he can trace it to be continuous with the cervix.

Note.—Palpation of the urethra and bladder will be considered in Chapter VI.

CHAPTER IV.

BIMANUAL EXAMINATION.

Palpation of the structures lying above the vaginal vault requires the exercise of both hands. This method, called the Bimanual, is of the greatest value, and it is most important that the student should be able to perform it methodically and intelligently.

The different Bimanuals are:—

1. *Abdomino-vaginal*.—One hand on the abdomen, one or two fingers of the other hand in the vagina.
2. *Abdomino-rectal*.—One hand on the abdomen, one or two fingers of the other hand in the rectum.
3. *Abdomino-recto-vaginal*.—One hand on the abdomen, one finger of other hand in rectum and one in vagina.
4. *Abdomino-vesical*.—One hand on the abdomen, one finger of the other hand in the bladder.
5. *Vesico-rectal*.—One finger of one hand in the bladder, one or two fingers of the other hand in the rectum.
6. *Vesico-recto-vaginal*.—One finger of one hand in the bladder, one finger of the other hand in the rectum and one in vagina.

The abdomino-vaginal and abdomino-rectal methods are those most commonly used; the others being seldom necessary. Except in favourable cases, as when the abdomen is thin and lax, an anæsthetic is needed to enable one to make a thorough Bimanual. The most perfect combined examination is the abdomino-rectal, using two fingers in the rectum.

THE DOUBLE BIMANUAL.

In order to palpate the abdomino pelvic contents thoroughly, one must alternately use each hand internally. The examiner should be ambi-dextrous. First, the fingers of one hand, say the right, are used internally, and the left hand externally; and subsequently the fingers of the left hand internally, and the right hand externally. One cannot palpate the structures, say in the left side of the pelvis, with the fingers of the right hand in the vagina, because then palpation is performed by the dorsal surface of the fingers.

THE ABDOMINO-VAGINAL EXAMINATION.

Method of practising the Bimanual.

The External Hand, which must be warm, is laid over the lower abdomen, and by gentle pawing renders the surface flaccid, then the hand presses downwards in the middle line from the promontory of the sacrum to the pubes. The patient is told to breathe deeply while the examiner presses his hand

more and more until it touches the uterus. In a difficult case, as when the abdomen is stout and resistant, a good plan is to press deeply during expiration, and continue the pressure till the next expiratory effort, when the parts are still further depressed. Pressure exerted in this way will generally enable the examiner to reach the uterine body. The rôle of the external hand is to steady and press down the abdomino-pelvic organs so that they may come within reach and be palpated by the internal fingers. While accomplishing this it also palpates the upper surface of the structures. Occasionally the uterus has to be elevated by the fingers in the vagina before it can be felt by the hand on the abdomen.

The Internal Hand.—Internally the bimanual examination begins where the vaginal ends. The body which the examiner, at the close of the vaginal examination, felt through one of the fornices (normally the anterior), and traced to be continuous with the cervix, is now felt between the external and internal hands to be the body of the uterus.

In order to feel the uterus bimanually the perineum is pushed back by the ulnar border of the examining fingers—this allows the tip of the fingers to reach a high level in the pelvis; then the forefinger is placed in the anterior fornix and the middle finger at the external os (Fig. 1)—this anteverts the uterus and brings it nearer the examiner's hands. It is necessary, in some cases, to place both fingers in front of

the cervix, whilst in others, as in retroversion, both fingers must be placed in the posterior fornix.

The uterus being now grasped between both hands, we note its

Position.—When the bladder and rectum are empty the uterus is anteverted and in the mesial plane of the body, its fundus lying behind the pubes. When the patient stands erect the long axis of the uterus is nearly parallel to the horizon (Fig. 1). *Abnormally* it may be anteposed (Fig. 4), either in, or to one side of, the mesial plane; or in lateral position, being placed in the right or left half of the pelvis, and more or less in the transverse axis of the brim. Again, it may be retroposed (Fig. 2), displaced backwards as a whole towards the sacrum, either in the middle line or one or other side of it. The uterus may lie with its long axis somewhat horizontally across the pelvis, with the fundus towards the sacrum, as in retroversion, or to one side, as in lateral version (Fig. 6). In some conditions, such as prolapse, the uterus is low-placed; it may even be outside the vulva (extra pelvic—Fig. 7). In inversion the uterine body lies partly in the vagina and partly in the cervical canal, being turned inside out. The uterus is sometimes elevated by tumours situated below it, so as to be above the pelvic brim.

Size.—The unimpregnated uterus measures three inches in length; the breadth at the fundus is two-and-three-quarter inches, and the thickness about an inch. Marked increase or diminution can easily be

recognised bimanually, but lesser variations in size require for their recognition considerable deftness on the part of the examiner.

The shape of the Uterine Body is triangular, with the apex downwards, the fundus and the sides being

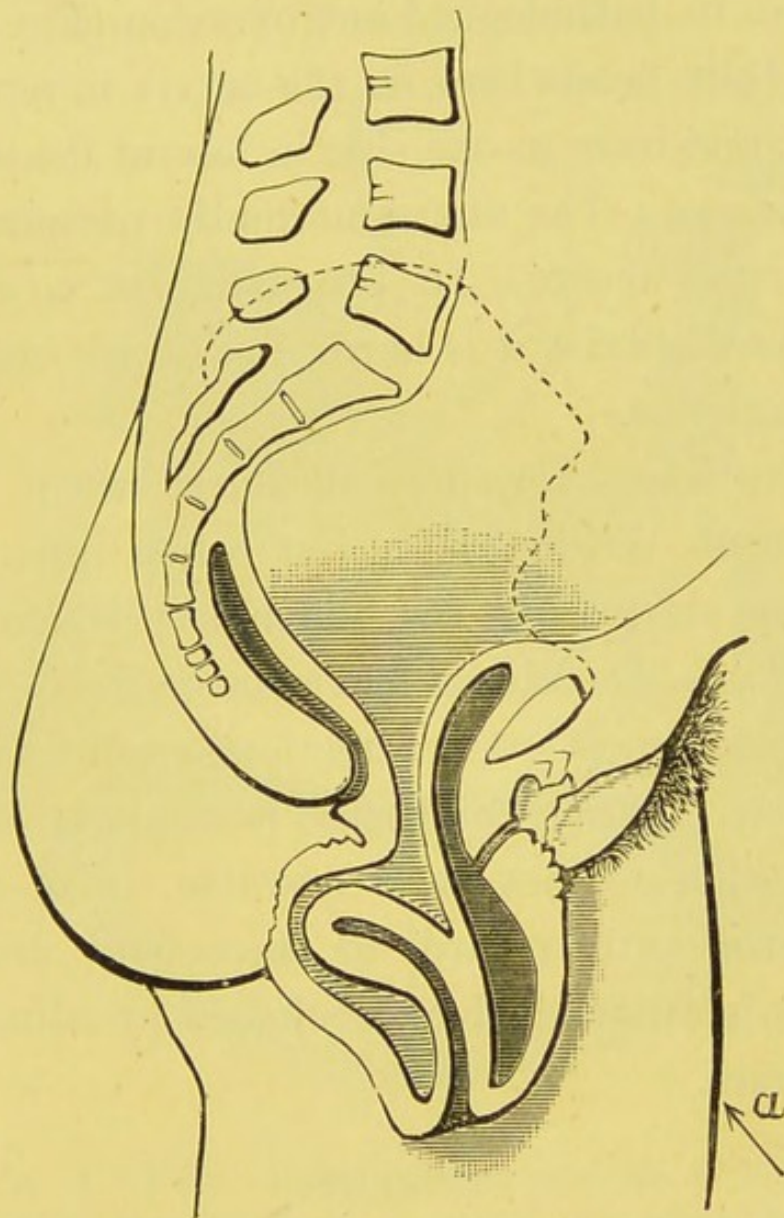


FIG. 7.—Prolapse of the uterus. (SCHULTZE.)

convex. The posterior surface is rounded at its upper part; the anterior surface is straight, and at the junction of the body and cervix there is a considerable angle, constituting the normal anteflexion of the uterus (Fig. 1).

Alterations in shape, *e.g.*, those caused by fibroid outgrowths, and likewise changes in the relation of the body to the cervix, can be readily detected. The normal anteflexion of the uterus is exaggerated in pathological anteflexion, and is abolished in pathological antroversion (Fig. 3). The uterine body bends back on the cervix in retroflexion (Fig. 5), and over to one side in lateral flexion.

Consistence.—The uterus normally presents a firm, elastic consistence. In pregnancy it is softened; when fibroids exist it is hard; in chronic metritis it is cartilaginous.

Sensitiveness.—The normal uterus when handled possesses no sensitiveness, but when inflammatory conditions are present the bimanual produces pain.

Mobility.—The uterus has a considerable range of mobility in almost every direction, but chiefly antero-posteriorly. When the uterus is displaced the question whether or not it is movable, is of the first importance with regard to successful treatment. Mobility is diminished or abolished by adhesions or by tumours.

OVARIES.

The ovaries lie behind the uterus and broad ligaments, in the plane of the pelvic inlet, near the side wall of the pelvis, and immediately below the inner edge of the psoas magnus muscle where the latter crosses the inlet. The ovary is attached to the uterus by the ovarian ligament, to the edge of the psoas

muscle in front of the sacro-iliac joint by the infundibulo-pelvic ligament, to the broad ligament by a fold of peritoneum, and to the fallopian tube by the ovarian fimbria. It is as it were slung between the side wall of the pelvis and the uterus by the

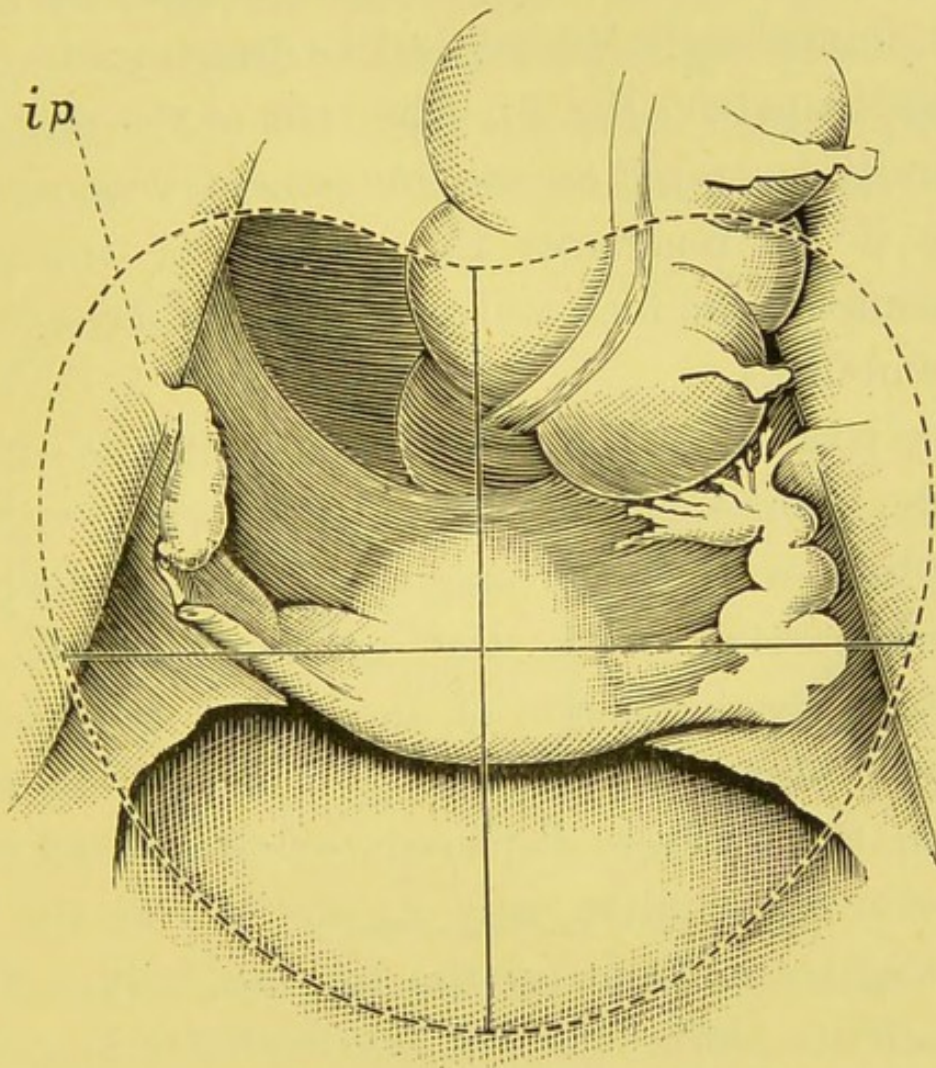


FIG. 8.—Pelvic inlet, showing position of ovary. The right tube has been cut away. *ip*. Infundibulo-pelvic ligament. (Modified from SCHULTZE.)

infundibulo-pelvic and ovarian ligaments, and as the former ligament occupies a higher level than the latter, the ovary is thus situated above and to one side of the uterus (Fig. 8). The inner edge of the psoas magnus is the best guide to the position of the

ovary, but as this muscle cannot always be easily felt, it is a good plan to divide the inlet into four parts by drawing a line at right angles to the conjugate of the brim so as to bisect it. In this way the inlet is divided into four quadrants. The ovaries are situated in each of the posterior quadrants close to the pelvic brim, immediately behind the line drawn transversely across the pelvis (Fig. 8). The brim of the pelvis can generally be traced on the integument without difficulty if we remember the position of the sacral promontory, one inch and a-half to two inches below the umbilicus.

The position of the ovary is only slightly affected by the normal movements of the uterus, with the exception of those of pregnancy, during which the ovaries ascend with the growing uterus. In posterior displacements of the uterus the relations between uterus and ovary are changed. In retroflexion the ovary is displaced somewhat backwards (retroverted Schultze calls it), and lies at the side, and slightly in front of the uterine body. If the infundibulo pelvic ligament is extended in length the ovary may reach the pouch of Douglas (Fig. 9).

PALPATION OF THE OVARIES.

The normal ovaries can usually be palpated. When the patient is stout, or when the ovaries are abnormally small, palpation may be difficult or impossible. With the aid of an anæsthetic, how-

ever, it is rare, even under the most unfavourable conditions, to fail in feeling the ovary. The enlarged or prolapsed ovary is more easily palpated than one normal in size and position.

To palpate the right ovary, the examiner places two fingers of the right hand in the right lateral fornix; the fingers of the left hand are placed over the right posterior quadrant, and exert pressure downwards towards the internal fingers, with

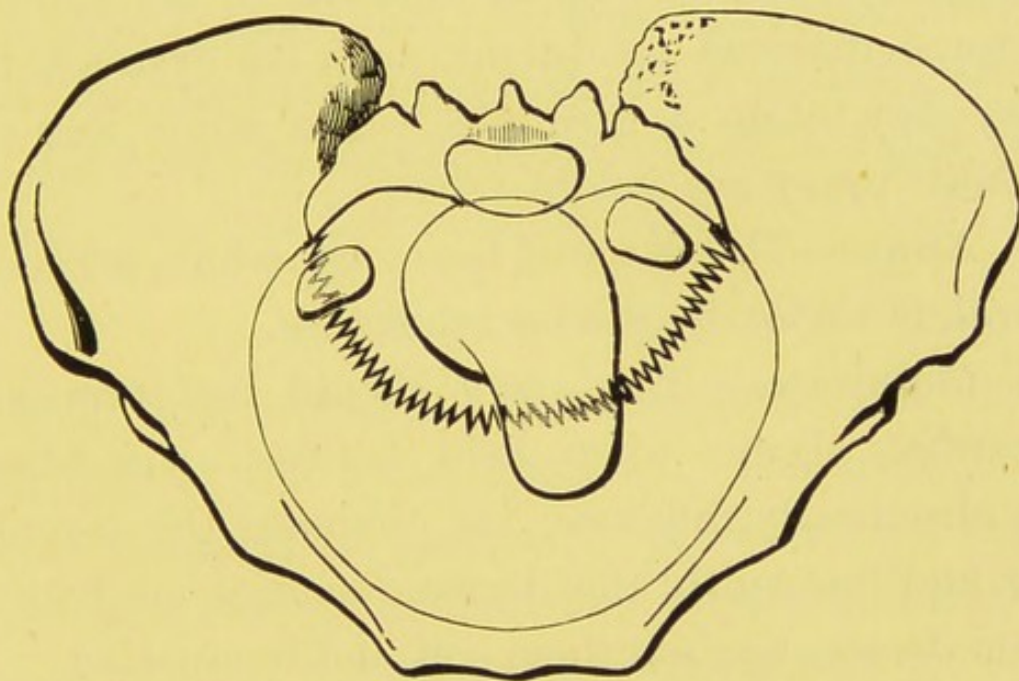


FIG. 9.—Right ovary at side of uterus. Left ovary in pouch of Douglas. (SCHULTZE.)

which the under surface of the ovary will be felt. The external hand depresses and steadies the ovary, while the internal fingers palpate. In favourable subjects the ovary may be distinctly felt between both hands, and often can be made to slip between the fingers.

In palpating the left ovary the hands are reversed. Two fingers of the left hand are placed in the left

lateral fornix, and the right hand is placed externally over the left posterior quadrant.

The examiner, having secured the ovary between his hands, has to determine

1. *Its position*, whether normal or displaced. When displaced it will generally be felt backwards or downwards, lying either at the bottom of one of the retrolateral pouches, or in the pouch of Douglas.

2. *Size*.—Normally about the size of an almond. In some diseased conditions, such as cystoma, the ovary may attain a great size. The senile and the cirrhotic ovary are small.

3. *Shape*.—The shape of the ovary, which normally is oval, is variously altered by disease.

4. *Consistence*.—The ovary should feel firm and somewhat elastic when held between the hands. The chronically inflamed, the cirrhotic, the myomatous, and frequently the dermoid ovaries are hard—cystic disease renders them soft and fluctuating.

5. *Sensitiveness*.—Moderate pressure on normal ovaries does not, as a rule, produce pain, but firm pressure frequently causes a feeling of nausea. Menstrual congestion, displacement, inflammatory, and other abnormal states of the ovary make it tender.

6. *Mobility*.—Normally the ovary is movable, but, owing to its attachments, its range is confined to narrow limits. As a result of inflammation of the peritoneum it is frequently fixed.

THE FALLOPIAN TUBES.

The healthy Fallopian tubes cannot be detected by palpation. When one opens the abdomen it is difficult to recognise them by direct touch; to recognise them by the ordinary bimanual method is impossible. It has been asserted that in a favourable case the tubes may be felt as they leave the uterus. This statement we must call in question, as we believe that in such a case the ovarian ligaments have been mistaken for the tubes. In disease, however, as when they are thickened by inflammation or new growths, or distended by serum, blood, pus, or a tubal pregnancy, they can be felt bimanually.

THE BROAD LIGAMENTS.

The finger placed in the lateral fornix lies beneath the base of the broad ligament. The layers of the broad ligament are frequently separated by various swellings, such as inflammatory exudation (cellulitis), blood effusion (hæmatoma), extra-uterine gestation, parovarian tumour, &c. As a result of cellulitis between the layers, cicatricial tissue forms, which shortens and thickens the ligaments, then a hard band of varying thickness is felt in the position of the broad ligament, narrowing the fornix, and drawing the uterus over to the affected side.

THE UTERO-SACRAL LIGAMENTS.

These ligaments, which pass from the posterior surface of the uterus at the level of the internal os,

upwards, outwards, and backwards to the second sacral vertebra, can be felt as two thin bands when the finger, pushed deeply into the posterior fornix, is moved from side to side. They are much better felt, however, per rectum. Like the broad ligaments, they become thickened and shortened as a result of inflammation of their cellular tissue, then they draw the uterus backwards towards the sacrum, with the result that pathological ante flexion is produced. They are lengthened in prolapse and in retroflexion of the uterus (Fig. 5).

THE ROUND LIGAMENTS.

The round ligaments cannot be recognised by palpation unless affected by diseased conditions, such as hydrocele or tumours.

THE OVARIAN LIGAMENTS.

The ovarian ligaments, under favourable circumstances, can be felt running from the inner end of the ovary to the side of the uterus.

THE POUCH OF DOUGLAS.

The pouch of Douglas is bounded behind by the rectum, at the sides by the utero-sacral ligaments, and in front by the supra-vaginal portion of the cervix and the uppermost part of the posterior vaginal wall to the extent of about an inch. Thus it can easily be explored through the posterior fornix.

When the uterus is in normal position, Douglas

pouch contains intestine; when retroflexed it contains the body of the uterus. As it is the most dependent part of the peritoneal cavity, ascitic fluid and blood (retro-uterine hæmatocele) find their way there (Fig. 4). The prolapsed ovary, inflammatory deposits, tumours of uterus and ovary, extra uterine fœtation, &c., may occupy the pouch, and be felt through the posterior fornix. Old inflammatory bands are frequent in this situation.

RECTAL AND ABDOMINO-RECTAL EXAMINATION.

Examination per rectum is of the highest value.

I. To ascertain the state of the rectum itself.

II. As a substitute for vaginal examination.

(a) In virgins.

(b) When vaginal examination is impracticable.

1. In vaginismus.

2. In absence, occlusion, or narrowing of the vagina.

3. When tumours occupy the vagina.

III. As a means of palpating the pelvic structures by combined manipulation (abdomino-rectal, abdomino-recto-vaginal).

This method should never be omitted in cases where the abdomino-vaginal examination is not clear and satisfactory.

The rectal wall is thin and yielding, and through it we can palpate the posterior surface of the uterus and the structures which lie behind it and at its

sides, with greater precision than through the firm vaginal walls.

Method of examination.—The fore-finger is placed over the anal orifice, and is pushed forwards through the sphincter into a wide cavity—the ampulla. In its passage the presence of hæmorrhoids, fissures, polypi, ulcers, stricture, &c., are noted. The recto-vaginal septum can now be explored between finger and thumb if the latter be placed in the vagina. In like manner by placing the thumb behind the coccyx, that bone can be palpated. The finger in the ampulla examines the mucous membrane, searches for fistulæ, and through the anterior rectal wall feels the vaginal portion of the cervix, and tumours in the vagina, such as uterine polypi, the inverted body of the uterus, hæmato colpos, tumours of the vaginal walls, &c. In passing the finger higher it generally meets with some little difficulty at the sphincter tertius. The rectum here is narrowed by the anterior wall sinking towards the ampulla, and the finger has to be carried backwards to find the opening. At this higher level the supra-vaginal portion of the cervix is felt; it appears large, and may be mistaken for the body of the uterus. It is well now to use two fingers internally, and to place the disengaged hand on the abdomen and press the uterus down against the fingers in the rectum, when the whole of the uterus may be felt bimanually. The aid of the volsella is at this stage especially useful, inasmuch as by fixing it in the vaginal portion the uterus can be straightened

and pulled down, so that the whole of its posterior surface can be palpated by the rectal fingers.

By the *abdomino-rectal* method we differentiate between a uterine polypus, which has come down into the vagina, and inversion of the uterus. In the former the polypus is felt in the vagina while the body of the uterus is in its normal position. In inversion the uterine body is absent from its usual site, being inverted in the vagina, while its place is occupied by a cup-shaped hollow.

The body of the retroverted or retroflexed uterus is readily distinguished through the rectum. The fingers passed between the utero-sacral ligaments recognise these structures as curved elastic bands, about the thickness of a crow's quill, converging towards the isthmus of the uterus. They are best felt in the puerperium, as they then share the uterine hypertrophy. Pathological conditions, such as shortening or thickening of one or both ligaments, can only be made out with accuracy by this method. The posterior surface of the broad ligament is also reached per rectum, and the ovary can be distinctly palpated. Cicatricial contraction of the cellular tissue of the broad ligaments, old inflammatory bands of the peritoneum, tumours between the layers of the broad ligaments, and in the peritoneal cavity, the pedicle of an ovarian or other tumour, diseased tubes, the iliac vessels, the anterior surface of the sacrum, the side walls of the pelvis, &c., are best felt through the rectum.

CHAPTER V.

INSTRUMENTAL AIDS TO DIAGNOSIS.

The experienced gynæcologist seldom requires instrumental aid, as by touch alone he is generally able to form a diagnosis. There are cases, however, in which even the most accomplished "toucheur" cannot dispense with such aid. For instance, it is impossible without the sound, cervical dilator, or curette, to determine the state of the interior of the uterus. The beginner who cannot rely on his touch needs instrumental assistance to confirm or refute the impression which he has arrived at by touch.

For such reasons, and as instruments are necessary for therapeutic purposes, it is right that we should learn how to use them.

VAGINAL SPECULA.

Vaginal specula are used for inspecting the vaginal portion of the cervix and the vaginal walls. By their aid we observe the colour, size, and shape of the vaginal portion, the condition of its mucous membrane, the size and shape of the external os, the presence of cervical tumours and of tumours protruding through the cervical canal, the character of uterine and vaginal secretion, the appearance of the

vaginal walls, the presence of fistulæ, vaginal tumours, &c. There are numerous specula. It is not within the scope of this work to describe all the various kinds. We shall content ourselves with discussing four, viz.,—Sim's, Trélat's, Cusco's, and Ferguson's

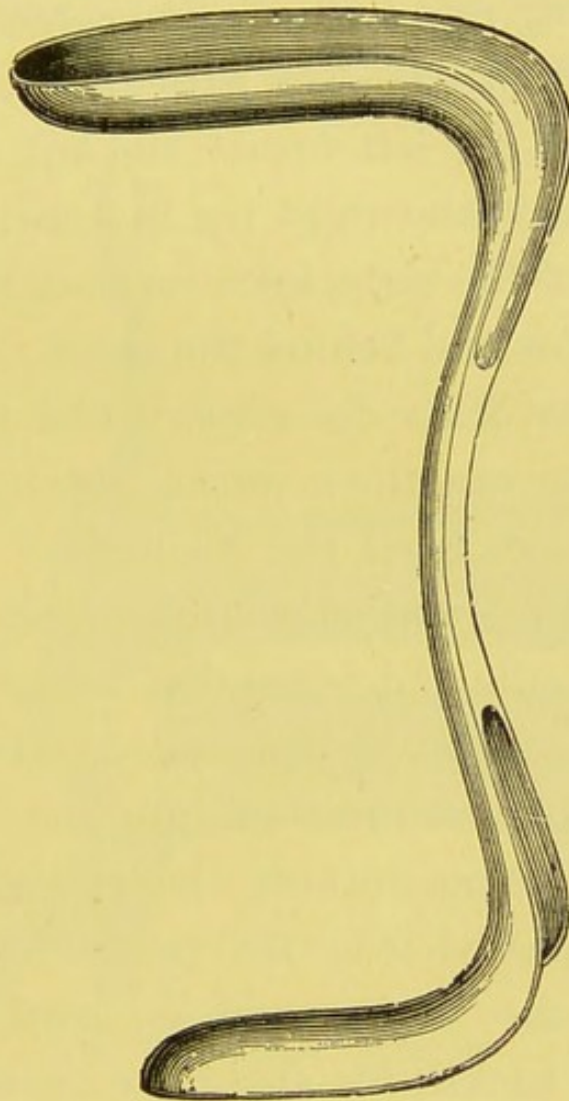


FIG. 10.—Sim's speculum.

and shall take them in what we consider their order of merit.

Sim's Duckbill Speculum is by far the best. It consists of two blades of different sizes connected by a handle. The blades are concave on their anterior aspect, and are joined at right angles to each extremity of the handle (Fig. 10). When a woman

assumes the semiprone posture, atmospheric pressure will separate the vaginal walls if the vulvar aperture be opened. Advantage is taken of this physical condition in using Sim's speculum, which, by hooking back the sacral segment of the pelvic floor, aids the natural opening up of the vagina which takes place when air is admitted. The patient in the semiprone position lies on her left breast, the left arm is placed behind the back, the right leg is drawn up and the inner aspect of the right knee rests on the bed. The left leg is below and behind the right.

How to pass Sim's Speculum.—The patient being semiprone, the examiner warms the speculum, and holds in the left hand the blade that is not to be passed in such a way that the thumb rests on the end of the handle and is parallel to it. The convex surface of the other blade is oiled. Two fingers of the right hand are inserted into the vagina, their dorsal aspect being towards the pubes. The tip of the blade is passed over the palmar surface of the fingers into the vagina and is gently insinuated upwards and backwards along the posterior vaginal wall. The index finger of the right hand feels that the cervix is in front of the blade. The perineum is then retracted and the speculum is tilted so that light is thrown on the cervix. By this means a good view of the vaginal portion and the anterior vaginal wall can usually be had. Sometimes the anterior vaginal wall has to be kept forward by a spatula. By fixing a volsella or tenaculum in the anterior lip

of the cervix and drawing it down, the parts can be well seen. In most cases an expert manipulator can expose and fix the cervix so as to leave the right hand free.

Sim's speculum may also be used with the patient in the lithotomy position, then the anterior vaginal wall must be kept out of the way by a spatula.

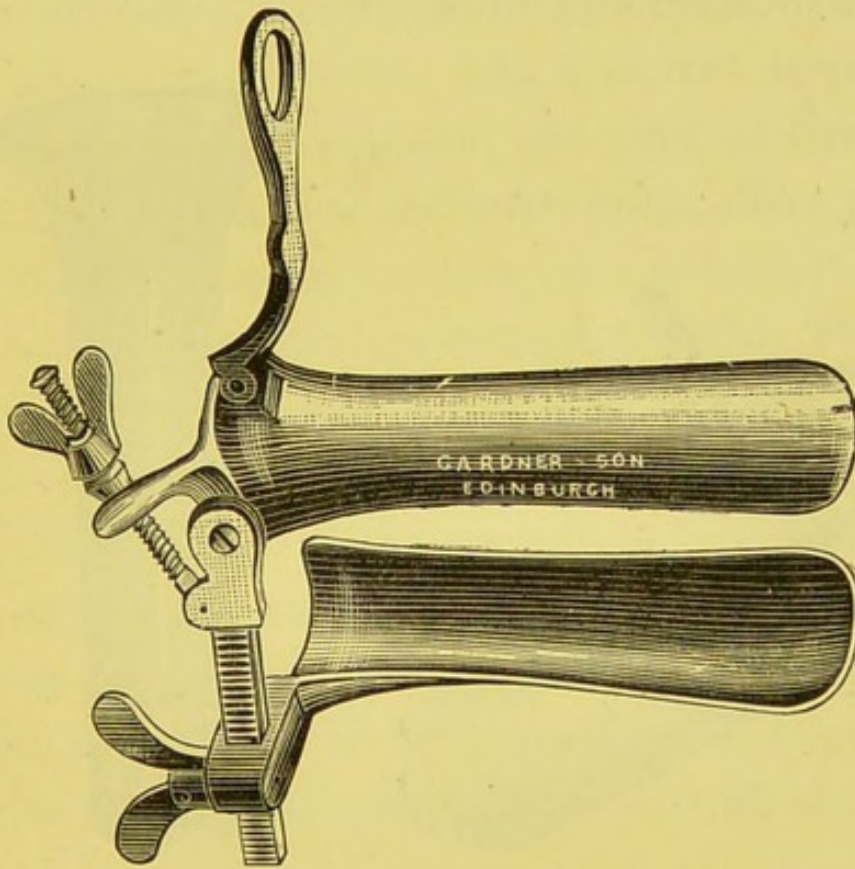


FIG. 11.—Trélat's speculum.

Sim's speculum opens widely the whole vagina, exposes the vaginal portion and the anterior vaginal wall, and allows us to pull down the cervix to the vulva (artificial prolapse). It is not self-retaining.

Trélat's, frequently called the *Rotunda Speculum*, is bivalve, and consists of an anterior and a posterior blade, a grooved bar, and two screws. The bar is attached to the posterior blade by a hinge joint

(Fig. 11). The instrument is introduced closed, the patient being in the left lateral position, then by means of the front screw the anterior blade is made to move along the grooved bar and press back the anterior vaginal wall, while the posterior screw causes the posterior blade to rotate backwards so that its tip recedes behind the cervix.

Trélat's speculum opens widely the whole vagina.

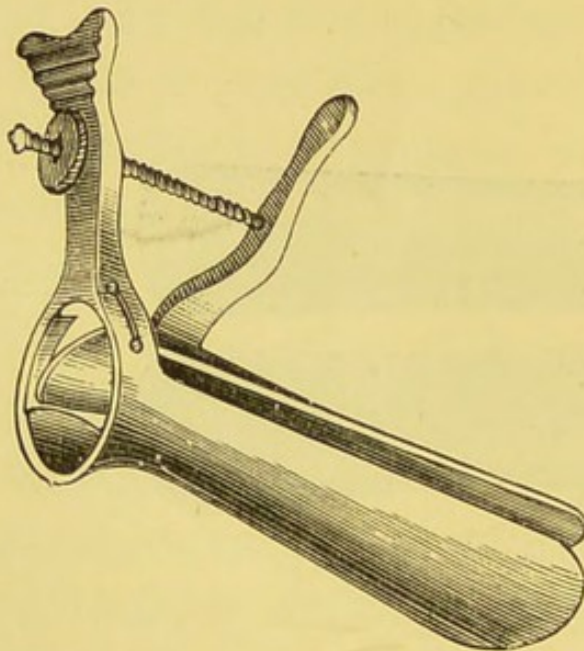


FIG. 12.—Cusco's speculum.

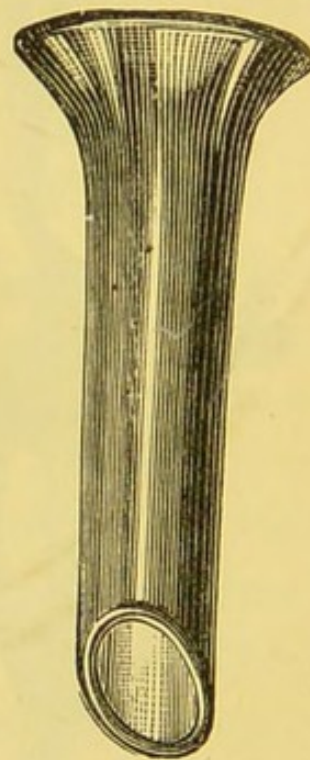


FIG. 13.—Ferguson's speculum.

exposes well the vaginal portion, prevents artificial prolapse of the uterus, and hides the vaginal walls. It is self-retaining.

Cusco's Speculum (Fig. 12) is bivalve, and consists of two blades and two handles, arranged in such a way that the blades separate when the handles are brought together. The instrument is passed in the left lateral position, and after the blades are inserted, the handles

are moved either towards the pubes or coccyx, and are then pressed together between the finger and thumb. By a screw arrangement the blades are kept apart, Cusco's speculum opens widely the vaginal vault, exposes the vaginal portion, prevents artificial prolapse of the uterus, and hides the vaginal walls. It is self-retaining.

Ferguson's speculum is cylindrical. It consists of a hollow tube of caoutchouc, with a mirror internally, bevelled at the proximal end, slanting at the distal (Fig. 13). It is made of different sizes. The patient lies in the left lateral position, the examiner introduces the speculum by depressing the fourchette, then it is gently pushed upwards and backwards to the vaginal roof, and rotated until the vaginal portion is caught in the end of the speculum.

This speculum does not open up the vaginal vault; it exposes the vaginal portion if not greatly hypertrophied, it prevents artificial prolapse of the uterus, and hides the vaginal walls. It is self-retaining.

ANAL SPECULA.

The small blade of Sim's duckbill makes a good anal speculum, and renders the use of one of special make unnecessary.

VOLSELLA.

The volsella is of more service in operative procedures than in diagnosis. For diagnostic purposes it is used for drawing down the uterus, in order that—

1. In conjunction with Sim's speculum, a good view of the vaginal portion may be obtained.
2. The examiner may palpate the ovaries and the posterior surface of the uterus per rectum.
3. The connection between an abdominal swelling and the uterus may be ascertained. The uterus is pulled down and held by a volsella, while upward traction is made on the abdominal swelling.

The volsella consists of a pair of shanks or handles, connected by a joint near their distal end, and




FIG. 14.—Brewis' volsella.

furnished with teeth. The teeth should be fine and sharp, and arranged so that their points meet, but do not overlap. The instrument is curved near the farther end, to allow the handles to lie between the patient's thighs, out of the examiner's way, when the vaginal portion is drawn down to the vulva. Every instrument should have a catch. The ordinary catch of Pean's forceps is perhaps the best (Fig. 14). The use of the volsella is contra-indicated whenever inflammatory conditions exist.

In using the volsella, the vaginal portion is exposed

by Sim's speculum, then the teeth of the instrument are fixed in the vaginal aspect of the vaginal portion. When the uterus is drawn down, it lies behind the symphysis pubis, with its long axis straightened.

THE UTERINE SOUND.

Many gynecologists have discarded the sound. They hold that its use is harmful, and that it is not needed in diagnosis.

To these conclusions we give a qualified dissent.

A. No harm can result if the sound be used gently, if the examiner's hands, the instrument, and the passages are aseptic, and if the position and curve of the uterus have first been made out by bimanual examination. With the exception of the cases mentioned below (B. 3, 4.) the sound must never be employed to find out the position of the uterus.

B. In diagnosis the sound is very helpful and even necessary in—

1. Determining the state of the interior of the uterus, as to roughness, &c.
2. Ascertaining whether stenosis exists.
3. Ascertaining the position of the uterine body when one or more tumours are present in the uterus or surrounding parts.
4. Ascertaining the position and size of the uterus when the patient is stout, and the uterus cannot be felt bimanually.
5. Verifying the impression which has been

formed by bimanual examination of the size of the uterus.

6. Ascertaining if, in a given case, the uterine cavity shares the enlargement of the uterus which has been made out bimanally.

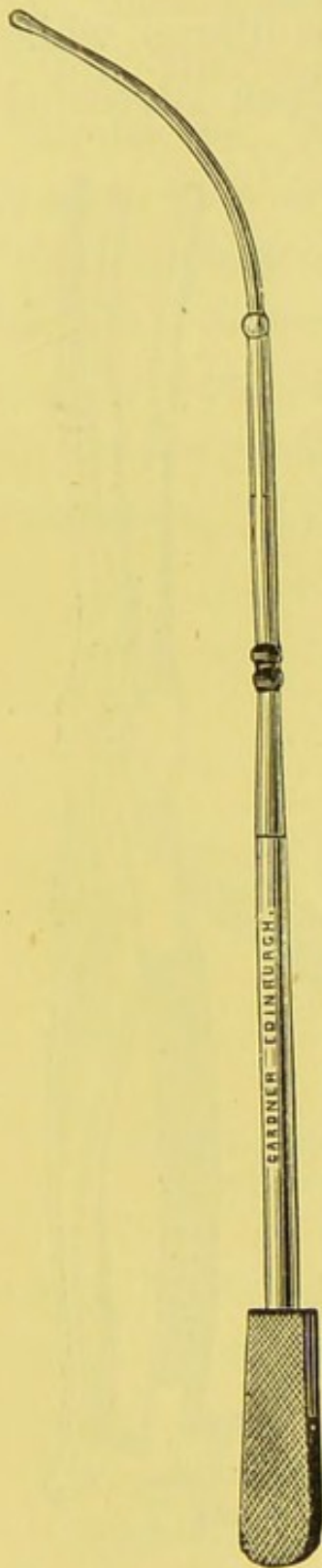
Description of the Sound.—It is only necessary to describe two sounds—viz., Sir James Simpson's, and Professor A. R. Simpson's. Sir James Simpson's instrument is made of copper, is nickle-plated, twelve inches in length having a fiddle-shaped handle, roughened on the side which corresponds to the point of the instrument, and smooth on the reversed side. The sound is graduated. It has a knob $2\frac{1}{2}$ inches from the point, at $4\frac{1}{2}$ inches there is a double knob, and at $3\frac{1}{2}$ inches, $5\frac{1}{2}$ inches, $6\frac{1}{2}$ inches, $7\frac{1}{2}$ inches, and $8\frac{1}{2}$ inches there are depressions in the posterior surface of the instrument.

Professor A. R. Simpson's (Fig 15) differs from the above, in that it is shorter, and its handle is broader. His instrument is perhaps the more useful of the two, as, owing to its length and the shape of the handle, it can be held in the uterus during a bimanual examination.

Method of using the Sound.—If the examiner is expert in performing the bimanual, he will have no difficulty in passing the sound.

Having first discovered by bimanual examination the position and curve of the uterus, he must then bend the sound to correspond to the uterine curve. The patient lies on her back. One or two fingers

of one hand are placed in the vagina with their palmar surface upwards, and their tips at the external os; the sound is held lightly in the other hand, and its point is guided along the internal fingers till it reaches the outer os, and then it is pushed onwards in the direction of the previously ascertained bend of the uterus. When the latter is anteverted and ante-flexed, the handle is depressed towards the perineum. When retroverted the point is pushed straight backwards. When retroflexed, the handle is raised towards the pubis. If the examiner is not dexterous in performing the bimanual, he should expose the vaginal portion with Sim's speculum, and draw down the uterus with a volsella. Then having straightened the sound, he will be able to pass it without difficulty.



Contra-Indications.—The sound is not to be passed—

1. If the patient is menstruating.
2. If the patient has missed a menstrual period, unless she has reached the menopause.
3. If acute inflammation of any of the pelvic organs exists.

FIG. 15.—Prof. A. R. Simpson's sound.

SOUND WITH BIMANUAL.

The bimanual examination of the uterus while the sound is held in its interior, has been advocated by Professor A. R. Simpson, and is useful in determining the exact position of the uterine body in cases where there are outgrowths of that organ. His sound is specially adapted for this examination.

CERVICAL DILATORS.

For diagnostic purposes the cervix is dilated to enable the finger to explore the interior of the uterus.

1. To ascertain the condition of the endometrium.

2. To detect the presence of tumours, incomplete abortions, &c.

In some instances dilatation of the cervix is required to allow the curette to enter the uterine cavity.

There are two classes of dilators—viz., the rapid and the slow.

Rapid dilators are of two kinds—the steel branched and the conical graduated.

Steel-branched dilators.—Of these there are many

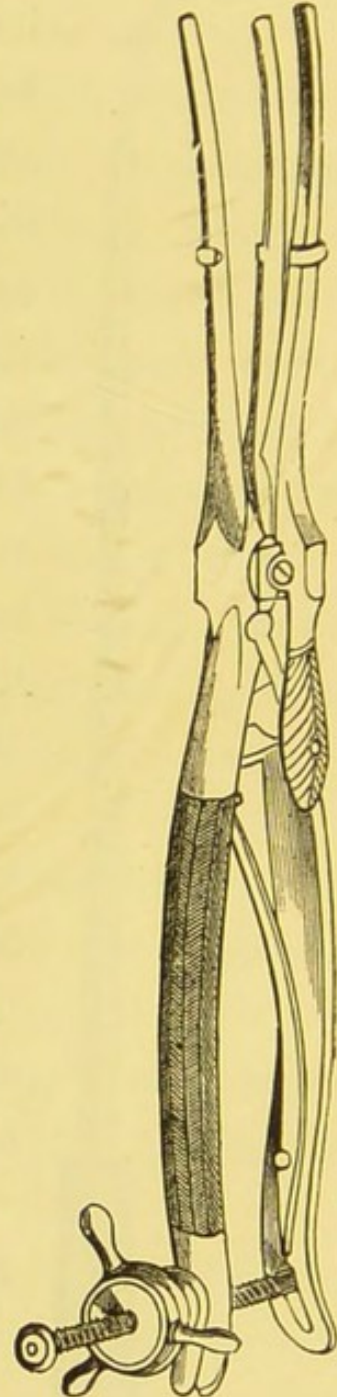

FIG. 16.—Sim's dilator.

varieties—the Goodell-Ellinger and Sim's are among the most perfect. The former instrument has two blades that open parallel to each other when the handles are brought together, which they do by means of a screw attachment, which at the same time enables the operator to dilate regularly and slowly. Sim's instrument differs from the above in having three blades (Fig. 16).

Conical graduated dilators are usually made of vulcanite. Peaslee's are of steel. Tait's, Hank's,

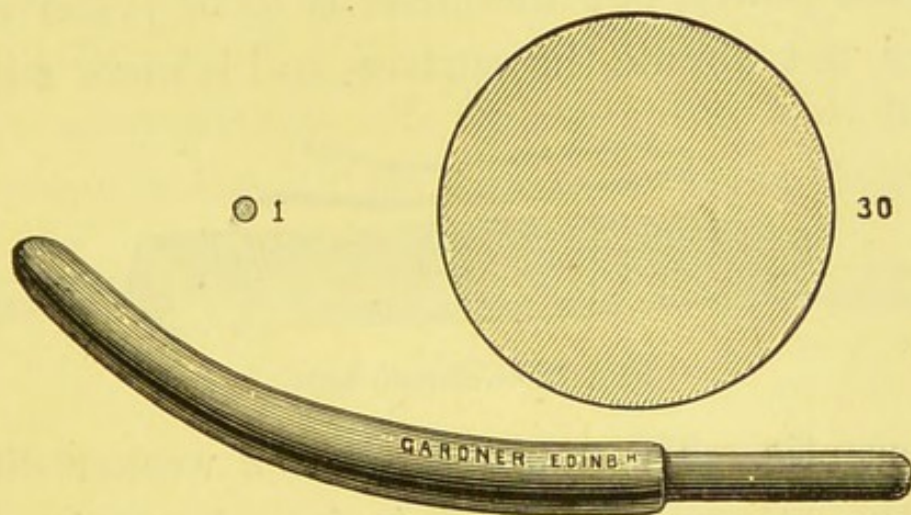


FIG. 17.—Hegar's dilator. The two upper figures show cross sections of smallest and largest sizes.

and Hegar's (Fig. 17), are those most commonly used. Hegar's, which we think the best, consist of a set of thirty graduated bougies, ranging in diameter from one-twelfth inch to one-and-one-twelfth inch.

The cervix is exposed by Sim's speculum, and steadied by a volsella, while the operator uses the steel-branched dilator. Hegar's dilators can be passed without the aid of a speculum; when the uterus is to the front counter pressure is applied to

the fundus; when it is to the back the cervix must be fixed by a volsella.

Slow dilators.—Slow dilatation of the cervical canal is accomplished by means of tents. Tents are of three kinds—viz., Sponge, Tangle (*laminaria digitata*), and Tupelo (*nyssa aquatilis*) (Fig. 18). When placed in the cervix they absorb the moisture of the parts and swell up. A tent takes from twelve to fifteen hours to expand to its full extent. The sponge and the tupelo tents are nearly equal in expansile power, but the latter is to be preferred as it does not abrade the surface, and is more sure of

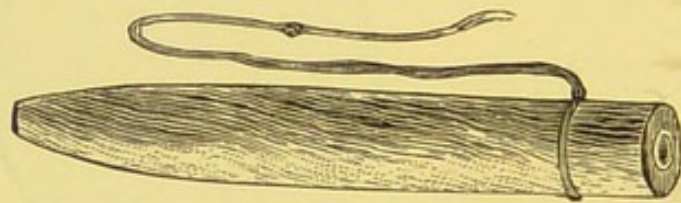


FIG. 18.—Tupelo tent.

being aseptic. The tangle tent is a weaker dilator than the others. A tent is introduced into the cervical canal by a pair of polypus forceps, after the cervix has been exposed by Sim's speculum, and steadied by volsella or tenaculum. Two or more tupelo or tangle tents may be passed side by side. A glycerine plug is left in the vagina.

Precautions.—In the use of dilators there is considerable danger of sepsis. This is avoided by rendering the vagina, the instruments, and the hands of the operator aseptic before and during the operation, and by swabbing out the interior of the uterus with pure carbolic acid, or irrigating it with

a solution of carbolic acid or corrosive sublimate after it has been explored by the finger. With the steel-branched dilators there is least fear of sepsis. We have known more than one death from septic infection follow dilatation with tents.

Contra-indications are the same as mentioned under uterine sound.

THE CURETTE.

The curette is useful in diagnosis for removing portions of tissue from the interior of the uterus for examination.

The granulations of endometritis, the mucous membrane in the diffuse form of sarcoma, fragments



FIG. 19.—Martin's curette.

of carcinoma, sarcoma, adenoma, or of placental remains, may be removed by the curette and submitted to microscopical examination, and a correct diagnosis thereby be arrived at.

Thomas' dull wire curette, which is flexible, and has a blunt edge, is sufficient in ordinary cases. Where it is necessary to remove a thick section or the entire depth of the mucous membrane, Recamier's or Martin's (Fig. 19), both of which are rigid and are provided with a sharp cutting edge, must be used. In using the curette the patient lies either semiprone or in the lithotomy position, Sim's speculum is passed, the cervix is steadied by

a volsella, and the curette introduced into the uterus. Previous dilatation of the cervix is sometimes needed.

Precautions are the same as those mentioned under cervical dilators.

Contra-indications same as given under uterine sound.

THE ASPIRATOR.

This instrument formerly was frequently used for finding out the nature of abdominal and pelvic tumours. Now it is seldom resorted to in the diagnosis of abdominal swellings, because these sometimes contain malignant elements, some of which may, during or after aspiration, escape into the peritoneal cavity, and give rise to malignant peritonitis. Around the site of tapping some peritonitis, ending in the formation of adhesions, usually takes place, rendering removal of the tumour more difficult. In pelvic swellings, aspiration may be performed per vaginam to diagnose the presence of pus, &c. The needle is guided along the finger placed in the vagina, and thrust into the part where fluctuation is most distinct, taking care to avoid a point where an artery is felt pulsating. The fullest antiseptic precautions are necessary.

EXPLORATORY INCISION

is sometimes necessary to determine the character of an abdominal or pelvic tumour, and to find out whether or not its removal is practicable.

CHAPTER VI.

THE URETHRA AND BLADDER.

EXAMINATION OF THE URETHRA.

The urethra is about $1\frac{3}{8}$ inches long, and extends from the meatus urinarius to the neck of the bladder. It is closely incorporated with the corresponding part of the anterior vaginal wall, and its direction is parallel to the plane of the pelvic brim. The meatus urinarius is situated at the base of the vestibule, and is felt as a round depression when the tip of the finger is placed against the anterior edge of the centre of the pubic arch.

Palpation of the Urethra.—The finger placed in the vagina ascertains the position, direction, and thickness of the urethra. In complete prolapse of the uterus, the position and direction are altered; the urethra is then extra-pelvic, and its direction is changed from upwards and backwards to downwards and backwards (Fig. 7). Increased thickness is felt in chronic urethritis. Neoplasms in the interior (polypi, papillomata, carcinoma, fibroma, &c.), and at the orifice (caruncle), foreign bodies, pouching of urethra (urethrocele), prolapse of mucous membrane at meatus, urethro-vaginal fistulæ, &c., can be recog-

nised by the finger. When urethritis is present, pus may be squeezed from the meatus.

Exploration of the interior of the urethra is made by the finger in the dilated canal, and by means of urethral specula. Neither of these practices gives satisfactory results. Exploration is most successfully carried out through a button hole in the urethra made by Emmet's method. A sound is passed into the urethra as a guide, and an incision $\frac{3}{4}$ of an inch in length is made vertically and mesially through the urethro-vaginal septum, taking care to avoid the meatus and the neck of the bladder. An opening is thus made into the urethra, through which the interior can be explored and inspected. The wound is closed by stitches.

EXAMINATION OF THE BLADDER.

Passing the Catheter.—In all affections of the bladder, the urine must be examined, and as that passed by a patient may contain vaginal discharges, it is necessary to use the catheter in order to avoid this admixture. The catheter must be aseptic, and it is well to sponge the vulva, and particularly the vestibule, with an antiseptic lotion beforehand.

The instrument is most easily passed when the patient lies on her back with the knees drawn up and separated. The examiner stands at the right side of the patient, and passes his right hand below her right thigh. The pulp of the index finger is then

placed against the anterior margin of the centre of the pubic arch, where the meatus will be felt as a round dimple imprisoned between the finger tip and the pubes. The forefinger is now slightly withdrawn to enable the catheter to enter the urethra and bladder (Fig. 20). A finger placed in the vagina at this stage

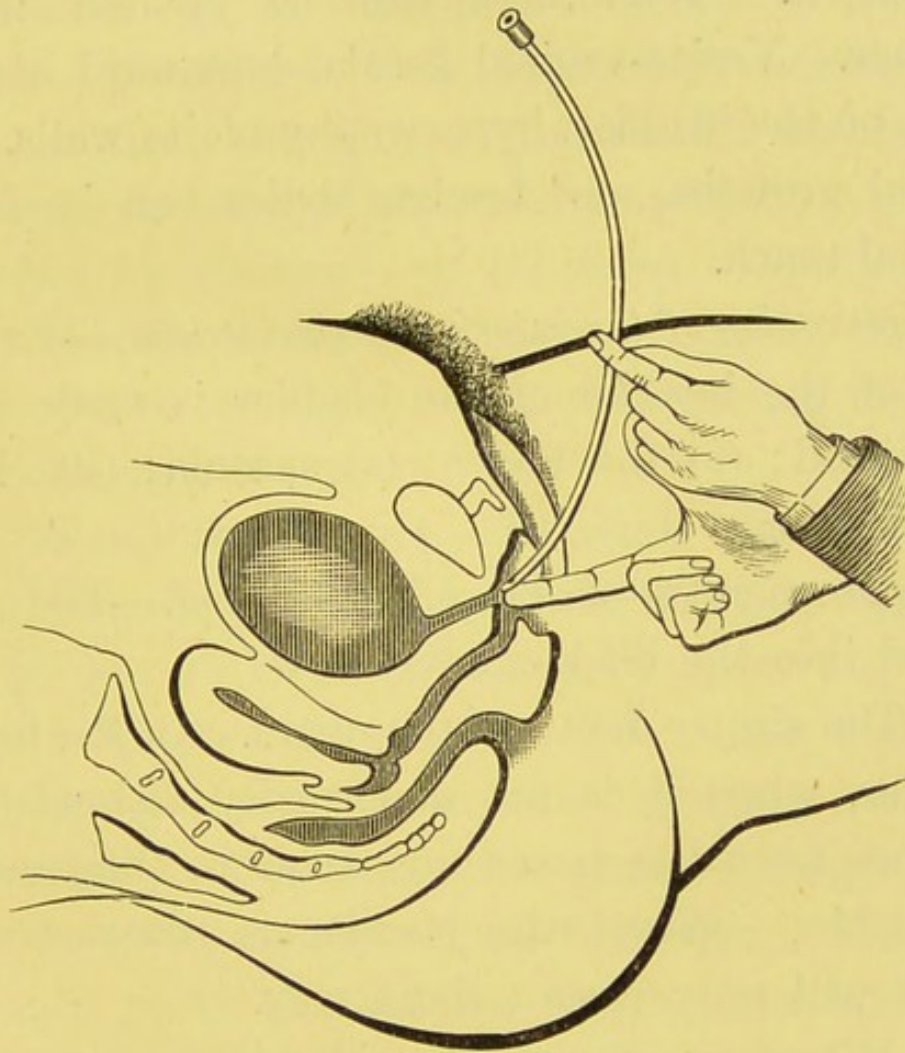


FIG. 20.—Passing the catheter.

makes sure that the instrument has entered the bladder.

The catheter may also be passed in the left lateral position.

Inspection.—The bladder when over-distended presents an oval swelling in the hypogastrium. In

cystocele a rounded protrusion formed by the base of the bladder can be seen at the vulva (Fig. 7).

Palpation.—When empty, the bladder lies behind the pubes, and can be palpated by the finger in the vagina. If the anterior vaginal wall is pressed against the pubes, the vesical walls are brought in apposition. Tenderness can be elicited in this manner. Vesico-vaginal fistula, downward displacement of the bladder, hypertrophy of its walls, intravesical growths, and foreign bodies can be felt by vaginal touch.

Exploration of the interior of the bladder.—Exploration of the interior of the bladder is made by (a) the sound; (b) the finger; (c) specula; (d) electric illumination.

Exploration by means of the sound.—The sound passed into the bladder tells us—

1. The size or depth of the organ. In the healthy bladder, when it is not abnormally distended, the distance from the meatus urinarius to the fundus is $4\frac{1}{2}$ inches. When the bladder is contracted the sound will only pass a short way.

2. Whether or not the bladder walls possess elasticity. In the normal viscus when the sound is pushed with some force against the wall with which it is in contact and the fingers grasping the instrument are suddenly withdrawn, it will be noticed that the sound rebounds for one or two inches. This elasticity is absent or impaired by disease.

3. The sensitiveness of the bladder walls. The

passage of the sound into the healthy bladder is painless. In acute cystitis the pain is intense.

4. Whether irregularities of the bladder walls, growths, or foreign bodies exist.

5. The position of the bladder. The bladder may be displaced upwards, downwards, or backwards. Its position can be determined by the sound. In operative procedures it is especially necessary to make out the exact site of the bladder beforehand to prevent its being inadvertently opened.

Exploration by means of the finger.—The interior of the bladder is digitally explored either through the urethra or through an artificial opening made in the vesico-vaginal septum.

1. Through the urethra. To admit the finger into the bladder the urethra must be dilated. This is accomplished by the finger itself, by Simon's specula, Sim's or Hegar's dilators, &c. To dilate with the finger the patient lies in the lithotomy position. The examiner first passes his smallest finger, then the next in size, and lastly his forefinger. The chief resistance is at the meatus, which some operators slit at the sides previous to the introduction of the finger. This is not necessary. Simon's specula are excellent dilators. They are a series of hard rubber tubes, whose diameters range from $\frac{3}{4}$ th of a centimetre to 2 centimetres. The distal end of each speculum is protected by a rounded piece of wood within, which is withdrawn after the instrument is passed. The specula are used successively, beginning

with the smallest. After the introduction of the largest, the finger easily enters the bladder. Hegar's uterine dilators or an ordinary set of male bougies will readily dilate the urethra. We have found Sim's cervical dilator (Fig. 16) most efficient for this purpose. Whatever method is adopted, the patient should be anæsthetised. The danger of dilatation is, that permanent incontinence may result. This should not take place unless the dilatation be carried further than is necessary to admit an average forefinger.

2. Through an artificial opening made in the vesico-vaginal septum. Vaginal cystotomy is seldom performed in the female for diagnostic purposes, but as a more thorough examination can be made with the finger through a vesico-vaginal incision than through the dilated urethra, we can imagine that in some cases this method may be resorted to with advantage.

The operation, which was introduced by Simon, is as follows:—A transverse incision about $1\frac{1}{2}$ inches long is made immediately in front of the external os uteri. From its middle another incision $\frac{4}{5}$ th of an inch in length is carried forwards towards the urethra, thus forming a T-shaped incision. Tenacula are inserted into the bladder wall through the opening, and traction is made while the other hand depresses the bladder forcibly above the pubes. By this means the bladder can be inverted into the vagina and inspection as well as palpation employed. After the examination is completed the cut edges

of the wound are carefully sutured, and the parts readily unite.

Abdomino-vesical Examination.—The finger introduced into the bladder through either the dilated urethra or the artificial opening explores the interior of the viscus; in this it is greatly aided by the hand placed on the hypogastrium pressing down the vault of the bladder against the internal finger.

The conditions which may be recognised in this manner are—diseases of the mucous membrane, the seat and extent of growths, the presence of fistulæ, foreign bodies, and of calculi (vesical and ureteral), &c.

Vesico-rectal Examination.—One finger of one hand being placed in the bladder and one or two fingers of the other hand in the rectum, the structures lying between these organs can be palpated. This is useful in obscure cases of disease in and around the uterus.

Exploration by means of Specula.—Various specula have been devised for inspecting the interior of the bladder. All of them are straight tubes with reflecting mirrors at their inner ends. The only one that shows the whole vesical interior is Rutenburg's. The patient is narcotised, the urethra is dilated, and the bladder is kept distended with air while the instrument is being used. Of other endoscopes, Skene's perhaps is the best. It is a glass tube fitting into a truncated or fenestrated case of vulcanite, and containing a small mirror which reflects the light. These instruments, though giving good results, must give place to electric illumination.

Exploration by means of Electric Illumination.—Electric illumination is practised by means of the cystoscope. This instrument resembles a calculus sound of 40 gauge (French), and is made up of beak, shaft, and ocular end.

The beak which enters the bladder contains, in a long oval aperture covered in with a thin plane of rock crystal, the small incandescent lamp which illuminates the interior. The shaft is a hollow tube furnished with lenses for magnifying the object examined. Rays of light from the part under examination enter the window which is situated at the elbow between the beak and the shaft. The ocular end possesses two binding screws for the battery wires, and a small switch for opening and shutting the current. A battery supplying a constant current of 6 to 8 volts is required. In using the cystoscope the bladder must contain from 6 to 8 ounces of urine or water. If the urine is at all murky it must be replaced by clear water. The beginner should practise on the dead subject, as there are many visual fallacies with which experience alone can render him familiar. In vesical disorders, cystoscopy, besides being a valuable assistance to digital exploration, enables us to watch the progress of disease and to find out the cause of symptoms. Its greatest use, however, is in cases of hæmaturia and pyuria, in showing whether the blood or pus originates in the bladder or kidney; in the latter instance the fluid can be seen issuing from the mouth of the ureter, and not only demon-

strates renal disease, but also which kidney is affected—a very important point when excision of the organ is contemplated.

EXAMINATION OF THE URETERS.

The ureters are examined by inspection, palpation, and catheterisation.

Inspection.—The orifices of the ureters can be inspected by the cystoscope, and present the appearance of slits upon elongated oval-shaped projections at the posterior angles of the trigone.

Palpation.—The ureters may be felt by the finger in the vagina through the anterior vaginal wall. They are hypertrophied during pregnancy, and can be made to roll between the finger and the foetal head (Howard Kelly).

Catheterisation is practised when urine direct from the kidney is wanted. The finger in the bladder recognises the ureteral orifice about an inch from the vesical neck, and half-an-inch from the median line at one end of the inter-ureteric ligament. The end of a fine catheter is carefully guided to the spot, and made to follow the canal of the ureter for a short distance; then the stop of the catheter is removed and the urine which escapes examined.

When the anterior vaginal wall is rendered tense a triangle of permanent folds can be seen which correspond topographically to the trigone of the bladder. Kelly catheterises the ureter without passing a finger into the bladder. The patient being in the lithotomy posture, and the vaginal

walls retracted by Sim's speculum, he, by observing the movements of the catheter along the floor of the bladder, is able to guide the instrument to the orifice of the ureter, which he recognises by the tripping of the point as it glides over the opening. Pawlik's plan is similar, but he operates in the genu-pectoral position.

Physical Examination of Other Systems.

A thorough systematic investigation of the other parts of the body is necessary in every gynæcological case, because first, we are dealing not only with a diseased part, but with a sick individual; and secondly, because affections of the sexual organs are sometimes secondary to other local or general disease.

Diagnosis.

In making a diagnosis we consider the symptoms and the physical signs.

From symptoms alone we cannot form a diagnosis, as they are often not reliable, being merely statements of subjective conditions, which may be either true or false, and in many diseases the symptoms differ little.

Physical signs, on the other hand, are reliable, as we feel and observe them for ourselves. In some instances they alone are sufficient to establish a diagnosis; in others, a careful consideration of the relation between the results of examination and the symptoms is necessary.





