

Operative surgery, adapted to the living and dead subject / by C.F. Maunder.

Contributors

Maunder, C. F. 1832-1879.
Royal College of Physicians of Edinburgh

Publication/Creation

London : J. Churchill, 1860-1861.

Persistent URL

<https://wellcomecollection.org/works/evhmb8j6>

Provider

Royal College of Physicians Edinburgh

License and attribution

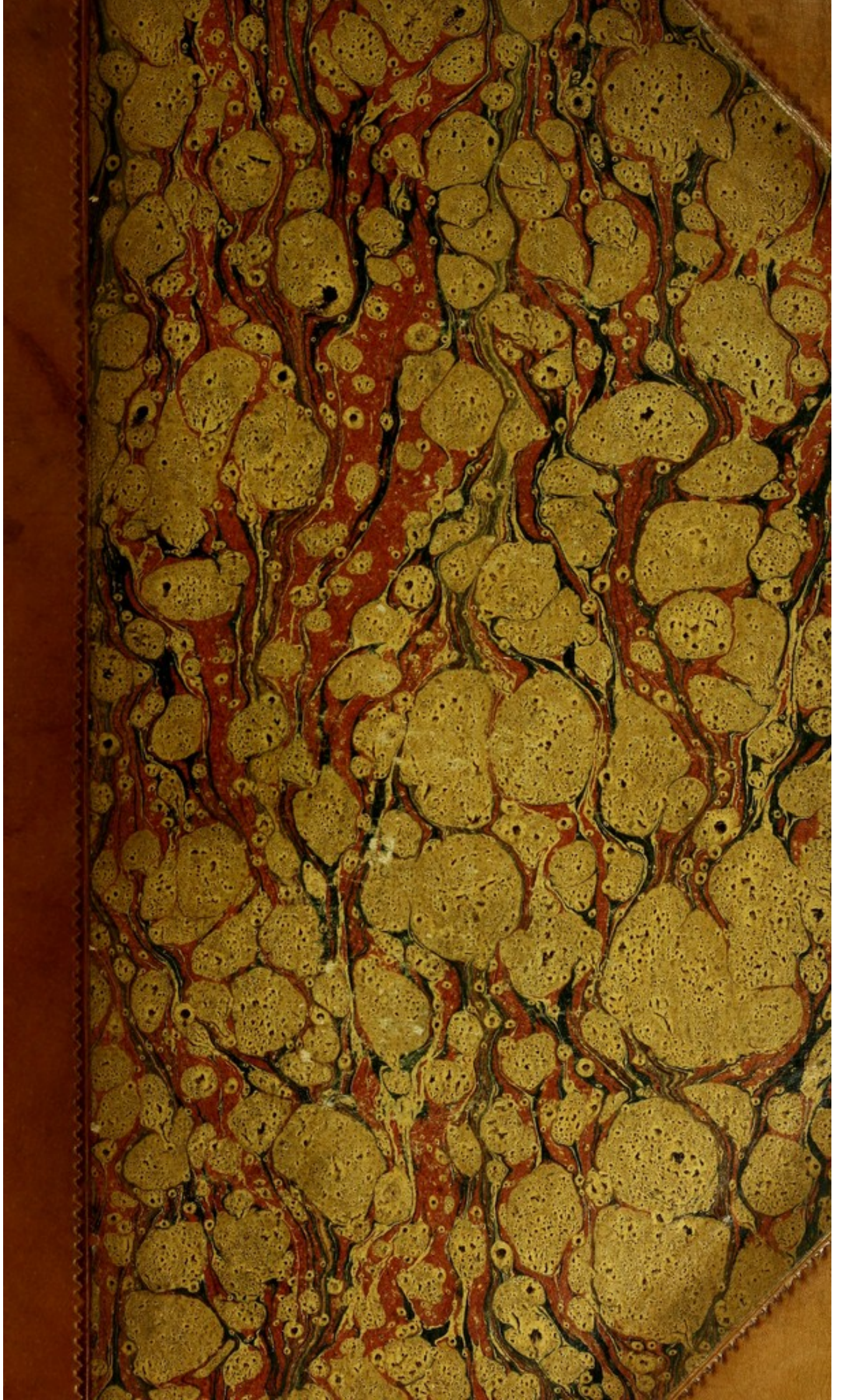
This material has been provided by This material has been provided by the Royal College of Physicians of Edinburgh. The original may be consulted at the Royal College of Physicians of Edinburgh. where the originals may be consulted.

This work has been identified as being free of known restrictions under copyright law, including all related and neighbouring rights and is being made available under the Creative Commons, Public Domain Mark.

You can copy, modify, distribute and perform the work, even for commercial purposes, without asking permission.





Wellcome Collection
183 Euston Road
London NW1 2BE UK
T +44 (0)20 7611 8722
E library@wellcomecollection.org
<https://wellcomecollection.org>



Ch 1. 24

R34049







Digitized by the Internet Archive
in 2015

<https://archive.org/details/b21957630>

OPERATIVE SURGERY,

ADAPTED TO THE

LIVING AND DEAD SUBJECT.

BY

C. F. MAUNDER,

*Translator and Editor of Ricord's Lectures on the Duality of Chancre, but the
Unity of the Syphilitic Poison.*

F.R.C.S. BY EXAMINATION, FELLOW OF THE MEDICAL AND PATHOLOGICAL SOCIETIES OF
LONDON, FORMERLY DEMONSTRATOR OF ANATOMY AND OF OPERATIVE SURGERY
IN PARIS, CIVIL ASSISTANT SURGEON ON THE STAFF OF THE ARMY IN
THE EAST DURING THE CRIMEAN WAR, DEMONSTRATOR OF
ANATOMY IN GUY'S HOSPITAL, AND JUNIOR SURGEON
TO THE GREAT NORTHERN HOSPITAL.

LONDON:
JOHN CHURCHILL, NEW BURLINGTON STREET.

MDCCCLX.

LIBRARY
COLL. REG.
MED. EDIN.

LONDON:
REED AND PARDON, PRINTERS,
PATERNOSTER ROW.

PREFACE.

WHEN conducting a course of operations on the Dead Subject in Paris, gentlemen working with me regretted that the English Professional Library did not contain a sufficiently concise systematic and illustrated guide to the operations applicable as well to the Dead as to the Living Subject.

While compiling this volume, with a view to satisfy the demand, I was forestalled in my idea by the publication of a work of a somewhat similar kind. Notwithstanding, I determined to carry out my project, and hope that I may not have failed to produce something useful to the student of Practical Surgery.

Let me observe, that I pretend to nothing new in this volume, my sole object being to give certain general rules for guidance, and to describe as clearly

and briefly as may be, what, in my judgment, is the best mode of performing certain operations.

It will be readily understood, that the cost of an illustrated work of this kind with original woodcuts would be enormous: in order therefore to offer this volume to the Student at a moderate price, I have borrowed, by permission, a large number of the illustrations from other authors.

C. F. MAUNDER.

29, NEW BROAD-STREET, E.C.

May, 1860.

CONTENTS.

PART I.

CHAPTER I.

	PAGE
Compress — Splint — Bandage — Strapping — Dislocation — Incision — Suture — To remove a suture — Serres fines — Knots	1—17

CHAPTER II.

Ligature—Application of ligature to tumours	18—21
---	-------

CHAPTER III.

OPERATIONS ON THE VASCULAR SYSTEM.

Cupping—Venæsection at the bend of the elbow—At the external jugular vein—Varix—Nævus—Trans- fusion of blood, and injection of saline fluids	22—30
--	-------

CHAPTER IV.

OPERATIONS ON THE ARTERIES.

Compression—Tortion—Cauterization—Arteriotomy— Ligature—The Tenaculum—Forceps—Application of Ligature—Sponging—Acupressure—Ligature in the continuity of an artery—Aneurism needle	31—44
---	-------

CHAPTER V.

Ligature of Special Arteries	45—96
--------------------------------------	-------

CHAPTER VI.

OPERATIONS ON THE BONES.

	PAGE
Excision of Upper Jaw—Of Lower Jaw—Of Symphysis —Of portion from Symphysis to Angle—Of portion from Angle to Articulation—Of Clavicle—Of Sca- pula—Of Head of Humerus—In the continuity of Humerus—Of Elbow-joint—Dressing the Wound —Of Radius and of Ulna—Of lower extremity of Ulna — Of Wrist-joint — Of metacarpal bone of Thumb—Of a phalangeal articulation—Of Hip- joint, Case of—In the continuity of Femur—Of Knee-joint, Case of—Of Fibula—Of Ankle-joint — Of Metatarso-phalangeal articulation — Bifid Fingers and Toes—Excision of Tarsal Bones—Un- united Fracture—Compound Fracture—Compound comminuted Fracture — Exostoses — Abscess in Bone—Necrosis—Death of the ungual phalanx— Exfoliation—Caries—The Trephine—Anchylosis	97—138

CHAPTER VII.

OPERATIONS ON THE SURFACE OF THE BODY.

Abscess—Acupuncture—Caustics—Exploration—Issue —Seton—Vaccination	139—144
--	---------

LIST OF WOODCUTS.

FIGURE	PAGE
1. Simple Roller	3
2. „ adapted to leg	4
3. „ adapted to arm	4
4. Double-headed bandage	4
5. „ „ adapted to head	5
6. Figure 8 bandage adapted to knee	5
7. „ „ adapted to ankle-joint	6
8 and 9. Back and front views of T bandage	6
10. Four-tailed bandage	7
11. Arm sling	8
12. An accumulator	10
13. Interrupted suture	14
14. Uninterrupted suture	14
15. Quill suture	15
16. Zigzag suture	15
17. Twisted suture	15
18. Serres fines	16
19. Simple knot	16
20. Double-reef knot	17
21. Surgeon's knot	17
22. Slip-knot	17
23. Clove-hitch	17
24. } Show the mode of applying a ligature to a subcutaneous	{19 {20
25. } tumour	
26. }	
27. }	
28. Cutaneous veins and nerves in front of elbow-joint	25
29. Venæsection at external jugular vein	26
30. Arteriotomy	33
31. Ligature in continuity of an artery	37
32. Opening sheath of artery, &c.	41
33. Aneurism needle	42
34. Ligature of arteria innominata	47
35. Ligature of common carotid	53
36. Ligature of third part of subclavian	61
37. Ligature of upper part of axillary artery	66
38. Ligature of lower part of axillary artery	68
39. Ligature of middle of brachial artery	71
40. Ligature of lower part of brachial artery	71
41. Ligature of upper third of radial artery	73

FIGURE	PAGE
42. Ligature of lower third of radial artery	74
43. Ligature of upper third of ulnar artery	75
44. Ligature of lower third of ulnar artery	76
45. Ligature of external iliac artery	79
46. Ligature of femoral artery at apex of Scarpa's triangle ..	84
47. Ligature of femoral artery at base of Scarpa's triangle ..	85
48. Ligature of posterior tibial artery at middle third ..	90
49. Ligature of posterior tibial artery at lower third ..	92
50. Ligature of anterior tibial artery	95
51. Ligature of dorsalis pedis artery	96
52. Chain saw	98
53. Excision of symphysis of jaw	104
54. Excision of jaw from angle to symphysis	105
55. Excision of head of humerus	110
56. Excision of elbow-joint	112
57. Excision of metacarpal bone of thumb	118
58. Excision of hip-joint	120
59. Excision of knee-joint	124
60. Excision of knee-joint by semi-lunar flap	126
61. Excision director	128
62. Trephine	134
63. Hey's saw	135
64. Bow saw (Butcher's)	138
65. Mode of introducing a seton	143
66. Seton needle	143

OPERATIVE SURGERY.

PART I.

CHAPTER I.

COMPRESS—SPLINT—BANDAGE—STRAPPING—DISLOCATION.

THE practice of surgery may be subdivided into “manipulative” and “operative;” the term “manipulative” being applied to the employment of certain supports, such as compresses, bandages, splints, and strapping; the term “operative” implying the use of cutting or wounding instruments.

A *compress* is used to maintain parts in apposition; to check hæmorrhage by offering resistance to a bandage; and may be made of lint, sponge, cork, lead, and even stone, both substance and size depending upon the requirements of the case.

Splints are employed to insure rest, to maintain or restore the natural form of the body, whether idio-pathically or traumatically altered. They are of

various shapes, sizes, and material : of *shape*, according to the form of the part to which they are to be applied, and the injury which they are called upon to remedy ; of *size*, in proportion to the stature of the patient ; and of *density*, corresponding to the amount of resistance to be borne.

In the case of fracture, of the leg for example, a splint to be of use must be well padded, and press equally on all parts ; it must also have two fixed points in order that it may counteract the action of muscles, one above, the other below the seat of fracture, say the knee and ankle—situations at which counter-extension and extension are made and maintained so long as may be necessary.

Bandages are of the utmost value, for without them the compress and splint would be useless. They are of themselves more or less sufficient to support and maintain portions of the body at rest, and in their natural relative positions ; and as the extent to which they may be multiplied is almost indefinite, I shall restrict myself by an allusion to the more useful only.

Bandages are of various lengths and widths, and are classified under a nomenclature in accordance with the supposed resemblance which they bear to certain well-known mathematical or other figures, such as the figure of 8 bandage, the T bandage. The object in the employment of a bandage being to procure rest and to give support, it is obviously desirable that pressure should be equable and the appli-

cation carefully and evenly effected. It should also, with few exceptions, be applied to favour the return of blood towards the heart—as, for example, from the fingers and toes upwards—lest strangulation and mortification unhappily follow the opposite mode of proceeding.

In order to prevent retraction of the soft parts after amputation, strapping or a bandage may, contrary to the rule, be cautiously adapted from above downwards.

The *simple roller* (fig. 1) of the required length and width is made by rolling a strip of calico tightly upon itself into the form of a cylinder, leaving one extremity free, the outer surface of which extremity should be first applied to the part of the body to be invested, while the cylinder is manipulated by the surgeon and gradually unrolled. In applying the simple roller or bandage, to the leg for example, in order to insure equal pressure, the free end being fixed by one or two turns, the roller should be carried gradually round and round the limb to the required height, and be thus unrolled without having been removed from the limb except to make a “turn,” and always under the same tension from the hand of the surgeon.

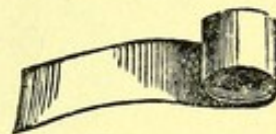


FIG. 1.

Fig. 2 shows the simple band adapted to a limb of conical shape, the leg.

Fig. 3 displays the band investing the arm, each circle of which overlaps the one below to the extent

of one-third or one-half, so as to insure complete investment; but the arm being of nearly the same

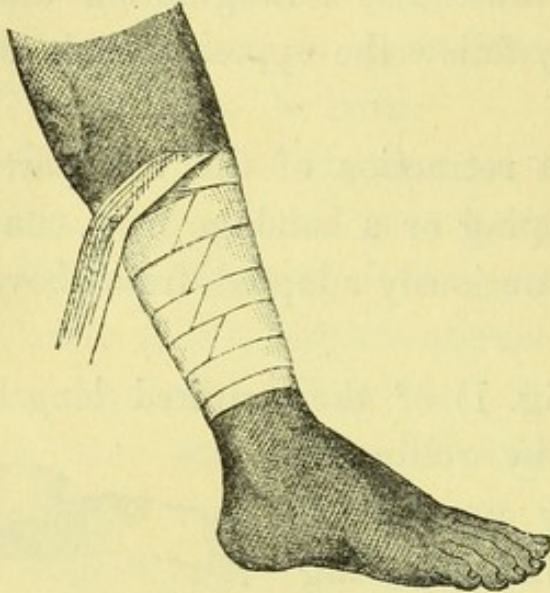


FIG. 2.

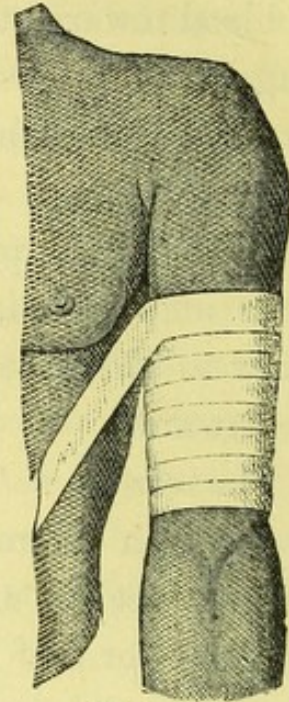


FIG. 3.

diameter throughout its extent, the "turns," as represented in fig. 2, are not required.

The *double-headed* bandage (fig. 4), formed by rolling up both ends of the calico till the cylinders meet in the centre of it, is applicable to the surgery



FIG. 4.

of the head. It is adapted by placing the external surface of the portion of the bandage between the cylinders upon the forehead. Holding a cylinder in each hand, carry them round to the back of the head, cross and change hands with the cylinders simultaneously, repeat the circle and crossing, carry one end of the bandage across the top of the head, first on one side of the median line and then on the other, from behind forwards and from before back-

wards alternately, taking care to fix each crossing by a circular turn of the other end of the bandage, and so on, from within to without till the head be covered.

Fig. 5 represents the *double-recurrent* bandage adapted.

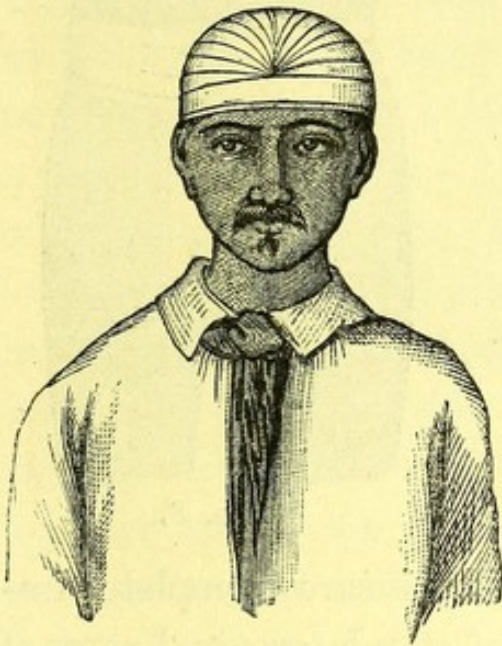

FIG. 5.

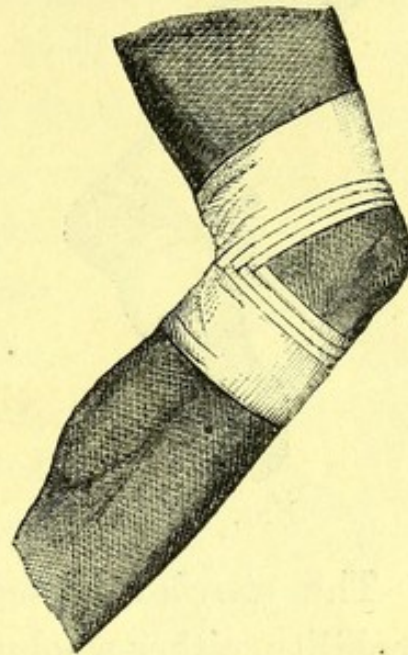


FIG. 6.

The *figure 8 bandage* is much employed, and is readily adapted to the joints, as in fig. 6, to the knee-joint, and in fig. 7, to the ankle-joint; it is especially applicable to fractures of the clavicle and surgery of the shoulder.

The *T bandage* (figs. 8 and 9) is employed in the surgery of the anus and vagina, and consists of a horizontal portion going round the pelvis, to which is attached behind, in the median line, a vertical portion: this passed under the perinæum, and split into two parts, one of which runs on either side of the scrotum, if the patient be a male, is attached by

pins or thread to the front and middle of the horizontal line.

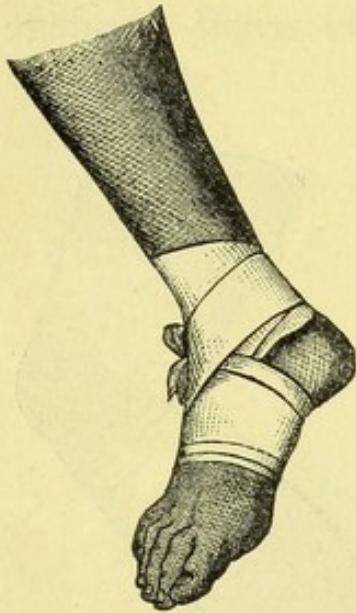


FIG. 7.

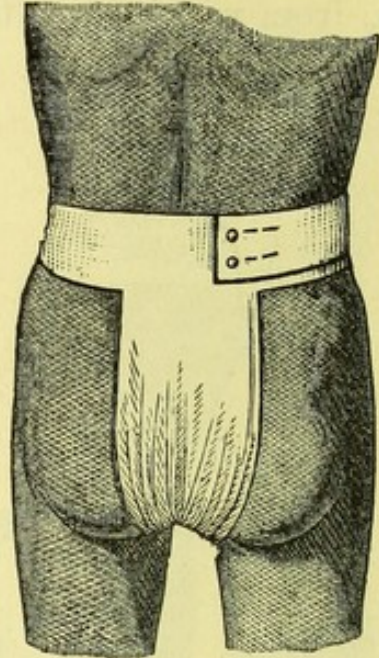


FIG. 8.

The *starched bandage*.—To insure complete im-

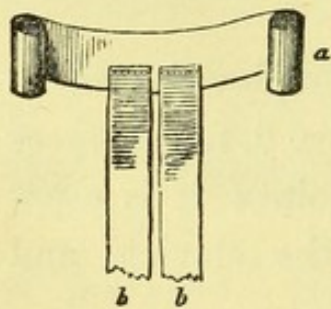


FIG. 9.

mobility, either a solution of starch, or equal parts of gum and chalk, moistened with water, and in which a bandage has been allowed to soak, and is also smeared during its application, is of eminent service in cases in which the injury need not be daily under the eye of

the surgeon. It insures rest by forming a solid case to the limb, and allows the patient to take gentle exercise without risk of disturbing the injury.

The *many-tailed bandage*, *buckles and straps*, and *tapes*, are superior to the simple roller in some cases of fracture, in being readily adapted or re-

moved without danger of disturbing the injured parts.

The *four-tailed bandage*, especially useful in injuries to the lower jaw, consists of a piece of wide roller split at either end into two portions to within a few inches of each other, the centre to correspond with the chin. The upper tail (*b*) of either side is to be carried behind the head, and there fixed by a knot and bow; or, as in fig. 10, the ends crossing each other behind may be brought forward and fixed on the forehead or side of the head (*a*). The lower tail (*c*) of either side, carried directly upwards, may be tied together on the top of the head, or, crossing the vertex, may be tied under the chin.

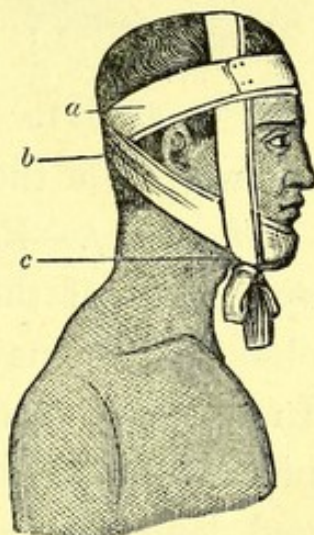

FIG. 10.

The *broad roller* for the chest or abdomen may be single or double-headed.

To *remove* the common roller, for example from the leg, undo the fastenings at the upper end, and unroll in a direction opposite to that pursued in adapting the bandage, passing the bandage alternately under and over the limb, and collecting it into a tolerably neat ball, rather than to drag the end as each turn is unrolled.

The *handkerchief*, of varied shape and size, will be found useful in many cases. It is commonly used as a sling for the hand and forearm (fig. 11), the

whole length of which should be included to prevent fatigue of any one part, and the hand should be

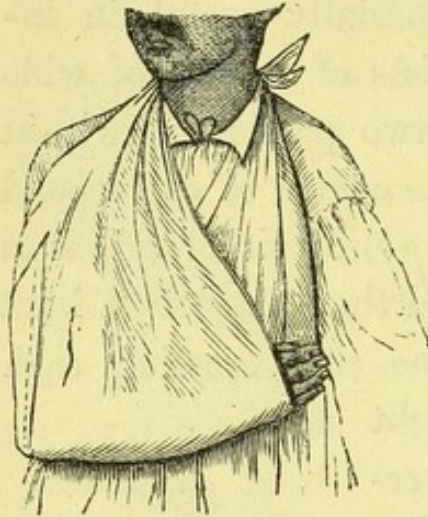

FIG. 11.

elevated above the elbow to favour the return of blood, and avoid swelling.

The *anti-chordee bandage*.—To prevent erections during the night, three or four turns of a bandage may be made round the root of the scrotum and penis, so as to bind the two organs together;

the weight of the testicles will prevent erection.

Strapping.—Besides its use in maintaining the apposition of the edges of wounds, similar general observations may be applied to it as to bandages. In cases of fractured ribs of one side only, broad pieces of strapping, from two to three inches wide, and long enough to reach from the spine to the sternum, are sometimes employed instead of a broad bandage. The strapping applied to the injured side only does not interfere with the movements of the opposite side.

In applying strapping to a wound, the adjoining surface should be wiped and dried, and then one end of the plaster should be fixed to the skin, first on one side of the wound, and to a moderate extent of surface. This done, the edges of the wound are to be held in apposition with the finger and thumb; and while traction is made on the adhering strapping,

the integuments on the opposite side should be also drawn towards the wound, so as to favour relaxation at the wound, and at this moment the strapping is passed across the wound and fixed on the opposite side.

The effect of strapping thus employed may be increased by adapting a compress of folded lint to each side of the wound previous to fixing the plaster as above described.

Unless the whole limb be bandaged or strapped from below upwards to the required extent, a single strip of plaster should not be made to cover the whole circumference of the limb; it would either interfere more or less with the cutaneous circulation, or prevent instead of assist approximation of the edges of a wound.

To remove strapping and other dressings from an open wound, commence at each end of the piece, raising the ends simultaneously towards the wound, so as to avoid tearing open the wound in any way. Under certain circumstances, dressings and bandages may be cut up by running a knife or pair of scissors along a director passed beneath them.

DISLOCATION.

The head of a bone being displaced, it becomes the surgeon, with few exceptions, to endeavour to restore it to its normal position. This act is termed "reduction," and consists in the application of forces in

different directions, with a view to put the displaced bone in such position that the muscles which normally assisted in maintaining it *in situ* may return it whence it came. With this object in view, two forces are usually employed—the one, “extension,” effected by making traction upon the distorted limb; the other, “counter-extension,” made by fixing the trunk or portion of limb so as to enable it to resist extension. These forces are brought to bear by manual or mechanical intervention, the latter comprising agents both simple and complex, from the clove-hitch to the pulleys.

Since the introduction and application of chloroform to dislocation, the surgeon can generally effect reduction unaided by mechanical agents; but cases are occasionally met with in which a large amount of force is requisite to restore the head of the bone to its normal position. For this purpose, I propose to employ vulcanized india-rubber, in the shape of Hodges' Accumulator.* Counter-extension is to be made in the usual way, while extension is to be effected by attaching one end of the accumulator to the dislocated limb, and the other end, when stretched, to a hook conveniently fixed. An accumulator four



FIG. 12.

inches in length (fig. 12), when stretched twenty-four inches, will exercise traction upon the limb equal to

* R. E. Hodges, 44, Southampton Row.

thirty pounds; and since a man pulling horizontally cannot exercise a force equivalent to more than from thirty to fifty pounds, it is obvious that one accumulator is equal nearly to one man. The advantages which the accumulator possesses over the pulleys are, that it is very portable, compact, untiring and inexpensive, and renders the surgeon quite independent of the manual assistance of others. The extending power is thus applied gradually, avoiding all risk of sudden jerkings and consequent laceration of soft parts, while the force may be increased or diminished to any extent, by adding to or lessening the number of accumulators employed.

With some few exceptions, the most ready mode of reducing a dislocated bone is to place the patient recumbent and under the influence of chloroform, so as to relax the muscles completely by means of the latter agent. If the humerus be displaced, the bone may be restored to its normal condition by pulling moderately upon and extending it with one hand, while the other hand is used either as a fulcrum, or to seize the bone near its head and *put* it into its place. Should the femur be dislocated, the hands of the surgeon may be employed either as above directed, for the humerus, or by seizing the displaced limb with both hands, one grasping the leg above the ankle, and the other the knee, then flexing the leg on the thigh and the thigh on the pelvis, while, at the same time, the thigh is abducted and rotated outwards, the head of the bone will glide into the acetabulum.

OPERATIONS.

Operations are either *minor* or *capital*: minor, such as a simple incision, or which usually cannot be said to endanger life; capital, such as an amputation, which cannot be performed without risking life; at the same time it should never be forgotten, that the most simple operation is occasionally followed by fatal consequences, and should, therefore, never be wantonly undertaken.

An operation implies a solution of continuity, effected by a cutting or wounding instrument; as, for example, the ordinary straight scalpel, or bistoury, used in the performance of very many operations.

The most simple operation is *an incision*, whether straight or otherwise.

To effect incision, the scalpel is held differently, in accordance with the fancy of the surgeon, the result which it is required to produce, or the region in which it is employed.

Incisions may be single or multiple. A simple incision is usually made with one sweep of the knife, and should be effected with a sharp knife, so as to avoid causing unnecessary pain, and offer no obstacle to speedy union. A knife, however sharp, is a fine saw, and to effect the required incision must be drawn across the part to be divided, with more or less force, and not be pressed only upon the part. The length of incision decided upon, the integuments may, if necessary, be shaved, fixed and made tense, either by the operator's left hand or by the aid of an assistant, care being taken not to disturb the relation of the in-

tegumental surface to the parts beneath. The scalpel held as a pen, either at a right angle or at an angle of 45° to the surface, is plunged into the integuments, which it is made to divide to the required extent, while carried towards or from the operator, and brought out after completing the incision at a right angle to the surface, so as to insure complete division. All secondary division of deeper parts should be made parallel to and of the same length as the primary. In performing a delicate operation, let the incision be rather long than short; it allows light to enter, gives space to work in, and cannot influence the result.

Suture.—The operation completed, it may be necessary to close the incision, the edges of the wound being approximated and kept in apposition by one of the varieties of suture, to effect which a needle and thread play an important part.

Needles are of various shapes and sizes, whether straight and cylindrical, straight and triangular, or curved and double-edged. The *hare-lip pin* has a button at one end, instead of an eye; it supports the twisted suture, the thread being adapted in the form of the fig. 8 (see fig. 17).

Threads are of various sizes and material, whether flaxen, silken, or metallic, according to the fancy of the surgeon, or the peculiar nature and seat of the wound.

Before using a suture, hæmorrhage should have ceased, all foreign bodies be removed, and the edges of the wound be adjusted by the eye and finger.

If possible, the lips of the wound being held together, the needle should be passed through both at once, and at a depth in proportion to the tension to be resisted. The knot should be drawn tight enough to insure apposition of the edges of the wound without the risk of strangulation, either directly or indirectly, from swelling. Tension may be moderated by the use of strapping and a bandage, and by a position favourable to the relaxation of integument and muscles. If possible, do not pass a suture through muscle.

Fig. 13 shows the ordinary *interrupted suture*, the knot being on one side of the wound that it may not interfere with close approximation of the lips of the latter. To effect this, a needle, armed with the requisite thread, is entered on one side of the wound

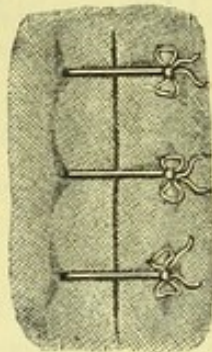


FIG. 13.




FIG. 14.

or through one lip of the incision, and brought out through the other side or lip. The edges of the wound being held in apposition, either a double knot or a single knot and bow is tied, and the suture is fixed.

The *uninterrupted suture* will be readily understood by a reference to fig. 14.

The *quill suture* (fig. 15) is made by passing a double ligature, and inclosing portions of quill, rolls of strapping, or elastic bougie, as *points d'appui*. This variety is employed when some force is requisite to keep the edges of a wound together, and also to approximate the deeper parts.

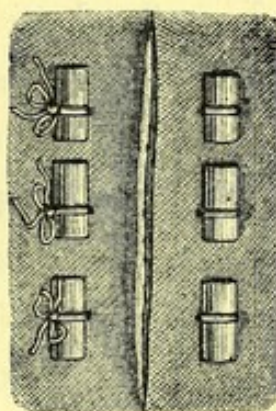


FIG. 15.

The introduction of a body capable of resisting traction prevents ulceration at the points of suture, by distributing the force over a larger area.

The *zigzag suture* (fig. 16) operates in a manner similar to the former.

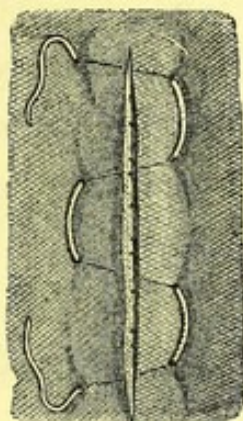


FIG. 16.

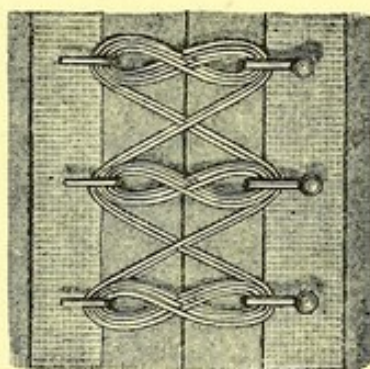


FIG. 17.

The *twisted suture* (fig. 17) has been already noticed.

The *metallic suture*.—In many cases, the metallic suture, whether of silver or of annealed iron wire, will be employed with advantage, inasmuch as it gives rise to less local irritation than the ordinary thread does, when left in for a similar period. It may be fixed by a knot or twist, or by buttons or clamps

passed along it; and, when adapted, squeezed upon and so fixed to it by a pair of appropriate forceps. These buttons and clamps have also the property of distributing the traction over a larger area, after the manner of the quill suture.

To *remove a suture*.—Previous to the removal of a suture, the edges of the wound, say in a stump, should be carefully maintained in apposition, by the application of strips of strapping, or other means of support, passed between the points of suture. The stump should also be well supported by the hands of an assistant, lest the flaps separate by their weight alone. Sutures may also be removed at intervals of a day or more, those being taken away first which cause the greater amount of irritation.

The *serres fines* (fig. 18) are delicate wire forceps, used instead of sutures in regions where the skin is very thin, as that of the prepuce; they are readily applied and removed.

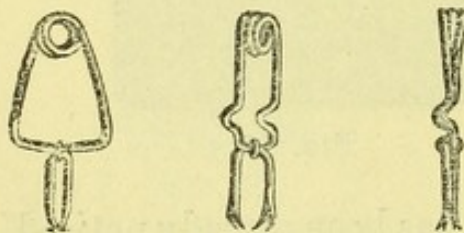


FIG. 18.

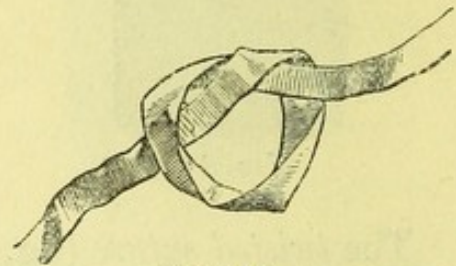


FIG. 19.

Various *knots* are employed in surgery, as the *simple knot* (fig. 19).

The *double-reef knot* (fig. 20), a repetition of the former.

The *surgeon's knot* (fig. 21), made by twisting one end of the ligature twice round the other end.

The *slip-knot* (fig. 22) is very useful where the

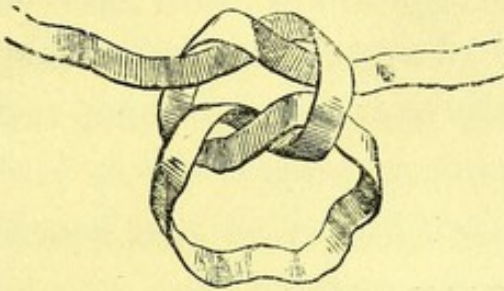


FIG. 20.

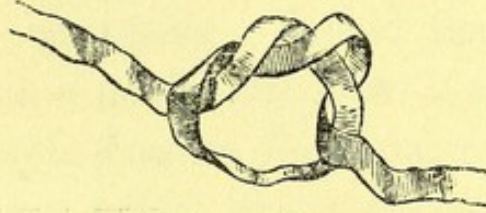


FIG. 21.

above cannot be readily applied ; it also is easily loosened and re-adjusted, and afterwards fixed by the simple knot.

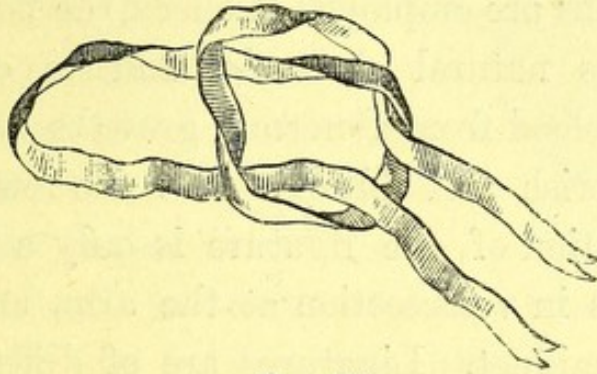


FIG. 22.

The *clove-hitch* (fig. 23) is the extending apparatus employed in the reduction of certain dislocations :

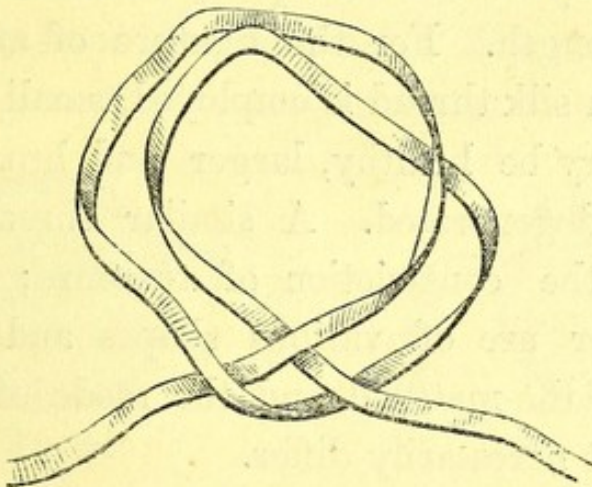


FIG. 23.

the more you pull, the more firmly it holds the part embraced by it.

CHAPTER II.

LIGATURE—APPLICATION OF LIGATURE TO TUMOURS.

LIGATURES are employed to check the flow of blood through its natural channels, and to cut off the supply of blood from abnormal growths, and so cause them to perish and fall off. In some few instances, the application of the ligature is only a temporary measure, as in venæsection at the arm, and the use of the tourniquet. Ligatures are of different material, whether of thread, of silk, of cord, or of wire, according to the whim of the surgeon, and the uses to which they are to be adapted, and also of proportionate strength. For the ligature of arteries, the well-known silk thread is employed, small and round if the artery be healthy, larger and broader if the vessel be degenerated. A similar thread may be used for the constriction of tumours; and since these latter are of various shapes and sizes, the selection of the material and the mode of its application must necessarily differ.

Should the tumour to be removed be attached to the trunk by a narrow base, its pedicle may be constricted

by a single thread tied tightly round it, the skin having been previously divided so as to form a groove for the ligature to lie in, and also to occasion less pain and expedite the sloughing. Should the base of the tumour be broad, a needle armed with a thread may be passed under the base of the tumour in one, two, or more directions, thus isolating portions of the tumour and rendering them susceptible to the ligature. Just before fastening the ligature, the tumour, if vascular and very tense, may be punctured with a lancet, in order to diminish its bulk.

Fig. 24 represents a subcutaneous tumour, the dark line being skin, and the dotted interior (*a*) the tumour itself, to be removed by three ligatures, of which the first (*c, d, e*) has been passed under the skin along part of the circumference, from *c* to *e*, on a curved cutting needle. A straight needle is now threaded with the same ligature, and passed across the base of the tumour (fig. 25), entering at *c*, and making exit at *b*, and carrying the thread (*d*)

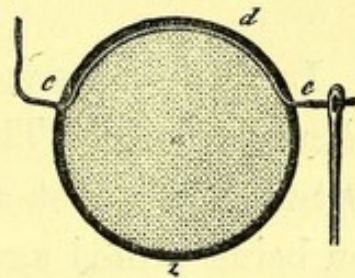


FIG. 24.

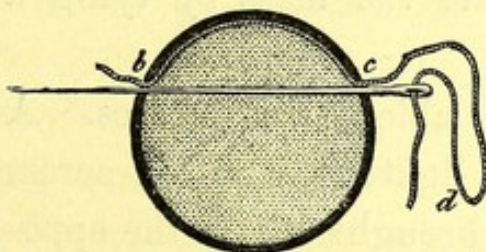


FIG. 25.

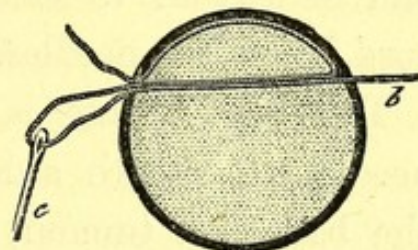


FIG. 26.

with it. Cut now the loop of the thread (*b*, fig. 26), and liberate the needle (*c*). By these means

the upper segment of the tumour is inclosed, and also one thread placed *in situ*, ready to assist in the constriction of the central portion of the tumour

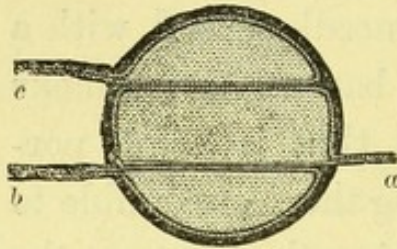


FIG. 27.

when the lower segment has been treated similarly to the upper. Fig. 27 shows the ligatures in position, and the tumour may be constricted at any moment by tying the ends (*a, b, c*).

In many cases it may be necessary to tighten the ligature daily. The most simple plan is to include, between the first and second knots, a thread which, on being pulled against the second knot, will loosen it, and permit of re-adjustment of the ligature. When practicable, the skin should be saved by dissecting it carefully off the surface of the tumour, if the subcutaneous method be not applicable to the case. Besides the above, the ingenuity of the surgeon will devise other modes of passing ligatures according to the requirements of the case: some practitioners pass needles across the base of a tumour, and endeavour to strangulate the mass by tying a cord below the needles.

The *figure 8 knot* is applicable to many cases. A needle armed with a double ligature is passed across the base of a tumour, and brought out on the opposite side; care being taken to have several inches of ligature on either side of the tumour. Select one thread near the needle and divide it, leaving the

other thread still in the needle; take now the originally free end of the thread just divided, and pass it through the eye of the needle, and thrust the latter, thus armed, across the tumour, at a right angle to the first ligature. A little careful manipulation will show that the fig. 8 form given to each of the two ligatures, enables each one to constrict two quarters of the tumour.

CHAPTER III.

OPERATIONS ON THE VASCULAR SYSTEM.

CUPPING—VENÆSECTION AT THE BEND OF THE ELBOW; AT THE EXTERNAL JUGULAR VEIN—VARIX—NÆVUS—TRANSFUSION OF BLOOD AND INJECTION OF SALINE FLUIDS.

CUPPING is performed with the ordinary *cupping-glass*, of which there are many shapes and sizes, in proportion to the quantity of blood to be drawn and the extent of surface to which the glass can be applied. The operation is performed either with or without scarification: the latter method is termed *dry cupping*, and is effected by exhausting the air of the cupping-glass by the lighted torch of a spirit lamp, or some other inflammable material, placed in it till combustion can be no longer sustained. The oxygen of the air having been consumed, the flame goes out, and at this moment the mouth of the glass should be gently pressed upon the surface of the body, when atmospheric pressure will cause the blood rushing to the spot in order to fill the vacuum in the glass to raise and redden the integument. The

operation is completed, and may be repeated at pleasure on the adjacent tissues. Care should be taken to select a soft and even surface for the application of the cupping-glass, perhaps even by shaving the part. To withdraw blood, the glass having been removed, the *scarificator* should be applied to, or scarification be made with a very sharp instrument on, the elevated integument. The skin divided, the air must be again exhausted, and the glass applied, when, if the operation is successful, blood will flow to the required quantity. It may be necessary to use the scarificator at more than one point, and to apply the glass repeatedly over the incisions. Should the integument be forced high into the glass, the edge of the latter may constrict the former and hinder the flow of blood; to avoid which inconvenience the operator should raise the glass gently from the body, so as to relieve the constriction, but avoiding the entrance of air. The operation completed, wash and dry the incisions, and close them with adhesive plaster.

Venesection.—Blood-letting is usually performed at the bend of the elbow, such position being convenient both for the surgeon and patient, and in the following way:—Tie a tape or finger bandage around the arm two inches above the elbow, sufficiently tight to prevent the return of blood up the arm through the superficial veins, but not so as to check the downward flow of blood through the brachial artery to the hand. Examine carefully the relation

of the veins at the bend of the elbow, and explore the surface with the finger, to ascertain that no artery be abnormally placed, as sometimes happens, and might, through negligence, be wounded. Ascertain the exact position of the median basilic vein with regard to the brachial artery, and select for the operation some portion of the vein not immediately over the artery. Support the arm of the patient by placing the palm and three inner fingers of the left hand behind the elbow, keeping the thumb and forefinger in front; the thumb to press on the vein below the position of the intended puncture, to prevent the escape of blood before a vessel can be placed to receive it, and the forefinger to press upon and steady the vein above the point of puncture. The lancet should be held by the semi-flexed thumb and forefinger of the right hand, the little finger of the latter resting on the fore-arm of the patient. Puncture of the integument and vein will be effected by extending the thumb and forefinger sharply, while the wound may be enlarged by causing the lancet to cut its way out in a forward direction. The vein should be opened obliquely, either from below, upwards and inwards, or upwards and outwards. To facilitate the flow of blood, the patient may exercise the muscles of the wounded fore-arm by squeezing something with the hand. The operation completed, place the thumb of the left hand upon the wound, and remove the bandage from the arm; cleanse the arm with sponge and water, and then put a thick pad of lint over the

wound, and apply a figure 8 bandage to maintain the compress in position, and exercise pressure sufficient to prevent the further flow of blood. The student may practise the use of the lancet on the veins of a cabbage-leaf with advantage.

Fig. 28 shows the relative position of the superficial veins and nerves in front of the elbow, also the brachial artery just as it is about

to pass behind the aponeurotic expansion from the tendon of the biceps. Passing from without to within, are seen the cephalic vein (*a*), external to the biceps muscle, formed by the junction of the radial (*b*), and median cephalic vein (*c*); *d* marks the union of a deep vein with the median vein of the fore-arm, and its bifurcation into median cephalic vein on the outer side of the tendon of the biceps, and the median basilic vein (*f*) on the

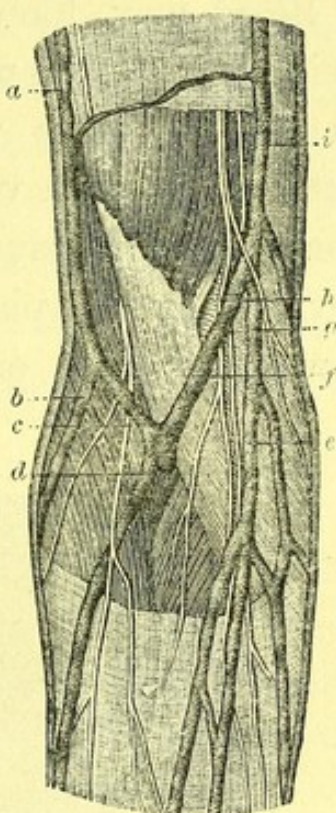


FIG. 28.

inner side of the biceps tendon, to which latter are joined the ulnar veins (*e, g*), so as to form the basilic vein (*i*). The median basilic vein is usually chosen for this operation because it is larger than the median cephalic, and more superficial than it, in consequence of being, as it were, stretched over the aponeurotic arch coming from the biceps. In this region, however, large branches of the internal cutaneous nerve pass

superficial to the vein, while the brachial artery (*h*) lies behind the vein; and for these two circumstances some persons bleed from the median cephalic vein. Again, it will be observed that the arrangement of veins in this region varies much, and in such cases it will be well to select the largest and most superficial vein in the neighbourhood.

Blood may likewise be drawn from any superficial vein, as from the veins of the scrotum, and external jugular vein. When operating on the external jugular vein, select a spot lying over the sterno-mastoid muscle. In this position the vein is covered by the platysma muscle; and in order to favour the flow of blood through the wound, the

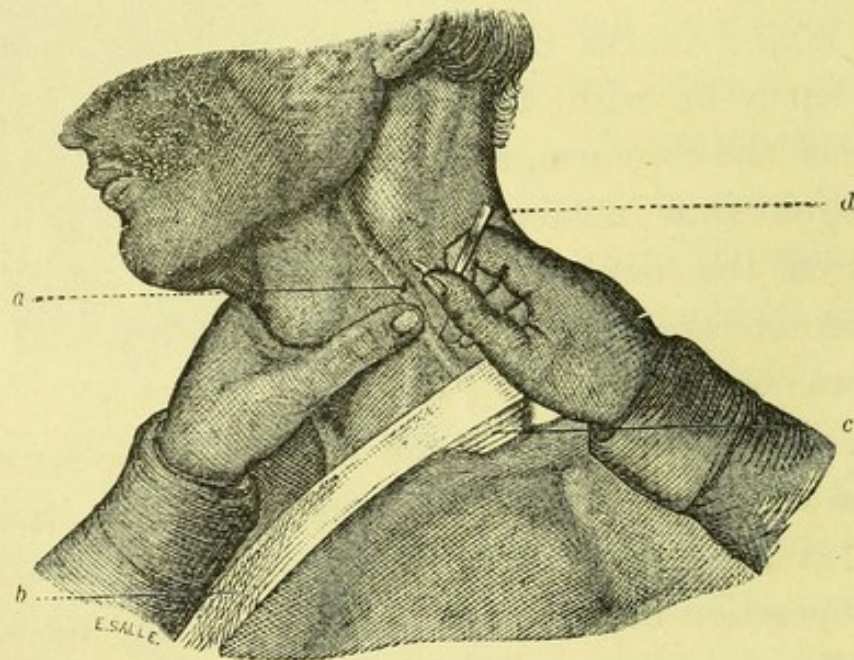


FIG. 29.

fibres of the platysma should be cut transversely, that is, from below, upwards and outwards, thus

allowing the divided muscular fibre to contract and hold the wound open, as it were, while the vein is divided obliquely. Pressure with the thumb below the point of puncture, or with a compress and bandage, will check the natural current of the blood, and render the vein prominent. Fig. 29 shows the mode of operating—*a*, the wound in the external jugular vein; *c*, the compress maintained in position on the vein by a bandage (*b*) carried under the opposite armpit; and *d*, the lancet held by the right forefinger and thumb. Pressure on the vein by means of the thumb or compress should always be kept up until the wound has been closed by lint and strapping, lest air enter the circulation and lead to fatal results.

VARIX.

Various operations have been proposed and resorted to for the cure of varicose veins; and of these, obliteration by needle and ligature, by cauterization, by injection of the perchloride of iron, and by subcutaneous division, rank first.

By *needle*: pass a needle transversely behind the vein, and a small portion of elastic bougie having being placed on the surface of the skin over and at a right angle to the needle, constrict the whole with moderate pressure by the twisted suture. The part may thus be left during from three to six days; also from three to six needles may be used on one extremity. If swelling and inflammation be not excessive, the needles may be allowed to cut their way out.

By *subcutaneous section* : pass two needles transversely behind the vein, with an interval of one inch and a half; apply a ligature about each needle, beginning with the uppermost, tight enough to stop the circulation, but not to strangulate the part. After the lapse of forty-eight hours, divide the vein subcutaneously between the ligatures, and apply a compress and bandage. After the lapse of another forty-eight hours the needles may be withdrawn. Care must be taken to pass the needle or pin behind and not through a vein.

By *cauterization* : the skin, to the extent of a shilling, over the position of the vein, is to be destroyed by the careful application of the *Vienna* paste. By this mode, the vein being either included in the slough, or implicated by the surrounding inflammation, its channel becomes closed.

By *the injection of the perchloride of iron in solution* : the vein having been punctured so as to admit the nozzle of a syringe charged with a solution of perchloride of iron, from four to ten drops, in proportion to the calibre of the vein, are to be injected, at intervals of five or eight inches. If an ulcer exists, the veins below may be similarly treated at one or two points. The wounds are to be closed by pieces of lint and strapping, and the patient kept quiet in bed.

NÆVUS.

Treatment by *ligature* as already described under article "Ligature."

By *pressure* : a mode only to be adopted when the aneurism by anastomosis lies over bone.

By *injection* of some irritant fluid, as tincture of iodine, or a solution of perchloride of iron: a puncture sufficiently large to admit the nozzle of a small syringe is made in the skin, and a quantity of the fluid, from five to fifteen drops, in proportion to the size of the tumour, is injected after *subcutaneous incision* has been adopted. Inflammation, followed either by obliteration and absorption or by suppuration and cicatrization, is the result.

By *seton* : one or more threads may be passed through the tumour.

By *vaccination* : applicable to very small examples of this disease.

By *subcutaneous incision* : the blade of a knife, or cutting needle, being passed in various directions, so as to break up or cut up the enlarged vessels.

By *actual cautery* : one or more wires being passed through the tumour, and heated by electricity.

By *ligature* of one or more arteries, or even a main artery : applicable to those cases in which arteries enter largely into the formation of the tumour, and perhaps previous to the free use of needles at various points, or under circumstances, consequent on position, where the tumour cannot be treated locally.

By *caustics* : one of these agents being applied to the surface, or introduced into the interior, on a probe or needle.

By *excision*: the surgeon must cut wide of the tumour, otherwise bleeding may be profuse.

When this plan can be adopted, it should be had recourse to, because, when the wound heals, a linear cicatrix is the result; but often, by other means which destroy much skin, an ugly scar is produced and increases in size as the patient, if a child, arrives at manhood.

In all cases the surgeon should destroy as little skin as possible, to avoid ugly scars and deformities.

TRANSFUSION OF BLOOD AND INJECTION OF SALINE FLUIDS.

This operative proceeding consists in laying bare a superficial vein of the arm by a parallel incision, and passing a ligature behind the vein, which is now to be opened to receive the nozzle of a syringe. The injection completed, the ligature and pipe, or syringe, are to be withdrawn, and the wound closed by compress and bandage.

CHAPTER IV.

OPERATIONS ON THE ARTERIES.

COMPRESSION — TORTION — CAUTERIZATION — ARTERIOTOMY — LIGATURE — THE TENACULUM — FORCEPS — APPLICATION OF LIGATURE — ACUPRESSURE — LIGATURE IN THE CONTINUITY OF AN ARTERY — ANEURISM NEEDLE.

COMPRESSION is either *direct* or *indirect*: direct, when made upon the vessel itself, without the intervention of soft parts, as in wounds of the arteries of the hand, and during the performance of operations, by the tips of the fingers; indirect, when made over the course of an artery, and something, such as the soft parts of the body, intervenes between the compress and the compressed. Compression may be either *partial* or *complete*: partial, where the flow of blood through an artery is moderated only, as in the treatment of aneurism, by pressure; complete, when the current is quite stopped, as it should be, during the performance of certain operations. The usual means of compression employed during operations are either the fingers of a trustworthy assistant or the tourniquet: the former means is preferable, provided that the operation does not last long enough to tire the fingers of the

assistant, who can, however, under most circumstances, be replaced by another; in this way, too, the venous circulation is not interfered with, and the patient loses less of the vital fluid than when the tourniquet is used. Of this instrument there are many varieties; the most simple consists of a pad to be placed over the artery, and exercising pressure thereon by means of a strap going round the limb and fastened by a buckle. This strap is objectionable, because it hinders the ready return of blood through the superficial veins. The best forms of tourniquet will be hereafter referred to.

When about to apply compression, the surgeon selects a spot at which the artery is comparatively superficial and lying over bone, against which it may be compressed. It will be readily understood that the skin will not bear the pad of a tourniquet pressing on it for a length of time; if, therefore, it be necessary to exert pressure on the course of any artery during a long period, two tourniquets should be adapted and tightened alternately, or one tourniquet and a weight suspended from a cradle, for example, as in the treatment of popliteal aneurism.

A pebble twisted up in a handkerchief, and the latter tied tightly round the limb; a wet and tightly rolled bandage; a door key, the handle of which is protected by a strip of lint wound round it, are good substitutes for the tourniquet.

Tortion.—When small vessels bleed, and it is important to close the wound without ligatures, the

extremity of the divided artery being seized by a pair of forceps should be twisted several times on itself, and the channel remaining closed, a further flow of blood is rendered impossible.

Cauterization.—The actual cautery may be used with advantage in regions in which, in consequence of the depth of the wound, a ligature cannot be applied; also in hæmorrhage from bone.

Arteriotomy.—The vessel usually selected for this operation is the anterior branch of the temporal artery (fig. 30, *a*). It is easily felt through the skin,

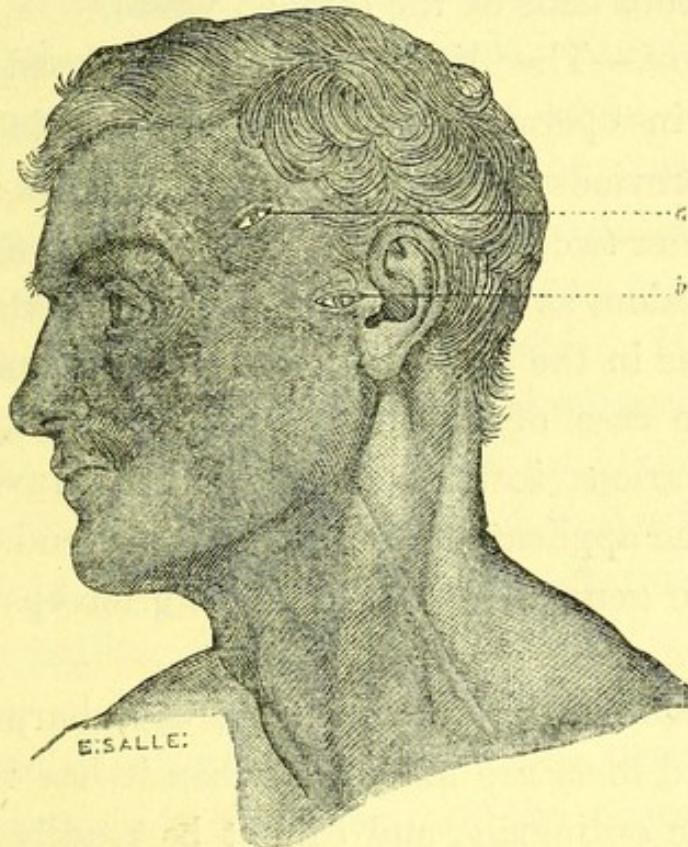


FIG. 30.

and can be readily compressed. Should this branch be small, the main trunk (*b*) may be opened, just over the zygoma, in front of the tragus.

To bleed from an artery, ascertain its position, and shave the part, if necessary; place the points of the forefinger and of the middle finger of the left hand with an interspace of about an inch upon the artery, in order to steady it; then, holding the knife in the right hand, divide the tissues layer by layer at right angles to the course of the vessel, till the artery be reached and opened. The desired quantity of blood having been taken, complete the section of the artery, and apply a compress and bandage. If the hæmorrhage be not controlled by this means, place a ligature on both ends of the divided vessel.

Ligature.—The ligature generally used in this country in operations on arteries, is made of silk, waxed previous to being applied. Arteries are ligatured under two conditions; either at their extremity after division, as after amputation, or in their continuity, as in the operation for true aneurism.

In the case of ligature of the extremity of an artery, various instruments have been invented to aid in the application of the ligature; and of these two are in general use, the dissecting forceps and the tenaculum.

The *tenaculum* may be described as a sharp-pointed hook, used to secure an artery when it has retracted more than ordinarily, and cannot be readily reached by the forceps. Generally some portion of the adjacent soft tissues are included by the ligature, thus delaying the separation of the same; the tenaculum therefore should never be used except

under extreme necessity. Sometimes the ligature will not hold even when the tenaculum has been employed. An instance of this kind happened to me after an amputation of the thigh. The end of the femoral artery was surrounded by tissues so thickened by old inflammatory deposit, that I could secure the vessel neither with the forceps nor with the tenaculum. I accordingly formed, by careful dissection, a pedicle of soft tissue including the artery, and, passing a double ligature on a needle, secured each half. The patient recovered.

The *forceps* most under the control of the surgeon is the common dissecting forceps, with moderately broad points. Many others are used, some with springs or fastenings, to maintain the points of the instrument in contact when so placed; others with springs and claws. These latter may be used by a surgeon operating without assistants. Having reflected upon the position of the chief vessels of the part, the surgeon should proceed to tie them in the order of size. The extremity of the artery being taken hold of by the forceps, the operator must ascertain by pulling *very gently* upon the vessel, and so isolating it *slightly*, that the adjacent soft parts are not included, whether muscle, fibrous tissue, vein, or nerve, lest pain be occasioned, and the separation of the ligature be delayed. To assist him the surgeon may use either his finger-nail or a second pair of forceps. The artery seized, an assistant manœuvres to cast a ligature around the forceps, and holding one end of

the thread in each hand forms the *simple knot* (see fig. 19) loosely about the forceps, gradually tightening and reducing the size of the loop thus formed until it encircles the artery, when it should be tied, so as to divide the two inner coats of the vessel and strangulate the outer. The assistant must avoid tying the end of the forceps instead of the artery, and, when fixing the ligature permanently upon the artery, must not disturb the vessel by dragging or pulling upon it, lest he interfere with the relation of the vessel to its sheath, and, by tearing the vasa vasorum, deprive the coats of the artery of their requisite supply of blood.

To insure a careful application of the ligature, the assistant, holding one end of the thread firmly in each hand, should place the point of one forefinger upon either thread in close proximity to the artery, and pull or tighten the thread by flexing the thumb, while the artery is maintained in position by the points of the fingers. Fig. 31 shows the mode of fixing a ligature in the continuity of an artery, also after the manner above described. To complete the ligature, tie a second knot like the first, or the surgeon's knot. The ligature completed, either twist the two ends together, or cut one end off near the artery, tying a knot in the distal extremity of the ligature of the main artery. Should there be more than one ligature, bring them all out at one angle of the wound, if possible, so as to interfere as little as need be with the healing process. The occurrence

of hæmorrhage having been guarded against by ligature of the chief vessels, pressure, which up

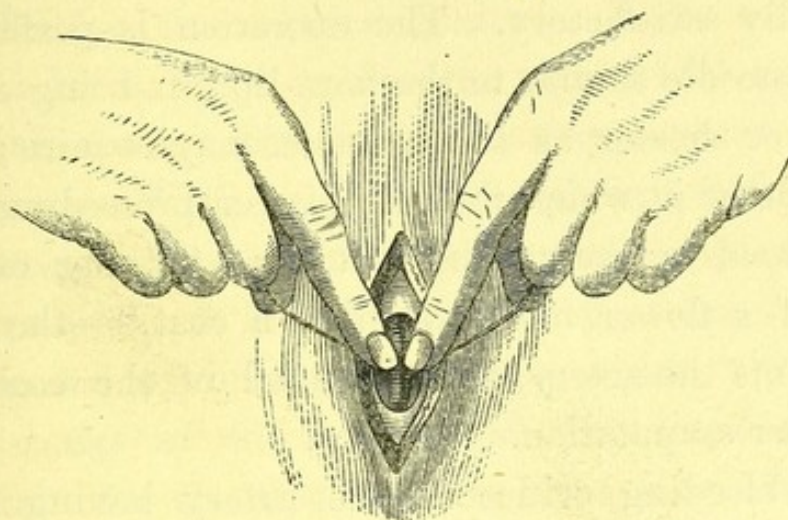


FIG. 31.

to this moment has been maintained upon the continuity of the main artery, should be suddenly removed, in order to test the efficiency of the ligatures already applied, and to indicate the necessity for any further application.

Sponging.—When applying ligatures to the extremities of arteries, a sponge is generally used to remove extravasated blood, and expose a bleeding orifice. For this purpose, the sponge should have been freed from dirt by washing, be of fine texture, and soft, and just moist. It is to be pressed with moderate force upon the surface to be examined, and when time has been allowed for absorption by it of effused fluids, should be quickly removed, so as to afford the operator the opportunity of seeing the exact spot whence the blood flows. The sponge is to be *pressed upon* and not *rubbed* roughly over the raw surface.

Acupressure.—The results of the trials of this mode of closing the extremities of divided arteries are decidedly satisfactory. The operation is performed with a needle similar to the hare-lip pin, being either longer or shorter as the occasion may require; and the manner in which the vessel is compressed may be understood by comparing it to the “fixing of the stem of a flower to the lapel of a coat,”—the stem represents the artery, and the lapel of the coat the flap after amputation.

The bleeding orifice of the artery having been recognised, the finger or thumb of the operator's left hand should be placed upon it, and the needle held in the right hand should enter the flap by its cutaneous surface obliquely, and being pushed through the flap should reappear on the raw surface on one side of the cut vessel, and a line or two nearer the heart than the orifice. The point of the needle must now be guided across the artery, and be made to transfix the flap on the other side of the vessel, the point reappearing on the cutaneous surface, in such a manner that the bridge or portion of needle seen on the raw surface may press upon the vessel and so prevent hæmorrhage. The needle may be left in the flap from fifty to seventy hours, and after withdrawal no hindrance is given to the rapid union of the flaps; whereas the ligature so long as it remains is a constant source of irritation, suppuration, and more or less gangrene.

Ligature in the continuity of an Artery.—Previous to

the application of a ligature in the continuity of an artery, the operator should contemplate with his mind's eye the relative anatomy of the region in which he is about to operate, and reflect upon the possible abnormalities which he may encounter in his progress. With the subject or patient before him, the surgeon should observe the various points of bone, the position of known muscles, ligaments, nerves, veins and tendons which bear a certain relation to the course of the artery, and would indicate the position for the first incision. He may also mark out upon the surface, with his eye, an imaginary line drawn between certain points, indicating the normal course of the artery, and if the subject be living test the correctness of his observation by the pulsation of the artery. The instruments requisite are, scalpel, director, pair of dissecting forceps, couple of copper spatula or of blunt hooks, aneurism needle, ligatures and sutures, with compress, strapping, and bandage.

The subject should be placed on the table, in a position, if possible, convenient both to the operator and to the patient. If necessary, the part should be shaved, and the operation begun by incising the skin and superficial fascia, immediately over and in a line with the artery in most instances. To indicate the length of incision, to steady the skin, and so to assist the action of the knife, the operator's left hand may be allowed to press firmly on the patient with the points of the fore and middle fingers separated and placed so as to mark the points at which the

incision is to be begun and to be terminated. Let this incision be free and cut cleanly at both ends, so as to allow plenty of space to work in, and light to enter. The edges of the wound will now become separated by the natural elasticity of the skin, and the surgeon must take care that his assistants do not drag upon the skin in such a manner as to alter the relation of the wound in the integument with the deeper structures. The various structures must now be divided in turn on a director, the operator carefully observing the nature and course of the tissues as they come into view, with the object of ascertaining his position with regard to the artery. To use the grooved director, the operator first raises the fascia in the centre of the wound with the dissecting forceps, and makes a small incision with the scalpel held in the right hand, sufficiently large to admit the end of the director, the flat of the blade being towards the patient. The point of the director is now introduced and pushed gently, rather beyond one extremity of the wound, behind the tissue to be divided, and the knife being now run along the groove sets the director free. The other half of the fascia is to be treated in a similar manner, and so all the layers of fascia till the sheath of the vessel be reached. Large veins and nerves and muscles should not be unnecessarily divided, but be held aside by a blunt hook or spatula. In using a director care should be taken, while passing it behind tissues, to keep the point well up against

the structure to be divided, by either elevating or depressing the handle, in order to avoid injury to deeper structures. The sheath of the vessel being reached, it is now to be seized with the forceps (fig. 32), and nicked sufficiently only to admit the point of the aneurism needle. This done, the knife may be laid aside; and holding the divided sheath, first on one side of the artery, and then on the other

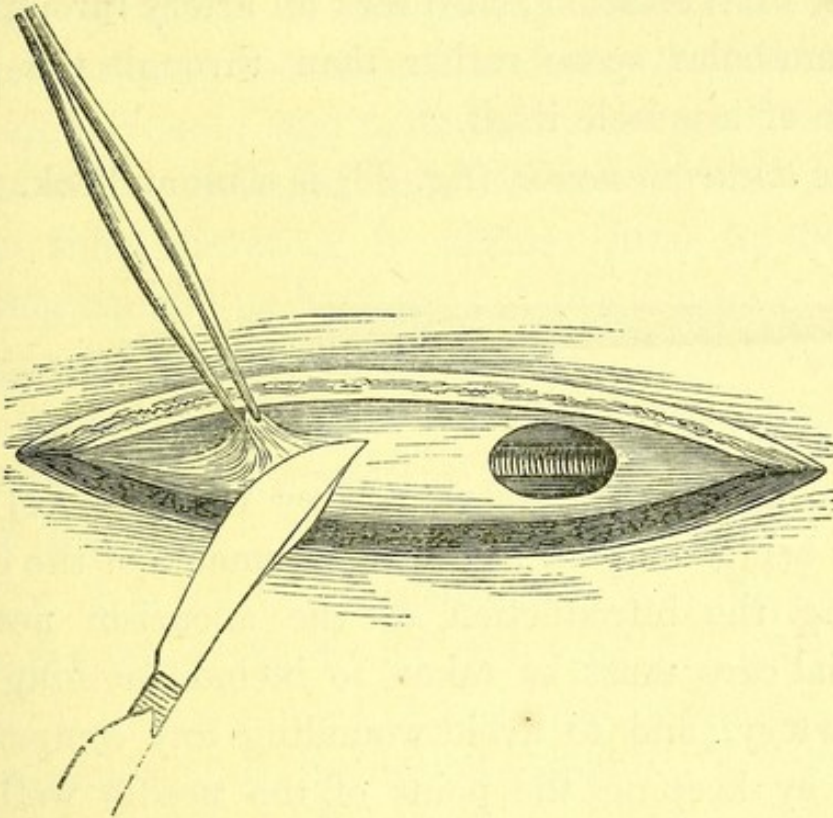


FIG. 32.*

side with the forceps, the operator gently and cautiously separates the sheath from the artery with

* Fig. 32 shows the sheath of the vessel seized by the forceps, and the knife held ready to nick the sheath, the flat of the blade being towards the patient. Also, the artery exposed when the sheath has been nicked.

the end of a director carefully introduced between them, so as to form a passage for the needle. The sheath must be separated from the artery as little as possible longitudinally, lest, by dividing the small vessels which nourish the coats of the artery, serious results follow. To assist in reaching an artery, strong unyielding fasciæ may be nicked transversely so as to widen the wound, and muscles should be put into a state of relaxation; also seek an artery through an intermuscular space rather than through the substance of a muscle itself.

The *aneurism needle* (fig. 33) is a blunt hook, with



FIG. 33.*

an eye at the extremity to carry the ligature, the curve being adapted to the requirements of the case. During the introduction of the aneurism needle, especial care must be taken to include nothing but the artery, and to avoid wounding any companion vein, by keeping the point of the needle well up against the artery, but without piercing its walls. The needle being armed with the ligature, the operator holding one side of the divided sheath with the forceps in the left hand, enters the end of the needle on that side on which the most important organs are situated, and brings it out on the opposite

* Walters, Moorgate-street.

side. One thread of the ligature must now be seized with a pair of forceps, and held firmly while the needle is withdrawn by the way it came, leaving a single ligature behind the artery. Sometimes the point of the needle requires to be freed from some areolar tissue which it has carried before it in its passage behind the artery; it should be liberated by cutting (not scraping) upon the end of the needle itself. Previous to completing the ligature, the operator should ascertain if he has placed it around the right vessel; and to do this must press with the point of his forefinger upon the artery, while, at the same time, elevating it slightly from its bed by pulling equally on both ends of the ligature. If by this means pulsation in the aneurismal sac be stopped, the operation has been so far successful, and the ligature may be completed by tying a double-reef knot (fig. 20).

The ends of the ligature may now be twisted, brought out of the wound, and fixed in a convenient position by strapping; then sutures, strapping, compress, and bandage having been applied, the operation is finished. The limb must be kept warm, and points of bone be protected from pressure. The limb should also be placed in such a position, that the artery which has undergone ligature may be relaxed as much as possible.

The ligature of an artery, such as the femoral, becomes detached from the fifteenth to the twentieth day, and its tenacity may be occasionally tested by

twisting it upon itself with the finger and thumb. From what has been said, it will appear that, in order to ligature an artery with the hope of a favourable result—

1st. A free incision should be made usually, but not invariably, over and parallel to the course of the artery.

2nd. Divide important organs which come into view as little as possible.

3rd. Disturb the relation of the artery to its sheath in the least necessary degree.

4th. Use a sharp, rather than a blunt instrument, to divide tissues.

5th. Be sure that the ligature has been placed around the artery, and not around any other organ; also, that no other organ is included with the artery.

6th. Place the ligature so far from the disease as is convenient, and at a distance, if practicable, from the origin of a large branch.

7th. Ascertain that the right artery is the subject of the ligature.

8th. The length of the incision made will depend partly upon the degree of obesity and muscularity of the subject.

In the case of wound in the continuity of an artery, seek the bleeding orifice, and place a ligature on either side of it, and close to it, and not upon the main trunk, at a distance from the wound.

CHAPTER V.

LIGATURE OF SPECIAL ARTERIES.

The Arteria Innominata. Anatomical relations.—

This artery runs from below upwards, and from left to right, from the arch of the aorta to the right sterno-clavicular articulation, opposite to which it divides into right carotid and right subclavian arteries. In front of it are the first piece of the sternum, the origins of the sterno-hyoid and thyroid muscles, and the left vena innominata crosses it; on the left are the root of the left carotid artery, and higher up the trachea; on the right is the right vena innominata; behind, are the trachea at first, and then the longus colli muscle.

OPERATION.

Various incisions have been proposed to facilitate the ligature of this vessel, and of these the following is convenient.

. External indications,—a fossa or pit above the clavicle, marking the cellular interval between the two heads of the sterno-mastoid muscle, more or less

visible, in proportion to the non-muscularity of the subject. The shoulders of the patient being raised, the head thrown back, and the face turned to the left, the sterno-mastoid muscle is put on the stretch, and the sternal and clavicular origins, with the intervening fossa, can be both seen and felt. Incise the skin, superficial fascia, and platysma, and deep fascia, to the extent of three inches, directly upwards over the fossa, between the muscular fasciculi, the incision being begun rather below the clavicle; now throw the head slightly forwards and separate the heads of the muscle with the fingers, after dividing the connecting areolar tissue; divide carefully on a director the layers of deep cervical fascia, which conceal the sheath, and also, if necessary, the sterno-hyoid and thyroid muscles transversely. By this proceeding, if the muscular fasciculi be well separated by assistants, the origin of the carotid and subclavian arteries is readily found, and the arteria innominata reached. The ligature should be passed from right to left, in order to avoid implicating the right vena innominata. While using the knife, the position of the anterior jugular vein behind the sterno-mastoid muscle, and also of the middle thyroid vein passing outwards across the root of the carotid artery to open into the internal jugular vein, must not be forgotten. Fig. 34 shows, *a* the internal, and *b* the external heads of the sterno-mastoid muscle forcibly separated by hooks, and exposing to view, embedded in more or less areolar tissue, *c*, the vertebral

artery; *d*, the pneumogastric nerve; *e*, the recurrent laryngeal nerve; *f*, the internal jugular vein, pulled aside; *g*, the first part of the subclavian and its branches; and *h*, the arteria innominata, with the ligature passed.

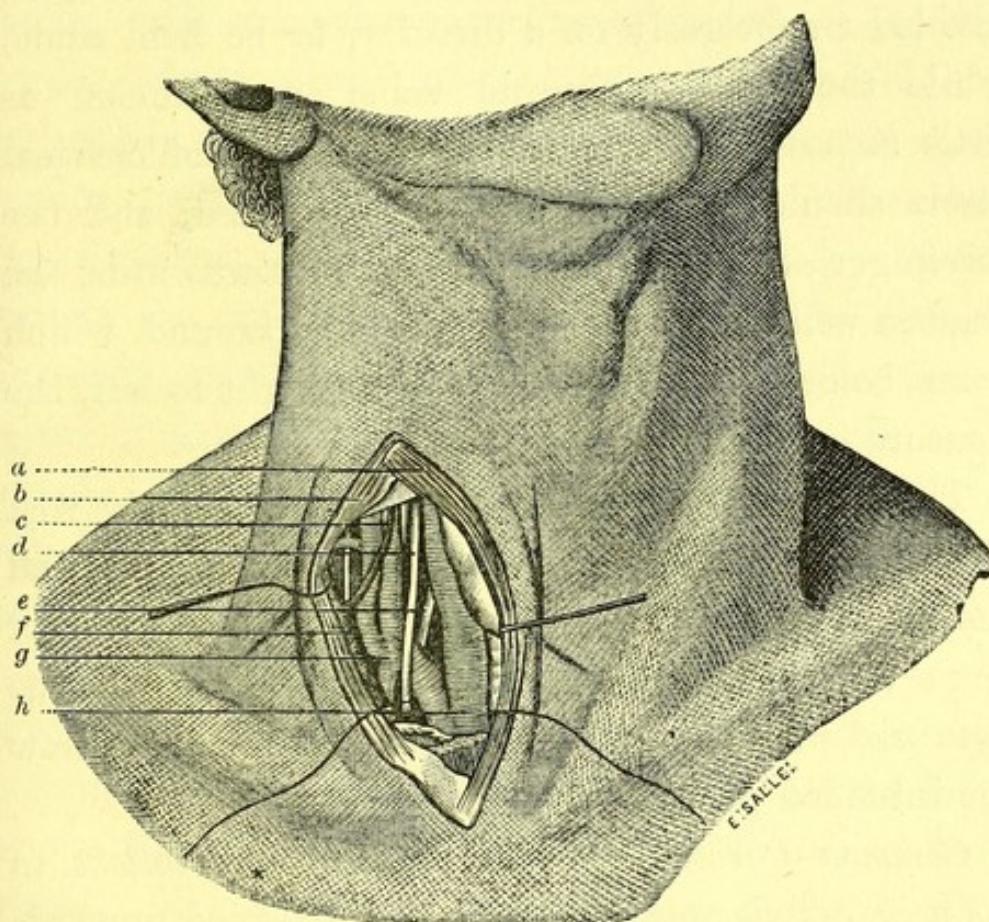


FIG. 34.

I have found the above incision to be enlarged with advantage by dividing along the clavicle the integument and sternal origin of the sterno-mastoid muscle, thus forming a flap.

Another method consists, the surgeon standing on the left hand side of the patient, in making an oblique incision across the root of the neck, commencing half an inch below the right sterno-clavi-

ular articulation, and terminating about two inches above the sternum at the inner margin of the left sterno-mastoid muscle. After dividing skin, superficial and deep fasciæ, the right sterno-thyroid and perhaps also the sterno-hyoid muscles, should be divided transversely on a director, or be held aside, while the inferior thyroid veins are wounded as little as possible. The intervening layer of cervical fascia should now be cautiously divided, and the forefinger of the left hand following downwards, the trachea will readily reach the artery, around which from before, backwards, and from right to left, the ligature is to be passed.

The application of a ligature to arteries at the root of the neck will be facilitated by throwing the head backwards and depressing the shoulder. Moderately large veins, too, if they must be divided, should be ligatured previous to division, both above and below the intended point of section.

Common Carotid Artery. Anatomical relations in the neck.—This vessel extends, in a direction upwards and outwards, from the bifurcation of the arteria innominata opposite the sterno-clavicular joint, to the upper border of the thyroid cartilage, where it divides into internal and external carotid arteries. It lies in a groove between the sterno-mastoid muscle on the outside and the trachea and larynx on the inside, and may be here compressed against the roots of the cervical transverse processes, by pressure directed backwards.

In front, the artery is crossed about its middle and opposite to the cricoid cartilage by the anterior belly of the omohyoid muscle. *Above* this muscle the vessel is comparatively superficial, being covered by skin, superficial fascia, platysma, deep cervical fascia, and somewhat overlapped by the anterior border of the sterno-mastoid muscle. Parallel to, and either without or within the sheath, is the descendens noni nerve; crossing it from within outwards, the superior thyroid vein. *Below* the omohyoid muscle the artery is deeply placed, being covered in by skin, superficial fascia, more or less platysma, layers of deep fascia, sternal head of sterno-mastoid muscle, sterno-hyoid and thyroid muscles, and is crossed from within outwards by the anterior jugular and middle thyroid veins. The internal jugular vein partially conceals the artery in front, excepting at the root of the neck, where is an interval in which is lodged the pneumogastric nerve. The lateral lobe of the thyroid body has an anterior relation to this vessel. The artery is attended in its sheath by the internal jugular vein to its right side, and the pneumogastric nerve behind and between the two blood-vessels. Behind the sheath, the artery rests on the recurrent laryngeal nerve, inferior thyroid artery, sympathetic nerve, longus colli and rectus anticus major muscles; internally it is bounded by the trachea and larynx; and on the outside by the internal jugular vein and pneumogastric nerve.

The above description is applicable equally to the

left common carotid in the neck, with this exception, that the internal jugular vein almost conceals the artery at the root of the neck.

OPERATION.

The common carotid artery may be ligatured at any point of its course, and with facility at the *point of selection above* the omohyoid muscle. An imaginary line on the surface drawn from the sternoclavicular joint to a mid-point between the mastoid process and the angle of the lower jaw, will sufficiently indicate the course of the artery. The head being thrown back, and the face turned to the opposite side, the surgeon ascertains the relation of the anterior border of the sterno-mastoid muscle to the artery, and will observe that the artery above the cricoid cartilage can be readily felt lying along the border of this muscle, and slightly overlapped by it.

To expose the artery, an incision begun opposite to the cricoid cartilage and carried upwards to the extent of about two and a half inches, or begun opposite the great cornu of the hyoid bone and carried downwards to a similar extent, along the inner border of the sterno-mastoid muscle, should divide in order, skin, superficial fascia, platysma, and deep fascia, and expose the fibres of the sterno-mastoid muscle. The edges of the wound being now held apart, and the superior thyroid vein and descendens noni nerve avoided, the sheath of the vessel should be opened so as to admit the aneurism needle to be

passed from without inwards. The coats of the internal jugular vein are so thin, and the vessel is often so close to the artery, that unless great caution be used, the vein will either be mistaken for fascia and opened with the knife, or perforated by the aneurism needle. Should the vein be injured, the wound only,* and not the whole calibre of the vein, may be closed by a fine ligature. To facilitate the passage of the aneurism needle, the vein may be compressed by the finger introduced at the upper angle of the wound. The pneumogastric nerve must be carefully avoided by the needle. As a guide to the artery, the course of the fibres of the various muscles exposed should be studied; those of the sterno-mastoid running from above, downwards and forwards, those of the sterno-hyoid and thyroid downwards and outwards.

To tie the common carotid *below* the omohyoid muscle, an incision, three inches in length, beginning at the sternum and carried upwards, should be made, also along the inner border of the sterno-mastoid muscle; but the operator must recollect that since the sterno-mastoid muscle crosses the artery obliquely in passing from the mastoid process to the sternum, the incision made as directed is not immediately over the artery, but internal to it. The skin, superficial fascia, platysma, and deep fascia being divided, the head should be carried slightly forward, whilst the sterno-mastoid muscle is either partially divided or pulled

* I adopted this mode successfully when assisting a friend in the removal of a tumour from the neck.

on one side, and the sterno-hyoid and thyroid muscles similarly treated on the other side. In opening the sheath and passing the ligature on the left side of the neck, the anterior relation of the internal jugular vein to the artery must not be forgotten.

The situation *best* adapted to expose the root of the common carotid artery on the right side, is that recommended for the ligature of the brachio-cephalic trunk, viz., the interval between the sternal and clavicular origins of the sterno-mastoid muscle.*

Fig. 35 shows one incision, made sufficiently long at the inner margin of the sterno-mastoid muscle, to expose the common carotid artery both above and below the omohyoid muscle; *a* is the anterior belly of the omohyoid muscle; *b* the common carotid artery; *c* the internal jugular vein; *d* the pneumogastric nerve; *e* the sterno-mastoid muscle pulled aside.†

External Carotid Artery. Anatomical relations.— This vessel extends from the bifurcation of the common carotid artery opposite the upper border of

* In an instance in which I tied the lower part of the common carotid, in the Crimea, for secondary hæmorrhage, after wound of an artery in the pterygo-maxillary fossa, the anatomical relation of parts was so altered by swelling that I accidentally ligatured the vessel between the two heads of the sterno-mastoid muscle. My attention was called to this mode of exposing the common carotid by observing that in Paris the man who injected the bodies with preservative fluid, selected this spot for exposing the artery with ease.

† It will be observed that in the plates the relative anatomy is not strictly correct, because, were it so, important organs referred to could not be displayed on paper.

the thyroid cartilage, to the neck of the condyle of the lower jaw. A line on the surface, drawn from a point mid-way between the angle of the jaw and

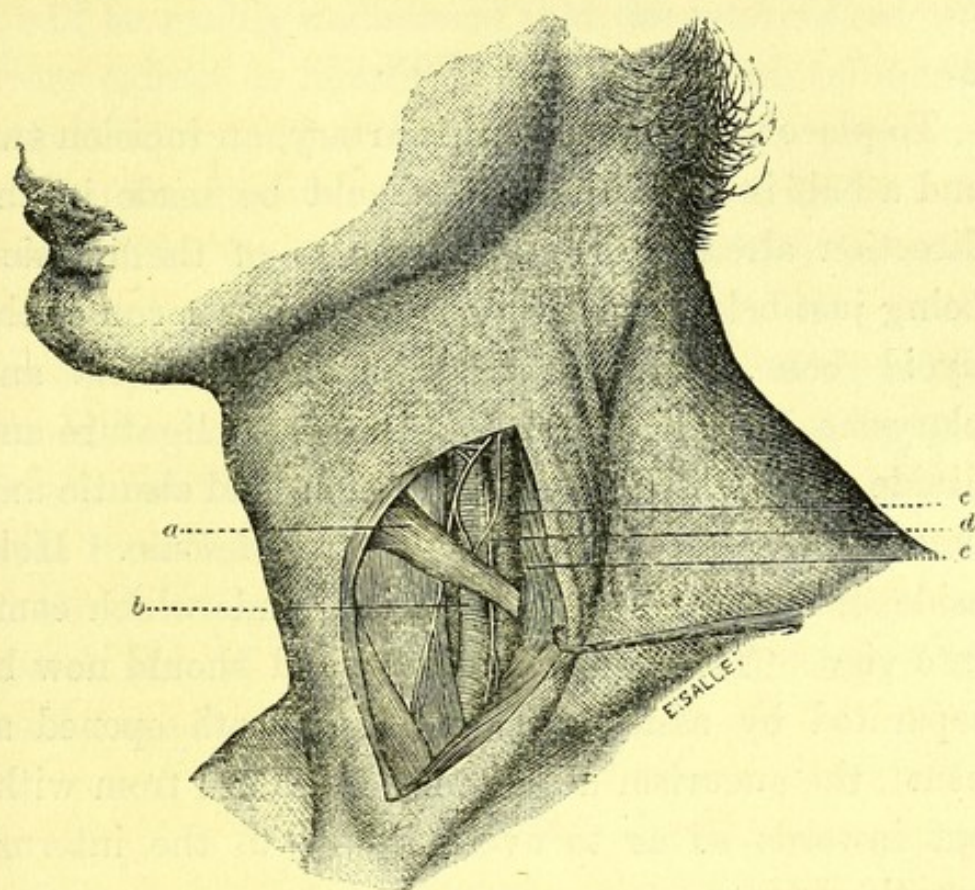


FIG. 35.

the mastoid process, downwards and forwards in the direction of the cricoid cartilage, will mark the course of the artery in the locality in which it is comparatively superficial. It is here covered in, before it is crossed by the digastric and stylo-hyoid muscles and the hypoglossal nerve, by the skin, superficial fascia and platysma, deep fascia, and slightly overlapped by the sterno-mastoid muscle. The internal carotid artery is on a plane, somewhat behind and external to the external carotid artery

in this region, as is also the internal jugular vein. The facial and lingual veins cross the external carotid artery from within outwards.

OPERATION.

To place a ligature on this artery, an incision two and a half inches in length should be made in the direction already given, the centre of the incision being just below the level of the greater cornu of the hyoid bone. Divide skin, superficial fascia and platysma, deep fascia, and, if necessary, ligature and divide veins which cross the incision, and also tie any branch of artery which may be troublesome. Hold aside or remove any lymphatic glands which come into view. The edges of the wound should now be separated by assistants; and the sheath opened as usual, the aneurism needle may be passed from without inwards so as to avoid injury to the internal carotid artery.

The Internal Carotid Artery. Anatomical relations in the Neck.—The internal carotid extends in the neck from the bifurcation of the common carotid to the base of the skull. Below the digastric and stylo-hyoid muscles, this vessel, like the external carotid, is comparatively superficial, and can be reached with tolerable facility in its position somewhat external to and behind the external carotid artery, and having the internal jugular vein to its outer side. But as the internal carotid ascends, it passes internal to the external carotid artery, and is

much deeper than it, lying along the side of the pharynx and on the prevertebral muscles.

Thus deeply situated beneath important structures, it will be readily understood that the internal carotid artery cannot be ligatured, without the risk of doing serious injury, above the point at which the posterior belly of the digastric muscle crosses it. Guthrie has described an operative proceeding by which he proposed to tie the vessel if wounded high up. It is, however, so complicated that almost any other mode should be tried first, especially one adopted by Dr. Keith, and attended by success. "An incision was made from below the ear, along the ascending ramus of the lower jaw to below its angle, and a ligature passed around the vessel with less difficulty than could have been anticipated."*

OPERATION.

To tie the internal carotid artery just above its origin, an incision should be made over it, and of dimensions similar to that employed to expose the external carotid, but behind the latter, and as it were a continuation of that used to expose the common carotid artery. The same parts will be divided as in exposing the external carotid artery; and the sheath being opened, the aneurism needle should be passed from without inwards between the internal

* A rather short description of the mode of performing a difficult operation?

jugular vein and the artery, and be brought out between the internal and external carotid arteries.

Superior Thyroid Artery.—This vessel may be exposed by an incision somewhat internal to, but parallel to, that made to lay bare the external carotid artery. It should be about two inches in length, and its centre should correspond to the upper border of the thyroid cartilage. After dividing the skin, superficial fascia, platysma, and deep fascia, the artery will be found passing upwards and inwards previous to bending downwards, and probably attended by its companion vein, which latter may or may not receive the lingual vein.

The Lingual Artery. Course and anatomical relations.—This vessel usually arises from the external carotid just below the greater cornu of the hyoid bone, and, passing inwards, forwards, and upwards, gets above the hyoid bone, and under cover of the hyo-glossus muscle.

OPERATION.

To expose the vessel, turn the face to the opposite side and make an incision one and a half inches in length, just above the great cornu of the hyoid bone and parallel to it, the centre of the incision to correspond with the point of the greater cornu, which should be made prominent by pressing upon the opposite side of the bone. Divide skin, superficial fascia and platysma, and deep fascia. The edges of the wound being separated, look for

the posterior belly of the digastric muscle, passing downwards and forwards; and, just below this, for the white cord of the hypoglossal nerve, also passing forwards. Feel for the great cornu of the hyoid bone, and observe the upward course of the fibres of the hyo-glossus muscle; and if its free border be visible, the artery will be found immediately behind it: should the free border not be visible, a few fibres of the hyo-glossus muscle divided transversely will allow the artery to be seen and ligatured. The facial vein, if seen, should be held on one side.

Another mode.—This vessel may also be ligatured in front of the posterior belly of the digastric muscle, by an incision begun nearer the middle line of the neck, but the submaxillary gland must be disturbed in order to reach it in this position, where it lies in a triangular space, bounded by the two bellies of the digastric muscle, and the hypoglossal nerve above, forming the base of the triangle. The hypoglossal nerve is superficial to the hyo-glossus muscle, but the lingual artery is beneath this muscle.

The Facial Artery.—This vessel, after passing deeply under the jaw, becomes superficial on the face. It first occupies a groove in the border of the lower jaw, an inch in front of the angle; then passes upon the side of the jaw, in front of the masseter muscle, upwards and inwards towards the angle of the mouth; while on the side of the jaw the vessel can readily be felt pulsating, and may be ligatured by an incision made over it and parallel to it. The

accompanying vein should not be included in the ligature.

An incision made transversely, instead of parallel, to the course of the artery, will be less likely to injure branches of the facial nerve, and may be preferred on that account.

The Occipital Artery.—This vessel may be exposed as soon as it has passed backwards from under cover of the mastoid process. On the surface, a line drawn from behind the mastoid process of the temporal bone towards the posterior occipital protuberance will mark the course of the artery. An incision made in the above direction, dividing the skin, aponeurosis of the sterno-mastoid muscle, and also the splenius capitis muscle, will expose the artery.

The Temporal Artery.—This vessel, as already mentioned in reference to arteriotomy (see fig. 30), may be readily exposed as it lies on the zygoma, about one-third of an inch in front of the tragus. An incision one inch in length should be made over and parallel to the course of the artery, dividing the integuments and some dense areolar tissue covering the artery. The temporal vein and auriculo-temporal nerve accompanying the artery must not be included in the ligature. The vein usually is behind the artery.

The Subclavian Artery.—This vessel extends, on the right side from the bifurcation of the innominate artery, opposite the sterno-clavicular articulation to the lower margin of the first rib. In its course it

forms a curve, with the convexity upwards, and, for the sake of description, is divided into three portions by the position of the scalenus anticus muscle, which corresponds to the second part of the vessel. The vessel on the left side, in the two outer thirds of its course, corresponds to a similar extent of the right subclavian artery; while its first portion extends almost vertically from the arch of the aorta to the inner border of the anterior scalenus muscle, behind which it passes outwards at nearly a right angle. The left subclavian artery is therefore more deeply placed in its whole course, than the right subclavian artery. Both may be compressed, above the clavicle, upon the first rib, with the handle of a door key protected by lint folded tightly round it.

The right subclavian artery may be ligatured in any part of its course with more or less difficulty, while ligature of the first part of the left subclavian artery may scarcely be attempted in consequence of its complicated relations.

FIRST PART.—*Anatomical relations.* In front, are integument, platysma more or less, deep fascia, sternomastoid, sterno-hyoid and sterno-thyroid muscles, cervical fascia, internal jugular vein, vertebral vein, pneumogastric nerve, phrenic nerve. Below, is the pleura. Behind, the recurrent laryngeal nerve and the sympathetic nerve.

OPERATION.

The vessel may be best exposed in this situation, by

a vertical incision (see fig. 34) three inches in length made opposite the interval between the sternal and clavicular heads of the sterno-mastoid muscle, dividing skin, superficial fascia, more or less platysma, deep fascia, cellular connexions between the heads of sterno-mastoid muscle, cervical fascia, sterno-hyoid and thyroid muscles (which may be cut transversely if necessary, or held aside), and cervical fascia. The veins and nerves referred to must be carefully held aside; and the sheath having been opened, the aneurism needle should be passed from before backwards, and from below upwards, keeping the point of the needle close to the vessel, lest the bag of the pleura be opened.

THIRD PART.—*Anatomical relations.* Here (fig. 36) the vessel (*b*) lies in the postero-inferior triangle of the neck, a space bounded internally by the sterno-mastoid muscle (*e*), above, by the posterior belly of the omohyoid muscle, and below, by the middle third of the clavicle. The vessel is covered in by skin, superficial fascia, platysma, and layers of cervical fascia; running parallel with and behind the clavicle, are the supra-scapular artery and vein; crossing the vessel from above downwards, and perforating the cervical fascia to join the subclavian vein, is the external jugular vein (*c*). Above, external to and behind the artery, are the nerves of the brachial plexus (*a*); below, the artery rests on the first rib; and in front and below it is the subclavian vein; in front, and internal to the artery, is the scalenus anticus muscle (*d*), attached to

the tubercle on the first rib, and separating the subclavian artery from the subclavian vein.

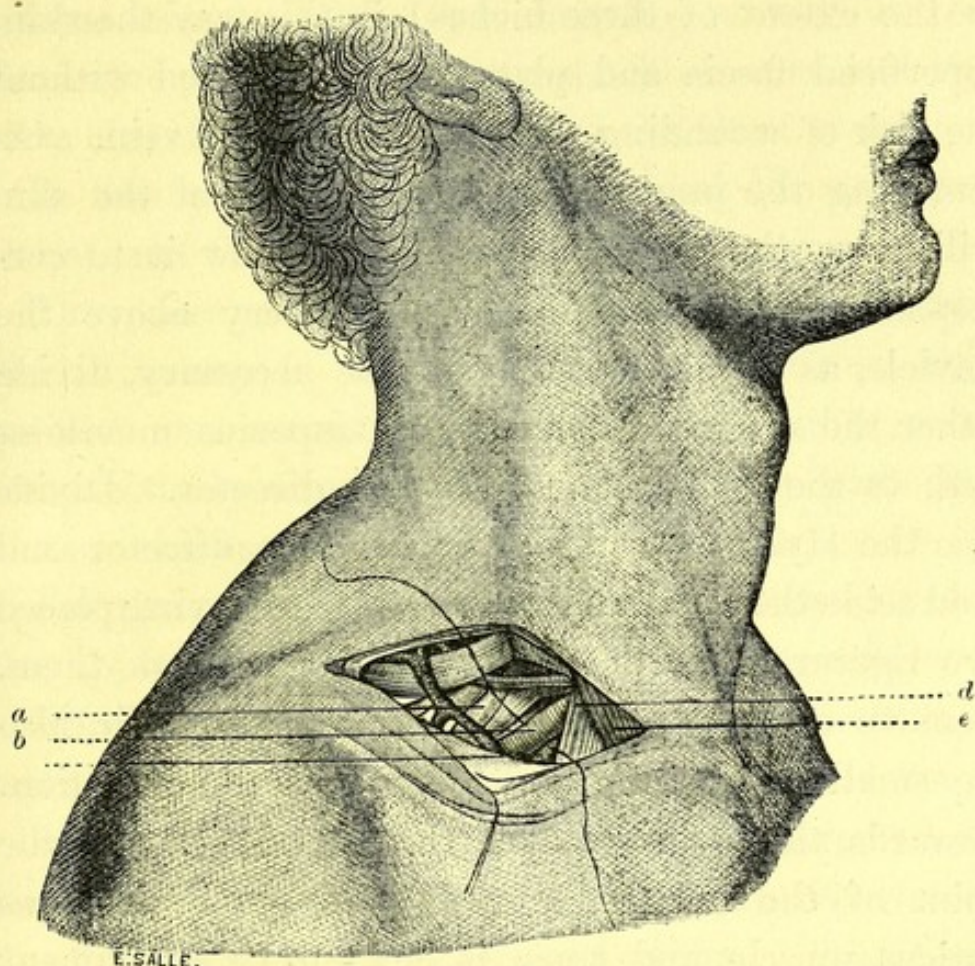


FIG. 36.

In some muscular subjects the trapezius and sternomastoid muscles take origin each from half the clavicle. In these instances, the subclavian artery would here be covered by an additional muscular layer.

OPERATION.

To expose this vessel, the patient having the head thrown back and face turned to the opposite side, and the shoulder depressed so as to lower the clavicle and render the artery as superficial as possible, draw

the integument down from the neck upon the clavicle, and divide it upon the middle of the bone to the extent of three inches: in this way the skin, superficial fascia and platysma are divided without the risk of wounding the external jugular vein. On removing the impediment, the elasticity of the skin will carry the wound upwards, and allow it to correspond to the position of the artery above the clavicle, as in the figure. If it be necessary, divide either the sterno-mastoid or the trapezius muscle or both to the required extent on a director. Divide also the layers of cervical fascia on a director and hold aside the external jugular vein, or, having placed two ligatures upon it, divide the vein between them. Remove or hold aside lymphatic glands. Tie also any small artery which interferes with the operation. Towards the inner angle of the wound feel with the point of the index finger for the round scalenus anticus muscle, and trace it down to its attachment to the tubercle on the first rib. Upon the rib external to the tubercle, the artery will be found. Open the sheath, and pass the needle from before backwards, taking care not to include a nerve of the brachial plexus, or even to pass a ligature around a nerve only.

I have repeatedly seen the ligature passed around the seventh cervical nerve.

If the above incision be insufficient, a second vertical cut may be made, falling at right angles either to the centre or to the inner extremity of the first.

SECOND PART.—This artery may be ligatured in the middle of its course by dividing the scalenus anticus muscle, behind which it lies, as well as the clavicular portion of sterno-mastoid muscle, and the parts already mentioned in tying the third part.

In this position, however, the artery lies over the pleura, and the phrenic nerve would be endangered.

The *point of selection* for ligature of the subclavian artery is the outer third, because in this position the vessel is tolerably high in the neck, comparatively superficial, out of relation with the pleura, and usually gives off no large branch.

For the sake of practice, the student may exercise the application of the ligature upon the vertebral, inferior-thyroid, and internal mammary arteries, branches of the first part of the subclavian artery.

Vertebral Artery.—This vessel may be exposed by dissection similar to that described for ligature of the first part of the subclavian artery. The finger introduced into the wound will detect the prominent anterior tubercle of the transverse process of the sixth cervical vertebra, and immediately below this the artery will usually be found ascending, to enter the foramen in the transverse process. The vertebral artery is placed between the longus colli muscle on the inside and the scalenus anticus muscle on the outside, is surrounded by branches of sympathetic nerve, and its accompanying vein is superficial to it.

Inferior-Thyroid Artery.—This vessel passes upwards and inwards in a tortuous manner behind the

sheath of the carotid artery, and may be ligatured while it lies between that vessel and the lateral lobe of the thyroid body. An incision about three inches in length should be made along the inner border of the sterno-mastoid muscle, the centre of the incision corresponding to the first rings of the trachea.

The thyroid body and the carotid sheath being held apart, the vessel will be found lying upon the longus colli muscle. The inferior-thyroid veins do not accompany the inferior-thyroid artery, but pass down in front of the trachea to join the innominate vein, while the middle thyroid veins will be seen crossing the line of the incision from within outwards, to open into the internal jugular vein, but quite superficial to the inferior-thyroid artery.

Internal Mammary Artery.—This vessel may be ligatured with tolerable facility where it lies behind the costal cartilages, between the internal intercostal muscle and the pleura.

Make an incision one inch in length parallel to and half an inch external to the border of the sternum, dividing the integument, pectoralis major muscle, aponeurotic expansion between the cartilages of the ribs supplying the place of external intercostal muscle, and internal intercostal muscle; the vessel will be found with its venæ comites, and must be ligatured carefully lest the pleural sac be opened.

Axillary Artery. Anatomical relations.—This vessel, the continuation of the subclavian artery, extends from the lower border of the first rib to the lower

border of the tendons of the latissimus dorsi and teres major muscles. It may be ligatured at any point with more or less difficulty, but opposite the lower border of the pectoralis major muscle with comparative ease. In the upper two-thirds of its course, this artery is covered in by one or both pectoral muscles.

In the upper third, it will be found between the clavicle and upper margin of the pectoralis minor muscle, having the brachial plexus above and external to it, the axillary vein below and internal to it, and, when distended with blood, slightly overlapping the artery.

OPERATION.

Various incisions have been proposed to lay bare the artery while it is behind the pectoral muscles, and of these one parallel to the clavicle is as convenient as any.

Make an incision at least three inches in length, just below and parallel to the middle of the clavicle, dividing the integuments, fibres of the pectoralis major muscle, a layer of fascia between the upper border of the pectoralis minor muscle and the clavicle on a director; and carefully avoiding the trunk of the thorocica-acromialis artery coming forward over the upper margin of the pectoralis minor muscle and the cephalic vein crossing the axillary artery from without inwards to join the axillary vein, open the sheath of the vessels prolonged from the costo-

coracoid membrane, and pass the aneurism needle from within, outwards and upwards, avoiding the vein on the inside and the nerves on the outside. Fig.

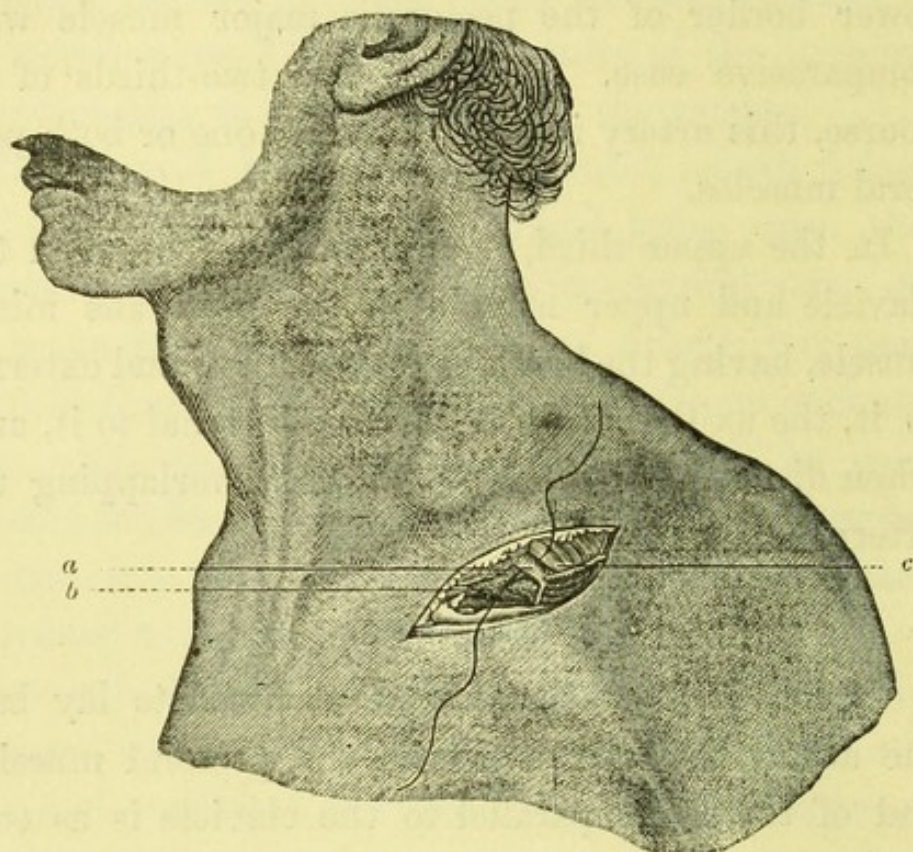


FIG. 37.

37 shows the artery (*a*) with the ligature *in situ*, the vein (*b*) below and internal to the artery, and the brachial plexus (*c*), which, in a surgical point of view, may be considered as one cord in this position, external to and above the vessel. Tie all vessels which bleed and impede the progress of the operation.

Another mode consists in making an incision from the clavicle downwards, corresponding to the interval between the pectoralis major and deltoid muscles. These muscles separated, the pectoralis minor passing upwards and outwards will come into

view, and may be divided on a director introduced above it. The sheath opened, the artery will be found surrounded by the nerves of the brachial plexus, the two heads of the median becoming blended in front of it, while the vein lies to the inner side of the artery. In consequence of the proximity of the nerves to the artery, the vessel cannot be readily ligatured in this position. Prior to making the first incision, the course of the cephalic vein lying in the groove between the pectoralis major and deltoid muscles should be determined by making pressure near the clavicle, so to obstruct the flow of blood through it.

Ligature of the Lower Third.—Below the pectoralis minor muscle the axillary artery may be readily exposed, while lying posteriorly on the tendons of the latissimus dorsi and teres major muscles, and externally on the coraco-brachialis muscle. It is covered in by skin, superficial and deep fasciæ; the median nerve is external to it, the internal cutaneous nerve is in front of it, and the axillary vein is internal to it.

To expose the axillary artery in its lower third, remove the arm from the side, and place it at nearly a right angle to the body. Feel for the round bundle of the coraco-brachialis muscle lying along the inner side of the arm, and immediately behind the anterior fold of the axilla. Now divide the space between the anterior and posterior folds of the axilla into thirds; the point of junction between the anterior and middle thirds will mark the position of the artery.

Make an incision two and a half inches in length, parallel to the course of the artery, and at a distance from the anterior fold, as described above, dividing the integument only; complete the remaining necessary incisions on a director, lest the vein be wounded; and the sheath being opened, pass the aneurism needle from within outward. Fig 38 shows the position of the patient's arm and the required incision, also the axillary vein (*a*), the arm-pit (*b*), the median nerve (*c*), the ulnar nerve (*d*) held aside, the internal cutaneous

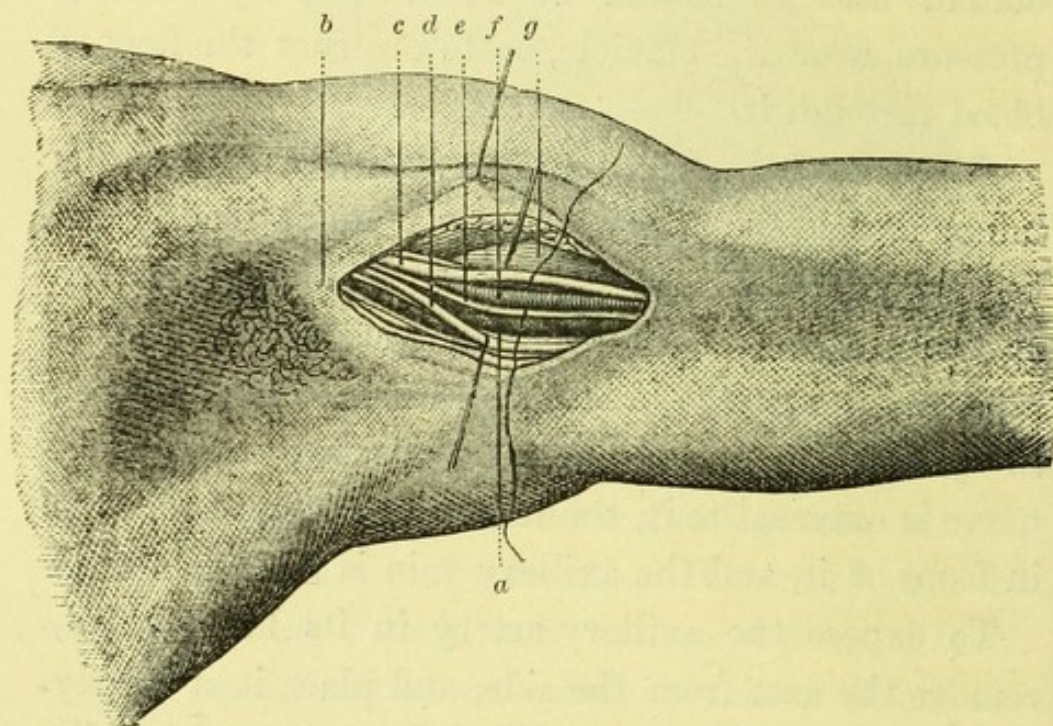


FIG. 38.

nerve (*e*), the axillary artery with the ligature in position (*f*), the coraco-brachialis muscle (*g*).

The *point of selection* for ligature of the axillary artery will be its lower third, because it is here comparatively superficial.

Brachial Artery. Anatomical relations.—This vessel extends from the termination of the axillary artery along the inner side of the upper half of the arm, but passing in front towards the lower part of the arm, to end in the middle of the bend of the elbow opposite to the neck of the radius. Throughout its extent it is covered in by skin, superficial fascia, and deep fascia, and in the middle of the arm is overlapped by the belly of the biceps muscle. The artery is attended by venæ comites, into one of which the basilic vein, running up to this point superficial to the artery, usually empties itself about the middle of the arm. The median nerve has different relations to the artery in various parts of the arm. Above, it is external to; in the middle, crosses in front or behind; below, it is internal to the vessel. The coraco-brachialis and biceps form a projection along the outer side of the whole course of the artery; and a groove or depression behind and internal to these muscles, readily seen and felt on the surface, also marks the position of this vessel. The round cord of the median nerve can usually be felt through the skin, and will serve as a guide to the artery.

OPERATION.

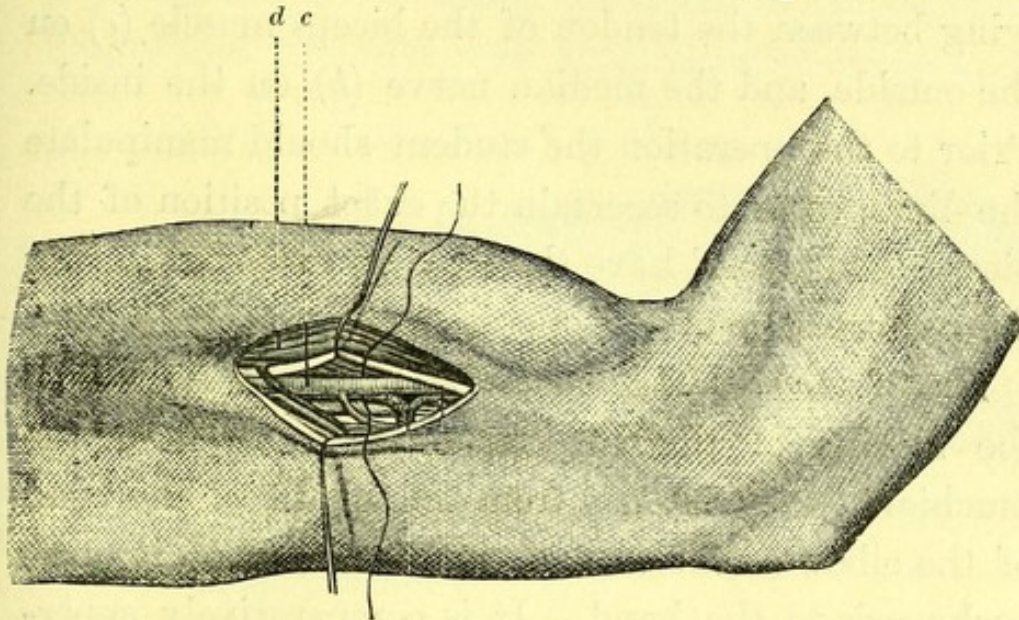
Ligature in the middle of the arm.—From what has been said above, the student will have determined the position of the artery; and since this vessel is superficial throughout, it may be ligatured with comparative ease at any point of its course.

An incision from two to three inches in length should be made, for example, in the middle of the arm, dividing only, and with care, the skin, lest the basilic vein be wounded; the superficial fascia and deep fascia should be divided upon a director just on the inner side of the median nerve, which latter can be readily felt by the finger lying usually in front of the artery, but occasionally behind it. Flex now the forearm, separate the edges of the wound, and draw the biceps muscle and median nerve aside; the artery will be found in its sheath, with a vena comes on either side of it. The operator must take care not to make his incision too far back, lest he fall upon the ulnar nerve instead of the median; he would never find the artery behind the ulnar nerve. When in doubt, observe the direction of the muscular fibres already exposed, and follow the course of the nerve for a short distance to ascertain the direction it is taking; the ulnar nerve, after reaching the middle of the arm, will be found passing downwards and backwards, and should not then be mistaken for the median. I have repeatedly seen the ulnar nerve mistaken for the median, by students performing operations under my superintendence in Paris.

Fig. 39 represents the operation in the middle of the arm. The edges of the wound are held apart, exposing the artery (*c*), the biceps muscle (*d*), venæ comites (*a*), the median nerve (*b*); the white cord of the ulnar nerve is also seen along the floor of the wound.

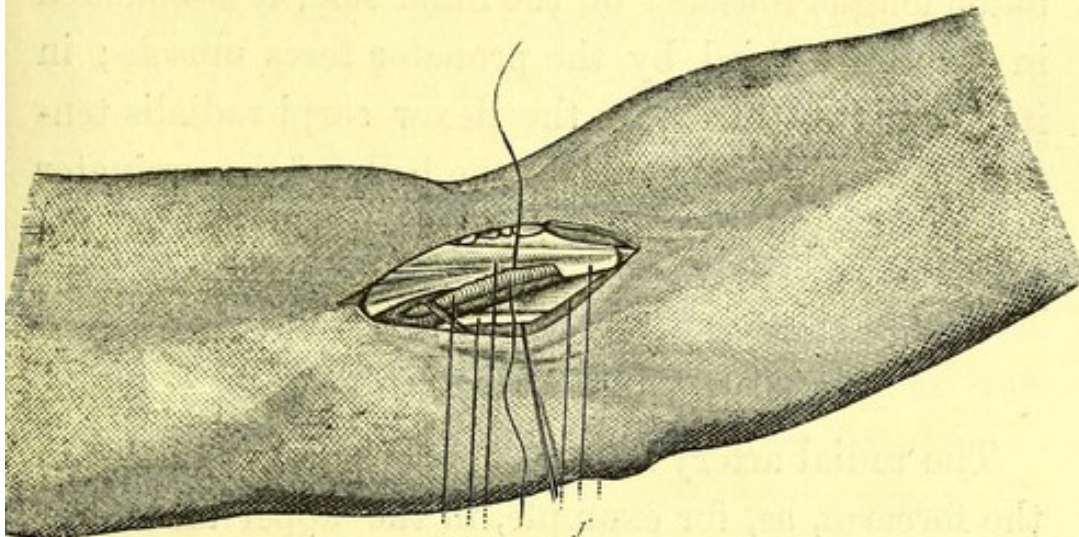
Ligature at the bend of the elbow.—The brachial

artery may also be readily reached at the bend of the elbow, where it lies on the front of the arm, beneath the aponeurotic expansion from the biceps tendon.



a b
FIG. 39.

An oblique incision, two and a half inches in length (fig. 40), should be made over the artery, on



a b c
FIG. 40.

the inner side of the tendon of the biceps, which will serve as a guide to the vessel. The large veins

of the region should not be unnecessarily divided. The tendinous aponeurosis (*f*) having been slit up, the artery (*a*) will be found attended by venæ comites and lying between the tendon of the biceps muscle (*c*) on the outside, and the median nerve (*b*) on the inside. Prior to the operation the student should manipulate the limb, so as to ascertain the exact position of the biceps tendon, and have the forearm extended during the performance of the operation.

Radial Artery. Anatomical relations.—This vessel, the smaller of the two terminal branches of the brachial artery, extends from the middle of the bend of the elbow to the root of the thumb, when it turns backwards to the hand. It is comparatively superficial in its whole extent, especially in the lower half of the forearm. The artery is bounded on its outer side throughout by the belly and tendon of the supinator longus muscle; on the inner side, it is bounded in its upper third by the pronator teres muscle; in its lower two-thirds, by the flexor carpi radialis tendon. In a muscular subject the belly of the supinator longus muscle overlaps the upper portion of the radial artery.

OPERATION.

The radial artery may be ligatured at any point in the forearm, as, for example, in the upper and lower thirds.

Ligature in the Upper Third.—In this position, before commencing the operation, the position of

superficial veins should be noticed, and by manipulation a groove may be traced downwards by the finger, marking the spot at which the bellies of the supinator longus and pronator radii teres muscles are in appo-

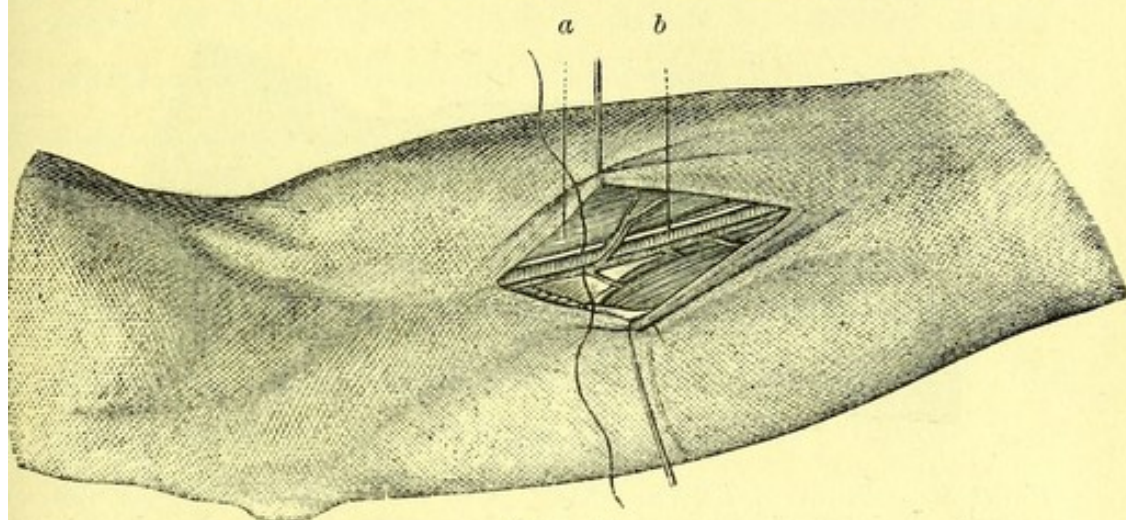


FIG. 41.

sition. Along this groove, over and parallel to the course of the artery, an incision (fig. 41) two inches in length should be made, dividing the skin and superficial fascia; the deep fascia should be slit up on a director, and after flexing the arm slightly, so as to relax the neighbouring muscles, and drawing aside the supinator longus muscle (*a*), the sheath containing the radial artery (*b*) and its venæ comites will be exposed, as also the radial nerve, to the outer side of the vessels. The ligature may be passed from without inwards, so as to avoid both nerve and vein.

Ligature at the Lower Third.—Here the vessel lies external to the tendon of the flexor carpi radialis muscle, which latter can be readily detected through the skin by manipulating the hand. An incision an inch and a half in length (fig. 42) should divide the

integuments, just external to the above tendon. Slit up the deep fascia (*a*) on a director, and having opened the sheath, pass the ligature around the artery (*c*), so as to avoid including either vein (*b*). The radial

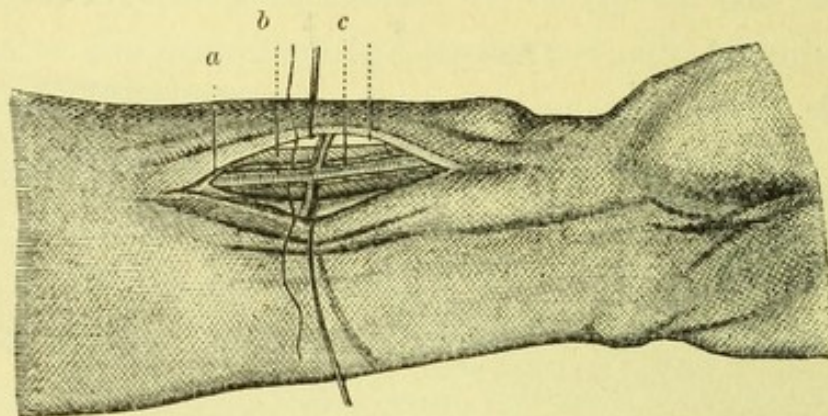


FIG. 42.

nerve does not accompany the artery in the lower third of its course.

Ulnar Artery.—This vessel, the larger of the two terminal branches of the brachial artery, is covered in by the superficial layer of muscles arising from the inner condyle. It extends from the centre of the bend of the elbow in a curved direction, the convexity looking inwards, to the outer side of the pisiform bone. The artery is thus deeply placed, and can only be ligatured with comparative ease in its lower third, in which position even it is not so superficial as the radial artery. The vessel may also be exposed at the junction of the middle with the upper third of the forearm.

OPERATION.

Ligature in the Upper Third.—A line drawn from the apex of the internal condyle, downwards and

forwards, to the outer side of the pisiform bone, will indicate the anterior and outer margin of the flexor carpi ulnaris muscle. The forearm being extended, an incision begun three fingers' breadth below the point of the inner condyle must be carried downwards in the direction indicated along the inner side of the forearm, dividing the integuments to the extent of three inches. Separate the edges of the wound, and look for a white pearly line, also running towards the hand, and indicating the septum between the flexor carpi ulnaris muscle on the inside and the flexor sublimis muscle on the outside; divide this aponeurotic line to the same extent as the integuments, taking especial care to get between the two muscles above indicated, and not into the substance of either. Flex now the hand and forearm, and separate the superficial set of muscles behind which the artery lies, from the flexor profundus digitorum upon which the vessel lies, with the forefingers. The

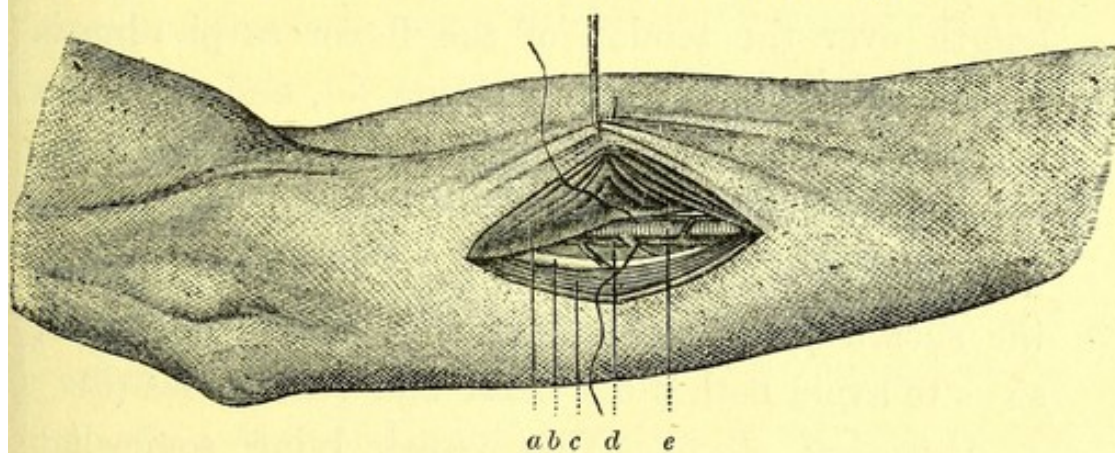


FIG. 43.

ulnar nerve will be first seen, and soon, external to it but on the same plane with it, the ulnar artery with

its venæ comites will be reached. Fig. 43 shows the operation above described, and the parts interested; the flexor sublimis muscle (*a*) pulled aside, the ulnar nerve (*b*) resting on the flexor profundus muscle (*c*), the ulnar artery (*e*), with its venæ comites (*d*).

Ligature in the Lower Third.—Here the artery lies between the tendons of the flexor carpi ulnaris muscle on the inside, and slightly overlapped by it, and the flexor sublimis on the outside. The hand being supine, make an incision (fig. 44) two inches in

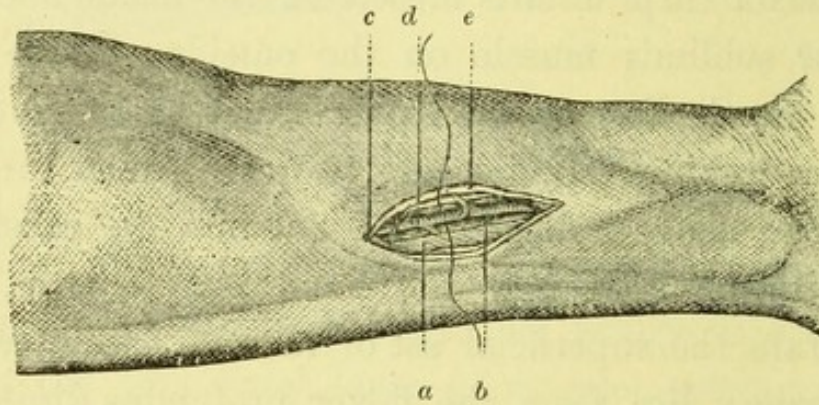


FIG. 44.

length over the tendon of the flexor carpi ulnaris muscle, dividing the integuments (*c*), and the deep fascia (*e*) on a director; flex the hand, and draw inwards the tendon of the flexor carpi ulnaris muscle (*a*), which overlaps the artery (*d*), and having opened the sheath pass the ligature from within outwards, so as to avoid both ulnar nerve and vena comes (*b*).

Abdominal Aorta.—This vessel, lying somewhat to the left of the median line, occupies the extent of the four upper lumbar vertebræ; it is covered in by peritoneum, and on its right side lies the inferior

vena cava. It may be ligatured between the origin of the inferior mesenteric artery and its bifurcation, by a vertical incision three or four inches in length, the middle of which should correspond to the umbilicus, but not include it, dividing the integuments, linea alba, and then on a director, the layer of peritoneum immediately behind this; separate now the edges of the wound, and while the small intestines are pushed over to the right side, scratch through the peritoneum, covering the aorta with a director, and carefully avoiding injury to the vena cava, pass the aneurism needle from right to left behind the artery.

Another and preferable mode.—Make an incision on the left side of the body from the tip of the last rib to the crest of the ilium, prolonging the same forwards along the crest, if necessary, and dividing integuments, muscles, and transversalis fascia only; with the fingers separate carefully the peritoneum from the parts behind it, until the aorta be reached, when the ligature must be passed as above directed.

Previous to the performance of operations, which might be rendered difficult by the presence of loaded bowels, a dose of castor oil, followed by an enema of warm water, should be administered. In order also to relax the abdominal muscles concerned in the operation, the thighs may be flexed upon the abdomen, and the head and shoulders also raised and bent forwards.

Common Iliac Arteries. Anatomical relations.—These vessels extend outwards, from the bifurcation of the abdominal aorta opposite to the lower margin of the fourth lumbar vertebra, to the intervertebral substance between the last lumbar vertebra and the sacrum, at which point they divide into internal and external iliac arteries. Both vessels are covered by peritoneum, and crossed by the ureter at the bifurcation. The relation of veins on either side differs: on the right side, the common iliac vein lies behind and external to its artery; on the left side, the common iliac vein is at first behind and internal to its artery, and afterwards behind the right common iliac artery.

External Iliac Artery. Anatomical relations.—This vessel extends downwards and outwards from the bifurcation of the common iliac artery, lying along the inner border of the psoas muscle, to the centre of Poupart's ligament; internal to and behind it is the external iliac vein; running upon it sometimes is a branch of the genito-crural nerve; near its termination, or about half an inch above Poupart's ligament, two large branches arise, deep epigastric and deep circumflex ilii arteries; the vein accompanying the latter artery crosses the external iliac artery from without inwards to join the external iliac vein. The artery is covered by peritoneum.

Internal Iliac Artery. Anatomical relations.—This vessel extends downwards from its bifurcation to the margin of the sacro-sciatic foramen. It lies on the

pyriformis muscle, and lumbo-sacral cord ; its companion vein is behind it ; in front, the ureter crosses the vessel ; the obturator nerve passes to its destination external to the artery, and the peritoneum covers it.

OPERATION.

Ligature of the External Iliac Artery.—This vessel is best reached by an incision, begun about half an inch above Poupart's ligament, at the junction of

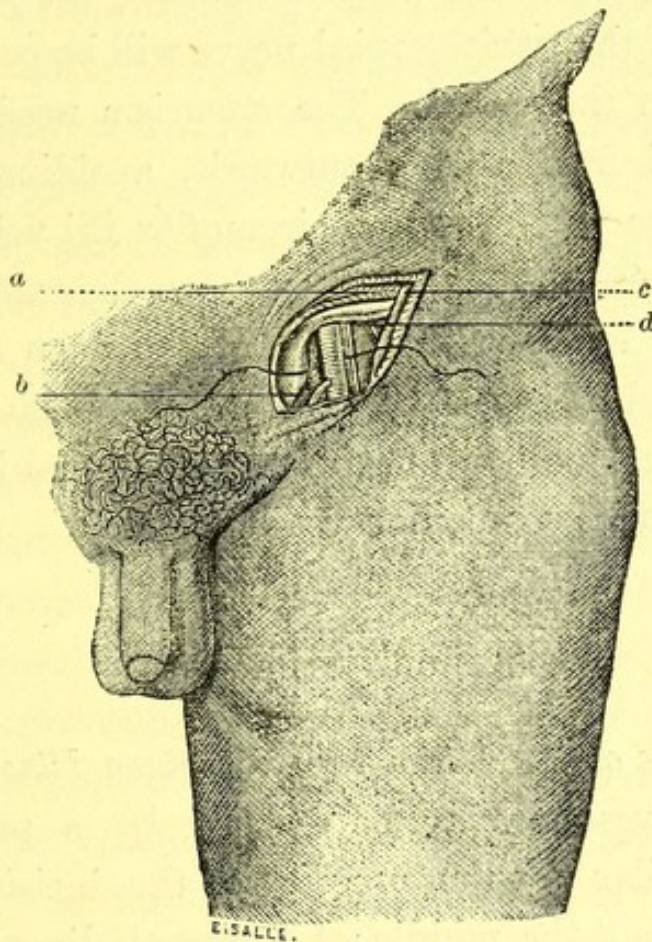


FIG. 45.

the inner and middle third of the space between the symphysis pubis and the antero-superior spine

of the ilium, and carried outwards to the extent of three inches towards the antero-superior spine of the ilium, parallel to Poupart's ligament. Divide thus the integuments, the aponeurosis of the external oblique muscle (*c*), raise or divide the fibres of the internal oblique and transversalis muscles (*a*) on a director; let an assistant hold aside the cord, and slit up the transversalis fascia also on a director; with the fingers carefully push up the peritoneum (*d*), and seek the artery above the origin of the deep epigastric and deep circumflex ilii arteries; a branch of the genito-crural nerve will be occasionally seen upon the vessel. The aneurism needle should be passed from within outwards, avoiding the external iliac vein, the deep circumflex ilii vein and the genito-crural nerve. Fig. 45 shows the external iliac artery (*b*) exposed, the origin of the deep epigastric artery, and the genito-crural nerve, in this instance, outside the main artery, and the external iliac vein, internal to its companion vessel.

OPERATION.

Ligature of the Internal and Common Iliac Arteries.
—These vessels may be exposed by a proceeding very similar to the preceding, the incision being begun about the middle of Poupart's ligament, and carried upwards and outwards, with the convexity looking downwards and outwards, to the extent of about five inches. Similar strata will be divided,

and all vessels which bleed should be immediately tied.

Femoral Artery. Anatomical relations. — This vessel extends through the upper two-thirds of the thigh, from the centre of Poupart's ligament to the opening in the adductor magnus muscle, through which it passes to become popliteal. On the surface, the thigh being abducted and rotated outwards, a line drawn from the centre of Poupart's ligament downwards and inwards, along the front and inner side of the thigh to the centre of the popliteal space, will indicate the course of the artery. In the upper third of the thigh the artery traverses Scarpa's triangle, from the centre of its base to its apex, and is covered in by skin, superficial fascia which at the upper and inner part consists of at least two layers with superficial vessels and lymphatic glands intervening, and fascia lata; one or two branches of the anterior crural nerve cross the artery from without inwards. On the outside, at the distance of about half an inch, lies the trunk of the anterior crural nerve, two large branches of which gradually approach the artery. On the inside, and not closely applied to the artery at first, is the femoral vein, which lower down is found posterior to the artery, and only separated from it by a very thin cellular septum. Behind the artery are certain muscles and portions of the profunda artery, profunda vein, and of the femoral vein. The profunda artery usually arises at the distance of about one inch and a

half below Poupart's ligament, from the posterior and outer side of the femoral artery, and pursues a course outwards, downwards, inwards, and then again downwards, parallel to but deeper than the femoral artery, thus forming a curve external to the femoral artery, and leaving a space between the two vessels, through which a knife might pass without wounding either of them. This fact is worthy of recollection in reference to wounds of the arteries of the thigh. It should also be borne in mind that a stab in a certain part of the thigh might transfix both femoral and profunda arteries.

OPERATION.

The femoral artery can be ligatured in any part of its course, but with comparative ease in Scarpa's triangle. In a case of popliteal aneurism requiring ligature of the main vessel, the *point of selection* for ligature is the apex of Scarpa's triangle, corresponding to the convergence of the adductor longus muscle from the inside and the sartorius muscle from the outside. This situation is preferred, because the artery is comparatively superficial, at a moderate distance from a large branch (profunda), through which, if nearer, the current of blood flowing might prevent union of the divided coats and the formation and organization of a firm clot to plug the vessel; the profunda artery being also above the ligature, the nutrition of the limb is not interfered with in a dangerous degree.

Ligature at the apex of Scarpa's triangle.—The patient being recumbent, with the leg partially flexed upon the thigh, and the thigh slightly abducted and rotated outwards, the position of the internal saphena vein should be ascertained by making pressure upon it near its junction with the femoral vein, so as to check the flow of blood through and cause it to swell; the position also of the sartorius muscle, especially the inner margin of the upper portion, which borders the artery and crosses the thigh from above inwards and downwards, should be ascertained by causing the subject, if living, to bring the muscle into action. The part having been shaved, if necessary, and the course of the artery known by its pulsation, if the subject be alive, and by the surface line indicated above, an incision commenced at a distance of four fingers' breadth below Poupart's ligament should divide the integuments only, parallel to the artery to the extent of three inches, leaving the saphena vein on its inner side; any lymphatic glands intervening should be held aside or removed, while the deep fascia is divided on a director. Seek now the inner margin of the sartorius muscle, the fibres of which run downwards and inwards, and along this border, or just under cover of it, the artery will be seated. The sheath of the vessel having been opened as directed, the aneurism needle must be passed with the utmost care around the artery from within outwards, the point of the needle being kept closely applied to the artery, lest the vein, which in this

locality is particularly near the artery and generally behind it, should be wounded. (I have repeatedly seen the vein wounded, and a segment of it included with the artery, where ligature of the femoral artery has been practised, by gentlemen attending my "course of operations" in Paris.) Fig. 46 shows the incision and parts interested in the above operation. The integuments are divided, as also the deep fas-

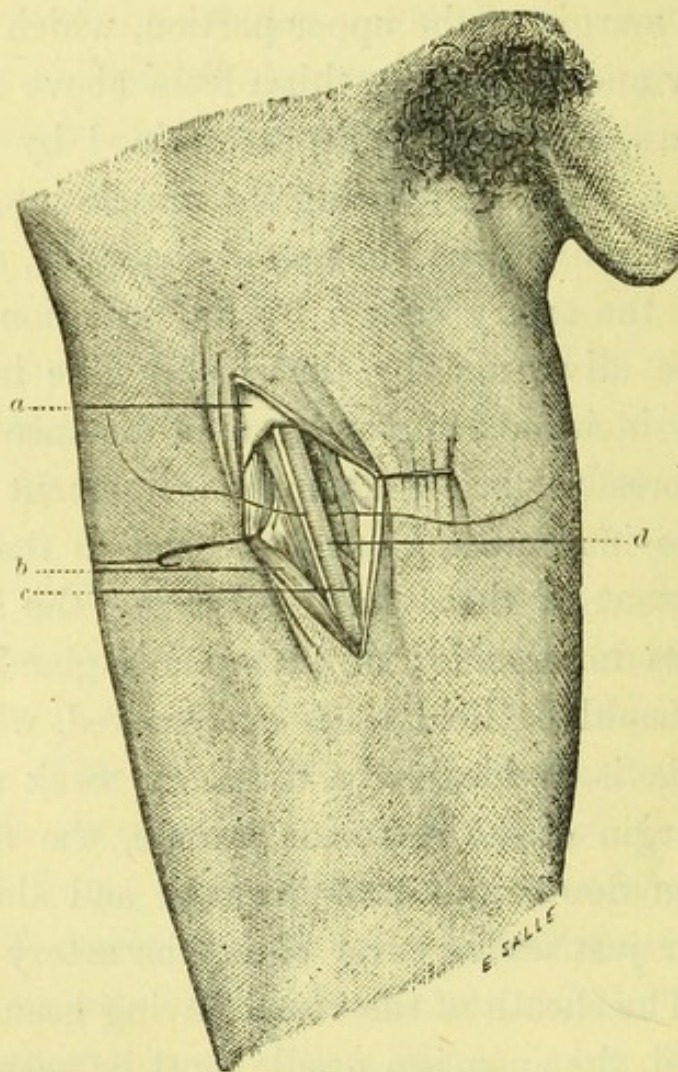


FIG. 46.

cia (*a*); the sartorius muscle (*b*) is pulled to the outer side, exposing the artery (*d*) and the vein (*c*).

Ligature at the base of Scarpa's triangle. — In this position the artery is superficially placed, being covered in by skin, superficial fascia, lymphatic glands, cribriform fascia or deep fascia, having the trunk of the anterior crural nerve on the outer side, about half an inch from it, the femoral vein on its inner side occupying the central partition of the crural sheath, but separated from the artery by a distinct and moderately firm cellular septum.

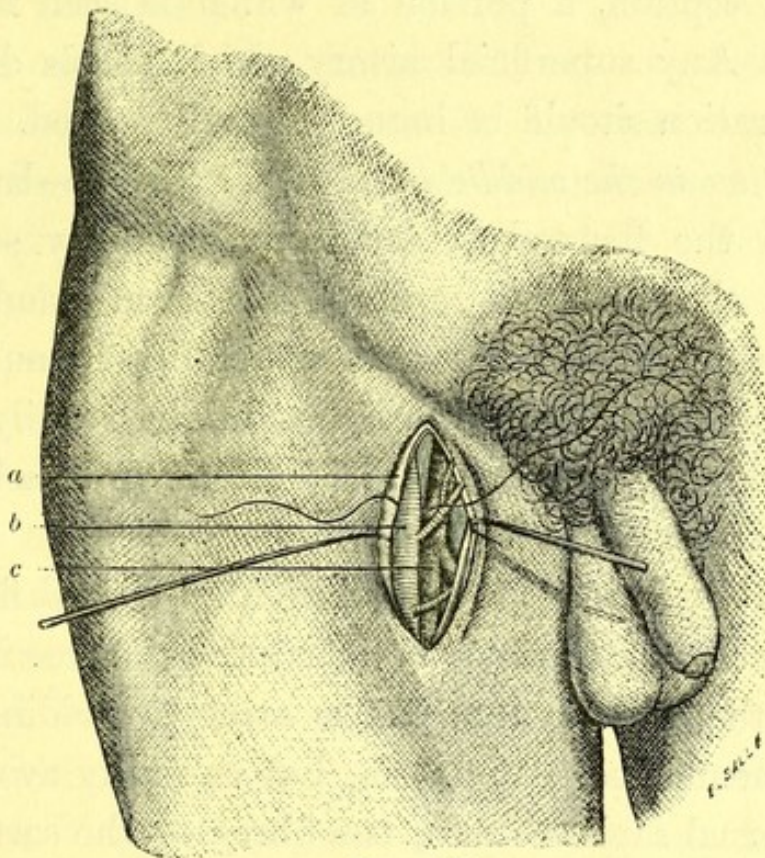


FIG. 47.

Make an incision in the direction of the artery already indicated, commencing at Poupart's ligament and terminating two inches below it, dividing the skin, and then the layers of fascia on a director, till the sheath be reached; open the sheath, and pass

the aneurism needle from within outwards. The vessel will thus be ligatured midway between the origins of the deep epigastric and deep circumflex ilii arteries, branches of the external iliac artery above, and the profunda artery, the largest branch of the femoral artery below. Fig 47 shows the parts exposed by the above incision; *a* is the deep fascia, *b* marks the artery, and *c* is the femoral vein, internal to the artery, and separated from it by a distinct septum, a portion of which is seen in the figure. Any superficial artery which bleeds during the operation should be immediately ligatured.

Ligature in the middle third of the Thigh.—In this position the femoral artery is more deeply seated, and in the case of popliteal aneurism would be nearer the disease; also the vessel lies in an aponeurotic canal, along which pus might readily and injuriously burrow. This site should never be selected from preference.

The limb being in the position of partial flexion and rotation outwards, make an incision three inches in length over the line of the artery; dividing the integuments and deep fascia, but carefully avoiding the internal saphena vein, the fibres of the sartorius muscle will now be exposed, and may be recognised by their downward course; separate the edges of the wound, and seek the anterior and outer margin of the last-named muscle, and turn it inwards, so as to expose the anterior and inner wall of Hunter's canal, formed by a fibrous aponeurosis, extending from the

tendons of the adductors longus and magnus downwards and inwards, to join the tendinous origin of the vastus internus muscle. This aponeurosis covers in the artery, also the femoral vein lying somewhat to the outer side and behind the artery, and the long saphena nerve lying in front and external to the artery. If the subject be thin, the long white cord of the saphena nerve may be readily seen through the aponeurosis, and will serve as a guide to the position of the artery.

The operator must be careful not to mistake the tendinous origin of the vastus internus muscle for the aponeurotic expansion above mentioned, nor the nerve or any branch of the nerve which supplies the vastus internus muscle, for the long saphena; both these sources of fallacy are external to the position of the artery. It may be remembered that the fibres of the vastus internus muscle run from above, downwards and outwards, while those of the sartorius in this position are nearly vertical.

Hunter's canal being now exposed, should be opened on a director to a similar extent as the superficial structures, so as to favour the exit of pus, if any forms, and to prevent burrowing of matter.

The sheath is to be opened as usual; and, not forgetting the close proximity of the vein to the artery, the aneurism needle should be passed from without to within, so as to avoid including either the nerve or vein in the ligature.

Popliteal Artery.—This vessel traverses the centre of the popliteal space vertically. In front of it are the femur, with more or less fat intervening, the posterior ligament of the knee-joint, and the popliteus muscle; behind the vessel and external to it are the popliteal vein, which in this region is joined by the short saphena vein from below, and the internal popliteal nerve, superficial to and also external to the vein; laterally the artery is bounded by the various muscles, inclosing the space. The deep fascia, a prolongation of the fascia lata, strengthened by additional transverse fibrous bands, binds together all the above organs, as well as some lymphatic glands which lie about the artery. In the lower half of this space branches of these popliteal vessels and internal popliteal nerve form a network about the artery, and therefore induce the surgeon to select the upper part of the vessel as the seat of ligature.

OPERATION.

The subject being prone and the leg extended, make a vertical incision from three to four inches in length along the centre of the popliteal space, two-thirds of the incision being above and one-third below the line of the articulation between the femur and tibia. Divide the integuments cautiously, so as not to wound the external saphena vein, slit up the deep fascia on a director, and then seek the internal popliteal nerve, the most superficial of the

three organs above mentioned ; flex the leg partially upon the thigh, so as to relax the parts, and let an assistant hold aside the above nerve ; now seek the vein which is still deeper than and internal to the nerve, and having found this vessel, seek the artery still deeper than and internal to the vein, and pass the aneurism needle from without to within. The various organs occupying this space are so bound together by the deep fascia, and the space thereby rendered so deep, that the artery cannot be readily reached unless a free incision be made.

Posterior Tibial Artery.—This vessel extends along the centre of the back of the leg between the two layers of muscles occupying that region, from the termination of the popliteal artery to a mid-point between the internal malleolus and the insertion of the tendo-achillis.

The artery is attended by venæ comites, and by the posterior tibial nerve, which in the upper fourth is internal to the artery, but in the lower three-fourths is external to that vessel.

OPERATION.

This vessel may be ligatured at any point of its course, and with comparative ease in the lower third of the leg where it is not covered by muscle.

Ligature at the middle third of the Leg.—The surgeon should first ascertain the position of the internal saphena vein ascending along the inner side of the

leg, and, having done so, make an incision (fig. 48) three or four inches in length, parallel to the inner

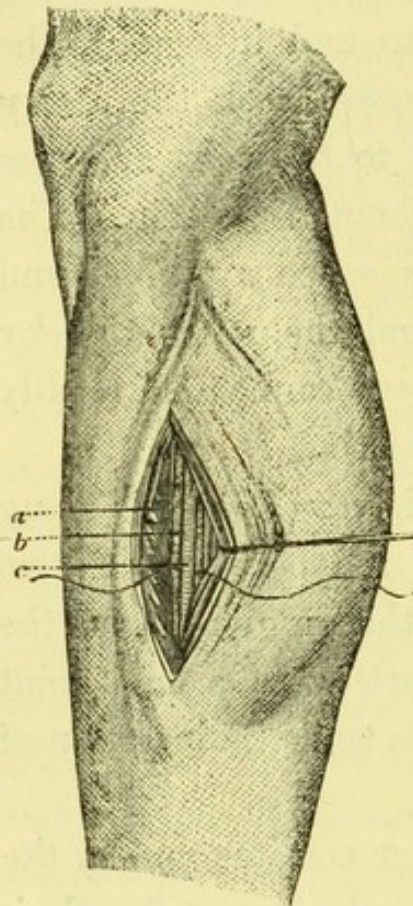


FIG. 48.

margin of the tibia and a finger's breadth behind it, dividing the integument and deep fascia. He will now probably see the free margin of the gastrocnemius muscle lying upon the soleus, which former should be held aside while the fibres of the soleus muscle (*a*) are cautiously divided to a similar extent as the integument, until a whitish fibrous membrane be reached. (I beg to draw especial attention to this "whitish fibrous membrane," because it is the tendinous origin of the

soleus muscle from the tibia, and not, as I have known students suppose, the aponeurosis separating the superficial from the deeper layer of muscles.) Slit up this tibial origin of the soleus on a director and seek for the pearly-looking intermuscular septum, the transverse fibres of which are sometimes distinctly seen, separating the two layers of muscles and binding the artery upon the tibialis posterior muscle (or rather upon the posterior tibial aponeurosis). Divide this intermuscular septum on a director also,

and seek the artery (*c*), external to the outer border of the tibia attended by venæ comites (*b*) and the posterior tibial nerve, the latter to its outer side. Pass the aneurism needle from without inwards. Some authorities advise that the soleus muscle should be detached close to the tibia; but it should be remembered that the flexor longus digitorum muscle also arises from the tibia, just external to the linear origin of the soleus and would almost surely be detached with the soleus; and if so, the operator would get into the substance of the flexor muscle and anterior to the artery instead of being behind it, as is desired. Any muscular branch of artery which bleeds should be immediately ligatured.

Another method consists in making a vertical incision along the middle of the back of the leg through the superficial muscles. This is not so convenient as the former, because the artery is further from the surface, and more injury is inflicted on the various organs interested.

Ligature at the lower third of the Leg.—In this position the vessel lies about midway between the tendo-achillis and the inner border of the tibia, is attended by venæ comites and by the posterior tibial nerve lying to its outer side; internal to the artery are the tendons of the tibialis posticus and flexor longus digitorum muscles.

The vessel may be readily reached in this locality by an incision (fig. 49) two inches in length parallel to the inner edge of the tibia, and a

finger's breadth posterior to it. By this method the artery will be ligatured about one inch above the inner

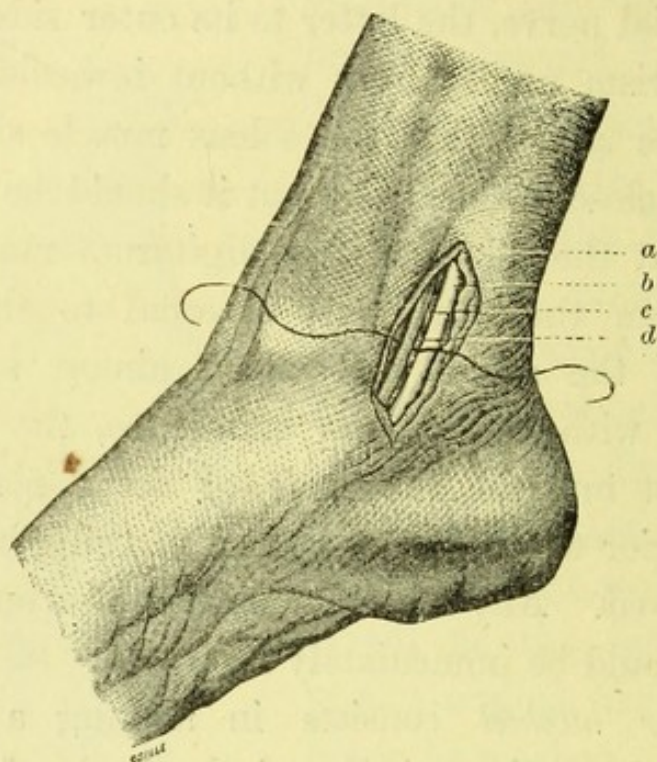


FIG. 49.

malleolus, and the parts to be divided are, the integuments and the deep fascia (*a*) on a director. Some fat will now be seen, and in it the sheath with the artery (*d*), and venæ comites (*c*). The posterior tibial nerve (*b*) is external to the artery. When performing this operation, the surgeon should be careful not to open the sheath of the tendons lying on the posterior surface of the tibia. Also, both in this and the former operation, the limb is resting on its outer surface; and the incision in both cases, although parallel to the artery, is not immediately over it, but rather on a plane posterior to the vessel. The artery in both instances must therefore be looked for anterior

to the direction given to the scalpel in effecting the integumental incision.

Anterior Tibial Artery.—On the surface, a line drawn from the inner side of the head of the fibula to a mid-point in front between the internal and external malleoli, will mark the course of the artery. In the upper three-fourths of the leg the artery rests upon the inter-osseous membrane; in the lower fourth, upon the tibia. It is more superficial below than above, in consequence of the diminution of the size of the tibia and muscles. On the outer side the vessel is bounded in the upper third by the extensor longus digitorum muscle, in the middle third by the extensor proprius pollicis, in the lower third by the extensor longus digitorum.

On the inner side the artery is bounded throughout by the tibialis anticus muscle, the outer border of which marks the course of the artery, and can be felt with tolerable facility when the muscle is in action. In front, in the upper two-thirds, the artery is concealed by the apposition of muscles above mentioned, deep fascia, and integument; in the lower third, besides integument and deep fascia, the vessel is crossed from without inwards by the extensor proprius pollicis muscle. Venæ comites accompany the artery, also the anterior tibial nerve, with uncertain position.

OPERATION.

This vessel may be ligatured at any point, but

with more ease towards the lower than upper extremity of the leg. In the upper third the vessel is very deeply seated; and as the muscles arise partly from the deep fascia covering them, the muscular space between the tibialis anticus on the inside and the extensor longus digitorum on the outside, cannot be readily found, although sometimes a whitish line will mark the position of the intermuscular septum.

Ligature in the middle third of the Leg.—Make an incision (fig. 50) three inches or more in length, over and parallel to the course of the artery, dividing the integument only. Seek now a white line in the deep fascia, marking the septum between the tibialis anticus on the inside and the extensor longus digitorum on the outside.

Divide this white line of deep fascia longitudinally, and nick it transversely also at one or two points, if it prevent ready separation of the edges of the wound.

Flex the foot upon the leg so as to relax muscles, and not forgetting that in the middle third of the leg the extensor proprius pollicis muscle lies to the outer side of the artery, and concealed from view by the apposition of the tibialis anticus and extensor longus digitorum, separate the edges of the wound by drawing the tibialis anticus muscle (*b*) to the inside, and the extensor proprius and extensor longus digitorum (*a*) to the outside. The nerve will probably be seen first, somewhat anterior to the artery (*d*), the

latter being attended by venæ comites (*c*). Pass the ligature according to rule.

The anterior and posterior tibial arteries may be readily compressed just above the ankle joint against the tibia.

The Dorsalis Pedis Artery.—On the surface, a line drawn from a mid-point between the malleoli to the base of the first metatarsal space, will mark the course of the artery. The tendon of the extensor proprius pollicis muscle lies to the inner side of the artery, and can be readily felt by manipulating the great toe, or bringing the muscle into action.

The tendons of the extensor communis digitorum muscle are external to the artery, and the innermost tendon of the extensor brevis digitorum crosses the vessel from without inwards, just before the latter dips into the sole of the foot.

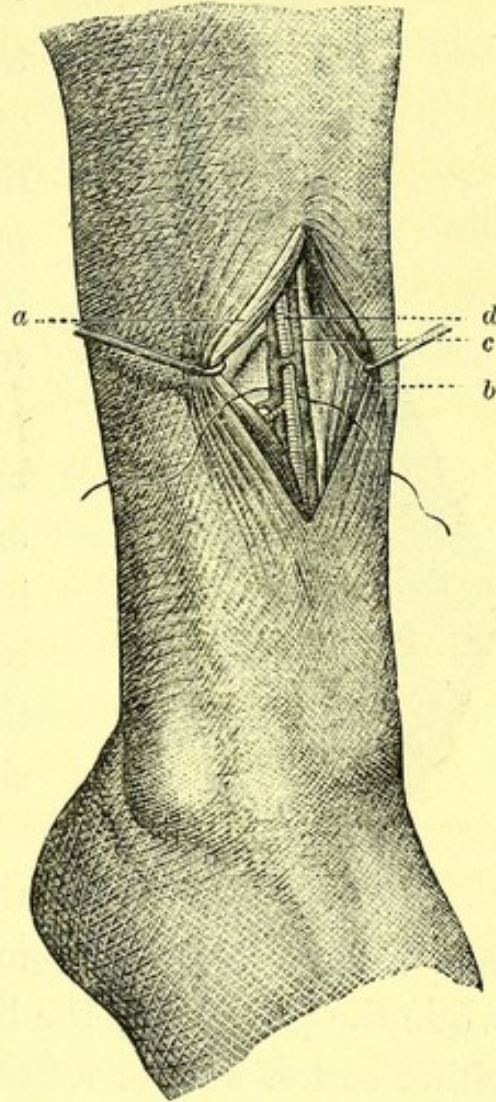


FIG. 50.

OPERATION.

Commence an incision about one finger's breadth

below the ankle joint, and carry it along the dorsum of the foot to the extent of one and a half

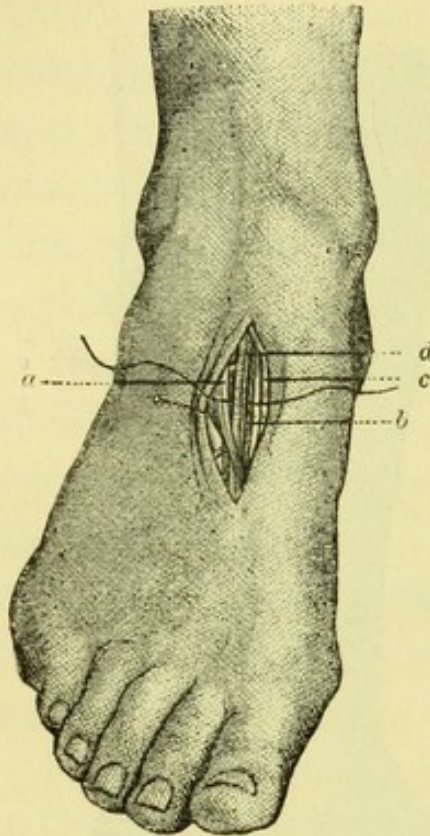


FIG. 51.

or two inches. Let the incision (fig. 51) be external to and parallel to the tendon of the extensor proprius pollicis muscle (*c*). Divide the integument carefully, then the deep fascia on a director, when the artery (*d*) will probably be seen attended by venæ comites (*b*), and crossed obliquely by the inner tendon of the extensor brevis digitorum muscle (*a*): the nerve is usually outside the artery.

After ligation of an artery the patient should be instructed to abstain from all muscular exertion, while the part below the ligation is kept warm with either cotton wool or a flannel bandage.

CHAPTER VI.

OPERATIONS ON THE BONES.

EXCISION OF JOINTS, BONES, AND PORTIONS OF BONES.

EXCISION has for its object the removal of the articular ends of bones, a portion of the shaft, or the whole of certain comparatively unimportant bones, with a view to the preservation of the rest of the limb or adjacent structures to the use of the patient.

It has certain advantages over amputation, inasmuch as it necessitates the removal of a smaller portion of the frame, and, if successful, leaves the patient with a mutilated but more or less useful limb.

Excision of the Upper Jaw.—The sutures which materially retain the upper jaw in position after division of the soft parts, and so prevent easy removal of it, are, one, between the ascending process and the nasal and frontal bones, a second, between the malar process and malar bone, and a third, the mesial articulation with the corresponding bone on the other side.

The patient being seated in a chair, at a convenient

height, his face turned towards the operator, and having his head supported by an assistant behind, the surgeon should stand somewhat in front, but on the side of the patient opposite to that on which he is about to operate. The operator proposes to divide the cheek from the angle of the mouth of the affected side to a point opposite to the centre of the malar bone of the same side, and effects his object either by puncturing the cheek from within the mouth (the former being made tense by the left forefinger and thumb of the operator, pulling upon the cheek on one side of the angle of the mouth, while an assistant pulls gently on the other side of the angle) opposite to the malar bone, and carrying it downwards, so as to divide the commissure of the lips; or, if the cheek be stretched over a tumour, the former may be divided from below upwards and outwards. The cheek must now be dissected upwards to the margin of the orbit, and the nasal cartilage of the affected side be separated from its attachment to the superior maxillary bone; branches of the superior maxillary nerve will of course have been cut across, as they emerge upon the cheek. Protecting the eye, divide with bone forceps the nasal process of the superior maxillary bone, opposite to the upper opening of the nasal duct. Take now one end of a "chain




FIG. 52.

saw" (fig. 52), temporarily detached from its handle,

and by means of a thread attached to it arm an aneurism needle with the saw, and pass the needle thus armed, from above through the spheno-maxillary fissure bringing it out below the malar bone in front of the origin of the masseter muscle. The thread should be now seized and held, while the needle is withdrawn as it came. The saw being now adjusted and the eye protected, the malar bone will be readily divided by a few strokes of the former. Extract one or two incisor teeth from the affected jaw, separate the velum palati by a transverse incision, from opposite its attachment to the posterior nasal spine outwards to a point just behind the last molar tooth; also incise the soft palate along the side of the articulation between the palate processes of the palate and superior maxillary bones. Again arm an aneurism needle with the chain saw, and pass it back along the floor of the nostril of the diseased side, making it reappear in the opening caused by the transverse incision in the velum palati. With a forceps seize the thread and bring it and one end of the saw out at the mouth, at the same time removing the aneurism needle by the nostril. Readjust the handle of the saw, and make it cut its way forward through the hard palate. The chief osseous connexions of the superior maxillary bone are now severed, and having introduced an elevator between the maxillary bones in front, slight force applied by means of the elevator used as a lever, while the sound maxillary bone serves as a fulcrum,

will break down the still existing unimportant bony adhesions.

With a strong pair of forceps holding the alveolar process, pull upon the loosened bone in a direction downwards and outwards, twisting it as it yields, so as to break down slight adhesions and to tear small vessels, using the knife sparingly, but to divide perhaps the superior maxillary nerve. Any vessel bleeding should be ligatured if it can be reached, otherwise be touched with the actual cautery.

Bleeding having ceased, the cavity should be filled with lint or sponge, and the wound carefully closed and sutured. After recovery the patient may be handed over to the dentist.

Any vessel bleeding during the operation may be ligatured at once.

On examining the bone thus extracted, it will be found that, besides portions of the palate, malar and other bones, usually a greater or lesser portion of the pterygoid process comes away also.

Another method.—To effect removal of the upper jaw many surgeons prefer to incise the upper lip in the median line, and then to carry the incision outwards in front of the nostril to the ala of the affected side, continuing it up along the side of the nose to within half an inch of the inner angle of the eye. This incision occupies the site of natural furrows for the most part, and after recovery is not so unsightly as that described above. It will suffice if there be not much distortion of the features, and also if only

a portion of the bone requires removal. Under circumstances of great enlargement, both of these incisions may be necessary to facilitate the operation, but it will be readily understood that the form and position of the incision must in some respects depend upon the seat and extent of disease. The bone forceps, straight and angular, also small saws, straight, semicircular, or with rounded angles, should be at hand in case of need ; indeed, some prefer using a small saw and bone forceps to divide the hard palate to the chain saw. Portions of the alveolar border of either jaw may be removed by the bone forceps and without incising the cheek.

Prior to removal of the upper jaw for enlargement of a doubtful nature connected with bulging of the antrum, the contents of the cavity may be tested by puncturing the same with a strong trocar, either through the socket of a decayed molar tooth extracted for that purpose, or through the anterior wall of the antrum.

Excision of the Lower Jaw.—The whole of this bone has been removed by one operation, but such proceeding would be much facilitated by a previous section of the symphysis. Excision of one half of the lower jaw may be performed as follows:—The patient being seated, and well supported behind, or semi-recumbent, and with his face turned towards the surgeon who stands somewhat in front but in either case on the patient's right, the operator makes a curved incision, the convexity looking down-

wards and backwards, commencing on the cheek at a point, if possible, not higher than the junction of the lobule of the ear with the face, and carrying it along the margin of the bone to the symphysis. At either or both ends of this cut he may let fall a short incision at a right angle, the one over the symphysis being short of dividing the free margin of the lip. One or both ends of the facial artery should be ligatured at once. The flap of integument and muscles may now be dissected close off the bone, a tooth extracted, if need be, and a small saw used to cut a groove in the outer surface of this naturally dense bone, if possible, external to the symphysis, so as not to disturb the mesial attachments of the tongue. With the bone forceps complete the section of the bone begun with the saw. Keeping the knife close to the bone, detach muscles and mucous membrane from the inner surface as high as and including the internal pterygoid muscle. Seize now the freed portion of the jaw with the left hand, and press upon it in a downward and backward direction, so as to bring down the coronoid process and tendon of the temporal muscle as much as possible. The position of the apex of this process known, pass up along the anterior margin of the same a round-pointed curved scissors, nicking the tendon of the temporal muscle in its progress till the attachment to the apex of the coronoid process be severed. Still pulling upon the loosened bone, twist it forcibly outwards, so as to tear the capsular ligament and the fleshy external

pterygoid muscle; then incise the external lateral ligament and minor attachments close to the bone till it comes away. Bleeding having ceased, close the wound by suture over strips of lint, introduced to fill the cavity. The ends of ligatures should be allowed to hang in the mouth, rather than be brought out through the edges of the wound.

Happily, in many instances, portions only of the lower jaw demand removal—as the symphysis, the part between the symphysis and angle, or between the angle and the articulation.

Excision of the Symphysis.—The dimensions of an incision to expose a portion of the jaw must depend in great measure upon the impediment consequent on the size of the body to be removed.

Fig. 53 shows the bone laid bare by a vertical incision in the mesian line, dividing the integuments from the margin of the lower lip to the hyoid bone. Two flaps were formed, and turned aside so as to expose the symphysis (*b*), and enable the operator, after extracting a tooth on either side, to separate the diseased portion by means of a saw and bone forceps.

To prevent retraction of the tongue, and probable suffocation, a ligature should be passed through the root of this organ, and be held firmly by an assistant (*e*), while the knife (*d*) separates the fragment of bone from its attachments behind. The operation completed, the wound is to be closed by the twisted suture, and the ligature holding the tongue should be brought out in front between the edges (*a, e*) of the

wound, and be fixed to one of the needles forming the suture, and be there maintained until the tongue

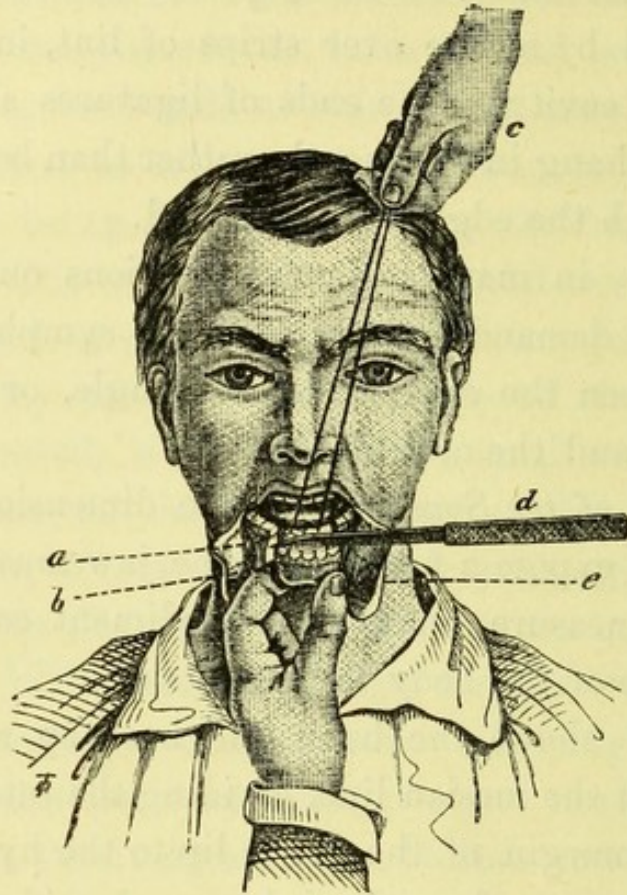


FIG. 53.

shall have contracted adhesions. Any falling together of the remaining lateral portions of the lower jaw, and consequent diminution in the area of the floor of the mouth, may be obviated by some dental apparatus, having for its object the maintenance of the teeth in one jaw opposite those in the other, until repair and consolidation have taken place.

In a case which came under my care in the Crimea, I removed the symphysis, and a Minié bullet lying among its fragments, by a horizontal incision along

the base of the jaw, and a second vertical cut in the median line of the lower lip short of dividing its red margin and falling at a right angle upon the first. Two angular flaps were then dissected up, and the bone and ball removed.

This case came under my care secondarily, when the external wound by which the ball entered was closed, and its presence unknown before the time of the operation. The gum and a portion of the posterior wall of the bone were left, and by this means the tongue was kept in tolerable position.

In all operations about the face, the red margin of the lips should, if possible, be left intact.

Excision of portion of Jaw from symphysis to angle.—

Fig. 54 shows the operation by lateral flap, formed by two incisions, one horizontal along the base of the jaw from the angle to the symphysis, the other vertical through the lower lip, meeting the end of the first at a right angle (*d*). The flap (*b*) is dissected up, exposing the portion of bone (*c*) to be removed. An incisor tooth having been extracted, the bone is partially divided near the symphysis with a small

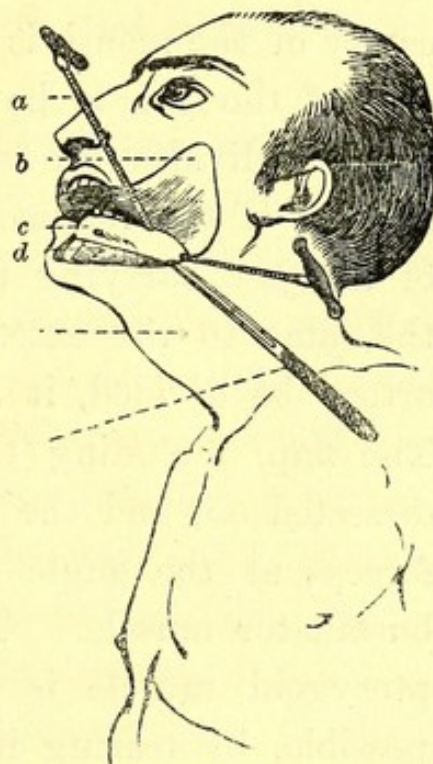


FIG. 54.

saw, and the section completed by the bone forceps;

the angle is to be cut across in a similar manner, or by the chain saw (*a*) introduced between it and the soft parts, as before directed, on an aneurism or other needle. The bone thus partially detached will be liberated altogether by a careful application of the knife to its inner surface. The facial artery, either one or both ends, should be ligatured as soon as divided. The edges of the wound are to be carefully adapted by suture, due attention being paid to the exact apposition of the edges at the red border of the lip. A notch, which sometimes follows division of the red border of a lip, may be prevented generally by a fine suture introduced at the very margin.

Excision of portion of Jaw from angle to articulation.

—The patient in this case may be recumbent, as the cavity of the mouth is not to be opened. With the side of the face to be operated upon uppermost, the surgeon divides the soft parts along the posterior margin of the ramus from the zygoma to the angle of the jaw, carrying the incision along the base of the same to the extent of an inch. If the facial artery be divided, it should be ligatured at once. The flap, including the masseter muscle, is to be dissected off, and the bone severed by the saw and forceps at the angle above the attachment of the buccinator muscle. The insertion of the internal pterygoid muscle is to be carefully detached, if possible, by tearing it with the finger from above downwards. The lower end of the ramus thus freed is to be seized and pulled downwards and backwards,

so as to depress the coronoid process. An assistant holding open the upper part of the wound, the operator divides the attachment of the temporal muscle to that process with a curved round-pointed scissors, and forcibly twisting the ramus outwards, tears through the attachments of the fleshy external pterygoid muscle and capsular ligament, and with a few cautious touches of the knife or scissors divides the remaining external lateral ligament and other minor attachments, and so completes the separation. Large branches of the facial nerve are severed by the above incision, and paralysis of the muscles by them supplied must be anticipated; also Steno's duct is severed. Bleeding having ceased, the edges of the wound should be most carefully adjusted, with the hope that the divided nerves and duct may soon reunite.

Excision of the Clavicle.—The large vessels in relation with this bone posteriorly and inferiorly render its removal a matter of danger and difficulty. Such proceeding may be effected by an incision along the bone from one extremity to the other; and, if necessary, this may be added to by one or two short right angular cuts made at the required spot. The bone having been bared, and its muscular attachments above and in front carefully divided, the "excision director" may be passed under the centre of the bone to protect the soft parts while the bone is sawn in two. Each half of the bone is now to be separately seized near the sawn end by a strong forceps, and

forcibly raised, while the operator cautiously divides the inferior muscular attachments as well as the ligaments of the articulation, cutting always upon the bone to be removed. The bone removed, the flaps may be readjusted, and the wound closed.

Excision of the Scapula.—The whole of this bone has been removed, both primarily and secondarily: in the first case, leaving the arm to the use of the patient; in the second instance, after the arm had been previously removed at the shoulder-joint. The incisions requisite must depend altogether upon the condition of the soft parts and the magnitude of the mass demanding removal, and must be determined by the surgeon in each particular case. In a general sense, it will be necessary to make at least two incisions—one from the tip of the acromion process along the axillary border of the scapula to the inferior angle of the same; the second running the whole length of the scapular spine to join the first, either at a right angle or some convenient curve. All vessels should be tied as soon as divided, the axillary being left intact.

Excision of the head of the Humerus.—The patient either seated in a chair or semi-recumbent, the surgeon should stand on the side of the subject corresponding with that of the arm on which he is about to operate, and somewhat in front. With the arm hanging naturally by the side, let the operator ascertain the position of the extremity of the acromion process, the coracoid process, and the portion of clavicle between these two.

Slight rotation will prove that a portion of the head of the humerus underlies the space thus inclosed, and into it holding the knife (a small catlin), point downwards and perpendicularly, let him plunge it so as to reach the head of the bone, taking care at the same time not to slip it into the axilla. From this point, depressing the handle, the tissues are to be divided down to the bone in a direction parallel with the long axis of the humerus as far down the arm as the point of union with the anterior fold of the axilla.

The edges of the wound are to be retracted by assistants, and the long tendon of the biceps muscle looked for; its sheath is to be slit up, as also the capsular ligament, when, if not already destroyed, the long tendon of the biceps should be slipped on one side. The muscular attachments to the tuberosities are now to be divided, if possible, by a semi-circular sweep of the knife beginning with the heel of the same. To do this the wound must be well opened by retractors, while the surgeon, holding the shaft of the humerus in his left hand, rotates it first inwards, supposing him to be operating on the right shoulder, in order to divide the attachment of muscles to the greater tuberosity; then gradually rotating outwards, he divides the capsule over the head of the bone and subscapularis muscle attached to the lesser tuberosity. One or two touches of the knife permit the head of the bone to appear through the wound, when the diseased portion can be readily removed with either a common or chain saw. Should

the glenoid cavity be also the seat of disease, its surface may be removed with a gouge or forceps. The upper part of the wound should be closed by suture, and the elbow be raised and fixed to the side.

The efficiency of the limb will greatly depend upon the amount of bone removed; the longer the portion excised, the greater the difficulty of adaptation to the glenoid cavity. Moderately firm adhesions to subjacent structures forming a pivot, or false joint, on which the bone may move on its own axis, but from which it cannot be removed, will also add to the utility of the limb.

Another method.—Fig. 55 shows the mode of operating preferred by some. The

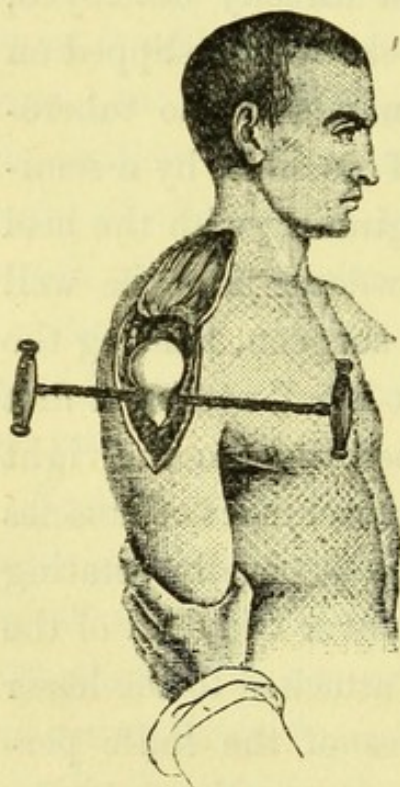


FIG. 55.

head of the bone is exposed by making a flap of the deltoid muscle; this turned up, the operation should be completed as described above. In removing the diseased head of the humerus, it is customary to saw transversely. In this way the new surface looks upwards only; but in order that it may look towards the glenoid cavity, in accordance with the original direction of the normal articular surface, I propose to saw off the disease in a

cular surface, I propose to saw off the disease in a

direction from below upwards and outwards, thus giving to the new surface a direction upwards and inwards. By this means I presume that the two surfaces could be better adapted. In examining the amount of disease present, care must be had not to confuse new bony excrescences with caries.

Excision in the continuity of the Humerus.—Operations which, if performed upon the lower extremity would probably prove fatal, may be attempted upon the corresponding bone of the upper limb with every chance of success.

In cases of *ununited* fracture of the humerus, after less formidable means have failed, the surgeon need not hesitate to cut down upon the seat of fracture in some convenient position, say the outer side of the arm, due respect being paid to the course of large vessels and nerves; and, having divided the fibrous tissues connecting the bony fragments, turn them out separately and remove their extremity with the saw.

Care should be taken to remove the whole of the uneven surface of each fragment, so as to leave two clean surfaces of bone in apposition after the completion of the operation. The case must henceforth be treated as one of compound fracture.

Excision of the Elbow-joint.—Experience in excision of joints has shown that the operation has been peculiarly successful in the case of the elbow-joint. Not only is the limb saved, but rendered most useful to the patient, who in some few cases acquires all those movements of which the healthy joint is capable.

The joint being comparatively superficial behind the posterior surface, is selected for the first incisions by which the bones may be exposed. The only important organ too in this neighbourhood is the ulnar nerve.

Previous to the operation the surgeon should ascertain the relative position of the point of the olecranon to the internal and external condyles of the humerus, recollecting also that the ulnar nerve lies in the hollow between the internal condyle and the olecranon, and which nerve in a healthy state of parts can be readily felt and rolled under the point of the thumb. The brachial artery and median

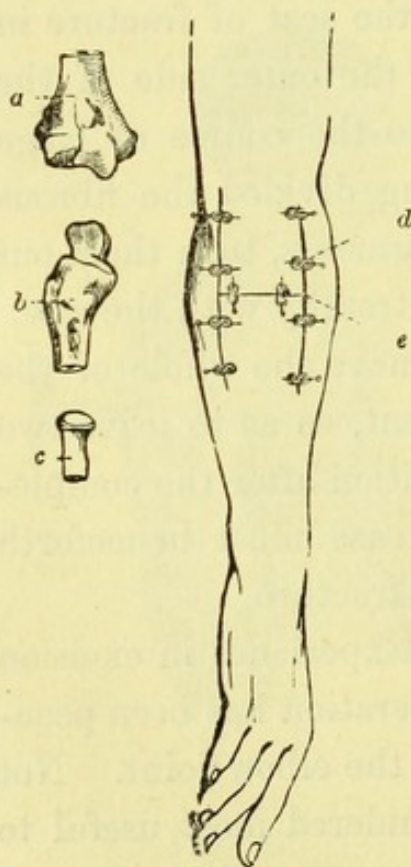


FIG. 56.

nerve are separated from the joint in front by the brachialis anticus muscle.

The extent of incision necessary to this operation will depend upon the state of the soft parts around. If the integument has been long subjected to inflammation it will be thickened, swelled, and tough, having lost its elasticity, and then free incisions will be necessary, such as the +, or H, fig. 56; two flaps are thus formed, the upper (*d*) being

reflected with the triceps muscle attached, the lower

when detached will expose the olecranon and radius. The transverse incision (*e*) corresponds to the point of the olecranon.

Another method.—Should the soft parts be little altered one longitudinal incision will suffice, as follows:—

To operate on either arm the surgeon should stand on the left hand side of his patient, who is recumbent. The arm of the patient should be flexed and carried across the front of the chest, the fore-arm being firmly held and supported by an assistant standing opposite to the operator, if the left elbow be the seat of disease, while the arm must be similarly held if the right elbow is to be removed. The ulnar nerve is to be felt for and pressed towards the internal condyle, and be there maintained and guarded from the knife during the reflexion of the integument and muscles on the inner side, by the point of the left thumb. A longitudinal incision is to be made along the middle of the posterior surface of the arm, to the extent of three fingers' breadth both above and below the point of the olecranon, dividing the soft parts down to the bone. Above the olecranon the triceps will be divided into two portions; each half is to be separated from the bone, likewise the integument and muscles from the internal and external condyles of the humerus and upper ends of the radius and ulna, the edge of the knife being always directed towards and cutting upon the bone. As soon as convenient the ulnar nerve should be

slipped over the internal condyle, and be there maintained. The olecranon will be exposed first, and should be removed either with a bone forceps or saw, thus exposing the interior of the joint, and allowing the operator to determine the amount of disease present and the extent of bone demanding removal. By forcibly flexing the arm and dividing ligamentous or muscular fibres still uncut, the extremities of the humerus, and of the radius and ulna united, may separately be made prominent, and be removed either with a common or chain saw. Usually no vessel requires to be ligatured, and the wound being closed the fore-arm should be bent at a right angle upon the arm with the hand prone, the whole limb being placed upon a well-padded rectangular splint. Should the case do well, "passive motion" should be employed, from three weeks to a month after the operation, to prevent bony ankylosis. *a, b, c* (see fig. 56), show respectively portions of humerus, ulna, and radius after removal. It is rarely necessary to remove so large a portion of either bone.

Dressing the Wound.—After injuries of or operations upon joints, and in cases in which the continuity of a bone has been destroyed, it will be well to disturb the limb as little as possible when the wound is cleansed and dressed. When the limb is *put up*, and it is necessary to invest its circumference with some dressing, such as strips of wet lint, which requires to be changed daily, this change may be effected without moving the limb, by pinning strips

of lint similar to those first used, each to one end of an original piece; then drawing gently upon the other end of the strip to be removed, the fresh piece will follow under the limb and replace the dirty portion.

Excision of the Radius, and of the Ulna.—The whole or portions of either of these bones may be excised with the necessary precautions, especially the lower end of the ulna, where it is comparatively superficial, and, although close to the wrist-joint, may be removed without opening this articulation. In removing portions of these bones, care must be had not to interfere unnecessarily with tendons, and to leave important vessels and nerves intact; and to do this the edge of the knife should be studiously kept close to the bone in progress of removal.

Operation.—To excise the lower portion of the ulna make an incision along its inner border of the requisite extent, beginning at the styloid process of the same. Detach carefully the extensor carpi ulnaris from behind, and the pronator quadratus and other muscular fibres in front, cutting close upon the bone to avoid injuring the ulnar vessels and nerve. Take now the “excision director,” and introduce the point on one side between the radius and ulna, thus traversing the inter-osseous membrane and bringing out the point on the other side of the ulna. Thus the bone is isolated; and the groove in the director having been turned uppermost, the saw may be applied without the risk of lacerating the soft parts.

Seize now the upper end of the portion of ulna to be removed with a pair of forceps, dragging upon the same, and dividing all remaining attachments short of the articular fibro-cartilage and external lateral ligament of the wrist-joint. By these means the fragment of bone will hang out of the wound, when the application of the bone forceps to the root of the styloid process will complete the separation without opening the wrist-joint. The triangular fibro-cartilage being attached to the base of the styloid process, the non-removal of the latter secures the integrity of the wrist-joint. The wound may be closed in the usual manner.

Excision of the Wrist-joint, &c.—This articulation may be removed with a view to saving the hand, by various incisions; as a *curved* incision with convexity downwards across the back of the wrist from one styloid process to the other, dividing tendons as well as integuments. The semi-lunar flap is dissected up; and the joint having been opened, the diseased portions of bone can be readily removed, but at the expense of the extensors of the fingers.

It is desirable to maintain the extensors of the thumb and fingers uncut; and with that view, the articulation may be removed by two *lateral* incisions, one along the inner border of the ulna, as already described, and a similar one along the border of the radius, to one or both of which perpendicular cuts a short transverse incision may, if deemed necessary, be added opposite to the joint, so as to form a small

flap; the required portions of the radius and ulna are to be removed, after the manner indicated in excision of the lower end of the ulna, due care being paid to preserve the extensors of the thumb and fingers, and also the parts in front of the joint, from injury. The extensors of the wrist need not be studiously preserved intact. The ends of the radius and ulna having been removed, the carpal bones may be made to protrude on either side through the wound, and can be readily disposed of. Should the case do well, the patient will have the use of his fingers and thumb at least.

Another method consists in making one incision only, and that along the inner side of the ulna and hand to the extent of two or three inches above, and the same below, the articulation. The soft parts in front and behind are to be carefully dissected off the bones; ligamentous fibres must be severed or torn through, when by forcible abduction the carpal bones may be made to protrude at the wound; these removed, the radius and ulna may be similarly treated. Should either the radial or ulnar arteries be accidentally or intentionally divided, both ends must be ligatured. The limb should be placed on a splint, with the hand prone, and after the lapse of some days, when the parts are beginning to solidify, passive motion should be attempted; the fingers, too, must be exercised from day to day.

Excision of the metacarpal bone of the Thumb.—This bone has been removed, leaving to the patient a

comparatively useful, although short member. The fleshy ball of the thumb forms a cushion, upon which the first phalanx rests, in such a manner as to offer a very fair amount of antagonism to the fingers.

Operation.— Make an incision along the outer border of the bone, beginning the third of an inch above the superior articulation, and terminating the same distance beyond the metacarpo-phalangeal articulation. At each extremity of this cut, two short transverse incisions may be made, running outwards, so as to allow of the formation of a flap, as in fig. 57. This flap containing the extensors primi

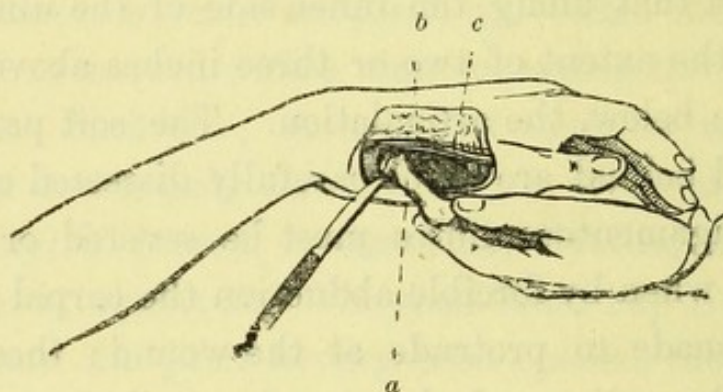


FIG. 57.

and secundi internodii (*b, c*), is to be dissected up, and the soft parts on the palmar surface are also to be carefully shaved off close to the bone, without injuring the tendon of the flexor longus pollicis muscle. An assistant holding aside the above-mentioned extensors, the surgeon opens the distal articulation on the dorsal surface, enters the joint, and divides all ligamentous attachments. This done,

the head of the bone (*a*) may be seized with the finger and thumb, and be made to protrude, while the knife divides the muscular attachments to the inner side, but with due attention to the proximity of the radial artery. Open now the distal articulation on the dorsal surface, dividing the insertion also of the extensor ossis metacarpi pollicis and other attachments, till the bone be freed. Close the wound in the usual manner. Should the radial artery or either of its terminal branches be wounded, both ends must be tied. Excision of either of the remaining four metacarpal bones is unnecessary, and perhaps unjustifiable by reason of their complicated carpal articulations; the probable injury which may be inflicted on the palm of the hand, and when accomplished, leaves the finger ill-supported, and perhaps even an obstacle to the general utility of the hand.

Excision of a phalangeal Articulation.—Such operation should be resorted to in cases in which the thumb or forefinger is the seat of disease or injury; these two members, and especially the thumb, being more valuable and useful to the patient, even in a mutilated condition, than any three fingers conjointly.

The operation is performed by making a longitudinal incision on the dorsal surface over the articulation, dissecting the soft parts laterally, opening the joint by severing the ligaments; and then causing the ends of the bones to protrude separately, they may be removed by the saw or bone forceps.

Passive motion may be attempted after some days, or ankylosis be encouraged at an obtuse angle.

Excision of the Hip-joint.—This operation should never be resorted to until rest, time, fresh air, and good diet have failed to arrest the disease. At length, when prophylactic measures have been proved to be of no avail, and the patient appears to be gradually growing worse, being worn out, either by excessive pain, or as it were dying of inanition consequent on profuse suppuration, the operation may be performed as a last resource.

The patient lying on the sound side, the position

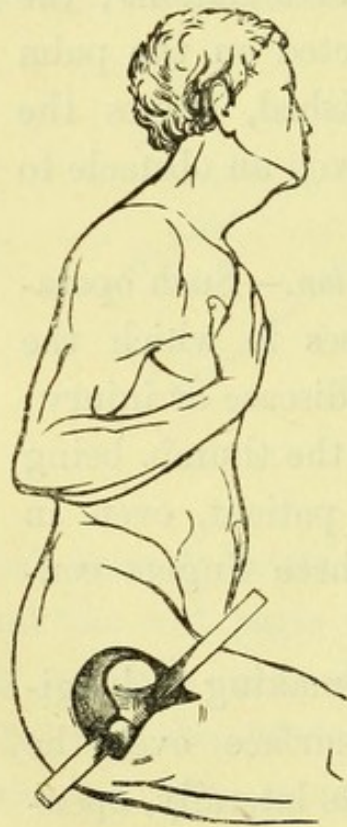


FIG. 58.

of the great trochanter should be ascertained, and the head of the bone may then be best exposed by making a semi-lunar incision (fig. 58) skirting three sides of the trochanter, the convexity being directed upwards. The flap thus marked out should be thrown down, and, cutting close to the bone, the muscular attachments to the great trochanter should be completely severed. The limb being rotated by an assistant, the position of the head of the bone may be ascertained

by the finger of the operator. The capsular ligament may be divided posteriorly and superiorly

close to the acetabulum ; and, this done, forcible adduction and rotation inwards will cause the head of the bone to protrude, and even rupture the round ligament if it be not already destroyed. The extent of disease being recognised, the chain or other saw may be adapted, and the portion of bone removed.

The extent of bone requiring removal cannot be previously determined upon. The articular surfaces having been carefully examined, as well as the adjacent bone, the judgment of the surgeon will decide upon the necessary ablation.

Whatever incision may be preferred, the position of the sciatic nerve behind, and of the anterior crural nerve and femoral artery in front of the articulation, must be borne in mind.

I have recently excised the head of the femur in a boy aged seven, in whom disease had existed during two years and a half. The buttock was riddled with sinuses ; and as the little patient was becoming gradually exhausted by the profuse discharge, I determined to give him a chance of life by having recourse to the knife. Messrs. Attwell, Cann, and Coleman kindly assisted me ; and finding on examination, when the patient was under the influence of chloroform, that the head of the bone was lying on the dorsum ilii, I made a simple incision from three to four inches in length over it and the great trochanter parallel to the long axis of the femur. This step allowed me to introduce the finger and sweep it round the head of the bone, which was

quite disconnected with the surrounding soft parts. Healthy muscular and ligamentous tissues were nowhere to be seen; and after dividing close to the healthy trochanter major a few fibrous bands which prevented easy protrusion of the diseased extremity, I caused the bone to appear through the wound by the aid of adduction and rotation inwards, and, protecting the soft parts by a spatula, removed the head, neck, and upper portion of the trochanter major with a saw and forceps. The acetabulum was in a state of caries, and several pieces of necrosed bone lying loose were removed by the finger. I also applied the curved bone forceps to the acetabulum, and removed portions of carious bone. The head and neck of the femur were in a state of caries.

Under the above circumstances, excision of the head of the femur is an easy operation compared with its performance on the dead but healthy subject in which muscles and ligaments offer a formidable obstacle to excision. In the above case not a table-spoonful of blood was lost, and no vessel required a ligature. In most cases the acetabulum will be likewise in a state of caries, and if so, as much as possible of the disease should be removed either by the curved bone forceps or the gouge.

The operation completed, the edges of the wound may be adapted as usual; and, during repair, gentle extension should be kept up in order to prevent retraction of the limb towards the dorsum ilii.

Excision in the continuity of the Femur.—Portions

of the femur have been cut down upon and removed, in cases of angular union after fracture and of ununited fracture. This is a formidable operation; but if resolved upon, the operator must select for his incision a point at which the bone is nearest the surface, and at a distance if possible from all important vessels and nerves. After the operation the case must be treated as one of compound fracture of the thigh.

In Paris, I have seen five inches of the middle of the shaft of the femur (the seat of a malignant tumour) of a lad removed. Such practice is frightfully hazardous, and quite unworthy to be ranked as an operation of conservative surgery.

Excision of the Knee-joint.—Excepting some cases of angular ankylosis, rendering the limb not only useless but an incumbrance to the proprietor, and for which excision of the parts corresponding to the original joint may be performed, after that the patient has been made aware of the risk; the same observations will apply to this as to the hip-joint, in reference to the selection of cases for operation, because time and experience are yet wanting to determine the value of this operation over that of amputation of the thigh. If determined upon, the articulation will be best exposed by one of two means, the choice of the form of incision being decided by the immediate intended removal or otherwise of the patella. The patient being recumbent, and the limb supported by two assistants, one taking charge of the

thigh and the other of the leg, the surgeon ascertains the position of the internal saphena vein by making pressure upon the inner side of the thigh, and so obstructing the flow of blood and causing the vein to swell.

The line of articulation between the tibia and femur is to be determined; and if the patella is to be removed, as in fig. 59 *a*, the joint may be opened by removing a portion of integument with the patella

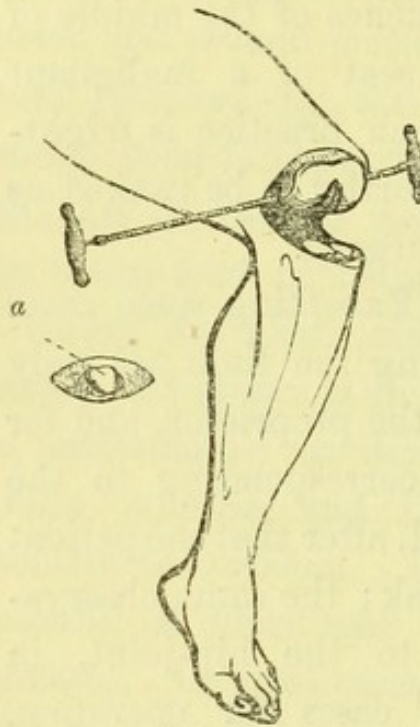


FIG. 59.

included by two semi-elliptical incisions, one passing above, the other below, this bone. Each incision is to be begun and terminated opposite to the articulation, and as far back as possible. The patella having been removed by dividing the quadriceps femoris above it and the ligamentum patellæ below it, the leg should be flexed by the assistant while the operator divides the in-

ternal and external lateral and the crucial ligaments, the latter with caution, remembering the position of the popliteal artery behind.

This done, the condyles of the femur will protrude (see fig. 59), and if necessary may be removed with the common saw after the knife has been carried round to divide the soft parts, and form a passage

for the former instrument. The required extent of tibia is to be isolated in a similar manner by the knife, and then removed by the saw. In performing excisions, the bow saw, with the teeth reversed, will be found of great service.

Another method.—In excising the knee-joint, I have found a semi-lunar incision convenient, and adopted such a short time since, when kindly assisted in the operation by Dr. J. M. Butler, of Woolwich, and Messrs. Adams, Tuck, and Woodman. The surgeon standing on the outside to operate upon the right limb, and on the inside to operate on the left knee, ascertains the point of attachment to the inner condyle of the femur of the tendon of the adductor magnus muscle, on the outside the point of attachment of a strong process of the fascia lata to the external condyle, also the attachment of the ligamentum patellæ to the tibia. These landmarks recognised, the semi-lunar incision is to be commenced over one condyle and carried down, and then across the limb, opposite to the lower end of the ligamentum patellæ, thence turning upwards, and terminated at the point delineated on the other condyle. This incision will inclose a well-rounded flap, base upwards, which may be readily turned up, so as to expose the patella and its connexions (fig. 60). This bone may be removed by a circular sweep round it, when the operation may be terminated as above directed. I have never found it necessary to tie any vessel. The operation completed, two or three

sutures may be used, and then the limb should be placed upon a long back splint, with foot-piece, two interrupted side splints, and to prevent rotation of

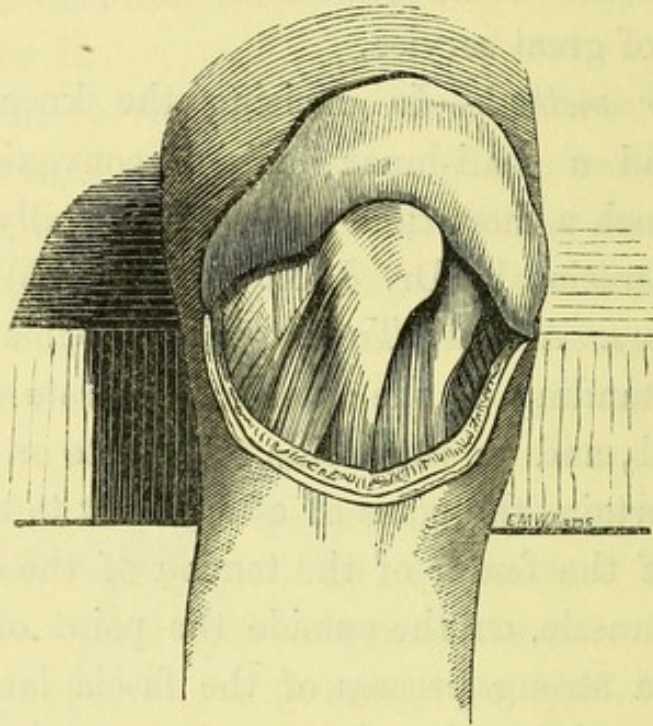


FIG. 60.

the thigh outwards a fourth splint may with advantage be adapted to the anterior surface of the thigh. These carefully adjusted, while the patient is under the influence of chloroform, will favour success. Bony ankylosis should be encouraged, the leg being flexed in the least possible degree upon the thigh.

Excision of the Fibula.—Portions of the fibula may be readily removed, in accordance with the plan laid down for operations of a similar kind on the upper extremity.

Excision of the Ankle-joint.—The bones forming

this articulation are so intimately connected with important organs that the joint cannot but be removed with difficulty.

In cases of compound dislocation, the original wound must be conveniently enlarged, if this operation be determined upon.

Should the case be otherwise than traumatic, the operator may expose the inferior extremities of the tibia and fibula consecutively, by a longitudinal incision over each bone; that over the tibia being joined at its lower extremity just below the internal malleolus by a short semi-lunar incision, corresponding with the margin and breadth of the malleolus.

The integuments should be carefully dissected off the bones to the required extent, when either the "excision director" (fig. 61) and common saw, or the chain saw may be employed, to sever the fibula.

Seizing now the upper end of the loosened fragment with a pair of forceps, the operator cautiously divides the inter-osseous and ligamentous attachments from above downwards, until the portion of bone is detached. The fragment of fibula having been removed, it becomes necessary to treat the tibia similarly. This bone is comparatively massive, and in such close relation with important organs that its section cannot be so readily effected. The articular surface of the astragalus should also be removed, either by the saw, forceps, or gouge. During the after-treatment the foot should be maintained at a right angle to the leg. Except in the case of

children, this operation is not preferable to that of amputation at the tibio-tarsal articulation.

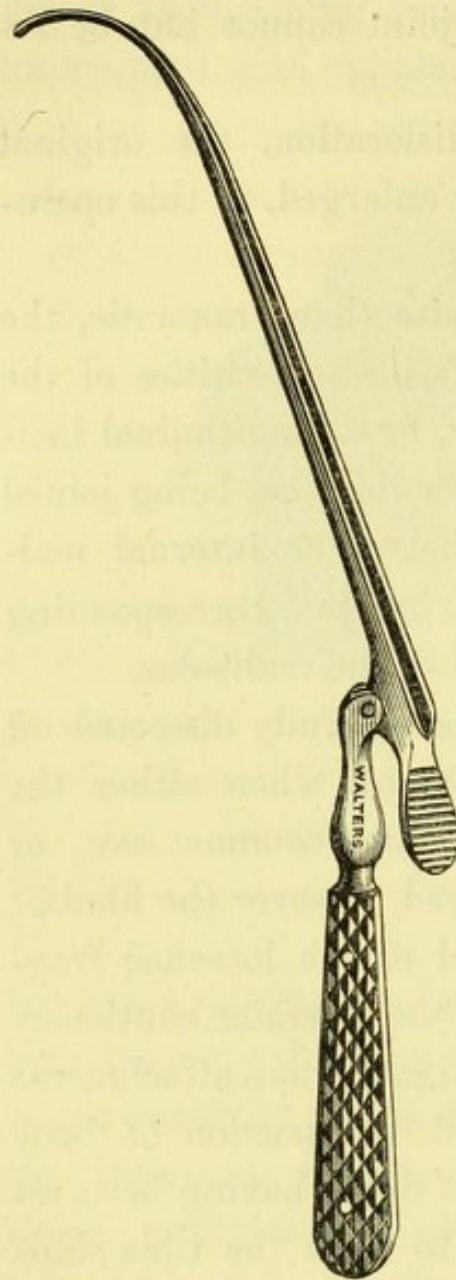


FIG. 61.

Excision of the metatarso-phalangeal Articulation.—

Excepting the joint of the great toe, no other metatarso-phalangeal articulation need be submitted to an operative proceeding short of amputation. The metatarso-phalangeal articulation may be best exposed by a free longitudinal incision along its inner side: this may be converted into an \times or \sphericalangle incision by a short cut opposite to the joint. The joint having been opened, the proximal end of the phalanx should be first protruded and be cut off with the bone forceps; this done, the head of the

metatarsal bone may be treated in a similar manner. I have seen a patient walk perfectly well after this operation has been performed.

A narrow-bladed knife should be used in operations about the joints of the toes and fingers.

Bifid Fingers and Toes.—This deformity may

be remedied by amputation of the supplementary member. Examine carefully the comparative merits of the two members, and remove the one which appears to be the less useful and most unlike the natural organ. One synovial membrane usually lines both bones as well as that upon which they rest. The supplementary member should therefore be removed in its continuity by dividing the bone obliquely with saw or cutting forceps, leaving as small a portion of bone as possible, short of opening the joint.

Excision of Tarsal Bones.—The astragalus is sometimes dislocated, and, unless immediately removed, gives rise to violent inflammation, which in many cases has proved fatal without even giving the patient a chance of life by amputation. The prominent displaced bone should be cut down upon and removed, with due regard to adjacent tendons, vessels, and nerves.

The foot after the operation should be kept at a right angle to the leg.

Ununited Fracture.—Excision of the ends of the fragments has been already referred to. As a less severe and often successful measure, fastening the ends of the bones together by means of ivory pegs driven into them may be adopted. The relation of one fragment to the other having been made out by careful manipulation, the surgeon punctures the integuments down to the bone at the point at which a peg is to be introduced, and bores a hole with a drill in the requisite direction, so as to include both fragments.

The drill removed, an ivory peg of the required length and thickness, say one and a half inches in length and the sixth of an inch in diameter at the largest extremity, may be driven in so as to unite the fragments, with a wooden mallet. In the case of the tibia two pegs will suffice, a small portion of each being allowed to project at the wound, in order that it may be seized with a forceps and removed at pleasure. Should the case do well, the pegs may be left in for a month, with the leg perfectly at rest. At the expiration of this time, the pegs having been removed, the limb should be carefully put up in a starched bandage, and so be kept for another month or six weeks.

Compound Fracture.—In certain cases of compound fracture, one fragment protrudes and cannot be readily replaced. To favour reduction, besides a position favourable to muscular relaxation followed by extension, either tenotomy may be useful, such as division of the tendo-achillis; or free incision of the soft parts parallel to the long axis of the protruded bone, apparently offering mechanical obstruction to reduction; or removal by the saw of the end of the projecting fragment; or, as in compound dislocation, removal of the protruded head of the bone.

Compound comminuted Fracture.—Small detached fragments of bone should be removed at once, if they can be reached without adding to the magnitude of the existing injury. The wound should be thoroughly cleansed of all foreign bodies also.

Exostoses.—Outgrowths of bone, if in any way troublesome, and not too near a joint, may be removed by cutting down upon them, due regard being paid to adjacent tendons, vessels, and nerves, and be removed by the saw, forceps, or gouge.

Abscess in Bone.—A crucial, or other convenient form of incision, should be made over the expected seat of matter and the flaps dissected up, when the trephine may be applied to open the cavity. Pus will be recognised by its oozing by the side of the trephine, or the cavity will be known to be opened by a diminution in the resistance offered to the working of the trephine.

Necrosis and Caries.—Certain operations are often resorted to, both to check the progress of caries and to assist nature in the ejection of dead bone.

Necrosis and Exfoliating Bone are usually seated within and upon the shaft of bones, while the seat of caries is generally the cancellous extremities of long bones and the small irregular bones. During the progress of a case of necrosis, in which more or less of the shaft of a bone dies, while, at the same time, new bone is developed around to maintain the natural conformation of the limb and give attachment to muscles, nature, by progressive absorption, establishes at different points fistulous openings or cloacæ, which communicate through the shell of new bone with the external world, and the sequestrum of bone within.

In process of time nature in some few cases

effects a cure, by ejecting the dead bone through one of these cloacæ; but this is an exception to the rule, and since dead bone is not absorbed, and therefore can never become smaller with a view to its expulsion, and since also it lies probably at a right angle to these cloacæ, and a mechanical impediment is also offered to its ejection by the surrounding shell of new bone, art may with advantage be called in to assist nature. To detect dead bone a probe is usually introduced through the fistulous opening, and the sensation communicated need only be felt once to be never forgotten. By fixing the probe firmly upon the dead bone, and moving it laterally, the sequestrum may be felt to yield, and, if so, the sooner it be removed the better. To do this, it may be necessary only to introduce a pair of forceps through the fistula, seize the sequestrum and withdraw it; or it may be needful to enlarge the fistula by incising the integuments, and to remove a portion of new bone with cutting forceps, trephine, or gouge, in order to admit the entrance of the forceps. Again, a sequestrum may be so large and long as to require division before it can be removed: this step will require a more extensive division of integuments, say the interval of two cloacæ, then the application of the trephine to remove a portion of the new shell, and admit the cutting forceps to divide the sequestrum; this done, each half of the dead bone can perhaps be removed with the forceps.

Death of the unguis phalanx is a frequent conse-

quence of acute inflammation. It is usually detached from one to two months after the commencement of the disease, and should be removed either through an existing opening, or by incision, leaving the nail and extremity of the finger to the use of the patient, as an organ of touch.

Exfoliation.—When a portion of bone has been deprived of its periosteum, it frequently dies, and is either thrown off by nature, or may be removed when loose by the surgeon.

This is a comparatively simple operation, being done by introducing a pair of forceps through the existing wound, seizing the dead portion of bone, and removing it with the same. Should the exfoliation be partially overlapped by the surrounding soft parts, suitable incisions will facilitate extraction. In cases of loss of pericranium, the surgeon should not too hastily condemn bone because it has lost its investing membrane: granulations will often spring up where they are little expected.

Caries.—This inveterate disease may sometimes be checked by gouging away the surface of bone on which it is seated, but more certainly, when practicable, by excising the whole of the affected bone; as for instance the os calcis. The surgeon must make choice of his incision according to the extent and position of the disease, due attention being paid to the locality of important tendons, vessels, and nerves, especially those on the inner side of the foot.

Strong nitric acid or the actual cautery may be employed to destroy caries.

Excision of joints for caries has been referred to.

The Trepphine (fig. 62).—This instrument is essen-

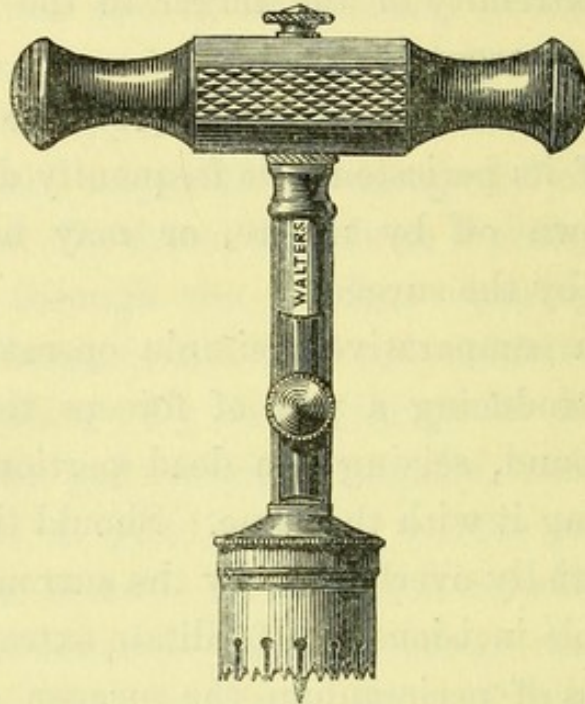


FIG. 62.

tially a circular saw, with a pin in the centre to fix it on the required spot. It is used to open bony cavities, especially that of the head, in cases of fracture, or to favour the discharge of certain injurious contents, as pus and extravasated blood. In either case a + or otherwise convenient incision is made, or an existing wound may be enlarged, so as to allow of the application of the instrument to the bone. Having been fixed with the central pin, the knife should be carried round to divide the pericranium cleanly, and prevent laceration of the same. The instrument is worked by alternating supination and

pronation, the pressure being lessened as the section is nearly completed, lest the contents of the head be injured. The progress of the operation must be tested at intervals by the removal of the trephine, and the introduction of a probe or toothpick to ascertain the depth of the incision; also, as soon as a groove has been made for the trephine to work in, the pin should be elevated lest it perforate the skull. It will be known when the diploe is reached, either by an oozing of blood or by diminution of resistance offered. The section completed, an elevator may be used to remove the loosened fragment. In the instance of fracture, whether simple or compound, with depressed bone, a segment only of the sound adjacent skull should be removed, sufficiently large to admit of the introduction of an elevator. In some cases a Hey's saw (fig. 63) may be substituted for the




FIG. 63.

trephine. In all cases as small a portion as possible of the skull should be removed, because the loss is rarely thoroughly made good by development of new bone.

Anchylosis may be partial or complete. *Partial*, as a result of the maintenance of a limb in one

position for a length of time, thus allowing the muscles to become wasted, inactive, contracted, and unable to accommodate themselves to any other position; or the bones forming an articulation, may be united by the intervention of fibrous tissue. This variety must be treated by forcible movement of the limb, and in many cases by forcible extension of the joint after division of tendons, the extension being kept up and increased by suitable apparatus.

Complete, as in cases of union of bones originally forming a joint, by bone. In some instances of this kind, it may be justifiable to break down by force the bony adhesions, with a view to restore the utility of a distorted member.

The comparative facility with which excision of joints is performed on the living and dead subject varies. In the case of long-standing disease in the living, the relative anatomy of the part is altered, the soft parts are agglutinated, have lost their elasticity, and become unyielding and adherent to adjacent structures, rendering their separation from the bones, and exposure of the diseased extremities, difficult. The bone, too, which is the seat of disease, becomes softened, and cannot, without the risk of fracturing the diseased portion, be used as a lever to assist the surgeon in exposing its extremity.

On the other hand, inflammation and non-use have so altered the character of the tissues in which the former is seated, that adjacent muscles are wasted, while ligamentous structures are either so softened

or destroyed as to offer very little impediment to the performance of the operation. In the dead subject, however, while the surgeon can employ the sound bone as a lever to assist in disarticulation, and can readily dissect the soft parts from off the bones, still the healthy ligaments offer a great obstacle to the performance of the operation. On the whole, however, I should say that excision of a joint may be performed more readily when the structures are healthy than when the seat of disease.

Fig. 64 shows the *bow* saw, the blade of which can be reversed at pleasure.

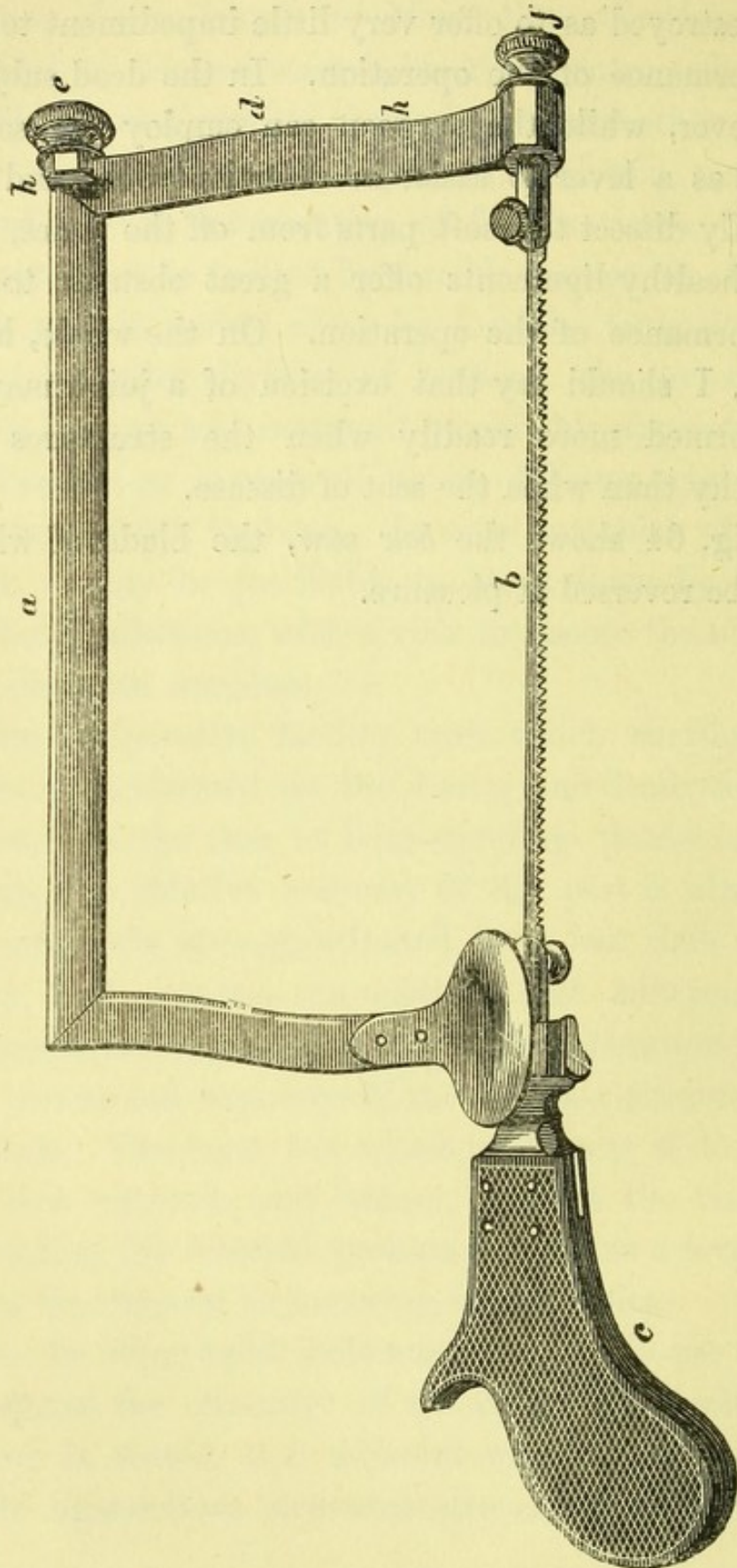


FIG. 64.

CHAPTER VII.

OPERATIONS ON THE SURFACE OF THE BODY.

Abscess, acute and chronic.—To evacuate an acute abscess, seek the spot at which the integuments are comparatively thin, and apparently about to give way by progressive absorption. This position may often be recognised by the finger detecting a softer and circumscribed spot, at which perhaps the cuticle is about to fall off. Select also the most depending point, so as to favour the discharge of pus; and incise the part parallel to the natural folds of skin that the cicatrix may not be readily seen afterwards. Also, in important regions open the abscess, holding the knife parallel to large vessels and nerves; and if the pus be deep, first divide the integument with a knife, and then through the wound thus made plunge a pair of dressing forceps into the sac of the abscess, separating the blades as soon as entered, in order to favour the discharge by enlarging the opening. In the neck, especially of a female, abscess should be opened as soon as possible, and with a small knife, to avoid an ugly scar. In the breast

abscess should be opened as soon as fluctuation can be detected, lest the pus burrow in different directions through the organ.

Chronic Abscess.—If it be decided to open a chronic abscess, it may be thought advisable to do so with a view to favour gradual contraction of the sac and prevent at the same time the entrance of air. To do this either a trocar and canula may be used, or a knife. To avoid entrance of air the skin should be punctured, either by making use of the natural elasticity of the same, by drawing it on one side of the intended point of puncture and at the same time plunging the instrument through the integument and sac of the abscess, which latter being evacuated to the required extent the skin may be allowed to return to its natural position, when the wound in the latter and in the sac of the abscess will no longer correspond; or, by passing the knife obliquely under the skin for some little distance, and then entering the sac of the abscess, by this means a valvular opening is made. In both instances a compress of lint and bandage, with more or less pressure, should be employed to favour contraction of the sac of the abscess. When opening large abscesses, the pus is shot out to a great distance sometimes, thus soiling the bed, the operator and his assistants. To avoid this accident, a temporary shield of paper or of gutta percha sheeting, three or four inches square, may be readily adjusted to the knife at the junction of its handle and blade. Should abscess be situated beneath

fasciæ, and the opening made to be permanent, a strip of oiled lint must be introduced and kept between the edges of the external wound for twenty-four hours, lest union take place before it is desirable.

Acupuncture.—This operation, as its name expresses, consists in the introduction of a sharp and long needle into the soft parts. It should be made to penetrate by a twisting motion.

Caustics, fluid and solid.—Fluid, such as the mineral acids, are best applied with a glass rod or glass brush. If to the skin, the surrounding part should be previously protected by the application of a piece or pieces of adhesive plaster, a hole of the requisite dimensions having been cut out of the centre. If to a wound, the surface having been previously dried, the margins of the same will perhaps determine the extent of the application. The pain attending the application of nitric acid to a sore, a chancre for example, may be almost immediately relieved by rubbing the surface (previously dried) over with nitrate of silver as soon as the acid has been applied.

Solid, in powder or stick.—If the skin be entire, the required extent of surface may be destroyed by isolating it as above described, and then by applying and leaving a certain portion of the caustic in contact with the same till the tissue is destroyed and the slough thrown off by ulceration, when continued applications may be made to destroy the deeper structures, as in treating malignant disease of the breast by caustic.

The actual cautery.—The red-hot iron applied to the surface is a powerful counter-irritant, and is attended in its use by comparatively little suffering. The shape of the portion of iron employed must depend upon the conformation of the part and the extent of surface to which it is to be applied. Its application is effected more rapidly than that of the “moxa,” is equally efficacious, and may replace it with advantage.

Exploration.—When tumours of a doubtful nature are presented to the surgeon, exploration of the same to clear up the doubt and determine their nature is often resorted to. Instruments used are either a trocar and canula, or grooved needle. The grooved needle is preferable, and should consist of a cylinder, *one quarter only* of the circumference of which has been cut away. Should the needle be *semicircular*, as very many in use are, the groove when the instrument enters the soft parts becomes occupied by a portion of integument which prevents the exit of contained fluid. Thick fluids will not readily flow through a small canula. Under such circumstances, a bristle or probe may be passed along the canula to encourage their egress. The exploration effected, the wound may be closed by a compress of lint and strapping.

Issue.—An issue is made either by incising the skin and introducing a foreign body, such as a pea, or rubbing in a caustic to keep up irritation, or by the application of some caustic to the surface.

Seton is made by introducing and maintaining a foreign body, such as a skein of thread, under a portion of integument. Its introduction is effected (fig. 65), by raising a fold of integument and carry-

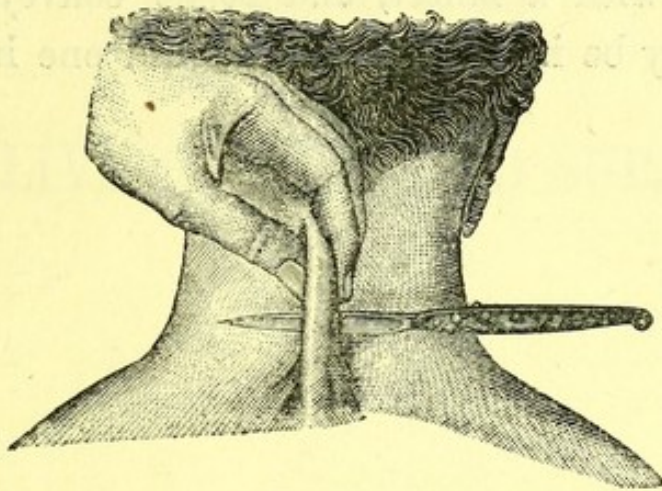


FIG. 65.

ing a knife, or better, a double-edged seton needle (fig. 66), armed with the thread, through the base




FIG. 66.

of it: the needle withdrawn, one end of the thread will project on either side of the wound, when to prevent accidental removal they may be tied loosely together.

The threads may be smeared with any irritant, if necessary, and, thus armed, be drawn through the wound at pleasure.

Vaccination is best practised with a fine grooved needle. Some of the contents of a well-developed vesicle, say on the eighth day, should be received

upon the needle, the point of which is to be introduced thus armed, at usually three points, under the cuticle. Or, while the skin is made tense with the finger and thumb of the left hand, scratches may be made with a lancet, and *points* conveying the lymph may be introduced and rubbed one into each scratch.

END OF PART I.

OPERATIVE SURGERY,

ADAPTED TO THE

LIVING AND DEAD SUBJECT.

BY

C. F. MAUNDER, F.R.C.S. BY EXAM.

ASSISTANT SURGEON, SURGICAL PATHOLOGIST, DEMONSTRATOR OF OPERATIVE SURGERY, LONDON HOSPITAL; TRANSLATOR AND EDITOR OF RICORD'S LECTURES ON THE DUALITY OF CHANCRE, BUT THE UNITY OF THE SYPHILITIC POISON; FELLOW OF THE MEDICAL AND PATHOLOGICAL SOCIETIES OF LONDON, FORMERLY DEMONSTRATOR OF ANATOMY AND OF OPERATIVE SURGERY IN PARIS, CIVIL ASSISTANT SURGEON ON THE STAFF OF THE ARMY IN THE EAST DURING THE CRIMEAN WAR, DEMONSTRATOR OF ANATOMY IN GUY'S HOSPITAL, AND JUNIOR SURGEON TO THE GREAT NORTHERN HOSPITAL.

LONDON :
JOHN CHURCHILL, NEW BURLINGTON STREET.

MDCCCLXI.

OPERATIVE SURGERY

LIVING AND DEAD SUBJECTS

G. F. MAUNDER, F.R.C.S.

THE PRINCIPLES AND PRACTICE OF OPERATIVE SURGERY, AS APPLIED TO THE LIVING AND DEAD SUBJECTS. BY G. F. MAUNDER, F.R.C.S. LONDON: REED AND PARDON, PRINTERS, PATERNOSTER ROW.

LONDON :
REED AND PARDON, PRINTERS,
PATERNOSTER ROW.

JOHN CHURCHILL, NEW BURLINGTON MARKET.

1881.

CONTENTS.

PART II.

CHAPTER I.

	PAGE
Amputation—By flap—Saw—After-treatment of Stump	1—8
Varieties and Modifications	10
Amputation by circular incision—Another method of ...	11--15
Comparative merits of amputation by flap and by circular incision	16
Amputation by oval incision	17
Amputation in the contiguity of a limb	17

CHAPTER II.

SPECIAL AMPUTATIONS.

LOWER EXTREMITY.

The Foot—The Toes—Amputation of Great Toe—By oval incision—By flap—Toes <i>en masse</i> —Metatarsal Bone—Metatarsal Bone of Great Toe—Fifth Metatarsal Bone—Metatarsal Bones <i>en masse</i> —Tarsometatarsal—Medio-tarsal—Another method of—Modification of medio-tarsal—Tibio-tarsal (Syme)—Tibio-tarsal (Pyrogoff)—Tibio-tarsal (Jules Roux)—Comparative value of the above transverse amputations of Foot	19—44
Amputation of the Leg—Lower third by flap—Teale's method—Upper third by flap	47—53

	PAGE
Amputation of the Thigh—Lower third—By circular incision—By flap—Middle and upper thirds—Hip-joint by anterior flap—By oval incision	56—66

CHAPTER III.

UPPER EXTREMITY.

The Fingers—Anatomy of—Amputation at joint of second and third phalanges by palmar flap—Of first and second phalanges by palmar flap—In continuity of a phalange by palmar flap—Either in the continuity or contiguity of a phalange by double flap—By Teale's method—At metacarpo-phalangeal articulation by lateral flap—By oval incision—Of whole or part of metacarpal bone—Of fifth metacarpal bone—By oval incision—By lateral flap—Of first metacarpal bone by oval incision—At wrist-joint by circular incision—By double flap	68—77
The Forearm—Amputation at elbow-joint	78—81
The Arm—Amputation at shoulder-joint—By external flap—By anterior and posterior flaps—By oval incision	82—87

CHAPTER IV.

SPECIAL OPERATIONS.

Tracheotomy—Laryngotomy—Paracentesis thoracis—Œsophagotomy—Gastrotomy—Paracentesis abdominis—The trocar	90—98
Abdominal hernia—The taxis—Herniotomy—Division of the stricture—Line of incision—Radical cure of (see Wood's method in Medico-Chirurgical Transactions, Vol. XLIII.)—The truss	99—108
Lumbar artificial anus—By transverse incision—By longitudinal incision	110
Ovariotomy	112
Removal of tumours—Removal of integument—Of mammary gland	115—117

CONTENTS.

V

	PAGE
Hare-lip—Single—Double—Complications—Cleft palate —Staphyloraphy—Abscision of tonsil—Plugging of posterior nostril—Catheterism of nasal duct—Of Eustachian tube—Removal of tongue by ligature— By excision—By <i>écraseur</i> 118—131	118—131
The Eye—Extirpation of globe—Strabismus—Artificial pupil by iridectomy—By iriddesis—Staphyloma, removed by abscision—Cataract—Extraction of lens —Schuft's method—Couching—Blepharoplasty ... 133—140	133—140
Rhinoplasty 141	141
Genito-urinary organs—Phymosis, by circumcision— Another method—By simple incision—Amputation of penis—Hydrocele—Tapping—To inject the sac of —Varicocele—By <i>écraseur</i> —By ligature—By sub- cutaneous section—Castration—The catheter— Stricture—By escharotic—By internal division—By external section (Syme)—By another method—By another method (Cock)—Puncture of bladder— Above pubis—Per rectum—Lithotomy—By lateral incision—The staff—The scalpel—The gorget—By median incision—Lithotrity—Catheterism in the female—Calculus in the female bladder—Tenotomy 142—171	142—171

The first of these is the fact that the
 population of the country has increased
 rapidly since the year 1850. This is
 due to a number of causes, the most
 important of which are the following:
 1. The discovery of gold in California
 in 1848, which attracted a large
 number of people to the country.
 2. The discovery of gold in Nevada
 in 1859, which also attracted a
 large number of people to the
 country.
 3. The discovery of gold in Colorado
 in 1859, which also attracted a
 large number of people to the
 country.
 4. The discovery of gold in Arizona
 in 1863, which also attracted a
 large number of people to the
 country.
 5. The discovery of gold in Idaho
 in 1860, which also attracted a
 large number of people to the
 country.
 6. The discovery of gold in Montana
 in 1862, which also attracted a
 large number of people to the
 country.
 7. The discovery of gold in Wyoming
 in 1869, which also attracted a
 large number of people to the
 country.
 8. The discovery of gold in Utah
 in 1864, which also attracted a
 large number of people to the
 country.
 9. The discovery of gold in New Mexico
 in 1861, which also attracted a
 large number of people to the
 country.
 10. The discovery of gold in Texas
 in 1858, which also attracted a
 large number of people to the
 country.

LIST OF WOODCUTS.

FIGURE	PAGE
1. Flap amputation	5
2. Flap amputation completed .. .	7
3. Removal of superfluous bone	9
4. Flap cut from skin to bone	10
5. Circular amputation	14
6. Circular amputation	15
7. Showing interior of circular stump ..	15
8. Amputation of toe	23
9. Shows cicatrix resulting	24
10. } Amputation of toes <i>en masse</i>	25
11. }	
12. Amputation of metatarsal bone	26
13. Amputation of metatarsal bone of great toe ..	28
14. Shows wound and parts interested	29
15. Shows linear cicatrix resulting in	29
16. } Amputation of little toe	30
17. }	
18. } Tarso-metatarsal amputation	31
19. }	35
20. Medio-tarsal amputation	37
21. } Another method	37
22. }	38
23. Tibio-tarsal amputation	41
24. Shows appearance of stump	42
25. } Pirogoff's method	43
26. }	
27. Jules Roux's method	43
28. Refers to postero-anterior arch of foot	45
29. } Teale's amputation	50
30. }	53
31. }	
32. }	
33. Amputation by <i>long external flap</i>	55
34. Amputation by <i>long anterior flap</i>	59
35. } Teale's method	60
36. }	63
37. }	
38. }	
39. Amputation at hip-joint	65
40. Hip-joint by oval incision	67
41. Amputation of finger	71
42. } By oval incision	72
43. }	73
44. }	

FIGURE	PAGE
45. Amputation of metacarpal bone	74
46. First metacarpal bone	75
47. Amputation at wrist-joint	78
48. Forearm, by Teale's method	80
49. The arm, by Teale's mode	83
50.)	
51. } Shoulder-joint	{ 86
52. }	{ 89
53. Hernia knife	103
54.)	
55. } Radical cure of hernia	{ 107
56. }	{ 109
57.)	
58. Lumbar artificial anus	112
59. Amputation of mamma	117
60. Posterior view of palate	121
61. Instruments for staphyloraphy	122
62.)	
63. } Staphyloraphy	{ 123
64. }	{ 124
65. Porte-aiguille	125
66. Plugging posterior nostril and catheterism of Eustachian tube ..	126
67. Removal of tongue	131
68.)	
69. } Écraseur	{ 133
70. Muscles of eye	134
71.)	
72. } Operations for cataract	{ 137
73. }	{ 139
74.)	
75.)	
76.)	
77. } Blepharoplasty	{ 140
78. }	{ 141
79.)	
80. Rhinoplasty	141
81.)	
82. } Circumcision	{ 142
83. Varicocele	147
84. Catheterism	149
85. Urethrotome	155
86. Trocar and canula	158
87. Side view of male pelvis	163
88. Relations of prostate	163
89. Median lithotomy	166
90. Position of lateral and median incisions	168
91. Lithotrite	168
92. Side view of female pelvis	171
93. Talipes equinus	172

OPERATIVE SURGERY.

PART II.

CHAPTER I.

AMPUTATION.

AMPUTATION is the term applied to the operation by which the whole or portion of a member is removed from the body, and has for its object the separation of that whole or portion of member which is deemed to be either congenitally, idiopathically, or traumatically useless or even injurious to its owner ; in order either, as a necessity to prolong life by substituting a lesser injury for a greater, and so to tax the reparative powers of nature as little as possible, or, as a means of affording relief and comfort.

The laws which are to guide the surgeon in his selection of cases for amputation cannot be precisely defined on paper. His decision must be formed by

a reference to *experience*; by a careful examination of the general condition of the patient as well as of the local abnormality; his age, habits, occupation, social position, and the probable consequences, whether amputation be or be not performed, must have their due share in determining his line of action. In the case of congenital or other malformation, time when for amputation may perhaps be arranged at leisure; in the instance of disease, its ravages, both general and local, will guide the surgeon; and in the case of injury, amputation cannot be performed too early, provided that the patient be not in a state of collapse. Should there be in the mind of the surgeon a doubt as to the necessity for immediate amputation, let him give the patient the benefit of that doubt, and delay the operation.

Amputation having been determined upon, the surgeon must not forget one important rule, *to remove as small a portion of the body as possible*, with a view to mutilate the patient as little as need be, and also to occasion the least degree of shock to the system. This rule may, however, be occasionally deviated from, and some exceptions will be mentioned hereafter. Bearing in mind the above rule and its exceptions, one of two points at which the member may be separated from the body should be chosen by the operator, and these are termed respectively *point of necessity* and *point of election*, meaning that the operator would prefer the point of election to the point of necessity, if he were convinced that the after

comfort gained to the patient, should he survive the operation at the point of election, would be more than equivalent to the risk incurred. Again, the social position, occupation, and prospects in life of the patient must be taken into consideration, because the man who has to earn his daily bread by physical exertion must be provided with a stump as serviceable as possible, while his more fortunate and wealthy co-sufferer, who is in a position to obtain a costly mechanical substitute, is perhaps content with a shapely rather than useful limb.

Amputation is effected by various methods, as by *flap*; by *circular incision*; by *oval incision*: these again are modified according to the fancy of the operator.

Amputation, to be conveniently performed, requires the aid of certain assistants and the use of certain instruments, and, to avoid repetition, I will detail an amputation, *according to rule*, at the middle of the thigh, by—

Double-flap.—The patient being recumbent, and at a height which shall allow the surgeon to perform his manipulations with ease, one or two assistants should take charge of the head and trunk of the subject; a third should be responsible for the main artery of the limb; a fourth must be in readiness to support the thigh above the intended point of section and also the flaps when cut; a fifth sustains the distal portion of the limb, and is prepared to ligature the vessels, &c. &c. Instruments and appliances may either be placed near to the surgeon or may be handed

to him as required. They consist in an appropriate tourniquet, knife, saw, scalpel, bone forceps, artery forceps, tenaculum, acupuncture needles (Part I., page 38, domestic needles are preferred), ligatures, sutures, strapping and scissors, lint, bandages, sponges, and brandy. The assistants being in position, the operator recognises the course of the main artery by its pulsation, and applies the tourniquet in readiness to compress the vessel against some portion of bone, the upper part of the shaft of the femur for example, the satisfactory application of which may be tested by ascertaining that there is no pulsation in the arteries below the point of compression. This done, assistants draw the patient towards the edge of the table and fix the sound limb with a bandage to a leg of the latter that it may not in any way interfere with the operation. The limb to be removed must be held horizontally. The operator, armed with a sharp-pointed knife the blade of which should be from two to three inches longer than the diameter of the limb at the intended point of section, stands according to his fancy either, on the outside or, on the inside, say outside in this instance, and grasping with his left hand the soft parts in front of the bone, raises them so as to have as much integument as possible in the anterior flap, and at the same moment enters the point of his knife on the outside and middle of the limb, and carries it across the thigh in front of the bone (slightly depressing the handle so as not to break the point) to a corresponding spot on the inside,

at which the point makes its exit. If now the operator can, by cutting towards the knee, and at the same time from heel to point of the knife, withdraw it and form a flap, the anterior flap is made, as in fig. 1, where it is turned back; the posterior flap

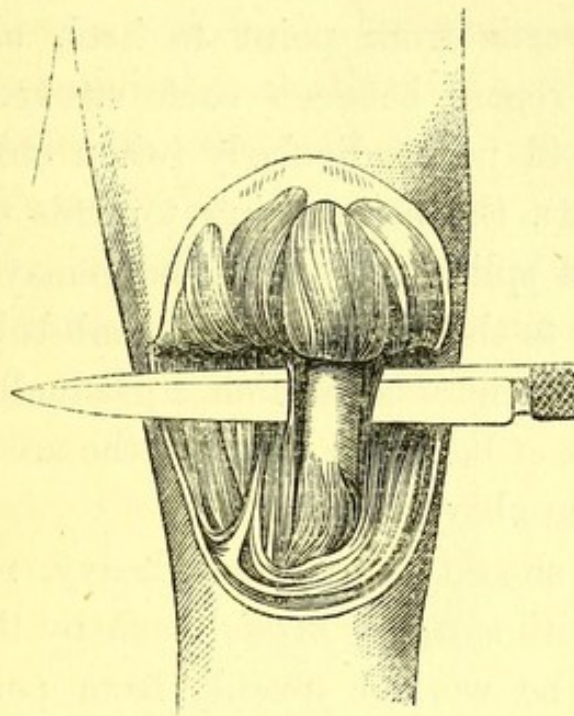


FIG. 1.

is made in a similar manner, the knife being passed behind, but not quite close to the bone, lest the main vessels likewise be pierced. If he cannot perform the above manœuvre, the flaps must be cut by a to-and-fro movement, as in using a saw. One or two sweeps of the knife around the bone close to the bases of the flaps, held aside by an assistant, sever the remaining attachments and the periosteum, and prepare the way for the

Saw.—To use this instrument, place first the heel

of it upon the bone, and draw it with firm pressure across the latter, from *heel to point*, so as to form a groove in which it is to be worked to and fro, but now from *point to heel*, and with moderate pressure, only when carried forward, from the hand of the surgeon. An English hand-saw cuts only when carried forwards from point to heel, allowing an interval of repose between each stroke. The saw should be held perpendicularly (when only one bone is interested), the point being towards the ground, in order that splintering of the bone may be avoided by opposing to the weight of the limb below the saw up to the moment of separation, a gradually diminishing segment of bone, the chord of the arc of which is directed from above downwards.

The saw should be tolerably heavy, requiring to be guided with *moderate pressure only* by the operator, and should be worked steadily from point to heel, rather than by short and irregular strokes. The ready application of the saw by a surgeon performing amputation, depends greatly upon the aid given by the assistants who hold the limb. The bone to be severed should be held horizontally lest it be cut obliquely, and firmly and steadily at two points, one above, the other below, the point of section. Thus, if it be the thigh bone, it will not be sufficient for the assistant to hold the leg below the knee, the condyles of the femur must be grasped by him, and be neither depressed nor elevated during the working of the saw. If there be two bones, both must be held

firmly and separately; otherwise, should both be grasped by one hand, they will probably become approximated, and interfere with the action of the saw, if, as is usual, one be divided before the other.

When two bones are to be severed—as tibia and fibula, or radius and ulna, for example—the saw should be first applied to the thickest and most firmly fixed; therefore to tibia and ulna respectively, including and completing the section of the fibula and of the radius, and terminating with the tibia and ulna. The section completed, as in fig. 2, showing

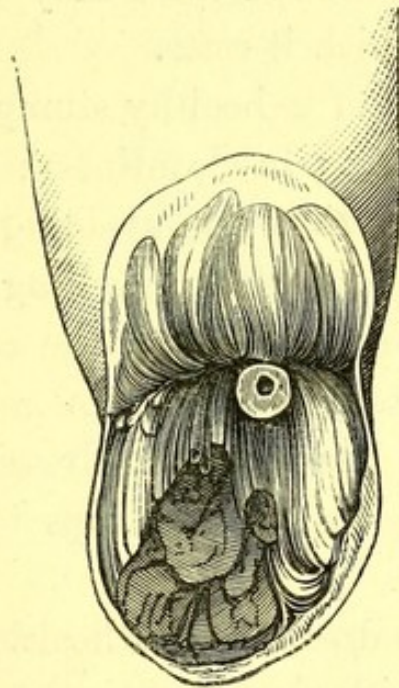


FIG. 2.

the two flaps, end of bone, and the main artery and vein, the assistant raises the stump to a convenient height, and supports the flaps while the vessels are being ligatured. (Part I. p. 34.) This step effected,

the surface of the flaps should be freed from coagula with a soft sponge (Part I. p. 37), be brought into apposition and their edges be adjusted, and be so maintained by suture (Part I. p. 13), by strips of adhesive plaster passed between the sutures, by a thick pad of lint placed upon the cutaneous surface of either flap, and by a bandage lightly applied from above downwards (Part I. p. 2), leaving the face of the stump exposed so as not to prevent the escape of secretions, or only protected by a piece of lint placed lightly upon it. The patient being returned to bed, the stump should be raised to a convenient height on a pillow, and if jactitation arise may be bandaged to the cushion on which it rests.

After-treatment of a healthy stump consists in the maintenance of rest; in cleanliness; in allowing free escape to all secretions; in avoiding constriction or tension at any point where swelling consequent on reaction comes on by removing the cause, whether it be bandage, plaster, or suture; in good support with the palms of the hands during dressing, with a view to disturb the relation of the flaps to each other as little as possible.

Delay the first dressing of a healthy stump as long as is consistent with cleanliness.

It is of importance to decide upon the requisite length of flaps, and as a rule each flap should be equal in length to rather less than one-third of the circumference of the limb, at the intended point of section of the bone; or, flaps of unequal length

should be, together, equivalent to two-thirds of the circumference of the limb. Let the flaps be too long rather than too short; and to insure accuracy, the operator may, if he please, measure the circumference of the limb and mark out the flaps on the surface with pen and ink. If, by an error in judgment, the soft parts be not long enough to cover the wound, a portion of bone may be removed after that the muscular attachments have been carefully detached by the knife held parallel to the long axis of the bone, as in fig. 3. This manœuvre will allow

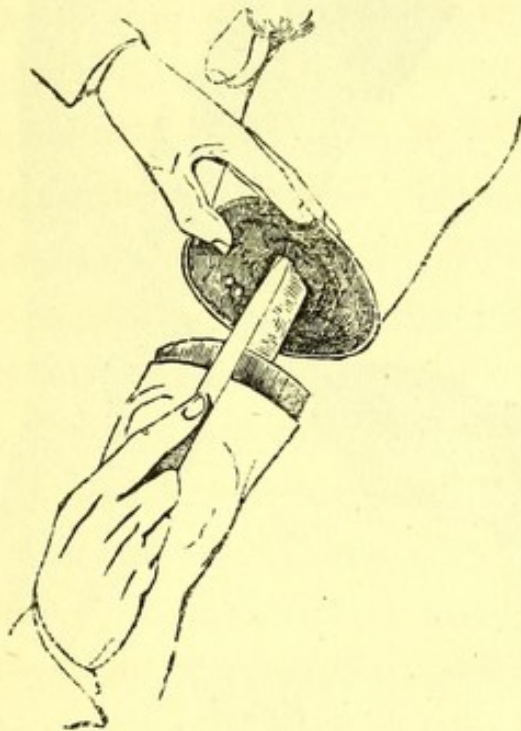


FIG. 3.

of retraction of the soft parts to the requisite extent, when the saw may be applied, and the protruded portion of bone be removed.

VARIETIES AND MODIFICATIONS.

Instead of making an anterior and posterior flap by transfixion, as above described, some surgeons cut the anterior flap from skin to bone and from below upwards (fig. 4), and afterwards form the posterior

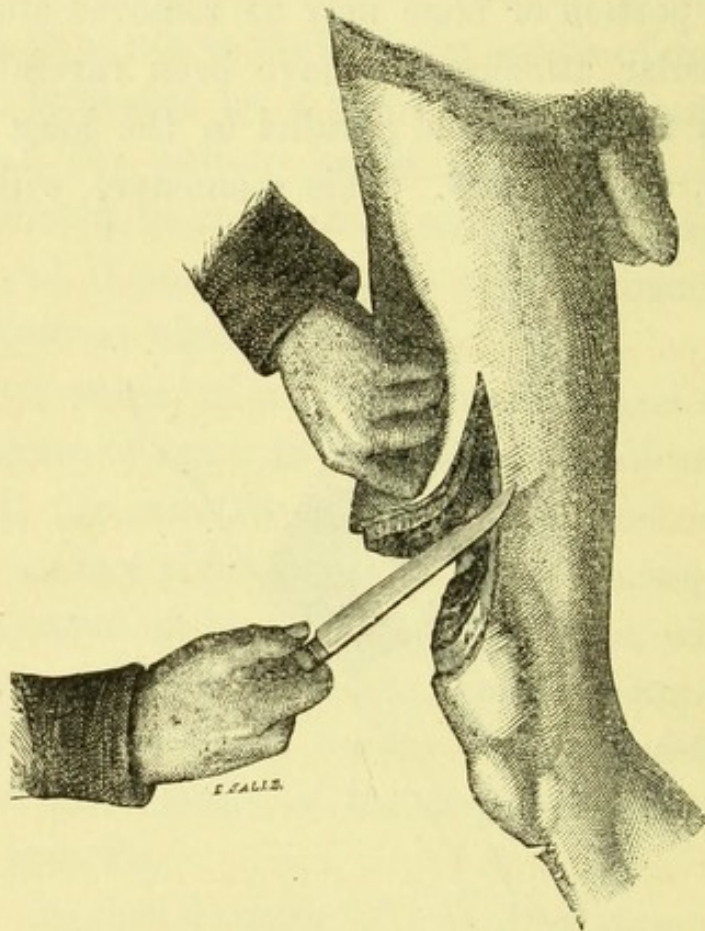


FIG. 4.

by transfixion; others, in any case, form the posterior flap first.

Again, in very muscular subjects, the knife may be made to traverse the limb at a distance from the bone, and so form two flaps, each being composed of *part*

only of the *muscular* structure and the integuments : the muscular structures remaining attached and adjacent to the bone must be divided by a circular sweep of the knife. By this mode the main vessels are cut transversely and run no risk of being wounded above their point of section, an accident which may happen by the ordinary method of transfixion.

Flaps of integument only may be preferred, the deeper structures being cut circularly at the intended point of section of the bone.

The ordinary operation by double flap (antero-posterior) may be replaced by lateral flaps, the steps of both operations being similar.

There is one objection to cutting by transfixion either the posterior flap or the flap which is to contain the main vessels first, and for this reason : these vessels, in certain regions, lie just behind the bone or bones, and as the operator generally endeavours to include a good share of integument in the first flap the knife is passed as near as possible to the bone or bones, and thus the vessels are often pierced as well as cut obliquely ; but if the flap which is not to carry the main vessels be cut first, the operator can readily manœuvre to keep at a distance from the track of these organs when forming the second flap.

AMPUTATION BY CIRCULAR INCISION.

As the term expresses, this operation is performed by one or more sweeps of the knife round the limb

till the soft parts are divided down to the bone, and the saw being applied, completes the separation. The success of this mode, as of the flap operation, will depend upon giving to the divided bone a sufficient covering of soft parts; and to insure this desideratum, various manœuvres have been resorted to from time to time.

The number and position of assistants, and similar instruments and appliances, are equally requisite for this as for the flap operation. Also, the steps of the operation, excepting the use of the knife, being alike, need not to be again detailed. With few exceptions, the surgeon will choose to stand on the outside of the limb, although, in any case, some prefer to have the left hand towards the trunk. The position chosen, the operator plants the sole of his left foot firmly upon the ground, while the right knee either approaches or rests also upon the floor; the left hand rests either upon the distal or proximal side of the limb, while the right hand holds the knife and is below the limb. The knife is usually *grasped* firmly by the hand of the surgeon, but when so held, the completion of the circular incision without removing the instrument from the body is difficult, and though effected, is an inelegant manœuvre. I do not wish to infer that it is necessary to the success of the operation to finish the circular incision by one sweep; a second cut completes the section very much to the convenience of the surgeon.

Another mode of holding the knife is as a pen, but

with its point upwards and directed somewhat towards the face of the operator, the edge being towards the limb to be removed.

The student may practise with advantage the method of holding and sweeping the knife round a limb with a paper-knife, when he will learn to imagine, what no description can teach, how firmly to hold the knife, and also to form some idea of the amount of pressure that may be requisite to divide the soft parts in making the circular incision. He will also observe that the knife is, as it were, on a pivot represented by the forefinger and thumb, and upon which it must be allowed to turn in such a manner that when the incision is completed, the knife will be on the side of the limb nearest to the operator with its point directed slightly downwards and towards him. The incision should be commenced with the heel of the knife placed upon the upper surface of the limb held horizontally, and be made partly by pressure and partly by drawing the knife slowly from the heel towards the point, as well as by an almost imperceptible to-and-fro movement. The handle of the knife should be smooth, and the blade heavy, and if held as described above, the circular incision may be completed with one sweep. Perhaps, for the oblique section of muscles so as to form a cone with the bone at its apex, the handle of the knife should be *grasped* as usual.

Previous to the commencement of the operation, the appointed assistant embraces with both hands

the proximal portion of the limb, and at the same time makes gentle but equable traction upon the integuments, so as to preserve as much skin as possible to cover the wound. (The assistant must avoid drawing up the skin *during* its section, otherwise its margin will be cut unevenly.)

The first incision should divide the integument, when traction from above and a few slight touches with the knife at the requisite points will perhaps allow it to be drawn up to a sufficient height; if this plan do not succeed, the integument must be dissected off the deep fascia as delineated in fig. 5.

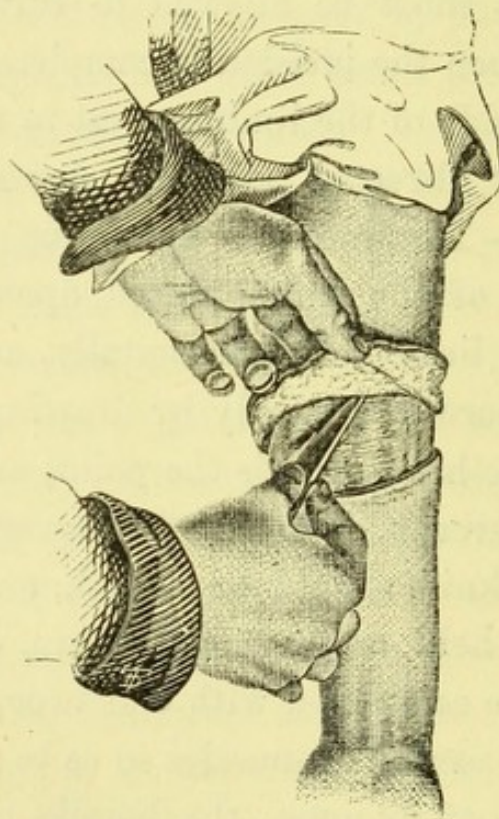


FIG. 5.

The first step completed, a second sweep round the limb as high as the retracted skin will permit, divides the muscles, vessels, and nerves; a third sweep

divides the periosteum, and lastly, the saw completes the separation.

Another method.—First step consists in division of skin and deep fascia followed by traction from above; secondly, a sweep of the knife should divide the superficial set of muscles close to the edge of the retracted skin—again traction from above; thirdly, division of the remaining muscles, blood-vessels, &c., close to the retracted soft parts, fig. 6; fourthly, division of periosteum, followed by the application of the saw.

In all amputations by circular incision, after the skin has been divided, the remaining soft parts should be cut obliquely from below upwards, the edge of the knife being, for this purpose, directed upwards and towards the bone throughout each circular sweep. By this means when the operation is completed, the end of the bone will be found to form the apex of a cone, the base of which is at the cut margin of the skin, as in fig. 7; the bone will also be well covered, and superabundance of soft parts is avoided; apposition of the raw surfaces and a sufficiently

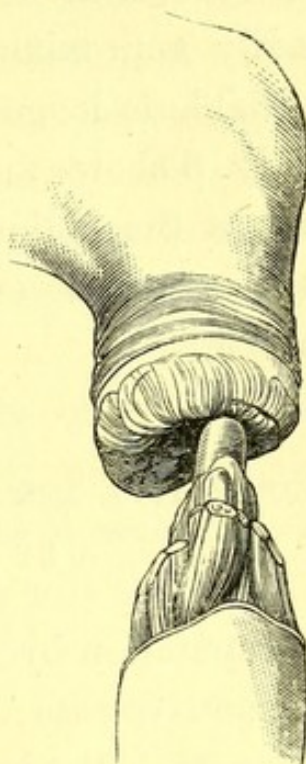


FIG. 6.

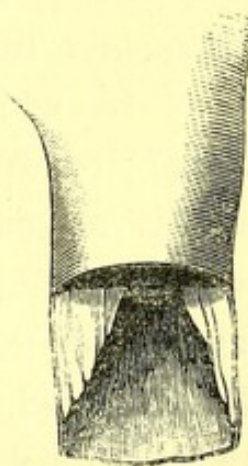


FIG. 7.

thick covering for the end of the bone is insured; whereas, after the completion of the operation begun as in fig. 5, skin alone serves to cover the end of the bone, and as its opposing surfaces cannot be readily approximated, a pouch in which secretions are liable to lodge is formed.

Fig. 6 shows the wrinkled condition of the skin as well as the obliquely cut muscles and exposed bone after repeated sweeps of the knife followed by traction.

COMPARATIVE MERITS OF AMPUTATION BY FLAP AND BY CIRCULAR INCISION.

Amputation by flap is performed rapidly and with comparative ease; a good covering of soft parts is preserved to the bone; flaps also afford mutual support, and their whole surfaces being readily approximated and easily maintained in apposition, oozing of blood is prevented and rapid union may be anticipated; a flap or flaps may be cut at any part of the circumference of a limb, under circumstances of disease or injury in which the circular mode could not be applied; on the other hand, a larger number of ligatures is requisite; vessels are liable to be wounded above the point of division when the flaps are cut by transfixion; these, as well as nerves and tendons, are often exposed, to some extent, on the surface of a flap, and must be dissected out and cut short, thus prolonging the operation. The flap operation, per-

formed indiscriminately, will in some cases be followed by retraction, resulting in a conical stump.

Amputation by circular incision, as at fig. 5, is tedious to the operator, and more painful to the patient; a less efficient covering is left to the bone. On the other hand, vessels, nerves, and tendons being cut short, do not require to be trimmed; fewer ligatures are necessary; there is less liability to retraction of soft parts, and the formation of a conical stump.

Thus it appears that each mode of performing amputation has its advantages and disadvantages, and practically each, or a modification of each method, is applicable to certain localities, as will be hereafter indicated.

AMPUTATION BY OVAL INCISION.

This method, which may be considered a modification of the circular, will be described under the head of *special amputations*.

AMPUTATION IN THE CONTIGUITY OF A LIMB.

Amputation in the contiguity of a limb, or through an articulation, is not so readily performed as may at first thought be supposed. In many instances, to be cleverly executed, it requires a thorough knowledge of the anatomy of the articulation in question: as, the relation of points of bone to each other; the position of ligaments which must be divided before

disarticulation can be effected; the most vulnerable part of the joint under certain conditions, whether of flexion, extension, or otherwise, &c.; still, with all this knowledge to aid, the surgeon will sometimes be baffled in his first attempts to open a joint.

Previous to performing amputation through a joint, the operator should manipulate the part carefully, with a view to discover some sure landmark to guide him to the articulation, so soon as it may be necessary to open it. Should this be impossible from the nature of the disease or injury necessitating amputation, the soft parts must be divided, and the line of articulation be sought for at the proper time, by repeated manipulations, and by a steady and cautious use of the knife, cutting and cutting upon the bone to be removed until the joint be found. It is at this stage of the operation that the surgeon should be reconciled to lose a little time while searching for the joint, if he has not hit upon it at first. By cautiously cutting and cutting upon the bone to be removed, as above advised, rather than upon the proximal side of the articulation, no permanent injury is inflicted.

CHAPTER II.

SPECIAL AMPUTATIONS.

LOWER EXTREMITY.

The Foot.—The framework of the foot is so complex, the articulations so numerous, and the partial amputations which are performed upon it so worthy of attention and repetition, that a study of its skeleton, with a view to the relative position of certain bony prominences and corresponding depressions, will not be misplaced. Carrying the finger from before backwards along the inner border of the foot, the following landmarks will be recognised: 1st, the large rounded head of the first metatarsal bone; 2nd, an ill-defined ridge or tubercle marking the base of the first metatarsal bone; 3rd, a projection of the internal cuneiform bone, a slight depression between these two latter indicating the position of their articulation; 4th, the tubercle of the scaphoid bone, between which and the internal cuneiform bone is a slight depression marking their articulation; behind the prominent scaphoid bone is the line of its articulation with the head of the astragalus. Proceeding in a similar manner along the outer margin

of the foot is the base of the fifth metatarsal bone, which articulates posteriorly with the cuboid bone, and one finger's breadth behind the base of the fifth metatarsal bone is the line of articulation of the cuboid bone with the calcaneum.

On the dorsal aspect, one finger's breadth in front of the ankle joint, a line drawn across the foot will correspond to the articulations between the astragalus and calcaneum behind and the scaphoid and cuboid in front.

The postero-anterior arch of the foot, upon which the greater part of the weight of the body is received, has two principal points of support, the heel and the ball of the great toe. If, therefore, either of these be removed, the vault of the arch will be lowered, and its strength and utility be diminished in proportion.

These observations lead me to speak first of amputation of—

The Toes.—These members may be amputated *en masse* at the metatarso-phalangeal articulation, or be separated individually in either their continuity or contiguity; but since their functions as prehensile organs cannot be called into play so long as thick-soled boots are worn, the four lesser toes are rendered comparatively useless, and amputation of one or more should be performed either through the first phalange or at the metatarso-phalangeal articulation.

This observation does not apply to the great toe, the smallest portion of the first phalange of which should be carefully husbanded in order that it may

assist in bearing its due share of the weight of the body thrown upon the ball of the great toe.

When performing partial amputation of the hand or foot, the blade of the scalpel or knife employed should be very *narrow*, in order that it may be passed readily between bones and through small articulations.

The main vessels may be compressed by the fingers and thumb of an assistant; in the case of the foot, just above the ankle joint, the fingers being employed to press the posterior tibial artery against the posterior surface of the tibia, while the thumb compresses the anterior tibial artery upon the lower end of the tibia in front.

During an operation for the removal of a toe, the adjacent toe or toes should be held aside by a loop of bandage cast over them.

If the plantar surface of the toes be examined, certain transverse markings will be observed; but since most adult toes are more or less deformed, these lines will not much assist in determining the point of articulation between the first and second phalanges, although the second line from before backwards will be often found opposite to the above articulation: in the case of the great toe no perceptible line exists.

On the dorsal surface, excepting the great toe, a small tubercle immediately in front of the articulation, and appertaining to the second phalange when well-developed, indicates the line of the articulation. Besides these anatomical aids, the operator should

flex and extend the bone to be removed, and even pull upon it, so as if possible to separate the articulating surfaces, and discover with his finger the line of the joint. Excepting the metatarso-phalangeal joint of the great toe, the remaining four are placed deeply in the sole of the foot, a fact to be remembered by the operator, who otherwise will be puzzled to find the articulation; the transverse line on the plantar surface at the junction of a toe with the sole of the foot is much in advance of the articulation, and consequently cannot be taken as a guide to the latter.

For mode of performing partial amputation of toes, see amputation of fingers.

Amputation of Great Toe (metatarso-phalangeal).—The head of the metatarsal bone is very large, and requires a wide extent of integument to cover it. Not forgetting the above fact, and husbanding the skin accordingly, the operation is similar to that performed at the metatarso-phalangeal articulation of the other toes, either by oval incision or by flap.

By *oval incision*.—Hold the condemned toe with the finger and thumb of the left hand firmly, and commence the incision on the dorsal surface opposite to the joint and in the median line of the toe, carrying it downwards and forwards along one side of the toe to the point of junction of the web with the toe, then through the transverse line, marking the junction of the toe with the sole, to a corresponding point on the other side, and terminate at the point of com-

mencement of the incision. Divide the extensor tendon, and open the joint on the dorsal surface; sever the lateral ligaments consecutively and carefully with the point of the knife, and also the flexor tendon's sheath and remaining slight attachments.

In removing either the great or little toe, as above described, let the incision on either side of both toes be prolonged to an equal distance.

Avoid plunging the point of the knife into the sole of the foot.

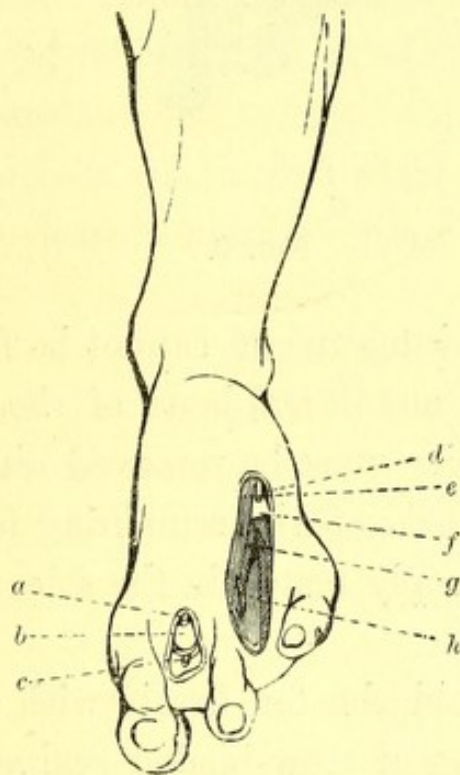


FIG. 8.

The wound and parts exposed in a similar amputation of the second toe are seen in fig. 8: *a*, the extensor tendon; *b*, the head of the metatarsal bone; *c*, the flexor tendon. *b b*, fig. 9, shows the linear cicatrix resulting when the edges of the wound have been

kept in apposition by suture and by the approximation of the adjacent toes.

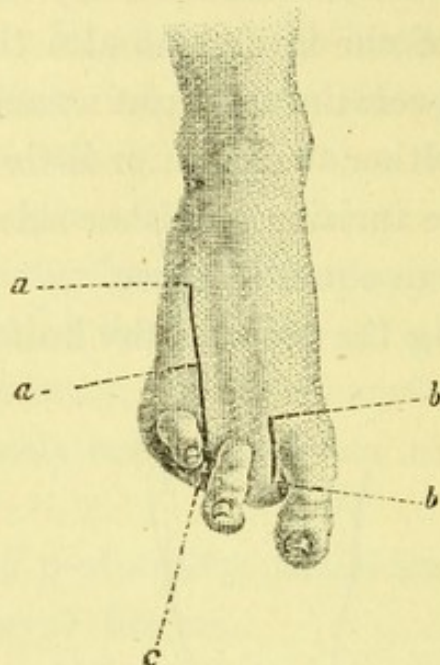


FIG. 9.

If sufficient integument cannot be found to cover the head of the metatarsal bone of the great toe, the exposed extremity must be removed either by saw or forceps; the heads of the remaining four metatarsal bones, being deeply seated in the sole, should not be taken away.

By *flap*.—Hold the toe firmly with the left hand, and with a long narrow-bladed scalpel cut one flap by transfixing the soft parts on one side of the toe from below upwards and backwards, causing the point of the knife to appear on the dorsal surface opposite to the articulation and in the middle line of the toe, by cutting forwards towards the extremity of the toe and as far as the junction of the web

with the toe, taking care to include as much integument as possible, one flap will be formed; now divide the extensor tendon with the point of the knife, and open the joint; pass the knife, point uppermost, across the joint after dividing the lateral ligaments and flexor tendons, and then form the second flap by cutting forwards, as in completing the first flap.

Toes en masse.—The toes may be removed together by two incisions—one on the dorsal, the other on the plantar aspect of the foot. Preserve as much integument as possible, to cover the head of the metatarsal bone of the great toe.

Holding the toes in the left hand, commence and terminate the dorsal incision either on the outer or

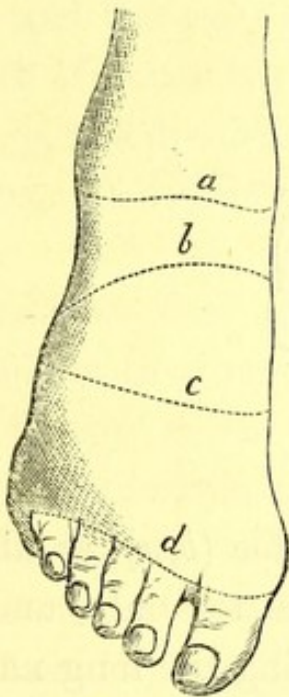


FIG. 10.



FIG. 11.

inner border of the foot, as much in front of the metatarso-phalangeal articulation as is consistent

with cutting a regular margin to the flap (as in fig. 10, *d*); now mark out the flap on the plantar surface by carrying an incision between the points already determined by the dorsal incision, along the lines of junction of the toes with the sole; divide the extensor tendons, traverse the joints severally and in order, and complete the operation by division of the flexor tendons. Fig. 11 shows the result of such an operation.

Metatarsal Bone, partial or entire.—Commence the incision on the dorsal surface at the intended point of section, or of disarticulation of the bone (fig. 12, *a*);

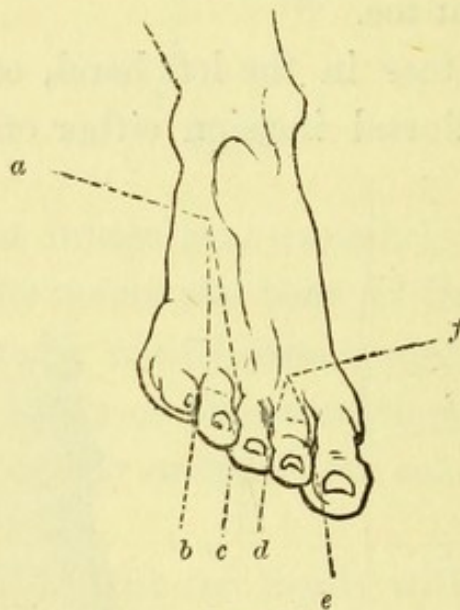


FIG. 12.

carry it towards and about the toe (*b, c*), as already described for the removal of the toe only, and terminate the incision at *a*. Holding the long narrow-bladed knife parallel to the long axis of the bone to be removed, carefully separate the muscular attachments, first on one side and then on the other side,

and then, to complete the section of the flexor tendons, cautiously pass the point and part of the blade of the knife under the bone, and cause it to protrude on one side, while the remaining portion of the blade with the handle of the knife is on the other side, thus giving it an oblique direction similar to that shown in fig. 45 ; by cutting forward towards the toe, the division of soft parts may be readily completed. Use the condemned toe as a lever, whilst the ligaments of the tarso-metatarsal articulation are being divided. Should the operator intend only to remove the anterior portion of a metatarsal bone, the bone-forceps, applied on the dorsal surface, with a direction downwards and forwards, cutting the bone obliquely, will suffice. The wound thus made is shown in fig. 8, and the parts exposed are, *d*, extensor tendon ; *e*, fibres of flexor brevis digitorum ; *f*, part of cuboid bone ; *g*, the divided interossei muscles ; *h*, the flexor tendons. A linear cicatrix (fig. 9, *a, a, c*) is the result.

Metatarsal Bone of Great Toe.—Observe that the direction of the line of articulation of the first metatarsal bone with the internal cuneiform bone is from within, downwards and outwards towards the head of the fifth metatarsal bone ; that the joint is in advance of that of the second metatarsal bone, and quite distinct from it ; that the dorsalis pedis artery dips into the sole of the foot close to the outer side of the joint. To remove this bone with the great toe, let an assistant draw the integument of the dorsum of the

foot towards the ankle-joint ; the operator should then commence his incision on the dorsal surface, and opposite to the articulation, carrying it downwards and forwards to one side of the toe, as far as the web *a*, around this former, as already described, and back to the point at which it was commenced ; thus a Δ shaped portion of integument is included (fig. 13).

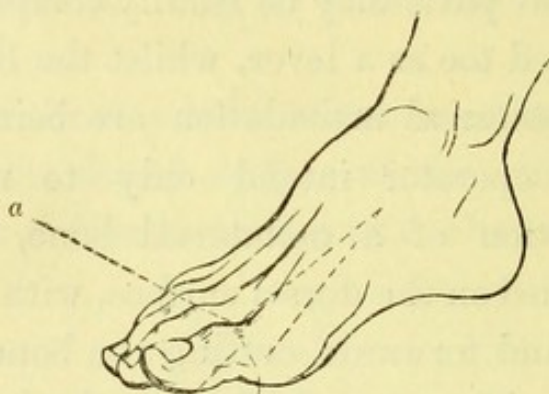

FIG. 13.

(Besides the above incision, a second may be made at the apex of the former and at a right angle to it, opposite to the metatarso-cuneiform joint, and extending down on the inside and towards the sole of the foot to the extent of an inch. By this means a flap is formed, and the above articulation is more readily exposed.) Carefully separate the soft parts from the metatarsal and sesamoid bones ; divide the ligaments of the articulation without either, carrying the knife up between the base of the second metatarsal bone and internal cuneiform bone, or wounding the adjacent dorsalis pedis artery ; and amputation is accomplished. Fig. 14 shows the wound and parts interested : *a*, the extensor tendon ; *b*, internal cunei-

form bone; *c*, the dorsalis pedis artery, cut across;

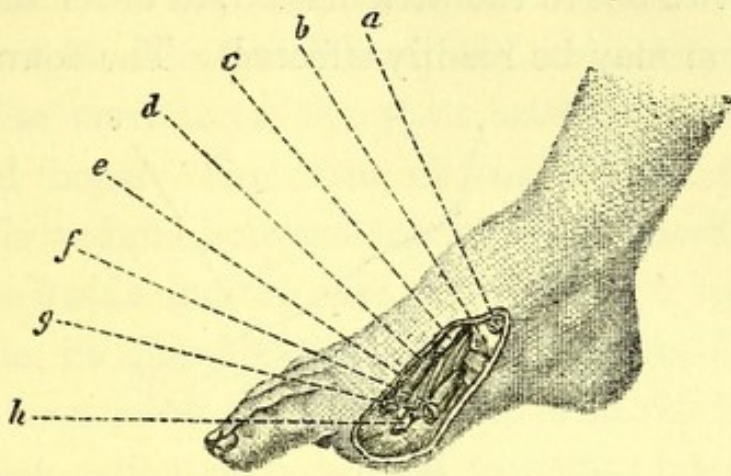


FIG. 14.

d, *e*, *f*, *g*, *h*, mark certain muscles which have been necessarily divided. Fig. 15, *a a a*, shows a linear cicatrix resulting.

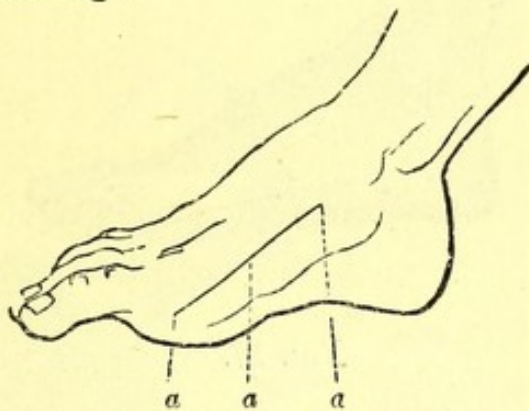


FIG. 15.

Fifth Metatarsal Bone.—This bone may be satisfactorily removed also by the oval incision, including an elongated triangular portion of integument with rounded corners. The tuberosity of this bone, to which is attached the tendon of the peroneus brevis muscle, the oblique direction of the line of articulation with the cuboid bone (from without, downwards and inwards towards the head of the first metatarsal

bone), render it necessary to commence the incision a line or two above the articulation, in order that disarticulation may be readily effected. The course and

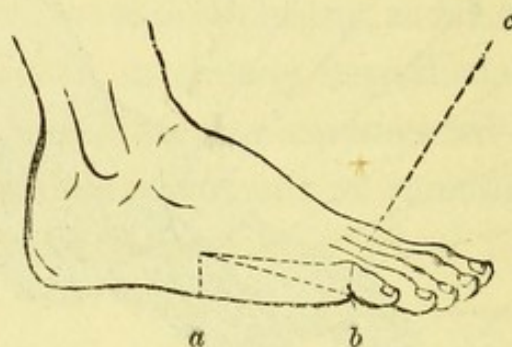


FIG. 16.

extent of incisions are indicated at fig. 16, *a*, *b*, *c*. A linear cicatrix (fig. 17, *a a a*) is the result.

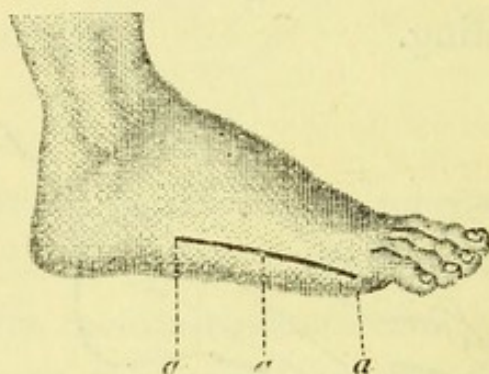


FIG. 17.

By this *oval* method or modification of it, as occasion requires, two or more metatarsal bones, with their corresponding toes, may be removed.

Metatarsal Bones en masse.—These bones may be amputated either in their continuity or in their contiguity.

Tarso-metatarsal Amputation (Lisfranc).—On the inner side of the foot a linear depression between the base of the first metatarsal bone and the internal

cuneiform bone marks the line of articulation between the two. On the outer side of the foot the tuberosity of the fifth metatarsal bone will indicate sufficiently well the position of the joint between this and the cuboid bone. The base of the second metatarsal bone is wedged between the internal cuneiform bone on the inside and the external cuneiform bone on the outside, its line of articulation with the middle cuneiform bone being about half an inch in the rear of the anterior articular surface of the internal cuneiform bone, and one quarter of an inch posterior to the anterior articular surface of the external cuneiform bone. (Fig. 18.) When performing the operation

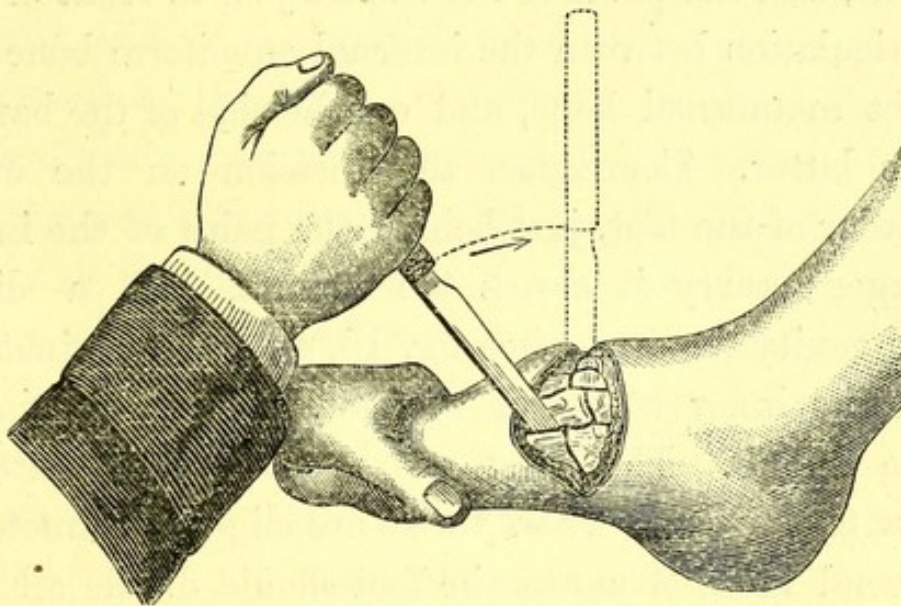


FIG. 18.

about to be described, the points of commencement and of termination, and the direction of three lines of articulation, must be borne in mind. On the outside, the line of articulation of the three external metatarsal bones with the cuboid and external cunei-

form bones has a direction from behind forwards and inwards ; on the inside, the line of articulation between the first metatarsal bone and the internal cuneiform bone has a direction from behind forwards and outwards ; in the middle, the articulation of the second metatarsal bone with those adjacent forms three sides of a square, of which two are parallel and look forwards and backwards, and the third from side to side.

To operate on the *right* foot it will be convenient to hold the member with the left hand placed upon the dorsum of the foot, the point of the forefinger being placed upon the base of the fifth metatarsal bone, and the point of the thumb just in front of the articulation between the internal cuneiform bone and first metatarsal bone, and on the side of the base of the latter. Commence the incision on the outer border of the foot, just behind the point of the index finger ; carry it across the dorsum, with a slight convexity forwards (see fig. 10, *c*), and terminate it on the inner border of the foot, behind the point of the thumb. This first cut should divide integuments only, and when these are slightly retracted a second incision across the foot should divide all soft parts down to the bones and on a level with the edge of the divided and retracted skin. Search now for the external *line of articulation* already mentioned, and having opened the joint of the fifth metatarsal bone with the cuboid bone, let the knife, almost *suo sponte*, follow the *line* to its termination on the out-

side of the second metatarsal bone ; open next, with the heel of the knife, the internal metatarso-cuneiform joint ; and lastly, grasping the handle of the knife (point directed downwards and backwards, fig. 18), cautiously introduce the point between the first and second metatarsal bones, and then between the second and third metatarsal bones, and having fixed it on an imaginary fulcrum or pivot, carry the handle and blade backwards so as to divide the ligaments which unite the sides of the base of the second metatarsal bone to those adjacent ; now, by cutting with the point of the knife upon the dorsum of the second metatarsal bone, the remaining dorsal ligament uniting it to the middle cuneiform bone will be severed, and if the foot be used as a lever and be depressed by the hand of the surgeon, the articulations already opened will be freely exposed to view, and the most difficult part of the operation be effected. Without injuring the sole, divide the plantar ligaments and tendon of the peroneus longus muscle attached to the base of the first metatarsal bone.

When dividing the above parts it will be well, almost imperceptibly to commence cutting the flap by nicking the integument on the outside with the point of the knife, and on the inside with the heel of the knife. (It is difficult to describe this manœuvre on paper ; the object is to avoid an ugly angle on either side by rounding off in a forward direction the original transverse cut on the dorsum.)

A flap is to be made from the sole, and to do this

place the knife across the wound, and the blade flat on the raw surface, and cut forwards close to the under surface of the metatarsal bones, and as far as the roots of the toes, not forgetting the position of the sesamoid bones which should also be removed; now measure the raw surface of the sole by bringing it up against the exposed cuneiform and cuboid bones, and having determined upon the requisite length of flap (allowing for retraction) which will cover the bones, grasp the condemned toes and metatarsal bones with the left hand, and holding the knife, point downwards and forwards, almost perpendicularly to the raw surface of the sole, cut away the toes and leave the flap. The flap should be longer on the inner than on the outer side of the foot, because the internal cuneiform bone is deeper than the cuboid; the angles of the flap should be slightly rounded at the same time that the toes are cut away, and its anterior margin be cut somewhat obliquely from above downwards and forwards.

To operate on the *left* foot it will be found convenient to take the sole of the foot in the palm of the hand, using the points of the finger and thumb as before directed. The steps of the operation should be performed in the above order, although one or more individual steps may be reversed. Fig. 19 shows the result of the operation on the left foot.

Medio-tarsal Amputation (Chopart).—In this operation the whole of the foot anterior to the astragalus and os calcis is removed. The landmarks are, on the

outer side of the foot, a point one finger's breadth behind the base of the fifth metatarsal bone, marking

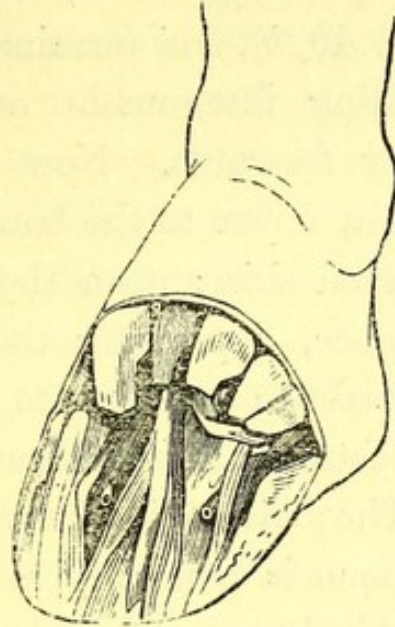


FIG. 19.

the line of articulation between the cuboid bone and os calcis; on the inner side, a point immediately posterior to the tubercle of the scaphoid bone, indicating the line of articulation between the astragalus and scaphoid bone: on the dorsum of the foot, a line at the distance of one finger's breadth in front of the ankle-joint will indicate the line of articulation which is to be traversed by the knife.

To operate on the *left* foot, hold the member with the sole in the palm of the left hand, and let the point of the forefinger rest upon the outer border of the foot just behind the base of the fifth metatarsal bone, while the point of the thumb rests upon the tubercle of the scaphoid bone on the inner side of the foot; behind these two points or landmarks the

first incision is to be begun and to be terminated. Commence the incision on the inner side of the foot, with a small amputating-knife ; carry it across the dorsum (see fig. 10, *b*), and terminate it at the point indicated, dividing integument only, and with a slight convexity forwards. Now divide all intervening structures down to the bones, and on a level with the retracted skin ; open the articulations on the dorsal surface, depressing the foot with some force, so as to assist in exposing to view the articular surfaces of the astragalus and calcaneum.

[*Caution.*—The articulation between the astragalus and scaphoid bone is generally more readily found, and will probably be opened first ; and on carrying the knife outwards to open the articulation between the os calcis and cuboid bone, the point of the knife is very liable to slip back upon the upper surface of the calcaneum, just external to the neck of the astragalus, and of course posterior to the calcaneo-cuboid joint. When superintending operations in Paris, I have repeatedly seen this accident happen to students ; and unless the operator be aware of the possibility of such an occurrence, he will be very much puzzled to extricate himself. This accident is only liable to happen when operating on the left foot, unless the operator use the knife with his left hand when operating upon the right foot. The black triangular space above the extremity of the os calcis in fig. 20, is the locality indicated.]

Sever the plantar ligaments without puncturing the

sole, and divide the tendon of the peroneus longus muscle, seen crossing the foot from without inwards. Cut the flap in the manner described in the tarso-metatarsal amputation. The head of the astragalus may or may not be removed at pleasure with the saw.

Fig. 20 shows the result of this operation on the left foot.

To operate on the *right* foot, hold it with the left hand placed upon the dorsum of the condemned member; and although individual steps of the operation will be reversed, it is not necessary to recapitulate the instructions.

Another method (Sedillot).—It is here proposed to obtain a flap from the inner side of the foot.

To operate on the right foot, and bearing in mind

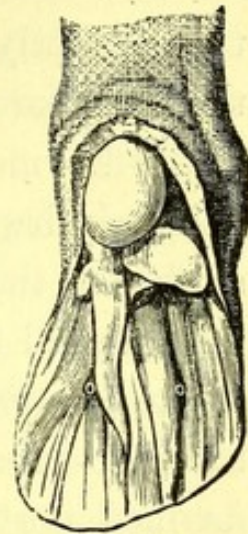

FIG. 20.

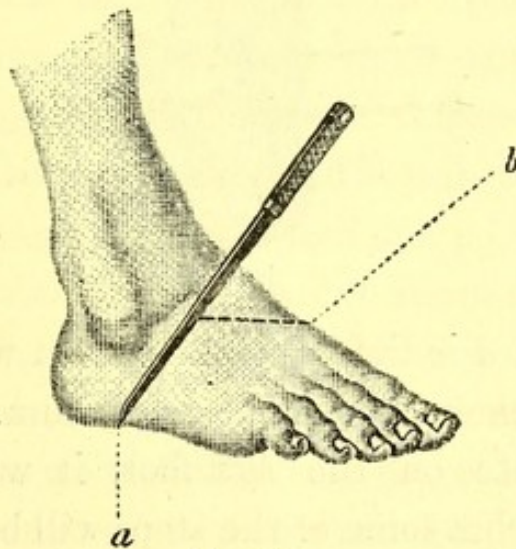


FIG. 21.

the situation of the various joints interested, com-

mence the incision at the outer border of the foot (fig. 21, *a*), and carry it to the centre of the dorsum, then turn abruptly forwards and inwards (see dotted line), to the inner border of the foot, *b*, as far as the central point of the first metatarsal bone ; now continue the incision obliquely backwards and outwards across the plantar surface to the point of commencement ; dissect back the internal flap, keeping the knife close to the bones, to the astragalo-scaphoid joint ; open this and also the calcaneo-cuboid articulation, and separate the condemned portion of foot from the remaining attachment of the sole. By this means it will be seen (fig. 22) that a flap, *c*, is formed from the inner side

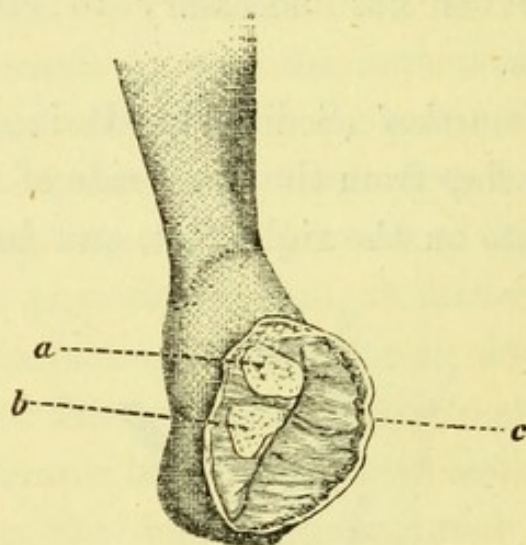


FIG. 22.

of the foot : *a* is the astragalus, from which the head has been removed ; *b* is the calcaneum.

To operate on the *left* foot, it will be readily understood that some of the steps will be conveniently reversed.

A modification of Chopart consists in leaving the

scaphoid, as well as the astragalus and calcaneum, to the use of the patient: the flap must be cut in due proportion.

Tibio-tarsal Amputation (Syme).—This operation consists in the removal of the whole foot, and of the malleoli and inferior articular surface of the tibia. Two incisions are made, in such a manner as to meet each other at a right angle. The foot being in such position as to be at a right angle with the leg, one incision is to be made through integuments only, in front of the ankle-joint, extending from one malleolus to the other. (See fig. 10, *a*.) The second is to be begun at one of the former: if on the inner side, at the apex of the internal malleolus; if on the outer side, just in *front* of the external malleolus,—because the latter being on a plane posterior and inferior to the former, the points of commencement and of termination of the second incision would, if begun at the *apex* of *each* malleolus, not be upon the same plane. Commence then the second incision at one of the above points, and carry it downwards to one border of the sole, now across the sole to the other border, and then upwards to join one point of termination of the first or anterior incision, dividing all structures down to the bone. This cut is at a right angle to the sole of the foot, the anterior part of the foot being, as it were, isolated by a rectangular incision. The leg must now be supported at a convenient height, and the foot be firmly held at a right angle to the leg, while the operator effects the most diffi-

cult part of the operation, *i. e.* the separation of the integuments of the heel from the inferior and posterior surfaces of the posterior portion of the os calcis. To do this readily, he must not forget the position of the tubercles on the inferior surface of the os calcis, and should be satisfied, at this point, with dissecting back the integument only, without including any portion of the plantar fascia in the flap. Should the surgeon cut down to the bone in front of the tubercles, dividing plantar fascia and superficial muscles, he will probably experience difficulty in dissecting back the heel-flap, because the edge of the knife will be liable to come into contact with the anterior surface of these tubercles, and so the operation will be prolonged.

Place the point of the left thumb in the wound and upon the bone, and cautiously cutting upon the bone, while the soft parts are protected by the thumbnail, reflect them from all parts of the os calcis, and as high behind as the attachment of the tendo Achillis, which is also to be divided at this moment. While separating the soft parts from the inner side, especial care must be taken to keep the edge of the knife close to the bone, lest the plantar vessels be wounded above the original point of section, and the vitality of the heel-flap be endangered. The flap completed, all intervening structures on the dorsum of the foot may be cut through to the ankle-joint at the margin of the already retracted skin, and the superior articular surface of the astragalus being re-

cognised, continue the disarticulation of the foot by a careful division of the external and internal lateral ligaments with the knife introduced from above between the sides of the astragalus and the malleoli; sever all posterior attachments and also any tendons still uncut, and lastly, any remaining muscular or other adhesion to the inner side of the os calcis, allowing the knife to follow the curve of the sustentaculum tali. The foot is now separated, and as soon as the soft parts have been dissected up so as to expose the malleoli fully, the saw is to be applied, and sufficient bone removed to include the mere articular surface of the tibia.

Fig. 23 shows the result of the operation: *a*, the tibia; *b*, the fibula; *c*, the hollow of the flap, whence the tubercle of calcis has been removed; *d*, the extremities of the divided plantar arteries.

The skin at the back of the tendo Achillis is thin, and is consequently very liable to be cut through, and a "button-hole" formed during the dissection of the flap. This aperture is often of service, allowing exit to secretions during the process of healing, which would otherwise lodge injuriously in the hollow flap; but since it is not one step in the operation it is to be avoided. The heel-flap is now to be

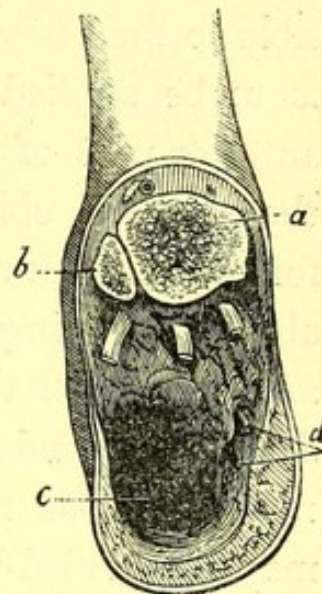


FIG. 23.

brought up into apposition with the anterior incision, and be so maintained by points of suture, as in fig. 24.

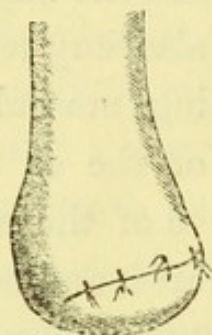

FIG. 24.

Tibio-tarsal Amputation (Pirogoff).—Two incisions similar to those recommended in Syme's operation, are to be made and to be followed by disarticulation of the astragalus, as above described; but here, for a time, similitude ceases.

The foot is to be forcibly depressed so as to expose and drag forward the upper surface of the astragalus, and of the os calcis; and upon the upper surface of the latter behind the astragalus, and as near as possible to the insertion of the tendo Achillis, the saw is to be applied and worked so as to separate the anterior part of the foot from the body by dividing the os calcis obliquely from above downwards and forwards. Remove now the malleoli, as recommended above, and bring the cut surface of the os calcis into apposition with the cut surfaces of the tibia and fibula. Should the tendo Achillis prevent the ready approximation of the fragment of os calcis and tibia, it may be divided by a knife introduced through the wound.

Fig. 25 shows the heel-flap with the posterior portion of os calcis, *a*, *in situ*.

Fig. 26 shows the appearance of the stump three months after Pirogoff's operation, taken from a

patient under the care of Mr. Maunder in the London Hospital.

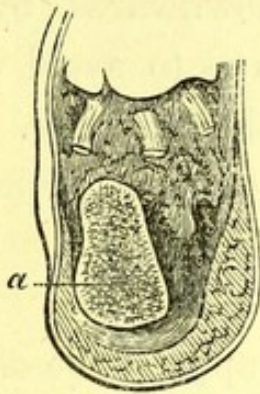


FIG. 25.

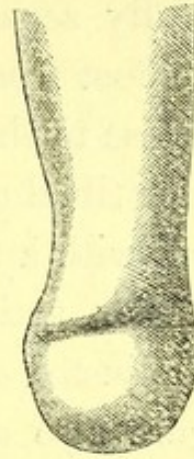

FIG. 26.

Tibio-tarsal Amputation (Jules Roux).—It is here proposed to obtain a flap principally from the inner side of the foot.

Commence the incision at the back of the heel, just at the point of junction of the tendo Achillis with the os calcis (fig. 27, *a*); carry it forwards on the outside of the foot immediately below the external malleolus, then turn inwards towards the inner border of the foot with a slight convexity forwards, passing from one to two fingers' breadth in front of the ankle-joint, and continue the incision round the inner border of the foot (*b*) and in a direction obliquely backwards along the sole of the foot, and terminate at the point of commencement, *a*. Open the ankle-

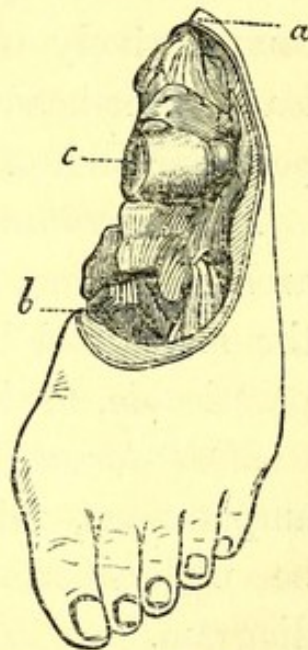


FIG. 27.

joint in front; disarticulate and sever first all external attachments, as well as that of the tendo Achillis, then carefully separate the soft parts on the inner side of the foot from above downwards, by keeping the knife close to the bones, so as to avoid wounding the posterior tibial artery and its branches. Remove the malleoli with a thin layer of tibia, including the whole inferior articular surface of it. The flap should be adjusted as usual.

The figure also shows the appearance of the foot when separated from the flap and leg: from *a* to *b* a portion only of the line of incision is seen; *c* is the astragalus.

COMPARATIVE VALUE OF THE ABOVE TRANSVERSE
AMPUTATIONS OF THE FOOT.

Amputation of Toes en masse.—By this, organs comparatively useless are alone removed, and by leaving the heads of the metatarsal bones, the antero-posterior arch of the foot is not shortened.

Tarso-metatarso Amputation.—The antero-posterior arch of the foot is here abbreviated by the length of the metatarsal bones, but should be preferred, when practicable, to the next.

Medio-tarsal Amputation.—Of the above-described amputations, this one is the least desirable, as may be understood by a reference to the following diagram.

A well-formed foot represents two arches, of which

the more important is the postero-anterior, indicated in fig. 28 by the arc F E G, and of which the

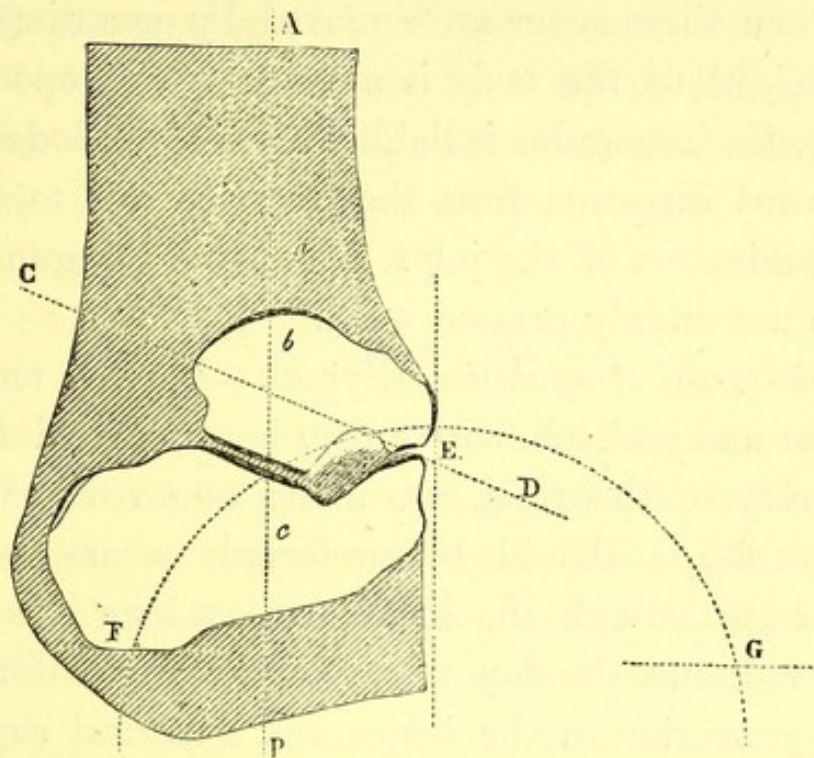


FIG. 28.

posterior extremity, F, is the heel, and the anterior extremity, G, is the ball of the great toe. The key of this arch is shown by the perpendicular line let fall at E. If, therefore, any portion, and especially the anterior half of the arch from E to G be cut away, it is evident that the weight of the body, falling perpendicularly in the direction of A B, and transmitted by the tibia, *a*, to the astragalus, *b*, which latter articulates with and rests upon the anterior part of the os calcis, *c*, and has a direction from above downwards and inwards, *c* D, will bring the anterior part of the astragalus and of the os calcis towards the ground, and tilt the heel up behind. In the natural condition of the foot, the weight of the body is received upon

the astragalus, and from this is distributed to the remaining bones of the tarsus and to the metatarsus; but when these latter are removed by operation, and the weight of the body is allowed to fall upon the stump, the astragalus is liable to become dislodged in a forward direction from the os calcis, and to cause disorganization of the joint, bones, and integuments, which are unduly pressed upon.

Tibio-tarsal Amputation (Syme).—By this method the foot and malleoli, with a thin layer of the inferior extremity of the tibia, are alone removed. When practicable, it should be preferred to amputation higher up through the leg, because a long stump is preserved, and the flap taken from the heel forms a good protection to the bones and a natural support for the body. It is preferable to Chopart, because certain bones which are disposed to caries, either idiopathically or in consequence of their altered anatomical relations, are removed. On the other hand, the flap is formed with great difficulty, and being hollow and composed of lowly-organized tissues, secretions are liable to lodge in the pouch, and sloughing occasionally occurs.

Pirogoff's method.—A desirable operation, because the limb is shortened less than by Syme's mode. It is applicable to cases of injury, rather than for the removal of carious bone; because, in the latter instance, the original disease is liable to recur in the portion of os calcis left in the stump. It is also easy of performance.

Roux's method.—Theoretically a desirable mode. The flap is moderately fleshy and well nourished, and a ready exit is afforded to all secretions.

All the above operations on the foot are open to the objection that pus is liable to travel along the sheaths of the tendons, and delay the cure.

AMPUTATION OF THE LEG.

The leg may be amputated at any point in its continuity. Two points are preferred—either the junction of the middle and lower third, or the junction of the upper and middle third. To the former an artificial foot, to the latter an artificial leg, may be adapted.

Stand on the outside to operate upon the right leg, on the inside to amputate the left limb.

Lower Third, by flap (a short anterior and long posterior).—Assistants and patient being in position, the operator should hold the leg with his left hand, placing the points of the forefinger and thumb respectively upon the fibula and posterior margin of the tibia, not only to serve as guides to indicate the spot at which the bones are to be severed, but also to determine the points of commencement and of termination of the incision, or of entrance and exit of the point of the knife when transfixing the limb. Cut the short anterior flap by commencing the incision on the further side of the leg, just behind the point of the forefinger, with a double-edged knife, and

carry the instrument across the front of the leg to the point of the thumb, in such a manner that a semilunar flap is marked out with convexity looking forwards. This done, enter the point of the knife behind the bones, transfix the limb on a level with the points of the thumb and forefinger, and cut the long posterior flap in the usual way. Dissect up the anterior flap to the requisite level, sweep the bones circularly at the bases of the flaps, and divide the interosseous muscles and membrane by passing the knife between the bones. The application of the saw completes the operation.

Should the crest of the tibia be sharp, the prominent angle may be removed by the saw.

Teale's method (by a long and a short rectangular flap) is somewhat the reverse of the above, and since it is applicable to this part of the leg, may be described at once.

The operation consists in cutting a long anterior flap (except in the case of the forearm, when the long flap is posterior), and a short posterior flap, and in the following manner and proportions. The united length of the two flaps should be equivalent to about two-thirds of the circumference of the limb at the point of division of the bone, while the short posterior flap should measure only one-fourth of the length of the anterior flap; also, the breadth of the anterior flap should be equal to one-half of the circumference of the limb. To form the anterior flap, make two parallel and longitudinal incisions through

integument only, of the requisite length, and in such position, that the main vessels shall be left in the posterior flap. At the distal extremities of the above incisions, make a third and transverse cut to join them at right angles, and dividing the tissues down to the bone. Dissect up now this flap from off the bone, and form the posterior flap by a semicircular sweep of the knife through the soft parts to the bone; separate this latter from the bone to the required height, and lastly sever the bone or bones as usual. By bringing the long flap into contact with the posterior flap, and so maintaining them by suture, the end of the bone will soon be found to occupy a position corresponding to the middle of the long flap.

Where two bones are interested, as in the leg and forearm, the interosseous muscles must be carefully dissected off the interosseous membrane, so as to form a part of the thickness of the flaps. This dissection renders the operation somewhat tedious, but no such obstacle is of course met with in the thigh or arm.

In the case of the lower part of the leg, Mr. Teale desires to advise the operator to be careful not to wound the anterior tibial artery at the base of the flap, lest sloughing of the latter ensue. This accident is best avoided by using the knife in dissecting up the long flap very little more than to detach the skin laterally and to divide the aponeurosis or deep fascia longitudinally at its attachment to the tibia on one side, and to the fibula on the other; the inter-

osseous muscles beneath may then be separated upwards from the tibia, interosseous membrane and fibula by the finger, with very little assistance from the knife.

Fig. 29 delineates the length and proportion of

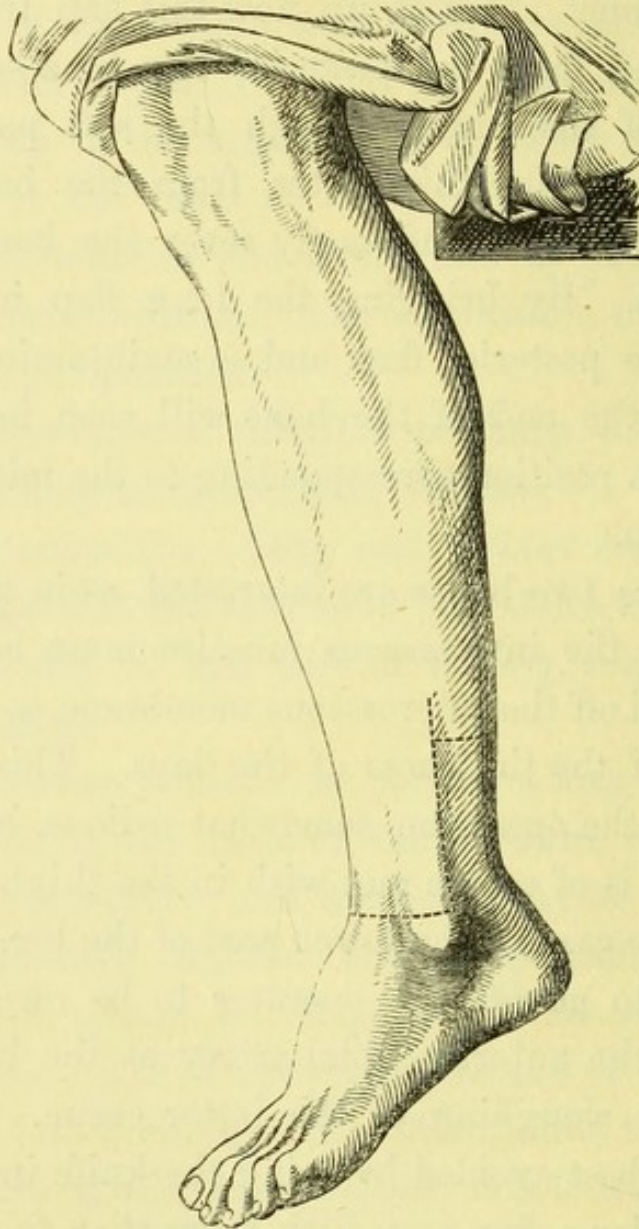


FIG. 29.

the flaps to be formed at the lower part of the leg.

Fig. 30 shows the flaps cut according to the above proportions.

Fig. 31 exhibits the appearance of the stump when

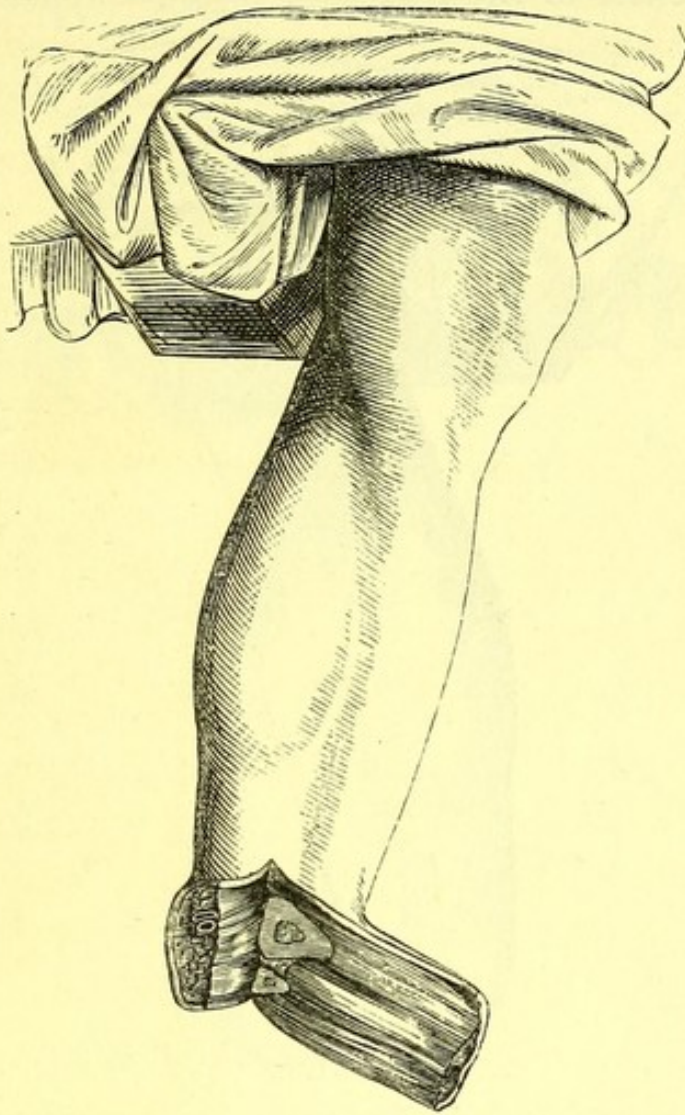


FIG. 30.

the flaps have been adjusted immediately after the operation.

Fig. 32 represents the stump after cicatrization has taken place.

Mr. Teale informs me that his experience since the publication of his work on the *rectangular flap operation* has fully substantiated the opinions therein expressed.

The chief advantage ascribed to this mode over others, consists in the fact that stumps resulting are

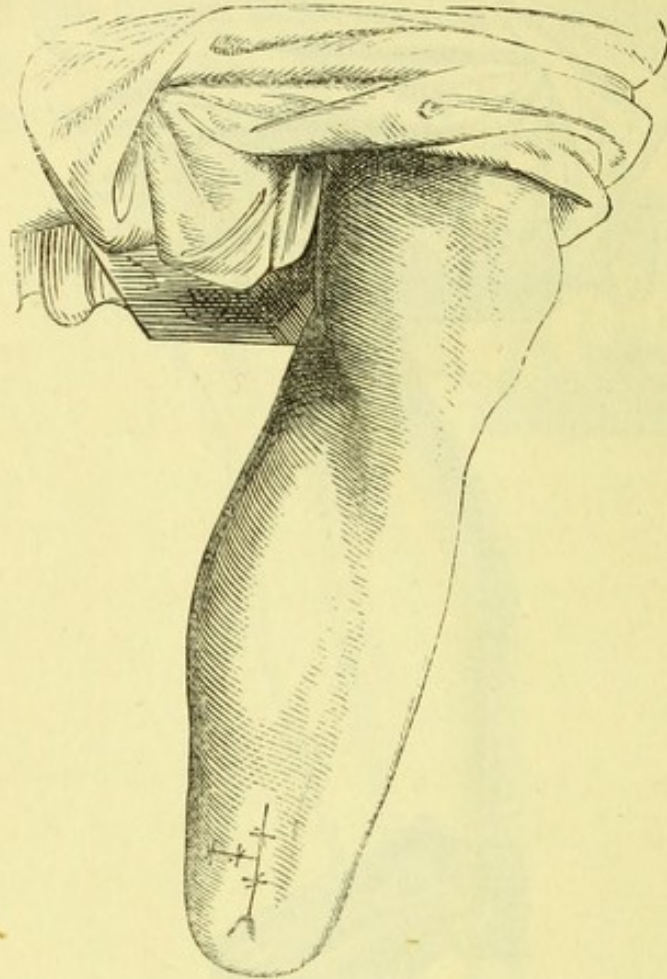


FIG. 31.

much more serviceable to the owner than stumps formed in any other way. The end of the bone is at a distance from the cicatrix, and being protected by a moveable covering of soft parts, great pressure can be borne without inconvenience; whereas, by the ordinary methods of amputation, the cicatrix is said to be generally adherent to the end of the bone, and pressure upon it is unendurable. All the more important vessels and nerves are also at a distance from the end of the bone.

Upper Third, by *flap* (a long posterior and short anterior flap).—The steps of this operation correspond

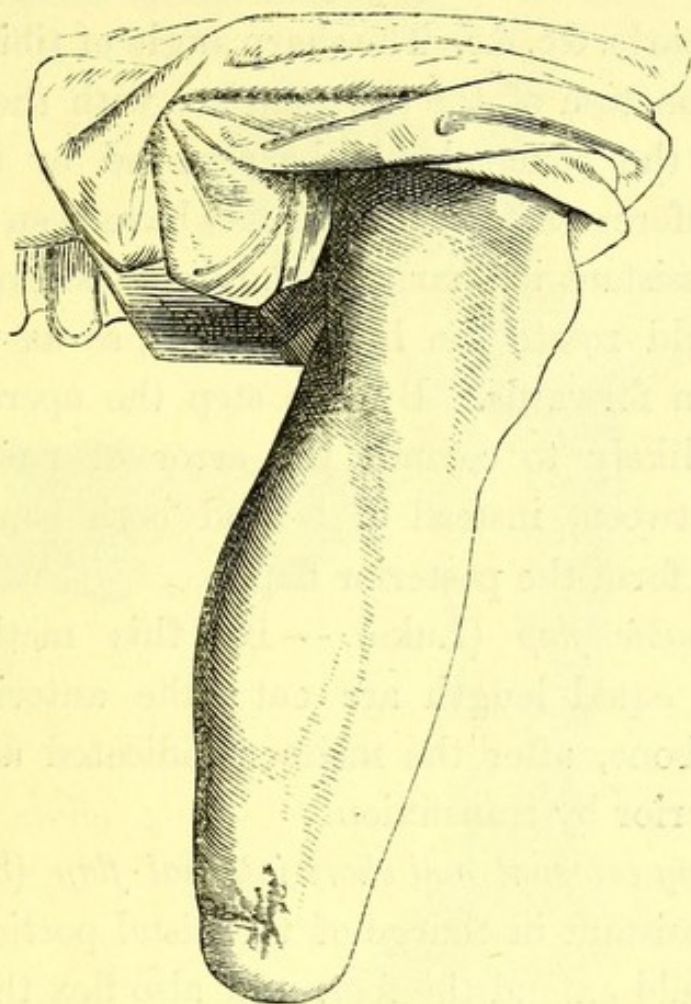


FIG. 32.

to those of the amputation at *lower third*. Place the points of the forefinger and thumb respectively upon the posterior margin of the tibia and fibula, to indicate the intended breadth of the flaps, and also the spot at which the bones are to be sawn across. Mark out the anterior flap first, beginning on the distal side of the limb behind the forefinger, and terminating on the proximal side behind the point of the thumb. This flap should be one-fourth of the

length of the posterior flap, and with convexity looking towards the foot. Transfix the limb behind the bones, and cut the long posterior flap. Divide interosseous parts, &c. &c. The sharp angle of tibia formed by the junction of the sawn surface with the natural crest of the bone, should be removed by the saw, either before or after that the bones have been divided.

The assistant in charge of the distal portion of the leg should rotate the limb inwards, so as to bring the fibula forwards. By this step the operator will be less likely to commit the error of passing his knife between, instead of behind both bones when about to form the posterior flap.

By *double flap* (Luke). — By this method two flaps of equal length are cut; the anterior from skin to bone, after the manner indicated at fig. 4; the posterior by transfixion.

By *long external and short internal flap* (Sedillot). — The assistant in charge of the distal portion of the limb should extend the foot, and also flex the leg to an angle of about 45° , so as to relax the muscles of the calf. Cut first the long external flap by transfixion, entering a long, narrow, single-edged knife on the front of the leg at a point midway between the crest of the tibia and fibula, and causing it to reappear in the calf of the leg after it has traversed the limb, close to, but external to the fibula, and taking care to include as much of the integument and of the muscle of the calf as possible. To aid in forming a broad flap, the operator's left hand should

seize and elevate the soft parts, so as to bring them within range of the knife (fig. 33). The leg is here shown insufficiently flexed.

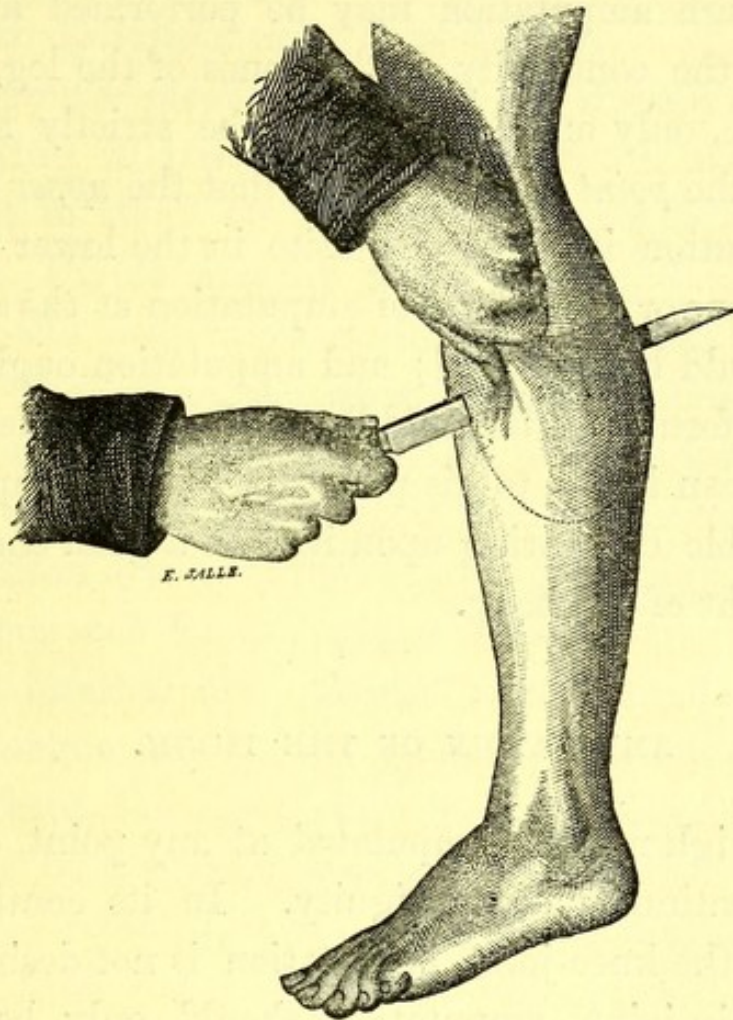


FIG. 33.

A well-rounded flap, in the direction of the dotted line, is to be cut out of the side of the leg, while a short anterior flap of integument must be formed on the inside in the usual manner; and when this latter has been dissected up to the requisite height, the operation may be completed as already described above.

In whatever manner amputation at the upper third

of the leg may be performed, the bones will be conveniently sawn across at the distance of three fingers' breadth below the tubercle of the tibia.

Although amputation may be performed at any point in the continuity of the bones of the leg, still, as a rule, only one locality may be strictly looked upon as the *point of election*, and that the *upper third*. The operation is rarely requisite in the lower third, because one or other form of amputation at the ankle-joint should be preferred; and amputation ought not to be performed in the middle of the leg, unless the surgeon can insure to his patient a sound stump, and one capable of bearing upon its face a good share of the weight of the body.

AMPUTATION OF THE THIGH.

The thigh may be amputated at any point, either of its continuity or contiguity. In its contiguity through the knee-joint, amputation is not desirable; at the hip-joint, amputation should only be performed as a *necessity*.

Lower Third.—This is the *point of election*, because through it amputation will be less severe than it would be if performed near the trunk; also, a useful stump is preserved to the patient.

In this locality, muscles on the posterior and internal aspects of the limb have their superior attachments at the pelvis, and when divided, will retract towards that point of origin, and in doing so,

are liable to carry the integument with them, to lay bare the divided end of the femur, and to induce a conical and useless stump. To avoid this accident, amputation either by circular incision, or by a modified flap operation, must be performed.

By *circular incision* (page 11).—Assistants and subject being in position, the operator will find it convenient to stand on the outside to operate on either thigh. Divide first by circular sweep the integuments and deep fascia as near to the patella as possible. This done, the assistant who embraces with both hands the proximal portion of the thigh, should make equable traction upon the integuments, while the surgeon divides at the required points any resisting adhesion, such for example as those existing opposite to the internal and external intermuscular septa. The integuments having yielded to the same extent throughout, the superficial set of muscles should be divided by a circular sweep, and in such a manner that the muscles at the back of the thigh are left longer than those in front, in order that all may be upon the same level when retraction has taken place. This effected, the assistant again retracts the divided tissues as much as possible, and now the operator, holding the knife with its edge looking upwards and towards the bone, severs the deep layer of muscles and all intervening structures down to the bone and close to the edge of the already retracted soft parts. The saw completes the separation.

If now the integuments and muscles be allowed to

fall over the bone, and their relative positions be examined, it will be seen that the bone is completely embedded in muscle, and forms the apex of a hollow cone, the base of which is represented by the cut margin of integument, fig. 7.

By *flap*.—In the lower third of the thigh the ordinary double flap operation, whether antero-posterior or lateral, is inadmissible for reasons above stated.

The method by flaps of *integument only* may be adopted. Having determined the point at which the bone is to be severed, two semilunar flaps of integument, with convexity towards the knee, are to be cut and dissected up to the requisite height; if antero-posterior flaps be preferred, a portion of the muscular structures on the front of the thigh may also be dissected up and be included in the flap: no muscular structure is to be left attached to the posterior flap, but the muscles on the back of the thigh should be cut long, and be carefully separated from the bone as high up as it may be necessary to apply the saw.

By leaving the hamstring muscles long and hanging into the wound unattached to the skin, the former can become retracted without carrying the skin with them.

In this instance, as in all cases, the knife should be held with its edge directed upwards and towards the bone when muscular structures are divided by a circular sweep.

By *long anterior flap* (Sedillot).—Cut a long semi-lunar flap, equal both in length and in breadth to two-thirds of the circumference of the limb, at the intended point of section of the bone; dissect up this flap composed of integument and muscular structure (see fig. 4), but not including the main vessels; divide the parts on the posterior aspect of the limb with one sweep down to the bone, and on a level with the base of the long flap. The application of the saw completes the operation. Fig. 34 shows the flap in apposition.

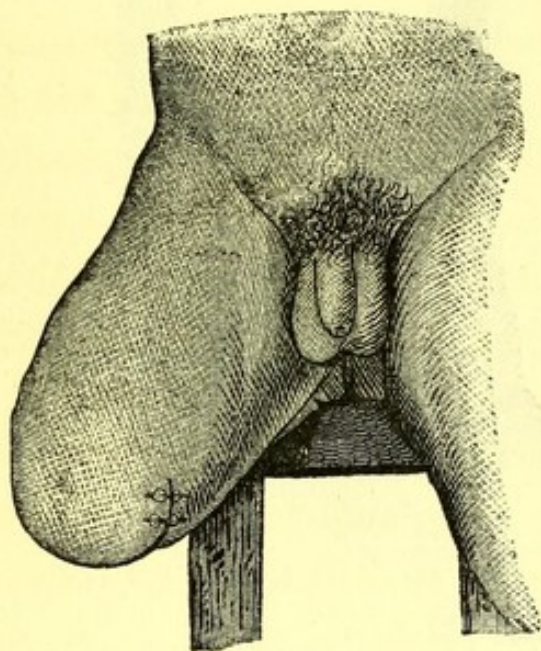


FIG. 34.

Teale's method (page 48) is equally applicable to this region, and is similar in principle to the above.

It appears to me that both these methods are open to the objection, that length of stump is sacrificed in order to obtain a long anterior flap.

The operation as executed at the lower third of the thigh is indicated in the following illustrations.

Fig. 35 shows the dotted lines, indicating the position and relative extent of the incisions.

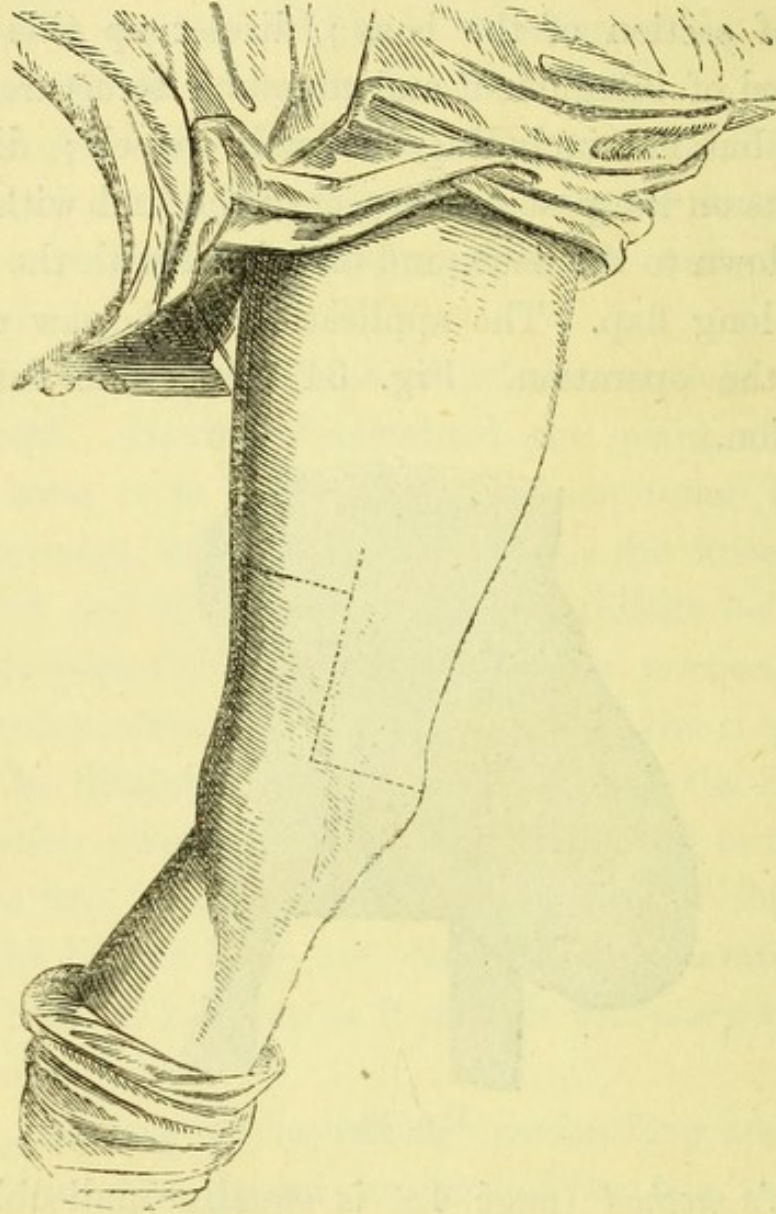


FIG. 35.

Fig. 36 illustrates the flaps formed according to the above relative proportions.

Fig. 37 gives the appearance of the stump when the flaps have been adjusted immediately after the operation.

Fig. 38 shows the condition of stump after cicatrization.

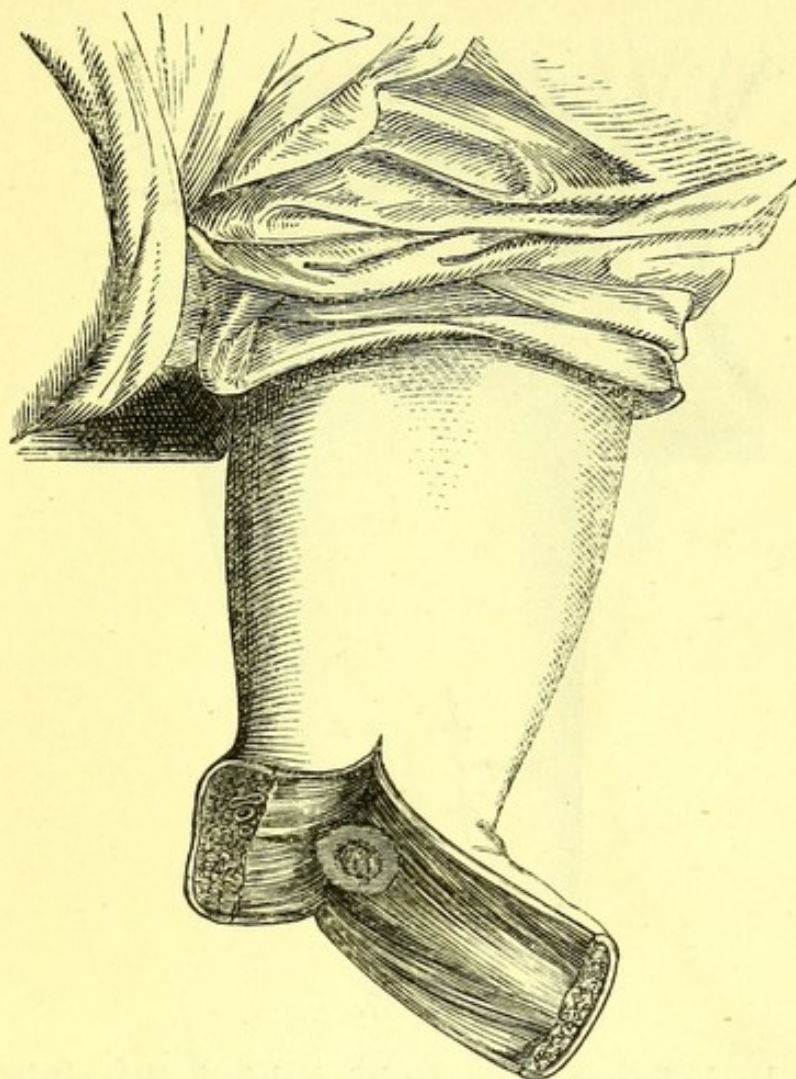


FIG. 36.

By *long posterior flap and short anterior flap*.—By this means a covering to the end of the bone is obtained from the posterior region of the leg, and the femur may be sawn across just above the condyles.

Cut first a short anterior semilunar flap in front of the knee and turn it up; open the knee-joint by dividing transversely the insertion of the quadriceps

femoris into the patella; flex the leg and traverse the joint, and after having severed the ligaments,

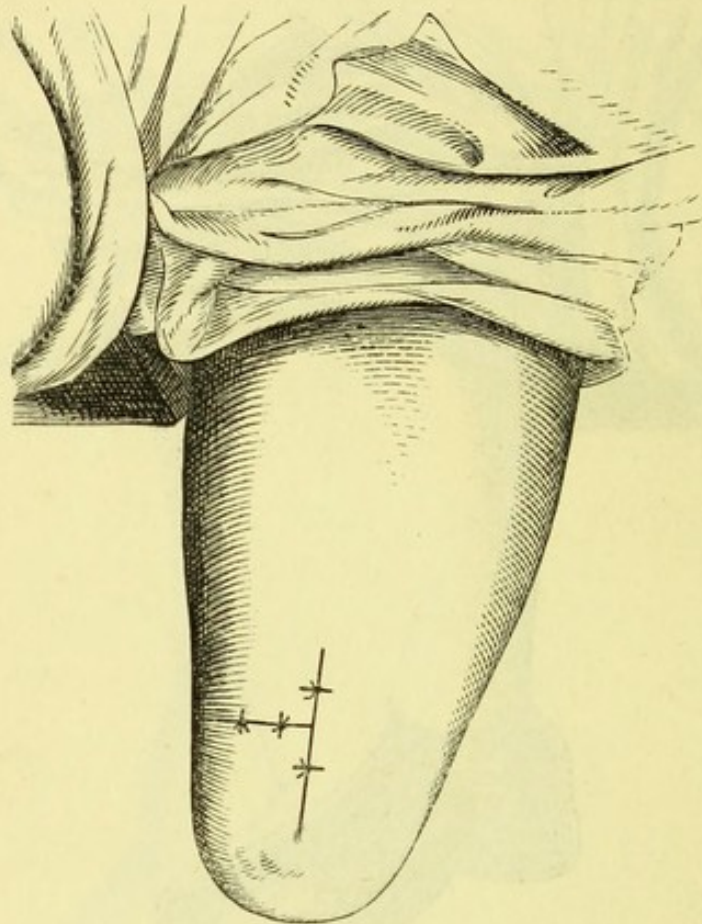


FIG. 37.

cautiously insinuate the knife behind the tibia and fibula, and cut a long posterior flap out of the calf of the leg. Sweep circularly the femur just above the condyles, and remove these latter with the saw.

In this way a long stump is preserved, and the end of the bone is also well covered.

When large nerves are visible on the face of a flap, they should be cut short.

I saw an excellent stump resulting from this mode in Mercer's Hospital, Dublin, under the care of Mr. Butcher.

Middle and Upper Thirds.—In these regions the muscles are severed at a shorter distance from their

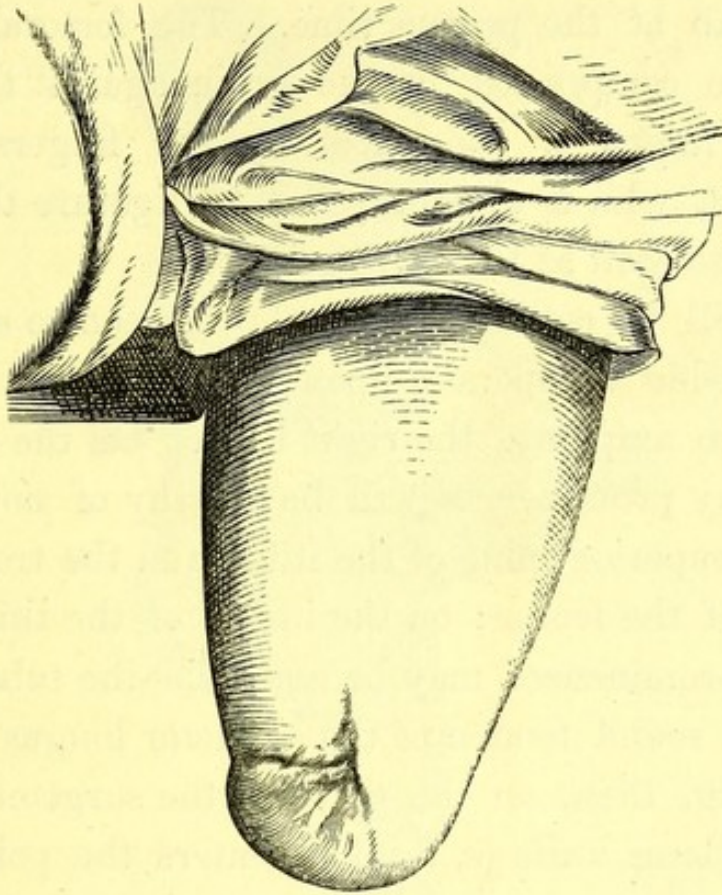


FIG. 38.

superior attachments than in the *lower third*, and consequently the amount of retraction will be much less in the former than in the latter case.

Amputation by the ordinary double flap by transfixion, is applicable here (see page 3).

Hip Joint.—Various modes have been adopted for disarticulation at this joint; and of these, two are preferred, and especially that

By *anterior flap.*—The buttocks of the subject should be well advanced upon the edge of a table; the trunk must be supported lest it also slip forwards;

the sound limb must be cared for, and the condemned limb be supported at the knee and ankle by a strong assistant, who must be prepared to abduct and rotate the limb at the proper time. The femoral artery must be compressed in the groin against the horizontal ramus of the pubis by the fingers of an assistant, who is also prepared to ligature the main vessels so soon as the flap be cut.

It will be convenient for the surgeon to stand on the outside to operate upon the left limb, on the inside to amputate the right limb. On the outside, two bony prominences will be worthy of note,—the antero-superior spine of the ilium and the trochanter major of the femur; on the inside of the thigh, two other prominences may be noticed,—the tuber ischii and the round tendon of the adductor longus muscle. Standing, then, on the outside, the surgeon, armed with a long knife (*e*, fig. 39), enters the point of it midway between the antero-superior spine of the ilium and the great trochanter of the femur (*d*), and causes it to make its appearance on the inside between the tuber ischii and tendon of the adductor longus muscle (*b*), avoiding to wound either the sound limb or scrotum (*a*), but causing the knife to pass close in front of the capsule of the joint, so as to avoid puncturing the femoral vessels. The soft parts in front of the thigh must now be grasped by the operator's left hand, so as to bring as much integument as possible within range of the knife, while a broad, long (half the length of the thigh), and well-rounded flap (*b, c, d*) be cut from above downwards. This flap is at once

seized, turned up, and assistants may proceed to ligature the larger vessels, while the operator effects

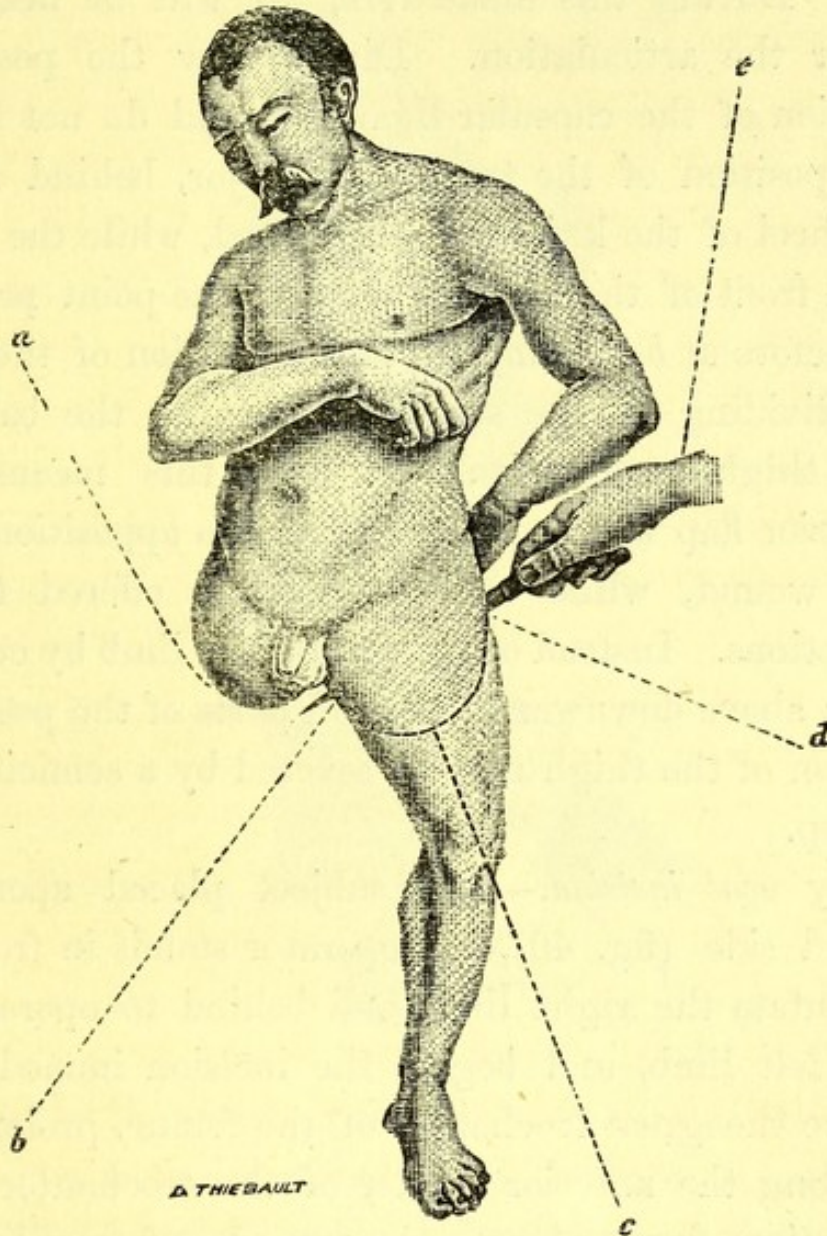


FIG. 39.

disarticulation. To open the joint is difficult with a long knife, and must be done cautiously, lest the point slip into dangerous regions. The capsule bared, attack it on the anterior and inner surfaces; and as soon as it is opened, the assistant should abduct and rotate the limb outwards, so as to cause

the head of the bone to protrude, and perhaps rupture the round ligament also; if not ruptured, it must be cut. During this manœuvre, air will be heard to enter the articulation. Divide now the posterior portion of the capsular ligament, and do not forget the position of the trochanter major, behind which the heel of the knife must be placed, while the blade is in front of the acetabulum and the point projects as before at *b*. Complete the separation of the limb by dividing all the structures forming the back of the thigh perpendicularly. By this means the anterior flap will be found to fall into apposition with the wound, while a ready exit is offered to all secretions. Instead of separating the limb by cutting from above downwards, the soft parts of the posterior region of the thigh may be severed by a semicircular sweep.

By *oval incision*.—The subject placed upon the sound side (fig. 40), the operator stands in front to amputate the right limb, and behind to operate on the left limb, and begins the incision immediately above the great trochanter of the femur, prolonging it along the anterior border of the trochanter in a direction from above, downwards, forwards and inwards, with slight convexity forwards across the front and inner side of the thigh to a point about three fingers' breadth in front of the tuber ischii, now turns outwards across the back of the thigh, and then upwards along the posterior margin of the great trochanter to terminate at the point of origin. This incision should divide integuments only. Now sever

muscular attachments to the trochanter close to the retracted skin, open the articulation from behind, and

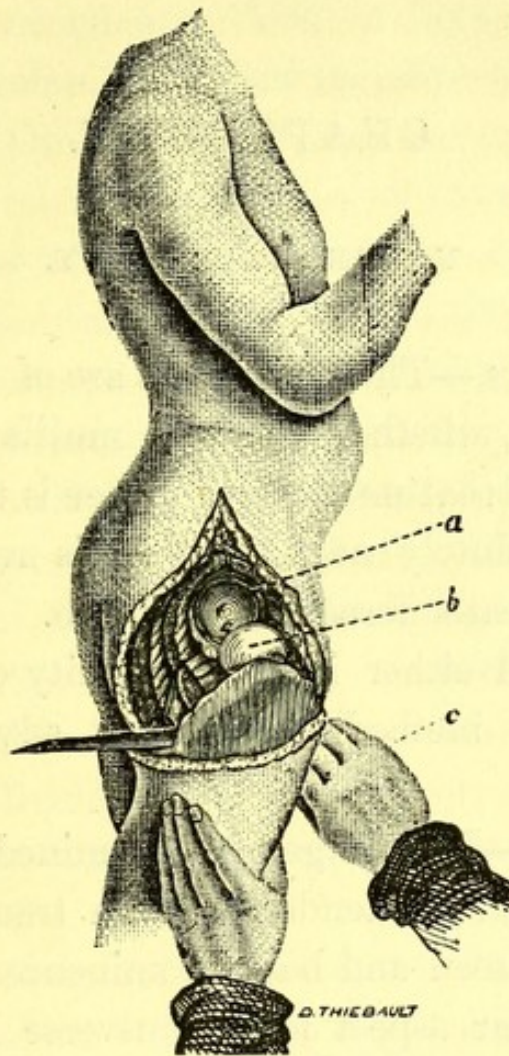


FIG. 40.

divide the ligamentum teres as soon as the assistant shall have caused the head of the femur (*b*) to protrude from the acetabulum (*a*) by rotation of the limb; place the knife (*c*) in the wound behind the bone, and sever the remaining soft parts and vessels while the assistant, following the knife with his hand, compresses the latter.

The fibro-cartilaginous border of the acetabulum and remains of the capsule may be removed with a scalpel.

CHAPTER III.

UPPER EXTREMITY.

The Fingers.—These members are of so great value to the owner, whether whole or mutilated by injury or operation, that no more of either is to be removed than is absolutely necessary. This remark applies with still greater force to the thumb. A finger may be amputated either in its continuity or contiguity, and various methods have been advised for this purpose.

Anatomy.—If a finger be examined from before backward, when extended, certain transverse markings will be seen and bony prominences may be felt. On the palmar aspect is a transverse linear depression in the skin, situated about a line posterior to the articulation of the second and third phalanges; further back are two well-marked lines with several incomplete lines between them—the posterior of the two former corresponds to the joint between the first and second phalanges; at the junction of the finger with the palm is another transverse depression, but which is much anterior to the metacarpo-phalangeal joint; the oblique markings in the palm are somewhat posterior to the joints to which they correspond.

On the dorsal surface the most distinct of the transverse lines corresponding either to the joint between the second and third, or between the first and second phalanges, is just opposite to the line of articulation. On the side of the finger opposite to the joint between the second and third phalanges, two elevations with a depression between, marking the line of articulation, may be recognised; on the dorsum and base of the second phalange a tubercle is situated, and immediately behind this is the articulation between the first and second phalanges. The superficial head of the metacarpal bone is not prominent; but if the finger be flexed to a right angle, the convex head becomes very prominent, and the line of articulation is much advanced. A tubercle, sometimes well marked, is situated on either side of the base of the first phalange, and is immediately in front of the joint.

Observations upon the second and third phalanges of the fingers are sufficiently applicable to the phalanges of the thumb, and need not to be repeated.

When operating upon the hand, the main vessels (radial and ulnar arteries) may be conveniently compressed against their respective bones by the fingers of an assistant, placed upon the anterior surface, while the thumbs rest upon the posterior surface of the forearm just above the wrist.

Amputation at the joint of the second and third phalanges, by *palmar flap*.

Assistants should hold aside the adjacent fingers,

with a loop of bandage cast around each. The operator holds the condemned phalange dorsum upwards, with the forefinger and thumb of his left hand, the thumb being upon the dorsal, the forefinger upon the palmar surface of the finger; recalling the anatomical landmarks mentioned above, and with a *narrow-bladed* knife he cuts transversely through the soft parts on the dorsal surface, directly into the joint of the extended finger. Flex now the phalange, and traverse the joint by dividing the lateral ligaments, first one and then the other, by elevating and depressing alternately the handle of the scalpel; turn the edge of the knife forwards so as to insinuate it behind the head of the condemned phalange, and cut forwards towards the tip of the finger, keeping the knife close to the bone while so doing; measure the length of flap requisite, by bringing up the raw surface of the soft parts which have been separated from the phalange against the exposed head of the second phalange, and complete the flap and remove the phalange by cutting forwards to the necessary extent.

Amputation at the joint of the first and second phalanges by *palmar flap*.

The above mode of operating is also to be observed at this joint. In either case the head of the phalange may be removed at pleasure. Fig. 41, *a*, shows the flap resulting.

Amputation in the *continuity* of a phalange by *palmar flap*.

The palmar flap is to be cut by transfixion, then the soft parts on the dorsum are to be divided transversely or with slight convexity forwards, when the bone may be severed either by saw or forceps.

Amputation either in the continuity or contiguity of a phalange by *double flap*.

Cut a semilunar dorsal flap in the usual way, from skin to bone, the points of origin and of termination of the incision being allowed to correspond with the intended point of section or of separation of the bone; from the second flap by transfixion, or by cutting forwards after that the joint has been traversed.

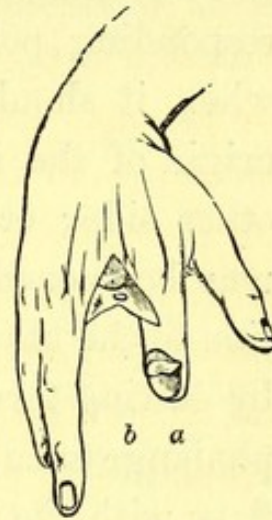


FIG. 41.

Amputation by *a short and a long rectangular flap*. (Teale's method, page 48.)

Of the above methods, that by *long anterior flap* is perhaps to be preferred, because the bone will be protected by a good covering of soft parts, and the cicatrix being upon the dorsum, will not be exposed to pressure.

Amputation at the metacarpo-phalangeal articulation by *lateral flaps*. The head of the metacarpal bone being very prominent, a due proportion of integument must be left to cover it. The incision is to be begun on the dorsal surface, opposite to the centre of the joint, and to be carried forwards along and near to the centre of the phalange towards the junc-

tion of the web with one side of the finger, at which point the knife is to be turned across the palmar surface along the groove in the integument to a corresponding point on the other side of the finger, when it should be conducted back to the point of origin of the incision, dividing the parts as on the other side; or, after having cut one flap, the joint may be opened and traversed by the knife from one side to the other, when the second flap may be made by cutting forwards and outwards by the side of the phalange to be removed. Fig. 41, *b*, shows the lateral flaps with the head of the metacarpal bone between them.

A finger having been removed, and the edges of the wound united by suture, the adjacent fingers should be at once approximated by a bandage.

By *oval incision*.—Commence the incision opposite

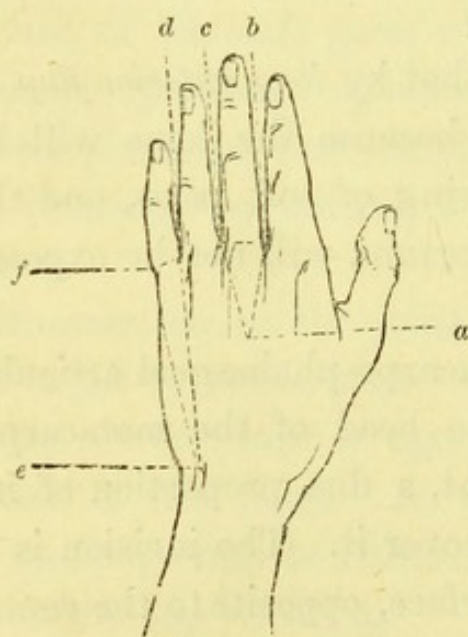


FIG. 42.

to the centre of the joint, and on the dorsal surface (fig. 42, *a*); carry it obliquely forwards along the side of the finger (*b*), traverse the groove on the palmar surface, here indicated by a dotted line on the dorsum, and return along the opposite side of the finger (*c*) to the point of

commencement. Divide the extensor tendon, traverse

the joint and complete the separation by section of the flexor tendons. Fig. 43 shows the result of the oval incision: *i* is the subcutaneous tissue of the

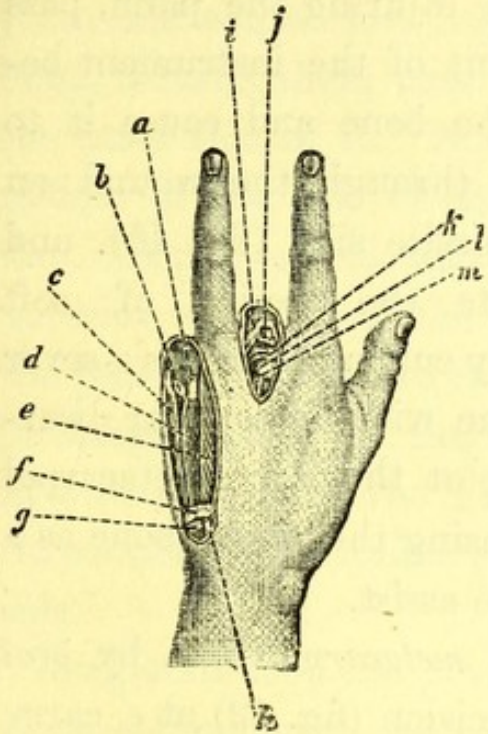


FIG. 43.

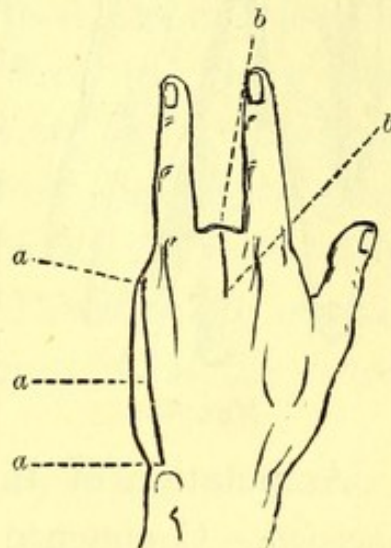


FIG. 44.

palm; *j*, the sheath of flexor tendons; *l*, the head of metacarpal bone; *m*, the extensor tendon. A linear cicatrix is the result (fig. 44, *bb*).

Should it not be thought necessary to preserve the normal width of the hand, the head of the metacarpal bone may be removed.

Amputation of *whole* or *part* of a metacarpal bone.—The cutaneous incision should be in the form of an elongated oval, or triangle with rounded angles, and made after the manner above described; the point of origin of the incision to correspond to the intended point of section or of separation of the bone. Separate the soft parts from the condemned bone with the

knife held parallel to the long axis of the latter, while the muscular attachments are being divided on

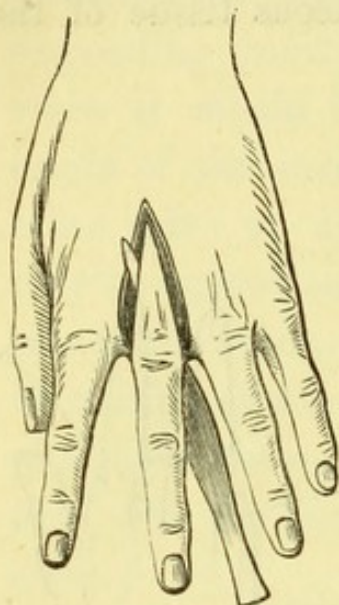


FIG. 45.

one side; then, cautiously and without injuring the palm, pass the point of the instrument behind the bone and cause it to appear through the wound on the opposite side (fig. 45), and complete the section of soft parts by cutting forwards: sever the bone with forceps, or disarticulate at the carpo-metacarpal joint, using the bared bone as a lever to assist.

Amputation of the *fifth metacarpal bone* by *oval incision*.—Commence the incision (fig. 42) at *e*, carry it forward along the dorsum to one side of the finger (*d*), as far as the junction of the web, then across the palmar surface of the finger in front of the normal groove, but on a level with the web, as indicated by dotted line (*f*); now back along the opposite side of the finger to *e*, the point of commencement. Carefully separate the attachments to the metacarpal bone without injuring the palm of the hand with the point of the knife, and using the bone as a lever to assist, disarticulate it at the carpo-metacarpal joint. The parts interested are shown at fig. 43: *h* is the extensor tendon; *f* the unciform bone; *a*, *b*, *c*, *d*, *e*, *g*, are muscles, &c. Fig. 44, *a a a*, shows the linear cicatrix resulting.

By *lateral flap*.—With the fingers and thumb of the left hand, seize the soft parts on the inner side of the hand and opposite to the carpo-metacarpal joint, and while elevating them, as it were, from the bone, transfix them close to the above joint, and on the inner side of it. Now cut forward as far as the middle of the side of the first phalange and form a flap. Separate the soft parts from the outer and anterior surfaces of the metacarpal bone, carrying the incision forward to the opposite side of the first phalange, as far as the junction of the web with it, and so isolate the finger. Disarticulate at the carpo-metacarpal joint by opening it on the outer side.

Amputation of the *first metacarpal bone by oval incision*.—Commence the incision (fig. 46) at *a*, on the dorsum of the hand opposite to the articulation between the os trapezium and the metacarpal bone; carry it forwards on one side of the same, in this instance to *d*, to the point of junction of the web with the thumb, then turn outwards and backwards across the palmar surface to *b*, as indicated by the dotted line *c*, and terminate at *a*. Carefully separate the soft parts from the bone, not forgetting the position of the radial artery at the ulnar side of the base of the latter, and complete the

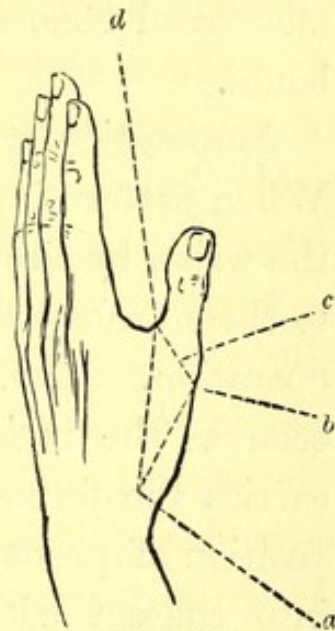


FIG. 46.

operation by disarticulation begun on the outer side of the joint.

The operator must avoid the error sometimes made, of removing the trapezium as well as the metacarpal bone. In the male adult, the joint between the os trapezium and the first metacarpal bone will be about the length of the unguis phalange of the surgeon's thumb, inferior to the apex of the styloid process of the radius.

I would again advise the student to use a *narrow-bladed* knife when operating in the contiguity of the bones of the hand and foot, otherwise he will often experience great difficulty in causing the instrument to traverse many of the articulations belonging to these members; also, to provide sufficient integument to cover the heads of prominent bones, such as of the metatarsal bone of great toe and of the metacarpal bones.

Amputation at the *wrist-joint* by *circular incision*.—When performing amputation of the fore-arm, or at the wrist, by circular incision, the movements natural to the member should be employed to facilitate the operation. The hand should be held supine, and so soon as the incision is begun, the assistant slowly carries the former from a state of supination into a position of pronation, thus bringing the integument into contact with the edge of the knife and so making the incision, rather than, as is usual, by carrying the knife around the limb, while the latter is held firm and immovable. This manœuvre

may be employed by a surgeon standing on the inside.

The circular incision should be made through the integuments only, and when retracted to the requisite height, the various tendons and other structures are to be divided at the margin of the skin down to the bones. To open the joint readily, the operator must recollect the form of the articulation, the convex carpal bones being received into the concavity of the radius and ulna; and having opened the joint on one side just below either styloid process, should cause the knife, held perpendicularly, to follow the convexity of the carpal bones and to sever the hand, as it were, with one sweep.

By *double flap* (antero-posterior).—In consequence of the natural prominence of the styloid processes and their tendency, therefore, to project at the angles of a wound, the flaps should be begun and be terminated a finger's breadth below them; also, in consequence of the mobility of the thumb, which, when adducted, causes puckering of the skin of the palm, the anterior flap should be marked out before the posterior be cut, otherwise the margin of the former would be irregular. The pisiform bone must be avoided when cutting the anterior flap.

The operator holding the condemned hand supine, with the thumb of it abducted, so as to make tense the integument of the palm, should mark out with the point of his knife a well-rounded semilunar palmar flap; this done, pronate the hand, and dissect

up to the requisite height, a similar flap of integument from the dorsum ; flex the hand forcibly, open the joint on the dorsal surface, and traverse it as in fig. 47 ; now turn the edge forwards, and avoiding

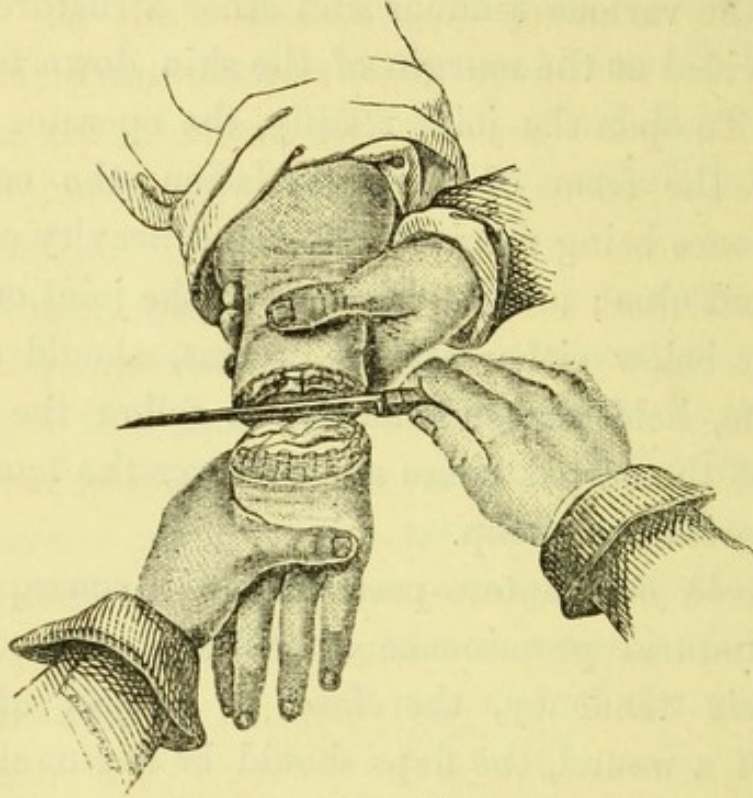


FIG. 47.

the pisiform bone, complete the palmar flap, the extent of which has previously been determined. Fig. 47 is intended to show the mode of operating at the wrist joint by *circular incision* ; but it is better to effect disarticulation with the knife held perpendicularly rather than horizontally,—the latter position being well adapted to opening the joint when amputation by flap is preferred.

The Fore-arm.—Amputation may be performed at any point of the fore-arm ; but all methods are not equally applicable to each region. The limb being conical,

with the apex of the cone towards the wrist, amputation by *circular incision* should not be attempted in the lower half because retraction of the integuments could not be readily effected by consequence of the increasing size of the limb towards the elbow. Again, in the lower half amputation by *ordinary double flap* is not desirable by reason of the presence of many tendons, which, if they did not slough, would be useless in a stump.

Teale's method is applicable to the lower half of forearm (page 48). Fig. 48 shows the necessary incisions.

In the *upper half* amputation either by *flap* or by *circular incision* may be practised.

Lower half by double cutaneous flap.—Either divide the integument by circular incision, as described above, and then let fall a parallel incision on either side of the arm to meet the first at a right angle, and so mark out two rectangular flaps of integument only; or, holding the hand prone, mark out an anterior and a posterior semilunar cutaneous flap: dissect up these to the requisite height; and now divide the muscles, &c., circularly down to the bones and as high as the bases of the flaps, sever the interosseous parts, and complete the separation with the saw. The ulna being the more firmly fixed bone, should be first attacked by the saw, then the radius is to be included and severed, while the separation is effected by completing the section of the ulna.

During the progress of the saw, it will be well for

the assistants in charge of the limb, both above and below the intended point of section, either to hold

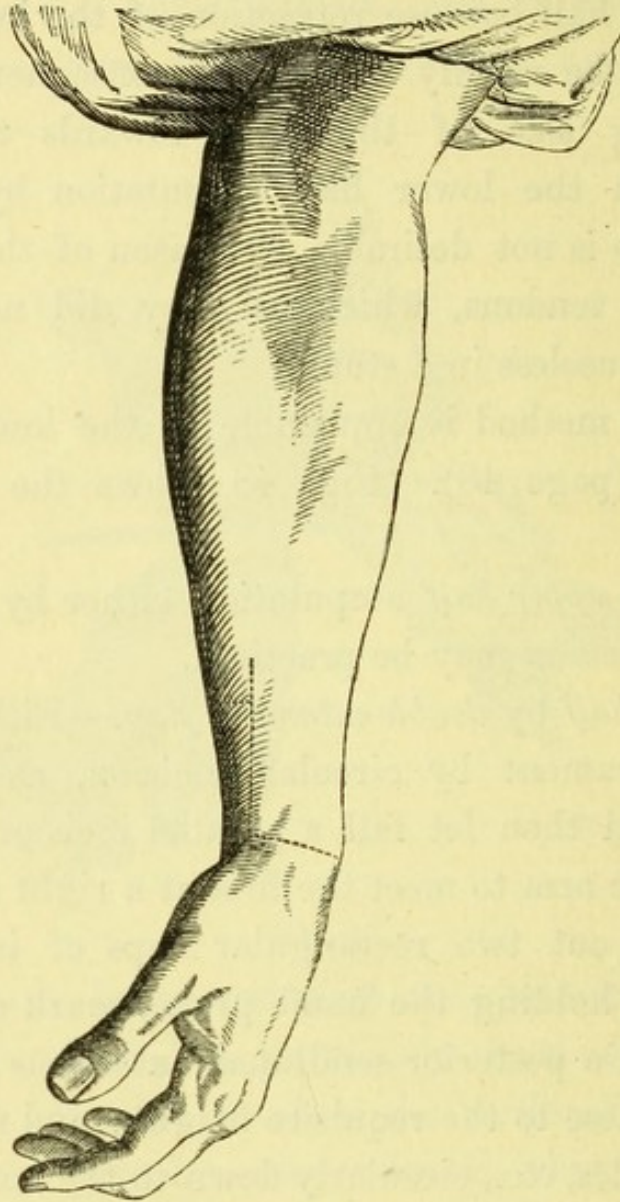


FIG. 48.

each bone separately with a finger and thumb, or to press his thumb between the bones with a view to maintain their relative positions during the working of the saw.

Tendons are liable to glide from the edge of the knife and to escape division during a circular sweep ;

they may, under these circumstances, be divided separately, by passing the knife under them.

Upper half.—In this region, amputation by *ordinary double flap*, or by *circular incision*, may be performed.

Elbow Joint.—If at all, amputation will be best performed at this articulation by *anterior flap*. To operate upon either arm, the surgeon will find it convenient to stand on the inner side. In consequence of the natural prominence of the condyles of the humerus, the knife should enter the limb nearly one finger's breadth below the internal condyle; and in order to allow also for retraction of the supinator longus and other muscles arising from the humerus, should reappear on the outer side at a point nearly two fingers' breadth below the outer condyle.

The hand being supine and the forearm slightly flexed, the surgeon stands on the inside; and while his left hand is employed to seize and preserve as much integument as possible in the anterior flap, the knife held in the right hand should transfix the limb obliquely in front of the bones at the points above-mentioned, and form a long anterior semilunar flap, by cutting downwards and forwards. An assistant should at once withdraw this flap, when the operator, passing the knife behind the limb, divides the soft parts covering the posterior half of the forearm with a semicircular sweep, and at the same time opens the humero-radial joint. Any soft parts remaining in front of the articulation must be severed,

as also the anterior and internal lateral ligaments, when the separation may be completed either with the saw, thus leaving the olecranon *in situ*, or by extension allowing the operator to pass the knife above the olecranon in order to divide its muscular attachments, and so the ulna is removed entire.

Amputation at the elbow joint is not a desirable operation, by reason of the large wound resulting.

The Arm.—Amputation by *circular* or *flap* method is equally applicable. The surgeon may stand on either side of the limb.

By *circular incision*.—Divide in the usual manner the integuments, and as soon as these have been well retracted by the appointed assistant, sever the superficial muscular fibres on a level with the retracted skin (except the biceps, which, having a high origin, may be cut lower, because it will become more retracted than the adjacent muscles); after a second retraction, divide all intervening structures down to the bone, the edge of the knife, during the circular section of the muscles, being directed upwards and towards the bone, thus dividing the muscular structures obliquely, and leaving the bone, which may now be sawn across, at the apex of a cone. Fig. 6 shows the effect of the circular incision upon the soft parts of the arm, aided by retraction from above.

By *double flap*.—Amputation by *ordinary antero-posterior* flaps by transfixion, care being taken to cut the anterior flap longer than the posterior to

allow for retraction of the biceps muscle; and by ordinary lateral flaps, may be performed.

Teale's method (page 48) is applicable in this region. Fig. 49 shows the relation and extent of the necessary incisions.

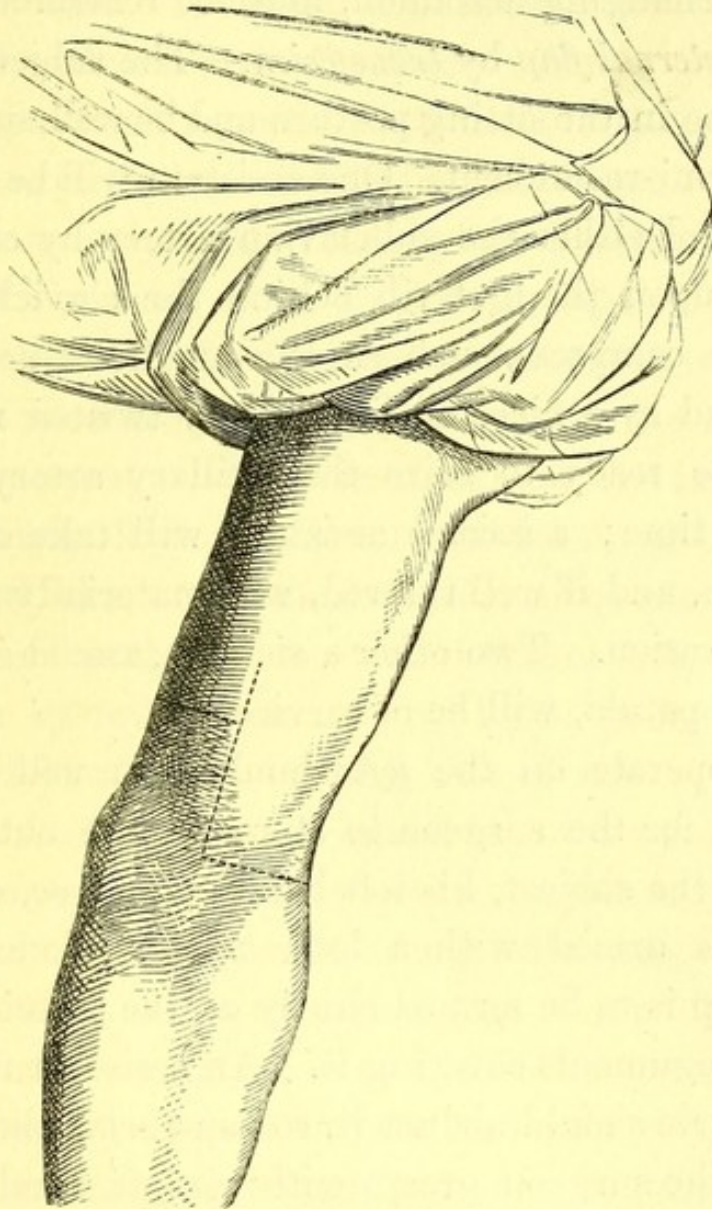


FIG. 49.

Shoulder Joint.—Various methods have been proposed for the performance of amputation at this articulation. The movements of which this joint is

capable in its normal state, as abduction, adduction, rotation both outwards and inwards, &c. ; the position of bony eminences, such as the lesser and greater tuberosities to which muscles are attached, and their relation to the coracoid process on the inside and to the overhanging acromion, must be remembered.

By *external flap by transfixion*.—The subject should either be in the sitting posture and be well supported, or be semi-recumbent. One assistant will be required to control either the subclavian artery by compressing it upon the first rib behind the clavicle with a suitable compress, such as the handle of a door key protected by a piece of lint tightly twisted round it, or to be ready to seize the axillary artery at the proper time ; a second assistant will take charge of the arm, and if well tutored, will materially facilitate the operation. Two other assistants, armed each with a bent spatula, will be of service.

To operate on the *left* shoulder it will be convenient for the surgeon to stand on the outside and behind the subject, his left hand being free, while the right is armed with a long narrow-bladed knife. The flap is to be formed chiefly of the deltoid muscle and integuments covering it. An assistant in charge of the arm should abduct it, so as to relax the deltoid, while the surgeon grasps with his left hand the soft parts covering the shoulder, in order to include as much as possible in the flap which is to be made by entering the point of the knife behind the joint near the base of the acromion process, passing it carefully

above the head of the bone without breaking its point against the greater tuberosity, and causing it to reappear in front just outside the coracoid process. This is a difficult manœuvre; and should the subject be alive and very muscular, it will be well to cut the flap from skin to bone, unless the muscles be thoroughly relaxed by chloroform. A flap as broad as possible, well rounded inferiorly and reaching down the arm to the insertion of the deltoid, should now be cut and be held up by an assistant. The appointed assistant now carries the elbow to the patient's side, and the surgeon seizes the arm about its middle with his left hand and rotates the head of the humerus outwards, so as to expose the insertion of the subscapularis muscle into the lesser tuberosity, to facilitate which an assistant holds aside, either with a spatula or his finger, the soft parts on the inside, while the operator, holding the knife point downwards and parallel to the long axis of the humerus, places the heel of the instrument upon the insertion of the subscapularis and severs its attachment, at the same time carrying the knife over the head of the bone and down across the insertions of muscles into the greater tuberosity, so as to divide the capsule and long tendon of the biceps and the tendons of the supraspinatus, infra-spinatus and teres minor muscles, while the arm is being passed from a state of extreme rotation outwards to a position of extreme rotation inwards. (When cutting across the muscles attached to the tuberosities, it must be remembered that a few

of the fibres both of the subscapularis and of the teres minor muscles, are inserted into the shaft of the humerus immediately below the tuberosities.) By this means the head of the bone will be liberated, and the knife is to be introduced between it and the glenoid cavity (see fig. 50); then the assistant seizes

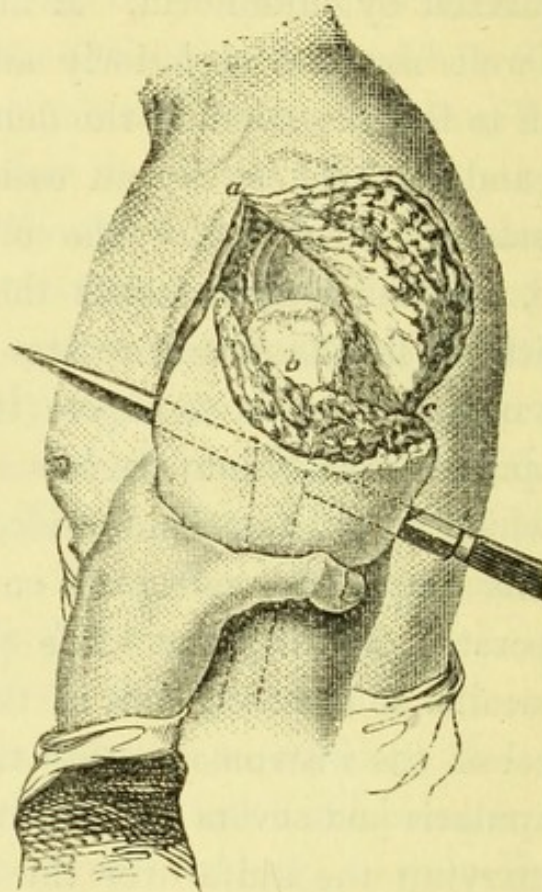


FIG. 50.

the soft parts on the inside, and compresses the axillary vessels, while the operator separates the limb by dividing all structures, intervening the knife and the surface, at the point of junction of the folds of the axilla with the arm.

To amputate the *right* extremity, the principal steps of the operation will be conveniently reversed.

By *anterior* and *posterior flaps*.—Excepting the use of the knife, the above instructions are applicable here.

To operate on the *left* shoulder, the surgeon will stand conveniently on the outside, and while manipulating the arm with his left hand, should enter the point of the knife held in the right hand immediately in front of the posterior cutaneous fold of the axilla; and, while elevating the elbow so as to depress the greater tuberosity and avoid striking it and carrying the instrument upwards and forwards, cause the point of it to reappear as much as possible in front of the apex of the acromion process, when the flap is to be formed by the knife cutting its way out in a downward direction as low as the junction of the posterior axillary fold with the arm (fig. 50, *a c*). Open the joint by dividing the capsule and adjacent tendons, pass the knife behind the head of the bone (*b*), and cut an anterior flap as low down as the junction of the anterior fold of the axilla with the arm. (When attempting to liberate the head of a bone, such as that of the femur or of the humerus, the knife must not be allowed to run round the globular extremity with the flat of the blade upon it, but the edge of the knife must be held at right angles to the bone at each stroke; if otherwise, the attached tendons, &c., will escape division.)

By *oval incision*.—Commence the incisions at the apex of the acromion process (*a*, fig. 51), and divide the integuments on either side of the arm in the

direction of *a b*, *a c*, each terminating at the junction of its respective axillary fold with the arm; retract

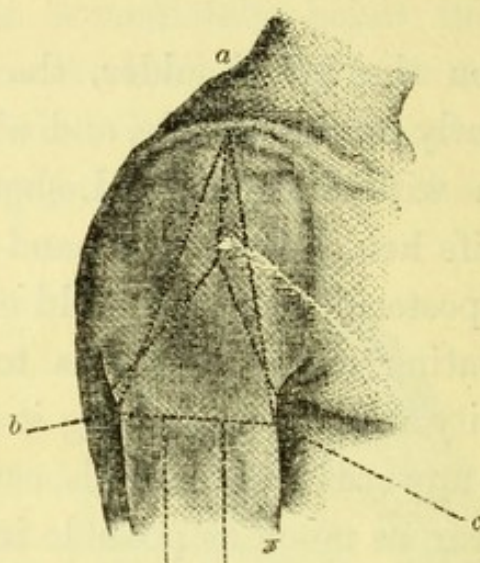


FIG. 51.

integument and sever the muscles down to the bone; disarticulate; pass the knife behind the humerus, and separate the limb by dividing the muscles, vessels and integument on the inside, on a level with *b* and *c*, as represented by the transverse line *b c*.

By this method the acromion is liable to protrude, and to avoid this accident, make first a perpendicular incision beginning at the apex of the acromion, and extending about two fingers' breadth down the arm, fig. 51; then complete the operation as above and as indicated by the dotted λ , and at fig. 52.

Of the various methods proposed for amputation at the shoulder joint, that by *external flap* is to be preferred, because a good covering to the wound is readily procured, and is also maintained by its own weight in position. Disarticulation can be effected with comparative ease.

It will be observed that the directions given above for performing amputation in certain regions are

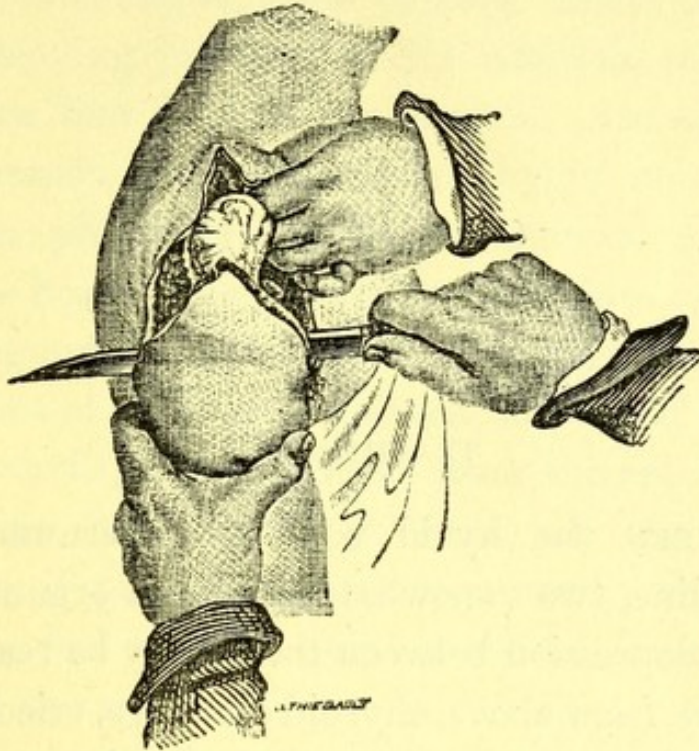


FIG. 52.

especially applicable when the integrity of the part has not been interfered with either by disease or injury; under the latter circumstances, the ingenuity of the surgeon will devise how and whence the covering for the wound may be formed.

CHAPTER IV.

SPECIAL OPERATIONS.

TRACHEOTOMY.

BETWEEN the hyoid bone and sternum in the median line, two somewhat prominent organs, with a shallow depression between them, may be readily felt. These are from above, thyroid cartilage, crico-thyroid membrane corresponding to the depression, and cricoid cartilage. Between the cricoid cartilage and the sternum lies the trachea. Of these organs the rings of the trachea are incomplete posteriorly, and so also is the thyroid cartilage. The cricoid cartilage is a complete ring and may therefore be firmly held and compressed between the finger and thumb without obstructing respiration. These parts are covered in front along the median line by integument and deep cervical fascia; the crico-thyroid membrane is crossed transversely by the crico-thyroid branch of the superior thyroid artery (the vessel running nearer to the thyroid than to the cricoid cartilage), the isthmus of the thyroid body lies upon the first ring of the trachea, and below this is a plexus of veins: also in front

of the trachea, but behind the first bone of the sternum, lie the vena innominata of the left side, the arteria innominata, and arising from the latter and ascending in front of the trachea, the arteria thyroidea ima is occasionally seen. On either side of the mesian line lies the sterno-hyoid muscle.

When practicable, place the subject recumbent with the head thrown back over a pillow, and incise the integument and deep fascia in the mesian line to the extent of an inch to an inch and a half from the cricoid cartilage downwards; sever the areolar tissue and veins immediately in front of the trachea, avoiding, if possible, but not necessarily, the thyroid isthmus; feel with the point of the forefinger for the rings of the trachea, and (while assistants with blunt hooks separate the edges of the wound and the adjacent borders of the sterno-hyoid muscles) open the trachea with a sharp-pointed bistoury from below upwards by dividing three or four of its rings longitudinally; if necessary, carefully introduce the canula, with or without a pilot, into the trachea, and maintain the same *in situ* by means of a tape passed around the neck. If the subject be alive, the constant rising and falling of the organ during deglutition and respiration will be often an obstacle to the act of opening the trachea; under these circumstances, if an adult, the cricoid cartilage may be held by the finger and thumb so as to fix the trachea; or, in the case of a child, a sharp hook inserted into the cricoid cartilage and entrusted to an assistant to

hold the organ elevated, will materially assist the operator.

Although the veins may bleed freely, open the trachea as quickly as possible, and the hæmorrhage will cease spontaneously.

The most difficult step of the operation is the introduction of a canula. To overcome the difficulty, I would suggest, to introduce the point of a *double* hook into the incised trachea, and holding the tube elevated with it, slip up the clasp and allow the halves of the hook to separate by their own elasticity and at the same time to open the wound in the trachea; now pass the canula into the wind-pipe. The double hook thus effects two objects—fixity of the trachea and widening of the incision already made into it.

Although a double canula be used, and the inner one be removed at intervals, cleaned and replaced, still mucus becomes inspissated, and, adhering to the extremity of the larger tube, offers a serious obstacle to respiration. This inconvenience may be remedied while the inner tube is being cleaned by the careful introduction of a small elastic catheter well warmed so as to soften it and oiled, quite through the larger tube just into the trachea. By this means a passage is cleared and obstruction removed.

Again, although a double canula be used, mucus collects at the further extremity and cannot always be removed, either by cleaning the inner tube or by the catheter; both must therefore be removed, cleaned

or replaced by others. This necessity occurred to me in a case recently under care, and in order to obviate the difficulty anticipated on reintroduction of the cleaned tubes, I first removed the inner canula, and then passed a small elastic catheter through the outer tube into the trachea, and maintaining it there withdrew the outer tube over the catheter, and as soon as it was cleaned passed it back again along the catheter still in the trachea, till it occupied its former position; the catheter was then removed from the trachea.

The catheter served as a tube by which respiration could be sustained, and also as a guide for the reintroduction of the canula after the manner of Wakley's Catheters.

When opening the trachea, avoid transfixing this tube, lest the œsophagus lying behind it be wounded.

In the absence of the above surgical appliances, a razor or sharp penknife will serve for the division of the tissues, and a quill will answer as a temporary substitute for the canula.

Instead of using a canula, a small piece of one or two rings of the trachea may be cut away.

Various instruments for the ready performance of tracheotomy have been invented; but as either of these will probably not be at hand when required, I shall not refer to them further.

LARYNGOTOMY.

This operation consists in opening the air-passage through the crico-thyroid membrane; it is performed

with greater facility than tracheotomy, but is rarely so advantageous as the latter, the opening being small when effected, and probably unnecessarily near to the seat of disease requiring surgical interference.

PARACENTESIS THORACIS.

Should there be no special indication, the cavity of the pleura will be conveniently opened at the space between the sixth and seventh ribs, external to their angles.

The operation may be effected either by a trocar and canula, or by a scalpel, or by caustic. If it be determined to draw off a certain quantity only of the contained fluid, the wound in the integument should correspond with that of the pleura, only temporarily, in order to ensure closure of the opening after the completion of the operation; should a permanent opening be required, the relation of the integument to the pleura need not to be altered. The point for puncture of the pleura having been determined upon within the limits of the middle third of the side of the chest affected, the skin is to be drawn either down or up and be so maintained until the completion of the operation, when the tractile force being removed, the wound in the integument will no longer correspond with that of the pleura; incise the skin on a level with the superior border of the rib, with a view to avoid the risk of wounding the intercostal artery, which in this region runs along the lower

border of the middle third of a rib; either continue to incise the muscles and even the pleura itself on the same level with a scalpel, or puncture the chest with a small trocar and canula. The contents having been drawn off to the requisite quantity, the skin may be allowed to return to its normal position, carrying the superficial wound with it, and so assisting with a compress and strapping which may now be adjusted to close the deeper wound. If danger from entrance of air be apprehended, either a piece of wet rag may be adapted to the canula as a valve, or a special instrument must be employed. As a caustic, potassa fusa will be useful. (Part I., page 141.)

ŒSOPHAGOTOMY.

In the cervical region, the œsophagus lies in front of the spine behind the trachea, but slightly to the left of the mesian line, and therefore can be more readily reached on the left than on the right side of the neck; external to it is the sheath of the carotid vessels. This tube begins at the termination of the pharynx opposite to the cricoid cartilage, and must therefore be reached, if at all, between that cartilage and the sternum.

Place the subject recumbent, with the head thrown back, and make an incision three inches in length along the anterior and inner border of the sternomastoid muscle, dividing skin, superficial fascia and platysma; throw forward the head so as to relax the

sterno-mastoid and other muscles, and let assistants separate the edges of the wound and protect the anterior jugular vein from injury; seek the outer border of the sterno-thyroid muscle, and cautiously slit up the cervical fascia upon a director along that border; this division of the fascia will expose, when the edges of the wound are well separated, thyroid veins, lower portion of lateral lobe of thyroid body, which, it must be remembered, is supplied by the inferior thyroid artery, and which vessel crosses deeply the upper part of the line of incision behind the carotid sheath, the internal jugular vein being very prominent; in the groove between the trachea and œsophagus is the recurrent laryngeal nerve. Introduce through the mouth into the œsophagus an elastic catheter, or a probang, in order to dilate the tube and to point out its exact position in the wound; open the tube by cutting upon the catheter, otherwise it will not be easy to find the interior of a canal the walls of which are naturally in contact.

In the case of a foreign body in the œsophagus, the projection of the same will probably indicate the spot at which the tube should be opened.

GASTROTOMY.

Place the subject recumbent, with the head and shoulders thrown forward, and make an incision from one to two inches in length along the outer border of the sheath of the rectus muscle, commencing at the

ninth rib. Divide integuments, muscular aponeuroses, intercostal vessels and nerves, transversalis fascia (which in this region is very thin), and peritoneum, the two latter on a director; introduce the forefinger of the left hand and feel for the stomach (which, if the subject be alive, will probably be contracted and smaller than usual). The position of the organ detected, a fold of its anterior wall should be seized, either with the finger and thumb, or by a pair of forceps, and be brought out at the wound; transfix the fold of stomach and both edges of the wound with needles and ligature at two points, with a view to keep the viscus at the wound while being opened with the knife, and also to serve as a means of maintaining the cut edges of the stomach in apposition with the margins of the wound in the integuments when the operation is completed. Incise the protruding portion of stomach, without severing the threads which are now traversing its cavity, sufficiently to admit the forefinger; and having secured by suture the edges of the aperture in the viscus to those of the skin, by making use of the sutures already referred to, the operation will be completed by the introduction of a suitable tube.

PARACENTESIS ABDOMINIS.

Having ascertained by physical examination that distension of the abdominal walls is due to the presence of fluid and not of solid matter, also that the intestines are not near the surface, and that the

urinary bladder is empty, place the subject upon the side, (if in the case of ovarian dropsy, upon the side corresponding to the supposed seat of the disease,) with a bandage applied around the abdomen, and entrusted to assistants to tighten and to compress the belly during and after the evacuation of its contents. Select a spot in the linea alba about midway between the umbilicus and the pubis, and having incised the skin with the point of a lancet, plunge a well-oiled and large trocar and canula into the abdomen. As soon as the trocar has entered, as will be known by an absence of resistance to its progress, withdraw the trocar, but push the canula further in to avoid the risk of its slipping out. The fluid having been drawn off, withdraw the canula and close the wound with lint and strapping, and support the whole abdomen with a thick pad and broad roller.

The Trocar.—When a trocar and canula are made to enter a cavity, the forefinger should be placed upon the canula at a short distance from the point of the trocar, that the instrument may not penetrate too far; also, a twisting motion should be given to the thrust, in order to facilitate the passage of the instrument through the soft parts, and to cause less pain to the subject if alive. The canula, too, should be removed by twisting it gently with the finger and thumb of one hand, whilst the fingers of the other hand, placed upon the integument around the puncture, offer resistance to the withdrawal of the tube.

ABDOMINAL HERNIA.

The Taxis.—A hernia being strangulated requires surgical interference; but before having recourse to the knife, the surgeon usually endeavours to return the protruded mass by pressure, effected by manipulation aided by other means. The principle of this taxis consists in the endeavour to lessen the bulk of the tumour both by diminishing the quantity of blood retained in the substance of it, and by expressing the contents of the bowel, if bowel there be, within limits which shall allow of the hernia being returned through the constricted aperture by which it left the abdomen.

Of the remedies employed to favour the success of the taxis, chloroform is to be preferred: it operates rapidly and without loss of time; by its agency, the patient is rendered insensible to pain; powerless as regards exerting muscular action, either upon the whole contents of the abdomen or in the immediate vicinity of the part interested in the strangulation; the effect of the drug soon subsides, leaving the patient in an almost equally favourable position to undergo herniotomy. The warm bath, opium, tartar emetic, and bloodletting are slower in operation, more lasting in their effects, and if the taxis be unsuccessful, the subject is probably in a condition less favourable to recovery after herniotomy than he was previous to the trial of any of these latter remedies. Besides these therapeutic agents, a knowledge of the relative

anatomy of the part interested will dictate the position in which the subject is to be placed during the employment of the taxis.

The tumour, taken into the hand of the surgeon, is to be compressed *upon itself*, at first gently and slowly, but increasingly and continuously, for the space of from five to fifteen minutes, while, at the same time, a direction exactly the reverse of that by which the hernia protruded is to be given to the tumour. The taxis having been fairly tried and failed, should not be re-attempted, and in the case of a recent hernia, the result of a blow, or great muscular exertion, in which the neck of the tumour is very narrow, very painful, and the patient in great agony, the taxis should not be even attempted; neither if gangrene be supposed to have supervened should this means be employed; on the other hand, in the instance of old herniæ, with symptoms of strangulation setting in, the taxis will often avail.

As a general rule, less evil will result by an early use of the knife than by delay and the repeated taxis.

I would repeat, that in applying taxis, the hernial tumour is not to be pressed bodily and forcibly against the ring by which it has made its exit, because, by so doing, the mass would have a tendency to spread and occupy a large extent of surface *around* the aperture, rather than to retrace its steps *through* the ring, but is to be compressed *upon itself*.

HERNIOTOMY.

Herniæ may occur at various points of the abdominal wall, but general principles will be applicable to all. Determine the variety of hernia in question; endeavour to ascertain the seat of stricture by observing, while compressing the tumour, the point at which the impulse or the yielding caused by pressure ceases; at that spot the seat of stricture will probably be found to exist. Shave the part if necessary; place the subject recumbent, and in such a position that muscles and fasciæ interested may be thoroughly relaxed.

Make an incision along the centre of and parallel with the long axis of the tumour, commencing just above the expected seat of stricture and terminating sufficiently low, that, in case of need, the contents of the sac may be easily exposed and examined; be prepared for any sudden movement on the part of the subject during the progress of the knife; divide the coverings of the hernia cautiously and separately on a director, always examining each layer as it comes into view, in order, if possible, to ascertain the relation of the edge of the knife to the hernial sac. As layer after layer is divided with more or less anatomical precision, the sac is at length reached, and may be recognised by its membranous character, in the case of a recent hernia being more or less transparent, and although some recent adhesions may exist, the finger can often be readily swept round it and

isolate it from the adjacent structures. The opened sac is known often by an escape of sero-sanguineous fluid; by recognition of its contents, whether bowel or omentum, or both, these organs varying from pink to port-wine colour, in proportion to the degree of strangulation to which they have been subjected—the bowel being more or less smooth, tense, and glistening, and the omentum, though fatty, being membranous. The operator may satisfy himself that he has *not yet* opened the sac by seizing and raising a portion of the tumour with his finger and thumb, and then, allowing this portion to glide away partially and slowly from his hold, he will feel a substance slip from him, while the covering which is visible remains in his grasp. The sac reached, the operator (except under special circumstances) should endeavour to return the protrusion into the abdomen without dividing its peritoneal covering; and to do this, should ascertain with the point of the forefinger of his left hand the position of the expected stricture, and endeavour to insert either the nail or a director between the constricting fibres and the neck of the sac as a guide to the bistoury: should the finger be used, the blunt-pointed bistoury must be run along it with its blade flat, and when inserted, the edge of the knife turned towards the stricture, can be made to divide it to the requisite extent by nicking the part at one or more points. When using a director, the knife must be carried along its groove.

Instead of attempting to sever the constricting

fibres by insinuating the knife between these and the sac, the former may be advantageously divided from without to within at one or more points; by this means the constricting ring will become stretched and enlarged, and will probably admit of reduction of the hernia without opening the sac.

This mode of liberating a stricture is especially applicable to cases of inguinal hernia. Fig. 53 shows

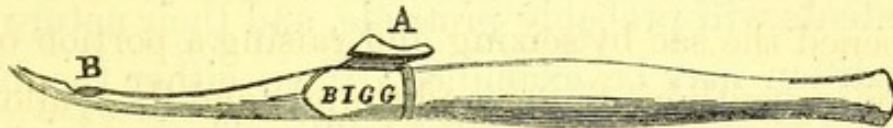


FIG. 53.

the blunt-pointed hernia knife, the edge of which is protected by a sliding sheath. The blade is to be introduced covered, and when through the strictured aperture, the sheath may be withdrawn to the requisite degree and the part be divided; this done, the sheath can be pushed forward again towards B by the thumb applied at A, and the knife be withdrawn. With this instrument, no risk is incurred of wounding the protruding bowel, and a director is not required.

The expected seat of stricture having been divided, the taxis re-applied will probably complete the operation; but if not, the sac must be opened. Seize the sac with a pair of forceps at the most depending part, and nick it (the knife being held with the flat of the blade towards the tumour, Part I. fig. 32) sufficiently to admit the end of a director, and slit it

up upon the latter to an extent similar to that of the incision in the integument, and in doing so, take care that some portion of the contents do not intervene the director and the sac and suffer division by the knife; also when the sac is opened, serous fluid, of variable colour and quantity, will probably flow out, and the contents may be more or less adherent to the internal surface, and will therefore incur a greater risk of being wounded. The sac being laid open, its contents will probably protrude, and their nature and condition may be examined; then, either the finger passed down to, or a director through the strictured foramen, will serve as a guide for the blunt-pointed bistoury by which the constriction is to be liberated by *nicking* the neck of the sac at one or more points; the taxis applied gently will probably reduce the hernia, and that portion is to be returned first which came down last, and intestine before omentum; close the wound, provided that there be no contra-indication, with sutures, strapping, compress and figure 8 bandage (the lower loop of the bandage should embrace the thigh, the upper loop the pelvis). The subject is to be placed in bed with the thighs semi-flexed upon the abdomen, and the knees supported by a pillow placed under them.

Division of the Stricture.—The mode of liberating a stricture must depend upon the relative anatomy of the parts adjacent to the hernia. In femoral rupture the usual seat of stricture is at Gimbernat's ligament, and to sever this structure the edge of the knife must

be directed inwards. The femoral ring is bounded in front by Poupart's ligament and the spermatic cord in the male; behind, by the horizontal ramus of the pubis; externally, by the femoral vein, only a thin septum of the femoral sheath intervening; and internally, by Gimbernat's ligament. Thus it will be seen that a hernia making exit at the crural ring and becoming strangulated, the stricture will be liberated with less risk of injury to neighbouring parts by nicking Gimbernat's ligament, and whether the sac be opened or not by cutting *inwards*.

In inguinal hernia (complete), it is usually quite impossible to decide whether or not the case be one of *direct* or *oblique* rupture; therefore, to avoid wounding the deep epigastric artery, it is desirable in *all* cases to sever the stricture in a direction nearly parallel to the course of this vessel, *i. e.* *upwards*.

In rarer forms of hernia the stricture must be divided on the principle of inflicting as little injury as possible; and in the case of umbilical hernia the knife must be used throughout the operation with extreme caution, because the tissues covering the rupture are often very thin, and the peritoneal sac is either equally so or adherent to the integuments.

Line of Incision.—It is customary to cut down upon a hernia by incising the intervening structures along the median line and long diameter of the tumour; but in order, in case of recovery, to avoid any inconvenience which might arise from pressure of the pad of a truss upon a cicatrix, the incision may be made

towards the inner side of the long axis of the tumour, and especially in the case of femoral hernia, where the seat of stricture is usually on the inner side.

RADICAL CURE.

In some cases of reducible inguinal hernia, it may be justifiable to attempt the *radical cure* by one of the modes recommended, and of which that of Wurtzer is perhaps to be preferred. This method consists in carrying a portion of the integument of the scrotum upon the point of the index finger through the external abdominal ring into the inguinal canal, and in maintaining it by a suitable instrument till inflammation is induced and adhesion results.

Place the subject recumbent, with the head and shoulders thrown forwards and the thigh of the affected side flexed so as to relax the parts interested in the operation; return the contents of the hernial sac into the abdomen, and let an assistant so maintain them by keeping his finger upon the internal abdominal ring till the operation be completed. With the point of the forefinger of the left hand, endeavour to push up through the external abdominal ring along the inguinal canal a portion of the integument of the scrotum; and when this invagination is effected to the highest point possible, the relation of it together with the finger to the adjacent structures, will probably be as follows:—in front, are the structures normally forming the anterior wall of the inguinal canal, and a portion of the hernial sac;

behind, are a portion of the hernial sac and the cord and structures forming the posterior wall of the inguinal canal. To maintain this *cul-de-sac* of integument in its new position, the instrument de-

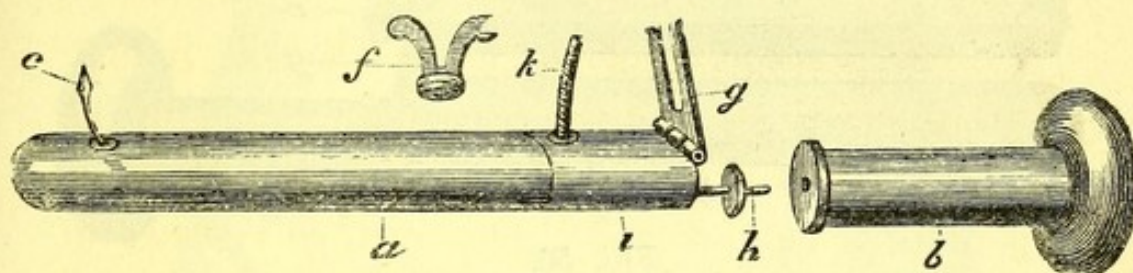


FIG. 54.

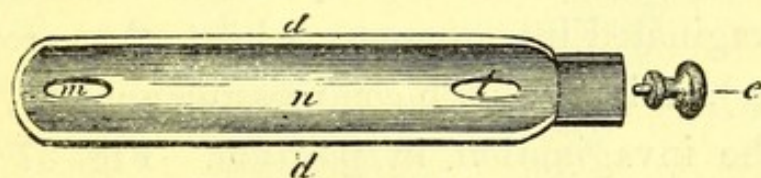


FIG. 55.

lined at figs. 54 and 55 is employed. It consists of a hollow cylinder (*a*) closed at one end, but perforated so as to give transit to the point of the needle (*c*), the blunt end (*h*) of which can be fixed in a handle (*b*); *g* is a movable support; *k* is a screw, curved and fixed; *f* is a nut; *d* is a plano-concave piece, perforated at *l*, *m*; *e* is a movable handle. The instrument is adjusted by causing the cylinder (*a*) to replace the finger in the *cul-de-sac* of integument; then the needle (*h*) is made to traverse the cylinder and to perforate at *c* all the structures anterior to the tube; this done, the plano-concave piece (*d*) is placed upon the surface of the skin, and is so maintained by *c*, *k*, and *g*. Fig. 56 shows the relation of the parts of the instrument to each other: the space

between *a* and *d* would be occupied when the instrument is in use by the parts forming the anterior wall

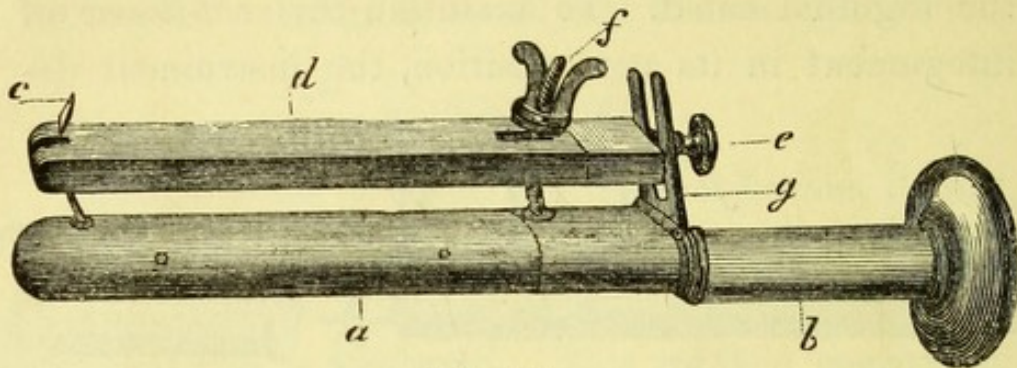


FIG. 56.

of the inguinal canal, and by the anterior half of the invaginated integument; whilst the protruded needle (*c*), assisted by the compressing nut (*f*), maintains the invagination in position. Fig. 57 shows the instrument, enlarged and modified, adapted to the subject. The size and number of cylinders employed will vary according to the requirements of the case.

The Truss.—In all kinds of rupture some sort of mechanical support should be worn, at least during the day. In many cases the apparatus may be removed at night, but should be replaced in the morning while the patient is recumbent, and before rising from bed. If a truss be used for the purpose of preventing protrusion of a portion of the contents of the abdominal cavity, it is of the utmost importance that the pad be applied over the spot or ring at which the hernia makes exit, and not at a distance from that ring. The necessity for this prevention will be evident by a reference to the probable good or ill effects resulting from the mode of application

of the pad of a truss intended to restrain a reducible oblique inguinal hernia ; in this case the pad should

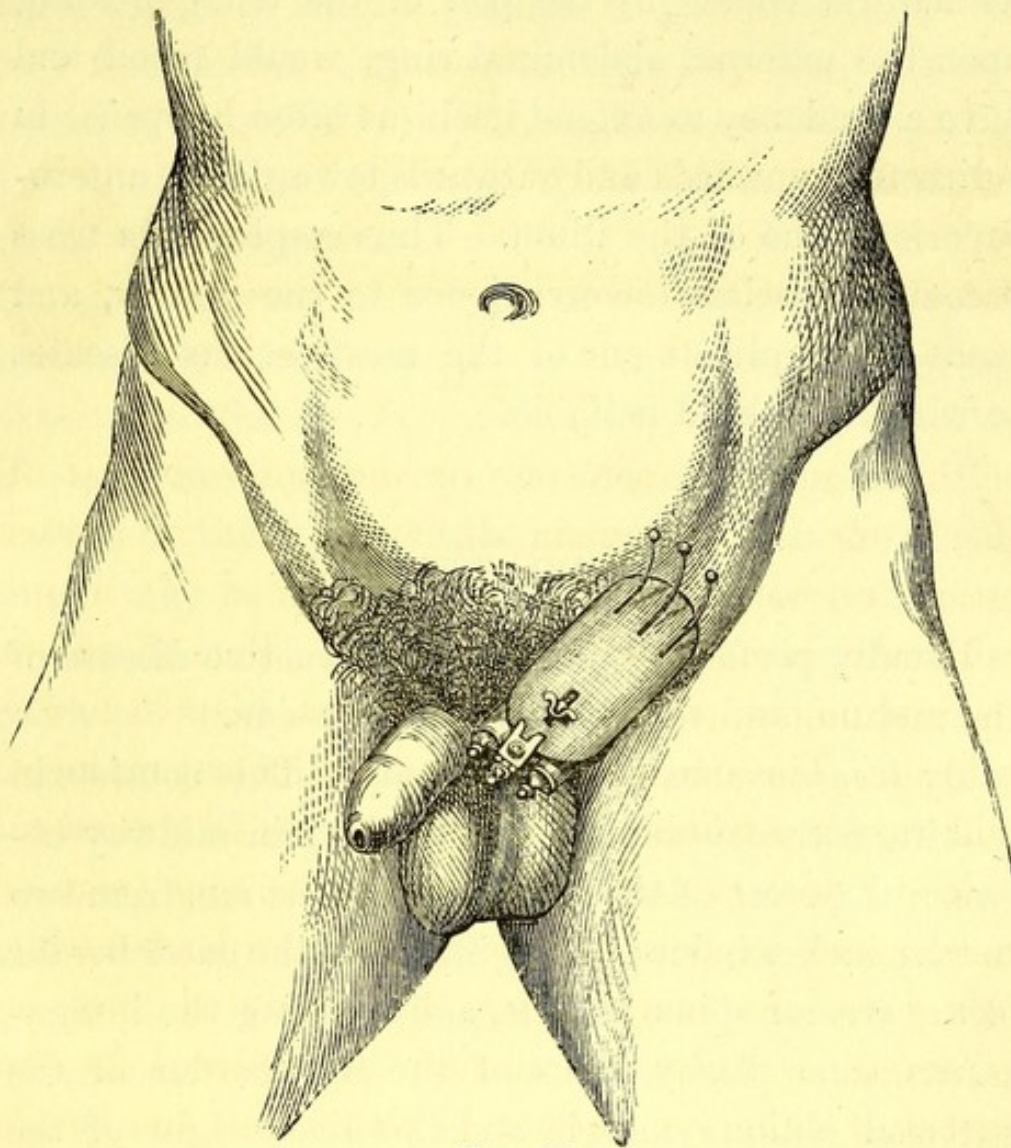


FIG. 57.

be opposite to the internal abdominal ring, the point at which the hernia leaves the abdomen, and not be placed, as is sometimes done, upon the external abdominal ring, which is only the point at which the hernia becoming complete appears, as it were, upon the surface. The effect of placing a truss upon the external abdominal ring in the case of oblique

inguinal hernia, would be that the rupture, descending along the inguinal canal and being checked in its natural course by the pad of the truss pressing upon the external abdominal ring, would recoil and have a tendency to extend itself (as often happens) in a direction upwards and outwards towards the antero-superior spine of the ilium. Thus employed, a truss becomes a useless inconvenience to the wearer, and tends to complicate one of the most serious diseases to which mankind is liable.

LUMBAR ARTIFICIAL ANUS.

Usually performed to relieve obstructive disease of the rectum, and therefore on the left side.

By *transverse incision* (Amussat).—This consists in making a transverse incision in the loin midway between the crest of the ilium and the last rib, from two to four inches in length, beginning at the outer border of the erector spinæ muscle, and dividing the integuments, some fleshy fibres of the free border of the external oblique muscle and the iliac origin of the latissimus dorsi, the origin of the internal oblique muscle and the tendon of the transversalis muscle—perhaps also the outer border of the quadratus lumborum muscle and sheath. Any vessel bleeding should be ligatured. Having divided the tendon of the transversalis, a quantity of loose areolar tissue and more or less fat alone conceal the intestine.

By *longitudinal incision* (Hilton).—Place the sub-

ject on the sound side, and if an adult, make a vertical incision in the costo-iliac space from two to three inches in length, parallel to the lumbar spines and four inches external to them, or one inch external to a vertical line drawn between the angle of the ninth rib and the crest of the ilium. Divide in order the integument, perhaps some fibres of the latissimus dorsi, the origin of the internal oblique, leaving the free margin of the external oblique external to the line of incision, the last dorsal nerve if seen coursing downwards and forwards, and the tendon of the transversalis muscle. This done, the finger may be introduced and the inferior extremity of the kidney, if felt, must not be mistaken for hardened fæces; more or less cellular tissue intervening must be either removed or turned aside, and the intestine will be reached, and should it be distended, pressure applied upon the anterior abdominal wall will probably cause it to bulge. Now pass a long needle armed with a ligature, so as to transfix the integument on either side as well as the intestine in the wound, and while thus fixed, open the bowel to the requisite extent. Complete the operation by fastening the margins of the wound in the colon to the edges of that in the integument, beginning with the suture already introduced, and adding as many more as may be necessary.

The object of these methods is to open the bowel without injuring the peritoneum, and for that reason either the ascending or descending colon is selected

in a locality where the viscus is usually uncovered posteriorly by peritoneum, in preference to the operation recommended by the older surgeons of opening the abdominal cavity above Poupart's ligament, in order to reach the sigmoid flexure. Fig. 58 shows

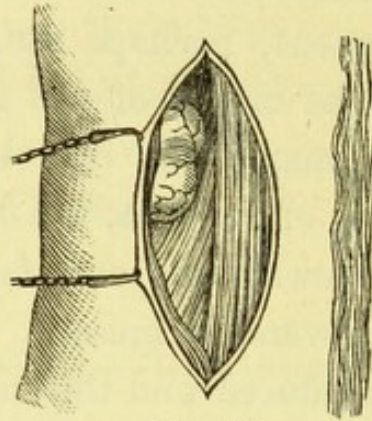


FIG. 58.

the line of incision on the left lumbar region. The integuments, &c., are incised, and the posterior layer of the sheath of the erector spinæ and of the quadratus lumborum muscles has been removed to show their relation and the course of their respective fibres. The longitudinal fibres are those of the erector spinæ; the fibres coursing from below upwards and inwards are those of the quadratus lumborum muscle, the outer border of which is consequently oblique; and overlapping it is a portion of intestine which has been forcibly pulled out through the wound.

OVARIOTOMY.

Place the subject recumbent, with the head and shoulders raised and thrown forwards, the buttocks

resting on the edge of a table or bed, while the legs hang over and are comfortably supported each on a chair or foot-rest. The operator stands between the thighs of the patient, having a bucket at his feet to receive the fluid contents of the cyst, and makes an incision in the linea alba between the umbilicus and the pubes, sufficiently large to admit his hand into the cavity of the abdomen to explore the exterior of the cyst. This exploratory incision may be enlarged, if necessary, as far as the ensiform cartilage in one direction, and the pubes in the other direction. Bearing in mind the tension to which the abdominal wall has been subjected and the consequent thinning of the parts covering the tumour, the integuments and linea alba must be cautiously divided, lest the abdomen be opened before it be expected. (I have known the cyst to be reached and its wall mistaken for the linea alba.) The peritoneum is to be slit up sufficiently to admit two fingers of the left hand, along which, forming a director for the knife and a protection to the organs behind, it is to be divided to the extent of the wound in the integuments; introduce the hand into the abdominal cavity and sweep it round the tumour, in order to ascertain its relation and extent of adhesion to the viscera, and probable amount of solid matter of which it may be partly composed; slight adhesions to the abdominal wall may be broken down at once; prepare to puncture the cyst through the wound at the most depending and fluctuating point with a full-sized trocar and canula, and at the

moment of puncture an assistant seizes the cyst wall, either with a hook or with long claw forceps, in order to maintain it at the wound and to prevent the escape of its contents into the cavity of the abdomen ; at the same time another assistant, standing on one side with his back to the subject, compresses the walls of the abdomen, with a hand placed on either side, in order also to prevent extravasation and to favour extraction. During the process of evacuation the tumour may gradually be drawn out of the abdomen through the wound, and the cyst may be incised to facilitate the more rapid escape of contents ; false membranes must be torn across, and adhesions to viscera, if they cannot be readily detached, must be liberated by isolating the adherent portion of cyst with the knife and leaving it attached. The tumour having been withdrawn, its pedicle is to be looked for, but before severing the latter, either a strong cord ligature is to be passed through its centre to secure each half, or a carefully adjusted clamp may replace the ligature. Whichever mode be adopted, a strong pin should transfix the pedicle on a level with the ligature, or behind the clamp ; so that in the case of hæmorrhage (supposing the subject alive) from the divided vessels of the pedicle, or unexpected partial retraction of the same towards the abdomen from the grip of the clamp, the bleeding vessel may be readily secured, and hæmorrhage into the abdominal cavity be avoided. In consequence of the variable density of a broad pedicle, it will be difficult to compress it

equally throughout, and therefore more or less risk of the thinner portions slipping back into the abdomen is incurred. (I have known this accident to happen, and the patient to die of hæmorrhage.) When the clamp is used, I would suggest that the cut margin of the pedicle be seared by the actual cautery, in order to avoid the possibility of hæmorrhage. The pedicle secured, the edges of the wound must be carefully adjusted and be kept in apposition, either by sutures or pins, one of the pins being made to transfix the pedicle in order to keep the portion which is either anterior to the ligature, or included in the clamp, outside of the abdominal cavity.

Judging from Mr. Wells' statistics, ovariectomy in certain cases is decidedly justifiable.

REMOVAL OF TUMOURS.

In the case of a tumour of a doubtful nature, it will be well to adopt *exploration*. (Part I. p. 142.)

Tumours may be removed by the knife with or without portions of integument covering them, either by a simple incision along the centre and long diameter of the growth, dividing the soft parts and then reflecting them so as to lay bare the mass and favour enucleation, or by any other form of incision which may facilitate removal, or by two incisions including a portion of integument which may be either firmly adherent, implicated by the disease, or too abundant.

Removal of Integument. — Healthy integument, covering and stretched over a tumour, is often removed with the growth, lest too much skin should remain to cover the wound. Speaking generally, this supposition is erroneous, and soon after an operation so performed, the integument is found to be retracted and the wound gaping, or sutures excite ulceration, and when removed the edges separate, delaying the cure, till at length a large cicatrix or an indolent ulcer results. This accident is especially liable to happen when a tumour, together with healthy integument, is removed from over a prominence, such as the shoulder.

As a rule, healthy integument should not be cut away unless it cover a *natural* tumour, such as the mammary gland, which organ being removed, the whole of the integument would be more than sufficient to cover the wound, and in the following proportion. Let the cutaneous surface represent the arc of the segment of a circle, and the deep surface the chord of that arc; the difference in length between the arc and its chord will represent the extent of integument which may be removed as an equivalent to the tumour also excised. Thus, if arc = 15 inches and chord = 10 inches, the difference of 5 inches will represent the width of integument at the centre of the mamma which may be removed, the width being gradually diminished towards the circumference. In the case of enlargement of the mammary gland by disease, the extent of integument to be

removed must be in proportion to the natural prominence of the healthy rather than of the diseased gland.

To excise the *mammary gland* or other tumour, one or more incisions may be employed, as in fig. 59,

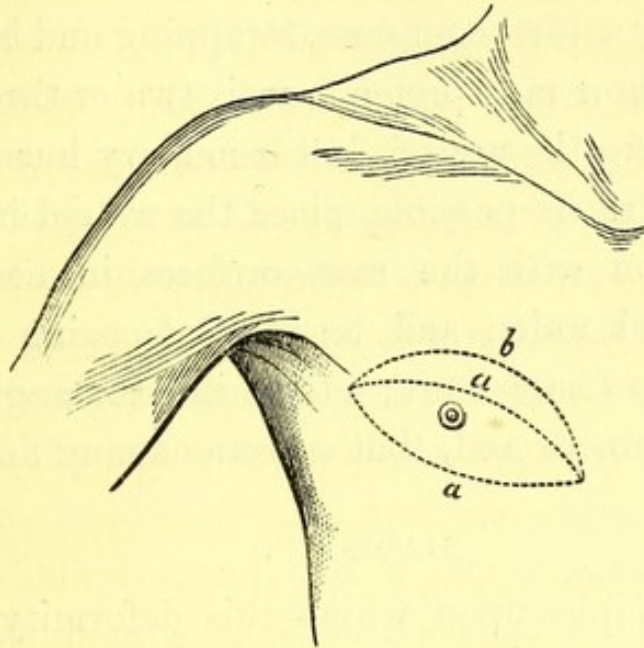


FIG. 59.

a a, including an oval portion, or *a b*, enclosing a semilunar portion of skin; begin the incision at the most depending part, and if more than one, the most depending incision first, that the blood may flow away and offer no obstacle to the ready completion of the operation. To prevent loss of blood, assistants should follow the knife closely, compressing the wound temporarily with sponge, and any large vessels with the points of the fingers. The tumour recognised, the skin is to be dissected off, and the dissection will be facilitated by the fingers of an assistant, or by spatulæ, the one seizing the tumour,

the other the integument, or hooks and clawed forceps may be substituted. During the dissection, keep the edge of the knife either upon or towards the tumour. Excision effected, examine the raw surfaces to ascertain that the whole mass has been removed, and when the vessels are ligatured the wound may be closed by suture, compress, strapping and bandage; or the operator may prefer to wait two or three hours before closing the wound, lest secondary hæmorrhage should occur. If possible, place the wound in a state of relaxation with the raw surfaces in contact to favour rapid union and to prevent oozing of blood or bagging of secretions; let the inferior angle of the incision be uncovered, that secretions may flow out.

HARE-LIP.

The principles upon which this deformity is to be remedied, whether single, double, or complicated, are similar, and consist in the attempt to close the fissure or fissures, either by the knife, by mechanical apparatus, or by both. The operation may be performed at any period of life, but that of infancy is preferable, because the healing and nutritive powers being more vigorous, wounds readily close, either by immediate union or by primary adhesion.

Single Hare-lip.—In this variety the fissure of the upper lip is on one side only of the median line.

Place the subject either recumbent or in the sitting posture; if a child, it should either be seated on the lap of a nurse, having a towel round the trunk to

confine the arms, or it may be recumbent with its head between the thighs of the operator who is seated, and the legs resting on the lap of an assistant, also seated opposite to the operator. Commence the operation by detaching, more or less, the lip from the gum on either side of the fissure in order to favour approximation of the edges of the fissure; seize the free margins of the cleft consecutively with a pair of claw forceps, and while an assistant holds the lip with his finger and thumb—both to assist the action of the knife and to compress the coronary artery, the operator pares the borders of the fissure by cutting away its margin, beginning at the angle and terminating at the free margin of the lip, thus an inverted Λ -shaped fissure results, and its edges are to be brought into contact and to be so maintained by two or more pins and the twisted suture (Part I., fig. 17); also it will be well to insert an interrupted suture at the red margin of the lip.

Double Hare-lip.—The steps of the operation will be similar to those given above, and usually both fissures may be closed at one time. In all cases be sure to vivify the angle of the fissure and to carry the incisions through the thickness of the lip itself, rather than too near the margin of the fissure. Besides the inverted Λ incision, other forms may be employed, according to the fancy of the surgeon and the requirements of the case.

Complications, such as an absence of the columna nasi, a projection of one or both incisor bones, cleft

hard palate, &c. &c., must be remedied by the ingenuity of the surgeon and of the dentist.*

CLEFT PALATE.

Staphyloraphy.—This operation should not be attempted unless with the consent of the patient, any resistance on the part of whom would render its performance very difficult and almost impossible. The object of the operation is to close an abnormal fissure in the median line of the soft palate. Each half of the velum is under the influence of five muscles, four of which when in action tend to abduction, and consequently to separate the one portion from the other when a median fissure exists. To maintain the part at rest and ensure approximation of the edges of this fissure, one or more of these abductors must be divided. (Fergusson.) Of these muscles the levator palati exercises the most influence on the velum, and next to it the palato-pharyngeus, the tensor palati and palato-glossus are of minor interest. In the normal palate, and when looking through the mouth, the position of the palato-glossus and of the palato-pharyngeus can be readily detected, the former forming under cover of mucous membrane the anterior pillar, the latter, the posterior pillar of the fauces: between these two is the tonsil. The position of the levator and of the tensor palati cannot be so easily seen, but a knowledge of their action upon the velum and of their origin, insertion and

* See Paper by Sercombe, in Trans. Odont. Soc.

consequent direction, will serve as a guide to their locality. Taking origin at the base of the skull, they pass from above downwards and inwards towards the mesian line, the levator being posterior to the tensor. The levator palati muscle is more superficial posteriorly, and for that reason some prefer to divide it from behind forwards and without making a button-hole in the velum.

Fig. 60 is a posterior view of the muscles of the

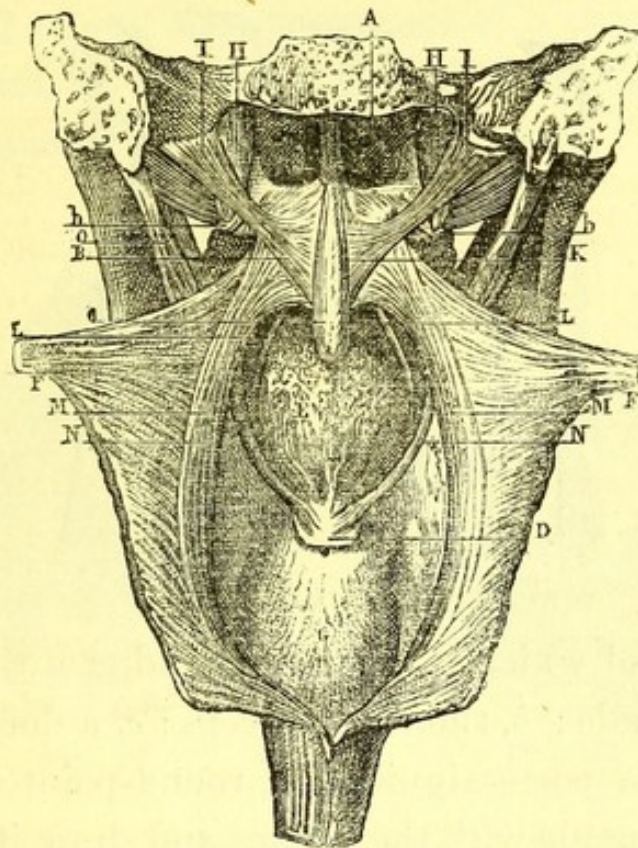


FIG. 60.

palate after that the pharynx has been opened behind in the mesian line. A is the body of the sphenoid bone with the posterior nares below; H is the tensor palati muscle, and *b* the hamular process of the internal pterygoid plate; I is the levator palati muscle,

and B its tendinous expansion ; L is the palato-glossus muscle ; M is the palato-pharyngeus muscle, the supero-posterior fibres of which have been removed ; other adjacent parts are also seen.

Operation.—Let the patient be seated with the face opposite to a good light, and the operator in front of the subject, but with his back to the window. An assistant should stand behind and steady the head. Instruments requisite are—fig. 61, *a*, the knife,

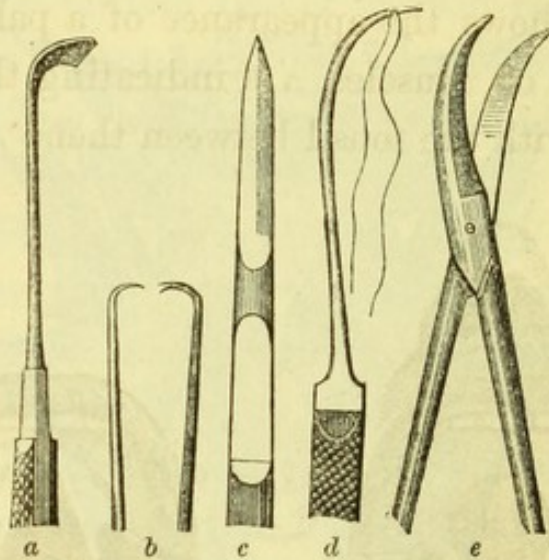


FIG. 61.

the blade of which is very short and at a right angle to the handle ; *b*, the claw-forceps ; *c*, a double-edged knife ; *d*, a porte-aiguille ; *e*, round-pointed scissors. Seize the uvula with the forceps and draw it forwards so as to put the palato-pharyngeus on the stretch, and then with the scissors sever the muscle transversely to the extent of a quarter of an inch ; the palato-glossus may be similarly treated. Still holding the uvula, pass the blade of the knife (*a*) back through the fissure, and having placed it upon the

posterior surface of the velum, cut, as it were, forwards into the substance of the palate in a direction downwards and outwards, just internal to the hamular process of the internal pterygoid plate, which can be felt through the mucous membrane just behind the last molar tooth. Divide the muscles on both sides, and their section may be recognised by an alteration in the shape of the fissure and their inability to contract.

Fig. 62 shows the appearance of a palate prior to the division of muscles, A B indicating the pillars of the fauces with the tonsil between them.

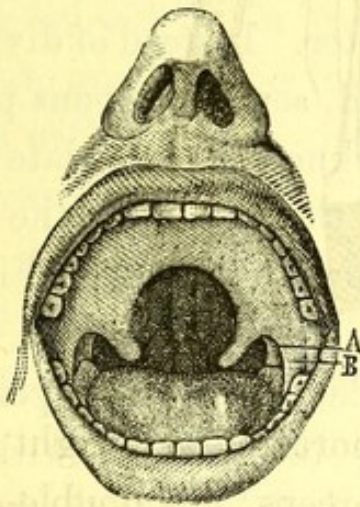


FIG. 62.

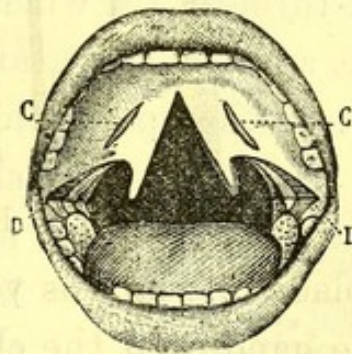


FIG. 63.

Fig. 63 shows the alteration in the shape of the fissure after section of muscles, C D marking the lines of division.

With a double-edged knife (*c*) pare the margin of the fissure and introduce two or more sutures with the *porte-aiguille*, and fix them loosely to allow for swelling, with the *slip knot* (Part I. fig. 22). The

thread is to be introduced on one side, first from before backwards, one end of it being seized with forceps and held firmly in the fissure, while the needle is withdrawn by the way it went and detached from the thread; the needle must be again threaded with the end of the ligature appearing through the fissure, when it is to be passed through the opposite side of the cleft from behind forwards, and then the suture may be fixed by the slip knot and the simple knot. Bleeding during the operation must be checked by gargling the throat with cold water, and if the levatores palati be divided *after* section of the pillars has been effected, frothy sanguineous sputum will not interfere with division of the latter. Instead of dividing the levator palati from behind, some surgeons prefer to cut through the whole thickness of the palate from before, and the appearance of the part after the completion of the operation is shown at fig. 64. Fig. 65

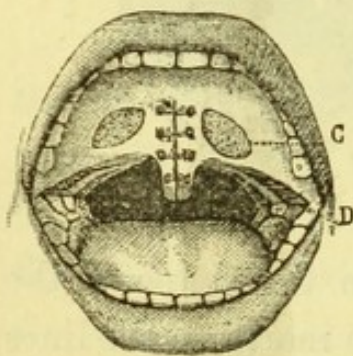


FIG. 64.

shows a porte-aiguille with movable point. The point A having been armed with the thread, is fixed into the handle at B, and having been made to traverse one border of a wound, pressure upon the spring c will dislodge the point A, and

allow of its being drawn out between the edges of a wound, when, having been re-adjusted in the handle, the opposite lip of the wound may be traversed by the needle and thread, and thus the ligature is placed

in situ, and can be tied at pleasure. Needle points of different sizes are contained in the handle at D.

This instrument is especially useful for the application of sutures at a distance from the surface of the body, as in the instance of cleft palate.

ABSCISION OF TONSIL.

In the absence of a guillotine the tonsil may be excised by the knife. The surgeon may stand either behind or in front of the patient, and, seizing the enlarged organ with a pair of claw-forceps, cuts away a portion of the gland in a direction from below upwards and inwards parallel with the pillars of the fauces. The knife employed should be a probe-pointed bistoury with a cutting edge near the point only; or, if an ordinary bistoury be employed, the posterior half of the blade should be rendered useless by wrapping a strip of lint around it, so as to avoid the possibility of wounding the upper lip. Avoid pulling the tonsil inwards with the forceps.

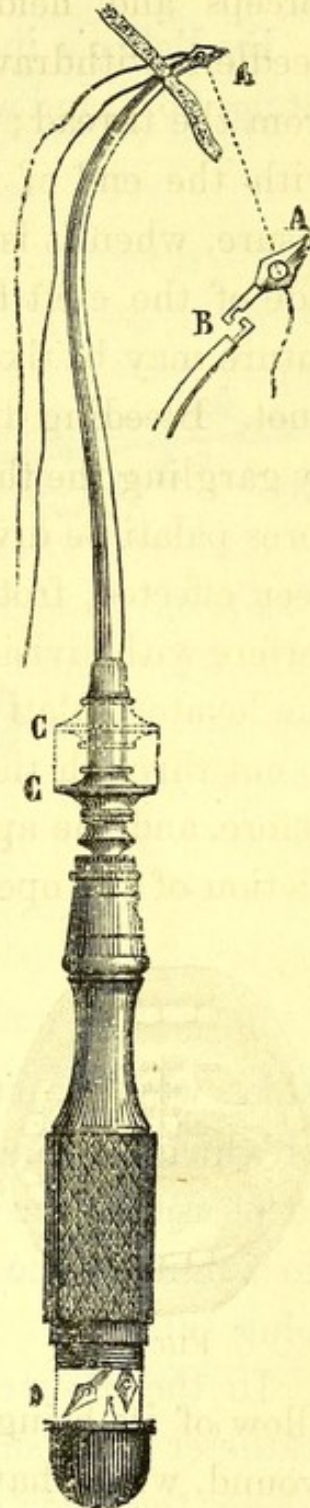


FIG. 65.

PLUGGING THE POSTERIOR NOSTRIL.

By Belloc's instrument, the use of which is shown at fig. 66 A, and which somewhat resembles a catheter,

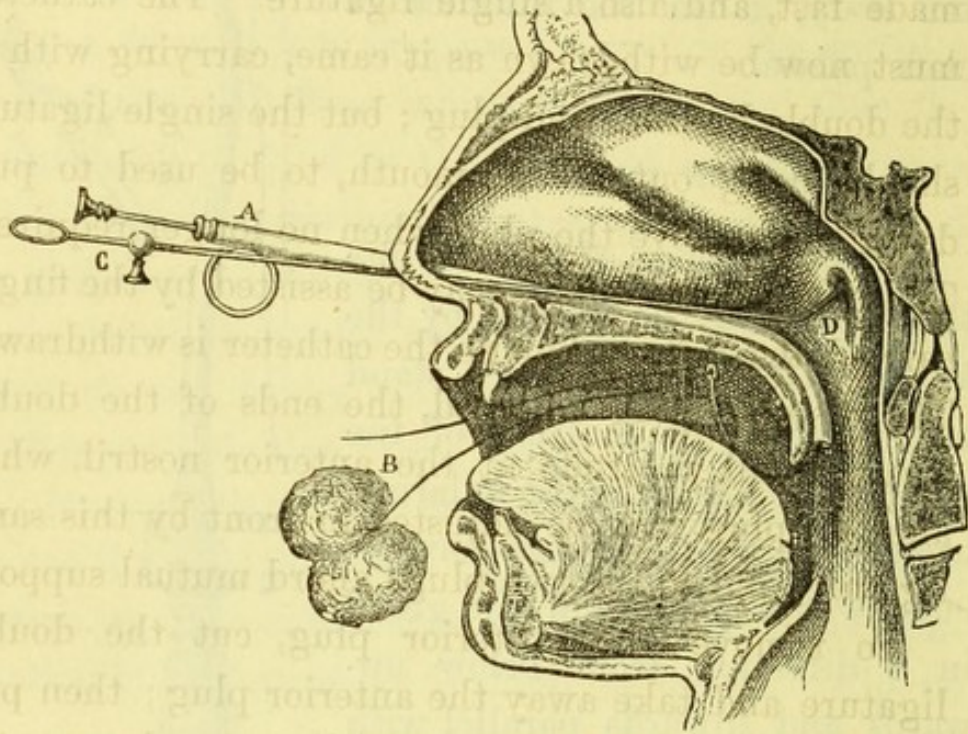


FIG. 66.

along which a piston can be worked, to the extremity of which a spring is attached and can be protruded at pleasure; the end of the spring is perforated so as to admit of the passage of a thread attached to the plug (B).

In the absence of Belloc's instrument, an elastic catheter will suffice. Pass the catheter backwards along the floor of the nostril into the pharynx, introduce the finger through the mouth and bring forward into that cavity either the extremity of the

catheter or a thread previously attached to the catheter, and attach the thread to the double ligature which holds the plug. The plug should be of soft sponge, about one inch in length and half an inch in width, and to its middle a double ligature should be made fast, and also a single ligature. The catheter must now be withdrawn as it came, carrying with it the double ligature and plug; but the single ligature should hang out of the mouth, to be used to pull down and remove the plug when no longer required. The placing of the plug may be assisted by the finger carried above the velum as the catheter is withdrawn. The posterior plug adjusted, the ends of the double ligature will protrude at the anterior nostril, when another plug may be adjusted in front by this same ligature, and so the two plugs afford mutual support.

To remove the posterior plug, cut the double ligature and take away the anterior plug; then pull upon the single ligature which protrudes at the mouth, and assist traction if necessary with a catheter passed back against the plug along the floor of the nostril.

CATHETERISM OF NASAL DUCT.

A probe may be introduced into the nasal duct, either along the lachrymal canal, or from the nostril.

To pass the sound *from the nostril* the instrument should have a shape somewhat similar to that of the italic letter *s*, and the operator, facing the subject

and holding one end of the probe with his finger and thumb, should pass the other end, oiled and point downwards, back along the floor of the nostril to the extent of about an inch. The end of the instrument will now correspond with the inferior turbinated bone, under cover of, and near to, the anterior extremity of which is the inferior opening of the duct; by slight rotation of the probe or supination of the hand, the extremity of the instrument will also get under cover of the inferior turbinated bone, when it should be carefully brought forward towards the anterior nostril, till its progress be impeded by the ascending process of the superior maxillary bone; it is now opposite to the opening of the duct, and by depressing the handle gently, will probably enter the canal.

To pass the sound *from above*, slit up the lachrymal canal with a pair of scissors, one blade of which must have been passed through the punctum along the canal in order to do so. By this means a gutter is formed, and along it the probe is to be carried, and to be introduced into the lachrymal sac, and then into the nasal duct by gradually raising the probe from the horizontal to the vertical position, and then directing it with gentle pressure downwards and slightly backwards and outwards.

Some prefer to lay open the lachrymal canal by slitting it up with a fine knife along a small grooved probe introduced at the punctum.

Catheterism may be repeated twice or thrice weekly.

CATHETERISM OF THE EUSTACHIAN TUBE.

The cartilaginous extremity of the Eustachian tube is situated in the pharynx posterior to the nose, about on a level with its outer wall and just above the inferior turbinated bone. To introduce the Eustachian catheter, stand in front of the subject and pass the curved extremity of the instrument, oiled and point downwards, along the floor of the nostril of the affected side to the posterior nasal aperture, and then either by rotation of the catheter or by supination of and depressing the hand, the point of the tube will be directed upwards and outwards, and will probably enter the canal.

Fig. 66 shows the instrument (c) traversing the nostril and entering the tube (D).

REMOVAL OF TONGUE.

The whole or portion of the tongue may be removed either by the knife or by ligature, or by the heated wire. To remove a portion of the anterior half of the tongue, the organ should be drawn out of the mouth and be so maintained temporarily, either by a ligature passed through the healthy structure, or by claw-forceps, held by an assistant while one of the above methods for removal is employed. When the knife is used, any vessel may either be ligatured or be touched by the actual cautery. The whole organ may also be removed, either by the knife, by ligature, or by the *écraseur*.

By *ligature*.—Incise the integument to the extent of half an inch above the os hyoides and in the median line of the neck; and through this wound pass into the mouth between the side of the tongue and the base of the lower maxilla, a porte-aiguille armed with a strong double ligature; retain the ligature in the mouth and cut the loop, but withdraw the needle as it came, thus leaving two ends of ligature in the latter cavity, and two depending at the wound in the neck. Reintroduce the needle on the other side, but without a ligature; and now carry one ligature already in the mouth across the dorsum of the root of the tongue, and put it through the eye of the needle while the other ligature is passed under the tip of the tongue in front of the frænum, and is also put through the eye of the needle; the needle thus threaded should be withdrawn at the wound in the neck, carrying the ends of the two ligatures with it, thus adding two to the two already depending at the wound. The opposing ends must be firmly tied together, when the organ will be strangulated. The knots must be tightened daily.

Excision.—Let the subject be seated, and the head be well supported from behind. The operator standing in front, incises the lower lip down to the bone and the integument as low as the hyoid bone in the mesian line, and having extracted one or two incisor teeth of the lower jaw, severs the symphysis with a *chain* (Part I. fig. 52) or other saw, either longitudinally or angularly (fig. 67, A, Sedillot). Forcibly

separate the halves of the jaw ; and having seized the tongue with a pair of strong claw-forceps, drag the

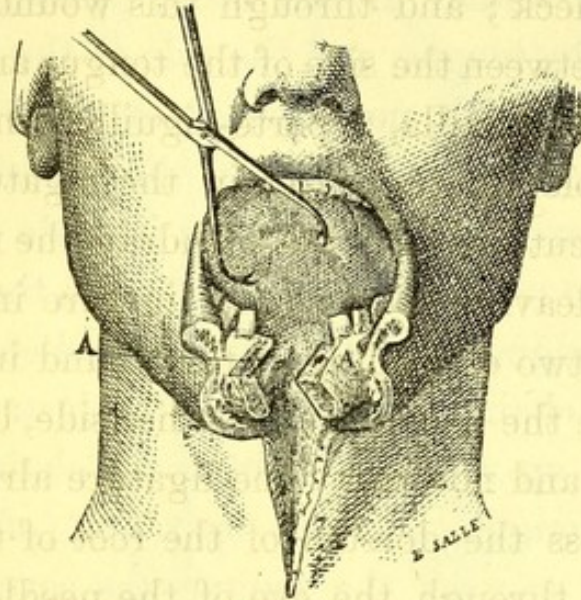


FIG. 67.

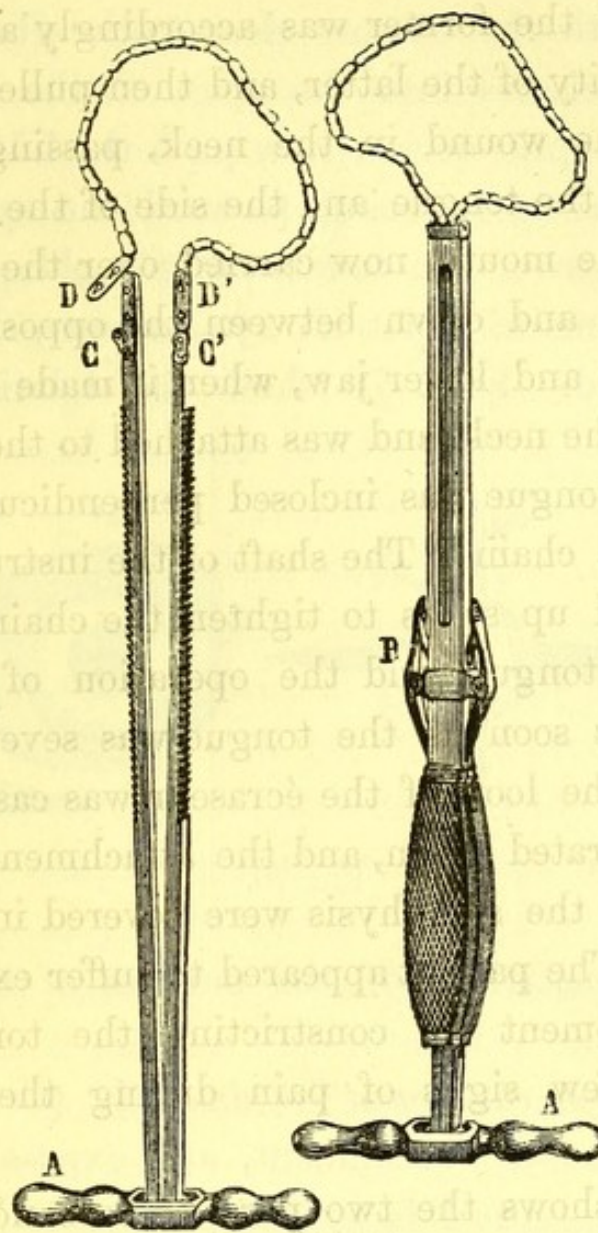
organ forwards and downwards, and separate it from its attachments with a straight round-pointed bistoury. By division of the lower jaw, ligatures or the actual cautery can be more rapidly employed to check hæmorrhage, and the *angular* section of the bone favours apposition of the surfaces and rapid union.

By *écraseur* (Chassaignac).—I have seen M. Chassaignac remove the tongue, and in the following manner. The patient was seated in a chair, and depending from the throat through a small wound in the mesian line above the os hyoides were the two extremities of a *tube à drainage*. This tube had been introduced some days previously in order to form a sinuous channel for the passage of the chain of the *écraseur*. The chain was to replace this tube, and

one end of the former was accordingly attached to one extremity of the latter, and then pulled upwards through the wound in the neck, passing between the side of the tongue and the side of the lower jaw to enter the mouth, now carried over the dorsum of the tongue and down between the opposite sides of the tongue and lower jaw, when it made exit at the wound in the neck, and was attached to the *écraseur*. Thus the tongue was inclosed perpendicularly by a loop of the chain. The shaft of the instrument was now pushed up so as to tighten the chain and constrict the tongue, and the operation of crushing begun. As soon as the tongue was severed longitudinally, the loop of the *écraseur* was cast over the almost separated organ, and the attachments of it to the back of the symphysis were severed in a similar manner. The patient appeared to suffer exceedingly at the moment of constricting the tongue, but exhibited few signs of pain during the work of separation.

Fig. 68 shows the two parallel bars notched externally, which traverse the cylinder of the *écraseur*, and which are attached at one extremity to the double lever (A), and can be attached to or detached from the chain at the other end (D C).

Fig. 69 shows the instrument complete. A is the double lever which acts alternately upon the parallel bars and upon the chain, lessening the loop of the latter and fixing it at each stroke by the spring (B), which catches in the notches of the parallel bars.



FIGS. 68, 69.

THE EYE.

Extirpation of the globe.—Place the subject recumbent, and expose the globe with a wire speculum; and by means of a pair of forceps and small curved round pointed scissors, circumcise the conjunctiva near to the margin of the cornea; with a blunt hook take up the tendon of each rectus muscle *seriatim*, and

sever it with the scissors close to the globe ; introduce the scissors into the apex of the orbit, and divide the optic nerve ; now push the lids back into the orbit so as to bring forward the eyeball, and after that sever the tendons of the oblique muscles and any remaining fascial attachments, till the eye be liberated. Figs. 70 show the relation of the

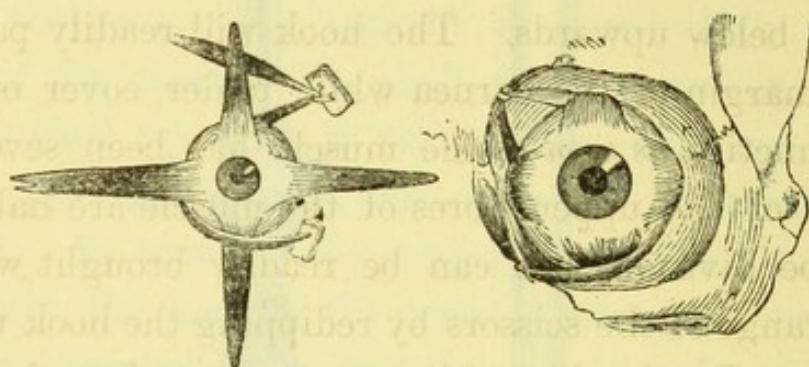


FIG. 70.

tendinous insertions of the muscles of the eye to each other.

Strabismus, convergent for example (Critchett).—Place the subject recumbent, and expose the globe by separating the lids with a speculum. The lower border of the internal rectus muscle is on a level with the inferior border of the cornea ; seize, therefore, the conjunctiva with a pair of small claw-forceps at a point midway between the cornea and the caruncula lachrymalis, and on a level with the lower border of the cornea, and open it with the round-pointed scissors sufficiently only to admit of the entrance beneath it of the scissors themselves ; divide, also, in a similar manner the sub-conjunctival fascia,

till the pearly sclerotic be reached ; now introduce the blunt hook through the opening in the sub-conjunctival fascia and pass it between the sclerotic and the rectus, and while thus placed, with the convexity of the blunt hook looking forwards so as to remove the muscle from contact with the globe, introduce the scissors through the fascial opening and divide the tendon internal to and parallel with the hook, *i. e.* from below upwards. The hook will readily pass to the margin of the cornea while under cover of the conjunctiva *as soon as* the muscle has been severed ; some of the upper fibres of the muscle are liable to escape division, but can be readily brought within the range of the scissors by redipping the hook under them. By simply making an aperture into the conjunctiva so as just to admit the point of the scissors only, rather than by practising division of the conjunctiva to a similar extent as the muscle itself, sinking of the caruncula, increased prominence and undue eversion are avoided.

Artificial pupil, by Iridectomy.—Place the subject recumbent and expose the surface of the globe by the speculum, and having determined the point at which the operation is to be performed, incise the cornea without wounding the iris at its junction with the sclerotic sufficiently to admit either the point of a fine pair of forceps or a fine blunt hook, with which a corresponding portion of iris is to be withdrawn through the wound in the cornea, and to be then cut off by a pair of scissors. A gap is thus

formed in the iris by which the rays of light can enter the eye.

By *Iriddesis* (Critchett).—Open the anterior chamber by puncturing the cornea as described above, but to a less degree; introduce a fine hook between the cornea and the iris, and seizing the pupillary margin of the latter with it, withdraw the membrane through the wound, but instead of cutting it off with the scissors retain it on the surface of the eye by inclosing it in a knot formed by casting a ligature about it; this knot strangulates the extracted portion of the iris and will be dislodged by ulceration, but insures union of that membrane to the wound of the cornea. This operation leads to the formation of a smaller artificial pupil than iridectomy does, and preserves the circular fibres of the iris and the contractility of the original pupil.

Staphyloma removed by abscision (Critchett).—Traverse the base of the protrusion with three or four small curved needles armed each with a fine silk ligature (somewhat after the manner of treating a *nævus*), and while the needles are thus *in situ* remove by two semi-elliptical incisions the projection inclosed by them; then remove the needles *seriatim* and substitute for them an equal number of interrupted sutures by means of the threads referred to, and by which the edges of the wound are to be maintained in contact. The semi-elliptical incisions should pass just within the points of entrance and of exit of the needles; and to favour ready approxima-

tion of the margins of the wound, may be prolonged on either side, beyond the staphyloma, into the sound structures. Upon this diminished but still existing globe, an artificial eye can be adapted with less perceptible deformity than when the entire eyeball is extirpated. By this method of operation the risk of hæmorrhage into the globe, or of suppuration of its cavity, is materially diminished; the greater part of the vitreous humour is retained, and the approximated edges usually unite by *immediate union*.

Cataract, extraction of lens.—Chloroform should not be administered. Place the subject recumbent and stand behind to operate with the right hand upon the right eye, but in front and on the right side to operate on the left eye if not ambidexter. The sound eye may be covered or not by a bandage during the operation. To expose the globe an assistant depresses the lower lid with the points of one

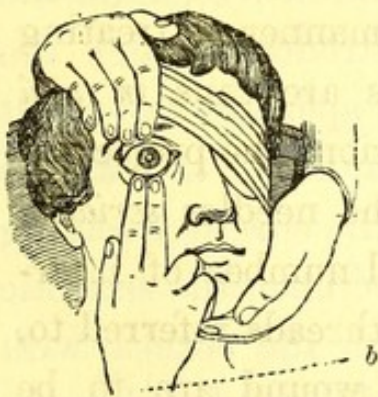

FIG. 71.

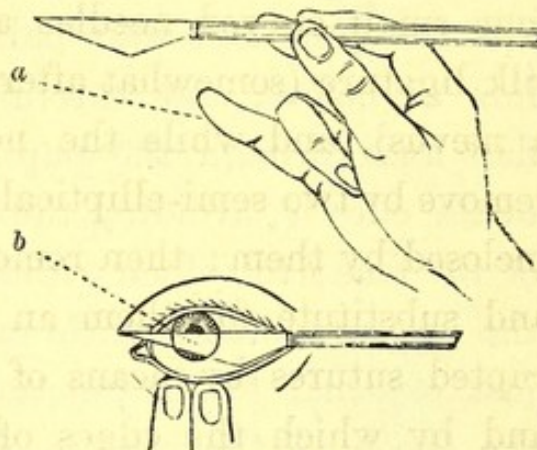


FIG. 72.

or two fingers, fig. 71 *b*, and fixes it so depressed, but not everted, upon the margin of the orbit, and

without exerting the least pressure upon the globe. The index and middle fingers of the operator's left hand are employed to draw up and to fix the upper lid, and to steady the globe without making undue pressure upon it. The operation is begun by forming a flap of the cornea, either the upper or lower half, according to the fancy of the surgeon; the upper half is usually preferred. Fig. 72 *a* shows the mode of holding the knife, the little finger being allowed to rest upon the head of the subject to steady the hand. The point of the knife is made to pierce the centre of the circumference of the cornea on the outer side just within its junction with the sclerotic, and having entered, is thrust steadily across the anterior chamber in front of the iris, making exit through the cornea at a corresponding point on the inside (*b*), and having *nearly* completed the semilunar flap, is to be withdrawn and to complete the flap with the point during the withdrawal; allow the lids to close and wait half a minute; separate the lids as before, and carefully introduce under the flap and through the pupillary aperture the point of the curette, avoiding the iris, and tear the capsule of the lens; this done withdraw the curette, avoiding the iris, and make gentle pressure upon the sclerotic just external to its junction with the cornea, with the spoon of the curette, in order to dislodge the lens, which having passed out at the wound, the operation is completed. Figs. 73, *a b*, show the curette behind the flap of the cornea. Figs. 74, *a b c*, show

the mode of forming the flap from the upper half of the cornea.

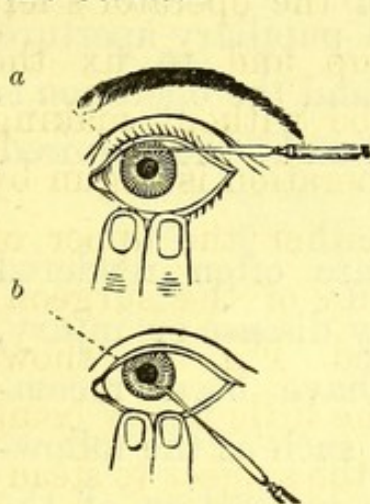


FIG. 73.

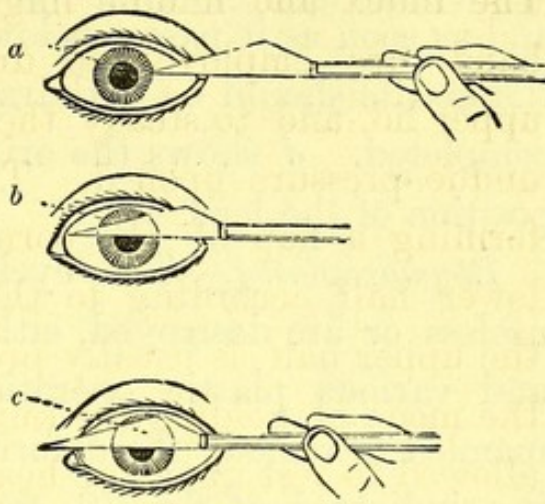


FIG. 74.

Schuff's method.—By this means the cornea is incised to a much less extent, and the lens is removed by a spoon. Those interested must refer to Schuff's remarks upon the subject.

Couching.—This operation is rarely performed, but has for its object the displacement of the lens from the axis of vision. The operator punctures the sclerotic about a line external to the margin of the cornea, usually opposite to its transverse diameter, with a needle rather broad near its point, and carries it inwards without wounding either the lens or the ciliary processes, causing it to appear behind the pupil, fig. 75 *b*, in its progress to the opposite side of the anterior chamber, when the flat of the needle

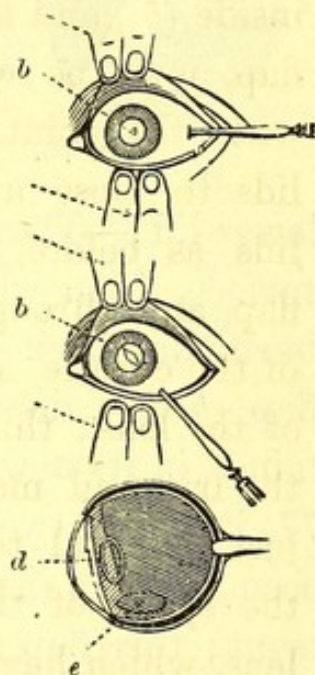


FIG. 75.

is to be pressed gently upon the anterior surface of the lens, in a direction backwards and downwards, and as soon as it passes below the pupillary aperture the needle should be withdrawn, and the operation is completed. *d* shows the original and *e* the acquired position of the lens.

Blepharoplasty.—The eyelids are often rendered useless or are destroyed, either by disease or injury, and various plastic operations have been recommended to remedy the deformity, such as the following, indicated at fig. 76, for the restoration of the

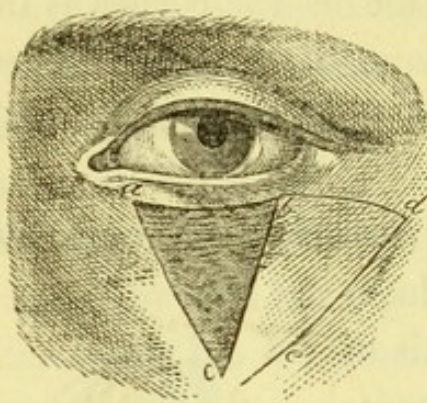


FIG. 76.

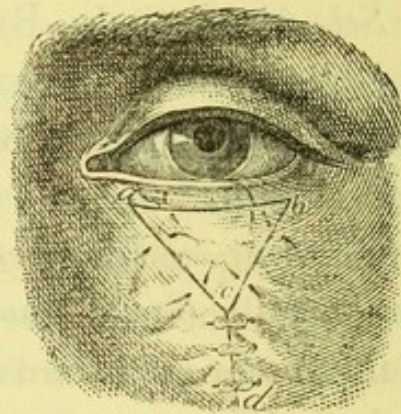


FIG. 77.

lower lid :—The dark triangular space (*a b c*) is a raw surface, from which cicatricial tissue, the result of burn, has been removed, and is to be replaced by a flap (*b d e*), dissected off the cheek, and to be maintained in its new position by fine sutures ; or, at fig. 77, in which two oblique incisions (*a c d*, *b c d*) have been made to inclose a **V**-shaped portion of integument ; this flap (*a c b*) is to be dissected up to an imaginary base (*a b*), and to be maintained in its new position by pins and sutures.

The upper lid may be replaced by integument taken from the temple or forehead, as shown in figs. 78 and 79.

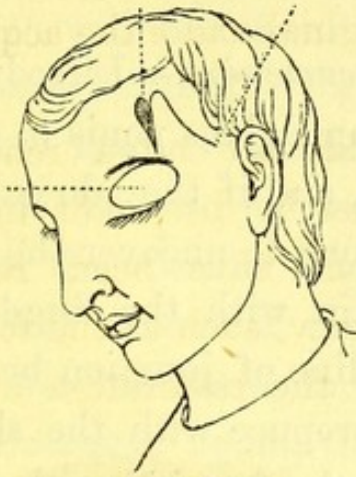


FIG. 78.

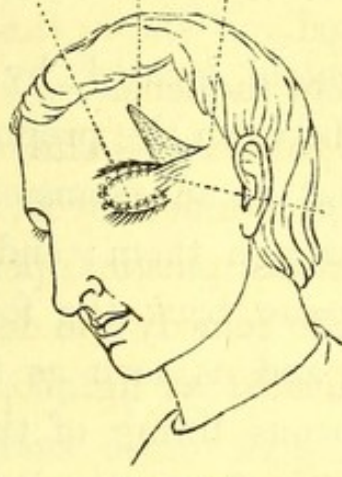


FIG. 79.

Rhinoplasty.—The nose, too, may be replaced by a portion of integument taken from the forehead, as shown at fig. 80. A large flap of integument (*a*) is to

be marked out and dissected off the forehead towards the root of the nose, at which point it is to be twisted on itself, but without strangulating the pedicle (*b*), in such a manner that it may fall over the nasal aperture, to the margins of which, previously paired, its edges are to be attached by suture;

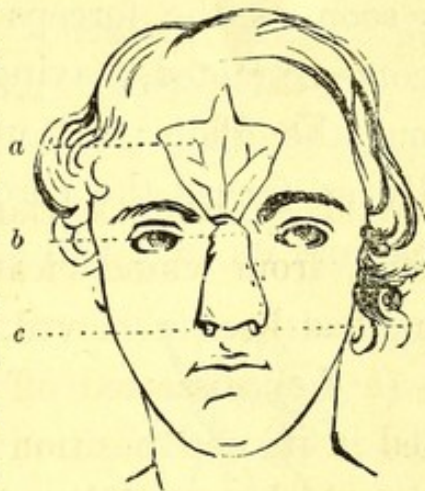


FIG. 80.

the portion of integument intended to replace the *columna nasi* must be fixed by suture to the centre of the upper lip, and the anterior nares are to be

kept patent by pieces of elastic catheter, *c c*, introduced on either side of the columna.

GENITO-URINARY ORGANS.

Phymosis treated by *circumcision*.—Introduce a probe between the prepuce and glans penis to ascertain that no adhesions exist, and if they do exist, to tear through them; endeavour to uncover the glans by drawing back the foreskin with the finger and thumb, and as soon as the line of junction between the mucous lining of the prepuce with the skin is seen, seize the extremity of the foreskin with a pair of forceps, fig. 81, and draw it forwards; now embrace the prepuce with the blades of dressing forceps anterior to the glans, and sever the former anterior to the dressing forceps with one sweep of the knife. As soon as the forceps are removed, the skin will become retracted, leaving the mucous membrane still about the glans; slit up this membrane longitudinally as far as the corona, when it may be turned back, and its edge will come into apposition with the

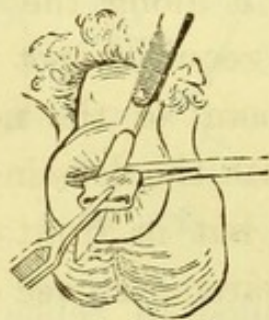


FIG. 81.

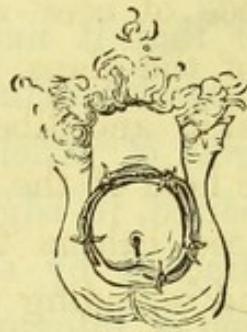


FIG. 82.

circular wound in the skin. The operation is com-

plete; but in the adult it will be well to introduce a few interrupted sutures, fig. 82, or better still the *serres fines*. (Part I. fig. 18.) Slight adhesions of the mucous membrane to the glans may be torn through with the thumb-nail.

Another method.—Unless care be taken, more skin and less mucous membrane than is desirable will be removed, because by reason of the anatomical conditions, the operator is able, as it were, to draw upon the whole extent of the skin of the *penis*, but only upon the mucous membrane lining the skin anterior to the corona; again, the glans being longer anteriorly than posteriorly, and the prepuce being supported posteriorly by the frænum, a greater length of foreskin should be removed from the anterior surface.

With these objects in view, discover, as above indicated, the junction of the mucous membrane with the anterior border of the skin of the prepuce, and while holding this margin with a pair of forceps, introduce through the preputial aperture (and not into the urethra) the point of a long needle protected by a piece of bees'-wax, carry it along the upper surface of the glans, and at the required spot pierce the foreskin and liberate the point of the needle; now take hold of the prepuce with the dressing forceps placed behind the needle, but in front of the glans, and including the whole circumference of the free margin of the prepuce, but less in length posteriorly than anteriorly; cut away the parts anterior

to the forceps. Complete the operation as above described.

By *simple incision*.—Introduce a director between the prepuce and glans down to the corona, either on the upper or under surface, and slit up the former longitudinally with a bistoury. This mode is useful in order to expose chancres or other disease. It must be remembered that should *soft chancres* exist, the new wound will in all probability become inoculated and take on chancrous ulceration; should an *indurated* chancre be present such result will not be.*

Amputation of the Penis (Hilton).—Introduce if possible No. 12 elastic catheter into the urethra, so as to define the extent of the corpus spongiosum; let an assistant draw the integument of the organ towards the pubis, that sufficient may be left to cover the wound, and then hold the body of the penis firmly between his finger and thumb, in order to compress the vessels. The operator defines the corpus spongiosum and at the intended point of amputation transfixes the organ with a narrow-bladed scalpel, so as to separate at this point the corpus spongiosum from the corpora cavernosa; the edge of the knife must now be turned up, and be made to cut its way out by severing the corpora cavernosa: this done, these bodies are to be dissected off the corpus spongiosum in a forward direction to the extent of a quarter of an inch, and the catheter being now withdrawn, the amputation is completed

* Ricord's "Lectures on Chancre," translated by Maunder.

by dividing the corpus spongiosum to the above extent anterior to the corpora cavernosa. The vessels having been ligatured, the projecting portion of corpus spongiosum is to be slit up longitudinally, so as to form two or three flaps, the borders of which are to be attached by suture to the margin of the integument. The advantage of this over the ordinary mode of amputation (by one sweep of the knife) is, that the orifice of the urethra is kept patent, and the tendency to contraction avoided.

Hydrocele. Tapping.—The testis is usually seated behind the distended tunica vaginalis, but occasionally it is in front of the swelling. The position of the testicle having been ascertained, the operator takes the tumour into the palm of his left hand, and makes tense the integument covering the lower part of it by pushing skin, testicle of opposite side, and penis, towards the pubis; this done, and avoiding any large vein which may be seen, he plunges a trocar and canula, oiled, in an upward direction, and not forgetting the locality of the testis, into the bottom of the sac, but rather anteriorly; and, as soon as resistance ceases, the trocar is to be withdrawn and at the same time the canula is pushed into the tumour up to its hilt, and is to be so left till the tunica vaginalis be evacuated. The canula withdrawn, the operation is completed.

To *inject* the sac, let the canula remain after that the contents have been drawn off, and through it the intended fluid may be introduced with a suitable

syringe. The canula should be well in the sac, lest the fluid intended for the interior of the latter escape into the areolar tissue of the scrotum; and, if desired, the fluid injected may be allowed to flow out also by the canula, and the latter is then withdrawn.

Varicocele. By *écraseur*.—An assistant should hold aside the vas deferens with his finger and thumb; then the dilated veins and small fold of skin of scrotum are to be taken up by the finger and thumb of the operator, while a long needle is made to transfix the fold of scrotum, passing, at the same time, in front of the vas, but behind the veins; a second needle is now introduced in a similar manner, but at an angle to the first, and the veins being thus isolated the loop of the chain of the *écraseur* is to be passed behind the needles (after the manner of treating a *nævus*), and the lever worked every half-minute till the circumscribed part be removed. Collodion may be applied to the almost invisible wound.

By *ligature*.—There are various methods. The most simple consists in passing a needle, armed with a strong ligature, through the scrotum and between the veins and vas deferens; then the needle must be reintroduced through the aperture by which it made exit; but this time it must carry the ligature between the veins and scrotum, making exit by the opening at which it had previously entered: thus the veins are inclosed by a loop of ligature, both ends of which hang out at one aperture, and include no portion of

skin; a knot tied tightly, strangulates the veins, which gradually become severed by ulceration.

When a ligature is employed, some means should be adopted by which the loop inclosing the veins is constantly becoming smaller and smaller, otherwise some time will elapse before the ligature is cast off. Fig. 83, *a*, represents a varicose condition of the veins of the testis; *b c* are ligatures, one in front of, the other behind these vessels; *d* is the vas deferens behind both ligatures.

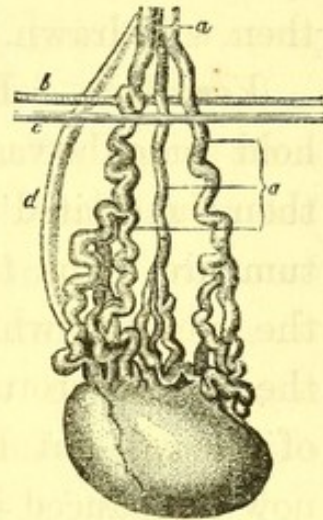


FIG. 83.

By *subcutaneous section* (H. Lee).—See Part I., p. 28.

Castration.—Place the subject recumbent, and shave the part, if necessary. Take the testicle into the palm of the left hand, and make tense the skin along the anterior surface of the tumour; make a longitudinal incision along the front of the organ, beginning just below the external abdominal ring, and terminating just above the lower end of the testis; by compressing the organ with the left hand it will protrude at the wound, and as soon as the tissues are divided down to the pearly tunica albuginea, and the cord is exposed, the latter is to be seized with a pair of claw-forceps and held by an assistant to prevent retraction, while the operator severs it and removes the testicle by dividing any existing attachments. The vessels of the cord—sper-

matic and artery of vas deferens—must be severally secured, as also any arteries of the scrotum; and as soon as the patient has thoroughly recovered, either from the effects of chloroform or the shock of the operation, the wound may be closed by sutures, compress, and bandage.

It will be better to defer closing the wound for some hours after the operation, rather than to do so before the circulation is thoroughly established and incur the risk of secondary hæmorrhage. Any portion of integument engaged in the disease must be removed with the testis by means of two semi-elliptical incisions, instead of one incision.

The Catheter.—To explore the urethra, place the subject recumbent, with the head and shoulders raised on a pillow, and the thighs also slightly flexed upon the abdomen and abducted. If alive, engage the patient in conversation.

Take a medium-sized metallic catheter or sound, well oiled and warmed, and holding it in the right hand, while the penis is held in the left hand (fig. 84), introduce the curved end of the instrument into the urethra, and allow it to glide towards the bladder almost by its own weight, at the same time elongating the penis upon the sound, so as to avoid the occurrence of any folds in the course of the urethra, which might impede the advance of the instrument. When passing the catheter, the navel should be exposed to view, and be in a line with the penis; the catheter should be parallel with this line, *i. e.* with

the median line of the body; its point should be kept up against the upper surface of the canal, and

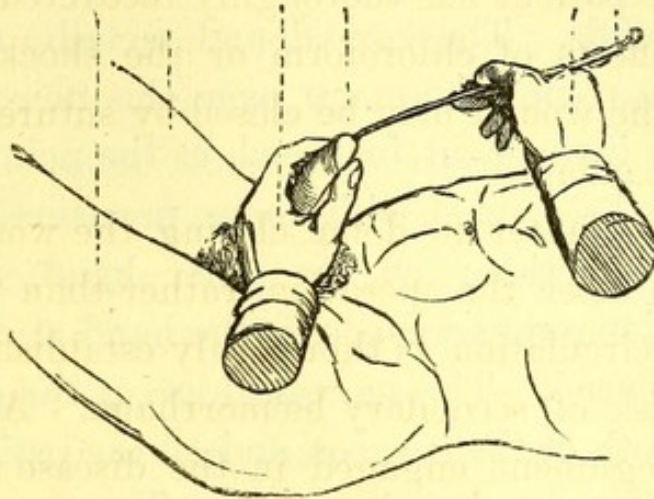


FIG. 84.

as it glides towards the bladder the different angles formed by it with the trunk will indicate the whereabouts of the point: when a right angle is formed, the point is in the membranous portion of the urethra opposite to the triangular ligament; and as the handle passes into the horizontal position between the thighs, the bladder is reached. In the healthy subject, provided that the bladder be not quite empty and contracted, the fact that the instrument is in the bladder may be known by the capability of rotating it with the finger and thumb applied to the handle; the rugæ also may be often felt.

* One of the diseases common to the urethra is stricture, in some form or other, consequent either on a permanent or temporary narrowing of the canal, the treatment of which by the catheter requires the most delicate manipulation.

Under the term "Catheterism" various instruments are employed, such as the metallic catheter, the elastic catheter, bougies of various material, and metallic sounds. The curved and metallic catheter or sound has one advantage over the non-metallic and flexible instrument, inasmuch as the point of the former can be guided with more precision in any particular direction; on the other hand, it often becomes a dangerous weapon in the hand of the rash or inexperienced. The successful use of the catheter demands, both of the surgeon and of the patient, the utmost patience and forbearance. The practitioner should at the outset explain to his patient, that any hurried attempt to reach the bladder will, in all probability, be followed by injurious rather than by beneficial results. In many instances, unfortunately, the surgeon, fearing lest his patient should become dissatisfied at an apparent failure if the bladder be not reached on the first or second attempt, inflicts, by his too anxious and forcible endeavour to reach that viscus, a laceration of the urethra, which is liable to be followed by extravasation of urine, the formation of false passages, or both. Doubtless the incautious use of the catheter, rather than the original disease, is the cause of the severe cases of stricture which come before the surgeon.

The surgeon should commence the treatment by an attempt to introduce a medium-sized catheter, and, having failed, let us suppose the existence of a permanent stricture, and to overcome this he should

carefully endeavour to pass a smaller and smaller instrument, metallic or otherwise, according to pleasure, until the size is arrived at which will pass through the stricture. Sometimes the instrument will enter the stricture, but will not traverse its whole extent; under these circumstances it should be retained, with gentle pressure, for perhaps ten or fifteen minutes, with the hope of inducing some amount of dilatation and absorption; also, when an instrument has traversed the stricture, it should be left in the urethra for a period of at least fifteen minutes, with a similar object in view.

An instrument of a certain diameter having traversed the stricture, the size of the instrument is to be gradually increased till No. 9, and certainly No. 12 at most, be reached, and will traverse the stricture with ease. (Wakley's instruments are very useful in the treatment of permanent stricture. The advantage which they enjoy consists in the absence of the necessity to re-seek the aperture of the strictured portion of the urethra when the guide for the cylinders has once traversed the stricture; whereas with the ordinary catheter, one must be withdrawn before another can be introduced, and if false passages exist, the second instrument may enter the wrong channel.)

The frequency with which catheterism should be practised, in an individual case, must depend upon the degree of local and constitutional irritation excited; in one case the attempt may be

made on alternate days, in another instance every third day, in a third case once a week.

But the surgeon may fail to reach the bladder by simple catheterism, and must employ other means to aid, such as the application of an escharotic, internal section, external section, or, in extreme cases, the bladder must be punctured.

By *escharotic*.—Introduce a medium-sized instrument as far as the stricture, and note the distance of the anterior orifice of the stricture from the meatus upon the instrument to be employed to carry the caustic, in order that the operator may know whether or not the caustic be in contact with the constriction. Take a bougie, No. 8 or 9, and scoop out one extremity so as to form a cup-shaped cavity, into which a piece of caustic potash, the size of the head of a “grandmother’s pin,” may be pressed just previous to the moment of introduction; oil the bougie, and thus armed, pass it rapidly down so as to bring its extremity into contact with the stricture, and so maintain it for the space of five minutes. Its operation will soon be felt by the patient, and the slough resulting should be looked for in the chamber utensil. One application may be beneficial, allowing the urine to flow in a larger stream than usual, but if necessary the operation may be repeated.

By *internal division*.—One of the many urethrotomes invented may be employed for this purpose.

By *external section* (Syme).—This method presupposes the *capability* of passing a small grooved

staff *through* the stricture (fig. 85 E), upon which the intervening structures are to be divided from without. The advantage of a staff consists in its serving as a guide to the urethra behind the stricture, into which portion of the canal the knife is to be first entered, and when inserted in the groove, is to be carried forward through the stricture, so as to divide the diseased tissues. An ordinary director is now passed into the urethra through the wound, towards the bladder, while a full-sized elastic catheter is introduced at the meatus, and having reached the wound, is guided into the bladder upon the director; the latter is then removed, but the former is maintained for four-and-twenty hours, after which it also may be taken out of the bladder. Probably for some days urine will flow, both at the wound and at the meatus; but as the former closes, and indeed for some weeks after the cure appears to be effected, a full-sized catheter must be occasionally passed along the urethra into the bladder.

Another method pre-supposes the *impossibility* of passing an instrument *through* the stricture. Pass a large metallic catheter down to the stricture, and make prominent its extremity; from without, cut down upon this, and open the urethra anterior to the stricture; now divide the indurated tissues in the median line in a direction towards the bladder, with the hope of finding the track of the urethra, and while so doing let the patient strain to make water, in order that any dilatation of the portion of urethra

behind the stricture consequent on this effort may indicate the line for the incision. The urethra opened, and the indurated tissues divided, the catheter must be carried on into the bladder and be there maintained for twenty-four hours, when it may be replaced by another.

It is always difficult to find the orifice of the urethra through a wound in its continuity; therefore, before removing one catheter from the bladder in order to replace it, an ordinary director should be introduced into the canal towards the bladder through the external wound, to serve as a guide for the catheter.

Either of the above methods employed in the perinæum is termed "perineal section," and it sometimes happens that the soft parts in this region are so thickened and indurated that the Syme's staff cannot be felt through them; and although the surgeon may divide the tissues with the greatest care, in order to arrive at the director, it is very possible that he may miss it, and continuing his incision on one or other side of it, get behind the director, and so fail in the accomplishment of the operation. In order to obviate the possibility of such an accident, I have introduced to the notice of the profession, through the medium of the *Medical Times and Gazette*, a sketch of a urethrotome (fig. 85), devised for that purpose. A represents the handle of the instrument, which, when in use, the surgeon should hold steadily with his left hand; B marks the position of a circular

joint, which allows the arm, D, to be moved forwards and backwards; c is an arc, which ensures the

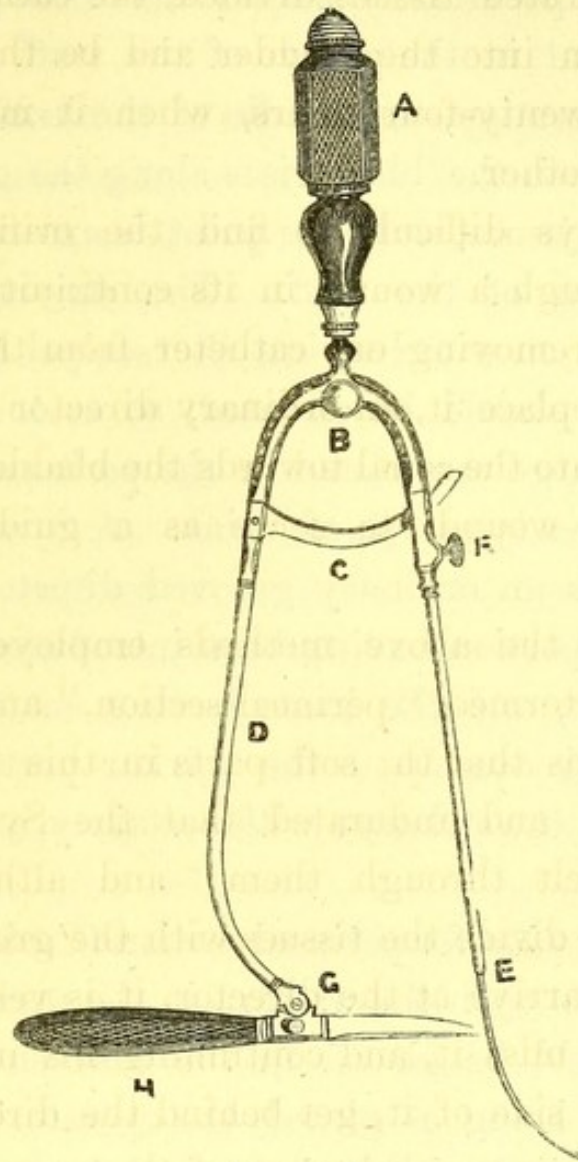


FIG. 85.

moving of the arm D parallel to the arm E; E is a Syme's staff, which may be either removed or fixed at pleasure by the finger-screw, F; G marks the position of a circular joint, which allows the double-edged scalpel, H, to be moved in a direction either upwards or downwards. The scalpel, H, is attached to the circular joint by a finger-screw. The sketch

represents the instrument in action, with the Syme's staff, E, in the stricture, and the scalpel, which has been made to penetrate the soft parts of the perinæum, with its point in the groove of the staff. To complete the operation, the handle of the knife must be depressed when the blade rises along the groove and divides the tissues, until its point is arrested by the thick portion of the staff. The stricture is now divided, and on withdrawing the scalpel the handle of the same should be elevated, so as to cause the blade to enlarge the wound in the perinæum, and so ensure the ready escape of urine. A Syme's staff is preferable to an ordinary grooved director, because the thicker portion having been introduced down to the stricture, and the knife having cut the tissues along the groove up to the thicker portion of the staff, divides the stricture with certainty, and nothing more.

Another method for perineal section (Cock).—When attempting to open the urethra in the perinæum, the subject should be placed in the lithotomy position. The patient being so placed, the operator's left forefinger, well oiled, should be passed into the rectum, to ascertain the exact position of the apex of the prostate, and be there maintained; with the right hand a double-edged scalpel incises the median line of the perinæum anterior to the anus, the point of the knife being carried back, with the intention of opening the membranous urethra in the direction of the apex of the prostate, to which latter the finger in the

rectum serves somewhat as a guide. As soon as the knife has entered the perinæum, it should not be withdrawn till the requisite section of parts is completed.

This mode of treatment is very applicable to cases in which extravasation of urine has occurred behind a stricture. A ready means of escape is thus offered, both to the urine already poured out into the surrounding parts and also to that afterwards secreted. While the perineal wound is patent, the stricture may be treated by the usual method.

Puncture of distended Bladder above the Pubis.—Place the subject recumbent, with the head and shoulders raised, and the thighs flexed and abducted. In the median line, and one finger's breadth above the pubis, incise the integuments sufficiently to admit the point of the trocar and canula, which whether straight or curved, are to be plunged into the bladder in this region; the trocar is to be withdrawn so soon as the bladder is entered, but the canula or an elastic catheter may be retained, by suitable tapes passed around the pelvis and thighs.

Puncture of Bladder per Rectum.—Place the subject in the lithotomy position, and pass the left forefinger into the rectum, to feel the distended bladder immediately behind the prostate, and in the median line; while the point of the finger rests against the bladder, introduce into the rectum the curved canula (fig. 86 *a*), its concavity looking upwards, and guiding it along the retained finger, place the end (*c*) also in

contact with the wall of the bladder : this done, the trocar (*b*) is to be run along the canula, and as soon as

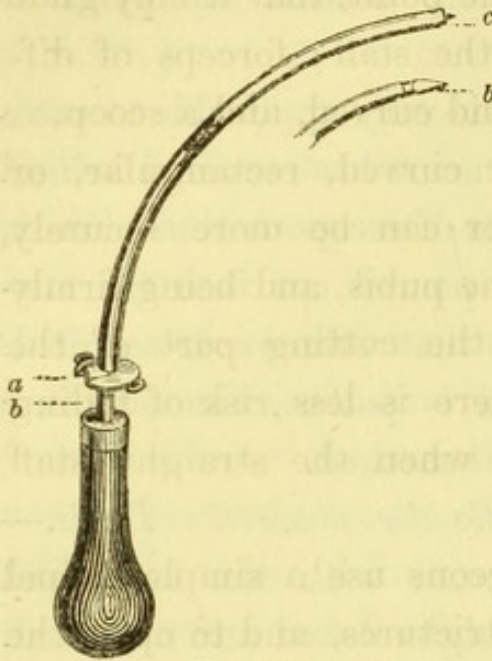


FIG. 86.

the point reaches the end of the canula (*c*), the instrument is to be made to penetrate the anterior wall of the rectum, and to enter the bladder; the bladder entered, the trocar is to be withdrawn, and the canula retained for many days, if necessary, by tapes attached to a band passed around the pelvis.

By relieving the bladder by puncture, and allowing the urine to flow away through an artificial opening, the urethra is put into a state of rest, and a favourable opportunity is afforded for treating the stricture.

Lithotomy.—Previous to the operation, the presence of a stone in the bladder should have been detected with the sound. On the night before the day fixed for operation, a dose of castor oil should be administered, and on the morning of the day, a warm water enema, to empty the rectum. Shave the perinæum, if necessary. Assistants necessary are : one for each lower extremity, a third to hold the staff, and a fourth to attend to the wants of the patient, &c. &c. The operation usually performed

in this country is by *lateral* incision; and instruments requisite are, a grooved staff; scalpel, the back of which is rounded towards the point, that it may glide readily in the groove of the staff; forceps of different sizes, both straight and curved, and a scoop.

The *staff* may be either curved, rectangular, or straight. The two former can be more securely fixed under the arch of the pubis, and being firmly held by the assistant till the cutting part of the operation be completed, there is less risk of failing to open the bladder than when the straight staff is used.

The Scalpel.—Some surgeons use a simple scalpel to divide the superficial strictures, and to open the membranous portion of the urethra only, and as soon as that is done, the scalpel is laid aside and replaced by a knife having a button at its extremity, and which is used to complete the section of parts; others use a gorget. The buttoned scalpel runs readily in the groove of the staff, and is less likely to transfix the bladder and to open the peritoneal cavity than the ordinary lithotomy knife.

The Gorget.—The blunt gorget either dilates or tears the prostate, while the cutting gorget divides the prostate with precision, and also on either side, if double-edged.

The urine should either be retained in the bladder some hours before the operation, or warm water may be injected at the time of the operation. Place the subject recumbent, and introduce the staff into the

bladder (the largest that will pass), and ascertain the presence of a stone before proceeding further; perhaps, if the subject be a child, or the prostate be much enlarged, the long curve of the staff will not dip sufficiently low towards the floor of the bladder, and will fail to detect the stone. Under these circumstances, the staff must be withdrawn, and a sound, with a short curve, be introduced, when, if the stone be felt, the operation may be proceeded with. On no account is the patient to be cut, unless the stone be recognised at the time of operation.

Don't mistake the promontory of the sacrum for a calculus.

The staff in the bladder, the subject is to be drawn to the edge of the table, so that the buttocks may project slightly beyond it, and the appointed assistants flex each a thigh upon the abdomen and the leg upon the thigh, and having attached one end of a suitable bandage to the wrist, the foot is placed in the palm of the corresponding hand, and the two are then to be firmly bound together; the head and shoulders are to be thrown forward, and the trunk is to be raised to an angle of about thirty degrees, on pillows. Each assistant in charge of a lower extremity holds the foot with one hand, and, if possible, should put the knee into his axilla, so as to have perfect command over the extremity, and should make pressure upon it in a direction downwards and inwards; the assistant on the other side does likewise; and thus the two antagonistic forces

have a tendency to fix the pelvis upon the table. The operator sits on a suitable stool, or kneels on a pillow, in front of the perinæum, his chin being on a level with the anus. At the last moment he satisfies himself that the staff is still in the bladder, and having hooked it firmly under the arch of the pubis, with the groove slightly inclined to the left, he entrusts the handle to an assistant, who, standing on one or other side of the subject, facing the operator, maintains the staff in the same position till desired to alter or remove it altogether; if requisite, one hand must be employed to hold aside the scrotum. The surgeon now surveys the perinæum, observing particularly the distance between the most prominent points of the tubera ischii, and determining with his eye the extent and course of the intended incision. The length of incision will vary in proportion to the age and degree of obesity of the subject, the probable size of the stone and depth of perinæum; it will, therefore, vary from one-and-a-half to three inches, although the skin of the perinæum in front of the anus may be incised freely in a forward direction to favour extraction of a large stone. In the adult, the incision is to be begun about one-and-a-half inches in front of the anus—in the child, about half that distance will suffice,—and is to be carried downwards and outwards on the left side to or beyond a point midway between the anus and most prominent point of the tuber ischii, or even rather nearer to the ischium than to the anus. As a guide

for the commencement of this oblique incision in the adult, the breadth of the two first fingers of the operator's left hand will assist, the length of the nail indicating the distance on the left from the raphe at which it is to be begun. In the child, one finger's breadth and half the length of the nail will suffice.

The surgeon, seated as above mentioned, holds the knife as he would a pen, and being on a low stool cannot fail to use it with the point directed upwards towards the umbilicus of the patient rather than inclined downwards towards the rectum. The incision is begun by entering the knife in the perinæum at the point indicated, and carrying it downwards in the right direction, and to the requisite extent, dividing probably the skin, common superficial fascia, a few fibres of the external sphincter, and some fat in the ischio-rectal space; another sweep of the knife from above downwards deepens the wound, dividing perhaps the deep perineal fascia, the transverse perinæi muscle and artery, and more ischio-rectal fat. The forefinger of the left hand should be passed into the upper end of the wound, to put aside the bulb, *a* (fig. 87 being a side view of the male genito-urinary organs, &c.), and to feel for the staff through the membranous portion (*b*); the staff recognised, the point of the knife (not carried too high, lest it wound the artery of the bulb) is to cut its way into it through the urethra, and the two metals having come into contact, the scalpel is to be run back along the groove into the bladder, cutting the prostate (*c*), in a direction

from above downwards and outwards, and perhaps nicking the neck of the bladder, and as it is with-

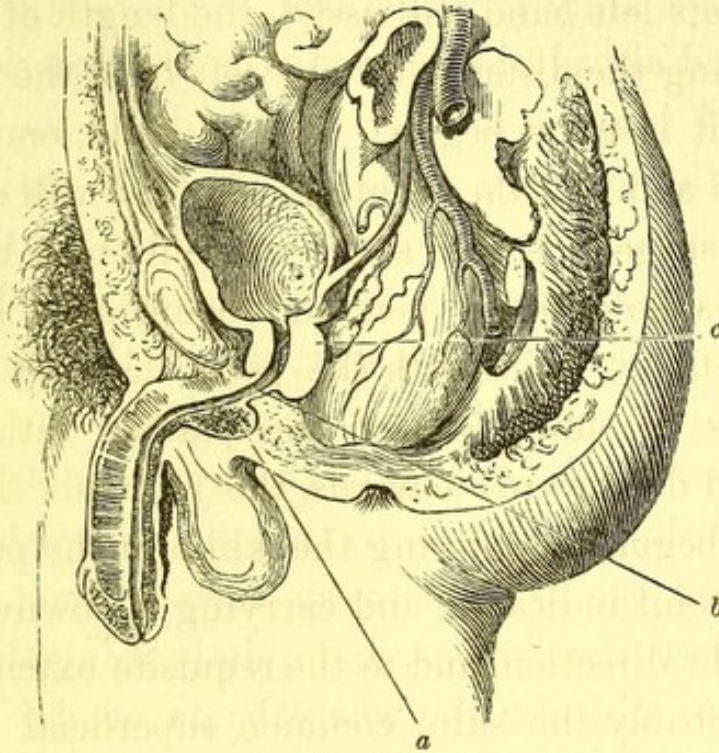


FIG. 87.

drawn, may be made to deepen the existing wound by dividing a few fibres of the levator ani muscle. Fig. 88 shows the relative position of the prostate and rectum beneath the arch of the pubes, the prostate being perforated by the urethra and traversed by dotted lines *c* coursing from the urethra in different directions, and indicating the variable depth of the gland; the greatest depth of the

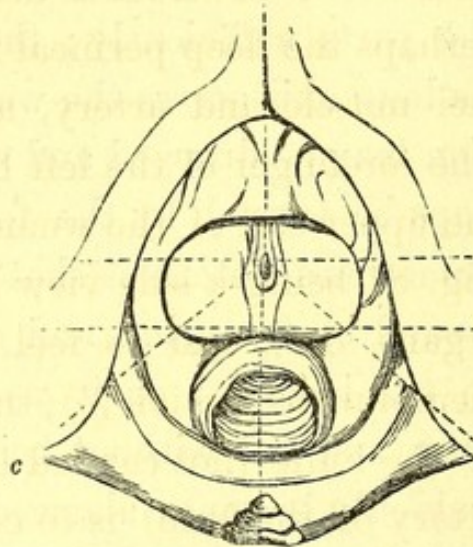


FIG. 88.

prostate being in direction from the urethra downwards and outwards to *c* or *e*.

As the knife is withdrawn, the forefinger of the left hand already in the wound is to be carried along the staff into the bladder, both to dilate the opening, to fill the aperture made by the knife and prevent the escape of urine, and also to feel and fix the stone. Desire the assistant to remove the staff; take now a suitable pair of forceps, warmed, in the right hand, and while removing the finger from the bladder, introduce the forceps, and as soon as possible separate their blades, with the hope that the first gush of urine may send the stone between them; if not so fortunate, close the forceps, and quietly using them as a sound to discover the whereabouts of the calculus, endeavour to seize it, and having succeeded, proceed to extract it by pulling gently forwards and downwards, and from side to side, so as gradually to dilate the parts sufficiently; the stone may be lying with its long axis across the wound, and to alter this position may be dropped and seized again, or it may perhaps be turned by the forefinger of the left hand. Sometimes a stone is shot out of the bladder into the wound by the urine, and consequently none is found in the bladder; or it may be carried out upon the floor, and fall without being heard, and the operator suddenly becomes alarmed lest he may have cut his patient unnecessarily. A small stone, or fragments of stone, may be removed by a scoop and finger. The stone may be so large that the incision on one side

only will not suffice for its extraction. Under these circumstances, it must either be broken by a lithotrite, or the opposite side of the prostate must be cut by introducing upon the finger retained in the bladder a straight probe-pointed bistoury, and directing its edge downwards and outwards towards the right-hand side. The stone having been extracted, the finger should be passed into the bladder, in order to ascertain that a second calculus does not exist, and fragments of stone may be removed by injecting warm water into the bladder through the wound.

Hæmorrhage from a superficial vessel may be checked by ligature; general bleeding, by plugging the wound with sponge around a tube previously introduced into the bladder, through which urine may escape. Slight bleeding will cease when the sides of the wound come into apposition by approximating the thighs. The operation completed, the bandages may be removed from the hands and feet, and the patient be returned to bed.

By *median* incision (Allarton).—Excepting the site and extent of incision, the above remarks will be equally applicable here.

The operation is performed by introducing the forefinger of the left hand into the rectum, to feel the apex of the prostate, the groove of the staff, and to press upon and fix the latter (fig. 89 showing a side view of the pelvis); then a long sharp-pointed knife held in the right hand, edge uppermost, is made to enter the perinæum in the median line, and about

half an inch in front of the anus, and is pushed on towards the bladder, and parallel with the finger,

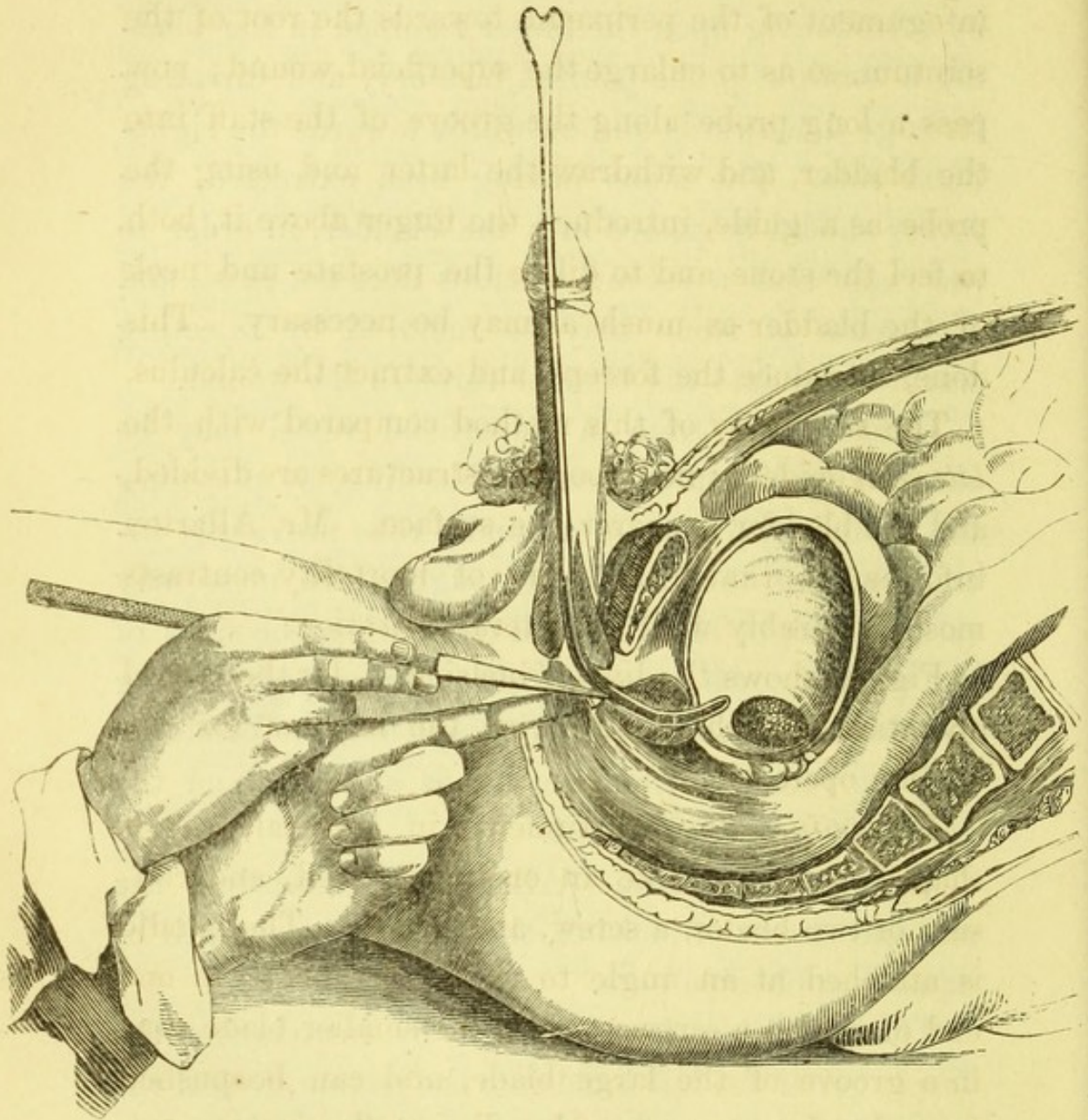


FIG. 89.

with a view to open the membranous portion of the urethra, and to enter the groove of the staff. The contact of the two metals having been recognised, the

knife is to be withdrawn in an upward direction, cutting the membranous urethra towards the bulb, and from behind forwards, and also severing the integument of the perinæum towards the root of the scrotum, so as to enlarge the superficial wound; now pass a long probe along the groove of the staff into the bladder, and withdraw the latter, and using the probe as a guide, introduce the finger above it, both to feel the stone and to dilate the prostate and neck of the bladder as much as may be necessary. This done, introduce the forceps, and extract the calculus.

The simplicity of this method compared with the *lateral* is evident; no important structures are divided, and the bladder is nearer the surface. Mr. Allarton informs me that “the ratio of mortality contrasts most favourably with the lateral operation.”

Fig. 90 shows the line of incision, A, for the lateral operation; B, the position of the incision for the median operation.

Lithotrity.—The instrument in general use is shaped somewhat like an ordinary sound, and consists of two blades, a screw, and handle. The handle is attached at an angle to the larger blade, in one end of which a screw works; the smaller blade runs in a groove of the large blade, and can be pushed home by the screw, fig. 91. To use the instrument, the subject should be recumbent with the pelvis raised on a pillow, and the legs hanging over the edge of the table or bed, and supported on chairs. The bladder should contain from six to eight ounces

of urine or of warm water previously injected, in order that the blades of the instrument may be

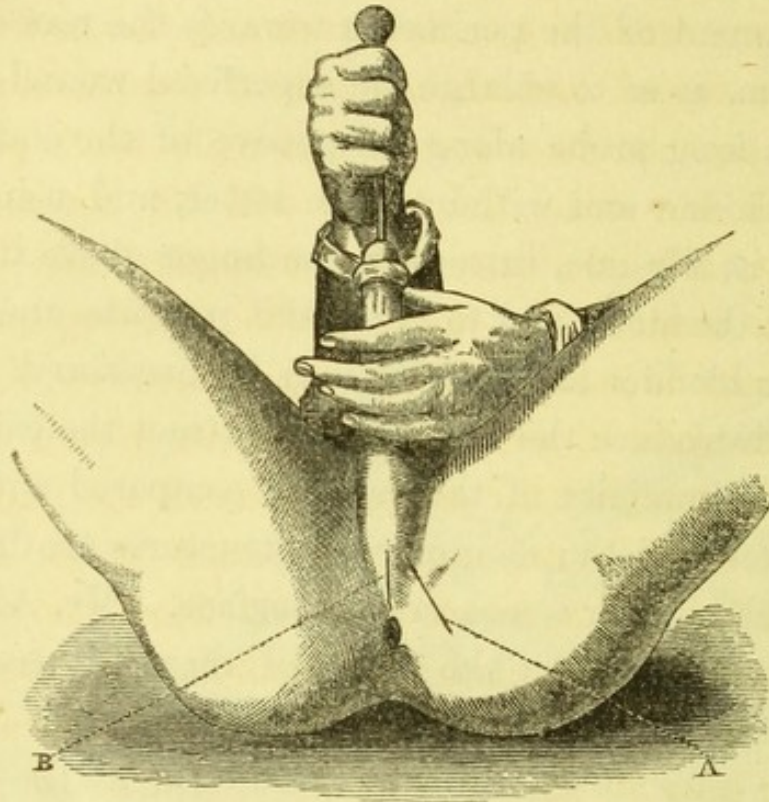


FIG. 90.

separated without risk of wounding that viscus. The surgeon faces the subject, standing between the




FIG. 91.

thighs, and cautiously introduces the closed lithotrite, oiled and warmed, into the bladder; he now feels for the stone, and having recognised its locality, separates

the blades of the lithotrite by drawing the female towards him along the groove of the male, but without altering the position of the latter. The blades being separated to a sufficient extent, the instrument may be dipped towards the floor of the bladder with the hope that the curve of the male blade passing beneath the stone, the latter will fall between the blades; this step executed, the female blade is to be pushed towards the floor of the bladder, and the stone may be seized, and if seized the screw, brought to bear upon it, will probably break it into two or more fragments: the attempt to catch the fragments and to crush them, may be repeated in the inverse proportion of its injurious effects upon the patient. The operation completed, the blades of the instrument are to be approximated and withdrawn, and another sitting may be arranged at the expiration of a week or more days, in accordance with the effects of the first operation, or supposing that the whole stone be not discharged after one operation. The sound should always be used previous to attempting lithotrity.

The stone broken, fragments will pass with the urine, and one may lodge in the urethra, and must be removed, either by pushing it back into the bladder with a full-sized catheter, or by extracting it with a bent probe or urethral forceps, or other means devised by the ingenuity of the surgeon to meet the circumstances of the case.

Lithotrity should always be attempted between the

ages of fifteen and fifty-five, provided that the urethra be capacious, the bladder tolerant of the presence of the instrument, and capable of containing from six to eight ounces of water. In the adult mortality after lithotomy is great; but in the boy the urethra is small and the bladder sensitive, and the mortality after lithotomy is slight; in the old man the prostate is more or less enlarged,—a circumstance favourable to lithotomy, because a free incision may be made in it without great risk; but unfavourable to lithotrity, because the fragments of calculus are liable to lodge in the vesical pouch behind the enlarged gland.

Catheterism in the Female.—Place the subject recumbent, with the right thigh semiflexed upon the abdomen; stand on the right side and introduce the tip of the forefinger of the left hand from before backwards, just within the orifice of the vagina; then gradually retracing this step, the finger passes out of the vagina, and immediately above it detects a slight depression corresponding to the meatus; the right hand, armed with a catheter warmed and oiled, is passed under the elevated thigh, and, guided by the point of the left forefinger still maintained at the meatus, the instrument enters the urethra and the bladder. If possible, do not expose the patient in order to evacuate the bladder.

Calculus in the Female Bladder.—The female urethra is short (fig. 92, *a*), and more readily dilated to a considerable extent than that of the male. Dilatation

of this canal by sponge tents, by Weiss's dilator, or by Arnott's hydraulic dilator, will usually suffice for the extraction of stone.

Lithotomy may be practised by introducing into the bladder a grooved staff, and upon this a straight probe-pointed knife, which latter is to lay open the

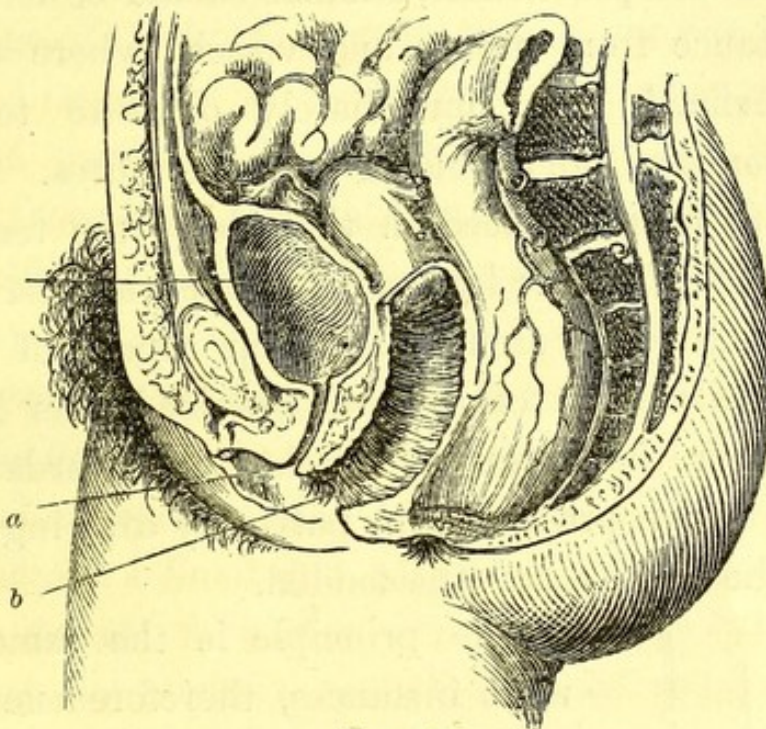


FIG. 92.

urethra on either the right or left side, or on both, external to the vagina in a direction downwards and to one side. Introduce the finger, and withdraw the staff, and having dilated the neck of the bladder sufficiently, insert the forceps and withdraw the calculus.

Tenotomy.—This operation has for its object the section of one or more tendons, which, being contracted, distort the limb and interfere with the healthy and useful movements of a joint. The *sub-*

cutaneous section of tendons is preferred, with a view to inflict as little injury as possible to the parts covering and adjacent to the tendon; also, to avoid the occurrence of suppuration by excluding the air, and so to promote rapid union of the divided ends of the tendon by the natural interposition of organizable lymph. When practicable, tendons should be divided at a distance from nerves and vessels, where they are superficial, not immediately opposite to an articulation, and are devoid of muscular fibres. The knife is to be introduced on the side of the tendon on which are the more important organs; and having passed transversely along the deep aspect of the tendon till its point reaches the opposite border of it, should sever the organ by cutting it towards the skin, partly by pressure and partly by drawing the edge of the blade across the tendon.

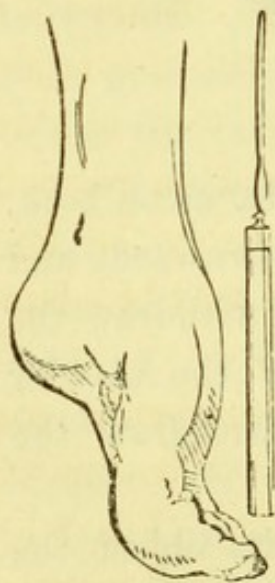


FIG. 93.

The principle is the same in most instances, therefore one example will suffice.

The tendon frequently requiring division is the tendo Achillis, the contracted state of which is shown in fig. 93. To divide this tendon, the subject will be conveniently placed on its face; one assistant should hold the leg while another endeavours to flex the foot upon the leg, and by so doing tighten the tendon; the operator, having previously clearly defined the extent


and position of the tendon, introduces the point of a fine knife (flat of the blade towards the leg) on the inner side of the tendon, and almost perpendicularly to the surface. Having penetrated to the margin of the tendon, the point of the blade must be made to turn round the border of it and to pass across it to the opposite margin; this done, the edge of the knife must be turned towards the tendon, and be caused to divide, partly by pressure against it and partly by drawing the blade of the knife across it from heel to point; when divided, the assistant holding the foot will experience a *snap*, which perhaps may be heard, and the operator will be able to detect a gap caused by the retraction of the end of the tendon connected with muscular fibre from the end attached to bone. Withdraw the knife *flat* as it entered, following it with the thumb, so as to express extravasated blood, and to prevent the entrance of air into the wound; close the wound with a compress, strapping, and a bandage from the toes upwards. Leave the parts at rest for a week, and on removing the compress the wound will probably be found healed, and an appropriate apparatus may be adapted to the limb.

After having punctured the integuments, some surgeons prefer to effect division of the tendon with either a square or probe-pointed knife. (Fig. 93.)

When performing a delicate operation, tenotomy for example, the hand using the knife should rest, even with the point of a finger only, upon the limb of

the subject, becoming, as it were, for the moment a part of the member itself, lest during any unexpected movement on the part of the patient the limb be brought into forcible contact with the knife, and serious injury be incurred.

THE END.



the subject, remaining as it were, for the moment a
 part of the number itself, but during any unexpected
 movement on the part of the subject the link be-
 comes free and remains with the hand, and
 may be used to count.

