

**On the surgical treatment of polypi of the larynx : and oedema of the glottis
/ by Horace Green.**

Contributors

Green, Horace, 1802-1866.
Royal College of Physicians of Edinburgh

Publication/Creation

New York : G.P. Putnam, 1852.

Persistent URL

<https://wellcomecollection.org/works/h3skhtx2>

Provider

Royal College of Physicians Edinburgh

License and attribution

This material has been provided by This material has been provided by the Royal College of Physicians of Edinburgh. The original may be consulted at the Royal College of Physicians of Edinburgh. where the originals may be consulted.

This work has been identified as being free of known restrictions under copyright law, including all related and neighbouring rights and is being made available under the Creative Commons, Public Domain Mark.

You can copy, modify, distribute and perform the work, even for commercial purposes, without asking permission.



Wellcome Collection
183 Euston Road
London NW1 2BE UK
T +44 (0)20 7611 8722
E library@wellcomecollection.org
<https://wellcomecollection.org>

POLYPI OF THE LARYNX
AND
EDEMA OF THE VOCALS
BY
DR. GREEN


76
H. P. 51.


R54541

By Order of the COLLEGE, This Book is, upon
no account whatsoever, to be taken out of
the Reading-Room until after the expiry of
One Month, from this date,

PHYSICIANS' HALL.

22nd Sept 1832





POLYPI OF THE LARYNX

THE POLYMER OF THE FUTURE

POLYPI OF THE LARYNX.



Digitized by the Internet Archive
in 2015

ON THE
SURGICAL TREATMENT
OF
POLYPI OF THE LARYNX,
AND
ŒDEMA OF THE GLOTTIS.

BY
HORACE GREEN, A. M., M. D.

President of the Faculty, and Professor of the Theory and Practice of Medicine, in the New York
Medical College; Member of the American Medical Association; Fellow of the
College of Physicians and Surgeons, N. Y.; and Honorary Member
of the Philadelphia Medical Society.

BIBLIOTH.
COLL. REG.
MED. EDIN.

NEW YORK:
G. P. PUTNAM, No. 10 PARK PLACE.
1852.

Entered according to an Act of Congress, in the year 1852,
By HORACE GREEN,
in the Clerk's Office of the District Court, for the Southern District of New York.

NEW YORK :
BAKER, GODWIN & CO., PRINTERS,
Tribune Buildings.

PREFACE.

THE publication of the following pages has been undertaken in order to give to the profession the personal observations of the author, on the nature and treatment of two of the most mortal affections of the air tubes.

Happily, polypus of the larynx and œdema glottidis are diseases, particularly the first named, of very rare occurrence: so, at least, it has ever been considered; and yet the author does not hesitate to express the opinion, and to leave it for future experience to confirm or invalidate, that foreign growths have occurred in the opening of the air-passages, in many instances, where their presence was neither suspected nor discovered; and that, if the attention of the profession should by any means be directed to this subject, it will be

found that the existence of polypus and other excrescences in these passages is an occurrence taking place much more frequently than has been supposed by medical practitioners.

We have now collected together all, or nearly all, the well authenticated histories of this disease; and the entire number amounts to some thirty-nine or forty cases only. Of these, seven or eight have been observed in our own country: all the remainder have been collected by authors in different parts of Europe. Of the whole number, four well marked cases of foreign growths in the larynx have occurred in the practice of the author, during the past five or six years; and within the same period, two other instances have been observed by an eminent surgeon in this city. If, therefore, six cases of these tumours have been recognized by two members of the profession within the above period, constituting nearly one-sixth of the whole number of observations yet collected in the entire history of the disease, is it not quite reasonable to suppose that a much larger number of instances of polypous growth than all those hitherto observed, have existed undiscovered, and have been in fact the undetected cause of death in many cases?

Amongst physicians of long experience and extensive opportunities for observation, not a few may

be found who will recall the occurrence of fatal cases in their own practice, where the patient, after having presented strange and anomalous symptoms during life, died suddenly, from some inexplicable cause. In some of these instances, it is not improbable that a polypous growth, gradually developed, in the opening of the larynx, may have been the true cause of the fatal termination.

But whether these conjectures are well founded or not, it is obviously important that all information which can be obtained with regard to the nature and treatment of a disease so obscure in its symptoms, and yet so inevitably fatal in its tendency, as polypus of the larynx, should be placed before the medical community.

In the forty cases of this disease to which allusion is made in the following pages, the result was fatal in every instance, with three exceptions. In one of these fortunate cases, the life of the patient was saved by the operation of laryngo-tracheotomy, which was performed by Professor Ehrmann of Strasburg. The other two cases came under the observation of the author, by whom they were successfully treated.

The happy result which, in so many instances, has followed the employment of topical applications in the treatment of *œdema glottidis*, has en-

couraged the author to commend, with much confidence, to his professional brethren, this method of treating one of the most formidable, and hitherto one of the most fatal, of all the diseases of the larynx.

12 Clinton-Place, New York, May, 1852.

CONTENTS.

	PAGE
Preface,	v

CHAPTER I.

<i>Polypi of the Larynx,</i>	9
Fatal nature of Polypi of the Larynx,	10
The probable occurrence of the disease in cases not detected,	11
Cases of the existence of Polypi, but not suspected by the attending physicians,	12
Importance of bringing the subject before the profession,	13

CHAPTER II.

<i>History of Polypi of the Larynx,</i>	14
Disease not recognized until after the middle of the last century,	<i>ib.</i>
Cases observed by Lieutaud and Bichat,	15
Fatal case recorded by Pelletau,	16
Two cases reported by Dr. Schultz,	17
Cases of Polypi observed by Andral and Senn, of Geneva,	20
Polypus observed by Albers, of Bonn,	21
Polypus observed by Dupuytren,	22
Polypus observed by Dr. Dawosky,	23
Mucous Polypus recorded by Trousseau and Belloc,	24
Fatal case recorded by Herbert Mayo,	27
History of a case recorded by M. Rendtorff,	28
Three cases of Polypi reported by M. Gluge,	29
Polypus detached and found in the trachea,	30
Death of M. Stassin, from Laryngeal Polypus,	31
Cauliflower excrescences found in the larynx,	33
Fatal case occurring in the Hospital of Strasburg,	34
Laryngotomy proposed in a case, by M. Ehrmann,	36

CONTENTS.

	PAGE.
Cases of Polypi of the Larynx recorded in American Journals,	39
Case reported by Dr. Cheesman,	<i>ib.</i>
Case in the "American Journal of Medical Sciences,"	40
Two cases observed by Dr. Parker,	41

CHAPTER III.

<i>Morbid Growths in the Larynx,</i>	44
Hydatid and cartilaginous tumours in the larynx,	45
Cases of Polypi of the Larynx removed by operations,	46
Laryngotomy practiced with success,	47
Operation described,	50
Death of the patient from typhoid fever,	54
Polypus of the larynx removed by an operation,	56
Appearance of the polypus tumour,	65
Case noticed by Mr. Ryland,	<i>ib.</i>
Cauliflower excrescences removed by an operation,	66
Encephaloid tumour blocking up the pharynx and glottis,	74
Removal of portions of the tumour,	79
Discovery of a tumour within the larynx,	83
Warty tumours within the larynx,	85
Polypus in the larynx detected by Dr. Hartwell,	86

CHAPTER IV.

<i>Diagnosis,</i>	88
Diagnostic signs of polypus of the larynx,	89
Movements of a foreign body in the larynx,	90
Alteration in the sound of the voice,	91
Dyspnœa a symptom of the presence of polypus,	91
<i>Causes of polypus growth,</i>	92
The disease the result of croup and whooping cough,	93
Complications with Tubercular phthisis,	94

CHAPTER V.

<i>Treatment of Polypus of the Larynx,</i>	95
Cases in which the polypi might have been removed,	97
Method of examining for polypus of the larynx,	99
Operation for Sessile tumours,	100
Laryngotomy, when demanded,	101
Method of practicing the operation,	102

CHAPTER VI.

<i>Œdema Glottidis,</i>	103
Symptoms of œdema of the glottis,	104
Fatal nature of the disease,	105
Case of œdema glottidis complicated with diphtheritic inflammation,	106
Treatment of the case by topical applications,	107
Case of Dr. S., œdema glottidis,	109
Fatal case of the disease,	112
Case of œdema reported by Dr. Scott,	115

CHAPTER VII.

<i>Treatment of Œdema Glottidis,</i>	117
Different measures employed,	118
The importance of bronchotomy,	<i>ib.</i>
Scarifications, by M. Lisfranc,	119
Treatment by Cauterization,	120
Employment of general remedies,	121
Explanation of Plates,	123

CONTENTS

CHAPTER VI

102	History of the disease
103	Diagnosis of a case of the disease
104	Pathogenesis of the disease
105	Case of infant treated with digitalis
106	Treatment of the case by digitalis
107	Case of the disease in a child
108	Pathogenesis of the disease
109	Case of disease reported by Dr. H. H.

CHAPTER VII

110	Treatment of the disease
111	History of the disease
112	Diagnosis of a case of the disease
113	The importance of the disease
114	Significance of the disease
115	Pathogenesis of the disease
116	Diagnosis of a case of the disease
117	Pathogenesis of the disease

CHAPTER VIII

118	History of the disease
119	Diagnosis of a case of the disease
120	Pathogenesis of the disease
121	Case of the disease in a child
122	Treatment of the case by digitalis
123	Case of the disease in a child
124	Pathogenesis of the disease
125	Case of the disease in a child

CHAPTER IX

126	History of the disease
127	Diagnosis of a case of the disease
128	Pathogenesis of the disease
129	Case of the disease in a child
130	Treatment of the case by digitalis
131	Case of the disease in a child
132	Pathogenesis of the disease
133	Case of the disease in a child

ON THE
SURGICAL TREATMENT
OF
POLYPI OF THE LARYNX,
AND
ŒDEMA OF THE GLOTTIS.

CHAPTER I.

POLYPI OF THE LARYNX.

THE valuable monograph on Polypi of the Larynx, published by Professor Ehrmann, of Strasburg, in 1850, has called the attention of the medical profession of Europe, and, to some extent, of our own country also, to this interesting but hitherto fatal disease.*

By his researches among medical authors, and by addressing inquiries to his colleagues in foreign Universities, M. Ehrmann has collected the history of all the cases of laryngeal polypi known to have existed, up to the time of the publication of his work.

* Histoire des Polypes du Larynx, par C. H. Ehrmann, Professeur à la Faculté de Médecine, etc., Strasbourg, 1850.

In the observations thus collected by this author, amounting to twenty-six in all, the result was fatal in every instance, except in one case which fell under his own notice, the detailed history of which he has given, and in which the life of the patient was saved by the operation of laryngotomy.

An account of this operation, as M. Ehrmann declares, being communicated to the Academy of Sciences, was well received; that learned body verified the fact, that this was the first time that a like attempt had been made, and had been followed with a happy result. The Section of Medicine of the Scientific Congress, which met at Aix-la-Chapelle, in 1847, also heard with interest a history of the operation which M. Ehrmann had performed; and the illustrious Stromeyer, who presided, pronounced it as being one of the happiest conquests of modern surgery.

Having operated in two cases, for the extraction of laryngeal tumours, with entire success, removing, in one instance, a polypus from the larynx, and in the other a growth of vegetating tumours, which had their origin, apparently, on or near the vocal ligaments, saving in both cases the individuals from inevitable death, without performing the operation of laryngotomy,—I have deemed the subject of sufficient importance to lay a detailed history of these cases before the medical profession of my country.

Availing myself, not only of the single facts

scattered through the works of different authors, but of the valuable observations collected by the industry of Prof. Ehrmann, I shall allude briefly to the authenticated history of these interesting pathological productions.

Although the instances of polypi in the larynx observed and recorded by all authors, up to the present time, are less than forty in number, yet there remains not a doubt, that in many instances these morbid growths have existed unobserved during life, and, having proved suddenly fatal, have remained undetected after death. The diagnosis of these excrescences is extremely difficult; the symptoms developed by their presence simulate those frequently observed in asthma, phthisis, œdema of the glottis, thickening of the mucous membrane of the larynx, and ulceration of the vocal ligaments.

From a view of all the cases yet observed, this conclusion is inevitable, remarks M. Ehrmann, "that polypi of the larynx, left to nature, become sooner or later the cause of sudden death."* Being attached, generally, by a pedicle, either to the ventricles of the larynx or to the cordæ vocales, the morbid body may be concealed in the glottis, and remain, even after the death of the patient, the undetected cause of the fatal termination.

That these developments have proved the pathological cause of death, altogether more frequently than the profession, generally, are aware, I have

* Op. Citat. p. 1.

been led to conclude, from the fact, that having discovered, accidentally, several years ago, the existence of a polypus in the larynx of a young lady (Case II.) who came under my care, I have since ascertained the existence of three other cases of laryngeal tumors, making in all four which have occurred in my own practice, during the last six years.

In all these cases, although the disease had existed for many years, and the patients had been not only menaced with frequent attacks of suffocation, but had been subjected, in each instance, to the examination and treatment of several eminent medical men, yet the presence of a morbid growth in the larynx had not, in either case, been for a moment suspected. Certainly, then, it is not a conjecture in any degree improbable, to suppose that in the past history of disease, the presence of polypi in the air-passages has proved, in many instances, the immediate cause of death in persons who have died suddenly and unexpectedly, whilst the agent of the fatal result has never been revealed.

In much the larger number of the cases of laryngeal polypi, whose histories have been collected, the tumours have been developed above the inferior vocal ligaments, and have had their pedunculated roots fixed, either in the sides of the ventricles, or to the vocal cords. In this way, having considerable mobility, the excrescence has floated in the cavity of the glottis, producing, ordi-

narily, but little inconvenience, until it had attained a volume sufficient to obstruct the glottis; or, on being thrust between its borders, by coughing or by violent respiration, and being there arrested, it has menaced suffocation.

To bring, therefore, before the profession, the subject of a disease so little understood and so fatal in its tendency, and to contribute in any degree to its diagnosis, cannot be deemed altogether a useless labor.

CHAPTER II.

HISTORY OF POLYPI OF THE LARYNX.

THE same physical causes which tend to the production of these morbid growths, having always existed, it seems surprising that not until after the middle of the last century do we find, among the ancient medical writers, any record of the disease.

In a work published by Lieutaud, in 1767,* the two following cases are related; and the observations are highly interesting from the circumstance that the author, in having italicized the word *asthmatici* in one, and *phthisici* in the other, would seem to indicate that the symptoms manifested during the life of the patient, simulated those of asthma and phthisis.

"I. *In cadavere cujusdam ASTHMATICI triginta annorum, qui perpetuo querebatur de quodam impedimento in trachœa, quod tussi et screatu expellere sæpius connabatur et morte subitanœa sublato, reperitur quidam POLYPUS variis radicibus laryngi infixus et versus glottidem obturamenti instar adactus; unde suffocatio inexpectata.*"

"II. *Secto cadavere cujusdam pueri duodecim*

* Historia Anatom. Med., lib. iv., observ. 63 et 64.

annorum, jampridem PHTHISICI et inexpectatâ morte rapti, in propatulum veniebat intrâ laryngem, corpus quoddam polyposum et racemosum tracheæ superiori parte, pediculo unico et peculiari ortum trahens et hinc fluitans; quo forte ad laryngem repulso suffocationem obierat æger."

More than thirty years after the publication of the cases by Lieutaud, Bichat, in Dessault's *Œuvres Chirurgicales*, alludes to three cases of polypi of the larynx, two of which were observed by Dessault, and a history of the third was communicated to him by a surgeon of his acquaintance.

In all these cases, the tumours were of a pyriform shape, having their pedicles inserted into one of the ventricles of the larynx. Thus, being mobile, and obeying the impulse of the air in respiration, they were ultimately pushed between the borders of the glottis, where, being arrested, death was produced by suffocation. This occurred in the case observed by Dessault; when the patient, after having been frequently threatened with suffocation, died suddenly, at length, from occlusion of the glottis, when the polypus had attained a size sufficient to fill up this aperture. Death from suffocation occurred in the same manner, in the case of polypus of the larynx, observed and recorded by Pelletan, in 1810.*

The patient, a man between thirty and forty years old, had been previously treated by Pelletan for gangrenous ulcers of the throat, from the pha-

* Clinique Chirurgicale, tom. 1st, p. 15, observ. 8.

ryngeal wall of which eschars were often detached. He had occasional attacks of dyspnœa so violent as, for a time, to threaten speedy death. From several of these he had escaped; but being at one time suddenly seized with one of these paroxysms, he threw himself headlong out of bed, with the air of a man who suffocates, and fell down apparently lifeless.

Pelletan, on being called, supposed that one of the eschars might have been separated from the throat, and had fallen into the opening of the glottis. With this impression, he performed carefully the operation of tracheotomy, breathed air into the lungs, and employed the vapor of ammonia, but without any effect. Satisfied of the death of the patient, he now continued the dissection of the parts, when there was found near the glottis a solid tumour, of the volume and form of a small nut (*petite noisette*), attached by a thin and long pedicle, which allowed it to float ordinarily, but having been crowded by a strong respiration into the aperture of the glottis, and being there arrested, it had destroyed the life of the patient.

"But *the cause of these accidents*, says Pelletan, could neither be known or attacked, dissection alone could reveal it."

Since this author wrote, however, the cause of the disease has, in several instances, been discovered in time to save the lives of the patients; and we hope, by contributing something more to our knowledge of the diagnosis and treatment of this serious

malady, other lives may be rescued from destruction.

Through the correspondence instituted by Professor Ehrmann, on the subject of polypi of the larynx, the history of several interesting cases was brought to light. The two following observations, which I have taken the liberty to abridge somewhat, were communicated to M. Ehrmann by Dr. Schultz, of Deux Ponts.

In the first case recorded by Dr. Schultz, the disease, which occurred in a boy aged six years, succeeded to an attack of croup, "which did not pursue its ordinary rapid progress, but passed slowly to the chronic stage." For a long time the child remained feverish, and his voice was always hoarse, but he gradually recovered, and ultimately regained his strength and fullness. In July, 1823, twenty weeks after the invasion of the first disease, this boy was suddenly taken with a fit of suffocation, in which he died. The autopsy revealed a fleshy tumour, resembling in form a French bean, attached by a pedicle to the base of the epiglottis. The excrescence was engaged in the opening of the glottis, obstructing entirely this aperture.

The second case was seen by Dr. Schultz only a short time before the death of the patient. A poor woman, forty-four years of age, called upon him, reduced to the lowest state of misery and destitution. Her laborious respiration could be heard before she entered his room. The voice was hoarse and whistling, and speaking was performed only by great

muscular efforts of the neck and chest. She had been hoarse for many weeks, and had complained of an embarrassment in her throat; but it was a recent and very great increase of these symptoms that had brought her to Dr. Schultz for aid. She was carried to the hospital, where she was immediately bled, and the usual remedies administered. A short interval of repose succeeded, which was soon followed by an attack of suffocative breathing, of which she died. Tracheotomy was performed, but without success.

On examining the body the next day, no traces of inflammation, in the whole extent of the air-tubes, could be found. But a movable, *fleshy excrescence*, situated at the base of the epiglottis and extending even to the opening of the trachea, was found, which entirely obstructed the larynx, and, consequently, interrupted completely the passage of air.

During the ten or twelve years that succeeded the recording of the two observations made by Dr. Schultz, some twelve or more cases of polypi of the larynx were observed by different pathologists in various parts of Europe.

A case of much interest is mentioned by Otto,* where a polypus having several lobules, and which is preserved in the museum at Breslau, was found in the larynx of a man who died from suffocation. The patient was sixty-five years old, and had been

* Seltene Beobachtungen zur Anatomie, etc., Berlin, 1824.

afflicted with a hoarseness many years. He complained of dyspnœa, and of a disagreeable sensation in swallowing solid food, as if some obstacle at the time closed the larynx. At length, in a fit of coughing, he ejected a small globular, fleshy mass of the size of a currant, and two days after a similar body, having the volume of a small cherry. Immediately after this the voice improved, and respiration was much easier. Some weeks later, a third body of the same size, similar to the first, and having a thin pedicle, was discharged. Soon after this, however, the hoarseness and difficulty of respiration reappeared, he became rapidly weaker, the dyspnœa was greatly increased, and the patient died, slowly suffocated.

The cartilages of the larynx were found much ossified, and a fleshy, nodulated tumour, of a very large size, was found occupying the glottis. It was composed of three oblong excrescences, each of the volume of a small nut, but united together, and having their pedicle attached to the inferior ligament of each side of the glottis. These tumors closed entirely the superior aperture of the larynx, causing the suffocation of which the patient died. The ventricles, the mucous membrane, and the other parts of the larynx, presented no alteration.

Andral refers,* in the *Clinique Medicale*, to two examples of polypus of the larynx, that he had observed in patients, both of whom were affected with tubercular phthisis. In one of them, the voice had

* *Clinique Medicale*, tom. ii., p. 194.

become almost completely extinguished; besides which the patient had complained, during his stay in the hospital, of a constant sensation of embarrassment and constriction in the region of the larynx. A polypus, with its pedicle attached to the bottom of one of the ventricles, was found occupying the cavity of the larynx, and projecting slightly above the glottis.

In the other case mentioned by Andral, a small, hard tumor, attached to the membrane above the superior ligament, was observed. This excrescence was composed of a great number of small, whitish granulations, which gave it the appearance of certain syphilitic vegetations; denominated *cauliflower* by physicians.

In 1826, a fatal case of laryngeal polypus was observed by Dr. Senn, of Geneva.* M. Clavel, who was aphonic, and had been treated for some time for laryngeal phthisis, died suddenly; and Dr. Senn was called upon by the authorities to inspect the body. No evidence of phthisis was present, on examination, but on opening the larynx from behind, *a tumour the size of a filbert, whitish, hard, and fibrous*, was discovered, having a pedicle, which was attached to the right ventricle. This excrescence occupied almost all of the superior part of the cavity of the larynx, so that when this organ was closed, it was extremely difficult to introduce a very small crow-quill. The tumour, which was syphilitic, was the true cause of death.

* Journal des Progrès des Sciences Medicales, tom. v., p. 230.

In a memoir, published in 1833,* by Urner, of Elberfeld, a long and very minute account of a case of polypus of the larynx is given, which was observed by Albers, of Bonn. The patient, a man aged fifty-four, was for many years affected with a dry, hard cough, followed at length with frequent and severe attacks of hæmoptysis. On presenting himself at the clinique of Bonn, this man had a very strongly-marked *habitus hæmopticus*. Pressure on the larynx caused pain; the respiration was hurried and difficult, the voice extinguished, and emaciation general.

A seton was placed over the lower part of the larynx, and appropriate general treatment employed, under which the health of the patient in some degree improved. After many months, and much treatment, which it is unnecessary to detail, the cough and expectoration greatly increased, and the dyspnœa was augmented to such a degree that the patient came very near being suffocated several times. He experienced, during these accesses, the feeling of a cork (*bouchon*) in the trachea; inspiration and expiration were equally difficult. In February, 1832, all the symptoms became greatly augmented, and in addition, there were present, difficulty in swallowing, and pain near the left cornu of the os-hyoides. In the month of March, the patient died.

On dissection, tubercular granulations were dis-

* Dissert. de tumorib. in cavo laryngis.—Bonn, 1833.

covered in the right lung, and a vomica was found in the upper lobe of the left lung.

The mucous membrane of the throat, and especially that in the vicinity of the glottis, was studied with little round corpuscles, formed by tumefied mucous glands. The larynx was voluminous, and on opening it, a round, fleshy tumour, of the size of a small nut, was observed between the inferior ligaments of the glottis, fixed by prolongations to the two inferior vocal cords.

Immediately behind the tumor, and between the two ventricles, which were here separated from each other farther than usual, an excavation was found, capable of receiving the movable body in such a manner that, when it fell into this cavity, it obstructed only one-half of the glottis. The mucous membrane of the glottis was thickened, and both ventricles were nearly effaced.

The case recorded by Dupuytren,* occurred, also, in an old man, who entered Hôtel Dieu to be treated for a disease of the urinary passages. He had suffered occasionally from attacks of suffocation, which were attributed to a suffocating asthma—to a spasm of the glottis; the integrity of the respiratory functions, in the intervals, removed all idea of the presence of angine disease in the air-passages; consequently he was not placed under any treatment. The patient suddenly died from suffocation. On opening the body, the glottis was

* *Leçons Orales*. tom. iii., p. 602.

found completely closed by a polypus, formed of cellular and vascular tissue, and covered by mucous membrane. It was attached to one of the lips of the glottis, was more than eighteen lines in length, and bifurcated at its free extremity. This polypus floated ordinarily in the cavity of the pharynx, and caused there no serious disturbance. But when, by a change of position, it was placed above the opening of the glottis, the suffocative attacks were produced; and it was in one, more severe than the rest, that the patient died.

In Hufeland's Journal* is recorded the history of a case, where a tumour was observed in the larynx of a child ten years old, by Dr. Dawosky, of Celle, Hanover. This patient had been the subject of frequent and severe attacks of croup; and a short time before the occurrence of the disease that proved fatal, he suffered from measles, but from this disease he was perfectly restored. Soon after his recovery, in consequence of having the perspiration suddenly checked, by taking a bath when greatly heated, he was seized with hoarseness, accompanied with tumefaction of the uvula and the tonsillary glands. The application of leeches near the affected parts, and the employment of antiphlogistic measures, reduced the inflammation. For six months the patient remained relieved, when he had another attack, requiring similar treatment. The relief now obtained, did not long continue. The

* Journal de Médecine Pratique, de Hufeland, tom. lxxx., 2d part, page 78.

hoarseness and difficulty of respiration was renewed; and, notwithstanding most energetic measures were employed, these symptoms became greatly aggravated, and the little patient was threatened with immediate suffocation. Confident that some foreign body was obstructing the opening of the air-passages, Dr. Dawosky proposed the operation of laryngotomy; but, notwithstanding the imminence of the danger, he could not obtain the consent of the parents, and the child soon expired, suffocated.

An examination of the neck of the body was alone permitted. On opening the larynx, a vegetant tumour, composed of small and large excrescences, in form resembling a bunch of grapes, completely obstructed the laryngeal cavity. The difficulty of respiration during life, and the cause of death, were perfectly explained.

The case recorded by Trousseau and Belloc,* and which I have abridged from this work, is one of much interest on account of the relief obtained by laryngotomy, although the patient died five days after the operation, from an acute attack of disease of the lungs.

The patient, M. de Serry, aged forty-two, an élève of the Polytechnic School, had always enjoyed good health, until 1834, when in June of that year, his voice began to lose its natural sound, and gradually became less distinct, until aphonia was completely established. Some relief was pro-

* *Traité de la Phthisie Laryngée*, p. 41.

cured by treatment; but this only lasted a few months, for in July, 1835, he again felt some difficulty of respiration, which so increased, in a few days, that he was threatened with immediate suffocation. When seen by M. Trousseau, the 11th of July, the patient enjoyed his natural powers, his pulse numbered from one hundred and fifteen to one hundred and twenty in a minute, and respiration was performed twenty-eight times in the same period. Inspiration and expiration seemed to be performed with equal difficulty.

In the evening, the respiration became exceedingly difficult; the night was passed in great agitation, and on the morning of the 12th, suffocation being imminent, the operation of laryngotomy was practiced by M. Trousseau, in the presence of Professors Fouquier and Roux, and Doctors Hamard and Danyau. A hemorrhage, which was readily checked by compression, was the only accident accompanying the operation. As soon as the canula was introduced, the oppressed respiration became easier, although still a little irregular and accelerated.

For five days after the operation, the patient was as well as could be hoped for, but at this time (the 16th) he began to complain of a pain in the right side, and had more frequent, and especially more fatiguing attacks of coughing than before. Percussion revealed, at the base of the right lung, and above the liver, decided dullness. He was bled one pound, cataplasms were placed upon the

painful spot, and sinapisms to the extremities, but no relief was obtained. The patient died, on the evening of the 17th, twenty-four hours after the access of the thoracic symptoms.

In the autopsy, sixteen hours after death, the larynx was first examined. The right aryteno-epiglottic ligament presented an œdematous tumefaction, which increased in size as it neared the larynx, and being flabby and hanging in the larynx, it was driven by strong inspiration into this organ, and must have very much embarrassed the respiration.

Some other portions of the larynx were tumefied, especially the inferior vocal cord, but the greatest change was in the left ventricle. Here, the cavity, which was bathed with a greyish secretion, extremely fetid, was filled by an accidental production, of lardaceous consistence, and of an ashy white color. A portion of this tumour, which was prolonged into the interval that separates the cricoid from the thyroid cartilage, appeared a little without, and behind the larynx; and here it assumed the consistence and hue of a mucous polypus.

No tubercles were discovered in the lungs; but adhesions were found, uniting the whole left lung to the costal pleura; and in the right pleura, there was an effusion of three pounds of reddish serum. All the inferior lobe of the right lung, was of a dark wine-lees color, without crepitation, easily torn, and when cut, there flowed from it a bloody, fetid, but not frothy liquid.

It is unnecessary to enumerate the minor pathological changes, that were observed.

Preserved in the Anatomical Museum of the Royal College, in London, is an interesting preparation, taken from the body of an elderly lady, in which a firm, whitish, elastic polypus grew by a pedicle from the root of the epiglottis. This specimen was presented by Mr. Charles Mayo, of Winchester, to Mr. Hubert Mayo, who alludes to the case in his work on Human Pathology,* and states, that the polypus had produced occasional suffocative seizures, in one of which the patient died.

A representation of this tumour was obtained by Mr. Ryland, who mentions the case,† and also gives an account of its structure, which was furnished him by his friend, Mr. Partridge, Professor of Anatomy in King's College, who made a section of the polypus, and examined closely into its structure and its attachments.

It appears to consist of fat, and cellular tissue, enclosed in the laryngeal mucous membrane, which is reflected over it, and which entirely forms its pedicle; the fatty substance of the tumour does not enter into the composition of the pedicle, which is formed of the mucous membrane and cellular tissue only. The pedicle, the attachment of which

* Outlines of Human Pathology, p. 514.

† A Treatise on the Diseases and Injuries of the Larynx and Trachea, pp. 228-9.

could not be seen before the section of the tumour was made, arises from the left vocal cord.

From the inaugural dissertation of M. Rendtorff, of Heidelberg, published in 1840, M. Ehrmann has obtained the history of a polypus, found in the larynx of a young man, aged seventeen, who came to the Clinique, Sept. 17, 1838, suffering under some slight indisposition, from which he was restored. But he soon returned, having a bad countenance, and complaining of great feebleness in his joints. His digestive system, however, and other organs, especially the larynx, presented nothing abnormal. A good regimen soon reëstablished all his forces, and after a few days, he again quit the hospital. On the 8th of October, he returned once more, complaining of weakness; his emaciation had increased; and soon after his return, the patient spoke, for the first time, of a collection of mucus in the throat, which forced him frequently to expectorate. He had no cough, and the throat appeared only slightly inflamed, the pulse was a little accelerated, and the respiration, at times, was slightly embarrassed. A soothing gargle, and a mild expectorant were prescribed. During the following night, the patient became suddenly worse; he complained of an abundant secretion, filling his throat; he was extremely agitated, respiration became more and more difficult, and in a short time he expired from suffocation.

The cause of his sudden death was found in the larynx. Upon opening this organ, on the posterior

median line, a polypus of the size of a filbert was discovered, springing from the aryteno-epiglottic ligament, and extending into the larynx, as far as the left superior vocal cord. The trachea, the bronchial tubes, and the heart were normal, but the lungs were gorged with blood.

Under the title of "*Dégénérescence de la membrane muqueuse de la trachée-artère et du larynx*,"* M. Gluge has reported three cases of polypi, which had been observed by him in the space of a short time.

The first case related by M. Gluge, occurred in a man aged fifty, an interne of the Military Hospital of Jéna, who, after complaining some time of attacks of dyspnœa, died very suddenly, before the nature of his malady was known.

On examining the body, a hard tumour, white and fibrous, was found in the interior of the larynx, attached to the posterior wall of this organ. The polypus, which was of the volume of a pigeon's egg, filled, so to speak, the whole cavity of the larynx, extended even as far as the third ring of the trachea, and so reducing the aperture of the air-passages, as hardly to allow the introduction of a slender probe.

The second case of laryngeal polypus, mentioned by M. Gluge, occurred in a man unknown to him during the patient's life. He died suddenly, and on examining the cadavre, a large tumour, of a

* Abhandlungen zur Physiologie und Pathologie, 1841, p. 91.

greyish, white color, was found in the interior of the larynx, which encroached so much on the right glottic ligament, and so narrowed the aerien canal, that a small quill could scarcely be passed through the remaining aperture. The other parts of the larynx were perfectly healthy.

In the third instance recorded by the above author, an attempt was made to save the life of the patient, by the operation of laryngotomy. A woman aged forty, of a robust constitution, had suffered for many years from a difficulty of respiration. Partial aphonia existed; and a tumefaction of the larynx, visible externally, caused the suspicion, that a grave organic disease existed; for which laryngo-tracheotomy was practiced, but without success, for the patient died very soon after the operation.

The lateral walls of the larynx were found greatly thickened, and a tumour springing from the membrane was brought to light, which had extended as far as the third ring of the trachea, burying itself with the muscles of that region. The morbid mass, occupied the place of the glottic ligaments, as no trace of the right vocal cords remained, and those of the left side, were reduced to almost the last vestige. The right ventricle had also disappeared.

In the *Gazette Médicale de Paris*,* is an extract from the London Medical Gazette, giving the

* 1844, p. 385.

history of a polypus, that was found after death, in the trachea of a woman who died suddenly after a fit of coughing.

A polypus as large as an almond was found in the trachea, *detached*, and having a long pedicle. It was at once supposed that the morbid body had come from some point in the larynx; but on examining the trachea, there was found on its interior wall, a short distance below the cricoid cartilage, a place rough and wounded, and it was evident that the tumour had become spontaneously detached, perhaps separated by the cough, and had caused the sudden death of the patient by suffocation.

A paper read before the Academy of Medicine of Paris,* in 1836, by Dr. Gerardin, contains the details of the case of M. Stassin, chief of the Hussars of the Chamber of Deputies, aged sixty-three years, who died of a laryngeal polypus. This case, which is one of much interest, is related in full by M. Ehrmann, and also in the work on Laryngeal Phthisis, by Trousseau and Belloc.

Two years before his death, the patient lost his voice suddenly, without any appreciable cause. The ordinary remedies, such as local depletion, counter irritation, fumigations, etc., had no effect to restore the voice. A cough supervened, with an expectoration of thick sputa; and for several months before his death, the patient had dyspnoea,

* Lecture faite à l'Académie de Médecine, Sept., 1836.

especially on taking exercise or in speaking, accompanied by a hissing inspiration.

When first called to see him, on the 13th July, 1836, M. Gerardin found him sitting up in bed, panting with hissing respiration, hoarse cough, voice extinguished, face red, eyes animated and prominent; in a word, there were all the symptoms of strangulation, with some indications of suffocative asthma. Full venesection was promptly employed, by which some relief was obtained. This abatement of the more urgent symptoms continued for several days, when the oppression of the chest, the panting, hissing respiration, became again greatly aggravated, requiring the adoption of a second bleeding from the arm, and the application of leeches, to the summit of the sternum. But these measures, which were several times repeated during the three weeks succeeding M. Gerardin's first visit, only seemed to afford temporary relief, whilst the strength of the patient was constantly decreasing.

At length, on the night of the first of August, the patient being threatened with immediate suffocation, was bled again; but there was no improvement: he gradually lost his sensibility, and died on the morning of the second of August.

Permission was not given to examine the body, though M. Gerardin was allowed to make an incision into the neck, from which he removed the larynx, and a part of the trachea. On opening these, there was found *a tumour as large as a filbert*,

of a white color, covered with *asperites* from one to two lines long. This vegetation had a short pedicle, occupying the right sinus.

It is known that syphilitic vegetations may invade the superior part of the air tubes, but this patient assured M. Gerardin, that he had never contracted the venereal disease. It is probable, that in this case, as well as in other instances since observed, that kind of tumour, known as the *cauliflower excrescence*, has originated in the larynx, independent of any syphilitic taint.

Similar vegetant excrescences were found in the larynx of a young child, in a case observed by Dr. Ruef, of Strasburg, and reported by M. Ehrmann.

A little girl about four years of age, quite healthy and robust, was observed to have a slight hoarseness of the voice, for which some simple remedy was directed by M. Ruef. After a few months, this symptom was sensibly augmented, and the embarrassment continuing to increase, the respiration soon became hissing (*sifflante*) and difficult, especially at night; but there was seldom a cough, and never any fever present. The respiratory murmur, perceived at first, through both lungs, gradually diminished. It was scarcely perceptible in the last days of life. The child died, slowly suffocated.

In the examination of the body, after death, the lungs were found gorged with blood, in some parts, and emphysematous in other portions. On open-

ing the larynx, which was perfectly proportioned, its internal face was found covered with *warty excrescences* that extended from the superior third of the epiglottis, even below the inferior vocal cords. The ventricles were free, but all the superior opening of the larynx, and the mucous surface of the glottic ligaments were invaded by these excrescences, filling in such manner the cavity of the larynx, as to leave but little or no space for the passage of the air.

The microscopic examinations of these vegetations, revealed no specific element; but all those found in mucous membranes in general were recognized.

In January, 1847, a Polish officer died in the Hospital at Strasburg,* having a laryngeal polypus, the existence of which was not suspected during the life of the patient. The interesting details of this case were related to M. Ehrmann, by Prof. Bertherand, of the Military Hospital of Strasburg. This man, who was sixty years of age, had observed for several years, an occasional embarrassment of his respiration and hoarseness of the voice. These symptoms were accompanied by a laryngeal cough, which disappeared in summer, but was aggravated in winter. During the six months preceding his entrance into the hospital, the difficulty of respiration was greatly increased, and the patient was frequently seized with instantaneous fits

* Op. citat., p. 27.

of suffocation. Divers physicians who had been consulted in regard to his case, had considered it one of œdema of the glottis.

On the 15th of October, 1846, this officer was brought to the hospital, suffering under a violent access of suffocation. The patient was insensible, his face livid, his respiration was slow, and asphyxia seemed imminent. Tracheotomy was immediately performed. Sinapisms were applied to the extremities, and venesection practiced during the day, but no sensible relief was obtained till towards night.

For several days following the operation, alarming symptoms of bronchial disease declared themselves, requiring to be combated, and during which time, great care was necessary to preserve the canula free of the mucus constantly accumulating at its internal orifice. Slight hemorrhages from the wound were occasioned by each movement of this instrument.

During the suffocative attacks, which from time to time continued to recur, great turgescence of the face and neck of the patient would be observed; and the thyroid gland at such times was greatly hypertrophied. Gargles were employed; and light cauterizations with the nitrate of silver were made to the back of the throat, and the patient was abundantly bled, but all to no purpose; the aphonia remained, the dyspnœa became extremely urgent; and, on the 24th of January, 1847, the patient died, suffocated, three months after his entrance into the hospital.

In the autopsy, the following pathological changes were observed: The thyroidal veins on the right side were in a varicose condition; the gland on the same side was greatly hypertrophied, and had crowded the pharynx and the œsophagus considerably to the left. The thyroid cartilage and the first ring of the trachea were necrosed. The epiglottis and the ventricles were in a healthy state; but on the interior of the larynx, a small *fusiform* polypus was found attached by a pedicle, and occupying the groove under the superior vocal ligaments.

The mucous membrane of the trachea and bronchial tubes was slightly inflamed; the base of the right lung engorged and adherent; and scattered through its parenchyma a number of small ulcers were observed, and here and there hard granulations of a nature difficult to determine. The liver presented the same alterations.

A microscopic examination of these degenerations of the lungs, liver, and thyroid gland, demonstrated them to be of a cancerous nature.

Of the twenty-five cases of polypi of the larynx, whose history has now been given, much the largest number of them occurred previous to the year 1837. During that year the following interesting case, which is extracted from the work of M. Ehrmann, came under that writer's observation, in which the operation of laryngotomy, as the only means of saving the life of the patient, was proposed, but unfortunately was not adopted.

Charles E.,* nine years old, of a good constitution, was sick, when two years old, of a slight indisposition, which only lasted a few days. After that he contracted a cough, which lasted all winter; the voice was not altered, and the cough, though dry, was not accompanied by any embarrassment in the respiration. From that time till he was eight years of age, he enjoyed good health. At this time, the voice, before clear and natural, became hoarse at intervals, and subsequently this character was continuous; a slight difficulty arose in the respiration, which, however, did not awaken the attention of his parents. The voice acquired a childish sound, which was accompanied neither by cough nor by any derangement of the other functions. During the first days of September, (1837) an oppression of the chest was observed; but this did not interrupt his going to school, and pursuing his habitual occupations. But soon the voice became hoarser; and, dyspnœa supervening, two leeches were applied over the region of the larynx; and after they had fallen off, the bleeding was continued by the application of an emollient cataplasm.

On the 10th of September, there existed a certain difficulty in the respiration, which caused M. Ehrmann to prescribe a new application of leeches to the neck, mustard foot-bath, and mercurial frictions upon the larynx. The evening of the 11th there was no amelioration; on the contrary, the

* Op. Citat., p. 18.

dyspnœa had augmented: the child was without pain, without agitation. M. E. administered an emetic, and although it operated, no favorable change took place. No cough being present, and the respiration becoming more and more embarrassing, whilst the disease manifested no symptoms of an acute inflammation of the laryngeal or bronchial mucous membrane, M. E. warned the parents, after all that had preceded, that he thought there was a foreign body in the interior of larynx, and that recently this product had so developed itself as to obstruct the free passage of air. His apprehensions were only too well founded; for soon aphonia became almost complete, greater difficulty took place in the respiration, and the livid countenance announced a serious trouble in the circulation. M. E. declared that an operation, the success of which could not, however, be assured, ought to be tried; but the proposition was not accepted. On the 11th and 12th, the symptoms became more and more alarming, the cyanosis and asphyxia were well established, and after several attacks of fainting, the child died.

After death, M. Ehrmann was only able to examine the larynx; but this was sufficient to explain the morbid phenomena observed during life. A fleshy excrescence was found, lobulated, of the volume of a small nut, fixed, by the aid of quite a large pedicle, to the whole extent of the left inferior ligament of the glottis. This tumour, soft, rounded, and quite smooth, obstructed completely

the glottic chink. It was of a pale red color; its consistence was similar to that of the fibro-cellular tissue; and all its external tissue, which was slightly nodulated, was continuous with the laryngeal mucous membrane. This membrane elsewhere, throughout all the vocal apparatus, showed no trace of organic alteration.

A lobulated excrescence, quite similar to that just described, is preserved in the Museum of Anatomy of Friburg. It belonged to the larynx of an adult, and was found implanted upon the inferior left ligament of the glottis; its great diameter is vertically directed; the two halves of the incised larynx being brought together, the polypus completely obstructed the glottic opening; but no data concerning the history of this disease, could be obtained.

All the preceding cases of morbid growths in the larynx have been observed by foreign practitioners. A few instances only of the occurrence of these tumours are to be found recorded in the journals of our own country.

In the *Transactions of the Physico-Medical Society of New York*,* a case is reported by Dr. J. C. Cheesman, of a boy, four years of age, who, in April, 1817, was observed to be laboring under symptoms resembling those of asthma. Embarrassed respiration, with full pulse and a cough were present. The child also complained of great dis-

* Vol. I, p. 413.

tress in the upper part of the throat. These symptoms, as it was stated by the mother of the boy, had existed some six or eight weeks. The patient was seen only three times by the attending physician, as the case grew rapidly worse. The breathing became extremely difficult, the pulse was feeble, stupor supervened, and the child died a few hours after the last visit made by the attending physician.

On examining the throat after the death of the child, the cause of difficulty was found at the aperture of the glottis. *Verrucae*, or fleshy excrescences were found studding the under surface of the epiglottis, and attached to the arytenoid cartilages in such a manner, and of such magnitude, as very nearly to close the opening of the larynx.

A case of "tumour within the larynx," which was reported to the *Boston Society for Medical Improvement*, is found recorded in the *American Journal of Medical Sciences*.* A man about fifty years of age, healthy and robust in all other respects, had suffered for twelve years or more, from hoarseness and embarrassed respiration. Two or three years preceding his death, complete aphonia had existed. There was also great dyspnoea on exertion, and when the patient was asleep, laborious respiration, with a distressing suffocative noise was present. After his death, which took place suddenly, a round, well defined tumour, seven lines

* July, 1851, p. 37.

in diameter, having a rough surface, and of a fleshy consistence, like a syphilitic wart, was found occupying the upper part of the larynx. It was situated posteriorly, below the ventricles of the larynx, and had attachments of considerable extent to each side of that cavity.

In the *New York Journal of Medicine*,* two cases of polypus of the larynx, are reported by Dr. S. Smith, which were observed by Dr. W. Parker, of this city.

"J. D., aged sixty, weaver by occupation, native of England, married, of good habits, and healthy parentage, had a severe attack of inflammation of the lungs, fifteen years since, which it was thought he could not survive; he, however, at length recovered and pursued his trade until six years ago, when he came to America. In this country, he was engaged in an establishment where, most of the time, he was enveloped in steam. While in this situation, he contracted a severe cold, accompanied by a hoarseness, which continued gradually increasing in severity, up to the time of his death. Succeeding this, he began to suffer difficulty of respiration, and often when the weather was cold and damp, the dyspnoea would be so great as to threaten immediate suffocation. For a time, his general health continued good; but as the disease advanced, deglutition began to be attended with much uneasiness about the larynx, amounting

* *New York Journal of Medicine*, Jan., 1852, p. 15, *et seq.*

often to threatened suffocation, and finally prevented him from swallowing any thing but soft or semi-fluid food. He now began to emaciate. On the day of his death, he was able to walk about his room, but he remarked to his wife that he could not live long. He died suddenly, and as if with cedema glottidis.

“*Autopsy*, sixteen hours after death. Both lungs free from adhesions, but distended with air, owing to the great degree of emphysema which existed; no tubercles were discovered. The trachea and larynx were removed, and upon laying them open, the *causa mortis* was revealed, viz.: a polypus attached by a pedicle to the right superior chorda vocalis; the body being of the size of a chestnut, and occupying the rima glottidis. The cartilages of the larynx were ossified. No other signs of disease in the thoracic or abdominal cavities. This polypus was of the kind called mucous polypus. A portion of the apex of the right lung, of the size of an orange, was removed after being firmly ligatured; this when dried, was incised and exhibited in a striking manner the degree of emphysema existing, many of the vesicles being of the size of a filbert.”

The second case was that of “M. B., a boy aged two years, of good constitution, and hitherto having enjoyed good health, was brought to the *college clinique* by his mother, who gave the following history of his case: About eight months previously, he had an attack of croup, from which

he never seemed to recover. His voice became hoarse, his breathing, always obstructed, at times became very difficult and almost suffocating, attended by a croupal cough; appetite good, bowels regular. The case was placed in charge of Mr. Osborne, now a physician of this city, who administered remedies suited to his condition. The symptoms increased in severity, especially the dyspnœa, and tracheotomy was finally thought to be indicated. It was not, however, performed, and the patient died in a paroxysm of dyspnœa, nine months after his first attack.

"*Autopsy*, twelve hours after death. Examination confined to the larynx. Upon laying this organ open, after being removed from the body, three warty excrescences were found surrounding the glottis and in the larynx, the former being so situated as nearly to close the rima. The trachea contained considerable tenacious mucus, which, lodging in the glottis, must have greatly increased the difficulty of respiration."

CHAPTER III.

MORBID GROWTHS IN THE LARYNX.

IN the preceding chapter, I have recorded, briefly, a history of all the known cases of polypi of the larynx in which the result has been fatal. I have examined many works, both ancient and modern, wherein a record of such tumours would be likely to have been made and recorded, had they been observed, without finding any well-authenticated history of other cases. Still, others may have been discovered, and their history recorded, and yet have escaped my observation. If so, this publication may serve to bring them to light.

Other morbid productions, differing, however, in their nature and structure from the true polypus, have been developed in the larynx and trachea. Two instances of the development of tumours of an anomalous character, and connected with the posterior part of the trachea, are recorded in the work of Morgagni.* In one of these cases, the morbid growth attained the size of half a chestnut, and

* Lib. ii., epist., xv.

was attached to the posterior part of the trachea. The other, which was still larger, was found projecting into the same tube; producing, by their pressure upon the trachea and the œsophagus, great difficulty of breathing and of swallowing.

Cases of the formation of *Hydatids* in the œsophagus, are narrated in the works of both ancient and modern writers.

Andral mentions an instance, where a hydatid, situated in one of the ventricles of the larynx, produced all the symptoms of a foreign body lodged in that cavity; and Portal, also, in his work on pulmonary phthisis, relates a case where a hydatid, which had formed in the thyroid gland and escaped from that body through an ulcerated opening into the trachea, suffocated the patient.*

Cartilaginous tumours have, in some rare cases, been found in the larynx. An instance of one of this nature is noticed in the Dublin Journal for September, 1835, as having been discovered in the larynx of a patient who died in the Charité Hospital in Berlin. A firm, osseo-cartilaginous tumour, of the size of a walnut, and covered by a mucous membrane, was found in the larynx after death. It was connected with the right thyro-arytenoid ligament, and by its pressure upon the rima glottidis, nearly obliterated the passage for the admission of air.

In a number of the Edinburgh Medical and

* Andral, Anat. Pathol., translation, tome. ii., p. 490.

Chirurgical Journal, Mr. Macilvain relates another similar case. To save the patient, an attempt was made to perform tracheotomy, but the operation was not finished, on account of some unusual distribution of the arteries, which obliged the surgeon to desist, and the patient died, suffocated. An examination of the larynx, revealed the presence of a firm, cartilaginous tumour, pressing upon and obstructing the opening of the glottis; and on the outside of the larynx, and connected with the internal one, another excrescence was found, which seemed to be joined to the thyroid gland.

I shall now refer to the few fortunate cases of this hitherto fatal disease—polypus of the larynx—where attempts made to save the lives of the sufferers, by surgical treatment, were crowned with success.

The fatal case recorded by M. Ehrmann, in 1837, the details of which have been given on a preceding page, as well as the past history of this disease, led that author to the conclusion that polypi of the larynx, abandoned to nature, proved, sooner or later, the cause of sudden death; and that the operation of laryngotomy seemed to him to offer the only means of safety. Indeed, the operation was proposed in this case, but the proposition was not accepted.

In 1844, another case of polypus of the larynx came under the observation of Professor Ehrmann,*

* Op. citat., pp. 23-5.

in which laryngotomy was performed, and the life of the patient saved.

The following is the history of the case, which I shall take the liberty of transcribing nearly verbal:

CASE I.*

"Polypus of the larynx fixed to the left inferior ligament of the glottis. Laryngotomy practiced with success."

"Caroline M., thirty-three years of age, of a good constitution, married for six years, and mother of healthy children, has enjoyed constantly good health, if the ailments of childhood, to which she had been subjected, be excepted.

"The particular functions of her sex have never presented any irregularity, and at no time have the respiratory passages been the seat of any disease whatever.

"It was in 1840 that, for the first time, Caroline M., and those around her, observed a slight change in the sound of her voice; at first rough and hoarse, it soon became quite veiled. This alteration took place insensibly, unaccompanied by any pain or difficulty in the exercise of speech, or even in simple respiration; aphonia came on later, and it had this peculiarity, that towards the end of the two pregnancies, it increased in a marked

* Op. citat., p. 23, et seq.

manner, diminishing after the accouchement, without entirely disappearing.

"After her last confinement, which took place the 15th of March, 1843, there was no variation in the hoarseness until the occurrence of an event which happened in March, 1844. Soon after the change observed in the larynx was noticed, the patient was able, by a sudden inspiration and expiration, to imitate the sound of a valve alternately opening and shutting.

"During deglutition, also, it sometimes happened that portions of the liquid swallowed would penetrate the larynx, and excite violent fits of coughing. It was on one of these occasions that the patient threw off at different times, by expectoration, small portions of tissue, similar to the tumour, afterwards removed by excision. No other accident occurred to disturb the exercise of the functions; and, with the exception of aphonia, no organic derangement had been observed; but soon the storm came.

"About the middle of March she left her home, but she had hardly gone a few steps before she felt an extreme difficulty of breathing, which obliged her to return. It seemed to her that a mechanical obstacle opposed the free entrance and exit of the air, and that a foreign body obstructed the throat. A few moments of repose served to bring back her usual calmness, by rendering her respiration free; when suddenly, after an effort of coughing, dyspnœa became extreme, and was accompanied

with agitation and distress. At times, the patient inspired a little more freely; but she apprehended every instant either an attack of coughing or an effort of vomiting, during which the difficulty of respiration became extreme, and the suffocation imminent. It was at this time I was called to see the patient by Dr. Schmidt. The previous history of the case, observed with the greatest care by my honorable colleague, left no doubt as to the nature and cause of the severe affection, for which our aid was sought.

"The polypus engaged between the lips of the glottis was no longer displaced; the respiration became more and more difficult, the bluish tint of the face, the smallness and frequency of the pulse, indicated serious trouble in the circulation. To wait any longer without acting, would compromise the life of the patient. The most pressing indication being to reëstablish the respiratory functions, we decided that it was necessary to perform the operation of laryngotomy. Our proposition, at first, met with some opposition, not from the patient—for her sufferings made her willing to submit to any thing—but from her family, with whom a surgical operation inspired horror. This hesitation made us lose nearly two hours, and thus prolonged the agonies of the patient, whose state became more and more alarming. After having tried all means of persuasion, we were able finally to overcome an obstinacy which threatened to prove fatal.

"I had the patient placed in an arm-chair, the

head being thrown backwards, and properly held. I divided the tissues of the anterior and middle part of the neck, commencing the incision at the point corresponding to the crico-thyroidean space, and carrying it on the median line towards, and near to, the border of the sternum. I successively separated, in this manner, the skin, the sub-cutaneous cellular tissue, the crico-thyroidean membrane, the cricoid cartilage, and the first two rings of the trachea. The small amount of blood which found its way into the air-tube, was soon rejected by expiration, which, from the division of the parts, was made with much facility, to the great relief of the patient. A curved canula, of the size of the little finger, was immediately placed in the wound in the respiratory tube, and confined by the aid of strong ribbons.

"The inexpressible relief which the patient enjoyed, and the need she felt for rest, after having endured, nearly three hours, the agonies of death, decided me to postpone to another time the incision of the larynx, and the removal of the foreign body which was developed there. To this delay may be attributed, in a great measure, the success of the operation.

"The irritation of the mucous membrane, produced by the contact of the canula, caused an abundant mucous secretion, which was rejected by a cough quite fatiguing. On the other hand, in the normal state of the patient, there was nothing to be desired; and at the end of forty-eight hours from

the first operation, the time seemed favorable for the performance of the second—the operation of laryngotomy. In this, I was assisted by Doctors Schmidt and Aronssohn.

“In order to be able to prolong, properly, the incision already existing, I caused the canula to be pulled down, and the vocal tube to be kept stretched, and in this way, after having determined by the touch, the line formed by the union of the two halves of the thyroid cartilage, and also that of its superior border, I continued the incision above, on the line indicated, as far as the os hyoides. The blood being carefully sponged away, and the halves of the divided larynx being separated, we then discovered the *polypus excrescence*, implanted along the inferior left ligament of the glottis. With one hand I seized it, by the aid of dissecting forceps, and with the other, armed with a bistoury, I excised it, and thus removed it in three portions, which, reunited, formed quite a voluminous mass. (See *Plate III., fig. 2.*) The whole of this tumour resembled, in form, that of a small cauliflower, presenting here and there, upon its surface, granulations round and fleshy.

“After the entire removal of this foreign body, we were able to assure ourselves of the disposition and state of the laryngeal cavity. It was smooth in its whole extent, with the exception of the point which the polypus occupied. We distinguished, perfectly, the movements of the arytenoid cartilages, which approached each other every time.

the internal surface of the cartilaginous cavity was touched with the finger.

"The incision of the larynx, having been carried directly upon the median line of the thyroid cartilage, the cutting instrument passed between the anterior attachments of the two thyro-arytenoid muscles, without interrupting their substance.

"As soon as the bleeding was arrested, and the larynx no longer touched, the two lips of the division, made in the thyroid cartilage, were approximated, and carefully reunited. Whilst I was operating, a little bloody expectoration was discharged, by the mouth, and reddish colored froth, escaped from time to time, in small quantity, through the canula. No other accident happened to interrupt or hinder the operation, which the patient supported with much calmness and courage.

"The dressing, very simple, consisted in the application of a little charpie between the lips of the wound, brought together by the aid of adhesive straps; the canula remaining in its place permitted the air to penetrate easily into the tracheal canal.

"The patient was placed in a bed, all movement was prohibited, and the most absolute silence enjoined. From time to time, she took only a little sugared water, which she swallowed without difficulty. The night which followed was tranquil, abundant mucosities passed by the metallic tube, which required it to be frequently cleansed.

"The next day a little reaction came on, the pulse was frequent, the skin was hot, and there was

agitation, yet no pain in the wound. Some diaphoretic drinks and a lavement were administered at night, which calmed the patient, and the second day every thing went on well. The patient was nourished by liquid aliments.

"As no swelling had originated in the parts interested, and as the air, on withdrawing the canula from the trachea, passed through the larynx without occasioning the least painful sensation, I brought the lower half of the wound in contact, the borders of which were in a suppurative state.

"From this moment the respiration took place by the natural passages, and the opening made in the trachea furnished only small quantities of mucous matter, which soon, also, passed by the larynx and mouth. The third day after the operation the patient was in the most favorable condition; respiration free, deglutition easy, no pain, no swelling of the sides of the incised organs; the voice only remained affected.

"The wound in the vocal tube healing rapidly, allowed no air to escape, only now and then a small amount, which each day was less in quantity; and finally, the 5th of April, twenty-one days after the operation, nothing passed by this opening. At this time, Caroline M. went into the country, to profit by the fine weather, and upon her return, eight days after, the wound of the neck was not only found completely closed, but the general health of the patient left nothing to desire. The aphonia only remained, and the cicatrix of the integuments,

over the larynx and trachea, followed without occasioning any embarrassment in all the movements of the air-tubes.

"Six months passed in this way, during which, relieved of her polypus, and of all the symptoms which were the consequence of it, Caroline M. enjoyed good health; all the functions had regained their habitual tone, the respiration especially was unobstructed. Unfortunately, in the month of October of the same year, a disease entirely foreign to, and independent of, the severe affection from which she had suffered previous attacks in the month of April, declared itself; an abdominal typhoid fever, true follicular enteritis, broke out, with symptoms so alarming, that, at the end of the second week, notwithstanding the best and most assiduous care, the patient died.

"The autopsy revealed the organic lesions usually found in these cases; but our attention was more particularly directed to the larynx, in order to find the changes which had occurred as the consequence of cicatrization of the parts interested in the operation, near the region of the seat of the polypus excrescence. (See Plate III., fig. 1.)

"Opened behind, and incised in the direction of the median line, the vocal tube did not offer, with the exception of the laryngeal surface, the least trace of alteration. The inferior left ligament of the glottis, a little shortened and slightly wrinkled, was prolonged, under form of lines of relief, towards the base of the epiglottis, and seemed, by

this direction, to diminish the extent of the corresponding ventricle. The laryngeal mucous membrane was continued over the surface of this vocal cord, and some little granulations were found seated along its length. Upon the folds of this tunic a granulation a little larger, and of a vesicular aspect, occupied the point of junction of the two inferior ligaments of the glottis. These granulations developed, upon the surfaces that the cutting instrument had touched: were they a commencement of the return of the primitive affection?

"The microscopic examination of the *polypus excised*, and of the granulations, of which we have just spoken, furnished the same elements as those of the laryngeal mucous membrane, only the epithelial cells were much more numerous than ordinary, and partook rather of the pavement form, than of the cylindrical; some rare traces of fibroplastic tissue were found mixed with the elements of granulation; their presence was owing, probably, to the neighborhood of the cicatrix, resulting from the removal of the polypus, and upon which some portions of hypertrophied mucous membrane were reproduced."

As we have seen, in the previous history of laryngeal polypi, several attempts had been made by different surgeons, to remove these excrescences by laryngotomy; but in no instance has the operation proved successful except in the above case, observed and recorded by M. Ehrmann.

I shall now proceed to recount the history of those cases which have fallen under my own notice; and which in this respect are unique—that they are the only instances, so far as I can learn, where polypi of the larynx have been removed and the lives of the patient saved, without practicing the operation of laryngotomy.

CASE II.

Polypus of the larynx, attached to the left ventricle or the left vocal ligament, and removed by an operation.

Late in January, 1839, I was called to visit the little daughter of the Hon. Mr. K——, of this city. This child, then between three and four years old, had been strong and healthy from birth, until a short time before I was requested to see her. Some two or three months preceding this first visit, as her parents informed me, there was observed a change in the tone of the child's voice, and a slight embarrassment in her respiration. This last symptom continuing to increase—and being moreover, more prominent at night than during the day—led the friends to suspect the presence of enlarged tonsils, and under this impression on their part, I was called to examine the case.

The external appearances of the child, I found on examining the case, were those indicative of

robust health. The only abnormal symptoms present, were a slight huskiness of the voice, respiration a little embarrassed, and a somewhat prominent appearance of the eyes; such as I have frequently observed in patients where the respiration has been obstructed by the presence of greatly enlarged tonsils. There was also present an occasional dry cough, which, like the labored respiration, was said by the parents to be more frequent and troublesome at night than during the day.

The presence of these symptoms, and the absence of all signs of thoracic disease, led me to infer that the cause of difficulty arose, as had been suggested, from an enlargement of the tonsillary glands. But, on inspecting the throat of the little patient, I was surprised to find only a partial enlargement of one of these glands. In fact, the physical obstruction thus presented, did not appear to be sufficient to account for the morbid symptoms that were observed.

As no other cause for their presence could be found, I determined to delay the operation a few days, and then, if the symptoms remained, to comply with the wishes of the parents, and remove the enlarged tonsils.

On the 4th of February, 1837, I again saw the patient, and found the same symptoms present that were observed at my first examination of the case. Accordingly—assisted by a medical friend who, at my request, had accompanied me in my visit to the patient, and who, on examining her case, coin-

cided with me in the propriety of an operation—I removed the enlarged portion of the right tonsillary gland. At this visit, a slight hypertrophy, also, of the left tonsil was observed, but the enlargement was not considered of sufficient extent to demand an excision of the part.

For several months after removing the tonsil the symptoms which seemed to call for the operation were mitigated to some extent; but we were all disappointed, particularly on the occurrence of warm weather, that they did not, as it was expected they would, abate altogether. The huskiness of the voice remained, and the embarrassed respiration; and the laryngeal cough continued, notwithstanding the operation. But, as the general health of the child remained unimpaired, no further measures were adopted, except the occasional administration of some mild expectorant whenever the cough was more than usually troublesome.

This condition of the patient, and these symptoms, remained nearly the same during the subsequent two or three years. At the commencement of 1844, when Miss K. was nearly ten years old, she had attained the size ordinarily observed in young girls of her age, and her general health was still good. But during the winter and spring of 1844, the symptoms, which I have heretofore enumerated, gradually became considerably augmented. The voice was now greatly changed, the breathing was more embarrassed, and at night she was subject to attacks which served greatly to

alarm her friends. During sleep, her respiration, which at night was always most laborious, would appear, sometimes, to be suddenly arrested, and she would spring up from her bed, greatly agitated, and struggle for a few moments, like a person being actually suffocated. Occasionally, this distressing symptom would occur several times during the same night; and yet no derangement of the digestive organs, nor of the general system, could be detected.

About this time, however, the left tonsil, which in 1837, was observed to be slightly hypertrophied, was found to have become considerably enlarged; and it was thought that this obstruction might have some relation to the increased morbid symptoms; and its removal, for this reason, was advised. As the summer of 1844 approached, hopes were entertained that the warm season, and country air, would have a favorable influence upon the health of the patient, and it was decided to postpone for a time, the removal of the enlarged tonsil. But neither the return of summer, nor the air of the country, had any effect whatever to mitigate her symptoms; and on her return to the city, I was urged by the friends of the patient to excise the remaining tonsil. This operation was performed on the 20th of August, 1844, and all the enlarged portion of the gland removed.

The hemorrhage that accompanied the extirpation of the gland, although considerable, was not more abundant than ordinarily attends this opera-

tion; yet to this circumstance may be attributed, I think, the partial relief that followed the reduction of the vascular action of the parts. Certain it is, that for a brief period after this operation, the urgent symptoms were, to some extent, mitigated, although, as it was afterwards ascertained, the cause was not removed.

The relief, however, was of short duration. The grandparents of Miss K. resided in a dry and healthful village of New England; and she was taken there by her friends, soon after the above operation was performed, and I did not see her again until Sept., 1845.

The history of her case, during this period of her residence in the country, I obtained from the friends of Miss K., after her return to the city. For several months after leaving her home, her general health seemed better than when living in the city; but the particular symptoms of her case, namely, the embarrassed breathing, the hoarseness of voice, and the suffocative attacks, were in no degree improved. During her stay in the country, she was seen by several medical men; and at one time, when the above symptoms were more than usually severe, an eminent surgeon being in the neighborhood, was called to see and examine her case; but no light was thrown upon the nature of her difficulties, nor was any relief obtained from the plans proposed. On the contrary, towards the close of the summer of 1845, the distressing symptoms under which she had so long

suffered, became considerably aggravated. Her general health also, began now to be more seriously affected; and her friends, justly alarmed at the increased severity of these symptoms, brought her back to the city early in the fall, and again placed her under my charge.

On the 16th of Sept., 1845, I saw Miss K., for the first time after her return to her home. A marked, unfavorable change in her appearance had taken place during her absence. Her countenance was expressive of anxiety; her voice was hoarse and uneven, at times nearly aphonic; the respiration was difficult, the eyes appeared prominent, and the chin was raised, and the head thrust a little forward, as if that position afforded some relief to the embarrassed respiration. The suffocative seizures were now more frequent, being at times very severe; and the patient appeared under great nervous excitement, as if constantly apprehensive of danger.

Her case was now subjected to a rigid examination, in order to ascertain whether any structural disease existed in any of the vital organs. But no indications of either thoracic or cardiac disease, could be detected. An inspection of the throat revealed a healthful condition of the tonsils and of the mucous membrane of the pharynx.

Recollecting that in some cases, which had previously fallen under my notice, where a thickening of the epiglottis had been attended by symptoms simulating, in some degree, those observed in the

case of Miss K., I proceeded to examine this organ, with a bent tongue spatula. I drew forward and depressed the tongue, so as to enable me to see the condition of the epiglottis. By this procedure, nearly the whole of this cartilage was brought into view, but no deviation from its usual normal aspect was observed. Whilst making this examination, and at the very moment when the tongue was depressed, and the epiglottis in full view, the patient gave a sudden, and rather violent cough, when a round, white, fibrous looking polypus appeared, momentarily, at the opening of the glottis, and then seemed as quickly to be drawn into the larynx. Again and again, was this operation repeated; and whenever the patient coughed, at the moment when the tongue was depressed, a portion of the polypus could be seen, not over the top of the epiglottis, but at the left lateral border of this cartilage. The mobility of the tumour was quite manifest. It appeared to be attached by its pedicle, to the left ventricle or the left vocal ligament; for on coughing, the current of air would force the body out of the glottis, sufficient to allow a portion of the tumour to be seen, on the side of the opening, just above the tip of the left arytenoid cartilage.

The cause of all the distressing symptoms, under which my patient had so long suffered, was fully apparent, and the question of the greatest moment now was, how that cause should be removed. The true nature, the difficulties, and the danger of the case, were stated to the friends of

the patient. The tumour must be removed, or the result, sooner or later, would be inevitably fatal !

I had at that time, in my possession, the work of Ryland, on Diseases and Injuries of the Larynx, and also, the Treatise of Trousseau and Belloc ; in both of which, cases of polypi of the larynx, to which I have already referred, are reported, in which the symptoms manifested bore a strong resemblance to some of the most prominent ones, observed in my patient's case ; and yet, at no time had I suspected the presence of a polypus in the larynx, until the discovery was made at this examination. In none of these cases had laryngotomy been practiced with the object of removing the foreign body. In the case observed by M. Trousseau, the operation was performed to prevent threatened suffocation. The patient died, subsequently, and the polypus was discovered after death.

I had, therefore, no precedent then, to authorize the practice of laryngotomy for the purpose of excising this tumour ; and before proposing the operation, I determined to make an attempt to remove the polypus through the opening of the glottis. Immediately, I procured the instruments that for many years I have been accustomed to employ in the excision of enlarged tonsils ; namely, a slender double hook having a long handle ; and also, a probe pointed knife with a strong handle and a delicate slender blade.

The nature of the operation desired to be practiced, and the part to be performed by the patient,

were all explained to this intelligent young lady. She was seated in a good light, before an open window, with her head thrown well back, and held firmly, by an assistant, in that position. With the flat handle of my knife, I depressed the tongue, and when the epiglottis was in view, I glided the double hook over the top of this cartilage, and a little on its laryngeal face. This operation caused the patient to cough; the tumour was again brought into view, and I endeavored to catch it with the hook, but it was so quickly drawn back into the larynx, that I failed to do it; and after making several ineffectual attempts, thus to fish up the polypus, I was obliged to desist for a time, to allow the patient to rest.

After a short period, we were able to renew our efforts, and at the second or third attempt, I succeeded in catching the hooks into the top of the tumour, and turning quickly the blade of the knife downwards, passed it over the left border of the glottis, and carrying the blade nearly an inch into the glottis, I cut from behind forwards, and happily, dividing the pedicle near its attachment, brought the entire tumour out of the larynx.

Some coughing followed this operation, and a few drops of blood, mingled with mucus were expectorated; but the irritation soon subsided, and on speaking, the patient's voice was found to be greatly improved. Some degree of hoarseness remained for a time, but this soon passed away; the voice became strong and clear; the embarrassed

respiration, the cough, the anxiety of countenance, and indeed, all the unfavorable symptoms rapidly disappeared, and Miss K., has for several years enjoyed excellent health.

The polypus (a representation of which is given in Plate I., fig. 2) was nearly round, being a little oblong, and of the size of a cherry. It was quite smooth, was covered by a mucous membrane, and presented all the characteristics of a fibrous tumour.

A sketch of the appearance of the tumour, as it presented itself at the aperture of the glottis, was taken by a gentleman who had a view of it several times before the operation, (Plate I., fig. 1.) A drawing, also, of the polypus, as it appeared after the operation, was made by the same gentleman.

In the Anatomical Museum of King's College, is a preparation of a larynx, in which is a polypus attached by a narrow pedicle to the left vocal cord. The patient died of phthisis, induced, probably, by the presence of this foreign body in the larynx. Mr. Ryland has given a drawing taken from this preparation, (see Plate IV.) and it will be seen that the polypus, though smaller, very much resembled the one removed from the larynx of Miss K. Of the history of this tumour, Mr. Ryland says very little is known, as the larynx which contains it was taken, for the purposes of dissection, from the body of a young woman who died, as stated, from pulmonary phthisis.

CASE III.

*Numerous small polypi, or cauliflower excrescences,
of the larynx removed by cauterization.*

In August, 1846, W. J., aged forty-two, a lawyer of some distinction in a neighboring city, came to New York for medical advice. He placed himself under my care, the 27th of the above month, and at that time gave me the following history of his case. Nearly three years before, whilst engaged in superintending the erection of a large public building, he was much exposed, during several successive weeks in the fall of the year, to a cold and damp atmosphere. He soon began to experience some soreness of the throat; a huskiness of the voice, and a slight, dry cough supervened, which seemed to proceed from an irritation in the upper part of the wind-pipe. For these symptoms he was treated, during the following winter and spring, by his family physician, with some of the ordinary remedies. At no time, however, did the hoarseness or the cough, in any degree, abate. On the contrary, these symptoms appeared constantly to increase, and in addition to them, the respiration, after a time, became considerably embarrassed; all these symptoms were always aggravated by any exposure to cold. At length, his voice was completely extinguished, and he was obliged to relinquish his profession, from inability to utter a sound above the lowest whisper.

During this time his general health, for the most part, remained good. Many remedies had been employed for the local difficulty, such as the different forms of counter-irritation, together with other appliances, both external and internal. But as all the unfavorable symptoms continued steadily to increase, notwithstanding these measures, he had sought other aid.

At my first interview with him, his case presented the following symptoms: Being naturally robust, and having a well-developed frame, his disease, whatever its nature, had not made much inroad upon his general health. His complexion was very sallow; he complained of some debility and of pain, and a feeling of constriction in the region of the larynx. Respiration, ordinarily, was quite difficult; but on making any exertion, as in ascending a slight elevation, or a flight of stairs, it became greatly embarrassed, and was attended with a hissing sound. Deglutition was performed with considerable difficulty. Complete aphonia existed, but it was aphonia of a peculiar character.

Persons who have a loss of voice, either from ulceration of the vocal ligaments, or from the thickening of the mucous membrane of the larynx, can be heard usually at the distance of several feet, although speaking in a whisper. But, in W. J's case, it was necessary to place the ear close to the mouth of the patient, to be able to understand a word he uttered; and even then it was difficult, as the voice sounded veiled, or, as if it was passing through moistened gauze.

A critical examination of the chest revealed no indications whatever of thoracic disease. Respiration, although feeble in both lungs, was, in other respects, perfectly normal; nor could signs of the existence of any organic disease in either of the other cavities be detected. He had a short cough, which, at times, was attended with some expectoration.

On inspecting the throat, the uvula was found much elongated, the pharyngeal mucous membrane was vascular, and its follicles enlarged; and on depressing the tongue, so as to expose the epiglottis, this organ was seen to be inflamed, and much thickened.

The presence of these symptoms, it was thought, indicated the existence of chronic laryngitis, attended with an hypertrophy of the lining membrane of the larynx, with, perhaps, ulcerations of the vocal ligaments.

A portion of the elongated uvula was removed, applications of a strong solution of nitrate of silver were made daily to the pharynx, and to the lingual and laryngeal faces of the epiglottis, and the Iodide of Potassium, in doses of five grains, twice a day, was administered. The applications of the nitrate of silver were continued about ten days, when Mr. J. was compelled to return to his home for a few weeks.

On the sixth of October he returned to New York, and the treatment was renewed. From this time until the fourth of November, a period of four

weeks, the solution of the nitrate of silver was applied daily, or every alternate day, to the glottis and into the larynx. Under this practice, the inflammation of the pharyngeal membrane and of the epiglottis disappeared; and, as far as could be seen, the throat presented a healthful aspect. But the difficulty in respiration was in no degree improved, and the aphonia was as complete as on the first day of his coming under my care. Deglutition, however, was performed with less difficulty; and although the patient was again obliged to return to his home for a few weeks, yet he was determined to come back and renew the treatment, so soon as his affairs would permit his return to the city.

Six weeks passed before he was able to fulfill his intention. On the thirteenth of December, he came back once more to New York, and again requested my attendance.

I saw at once, on visiting Mr. J., that an unfavorable change had taken place with him during his absence. Respiration was now performed with great difficulty; the voice entirely lost; the pulse was frequent and quite feeble; the face was of a livid paleness; his cough had increased in frequency; and all the symptoms indicated the imperfect manner in which aeration was performed.

His lungs were again examined, and, as on the first examination, the only abnormal symptom discovered in the chest was feeble respiration. The patient attributed all his difficulties *to the obstruction in his wind-pipe.*

That the opening of the air-passages was blocked up by some foreign substance was quite apparent; but the precise *nature* of that obstruction it was difficult to determine. The embarrassed respiration was a constant symptom. There were no intervals of comparative ease; nor, on the other hand, were there, with Mr. J., any sudden and violent seizures threatening immediate suffocation, as occurred in the case of Miss K.

As yet, in making applications of the nitrate of silver to the larynx of Mr. J., I had never passed the sponge-probang through the inferior vocal ligaments, and I determined now to attempt this operation.

In renewing the local treatment at this time, the strength of the solution was increased, nearly to that of one drachm of the salt to an ounce of water; and with the sponge wet with this solution, I attempted to pass a small instrument, not only into the larynx, but through the vocal cords. But in this I failed; the sponge could be passed easily into the glottis, and down to the inferior ligaments, but not through them. Here, the instrument seemed to meet with an obstruction that prevented its further introduction. On the following day (14th), I repeated the operation, but could not pass the sponge, as I had frequently done in other cases, into the trachea. The same application was made on the 16th and on the 17th, and was carried, as before, down to the vocal cords, and the

sponge pressed upon the rima glottidis, that the cauterizing fluid might pass into the trachea.

On making the application on the 18th, I made use of an instrument, a size smaller than I had previously employed in this case, and when the sponge reached the inferior ligaments, I made a slight pressure upon the rima glottidis, and the instrument passed readily through and into the trachea.

On withdrawing the probang, I observed several small bodies attached to the sponge, and at the same time, the patient coughed and brought up into his mouth, several more of the same minute excrescences.

Some ten or twelve of these substances, were collected by Dr. J. Hancock Douglas, who was assisting me in the operation, and were found to be very small polypi, of the kind usually denominated vegetant, or cauliflower excrescences. These bodies were of different sizes, varying in volume, from that of a millet seed, up to the size of a large duck-shot.

Each one presented, as was found by examining them with a magnifying glass, all the characteristics of a perfectly formed polypus, being covered with a mucous membrane, and having a delicate pedicle, by which it was attached to its base.

Little or no irritation, above that which had attended the previous applications, followed the one that dislodged these foreign bodies.

These applications of the nitrate of silver, were now continued daily, for more than two weeks

longer; and at nearly every operation, when the instrument was passed below the vocal ligaments, more or less of these small excrescences were brought away. On the 24th, especially, six days after the first appearance of these bodies, a large number were discharged at the time of making, and immediately after the application.

The cauterization was continued until the eighth of January, but after the 31st of December, there were no more of these excrescent tumours discharged. The whole number of these bodies dislodged from the larynx during this time, namely, from the 18th to the last of December, must have exceeded thirty in number. Many of these were collected at the time, but some were expectorated after the operation, and lost. Figure 4, in Plate I., is a good representation of some of the separate small tumours, and figure 3, in the same plate, of their appearance when grouped together, and as they probably were in the larynx.

The change that took place with my patient, after the removal of these excrescences, that appeared to have nearly blocked up the rima glottidis, was of the happiest character. Immediately after passing the sponge, on the 18th, through the vocal cords, and removing a part of the obstruction, the dyspnoea was diminished, the patient's respiration was less embarrassed; and after each subsequent application, all his unfavorable symptoms diminished more and more. On the 1st of Jan., soon after ejecting the last of the tumours removed,

the respiration became comparatively easy, his general health was much improved, his cough abated, and although his voice did not return so that he was able to "speak out," yet its volume was much augmented; its hissing character had disappeared, and his whisper was loud enough to be heard distinctly across a large room. The applications were continued a week longer, for two reasons; that the cauterization might have the effect to arrest any further development of the excrescences, and also because the hope was entertained that the aphonia might be removed.

On the 8th of January, twenty days after the removal of the first crop of tumours, the patient went home, improved in every respect, but still unable to converse in a loud tone.

Two months after Mr. J. left New York, I received a letter from him, informing me that he "had improved very much in healthful appearance, had gained some flesh, and had *no unpleasant feelings about the chest*," that the volume of his voice was said to have improved, although he could not yet "speak out."

Two weeks later, I received another letter from him, dated March 22d, 1847, in which he writes—"Yesterday, I am happy to say, I was able to speak several words very audibly, though coarsely. My impression is, that I am looking better, and gaining something every day, notwithstanding the many and severe changes in the weather."

July the 8th, 1850, almost four years after Mr.

J. came under my care, he was in New York, and called to see me. He still conversed, ordinarily, in a strong whisper, and was only able by exertion, to speak aloud. But his general health was very good, and he had no symptoms that indicated the presence of any excrescences in the larynx. The partial aphonia that still remained was, probably, dependent upon a hypertrophied condition of the mucous, and, perhaps, cellular tissues in the vicinity of the vocal cords.

CASE IV.

Immense encephaloid tumour, filling and completely blocking up the pharynx, and nearly closing the glottis.

Mrs. G., aged thirty, the widow of a deceased clergyman, was brought to New York, July 30th, 1848. She was accompanied by her father, Dr. Hastings, an old and highly respectable physician, of Clinton, New York, who called on me immediately after their arrival in this city, and desired me to visit his daughter without delay, as she was, he assured me, in a most suffering and dangerous condition.

I accompanied him at once to her residence, and found this lady, as her father had stated, in a most deplorable situation; but, before describing this condition, I will give the previous history of Mrs. G's case, as it was afterwards furnished me by her father, in writing.

"It is now more than a year since my daughter complained of occasional sore throat and difficulty of swallowing. Her complaints were not considered alarming; but, as there was a redness of the throat and slight ulceration between, and back of, the tonsils to be seen, a weak solution of nitrate of silver was applied, and some counter irritation made with croton oil, &c., externally. She was able to oversee her domestic concerns, and go abroad, till about the middle of January last, when it was considered expedient for her to be confined to the house.

"The medicines used, in addition to the local applications, were blue pill in small doses, followed by magnesia and rhubarb. She being much debilitated, citrate of iron, quinine, wine, and porter, were given her occasionally, and, as she thought, without benefit; and the iodide of potassium was taken for some time, followed by the chloride of mercury in a syrup of sarsaparilla.

"About the first of April, soon after the application of a blister to her throat, the swelling of the gland was discovered, which was considered to be of a scrofulous character. During the months of April and May, she suffered much from sore throat; with pains in her ears when she attempted to swallow; pain in her throat, extending to her ears and nostrils, was sometimes severe, and of a spasmodic character. Supposing that it might proceed from irritation of the nerves, tincture of aconite was given,

as was thought, with benefit. The cod-liver oil was also taken by her for several weeks.

“Her complaints not being permanently relieved, it was considered best to make trial of the sea air and diet. Accordingly, about the 20th of June, she went to New York, from thence to New Haven and Fair Haven. Her appetite soon improved, and she was able to swallow some solid food. She gained strength, and was able to ride in a carriage, two or three miles, without great fatigue. I left her about the last of June, with hopes of her recovery. Her appetite soon became less, and she was oppressed in her breathing—referring this oppression to a stricture across the chest. Her difficulty of swallowing returned. She was at this time on the Sound, and the weather was changeable and unfavorable. She was, therefore, removed to Fair Haven, and came under the care of Dr. Thompson. The Doctor gave her an emetic for her nausea and difficult respiration, which operated favorably. The next day, in using the sponge to her throat, he discovered a tumour in the upper part of the œsophagus. He was alarmed at her situation, and called Drs. Knight and Ives in counsel. They pronounced her disease to be a malignant fungus, and, in their opinion, incurable.

“I arrived at Fair Haven on the 28th of July. She was then unable to swallow without causing strangulation. At most, one to two spoonfuls only could be taken in the twenty-four hours. She was faint for want of food, and there was great diffi-

culty in respiration, similar to that which is observed in croup. We left soon, and arrived at New York July 30th."

Mrs. G. was brought to the house of one of her friends in the city, and was seen by me very soon after her arrival.

I found her almost exhausted. She was supported in nearly a sitting posture, with her head thrown back, and was breathing with very great difficulty, much like a person laboring under œdema or spasm of the glottis; the face was livid, pulse very feeble, and extremities cold. The patient had not swallowed a morsel of food, not even a drop of liquid, for several days. Three days before she reached New York, one or two spoonfuls of thin gruel had been taken, which was all the nourishment that she had had for five days.

I proceeded at once to ascertain the nature of the obstacle that embarrassed respiration and deglutition. Externally, on the right side of the neck, a swelling of considerable size was observed; and upon looking into the mouth, a large, irregular, fungoid-looking tumour was discovered projecting, apparently, out of the œsophagus, and filling entirely the pharyngeal cavity in such a manner as to block up the opening of the œsophagus, and to preclude the possibility of deglutition.

Passing my two fingers over the top of the tumour, and between it and the posterior wall of the pharynx, I endeavored to carry the point of one finger down towards the œsophagus, but was not

able to do this, as the passage was entirely closed. On making still further examination, the tumour was found to have its attachment, apparently, to the right side of the larynx, or in the right fossa at the root of the tongue. On this side it seemed immovable, but the lobulated portion that filled up the left side of the pharynx, could be slightly moved. Upon passing the finger on the laryngeal face of the epiglottis, a portion of the tumour could be felt pressing the epiglottis against the base of the tongue, and closing almost entirely the opening into the larynx. Indeed, it was quite apparent that the patient would soon be suffocated, even if she did not speedily die from starvation.

Mrs. G., who was a most intelligent and interesting lady, was perfectly resigned to her fate, knowing full well that nothing could be effected to afford her permanent relief; but she expressed an earnest desire that something might be done to prolong her life, so that, if possible, she could reach her home, to die among her friends.

It was proposed, after consultation with her father, to attempt to remove a portion of the tumour occupying the left side of the pharynx—sufficient, if possible, to allow the stomach-tube to pass into the œsophagus. On mentioning this to the patient, she not only consented to the operation, but urged its adoption at once. Having prepared a saturated solution of nitrate of silver, to arrest the anticipated hemorrhage, I seized the upper and left lateral part of the tumour with a double

tenaculum, and with the bistoury knife excised a large portion of the mass, amounting nearly to one ounce in weight. The bleeding was profuse, but was quickly arrested by the solution of nitrate of silver, which was applied freely to the cut surface.

After a little delay, another portion lower down, and quite as large, was removed in the same way. As soon as the hemorrhage was arrested, an effort was made to introduce the stomach-tube, which was now passed without much difficulty, and a large bowl of chicken-tea was pumped immediately into the patient's stomach; and this was followed by a glass of wine and water.

Although the patient's respiration was still greatly embarrassed, she could not be restrained from expressing her gratitude for this relief from impending starvation.

The portion of the tumour removed was of a whitish gray color, and of a pulpy, gelatinous consistence, presenting, in short, the encephaloid appearance which is characteristic of fungoid growths.

After waiting a suitable time, another portion of nourishment was introduced into the stomach, which seemed greatly to revive the patient; and she then expressed a desire that an effort should be made to remove that part of the tumour that was obstructing the opening of the wind-pipe.

An attempt was made to explore, with the finger, the boundaries of this excrescence, and to ascertain its attachments; but it seemed impossible to determine whether it was a lateral lobe of the large

tumour, or had its attachments within the glottis. On depressing the tongue so as to bring the epiglottis into view, the tumour, which was the size of a musket-ball, and of an irregular, oval shape, could be seen rising a little above this cartilage, and appeared as if it must soon completely occlude the opening of the larynx, and produce death by suffocation.

I therefore determined to attempt its removal. Standing behind the patient, with her head thrown back and supported, and the tongue depressed by the father, I passed the long double tenaculum over the left border of the glottis, and, seizing the excrescence, drew it gently up; then conveying the probe-pointed knife between it and the epiglottis, cut from before backwards, dividing in this way its connection with the main body, and removed the tumour. The hemorrhage that followed was soon arrested by the caustic. Great and immediate relief followed this operation. The patient could now breathe with much freedom, and the night that succeeded these operations was passed with more refreshing sleep and comfort to the patient than she had enjoyed during many previous weeks.

The next day the patient complained of little or no soreness from the operation; she was stronger, and was much improved in her appearance. Twice during this day the tube was passed, and as much nourishment as was required was introduced into the patient's stomach; the nitrate of silver was applied daily to the diseased mass, which tended

much to repress its rapid development. Still, it was necessary, on the second day after the first operation, so luxuriant was its growth, to remove another large portion of the tumour, to enable us to pass the stomach-tube and supply nourishment to the patient.

Mrs. G. remained nine days in the city, and during that period she gained much strength; notwithstanding it became necessary, several times, to excise a portion of this morbid growth, in order to clear the way for the elastic tube; yet these operations occasioned but little pain, and the hemorrhage that followed was readily arrested by the caustic solution.

By pursuing this course, we were enabled to introduce into the stomach of this suffering lady all the nourishment necessary for her support; and, notwithstanding the disease was constantly progressing, she regained, in the course of a week, so much strength that she could walk about her room; and on the 8th of August, nine days after her arrival in the city, she left, with her father, for their home, in Clinton; where they arrived, by easy journeys, on the 12th of August. She lived until the 30th of the same month.

The following brief history of Mrs. G's case, after her return home, is extracted from a letter received from her father soon after the death of his daughter:

"For several days after we arrived home, my daughter was more comfortable; her respiration

was not so much impeded. The air, she said, refreshed her. Part of the tumour was removed every second day, and the nitrate of silver applied two or three times every day.

"This course kept the top of the tumour from increasing; but it increased lower down the œsophagus, rendering it difficult to introduce the stomach-tube.

"The external tumour enlarged daily, and caused much suffering when she lay on that side. For three or four days previous to her decease, her breathing became more laborious, pulse quick, attended with efforts to cough; the last twenty-four hours she was deranged most of the time, and was comatose.

"She died yesterday, thirty-one days after the removal of the first portion of the tumour, in New York. To-day her neck has been examined. The appearance of the diseased parts, and their connection with the trachea, has led me to wonder how she could live as long as she did. I intend to forward the parts removed, to you, the first convenient opportunity. In the mean time, I remain your much obliged and grateful friend,

SETH HASTINGS."

A few days after receiving this letter, a friend of the writer called, and left me the larynx and tumour, which had been removed together, and of which a representation is given in Plate II.

Attached to the right side of the larynx, and extending from the right corner of the os hyoides

to the sternal end of the clavicle, was a large, irregular, fungous tumour, five inches in length, and, in its greatest thickness, three inches in diameter.

The lower portion of the tumour, that part which extended down the œsophagus, was much the largest, and must have been of sufficient volume to have blocked up completely the œsophageal tube.

The thyroid gland was also greatly enlarged, and, with the lower lobe of the excrescence, must have contributed to form the large external tumour that was so troublesome before the patient's death. On examining the connection of the tumour with the larynx, it was observed that its attachments were limited to a small space on the right side, extending from the lower border of the cricoid cartilage, over two or three of the superior rings of the trachea. The larynx and trachea were now laid open by an incision along their posterior median line, and this limited connection of the tumour with the larynx was at once explained. Within the larynx, on the right side, was a *vegetant excrescence, of the size of a hazel-nut*, having its attachments, apparently, to the lower edge of the cricoid cartilage and the first ring of the trachea.

This tumour within the larynx presented nearly the same characteristics with those of the larger tumour; and, on examination, it was found that they were connected together by an opening about one-third of an inch in diameter, which had been formed by destroying to this extent the upper ring

of the trachea, and a portion of the lower border of the cricoid cartilage.

A question of much interest now occurs, which it is difficult positively to decide: Did this disease commence *within* the larynx or on its external surface? If on the internal surface, which seems most probable, why was the development of the tumour so limited within the tube, whilst it grew so rapidly, and to such an enormous extent, after escaping from the larynx into the cesophagus?

Strange, too, that this patient should have lived so long, when three *fatal* causes were at the same time in full operation; namely, a disease of a malignant nature, an irremovable obstacle to deglutition, and the existence of a tumour within the larynx, that was liable, at any moment, to produce suffocation.

In M. Rayer's work on diseases of the skin,* mention is made of an excrescence, resembling a cauliflower, which was discovered in the larynx of a woman, who was an inmate of La Charité. The tumour was attached near the upper edge of the left ventricle of the larynx, and extended itself above the superior aperture of the glottis.

M. Roux recognized it by the touch, and its presence was also indicated by a suffocating dyspnoea, with a whistling of the air in the larynx, during inspiration especially. The same author alludes to a similar excrescence having occurred in the larynx of a man; and in the paper of M. Ur-

* *Maladies de la peau*, tom. II., p. 422.

ner, to which reference has been made, a case of much interest is recorded, one which is alluded to by both Ryland and Ehrmann, where a large growth of warty tumours was found in the larynx of a strong, robust man, a native of Louvaine, for the removal of which, laryngotomy was performed.

The thyroid cartilage was divided through its whole extent, when a mass of warty excrescences, which filled the whole larynx, was discovered. The tumours were cauterized with the nitrate of mercury, but they grew still more rapidly, when the actual cautery was employed, but without any lasting benefit; and, although the patient was living at the time of writing, no doubt remained in the mind of the medical attendant, as to the fatal issue of the disease.

It is stated, in the commencement of these pages, that during the last few years as many as four cases of laryngeal tumours have occurred in my practice. The following instance, although the individual was not seen by myself, is included in this number, as the lady was brought to this city, to be placed under my care; and I shall record here all I know of the case, imperfect as the history is, with the hope that, by so doing, I may call the attention of some of the medical gentlemen under whose care the patient had previously been, to the character of the disease, and to the important truth that an operation will be necessary to save the life of the individual, if perchance the disease has not already proved fatal.

CASE V.

During the last week of August, 1851, the Rev. Mr. ———, from the State of Ohio, brought to this city his wife, for the purpose of placing her under my care. At this time I had not returned from Europe, where I had been spending the summer; and Mrs. ———'s case was examined by my friend and assistant, Dr. S. C. Hartwell, who had charge of my patients during my absence.

This lady, as it was stated to Dr. Hartwell, had for a long time been seriously affected with some "anomalous disease of the throat," on account of which many different medical gentlemen had, at one time or another, been consulted. None of her attendants had been able to understand the true character of the disease, nor had the treatment employed afforded her any relief.

For several years, Mrs. ——— had been troubled with a cough, some hoarseness and difficulty of breathing, with occasional attacks of dyspnoea, so severe, at times, as to threaten immediate suffocation.

These, and other symptoms of which this lady complained, so nearly resembled those observed in the case of Miss K., with the history of whose disease Dr. Hartwell was familiar, as to lead him at once to suspect the presence of some foreign body in the larynx.

On depressing the tongue of the patient, so as

to bring the epiglottis into view, his suspicions were confirmed by seeing the upper portion of a polypus, which was forced up into the opening of the glottis when the patient coughed with violence. One or two of the medical friends of Dr. H. were present, and also had an opportunity of seeing the tumour.

Dr. H. stated to the husband of the patient, that an operation would be necessary, to remove the difficulty under which his wife was laboring; and it was agreed, that after a visit to some friends in the country they should return to the city, the following week, when it was expected I should have returned home, and would then have the operation performed. With this understanding the patient left, but she never returned; and, as my assistant failed to obtain the name and residence of the patient, nothing further is known of the history of her case. Alarmed, probably, at the suggestion of an *operation*, and not fully satisfied of the fatal tendency of the disease, she may have hesitated, until some suffocative seizure occurred sufficiently severe to destroy life.

The amount of mobility belonging to this tumour, proved that it was not sessile, but that it was attached by a pedicle, which might, in all probability, have been divided, and the polypus removed through the opening of the glottis.

CHAPTER IV.

DIAGNOSIS.

IF we examine into the history of all the well-authenticated cases of polypi of the larynx yet recorded, it will be found that the symptoms indicative of the existence of these growths, are not sufficiently defined to warrant us in laying down positive rules of diagnosis.

As we have seen, the form, the size, and the structure of polypus excrescences are quite variable. They are, says M. Ehrmann, "sometimes rounded, sometimes nodulated or in clusters, granular or lobulated; most generally they are pediculated, and sometimes they have a condylomatous appearance." In their attachments, also, they vary. Most commonly, they are found about the glottis, fixed to the inferior vocal ligaments; sometimes they spring from the ventricles, from the base of the epiglottis, and, less frequently, from the substance of the aryteno-epiglottic ligaments. Consequently, the diagnostic manifestations will be greatly varied, by these different conditions, as to form, size, structure, and location.

M. Ehrmann asserts that we have but one certain sign of the existence of this disease,—the discharge, by expectoration, of some portions of the tumour, as occurred in the case of Caroline M——. It was this circumstance which determined M. Ehrmann to practice, in her case, laryngotomy.

The same positive evidence of the presence of polypus tumours, existed in the observation recorded by Otto, in which case the patient expectorated on three different occasions, during a paroxysm of coughing, *a small globular fleshy mass*, supplied, in one instance, with a very delicate pedicle.

Diagnostic testimony equally conclusive, may be furnished by *seeing the polypus*, as was done in two cases, which I have given, and which might have been accomplished in several of the observations recorded by M. Ehrmann; particularly could this have been done in Rayer's case, where the tumour having prolonged itself above the superior opening of the glottis, was detected by the touch, by M. Roux, who introduced his finger into the patient's mouth.

The existence, therefore, of any one or more of these conditions, to which reference has been made, especially if preceded or attended by embarrassed respiration and an altered state of the voice, would furnish conclusive evidence of the presence of polypus of the larynx. But long before the disease shall have reached this stage the life of the patient will be jeoparded, and may, indeed, be suddenly

arrested by asphyxia, produced by some chance displacement of the tumour. This occurred in the case described by Urner (pp. 21-2), where a small, round polypus, attached by two pedicles to the inferior vocal cords, was lodged in a cavity near the base of the epiglottis. During expiration the tumour, retained by its pedicles, was kept in this position ; but at each inspiration it was brought down upon the glottic chink. At length, a violent inspiration forced the tumour between the lips of the glottis, where it remained engaged, and by suffocation destroyed the life of the patient.

It becomes, then, a matter of great importance to establish such other diagnostic symptoms as will enable us to detect, if possible, the existence of the disease, before it has advanced to this, its almost fatal stage.

So insidious, however, has been the progress of the disease, in some instances, that the sudden death of the patient has afforded the first indication of the existence of the tumour. But more generally, prominent symptoms, for a long period, attend the course of the disease.

In some cases polypus tumours are sessile ; but in a majority of instances they are pediculated, and, consequently, mobile, to a greater or less extent.

Under such circumstances the movements of a foreign body in the larynx, may sometimes be observed by the patient during respiration.

In one of the cases recorded by M. Ehrmann, the individual could imitate, by a rapid movement

of inspiration and expiration, the sound of a valve alternately opening and closing. The occurrence of such a symptom would be highly characteristic of the disease.

An alteration in the sound of the voice is one of the most constant symptoms in polypus of the larynx. The change may vary greatly in degree.

In some instances it will amount only to a slight alteration in the tone of the voice, in others complete aphonia will be present. The extinction of the voice may occur at once, as in the case observed by M. Gerardin. In this instance the first symptom was a sudden loss of voice without any appreciable cause, followed in the course of a few months by a hoarse cough, dyspnoea, and, at the end of two years, death by slow suffocation. On the other hand, the alteration in the sound of the voice may come on gradually, as in the case of Miss K., and that of the Polish officer to which M. Ehrmann alludes.

But whether slow or sudden in its access, aphonia, partial or complete, has been present in a large proportion of the cases of laryngeal polypi.

Another prominent symptom of polypus of the larynx is dyspnoea. The embarrassed respiration may be slight at first; but as the disease advances, this symptom, generally, steadily augments until, at length, alarming suffocative attacks will occur, threatening to destroy the patient's life, followed, perhaps, with intervals of perfectly free respiration.

The character of the respiratory sounds is

generally such as is indicative of the presence of a foreign body of some kind, preventing a free passage of the air to and from the lungs.

In some instances the respiration has a veiled or hissing sound, as if the air was passing through a sieve, or a piece of gauze. This occurred in the case of Mr. J. (case III.), and in that of Mr. Stassin, as reported by Trousseau and Belloc.

In the former instance numerous small tumours of the cauliflower kind existed; and in the latter a vegetant tumour, *covered with asperites, from one to two lines long*, occupied the right sinus.

A cough almost always exists, in this disease; but it has nothing peculiar to render it symptomatic of the affection.

Nearly all these symptoms that have been enumerated, are reported to have been present in some of the cases mentioned, of laryngeal polypus; but in other instances, only one or two of them are spoken of as having occurred. Hoarseness, aphonia, and dyspnoea, with occasional suffocative attacks, are the most constant and characteristic symptoms of the disease; and their value in diagnosis will be in accordance with the length of time they have existed.

CAUSES OF POLYPUS GROWTHS.

If the characteristic symptoms of these tumours are of difficult definition, the causes which tend to their development are still more obscure.

In several instances recorded, the disease seems to have been the sequent of repeated attacks of croup. M. Dawosky calls attention to this cause, in the case he has reported, and expresses the conviction that the development of the disease in this instance, must be attributed to the repeated attacks of croup, under which the child had previously suffered. But has it not happened, that this has occurred, in cases innumerable, without being followed, in any one instance, by a polypus growth; and may not that morbid condition of the lining membrane of the larynx which, in this case, rendered "the slightest chilling exposure to a current of air, the cause invariably, of a very hoarse cough," have been the predisposing antecedent of both the excrescence and the croup?

Unquestionably, long-continued irritation of the larynx, from any cause, may result in the formation of adventitious growths. An instance is related by Dr. Watson, in his Lectures, of the occurrence of a growth of warts, in the larynx of a boy aged eleven, which seemed to follow an attack of *hooping-cough*. For several weeks preceding his death, the patient spoke in a whisper, complained of difficult breathing, and of cough. He died suddenly, in a suffocative paroxysm. At the opening of the larynx, a warty growth was found, involving the base of the epiglottis and the vocal cords, closing, almost entirely, the rima glottidis. "The excrescences sprung *chiefly* from one continuous base, and branch-

ed out precisely after the manner of what is vulgarly called a seedy wart.

There were, however, several distinct smaller growths of warts; the main excrescence having several heads, passed upwards, from and through the rima, and so came to act, partly as a valve during inspiration, which was always sensibly more difficult than expiration.*

Tubercular phthisis was found complicated with some of the cases of polypus whose history has been given; and yet no inference can be drawn from these cases, or others, to favor the conclusion that pulmonary disease tends, in any degree, to develop these morbid growths in the larynx. As yet, their origin is unknown.

* Lectures on the Principles and Practice of Physic. By Thomas Watson, M. D., Am. Ed., p. 451.

CHAPTER V.

TREATMENT OF POLYPUS OF THE LARYNX.

HITHERTO, the measures proposed for the treatment of laryngeal polypus have been few indeed.

The removal of these tumours by the operation of laryngo-tracheotomy is the only plan suggested by M. Ehrmann.

On this subject Mr. Ryland remarks, "If it were possible to ascertain the existence of a polypus in the larynx during life, it would be the duty of the surgeon to attempt its removal by the knife, or by a ligature around its base. For this purpose it would be necessary to divide the cricoid cartilage, and probably the thyroid also; but as the consequences of polypus remaining are always mortal, at some period or another, it would be right to give the patient this chance of relief from otherwise certain destruction."*

With regard to the fatal tendency of polypus

* Op. citat., p. 230.

of the larynx, but one opinion can be entertained; and all writers who have considered the disease, express the conviction that the performance of laryngotomy alone promises to the patient permanent relief.

From their form and the position sometimes occupied by these tumours, this operation undoubtedly will be required for their removal, in perhaps a large proportion of cases; but it is maintained that the surgeon has it in his power to rid the larynx of these fatal outgrowths, in many instances, by an operation less difficult and less dangerous than the division of the crico-thyroid cartilages. In some of the cases, too, whose history has been given, the tumours might have been removed, it is believed, and the patients saved by a timely operation. In confirmation of this opinion, let us refer to the character of some of these developments.

A very small proportion of these tumours have been sessile; all or nearly all, as we have seen, have been seated above the inferior vocal cords, having had their pediculated roots attached to the lips of the glottis, the base of the epiglottis, or fixed, either in the sides of the ventricles or to the vocal ligaments. In very few instances have they been developed far within the larynx. Ordinarily, they have possessed considerable mobility, with pedicles sufficiently elongated, in many instances, to allow the tumour to be pushed between the lips of the glottis, and in some cases even, to be thrust out of the larynx by coughing or strong expiration.

In cases of this nature it would be in the power of the surgeon to discover the existence of the polypus, and, by proper manipulation, to remove it by torsion or excision.

In the observation recorded by Dupuytren, to which allusion has already been made, the polypus that destroyed the life of the patient was attached by its pedicle to one of the lips of the glottis, and, ordinarily, floated in the cavity of the pharynx, producing in this position but little disturbance. Whenever, by inspiration or other cause, the tumour was drawn over the aperture of the glottis, it caused suffocative attacks, in one of which death at length occurred.

In this instance the polypus, had its presence been detected, might have been readily removed, probably in the same manner that it was in the case of Miss K.

In the examples observed by Dessault, three cases in all, the tumour in each instance had its pedicle inserted into one of the ventricles of the larynx, and being pushed between the borders of the glottis in respiration, was ultimately arrested there, and caused the death of the patient by suffocation.

Attached in the same manner to the right ventricle, and occupying the superior part of the larynx, was the fibrous tumour discovered, by Dr. Senn, of Geneva, after the death of the patient; and in the case referred to by Rendtorff, of Heidelberg, the polypus, which was of the size of a filbert, was found

springing from the aryteno-epiglottic ligament—the border of the glottis.

When we remember that in nearly all persons, by means of an appropriate spatula, the tongue may be depressed in such a manner as to bring the epiglottis well into view, we can understand, I think, how in such cases of polypi as those to which I have just referred, these excrescences may, in most instances, be detected by inspecting the throat in the manner described.

In this way was the tumour of the larynx detected by Dr. Hartwell, in the case of the lady referred to in the preceding chapter; and had this patient returned, as was agreed upon, and submitted to the operation proposed, the polypus, I have little doubt, might have been removed through the aperture of the glottis.

Should, then, any or a part of the symptoms in any case be present, which, under the head of diagnosis, have been enumerated as characteristic of polypus of the larynx, we should proceed at once to obtain, if possible, in the way proposed, ocular confirmation of the existence of the suspected tumour; particularly should this inquiry be instituted when the indications of which we have spoken being present, their cause cannot be discovered in any of the ordinary laryngeal, or thoracic changes. Had this inspection been made before the death of the patient, in the case of Dr. Parker, of this city, the polypus would, in all probability, have been discovered, as the tumour, which was of the size of a

chestnut, was fixed by its pedicle to the right superior vocal cord, and, consequently, even had it possessed but limited mobility, must have extended so far between the lips of the glottis as to have been visible when the base of the tongue was well depressed, or if not visible, could have been felt by the finger passed over the laryngeal face of the epiglottis.

Dr. Parker was summoned in haste to see this case, in consultation; but the patient died before his arrival. Had this accomplished surgeon been called in time to have discovered the existence of this morbid growth, he would have been able, probably, to have removed the tumour by excision.

To make that examination which will be necessary to detect a polypus in the larynx, where we have reason to suspect the existence of such a growth, the patient should be placed opposite a good light, with his head supported by an assistant standing behind him; the operator, with a strong bent spatula should slowly depress and drag forward the tongue, until the epiglottis is brought well into view. At this moment the patient should be directed to cough forcibly, when a portion of the polypus, if it be floating in the cavity of the glottis, as is frequently the case, may be seen, momentarily, over the aryteno-epiglottic border. Should we fail in this, the finger should be carried deep into the throat, to the opening of the glottis, and an attempt be made to feel the tumour, in the same way that we detect the swelling in œdema of

the glottis. If, by this procedure, a polypus should be discovered in the larynx, a determined attempt for its removal should be made, inasmuch as the patient, unless this can be effected, will have no "chance of relief from otherwise certain destruction."

The operation may be performed in the following manner:—The patient must be placed in a low seat, opposite a full light, with the head thrown back and resting against the operator, who should stand behind the patient, whilst an assistant depresses the tongue in the same way that has been directed to be done in examining for the polypus.

If, when the epiglottis is brought into view, the tumour, or part of it, can be seen, attempts must be made to catch it with the double hook, held in the left hand of the operator; and if in this he is successful, he should endeavor, with the probe-pointed knife in the right hand, to divide the pedicle of the polypus, and with the tenaculum remove it from the larynx. Or, the operator may be able to seize the tumour with a pair of slender forceps, and, by twisting and tearing, succeed, if it is attached by a slender pedicle, in bringing it away. But this will be attended with more difficulty and danger than excision; especially will this be the case if the polypus is confined by a thick or tendinous pedicle, or is fixed to the vocal ligaments.

Troublesome hemorrhage will not be likely to follow the removal of the tumour with the knife; but should it occur, the parts may be cauterized by means of the sponge-probang, with a strong solu-

tion of the nitrate of silver, which will not only serve to arrest the bleeding, but will have a tendency to prevent any renewed growth of the excrescence.

If, on making thorough and repeated examinations (for we should not decide from a single inspection of the throat), no polypus can be detected, repeated applications of a strong solution of the nitrate of silver should be made, as was done in the case of W. J. (observation III.), to the glottis, and into the larynx of the patient; especially ought this treatment to be adopted if complete aphonia exists, if the *hissing* and embarrassed respiration be present,—symptoms that indicate the existence of a growth of the cauliflower kind, or of a vegetant excrescence, such as occurred in the above case, and in that of M. Stassin, as described by Trousseau and Belloc.

Should success not attend the employment of either of these plans, and the symptoms present are such as strongly indicate the existence of a foreign body in the upper portion of the air-passages, laryngotomy will be demanded, and must be practiced, if we would save the life of the patient.

This operation has been performed in this disease, already, in five cases, but was attended with success only in the case observed by M. Ehrmann, the history of which has been given in a preceding chapter.

Yet in all these instances, with the exception of the last case, laryngotomy was practiced under cir-

cumstances where success could not have been anticipated, inasmuch as in three of the cases—those observed by Trousseau and Belloc, and by Gluge and Bertherand—the tumours were not recognized during the life of the patients, and the operation was performed for the purpose of preserving the individuals from immediate suffocation.

In the fourth instance, M. Brauers, of Belgium, opened the larynx of the patient, as noticed on a former page, and endeavored to destroy the excrescences, by cauterization. But in M. Ehrmann's case, laryngo-tracheotomy was successfully performed; and the polypus being removed by excision, the life of the patient was saved.

It will be advisable to adopt the plan recommended by M. Ehrmann, when the operation of laryngotomy is practiced for the removal of polypus from the larynx.

After making the opening, and introducing the curved canula into the wound in the respiratory tube, the incision of the larynx and the removal of the foreign body was postponed until the patient had recovered from the fatigue and exhaustion consequent upon the first operation. To this delay M. Ehrmann attributed, in a great measure, the success of the operation.

CHAPTER VI.

ŒDEMA GLOTTIDIS.

WHEN inflammation attacks the superior aperture of the larynx, and is followed by an infiltration of serum, or of sero-purulent fluid, into the submucous cellular tissues of the aryteno-epiglottic cartilages, the disease is termed œdema of the glottis.

In an interesting memoir by M. Sestier, published in a recent number of the *Archives Générales de Médecine*,* on the results of the operation of Bronchotomy in the treatment of œdema glottidis, the above writer describes this affection as characterized anatomically by an infiltration of the aryteno-epiglottic folds only in some instances, but in many others as involving other parts of the upper portion of the larynx; that the infiltration is formed sometimes of a serous fluid, sometimes of plastic lymph, at others it is sero-purulent; and again it is of a purulent nature. Hence, the denomination *œdema*

* Archives Générales de Médecine, tom. xxxiii., 1850, p. 387.

of the glottis, is not strictly accurate in the opinion of this writer.

“ Nous proposons de lui substituer celle d'*angine infiltro-laryngée*, qui indique que, dans cette maladie, la respiration est gênée, que cette gêne provient d'un obstacle placé au larynx, et que cet obstacle est dû à l'infiltration des tissus, d'ailleurs sans spécifier la nature du liquide infiltré.”*

Cruveilhier† has described œdema of the glottis as being attended by a constantly increasing impediment in respiration; by a sensation in the upper part of the wind-pipe, as if this tube was obstructed by some foreign body; by a croupal voice, a hoarse and spasmodic cough; and by the occurrence of frequent suffocative attacks. One of the most characteristic symptoms of the disease is manifested in the respiration. The act of inspiration is attended with much difficulty and distress, whilst expiration, on the other hand, is performed with ease.

“ The difficulty of performing inspiration during the existence of this disease,” remarks Mr. Ryland, “ is perfectly accounted for by the mechanical arrangement of the tumefied edges of the glottis; for on every attempt to expand the chest, the air, rushing from the pharynx in the direction of the rima, presses them towards each other, and causes them to close, more or less completely, the superior aperture of the larynx; whilst during expiration the

* 2 Op. citat., p. 388.

† Dict. de. Med. Prat., art. Laryngite.

air passing from the trachea, separates the sides of the glottis, and thus escapes with the greatest facility."*

The fatal character of œdema of the glottis is well known. Dr. Bayle, who was the first to describe accurately the disease, has recorded but one recovery in seventeen cases; and M. Valleix, whose essay on cedematous laryngeal angina, before the Academy of Medicine of Paris, is the best history of the disease written, has collected and recorded forty cases, of which number, the disease proved fatal in thirty-one instances. In the memoir of M. Sestier, just alluded to, the results in one hundred and sixty-eight cases are given. One hundred and twenty seven of this number died;† and in the two cases reported by Dr. Ryland, the disease proved fatal in both instances.

As several cases of this uncommon and most dangerous malady have been treated by me, by means of topical medication, and, as I know of no instances on record where œdema of the glottis has been successfully managed by applications of the nitrate of silver to the affected parts, I shall make no apology for giving a brief history of the treatment I have adopted.

* A Treatise on the Diseases and Injuries of the Larynx and Trachea; By F. Ryland, pp. 62-3.

† Op. citat. p. 399.

CASE I.

Case of Œdema Glottidis, complicated with diphthêritic inflammation.

Jan. 1st., 1851.—James McConner, laborer, while at work in the water contracted a severe cold. This was neglected several days, until soreness of the throat, with loss of voice and difficulty of breathing, induced him to seek medical advice. At first an apothecary in the neighborhood was consulted, who administered some laxative remedies. The disease increasing, and the symptoms becoming urgent, his friends, much alarmed, took him into a carriage and drove to my office. When the patient arrived he was laboring under a paroxysm of dyspnoea, so violent that my friend and assistant, Dr. Hartwell, who was present, thought with myself that the operation of tracheotomy would be required at once, to save the life of the patient. Inspiration, which was performed with the greatest difficulty, was attended with a whistling sound, the face was livid, the hands cold, and the pulse small, frequent, and weak.

So violent was the struggling for breath with the patient, that I immediately passed my finger down to the opening of the glottis, to ascertain the nature of the obstructing agent. By this procedure the difficulty was at once detected. A round, soft tumour was felt at the base of the tongue,

which proved to be the epiglottis, greatly swollen ; and below this the arytenoid cartilages, or lips of the glottis were found œdematous, from infiltration of fluid into their sub-mucous cellular tissues, to such an extent, apparently, as to close almost completely the aperture of the larynx.

Having seen speedy, and most happy effects follow, in several instances, the application of a concentrated solution of nitrate of silver to œdema of the uvula from infiltration, I determined to apply this remedy at once to the engorged parts. A solution of some sixty grains to the ounce of water was applied very freely to the epiglottis, to the lips of the glottis ; and an attempt was made by means of a small sponge, to pass some of the fluid into the ventricles of the larynx. For a few moments the laborious respiration seemed increased ; but soon the patient expectorated, with much difficulty, a great quantity of adhesive, ropy mucus ; and the parts were again cauterized by the solution. This operation was performed the third time before the patient left the office.

After an hour's delay the laborious respiration was in some degree mitigated ; and he was taken into the carriage by his friends, and conveyed to his dwelling. From this time the attendance on the patient was continued by my assistant, Dr. Hartwell, who has kindly furnished me with his notes of the case.

Six leeches were applied to the throat, three on each side of the larynx, after the patient returned

home, and nauseating doses of tartarized antimony administered. At seven o'clock in the evening he was visited by Dr. Hartwell, who found him laboring under a severe paroxysm of dyspnœa. Inspiration especially, which was attended by a stridulous sound, was performed with the greatest difficulty. Unable to lie down or to speak, the patient was sitting erect and making signs of great pain in the laryngeal region. The nitrate of silver was applied very freely to the larynx; the application was immediately followed with some relief to respiration. The antimony was continued; submur. Hydrarg. in ten-grain doses, was administered every fourth hour.

"Jan. 2d." (I quote from the notes of Dr. H.), "received a message to visit the patient immediately. Found him sitting up before an open window, with every muscle of respiration laboring excessively to supply the lungs; the countenance more livid than on the day previous, the pulse 130, small, quick, and weak. The medicine had operated as cathartic and emesis, but he had obtained no sleep. Applied the sponge, guided by the first two fingers of the left hand placed upon the epiglottis, freely to the glottis. On withdrawing the sponge, it was covered with flakes of false membrane, portions of which were also coughed up; the breathing was somewhat relieved by the operation. Before leaving the patient, I applied the sponge twice to the diseased parts, where they could be reached, and

with the effect of bringing away more of the false membrane; applied some leeches again.

"One o'clock, P.M.—Again saw the patient, the breathing was easier, the pulse 120; but no sound of voice could be obtained: great difficulty of swallowing.

"Ten o'clock, P. M.—Patient still more relieved, the applications were again made to the glottis.

"Jan. 3d.—Found the patient breathing with more freedom. Expectoration increased; can speak only in a whisper.

"Jan. 4.—The symptoms all improved. Respiration is comparatively easy, the pulse 100, the epiglottis much reduced in size; and the patient can articulate above a whisper."

From this time the patient improved rapidly; and about the tenth day he called at my office, restored to a good degree of health; but it was several weeks before the natural tones of his voice were restored.

CASE II.

Early last spring, about four o'clock in the morning, I received a message to visit, as quickly as possible, Dr. S——, an intelligent young physician, residing in the upper part of the city, who, as I learned from his friend who came for me, was being nearly suffocated from an inflammation of the throat. As the request was urgent, and a carriage waiting for me at the door, I left immediately, and

was driven directly to the doctor's house. I found him sitting up, for he was unable to lie down, with a countenance pale and expressive of great agony. The voice was extinguished, the respiration stridulous, and was performed with the greatest difficulty; inspiration was especially difficult, and was attended with the crowing sound; but expiration was easy.

Dr. S. informed me in a whisper, that he had passed a sleepless night, and unless he could obtain relief by some means, he felt he must suffocate.

On depressing the patient's tongue, his epiglottis could be seen swollen to the size and shape of a large strawberry; and, by passing the finger below this, the œdema of the glottis was distinctly felt. As many of the ordinary remedies had been employed without benefit—for the distressing symptoms had continued to increase—I proposed cauterization. To this Dr. S. willingly assented; and, before leaving the room, I applied a concentrated solution of the nitrate of silver, three times to the epiglottis, to the arytenoid cartilages, and with a small sponge introduced the fluid into the opening of the glottis. An abundant expectoration of adhesive mucus was thrown off, and the oppressive dyspnœa was much relieved.

After prescribing the following mixture, I left Dr. S., promising to return in a few hours:

R̄ Ant. et Potass. tart.	. . .	gr. ij
Liquor Ammon. Acetatis,	. . .	ʒ ij
Syrupi Tolutan,	. . .	ʒ i

℞ A fluid drachm to be taken every hour.

Two o'clock, P. M.—I found my patient still unable to lie down, although he had obtained some sleep, while sitting in his easy chair. The difficulty of respiration was greatly relieved, the croupy or stridulous sound, which attended the act of inspiration in the morning, had nearly disappeared; and, on inspecting the epiglottis, I found the œdema considerably abated.

The nitrate of silver was again applied to all the parts that could be reached by the sponge; and as the œdema about the lips of the glottis had diminished, the application could be made with more freedom to the interior of the glottis.

The expectorant was continued. On the following day I visited Dr. S., and was much pleased to find that he had passed, comparatively, an easy night. Every symptom had improved. The respiration was nearly natural, the voice was partially restored, and the œdema of the epiglottis, to a great extent, had disappeared. After the second application of the solution, there was a free expectoration of adhesive, muco-purulent matter, which was kept up during several hours, and was followed by great relief to the patient.

From this time no further local treatment was required, and in the course of a few days the doctor resumed his professional duties.

The influence of topical treatment in arresting the disease under consideration, as well as the nature of this affection when not met by appropriate remedial measures, was well illustrated by a case of

melancholy interest that fell under my observation in the fall of 1849.

Mr. O——, a young merchant of this city, was attacked with œdema of the glottis, from which he recovered after repeated applications of a very strong solution of nitrate of silver, to the infiltrated tissues. I saw him on the 22d of November, with my friend, Dr. J. Foster Jenkins, at which time—the disease having continued several days before I was called—his symptoms were extremely urgent.

The œdema had involved not only the tissues of the aryteno-epiglottic ligaments, but the uvula was infiltrated with serum, and so much elongated that it was concluded to remove a part of the pendulous portion. Assisted by Dr. Jenkins, I truncated the uvula; and immediately afterwards applications were made to all the œdematous parts. As in the preceding case, great relief followed the abundant expectoration that the applications induced. The treatment was continued for several days, and the patient recovered perfectly.

The next year this same gentleman, whilst on a visit to his mother,—a widow lady, residing in the country,—was attacked with the disease.

General treatment, such as is usually employed in these cases, was now adopted. Neither cauterization, nor scarifications were resorted to. All the unfavorable symptoms increased with great rapidity; and within forty-eight hours of the invasion of the disease, the patient died from suffocation.

In the preceding cases of œdema glottidis, it will be noticed that the disease was idiopathic, or at least supervened on an attack of ordinary angina; and did not occur, as is usually the case, in persons debilitated by chronic affections, or in convalescents from acute disease.

Several other cases have fallen under my notice, where the affection occurred in individuals recovering from, or debilitated by, other diseases. I shall allude to one case only of this nature.

Late one evening last year, my friend, Dr. A. L. Cox, called at my office, and desired me to accompany him to visit a lady of this city, who was suffering under a disease of the throat, of a very grave character.

The patient, who was a feeble lady, about fifty years old, had suffered some days from a temporary illness, and had been under the care of a homœopathist. After several days sickness, she was attacked with a cough, and a difficulty of respiration, which became so alarming that the homœopathist was discharged, and Dr. C. called to attend the patient. He found her suffering from an attack of œdema of the glottis, in an advanced stage of the disease; and, after prescribing an emetic, and some expectorant remedies, without any apparent relief, he requested me to see the patient with him.

We found her supported in a sitting posture in bed, her head thrown back, and the muscles of respiration laboring violently to expand the chest, while every act of inspiration was attended with a

crowing or stridulous sound. The face was livid, the pulse very weak and rapid; and the patient with her hands to her throat, implored us to do something for her relief, *there*.

On depressing the tongue, with a bent spatula, the epiglottis, distended by infiltration, appeared like a round tumour at the base of the tongue, and the puffy and œdematous condition of the aperture of the glottis could be detected by the finger.*

The stage of the disease, and the debilitated condition of the patient, precluded the idea of even local depletion, and it was resolved to employ cauterization to the œdematous parts.

An application of the solution of the nitrate of silver, of the strength of sixty grains to the ounce of water, was made by Dr. C. to the top of the larynx, and about the epiglottis; and this operation was repeated several times during the hour we remained with the patient. An abundant muco-purulent secretion was thrown off during this time; and so great was the relief afforded by this treatment that the patient expressed her gratitude repeatedly before we left her house.

* In some cases of œdema of the glottis, the infiltration does not involve, wholly, the tissues of the epiglottis. But in most instances, if the disease is not arrested early, so great becomes the œdema of this organ that it loses entirely its natural aspect, and it is then found presenting the appearance of a round, puffy tumour at the base of the tongue. Thus changed, it has been mistaken for an *adventitious* growth. This occurred in a case in this city; where two attending physicians were making preparations to excise the "tumour," when a third gentleman was called in consultation, who suggested to the operators that the enlargement might be an œdematous epiglottis.

Early the next morning the attending physician, on calling, found his patient greatly relieved.

The cauterization was again repeated, and the improvement after this was still more rapid. Under a supporting plan of general treatment, she was soon restored to health.

In a paper read before the Edinburgh Medico-Chirurgical Society, by Dr. John Scott, one of the oldest and most distinguished physicians of Edinburgh—a paper which was afterwards published in the “Monthly Journal of Medical Science” for 1850—many interesting cases of laryngeal diseases, successfully treated by topical measures, are there recorded.

I shall extract from that Journal but one of the cases reported by Dr. Scott, the particulars of which were furnished him by his friend, Dr. Brown, of Edinburgh; and which, from the history of the symptoms given, appears to have been a case of œdema of the glottis, following or complicated with inflammation of the mucous membrane of the parts.

“CASE.—J. S. S., aged forty-three, strong, active, and healthy, had a severe attack of erysipelatous sore throat, which required vigorous treatment, local and general. He was recovering—when I was sent for, the message being that Mr. S—— was dying. Meeting fortunately with Dr. Scott, he accompanied me. The patient had all the appearance of imminent death; his face expressive of extreme terror and anguish; the extremities cold; the pulse hardly to be counted, from its rapidity and weak-

ness ; the breathing all but impossible, apparently from some affection at the top of the windpipe ; the voice was gone. On looking deeply into the throat, the pharynx and top of the larynx were seen of a deep red.

"The patient being too weak for blood-letting, and too ill for any slower means of relief, Dr. Scott applied the solution of the nitrate of silver, which he happened to have with him. He got the sponge completely into the larynx. Mr. S—— almost instantly expressed, by signs, his relief. In the evening he could speak a little, and was able to lie down in bed, and was in all respects better. He was blistered, and had calomel and opium.

"Next morning, he was much better. The sponge was again applied, without any difficulty. He recovered rapidly, and has been for more than two years in perfect health, attributing without any hesitation the saving of his life to the sponge and the caustic."

CHAPTER VII.

OF THE TREATMENT OF ŒDEMA GLOTTIDIS.

HAVING already exceeded the limits within which it was originally intended to confine the pages of this work, I shall not stop to describe any more particularly than has already been done, the pathology of œdema glottidis, or its diagnosis, but shall proceed, at once, to a consideration of the treatment of the affection.

Œdema of the glottis may exist under two forms, or varieties. When the disease occurs independent of any other local affection, it is termed *idiopathic*; and *secondary*, when it follows diseased action of the larynx, or of any of its neighbouring tissues. Not unfrequently the affection arises during convalescence from typhus, and other forms of fever. It originates also from inflammation, and from ulcerations of the lining membrane of the larynx. The inflammatory action, however, is sub-acute in

its character, and is unattended in the early stage of the disease by any constitutional disturbance.

The principal measures hitherto adopted for the treatment of œdema of the glottis, have been depletion, both general and local, emetics, blisters, scarifications and bronchotomy. When the respiration in this disease becomes seriously obstructed, and attacks of impending suffocation come on, bronchotomy, says Mr. Ryland, "is the only measure on which the slightest reliance can be placed."

The importance of this operation, in the treatment of œdema of the glottis, is well illustrated in the memoir of M. Sestier, to which allusion has already been made. This memoir is founded on the analysis of one hundred and sixty-eight observations of œdema glottidis, many of which were communicated to the author, and some of which were observed by himself. In one hundred and thirty-two of these cases, the ordinary treatment was adopted; and of this number one hundred and four died, with only twenty-eight recoveries.

In thirty-six cases the operation of bronchotomy was performed; and of this number, there were thirteen recoveries, and twenty-three deaths. The proportion of deaths, therefore, in those cases treated without bronchotomy, was about four-fifths of the whole number; on the other hand, over one-third of those patients on whom the operation was performed, recovered.

It should be remarked, adds this author, that in *all* these cases where bronchotomy was practiced,

the disease was *excessively severe*, whilst this was not always the case in those instances where recourse was not had to the operation.*

M. Lisfranc, who was the first to recommend and employ the method of puncturing, or scarifying, the engorged and swollen lips of the glottis, in order thereby to lessen the intumescence, has reported five cases wherein this treatment was successful. The same plan has recently been adopted in the New York Hospital; and several cases have been reported by Dr. Buck, one of the surgeons of this charity, where scarifications of the œdematous parts proved, apparently, the means of restoring the patients.

The difficulty and danger of scarifying the parts involved in this disease, must be apparent to all. The infiltration takes place in the sub-mucous cellular tissues; and to be effectual the incisions must be carried into these tissues; and blood-vessels, of such magnitude as to produce troublesome hemorrhage, may be wounded. On the other hand, in cauterizing the parts, after the manner recommended in these pages, there is neither difficulty nor danger.

In treating œdema of the glottis by topical medication, a strong solution of the crystals of nitrate of silver, of the strength of two scruples or a drachm of the salt to an ounce of water, should be employed.

In inflammation of the mucous membrane of

* Archives Générales de Médecine, tom., xxiii., 1850, p. 390.

the larynx, of whatever grade, whether sub-acute or acute, the disease, it should be remembered, will be aggravated by the application of a *weak* preparation of the nitrate of silver to the inflamed parts. Solutions of the strength of five or ten grains to the ounce of water, operate as a stimulant when applied to an inflamed mucous-surface, tending, invariably, to increase the inflammation; but a directly opposite effect is produced by a concentrated solution of the silver—namely, that of arresting or changing the diseased action—whilst its application is quickly followed by a copious, mucous discharge from the engorged membrane. The first application with the sponge-probang should be made to the pharynx, and the top of the epiglottis; and, after a delay of ten or fifteen minutes, the measure may be repeated, and the sponge, wet with the solution, be freely applied to the base of the epiglottis, and over the œdematous lips of the glottis. This application should be repeated every hour or two hours, according to the urgency of the disease and the effect produced by the operation; and an attempt should be made, each time, to carry the sponge between the lips of the glottis. As the œdema at the opening of the larynx subsides, this may be done, and the application of the caustic solution be made to the interior of the glottis.

Other measures may be adopted, to aid the local treatment. The detraction of blood, by means of a few leeches applied to the sides of the larynx, may be required; and the internal administration

of small doses of tartar-emetic are advised by some writers; but great caution should be observed in its employment, on account of the depressing nature of this remedy. Calomel is, unquestionably, a valuable medicine in this disease, as it tends, in the opinion of Mr. Ryland, either by its purgative effect or by its specific action on the general system, to check the inflammation of the glottis, and promote the absorption of the effused fluid. It should be administered in full doses in the early stages of the disease.

The employment of all general remedies, however, as experience in the management of this disease has shown, will be likely to prove abortive unless the topical treatment is perseveringly pursued.

Should the vigorous adoption of all these remedial measures fail to arrest the disease, and the increasing difficulty of respiration, and the occurrence of suffocative seizures, threaten immediate and imminent danger, Bronchotomy should be practiced without delay.

The happy results, however, which followed the topical treatment of œdema of the glottis in the cases recorded in these pages, leads me confidently to believe, that this measure, if timely and appropriately adopted, will prevent the necessity of the operation in a great proportion of cases, by arresting the disease.

of small doses of tartar emetic are advised by some writers; but great caution should be observed in its employment on account of the depressing nature of this remedy. Calomel is unquestionably a valuable medicine in this disease, as it tends to the solution of the lymph, either by its purgative effect or by its specific action on the general system, to check the inflammation of the middle ear, and promote the absorption of the effused fluid. It should be administered in full doses in the early stages of the disease.

The employment of all general remedies, however, as experience in the management of this disease has shown, will be likely to prove abortive unless the topical treatment is perseveringly pursued.

Should the vigorous solution of all these remedial measures fail to arrest the disease, and the increasing difficulty of respiration and the occurrence of suffocative seizures, threaten immediate and imminent danger, tracheotomy should be practiced without delay.

The happy results, however, which followed the topical treatment of some of the cases in the cases recorded in these pages leads me confidently to believe, that this measure, if timely and appropriately adapted, will prevent the necessity of the operation in a great proportion of cases by arresting the disease.

EXPLANATION OF THE PLATES.

PLATE I.

FIG. 1. This figure exhibits a very correct view of the position of the polypus, as it was seen in the throat of Miss K.— before the operation. The mouth being open, and the tongue depressed by the bent spatula, the top of the epiglottis is brought into view, over the left border of which (A) is seen a small portion of the polypus, as it was revealed momentarily, by the coughing of the patient.

FIG. 2. The appearance of the polypous tumour after its removal by a division of its pedicle.

FIG. 3. Presents a good view of some of the individual excrescences which were removed from the larynx of Mr. J.— (Case III) by cauterization.

FIG. 4. The appearance of the same cauliflower excrescences, as they were probably aggregated together in the larynx.

PLATE II.

This plate represents the larynx which was taken from the body of Mrs. G.— (Case IV), and attached to it a large mass of the encephaloid tumour which served to block up the œsophagus during life. The trachea, opened from behind, reveals the cauliflower excrescence (B) discovered in the larynx, after the death of the patient.

PLATE III.

(from Prof. Ehrmann.)

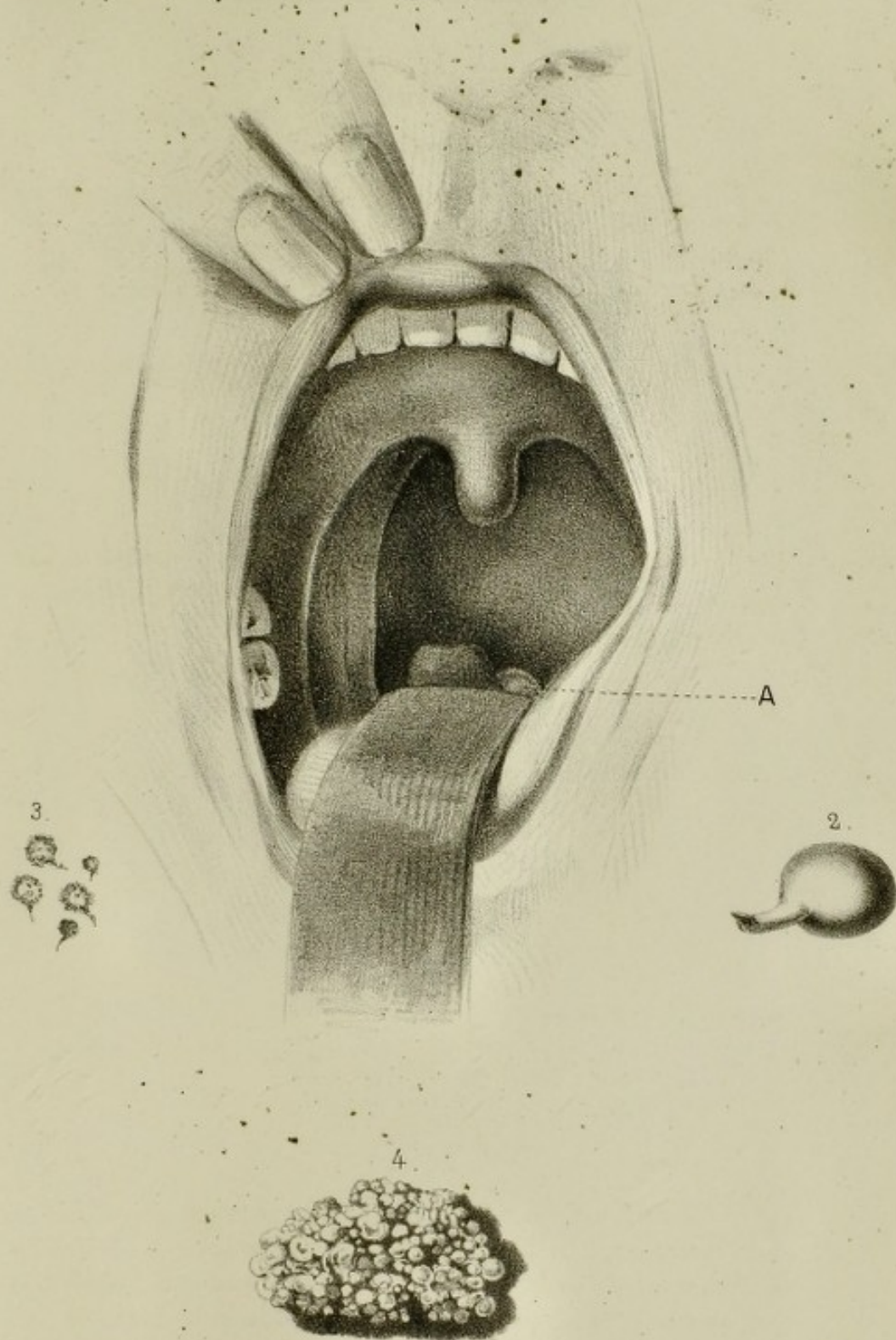
FIG. 1. Exhibits a view of the larynx of the patient upon whom M. Ehrmann performed successfully the operation of laryngo-tracheotomy for the removal of a polypus; but who, seven months after, died of typhoid fever.


FIG. 2. The polypus of the larynx removed by the above operation.

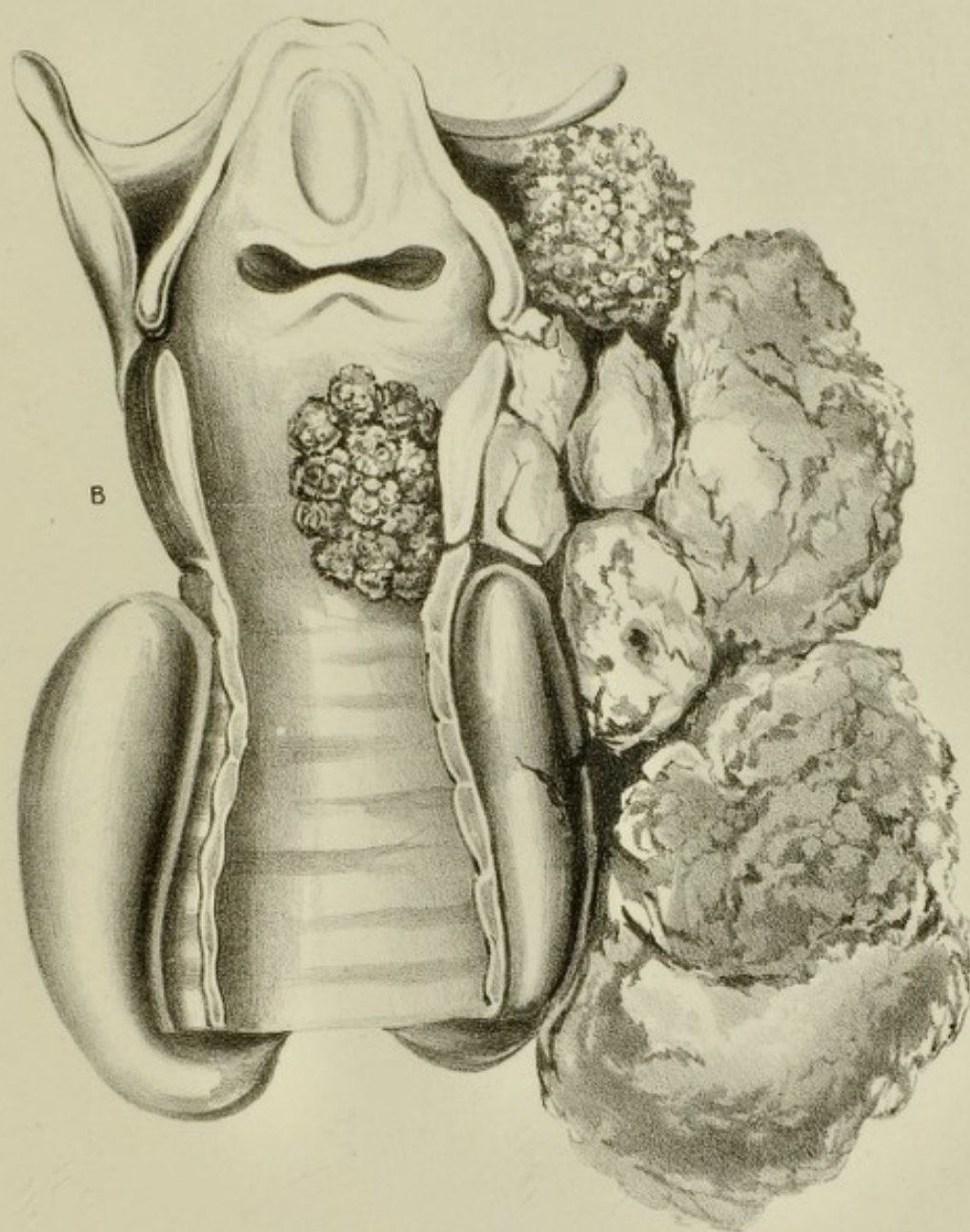
PLATE IV.

This plate, taken from Dr. Ryland's work on Diseases of the Larynx, represents a small polypus, attached by a narrow pedicle to the left vocal cord.

Fig 1








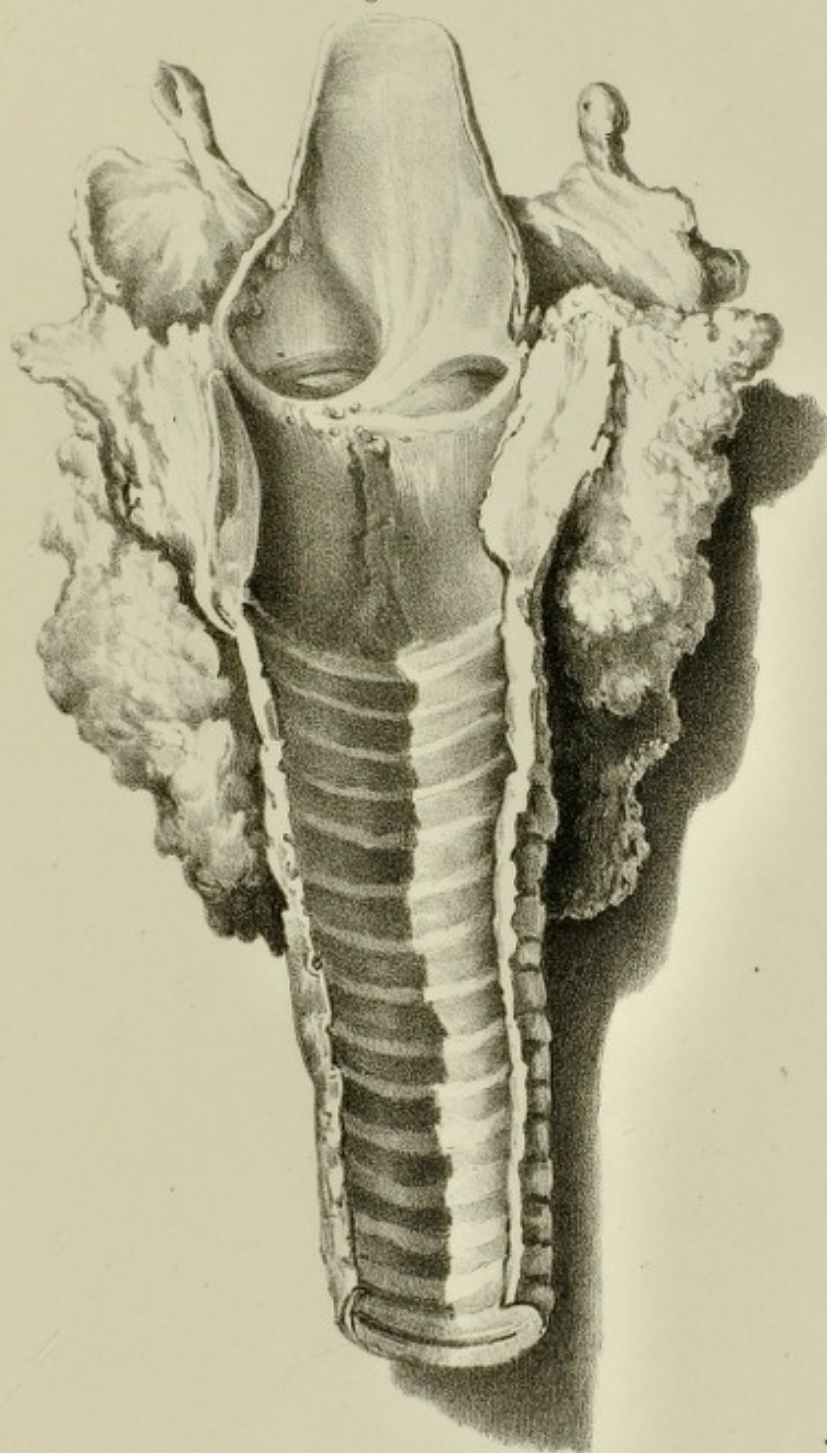


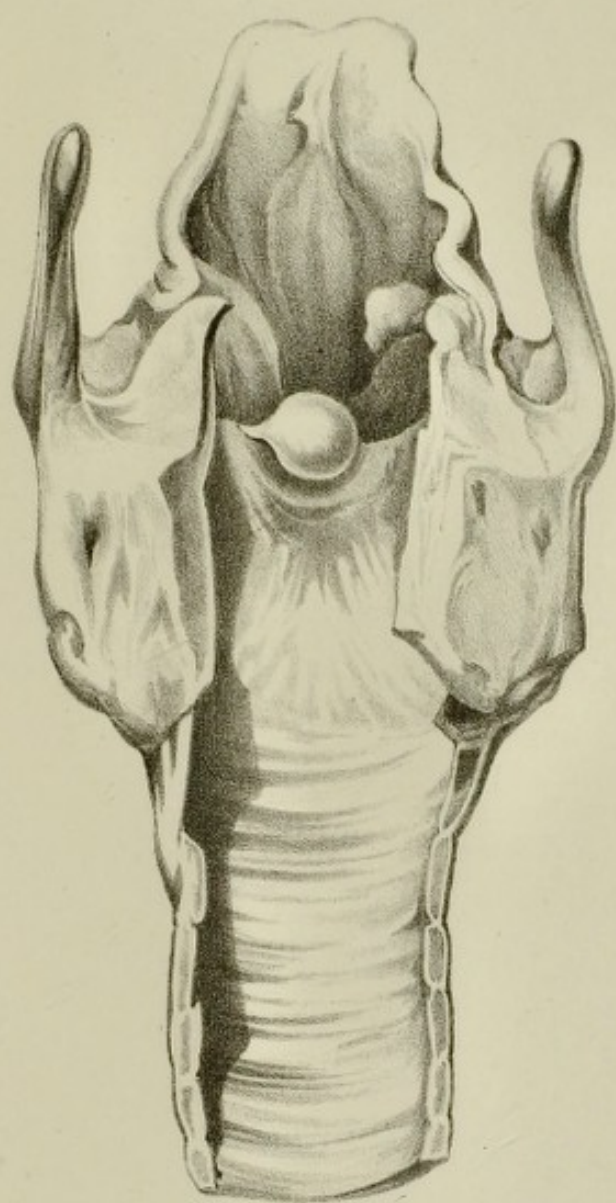
Fig. 2.

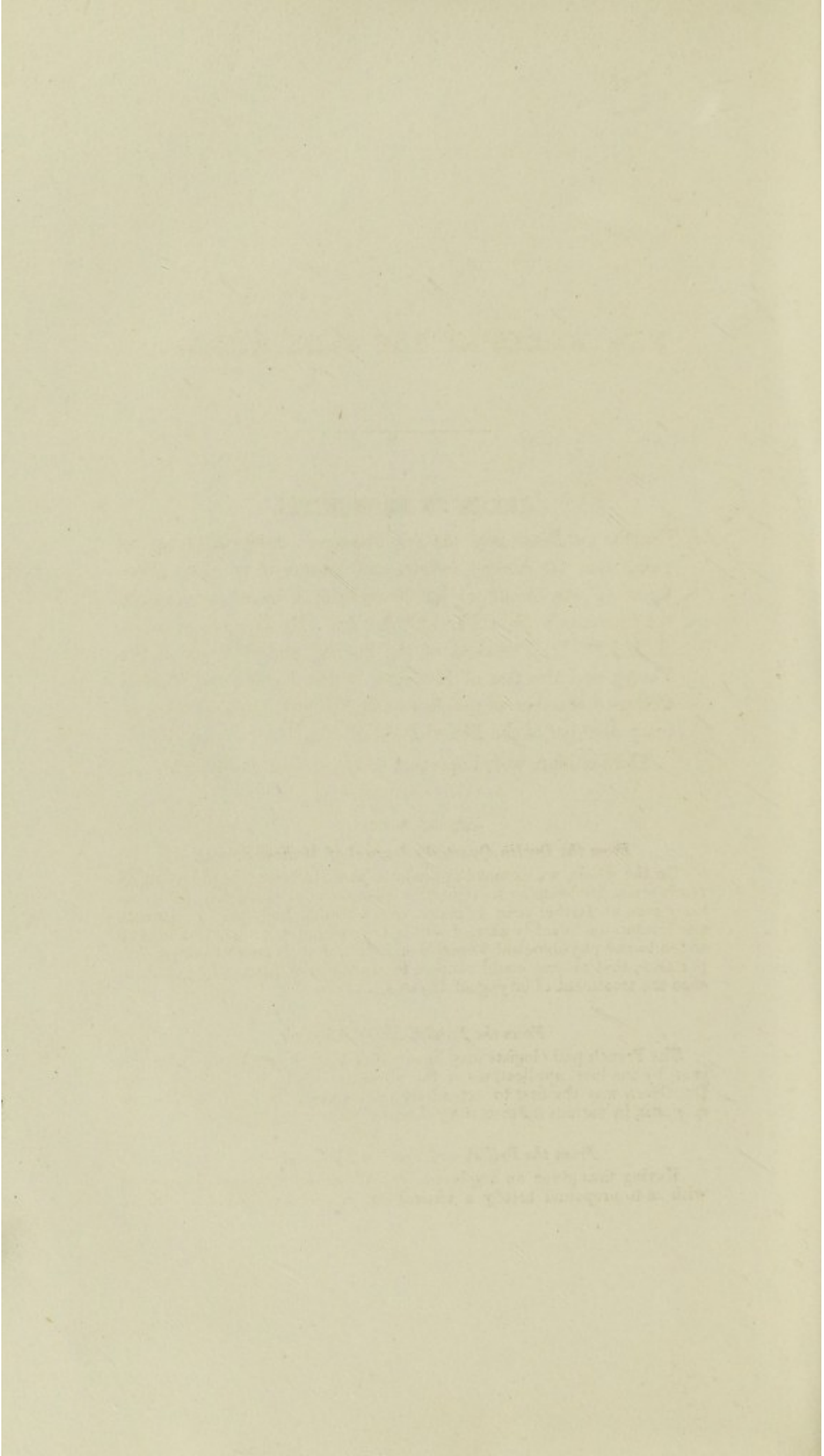


Fig. 1.









NEW WORKS BY THE SAME AUTHOR.

GREEN ON BRONCHITIS.

A Treatise on Diseases of the Air-Passages ; comprising an inquiry into the history, causes, and treatment of those affections of the throat called Bronchitis, Chronic Laryngitis, "Clergyman's Sore Throat," &c. &c. By HORACE GREEN, A. M., M. D., President of the Faculty, and Professor of the Theory and Practice of Medicine, in the New York Medical College ; Member of the American Medical Association, Honorary Member of the Philadelphia Medical Society, &c. &c.

Third edition, with important additions, just published.

CRITICAL NOTICES.

From the Dublin Quarterly Journal of Medical Science.

On the whole, we cannot but consider that Dr. Green is deserving of much praise for bringing to light this new remedy. Had his investigations gone no farther than to prove that a foreign body may, under certain limitations, be safely carried within the rima glottidis, he would have added to our physiological knowledge a fact of such great practical importance, that no one could venture to predict how far it may yet influence the treatment of laryngeal diseases.

From the London Medical Gazette.

The French pathologists may have anticipated the author, in some degree, by the local applications of the nitrate of silver to the fauces ; but Dr. Green was the first to extend its use successfully to parts *below the epiglottis*, in various inflammatory diseases of the vocal organs.

From the British and Foreign Medical Review.

Having thus given an ample analysis of Dr. Green's work, it remains with us to propound briefly a critical estimate of its value. We think

that the author has not only made a most valuable addition to practical or empirical medicine, but that the results of his method of treatment will lead to important changes in the prophylaxis and cure of pulmonary phthisis.

It would appear from various testifying documents which the author has collected together in an Appendix, that his statement as to the practicability and safety of topical medication in laryngeal disease was met by some of his countrymen by a sneering incredulity. There can be no doubt, however, that this part of the question is set entirely at rest; nor does the previous publication of the methods used by Bell, Vance, and Trousseau and Belloc, detract at all from the merit due to Dr. Green, for his persevering and successful attempts to render the treatment of some forms of pulmonary diseases more effectual and certain.

We have adopted this mode of treatment recommended by him, and can corroborate his statements as to its great value. Cases of pulmonary affection have in our hands been brought to a satisfactory termination, which we are quite sure, under the treatment ordinarily adopted, would have terminated fatally; and we remember individuals whose cases terminated fatally, who (we feel equally certain) need not have died, at least of that disease which cut them off. This much is due to Dr. Green.

From the Edinburgh Medical and Surgical Journal.

This is the appropriate and effective remedy for the alleviation and removal of follicular disease.

From a Clinical Lecture, by Professor Bennett, in the Edinburgh Monthly Journal of Medical Science.

This practice, introduced by Dr. Horace Green, of New York, consists in the direct application of a solution of nitrate of silver to the interior of the larynx and trachea. Numerous attempts had been made, with more or less success, by Sir C. Bell, Mr. Vance, Mr. Cusack, and MM. Trousseau and Belloc, to carry this practice into effect; and the results obtained, even by their imperfect efforts, exhibited the great advantages which were to be derived from it in the treatment of laryngeal diseases. Now, thanks to Dr. Green, we can with safety and certainty apply various solutions directly to the parts affected.

From the Dublin Quarterly Journal of Medical Science.

MM. Trousseau and Belloc employed a solution of the strength of two drachms to the ounce, or sometimes to the half ounce, of distilled water. Their method of applying it was either by means of a small silver syringe with a long curved tube, which could be introduced beyond the epiglottis, or by saturating a bit of sponge attached to a rod of whalebone, which, being pressed firmly against the back of the pharynx, discharges some of the solution into the glottis, principally by the involuntary effort of deglutition which it excites. This latter method we have ourselves frequently used with much success. But Dr. Green has found another method of applying the solution to the laryngeal mucous membrane, so simple and so efficacious, that, as we before remarked, he has been induced to publish this volume upon its merits. * * * * *

We shall only say, that we are fully convinced of the originality of ob-

ervation displayed by our author, and of the perfect truth of the statements contained in his Treatise.

From the New York Journal of Medicine.

The work is got up in the best style of art; clear type, white paper, and beautifully executed colored plates, representing different forms of follicular disease and uvular enlargement, render it attractive to the eye, while its contents commend it to the notice of the practical physician. We hope it will receive, as it richly deserves, the patronage of the entire profession.

Observations on the Pathology of Croup; with Remarks on its Treatment by Topical Medications. By HORACE GREEN, A. M., M. D., etc. *The Second Edition.*

From the London Lancet.

In conclusion, we must assure our readers that the little work before us is one promising the greatest practical interest, and reflects very great credit on Dr. Green for having introduced a practice which he unequivocally proves is more successful than any other remedial measures brought to bear on that appalling disease. * * * * *

We can only say, we heartily recommend to our readers and the profession generally, this clever and valuable monograph; and we trust that in this country, as well as in America, it may have an extensive circulation.

From the British and Foreign Medico-Chirurgical Review.

We shall now proceed to give a brief outline of Dr. Horace Green's interesting brochure. The Author's object is to recommend to the notice of the profession a remedy which he has found attended with the happiest results in one of the most dangerous and fatal diseases in children, viz., Croup. * * * * * Seeing the inutility of the ordinary, or routine, system of treating Croup, Dr. Green boldly enters into a new field of inquiry, and with success.

From the London Medical Gazette.

We would advise our readers to possess themselves of this excellent little monograph on Croup. To the junior practitioner it will afford safe guidance—to the senior it will convey valuable hints.

From an Article on Croup, by Dr. John Ware, Boston Medical and Surgical Journal.

For the suggestion and adoption of this valuable addition to our means of treating this formidable disease, we are indebted, as is well known, to the enterprise of Dr. Horace Green, of New York. The profession, I think, owe to him a large debt of gratitude, for the energy and perseverance manifested in the introduction of this remedy; and I am the more disposed to render this tribute to him, because so many attempts have been made to detract from his merit in relation to it.

I am well satisfied from what I have now seen of this method of treat-

ing Croup, as compared with that which has been followed for so many years, that it has the advantages which were pointed out in one of the preceding papers.

From the London Medical Gazette.

These two volumes will bear a most favorable comparison with the majority of medical works that have issued from the American press; too many of which are but plagiarized compilations. Those now before us are the result of accurate and diligent personal observation, practical in their character, and, to a great extent, novel in the views advanced.

THE HISTORY OF THE

THE HISTORY OF THE

THE HISTORY OF THE

THE HISTORY OF THE

THE HISTORY OF THE

THE HISTORY OF THE

THE HISTORY OF THE

THE HISTORY OF THE

THE HISTORY OF THE

THE HISTORY OF THE

THE HISTORY OF THE

THE HISTORY OF THE

THE HISTORY OF THE

THE HISTORY OF THE

THE HISTORY OF THE

THE HISTORY OF THE

THE HISTORY OF THE

THE HISTORY OF THE

THE HISTORY OF THE

THE HISTORY OF THE

THE HISTORY OF THE

THE HISTORY OF THE

THE HISTORY OF THE

THE HISTORY OF THE

THE HISTORY OF THE

THE HISTORY OF THE

THE HISTORY OF THE

THE HISTORY OF THE

THE HISTORY OF THE

THE HISTORY OF THE UNITED STATES

OF THE UNITED STATES OF AMERICA
FROM THE FIRST SETTLEMENTS TO THE PRESENT TIME

BY JAMES OSGOOD

THE HISTORY OF THE UNITED STATES
OF AMERICA
FROM THE FIRST SETTLEMENTS TO THE PRESENT TIME
BY JAMES OSGOOD

THE HISTORY OF THE UNITED STATES
OF AMERICA
FROM THE FIRST SETTLEMENTS TO THE PRESENT TIME
BY JAMES OSGOOD

THE HISTORY OF THE UNITED STATES
OF AMERICA
FROM THE FIRST SETTLEMENTS TO THE PRESENT TIME
BY JAMES OSGOOD

THE HISTORY OF THE UNITED STATES
OF AMERICA
FROM THE FIRST SETTLEMENTS TO THE PRESENT TIME
BY JAMES OSGOOD

THE HISTORY OF THE UNITED STATES
OF AMERICA
FROM THE FIRST SETTLEMENTS TO THE PRESENT TIME
BY JAMES OSGOOD

THE HISTORY OF THE UNITED STATES
OF AMERICA
FROM THE FIRST SETTLEMENTS TO THE PRESENT TIME
BY JAMES OSGOOD

THE HISTORY OF THE UNITED STATES
OF AMERICA
FROM THE FIRST SETTLEMENTS TO THE PRESENT TIME
BY JAMES OSGOOD


THE HISTORY OF THE UNITED STATES
OF AMERICA
FROM THE FIRST SETTLEMENTS TO THE PRESENT TIME
BY JAMES OSGOOD


THE HISTORY OF THE UNITED STATES
OF AMERICA
FROM THE FIRST SETTLEMENTS TO THE PRESENT TIME
BY JAMES OSGOOD

THE HISTORY OF THE UNITED STATES
OF AMERICA
FROM THE FIRST SETTLEMENTS TO THE PRESENT TIME
BY JAMES OSGOOD

THE HISTORY OF THE UNITED STATES
OF AMERICA
FROM THE FIRST SETTLEMENTS TO THE PRESENT TIME
BY JAMES OSGOOD

THE HISTORY OF THE UNITED STATES
OF AMERICA
FROM THE FIRST SETTLEMENTS TO THE PRESENT TIME
BY JAMES OSGOOD





2/6

