

## **On the surgery of the face / by Francis Mason.**

### **Contributors**

Mason, Francis.  
Royal College of Physicians of Edinburgh

### **Publication/Creation**

London : J. & A. Churchill, 1878.

### **Persistent URL**

<https://wellcomecollection.org/works/tv3dkpcg>

### **Provider**

Royal College of Physicians Edinburgh

### **License and attribution**

This material has been provided by This material has been provided by the Royal College of Physicians of Edinburgh. The original may be consulted at the Royal College of Physicians of Edinburgh. where the originals may be consulted.


This work has been identified as being free of known restrictions under copyright law, including all related and neighbouring rights and is being made available under the Creative Commons, Public Domain Mark.

You can copy, modify, distribute and perform the work, even for commercial purposes, without asking permission.



Wellcome Collection  
183 Euston Road  
London NW1 2BE UK  
T +44 (0)20 7611 8722  
E [library@wellcomecollection.org](mailto:library@wellcomecollection.org)  
<https://wellcomecollection.org>







767 35









11  
h6

July 35

R39126



ON  
THE SURGERY OF THE FACE



*By the same Author,*  
**HARE-LIP AND CLEFT PALATE.**

With 66 Engravings, 8vo, 6s.

ON


# THE SURGERY OF THE FACE

BY

FRANCIS MASON, F.R.C.S.,

SURGEON, AND LECTURER ON ANATOMY AT ST. THOMAS'S HOSPITAL;  
HON. FELLOW OF KING'S COLLEGE, LONDON, ETC.

*WITH ONE HUNDRED ILLUSTRATIONS*



LONDON  
J. & A. CHURCHILL, NEW BURLINGTON STREET

1878



THE UNIVERSITY OF CHICAGO PRESS

CHICAGO, ILL.

1911

PRINTED IN GREAT BRITAIN

TO THE PRESIDENT  
(GEORGE BUCHANAN, M.D.),  
COUNCIL, AND FELLOWS OF THE MEDICAL SOCIETY  
OF LONDON,

*This Volume,*

COMPRISING

THE LETTSOMIAN LECTURES


DELIVERED DURING THE

SESSION 1877-78,

IS

VERY RESPECTFULLY DEDICATED.





## PREFACE.

---


THE three lectures contained in the accompanying volume were delivered at the Medical Society of London in the early part of this year, and were subsequently published in the pages of the 'Lancet.' In obedience to the flattering request of several Fellows of the Society and other friends I now venture to reproduce them collectively in the hope that they will receive the kindly judgment and favourable consideration of my professional brethren.

In order to facilitate reference I have prepared a full index of contents, which will be found at the end of the work.

FRANCIS MASON.

5, BROOK STREET,  
GROSVENOR SQUARE;  
*October, 1878.*





THE  
SURGERY OF THE FACE.

---

LECTURE I.

DISEASES OF THE FACE.

MR. PRESIDENT AND GENTLEMEN,—My first and most obvious duty is to express to the Council my sincere thanks for the honour they have conferred upon me by electing me as the Lettsomian lecturer for the current session. I must confess that whilst I am deeply sensible of the compliment that has been paid me, I am at the same time profoundly conscious of the responsibility that so distinguished a position involves.

In contemplating how I might best occupy the time allotted to the three lectures that I shall have the honour of delivering, I remembered that for many years I had taken considerable interest in the surgery of the face, mouth, throat, and contiguous



parts, and, as I had collected several thousand references bearing on these regions—representing, as may be supposed, an immense amount of valuable information—I came to the conclusion that if I sifted some of these references, I might be enabled to submit to the Fellows of the Society many points of more than ordinary or passing interest. I venture therefore to engage your attention by describing, as far as my limited time will allow, the surgery of the face, and in bringing this subject before you, I must beg your kind indulgence, inasmuch as I shall necessarily have to refer to many topics with which I feel sure you are all more or less familiar; and I wish to say, at starting, that my object is not to excite sensation, or to provoke controversy by placing before you novelties, but is rather to group together a number of cases I have culled from various sources, including many that have been under my own observation, and which have special reference to the surgery of a region which from its conspicuousness forms a very important part of the human body.

My first lecture will be devoted to the diseases, the second to injuries, and the third to the deformities of the face.

In order to render my subject as complete as possible, it will be necessary for me to make a few observations on skin diseases, and these need not detain us long.



## ERYTHEMA, ROSEOLA, AND URTICARIA.

These diseases are not unfrequently met with on the face, and resemble each other in many particulars.

*Erythema.*

In erythema the face is covered more or less with blotches of either a bright red or bluish hue. The eruption depends upon various causes, into which I need not now enter, but I may make a passing reference to the peculiar erythematous blush that is occasionally noticed on the body after surgical operations even of the most trivial kind. The face often participates in the general eruption, which has almost a scarlatinal character. It is amenable to simple treatment, and is chiefly important from a diagnostic point of view. Erythema circinatum is particularly seen on the chin and lips, and appears as distinct circles, or segments of circles. Erythema nodosum is sometimes observed on the forehead, and very much resembles the same disease noticed on the front of the legs in delicate women. It has been mistaken for nodes, but with a little care a correct diagnosis may be arrived at.

*Roseola.*

In roseola there is less swelling of the skin. The eruption is first of a bright red, which gradually



subsides into a deep rosy hue. In this disorder there is more or less redness about the palate and fauces.

### *Urticaria.*

Urticaria or nettle-rash is sometimes limited to the face, and seems to be an aggravated form of erythema or roseola, its characteristic point being the presence of a number of elevations or wheals of variable shape, which are produced by spasm of the muscular fibres of the skin, with a slight effusion of serum. Mr. Erasmus Wilson has pointed out that in the wheals of urticaria an alternate contraction and relaxation of the muscular fibres may be observed, which gives an appearance of pulsation, as of an ebb and flow of blood in the capillary vessels.\*

All these eruptions may, in most instances, be traced to some error in diet, and are prevalent at particular seasons of the year, especially if there be sudden alternations of temperature. I need not add that certain medicines produce similar eruptions. As a rule these diseases require but little treatment beyond attention to diet, with the administration of saline purgatives, alteratives, and suitable tonics.

### LICHEN.

Lichen is often found on the face of infants and

\* 'Diseases of Skin,' p. 264.



children, and seems to be due to the irritation caused by teething. The eruption is easily recognised, and if the finger be passed lightly over the skin of the part affected, the cutaneous surface feels like a delicate nutmeg grater. There is generally more or less erythema present. In simple cases the eruption undergoes desquamation, and thus a cure is effected, whereas in the more severe forms, as in lichen agrius, there is considerable inflammatory action, inducing a copious serous discharge, almost amounting to eczema, and accompanied by much constitutional disturbance.

### HERPES.

Herpes is commonly met with on the face, attacking chiefly the lips, eyebrows and ears. The vesicles, which are dome-shaped, appear in groups of patches, more or less circular in form. Moreover, they are frequently found to coincide exactly with the cutaneous distribution of certain nerves. Thus, in one case reported,\* the eruption was limited to the distribution of the left supra-orbital nerve, and throughout showed its distinctive nerve character. Five days before the eruption appeared there was constant neuralgia in the exact course of this nerve. The vesicles ran upwards over the forehead, and as far as the top of the head, in a

\* 'Brit. Med. Journ.,' May 5, 1866, p. 470.



longitudinal direction. The eruption was markedly limited to the left side of the forehead and head, the side of the nose, and to the left upper eyelid. Sir James Paget has placed on record \* an interesting example in which the parts supplied by the second division of the right fifth cerebral nerve were implicated. In this instance, as in the previous one, extreme pain preceded the eruption. This case was, moreover, considered unique in having necrosis of the jaw as a consequence of the intense inflammation of the palate and gums. Twenty-six days from the commencement of the disease one of the bicuspid teeth of the right side of the upper jaw fell out, on the next another, and in a few days later the canine and both incisors. The herpetic eruption was also noticed on the roof of the mouth.

#### ECZEMA.

The eyebrows and ears are no uncommon situations for eczema. In this eruption there is a constant serous exudation, hence its title "humid tetter." The vesicles have a pointed or acuminate form, and if the disease remain unchecked, it assumes a somewhat purulent character, bordering on impetigo, and known as eczema impetiginodes,

\* 'Brit. Med. Journ.,' Oct. 13, 1866, p. 402.



a disease frequently noticed on the alæ of the nose and on the lips of ill-fed children.

The eruptions of *impetigo* and *ecthyma* often co-exist, and I need hardly add that their main difference is that in *impetigo* the eruption is generally confluent, whereas in *ecthyma* the pustules are solitary, and have an inflamed base.

The constitutional treatment of these diseases must be conducted on general principles, but local applications are particularly suitable when there is much serous exudation. Ointments of a simple character, such as zinc ointment or compound subacetate of lead ointment, are especially serviceable, as they prevent evaporation, and thus obviate the production of scabs.

### PSORIASIS AND LEPRA.

These affections are occasionally met with on the face. They are characterised by their dryness, and in this respect differ essentially from eczema. Psoriasis that follows the infecting or true syphilitic sore does not, I venture to believe, commonly affect the face, and when this part is attacked, the inference is, as I think, that the patient has been rather severely poisoned by the disease. The severity of the attack is further indicated by the eruption appearing simultaneously on the palms of the hands and the soles of the feet. From some



cause the face and the dorsum of the hands—parts exposed to atmospheric influences and exposed also to observation—seem, fortunately for the sufferer, to possess comparative immunity. I may add that I have at the present time under observation four well-marked instances which serve to illustrate this point remarkably well. All the patients have patches of psoriasis which have manifested themselves on the abdominal wall and on the flexor side of the forearms at the usual period after the appearance of the primary sore, but the eruption stops short at the wrist. In other words, these patients when dressed could not be accused of being the subjects of syphilis. One patient, referring to his condition, said, “I can and do mix in society as usual, but should not like to join my friends at the swimming-bath.” The administration of arsenic, iron, iodide of potassium, and the perchloride or other preparations of mercury, generally effects a cure. Locally the white precipitate ointment may be advantageously employed.

### PARASITIC DISEASES.

Of the parasitic diseases we have the type of the animal parasite in *scabies*, which is said by some authorities never to attack the face, but I am sure that it is occasionally found in this region. When



it occurs in this part, Dr. Tilbury Fox\* has noticed that it is occasionally accompanied by sympathetic eczema about the scalp, and in children by ecthymatous pustules.

The *tineæ* or vegetable parasites are not unfrequently seen on the face. Thus *tinea circinata* is occasionally observed on the chin and on the cheek, as shown in the woodcut (Fig. 1, taken from a

FIG. 1.



photograph). *Tinea decalvans* manifests itself as bald patches on the skin in the region of the whiskers or beard, and *tinea sycosis* especially attacks the chin. I may say briefly respecting the treatment, that ointments containing sulphur are invaluable in scabies, and slight mercurial preparations are useful in the different forms of *tineæ*.

\* 'Skin Diseases,' p. 305.



## ACNE.

The only other affection to which I need now refer is acne, which is perhaps the most common of all diseases of the skin of the face. *Acne punctata* appears as small black spots, which are the orifices of the sebaceous follicles blocked up with sebaceous matter, dirt, and soap. Its most usual situations are those that escape the friction of the towel after washing. Thus the disease is particularly noticed on the cheeks, beneath the prominence of the malar bone, between the chin and lower lip, on the side of the nose, in the temporal region, and especially in the concha of the ear. In *acne simplex* there is peri-follicular inflammation, and very often the black spots of *acne punctata* may be observed at the summit of the small pustules. In *acne indurata* the inflammatory action is of subacute character. Here the black spot is seldom observable, but instead there is a hard, somewhat diffused lump, which is readily appreciable to the touch. These varieties of acne are essentially diseases of early adult life, and are met with, as a rule, from puberty to about the age of thirty. They are often rebellious to treatment, but may be kept in abeyance by the patient attending strictly to diet and by irritating the parts as little as possible. It is best not to wash the face more frequently than is



absolutely necessary, and warm water alone, without soap, should be used. The part should be dried with a soft towel. A more active plan of treatment is, however, required in inveterate cases of acne, and the vigorous application of soft soap is highly recommended by some writers. Dr. Robert Liveing\* finds that the following method of treatment succeeds in a large number of obstinate and troublesome cases :—

1st. The face should be steamed every night by holding it over a basin of hot water for a few minutes.

2nd. The skin should then be well rubbed for five or ten minutes with soap and flannel, or a soft nail-brush may be used with advantage when the skin will bear it; the soap should then be sponged off with warm water.

3rd. When the face has been dried, a lotion composed of half an ounce of precipitated sulphur, two drachms of glycerine, one ounce of spirits of wine, three ounces each of lime-water and rose-water should be thoroughly applied and allowed to dry, and to remain on all night. If the skin is greasy, the addition of some ether to the lotion is an advantage.

*Acne rosacea* seldom appears before the age of forty, and thus differs from the other varieties

\* 'Lancet,' Jan. 19, 1878, p. 83.



already described. The face is especially its local habitation. It is observed partly on the nose, and extends laterally to the cheeks as a reddish patch, on which a few pustules are here and there scattered. Although it is often attributed by the ignorant to high living, it is very frequently an indication of imperfect digestion, and occurs, as is very well known, in persons of the most abstemious habits.

### BOILS AND CARBUNCLES.

Boils and carbuncles occasionally attack the lips, cheeks, and forehead. They cause great disfigurement, and are attended with more or less, but sometimes a considerable amount of, pain. The more circumscribed swelling in a boil gives it its distinctive character, and it comes, from time to time, in this, as in other parts of the body, in crops, whereas carbuncle is usually solitary, and there is a diffuse, brawny, and peculiar hardness due to the arrangement of the soft structures comprising the lips, cheeks, and neighbouring parts. With regard to local treatment the question of making incisions seems still to be *sub judice*. I venture to think that in most instances boils and carbuncles are better left to nature, the surgeon merely assisting by advising the free application of warm-water dressings. By this mode of treatment the surrounding parts become thoroughly relaxed,



and thus the inflammatory products are more readily carried off. It is not often that facial carbuncle is followed by a fatal termination, yet Dr. Cockle brought before the notice of our Society in 1874 an example of death from this disease, which was situated on the left side of the upper lip.\* Mr. Cæsar Hawkins also reports a fatal case of a carbuncle which attacked the chin, and was as large as a tennis ball.† Both these patients died of pyæmia. Again, Mr. Thomas Smith has directed attention to two deaths from facial carbuncle. He attributed the fatality of this form of carbuncle to the susceptibility of the face to erysipelas and œdema, and also to the peculiarities of the venous circulation shown by the sudden deaths that have been occasionally noticed after injecting nævi of the face with strong styptics, such as the tincture of the perchloride of iron.‡

#### ABSCESSSES.

Abscesses of idiopathic origin are not very common, but they are occasionally seen on the face, and the usual variety is that which is known as strumous abscess. It is of slow growth, and exists as a collection of sero-purulent fluid, immediately under a reddened, thin, and generally oblong

\* 'Proceedings of Med. Soc.,' vol. i, p. 163.

† 'The Lancet,' Nov. 17, 1860, p. 487.

‡ 'Brit. Med. Journ.,' Jan. 22, 1870, p. 94.



portion of skin, the cheek being a common situation. A good plan of treating these abscesses is to make a small opening in a dependent position, which allows the contents to exude spontaneously. If, in addition, a pad of lint of suitable size be applied over the abscess, a re-accumulation of the matter is obviated. These abscesses are comparatively painless, their progress is slow, yet even with the greatest care and attention they are frequently followed by ugly cicatrices, which are well shown in Fig. 2, taken from a photograph.

FIG. 2.



Fistulous openings on various parts of the face are not unfrequently met with as the result of decayed teeth, or of necrosis of the subjacent bones, the lower jaw, for example, as shown in the accom-

panying woodcut (Fig. 3), taken from a photograph. Or they may depend upon the presence of other foreign bodies, as in a case that was under the care

FIG. 3.



of Mr. Henry Smith, which was sent to him in the belief that there was necrosis of the jaw. After a careful examination, Mr. Smith discovered and removed a piece of tobacco-pipe, about three inches long, which had been imbedded in the cheek for several years.\*

Sometimes the disease may be traced to the antrum, as in a case that Dr. Richardson kindly placed under my care about two years ago. In operating on the patient I thought it advisable to

\* 'Assoc. Med. Journ.,' Nov. 10, 1854, p. 1017.



divide the upper lip in the median line, and having separated the soft parts from the bone I freely opened the antral cavity. A large quantity of offensive cheesy material was evacuated, and the patient made an excellent recovery. Figs. 4 and 5,

FIG. 4.



FIG. 5.



taken from photographs, are intended to show the condition of the patient before and after the operation.

Abscesses connected simply with the soft parts may be complicated with erysipelas, but they are rarely dangerous to life. Dr. Bacon, of the Fulbourne Lunatic Asylum, has, however, placed on record an interesting example to prove that even death may occasionally occur in such cases. His patient was a lunatic who had an abscess of the cheek caused by a decayed tooth. In three or four days from the commencement of the attack the patient died comatose from the extension of the inflammation into the brain.\*

#### ULCERS.

Ulcers of infinite variety are met with on the face, and are frequently the result of injuries by which the soft parts have become more or less damaged; or they may arise idiopathically, as in rodent ulcer and epithelioma, of which I shall speak presently.†

The *cachectic ulcer* is frequently found on the face. It begins as one or more hard lumps of variable size in the subcutaneous tissue, in which at first there is but little pain. To these indurations the name of "gummata" has been applied, and

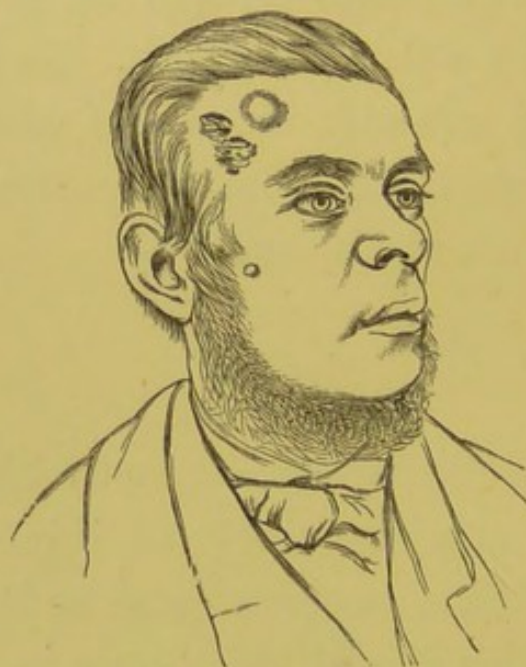\* 'Medical Times and Gazette,' Nov. 21st, 1868, p. 584.

† See Clinical Lectures by author on "Ulcers," 'The Lancet,' September 15th, 1877.



they are said to be usually due to syphilitic taint. There are, however, many examples of this ulcer, in which the history of syphilis is entirely wanting. Thus, I here show you several photographs of patients having such ulcers, and in none of these instances was there, as far as I could make out, the slightest trace of syphilis. Fig. 6 affords a good illustration of one of these patients.

FIG. 6.



Whilst on the subject of ulcers, I must not omit to refer to the possible presence of the true infecting syphilitic sore which has been met with on various parts of the face. These sores are important chiefly from a diagnostic point of view, for they have not unfrequently been mistaken for cancer, and have been treated accordingly. In illustration of this point, I may say that in 1872 I



saw a man at the hospital, who was twenty-six years of age, and had been operated upon three times within two months for, as he said, cancer of the lower lip. When I saw him he had about his body the clearest evidence of constitutional mischief. What remained of the lower lip presented an uneven, jagged, white patchy appearance, which seemed to me, as well as to those who examined him, to be markedly characteristic of syphilitic infection. He was placed on the solution of perchloride of mercury, and he recovered. His object in applying at the hospital was to undergo a further operation.\*

By the kindness of Mr. Royes Bell I am enabled to show you a photograph of one of his patients, having a well-marked infecting sore on the upper lip.

### CYSTS.

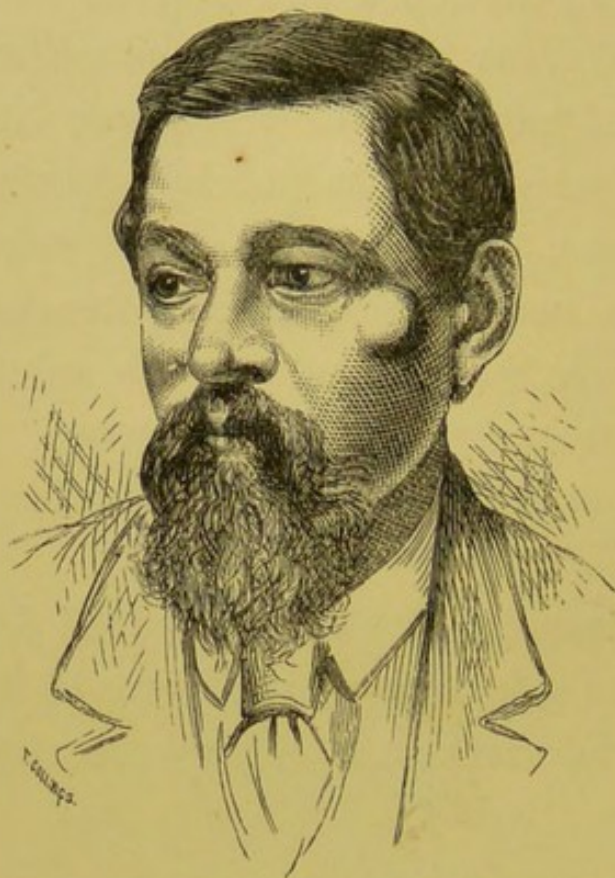Cysts, or cystic tumours, of various kinds are frequently found on the face. Perhaps the commonest variety is the sebaceous tumour, well represented in Fig. 7 (taken from a photograph). Such cysts are of slow growth, and often present at their summit a black spot, as was the case in the patient just referred to. They are, as a rule, dome-shaped, and their outline differs in this respect from fatty

\* See a paper, by the author, on "Infecting Sores on the Lips," 'St. Thomas's Hospital Reports,' 1873.



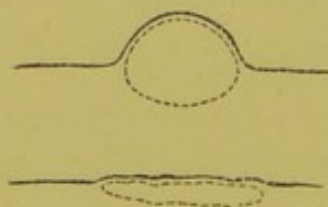
tumours, which generally present a more flattened form, and are seldom met with in this region. This

FIG. 7.



rough diagram (Fig. 8) is introduced to show the comparative appearance, on section, between a sebaceous cyst and a fatty tumour.

FIG. 8.



Cystic tumours are usually subcutaneous. Occasionally, however, as in the frontal region, they are

submuscular, or subaponeurotic. Sometimes they are met with in connection with the mouth, or even with the cavity of the nose, as in a remarkable instance reported by Mr. Mungo Park,\* in which the tumour, being so situated, displaced the nasal bones considerably. Their contents vary in character; thus they may either be of cheesy consistence, being principally composed of cholesterine, fat, and epithelial scales, or they may be of a more fluid nature.

Hydatid cysts are occasionally met with on the lips and eyelids, and the dermoid cysts are generally situated in the region of the eyebrow, and often contain hair, as in this example (specimen shown), which I removed from a patient aged twenty-two. I am indebted to Mr. Wagstaffe for enabling me to show two drawings which illustrate the mode of origin of such cysts; one was from the inner angle of the orbit, and the other from the temporal region.

The best mode, in my opinion, of removing cystic tumours is to transfix them, by which a free opening is at the same time made into the cyst cavity. After the contents of the sac have been squeezed out, the cyst itself becomes more evident, and is easily dissected from the surrounding parts, without much hæmorrhage, provided care be taken to keep the knife close to the sac.

\* 'The Lancet,' 1841—42, vol. i, p. 886.



The removal of cysts situated in the region of the brow is often attended with troublesome hæmorrhage which hampers the operator. It is well, under such circumstances, to suspend the operation for a few minutes until the bleeding has ceased. Fine silk stitches may be employed to bring the edges of the skin-wound together, or really good adhesive plaster is frequently all that is required. Such plaster may be obtained of Messrs. Savory and Moore, of Bond Street, or of Mr. Martindale, of New Cavendish Street. In children it is of special importance to bring the edges accurately together, in order to obviate a subsequent scar.

Blood-tumours, or hæmatomata, are occasionally seen on the ears (Fig. 9) and are said to be frequently met with in insane and idiotic persons. In

FIG. 9.





referring to such cysts, Dr. Grüber observes that, inasmuch as he has noticed finger-marks, these tumours may often be traced to rough handling either by the patients or by others.\*

### TUMOURS.

It would be obviously impossible for me to enter into a full description of the different varieties of tumours that have been met with on the face. I can, therefore, only refer to a few which appear to possess more than ordinary interest.

#### *Fatty Tumours.*

These are rarely observed on the face, and the exemption in this region is remarkably illustrated in a case reported by M. Danez. At a post-mortem examination of a man no less than 215 fatty growths were found in different parts of the body. The only situation that was quite free from such tumours was the face.† I happen to know at the present time a gentleman who has at least sixty such tumours on the arms, legs, and trunk, but he has none on the face.

The diagnosis of fatty tumours is not at all times

\* See Lennox Browne's paper on "Othœmatoma, or the Insane Ear," in 'West Riding Lunatic Asylum Reports,' edited by Crichton Browne, vol. v, 1875, p. 149. See also 'Brit. Med. Journ.,' May 4th, 1861, p. 469.

† 'Med. Times and Gaz.,' October 27th, 1866, p. 464.



easy, but a method has been suggested of solving the difficulty, which consists in applying ether or ice to the part, in the case of a doubtful tumour. If the growth is felt to become harder, the presumption is that the tumour is fatty.\*

Fatty tumours under the eyebrow have been mistaken for nævi,† and a growth of this kind in the temporal region was regarded as an aneurism, for which the carotid artery was tied. Subsequently the patient died, and at the post-mortem examination the true nature of the tumour was revealed.‡ Fatty tumours are occasionally met with either in the substance of the cheek or lying immediately under the mucous membrane of the mouth. Four years ago I removed a small growth of this kind through the mouth. It was, singularly, non-adherent to the surrounding parts, and consisted of soft fat. A tumour thus situated has been mistaken for a cyst in connection with Steno's duct, as in a case under Mr. Ward's care at the London Hospital.§

Fig. 10 shows a glandular tumour in the upper lip which I removed from a patient at the Westminster Hospital in 1868. The woman was forty-five years old, and was struck on the lip when she was four years of age. Mr. Goodhart has reported

\* 'The Lancet,' August 2nd, 1873, p. 157.

† 'Med. Times,' vol. xxviii, 1853, p. 630.

‡ 'The Lancet,' vol. i, 1835, p. 689.

§ 'Med. Times,' vol. xx, 1849, p. 451.

FIG. 10.



three cases of a somewhat similar character in the 'Pathological Transactions,' vol. xxviii, p. 213.

FIG. 11.



Fig. 11 represents a tumour of a myxomatous character which I took from a patient thirty-five



years of age. It had been growing for about ten years, and was scarcely observable before operation, as he managed to hide it very cleverly with his whiskers.

Tumours invading the parotid region are of constant occurrence. Some of them are a mere temporary enlargement due to inflammatory effusion, as in this case, taken from a photograph (Fig. 12), in

FIG. 12.




which the swelling disappeared after the application of tincture of iodine and the adoption of an alterative constitutional treatment.

The more important tumours in this region, how-

ever, consist, as a rule, of mixed glandular and cartilaginous tissues, with here and there cyst-formations. Such a case is shown in Fig. 13. The

FIG. 13.



patient was under my care at the Westminster Hospital. The tumour commenced as a small nodule about forty years before he came under observation, and after removal weighed over four pounds.

The probability of return after removal of course depends upon the character of the tumour: for example, in some soft sarcomata recurrence takes place very rapidly, as in a case that was under the care of Mr. Barnard Holt, in which he performed two operations within twelve months. In other examples the growth increases very slowly; thus, Mr. S. Jones removed a pendulous growth from the parotid region of a patient, aged fifty-eight, who



stated that twenty-eight years previously a tumour had been removed from about the same situation.\* Perhaps one of the most remarkable tumours of this kind was that of which I show you photographs, operated on by the late Sir William Fergusson.† I assisted at the operation, and the sterno-mastoid muscle was found to be spread over the tumour, which weighed  $9\frac{1}{2}$  lbs. There was considerable hæmorrhage.

*Apropos* of hæmorrhage, I may add parenthetically that in dealing with parotid tumours it is as well, as a last step before their final removal, for the surgeon to place a ligature on the vessels supplying the growth at the bottom of the wound. Without this precaution, the vessels are apt to retract, and are not easily secured afterwards. Even tumours having apparently a distinct pedicle often bleed very freely. Thus Mr. Hussey, of Oxford, removed a pendulous growth connected with the face weighing 3 lbs., from a patient aged seventy-three, and the operation was, according to the report, attended “with profuse and almost fatal hæmorrhage.”‡

It is alleged that complete extirpation of the parotid has been practised, but, considering the anatomical relations of this organ, it seems almost impossible to effect its entire removal without

\* ‘Path. Soc. Trans.,’ 1872.

† ‘Practical Surgery,’ 1870, 5th ed., p. 578.

‡ ‘The Lancet,’ January 13th, 1877, p. 52.



serious risk to the patient. However, Dr. Valentine Mott states \* that the operation has been frequently performed; and M. Marzolo, an Italian surgeon, gives an account of the case of a woman, aged fifty, "from whom he had removed the entire parotid without injuring the facial nerve or the external carotid artery."† Sir William Fergusson,‡ in recording his experience on this point nearly forty years ago, stated "that in no instance had he seen a case in his own practice to which the description of extirpation of the parotid gland was applicable;" and writing more recently, in 1870, he adds, "that when tumours near the parotid are small, that gland is slightly compressed, and when large most of it has disappeared."§

### *Sarcomatous Tumours.*

Sarcomatous tumours, in their varied forms, are not unfrequently observed on the face. Fig. 14, taken from a photograph, illustrates a case that was under my care at St. Thomas's Hospital two years ago. After removal, Mr. Stewart, the curator of the museum, kindly examined the growth microscopically, and pronounced it to be a round-celled sarcoma. The tumour recurred within a year, and

\* 'The Lancet,' 1842—43.

† 'Gaz. Méd. de Paris,' January 5th, 1861, p. 9.

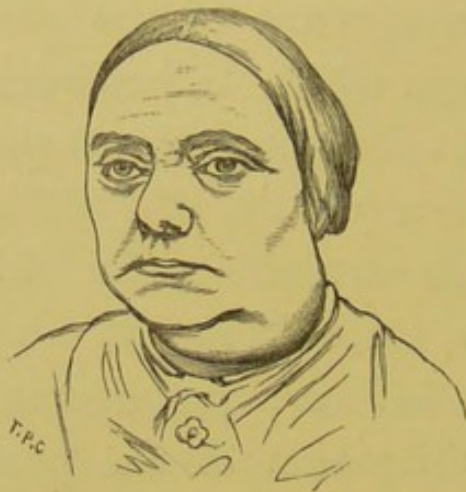‡ 'The Lancet,' 1842—43, vol. ii, p. 217.

§ 'Practical Surgery,' p. 574, 5th ed., 1870.



in a few months after the patient died. Another and perhaps rarer form of tumour is the *melanotic*

FIG. 14.



*sarcoma*, of which I show you photographs. The patient was a man aged sixty-four, who was under my care at St. Thomas's Hospital in 1872.\* He had a congenital mole, which gave no inconvenience whatever for over threescore years. The tumour commenced to grow from the skin quite close to the mole, if not from the mole itself. The chief point of interest in the case was the probability of its recurrence after operation, for there were several enlarged glands in the right submaxillary region, which I endeavoured to remove, but the surrounding parts were so implicated that I was compelled to leave some of the disease. Nevertheless, the patient made a rapid and excellent recovery, and was quite well about a month ago, as I ascertained from his wife, whose

\* 'Brit. Med. Journ.,' October 4th, 1873, p. 393.

letter, dated Dec. 3rd, 1877, is appended to the photographs I send round. There has therefore been no return of the disease for a period of over five years. Figs. 15, 16, and 17, show the patient

FIG. 15.

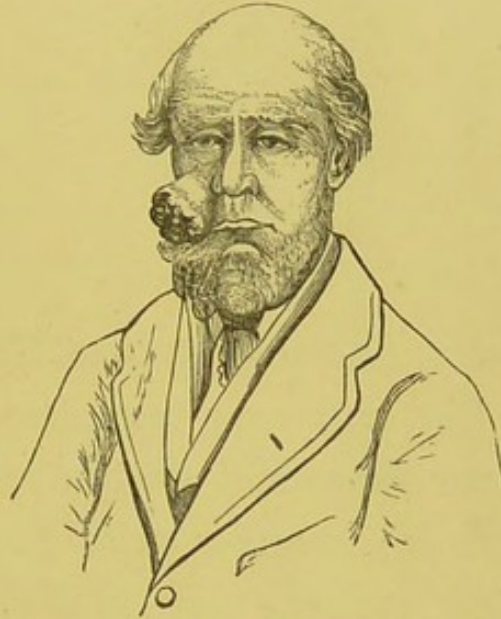

FIG. 16.

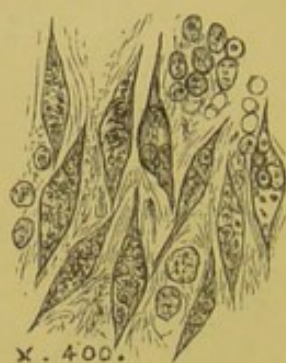

before and ten days after the operation with the microscopic appearance of the tumour.



Sir James Paget, in a lecture on tumours in connection with moles,\* refers to a case of a somewhat

FIG. 17.



similar character : The patient was sixty years old, healthy all his life, and very temperate, and in the site of the tumour there had been a mole as long as he could remember ; it never gave him any trouble until about nine months previously, when, with some tingling, it began to enlarge, and continued to do so up to the time of his admission. Liston refers to another case in a patient aged forty.†

### HYPERTROPHY.

Hypertrophy of the integument of the nose—the lipoma of some writers—is not infrequently observed. The growth appears to be an excess of the fibro-areolar tissue with some enlargement of the sebaceous glands. Many cases of the kind are

\* 'Med. Times and Gaz.,' January 16th, 1864.

† 'The Lancet,' 1840, vol. ii, p. 794.



on record, but one remarkable instance is reported by Mr. Pollock.\* The patient was a woman aged seventy-three, and the growth was eight inches in circumference, being the shape of an ordinary pear. Another remarkable example is one that was under the care of Sir William Fergusson, of which I show you photographs before and after operation. The growths were cut away with a scalpel. M. Ollier is stated to remove such tumours by making an incision in the middle line, and separating the excrescence on each side, like taking off the green covering of a walnut.†

In very rare cases the external ear or pinna undergoes hypertrophy, but generally the enlargement is only temporary, and is due to the inflammatory thickening of the part. Boyer, however, met with a genuine case of hypertrophy, in which the ear was so large that it covered a great part of the cheek.

### HORNY GROWTHS.

Horny growths occur on different parts of the face. They either consist of epithelium in various stages of dryness, or they may originate in the sebaceous follicles by a continuous proliferation of their epithelial contents. Mr. Canton describes a

\* 'The Lancet,' 1864, vol ii, p. 152.

† 'Brit. Med. Journ.,' Nov. 22, 1873, p. 604.



good example on the upper eyelid,\* and Mr. Cock, of Guy's Hospital, another instance on the lower lip.† And a third and still more interesting case is recorded in the 'Pathological Transactions' by Mr. Charles Roberts, of York. The growth was taken from the face of a woman, aged seventy-five.‡ And, lastly, this specimen of a horny growth from the museum of St. Thomas's Hospital is of considerable interest. The growth measured ten inches in length, and was removed from the upper part of a man's forehead.

#### CARCINOMATA.

*Epithelioma* or the epithelial form of cancer is that most frequently observed on the face. It attacks the nose (as shown in Fig. 18) or the cheeks and lips, and relatively by far most frequently the lower lip (Fig. 19). Sir Astley Cooper stated that, of 200 cases that he had seen of this disease, in only one was the upper lip the seat of the affection. It is essentially a disease of adult life, for Lebert states that, of 17 persons upon whom he operated for this disease, 2 only were under the age of thirty-five;§ and M. Fleury, of Clermont, observes that between 1845 and 1855 he had operated on 86 patients, 71 being

\* Path. Soc., Oct. 21st, 1862.

† 'Med. Times,' Nov. 8th, 1856, p. 471.

‡ 'Path. Soc. Trans.,' 1865, p. 267.

§ 'Med. Times and Gaz.,' Jan. 25th, 1873, p. 81.

men and 15 women, and not one of them was less than forty-three years of age.

FIG. 18.




FIG. 19.



The comparative frequency of epithelial cancer may be gathered from the observations made by Mr. Erasmus Wilson, who remarks that, of 2000



cases of cutaneous disease, epithelioma occurred 11 times; in other words, about 1 in every 200. In 20 cases it was more than twice as frequent in males as in females. In two thirds of that number it occurred after the age of fifty, several of the patients being above sixty, and its general duration at the time of coming under treatment ranged between two and fifteen years. In all the 20 cases the disease manifested itself on the face or its immediate neighbourhood; in 9 it appeared on the cheek; in 8 upon the nose; while in one case it was developed on the eyebrow, near its outer extremity, in another on the temple, and in a third, upon the mastoid process.\*

Tobacco-smoking is alleged to be a common cause of epithelioma of the lip. Roux held this opinion, but Fleury noticed the remarkable fact that his patients came from a district where smoking was almost unpractised.†

*Colloid cancer* of the face appears to be very rarely met with, but one example occurring in the upper lip is recorded by Mr. Curling.‡ The patient was a young man, and the growth had existed for five months. Dr. Andrew Clark examined the specimen microscopically.

One of the specimens on the table is a section of a skull, projecting into the cavity of which is an

\* 'Diseases of the Skin,' p. 431.

† 'Gaz. Médicale,' No. 35; 'Med. Times,' Oct. 29th, 1859, p. 439.

‡ 'The Lancet,' July 7th, 1860, p. 8.



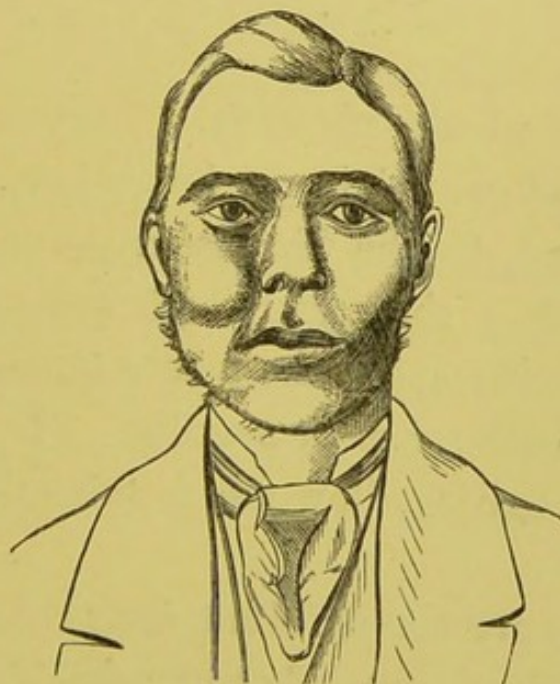*encephaloid growth.* It was taken from a patient from whom the parotid gland had been removed by Mr. Solly for encephaloid disease.\*

#### DISEASES OF THE JAWS, &c.

I regret that time will not allow me to speak fully of the different diseases of the jaws, although I fear that I can add but little to what Mr. Heath has published on the subject; but the tumours connected with these and other bones of the face may, I venture to think, be reduced to a very simple classification. Thus:

1st. We have cysts in the upper and lower jaws, of which I show you specimens from St. Thomas's Hospital Museum; Figs. 20 and 21 illustrate such

FIG. 20.



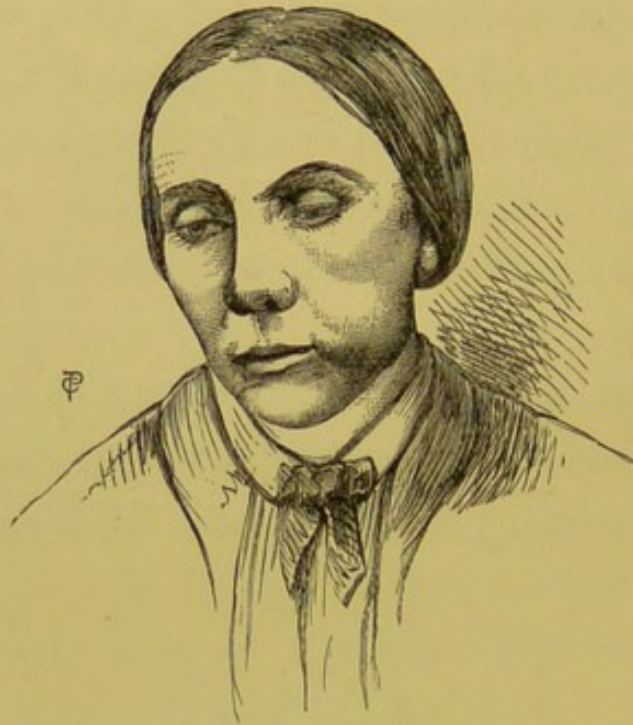
\* St. Thomas's Hospital Museum, c. 198.



diseases, the latter figure being taken from a patient who was under the care of Mr. Royes Bell.

2nd. There are the fibromata or fibrous tumours, which usually spring in the upper jaw from one of two situations, either the interior of the antrum, or

FIG. 21.



some portion of the alveolus. They are the commonest form of growth in the lower jaw. Cysts may be superadded to the fibrous structure, as in this case, of which I show you a photograph, of fibrocystic disease involving the palate bones and palatal processes of both superior maxillæ. Mr. MacCormac was kind enough to allow me to take charge of this patient.

3rd. There are the different forms of sarcomatous tumours. Here are photographs, taken before and after operation, of a patient from whom I



removed a spindle-celled sarcoma in April last. The tumour apparently commenced in the roof of the mouth, and subsequently implicated the antrum. An incision was made in the middle line of the upper lip, and the whole of the right superior maxilla, excepting the orbital surface, with a considerable portion of the soft palate, was removed.\* [This patient was exhibited to the Fellows.]

4th. There are the enchondromata or cartilaginous tumours.

5th. The osteomata or bony tumours.†

6th. The carcinomata, of which the medullary or encephaloid cancer is the most common variety, although cases of scirrhus are recorded as involving both the upper and lower jaws.

7th. Lastly, there are the vascular tumours.

By permission of the treasurer, I am enabled to show you several typical specimens from the museum of St. Thomas's Hospital, to illustrate most of these diseases.

A brief reference may now be made to the preliminary skin incisions which are generally employed at the present day in removing tumours of the upper jaw. Sir William Fergusson seems to have perfected the planning of these incisions, and I imagine that few surgeons would now think of gashing the cheek

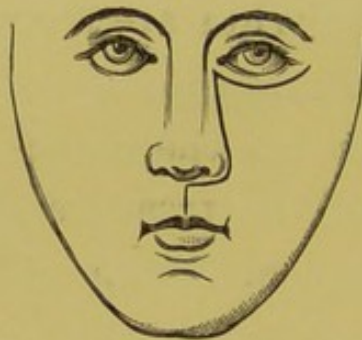\* 'Med. Times and Gaz.,' Oct. 6th, 1877, p. 387.

† See 'Erichsen's Surgery,' vol. i, p. 756, for ivory exostosis occurring on face; also 'Bryant's Surgery,' vol. ii, p. 500, fig. 506.



from the angle of the mouth to the external ear. Before applying the knife to the skin of the face, the surgeon should be quite sure that an incision is absolutely required, for many growths of small size, and cysts connected with the upper and lower jaws, may be operated on through the open mouth, without cutting the lip. Assuming incisions to be necessary, a considerable and often sufficient amount of room is afforded by dividing the upper lip exactly in the median line, carrying the wound into one or both nostrils as shown in fig. 22. If more room is

FIG. 22.



required, a second incision may be made upwards along the side of the nose, at the junction of the ala with the cheek; and a third may, if necessary, be employed, extending in a horizontal and somewhat curved manner under the lower eyelid towards the zygoma. After the diseased part has been removed the cut surfaces may be united by the ordinary interrupted suture made of silk, which seems to me to be preferable to silver wire. In closing the lip, some surgeons use hare-lip pins and the twisted suture,



but I fail to perceive that this plan possesses any advantage over the ordinary interrupted suture.

Dieffenbach seems to have been fully alive to the importance of not disfiguring the patient unnecessarily. Thus, in a paper on "Resection of the Facial Bones," published in 1838,\* he says: "I began the operation by dividing the face in the median line, commencing between the eyebrows, and extended this incision downwards to the nose and upper lip; I then made a transverse incision parallel with the aperture of the eyelid, and separated the soft parts—*i.e.*, half the nose, the lower eyelid, the upper lip, and the cheek—from the tumour, and turned back the flap towards the ear." He adds that, by dividing the face along the median line "I have suggested a new method of operation, the effect of which is to prevent the paralysis of one side of the face, the infallible consequence of commencing our incisions on the posterior part of the cheek."

Respecting operations on the lower jaw, I need only add that, if incisions are required in the skin, they should be so planned as to leave as little scar as possible.

The removal of tumours involving the greater part of the upper and lower jaws by the subperiosteal method has been practised by Langenbeck, Ollier, von Pitha, and by surgeons in this country.

Nearly forty years ago Signoroni practised a sub-

\* 'The Lancet,' 1838, vol. i, p. 692.



cutaneous extirpation of the lower jaw without making any external or skin incision. The patient was a young woman who had osteo-sarcoma. He divided the operation into three stages:—1st. The isolation of the tumour; 2nd. The division of the diseased bone; 3rd. The extraction of the detached part.\* More recently Mr. Maunder has performed a somewhat similar operation and has placed on record the notes of two cases which were under his treatment.†

### NÆVUS.

Nævus is not unfrequently found on the face, and, when of rapid growth, may cause great disfigurement. It is met with, first, either as the cutaneous variety, as in this instance, situated on the ear (Fig. 23). Secondly, it may be subcutaneous, and

FIG. 23.

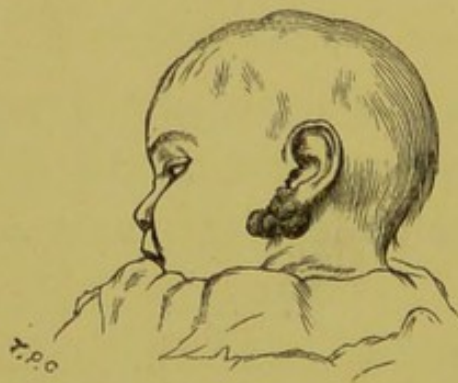
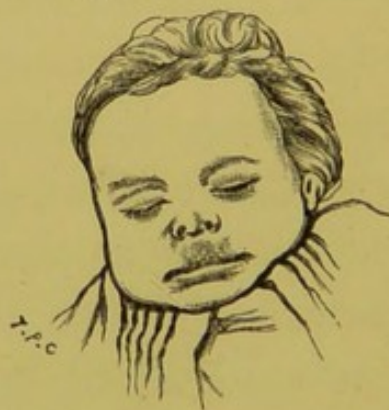
FIG. 24.



not involve the skin, when it is generally observed

\* 'Med. Times,' Sept. 10, 1842, vol. 6, p. 381.

† 'British Medical Journal' for 1872, vol. i, p. 48, and for 1873, vol. i, p. 611.



about the lips (Fig. 24), on the cheeks, and over the parotid region. Or, thirdly, it may be of the mixed kind, as is shown in this sketch I show you, taken from a patient under the care of Mr. Croft.

Nævus seldom produces displacement of the neighbouring bones. Mr. Bryant, however, describes a case in which a nævus of the lip flattened the teeth of both jaws.\*

It is not unusual to find two or more nævi on the same patient. Mr. Croly, of Ireland, reports a case in which there were four distinct nævi, one situated on the lower lip, a second in the right parotid region, a third at the back of the neck, and a fourth on the tongue.† A still more remarkable instance is recorded of symmetrical nævi, the size of a sixpence, occurring in twins, male and female, eight years of age.‡

The question of operation is one of some importance, and before the surgeon proceeds to effect a radical cure, and thus perhaps produce a permanent cicatrix, he should not forget that many nævi disappear without surgical interference. The cutaneous nævus is especially the variety to which this remark applies. I do not think there can be a doubt that some nævi do wither away spontaneously, for they are very rarely met with in the adult.

\* 'Practice of Surgery,' vol. i, p. 444.

Brit. Med. Journ., April 2, 1870, p. 348.

† 'Med. Times and Gaz.,' Feb. 3rd, 1872, p. 130.



If the nævus be situated on the lip it may be compressed with an instrument something like a pair of castanets as recommended by Dupuytren,\* or it may be subcutaneously ruptured as in a case recorded by Dr. Mezger, of Amsterdam.† He rapidly squeezed the nævus so as to rupture the vessels when quite full.

The thermo-cautery is very useful in superficial nævi, and so is a hot needle applied at a black heat.‡ The elastic ligature has its advocates, and in very severe cases it may be necessary to tie the common carotid artery.

In the subcutaneous variety which are so frequently found on the lips and cheeks, I have for some years used the electrolytic treatment with excellent results.§ Dr. Althaus and Mr. Knott, of St. Mary's Hospital,|| Dr. Duncan, of Edinburgh,¶ and Dr. Beard,\*\* have contributed valuable papers on this subject to which I would refer you. I will only add that, from personal experience, I am enabled completely to corroborate their views as to the efficacy of this treatment in suitable cases.

With regard to the cure of nævi, I need not

\* 'Lancet,' 1833, vol. 2, p. 169.

† 'Archiv. für Klin. Chirurgie,' Band xiii ('Brit. Med. Journ.,' Dec. 23, 1871, p. 730).

‡ 'Lancet,' March 14, 1863, p. 294.

§ 'Brit. Med. Journ.,' 1867, vol. i, p. 539.

|| 'Lancet,' vol. i, 1875, p. 402.

¶ 'Brit. Med. Journ.,' June 10, 1876.

\*\* 'New York Med. Journ.,' Dec. 1877.



occupy time by referring in detail to the various methods of treating such tumours, whether by the application of continuous pressure, or by the actual or other form of cautery, or by obliterating the neighbouring vessels by acupressure, as in a case reported by Mr. Bellamy,\* or by enucleation, as advocated by Mr. Teale, of Leeds,† or by the use of styptic injections, &c., but will conclude this lecture by alluding to some of the more complicated methods of applying the ligature.

Practically, these methods resolve themselves into two classes: 1st, those in which the skin is not included, a very important consideration when the nævus is situated on a conspicuous part, such as the face; and, secondly, those in which the skin is included.

The ligature may be carried subcutaneously in a variety of ways which have been practised by Ricord, von Pitha (in 1847), Curling,‡ John Adams,§ and others. Thus, the whole of the nævus may be encircled without the skin being involved, in the following manner:—A surgical needle of suitable size (but not in a handle) is entered at the skin at A (Fig. 25), and is made to go half round the circumference of the nævus (as indicated by the arrow), penetrating the skin at B. It is then re-entered at

\* 'Brit. Med. Journ.,' Dec. 9, 1871, p. 668.

† Med. Chir. Soc., Feb. 26, 1867.

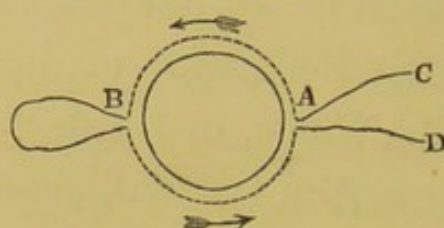
‡ Curling, 'London Med. Gaz.,' vol. 10, 1850, p. 136.

§ Adams, 'Med. Times,' 1851, new series, vol. ii, p. 178.



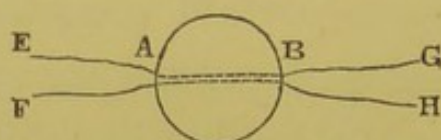
B and carried round the other half of the nævus, and made to emerge at the first point of puncture A. The two ends c, d, are then tied, and thus the skin

FIG. 25.



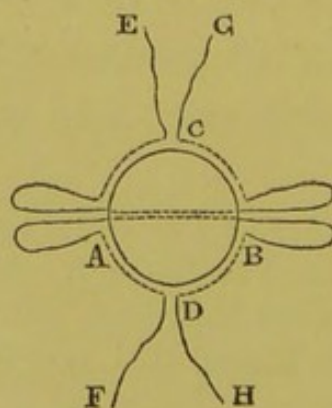
is left intact. Or, the nævus may be divided in halves subcutaneously thus :—(Fig. 26) An ordinary surgical

FIG. 26.



needle (without a handle) armed with a thread is carried under the nævus from A to B, and the two ends near the needle divided (G, H). The needle is then to be threaded with say G, and is passed round for a quarter of the circumference of the nævus subcutaneously, and is made to emerge at c (Fig. 27).

FIG. 27.



The corresponding end E (Fig. 26) is treated in like manner, and made to emerge at c (Fig. 27). The ends E, G, are then tied. The ends H and F are dealt with in the same way, being made to emerge at D, as the woodcut indicates.\*

The operation devised by Mr. John Wood like the last divides the nævus into two portions.† A needle *in a handle* is armed with a long stout thread, and made to pass from above downwards under the nævus from A to B (Fig. 28). A loop is left at c.

FIG. 28.

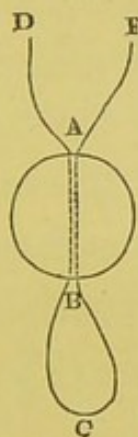
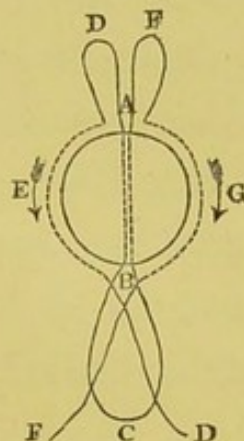


FIG. 29.



The needle is withdrawn, having still one of the free ends on it (say D). The needle carrying D is now introduced into the hole in the skin A, and is passed around the circumference of the tumour in the direction of the arrow E, and made to emerge through the skin at B (Fig. 29). The thread is now taken away from the needle, and the latter unarmed

\* Birkett, 'Guy's Hospital Reports,' 2nd series, vol. vii, part ii, 1851, p. 294.

† 'Med. Times and Gaz.,' July 31, 1858, p. 113; Oct. 28, 1865, p. 468.



is withdrawn at A. The end F (Fig. 28) is now threaded and carried round the opposite side of the tumour in like manner in the direction of the arrow G (Fig. 29), and is made to emerge at B. The thread being removed the needle is withdrawn unarmed as before. In order to complete the operation the two ends D and F are passed through the loop C, and having been drawn tightly are fastened in a bow (not in a knot) so that the ligature may be tightened from day to day, until it cuts its way out at the aperture B. It will thus be seen that the threads emerge from one small hole in a depending position which may be arranged in accordance with the position of the nævus.

More recently Mr. Jardine Murray has described another operation.\* An ordinary surgical needle (not in a handle) armed with a thread is passed under the nævus from A to B (Fig. 30). The

FIG. 30.

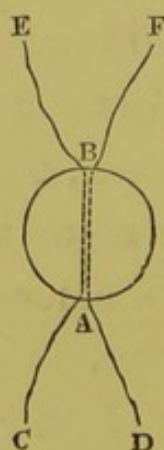
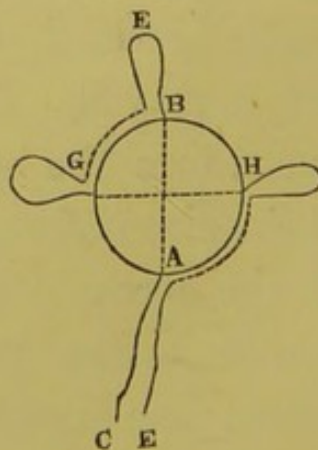


FIG. 31.



loop is cut close to the needle, so that there remain

\* 'Lancet,' March 19, 1864, p. 321.



four ends c, d, and e, f. The needle (or another with a blunt point as Mr. Murray suggests) is now threaded with one end, say e, and is made to pass subcutaneously around a quarter of the tumour from b to g, penetrating the skin at g (Fig. 31). It is then passed under the nævus from g to h, emerging at h. It is again introduced at h, is passed from h to a, emerging through the skin at a. The needle being now released is threaded with the end f, which it carries subcutaneously first from f to h, then from h to g, and, lastly, from g to a, and is then released. The ends c, e, and d, f, all emerging from the single aperture in the skin at a are tied respectively, and thus the nævus is subcutaneously surrounded and cut into four parts. For the sake of clearness the course of one thread only c, e, is shown in the diagram.

I will now speak of two methods of ligature in which the skin is included :

Sir William Fergusson's knot was first published in the 'Edinburgh Monthly Journal of Medical Science' for 1847. At that time Sir William used a needle in a handle, but latterly he preferred the common surgical needle. The operation may be performed thus :—A needle having a large eye, and threaded with a ligature of good length, is entered at a, and passed under the nævus, emerging at b (Fig. 32). One side of the loop is to be cut (say e) (Fig. 33). The opposite end of the cut side (f) is then



FIG. 32.

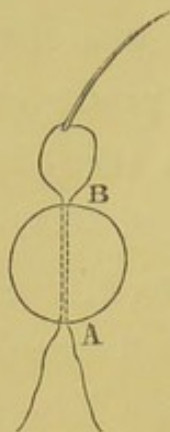


FIG. 33.

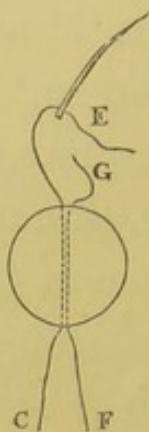
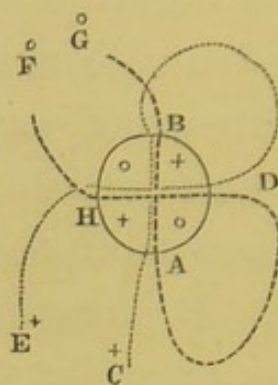


FIG. 34.



threaded, and the needle carrying the two ends *E* and *F* is passed under the nævus at right angles from *D* to *H* (Fig. 34). The needle is now to be

FIG. 35.

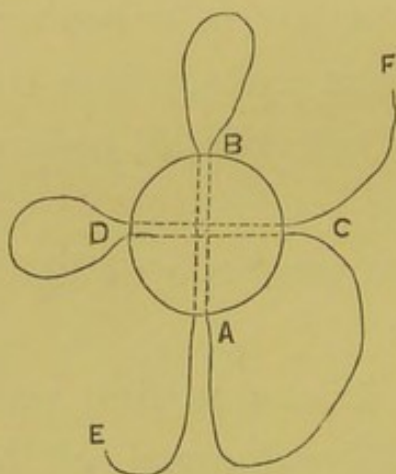
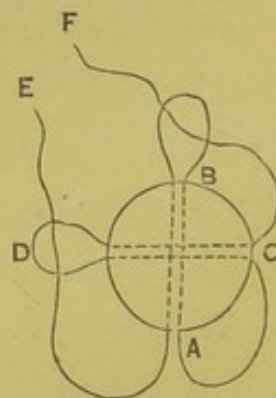


FIG. 36.



released, and the corresponding ends  $E^+$ ,  $C$ , and  $F^\circ$ ,  $G^\circ$  (Fig 34), respectively tied tightly. Thus, the tumour is encircled, and cut into four pieces.

Another knot devised by Mr. Wood, and which includes the skin, is applicable to large nævi, and as it is secured with a single bow can be tightened from day to day. A needle in a handle is threaded

and passed under the nævus from A to B (Fig. 35), a loop is left at B, and the needle withdrawn. The needle still armed with one end (say A), is now passed at right angles from C to D, and another loop left. The needle is withdrawn on the end F, and is then released. All that is necessary to complete the operation is to pass the two ends E and F through the loops B and D, and tie them in a bow (Fig. 36). By this method the nævus may be tightened from day to day until it is cut through. Before tying the threads it is well in this as in Fergusson's knot to snip the healthy skin at the circumference of the nævus with scissors. This procedure provides a groove in which the threads may conveniently lie, and obviates the pain incidental to the ulcerative process.

In my next lecture I shall speak of injuries of the face.



## LECTURE II.

### INJURIES OF THE FACE.

MR. PRESIDENT AND GENTLEMEN,—You will remember that in my last lecture I alluded to some of the principal diseases of the face, and now with your permission I will refer to a few of the injuries incidental to this part.

Considering its exposed situation, the face has comparative immunity from accidents of all kinds, and this immunity may be thus explained:—First, because the head is extremely movable in all directions; and, secondly, because the hands and arms intuitively protect the part.

It is not within the scope of this lecture that I should speak of fatal injuries occasioned by gas explosions, railway accidents, the bursting of shells and gunshot wounds received in warfare, which I think may be well left to the imagination. I shall therefore confine my observations to such injuries as are usually remediable, and which are therefore consistent with life.

Lacerated wounds of great extent are frequently occasioned by broken glass. Thus, not long ago, I



saw a barmaid whose face was terribly disfigured by the bursting of a soda-water bottle; and also another patient, a plumber, who was rendered a pitiable object by falling head foremost for a distance of twenty feet through a skylight. Again, I once had the opportunity of seeing a cabinet maker who had a very severe wound of the face occasioned by a circular saw. But perhaps the worst examples of such injuries were two, one in which the face was literally smashed by a cricket-bat coming in full contact with the face, and the other was the result of a direct blow on the part from a cricket ball, of which I show you photographs.

Injuries of the face must be treated on the ordinary principles of surgery, but in this region it is of paramount consequence to procure, if possible, immediate union, and thus preserve the patient's personal appearance. Therefore, after the wound has been thoroughly cleansed from dirt, glass, or other foreign substances, the edges should be brought together accurately with good sticking plaster.\* Sutures may be employed, but they should be dispensed with if possible inasmuch as they cause additional scars. If used the sutures should be of fine silk, which is, I think, preferable to silver wire, for the removal of the latter requires some little skill, and I am sure that if there be any tension, the

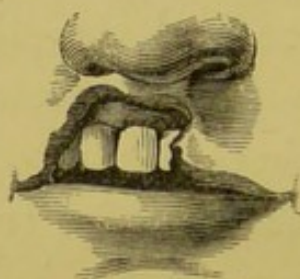
\* An excellent preparation known as india rubber plaster may be obtained of Messrs. Savory and Moore, of New Bond Street.



wire cuts its way through the cutaneous structures much more rapidly than silk does.

In injuries of the lips, harelip-pins with the twisted suture are very commonly used to unite the parts, but I employ, by preference, the ordinary interrupted suture, made of silk. Even simple strapping, efficiently applied, answers the purpose completely. This woodcut (Fig. 37), taken from a

FIG. 37.



photograph, illustrates a case in which a portion of the lip had been bitten away by a woman, and in which the parts were successfully brought together with strapping only.

In speaking of injuries of the face, Mr. Holmes Coote aptly remarks \* “that wounds in this region caused by the violent action of blunt instruments have often the same appearance as if inflicted by the sharp cutting edge of a knife. For example, the sharp border of the superior maxillary and malar bones, or the edges of the teeth, will, when a blunt body presses against them, cut through the

\* ‘Holmes’ Surgery,’ vol. ii, p. 428.



skin and subjacent soft parts, and cause an injury closely resembling an ordinary incised wound.” As an instance in point, Mr. Erichsen relates\* the case of a man who was admitted into the hospital drunk and much bruised about the face. “Shortly after admission he vomited a large quantity of blood, which was at first supposed to proceed from some internal injury, but, on examining his lip, it was found that the hæmorrhage was from the coronary artery of the lip, which was divided with the mucous membrane.”

In injuries of the face in children it is of great moment that the scar should be reduced to a minimum, and the same rule applies, as already referred to in my previous lecture, to wounds made by the surgeon in removing cysts or other tumours, nævi, &c., at an early period of life. It is, I suppose, an accepted pathological axiom that all scars grow in proportion to the growth of the body, and the question of the probable disappearance of cicatrices is one of more than ordinary interest, especially from a medico-legal point of view. As bearing on this question, it will be in the recollection of the fellows that Mr. W. Adams read a paper on the subject at this Society in 1873, and alluded to four cases, amongst them one of a young lady who, when a baby a year old, was operated on for nævus by excision in the region of the breast. The scar left

\* ‘Science and Art of Surgery.’ vol. i, p. 597, seventh edition.



at the time was less than an inch and a half, but at nineteen years of age it was found to have increased enormously, measuring three inches in diameter. The case showed that when a portion of the skin has been destroyed, the cicatrix appears to be persistent through life, and grows *pari passu* with the rest of the body, or rather with the portion of the body over which it may be placed. The increased size of the vaccination scars observed in the adult seems to prove this. Sir James Paget puts the case well in saying that "the scar of a child, when once completely formed, grows as the body does, at the same rate and according to the same general rule, so that a scar which the child might have said was as long as his own forefinger will still be as long as his forefinger when he grows to be a man."

*Apropos* of this part of the subject, you will perhaps remember that about two years ago I showed a patient, a girl aged fifteen [photograph shown] who had a cicatrix, about an inch and a quarter in diameter, situated over the left breast, which was the result of an operation for nævus performed when she was three months old, the scar after the operation being about the size of a sixpence. As the breast developed, so the cicatrix became proportionately larger. I venture to cite this case, not as strictly relating to the part of which I am now treating, but because it illustrates in a remarkable manner the fact that cicatrices increase not



only in proportion to the growth of the body, but that they grow in proportion to the development of the organ on which they are placed.\*

I am, however, glad to be able to adduce a more apposite example to illustrate the growth of such cicatrices (represented in Fig. 38). In November

FIG. 38.



last a young man consulted me with reference to a circular scar situated on his right cheek, and which was thought to be growing rapidly. He was eighteen years of age, and his mother informed me that when he was a baby he had a very small *nævus* in the situation of the cicatrix, which was cured by ligature. His mother was assured at the time of the operation that as he grew up the scar would

\* 'Med. Soc. Proceedings,' vol. iii, p. 60.



disappear, and she was therefore rather astonished, not to say disappointed, to find that it was now three times as large as it was in babyhood. The explanation of this enlargement lay in the fact that the young man was getting, as his mother remarked, unusually "fat in the face."

### BURNS AND SCALDS.

With regard to the management of burns and scalds in the region of the face (and I allude to such cases as are not beyond surgical aid), the popular treatment at the present day seems to be the application of carron oil. At St. Thomas's Hospital we frequently employ this remedy; but in the children's ward, into which these accidents are almost daily admitted, a mixture of whiting and acetic acid is used. It is prepared in the following manner: one part of acetic acid is mixed with twelve parts of water, and whiting is added until the fluid becomes of the consistence of cream. The mixture is applied lightly with a brush during effervescence, and in addition the part is usually covered with soft linen and cotton-wool.\* The soothing effects of this preparation are so marked that I confidently recommend it for more general use. It is very clean, and

\* See a paper by the author on Burns and Scalds in 'St. Thomas's Hospital Reports,' vol. v, 1874.

is especially useful in burns and scalds of the face and neighbouring parts. The deformities occasioned by burns and scalds are well illustrated in Figs. 39, 40,

FIG. 39.

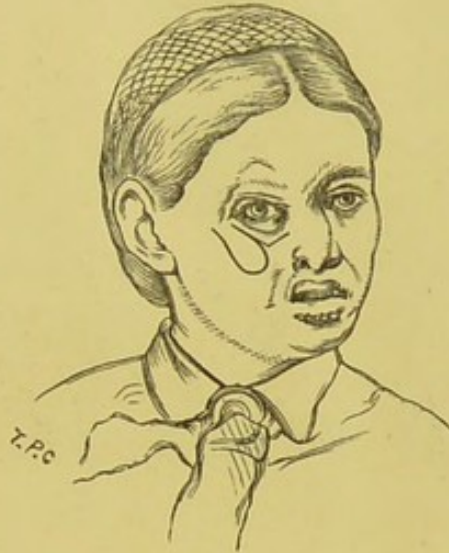

FIG. 40.



41, and 42, taken from photographs; but of these, with their treatment, I shall speak in my next lecture.



FIG. 41.

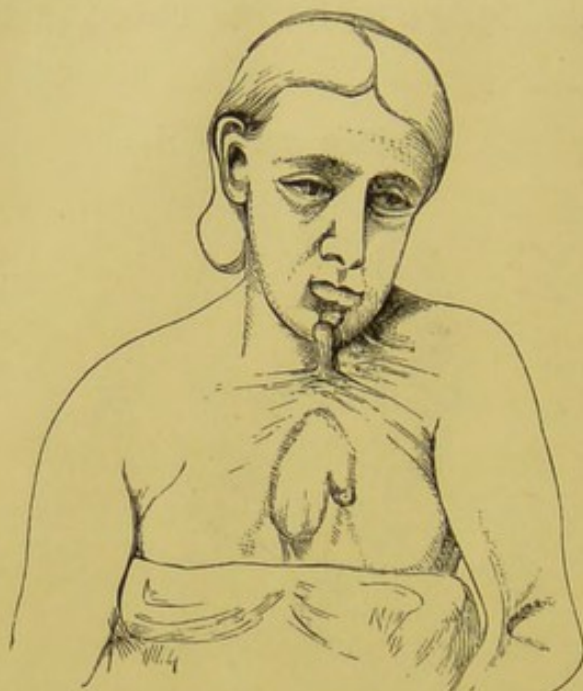

FIG. 42.



## INJURIES OF THE PAROTID GLAND AND ITS DUCT.

Cases are reported in which the duct of the parotid gland has been ruptured subcutaneously by a blow, and in which the salivary secretion has burrowed in all directions, giving the patient an emphysematous appearance, and causing much disfigurement of the face and neck. The duct has also been partially destroyed by ulceration in severe cases of lupus or cancrum oris; and it has been divided, either of necessity or unintentionally, by the surgeon in operating on the cheek, or in removing tumours from the jaw. Sabre wounds have in some instances been followed by salivary fistula. In a case of this kind of fistula which resulted from the patient falling on a red-hot poker I adopted a simple plan of treatment. A probe was passed through the mouth and made to emerge from the fistulous aperture in the cheek; then, having bent the instrument slightly, it was pushed along the duct as far as possible in the direction towards the gland. The probe thus fixed was retained for the remainder of the day (altogether about eight hours), and at night it was removed. Three days afterwards it was again introduced through the mouth, and passed readily towards the gland. After the first introduction the saliva ceased to flow from the opening in the cheek. Mr.



Pick, of St. George's Hospital, has treated a case much in the same manner in a patient aged twenty.\* An attempt was made to pass a probe in order to ascertain if any opening existed into the mouth, but the instrument being too large, further attempt was abandoned until a smaller one could be procured. "The following morning the patient was surprised to find that her pillow, which had been previously saturated with moisture, was quite dry, and upon examination it was found that the opening was completely closed."†

Fistulous openings in connection with the parotid gland itself are of very rare occurrence, yet they are known to have been produced by the opening of an abscess behind the jaw, and have even followed a peculiar inflammation of the gland structure. I had the opportunity of watching a case of this kind occasioned by a burn which destroyed the ear and neighbouring parts. There were nine or ten minute spots over the parotid gland from which saliva exuded. The patient got quite well after a free use of the solid nitrate of silver and the firm application of a bandage.

\* The 'Lancet,' Feb. 19th, 1870.

† See article "Surgery of the Mouth," by author, 'Monthly Review of Dental Surgery,' Jan., 1873, p. 364.



## SLOUGHING OF THE FACE.

Owing to the extreme vascularity of the part, sloughing seldom occurs on the face, and, when met with generally depends upon the direct application of intense heat, such as red-hot iron, &c. Injuries even at a distance from the face, say in the neck, are sometimes followed by sloughing of the nose or ears—that is to say, parts to which the blood is with most difficulty sent. Sir James Paget\* quotes several examples to show how portions of the body may mortify from the absence or deficient supply of fresh blood, and refers to a specimen in the Museum of the College of Surgeons, which is of especial interest in connection with the surgery of the face. The specimen was the larynx of a man who, while in low health, cut his throat, and suffered a great loss of blood. Before he died his nose sloughed.

## TREATMENT OF DETACHED SOFT PARTS.

However mutilated the skin of the face may be, the surgeon should under all circumstances endeavour to bring the edges of the wound accurately together, and even if a portion should be completely detached by accident or design, an attempt should

\* 'Lectures on Surgical Pathology,' p. 25, third edition, 1870.



be made to restore the part to its pristine position. There are numerous instances on record in which the nose has been replaced, and an interesting example of this kind is reported by Dr. Malfatti.\* A soldier had his nose cut off by a sabre. The piece was taken up from the ground on which it lay, was cleaned and reapplied, being secured in its place by sutures. The case did perfectly well. Again, Mr. Spencer Watson† relates the case of a gentleman who, when he was a child, cut off a portion of the end of his nose with a carving-knife. His mother, with great presence of mind, instantly replaced it, and kept it in position by means of a plaster composed of brown paper smeared with soap and sugar. The severed parts completely united, and only a trace of the original injury was left. A somewhat similar case in an adult came under my observation when I was house-surgeon at King's College Hospital. In this instance I reapplied the greater part of the nose,‡ and Mr. Slayter, the then house-surgeon at the Westminster Hospital, afterwards reported three cases, one in which the nose was readjusted, the second in which three teeth had been replaced, and a third in which a portion of the scalp had been knocked off with a quart pot, and had been sewn on successfully.

\* 'Brit. Med. Journ.,' Dec. 21st, 1872, p. 690.

† 'Diseases of the Nose,' p. 296.

‡ 'The Lancet,' Sept. 7th, 1861.



## INJURIES OF BONES OF FACE.

With regard to injuries of the bones of the face, perhaps the nasal bones are those most frequently fractured or dislocated. In either case the parts should be brought into their normal position as soon as possible after the accident, and if once in their proper place, are little apt to shift, because, as is well known, there are no muscles directly attached to them. Mr. W. Adams who gave us a paper on this subject in 1875, observes that such cases may be divided into two classes—(1) those in which the injury is limited to the cartilaginous portions, and (2) those in which the nasal bones are fractured. The principle he advocates in all such instances is to straighten the bent cartilaginous septum with a pair of strong forceps having flat parallel blades, and when the nasal bones are depressed, to raise them also with the same instrument.\* Diefenbach† operated by a subcutaneous method in two cases in which the nose was thrown outwards on the cheek, one nostril being turned upwards and the other downwards. He introduced a narrow bistoury under the skin of the bridge, dividing the union of the cartilage with the bones, and separated

\* 'Med. Soc. Proceedings,' vol. ii., 1875, p. 99

† 'Prov. Med. Journal,' vol. iv, p. 141.



the alæ and septum, every part of the operation being subcutaneous.

Whilst it is expedient in adults to bring the displaced parts in apposition as speedily as possible, it is even of greater importance to effect this in children, for Mr. Hilton has shown that the expansion of the sphenoid bone pushes forwards the vomer and the septum nasi, and subsequently also the nasal bones. Any injury therefore of the nasal bones attended with displacement to either side would necessarily result in a progressive deformity, since the bones would continue to grow in the abnormal direction.\*

In cases of severe burns, involving the eyelids or the nose, great care should be taken to retain the external apertures. Mr. Le Gros Clark has reported a case which he treated successfully by incising the anterior nares and keeping the parts open with a trocar.†

Blows inflicted on the nose are occasionally followed by abscess and exfoliation of the nasal bones, but such consequences may in many cases be averted by timely incisions, as in a case under the care of Mr. J. Hutchinson, in which there were two inflamed swellings of equal size symmetrically situated on either side of the bridge of the nose in such a manner as to extend its transverse measurement to about

\* 'Cooper Forster: 'Surgical Diseases of Children,' p. 13.

† 'Med. Times and Gaz.,' Dec. 15th, 1860, p. 584.



an inch and a half. The abscesses were laid open freely, and the patient did well. Injuries to the nose of even trivial character are occasionally followed by a fatal result. Thus, Dr. Keeling, of Sheffield, reports\* the case of a patient who was struck with a piece of iron on the forehead and nose. There was a simple fracture of the nasal bones without much displacement. The patient died, and on opening the calvaria the dura mater was found much lacerated. Five ounces of pus escaped, and the crista galli, with the perpendicular plate of the ethmoid, was found to be separated from the cribriform plate, quite loose, and imbedded in the substance of the brain. Mr. Bryant also quotes a case in which a severe blow upon the jaw produced a fracture of the middle fossa of the base of the skull.

#### EMPHYSEMA.

Emphysema of the face and neck is not unfrequently met with when the bones of the face or the frontal sinuses are damaged. Thus, I once saw a man who, whilst walking, received on the right side of his face the whole weight of a long rod of iron which was being carelessly carried by another person. There was a very superficial wound situated over the malar bone, and no apparent displacement of the

\* The 'Lancet,' March 13th, 1869, p. 362.



bones. In two or three days, however, the patient's face on the injured side was very puffy and emphysematous, being nearly twice its normal size. The swelling entirely disappeared in ten days.

The following case occurred in the practice of Mr. Prescott Hewett.\* The patient was twenty-three years of age, and fell during a fit on the left upper jaw, which was displaced, but firmly fixed. The following day the emphysema had spread to the hyoid bone, and went as low down as the cricoid cartilage; but it all disappeared within a week from the time of the accident, and the patient made a good recovery. Emphysema of the eyelids, resulting from fracture of the os planum of the ethmoid, has been referred to by Dupuytren.†

Dr. Keith, of Aberdeen, has most truly observed that "wounds of the face however ghastly to look at, are not dangerous to life," and some remarkable recoveries are on record after very extensive injuries to the bones and soft parts in this region. The following may be taken as an example, the patient having been under the care of Baron Larrey.‡ The patient was a soldier aged twenty-three, who attempted suicide on March 4th, 1823, by shooting himself. "In the left ramus of the lower jaw there was a large irregular aperture by which the ball had

\* The 'Lancet,' vol. i, 1875, p. 231.

† The 'Lancet,' vol. ii, 1834, p. 109.

‡ "Clin. Chirurg.," 'The Lancet,' vol. ii, 1829, p. 186.



entered. It made its way through the lower and upper jaw, the left nasal cavity and orbit, and had come out at the left side of the root of the nose. The jaw bones were crushed to fragments, part of the tongue was lacerated, the lower parietes of the orbit fractured, and the eye had burst the eyelids; the nose and upper lip were torn into several flaps, and the lachrymal and frontal bones fractured." He made a good recovery.

Another case is reported by Professor Longmore, of Netley,\* which he believed to be unique, inasmuch as it was followed by total dumbness without direct injury to the organ of voice. A soldier was struck just below the centre of the lower lip during a charge of his regiment on Sept. 21st, 1860, by a musket-ball. The two incisors, the canine, and one bicuspid on the left side were carried away, and the ball lodged in the soft tissues of the floor of the mouth behind the *frænum linguæ*. Immediately after the injury there was complete loss of the power of articulation. The ball was not removed till the twenty-third day after the injury, and was then extracted from within the mouth. The sequel of the case may be briefly told, for, about two years after (at the end of July, 1862) the man suddenly recovered his speech while in a state of excitement during an altercation at a public-house. Professor Longmore was inclined to attribute the dumbness to "nervous

\* 'Brit. Med. Journ.,' Dec. 19th, 1863, p. 670.



shock," in addition to the structural lesions, and to class the case with those of temporary aphonia which sometimes occurs from hysteria, fright, &c., and where the recovery of speech is often sudden. Dr. Aitken, however, who saw the case, thought that the loss of voice was due to injury of the muscles of the tongue and to the disturbance of the ninth nerve.

A third interesting case is reported by Dr. M'Quillen, of Philadelphia,\* of which I show you drawings.

#### DISLOCATION OF THE SUPERIOR MAXILLA.

Simple disarticulation of the superior maxillary bones is a very rare accident, but Mr. John Salter, of Tolleshunt d'Arcy, reports such a case.† "The dislocation was," he says, "beyond doubt, inasmuch as the bones, in their wedge-shaped entirety, could be freely moved backwards and forwards, upwards and downwards, and from side to side. The separation of the malar bones from their articulation was no less distinct. A gutta-percha splint was applied, but it was several months before the patient, aged thirty, could bite solid food." In this case, at the time of the accident, the face felt like a quantity of

\* 'Monthly Review of Dental Surgery,' vol. iv, No. 5, for Oct. 1875.

† 'Med. Times and Gazette,' June 5th, 1869, p. 600.



“loose bones.” Mr. South, in speaking of a somewhat similar accident, describes the bones as feeling like “beans in a bag.”

A curious case of dislocation of the left superior maxilla was under my care in the summer of 1876. The patient, a woman, was thrown from a cart, and alighted on her left cheek on some prominent object (she believed a loose stone). On examination a distinct depression of about half an inch was seen on the injured side, and on placing the finger behind the soft palate, there was an evident prominence. The patient was perfectly free from pain or annoyance, and left the hospital in about ten days, apparently as well as ever, with the exception of the depression above referred to. Mr. Houghton\* reports a case of depression of the superior maxillæ, in which the parts were so displaced that the patient could not protrude the tongue until the bones were readjusted.

I am indebted to Mr. Walter T. Clegg for the following notes of an interesting case that was under the care of Mr. Bickersteth, of Liverpool. A gentleman on board a ferry steamer was standing near the hawser which was fastening the steamer to the Rock Ferry Landing Stage. A sudden strain snapped the iron hook attached to the rope, so that it shot up, struck him on the face, and sent him reeling across the deck. When examined by Mr. Bickersteth immediately after the accident, the

\* ‘Brit. Med. Journ.,’ Jan. 2nd, 1858, p. 15.



mouth seemed to be filled by a piece of bloody meat, but on further investigation this proved to be the muscles attached to the upper jaw; the orbital plate of the superior maxilla of the injured side was found beneath the cheek, whilst the palate process with the alveolar ridge and teeth were, for the time, situated in the upper part of the pharynx, looking towards the bodies of the upper cervical vertebræ. The facial surface took the place of the roof of the mouth, jamming the jaws open. The soft palate was not, however, torn through, but considerably stretched. In fact the superior maxilla of one side was turned completely on its axis.

The detached mass was carefully replaced by Mr. Bickersteth and fixed, the lower jaw was then closed and firmly bound up as a support. The whole rapidly united with scarcely any deformity.

#### DISLOCATION OF THE LOWER JAW.

The usual causes of dislocation of the lower jaw, such as yawning, the attempt to bite an apple or other substances, are too obvious to need reference at the present time. This luxation is known to occur occasionally, though very rarely, during the extraction of teeth, and Mr. James Salter, in a



series of papers\* alludes to such cases, and with characteristic candour, speaks of this accident occurring in his own practice when he was taking a model of the lower jaw in a patient aged seventy. Mr. Salter took the upper model first, and then, having taken that of the lower jaw, he noticed that the patient did not shut her mouth; it was fixed wide open. The reduction of the dislocation was easily effected, and the patient stated that she frequently "put out" her jaw in yawning and laughing. Mr. Merson also relates a similar case.† Such displacements have been known to occur during a laryngoscopic examination, and I know of one instance in which, in the operation for cleft palate, the gag had been so vigorously applied as to produce a similar deformity.

Mr. Edwin Morris, of Spalding, refers to a case of dislocation of the jaw which he believed to be the result of tongue-sucking.‡ The patient was a young lady, aged fifteen, who was awakened from her sleep with pain under her ears, and inability to close the jaws, or to articulate plainly. The patient was addicted from infancy to tongue-sucking during sleep, and Mr. Morris thought that the continual action of the pterygoid muscles had so preternaturally loosened the ligaments and muscular

\* 'Brit. Journal of Dental Science,' July, 1871, p. 311.

† 'Monthly Review of Dental Surgery,' Aug., 1875.

‡ 'Brit. Med. Journ.,' Aug. 31st, 1872, p. 242.



structures supporting the joints as to render them unable to resist their violent action during sleep.

Dr. Ballard speaks of a similar dislocation, the result of thumb-sucking.\* In reference to thumb-sucking I may add that Dr. Dobell has observed in patients who are given to this practice that there is a peculiar and rather common deformity of the chest, caused by the habit of sucking the thumb in infancy and early childhood. The weight of the arm on the thorax of the child during sleep produces depression of the ribs in the line occupied by the arm when the thumb is placed in the mouth.

I need not enter fully into the various theories as to the mechanism of dislocation of the lower jaw. Petit, Boyer, Astley Cooper, and others have pointed out that the condyle lies in front of the transverse root of the zygoma, and is there held either by muscular contraction or by the resistance of the zygoma. Malgaigne and Nélaton thought that the coronoid process came in contact with the malar bone, and believed that, in order to effect reduction, it was only necessary to place the two thumbs on the coronoid processes after the patient has opened his mouth, and, without taking hold of the jaw or making any fulcrum, to press the condyles back into their places.† Mr. Barnard Holt, writing in 1840,‡ suggested a somewhat similar method,

\* 'Brit. Med. Journ.,' vol. ii, 1872, p. 327.

† The 'Lancet,' 1850, vol. i, p. 663. ‡ Ibid., 1840-41, vol. ii, p. 270.



but depressed the angles of the jaw from the outside. Thus, he says, "the surgeon stationing himself behind and above the patient, places the thumb of either hand upon the angles of the jaw on a level with the insertion of the posterior fibres of the masseter muscles, and then presses downwards and backwards." Other observers, as Maisonneuve and Weber, believe that the coronoid process does not become fixed against the malar bone; and Mr. Heath corroborates their view on this point, for, from experiments he himself made, he found that "in the macerated skull it is easy to dislocate the condyle so far in front of the articular eminence as to cause the coronoid process to be hooked against the malar bone, but this is by no means easy on the subject, even when the parts are dissected, and can only be accomplished by tearing the structures of the joint very considerably."\*

The relaxation of muscles appears to be the chief means of effecting the reduction, and thus it is in many instances sufficient to divert the patient's attention. M. Clement speaks of cases in which after very painful efforts at reduction the condyles suddenly returned to their cavities during an examination of the mouth.† A remarkable case, illustrating the spontaneous reduction of the lower jaw

\* 'Injuries of Jaws,' p. 83.

† 'Lyon Medicale,' Sept. 11th. 'Med. Times and Gaz.,' Sept. 24th, 1870, p. 359.



in dislocation, was under my observation at St. Thomas's Hospital two years ago. The patient was a middle-aged woman, who stated that for several years she had been subject to luxation of the lower jaw, which happened sometimes twice a week. At times the dislocation was easy of reduction, but she had got so accustomed to the condition that she was in the habit of going to bed with the parts unreduced, and she invariably found when she awoke that the jaw was in its proper position.

#### FRACTURE OF LOWER JAW.

Fracture of the lower jaw most usually occurs between the lateral incisor and the canine teeth, this situation being perhaps the weakest part of the bone. The inferior maxilla may, however, be broken in other situations—at the symphysis, the angle, or at the neck of the condyle. An interesting case, from a diagnostic point of view, in which the neck of the condyle was fractured, is recorded by Mr. T. Holmes.\* In this example there was displacement of the lower fragment into the meatus auditorius externus, with serous discharge from the ear. The case was interesting, as showing the source from which a sero-sanguineous discharge may come, whether it may depend on a fracture at the base of

\* 'Path. Trans.,' 1861, p. 159.



the skull, or whether merely from a fracture of the external auditory meatus.

Fracture of the neck of the jaw by *contre-coup* is still more rare, yet such a case has been described by Dr. Cockburn, of the Royal Engineers.\* The injury was caused by a blow of the fist, received at the left side of the face. The least attempt to open the mouth caused much pain at a point close to the tragus of the right ear. It was easy to guess the nature of the injury, and it required but little manipulation to detect a simple fracture of the condyloid process of the right side, at a point very close to the insertion of the external pterygoid muscle. The fracture was put up in the usual manner, with a splint of gutta-percha moulded to the lower jaw, the usual chin-sling bandage, with a piece of cork between the teeth. The case did perfectly well.

Fractures of the lower jaw, as a rule, unite most perfectly, and however great the primary displacement may be, experience proves that the muscles resume their harmonious action, and in the end a most satisfactory result is obtained. In some instances, however, the bones unite very irregularly, thus, in a case of this kind, Mr. Bickersteth, of Liverpool, had to divide the bone with a saw, and then nailed the parts together with small brass pins.†

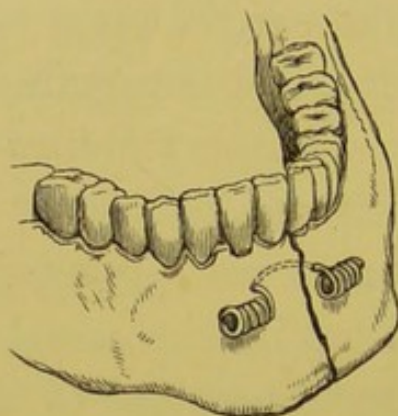
\* 'Brit. Med. Journ.,' Dec. 28th, 1867, p. 590.

† 'Brit. Med. Journ.,' Nov. 30th, 1861. p. 588.



The plan of fastening the broken ends together with wire passed over the teeth is of ancient date, but the wire so placed is very apt to slip. Mr. Thomas, of Liverpool, speaks highly of a plan he has successfully adopted of boring a hole with a drill on each side about a quarter of an inch from the

FIG. 43.



fracture (Fig. 43). Through these holes a wire is passed, and twisted in the form of a coil. The immediate effect in one case was that from the first day the patient expressed himself as able to use the jaw.\*

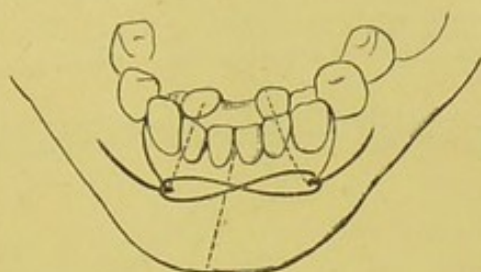
Another plan is that practised by Mr. Wheelhouse, of Leeds, and represented in the accompanying diagram (Fig. 44).† Two holes are bored with a drill through the substance of the jaw-bone, one on either side of the fracture. Through these holes two pins, having flat, circular, and perforated heads,

\* The 'Lancet,' Jan. 19th, 1867, p. 79.

† The 'Lancet,' Aug. 17th, 1867, p. 195.

are passed from behind forwards, and their points bent in opposite directions. The perforated heads

FIG. 44.



are then threaded with good stout silk ligature, which is brought forward over the teeth, and a figure-of-8 suture made round the reversed ends of the pins.

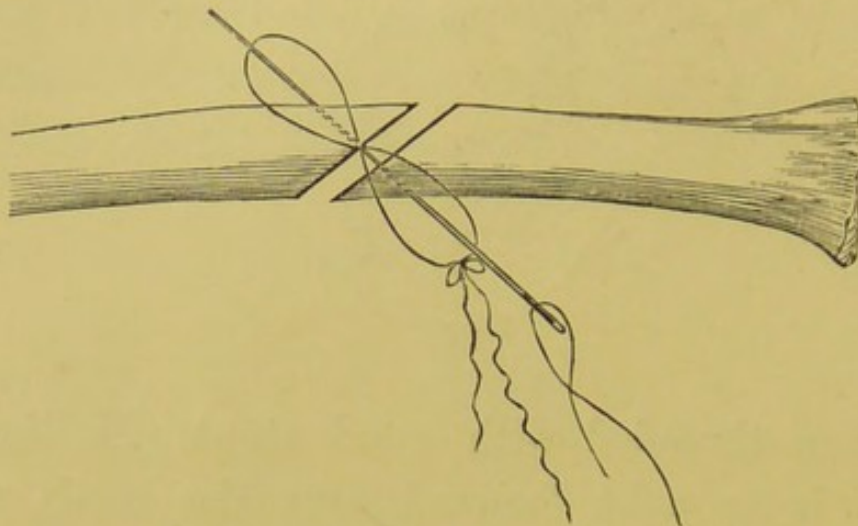
And, lastly, although I have not yet had an opportunity of testing it, I take the liberty of referring to a simple plan of uniting broken bones, which I successfully employed in 1871 in a case of ununited fracture of both bones of the forearm, an account of which is published in the 'Medico-Chirurgical Transactions.'\* This method might, I venture to think, be advantageously used in suitable cases of fracture of the lower jaw. Its principle is well illustrated in the woodcut (Fig. 45), which represents it as applied to one of the bones of the forearm. It will be perceived that it is nothing more than the twisted suture, and that by withdrawing the needle the wire or thread is of course released. In adopting this

\* Vol. liv, 1871, p. 313.



method I imagine that the risk of damaging the bone is very slight. Various other kinds of mechanical

FIG. 45.



apparatus for keeping the fragments together have been devised by Mr. James Salter,\* Mr. Gunning, Mr. Berkeley Hill,† Mr. Moon,‡ and others.

In those rare examples in which bony union fails to take place there is abundant scope for ingenuity on the part of surgeons practising dental surgery. Thus Mr. W. D. Napier has furnished me with the particulars of a case of ununited fracture of the lower jaw which was sent to him by the late Sir William Fergusson, in August, 1867. The patient had been frightfully wounded during the siege of Lucknow, and besides having the lower jaw fractured in three places, had also a large portion of the superior maxilla carried away by a cannon ball. Exfoliation

\* The 'Lancet,' June 16th, 1860, p. 593.

† 'Essentials of Bandaging,' p. 32.

‡ 'Guy's Hospital Reports,' vol. xix, 1874.



to a considerable extent took place in the lower jaw, which, together with the loss of many teeth, caused an ugly and inconvenient contraction. There was no bony union whatever, but Mr. Napier so constructed an apparatus as to completely restore the power of mastication.

### PERMANENT CLOSURE OF THE JAWS.

In all cases of permanent closure of the jaws in which the lower jaw is fixed by cicatrices, whether caused by injury or by disease, the mere division of the cicatricial band is seldom sufficient to effect a complete cure, for the wound heals rapidly, and the cicatrix, as a rule, becomes even more dense than before. In operating on such cases, Mr. Callender suggests that after the free division of the cicatrix a portion of the alveolar border, together with the teeth, should be removed.\*

The division of the masseter muscles has been adopted in certain cases, both subcutaneously and by a submucous method through the mouth.† The operations that meet with most favour at the present day are (1) that proposed by Rizzoli, of Bologna, in which the bone is simply divided, and (2) that practised by Esmarch, which consists in removing a

\* The 'Lancet,' June 18th, 1870, p. 873.

† 'Prov. Med. Journal,' vol. iii, 1841-2, p. 345.

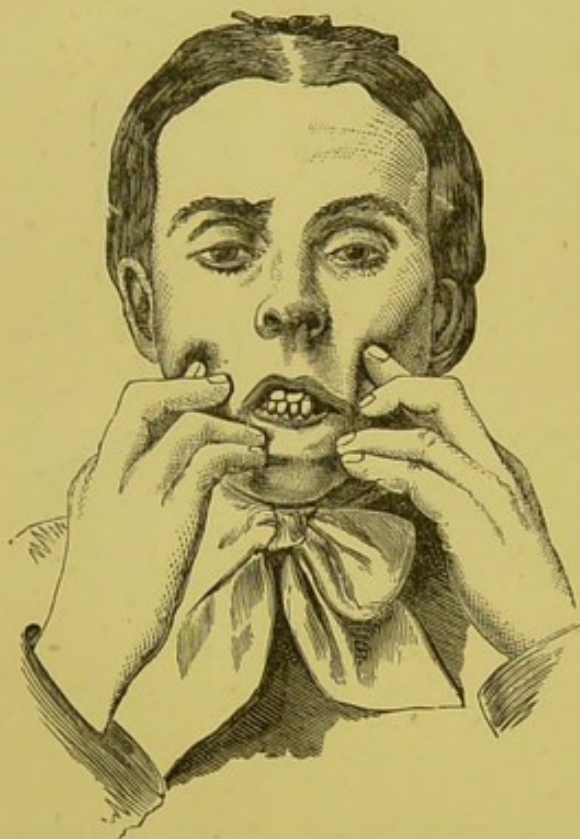


portion of bone. Esmarch's operation has been performed by Messrs. Mitchell Henry, Barnard Holt, Heath, Lawson, Mac Cormac, M. Richet, by myself, and other surgeons. Most of these cases have been published, and I therefore need not detain you further than by saying that the operations were undertaken either on account of a dense cicatrix existing between the jaw and the cheek, the result of injury or disease, or for ankylosis of the temporo-maxillary articulation. The case on which I operated belonged to the latter class, and the joint on one side only was affected. The patient was a woman aged twenty-nine, who thirteen years previously had scarlet fever. Abscesses formed in the temporo-maxillary region, and she recovered with fixed jaws. A horizontal incision was made, about two inches in length, in the soft parts under the body of the jaw on the right side; the soft tissues were then separated from the bone, and an opening made into the mouth between the teeth and the cheek. A narrow saw was applied vertically in the space between the first and second bicuspid teeth, and the bone divided with the help of the cutting forceps. After this section the left side of the jaw was found to be freely movable, but the right side was firmly fixed. A piece of bone nearly an inch in length was then removed from the right or ankylosed side. There was no hæmorrhage worthy of remark, and the wound was closed



with silk sutures. She unfortunately had an attack of erysipelas which retarded her progress considerably, but the result was that when she left the hospital she could open her mouth for about three quarters of an inch.\* Figs. 46 and 47, taken from

FIG. 46.



photographs, represent the patient before and after the operation.

Dr. Maas relates† a case in which there was bilateral ankylosis of the jaw. The patient was a man aged twenty-seven, who had scarlet fever when he was seven years old, and since the age of ten he

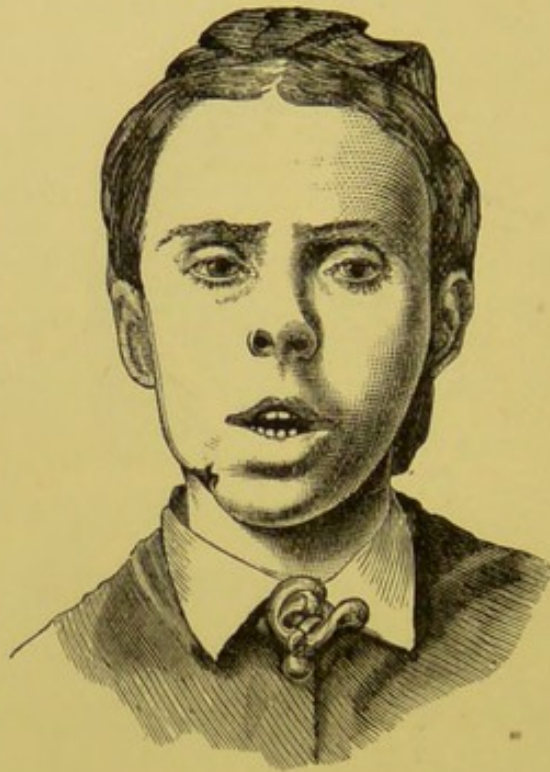\* 'Med. Times and Gaz.,' July 1st, 1876, p. 7.

† 'Archiv. für Klin. Chirurg.,' Band xiii, Heft 3.



had not been able to move the jaw at all. The secondary dentition was attended with great difficulty in the removal of the milk teeth, and the new

FIG. 47.



teeth were for the most part displaced laterally. Herr Middeldorpf operated on the right side, according to Esmarch's plan, with good result, and Dr. Fischer about four months after operated on the left side with great improvement.\*

It is seldom that an opportunity is afforded of examining the pathological condition of the parts after operation, but M. Boinet reports one such

\* 'Brit. Med. Journ.,' June 1st, 1872, p. 585.

example.\* The patient was a little girl who had immobility of the lower jaw following gangrene of the mouth. Rizzoli's operation was performed, and matters appeared at first to go on well, but at the end of three months the divided portions began to unite, and in eight months there was complete consolidation. M. Boinet then performed Esmarch's operation, removing a wedge-shaped piece of bone, with the base at the lower border of the jaw and the apex at the alveolar ridge. The operation was performed in June, 1863, and six weeks or two months afterwards the patient could eat any kind of solid food. In the beginning of September, 1866, she died of phthisis, having up to the time of her death retained the mobility of the jaw. On examining the bone, it was found that there was a false joint between the divided portions, and there was an arrest of development of the bone and atrophy of the muscles inserted into it.

#### FOREIGN BODIES IN THE NOSE AND EARS.

Foreign bodies, such as cherry-stones, locust-beans, brass rings, slate pencils, screws, buttons, pieces of wood, peas, &c., are not unfrequently met

\* 'Gazette Médicale de Lyon,' October 1st, 1866; 'Brit. Med. Journ.,' November 17th, 1866, p. 552.



with in the aural and nasal cavities of children, and even in adults. Such substances have been known to remain in one or other of these cavities for well-nigh a lifetime, causing little or no inconvenience. Thus a case is related of a lady from whose nostril a foreign body was dislodged during the act of sneezing; it was found to be a button which had belonged to her little brother when they were both infants.\* Another case is recorded† in which a piece of slate pencil was removed from a woman's ear, which had been put there when she was at school "forty years before." And a third instance, a patient of Mr. Winterbotham's, of Cheltenham, in which a cherry-stone had been in the ear for sixty years.‡ Mr. Hargood, of Eastbourne, also recently reported the case of a gentleman, aged forty-one, from whose ear a piece of cedar wood was removed by syringing. "The patient remembered distinctly the fact of its introduction when he was a boy at school at least thirty years before. No attempt had been made to extract it, and its presence had not troubled him until now."§

It occasionally happens, however, that a good deal of inflammatory action is set up by the foreign body. As a case in point, I may mention that of a

\* The 'Lancet,' July 2nd, 1859, p. 13.

† Ibid., May 11th, 1867, p. 591.

‡ 'Med. Times and Gaz.,' vol. ii, 1866, p. 497.

§ 'Brit. Med. Journ.,' Jan. 5th, 1878, p. 12.



girl who was under my care at the hospital, and who was admitted on account of having a small stone in her ear. She subsequently had paralysis of the facial nerve. Mr. Jonathan Hutchinson alludes to the case of a child who not only had facial palsy, but died of meningitis caused by the presence of a locust-bean in the ear.

There are various instruments employed for removing foreign bodies from the ear, each good in its way. A loop of wire, a scoop, or a needle with the point just slightly turned up, or a pair of forceps of suitable size may be used.

It is not always easy to detect the exact character of the foreign body, and as bearing on this point I may incidentally refer to the case of the man who is here this evening in the adjoining room. About fifteen months ago he was accidentally shot behind the left ear. The patient was seen by my friend, Mr. Henry Jacobs, of Kensington, who has given me the opportunity of examining him with reference to the lodgment or not of the bullet, for the latter could not be discovered after the accident. There is a constant discharge from the ear, and, as you will observe, well-marked facial palsy. My colleague, Dr. Stone, has kindly constructed a clever electrical apparatus by which we are enabled to detect the unquestionable presence of the bullet. Dr. Stone has done us the honour to be present, and I think you will agree that the Society is much indebted to



him for the trouble he has taken in bringing the apparatus here, and of thus giving the Fellows the opportunity of witnessing so interesting an experiment.

[The apparatus constructed by Dr. Stone consisted of two fine pieces of silver wire, covered with silk, which were wound together in a single strand to imitate a probe, about three inches in length. The whole was insulated and stiffened with shellac, the ends being left loose for connection with a battery and galvanometer. The joined ends at the opposite extremity were cut, so as to leave two little discs of clean silver. On placing these discs in contact with the foreign body in the ear, the galvanometer was visibly deflected, indicating the presence of a metallic substance, which was naturally assumed to be the bullet. The exposed surfaces of the discs were intentionally kept as small, and the insulation as perfect, as possible, to prevent the transmission of a perceptible current by the fluids of the sinus.]

Living larvæ have been found in the meatus of the ear. Dr. Routh publishes such a case:—The patient was a gentleman who three years before was tormented with a fly near his ear. Convulsions followed the presence of the larvæ, but the patient recovered, although he remained deaf.\* Dr. Blake, of Boston, has seen four such cases.†

\* The 'Lancet,' 1849, vol. i, p. 588.

† The 'Lancet,' 1872, vol. ii, p. 861.



Dr. Kealy, of Gosport, reports a case to show the curious course taken by a pin that had been introduced into the external meatus. It passed through the middle ear, probably along the Eustachian tube, and was extracted by the patient from her throat by hooking it with her finger.\*

In dealing with foreign bodies situated in the external auditory meatus, syringing the passage will often suffice to effect removal. In many cases, however, forceps and other instruments must be used, but then they should be employed with the greatest caution. As a rule, if left alone, the foreign body becomes loose, and falls out on the pillow as the patient lies in bed. In extracting foreign bodies from the ear M. Debout† has recommended that the mouth of the patient should at the same time be kept open. It is sufficient, he remarks, to introduce the end of one's finger (and the Fellows may try it on their own person) into the external auditory canal, and to make the lower jaw move, in order to become convinced of the enlargement that the canal undergoes each time the condyle of the jaw is made to move. Dr. Voltolini offers some very sensible and practical remarks on this subject, which I venture to quote.‡ He says : "The first thing we have to do is to assure

\* 'Med Times. and Gaz.,' Dec. 17th, 1859, p. 602.

† 'Brit. Med. Journ.,' May 4th, 1865, p. 229.

‡ 'Brit. and For. Med.-Chir. Review;' 'Brit. Med. Journ.,' March 19th, 1864, p. 315.



ourselves that a foreign body is really in the ear, for it by no means rarely happens that persons apply to the surgeon under the belief that an insect or other substance is present, but which a more exact inspection fails to discover," He adds we should never employ force, and in saying this he did not wish to convey the idea that foreign bodies should always be left in the ear, but that matters should not be made worse by violent manipulations. Still more recently, Mr. Dalby\* has laid down a very practical law that no attempt should be made to remove a foreign body from the ear unless the auditory canal be thoroughly illuminated. Where this rule is broken the tympanic membrane will most probably be ruptured, and thus the life of the patient placed in imminent peril.

#### FOREIGN BODIES IN THE ORBIT AND FACE.

The limits of my time prevent me from entering into the different injuries of the orbit and its contents, and I regret this the more inasmuch as wounds in the neighbourhood of the eye frequently give rise to various anomalous symptoms. In fencing, the foil has occasionally passed straight through the orbit, and has penetrated the brain, in some cases, even without injuring the globe of the eye.

\* 'Brit. Med. Journ.,' Dec. 15th, 1877, p. 847.



The specimen on the table, from the museum of St. Thomas's Hospital, is one of great interest, as illustrating the curious course taken by a portion of a table-knife, which entered the cavity of the skull through the orbit. A girl was mixing some detonating powder with a large table knife. An explosion took place, and she was severely burnt about the face, for which she was admitted into St. Thomas's Hospital. A part of the knife could not be discovered in the room in which the accident occurred. The girl died about a week after admission, and at the post-mortem examination the missing portion was found in the position you now see it, that is, vertically between the vertex and base of the cranial cavity.

Mr. George Lawson\* refers to a case reported by Mr. B. Carter in No. 4 of the 'Ophthalmic Review,' p. 337, in which a piece of iron hat-peg about three inches long, and weighing twenty-five scruples, was impacted in the orbit, and remained there for a number of days without the patient being aware of its presence. It was then extracted by the late Mr. Clarke, of Gloucester, and the man made a rapid recovery without any impairment of the sight of the eye. Another case to which the same author alludes is one that occurred in the practice of Nélaton. The patient, aged 26, had a lachrymal fistula, the result of a blow received three years previously

\* "Injuries of the Eye, Orbit, and Eyelids," 1867.



from the handle of an umbrella. Nélaton believed there was some foreign body present, and after having made an incision, withdrew a piece of ivory handle, such as is often affixed to umbrellas, about an inch and a half in length. After a few days the patient left the hospital with his vision improved and with the fistula nearly healed.

My friend, Mr. Jeaffreson, of Newcastle-on-Tyne, informs me that a case came under his observation in which a large portion of a spectacle frame entered the orbit and was found, after death, imbedded in the substance of the brain. The patient had few symptoms to indicate the presence of the foreign body, and remained fairly well for a few months after the accident, when he died in an epileptic fit.

Mr. Lawson \* has placed on record an interesting account of the lodgment of a large piece of stick in the orbit itself, accompanied with paralysis of all the muscles of the orbit. I may also refer to a somewhat remarkable case that was under the observation of Mr. Furneaux Jordan :† “A man, who was employed in threshing, became the subject of severe ophthalmia. At the expiration of several weeks the patient, whilst pressing his finger on the lower eyelid, suddenly ejected from a comfortable bed of warm pus a grain of wheat, which had shot forth a vigorous green sprout.” Foreign bodies

\* The ‘Lancet,’ Sept. 15th, 1877, p. 390.

† ‘Med. Times and Gaz.,’ Feb. 22nd, 1862, p. 203.



will remain imbedded in the face for days, months, or even years without giving rise to any discomfort. Thus I not long ago removed from a gentleman's face eight or ten shots, which had caused no inconvenience whatever for twelve years.

Substances of different kinds are occasionally found lodged in various parts of the face without the patient being at all aware of their presence. In 1868 I saw a man, aged forty-two, at the Westminster Hospital, who had a swelling on the lower lip on the left side. He had been told he had cancer, and sought advice on that account. It appeared that he had fallen from a scaffolding two or three months previously, and had sustained considerable injury to his scalp and face, and his lower jaw was fractured. He had been a patient elsewhere, and stated that when he was under treatment he had fits. On examining the part, the lip was found a good deal swollen, and rather tender to the touch. I made a puncture, when the knife impinged on a hard substance, which proved to be a portion of the crown of the left lateral incisor of the lower jaw, which the patient said he missed after the accident. It was decayed at the neck, and had sharp edges. The patient made a good recovery.

Another instance is recorded \* in which a canine tooth was lodged in the thickness of the lower lip

\* The 'Lancet,' May 17th, 1862.



simulating a cancerous tumour. The patient was a lady forty years of age, who had always suffered with her teeth, and had but few incisors left, the rest of the jaws presenting roots more or less firmly wedged, and the alveoli more or less decayed. Towards the end of the year 1854 she felt a small tumour forming in the lower lip of the left side. Pain was subsequently experienced, and a few months afterwards the patient could hardly eat. She sent for her medical attendant, who made a crucial incision, and discovered a long root of the canine tooth which had been imbedded in the substance of the lip.

Another case is related by Mr. W. H. Folker,\* of the North Staffordshire Infirmary. The patient was sixteen years of age, a joiner, and was admitted August 29th, 1867, on account of a tumour existing in the substance of the upper lip. The swelling was on the right side of the mesial line corresponding to the right central incisor tooth (which was noticed to be wanting), and it seemed to be formed by hypertrophied lip. It caused a good deal of deformity, as the patient was unable accurately to close his lips. The tumour felt hard, but was not painful. On carefully examining the swelling, a small aperture was perceived at its base; and on passing a fine probe a hard substance was felt, which was diagnosed to be a tooth. On August

\* The 'Lancet,' October, 1868.



31st, an incision having been made through the tumour, a tooth was found at its base. After its removal the swelling disappeared, and the patient was discharged the following day.

Mr. Haynes Walton has reported a case\* of a patient, aged thirty-five, who, three years and a half before, had a fall, and lost his right upper lateral incisor. He had much pain, and a few weeks later an abscess formed, which discharged through a small opening in the cheek as well as through the alveolus of a lost tooth. Then another abscess formed, leaving a sinus open in the right cheek. On probing this, a hard substance was found. The wound was opened up, and a perfect incisor tooth, lying loose in the antrum, was removed.

I need scarcely add that carious teeth, which may be almost regarded as foreign bodies, give rise, as all surgeons practising dental surgery are aware, to an endless variety of anomalous symptoms, such as neuralgia, squint, wry-neck, closure of jaws, epilepsy, &c. Mr. Hancock † has reported several such cases. One was a patient whose jaw had been closed for twelve months; a second, a girl affected with wry-neck; a third, a case of supposed tumour of the cheek; a fourth, a case of amaurosis lasting for a month; a fifth, a man who was totally blind in the right eye for eight months; and a sixth, a patient

\* 'Medical Times,' November, 1869.

† The 'Lancet,' 1859.



with strabismus and ptosis. Mr. Adams Parker\* and Mr. Samuel Smith† have contributed similar examples.

In conclusion, I will refer to an interesting case that was under the care of Dr. George Johnson,‡ in which tetanus, with facial neuralgia and palsy, and a recurrence of epilepsy, were excited by a foreign body imbedded in the cheek. The patient was a wheelwright, aged forty-four, who, on July 4th, 1872, was cut on the cheek by a blow from an iron axle that fell upon his face. The wound was strapped up by a chemist, and healed, but remained very painful. On the 12th he had an epileptic fit. In early life he had been subject to epilepsy, but until the occasion mentioned had been free from fits for twelve years. On the morning of the 13th—that is, about ten days after the accident—he had difficulty in opening his mouth. The left masseter muscle felt prominently hard and rigid. There was a scar, about three fourths of an inch long, an inch below the left eye, the cicatrix being hard and very tender to the touch. Dr. Johnson, believing that there was a foreign body present, directed the house-surgeon to cut through the cicatrix, when a sharp, angular piece of flint, nearly as large as a grain of wheat, was discovered and removed. With this the

\* The 'Lancet,' vol. i, 1862.

† The 'Lancet,' vol. i, 1857.

‡ 'Clinical Society,' Nov. 8th, 1872.

symptoms gradually passed away. The chief interest of the case, as Dr. Johnson remarked, consisted in the fact that formidable nervous symptoms were excited by the presence of a foreign body of small size beneath the cicatrix of a recently healed wound.

In my next, and concluding lecture I hope to speak of the "Deformities of the face with their treatment."



## LECTURE III.

### DEFORMITIES OF THE FACE.

MR. PRESIDENT AND GENTLEMEN.—Having briefly disposed of the diseases and injuries of the face, I purpose, with your permission, in this, my concluding lecture, to describe some of the principal deformities that are met with in this region, with their appropriate treatment. I shall pass over such congenital malformations as do not come within the scope of the surgeon's art; those I mean that would be generally classified as monstrosities.

In a paper "On the Relation of the Teeth and Mouth to Mental Development"\* Dr. Langdon Down lays stress on the characteristic features of the lips in congenital idiots. The lips, he says, are in such persons usually thick, the thickness being greatly more marked in the lower than in the upper one. In addition to the thickening they are often striated and marked by transverse fissures. They are frequently deficient in muscular power, and the

\* 'Trans. Odontological Soc.,' vols. iii and iv, 1871—72, p. 14.



want of muscular action interferes with their prehensile function, and also induces a tendency for the saliva to run over the chin. The mucous membrane is extremely liable to chronic inflammation, and ulceration is induced by the slightest pressure against prominent or uneven teeth. The glands of the mucous membrane of the mouth generally, as well as the salivary glands, are usually hypertrophied. Again,\* the same writer alludes to certain semilunar folds of skin at the inner canthus of the eye—folds which, he believes, are more frequently present in feeble-minded children than in others, and which he describes as epicanthic folds. They are, according to his experience, marks of developmental degeneracy, and should always be looked for in doubtful cases. Then he remarks that the seat of implantation of the ear in idiots is usually placed further back in relation to the head and face than in normal children. The mouth is arched or gothic-shaped. The tongue is increased in size; it is rugous, fissured, and its papillæ are enlarged. Again, the angle of the jaw is more obtuse than usual.

#### HARELIP.

Perhaps one of the commonest congenital deformities of the face is harelip, of which various

\* 'Trans. Obstet. Soc. of London,' vol. xviii, 1876.



examples are shown in figs. 48, 49, 50, 51, and 52. Having written so recently on this subject,\* I have little to add to what has been already published; but I may be permitted to dwell for a moment on one or two points in connexion with this deformity.

FIG. 48.

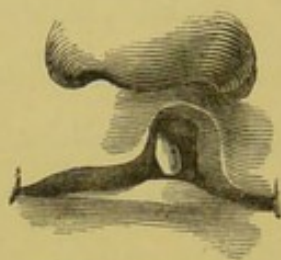


FIG. 49.

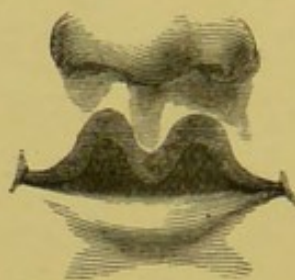


FIG. 50.

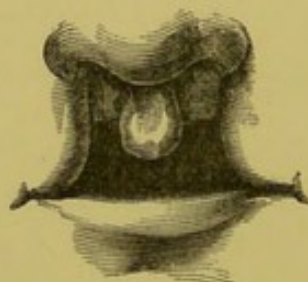
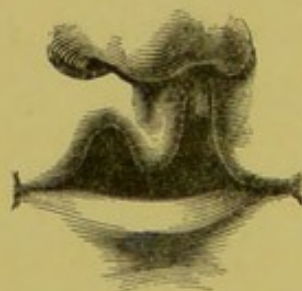


FIG. 51.

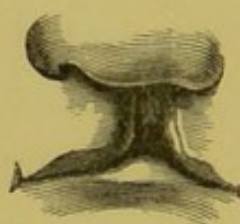

FIG. 52.



1st. Respecting the intermaxillary or premaxillary bones. I think there can be no doubt that when

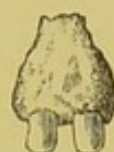\* See author 'On Harelip and Cleft Palate,' Churchill, 1877.

harelip is associated with a fissure of the hard palate, the fissure takes the place of the lateral incisor tooth of one or both sides, as the case may be. In other words, the lateral incisor is usually wanting. Figures 53 and 54 indicate these points, but the actual specimens, which I hand round, as

FIG. 53.



FIG. 54.



well as the photographs, put the matter, I think, beyond doubt. This specimen especially, from the collection of the late Sir William Fergusson, is of more than ordinary interest, for it shows one of the results of pushing back the intermaxillary bones, a plan of treatment adopted by some surgeons. It will be observed, first, that the central incisors alone are present; and, secondly, that they are situated horizontally backwards; indeed, before removal they really occupied the anterior part of the roof of the mouth.\*

It is extremely rare to find a case of double harelip with no fissure of the palate whatever, but I have seen one case, and another is now under the care of my colleague, Mr. Croft, at St. Thomas's Hospital.

2nd. The hereditary character of harelip is in

\* 'Brit. Med. Journ.,' Dec. 25, 1875, p. 772.



very many instances, I find, conspicuous by its absence, but occasionally it is very striking. Thus, Dr. Buck\* gives an account of a family in which there was a very remarkable hereditary history:—  
“Mrs. M— and her three children (all girls) came under his notice in January, 1871. The mother herself bore the marks of a successful operation for harelip performed in childhood. She had a brother and sister with harelip; and besides the three living children above referred to, she had had four others, who had all died in early infancy; three of these had harelip, and the fourth one only was a perfect child. In other words, there were nine instances of the deformity in two generations of a single family.

3rd. I may perhaps be allowed to make one or two practical remarks respecting the method of operating. The harelip pin with the twisted suture is very commonly employed to bring the edges together, but, without entirely discarding this method of approximating the parts, I feel sure that the usual interrupted suture of silk may in most cases be employed with great advantage, and, I believe, with certain precautions, it is in many instances preferable; but whether the twisted or interrupted suture be used, the success of the operation mainly depends, first, on the soft parts being thoroughly freed from the subjacent bone; secondly, on the edges of the fissure being so pared that a good

\* ‘Reparative Surgery,’ 1877, p. 130.



broad raw surface is left; and thirdly, on the patient being incessantly watched for three or four days by a skilled nurse, who should support the newly united surfaces by making continuous but gentle pressure on each cheek. I have little confidence in the use of mechanical appliances *after* the operation; for, in nursing the child, they are apt to shift their place, and often do more harm than good. They are, however, invaluable as aids in bringing the two superior maxillæ together if worn *before* operative procedure is undertaken. Again, strapping is of especial service before the operation, but afterwards it cannot be with safety solely relied on.

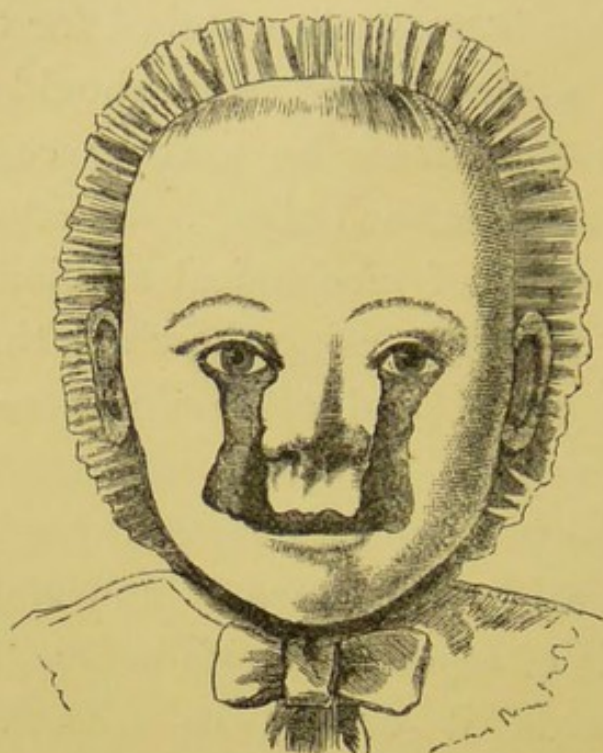
Besides the ordinary forms of harelip, fissures of the lips extend in other directions: thus, Mr. Ward describes a case\* in which the fissure extended into the right cheek. Another more remarkable example is recorded† in which a boy was born with a "very large mouth." At seventeen years of age his mouth was six and a half inches in diameter, extending from one ear to the other, so that the tongue always hung between the teeth. Langenbeck operated on the lips and brought the parts together. Again, a remarkable instance is reported by M. Guersant, in which the fissure on each side extended towards the eyelids. (Fig. 55.)

\* The 'Lancet,' May 28, 1859, p. 536.

† Ibid.; vol. xiii, 1827-28, p. 462.



FIG. 55.



CLEFT PALATE.

The mention of harelip almost necessitates a few words on fissure of the palate, of which several varieties are exhibited in the diagrams I here show you. (Figs. 56, 57, 58, 59, 60, 61, 62.) It is extremely rare to meet with a case of fissure of the soft palate in which there is an entire absence of the uvula, but such a case I have the opportunity of showing you to-night. You will observe that there is not a vestige of uvula, the fissured palate being directly continuous with the pharynx on each side.

Respecting cleft palate I have little to add to what I have already laid before the profession. I may, however, say that in the majority of cases in which

FIG. 56.

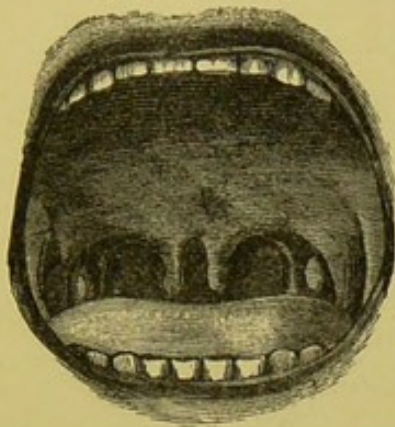


FIG. 57.

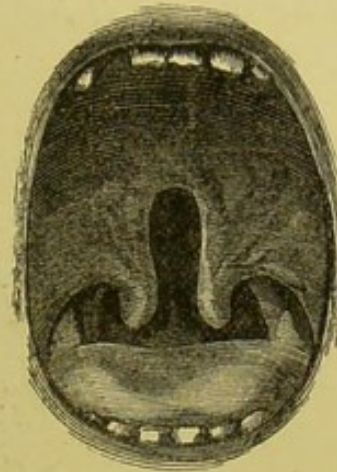


FIG. 58.

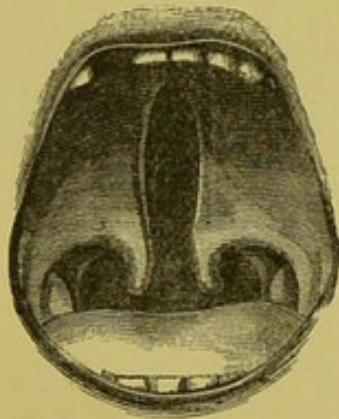


FIG. 59.

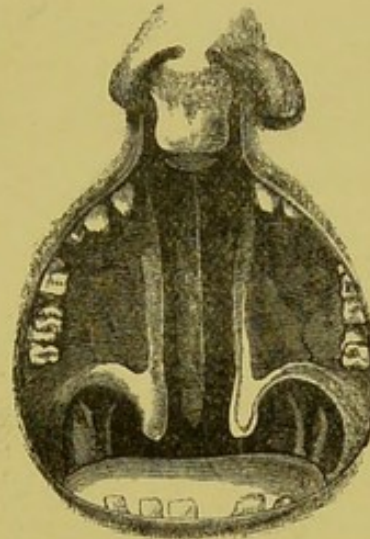


FIG. 60.

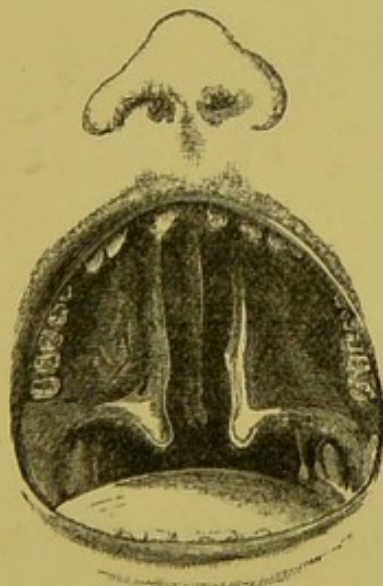
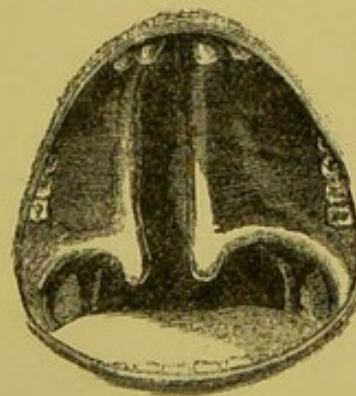


FIG. 61.





the hard palate is involved I perform the muco-periosteal or Langenbeck's operation shown in

FIG. 62.

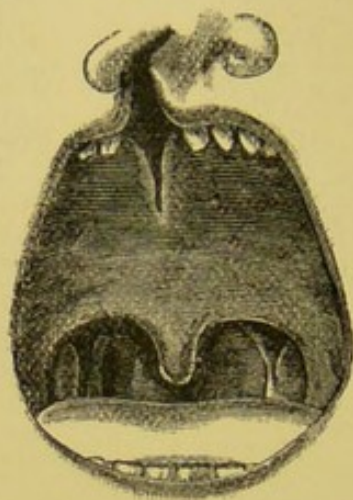
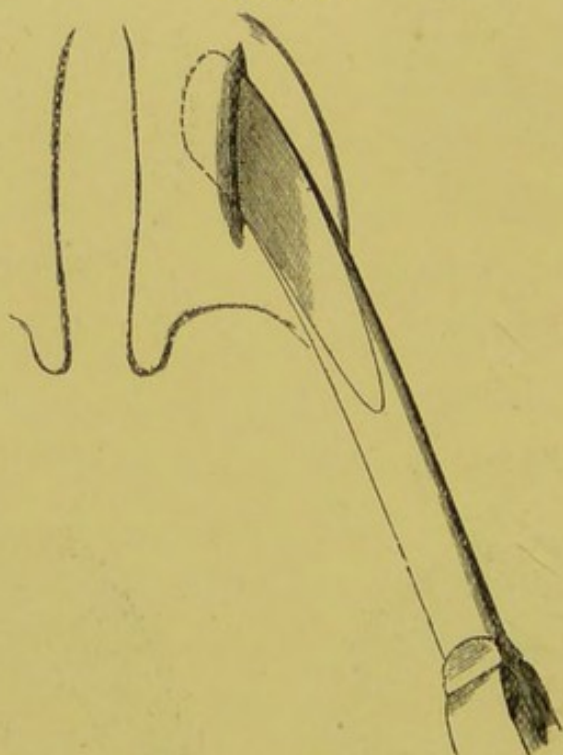
Fig. 63, in preference to Dieffenbach's method of procedure. Dieffenbach's plan of dividing the

FIG. 63.



entire bony palate with a chisel, and which was introduced into this country by the late Sir W.

Fergusson, has the disadvantage that it is sometimes followed by exfoliation of bone. This untoward result, however, may to some extent be obviated by boring a few holes with an ordinary bradawl in the line in which the chisel is to be applied, a plan I suggested in the 'Lancet' of October 24th, 1874, p. 578, and which is indicated in Figs. 64, 65. Again, the closure of the hard palate is often attended with troublesome hæmorrhage, but the bleeding may be instantly arrested by plugging the wounds on each side with dry lint, after which the operation may be completed without difficulty. I referred to this practice in the 'Lancet,' of July

FIG. 64.

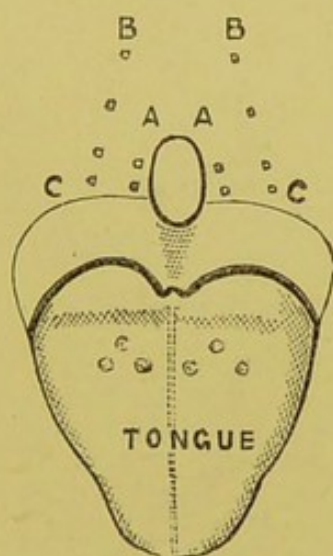
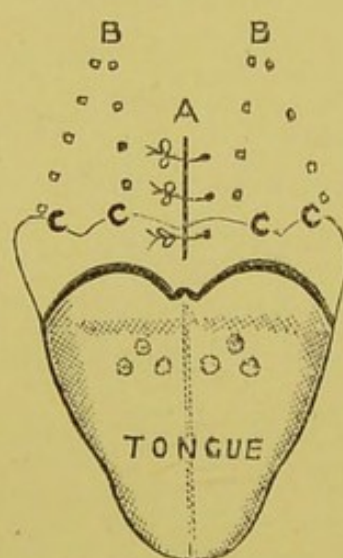


FIG. 65.



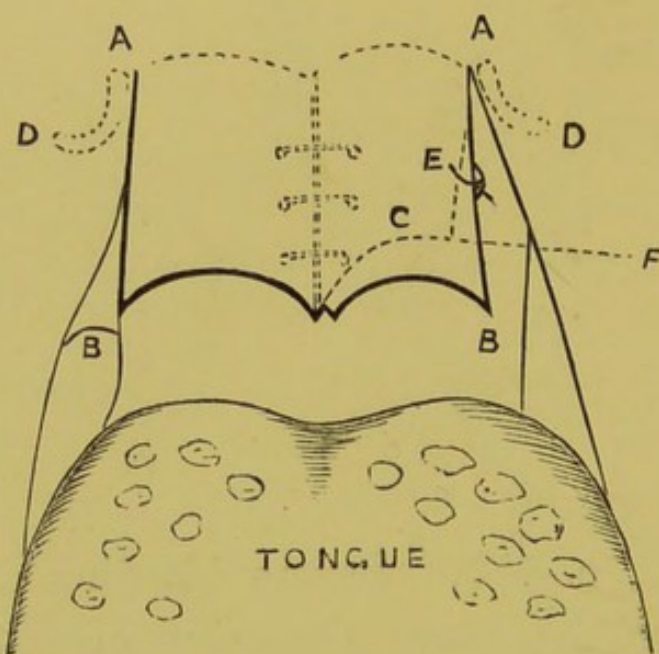
29th, 1876, p. 170. Severe bleeding of an intermediary or secondary character occasionally, but very rarely, occurs. Such a case has, however, been recently reported by Mr. Marsh.\*

\* The 'Lancet,' Jan. 19, 1878.



The chief object of the operations for cleft palate is, of course, the improvement of the voice. I need not refer to my views on the subject further than to say that a cleft in the soft palate is not a mere rent or slit in the parts, but is an actual deficiency or want of tissue. Hence, after the edges of the soft palate are brought together, the part remains as a tight curtain, stretched between the mouth and posterior nares. The result is that, in speaking, the air, instead of passing into the mouth, gains access to the nostril, and thus the peculiar nasal twang is maintained. I therefore venture again to recommend the performance of a very slight operation, an account of which I published in 1869.\* It

FIG. 66.



must be understood that this procedure is an entirely independent operation, and should be per-

\* The 'Lancet,' vol. ii, 1869, p. 198.



formed only when the surgeon is perfectly satisfied that firm union between the previously fissured parts has taken place. The sides are divided in the line from A to B (Fig. 66). These incisions release the part on each side and the palate is, so to speak, converted into a huge uvula.

### CONGENITAL DEFICIENCIES OF BONES OF FACE, &c.

Besides congenital defects of the superior maxillæ and the palate bones, there are cases recorded of deficiency in other bones about the face. Thus Delpech \* gives a description of a patient who had a congenital absence of the right nasal and lachrymal bones, the nasal process of the superior maxillary, and of the soft parts.

Again, Dr. Samelson exhibited at the Manchester Medical Society a patient, aged twenty-three, who had a congenital defect of the frontal bone. There was a somewhat thickened integument extending over a cavity produced by the absence of the bone. Within the gap the cerebral pulsation was very plainly visible.†

Mr. Gay has favoured me with the notes of a case in which there was congenital absence of the nasal bones. The rough sketch I send round will afford

\* The 'Lancet,' 1829-30, p. 260.

† 'Brit. Med. Journ.,' Feb. 3, 1872, p. 137.



some idea of the condition of the parts. Further, Mr. Bryant, in his work on Surgery, refers to a case of Mr. Poland's of meningocele, which caused a considerable prominence over the nasal bones.

Dr. Lichtenberg also reports a remarkable instance of a congenital tumour which protruded through the mouth of a newly born babe. The growth overlapped the chin, and rested with its base on the sternum. From the appearance, Dr. Lichtenberg believed the case to be one of polypus, and after putting on a ligature as tightly as possible, cut off the tumour. Three or four days after, the patient died of convulsions. At the post-mortem examination the pedicle of the tumour was found to perforate the sella turcica, and was there attached to an oval tumour which was connected with the brain.\* Such a case as this should make us remember that it is not always easy to pronounce a decided opinion as to the exact nature of a congenital tumour. Whilst I am on this subject, I may allude to an instance that was under the care of my former colleague, Mr. Henry Arnott, which showed the difficulty of arriving at a correct diagnosis. There was a round sessile swelling, the size of a large walnut, situated just in front of the anterior fontanelle, in a child eight months old. The history of the case pointed very decidedly to the tumour being a meningocele. No operative

\* 'Path. Trans.,' vol. xviii, 1867, p. 251.



treatment was adopted, and the patient died of broncho-pneumonia. At the post-mortem examination the swelling proved to be a cyst of a dermoid character, and was quite unconnected with the interior of the skull. The mistake (adds Mr. Arnott) in this instance mattered little; but fatal errors have been committed by surgeons mistaking meningocele for simple dermoid cysts, and undertaking their removal.\*

Again, Mr. Gay tells me he now has under observation a case in which there was a swelling, the size of a small walnut, situated at the front part of the left temporal fossa. The patient was seventeen years of age, and the swelling had become prominent for the last ten years. Mr. Gay believes he had discovered the true nature of the tumour by cutting down, but not into it, for rather severe symptoms followed the operation. No pressure on it, or other efforts to detect the real nature of the swelling, answered before exploration. The tumour was thought to be a meningocele.

#### CONGENITAL MALFORMATION OF EARS, JAWS, &c.

*Congenital malformation of the ears* of a slight kind is not uncommon, and we occasionally meet

\* 'Path. Trans.,' vol. xxv, 1874, p. 230.



with supernumerary auricles. Mr. Birkett has published a case of this nature in which the extra auricular appendages were situated rather lower than the angles of the jaw on each side of the neck.\* A supernumerary eyelid has also been observed by M. Dubois,† but it proved to be nothing more than a fold of conjunctiva.

Sir James Paget has given increased stimulus to the study of the subject of congenital malformation of the ears in an admirable paper lately read at the Royal Medical and Chirurgical Society on branchial fistulæ in the external ears.‡ The cases he described showed a remarkable hereditary tendency, and occurred in the family of a gentleman perfectly well formed in other respects, who had himself a branchial fistula on the right side of the neck. His father and a sister, as well as four of his own children, had similar malformations; the fistula in two of the latter being on the left side, and in the other two symmetrically disposed on each side of the neck. But, in addition to these cervical fistulæ, the gentleman himself, his sister, and five of his children, each had fistulæ in the helix of one or both ears. The aural fistulæ were minute, their orifices small, and their canal half an inch in length, passing from below forwards and downwards, being

\* 'Path. Trans.,' vol. ix, p. 448.

† 'Med. Times and Gaz.,' Jan. 16, 1864, p. 78.

‡ 'Lancet,' Dec. 1, 1877, p. 804.



less soft and flexible than the cervical fistulæ, producing no secretion, and giving no distress.

In 1870 a remarkable case of this kind was exhibited at the Pathological Society of Reading, by Dr. Moxhay, of deformities of the ears and face,

FIG. 67.



shown in Fig. 67 (taken from a photograph for which I am indebted to Dr. Moxhay). He says: "In addition to the proper complement of two perfect ears, there were on the right side three rudimentary auricles, one rather a perfect specimen. On the left side there were two of these abnormal growths, one representing a fleshy lump, with cartilage in and beneath its substance, just below and in front of the proper ear; the second being a mere projecting tubercle, but exhibiting, when removed, a cartilaginous meatus dipping deeply. A congenital deficiency of the right ramus of the lower jaw also existed, which gave a singularly strange



expression to the face, resembling somewhat the drawing down of the chin by the cicatrices of burns. Dr. Moxhay stated that a curious reason was given by the mother of the child for these abnormalities. It seems that, when pregnant, the woman was suddenly frightened by a boy who was the subject of contraction in the neck which drew down the chin and lips in a manner very similar to the deformities described above. Upon receiving the fright the poor woman immediately put up her hands to her ears." At my request Dr. Moxhay kindly examined this patient in November last—that is, seven years after she first came under observation—and in reply to my inquiry stated that the jaw was absent from the first molar on the right side, and he could put his finger into the glenoid cavity from the inside of the mouth. There was no condyle, but there was a band of slightly firm tissue where the jaw ought to be. The girl was intelligent, and could speak well.

I here show you, through the courtesy of Mr. Royes Bell, photographs of the ears of another patient with a somewhat similar deformity, the right ear being represented in Fig. 68. The appendages were merely small pieces of loose skin containing no cartilage. The fistulæ in this case were not well-marked, and there was no family history to indicate its hereditary nature. The characteristic shortening of the lower jaw is also well shown.



Whilst on the subject of malformation of the ears, I may briefly refer to one or two examples of cervical fistula, for I think some of these cases are overlooked. Heusinger reports two examples. One occurred in a girl aged fifteen, and in this instance the cutaneous orifice of

FIG. 68.



the fistula, having a diameter of about one fifth of an inch, was situated at the upper edge of the sternum, near the sterno-clavicular articulation and the inner edge of the sterno-mastoid muscle. The canal of the fistula was nearly an inch long, and directed vertically upwards, ending in a *cul-de-sac* having a diameter of two fifths of an inch. In another case, occurring in a girl seven



years of age, the external ears, especially the right, were slightly malformed. On the left side of the neck, a little above the thyroid cartilage, was a small orifice, surmounted by a projecting crest of skin, in which there appeared to be a particle of bone or cartilage. The orifice led into a canal which proceeded *towards* the pharynx above the hyoid bone, but no internal opening could be found.\* Dr. F. Mayer has also reported a similar case.

Two examples of this congenital malformation in the neck have come under my observation—one at the hospital about six years ago, and a second in private practice in the autumn of 1876; in the latter case I had the advantage of Sir James Paget's opinion. The patient was a young lady, aged nineteen, who had two minute orifices at the inner side of each sterno-mastoid muscle, just above the sterno-clavicular articulation, which occasionally discharged a mucous secretion. A small probe could be introduced for several inches in the upward direction, almost to the angles of the jaw. The patient was under the impression that the fistulæ opened internally, but I could not satisfy myself, after careful examination, that such was the case.

Dr. Munro, of Radstock, has published† a case in which there was a complete absence of the meatus

\* 'Virchow's Archiv,' and 'Gaz. Méd. de Paris,' June 16th, 1866.

† The 'Lancet,' July 10th, 1869, p. 41.



auditorius externus of the right side, although the pinna, or external ear, was perfectly normal; and Dr. Fleischmann, of Cheltenham, gives an account of a similar instance\* occurring in a little girl, and on whom he endeavoured to establish a permanent aperture by means of the galvanic battery with very fine needles; but the parts healed up soon after, notwithstanding every effort was made to keep them open. Mr. Hinton, however, is stated to have cured such cases by dividing the false membrane and introducing tents into the aperture.†

#### MATERNAL IMPRESSIONS.

Congenital malformations are often traced to maternal impressions. Dr. R. J. Lee, who gave us an interesting and instructive paper on the subject in November last, expressed a decided opinion that maternal impressions may be divided into two classes—viz., those producing lesions of the surface of the body, and those which were the effect of changes in the nervous and arterial system.‡ I may mention one or two instances which appear to have characteristic significance. The first is reported by Mr. Curgenvin, as follows:—"A woman during pregnancy was horrified at seeing a man

\* 'Lancet,' July 24th, 1869, p. 151.

† Holmes' 'System of Surgery,' vol. iii, p. 135.

‡ 'The Lancet,' Nov. 3rd, 1877, p. 651.



whose ear had been mutilated. Her child, a girl, was born with her right ear presenting a similar appearance. This child grew up, and her sister, whilst pregnant, and during a fit of anger, called her 'old one ear.' She retorted by saying that one day she would be sorry for speaking of her deformity in that manner. The result was that the sister's child, a boy, was born with his right ear deformed like his aunt's." Another remarkable case came under my own observation. About a year after the burning of Covent Garden Theatre after a series of performances terminating in a *bal masqué*, a child was brought to King's College Hospital the half of whose body, including the face, closely resembled a piece of charred wood. It appeared that the mother during pregnancy resided opposite the theatre at the time of the fire, and attributed the condition of the child to the fright that the fire occasioned.

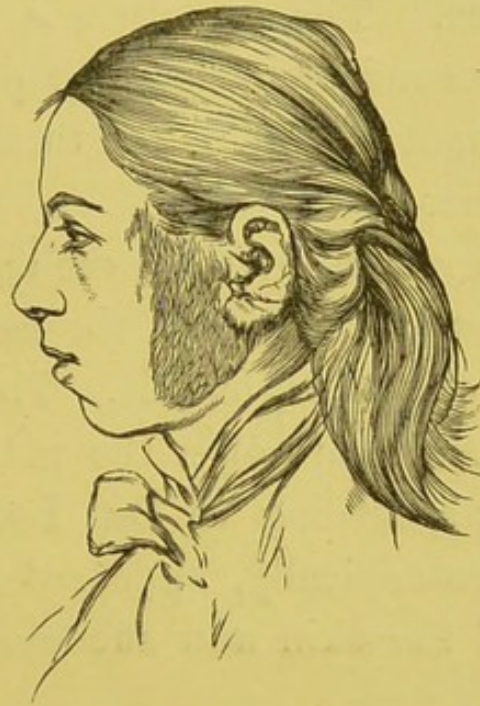
Mr. Morratt Baker (to whom I am indebted for the photographs I hand round) has published an interesting case of a hairy mole of congenital origin on which he had successfully operated. The supposed cause of the deformity in this case was that the mother during pregnancy was frightened by a monkey in a travelling menagerie. A somewhat similar case, shown in this woodcut (Fig. 69), taken from a photograph, came under my notice about three years ago. The mother attributed the deformity to



a fright occasioned by seeing a rat. I proposed to attempt a partial destruction of the deformity, but the patient objected to any surgical interference.

Dr. Buck\* reports a case of abnormal growth of hair on the forehead (congenital). The patient, aged thirteen, had a hairy mole over the left eye,

[FIG. 69.



looking like mouse-skin. The growth was removed partially by the actual cautery, but chiefly by caustic potash.

#### CONGENITAL HYPERTROPHY OF FACE, LIPS, &c.

Valentine Mott† describes a peculiar form of tumour of the skin occurring in a boy aged fourteen,

\* 'Reparative Surgery,' p. 165.

† 'Med.-Chir. Trans.,' vol. xxxvii (1854), p. 158.



who had a deformity of the entire half of the left side of his head and face. It consisted of three layers of tumours from the crown of the head to some distance below the base of the lower jaw. It commenced as a pimple soon after birth. The mass involved the scalp of one side of the head, one-half of the nose, the upper and lower lips, and the whole side of the face. The growth was removed, but recurred. A second operation was performed, but with no permanent benefit, as the tumour continued to increase in size.

Another case related by the same author was that of a boy aged twelve, who had the same thing, but of less extent, on the right side. The growth was removed, and six years after the patient was well. The specimen, according to Dr. Lovett, who examined it microscopically, appeared to consist of hypertrophy of the skin and subcutaneous areolar tissue.

Mr. Jardine Murray has described a very unusual congenital malformation of the lower lip, in which two sacculi existed.\* The deformity occurred in four members of the same family. Mr. Murray thus describes the condition:—"About a quarter of an inch from the external edge of the pink mucous membrane of the prolabium are two crescentic openings, exactly similar in appearance and symmetrical in position, one placed on either side of the

\* 'Brit. and For. Med.-Chir. Rev.,' vol. xxvi (1860), p. 502.



mesial line. The horns of the crescent are directed forwards, and a little outwards. A probe inserted into one of these openings passes downwards on the inner side of the lip under a considerable thickness of mucous membrane, to the depth of half an inch. Into each pouch a split pea might readily be introduced. The pouches do not communicate with each other; they secrete glairy mucus, and their presence does not occasion any inconvenience. Sacculi in every respect precisely similar to these are present in the under-lip of the father of this family and of his third and eighth children, all of whom were born with the additional malformation of harelip."

By the kindness of Mr. Jardine Murray I am enabled to show you photographs, before and after operation, of a case of congenital hypertrophy of the upper lip which was cured by the removal of an elliptical portion. Mr. T. Holmes\* refers to a somewhat similar example occurring in a child, two and a half years old, who had considerable enlargement of the upper lip. An elliptical piece was removed, which, on examination, presented the appearance of "ordinary rather condensed cellular tissue." The mother stated that she was sure that the condition of the lip was congenital, and attributed it to her having been struck on her lip by her husband during her pregnancy.

\* 'Surgical Treatment of Children's Diseases,' 1868, p. 27.



Dr. Buck\* relates the case of a man, aged twenty-five, who was admitted into St. Luke's Hospital, America, with a congenital nævoid growth of the lower lip. The lower lip was more than double the thickness of the upper, and proportionately increased in all directions. A V-shaped piece was removed with good result.

*Congenital absence of the nose* is very rare. Of course the floor of the nostrils is more or less wanting in cases of cleft palate. Lateral displacements of congenital origin are sometimes met with, and may be dealt with according to circumstances. I alluded to the treatment of such cases in my last lecture.

*Imperforate nostrils* of congenital origin are very rarely brought under the notice of the surgeon. I saw one case at King's College Hospital in a newly born baby, but the child died almost immediately after birth, so that there was no opportunity of attempting a cure. Mr. Thomas Smith, however, refers to an instance† which was under his care in a child, aged five, who suffered from "insufficient nasal aperture." Great improvement followed an operation, which consisted in passing a narrow bistoury into the nostril and retaining a piece of gum-elastic catheter.

\* 'Reparative Surgery,' p. 159.

† 'Med. Times and Gazette,' March 28th, 1863, p. 320.



## NON-CONGENITAL DEFORMITIES OF THE FACE.

Having disposed of the congenital malformations, I now pass on to consider the deformities of the face occasioned by accident or disease.

A very rare case of unilateral atrophy of the face, caused by pressure of a thin cicatrix on the left side of the face and neck, is reported by Dr. Hering in Langenbeck's 'Surgery' (1867); and an interesting example of hypertrophy of the lower part of the face has been published by Mr. Barwell,\* by whose kindness I am enabled to show you these photographs. The patient was 20 years of age, and about five years previously went to bed one night perfectly well. On the following morning, on waking, he found that his face was distended and swollen, and the mouth drawn to one side. The swelling was unaccompanied by heat, pain, or redness, and the cheeks were much thickened, the greatest swelling being in the lower part of the face, extending upwards to the malar bone. The lips were greatly thickened, everted, and almost pendulous, and there were no cracks or indurations of the lips. The tongue, soft palate, and jaws were unaffected. From the situation of the swelling it was evident that it lay in the region supplied by the facial arteries, which were obviously enlarged. Mr.

\* 'Clinical Society,' March 12th, 1875.



Barwell placed a ligature on both facial arteries but with very little improvement. He thought that the only further treatment that could be adopted was to excise some of the mucous membrane of the lips, but the patient was averse to further measures.

Mr. Barwell informs me that when he last saw the patient, that is ten months after operation, there was but slight diminution of the part.

Tumours of the lips of course produce more or less deformity, and to these I referred in my first lecture on the diseases of the face.

#### PLASTIC OPERATIONS ON THE FACE.

The infinite variety of the deformities occasioned by accident or disease at once renders the subject of plastic surgery of the face one of more than ordinary interest. Moreover, as no fixed rule can be laid down as to treatment the surgeon has, in many instances, to exercise some ingenuity in designing and carrying out such operative measures as he may think expedient.

With regard to operations, it will be well to consider them as two distinct classes—(1) Those that are undertaken for disease, and to remedy deformities necessarily occasioned by the surgeon in removing epitheliomatous or other growths ; and (2)



those that are undertaken to improve deformities occasioned by accident, such as burns, gunshot injuries, &c.

Respecting the upper and lower lips much may be done without resorting to the transplantation of skin. The soft parts of the face are so mobile that with proper precautions they may be stretched to almost any extent, the one point necessary being that the soft structures should be thoroughly separated from the subjacent bone; hence some surgeons, Mr. Furneaux Jordan\* amongst the number, speak confidently of making a mouth with one lip, either upper or lower.

#### THE FORMATION OF A NEW UPPER LIP.

Various plans have been suggested and practised to form a new upper lip. Thus Bérard† made two parallel and almost vertical incisions, so as to include a portion of the skin of the cheek on each side of the nose, and, bringing the flaps downwards, united them in the middle line. Mr. Morgan practised a similar plan in 1829.‡ Sédillot§ dissected a square portion of skin from each cheek, and united

\* 'Surgical Injuries,' p. 18.

† Follin et Duplay, 'Traité Élémentaire de Pathologie externe,' vol. iv, 1875, p. 657.

‡ 'Lancet,' 1829-30, vol. i, p. 357.

§ 'Prov. Journal,' 1848, vol. xii, p. 90.



the parts in the centre, as shown in Fig. 70, representing the operation as applied to double harelip. Dieffenbach\* made an **S**-shaped incision on each side of the alæ of the nose, and, detaching the flaps, brought them down to the median line (Figs. 71 and 72). The late Mr. Teale, of Leeds, in operating

FIG. 70.

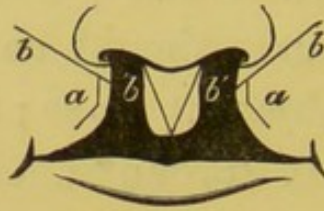


FIG. 71.

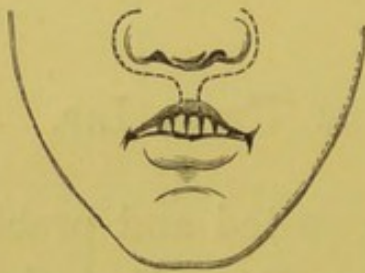


FIG. 72.

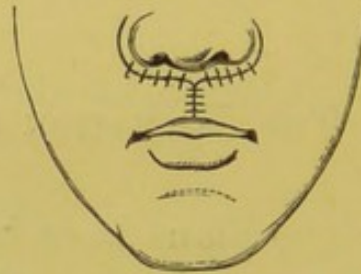
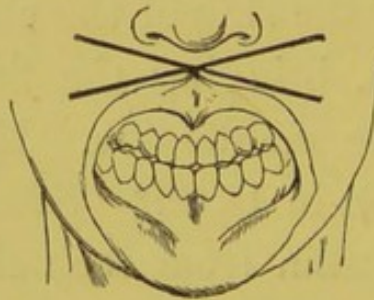

FIG. 73.



for the restoration of the upper lip after burns, made a crucial incision, having its point of inter-

\* Follin et Duplay, op. cit., p. 657.



section immediately below the septum of the nose (Fig. 73). "Each limb of this incision," he says, "is about one and a half inch in length. The two limbs on each side diverge moderately as they pass outwards to the cheek, and enclose between them an acutely angular flap of skin and other tissues. The crucial incision is extended deeply through the entire substance of the imperfect lip and the cheeks. The parts implicated in the incision are then freely loosed from their attachments to the superior maxillary bone by the knife being passed upwards between the bone and the remnant of lip. The parts being thus detached, the two lateral angular flaps are drawn across the median line, dovetailing with each other and thereby increasing the depth of the lip at the expense of its breadth. In this position the flaps are retained by one pin and twisted suture."\*

In a case of severe burn of the face which was recently under my care, and in which there was great eversion of the upper lip, I made a **V**-shaped incision through the whole thickness of the part, leaving the prolabium; the edges were then brought down, and when the raw surfaces were united, the incision assumed the form of a **Y**. I referred to this patient in my last lecture (see Fig. 40, p. 59).

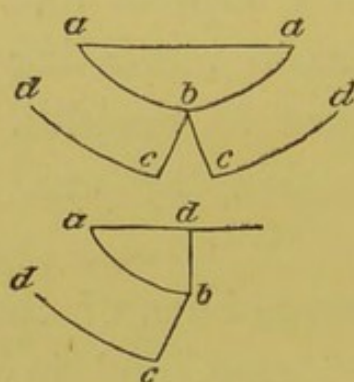
\* · On Plastic Operations,' 1857.



## RESTORATION OF LOWER LIP.

In remedying deformities of the lower lip after removal of disease, Buchanan's operation, which was first performed by that surgeon for cancer on May 20th, 1835, is well worthy of imitation in suitable cases. It is thus described by Mr. Buchanan\* :—"The line *a a* (Fig. 74) represents the commissure of the mouth, and the semi-

FIG. 74.

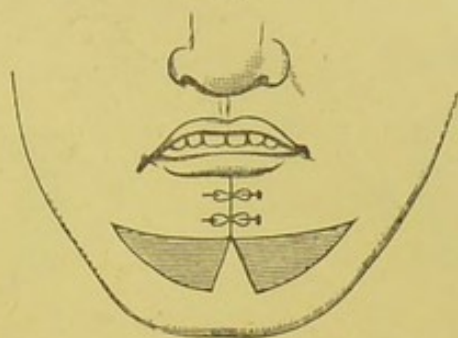


elliptical line *a b a* the incision by which the carcinomatous mass was removed. The new lip was formed by means of two flaps taken from the sides of the chin, each, however, by a curvilinear incision, *b c*, and a straight one, *d c*. These flaps were raised and brought together in the mesial line" (Fig. 75).

\* 'Lond. Med. Gazette,' vol. i, 1842, p. 79.

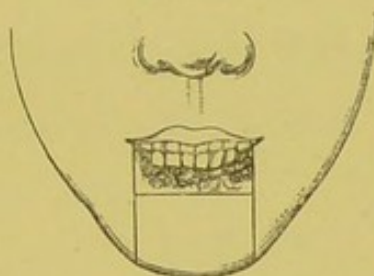


FIG. 75.



Chopart operated thus (Fig. 76):—He made a vertical cut from the free edge of the lip on each

FIG. 76.



side of the disease, and carried the incisions under the chin. A quadrilateral flap was then dissected off from above downwards, and after the disease was removed by a transverse incision the remaining healthy portion of skin was brought up and fixed to the angles of the upper lip. Roux removed the disease by a semicircular incision, and after thoroughly separating the margins from the maxillary bone kept the raw surfaces in contact with a bandage. In suitable cases a flap of skin may be taken from each side and the parts brought together in the median line\* as shown in the accompanying woodcuts (Figs. 77 and 78).

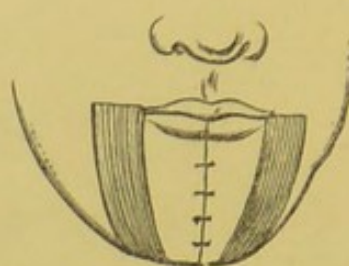
\* Follin et Duplay, vol. iv, p. 655, 1875.



FIG. 77.

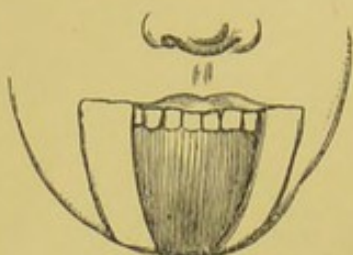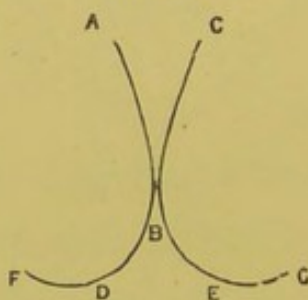


FIG. 78.



Syme's operation may be described in his own words :—"Two incisions are made from the angle of the mouth so as to meet at the chin, and thus the morbid part is removed in a triangular form. The lines A, B and B, C (Fig. 79), being supposed to

FIG. 79.

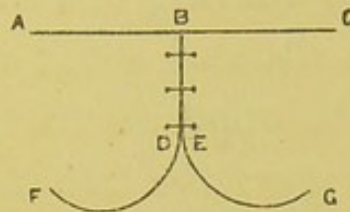


represent these incisions, I cut from the point B outwards and downwards on each side to D and E in a straight direction, and then, with a slight curve outwards and upwards, to F and G. The flaps A, B, D, F, and C, B, E, G, are next detached from their subjacent connections and raised upwards, so that the edges A, B, and C, B, come into a horizontal line, while those represented by B, D, and B, E, meet together in a vertical direction, and the lateral extensions to F and G allow sufficient freedom to



prevent any puckering or overstraining.”\* (Fig. 80). Mr. Tyrrell performed a similar operation at

FIG. 80.



St. Thomas's Hospital in 1829, and the case is reported with a woodcut in the 'Lancet'† of that year.

For extreme deformities of the lower lip from burns, I believe the best kind of operation is that designed by the late Mr. Teale, which he thus describes (see Figs. 81 and 82):

FIG. 81.‡

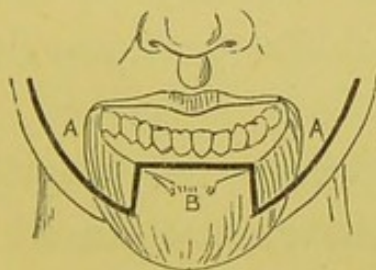
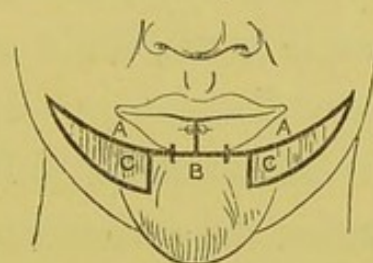


FIG. 82.‡



“Two vertical incisions, about three quarters of an inch in extent, are made through the everted lip down to the bone; these incisions are so placed as to divide the upper portion of the everted lip into three parts, the middle being equal to one

\* Miller's 'Practice of Surgery,' 1856, p. 163.

† The 'Lancet,' 1829-30, vol. i, p. 548.

‡ A. A. Lateral flaps formed of everted lower lip and cheek; and B. Central portion of everted lower lip.

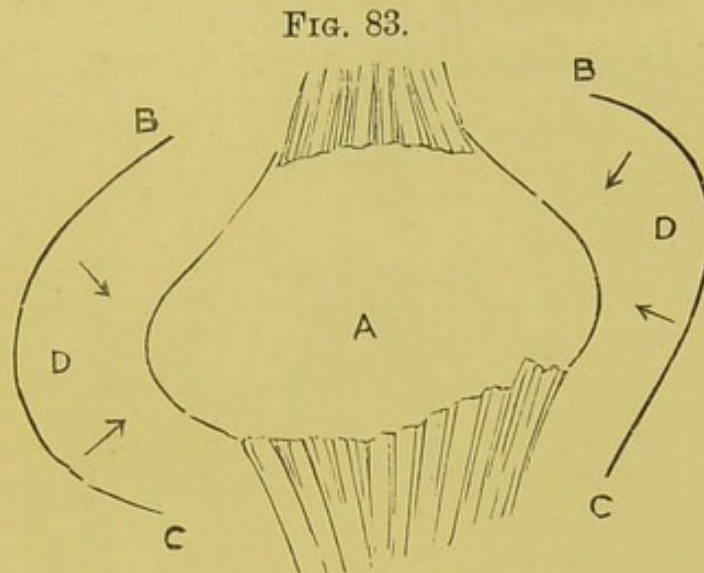


half of the natural breadth of the lip, while the two lateral portions are each equal to one fourth. From the lower end of each vertical incision the knife is carried in a curving direction outwards and upwards to a point situated about one inch from the angle of the mouth opposite to the second molar tooth of the upper jaw; the two flaps thus marked out and deeply incised are then separated from the bone, the mucous membrane uniting them to the alveoli being freely divided; lastly, a bare surface is made along the alveolar border of the middle portion of the everted lip. The incisions being now completed, the lateral flaps are drawn upwards and united by twisted sutures to each other in the median line and to the middle portion of the everted lip at their inferior border. In this way a new lip is, as it were, built upon the middle portion of the old one."

In relation to this subject I may be permitted to refer to a case under my observation, in which there was great deformity of the face, neck, and chest, with a gradual and daily increasing dragging down of the lower lip. In this instance I performed an operation known as *autoplastie par glissement*. The cicatrix was divided at the centre from side to side, the incision reaching to healthy skin at each extremity. The two halves were then thoroughly separated from the subjacent textures in the upward and downward direction, and the tough



areolar tissue in the wound notched with the knife as deeply as the important neighbouring vessels would safely permit, thus leaving an open wound as shown in Fig. 83 A.



An incision was then made on each side, from B to C, and the respective flaps (D D) dissected towards the wound in the direction of the arrows. Thus, two bridges were formed which were raised and without difficulty carried to the centre of the wound, their concavities meeting as convexities in the middle line as shown in Fig. 84.

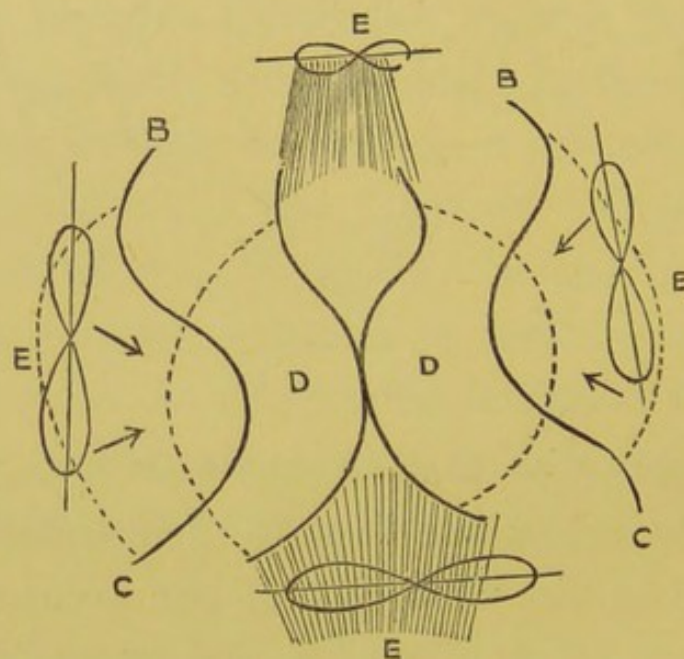
In this way the wound caused by the division of the cicatrix was almost completely filled by the two bridges of healthy skin, two raw surfaces of healthy tissue being left in the sites from which the bridges had been taken.

It will be observed that by this method two important indications are fulfilled. In the first place,



the wound is occupied by healthy elastic and extensible skin, and, again, the skin being taken in the form of a bridge is necessarily attached at each extremity so that its vascularity is almost to a certainty maintained, at least the chance of its sloughing is reduced to a minimum. Moreover,

FIG. 84.



its vitality is still further insured by its adaptation to the subjacent raw surface. Figs. 85 and 86 (taken from photographs) show the patient before and after the operation.

I take the opportunity of presenting to your notice two diagrams (Figs. 87 and 88, taken from photographs) which illustrate a plan I adopted in the case of a cicatrix which was rapidly producing great deformity. The cicatrix was divided and dissected



FIG. 85.

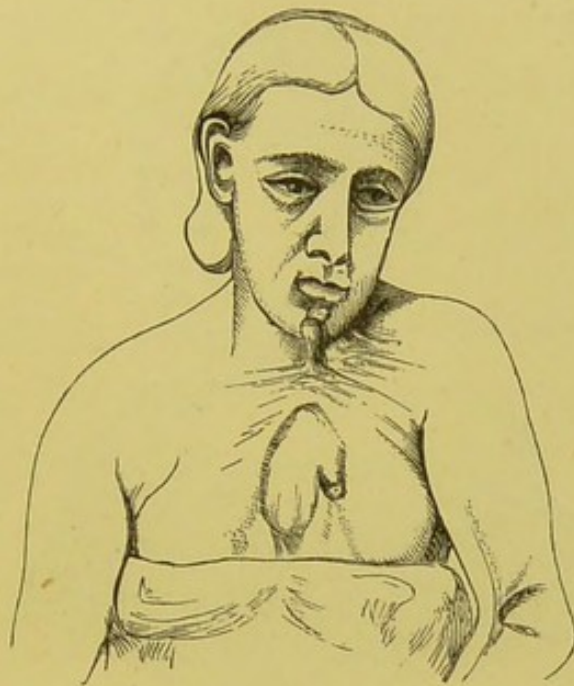


FIG. 86.

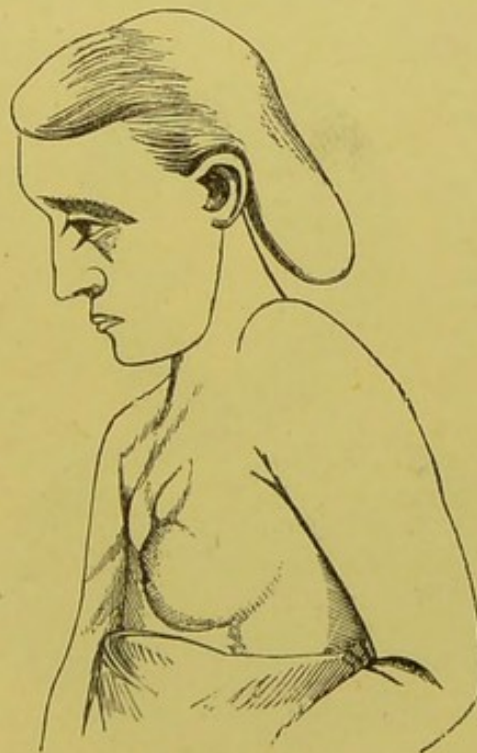




FIG. 87.



FIG. 88.





up under the jaw, after which a flap was taken from the chest and turned on its pedicle. The details of the operation are fully described in the 'St. Thomas's Hospital Reports' for 1872.

#### CONTRACTED LIPS FROM INJURIES.

The steady and intractable contraction that in some cases follows injuries, especially burns in the regions of the mouth, produces the greatest possible discomfort to the patient. In order to obviate this inconvenience, M. Serre, of Montpellier, practised an operation which seems to be of value in suitable cases.\* It consisted in carrying the knife from the angles of the mouth into the cheek to a sufficient distance, and afterwards stitching together the skin and mucous membrane of the now newly formed upper and lower lips. (Figs. 89 and 90.)

FIG. 89.

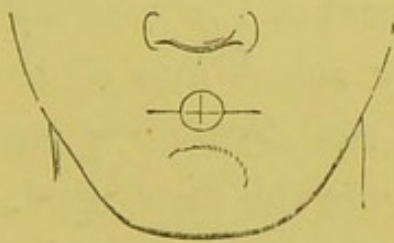
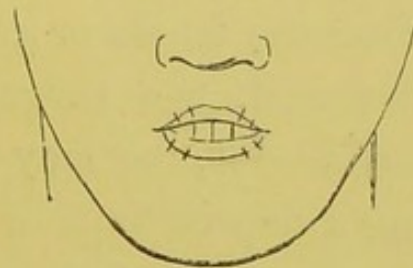


FIG. 90.



Some years ago I operated on a girl who had an extremely contracted mouth, consequent on a burn, in the following manner:—I passed a wire through the cheek about half an inch from each

\* 'Traité sur l'Art de Restaurer les Difformités de la Face,' 1842.



angle of the mouth, and allowed the wires to remain until a permanent hole was established. When the hole had quite healed, I introduced a knife through the aperture and divided the soft structures into the mouth, and stitched the mucous and cutaneous surfaces together. Mr. Husband, of York, refers to a case of much the same kind that was under his care. The patient was a young man, aged nineteen, who was severely burnt when he was six months old. The mouth in this instance was all but closed before operative procedure was adopted.\*

#### RESTORATION OF THE NOSE.

In a lecture delivered at the College of Surgeons in 1834, Sir Charles Bell aptly remarked that "the nose is the organ that chiefly distinguishes the face of man from brutes."†

When the whole or greater part of the nose has to be restored, the surgeon may select one of three methods—1st, he may adopt the French plan of taking a flap or flaps of skin from the face; 2nd, he may employ the Indian method, which consists in taking a flap of skin from the forehead; or 3rd, he may choose the Italian or Taliacotian operation.

The history of rhinoplastic surgery is of very

\* 'Med. Times,' Jan. 3rd, 1857, p. 91.

† The 'Lancet,' 1834, vol. ii, p. 829.



ancient date. The operation was known and practised at a very early period of surgery in India by the Brahmins. Galen recommends "the surgeon, when a wound or ulcer shall have destroyed the whole or a part of the nose, to make a new one at the expense of the integuments of the face." From India the Sicilian surgeons in all probability received their ideas on the art of restoring noses, and the earliest record we possess on this subject is the report of a Neapolitan bishop in 1442, on an operation of rhinoplasty, performed by Branca.\*

I will now speak of these methods categorically :—1st. With regard to restoring deformities of the nose by the French method (*la méthode par déplacement*) M. Serret† recommends that the skin should be freely separated on either side, and each portion lifted towards the median line (Figs. 91, 92); or again the incision may be extended laterally into

FIG. 91.

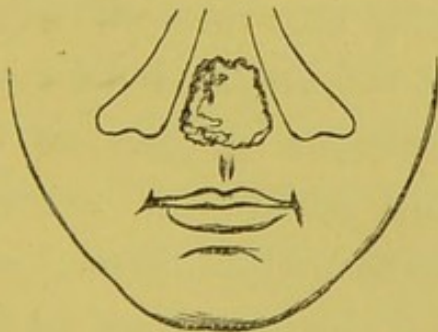
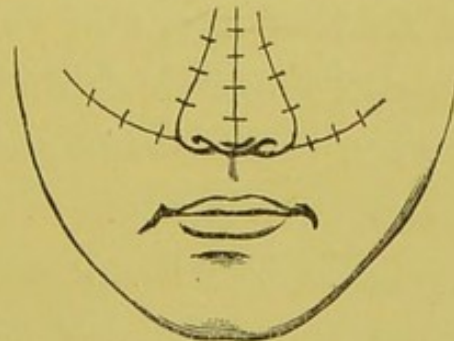


FIG. 92.



\* The Lancet, 1835, vol. i, p. 386.

† Op. cit.

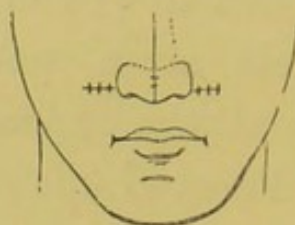


the cheek, as recommended by M. Labat (Figs. 93, 94). Perhaps the peculiar advantage of the

FIG. 93.



FIG. 94.



French method is that it may be employed in those cases in which the Indian operation has failed; thus in a case reported by Mr. John Wood, of King's College Hospital,\* which had been previously unsuccessfully operated on by the Indian method, two large leaf-shaped flaps were taken from the integument of the face on either side of the central chasm, the pedicles of which were directed towards the corresponding internal canthus, and made broad in order to permit a full vascular supply to the bodies of the flaps. After this stage of the operation had been completed the upper lip was divided from above downwards, on either side of the median line, and an oblong flap formed, which was still more elongated by a slit having been made between the mucous and cutaneous surfaces, as far as the free borders of the lip which was not cut through. The long and thin flap thus formed was turned upwards, and fastened by a suture to the upper edge of the nasal chasm, and the external flaps

\* The 'Lancet,' Feb. 26th, 1870.



were then carried inwards from the cheeks, and applied over its anterior raw and bleeding surface. The wound in the upper lip was then closed by pins and the twisted suture. The soft tissues of the cheeks were previously detached over a great extent from the bone beneath, in order to facilitate the inward gliding of the integument over the raw surfaces, and also to prevent the zygomatic muscles from acting on the new nose.

2nd. The Indian or Kooman operation is stated to have been introduced to the notice of European surgeons by our countryman, a Mr. Lucas, since which it has been employed by Carpue, Travers, Liston, and other surgeons. Mr. Travers performed this operation with partial success on a patient thirty-four years of age, at St. Thomas's Hospital, in November, 1822. The edges of the nose having been first pared, a piece of skin was taken from the forehead, and after adjustment dossils of lint were placed in the nostrils to support the newly made nasal organ. In this case the lower two thirds of the frontal flap sloughed, but at the upper part of the nose a small piece of new skin remained.

Dieffenbach, who was a master in rhinoplastic, as, indeed, he was in every other department of surgery, gives several practical hints as to the performance of the operation, which are embodied in a paper which appeared in the 'Lancet,' vol. i, 1835, p. 388. His method may be thus briefly described:—The patient



being seated on a chair, the operation was begun by raising the cicatrised skin to the extent of about three lines in width from the remnants of the cartilages of the nose. Dieffenbach, you will observe, was not content with simply removing the edges of the cartilages because under these circumstances there was less chance of union. After having revived the edge of the imperfect septum, he proceeded to make the incisions on the forehead. From the lowest point of the two diverging incisions a cut was extended downwards on each side. The incision of the left side was not carried beyond the level of the angle of the eye, but that on the right side was prolonged for some distance on the nose (see Fig. 96). The flap was then detached from the forehead, with due precaution against including the pericranium and the parts brought into careful apposition. Langenbeck advised that the *pericranium* should be included in the skin flap, in order that by the after development of osseous tissue a finer and better nasal organ might be left.\*

I may briefly refer to one or two other minor points; thus, in order to bring the edges of the frontal wound more readily together, Dieffenbach made lateral incisions in the regions of the temples by which the cutaneous structures are relieved. Incisions so placed do not affect the patient's personal appearance because they are afterwards concealed

\* Erichsen's 'Surgery,' 7th edition, vol. ii, p. 499.



by the hair. In forming the frontal flaps Dieffenbach, as already stated, employed a somewhat diamond-shaped incision, thus:—(Fig. 96); Delpech made three small slips of equal size (Fig. 97), and Carpie preferred an incision something like an inverted ace of clubs (Fig. 98).\* Again, M. Bonnet,† of Lyons,

FIG. 96.

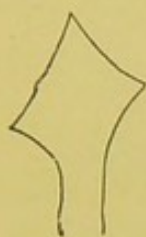

FIG. 97.

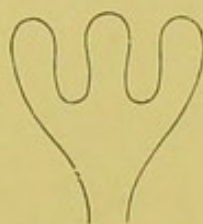
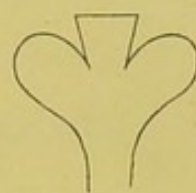

FIG. 98.



believed that in many cases a new nose might be made from the upper lip alone, but this operation is most useful when one ala only has to be repaired. Dieffenbach and Serre utilized the *skin* of the upper lip to form a new columna, and Blandin proposed to cut out a piece of the lip in its *entire* thickness to replace the lost septum.

Dr. Lichtenberg and our honorary secretary, Mr. Astley Bloxam, have shown themselves assiduous workers in this department of surgical science and art, and the photographs I hand round illustrate remarkably well the success which has attended their efforts.

Whilst on this subject I may perhaps be permitted to refer to a case that was under my

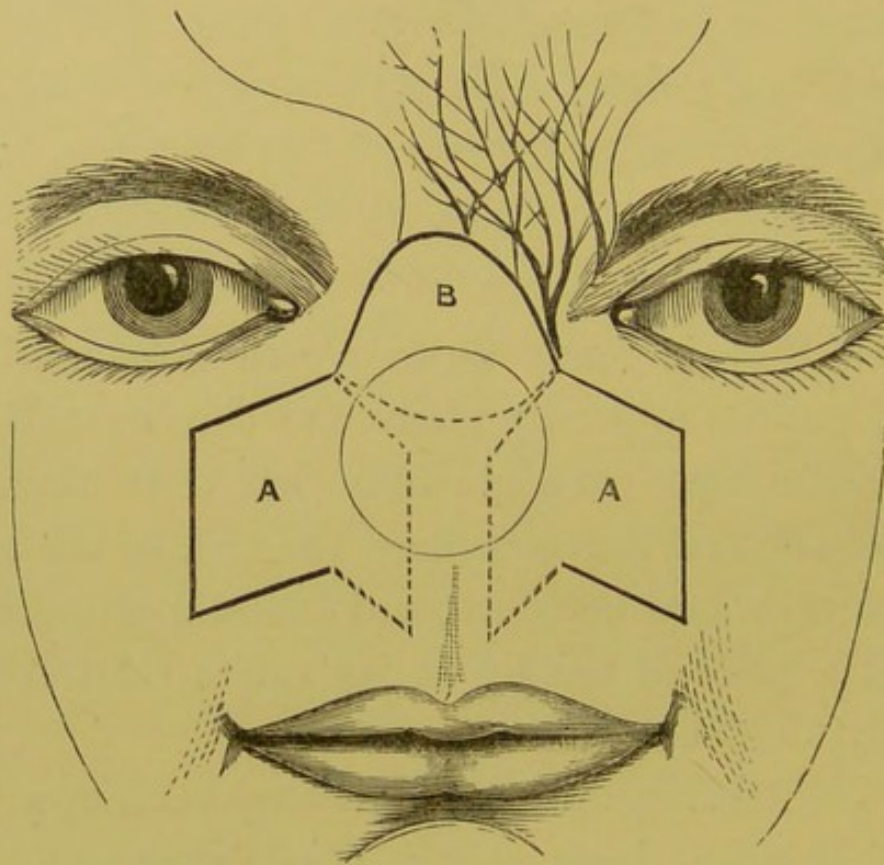
\* The 'Lancet,' 1832, vol. i, p. 700.

† The 'Lancet,' 1847, vol. ii, p. 261.



own care at the Westminster Hospital in 1871, in which I performed what may be termed a mixed method, and which I had never previously seen practised. Three flaps were taken, two from the cheek and one from over the nasal bones (Fig. 95, A, A, B). These flaps were raised and turned inwards

FIG. 95.



and downwards respectively, as shown by the dotted lines. A portion of skin was then taken from the forehead, and being twisted at its pedicle, its raw surface was applied and fixed with sutures to the other three raw surfaces.\* I may add that in this case, when the wound of the forehead was granu-

\* 'The Lancet,' June 10th, 1871, p. 780.



lating, I took a piece of skin the size of a shilling from the patient's arm and transferred it to the granulating surface with marked benefit to his personal appearance. The patient made a very good recovery, and both he and I were well satisfied with what had been done. My only regret now is that, from circumstances beyond my control, I cannot show you his photograph after the operation, but the case when under treatment was sufficiently well known both at the Westminster and at St. Thomas's Hospital.

3rd. Respecting the Italian or Taliacotian operation, Alexander Benedictus, a Veronese, of Padua, appears to have been the first to write on the subject in 1495, and gives the following description of the operation, which was really much the same as that practised afterwards by Taliacotius. The operator dissected the upper skin of the arm with a razor, and then, paring off the remaining edges of the nostrils, or if necessary cutting the latter away, he bound the arm to the head, in order that wound might adhere to wound. After this, the wounds having conglutinated, he separated from the arm with the knife as much as was wanted for the restoration of the nose. He adds, however, that these artificial noses badly endure a severe winter, and he recommends his patients to use them gently, lest they be torn from the trunk.\* Apropos of this, I

\* 'Lancet,' 1823-24, vols. i and ii, p. 169.



may remind you of the superstitious stories to which Butler refers in his well-known lines in *Hudibras*,\* and you know the legend of the nobleman in Italy who lost a great part of his nose in a duel, and prevailed on one of his slaves to suffer a piece of the flesh of his arm to be cut out, which was so managed by a skilful surgeon as to serve in the place of a natural nose. The slave being rewarded and set free, went to Naples, where he fell sick and died, immediately on which gangrene appeared on the nobleman's nose. Gabriel Fallopio, who died in 1562, alludes to the same method of operation; and Ambrose Parè, whose work was printed in 1561, also refers to this subject. Vesalius, too, printed an account in 1569 of the restoration of the nose by supplying the deficient parts from the arm. Again, Stephen Gourmelen in 1580, states in print, that the nose might be formed or refitted either from the arm of the patient, or from the nose of a slave. In Serre's work there is an illustration to show that a new nose may be formed from the skin of the palm of the hand.

The method adopted by Taliacotius was, first, to make a paper model of the proposed end of the nose, and this, when flattened, served as a pattern for shaping the graft or flap of skin which was to be taken from the patient's arm. The portion of integument was then raised and twisted, and brought

\* 'The Lancet,' vols. i and ii, 1823-4, pp. 169, 171.



in contact with the face. He then proceeded to dissect away the edge of the deficient nasal organ, and bringing up the graft to the nose, by lifting the arm, to which it at one end still adhered, fastened it in its place by ligatures. The graft or flap of skin having been thus applied to the defective nose, the patient was bound, so that he could not stir in any direction. At the end of twelve days the patient's arm was released from his face, the septum was modelled, plasters and bandages applied, and great care was taken for some time to defend the new nose from accidental injury.

The Taliacotian operation seems almost to have died with its supposed author, for in the medical journals I do not remember to have met with a single instance (with one exception, and this was to restore the lip) in which this operation has been published. In speaking thus I am willing to concede that some examples of the genuine Taliacotian operation may be on record; if so, they have, escaped my observation. I have, however, certainly met with several cases which have been described as such, but which I have found, on reading the history, to be instances illustrating the Indian method of treatment.

My colleague, Mr. Mac Cormac, has performed the Taliacotian operation on two occasions. Once on a girl, aged sixteen, on February 12th, 1877, whose case has been fully reported in the Transactions of



the Clinical Society. The deformity was occasioned by sloughing after injecting a nævus at the root of the nose with the perntrate of iron. In this instance a flap was taken from the inner aspect of the left upper arm, more than double the size of the estimated deficiency of the nose, and the flap included the subcutaneous fat down to the muscular sheath. The portion of skin from the arm was separated after an interval of twenty-one days. Dr. James Hardie, of Manchester, has placed on record a novel rhinoplastic operation, by which additional solidity may be given to the newly formed nose by transplanting, as a preliminary step, the first phalanx of the forefinger of the patient's left hand to the stump of the nose, which thus serves as an osseous basis of support for the cutaneous covering.\* I may add that those Fellows of the Society who take interest in rhinoplastic surgery may be glad to know that we are fortunate enough to have in our library a copy of Taliacotius's work which was published in 1597.

As to the result of these operations, there is one point to which I may refer, and it is the peculiar bloodless appearance of the newly-formed nose. Perhaps this may to some extent be remedied by tattooing the part, as practised by Professor Schuh, of Vienna. He employed it in the case of a young

\* 'Brit. Med. Journ.,' 1875, vol. ii, p. 393, and ditto, 1877, vol. ii, p. 300.



girl whose upper lip was formed from the skin of her arm, and which in eighteen months had not gained the normal redness of the lips.\* The operation consisted of taking from ten to twenty needles, each surrounded with silk, and united into a bundle. They were dipped into a liquid of vermilion, and pricked into the lip until it took a natural colour.

### RESTORATION OF EYELIDS.

I need say little respecting the plastic surgery of the eyelids, for the deformities occasioned either by disease or injury in this region must be treated on their respective merits, and most of the operations are described in works on ophthalmology. I may, however, refer to a case of epithelioma involving

FIG. 99.

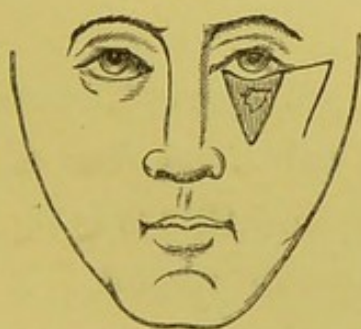
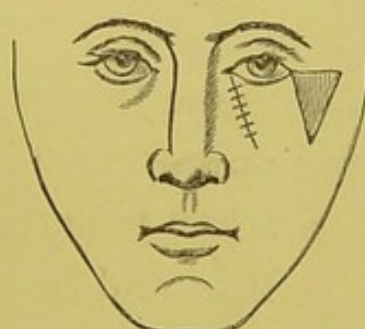

FIG. 100.



the lower eyelid in which I removed the disease by a V-shaped incision. A lateral flap of healthy skin was then detached and twisted on its pedicle, which

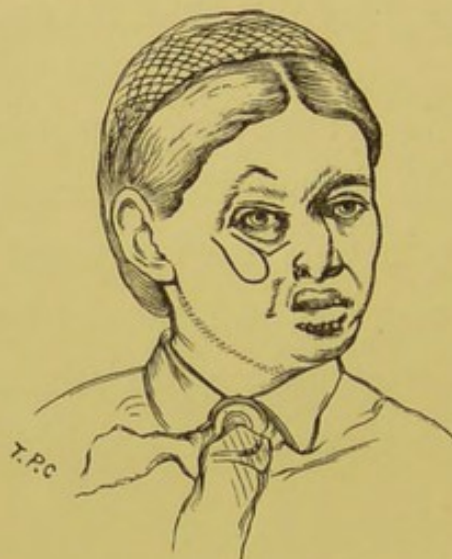\* 'Med. Times,' Feb. 5th, 1859, p. 150.



became a very good substitute for the part taken away. The operation will be best understood by the accompanying figures (Figs. 99, 100) taken from Serre's work.

Again, in another case of severe ectropium after a burn, occurring in a woman who was recently under my care at St. Thomas's Hospital, I performed the following operation (Fig. 101). A **V**-shaped incision

FIG. 101.



was made under the eye, and the soft parts thoroughly dissected upwards towards the orbit. A flap of skin was then taken from the cheek, and this was twisted on its pedicle and inserted into the wound. I performed a somewhat similar operation to improve the less marked ectropium in the upper lid, but a portion of the flap which I took from the forehead sloughed. There was, nevertheless, some slight improvement. The case was not a favourable one for operation,



inasmuch as the whole of the face was a mass of cicatrix.

In bringing these lectures to a close I am willing to admit that the preparation of them has caused me no slight amount of labour and anxiety, but let me assure you that I am richly rewarded by the warm support and encouragement you have so generously accorded me. My object has been to deal with the surgery of the face from a practical point of view, and I have done my best to render the subject as attractive and interesting as possible. In conclusion, I venture to ask you to accept my most sincere thanks for your kind and considerate attention, and I earnestly hope you will not deem me unworthy of the distinguished position in which I have been placed.

---







# INDEX.

---

## A.

- Abscess, 13  
..... death from, 17  
..... strumous, 13  
..... treatment of, 14  
Absence, congenital, of nose, 122  
..... of uvula, 104  
Acetic acid and whiting, treatment of burns by, 58  
..... scalds by, 58  
Acne, 10  
..... indurata, 10  
..... punctata, 10  
..... rosacea, 11  
..... simplex, 10  
Acupressure, treatment of nævus by, 45  
Adams, W., on cicatrices, 55  
Anchylosis, bilateral, of lower jaw, 83  
..... of lower jaw, pathology of, 84  
Antrum, disease of, 15  
..... loose tooth in, 95  
Apparatus for detecting bullet in ear, W. H. Stone's, 87  
Atrophy of face, unilateral, 123  
Author's case of bullet in ear, 87  
..... closure of jaws, 82  
..... fibro-cystic disease of upper jaw, 38  
..... formation of new nose, 144  
..... formation of new upper lip, 126  
..... spontaneous reduction of lower jaw, 75  
..... cases of cervical fistula, 116  
..... growth of cicatrix, 56



- Author's cases of restoration of eyelids, 149
- ..... method of dividing bone in cleft palate, 107
- ..... operation for cleft palate, 106
- ..... operation for improving voice after staphyloraphy, 108
- ..... plan of removing cystic tumours, 21
- ..... proposed treatment of fracture of inferior maxilla, 80
- ..... lower jaw, 80

## B.

- Barwell on unilateral atrophy of face, 123
- Battery, electric, to detect a bullet in ear, 87
- Bickersteth's plan of treating fracture of lower jaw, 77
- Bilateral ankylosis of lower jaw, 83
- Blood tumours, 22
- Blows on nose, 66
- Bodies, foreign, in face, 90
- ..... orbit, 90
- Boils, 12
- Bones of face, congenital deficiency of, 109
- ..... injuries of, 65
- ..... intermaxillary in harelip, 100
- ..... nasal, congenital absence of, 109
- Branchial fistula, 112
- ..... Paget on, 112
- Buchanan's operation for restoring lower lip, 128
- Bullet in ear, author's case of, 87
- Burns and scalds, deformities from, 58
- ..... lips contracted from, 137
- ..... their treatment, 58
- ..... by acetic acid and whiting, 58

## C.

- Cachectic ulcer, 17.
- Callender on permanent closure of jaws, 81
- Cancer, colloid, of face, 36
- ..... encephaloid, 37
- ..... epithelial, 34



- Carbuncle, 12
  - ..... facial, death from, 13
  - ..... treatment of, 12
- Carcinomatous tumours of jaws, 39
- Carcinoma, 34
- Cartilaginous tumours of jaws, 39
- Case, author's, of formation of new nose, 144
- Cervical fistula, 115
  - ..... author's cases of, 116
- Cheek, fatty tumours of, 24
  - ..... foreign body in, tetanus from, 96
  - ..... tobacco-pipe removed from, 15
- Chopart's operation for forming new lower lip, 129
- Cicatrices, Adams, W., on, 55
  - ..... Paget on growth of, 56
- Cicatrix, author's cases of growth of, 56
  - ..... its growth in proportion to growth of part, 56
  - ..... its persistence, 55
- Circular saw, wound of face from, 53
- Classification of diseases of jaws, 37
- Cleft palate, 104
  - ..... Dieffenbach's operation for, 106
  - ..... Langenbeck's operation for, 106
  - ..... operation for, 104
  - ..... varieties of, 104
- Closure of jaws, author's case of, 82
  - ..... Esmarch's operation for, 81
  - ..... permanent, 81
  - ..... Rizzoli's operation for, 81
- Colloid cancer of face, 36
- Congenital absence of nose, 122
  - ..... deficiency of bones of face, 109
  - ..... deformities of ears, 113
  - ..... hypertrophy of face, 119
  - ..... lower lip, 122
  - ..... upper lip, 121
  - ..... idiots, lips in, 98
  - ..... malformation of lower lip, 120
- Contracted lips from burns, 137
  - ..... neck, operations for, 133
- Cricket ball, wound of face from, 53

- Cutaneous nævus, 42  
 Cystic tumours, 19  
     ..... diagnosis of, 20  
     ..... of nose, 21  
     ..... sub-aponeurotic, 21  
     ..... sub-muscular, 21  
     ..... their removal, 21  
     ..... treatment of, 21  
 Cysts, 19  
     ..... hydatid, of eyelids, 21  
     ..... lips, 21  
     ..... of lower and upper jaws, 37

## D.

- Death from abscess, 17  
     ..... facial carbuncle, 13  
     ..... foreign body in ear, 87  
 Deficiency, congenital, of bones of face, 109  
 Deformities, congenital, of ears, 113  
     ..... of face, 98—150  
     ..... from burns and scalds, 58  
     ..... non-congenital of face, 123  
 Detached portions of face, treatment of, 63  
     ..... nose, treatment of, 63  
 Diagnosis of fatty tumours of cheek, 24  
     ..... infecting sore, 119  
 Dieffenbach on rhinoplastic surgery, 141  
 Dieffenbach's plan of removing tumours of upper jaw, 41  
 Disease of antrum, 15  
     ..... fibro-cystic, of upper jaw, 38  
 Diseases of face, 1—51  
     ..... jaws, 37  
     ..... classification, 37  
     ..... parasitic, 8  
 Dislocation of inferior maxilla, 72  
     ..... treatment of, 74  
     ..... lower jaw, 72  
     ..... from tongue sucking, 72  
     ..... from thumb sucking, 74



- Dislocation of lower jaw, its mechanism, 74
  - ..... spontaneous reduction of, 76
  - ..... treatment of, 74
  - ..... superior maxilla, 70
  - ..... upper jaw, 70
- Down, Langdon, on epicanthic folds, 99
- Duct of parotid gland, injuries of, 61

## E.

- Ear, external, hypertrophy of, 33
  - ..... larvæ in, 88
  - ..... pin in, passing down Eustachian tube, 89
- Ears, blood tumours of, 22
  - ..... congenital deformities of, 113
  - ..... foreign bodies in, 85
  - ..... hæmatoma of, 22
- Ecthyma, 7
- Ectropium, treatment of, 150
- Eczema, 6
  - ..... impetiginodes, 6
- Electric battery to detect a bullet in ear, 87
- Electrolytic treatment of nævus, 44
- Emphysema of eyelids, 68
  - ..... face, 66
- Encephaloid cancer, 37
  - ..... tumours of jaws, 39
- Enchondromatous tumours of jaws, 39
- Enucleation, treatment of nævus by, 45
- Epicanthic folds, Langdon Down on, 99
- Epithelioma, 34
  - ..... of lip, 34
  - ..... of nose, 34
- Eruptions on face, 3
  - ..... scarlatinal, after operations, 3
- Erythema, 3
  - ..... circinatum, 3
  - ..... nodosum, 3
- Esmarch's operation for closure of jaws, 81
- Ether, its use in detecting fatty tumours, 24

- External ear, hypertrophy of, 33
- Extirpation of lower jaw, 42
- Eyelid, horny growth of upper, 34
- Eyelids, author's cases of restoration of, 149
  - ..... emphysema of, 68
  - ..... hydatid cysts of, 21
  - ..... restoration of, 149

## F.

- Face, colloid cancer of, 36
  - ..... congenital deficiency of bones of, 109
  - ..... hypertrophy of, 119
  - ..... deformities of, 98—150
    - ..... from burns and scalds, 58
  - ..... detached portions, treatment of, 63
  - ..... diseases of, 1—51
  - ..... emphysema of, 66
  - ..... eruptions on, 3
  - ..... fatty tumours of, 23
    - ..... rare in face, 23
  - ..... foreign bodies in, 90
  - ..... gunshot wounds of, 69
  - ..... hairy mole on, 118
  - ..... infecting sores on, 18
  - ..... injuries of, 52—97
  - ..... non-congenital deformities of, 123
  - ..... plastic operations on, 124
  - ..... scars of, their persistence through life, 55
  - ..... sloughing of, 63
  - ..... unilateral atrophy of, 123
  - ..... wound of, from bursting of soda-water bottle, 53
    - ..... circular saw, 53
    - ..... cricket ball, 53
- Facial carbuncle, death from, 13
- Fatty tumours, 23
  - ..... comparatively rare in face, 23
  - ..... diagnosis of, 20
  - ..... method of arriving at diagnosis, 24
  - ..... of cheek, 24



- Fatty tumours of cheek, their diagnosis, 24  
 ..... their diagnosis from nævi, 24  
 Fergusson's case, hypertrophy of nose, 33  
 ..... knot for nævus, including skin, 49  
 Fibro-cystic disease of upper jaw, 38  
 Fibrous tumours of jaws, 38  
 Fistula, cervical, 115  
 ..... author's cases of, 116  
 Fistulæ, branchial, 112  
 Fistulous openings on face, 14  
 ..... of parotid gland, 62  
 Foreign bodies from ear, instruments for removing, 87  
 ..... body in face, 90  
 ..... nose and ears, 85  
 ..... orbit, 90  
 ..... cheek, tetanus from, 96  
 ..... ear, death from, 87  
 Formation of new lower lip, 128  
 Fox, Tilbury, on scabies, 9  
 Fracture of inferior maxilla, 76  
 ..... author's proposed treatment of, 80  
 ..... Thomas's plan of treatment, 77  
 ..... treatment, 77—80  
 ..... Wheelhouse's plan of treatment, 78  
 ..... lower jaw, 76  
 ..... author's proposed treatment, 80  
 ..... Bickersteth's plan of treatment, 77  
 ..... mechanical appliance in, 80  
 ..... treatment, 77—80  
 ..... Wheelhouse's plan of treatment, 78  
 ..... neck of inferior maxilla by *contrecoup*, 77  
 ..... un-united, of inferior maxilla, 80  
 French method of restoring nose, 139  
 Frontal flaps, different kinds, to form new nose, 143

## G.

- Gland, parotid, fistulous opening of, 62  
 ..... injuries of, 61  
 Glandular tumours, 24

Growth of cicatrix, author's cases of, 56  
 Growths, horny, 33  
     ..... on lower lip, 34  
     ..... on upper eyelid, 34  
 Gummata, 17  
 Gunshot wounds of face, 69

## H.

Hæmatoma, 22  
     ..... of ears, 22  
 Hæmorrhage in removing parotid tumours, 27  
 Hairy mole on face, 118  
 Harelip, 99  
     ..... hereditary character of, 101  
     ..... intermaxillary bones in, 100  
     ..... operation for, 102  
 Heath, observation on dislocation of lower jaw, 74  
 Hereditary character of harelip, 101  
 Herpes, 5  
     ..... in course of certain nerves, 5  
 Holt, on dislocation of lower jaw, 74  
 Horny growth on lower lip, 34  
     ..... on upper eyelid, 34  
 Horny growths, 33  
 Humid tetter, 6  
 Hydatid cysts of eyelids, 21  
     ..... lips, 21  
 Hypertrophy, 32  
     ..... congenital, of face, 119  
     ..... lower lip, 122  
     ..... upper lip, 121  
     ..... of external ear, 33  
     ..... nose, 32  
     ..... Fergusson's case, 33  
     ..... Pollock's case, 33

## I.

Idiots, congenital lips in, 98  
 Imperforate nostrils, 122



- Impetiginodes, eczema, 6
- Impetigo, 7
- Impressions, maternal, 117
- Incision in skin for removing tumours of jaws, 39
- Infecting sores on face, 18
- Inferior maxilla, dislocation of, 72
  - ..... fracture of, 76
  - ..... Thomas's plan of treatment, 77
  - ..... treatment, 77—80
  - ..... Wheelhouse's plan of treatment, 78
  - ..... Holt's plan of reducing dislocated, 74
  - ..... un-united fractures of, 80
- Iodine, treatment of parotid tumours by, 26
- Indian operation for restoring nose, 141
- Intermaxillary bones in harelip, 100
- Injuries of face, 52—97
  - ..... bones of face, 65
  - ..... parotid gland, 61
- Italian operation for forming new nose, 145

## J.

- Jaw, fibro-cystic disease of upper, 38
  - ..... lower, dislocation of, 72
    - ..... from thumb sucking, 74
    - ..... tongue sucking, 72
    - ..... Holt's plan of reducing, 74
    - ..... treatment, 74
  - ..... fracture of, 76
    - ..... treatment, 77—80
  - ..... removal of, 41
  - ..... un-united fracture of, Napier's case, 80
  - ..... necrosis of, 15
  - ..... upper, Dieffenbach's plan of removing, 41
    - ..... dislocation of, 70
- Jaws, carcinomatous tumours of, 39
  - ..... cartilaginous tumours of, 39
  - ..... classification of diseases of, 37
  - ..... closure of, author's case, 82
  - ..... cysts of, 37

- Jaws, diseases of, 37  
 ..... encephaloid tumours of, 39  
 ..... enchondromatous tumours of, 39  
 ..... fibrous tumours of, 38  
 ..... medullary tumours of, 39  
 ..... osteomatous tumours of, 39  
 ..... permanent closure of, 81  
 ..... sarcomatous tumours of, 38  
 ..... scirrhus tumours of, 39  
 ..... tumours of, their removal, 39  
 ..... vascular tumours of, 39

## K.

- Knots, various, for tying nævus, 43—48

## L.

- Lacerated wounds of face, 52  
 Larvæ in ear, 88  
 Lee, R. J., on maternal impressions, 117  
 Lepra, 7  
 Lichen, 4  
 Lip, epithelioma of, 34  
 ..... horny growth on lower, 34  
 ..... lower, Chopart's operation for forming new, 129  
 ..... congenital hypertrophy of, 122  
 ..... formation of new, 128  
 ..... hypertrophy of, 122  
 ..... Roux's operation for forming new, 129  
 ..... Syme's operation for forming new, 130  
 ..... Teale's operation for forming new, 131  
 ..... tooth imbedded in, 93  
 ..... wounds of mucous membrane of, 55  
 ..... upper, formation of new, 125  
 ..... tooth imbedded in, 94  
 Lips contracted from burns, 137  
 ..... hydatid cysts of, 21  
 ..... in congenital idiots, 98



- Liveing, R., on the treatment of acne, 11  
 Lower jaw, bilateral ankylosis of, 83  
     ..... dislocation of, 72  
     ..... from thumb-sucking, 74  
     ..... tongue sucking, 72  
     ..... Heath on, 74  
     ..... Holt's method of reducing, 74  
     ..... its mechanism, 74  
     ..... treatment, 74  
     ..... fracture of, 76  
     ..... Bickersteth's plan of treatment, 77  
     ..... mechanical appliance in, 80  
     ..... treatment, 77—80  
     ..... Wheelhouse's plan of treatment, 78  
     ..... Napier's case of un-united, 80  
     ..... necrosis of, 15  
     ..... pathology of ankylosed, 84  
     ..... removal of, 41  
     ..... spontaneous reduction of dislocated, 76  
     ..... un-united fracture of, 80  
     ..... lip, Chopart's operation for forming new, 129  
     ..... congenital malformation of, 120  
     ..... Roux's operation for forming new, 129  
     ..... Syme's operation for forming new, 130  
     ..... Teale's operation for forming new, 131

## M.

- Malformation, congenital, of lower lip, 120  
 Maternal impressions, 117  
     ..... R. J. Lee on, 117  
 Maunder, on subcutaneous extirpation of lower jaw, 42  
 Maxilla, inferior, dislocation of, 72  
     ..... treatment, 74  
     ..... fracture of, 76  
     ..... Wheelhouse's plan of treatment, 78  
     ..... treatment of, 77-80  
     ..... un-united fracture of, 80  
     ..... superior, dislocation of, 70  
 Mechanical appliances in fracture of lower jaw, 80

Mechanism of dislocation of lower jaw, 74  
 Medullary tumours of jaws, 39  
 Melanotic sarcoma, 30  
 Meningocele, 110  
 Mixed nævus, 42  
 Mole, hairy, on face, 118  
 Mouth, cystic tumours in, 21  
 Moxhay on congenital deformities of ears, 113  
 Mucous membrane of lip, wounds of, 55  
 Multiple nævi, 43  
 Murray's, Jardine, plan of subcutaneous ligature of nævus, 48  
 Myxomatous tumours, 25

## N.

Nævi, their diagnosis from fatty tumours, 24  
     ..... multiple, 43  
     ..... symmetrical, 43  
 Nævus, 42  
     ..... cutaneous, 42  
     ..... effect on neighbouring bones, 43  
     ..... electrolytic treatment of, 44  
     ..... Fergusson's knot for, including skin, 49  
     ..... mixed, 42  
     ..... Murray's subcutaneous knot for, 48  
     ..... operations for, 43-48  
     ..... subcutaneous, 42  
     .....                      ligature of, 45  
     .....                      Wood's plan, 47  
     ..... treatment by acupressure, 45  
     .....                      enucleation, 45  
     .....                      subcutaneous rupture, 44  
     .....                      with thermo-cautery, 44  
     ..... Wood's knot including skin, 50  
     .....                      subcutaneous knot for nævus, 47  
 Napier, on un-united fracture of lower jaw, 80  
 Nasal bones, congenital absence of, 109  
 Neck, contracted, operations for, 133  
 Necrosis of jaw, 15  
 New nose, author's case of formation of, 144



- New upper lip, to form, 125  
 Non-congenital deformities of face, 123  
 Nose, blows on, 66  
     ..... congenital absence of, 122  
     ..... cystic tumours of, 21  
     ..... detached portions, treatment of, 63  
     ..... epithelioma of, 34  
     ..... foreign bodies in, 85  
     ..... French method of restoring, 139  
     ..... hypertrophy of, 32  
     ..... Indian method of restoring, 141  
     ..... new, author's case of formation of, 144  
     ..... Italian operation for forming, 145  
     ..... Taliacotian operation for forming, 145  
     ..... restoration of, 138  
 Nostrils, imperforate, 122

## O.

- Openings, fistulous, 14  
 Operation, Buchanan's for forming new lower lip, 128  
     ..... for cleft palate, author's views, 106  
     ..... harelip, author's views, 102  
     ..... Chopart's, for forming new lower lip, 129  
     ..... Esmarch's, for closure of jaws, 81  
     ..... French method of restoring nose, 131  
     ..... Indian, for restoring nose, 141  
     ..... Italian, for forming new nose, 145  
     ..... Rizzoli's, for closure of jaws, 81  
     ..... Roux's for forming new lower lip, 129  
     ..... Syme's, for forming new lower lip, 130  
     ..... Taliacotian, for forming new nose, 145  
     ..... Teale's, for forming new lower lip, 131  
 Operations for contracted neck, 132  
     ..... nævus, 43—48  
     ..... plastic, on face, 124  
 Orbit, foreign bodies in, 90  
 Osteomatous tumours of jaws, 39

## P.

- Paget, on branchial fistulæ, 112  
     ..... growth of cicatrices, 56  
     ..... scars, 56  
 Palate, cleft, 104  
     ..... fissure of, with absence of uvula, 104  
 Parasitic diseases, 8  
 Parotid gland, duct of, injuries, 61  
     ..... fistulous opening of, 62  
     ..... injuries of, 61  
     ..... tumours, 26  
         ..... chance of return, 27  
         ..... hæmorrhage in removing, 27  
         ..... treatment by iodine, 37  
 Pathology of ankylosis of lower jaw, 84  
 Permanent closure of jaws, 81  
 Persistence of scars of face through life, 55  
 Pin in ear passing down Eustachian tube, 89  
 Plastic operations on face, 124  
 Pollock's case, hypertrophy of nose, 33  
 Psoriasis, 7  
     ..... syphilitic, 7

## R.

- Removal of cystic tumours, 21  
     ..... lower jaw, 41  
     ..... by subperiosteal method, 42  
     ..... tumours of jaws, 39  
         ..... by subperiosteal method, 41, 42  
 Restoration of eyelids, 149  
 Restoring nose by French method, 139  
     ..... Indian method, 141  
     ..... Italian method, 145  
     ..... lower lip, 128  
     ..... nose, 138  
 Rizzoli's operation for closure of jaws, 81  
 Rhinoplastic surgery, Dieffenbach on, 141  
 Roseola, 3  
 Roux's operation for forming new lower lip, 129



## S.

- Sarcoma, melanotic, 30  
 Sarcomatous tumours, 29  
 ..... of jaws, 38  
 Scabies, 8  
 ..... Tilbury Fox on, 9  
 Scalds and burns, deformities from, 58  
 ..... their treatment, 58  
 ..... by acetic acid and whiting, 58  
 Scarlatinal eruption after operations, 3  
 Scars of face, their persistence through life, 55  
 ..... Paget on growth of, 56  
 Scirrhus tumours of jaws, 39  
 Sebaceous tumours, 19  
 Signoroni's plan of subcutaneous extirpation of lower jaw, 13  
 Silk sutures preferable to silver, 53  
 Silver sutures objected to, 53  
 Sloughing of face, 63  
 Smoking tobacco, a supposed cause of epithelioma of lip, 36  
 Soda-water bottle, severe wounds from bursting of, 53  
 Sores, infecting, on face, 18  
 Spontaneous reduction of dislocated lower jaw, 76  
 Staphyloraphy, author on improving voice after, 108  
 Stone's, W. H., apparatus for detecting bullet in ear, 87  
 Strapping to bring wounded parts together, 54  
 Strumous abscess, 13  
 Sub-aponeurotic cystic tumours, 21  
 Subcutaneous ligature of nævus, 45  
 ..... Murray's plan, 48  
 ..... Wood's plan, 57  
 ..... rupture of nævus, 44  
 ..... nævus, 42  
 Sub-muscular cystic tumours, 21  
 Subperiosteal method of removing lower jaw, 42  
 ..... plan of removing tumours of jaws, 41, 42  
 ..... Signorini's, of, extirpation of lower jaw, 42  
 Superior maxilla, dislocation of, 33  
 Sutures, silk preferable to silver, 53  
 Symmetrical nævi, 43  
 Syme's operation for forming new lower lip, 130





- Treatment of syphilitic psoriasis, 8  
 ..... psoriasis, 7  
 ..... tinea circinata, 9  
 ..... decalvans, 9  
 ..... sycosis, 9  
 Tinea sycosis, 9  
 Tobacco-pipe, portion of, removed from cheek, 15  
 ..... smoking a supposed cause of epithelioma of lip, 36  
 Tongue sucking, dislocation of lower jaw from, 74  
 Tooth imbedded in lower lip, 93  
 ..... upper lip, 94  
 ..... loose in antrum, 95  
 Tumours, 23  
 ..... blood, 22  
 ..... cartilaginous, of jaws, 39  
 ..... cystic, their removal, 21  
 ..... of nose, 21  
 ..... sub-aponeurotic, 21  
 ..... sub-muscular, 21  
 ..... enchondromatous, of jaws, 39  
 ..... fatty, of cheek, their diagnosis, 24  
 ..... their diagnosis from nævi, 24  
 ..... fibrous, of jaws, 38  
 ..... glandular, 24  
 ..... medullary of jaws, 39  
 ..... myxomatous, 25  
 ..... osteomatous, of jaws, 39  
 ..... parotid, 26  
 ..... hæmorrhage in removing, 27  
 ..... sarcomatous, 29  
 ..... of jaws, 38  
 ..... scirrhus, of jaws, 39  
 ..... vascular, of jaws, 39

## U.

- Ulcer, cachectic, 17  
 Ulcers, 17  
 Unilateral atrophy of face, 123  
 Un-united fractures of lower jaw, 80

- Upper jaw, Dieffenbach's plan of removing, 41  
..... dislocation of, 70  
..... lip, congenital hypertrophy of, 121  
..... formation of new, 125  
Urticaria, 4  
..... cause of wheals in, 4  
Uvula, absence of, 104


## V.

- Vascular tumours of jaws, 39  
Voice, author on improving, after staphyloraphy, 108

## W.

- Wilson, Erasmus, on urticaria,  
Wood's knot for nævus, including skin, 50  
..... plan of subcutaneous ligature of nævus, 47  
Wound of face from bursting of soda-water bottle, 53  
..... circular saw, 53  
..... cricket ball, 53  
Wounds of face, 52  
..... gunshot, 69  
..... mucous membrane of lip, 55





*London, New Burlington Street.  
July, 1878.*

SELECTION  
FROM  
MESSRS J. & A. CHURCHILL'S  
General Catalogue  
COMPRISING  
ALL RECENT WORKS PUBLISHED BY THEM  
ON THE  
ART AND SCIENCE  
OF  
M E D I C I N E



# INDEX

	PAGE		PAGE
Acton on the Reproductive Organs . . . . .	8	Cullingworth's Nurse's Companion . . . . .	14
Adams (W.) on Clubfoot . . . . .	6	Curling's Diseases of the Rectum . . . . .	7
— (R.) on Rheumatic Gout . . . . .	18	Dalby on the Ear . . . . .	6
Allen on Aural Catarrh . . . . .	6	Dalton's Human Physiology . . . . .	9
Allingham on Diseases of Rectum . . . . .	8	Day on Children's Diseases . . . . .	13
Anatomical Remembrancer . . . . .	11	— on Headaches . . . . .	18
Anderson (McC.) on Eczema . . . . .	19	De Valcourt on Cannes . . . . .	16
— (McC.) on Parasitic Affec- tions . . . . .	19	Dobell's Lectures on Winter Cough . . . . .	15
Arnott on Cancer . . . . .	19	— First Stage of Consumption . . . . .	15
Aveling's English Midwives . . . . .	14	Domville's Manual for Hospital Nurses . . . . .	14
Balfour's Diseases of the Heart . . . . .	16	Druitt's Surgeon's Vade-Mecum . . . . .	4
Bantock's Rupture of Perineum . . . . .	14	Dunglison's Medical Dictionary . . . . .	22
Barclay's Medical Diagnosis . . . . .	11	Ellis's Manual of Diseases of Children . . . . .	12
Barker's Puerperal Diseases . . . . .	13	Fayrer's Observations in India . . . . .	4
Barnes' Obstetric Operations . . . . .	14	Fergusson's Practical Surgery . . . . .	4
— Diseases of Women . . . . .	14	Fenwick's Guide to Medical Diagnosis . . . . .	11
Basham on Renal Diseases . . . . .	8	— on the Stomach, &c. . . . .	18
— on Diseases of the Kidneys . . . . .	8	Flint on Phthisis . . . . .	15
Beale on Kidney Diseases . . . . .	8	— on Percussion and Auscultation . . . . .	15
— on Microscope in Medicine . . . . .	11	Flower's Nerves of the Human Body . . . . .	10
Bellamy's Guide to Surgical Ana- tomy . . . . .	10	Foster's Clinical Medicine . . . . .	12
Bennet's Winter and Spring on the Mediterranean . . . . .	16	Fox (T.) Atlas of Skin Diseases . . . . .	19
— Pulmonary Consumption . . . . .	16	Fox and Farquhar's Skin Diseases of India . . . . .	20
— Nutrition . . . . .	18	Frey's Histology . . . . .	9
Bennett (J. R.) on Cancerous Growths . . . . .	19	Gamgee on Fractures of the Limbs . . . . .	4
Berkart's Asthma . . . . .	15	— on Treatment of Wounds . . . . .	4
Bigg's Orthopraxy . . . . .	6	Gant's Science and Practice of Surgery . . . . .	4
Binz's Elements of Therapeutics . . . . .	12	— Diseases of the Bladder . . . . .	8
Black on the Urinary Organs . . . . .	8	Gaskoin on Psoriasis or Lepra . . . . .	19
Bose's Rational Therapeutics . . . . .	11	Glenn's Laws affecting Medical Men . . . . .	20
— Recognisant Medicine . . . . .	11	Godlee's Atlas of Human Anatomy . . . . .	11
Braune's Topographical Anatomy . . . . .	11	Gordon on Fractures . . . . .	6
Brodhurst's Orthopædic Surgery . . . . .	6	Habershon on Diseases of the Liver . . . . .	17
Bryant's Practice of Surgery . . . . .	4	— on Diseases of the Stomach . . . . .	17
Bucknill and Tuke's Psychological Medicine . . . . .	21	— on the Pneumogastric Nerve . . . . .	17
Burdett's Cottage Hospital . . . . .	15	Hancock's Surgery of Foot and Ankle . . . . .	6
Burnett on the Ear . . . . .	6	Harris on Lithotomy . . . . .	7
Buzzard on Syphilitic Nervous Affec- tions . . . . .	8	Harrison's Stricture of Urethra . . . . .	7
Carpenter's Human Physiology . . . . .	10	Hayden on the Heart . . . . .	16
Carter on Mycetoma . . . . .	20	Heath's Minor Surgery and Bandaging . . . . .	5
Cauty on Diseases of the Skin . . . . .	20	— Diseases and Injuries of Jaws . . . . .	5
Chapman on Neuralgia . . . . .	18	— Operative Surgery . . . . .	5
Charteris' Practice of Medicine . . . . .	11	— Practical Anatomy . . . . .	10
Clark's Outlines of Surgery . . . . .	4	Higgins' Ophthalmic Practice . . . . .	22
— Surgical Diagnosis . . . . .	5	Holden's Landmarks . . . . .	10
Clay's Obstetric Surgery . . . . .	13	Holt on Stricture of the Urethra . . . . .	7
Cobbold on Worms . . . . .	20	Hood on Gout, Rheumatism, &c. . . . .	18
Coles' Dental Mechanics . . . . .	23	Hooper's Physician's Vade-Mecum . . . . .	11
Cooper's Surgical Dictionary . . . . .	4	Horton's Tropical Diseases . . . . .	17
Cormack's Clinical Studies . . . . .	12	Hutchinson's Clinical Surgery . . . . .	5
Cottle's Hair in Health and Disease . . . . .	28	Huth's Marriage of Near Kin . . . . .	9
Coulson on Syphilis . . . . .	9	Ireland's Idiocy and Imbecility . . . . .	21
— on Stone in the Bladder . . . . .	9	James' Sore Throat . . . . .	16
		Jones (C. H.) and Sieveking's Patho- logical Anatomy . . . . .	10
		— (C. H.) on Functional Nervous Disorders . . . . .	18



	PAGE		PAGE
Jones (H. McN.) Aural Surgery . . .	6	Smith (J.) Dental Anatomy . . .	23
Jones (Wharton) Ophthalmic Medi- cine and Surgery . . .	23	Smith (W. R.) Nursing . . .	14
Jordan's Surgical Inflammations . . .	6	Spender's Bath Waters . . .	16
— Surgical Inquiries . . .	6	Steiner's Diseases of Children . . .	13
Leber and Rottenstein's Dental Caries	23	Stowe's Toxicological Chart . . .	20
Lee (H.) Practical Pathology . . .	8	Sullivan's Tropical Diseases . . .	17
— on Syphilis . . .	8	Swain's Surgical Emergencies . . .	5
Leared on Imperfect Digestion . . .	18	Swayne's Obstetric Aphorisms . . .	14
Liebreich's Atlas of Ophthalmoscopy	22	Taft's Operative Dentistry . . .	23
Living on Megrim, &c. . .	18	Tait's Hospital Mortality . . .	14
Macdonald's Examination of Water . .	21	Taylor's Principles of Medical Juris- prudence . . .	20
Mackenzie on Growths in the Larynx	15	— Manual of Medical Juris- prudence . . .	20
Macnamara on Diseases of the Eye . .	22	— Poisons in relation to Medical Jurisprudence . . .	20
Madden's Health Resorts . . .	17	Thompson's Stricture of Urethra . .	7
Marsden on certain Forms of Cancer	19	— Practical Lithotomy and Lithotripsy . . .	7
Mason on Harelip and Cleft Palate . .	5	— Diseases of Urinary Organs	7
Maunder's Operative Surgery . . .	4	— Diseases of the Prostate . . .	7
— Surgery of Arteries . . .	4	— Calculous Disease . . .	7
Mayne's Medical Vocabulary . . .	22	Thornton on Tracheotomy . . .	16
Meryon's System of Nerves . . .	18	Thorowgood on Asthma . . .	15
Moore's Family Medicine for India . .	17	— on Materia Medica . . .	12
Ogston's Medical Jurisprudence . . .	20	Thudichum's Pathology of Urine . .	9
Parkes' Manual of Practical Hygiene	21	Tibbits' Medical Electricity . . .	22
Parkin's Epidemiology . . .	23	— Map of Motor Points . . .	22
Pavy on Food and Dietetics . . .	18	Tilt's Uterine Therapeutics . . .	13
Peacock's Valvular Disease . . .	15	— Change of Life . . .	13
Phillips' Materia Medica . . .	12	— Health in India . . .	17
Pirrie's Surgery . . .	4	Tomes' (C. S.) Dental Anatomy . .	23
Pollock's Rheumatism . . .	19	— (J. and C. S.) Dental Surgery	23
Ramsbotham's Obstetrics . . .	13	Tufnell's Internal Aneurism . . .	7
Reynolds' Uses of Electricity . . .	22	Tuke on the Influence of the Mind upon the Body . . .	21
Roberts' Practice of Midwifery . . .	13	Van Buren on Diseases of the Genito- Urinary Organs . . .	9
Roussel's Transfusion of Blood . . .	5	Veitch's Handbook for Nurses . . .	14
Routh's Infant Feeding . . .	12	Virchow's Post-mortem Examinations	10
Roy's Burdwan Fever . . .	17	Wagstaffe's Human Osteology . . .	10
Royle and Harley's Materia Medica . .	12	Walton's Diseases of the Eye . . .	22
Rutherford's Practical Histology . . .	9	Ward on Affections of the Liver . .	17
Sabben and Browne's Handbook of Law and Lunacy . . .	21	Waring's Practical Therapeutics . .	12
Salts' Medico-Electric Apparatus . .	22	— Bazaar Medicines of India . .	17
Sanderson's Physiological Handbook . .	9	Waters on Diseases of the Chest . .	15
Sansom's Diseases of the Heart . . .	16	Wells (Soelberg) on Diseases of the Eye	23
Savage on the Female Pelvic Organs	5	— Long, Short, and Weak Sight . .	23
Savory's Domestic Medicine . . .	14	Wells (Spencer) on Diseases of the Ovaries . . .	13
Sayre's Orthopædic Surgery . . .	7	Wilks' Diseases of Nervous System . .	18
Schroeder's Manual of Midwifery . . .	13	— Pathological Anatomy . . .	10
Semple on the Heart . . .	15	Wilson's (E.) Anatomist's Vade- Mecum . . .	11
Sewill's Dental Anatomy . . .	23	— Diseases of the Skin . . .	19
Shapter's Diseases of the Heart . . .	16	— Lectures on Ekzema . . .	19
Shaw's Medical Remembrancer . . .	12	— Lectures on Dermatology . . .	19
Sheppard on Madness . . .	21	Wilson's (G.) Handbook of Hygiene . .	21
Sibson's Medical Anatomy . . .	10	Woodman & Tidy's Forensic Medicine	21
Sieveking's Life Assurance . . .	21		
Smith (E.) Wasting Diseases of Children . . .	12		
— Clinical Studies . . .	12		
Smith (Henry) Surgery of the Rectum	8		
Smith (Heywood) Gynæcology . . .	13		



**THE PRACTICE OF SURGERY :**

a Manual by THOMAS BRYANT, F.R.C.S., Surgeon to Guy's Hospital.  
Second Edition, 2 vols., crown 8vo, with 559 Engravings, 25s. [1876]

**THE PRINCIPLES AND PRACTICE OF SURGERY,**

by WILLIAM PIRRIE, F.R.S.E., Professor of Surgery in the University  
of Aberdeen. Third Edition, 8vo, with 490 Engravings, 28s. [1873]

**A SYSTEM OF PRACTICAL SURGERY,**

by Sir WILLIAM FERGUSSON, Bart., F.R.C.S., F.R.S. Fifth Edition,  
8vo, with 463 Engravings, 21s. [1870]

**OPERATIVE SURGERY,**

by C. F. MAUNDER, F.R.C.S., Surgeon to the London Hospital.  
Second Edition, post 8vo, with 164 Engravings, 6s. [1872]

BY THE SAME AUTHOR.

**SURGERY OF THE ARTERIES :**

Lettsomian Lectures for 1875, on Aneurisms, Wounds, Hæmorrhages,  
&c. Post 8vo, with 18 Engravings, 5s. [1875]

**THE SURGEON'S VADE-MECUM,**

a Manual of Modern Surgery, by ROBERT DRUITT. Eleventh Edition,  
fcap. 8vo, with 369 Engravings, 14s. [1878]

**THE SCIENCE AND PRACTICE OF SURGERY :**

a complete System and Textbook by F. J. GANT, F.R.C.S., Senior Sur-  
geon to the Royal Free Hospital. 8vo, with 470 Engravings, 24s. [1871]

**OUTLINES OF SURGERY AND SURGICAL PATHOLOGY,**

including the Diagnosis and Treatment of Obscure and Urgent  
Cases, and the Surgical Anatomy of some Important Structures and  
Regions, by F. LE GROS CLARK, F.R.S., Consulting Surgeon to St.  
Thomas's Hospital. Second Edition, Revised and Expanded by the  
Author, assisted by W. W. WAGSTAFFE, F.R.C.S., Assistant-Surgeon  
to St. Thomas's Hospital. 8vo, 10s. 6d. [1872]

**CLINICAL AND PATHOLOGICAL OBSERVATIONS IN INDIA,**

by Sir J. FAYRER, K.C.S.I., M.D., F.R.C.P. Lond., F.R.S.E., Honorary  
Physician to the Queen. 8vo, with Engravings, 20s. [1873]

**DICTIONARY OF PRACTICAL SURGERY**

and Encyclopædia of Surgical Science, by SAMUEL COOPER. New  
Edition, by SAMUEL A. LANE, Consulting Surgeon to St. Mary's and  
to the Lock Hospitals; assisted by various Eminent Surgeons. 2 vols.  
8vo, 50s. [1861 and 1872]

**TREATMENT OF WOUNDS :**

Clinical Lectures, by SAMPSON GAMGEE, F.R.S.E., Surgeon to the  
Queen's Hospital, Birmingham. Crown 8vo, with Engravings, 5s. [1878]

BY THE SAME AUTHOR,

**FRACTURES OF THE LIMBS**

and their Treatment. 8vo, with Plates, 10s. 6d. [1871]



**SURGICAL EMERGENCIES**

together with the Emergencies attendant on Parturition and the Treatment of Poisoning: a Manual for the use of General Practitioners, by WILLIAM P. SWAIN, F.R.C.S., Surgeon to the Royal Albert Hospital, Devonport. Second Edition, post 8vo, with 104 Engravings, 6s. 6d. [1876]

**TRANSFUSION OF HUMAN BLOOD:**

with Table of 50 cases, by Dr. ROUSSEL, of Geneva. Translated by CLAUDE GUINNESS, B.A. With a Preface by SIR JAMES PAGET, Bart. Crown 8vo, 2s. 6d. [1877]

**ILLUSTRATIONS OF CLINICAL SURGERY,**

consisting of Coloured Plates, Photographs, Woodcuts, Diagrams, &c., illustrating Surgical Diseases, Symptoms and Accidents; also Operations and other methods of Treatment. By JONATHAN HUTCHINSON, F.R.C.S., Senior Surgeon to the London Hospital. In Quarterly Fasciculi. Fasc. I to XI already issued. 6s. 6d. each. Fasciculi I to X bound, with Appendix and Index, £3 10s. [1876-8]

**PRINCIPLES OF SURGICAL DIAGNOSIS**

especially in Relation to Shock and Visceral Lesions, by F. LE GROS CLARK, F.R.C.S., Consulting Surgeon to St. Thomas's Hospital. 8vo, 10s. 6d. [1870]

**MINOR SURGERY AND BANDAGING:**

a Manual for the Use of House-Surgeons, Dressers, and Junior Practitioners, by CHRISTOPHER HEATH, F.R.C.S., Surgeon to University College Hospital, and Holme Professor of Surgery in University College. Fifth Edition, fcap 8vo, with 86 Engravings, 5s. 6d. [1875]

BY THE SAME AUTHOR,

**INJURIES AND DISEASES OF THE JAWS:**

JACKSONIAN PRIZE ESSAY. Second Edition, 8vo, with 164 Engravings, 12s. [1872]

BY THE SAME AUTHOR.

**A COURSE OF OPERATIVE SURGERY:**

with 20 Plates drawn from Nature by M. LÉVEILLÉ, and coloured by hand under his direction. Large 8vo. 40s. [1877]

**HARE-LIP AND CLEFT PALATE,**

by FRANCIS MASON, F.R.C.S., Surgeon and Lecturer on Anatomy at St. Thomas's Hospital. With 66 Engravings, 8vo, 6s. [1877]

**THE FEMALE PELVIC ORGANS,**

their Surgery, Surgical Pathology, and Surgical Anatomy, in a Series of Coloured Plates taken from Nature: with Commentaries, Notes, and Cases, by HENRY SAVAGE, M.D. Lond., F.R.C.S., Consulting Officer of the Samaritan Free Hospital. Third Edition, 4to, £1 15s. [1875]



**FRACTURES OF THE LOWER END OF THE RADIUS,**

Fractures of the Clavicle, and on the Reduction of the Recent Inward Dislocations of the Shoulder Joint. By ALEXANDER GORDON, M.D., Professor of Surgery in Queen's College, Belfast. With Engravings, 8vo, 5s. [1875]

**DISEASES AND INJURIES OF THE EAR,**

by W. B. DALBY, F.R.C.S., M.B., Aural Surgeon and Lecturer on Aural Surgery at St. George's Hospital. Crown 8vo, with 21 Engravings, 6s. 6d. [1873]

**AURAL SURGERY ;**

A Practical Treatise, by H. MACNAUGHTON JONES, M.D., Surgeon to the Cork Ophthalmic and Aural Hospital. With 46 Engravings, crown 8vo, 5s. [1878.]

**THE EAR :**

its Anatomy, Physiology, and Diseases. A Practical Treatise, by CHARLES H. BURNETT, A.M., M.D., Aural Surgeon to the Presbyterian Hospital, and Surgeon in Charge of the Infirmary for Diseases of the Ear, Philadelphia. With 87 Engravings, 8vo, 18s. [1877]

**AURAL CATARRH ;**

or, the Commonest Forms of Deafness, and their Cure, by PETER ALLEN, M.D., F.R.C.S.E., late Aural Surgeon to St. Mary's Hospital. Second Edition, crown 8vo, with Engravings, 8s. 6d. [1874]

**CLUBFOOT :**

its Causes, Pathology, and Treatment; being the Jacksonian Prize Essay by WM. ADAMS, F.R.C.S., Surgeon to the Great Northern Hospital. Second Edition, 8vo, with 106 Engravings and 6 Lithographic Plates, 15s. [1873]

**ORTHOPÆDIC SURGERY :**

Lectures delivered at St. George's Hospital, by BERNARD E. BRODHURST, F.R.C.S., Surgeon to the Royal Orthopædic Hospital. Second Edition, 8vo, with Engravings, 12s. 6d. [1876]

**OPERATIVE SURGERY OF THE FOOT AND ANKLE,**

by HENRY HANCOCK, F.R.C.S., Consulting Surgeon to Charing Cross Hospital. 8vo, with Engravings, 15s. [1873]

**THE TREATMENT OF SURGICAL INFLAMMATIONS**

by a New Method, which greatly shortens their Duration, by FURNEAUX JORDAN, F.R.C.S., Professor of Surgery in Queen's College, Birmingham. 8vo, with Plates, 7s. 6d. [1870]

BY THE SAME AUTHOR,

**SURGICAL INQUIRIES.**

With numerous Lithographic Plates. 8vo, 5s. [1873]

**ORTHOPRAXY :**

the Mechanical Treatment of Deformities, Debilities, and Deficiencies of the Human Frame, by H. HEATHER BIGG, Associate of the Institute of Civil Engineers. Third Edition, with 319 Engravings, 8vo, 15s. [1877]



**ORTHOPÆDIC SURGERY :**

and Diseases of the Joints. Lectures by LEWIS A. SAYRE, M.D., Professor of Orthopædic Surgery, Fractures and Dislocations, and Clinical Surgery, in Bellevue Hospital Medical College, New York. With 274 Wood Engravings, 8vo, 20s. [1876]

**INTERNAL ANEURISM :**

Its Successful Treatment by Consolidation of the Contents of the Sac. By T. JOLIFFE TUFNELL, F.R.C.S.I., President of the Royal College of Surgeons in Ireland. With Coloured Plates. Second Edition, royal 8vo, 5s. [1875]

**DISEASES OF THE RECTUM,**

by THOMAS B. CURLING, F.R.S., Consulting Surgeon to the London Hospital. Fourth Edition, Revised, 8vo, 7s. 6d. [1876]

**STRICTURE OF THE URETHRA**

and Urinary Fistulæ; their Pathology and Treatment: Jacksonian Prize Essay by Sir HENRY THOMPSON, F.R.C.S., Emeritus Professor of Surgery to University College. Third Edition, 8vo, with Plates, 10s. [1869]

BY THE SAME AUTHOR,

**PRACTICAL LITHOTOMY AND LITHOTRITY ;**

or, An Inquiry into the best Modes of removing Stone from the Bladder. Second Edition, 8vo, with numerous Engravings. 10s. [1871]

ALSO,

**DISEASES OF THE URINARY ORGANS :**

(Clinical Lectures). Fourth Edition, 8vo, with 2 Plates and 59 Engravings, 12s. [1876]

ALSO,

**DISEASES OF THE PROSTATE :**

their Pathology and Treatment. Fourth Edition, 8vo, with numerous Plates, 10s. [1873]

ALSO,

**THE PREVENTIVE TREATMENT OF CALCULOUS DISEASE**

and the Use of Solvent Remedies. Second Edition, fcap. 8vo, 2s. 6d. [1876]

**STRICTURE OF THE URETHRA**

and its Immediate Treatment, by BARNARD HOLT, F.R.C.S., Consulting Surgeon to the Westminster Hospital. Third Edition, 8vo, 6s. [1868]

**STRICTURE OF THE URETHRA,**

and other Diseases of the Urinary Organs, by REGINALD HARRISON, F.R.C.S., Surgeon to the Liverpool Royal Infirmary. With 10 plates, 8vo, 7s. 6d. [1878.]

**LITHOTOMY AND EXTRACTION OF STONE**

from the Bladder, Urethra, and Prostate of the Male, and from the Bladder of the Female, by W. POULETT HARRIS, M.D., Surgeon-Major H.M. Bengal Medical Service. With Engravings, 8vo, 10s. 6d. [1876]



**THE SURGERY OF THE RECTUM :**

Lettsomian Lectures by HENRY SMITH, F.R.C.S., Professor of Surgery in King's College, Surgeon to King's College Hospital. Fourth Edition, fcap. 8vo, 5s. [1876]

**FISTULA, HÆMORRHOIDS, PAINFUL ULCER,**

Stricture, Prolapsus, and other Diseases of the Rectum: their Diagnosis and Treatment, by WM. A. LLINGHAM, F.R.C.S., Surgeon to St. Mark's Hospital for Fistula, &c. Second Edition, 8vo, 7s. [1872]

**KIDNEY DISEASES, URINARY DEPOSITS,**

and Calculous Disorders by LIONEL S. BEALE, M.B., F.R.S., F.R.C.P., Physician to King's College Hospital. Third Edition, 8vo, with 70 Plates, 25s. [1868]

**DISEASES OF THE BLADDER,**

Prostate Gland and Urethra, including a practical view of Urinary Diseases, Deposits and Calculi, by F. J. GANT, F.R.C.S., Senior Surgeon to the Royal Free Hospital. Fourth Edition, crown 8vo, with Engravings, 10s. 6d. [1876]

**RENAL DISEASES :**

a Clinical Guide to their Diagnosis and Treatment by W. R. BASHAM, M.D., F.R.C.P., late Senior Physician to the Westminster Hospital. Post 8vo, 7s. [1870]

BY THE SAME AUTHOR,

**THE DIAGNOSIS OF DISEASES OF THE KIDNEYS,**

with Aids thereto. 8vo, with 10 Plates, 5s. [1872]

**THE REPRODUCTIVE ORGANS**

in Childhood, Youth, Adult Age, and Advanced Life (Functions and Disorders of), considered in their Physiological, Social, and Moral Relations, by WILLIAM ACTON, M.R.C.S. Sixth Edition, 8vo, 12s. [1875]

**URINARY AND REPRODUCTIVE ORGANS :**

their Functional Diseases, by D. CAMPBELL BLACK, M.D., L.R.C.S. Edin. Second Edition. 8vo, 10s. 6d. [1875]

**PRACTICAL PATHOLOGY :**

containing Lectures on Suppurative Fever, Diseases of the Veins, Hæmorrhoidal Tumours, Diseases of the Rectum, Syphilis, Gonorrhæal Ophthalmia, &c., by HENRY LEE, F.R.C.S., Surgeon to St. George's Hospital. Third Edition, in 2 vols. 8vo, 10s. each. [1870]

BY THE SAME AUTHOR,

**LECTURES ON SYPHILIS,**

and on some forms of Local Disease, affecting principally the Organs of Generation. With Engravings, 8vo, 10s. [1875]

**SYPHILITIC NERVOUS AFFECTIONS :**

Their Clinical Aspects, by THOMAS BUZZARD, M.D., F.R.C.P. Lond., Physician to the National Hospital for Paralysis and Epilepsy. Post 8vo, 5s. [1874]



**PATHOLOGY OF THE URINE,**

including a Complete Guide to its Analysis, by J. L. W. THUDICHUM, M.D., F.R.C.P. Second Edition, rewritten and enlarged, with Engravings, 8vo, 15s. [1877]

**GENITO-URINARY ORGANS, INCLUDING SYPHILIS:**

A Practical Treatise on their Surgical Diseases, designed as a Manual for Students and Practitioners, by W. H. VAN BUREN, M.D., Professor of the Principles of Surgery in Bellevue Hospital Medical College, New York, and E. L. KEYES, M.D., Professor of Dermatology in Bellevue Hospital Medical College, New York. Royal 8vo, with 140 Engravings, 21s. [1874]

**SYPHILIS:**

A Treatise by WALTER J. COULSON, F.R.C.S., Surgeon to the Lock Hospital. 8vo, 10s. [1869]

BY THE SAME AUTHOR,

**STONE IN THE BLADDER:**

Its Prevention, Early Symptoms, and Treatment by Lithotrity. 8vo, 6s. [1868]

**HISTOLOGY AND HISTO-CHEMISTRY OF MAN:**

A Treatise on the Elements of Composition and Structure of the Human Body, by HEINRICH FREY, Professor of Medicine in Zurich. Translated from the Fourth German Edition by ARTHUR E. J. BARKER, Assistant-Surgeon to University College Hospital. And Revised by the Author. 8vo, with 608 Engravings, 21s. [1874]

**HUMAN PHYSIOLOGY:**

A Treatise designed for the Use of Students and Practitioners of Medicine, by JOHN C. DALTON, M.D., Professor of Physiology and Hygiene in the College of Physicians and Surgeons, New York. Sixth Edition, royal 8vo, with 316 Engravings, 20s. [1875]

**HANDBOOK FOR THE PHYSIOLOGICAL LABORATORY,**

by E. KLEIN, M.D., F.R.S., Assistant Professor in the Pathological Laboratory of the Brown Institution, London; J. BURDON-SANDERSON, M.D., F.R.S., Professor of Practical Physiology in University College, London; MICHAEL FOSTER, M.D., F.R.S., Prælector of Physiology in Trinity College, Cambridge; and T. LAUDER BRUNTON, M.D., F.R.S., Lecturer on Materia Medica at St. Bartholomew's Hospital; edited by J. BURDON-SANDERSON. 8vo, with 123 Plates, 24s. [1873]

**PRACTICAL HISTOLOGY:**

By WILLIAM RUTHERFORD, M.D., Professor of the Institutes of Medicine in the University of Edinburgh. Second Edition, with 63 Engravings. Crown 8vo (with additional leaves for notes), 6s. [1876]

**THE MARRIAGE OF NEAR KIN,**

Considered with respect to the Laws of Nations, Results of Experience, and the Teachings of Biology, by ALFRED H. HUTH. 8vo, 14s. [1875]



**PRINCIPLES OF HUMAN PHYSIOLOGY,**

by W. B. CARPENTER, C.B., M.D., F.R.S. Eighth Edition by HENRY POWER, M.B., F.R.C.S., Examiner in Natural Science, University of Oxford, and in Natural Science and Medicine, University of Cambridge. 8vo, with 3 Steel Plates and 371 Engravings, 3ls. 6d. [1876]

**STUDENTS' GUIDE TO HUMAN OSTEOLOGY,**

By WILLIAM WARWICK WAGSTAFFE, F.R.C.S., Assistant-Surgeon and Lecturer on Anatomy, St. Thomas's Hospital. With 23 Plates and 66 Engravings. Fcap. 8vo, 10s. 6d. [1875]

**LANDMARKS, MEDICAL AND SURGICAL,**

By LUTHER HOLDEN, F.R.C.S., Senior Surgeon to St. Bartholomew's Hospital. Second Edition, 8vo, 3s. 6d. [1877]

**PATHOLOGICAL ANATOMY :**

Lectures by SAMUEL WILKS, M.D., F.R.S., Physician to, and Lecturer on Medicine at, Guy's Hospital; and WALTER MOXON, M.D., F.R.C.P., Physician to, and Lecturer on Materia Medica at, Guy's Hospital. Second Edition, 8vo, with Plates, 18s. [1875]

**PATHOLOGICAL ANATOMY :**

A Manual by C. HANDFIELD JONES, M.B., F.R.S., Physician to St. Mary's Hospital, and EDWARD H. SIEVEKING, M.D., F.R.C.P., Physician to St. Mary's Hospital. Edited by J. F. PAYNE, M.D., F.R.C.P., Assistant Physician and Lecturer on General Pathology at St. Thomas's Hospital. Second Edition, crown 8vo, with 195 Engravings, 16s. [1875]

**POST-MORTEM EXAMINATIONS :**

a Description and Explanation of the Method of Performing them, with especial Reference to Medico-Legal Practice. By Professor RUDOLPH VIRCHOW, of Berlin. Fcap 8vo, 2s. 6d. [1876]

**STUDENT'S GUIDE TO SURGICAL ANATOMY :**

a Text-book for the Pass Examination, by E. BELLAMY, F.R.C.S., Surgeon and Lecturer on Anatomy at Charing Cross Hospital. Fcap 8vo, with 50 Engravings, 6s. 6d. [1873]

**DIAGRAMS OF THE NERVES OF THE HUMAN BODY,**

Exhibiting their Origin, Divisions, and Connexions, with their Distribution, by WILLIAM H. FLOWER, F.R.S., Conservator of Museum, Royal College of Surgeons. Second Edition, roy. 4to, 12s. [1872]

**PRACTICAL ANATOMY :**

a Manual of Dissections by CHRISTOPHER HEATH, F.R.C.S., Surgeon to University College Hospital, and Holme Professor of Surgery in University College. Fourth Edition, crown 8vo, with 16 Coloured Plates and 264 Engravings, 14s. [1877]

**MEDICAL ANATOMY,**

by FRANCIS SIBSON, M.D., F.R.C.P., F.R.S. Imp. folio, with 21 coloured Plates, cloth, 42s., half-morocco, 50s. [1869]



**AN ATLAS OF HUMAN ANATOMY :**

illustrating most of the ordinary Dissections, and many not usually practised by the Student. To be completed in 12 or 13 Bi-monthly Parts, each containing 4 Coloured Plates, with Explanatory Text. By RICKMAN J. GODLEE, M.S., F.R.C.S., Assistant Surgeon to University College Hospital, and Senior Demonstrator of Anatomy in University College. Imp. 4to, 7s. 6d. each Part. [1877-8]

**THE ANATOMIST'S VADE-MECUM :**

a System of Human Anatomy by ERASMUS WILSON, F.R.C.S., F.R.S. Ninth Edition, by G. BUCHANAN, M.A., M.D., Professor of Clinical Surgery in the University of Glasgow, and HENRY E. CLARK, F.F.P.S., Lecturer on Anatomy at the Glasgow Royal Infirmary School of Medicine. Crown 8vo, with 371 Engravings, 14s. [1873]

**ATLAS OF TOPOGRAPHICAL ANATOMY,**

after Plane Sections of Frozen Bodies. By WILHELM BRAUNE, Professor of Anatomy in the University of Leipzig. Translated by EDWARD BELLAMY, F.R.C.S., Surgeon to, and Lecturer on Anatomy, &c., at, Charing Cross Hospital. With 34 Photo-lithographic Plates and 46 Woodcuts. Large Imp. 8vo, 40s. [1877]

**THE STUDENT'S GUIDE TO THE PRACTICE OF MEDICINE,**

by MATTHEW CHARTERIS, M.D., Professor of Medicine in Anderson's College, and Lecturer on Clinical Medicine in the Royal Infirmary, Glasgow. With Engravings on Copper and Wood, fcap. 8vo, 6s. 6d. [1877]

**THE MICROSCOPE IN MEDICINE,**

by LIONEL S. BEALE, M.B., F.R.S., Physician to King's College Hospital. Fourth Edition, with 86 Plates, 8vo, 21s. [1877]

**THE STUDENT'S GUIDE TO MEDICAL DIAGNOSIS,**

by SAMUEL FENWICK, M.D., F.R.C.P., Physician to the London Hospital. Fourth Edition, fcap. 8vo, with 106 Engravings, 6s. 6d. [1876]

**A MANUAL OF MEDICAL DIAGNOSIS,**

by A. W. BARCLAY, M.D., F.R.C.P., Physician to, and Lecturer on Medicine at, St. George's Hospital. Third Edition, fcap 8vo, 10s. 6d. [1876]

**THE ANATOMICAL REMEMBRANCER ;**

or, Complete Pocket Anatomist. Eighth Edition, 32mo, 3s. 6d. [1876]

**HOOPER'S PHYSICIAN'S VADE-MECUM ;**

or, Manual of the Principles and Practice of Physic, Ninth Edition by W. A. GUY, M.B., F.R.S., and JOHN HARLEY, M.D., F.R.C.P. Fcap 8vo, with Engravings, 12s. 6d. [1874]

**A NEW SYSTEM OF MEDICINE ;**

entitled Recognisant Medicine, or the State of the Sick, by BHOLANOTH BOSE, M.D., Indian Medical Service. 8vo, 10s. 6d. [1877]

BY THE SAME AUTHOR.

**PRINCIPLES OF RATIONAL THERAPEUTICS.**

Commenced as an Inquiry into the Relative Value of Quinine and Arsenic in Ague. 8vo, 4s. 6d. [1877]



**THE MEDICAL REMEMBRANCER;**

or, Book of Emergencies. By E. SHAW, M.R.C.S. Fifth Edition by JONATHAN HUTCHINSON, F.R.C.S., Senior Surgeon to the London Hospital. 32mo, 2s. 6d. [1867]

**MATERIA MEDICA AND THERAPEUTICS:**

(Vegetable Kingdom), by CHARLES D. F. PHILLIPS, M.D., F.R.C.S.E. 8vo, 15s. [1874]

**CLINICAL MEDICINE:**

Lectures and Essays by BALTHAZAR FOSTER, M.D., F.R.C.P. Lond., Professor of Medicine in Queen's College, Birmingham. 8vo, 10s. 6d. [1874]

**CLINICAL STUDIES:**

Illustrated by Cases observed in Hospital and Private Practice, by Sir J. ROSE CORMACK, M.D., F.R.S.E., Physician to the Hertford British Hospital of Paris. 2 vols., post 8vo, 20s. [1876]

**ROYLE'S MANUAL OF MATERIA MEDICA AND THERAPEUTICS.**

Sixth Edition by JOHN HARLEY, M.D., F.R.C.P., Assistant Physician to, and Joint Lecturer on Physiology at, St. Thomas's Hospital. Crown 8vo, with 139 Engravings, 15s. [1876]

**PRACTICAL THERAPEUTICS:**

A Manual by E. J. WARING, M.D., F.R.C.P. Lond. Third Edition, fcap 8vo, 12s. 6d. [1871]

**THE ELEMENTS OF THERAPEUTICS.**

A Clinical Guide to the Action of Drugs, by C. BINZ, M.D., Professor of Pharmacology in the University of Bonn. Translated and Edited with Additions, in Conformity with the British and American Pharmacopœias, by EDWARD I. SPARKS, M.A., M.B. Oxon., formerly Radcliffe Travelling Fellow. Crown 8vo, 8s. 6d. [1877]

**THE STUDENT'S GUIDE TO MATERIA MEDICA,**

by JOHN C. THOROWGOOD, M.D., F.R.C.P. Lond., Physician to the City of London Hospital for Diseases of the Chest. Fcap 8vo, with Engravings, 6s. 6d. [1874]

**THE DISEASES OF CHILDREN:**

A Practical Manual, with a Formulary, by EDWARD ELLIS, M.D., late Senior Physician to the Victoria Hospital for Children. Third Edition, crown 8vo, 7s. 6d. [1878]

**THE WASTING DISEASES OF CHILDREN,**

by EUSTACE SMITH, M.D., F.R.C.P. Lond., Physician to the King of the Belgians, Physician to the East London Hospital for Children. Second Edition, post 8vo, 7s. 6d. [1870]

BY THE SAME AUTHOR,

**CLINICAL STUDIES OF DISEASE IN CHILDREN.**

Post 8vo, 7s. 6d. [1876]

**INFANT FEEDING AND ITS INFLUENCE ON LIFE;**

or, the Causes and Prevention of Infant Mortality, by CHARLES H. F. ROUTH, M.D., Senior Physician to the Samaritan Hospital for Women and Children. Third Edition, fcap 8vo, 7s. 6d. [1876]



## COMPENDIUM OF CHILDREN'S DISEASES :

A Handbook for Practitioners and Students, by JOHANN STEINER, M.D., Professor in the University of Prague. Translated from the Second German Edition by LAWSON TAIT, F.R.C.S., Surgeon to the Birmingham Hospital for Women. 8vo, 12s. 6d. [1874]

## THE DISEASES OF CHILDREN :

Essays by WILLIAM HENRY DAY, M.D., Physician to the Samaritan Hospital for Diseases of Women and Children. Fcap 8vo, 5s. [1873]

## PUERPERAL DISEASES :

Clinical Lectures by FORDYCE BARKER, M.D., Obstetric Physician to Bellevue Hospital, New York. 8vo, 15s. [1874]

## THE STUDENT'S GUIDE TO THE PRACTICE OF MIDWIFERY,

by D. LLOYD ROBERTS, M.D., F.R.C.P., Physician to St. Mary's Hospital, Manchester. Fcap. 8vo, with 95 Engravings, 6s. 6d. [1875]

## OBSTETRIC MEDICINE AND SURGERY,

Their Principles and Practice, by F. H. RAMSBOTHAM, M.D., F.R.C.P. Fifth Edition, 8vo, with 120 Plates, 22s. [1867]

## OBSTETRIC SURGERY :

A Complete Handbook, giving Short Rules of Practice in every Emergency, from the Simplest to the most Formidable Operations connected with the Science of Obstetricy, by CHARLES CLAY, Ext.L.R.C.P. Lond., L.R.C.S.E., late Senior Surgeon and Lecturer on Midwifery, St. Mary's Hospital, Manchester. Fcap 8vo, with 91 Engravings, 6s. 6d. [1874]

## SCHROEDER'S MANUAL OF MIDWIFERY,

including the Pathology of Pregnancy and the Puerperal State. Translated by CHARLES H. CARTER, B.A., M.D. 8vo, with Engravings, 12s. 6d. [1873]

## A HANDBOOK OF UTERINE THERAPEUTICS,

and of Diseases of Women, by E. J. TILT, M.D., M.R.C.P. Fourth Edition, post 8vo, 10s. [1878]

BY THE SAME AUTHOR,

## THE CHANGE OF LIFE

in Health and Disease : a Practical Treatise on the Nervous and other Affections incidental to Women at the Decline of Life. Third Edition, 8vo, 10s. 6d. [1870]

## DISEASES OF THE OVARIES :

their Diagnosis and Treatment, by T. SPENCER WELLS, F.R.C.S., Surgeon to the Queen's Household and to the Samaritan Hospital. 8vo, with about 150 Engravings, 21s. [1872]

## PRACTICAL GYNÆCOLOGY :

A Handbook of the Diseases of Women, by HEYWOOD SMITH, M.D. Oxon., Physician to the Hospital for Women and to the British Lying-in Hospital. With Engravings, crown 8vo, 5s. 6d. [1877]



## OBSTETRIC OPERATIONS,

including the Treatment of Hæmorrhage, and forming a Guide to the Management of Difficult Labour; Lectures by ROBERT BARNES, M.D., F.R.C.P., Obstetric Physician and Lecturer on Obstetrics and the Diseases of Women and Children at St. George's Hospital. Third Edition, 8vo, with 124 Engravings, 18s. [1875]

BY THE SAME AUTHOR,

## MEDICAL AND SURGICAL DISEASES OF WOMEN:

a Clinical History. Second Edition, 8vo, with 181 Engravings. [1878]

## OBSTETRIC APHORISMS:

for the Use of Students commencing Midwifery Practice by J. G. SWAYNE, M.D., Consulting Physician-Accoucheur to the Bristol General Hospital, and Lecturer on Obstetric Medicine at the Bristol Medical School. Sixth Edition, fcap 8vo, with Engravings, 3s. 6d. [1876]

## RUPTURE OF THE FEMALE PERINEUM,

Its treatment, immediate and remote, by GEORGE G. BANTOCK, M.D., Surgeon (for In-patients) to the Samaritan Free Hospital for Women and Children. With 2 plates, 8vo, 3s. 6d. [1878.]

## HANDBOOK FOR NURSES FOR THE SICK,

by ZEPHERINA P. VEITCH. Second Edition, crown 8vo, 3s. 6d. [1876]

## A MANUAL FOR HOSPITAL NURSES

and others engaged in Attending on the Sick by EDWARD J. DOMVILLE, L.R.C.P., M.R.C.S., Surgeon to the Exeter Lying-in Charity. Third Edition, crown 8vo, 2s. 6d. [1878]

## THE NURSE'S COMPANION:

A Manual of General and Monthly Nursing, by CHARLES J. CULLINGWORTH, Surgeon to St. Mary's Hospital, Manchester. Fcap. 8vo, 2s. 6d. [1876]

## LECTURES ON NURSING,

by WILLIAM ROBERT SMITH, M.B., Honorary Medical Officer, Hospital for Sick Children, Sheffield. Second Edition, with 26 Engravings. Post 8vo, 6s. [1878]

## HOSPITAL MORTALITY

being a Statistical Investigation of the Returns of the Hospitals of Great Britain and Ireland for fifteen years, by LAWSON TAIT, F.R.C.S., F.S.S. 8vo, 8s. 6d. [1877]

## ENGLISH MIDWIVES:

their History and Prospects, by J. H. AVELING, M.D., Physician to the Chelsea Hospital for Women, Examiner of Midwives for the Obstetrical Society of London. Crown 8vo, 5s. [1872]

## A COMPENDIUM OF DOMESTIC MEDICINE

and Companion to the Medicine Chest; intended as a Source of Easy Reference for Clergymen, and for Families residing at a Distance from Professional Assistance, by JOHN SAVORY, M.S.A. Ninth Edition, 12mo, 5s. [1878]



**THE COTTAGE HOSPITAL:**

Its Origin, Progress, Management, and Work, by HENRY C. BURDETT, the Seaman's Hospital, Greenwich. With Engravings, crown 8vo, 7s. 6d. [1877]

**WINTER COUGH:**

(Catarrh, Bronchitis, Emphysema, Asthma), Lectures by HORACE DOBELL, M.D., Consulting Physician to the Royal Hospital for Diseases of the Chest. Third Edition, with Coloured Plates, 8vo, 1s. 6d. [1875]

BY THE SAME AUTHOR,

**THE TRUE FIRST STAGE OF CONSUMPTION.**

(Lectures.) Crown 8vo, 3s. 6d. [1867]

**DISEASES OF THE CHEST:**

Contributions to their Clinical History, Pathology, and Treatment, by A. T. H. WATERS, M.D., F.R.C.P., Physician to the Liverpool Royal Infirmary. Second Edition, 8vo, with Plates, 15s. [1873]

**NOTES ON ASTHMA;**

its Forms and Treatment, by JOHN C. THOROWGOOD, M.D. Lond., F.R.C.P., Physician to the Hospital for Diseases of the Chest, Victoria Park. Third Edition, crown 8vo, 4s. 6d. [1878]

**ASTHMA**

Its Pathology and Treatment, by J. B. BERKART, M.D., Assistant Physician to the City of London Hospital for Diseases of the Chest. 8vo, 7s. 6d. [1878]

**PROGNOSIS IN CASES OF VALVULAR DISEASE OF THE**

Heart, by THOMAS B. PEACOCK, M.D., F.R.C.P., Honorary Consulting Physician to St. Thomas's Hospital. 8vo, 3s. 6d. [1877]

**DISEASES OF THE HEART:**

Their Pathology, Diagnosis, Prognosis, and Treatment (a Manual), by ROBERT H. SEMPLE, M.D., F.R.C.P., Physician to the Hospital for Diseases of the Throat. 8vo, 8s. 6d. [1875]

**PHTHISIS:**

In a series of Clinical Studies, by AUSTIN FLINT, M.D., Professor of the Principles and Practice of Medicine and of Clinical Medicine in the Bellevue Hospital Medical College. 8vo, 16s. [1875]

BY THE SAME AUTHOR,

**A MANUAL OF PERCUSSION AND AUSCULTATION,**

of the Physical Diagnosis of Diseases of the Lungs and Heart, and of Thoracic Aneurism. Post 8vo, 6s. 6d. [1876]

**GROWTHS IN THE LARYNX,**

with Reports and an Analysis of 100 consecutive Cases treated since the Invention of the Laryngoscope by MORELL MACKENZIE, M.D. Lond., M.R.C.P., Physician to the Hospital for Diseases of the Throat. 8vo, with Coloured Plates, 12s. 6d. [1871]



**DISEASES OF THE HEART AND AORTA,**

By THOMAS HAYDEN, F.K.Q.C.P. Irel., Physician to the Mater Misericordiæ Hospital, Dublin. With 80 Engravings. 8vo, 25s. [1875]

**DISEASES OF THE HEART**

and of the Lungs in Connexion therewith—Notes and Observations by THOMAS SHAPTER, M.D., F.R.C.P. Lond., Senior Physician to the Devon and Exeter Hospital. 8vo, 7s. 6d. [1874]

**DISEASES OF THE HEART AND AORTA:**

Clinical Lectures by GEORGE W. BALFOUR, M.D., F.R.C.P., Physician to, and Lecturer on Clinical Medicine in, the Royal Infirmary, Edinburgh. 8vo, with Engravings, 12s. 6d. [1876]

**PHYSICAL DIAGNOSIS OF DISEASES OF THE HEART.**

Lectures by ARTHUR E. SANSOM, M.D., F.R.C.P., Assistant Physician to the London Hospital. Second Edition, with Engravings, fcap. 8vo, 4s. 6d. [1876]

**TRACHEOTOMY,**

especially in Relation to Diseases of the Larynx and Trachea, by PUGIN THORNTON, M.R.C.S., late Surgeon to the Hospital for Diseases of the Throat. With Photographic Plates and Woodcuts, 8vo, 5s. 6d. [1876]

**SORE THROAT:**

Its Nature, Varieties, and Treatment, including the Connexion between Affections of the Throat and other Diseases. By PROSSER JAMES, M.D., Lecturer on Materia Medica and Therapeutics at the London Hospital, Physician to the Hospital for Diseases of the Throat. Third Edition, with Coloured Plates, 5s. 6d. [1878.]

**SKETCH OF CANNES AND ITS CLIMATE,**

by TH. DE VALCOURT, M.D. Paris, Physician at Cannes. Second Edition, with Photographic View and 6 Meteorological Charts. Crown 8vo, 2s. 6d. [1873]

**WINTER AND SPRING**

on the Shores of the Mediterranean; or, the Genoese Rivas, Italy, Spain, Greece, the Archipelago, Constantinople, Corsica, Sardinia, Sicily, Corfu, Malta, Tunis, Algeria, Smyrna, Asia Minor, with Biarritz and Arcachon, as Winter Climates. By HENRY BENNET, M.D. Fifth Edition, post 8vo, with numerous Plates, Maps, and Engravings, 12s. 6d. [1874]

BY THE SAME AUTHOR,

**TREATMENT OF PULMONARY CONSUMPTION**

by Hygiene, Climate, and Medicine. Second Edition, 8vo, 5s. [1871]

**THE BATH THERMAL WATERS:**

Historical, Social, and Medical, by JOHN KENT SPENDER, M.D., Surgeon to the Mineral Water Hospital, Bath. With an Appendix on the Climate of Bath by the Rev. L. BLOMEFIELD, M.A., F.L.S., F.G.S. 8vo, 7s. 6d. [1877]



## PRINCIPAL HEALTH RESORTS

of Europe and Africa, and their Use in the Treatment of Chronic Diseases. A Handbook by THOMAS MORE MADDEN, M.D., M.R.I.A., Vice-President of the Dublin Obstetrical Society. 8vo, 10s. [1876]

## ENDEMIC DISEASES OF TROPICAL CLIMATES,

with their Treatment, by JOHN SULLIVAN, M.D., M.R.C.P. Post 8vo, 6s. [1877]

## FAMILY MEDICINE FOR INDIA :

A Manual, by WILLIAM J. MOORE, M.D., Surgeon-Major H.M. Indian Medical Service. Published under the Authority of the Government of India. Third Edition, post 8vo, with 60 Engravings. [In the press]

## DISEASES OF TROPICAL CLIMATES

and their Treatment : with Hints for the Preservation of Health in the Tropics, by JAMES A. HORTON, M.D., Surgeon-Major, Army Medical Department. Post 8vo, 12s. 6d. [1874]

## HEALTH IN INDIA FOR BRITISH WOMEN

and on the Prevention of Disease in Tropical Climates by EDWARD J. TILT, M.D., Consulting Physician-Accoucheur to the Farringdon General Dispensary. Fourth Edition, crown 8vo, 5s. [1875]

## BURDWAN FEVER,

or the Epidemic Fever of Lower Bengal (Causes, Symptoms, and Treatment), by GOPAUL CHUNDER ROY, M.D., Surgeon Bengal Establishment. New Edition, 8vo, 5s. [1876]

## BAZAAR MEDICINES OF INDIA

and Common Medical Plants : Remarks on their Uses, with Full Index of Diseases, indicating their Treatment by these and other Agents procurable throughout India, &c., by EDWARD J. WARING, M.D., F.R.C.P. Lond., Retired Surgeon H.M. Indian Army. Third Edition. Fcap 8vo, 5s. [1875]

## SOME AFFECTIONS OF THE LIVER

and Intestinal Canal ; with Remarks on Ague and its Sequelæ, Scurvy, Purpura, &c., by STEPHEN H. WARD, M.D. Lond., F.R.C.P., Physician to the Seamen's Hospital, Greenwich. 8vo, 7s. [1872]

## DISEASES OF THE LIVER :

Lettsomian Lectures for 1872 by S. O. HABERSHON, M.D., F.R.C.P., Senior Physician to Guy's Hospital. Post 8vo, 3s. 6d. [1872]

BY THE SAME AUTHOR,

## DISEASES OF THE STOMACH : DYSPEPSIA.

Second Edition, crown 8vo, 5s.

BY THE SAME AUTHOR,

## PATHOLOGY OF THE PNEUMOGASTRIC NERVE,

being the Lumleian Lectures for 1876. Post 8vo, 3s. 6d. [1877]



**FUNCTIONAL NERVOUS DISORDERS :**

Studies by C. HANDFIELD JONES, M.B., F.R.C.P., F.R.S., Physician to St. Mary's Hospital. Second Edition, 8vo, 18s. [1870]

**LECTURES ON DISEASES OF THE NERVOUS SYSTEM,**

by SAMUEL WILKS, M.D., F.R.S., Physician to, and Lecturer on Medicine at, Guy's Hospital. 8vo, 15s. [1878]

**NUTRITION IN HEALTH AND DISEASE :**

A Contribution to Hygiene and to Clinical Medicine. By HENRY BENNET, M.D. Third Edition. 8vo, 7s. Cheap Edition, Fcap. 8vo, 2s. 6d. [1877]

**THE STOMACH AND DUODENUM :**

Their Morbid States and their Relations to the Diseases of other Organs, by SAMUEL FENWICK, M.D., F.R.C.P., Physician to the London Hospital. 8vo, with 10 Plates, 12s. [1868]

**FOOD AND DIETETICS,**

Physiologically and Therapeutically Considered. By FREDERICK W. PAVY, M.D., F.R.S., Physician to Guy's Hospital. Second Edition, 8vo, 15s. [1875]

**HEADACHES :**

their Causes, Nature, and Treatment. By WILLIAM H. DAY, M.D., Physician to the Samaritan Free Hospital for Women and Children. Second Edition, crown 8vo, with Engravings. 6s. 6d. [1878]

**IMPERFECT DIGESTION :**

its Causes and Treatment by ARTHUR LEARED, M.D., F.R.C.P., Senior Physician to the Great Northern Hospital. Sixth Edition, fcap 8vo, 4s. 6d. [1875]

**MEGRIM, SICK-HEADACHE,**

and some Allied Disorders : a Contribution to the Pathology of Nerve-Storms, by EDWARD LIVEING, M.D. Cantab., F.R.C.P., Hon. Fellow of King's College, London. 8vo, with Coloured Plate, 15s. [1873]

**NEURALGIA AND KINDRED DISEASES**

of the Nervous System : their Nature, Causes, and Treatment, with a series of Cases, by JOHN CHAPMAN, M.D., M.R.C.P. 8vo, 14s. [1873]

**THE SYMPATHETIC SYSTEM OF NERVES,**

and their Functions as a Physiological Basis for a Rational System of Therapeutics by EDWARD MERYON, M.D., F.R.C.P., Physician to the Hospital for Diseases of the Nervous System. 8vo, 3s. 6d. [1872]

**RHEUMATIC GOUT,**

or Chronic Rheumatic Arthritis of all the Joints; a Treatise by ROBERT ADAMS, M.D., M.R.I.A., late Surgeon to H.M. the Queen in Ireland, and Regius Professor of Surgery in the University of Dublin. Second Edition, 8vo, with Atlas of Plates, 21s. [1872]

**GOUT, RHEUMATISM,**

and the Allied Affections; a Treatise by PETER HOOD, M.D. Crown 8vo, 10s. 6d. [1871]



**RHEUMATISM :**

Notes by JULIUS POLLOCK, M.D., F.R.C.P., Senior Physician to, and Lecturer on Medicine at, Charing Cross Hospital. Fcap. 8vo, 2s. 6d.

[1878.]

**CANCER :**

its varieties, their Histology and Diagnosis, by HENRY ARNOTT, F.R.C.S., late Assistant-Surgeon to, and Lecturer on Morbid Anatomy at, St. Thomas's Hospital. 8vo, with 5 Plates and 22 Engravings, 5s. 6d.

[1872]

**CANCEROUS AND OTHER INTRA-THORACIC GROWTHS :**

their Natural History and Diagnosis, by J. RISDON BENNETT, M.D., F.R.C.P., Member of the General Medical Council. Post 8vo, with Plates, 8s.

[1872]

**CERTAIN FORMS OF CANCER,**

with a New and successful Mode of Treating it, to which is prefixed a Practical and Systematic Description of all the varieties of this Disease, by ALEX. MARSDEN, M.D., F.R.C.S.E., Consulting Surgeon to the Royal Free Hospital, and Senior Surgeon to the Cancer Hospital. Second Edition, with Coloured Plates, 8vo, 8s. 6d.

[1873]

**ATLAS OF SKIN DISEASES :**

a series of Illustrations, with Descriptive Text and Notes upon Treatment. By TILBURY FOX, M.D., F.R.C.P., Physician to the Department for Skin Diseases in University College Hospital. With 72 Coloured Plates, royal 4to, half morocco, £6 6s.

[1877]

**DISEASES OF THE SKIN :**

a System of Cutaneous Medicine by ERASMUS WILSON, F.R.C.S., F.R.S. Sixth Edition, 8vo, 18s., with Coloured Plates, 36s.

[1867]

BY THE SAME AUTHOR,

**LECTURES ON EKZEMA**

and Ekzematous Affections: with an Introduction on the General Pathology of the Skin, and an Appendix of Essays and Cases. 8vo, 10s. 6d.

[1870]

ALSO,

**LECTURES ON DERMATOLOGY :**

delivered at the Royal College of Surgeons, 1870, 6s. ; 1871-3, 10s. 6d., 1874-5, 10s. 6d.

**ECZEMA :**

by McCALL ANDERSON, M.D., Professor of Clinical Medicine in the University of Glasgow. Third Edition, 8vo, with Engravings, 7s. 6d.

[1874]

BY THE SAME AUTHOR,

**PARASITIC AFFECTIONS OF THE SKIN**

Second Edition, 8vo, with Engravings, 7s. 6d.

[1868]

**PSORIASIS OR LEPRO,**

by GEORGE GASKOIN, M.R.C.S., Surgeon to the British Hospital for Diseases of the Skin. 8vo, 5s.

[1875]



## MYCETOMA ;

or, the Fungus Disease of India, by H. VANDYKE CARTER, M.D., Surgeon-Major H.M. Indian Army. 4to, with 11 Coloured Plates, 42s. [1874]

## CERTAIN ENDEMIC SKIN AND OTHER DISEASES

of India and Hot Climates generally, by TILBURY FOX, M.D., F.R.C.P., and T. FARQUHAR, M.D. (Published under the sanction of the Secretary of State for India in Council). 8vo, 10s. 6d. [1876]

## DISEASES OF THE SKIN,

in Twenty-four Letters on the Principles and Practice of Cutaneous Medicine, by HENRY EVANS CAUTY, M.R.C.S., Surgeon to the Liverpool Dispensary for Diseases of the Skin, 8vo, 12s. 6d. [1874]

## THE HAIR IN HEALTH AND DISEASE,

by E. WYNDHAM COTTLE, F.R.C.S., Senior Assistant Surgeon to the Hospital for Diseases of the Skin, Blackfriars. Fcap. 8vo, 2s. 6d. [1877]

## WORMS:

a Series of Lectures delivered at the Middlesex Hospital on Practical Helminthology by T. SPENCER COBBOLD, M.D., F.R.S. Post 8vo, 5s. [1872]

## THE LAWS AFFECTING MEDICAL MEN:

a Manual by ROBERT G. GLENN, LL.B., Barrister-at-Law; with a Chapter on Medical Etiquette by Dr. A. CARPENTER. 8vo, 14s. [1871]

## MEDICAL JURISPRUDENCE,

Its Principles and Practice, by ALFRED S. TAYLOR, M.D., F.R.C.P., F.R.S. Second Edition, 2 vols., 8vo, with 189 Engravings, £1 11s. 6d. [1873]

BY THE SAME AUTHOR,

## A MANUAL OF MEDICAL JURISPRUDENCE.

Ninth Edition. Crown 8vo, with Engravings, 14s. [1874]

ALSO,

## POISONS,

in Relation to Medical Jurisprudence and Medicine. Third Edition, crown 8vo, with 104 Engravings, 16s. [1875]

## MEDICAL JURISPRUDENCE:

Lectures by FRANCIS OGSTON, M.D., Professor of Medical Jurisprudence and Medical Logic in the University of Aberdeen. Edited by FRANCIS OGSTON, Jun., M.D., Assistant to the Professor of Medical Jurisprudence and Lecturer on Practical Toxicology in the University of Aberdeen. 8vo, with 12 Copper Plates, 18s. [1878]

## A TOXICOLOGICAL CHART,

exhibiting at one View the Symptoms, Treatment, and mode of Detecting the various Poisons—Mineral, Vegetable, and Animal: with Concise Directions for the Treatment of Suspended Animation, by WILLIAM STOWE, M.R.C.S.E. Thirteenth Edition, 2s.; on roller, 5s. [1872]



**A HANDY-BOOK OF FORENSIC MEDICINE AND TOXICOLOGY,**  
by W. BATHURST WOODMAN, M.D., F.R.C.P., Assistant Physician  
and Co-Lecturer on Physiology and Histology at the London Hospital;  
and C. MEYMOTT TIDY, M.D., F.C.S., Professor of Chemistry and of  
Medical Jurisprudence and Public Health at the London Hospital.  
With 8 Lithographic Plates and 116 Engravings, 8vo, 31s. 6d. [1877]

**THE MEDICAL ADVISER IN LIFE ASSURANCE,**  
by EDWARD HENRY SIEVEKING, M.D., F.R.C.P., Physician to St.  
Mary's and the Lock Hospitals; Physician-Extraordinary to the  
Queen; Physician-in-Ordinary to the Prince of Wales, &c. Crown  
8vo, 6s. [1874]

**IDIOCY AND IMBECILITY,**  
by WILLIAM W. IRELAND, M.D., Medical Superintendent of the  
Scottish National Institution for the Education of Imbecile Children  
at Larbert, Stirlingshire. With Engravings, 8vo, 14s. [1877]

**PSYCHOLOGICAL MEDICINE :**  
a Manual, containing the Lunacy Laws, the Nosology, Ætiology,  
Statistics, Description, Diagnosis, Pathology (including Morbid His-  
tology), and Treatment of Insanity, by J. C. BUCKNILL, M.D.,  
F.R.S., and D. H. TUKE, M.D., F.R.C.P. Third Edition, 8vo, with  
10 Plates and 34 Engravings, 25s. [1873]

**MADNESS :**  
in its Medical, Legal, and Social Aspects, Lectures by EDGAR  
SHEPPARD, M.D., M.R.C.P., Professor of Psychological Medicine in  
King's College; one of the Medical Superintendents of the Colney  
Hatch Lunatic Asylum. 8vo, 6s. 6d. [1873]

**HANDBOOK OF LAW AND LUNACY;**  
or, the Medical Practitioner's Complete Guide in all Matters relating  
to Lunacy Practice, by J. T. SABBEN, M.D., and J. H. BALFOUR  
BROWNE, Barrister-at-Law. 8vo, 5s. [1872]

**INFLUENCE OF THE MIND UPON THE BODY**  
in Health and Disease, Illustrations designed to elucidate the Action  
of the Imagination, by DANIEL HACK TUKE, M.D., F.R.C.P.  
8vo, 14s. [1872]

**A MANUAL OF PRACTICAL HYGIENE,**  
by E. A. PARKES, M.D., F.R.S. Fifth Edition, by F. DE CHAUMONT,  
M.D., Professor of Military Hygiene in the Army Medical School.  
8vo, with 9 Plates and 112 Engravings, 18s. [1878]

**A HANDBOOK OF HYGIENE AND SANITARY SCIENCE,**  
by GEORGE WILSON, M.A., M.D., Medical Officer of Health for Mid-  
Warwickshire. Third Edition, post 8vo, with Engravings, 10s. 6d.  
[1877]

**MICROSCOPICAL EXAMINATION OF DRINKING WATER :**  
A Guide, by JOHN D. MACDONALD, M.D., F.R.S., Assistant Pro-  
fessor of Naval Hygiene, Army Medical School. 8vo, with 24 Plates,  
7s. 6d. [1875]



**HANDBOOK OF MEDICAL AND SURGICAL ELECTRICITY,**

by HERBERT TIBBITS, M.D., F.R.C.P.E., Medical Superintendent of the National Hospital for the Paralysed and Epileptic. Second Edition 8vo, with 95 Engravings, 9s. [1877]

BY THE SAME AUTHOR.

**A MAP OF ZIEMSEN'S MOTOR POINTS OF THE HUMAN BODY :**

a Guide to Localised Electrification. Mounted on Rollers, 35 × 21. With 20 Illustrations, 5s. [1877]

**CLINICAL USES OF ELECTRICITY ;**

Lectures delivered at University College Hospital by J. RUSSELL REYNOLDS, M.D. Lond., F.R.C.P., F.R.S., Professor of Medicine in University College. Second Edition, post 8vo, 3s. 6d. [1873]

**MEDICO-ELECTRIC APPARATUS :**

A Practical Description of every Form in Modern Use, with Plain Directions for Mounting, Charging, and Working, by SALT & SON, Birmingham. Second Edition, revised and enlarged, with 33 Engravings, 8vo, 2s. 6d. [1877]

**A DICTIONARY OF MEDICAL SCIENCE ;**

containing a concise explanation of the various subjects and terms of Medicine, &c. ; Notices of Climate and Mineral Waters ; Formulæ for Officinal, Empirical, and Dietetic Preparations ; with the Accentuation and Etymology of the terms and the French and other Synonyms, by ROBLEY DUNGLISON, M.D., LL.D. New Edition, royal 8vo, 28s. [1874]

**A MEDICAL VOCABULARY ;**

being an Explanation of all Terms and Phrases used in the various Departments of Medical Science and Practice, giving their derivation, meaning, application, and pronunciation, by ROBERT G. MAYNE, M.D., LL.D. Fourth Edition, fcap 8vo, 10s. [1875]

**ATLAS OF OPHTHALMOSCOPY,**

by R. LIEBREICH, Ophthalmic Surgeon to St. Thomas's Hospital. Translated into English by H. ROSBOROUGH SWANZY, M.B. Dub. Second Edition, containing 59 Figures, 4to, £1 10s. [1870]

**DISEASES OF THE EYE :**

a Manual by C. MACNAMARA, F.R.C.S., Surgeon to Westminster Hospital. Third Edition, fcap. 8vo, with Coloured Plates and Engravings, 12s. 6d. [1876]

**DISEASES OF THE EYE :**

A Practical Treatise by HAYNES WALTON, F.R.C.S., Surgeon to St. Mary's Hospital and in charge of its Ophthalmological Department. Third Edition, 8vo, with 3 Plates and nearly 300 Engravings, 25s. [1875]

**HINTS ON OPHTHALMIC OUT-PATIENT PRACTICE,**

by CHARLES HIGGENS, F.R.C.S., Ophthalmic Assistant Surgeon to, and Lecturer on Ophthalmology at, Guy's Hospital. 87 pp., fcap. 8vo, 2s. 6d. [1877]



## OPHTHALMIC MEDICINE AND SURGERY:

a Manual by T. WHARTON JONES, F.R.C.S., F.R.S., Professor of Ophthalmic Medicine and Surgery in University College. Third Edition, fcap. 8vo, with 9 Coloured Plates and 173 Engravings, 12s. 6d. [1865]

## DISEASES OF THE EYE:

A Treatise by J. SOELBERG WELLS, F.R.C.S., Ophthalmic Surgeon to King's College Hospital and Surgeon to the Royal London Ophthalmic Hospital. Third Edition, 8vo, with Coloured Plates and Engravings, 25s. [1873]

BY THE SAME AUTHOR,

## LONG, SHORT, AND WEAK SIGHT,

and their Treatment by the Scientific use of Spectacles. Fourth Edition, 8vo, 6s. [1873]

## A SYSTEM OF DENTAL SURGERY,

by JOHN TOMES, F.R.S., and CHARLES S. TOMES, M.A., F.R.S., Lecturer on Dental Anatomy and Physiology at the Dental Hospital of London. Second Edition, fcap 8vo, with 268 Engravings, 14s. [1873]

## DENTAL ANATOMY, HUMAN AND COMPARATIVE:

A Manual, by CHARLES S. TOMES, M.A., F.R.S., Lecturer on Dental Anatomy and Physiology at the Dental Hospital of London. With 179 Engravings, crown 8vo, 10s. 6d. [1876]

## A MANUAL OF DENTAL MECHANICS,

with an Account of the Materials and Appliances used in Mechanical Dentistry, by OAKLEY COLES, L.D.S., R.C.S., Surgeon-Dentist to the Hospital for Diseases of the Throat. Second Edition, crown 8vo, with 140 Engravings, 7s. 6d. [1876]

## HANDBOOK OF DENTAL ANATOMY

and Surgery for the use of Students and Practitioners by JOHN SMITH, M.D., F.R.S. Edin., Surgeon-Dentist to the Queen in Scotland. Second Edition, fcap 8vo, 4s. 6d. [1871]

## STUDENT'S GUIDE TO DENTAL ANATOMY AND SURGERY,

by HENRY SEWILL, M.R.C.S., L.D.S., Dentist to the West London Hospital. With 77 Engravings, fcap. 8vo, 5s. 6d. [1876]

## OPERATIVE DENTISTRY:

A Practical Treatise, by JONATHAN TAFT, D.D.S., Professor of Operative Dentistry in the Ohio College of Dental Surgery. Third Edition, thoroughly revised, with many additions, and 134 Engravings, 8vo, 18s. [1877]

## DENTAL CARIES

and its Causes: an Investigation into the influence of Fungi in the Destruction of the Teeth, by Drs. LEBER and ROTTENSTEIN. Translated by H. CHANDLER, D.M.D., Professor in the Dental School of Harvard University. With Illustrations, royal 8vo, 5s. [1878.]

## EPIDEMIOLOGY;

or, the Remote Cause of Epidemic Diseases in the Animal and in the Vegetable Creation, by JOHN PARKIN, M.D., F.R.C.P.E. Part I, Contagion—Modern Theories—Cholera—Epizootics. 8vo, 5s. [1873]



The following CATALOGUES issued by Messrs CHURCHILL will be forwarded post free on application :

1. *Messrs Churchill's General List of nearly 600 works on Medicine, Surgery, Midwifery, Materia Medica, Hygiene, Anatomy, Physiology, Chemistry, &c., &c., with a complete Index to their Titles, for easy reference.*

N.B.—*This List includes Nos. 2 and 3.*

2. *Selection from Messrs Churchill's General List, comprising all recent Works published by them on the Art and Science of Medicine.*

3. *A descriptive List of Messrs Churchill's Works on Chemistry, Pharmacy, Botany, Photography, Zoology, and other branches of Science.*

4. *Messrs Churchill's Red-Letter List, giving the Titles of forthcoming New Works and New Editions.*

[Published every October.]


5. *The Medical Intelligencer, an Annual List of New Works and New Editions published by Messrs J. & A. Churchill, together with Particulars of the Periodicals issued from their House.*

[Sent in January of each year to every Medical Practitioner in the United Kingdom whose name and address can be ascertained. A large number are also sent to the United States of America, Continental Europe, India, and the Colonies.]

---

MESSRS CHURCHILL have a special arrangement with MESSRS LINDSAY & BLAKISTON, OF PHILADELPHIA, in accordance with which that Firm act as their Agents for the United States of America, either keeping in Stock most of Messrs CHURCHILL's Books, or reprinting them on Terms advantageous to Authors. Many of the Works in this Catalogue may therefore be easily obtained in America.











54



