

On synostotic crania among aboriginal race [i.e. races] of man / by Joseph Barnard Davis.

Contributors

Davis, Joseph Barnard, 1801-1881.
Royal College of Physicians of Edinburgh

Publication/Creation

Haarlem : De Erven Loosjes, 1865.

Persistent URL

<https://wellcomecollection.org/works/f7stwu9z>

Provider

Royal College of Physicians Edinburgh

License and attribution


This material has been provided by This material has been provided by the Royal College of Physicians of Edinburgh. The original may be consulted at the Royal College of Physicians of Edinburgh. where the originals may be consulted.

This work has been identified as being free of known restrictions under copyright law, including all related and neighbouring rights and is being made available under the Creative Commons, Public Domain Mark.

You can copy, modify, distribute and perform the work, even for commercial purposes, without asking permission.




Wellcome Collection
183 Euston Road
London NW1 2BE UK
T +44 (0)20 7611 8722
E library@wellcomecollection.org
<https://wellcomecollection.org>



* Fa 10. 10

R36479

ON
SYNOSTOTIC CRANIA
AMONG
ABORIGINAL RACES OF MAN.



Digitized by the Internet Archive
in 2015

<https://archive.org/details/b21952930>

ON
SYNOSTOTIC CRANIA


AMONG

ABORIGINAL RACE OF MAN,

BY

JOSEPH BARNARD DAVIS. M. D.

PUBLISHED BY THE DUTCH SOCIETY OF SCIENCES OF HAARLEM.



HAARLEM,
DE ERVEN LOOSJES.
1865.

ON

SYZOSTOTIC GRAZIA

A 1884

ABORIGINAL RACE OF MAN.

BY

JOSEPH BARNARD DAVIS, M.D.

PUBLISHED BY THE BOARD OF REGENTS OF HARVARD



DE ERVEN JOOSJES
HARLEM
1884

ON
SYNOSTOTIC CRANIA

AMONG
ABORIGINAL RACES OF MAN,

BY
JOSEPH BARNARD DAVIS. M. D.

ON
SYNOSTOTIC CRANIA

AMONG
ABORIGINAL RACES OF MAN.

Some attention has been directed of late years, chiefly by different distinguished continental anatomists, to the deformities and irregularities of the human skull, which are intimately connected with a premature and abnormal obliteration of its sutures (*Synostosis*). The subject has been studied, in the main, in relation to Cretinism, as it was in the dissection of unfortunate creatures who had suffered from this endemic disease, that this peculiar closure of the sutures was first profitably observed. Up to the present time it has not excited any attention whatever in England, and hitherto its occurrence has scarcely been at all noted or described in any but European races; and in few of these has it been noticed, save in the cretins of Southern Europe. Hence cranial synostosis has attracted much less consideration than from its importance it is entitled to.

It is proposed to bring forward some cases of this singular anomalous condition of the cranial bones, which have been met with among races of people justly entitled to the designation of *aboriginal*. This may prove a valid contribution to a curious subject of inquiry, which, in all its extent, involves, besides accurate descriptions of the various kinds of

abnormal ossification of sutures, their causes and their effects, not merely upon the development and the form of the calvarium, but upon the brain also, and upon its functions.

SÖMMERING, in his great work on anatomy, referred to the early closure of the sutures as a modifying influence on the form of the skull: Dr. J. C. G. LUCÆ, now Professor of anatomy at Frankfort-on-the-Main, who long devoted his attention to the unsymmetrical forms of the skull, in his inaugural Dissertation upon that subject, figured a wry calvarium from a German cemetery and preserved in the museum at Marburg ¹⁾. In this example, which the author considered to be the first instance mentioned by anatomical writers, the right parietal appears to have a firm ossific union with the right half of the frontal bone, and this portion of the coronal suture seems to be entirely obliterated. Dr. LUCÆ, however, was of opinion that the bone on the right side of the calvaria, occupying the place of the parietal and half of the frontal, was really formed from *one centre of ossification*. With this view Professor VIRCHOW concurred ²⁾. A later examination of this skull, which has again been carefully and accurately figured, by Professor HERMANN WELCKER, renders it almost certain that this is one of the usual cases of obliteration by synostosis of the right half of the coronal suture, some slight traces of which may still be perceived ³⁾. Professor JOSEPH ENGEL, of Vienna, in his work on skull-forms, described and arranged a few synostotic crania, of which he gave figures and measurements, in exemplification of his views ⁴⁾. Dr. F. C. STAHL, in his researches on cretinism, pointed out the influence of the effacement of one half of the coronal suture in producing the asymmetrical and wry skull, which occurs in cretins ⁵⁾. Profes-

¹⁾ *De symmetria et asymmetria organ. animal. imprimis cranii*. 1839.

²⁾ *Gesammelte Abhandlungen zur wissenschaftlichen Medicin*. 1856. II. S. 937 and 991.

³⁾ *Untersuchungen über Wachsthum und Bau des menschlichen Schädels*. 1862. S. 111. Taf. XII. Fig. 2 and 3.

⁴⁾ *Untersuchungen über Schädelformen*. 1851. 8°.

⁵⁾ *Neue Beiträge zur Physiognomik und pathologischen Anatomie der Idiotia Endemica, (genannt Cretinismus)*. Zweite Auflage. 1851. S. 67.

sor HYRTL also, of Vienna, in his Anatomical Treatises, indicated the too early closure of the sutures as a cause of unnatural forms of the skull. But RUDOLF VIRCHOW, Professor of Pathological Anatomy at Berlin, subsequently, and, like STAHL, when engaged in the study of cretinism, investigated this morbid state of the cranial bones much more fully ¹. He directed his attention to deformed skulls and obliterated sutures in various anatomical museums, and concluded that there exists a series of difformities which is owing to premature and irregular ossification of the sutures.

VIRCHOW arranged the different skull-forms, produced by synostosis of the cranial bones, under three principal heads ²).

1. *The obliquely contracted (wry) skull.*

There are two varieties. *a.* An *anterior*, from synostosis of one half of the coronal suture. *b.* A *posterior*, from synostosis of one limb of the lambdoidal suture.

2. *The transversely contracted (long) skull.*

Of this he enumerates four varieties. *a.* Synostosis of the parietals from obliteration of the sagittal suture. *b.* Synostosis of the frontal with the great wings of the sphenoid, from ossification of the spheno-frontal suture. *c.* Synostosis of the parietal and sphenoid, from effacement of the spheno-parietal suture. *d.* Synostosis of the parietal and temporal, by ossification of the squamous suture.

3. *The longitudinally contracted (short) skull.*

Some of these synostoses may occur on one, or on both sides of the skull, in different cases; and they present themselves in different combinations.

Professor VIRCHOW pointed out that in the contractions of the calva-

¹) *Ueber den Cretinismus, namentlich in Franken, und über pathologischen Schädelformen.* Würzburg. Verhand. Bd. II. S. 230. 1851. Gesamm. Abhandl. 1856. S. 891.

²) *Op. cit.* S. 899.

rium in different directions, which depend on synostosis of the bones, there is often seen a coexistent undue dilatation, or expansion of this spheroid in other directions. This he justly regarded as *compensatory*. The development of the brain being arrested in one direction by the closure of the sutures, it grows in another, perhaps excessively, where the sutures are open. This system of *compensation* contributes greatly to the strange anomalies in the form of the cranium, produced by premature ossification of the sutures.

The cartilaginous substance forming a suture presents the *nidus* for the deposition of the earthy salts of bone, and is essential to the progress of ossification. When this substance disappears by obliteration of the suture, the spheroidal calvarium can no longer grow in the direction of the plane at right angles to the suture, i. e. the cranial bones cease to increase at their edges. Hence VIRCHOW enunciated the law, that, *in the synostosis of a suture, the development of the skull is always arrested in the direction perpendicular to the synostotic suture*¹).

Professor VIRCHOW also proposed a nomenclature for many of the *pathological forms of the skull*, to which it will be desirable to refer upon one or two points. Under his third head, *Dolichocephali*, or *long heads*, he ranges: *a*. Superior middle synostosis, which embraces *Simple Dolichocephali* (Synostosis of the sagittal suture), and *Wedge-shaped heads, Sphenocephali*²) (Synostosis of the sagittal suture, with compensatory development of the region of the great fontanel). *b*. Lower lateral synostosis: which includes *Narrow heads, Leptocephali*, (Synostosis of the frontal and sphenoidal bones); and *Saddle-shaped heads, Klinocephali*, (Synostosis of the parietal and sphenoid or temporal bones).

Professor LUCÆ has devoted much attention to synostotic crania, in his work entitled, *Zur Architectur des Menschenschädels*, Frankf. a./M. 1857.

¹) *Op. cit.* S. 936.

²) This term *sphenocephalus* is an objectionable one in craniology, unless it be explained in what sense or direction the wedge-shape obtains. It has been applied in very different ways, and admits of application in every aspect of the skull. Prof. M. J. WEBER. *Die Lehre von den Ur- und Racen-formen der Schädel und Becken des Menschen* 1830. S. 21.

This book is elaborately illustrated with lithographs designed upon a new plan, the intention of which is to represent the outlines geometrically, i. e. true to measure, and without regard to the optical effects of visual perception ¹⁾. In this volume LUCAE has examined the subject of the arrangement of synostotic and other pathological crania critically, pointing out its difficulties, and proposes a distribution under six divisions. He makes twelve species of synostotic skulls. As the entire subject is little understood, it has been suggested to give the arrangements of VIRCHOW and LUCAE in a tabular form:

VIRCHOW.

1. *Simple Makrocephali*:

- a. Waterheads, *Hydrocephali*.
- b. Greatheads, *Kephalones*.

2. *Simple Mikrocephali*:

Dwarfheads. *Nannocephali*.

3. *Dolichocephali*. Longheads.

- a. Upper middle synostosis:
Simple Dolichocephali (synostosis of the sagittal suture).
Wedgeheads, *sphenocephali* (Synostosis of the sagittal suture, with compensatory development of the region of the great fontanel).

LUCAE.

I. *Megalocephali* ²⁾.

- a. Waterheads. *Hydrocephalones*.
- b. Greatheads, *Cephalones*.

II. *Microcephali*.

III. *Brachycephali*, Shortheads.

- a. Simple *brachycephali* (too early synostosis of the basilar — *pars basilaris ossis occipitis* — and the sphenoid bone).
- b. *Pachycephali*, Thickheads. — Synostosis of the parietals with the scaly portion of the occipital.
- c. *Acrocephali*, Spireheads (Oxy-

¹⁾ He had previously fully explained his method in his: *Zur Organischen Formenlehre*. 1844.

²⁾ Prof. LUCAE very judiciously proposes to abandon the use of the ancient, but inappropriate and indefinite, term *macrocephalus*, which simply means long head, and has been replaced in modern craniology by *dolichocephalus*.

- b. Lower lateral synostosis :
Narrowheads. *Leptocephali*
(Synostosis of the frontal and
sphenoidal bones). — Saddle-
heads, *kli-nocephali* (Synosto-
sis of the parietal and sphe-
noidal or temporal bones).

4. *Brachycephali*, Shortheads.

- a. Posterior synostosis:
Thickheads, *Pachycephali*
(Synostosis of the parietals
with the scaly portion of
the occipital).
Pointed or sugarloafheads,
Oxycephali (Synostosis of the
parietals with the occipital and
temporal bones, and compen-
satory development of the
anterior fontanel region).
b. Superior anterior and lateral
synostosis.
Flatheads, *Platycephali* (Ex-
tended synostosis of the frontal
and parietal bones).
Roundheads, *Trochocephali*
(Partial synostosis of the fron-
tal and parietal bones in the
middle of the half of the
coronal suture).
Wryheads, *Plagiocephali* (one-
sided synostosis of the frontal
and parietal bones).

cephali, pointed heads). —
Synostosis of the parietals
with the frontal bone, and
development of the great
fontanel region.

- d. *Leptocephali*, Thinheads. —
Synostosis of the lower parts
of the coronal suture.

IV. *Stenocephali*, Narrow-heads.
Macrocephali (*Dolichocephali*)
Longheads. — Synostosis of
the sagittal suture, with com-
pensatory development of the
parietals, in length.

- b. *Sphenocephali*, Wedgeheads.
— Synostosis of the sagittal
suture, with compensatory
development of the great font-
anel, in height.

- c. *Apiocephali*, Pyriformheads.
— Synostosis of the occipito-
mastoid suture, with compen-
satory development of the
parietals, in breadth.

V. *Bathycephali*, Depressed heads.

- a. *Kli-nocephali*, Saddleheads.
— Synostosis of the parietals
with the *alæ majores* of the
sphenoidal, or of the parietals
with the middle of the scaly
portion of the temporal.

- b. *Tapeinocephali*, Lowheads.
— Synostosis of the *alæ ma-*

c. Lower middle synostosis.

Simple brachycephali (too early synostosis of the *pars basilaris ossis occipitis* and the sphenoidal bone ¹⁾).

jores of the sphenoid with the frontal.

c. *Platycephali*, Flatheads. —

Synostosis between the frontal, parietal and the squamous portion of the temporal.

d. *Kyphocephali*, Humpheaded.

— Synostosis between the posterior part of the squamous plates of the temporals and the parietal bones, with Wormian bones in the lambdoidal suture.

VI. *Plagiocephali*, Wryheads. —

Synostosis of a side suture on one side ²⁾).

In the pages of his very valuable Memoir, VIRCHOW has figured many examples of cretin and other skulls, exhibiting synostotic deformation, to which he has added illustrative notes. The subject of the 13th figure he speaks of as a „Kielförmige” (boat-shaped) calvarium with obliterated sagittal suture, the region of which projects outwards, whilst the lateral parts of the skull are compressed. In this case, Professor K. E. VON BAER has pointed out that „Kielförmige”, is a misprint for „Keilförmige” (wedge-shaped); but the calvarium is truly boat-shaped and that in the very sense which induced VON BAER to apply the term *scaphocephalus* to such calvaria. The subject of figures 18 and 19, under the head of „the only complete wedge-shaped head”, *sphenocephalus*, VIRCHOW describes as having „entire obliteration of the sagittal suture, large flat posterior fontanel-bones, wedge-shaped projection of the anterior fontanel-region, with protuberance of the whole sagittal region,

¹⁾ *Op. cit.* S. 901.

²⁾ *Architectur des Menschenschädels.* S. 69.

very broad forehead, strongly projecting occiput, and a total absence of *tubera parietalia*"¹⁾).

The illustrious Professor K. E. VON BAER of St. Petersburg, in his elaborate dissertation on Macrocephalic skulls²⁾, has proposed to apply the name *scaphocephali* to deformed calvaria which are very narrow, and as it were compressed at the sides, in which there is no trace of the sagittal suture, but the sagittal region is elevated into a *carina*, and in which this *carina* is prolonged both before and behind into an arch. By this means the skull-cap acquires the form of an ancient boat, having a keel, with its bottom turned upwards. In the opinion of VON BAER, this remarkable deformity arises congenitally, from the presence of *one* middle centre of ossification for the two parietals, or, in other words, that there exists only one parietal. This designation of *scaphocephalus* has been adopted by the latest writer upon the subject, Prof. HERMANN WELCKER of Halle³⁾; who does not concur with VON BAER on the question of the origin of the parietals from *one* centre of ossification. The appellation itself is exceedingly appropriate to the form of synostotic calvarium which is embraced in the definition. When the subject is more fully understood and the many varieties and combinations of synostoses have been noted, the rich nomenclature of VIRCHOW and LUCAS will not be found at all too copious to embrace them all. It should be remarked that VON BAER, when he wrote his learned Memoir, had only met with three examples of the synostosis, or more properly, as he regards it, congenital absence of the sagittal suture, to which he applies the term

¹⁾ S. 909.

²⁾ *Die Makrokephalen im Boden der Krym und Oesterreichs, verglichen mit der Bildungs-Abweichung, welche BLUMENBACH Macrocephalus genannt hat.* Out of the *Mém. de l'Acad. imp. des Sciences de St. Petersb.* VIIe Série. Tome II. N°. 6. 1860, — a copy of which, printed separately, I owe to the great politeness of Prof. VON BAER. The late Prof. JNO. QUEKETT applied the term „boat-shaped” to an example of this abnormality in a cranium from Scotland, in the Museum of the Roy. Coll. of Surg. London. N°. 5732. In this case the distinguished Prof. OWEN omitted to note, in the printed Catalogue, the obliteration of the sagittal suture, although in two others, Nos. 5556 and 7, Hindoo skulls, he has recorded the fact merely.

³⁾ *Untersuchungen über Wachsthum und Bau des menschlichen Schädels.* Erster Theil. 1862.

scaphocephalus. One of these was the famous calvarium of BLUMENBACH's Table III, *Asiatae macrocephali*; the second was a still more lengthened skull, also in the Blumenbachian collection at Göttingen, labelled, „*Danus*;” and the third the cranium of a Gipsy of 20 years of age, in the Bonn collection. From this statement it must be inferred that the Museums of St. Petersburg do not contain any example of this particular deformation. When to this is added the remark of Prof. WELCKER, that he likewise knows of but three instances of adult scaphocephalic skulls, two of these being the same Göttingen specimens mentioned by VON BAER, and the third one which is in the collection at Halle, it may be concluded that the abnormality is rare. Yet, I am ready to doubt, whether it be of such extreme rarity. I possess two examples of the scaphocephalic form of VON BAER. One of these was found some years ago, at a depth of 18 feet, in making excavations in Clothfair, London; and the other is the skull of an Australian, which will be more fully described hereafter. I have also observed in different collections in England at least eight others.

But to conclude the brief history of the subject, I must mention the memoir of Dr. HUMPHRY MINCHIN, of Dublin, who met with this abnormality in the living subject ¹⁾. This was an extreme instance of scaphocephalism in a boy of 9 years age, who, when 4 years older, was still in „full health and vigour, remarkably quick and intelligent; nor has he been known to evince any symptom leading to the suspicion of cerebral disease.” The result of Dr. MINCHIN's inquiries was „sufficient to establish the congenital nature of the cranial form in this instance and to discountenance the hypothesis either of morbid cerebral action, or manual compression”. Dr. MINCHIN had the good fortune to meet with another example of scaphocephalism, in the skull of a boy of the age of two years and a half, who had died of acute phthisis, after measles. In this case also, „the child had been good humoured and

¹⁾ *Contributions to Craniology*. Dublin Quart. Journ. Med. Sc. Nov. 1856. A separately printed copy Dr. MINCHIN was kind enough to supply me with.

playful, and by no means deficient in intelligence", and did not suffer from head symptoms in his last illness. The greatest peculiarity in the calvarium of this boy shall be described in Dr. MINCHIN's own words. „This skull exhibits a remarkable development of the antero-posterior elongation, associated also with a total absence of sagittal suture, and, further, upon looking closely to the vertical ridge, or "carina", which occupies the place usually assigned to the suture arising from the junction of the two parietals, there is plainly to be observed what I conceive to be the point of ossific origin of *a single vertical bone*; indeed, the stellate or radiate appearance of this part, a condition commonly seen in the vicinity of ossific centres, is so unequivocally evident, that this fact, together with a total absence of a similar radiation from the regions usually occupied by the parietal protuberances (which in this cranium are flattened in a remarkable degree), would contribute strongly to favour the presumption that the ossification of the dome has proceeded, in the present case, from the vertex alone and not from the sides." Dr. MINCHIN's conclusion is, that the crania which have since been denominated *scaphocephalic*, and which I have spoken of as owing their form to a premature synostosis of the sagittal suture, necessarily result from the abnormal occurrence of only *one* central and vertical centre of ossification for the parietal bones; and he was the first to enunciate this doctrine, which now has the weighty support of Prof. VON BAER. Dr. MINCHIN's case presents apparent evidence of such a primitive vertical centre of ossification; and a calvarium in the Museum of the Royal college of surgeons of Ireland exhibits the same appearance of stellate radiation from the vertical region of the parietals, according to the wood-cuts in Dr. MINCHIN's treatise. In my calvarium from Clothfair there are some very faint traces of an appearance of radiation from a central spot, a little behind the middle of the parietals, taken lengthwise. Still, that the abnormality is to be attributed to the existence of only a single centre of ossification, as Dr. MINCHIN and Prof. VON BAER have maintained, will require much further investigation and more decided evidence, especially derived from foetal crania, before it can be admitted.

The instance of a remarkable calvarium ¹⁾, believed to be English, in my collection, which affords an example of wryhead closely coinciding with the Marburg specimen, is quite opposed to the doctrine of defect of centres of ossification as the cause of these abnormalities. In the Marburg calvarium, as already related, the right half of the coronal suture appeared to have been abnormally absent during intra-uterine life both to LUCÆ and VIRCHOW, although WELCKER has since detected traces of it, and the two former concluded that there had been only one centre of ossification for the right parietal and this half of the frontal. My calvarium exhibits no trace whatever of the right half of the coronal suture. The right parietal and the frontal bones are perfectly continuous. Yet the presence of both the frontal eminences, and of an elevation indicating the right parietal protuberance also, point satisfactorily to the existence of the three normal centres of ossification ²⁾.

As our attention has been so principally directed to synostosis of the sagittal suture, I will now bring forward the adult cranium of an Australian in which this exists.

I. This remarkable skull of a man, who appears to have reached the age of about 50 years, is derived from the Colony of New-South-Wales. He belonged to a tribe domiciled on the Mc Leay river, a navigable stream, thickly wooded on its banks, about 200 miles north of Sydney. I have been fortunate enough to acquire a normal skull, (II.) also of a man and of about the same age, of this tribe. This will prove of

¹⁾ In the course of these remarks I have used the terms calvarium, etc. in a scientific sense, which may require to be defined. *Cranium* is used for the bones of the head in a complete state; *calvarium*, for these bones, when the lower jaw is absent; *calvaria*, for the bones of the vault of the brain-case.

²⁾ In order to complete the history of the elucidation of the subject of synostotic crania, I must not omit to refer to a very exact explanatory Memoir, illustrated by good figures from the Author's own drawings, by Dr. J. VAN DER HOEVEN JR. in the *Verhandlungen der Kaiserl. Leopold. Carol. Akademie*. Band 29. In this essay, the author describes two curious synostotic skulls in the Museum of his excellent Father, the illustrious Prof. J. VAN DER HOEVEN of Leyden. One of these is the skull of a Hottentot woman from the Cape of Good Hope, and the other that of a woman from Nymegen. Both are singular examples of deformation from premature synostosis.

value for comparison. The synostotic cranium presents an example of a curious custom which prevails among many of the tribes of Australians, to mark the period of puberty of the young men, and to sanction their admission into the manly state and privileges. The practice is to punch out one of the incisor teeth of the upper mandible, on the left side. In some instances this operation has not been done quite so cleverly as in this, whether from want of expertness in the operator, or from the refractory behaviour of the sufferer. In the skull of a man of the Piccaninny Creek Tribe, in the Colony of Victoria, in my collection, the two upper incisors and the canine also of the left side have all been punched out, doubtless to the great dismay of the youthful aspirant.

This singular cranium I., which would be designated *scaphocephalic* by VON BAER and WELCKER, and *sphenocephalic* by VIRCHOW and LUCÆ exhibits no indication of a sagittal suture, either within or without, and has no parietal tuberosities, on the contrary, the parietals present a large flat-arched surface, as it were compressed, which is pretty equable, and they unite together in a narrow arch, which is ridged in the centre. These bones are very long, and exhibit the large surface for the attachment of the crotaphite muscle, terminating in the semicircular line at a great elevation, which is common to the Australian race. The bone is thick at the vertical ridge, scabrous on the surface and covered with vascular pores, among which the two *foramina parietalia*, one on each side, occupy their usual places, about the junction of the middle with the posterior third of the surface, another being seen on the left side, about the junction of the middle with the anterior third ¹⁾. There is no

¹⁾ Prof. WELCKER very justly concludes that the existence or the absence of these foramina is of great weight in deciding the question of the primary presence of two distinct parietal bones. His researches among foetal skulls show that the foramina are formed in early fissures of the parietals, and at their edges; so that the presence of one or two indicates a period at which the bones had not coalesced. *Ueber zwei seltene Difformitäten des menschl. Schädels, Scaphocephalus und Trigonocephalus*. 1863. S. 5. In the calvarium from Clothfair, London, there is one fine *foramen parietale*, on the right side.

The American Indian slave boy (III), has two parietal foramina on the left side, and three or four small foramina on the right side.

trace whatever of any radiation of bony fibres from a common centre of ossification. The frontal and occipital bones are both narrow, especially the latter, although the measurements do not exhibit this. The former presents an indication of an injury during life, an appearance which is frequent among the skulls of Australians. The frontal bone is much more elevated and prominent than in the normal skull; the form of the face in the latter being prognathous, whilst in the former it is as it were orthognathous. The occipital also bulges out in its upper portion, while the lower is horizontal below the tuberosity. The compensatory development has in this case been predominantly directed forwards, so as to produce fulness in the frontal region and great elevation about the coronal suture, from which point the vertex slopes downwards towards the occiput. The parietal *carina* or ridge is prolonged to the middle of the frontal, and to the upper part of the occipital. The coronal suture does not take its usual course, obliquely entering the parietals on each side to a central point, but encroaches much more on the frontal bone, in the whole of the middle part of the skull. It does not present any central process or distinct beak of the parietal (*Schnebbe*), such as VIRCHOW describes. On the contrary, the united parietals terminate in this suture with a blunt irregular projection, much more distinct on the right side than the left. The *right* squamous suture of this cranium is entirely obliterated, this side of the calvarium in the temporal region being slightly flatter than the left. All the other sutures are distinct. The sphenoparietal sutures are very short.

It appears from the table of measurements: 1. That the capacity of the scaphocephalic skull is only one ounce less than that of the normal one; hence it is apparent that the compensatory development in the frontal and occipital regions has very nearly equalled the lateral contraction, occasioned by the synostotic state of the parietals and left temporal. 2. The circumference, the fronto-occipital arch and the length have been increased by the deformity. 3. The intermastoid arch, the breadth and height of the calvarium, and both the length and breadth of the face, have been diminished.

The brain having had space for its development so nearly equal to that of the normal state, there is no reason to infer that the mental powers of this man were less than those of his fellow. The fact of his having arrived at such a mature age rather proves, on the contrary, that he had attained to the average cultivation of his race, in all those arts essential to life and enjoyment, and in which the savage is so exceedingly expert and accomplished — for without them, in an uncivilized, self-dependent state, life must inevitably perish. Life was clearly compatible with, and was not materially, if at all, abridged by the abnormal condition of the bones of the calvarium.

III. Another interesting instance of scaphocephalism is presented in the cranium of an Indian from the district of the Columbia River, North Western America, who is said to have been a slave boy, and who appears to have been from 10 to 11 years of age. In this case, there is no perceptible trace of sagittal suture, either on the outer or inner surface, whilst every other suture is open, even the intermaxillary is not quite obliterated. The vertex is devoid of every indication of radiation. The sides of the bi-parietal are flat, except a very slight elevation in the situation of each tuberosity. There is a perceptible carina which runs onwards to the forehead. The bi-parietal exhibits the central projection or beak in the course of the coronal suture, (*Schnebbe* of *VIRCHOW*). The outline of this cranium does not present the same slope from the frontal to the occipital, as is seen in the abnormal Australian, since it has a distinct prominence just behind the middle of the bi-parietal. There are two small irregular triquetral bones on the left side, one in the squamous suture, and the other at the point at which the coronal meets the great wing of the sphenoid bone. The calvarium is remarkable for the regularity of its boat-shape. The term scaphocephalous has the greatest appropriateness when applied to it. I am not aware of any previous example of scaphocephalism in the cranium of a North American Indian of any tribe. And, as no instance is depicted in *MORTON's* magnificent book, „*Crania Americana*”, nor mentioned in his „*Catalogue*”, (in which, however, such points are generally passed over), it might

be presumed to be of great rarity among the American races. Further research is required to decide this.

IV. The calvarium of „Pofii”, a man of 38 years of age, of the Tافiti tribe, in the valley of Hanatekua, island of Ohiva Hoa, in the Marquesan archipelago, presents a very peculiar form of synostosis of the sagittal suture, combined with synostosis of the far greater part of the lambdoidal ¹⁾. The result of this premature obliteration of sutures in the calvarium of „Pofii,” is the production of a singular deformation. The bi-parietal makes a sudden perpendicular descent from an elevated point just behind the middle of its length, and joins the scaly portion of the occipital. This latter bone continues its course, inclining forwards, to the *foramen magnum*. So that the calvarium acquires a truncated appearance, as if it had been cut off behind. The brain-case has received a compensatory development at the forepart and at the sides, where the sutures were open, by which means it has obtained a cuboid form, with a square forehead. The coronal suture is *apparently* thrown back nearly to the middle of the length of the calvarium, and is devoid of the usual serrations in the greater part of its course. There is a triquetral bone on the left side, at the junction of the sphenoid and *pars squamosa* with the parietal, and another of different shape in the same place on the right side ²⁾. This calvarium presents a combination of synostoses which is not clearly embraced in the nomenclature of either VIRCHOW or LUCAE. It exhibits the synostoses belonging to both of their divisions dolichocephali and brachycephali, and comes nearest in its conformation to their *pachycephali*. It is scarcely necessary to add, that no such abnormality has been before described in any race of the Polynesian Islanders.

V. The skull of a man of uncertain age, of the Kanaka, or Sandwich Island race, presents an instance of the variety b. among VIRCHOW's *Brachycephali*, viz. superior, anterior and lateral synostosis; although the Professor appears not to have met with the precise variety exhibited

¹⁾ I follow the example of VIRCHOW in speaking of synostosis of a *suture*, for convenience. Properly it is synostosis of the bones entering into the suture.

²⁾ Fontanel bones of the *fonticuli sphenoidales*.

in this cranium; for, in this case, there is no *lateral* synostosis, it is merely superior and anterior. It is a small, thick, slightly wry skull of very much of a square form, which has had its chief compensatory development downwards. The sagittal and coronal sutures are obliterated, the latter not being so entirely effaced but that its former course may be imperfectly traced; whilst all the others remain in a patent state. This man also has undergone the operation of tooth-punching, for the Kanakas have a similar custom to that of the Australians; yet it is not peculiar to the males and is not performed at one particular period of life, but is adopted on different occasions, as a sign of mourning for a deceased chief, etc. and is made to extend its harsh sway over a greater number of teeth. The upper outer incisor on the right side, and the whole of the lower incisors, have been eradicated in early life ¹⁾.

In the Table of Measurements I have included those of the normal Australian skull, besides those of the scaphocephalic Australian; those of the calvarium of „Pofii,” the synostotic Ohivahoan; and those of the skull of the Kanaka. The scaphocephalic cranium of the North American Indian slave boy is not admitted, on account of his immature age.

The bones of the cranium are formed by two distinct processes of ossification. Those of the *primordial skull*, chiefly of the base, from cartilaginous nuclei. Those of the calvaria, or vault, in a membranous capsule, on the outside of the primordial cranium ²⁾. The points of ossification

¹⁾ In the imperfect calvarium of a *Pokomame* in my collection, from Guatemala, a race which practised an extraordinary distortion on the skulls of infants, by a considerable counter-pressure on the occipital and frontal regions, there is a perfect ossification and obliteration of the sagittal suture. As the other sutures are quite patent, there is reason to conclude that this is a case of premature synostosis. And, as the calvarium has only undergone that deformation which has been occasioned by art, it is most probable that the synostosis of the sagittal suture took place in intra-uterine life. The bi-parietal has become strongly arched antero-posteriorly, and also greatly bulged out at the sides. This distortion constitutes the *tête canéiforme relevée* of Dr. L. A. Gosse, *Déformations artificielles du Crâne*, 1855, p. 24.

²⁾ Om Primordial-Craniet, af L. JACOBSON, *Förhandlingar vid de Skandinaviske Naturforskarnes tredje Möte*, i Stockholm, 1842, S. 739. — H. SPÖNDLI, *Ueber den Primordial-Schädel*, 1846. S. 27.

in the latter are sometimes much more numerous than the rule, and the consequence of this irregularity of development is an unusual expansion of the calvaria at the spot in which Wormian bones are situated. The elder MONRO described a skull with a great number of triquetral bones ¹⁾. And the distinguished Professor of Physiology and Anatomy at Helsingfors, Dr. E. J. BONSDORFF, has given an account and figures of another, in which the parietal bone on the left side was composed of 16 separate ossicles, and that on the right side of 8, whilst the occipital was made up of 8 others ²⁾.

It has been maintained by eminent anatomists that the brain acquires its full growth at ages as early as 3 and 7 years, but it is now well ascertained that the process of cerebral development continues till mature age, and that, even after that period of life, the cerebral mass may contract in size ³⁾; thus is required a freedom of expansion of the cranial bones by some remains of a cartilaginous condition of their sutures.

Dr. MINCHIN and others have affirmed, with the greatest probability, that scaphocephalism is congenital. But in one of the instances in which I have had the opportunity to see it in the living subject, the testimony of the mother of the child was averse to this view. This was in the case of a fine, stout, healthy, active and intelligent child, named George Baskerfield, aged 7 months, who was just beginning to articulate „dad, dad.” The sagittal and coronal sutures appeared to be quite closed. The forehead was upright, prominent, and full at the sides; the calvaria flat at the sides and sloping upwards to a long ridge which ran from the frontal to the occipital; the latter bone had a sort of globular projection backwards. The perpendicular height of the calvarium above the auditory foramina

¹⁾ *Edinburg Medical Essays*, Vol. V, N°. 16. Tab. II.

²⁾ *Beskrifning af ett missbildadt cranium hos en Man. Acta Soc. Scient. Fennicæ. T. II. pars II. 1847. p. 1283. etc.*

³⁾ Dr. THOS. B. PEACOCK fixes „the attainment of the maximum of development at from the 20th to the 25th year; a very marked decrease in weight obtains in advanced age.” *Tables of the weights of the Brain, etc.* Reprinted from the „*Month. Journ. Med. Sci.*” 1861. p. 21. Obliginglly transmitted to me by the author.

was about the same as in the North American Indian slave boy's skull, viz. 4.5 inches, which is equal to 114 millimetres; and the length of the calvarium was 7.1 inches or 179 mm. The mother's statement, if it might be relied upon, was distinct, that, *at birth, the sutures were open*. No doubt, this was a mistake.

The compatibility of these synostotic irregularities with life cannot be questioned, although, in some cases, they may tend to abridge it; and the testimony has hitherto been unanimous that they do not interfere with the intellectual functions ¹⁾. This is a point of great interest, which has an intimate bearing upon the question of the injurious influences of artificial distortion of the cranium. Authorities are much divided upon this latter point. Many, with MORTON and CATLIN, have positively affirmed, that the fantastic deformities impressed upon the skull by the American Indians, have no prejudicial consequences upon the functions of the brain, but that those who exhibit these deformations are as acute and intelligent as others of the tribe without them. Others, on the contrary, as Drs. FOVILLE, LUNIER and L. A. GOSSE, who have had opportunities of witnessing the effects of those slighter deformities of the skull, which arise, without design and as it were accidentally, among different European people, principally from the mode of covering and dressing the head by constricting bands, maintain that they have a tendency to interfere with the due performance of the functions of the brain and to lead to moral lesions. Such persons are frequently met with in the lunatic asylums in the South of France. It is possible that races of totally different kinds of cultivation, may vary materially in respect of bearing an interference with the central organ of the nervous system, and that those who are called savage may have a higher tolerance of such interference. There are many facts relating to the Australian tribes which might be quoted to give countenance to this view.

I may observe that these undesigned and slight distortions of the cranium, by artificial means, are not so confined to the French as has

¹⁾ Dr. LUCAE may be quoted to this effect. *Zur Architectur*, u. s. w. S. 70.

been considered. I am not aware that they have ever been observed, or their existence recorded in other modern people of Europe. But that they are to be met with among the Russians, I am satisfied from the examination of a number of examples I have of Russian skulls. They are also to be seen among Dutch and even among English skulls, and I have no doubt may be found among the crania of most European nations. They are slight and easily overlooked, unless special attention be directed to them.

Admitting that, in the normal state, the brain and its including case, the skull, grow together, and that the former does not exercise an absolutely predominating influence over the development of the latter; still, when the cranium has become wholly or mainly a shut box, it can allow no longer of any material modification from within.

The effect of the more partial synostotic difformities is, by means of the compensatory action which has been described in these cases, that, in general, the cranial cavity is not materially encroached upon. The mass of brain may be equal, or nearly equal to that in the normal state, the chief difference being that the relative positions of the different parts of the cerebral organs are slightly changed. These, according to the researches of Mr. ROBT. GARNER, *in the normal state*, appear to have somewhat definite relations with the sutures ¹⁾. But I am not aware that a small change in the relative position of the different portions of the cerebral mass, such as must occur in synostotic crania, can of itself seriously interfere with the functions of the brain ²⁾. Still, where this soft and pliant mass is as it were *compressed*, I have reason to think it probable that its functions are interfered with, especially its moral functions. I have the cranium of a convict who was executed on Norfolk Island, which I owe to the kindness of Admiral H. M. DENHAM. This

¹⁾ *Report of the British Association*, 1862. p. 126.

²⁾ LUCÆ has remarked that these changes show how erroneous it is to conclude, from the surface of the skull, as to the condition and activity of individual parts of the brain lying under that surface. *Schädel bekannter Personen*. S. 70.

man was executed there, when that beautiful isle was appropriated to the reception of the most dangerous and irreclaimable convicts from the other penal settlements. It is a microcephalic skull, rather dolichocephalic, of a man of apparently about 40 years of age. It exhibits a perfect ossification of the sagittal and of the greater portion of the lambdoidal sutures. The coronal suture is partially obliterated at the sides in the temporal regions, and can only be distinguished by faint traces in all its middle part. In this case there has not been any compensatory development of moment in other directions. The calvarium is not abridged in its length which is 7.1 inches equal to 179 millimeters; probably it is a little elongated. It is however very narrow, being only 4.8 inches or 122 m.m. at its widest part, between the temporal bones. So that the result is a very small, dwarfed, almost *cylindrical* calvarium. The internal capacity is only 50 ounces of sand, which is equal to 71.4 cubic inches or 1169 cubic centimetres ¹⁾. This is a striking example of moral depravity, accompanied with and most likely dependent upon the very defective state of the development of the brain. In the skull of „Peron,” a Spaniard, of not more than 50 years of age, which was formerly in the Museum of JOSHUA BROOKES, the eminent anatomist, there is a pretty general synostosis of the sutures, as well as *hyperostosis*, and, although it does not look small, it may be regarded as somewhat microcephalic. Peron, who had lost his right arm, whilst commemorating the battle of Waterloo, assassinated an English soldier with a fork held in his left hand. The skull is very thick and heavy from hyperostosis. All the central portion of the lambdoidal, nearly all the sagittal, the whole of the coronal, the right sphenoparietal and the internasal sutures are obliterated. This extensive synostosis is most probably connected with the hyperostotic state of the bones, and by no means congenital. It also exhibits marks of that distortion denominated *tête annulaire* by GOSSE. The skull is awry, and has an internal capacity of only 68 ounces of sand, or 82.3 cubic inches, which is

¹⁾ The internal capacity of this cylindrocephalic skull is considerably below the mean of that of the crania of any race in MORTON'S great table.

equal to 1348 cubic centimetres. The cranium of another murderer, „Owen,” a Cambrian, supposed to have been about 40 years of age, also from the collection of BROOKES, presents much of the same long, low and narrow cylindrical form as that of the Norfolk Island convict. All the sutures effaced in the skull of Peron are ossified in this, on both sides. I have other examples of the skulls of criminals which exhibit synostoses, and Prof. LUCÆ figures the cranium of a woman named „Christiana Ruthardt,” who was executed for poisoning, with the same peculiarity. He also delineates a most extraordinary cranium of a criminal, who died in a prison for secondary offences at Ziegenheim, which very closely imitates the peculiar forms of the distorted heads of the ancient Peruvians. All the bones were ossified together, except the right squamous portion of the temporal and the parietal ¹⁾. In the latter division of his volume, Dr. LUCÆ depicts and tabulates the measurements of a number of skulls of criminals, and in these an obliteration of sutures, sometimes asserted to be early, approaches to the rule. It is observed in about half of them, three being said to be remarkably small ²⁾. But it is not necessary to dwell further upon the question: whether premature synostosis of the sutures, especially when pretty general, and not accompanied with compensatory development, interferes with the due performance of the functions of the brain. That it does so, I believe, the evidence is almost conclusive ³⁾.

In the case of the Norfolk Island convict, the whole of the hemispheres of the brain must have been subject, not merely to an arrest of development, but to some degree of abnormal compression, while the base of the cerebrum might be somewhat freer from this constricted condition. And the same may be affirmed in the case of Peron, the Spaniard. I also observe that, in both these skulls, the inside of the calvarium, which, in the normal state, is marked by depressions, corresponding to the convolutions on the surface of the hemispheres, is unusually plain and

¹⁾ *Zur Architectur. Schädel abnormer Form. Taf. VI.*

²⁾ *Schädel bekannter Personen.*

³⁾ The calvarium of the woman executed at Paris, „Le Couffe,” may be referred to. VIMONT, *Traité de Phrénologie*, 1836, Fol. Pl. CXII, Fig. 1.

smooth. As the hemispheres are generally regarded to be in immediate connection with the higher faculties of the mind, where we find them subjected to compression and their development arrested, it is fair to infer that these faculties will be found in abeyance, and the more animal propensities in vigorous and unrestrained action. And, reciprocally, when we find criminals of the deepest dye exhibit the peculiar synostotic deformation of the calvarium, which must produce this compression and arrest of development of the hemispheres in the greatest degree, it seems a logical conclusion, that the series of phenomena stand in the relation to each other of cause and effect ¹⁾.

¹⁾ I have not thought it necessary to discuss the causes of synostoses, of which it is probable but little can be ascertained. It has been considered that „pressure and manipulation of the sides of the head in infancy,” is a prominent *cause of synostosis of the cranial bones*. Manipulation, without continued pressure, would, I believe, be wholly inoperative in changing the natural form of the cranium. The skull of „Pofii” might possibly be quoted in support of this theory, as the Sandwich Islanders have the custom of compressing the heads of infants in the occipital region; but „Pofii” was a Marquesan Islander, and I am not aware that this custom extends to the Marquesas. Besides, „Pofii’s” cranium is too plainly an instance of abnormal synostosis, in foetal life, or very early infancy, to be regarded in its deformity as in any way the result of pressure. And that pressure is not an efficient cause of synostosis we have good negative evidence in the skulls of those nations which subject the head to artificial deformations. In about 50 of these crania in my collection, I observe very few in which there is any particular tendency to premature ossification of sutures, unless it be in the skull of the Pokomame. But in this the obliterated sagittal suture runs at right angles to the direction in which the pressure was applied, a direction the most unlikely to occasion its obliteration.

Dr. GOSSE devotes a section of his careful and elaborate work, (*Déformations du Crâne*), to heads *artificially flattened at the sides*, but the cases he quotes do not bear out very strictly such a mode of compression. They are mostly examples of elongation of the head, which has not by any means been compressed on the sides only. The oldest reference to distortion of the head by art, that practised by the *Macrocephali* of HIPPOCRATES and STRABO, produced long heads, and as we have no description of the method employed, we are not justified in concluding that it was a contrivance for flattening the sides of the head. The „macrocephalus” of BLUMENBACH’s Table III, is but an instance of the too early synostosis of the parietals. KLAPROTH’s reference to the Abases of the Caucasus, and the case of the Kabyle skull in the Museum of the École de Médecine, at Paris, are perhaps the best evidences Dr. Gosse has produced. That the heads of the Arabs, and especially those of north Africa, have been subjected to pressure *at the sides* in particular, is probably more doubtful. In a series of

I have no doubt, that the synostoses which gave rise to the microcephalism of the Norfolk Island convict, took place long before the full development of the brain. The abnormal form and conditions of the skull appear to be quite conclusive upon this point. The greater compression of the surface of the hemispheres than other portions of the encephalon, can only be regarded as a hypothetical view. Indeed, upon the question, whether the convolutions are the seat of the higher functions of the brain, physiologists are not at present quite unanimous. Still, the fact of the unusual prevalence of synostosed bones in the crania of criminals, I believe must be admitted. That these synostoses, in many cases, influence the brain by arresting its development, appears to be equally indisputable. The low moral character and base propensities generally displayed by microcephalic idiots is also admitted, and gives material support to the view I have taken. Hence, the inferences I have been induced to draw, that, in some cases of synostosis of the bones of the calvarium, the brain suffers an arrest in its development which interferes with its functions, bears such an appearance of probability as to deserve further investigation.

beautiful drawings of the races of Algeria, for which I am deeply indebted to the kindness of the distinguished Professor MILNE EDWARDS, and taken during his visit in 1835, there is no sensible appearance of such lateral pressure. They embrace Moors, Arabs, Biskris, Mozabites, Kabyles, Negroes and Mulattos. And the Hottentot cranium, in the Galerie anthropologique of the Jardin des Plantes, referred to and described by Dr. Gosse, is plainly an instance of interparietal synostosis.

Note. My collection contains a good number of synostotic crania which have not been alluded to. An enumeration of a few of them may be added here. N°. 689. KHAS, of Nepal. a *makrocephalus* of LUCAE. — N°. 801. VEDAH, aborigine of Ceylon. a *makro-klino-cephalus* of LUCAE. — N°. 804. VEDAH, a *klinocephalus*. — N°. 884. HINDOO, a *makrocephalus*. — N°. 1145. LAPP, a *klino-pachy-cephalus*. — N°. 1146. LAPP, a *Scaphocephalus*.

ADDITIONS.

The time which has elapsed since the above memoir was written, has afforded opportunities for further observations upon aboriginal crania affected with synostoses, the result of irregular development. These observations and a few conclusions deduced from them, seem to render it desirable that some additional notes should be appended here.

1. The first point of importance is, that, viewing the premature ossification of the sutures in its relation to deformation of the calvarium, numerous examples prove that *this deformation is by no means a necessary and invariable consequence of synostosis.*

No. 915 of my collection, the small skull of an *Australian* woman, of about 17 years of age, (the two *dentes sapientiae*, or *m* 3 of OWEN, are still deep in the alveoli, yet the spheno-basilar synchondrosis is quite ossified,) exhibits an entire obliteration of the sagittal suture. All the other sutures, usually open, are quite free from ossification. In this case there is no approach to any deformity, not even to *dolichocephalism*. In the fine large calvarium of a *Fatuhivan*, No. 789, from the island of Fatuhiva, one of the Marquesas, which has belonged to a man of about 17 years of age, the sagittal suture is wholly obliterated, the others are

still open. The *dentes sapientiae* are not quite extruded from the alveoli and the spheno-basilar synchondrosis is only partially ossified. In this calvarium there is no deformation, unless it be a slight indication of *klinocephalism*, in a merely perceptible depression passing across the biparietal, immediately behind the coronal suture. In these instances and others also, the premature ossification of the suture has taken place without any *compensatory development* in the frontal or occipital region, to give space for the growth of the brain. LUCAE has already said: „Die Compensation scheint nämlich für die gleiche Synostose nicht immer dieselbe zu sein, und wenn sie es auch wäre, so ist sie wenigstens bis jetzt noch *nicht für alle Fälle beobachtet*.“ (*Zur Architectur des Menschenschädels*. S. 67.) — No. 100, the small cranium of an *African Negro* woman, of about 30 years of age, is almost a counterpart of these examples. The sagittal suture is entirely obliterated, yet there is no other deformity, save a very slight *klinocephalism*.

2. In the second place, the deformations of the calvarium resulting from synostoses, which have been named so correctly and described with such precision, *do not necessarily and invariably follow the premature ossification of those sutures to which they have been ascribed, and are sometimes occasioned by synostoses to which they have not been attributed*.

No. 540 is the incomplete calvarium of a *Kafir* man, of middle age, from the battle field of Gwanga, in South Africa. The sagittal suture is ossified, the other sutures open. The only resulting deformity is a moderate contraction, running across the fore part of the parietals from one alisphenoid to the other. This constitutes the *tête annulaire* of Foville, when produced by bandaging the head, and is the *Klinocephalism* of VIRCHOW and LUCAE. — No. 294, is the calvarium of an *Ebo* woman, of about 30 years of age, from the neighbourhood of Old Calabar, on the West coast of Africa. In this calvarium again the sagittal suture is wholly ossified and the other sutures open. There is only a slight *dolichocephalism*, no *scaphocephalism* whatever; on the contrary, the region of the sagittal suture is low, like the rest of the vault of the skull. There is, however, slight *klinocephalism*, which is ascribed by VIRCHOW

and LUCÆ to ossification of the speno-parietal and squamous sutures, both of which sutures are quite free in this calvarium. — No. 605 is the fine skull of a *Kanaka* man from the Island of Oahu, in the Hawaiian group, who has been about 50 years of age. It presents a premature obliteration of the sagittal suture and a trivial *klinoccephalism*. In this example LUCÆ's definition is correct. There is an ossification of the speno-frontal and the speno-parietal sutures. In No. 784, the calvarium of a *Fatuhivan* man, of at least 50 years of age, there is not the slightest trace of the sagittal suture, but the speno-parietal and squamous sutures are as open as usual, yet it exhibits marked *klinoccephalism*. — No. 1072 is the cranium of an *African Negro* woman, probably of about 30 years of age, of the *Osekani Tribe*, from the region of the Gaboon River, under the equator. In this example there is an occlusion of the sagittal suture quite complete, except about an inch of its anterior extremity. Like No. 294, this calvarium is low and it is not longer than usual. The only deviation of form is a slight *klinoccephalism*. — The next example to which I have to refer is another skull of a *Kanaka*, from the Island of Uahu. It has belonged to a man advanced in life, but there cannot be a question that the sagittal suture has been prematurely ossified, probably in foetal life, so that no trace of it is left behind. Perhaps as the natural consequence of age, the middle portions of the lambdoidal and the middle and lateral portions of the coronal sutures are partially obliterated. The squamous sutures are quite open, and all the sutures round the alisphenoid on the right side are in the same state — those of the left side are not quite so free, still not effaced. In this calvarium there is neither *dolichocephalism* nor *scaphocephalism*, still it is considerably deformed. The deformation is a contraction, extending across the fore part of the parietals from one alisphenoid to the other. The calvarium presents a very striking example of *klinoccephalism*. Thus it proves, that this synostotic deformation is not entirely dependent on the particular synostoses to which it has been attributed. It also shows, when supported by the other examples which I have adduced, that *klinoccephalism* is not an uncommon result of ossification of the sagittal suture.

3. In the third place, it may be stated that *scaphocephalism* is far from being the usual result of the too early ossification of the sagittal suture. On the contrary, is it a rare and exceptional result of the synostosis of the parietals. The evidence derived from the crania in my collection fully proves this.

I have 27 skulls in which there is no appearance of the sagittal suture. In all these it is either completely obliterated or very nearly so, for I have purposely omitted the cases in which the ossification is only partial and incomplete. Among these 27 calvaria, only 4 can be said to be *scaphocephalic*, i. e. to present the carina or ridge in the position of the sagittal suture and the compensatory elongation in the frontal and occipital regions. In one of these, the cranium of a *Lapp* man, of about 30 years of age, the signs of *scaphocephalism* are very slight. In the three others they are strongly marked and very decided. These are No. 1122, the skull of the *Australian*, described above, No. 69, the ancient calvarium found in Cloth-fair in London, and No. 884, the incomplete calvarium of a *Hindoo* from Gazepoor, in Bengal. This is in all probability the relic of a woman. Hence it appears that true *scaphocephalism* is rare even among crania presenting synostosis of the parietals. It appears, as far as my observations go, to occur in only one case out of seven. In other words, the ossification of the sagittal suture takes place even in early life without any *compensatory development* at all, or the compensatory development merely produces *VIRCHOW's simple dolichocephalism*.

Seeing that true *scaphocephalism* is an infrequent result of premature ossification of the sagittal suture, it should be stated that there are instances of such anormal condition in which the line of this suture is distinctly *depressed*, instead of being elevated into a ridge. In No. 628, the skull of a *Kanaka* woman, of perhaps 50 years of age, from the Island of Uahu, the sagittal suture has been wholly ossified and obliterated at an early period of life. The calvarium is not at all lengthened, and about an inch from the coronal suture commences a *depression* following the line of the obliterated suture and widening and deepening

as it runs backwards to the lambdoidal suture, where the depression ceases. This example of synostosis of the parietals shows an entire absence of compensation. In No. 434, another *Kanaka* cranium of a young woman, of about 20 years of age, the sagittal suture is wholly obliterated, and is replaced by a *depression* only less deep than in the foregoing example. The acute WELCKER has already made the judicious note: „Ich bemerke noch, dass auch *Zwischen-formen* zwischen dem ausgeprägten Scaphocephalus und den gewöhnlicheren Formen des Dolichocephalus synostoticus vorkommen, Formen, welche ihre Entstehung einer in das spätere Fötus- und früheste Kindesalter fallenden Verschmelzung der Pfeilnaht verdanken mögen." Ueber zwei seltene Difformitäten des menschl. Schädels, Scaphocephalus und Trigoncephalus. S. 7. Abhandl. d. Naturforsch. Gesellsch. zu Halle, 1863.

4. *There is a series of crania which, in their natural development, present such a degree of length and of narrowness, as almost to deserve to be distinguished by the name of natural scaphocephali.* The skulls to which I allude occur among the inhabitants of New Caledonia, the New Hebrides and the Caroline Islands. They are not universal among these people, who sometimes unintentionally flatten the occipital region of their infants by the mode of nursing they make use of. Still many of their crania are so remarkably long and narrow and so elevated along the line of the axis of the sagittal suture, as to be worthy of a distinction among all dolichocephalic races by the designation scaphocephalic; without any reference to the closure of any sutures, but in the open state of all those usually open ¹). Hence scaphocephalism among these people justly becomes one of their race characters ²). The crania of these people are so peculiar, and so distinct from

¹) Perhaps the name *Kumbecephalic*, invented by my friend Professor DANIEL WILSON to distinguish very dolichocephalic calvaria, might, to prevent confusion, be appropriated to these natural dolichocephali in an extreme degree. *Prehistoric Annals of Scotland*, 1851. p. 166.

²) Dr. WELCKER has already claimed, as a national peculiarity, the approximation to scaphocephalism in the *Greenland* skull, more correctly, the *pyramidal* form among the *Esquimaux*. *Wachsthum und Bau des menschl. Schädels*, S. 118.

all others, as to deserve to be elevated into a class, and perhaps to be placed in the same line as the classes Caucasian, Mongolian and Ethiopian.

5. The further investigation of the subject of the synostosis of the parietal bones does not afford any additional support to the doctrine of Dr. MINCHIN and VON BAER, that scaphocephalism is dependent upon the parietals having, in some cases, but one centre of ossification, situated in the mesial line and developing a uniparietal. Among the whole of the skulls that present a continuous plate of bone in the situation of the sagittal suture which have come under my observation, there is not one exhibiting that radiation of osseous fibres from a central point described and figured by Dr. MINCHIN. Dr. WELCKER's further and very careful observations upon all the examples of scaphocephali he has been able to examine, which he has recounted at length in the valuable Memoir just quoted, leads him to the conclusion: „die ursprüngliche Anwesenheit der Pfeilnaht für alle Scaphocephali jetzt mit Bestimmtheit behaupten zu dürfen." S. 5.

6. I wish to offer an additional remark upon a subject of inquiry which I am inclined to think is not yet definitively decided. Some of those who have written upon synostosis of the cranial bones have unhesitatingly maintained, that *those races who interfere with the natural forms of the skull are pre-eminently distinguished for premature ossification of the sutures*, and hence, that all artificial compression of the head predisposes to synostoses. My opportunities for further observation induce me to doubt, whether synostosis of the cranial bones is more frequent in races who distort the skull, and whether artificial compression has any influence in causing premature ossification of the sutures. The subject seems to demand a much more thorough investigation before a satisfactory conclusion can be arrived at. It cannot be disputed that these developmental irregularities occur among people who practice, whether intentionally or otherwise, the arts of deformation on the tender infantile cranium. I have adduced many instances among the Kanakas, a people who resort to different means to modify the form of the head. Still synostoses are not at all peculiar to these people.

WELCKER believes he has observed premature obliteration of sutures in the line, in which the bandages for distorting the skull have compressed the cranial bones ¹⁾.

The arguments adduced by WELCKER appear to render it certain that the synostosis of the parietals, which results in scaphocephalism, takes place during foetal existence, before artificial interference can be applied. Among a series of *Italian* skulls which I owe to the generous exertions of Dr. GIUSTINIANO NICOLUCCI, the distinguished Italian ethnologist and craniologist, I find synostoses exceedingly frequent. So much so, that, out of 11 crania, 5 are remarkable for the premature ossification of one or more of their sutures. I have made particular inquiry respecting the modes adopted by the people of the different provinces of Italy in the nursing of infants, and cannot ascertain that any of them compress the head. Among a fine series of ancient *Lapp* skulls recently placed in my hands, amounting to 8 in number, two are synostotic. Another exhibits parieto-occipital flattening from nursing. I am, however, somewhat in doubt, whether the Lapps may not have nursed their infants in old times on a cradle board.

At first view, it does not appear probable that compression of the head in one direction, say antero-posteriorly, as in the *Pokomame* calvarium, should result in the premature ossification of a suture as the sagittal, running in the *same direction*; and that the same compression should operate alike prejudicially upon the sutures running in an *opposite direction*, or in that perpendicular to the line of the compressing force. All that I can now add is, that an examination of the skulls of Flatheads and other American races in my collection, does not render support to the doctrine maintained by some, that artificial compression of the skull disposes it in a material degree to synostosis.

Since what precedes was written, the fine skull of a Flathead, of a Tribe on the North East coast of Vancouver's Island, has come into my possession, by the kindness of Mr. W. L. GREEN, of Hololulu, in the

¹⁾ *Opus cit.* S. 15.

Sandwich Islands. It is a curious instance of distortion and of synostosis also. It is the cranium of a man, of probably about 50 years of age, as doubtfully indicated by the teeth, the state of the sutures not affording any guide to the approximate age. Its peculiar and most remarkable *form* is plagiocephalous, from artificial distortion. It is very short, and very wide in the interparietal and intertemporal regions, which have been rendered wry by the distortion. The frontal region is depressed, with a ridge running along the centre of the *os frontis*. The parieto-occipital region is extensively flattened, obliquely, so as to be depressed much more on the right side than on the left. The general form of the calvarium is thus rendered very irregular. With respect to the sutures, the sphenofrontal, the sphenoparietal, the coronal, the sagittal and the lambdoidal are all ossified. There are only some very faint traces of one or two of these sutures to be perceived. Still, the sphenotemporal sutures and the squamous sutures are quite open, on both sides of the skull. This is a singular instance of extensive synostoses in an artificially deformed cranium, but does not appear to tend to show, that the interference of art has had any influence in causing the synostoses. Perhaps the most extraordinary feature in this skull is that the *foramen magnum* is rendered exceedingly oblique, so as to form an irregular oval, with its long axis extending from a point in a line with the right pterygoid process of the sphenoid, to a point opposite situated in a line with the left outer extremity of the superior transverse ridge of the occipital bone, or with the middle of the left limb of the lambdoidal suture.

7. It seems desirable to express the opinion decidedly, that *the subject of synostotic skulls, as well as of those deformed in other ways, deserves far more attention and estimation among craniologists than it has hitherto received.* The human cranium is subject to developemental irregularities; to pathological conditions; to artificial deformations, both voluntary and involuntary, as Dr. Gosse has named them; and to posthumous modifications, all of which interfere with and alter its normal forms. When it is recollected, how high a degree of importance has been justly attributed to the normal configuration of the skull in the study of anthro-

pology, a science which has such various and momentous applications, the need of a close, full and discriminating investigation of the kinds and degrees of the influences interfering with such configuration, must be at once apparent ¹⁾).

8. The most extraordinary case of scaphocephalism on record, is that described in the Inaugural Dissertation of Dr. JOSEPH SCHADE ²⁾ It occurred in a man of Stettin, in Pomerania, who died at the age of 38 years, in the workhouse there. Dr. SCHADE has given a small figure of this cranium, which is preserved in the Anatomical Museum at Greifswald. From the importance of this skull in the history of scaphocephalism, and from the fact of its not having attracted the attention of the principal writers upon the subject, VON BAER and WELCKER, it becomes very desirable to notice it fully here. By the great politeness of Professor BUDGE of Greifswald, and by the very kind attentions of Professor W. KEFERSTEIN of Göttingen, I am enabled to do so, and to give three views of this curious cranium, of the natural size, as well as to append some account of its peculiarities, and also add its measurements to the Table. Its scaphocephalism appears to be more exaggerated than that of any other example of the deformation hitherto described. And the interest attached to the case is greatly increased by a particular account of the subject when living, from the pen of Dr. BRAUMÜLLER, who knew him from his childhood. When a child, he was often seen by Dr. BRAUMÜLLER, who passed him frequently on his way to the baths in the suburbs of the town, where the boy lived. Dr. BRAUMÜLLER says, he used to look out for him and was not satisfied unless he saw him, although he never beheld him without a shudder. The wonderfully

¹⁾ In a memoir read before the Skandinaviska Naturforskare-sällskap, at Stockholm, in July, 1863, I have endeavoured to explain and support this view, by an enumeration of all the different species of disturbing influences which act upon and interfere with the normal form of the cranium. That most eminent craniologist, Prof. ANDERS RETZIUS, already foresaw the necessity for carefully separating abnormal skulls in his earliest communication to this Society. *Över Formen af Nordboarners Cranier*. 1842.

²⁾ De singulari cranii cuiusdam deformitate. Auctore JOSEPHO SCHADE. Gryphiae 1858.

prominent forehead of the boy, and consequent remarkably deformed face were particularly conspicuous. The boy perceived that every one who first beheld him was frightened with him. When he was sent to school, his schoolfellows would not sit by him, not one would associate with him, nor play with him. They shunned him, pushed him to one side, and he drew back sullenly and mistrustfully. Yet in the school he learned easily; he learned reading, writing and accounts; and afterwards received religious instruction readily, and had as much desire for learning as any healthy youth. His widowed mother was unable to get him taught a trade from his repulsive appearance. In consequence they were both taken into the Stettin workhouse, where the youth was taught to weave, which art he learned with facility. When he had acquired this art, he would have been able to support himself, but for his strange deformity, which caused him to avoid society and others to shun him. At the age of 20 years, he manifested a strong desire to remove from Stettin to work and to live. It was arranged that he should go to a small town in Lower Pomerania, as a journeyman weaver. But it had not been duly considered that his appearance would be regarded as so frightful. „Dicke schwarze, in einander übergehende Augenbrauen, starres, schwarzes wüstes Haar; der Man konnte nicht zum Himmel hinaufsehen, weil beim Erheben des Kopfes das Hinterhaupt gegen die Halswirbel stiess ¹⁾.” He was obliged to return to the Stettin workhouse, where, from vexation, he began to give himself up to drunkenness and gave occasion to some dissatisfaction. He showed himself to be quarrelsome and very offensive, but never in any way gave rise to the suspicion of an unsoundness of mind. He died there of pleurisy. His parents and relations were well-formed and his birth was normal. Such is Dr. BRAUMÜLLER's account, which is the fullest and most particular we yet possess of any subject of scaphocephalism, hence I have been induced to quote it somewhat at length.

Dr. SCHADE informs us, that the bones of the cranium were thin

¹⁾ *Op. cit.* p. 5.

and light. „Praecipue notatu dignum est, quod propter perfectas omnium cranii ossium conjunctiones ne ullum quidem suturarum vestigium animadvertitur; cranium ex uno osse formatum esse videtur ¹⁾.”

By Professor KEFERSTEIN's goodness, I am able to relate, that the *ossa parietalia* present a distinct *carina*, running along the middle of the biparietal, but which is not prolonged down the *os frontale*. The *lineae temporales*, s. *lineae semicirculares* of the parietal bones are very marked. On the left side of the skull, the *sutura coronalis* may yet be traced, but is perfectly obliterated on the right side, and in the rest of the skull all the sutures, (*sutura sagittalis*, *temporalis*, *lambdoidea*,) are completely ossified, both on the outside and on the inside of the calvaria. There are also faint traces of the sutures surrounding the alisphenoids, although these are likewise quite closed. The *pars pyramidalis* of the temporal bones is synostosed with the *basis* of the occipital. And all the sutures of the face are equally synostosed. The right side of the cranium is convex, and the left side slightly concave. The *basis cranii* has, at the same time, a very characteristic appearance. But these peculiarities will be rendered apparent in the Plates, which I am so fortunate as to present. These have been very accurately drawn by Mr. OTTO PETERS, of Göttingen, and afford a much more complete and correct image of the curious original than Dr. SCHADE's miniature figure.

9. It was a very unexpected occurrence to me, recently, to meet with another scaphocephalic cranium of an Australian. This is the skull of a young man, of about 30 years of age, from the Colony of Victoria, and was found in the branches of a tree, in 1863. In this case the sagittal suture is entirely traceless both externally and internally, and the two parietal bones are perfectly ossified together. Its course is marked by a *carina* for the two anterior thirds of its length, which also advances upon the frontal bone a little way. There is a good sized *parietal foramen* on the left side. The middle portion of the coronal suture, between the *lineae semicirculares*, is ossified. The whole of the

¹⁾ *Op. cit.* p. 7.

suture is obliterated on the inside of the calvarium, and the left side of the portion named on the outside; the right is still traceable. All the other sutures of the skull, usually open at thirty years of age, are quite free. In the right spheno-parietal there are two triquetral bones; a large one, and one much smaller.

The effects of the ossification of the sagittal and partial ossification of the coronal suture, the former of which appears to have been foetal and the latter probably infantile, are the usual lateral contraction of the calvarium, although the parietal tuberosities are still slightly indicated, and a semiglobular prominence of the supra-occipital region, which is compensatory. To this development of the brain in a posterior direction the perfectly open state of the lambdoidal suture has materially contributed. In this case, the usual anterior development of the brain in the frontal region has been arrested, or prevented by the premature closure of all the middle portion of the coronal suture. So that the frontal bone is not swollen out and prominent, but is flat and low.

In almost all other respects this long flat cranium exhibits the characters of the race to which it belongs. There is one exception. It is much thinner than usual, and consequently lighter. It is very prognathous, has a prominent supraciliary ridge, a narrow frontal region, marked by vascular grooves in the bone, wide zygomatic arches, and is rather small for its sex. The tribe to which this man has belonged appears not to have practised the custom of punching out the incisor teeth. The disposal of the dead among the branches of trees is not uncommon with the Australians. This second scaphocephalic skull, which, as I have explained, from the particular combination of sutures ossified, does not present the usual scaphocephalic form in so exaggerated a degree, is N^o. VI in the Table of Mésurements. The curious fact of the discovery of this second example of scaphocephalism among Australians is a remarkable occurrence, and comes very opportunely to enable me to introduce its description into this memoir.

10. Certain races possess a super-activity in the process of ossification of the bones of the head. Many of the Negro and Australian races are

remarkable for the great thickness and weight of their skulls. And, in the same way, these races are distinguished for a proneness to closure of the sutures, which takes place at an earlier period of life than among European races ¹). Professor WELCKER has, by numerous observations, deduced the conclusion, that the *frontal suture* in European races is found open in adult skulls in one case in nine, whilst, in African and American races, it is seen in one case in fifty two or fifty three only ²). As the ages of these skulls could not be precisely determined, such mathematical results may not be found to be strictly correct, but, the broad fact of the much greater proneness to closure of sutures in the latter races, admits of no question. In 127 crania of African people in my own collection, only two, and these are skulls of Guanches, the ancient inhabitants of the Island of Teneriffe, have frontal sutures. Professor GRATIOLET has said, not only, that the growth of the brain ceases sooner in those races in which the sutures close early, but also, that there is a difference between the higher and the lower races as to the order in which the sutures are closed normally. In the latter, the anterior sutures close before the posterior, and, in the higher races, it is the reverse, the posterior sutures close earlier than the anterior. M. GRATIOLET bases an argument, for the greater perfectibility of these higher races, upon this asserted fact.

¹) In one of my Australian crania, that of a young woman of about 17 years of age, No. 915a, there is not the slightest trace of a sagittal suture. One *foramen parietale* is very distinct. In this skull, although the synostosis of the parietals has in all likelihood taken place at an intra-uterine period of life, there is no scaphocephalism, or other deformation whatever. In the cranium of the skeleton of a man of a tribe of South Australia, just received from that Colony, the sagittal suture is ossified, as well as all the middle portions of the lambdoidal. This man's age appears not to have exceeded 40 years. These facts confirm the view, that the Australian races are prone to ossification of sutures. Notwithstanding this, *true scaphocephalism* seems to be rare among Negro races, and more frequent among Australian races.

²) *Opus cit.* S. 99.

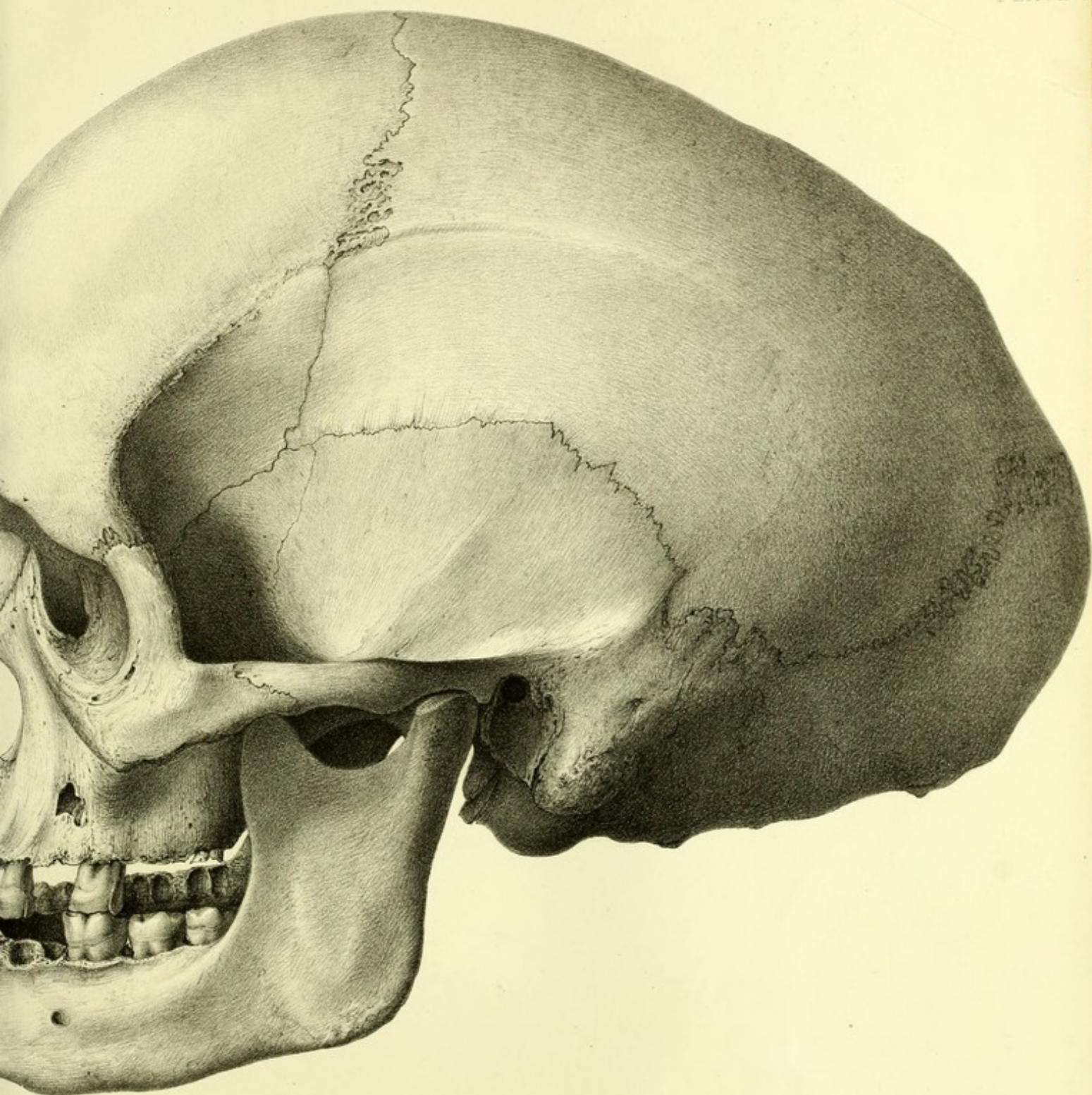
DESCRIPTION OF THE PLATES.

(All lithographed of the natural size.)

-
- | | | | |
|-------|-------|--|-------------------|
| Plate | I. | Scaphocephalic cranium of an Australian, from New South Wales. | A. Profile View. |
| " | II. | Ditto | B. Face View. |
| " | III. | Ditto | C. Back View. |
| " | IV. | Normal cranium of an Australian, from New South Wales. | |
| " | V. | Scaphocephalic cranium of a North American Indian Boy, from the N. W. coast. | A. Profile View. |
| " | VI. | Ditto | B. Back View. |
| " | VII. | Pachycephalic calvarium of „Pofii," a Marquesan, from the Island of Ohiva-Hoa. | |
| " | VIII. | Brachycephalic cranium of a Kanaka, from the Island of Oahu. | |
| " | IX. | Scaphocephalic cranium of a Weaver of Stettin, in Pomerania. | A. Profile View. |
| " | X. | Ditto | B. Vertical View. |
| " | XI. | Ditto | C. Base View. |
-

TABLE OF MEASUREMENTS.

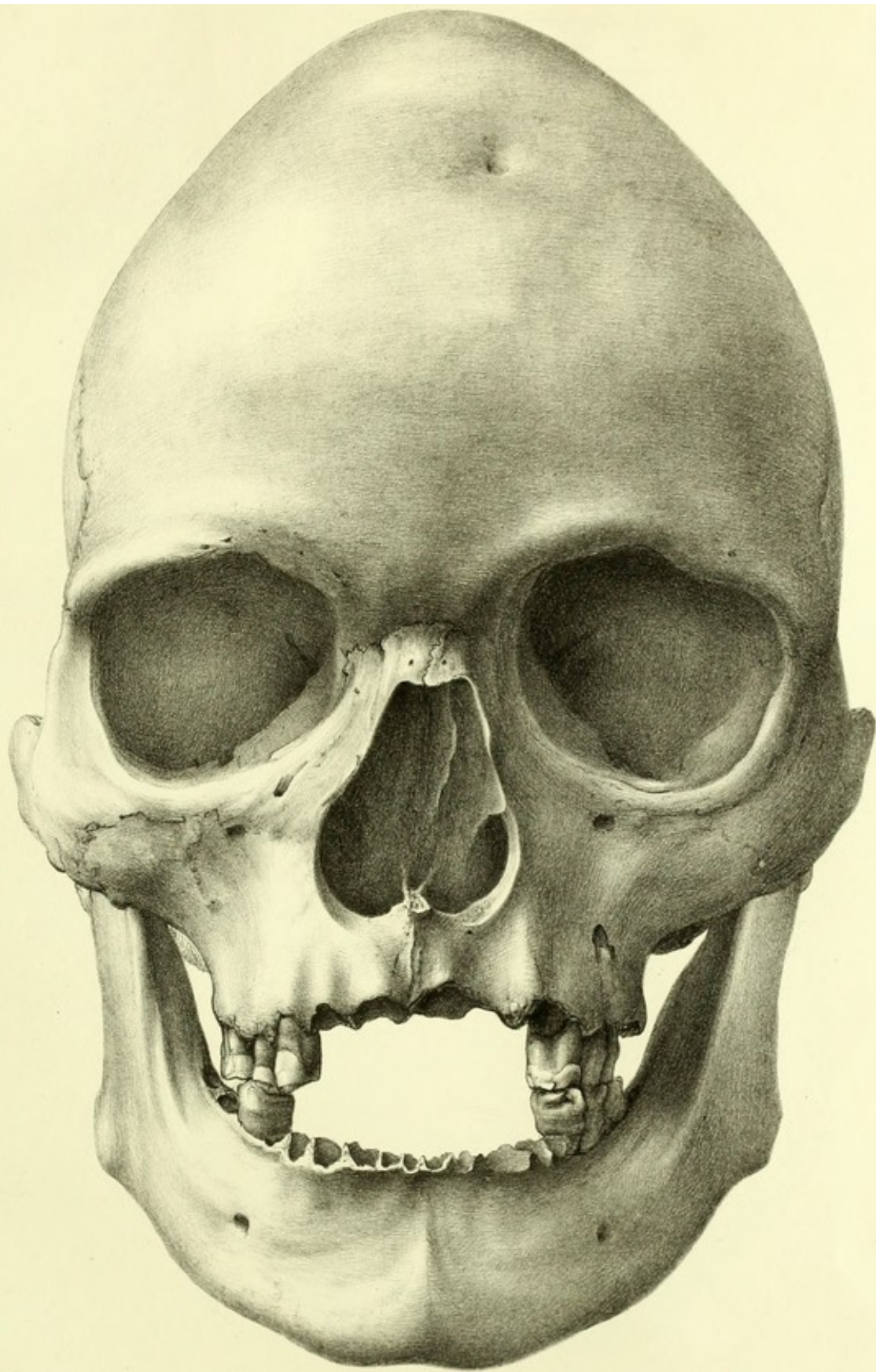
	AUSTRALIAN. II. Normal Skull.	AUSTRALIAN. I. Abnormal Skull.	OHIVAHUAN. IV. Skull of „Pofii.”	KANAKA. V. Sandwich Islander.	AUSTRALIAN. VI. Victorian Tribe.	FOERERIAN. VII. Greifswald Skull.
A. Internal capacity, in ounces avoidsup. of sand.....	71 ounces, or 89.5 cubic inches, or 1471 cubic centimetres.	73 ounces, or 88.3 cubic inches, or 1450 cubic centimetres.	79 ounces, or 100.8 cubic inches, or 1651 cubic centimetres.	61 ounces, or 74.0 cubic inches, or 1212 cubic centimetres.	72 ounces, or 87.8 cubic inches, or 1439 cubic centimetres.	21.7 inches, or 548 millimetres.
B. Circumference, in inches.....	20.3 inches, or 515 millimetres.	21.8 inches, or 553 millimetres.	19.5 inches, or 494 millimetres.	18.0 inches, or 457 millimetres.	21.2 inches, or 538 millimetres.	21.7 inches, or 548 millimetres.
C. Fronto-occipital arch.....	14.5 " " 368 "	16.7 " " 423 "	14.0 " " 354 "	13.5 " " 343 "	14.3 " " 363 "	17.4 " " 442 "
a. Length of Frontal.....	5.1 " " 129 "	5.6 " " 143 "	6.0 " " 152 "	5.0 " " 127 "	6.4 " " 161 "
Δ. " " Parietals.....	5.2 " " 133 "	5.9 " " 149 "	5.0 " " 127 "
c. " " Occipital.....	4.2 " " 107 "	5.2 " " 133 "	4.3 " " 109 "	4.3 " " 109 "
D. Intermastoid arch.....	14.6 " " 370 "	12.2 " " 310 "	14.9 " " 378 "	14.5 " " 368 "	13.9 " " 352 "	15.2 " " 384 "
E. Greatest length.....	7.2 " " 182 "	8.3 " " 210 "	6.4 " " 162 "	6.3 " " 158 "	7.7 " " 195 "	8.7 " " 218 "
F. Greatest breadth (interparietal).....	5.4 " " 137 " (interp.)	4.8 " " 121 " (interp.)	5.3 " " 134 " (interp.)	5.0 " " 127 "	5.2 " " 133 "
a. Breadth of Frontal.....	4.4 " " 112 "	4.4 " " 112 "	5.2 " " 133 "	4.3 " " 109 "	4.5 " " 114 "	4.7 " " 119 "
Δ. " " Parietals.....	5.1 " " 129 "	4.2 " " 107 "	4.6 " " 117 "	4.6 " " 117 "	4.3 " " 109 "	4.5 " " 114 "
c. " " Occipital.....	4.2 " " 107 "	4.2 " " 107 "	4.0 " " 102 "	3.9 " " 99 "	3.8 " " 96 "
G. Greatest height.....	5.5 " " 139 "	5.3 " " 134 "	5.8 " " 147 "	5.2 " " 133 "	5.1 " " 130 "
a. Height of Frontal.....	4.6 " " 117 "	5.1 " " 130 "	5.3 " " 134 "	4.7 " " 119 "	4.5 " " 114 "
Δ. " " Parietals.....	4.7 " " 119 "	4.6 " " 117 "	5.1 " " 130 "	4.8 " " 121 "	4.5 " " 114 "
c. " " Occipital.....	4.1 " " 104 "	4.2 " " 107 "	3.0 " " 76 "	3.9 " " 99 "	4.2 " " 107 "
H. Length of Face.....	4.9 " " 125 "	4.3 " " 109 "	4.4 " " 112 "	5.0 " " 127 "	4.2 " " 107 "
I. Breadth of Face.....	5.6 " " 143 "	5.1 " " 130 "	5.6 " " 143 "	5.0 " " 127 "	5.6 " " 143 "	4.7 " " 119 "
J. Proportion of breadth to length, taken as 100.....	.75	.57	.82	.79	.67
K. Proportion of height to length, taken as 100.....	.76	.63	.90	.83	.66



SCAPHOCEPHALIC CRANIUM OF AN AUSTRALIAN.

A. Profile View.

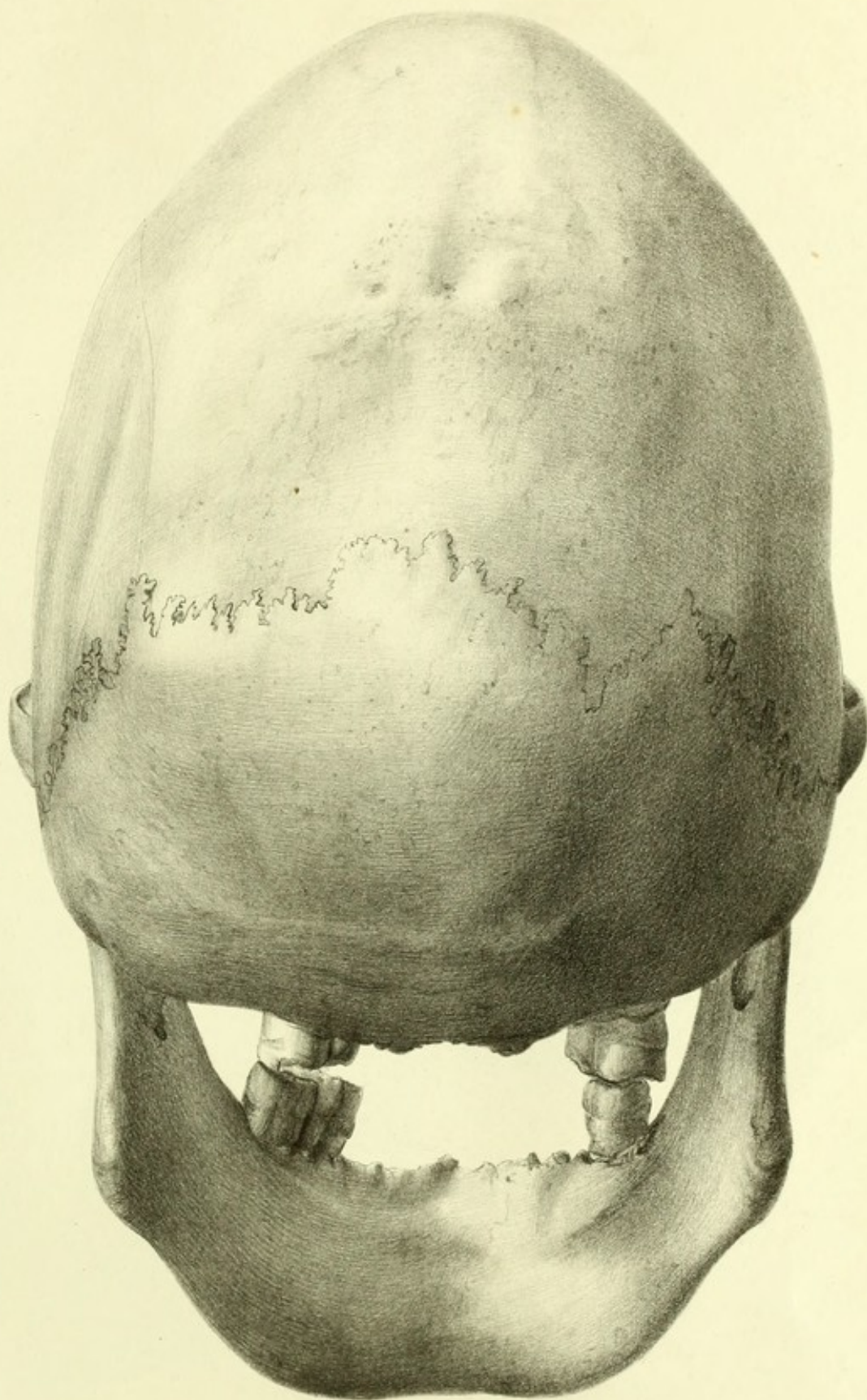
Lith v Emrik & Binger



SCAPHOCEPHALIC CRANIUM OF AN AUSTRALIAN

B. face View

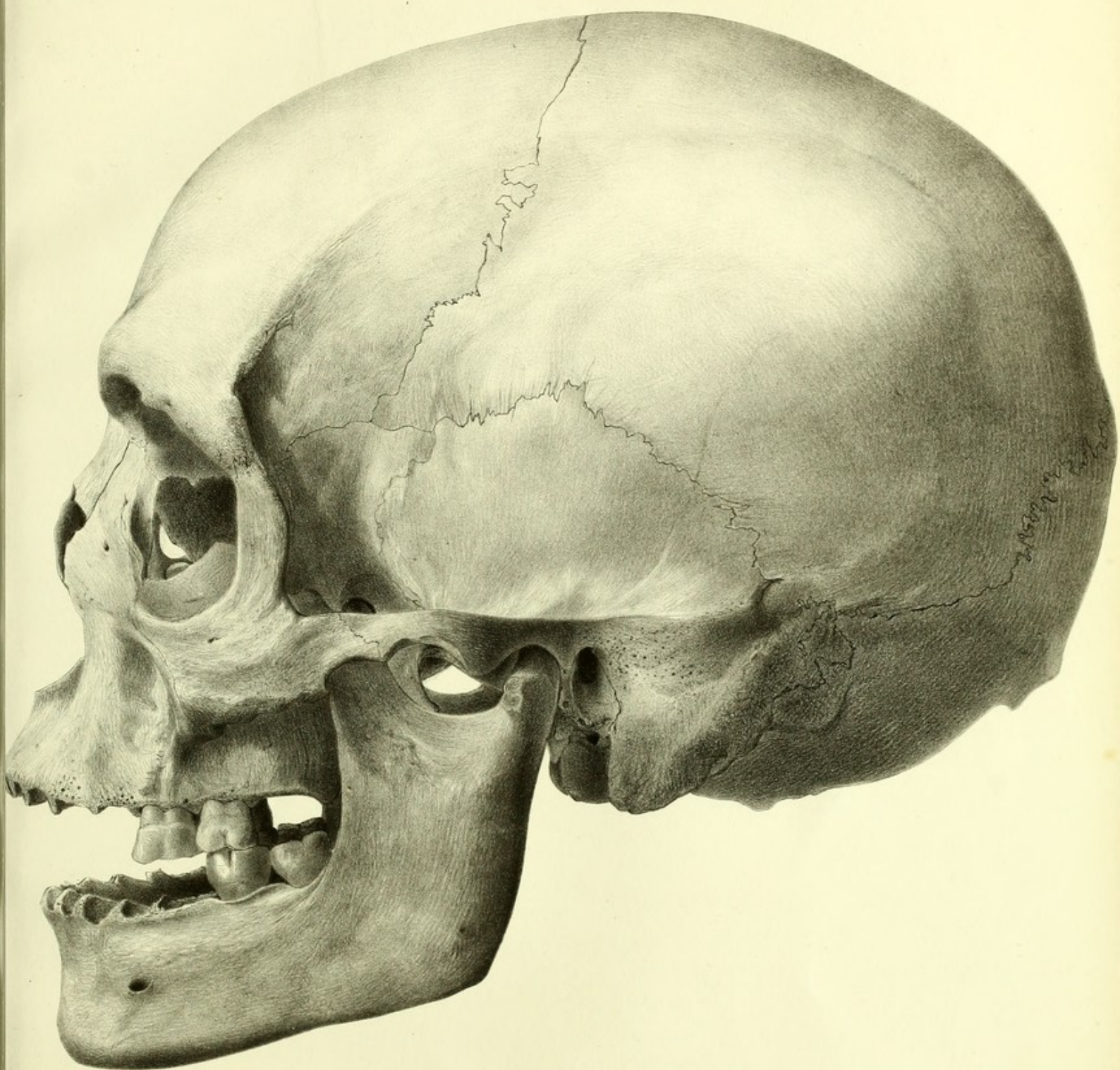
Lith v. Emrik & Binger



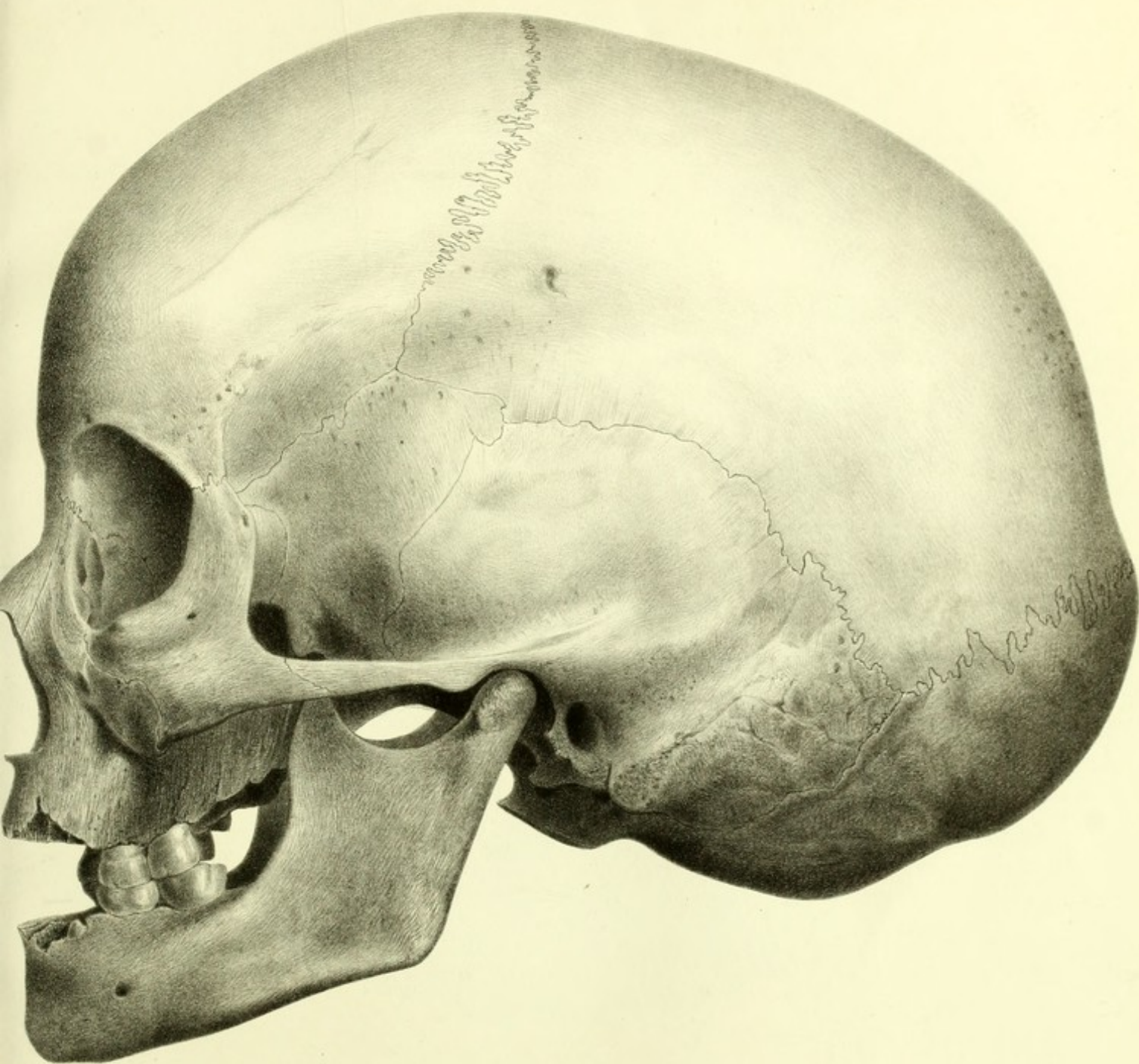
SCAPHOCEPHALIC CRANIUM OF AN AUSTRALIAN.

C. Back View

Lith v. Emrik & Binger



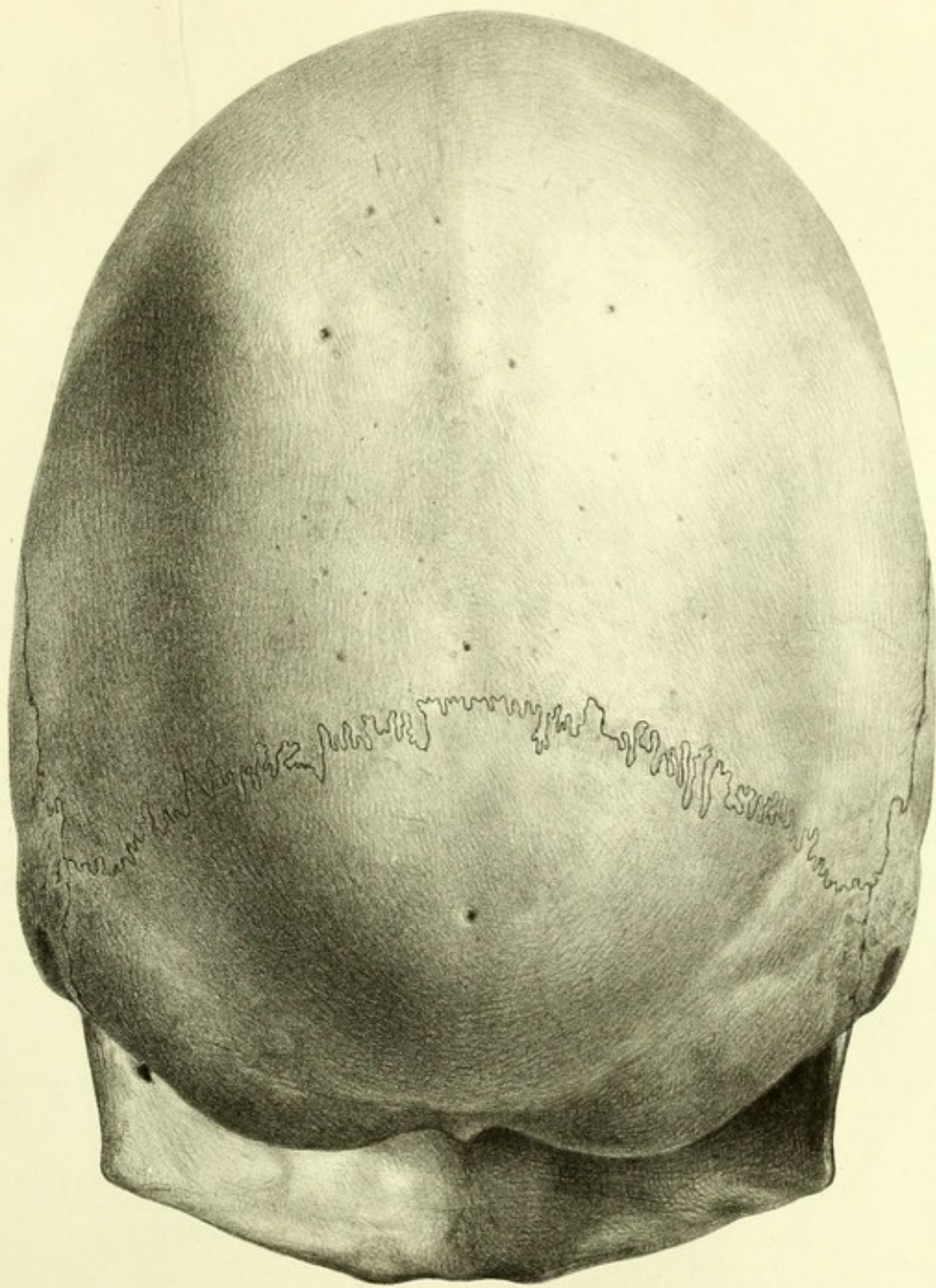
NORMAL CRANIUM OF AN AUSTRALIAN.



SCAPHOCEPHALIC CRANIUM OF A NORTH AMERICAN INDIAN

A Profile View.

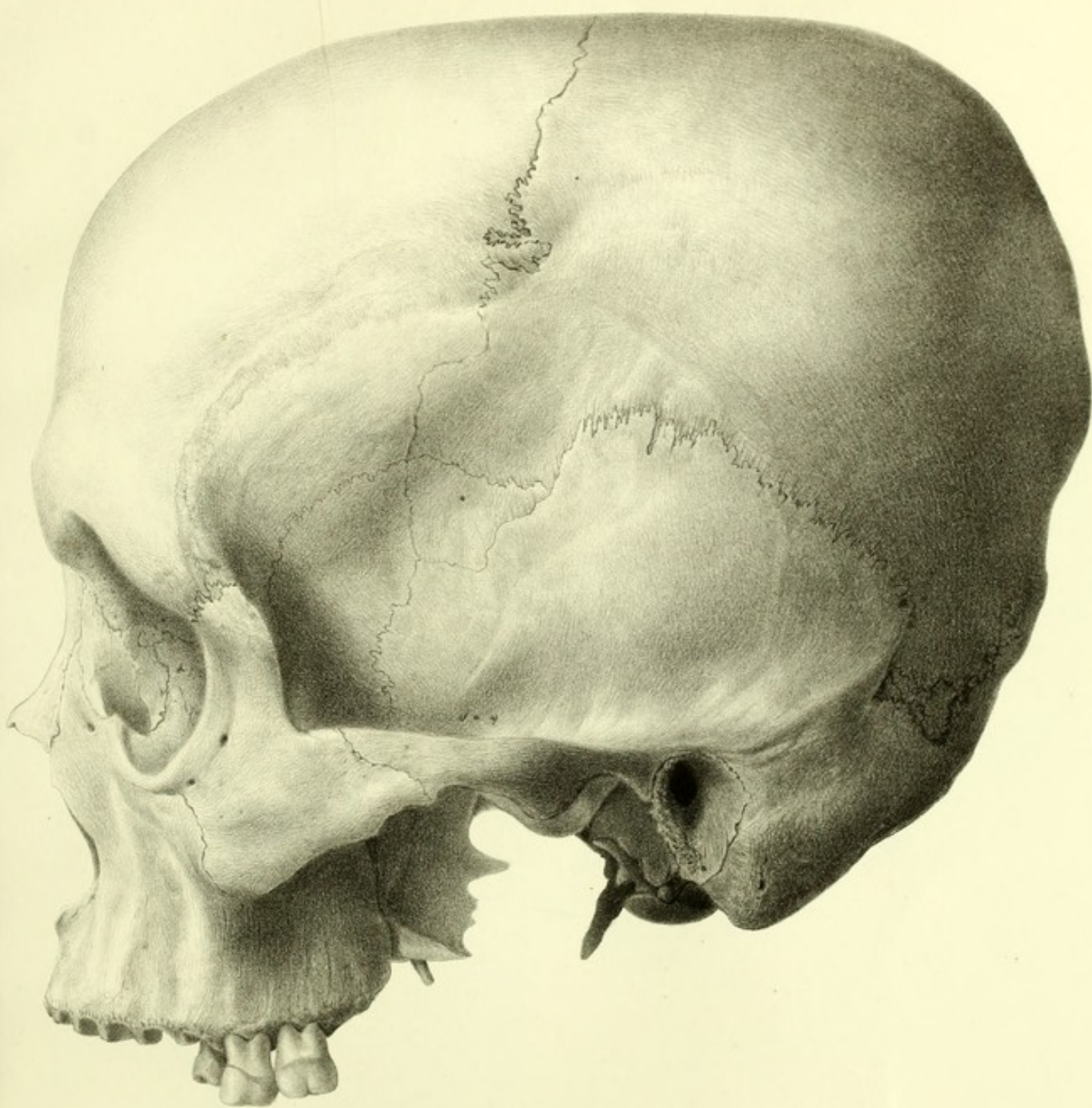
Lith. v. Emrik & Binger.



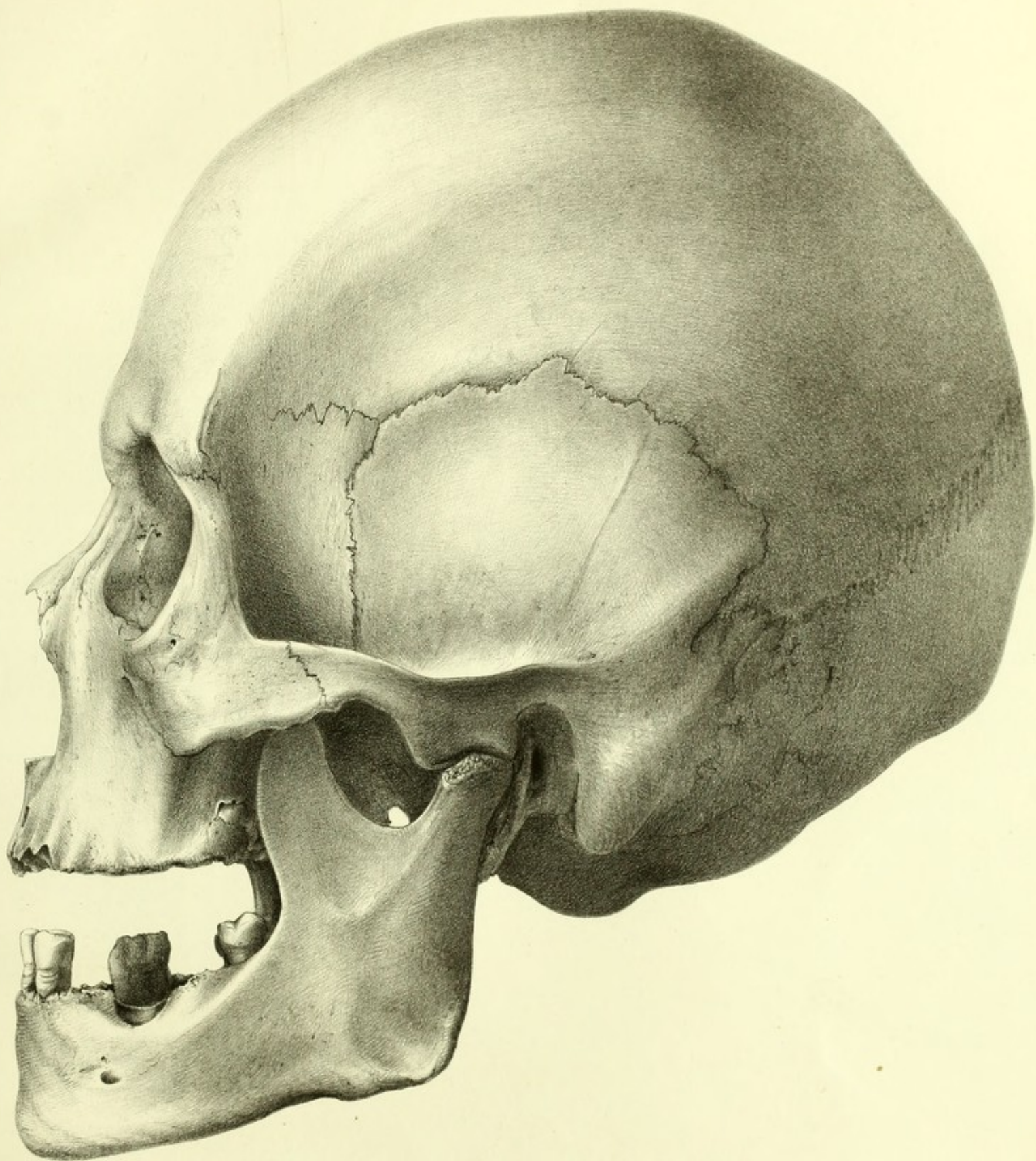
SCAPHOCEPHALIC CRANIUM OF A NORTH AMERICAN INDIAN

B Back View

Lith v Emrik & B

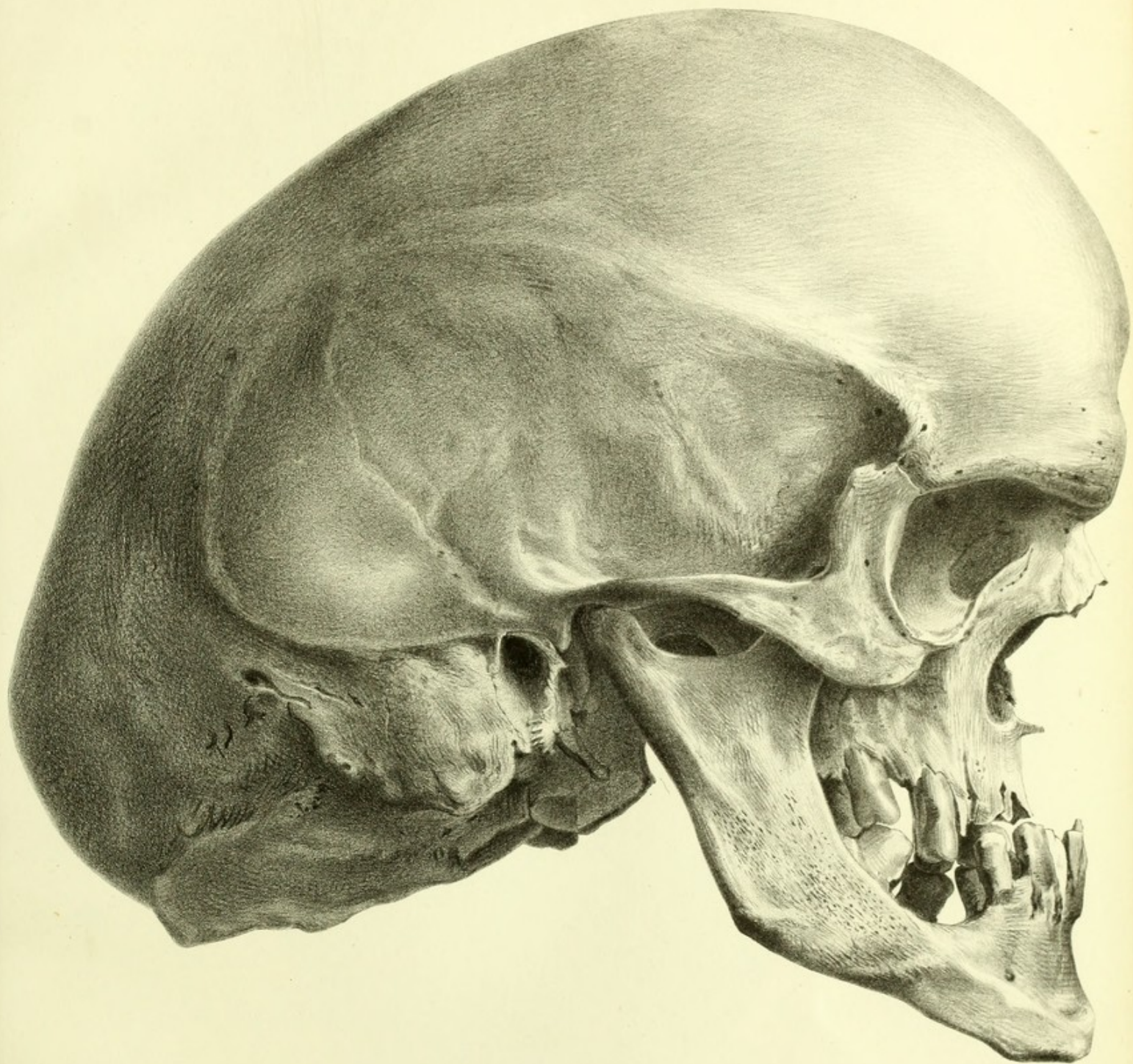

PACHYCEPHALIC CALVARIUM OF *POFII*, A MARQUESAN ISLANDER.



BRACHYCEPHALIC CRANIUM OF A SANDWICH ISLANDER.

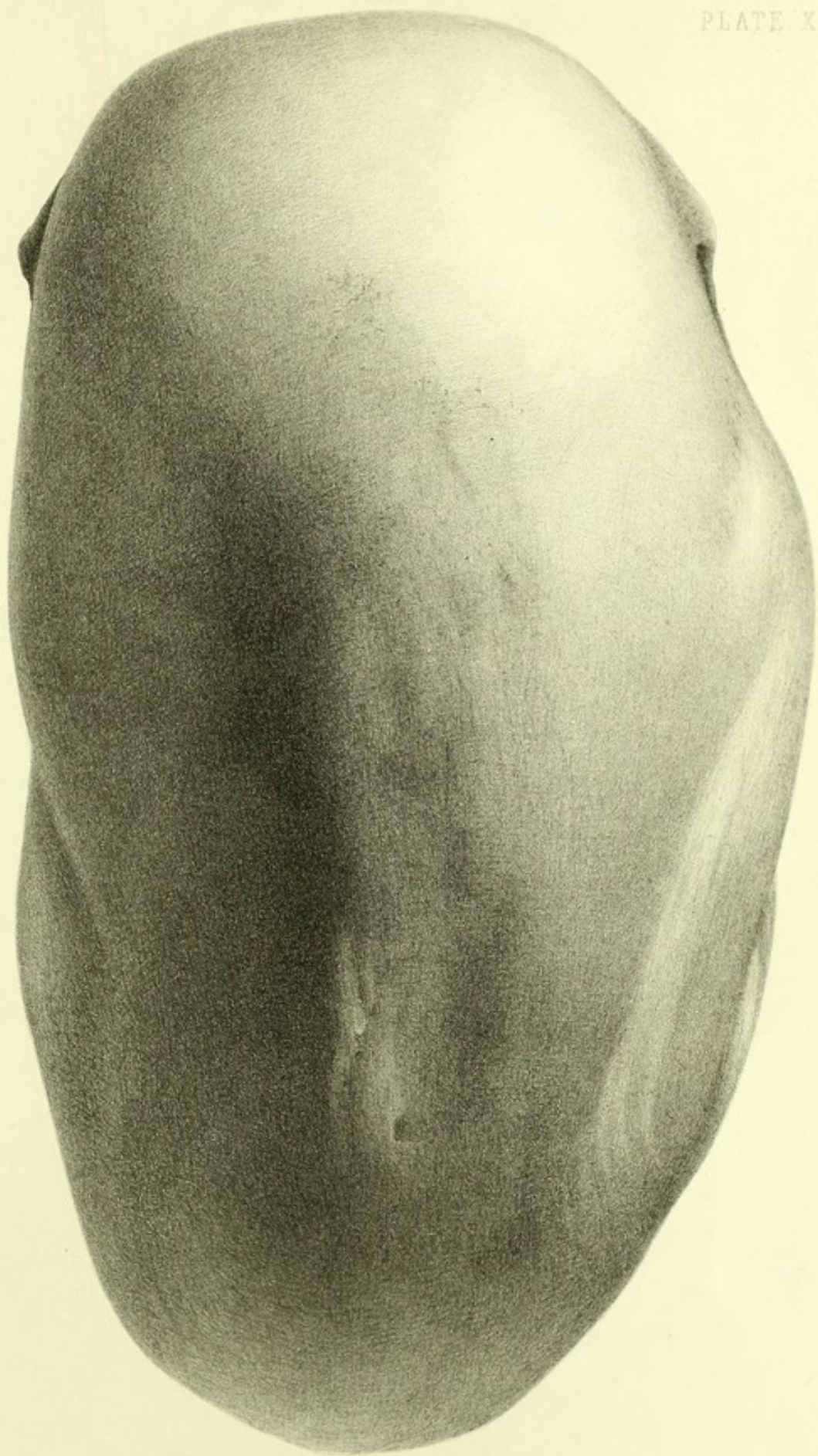
Lith. Emrik & Binger



SCAPHOCEPHALIC CRANIUM OF A POMERANIAN WEAVER.

A Profile View

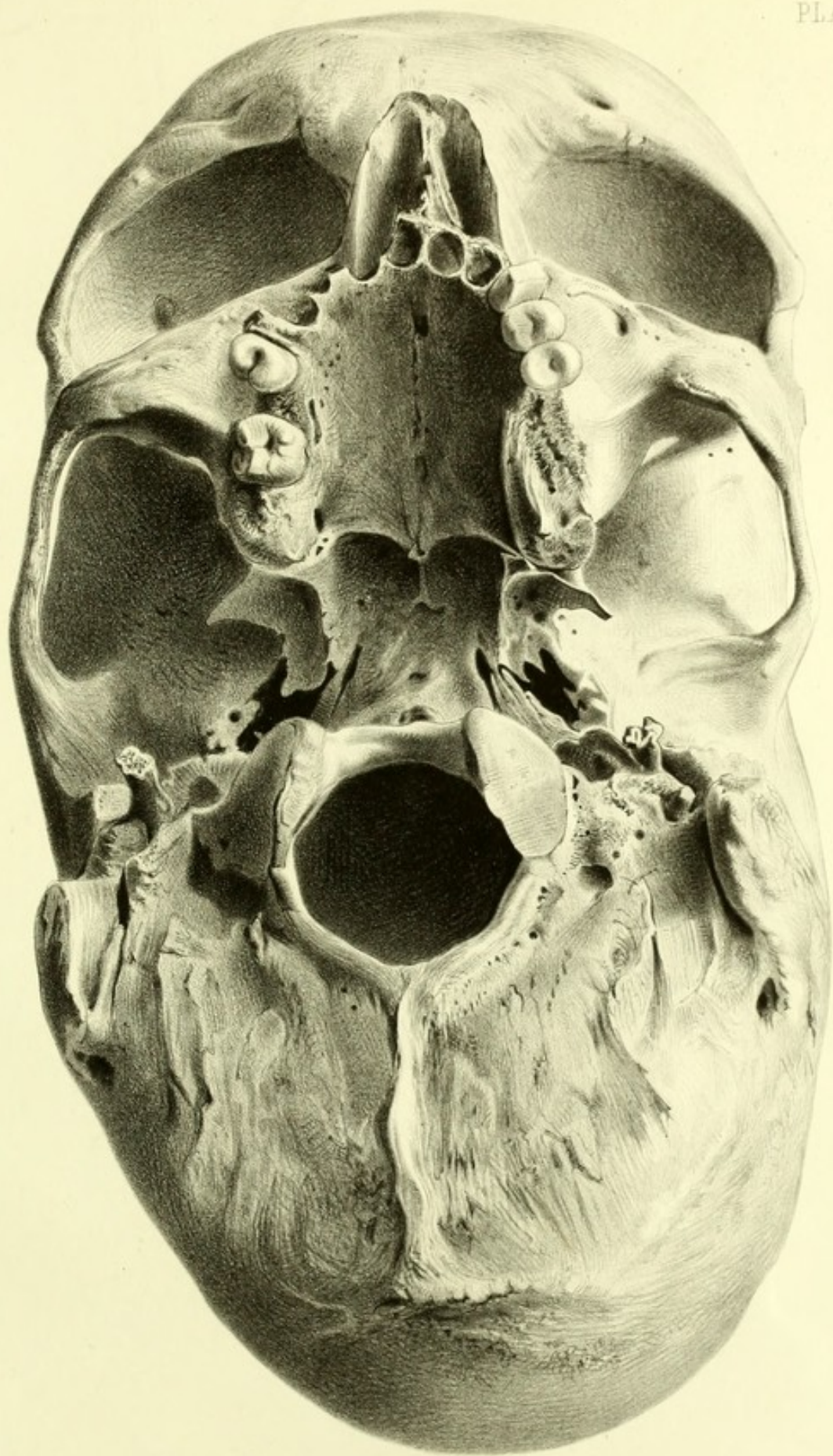
Lith. v. Emrik & Binger



SCAPHOCEPHALIC CRANIUM OF A POMERANIAN WEAVER.

B. Vertical View.

Lith v. Emrik & Binger.



SCAPHOCEPHALIC CRANIUM OF A POMERANIAN WEAVER.

C. Base View.

