

**The malformations, diseases and injuries of the fingers and toes and their surgical treatment / by Thomas Annandale.**

**Contributors**

Annandale, Thomas, 1839-1908.  
Royal College of Physicians of Edinburgh

**Publication/Creation**

Edinburgh : Edmonston & Douglas, 1865.

**Persistent URL**

<https://wellcomecollection.org/works/nzqq3vq9>

**Provider**

Royal College of Physicians Edinburgh

**License and attribution**


This material has been provided by This material has been provided by the Royal College of Physicians of Edinburgh. The original may be consulted at the Royal College of Physicians of Edinburgh. where the originals may be consulted.

This work has been identified as being free of known restrictions under copyright law, including all related and neighbouring rights and is being made available under the Creative Commons, Public Domain Mark.

You can copy, modify, distribute and perform the work, even for commercial purposes, without asking permission.



Wellcome Collection  
183 Euston Road  
London NW1 2BE UK  
T +44 (0)20 7611 8722  
E [library@wellcomecollection.org](mailto:library@wellcomecollection.org)  
<https://wellcomecollection.org>



6d 6.18



Cd 6.18

THE MALFORMATIONS, DISEASES  
AND INJURIES

OF

THE FINGERS AND TOES.

EDINBURGH : PRINTED BY THOMAS CONSTABLE,

FOR

EDMONSTON AND DOUGLAS.

LONDON, . . . . . HAMILTON, ADAMS, AND CO.

CAMBRIDGE, . . . . . MACMILLAN AND CO.

DUBLIN, . . . . . M<sup>l</sup>GLASHAN AND GILL.

GLASGOW, . . . . . JAMES MACLEHOSE.

THE MALFORMATIONS, DISEASES  
AND INJURIES OF THE FINGERS  
AND TOES


AND THEIR SURGICAL TREATMENT

BY

THOMAS ANNANDALE, F.R.C.S. EDIN.

LECTURER ON SURGERY

ASSISTANT SURGEON TO THE EDINBURGH ROYAL INFIRMARY



THE JACKSONIAN PRIZE ESSAY FOR THE YEAR 1864

EDINBURGH  
EDMONSTON & DOUGLAS

1865.

THE UNIVERSITY OF CHICAGO

LIBRARY OF THE UNIVERSITY OF CHICAGO

1911

THE UNIVERSITY OF CHICAGO

THE UNIVERSITY OF CHICAGO

THE UNIVERSITY OF CHICAGO

THE UNIVERSITY OF CHICAGO

THE UNIVERSITY OF CHICAGO

DEDICATED

TO

JAMES SYME, Esq.,

PROFESSOR OF CLINICAL SURGERY IN THE UNIVERSITY

OF EDINBURGH,

WITH THE AUTHOR'S BEST FEELINGS OF

GRATITUDE AND ESTEEM.



Digitized by the Internet Archive  
in 2015

## P R E F A C E.

THIS Essay was submitted to the Council of the Royal College of Surgeons of England in the month of December 1864, in competition for the Jacksonian Prize, "On the Malformations, Diseases, and Injuries of the Fingers and Toes, and their Surgical Treatment," and in the spring of the present year the Prize was awarded to it.

In preparing it for the press, I have incorporated with the original Essay a number of additional facts and cases which have come under my notice since the time when it was given in for competition.

I venture now to offer it to the profession in its revised form, and am the more encouraged to do so from the fact that I have not been able to find any book which treats specially of these diseases.

In my original Essay the affections of the fingers

and toes were treated of in five chapters. These were—

1. The Congenital Affections.
2. The Inflammatory Affections.
3. The Tumours.
4. The Injuries.
5. The Non-congenital Contractions and Distortions.

The same order has been followed in this volume, but several additions have been made to each chapter, and two short new chapters have been added on the Resections and Amputations of the Digits.

I must here express the obligations which I am under to Professors Syme and Goodsir. To the former gentleman, for allowing me to make free use of many valuable cases both in his Hospital and private practice; and to the latter, for kind permission to examine and take drawings of numerous preparations in the Anatomical Museum of the Edinburgh University.

To the Surgeons and House-Surgeon of the Newcastle-upon-Tyne Infirmary, to the Curators of the Museum of the Royal College of Surgeons of Edin-

burgh, and to many other kind professional friends, my best thanks are due for their courtesy in placing patients and preparations at my disposal.

To my friends Mr. Turner and Dr. Pettigrew I am also deeply indebted for much assistance and advice in preparing this work for publication.

The illustrations, with the exception of Figs. 22, 29, 36, and 44, copied from Otto, have all been taken from original cases and dissections, and have been faithfully drawn on stone by Mr. Aldous, of Liverpool Street, London.

3, HOPE STREET, CHARLOTTE SQUARE,  
*September 1865.*



## CONTENTS.

### CHAPTER I.

#### CONGENITAL AFFECTIONS OF THE DIGITS.

	PAGE
Congenital Hypertrophy, . . . . .	3
Congenital Deficiencies, . . . . .	10
Supernumerary Fingers and Toes, . . . . .	26
Congenital Union, . . . . .	46
Congenital Contractions and Dislocations, . . . . .	61
Congenital Tumours, . . . . .	67

### CHAPTER II.

#### INFLAMMATORY DISEASES OF THE DIGITS.

Acute Inflammation of the Skin and Areolar Tissue, . . . . .	74
Acute Inflammation of the Tendons and their Sheaths, . . . . .	82
Acute Inflammation of the Periosteum and Bone, . . . . .	86
Diffuse Cellular Inflammation, . . . . .	94
Chronic Inflammation of the Tendons and their Sheaths, . . . . .	96
Onychia, . . . . .	97
Disease of the Nails, . . . . .	101
Ingrowing Toe Nail, . . . . .	103
Syphilitic Affections of the Nails, . . . . .	106
Ulceration of the Soft Textures of the Digits, . . . . .	108
Acute Bursitis, . . . . .	110
Chronic Bursitis, . . . . .	111

	PAGE
Ganglia, . . . . .	113
Bunion, . . . . .	115
Acute Synovitis, . . . . .	124
Chronic Synovitis, . . . . .	125
Pulpy Degeneration of the Synovial Membrane, . . . . .	126
Ulceration and Degeneration of the Articular Cartilages, . . . . .	127
Inflammation of the Articular Extremities of the Digital Bones, . . . . .	129
Tubercular Deposit in the Digital Bones, . . . . .	129
Chronic Rheumatic Arthritis, . . . . .	130
Gouty Inflammation of the Digital Joints, . . . . .	131
Changes which take place in the Digital Joints after their Disorganization by Inflammatory Disease, . . . . .	132
Anchylosis, . . . . .	133
Chronic Periostitis, . . . . .	138
Chronic Ostitis, . . . . .	139
Caries, . . . . .	140
Ulceration of Bone, . . . . .	147
Fatty Degeneration of Bone, . . . . .	147
Fungus Disease of the Foot, . . . . .	148

## CHAPTER III.

## TUMOURS OF THE DIGITS.

Warts, . . . . .	151
Corns, . . . . .	153
Epithelial Cancer, . . . . .	156
Melanotic Cancer, . . . . .	157
Fatty Tumours, . . . . .	158
Cystic Tumours, . . . . .	158
Fibrous Tumours of the Soft Parts, . . . . .	159
Cartilaginous Tumours of the Soft Parts, . . . . .	159

# CONTENTS.

xiii

	PAGE
Osseous Tumours of the Soft Parts, . . . . .	159
Recurrent Fibrous Tumour, . . . . .	160
Subcutaneous Tubercle, . . . . .	162
Neuroma, . . . . .	162
Aneurism, . . . . .	163
Fibrous Tumours of the Periosteum, . . . . .	165
Melanosis of the Periosteum, . . . . .	167
Cartilaginous Tumours of the Bone, . . . . .	168
Myeloid Tumours of the Bone, . . . . .	173
Medullary Tumours of the Bone, . . . . .	174
Exostosis, . . . . .	176
Entozoa in Bone, . . . . .	180

## CHAPTER IV.

### INJURIES OF THE DIGITS.

Chilblains, . . . . .	181
Frost-bite, . . . . .	184
Burns and Scalds, . . . . .	188
Bruises, . . . . .	188
Wounds, . . . . .	190
Digits and Tendons torn off by Accident, . . . . .	193
Reunion of Portions of Digits after being separated from the Body, . . . . .	194
Wounds inflicted by Bites and Stings, . . . . .	194
Foreign Bodies in the Tissues of the Digits, . . . . .	195
Bruises, Wounds, and other Injuries of the Nerves, . . . . .	198
Gangrene, . . . . .	213
Senile Gangrene, . . . . .	215
Bruises and Wounds of the Bursæ and Joints, . . . . .	217
Dislocations, . . . . .	218
Fractures, . . . . .	227

## CHAPTER V.

## NON-CONGENITAL CONTRACTIONS AND DISTORTIONS OF THE DIGITS.

	PAGE
Distortions, the result of Inflammation of the different Textures of the Digits or Extremities, . . . . .	238
Distortions from Affections of the Nervous System, . . . . .	245
Distortions the result of Injuries, the Growth of Tumours, or some form of Pressure, . . . . .	254

## CHAPTER VI.

## EXCISION OF THE JOINTS AND BONES OF THE DIGITS.

Excision of the Joints, . . . . .	261
Excision of the Bones, . . . . .	268

## CHAPTER VII.

## AMPUTATIONS OF THE FINGERS AND TOES.

Amputation of the Fingers, . . . . .	274
Amputation of the Toes, . . . . .	282

## LIST OF CASES.

CASE	PAGE
1. Congenital hypertrophy of the middle and index fingers,	5
2. Congenital hypertrophy of the thumb, and other portions of the upper extremity, . . . . .	6
3. Hypertrophy of both great toes, . . . . .	8
4. Congenital absence of fingers in both hands, . . . . .	11
5. Congenital absence of four fingers, . . . . .	12
6. Congenital absence of the distal phalanx of the little finger in both hands, . . . . .	15
7. Congenital deficiency of certain fingers in both hands,	16
8. Congenital deficiency of certain fingers in both hands,	17
9. Congenital deficiency of the whole upper extremity, with congenital absence of two digits, . . . . .	18
10. Intra-uterine amputation of all the digits, . . . . .	20
11. Intra-uterine amputation of two fingers, and partial constriction of a third finger of one hand, . . . . .	22
12. Supernumerary fingers and toe of the "first variety,"	30
13. Supernumerary thumb and finger in both hands associ- ated with congenital union, . . . . .	36
14. Supernumerary great toes resembling thumbs, with supernumerary little fingers, . . . . .	38
15. Supernumerary great toe on left foot ; talipes varus of right foot, with congenital absence and union of some of the fingers, . . . . .	39
16. Supernumerary great toe associated with congenital union, . . . . .	40
17. Congenital union of fingers and toes of both hands and feet, . . . . .	50

CASE	PAGE
18. Congenital contraction of certain fingers of both hands, and of the great toe of one foot, . . . . .	61
19. Congenital pedunculated tumours of the fingers, . . . . .	68
20. Congenital fibro-cellular tumour of the thumb associated with a cartilaginous tumour of the bone, . . . . .	70
21. Disease of the nails, . . . . .	102
22. Ulcer of the great toe depending on a fungous protrusion of the synovial membrane, . . . . .	109
23. Bunion on the sole of the foot, . . . . .	117
24. Ulceration of the cartilages of the phalangeal joint of a finger. Excision of the joint, . . . . .	128
25. Fibrous ankylosis of a metatarso-phalangeal joint, . . . . .	133
26. Melanotic tumour affecting the skin of the great toe, . . . . .	157
27. Fibrous tumour of the thumb, . . . . .	159
28. Fibrous tumour growing from the periosteum of two toes, . . . . .	166
29. Melanotic tumour of the periosteum of a finger, . . . . .	167
30. Medullary tumour affecting the bone of a finger, . . . . .	175
31. Exostosis growing from the distal phalanx of the great toe, . . . . .	178
32. Lacerated wound of the thumb, followed by tetanus, . . . . .	191
33. Paralysis and atrophy of the muscles of the thumb the result of injury, . . . . .	200
34. Painful cicatrix at the extremity of a finger, . . . . .	202
35. Wound of a digital nerve followed by paralysis, burning sensations, and other abnormal symptoms, . . . . .	203
36. Excision of the metacarpo-phalangeal joints of all the fingers, . . . . .	261
37. Excision of the carpo-metacarpal joint of the thumb, . . . . .	262

## CHAPTER I.

### CONGENITAL AFFECTIONS OF THE DIGITS.

MANY of the congenital affections of the digits possess much interest in an anatomical and physiological point of view ; but it appears to me that I shall best fulfil the objects of this work by considering the subject in a purely surgical manner, especially as many of these abnormalities can be cured, or at any rate relieved, by operative means. Any classification of these deformities which may be made in the following observations, will therefore be merely for the convenience of studying them practically.

I purpose to consider the congenital malformations of the fingers and toes under six heads :—

1. Congenital Hypertrophy.
2. Congenital Deficiencies.
3. Supernumerary Fingers and Toes.
4. Congenital Union.
5. Congenital Contraction.
6. Congenital Tumours.

Before commencing a description of these, I wish to say a word in regard to the hereditary transmission and causes of such abnormalities. I have thought it unnecessary to enter particularly into this part of the subject; but from inquiries into the histories of the numerous cases which have been brought under my notice, it is evident to me that such congenital deformities may either be hereditary (being transmitted from one generation to another through one or more members of a family), or they may occur in a single member of a family independent of any hereditary tendency, and where there has been no trace of any such abnormality in either the father or mother's family for generations back.

Although I have frequently listened to curious and apparently truthful accounts given by mothers, in order to explain the cause of such deformities in their children, I am not prepared to agree *in toto* with these explanations. Some of these assigned causes will be related in the history of certain of the cases which have come under my own observation. As this point is of no practical importance to the surgeon, it is not my intention to refer again to it.

### 1. *Congenital Hypertrophy.*

A slight increase in the usual length and volume of some of the fingers and toes is not uncommon, but the disease which is now to be described is such an exaggeration of the natural size of these organs, and produces so much deformity, that it is readily recognised. Digits which are thus malformed are usually noticed at birth to be larger than their fellows; and as the child grows, these organs increase in size more rapidly, and to a greater extent, than takes place in the natural condition of these parts. This affection merely consists of an increased development of all the normal tissues which compose the digits. In some cases this hypertrophy is more marked in one or other of the textures (the areolar and muscular especially), but in the majority of instances the hypertrophy is found to affect all equally.

The arteries going to the affected parts are usually found to be much enlarged, and it was also observed by Dr. John Reid that the temperature of the hypertrophied digit was higher than that of the normal ones.

This disease generally attacks one or more fingers, the remaining digits being natural in appearance. It may, however, be associated with a similar con-

dition of the whole upper extremity, or with some other deformity of the hand.

Mr. Curling, in a paper read before the Medico-Chirurgical Society, relates an interesting case of this disease affecting some of the fingers of both hands, and also refers to several other cases of a similar nature.<sup>1</sup>

Mr. Curling, in the same paper, states that in most of these cases the hypertrophied organs were bent to one side. In the examples of this disease which I have had an opportunity of examining, there has usually been more or less distortion of the affected organs, but the distortion was not always lateral. In one instance the enlarged digit was bent backwards.

Mr. Power has also described an example of this deformity, in which the middle finger only was affected.<sup>2</sup>

Dr. John Reid relates three cases of hypertrophied digits. In the first case, the whole upper extremity was affected; in the second, the thumb and one finger; and in the third, the third toe was the digit implicated.<sup>3</sup> Fingers and toes which suffer from

<sup>1</sup> *Med. Chir. Trans.*, vol. xxviii.

<sup>2</sup> *Dub. Journal of Med. and Chem. Science*, vol. xvii.

<sup>3</sup> *Edin. Med. Journal* for 1843, p. 198.

this malformation, although merely exaggerations of natural organs, are never sufficiently movable and useful, and from their bulk, are very much in the way, and apt to interfere with the movements of the other digits. Fig. 1, Plate I., is taken from a sketch (reduced one-third) of the dorsal surface of the hand of a little girl, whose case I will now relate, as it is an excellent example of this malformation.

CASE 1.—*Congenital Hypertrophy of the Middle and Index Fingers.*

M. M., aged three years, was admitted into the Clinical Surgical Wards of the Royal Infirmary of Edinburgh on the 19th of April 1859. The child was healthy and well formed, with the exception of a deformity of the fingers of the left hand. At birth, it was noticed that the index and middle fingers of this hand were much longer than the others; and as the child grew these fingers still increased in size. Fig. 1 illustrates the appearance of the affected hand. The fingers were quite useless, and possessed very little free movement. The hypertrophied condition was quite confined to these two fingers, the remaining digits being perfectly natural. As these enlarged fingers were a great inconvenience, they were removed at their metacarpo-phalangeal joints. The little patient made a slow but good recovery. An examination of the amputated fingers showed that the disease consisted of an hypertrophy of all the tissues which usually compose the digits.

Fig. 2, Plate I., is another example of this deformity, taken and reduced one-third from a cast in my possession, duplicates of which are in the museum of the Newcastle School of Medicine. In this case the thumb and index finger are affected, the other digits being quite normal. Fig. 3, Plate I., is from the cast of the hand mentioned in the next case.

CASE 2.—*Congenital Hypertrophy of the Thumb and other portions of the Upper Extremity.*

A. T., aged seven, an intelligent boy, one of a family of eleven, all of whom are well formed, with the exception of the patient. When this boy was born, his parents noticed that his right thumb was distorted, and broader than its fellow. When the patient was about a year old, the ball of the same thumb began to enlarge, and the forearm became more bulky than that of the opposite side. As the boy grew, the thumb and forearm increased very much in size, and when he was three years old a cast of the hand was taken. It was from this cast that Fig. 3, reduced one-half, was obtained. The diseased parts have become doubled in size since that time, and a few months ago I had an opportunity of examining the patient; I found that the ball of the thumb now formed a tumour the size of an infant's head, from the summit of which the hypertrophied and distorted thumb protruded.

The thumb possessed a perfect nail, but was only very slightly movable. It was bent backwards, and could not be straightened. On the radial side of the forearm there

was another swelling continuous with that formed by the ball of the thumb, and about half as large. This latter swelling was apparently composed of hypertrophied areolar tissue. The muscles of the forearm were all enlarged, and felt softer than natural. The muscles of this arm were also hypertrophied, the deltoid muscle forming a round and prominent tumour at the shoulder, and having double the bulk of the same muscle on the opposite side. The scapular muscles were natural, with the exception of the supra-spinatus, which was enlarged, and formed an elongated tumour above and behind the clavicle.

The humerus and bones of the forearm felt slightly larger than those of the other arm. The other fingers of this hand were quite normal and movable, but were pushed inwards by the hypertrophied thumb.

There was no history in this case of any hereditary malformation.

Fig. 4, Plate I., is taken from a cast which is now in the museum of the Newcastle-upon-Tyne Infirmary. In this example the middle and ring fingers are affected, but there is also atrophy and deformity of the other digits of the hand.

Congenital hypertrophy is met with in the toes as well as in the fingers, the affection being exactly of the same nature in both. Dr. John Reid and Mr. Curling both mention cases of this affection in the toes.

Mr. Sydney Jones<sup>1</sup> showed at a meeting of the

<sup>1</sup> *Lancet*, November 12, 1864.

Pathological Society of London, on the 1st of November 1864, a case of hypertrophy of the second toe.

The following is an interesting case of congenital hypertrophy of both great toes :—

CASE 3.—*Hypertrophy of both Great Toes.*

Miss ———, aged sixteen, applied to Mr. Syme on account of an enlargement of both great toes, which projected for about an inch beyond the other toes, so that she could not wear boots or shoes except of very large size. She was also constantly troubled with irritation and inflammation of bursal swellings which formed on the toes, and prevented her walking for many days at a time. As the patient was extremely anxious to have, as she said, her great toes “shortened,” these digits were amputated through their first phalangeal joint, a good posterior flap being taken from the soft textures of the plantar aspect of their extremities.

The wounds were firmly healed in about a fortnight, and the result was quite satisfactory.

I have in my collection a cast which was taken from the foot of a man, aged thirty-five, whose great and second toes were affected with congenital hypertrophy. The phalanges and the part of the metatarsus connected with these two toes were so much enlarged that the circumference of the whole foot round its metatarso-phalangeal articulations measured  $13\frac{3}{8}$  inches. This increase in the width

of the foot was entirely owing to the hypertrophy of the two digits, as the other toes were natural in size. The great toe measured 4 inches in length from its metatarso-phalangeal joint to its extremity, and its circumference at the base was  $7\frac{1}{2}$  inches. The second toe was  $5\frac{1}{2}$  inches in circumference at the base, its extremity being distorted and turned round towards the outer aspect of the foot.

*Treatment.*—As pressure does not appear to produce any satisfactory result in reducing the enlargement of the digits affected with hypertrophy, and as such digits are usually quite useless, and also very troublesome from their bulk, the only treatment that can be adopted is amputation of the diseased organs, provided this can be done without injury to the remaining members, and with some prospect of improving the usefulness of the hand or foot. In removing hypertrophied digits, it will be right to take away the portion of the metacarpus or metatarsus, as well as the phalanges connected with the affected fingers or toes, if it be implicated in the disease.

In some instances a partial amputation of the hypertrophied organ may be sufficient. In cases such as that illustrated in Fig. 3, the diseased condition of the other parts of the arm is a serious

objection to any operation being performed, but still I think that the thumb and the tumour at its base might be taken away with advantage, as the growth of this portion is gradually distorting and impairing the usefulness of the hand.

## 2. *Congenital Deficiencies.*

These deformities may consist of a diminution in the number of the fingers or toes, or they may depend on a diminution in the number and bulk of the segments of which the digits are generally composed. The former of these conditions is usually associated with the latter, the digits which are present being often deficient in their development. The latter condition is also found in cases where there are the ordinary number of fingers and toes; and it will be seen afterwards, that additional or supernumerary fingers and toes are generally more or less undeveloped. A diminution in the number of the fingers and toes, or a deficiency in their development, is also occasionally found in connexion with other congenital deficiencies of the extremities.

Professor Simpson<sup>1</sup> and Dr. Montgomery<sup>2</sup> have described cases in which portions of the digits and

<sup>1</sup> Simpson's *Obstetric Works*, vol. ii. p. 375.

<sup>2</sup> Todd's *Cyclopædia of Anatomy and Physiology*, "Fœtus."

extremities have been spontaneously amputated *in utero*, and Dr. Simpson has also directed attention to cases where certain rudimentary digits sprout out, as it were, from the end of such stumps.

I proceed now to give examples of deficiencies in the number of the digits; Figs. 5 and 6, Plate I., are taken from the hands of a young woman whose case is described below :—

CASE 4.—*Congenital Absence of Fingers in both Hands.*

A. W., a woman aged twenty nine, one of a family of six, none of whom had any deformity except herself. In both hands of this patient, and in one of her feet, there is an absence of certain digits. The right hand, represented in Fig. 5, has only four fingers, all of which are more or less atrophied and distorted. The thumb is very small, and the index and middle fingers are firmly united, the middle finger being also contracted. The little finger is the one which is most perfect, and is the only one that can be used with any freedom. The left hand, shown in Fig. 6, has only one finger, apparently the index, which, although small, is complete, and admits of free movement. The carpus of this hand is not fully developed, but the wrist joint is perfect. The girl is able to sew, grasp and lift things, by means of the little finger of the right hand. In sewing she holds the needle with this finger, and having pierced the work, she draws the needle and thread through with her teeth. The remaining fingers and the thumb of this hand are only slightly movable. The single finger of

the left hand is very useful, and she is able to carry a pail of water on it. This patient's foot is represented in Fig. 18, Plate II.; the whole of the toes are atrophied and united, the great toe being least developed.

When lately in Carlisle, Mr. Temperly, surgeon, was kind enough to show me the case from whose hand Fig. 7, Plate I., is taken. The patient was an intelligent little girl, aged four and a half years, who was well developed, with the exception of her left hand. This hand had only a thumb and little finger. The thumb was double, there being two first phalangeal bones united, but only one second phalanx. The metacarpal bones of the index and middle finger were wanting. The metacarpal bone of the ring finger could be readily felt, its distal extremity being free. The two digits were freely movable, and objects could be firmly grasped between them.

I am indebted to Dr. Legat of South Shields for notes of this case, which is illustrated by Fig. 35 :—

CASE 5.—*Congenital Absence of Four Fingers.*

The patient, a little girl aged three years, was one of a family of five children, none of whom presented any deformity except herself. The left hand possessed only a thumb, which was well developed and movable. The mother of this child stated that, when in the early months of pregnancy, before the birth of the patient, a man came

to her door begging, and showed his hand, which had had all the fingers amputated, the thumb only being left.

Fig. 8, Plate I., is taken from the hand of a little girl whom Dr. Andrew Inglis was kind enough to bring under my notice. The patient was six years old, and had only two fingers and a thumb, the index and middle fingers being absent.

The little finger consisted of only two phalanges, and was firmly connected along its whole length to the ring finger, which was composed of only one phalangeal bone surmounted by a nail. These united digits had no movement except that which took place at their metacarpo-phalangeal joints, but the thumb could be approximated to these digits, and objects grasped in this way. Meckel,<sup>1</sup> Otto,<sup>2</sup> Cruveilhier,<sup>3</sup> Vrolik,<sup>4</sup> Professor Struthers,<sup>5</sup> and other authors, have figured and described cases of congenital deficiency in the number of the digits.

Deficiencies in the number of the digits may be simulated, and may depend on the union or fusion

<sup>1</sup> *Handbuch der pathologischen Anatomie*, vol. i. p. 751. e. s. Leipzig, 1812.

<sup>2</sup> *Monstrorum Sex centorum Descriptio Anatomica*.

<sup>3</sup> *Cruveilhier Anatomie Pathologique*, Tome ii.

<sup>4</sup> "Teratology," in Todd's *Cyclopædia*, and Tab. ad illustrand. Embryogen. 1849.

<sup>5</sup> *Edin. New Philosoph. Journal* for July 1863.

of certain of the parts composing two or more fingers. Fig. 9, Plate 1., is from the dorsal aspect of the hand of a child aged sixteen months, which, through the kindness of Dr. Campbell of Alva, I was able to examine and sketch. On first looking at the hand, there were apparently only three fingers present, the ring finger being the one absent; the middle and little fingers were webbed.

On more careful examination, however, I found that the first phalanx of the ring finger lay obliquely in the web between the middle and little fingers, and that the last two phalanges of the same finger were united to the corresponding phalanges of the little finger. These two sets of phalangeal bones could be felt distinctly, and the nail which was common to the two was slightly grooved down its centre. Fig. 10, Plate II., was taken from the hand of an infant six weeks old, a patient of Dr. J. A. Sidey of Edinburgh, who was good enough to give me an opportunity of examining the case. Both hands were deformed; the right hand had apparently only three fingers, but there were four distinct metacarpo-phalangeal joints, and four first phalangeal bones belonging to four fingers. In the middle finger the first phalangeal bone became united to the corresponding one of the ring finger, and these two fingers had only

one set of second and third phalanges common to both and surmounted by a single nail. The left hand had the index, middle, and ring fingers united. The double finger of the right hand was freely movable.

The next illustrations are taken from fingers which are affected with a diminution in the number of their segments only, the remaining segments being either natural in their development, or having their tissues more or less atrophied.

The first case is that of a girl whose hands I lately examined ; both her little fingers were deficient from an absence of their last phalangeal bone, the remaining phalanges of these fingers were perfect.

CASE 6.—*Congenital Absence of the Distal Phalanx of the Little Finger in both Hands.*

The patient was a girl, aged twelve, whose only deformity was a deficiency in both little fingers.

These digits were shorter than natural, and on examination this was found to depend on a deficiency of the last phalanx, which consisted merely of soft texture, surmounted by a nail, there being no bone present.

In these cases an entire absence of two or more phalanges may occur, or again, there may be no phalanx at all, the finger being merely represented by a pad of soft tissue, surmounted by a nail. Figs.

11 and 12, Plate II., are taken from casts in the Anatomical Museum of the Edinburgh University.

The dissections of these hands are also preserved in the same museum, and having, through the kindness of Professor Goodsir, had an opportunity of examining these preparations, I give a description of them under Case 7. The right hand, Fig. 12, has the usual number of fingers, but the ring and little fingers are very much diminished in size, and this depends on a diminution in the number of their phalanges. The left hand, Fig 11, has also the usual number of fingers, but the index finger is only represented by a small rounded fleshy prominence, surmounted by a well-developed nail.

CASE 7.—*Congenital Deficiency of Certain Fingers in both Hands.*

The patient was a girl, aged fourteen, who was born with a malformation of both hands. The dissection of the right hand showed that its ring finger had only two phalangeal bones which were not fully developed, and were merely connected to the extremity of their metacarpal bone by means of some areolar tissue, and a small slip from the flexor tendon of the fingers, the extensor tendon did not pass farther than the metacarpal bone. There was, therefore, no distinct metacarpo phalangeal joint. The little finger of the same hand had also only two phalangeal bones, which were small in size, and loosely attached by

areolar tissue and small slips from the extensor and flexor tendons to the extremity of their metacarpal bone, which was not quite half its natural length. The dissection of the left hand showed that there was no bone in the rudimentary index finger, but that this finger merely consisted of areolar tissue, skin, and a nail, and was connected to the head of its metacarpal bone (which was of natural size) by means of a little fibrous tissue and the termination of the flexor tendon. The digital arteries formed an arch on the palmar aspect of this abortive digit similar to that which is found at the extremity of a natural organ.

The following case also illustrates a somewhat similar deformity :—

#### CASE 8.

On the 19th of May 1865, I was asked to examine the right hand of Mrs. ———, aged fifty, the patient having been born with a malformation of this hand. The index, middle, and ring fingers were atrophied. They were only about a quarter of an inch in length, and each consisted of a single phalanx (not fully developed) surmounted by a distinct nail. The thumb and little finger were natural. All the metacarpal bones and rest of the hand were perfect. The hand was very useful, as the thumb and little finger could be readily approximated, and objects firmly grasped between them. The patient had no other deformity, and there was no hereditary history of any similar malformations.

Fig. 13, Plate II., is taken from a cast in the museum of the Newcastle-upon-Tyne Infirmary. It

represents the dorsal aspect of a hand which has the usual number of fingers, but these digits are all, including the thumb, deficient; the thumb and index fingers are most developed, the remaining fingers being all united together. Fig. 14, Plate II., is also taken from a cast in the same museum. It shows the dorsal aspect of the hand of a child which has the usual number of fingers, but the index, ring, and little fingers are all imperfect, especially the two latter; the middle finger and the thumb are natural.

The next cases are examples of a diminution in the number of the digits associated with congenital deficiencies of the upper extremity. Fig. 15, Plate II. (reduced one-third), is drawn from a cast which I had taken of the arm described in Case 9. The hand of this malformed arm had only three fingers, apparently the index, middle, and ring ones. These fingers had their corresponding metacarpal bones well developed, and also the usual number of phalanges.

CASE 9.—*Congenital Deficiency of the whole Upper Extremity, with Congenital Absence of Two Digits.*

This patient was a lad aged twenty-one, whom, through the kindness of Dr. Elliot of Carlisle, I had an opportunity of examining last April. The lad was well grown and developed, with the exception of the right upper ex-

tremity and scapula. This extremity was very short, but possessed an arm, forearm, and hand, with perfect shoulder, elbow, and wrist-joints, all of which were quite movable.

The arm measured, from the acromion process to the elbow,  $8\frac{1}{2}$  inches, and from the elbow to the distal ends of the metacarpal bones (the hand being closed),  $7\frac{1}{2}$  inches. The left arm was of natural size, its measurement being, from the acromion to the elbow,  $14\frac{3}{4}$  inches, and from the elbow to the distal extremity of the metacarpal bones,  $13\frac{3}{4}$  inches. The right scapula was only half the size of the left one, the right scapular and pectoral muscles being also much atrophied. The inferior border of the right pectoralis major muscle was much lower than its fellow on the left side, the right nipple being an inch at least below the level of the left one, so that the axillary space was lengthened from above downwards. The hand of this deficient arm had only three fingers (apparently the index, middle, and ring), which were connected to three normal metacarpal bones. These fingers, as well as the joints of the whole arm, were quite serviceable, and could be used in many ways. The patient wrote with his left hand.

Förster figures in his work<sup>1</sup> a curious example of a similar deformity, which is copied from Wieber's *Diss. Nonnulla de prima Formatione Cohibita*. Berlin, 1838. It represents an arm in which the humerus was present, but the ulna was the only bone in the forearm. There were only five bones

<sup>1</sup> *Die Missbildungen des Menschen*. Jena, 1861. Plate XII., Fig. 19.

in the carpus, the scaphoid, trapezium, and trapezoid being absent. There were only three metacarpal bones, and two fingers present, the little and ring ones. The interesting point in this case is that the carpal and metacarpal bones, which would naturally be connected with the absent radius, are wanting.

Otto<sup>1</sup> and Vrolik<sup>2</sup> also figure cases of imperfect digits associated with deficiencies of the upper extremity. Fig. 37, Plate IV., is taken from a rough sketch, for which I am indebted to Dr. Falla of Jedburgh. The infant from which the drawing was taken only lived fourteen days, and was born with an entire absence of both forearms and both hands. The upper extremities terminated in stumps at the point where the elbow-joint should have been, a single finger being loosely attached to the end of each stump. This child was the sixth by the same father and mother. It presented no other deformity, but was born about a month before its full time.

The following cases are evidently examples of intra-uterine amputation, with reproduction of rudimentary digits :—

#### CASE 10.

A boy, aged nine years, whom I saw a few months

<sup>1</sup> *Loc. cit.*, Tab. 16.

<sup>2</sup> Todd's *Cyclopædia of Anatomy and Physiology*, Art. "Teratology."

ago, with a congenital malformation of one hand. The wrist-joint was perfect, but the hand formed a sort of stump, from the extremity of which there projected a prominence representing the thumb, and four smaller ones, which were situated in the position of the four fingers. None of these digits possessed any nails. Fig. 51, Plate v., is taken from this hand.

Fig. 16, Plate II., I took from the hand of an infant, a patient of Dr. May of Newcastle, who kindly allowed me to visit the case. This hand presented the same deformity as in the last case, but the stump of the thumb had a rudimentary nail on its summit. I have notes and sketches of other cases similar to the two just described. I had sent me last year a sketch of the forearm and hand of a boy aged twelve. The whole arm was congenitally atrophied, having scarcely grown at all since birth. This deficient arm terminated at the hand in a stump, which had four little prominences or rudimentary digits projecting from it, as in Fig. 16. Dr. Montgomery was of opinion that these intra-uterine amputations were caused by bands or ligatures of organized lymph, the result of some inflammatory process. The following case is, I think, a good illustration of the effects produced on the fingers by such intra-uterine constriction :—

CASE 11.—*Intra-uterine Amputation of two Fingers, and Partial Constriction of a Third Finger of one Hand.*

William L., aged four, admitted into the Clinical Surgical Wards of the Royal Infirmary of Edinburgh with congenital malformations of both hands and feet. The little and ring fingers of the left hand had suffered amputation "in utero" through the distal end of their first phalanges. These fingers were therefore represented by two short stumps having a distinct cicatrix on their summit. The index finger of the same hand had a well-marked constriction round its base, as if a cord had been tied round it. The other hand and both feet of this patient presented interesting malformations, but these will be described under "Union of Fingers," as they belong to that series.

Congenital deficiencies of the toes occur under similar conditions as in the fingers, but the deformity produced by undeveloped toes will not be so likely to require surgical interference, as in many instances it is the unnatural appearance only of these abnormalities in the hand that calls for an operation.

I will, however, give a few examples of deficiencies in the digits of the foot. Fig. 17, Plate II., is taken from a cast in the museum of the Newcastle Infirmary. It is the dorsal aspect of a foot which has only four toes. All these digits are imperfect, and the fourth one is very rudimentary. The whole

foot is much shortened, and this depends on a deficiency in the tarsus and metatarsus. In the same museum there is a cast exhibiting the under surface of the foot of a child, which has the usual number of toes, but they are all imperfect. The whole foot, as in the last case, is shortened, and not fully developed. In the same museum there is a cast of the foot of a child, which has only three toes, the fourth and fifth being absent; the corresponding metatarsal bones of these two toes are also wanting. Fig. 18, Plate II., is from the left foot of the patient whose hands are represented in Plate I. This foot had the usual number of digits, but the great toe possessed no nail, and was not fully developed. The other toes were curiously massed together along their whole length, their nails being united and blended with one another. The foot itself was much stunted in its growth, but the patient was able to walk upon it.

*Treatment.*—Fingers which are deficient in number only are not subjects for a surgical operation.

From the history of the cases mentioned, we learn that although certain fingers may be absent, the remaining ones are useful, provided there be no other deformity present.

When, however, fingers are deformed or deficient

in their development, no matter whether the number be diminished, increased, or normal, the hand so malformed may occasionally be improved in appearance and usefulness by surgical means, and in some instances such fingers may be removed altogether with advantage. Thus the hand shown in Fig. 9 would be much improved by the division of the web which connects the two fingers, and by the removal of the phalangeal bone, which lies obliquely in this web; the other phalanges of this apparently deficient finger are too intimately connected with those of the little finger to admit of any attempt at separation; but by leaving their bones in their present position, and freeing the fleshy union between the two fingers, a very useful hand might be made. In cases such as shown in Fig. 10, where one or more phalangeal bones are common to two fingers, an operation cannot be of any service, but these fingers are usually quite movable and serviceable, and their appearance is by no means so unnatural as many other abnormalities of the digits. There can be no doubt that deformed fingers, such as are represented in Figs. 11 and 12, should be removed altogether, for they are generally perfectly useless; and their attachments to the hand or other fingers are so slight that they admit of no proper movements.

Besides, the appearance of such fingers is very unpleasant to most people to witness, and a small cicatrix on the hand is much to be preferred to the unnatural spectacle of the abortive fingers. These fingers should be removed as early as possible, for there will be much less deformity of the hand left if this is done before the parts have attained their full size.

The same rule is applicable to cases of supernumerary fingers and thumbs, and will be again referred to when speaking of this class of malformations. Congenital deficiencies, as shown in Fig. 13, will not admit of improvement by an operation; but the union of the fingers which exists in this hand might be separated with advantage by some of the methods which will be described under "Union of Fingers and Toes." I have thought it right to refer to deformities depending on congenital deficiency of the whole upper extremity, and to those which we have seen result from intra-uterine amputation; but such cases are not likely to present themselves to the surgeon in any form which would admit of their being treated surgically.

The cases of deficient toes which I have figured, although curious and interesting as examples of abnormalities, are not cases which could be bene-

fited by an operation. Instances of these deformities might, however, be met with, in which the removal of the toes or some other operation might be beneficial. I lately saw the cast of a child's foot, which showed an absence of two toes associated with club-foot. In such a case it would be proper to treat the club-foot in the usual way, as the foot was otherwise well developed.

### 3. *Supernumerary Fingers and Toes.*

M. Gaillard,<sup>1</sup> surgeon to the Hôtel Dieu, at Poitiers, states that he has met with three varieties of these deformities in the digits.

1st. The finger is only bifid, articulating with the metacarpus by a single head.

2d. Two fingers are placed in juxtaposition, being articulated side by side, only one articular capsule surrounding the head of the metacarpal bone.

3d. (rarest). The supernumerary finger is entirely isolated, and implanted on a special articular surface of the metacarpus, the superfluous part almost always being a thumb or great toe.

I prefer, however, to consider supernumerary fingers and toes under the following heads:—

1st. As a deficient organ attached loosely or by

<sup>1</sup> *Gazette Méd.* for 1862, No. 43.

a narrow pedicle to the hand, foot, or another digit.

2*d.* As a more or less developed organ, free at its extremity, and articulating with the head or sides of a metacarpal, metatarsal, or phalangeal bone, which is common to it and another digit.

3*d.* As a fully developed organ, having its own metacarpal or metatarsal and phalangeal bones distinct.

4*th.* As a more or less developed organ intimately united along its whole length to another digit, and having either an additional metacarpal or metatarsal bone of its own, or articulating with the head of one which is common to it and the other digit.

Fingers and toes are most commonly increased in number by one only, but cases are on record in which this number has been greater.

In the *London Med. Gazette* for April 12, 1834, is recorded the case of a young man aged nineteen, who was under the care of Mr. Arnott, in the Middlesex Hospital. This patient had thirteen toes—seven on the left foot, six on the right; he had also originally fourteen fingers, but two of them were removed shortly after birth.

In the *Copenhagen Transactions*, J. Bartholine describes a skeleton which had seven fingers on

the right hand, and six on the left, and the thumb double ; the right foot had eight toes, the left nine. Saviard<sup>1</sup> saw a new-born infant at the Hôtel Dieu, in Paris, which had ten fingers and ten toes in each hand and foot. Voight<sup>1</sup> records a case in which there were thirteen fingers on each hand, and twelve toes on each foot. Förster<sup>2</sup> gives a sketch of a hand and foot, in both of which there were nine fingers and nine toes. Mr. Jardine Murray<sup>3</sup> reports a case of double hand, in which the patient, a woman aged thirty-eight, had eight fingers. I shall afterwards have to relate the case of a woman who had six fingers and two thumbs on each hand, and also another case, in which there were eight toes on one foot. Professor Struthers<sup>4</sup> mentions a case of a boy who had seven digits on the left hand, and the one corresponding to the thumb double at its distal segment, making so far an eighth digit. There were seven distinct metacarpal bones. Mr. Athol Johnston<sup>5</sup> records a case in which there were nine toes on one foot. Cases are occasionally met with in which a digit is increased by the addition of one

<sup>1</sup> Cooper's *Surgical Dict.*, "Fingers."

<sup>2</sup> Förster, *loc. cit.*, Tab. 8, Figs. 27 and 28.

<sup>3</sup> *Med. Chir. Trans.*, vol. xlv.

<sup>4</sup> *Loc. cit.*

<sup>5</sup> *Trans. Path. Soc.*, vol. ix. p. 427.

phalanx. The thumb is the digit which is thus usually increased. Fig. 19, Plate II., I took from a case of this kind, which Dr. Carlyle, of Carlisle, asked me to see. The hand was perfectly developed in every way, except that the thumb resembled a long forefinger, having three phalanges. The patient was a girl aged thirteen, and was otherwise well formed. Since then I have met with other similar cases.

Fig. 20, Plate II., is an example of the most common form of the *first variety*. I have on several occasions removed such supernumerary digits, and, on dissecting them, have found that they consisted of either one or two atrophied phalanges, surmounted by a small nail, and attached by a narrow pedicle to the skin and areolar tissue of the hand. These supernumerary fingers are most common on the ulnar side of the hand, and they may be connected either to this surface or to the same aspect of the little finger. Atrophied fingers or thumbs, having the same structure, are occasionally met with on the radial and other surfaces of the hand. Otto figures an example of one of these atrophied digits attached to the radial side of the hand. As the thumb itself is absent in this case, it is probably represented by the deficient digit. I have met with one case in

which a supernumerary digit was connected to the palmar aspect of the hand. Fig. 21, Plate III., is from a rough sketch taken from this case. The patient was two weeks old, and otherwise healthy. The supernumerary digit was attached by a narrow pedicle to the skin over the ball of the thumb. I easily removed this digit, by dividing the pedicle close to its base ; an artery of some size spouted freely, and was therefore ligatured. This variety of supernumerary digits may be present either on one hand or both.

Dr. Campbell of Alva showed me the following case :—

CASE 12.—*Supernumerary Fingers and Toe of the  
“ First Variety.”*

The patient was a boy, aged fourteen, who had a rudimentary finger on the right hand connected loosely to its ulnar aspect. He had also at birth a supernumerary finger attached loosely by a pedicle to the ulnar side of the left hand, but it was removed when he was an infant. This patient had also six toes on each foot. The supernumerary digits possessed only very slight movement, and were quite useless. The lad was one of a large family, and four of his brothers and one sister had exactly the same deformity of the hands and feet.

Cases of the second variety may, as we have already said, either articulate with the head or side

of a metacarpal, metatarsal, or phalangeal bone. In the former of these the additional digit either articulates with the surface on the head of the metacarpal, metatarsal, or phalangeal bone which is common to it and the digit next it (this surface being somewhat expanded), or, the distal end of these bones may be bifurcated, and thus form a separate articular surface for each finger or toe. When there is only one articular surface for the two fingers, it generally happens that one capsular ligament surrounds the articular extremities of both digits. This is also the case sometimes, when, by the bifurcation of the metacarpal, metatarsal, or phalangeal bone, two articular surfaces are formed ; but in these cases there may be two distinct capsular ligaments.

In the latter form, the articular surface for the additional digit is usually placed immediately below the distal articular extremity of a metacarpal, metatarsal, or phalangeal bone, and such articulations have generally a distinct capsular ligament of their own. Fig. 22, Plate III., taken from Otto, shows the most common situation of such an articular facet.

Additional fingers and thumbs of the second variety vary in their degree of development ; they are, however, not generally so movable as to be of

much use, but they are occasionally met with (especially in the case of an additional thumb), so intimately connected with another digit that their removal would be attended with inconvenience. Fig. 23, Plate III., is from a cast in the museum of the Newcastle Infirmary, which represents the dorsal aspect of the right hand of a man who had a supernumerary finger connected to the distal extremity of the first phalanx of the little finger, the supernumerary finger is not fully developed, and has no nail. Fig. 24, Plate III., for which I am indebted to Dr. Renton of Shotley, was taken from the hand of a woman, aged fifty, who had an additional thumb, consisting of two well-developed phalanges, which articulated with the summit of a metacarpal bone, common to it and another similar digit. Fig. 38, Plate IV., represents another example of a similar deformity, the external digit being smaller than the inner one, as is often the case. The patient from whose hand this sketch was taken was a boy, aged twelve. The supernumerary digit was only very slightly movable. In cases where supernumerary thumbs like the ones just described are present, the two usually move together, and in grasping objects are both opposed towards the hand in the same way; but in a case which is illustrated by Fig. 25,

Plate III., the two thumbs were opposed somewhat to one another, and objects could be firmly grasped between them. The patient was a young man who acted as mate of a vessel, and found his hand perfectly useful. For a note of this case I am indebted to Dr. Strachan, junior, of Dollar.

A few years ago I assisted Mr. Syme to remove a supernumerary thumb from the hand of a young lady. In this case the additional digit had a distinct articular surface on the radial side of the metacarpal bone of the thumb, immediately below the metacarpo-phalangeal joint, and there was a distinct capsular ligament surrounding the articulation of the supernumerary digit.

The third variety of supernumerary fingers consists of an independent digit, having its own metacarpal bone. In all the cases of this kind that I have seen or heard of, the additional digit has been fully developed, but it is quite possible that a supernumerary metacarpal bone might exist, with a deficient digit connected to it.

There may be more than one of these additional fingers, and cases have already been mentioned in which several supernumerary metacarpal bones, with well-developed digits connected to them, have been present.

In considering the fourth variety of supernumerary digits, a curious case will be related, in which there were two thumbs and two metacarpal bones on each hand, but these were intimately united along their whole length. (See Case 13.) Fig. 29, Plate III., is taken from Otto's plates, and represents the bones of a hand which has a supernumerary metacarpal bone, and an additional finger. The movements of these additional well-developed fingers are generally quite independent and free; and although their presence is a deformity, their removal will not generally be attended with any advantage, especially when there is only one such present.

The thumb is the digit which most commonly exhibits the fourth variety of supernumerary digits, for all the cases of the kind that I have seen have been in this situation. The union between the normal and supernumerary digit is usually very complete, and does not generally admit of any satisfactory separation. Instances are, however, occasionally met with in which this union is not so firm, and does not extend along their whole length.

The double organ formed by the coalescence of the additional digit with the thumb or finger next

it is in most cases freely movable and serviceable, although unnatural in appearance. Fig. 41, Plate iv., is taken from a cast of a woman's hand which I lately had an opportunity of examining. Her right hand, on first sight, appeared to have three thumbs joined together, as there were three distinct nails; but on careful examination I found that there were only two metacarpal bones, each one having its own set of phalangeal bones connected to its distal extremity, but all these bones were intimately connected together along their whole length. Fig. 49, Plate v., is from a sketch of the dorsal aspect of this thumb. There was also a supernumerary little finger of the first variety attached to the ulnar side of this hand. The remaining fingers were all joined together along their whole extent, with the exception of the forefinger, which was free from its first phalangeal joint. Her left hand (Fig. 41) had also a similar double thumb, but its phalanges were somewhat contracted. There were only two nails on this digit, which became almost continuous with one another. The remaining fingers were united in the same way as those of the other hand, and a similar supernumerary finger existed. The following is a history of this case :—

CASE 13.—*Supernumerary Thumb and Finger in both Hands, associated with Congenital Union.*

In April 1864, I had an opportunity of examining Mrs. T., aged fifty, both of whose hands presented a most curious deformity. The patient's grandfather, father, and three of her own children, had deformities of the hand, but not all of the same nature.

In the right hand the thumb was double, having two metacarpal bones, and two sets of phalanges, with three distinct nails. On this hand there was also a supernumerary little finger of the "first variety." The fingers of this hand were all united along their whole length, with the exception of the index finger, which had been freed for about half its length by an operation.

The left hand had also a double thumb of the same nature as the right one, but with only two nails. There was also a supernumerary little finger on this hand, and the fingers were all united, with the exception of the index one, which had been separated by an operation. The thumb of this hand was somewhat contracted, and not so movable as the one on the other hand. The fingers of both hands were freely movable together, and the hands could be usefully employed in many ways. (See Fig. 14.)

Fig. 27, Plate III., I took from the hand of a man aged fifty, who had a thumb with one metacarpal bone, but two sets of phalangeal bones, which articulated with its distal extremity. These phalangeal bones were intimately united along their whole

length, and there were two distinct nails present. The man was a labourer in an iron foundry, and found the thumb quite as useful as an ordinary digit.

Supernumerary toes may be classed under the same varieties as supernumerary fingers. As, however, the surgical treatment of these abnormalities in both the fingers and toes is to be conducted on the same principles, it is not necessary that I should quote many examples of all these varieties in the toes. I will merely refer to one or two cases as illustrations. The following are examples of the second variety of supernumerary toes:—Fig. 30, Plate III., is from the foot of a child aged ten months, both of whose feet were affected. The additional toe was of the second kind, but it was united for nearly its whole length to the little toe by a web of skin. Fig. 28, Plate III., is from a cast in the Newcastle Infirmary Museum. The supernumerary toe in this case also belonged to the second variety, but the little toe had been pushed inwards, and lay over its neighbour. Fig. 32, Plate III., is taken from a very interesting case of additional great toe, for which I am indebted to Dr. Bolton of Newcastle. The toe in this case was well developed, and articulated with the side of the metatarsal bone

of the great toe. It was very freely movable, and resembled in this respect a thumb rather than a toe.

The great toe itself was somewhat stunted, and the additional toe could be opposed to the foot, and objects grasped firmly between them. Dr. Bolton has also sent me notes of a second case, in which there was a similar deformity of the foot, but associated with club-foot. The next two cases are from Dr. Bolton's notes of the examples just referred to.

CASE 14.—*Supernumerary Great Toes, resembling Thumbs, with Supernumerary Little Fingers.*

This patient, a child, had a supernumerary digit connected with the first phalangeal joint of each little finger.

On each foot there was a well-developed supernumerary toe connected to the inner aspect of the metatarso-phalangeal joint of the great toe. These supernumerary toes possessed great freedom of movement in every direction, and objects could be firmly grasped between them and the sole of the foot. The normal big toes of these feet were small, and somewhat atrophied. Both the additional toes were removed when the child was about two years of age, and he now walks quite well. The mother assigned the following cause for the malformation. She stated that his grandmother had a habit of squatting down (after the manner of colliers) before the fire in her

night-dress to smoke her pipe. Although advanced in years, this old lady was very active, and was wont to display her agility by raising herself from this elegant posture by merely crossing her hands over her feet. The mother of the little patient, when a few weeks gone in the family way, strained herself in endeavouring to perform the same feat, and to this she attributed the deformity of her child. (See Fig. 32.)

CASE 15.—*Supernumerary Great Toe on Left Foot, Talipes Varus of Right Foot, with Congenital Absence and Union of some of the Fingers.*

This patient was a child whose left foot had a supernumerary great toe exactly similar to those described in last case. There was congenital talipes varus of the right foot, and there was entire absence of the middle finger of the right hand, with congenital union of the index and ring ones. This supernumerary great toe was removed, and the club-foot successfully cured.

The next case belongs to the third variety. The patient, a girl, aged seven, had eight metatarsal bones and eight toes on one foot. This foot had the appearance as if a portion of another foot had been added to its inner side. Commencing at the inner aspect of the foot, there was first a big toe, then two smaller ones, which were webbed, then a larger toe, apparently a second great toe, and external to this four ordinary toes. This malforma-

tion made the foot much broader than its fellow, but otherwise it was quite useful. Fig. 26, Plate III., represents an example of the fourth variety. It was taken from the foot of a child aged two months, whom Dr. Paxton of Norham was good enough to show me. On this foot there was an additional great toe, with an additional metatarsal bone, the supernumerary toe being united to the great toe along its whole extent. The great toe, together with the supernumerary digit, was displaced inwards, forming an angle with the rest of the foot.

CASE 16.—*Supernumerary Great Toe, associated with  
Congenital Union.*

A male child, aged eight weeks, a patient of Dr. Paxton's of Norham, with a supernumerary great toe on the left foot. This additional toe was firmly united along its whole length to the natural great toe. It had a distinct metatarsal bone of its own, which was displaced inwards, together with the toe to which it was united. This malformation formed an ugly deformity of the foot, which is shown in Fig. 26, Plate III. The child had no other deformity.

*Treatment.*—This will be best considered under the different varieties. Those digits which are merely increased by the addition of one phalanx, are not amenable to treatment.

The first variety of additional fingers should

always be treated by the removal of the superfluous digit, and this ought to be done as early as possible. The operation required for the removal of such digits is very simple, and consists in dividing the pedicle which attaches them to the hand. The pedicle must be divided close to its point of attachment to the skin, so that no remains of it may be left. In very young infants care should be taken that no hemorrhage takes place from the divided pedicle, for I have seen this texture, when cut across, bleed freely from a small spouting artery. If such an atrophied digit should be found connected to the foot or toes, it ought to be removed in the same manner.

The deformity produced by cases of the second variety can often be remedied by the removal of the additional digit, but the operation in these cases is slightly more serious than that which is necessary in examples of the first variety. We have said that some of these additional digits have separate articular surfaces, while others again are connected to a surface which is common to another digit; and, in regard to these latter cases, we also mentioned that the capsular ligament usually surrounded the articular extremities of the two fingers. It is this latter circumstance which makes the operation for

the removal of such digits more important, as we may require to open into a synovial cavity, which is connected with more than one digit. In cases such as are shown in Figs. 22, 32, and 38, the removal of the superfluous digit is very easy. The articular surface being on the side of a metacarpal, metatarsal, or phalangeal bone, there is not much risk of injuring the joint of the other digit, so that although we require to cut through a greater amount of tissue than in cases of the first variety, these tissues are not important ones. The operation in these cases should, as in examples of the first variety, be performed as early as can be done with safety to the patient. In cutting off such additional fingers or toes, the incisions must be arranged so that the edges of the wound join nicely together, and leave as small a cicatrix as possible. The hand of the young lady (p. 33), whose case I have mentioned, was much improved by the removal of the supernumerary thumb. In both Dr. Bolton's cases, the removal of the additional toes from their inconvenient situation was quite successful, the little patients being able to walk freely after the operation. In the second case, the club-foot was cured by surgical treatment at the same time.

In cases where the additional digit is connected to the head of a metacarpal, metatarsal, or phalangeal bone, and in some cases where the extremities of these bones become bifurcated, we must again take into consideration that it may be necessary to open into a synovial capsule, belonging not only to the digit to be removed but also to the adjacent one. If the additional digit be very intimately connected with another finger at its articulation, and especially if this be a thumb, it is, I think, very questionable whether it should be removed, for the operation is almost sure to damage more or less the usefulness of the remaining digit, and thus the efficiency of the hand may be sacrificed in order to get quit of a deformity which is merely unpleasant from its unnatural appearance.

I met with a case very lately in which a supernumerary thumb articulated with the head of the metacarpal bone of the natural thumb, but the additional thumb in this instance was distorted and immovable. In such a case, it would be right to take away the additional digit. The removal of an additional little finger under the same circumstances is not liable to be attended by any impairment to the usefulness of the hand, and, therefore, such superfluous digits may, in most instances, be re-

moved with advantage. If the case should be one in which the distal extremity of a metacarpal bone has bifurcated, I should be inclined, in some instances, to cut off also that prominent portion of it with which the finger articulates, as if left it might cause an ugly projection on the side of the hand.

Additional toes of this form must be treated in the same way. If the supernumerary toe should be placed in an awkward position, or should cause much deformity of the foot, it ought to be removed. The foot illustrated in Fig. 26 would probably be best remedied by the removal of the additional toe and the one to which it is connected, both being displaced in an inconvenient manner. I have already said that the removal of supernumerary digits should be performed as soon as can possibly be done with safety, for the presence of an additional digit, if at all intimately connected with another finger or toe, is apt to interfere with its proper development, and consequently weaken its powers of movement and usefulness. In removing additional digits, care must be taken to take away the whole of the superfluous part, for there are cases on record in which such digits have grown again after they have been partially cut off.

A curious instance of this is related by Mr. White.

The patient was a boy, aged three, who was born with two thumbs upon one hand, or rather a thumb double from the first joint. The outer thumb was less than the other, and both possessed a perfect nail. The outer thumb was removed, but it grew again, and a new nail formed on it. It was cut off a second time by another surgeon, but it again reappeared, with a fresh nail developed on its extremity.<sup>1</sup>

Professor Struthers<sup>2</sup> also mentions a case in which Dr. Hamilton cut off a supernumerary thumb, but left for security the proximal end of its first phalanx, and this stump has since grown to some extent.

The third variety of supernumerary digits very rarely calls for surgical interference, as we have seen that such digits possess a metacarpal or metatarsal bone of their own, and usually have independent and useful movements. If, however, a case should be met with in which it was thought advisable to remove such digits, they must be taken away so as to leave as little deformity and impairment of the usefulness of the hand or foot as possible.

The treatment of the fourth variety properly

<sup>1</sup> *On the Regeneration of Animal Substances*, by C. White, Esq.

<sup>2</sup> *Loc. cit.*

belongs to that which will be considered under "Union of Fingers and Toes." In some of these cases it might be necessary to remove a supernumerary digit, or to separate its bond of union.

In amputating such supernumerary digits, a good flap or flaps should be taken from the soft parts of the digit to be removed, in order to make up for any deficiency of their textures which may exist on the lateral aspects of the finger or toe to which the amputated digit was connected. In the cases of this variety that I have mentioned, any separation of the united supernumerary digits would have been impossible, but in examples where this union was not so complete, it might be useful to sever the bond between the additional digit and its neighbour.

#### 4. *Congenital Union of the Fingers and Toes.*

Two or more digits may be united—

1st. By loose folds of skin only (the true webbed condition).

2d. By a more intimate connexion of the skin and deeper soft textures.

3d. By the union or fusion of the bones as well as the soft textures.

Besides these forms of union, the digits of one hand or foot, or of both hands and feet, may be

all massed together into one lump, so that it may be almost impossible to distinguish the individual fingers or toes.<sup>1</sup>

In all these varieties of congenital deformity the union may be confined to a portion only of the extent of the digits, or it may extend along their whole length. In a few rare instances the tips only of the fingers may be united, the remaining portion being free.

Figs. 45 and 46, Plate v., are taken from the dorsal and palmar aspects of a hand which presents an interesting example of this latter form of union. The patient from whom these drawings were taken was the little boy whose left hand has already been described under Case 11.

*Congenital Union of the Extremities of the Fingers  
and Toes.*

*Right Hand.*—The second and third phalanges of all the fingers and the thumb were massed together. The first phalanges of each finger and thumb were distinct, being separated by a narrow slit, which passed completely through from the dorsal to the palmar aspect. The first phalangeal bones of the thumb and fingers were well developed, but the second and third phalangeal bones of the thumb and fingers were so mingled with one another that it was impossible to distinguish the bones of each

<sup>1</sup> See Otto, *loc. cit.*, Tabs. 5 and 21, and Vrolik, *loc. cit.*

finger. These bones were not, however, complete, and the soft tissues of the extremities of the fingers were apparently also deficient. There was only one nail present, but it was difficult to determine to which finger it belonged. The metacarpus and metacarpo-phalangeal joints were perfect. The skin uniting the digits was lax, and there was some independent movement in all the fingers, but it was much prevented by the union which existed.

*Right Foot.*—The great toe and three toes next it were all united together. These digits consisted of only one phalangeal bone each, and possessed no nail. The little toe was natural and free.

*Left Foot.*—The great and little toes were perfect and natural. The second, third, and fourth toes were all united at their extremities in a similar way to the fingers of the right hand. The mass formed by the union of these three toes had only two small nails connected with it.

The union between the fingers and thumb of this patient's hand was separated by Mr. Syme; and although, when the wounds were healed, the freed digits were not perfect, the hand was rendered much more useful, as objects could be firmly grasped between the stumps of the thumb and fingers.

Fig. 36, Plate IV., is taken from Otto, and also illustrates this condition.

The first variety then forms the true webbed condition. It appears to depend on an increase in the development and extent of those folds of skin which

exist naturally between the fingers, these folds of skin consisting of two layers of integument, having between them a certain amount of areolar tissue, together with nerves and blood-vessels. This form of union, although it does not interfere much with the movements of the united fingers, may limit their individual usefulness, and, at the same time, destroy the proper appearance of the hand. We are therefore sometimes called upon to remedy this deformity. The natural folds of skin between the fingers and toes vary in their extent in different individuals, but a deformity is only produced when such folds extend for some distance up the sides of the digits.

In the second variety the same covering of integument usually envelops two or more fingers, so that the united digits are firmly bound together, and incapable of any individual movement. In most of these cases there is a shallow groove or line running down between the united digits, and marking the division between their phalangeal bones. Two digits united in this manner may have only one nail common to both, but usually, when the nail is single, it is grooved down its centre. In other cases there are two or more distinct nails. On examining examples of this kind of union we can generally readily detect the separate bones of each finger, and

are able to feel an interval more or less marked between them. Figs. 31 and 33, Plate III., are taken from the hands of a child aged five months. The right hand, Fig. 33, had the middle and ring fingers firmly united along their whole length. There were two distinct nails, and the bones of each finger could be felt quite separate.

The left hand had the index, middle, and little fingers all united along almost their entire length in the same manner, a small portion of their extremities only being free. Fig. 48, Plate v., is taken from a drawing of the left hand of a still-born infant, which, through the kindness of Dr. Sidey, I was allowed to examine. The following is an account of the case :—

CASE 17.—*Congenital Union of Fingers and Toes of both Hands and Feet.*

A male infant, born at the full period, but only survived a short time. It presented the following deformities:—The right hand had all the fingers firmly united together along their whole length, after the manner of the second variety. The nails of the index, middle, and ring fingers were also intimately united. The bones of the digits of this hand could be felt to be distinct. The thumb of this hand was united to the index finger, so that all the fingers and thumb formed one mass. The left hand had all its fingers united in the same manner as the right, but the thumb

was free, and not connected to the other digits. This thumb was distorted at its first phalangeal articulation, being displaced towards the radial side. Both feet had all their toes united together in the same way, except that the extremity of the great toe of each foot was free for about the eighth of an inch.

Fig. 39, Plate IV., is taken from a sketch which Dr. Howden, jun., of Haddington, sent me. It represents one hand of a man, aged thirty-six, who had the ring and middle fingers of both hands united in the way I have just described.

Fig. 47, Plate V., is from a photograph, for which I am indebted to Dr. Ward of Blyth. It represents the left hand of an old woman who had all her fingers united in both hands.

In the third variety, the bones as well as the soft parts of two or more digits become united. The most frequent form of this union is that in which a third, or both a second and third, phalangeal bone is common to two fingers, each of these united fingers having its own metacarpal and first phalangeal bones distinct. Besides the firm union caused by this condition of the bones, the soft textures are also united, resembling, in this respect, cases of the second variety of congenital union. We have already illustrated this condition in Fig. 10, when treating of deficient fingers. I saw an infant

lately who had both hands similarly affected, the ring and middle fingers being intimately connected along their whole length, and with only one last phalangeal bone between them. Fig 44, Plate IV., from Otto, shows the bones of a hand in which one set of second and third phalangeal bones is common to two fingers. In some instances of this variety the bones themselves are united to one another, and in such cases a groove can generally be felt running along the bony mass, and indicating the line of separation between the bones of the two fingers.

Congenital union of the toes may be found exhibiting the same varieties as the fingers, and therefore requires no special consideration. When this condition occurs in the toes in its simplest form, it does not appear to give rise to any inconvenience, as patients who possess this abnormality are able to use their feet quite as well as those who have no deformity in this region. Fig. 40, Plate IV., is taken from a cast in the museum of the Edinburgh College of Surgeons, and represents a foot which has all the toes united after the manner of the first variety, the union extending along nearly their whole length. Fig. 30, Plate III., and Fig. 34, Plate IV., are examples of the second kind of union. The union

in neither of these cases is very firm, and does not extend the whole length of the toes, the extremities of the connected digits being free in both instances. Fig. 30 is from the foot of a boy, aged fifteen months, who had the fourth and fifth toes united. Fig. 34 is from the foot of a young lady, aged fourteen, whose second and third toes were similarly united.

Förster<sup>1</sup> figures a foot which is preserved in the Pathological Museum of Göttingen. It has the second and third toes united, but these digits are much larger and thicker than the other toes.

*Treatment.*—Digits which are united by their extremities only, can be readily separated by the division of the tissues which connect them. The result of such an operation will depend very much on the development of the united organs; but in most cases, as in Case 11, the operation is likely to be of some service, and to improve the usefulness of the hand. The operation required for treating the first variety of congenital union in both the fingers and toes is generally very simple, division of the folds of skin which unite the digits being all that is necessary. A difficulty, however, is often experienced in successfully treating such cases after an opera-

<sup>1</sup> *Loc. cit.*, Plate XII., Fig. 19.

tion, which depends on the great tendency there is for re-union to take place during the healing and contraction of the wound. To counteract this evil, various operations have been suggested. Many of these methods are described in the new edition of Cooper's *Surgical Dictionary*. One of these plans, which has been proposed by M. Nelaton, I now describe, as it is given in that work. "It consists in dividing the web into a posterior and anterior flap, the posterior flap being intended to cover the raw surface of one finger, and the anterior that of the other. Each flap is formed by one longitudinal and two transverse incisions. Each is the counterpart of the other, and has three edges unattached, and one attached.

"A longitudinal incision is made in the centre of the phalanx of one finger on its dorsal aspect for the posterior flap, on the palmar aspect of the other for the anterior flap. The length of the incision must correspond with the depth of the web. From either extremity of the longitudinal incision a small transverse one is to be made towards the phalanx of the connected finger. The lower transverse incision will correspond to the free edges of the web; the upper one will cross the cleft between the fingers. Each flap is now to be dissected back

towards the continuous fingers ; in doing this the two folds of the web will be separated from each other, one entering into the formation of the posterior flap, the other into the formation of the anterior. Each flap will now be found to be attached by one edge only, and is to be wrapped round the denuded surface of the finger to which it is attached ; the flaps are to be adjusted by strips of adhesive plaster and by sutures."<sup>1</sup>

The principal objection to this ingenious operation appears to me to be that it necessitates cutting into the centre of the palmar and dorsal aspects of the fingers, in order to get a flap to cover their sides. I do not think it would be necessary to carry out the principle of this operation to its full extent in cases where the web or fold of skin is loose. It would be preferable, in such cases, to make the longitudinal incisions along the sides of each finger instead of along the centre of the palmar and dorsal aspects, and having as it were split up the web into two flaps, to adjust them as in M. Nelaton's plan. If the web was very loose, I should think it sufficient to make a longitudinal incision through its centre and along its whole extent, and then to split up each half of the divided

<sup>1</sup> Cooper's *Surgical Dict.*, edited by Lane.

web. The edges of the two flaps thus formed on either side should then be brought together by means of sutures. Whichever of these operations is adopted, the after-dressing of the wounds must be carefully attended to, in order to prevent any undue contraction or re-union of the wounds. In dressing such wounds, I generally use narrow strips of wet lint rolled round each finger, and find that this makes a clean and efficient application. When the wounds are nearly cicatrized, the fingers should be exercised constantly to prevent any stiffness of the parts ensuing.

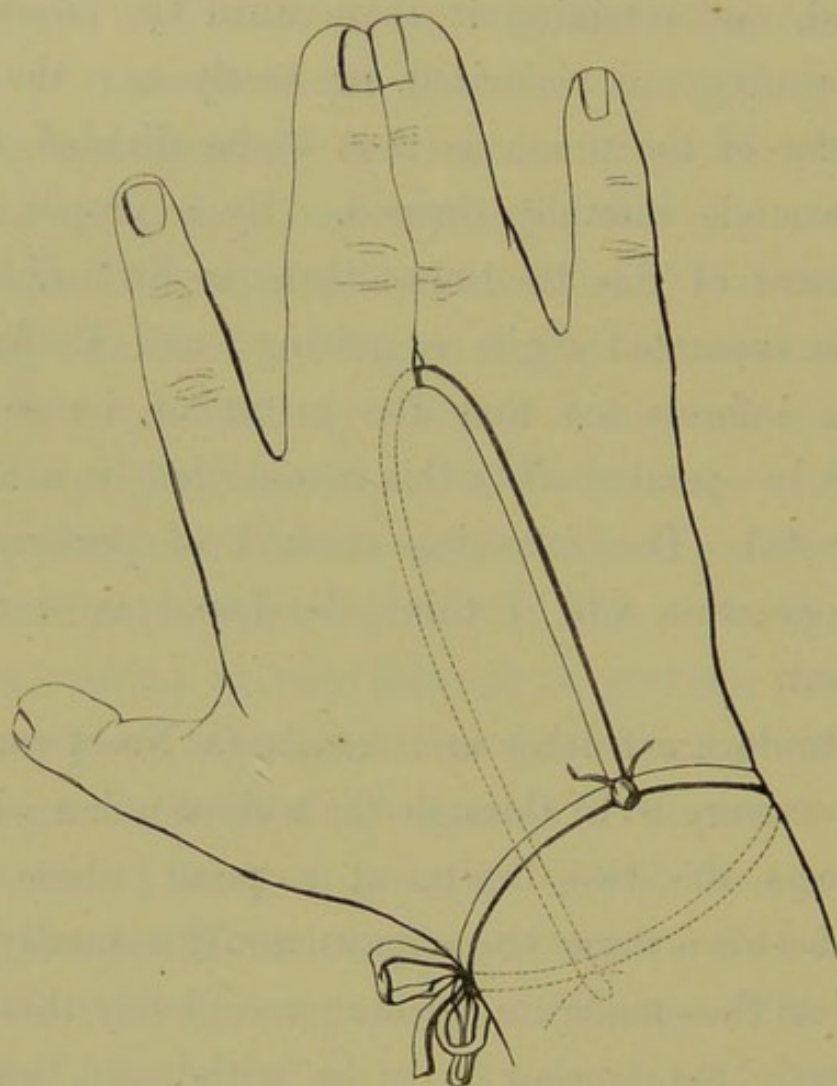
The surgical treatment of the second variety of congenital union has not hitherto been satisfactory, the intimate connexion of the soft parts in such cases making it very difficult to prevent re-union taking place after operations have been performed to separate the bond of union. The treatment, however, that I am now going to describe has proved very successful, and I venture to hope that it will be of service in cases of this deformity. The principle of this operation is not new, but the method of its performance is, as far as I am aware, original. This plan of operating is mentioned by the late Mr. Liston,<sup>1</sup> but it does not appear ever to have been practised until lately, when Professor Lister

<sup>1</sup> *Operative Surgery*, by Liston, p. 474.

of Glasgow treated a case of united digits in this way. The operation consists in making a perforation through the proximal end of the web or band of union, introducing some foreign body into the wound, and retaining it there until the edges of the opening are cicatrized, or nearly so; the remainder of the union is then to be divided, and the wounds carefully dressed. By a proper employment of this treatment there is little chance of the separated digits re-uniting; and Professor Lister informs me that the result of a case on which he operated after this manner has been most successful. The following method of performing this operation will, I think, be found most convenient.

Introduce a trochar and canula (a No. 4 canula answers very well) through the web or union which connects the two digits, at a point where the cleft between these two organs would naturally be. Having thus made an opening completely through the web, the trochar is to be withdrawn, and a piece of Indian-rubber cord, about the thickness of a No. 8 catheter, passed through the canula; the canula may now be removed, leaving the cord in the wound; one end of the cord is to be carried along the dorsum of the hand, and secured to a

band passed round the wrist, the other end is to be carried along the palm of the hand, and secured at the wrist in the same manner, as is illustrated by the diagram. The advantage of this plan



is that the cord being soft and elastic, allows the hand to move freely without disarranging the apparatus, while at the same time it also acts as an efficient foreign body. In cases where the union is not quite so firm, I have divided the whole union

at once, separated the two layers of the skin at the side of the connected digits, brought the edges of these wounds together with sutures, and then introduced the elastic cord between the divided fingers, adjusting it in the same way at the wrist. This treatment prevents the wounds at the side of the fingers re-uniting, and keeps up a gentle pressure on the lower part of the cleft. Even in this method of operating, great care is required in conducting the after treatment. About nine months ago I divided in this way a very firm union between the ring and middle fingers of a child, fifteen months old. The wounds gradually healed, and in a few weeks the case was so well, and, as I thought, so safe from any return of the deformity, that I ceased attending it. I heard no word of the patient until a week ago, when, on being asked to see the child, I was much annoyed to find that some contraction had taken place in the fingers operated on, and also a slight re-union, which was, however, confined to their proximal portion. These fingers will, I think, be readily put right by a slight operation; but it shows the great tendency that there is for contraction to take place after such operations, and the necessity therefore for counter-acting it by proper means. Some swelling of the

hand and fingers usually follows these operations, but it soon subsides under the use of a little fomentation. The wound should be kept clean, and dressed with strips of wet lint.

This form of treatment is especially applicable to cases of the second variety, but it may be also beneficially practised in examples of the first variety, in which the web or fold of skin is very tight.

Cases of the third variety, in which there are one or more phalanges common to two fingers, will very rarely be improved by an operation.

Those cases in which the bones are themselves united or massed together will also seldom admit of successful surgical treatment. It would, no doubt, be possible in some of these cases to make certain divisions in the mass, but such artificial digits would not be likely to serve any useful purpose, and the operation might lead to an inconvenient condition of the parts.

We have said that the toes when affected with deformity do not generally suffer in their usefulness, but cases might be met with in which it would be proper to separate united toes; the principles of treatment which are applicable for cases of united fingers, will also guide us in our operations on the toes.

5. *Congenital Contractions and Dislocations of the Fingers and Toes.*

Congenital contractions of the fingers and toes may be associated with congenital distortion of the hand and foot, as in the different forms of club-hand and club-foot. They may also be found as complications in the other congenital abnormalities of the digits. In the sketches of deficient and supernumerary digits, some of these contractions have been already illustrated.

In addition to these complicated forms of congenital contractions, one or more fingers or toes are occasionally found at birth to be contracted, without any other abnormality of the hand or foot. The following case is an illustrative example of this congenital deformity :—

CASE 18.—*Congenital Contraction of certain Fingers of both Hands, and of the Great Toe of one Foot.*

A boy, aged eleven, applied to Mr. Syme for advice in regard to a deformity of the fingers. In the right hand the index and little fingers were fixed in a semiflexed position at their first phalangeal joints. These joints were only very slightly movable, full extension of the fingers not being permitted. The thumb of the same hand was stiff, and in the extended position. The other fingers of this hand were natural. In the left hand the index and

little fingers were semiflexed as in the right hand. The thumb of this hand was also stiff and extended. The whole muscular power in both forearms and arms was apparently weak. The right foot had the great toe slightly contracted. The toes of the left foot were natural.

The contraction of the fingers in this case was caused principally by a contraction of all the soft textures external to the flexor tendons, and as the power of extension was so weak, the case was not one that could be satisfactorily treated.

This contraction of a finger or toe is not always well marked when the child is born, for the deformity may at first be slight, and escape notice; but as the child grows the distortion becomes more marked, and if means be not used to counteract it, the deformity has a tendency to become worse and worse, although its progress is generally slow. Such congenital contractions are occasionally hereditary, and I have on several occasions seen children of the account of very slight contractions of the toes, upper classes brought to obtain surgical advice on because their parents or grand-parents had been similarly affected when young, and had suffered inconvenience from the gradual aggravation of the complaint. Otto illustrates a decided congenital contraction of two fingers in one hand. A short time ago I examined the hands of a man aged

thirty-five, both of whose little fingers had been contracted at birth, although not to such an extent as they are at present. Both the affected fingers were in the semiflexed position, and could not be extended to their full extent. Curiously enough, the eldest child of this man, a girl aged four, had the same congenital deformity, but the contraction was not so excessive as in the case of her father. The flexor tendons of the digits are those most frequently concerned in this complaint, but I have seen cases in which the extensor tendon of the toes was at fault. A not uncommon form of contraction is met with in the second toe ; and although the distortion arising from this contraction may not be observed until the child is several years old, and begins to walk, I have on more than one occasion been able to trace a congenital, and in some an hereditary, history of the malformation. This condition of the second toe is no doubt aggravated by the pressure of short or ill-fitting boots and shoes ; and a similar distortion of this toe is frequently produced by the latter cause alone, but I think that this contraction may exist also as a purely congenital affection.

When first seen, the contraction of this toe may be very slight ; but if some means be not used to

prevent further distortion, the toe causes much inconvenience and trouble. I have observed two forms of this distortion, one in which the point of the toe is bent downwards towards the ground, so that the nail, instead of being horizontal, or nearly so, becomes directed perpendicularly downwards; and as the disease advances it is very apt to be forced into the soft textures at the extremity of the toe, giving rise to much pain. This first form is shown in Fig. 56, Plate VI., which was taken from the second toe of a gentleman aged twenty-one, both of whose feet had been affected for many years.

In the second form, the joint between the first and second phalanges is flexed, but the third phalanx is drawn upwards, as in Fig. 58, Plate VI. In some severe cases the toe is quite folded back upon itself, so as to dislocate the bones. This is well seen in Fig. 58, which I took from a toe amputated on account of this deformity. Fig. 59, Plate VI., is taken from a section of the same toe. The patient was a young lady aged twelve, and the deformity had been noticed for five years. Fig. 57, Plate VI., represents the bones of a toe which was so distorted as to require amputation. The patient, a gentleman aged twenty-three, had been troubled for six years with the complaint.

Contractions may occur in any other of the toes. I was lately attending with Mr. Syme a young lady, aged ten, who had well-marked contraction of the extensor tendons of both great toes. The parents of the child had noticed a peculiarity about these toes ever since she was an infant, but it was only when the distortion began to increase that they applied for surgical advice. The great toes in this case were drawn backwards, and also slightly flexed, so that they could not be placed flat on the ground. The extensor tendons were divided in both toes, and a gutta-percha splint applied on their palmar aspect for some weeks after the operation. By these means the toes were relieved of their distortion.

It would thus seem that in these contracted toes either the flexor or extensor tendons, or both, may be the contracting agents. Dupuytren gives the history of a family in which three of its members had congenital contraction of certain toes, from a contracted state of the plantar fascia.<sup>1</sup> Cases are also occasionally met with in which a toe at birth overlaps an adjoining digit.

Congenital dislocations of the fingers at their metacarpo-phalangeal and phalangeal joints have

<sup>1</sup> Dupuytren, *Clinical Lectures*, by Le Gros Clark, Sydenham Society, p. 239.

been recorded. The metatarso-phalangeal articulations have likewise been noticed to suffer from a similar distortion. In these dislocations the bones may be displaced either backwards, forwards, or laterally. I have in my possession a rough sketch of the fingers of a gentleman who had a partial and congenital lateral dislocation of the fingers of both hands. Another member of his family (an uncle, I believe) had a similar deformity.

*Treatment.*—In cases of congenital contraction of the digits seen soon after birth, it will be proper to apply gentle extension to them, as the distortion may not be permanent. If we find that the contraction depends on an abnormal state of the tendons or fascia, we must then resort to some treatment which will counteract this condition. The slight forms of this contraction will be best treated by the application of some simple mechanical apparatus, so as to straighten the affected digit. A splint of wood or gutta percha, well padded with some soft substance, and secured to the palmar surface of the finger or toe with a narrow bandage or with strips of plaister, will in some cases cure this deformity. Special mechanical apparatus has been suggested and described, for the cure of contracted fingers and toes, by Mr. Bigg. In suitable cases,

such contrivances may be usefully employed, either alone or in combination with division of the tendons concerned. If, however, these means should not succeed, or if the contraction be excessive, the tendons causing the distortion must be divided subcutaneously, and then the splint and bandage applied, and kept on until the cure is completed. In those cases of this complaint in which the bones have become much displaced, or in which the finger or toe has resisted the other methods of treatment, amputation of the distorted digit ought to be performed, as it is the only way to get rid of what is often a most troublesome and painful affection. We have said that the progress of congenital contractions is slow ; and as the treatment of such cases is unsatisfactory in very young children, it will often be better to defer any surgical interference for some little time. If a toe be found overlapping another, means should be tried to bring back the digit to its proper situation, and if these means do not succeed, it will be right to remove the toe if it is giving rise to inconvenience.

#### 6. *Congenital Tumours.*

The following different kinds of tumours have been found growing in connexion with the digits at birth :—

1st. Pedunculated growths or excrescences of the skin.

2d. Fatty growths.

3d. Fibrous growths.

4th. Cartilaginous growths.

None of these tumours are common as congenital affections of the digits, but cases illustrating all the forms are on record. Fig. 42, Plate IV., represents a most interesting example of the first variety; for this sketch I am indebted to Dr. Bolton of Newcastle.

CASE 19.—*Congenital Pedunculated Tumours of the Fingers.*

The patient, a child, was brought by its mother to seek advice in regard to two small tumours which grew from the little fingers of her infant's hands.

These tumours bore a close resemblance in size and appearance to half-ripe cherries, each of them having a red patch on the side. They were attached by means of a stalk to the ulnar aspect of the little fingers, and are well represented in Fig. 42. They were removed by dividing the stalk, and no bad consequences followed.

The mother of the patient stated that she had a presentiment before the birth of this child, that when it was born there would be some mark on its hands; and she further stated in explanation, that, when in her early months of pregnancy, she took a great longing for cherries.

Her husband, as soon as he could obtain some of this fruit, hurried with them into her room, and threw several bunches towards her, and she, in her eager attempt to catch some in her outstretched hands, missed them and they slipped through her fingers.

Dr. Montgomery<sup>1</sup> relates a case somewhat similar to this one. Through the kindness of Dr. Moir of Edinburgh, I had an opportunity of examining the foot of a little boy, aged four, a patient in the Children's Hospital. This boy had a sort of outgrowth from the skin and areolar tissue, extending the whole length of the inner aspect of the great toe. This growth was continuous with the soft tissues of the great toe, and only separated from it by a depression or cleft, which did not, however, pass through its whole thickness. It is illustrated in Fig. 43, Plate IV. A case of the second kind of tumour (the fatty) is mentioned by Mr. Gay in the *Pathological Transactions*.<sup>2</sup> The patient, an infant, aged seven months, was born with a tumour on the sole of the foot. An attempt had been made to remove this tumour when the child was a few weeks old. The tumour had now reached the size of an orange, and extended from the fissure of the

<sup>1</sup> Todd's *Cyclopædia of Anatomy and Physiology*, "Fœtus."

<sup>2</sup> *Trans. Path. Society*, vol. xiv.

toe almost to the heel. The foot was therefore amputated. On examination, the tumour was found to consist of fat, containing more areolar or connective tissue than usual.

Mr. Bryant<sup>1</sup> has observed that fatty tumours, when congenital, not unfrequently assume the appearance of a diffused growth without distinct limits. The same author has also placed on record two cases illustrating the third and fourth kinds of tumour. The one was a fibro-plastic tumour, which grew from the little toe of a girl, aged eight. The tumour was of the size of a walnut, and occupied the whole of the extreme phalanx of the toe. The toe was amputated together with the tumour. I met lately with an interesting case of congenital fibro-cellular tumour situated over the metacarpal bone of the thumb, and connected with the same bone was a small cartilaginous tumour. The patient was a boy, aged four. The following is a history of this case :—

CASE 20. — *Congenital Fibro-Cellular Tumour of the Thumb associated with a Cartilaginous Tumour of the Bone.*

The patient, a healthy little boy, aged four, was noticed at birth to have an enlargement of the thumb of one hand, which had gradually increased in size.

<sup>1</sup> *Surgical Diseases of Children*, Bryant.

The boy had never complained of any pain, and it was only the swelling that attracted the parents' attention. On examination, I found a circumscribed tumour, the size of a small pigeon's egg, lying over the dorsal and radial aspects of the metacarpal bone of the thumb.

The tumour lay loose in the subcutaneous tissue, and felt as if composed of areolar or fibro-cellular tissue. There was a second tumour on the palmar aspect of the same bone, firmly attached to it, and having no connexion with the first tumour. It was of the size of a small marble, and had all the characters of a cartilaginous growth.

No positive history could be obtained as to whether both tumours were congenital or not, but the parents referred the swelling noticed at birth to the first tumour.

A drawing of the hand is shown in Fig. 50, Plate v.

Mr. Bryant's second case was that of a woman, aged thirty-eight, who had a cartilaginous tumour growing from the little finger. It had existed at birth, and had been gradually growing since that time. Other kinds of tumours occur congenitally in different parts of the body, but, as far as I can learn, those that I have mentioned are the only ones which as yet have been found in connexion with the digits.

*Treatment.*—The treatment of the first kind of congenital tumour is so simple, that it may be performed at a very early age. The pedicle or stalk

is to be cut through close to its point of attachment to the digit, and similar precautions taken to prevent hæmorrhage, as in cases of the first variety of supernumerary digits. The operation, however, which is required for the extirpation or removal of the other kinds of congenital tumours is more serious, and should therefore, generally, be delayed till the child has passed its early infancy, provided the tumour be not growing rapidly, or involving neighbouring parts. In cases where the bone or much of the soft texture is implicated, it may be necessary to remove the digit, or portions of it, along with the tumour, but the nature, connexions, and extent of the tumour will guide us in our treatment of each particular case.

## CHAPTER II.

### INFLAMMATORY DISEASES OF THE FINGERS AND TOES.

THESE will be considered under the following heads :—

1. Inflammatory Diseases of the Soft Parts.
2. Inflammatory Diseases of the Bursæ and Joints.
3. Inflammatory Diseases of the Periosteum and Bone.

(1.) The integument of the fingers and toes may, like that of the other parts of the body, be attacked with erythematous and erysipelatous inflammation, but it is unnecessary in this work to give a special description of these, as they occur in the digits, for they in no wise differ from erysipelas and erythema in other situations.

Most of the acute inflammatory affections of the digits are usually designated under the terms whitlow or paronychia,—different degrees or varieties of whitlow being distinguished according to the tissue affected. Inflammation, as it attacks the textures

of the digits, does not differ in any way from that which occurs in other regions; but as the digits, especially those of the upper extremity, are so much exposed to injury and to the action of irritating causes, the surgeon is very frequently called upon to treat inflammation and its effects in both the fingers and toes. Three different degrees of whitlow are now generally distinguished, although some authors have described more varieties, and others only two.<sup>1</sup>

I intend, however, to describe—

1st. Acute inflammation affecting the skin and areolar tissue.

2d. Acute inflammation affecting the tendons and their sheaths.

3d. Acute inflammation affecting the periosteum and bone.

The first two of these naturally belong to the first subdivision of this Chapter, but as the whole three will be best studied together, it is my intention to consider all these three varieties before proceeding to the description of the other inflammatory affections of the soft parts of the digits.

The first of these, then, is the acute inflammation

<sup>1</sup> See a paper by Dr. Craigie in *Edinburgh Medical and Surgical Journal*, vol. xxix.

of the skin and areolar tissue, or the simplest form of whitlow. In some cases of this kind the inflammation may originate in the skin, and it may either be confined to that structure, or spread to the connective tissue below it ; but in the majority of instances the inflammatory process commences in the areolar tissue, and in its progress involves the skin.

When confined to the skin only, the affection appears as a slight blush, with a small amount of swelling, and more or less itching or burning, which scarcely ever amounts to pain. A very usual situation of this form of inflammation is on the dorsal, palmar, or lateral aspect of the extremities of the digits. There may be some little redness passing up the finger, but this does not generally occur to any great extent. If such cases are allowed to proceed without interference, a small blister forms on the affected part, underneath which is a thin purulent fluid or a dark-coloured serum. When the blister opens, a superficial ulcer may remain. Constitutional disturbance in this form of the disease is not generally present ; and if it does exist, it is only in very irritable or sensitive temperaments. This inflammation usually depends on the contact of some irritating or poisonous substance with the unbroken surface. It may also result from a very superficial

abrasion or scratch of the skin, with exposure to similar irritating matters. In some persons the mere contact of the irritating discharges from certain wounds is quite sufficient to cause this, or even a worse form of inflammation. Several fingers may be affected with this inflammation at the same time, or they may be attacked with it in succession. Mr. Todd<sup>1</sup> has described, under the term "paronychia gangrenosa," an affection of the fingers resembling this form of whitlow, but followed by more serious results, and commencing without any apparent cause.

When the areolar tissue is attacked, the symptoms are more severe, and there is more swelling of the finger than when the skin only is implicated. The swelling is situated not only on the flexor surface, which I may here state is the aspect of the fingers usually attacked with whitlow in all its forms, but also on its dorsal and lateral aspects. There is often a good deal of pain and throbbing in the finger, the pain not always being confined to the finger, but passing up the forearm and arm, and in some cases causing swelling and irritation in the glands of the axilla. When suppuration has taken place in these cases, we frequently find that although the lateral and dorsal aspects of the finger are of a bright red

<sup>1</sup> *Dublin Hospital Reports*, vol. ii.

colour, the palmar aspect is whitish or yellowish in appearance. Fluctuation, too, can generally be detected on the flexor surface of the digit at this stage; and when pressure is made over this situation, pain is complained of. If the matter be not let out by incision, the skin gradually gives way, and one or more ragged openings are formed, through which portions of sloughing texture often protrude. There may be considerable constitutional irritation in such cases, with want of sleep and general restlessness. When such inflammation is confined to the areolar tissue over the first and second phalanges, the result is not generally bad, unless the case has been very much neglected; but when the disease affects the pulp at the point of the finger, the consequences are apt to be more serious, which is owing to the close connexion of the areolar tissue to the periosteum, bone, and insertion of the deep flexor tendon, the sheath of the tendons being entirely deficient in this situation, and allowing of the immediate extension of the inflammation to the deeper textures. It is for this reason also that we frequently have necrosis of the last phalangeal bone taking place in this form of whitlow, especially if the case has not been treated actively and early. Neglect of this form of whitlow may also lead to

extension of the inflammation to the tendon and its sheath, causing in its progress destruction of the tendon, and the death of the bone. I have examined several fingers lately which had been attacked with this kind of whitlow, and in which the inflammation had at first been entirely confined to the pulp at the tip of the digit, but the disease having spread, had caused destruction of the whole or portions of the third and second phalangeal bones. Figs. 61, 62, and 63, Plate VI., are from second and third phalangeal bones which have been removed from cases of this kind. Fig. 60, Plate VI., is a good representation of the entire death of the second and third phalangeal bones in a case of whitlow, commencing at the tip of the finger. The disease had existed for two months before any incision was made into it; and when seen by the surgeon who removed the finger, the bones were in the condition shown in the sketch. I saw lately a lady, aged about thirty, who accidentally pricked the extremity of her finger with a common pin. Inflammation followed the accident, and led to suppuration, which spread along the sheath of the tendon into the hand and forearm. The distal phalanx and part of the second came away, the latter with a portion of tendon adhering to it. The deformity of the finger made its amputation

necessary. On making a careful examination of the finger removed, traces of inflammation along the whole length of the sheath of the flexor tendons were found. The second and third phalanges were the only bones which had been implicated in the inflammation.

Whitlow attacking the areolar tissue on the palmar aspect of the ungual phalanx of a finger or thumb, is more likely to be attended by serious consequences and extension of the inflammation to the deeper parts, than the same form of the affection would be if it were situated over the first or second phalanges. The sheath of the flexor tendons in these latter situations, in most instances, prevents inflammation, originating in the areolar tissue, from spreading to the deeper texture. It is, I think, too generally supposed that the inflammation spreads from the areolar tissue to the sheaths of the tendons. This, undoubtedly, may take place when the inflammation is over the last phalanx, but here it is owing, as we have already said, to the anatomical relation of the textures to one another. Since my attention was directed to this subject, I have found that whitlow attacking the areolar tissue over the first and second phalanges usually recovers under proper treatment, without the slightest extension of the

inflammation to the deeper textures, while the same form of inflammation, treated in the same manner, and at as early a stage when it affects the extremity of a finger, is not unfrequently followed by the destruction of the tendon or bone. It is not at all uncommon in this kind of whitlow, at the point of the digit, to find the extremity of the flexor tendon dying, and coming away as a small slough, occasionally having small particles of bone connected to it, and leaving the phalangeal bone bare and rough to the touch. The bone, although in this state, may not necessarily be entirely destroyed, but may recover, and the finger regain its proper strength. As another proof that the fibrous sheath resists the extension of the inflammation from the more superficial tissues, I would mention the fact that, in many of the worst forms of the second variety of whitlow, namely that which attacks the sheaths of the tendons, the phalangeal joints remain unaffected. This fact has not generally been noticed by writers on the subject, but I have repeatedly, when making sections of fingers affected with this kind of inflammation, found, much to my surprise, that the textures of the joints, although so intimately connected with the inflamed tendinous sheaths, were perfectly healthy, and presented no

trace of inflammation. From an examination also of the macerated bones removed from such whitlowed fingers, I have seen that their articular extremities were rarely implicated in the disease.

Whitlow, then, when it attacks the areolar tissue of the finger, is not generally serious, unless it affects the pulp at the extremity of the digits; and even in this situation it may often, I think, be prevented from spreading by early and efficient treatment, but still the disease is not so tractable in this as in the other portions of the finger. The causes of this kind of whitlow are generally some external injury, especially small punctured wounds, inflicted by pins, needles, or any other sharp body, with or without the contact, either at the time of the accident or afterwards, of some putrid or fresh animal matter, or other irritating substance. Bruises, too, and other injuries not unfrequently lead to this kind of inflammation. Occasionally this inflammation appears to arise without any cause, but in such cases the injury or wound may have been so slight as not to have been observed. More or less deformity of the finger may result from this affection, but its amount will depend on the extent to which the bone or tendon has become involved.

The treatment of these cases will be considered

afterwards in connexion with that of the other varieties of whitlow.

The second form of whitlow may be caused by inflammation, which originates in the sheath of the tendon, or it may depend, in some cases, upon an extension of the disease from the areolar tissue, periosteum, or bone. The symptoms of this variety of whitlow are usually severe. The pain is great, and is accompanied by a feeling of tension and throbbing in the part. The dorsal surface of the finger and the whole hand soon become red and swollen, and in aggravated cases the redness and swelling may extend up into the hand and forearm. The lymphatics of the arm and the axillary glands often become inflamed, and suppuration may take place in and around these structures. The constitutional symptoms of this form of whitlow are usually excessive. The patient can get no sleep, and there is constant restlessness, and all the other signs of irritative fever present. There is no form of inflammation in which early and efficient treatment gives so much relief as in these cases. The great suffering and intensity of the symptoms depend on the fact that the inflammation takes place within a canal formed of unyielding fibrous structure, so that the products of the inflammation are confined in

this canal. If the fibrous sheath, when attacked by inflammation, is not freely laid open by incision before the disease has made much progress, the inflammation is apt to spread along the course of the tendons into the hand and forearm, and give rise in these situations to suppuration and destruction of the tissues. When inflammation attacks the lining membrane of the sheaths of the tendons, the first result is an effusion of lymph into the canal. Suppuration, at first limited, then takes place, and, if not relieved, more or less destruction of the tendinous structures takes place, owing to the pressure to which they are subjected by the inflammatory effusion. Tendons, we know, have not so strong a vitality as many other tissues, and therefore they speedily perish when attacked by inflammation or when injured. In whitlowed fingers of this variety which have been neglected, or in which the disease has been very rapid in its progress, it is common to find one or more openings in the soft parts, and protruding through them portions of sloughing tendon or other tissue may be seen. It is the destruction of tendon which makes the result of these cases so serious ; for when a large portion of tendon has become destroyed, the finger is almost certain to be distorted, and useless after recovery

has taken place. Some authors describe the joints and bones as generally involved in such cases, but from my researches into the pathology of these affections, I have found that this rarely takes place unless in the case of the last phalanx, or when the disease has been improperly treated. In cases of injury, exposure to cold, heat, or other irritating causes, all the tissues, both soft and bony, of a finger, may be attacked by inflammation, but the bone is not affected in these instances by extension of the inflammation, it is attacked simultaneously with the other tissues. In making dissections of many examples of the second form of whitlow, I found not the slightest affection of the periosteum, bones, or joints, but the disease was entirely confined to the soft textures, and to the tendons and their sheaths. Fig. 64, Plate VI., is taken from a well-marked example of this form of whitlow, which had existed three weeks. Fig. 65, Plate VI., is a section of the same finger, and although more of a diagram than a sketch, it shows the condition of the different textures. The bones, joints, and periosteum were perfectly healthy, but inside the sheath of the flexor tendon there was a considerable effusion of inflammatory lymph, in which suppuration was going on. This collection of lymph had pressed upon and

stretched the flexor tendon. A good deal of inflammatory swelling of the more superficial parts of the finger, especially on the dorsal aspect, also existed, and there were two external openings discharging pus. Fig. 66, Plate VI., is taken from a finger amputated on account of its distorted condition. It had been affected with the same form of whitlow some years before, and a large portion of the flexor tendon had perished. Fig. 67 is from a section of the same digit, and it will be seen from it that the bones and joints are quite healthy, the destruction of the tendon and other soft parts, and the consequent contraction, being the only morbid condition. The amount of contraction and distortion in these cases varies. The more destruction there is of the tissues, the greater will be the deformity.

The causes of this kind of whitlow are similar to those of the more superficial varieties, but the injuries which produce inflammation of the deeper textures are usually more severe. When the disease is produced by a punctured wound, I think it generally happens that the pin or other sharp-pointed body enters the sheath of the tendon, and so directly injures it. We have already said that inflammation may extend from the superficial textures to the deeper ones, but that this does

not happen so frequently as has generally been supposed.

When the periosteum and bone become affected, the last variety of whitlow is the result.

This form of inflammation may originate in the periosteum and bone, and is followed by morbid changes similar to those which take place in acute inflammation of other bones. The periosteum and bone may also occasionally be involved in the progress of the other varieties of whitlow. The symptoms of the disease, when the periosteum and bone are affected, resemble very much those of the second variety. There is severe pain, and a feeling of tension in the part affected, with more or less constitutional disturbance. In cases where the inflammation originates in the soft parts, the usual symptoms of this affection, as met with in the different textures, will be present, and we only become aware of the implication of the bone by seeing or feeling the effects which are produced on its structure.

Cases where the bones of the digits are attacked with inflammation, which very speedily causes caries of their tissues, and suppuration of the soft textures are occasionally met with. These cases are usually the result of injury, and as they differ somewhat from those of whitlow, I shall describe

them in considering "Caries" of the bones of the digits.

The most usual effect of acute inflammation of the bone and periosteum is, as we would suppose, necrosis of a greater or less amount of the bony texture involved. Caries of the bone occasionally takes place, but this is usually associated with necrosis. In acute inflammation of the bones of the fingers, the result of whitlow, I have seen the external surface of the bone merely roughened and porous on its surface, presenting a similar appearance to what is met with after osteitis in other bones. In considering the other inflammatory diseases of the bones of the digits, we shall have to refer to the effects produced by more chronic inflammation. But I would now say a few words in regard to the necrosis of the phalangeal bones, as it occurs in the different varieties of whitlow.

The whole of one or more phalangeal bones may become necrosed. This is well illustrated in Fig. 60, also in Figs. 61, 62, and 63. The necrosis may be limited to a portion of one phalanx, the remainder of the bone being destroyed by ulceration. This is well shown by a preparation in my collection, which was taken from the macerated bones of a whitlowed finger. A portion of the second phalanx

had become necrosed, and the other portion, with the exception of the articular extremities, had been destroyed by ulceration. The articular extremities were perfectly healthy, and unaffected by the inflammation.

The necrosis may be limited to portions of the external table of bone. This is the form of necrosis which appears to occur when the inflammation has been confined to the flexor surface of the bone, and has probably depended on the extension of the disease from the sheaths of the tendons. Another preparation in my collection is an excellent illustration of this condition. The external table of the bone on the flexor surface of the phalanges is dead, and separation of the necrosed parts is gradually taking place. In this specimen the necrosis is confined to that part of the bone with which the sheath of the flexor tendon is connected. The articular surfaces in this case also remain unaffected. In cases of whitlow the phalangeal joints are almost never primarily involved in the inflammation, unless they have received some injury at the commencement of the attack. Their secondary involvement is also comparatively rare.

Acute inflammatory affections of the toes do not require to be considered separately, as they have the

same symptoms, and run the same course as in the fingers.

*Treatment of Whitlow.* — A whitlow may be caused, or at any rate much aggravated, by a temporary unhealthy state of the constitution, or by some peculiarity in the patient, and therefore the constitutional state should always be carefully attended to in cases of whitlow. The local treatment is of great consequence, as it is only by using prompt and active means that the more severe forms of this affection can be prevented from causing serious destruction of the tissues of the digits. That form of whitlow which is confined to the skin does not generally call for much active treatment. Before vesication has taken place, I have found that painting the affected part with a solution of nitrate of silver, or gently rubbing it with the solid stick, often stays the further progress of the disease, and relieves the unpleasant burning sensation which is usually present in these cases. If blisters form, they should be opened, and the loose cuticle cut away, a small poultice or some simple water dressing being applied until the superficial inflammation has subsided. When a succession of these whitlows attacks the fingers, it is usually owing to some unhealthy state of the system. We should, therefore,

in such instances employ those remedies which may be necessary to bring the patient's health into a proper condition.

When the inflammation has attacked the areolar tissue, the proper treatment is to make a free longitudinal incision into the affected part ; this incision ought to be made along the centre of the flexor surface of the finger, for it is here that suppuration most usually takes place.

It is a good rule in this and the other forms of whitlow, not always to wait until suppuration can be detected, but to make the incision as soon as the inflammatory symptoms are well marked.

When the disease is situated over the ungual phalanx, this rule should especially be followed, as we have seen how great a tendency there is for the deeper structures to become involved. A clean and free incision, when made in the proper situation, can never do any harm, and is always of great service in checking the inflammatory process, and relieving the painful symptoms even when suppuration is not present. At the same time the finger should often be fomented with hot water, and soothing poultices applied, or, what is often better, a double fold of lint dipped in warm water, and kept moist by means of gutta percha or oil-silk placed over it. As soon

as the inflammation has ceased, these warm applications must be discontinued, and all loose portions of skin cut off from around the wound. Any dead portions of tendon or bone must be removed as soon as they are loose, and the wound dressed with some simple dressing until it is healed. The redness and swelling which occur on the lateral and dorsal aspects of the digits in cases of whitlow are often deceptive, and apt to mislead the surgeon from the true situation of the disease; consequently I have, on several occasions, seen cases in which incisions had been made in these situations in order to relieve suppuration, which was entirely confined to the flexor aspect of the finger. We can very rarely be wrong if we make our incision on the palmar aspect, for although suppuration does occasionally take place on the other surfaces, it is usually only secondary, and not of much importance.

If, during the inflammatory stage of this affection, the constitutional symptoms be very severe, opium in some form may be given with advantage. The bowels must not be allowed to become constipated. A good purge has often an excellent effect upon this complaint. When inflammation is present in the sheaths of the tendons, the same treatment must be adopted as in that which attacks the areolar tissue,

only the incision must be made deeper, so as freely to lay open the sheath. From what we know of the pathology of this kind of whitlow, we at once perceive how important it is to open the fibrous sheath as soon as possible, not only to relieve the painful symptoms, but also to save the enclosed important structures. In spite even of early treatment in these cases, portions of the tendon will occasionally perish, but still an incision into the parts will best prevent their further destruction.

When portions of the flexor tendons become thus destroyed, the finger is certain to contract more or less during the progress of healing, but a great deal can be done to counteract this by careful and constant movements of the affected digits; this, of course, must be left very much to the perseverance of the patients themselves, and I have seen several fingers which had suffered severely in this way become tolerably useful, owing to an intelligent and prolonged employment of such means. If a finger should be so contracted as to be useless and inconvenient, as in Fig. 66, it would be much better to amputate it. It is impossible to distinguish between those cases of whitlow in which the bone and its covering are affected, and those in which the sheaths of the tendons are the inflamed textures,

but this is of little consequence, as the treatment required for both is the same.

When a phalangeal bone has perished entirely, it may be removed alone, and, in the case of the ungual phalanx, this may be done without destroying much the usefulness of the finger.

The second or third phalangeal bones, or portions of them, may also occasionally be removed in the same way, but the result is not so satisfactory. When more than one phalangeal bone is diseased, or when great destruction of the soft textures has taken place, the immediate amputation of the finger will generally be the best practice, but the surgeon must be guided in such cases by the probable future usefulness of the digit. If the digit is to be of no use when the wounds are healed, it will be much better to cut it off at once. When suppuration takes place in the palm of the hand or in the forearm, from extension of the inflammation along the sheaths of the tendons, free incisions must be made in these situations, to give exit to the matter. The constitutional symptoms in the worst cases of whitlow are usually severe, and the patients will require in such cases to have opiates, and sometimes stimulants and tonics, freely administered. Stiffness of the flexor muscles and tendons

of the fingers is very apt to ensue after this inflammation. Nothing can relieve this but friction and gentle movements of the forearm and digits perseveringly employed. Whitlow is not often met with in the toes, but it requires the same treatment as in the fingers.

*Diffuse Cellular Inflammation.*

In addition to the different forms of whitlow I have just described, the soft textures of the digits are liable to be affected with a diffuse cellular inflammation, which is characterized by its rapid progress, the speedy destruction of the parts which it attacks, and the severe constitutional symptoms which accompany it, so that a fatal result not unfrequently ensues.

It is in fact the same form of diffuse cellular inflammation which occurs in other parts of the body, as a result of injury, or the inoculation of some poisonous matter. In the digits this inflammation may be produced by a wound or other injury ; and it is that kind of inflammation which occasionally follows wounds of the fingers received in dissecting or in making *post-mortem* examinations.<sup>1</sup>

<sup>1</sup> See a paper by Dr. Aitken, "On the Effects of Punctures received in Dissection ;" also, Travers "On Constitutional Irritation."

When this affection originates in the digits, it soon spreads to the hand, forearm, and in severe cases to the arm and side of the chest, giving rise to great swelling and redness in these regions. Diffuse suppuration of the cellular tissue, and not unfrequently sloughing of the textures attacked, soon follows, and the patient in some instances quickly dies from the severity of the constitutional symptoms, or he may linger on for some little time, and sink from exhaustion. A weak or unhealthy condition of the constitution would appear to predispose to this affection. Not long ago I had an opportunity of seeing a patient who laboured under this disease. He was a man, aged sixty-one, who one week previously had bruised the thumb of his right hand. Two days after the accident the thumb and hand were red and swollen, and the next day the forearm had also become implicated. The swelling increased very rapidly, and when I saw him the whole hand and forearm were very much swelled, and of a deep red colour, and there were vesications on the integument of the thumb and hand. The patient was in a very feeble condition, and complained of burning pain in the affected parts. A few days after, sloughing attacked the back of the hand, and

destroyed so large a portion of the soft texture in this situation as to necessitate amputation of the arm.

*Treatment.*—This disease must be treated by making early and free incisions into the areolar tissue of the swollen parts, and then applying hot poultices or fomentations. Opium, tonics, and stimulants must also be perseveringly administered. If suppuration takes place in the axilla or other situations, incisions will require to be made there to give exit to the matter.

*Chronic Inflammation of the Tendons and their Sheaths.*

The digital tendons and their sheaths are occasionally attacked with chronic inflammation, which comes on gradually, and is usually the result of some over-exertion of the digits. This affection leads to a certain amount of stiffening, and occasionally to contraction of the fingers; and when the tendons are moved a sort of crackling sensation is felt. The flexor tendons are most frequently involved. I lately saw a woman, aged fifty, who had this affection of the flexor tendons of one finger. The disease had commenced without any apparent cause, and the digit was becoming gradually contracted in consequence at its last pha-

langeal joint. The tendons and their sheaths may also become the seat of chronic inflammation, the result of rheumatic arthritis, or of some other articular disease.

The treatment of such cases will depend upon their origin. If no other disease be present, gentle friction with warm bathing ; and in obstinate cases, the application of a blister will probably be the most successful means of affording relief. The treatment of the distortion of the digits which follows gouty or rheumatic inflammation, will be considered under the non-congenital contractions of the digits, Chapter v.

*Affections of the Nails, and their neighbouring Soft Textures.*

Onychia. This term is usually applied to an inflammation which attacks the matrix of the nail, causing ulceration of it, and gradually involving the soft textures around.

This disease is sometimes the effect of an injury, but it more frequently occurs as a result of some unhealthy state of the constitution. Simple cases of the disease are met with in which the margins only of the nails are affected, and in very mild cases the inflammation may be confined to one

side. The simpler forms of the affection commence with the usual signs of inflammation in the soft textures around the nail. These textures become red, painful, and swollen, the nail itself becomes affected, and its margin or margins in the neighbourhood of the inflammatory process roughened and displaced. Suppuration and ulceration follow the inflammation, and a sore is formed, which is often kept in a state of irritation by the uneven margin of the nail pressing against it.

If the disease be not checked at this stage, it may gradually spread to the matrix and soft textures under the nail. The nail becomes loosened by the unhealthy ulceration below it, and it is often seen with its edges and root roughened and raised up, the ulcerated surface occasionally overlapping its margins. I examined, a short time since, the finger of a man, aged thirty, who, one month before, had scratched the skin over the base of one of his nails. Inflammation followed the injury, and gradually spread all round the nail. The soft textures surrounding its margins were much swollen, and were suppurating. The root and margins of the nail were quite loose and jagged in appearance, and unhealthy ulceration existed underneath it. The nail was removed, and nitrate of silver freely applied to the ulceration, with

the effect of curing the disease in a short time. Another case, which I saw at the same time, was that of a man, aged twenty-four, who had suffered twelve months from inflammatory swelling and unhealthy ulceration round the inner half of the margin and matrix of the nail of the thumb; this side of the nail was raised up and loosened by the ulceration underneath it. The inner half only of the nail was removed in this case, and the nitrate of silver applied freely to the sore. On examining the portion of nail removed, its margin and root were rough, as if they had been eaten away. When this affection assumes a more severe form, it becomes at times a very troublesome complaint; so much so, that Mr. Wardrop<sup>1</sup> has applied to it the term, "Onychia Maligna." These cases, which are most frequently seen in unhealthy children, may follow some slight injury, but they also occur without any apparent local cause. In this variety of the disease, the whole of the soft textures around the nail and at the extremity of the finger become red and swollen, and cause the end of the digit to be bulbous in appearance. Unhealthy ulceration, with discharge of thin ichorous and foetid matter is present underneath and around the nail, the nail becomes loosened and

<sup>1</sup> *Med. Chir. Trans.* vol. v.

altered in colour, and is in some cases partially buried by the surrounding swollen and ulcerated soft tissues. The swelling may extend some little distance down the finger, the affected portion being usually of a dark red or purple colour. In cases which have been long neglected, or which have resisted treatment, the bones at the extremity of the finger become expanded and occasionally diseased. There is always more or less constitutional disturbance present in these cases. Fig. 68, Plate VII., was taken from the hand of a boy, aged seven, who had suffered two months from the disease. It is an excellent example of the severe form of this complaint, and resembles very much the illustration given by Mr. Wardrop in his paper on the subject.<sup>1</sup>

*Treatment.*—The treatment of the simpler forms of onychia which will usually be found efficacious, is to touch the surface of the ulceration with nitrate of silver, and endeavour to excite a healthy action in it. If the nail should be loose, or appear to be keeping up irritation, it ought to be removed, and simple dressing applied to the sore till it is healed.

The more severe forms of this complaint are best

<sup>1</sup> See a paper on this affection by M. H. Royer-Collard in the *Répertoire Général*, edited by Breschet, vol. ii. p. 108; also another paper in the same work, vol. iv., by F. Lébut.

treated by removing the nail at once, and by freely applying caustic potass, nitric acid, or nitrate of silver to the sores: the application should be repeated more than once, if necessary.

Constitutional treatment in these cases will often be of much benefit, as this disease is so often connected with an unhealthy condition of the general system. In obstinate cases of onychia the matrix of the nail has been cut out or destroyed by some surgeons, but if the caustic be freely applied to the unhealthy textures when the nail is removed, this operation can never be required. Amputation of the extremity of the digit will be the best proceeding if this treatment fails.

Inflammation and ulceration of the soft textures under and around the nails may occur in several or all the fingers and toes as a result of syphilis or some constitutional derangement. The syphilitic affections of the nails will presently receive a special notice.

#### *Disease of the Nails.*

The nails of the fingers and toes are occasionally themselves attacked with disease, from the effects of which their structure gradually undergoes a change. The French have described a disease of the nails under the term "Psoriasis of the Nails."

Dr. Richardson<sup>1</sup> has given an account of an affection of the nails, and has figured the appearance which they present in such cases. I have met with one curious example of disease of the nails, and took rough sketches of it at the time. One of the hands from this case is represented in Fig. 69, Plate VII. The disease in the case referred to resembled somewhat that described by Dr. Richardson ; but, in addition, several of the last phalangeal joints of the digits were swollen and painful. The following is an account of this case :—

CASE 21.—*Disease of the Nails.*

Mrs. ———, aged sixty-four, applied for advice on account of an affection of the nails of both hands and feet.

The disease first commenced sixteen years ago, by a slight discoloration of the extremities of some of the nails, but she had not suffered much from the disease until three years ago, when the joints of the distal phalanges of some of the fingers began to swell and become very painful. The nails also became discoloured and thickened, and presented the distorted appearance shown in Fig. 69, Plate VII.

On examination, most of the nails of both hands and feet were thus affected, and several of the distal phalangeal joints of the fingers were swollen and stiff. The patient

<sup>1</sup> Clinical Essay by Dr. Richardson, *Asclepiad*, vol. i.

states that she suffers at times great pain in these joints, and that the pain is worse in damp and cold weather.

*Treatment.*—Dr. Richardson found that the internal administration of arsenic was most successful in curing the disease of the nails to which I have referred.

If the nails of the digits are not cut at certain intervals, they may grow to a great length. Nails when allowed to grow in this way usually become hypertrophied, and resemble horny growths. I have seen such nails project several inches beyond the extremities of the digits. Fig. 72, Plate VII., illustrates this condition of the nails in the toes.

A troublesome form of ulceration is met with at the margins of the nails of the toes.

The great toe is the one most frequently affected. “Ingrowing” of the nail and other terms applied to this disease are apt to give rise to a false impression as to its true nature. It is not the nail itself that grows in or becomes inverted, but it is the soft textures at its sides that become inflamed, swollen, and pushed over its margins. The disease is usually the effect of pressure produced by wearing tight boots or shoes, and even the pressure of tight stockings seems sufficient in some cases to cause it. As a proof that this pressure is the most frequent cause,

Dr. Smyth<sup>1</sup> of Maryland has observed that the disease never occurs in negroes who wear no boots or shoes. I have, however, seen this affection originate in cases where there had apparently been no pressure applied to the toes. As a result of lateral pressure or other irritation to which the extremity of the great toe is subjected, the soft textures at the side of the nail become forced against its margin; inflammation, suppuration, and ulceration result; so that these textures become swollen, raised up, and rest against the edge of the nail, and in some cases overlap it. Very frequently too the patient, fancying that the nail is at fault, cuts or scrapes the edge which lies against the ulcerated surface. This proceeding, although it may give temporary relief, only increases the complaint; for, as the nail grows, there is now a rough margin of the nail pressing against the sore and keeping up the irritation of the soft textures.

This condition most frequently occurs on the outer margin of the nail of the great toe; it may, however, affect both margins, and sometimes both great toes suffer from the complaint at the same time. The smaller toes are also occasionally affected with the disease.

<sup>1</sup> *North American Archives*, for March 1835.

*Treatment.*—Great varieties of treatment have been proposed to remedy this complaint, the principal of these are the application of the nitrate of silver, or some other caustic, to the nail itself and to the ulcerated surface, or the insertion of some substance between the edge of the nail and the sore against which it presses.<sup>1</sup> Although these methods of treatment may be sufficient to cure mild cases of the disease, they are painful, tedious in their application, and usually insufficient in severe cases. The plan proposed by M. Dupuytren<sup>2</sup> is certainly the best. It consists in dividing the nail longitudinally down to the root, and then with a pair of forceps tearing out that portion of it which lies against the sore. If both sides of the nail are affected, the whole nail is to be removed in the same way, by cutting down its centre and removing each half separately. Water or some other simple dressing should then be applied till the sore is healed. Some surgeons object to this operation as being painful and severe. Having performed the operation on several occasions, and

<sup>1</sup> For an account of some of these methods see the following references:—*Lancet*, Aug. 30, 1856; *Philada. Med. Examiner*, Aug. 1855; *Liverpool Med. Chir. Journal*, Jan. 1858; *Drei Chirurgische Abhandlungen* (Von Dr. Zeis).

<sup>2</sup> Dupuytren, *Clin. Lect.* p. 241.

seen it frequently done by other surgeons, I have not found that the operation was attended with such great pain as is usually supposed; and I am quite sure that the patients on whom the operation was performed recovered more quickly and more surely than they would have done under any other method of treatment. If the parts should be very sensitive, the operation may be performed under chloroform. The nails of the toes and the soft textures around them are also liable to other forms of disease similar to those which are met with in and around the nails of the fingers.

*Syphilitic Affections of the Nails.*

The matrix of the nails and the soft parts around them are liable to be attacked with inflammation and ulceration in the progress of syphilitic disease. There appears to be two forms of this affection. One in which the root of the nail is inflamed, the skin around it having the usual coppery hue which is characteristic of syphilitic cutaneous affections. As a result of this inflammation, the affected skin desquamates, or, occasionally, pustules form on it. This form of the disease does not affect the structure of the nails much. The other variety consists of an inflammation and ulceration of the matrix of

the nail, resembling in this respect the onychia already described. The ulceration at the root of the nail in syphilitic onychia is dark coloured and unhealthy in appearance, the margins of the ulceration being generally of a deep red copper colour. This ulceration attacks both fingers and toes, but most frequently the former, and is often very obstinate in its nature, difficult to heal, and apt to recur. As a result of the ulceration of the matrix, the nail itself undergoes alteration, it becomes dry, wrinkled in appearance, and loosened from its surrounding connexions, and if not removed would soon fall off. In some cases the nails become dry and discoloured, and are thrown off without the presence of such ulceration; and cases have been observed in which the nails were shed in this way several times successively, being reproduced after each shedding. Another result of syphilis in the digits is an ulceration of the soft parts. One of the most common situations of this ulceration is between the toes, and occasionally between the fingers. These ulcerations have all the characteristics of syphilitic sores, the discharge from them being frequently very offensive.

*Treatment.*—The inflammation and ulceration of the digits depending on syphilitic diseases will re-

quire to be treated by the administration of those constitutional remedies which have been found serviceable in curing syphilis. The local treatment consists in keeping the affected parts clean, removing any loose or ragged portions of nail, and applying some simple dressing to the sores. If the sores do not heal under this treatment, dilute red oxide, or biniodide of mercury ointment spread on lint, or the black wash, should be applied to them.

*Strumous and other Inflammations, and Ulcerations of the Soft Textures of the Digits.*

The soft textures of the fingers and toes may be attacked with inflammation of a strumous or other constitutional nature, and they also become involved sooner or later in the progress of inflammation originating in the bone or periosteum. The inflammation in these cases is usually somewhat chronic in its nature, and often ends in unhealthy ulcerating sores, which are apt to undermine the skin, and are slow to heal.

Such ulcerations of the digits occur under a variety of forms. The following case is one in which a large ulcer, situated on the great toe, consisted of a sort of fungous protrusion of the synovial membrane of one of the joints.

CASE 22.—*Ulcer of the Great Toe, depending on a Fungous Protrusion of the Synovial Membrane.*

Mary H., aged thirteen, admitted into the Clinical Surgical Wards of the Edinburgh Infirmary with a large ulcer on the great toe. The patient says that two months ago she began to suffer from pain and swelling in the toe. Poultices were applied, and their use was shortly followed by suppuration and ulceration, which have continued until the present time. On examination, the great toe was found to be much swelled in its whole extent and over its metatarso-phalangeal joint. On the outer aspect of the toe there was a large prominent granulating sore, the size of a five-shilling piece, occupying its lateral and a portion of its dorsal aspect. The ulcer involved the first phalangeal joint of the digit, and was discharging matter freely. The toe was amputated at its metatarso-phalangeal articulation, with a favourable result.

On examination of the amputated toe, the granulating sore was found to be continuous with the synovial membrane of the first phalangeal joint, which was very much thickened and in a state of pulpy degeneration. A section of the phalangeal bones showed that their cancellated texture was infiltrated with yellow tubercular deposit.

*Treatment.*—Ulcers depending upon constitutional causes will require to be treated by constitutional means, the local treatment consisting in keeping the sores clean and applying some simple dressing. Sores which become indolent in their

nature will occasionally be made to heal by the application of a small blister over their surface. I lately completely cured a sore of this kind on the great toe of a patient, which had resisted all treatment for several years.

*Inflammatory Affections of the Bursæ and Joints.*

The subcutaneous bursæ, which are naturally situated over the joints of the digits, may suffer from acute or chronic inflammation. This inflammation may be caused by some constitutional disease, such as gout or rheumatism, but it is more frequently the result of a wound, bruise, or other injury. Schreger<sup>1</sup> has described and figured the subcutaneous bursæ which exist in the digits. In the fifth plate of his book, he shows that these bursæ are situated on the dorsal aspects of the phalangeal joints of the fingers and toes, and also on the lateral aspect of the great toe.

These bursæ when attacked with acute inflammation present the same appearance as is seen in inflammation of the larger bursæ; they become swollen, red, and painful, the parts around being also apparently involved in the inflammation.

<sup>1</sup> Schreger, *De Bursis Mucosis Subcutaneis*.

Suppuration of the sac soon follows if the inflammation does not subside. I have seen inflammation of the digital bursæ following injuries simulate very closely inflammation of the metacarpo-phalangeal and phalangeal joints. Chronic inflammation or enlargement of these bursæ is also met with as a result of injury. In this affection the bursal sac gradually enlarges, and an excess of fluid is secreted by its lining membrane, the result of this condition being a fluctuating painless tumour in the position of the bursa. As the disease advances, the walls of the sac may become thickened, so that the tumour is more firm to the touch. Occasionally, also, the contents of the sac become quite solid. Fig. 70, Plate VII., is a good example of a chronic enlargement of one of the bursæ over the dorsal aspect of the first phalangeal joint of a forefinger. The disease in this case originated from a bruise received some years before. The tumour was composed of a thickened bursal sac which contained a small quantity of fluid; the neighbouring joint was quite healthy and unaffected. It is not uncommon to find small enlargements somewhat resembling flattened corns over the dorsal aspect of the phalangeal joints of the fingers. Such tumours are usually situated on one side of this aspect of

the joint, not in the centre, and sometimes there are two such swellings, one on each side.

These swellings depend upon an enlargement of the bursæ, which exist naturally in those situations, with a more or less thickened condition of the cuticle over them. Solid or semi-solid tumours, the result of enlarged bursæ, form also occasionally on the palmar aspect of the fingers; and I lately saw a series of such tumours removed from this situation. The tumours were quite movable, and lay immediately under the skin, anterior to the sheaths of the flexor tendons. Besides the natural subcutaneous bursæ of the digits, we may have adventitious ones formed as the result of pressure. This is seen in the effects produced by the constant pressure or friction of instruments or tools used in certain trades. I have notes and a sketch of a curious example of this condition. They were taken from a man, aged fifty-five, who followed the occupation of a coach trimmer, and required to use a thimble, which always pressed on one finger. A swelling formed on the dorsal aspect of this finger twenty-seven years ago, which had been getting gradually larger ever since. The tumour consisted of two continuous portions, one of which, being movable, lay over the dorsal surface of the finger, and had

become partially ossified ; the other portion, also freely movable, felt soft and elastic, and protruded from the lateral aspect of the finger, so that a sort of cleft was left between it and the side of the digit.

Mr. Key,<sup>1</sup> in his paper on "Ganglion and Bunion," has described ganglia, which are occasionally met with over the flexor, but more frequently over the extensor tendons of the fingers, where they pass over the joints. These swellings often give rise to much pain, and are accompanied by a sense of weakness in the part. I have known such ganglia simulate a neuroma of the fingers, both in symptoms and in appearance. Mr. Key recommends that these ganglia should be treated by puncturing them, evacuating the contents of the cyst, and applying pressure for some time after.

Mr. Holden has directed attention to small hernia-like protrusions of the synovial membrane through the sheaths of the flexor tendons of the fingers ;<sup>2</sup> these vary in size, from a pin's head to a pea, are firm to the touch, and are filled with a reddish substance, having the consistence of jelly. I have myself frequently observed these tumours in the dead body. Mr. Holden has also noticed them in

<sup>1</sup> Guy's Hospital Reports, vol. i.

<sup>2</sup> Holden's *Manual of Anatomy*, p. 240, second edition.

the living hand, and he found that they interfered with the free movement of the fingers.

The normal subcutaneous bursæ of the toes are liable to inflammation, and adventitious bursæ may also form sometimes in connexion with corns and bunions. The bursæ over the metatarso-phalangeal joints of the great and little toes are especially liable to become inflamed and enlarged owing to the pressure of tight boots or shoes.

When the bursa over the metatarso-phalangeal joint of the great toe is affected in this way, it constitutes that troublesome disease called Bunion. Fig. 73, Plate VII., illustrates an enlarged condition of the bursæ over the dorsal aspect of the toes, and also shows the most common form of bunion. Not long ago I met with a curious case of inflammation and ulceration of a bursa which lay over the plantar aspect of the metatarso-phalangeal joint of one of the smaller toes. The patient, a man aged sixty, had suffered for some years from a contraction of the second toe, and a painful swelling on the sole of the foot; ulceration commenced on the surface of this swelling, and gave him so much annoyance that he was anxious to have the toe removed. As the toe was quite distorted, his wish was acceded to, and I found, on examination, that the ulcer

opened into a thickened bursal sac, which lay over the head of the metatarsal bone. The head of this bone was much enlarged, and the first phalangeal bone had become dislocated forwards. Fig. 71, Plate VII., is a sketch taken from the bones of this toe, which were dried in their abnormal position. I have since seen a second case of this kind affecting the third toe, and have also dissected several cases in which the bursæ over the outer aspect of the metatarso-phalangeal and first phalangeal joints of the little toe were enlarged and their sacs thickened.

Sir Benjamin Brodie<sup>1</sup> has shown that a complete corn, whether hard or soft, consists not only of thickened cuticle, but also of a small bursa which forms underneath this cuticle; and that this bursa is occasionally attacked with inflammation which may end in suppuration, and give rise to great pain and irritation, until the matter be let out.

*Bunion.*—The term “bunion” is, as we have already stated, usually confined to a thickened condition of the cuticle, together with the formation or enlargement of a bursa over the metatarso-phalangeal joint of the great toe. Bursæ occur normally in this situation, and when inflamed

<sup>1</sup> Brodie's *Lectures on Path. and Surgery*, p. 215.

from any local or constitutional cause, may give rise to this complaint; but occasionally a bunion may be due to the formation of an adventitious bursa.

The most frequent site of bunion is on the inner aspect of this joint, but the disease may occur on the dorsal or plantar aspect of the same articulation. This affection usually depends on an unnatural distortion of the foot, caused by wearing ill-fitting boots or shoes. Short boots and shoes, or those which are narrow across the toes, especially if made of hard and unyielding leather, are almost certain to distort the foot if worn for any length of time. One effect of the irregular pressure of such boots and shoes is to cause a gradual giving way or stretching of the ligaments of the metatarso-phalangeal joints of the great toe, with a partial dislocation of the phalanges. The flexor tendons and sesamoid bones also become displaced, and in consequence aggravate the contraction. The dislocation of the phalangeal bones in cases of bunion may take place in several directions, but the most common is that in which the great toe is forced outwards, over or under the second toe, leaving the articular surface on the inner side of the metatarsal bone prominent and exposed. It is this projection pressing against the soft textures on the inner side of the foot which

causes the thickening of the cuticle, and leads to the irritation of the bursa.

The great toe may also be displaced downwards or upwards, leaving, in the one case, the dorsal, and in the other, the plantar surface of the head of the metatarsal bone prominent, and giving rise to a bunion in either of these situations. I have occasionally, on inquiring into the history of cases of bunion, been told by patients that they attributed the commencement of their disease to a sprain or bruise of the joint. Very lately an example of bunion, occurring in the sole of the foot, which was produced, according to the patient's account, by a sprain, came under my notice.

CASE 23.—*Bunion on the Sole of the Foot.*

Mr. ———, aged twenty-four, twelve years ago injured his foot when jumping from a cart, and about a year after a swelling formed on the plantar aspect of the metatarso-phalangeal joint of the great toe. Shortly after this the joint became distorted, and caused inconvenience when walking.

For the last six years this distortion has been slowly increasing, and the other toes have become somewhat drawn up and contracted, giving rise to shortening of the whole foot. He is only able to walk by having a deep depression made in the sole of his boot, into which the prominence of the distorted joint fits, and even then he

walks principally on the outer side of the foot. On examination, the metatarso-phalangeal joint of the great toe was much distorted, and formed a prominent swelling on the sole and inner side of the foot. A thickened bursa was developed over this prominence, and was very tender when touched. The skin on the outer aspect of the sole of the foot was much thickened, as it was on this part that the patient principally rested when walking.

Chronic rheumatic arthritis also attacks the joints of the great toe, and gives rise to thickening of its structures, and to distortion of the bones. This condition has been referred to by Mr. Canton.<sup>1</sup> Dr. Adams<sup>2</sup> has directed attention to a well-marked specimen of this disease in the metatarso-phalangeal joint of a great toe, which was exhibited by Professor R. W. Smith at the Pathological Society. If a bunion has existed for some time, the prominent portion of the head of the metatarsal bone becomes enlarged, and often nodulated on its surface; sometimes a sort of extension of the smooth articular surface takes place on the same bone. Figs. 74, and 75, Plate VII., are excellent examples of the distortion of the feet, which occurs in cases of bunion, and which may also cause enlargement of

<sup>1</sup> "Surgical and Pathological Observations," by Mr. Canton, *Lancet*, 1850.

<sup>2</sup> Adams on *Rheumatic Gout*, p. 264.

the bursæ over the metatarso-phalangeal joints of the little toe on the outer side of the foot. They are taken from the bones of feet which I carefully dried and prepared in their abnormal position. In Fig. 75 the phalangeal bones of the great toe are dislocated outwards, and the head of the metatarsal bone is displaced inwards, so that the first phalanx rests quite on the outer edge of its articular surface. The sesamoid bones are displaced outwards, and the head of the metatarsal bone has become thickened and nodulated. Fig. 74 shows a similar condition. Fig. 93, Plate IX., is another example of the same distortion, drawn from the bones of a great toe in which the displacement of the phalanges is not so excessive. I have in my collection a preparation which shows a displacement of the phalanges of the great toe downwards. The head of the metatarsal bone is enlarged and prominent on the dorsal aspect of the foot, and situated over this prominence is an enlarged bursa.

When the cuticle has become thickened and the bursa enlarged so as to constitute a bunion, inflammation not unfrequently attacks the bursal sac, especially if the cause of pressure or irritation be continued. The inflammation which attacks a bunion may be either acute or chronic. When

acute, it is often a most painful complaint, for it is apt to cause suppuration in and around the bursal sac, and this may be followed by ulceration, and in some cases by caries and exfoliation of the bone, or disease of the joint itself.

I have seen more than one great toe removed for an affection of the bones and joint produced by aggravated bunion.

When the inflammation is more chronic, the bursal sac may become merely thickened, and contain more or less fluid, but it is very liable in this condition to become acutely inflamed when any irritation or extra pressure has been applied to it.

*Treatment.*—When bursal tumours on the fingers are attacked with acute inflammation, they must be treated by the application of hot fomentations and other soothing means. If the disease should depend on gout or rheumatism, the proper constitutional treatment of these affections must be adopted. When suppuration takes place, a free exit ought to be given to the matter, for if it is allowed to remain shut up in the sac much pain and irritation are excited. When these bursæ are connected with tendons, or, as has been noticed in a few rare cases, with the joints themselves, the inflammation may spread to these structures ; but if pus has formed in

the sac, the proper treatment will still be to lay open the sac by incision. When the acute inflammation is the result of a wound of the bursa, it may be necessary to enlarge this wound if the matter has not a free drain through the original opening.

In chronic enlargement of the bursæ of the fingers, the tumour is most likely to be relieved by the application of blisters combined with pressure.

If this treatment does not succeed, and the tumour contains much fluid, it ought to be punctured, the fluid drawn off, and a blister applied. Such chronic enlargements of the bursæ, however, if not of large size, generally give rise to no inconvenience, and do not interfere much with the usefulness of the fingers.

If bursal tumours of the fingers should have become solid, or nearly so, they may be cut out, provided they are quite subcutaneous, loose, and unconnected with deeper or important structures. These solid tumours, when occurring on the dorsal aspect of the joints, will rarely admit of removal, as they are usually connected with the tendons or joints ; but, as we have already mentioned, solid bursæ may be removed with success from the palmar surface of the fingers when superficial to the sheaths of the tendons. The pus which occasionally forms in con-

nexion with the inflamed bursa of a corn is best let out by removing the hardened cuticle in the way suggested and successfully practised by Sir B. Brodie. If the bursa connected with a bunion be acutely inflamed, it requires to be treated by the application of soothing remedies; and if suppuration take place, the matter should be evacuated by incision. Soothing poultices or water-dressing ought to be applied until the inflammation has ceased, and then some simple ointment or other dressing may be used till the wound heals. Occasionally it is advisable to destroy the lining membrane of the bursa, if the inflammation has not already done so. Sir B. Brodie recommended for this purpose the application of strong nitric acid. A blister, however, applied over the bunion will best promote the healing of the wound or ulcer, and cause absorption of the thickened sac. The patient should be kept quiet, and not allowed to walk about or wear anything on the foot that may press upon or irritate the affected parts. Mr. Key recommends that the suppuration in such cases should not be interfered with, but that the pus should be allowed to find its own way to the surface. This proceeding is contrary to good principles of surgery, and ought therefore never to be adopted.

Chronic enlargements of the bursæ in cases of bunion where the bones have not become much distorted, are frequently cured, and always much relieved by the application of one or more blisters over their whole surface. These enlargements are also temporarily relieved by using some means to take off the pressure of the boot or shoe from that part of the foot which is implicated. This may be effected by getting the portion of the boot or shoe which lies over the bunion made loose and of some soft material, so that a sort of cup is formed which admits the swelling. When the bunion is on the plantar surface of the foot, a hollow may be made in the sole of the boot or shoe large enough to receive it. Plasters made of a horse-shoe form, so as nearly to surround the bunion and keep off pressure from it, are often also useful, in giving temporary relief. Some means may occasionally be employed to bring back the distorted bones to their original position, but if they have become much displaced this will generally be impracticable, and the attempt may only lead to further irritation. If the joint has become affected and the bone diseased, amputation of the toe and the head of the metatarsal bone will generally be the only remedy.

*Diseases of the Joints.*

The different textures which enter into the formation of the joints of the fingers and toes are liable to be attacked by acute or chronic inflammation, and to undergo the same morbid changes which take place in the larger articulations, so that similar diseases give rise to the same symptoms in both the larger and smaller joints.

Inflammation of the smaller joints is either produced by a wound or other injury, or it may occur as a result of some constitutional affection.

Acute synovitis of the digital articulations is usually the result of a wound or other injury. In rheumatic fever or gout the synovial membrane of these joints may also become acutely inflamed. When the inflammation is caused by a wound of the articulation, suppuration usually speedily follows, the articular cartilages become more or less destroyed, the bones diseased, and the joint disorganized. As a result of this condition of the joint, fibrous or bony ankylosis may take place if the digit be uninterfered with. Fig. 76, Plate VII., is taken from a finger, the first phalangeal joint of which had been injured four months previously, and had suffered acute inflammation in consequence. The joint was swollen, and only

very slightly movable, and as the finger was quite useless, it was amputated. Fig. 77, Plate VII., is from a section of the same finger, and it shows the condition of the joint; the cartilages were entirely gone, and a sort of fibrous ankylosis existed between the extremities of the first and second phalangeal bones. Figs. 79 and 80, Plate VII., are from specimens in which bony ankylosis of the phalangeal joints of the digits had taken place as a result of inflammation. Fig. 80 is from a preparation in the Edinburgh University Anatomical Museum. Fig. 79 is from a preparation in the museum of the Newcastle School of Medicine.

In dissecting cases of diseased phalangeal joints which have suffered from more than one attack of acute inflammation, or in which an acute attack has become chronic, I have found the synovial membrane much thickened; but the disease was usually associated with, and in certain cases apparently produced by, some chronic inflammation of the bone. Mr. Bryant<sup>1</sup> relates a case in which he found the synovial membrane of one of the phalangeal joints nearly half an inch thick.

Chronic inflammation of the synovial membrane

<sup>1</sup> Bryant on *Diseases and Injuries of the Joints*, p. 31.

of these joints occasionally follows a bruise, strain, or over-exertion of the fingers, but it frequently also is caused by some constitutional affection. As a result of chronic inflammation of this membrane, more or less effusion may take place into the cavity of the joint, and give rise to a considerable fluctuating swelling of the articulation. Fig. 96, Plate IX., was taken from a thumb, the phalangeal joint of which was affected with chronic synovitis, and effusion into its synovial cavity. The diseased joint of this thumb was fully twice the size of the opposite one, which was quite healthy. The patient was a washerwoman, who had sprained her thumb six months before.

Chronic inflammation and pulpy degeneration of the synovial membrane of the digital joints, the result of strumous disease, is also met with. As a consequence of this condition of the synovial membrane, there is usually an irregular swelling of the joint affected. This swelling is elastic to the touch, and is not always confined to the joint itself, but may pass some little distance up or down the finger. The following illustration is a well-marked example of chronic inflammation, originating in the synovial membrane of a metacarpo-phalangeal joint of a finger, and depending on strumous dis-

ease. Fig. 81, Plate VIII., is from a drawing of the preparation in its recent state. The synovial membrane in this case was more than half an inch thick, and almost entirely overlapped the articular surfaces. It exactly resembled in appearance the pulpy degeneration of the synovial membrane, which is met with in the knee and other large joints. Portions of the articular cartilage on the head of the metacarpal bone were necrosed and beginning to separate, and caries was commencing in the head of the bone. Mr. South<sup>1</sup> refers to a case, in which Mr. Hodgson of Birmingham had found this same condition in one of the digital joints. In Case 22, the synovial membrane of the phalangeal joint of a toe was much thickened and affected with pulpy degeneration, the peculiarity of the case being that the diseased membrane protruded externally in the form of a fungus.

The articular cartilages which enter into the formation of the digital joints are liable to degeneration and destruction, and the symptoms which characterize ulceration of these structures in the larger joints are also met with in the smaller articulations. In order to illustrate this affection in a digital joint, I relate Case 24 :—

<sup>1</sup> South's edition of *Chelius' Surgery*, vol. i. p. 218.

CASE 24.—*Ulceration of the Cartilages of the Phalangeal Joint of a Finger. Excision of the Joint.*

A. B., aged twenty-five, applied to me for advice on account of pain and swelling in one of the joints of her middle finger. About a year ago the first phalangeal joint of this finger became swollen and painful. It remained in much the same state until two months ago, when the symptoms increased in severity. The pain in the joint prevented her sleeping, and the whole hand became quite useless in consequence of the affection in the finger. On examination, I found that the joint was swollen, painful when pressed, and during the movements of the finger. The swelling not only involved the joint, but extended for about half an inch down the first phalanx. Blistering was recommended, and carefully employed, but without any benefit. I therefore suggested to her excision of the joint, as I thought it a favourable case for trying this operation. She at once consented, and I accordingly excised the joint, employing the longitudinal incision on the lateral border of the dorsal aspect of the finger, as is shown by the line 1 in Fig. 127, Plate XII. The operation was performed without any injury to either flexor or extensor tendons, or to the blood-vessels and nerves. The portions removed from the joint measured altogether about a quarter of an inch in length. The synovial membrane of the joint was a good deal thickened, and the cartilages of the joint were in a state of ulceration. The bones where divided were quite healthy. The finger was placed on a straight splint, and water-dressing applied. Four days after a good deal of swelling had followed the

operation, but the wound was otherwise looking well. Two days after this passive movements of the finger were commenced.

The progress of the case from this time was quite satisfactory, a small abscess formed at one side of the finger, but it was quite superficial. Passive movements of the finger were regularly practised. At the end of about three weeks the patient returned to the country, the wound not yet being healed, but progressing favourably.

The articular extremities of the metatarsal, metacarpal, or phalangeal bones are liable to be attacked with inflammation, which is not unfrequently the result of tubercular deposit in their cancellated tissue. Fig. 85, Plate VIII., is a good illustration of tubercular deposit in the head of a metatarsal bone, which was beginning to cause suppuration and caries of the cancellated texture. The drawing was taken from a fresh section of the great toe and metatarsal bone of a lad, aged eight, who had suffered from the disease for about a year. The soft parts over the metatarso-phalangeal joint were much swelled, and there were several openings which passed down into the interior of the bone. A pin has been introduced through one of these sinuses, and is shown in the sketch leading to the diseased bone. The joint was perfectly entire and healthy. In several other sections of digital bones which I have made,

tubercular matter has been present in their interior. In some cases the tubercular matter was apparently of very recent origin, as the bone around had not been destroyed.

The usual result of inflammation of the articular extremities of the digital bones, depending on tubercular deposit in their interior, is caries of the cancellated texture around, and gradual implication of the joint. In such cases we occasionally find the articular cartilage becoming necrosed, and separating in pieces of considerable size, or in one entire shell. The progress of these cases varies in different instances. In some the disease is rapid in its course, and soon involves the joint and the rest of the bone, while in others it may be some time before the joint becomes affected.

The joints of the digits are not unfrequently affected with chronic inflammation of a rheumatic nature. This chronic rheumatic arthritis attacks the smaller joints in the same manner as the large articulations, and gives rise to those peculiar changes in their tissues which are characteristic of this affection. The disease commences with chronic inflammation of the synovial membrane, and more or less effusion of fluid into the cavity of the joint; the synovial membrane and ligamentous textures be-

come gradually thickened, and alterations take place in the articular extremities of the bones; the articular cartilage disappears, and the extensor tendons become displaced, and lie in new grooves made by their friction. As a result of these changes in the structures of the digital joints, those peculiar distortions of the fingers and toes take place which have been so well described and figured by Dr. Adams.<sup>1</sup> Suppuration very rarely results from this form of inflammation in the digital joints, but the disease generally slowly proceeds, and the distortion of the digits gradually increases in severity. This complaint may follow some sprain or injury of the hand or foot, but most commonly it originates without any local cause. I saw a man, a short time ago, whose hand was very much distorted, and all the fingers contracted from the effects of chronic arthritis. This patient stated that the disease commenced after a severe sprain of the hand.

In gout the joints of the digits become attacked by inflammation, and in consequence deposits of a white chalky-looking substance (urate of soda) take place in and around them.

This substance is deposited at first in a liquid form, but becomes gradually hard and firm, and gives rise

<sup>1</sup> Adams on *Rheumatic Gout*.

to that nodulated, swollen, and stiffened condition of the smaller joints which is seen in patients who have suffered from frequent attacks of gout.

I have found the following changes taking place in the digital joints after their disorganization by inflammatory disease :—

1st. The articular extremities of the bones may be hollowed out and destroyed, no reparation taking place.

2d. Bony or fibrous ankylosis, more or less complete, may result.

3d. A sort of new and movable joint may be formed by the growth of new processes of bone.

When lately dissecting the finger of a woman, aged twenty-seven, who had suffered for four years from disease of the metacarpo-phalangeal joint, I found that this joint was quite disorganized; the synovial membrane was thickened, the cartilages had disappeared, and the osseous texture at the extremity of the phalangeal bone had become destroyed so as to leave a hollow, in which the head of the metacarpal bone was lying. I have since examined similar specimens.

Examples of osseous and fibrous ankylosis have been already referred to, and are shown in Figs. 77, 79, and 80, Plate VII.

The following case of fibrous ankylosis of a metatarso-phalangeal joint is illustrated in Fig. 82, Plate VIII.

CASE 25.—*Fibrous Ankylosis of a Metatarso-Phalangeal Joint.*

The patient, a boy, aged twelve, had suffered from disease in the great toe ever since he was two years old. This toe was much shortened, and its metatarso-phalangeal joint was ankylosed. The toe was amputated, and the condition of its textures is shown in Fig. 82, Plate VIII, which was taken from a section of the toe immediately after its removal. The metatarso-phalangeal joint was destroyed, and fully one-half of the first phalangeal bone had disappeared along with its articular surface; the head of the metatarsal bone was hollowed out, a curious process or condyle being left on each side; the sesamoid bones had become ankylosed to the under surface of the new joint. The space between the altered bones was filled up with dense fibrous tissue, which firmly united their extremities, and caused ankylosis of this new articulation. In the centre of this fibrous mass there was a small abscess surrounding a little piece of dead bone.

Ankylosis of the smaller joints may also be caused by changes which have taken place in the tendons and other soft textures external to the joint.

Fig. 78, Plate VII., is from a case in which a new

joint had been formed. The patient, in this instance, was a woman aged forty-five, who, two years ago, was attacked with inflammation of the first phalangeal joint of the middle finger. The joint suppurated, and an opening formed, and discharged matter for six months; the wound then healed for a short time, but again opened out, and recommenced to discharge. The finger was amputated, and, on examination of the joint, it was found that the whole of the articular cartilage had disappeared, and a portion of the extremity of the first phalanx had been destroyed. The end of the second phalanx was expanded, and hollowed out at its base, and on each side a process of the bone or condyle had formed, between which the head of the first phalanx was received.

The ligaments of the smaller joints occasionally suffer from chronic inflammation, and these structures may also become destroyed in the progress of the disorganization of a joint.

*Treatment.*—The treatment of the different inflammatory diseases of the smaller joints is the same as that which is required in similar affections of the larger articulations. If the inflammation be acute, hot fomentations and other soothing local applications, with perfect rest of the joint, should be employed,

and if suppuration takes place within the joint, an incision ought to be made on its lateral aspect, to give exit to the pus. When acute inflammation of the synovial membrane has become chronic, or when this membrane has suffered from chronic inflammation from the first, the proper treatment is to apply one or more blisters over the affected joint. Gentle and steady pressure made by passing stripes of plaster and a bandage round the joint may be also usefully employed, the joint at the same time being supported by some simple splint. The joint, however, must not be kept at rest for any length of time, as ankylosis would be apt to result. Passive movements should be occasionally practised, provided all acute symptoms have disappeared. When, from the symptoms, it appears that the articular cartilage is affected, either excision or amputation will have to be resorted to, as the result of such disease must be more or less ankylosis of the articulation, a condition which in most cases makes the digit an inconvenience. When disorganization of a joint has taken place, amputation of the affected digit will usually be necessary; in some cases, it may be right to attempt excision of the articulation; but in regard to the performance of this latter operation, we must be guided by a consideration of the pro-

bable usefulness or non-usefulness of the finger or toe if allowed to remain. The subject of resection of the digital joints will be considered more fully in Chapter VI. In cases of ankylosis of the digital joints, amputation will be advisable in most instances, unless the finger or toe can be usefully employed. When chronic synovitis of the digital joints depends on constitutional causes, such as scrofula, rheumatism, or gout, the constitutional treatment which is appropriate for each must be adopted. If the disease is of a strumous origin, the only local treatment necessary is to keep the joint at rest, and if there is much pain to apply fomentations. If the joint should suppurate and become disorganized, amputation of the digit will generally be required; but if the patient is young, and suffering from the disease in more than one joint, or in some other parts of the body, it is better to leave the case to nature, provided the local complaint is not causing constitutional irritation. Although such cases are usually tedious, they often make much better recoveries than could be expected. When the extremities of the digital bones are the seat of disease, it often appears as if the joints also were implicated, but in such cases the joints are not necessarily at first involved, and therefore we may

hope for a more favourable prognosis if the joint remains unaffected.

The local treatment of rheumatic arthritis is not by any means satisfactory, for the disease gradually progresses in spite of our best efforts to check it. Dr. Adams recommends, in the early stage of the complaint, leeching, warm fomentations, and bathing with hot water. When the disease has become chronic, warm bathing, and the use of medicated springs or baths, would appear to be the only local treatment that affords relief. The local treatment of gouty inflammation in the smaller joints is also in the acute stage soothing, and afterwards warm bathing and mineral waters are useful in relieving the stiffness of the joints. Weak alkaline solutions, and solutions of iodide of potassium, have also been recommended as applications to joints affected with this form of inflammation. It is better not to interfere with the chalky formations which take place in this disease, but rather to allow nature to get rid of the foreign substance ; this may be encouraged by the application of warm poultices and fomentations, as long as any irritation of the surrounding parts remains ; but the disease, from its implicating the important tissues in and around the joint, is too generally followed by deformity and stiffening of the digits in spite of all treatment.

*Inflammatory Diseases of the Periosteum and Bones.*

I have already referred to acute inflammation of the periosteum and bone when describing whitlow, and have illustrated the pathological effects which result from this inflammation. Let us now, therefore, consider for a moment the chronic inflammatory affections of these structures, and then we will pass to the subject of caries.

The periosteum generally becomes more or less involved in the strumous inflammation which attacks the bones of the digits ; in such cases it becomes thickened and gelatinous, and as the disease progresses portions of it are destroyed by ulceration.

Chronic inflammation confined to the periosteum is comparatively rare, for when this texture is inflamed there is usually inflammation of the bone also. I dissected lately a finger, the metacarpal bone of which had apparently suffered from uncomplicated chronic periostitis. Nearly the whole of this bone is shown in Fig. 83, Plate VIII. ; and Fig. 84, Plate VIII., is a section of the same bone. The bone itself was quite healthy, but a new osseous deposit had taken place entirely external to its outer table. The patient from whom this

finger was removed was a young woman, who had suffered for some years from the symptoms of chronic inflammation of the periosteum of one of her metacarpal bones. It is impossible to distinguish between the symptoms of chronic inflammation of the periosteum and those of inflammation of the bone, especially as these structures are usually both implicated at the same time; but this is not of much consequence, as the treatment for both is the same. When chronic inflammation attacks the bones of the digits, it is followed, as in the case of other bones, by thickening and condensation of the osseous texture. Figs. 86 and 87, Plate VIII., are taken from a well-marked example of this disease; they represent the metacarpal and first phalangeal bones of a thumb which I amputated a few years ago. The patient was a young man, aged twenty-two, who had suffered from agonizing pain in the thumb and wrist for two years, and had undergone a variety of treatment which gave him no relief. The patient begged me to cut off his thumb, arm, or do anything I liked which would relieve the pain, as he could not bear it any longer. I accordingly removed the thumb and its metacarpal bone, with the effect of entirely curing the pain. On examining the bones of this thumb, I found that

the external table of the metacarpal bone was nearly half an inch thick, and the cancellated texture was almost obliterated; the periosteum was also thickened, and the metacarpo-phalangeal joint destroyed, its articular surfaces having disappeared. A curious process projected from each side of the phalangeal extremity of the metacarpal bone, and with these the first phalangeal bone articulated. The compact tissue of the first phalangeal bone was also thickened, but not to such an extent as that of the metacarpal bone.

### *Caries.*

Caries of the bones of the fingers and toes is sometimes the result of injury, but more frequently depends on constitutional causes. This disease varies in the rapidity of its progress in different cases. In some instances it causes total destruction of a bone in a few weeks, while in others it may take a much longer time to run its course. The following is an example of caries, the result of injury:—The patient, a man aged twenty-three, five weeks ago ran a thorn into the dorsal surface of his finger, inflammation and suppuration followed the accident; and when the patient applied for advice, the soft parts of the finger were much

swelled, and unhealthy suppuration was going on in them; there were three sinuses over the second phalanx which led down to diseased bone. The finger was amputated, and on examination of it the greater portion of the second phalanx was found to have been destroyed by caries; the first phalangeal joint was inflamed, and its cartilages beginning to ulcerate. Fig. 94, Plate IX., is a sketch showing the appearance of this finger. Fig. 95, Plate IX., is from a drawing of the same finger taken after the skin had been removed; it shows the suppurating and pulpy condition of the soft textures, with portions of carious bone lying in them. Cases like the one just related, the result of this or similar injury, are not uncommon;—their distinguishing characteristic being the rapidity with which the soft textures become affected with suppuration, the bone destroyed, and the joints implicated. I dissected another forefinger lately, in which the first phalanx, metacarpo-phalangeal joint, and metacarpal bone had become in great part destroyed from exactly the same cause. The disease had run its progress in four weeks.

I would distinguish such cases from those of whitlow, as they appear to depend on an acute inflammation which attacks all the textures of the

digits at the same time, and which may originate on any aspect of the finger, according to the situation of the original injury. These cases are not usually attended by such painful symptoms as the second and third varieties of whitlow.

The inflammation of the bone in strumous caries either attacks the bones immediately, and is followed by the exudation of the unhealthy products which are characteristic of scrofulous disease, or a deposit of tubercular matter first takes place in the interior of the bone, and gives rise to inflammation of the bony texture around, caries being the usual result in both cases. Fig. 85, Plate VIII., has already been described as a case in which there was a limited tubercular deposit in the head of the metatarsal bone of the great toe, giving rise to inflammation and caries of the bone around it. Strumous caries of the bones of the digits commences with the usual symptoms of inflammation of the bone affected; these symptoms, however, are not usually so violent as in acute inflammation of the periosteum and bone. The osseous texture becomes softened, the periosteum thickened and inflamed, and the soft textures soon swell, and inflame also. Suppuration, with deposit of the characteristic scrofulous matter, takes place in or around the diseased bone,

and fistulous openings form, which communicate with the disease either directly or indirectly, and in the discharge which continues to run from these sinuses as long as any diseased bone remains, there are frequently minute particles of carious bone. Sometimes, also, larger portions of necrosed bony texture come away in the same manner. On examining a finger or toe which has been for some time affected with this form of caries, by introducing a probe into one of the sinuses we feel the bone soft and rough, with more or less of its texture destroyed, or the bone may be enlarged and expanded, and the probe pass into its interior, portions of diseased bone being detected there. The thickening and expansion of the periosteum, and a growth of new bone around the disease, explain this enlargement.

The soft textures around the carious bone usually become converted into a pulpy substance, portions of which protrude through the fistulous openings. This substance consists principally of soft unhealthy granulations, mixed with purulent discharge and tubercular matter, and in it there are often loose portions of carious bone. On examination of the bones affected with strumous caries in its early stage, we generally find that the disease has origi-

nated in the cancellated texture, but occasionally it commences on the external surface of the bone. In the following case, the caries was confined to the outer table of the bone :—E. A., aged twelve, has had a disease of the fourth toe for two years. It commenced with inflammation and suppuration over the dorsal surface of the toe ; an abscess was opened in this situation, and a fistulous opening has remained ever since, through which two small pieces of bone have come away. On examining the toe, a sinus on the dorsal aspect of its metatarsal bone was found near its middle ; on introducing a probe, it came into contact with diseased bone. The toe, together with its metatarsal bone, was removed, and on dissection a carious ulcer, the size of a fourpenny bit, was met with on the dorsal surface of this bone ; no other disease could be detected.

When caries commences in the interior of the bone, its progress is sometimes very rapid, the bony texture being destroyed so quickly that there is no time for new bone to be produced ; and as the periosteum is involved in the inflammation, the external table of the bone also perishes, so that we have necrosis of both hard and cancellated textures, as well as caries going on at the same

time. In such cases there is soon no trace of the bone left, except perhaps its articular extremities, with a few portions of dead bony texture which have been too large to escape by the opening or sinus in the soft parts. Fig. 104, Plate x., is an excellent example of destruction of the bone in strumous caries. It was taken from the bones of a great toe, in which almost the whole of one phalanx had disappeared. In the preparation from which Fig. 107, Plate x., was taken, there had been a good deal of new bone thrown out, but the caries was still going on, and had caused destruction of all the cancellated texture, and a considerable amount of the hard also. I have seen, in cases of caries, a portion of the bony texture at the extremity of a phalanx hollowed out and destroyed, a circumscribed cavity being left in the bone. Fig. 100, Plate ix., is taken from the last phalanx of a great toe, and illustrates this condition.

When the caries is more chronic in its progress, the bone becomes gradually expanded, new bone is thrown out, and often encloses portions of necrosed cancellated texture: the appearance presented by the macerated bones from such cases is often very interesting. Figs. 105 and 109, Plate x., illustrate this condition of the digital bones. It occasionally

happens that, while the new bone is being thrown out, the diseased bone gradually breaks down and disappears, so that in this way a natural cure of the disease may take place. Fig. 109, Plate x., is from an interesting preparation of the metatarsal and phalangeal bones of the great toe of a young man who had suffered from caries in the metatarsal bone for fourteen years. During all this time the sinuses in connexion with the diseased bone had continued to discharge matter. They occasionally dried up for a short period, but soon opened out again. As the patient suffered much annoyance from the disease, he was anxious to have the toe removed. This operation was performed, and the bones removed carefully macerated. The preparation well illustrated nature's efforts to cure the disease. The dorsal and lateral surfaces of the metatarsal bone had disappeared, with the exception of a longitudinal and transverse arch of bone, which divided these surfaces into four parts. The plantar aspect was entire, and enclosed within the arches and this surface were two portions of dead cancellated texture. These had evidently been the cause of irritation, and if they could have been absorbed or removed, there was apparently nothing to have prevented a complete cure taking place. In such

cases, however, where the disease has lasted for a long time, the implication of the other textures generally demands a more severe operation. In the case I have just mentioned, the distortion of the toe was so great that its amputation was the only method of affording relief.

Ulceration or absorption of the bones of the digits takes place from other causes. These bones may become entirely destroyed in the progress of a cancerous or other ulceration originating in the soft parts. Fig. 106, Plate x., is taken from the remains of a metacarpal bone of a little finger which had been almost entirely destroyed from this cause. The articular surfaces of this bone were entire, and formed a thin shell at each extremity. The patient, a man aged sixty, had a cancerous ulceration on the dorsum of the hand of two years' standing.

We also find the bones of the digits becoming more or less absorbed by the pressure of tumours, either simple or malignant in their nature.

The bones of the digits may undergo a sort of fatty degeneration. I have seen one case of this kind. The patient, a woman aged eighteen, was otherwise healthy, but suffered so much from a pain and swelling in one of her great toes and its metatarsal bone, that it was found necessary to amputate

these structures. On examination of the bones, I found them soft, greasy, and easily cut with a knife. On section, the external table of the bone was so thin as to be quite transparent, and the cancellated texture was almost entirely converted into fat. I had intended to investigate this case more carefully, but the patient having left for the country, I had no opportunity of seeing her again.

The metatarsal and phalangeal bones sometimes become implicated in that peculiar fungus disease of the foot which is met with in India, and for an account of the true nature and pathology of which we are indebted to Dr. H. V. Carter.<sup>1</sup> Dr. Carter has shown that the changes which take place in the bones of the feet in this affection consist in the formation of cavities more or less spherical in shape, and varying in size from that of a pin's head to a round bullet. These cavities, which frequently open into one another, are filled with masses of the fungi which are characteristic of the disease. Dr. Carter could not detect any pus or tubercular deposit in connexion with the bone, but found the osseous texture surrounding the cavities quite healthy.

*Treatment.*—In the acute inflammation of the periosteum or bones of the digits, hot fomentations

<sup>1</sup> *Trans. of Bombay Med. and Physical Soc.*, No. vi. (new series.)

and other soothing means must be employed. If there is much pain, a free incision down to the bone will often give great relief, and may prevent the serious consequences which are apt to take place from this inflammation. If a whole or part of a phalanx become necrosed, it should be taken away as soon as it is loose.

In chronic inflammation of these structures, constitutional remedies, combined with the local application of blisters, will be the proper treatment; and if such cases resist these means, and implicate the joints, amputation of the affected digit must be resorted to. When the phalangeal, metacarpal, or metatarsal bones are affected with strumous caries, the constitution must be carefully attended to. Any acute local symptoms are to be treated by soothing applications. If the local disease causes destruction of the bones and the joints, amputation of the diseased digit or digits will often be the only remedy; but operations should not be performed on these cases too hastily, especially in the young, unless the constitution is suffering much from the irritation of the local complaint, for under good constitutional treatment the local disease may be gradually cured. Occasionally, when caries and necrosis are confined to one phalangeal, metacarpal, or metatarsal bone, the

affected bone alone may be taken away, the rest of the digit being left. Before performing such an operation, however, we ought to consider whether or not the digit so treated will be of any use when the wounds are healed. I have seen several cases in which one of these bones had been excised for disease, and although in a few the digits were of some use, in others the finger or toe was merely a useless appendage connected to the hand or foot.

## CHAPTER III.

### TUMOURS OF THE DIGITS.

THESE will be described as follows :—

1st. Tumours of the Soft Textures.

2d. Tumours of the Periosteum and Bone.

#### 1. *Warts.*

These growths are very common on the integument of the fingers. They usually consist of an hypertrophied condition of the papillæ of the skin, and may either have a broad base, or may be only attached by a narrow neck or stalk. The appearance of these growths is too well known to need description. They sometimes grow suddenly and in considerable quantities, but they also occur isolated or few in number. Occasionally warts disappear spontaneously, especially in young people; but if they continue to grow, they give rise to much annoyance from their ugly appearance and liability to become irritated by injury. In people past the

middle period of life these growths may become the seat of epithelial cancer. I have seen two or three cases of epithelial cancer of the hand which had originated from warts. These growths may spring from any part of the hand or digits. A young gentleman applied to me the other day for advice on account of a wart which grew from the skin on the dorsal aspect of the extremity of one of his fingers, and extended under the nail for nearly half of its extent. Mr. Thomas Smith<sup>1</sup> refers to warts which grow beneath and at the sides of the nails of the digits, under the term "Sub-ungual Warts."

I was consulted not long ago by a little girl, about six years of age, who had a small and painful wart on the outer aspect of the extremity of the great toe, close to the root of the nail. This growth, from rubbing against the second toe, caused a good deal of irritation.

Mr. Smith has also noticed that warts in some instances are hereditary, and he relates a well-marked example of the kind.

*Treatment.*—Warts when troublesome are best treated by the application of some caustic, such as acetic or nitric acid. Tincture of iodine or tincture of the muriate of iron are in some cases sufficient to

<sup>1</sup> Holme's *System of Surgery*, vol. iv.

destroy the vitality of these growths. If the wart resists all these applications, it should be pared down as far as possible, and then one of the stronger acids applied freely to its base. Excision of the growth might be advisable in some cases where it was giving rise to inconvenience, and had resisted the treatment by caustic. Pedunculated warts may be treated by tying a piece of Indian-rubber thread round their pedicle, as has been suggested by Mr. Nisbett of Wolverhampton, which causes them to dry up and fall off in a few days. When epithelial cancer has attacked these growths, the disease must be entirely removed by amputation of the hand or digit (provided the glandular system has not become implicated), or by the application of some powerful caustic, such as the chloride of zinc or sulphuric acid.

### *Corns.*

Corns are of two kinds, hard and soft.

The hard corn is principally found on the outer aspect of the little toe, on the dorsal surface of the other toes, and occasionally on the sole of the foot.

The soft corn usually occurs between the toes, on one of their lateral aspects, or at their angles of junction. The hard corn consists of thickened

cuticle, and when complete, according to Sir B. Brodie,<sup>1</sup> of an adventitious bursa, which forms under the thickened skin. Bursæ do not, however, exist in all cases of corns, but when the corn is of long standing, they are usually present.

The soft corn is composed of the same structures, only the thickened integument remains soft and moist. Both varieties of corns are most frequently caused by the pressure of tight boots or shoes. They are usually more troublesome in hot weather, or when the feet are kept too warm by wearing thick woollen stockings. Changes of weather cause the corns of some persons to become irritable and painful. Both varieties of corns are liable to become irritated and inflamed, and when in this state are often very painful, especially if any pressure be kept up on them. Suppuration occasionally also takes place in the bursa which forms underneath a corn, and gives rise to great suffering until the matter is let out. Ulceration has also been known to follow this condition, and to cause perforation of a joint or destruction of the bone.

*Treatment.*—The treatment for the hard corn is either palliative or radical. The palliative treatment consists in wearing boots and shoes of soft

<sup>1</sup> *Loc. cit.*

material, or which will not press upon the affected part of the foot, in using plasters which will keep off pressure from the corn, or in paring the corn down to the level of the surrounding skin, and then applying some escharotic, such as the nitrate of silver or acetic acid.

I know of no better palliative treatment than that of paring the corn, and applying nitrate of silver to its base ; this proceeding is usually quite painless. Some of the palliative means I have mentioned will occasionally completely cure hard corns.

The radical treatment is to cut out or extract the corn. A hard corn requires to be extracted with a sharp-pointed instrument, and with care the operation may be performed without causing much inconvenience. Hard corns, when situated on the sole of the foot, even when small, often give rise to much discomfort, and prevent the patient from walking, so when met with, they should be carefully treated or extracted. Soft corns may be relieved or cured by the same means as hard corns ; but in applying escharotics, it is not necessary to use them so freely, as the skin is more tender. If corns be situated at the sides of or between the toes, and be kept irritated by the friction of two

toes against one another, relief is sometimes obtained by fastening these two toes together, so as to prevent the friction taking place. This is best done by means of a strip of adhesive plaister passed round so as to include both digits. When either a hard or soft corn becomes inflamed, soothing applications should be made to it, and if suppuration should take place in the bursal sac below, the matter must be at once let out by removing the hardened cuticle over it. When corns depend on distortion or overlapping of the toes, an endeavour ought to be made to bring back the digits to their proper position, and if this be not successful, it will be necessary, in some cases, to amputate the displaced digit.

### *Epithelioma.*

This disease occasionally attacks the integument of the digits, or it may spread from the integument of the hand, and involve a finger or toe in its progress. In the Museum of the Edinburgh College of Surgeons, there is a preparation consisting of the thumb of an old woman, eighty years of age. The integument of this thumb below the nail, and for about half an inch on the palmar aspect, is affected with epithelial cancer. In Holmes' *Surgery*,<sup>1</sup> a case is mentioned

<sup>1</sup> Vol. i. p. 532.

in which Mr. Oliver Chalk amputated both lower limbs of a man, in whom bunions, after remaining for many years unhealed, had become affected with epithelial cancer.

Melanotic cancer occasionally attacks the skin of the digits. The following is a case in which the skin of the great toe was affected with this disease:—

CASE 26.—*Melanotic Tumour affecting the Skin of the Great Toe.*

J. S., aged forty-eight, admitted into the Clinical Surgical Wards of the Royal Infirmary of Edinburgh.

Two years before admission, the patient first observed a small growth between the great and second toes. It gradually increased in size, and blood was occasionally discharged from its surface.

It still continued to get larger, and to extend itself towards both the dorsal and plantar aspects of the toes. When examined, the tumour presented all the appearance of melanotic cancer. It extended from the nail on the dorsal surface of the great toe to the cleft between the great and second toe, and filled up the space between these two digits. The great toe was removed at its metatarsophalangeal joint, together with the tumour, with a favourable result.

*Treatment.*—When epithelial or other cancer attacks the integuments of the digits, it may, if limited in extent, be destroyed by some powerful caustic, such as the chloride of zinc paste; but if

much of the skin of the digit be involved, it will be better to amputate the finger or toe if the case is otherwise suitable for the operation.

*Fatty Tumours.*

These tumours are rare in the digits, and when they do occur are usually of a diffuse kind, and continuous with the subcutaneous tissue of the part.

*Cystic Tumours.*

These tumours are occasionally found under the skin of the digits. I have on two different occasions cut out small encysted tumours from the palmar aspect of the fingers ; they lay immediately underneath the integument, and their contents were similar to those which are found in the common wen. In connexion with affections of the bursæ, I mentioned that the contents of a superficial bursa might become solid, or nearly so, and at the same time reference was made to the ganglia and synovial tumours which are found in the digits. All these affections may be looked upon as resembling cystic tumours.

*Treatment.*—Cystic tumours, when occurring in the superficial textures of the digits, are easily cut out. If such cysts contain thin and serous fluid,

they may be punctured, and a blister or pressure applied for some time after the operation. These means will generally be sufficient to cure the complaint.

*Fibrous, Cartilaginous, and Osseous Tumours.*

These tumours are occasionally found in the soft textures of the digits, unconnected with the tendons, periosteum, or bone; but much more frequently they occur in connexion with the latter tissues.

A patient was admitted into the Clinical Surgical Wards of the Edinburgh Royal Infirmary, about twelve years ago, with a fibrous tumour about the size of a hen's egg lying free in the areolar tissue, on the palmar aspect of the thumb, and extending between the folds of skin which separate the thumb and forefinger. On examination of the tumour after removal, its microscopic structure consisted of oval nucleated fibre cells, granules, and blood-vessels. The denser portions were composed of elongated fibres. The following is an account of this case :—

CASE 27.—*Fibrous Tumour of the Thumb.*

J. T., aged fifty, admitted into the Clinical Surgical Wards of the Royal Infirmary of Edinburgh with a tumour of the thumb. The tumour was of the size of a

small hen's egg, and lay partly on the palmar surface of the thumb, and partly in the fold between the thumb and forefinger. It was perfectly free and movable, and unattached to the tissues around. The patient attributed the growth of the tumour to the pressure of a plough handle. The tumour was readily removed. Its microscopic examination showed oval nucleated fibre cells, with a considerable quantity of granular matter. A section from the dense part of the tumour exhibited well-marked fibres.

Mr. P. Hewitt removed an osseous tumour, the size of a small walnut, from the areolar tissue between the adductor pollicis and first inter-osseous muscle. It had no attachments, except to the sheath of the flexor tendons. It was composed entirely of compact bony tissue, without any trace of cartilage, and was covered by a periosteum.

A case of recurrent fibrous tumour of the hand is reported in the 14th volume of the Pathological Transactions of London by Mr. C. Heath. The tumour commenced as a small hard lump between the first and second metacarpal bones. Several operations and amputations were performed for its removal, but it always recurred, and on the last occasion the arm was removed at the shoulder-joint.

Fibrous tumours are occasionally found in the

digits, closely connected to the sheaths of the tendons, and I have met with one case in which such a tumour was situated inside the sheath of the extensor tendons on the back of the hand, and was closely connected to the tendons themselves. Two years ago a young woman was admitted into the Clinical Wards of the Edinburgh Royal Infirmary, with a fibrous tumour on the palmar aspect of the hand. It lay immediately under the muscles of the thumb, felt hard to the touch, and was firmly fixed to the deeper tissues.

In its removal a portion of the sheath of the flexor tendons of the thumb had to be cut out, as the tumour was firmly adherent to that structure. The tumour was about the size of a small walnut, and was composed of dense fibrous texture. The wound healed well, but some contraction and stiffness of the thumb followed the operation.

Small cartilaginous tumours sometimes occur in the substance of the tendons of the digits. In one instance I found a tumour of this kind, about the size of a pea, developed in the tendon of the flexor longus pollicis of the foot. The tumour had become partially ossified.

*Treatment.*—When a fibrous, cartilaginous, or osseous tumour lies in the areolar tissue, and is un-

connected with the deeper textures, it is easily cut out ; but when such a tumour is attached to the sheaths of the tendons, the operation is not likely to be so successful in its result, as more or less stiffness and contraction of the digit or digits is apt to follow the injury done to the sheath and tendon.

*Painful Subcutaneous Tubercle.*

Mr. Paget<sup>1</sup> refers to a case in which a tumour of this kind had existed for many years at the extremity of a woman's thumb. Mr. Syme informs me that he once removed one of these tumours from underneath the nail of a finger. The patient, a lady, had suffered great pain in the finger for some years, and had obtained no relief from various kinds of treatment. She was anxious to have the finger amputated, but Mr. Syme, noticing that the nail was slightly raised up, determined to try the effect of removing the nail alone ; and on doing so he found a small subcutaneous tubercle, which, being loosely connected, was readily removed, and the patient was quite relieved of her painful symptoms.

*Neuromatous Tumours.*

These tumours have been found implicating a

<sup>1</sup> *Lectures on Surgical Pathology*, edited by W. Turner, p. 466.

digital nerve. Dr. Smith<sup>1</sup> gives two illustrations of neuroma occurring on the digital branches of the median nerve of the index finger. One of these is copied from Cruveilhier. Dr. Smith gives a third illustration of a serous cyst which was developed among the branches of the median nerve distributed to the thumb. I know of the case of a gentleman who had one of these tumours removed from the palmar aspect of the thumb. The tumour was very sensitive and painful when touched. This class of tumours, when they give rise to inconvenience, should be cut out. A ganglion, or other tumour of the digits, when situated in the region of a digital nerve, may simulate a neuroma, both in symptoms and appearance.

#### *Aneurismal Tumours.*

These tumours are not common in the digits. Only one case of aneurism of a digital artery has come under my notice. A case of a pulsating tumour of the digits is reported by Mr. Wardrop,<sup>2</sup> and another case has been related by Mr. Russell.<sup>3</sup>

<sup>1</sup> Dr. Smith on *Neuroma*, Plate III., Figs. 1, 3, and 7.

<sup>2</sup> *Med. Chir. Trans.*, vol. ix.

<sup>3</sup> *Med. Gazette*, vol. xviii. p. 173.

Cruveilhier<sup>1</sup> has figured a very curious condition of the veins of the hand and fingers which gave rise to numerous small tumours of a bluish colour.

The case of aneurism which came under my own observation was that of a woman aged forty-one, who nine weeks before had pricked her ring-finger on its ulnar side with a sharp hook. The finger was bandaged tightly up immediately after the accident, and about two weeks after the patient noticed a small swelling over the situation of the wound. This swelling had gradually increased in size. On examination I found a pulsating tumour, the size of a small marble, on the side of the ring-finger. A distinct thrill could be felt on placing a finger on the swelling.

When pressure was applied to the ulnar artery at the wrist, the pulsation in the tumour was very much diminished, but did not entirely cease.

Treatment by pressure was practised for some weeks, with the effect of diminishing the pulsation in the tumour, but the patient became restless, and insisted upon returning home without further treatment.

*Treatment.*—The proper method of treating a case like the one just referred to, would be to open

<sup>1</sup> Cruveilhier, *Anatomie Pathologique*, tome ii.

the aneurismal sac, and tie both ends of the vessel at the point of its communication with the aneurism.

When aneurism by anastomosis affects the digits, as in Mr. Wardrop's and Mr. Russell's cases, the tumour itself must be destroyed either by ligature or caustic. In Mr. Wardrop's case both radial and ulnar arteries were tied without any beneficial result on the tumour.

*Tumours of the Periosteum and Bone.*

Fibrous tumours are met with originating in the periosteum of the digits, and in their growth they sometimes cause absorption of the bony texture.

Tumours of this kind are more or less lobulated, and their structure usually consists of dense fibrous tissue. Fig. 89, Plate VIII., shows a fibrous tumour growing from the periosteum of the first phalanx of the thumb, and from a mass of fibrous tissue which represented its metacarpal bone. The metacarpal bone of this thumb, along with a small tumour which was growing from its periosteum, had been previously removed, but the disease had recurred in the cicatrix and in the periosteum of the first phalangeal bone. At the second operation the whole of the thumb, together with the tumour, was taken away. A section made through the bones of the

thumb and the tumour showed that the disease had sprung from the periosteum. Fig. 90, Plate VIII., represents a fibrous tumour which grew from the periosteum of the second and third metatarsal bones. The tumour was firmly wedged between these bones, and projected both on the dorsal and palmar aspects of the foot. It was lobulated, firm in texture, and had caused absorption of the external table of the bones in one or two places. A history of this case is given under Case 28.

CASE 28.—*Fibrous Tumour growing from the Periosteum of two Toes.*

J. S., aged fourteen, admitted into the Clinical Surgical Wards of the Edinburgh Infirmary. Two years ago the patient first observed a small tumour at the base of the second toe of the right foot. Since that time the tumour has steadily increased in size. On examination of the foot, a tumour as large as a medium-sized potato was found lying between the metatarsal bones of the second and third toes. The tumour was firmly adherent to these bones, and formed a prominence on both the dorsal and palmar aspects of the foot. The tumour was removed, along with the two metatarsal bones and their phalanges, and the patient made a good recovery.

*Melanosis.*

The following case is one of melanotic tumour, originating in the periosteum of the phalangeal

bone of a finger. The patient was a woman, aged fifty-six. An account of her case is given in Case 29. Fig. 97, Plate 1X., is a rough sketch taken from the disease.

CASE 29.—*Melanotic Tumour of the Periosteum of a Finger.*

E. A., aged fifty-six, admitted into the Clinical Wards of the Edinburgh Infirmary. Fifteen months ago a small red sore formed at the side of the nail of the index finger of the right hand. A swelling gradually formed around this sore, and the patient applied to a surgeon, who removed the entire nail of this finger. The tumour slowly increased, and involved the whole circumference of the finger. On her admission, the extremity of this finger had lost its natural appearance. On its dorsal aspect a black fungoid mass arose from the neighbouring healthy skin, which it slightly overlapped. On the palmar aspect no abrupt line of demarcation existed between the diseased and healthy parts. The cutaneous structure on this aspect was much altered in character and appearance. It was of a pale ashy colour, moist and villous on the surface. Between the dorsal and palmar portions of the tumour, there was a bright red line of from three to four lines in width. This line separated the tumour into two distinct parts. The size of the whole tumour was about that of a pigeon's egg. The finger was amputated, and a section of the tumour showed that its structure was cancerous. Its substance was tolerably firm in some parts, soft in others, and the tumour arose from the periosteum of the distal phalangeal bone. Its cut section was black on the dorsal surface of the bone; white interspersed with black patches

on the palmar surface. The microscopic examination showed large cancer cells of all forms, the cells from the dark portion of the tumour being filled with black pigment.

*Treatment.*—The treatment of periosteal tumours will depend on their extent. If much of the periosteum is implicated, amputation of the digits affected, or portions of them, along with the tumour, will be the only satisfactory method of entirely removing the disease.

*Enchondroma.*

Cartilaginous tumours are met with in the bones of the digits more frequently than any other kind of tumour. Mr. Paget<sup>1</sup> has given a most interesting account of these growths as they occur in the hand and fingers. These tumours may occur singly, only one bone being affected, or they may involve the bones of several or all the fingers and their metacarpal bones. Figs. 101 and 98 are taken from fingers in which the tumour was confined to one digit and to one bone. Fig. 91, Plate VIII., taken from a cast in the Museum of the Edinburgh College of Surgeons, illustrates an example of this kind of tumour affecting all the fingers.

<sup>1</sup> *Loc. cit.*, p. 506.

These tumours may originate in the interior of a phalangeal, metacarpal, or metatarsal bone, and in their growth gradually expand a portion or the whole of the circumference of the outer table of the bone, the cancellated texture disappearing, so that on examining such cases we find that the structure of the tumour is usually surrounded by a more or less complete bony cyst or capsule, which is formed of the expanded bone.

The growth in the interior of the bone may expand the bone equally on all sides, and thus form a tumour of a globular shape, but it more generally expands the bone on one side only, so that, as Mr. Paget states, "when this happens in the metacarpus, it is often hard to tell which of the two adjacent metacarpal bones should be cut out in case of need."

Occasionally the tumour bursts through the external table of the bone at one or more points, and then spreads out and overlaps this surface.

Cartilaginous tumours are also sometimes met with in the digits which spring from the outer table of the bone. In the cases of the kind that have come under my notice, the external tumours appeared as small tubercles rising from the external surface of the bone. On making sections of such

tumours, I have always found that the cartilaginous structure was also infiltrated into the cancellated texture in the interior of the bone. Fig. 92, Plate VIII., is from an interesting example of this condition. It represents the bones of a thumb which was amputated on account of this disease. The patient, a young gentleman, had had the tumour merely shaved off by another surgeon, but it soon grew again, and also appeared in other parts of the digit. On examination of this preparation it was found that the nail had been pushed up and partially destroyed by a series of small cartilaginous nodules which sprang from the dorsal aspect of the distal phalangeal bone. On the lateral aspect of the first phalangeal bone there was also another larger mass of similar nodules. These growths apparently sprang from the outer table of the bone, and had no connexion with the interior; but a section of the bone showed that the cancellated texture was also infiltrated with the morbid growth.

I have several times observed a similar pathological condition in the larger bones. Cartilaginous tumours of the digits are sometimes confined to the distal phalanx of a finger or toe. I saw, not long ago, a woman aged forty, who had one of these tumours, which grew from the distal phalanx of a

finger, and was quite confined to that bone. The tumour had existed for three years. I have since met with another example of this kind. Sometimes these tumours attain a very large size. Mr. Paget figures a case of the kind, and there is an excellent preparation illustrating the same condition in the Edinburgh University Anatomical Museum.

Cartilaginous tumours may be attacked with ulceration, and a considerable portion of their substance destroyed by it. In the case from which Fig. 88, Plate VIII., was taken, ulceration had commenced on the summit of the tumour, had gradually spread, and formed a considerable cavity in its substance.

The consistence of these tumours varies. I have seen their structure soft, and not much thicker than glue, resembling very much in appearance the flesh of an unboiled crab. Much more generally, however, the cartilaginous structure is firm. In many examples of this kind of tumour, there are points of ossification scattered through their substance, and occasionally we find the tumour almost entirely ossified, and surrounded by a bony capsule—the expanded external table of the bone.

The ossification of these tumours, and the ex-

pansion of the outer table of the bone, is illustrated in Figs. 110 and 99. Fig. 110, Plate XL, is from the second phalangeal bone of a finger which is in the Edinburgh University Anatomical Museum. The entire substance of the tumour in this case has been converted into bone resembling cancellated texture, and the outer table of the bone has become expanded. There are other preparations in the same museum which illustrate a similar condition. I have also seen preparations in which several fingers of one hand had their phalangeal and metacarpal bones thus expanded into bony cysts. Mr. Adams<sup>1</sup> relates and figures a case of this kind. Fig. 108 illustrates the expansion of the bone into a cyst, but in this case the expansion was caused by a myeloid tumour.

These tumours do not usually give rise to much pain, and, when single and small, cause little inconvenience; but as they increase in size they are apt to become troublesome from their bulk. When more than one digit is affected, the hand or foot becomes distorted and its movements interfered with. The diagnosis of these tumours is usually quite easy; they are always firmly connected with the bone in which or from which they grow; they

<sup>1</sup> *Ency. of Anat. and Physiology*, vol. ii.

differ somewhat in feel, according to the consistence of their substance, but most usually they are firm to the touch; and in those cases in which the growth has expanded the bone, or in which its substance has become ossified, the tumour feels as if it were solid bone.

*Myeloid Tumours.*

The first phalangeal bone of the finger, from which Fig. 108, Plate x., is taken, has been expanded into a bony cyst. The contents of this cyst exactly resembled those which are found in myeloid tumours of the bone, the structure of which is described by Mr. Paget.<sup>1</sup>

The contents of this cyst had the consistence of size, they were of a light brown colour, and projecting into this soft mass there were thin plates and fine spicula of bone, which divided the tumour into cells or compartments like the breast of a crab. During the maceration of the bone the contents of the cyst were destroyed. The sketch is taken from the dried preparation of the bone.

*Treatment.*—From what we know of the pathology of cartilaginous and myeloid tumours of bone, there can be no doubt that when a phalangeal, meta-

<sup>1</sup> *Loc. cit.*

carpal, or metatarsal bone is affected with these tumours, the removal of the entire bone in which or from which the growth originates can be the only satisfactory treatment. Cases are occasionally met with in which the tumour apparently affects the external table of the bone only, and at first sight it might be thought that such tumours could be successfully removed alone, but the only safeguard against the return of the disease is to take away the whole bone. In some cases it may be possible to save a finger or toe when one bone only is affected, by taking away this bone together with the tumour; but we must be guided in our choice between this proceeding, and the amputation of the whole or part of digit, by the particular circumstances of the case. In cases where more than one digit is affected with these tumours, we should endeavour to save as much of the hand as possible, by removing only those parts which are diseased. If two digits, or even one, or part of one, can be thus saved, it will be advantageous to the after usefulness of the hand.

#### *Medullary Cancer.*

This form of cancer occasionally attacks the bones of the digits. In one case which I had an opportunity of dissecting, the disease had originated in

the interior of the first phalangeal bone of a finger. This case is figured in Fig. 102, Plate IX., and a section of the finger and tumour is shown in Fig. 103.

CASE 30.—*Medullary Tumour affecting the Bone of a Finger.*

M. A., aged sixty, admitted into the Clinical Wards of the Edinburgh Infirmary. Five years before admission the patient noticed a slight swelling of the first phalanx of the ring-finger, which, however, only began to increase in size two years ago, and since then has grown very rapidly. On examination, there was a tumour of the size of a hen's egg involving the last phalanx of the ring-finger. The tumour was soft and elastic to the touch. The finger was amputated, and, on examination, it was found that the whole of the bone had become absorbed by the tumour. A thin layer of articular cartilage remained at each extremity. The periosteum formed a capsule round the tumour. The substance of the tumour was soft, of a greyish white colour, with here and there yellow patches.

Auvert<sup>1</sup> figures two examples of medullary tumours in the digits. In both cases the thumb was the digit affected.

Mr. Paget<sup>2</sup> gives the microscopic appearance of the cells which composed a medullary tumour that grew round the last phalanx of a great toe.

<sup>1</sup> *Praxis Med. Chir. Auvert.*, Tab. 114, Figs. 1 and 2.

<sup>2</sup> *Loc. cit.*, p. 650.

*Treatment.*—Amputation of the affected digit along with the tumour, is the only satisfactory treatment of such cases.

*Exostosis.*

I have met with two excellent examples of this kind of tumour in connexion with the bones of the fingers. The first case, represented in Fig. 113, Plate XI., was one in which the first phalanx had an exostosis growing from its distal extremity. The tumour was connected to the bone by a broad base, and its outer surface was invested by the periosteum. A section of this tumour showed that the structure of the exostosis was continuous with that of the phalanx. The tumour so involved the first phalangeal joint that it could not have been removed without injuring this articulation. The finger was accordingly amputated. Fig. 104, Plate XI., was taken from a case in which the tumour sprang from the proximal end of the second phalanx of a finger. The exostosis, in this instance, grew from the outer table of the bone, and was only continuous at one point with the cancellated texture. The outer table round this point appeared to be undergoing a gradual absorption. The tumour itself was attached to the bone by a broad base.

It was lobulated in shape, and had extended downwards, so as to overlap the first phalangeal joint.

Mr. Paget refers to the case of a boy, aged six, who had osseous outgrowths from several of his bones, one of which sprang from a phalangeal bone of his forefinger.

An exostosis is not unfrequently met with, growing from the distal phalanx of the great toe. This same form of exostosis has, in a few rare cases, been found growing from the bones of the other toes. Mr. Paget says that he has only seen two such cases, and in both the tumours sprang from the last phalanx of the little toe.

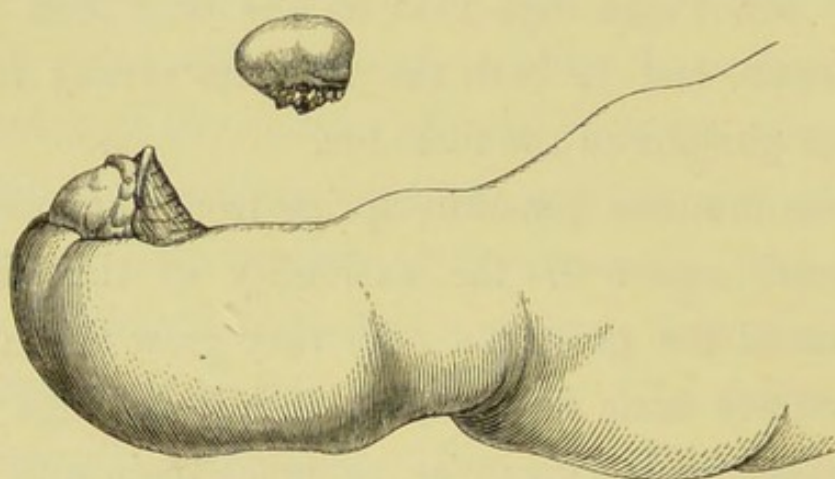
These tumours generally spring from the margin or dorsal aspect of the extremity of the distal phalanx of the great toe. As they grow they gradually force aside the nail, or cause it to bulge up, and consequently give rise to much pain and inconvenience. The soft parts over the summit of these tumours sometimes ulcerate, and occasion great discomfort.

The exostosis is sometimes connected to the bone by a broad base, at other times by a narrow pedicle only. Cases of this kind of exostosis are usually easily distinguished, but the presence of an ulcer over the tumour, or an inflamed state of the

parts around, may prevent the surgeon ascertaining the true nature of the case. The following is a good example of exostosis of the great toe.

CASE 31.—*Exostosis growing from the Distal Phalanx of the Great Toe.*

J. S., aged eighteen, admitted into the Clinical Surgical Wards of the Royal Infirmary with an exostosis growing from the distal phalanx of the great toe. The tumour first commenced to appear about two years ago, and did not at



first cause any inconvenience, but as it increased in size gave a good deal of annoyance, obliging her to have a piece of her boot cut out so as to take off pressure from the extremity of the toe. The tumour was about the size of a small nut, and of a rounded shape. It sprang from the dorsal aspect of the extremity of the distal phalanx of the toe, and in its growth had pushed the end of the nail upwards. The tumour was readily removed by cutting the nail away from around it, dividing the skin

round its base, and clipping through its neck with a pair of bone forceps. The appearance of the tumour viewed laterally before removal is shown in the accompanying woodcut, and a representation of the tumour itself after dissection is also given.

I also give, in Plate XI., several other illustrations of this kind of tumour, all of which are taken from preparations in the Edinburgh University Anatomical Museum. This museum is indebted to the late Mr. Liston for these preparations. Fig. 111 is a good example of the most common appearance and situation of these growths. Fig. 112 is a section of one of these tumours which sprang from the dorsal aspect of the distal phalanx. Fig. 116 is a distal phalanx after maceration, with an exostosis springing from its margin. I have had opportunities of dissecting several fresh specimens of this kind of exostosis, and have always found that the external layers consisted of cartilage, the neck and a small nucleus, as it were, being composed of bone.

*Treatment.*—In the examples of exostosis of the bones of the fingers which I have mentioned, it was found necessary to amputate the digits, as the tumours could not have been removed without injury to the joints, and their attachment to the bone was so broad that it would not have been

advisable to remove the tumours alone by dividing it. If, however, an exostosis should be met with in connexion with the bone of a finger, which, from its situation and narrow neck, admitted of easy removal, it would certainly be right to take away the tumour alone by cutting through its pedicle. That form of exostosis which affects the toes is usually easily remedied by first cutting away the nail (if necessary), dividing the skin round the base of the tumour, and then snipping through its neck with a pair of bone forceps. If the tumour is thoroughly removed, the disease rarely returns, but if a case should prove obstinate, amputation or excision of the distal phalanx must be resorted to.

#### *Entozoa in Bone.*

The only case which I can find on record in which parasitic animals have been developed in the bones of the digits, is the one referred to by Mr. Stanley.<sup>1</sup> The entozoa in this case was the *Cysticercus cellulosæ*, and was found in the first phalanx of a forefinger.

<sup>1</sup> *Diseases of the Bones*, by Stanley, p. 189.

## CHAPTER IV.

### INJURIES OF THE DIGITS.

- 1st. Injuries of the Soft Parts.
- 2d. Injuries of the Bursæ and Joints.
- 3d. Injuries of the Periosteum and Bone.

The digits, especially those of the upper extremity, are very liable to suffer from all kinds of injuries, and although many of these injuries may appear at first sight to be of little importance, it is very necessary that we should be able to treat them properly, for a very simple hurt, if neglected, may lessen the usefulness of the hands, feet, or digits.

#### 1. *Chilblains.*

The fingers and toes are frequently attacked with chilblains, as a result of their exposure to cold or to changes of temperature. Some individuals are undoubtedly more predisposed to this affection than others. Young people, females especially, are most liable to be affected with chilblains;

but all classes of persons may suffer from them, although, as would be expected, those who are delicately nurtured, or of weak constitution, are more easily and more quickly influenced by cold or changes of temperature. Chilblains, as seen in the digits, vary in their degree of intensity. In the simplest form, there is a slight redness and swelling of the digit (the redness being dark in colour, or approaching a bluish tint), with itchiness of the skin implicated.

If the disease is more severe, there is a greater amount of redness and swelling, which produces an ugly and deformed appearance of the digits; excessive itchiness, with a sensation of burning in the parts, is always more or less present. In this variety blisters not unfrequently form on the swollen textures, and when these blisters burst, or are opened, irritable ulcerations may be found underneath them. In the worst examples of this complaint, the ulceration may spread and destroy the soft tissues of the digit, or sloughing may take place, and lead to the destruction of the finger or toe affected.

*Treatment.*—Those persons who have once been affected with chilblains should be careful to avoid exposure to cold, or any action (such as placing the

feet or hands close to the fire immediately after they have been under the influence of cold or wet) which may expose the digits to sudden extremes of temperature.

During winter and spring, such patients would do well to use water with merely the chill taken off for washing purposes, instead of employing hot water. When, however, chilblains have attacked the digits, some treatment is usually required to relieve the excessive itching, and to diminish the swelling of the soft textures. For this purpose stimulating applications are generally recommended and used in the form of liniment or lotion.

Almost any stimulating liniment is useful in this complaint. Mr. T. Spencer Wells<sup>1</sup> recommends a solution of camphor in eau-de-cologne for patients in the upper classes, and equal parts of turpentine and olive oil for dispensary patients.

Tincture of cantharides, combined with soap liniment, is also a useful application. I have also used a solution of the nitrate of silver with great advantage, painting the surface of the chilblain with it. This treatment speedily relieves the itchiness, and checks the complaint; the only objection to its use being that it blackens the skin, and thus causes a disfigure-

<sup>1</sup> Cooper's *Surgical Dict.*, edited by Lane.

ment for some days after it is applied. When the ulcers that form in chilblains are slow to heal, tincture of myrrh, or the ointment of the red oxide of mercury, are useful applications to make to the sores ; but if the ulceration should spread, or if sloughing takes place, the case must be treated by poultices and other soothing means.

*Frost-Bite.*

This affection of the fingers and toes is the result of their exposure to a more intense or more continued cold than occasions chilblains, especially if associated with moisture. I have frequently seen sailors arrive at our northern ports with frost-bite of the fingers and toes, having been exposed to cold and stormy weather for several days or weeks, and during the greater part of this time having had their hands and feet constantly wet. During severe winters in this country, I have also seen many cases of frost-bite among navvies and labourers who have been employed in clearing the snow from the railway lines.

When the feet or hands are exposed to severe or long-continued cold, and are then suddenly brought into contact with heat in any form, gangrene of the digits is often the result, and cases of the kind are

constantly brought to our hospitals in this country during the colder months. In the Crimean war the soldiers who were much exposed to cold suffered extensively from frost-bite of a peculiar form. Dr. Macleod,<sup>1</sup> and other of the English surgeons, thought that it depended on the combined effects of cold and scurvy; while Dr. Thalozan looked upon this affection as allied to a disease which appeared epidemically in France some years ago, and was then termed "acrodynia."

In cases of frost-bite, the vitality of a finger or toe may be entirely destroyed, and immediate gangrene be the result; but more frequently the vitality of the part is only at first weakened, and inflammation having ensued mortification follows. It is of great consequence, therefore, in treating cases of frost-bite, when seen early, to avoid all applications which may excite inflammation in the frost-bitten part.

Frost-bite of a finger or toe generally commences with a feeling of numbness in the digit or digits implicated, which may continue until the part is quite dead, or may be followed by a pricking or burning sensation. If inflammation supervene, the usual symptoms are present. When the frost-

<sup>1</sup> Macleod's *Surgery of the Crimean War*, p. 79.

bitten parts have been killed at once, they assume the ordinary ash-grey or black colour, which is characteristic of gangrene, and soon become shrunken and shrivelled up. It is most common, however, in this country, to find the frost-bitten digits in a state of inflammation, and they are then red and swollen, with much burning heat in and around them. Blisters are often also present on the surface of the affected parts. If the inflammation be not checked, mortification of a greater or less extent of the affected tissue usually results, and a line of demarcation forms between the living and dead tissues, as in other forms of gangrene. I have seen cases in which both feet have become separated above the ankle joint from the effects of frost-bite.

*Treatment.*—It very rarely happens that the surgeon sees cases of frost-bite early enough to prevent inflammation attacking the part which may not at first have been entirely destroyed ; for when patients feel the effects of the exposure to cold, they or their friends generally resort to the application of heat or other stimulating means. This treatment is very apt to excite inflammation, which not unfrequently ends in mortification. When, however, a case of frost-bite is seen before inflammation has

taken place, careful attempts should be made to restore the temperature of the frozen tissues. This will be best done by applying snow, or snow and water, and if snow cannot be obtained, some cooling lotion, until the heat of the affected part returns, and then warmth may be gradually applied to it. When inflammation has attacked a frost-bitten digit, soothing applications must be employed until the inflammatory attack has subsided. If mortification result, they should be continued until a distinct line of demarcation has formed, and then, but not till then, an operation may be performed for the dead tissues, and for the covering of the exposed bone. The nature of the operation will depend upon the amount of tissue destroyed. In some cases it may be sufficient to saw through the bone at the line of separation, while in others it will be advisable to amputate above this line in order to obtain a good flap to cover the exposed bone. When there is much pain and constitutional irritation present in cases of frost-bite, opiates may be administered with advantage, and if (as is often the case in hospital patients) the patient has been ill-fed as well as exposed to cold, a generous diet ought to be given.

*Burns and Scalds.*

The fingers and toes may suffer from the effects of too great heat applied either in a liquid or solid form, or from the action of chemical substances. The skin only may be injured, with or without vesication, or the burn may be more severe, causing vesication and suppuration. Portions of the tissues of the digits may be also destroyed or charred by the application of great heat.

*Treatment.*—Scalds and burns, when they occur in the digits, require no special treatment. The milder varieties are best treated by the application of dry cotton wadding, and, if there is much pain, the wadding may be soaked in a mixture of equal parts of olive oil and lime-water. When the burn affects the deeper textures, or has completely charred the digit, poultices should be employed until the sloughs separate, and then, if necessary, an operation may be performed in order to obtain a covering for the exposed bone, or to remove useless parts.

*Bruises.*

The digits, especially those of the hand, are frequently bruised. Such bruises may be only slight, and give rise to limited extravasations of blood into the soft tissues, or they may be severe, and cause

considerable swelling, and impair the mobility of the digit.

One or more digits may sustain a severe bruise, and their tissues become so much discoloured, and their temperature diminished, that they may appear to have mortified. I remember seeing a remarkable example of this. The patient, a man aged forty, while standing on some machinery, had his foot drawn in between two rollers. On examination of the foot an hour after the accident, it was swollen, dark in colour, and felt cold to the touch. The vitality of this foot was apparently destroyed, but two days after the tissues began to recover, and soon regained their natural condition. Bruises, we have already seen, may also be the cause of whitlow.

When the extremities of the digits are severely bruised, the nails are frequently injured, extravasation of blood taking place underneath and around them, and, as a result, they may become gradually loosened, and fall off. This process of separation is usually tedious, and the patient often inquires of the surgeon if the nail will grow again, and preserve its proper appearance. When the injury is a simple bruise, we may almost be quite sure that a new nail will form; and if the matrix of the nail retains its proper position and shape, it is probable

that the new structure will be of a natural appearance. When, however, the tissues at the extremities of the digits have been destroyed or distorted, the new nail is apt to be deformed and irregular in its growth. If the entire matrix be destroyed, the reproduction of a new nail can scarcely take place. In severe bruises and strains of the digits, it is frequently some time before these organs regain their full usefulness, owing to the injury done to the tendons and other soft textures. If the joints, however, remain unaffected, the digits will generally recover in the course of time.

Rupture of the interossei muscles is an accident which has, I believe, been distinguished. The peculiar symptom of this accident is an inability to adduct or abduct the fingers.

*Treatment.*—Bruises of the digits should be treated by the application of warm fomentations until the swelling and pain have diminished. If suppuration takes place, the case must be treated like one of whitlow. When the nails have become injured, they should be removed as soon as they are loose.

#### *Wounds.*

All kinds of wounds may be inflicted on the

soft tissues of the digits. Punctured wounds, with or without the contact of poisonous matter, are frequently the cause of whitlow. In wounds of the digits the arteries are frequently injured, and may bleed freely for a time, but the hæmorrhage is usually readily arrested by pressure or ligatures. The soft tissues of the digits are often severely lacerated by machinery and other accidents. Severe lacerated wounds of the fingers are also occasionally caused by gun-shot wounds, or by the explosion of gunpowder contained in a bottle, flask, or other receptacle ; as these latter injuries not unfrequently happen during the act of emptying gunpowder on to some inflammable material, the wounds are especially apt to occur in the space between the thumb and forefinger. These wounds are sometimes followed by considerable constitutional irritation, and I have known tetanus result in several instances after this kind of wound, and prove fatal. The following is an example of such an injury :—

CASE 32.—*Lacerated Wound of the Thumb followed by Tetanus.*

Master ———, aged thirteen. Five days ago a gunpowder flask burst in the patient's hand, and caused a severe lacerated wound in the space between the thumb

and forefinger. The boy continued to do well, with the exception of some swelling of the thumb, until the evening of the fourth day after the accident, when he began to complain of stiffness in his neck, and starting of the muscles of the injured arm. His parents also noticed at this time that he was not able to open his jaws to their full extent. The following morning, I was asked to see him, and found the trismus and other tetanic symptoms well marked. There was a deep granulating wound extending two-thirds round the base of the thumb. There was no fracture of the bones, but the metacarpo-phalangeal joint was displaced, and apparently opened into. The soft parts forming the ball of the thumb were much lacerated. The fingers of the affected hand were firmly contracted, and the patient had not the power to extend them. Thinking it right to remove any local cause of irritation, I amputated the thumb, together with its metacarpal bone. The operation did not appear to give any relief, the tetanic symptoms, which were treated with opium and inhalation of chloroform, still continued, and the patient died the following day.

The flexor and extensor tendons of the digits when wounded may become inflamed, and in consequence portions of them may die. If these structures should be completely divided, the movements of the corresponding fingers and toes are interfered with. Contractions of the digits frequently follow injuries of the tendons, and careful treatment is required to prevent or lessen this deformity. Last

winter, a young gentleman applied to me on account of a want of power to flex the distal phalanx of the forefinger; he could flex the first and second phalanges perfectly, but during this action the third phalanx remained extended. The movements of all the other fingers were perfect. There was a transverse cicatrix on the palmar aspect of the middle phalanx of the affected finger. Five years ago, the patient had received a deep wound in this situation, which caused a want of power to flex the last joint immediately after the accident. Since then this power has never returned. On examination, I found that the wound must have divided the deep flexor tendon just where it becomes superficial, after piercing the tendon of the flexor sublimis. This fact quite explained the nature of the case.

A thumb or finger is occasionally torn completely off, and a considerable portion of tendon may be drawn out at the same time. I have seen two such cases, in one of which a piece of tendon, six inches in length, was thus torn off along with a finger. Fig. 115, Plate XI., is taken from a preparation in the Edinburgh College of Surgeons' Museum. It consists of a thumb and portion of the tendon of the flexor longus pollicis which had been torn off

in this way. These cases are not usually attended by so much disturbance of the parts as would be expected; the wound left is always more or less lacerated, but the forearm, from which the tendon has been drawn, does not necessarily suffer from the accident. I have known a finger torn away, along with a portion of tendon, in the following manner:—A gentleman, when walking in the street, slipped, and put out his hand to catch some railings, the railings caught a ring which he wore on one of his fingers, and the force of his fall tore off this finger along with the ring.

Digits, or portions of them, are sometimes completely or nearly cut off by accident. There are several curious examples on record, in which portions of fingers or toes that have been entirely severed from the body have become reunited on being carefully adjusted in their former position.<sup>1</sup>

The digits may be wounded by the bites of animals or reptiles, and by the stings of certain insects and plants. These wounds may be simple or complicated, with the introduction of some poisonous matter. Simple wounds inflicted by the teeth

<sup>1</sup> See the following references:—*Dublin Quarterly Journal of Med. Science*, August 1865; *Brit. Med. Journal*, January 1862; *Dublin Journal of Med. and Chir. Science*.

of animals are often slow to heal, and may cause a good deal of local and glandular irritation. The bite of the common adder of this country has been known to give rise to great constitutional disturbance, but does not generally prove fatal to man. The local irritation caused by the stings of certain insects and plants is, in irritable constitutions, sometimes attended by much suffering.

Foreign bodies, such as pieces of glass, splinters of wood, thorns, portions of needles and pins, and other bodies are frequently forced into, and become lodged in the soft parts of the digits. Very small portions of glass may become lodged in the soft tissues of the fingers, and cause irritation. I saw the other day a piece of glass, not larger than a small pin's head, removed from the dorsal aspect of a finger. It had been there some months, and had given rise to a good deal of pain and uneasiness. If not speedily removed, these foreign bodies give rise to inflammation, or they may cause serious irritation by pressing upon or injuring a nerve. These substances occasionally lodge in the textures of the fingers and toes, and become encysted, giving rise to no inconvenience. In dissecting a finger lately, I found a portion of a hair-pin fully half an inch in length lying across the palmar aspect of its first phalanx,

immediately under the skin. It was completely surrounded by a capsule of some thickness, which was firmly fixed to the tissues below, so that the foreign body was quite immovable. The cicatrices left by wounds of the digits occasionally become irritable and painful. (See Case 34, referred to under Injuries of the Nerves.)

*Treatment.*—Wounds of the digits must be treated according to their nature. If there is much laceration or destruction of the soft textures, it will usually be best to amputate the injured finger or toe at once, as there is always a risk of such accidents giving rise to some serious constitutional irritation, and even if the wounds do heal, the digit is almost certain to be stiff and useless. Although the removal of the thumb in Case 32 was not followed by relief, it may be right, in some instances, when tetanus or other nervous affections follow injuries of the digits, to amputate the digit or digits implicated, in order to remove a local cause of irritation.

I saw, a few days ago, another case of tetanus following a gunshot injury of the ball of the thumb and hand. In this case the symptoms of tetanus came on about the fifth day after the accident. Amputation of the forearm was performed five days

after. No relief followed, and the patient died the day after the operation.

When the tendons of a digit are divided, the edges of the wound should be carefully adjusted, and the finger so secured that the extremities of the cut tendon may be kept as much as possible in contact. After union has taken place, careful movements of the digit or digits should be practised. When portions of digits are entirely separated by accident, it will be right to attempt to unite the severed portion, if it can be obtained. Both the cut surfaces should be carefully cleaned, and then accurately applied to one another, and kept so for two or three days, at which time, if union has not taken place, the severed portion will have become dead, and must be removed. When wounds of the digits are complicated by the introduction of some poisonous fluid, the poison should be extracted as soon as possible by means of suction and incisions, or its effects neutralized by the application of strong ammonia, or some powerful caustic to all parts of the wound.

When the stings of insects become lodged in a wound, they should be picked out as soon as possible. If the constitutional symptoms are severe in such cases, opium and stimulants must be freely administered.

If foreign bodies have become lodged in the soft parts of the digits, they should be removed as soon as possible. It is often difficult to find portions of needles or other fine bodies which have been forced into the fingers or toes ; but if they cannot be detected, the tissues should not be much disturbed, for the foreign body will either work its way to the surface somewhere, or will become encysted, and so cause little inconvenience.

*Bruises, Wounds, and other Injuries of the Nerves  
connected with the Fingers and Toes.*

I propose here to devote some special remarks to this class of accidents, as it is one of extreme interest. These remarks will be illustrated by three cases which have come under my own observation.

Bruises and strains of the nerves of the upper extremity not unfrequently lead to more or less paralysis of motion and sensibility of the fingers and thumb. A blow or fall on the lower part of the neck or the shoulder, or on other portions of the arm, may injure some of the nerves, and be followed by paralysis of one or more groups of muscles, and consequent loss of power in the digits.

Mr. Paget,<sup>1</sup> and Drs. Mitchell, Morehouse, and Keen,<sup>2</sup> have recorded some interesting examples of such injuries.

The strains and lacerations of the nerves, which occasionally take place in dislocations of the upper extremity, are apt to be followed by similar results. Paralysis of the muscles of the arm has also been met with in cases where the limb has been forcibly pulled or dragged, as in the attempt to lift up a person by the arm. Mr. Paget relates two interesting cases, one in which loss of power in both hands followed the application of tight ligatures round the arms and wrists, and another in which, from a similar cause, one hand became paralysed. Another occasional cause of loss of power in the digits of the upper extremity is that which sometimes occurs when a patient falls asleep with his arm under him, or in some other awkward position.

After the injuries just described, paralysis of motion is, as a rule, much more marked than paralysis of sensation. The paralysis may follow these accidents immediately, and may be temporary or permanent in its character, or, as not unfrequently happens, it may come on gradually some time after.

<sup>1</sup> *Medical Times and Gazette*, March 26, 1864.

<sup>2</sup> *Gunshot Injuries of Nerves*. Philadelphia, 1864.

In the former case, the injury has acted on the nerve or nerves immediately ; while, in the latter, the result is produced by secondary changes in the nerve, and consequent wasting of the muscular and other tissues.

Drs. Mitchell, Morehouse, and Keen, have directed attention to cases where an injury of one nerve has been followed by the gradual extension of disease to neighbouring nerves.

The following case is an example of paralysis following a blow :—

CASE 33.—*Paralysis and Atrophy of the Muscles of the Thumb the result of Injury.*

A woman, aged forty-five, eighteen months ago, bruised the ball of her right thumb with a large packet of books. Soon after the accident, the movements of the thumb became gradually weakened, especially those of abduction and adduction. Since then, these movements have been getting still feebler. On examination of the affected hand, the muscles forming the ball of the thumb were found to be much atrophied, having only half the bulk of those of the other hand. The movements of flexion and extension were almost perfect, but abduction and adduction were very feeble, and consequently the power of grasping objects between the thumb and fingers was very slight.

Brown Sequard refers to a similar case of atrophy of the muscles of the thumb, the result of an injury

to the ulnar nerve. Before considering more in detail the effects which are met with as a result of bruises of the nerves of the digits, I wish to say a word or two in regard to wounds of these nerves, as both injuries may be followed by the same symptoms.

The nerves connected with the upper extremity may be entirely or partially divided by a wound. In the former instance, loss of motion and sensibility, more or less complete, immediately results in those parts, supplied by the injured nerves. If the nerve should unite properly, these parts may gradually regain their power. Complete paralysis of sensibility does not always follow the division of a nerve, but the motor power is usually quite destroyed for a time at least. When a nerve is only partially divided, the paralysis is not generally so complete as in the former instance.

Wounds of the digital nerves have been known to give rise to attacks of epilepsy and hysteria. Sir B. Brodie and Brown Sequard both refer to cases of this kind. These injuries, too, are not unfrequently followed by changes in the nutrition of the tissues, and by other symptoms, which cause great distress and deformity. Sir B. Brodie has recorded two cases in which the ulnar nerve was divided by accident. In

one, the little finger was cold, insensible, and covered with purple blotches; in the other, this finger occasionally became of a purple hue, and then a blister formed, having a superficial ulcer underneath, which gradually healed. Even slight cuts on the fingers or thumb, which have implicated some small nervous branch, are occasionally followed by a feeling of numbness, or other unpleasant sensation, which symptoms may last for a considerable time. A foreign body may become lodged in or near a nerve, and lead to unpleasant symptoms by keeping up irritation. I have also seen cases in which the cicatrix of a wound of the digits has become very painful, apparently owing to the implication of some nervous twig. The following is an example of this condition :—

CASE 34.—*Painful Cicatrix at the Extremity of a Finger.*

A woman, aged twenty-five, five months ago received a cut on the palmar aspect of the extremity of the middle finger of one hand. The wound healed well, and without any peculiarity; but ever since she has suffered from constant pain in the cicatrix, and down both sides of the finger. The cicatrix and parts around were very sensitive to the touch.

I now proceed to describe the effects which may follow any injury of the nerves of the extremities,

confining my remarks as much as possible to those which are met with in the fingers and toes. As the following very interesting case of injury to a digital nerve illustrates many of the symptoms which have been noticed to follow these injuries, an account of it will be an excellent introduction :—

CASE 35.—*Wound of a Digital Nerve, followed by Paralysis, Burning Sensations, and other Abnormal Symptoms.*

Mrs. —, aged sixty-four, applied to Mr. Syme, June 28, 1865, for a very painful complaint of one finger. Nine months ago, the patient accidentally inflicted with a knife a wound over the palmar and lateral aspect of the first phalanx of the ring-finger of the left hand. The wound healed quickly, and without any inconvenience. One month after the accident (the wound being then perfectly healed) she first began to suffer from pain in the cicatrix, and round about it. This part became very sensitive, so that the slightest touch caused great agony. Some swelling of the fingers and hand then took place, and the pain, and a burning sensation, passed up into the hand, forearm, and elbow, occasionally also shooting up into the arm. At this time her medical attendant made an incision near the cicatrix, but it was followed by only a very slight temporary relief. Blisters were also employed, but without any benefit resulting. The burning sensation was now not only confined to the affected arm and hand, but was often very severe in the right hand and forearm, and also sometimes in the soles of both feet. She then placed

herself under the care of an eminent physician, who treated her most carefully with a variety of local applications, among which were chloroform, belladonna, aconite, etc. Not obtaining relief from these means, she came to Edinburgh for advice.

On examination of the left arm, the elbow, wrist, and digital joints were stiff and painful. The fingers were tapered, and their skin had the characteristic glazed or glossy appearance (which was first observed by Mr. Paget in cases of injury of the nerves) well marked. The colour of the skin was pale, with a slightly yellow tinge. The nails were dry and brittle. The glossy state of the skin was also present on the dorsal surface of the hand, and for a little distance up the forearm. The left hand and all its digits were very sensitive, but the injured finger was most markedly so, especially at its extremity, and on its palmar aspect. The slightest touch on this finger caused such distressing pain that the patient would scarcely permit the hand to be approached, much less touched. On a careful examination of the affected finger, a cicatrix was distinguished in the situation of the original wound. On pressing over this point great pain was complained of.

The right hand was also slightly stiff. Its palmar aspect had a shrivelled and wrinkled appearance, but was not tender on pressure. The patient suffers very much from the pain and burning sensation. These symptoms are almost constant, but are more severe at some times than at others. Occasionally they are temporarily suspended, but this does not last long. The pain from which the patient suffers is like that of neuralgia, but it is the

peculiar burning sensation of which she complains most. This sensation she compares to the application of a hot iron; and it attacks not only the affected hand, but passes up into the forearm and arm of the same side. It is often very severe in the right hand, and is also sometimes present in the soles of her feet, but here it is not so bad as in the hands.

The patient's general health is apparently good, and there is no history or symptom of any other nervous disease. Her friends think that she is a little more "nervous" than she used to be; but this is scarcely to be wondered at, considering what she has suffered; and, in fact, if she had not had a very good constitution, her general health would not have been so good as it is.

*June 31st.*—Having carefully considered the case, Mr. Syme thought it right to propose amputation of the affected finger, as the history clearly showed that the symptoms dated from the injury to its nerve, and the extreme sensitiveness of this finger pointed to it as the probable source of the painful symptoms in the other regions. The patient willingly agreed to the operation, and the finger was therefore removed at its metacarpophalangeal joint.

*July 3d.*—Patient feels the affected hand much easier, but still has occasional attacks of the burning sensation in the right hand. Finger was dressed for first time. The wound looks well.

*July 6th.*—Last night the patient had a severe attack of the burning sensation in both hands, but is easier again this morning. Wound is dressed daily, and is healing nicely.

*July 10th.*—Patient has been gradually improving for the last few days. She is very much better to-day, and is quite free from her old pains. She allowed me to grasp the affected hand freely, move the fingers and wrist joint, and in fact handle the limb in a way she could not for a moment have borne before the operation. The peculiar glossy state of the skin is not nearly so well marked now. Ligatures have all come away, and the wound is nearly healed.

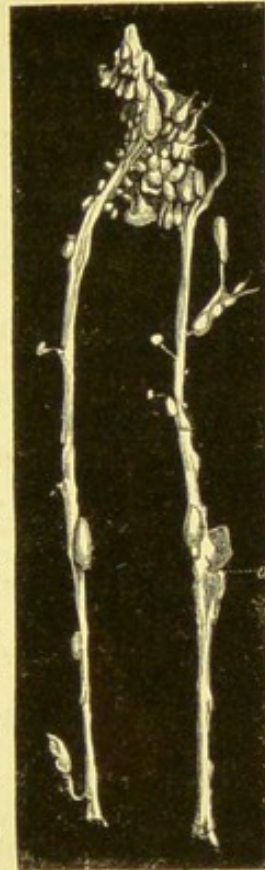
*July 15th.*—Since last date patient has had some return of the burning sensation, but it is not so bad as it used to be. She was anxious to return to the country, as the hand was so well, and, accordingly, to-day left town, promising to report progress.

*August 12th.*—The patient's daughter writes to-day, and states that her mother's general health is much improved. She still suffers occasionally from the burning sensation in the left hand, but it is not so severe as formerly. The wound is quite healed, and the whole hand and arm are more easily moved than before. The burning sensation has, however, increased in intensity in the right hand, which has become somewhat swollen and its joints stiffened.

#### *Examination of Finger after Amputation.*

Two hours after the finger had been removed, I made a careful dissection of its nerves, and found that the nerve which usually runs along the radial border of the palmar aspect of the digits had been injured at the point corresponding to the cicatrix of the original wound. At this point the nerve had been apparently partially

divided, and had become re-united. There was an enlargement of the nerve at the situation of the injury. This enlargement of the nerve extended for about the eighth of an inch above and below where it had been wounded. In appearance it was more vascular than the other nervous tissue, and looked as if suffering from some slight inflammatory process. In addition to this condition of the injured nerve, the Paccinian bodies in connexion with the nerves and their branches on the palmar aspect of the finger were particularly well developed. For this reason, I had a careful drawing taken from my dissection of these nerves, and the accompanying woodcut is from this drawing. The line *a* points to the place where the nerve had been injured. The drawing does not represent the whole of the Paccinian bodies which were connected with the nerves of this finger, for, in dissecting them out of the fatty and areolar tissue, a considerable number were lost and destroyed.



The case just related is one of great interest. The symptoms distinctly commenced from the date of the infliction of the wound. The pain, the peculiar burning sensation, the glossy state of the skin, the interference with nutrition, and the condition of the joints, are symptoms which were

noticed in many of the cases recorded by Drs. Mitchell, Morehouse, and Keen. These symptoms, and others presently to be described, may follow any injury of a nerve.

The pain which is present after injuries of nerves, may be neuralgic in its character, or it may consist of that peculiar burning sensation which was so well marked in the case I have just reported. This burning sensation varies in intensity in different cases. In some instances it causes great suffering from its severity. A peculiarity in regard to it in Case 35, was its occurrence not only in the affected hand, but also in the same forearm, the opposite hand and forearm, and in both feet.

The glossy state of the skin generally present when the burning sensation is felt, is one of the most characteristic effects which follows injuries of nerves. It may attack all, or some only of the digits, causing them to become smooth and shining in appearance, and of a deep red or mottled colour; sometimes the skin is pale in colour. Mr. Paget has compared their appearance when in this state to that of a permanent chilblain. Such fingers generally become deprived of hairs, and their skin is apt to crack, and sometimes becomes affected with eczematous eruptions. Drs. Mitchell, Morehouse, and

Keen have shown that the nails, too, are liable to alteration after injuries of the nerves. This alteration may consist of a curving and lateral arching, or the skin at the end of the nail becomes retracted and exposes the matrix.

Edematous swelling is also occasionally a symptom after entire division, or other severe injury of a nerve.

Interference with the nutrition of the muscular and other tissues is an almost constant result of injury to a nerve. The amount of atrophy of the muscles varies in different cases. In some instances a portion only of a muscle is affected, but more commonly one or more groups of muscles suffer. This condition of the muscular tissue of the extremities may lead to loss of power, distortion, and occasionally to spasmodic contraction of the digits.

The swelling and stiffness of the joints which was present in Case 35, was also observed in several of those cases reported by the American surgeons already referred to.

I am not aware that any investigations have been made into the pathology of cases of injuries of the nerves, which have been followed by the various symptoms just described. From the dissection of the finger in Case 35, it was found that the nerve

had been injured at the point corresponding to the original wound caused by the accident, and that at this point the nervous tissue was apparently suffering from chronic inflammation or irritation. Again, the Paccinian bodies, in comparison with the drawings of these structures figured by Sharpey, and Todd, and Bowman, were unusually well developed, as will be seen from the illustration, which was taken for me by a careful artist from my fresh dissection of the nerves.

It is unnecessary to describe separately the injuries of the nerves connected with the digits of the foot. These injuries are not nearly so frequently met with as those in the digits of the upper extremity, but the same variety of symptoms may follow injuries of the nerves in both the lower and upper limbs.

*Treatment.*—When a nerve is bruised, strained, or wounded, we should endeavour, by rest and soothing applications, to prevent any further irritation taking place. If a foreign body has lodged in or near a nerve, it ought to be removed at once, if this can be done with safety; for, if allowed to remain, it will be very apt, sooner or later, to irritate the nervous tissue. When a nerve is divided by accident, its ends should be brought together as

closely as possible, in order to give them a chance of uniting properly. A nerve which is even partially divided, appears in some instances to be a cause of painful symptoms. In such cases it might be right to complete the division of the nerve by incision, if relief could not be obtained by other simpler means.

The burning sensation, which is one of the most distressing symptoms after injuries of nerves, is, according to the experience of the American surgeons already quoted, best treated by the application of blisters, or blistering fluid, to the affected regions. The same authors found that the pain following these injuries most readily yielded to leeching (especially if there was tenderness on pressure), and to the hypodermic injection of morphia. The atrophy of the muscular and other tissues is best relieved by shampooing, friction, and passive movements, together with the use of the warm douche. Paralysis of the digits in these cases can only be satisfactorily removed by the careful, and, if need be, long-continued employment of the galvanic battery. Undoubtedly we meet with cases of paralysis in which galvanism will not effect a cure, but as this treatment affords the best chance of restoring power and tone to the muscles, it is right to try it in most instances.

The distortion of the digits and the stiffness of the joints which follow injuries of the nerves, require appropriate treatment. Such distortion may be relieved by the use of simple mechanical apparatus, or their effects may be partially counteracted by the employment of one or more Indian-rubber or elastic bands adjusted and fixed along the hand and forearm as substitutes for the paralysed muscles. The stiffness of the joints will be best overcome by warm bathing, gentle movements, and friction. Division or resection of portions of the nerves has been tried as a cure for the painful symptoms following such injuries, but the operation has not been attended with much success.

Mr. Ferguson<sup>1</sup> mentions two cases, one in which he divided the median nerve at the wrist, in order to relieve the painful symptoms produced by a tumour in the palm of the hand. The operation was followed by very little improvement. The other case was that of a painful ulcer on the arm, a little above the inner condyle. To relieve the painful symptoms a portion of the ulnar nerve was cut out. The operation cured the pain, and the ulcer healed; but the little finger and ulnar side of the ring-finger remained paralysed.

<sup>1</sup> *Practical Surgery*, p. 287.

Where we have a distinct history of a local injury of a digital nerve, as in Case 35, it will be proper to resort to amputation of the affected digit, or even of more of the limb, provided other means have failed to relieve painful symptoms, such as we have described. Besides the local methods of treatment, the patient's general health must be carefully attended to, the bowels regulated, tonics and good diet administered, and fresh bracing air recommended.

*Gangrene of the Digits.*

I have mentioned that inflammation of the digits may give rise to their complete mortification, and I have also referred to the effect of cold and heat in causing gangrene, so that I will now proceed to enumerate some of the other causes of gangrene in the digits. Injuries of all kinds may cause the immediate death of a digit, or may so weaken its tissues that when inflammation attacks it, it soon perishes.

I saw a little boy lately who had severely bruised his thumb by a heavy body falling on it. The injury had fractured the first phalangeal bone transversely, but there was no wound of the soft parts. Three days after the thumb mortified, and a line of demarcation formed immediately below the meta-

carpo-phalangeal joint. The thumb was then removed at the articulation.

A short time ago I saw a man whose thumb had been seized by a horse. There was a wound almost entirely round the base of this digit; two days after, the thumb was quite black, and in about a fortnight separated at the metacarpo-phalangeal joint.

Any obstruction to the circulation in the blood-vessels of the upper extremities may cause gangrene of the fingers. In obstructions of the axillary and brachial arteries it is not uncommon to find merely the tips of the fingers become numb, their temperature diminished, and their circulation very weak. In some instances such fingers gradually recover their proper temperature and circulation, while in other cases gangrene results. These cases are often tedious in their progress, and the weakened parts require to be carefully guarded from any irritation which would be likely to set up inflammation in them. Dr. John W. Ogle<sup>1</sup> has recorded an interesting case of ulceration of the fleshy parts of all the fingers, loss of the nails, and separation of the last two phalanges of two fingers, in consequence of an arrest in the circulation in all the main arterial branches of both arms and legs.

<sup>1</sup> *Trans. Path. Soc.*, vol. xv.

*Senile Gangrene.*

This form of gangrene is most usually found in the toes. It depends upon a gradual diminution in the circulation of the lower extremities, which is generally owing to a diseased state of the coats of the arteries, and in many cases to a weakened condition of the nervous action of the tissues themselves. This kind of gangrene is commonly met with in the aged, or those past the middle period of life ; it has, however, been noticed to occur at an earlier period.

This affection is not always confined to the toes, but may spread and involve other parts of the foot or leg.

The affection has been divided into dry and moist. In the *moist* form the disease commences with a feeling of uneasiness or pain in the foot, the foot or one or more toes swells, and then a dark spot appears in some part of this swelling, most generally near the extremity of a toe. Round this dark spot the soft textures become inflamed, vesications form, the cuticle separates, and a sloughing ulcer results. The disease slowly spreads, and may either kill the patient from the constitutional irritation which it produces, or having destroyed a certain amount of the foot, the dead parts separate, and the wound heals up.

In the *dry* form one or more of the toes become dead, black in colour, and gradually shrivel up, without causing much pain or other inconvenience. After the disease has destroyed one or more toes, or portions of them, it may become stayed, the dead parts come away, and a wound is left which is usually slow to heal. This form of the affection is generally slow in its progress. I have seen cases in which it took many months for even one toe to separate in this manner.

Mortification of the digits and other portions of the body is occasionally produced by eating diseased wheat or rye. The local nature of this form of gangrene does not, however, call for any special observations.

*Treatment.*—Operative measures are not usually advisable in gangrene of the digits before the line of demarcation has distinctly formed, and the gangrene, from whatever cause, has quite stayed its progress.

The only exception to this is in cases where a digit has been so injured as to give rise to its death at the time, or soon after the accident. In such cases it will generally be right to amputate the digit at once beyond the injured part. Exceptional cases may occur in which it would be proper to

delay the operation, but the ordinary rules will guide us as to the proper course to pursue.

In senile gangrene, and that which depends upon other obstructions of the circulation, it is of great consequence to protect the weakened parts from any source of injury or inflammation. In cases of senile gangrene, it has been shown by Mr. Syme that a milk and farinaceous diet is most beneficial; opiates, too, should be freely given in this disease when there is much pain and restlessness. To the gangrenous parts themselves soothing poultices and other applications of the kind should be made. Charcoal, or Condyl's Disinfecting Fluid, may be usefully conjoined with poultices. No local treatment is usually required in the dry form of gangrene until the dead parts separate. A little cotton wadding may be wrapped round the affected foot, and the diseased limb should be kept in perfect rest.

*Injuries of the Bursæ and Joints.*

The bursæ over the digital joints may be bruised or wounded. These injuries may give rise to acute or chronic inflammation of the bursal sac, the treatment of which has been already considered.

The digital joints are subject to injuries of all kinds. They may be bruised or wounded with or

without loss of tissue or injury to the bones. When the smaller joints are opened by a clean wound, it is sometimes advisable to perform excision of the articular extremities of the bones, as it will in many cases prevent or lessen the risk of ankylosis. If the joint be injured, and the tissues around much destroyed, it will usually be better to amputate the affected digit.

*Dislocations.*

The articular extremities of the digital bones may suffer a simple or compound dislocation, or they may be dislocated and fractured at the same time.

*Dislocations of the Carpo-metacarpal and Tarso-metatarsal Articulations.*

The carpo-metacarpal joints may be dislocated, either forwards or backwards, the former being the rarest. The thumb is the digit most frequently dislocated at this joint, but Malgaigne has collected three cases in which the other digits were dislocated at their carpo-metacarpal articulations. Hamilton<sup>1</sup> refers to these cases in his work on *Fractures and Dislocations*.

<sup>1</sup> Hamilton on *Fractures and Dislocations*, p. 606.

A few months ago, I examined the hand of a woman, aged thirty-eight, the metacarpal bone of whose right thumb was dislocated forwards on to the carpus. This patient was seized with infantile paralysis of the right arm when about a year old, and after this her parents first noticed the distortion of the thumb. I have also seen one case of compound dislocation of the carpo-metacarpal joint of a thumb. An account of the last of these cases is given in Chapter VI.

Simple dislocations of the carpo-metacarpal articulations are usually caused by a fall or blow upon the digits. The symptoms of the injury are usually well marked, the altered position of the bones being readily detected.

Dislocations, both simple and compound, of the tarso-metatarsal joints occasionally take place.

The former are usually produced by falls on the feet, while the latter may be caused by violence applied in any form. Dupuytren,<sup>1</sup> Smith,<sup>2</sup> Hamilton,<sup>3</sup> and other surgeons, have related cases of these dislocations.

*Treatment.*—Reduction of the dislocations of the

<sup>1</sup> Dupuytren on *Diseases and Injuries of the Bones*, translated for the Sydenham Society, p. 152.

<sup>2</sup> *Fractures and Dislocations*, by R. W. Smith, p. 229.

<sup>3</sup> *Loc. cit.*

carpo-metacarpal joints is best accomplished by manipulation alone, or by extension along with manipulation. Great care is required to keep the dislocated bone in its place after the reduction ; for this reason a splint and bandage should be applied for some little time after. When the dislocation is compound, or associated with a wound of the joint, excision of one or both of the articular extremities of the bone will usually be advisable, provided the parts are not so injured as to call for amputation. The great mortality of Dupuytren's cases of compound dislocation of the first phalanx of the thumb would, I think, have been much diminished by the excision of the dislocated portion of bone, instead of the violent means which were employed in order to effect reduction, and which, in many of the cases, caused so much local and constitutional irritation that death was the result.

When the whole of the tarso-metatarsal articulations of one foot are displaced, reduction is generally easily accomplished ; but when only one or two of these joints are dislocated, the reduction is often very difficult. Extension of the foot, with manipulation of the dislocated bones, is the means by which reduction is to be effected.

*Dislocations of the Metacarpo and Metatarso  
Phalangeal Articulations.*

The first phalanges of the thumb and fingers may be dislocated at their metacarpal joints in two directions, namely, *backwards* and *forwards*. The first of these is the more common, and both accidents are most frequently met with in the thumb, the index and little fingers being the other digits most liable to this injury. Simple dislocation backwards of the first phalanx of the thumb is an accident which is usually caused by blows or falls on that digit. The injury is generally easily recognised, the thumb being forced outwards, and forming an angle with the distal extremity of the metacarpal bone, the last phalanx is flexed on the first, and we can usually see and feel the head of the metacarpal bone projecting on the palmar surface of the hand. Although these are the most usual signs of this injury, cases have been noticed in which the phalanges of the thumb were extended upon the metacarpal bone in almost a straight line.

The difficulty which is frequently met with in the reduction of this dislocation has given rise to various opinions in regard to the cause of this difficulty, and several different methods have therefore been suggested for overcoming it. It is unnecessary to

mention all these different opinions; but from a study of the subject, and from experiments performed on the dead body, I agree with those surgeons who consider that the difficulty in reducing this dislocation is owing to the head of the metacarpal bone being forced between the sesamoid bones and the insertions of the flexor brevis-pollicis muscle. In some few cases the difficulty may depend, as has been described by Mr. Wordsworth,<sup>1</sup> upon the malposition of the tendon of the long flexor.

Dislocations of the first phalanx of the thumb "forwards" are produced by very much the same causes as dislocations "backwards." It is not unfrequently caused when a blow is struck with the closed fist, as in pugilistic encounters. The symptoms of this accident are also well marked, the end of the metacarpal bone projects on the dorsal aspect of the hand, and the phalanges of the thumb are extended. In two examples of this dislocation which I have had an opportunity of studying, there was more or less rotation outwards of the phalanges. Fig. 117, Plate XI., is taken from the hand of a man, aged thirty-four, who, twelve years ago, dislocated his thumb when fighting, and never applied for surgical advice. The first phalanx was dislo-

<sup>1</sup> *Lancet*, for October 17, 1863.

cated on to the palmar aspect of the metacarpal bone. The phalanges were rotated outwards, so that the palmar aspect of the thumb faced, as it were, the same aspect of the index finger. The head of the metacarpal bone formed a most prominent projection in the space between the thumb and index finger.

There is a cast of the hand of a pugilist in the Edinburgh College of Surgeons' Museum, which exhibits a similar dislocation. In this example the phalanges are also rotated outwards, but not to such an extent as in the former case. The head of the metacarpal bone projects on the radial side of the phalanges.

*Treatment.*—The best method of reducing dislocations at the metacarpo-phalangeal joint, if simple extension and manipulation are not successful, is to grasp the thumb or finger affected, and forcibly flex it on to the palm of the hand, at the same time pressure should be made upon the projecting extremity of the first phalanx. When the end of the phalangeal bone has reached the level of the articular surface of its metacarpal bone, the finger or thumb should be freely rotated and moved until the bone slips into its proper place. I have known dislocations of the thumb reduced in this way after

they had been unsuccessfully treated by prolonged and severe extension. Forcible flexion of the digit backwards, or what is called dorsal flexion, has also been successfully adopted by some surgeons in reducing these dislocations.

When these dislocations are compound, excision of the joint or joints involved, including the displaced bone, will usually give the best result, as in Case 36, which is referred to in considering resections of the digital joints. It may sometimes happen that a simple dislocation of a thumb or finger cannot be reduced even by the method of extreme flexion. In such cases division of the lateral ligaments or other obstructing structures has been practised, but this proceeding is apt to be followed by inflammation of the joint, and consequent stiffness of the digit. It will no doubt be right, in certain instances, to endeavour by careful subcutaneous incision to overcome the difficulty by dividing one or both heads of the flexor brevis pollicis, but if this proceeding is not successful, or if inflammation should follow its performance, excision of the articulation would probably give the most satisfactory result.

The phalanges of the toes may be dislocated at their metatarso-phalangeal joints. Simple disloca-

tion of these articulations is caused by blows or falls on the ends of the toes. This dislocation has also been produced when a person has fallen from his horse and his foot has been caught in the stirrup. Compound dislocation may be produced by almost any violence.

In simple dislocation of the first phalanx of the great toe, this digit is usually displaced upwards, the head of the phalanx forming a prominence on the dorsum of the foot. This accident is sometimes attended by the same difficulties in its reduction as the corresponding injury of the thumb, and the same rules for effecting reduction are applicable to both.

Simple dislocations of the smaller toes at this joint can generally be reduced by extension and manipulation.

#### *Dislocations of the Phalangeal Joints.*

The phalangeal bones of the thumb and fingers may be dislocated at their phalangeal joints in three directions—*backwards*, *forwards*, and *laterally*.

Dislocation *backwards* of the last phalanx of the thumb is not an unfrequent injury. This luxation may be simple, but it is often compound, and attended with laceration of the soft parts.

Dislocation of this bone has also been met with both forwards and laterally.

Dislocations of the second and third phalanges of the fingers is an injury which is occasionally produced by blows and falls on the extremity of the digits, and sometimes occurs in cricket and other games in attempts to catch a hard ball when in motion.

Dislocations of the phalanges of the fingers may be complicated, with simple fracture of the articular ends of the bones; or they may be compound, with or without fracture of the bones. The cases of lateral dislocation of the phalangeal articulations which have as yet been observed, have been compound and incomplete. Mr. Holthouse<sup>1</sup> has recorded two cases of compound and incomplete lateral dislocations of the thumb. Fig. 118, Plate XI., is taken from a cast of a hand, now in my possession, which was kindly given to me by Dr. Elliot of Carlisle. It represents a simple lateral dislocation of the second phalanx of the thumb. Fig. 121, Plate XI., is an example of a compound incomplete lateral dislocation of the second phalangeal bone of a finger complicated with a fracture through the articular extremity of the first phalanx. Malgaigne has re-

<sup>1</sup> *Trans. Path. Society of London*, Feb. 18, 1862.

ported two cases of compound luxation of the last phalanx,—one case being in the index finger, the other in the ring-finger.

*Treatment.*—The different dislocations of the phalanges are readily reduced, when seen soon after the accident, by the same means which are successful in the dislocations of the other digital articulations.

When such dislocations are compound, they must either be treated by excision, or, if the soft parts and bones are much injured, by amputation.

In employing extension in the reduction of dislocations of the digits, it is sometimes necessary to use some apparatus in order more effectually to lay hold of the distal extremity of a finger or toe. A common clove hitch, made with a piece of bandage or tape, answers the purpose in most cases. I have seen one of the “Indian puzzles” which Mr. Hamilton has figured in his work applied. It is an effectual means of holding the finger, and considerable force can be employed with it.

#### *Injuries of the Bones.*

The bones of the digits may suffer from simple or compound fractures. The latter are most frequently met with, and are often complicated with

laceration and destruction of the soft parts. Fractures of these bones, whether simple or compound, may be single or comminuted. Such injuries may be limited to one or more digits, or they may merely form part of a more extensive injury of the hand or foot.

*Fractures of the Metacarpal and Metatarsal Bones.*

Simple fracture of the metacarpal bones is usually produced by direct blows, such as a kick from a horse or a stroke from a stick; it is also sometimes caused when a blow is struck with the closed fist, or by a fall on the back of the hand. The last case of fracture of this bone which I saw, was that of a man, about thirty years of age, who was thrown from his horse, and fell upon the back of his right hand, fracturing the fourth and fifth metacarpal bones at a point between their middle and phalangeal extremities.

The fracture of a metacarpal bone may take place in any part of its extent, and the fragments may retain their natural position, or may become displaced. When there is little displacement of the fragments, the diagnosis of this fracture is sometimes difficult, especially if much swelling has

followed the accident. Fracture of the metacarpal bone of the thumb is generally easily distinguished. The metacarpal bones may suffer from compound or comminuted fractures which may be uncomplicated, but are more frequently attended with laceration of the soft textures, and injury to other parts of the hand.

Fractures of the metatarsal bones are most frequently compound, and caused by severe injury. If simple, they are of the same nature, and require the same treatment as those of the metacarpus.

*Treatment.*—The treatment of simple fracture of the metacarpal bones is not difficult; if there is no displacement, a bandage applied carefully round the hand is usually all that is required. If there is any overlapping or distortion of the fragments, they should be replaced as accurately as possible, and a pad or splint applied, by means of a bandage, to keep them in position. In fracture of the metacarpal bone of the thumb, it will usually be advisable to apply a narrow splint of pasteboard or wood on its palmar aspect. The splint should pass down into the palm of the hand, and cover the ball of the thumb. When the fracture of a metacarpal bone takes place near one of the articulations, careful movement of the digits ought to be em-

ployed at the end of a fortnight or three weeks after the injury.

Compound fractures of the metacarpal and metatarsal bones are often so severe as to necessitate amputation ; but if the case is otherwise favourable, attempts may be made to save the part, any loose or protruding portions of bone being carefully removed.

*Fracture of the Phalangeal Bones.*

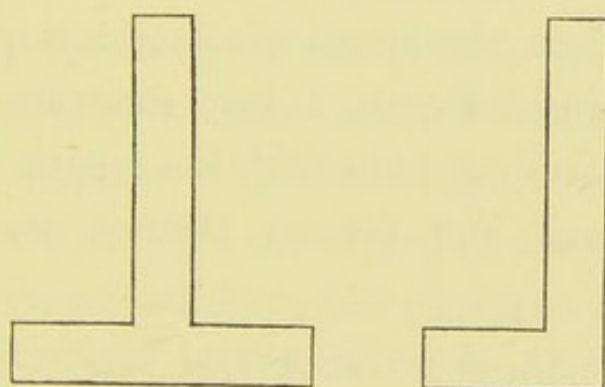
Simple fracture may take place through any of the phalangeal bones, but the first phalanx is the one most frequently injured in this way.

A phalangeal bone is sometimes fractured close to one of the joints ; and, in some cases, the fracture extends into the joint. The diagnosis of these injuries is not usually difficult.

*Treatment.*—In treating most simple fractures of the first phalanx, the best method of keeping the fragments of the bone in position and at rest is to place a rounded pad in the palm of the hand, and having flexed the injured digit firmly over it, to secure the hand with a bandage in that position. A rolled-up bandage, or a cork covered with some soft material, makes a most convenient form of pad for this purpose. Exceptional cases of fracture of this

bone may occasionally occur, which will be best treated by placing the finger in the extended position. Fractures of the second and third phalanges should be treated by placing the injured finger in the extended position, and applying along its palmar aspect a narrow splint of pasteboard, wood, or gutta-percha, lined with some soft material,—the splint ought to extend slightly beyond the extremity of the digit.

Mr. Coleman<sup>1</sup> has described and figured a form of splint which he has found very efficacious in treating fractures of the fingers. This splint may be used in either of the shapes shown in the accompanying woodcuts, and may be made of wood,



gutta-percha, or pasteboard. When it is adjusted to the finger, the cross piece rests on the palm at the base of the digit, and the longitudinal portion

<sup>1</sup> *Lancet* for April 15, 1865.

runs along its palmar aspect. I lately employed this splint in one case, and was convinced of its advantages over the ordinary straight splint. Fractures of the phalangeal bones of the toes require to be treated in the same manner as those of the corresponding bones of the fingers.

Compound fractures of the phalangeal bones are usually comminuted, and may take place in almost any direction. A phalangeal bone will occasionally be cut through, and a portion of the digit thus completely severed. We have already referred to examples in which such severed digits have reunited. When the digital bones are subjected to much pressure, the fracture may split up the bone, and a joint may thus be opened into, although situated at some distance from the actual place of injury. In dissecting injured fingers, I have sometimes found a fissure extending fully half the length of a phalangeal bone, and passing through its articular extremity.

In Plate XI., there are several illustrations which have been taken from examples of compound fractures of the phalangeal bones of the fingers. Figs. 119, 120, and 121, illustrate transverse and oblique fractures of the phalanges of the fingers. In Fig. 126, the fracture is associated with a dis-

placement of the articular extremity of the first phalangeal bone. This portion of the bone has been turned quite over, so that its articular surface presents itself on the dorsal aspect. In Fig. 125, the fracture of the distal phalanx is associated with a bending of the second phalangeal bone. Fig. 123 is an example of a longitudinal and comminuted fracture of one of these bones. Fig. 124 is taken from a finger which was injured by a gunshot wound. The patient from whom it was removed was a young gentleman, through whose hand a charge of small shot passed. The muzzle of the gun was within a few inches of the hand at the time, so that the shot passed through like a bullet, and destroyed the metacarpo-phalangeal joint of the middle finger. There was an opening the size of a sixpence through the hand in this situation, but no other apparent injury. On dissecting the amputated finger, I found a single shot lying in a small cavity on the palmar aspect of the last phalanx; there was no external wound, and the shot appeared to have run up the finger underneath the skin, and lodged in this situation.

*Treatment.*—Compound fractures of the phalangeal bones of the fingers and toes, especially if comminuted, will in most cases require amputation

of the digits, as they are usually complicated with destruction of the soft textures.

In favourable cases, an attempt may be made to save the finger or toe by removing any loose portions of bone and placing the injured digit on a splint; the wound being kept clean and carefully dressed. In a case of compound fracture of the second phalanx of a finger which I once attempted to save, I could obtain no union of the bone; the wound was healing nicely, but some weeks after the accident there was not the slightest attempt at union. The finger was accordingly amputated, and on dissection I found a small loose fragment of bone lying between the ends of the fracture. There were no signs of any osseous deposit in the neighbourhood of the fracture.

In treating severe injuries of the hand and fingers, it is of great consequence that we should save as much of these structures as possible, provided it is likely to be of use afterwards. We are often called upon to treat accidents of the hand in which all the digits are more or less injured, either by laceration of their soft textures alone, or by injury of the bones as well. I have seen cases in which the skin was completely torn off from the whole dorsal aspect of the hand; the nerves, tendons, and other

structures being exposed as in a dissection. When more than one of the digits are destroyed, it becomes a matter of great importance to save even a half, or smaller portion of a finger or thumb. Many a person has become accustomed to make good use of one or two fingers, or of one finger and a thumb, and has even been able to get some advantage from the stump of a hand in which no digits were left, after severe injuries of this kind. Three years ago, I was called upon to treat a severe laceration of the hand in a little boy, which had been caused by machinery. All the fingers and most of the hand were quite destroyed, the thumb only being uninjured. With some care, I was able to save a small bit of the index-finger, and this small portion made all the difference in the stump of the hand between a mere hook (which the thumb alone could only have been), and a pair of useful forceps, for the thumb could be opposed against this remnant of finger, and objects firmly grasped between them.<sup>1</sup> Most operating surgeons can now reckon in their experience similar cases in which entire digits, or portions, have been thus advantageously saved. I lately had

<sup>1</sup> I had an opportunity very lately of examining this hand, when I found that the stump of the index-finger had become hypertrophied; the bone and soft tissues having nearly twice the bulk of the thumb of the same hand.

an opportunity of examining two curious stumps, resulting from injury of the hand. In neither of these was there any portion of the digits left, and yet the patients could hold a pen or pencil. The first of these cases, illustrated in Fig. 55, Plate v., was that of a man aged 45, who had received a gunshot injury of the right hand. There were no traces of any fingers or thumb, but there were two prominences at the extremity of the stump, with a cleft between them. A pen or pencil placed in this cleft could be grasped, and the patient was thus able to write.

The second case was a boy aged sixteen, who six years ago had both his hands severely burned. Nothing was left of the right hand but a short stump, at the extremity of which was a slight projection. Between this projection and the rest of the stump he was able to place a pen or pencil, and holding it in that position by means of the stump of the left hand, could write well and freely.

In my observations on wounds of the digits, I referred to the constitutional irritation which such wounds sometimes cause. The same remarks are applicable to compound fractures and dislocations of the digits. These injuries are in some constitutions extremely liable to give rise to much general

irritation. For this reason we ought not to carry conservative principles too far in treating severe injuries of the digits. It will be much better to amputate one or more digits than to endanger the life of a patient.

## CHAPTER V.

### NON-CONGENITAL CONTRACTIONS AND DISTORTIONS OF THE DIGITS.

ALTHOUGH many of the causes which produce non-congenital contractions and distortions of the digits have been mentioned in the description of the different diseases and injuries of the fingers and toes, I have thought it right to devote a special chapter to the consideration of the nature and treatment of these deformities, as it is often of great importance to prevent or relieve them.

These deformities—

1st. May result from inflammation of the different textures of the digits or extremities.

2d. They may be caused by affections of the nervous system.

3d. They may be the effect of injuries, the growth of tumours, or some form of pressure.

1. Acute inflammation, with or without suppuration of the soft textures of the forearm, hand, or

fingers, is often followed by more or less contraction or stiffness of the digits. This inflammation may commence in the forearm or hand, but more frequently it originates in a finger, and spreads to the former situations. The acute inflammation which originates in and spreads along the sheaths of the tendons, is that which is most likely to be followed by serious distortion of the fingers.

Acute and chronic inflammation, without suppuration in the forearm, may cause stiffening or contraction of the fingers, by glueing the muscles and other soft textures together, and so interfering with their movements. The effects from this cause are, however, not so likely to be permanent as in those cases of inflammation which are followed by destruction of texture.

Acute inflammation, with suppuration in the hand or fingers, when superficial, is not usually followed by any interference with the functions of the digits ; but when this inflammation and suppuration attacks the tendons and their sheaths, the result is too frequently a contraction or stiffening of one or more fingers. This contraction may either depend on the adhesion of the tendons to their sheaths, or it may depend on the destruction of portions of the tendons themselves, the latter being the more serious

evil. The sheaths of the flexor tendons are most liable to be attacked by acute inflammation, consequently the fingers are usually contracted in the flexed position. The contraction may be slight, or the finger may be firmly bound down to the palm of the hand, as is shown in Figs. 66 and 67, Plate VI.

Acute inflammation of the bones or joints may cause distortion or contraction of the digits, either by leading to destruction of the bone and implication of the soft textures, or by producing ankylosis of the articulations.

Acute inflammation of the different textures of the leg, foot, or toes may lead to similar contractions and distortions of the toes.

Chronic inflammation of some of the soft textures of the hand occasionally gives rise to contraction of the fingers. This has been especially noticed in connexion with a peculiar condition of the palmar fascia, which, by the contraction of its digital processes, gradually distorts one or more of the fingers. Such cases usually commence without any pain. A thickening or prominence of the process of the palmar fascia, which proceeds to the affected finger, slowly takes place. The prominent process of the fascia often resembles a tightened tendon, and is

frequently more or less adherent to the skin. As the disease advances, the finger or fingers become gradually flexed, and in extreme cases firmly bound down to the palm of the hand.

Any of the fingers may become thus distorted, and frequently the disease implicates two or more fingers in succession. The little, ring, and middle fingers are most frequently affected, but the index finger and thumb may likewise suffer. Some authors consider that the disease depends on constitutional causes of a gouty or rheumatic tendency. Others again have thought that the disease was owing to some local injury or irritation. On whatever cause it may depend, it usually steadily progresses, and makes the affected fingers quite useless.

A similar condition of the plantar fascia may lead to permanent flexion of the toes. I had the good fortune lately to have an opportunity of dissecting a well-marked example of this affection. Fig. 54, Plate v., is taken from this dissection. All the toes in this foot were firmly flexed. After carefully dissecting off the skin from the sole of the foot, I exposed the whole extent of the plantar fascia, together with its digital processes. The whole fascia appeared thicker than natural, and was slightly contracted. After getting a drawing

made of the parts, I cut across the plantar fascia about a quarter of an inch from its attachment to the os calcis, and immediately the toes became straight and quite movable.

Chronic rheumatic arthritis and gouty inflammation of the different digital joints are frequent causes of the distortion of the fingers.

The chronic inflammation of the tendons and their sheaths, which has already been described in Chapter II., may also lead to stiffness of the digit or digits implicated.

*Treatment.*—Contractions and stiffening of the fingers depending on acute inflammation in the forearm, hand, or digits, generally resist treatment when there has been much destruction of the tendinous structure, but still perseverance in practising movements of the affected digits will sometimes considerably improve the deformity. In cases of contraction, some simple mechanical apparatus ought to be applied along the affected fingers, so as gradually to extend them. When these distortions are due to the contraction of one or more tendons, and these tendons can be felt tense and contracted, they should be divided subcutaneously, either in the forearm, hand, or fingers, as may be most convenient.

Complete ankylosis of the digital articulations can only be treated by the removal of the digit, if the deformity should prove troublesome. In deciding as to the removal or non-removal of a distorted finger, we should remember the fact that certain of the fingers are of greater importance than others, according to the patient's particular trade or employment, so that in some cases the removal of even a distorted finger might seriously interfere with his or her occupation.

Distortions of the fingers which depend on a contracted state of the palmar fascia are generally amenable to treatment. This treatment consists in dividing subcutaneously the contracted process of the palmar fascia which is connected with the affected finger. Dupuytren<sup>1</sup> recommended that a free incision should be made across the base of the finger, and the palmar fascia divided in this way. It is quite unnecessary, however, in most cases, to divide the skin, the subcutaneous division being quite effectual. If the flexor tendon should have become contracted, it ought also to be divided. I have, however, seen examples of this affection, in which the fascia had become so firmly adherent to

<sup>1</sup> Dupuytren, *Clinical Lectures*, translated by Le Gros Clark, p. 220.

the skin that its subcutaneous division was impossible. In slight cases of this affection the cure may sometimes be accomplished by the use of mechanical means, applied so as to straighten the finger; but in the majority of cases it is better to divide the fascia. I have met with cases of this affection in which a contracted finger had been forcibly straightened by accident. One instance occurred in a gentleman, aged forty-five, who had the middle finger of one hand contracted from this cause. About two years ago, when getting over a hedge, the finger caught against a stake, was forcibly straightened, and has remained perfectly well ever since. Contractions of the toes from an abnormal condition of the plantar fascia should be treated on the same principle as contractions of the palmar fascia. If all are contracted, I would prefer dividing the plantar fascia subcutaneously close to the os calcis. Distortions of the digits depending on rheumatic or gouty inflammation of their articulations are not usually remedied by any surgical treatment, as these diseases lead to permanent changes in the structure of the joints. Warm bathing, with gentle exercise and friction, are the only means likely to afford any relief.

2. *Contractions and Distortions of the Digits from Affections of the Nervous System.*

We have already considered at some length the contractions, loss of power, and abnormal conditions of the digits which may be produced by wounds, bruises, and other injuries of the nerves which are connected with them. (See *Injuries of Nerves*, Chapter IV.) We will now therefore proceed to study some of the nervous affections of the digits which depend on other causes.

Paralysis, spasmodic contractions, and abnormal sensations of the digits, may be merely a symptom (not unfrequently the first symptom) of some disease affecting the great nervous centres, or they may be "local," and confined to certain regions, to a single muscle, or to one or more groups of muscles. Paralysis and other abnormal conditions of the digits depending on the former cause are usually accompanied or soon followed by other signs of general nervous disease. This implication of other portions of the nervous system distinguishes such cases from those of a "local" character.

Romberg<sup>1</sup> relates the case of a man who laboured under disease of the cerebellum, which first showed itself by a difficulty in writing and other manual

<sup>1</sup> Romberg on *Diseases of the Nervous System*, vol. i.

occupations. The same author relates another case, of a boy who was affected with a convulsive movement of the fingers of the right hand, which was merely the precursor of an attack of epilepsy. Among the nervous affections which I have termed local, are those met with in certain persons who require to use their fingers actively and constantly in following their occupation. Thus writers, sempstresses, musicians, shoemakers, and others, are occasionally affected with a palsy, or spasmodic contraction of the muscles which move those fingers which are used in their professions or trades. The peculiarity of these affections is that the paralysis or contraction only takes place when they use the fingers in their particular employments, the other movements of the fingers being performed with perfect facility. For instance, in what is called "Writers' Cramp," the patient is able to use his fingers perfectly in all movements except those required in writing. Romberg relates the case of a smith, who suffered from a rigid contraction of the muscles of the forearm whenever he took hold of the hammer to fetch a blow. All the other movements of the arm were perfect.

I propose now to give a short description of that nervous affection of the fingers which is sometimes

met with in clerks and others who require to write much, as it may be taken as a type of the other affections of a similar nature.

*Writers' Cramp.*

This affection has also been termed "Scriveners' Palsy." It most frequently occurs in males, but has also been seen in women. The peculiarity of this disease is that although the slightest attempts to write bring on a palsy, or spasmodic contraction of the thumb and fore and middle fingers, the other movements of these fingers are not attended by any abnormality. When a patient has this disease well marked, any effort to write brings on the spasmodic contractions of the fingers and thumb, so that the pen starts up and down, and is jerked about in an extraordinary manner. If the patient continues in his attempt to write, the symptoms become aggravated, and in some cases the muscles of the forearm, and even the arm, contract violently. Occasionally a trembling or shaking palsy of the hand puts a stop to the act of writing. When the patient ceases to write, the contractions or palsy are immediately stayed. Even in severe cases of the disease there is no other affection of the nervous functions of the arm.

Mr. Solly<sup>1</sup> has published some interesting lectures on this affection, and in them has recorded the histories of several patients who suffered from this kind of paralysis of the digits. Mr. Solly has observed that "Writers' Cramp" may commence with a feeling of fatigue or pain, together with stiffness in the thumb and fingers of the hand employed in writing, or in the whole hand; and if the writing be persevered in, the symptoms become more and more aggravated, until at length the act of writing becomes impossible, owing to the spasms or palsy of the digits.

It has been noticed by Halse, and also by Solly, that in some of those cases of palsy occurring in writers and musicians, there is an aching or uneasiness in the lower cervical and upper dorsal portion of the spine. For this reason Mr. Solly is of opinion that the scriveners' palsy has its origin in the spinal cord. Our knowledge of the pathology of this disease is not, however, I think, as yet sufficient to determine the exact cause or seat of the complaint.

Another form of spasmodic contraction of the digits is named Carpopedal Convulsion. It is generally met with in children during the first

<sup>1</sup> *Surgical Experiences*, by Solly, p. 205.

three years of life, and affects both hands and feet at the same time. The fingers are bent across the palm of the hand, with the thumb underneath, and cannot be extended without causing great pain. The toes also become doubled up, the big toe being generally abducted and the foot extended. In some cases, a small amount of swelling and redness of the hands and feet has been noticed. The affection occurs periodically, and lasts for a few days or weeks. It appears to be caused by intestinal irritation or teething.

A short time ago, I met with a curious spasmodic affection of one finger. The patient, a woman in good health, aged thirty, when she attempted to extend the ring-finger of the right hand separately or along with the other fingers, could not at first perform this movement; but when the other digits were almost fully extended, this finger gave a sudden jerk, and so became straightened. The disease had existed several months, and there was no apparent cause for it. I noticed, however, that at times when the patient's attention was taken away from the finger, the peculiarity was not so well marked.

A common cause of the local paralysis of certain muscles connected with the digits of the upper

extremity, is that form of palsy which is produced by lead poisoning. The paralysis most frequently attacks the extensor, supinator, and adductor groups of muscles, and may occur on one or both sides of the body. When the extensor muscles of the digits are thus paralysed, the fingers become semi-flexed, and cannot be fully extended. In the *Medical Times* for August 11, 1860, Dr. Taylor has reported a case of palsy affecting both hands, and depending on this cause. The patient, a man aged forty-seven, for a year and a half had drunk water which had been stored in a lead cistern. Dr. Taylor treated this case successfully by the application of galvanism to the paralysed muscles.

Certain of the muscles of the thumb may be alone paralysed in lead poisoning, and cause a want of proper movement in this digit. If the disease is of long standing, the fingers sometimes become much distorted, and even displacement of the bones of the hand may take place.

The toes are occasionally similarly affected in lead palsy.

Romberg has directed attention to an affection which he has noticed only in washerwomen. It consists of a sensation of numbness in both hands and forearms, with a pricking sensation in the tips

of the fingers. The power of motion is not interfered with.

*Treatment.*—The treatment of Writers' Cramp, and other affections of a similar nature, has as yet been very unsatisfactory. Stromeyer divided subcutaneously the tendon of the flexor longus pollicis in one case, and on the fourteenth day the patient was able to write and play the piano perfectly. Dieffenbach also operated upon several cases, but the operation had no effect in curing the disease.

A great variety of other means has been employed in treating this affection, but they have all proved ineffectual. From the experience of Mr. Solly in the treatment of Writers' Cramp, it would appear that entire rest from the particular occupation which has led to the disease affords the best chance of recovery. Along with the rest, tonics (iron, quinine, etc.) should be given. At the same time, fresh and bracing air is of good service in improving the general health. In obstinate cases small doses of strychnine may be carefully tried; but the entire rest of the fingers, from those movements which excite the disease, apparently forms the most essential part of the treatment. Mr. Hulke<sup>1</sup> reports the case of a woman, a copyist, aged twenty-

<sup>1</sup> *Med. Times and Gazette* for May 27, 1865.

six, who had been troubled for a year with spasmodic irregular contractions of the thumb and fore and middle fingers when she attempted to write. She was ordered to give up writing, douche the hand, and take cinchona. Under this treatment she steadily improved, and in nine months was able to write quite well.

Patients who suffer from a slight form of this kind of palsy are sometimes enabled to write properly, either by modifying the manner of holding their pen, or by the employment of penholders which have connected to them supports for the fingers. I know one gentleman who is unable to write for any length of time when he holds his pen in the usual way. This patient has fixed to the extremity of a short penholder an oval-shaped pad about the size of a small pear. In writing, he holds the pad between the thumb and forefinger, with its apex resting on the palmar surface of the fingers; the pen itself is brought out between the middle and ring-fingers, and used in this position. By adopting this method, he is able to write freely and distinctly.

Cases of palsy of the fingers and toes depending on lead poisoning require the appropriate treatment for that disease. The patient must at once avoid

the source of the poisoning, and use frequent warm baths. Sulphur baths, made by adding from two to four ounces of the sulphuret of potassium to twenty or thirty gallons of water, have been specially recommended for eliminating the poison in this disease. The internal use of iodide of potassium is also found useful in these cases, but it requires to be carefully administered. If the muscles do not begin to recover after the employment of these general means, blisters or galvanism may be applied as stimulants over them. Dr. Taylor, in his remarks on the treatment of the case already referred to, directs attention to a very useful form of support for hands affected with this kind of palsy. Dr. Inman<sup>1</sup> of Liverpool had previously used a similar apparatus, which consists of a piece of flat elastic band stitched by one end to the back of an ordinary glove, the other end being tied by means of tape above the elbow. This apparatus effectually supports the wrist, and at the same time allows the weakened muscles to act.

The carpopedal contraction of the fingers and toes is to be treated by removing any cause of irritation in the mouth or intestinal canal. If the gums be swollen or irritable, they should be freely

<sup>1</sup> *Liverpool Med. Chir. Trans.*, vol. i.

incised, and, if necessary, the bowels ought to be purged.

*3. Contractions and Distortions of the Digits the result of Injuries, the growth of Tumours or some form of Pressure.*

The contraction of tendons after they have been wounded in the forearm, hand, or fingers, is a frequent cause of contraction or stiffening of the fingers, with which the divided tendon or tendons are connected.

Bruises, fractures, and dislocations of the bones of the forearm, hand, or fingers, may be followed by contractions of the digits; the accident may have caused rupture and laceration of the muscles and tendons, or the inflammatory process necessary for the union of the fracture may implicate these structures, and cause them to become adherent to one another, and to the bone and periosteum. There is one fracture of the forearm that is almost invariably followed by stiffening of the fingers, and that is the fracture through the lower end of the radius. I have had an opportunity of seeing dissections of old-standing examples of such fractures, and have noticed that the tendons over the seat of the fracture were not only adherent to their

sheaths, and to the annular ligaments of the wrist-joint, but were sometimes atrophied, or matted together, or adherent to the lower end of the fractured radius.

The various injuries of the nerves connected with the digits may also lead to contraction or distortion. These affections have already been fully considered in Chapter IV.

Burns and scalds of any part of the upper extremity or digits, may lead to contractions of the hand and fingers. I have also seen a chilblain lead to a slight contraction of a finger, although the skin had never been broken.

Tumours which have originated in the textures of the forearm and hand may, in their growth, push aside or stretch the tendons of a digit, and thus cause contraction. The incisions required for the removal of tumours in these situations may divide muscles and tendons, and in some cases it may be necessary to take away portions of these structures. Such operations may therefore be followed by more or less contraction of the digits.

The toes may become distorted from very much the same causes as the fingers.

The contractions of the digits from continued pressure is seen in those distortions of the fingers

which are produced in following certain trades, and in the common deformities of the toes which result from the use of tight or ill-fitting boots and shoes.

Pressure exercised in this way causes the toes either to become distorted laterally, so that they overlap each other, or to become flexed, or bent back upon themselves.

All the toes may be distorted laterally, and lie compressed against, or overlap one another, or one or two toes only may completely overlap their neighbours. The great, second, and fifth toes are the ones which most usually lie over, or under their neighbours; and from the awkward position in which they are thus placed often cause much inconvenience. The third and fourth toes may occasionally also be distorted in this manner.

When a toe has thus lain across or underneath another for some time, either of the two may become flattened out by the pressure, and even the bones, especially the last phalanx, may suffer in this way.

Having dissected and prepared one of these compressed toes, I found that the last phalangeal bone was much broader and flatter than usual. Figs. 52 and 53, Plate v., and Fig. 73, Plate vii.,

illustrate these distortions of the toes. Figs. 74 and 75, Plate VII., already referred to, show the altered position of the bones of the toes in these cases.

The contracted and flexed condition of the toes may originally have been congenital, and become gradually aggravated, or it may be solely the result of undue pressure.

The toes which most frequently suffer in this way are the second and third. Their contraction appears to me to depend, in some cases, upon their length. In the majority of persons, the extremity of the second toe projects beyond that of the great toe, and in some cases the third toe is longer than either. When a shoemaker measures the length of a foot, he usually takes the measurement from the extremity of the great toe to the heel, so that if any of the other toes should be longer than the great toe, they suffer more or less from the pressure of the boot or shoe, which is too short for them. Another cause of this distortion is an unyielding condition of the textures of which the boot or shoe is made. Some of these contractions of the toes have been illustrated in Plate VI.

*Treatment.*—Contractions and distortions of the

fingers depending on wounds, and other injuries of the forearm, hand, or digits, will be best avoided or diminished by attending carefully to their treatment during the process of healing.

When the tendons are divided, their cut ends should be adjusted as carefully as possible; and when the wound is healed, or nearly so, careful movements of the fingers implicated should be employed.

In fractures, especially those near the wrist-joint, the movement of the fingers is of the greatest importance, and ought to be commenced at an early period after the accident. If the broken bones be carefully retained in position by some apparatus which will not include the digits, there can be no harm in commencing such movements within a week or so after the fracture has been set. I think that we are often too chary in employing such movements at an early period.

The contractions caused by burns and scalds can often be much relieved by the use of mechanical means, as long as the cicatrices are recent. In certain cases, it might be right to conjoin tenotomy with this treatment, or to perform some plastic operation.

If tumours in their growth impede the action of

muscles or tendons, they ought to be removed, provided other circumstances are favourable. In such cases, a complete cure can only be looked for when the tumour is removed, without division or destruction of the muscles and tendons.

Should contracted or stiff fingers have resisted all treatment, and have become merely troublesome appendages to the hand, it will be better to amputate them.

When toes become distorted from wearing ill-fitting boots or shoes, means should be used to prevent this deformity from increasing. These consist in having boots and shoes constructed on proper principles, for which purpose the patient should employ an intelligent shoemaker, and should have a last made for his individual use.

“Ready-made” boots and shoes are fruitful agents in producing distorted toes. If a toe completely overlaps another, and cannot be brought back to its proper position, it will be right to remove it. Contracted toes can generally be remedied by surgical and mechanical means, when the complaint is not very severe. If necessary, the flexor or extensor tendons should be divided subcutaneously, and then some simple mechanical contrivance employed to keep or restore the digit in its proper

position. Cases of contracted toes, which have been allowed to advance until the bones and joints are displaced, or which have resisted milder treatment, should be amputated, as they usually give rise to considerable inconvenience.

## CHAPTER VI.

### EXCISION OF THE JOINTS AND BONES OF THE DIGITS.

#### *Excision of the Joints.*

In the *Edinburgh Medical Journal* for September 1862, I published a short paper on "Excision of some of the Smaller Joints," and in it gave an account of the two following cases:—

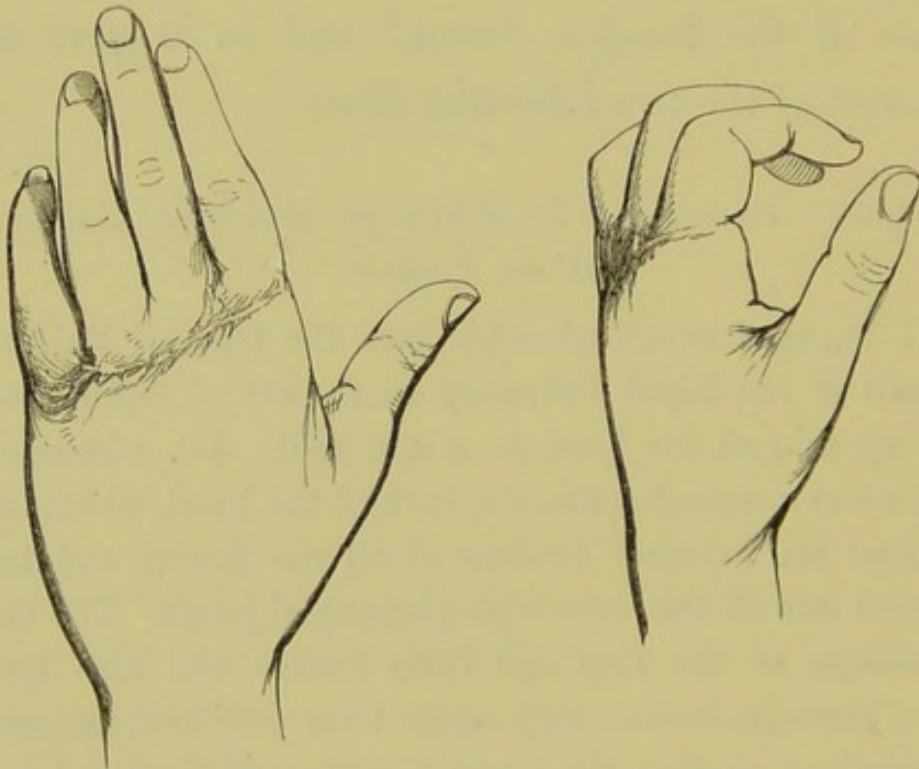
#### CASE 36.—*Excision of the Metacarpo-phalangeal Joints of all the Fingers.*

G. M., aged seven, admitted into the Clinical Surgical Wards of the Royal Infirmary on the 1st of April 1861, having injured his hand in a saw-mill. On admission, there was a wound across the back of the hand, which had divided the extensor tendons of all the fingers, and had opened into all the metacarpo-phalangeal joints. The first phalanges of the ring and little fingers had also been sawn through, immediately above their proximal articular extremities, so that the anterior portion of the hand was only attached to the posterior portion by little more than the flexor tendons and skin on the palm of the hand. The thumb was uninjured. Thinking it right to give the hand a chance of recovery, I cut off the articular extremities

of the metacarpal and phalangeal bones connected with the metacarpo-phalangeal joints of the four fingers. The hand was then placed on a splint, and light dressing applied. The wound healed well, and on the 8th of May the patient was dismissed quite well.

On the 2d of July 1862, more than a year after the operation, I had an opportunity of examining the hand, and found that its appearance was wonderfully natural. It was slightly shortened, but was quite movable and useful. Complete flexion could not be performed.

The accompanying woodcuts illustrate the hand of this case in the extended and flexed positions.



CASE 37.—*Excision of the Carpo-metacarpal Joint of the Thumb.*

J. M., aged sixteen, admitted into the Royal Infirmary of Edinburgh, Feb. 18th, 1861, for an injury on the outer

side of the wrist-joint, which had been caused by a stroke from the sharp edge of an axe. On examination, there was a wound about an inch in length, across the outer aspect of the carpo-metacarpal joint of the thumb. This wound had opened into the articulation, and had partially divided the extensor tendons of the thumb; the end of the metacarpal bone was projecting through the wound. Several attempts were made to reduce the protruding bone, but it always slipped out of its place again when the extending force was withdrawn. I therefore sawed off the head of the metacarpal bone, and brought the edges of the wound together. The wound healed rapidly, and the patient was dismissed cured on the 1st of March. The thumb retained all its movements, with only very slight stiffness.

I have performed excisions of the smaller joints in other cases of a similar nature; and Dr. F. Steell, now of Birmingham, has lately been good enough to send me notes of a case, in which he excised the first phalangeal joint of the ring-finger for a wound of that articulation with an excellent result. The patient, a boy, aged fifteen, had severely injured his hand by machinery. The index, middle, and little fingers were so badly hurt that they required to be amputated at once. The ring-finger had a small wound on the lateral aspect of its first phalangeal joint, which had opened into the articulation and detached a portion of the articular cartilage.

Dr. Steell thinking it right to endeavour to prevent ankylosis, and save the movement of the joint, made an incision along its lateral aspect, and cut off the articular extremities of the first and second phalangeal bones. Passive movements of the fingers were commenced soon after the operation, and perseveringly continued daily. The wound healed in about a month. Three months after the operation the movements and condition of the finger were most satisfactory.

Dr. R. H. Ramsay, now of Torquay, has also kindly sent me a note of two cases, in which he excised the metacarpo-phalangeal joints for supuration and destruction of these articulations following injury. Movable and useful joints resulted in both cases.

In the paper already referred to, I stated that excision of the digital joints was not "advisable," except in cases of injury, owing to the fact, that the affections of these articulations frequently commenced in the bones, and therefore the resection of the joint only would not take away the entire disease. Although I am still of opinion that this operation will be most frequently called for in cases which are the result of injury, either immediate or secondary, further experience has convinced me that it

may occasionally be successfully adopted in diseases of the smaller articulations, provided the disease has originated in and is quite confined to the joint. I have given an account, in Case 24, of one patient in whom I excised a phalangeal joint for disease.

Mr. Butcher<sup>1</sup> has recorded a case in which he excised the metatarso-phalangeal joint of the great toe for disease with good success, and has referred to other cases where resection was performed at the same joint by Professor Pancoast, and Messieurs Friche, Kramer, Blandin, Jobert, and Champion. Some of these operations were done on account of compound dislocation of the head of the metatarsal bone, others for disease of the articulation. About two months ago, a case of compound dislocation of the head of the metatarsal bone of the great toe was admitted into the Clinical Surgical Wards of the Infirmary. The dislocated portion of bone was sawn off, and the articular surface of the phalangeal bone also removed, by Dr. John Chiene, the resident surgeon. At the end of five weeks, the wound had firmly healed, and the result of the case has been most successful. The toe was slightly shortened, but there was no other perceptible deformity.

<sup>1</sup> *Operative and Conservative Surgery*, p. 353.

From the success which has attended these cases of excision of the digital joints, I think we are justified in recommending the adoption of this operation in favourable cases. I will now, therefore, proceed to say a word or two in regard to the best method of performing resection of the smaller joints.

*Excision of the Phalangeal Joints of the Fingers.*

The phalangeal joints of the fingers will be most conveniently excised by making a longitudinal incision, about an inch in length, on the lateral aspect of the dorsal surface of the articulation, as is shown in Plate XII., at 1. (The fingers of the hand in Fig. 126 are all slightly turned round, in order to show some of the other incisions, so that the line, No. 1, looks rather nearer the centre of the dorsal surface than it is meant to be.) The incision should be carried quite down to the joint, and the lateral ligaments divided. When this is done, the articular extremities of the phalangeal bones can be readily turned out, the soft textures carefully separated from them, and as much of the bone sawn off as may be necessary. The edges of the wound should now be brought together, and the finger placed on a straight splint, in order to keep the divided bones in proper position. Careful

passive movements of the joint and finger should be commenced a few days after the operation, and daily continued until the cure is completed.

The advantage of this incision is that it gives free access to the joint, without dividing either flexor or extensor tendons, and without injuring the nerves or blood-vessels. In cases of wounds and compound dislocations of these joints, we may be able, in some instances, to excise the joint through the opening made by the accident, or, if necessary, by slightly enlarging it. When the wound is very small, it will be better to make the incision I have recommended, for it is certainly the most convenient one for the purpose.

*Excision of the Metacarpo-phalangeal Joints of the Fingers.*

These joints may be excised either for disease or injury, provided the case be proper for such an operation. A longitudinal incision, made over the dorsal and lateral surface of the articulation, will be found the most suitable for exposing the joint. The line of this incision is shown in Fig. 126, at 2. The after treatment of this operation must be conducted in the same way as in the resection of the phalangeal joints.

The carpo-metacarpal joints may occasionally be excised with success, as in Case 37. These operations will most generally be for injury, and our incisions for exposing the joint must be made in the most convenient situation.

*Excision of the Joints of the Toes.*

Excision of the joints of the smaller toes is not an operation which can be of much service, as the saving of a portion of one of these digits will not usually tend to preserve any more usefulness to the foot. Resection of the joints of the great toe may, however, be performed in some instances with advantage, as has been proved by the experience of those surgeons already referred to at page 265. Excision of the joints of this toe will be most conveniently practised by following the method which has been recommended for cutting out the articulations of the fingers, the incision, when required, being made on the dorsal and lateral aspect of the joint to be removed.

*Excision of the Bones of the Digits. Excision of the Phalangeal Bones.*

The distal phalanx may frequently be removed with success when it is affected with caries or

necrosis. Occasionally, also, when a tumour grows in connexion with this bone, and does not implicate the soft textures, the bone together with the tumour may be excised, the soft parts and nail being left uninterfered with. Should this bone have suffered from injury which is confined to the extremity of a finger, its removal will often be the best method of preserving the remainder of the digit, if it be advisable to do so. In cases where this bone has become necrosed, we must wait until it is detached, or nearly so, from the surrounding tissues, for it will then be readily seized with forceps and extracted. In these cases the bone usually remains longest attached at its point of connexion with the second phalanx, the strong lateral ligaments which connect the two bones being the last tissues to become destroyed. The incision required for excising this bone will vary according to circumstances. In most instances it is only necessary to enlarge a sinus or wound, in order to expose the bone, and remove it. When this bone requires to be taken out along with a tumour, the best plan is to commence an incision on the lateral aspect of the distal phalanx, about its middle, and carry it round the palmar surface of the extremity of the finger, close to the free edge of the nail, to

a point on the other lateral aspect corresponding to that at which the incision was begun. The flap thus formed should be dissected off and turned over, so as to expose the bone and the growth, which can then be easily removed by carefully separating their other attachments. As soon as the excision is accomplished the flap should be readjusted. By this method the pulp at the extremity of the finger, as well as the matrix of the nail, can sometimes be saved entire. Excision of the corresponding phalanx of the toes is an operation which will rarely be called for, but cases may occasionally occur (especially in the great toe) where it would be right to attempt to save a toe by this proceeding.

Resection of either the first or second phalanges for disease or injury cannot frequently be performed with much prospect of success, for the entire removal of one of these bones will, in most cases, leave the finger or toe in a very useless state. Cases, however, have been recorded in which a considerable portion or the whole of one of these bones has been taken away with a good result, and therefore we may be justified, in favourable instances, in attempting to save a digit by this operation. The most favourable cases for such an

operation are probably those of necrosis, especially if the patient be young. The incision required for removing these bones will, as a rule, be most conveniently made on the dorsal and lateral surface of the bone to be excised. It will be necessary after these operations to support the digit on a splint until the parts have acquired some strength.

*Excision of the Metacarpal and Metatarsal Bones.*

Excision of these bones has been performed on several occasions with good results, both for disease and injury.<sup>1</sup> Mr. Syme<sup>2</sup> has also recorded one case in which he excised the metacarpal bone of a thumb, together with a tumour which grew from it. I have had opportunities of examining several cases in which excision of the metacarpal and metatarsal bones had been performed for disease. In some of these, the result was very encouraging; but in others, the digit in connexion with the excised bone only remained attached to the hand or foot as a loose and useless appendage. The most favourable

<sup>1</sup> See the following references:—Erichsen, *Science and Art of Surgery*, 4th edition, p. 770; Holmes, in *Lancet* for May 27th 1865; Dr. Page and Mr. Porson in *British Medical Journal* for 1864, vol. ii. p. 58; Butcher, *loc. cit.*, p. 355.

<sup>2</sup> *Observations in Clinical Surgery.*

case I have seen, was one which Dr. James, of Dunbar, was good enough to show me. The patient was a little girl, who had suffered from disease in the metatarsal bone of one of her great toes for some time. Dr. James, on probing a sinus which existed on the lateral aspect of the toe, found that this bone was lying loose and necrosed; he accordingly enlarged the sinus, and readily extracted the entire bone. I have this bone now in my possession, and it is an excellent example of complete necrosis of the whole metatarsal bone.

As in the phalangeal bones, cases of necrosis of the metacarpal and metatarsal bones will, I think, be found to be the most favourable ones for resection, and to give the best results, especially in young patients. These bones, however, may also be removed for other disease or injury, in favourable circumstances, with advantage; but the operation should not be attempted unless there is some prospect of a useful digit remaining. In performing excision of these and the other bones, the periosteum should be saved as much as possible. In cases where the articular extremities of the bones are not affected with disease or injury, it may be advisable occasionally to leave these portions of the bone behind, and only remove the diseased or injured

portion ; but this partial excision (especially in the case of disease) will very rarely be so satisfactory as the complete removal of the bone.

The thumb, index-finger, and great toe are the digits the metacarpal or metatarsal bones of which are most suitable for resection. The removal of the other metacarpal or metatarsal bones, without also taking away their corresponding digit, will not generally be advantageous to the after usefulness of the hand or foot.

## CHAPTER VII.

### AMPUTATIONS OF THE FINGERS AND TOES.

THE different affections and injuries of the fingers and toes which may require to be treated by amputation have already been considered ; but I wish in this chapter to say a few words in regard to the best methods of performing these operations.

#### *Amputation of the Distal Phalanx of the Fingers.*

Amputation of this phalanx is not so often required as the removal of the entire finger ; for when the disease is confined to the distal phalanx, the removal of the diseased bone is usually sufficient, and therefore the soft textures do not need to be taken away. Injuries which are confined to the last phalanx will rarely admit of a regular amputation being performed, owing to the loss of the soft textures, so that the best thing we can do in the majority of these cases is to remove any

loose or projecting portions of bone, and in this way allow the soft parts to heal. We occasionally, however, meet with cases in which it may be advisable and possible to remove the last phalanx by a regular amputation. For instance, tumours growing from the bony or soft textures of the distal phalanx, and confined to it, may be removed by an amputation at this situation.

If the case permits of a regular amputation being performed, the best plan is to take a good flap from the palmar surface of the extremity of the finger, and then to turn this flap over, so as to cover the end of the second phalangeal bone. In making this flap, we may either do so by transfixion, and then cutting across the joint ; or, what is better, we may first cut across the dorsal aspect of the joint, and having opened into it and divided the lateral ligaments, then cut the palmar flap. The palmar flap ought to be made as long and bulky as possible, in order that it may cover the exposed bone. If sufficient flap cannot be obtained to cover the bone, the articular extremity of the second phalanx may be cut off with the saw or bone-forceps ; the numerals 3, 3, in Fig. 126, Plate XII., show the line of the incisions for this amputation.

*Amputation of the Second Phalanx of the Fingers.*

When more than the extremity of a finger requires to be taken away, it is in the majority of cases much better to remove the whole finger. The exceptions to this are in the case of the index finger and thumb ; for, in people who require to use their hands much, any portions of these digits that can be saved will often insure usefulness to the hand implicated. Again, when several of the fingers require to be removed, or have been previously wanting, even a small bit of any finger may maintain some usefulness to the hand, especially if the thumb, or a portion of it, remain.

Fingers may be removed at the joint between the second and distal phalanges, or at any point in the extent of the second phalanx, by sawing through the bone. In either instance, two flaps of equal length should be taken from the dorsal and palmar surfaces, or from the lateral aspects (whichever be most convenient), as is shown in Fig. 126, by the lines 4 and 5. It may not always be possible to obtain two flaps in this amputation ; and therefore, in such cases, we must endeavour to make one long single flap from the most convenient situation, and turn it over as in the amputation of the distal phalanx.

*Amputation of the Fingers at their Metacarpophalangeal Joints.*

Amputation of all the fingers at this joint is performed on the same plan—namely, by cutting a flap from each side, and then removing the finger by disarticulation. In the case of the index and little fingers, it is generally advisable to make the flap on the exposed aspect of the stump a little larger than the other, so that the line of the cicatrix may be turned away as much as possible from this surface (see the lines 8 and 10, Fig. 126). For example, in amputating the index finger, the outer flap should be made sufficiently ample to turn over the exposed metacarpal bone, in order that the cicatrix of the hand may be close to the base of the middle finger. In amputating the thumb at this joint, I have found that a circular amputation, or one made by taking two short semi-lunar flaps from the sides of the digit, gives the best results. The circular operation is a little more tedious in its performance, but its advantages are that it does not interfere with the ball of the thumb, and the cicatrix left when the wound is healed is very small. In doing this amputation, the soft textures must be well retracted by an assistant, and then an incision is to be made round the thumb, about half an inch

above its metacarpo-phalangeal joint, the knife being carried quite down to the bone, so as to divide all the parts superficial to it. Having carefully separated these tissues by cutting round the bone, and close to it, the joint should be opened into, and disarticulation accomplished. If sufficient flap be not obtained in this way, the head of the metacarpal bone may be cut off.

The amputation, by two semi-lunar flaps, is easily performed, by cutting first one flap, and then the other, exposing the joint and disarticulating.

The lines of incision for the circular and flap amputations of the thumb at this joint are shown at 6 and 7, Plate XII.

In amputating the ring and middle fingers at this joint, two equal flaps are to be made in the following manner :—

Enter the point of the knife over the centre of the dorsal aspect of the joint, and then carry the knife (first on one side and then on the other) obliquely down through the middle of the web uniting the fingers, as far as its free edge. When this edge is reached, the incision should be carried round the base of the digit to be removed, so that the palm of the hand be not encroached upon ; the articulation is in this way thoroughly exposed, and

disarticulation can be readily accomplished. The incisions for this amputation are shown at Plate IX. Fig. 126. If it is not possible to obtain two lateral flaps in amputating these or the other fingers, a covering for the end of the metacarpal bone may be obtained by cutting one long single flap from the palmar, dorsal, or lateral aspect of the digit.

In removing the index and little fingers, the two flaps may either be made before disarticulating, as in the case of the other fingers, or one flap may be first cut, the joint opened into and disarticulated, and then the second flap formed.

We must here consider for a moment the question in regard to the removal of the head of the metacarpal bone in all these amputations. Experience has shown that it is better to take away the head of the metacarpal bone when we remove the fingers at this joint. The removal of this portion of bone allows the parts to be brought more intimately together, and therefore diminishes the amount of deformity; and this proceeding has been found not to interfere with the after strength of the hand. In the case of the index and little fingers, the head of the metacarpal bone should be sawn off obliquely, so as to avoid any undue prominence of the divided bone. In amputating the thumb at this joint, it is

better to leave the head of the metacarpal bone uninterfered with, provided there be sufficient flap to cover it properly.

*Amputation of the Fingers, together with their Metacarpal Bones.*

When the metacarpal bone of the thumb or fingers is affected with disease or injury, the corresponding digit not being implicated, it becomes a question whether or not we should attempt to save the finger or thumb by removing only the injured or diseased bone. We have already said that the metacarpal bones of the thumb and index finger may be excised alone with a successful result, and have quoted some examples of this operation. In favourable cases, it will therefore be right in this way to attempt to save a thumb or finger (especially if it be an index one). When both the metacarpal bone and finger or thumb are affected, we must remove them together; and in most cases it will be proper to remove the entire metacarpal bone, especially if the operation be performed for disease. The best method of removing a metacarpal bone, together with a finger or thumb, is to carry an incision along the dorsal aspect of this bone, commencing at a point over its carpo-metacarpal

articulation, and terminating at the centre of the metacarpo-phalangeal joint. The two lateral flaps usually made for the removal of a finger, or, in the case of the thumb, the two short semi-lunar flaps, or the circular one, should then be cut, the tissues dissected from the metacarpal bone, the carpo-metacarpal joint disarticulated, and the entire digit, together with its metacarpal bone, in this way removed. In separating the tissues from the metacarpal bone, the knife ought to be kept close to the bone, in order to avoid injuring the important structures in the palm of the hand. This operation may also be performed by entering the knife over the carpo-metacarpal joint, running it along the dorsal aspect of the metacarpal bone as far as the centre of the knuckle, and then, without lifting the knife, carrying the incision round the base of the finger to be removed, so as to join it with the dorsal one. The line of incision for the removal of the metacarpal bone of the thumb is given in Plate XII., at 11.

It occasionally happens that we may require to amputate more than one and even all the digits, for injury or disease. In such cases we must make a flap or flaps from the most convenient situation, so as to cover the exposed bones. No rules can be

laid down in regard to such operations, but the surgeon must be guided by the circumstances of each particular case. The saving of even a small portion of a finger, as I have before said, may be of great service in these cases.

*Amputations of the Toes.*

Amputation of the toes is to be performed on the same principles as amputation of the fingers. It very rarely happens (except in the case of the great toe) that a partial amputation of these digits is required, or is advisable, for the stump left by such an operation would, in most cases, be an inconvenience.

In amputating the first phalanx of the great toe, the same incisions are to be employed as in the removal of this part in the fingers—a good flap being taken from the plantar aspect of the extremity of the toe. If more than the first phalanx of this toe requires to be removed, without also necessitating the cutting off of the head of the metacarpal bone, I have found that a circular amputation at the metatarso-phalangeal joint, performed on the same principle as that at the corresponding joint of the thumb, leaves a useful stump.

The smaller toes are best removed at their meta-


tarso-phalangeal joints, by the same method which has been recommended for taking away the fingers at their metacarpo-phalangeal articulations, the plantar aspect of the foot being kept intact. It will not always be necessary to remove the head of the metatarsal bone in this amputation, as it lies deeper and more protected than the corresponding part of the metacarpal bone. In amputating the little and great toes at this joint, it will be advisable to make the one flap sufficiently free, so that the cicatrix may be away from the exposed surface of the stump. In cases where sufficient flap cannot be obtained to cover well the heads of the metatarsal bones, these portions of bone ought to be removed, as their prominence may lead to inconvenience.


When the metatarsal bones are alone diseased or injured, they may, in favourable cases, as we have already considered, be removed, without interfering with the toes; but when the phalangeal bones are implicated as well, both the toe and the entire metatarsal bone must be taken away. The removal of portions of the metatarsal bone for disease is not, as a rule, good practice; for pathology shows that although the disease may apparently affect only the extremity of this bone, its whole osseous texture is usually involved. The great and little toes are those most

frequently requiring to be removed, together with their metatarsal bones; for when the metatarsal bones of the other toes are diseased, and do not admit of resection, a partial or complete amputation of the foot will, in the majority of cases, be advisable.

In amputating a toe, together with its metatarsal bone, an incision is to be commenced over the tarso-metatarsal joint of the toe to be removed, and is then to be carried along the dorsal aspect of the metatarsal bone, as far as the metatarso-phalangeal joint. When this point is reached, the two lateral flaps are to be cut from the sides of the toes, the metatarsal bone carefully dissected from its connexions, and then, by disarticulating at the tarso-metatarsal articulation, the toe and its metatarsal bone are readily separated together. In dissecting the tissues from the bone, the knife must be kept close to it, so as to avoid the blood-vessels and other tissues in the sole of the foot. In performing this operation on the great toe, considerable difficulty is often experienced in securing the dorsal artery of the foot when wounded, as it lies in the space between the metatarsal bones of the first and second toes. Both ends of this vessel ought to be carefully tied if it is wounded, for troublesome hæmorrhage may result if this is not done.

After amputations of the fingers and toes, we may have inflammation and suppuration spreading up into the hand or foot. It is not very uncommon, after many of the partial amputations performed on the fingers, to have abscesses forming in the hand or forearm, and giving rise to much pain, and delaying the satisfactory healing of the stump. When this takes place, any stitches which are causing tension should be removed from the stump, warm fomentations diligently applied, and if suppuration takes place, incisions made to give exit to the matter.





# PLATE I.

FIG.		PAGE
1.	Congenital hypertrophy, with lateral distortion of the index and middle fingers, . . . . .	5
2.	Congenital hypertrophy, with lateral distortion of the thumb and forefinger, . . . . .	6
3.	Congenital hypertrophy, with distortion backwards of the thumb, . . . . .	6
4.	Congenital hypertrophy of the middle and ring fingers, with congenital deficiency of the other digits, .	7
5.	Congenital absence of one finger, and atrophy of the others, . . . . .	11
6.	Congenital absence of the thumb and three fingers, .	11
7.	Congenital absence of three fingers, . . . . .	12
8.	Congenital absence of two fingers, . . . . .	13
9.	Simulated absence of one finger, with a webbed condition of the middle and little fingers, . . . . .	14

PLATE 1.

Fig 2.

Fig. 1.

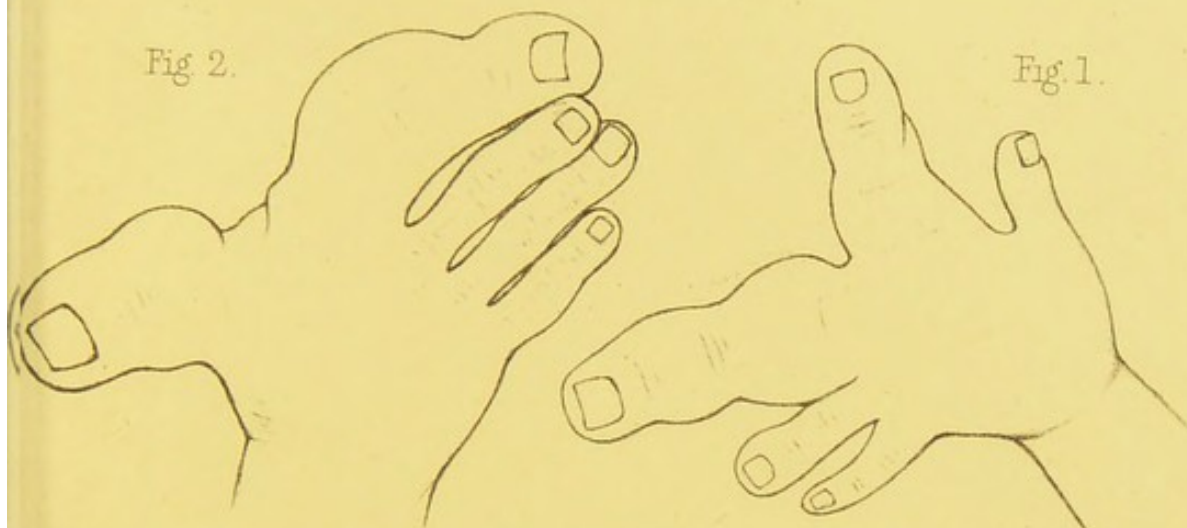


Fig 6.

Fig. 3.

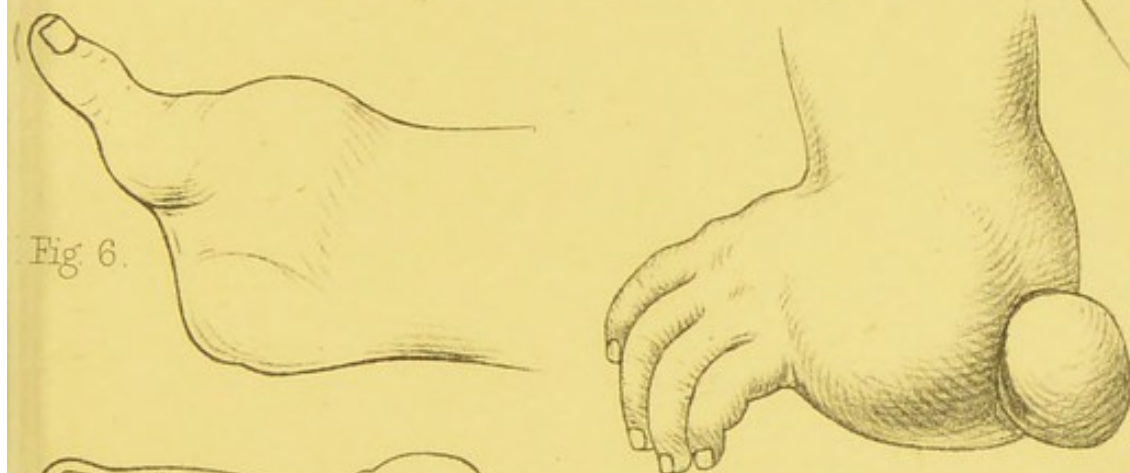

Fig 4

Fig. 5.

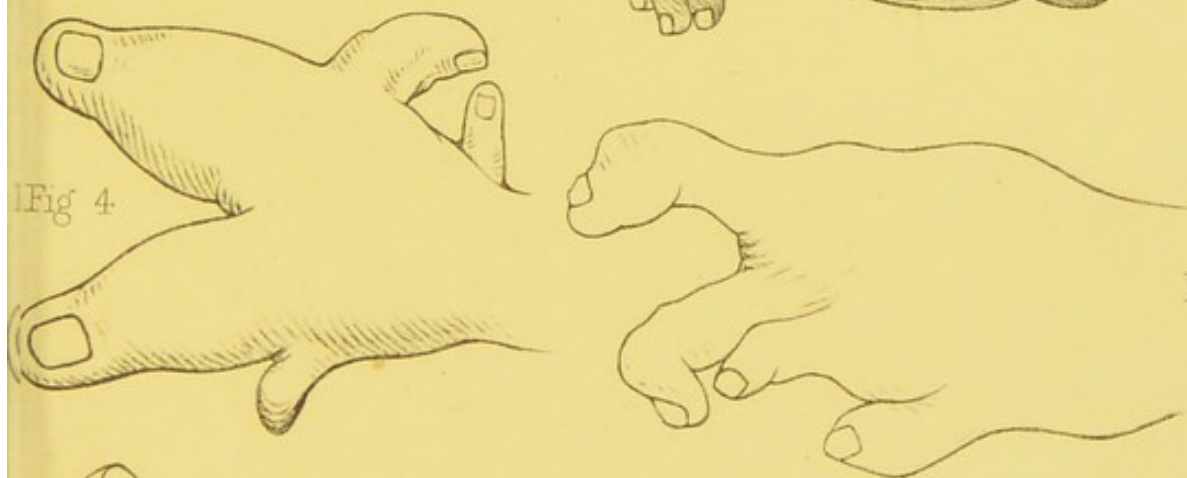
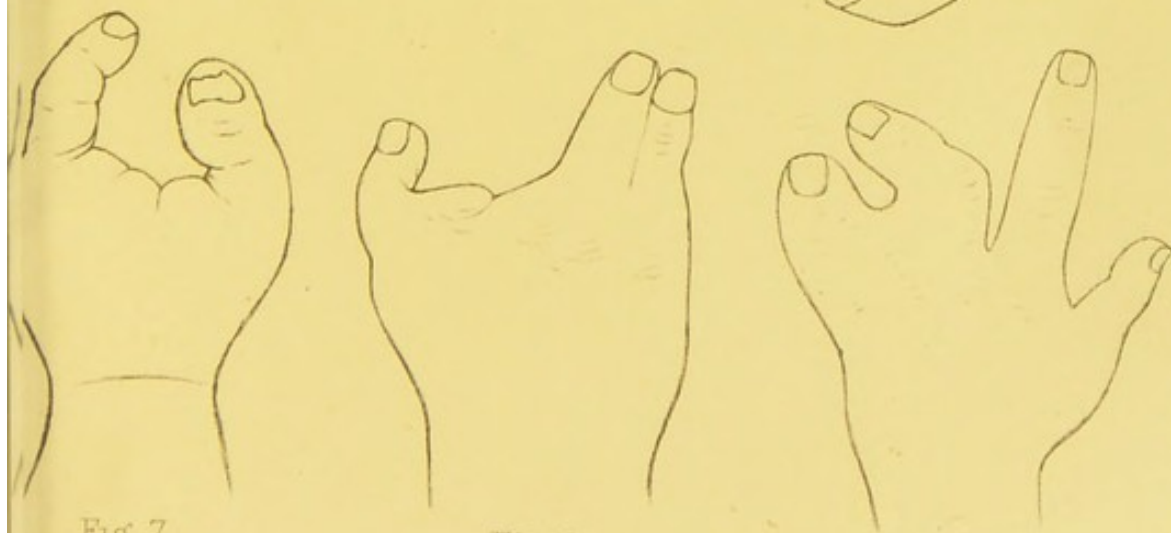


Fig. 7.

Fig. 8.

Fig. 9.







## PLATE II.

FIG.	PAGE
10. Congenital union of the middle and ring fingers simulating an absence of one finger, . . . . .	14
11. Congenital absence of all the phalanges of a forefinger,	16
12. Congenital absence of one phalanx in the ring and little fingers, . . . . .	16
13. Congenital deficiency of the thumb and fingers, . . . .	17
14. Congenital deficiency of the index, ring, and little fingers, . . . . .	18
15. Congenital deficiency of the whole upper extremity, with congenital absence of the thumb and one finger,	18
16. Abortive digits springing from a stump, the result of intra-uterine amputation, . . . . .	21
17. Congenital absence of one toe, . . . . .	22
18. Congenital deficiency of the toes associated with congenital union, . . . . .	23
19. Hand showing a thumb which had three phalanges, and resembled in appearance a forefinger, . . . . .	29
20. Supernumerary finger of the "first" variety attached to the ulnar aspect of the little finger, . . . . .	29

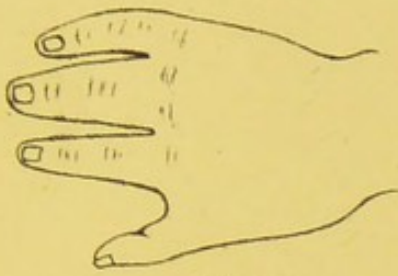

Fig. 10.

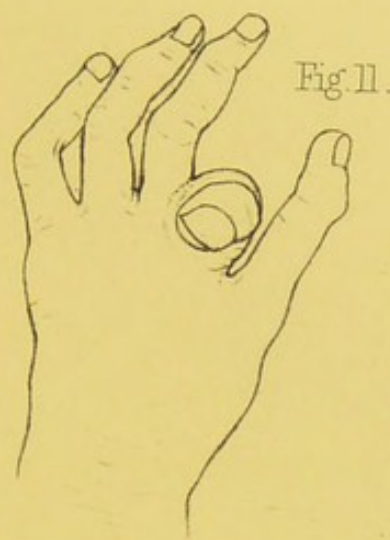


Fig. 11.

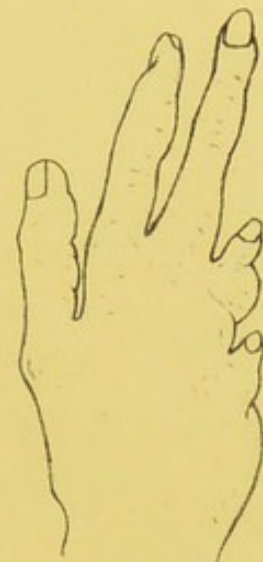

Fig. 12.

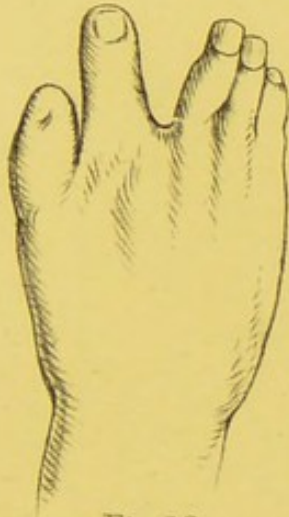


Fig. 13.

Fig. 14.

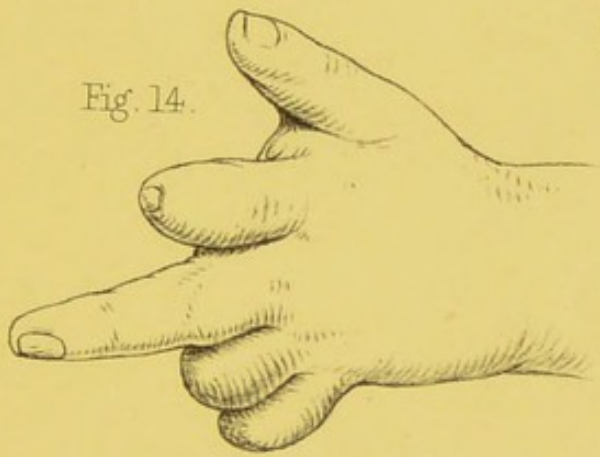


Fig. 15.

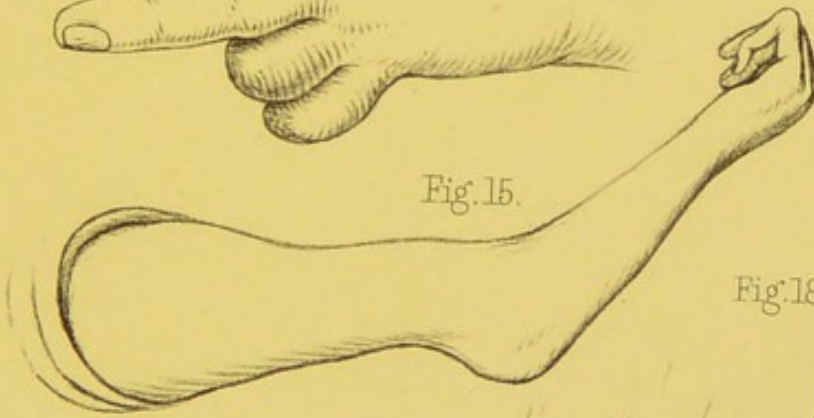


Fig. 18.

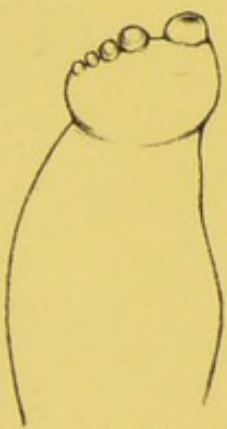


Fig. 16.

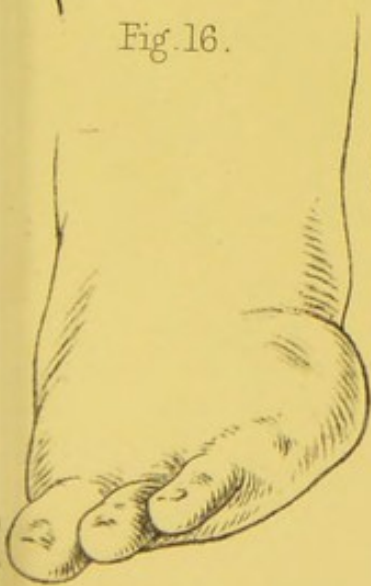

Fig. 17.

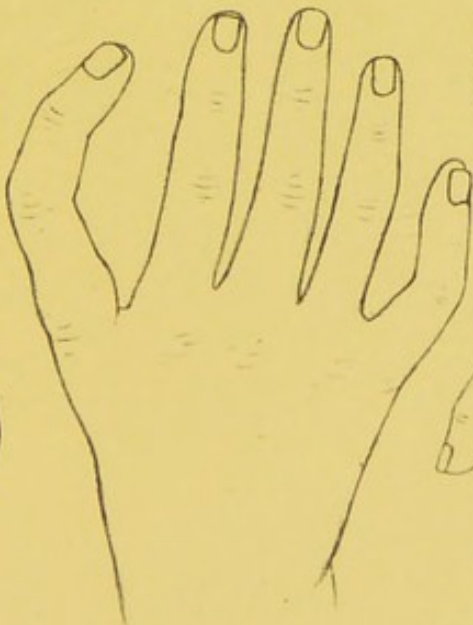


Fig. 19.

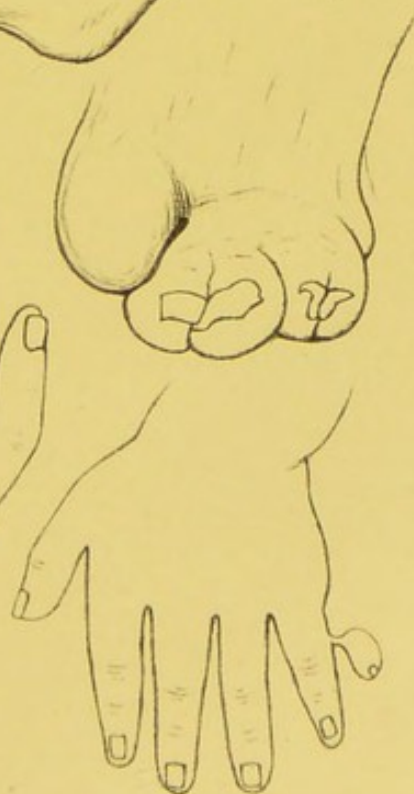


Fig. 20.

Harrisons lith.

Lens Aldous, del et lith.





### PLATE III.

FIG.	PAGE
21. Supernumerary finger of the "first" variety connected to the ball of the thumb, . . . . .	30
22. Supernumerary finger of the "second" variety articulating with the metacarpal bone of the little finger, from Otto, . . . . .	31
23. Supernumerary finger of the "second" variety articulating with the head of the metacarpal bone of the little finger, . . . . .	32
24. Supernumerary thumb of the "second" variety, . . . . .	32
25. Supernumerary thumb of the "second" variety, . . . . .	32
26. Supernumerary great toe of the "fourth" variety, . . . . .	40
27. Supernumerary thumb of the "fourth" variety, . . . . .	36
28. Supernumerary little toe of the "second" variety, . . . . .	37
29. Supernumerary finger of the "third" variety, from Otto, . . . . .	34
30. Supernumerary little toe of the "second" variety, . . . . .	37
31. Congenital union of the middle, ring, and little fingers, . . . . .	50
32. Supernumerary great toes of the "second" variety, connected to the sides of the metatarsal bones of the great toes, . . . . .	37
33. Congenital union of the middle and ring fingers, . . . . .	50

PLATE 3.

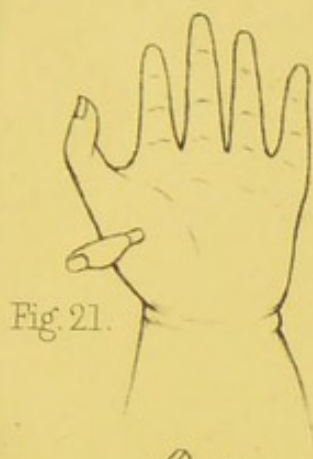


Fig. 21.

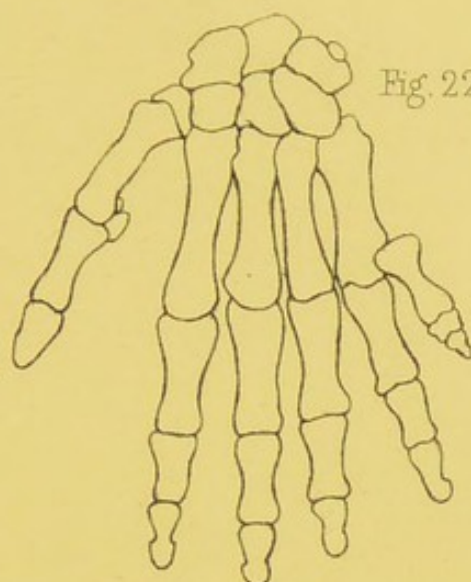


Fig. 22.

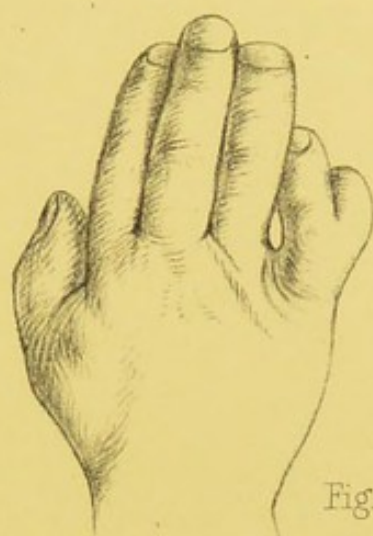


Fig. 23.

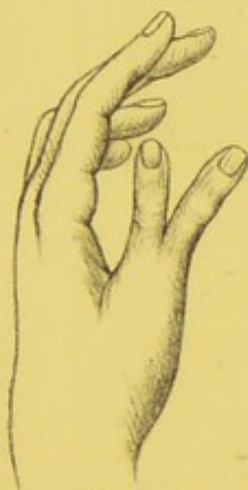

Fig. 24.

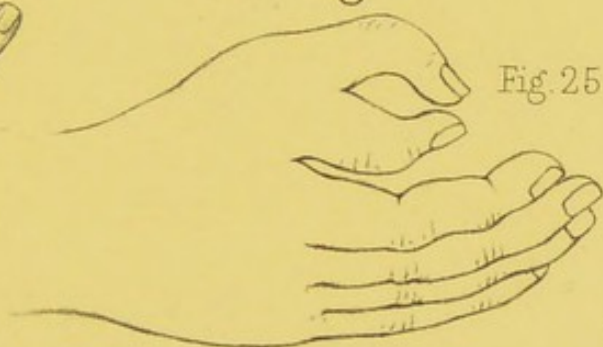

Fig. 25.

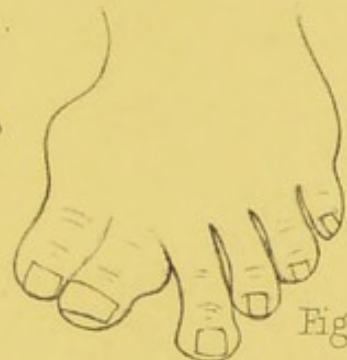

Fig. 26.

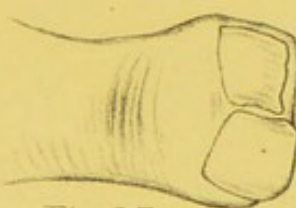


Fig. 27.

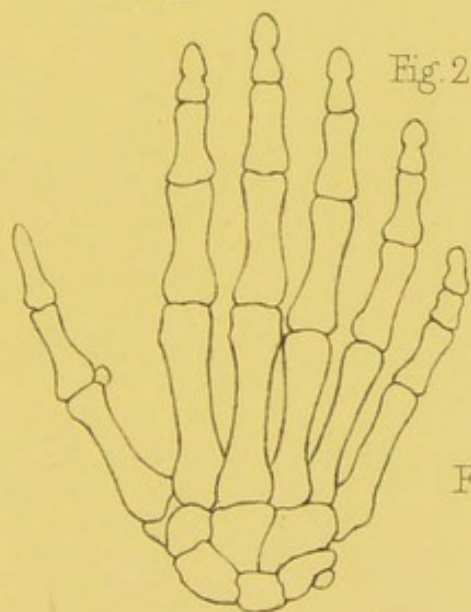


Fig. 29.

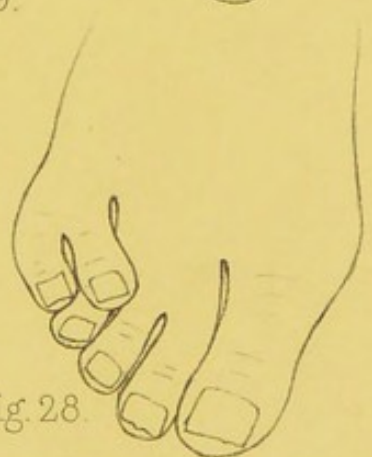

Fig. 28.

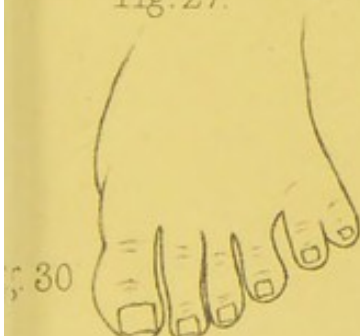


Fig. 30.

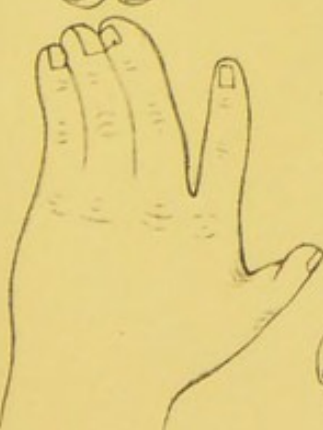

Fig. 31.

Fig. 32.

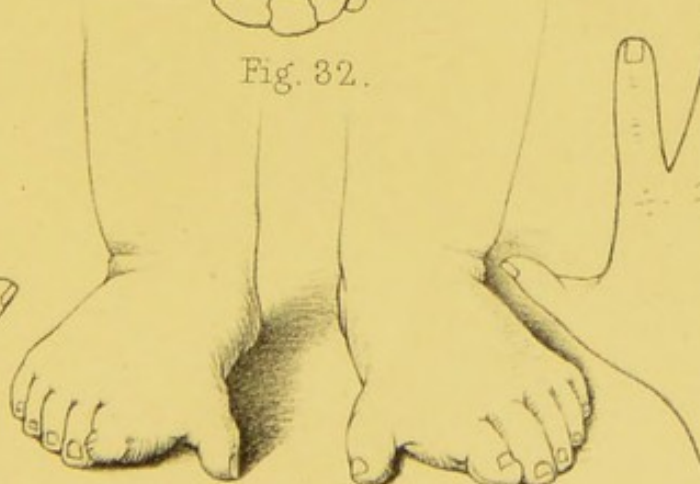
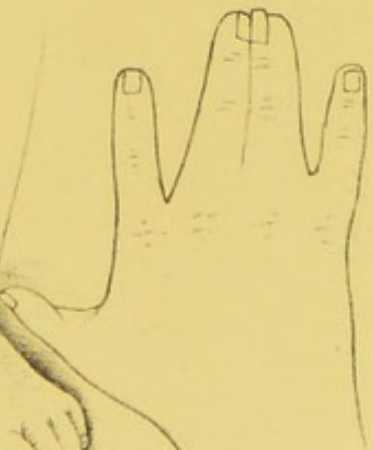


Fig. 33.







# PLATE IV.

FIG.	PAGE
34. Congenital union of the second and third toes, . . .	52
35. Congenital absence of all the fingers, . . . . .	12
36. Congenital union of the extremities of the middle and ring fingers, from Otto, . . . . .	48
37. Congenital deficiency of both upper extremities, . . .	20
38. Supernumerary thumb of the "second" variety, . . .	32
39. Congenital union of the ring and middle fingers, . . .	51
40. Webbed condition of all the toes, . . . . .	52
41. Supernumerary thumb of the "fourth" variety, and supernumerary little finger of the "first" variety, . .	35
42. Congenital pedunculated tumours connected to the little fingers, . . . . .	68
43. Congenital tumour connected to the side of the great toe, . . . . .	69
44. The bones of two fingers having one set of second and third phalanges common to both, from Otto, . . .	52

PLATE 4.

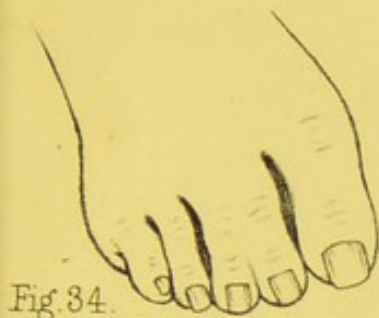


Fig. 34.

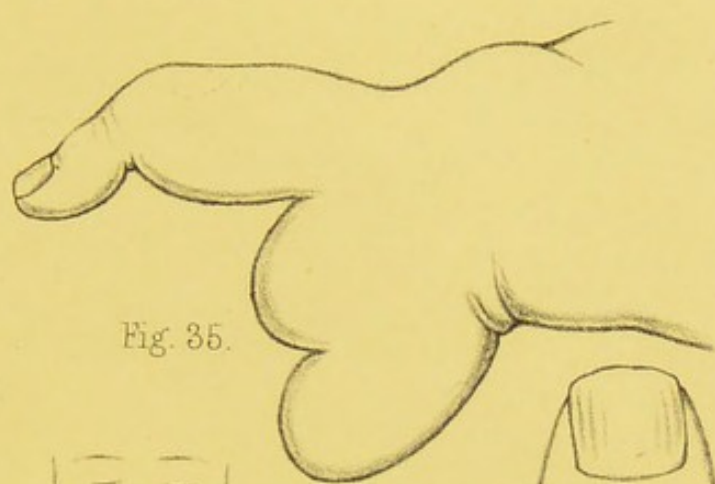


Fig. 35.

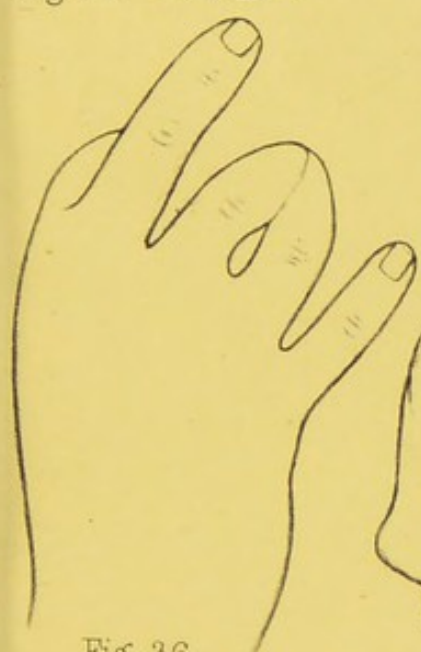

Fig. 36.

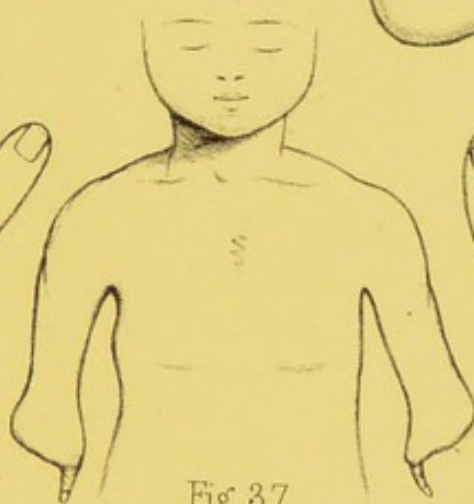


Fig. 37.

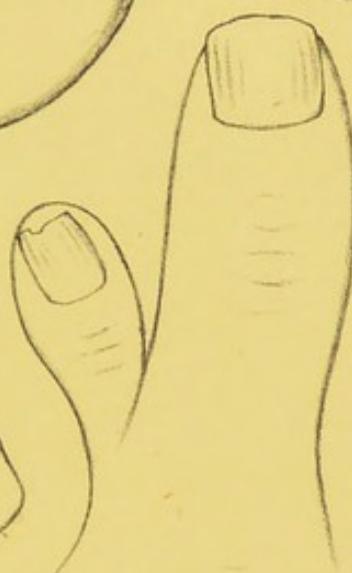

Fig. 38.

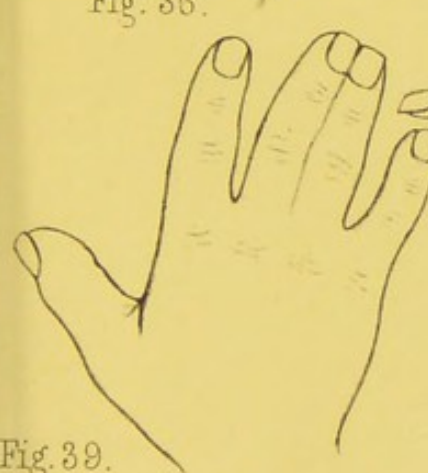


Fig. 39.

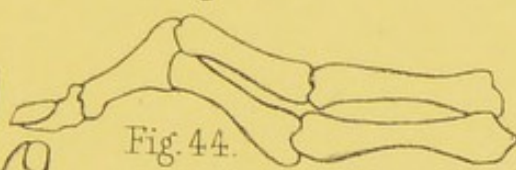


Fig. 44.

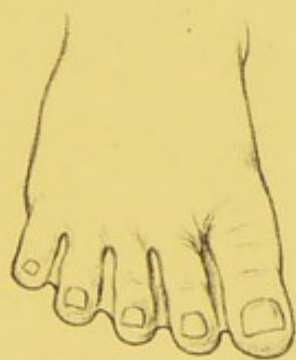

Fig. 40.

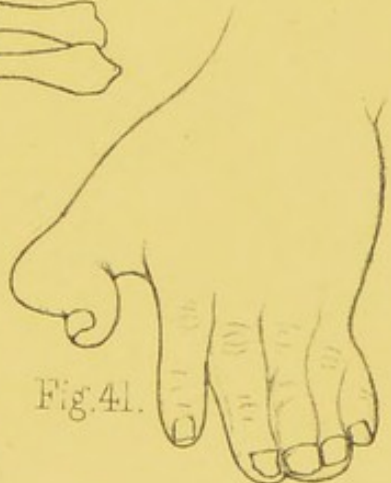

Fig. 41.

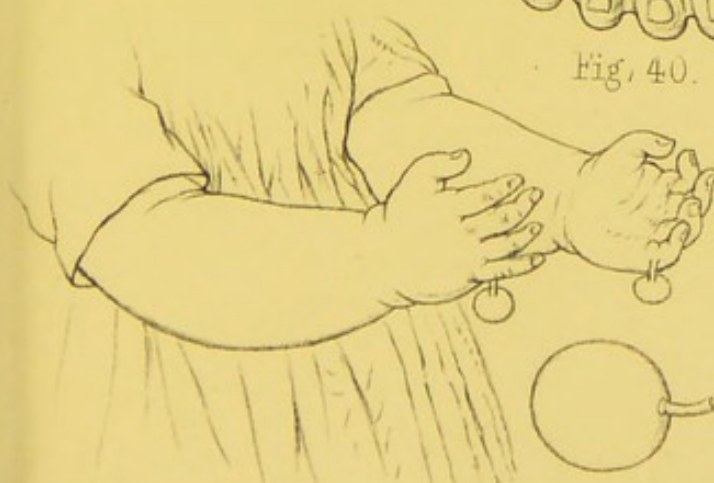

Fig. 42.

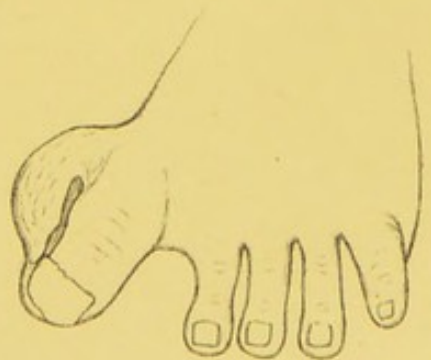



Fig. 43.





# PLATE V.

FIG.	PAGE
45. Palmar surface of a hand in which there was congenital union and deficiency of the extremities of all the digits. Pieces of whalebone have been passed through the fissures which separated the first phalanges, . . . . .	47
46. Dorsal surface of the same hand, . . . . .	47
47. Congenital union of all the fingers, . . . . .	51
48. Congenital union of all the fingers, with distortion of the thumb, . . . . .	50
49. Supernumerary thumb of the "fourth" variety, having three nails, . . . . .	35
50. Fibro-cellular tumour of the thumb associated with a cartilaginous tumour of the metacarpal bone, . . . . .	71
51. Stump of a hand with abortive digits, the result of intra-uterine amputation, . . . . .	21
52. Distortion of the little toe, . . . . .	256
53. Distortion of the second toe, . . . . .	256
54. Dissection of the plantar fascia of a foot in which all the toes were contracted, . . . . .	241
55. Stump of a hand, the result of injury, in which there was a cleft capable of grasping a pen or pencil, . . . . .	236

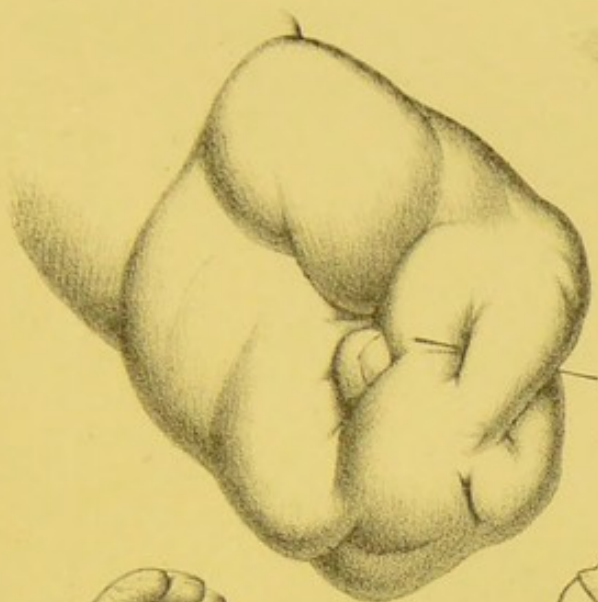


Fig. 45.

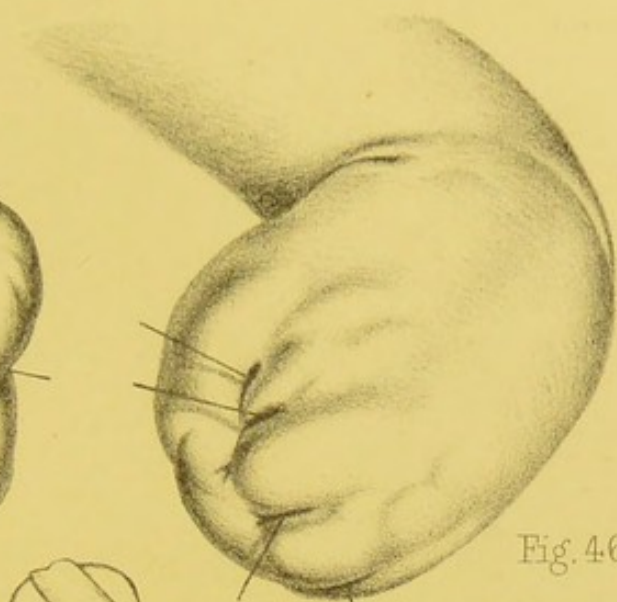


Fig. 46.

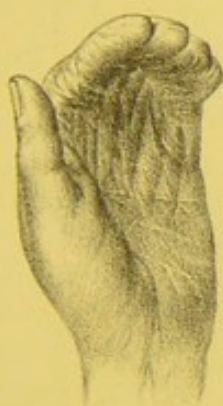

Fig. 47.

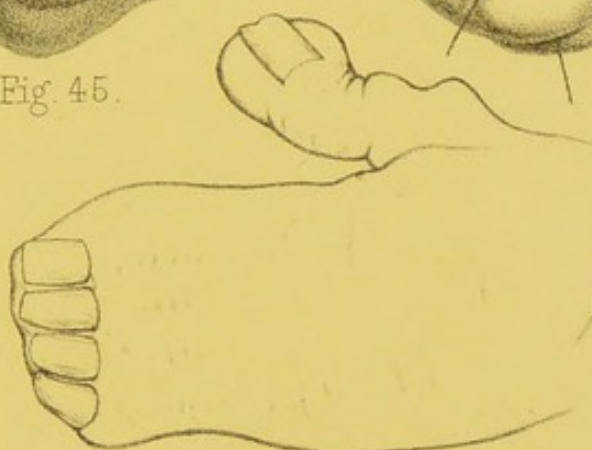


Fig. 48.

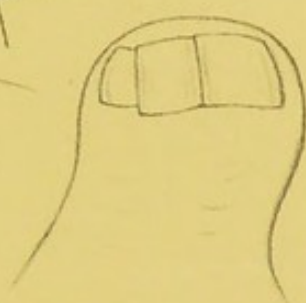


Fig. 49.

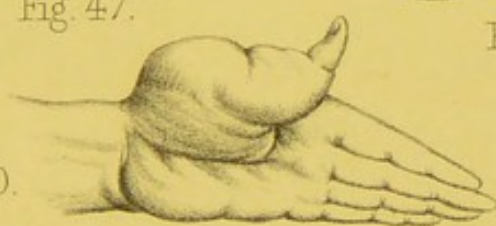

Fig. 50.

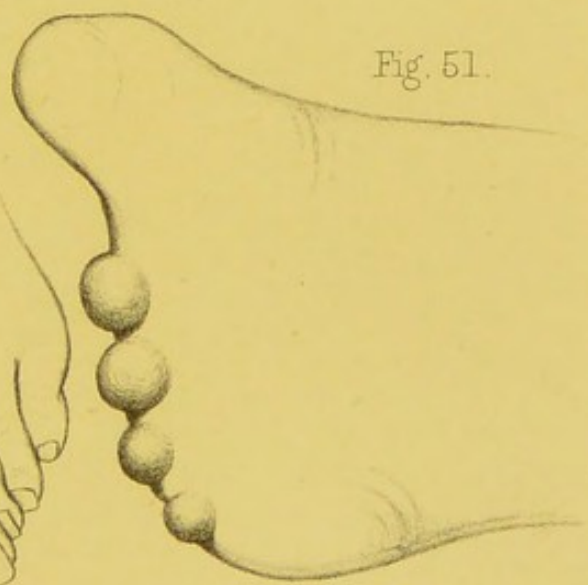


Fig. 51.

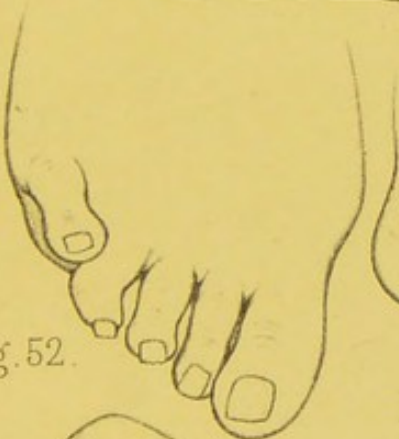

Fig. 52.

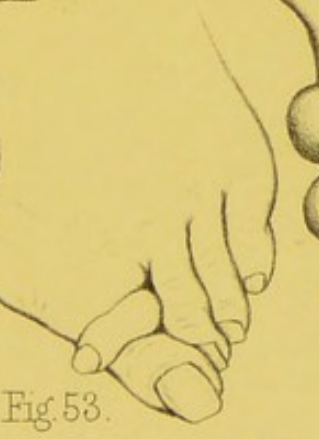

Fig. 53.

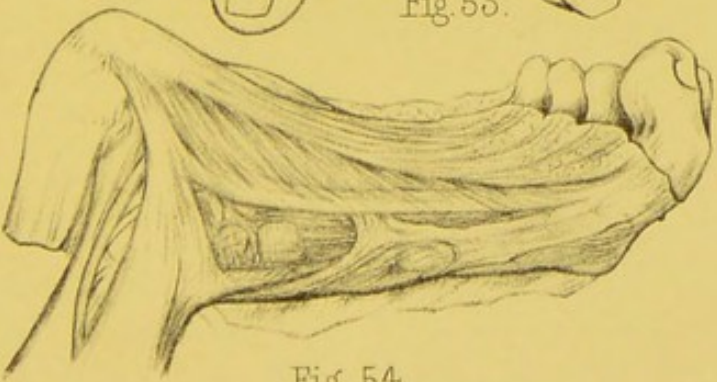


Fig. 54.

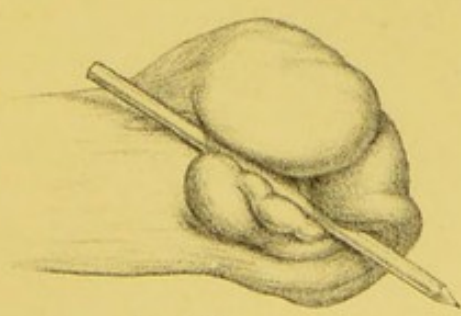



Fig. 55.





## PLATE VI.

FIG.	PAGE
56. Contraction of the second toe, . . . . .	64
57. Bones from another contracted second toe, . . . . .	64
58. Excessive contraction of a second toe, leading to dislocation of the bones, . . . . .	64
59. Section of the same toe, showing the displacement of the bones, . . . . .	64
60. Necrosis of the second and third phalangeal bones of a finger, the result of acute inflammation, . . . . .	78
61, 62, and 63. Phalangeal bones which have become necrosed in the progress of acute inflammation of the fingers, . . . . .	78
64. A finger affected with whitlow of the "second" kind, . . . . .	84
65. Section of the same finger, showing the effusion which has taken place into the sheath of the flexor tendons, and the general swelling of the soft parts, . . . . .	84
66. Contraction of a finger after acute inflammation, owing to destruction of its flexor tendons, . . . . .	85
67. Section of the same finger, showing the contraction and destruction of the flexor tendons, but a healthy condition of all the other textures, . . . . .	85

PLATE 6.

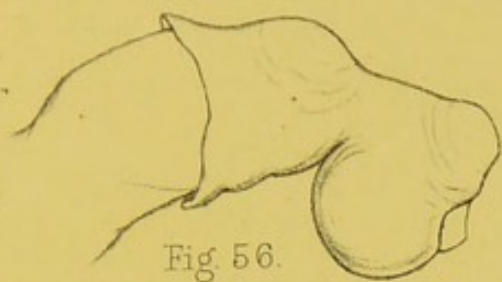


Fig. 56.

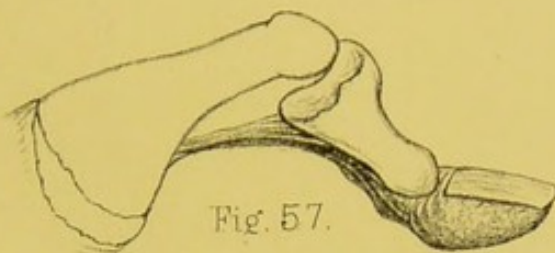


Fig. 57.

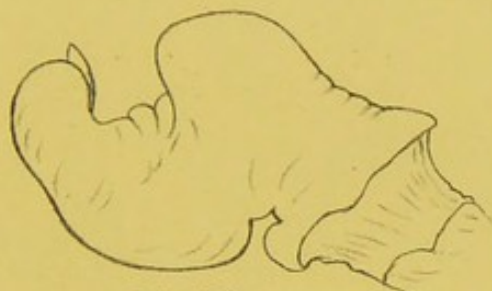

Fig. 58.

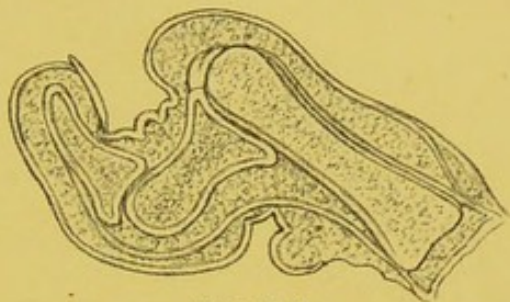


Fig. 59.

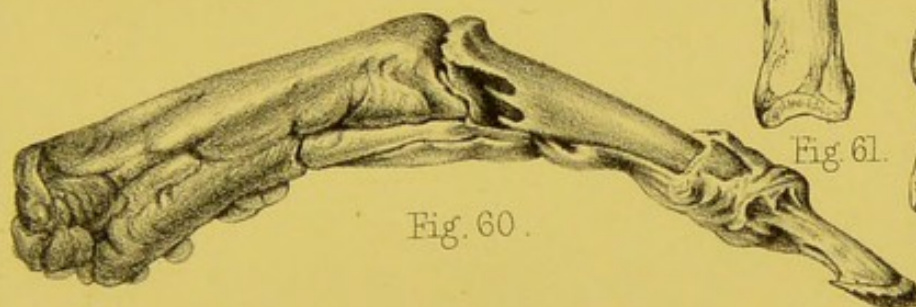


Fig. 60.

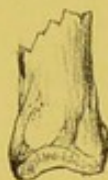

Fig. 61.

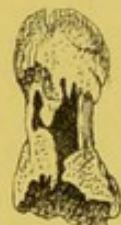

Fig. 62.

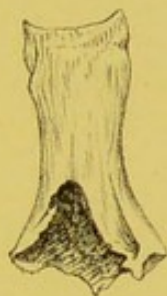

Fig. 63.

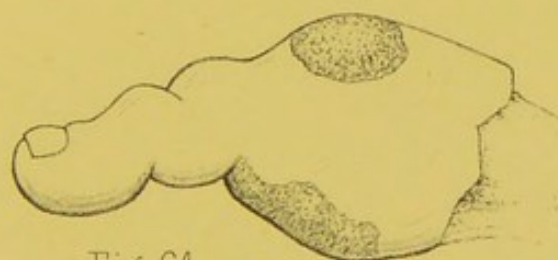

Fig. 64.

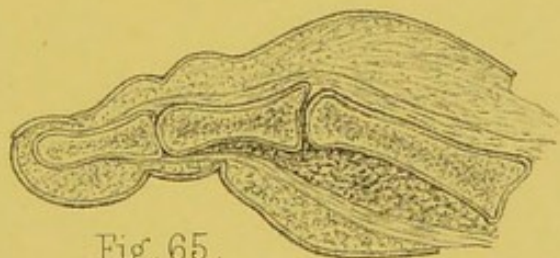


Fig. 65.

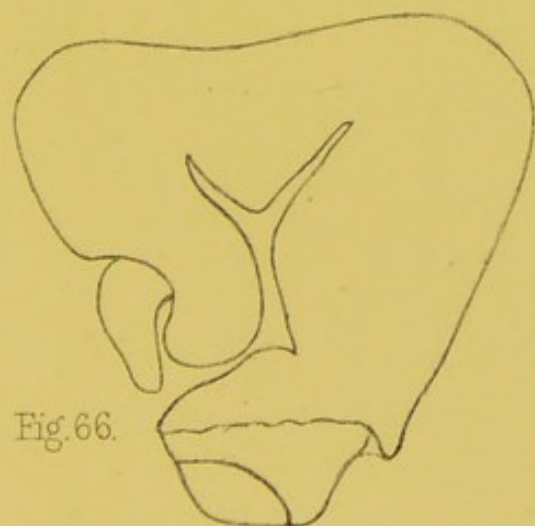


Fig. 66.

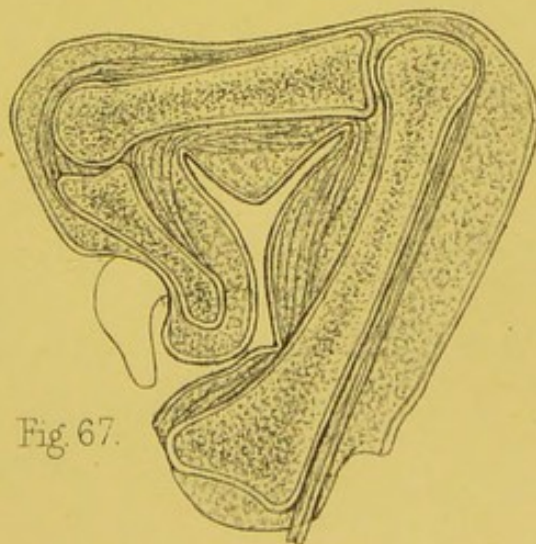



Fig. 67.





## PLATE VII.

FIG.	PAGE
68. Hand showing a finger affected with "Onychia Maligna," . . . . .	100
69. Curious affection of the nails, with enlargement of the last phalangeal joints, . . . . .	102
70. Enlargement of one of the bursæ over a phalangeal joint of a finger, . . . . .	111
71. Contraction of a second toe, with dislocation and enlargement of the head of its metatarsal bone, causing a bursal swelling in the sole of the foot, . . . . .	115
72. Hypertrophy of the nails of the toes, . . . . .	103
73. Foot showing a bunion on its inner aspect, and also an enlargement of the bursæ over the dorsal aspect of the phalangeal joints of the smaller toes, . . . . .	114
74. Dissection of the bones, tendons, and ligaments of a distorted foot. The displacement of the great toe and the projection and enlargement of the head of its metatarsal bone are characteristic of the condition of these parts in aggravated cases of bunion, . . . . .	118
75. From another foot similarly distorted, the tendons having been removed, . . . . .	118
76. Fibrous ankylosis of a phalangeal joint of a finger, the result of chronic inflammation, . . . . .	124
77. Section of the same finger showing the condition of the joint, . . . . .	125
78. Bones of a finger showing a new phalangeal joint, formed after disorganization of the original joint by disease, . . . . .	133
79, 80. Bony ankylosis of the phalangeal joints of the fingers, . . . . .	125

Fig. 68.

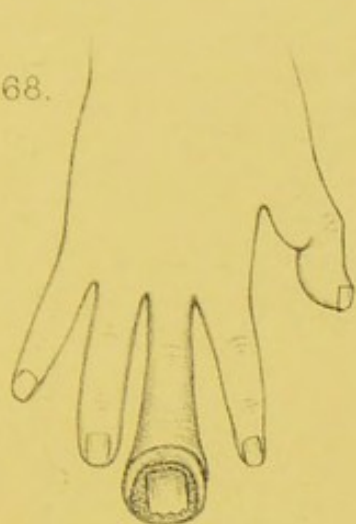


Fig. 69.

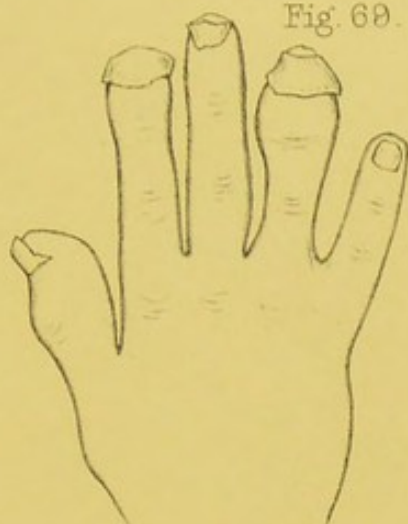


Fig. 70.

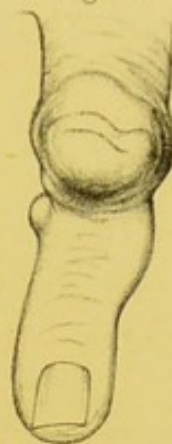

Fig. 71.

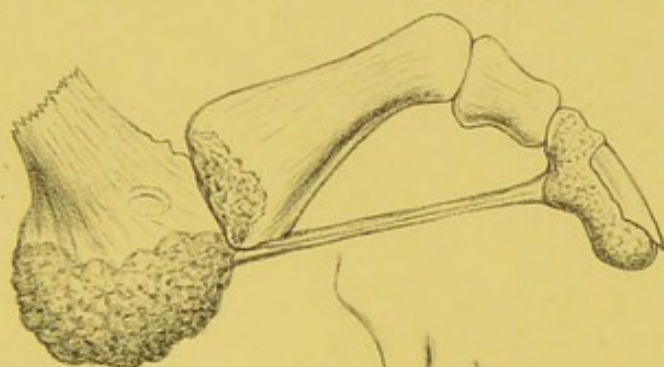

Fig. 73.

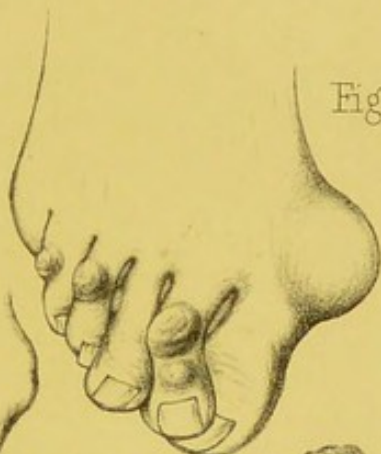

Fig. 72.

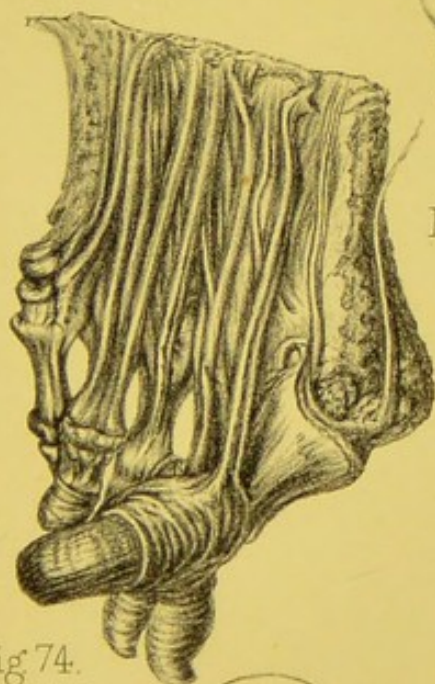
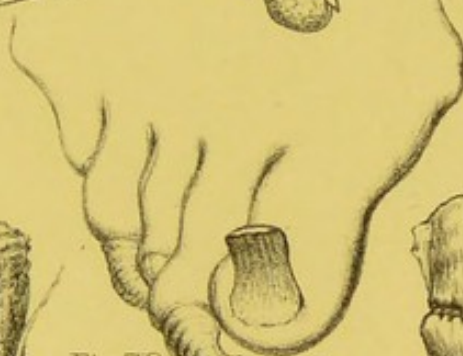


Fig. 74.

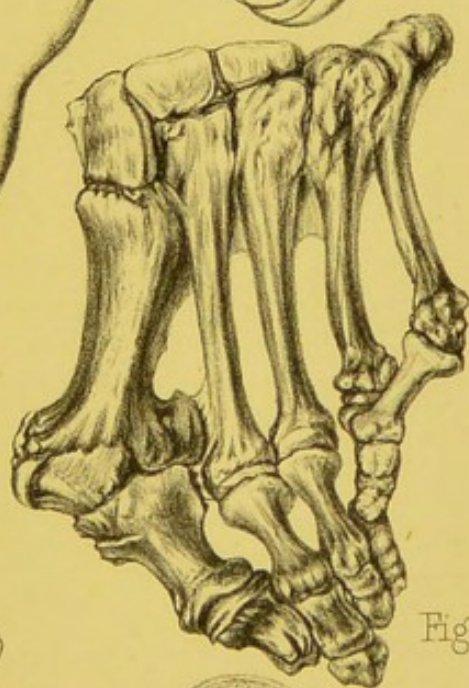


Fig. 75.

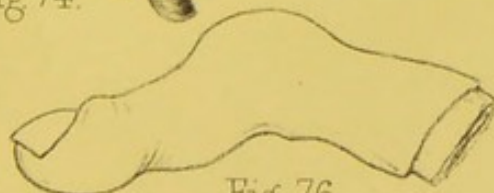


Fig. 76.

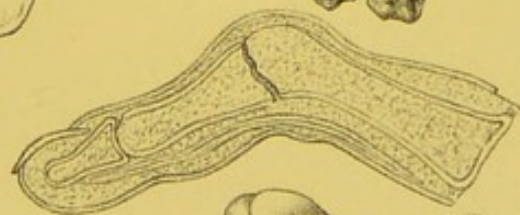


Fig. 77.

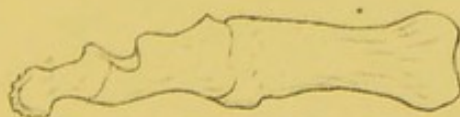


Fig. 79.


Fig. 78.

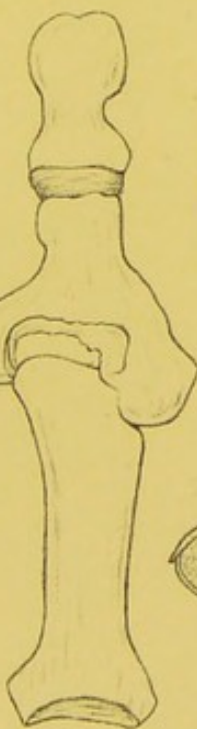
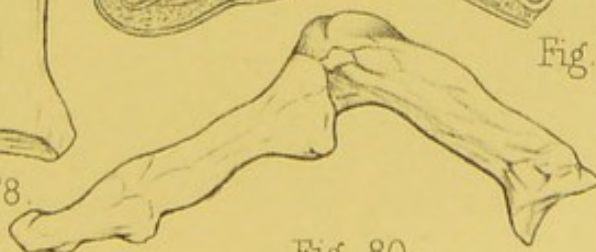
Fig. 80.







# PLATE VIII.

FIG.	PAGE
81. Pulpy degeneration of the synovial membrane of the metacarpo-phalangeal joint of a finger. The line A points to the thickened synovial membrane, . . .	127
82. Section of a great toe showing fibrous ankylosis of its phalangeal joint, . . . . .	133
83. Portion of a metacarpal bone, the periosteum of which had been affected with chronic inflammation, . . .	138
84. Section of the same bone showing a deposit of new osseous material external to the outer layer of the bone, . . . . .	138
85. Section of a great toe, showing deposit of tubercular matter in the cancellated texture of the articular extremity of the metatarsal bone, with caries of the surrounding bony tissue. A pin has been passed through one of the external sinuses into the diseased portion of the bone, . . . . .	129
86. The metacarpal and first phalangeal bones of a thumb which had suffered from chronic inflammation. Two new processes had been formed at the distal extremity of the metacarpal bone with which the first phalanx articulated, . . . . .	139
87. Section of the same bone showing a great increase in the thickness of the compact layer, and almost entire obliteration of the cancellated texture, . . . . .	139
88. Cartilaginous tumour of a finger which had ulcerated at one point, . . . . .	171
89. Lobulated fibrous tumour growing from the periosteum of the bones of a thumb, . . . . .	165
90. Fibrous tumour growing from the periosteum of the metatarsal bones of two toes, . . . . .	166
91. A hand in which all the digits have cartilaginous tumours growing in connexion with them, . . .	168
92. The bones of a thumb which had small tuberculated cartilaginous tumours growing from their external surface, . . . . .	170

Fig. 81.

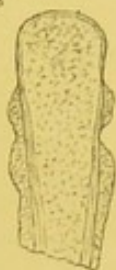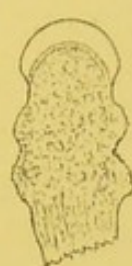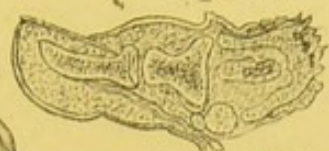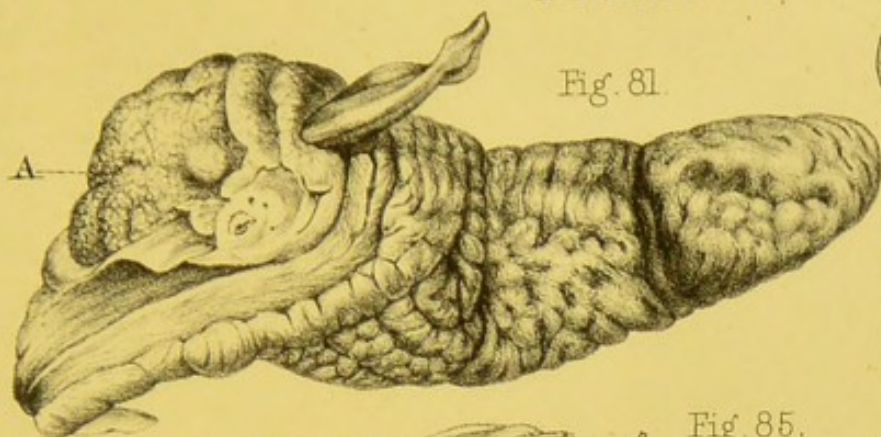


Fig. 85.

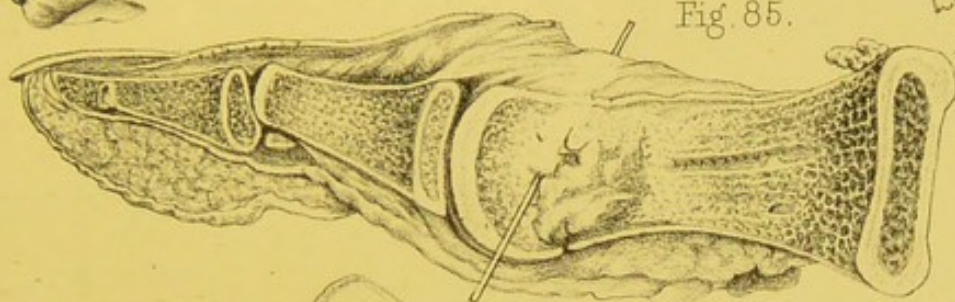


Fig. 83. Fig. 84.

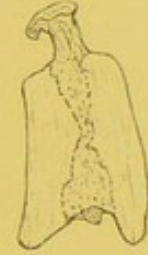
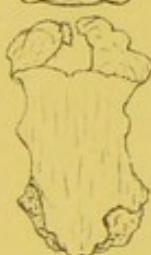
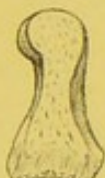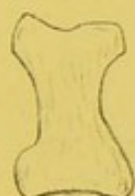Fig. 86.

Fig. 87.

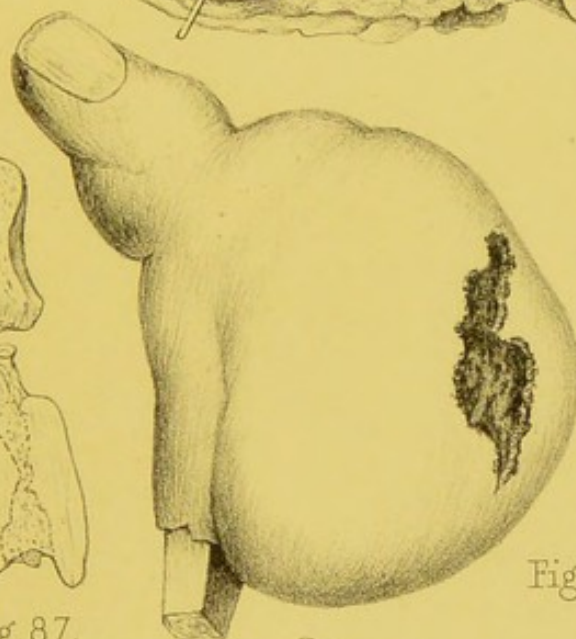


Fig. 88.

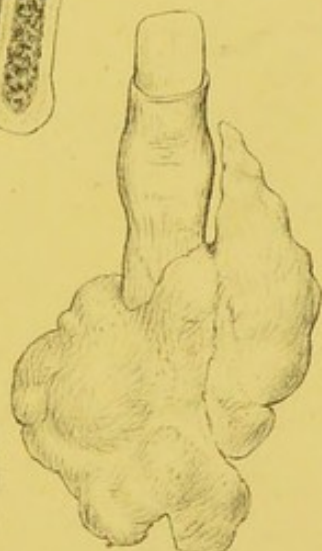

Fig. 89.

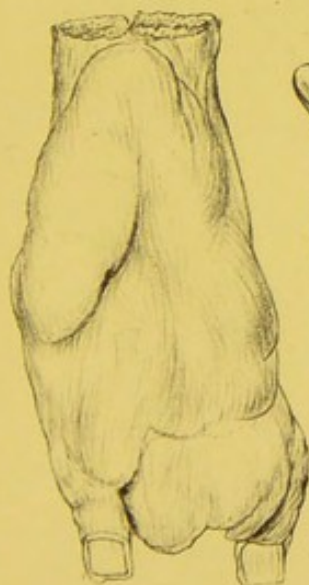

Fig. 90.

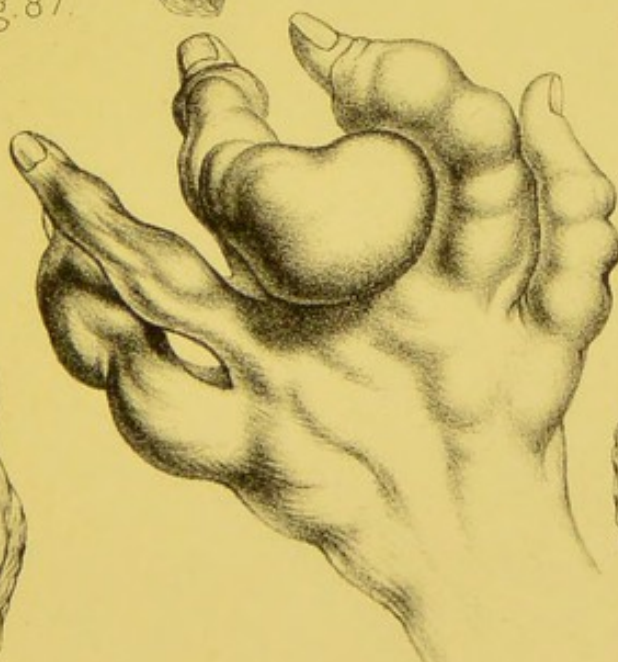


Fig. 91.

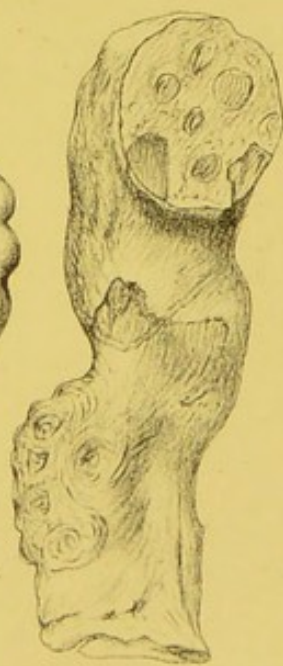



Fig. 92.





## PLATE IX.

FIG.	PAGE
93. The bones of a great toe from a case of bunion,	119
94. Acute caries of the bones of a finger, the result of injury, . . . . .	141
95. The same finger after the skin had been dissected off, showing the pulpy state of the soft parts, with portions of carious bone lying in them, . . . . .	141
96. Chronic synovitis of the phalangeal joint of a thumb,	126
97. Melanotic tumour growing from the soft parts at the extremity of a finger, . . . . .	167
98. Cartilaginous tumour growing from the phalangeal bone of a finger, . . . . .	168
99. A section of a cartilaginous tumour of a finger,	172
100. Distal phalanx of a great toe, with a carious cavity in its substance, . . . . .	145
101. Cartilaginous tumour of a finger, . . . . .	168
102. Encephaloid tumour affecting the first phalangeal bone of a finger, . . . . .	175
103. Section of the same finger and tumour, showing the entire absorption of the bone which had taken place in the growth of the tumour, . . . . .	175

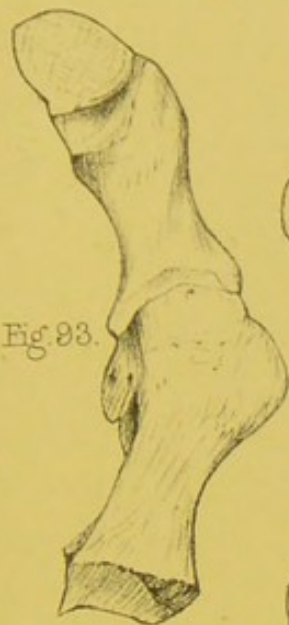


Fig. 93.

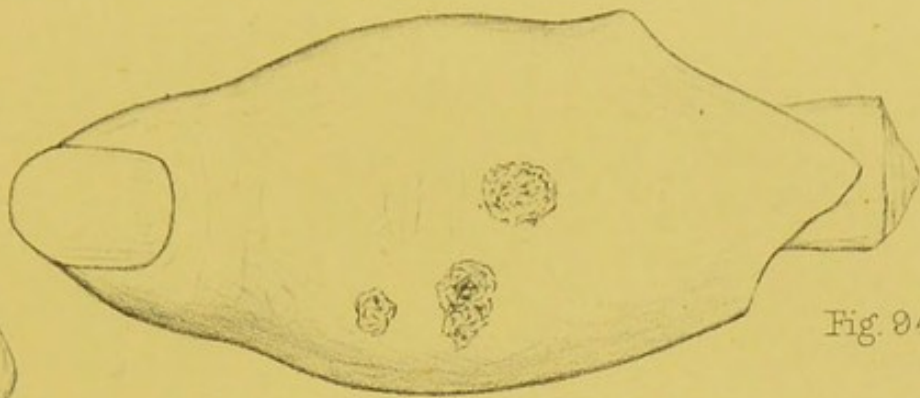


Fig. 94.

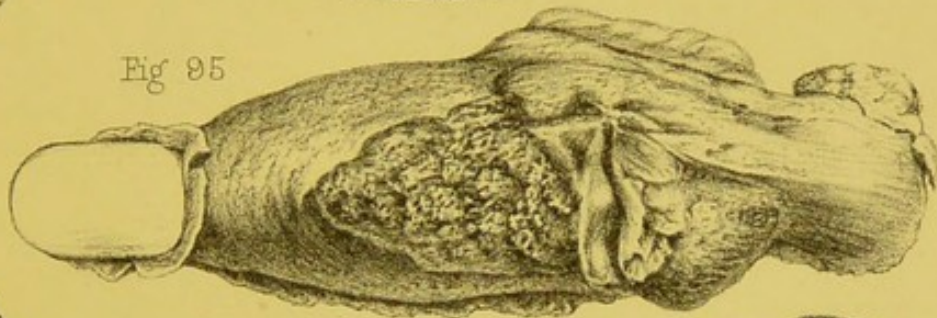


Fig. 95.

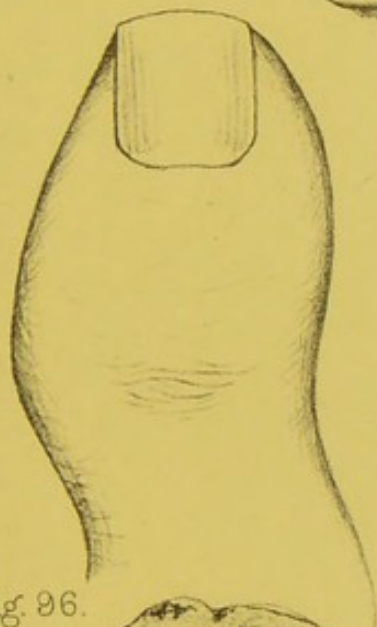


Fig. 96.

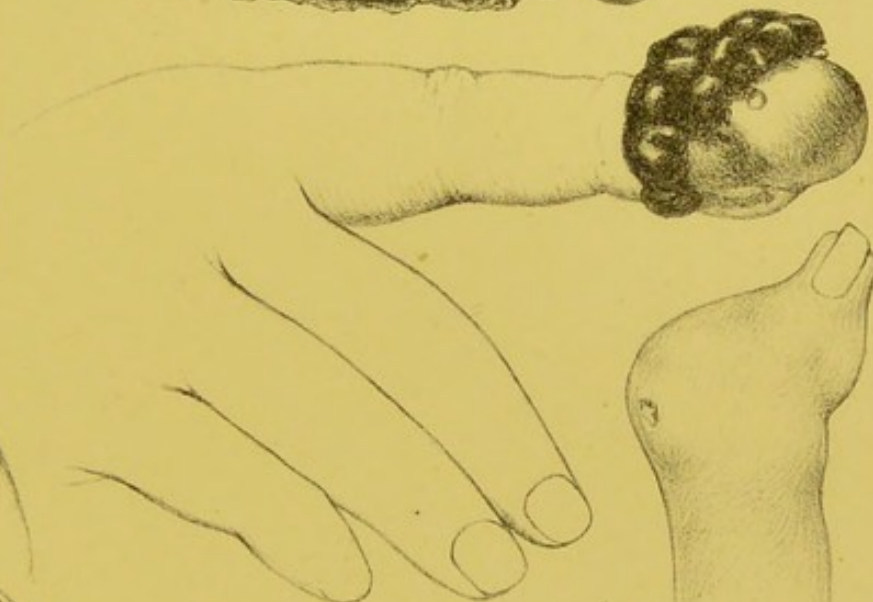

Fig. 97.

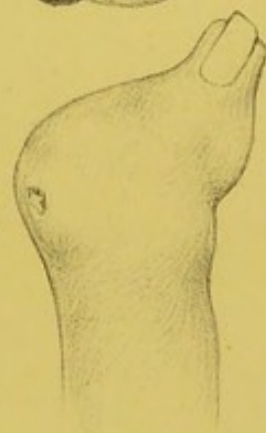


Fig. 98.

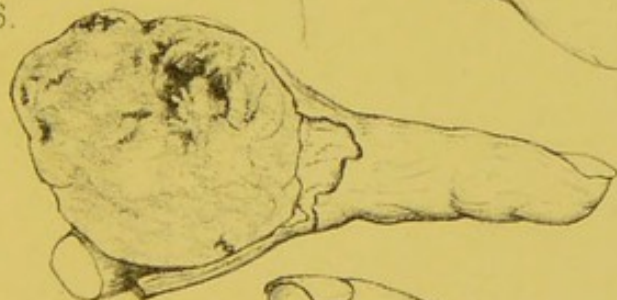

Fig. 99.

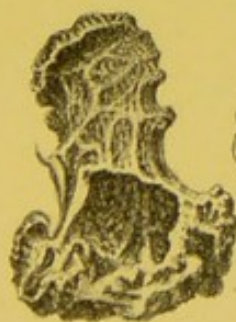

Fig. 100.

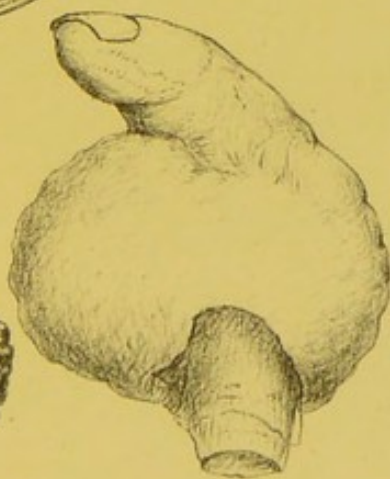


Fig. 101.

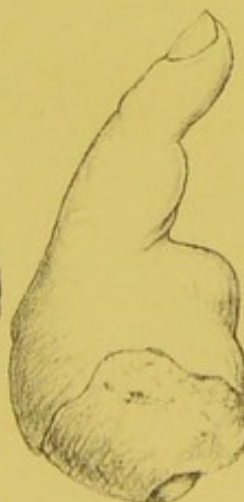

Fig. 102.

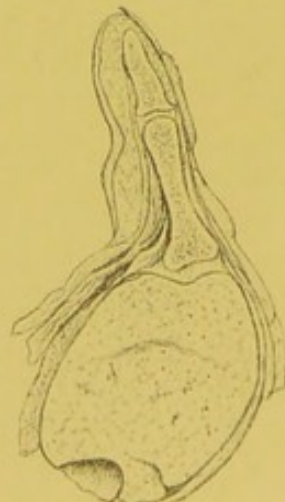



Fig. 103.





## PLATE X.

FIG.	PAGE
104. Metatarsal and phalangeal bones of a great toe which had been in great part destroyed by caries, . . .	145
105. The phalangeal bones of a finger, the first phalanx of which was affected with cario-necrosis. The outer table of the bone had become expanded, and enclosed sequestra of cancellated texture, . . .	145
106. The metacarpal and first phalangeal bones of a finger, showing almost entire destruction of the latter bone by cancerous ulceration, which originated in the skin of the hand, . . . . .	147
107. The phalangeal bones of a finger, showing cario-necrosis of the first phalanx. The outer table of this bone was expanded, and enclosed dead cancellated texture, . . . . .	145
108. The phalangeal bones of a finger, showing an expansion of the outer table of the first phalanx, which had been produced by the growth of a myeloid tumour in its interior, . . . . .	172
109. The metatarsal and phalangeal bones of a great toe, showing an expansion of the external table of the metatarsal bone, and the formation of bony arches which enclosed necrosed portions of cancellated texture, . . . . .	145

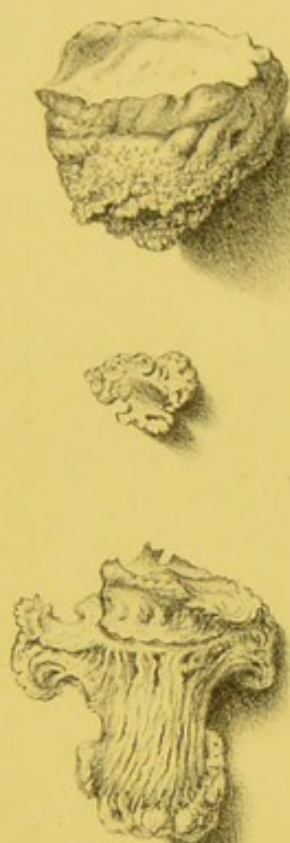


Fig. 104.

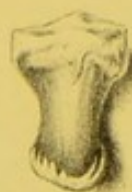
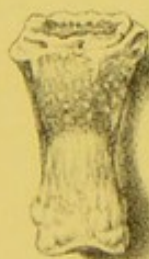
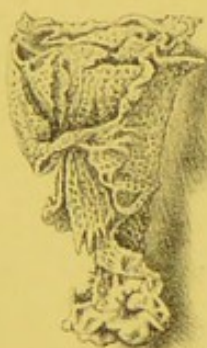Fig. 107.

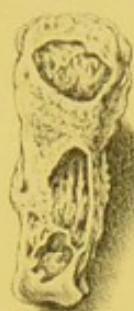

Fig. 105.

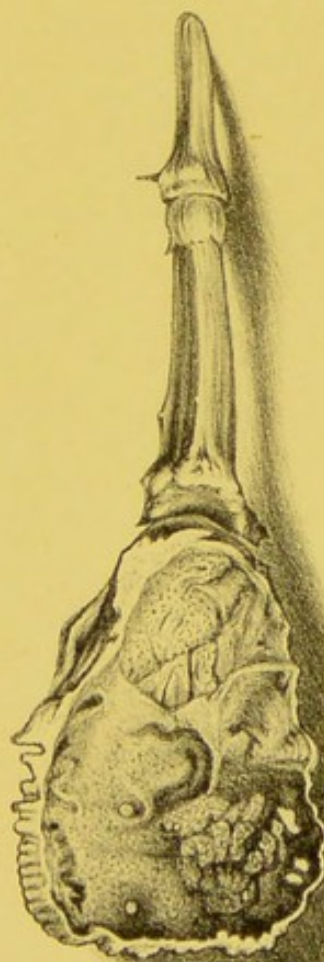

Fig. 108.

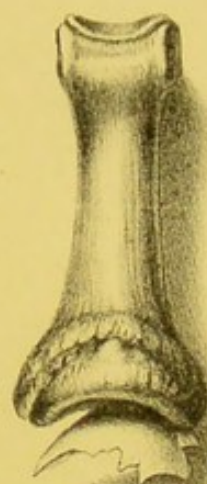


Fig. 106.

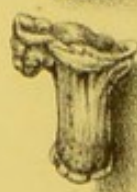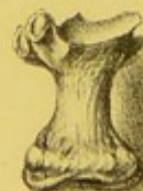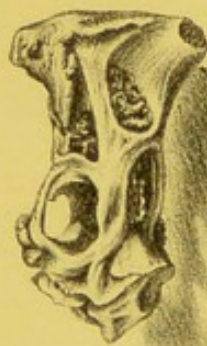



Fig. 109.





# PLATE XI.

FIG.	PAGE
110. Section of a phalangeal bone of a finger, and cartilaginous tumour which had become entirely ossified,	172
111. Exostosis growing from the distal phalanx of a great toe; the nail has been partially cut away in order to expose the tumour,	179
112. Section of the distal phalanx of a great toe, and of an exostosis growing from its extremity,	179
113. The bones of a finger, showing an exostosis growing from the distal extremity of the first phalanx,	176
114. The bones of a finger, showing an exostosis growing from the proximal extremity of the second phalanx,	176
115. Thumb with portion of tendon, both of which had been torn off by accident,	193
116. Distal phalangeal bone of a great toe with an exostosis growing from it,	179
117. Dislocation forwards of the first phalanx of a thumb,	222
118. Lateral dislocation of the distal phalanx of a thumb,	226
119, 120, 121, and 123. Phalangeal bones of fingers showing transverse, longitudinal, and comminuted fractures,	232
122. Bones of a finger, showing partial dislocation and fracture of the articular extremity of the first phalanx,	226
124. Gun-shot injury of the first phalangeal bone of a finger, with lodgment of a single shot in the substance of the distal phalanx,	233
125. Fracture of a distal phalangeal bone, with bending of the second phalanx,	232
126. Fracture through the extremity of a first phalangeal bone, with displacement of the articular fragment, and fracture of the second phalanx,	232

Fig. 110.

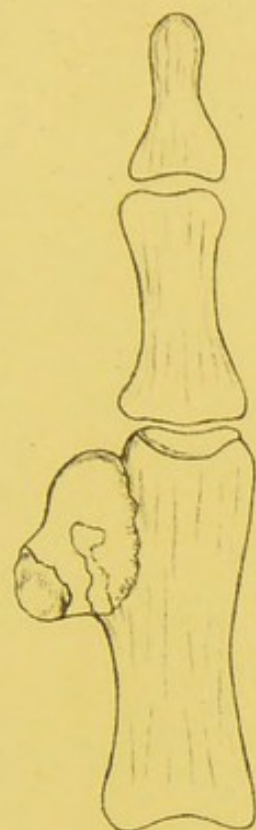
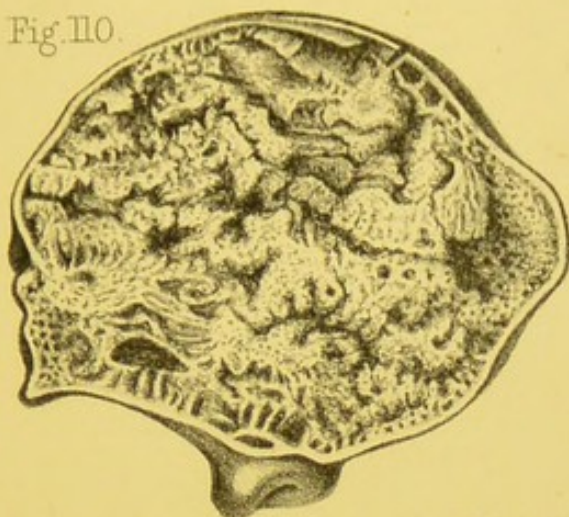


Fig. 113.

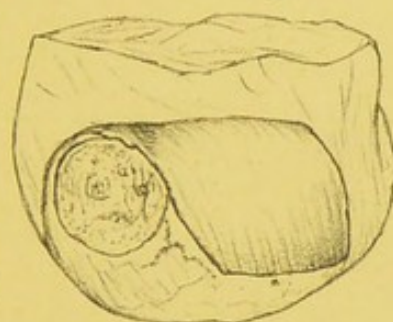


Fig. 111.

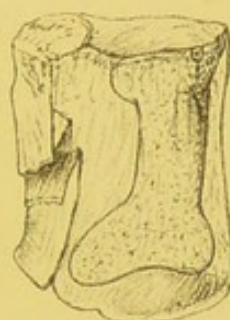


Fig. 112.

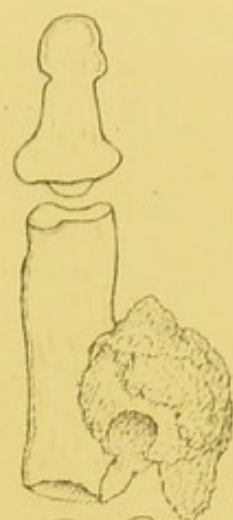

Fig. 114.

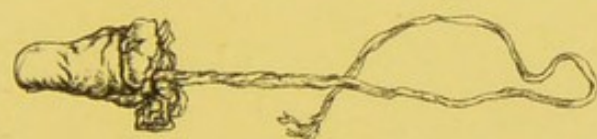

Fig. 115.

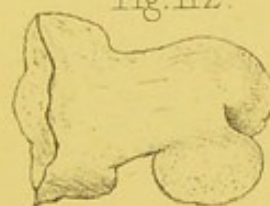

Fig. 116.

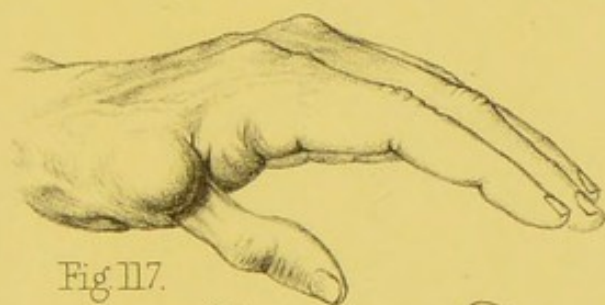


Fig. 117.

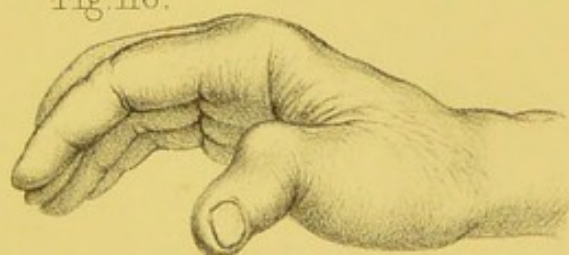

Fig. 118.

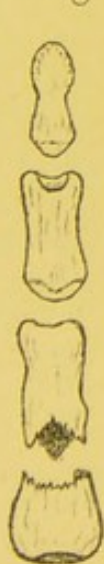

Fig. 119.

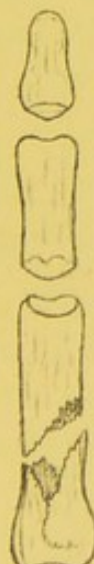

Fig. 120.

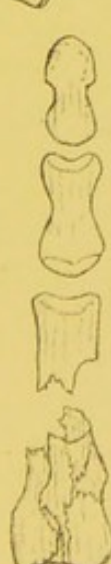

Fig. 121.

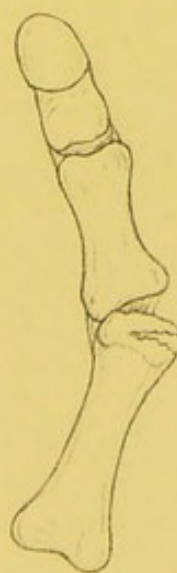

Fig. 122.

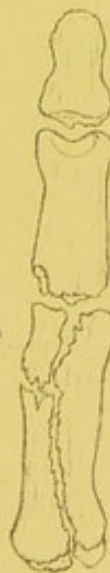

Fig. 123.

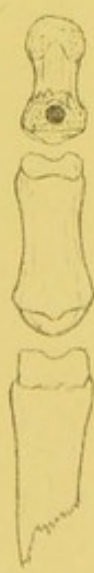

Fig. 124.

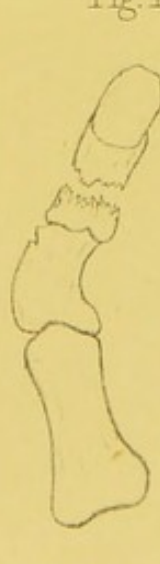


Fig. 125.

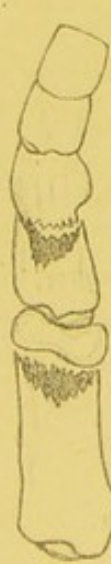

Fig. 126.





## PLATE XII.

FIG.	PAGE
127. Line 1. Incision for the resection of the phalangeal joints, . . . . .	266
Line 2. Incision for the resection of the metacarpo-phalangeal joints, . . . . .	267
Lines 3 and 3. Incisions for amputating the distal phalanx, . . . . .	275
Lines 4 and 5. Incisions for amputating the second phalanx, . . . . .	276
Line 6. Incision for the circular amputation at the metacarpo-phalangeal joint of the thumb, . . . . .	278
Line 7. Incisions for amputating at the same joint by two short flaps, . . . . .	278
Line 8. Incisions for amputating the index finger at its metacarpo-phalangeal joint, . . . . .	277
Line 9. Incisions for amputating the middle and ring finger at the same joint, . . . . .	279
Line 10. Incisions for amputating the little finger at the same joint, . . . . .	277
Line 11. Incision for removing the metacarpal bone of the thumb, . . . . .	281

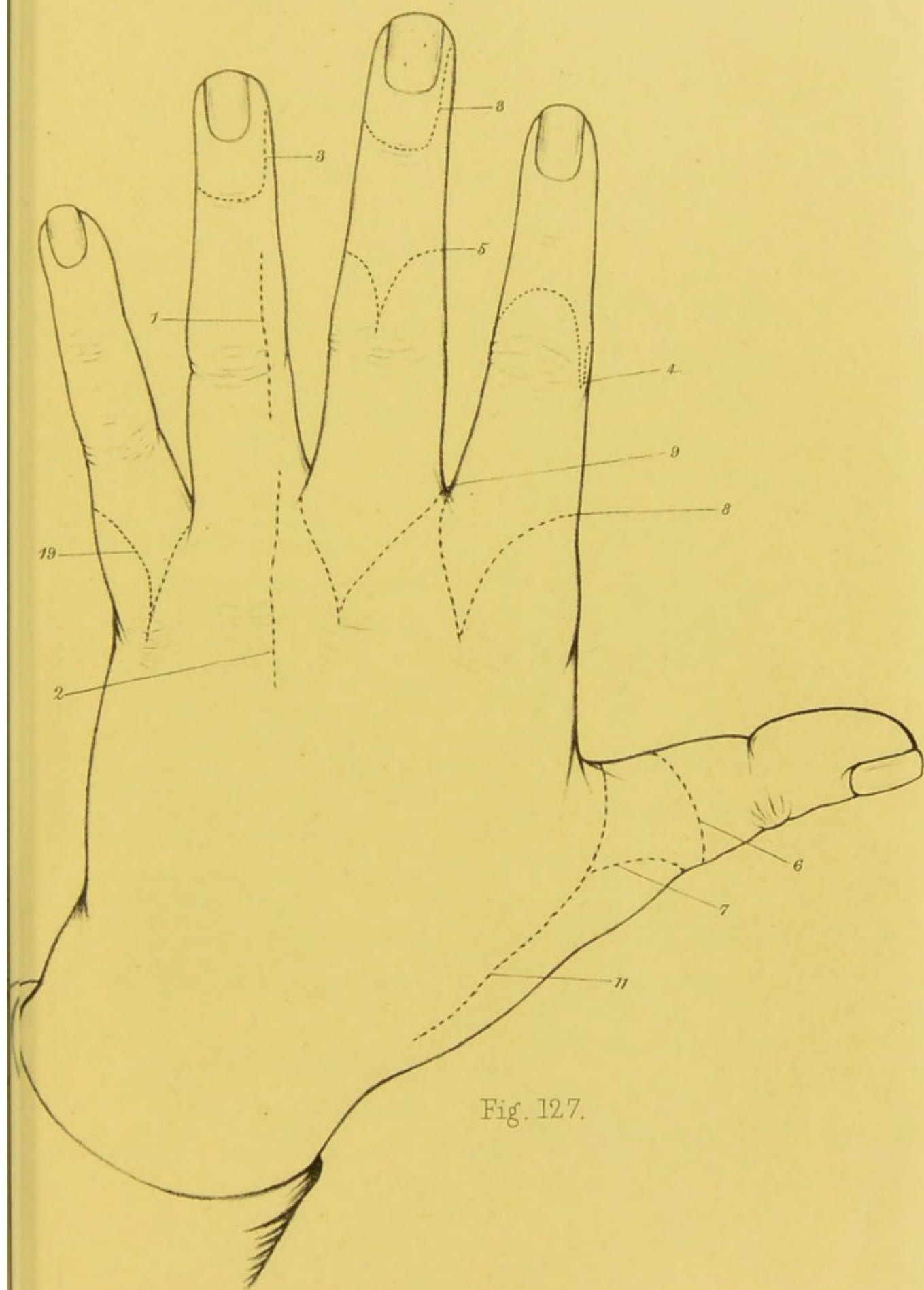


Fig. 127.



## INDEX.

- ACRODYNIA, 185.
- Adams, Dr., rheumatic arthritis in the digital joints, 131; in the metatarso-phalangeal joint of a great toe, 118; treatment of, 137.
- Adams, Mr., expansion of digital bones into cysts, 172.
- Amputation of fingers and toes, 274.
- of distal phalanx, 274.
- of second phalanx, 276.
- at metacarpo-phalangeal joint, 277.
- of fingers, together with their metacarpal bones, 279.
- removal of head of metacarpal bone in, 279.
- of the toes, 282.
- of the toes, together with their metatarsal bones, 284.
- after treatment of, 285.
- Anchylolysis of digital joints, 124.
- Aneurism of digital artery, 163.
- Arnott, Mr., case of supernumerary digits, 27.
- Articulation of supernumerary digits, 31.
- Arteries, enlargement of, in congenital hypertrophy, 3.
- wounds of, 191.
- presence of in pedicle of supernumerary digits, 41.
- Auvert, medullary tumour of thumb, 175.
- BARTHOLINE, J.: supernumerary digits, 27.
- Blandin, M., excision of metatarso-phalangeal joint, 265.
- Bolton, Dr., supernumerary toes, 38.
- Bolton, Dr., congenital pedunculated tumours, 68.
- Bones, digital, acute inflammation of, 86.
- chronic inflammation of, 139.
- necrosis of, 87.
- cancerous ulceration of, 147.
- caries of, 140.
- absorption of, by pressure of tumours, 147.
- fatty degeneration of, 147.
- inflammation of articular extremities of, 129.
- tubercular deposit in, 129.
- cartilaginous tumours of, 168.
- medullary tumours of, 174.
- myeloid tumours of, 173.
- osseous tumours of, 176.
- injuries of, 227.
- excision of, 268.
- entozoa in, 180.
- Bowman, Mr., Paccinian bodies, 210.
- Brodie, Sir B., division of ulnar nerve, 201.
- hysteria following injury of nerve, 201.
- bursa in connexion with corns, 115.
- treatment of bunion, 122.
- Brown, Sequard, atrophy of muscles of the thumb following an injury of ulnar nerve, 201.
- epilepsy following injury of a digital nerve, 201.
- Bruises, 188.
- Bryant, Mr., congenital fatty tumours, 70.
- congenital fibro-plastic and cartilaginous tumours, 70.
- thickening of synovial membrane in a digital joint, 125.

- Bunion, 115.  
 — inflammation and ulceration of bursal sac of, 119.  
 — distortion of bones and joints in, 116, 118.  
 — disease of joints and bones in, 120.  
 — situations of, 116.  
 — epithelial cancer of, 157.  
 — treatment of, 120.  
 Burns, 188.  
 Bursæ, inflammation of, 110.  
 — thickening of sac of, 111.  
 — wounds and bruises of, 217.  
 — becoming solid, 111.  
 Butcher, Mr., excision of metatarso-phalangeal joint, 265.  
 — excision of bones, 271.
- CAMPBELL, Dr., case of simulated absence of one digit, 14.  
 — case of supernumerary digits, 30.  
 Cancer, epithelial, 156.  
 — melanotic, 157, 166.  
 — medullary, 164.  
 Carlyle, Dr., case of supernumerary phalanx in thumb, 29.  
 Carter, Dr. H. V., fungus disease of foot, 148.  
 Canton, Mr., rheumatic arthritis of joints of great toe, 118.  
 Caries, the result of injury, 140.  
 — the result of strumous disease, 142.  
 Cartilage, degeneration and ulceration of, in digital joints, 127.  
 Carpopedal convulsions, 248.  
 Chalk, Mr. Oliver, case of epithelial cancer affecting bunions, 157.  
 Champion, Mr., excision of metatarso-phalangeal joint, 265.  
 Chiene, Dr. John, excision of metatarso-phalangeal joint, 265.  
 Chilblains, 181.  
 Cicatrix, painful, 202.  
 Coleman, Mr., splint for fractured digits, 231.  
 Convulsions, carpopedal, 248.  
 Contractions, congenital, 61.  
 Contractions, non-congenital, 238.  
 — spasmodic, 245.  
 Corns, 153.  
 — inflammation of, 154.  
 — treatment, radical and palliative of, 155.  
 Craigie, Dr., on whitlow, 74.  
 Cruveilhier, congenital deficiencies of the digits, 13.  
 — venous tumours of hand and digits, 164.  
 Curling, Mr., hypertrophy of digits, 4.  
 Cysticercus cellulosæ in bones of finger, 180.
- DEFICIENCIES, congenital, in number of fingers, 11.  
 — simulated, 13.  
 — in number of phalanges, 15.  
 — of upper extremity, 18, 20.  
 — in toes, 22.  
 Dieffenbach, division of tendons in Writers' Cramp, 251.  
 Digits torn off by accident, 193.  
 Dislocations, congenital, 65.  
 — of carpo-metacarpal joints, 218.  
 — of tarso-metatarsal joints, 219.  
 — of metacarpo-phalangeal joints, 221.  
 — of metatarso-phalangeal joints, 224.  
 — of phalangeal joints, 225.  
 Distortions of digits in congenital hypertrophy, 4.  
 — non-congenital, the result of inflammation, 238.  
 — from contraction of palmar fascia, 240.  
 — from contraction of plantar fascia, 241.  
 — from affections of the nervous system, 245.  
 — the result of injury, 254.  
 — from the growth of tumours, 254.  
 Dupuytren, M., case of congenital contraction of toes, 65.  
 — treatment of ingrowing toe nail, 105.  
 — dislocation of tarso-metatarsal joints, 219.

- ELLIOT, Dr., lateral dislocation of phalanx of thumb, 226.  
 — congenital deficiency of upper extremity, 18.  
 Entozoa in bone, 180.  
 Erichsen, Mr., excision of metacarpal bones, 271.  
 Erysipelas, 73.  
 Erythema, 73.  
 Excision of the digital joints, 261.  
 — of the phalangeal joints, 266.  
 — of metacarpo-phalangeal joints, 267.  
 — of joints of toes, 268.  
 — of phalangeal bones, 268.  
 — of metacarpal bones, 271.  
 — of metatarsal bones, 271.  
 Exostosis of the fingers, 176.  
 — of the toes, 177.
- FALLA, Dr., case of congenital deficiency of both upper extremities, 20.  
 Fascia, palmar, contraction of, 240.  
 — plantar, contraction of, 241.  
 Ferguson, Mr., division of nerves, 212.  
 Foot, fungus disease of, 148.  
 Foreign bodies lodged in digits, 195.  
 Förster, congenital deficiencies, 19.  
 — supernumerary digits, 28.  
 — congenital union of toes, 53.  
 Fractures of metacarpal bones, 228.  
 — of metatarsal bones, 229.  
 — of phalanges, 230.  
 Friche, Mr., excision of metatarso-phalangeal joint, 265.  
 Frost-bite, 184.
- GAILLARD, M., on varieties of supernumerary digits, 26.  
 Galvanism in paralysis of digits, 211.  
 Ganglion, 113.  
 Gangrene, the result of injury, 213.  
 — senile, 215.  
 — from obstructions of the circulation, 214.  
 Gouty inflammation of digital joints, 131.
- HALSE, affection of spine in Writers' Cramp, 248.
- HAMILTON, Dr., dislocation of carpo-metacarpal and tarso-metatarsal joints, 218, 219.  
 Heath, Mr. C., case of recurrent fibrous tumour of hand, 160.  
 Hereditary transmission of congenital deformities, 2.  
 Hewitt, Mr., case of osseous tumour in soft textures of the hand, 160.  
 Hodgson, Mr., case of pulpy degeneration of the synovial membrane of a digital joint, 127.  
 Holden, Mr., protrusion of synovial membrane through sheaths of flexor tendons, 113.  
 Holthouse, Mr., compound lateral dislocation of thumb, 226.  
 Holmes, Mr., excision of metatarsal bones, 271.  
 Howden, Dr., case of supernumerary digits, 51.  
 Hulke, Mr., case of Writers' Cramp, 251.  
 Hypertrophy, congenital, 3.
- INDIAN puzzle, use of, in reducing dislocations of the digits, 227.  
 Inflammation, diffuse cellular, 94.  
 — strumous, 108.  
 Ingrowing of toe nail, 103.  
 Injuries of hand and fingers, importance of saving portions in, 234.
- JAMES, Dr., excision of metatarsal bone, 271.  
 Johnston, Mr. Arthur, case of supernumerary digits, 28.
- Joints, acute inflammation of, 124.  
 — ankylosis of, 125.  
 — chronic inflammation of, 125.  
 — pulpy degeneration of synovial membrane of, 126.  
 — disease of articular cartilages of, 127.  
 — rheumatic arthritis of, 130.  
 — gouty inflammation of, 131.  
 — changes in, after disorganization by disease, 132.  
 — new formation of, 133.  
 — swelling of, after injury of nerves, 209.

- Joints, bruises and wounds of, 217.  
 — dislocations of, 218.  
 — excisions of, 261.  
 Jones, Mr. Sydney, case of hypertrophy of second toe, 8.
- KEEN, Dr., on injuries of nerves, 199.  
 Key, Mr., on ganglion and bunion, 113.  
 Kramer, M., excision of metatarso-phalangeal joint, 265.
- LEGAT, Dr., case of congenital absence of four fingers, 12.  
 Ligaments, chronic inflammation and destruction of, 134.  
 Lister, Professor, operation for congenital union of fingers, 57.  
 Liston, suggestion for treating congenital union of fingers, 56.
- MACLEOD, Dr., frost-bite in Crimea, 185.  
 Malgaigne, dislocation of carpo-metacarpal joints, 218.  
 May, Dr., case of intra-uterine amputation of the fingers, 21.  
 Meckel, cases of congenital deficiency, 13.  
 Melanosis of skin, 157.  
 — of periosteum, 166.  
 Mitchell, Dr., on injuries of the nerves, 199.  
 Moir, Dr., case of congenital tumour of toe, 69.  
 Montgomery, Dr., amputation of digits *in utero*, 10, 21.  
 — case of congenital tumour of finger, 69.  
 Morehouse, Dr., on injuries of the nerves, 199.  
 Morphia, hypodermic injection of, to relieve pain, 211.  
 Murray, Mr. Jardine, case of double hand, 28.  
 Muscles, interossei rupture of, 190.  
 — atrophy of, 209.  
 — paralysis of, 199, 200, 201.  
 Myeloid tumour, 173.
- NAILS, affections of, 97.  
 Nails, syphilitic affections of, 106.  
 — hypertrophy of, 103.  
 — ingrowing of, in toes, 103.  
 — alterations in, after injuries of nerves, 209.  
 — injuries of, 189.  
 — reproduction of, 189.  
 — psoriasis of, 101.  
 Necrosis of bones of digits, 87.  
 Nelaton, M., operation for congenital union of the fingers, 54.  
 Nerves, bruises and wounds of, 198.  
 — division or resection of, 212.  
 Neuroma, 162.  
 Nisbett, Mr., treatment of pedunculated warts, 153.  
 Nutrition, interference with, after injuries of nerves, 209.
- ONYCHIA, 97.  
 — malignant, 99.  
 Ossification of cartilaginous tumours, 171.  
 Otto, cases of congenital deficiencies, 13.  
 — deficiency of upper extremity, 20.  
 — atrophied digit attached to hand, 29.
- PACCINIAN bodies, dissection of, 207.  
 Page, Dr., excision of metatarsal bones, 27.  
 Paget, Mr., case of subcutaneous tubercle, 162.  
 — cartilaginous tumours of hand and fingers, 168.  
 — medullary tumour of great toe, 175.  
 — exostosis of little toe, 177.  
 — injuries of nerves, 199.  
 — glossy state of skin after injury of nerves, 208.  
 Painful subcutaneous tubercle, 162.  
 Pancoast, Professor, excision of metatarso-phalangeal joint, 265.  
 Paralysis of digits, 245.  
 — from lead poisoning, 249.  
 Paxton, Dr., case of supernumerary great toe, 40.  
 Periosteum, fibrous tumour of, 165.

- Periosteum, melanotic tumour of, 166.  
 — acute inflammation of, 86.  
 — chronic inflammation of, 138.  
 Plasters, use of, in bunion, 123.  
 Porson, Dr., excision of metatarsal bones, 271.  
 Power, Mr., case of hypertrophy of finger, 4.  
 Psoriasis of nails, 101.  
  
 RADIUS, congenital absence of, 19.  
 — fracture of, a cause of distorted digits, 258.  
 Ramsay, Dr., excision of metacarpophalangeal joints, 264.  
 Recurrent fibrous tumour, 160.  
 Reid, Dr. John, cases of hypertrophied digits, 4.  
 — temperature of hypertrophied digits, 3.  
 Richardson, Dr., on disease of nails, 102.  
 Romberg, nervous affections of digits, 245, 246.  
 — nervous affection in washerwomen, 250.  
 Russel, Mr., pulsating tumour of digits, 163.  
  
 SAVIARD, case of supernumerary digits, 28.  
 Scalds, 188.  
 Schreger, subcutaneous bursæ, 110.  
 Sensation, burning, after injuries of nerves, 208.  
 Sharpey, Dr., Paccinian bodies, 210.  
 Sidey, Dr. J., case of simulated absence of a finger, 14.  
 Simpson, Professor, on intra-uterine amputation, 10.  
 Simulated deficiency in number of digits, 13.  
 Skin, glossy state of, after injuries to nerves, 208.  
 — eczematous, eruptions of, 208.  
 Smith, Dr., on neuroma, 163.  
 Smith, Mr. J., on sub-ungual warts, 152.  
 Smith, Mr. R. W., dislocation of tarso-metatarsal joints, 219.  
 Smyth, Dr., on ingrowing toe nail, 104.  
 Solly, Mr., on Writers' Cramp, 248.  
 Stanley, Mr., entozoa in a digital bone, 180.  
 Steel, Dr., excision of phalangeal joint, 263.  
 Stromeyer, division of tendon in Writers' Cramp, 251.  
 Struthers, Professor, case of congenital deficiency of digits, 13.  
 — cases of supernumerary digits, 28.  
 Stumps useful after injuries of hands, 236.  
 Supernumerary fingers and toes, 26.  
 — phalanx in thumb, 29.  
 — digits, classification of, 26.  
 Swelling, œdematous, after injuries of nerves, 209.  
 Syme, Mr., case of subcutaneous tubercular under the nail of a finger, 162.  
 — Senile gangrene, treatment of, 217.  
 — case of supernumerary thumb, 33.  
 — excision of metacarpal bone of thumb, together with a tumour, 271.  
 Synovial membrane, protrusion of, in form of a fungus, 108.  
 — protrusion of, through sheaths of flexor tendons, 113.  
 — acute inflammation of, 124.  
 — thickened condition of, 125.  
 — chronic inflammation of, 125.  
 — pulpy degeneration of, 126.  
  
 TAYLOR, Dr., case of lead poisoning, 250.  
 — apparatus for palsied digits, 253.  
 Temperature of hypertrophied digits, 3.  
 Temperley, Mr., case of congenital absence of three fingers, 12.  
 Tendons, acute inflammation of, 82.  
 — chronic inflammation of, 96.  
 — destruction of, in whitlow, 83.  
 — portions of, drawn out by accident, 193.  
 — injuries of, 192.  
 Tetanus following lacerated wounds of hand, 191, 196.

- Thalozan, Dr., on frost-bite in Crimea, 185.
- Todd, Mr., "paronychia gangrenosa," 76.
- Todd, Dr., on Paccinian bodies, 210.
- Toes, overlapping of, 256.
- congenital contractions of, 63.
- non-congenital contractions of, 257.
- compression of, in cases of overlapping, 256.
- Tumours, congenital, 67.
- of the soft textures, 151.
- epithelial, 156.
- melanotic, 157.
- fatty, 158.
- cystic, 158.
- fibrous, 159.
- cartilaginous, 159.
- osseous, 160.
- subcutaneous tubercle, 162.
- neuromatous, 162.
- aneurismal, 163.
- of the periosteum and bone, 165.
- fibrous, 166.
- melanotic, 166.
- cartilaginous, 168.
- myeloid, 173.
- medullary, 174.
- osseous, 176.
- UNION, congenital, of the fingers and toes, 46.
- varieties of, 46.
- treatment of, 53.
- Ulceration, syphilitic, 107.
- strumous, 108.
- of cartilaginous tumours, 171.
- Ulceration of articular cartilage, 127.
- WARD, Dr., case of congenital union of the fingers, 51.
- Wardrop, Mr., on "Onychia Maligna," 99.
- pulsating tumour of digits, 163.
- Warts, 151.
- sub-ungual, 152.
- hereditary, 152.
- Webbed digits, 48.
- Wells, Mr. Spencer, treatment of chilblains, 183.
- White, Mr., case in which a supernumerary thumb grew again after removal, 45.
- Whitlow, varieties of, 74.
- destruction of tendon in, 83.
- destruction of bone in, 87.
- treatment of, 89.
- Wounds, 190.
- gunshot, 191.
- of tendons, 192.
- inflicted by bites and stings, 194.
- of nerves, 201.
- of bursæ and joints, 217.
- of bone, 227.
- remarks in regard to constitutional irritation following, 236.
- Writers' Cramp, 247.
- VOIGHT, case of supernumerary digits, 28.
- Vrolik, cases of congenital deficiencies of the digits and upper extremity, 13, 20.

ERRATUM.—In p. 176, l. 17, *for* Fig. 104, *read* Fig. 114.

