

**Lectures on certain diseases of the jaws : delivered at the Royal College of Surgeons of England, 1887 / by Christopher Heath.**

**Contributors**

Heath, Christopher, 1835-1905.  
Royal College of Physicians of Edinburgh

**Publication/Creation**

London : J. & A. Churchill, [1887]

**Persistent URL**

<https://wellcomecollection.org/works/kq53qv5f>

**Provider**

Royal College of Physicians Edinburgh

**License and attribution**

This material has been provided by This material has been provided by the Royal College of Physicians of Edinburgh. The original may be consulted at the Royal College of Physicians of Edinburgh. where the originals may be consulted.

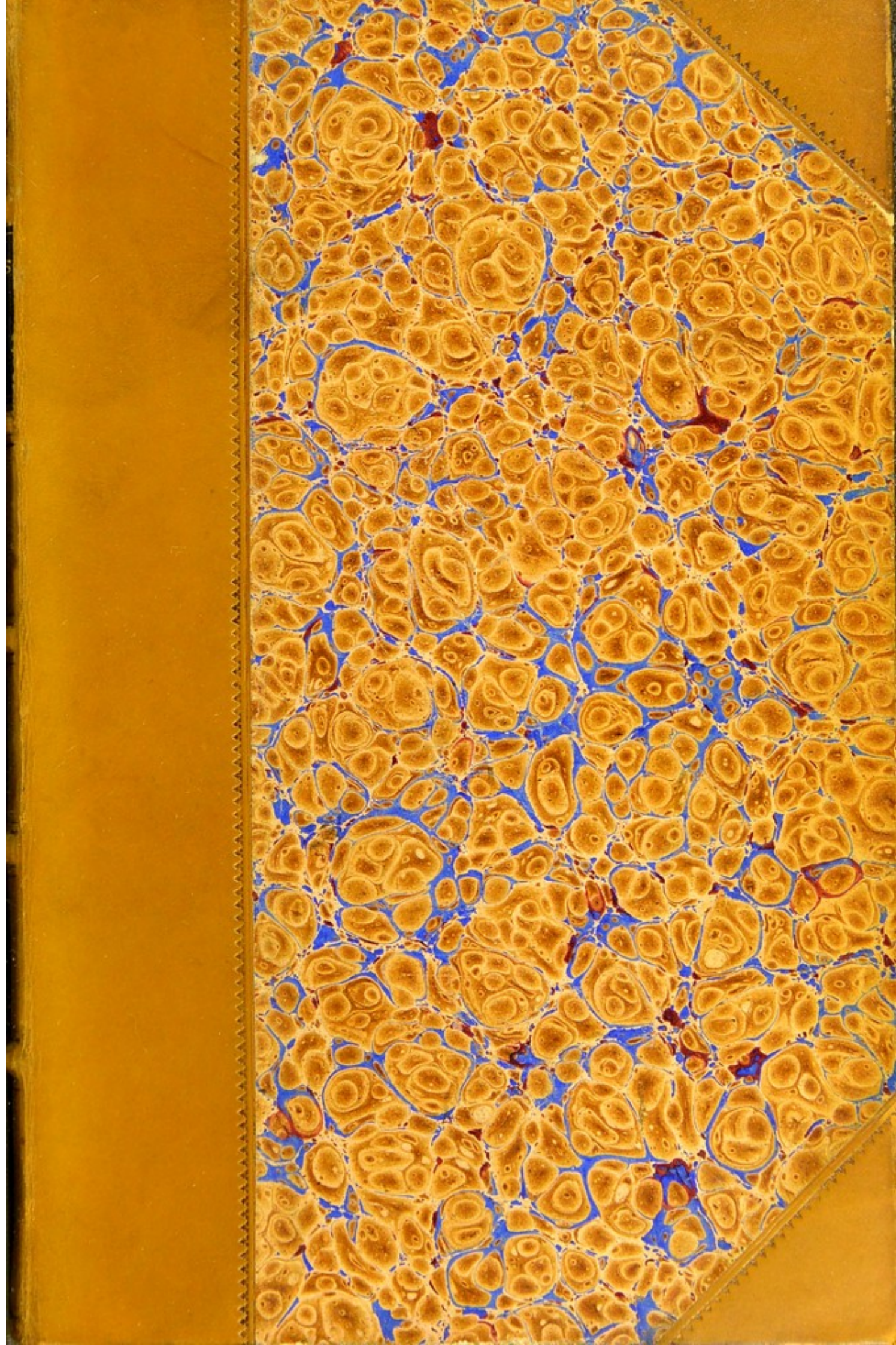
This work has been identified as being free of known restrictions under copyright law, including all related and neighbouring rights and is being made available under the Creative Commons, Public Domain Mark.

You can copy, modify, distribute and perform the work, even for commercial purposes, without asking permission.



Wellcome Collection  
183 Euston Road  
London NW1 2BE UK  
T +44 (0)20 7611 8722  
E [library@wellcomecollection.org](mailto:library@wellcomecollection.org)  
<https://wellcomecollection.org>







\* Feb. 7. 26.

R38098













# LECTURES

ON CERTAIN

# DISEASES OF THE JAWS

DELIVERED AT THE ROYAL COLLEGE OF SURGEONS  
OF ENGLAND, 1887.

BY

CHRISTOPHER HEATH, F.R.C.S.,

*Hunterian Professor of Surgery and Pathology in the College;  
Holme Professor of Clinical Surgery in University College,  
London, &c.*



---

ILLUSTRATED.

---

LONDON:

J. & A. CHURCHILL, NEW BURLINGTON ST.

PRICE HALF-A-CROWN.



THE CATHOLICS

OF THE

DECEASED OF THE FAITH

AND THE DECEASED OF THE FAITH

AND THE DECEASED OF THE FAITH

CHRISTIANITY DECEASED OF THE FAITH

AND THE DECEASED OF THE FAITH

AND THE DECEASED OF THE FAITH

AND THE DECEASED OF THE FAITH

AND THE DECEASED OF THE FAITH

AND THE DECEASED OF THE FAITH

AND THE DECEASED OF THE FAITH

AND THE DECEASED OF THE FAITH

## LECTURES ON CERTAIN DISEASES OF THE JAWS.

Delivered at the Royal College of Surgeons of England,  
June, 1887.

By CHRISTOPHER HEATH, F.R.C.S., Hunterian Professor  
of Surgery and Pathology.

### LECTURE I.—ON CYSTIC DISEASES OF THE JAWS.

MR. PRESIDENT AND GENTLEMEN.—The occupant of the Hunterian Chair of Surgery and Pathology in this College has a large choice of subjects on which to address you, and my predecessors in office have accordingly ranged at will over the domain of surgery. I propose to confine myself to a comparatively small portion of surgery, but one of no little importance, and shall have the opportunity of referring for illustration to that splendid collection of pathological specimens which, begun by Hunter, has in this special department been greatly enriched by the labours of Liston and Fergusson, and is now without a rival in its perfection.

The "Injuries and Morbid Affections of the Maxillary Bones and Antrum" was proposed as the subject of the Jacksonian Prize in this College in the year 1827, but no dissertation was sent in for competition. The same thing again occurred in 1842, and this is the more remarkable, because the majority of Liston's great cases had occurred before that date, and both he and Fergusson were then actively engaged in instructing large numbers of pupils, some of whom might have reduced their teaching to paper.

In 1867, "The Injuries and Diseases of the Jaws, including those of the Antrum, with the treatment by Operation, or otherwise," was again put forth as the subject for the Jacksonian Prize Dissertation, and having seen much of Sir William Fergusson's practice, and having myself done some



little work in the same direction, I ventured to compete, and had the satisfaction both of being successful and of adding to the museum a considerable number of valuable preparations, many of which I shall bring before you.

#### DISEASES OF THE ANTRUM.

The antrum maxillare or sinus of the upper jaw was known as early as the days of Galen, but was first described with any degree of accuracy by our fellow-countryman, Nathaniel Highmore, of Sherborne, whose *Disquisitio Anatomica Corporis Humani* was published at the Hague in 1651. By the kindness of a former pupil, Mr. W. H. Williams, of Sherborne, whose wife is a direct descendant of Nathaniel Highmore, I am enabled to place before you the author's own copy of his anatomical work, bearing on the title-page the signatures of successive incumbents of the Sherborne practice. And yet it is remarkable that the copy of the same work in our College library is more perfect in containing a curious allegorical frontispiece, which is wanting in the Sherborne copy, although the *Frontis physiognomica descriptio* is there. At page 227 of this work will be found a plate illustrating (not quite correctly) the anatomy of the antrum, and from it Figs. 1 and 2 are reproduced. In another figure is shown a curiously inaccurate drawing of the antrum, which, as the

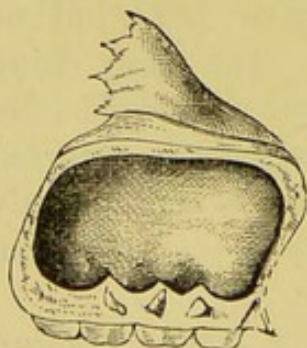


Fig 1.

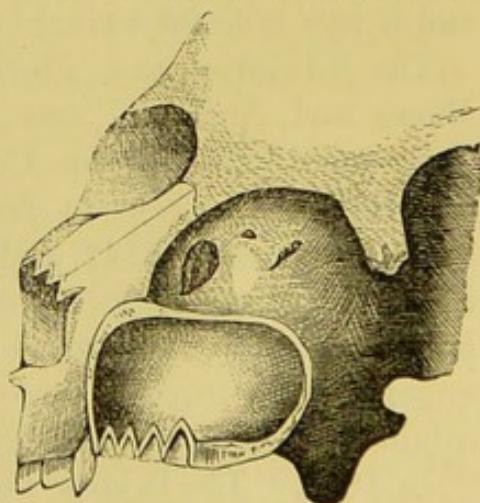


Fig 2.

author says, "is more frequently empty, but is sometimes found filled with mucus, into which the humours from the head are able to distil by a certain meatus from the cavity in



the frontal bone and from the ethmoid bone." I need hardly say that there is no such communication with the frontal sinus as is here figured any more than there is any passage from the pituitary fossa to the palate, which is given in the same drawing.

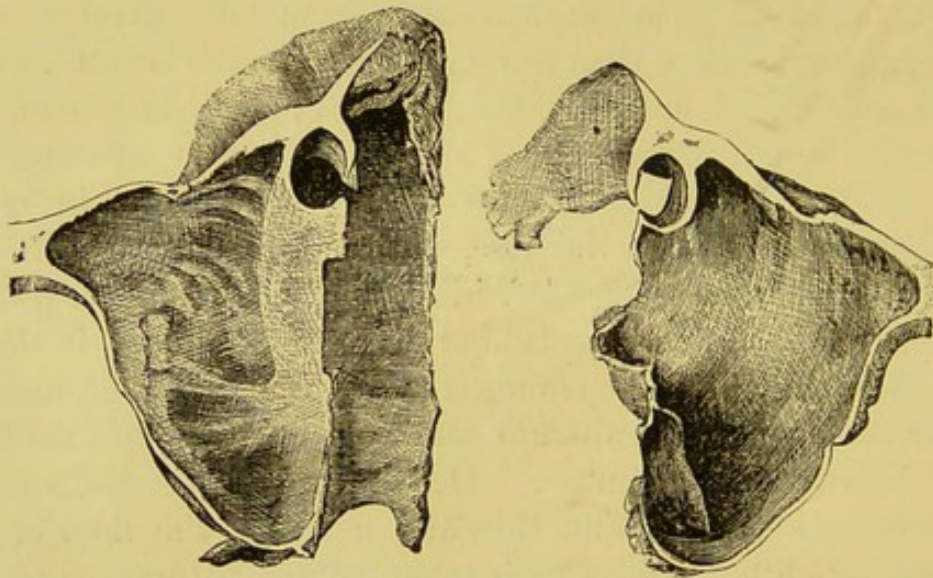
The only normal opening from the antrum is into the middle meatus of the nose, and this is shown on the section of the skull before you, on one side with the mucous membrane *in situ*, and on the other with it removed. The size of the aperture found in a macerated superior maxilla gives a very exaggerated idea of the opening in the articulated skull, where it is encroached upon by the palate, inferior turbinate, and ethmoid bones, which narrow and subdivide the opening into two parts. In the recent subject these are covered in by the mucous membrane of the nose, so that ordinarily there is only a small oblique aperture left in front of the unciform process of the ethmoid, and close behind the infundibulum. It should be observed that this opening is at the upper part of, and not near the floor of, the antrum, and that it opens into the middle meatus of the nose. Occasionally a second smaller aperture is found behind this, and nearer to the floor of the sinus, which has always been regarded as a natural formation. M. Giralès, however, in his *Recherches sur les Kystes Muqueux du Sinus Maxillaire* (Paris, 1860), maintains that the posterior opening, when it exists, is always the result of pathological change, and that the anterior opening is into the infundibulum, and not into the meatus itself. I believe that slight variations in the position of the opening exist; but it is undoubted that the aperture is very minute, and quite inaccessible from the nose.

Highmore describes the antrum as "a hollow, spherical or somewhat oblong in shape, and large enough to hold the terminal phalanx of the great toe." The fact is, that the size of the antrum is very variable, and this point was carefully investigated some years ago by the late Mr. W. A. N. Cattlin, F.R.C.S., who published a valuable paper in the *Odontological Society's Transactions*, Vol. ii, from which the following illustrations are taken.



As the result of the examination of a hundred specimens, Mr. Cattlin found that, as a rule, the antrum is larger in the male than in the female, and that it diminishes in size with extreme age. In the young subject likewise the cavity is small, and its walls comparatively thick. Fig. 3 shows in

Fig 3.



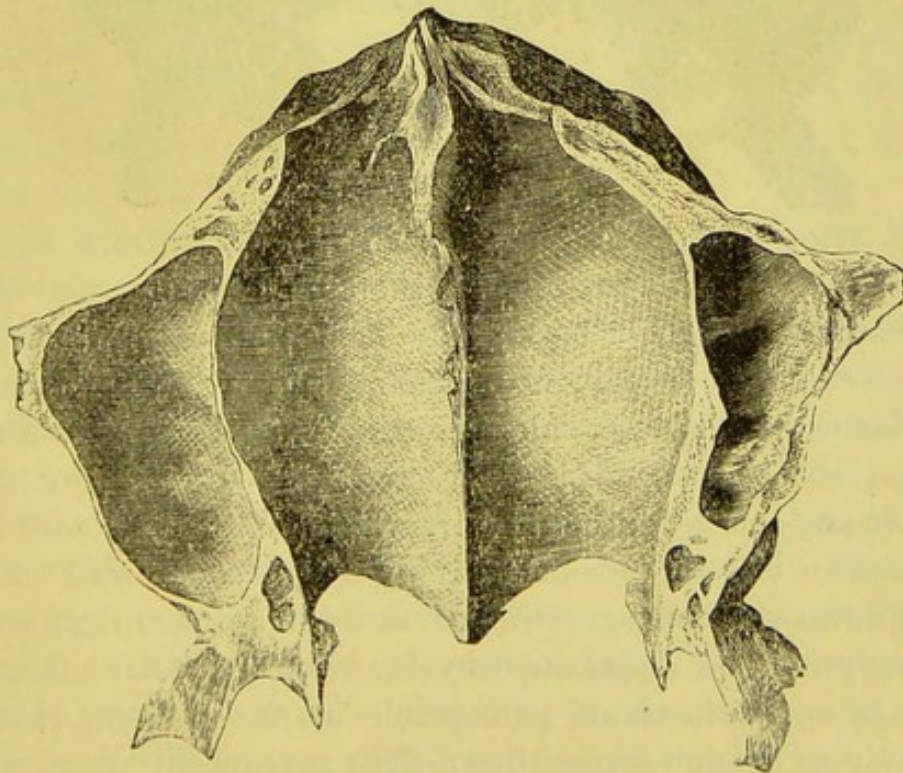
a transverse section both the roof and floor of an adult antrum of the common shape and size, capable of containing two drachms and a half of fluid ; but a large adult antrum may be capable of containing eight drachms of fluid, whilst a small adult antrum containing only one drachm of fluid has been seen. The two antra are often unsymmetrical in size and shape ; thus Fig. 4 shows a much larger and deeper cavity on one side than on the other. The antrum may even extend irregularly into the malar bone, forming a supplementary cavity there ; but the most remarkable variation is due to the development of the ridges of bone which subdivide the cavity ; these are very variable in size and shape. Fossæ of considerable depth are often found in the floor of the antrum, particularly at the anterior and posterior extremities, of which Fig. 5 is a good example, showing on one side a perforation by an



alveolar abscess. A rare form is when fossæ or cells are developed beneath the orbital plate, or a *cul de sac* is formed close to the lachrymal groove.

*Suppuration in the antrum*, or, as it is sometimes termed, *abscess*, is ordinarily the result of inflammation extending from the teeth to the lining membrane of the cavity; and the disease might, therefore, be not incorrectly termed an empyema, as proposed by Otto Weber. The roots of the first and second molar teeth often, and the bicuspid and canine occasionally, form prominences in the floor of the antrum; and when these teeth become carious, the thin plate of bone covering their fangs not unfrequently becomes affected, and disease is set up in the cavity. The fangs of the first molar

Fig. 4.

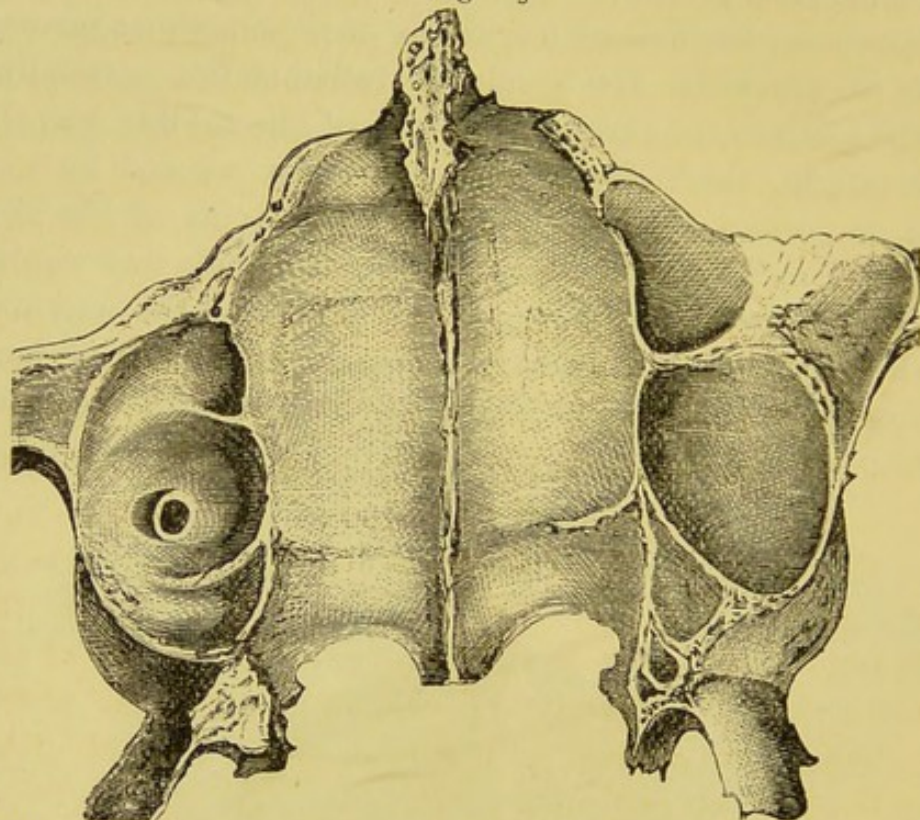


tooth are occasionally found in health to be uncovered by bone, and to project beneath the lining membrane of the antrum; and, under these circumstances, irritation and inflammation would be still more likely to occur. But an abscess may be formed in the alveolus, and eventually burst



into the antrum, though connected originally with teeth not usually in relation with the cavity.

Fig. 5.



The symptoms of suppuration in the antrum are at first simply those of inflammation of the lining membrane—dull, deep-seated pain shooting up the face and to the forehead, tenderness of the cheek, with some fever and constitutional disturbance; but occasionally the pain is most acute, and of a sharp, stabbing, neuralgic character. A slight rigor may usher in the formation of matter, which will find its way into the nostril when the patient is lying on his sound side, either through the normal aperture or through an opening caused by absorption, as maintained by M. Giraldès. An offensive odour is now sometimes perceptible to the patient, though not to those around him—thus differing markedly from what occurs in ozæna—and a sudden discharge of matter from the nostril when blowing the nose, may relieve all the symptoms for the moment. The more common course of events is, however, that without any acute pain the patient notices that he has a purulent discharge from the nose when blowing it, and perhaps is aware that, when lying down, the discharge



finds its way into the throat. This latter point is often overlooked, however, though there may be a complaint of a very disagreeable taste in the mouth and a tendency to nausea in the morning, with a hawking up of pellets of inspissated pus.

With all this there is no distension of the antrum, and it is this fact which frequently misleads the practitioner. It is certain, however, that in health there is invariably an opening between the antrum and the nostril; and that, even when this is closed, the wall is very thin and readily absorbed; and it is quite exceptional, therefore, when the antrum is so distended with pus as to give rise to any prominence of the cheek. Undoubtedly cases of this kind have been recorded, but it may be doubted whether some of them were not examples of cyst, the contents of which had become purulent; for we know that cysts in the wall of the antrum readily produce great deformity. The natural opening into the nose is not at the level of the bottom of the cavity of the antrum; and hence there is always a small residuum of discharge, which the patient can only partially get rid of by holding the head on one side.

Given, a patient who complains of purulent discharge from the nostril, with occasionally a disagreeable smell, and the case is too apt to be put down as one of ozæna, and treated by nasal douches, snuffs, etc. But, as already mentioned, the offensive smell is perceived only by the patient, and not by his friends, the reverse being the case in ozæna; and, again, the discharge is only occasional, is determined by the position of the head, and is simply purulent, whereas in ozæna the discharge is constant, and mixed with offensive crusts from the nasal cavities. Again, the dull ache, varied occasionally by acute pain, is apt to be referred to the teeth alone, and the most careful examination may fail to detect any special tenderness in any one tooth. Hence, after exhausting the usual routine remedies for neuralgia, I have known wholesale extraction of useful teeth undertaken with no benefit, unless it should fortunately happen that the tooth which has perforated the antrum should be extracted early, when the discharge of pus at once clears up the nature of the case.



A still more serious result may ensue if the neuralgia should, as it often does, take the form of frontal headache, and thus lead the surgeon to suppose that the discharge comes from the frontal sinus. I have twice been consulted in cases in which enterprising surgeons had proposed to trephine the frontal sinus, regardless of the serious injury to the patient's good looks, for chronic discharge which I proved to be solely due to suppuration in the antrum.

The more ordinary consequence, however, of an unrecognised empyema of the antrum is the damage done to the digestive organs by the constant swallowing of purulent fluid during sleep. Under these circumstances, the patient is always ailing, is unable to take food in the morning, and may be reduced to a state of great prostration, even dangerous to life. The usual remedies for indigestion are likely to be of little service so long as the purulent drain continues.

In exceptional cases the pus, not finding an exit, distends the antrum, causing partial absorption of the walls, and thus both bulging out the cheek and thrusting up the floor of the orbit. Under these circumstances, the affection is readily recognised by the peculiar crackling which is perceived when the thinned bone is pressed upon, and the matter, if not evacuated, will shortly find a way out for itself, either by the side of the teeth, through the front wall of the antrum, or through the floor of the orbit; in either of which cases considerable necrosis and ultimate scar are likely to be the consequences. The possibility of both antra being affected either simultaneously or consecutively, must not be overlooked.

The elevation of the floor of the orbit already described may simply displace the eyeball and render it temporarily blind, as in a case recorded by Mr. J. Smith, of Leeds (*Lancet*, February 14th, 1857), or it may lead to permanent amaurosis—a point to which Mr. Salter called especial attention in the *Medico-Chirurgical Transactions* for 1862.

The treatment of suppuration of the antrum consists, in the first place, in the extraction of all decayed teeth or stumps in the affected jaw, and with this object in view those teeth which are apparently sound should be tested with a sharp



knock with some metal instrument, when, if tender, they should be extracted. If the cause of the mischief be removed in time, the inflammation will subside under fomentation and the application of a leech to the gum; but if matter has formed, it must be evacuated without delay. If the extraction of a tooth is followed by the flow of pus, the enlargement of the aperture in the socket by the introduction of a trocar is at once the readiest and simplest mode of evacuating the matter; but if all the teeth are apparently sound, it will be advisable to perforate the alveolus above the gum with a trocar, gimlet, or strong pair of scissors, and similar treatment would be required in the rare case of suppuration occurring after loss of the teeth in old people. If it be determined to sacrifice a tooth, the first molar is to be preferred for extraction, both on account of the depth of its socket and also because, as mentioned by Salter, it is more liable to decay than the other teeth. In puncturing through the socket of a tooth with a trocar, it is well to gauge the depth to which the instrument may safely go with the fingers of the hand which grasps it, lest injury should be unwittingly inflicted on the orbital plate by the trocar entering unexpectedly, or if preferred, a trocar with a stop may be employed.

After considerable experience of both methods, I prefer the puncture above the alveolus, except when a tooth obviously requires extraction, because I find that the aperture is less liable to close up than when made through the alveolus, and because food is less likely to find its way into the antrum. It is necessary, however, not to direct the trocar quite horizontally, but a little upwards, lest in a case of highly-arched palate the floor of the antrum should be injured, as I have known on one occasion, but then fortunately with no permanent damage, except the exfoliation of a minute portion of the palate.

Whatever method may be adopted for emptying the antrum, it is important that the cavity should be thoroughly cleansed by the forcible injection of warm water until it runs freely from the nostril. For this purpose an ordinary glass syringe is quite insufficient, but I have satisfactorily employed



an ordinary Eustachian catheter for the purpose, to which an india-rubber injecting bottle is adapted. After a time, and with a little instruction, patients can learn to dispense with the syringe by forcing a mouthful of water through the antrum by the action of the buccinator muscles. After thoroughly cleansing, some detergent and slightly astringent lotion should be injected to restore the healthy condition of the mucous membrane, and for this purpose weak solutions of permanganate of potash or sulphate of zinc answer admirably; but these cases are exceedingly tedious, as a rule and take many months for their cure. If the perforation has been made through the socket of a tooth, care must be taken that particles of food do not gain admission to the antrum, and this may be accomplished by plugging the hole with cotton wool, or, as suggested by Salter, by fitting a metal plate to the mouth with a small tube to fill the aperture, which can be corked at pleasure, and will serve as a pipe for injection.

Ordinarily the pus is readily evacuated through the nostril, but I have seen large masses of offensive inspissated pus block up the opening into the nose and require very forcible and repeated syringing for their removal, and the same thing applies to clots of blood, which occasionally give trouble. A still more serious event is when a mass of inspissated pus gives rise to symptoms closely resembling those of a tumour of the upper jaw, and without producing that absorption which gives rise to the crackling characteristic of the presence of fluid. The following case of this kind occurred in my own practice, and the late Mr. Mason published a very similar one. A woman, aged 43, was admitted under my care, complaining of pain and swelling of the left side of the face. There was an ill-defined swelling over the region of the left upper jaw, and the angle of the mouth on that side was drawn downwards. The swelling was both hard and tender; the skin over it appeared unaffected. In the mouth there was a tense, elastic, and tender swelling over the left half of the hard palate, displacing the alveolar process downwards. Slight discharge oozed from a small opening in the mucous membrane opposite the last upper molar tooth, the swelling



being softer about this spot than elsewhere. The left nostril was blocked, its external wall being pushed inwards, and the patient complained of some discharge from it. The neighbouring lymphatic glands were not enlarged, and, with the exception of occasional pain in the tumour, the patient suffered no inconvenience, her general health being excellent.

She had noticed the swelling for about two years, and its commencement was attributed to exposure to cold. At times the swelling increased, and became more troublesome, especially after prolonged overwork. No history of syphilis could be obtained, and her family history was good.

Believing that I had to deal with a solid tumour of the jaw, I made an incision through the upper lip in the median line, prolonging it into the nostril of the affected side. The alveolus and hard palate having been divided with saw and bone-forceps, a way was made into the antrum, and a pultaceous offensive mass, about the size of a hen's egg, was turned out with the finger. On microscopical examination this was found to consist of fatty *débris*, granular pus-cells, and acicular crystals. As the larger portion of the left half of the hard palate was partially loosened and absorbed, it was removed with the forceps. The cavity of the wound was stuffed with a strip of lint, and the patient made an uninterruptedly good recovery.

The possible subdivision of the floor of the antrum by bony septa, already described, must be borne in mind in operating upon this cavity, and especially if there is reason to suspect the presence of any foreign body which may be keeping up irritation. In his paper already referred to, Mr. Cattlin narrates the case of the fang of a tooth lodging in one of these subdivisions, from which it was extracted with difficulty.

*Hydrops Antri*, "dropsy of the antrum," is an old name (which should, I think, be abandoned) for a disease which has long been recognised, though, within the last few years, opinions have changed as to the pathology of the affection. The history of these cases is one of gradual, painless dilatation of the upper jaw, until its outer wall becomes so thin as to crackle like parchment upon pressure being made, or at



certain points being so absorbed that fluctuation is readily perceptible. Occasionally the other walls of the jaw yield, though more slowly, to the persistent pressure, the palate becoming flattened, and the nostril blocked by the bulging of the internal wall. On the extraction of a molar tooth and perforation through its socket, as described under the previous section, or more frequently by an incision through the osseomembranous wall of the cyst, a quantity of clear or yellowish serous fluid is evacuated, which frequently contains flakes of cholesterine floating in it. After the evacuation of the fluid the swelling ordinarily subsides, the maxilla resuming its normal relations, and the opening closing.

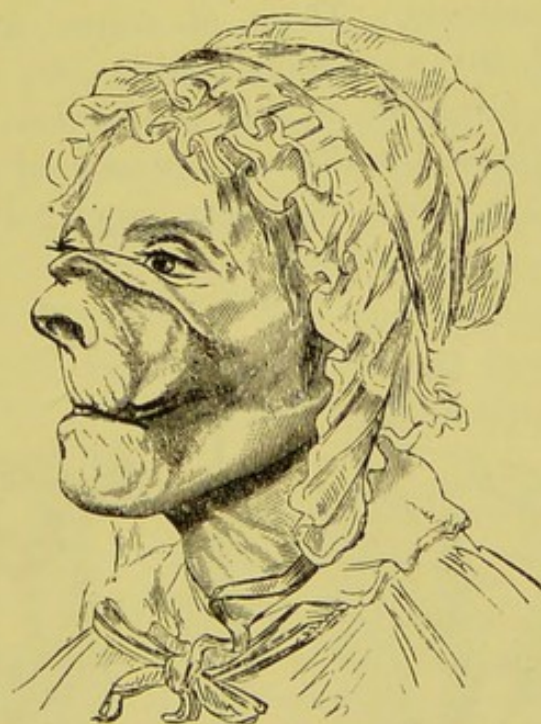The old explanation of these phenomena was that the aperture between the antrum and the nostril having become accidentally obstructed, the mucous secretion, which was presumed to be constantly taking place within the cavity, was thought to be imprisoned, and, by its gradual accumulation, to produce the symptoms which have been described. Following up this idea, we find surgeons, and among others Jourdain, of Paris (1765), who very accurately described the affection, recommending the restoration of the nasal orifice by probing—a useless operation, still described in many foreign manuals of operative surgery. Bordenave, in his *Observations on Diseases of the Maxillary Sinus* (Sydenham Society's translation, 1848), gives full details of this method of probing and injecting, but, after showing that there is great difficulty and uncertainty in finding the natural orifice, remarks that "there are very few cases in which the employment of injections through the natural openings, in the manner above described, would effect a complete cure." It is certain, however, that some of these cases, and very probably all of them, originate in the growth of a cyst or cysts within the antrum, or more commonly in the wall of the antrum, which either grow to such a size as to be mistaken for the cavity of the antrum when opened, or break into the antrum by absorption of the cyst-wall, so that on subsequent examination no evidence of cyst-formation can be discovered. This explanation is, as pointed out by Coleman, supported by the fact that in these cases of so-



called hydrops antri the contained fluid in no respect resembles ordinary mucus, but is invariably a clear, more or less yellow, fluid, frequently containing cholesterine in considerable quantity. In these respects it closely resembles that found in well-marked cases of cystic growth, which have been examined in various stages of development.

A remarkable case of distension of the antrum is narrated by Sir William Fergusson, and I am able to show you the preparation, which is preserved in the King's College Museum. It was taken many years ago from a subject in the dissecting room, and from the person of an old woman. The tumour, which was of very large size, had burst shortly before death, leaving the remarkable deformity shown in Fig. 6, which is due to the complete absorption of the front

Fig 6,



wall of the antrum and its collapse, by which a prominent horizontal ridge of bone, formed by the upper wall of the antrum, has been left immediately below the orbit. The preparation shows great distension of the antrum, the diameter of which varies in different parts from two to two and a half inches, and the bony wall is so thinned out as to resemble parchment. The gums are edentulous. There is no communication between the nose or mouth and the cavity,

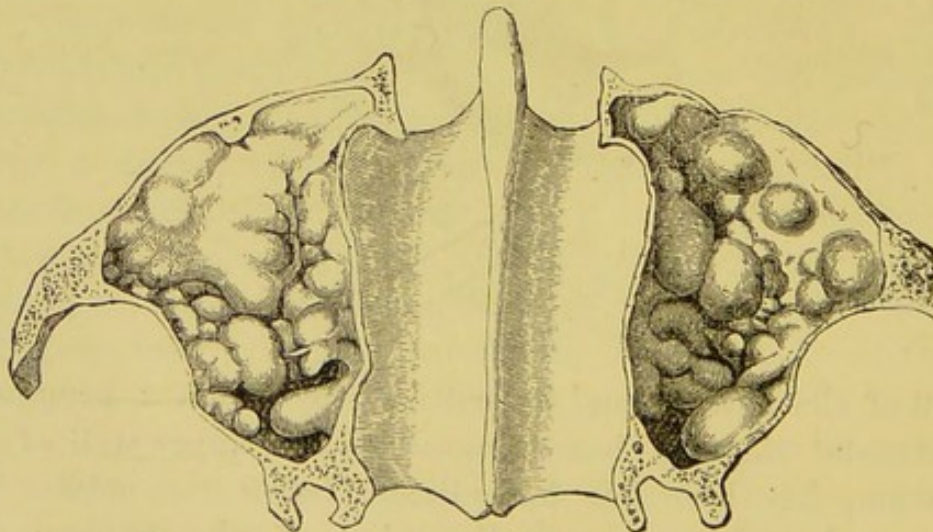


which is lined with a membrane covered with laminated deposit. Whether this was originally a case of cystic growth or a chronic abscess, it is impossible now to decide, but it is, so far as I am aware, a unique *post-mortem* specimen of this distension.

M. Giraldes would appear to have been the first author upon the subject of cysts of the antrum, and his thesis gained the Montyon Prize in 1853 ; but Mr. W. Adams may fairly claim priority of investigation, as shown by specimens preserved in St. Thomas's Museum—as indeed is acknowledged by M. Giraldes.

Mr. Adams's specimens, which I am enabled to produce before you show each a cyst of oval outline, attached to the inner wall of the antrum, and measuring rather more than an inch and three-quarters of an inch respectively in their long diameters. These, of course, are too small to have produced any symptoms during life. The specimens given by M. Giraldes, in his *Recherches sur les Kystes Muqueux du Sinus Maxillaire*, from one of which the illustration (Fig 7) is taken, show very varying degrees of cystic

Fig 7.



growth in the mucous membrane of the antrum. In one instance there is a single cyst at the floor of the antrum, into which an opening has been made, whilst in the others the cysts are



very numerous and of very variable sizes, depending, apparently, upon a cystic degeneration of the entire mucous membrane. M. Giraldes explains the formation of these cysts as being due to the dilatation of the glandular follicles of the mucous membrane, and urges that the ordinary operation of tapping the antrum would be useless in such cases, but that it would be necessary to open up the antrum so as to get at the seat of the disease. Fortunately these numerous cysts appear to be of slower growth than the single cysts, for it would be impossible to extirpate such numbers as are here seen (Fig. 7) without removing the entire jaw.

The contents of these cysts appear to be at first clear fluid, but of a viscid nature; when more fully developed the fluid becomes flaky, from the presence of cholesterine, and occasionally assumes a greenish tint; it may also become purulent, and Maisonneuve has recorded a case where pressure on the cheek produced a flow of butter-like fluid from the nose in a young woman who, for a year, had suffered from a tumour of the right upper jaw, which had been pronounced malignant, the face being enlarged and the nostril obstructed. Here puncture from the nostril, combined with pressure and injections, effected a cure, and the case must be considered as one cyst of the antrum, but whether a mucous cyst, the contents of which had undergone solidification, or a separate formation, must remain doubtful.

*Treatment.*—The treatment of cystic disease of the jaw is generally sufficiently simple. The bony wall being most commonly, to some extent, absorbed, it is only necessary to incise the distended membrane and evacuate the fluid. The finger then passes readily into the cyst, and can examine its interior, searching for any growth or tooth which may be lodged within. With curved scissors the opening can then be enlarged by cutting away the membranous wall sufficiently to allow a free passage for any discharge. The use of a simple stimulating lotion with a syringe is then all that is required to effect a cure, which, though slow, is permanent. I have treated a considerable number of cases of cyst of the jaw in this manner, and with uniformly good results.



Broca recommends to remove the membrane covering the inner wall of the cyst, and gives a case in which Nélaton discovered a plate of bony tissue derived from a malformed tooth on the inner aspect of a cyst, but this is in most cases a quite unnecessary complication of what is usually a very simple matter.

*Polypus of the Antrum.*—This is not a common affection, though by no means so very rare as stated by Paget. Luschka has investigated the subject, and found polypi five times in sixty subjects, some being two centimetres in length. He gives a drawing, showing a large number of these polypoid growths in an antrum, which he considers to be hypertrophies of the submucous connective tissue, covered with mucous membrane. Billroth also describes a good example of large polypus of the antrum with a long pedicle, and regards it as a very rare affection, and there is a good specimen in University College Museum (No. 658).

These polypi are closely allied apparently to the small cystic growths in the mucous membrane of the antrum described by Giraldès. Both affections consist essentially in hypertrophy of some elements of the mucous and submucous tissues. When the connective or areolar tissue predominates, the fleshy polypus is produced; when the glandular element is especially affected we have the cystic form produced. Intermediately, when the fibrous element is very loose and we have some glandular hypertrophy, the semi-gelatinous polypus is produced, which closely resembles the nasal polypus.

Polypi of the antrum are well supplied with blood-vessels, and bleed freely when interfered with. In some instances they appear to have a malignant character, or at least are the forerunners of malignant disease occurring in the antrum and jaw. Vidal de Cassis, who totally denies the existence of any true polypoid growths in the antrum, says that what have been mistaken for them most frequently are colloid tumours of the periosteum, but believes that many of the examples are cases of cystic growth. Syme, also, following the example of John Bell, maintains that polypi of the antrum



always intrude from the nose, and are never developed in the antrum itself.

Sir James Paget has put on record (*Clinical Soc. Trans.*, xii) a case of polypus of the antrum in which a constant flow of clear watery fluid from the nose was the only symptom. At the *post-mortem* examination, "the floor of the antrum was covered with two broad-based convex polypoid growths, deep clear yellow with the fluid infiltrated in their tender, tissue, and covered with exceedingly thin, smooth membrane traversed by branching blood-vessels. They were of rounded shape, about two-thirds of an inch in diameter and half an inch in depth; they looked like very thin-walled cysts, but were formed of very fine membranous or filamentous tissue, infiltrated with serum."

*Cysts in connection with the teeth* may be classed under two heads: first, cysts connected with the roots of fully developed teeth; and, secondly, cysts connected with imperfectly developed teeth, to which the term "dentigerous cysts" has been applied in modern times. Both kinds may occur in either jaw, and, in the case of the upper jaw, may be confounded with collections of fluid in the antrum, or may secondarily involve that cavity.

Cysts of small size in connection with the fangs of permanent teeth are frequently found on their extraction, but give rise to no symptoms demanding surgical interference, though they cause pain from pressure on the dental nerves. Occasionally, however, they grow to a large size, in which case they produce absorption of the containing alveolus, and give rise to a prominent swelling. They lie beneath the periosteum of the fang, and hence have been named by Magitôt periosteal cysts. The contained fluid is rich in cholesterine.

Three specimens of cysts connected with the fangs of teeth, for which I was indebted to Mr. Holborow King, are now in the Museum of the College of Surgeons (2161). Two of them (Figs. 9, 10) are quite small (one being remarkable for the length of its pedicle); the third (Fig. 8), is of the

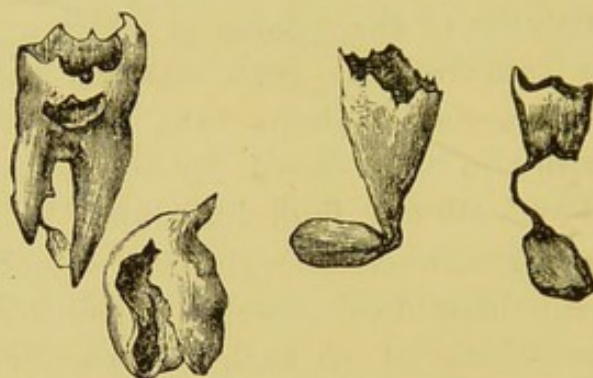


size of a hazel-nut, and was torn in extraction. The contents

Fig. 8.

Fig. 9.

Fig. 10.



of the cysts were found, on microscopic examination, to consist of degenerating pus; their walls were formed of fibrous and granulation tissues, and they had no epithelial lining. This would confirm the view of Mr. Tomes that the morbid process is probably identical with that resulting in the formation of alveolar abscess, but, being less acute, a serous cyst is formed instead of a suppurating sac. In the Museum of the College of Surgeons is another specimen of a vascular thick-walled cyst, attached to one side of the fang of an incisor tooth (2161A).

Large cysts, which produce more or less absorption of the outer wall of the maxilla, are, in my experience, very common consequences of the retention of diseased teeth, but seem to give surprisingly little inconvenience to the patients, even when of large size and producing considerable deformity of the face. They are commonly confounded with cystic degeneration of the antrum.

*Treatment.*—An incision into the cyst evacuates a dark-coloured, clear fluid, unless inflammation should have been excited, when the contents become purulent. It is advisable to cut away the thin outer wall of the cyst freely with scissors, or, if necessary, with bone-forceps, so that the cavity may granulate up. If an incision only is made, the edges are apt to fall together and re-unite with a reproduction of the fluid, unless an india-rubber drainage-tube is inserted, which can be attached by a thread to a neighbouring tooth.



*Single Cysts* in the lower jaw, as in the upper, may originate in connection with the fully developed teeth, and, as in the case of dentigerous cysts, may give rise to the suspicion of a more severe affection.

According to Broca, the great majority of cysts of the jaws have their origin in tooth-follicles. These are shut sacs, but do not enclose a true cavity, for the space between the wall and the outer surface of the dental papilla is occupied by the enamel-organ, an organised body, but very soft and gelatinous, apt to disappear under morbid influences, and thus leaving in the follicle a cavity ready to be transformed into a cyst. Dental cysts may originate in the follicles of the first or second dentition, or in the follicles of supernumerary teeth. Their contents are ordinarily clear fluid, sometimes bloody, occasionally filamentous or gelatinous, and still more rarely they contain a sebaceous matter like mastic, composed almost entirely of epithelium.

But periosteal cysts occur in the lower jaw without any apparent immediate connection with the teeth, though very possibly some irritation connected with these organs may have been the original cause of the mischief. The patient finds that he has a slowly-growing tumour of the jaw, which is painless, and gives him no trouble except from the deformity. The outer plate yields ordinarily to the pressure of the growing cyst, and thus a prominent smooth tumour is formed, over which the skin is freely moveable. When the bony wall is sufficiently attenuated, the peculiar crackling already described may be produced on pressure; and, if the disease is still unchecked, the bone becomes entirely absorbed, and nothing but a membranous cyst, with particles of osseous matter embedded in it, remains. Of this a remarkable specimen from a woman aged 45 is to be seen in St. George's Hospital Museum (II. 150). The cyst is for the most part single, and contains merely fluid, which may be clear or more or less coloured.

*Cysts in connection with undeveloped teeth, or Dentigerous Cysts* (coronary cysts of Magitôt), may occur in either jaw. These, as already mentioned, may suppurate and give rise to



abscess, which may be confounded with suppuration within the antrum, or may project into the antrum, filling the cavity or communicating with it.

Dentigerous cysts arise in connection with teeth which from some cause have remained within the jaw, and have undergone a certain amount of irritation. They are almost invariably connected with permanent teeth, though Mr. Salter mentions a case in connection with a temporary molar occurring in the practice of Mr. Alexander Edwards, late of Edinburgh; and in a remarkable specimen belonging to Mr. Cartwright, which will be afterwards referred to, the tooth is a supernumerary one. I have also myself met with an example of cyst connected with a temporary tooth in a boy aged 4, brought to me by Mr. C. J. Fox. In this case the temporary right canine tooth was wanting, and there was a cyst developed in its situation, on cutting into which I extracted seven small irregular nodules of dentine and enamel, but no complete tooth, this being, therefore, an example of the odonto-plastic cyst of Magitôt.

Mr. Tomes explains the formation of cysts in connection with retained teeth by referring to the fact that, when the development of the enamel of a tooth is completed, its outer surface becomes perfectly detached from the investing soft tissue, and a small quantity of transparent fluid not uncommonly collects in the interval so formed. This fluid ordinarily is discharged when the tooth is cut; but when from some cause the eruption of the tooth is prevented, it increases in quantity, gradually distending the surrounding tissues in the form of a cyst.

For further microscopic details, and for a full discussion of Magitôt's views, I may refer to Mr. F. Eve's very able lecture on Cystic Tumours of the Jaws, delivered in this theatre, and published in the *British Medical Journal*, January 6th, 1883.

When dentigerous cysts occur in the lower jaw, they form more isolated and prominent tumours than in the case of the upper jaw, and in some cases the projecting bony wall has been removed. In St. Bartholomew's Museum is a specimen



of the kind (L. 119), consisting of a portion of a bony cyst, which was removed by Mr. Earle from the external and lateral part of a lower jaw. The cyst is lined with a thick and soft membrane, which has been in part separated from it. The cavity of the cyst was filled with a glairy fluid, and at the bottom of it a canine tooth of the second set was adherent to the lining membrane. The case is referred to by Stanley, who gives an accurate drawing of the preparation. In the Museum of the College of Surgeons there is a very similar preparation (2196), showing a bony cyst of oval shape one inch in its long diameter, lined with a thick, well-formed membrane, containing an imperfectly-formed bicuspid tooth, which was removed by Mr. Wormald from the lower jaw of a female, aged 17, whose case will be found in the *Lancet*, June 22nd, 1850.

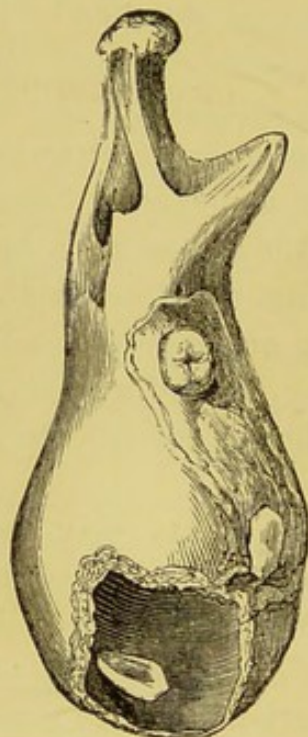
Cases of dentigerous cysts may be mistaken for solid tumours. Thus, Gensoul, of Lyons, has recorded the case of a girl aged 13, whose antrum was distended with a large collection of yellow fluid, and contained a canine tooth attached to its wall, in whom he had made the incisions necessary for the removal of the tumour before he discovered its nature. Mr. Syme also has related the case of a woman aged 31, on whom he operated for a tumour of the upper jaw, of four months' standing, by laying open the cheek and removing the tumour with the bone forceps. "The tumour was found to consist of a dense cyst, lined throughout with earthy matter in a crystalline form, and containing a clear, glairy fluid, together with the crown of a tooth, apparently the lateral incisor." In a cavity beyond the tumour was found a fully-formed canine tooth, encrusted with a thin plate of bone. The teeth are said to have belonged to the temporary set.

When the cyst occurs in the lower jaw, and is less prominent than in the two cases already mentioned, giving rise rather to a general expansion of the bone than a distinct tumour, the disease may be mistaken for a solid tumour of the lower jaw. A case of this kind occurred to that excellent surgeon, the late Mr. S. W. Fearn, of Derby, who had the courage and honesty to publish the case (*British Medical*



*Journal*, August 27th, 1864), and to whom I was indebted for the very valuable preparation (College of Surgeons Museum, 2195), from which the drawing (Fig. 11) was made.

Fig 11.



Mr. Fearn's patient was a girl aged 13, who had a large resistant tumour of the left side of the lower jaw, which had been growing six months. There was some enlargement also of the right side, and the teeth there were very irregular. The teeth on the left side had been extracted, with the exception of the second molar and a temporary molar. No opening could be detected in the tumour, though there was a constant offensive discharge from its surface. Mr. Fearn removed the left half of the jaw from the symphysis to the articulation, and on division of the bone with the saw, a quantity of foetid pus escaped. The tumour proved to be a bony cyst, formed by the expansion of the two plates of the jaw, which extended for some distance to the right of the symphysis—a very unusual occurrence. The cavity is lined with a thick vascular membrane, and at the bottom the canine tooth will be seen projecting from the wall. The case was evidently, therefore, one of dentigerous cyst, due to the non-development of the canine tooth, the contents of which had,



from some cause, become purulent. The mental foramen, with the nerve emerging, is still visible in the preparation. The patient made a good recovery.

A very similar case is recorded by Dr. Forget, in his essay on *Les Anomalies Dentaires et leur Influence sur la Production des Maladies des Os Maxillaires*, 1859. Mr. Underwood has allowed me to have the accompanying drawing (Fig 12).

Fig. 12.

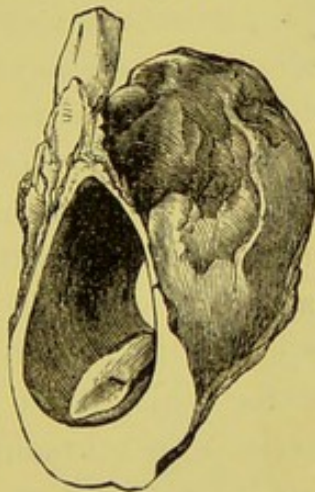
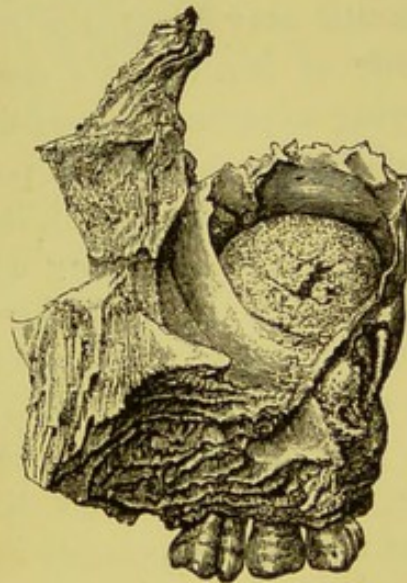


Fig. 13.



taken from the model of a preparation which he possesses showing very beautifully a cyst of the lower jaw, which was removed by M. Maisonneuve by sawing through the bone at two points. The canine tooth is seen lying horizontally at the bottom of the cyst. The patient, aged 56, had a swelling in the lower jaw near the chin, and an opening formed behind one of his front teeth, from which a saline fluid escaped. The man made a good recovery from the operation.

Dentigerous cysts, like other cysts, may undergo alteration, not only of the contents, but of the cyst-wall. The opportunities for recognising such changes are exceedingly rare, and the only known specimen of the kind is one in the possession of Mr. Samuel Cartwright, which shows calcification of the cyst-wall. The preparation (Fig. 13) is one of the right superior maxilla, which, having been opened, shows a bony cyst within the antrum and attached to its floor, but unconnected with it elsewhere. The cyst has been opened and contains a supernumerary tooth loose in its cavity,



though no doubt originally attached to its base. This is clearly a case of dentigerous cyst which has undergone calcification, and which, had it been expanded to a greater degree before this change took place, would in all probability have been inseparably united with the walls of the antrum.

The diagnosis of dentigerous cysts from other cysts is exceedingly difficult until they are opened, as, indeed, is the recognition of any form of cyst. A careful examination of the mouth may reveal the absence of a permanent tooth, or, as in one of Mr. Salter's cases, may show a temporary tooth occupying a permanent position, and this would direct the mind of the surgeon to the possible existence of a dentigerous cyst. On the other hand, however, it must be remembered that teeth may be wanting without being connected with any disease; thus, I am acquainted with a family who have the hereditary peculiarity of a single bicuspid tooth on each side. When a cyst is sufficiently expanded for the wall to yield under the finger with the characteristic parchment-like crackle, there can be no difficulty in its recognition, but without this it is impossible in all cases to distinguish between a cyst and a slow-growing, solid tumour. Under these circumstances, it is well to insist upon the propriety of making an exploratory puncture in all cases which are not obviously solid growths, and have sprouted so that their nature can be certainly recognised. The puncture, being made within the mouth, will be of no moment should a more severe operation subsequently be necessary.

The accompanying engraving (Fig. 14) shows a cyst of the lower jaw occurring in a man aged 34, who was under my care in 1878. The swelling began nine years before, and was of the size of an ordinary orange, round, very hard, and fixed to the angle of the lower jaw on the right side. Its edges were well defined, there was no fluctuation nor pulsation, except that of the facial artery, which was stretched over the tumour. Externally the tumour appeared to be solid, but, examined from the mouth, the anterior part of the wall yielded slightly to firm pressure. On puncturing from the mouth through the bony wall, I entered a large empty



cavity lined with soft tissue, which on microscopical examination showed portions of hyaline cartilage and cartilage with

Fig. 14.



a faintly fibrous matrix, surrounded by and gradually passing into oval and spindle cells. The bony walls of the cyst were broken down and partially cut away, and this proceeding was repeated a fortnight later. The tumour gradually diminished as suppuration went on, several pieces of bone being removed, and, six weeks after the cyst had been opened, a tooth was felt fixed at the bottom of the cavity, and on being extracted proved to be a bicuspid with a perfect crown and two small fangs. After this the cavity closed, and the swelling entirely disappeared. The case is remarkable both for the age of the patient and also for the fact that the cyst was empty, the fluid which must have been present at one time having become absorbed. A careful search for a tooth was made at the time of the operation, but one could not be found, and its discovery at a later date was probably due to the destruction by suppuration of the lining membrane of the cyst, which had completely enveloped it.



In the Museum of the Royal College of Surgeons is a preparation (2194) of the right side of the body of the lower jaw, completely and uniformly dilated into a large spherical cyst. No tooth or rudiment of a tooth can be discovered in the cyst, but its inner surface is lined by a layer of small epithelial cells, and is thrown, in places, into thick projecting folds. Mr. Eve considers it probable that the cyst originated in the enamel-organ of an abortive wisdom or supernumerary tooth, and hence would consider it an example of the follicular cyst developed in the embryonic period (Magitôt).

*Treatment.*—The treatment of dentigerous cysts is the same as for ordinary cysts, namely, a free incision and the subsequent extraction of the contained tooth. For the cure of many of these cases simple puncture will not suffice, and it will be necessary to remove a portion of the front wall of the cyst, and to fill the cavity with lint so as to induce granulation and gradual obliteration. This may be accomplished in most instances without any incision of the integuments, and in a few more extensive cases by simply dividing the lip, and carrying the incision into the nostril.

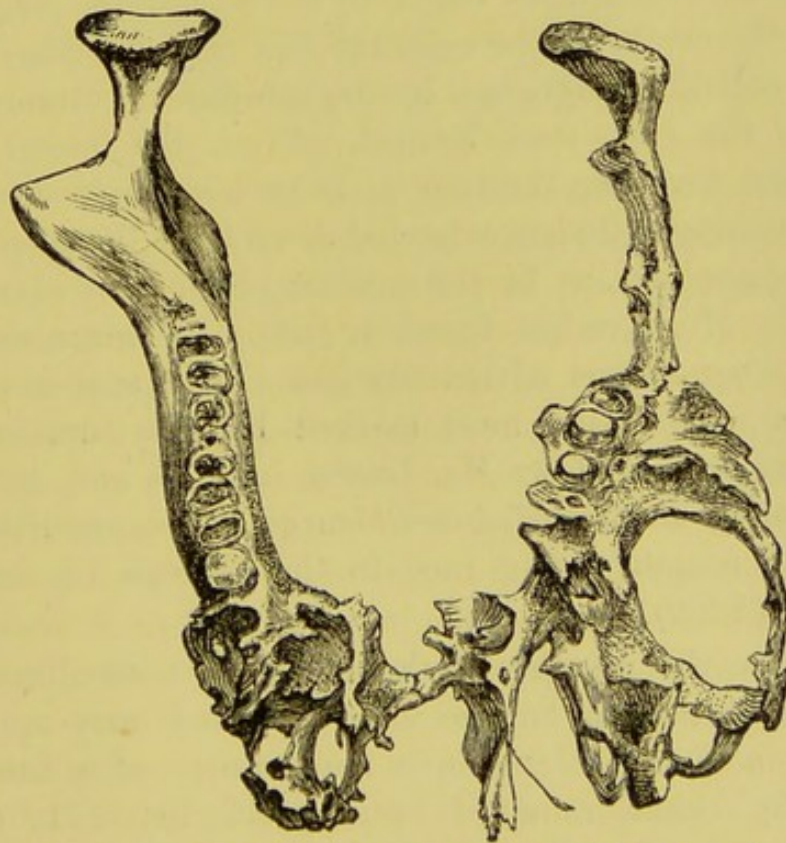
During the last few years very considerable light has been thrown upon the clinical history and pathology of certain cystic tumours of the jaws, both by cases occurring in my own practice and by the careful microscopic investigation of these and others by Mr. Frederick Eve, who embodied his results in a lecture given at the College of Surgeons in 1882, and published in the *British Medical Journal* of January 6th, 1883. Mr. Eve believes that, so far from multilocular cysts having a dental origin, they are produced by an ingrowth of the epithelium of the gum. They have frequently followed some form of injury, irritation by decayed teeth, or long continued inflammation, which have induced an increased supply of blood to the parts. The multilocular cystic tumours are slow of growth, they have very little tendency to implicate surrounding parts or the neighbouring lymphatic glands, and, if completely removed, rarely recur and still more rarely become disseminated through the system. Their comparative innocence is probably explained by the bony capsule



forming their boundary, by their low degree of vascularity and by the remarkable tendency of the epithelial cells composing them to undergo degenerative changes.

Multilocular cysts are more often found in the lower than in the upper jaw, and in most cases in direct connection with teeth or stumps. In the *Guy's Hospital Reports* for 1847 is the notice of a case of the kind by Dr. Wilks, in a girl, aged 18, in whom there had been an enlargement of the right side of the lower jaw for twelve years. The tumour, on removal, proved to be a cystic growth: "there being four or five large cells between the internal and external plates of bone, which appeared like expanded alveoli, all of them containing fangs of teeth. The cells contained a glairy fluid." Very considerable alteration in the form of the maxilla may be produced by growths of this kind, of which a good example is seen in the drawing (Fig. 15) from a macerated specimen in St. Bartholemew's Museum (1.308). Here the bone is

Fig. 15.



irregularly expanded in great part to form septa between cysts. These, which were independent of one another, had



their origin in the interior of the bone, were lined by a highly vascular membrane, and contained thin serous, or grumous, blood-tinged fluid. The walls of some of the cysts were thin and yielding, but others were thick and resisting, and this was particularly the case with the most posterior cyst on the left side, which had pressed upon and caused absorption of the left ramus and coronoid process. The preparation was taken after death from an old man, aged 75, who had noticed the enlargement for five years when he came under Mr. Coote's care in St. Bartholomew's Hospital in 1857.

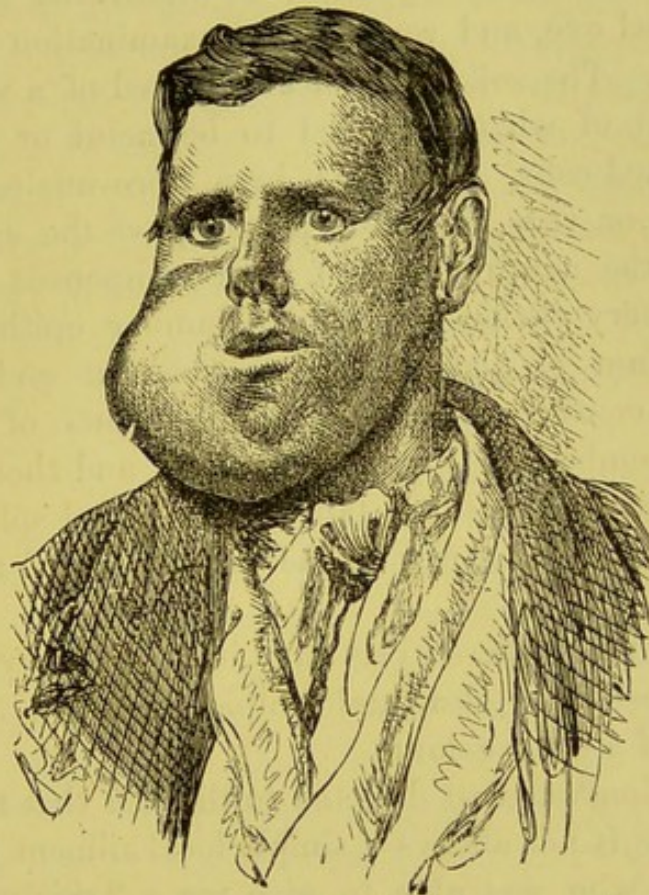
The microscopic character of the solid material found more or less in all cases of multilocular cyst is well given in the following report by Mr. Eve upon a very well-marked recent specimen of the disease, contributed to the St. Bartholomew's Hospital Museum (I. 536) by Mr. Keetley. "The solid portion of the tumour was composed of columns of cells and nuclei of the epithelial type, which, when cut transversely, presented the appearance of alveoli; similar small columns branched out from the side of the larger. The cells in the centre of the columns had in many places undergone a colloid change, and by the complete metamorphosis of the cells the cysts were formed. From the buccal mucous membrane covering the tumour in certain parts club-shaped and branching cylinders extended down from the deep stratum of the epithelium, as in the ordinary formation of epithelial cancer." Mr. Eve has found precisely the same characters in twelve specimens of multilocular cystic tumours he has examined, one of the most marked being a tumour of the upper jaw, removed by Mr. Liston in 1836, and referred to in his paper in the *Medico-Chirurgical Transactions*, Vol. XX., the tumour being now in the College of Surgeons' Museum (2202).

To show the identity of the foregoing with the tumours hitherto classed as "cystic sarcomata," I may quote the description of the microscopic appearances of a tumour of the latter kind removed by myself, in 1871, from a patient aged 22, whose portrait before the operation is given in Fig. 16. "The tumour was composed microscopic-



ally of straight or tortuous columns of epithelial cells, those forming the margin being elongated or cylindrical, and

Fig. 16.



radiating towards the centre. At the margin of the small ulcerated opening in the gum, papillary processes extended downwards from the deep stratum of the epithelium, and were continuous with the columns forming the tumour" (College of Surgeons' Museum, 2203). The half of this tumour, deposited in the Museum of University College, is described in the valuable catalogue by Mr. Marcus Beck as a "gland-like tumour of bone," and its structure is identical with that of a tumour described by Mr. Wagstaffe, in the *Pathological Society's Transactions*, Vol. XXII. Mr. Wagstaffe found that the growth was composed of innumerable cysts and a solid matrix, through which a certain amount of bone was scattered; that the cysts were lined by a layer of large globular epithelium; that into the interior of the larger cysts other smaller cysts projected, and these endogenous cysts took their origin in the epithelial lining, and not in the



matrix of the growth. Other cysts were also freely scattered throughout the structure, but the endogenous formations were so marked that they could be discovered as little balls by the naked eye, and removed for examination by the point of a needle. The solid structure consisted of a very peculiar arrangement of what appeared to be acini or cylinders of closely-packed cells, supported by a fibro-nucleated matrix. These acini, or rods, in many places gave the appearance of tubes from the arrangement of their component cells, which resembled very curiously that of columnar epithelium, or of the epithelium of gland-follicles. The cut ends, however, showed no central canal. The constituents of these rods were nuclei embedded in plastic matter, and these separated by manipulation into small tailed or so-called spindle cells of similar size and character to the corpuseles of an ordinary sarcoma.

The contents of these cysts vary in consistency and colour in some cases being clear and limpid, in others almost gelatinous and of a dark colour.

My attention was first directed to the fact that multilocular cystic disease is not always a simple local ailment by the case of a patient who was able to give me a "thirty-five years' history of a maxillary tumour," which I communicated in 1880 to the Association of Surgeons Practising Dental Surgery (*British Medical Journal*, May 22nd, 1880). The patient, when he first came under my notice in 1877, was a healthy country gentleman, who said that as long as he could remember there had been some enlargement of the right side of the lower jaw. In 1845 this enlargement increased very rapidly, and in 1847 Sir W. Fergusson removed a tumour of the right side, sawing through the ramus horizontally and the body of the jaw close to the canine tooth. The tumour was apparently of a fibroid character, having a large cyst developed in it, and is now in the Museum of King's College. He continued in good health for fifteen years, and then noticed the formation of a cyst in the incisor region, which had frequently been tapped by Sir W. Fergusson. In July, 1877, I found cystic disease of the left side of the body of the



jaw extending to the molar region, and operated by extracting all the teeth, opening up the cysts freely, and clearing out some solid growth with the gouge. From this the patient made a good recovery, with considerable consolidation of the bone; but in the November following one cyst was found to have developed anew in the incisor region, and this was treated in a similar manner. A year later a fresh development of cyst had taken place, and the operation was repeated with a good result, so that in February, 1879, the jaw was completely consolidated and the patient was advised to have some artificial teeth fitted. In November, 1879, the patient reappeared with a large solid tumour involving the left side of the body of the jaw, which, noticed first in June, had grown rapidly of late, and now involved the skin for an area of a square inch. On December 2nd I removed the tumour by sawing through the bone immediately in front of the left masseter, and also removed a piece of infiltrated skin from the left of the median line. The wound was brought together with harelip-pins and sutures, and only one artery (facial) was ligatured. The patient made a good recovery, took food with a spoon, and was able to talk intelligibly after the first week, although now deprived of the entire body of the jaw. The lower end of the wound being left open, afforded a thorough drain for discharge. The patient returned early in February, when the skin near the wound was found to be increasingly infiltrated, and a tumour of the size of an orange was found beneath the right deltoid. He had strained the right arm in getting into a hip-bath, but it was quite clear that the humerus had not been struck. The tumour was painful, but the bone was sound, the head moving with the shaft. A week later the patient was found to have a tumour in the pelvis, pressing upon the rectum, and springing from the interior of the right innominate bone. From this time he gradually lost strength, and died at the end of March. The second tumour was pronounced by Mr. Doran to be a round-celled sarcoma, and the same growth was found in the piece of skin that was removed. The earlier tumour appeared to be a fibroid or a spindle-celled sarcoma. No *post-*



*mortem* examination of the internal growths could be obtained.

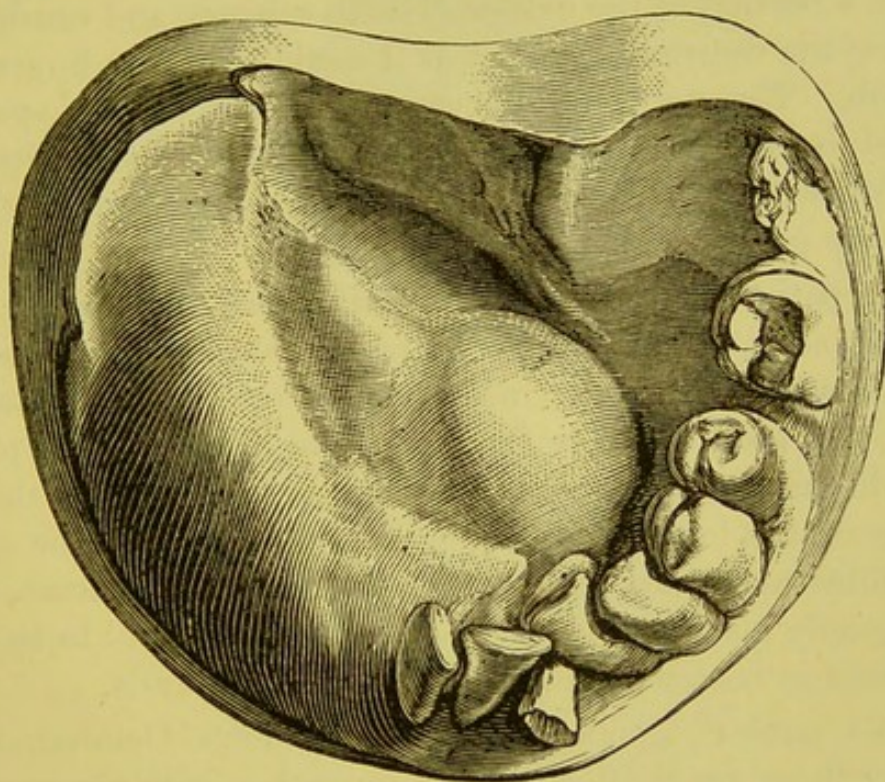
The specimen is preserved in the Museum of the College of Surgeons (2204), and Mr. Eve's further examination confirms the fact that the bulk of the tumour is round-celled sarcoma, but in addition the upper portion of tumour contains isolated masses composed of tortuous closely-crowded columns of small epithelial cells.

The second case bearing upon the same question was in a woman aged 44, who was admitted into University College Hospital, on November 3rd, 1875, with the following history. About nine years before, the patient first noticed a lump of the size of a pea beneath the tongue, on the right side, which gave her some pain, and for which a tooth was extracted. From that time she had a succession of abscesses (?) in the lower jaw, some of which discharged in the mouth, and one externally, and for which she had several teeth extracted. Dr. Parsons, of Dover, had sent her to me three years before, and I then recommended her to come into the hospital; but she declined, and went on with a steadily increasing tumour of the lower jaw on the right side. About nine months before admission, the tumour seems to have begun to increase with some rapidity, and within the last two months the following characteristic event happened. While eating, the patient felt a sudden crack in the lower jaw, and this occurred twice in the same week; and upon each occasion she felt great pain in the floor of the mouth and upon moving the tongue. Upon admission, there was really very little to be seen externally, and a photograph taken at the time shows that, excepting a very small projection beneath the skin in front of the angle of the jaw, there was nothing to call attention to the patient's face. On looking into the mouth, however, the tumour was at once obvious, and is seen in a cast taken from the jaw at that time (Fig. 17). The right side of the lower jaw is seen to be greatly expanded from immediately in front of the ramus to beyond the median line, the tumour measuring two inches across at the broadest part, and reaching under the tongue. Its surface was lobulated and rounded, firm and osseous in the greater part, but yielding distinctly



on pressure in two or three places. The mucous membrane was entire over the tumour, except at one point where there

Fig. 17.



was an opening, from which a discharge constantly exuded. The incisor teeth of the right side were displaced over to the opposite side, and were loose. The central incisor of the left side was displaced completely in front of the other teeth. The left canine and bicuspid were firmly fixed. Notwithstanding the size of the tumour, the outline of the lower border of the jaw was scarcely interfered with, the disease being mainly confined to the alveolar portion of the bone ; and I, therefore, decided to operate from within the mouth, so as to avoid, if possible, all external scar.

On November 10th the patient was put under chloroform, and, a gag having been introduced on the left side, I first extracted the four incisors, and then made a free incision with a stout scalpel along the upper surface of the tumour, cutting easily through the thin bone and thick membrane forming its upper wall. A quantity of dark-coloured cystic fluid at once escaped, and I then cleared out the semi-solid contents



with the finger and gouge. The finger introduced into the cavity passed completely under the canine and bicuspid teeth of the opposite side without disturbing them. I next cut away a portion of the cyst-wall with scissors, and crushed together the remainder, as far as I could, with my fingers and thumb. The actual cautery was applied to one spouting vessel in the margin of the alveolus, and the cavity was stuffed with lint dipped in a solution of chloride of zinc (twenty grains to the ounce).

The patient had very little constitutional disturbance; the plugs were gradually removed from the cavity of the jaw, which was carefully syringed out frequently with Condyl's fluid, and soon began to granulate and fill up. The patient was discharged a month after the operation, when the two plates of the lower jaw had come together, and the cavity was filled up almost completely by granulation-tissue, there being only a shallow cavity half an inch long still to be filled up midway between the angle and the symphysis.

This patient again presented herself in October, 1878, nearly three years after the first operation, with a recurrence of the cysts, which were treated again by the gouging and crushing in. In August, 1882, she again appeared with a formidable tumour of the lower jaw, which had already sprouted through the chin at more than one point (Fig. 18).

There could be no question now of the necessity for excising the portion of jaw involved, and this I accordingly did, removing from an inch in front of the angle on the left side to the right temporo-maxillary articulation. The patient made a good recovery, and has remained well.

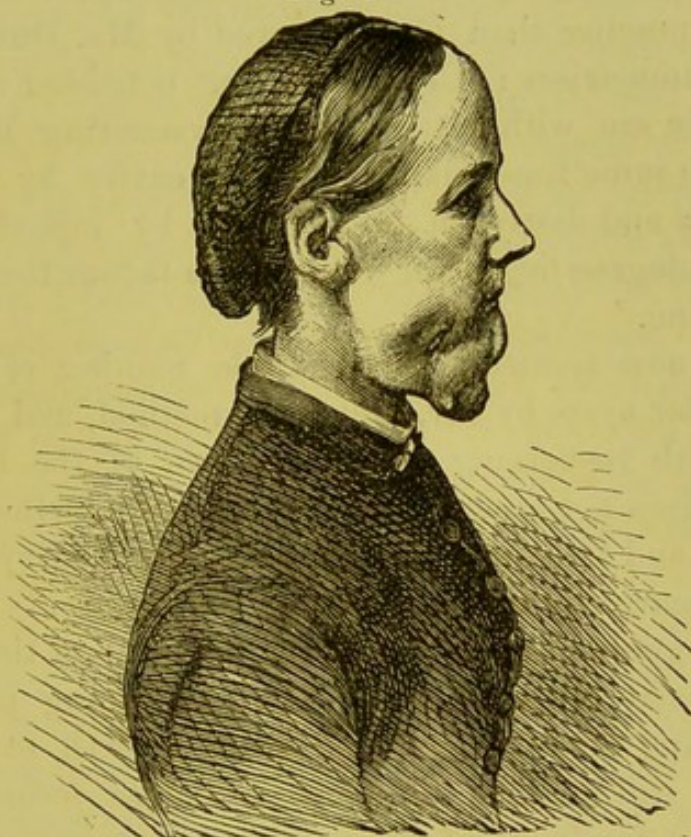
There can, then, I think, be no doubt that under the term "multilocular cystic epithelial tumour," as proposed by Mr. Eve, we may include the old multilocular cysts and cystic sarcomata, both having a distinct tendency to be reproduced locally, and in certain cases to become disseminated.

*Treatment.*—Mr. Butcher, of Dublin, has for some years treated cases of multilocular cyst of the lower jaw through the mouth, by dividing the mucous membrane over the cyst freely, and then with gouge and bone-forceps removing the



expanded external plate of the bone, with the contents and lining membrane of the cyst. In this operation, the teeth are

Fig. 18.



interfered with as little as possible, and appear to remain firm. Granulations rapidly spring up from the denuded bone, and fill the wound made in the mouth; the cheek resumes its ordinary appearance, and no deformity or scar is left. In his work on *Operative and Conservative Surgery*, Mr. Butcher narrates three cases treated in this manner, and remarks that "the proceeding according to this plan is troublesome and difficult, but its value to the patient in having no deformity left is priceless." A valuable caution is here given respecting the facial artery, which might, without care, be divided from within the mouth in a position where it would be very difficult to secure it. Mr. Butcher also narrates and gives a drawing of a case in which, finding the disease too extensive to be treated from the mouth, he adopted Dupuytren's external incision, and then levelled the projection to the line of the healthy bone with the best results, the incision being completely hidden behind the bone.

Dr. Mason Warren has also (*Boston Medical and Surgical*



*Juornal*, 1866 written upon the treatment of cysts of the jaws, and strongly recommends a milder and even more conservative practice than that followed by Mr. Butcher, which he thus summarises: "The treatment consisted in the puncture of the sac within the mouth, evacuating its contents, and at the same time obliterating its cavity by crushing in its walls; and lastly, in keeping up, by injections, etc., a sufficient degree of irritation to favour the desposition of new bone."

I have now treated a considerable number of simple and multilocular cysts by Mr. Butcher's method, and, as has been noted, with recurrence in at least two of the latter. Mr. Butcher does not appear to have met with further trouble in his cases, and this may depend upon his "carrying out the gouging fearlessly and far wide of the disease." I should in future be guided by the age of the patient and the amount of solid material found in the cysts. In young persons with cysts having fluid contents and little growth in the bone, I should be still inclined to adopt palliative measures and to gouge very freely, carefully watching the case with a view to a more radical proceeding, should further development take place. In cases of much solid deposit in connection with multilocular cysts, and still more in cases of solid tumour with one or more large cysts, there should, I think, be no doubt as to the removal of one-half or more of the lower jaw, or of any portion of the upper jaw involved.

---

## LECTURE II.—TUMOURS OF THE JAW

MR. President and Gentlemen,—In my last lecture I discussed the cystic affections of the jaws, and referred, among others, to the dentigerous cyst due to a misplaced tooth. It does not, however require the development of a cyst to render a misplaced tooth important, for there are many recorded instances in which mere displacement of a tooth from its normal position has given rise to deformity and the suspicion of grave disease.

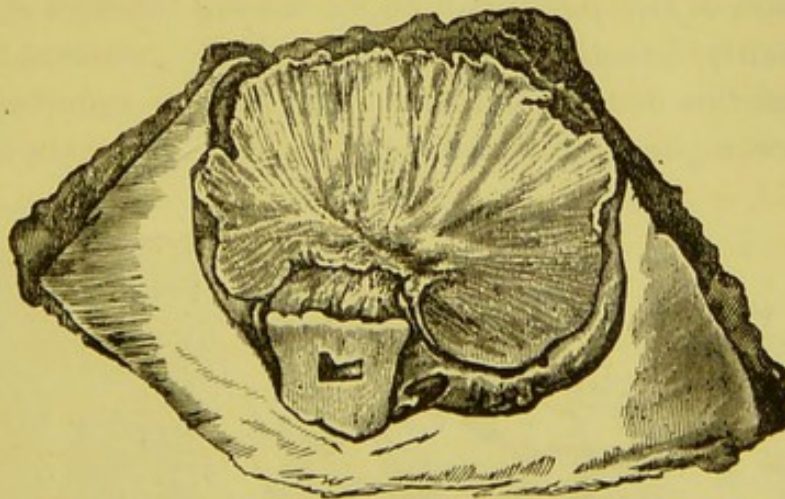
Even more remarkable, however, than mere malposition are certain modifications which the molar teeth occasionally



undergo during their development, giving rise to most interesting tumours of the jaw, which have been specially studied and described under the name *Odontomes* by Broca. These tumours depend upon some modification of the germ of the tooth before the formation of the cap of dentine, and belong to Broca's second class, *odontomes odonto-plastiques* or *odontomes bulbaires*. The result is the formation of an irregular mass of dental tissues in no way resembling a tooth in shape.

There are, I believe, but nine cases of this form of odontoma recorded, and these all occurred in the lower jaw. The first case was communicated to the Faculty of Medicine of Paris in 1809, by M. Oudet. The patient, a man aged 25, had on the right side of the lower jaw a mass occupying the position of the premolar teeth, which on removal proved to be composed of dentine and enamel. A similar mass on the left side was not removed. The second case occurred some years back, in the practice of Sir William Fergusson, by whom the tumour was removed with a portion of the jaw, and is described by Sir J. Tomes, from whose work a drawing of a section of the tumour is taken (Fig. 19). The second molar of the lower jaw

Fig. 19.



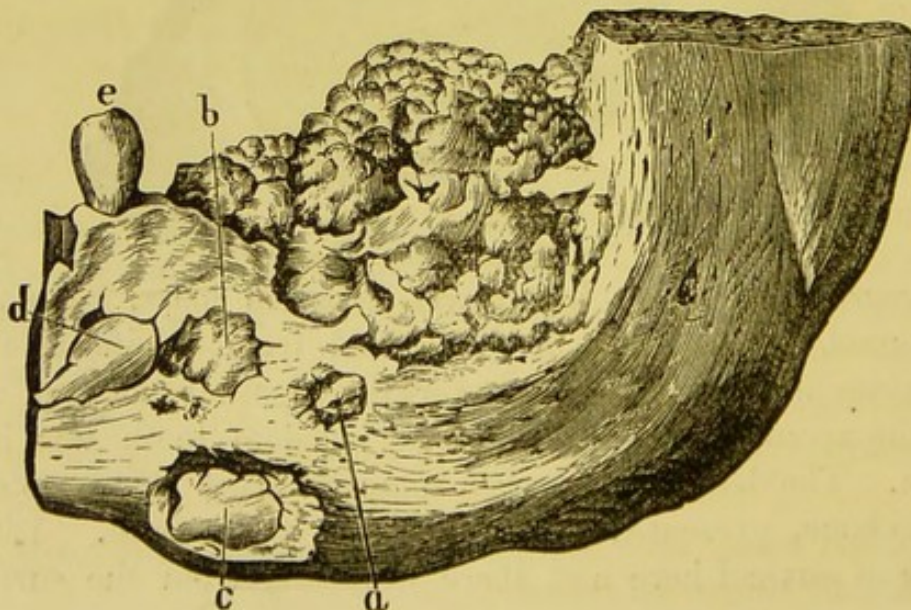
was represented by an irregularly flattened mass, composed of enamel, dentine, and bone, derived from calcification of remnants of the dentine pulp, thrown together without any definite arrangement, by which the wisdom tooth was held down. The dental mass, when removed from its receptacle in the bone, presented no resemblance to a tooth. Little beads of enamel here and there projected from the surface



which was generally rough and irregular. The naked-eye appearance of the section is accurately given in the wood-cut, the radiate character in which shows the arrangement of the component tissues, which, by the aid of the microscope, are seen at places to alternate. The alternation is mainly effected by the dentine and bony tissue, and these, indeed form the great bulk of the mass. The appearances presented, prior to the operation, consisted in enlargement of the jaw posterior to the first permanent molar tooth, with a hard, brown-looking body projecting but slightly from the surface of the gum. This projecting portion was, in fact, the upper surface of the aberrant tooth; and the nodules of enamel were, for the most part, situated in this part of the mass.

The third case occurred to Dr. Forget in the person of a young man, aged 20, who presented himself in 1855 with a disease of the lower jaw, from which he had suffered since he was 5 years old. Upon looking into the mouth, a round smooth tumour, hard and unyielding, was seen occupying nearly the whole of the left side of the jaw. None of the teeth beyond the first bicuspid were present. Dr. Forget removed the portion of the jaw involved by sawing through it in front of the bicuspid tooth, and also through the ramus at the level of the inferior dental foramen. The portion removed is seen in the accompanying drawing (Fig. 20). An examination of

Fig. 20.





the portion which had been removed showed that the jaw between the ramus and the first bicuspid tooth was converted into a cavity, which was occupied by a hard oval mass, of the size of an egg, having an uneven surface covered here and there with minute tubercles, which were invested by a layer of enamel penetrating into the substance of the bone, and easily recognisable by its shining appearance and peculiar colour. A section of the tumour showed that it consisted of a compact tissue of the consistence of ivory, of a greyish-white colour, in the interior of which it was possible to perceive, with the naked eye, a kind of regular arrangement of the elements which entered into its composition. Between the tumour and the osseous cyst was a thick membrane, apparently of a fibro-cellular structure. At the anterior extremity of the base of the tumour was a depression in which the crown of an inverted molar tooth was wedged in between it and the maxilla. This tooth is seen in Fig. 20, *c*, where a portion of bone has been cut away; *a* and *b* mark portions of the tumour projecting through the jaw, and *d* is the second bicuspid tooth lying below the first, *e*.

The microscopic examination of the tumour showed it to be composed principally of dentine, with enamel on the surface and dipping into the crevices, at the bottom of which, as well as in other parts, portions of cementum were found.

The fourth case of the kind was brought under the notice of the Odontological Society of Great Britain, in December, 1862, by the late Mr. W. A. Harrison, F.R.C.S. The specimen closely resembled those already described, and came from the left side of the lower jaw of a lunatic, where it occupied the space between the incisor and molar teeth. It came away spontaneously, leaving a long deep groove, large enough to receive the last joint of the thumb, which soon granulated and contracted.

The fifth case is given in Heider and Wedl's *Atlas zur Pathologie der Zähne*, and closely resembles Sir J. Tomes's case, the second molar tooth of the right side being developed into a large irregular mass, and holding down the wisdom tooth. It was easily removed.



Mr. Annandale has reported a sixth case, occurring in the lower jaw of a young woman, aged 17, who had never had any molar teeth on the left side. A nodulated mass, which somewhat resembled a piece of necrosed bone, projected above the gum, and was firmly fixed. Mr. Annandale dislodged the growth, and removed it through the mouth. It measured an inch and a half, by an inch and a quarter, and weighed 300 grains, and on section showed that a cap of enamel, varying in thickness, was arranged over a portion of the irregular surface of the mass. Beneath this, well-formed dentine, forming a considerable thickness, was met with, and still deeper in the substance of the mass, true bone, containing lacunæ, canaliculi, and Haversian canals, was seen to be intermingled in a confused manner with portions of dentine, so as to form the substance called by histologists "osteo-dentine."

The seventh case occurred in the practice of Dr. Goodwillie, of New York, and is mentioned in Agnew's *Surgery*, vol. ii. It appears to have been removed with the angle of the jaw.

An eighth case has been recorded by myself in the *Clinical Society's Transactions*, vol. xv. The mass measured an inch

Fig. 21.

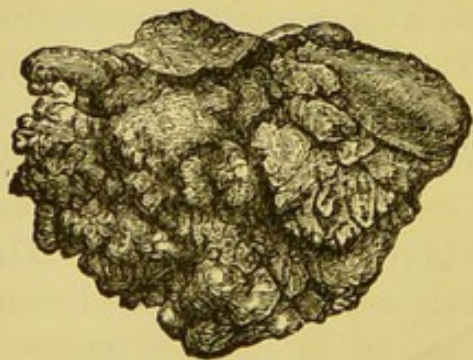
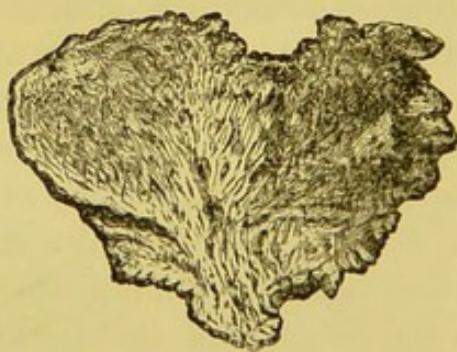


Fig. 22.



and a quarter antero-posteriorly, an inch transversely, and an inch and a half from above downwards. It weighed 315 grains, and is shown in Figs 21. and 22.

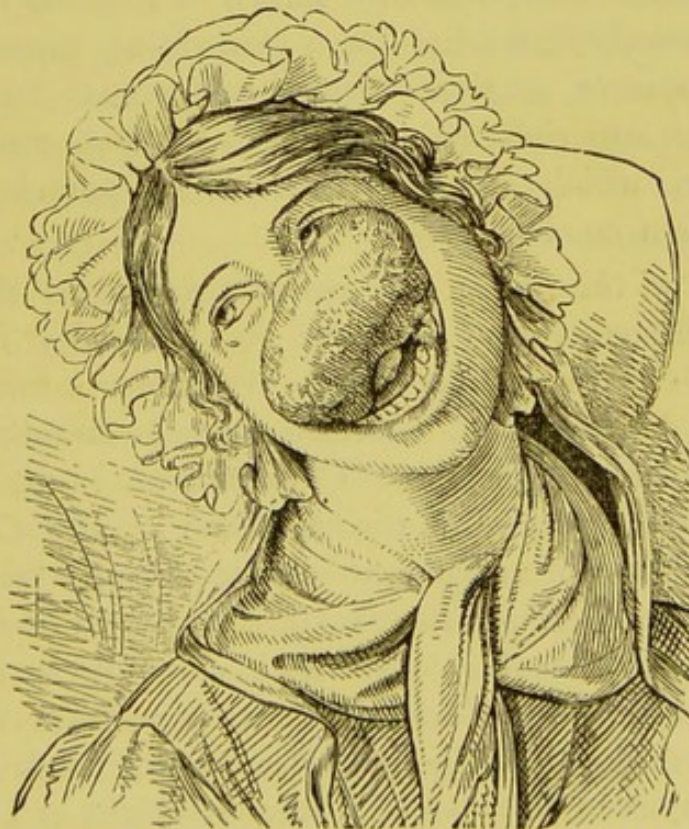Dr. Arkovy, of Buda Pesth, has recently recorded a ninth example, closely resembling the foregoing. All these specimens were met with in young adults, and only the first, fifth, sixth, eighth, and ninth were extracted from the jaw by the surgeon; in Mr. Harrison's case the mass coming away spontaneously, and in Sir John Tomes's and Dr. Forget's cases a considerable



portion of the lower jaw being removed by such experienced surgeons as Sir William Fergusson and M. Maisonneuve. In my own case I must confess that I did not appreciate at first the nature of the tumour, and recommended the removal of a portion of the jaw, and it was only during a subsequent operation, undertaken for supposed necrosis, that the true nature of the case became apparent.

A *fibrous epulis*, if allowed to grow to a large size, will produce external deformity of the face, and although attached to the upper jaw, may hang down so as to simulate disease of the lower jaw. This was well seen in a woman aged 27, who had an epulis of the upper jaw of seven years' growth, which hung down to the level of the angle of the jaw, and who was under the care of Mr. Erichsen, by whom the tumour was removed in 1861, with perfect success. Perhaps the most remarkable case of epuloid growth on record, however, is Mr. Liston's well-known patient Mary Griffiths, from whom, in October 1836, he removed the growth shown in the accompanying drawing, Fig. 23.

Fig. 23.



The patient had laboured under the disease for eight years,



and had been subjected to a partial removal of the growth when of inconsiderable size. The tumour was of a simple fibrous structure. The growth sprang originally from the gums and sockets of the incisors and canine tooth of the left side ; at an early period it protruded from the mouth, unconfined and uninfluenced by the pressure of the lips or cheek. It had assumed a most formidable size and appearance, concealed the palate and pharynx, and gave rise to great inconvenience and continued suffering. The surface had been broken by ulceration, but upon a close inspection of the projecting part and of that covered by the cheek, it was found to possess a firm consistence, and to present the same peculiar botryoidal arrangement of its parts as the others of a simple and benign nature. The operation proved perfectly successful. The preparation is in the Museum of the College of Surgeons (2193).

A case very similar in many respects to the preceding one was successfully operated upon in 1869 by Professor Kinloch, of Charleston. The patient was a negress aged 25, and presented much the appearance shown in Fig. 5, the mouth being enormously distended by a protruding growth, which appeared to have originated in the alveolus but to have involved the superior maxilla. Dr. Kinloch removed the whole mass, which weighed nearly two pounds, and the patient made a good recovery.

*Fibroma of the upper jaw* closely resembles the fibrous tumours of other parts of the body, and especially in connection with the uterus. It is dense in structure but not unfrequently lobulated, and, on section, slender bundles of intersecting fibres may occasionally be traced in it, of which there are good examples in the Museum of the College of Surgeons. The fibrous tumour usually springs from one of two situations, either the interior of the antrum or from some portion of the alveolus. In both cases it is intimately connected with the periosteum, in this respect resembling epulis. Occasionally the growth appears to follow some slight injury, as in the case of a lady, a patient of Dr. Neale, from whom, in 1870, I successfully removed a fibrous tumour



occupying the interior of the antrum which had followed a blow given by her child, and which may have been a fibrous odontoma. The fibrous tumour grows slowly, but surely, involving in its progress the surrounding structures. When arising in the antrum, it first expands the walls of that cavity, bulging out the face and forming tumours in the palate and the floor of the orbit, and subsequently produces absorption of the osseous walls, and spreads unchecked in all directions. (See St. George's Hospital Museum, II. 160.)

When it arises from the alveolus, a fibrous tumour may encroach on both the facial and the palatine surfaces of the jaw, crushing in the antrum, although not involving its interior. Of this a good example is seen in a preparation (2238) in the College of Surgeons, of an upper jaw removed by Mr. Liston. Here the tumour, which is affixed to the alveolar border near the molar teeth, extends inwards so as to cover the palatine portion of the jaw, and outwards so as to conceal all the bicuspid and molar teeth, with the exception of the last. The walls of the antrum are pressed inwards, but its interior is healthy. The patient was a woman, thirty years old; and the tumour was observed four years before its removal, which was successful. On the other hand, fibrous tumours, though commencing in the alveolus, may secondarily involve the antrum when they have attained considerable size, producing complete absorption of the walls, and projecting into the nose and through the palate. Of this a preparation in the College of Surgeons' Museum (2236) of an upper jaw, also removed by Mr. Liston, affords a good example. Here the patient was only 21, and the growth first appeared on the outer side of the gum of the left upper jaw four years before the operation. It was cut off six months after its first appearance, but returned, and eighteen months after was removed, with a portion of the alveolar process, but reappeared in a few weeks. Fig. 24, from Liston's *Practical Surgery*, shows the patient before the operation. It may be noticed here, as in the case of a large epulis, that disease of the upper jaw often resembles, externally, a tumour of the inferior maxilla.



The enormous size to which fibrous tumours of the upper jaw may grow without destroying the patient is well seen in

Fig. 24.

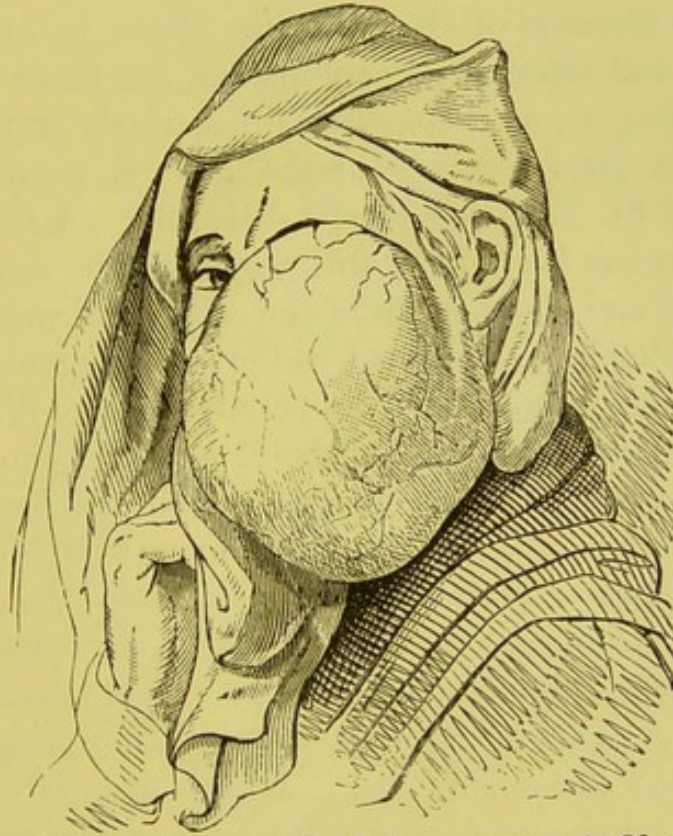

the accompanying drawing (Fig. 25) of Mr. Liston's celebrated case of Mrs. Frazer, from whom that eminent surgeon successfully removed the growth. The tumour is preserved in the Museum of the College of Surgeons (2241) and its diameters are, vertically, 7 inches ; transversely 7 inches ; from before backwards, nearly 6 inches. Contrary to the ordinary practice, a portion of the integument was removed with the tumour, measuring 12 inches in length and 10 in breadth, and this left a gap in the skin of the face upon the patient's recovery. The growth of this tumour was connected apparently in a curious way with the the performance of the uterine functions. The patient was 40 years old, and the tumour began to grow six years before its removal in consequence of a blow in the region of the antrum. Its progress at first was slow and not painful, but at the end of two years a distinct tumour was felt in the cheek. During the next two years it grew rapidly, especially during a period of gestation, but still without much pain. In the fifth year of its growth she bore a second child, after which the catamenia ceased to flow, and the tumour was subject to monthly



augmentations of its vascularity, and slight hæmorrhages occurred from its inner, though not ulcerated, surface, and from the adjacent parts of the gum.

Fig. 25.



A remarkable feature, noticed in a case of fibrous tumour of the antrum, in a young man aged 18, under the care of Sir. J. Paget in 1860, was a distinct pulsation in a portion of the tumour which projected into the orbit. The pulsation was slight but decided, and was synchronous with the radial pulse. The case was clearly not one of malignant disease, but proved to be an ordinary fibrous tumour upon removal. No satisfactory explanation seems possible of the case, which I believe to be unique. Suppuration has occurred in connection with fibrous tumours of the jaw, but only, I believe, when they have been punctured with a view to exploration and diagnosis. Of this the tumour removed from Janet Campbell, and preserved in the Museum of the College of Surgeons (2239) is an example. Simple fibrous tumours occasionally recur after removal, but it is doubtful whether in these cases the whole of the disease has been eradicated. According to O. Weber, they are usually connected with the lining of the



Haversian canals of the surrounding bone, and though he believes that these processes may sometimes be effectually detached, he advises the practice ordinarily followed of removing a portion of the bone.

Fibrous tumours of the jaw, like those in other parts of the body, and especially in the uterus, are liable to calcareous degeneration, or, as is sometimes incorrectly stated, to ossific deposit. A good specimen of the kind is preserved in the Museum of St. Thomas's Hospital (I. 18.). A thin section of this tumour has been dried and preserved, in order to show the amount and distribution of the calcareous matter (I. 19).

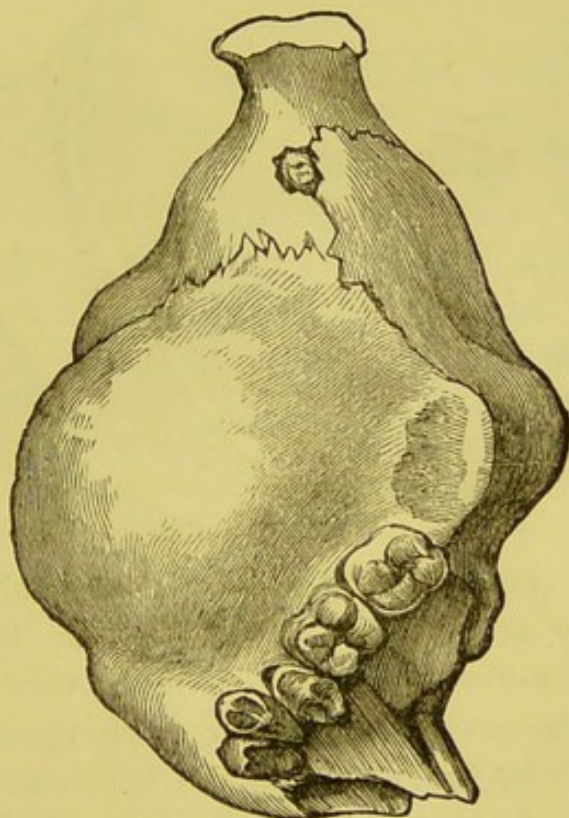
A remarkable example of calcareous degeneration of a fibrous tumour occurred in the practice of Sir. W. Fergusson, and the preparation is now in the Museum of the College of Surgeons (2242). It is a fibrous tumour of the left upper jaw, of some years' growth from a woman aged 50, containing numerous calcareous particles and acicular crystals, and, in addition, enclosing a suppurating cavity, in which was a mass about an inch in diameter, found by Dr. Goodhart to consist of acicular crystals of mineral matter, entangling in places nucleated and shrivelled cells. This is clearly an example of extreme calcareous degeneration undergoing necrosis.

Fibrous tumour is the commonest form of growth in the lower jaw, and, as pointed out by Paget, this may take the endosteal or periosteal form. The formation of fibrous tumours between the plates of the lower jaw originates, I believe, in the majority of cases in some inflammatory deposit due to the irritation of decayed teeth. By the slow growth of the tumour the jaw is expanded, the outer plate yielding more readily than the inner, as is well seen in a preparation in University College Museum (Fig. 26), which also shows a curious transportation of the wisdom tooth close up to the condyle of the jaw by the growth of the tumour, being probably connected with it in some way. In the College of Surgeons' Museum (2219) is a good specimen of endosteal fibrous tumour, which Sir Spencer Wells removed with the jaw from the symphysis to the angle, in a woman aged 27. The tumour occupied the left side of the lower jaw, and had



existed for four years, being connected with decayed teeth, one of which on being extracted shortly before the operation brought a small portion of the tumour away with it.

Fig. 26.

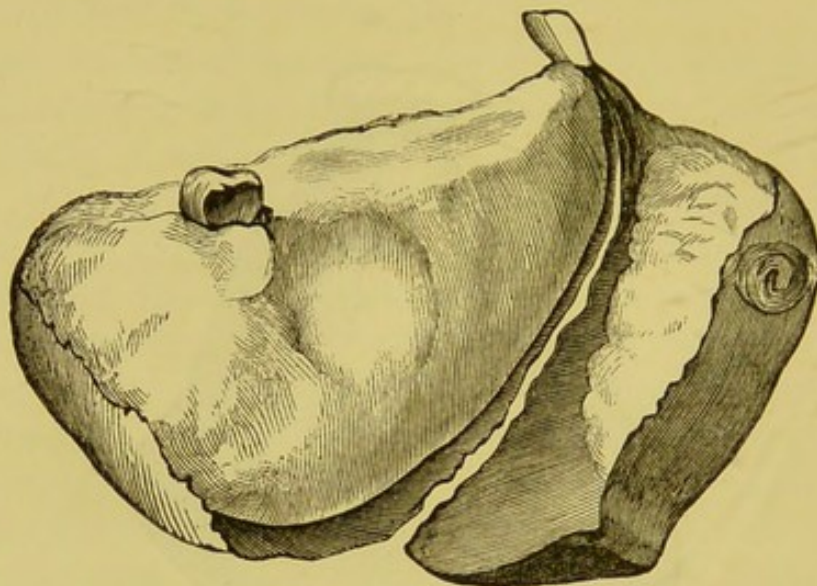


It may, I think, be doubted whether a milder treatment than that of removal of the whole thickness of the bone containing tumours of this description might not sometimes be adopted with advantage. A specimen in the Museum of King's College, which is represented in Fig. 27, admirably illustrates this view. It is a fibrous tumour, removed, when I happened to be present, by Sir William Fergusson, from a woman who had undergone two previous operations. Having sawn the jaw partly through on each side of the tumour, the operator applied the bone-forceps to complete one of the sections, when the outer plate of the jaw with the greater part of the tumour came away, leaving only a small portion of it adhering to the inner plate. Owing to the jaw being already divided, it was considered better to complete the operation as originally intended, and the patient made a good recovery. The preparation referred to illustrates also



the connection of the teeth with fibrous tumours, a diseased molar tooth being implanted in the upper part of the tumour.

Fig. 27.



Though of slow growth under ordinary circumstances, a fibrous tumour of the jaw, if irritated by the injudicious application of useless remedies with the view of producing absorption of the growth, may assume enormous proportions, and destroy life by the irritation and continuous discharge it gives rise to. A preparation in King's College Museum shows a fibrous tumour of large size, involving nearly the whole of the left side of the lower jaw. Its interior is hollowed out into a large cavity with sloughing walls ; and there is a large aperture communicating with it, surrounded by healthy kin. The patient's portrait, taken about six weeks before her death is seen in Fig. 28. The case was evidently one of ordinary fibrous tumour depending originally upon diseased teeth, which, by dint of incisions and injections of iodine into the growth, followed by a seton introduced into the skin, was brought into such a condition that, upon the receipt of a blow, it rapidly brought the patient to her death-bed. *See Lvsron,*

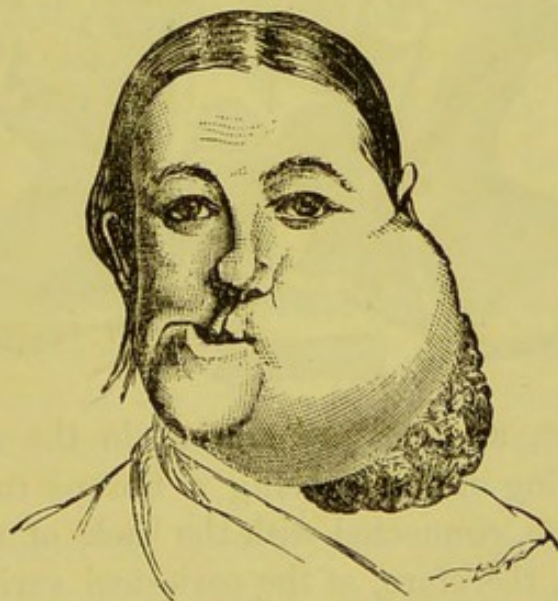
A remarkable and unique feature in connection with the case of large tumour above referred to is seen in Fig. 29, which shows the front of the base of the skull of the patient. The long-continued pressure of the tumour of the lower jaw



had given rise to a remarkable contraction of the hard palate and alveolus, the teeth being crushed together so as to overlap one another; and at the same time an expansion of the malar bone and zygoma has ensued, which is accurately shown in the figure.

A large tumour of the same kind, weighing eighteen ounces, which has encroached upon the condyle and coronoid process and projected into the mouth as well as on the surface is preserved in University College Museum (652), and was removed by Mr. Liston in 1846; and a similar growth, successfully removed by Professor William Beaumont, of Toronto, from a boy of 7, which is considerably infiltrated with calcareous matter, is in the Museum of the College of Surgeons (2218), and was originally considered to be,

Fig. 28.



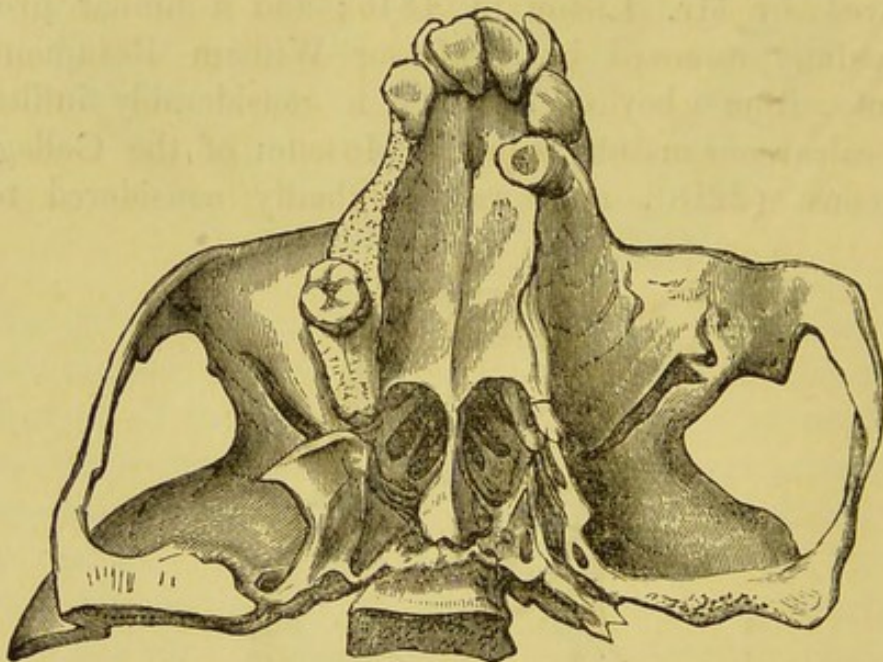
cartilaginous. It weighed eight ounces avoirdupois, with a long diameter of  $3\frac{4}{10}$  inches and a short diameter of  $2\frac{8}{10}$  inches and involved the whole of the left side of the bone.

Fibrous tumour is most frequently developed in the side of the lower jaw, where the space between the plates is larger than elsewhere, and may occupy the dental canal, as in a case of Mr. Cock's, in which the dental nerve passed through the tumour, necessitating its removal in two parts. Occasionally, however, fibrous tumour invades the symphysis, and



here, owing to the restricted amount of expansion of which the bone is capable, absorption of the anterior surface takes place at an early date, and the tumour projects, involving also the adjacent bone. A preparation in University College (655) shows the symphysis affected in this way, which was removed, with a portion of healthy bone on each side, by Mr. Liston. A section shows the structure very well, and at the lower part of a small cyst has been developed. In connection

Fig.29.



with the subject, another preparation in the same museum (654) is deserving of notice, being a fibrous tumour, of the size of an orange, connected with the back of the symphysis and apparently, therefore, of the periosteal variety.

The *periosteal variety* of fibrous tumour is not distinguishable from epulis except by its size. Like epulis, it has spicula of bone springing from the jaw, permeating it for a short distance; and beyond them radiating lines may be seen in the fibrous tissue. Preparation 2221 in the Museum of the College of Surgeons, for which I was indebted to Mr. Lee of the Salisbury Infirmary, illustrates this form of disease very well, the fibrous growth being closely connected with the periosteum of the front of the jaw. The disease may, however, almost completely surround the jaw, as in the pre-



paration in St. Bartholomew's Hospital, drawn by Sir. J. Paget in his *Surgical Pathology*.

*Enchondroma* of the upper jaw is of uncommon occurrence, but the jaw may become involved in cartilaginous tumours springing from other bones of the face. Of this there is an example in St. George's Hospital Museum (XVII. 66), taken from a young woman who, seven years before her death, began to suffer from soft elastic tumours on the inner side of the orbits. Two years after, the right maxillary bone was fuller below the orbit than the left, and the right half of the bony palate was larger and more depressed than the other; but in neither of these parts was there any softening. Gradually the eye-balls were protruded; and the sight was lost. Two years later, it was noticed that the superior maxillary bones projected nearly an inch beyond the inferior, so that she had some difficulty in masticating. A portrait of this patient is preserved in St. George's Museum. The tumour was found to project into the cranium, the orbits, the antra, and the nasal, zygomatic, and pterygo-maxillary fossæ. All the fossæ were quite filled up by the growth, and the bones of the face and orbits extensively absorbed. The hard palate was pressed downwards, so that the teeth on the two sides deviated from the natural line, and the left central incisor crossed that of the right side. Microscopical examination of the tumour showed it to be composed principally of cartilage.

In the Museum of St. Bartholomew's Hospital is another *post mortem* specimen of cartilaginous tumour of the face, from a lad of 16 (XII. 1773), occupying the situation of the superior maxillary bones, which are completely absorbed. Above, the tumour has extended through the left side of the base of the skull into its cavity, where it forms a large projection in the situation of the anterior lobes of the cerebrum; below, it is united to the soft palate; in front, it protrudes and distends the left nostril, and has caused the ulceration of a part of the integuments of the face. The outer surface of the tumour is nodulated; its interior, shown by the section, is formed of close-set nodules and masses of cartilage, partially



and irregularly ossified, and in some parts intersected by layers of a softer, probably fibrous tissue. A portion of its external surface projecting below the left nostril has sloughed. This case is drawn in Mr. Stanley's illustrations to his work on *Diseases of the Bones*, and both it and the preceding preparation illustrate very well the tendency of cartilaginous tumours to invade all the surrounding structure, and fill the several cavities.

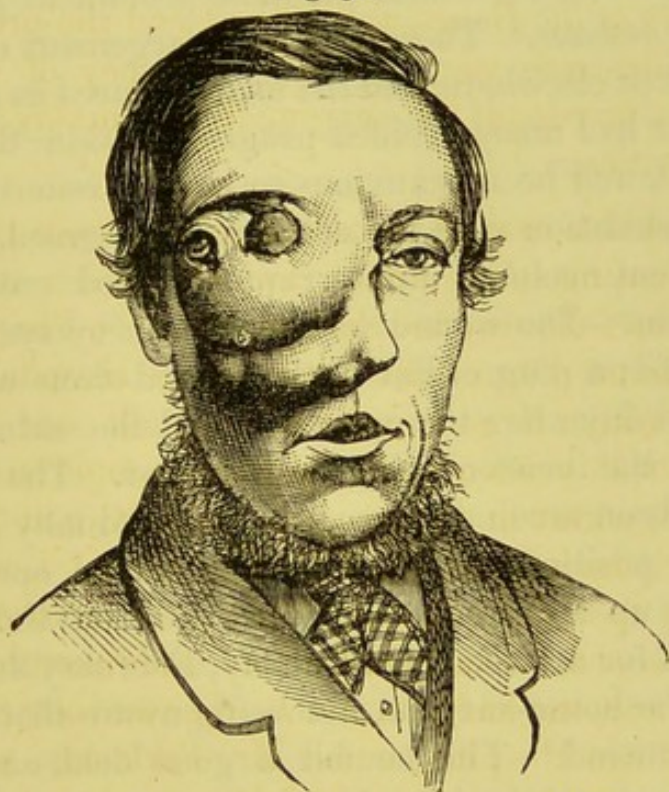A remarkable case of recurrent cartilaginous tumour of the face, originating in the upper jaw, was under my own care of which the following are the particulars:—The patient, aged 34, was admitted into University College Hospital on January 1st, 1868, with a large tumour of the right side of the face. When about 17 years of age he noticed a pimple on the right side of his nose, which increased pretty rapidly, and three months after (1851) he went to St. Thomas's Hospital, when Mr. Le Gros Clark operated, and removed a tumour as large as a walnut. He quite recovered, and was well for a few months, but within a year the tumour had returned. He was then admitted into King's College Hospital, under Mr. Partridge, who, in June, 1852, removed the tumour, which was of an osteo-cartilaginous character, oblong in shape, and of the size of a large walnut, projecting slightly into the antrum, and involving the nasal process of the superior maxillary bone, but in no way implicating the mouth or orbit. From this operation the patient made a good recovery, except that a small fistulous opening was left in the cheek. The man continued in good health until 1857, when he went to America, and after arriving there he found the tumour beginning to appear again, and in 1860 Professor Gunn operated at Anne Harbour, in the state of Michigan, and removed the entire right upper jaw. The tumour, however, began to grow again rapidly, and projected on the face. The surgeons at Maple Rapids, where he lived, wanted to operate again, but the patient declined, and returned to England in 1865. Soon after this an abscess formed in the upper part of the tumour, which was lanced with great relief, but the incision thus made had



never closed, owing to the stretching of the skin by the tumour.

The patient's appearance on admission was most unsightly (Fig, 30). the right side of the face being greatly disfigured

Fig. 30.



by a large tumour, by which the eye was thrust completely aside, but without loss of vision. Immediately to the inner side of the eye was an open granulating sore of the size of a florin, the result of the incision for the evacuation of matter already referred to. The tumour appeared externally to consist of two portions, separated by a horizontal sulcus, at the bottom of which the fistulous opening resulting from the second operation was still visible. The upper and more prominent portion had invaded the orbit, reaching to its upper border, and extending beyond the middle line of the nose. A small portion of this had, within the previous two months, projected through the left nasal bone. The lower portion of the tumour involved the ala of the nose and adjacent portion of the cheek, both of which were much distorted; on a small projecting portion of this the skin was adherent. Both the nostrils were completely blocked and had been so for months. Within the mouth it was seen that the whole of the right side of the hard palate had been removed;



and in its place there was a smooth, red, oval mass, coming down to the level of the teeth of the opposite side. The scars in the middle line of the lip and on the cheek, resulting from former operations, were still visible. The tumour was solid and not tender to the touch, the most prominent point being apparently osseous. There was no enlargement of the glands in the neck or elsewhere, and the man appeared in good health. The tumour had made decided progress within the previous few months, and he was anxious to have it removed to which after a consultation with my colleagues, I agreed.

The patient made an uninterruptedly good recovery from the operation. The wound was kept clean by syringing with Condyl's fluid; a plug of lint in the frontal sinus was removed on the third day after the operation, and the sutures on the eighth day, the incision being well united. The right eye, which had been much displaced, began gradually to recover its proper position. A fortnight after the operation, the patient was up and about the ward, and on February 1st, he went out for a walk. On Sunday, February 2nd, he again went out, the house-surgeon not being aware that there was a bitter east wind. This he felt a good deal, and the next day his face was noticed to be swollen and red. This had increased on the following day, when I saw him, and it was evident that an attack of erysipelas was coming on. The patient was at once placed in a separate ward, and active treatment adopted. The erysipelas spread, however, and affected the throat, so that on February 7th he was able to swallow but little, and was becoming rapidly exhausted. By the frequent use of the stomach-pump nourishment was introduced into the stomach, and he rallied for a day or two. Symptoms of pyæmia, however, now manifested themselves, and the patient rapidly lost ground and, after lingering for a week, died on February 17th.

At the *post-mortem* examination the incisions in the face were cicatrised, but the site of the tumour was granulating and encrusted with mucus in parts. On removing the brain, it and the membranes were found perfectly healthy; but the plate of bone between the frontal sinus and the cranial cavity



was so thin that it broke in the removal of the brain. There was no appearance of any remnant of tumour either in the frontal sinus or elsewhere, the walls of the large cavity left by its removal being healthy (University College, 616). In the thorax there was abundant evidence of pyæmia, the lungs being filled with pyæmic abscesses. The tumour weighed nine ounces, and consisted of a loose cartilaginous material enclosed in a bony cyst, from which spicula were sent into the interior. At two points, and particularly at the most prominent portion of the tumour, the bone was of considerable thickness.

In many cases of enchondroma a certain amount of fibrous tissue is found mixed with the cartilage, and in some cases, particularly those of slow growth and of long standing, the fibrous has, to the naked eye, almost replaced the cartilaginous element. Of this, an enchondromatous tumour, removed by Mr. Square, of Plymouth, in November, 1866, and kindly given me by that gentleman, is an excellent example. The tumour was of the size of an orange, and occupied the right superior maxilla of a woman, age 47. It had been growing for ten years, and Mr. Square successfully removed it. The preparation, now in the Museum of the College of Surgeons (2216), and of which a section has been made, shows a surface closely resembling a fibrous tumour, but in which cartilage cells are readily found under the microscope. The preparation shows a deep groove in the buccal surface of the tumour caused by the teeth of the lower jaw.

The ossific deposit, beginning at several separate points, which is not infrequently found in connection with enchondromata of other parts of the body, may take place in enchondroma of the upper jaw. A very excellent example of this was published by the late Mr. Maurice Collis, of Dublin (*Dublin Quarterly Journal*, August, 1867), and the appearance of the patient is well shown in the lithographic illustrations which accompany that paper.

Enchondroma of the lower jaw is not common, but is found of two forms, the endosteal, and periosteal, thus resembling fibroma. A case is recorded by Sir Astley Cooper, in his "Essay



on Exostosis," and is remarkable both for the sound pathological views and strictly conservative treatment he therein advocates. The patient was 19, and had had a growth in the side of the lower jaw for three years. Sir Astley exposed the tumour and gouged it away, exposing the dental nerve, and the patient made a good recovery. Sir James Paget has recorded (*Medico-Chirurgical Transactions*, 1871), a very similar case of cartilaginous tumour in the lower jaw of a lady 45 years old. It had been growing during two or three years, extended along the space between the first bicuspid and last molar teeth, was deep set in the jaw, expanding both the walls, and rising to almost the level of the molar teeth. He gouged it out, leaving the base of the jaw untouched, and not cutting any part of the cheek or lip. It did not recur.

The periosteal form of enchondroma springs from the membrane covering any portion of the bone, but most frequently affects the body. It grows to an enormous size, and may cause death either by interfering with respiration, as in Sir Astley Cooper's case, or with deglutition, as in the case from which the preparation in the College of Surgeons (2215) was taken.

*Osteoma*.—The simplest form of osseous tumour of the upper jaw is an hypertrophy of the whole or of some portion of the bone. In October, 1883, I had under my care in University College Hospital a young woman, aged 25, in whom a painless enlargement of the right upper jaw had been noticed for ten years, encroaching upon the palate and bulging out the cheek. I successfully removed the whole upper jaw, and on section the tumour was found to be simple bone, very dense, but otherwise healthy. One half of the specimen is in University College, and the other in the College of Surgeons' Museum (2211 A).

Besides this form of bony tumour, due apparently to an increase of the cancellous structure of the bone, specimens of tumour as hard as ivory have from time to time been met with. Perhaps the most remarkable of these is one described by Mr. Hilton in the *Guy's Hospital Reports*, vol. i, p. 493, from the fact that the tumour separated spontaneously from



the face. The patient was a man, aged 36, who, twenty-three years before Mr. Hilton saw him, noticed a pimple below the left eye, close to the nose, which he irritated, and from that spot the tumour appears to have originated. The tumour, in its growth, displaced the eyeball, giving rise to excruciating pain, which subsided on the bursting of the ball. It began to loosen by a process of ulceration around its margin six years before it fell out, which event was unattended by either bleeding or pain; the tumour weighed  $14\frac{1}{4}$  ounces. It was tuberculated externally, and an irregular cavity existed at the posterior part. A section presented a very hard polished surface resembling ivory, and exhibited lines in concentric curves, enlarging as they were traced from the posterior part. The huge cavity left by the tumour was bounded below by the floor of the nose and antrum, above by the frontal and ethmoid bones, internally by the septum nasi, and externally by the orbit, which had been considerably encroached upon by the tumour. This patient was alive in 1865, thirty years after the prolapse of the tumour.

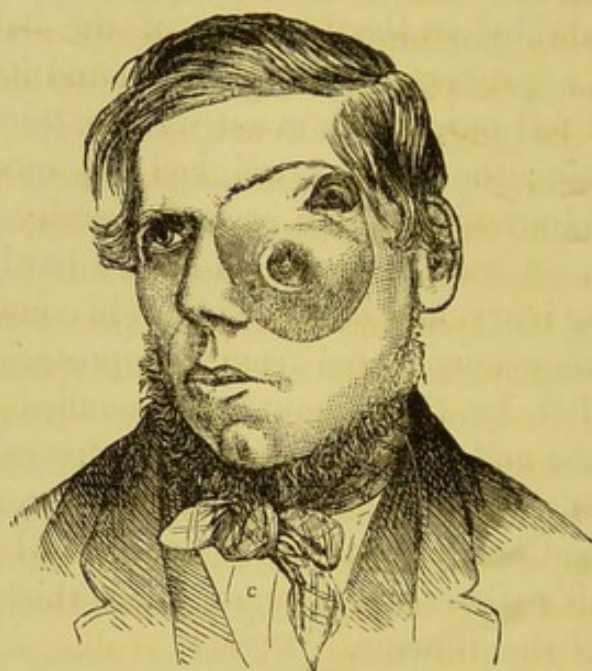A case in many respects resembling Mr. Hilton's case, was under the care of Sir William Fergusson, whom I had the opportunity of seeing operate upon it. The patient was a young man, aged 21, who had first noticed the swelling on the left side of the face twelve years before. It grew for six or seven years, and then remained stationary. Two years before he had consulted a quack, who attempted to destroy it with caustic, and produced the large hole, seen in the lower part of the tumour (Fig. 31).

On admission to King's College Hospital there was a swelling on the left side of the face about the size of an apple extending from the eyebrow to a line less than one inch above the mouth. Internally it encroached upon the nose, displacing it a little, the nasal bone being pushed forwards and the left ala flattened on the columna; the mass was felt by the finger in the mouth above the gums. The nostril on the same side was perfectly blocked up, the patient being totally unable to breathe through it; the right nostril however, was quite free. Outwards, the tumour extended to the angle of the orbit; the



arch was, however, not displaced, but the tumour extended slightly above it. The floor of the orbit seemed displaced.

Fig. 31.



The eyeball was seen imbedded in the most prominent and central part of the tumour, and removed more than an inch from its natural position in the orbit, which was entirely blocked up by the mass. There was no extension into the pharynx. The tumour was everywhere hard, with a slight blush over the surface. In its centre was a round opening, produced by the caustic applied two years previously, of about the size of a shilling, deep, and displaying in its floor black necrosed bone, and discharging pus. The patient said he had suffered neither headache nor pain in the tumour since its commencement twelve years before, and that his sight had been unaffected. Sir William Fergusson operated upon this patient on November 30th, 1867, and succeeded in removing the whole of the prominent tumour, weighing  $10\frac{1}{2}$  ounces, which consisted, in all its anterior part, of nodulated bone as hard as ivory, and posteriorly, of very dense ordinary bone mixed with a small amount of cartilage. A section showed an ivorylike mass closely resembling Mr. Hilton's specimen



connected with a mass of very much condensed bone. The tumour sprang apparently as in the former case, from the upper part of the maxilla, and had invaded the antrum, orbit and nostril. The palate was in no way involved in the growth, and was preserved entire at the operation, Sir William Fergusson sawing horizontally immediately above it. Unfortunately the sick patient sank rather suddenly from inflammation of the lungs on the fourth day.

At the *post-mortem* examination, after the removal of the brain, it was found that the affection of the bone involved the base of the skull, there being a projection of the size of a hazel nut from the sphenoid near the optic foramen. This involved the foramen and extended along the sphenoidal fissure, the optic, third, and fourth nerves passing through the condensed bone of which it was composed. The brain was unaffected (*vide Lancet*, February 8th, 1868).

The Specimen was exhibited to the Pathological Society of London, and was reported upon by a committee. The report of this committee, drawn up by Mr. Hulke, which will be found *in extenso* in vol. xix of the *Pathological Transactions*, expresses an opinion that "the hard part of the tumour has been directly formed by the exogenous growth of successive layers of dense bony tissue under the periosteum, which opinion is confirmed by the absence from the hard tissue of the regular Haversian systems so characteristic of secondary bone."

In both these cases the tumour appears to have taken its origin in the upper wall of the antrum, and to have grown forwards ; but tumours of the same kind have been found completely within the superior maxilla, the anterior wall of which has been merely expanded by the growth behind it. Of this, two cases reported within the last few years by Mr. Michon and Dr. Duka are good examples.

Dr. Duka's case is reported in the *Pathological Society's Transactions*, vol. XVII and occurred in a female native of Bengal, aged 26, and on the right side of the face, which was not much deformed. There was a discharge from the right nostril, which was obstructed, and, on examination, a hard



tumour was found within it, which was movable, but could not be extracted, and which had existed six years.

Dr. Duka, failing to extract the tumour by laying open the nostril, resorted to the somewhat unusual proceeding of cutting a wedge out of the hard palate, and thus, after an operation of three-quarters of an hour, without chloroform, succeeded in removing the growth. The patient recovered. The tumour (3497) is preserved in St. George's Hospital Museum. It has an oblong shape, and is not unlike a middle-sized potato, with depressions and elevation passing irregularly over it. The whole bony mass, which is of a compact ivory-like character, weighs 1,060 grains; its long diameter is nearly three inches, the short one, an inch and two lines, and the longest circumference seven inches. The microscope gives evidence of structure closely resembling that of M. Michon's tumour. There are no distinct Haversian systems, but abundance of lacunæ arranged around vascular canals. In some parts of the tumour the characters are very much like those of simple ossified cartilage, clusters of large ossified cells being packed closely together. This case is remarkable from the fact that the attachment of the tumour had given way, and that it was therefore loose in the antrum.

*Osteoma* affects the lower jaw in two forms: the cancellated and the ivory exostosis. The former is, no doubt, in many cases the result of ossification of enchondroma, as, for instance, a specimen (C, 203) preserved in St. Thomas's Museum, which is of a spongy texture, and which is stated by Sir Astley Cooper to have been removed by Mr. Cline. Occasionally, however, a conversion of the whole thickness of bone into a lobulated mass of spongy bone is met with, of which an excellent example is preserved in St. George's Hospital Museum (II, 185). In this case, the tumour, which was of the size of the fist, had been growing for five years, and had been on one occasion partially removed. Mr. Tatum successfully removed the entire portion of jaw affected. A case in which a circumscribed bony tumour, measuring from two-thirds to three-fourths of an inch in diameter, and composed of hard, finely-cancellous bone, was lodged in the inter



rior of the angle of the jaw is given by Sir J. Paget in the *Medico-Chirurgical Transactions*, vol. liv.

Ivory exostosis appears to affect by preference the angle of the jaw. Of this a good specimen is preserved in St. George's Hospital (II, 191); and O. Weber figures a sections of a large ivory exostosis in the same region removed by Chelius. The best example of the kind, however, is in the College of Surgeons (2212), having been presented by Mr. J. F. South. The preparation (*post-mortem*) shows part of the right side of the lower jaw, with sections of a large bony tumour at its angle. The angle of the jaw rests in a deep groove on the middle of the upper surface of the tumour, and in some situations their respective substances are continuous. The tumour projects both below and on each side of the jaw, is of irregular shape, measures nearly three inches in its chief diameter and is deeply nodulated. It is composed throughout of bone, uniform in texture, and as hard and heavy as ivory.

In the Museum of St. Bartholomew's Hospital is the lower jaw of a young person (1,3257), with two symmetrical eburnated exostoses springing from the inner surface of the alveolar portion of the bone on either side of the symphysis, corresponding in position to the bicuspid and first molar teeth. The markings and slight lobulations of the bony outgrowths are more or less symmetrical. The rami of the jaw are unusually widely separated.

In May, 1870, I removed an ivory exostosis from a young woman, aged 32, a patient of Mr. Ceely, of Aylesbury. There had been a painless enlargement of the side of the lower jaw for five years, and there was also a smaller enlargement of the right side. A small exostosis also existed on the left pubes. I made an incision behind the jaw and sawed off the growth level to the bone, removing a dense ivory growth measuring two inches in length, one inch in width, and three-eighths of an inch thick in the centre (University College Museum, 635). The exterior of the growth presented a finely reticulated appearance, and at the upper part was a small depression filled with cartilage in the recent state. Two years after the operation, I was informed by Mr. Ceely that



there had been no reappearance of the growth, and that the other exostosis remained *in statu quo*, and four years latter I saw the patient, who continued quite well.

When the exostosis forms a distinct and circumscribed growth, whether it be of the cancellous or ivory character, it should be sawn off the bone at the level of the healthy surface, and will in all probability not recur. When, however, the whole thickness of the bone is involved, as in Mr. Tatum's or Mr. South's case, it will be necessary to remove the portion of the bone. Should the tumour be imbedded between the plates of the jaw, it should be enucleated, if possible without any external incision, as in Sir J. Paget's case already mentioned.

*Sarcomatous Tumours.*—Under the term sarcoma, modern pathologists include all tumours composed of tissue, which is either purely embryonic, or is undergoing one of the primary modifications seen in the development of adult connective tissue (Erichsen).

In connection with the jaws, various forms of sarcoma are found, many of which have hitherto been known by other names, and many recurrent growths formerly called cancers come properly into this class.

The spindle-celled sarcoma is of frequent occurrence in the upper jaw, forming many of the specimens formerly indiscriminately named "osteosarcoma." It is usually of a yellower colour than the fibrous tumour, and of softer consistence, and on section it exudes a serous fluid. The spindle-shaped cells are often of great length and size, and each cell contains one or more oval nuclei, the intercellular substance being homogeneous.

Under the name of "albuminous sarcoma," Mr. Liston has described a case which appears to be of this kind, in the *Lancet*, November 26th, 1836, which proved fatal after removal of the tumour. The patient was 24 years of age, and the disease appeared to have originated in a blow, and grew with tolerable rapidity. The tumour, which is preserved in the College of Surgeons' Museum (2202), is oval in form, its chief diameters being about two inches by three



inches, and contained spaces in which was a glairy fluid, coagulable by heat.

*Spindle-celled Sarcoma* frequently attacks the lower jaw, and may prove fatal, by obstruction either to respiration or deglutition, if allowed to grow unchecked for many years. Some of the earliest removals of portions of the lower jaw were for growths of this description which had attained a large size, and the names of Crampton, Cusack, and Syme are connected with these operations. The Museum of the College of Surgeons of Ireland is especially rich in tumours of this class, and possesses also a cast of the head of a patient who died with a large tumour of the lower jaw, which has been injected and divided.

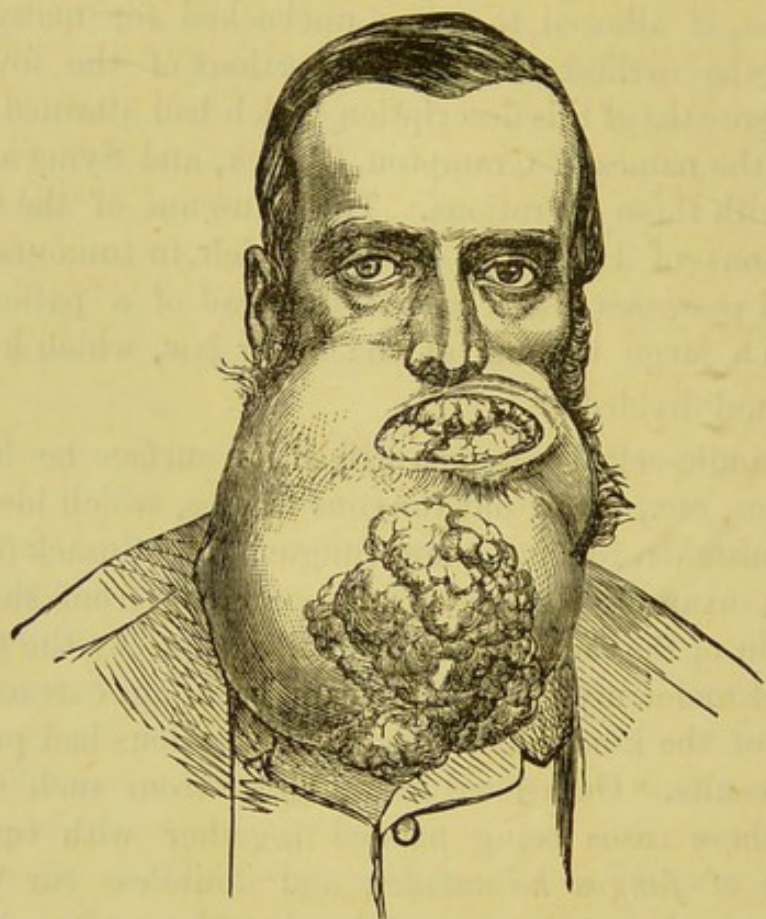
The spindle-celled sarcoma will, if its surface be irritated by caustics, etc., throw out fungous masses, which bleed, and may be mistaken for malignant fungus. Mr. Cusack (*loc. cit.*) gives an example of this result occurring from sloughing of the skin of the face, due to over-distension by the tumour, and I had under my care some years back an extraordinary instance of the kind, where quack applications had produced similar results. Occasional hæmorrhage from such surfaces led to these cases being massed together with cancer as examples of *fungus hæmatodes*, and doubtless Sir William Fergusson's observation is correct, that the rarity of fungus hæmatodes in the present day, is due to the early treatment to which cases of this kind are submitted.

The portrait of the patient formerly under my own care, to whom I have alluded, is shown in Fig. 32, taken from a photograph. The enormous size of the tumour can be best appreciated by the figure, the measurements being as follows: from the lobule of one ear round the chin to the lobule of the other was  $19\frac{1}{2}$  inches; from the edge of the lower lip over the chin to the *pomum Adami*, 13 inches; and the width of the face was 14 inches. The circumference of the lips was  $9\frac{1}{2}$  inches. The patient was only 32, and the disease appeared to have commenced eleven years before in a swelling below the right canine tooth, but the whole of the large growth had taken place within four or five years. The fungus pro-



trusions were, as has been mentioned, the result of the application of quack remedies. The patient, when he came under my notice, was in a miserable condition, being nearly starved,

Fig. 32.



owing to the tumour forming a projecting mass within the mouth, which completely concealed the tongue, and was nearly in contact with the palate. I succeeded in removing the tumour by sawing in front of the left angle and disarticulating on the right side, with very little loss of blood; but the patient died exhausted on the sixth day. The tumour weighed 4 lb. 6 oz., and is now in the Museum of the College of Surgeons (2234). A section has been made to show its structure, which is precisely that described by Sir P. Crampton, the mass being made up of fibro-cellular tissue of different degrees of density, with here and there small nodules of bone, and a few small cysts interspersed through its structure. The tumour evidently commenced in the interior of the jaw, the outer plate being considerably expanded and destroyed in parts, while the inner remains



perfect, and can be seen in the condition in which it was left at the operation. The mass, in growing, has carried up the teeth with it ; and they project from it at irregular intervals, a considerable portion of the growth, and probably the most recently formed part, being posterior to them, occupying as it did the mouth, and lying among the muscles beneath the tongue. The fungoid masses are covered with granulations, but otherwise differ in no way from the rest of the growth.

Mr. Eve has recently re-examined this tumour, and has found scattered throughout it masses and cylinders of epithelial cells, resembling the epithelial elements of the cystic tumours of the lower jaw described in my first lecture. They were composed of large irregularly shaped or branched masses, and of small columns composed of round epithelial cells, with a layer of peripheral elongated cells. (For drawing, see lecture by Mr. Eve, *British Medical Journal*, Jan. 6, 1883.)

Under the head of Spindle-celled Sarcoma must be included the cases which have hitherto been classed as "recurrent fibroid," of which Mr. Lawson's is a good example. The preparation is in the College Museum (2230 A.)

*Myeloid Sarcoma* is found in the upper as well as in the lower jaw, in which latter position the specimen first described by Sir J. Paget arose. The occurrence of myeloid cells in specimens of epulis has been already referred to, and it might naturally be expected, therefore, that the same characters might be discovered in tumours of the jaw. In fact, Dr. Eugène Nélaton, in a valuable treatise published in 1860, *Des Tumeurs à Myélopaxes*, says "le siège d'élection des tumeurs à myélopaxes est, sans contredit, dans les os maxillaires, particulièrement au niveau de leur bord alvéolaire," and supports his statement by quoting twenty-nine cases of the disease in this situation.

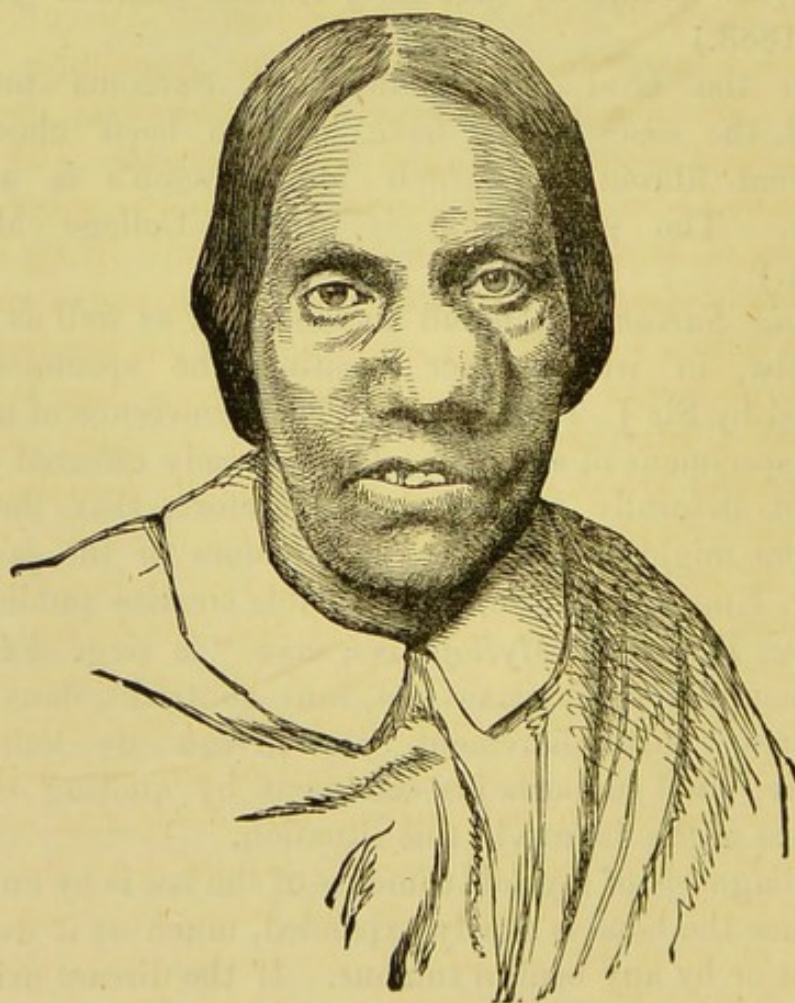
The diagnosis of myeloid tumours of the jaw is by no means easy, since the bone is slowly expanded, much as it would be by a cyst or by any benign tumour. If the disease originate in the exterior of the bone, or, when springing from the



interior, if sufficient absorption of the bone have taken place to allow the tumour to appear beneath the mucous membrane, the characteristic dark maroon colour of the tumour may be perceived. Cysts occasionally form in the substance of a myeloid tumour, and an exploratory puncture of these may yield fluid in which the characteristic myeloid cells may be discovered microscopically.

Myeloid disease occurs mostly before the age of 25. Sir J. Paget (*Surgical Pathology*, page 524) quotes two cases of Sir William Lawrence's, occurring in the upper jaws of women of 21 and 22 years of age, the latter of which illustrates extremely well the recurrence of myeloid growths (of which there can be no question), and also the very curious fact that a tumour on the opposite side to that

Fig. 33.



removed, and which presented appearances exactly correspond-



ing to it, spontaneously subsided. The specimen is in St. Bartholomew's Hospital Museum (l. 459).

Fig. 33 shows a patient from whom Mr. Canton removed a myeloid tumour in 1864. She was 35 years old, and the tumour appeared to have followed a blow. It had been twice removed before she came under Mr. Canton's care, and that gentleman successfully removed the left superior maxilla with the tumour, a portion of which hung down into the pharynx.

The subsequent history of this patient is given as follows in the *Lancet* of January 26, 1872, and it is remarkable that the tumour on one side should have had a character differing from that on the other: "In June, 1871, she again presented herself at the Charing Cross Hospital with a large tumour filling up the antrum of the right upper maxilla, and extending forwards, causing a projection of the upper lip. Mr. Canton accordingly removed the remaining upper maxilla. The operation was perfectly successful, and presented in itself no points of particular interest. The edges of the incision were brought together with silver sutures, and no dressing of any kind was used, the mouth being simply kept perfectly clean and sweet by the frequent use of Condyl's fluid. Within a week of the operation she left her bed, and within three weeks she was discharged from the hospital. Five months later the patient wrote to say that she had enjoyed perfect health since she had left the hospital. On microscopic examination the tumour proved to be simply fibrous. It had been growing for a year before removal. Notwithstanding that a great part of the framework of the face had been taken away, and that a portion of the orbital plate was removed at both operations, there was remarkably little deformity of the face. The patient had lost all power of muscular expression, but beyond this there was nothing to attract attention, except a slight falling in of the upper lip on the right side. There was no falling in of the nose, the raphe of what was the roof of the mouth deriving great support from a firm pseudo-palate, which had formed of cicatricial tissue after the first operation. The cicatrices of



the incisions were scarcely noticeable, as they followed the natural lines of the face."

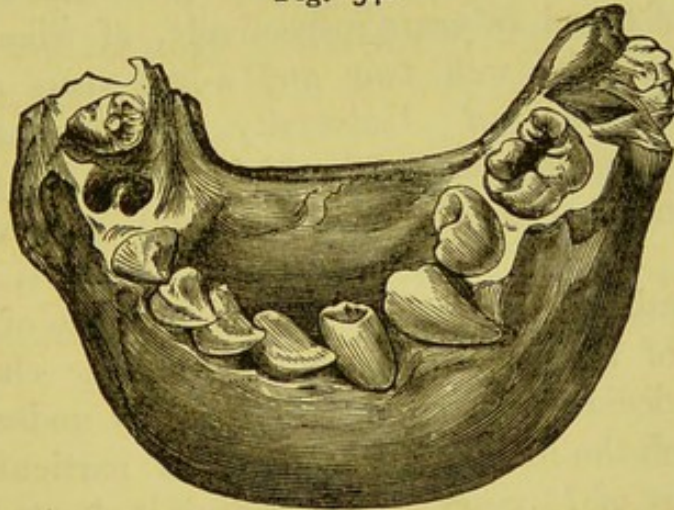
In the Museum of the College of Surgeons are two specimens (2245 and A), the two superior maxillæ of a woman aged 21, which were given me by Messrs. Andrews and Coates, of Salisbury, who removed them. The left upper jaw has been macerated, showing a calcified tumour springing from the anterior part ; the right jaw has a growth involving the anterior portion extending into the nasal fossa. The growth in these cases was regarded by the operators as an example of scirrhus, but I am enabled, by the kindness of Dr. Lush, of Weymouth, to correct this statement, by a record which he has of the microscopic details observed when the tumours were recent, showing the growths to have been really myeloid.

*Myeloid Sarcoma* is frequently met with in the lower jaw, and it was here that the disease occurred in the case from which Sir J. Paget drew his description. The case is quoted by Mr. Stanley as an example of "tumour of bone, composed of a soft, very vascular substance, having the characters of erectile tissue," but his general description corresponds precisely to that of Sir J. Paget. Figs. 1 and 2 of Plate 13 in Mr. Stanley's atlas show the tumour *in situ* and a section of the jaw after removal. "The patient was a boy in St. Bartholomew's Hospital, and the growth occupied the symphysis of the lower jaw, and protruding into the mouth, presented a very vascular surface of a mottled red and purple colour, resembling the exterior of some nævi. The tumour was not tender to the touch, and had not been accompanied by pain ; it was once destroyed by caustic to the level of the alveolar border of the jaw, but was quickly reproduced ; it was then wholly removed with the portion of the jaw in which it originated, and the cure was permanent. The morbid substance was found imbedded in the cancellous texture of the jaw ; it was soft, of a dark-red colour, closely resembling the tissue of healthy spleen." (Stanley, *On Diseases of Bone*, p. 185).



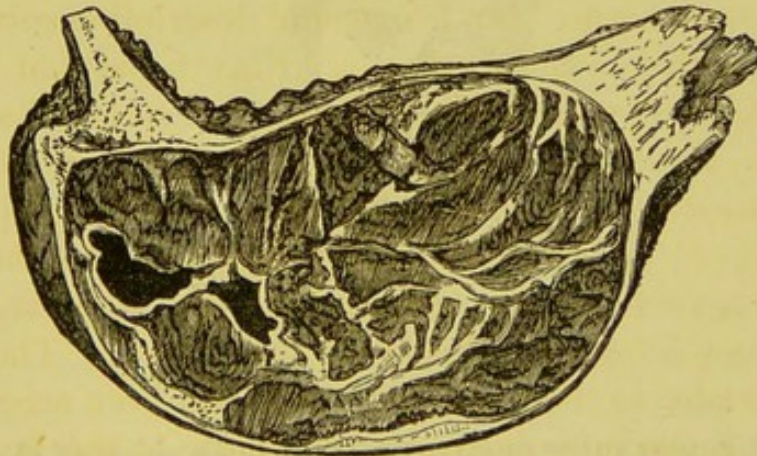A valuable preparation is in the College of Surgeons Museum (421 A), of myeloid tumour of the symphysis and body of the jaw, removed by Mr. Craven, of Hull, from a young woman of 18, who made a good recovery after the operation. Figs. 34 and 35 show very satisfactorily the

Fig. 34.



appearance of the specimen, which has been divided horizontally. The tumour was of between two and three years' growth, and was covered with healthy mucous mem-

Fig. 35.



brane. Its section shows a well-marked specimen of myeloid disease imbedded between the plates of the lower jaw ; its tissue is of the ordinary friable character, resembling spleen, but somewhat decolorised by immersion in spirit, and it is intersected by fibrous septa. Two cysts may be seen in the section ; these being of frequent occurrence in myeloid growths. The microscopic examination of Mr. Craven's



specimen was unsatisfactory, owing to its previous immersion in spirit, but there can be no question, from the naked-eye appearances, of the nature of the growth.

In the Museum of St. George's Hospital are four specimens of myeloid disease affecting the lower jaw (II. 166, 167, 168, 169), two of which have no history; the others were removed from girls of 8 and 5 years respectively, of whom the first was known to be well two and a-half years afterwards. In the Museum of University College are three excellent specimens, removed by Liston (680, 1, 2), and there are three in St. Bartholomew's Hospital, all from young persons.

A remarkable, and I believe unique, example of disease of both sides of the lower jaw, the microscopic characters of which were decidedly myeloid, was formerly under my own care, of which the following are the brief particulars:—The patient, a boy of  $7\frac{1}{2}$  years, whose portrait is shown in Fig. 36

Fig. 36.




presented a remarkable enlargement of both sides of the lower jaw, giving his face a very square appearance. The affection had come on gradually and painlessly from the age of a year and a-half, and at the time I operated upon him the width of the jaw, as measured with calipers, was five inches, the width of an average adult jaw being only four inches. The growths were evidently projections from the outer surfaces of the angles of the jaws, the inner surface of the bone being



natural, and the mucous membrane of the mouth not interfered with. In September and October, 1867, I removed the right and afterwards the left tumour through incisions behind the margin of the jaw, and without opening into the mouth. The main part of each projection was sawn off the jaw, and are now in the College of Surgeons' Museum (2232), closely resembling large mussel-shells filled with a cartilaginous-looking substance, which, however (and especially some darker portions), gave distinct microscopic evidence of myeloid structure. A good deal of this material, which seemed to fill the interior of the bone, was gouged away, and the symmetry of the face restored as far as possible. The boy made a good recovery, and Fig. 37, from a photograph,

Fig. 37.



shows his condition three months after the second operation, and there appears to have been no tendency to recurrence.

*Chondro-sarcoma* is characterised by rapidity of growth and by early recurrence after removal. The primary tumour is mainly enchondroma, but the recurrent growths are chiefly composed of small round-celled sarcoma, which tends to produce internal deposits through the vascular system.

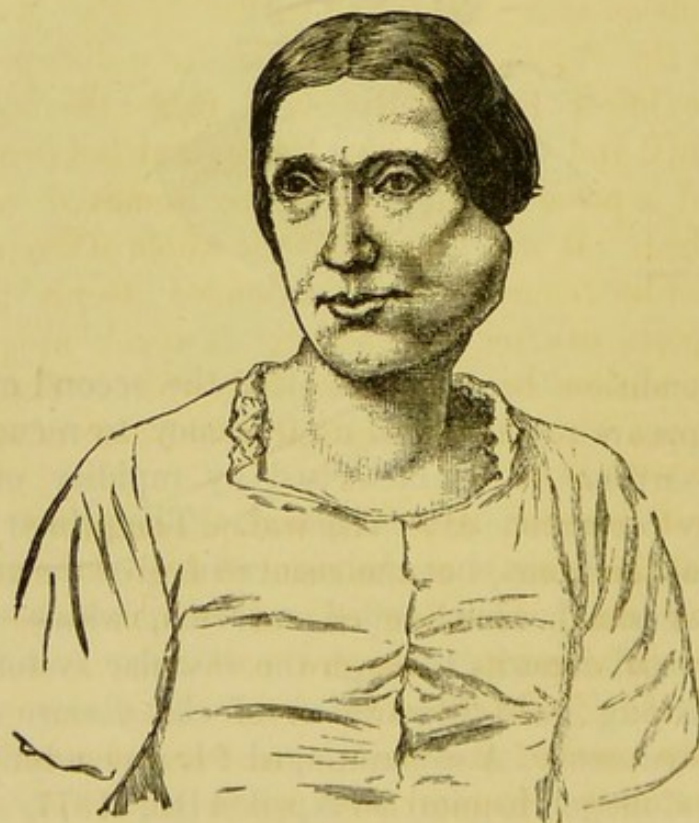
The following good illustration of the disease occurred under my own care. A woman, aged 44, was admitted into University College Hospital on April 11th, 1877, with the following history :—She first noticed a swelling connected



with the left side of the lower jaw nine months before. The swelling was painful, and accompanied by numbness over the chin. Twenty years before she had received a violent blow over the jaw, when attendant in a lunatic asylum. The family history threw no light on the case. The patient had always enjoyed good health.

On admission, there was a large tumour on the left side of the lower jaw, and firmly connected with the inner and outer surfaces of the bone, extending from an inch behind the symphysis to the angle. The growth generally was firm and elastic, though some parts were much softer than others. The border of the tumour was well defined, and the skin was freely moveable over it. A nodule, the size of a walnut, projected between the teeth into the cavity of the mouth. The patient complained of shooting pains in the tumour, which ran along the lower lip. There was no enlargement of lymphatic glands, and no other tumour. The general health was good. The patient's appearance is shown in Fig. 38.

Fig. 38.



On April 14th I removed the tumour with the bone involved,



from the left of the symphysis to an inch above the angle, and the patient made a good recovery.

Eleven weeks after discharge she was re-admitted. The lower borders of the segments of the previously divided jaw had united by fibrous union, but a V-shaped notch existed at the upper border large enough to admit the tip of the finger. Recurrence of the growth had taken place in connection with both divisions of bone. There was a tumour as large as a hen's egg beneath the chin, but this could not be felt through the mouth, whilst a second and larger one caused bulging on the left cheek, and was mainly situated over the ramus of the jaw; it projected into the oral cavity and rendered articulation indistinct, although there was no difficulty in deglutition. The skin was freely moveable over both masses; there was merely a linear cicatrix at the line of the old incision. The lymphatic glands were not enlarged, and the general health was good.

A second operation was done on August 1st, 1877. It being found impossible to remove the tumour by the mouth, I made an incision along the lower border of the jaw, from two inches to the right of the symphysis for a distance of six inches. The lower lip was dissected from the bone and turned upwards, and the jaw sawn through at the symphysis, which allowed a piece on the left to be removed with the growth attached. It was found that the whole of the posterior mass could not be removed, as it extended deeply into the pterygoid region, so after enucleating as much as possible, the operation was not further proceeded with. The wound was syringed out with strong solution of chloride of zinc, and then plugged with lint.

For the first fourteen days the wound continued to heal rapidly, but at this time it commenced to fungate, and on the twentieth day sharp bleeding ensued, which required the actual cautery to arrest it. Severe pain was more or less constant, and the discharge very fetid. On the 28th the fungating mass reached the clavicle, and completely hid the left side of the neck; hæmorrhage again occurred, and the cautery was employed.

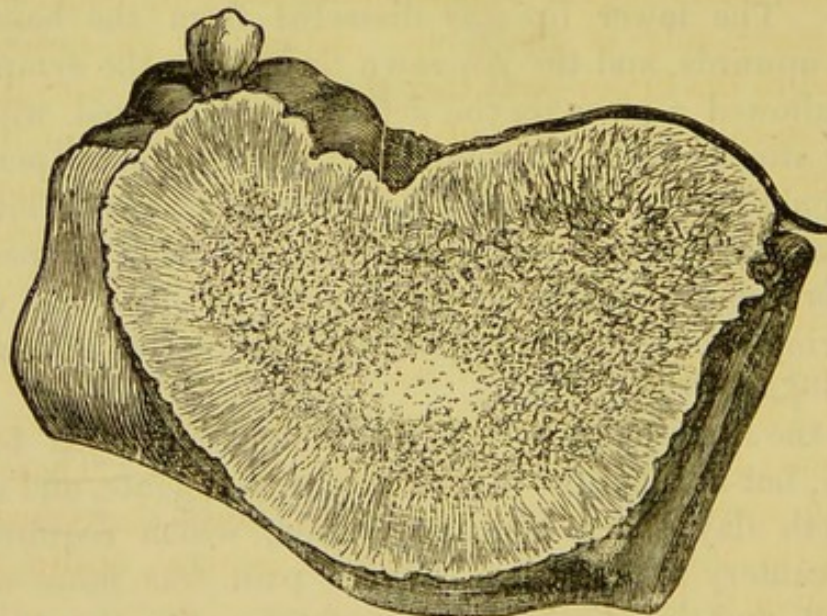


In spite of a supporting plan of treatment the general health rapidly failed, the patient fell into a semi-comatose condition, got more and more asthenic and cachectic, and died on the forty-third day after the second operation.

*Ossifying Sarcoma and Osteoid Chondro-sarcoma* imply the occurrence of ossification in tumours containing sarcomatous elements, and include the cases hitherto described as "osteoid cancer." A good specimen of the kind is preserved in the Museum of the College of Surgeons (1712), of which the history with an accompanying drawing is recorded in Mr. Howship's *Surgical Observations*. The specimen has been macerated, and the part which remains consists of an oval mass of light cancellous bone about five inches in its chief diameter, and very slightly connected with the remaining bones of the face.

*Ossifying sarcoma*, in which ossification takes place extensively in a matrix of sarcomatous tissue, occurs in the lower jaw, and as in the following case, presents at first most of the characters of an ordinary osteoma. Fig 39 shows the

Fig. 39.



portion of the lower jaw at first removed, with a section of the tumour (College of Surgeons' Museum. 2241 A), which is difficult to distinguish from ordinary bone, except by the striation seen best at its margins. The rapid



recurrence of the disease in a soft form showed the true nature of the case, and the patient died exhausted within a year of the first operation.

W. G., aged 50, was admitted into University College Hospital on May 9th, 1881. About five months previously he noticed a pricking pain about the left side of the lower jaw, and soon a lump appeared outside the bicuspid teeth ; it grew steadily but slowly, until one month before admission. At this time the patient had several teeth extracted, and the increase in the size of the growth became rapid after this interference ; there was constant gnawing pain. The patient believed exposure to the cold to have been the cause of the swelling. Both his parents died of "old age," and had no kind of tumour.

On admission, the lower part of the left cheek was bulged outwards considerably by a very hard round swelling, which covered the outer side of the left half of the lower jaw from a short distance in front of the angle almost to the left canine ; the lower edge of the bone was concealed by slight projection of the mass below it ; and on pressing upwards in the submaxillary region a considerable swelling could be felt on the inner side of the bone. Altogether the impression conveyed to the fingers was that the growth was central, and that the so-called expansion of bone had occurred over it. No teeth were present on the left side behind the canine, the alveolus was widened, and presented posteriorly, several low rounded swellings, covered by mucous membrane, soft or even cystic ; whilst in front lay a large crater-like ulcer, at the bottom of which no bone was bare. The tongue and floor of the mouth were normal. A small, not tender gland could be felt behind the angle of the jaw. There was moderate constant pain in the part, much increased by hanging the head down. As regards general health there was nothing to be desired.

On May 11th ether was given, and the growth removed by an incision from the left angle to the symphysis ; the jaw was sawn through to the left of the symphysis ; the soft,



parts stripped from the growth, and then the bone was divided near the angle. The wound was closed by wire sutures, and dressed with cotton wool.

The wound was all but healed on the eighth day, quite so on the twentieth, when the man left the hospital feeling quite well.

In three months, however, he was re-admitted, having had a distinct recurrence for six weeks, with much constant pain. His health was still very good.

On September 6th, 1881, the whole of this mass, together with the ramus, coronoid process, and condyle of the jaw were removed by the ordinary incision for the removal of half the lower jaw.

The patient again recovered, without any bad symptoms. The hinder part of the wound gaped widely, but it was healing steadily, and there was no obvious recurrence on October 8th, when the patient left the hospital.

On January 30th, 1882, the patient was again admitted having noticed a recurrence of the growth two months. The left cheek was now enormously swollen, and the angle of the mouth pushed forwards by a mass of new growth, fungating into the mouth along the line of the jaw, but elsewhere covered by mucous membrane. The old wound was healed, but an ulcer an inch and a half by half an inch, round which there was a good deal of firm infiltration at its posterior end. The growth was firm and elastic at some points, bony at others, adherent to the symphysis, but not very firmly. The whole face was oedematous; the left temporal fossa rather full, and the seat of much pain. The man was still pretty strong.

On February 2nd the old incision was opened up, and the main part of the growth turned out; but, as it seemed to involve the tonsil and carotid vessels, and to spread into the temporal fossa, much had to be left.

Again the patient made a good recovery. The anterior part of the wound healed, but the posterior gaped widely, and he went out with a large hole here. Pain in the temporal region continued. He died at home on April 5th,



having been able to walk up and down stairs to the last. The total duration of the disease would, therefore, seem to have been about seventeen months.

*Round-celled Sarcoma and Epithelioma.*—Round-celled sarcoma or medullary sarcoma is of frequent occurrence in the upper jaw, and, from its vascularity and rapidity of growth, it has often been mistaken for medullary cancer, which in its clinical history it closely resembles. In the majority of cases the disease begins in the antrum; for the protruding masses, which are found in the nose or mouth, are but secondary to a formation within that cavity. One of Mr. Liston's cases is conclusive on the point, the preparation being preserved in the College of Surgeons (1059).

Medullary sarcoma of the jaw closely resembles the same disease in other parts of the body; rapidity of growth, with softness and a tendency to fungate on the part of the tumour itself, being the main characteristics. The direction which the disease takes, and the effects therefore which it produces, will vary in different examples. Frequently it forms a considerable projection on the cheek, causing epiphora from closure of the nasal duct and œdema of the lower eyelid, and in the later stages enlargement of the facial veins, without the least invasion of the hard palate, and with but slight interference with the nostril. The specimen of medullary sarcoma in the College of Surgeons' Museum, 2243, illustrates the point, a large tumour being developed externally. The patient was a man aged 34, who came under the care of Mr. Craven, of Hull, in 1863, with a large rounded tumour of the right cheek, of the size of an orange, extending from the external process of the frontal bone and zygoma above to the angle of the mouth below (almost completely closing the right eye), and from the side of the nose to the ramus of the lower jaw. The colour of the integument was natural except at the upper part below the eye, where it presented a rather livid appearance, and several veins, not of large size. It was very firm to the touch, but elastic, especially at the outer part. Pressure and handling caused little or no pain. The interior of the mouth on the right side, from the alveolar



process (which was concealed by the growth, or embraced in it) to the inside of the distended cheek, presented a large excavated sore of a greyish sloughy aspect and foetid odour. This part of the tumour was softer to the touch than that which showed itself externally. It did not encroach on the palate which was of the natural width. There were no enlarged glands beneath the jaw. The patient seemed a pretty healthy man. The tumour had been growing seventeen weeks. Mr. Craven excised the tumour, and the patient made a good recovery, but died fifteen months afterwards from a recurrence of the disease. The tumour was rounded and lobed, especially that part which occupied the pterygo-maxillary fossa, and was firm on section. The cut surface was smooth, becoming slightly granular after prolonged exposure. To the naked eye the tumour had the appearance of a malignant growth. Under the microscope, the juice scraped off the cut surface showed no fibrous element, but simply a mass of apparently broken-up cells and granular matter.

On the other hand, the disease may at an early period involve the alveolus and palate, or the nose, and it is these cases which are sometimes attributed to the presence of decayed teeth, or are mistaken for ordinary nasal polypi. Of this a preparation (College of Surgeons' Museum, 2248), which was also from a patient of Mr. Craven (to whom I was indebted for both valuable preparations), is an instance. Here the disease showed itself first in the gums, where it formed a fungating mass, and soon obstructed the nostril. This last symptom was due to a fungus, almost papillary in appearance, which springs from the nasal surface of the tumour. Mr. Craven removed the tumour in March, 1866, but within a year the disease returned and proved fatal.

The disease may extend across the median line and involve portions of both maxillæ, especially the palatine plates. This is not necessarily a bar to operative interference, provided other circumstances are favourable.

Round-celled sarcoma occasionally involves both upper and lower jaws, beginning, I believe, mostly in the upper, and extending to the lower. A man was under my care in 1877



with an enormous swelling of the left side of the face. I ventured, under chloroform, to introduce my finger into the mouth to explore the extent of the growth, but I found it so extensively attached to both upper and lower jaws that removal was clearly impossible. The examination gave rise to sharp hæmorrhage, due to the great vascularity of the growth, and this was checked with some difficulty with the persulphate of iron.

I met with the same implication of the lower jaw, though to a lesser extent, in a lady, from whom I removed the upper jaw in consultation with Dr. Cæsar. In this case the coronoid process was involved, and was removed with bone-forceps; but recurrence of the disease took place, and the patient did not survive the operation four months.

*Round-celled or Medullary Sarcoma* begins usually in the interior of the lower jaw, producing rapid expansion of it, and ultimately breaking through into the mouth, and also through the skin of the face if allowed to proceed unchecked. A specimen in University College Museum (666) is a good example of disease. The morbid growth projects chiefly on the outer side and its most prominent part has protruded through the skin, forming an overhanging nummular projection which has an open reticular surface. On the inner side the tumour has invaded the jaw, in places destroying its entire thickness. The growth, however, scarcely projects into the mouth. As seen on the divided surface, it is composed of a soft, granular, yellowish basis, supported and parted into small polyhedral masses by narrow lines of fibrous tissue; its limit is everywhere definable. Microscopic examination shows the tumour to have all the characters of a large round-celled sarcoma.

Many of the museum specimens hitherto described as medullary cancer are really examples of round-celled sarcoma, and the following case of Mr. Liston's in the College of Surgeons (2230) may be quoted as an instance of the size to which round-celled sarcoma may grow: Part of a lower jaw, including the left condyle, the alveolus of the right first molar tooth, and all the intermediate parts which, with an



enormous tumour upon them, were removed by operation. The left ascending portion and side of the jaw as far as the canine tooth are completely enclosed by the tumour, and it covers both surfaces of the jaw as far as the right canine tooth. A round lobulated mass projects downwards and forwards, and in the opposite direction the tumour projects into the mouth with a rough fungous surface, in which a displaced molar tooth is seen. The interior of the tumour is indistinctly lobulated, composed of round masses connected by cellular tissue, and of a soft texture; it is invested by a thick capsule.

*Epithelioma* occurs in the upper jaw in two forms, the squamous and columnar; and the former always begins in the gum or palate. Columnar epithelioma always begins in the antrum, which it often fills, and then secondarily involves the palate; or it may attack the outer wall only of the antrum and then protrude on the face. Occurring usually in patients over forty years of age, the disease begins very insidiously, the patient complaining, perhaps, of neuralgia or of uneasiness in the face, but of little more. When the antrum has become distended, the epithelioma is apt to involve the palate by absorption and eventual fungation, and then protrude into the nostril and orbits.

In the Museum of the College of Surgeons is a preparation (2235) of the right superior maxilla with a soft white tumour filling the antrum and protruding into the nose and orbit, which I removed from a gentleman aged 51, who five years before the operation noticed "lumps in the hard palate," which were lanced, but never healed, though appearing to diminish in size. About four years later his right nostril became blocked, and there was protrusion of the eye. I removed the jaw very freely, but recurrence took place at the back of the orbit, and it became necessary to remove the eyeball in order to clear out the growth effectually, but time showed that a cure had not been effected. The morbid growth in this case is unattached to the wall of the antrum, except behind, where it extends into the substance of the gums and palate. Mr. Eve's microscopic



examination shows it to consist of closely-packed and very tortuous columns of small round epithelium ; a few of them had a lumen, around which the cells were arranged in a regular manner as in tubular glands. The stroma was composed of sarcomatous tissue. This case is one of unusual duration for an example of pure epithelioma ; the fact that the tumour is a mixture of epithelioma and sarcoma probably gives the clue to it, although the subsequent history is distinctly that of epithelioma.

*Epithelioma* occurs in the lower jaw in two forms, the columnar and the squamous. Columnar epithelioma occurs in connection with multilocular cysts and with single cysts, and has been already fully discussed. Squamous epithelioma is the more common form of disease, and is found both in connection with ulceration of the gums and as a tumour of the jaw. The following, under my own care, is a typical case of the latter form of the disease. A man, aged 56, first noticed a swelling in his face four months before his admission ; he used to have toothache, and had lost all the teeth behind the left lateral incisor in the lower jaw. When first noticed, the tumour was about the size of a small walnut, and was situated on the left ramus near the angle of the jaw. It was not painful or tender to the touch, but grew steadily. On admission to University College Hospital, there was on the left side of the lower jaw a rounded, smooth swelling, which extended from the middle of the vertical ramus of the jaw to the level of the hyoid bone below and forwards nearly to the symphysis. The swelling was firm and inelastic, and the skin over it was normal, except that it was slightly reddened over the anterior half of the growth. Inside the mouth the growth projected as a large red roundish mass, with the surface flattened and sloughy. It reached as far backward as the vertical ramus, and encroached upon the floor of the mouth. I removed the tumour with the portion of the lower jaw implicated, by dividing the lower lip in the median line and carrying an incision beyond the angle of the jaw. The jaw was sawn to the right of the median line, between the incisor and the canine teeth, and the tongue being secured with a



thread, the bone was disarticulated on the left side with some little difficulty, owing to the tumour breaking away from the upper part. Consequently the coronoid process was nipped off with the bone-forceps, and left *in situ*, and an elevator was used to lift the condyle out. There was very little bleeding, and only one or two ligatures were applied. The wound was sprinkled with iodoform, and brought together with wire sutures, drainage being provided for.

The patient made an uninterruptedly good recovery, and left the hospital in thirty days. The part removed consisted of the remains of the left half of the bone, the part between the vertical ramus and the central incisors being almost entirely destroyed by the growth, only a shell of bone remaining at each end. On section the growth was of a dead white colour where oldest, with a firm margin advancing into the surrounding tissues. It consisted of a fibrous stroma, in which were scattered numerous leucocytes and spindle cells, with large masses of squamous epithelium cells, many of which were collected into bird's-nest groups. The specimen is in University College Museum.

The general characters of squamous epithelioma of the jaw are well seen in the foregoing case. Rapidity of growth, with destruction of the bone, and fungation into the mouth are the leading characteristics, and nothing but early and free removal offers any chance of relief. In the above case the jaw in its upper part was apparently healthy, but I had no hesitation in disarticulating so as to be thoroughly beyond the disease, and I also went well into healthy bone at the point of section, so as to avoid, as far as possible, all risk of recurrence.

The question of the necessity for the removal of large portions of bone in cases of cancer of the lower jaw may be here referred to. Some surgeons maintain that in a case of cancer it is necessary to amputate at the joint above the disease in order to obtain immunity. But, if this doctrine is to be carried out fully, the entire lower jaw should be removed for disease of one side, for though the bone was originally developed in two halves, there is nothing to prevent malignant disease spread-



ing across the symphysis, as was seen in the case of epithelioma under my own care.

The lower jaw is liable to be invaded by epithelioma spreading to it from the tongue and lip, and may be affected by both epithelioma and sarcoma developed in the neighbouring lymphatic glands. On more than one occasion I have found epithelioma of the anterior part of the tongue attached to and infiltrating the central portion of the lower jaw, and have been obliged to cut out the incisive region with good result. The most remarkable case was one of a man, aged 52, who was under my care in 1875 with extensive epithelioma of the front of the tongue, which was firmly fixed by its tip to the lower jaw, with great enlargement of the submaxillary glands and infiltration of the sub-maxillary tissues. He suffered acutely from occipital pain, which it is difficult to explain, and was willing to submit to any operation for relief. I divided the jaw on each side one inch and a half from the symphysis, and then removed the front of the tongue, the centre of the jaw, and all the sublingual structures, with the galvanic *écraseur* (University College Museum, 1023). The patient made a rapid recovery, the two portions of jaw fell together, and are now united at an angle by tough fibrous tissue, and the man, who was alive and well in 1883, has covered the deformity by growing a beard.

In January, 1879, I performed nearly as extensive an operation on a man, aged 68, removing the lower jaw from the right incisors to the left angle, for extensive epithelioma of the jaw and floor of the mouth, the patient making a good recovery and being in perfect health two years later, but dying with recurrence of the disease eventually (*Lancet*, November 20th, 1880).

In the cases of recurrent epithelioma of the lip, when the disease shows itself in the submental glands, which become adherent to and implicate the bone, it is possible to give relief, for a time at least, by sawing out the portion of bone involved, as I did in an old man in May, 1876. In two instances I have sawn off the chin only, without breaking the line of the alveolus or opening the cavity of the mouth. Fig. 40



shows the first patient on whom I performed the operation.

Fig. 41 shows an epitheliomatous growth secondary to that of the lip, which has attained the large size of the tumour in the present case. It is unusual to find so extensive an involvement of the bone, as in this instance, with such slight glandular affection, the secondary growths generally appearing in the glands under the jaw, and involving the bone later and to a much less extent.

During the last few years a new disease affecting the jaws, as well as other parts of the body, has been recognised under



Fig. 40.

the name of Actinomycosis, and the College Museum is fortunate in possessing two specimens occurring in the lower jaw and one in the upper jaw of the heifer, which I now bring before you.

2254 B is the lower jaw of a heifer affected with actinomycosis. All that portion of the jaw containing the grinding-teeth is greatly enlarged by a growth projecting prominently from its lower border and both its surfaces. A vertical section has been made through the jaw immediately



on the inside of the the teeth, and another vertical section through the growth projecting from its outer surface. The sections show that the growth is composed of a soft, pale, medulla-like substance, punctated or dotted with numerous minute cavities. It infiltrates widely, and in some places has completely penetrated the jaw. On pressure, worm-like masses of pultaceous material could be expressed from the puncta or small cavities above noted. This material, under the microscope, was found to contain large numbers of acti-



Fig. 41.

nomycetes. The mucous membrane of the gum on the outside of the teeth is thickened, and passing down through it into the substance of the bone are two sinuses, into which portions of glass rod are inserted.

The animal was 18 months old. An enlargement of the right side of the lower jaw was noticed nine months before it was killed. No disease of any other part was found.

2254 C is the right upper jaw of a heifer affected with



actinomycosis. The external surface is bulged outwards, and the antrum is filled with the growth.

2254 D is the left lower jaw of the same animal, showing a rounded expansion of the bone, due to an actinomycotic growth.

The disease began in the upper jaw eight months before the animal was killed. An enlargement of the lower jaw had only been noticed a few weeks.

These valuable specimens were presented to the College Museum by Alfred Lingard, Esq., in 1886.

These tumours have to the naked eye the appearance of ordinary sarcomatous growths, but under the microscope

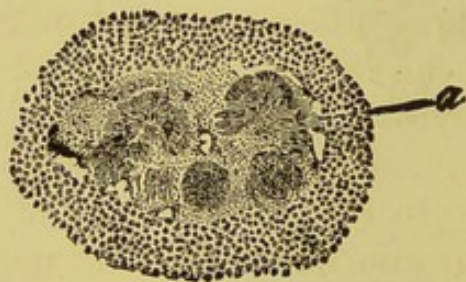


Fig. 42.

A group  $\times$  A Zeiss (3-5ths inch) shows probably the earliest stage of growth: each separate collection of fungus consisting of fine filaments radiating from a common centre.

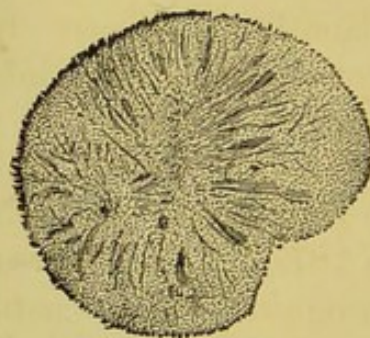


Fig. 43.

The portion of fungus marked a Fig. 42  $\times$  D Zeiss (1-7th inch near- Under this power some of the filaments are apparently thicker than the majority and are club-shaped.

show at various points masses of the vegetable fungus characteristic of the disease.

For the above figures I am indebted to a paper by Dr. Markham Skerritt, of Clifton, which was published in the *International Journal of Medical Sciences*, January, 1887.

The disease has invaded both the upper and lower jaws in man, but no case of that particular form of the disease has, so far as I am aware, been met with in this country, and my information on the subject is, therefore, second-hand.

In 1877 Bollinger first described as a new fungoid disease a peculiar affection of the jaws of cattle, which up to that time had been looked upon by some as scrofulous disease, by others as osteo-sarcoma. According to his description the



affection consists in the development of a whitish tumour, which starts from the posterior part of the alveolus, or from the spongy part of the bone, distends the bone and bursts through it, generally outwards, destroying all the tissues in its course. The substance of the irregular nodulated tumour is for the most part soft and juicy, and shows on section a large number of yellow, abscess-like points. Microscopically the tumour consists of granulation-tissue with minute abscesses here and there, in which lie peculiar yellowish bodies about the size of a hemp-seed. These bodies are also found in similar tumours in the tongue, pharynx, larynx, and mucous membrane of the stomach, and in the neighbouring lymphatic glands. When examined more minutely they present a gland-like, mulberry appearance, consisting of closely-interwoven threads and club-shaped bodies. Harz suggested that the growth should be called actinomyces (ray fungus) and hence the disease is termed Actinomycosis.

In man the organism was observed and described by Israel in 1877, but it appears that Ponfick, in 1879, was the first to recognise the true nature of the disease, and to establish its identity with the condition previously described by Bollinger as met with in cattle.

The most recent contribution to the literature of actinomycosis in jaws is by Dr. P. Moosbrugger, who has published in Brun's *Beiträge zur klinischen Chirurgie* a report on the disease as observed in the Tübingen *clinique*. He believes that in both animals and man infection takes place by inoculation of the organism on a broken surface. With most authors he holds that in animals the point of inoculation is either in the mouth, fauces, or pharynx, through abrasions due to hard food. Animals may also be infected through abrasions of the skin of the neck, produced by rubbing the part against the manger or crib. Barley seems to be suspected by several observers to be the food which contains the organism.

Moosbrugger regards it as improbable that the human subject is inoculated either directly from the beast or indirectly through using its flesh for food. He thinks it not



improbable that man, like the animal, is infected through the use of grain as food, or through inhalation of the spores of the organism; perhaps, also, occasionally by chewing straws or grain infested with the latter.

Inoculation may take place through carious teeth or damaged alveoli, and thus reach the periosteum or soft parts of the jaw. It may also occur on altered mucous membrane, on a wounded cutaneous surface, or a spot breaking down from disease.

The first effect of the presence of the organism in human tissues is the formation of abundant granulation-tissue, so soft in many cases as actually to fluctuate, but without any production of true pus. If pus is eventually present, it is due to the admixture of ordinary micrococci with the special actinomyces.

Of the 75 cases recorded, 29 were inoculated in the neighbourhood of the lower jaw, floor of the mouth and throat, 9 in the upper jaw and cheek, 2 in the œsophagus, 1 in the tongue, 11 in the intestine, 14 in the air-passages and lung, 7 unknown; 55 were males, 21 females.

Actinomycosis of the upper jaw appears to offer a worse prognosis than that of the lower jaw. In the majority of cases the individuals affected belonged to callings which did not bring them into direct contact with diseased cattle.

The cases observed in the *Tübingen clinique* were 10 in number; to these is added 1 from Königsberg. Of these 11 the disease started in the lower jaw in 6; in the upper jaw in 1; in the cheek over the upper jaw in 2; in the lungs in 2. In 4 of the 6 cases in which the disease began in the lower jaw the onset was accompanied by severe toothache; the same was the case with 2 out of 3 of the upper-jaw cases. It started just as frequently around sound as carious teeth.

The first visible evidence of actinomycosis is always a hard, smooth, or elastic (often painless) tumour, apparently seated under the periosteum. This swelling spreads to the soft parts around, sooner or later, either by direct extension or through lymphatic channels, and forms nodular masses with white shreddy or granular foci. On incision into the swell-



ing, serum containing little white granules escaped, but no pus in simple cases. In one simple case with sinuses the temperature was normal. In another, where sinuses had formed, there was high fever.

All the jaw cases recovered after operation except one upper jaw), the two lung cases died.

The operative measures embraced incision and thorough scraping with sharp spoons.

When starting in the jaws the inoculation always appeared to take place around a molar tooth.

The characteristic actinomyces was demonstrated microscopically in every one of Moosbrugger's cases.

---

### LECTURE III.—DISEASES OF THE TEMPORO-MAXILLARY ARTICULATION AND CLOSURE OF THE JAWS.

The temporo-maxillary articulation is, like other joints, the subject of inflammation due to constitutional and local causes, to which latter its exposed position would seem to render it particularly liable. Yet it is remarkable that acute disease of the temporo-maxillary joint is hardly recorded, and I think the explanation is to be found in the fact that it is often confounded with acute affections of the ear, and that mischief beginning in the articulation may induce purulent discharge from the meatus in children. No doubt in cases of suppuration of the middle ear the temporo-maxillary articulation may become involved through the floor of the meatus, in which a hiatus often exists in children; but, on the other hand, I have seen cases in which, from disease of the temporo-maxillary joint, perforation had ensued, and the condyle had found its way into the meatus. That destructive disease of this articulation is not very infrequent, is evident from the number of museum specimens extant of complete ankylosis, and of the numerous cases of fibrous ankylosis which have been met with in practice.



In his *Practical Observations in Surgery* (1816), Mr. John Howship describes a case of "scrofulous inflammation of the face followed by ankylosis of the jaw" in a man, aged 56, who dated the origin of the disease from a cold taken at the age of 4. The original illustration shows complete bony ankylosis of the lower jaw to the temporal bone on the left side. On the right side the shape of the joint is considerably modified, as may be seen in the specimen in the College of Surgeons' Museum (1949).

In the Museum of University College is another specimen (849), showing an earlier stage of the same condition. The

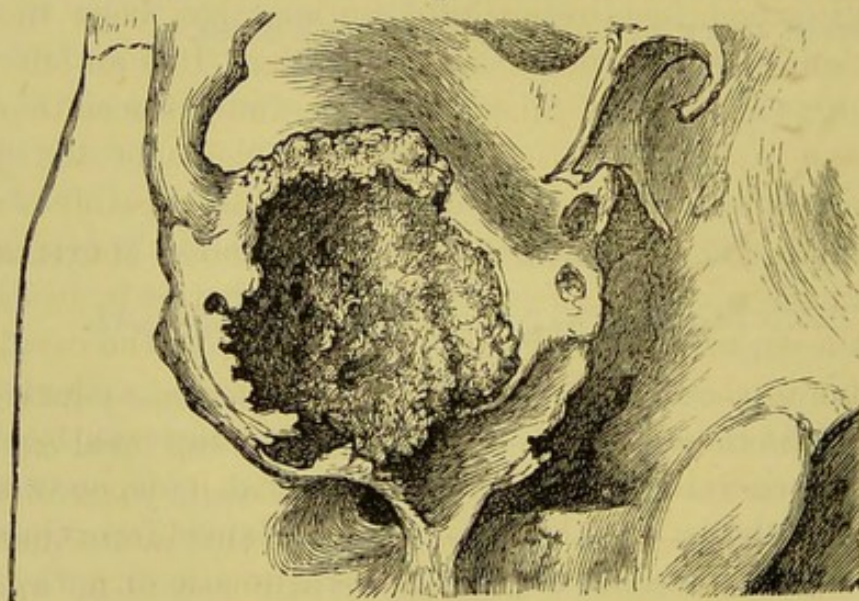


Fig. 44.

condyle is immovably united to the corresponding part of the temporal bone, the contiguous surfaces being very irregular but mutually adapted, and separated in part by a thin line of shrunken fibrous tissue. Considerable portions of each of the surfaces have been destroyed, the condyloid part of the jaw is much enlarged in the antero-posterior direction, so as to lie in contact both with the glenoid fossa and the articular eminence in front of it. Also in St. Bartholomew's Hospital Museum is a specimen (I. 664), of which I have been allowed to take a drawing (Fig. 44), showing the results of disease of the right articulation for the lower jaw, a quantity of rough new bone having been formed, from which the condyle appears to have forcibly broken away.



Cases of fibrous ankylosis of the temporo-maxillary articulation, recognised and treated as such during life, have been recorded by several surgeons, but I would especially refer to two published by Mr. Spanton, of Hanley (*Lancet*, April 16th, 1881), because that gentleman proved the correctness of his diagnosis by dividing the fibrous bands with a tenotome passed into the articulation, and then succeeded in screwing open the mouth. The patients were girls, aged 10 and 9 respectively, and in both cases the disease of the temporo-maxillary joint had followed scarlet fever.

The only disease of the temporo-maxillary joint hitherto generally recognised by surgical authors, has been the so-called "sub-luxation" of Sir Astley Cooper. It is an affection occurring principally in delicate women, and has been thought to depend upon relaxation of the ligaments of the joint permitting a too free movement of the bone, possibly a slipping of the inter-articular cartilage. From a considerable acquaintance with this affection, I believe that it is, in many cases at least, unconnected with any slipping of the cartilage, but is due to rheumatic or gouty changes in the articulation. The fact that these patients suffer most in damp weather and when the general health is feeble shows that it depends upon arthritic diathesis, and the relief that is obtained from counter-irritation and the exhibition of anti-rheumatic or anti-gouty remedies, proves that the complaint cannot be always due to purely mechanical causes. Professor Annandale, of Edinburgh, however, believes that, as in the case of the semilunar cartilages of the knee, the inter-articular cartilage of the temporo-maxillary joint may become displaced either by a sudden tearing of its connections or by a gradual stretching of them. In order to remedy the displacement, Mr. Annandale has devised and practised the following operation. An incision, slightly curved, about three-quarters of an inch in length, is made over the posterior margin of the external lateral ligament of the temporo-maxillary joint, and is carried down to its capsule. Any small bleeding vessels having been secured the capsule is divided, and the inter-articular cartilage is seized, drawn into position, and secured to the periosteum and



other tissues at the outer margin of the articulation by a catgut suture.

The researches of the late Dr. Robert Adams and Dr. R. W. Smith, of Dublin, have shown that rheumatoid arthritis occasionally affects the temporo-maxillary articulation, and the former author has in his *Atlas*, figured the remarkable hypertrophy of the neck of the condyle of the jaw, occurring in the case of a woman aged 30, to which I shall have occasion to refer more particularly later on.

Cruveilhier, who first described an example of rheumatoid arthritis of the temporo-maxillary articulation (*Anatomie Pathologique*, vol. ix), says: "I have never seen the disease I call wearing away of the articular cartilages better marked than it was in this case. The condyle of the lower jaw did not exist; it might be supposed to have been sawn off horizontally at the line of junction of the head with the neck, and that which remained of the neck had been flattened. The articular part

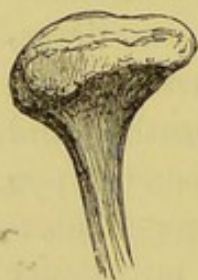

Fig. 45.

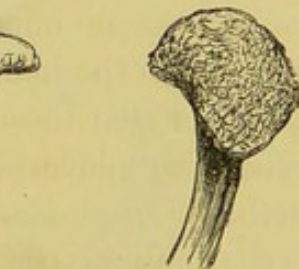
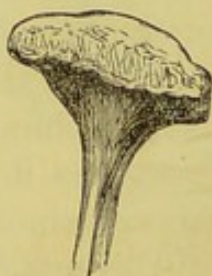

Fig. 46.

of the glenoid cavity was represented merely by a plane surface; no trace of inter-articular cartilage or cartilage of incrustation existed. Both surfaces of the altered articulation were remarkably red."

I have never had the opportunity of examining a recent example of this disease, but as far as can be judged from museum specimens, the articular surface of the condyles is flattened and somewhat altered in direction in the less marked instances (Fig. 45), and absorption of the neck, with complete wearing away of the articular surfaces (Fig. 46), occurs in the older and more advanced cases. I agree with Dr. Adams, that eburnation of the articular surfaces, or the occurrence of porcellaneous deposit in the temporo-maxillary articulation, is



very rare. The description quoted from the St. Bartholomew's Catalogue by Dr. Adams, refers to preparation No. 551

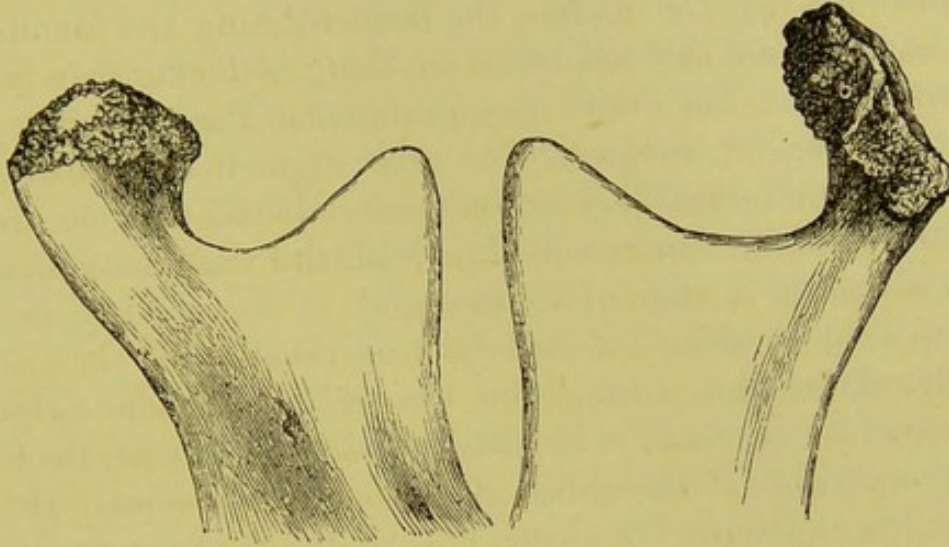


Fig. 47.

in that museum (Fig. 47) and is as follows :

“There has been disease in one of the articulations of the jaw, producing absorption of the the articular cartilage, with a deposit of bone around the circumference of the glenoid cavity. The corresponding condyle is in part removed by absorption; its surface is rough, except at one point, where it is highly polished and has an ivory-like texture.”

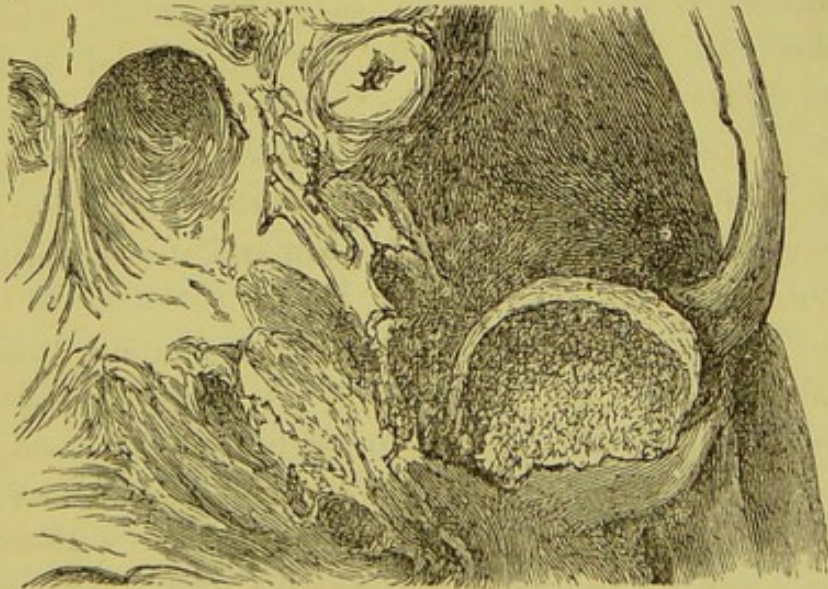


Fig. 48.

Enlargement of the glenoid cavity is common in these cases, and is well seen in Fig. 48, taken from the same specimen



in St. Bartholomew's Hospital. Absorption of bone must of course occur in these cases, but it is worthy of remark that, as pointed out by Dr. Adams, the bone forming the fundus of the cavity is not thinned, but, if anything, is thicker than in the normal state. The entire disappearance of the inter-articular fibro-cartilage is, apparently, an early event in chronic disease of the temporo-maxillary articulation. It had entirely disappeared in all the few recorded *post-mortem* examinations, and was absent in a case of hypertrophy of the condyle in the living subject which I successfully operated upon.

Mr. Arbuthnot Lane, who has published some original views on the mechanical causation and pathology of rheumatoid arthritis (*Pathological Society's Transactions*, 1886), describes as follows the changes which ensue in the temporo-maxillary articulation in feeble old age after the teeth have fallen out: "These changes are frequently very marked. The fibro-cartilage is very often completely removed, the only relic of it to be found being a fimbriated margin attached to the inner aspect of the loose capsule. In other cases the cartilage is rendered thin throughout its extent, and in others, again, it is perforated internally and posteriorly. The appearance presented by the articular surface of the head of the jaw, varies considerably. In some cases the head, while not diminished in breadth, loses its convexity, and is instead flattened on its upper surface, the flat facet being quadrilateral in form. It may present a partial covering of cartilage, but in very many cases the bone presents instead a porous granular aspect. In such cases the eminentia is usually quite removed, the original elevation being replaced by a flat surface, which is continuous with that forming the back part of the glenoid cavity. This surface is usually completely deprived of its articular cartilage. Sometimes the head of the jaw is much constricted transversely, and presents a slight rounded convexity, which articulates with the inner part only of the glenoid cavity, having cut for itself a longitudinal channel through the inner portion of the eminentia articularis, the outer portion of this convex surface of bone presenting but slight changes." These alterations in shape of the condyle



of the jaws are well seen in the specimens before you, for which I was indebted to the late Mr. Edwin Canton, and which I propose to place in the College Museum. Fig 45 & 46.

These changes, in Mr. Lane's opinion, are due to the loss of teeth, and to the consequent modification in the normal movements of the temporo-maxillary articulation, and the general atrophy of the muscles of mastication, especially of those that serve to approximate the jaws, namely, the masseter and internal pterygoid. It is owing to the action of these two muscles that the form of the angle of the jaw varies at different periods of life. As these muscles are used with great vigour during young adult life, the surfaces of bone into which they are inserted become strong and dense, and marked by vertical ridges indicating the attachment of the tendinous insertions of the muscles, especially of the masseter, and it is owing to the action of the latter muscle that the margin of the ramus is everted. As these muscles atrophy and become almost, if not completely, functionless, the portions of the bone into which they are inserted lose their prominent ridges, and their everted margin, and become rounded and wasted in a similar manner to that in which that portion of the great tuberosity of the humerus which receives the insertion of the supraspinatus atrophies in feeble old age. It is this atrophy of the angle which causes the appearance of the jaw peculiar to edentulous old age. The atrophy of the fibro-cartilage is due partly to an atrophy common to it and the muscle inserted into it, and partly to the loss of the movements of flexion of the temporo-maxillary articulation, and to their replacement by a simple antero-posterior movement of the opposing surfaces of bone upon one another. After the fibro-cartilage is removed, the articular cartilage is also destroyed, the surfaces of bone being brought into direct contact. By their mutual friction they destroy one another, and the amount of destruction will depend on the amount and character of the movement to which the bones are exposed, and the vitality of the osseous and nervous systems.

When this normal senile degeneration in the temporo-maxillary articulation is well marked, and occurs in an ataxic



patient, the condition is described as Charcot's disease. This joint, more than any other in the old subject, undergoes great modification in its form and character.

*Hypertrophy of the Neck and Condyle* was observed by Dr. Adams in the case of rheumatoid arthritis of the temporomaxillary joint already referred to, and is beautifully shown in Plate 2 of his admirable *Atlas*. Though occurring in a woman of only 30, there can, I think, be no doubt, from the description and drawings of her hands and feet, that the patient was the subject of rheumatoid arthritis. It is by no means certain, however, that the hypertrophy of the neck and condyle must be considered to be the results of that disease, for, as I shall show, this same rare deformity has been found in patients otherwise healthy.

Dr. Adams's patient, M.K., aged 30, was admitted into the Richmond Hospital in the year 1835. She was altogether disabled from earning a livelihood, in consequence of her having been afflicted with chronic rheumatic disease in most of her joints. Her face was quite awry, her chin slightly advanced, and its central point passed one inch across the middle line towards the left side. The fingers of both her hands from the metacarpal joints were in the same manner adduced towards the ulnar side and strongly flexed, and the first phalanx of the little finger of the right hand was dislocated towards the palmar surface of the last metacarpal bone. She complained of pains in all her joints, but principally in her wrists, hands, and feet; but it was remarked that the toes of both her feet were distorted, and some of them elevated above the level of the rest. When interrogated particularly as to her lower jaw, she said she had a constant aching in it and in the right side of the face. She also made the usual complaint of the changes in the weather causing an aggravation of her sufferings. She seemed uniformly querulous, and had a sad expression of countenance, indicative of suffering. Speaking and eating caused her to feel some pain in her ear and in the articulation of her jaw. To open her mouth completely she felt was impossible; and she stated that whenever she moved the lower jaw she was conscious of



hearing some peculiar noise in her right ear, corresponding with each motion of the joint. The previous history of her case collected from her was that she had always resided in a damp cabin in the county of Wicklow with her parents, who were very poor; that she never had anything the matter with either her jaw or her hands, nor did she remember that she ever had been ill until about five years before period of her admission into hospital, when she had been attacked with rheumatic fever, which lasted some weeks, but from the effects of which she never recovered. In short, from her own account it would appear that the acute attack passed at once into the chronic disease now described. Her sufferings becoming daily more extended and severe, she at length came to Dublin for advice, and was for some months in hospital under treatment, which, however, as might have been anticipated in such a case of confirmed disease, was of but little use; and, being destitute and unable to support herself, she was transferred to the neighbouring North Union Workhouse. When she had been for about three years an inmate of this institution (during which her disease underwent no improvement), she became suddenly affected, on July 28th, 1840, with acute oedema of the larynx, which at that time seemed to prevail epidemically. This attack, after a few hours' illness, proved fatal to her.

*Post-Mortem Examination.*—Having, through the kindness of Dr. Gordon, first procured a cast of her face, the articulation of the lower jaw was then exposed by dissection. When the thickened capsular ligament was cut into, the condyle of the lower jaw was found divested of all cartilaginous covering; it presented a rough, scabrous-looking surface. The neck of the condyle was more than an inch long, and was double the size of the neck of the opposite condyle. From its inner side a large bony spiculum, about one quarter of an inch long, grew upwards and inwards immediately in front of the internal lateral ligament. The inter-articular fibro-cartilage was altogether removed, as well as all cartilaginous covering from the articular portion of the glenoid cavity, which was smooth, and expanded to nearly twice its normal size, at the



expense of the maxillary eminence and root of the zygoma. The right ramus of the lower jaw, from its angle to the head of the bone inclusive, was not only an inch longer than natural, but was also much thicker than the ramus of the left side, and was also bowed outwards—circumstances which accounted for the swollen appearance of the right side of the face and the projection of the chin to the left. (R. Adams, M.D., *On Rheumatic Gout*, p. 268.)

Fig. 49 shows a lower jaw so like that figured in Adams's *Atlas* in every respect, that the preparations are evidently

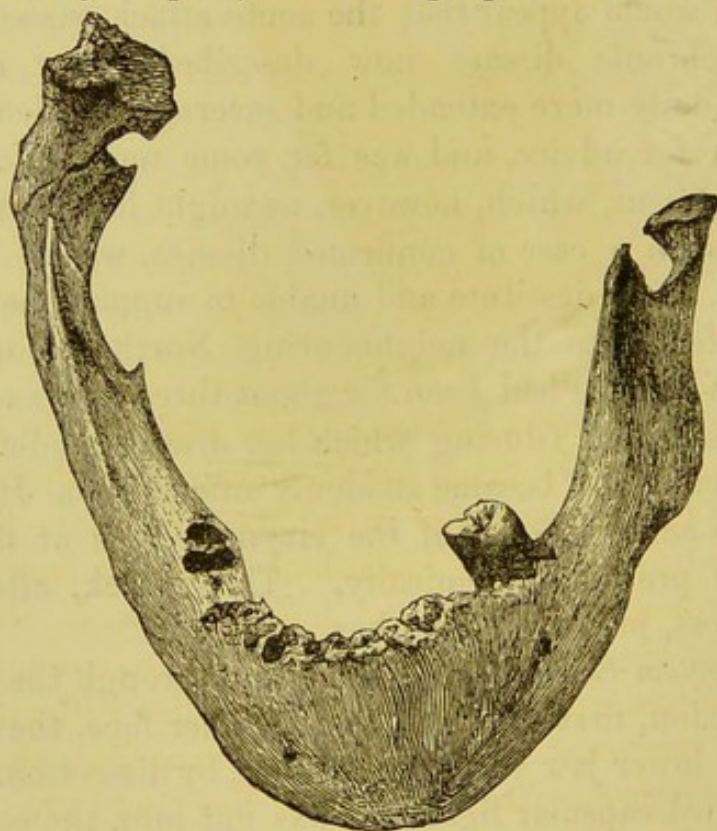


Fig. 49.

identical in their nature. It was presented to the College of Surgeons' Museum (2205) by Mr. Jeremiah McCarthy, and is thus described by Mr. Eve :

“A lower jaw with a mass of bone, having somewhat the form of an inverted pyramid, attached to the thickened neck of the right condyloid process. The upper surface of the mass, corresponding to the base of the pyramid, is flat and smooth, as if it had been covered with fibro-cartilage (Fig. 50). Upon its inner side is a deep indentation, from which a fissure



extends outwards and downwards nearly to the external surface of the bone. The indentation and the fissure constitute

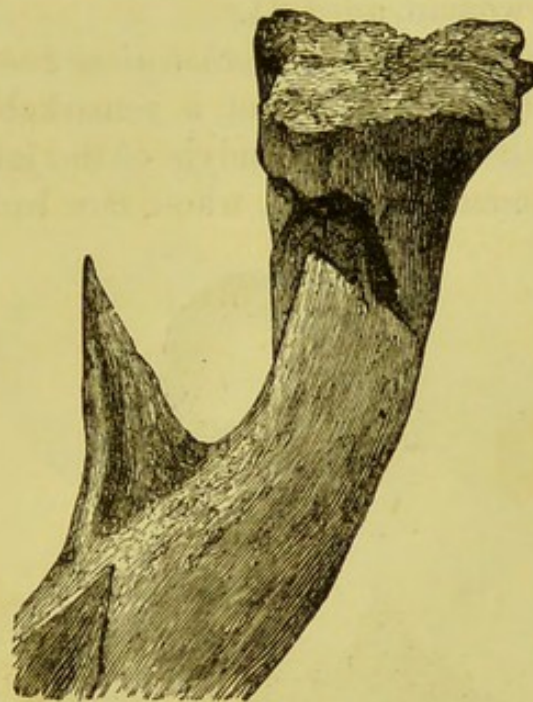


Fig. 50.

the upper boundary of a portion of bone which, from its form and position, might be taken for an enlarged condyle. The right half of the jaw is larger in all its dimensions than the left half, the breadth of the horizontal ramus in front of the angle being double that on the left side, which, from the slenderness of the coronoid and condyloid processes, appears atrophied. From a middle-aged man, who died with apoplexy. There was a remarkable deformity of the face from the deviation of the symphysis from the middle line; and the projection of the enlarged condyle was considerable. The base of the skull was not examined, and nothing was found in the *post-mortem* examination except atheroma of the vessels. Nothing unusual had been noticed about his mouth in childhood, nor could any account of an injury be obtained."

A remarkable example of hypertrophy of the condyle of the jaw was placed in the Museum of the Westminster Hospital by Mr. Pearce Gould, and is described in the *Pathological Society's Transactions*, vol. xxxiii. I am enabled to exhibit both the preparation and drawing, from which it



will be seen that the whole bone is remarkably asymmetrical, the left side being much larger than the right. It was removed from a woman, aged 24.

In the 34th volume of the *Pathological Society's Transactions* will be found the record of a remarkable specimen of hypertrophy of the neck and condyle of the jaw, removed by myself from a woman, aged 36, whose face had for ten years



Fig 51.

become gradually more deformed, by the increasing displacement of the chin to the right side and the projection outwards of the left condyloid process. The movements of the jaw were restricted, and the length of the left ascending ramus was three inches, that of the right one inch and a-half. She had an attack of hemiplegia, implicating the left side of the face, when she was 25 years of age, and from this affection her limbs had covered perfectly and her face partially.

The appearance of the patient (who was sent to me by Dr. Williams, of Sherborne) is seen in Fig. 51, and the piece of bone removed is accurately shown in the drawing (Fig. 52), the hypertrophied condyle measuring one inch and three-



quarters from before backwards, and one inch across, and being covered with fibro-cartilage. A section of the preparation shows it to be composed of cancellous bone with large rounded spaces, and its walls are formed of a thin layer of compact bone. The fissure observed in Mr. McCarthy's case does not exist in this specimen. If the condyle thus shown is compared with Fig. 50, which represents the condyle of

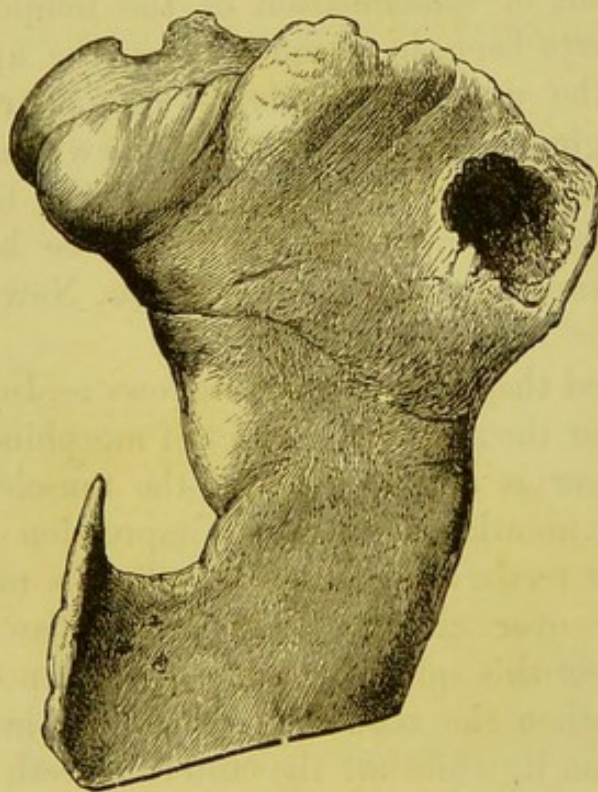


Fig 52.

Mr. McCarthy's case, of the natural size, there can be little doubt that my preparation, Mr. McCarthy's and Dr. Adams's all belong to the same category ; and yet in Mr. McCarthy's probably, and certainly in my own case, this was the only joint affected. It must be concluded, then, I think, that hypertrophy of the neck and condyle may occur in otherwise healthy patients, and I believe that I saw, in consultation with Mr. Nathaniel Stevenson, the early stage of this curious condition in a young healthy lady, aged about 20, in whom the lower teeth had gradually become displaced from no known cause, so as to disarrange the normal bite. I here detected, what was then new to me, some hypertrophy of the



neck of the jaw on one side, and recommended blistering and a course of iodide of potassium without any marked benefit, except that the deformity has not increased. In the patient whose portrait is given in Fig. 51, the deformity was so great as to warrant surgical interference, and the result has been very satisfactory, the face being brought straight and the patient having free movement of the jaw.

The treatment of inflammation of the temporo-maxillary joint has hitherto been, in chronic cases, the application of blisters and the use of a bandage—particularly an elastic bandage at night. Dr. Goodwillie, of New York, has, however, contrived an ingenious method of fixing the lower jaw effectually in cases of arthritis, which will be best described in his own words (*Archives of Medicine*, New York, June, 1881):

“The method that I employ is as follows:—In this case the patient is under the anæsthetic effect of morphine and nitrous oxide. If there is any rigidity of the muscles, cautiously force open the mouth and take an impression of either the upper or lower teeth, and a rubber splint is made from the cast to cover over all the teeth in one jaw. Upon the posterior part of this splint is made a prominence or fulcrum (*D*), so that when the mouth is closed the most posterior teeth close upon it, while all the anterior teeth are left free. The next step is to take a plaster-of-Paris impression of the chin, and from this make a splint (*A*). On each end of the splint is made a place for fastening elastic straps (*B*) that pass up on each side of the head to a close-fitting skull-cap (*C*). (See Fig. 53.)

“When the apparatus is in place and the elastic straps tightened so as to lift the chin, then pressure is brought to bear on the fulcrum at the posterior molar tooth, and so by this means extension is made at the joints, and the inflamed surfaces within the joints are relieved from pressure; then immediate relief is experienced.”

I have no experience of this method, but it appears to be based upon sound surgical principles, and the cases illus-



trative of its use given by Dr. Goodwillie attest its usefulness.

In the cases of fibrous ankylosis resulting from the cure of arthritis, it is open to the surgeon to have recourse to mechanical means to break down the adhesions; and to illustrate the difficulties to be overcome, I may refer to another case of Dr. Goodwillie's (*New York Medical Journal*, July, 1875):—The patient was a girl, aged 10, who, five years before, had fallen over the bannisters, breaking and dislocat-



Fig. 53.

ing the jaw, with the result of the jaws being firmly closed. The apparatus employed is seen in Fig. 54.

One of the chief sources of interruption in treatment is periodontitis from the great amount of force used on the teeth. To prevent this, Dr. Goodwillie protects them with an interdental splint of hard rubber. These splints at first are necessarily very small, and confined to the front teeth; but, as the case progresses, longer and more perfect ones are made. In this case the rubber splints were enclosed in metal splints made of German silver, as this metal is tough and unyielding. These splints were made fast to the teeth by straps that passed from strong wire arms at the sides to a



skull-cap, and the lower one was strapped to a pad on the chin. This pad was also attached to the lower splint by means of a ratchet and spring.

From the point of each splint an arm, three-fourths of an

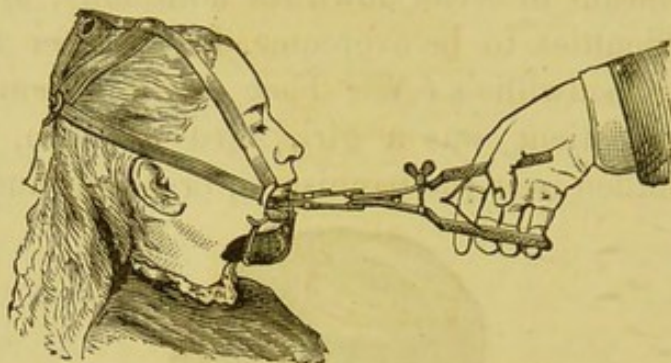

Fig. 54.

inch broad, extends out one inch and a quarter, and to these is clasped the oral speculum when in use (Fig. 55). The inclined planes of the speculum pass in between these arms, and they are held by clasps. The inclined planes are attached by moveable joints to a distending forceps, so that when the handles are approximated, the inclined planes are separated at their attached ends. Each handle is made in two sections, and the spring that separates the handle is enclosed between them to protect them from injury.

In forcing the speculum between the splints, the instrument is grasped by one of the handles, and when in place both handles are approximated. If more force is desired, or the mouth is to be held open at any point, the screw at the handle may be used.

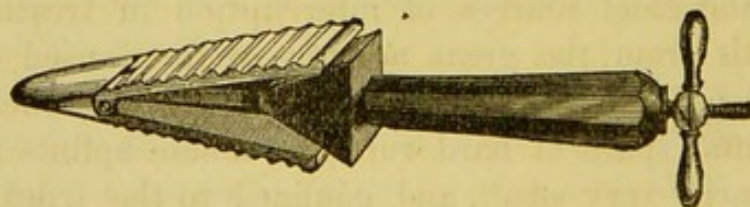


Fig. 55.

In stretching the masseter and temporal muscles, Dr. Goodwillie uses an oral speculum, devised by him some years ago (Fig. 55). It consists of a shaft, to the flat end of which are attached two wings or inclined planes, upon which the



teeth rest. The other end of the shaft has a thread cut on it, and a screw, this passes through an handle, one end of which is wedge-shaped. By turning the screw on the other end of the handle, the inclined planes diverge or converge.

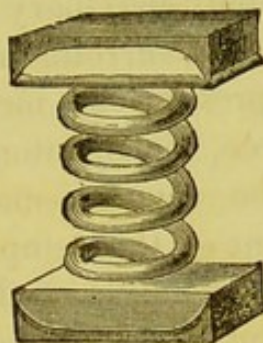


Fig. 56.

Fig. 56 represents a spiral-spring speculum for the patients to employ by placing it between the teeth and biting upon it. Longer springs are used as the mouth gradually opens.

It need hardly be said that treatment by this method would extend over many months, and would severely try the endurance of both patient and surgeon. A simpler method is the division of adhesions formed between the condyle and glenoid cavity, as practised by Mr. Spanton in the cases already referred to, in both of which, as I learn from that gentleman, a good result ensued.

The first was a girl, aged 10, Ada M. R., who was admitted into the North Staffordshire Infirmary in April, 1880. About six years before she had scarlet fever, which resulted in hip-joint disease, and in a subsequent closure of the mouth, which had never been relieved. On admission she was very thin and ill-nourished, owing to her inability to masticate food. The mouth was firmly closed, and under chloroform it was found impossible to open it, although one tooth was broken in the attempt. There were no marks of cicatrices either in the mouth or externally; the digastric muscles were fully developed, and there was no unusual rigidity of the masseter or temporal muscles, nor was there any glandular swelling or other apparent cause for the condition of the mouth. The right hip was dislocated from disease of the joint, coincident apparently with the temporo-maxillary affection, but in a



perfectly quiet state. She was able to take only liquid food, or such as she could squeeze with her fingers between the teeth.

Believing that the immobility was dependent on an ankylosed state of the temporo-maxillary joints, with probable contraction of the ligaments surrounding them, and failing to make the slightest impression by means of a gag with any justifiable amount of force, Mr. Spanton passed a very narrow tenotomy knife into the temporo-maxillary joint on each side, immediately in front of the temporal artery, and then passed it freely round the condyle of the inferior maxilla as far as he deemed prudent, dividing completely the external lateral ligament of the joint, and partially the insertion of the external pterygoid muscle, keeping the back of the knife towards the temporal, and carefully measuring the depth of the incision so as to avoid the middle meningeal artery. Very little hæmorrhage occurred; and as soon as this procedure was effected, Mr. Spanton found that the joints yielded at once to the gag, and that the mouth could be opened to the extent of more than an inch. For a day or two some soreness was complained of, but the gag was used almost daily, and seven weeks afterwards the patient left the Infirmary able to open the mouth fairly well and to masticate her food. As the result of this her general health greatly improved. She continued well, and she was able to go to school, but the use of the gag was from time to time neglected, and by degrees the stiffness began to return. At the end of November she came under Mr. Spanton's care again, very much improved in health, but with the mouth closed so far as only to admit of the tip of one's finger. He accordingly repeated the operation, taking care to divide the structures, especially anteriorly, more freely than on the former occasion; and the result has been much more marked than it was before. She can now open the mouth to some extent without assistance, and with the use of force it can be opened wide without causing pain. There is, however, very slight lateral movement.

The second case is that of a girl, aged 9, Sarah Ann B., who was brought to Mr. Spanton in November, 1879, for a



closed mouth. She was a delicate-looking child had been deaf from early childhood, and about two years and a half before had scarlet fever, after which the gradual closure of the jaws took place. This was naturally accompanied by a corresponding decline in her health and strength, for which her friends sought relief. The mouth was quite firmly closed, and with no legitimate amount of force could it be moved. Under chloroform Mr. Spanton operated as in the former case, and by means of a screw-gag opened the mouth freely. No untoward symptoms beyond some swelling and tenderness about the temporo-maxillary joints occurred, and by the frequent use of the gag by the patient's friends at home, she can now open her mouth sufficiently to take any kind of food, and is recovering very fair lateral movement also. She can open it to the extent of more than half an inch without assistance, and is able to masticate her food thoroughly. This has led, as it was hoped it would, to a corresponding improvement in her general health.

In cases of fibrous ankylosis there is the possibility of removing the condyle, as has been done by Mr. Davies-Colley, and probably by others; or, as proposed by Dr. Ewing Mears (*American Journal of Medical Science*, October, 1883), of dividing the ramus of the jaw, and excising through the mouth, the condyle with the coronoid process and sigmoid notch.

The method of operation is as follows; a straight sharp-pointed bistoury is introduced beneath the masseter muscle on a level with the last molar tooth of the lower jaw. Into the wound thus made the blade of a Adams' saw is passed, and the ramus sawn through. The periosteum, with the overlying masseter muscle, is raised by the periosteal elevator, and the wound thus enlarged. The insertion of the temporal muscle is now divided by a probe-pointed bistoury. The tissues on the inner surface are separated by the elevator, the bone seized by the lion-jawed forceps, and an effort made to dislodge it by forcibly twisting it outwards. If it yields at the neck of the condyle, the process is afterwards chiselled out. If sufficient space is acquired without removal of the firmly ankylosed process, it is permitted to remain, the object



being to provide ample space for the formation of an artificial joint. Section of the masseter muscle is made, if its tense condition demands it. Hæmorrhage, which arises from the division of muscular arterial branches and possibly of the inferior dental artery, is controlled by pressure effected by packing the wound cavity with sponges. Wounding of the internal maxillary artery is to be avoided by careful use of the instrument in close contact with the bone in the upper and inner portions.

A case of the removal of both condyles for fibrous ankylosis is quoted by the *Wiener Med. Wochenschrift*, of July 6th, 1872, from the proceedings of the Royal Academy of Medicine in Bologna. It occurred in the practice of Dr. Bottini. The patient was a lad, aged 17, who, at the age of seven, had fallen on the jaw, and had gradually lost the power of opening his mouth, so that at last, for some months, he was unable to separate the jaws to any extent. Dr. Bottin introduced wedges, but these were very irksome to the patient and were removed. Resection of the articular head of the bone was then performed on one side; this had no noticeable result, but on the operation being repeated on the other side, the jaw could be moved freely. At the end of six weeks the wound had healed, and the motion of the jaw was normal. The only morbid change that could be discovered was the absence of the inter-articular fibro-cartilage.

In cases of rheumatoid arthritis in which the suffering is great, excision of the condyle seems to offer the best means of giving relief. The first removal of the condyle was by Professor Humphry, of Cambridge (*Med. Association Journal*, 1856), and was undertaken for chronic rheumatic arthritis. He exposed the condyle by a curved incision from the side of the orbit across the zygoma to the ear, passing a little above the temporo-maxillary articulation, and a second incision from the termination of the first directly upwards in front of the ear across the zygoma again, avoiding the temporal artery. The flap thus made was reflected, and the neck of the condyle cut through with a narrow saw.

In cases of complete fixation, resection of the condyle



appears to offer one of the best and safest methods of treatment. In 1874 Dr. Gross, of Philadelphia, resected the condyle with a portion of the neck of the jaw in a girl aged seven, but does not mention the method he pursued. Mr. Croft has lent me the photographs of a child in whom he resected the condyle on both sides consecutively, with very good results; and I am indebted to Mr. Davy, of the Westminster Hospital, for the loan of three condyles two of which he removed from living patients with the best results. Mr. Davy's first case was in a woman aged fifty, who had complete closure of the jaws, and from whom the left condyle was removed in October, 1878. She made a rapid recovery, with perfect mastication, but died from the bursting of an aortic aneurysm on December 8th, and the remainder of the jaw was then obtained. Mr. Davy's second case was in a man aged forty-seven, who recovered perfect use of the jaw. The third specimen is a *post-mortem* one, and illustrates the changes due to chronic rheumatic arthritis already described.

In 1883 I exposed the ankylosed joint in a boy aged seven by an incision in front of the ear, and with a chisel divided the neck of the bone, and removed half an inch of bone in the situation of the condyle, with very good results as regards movement, and with no obvious damage to the facial nerve.

A case of complete synostosis of the jaw was successfully treated by a different method by Dr. James Little, of New York, in 1873. The patient was aged nineteen, and had some years before suffered from suppuration of the temporo-maxillary articulation, leading to ankylosis. Dr. Little made an incision along the lower border of the jaw, and turned up the masseter, when the neck of the condyle was seen to be very much enlarged, and continuous with the temporal bone.

A trephine, half an inch in diameter, was then applied, and a button of bone three-eighths of an inch in thickness was removed. The portion of bone on each side of the opening was then cut through with a chisel, and the neck of the condyle cut away piece by piece, so as to leave no portion



projecting from the temporal bone. The result was quite satisfactory.

A similar operation, but performed by a different method, was successfully undertaken by Dr. Robert Abbe, of New York, in a boy aged ten, who had suffered from otitis media and suppuration of the joint some years before. A vertical incision was made in front of the ear, and a horizontal one meeting its upper end was carried along the lower border of the zygoma. The parotid, with the facial nerve, was drawn down, and with a periosteal elevator the posterior fibres of the masseter were cleared away, and the articulation exposed. A narrow osteotomy chisel was now applied to the neck of the condyle, and carefully driven half through the bone, and by forcibly opening the mouth the bone was broken through. The neck of the condyle was then removed piecemeal, but the condyle was left *in situ*. The result was satisfactory.

Sédillot mentions that in a case of true ankylosis of the temporo-maxillary articulation, M. Grube, in 1863, carried a straight chisel through the mouth to the neck of the jaw, which broke by hammering. Some months later, he divided the masseter subcutaneously, and the cure, by the formation of a false joint, was permanent. In 1879 I performed the same operation in a child aged six, but the results were unsatisfactory. Suppuration was set up, and required an external opening, and the movement, which was free at first, became as limited as before the operation, and I subsequently excised the condyle. It would appear, therefore, that mere division of the neck of the bone does not offer such good prospect of a permanent false joint as removal of the neck or the condyle, though these operations are necessarily more severe.

Esmarch's operation of removing a wedge in front of the masseter is as applicable to cases of ankylosis from disease of the joint as to cases of cicatrix, and Fischer (*Archiv. für Klin. Chirurgie*, Bd. xiii., Hft. 3) appears to have performed the operation on both sides of the jaw, in a case of bilateral ankylosis of the temporo-maxillary articulation, with very



good result, the patient obtaining complete and useful control over the central movable portion of the jaw.

I have recently performed an operation which appears to me to possess equal advantages over other proceedings undertaken for ankylosis of the temporo-maxillary articulation, and which consists in the division of the ramus of the lower jaw beneath the masseter by a saw introduced from the mouth. The patient was a young gentleman aged sixteen, who came under my care in 1886 with complete closure of the jaws due to ankylosis of the left temporo-maxillary articulation. He had scarlet fever in 1881, and the disease followed upon this. In 1882, and twice in 1883, attempts were made to screw the mouth open, with only partial and very temporary success; and when I saw him, the application of the powerful screw-gag I show produced no effect. In December last I made a small incision within the mouth immediately above the last molar tooth, and having passed a steel director to clear the way, I was able to push an Adams saw beneath the masseter and to divide the ramus horizontally. No hæmorrhage occurred from the inferior dental artery, though the accompanying nerve was subsequently found to have been damaged.

The patient was able to open his mouth as soon as he recovered from the chloroform, and made a rapid recovery. Unfortunately, he caught cold on the railway journey home and an abscess formed and pointed behind the jaw, but has left only a dimple. The patient can now open his mouth, so that there are nine-sixteenths of an inch between the incisor teeth, and his condition is a most satisfactory one.

CLOSURE OF THE JAWS may be conveniently divided into temporary or spasmodic, and permanent due to contracted cicatrices or ankylosis of the joint.

*Spasmodic Closure of the Jaws*, which may be of several weeks' duration, is almost invariably connected with the eruption of the wisdom-teeth of the lower jaw. Owing to want of room between the second molar and the ramus of the jaw, or owing to some malposition of the tooth itself, the wisdom tooth is unable to assume its normal position, and by the pressure which it exerts on the neighbouring structures, sets



up irritation, which induces a state of tonic spasm of the masseter and internal pterygoid muscles. This fact has long been known to dental surgeons, and is especially alluded to by Mr. Salter in his essay on "Surgical Diseases connected with the Teeth."

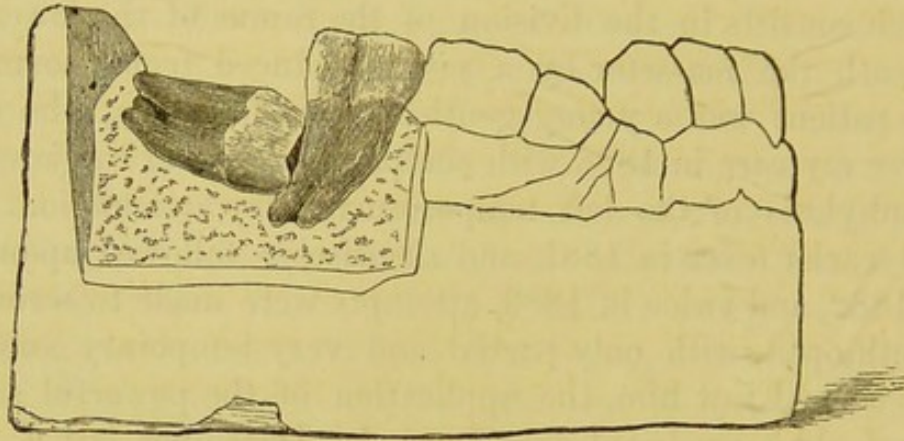


Fig. 57.

The accompanying engraving (Fig. 57), for which I am indebted to Mr. Felix Weiss, shows the condition of parts found by him in a gentleman, aged 43, who suffered long and severely from pain and spasmodic closure of the jaws, due to the irritation caused by the wisdom-tooth lying imbedded horizontally in the alveolus, and pressing against the fang of the second molar. It was only after the extraction of the second molar that the wisdom-tooth was found and removed, with complete relief of the symptoms.

The majority of these cases occur about the age of 20, when the eruption of the wisdom-tooth is to be expected, and the diagnosis is readily made. The treatment is obvious. The mouth must be opened, under chloroform, by a screw gag, or by a spiral screw wedge of boxwood, and either room must be made for the wisdom-tooth by extracting the second molar, or, if it can be reached, the wisdom-tooth itself may be removed.

The impeded eruption of wisdom-teeth gives rise to various and apparently anomalous symptoms, which are often not traced to their true source, such as persistent neuralgia, not always referred to the part involved; but the most serious result is the formation of abscesses, which burrow widely about



the angle of the jaw and cheek, leading to great scarring and permanent deformity. In a young lady, seen by me in consultation some months back, the mischief resulting from an impacted wisdom-tooth was sufficient to put her life in some jeopardy, and has left her face permanently scarred by extensive abscesses.

*Permanent Closure of the Jaws.*—Cases of permanent closure of the jaw from cicatrices within the mouth, etc., are not of very rare occurrence ; but their description and treatment seem to have been very generally neglected by modern English authors.

By far the most complete account of this affection is given by Dr. Samuel Gross, of Philadelphia, in his large work on surgery, from which I take the following quotation :

“ *Ankylosis, or Immobility of the Jaw.*—This distressing affection, which may be produced in a variety of ways, may exist in such a degree as to render the patient entirely unable to open his mouth or to masticate his food.

“ The most common cause, according to my observation, is profuse ptyalism, followed by gangrene of the cheeks, lips, and jaw, and the formation of firm, dense, unyielding, inextensible tissue, by which the lower jaw is closely and tightly pressed against the upper. Such an occurrence used to be extremely frequent in our south-western States during the prevalence of the calomel practice, as it was termed, but is now, fortunately, rapidly diminishing.

“ Children of a delicate, strumous constitution, worn out by the conjoint influence of mercury and scarlatina, measles, or typhoid fever, are its most common victims ; but I have also seen many cases of it in adults and elderly subjects. In the worst cases there is always extensive perforation of the cheeks, permitting a constant escape of the saliva, and inducing the most disgusting disfigurement.

“ Secondly, the affection may depend upon the ankylosis of the temporo-maxillary joints, in consequence of injury, as a severe sprain or concussion, or arthritic inflammation, leading to a deposition of plastic matter, and the conversion of this



substance into cellulo-fibrous, cartilaginous, or osseous tissue. I have met with quite a number of such cases, several in very young subjects.

“Thirdly, the immobility is occasioned by a kind of osseous bridge, extending from the lower to the upper jaw, or from the lower jaw to the temporal bone; such an occurrence, however, is not common, and is chiefly met with in persons who have suffered from chronic articular arthritis.

“Finally, immobility of the jaw may be caused by the pressure of a neighbouring tumour, especially if it occupies the parotid region, so as to make a direct impression upon the temporo-maxillary joint.”

I must now refer to an essay by Dr. Frederick Esmarch, Professor of Surgery in the University of Kiel, on “The Treatment of Closure of the Jaws from Cicatrices,”\* in which he investigates the pathology of the affection, and describes an operation for its relief by the formation of an artificial joint in the lower jaw—an operation which has given most satisfactory results in cases under my own treatment.

This proposal of Professor Esmarch to form a false joint in front of the cicatrix was suggested to him by a case which came under his care in 1854, in which considerable destruction of the cheek and contraction of the cicatrix had occurred, together with immobility of the lower jaw and necrosis of a portion of it. The bone having been removed, it was found that mobility was restored, and a useful amount of movement obtained. Professor Esmarch therefore suggested, at the Congress of Göttingen, in 1855, the removal of a piece of bone in cases of contracted cicatrix; but did not happen to meet with a case suitable for the operation until after it had been successfully performed by Dr. Wilms, of Berlin, in 1858, shortly after which he himself operated upon at a case at Kiel, and with the best results. The operation was subsequently performed by Dittel of Vienna, and by Wagner of Königsberg.

Shortly after this proposal of Esmarch, it would appear

---

\* Die Behandlung der narbigen Kieferklemme durch Bildung eines künstlichen Gelenkes um Unterkiefer. Kiel, 1860.



that Professor Rizzoli, of Bologna, quite independently conceived a somewhat similar idea, but modified the proceeding by merely cutting through the jaw, without removing any portion of bone. He operated in this way first in 1857, and subsequently had three other successful cases. In Rizzoli's cases no external incision appears to have been made, but the section was accomplished from the mouth with powerful forceps. This proceeding has been followed by Professor Esterle, from whose essay in the *Annali Universali di Medicina* I have extracted these particulars.

Esmarch's operation appears to me to possess a decided advantage over that of Rizzoli, in the fact that a piece of bone is removed, by which the formation of a false joint is facilitated, as we know by experience in cases of resection of the elbow, etc.; and the external incision can never be a matter of any importance, whilst it admits of the application of the saw, and so avoids risk of splintering the bone.

Mr. Mitchell Henry was, I believe, the first surgeon to put Esmarch's operation into practice in this country, he having performed it a few weeks before myself. The patient was a female, on whom a variety of operations had been performed (among others, division of the masseter), and whom I had had under my own care at the St. George's and St. James's Dispensary, two years before, when I divided the cicatrices freely, and screwed the mouth open, but without permanent benefit. Mr. Henry employed the chain saw, and removed about half an inch of bone. The patient, unfortunately, sank a few days afterwards, apparently from pyæmia and exhaustion. In my own cases I used an ordinary narrow saw, in preference to the chain, and was enabled to remove sufficient bone to give free movement, through a small incision along the edge of the jaw.

The subject of the contraction of cicatrices in the mouth, and their treatment, though it has attracted little notice among British authors, has, on the contrary, excited much attention in Paris, and has furnished the topic of frequent discussions at the Société de Chirurgie. Since the date of the publication of a paper upon the subject by M. Verneuil (*Archives*



*Générales*, 1860), several operations have been performed by French surgeons, but apparently with but little success, since in cases operated on both by the method of Esmarch and of Rizzoli reunion of the divided jaw has taken place.

Thus, on February 4th, 1863, M. Boinet brought before the Society a little girl on whom he had previously performed what he terms Esmarch's operation (but which appears to have consisted in the simple division of the jaw, recommended by Rizzoli, and not the removal of a wedge of bone, as originally proposed by Esmarch), and in whom the bone had reunited. M. Deguise thereupon quoted a case in which he had removed a centimètre and a half of bone with the same unsatisfactory result, and expressed a doubt whether a single successful case could be produced. On February 11th, 1863, M. Deguise brought the case he had alluded to before the Society, and showed that the failure "depended upon the formation of an osseous callus at the level of the resected portion." At the same meeting M. Bauchet showed a young Syrian girl in whom contraction of the left side had taken place, together with a loss of substance of the cheek and commissure of the lips, equalling a five-franc piece in size. In this case a centimètre and a half of the jaw was removed; and though extensive suppuration and necrosis of the jaw ensued, the girl made a good recovery, and at that date (February 4th) a very satisfactory amount of movement and power of mastication had been obtained.

On July 29th, 1864, M. Verneuil communicated to the Société de Chirurgie the histories of several cases operated upon by M. Rizzoli himself, the results of which were most satisfactory. In the first, the operation (simple division of the jaw from within the mouth) was performed in 1857, and after six years the boy was able to eat solid food most satisfactorily; the second case, operated upon in the same year, was equally good. In the third case, operated upon in 1858, the mouth could not be widely opened, and the child had some difficulty in speaking. The fourth case, operated upon in 1860, was most satisfactory. M. Verneuil also mentioned a fatal case which occurred in M. Rizzoli's practice, and alluded to



my paper in the *Dublin Quarterly Journal* of May, 1863.

It would appear that M. Rizzoli had adopted the plan of inserting a foreign body, such as a piece of gutta-percha, between the cut surfaces of bone, with the view of preventing their reunion, and the possibility of doing this was roundly denied by one of the speakers at the *Société de Chirurgie*. There appears to me, however, to be no difficulty in effecting this, provided the section be made from within the mouth and without external incision, as proposed by M. Rizzoli, but I cannot speak with certainty, having no experience of his operation.

One observation of M. Verneuil's is, I think, worthy of notice—namely, that all Rizzoli's successful cases have been examples of contraction within the mouth without loss of substance of the cheek, whereas the unsuccessful cases of the operation which had occurred in Paris had suffered considerable damage in the soft tissues ; and he suggests that in these cases Esmarch's operation may be more properly applicable. In one of my cases the loss of substance in the cheek had been replaced by a dense cicatrix, which it would have been unwise to interfere with from within the mouth, and at the same time, owing to its firm contradiction, it would have been impossible to have performed Rizzoli's operation in the way he recommends—namely, without any external incision. I therefore resorted to Esmarch's proceeding, with the results of which I have every reason to be satisfied.

The first case in which I performed Esmarch's operation was that of a boy aged 15, who was sent to me by Mr. Martin, of Portsmouth, in 1862, with complete closure of the jaws, the result of the contraction of cicatrices within the mouth following extensive necrosis. The cicatrices had been divided, and his mouth screwed open in 1856, but without permanent benefit, and he obtained his food by rubbing it between his teeth, or by putting it through an aperture between the teeth on the right side. The mouth was firmly closed, the teeth overlapping ; there was a cicatrix at the right angle of the mouth, and a dense band could be felt within the mouth on the same side. Fig. 58 shows his condition on admission. I



made an incision two inches long upon the lower border of the jaw, in front of the right masseter, and removed a wedge of bone measuring rather more than a quarter of an inch along the upper, and half an inch along the lower border. The piece contained the mental foramen. The mouth could now be freely opened, and the boy was discharged at the end of a month, able to open his mouth, as seen in Fig. 59; the distance between the teeth being seven-eighths of an inch.

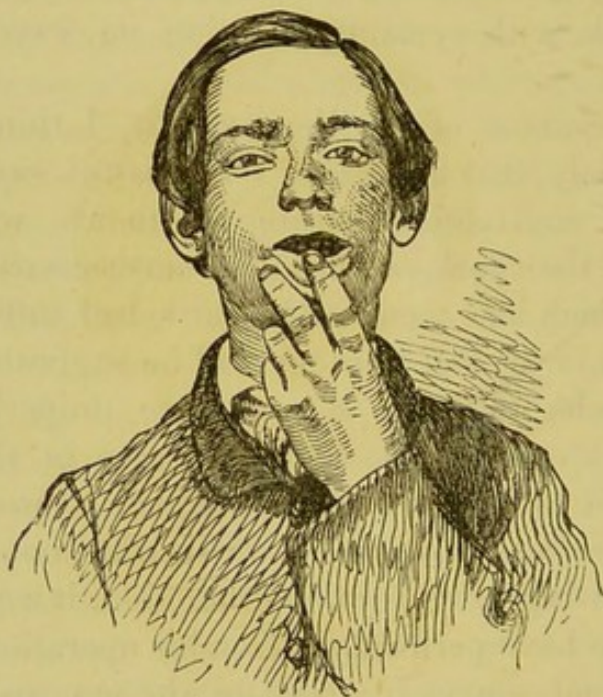


Fig. 58.

The second case in which I operated in the same manner was complicated by the presence of a dense cicatrix, occupying nearly the whole of the cheek of the affected side. The angle of the mouth had also given way during a recent attack of fever, and the patient presented the unsightly appearance shown in Fig. 60. The patient was aged 23, and the sloughing and contraction occurred at the age of 6. She was sent to me by Mr. Bullen, of the Lambeth Infirmary, in January, 1864. I made an incision along the border of the jaw, and, as in the former case, removed a wedge of bone measuring seven-eighths of an inch along its lower border. This also contained the mental foramen. The patient's mouth could now be opened to the extent of half an inch. I made two



subsequent attempts to remove the deformity of the cheek by plastic operations, but only succeeded in restoring the commissure of the lips, the vitality of the cicatricial tissue being too low to admit of its uniting with other tissues. At the time of her discharge the commissure of the lip was half an inch in breadth ; and with a piece of plaster over the opening which was left behind it, the patient was very comfortable. Fig. 61 shows her condition at this time with the mouth open.

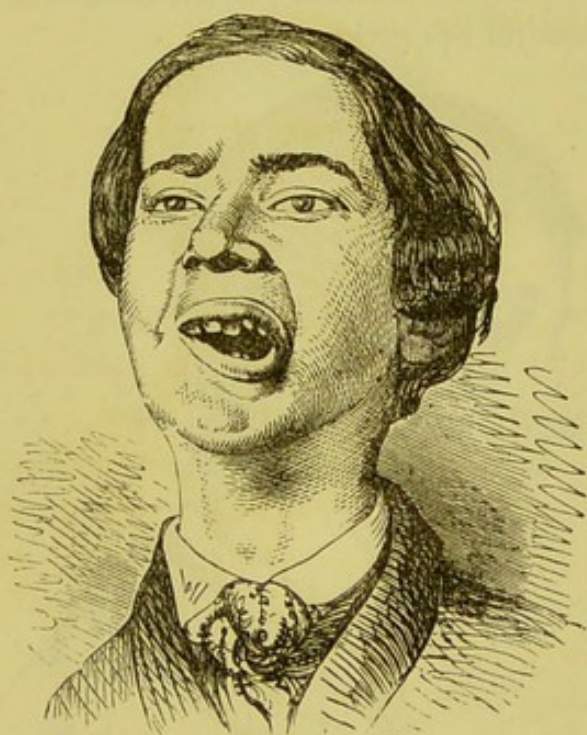


Fig. 59.

With regard to the permanence of the relief afforded in these cases, I may mention that B. B., the boy on whom I operated in July, 1862, continues in perfect health, and is able to take plenty of nourishment, although the movements of the jaw have very decidedly diminished, owing, apparently, to contraction of the fibrous tissues around the new joint, due, as the patient and his mother believe, in the first instance, to the cold of the severe winter following the operation, from which he suffered considerably.

In March, 1865, I had the boy up from the country, and found that the space between the left molar teeth had diminished from seven-eighths to one-eighth of an inch, and that



between the left lateral incisors, from five-eighths to a quarter of an inch. The movement was still free enough to show that osseous ankylosis had not taken place in the new joint; but whether the contraction was due simply to changes at that point or to the contraction of some band it was impossible to determine, as the boy positively refused all interference, either with or without chloroform. In this case, however, I believe that I was not sufficiently careful to make the section of the bone entirely in front of the cicatrices, a point I bore in mind in the second operation.

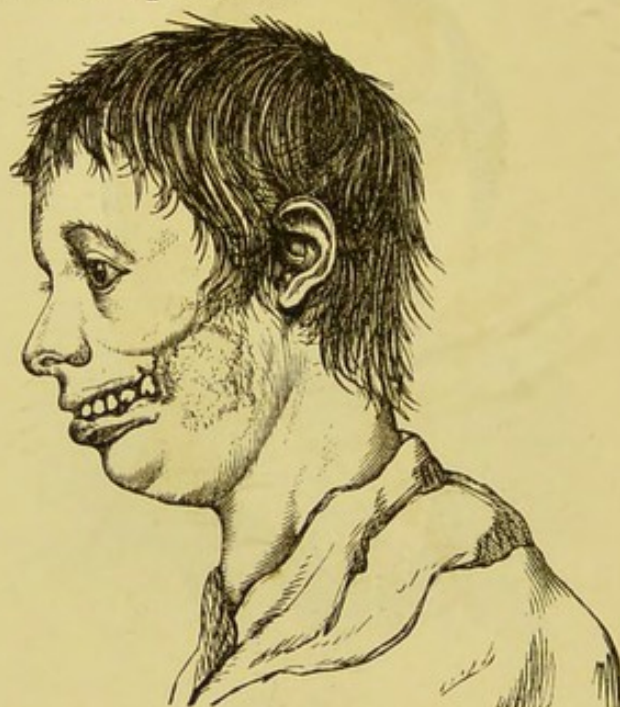

Fig. 60.

The second patient, E. J., is in perfect health, and has good use of her jaw. I saw her at Plymouth, in April of this year, in good health, and with perfect movement of the joint. The opening in the cheek remained the same.

In 1883, I again performed the operation in University College Hospital, on a woman, aged 32, who was kicked by a horse on the right side of the face, when 11 years of age, since which she had had more or less closure of the jaws. The teeth were firmly closed, the lower incisors being forced outwards. It was clearly a case of ankylosis of the temporo-maxillary articulation, and I should have preferred to operate



in that region but for the patient's anxiety to be relieved as soon as possible, in order to return to her family. She recovered, with good use of the jaw.

In connection with this subject, and to show the pathological result of the proceeding, I may refer to the following account of the *post-mortem* examination of a case of Esmarch's operation, read before the Société Impériale de Chirurgie, September 5th, 1886. M. Boinet showed the lower jaw of a girl who had closure of the jaws, from cicatrices resulting

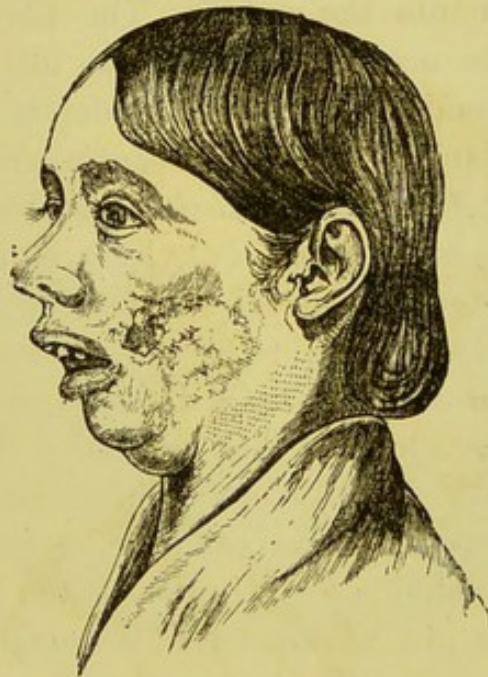

Fig. 61.

from cancrum oris. Rizzoli's operation had been performed at the beginning of 1860, but failed at the end of twelve months. In 1863 a wedge was removed with perfect success. She died of phthisis in 1866.

"The right ramus of the jaw is deformed, being shorter and broader than on the opposite side. The condyle and the coronoid process are less separated and shorter than on the left side, and the sigmoid notch is shallower. The left temporo-maxillary articulation has lost much of its mobility, and the ligaments are shortened. The sections had been made in the middle of the body of the bone, the angle being intact. The lower border of the jaw presents a difference in length of one centimètre and a half between the two sides,



which corresponds to the breadth of the wedge of bone removed at the operation. The osseous tissue of the ascending ramus appeared reddened ; the dental nerve was natural at its entry into the inferior dental foramen. Between the two portions of the jaw there exists a very complete false joint, which is permanent three years after the operation ; it is very mobile, and the parts which serve as the hinge are fibrous and stretched so that the middle portion of the jaw can fall ; during life this was sufficient to allow easily the introduction of the forefinger into the mouth. The fibrous tissue which unites the bones occupies the whole interval between the bones, and extends for the whole depth of the jaw. Its breadth appears to be quite half a centimètre, and its strength uniform."—*Gazette Hebdomadaire*, October 12th, 1866.

In a few cases of bilateral ankylosis it has been thought advisable to perform Esmarch's operation on both sides of the jaw. Thus Dr. Maas, of Breslau, relates in the *Archiv. für Klin. Chirurg.* (Band xiii, Heft 3) the case of a man, aged 27, who was admitted into hospital with ankylosis of the jaw on both sides. It had come on after an attack of scarlet fever when he was seven years old, being preceded by severe pain in the part ; and since the age of ten he had not been able to move the jaw at all. The secondary dentition was attended with great difficulty in the removal of the milk teeth ; and the new teeth were irregularly developed, and for the most part were displaced laterally. The patient, on admission, was of anæmic appearance, though in moderately good condition ; the lower jaw was imperfectly developed. Speech was somewhat muffled, but was quite intelligible. Not the least movement of the jaw could be produced under anæsthesia. Herr Middeldorpf operated on the right side, removing a wedge-shaped piece of bone, as recommended by Esmarch, near the angle. The result of this was the formation of a false joint, with power of opening the mouth passively to the extent of about an inch. Between four and five months later, Dr. Fischer performed a similar operation on the left side ; four months after this, the patient could voluntarily open his mouth without pain to the extent of about an inch



and a quarter, and his general condition was much improved.

The treatment of cicatricial contraction within the mouth by simple division has been proved over and over again to be worse than useless. The difficulties experienced in these cases, and the failures which so often accompany the methods employed, induced Dr. Ewing Mears, of Philadelphia, to make an effort to effect division of the dense tissue by means of a ligature, believing that reunion could thus be partially, if not completely, prevented.

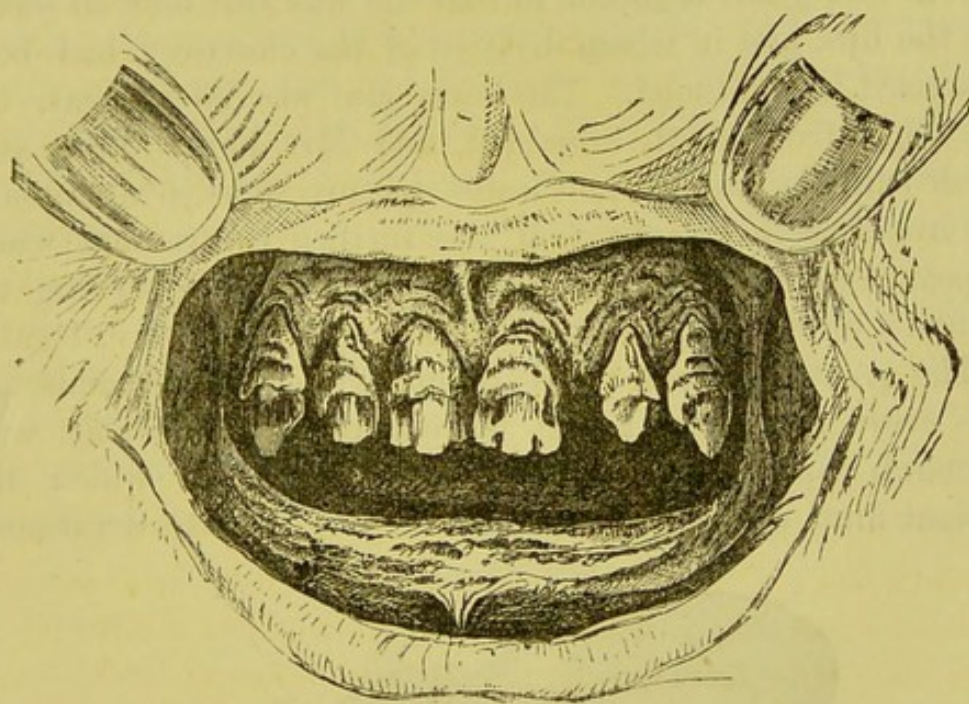


Fig. 62.

Having armed a strong-handled needle with a double-twisted, carbolised silk ligature, Dr. Mears passed it from the angle of the mouth backward between the integument and the outer surface of the cicatricial mass, and caused the point to emerge just behind the last molar tooth of the lower jaw. In this manner he surrounded the cicatricial tissue with the ligature, which was tied loosely and moved each day for a week, so as to establish a canal which would not readily close. At the expiration of a week, Dr. Mears tightened the ligature slightly, and every third day for the next two weeks made slight torsion, passing a probe meanwhile along the track of the ligature. In this way the dense tissue was slowly



divided, union not taking place at the bottom of the wound, and the jaws were separated three-quarters of an inch, sufficient for all practical purposes. The patient went to his home in the country, and four months later returned.

When suitable apparatus is adapted to the jaws, so as to prevent re-contraction, a very good result may, with patience, be produced in cases uncomplicated by destruction of the cheek itself. Fig. 62 shows a sketch of the mouth of a woman who had cicatricial bands on each side, binding the cheeks and gums together so that she was able only to separate the lips, and in whom division of the cicatrices had been practised in childhood. The lower jaw was edentulous, but the upper front teeth remained, and Mr. Felix Weiss succeeded in adapting a small lower denture so as to antagonise the upper teeth and prevent the further contraction which appeared imminent, at the same time greatly improving the patient's power of articulation (*Brit. Dent. J.*, May, 1880.)

The great drawback to treatment by division of bands, and one with regard to which it contrasts unfavourably with Esmarch's proceeding, is the amount of pain which the patient must of necessity undergo during the after-treatment.

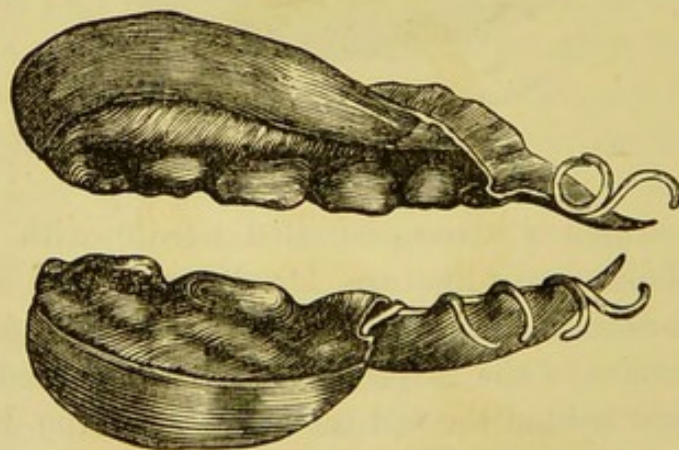


Fig. 63.

It requires no small amount of courage on the part of the patient, and some determination on the part of the attendant to carry out the necessary manipulations within the mouth, more particularly during the first few days after the operation; and even after the shields are fitted to the mouth, they



cause some pain and inconvenience, to which only those who have arrived at years of discretion will submit.

Fig. 63 shows the form of the silver "shields" adapted to the upper and lower jaws by the late Mr. Clendon, formerly dental surgeon to the Westminster Hospital, in a case of Mr. Barnard Holt's. The patient was a girl aged 17, and was under Mr. Holt's care in 1862, having five years before had fever, with an abscess of the cheek on the right side, which led to such contraction and adhesion of the mucous membrane to the jaw as to cause great difficulty in opening the mouth. Some attempts had been made to open her mouth by the screw, &c., and in 1860 Mr. Holt divided some of the cicatrix with temporary benefit. Mr. Holt now divided the cicatrix within the cheek freely under chloroform, and encountered a firm plate of bone extending between the alveoli of the two jaws, which necessitated the use of a saw for its division. Mr. Clendon subsequently fitted the above-mentioned shields to the teeth, and wedges were gradually introduced between them to separate the jaws. This treatment was continued for three months, when she was able to open the mouth to the full extent, as seen in Fig. 64.

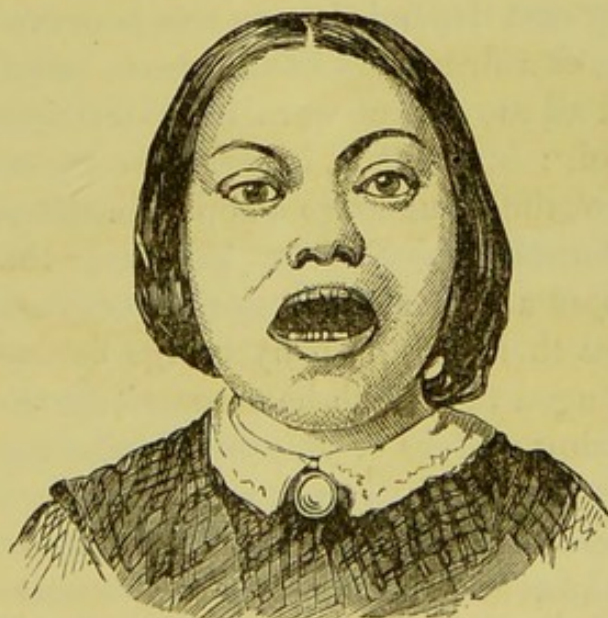

Fig. 64.

The effect of the use of shields seems to have been not merely to prevent adhesions between the inside of the cheek



and the alveolus, but to re-establish, to a great extent, the sulcus of mucous membrane at the base of the alveolus, upon which so much stress is laid by Professor Esmarch. Surgical experiences in cases of ruptured perineum, &c., shows how soon mucous membrane is reproduced where it has once existed, or even appears on adjacent parts, where its presence gives rise to inconvenience ; and there can be no question that in this case the mucous lining of the cheek has been reproduced to a great extent, and particularly near the lower alveolus. Esmarch's theory, that there must be some portion of old mucous membrane remaining which afterwards becomes stretched, is certainly untenable, at least as regards this case, for without doubt the whole lining of the cheek and the outside of the alveoli were perfectly raw, owing to the division of the firm cicatrices.

The cause of non-success in former attempts at mechanical appliances is to be found, I think, in the fact that they have all been directed simply to keeping the jaws apart, without any reference to the re-establishment of the mucous lining of the cheek, upon which, as Professor Esmarch says, the movements of the jaw so much depend. That the success in the foregoing case depended upon this is proved, I think, by the existence of a firm band in the cheek which would effectually control all movement were its extremities attached to the two alveoli ; but as it is, it gives no inconvenience, and will in all probability undergo atrophy in the course of time.

At the Odontological Society, in June, 1864, Mr. Cartwright narrated a very similar case of contraction (with the exception that there was no bony bridge between the alveoli) in a woman, aged 38, which he successfully treated by similar means, using wedges of vulcanised india-rubber affixed to the shields to obtain the necessary extension.

The occurrence of an osseous lamella or bridge between the two jaws is a rare but not unique occurrence. In the *Medical Gazette* of July 4th, 1845, Mr. J. G. French has reported and figured an excellent example of ankylosis produced by a bridge of bone, which occurred under his care at the St. James's Infirmary.



The patient was aged 22 at the time of his death, and the closure of the jaws dated from infancy. He was fed through an aperture made by the removal of the incisors on the left side. At the age of 14, an operation for his benefit had been undertaken by an eminent surgeon, and incisions in the mouth had been made with this object, but without any good result. On *post-mortem* examination, the jaws were perfectly united on the left side, and only the smallest degree of motion was possible on the right; the soft parts were removed and the base of the skull was macerated, when ankylosis was discovered to exist between the upper and lower jaws on the left side, the ramus of the inferior maxilla, immediately internal to the mental foramen, extending upwards by a broad thin plate, and uniting with a corresponding plate of the superior maxilla, a cartilaginous material forming the bond of union. The articulation of the jaw was normal.

Mr. Trueman also mentioned in the discussion which followed the narration of Mr. Cartwright's case (*British Journal of Dental Science*, June, 1864) that he remembered seeing in the Museum at Berlin a very curious case where cicatrices existed on both sides of the mouth, which were completely ossified, so that the preparation showed the two jaws united by filaments of bone, on either side of the jaw externally.

Subsequently to Mr. Holt's case, I had under my care a patient with a very severe form of contraction, namely, on both sides of the mouth. The patient was aged 18, and the contraction dated from her fifth year, when she had fever. Various attempts had been made to give her relief by dividing the cicatrices and using wedges, etc., without benefit; and when she came under my care she had no power of separating the jaws at all, and the cheeks were firmly attached to the alveoli from the angles of the mouth. Having secured Mr. Clendon's co-operation, I freely divided the cicatrices, and after repeated trials that gentleman succeeded in fitting in shields resembling those used in Mr. Holt's case, but reaching over both sides. It was found necessary to extract all the teeth, and after more than three months' assiduous care and frequent modification of the shields, the patient being con-



stantly placed under the influence of chloroform for the purpose, a very satisfactory result was obtained, there being exactly one inch between the metal shields in the incisive region, which would have left about half an inch if the teeth had been *in situ*.

Having thus shown that closure of the jaws depends upon various causes, and is amenable to various methods of treatment, of which I have had personal experience, I think I may venture to contrast these methods.

In cases of cicatrix, I give the preference to Esmarch's method of removing a wedge from the lower jaw on one or both sides. The operation is a comparatively easy one, and in cases where only one side of the jaw is affected, restores the patient a very useful though one-sided amount of masticatory power in two or three weeks, and with very little suffering or annoyance.

In cases of fibrous ankylosis of the temporo-maxillary joint it may be worth while to try division of the adhesions, and failing that to resect the condyle.

In cases of bony ankylosis of the joint, division of the ramus of the jaw beneath the masseter appears to me the least dangerous and most satisfactory proceeding.







