An introduction to human anatomy : including the anatomy of the tissues / by William Turner.

Contributors

Turner, Wm. Sir, 1832-1916.
Royal College of Physicians of Edinburgh

Publication/Creation

Edinburgh : A. & C. Black, 1882.

Persistent URL

https://wellcomecollection.org/works/cnuh38ph

Provider

Royal College of Physicians Edinburgh

License and attribution

This material has been provided by This material has been provided by the Royal College of Physicians of Edinburgh. The original may be consulted at the Royal College of Physicians of Edinburgh. where the originals may be consulted.
This work has been identified as being free of known restrictions under copyright law, including all related and neighbouring rights and is being made available under the Creative Commons, Public Domain Mark.

You can copy, modify, distribute and perform the work, even for commercial purposes, without asking permission.

Wellcome Collection
183 Euston Road
London NW1 2BE UK
T +44 (0)20 7611 8722
E library@wellcomecollection.org
https://wellcomecollection.org


MACLACHLAN
&
STEWART
64
SOUTH BRIDGE
EDINBURGH
1864

6/

Fc X 4.2

Digitized by the Internet Archive
in 2015

https://archive.org/details/b21915775

INTRODUCTION

TO

HUMAN ANATOMY

PRESENTED FROM
THE LIBRARY
OF THE LATE
PROFESSOR G. M. ROBERTSON.
1932.

By the Same,

In demy 8vo, sewed, Price 5s.

LECTURES ON THE COMPARATIVE ANATOMY OF THE PLACENTA

(*First Series*)

George M. Robertson

AN

INTRODUCTION

TO

HUMAN ANATOMY

INCLUDING THE

ANATOMY OF THE TISSUES

BY

WILLIAM TURNER, M.B., F.R.SS. L & E.

PROFESSOR OF ANATOMY IN THE UNIVERSITY OF EDINBURGH
MEMBER OF THE GENERAL MEDICAL COUNCIL

REVISED EDITION

EDINBURGH
ADAM & CHARLES BLACK
1882

(*All rights reserved.*)

NEILL AND COMPANY, EDINBURGH,
GOVERNMENT BOOK AND LAW PRINTERS FOR SCOTLAND.



PREFACE.

THIS Introduction to Human Anatomy was prepared as the Article "Anatomy" for the Ninth Edition of the "Encyclopædia Britannica," now in course of publication. It has no pretence to be an exhaustive treatise on the subject, and in writing it, my object has been to give an exposition of the principles on which the human body is constructed, rather than to put before the reader a detailed description of the several organs. At the suggestion of the publishers it has been reproduced in a separate volume.

The illustrations, except when otherwise stated in the text, are original. The figures of the dissected parts are from drawings by Dr W. M. Banks and Dr J. Halliday Scott. The great majority of the illustrations of the microscopic objects have been drawn on the wood, from original material and specimens, by Drs J. C. Ewart and J. Halliday Scott, and by Mr C. Berjeau, to each of whom I desire to

express my thanks for the care that has been taken in delineating the several objects. Except when stated otherwise, the microscopic specimens, from which the illustrations of the minute anatomy of the organs have been taken, were prepared, with his customary care and skill, by my assistant, Mr A. B. Stirling. For the use of the woodcuts, in illustration of Dr Thin's observations, I am indebted to that gentleman, and to the publishers of the *Edinburgh Medical Journal*. My thanks are also due to my friend, Dr J. A. Russell, for the trouble he has bestowed in revising the proof-sheets of the latter half of the book.

March 1877.

Part I., containing Chapters I. to VI., having been for some time out of print, I have, in revising this reprint, taken the opportunity of making such additions and alterations as were required in the present state of the subject.

February, 1882.

CONTENTS.

PAGE

Introduction, ... 1
Special Anatomy of the Human Body, . . . 3

CHAPTER I.

Skeleton, ... 8
Axial Skeleton—Spine, ... 9
,, ,, Thorax, ... 17
,, ,, Head, ... 20
Appendicular Skeleton—Upper Limb, . . . 36
,, ,, Lower Limb, . . . 44
Development and Homologies of Skeleton, . . 54

CHAPTER II.

Joints and Muscles, ... 63
General Observations on Joints, ... 63
General Observations on Muscles, ... 69
Joints and Muscles of the Axial Skeleton, . . . 73
Joints and Muscles of the Upper Limb, . . . 92
Joints and Muscles of the Lower Limb, . . . 101
Development and Homologies of the Voluntary Muscles, . 111

CHAPTER III.

Anatomy of the Textures or Tissues, Introductory, . 113
General Considerations on Cells, ... 115
Cells suspended in Fluids, ... 124
The Blood, ... 124
The Lymph and Chyle, ... 130

PAGE
Cells arranged on Free Surfaces, ... 131
Epithelium, ... 132
Endothelium, ... 139
Cells placed interstitially in a Matrix, . . . 143
Connective Tissue, ... 144
Adipose Tissue, ... 152
Pigmentary Tissue, ... 154
Cartilaginous Tissue, ... 155
Osseous Tissue, ... 162
Muscular Tissue, ... 175

CHAPTER V.

Nervous System, ... 186
Nervous Tissue, ... 188
Descriptive Anatomy of the Cerebro-Spinal Nervous System, 205
Development of the Cerebro-Spinal Nervous Axis, . 206
Membranes of Brain and Spinal Cord, . . . 212
Spinal Cord, ... 219
Origin, Arrangement, and Distribution of the Spinal Nerves, 229
The Brain, or Encephalon, ... 244
Medulla Oblongata, ... 244
Pons 252
Cerebellum, ... 254
Crura Cerebri, ... 262
Corpora Quadrigemina, ... 263
Cerebrum, ... 266
Outer Surface of Hemisphere, ... 268
Inner and Tentorial Surfaces of Hemisphere, . . 275
Internal Structure of the Cerebrum, . . . 287
Cerebral Organology, ... 298
Mass and Weight of the Brain, ... 300
Origin, Arrangement, and Distribution of the Encephalic Nerves, ... 303
The Sympathetic Nervous System, ... 318

CHAPTER VI.

Organs of Sense, ... 325
The Nose, ... 326
The Eyeball, ... 331
External, or Fibrous Tunic, ... 333
Middle, or Vascular Tunic, ... 338

PAGE
Internal, or Nervous Tu nic . . . 343
Refracting Media, ... 351
Accessory Parts to the Eyeball, ... 355
The Ear, ... 360
External Ear, ... 360
Middle Ear, ... 362
Internal Ear, ... 366
The Tongue, ... 377
The Skin, ... 383

CHAPTER VII.

Vascular System, ... 393
Blood-Vascular System, ... 394
The Pericardium, ... 395
The Heart, ... 397
The Arteries, ... 414
Pulmonary Group of Arteries, ... 416
Aortic or Systemic Arteries, ... 417
Visceral Branches of Aorta, ... 421
Parietal Branches of Aorta, ... 428
Branches of Aorta for Head, Neck, and Upper Limbs, 434
Branches of Aorta for Pelvis and Lower Limbs, . 471
Structure of the Arteries, ... 493
The Blood Capillaries, ... 497
The Veins, ... 500
Pulmonary Group of Veins, ... 501
Systemic Group of Veins, ... 502
Portal Venous System, ... 522
Structure of the Veins, ... 526
Lymph-Vascular System, ... 529
Lymphatic Vessels, ... 529
Lymphoid Organs, ... 545
Lymph Follicles, ... 546
Lymphatic Glands, ... 549
The Ductless Glands, ... 554
The Spleen, ... 555
Thymus Gland, ... 565
Thyroid Gland, ... 567
Supra Renal Capsules, ... 570
Pituitary Gland, ... 573
Pineal Gland, ... 574
Development of the Vascular System, . . . 575

CHAPTER VIII.

PAGE
Larynx or Organ of Voice, ... 587

CHAPTER IX.

Respiratory System, ... 604
Thorax, ... 605
The Windpipe, ... 614
The Pleuræ, ... 619
The Lungs, ... 626

CHAPTER X.

Organs of Digestion, ... 643
Alimentary Canal, ... 643
Mouth 646
Mucous and Salivary Glands of Mouth . . 653
Pharynx, ... 659
Œsophagus, ... 669
Abdominal Cavity and Peritoneum, . . . 672
Stomach, ... 685
Intestinal Canal, ... 696
Liver, ... 724
Pancreas, ... 743
Teeth, ... 745
Development of Digestive and Respiratory Systems, . 773

CHAPTER XI.

Urinary System, ... 779
Kidneys, ... 776
Ureters, ... 792
Bladder, ... 793
Urethra, ... 800

CHAPTER XII.

Reproductive System, ... 801
Male Organs of Reproduction, ... 801
Testes and Spermatic Cords, ... 802
Prostate Gland, ... 814

PAGE

Cowper's Glands, ... 817
Urethra, ... 818
Penis, ... 820
Female Organs of Reproduction, ... 825
Ovaries, ... 826
Par-ovarium, ... 836
Fallopian Tubes, ... 836
Uterus, ... 838
Vagina, ... 847
Development of the Urinary and Reproductive Systems, . 854

CHAPTER XIII.

The Placenta, ... 861

ERRATA.

Page 54, lines 21 and 37, *for* primitive, *read* dorsal.
,, 424, line 5, *for* left, *read* right.
,, 469, ,, 3 from foot, *for* thyro, *read* thyroid.
,, 483, ,, 4 ,, ,, metacarpal, *read* metatarsal.
,, 579, ,, 14 ,, ,, animals, *read* mammals.
,, 579, ,, 2 ,, ,, forms, *read* form.
,, 667, ,, 2, *for* in, *read* of.
,, 675, ,, 2, *for* epithelium, *read* endothelium.
,, 782, ,, 1, *for* upper, *read* lower.
,, 843, ,, 18, *for* mucous, *read* mucus.

HUMAN ANATOMY.

INTRODUCTION.

ANATOMY (*Ἀνατομή*) means in its literal sense the dissection or separation of parts by cutting, but in its usual acceptation it is employed to denote the science the province of which is to determine the form, structure, and construction of organised bodies, *i.e.*, of bodies which either are or have been living. It is therefore a department of the science of BIOLOGY. It resolves itself into two great divisions—ANIMAL ANATOMY or ZOOTOMY, the object of which is to investigate the form, structure, and construction of animals; and VEGETABLE ANATOMY or PHYTOTOMY, the object of which is to elucidate the anatomy of plants. ANIMAL ANATOMY, again, naturally resolves itself into two divisions: one in which the form, structure, and construction of two or more animals are compared with each other, so as to bring out their features of resemblance or dissimilarity,—this is called COMPARATIVE ANATOMY; the other, in which the form, structure, and construction of parts in a single animal are considered, which is termed SPECIAL ANATOMY. The special anatomy of an animal may be studied from various points of view: (*a*) with

reference to the succession of forms which it exhibits at various periods from its first appearance as an embryo to the assumption of its adult characters, this is termed Developmental or Embryological Anatomy; (*b*) with reference either to the form of the animal and of its constituent parts, or to the investigation of the laws by which form is determined, termed Morphological Anatomy; (*c*) with reference to the function, use, or purpose performed by a part or structure in an animal, termed Teleological or Physiological Anatomy; (*d*) with reference merely to the relative position of different parts or structures, termed Topographical or Regional Anatomy, and as a knowledge of the anatomy of regions is important to the surgeon and physician, this branch is sometimes called Surgical and Medical Anatomy; (*e*) with reference to the structure and general properties of the tissues or textures which enter into the construction of the parts or organs of animals; to this branch of study have been applied the terms General Anatomy, Anatomy of Textures, Histology, and, from the microscope being so largely employed in the examination of the textures, Microscopic or Minute Anatomy; (*f*) with reference to the changes induced by disease in the organs or tissues, termed Morbid or Pathological Anatomy. From its manifold aspects Anatomy forms the basis of the Biological Sciences. As a knowledge of the laws of motion is essential, and must be constantly recurred to at every step before any true progress can be made in the investigation of the physical sciences, so must the structure of the human and animal frame be constantly appealed to by the zoologist in all attempts at classification; by the physiologist in all inquiries into the functions performed by the organs and textures in a state of health, and into the special

adaptation of parts to particular uses ; and by the physician in considering the alterations or disturbance of the structure and functions of parts in the course of disease. To describe the anatomy of the multitudinous forms of animal life from these different points of view would require, not one, but several voluminous treatises, and would much exceed the compass of this volume, which is intended to be an introduction to the Special Anatomy of the Human Body in a state of health ; in other words, to be a short treatise on HUMAN ANATOMY OR ANTHROPOTOMY. As forming a department of the general science of Comparative Anatomy, the anatomy of Man is interesting not only to men of science generally, but, from its intimate connection with the several divisions of the art of healing, and with the study of the functions of the human body, possesses the highest importance to the physician, surgeon, and physiologist.

SPECIAL ANATOMY OF THE HUMAN BODY.

Man, zoologically speaking, belongs to the Mammalian class of the Vertebrate sub-kingdom, *i.e.*, his young are brought forth alive, and nourished during infancy on milk secreted in mammary or milk-forming glands. In common with all vertebrate organisms, he possesses a spine or vertebral column and a skull, in which are contained the spinal marrow and the brain, and in relation to the ventral surface of the spinal column are situated the several divisions of the alimentary canal.

But man possesses certain special or distinctive anatomical characters. The most noticeable, as seen on an external inspection of his body, is his erect position, which is associated with his higher intelligence. He is,

indeed, the only living creature that can walk or stand erect, *i.e.*, with the axis of the spine vertical; with the hip and knee joints capable of being fully extended, so that the leg is brought into line with the thigh; with the foot so planted on the ground that it rests on the heel behind and on the roots of the toes in front; with the upper limbs so arranged as to act, not as instruments of support and progression, but of prehension; and with the head so balanced on the top of the spine that the face and eyes look directly to the front. His bones, joints, and muscles are constructed and arranged so as to enable him to preserve the erect attitude without fatigue. In other vertebrata the axis of the spine is oblique or horizontal, the hip and knee joints are permanently bent at a more or less acute angle, the limbs, corresponding to the human upper extremities, are, in the form of legs, wings, or fins, instruments of progression, and the head is articulated with the spine at or near the hinder end of the skull. Owing to the oblique or horizontal attitude of the body in the vertebrata generally, and its erect position in man, the terms which are employed in describing the relative position of different

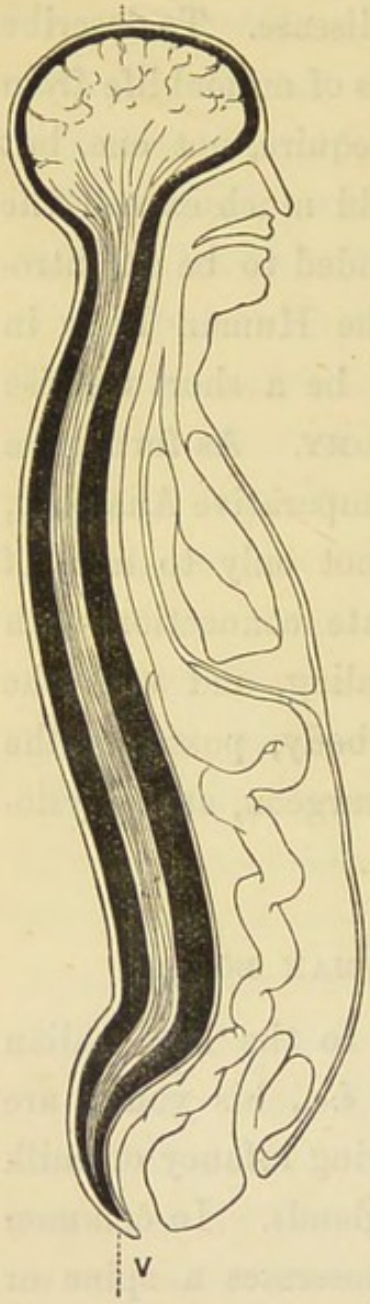

FIG. 1.—Diagrammatic Section through the Human Head and Trunk. The skull and spine, darkly shaded, and containing the cerebro-spinal nervous axis, are dorsal, or at the back. The alimentary and respiratory tubes, seen in outline, are ventral, or at the front. The dotted line V represents the vertical axis of the trunk.

parts are not used in the same sense by the human and comparative anatomist. Thus, parts which are *superior*, or above other parts in the human body, are *anterior*, or in front, in other vertebrata; parts which are *inferior* in man are *posterior* in other vertebrates; parts which are *posterior*, or behind, in man, are *superior* in other vertebrata; parts which are *anterior* in man are *inferior* or below in other vertebrates. To obviate the confusion which must necessarily arise when comparing the human body with that of other vertebrates,

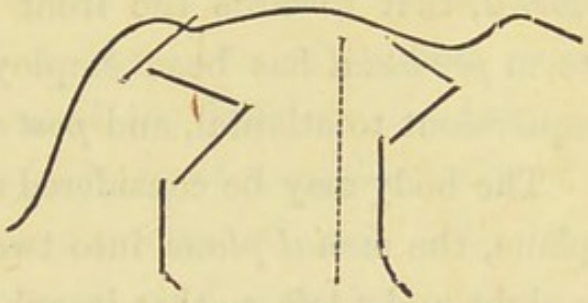

FIG. 2.—Outline Diagram of a Quadruped; the axis of the spine is almost at right angles to the vertical dotted line. (*After Goodsir.*)



FIG. 3.—Outline Diagram of a Bird. The axis of the spine lies obliquely to the vertical dotted line. (*After Goodsir.*)

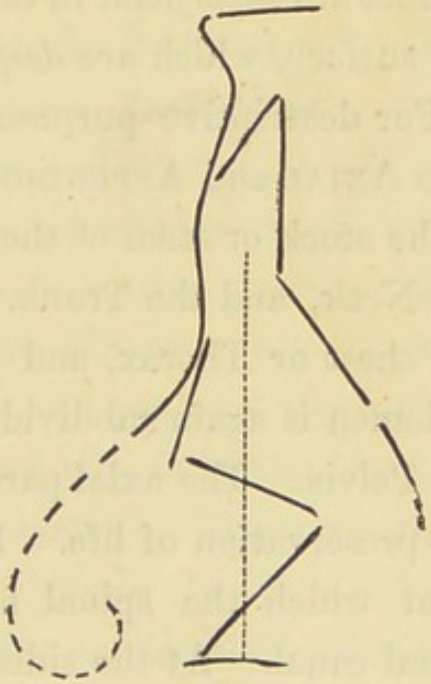

FIG. 4.—Outline Diagram of a Monkey in the semi-erect position. The axis of the spine lies obliquely to the vertical dotted line. (*After Goodsir.*)

certain descriptive terms have been recommended which may be employed whether the position of the body be erect or non-erect. Thus, the aspect of parts directed towards

the head is *cephalic* or *atlantal*, that directed towards the coccyx is *caudal* or *sacral*, that towards the back is *dorsal*, that towards the front is *ventral* or *hæmal*. The term *pre-axial* has been employed by some anatomists as equivalent to atlantal, and *post-axial* to sacral.

The body may be considered as divided by an imaginary plane, the *mesial plane*, into two lateral and similar halves, a right and a left, so that it exhibits a bilateral symmetry; the line in front where the plane reaches the surface of the body is the *anterior mesial line*, the line behind, where it reaches the surface, is the *posterior mesial line*. The constituent parts of the body are described as being *external* or *internal* to each other, according to their relative position to this plane, or these lines. Parts which are near the surface are *superficial* in relation to those lying further from the surface, which are *deep*.

For descriptive purposes, also, we may divide the body into AXIAL and APPENDICULAR portions. The AXIAL part is the stock or stem of the body, and consists of the Head, the Neck, and the Trunk. The trunk is subdivided into the chest or Thorax, and the belly or Abdomen; and the abdomen is again subdivided into the Abdomen Proper and the Pelvis. The axial part contains the organs essential to the preservation of life. In the head is lodged the brain, from which the spinal marrow is prolonged down the spinal canal. At the sides of the head are the ears, and opening on to the face are the eyes, nostrils, and mouth. Prolonged down the neck are the gullet and windpipe, with the latter of which is associated the organ of voice. Within the chest lie the heart, lungs, and gullet; and in the abdomen are contained the stomach, intestine, liver, spleen, pancreas, kidneys, and other organs concerned in the urinary

and generative functions. The APPENDICULAR part forms the limbs, which do not contain organs essential to life. In man the limbs are called Upper and Lower—the former are instruments of prehension, the latter of support and progression. The subdivisions of the body are not homogeneous in structure, but are built up of several systems of organs, each system being characterised not only by peculiarities in form, appearance, and structure, but by possessing special functions and uses. Thus the bones collectively form the Osseous system; the joints the Articulatory system; the muscles, which move the bones at the joints, the Muscular system; and these several systems collectively constitute the organs of Locomotion. The brain, spinal marrow, sympathetic ganglia, and nerves, form the Nervous system, with which are intimately associated the organs of Sense; the skin, with the hair and nails, the Tegumentary system; the heart, the blood-vessels, and lymph-vessels, the Vascular system; the lungs and windpipe, the Respiratory system; the alimentary canal, with the glands opening into it, the Digestive system; the kidneys, bladder, and urethra, the Urinary system; the testicles, spermatic ducts, prostate and penis in the male, with the ovaries, uterus, vagina and clitoris in the female, the Generative or Reproductive system. These various systems are so arranged with reference to each other as to form that organic whole which we term the Human Body.

The Organs of Locomotion will first attract our attention.

CHAPTER I.

SKELETON.

Osseous System—Osteology—Skeleton.—The word Skeleton (from σκέλλω, *to dry*) signifies literally the dry or hard parts of the body. When used in a limited sense it is applied merely to the bones, but when used in a wider and more philosophic sense it comprises not only the bones or osseous skeleton, but the cartilages and fibrous membranes which complete the framework of the body. The first evidence of a skeleton in the embryo is the appearance of membranes in many parts of which cartilage is developed, and in course of time this cartilage is converted into bone. In some animals, however, as in the cartilaginous fish, the osseous conversion does not take place, and the skeleton remains permanently cartilaginous; in the very remarkable fish called Lancelet, or *Amphioxus*, the skeleton consists almost entirely of fibrous membrane.

The skeleton serves as a basis of support for the soft parts, as affording surfaces of attachment for muscles and as a protection for many delicate organs. In the vertebrata the osseous skeleton is clothed by the muscles and skin, and is technically called an *endo-skeleton*. In invertebrata (*e.g.*, the crustacea) the skeleton is usually on the surface of the body, and is termed an *exo-* or *dermo-skeleton*. In some vertebrates (*e.g.*, the armadillo, tortoise, and sturgeon),

in addition to the proper endo-skeleton, skeletal plates are developed in connection with the integument, so that they possess a dermo-skeleton likewise. In some vertebrates, also, a partial skeleton is formed within the substance of some of the viscera—*e.g.*, in ruminant animals a bone is situated in the heart; in the walrus and other carnivora, in rodents, bats, and some monkeys, a bone lies in the penis; and in the leopard, jackal, and other carnivora, a cartilaginous style lies in the middle of the tongue. These parts form a *splanchno-* or *visceral skeleton.* The cartilaginous framework of the windpipe may also be referred to the splanchno-skeleton, and the teeth to the dermo-skeleton, and in these respects man possesses representatives of both the exo- and splanchno-skeleton, though like other vertebrates his skeleton is chiefly an endo-skeleton.

In each of the great divisions of the body an endo-skeleton exists, so that we may speak of an Axial Skeleton and an Appendicular Skeleton. The Axial Skeleton consists of the bones of the spine and head, the ribs, and the breastbone; the Appendicular Skeleton, of the bones of the limbs. The number of bones in the skeleton varies at different periods of life. In the adult there are about 210, but in the child they are more numerous; for in the process of consolidation of the skeleton certain bones originally distinct become fused together.

Axial Skeleton.

SPINE.

The Spine, Spinal or Vertebral Column, chine, or backbone, consists of a number of superimposed bones which are named Vertebræ, because they can move or turn somewhat on each other. It lies in the middle of the back

of the neck and trunk; has the cranium at its summit; the ribs at its sides, which in their turn support the upper limbs; whilst the pelvis, with the lower limbs, is jointed to its lower end. The spine consists in an adult of twenty-six bones, in a young child of thirty-three, certain of the bones in the spine of the child becoming ankylosed or blended with each other in the adult. These blended bones lose their mobility, and are called *false* or fixed vertebræ; whilst those which retain their mobility are the *true* or movable vertebræ. In the vertebrata the bones of the spine are arranged in groups, which may be named from their position—verte bræ of the neck or cervical; of the chest, dorsal or thoracic; of the loins, lumbar; of the pelvis, sacral; and of the tail, coccygeal or caudal; and the number of vertebræ in each group may be expressed in a formula. In man the formula is as follows:—

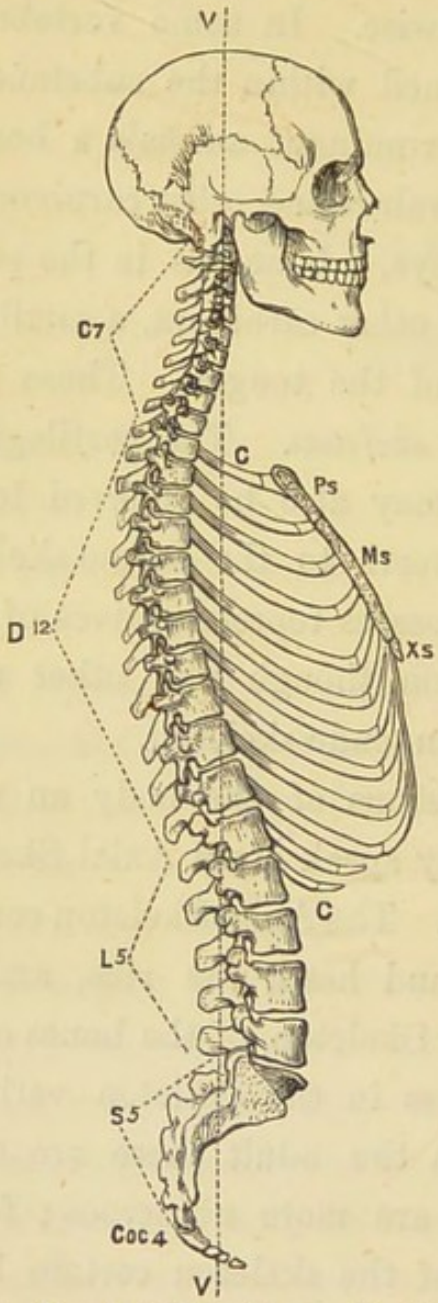

Fig. 5.—The Axial Skeleton. C_7, the cervical vertebræ; D_{12}, the dorsal; L_5, the lumbar; S_5, the sacral; Coc_4, the coccygeal; CC, the series of twelve ribs on one side; Ps, the pre-sternum; Ms, the meso-sternum; Xs, the xiphi-sternum. The dotted line VV represents the vertical axis of the spine.

$C_7D_{12}L_5S_5Coc_4 = 33$ bones, as seen in the child; but the five sacral vertebræ fuse together into a single bone—the sacrum—and the four coccygeal into the single coccyx.

Hence the sacrum and coccyx of the adult are the false, whilst the lumbar, dorsal, and cervical are the true vertebræ.

The vertebræ are irregularly-shaped bones, but as a rule have certain characters in common. Each possesses a body and an arch, which enclose a ring, with certain processes and notches. The Body, or Centrum, is a short cylinder, which by its upper and lower surfaces is connected by means of fibro-cartilage with the bodies of the vertebræ immediately above and below. The collective series of vertebral bodies forms the great column of the spine. The Arch, also called Neural Arch, because it encloses the spinal marrow or nervous axis, springs from the back of the body, and consists of two symmetrical halves united behind in the middle line. Each half consists of an anterior part or *pedicle*, and a posterior part or *lamina*. The Rings collectively form the spinal canal. The Processes usually spring from the arch. The *spinous process* projects backwards from the junction of the two laminæ, and the collective series of these processes gives to the entire column the spiny character from which has arisen the term Spine, applied to it. The *transverse processes* project outwards, one from each side of the arch. The *articular processes* project, two upwards and two downwards, and are for connecting adjacent vertebræ together. The Notches, situated one on the upper and one on the lower border of each pedicle, form in the articulated spine the intervertebral foramina through which the nerves pass out of the spinal canal.

The vertebræ in each group have characters which specially distinguish them. In man and all mammals, with few exceptions, whatever be the length of the neck, the Cervical Vertebræ are seven in number. The exceptions

Bradypus tridactylus

are the three-toed sloth, which has nine, and Hoffmann's sloth and the manatee, in which there are only six. In many whales the seven cervicals are fused in the adult into a single bone. In man the body of a cervical vertebra is comparatively small, its upper surface is transversely concave, and its lower transversely convex: the arch has long and obliquely sloping laminæ: the ring is large and triangular: the spine is short, bifid, and horizontal: each transverse process consists of two bars of bone, the anterior springs from the side of the body, the posterior from the arch, they unite to enclose the *vertebrarterial foramen*, through which, in the upper six vertebræ, the vertebral artery passes; each bar ends externally in a tubercle: the articular processes are flat and oblique: the upper pair of notches are deeper than the lower. The 1st, 2d, and 7th cervical vertebræ have special characters. The 1st, or *Atlas*, has no body and only a rudimentary spine: its ring is very large: on each side of the ring is a thick mass of bone, the *lateral mass*, by which it articulates with the occipital bone above and the second vertebra below: the *anterior arch* forms the front of the ring and articulates behind with the odontoid process, whilst in front it has a small tubercle: each lamina is rounded and grooved above for the vertebral artery and suboccipital nerve: the transverse processes are long but not bifid. The 2d, or *Axis* or *Vertebra dentata*, has its body surmounted by a thick tooth-like *odontoid* process, which is the body of the atlas displaced from its proper vertebra and fused with the axis. This process forms a pivot about which the atlas and head move in turning the head from one side to the other: the spine is large, thick, and deeply bifid: the transverse processes are short and scarcely bifid: the laminæ are

large: the superior articular processes look upwards. The 7th, or *Vertebra prominens*, has a long prominent spine, which is not bifid, and a small foramen at the root of the transverse process. In the human spine the *distinguishing character* of all the cervical vertebræ is the foramen at the root of the transverse process, but amongst mammals this is not an invariable character, for in the cetacea the transverse process of the atlas is imperforate, and in the horse, ruminants, and many quadrumana, the 7th cervical vertebra has no foramen at the root of its transverse process.

The Dorsal Vertebræ, more appropriately called Costal or Thoracic, are twelve in number in the human spine; but amongst mammals they range from eleven in the armadillo to twenty-two in the Cape hyrax and Hoffmann's sloth. They are intermediate in size and position to the cervical and lumbar vertebræ, and the *distinguishing character* is one or two smooth surfaces on each side of the body for articulation with the head of one or two ribs. The body is heart-shaped: the arch is short and with imbricated laminæ: the ring is nearly circular: the spine is oblique, elongated, and bayonet-shaped: the transverse processes are directed back and out, not bifid, and with an articular surface in front for the tubercle of a rib: the articular processes are flat and nearly vertical: the superior notches shallow, the inferior deep. The 1st, 12th, 11th, 10th, and sometimes the 9th, dorsal vertebræ are characteristic. The 1st is in shape like the 7th cervical, but has no foramen at the root of the transverse process, and has two articular facets on each side of the body. The 9th has sometimes only one facet at the side of the body. The 10th, 11th, and 12th have invariably only a single facet on each side of the body, and their spines approximate in shape to those of

the lumbar vertebræ. In the 11th and 12th the transverse processes are stunted and non-articular, and present three tubercles, an external or *costal*, a superior or *mammillary*, and an inferior or *accessory*. The 12th has its lower articular processes vertical and convex forwards and outwards, like those of a lumbar vertebra.

The Lumbar Vertebræ in man are five in number, but amongst mammals they range from two in the platypus to eight in the hyrax or agouti. They are the lowest of the true vertebræ, and also the largest. The body is elongated transversely: the arch has short, deep laminæ: the ring is triangular: the spine is massive, horizontal, hatchet-shaped: the transverse processes are long and pointed: the articular are strong and vertical, the superior pair concave, the inferior convex from side to side: the inferior notches, as in the dorsal vertebræ, are deeper than the superior. In the lumbar vertebræ an *accessory* process projects from the base of each transverse process, and a *mammillary* process from each superior articular process. In man these are small and rudimentary; but in some mammals, as the kangaroo, armadillo, and scaly ant-eater, the mammillary tubercles are large, and in the baboon, dog, cat, and beaver the accessory processes are well developed. The 5th lumbar vertebra has its body thicker in front than behind; its spine is less massive, its transverse processes are short and conical, and its lower articular processes are flattened.

The Sacrum is composed of five originally separate vertebræ fused into a single bone. In the bandicoot it consists of a single vertebra, whilst it is formed of eight in the armadillo. The relative size and completeness of the sacrum are associated with the development of the haunch bones and of the lower limbs. In whales, where the pelvic

bones are rudimentary and there are no hind limbs, there is no sacrum. The sacrum forms the posterior wall of the pelvis, is triangular in form, and possesses two surfaces, two borders, a base, and an apex. The anterior or pelvic surface is concave, and marked by four transverse lines, which indicate its original division into five bones, and by four pairs of foramina, through which are transmitted the anterior sacral nerves. Its posterior surface is convex, and corresponds to the spines and laminæ of the true vertebræ; in the middle line are the rudimentary spines, on each side of which are two rows of tubercles, the inner are the conjoined articular and mammillary processes, the outer the transverse processes of the originally distinct vertebræ: in addition, four pairs of foramina transmit the posterior sacral nerves from the sacral canal, which extends through the bone from base to apex, and forms the lower end of the spinal canal. By its borders the sacrum articulates with the haunch-bones, by its base with the last lumbar vertebra, by its apex with the coccyx. The human sacrum is broader in proportion to its length than in other mammals; this great breadth gives solidity to the lower part of the spine, and, conjoined with the size of the lateral articular surfaces, it permits a more perfect junction with the haunch-bones, and is correlated with the erect position. Owing to the need in woman for a wide pelvis, the sacrum is broader than in man.

The Coccyx consists of only four vertebræ in the human spine. It is the rudimentary tail, but instead of projecting back, as in mammals generally, is curved forwards, and is not visible externally, an arrangement which is also found in the anthropoid apes and in Hoffmann's sloth. In the spider monkeys as many as thirty-three vertebræ are found

in the tail, and in the long-tailed pangolin the number reaches forty-six. Not only is the tail itself rudimentary in man, but the vertebræ of which it is composed are small, and represent merely the bodies of the true vertebræ. As there are no arches, the ring is not formed, and the spinal canal does not extend, therefore, beyond the apex of the sacrum. The first coccygeal vertebra, in addition to a body, possesses two processes or *cornua*, which are jointed with two corresponding *cornua* from the last sacral vertebra.

The Human Spine is more uniform in length in persons of the same race than might be supposed from the individual differences in stature, the variation in the height of the body in adults being due chiefly to differences in the length of the lower limbs. The average length of the spine is 28 inches; its widest part is at the base of the sacrum, from which it tapers down to the tip of the coccyx. It diminishes also in breadth from the base of the sacrum upwards to the region of the neck. Owing to the projection of the spines behind and the transverse processes on each side, it presents an irregular outline on those aspects; but in front it is more uniformly rounded, owing to the convex form of the antero-lateral surfaces of the bodies of its respective vertebræ. In its general contour two series of curves may be seen, an antero-posterior and a lateral. The antero-posterior is the more important. In the infant at the time of birth the sacro-coccygeal part of the spine is concave forwards, but the rest of the spine, except a slight forward concavity in the series of dorsal vertebræ, is almost straight. When the infant begins to sit up in the arms of its nurse, a convexity forwards in the region of the neck appears, and subsequently, as the child learns to walk, a convexity forwards in the region of the loins. Hence in

the adult spine a series of convexo-concave curves are found, which are alternate and mutually dependent, and are associated with the erect attitude of man. In the human spine alone are the lumbar vertebræ prominently convex forward. A lateral curve, convex to the right, opposite the 3d, 4th, and 5th dorsal vertebræ, with compensatory curves convex to the left immediately above and below, is due apparently to the much greater use of the muscles of the right arm over those of the left, drawing the spine in that region somewhat to the right. In disease of the spine its natural curvatures are much increased, and the deformity known as humpback is produced. As the spine forms the central part of the axial skeleton, it acts as a column to support not only the weight of the body, but all that can be carried on the head, on the back, and by the upper limbs : by its transverse and spinous processes it gives attachment to numerous muscles, and the transverse processes of its dorsal vertebræ are also for articulation with the ribs.

THORAX.

The THORAX, PECTUS, or CHEST is a cavity or enclosure the walls of which are formed in part of bone and of cartilage. Its skeleton consists of the sternum in front, the twelve dorsal vertebræ behind, and the twelve ribs, with their corresponding cartilages, on each side (fig. 5, also p. 605).

The Sternum or Breast Bone is an elongated bone which inclines downwards and forwards in the front wall of the chest. It consists of three parts—an upper, called manubrium or *pre-sternum;* a middle, the body or *meso-sternum;* and a lower, the ensiform process or *xiphi-sternum.* Its anterior and posterior surfaces are marked by transverse lines, which indicate the three parts of the bone and also the

division of the meso-sternum itself into four segments. Each lateral border of the bone is marked by seven depressed surfaces for articulation with the seven upper ribs. At the upper border of the pre-sternum are two depressions for articulation with the clavicle. The xiphi-sternum remains cartilaginous up to a late period of life, and from its pointed form has been named the *ensiform cartilage.*

The Ribs or Costæ, twenty-four in number, twelve on each side of the thorax, consist not only of bone but of a bar of cartilage continuous with the anterior end of each bone, called a *costal cartilage*, so that they furnish examples of a cartilaginous skeleton in the adult human body; in aged persons these cartilages usually become converted into bone. The upper seven ribs are connected by their costal cartilages to the side of the sternum, and are called *sternal* or *true* ribs; the lower five do not reach the sternum, and are named *a-sternal* or *false*, and of these the two lowest, from being unattached in front, are called *free* or *floating.* All the ribs are articulated behind to the dorsal vertebræ, and as they are symmetrical on the two sides of the body, the ribs in any given animal are always twice as numerous as the dorsal vertebræ in that animal. They form a series of osseo-cartilaginous arches, which extend more or less perfectly around the sides of the chest. A rib is an elongated curved bone, with a head, neck, tubercle, and shaft. The *head* usually possesses two articular surfaces, and is connected to the side of the body of two adjacent dorsal vertebræ; the *neck* is a constricted part of the bone, uniting the head to the shaft; the *tubercle*, close to the junction of the shaft and neck, articulates with the transverse process of the vertebra with which it corresponds numerically. The *shaft* is compressed, possesses an inner and outer surface,

and an upper and lower border, but from the shaft being somewhat twisted on itself, the direction of the surfaces and borders is not uniform throughout the length of the bone. The ribs slope from the spine at first outwards, downwards, and backwards, then downwards and forwards, and where the curve changes from the backward to the forward direction an *angle* is formed on the rib. The 1st, 10th, 11th, and 12th ribs are distinctive; they articulate each with only a single vertebra, so that only a single surface exists on the head: the surfaces of the shaft of the 1st rib are almost horizontal; the upper surface and inner border have a ridge and tubercle, the *scalene tubercle* for the attachment of the scalenus anticus muscle, behind which is a groove for the subclavian artery, and in front a groove for the subclavian vein: the surfaces of the 2d rib are very oblique, and the outer is marked by a ridge for the serratus magnus muscle: the 11th and 12th ribs are rudimentary, have neither neck nor tubercle, and are pointed anteriorly. The ribs are by no means uniform in length: they increase from the 1st to the 7th or 8th, and then diminish to the 12th; the 1st and 12th are therefore the shortest ribs. The 1st and 2d costal cartilages are almost horizontal, but the others are directed upwards and inwards.

In its general form the chest may be likened to a truncated cone. It is rounded at the sides and flattened in front and behind, so that a man can lie either on his back or his belly. Its truncated apex slopes downwards and forwards, is small in size, and allows of the passage of the windpipe, gullet, large veins, and nerves into the chest, and of several large arteries out of the chest into the neck. The base or lower boundary of the cavity is much larger than the apex, slopes downwards and backwards, and is occupied by the

diaphragm, a muscle which separates the chest from the cavity of the abdomen. The transverse diameter is greater than the antero-posterior, and the antero-posterior is greater laterally, where the lungs are lodged, than in the mesial plane, which is occupied by the heart.

HEAD.

The HEAD forms the summit of the axial part of the body, and consists of two portions, the Cranium and the Face.

The SKULL, or skeleton of the head is usually said to be

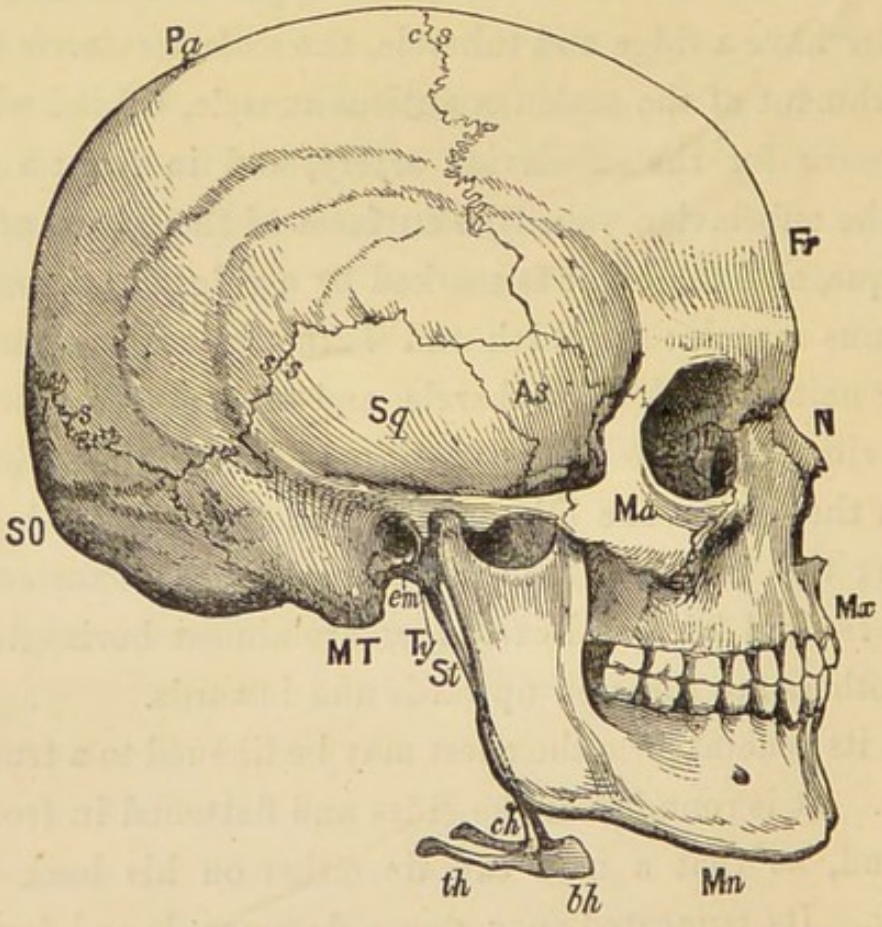

FIG. 6.—Profile of the Skull. Fr, frontal bone; Pa, parietal; SO, supra-occipital; Sq, squamous-temporal; MT, mastoid-temporal; Ty, tympanic; St, styloid-temporal; As, ali-sphenoid; E, os planum of ethmoid; L, lachrymal; N, nasal; Mx, superior maxilla; Ma, malar; Mn, mandible; *bh*, basi-hyal; *th*, thyro-hyal; *ch*, cerato-hyal; *em*, external meatus; *cs*, coronal suture; *ls*, lambdoidal suture; *ss*, squamous suture.

composed of 22 bones, 8 forming the cranium, 14 the face. But to these should be added the 3 pairs of tympanic

ossicles and the hyoid bone, making in all 29 bones. The 8 bones of the cranium are so united together by their edges as to form the walls of a box or cavity, the cranial cavity, in which the brain is lodged. The box of the cranium possesses a base or floor, a vault or roof, an anterior, a posterior, and two lateral walls. The posterior wall is formed by the *occipital* bone, which also extends for some distance forwards along the middle of the base; in front of the basal part of the occipital is the *sphenoid*, which also

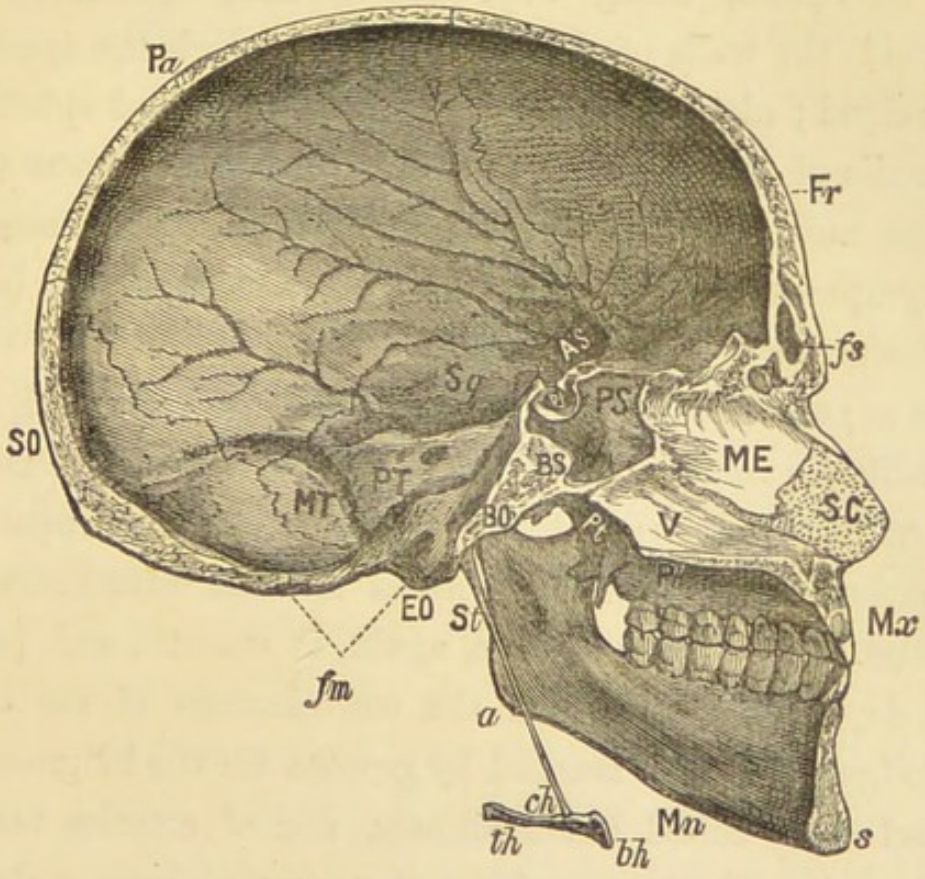

FIG. 7.—Section through the Skull immediately to the right of the mesial plane. The lettering as in Fig. 6, with, in addition, BO, basi-occipital; EO, ex-occipital; PT, petrous-temporal; BS, post-sphenoid; PS, pre-sphenoid (the letters are placed in the sphenoidal sinus); OS, orbito-sphenoid; ME, mes-ethmoid; SC, septal cartilage of nose; V, vomer; Pl, palate; Pt, pterygoid of sphenoid; *fs*, frontal sinus; Pf, pituitary fossa; *fm*, foramen magnum; *a*, angle, and *s*, symphysis of lower jaw.

sends a process upwards on each side of the skull; in front of the basal part of the sphenoid is the *ethmoid*; mounting upwards in front of the ethmoid is the *frontal*, which forms

the forehead, and closes in the front of the cranial box; forming the vault and side walls are the two *parietal* bones; completing the side walls, and extending for a short distance along the side of the floor, are the two *temporal* bones; the *vertex* is the summit of the skull at the junction of the two parietal bones with each other.

The fourteen bones of the face, which are situated below and in front of the cranium, enter into the formation of the walls of cavities which open on the front of the face; thus they complete, along with the frontal, sphenoid, and ethmoid, the walls of the two orbits in which the eye-balls are lodged; along with the frontal, ethmoid, and sphenoid, the walls of the nostrils; and they form the osseous walls of the mouth. The six tympanic ossicles are placed in the tympanic cavities. The hyoid lies in the neck below the lower jaw.

As a general rule, the cranial bones are expanded, and plate-like in form. The *outer* surface of each bone assists in forming the exterior of the cranium, and not unfrequently is marked by ridges or processes for the attachment of muscles. The *inner* surface, again, is smooth, and pitted with depressions, in which the convolutions of the brain are lodged, and also marked by grooves for the lodgment of dilated veins called blood sinuses, and of arteries termed meningeal. The two surfaces of a cranial bone, dense in structure, are called its *tables*, outer and inner, and are separated from each other by bone, looser and more spongy in its texture, called the *diploë*. In some localities, more especially in certain of the bones which form the walls of the nostrils, the diploë disappears, and comparatively wide interspaces, which contain air, separate the two tables, and are called *air-sinuses*. The margins of the bones are

denticulated, and it is by the interlocking of the denticulations of adjacent bones that they are jointed together, the joints being named *sutures*. The bones are pierced by holes or *foramina*, and similar holes exist between the adjacent margins of some of the bones. These foramina are mostly situated in the floor of the skull; they transmit arteries into the cranial cavity to supply the brain and the inner table with blood, and veins and nerves out of the cavity. The largest of these holes is called *foramen magnum*. It lies in the occipital bone, immediately above the ring of the atlas; through it the spinal marrow becomes continuous with the brain, and the vertebral arteries enter to supply the brain with blood.

The Occipital, or bone of the Back of the Head (figs. 6 and 7), consists of four originally distinct pieces fused into a curved plate-like bone. Its divisions are arranged around the foramen magnum—the basilar part, *basi-occipital*, in front; the condyloid parts, *ex-occipitals*, one on each side; and the tabular part, or *supra-occipital*, behind. The anterior surface of the supra-occipital is divided into four fossæ, in the two upper are lodged the occipital lobes of the cerebrum, in the two lower the cerebellum; the upper and lower pairs of fossæ are separated by a transverse groove for the lodgment of the lateral venous sinus. The posterior surface is marked by a protuberance, by two transverse curved lines and by a vertical crest; by its margin the supra-occipital articulates with the parietal and mastoid temporal bones. Each ex-occipital has on its under surface a smooth condyle for articulation with the atlas; in front of the condyle is a foramen which transmits the 9th cranial or hypoglossal nerve, and behind it a foramen sometimes exists for the transmission of a vein: external to each

condyle is the *jugal process*, which is grooved superiorly for the lateral sinus, and has anteriorly the *jugal notch* for the internal jugular vein. The basi-occipital articulates and, in the adult skull, is fused with the body of the sphenoid (fig. 7). The upper surface of the basi-occipital is grooved for the lodgment of the medulla oblongata.

Sometimes the part of the supra-occipital situated above the protuberance and upper curved line ossifies as an independent bone, called *interparietal*. In some mammals, as the sheep, the existence of an interparietal in the young skull is the rule and not the exception.

The Sphenoid or Wedge-shaped bone (fig. 7) lies at the base of the skull; it articulates behind with the occipital; in front with the ethmoid and frontal; by its lateral processes or wings with the frontal, parietal, temporal, and malar bones; and below with the vomer and palate. It binds together all the bones of the cranium, articulates with five bones of the face, and for constructive purposes is the most important bone of the head. It consists of a centrum or body, with which four pairs of processes are connected. The body has a deep depression on its upper surface, compared in shape to a Turkish saddle, in which is lodged the pituitary body; hence it is called *pituitary fossa*. In front of this fossa is the *olivary process*, which marks the union of the *pre-* and *post-sphenoidal* subdivisions of the body of this bone; the body is grooved laterally for the internal carotid artery and the cavernous blood sinuses; it is hollowed out in its interior to form the *sphenoidal air-sinuses*, which are partially closed in front by a pair of small bony plates, the *sphenoidal spongy bones*, or bones of Bertin. Behind the pituitary fossa is the pair of *posterior clinoid processes* from which the bone slopes back to the basi-occipital; this slope is called the *dorsum sellæ*, and on it rests the pons Varolii.

From the post-sphenoidal division of the body the great wings, or *ali-sphenoids*, pass outwards and upwards to the sides of the skull, and each sends backwards and downwards a pointed *spinous process*. From the presphenoidal division of the body the lesser wings, *orbito-sphenoids*, pass outwards, and assist in forming the roof of each orbit; each orbito-sphenoid ends internally in a knob-like process called *anterior clinoid*, and at its root is the *optic foramen*, which transmits the 2d nerve, or nerve of sight, and the ophthalmic artery, into the orbit. From the great wing on each side, close to its junction with the body, the *internal and external pterygoid processes* project downwards, and the internal process ends in a slender hook termed the *hamular* process. The ali-sphenoid is pierced by *foramina* called *rotundum*, *ovale*, and *spinosum*: the f. rotundum transmits the second and the f. ovale the third division of the 5th cranial nerve, whilst the f. spinosum transmits the middle meningeal artery to the membranes of the brain; between the orbito- and ali-sphenoids is the *sphenoidal fissure* which transmits the 3d, 4th, 6th nerves, the first division of the 5th cranial nerve and the ophthalmic vein into the orbit; at the root of the pterygoid processes is the *vidian* canal, for the transmission of a nerve and vessels of the same name.

The Ethmoid, or Sieve-like bone (fig. 7), is situated between the two orbital plates of the frontal, in front of the body of the sphenoid and above the vomer, inferior turbinated, palate and superior maxillary bones. It is cuboidal in shape, and is composed of a central portion and two lateral masses, which are connected together by a thin horizontal plate pierced with holes like a sieve, and called *cribriform*. This cribriform plate forms a part of the floor of the cranial cavity; on it rest the two olfactory

bulbs, and the branches of the nerves of smell, called olfactory or 1st cranial nerves, pass from the bulbs through the holes in this plate into the nose. The central portion of the bone (*mes-ethmoid*) is a mesial perpendicular plate; it forms a part of the nasal septum, reaches at its anterior border the nasal bones, and projects above the cribriform plate as the *crista galli*. Each lateral mass consists of an external smooth plate, *os planum*, which assists in forming the inner wall of the orbit, and of an internal convoluted part called *superior* and *middle spongy* plates or *ethmo-turbinals*, which enter into the formation of the outer wall of the nostril. These turbinals are associated with the distribution of the nerves of smell; in the toothed whales, where there are no olfactory nerves, the turbinals are absent, whilst in some mammals, as the crested seal, they assume a highly convoluted form. The lateral masses are hollowed out into air-sinuses, called *ethmoidal cells*, which communicate with the nostrils and with corresponding sinuses in the sphenoid and frontal bones. These cells are partially closed in on each side by the lachrymal bone.

The Frontal, or bone of the Forehead (figs. 6 and 7), consists originally of a right and left lateral half, united by the frontal suture in the middle line of the forehead. As a rule, this suture disappears in early life, and a single greatly curved bone is formed. It lies in front of the sphenoid and parietals with which it articulates. The bone is convex forwards, to form the rounded forehead, and presents two *eminences*, the centres of ossification of the bone; at the root of the nose is an elevation called *glabella*, extending outwards, from which, on each side, is the *supra-ciliary ridge*, corresponding to the position of the eyebrow. In the crania of some races, *e.g.*, the Australian,

the forward projection of the glabella and supra-ciliary ridges is considerable; and in the well-known skull from the valley of the Neander it has reached a remarkable size. These ridges and the glabella mark the position of the air-sinuses in the frontal bone. The upper border of each orbit, which ends internally and externally in a process of bone called *angular*, forms the lower boundary of the fore-head, and has a *notch* or *foramen* for the supra-orbital nerve. The external angular process articulates with the malar, the internal with the nasal and superior maxilla. The cerebral surface of the bone is deeply concave, for the reception of the frontal lobes of the brain; the concavity is deepened by the backward projection of the two thin *orbital plates*, the roofs of the orbits, which are separated from each other by the *ethmoidal notch;* at the margins of this notch are openings into the frontal air-sinuses, and here it articulates with the lachrymal and ethmoid.

The Parietal bones, two in number (figs. 6 and 7), form the greater part of the side wall of the skull, and mount upwards to the vertex, where they unite to form the *sagittal suture.* Each bone is quadrilateral in form, and has about the centre of its outer surface an *eminence*, the centre of ossification of the bone, with which a hollow on the cerebral surface, lodging a convolution of the parietal lobe of the brain, corresponds. Below the eminence is the curved *temporal ridge*, usually double, and below the ridge the *temporal surface* of the bone. Three of its margins are strongly denticulated, for junction behind with the occipital, in front with the frontal, and mesially with the corresponding parietal; the fourth is scale-like, for union with the temporal, and forms the *squamous* suture; near the upper margin on the cerebral surface is a groove for

the lodgment of the *superior longitudinal* venous *sinus.* The anterior inferior angle articulates with the ali-sphenoid, and is marked by a groove for the middle meningeal artery; the posterior inferior is grooved for the *lateral* venous *sinus*, and articulates with the mastoid of the temporal.

The Temporal bones, two in number (figs. 6 and 7), are placed at the sides and base of the skull, and contain the organs of hearing. Each bone consists originally of four divisions—*squamoso-zygomatic*, *tympanic*, *petromastoid*, and *styloid*—which in course of time fuse together to form an irregular-shaped bone. The squamous part of the squamoso-zygomatic forms the thin plate on the side of the skull familiarly known as the "temple," and articulates with the parietal and ali-sphenoid. The zygoma extends horizontally forwards as a distinct arched process, and joins the malar or cheek-bone. At the root of the zygoma is a smooth fossa, called *glenoid*, which articulates with the condyle of the lower jaw. The tympanic portion forms in the fœtus a ring, which expands subsequently into a curved plate that forms the *auditory* and *vaginal processes* which bound the *external meatus*, or passage into the tympanum or middle ear. The tympanic and squamoso-zygomatic parts of the bone fuse together; but a fissure, called *Glaserian*, situated behind the glenoid fossa, marks their original separation; in this fissure the slender process of the malleus (one of the tympanic ossicles) is lodged. The petro-mastoid or periotic part of the temporal contains the organ of hearing, and is complicated in its internal anatomy. It extends forwards and inwards along the floor of the skull, and forms on the exterior of the skull the large nipple-shaped *mastoid process.* This process is rough on its outer surface, for the attachment of muscles, grooved on

its inner surface for the lateral venous blood sinus, and hollowed out within into the *mastoid cells*, or air-sinuses, which communicate with the tympanum or middle ear; it articulates with the occipital. The petrous-temporal is distinguished by its stony hardness, and has the form of a three-sided pyramid. Its apex lies in relation to the side of the body of the sphenoid; its base corresponds to the tympanic cavity and external meatus; its under surface is rough, and forms a part of the under surface of the skull; its anterior and posterior surfaces are smooth and within the cranial cavity. Its upper border is grooved for the superior petrosal blood sinus, its lower border for the inferior petrosal. The petrous part of the bone is traversed by a canal which transmits the internal carotid artery and sympathetic nervous cord into the cranial cavity; in its posterior surface is a passage, *internal meatus*, down which the 7th cranial nerve proceeds; at the bottom of the meatus the auditory part of that nerve enters the internal ear, whilst the facial part of the nerve which goes to the muscles of the face traverses a canal in the bone, called *aqueduct of Fallopius*, which ends externally, between the styloid and mastoid processes, in the *stylo-mastoid foramen*. The styloid process is a slender part of the bone which projects downwards from the vaginal process of the tympanic plate, and is joined to the small cornu of the hyoid bone by the stylo-hyoid ligament. It consists of two elements, a tympano-hyal and a stylo-hyal, and does not unite with the rest of the bone until a comparatively late period. The petrous-temporal and ex-occipital articulate, but between them is the *jugular foramen*, which transmits out of the skull the 8th cranial nerve and the internal jugular vein.

The fourteen bones of the Face are, as a rule, much smaller

than those of the Cranium. They are, two superior maxillary, two palate, two malar, two nasal, two lachrymal, two inferior turbinal, a vomer, and an inferior maxilla.

The Superior Maxillæ, or bones of the Upper Jaw (figs. 6 and 7), form the skeleton of a large part of the face, and of the walls of the cavities of the nose, mouth, and orbit; around them the other bones of the face are grouped. The facial surface of each bone has a rough *malar process* for articulation with the malar bone; in front of this is the *infra-orbital foramen* for the infra-orbital nerve and vessels, also the *canine fossa* and *incisor fossa;* behind are several small foramina for the transmission of nerves and vessels to the teeth in the upper jaw. The orbital surface is smooth, forms the floor of the orbit, possesses a canal in which the infra-orbital nerve and vessels run and articulates by its inner border with the ethmoid and lachrymal. The nasal surface forms a part of the outer wall and floor of the nostril, and presents a hole leading into a large hollow in the substance of the bone, called the *antrum*, or superior maxillary air-sinus: it articulates with the inferior turbinal and palate bones. The nasal and facial surfaces become continuous with each other at the anterior aperture of the nose, and from them a strong *ascending process* joins the frontal bone close to the glabella; this process articulates behind with the lachrymal and in front with the nasal bone. The palatal surface forms a part of the bony roof of the mouth, and presents in front a small hole (the *incisive foramen*) which communicates with the nose; in the sheep and many other mammals this hole is of large size. The palatal surface is bounded externally by a thick elevated border, in which are the sockets, or *alveoli*, for the fangs of the teeth; this surface articulates internally by a

narrow border with the other superior maxilla and with the vomer, and, posteriorly, with the palate bone.

The Palate-bone (fig. 7) articulates with the inner surface and posterior palatal border of the superior maxilla, and separates it from the sphenoid. It is in shape not unlike the capital letter L; the *horizontal plate* forms by its lower surface the back of the bony roof of the mouth, and by its upper the back of the floor of the nose: it articulates mesially with its fellow and with the vomer. The *ascending plate* assists in forming the outer wall of the nose, has a horizontal ridge on its inner surface for the inferior turbinal, and is divided superiorly by the *spheno-palatine notch* into an anterior, or *orbital*, and a posterior, or *sphenoidal process*, by which it articulates with the maxillary, ethmoid, and sphenoid. At the junction of the two plates is the *pyramidal process*, which articulates with the lower ends of the pterygoid processes of the sphenoid: near the root of this process are the *posterior palatine foramina.*

The Vomer (fig. 7), shaped like a ploughshare, lies vertically in the mesial plane of the nose, and forms a large part of the partition which separates one nostril from the other. It articulates above with the under surface of the body of the sphenoid and the mes-ethmoid; below with the palatal processes of the superior maxillæ and palate-bones; in front with the septal cartilage of the nose, whilst the posterior border is free, and forms the hinder edge of the nasal septum.

The Inferior Turbinated is a slightly convoluted bone situated below the middle turbinal of the ethmoid, on the outer wall of the nose, where it articulates with the superior maxilla, palate ethmoid, and lachrymal bones.

The Lachrymal (fig. 6) is a small scale-like bone, in shape not unlike a finger-nail, placed at the inner wall of

the orbit, and fitting between the ethmoid, superior maxilla, and frontal bones. It has a groove on the outer surface, in which is lodged the lachrymal sac.

The Nasal (fig. 6) is a thin, elongated bone, which, articulating with its fellow in the middle line and with the mes-ethmoid, forms the bony bridge of the nose; above, it articulates with the frontal, and by its outer border with the ascending process of the superior maxilla.

The Malar bone (fig. 6), irregular in shape, forms the prominence of the cheek, and completes the outer wall of the orbit. It rests upon the superior maxilla; by its *orbital plate* it articulates with the ali-sphenoid; by its *ascending process*, with the external angular process of the frontal; by its *posterior process* with the zygomatic process of the temporal, so as to complete the zygomatic arch. It is pierced by one or more *malar foramina.*

The Inferior Maxilla, Lower Jaw, or Mandible (figs. 6 and 7), a large horse-shoe shaped bone, has (the hyoid and tympanic ossicles excepted) the distinction of being the only movable bone of the head. It consists originally of two separate halves, which unite during the first year of life into a single bone at the *symphysis* or chin. A characteristic feature of the human lower jaw is the forward slope at the chin, for in other mammals the symphysis inclines backwards. The bone consists of a body and two rami. In the upper border of the body are the sockets for the lower teeth. Its outer surface shows the *incisor fossa*, the *mental foramen*, and an *oblique line* for muscular attachment: its inner surface the *genial tubercles*, and the *mylohoid ridge.* Posteriorly the bone ascends almost vertically, as the *ascending ramus*, and terminates in two processes separated by the *sigmoid notch*,—an anterior, or *coronoid*

process, for the insertion of the temporal muscle, and a posterior, or *condyle*, for articulation with the glenoid fossa of the temporal bone. Where the ascending ramus joins the body of the bone almost a right *angle* is formed, and here the masseter and internal pterygoid muscles are inserted. On the inner surface of the ramus is the *inferior dental foramen*, communicating with the canal below the sockets for the teeth in which lie the nerves and blood-vessels for the teeth.

The Hyoid bone lies in the neck, a little below the inferior maxilla (figs. 6 and 7). It is shaped like the letter U, and consists of a body, or *basi-hyal*, from which two great cornua or *thyro-hyals* project backwards. At the junction of the body and great horns two smaller cornua, or *cerato-hyals*, project upwards, and are connected with the styloid processes of the temporal bones, or *stylo-hyals*, by the stylo-hyoid ligaments, or *epi-hyals*. The hyoid gives origin to the muscles of the tongue, and lies above the thyroid cartilage of the larynx, to which it is attached by ligaments.

In its general form the Skull is ovoid, with the long axis extending antero-posteriorly, the frontal and occipital ends rounded, and the sides somewhat flattened. Its average length in the people of the British Islands is a little more than 7 inches; its greatest breadth about $5\frac{1}{2}$ inches; and its height, from the plane of the foramen magnum to the vertex, about $5\frac{1}{4}$ inches. Its greatest circumference is about 21 inches. The breadth of the face across the zygomatic arches is about 5 inches. The average capacity of the brain cavity is 92 cubic inches. The British skull is mesati-cephalic and orthognathic.[1]

[1] Human Crania may be arranged in three groups according to their proportion of length and breadth. When the breadth is to the length less than 75 to 100 they are dolico-cephalic; when between 75 and 80 to 100, mesati-cephalic; when more than 80 to 100, brachy-cephalic.

The lateral regions of the skull are called the *temporal fossæ*, and give origin to the temporal muscles. Under cover of each zygomatic arch is the *zygomatic fossa*. At the bottom of this is a hollow between the superior maxilla and sphenoid, called *spheno-maxillary fossa*, from which the *pterygo-maxillary fissure* extends downwards between the pterygoid plates, palate bone and superior maxilla, and the *spheno-maxillary fissure* extends upwards into the orbit.

Each Orbit is a four-walled pyramidal cavity, with the base directed forward to the face, and the apex backward to the brain cavity. The roof is formed by the orbital plate of the frontal and the orbito-sphenoid; the floor by the orbital plates of the malar, superior maxilla, and palate; the inner wall by the ascending process of superior maxilla, lachrymal, os planum of ethmoid and the sphenoid; the outer wall by the ali-sphenoid and malar. At the apex are the foramen opticum and sphenoidal fissure; between the floor and outer wall is the spheno-maxillary fissure; in the floor is the infra-orbital canal; in the outer wall the malar foramina; in the inner wall the lachrymal groove and anterior and posterior ethmoidal foramina; at the anterior border of the roof is the supra-orbital foramen or notch.

The Nostrils open on the front of the face by a large aperture situated between the two superior maxillæ, and bounded above by the two nasals. The sides of the opening pass down almost vertically to join the floor, and are not rounded off as in the ape's skull; from the centre of the floor a sharp process, the *nasal spine* of the superior maxillæ, projects forwards, and forms a characteristic feature of the human skull. Attached to the sides of the opening are the lateral cartilages of the nose, which form the wings of the nostrils, and so modify the position of

their openings that in the face they look downwards. The floor of the nose is formed by the palates and superior maxillæ; the roof by the cribriform plate of the ethmoid, frontal, nasal, and sphenoidal spongy bones. The nostrils are separated from each other by a vertical mesial partition composed of the mes-ethmoid, vomer, and triangular nasal cartilage, the last-named of which projects forward beyond the anterior surface of the upper jaw, and contributes materially to the prominence of the nose. The outer wall of each nostril is formed by the superior maxilla, palate, nasal, internal pterygoid, and convoluted turbinals: the turbinals are separated from each other by horizontal passages extending antero-posteriorly; the *superior* passage or *meatus* lies between the superior and middle turbinals of the ethmoid, and is continued into the sphenoidal and posterior ethmoidal air-sinuses; the *middle meatus* lies between the middle and inferior turbinals, and is continued into the frontal, anterior ethmoidal, and maxillary air-sinuses. These sinuses are therefore extensions of the nasal chamber or respiratory passage, and correspond with the air cavities which exist in so many of the bones of birds. The *inferior meatus* lies between the inferior turbinal and the floor of the nose; into its anterior part the nasal duct opens, which conveys the tears from the front of the eyeball. The posterior openings of the nose are separated from each other by the hinder edge of the vomer, and are placed between the internal pterygoid plates of the sphenoid.

The skull varies in appearance at different periods of life. In infancy the face is small, about $\frac{1}{8}$th of the size of the entire head, for the teeth are still rudimentary and the jaws are feeble; the centres of ossification of the cranial bones are prominent; the forehead projects; the skull is widest at the parietal eminences; the air-sinuses, and bony ridges corresponding to them, have not formed. In the adult

the face is about half the size of the head, and its vertical diameter is greatly elongated, from the growth of the antrum, the nose, and the dental borders of the jaws; and the angle of the lower jaw is almost a right angle. In old age the teeth fall out, the jaws shrink in, their dental borders become absorbed, the angle of the lower jaw, as in infancy, is obtuse; both the vertex and floor of the skull become flattened, and the sides bulge outwards,—changes due to gravitation and the subsidence of the bones by their own weight.

The skull of a woman is smaller and lighter, with the muscular ridges and projections due to the air-sinuses less strongly marked than in a man, but with the eminences or centres of ossification more prominent. The more feeble air-sinuses imply a more restricted respiratory activity and a less active mode of life than in a man. The internal capacity is about 10 per cent. less than that of the male. The face is smaller in proportion to the cranium; the cranium is more flattened at the vertex, and the height is consequently not so great in proportion to the length as in the man. In the adult female skull, therefore, the infantile characters are less departed from than is the case in the male.

Appendicular Skeleton.

SUPERIOR EXTREMITY OR UPPER LIMB.

The Upper Limb may be divided into a proximal part or Shoulder, a distal part or Hand, and an intermediate Shaft, which consists of an upper arm or *brachium*, and a fore-arm or *anti-brachium*. In each of these divisions certain bones are found: in the shoulder, the clavicle and scapula; in the upper arm, the humerus; in the fore-arm, the radius and ulna, the bone of the upper arm in man being longer than the bones of the fore-arm; in the hand, the carpal and metacarpal bones and the phalanges. The scapula and clavicle together form an imperfect bony arch, the Scapular Arch or Shoulder Girdle; the shaft and hand form a free divergent Appendage. The shoulder girdle is the direct medium of connection between the axial skeleton and the divergent part of the limb; its anterior segment, the clavicle, articulates with the upper end of the sternum,

whilst its posterior segment, the scapula, approaches, but does not reach, the dorsal spines.

The Clavicle, or Collar Bone (fig. 9), is an elongated bone which extends from the upper end of the sternum horizontally outwards, to articulate with the acromion process of the scapula. It presents a strong sigmoidal curve, which is associated with the transverse and horizontal direction of the axis of the human shoulder. It is slender in the female, but powerful in muscular males; its sternal end is thick and somewhat triangular; its acromial end, flattened from above downwards, has an oval articular

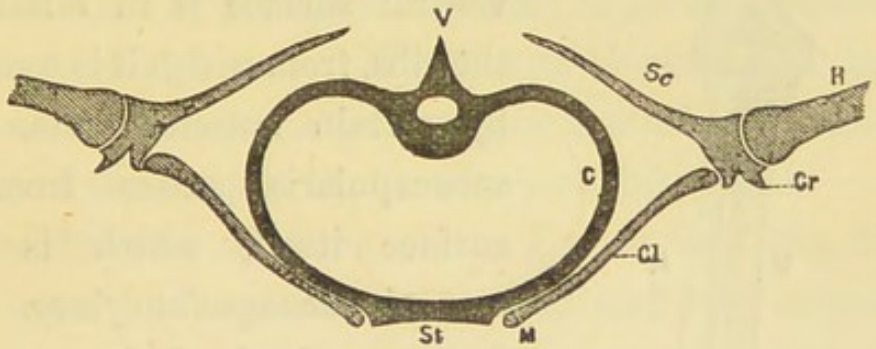

FIG. 8.—Diagrammatic Transverse Section to represent the relations of the Shoulder Girdle to the Trunk. V, a Dorsal Vertebra; C, a Rib; St, the Sternum; Sc, the Scapula; Cr, the Coracoid; Cl, the Clavicle; M, the Meniscus at its sternal end; H, the Humerus.

surface for the acromion. Its shaft has four surfaces for the attachment of muscles; a strong ligament, connecting it with the coracoid, is attached to the under surface, near the outer end, whilst near the inner a strong ligament passes between it and the 1st rib. The clavicle is absent in hoofed quadrupeds, in seals and whales, and is feeble in the carnivora; but is well formed, not only in man, but in apes, bats, and in many rodents and insectivora.

The Scapula, or Shoulder Blade (fig. 9), is the most important bone of the shoulder girdle, and is present in all mammals. It lies at the upper and back part of the wall of the chest, reaching from the 2d to the 7th

rib. Its form is plate-like and triangular, with three surfaces, three borders, and three angles. The fundamental form of the scapula, as seen in the mole, is that of a three-sided prismatic rod, and its assumption of the plate or blade-like character in man is in connection with the great development of the muscles which rotate the humerus at the shoulder joint. Its costal or ventral surface is in relation to the ribs, from which it is separated by certain muscles: one, called subscapularis, arises from the surface itself, which is often termed *subscapular fossa*. The dorsum or back of the scapula is traversed from behind forwards by a prominent *spine*, which lies in the proper axis of the scapula, and subdivides this aspect of the bone into a surface above the spine, the *supra-* or *pre-spinous fossa*, and one below the spine, the *infra-* or *post-spinous fossa*. The spine arches forwards, to end in a broad flattened process, the *acromion*, which has an oval articular surface for the clavicle; both spine and acromion are largely developed in the human

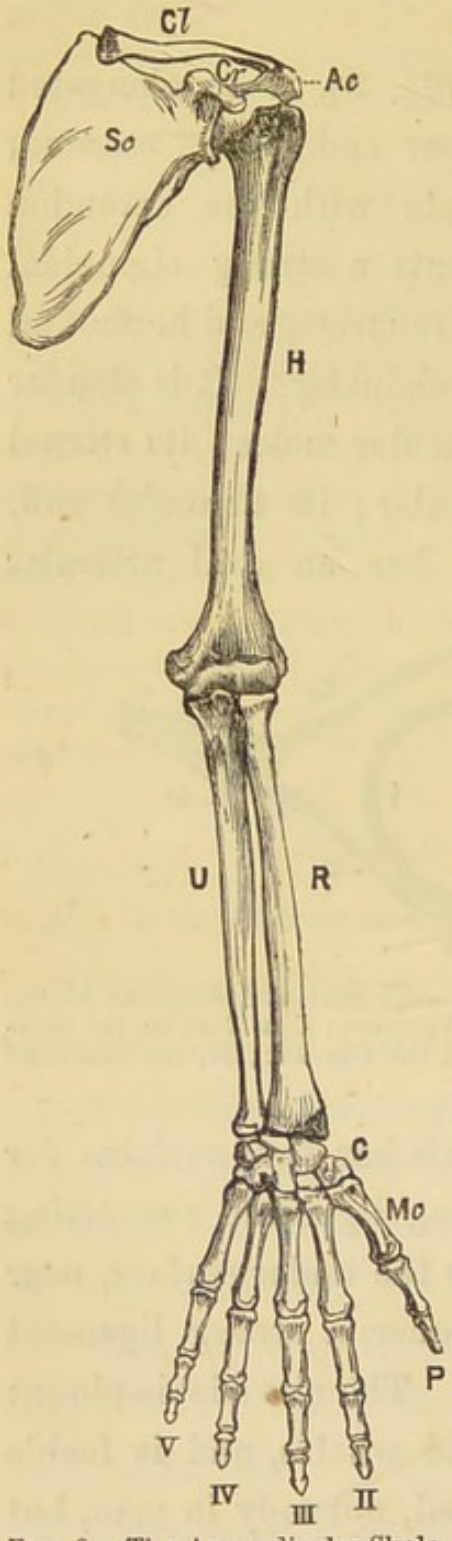

FIG. 9.—The Appendicular Skeleton of the Left Upper Limb. Cl, clavicle; Sc, scapula; Ac, acromion process; Cr, coracoid process of scapula; H, humerus; R, radius; U, ulna; C, opposite the eight carpal bones; Mc, opposite the five metacarpal bones; P, pollex, or thumb; II. index, III. middle, IV. ring, V little finger.

scapula in correlation with the great size of the trapezius and deltoid muscles, which are concerned in the elevation and abduction of the upper limb. The borders of the scapula, *posterior*, *superior*, *anterior*, give attachment to several muscles. The angles are *inferior*, *supero-posterior*, and *supero-anterior*. The supero-anterior is the most important; it is truncated, and presents a large, shallow, oval, smooth surface, the *glenoid fossa*, for articulation with the humerus, to form the shoulder joint. Overhanging the glenoid fossa is a curved beak-like process, the *coracoid*, which is of importance as corresponding with the separate coracoid bone of birds and reptiles: it gives attachment to muscles and ligaments. The line of demarcation between the coracoid and the scapula proper is marked on the upper border of the scapula by the suprascapular notch.

The Humerus, or bone of the Upper Arm (fig. 9), is a long bone, and consists of a shaft and two extremities. The upper extremity of this bone possesses a convex spheroidal smooth surface, the *head*, for articulation with the glenoid fossa of the scapula; it is surrounded by a narrow constricted *anatomical neck*, and where the neck and shaft become continuous with each other, two *tuberosities* are found, to which are attached the rotator muscles arising from the scapular fossæ. Between the tuberosities is the *bicipital groove* in which the long tendon of the biceps rests; this groove is bounded in front and behind by the *bicipital ridges*. A line drawn through the head of the humerus perpendicular to the middle of its articular surface, forms with the axis of the shaft of the bone an angle of 40°. The shaft of the humerus is cylindriform above, but three-sided and expanded below; about midway down the outer surface is a rough ridge for the insertion

of the deltoid muscle, and on the inner surface another rough mark for the insertion of the coraco-brachialis. The demarcation between the cylindriform and three-sided parts of the shaft is marked by the shallow *musculo-spiral groove* winding round the back of the bone, in which the musculo-spiral nerve is lodged. The lower extremity of the humerus consists of an articular and a non-articular portion. The articular presents a small head or *capitellum* for the radius, and a pulley or *trochlea* for the movements of the ulna in flexion and extension of the limb. The non-articular part consists of two condyloid eminences, internal and external. The external, or *epicondyle*, has a ridge passing up the outer border of the bone; the ridge and eminence give origin to the supinator and extensor muscles in the fore-arm. From the internal eminence, or *epi-trochlea*, a ridge passes up the inner border of the shaft of the bone; this eminence gives origin to the pronator and flexor muscles in the fore-arm. In nearly two per cent. of the bodies examined in the anatomy-rooms in the University of Edinburgh, a hooked process has been seen projecting from the shaft of the bone, about 2 inches above the epi-trochlea; this process is connected to the epi-trochlea by a fibrous band, so as to form a *foramen*, which has been called *supra-condyloid*. In these cases the median nerve invariably passes through the foramen, and is usually accompanied by the brachial artery. In the feline carnivora and some other mammals a foramen constantly occurs in this part of the humerus, through which, as a rule, both nerve and artery proceed, though in the common and ringed seals it transmits only the nerve.

The two bones of the fore-arm can change their relative position to each other. In one position, which is called *Supine*, they lie parallel,

the radius being the more external bone, and the palm of the hand being directed forwards ; in the other or *Prone* position the radius crosses obliquely in front of the ulna, and the palm of the hand is directed backwards. The bones of the fore-arm, and those of the hand are placed in the supine position when they are described.

The Radius (fig. 9) is the outer bone of the Fore-arm, and like all long bones possesses a shaft and two extremities. The upper extremity or *head* has a shallow, smooth cup for moving on the capitellum of the humerus ; the outer margin of the cup is also smooth, for articulation with the ulna and annular ligament ; below the cup is a constricted *neck*, and immediately below the neck a *tuberosity* for the insertion of the biceps. The shaft of the bone possesses three surfaces for the attachment of muscles, and a sharp inner border for the interosseous membrane. The lower end of the bone is much broader than the upper, and is marked posteriorly by grooves for the extensor tendons passing to the back of the hand : from its outer border a pointed *styloid* process projects downwards ; its inner border has a smooth shallow fossa for articulation with the ulna, and its broad lower surface is smooth and concave, for articulation with the scaphoid and semilunar bones of the wrist.

The Ulna (fig. 9) is the inner bone of the Fore-arm. Its upper end is divided into two strong processes by a deep fossa, the *greater sigmoid cavity*, which possesses a smooth surface for articulation with the trochlea of the humerus. The anterior or *coronoid* process is marked by an oblique ridge for the insertion of the brachialis anticus, whilst the posterior or *olecranon* process gives insertion to the large triceps muscle of the upper arm. Immediately below the outer border of the great sigmoid cavity is the *small sigmoid cavity* for articulation with the side of the head of the radius. The shaft of the bone has three surfaces for the

attachment of muscles, and a sharp outer border for the interosseous membrane. The lower end, much smaller than the upper, has a pointed *styloid* process and a smooth articular surface, the outer portion of which is for the lower end of the radius, the lower portion for moving on the triangular fibro-cartilage of the wrist joint. This end is grooved behind for the tendon of the extensor carpi ulnaris.

The Hand consists of the Carpus or wrist, of the Metacarpus or palm, and of five free Digits, the thumb and four fingers. Anatomists describe it with the palm turned to the front, and with its axis in line with the axis of the fore-arm. The Carpal or Wrist bones (fig. 9), eight in number and small in size, are arranged in two rows, a *proximal—i.e.* a row next the fore-arm,—consisting of the Scaphoid, Semilunar, Cuneiform, and Pisiform; and a *distal—i.e.*, a row next the bones of the palm,—consisting of the Trapezium, Trapezoid, Os Magnum, and Unciform; the bones in each row being named in their order from the radial or outer to the ulnar or inner side of the wrist. Except the pisiform bone, shaped like a split pea, which articulates with the front of the cuneiform, each carpal bone is short and irregularly cuboidal in shape; its anterior (or palmar) surface and its posterior (or dorsal) are rough, for the attachment of ligaments; its superior and inferior surfaces are invariably smooth, for articulation with adjacent bones; the inner and outer surfaces are also smooth for articulation, except the outer surface of the scaphoid and trapezium (the two external bones of the carpus), and the inner surface of the cuneiform and unciform (the two internal bones). The pisiform articulates with only one bone; the cuneiform with three and with the triangular fibro-cartilage; the trapezoid and trapezium each with

four; the scaphoid, semilunar, and unciform each with five; and the os magnum with seven.

Occasionally a ninth or supernumerary bone may arise from the division of the scaphoid, semilunar, or trapezoid into two pieces, or from a separate ossification of the styloid process of the 3d metacarpal: more rarely a distinct bone is found in the human wrist intercalated between the trapezoid, os magnum, semilunar, and scaphoid, which corresponds in position to the os centrale, found constantly in the wrist of the orang, gibbon, the tailed apes, and many rodents and insectivora.

The Metacarpal bones, or bones of the Palm of the Hand, are five in number (fig. 9). They are miniature long bones, and each possesses a shaft and two extremities. The metacarpal of the thumb is the shortest, and diverges outwards from the rest: its carpal extremity is saddle-shaped, for articulation with the trapezium; its shaft is somewhat compressed, and its phalangeal end is smooth and rounded, for the first phalanx of the thumb. The four other metacarpal bones belong to the four fingers; they are almost parallel to each other, and diminish in size from the 2d to the 5th. The 1st, 3d, and 5th metacarpals articulate, each with a single carpal bone, viz., the 1st with the trapezium, the 3d with the os magnum, the 5th with the unciform. The 2d metacarpal articulates with three carpals—the trapezoid, trapezium, and os magnum. The 4th metacarpal with two carpals,—the os magnum and unciform. The 3d and 4th metacarpals articulate on each side with the contiguous metacarpals: the 2d and 5th on one side only, viz., the 2d on its inner side with the 3d metacarpal, and the 5th on its outer side with the 4th; the 1st does not articulate with any metacarpal. (See page 53.)

The number of Digits in the hand is five, which is the highest number found in the mammalia. They are distinguished by the names of Pollex or thumb, and Index,

Middle, Ring, and Little fingers. The skeleton consists of fourteen bones, named Phalanges, of which the thumb possesses two, and each of the four fingers three. The phalanx next the metacarpal bone is the first, that which carries the nail is the terminal or ungual phalanx, whilst the intermediate bone is the second phalanx. Each is a miniature long bone, with two articular extremities and an intermediate shaft, except the terminal phalanges, which have an articular surface only at their proximal ends, the distal end being rounded and rough, to afford a surface for the lodgment of the nail.

LOWER LIMB.

The INFERIOR or PELVIC EXTREMITY, or LOWER LIMB, consists of a proximal part or Haunch, a distal part or Foot, and an intermediate Shaft subdivided into thigh and leg. Each part has its appropriate skeleton: in the haunch, the pelvic or innominate bone; in the thigh, the femur; in the leg, the tibia and fibula (the thigh-bone in man being longer than the leg-bones); in front of the knee, the patella; in the foot, the tarsal and metatarsal bones and phalanges. The bone of the haunch forms an arch or Pelvic Girdle, which articulates behind with the side of the sacrum, and arches forward to articulate with the opposite haunch bone at the pubic symphysis. It is the direct medium of con-

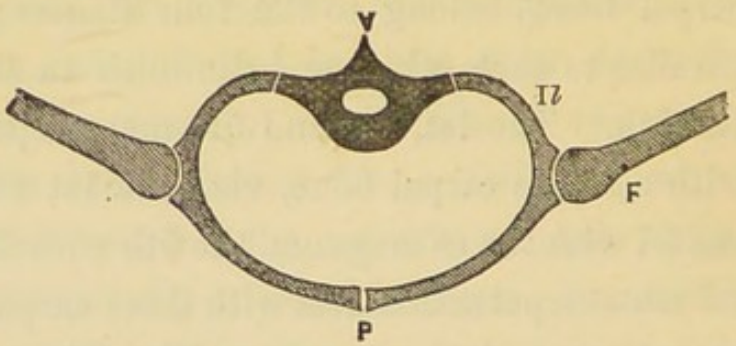

FIG. 10.—Diagrammatic Transverse Section to represent the relations of the Pelvic Girdle to the Trunk. V, a sacral vertebra; Il, the ilium; P, the two pubic bones meeting in front at the symphysis; F, the femur.

nection between the axial skeleton and the shaft and foot, which form a free divergent Appendage.

The Os Innominatum, or Haunch-bone, is a large irregular plate-like bone, which forms the lateral and anterior boundary of the cavity of the pelvis. In early life it consists of three bones—ilium, ischium, and os pubis—which unite about the twenty-fifth year into a single bone. These bones converge, and join to form a deep fossa or cup, the *acetabulum* or *cotyloid cavity*, on the outer surface of the bone, which lodges the head of the thigh-bone at the hip-joint. One-fifth of this cup is formed by the os pubis, a little more than two-fifths by the ischium, and a little less by the ilium. At the bottom of the acetabulum is a depression, to the sides of which the *inter-articular* or *round ligament* of the hip-joint is attached. From the acetabulum the ilium extends upwards and backwards, the ischium downwards and backwards, the os pubis forwards and inwards. In front of the acetabulum is a large hole, the *obturator* or *thyroid foramen*, which is bounded by the ischium and os pubis; behind the acetabulum is the *great sciatic notch* which is bounded by the ischium and ilium.

The Ilium (fig. 11) in man is a sinuous plate-like bone. In its most simple form, as in the kangaroo, it is a three-sided, prismatic, rod-like bone, one end of which enters into the formation of the acetabulum, whilst the other is free, and forms the iliac crest. In man, notwithstanding its expanded form, three surfaces may also be recognized, corresponding to the surfaces in the ilium of the kangaroo; and, as in that animal, the lower end aids in forming the acetabulum, while the upper end forms the iliac crest, which, in man, in conformity with the general expansion of the bone, is elongated into the sinuous *crista ilii*. The

crest is of great importance, for it affords attachment to the broad muscles which form the wall of the abdominal cavity. One surface of the ilium is *posterior* or *external*, and marked by the *posterior*, *superior*, and *inferior curved lines* which divide it into four areas for the origin of the three gluteal muscles and of the rectus femoris; another surface is *anterior*, and hollowed out to give origin to the iliacus muscle; the third or *internal* surface articulates posteriorly with the sacrum, whilst anteriorly it forms a part of the wall of the true pelvis. The posterior is separated from the anterior surface by a border which joins the anterior end of the crest, where it forms a process, the *anterior superior spine:* about the middle of this border is the *anterior inferior spine.* Between the posterior and internal surfaces is a border on which are found the *postero-superior* and *inferior spines;*

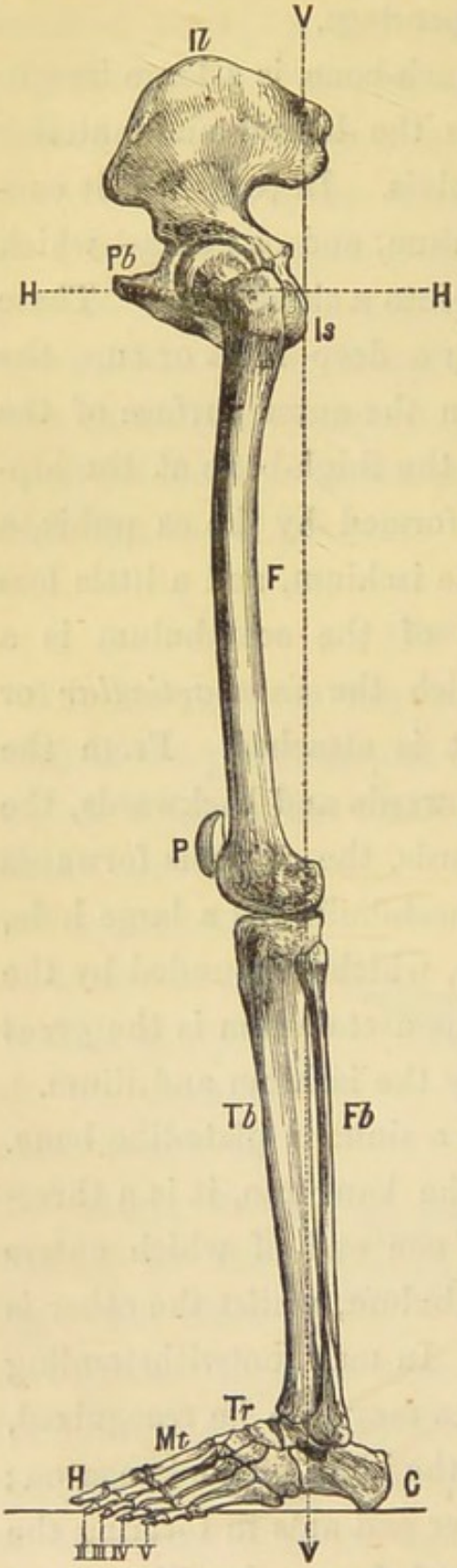

FIG. 11.—The Appendicular Skeleton of the Left Lower Limb. Il, ilium, Is ischium, Pb, os pubis, the three parts of the innominate bone; F, femur; P, patella; Tb, tibia; Fb, fibula; Tr, opposite the seven tarsal bones; C, os calcis, forming prominence of heel; Mt, opposite the five metatarsal bones; H, hallux or great toe; II. second, III. third, IV. fourth, V. fifth or little toe. The dotted line HH represents the horizontal plane; the dotted line V V is in line with the axis of the spine.

between the anterior and internal surfaces is the *pectineal* border, which forms part of the line of separation between the true and false pelvis.

The os Pubis (fig. 11) is also a three-sided, prismatic, rod-like bone, the fundamental form of which is obscured by the modification in shape of its inner end. In human anatomy it is customary to regard it as consisting of a *body* and of two branches, a *horizontal* and a *descending ramus*. The body and horizontal ramus form the fundamental prismatic rod, and the descending ramus is merely a special offshoot from the inner end of the rod. The outer end of the rod enters into the formation of the acetabulum; the inner end is expanded into the body of the os pubis, and has a broad margin, or *symphysis*, for articulation with the os pubis on the opposite side. At the upper border of the body is the *crest*, which ends externally in the *spine*, internally in the *angle*. The three surfaces of the pubic rod are—a *superior*, for the origin of the pectineus muscle; a *posterior*, which enters into the wall of the true pelvis; and an *inferior*, which forms the upper boundary of the obturator foramen. The descending ramus is a downward prolongation of the body of the bone which joins the ischium, and aids in forming the side of the pubic arch. The junction of the outer end of the pubis with the ilium is marked by the *pectineal eminence*. The superior and posterior surfaces of the pubic rod are separated by the sharp *pectineal line*, which, starting from the *spine* of the os pubis, runs outwards to aid in forming the brim of the true pelvis; the posterior and inferior surfaces are separated by a ridge next the obturator foramen, which is grooved for the obturator vessels and nerve.

The Ischium (fig. 11), like the ilium and os pubis, has the fundamental form of a three-sided prismatic rod. One

extremity (the upper) completes the acetabulum, whilst the lower forms the large tuberosity, or *tuber ischii.* The surfaces of the bone are *internal* or pelvic, *posterior,* and *anterior.* The pelvic and posterior surfaces are separated from each other by a sharp border, on which is seen the *ischial spine;* between the spine and tuberosity is the *small sciatic notch* for the obturator internus muscle. The pelvic and anterior surfaces are separated by a border, which forms a part of the boundary of the obturator foramen: the border between the posterior and anterior surfaces is feebly marked and grooved for the obturator externus muscle. The tuberosity, a thick, rough, and strong process, gives origin to the hamstring and other muscles: on it the body rests in the sitting posture; an offshoot, or *ramus,* ascends from it to join the descending ramus of the pubis, and completes both the pubic arch and the margin of the obturator foramen.

By the articulation of the two innominate bones with each other in front at the pubic symphysis, and with the sides of the sacrum behind, the osseous walls of the cavity of the PELVIS are formed. This cavity is divided into a false and a true pelvis. The *false pelvis* lies between the expanded wing-like portions of the two ilia. The *true pelvis* lies below the two pectineal lines and the base of the sacrum, which bound its upper orifice, and form the brim of the true pelvis, or *pelvic inlet;* whilst its lower orifice or *pelvic outlet* is bounded behind by the coccyx, laterally by the ischial tuberosities, and in front by the pubic arch. In the erect attitude the pelvis is so inclined that the plane of the brim forms with the horizontal plane an angle of from 60° to 65°. The axis of the cavity is curved, and is represented by a line drawn perpendicularly to the planes

of the brim, the cavity, and the outlet; at the brim it is directed upwards and forwards, at the outlet downwards and a little forwards. Owing to the inclination of the pelvis, the base of the sacrum is nearly 4 inches higher than the upper border of the pubic symphysis.

The female pelvis is distinguished from the male by certain sexual characters. The bones are more slender, the ridges and processes for muscular attachment more feeble, the breadth and capacity greater, the depth less, the ilia more expanded, giving the greater breadth to the hips of a woman than a man; the inlet more nearly circular, the pubic arch wider, the distance between the ischial tuberosities greater, and the obturator foramen larger in the female than in the male. The greater capacity of the woman's than the man's pelvis is to afford greater room for the expansion of the uterus during pregnancy, and for the expulsion of the child at the time of birth.

The Femur or Thigh-bone (fig. 11) is the longest bone in the body, and consists of a shaft and two extremities. The upper extremity or *head* possesses a smooth convex surface, on which is an oval roughened fossa, for the attachment of the inter-articular ligamentum teres of the hip; from the head a strong elongated *neck* passes downwards and outwards to join the upper end of the shaft; the place of junction is marked by two processes or *trochanters:* the *external* is of great size, and to it are attached many muscles; the *internal* is much smaller, and gives attachment to the psoas and iliacus muscles. A line drawn through the axis of the head and neck forms with a vertical line drawn through the shaft an angle of 30°; in a woman this angle is less obtuse than in a man, and the obliquity of the shaft of the femur is greater in the former than in the latter. The shaft is almost cylindrical about its centre, but expanded above and below; it gives origin to the vasti and crureus muscles; behind there is a rough ridge, which, though called *linea aspera*, is really a narrow surface

and not a line; it gives attachment to several muscles. The lower end of the bone presents a large smooth articular surface for the knee-joint, the anterior portion of which forms a *trochlea* or pulley for the movements of the patella, whilst the lower and posterior part is divided into two convex *condyles* by a deep *intercondyloid fossa* which gives attachment to the crucial ligaments of the knee. The inner and outer surfaces of the condyles are called *tuberosities*, and are rough for the attachment of muscles and the lateral ligaments of the knee, and the outer tuberosity is grooved externally for the tendon of the popliteus.

The Patella or Knee-pan (fig. 11) is a small triangular flattened bone developed in the tendon of the extensor muscles of the leg. Its anterior surface and sides are rough, for the attachment of that tendon; its posterior surface is smooth, and enters into the formation of the knee-joint.

Between the two bones of the leg there are no movements of pronation and supination as between the two bones of the fore-arm. The tibia and fibula are fixed in position; the fibula is always external, the tibia internal.

The Tibia or Shin-bone (fig. 11) is the larger and more important of the two bones of the leg; the femur moves and rests upon its upper end, and down it the weight of the body in the erect position is transmitted to the foot. Except the femur, it is the longest bone of the skeleton, and consists of a shaft and two extremities. The upper extremity is broad, and is expanded into two *tuberosities* the *external* of which has a small articular facet inferiorly for the head of the fibula, and the *internal* is grooved for the tendon of the semi-membranosus; superiorly, the tuberosities have two smooth surfaces, for articulation with the condyles of the femur; they are separated by an

intermediate rough surface, from which a short *spine* projects, which gives attachments to the inter-articular crucial ligaments and semilunar cartilages of the knee, and lies opposite the inter-condyloid fossa of the femur. The shaft of the bone is three-sided; its inner surface is subcutaneous, and forms the shin; its outer and posterior surfaces are for the origin of muscles; the anterior border forms the sharp ridge of the shin, and terminates superiorly in a *tubercle* for the insertion of the extensor tendon of the leg; the outer border of the bone gives attachment to the inter-osseous membrane of the leg. The lower end of the bone, smaller than the upper, is prolonged into a broad process, *internal malleolus*, which forms the inner prominence of the ankle: its under surface is smooth for articulation with the astragalus; externally it articulates with the lower end of the fibula; behind it is grooved for the tibialis posticus and the flexors of the toes.

The Fibula, or Splint-bone of the leg (fig. 11), is a slender long bone with a shaft and two extremities. The upper end or *head* articulates with the outer tuberosity of the tibia, and gives insertion to the biceps muscle and external lateral ligament of the knee. The shaft is three-sided, and gives origin to many muscles; along the inner surface is a slender ridge for the attachment of the interosseous membrane. The lower end has a strong process, *external malleolus*, projecting downwards to form the outer prominence of the ankle; it has a smooth inner surface for articulation with the astragalus, above which is a rough surface for the attachment of the interosseous ligament between the tibia and fibula; behind it is grooved for the tendons of the peroneus longus and brevis.

The Foot consists of the Tarsus, the Metatarsus, and the

five free Digits or Toes, which is the maximum number found in mammals. The human foot is placed in the prone position, with the sole or plantar surface in relation to the ground; the dorsum or back of the foot directed upwards; the axis of the foot at about a right angle to the axis of the leg; and the great toe or hallux, which is the corresponding digit to the thumb, at the inner border of the foot. The human foot, therefore, is a pentadactylous, plantigrade foot.

The bones of the Tarsus, or Ankle (fig. 11, Tr), are seven in number, and are arranged in two transverse rows,—a proximal, next the bones of the leg, consisting of the Astragalus, Os Calcis, and Scaphoid; a distal, next the metatarsus, consisting of the Cuboid, Ecto-, Meso-, and Ento-cuneiform. If the tarsal bones be looked at along with those of the metatarsus and toes, the bones of the foot may be arranged in two longitudinal columns,—an outer, consisting of the os calcis, cuboid, and the metatarsal bones and phalanges of the 4th and 5th toes; an inner column consisting of the astragalus, scaphoid, three cuneiform, and the metatarsal bones and phalanges of the 1st, 2d, and 3d toes. The tarsal, like the carpal bones, are short and irregularly cuboidal; the dorsal and plantar surfaces are as a rule rough for ligaments, but as the astragalus is locked in between the bones of the leg and the os calcis, its dorsal and plantar surfaces, as well as the dorsum of the os calcis, are smooth for articulation; similarly, its lateral surfaces are smooth for articulation with the two malleoli. Except the posterior surface of the os calcis which projects backwards to form the prominence of the heel, and the posterior surface of the astragalus which is grooved for the tendon of the flexor longus hallucis, the tarsal bones have their anterior and posterior surfaces smooth for articulation.

Their lateral surfaces are also articular, except the outer surfaces of the os calcis, and cuboid, which form the outer border; and the inner surfaces of the os calcis, scaphoid, and ento-cuneiform, which form the inner border of the tarsus. The os calcis articulates with two bones; the astragalus, ento- and meso-cuneiform each with four; the scaphoid and cuboid each with five; and the ecto-cuneiform with six bones.

A supernumerary bone is sometimes found in the human tarsus, from a division of either the ento-cuneiform, astragalus, os calcis, or cuboid into two parts. In some rodents and other mammals eight is the normal number of bones in the tarsus.

The Metatarsal bones and the Phalanges of the toes agree in number and general form with the metacarpal bones and the phalanges in the hand. The bones of the 1st or great toe or Hallux are more massive than those of the other digits, and this digit, unlike the thumb or pollex, does not diverge from the other digits, but lies almost parallel to them. The phalanges of the four outer toes are much smaller than those of the fingers. The 1st metatarsal is the thickest and shortest. The 2d is the longest, and from it they diminish in length to the 5th. The tarsal end of the 5th projects backwards as a strong process on the outer side of the foot. The 1st, 3d, and 5th metatarsals articulate each with a single tarsal bone, viz., the 1st with the ento-cuneiform, the 3d with the ecto-cuneiform, the 5th with the cuboid. The 2d metatarsal articulates with three tarsals—the ento-, meso-, and ecto-cuneiform. The 4th metatarsal with two tarsals—the ecto-cuneiform and cuboid. The 3d and 4th metatarsals articulate on each side with the contiguous metatarsals; the 2d and 5th on one side only, viz., the 2d on its outer side with the 3d metatarsal, and the 5th on its inner side with the 4th; the 1st does not articulate with any metatarsal. (See p. 43.)

Development and Homologies of the Skeleton.

It will now be advisable to consider briefly the development of the skeleton, and along with the study of its genesis to compare its several parts with each other, in order to ascertain if correspondences in their arrangement and mode of origin exist, even if they differ in the function or office which they perform. When two or more parts or organs correspond with each other in structure, relative position, and development, we say they are homologous parts, or *homologues;* whilst parts which have the same function, but do not correspond in structure, relative position, and development, are analogous parts, or *analogues.* Homologous parts have therefore a morphological identity with each other, whilst analogous parts have a physiological agreement. The same parts may be both homologous and analogous, as the fore-limbs of a bat and a bird, both of which, with the same fundamental type of structure, are subservient to flight. In other cases analogous parts are not homologues, as the wing of the insect, which, though subservient to flight, is fundamentally different from the wing of the bat or bird.

The area of the blastoderm in the fertilized vertebrate ovum, in which the embryo is formed, consists of three layers of cells, named respectively from without inwards, *epiblast*, *mesoblast*, and *hypoblast.* The skeleton is produced by a special differentiation of the cells of the mesoblast. In the *embryonic area* an axial, dorsal, *primitive groove* appears, which marks the beginning of the cranio-spinal region of the young embryo. The sides of this groove become elevated as thin membranes, and form the *dorsal laminæ* or *medullary folds*, which, continuing to grow, meet mesially and enclose the epiblast, from which the brain and spinal cord are developed (fig. 11*). At the bottom of the primitive groove an elongated axial rod, the *chorda dorsalis* or *notochord*, is formed, which constitutes the primitive axial skeleton, and marks the position of the bodies of the future vertebræ. The mesoblast, situated at the sides of the chorda dorsalis in the spinal region, forms a series of definite masses, the *primordial* or *proto-vertebræ.* The proto-vertebræ in part differentiate into cartilage, which surrounds the notochord,

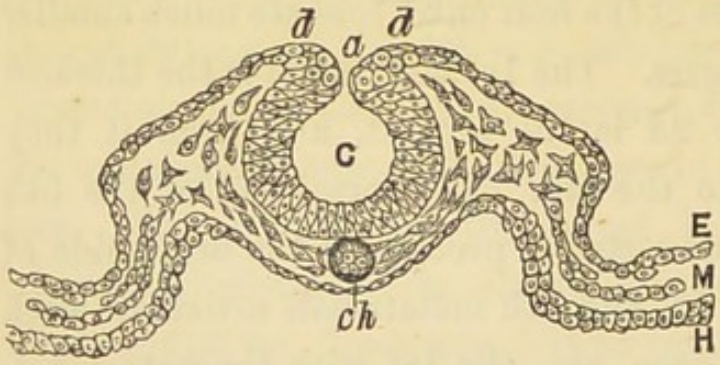

Fig. 11*.—Transverse-Vertical Section through the Blastoderm of a Chick at the end of the second day. E, epiblast; M, mesoblast; H, hypoblast. C, the primitive groove closing in to form the axial or central canal; *d*, *d*, the elevated sides of the groove or dorsal laminæ, which subsequently blend opposite *a*; *ch*, chorda dorsalis. (*After Schenk.*)

and at first is said to form a continuous cartilaginous investment for it, but subsequently the cartilage becomes segmented. About the same time a differentiation of the mesoblast cells in the dorsal laminæ into cartilaginous neural arches takes place and thirty-three cartilaginous vertebræ arise, corresponding in number to the future osseous vertebræ. The formation of these cartilaginous vertebræ is completed in the human embryo about the fourth month of intra-uterine life. The bodies of the cartilaginous vertebræ are connected together by plates or discs of intervening fibro-cartilage, which are also developed around the chorda dorsalis. After the enclosure of the rod-like chorda by the cartilaginous vertebræ and the inter-vertebral discs it disappears, no remains being found in the adult human body, or in that of the higher vertebrates, except perhaps some slight traces in the soft pulpy centres of the inter-vertebral discs; in Cyclostomata and in the cartilaginous fish it remains as a more or less complete structure throughout life.

In each of the cartilaginous vertebræ bone begins to form and to spread beyond its original point of formation, which is called a *centre of ossification;* the greater part of a vertebral body is formed from one of these centres, and each half of the neural arch from another; whilst small ossific centres arise for the tips of the spinous, transverse, and mammillary processes, and a special plate appears for both the upper and lower surfaces of the body; the fusion of the various centres together to form a complete vertebra takes place between the twentieth and twenty-fifth year. The Atlas has a separate centre for each lateral mass with its half of the neural arch, and one for the anterior arch. The Axis, in addition to the ossific centres found in the vertebræ generally, has one or two for the odontoid process. The 7th cervical vertebra has the anterior bar of its transverse process developed from a separate centre. Each coccygeal vertebra possesses only a single centre, which represents the body of the bone.

About the time when the dorsal laminæ meet to enclose the epiblast, which becomes developed into the brain and spinal cord, the germinal layers of the young embryo grow towards its anterior or ventral surface. A splitting of the mesoblast on each side of the vertebral region into two layers, a *somato-pleure,* or body-wall layer, and a *splanchno-pleure,* or visceral-wall layer takes place. The somato-pleure on each side, and the epiblast covering it, eventually meet in the ventral mesial line, and enclose the body cavity in which the thoracic and abdominal viscera are developed. In the somato-pleure on each side of the body cavity twelve cartilaginous rods, the future ribs, are developed; and, connected with the anterior ends of the seven pairs of upper ribs, the cartilaginous sternum is formed. Each rib ossifies from one centre for its shaft, and one each for the head and tubercle. The sternum ossifies in transverse segments,—one for the pre-sternum,

one or sometimes two for each of the four subdivisions of the meso-sternum, and one for the xiphi-sternum. The complete ossification and fusion of the different parts of the sternum into a single bone does not take place until an advanced age.

The Axial part of the skeleton, formed by the vertebræ, ribs, and sternum, is built up of a series of thirty-three transverse segments, equal in number, therefore, to the bones of the spine; so that each vertebra, according as it is, or is not, articulated with a pair of ribs and a segment of the sternum, constitutes a complete or incomplete transverse segment. These several segments are serially homologous with each other, but the homology is not so complete in some of the segments as in the others. In the coccygeal, sacral, and lumbar regions of man and most vertebrates, only the vertebral portion of each skeletal segment is represented, though in the abdominal wall of the crocodiles abdominal ribs and a sternum are developed. In the thoracic region the five lowest dorsal vertebræ have five pairs of ribs developed in connection with them; whilst the seven highest vertebræ have not only their corresponding pairs of ribs, but also a sternum, which bone, however, has only six transverse segments. In the cervical region seven vertebræ are found, but the anterior bar of the transverse process, although fused with the vertebral body, is homologous with a rib, for in man it sometimes develops as a distinct movable rib in connection with the seventh cervical; and in the crocodiles small movable ribs are regularly developed in connection with the different cervical vertebræ. The bodies and neural arches of the vertebræ are serially homologous with each other; as a rule this is also the case with their processes, but the articular processes of the atlas and the superior pair of the axis, although functionally analogous, are not homologous with the articular processes of the other vertebræ, but with the articular surfaces for the ribs on the bodies of the dorsal vertebræ, for they lie in front of, and not behind, the vertebral notches through which the spinal nerves are transmitted (Cleland). The development of the odontoid process of the axis shows it to be the body of the atlas displaced from its proper bone and fused with the body of the axis.

The Skull arises in the membrane-like mesoblast forming the walls of the anterior dilated end of the primitive groove. The anterior end of the chorda dorsalis lies mesially in the floor of the embryonic cranium as far as the posterior wall of the pituitary fossa. On each side of and close to the chorda, a bar appears, the *parachordal cartilage* of Parker, which extends almost as far forward as the anterior end of the chorda. Two cartilaginous bars, the *trabeculæ*, are also formed below the fore part of the brain, which grow backwards, so as to surround the front and sides of the pituitary fossa. The trabeculæ fuse together anteriorly and mesially, whilst posteriorly they coalesce

with the parachordal cartilages, which by this time have invested the chorda dorsalis. External to each parachordal the periotic cartilage forms the ear capsule, which fuses with the parachordal cartilage. In this way a continuous mass of cartilage lies along the floor of the embryonic cranium. This cartilage grows backwards, encloses the foramen magnum, and forms the occipital end of the cranium. The trabecular cartilages grow forwards into the nasal region and form the mesethmoid septal cartilage and the lateral ethmoid or ethmo-turbinal cartilages. The cartilage in the region of the pituitary fossa grows outwards, as the ali-sphenoids and orbito-sphenoids. In this manner an unsegmented cartilaginous base or floor of the cranium arises, which represents the ethmoidal, sphenoidal, periotic, and occipital regions of the cranium. In the occipital cartilaginous area the basi- and ex-occipitals arise, each from a separate centre of ossification; whilst the supra-occipital, situated below the protuberance and superior curved line, arises from a pair of centres; the part of the supra-occipital above the curved line, which represents the interparietal bone found in some mammals, arises from another pair of centres in the membranous cranium; the whole ultimately coalesce to form the occipital bone. In the sphenoidal cartilaginous area the pre-sphenoid and orbito-sphenoids arise by the coalescence of two pairs of ossific centres; the post-sphenoid by the coalescence of one or two pairs of centres; each ali-sphenoid from a single centre, from which the external pterygoid is also produced; each internal pterygoid from a centre in the pterygo-palatine bar of cartilage. The sphenoidal spongy bones arise in membrane in front of the pre-sphenoid. By the fusion of these different parts the sphenoid is formed. In the ethmoidal cartilaginous area the mes-ethmoid and lateral masses arise each from a distinct centre, which join to form the ethmoid bone. Below the ethmoid each inferior turbinal arises in cartilage from a single centre. In the periotic cartilaginous capsule the petro-mastoid part of the temporal arises by the fusion of at least three centres, peri-, pro-, and opisth-otic, and subsequently blends with the squamoso-zygomatic and tympanic elements which ossify each from a distinct centre in the membranous cranium. The mesoblast forming the vault of the cranium does not differentiate into cartilage, but remains membranous, and in it, in addition to the portions of the occipital and temporal bones already referred to, the two parietal bones and the two halves of the frontal bone arise each from a distinct centre. The face is formed by a mesial *fronto-nasal lobe* which grows downwards, and in which the nasal bones are formed by ossification in membrane; by a pair of lateral *maxillo-palatine* lobes and by four pairs of *visceral* or *branchial arches*, situated below the maxillary, the three lowest pairs of which contribute to the formation of the neck. A mesial cleft at first separates the pair of maxil-

lary lobes from each other, also the visceral arches on each side, but these lobes and arches subsequently coalesce in the mesial line, and close up the front of the face and upper part of the neck. A bar of cartilage, the *palato-pterygoid*, appears in the inner edge of each maxillo-palatine lobe, in the anterior end of which the palate bone arises, in the posterior the internal pterygoid plate of the sphenoid. The superior maxilla, malar, and lachrymal bones arise in the same lobe, but from ossification in membrane. The human superior maxilla, as was pointed out by Vicq d'Azyr and by Goethe, represents both the superior and pre-maxillary bones of other vertebrates, as is proved by a suture not unfrequently seen on the palate between the canine and outermost incisor tooth, and by the persistence of a distinct fissure between them in some forms of hare-lip and cleft palate. Th. Kölliker has seen in embryos of the 8th or 9th week a distinct centre of ossification for the human premaxilla. The vomer ossifies in the fibrous membrane which covers the sides of the lower and posterior part of the septal cartilage of the nose. Between the fronto-nasal and maxillo-palatine lobes is a fissure, the *eye slit*, in which the eyeball is developed, and which becomes the orbit and lachrymo-nasal duct. Between the maxillo-palatine lobe and 1st visceral arch is the *primitive mouth slit*, which, by the growth inwards of the palate plates of the superior maxillary and palate bones, becomes converted into the nasal and buccal cavities. When the plates do not meet and articulate mesially, then the central form of cleft palate is produced. The pair of incisive foramina are the remains of the primitive communication between the nose and mouth. The visceral arches are all *post-oral*, and are separated from each other by clefts or fissures, like the branchial or gill clefts of a fish. In the 1st visceral or *mandibular arch*, a cartilaginous rod appears, called *Meckel's cartilage;* the proximal end of this rod becomes enclosed in the cavity of the tympanum, and ossifies as the malleus; around the rest of the rod the lower jaw arises from ossification in membrane, and the cartilage itself atrophies and disappears. In the 2d visceral, or *stylo-hyoid* arch, a cartilaginous rod appears; the proximal end of this rod becomes enclosed in the tympanum, and ossifies as the incus; the rest of the rod becomes converted into the tympano-hyal and stylo-hyal elements of the styloid process of the temporal bone, the stylo-hyoid ligament, and the small cornu of the hyoid. The stapes by some is also regarded as an ossification of this cartilage, but Parker has shown it to be a special ossification of the peri-otic cartilage in the region of the fenestra ovalis. Between the 1st and 2d visceral arches is the *ear slit*, which becomes the Eustachian tube, the tympanum, and the external auditory meatus. In the 3d visceral or *thyro-hyoid* arch, a rod of cartilage forms which ossifies as the great cornu and body of the hyoid bone. The slit

between the 2d and 3d visceral arches disappears, although in rare cases it has been seen to persist as a cleft or branchial fissure in the neck. The 4th visceral arch and corresponding clefts disappear, and leave no representatives in the neck.

Since the time when Oken and Goethe propounded the theory that the skull was built up of several vertebræ, the Vertebral Structure of the skull has led to much discussion amongst anatomists. Every one admits that the skull is in series with the spine, that the cranial cavity is continuous with the spinal canal, and that the cranial vault is formed in the wall of the embryonic cerebro-spinal canal. The skull also, like the spine, is transversely segmented, but whether we regard these segments as vertebræ or not will depend upon the conception we entertain of the meaning of the term vertebra. If with Owen we define a vertebra to be "one of those segments of the endo-skeleton which constitute the axis of the body and the protective canals of the nervous and vascular trunks," then we may support the vertebral nature of the cranial segments on the following grounds:—1*st*, The presence of a series of bones extending forwards from the foramen magnum along the basis cranii, in series with the bodies of the spinal vertebræ,—*e.g.*, the basi-occipital, post-sphenoid, pre-sphenoid, mes-ethmoid (fig. 7); 2*d*, The presence of a series of neural arches which enclose and complete the wall of the cranial cavity, and lie in series with the neural arches of the spinal vertebræ,—*e.g.*, the ex- and supra-occipitals, which form the neural arches of the basi-occipital segment; the ali-sphenoids and parietals, which form the neural arches of the post-sphenoid segment; the orbito-sphenoids and frontal, which form the neural arches of the pre-sphenoid segment; the lateral ethmoid and nasal, which form the neural arches of the ethmoido-nasal segment; 3*d*, The presence of a series of visceral arches of which the mandibular and stylo-hyoidean enclose the alimentary and vascular canals, just as the ribs enclose them in the thorax; and 4*th*, The presence of foramina between the cranial segments, like the intervertebral foramina between the spinal vertebræ, for the transmission of nerves,—*e.g.*, the sphenoidal fissure and the jugular foramen.

But if we are to regard a vertebra as a segment of the axial skeleton, which in the course of its formation passes through a definite series of developmental changes, the cranial segments cannot be regarded as vertebræ in the same sense as the spinal segments; for, 1*st*, The chorda dorsalis is not co-equal in length with the basis cranii, as it is with the bodies of the spinal vertebræ, so that if the basi-occipital and post-sphenoid segments, the bodies of which are developed around it, were to be regarded as cranial vertebræ, the pre-sphenoidal and ethmoido-nasal would not be morphologically the same, as they are formed in front of the anterior end of the chorda. 2*d*, Proto-vertebræ are formed

in the spine, but not in the basis cranii. 3*d*, The spine is transversely segmented in its cartilaginous stage of development, but the skull is not. 4*th*, The transverse segmentation of the skull only appears when the bones are formed, but the individuality of the segments becomes again concealed by the fusion of the pre- and post-sphenoids and the basi-occipital into a continuous bar of bone, a condition which is not found in the spine except in the sacro-coccygeal region. 5*th*, The neural arches in the spine are, like the bodies, ossified in cartilage, but in the cranium they are for the most part ossified in membrane. These differences in the mode of development of the spine and skull may be summarised as below :—

Spine.

1*st Stage.*	2*d Stage.*	3*d Stage.*	4*th Stage.*
Unsegmented chorda in whole length.	Proto-vertebræ.	Segmented cartilage.	Segmented bones.

Skull.

Unsegmented chorda in part.	No proto-vertebræ.	Unsegmented cartilage and membrane.	Segmented bones.

It is evident, therefore, that, although both skull and spine are developed in the mesoblast walls of the primitive groove, yet, to quote the words of Huxley, "though they are identical in general plan of construction, the two begin to diverge as soon as the one puts on the special character of a skull and the other that of a vertebral column ; the skull is no more a modified vertebral column than the vertebral column is a modified skull."

The LIMBS, at their first appearance, sprout like little buds or lappets from the sides of the trunk. They consist of mesoblast invested by the epiblast from which the cuticle is derived. A portion of the mesoblast differentiates into cartilage which assumes the shape of the future bones, and as the limbs grow outwards, manifestations of joints appear, and the division of each limb into its several segments takes place. The clavicle is the first to ossify, its centre appearing about the 6th week, and the ossification of the shaft is in fibrous membrane though the ends are cartilaginous, and a central axis of cartilage occupies the shaft (Gegenbaur). The scapula ossifies from one centre for its expanded plate and spine, two small centres each for the acromion and vertebral border, and one for the coracoid. In many vertebrates, more especially birds and reptiles, the coracoid is a distinct bone from the scapula, but they articulate with each other to form the glenoid fossa. Each of the three rod-like bones of which the innominate bone is composed ossifies from one centre for the shaft of the bone, and one for each extremity ; in the ilium these terminal centres are situated at the

crest and acetabulum ; in the ischium, at the tuber and acetabulum ; and in the os pubis, at the symphysis and acetabulum. Each of the long bones of the shafts of the limbs ossifies from a single centre for the shaft, and one or more centres for each articular extremity. Each carpal and tarsal bone ossifies from a single centre, except the os calcis, which possesses an independent centre for its posterior surface. The metacarpal and metatarsal bones and the phalanges ossify each from two centres, one for the shaft and one for one of the extremities. In the metacarpal bones of the fingers and in the four outer metatarsals, the distal end is that which ossifies independently; in the metacarpal of the thumb, in the metatarsal of the great toe, and in all the phalanges, the proximal end is that which ossifies independently. As the method of ossification of the first metacarpal and first metatarsal corresponds with that of the phalanges, some anatomists hold that these bones are really the first phalanges of their respective digits, and that the bone which is absent in these digits, as compared with the other digits, is not a phalanx, but a meta-carpal or meta-tarsal bone. When the extremity of a long bone, or a process of a bone, ossifies from a centre distinct from the centre from which the body of the bone arises, it is called an *epiphysis*. The epiphysis is united to the shaft of the growing bone by an intermediate plate of cartilage, and so long as any of this cartilage remains unossified the bone can continue to grow in length. The ossification is not completed in the skeleton until from the twentieth to the twenty-fifth year. In the case of the long bones, the epiphysis situated at the end of the bone, towards which the canal in the shaft which transmits the nutrient artery is directed, ossifies to the shaft before the epiphysis at the other end. In the humerus, tibia, and fibula, where the canal is directed downwards, the epiphyses at the lower ends of the bones first unite with the shaft ; whilst in the femur, radius, and ulna, where the canal is directed upwards, the ossification first takes place between the upper epiphysis and the shaft.

All anatomists hold that the bones of the shaft and distal part of a limb belong to the appendicular part of the skeleton, but there is a difference of opinion as to the place in the skeleton to which the bones of the shoulder girdle and haunch are to be referred. Owen considers that the scapular and pelvic arches belong to the axial skeleton, and are homologous with the ribs ; the scapula and coracoid as the visceral or rib-arch of the occipital vertebra, the clavicle of the atlas, and the innominate bone of the upper sacral vertebræ. Goodsir objected to this conclusion of Owen's on the ground that the shoulder girdle was not in series with the visceral arches, but was developed outside the visceral wall, at the junction of the cervical and thoracic regions; from which region the upper limb receives its nerves, and not from the occipito-atlantal region, whence the nerves would have proceeded had the

limb been an appendage of the rib-arches of those segments. Owen's argument for regarding the scapula and coracoid as the costal arch of the occipital vertebra is because in fish the scapula is attached to the occipital bone by a bone which Cuvier called the supra-scapula, and which he believed to be homologous with the supra-scapular cartilage of other vertebrates. Parker has however pointed out that the so-called supra-scapula of a fish is not homologous with the supra-scapula of a reptile or mammal, that it is not a cartilage bone, but is a splint or scale-like bone, developed as a part of the dermo-skeleton. Between the scapula and coracoid and the innominate bone, anatomists have long recognised serial homologies to exist; the scapula is generally admitted to be the homotype of the ilium and the coracoid of the ischium, so that if these elements of the shoulder girdle be not a costal arch, neither can those of the pelvic girdle. The clavicle has by some been regarded as the homotype of the os pubis; but in all probability the os pubis is homologous with the procoracoid bone which is found in the amphibia and some reptiles, but is absent in crocodiles, birds, and mammals; whilst the shaft of the clavicle is represented in the pelvic girdle, not by a bone, but by a fibrous band called Poupart's ligament. Between the bones of the shafts of the limbs homologies exist: the humerus is the homotype of the femur, the radius of the tibia, the ulna of the fibula; whilst the patella has no representative in the human upper limb. The scaphoid and semilunar bones in the carpus are homotypes of the astragalus in the tarsus, the cuneiform is the homotype of the os calcis, the cuboid of the unciform, the trapezium of the ento-cuneiform, the trapezoid of the meso- and the os magnum of the ecto-cuneiform. The tarsal scaphoid is not, as a rule, represented in the human carpus, but its homotype is the os centrale found in many mammals. The carpal pisiform is a sesamoid bone developed in the tendon of a muscle. The metacarpal bones and phalanges are homologous with the metatarsal bones and phalanges; the thumb with the great toe, and the fingers with the four outer toes. During the growth of the limbs outward, and their change from the simple lappet-like form to their elongated condition, a rotation of the proximal segment of the shaft takes place—that of the upper limb a quarter of a circle backward, that of the lower limb a quarter of a circle forward—to produce in the former case a supine position of the fore-arm and hand, with the thumb as the outermost digit; in the latter case, a prone condition of the leg and foot, with the great toe as the innermost digit. The range of movement at the radio-ulnar joints enables us, however, to pronate the hand and fore-arm by throwing the radius across the ulna, so as to make the thumb the innermost digit. In many quadrupeds the fore-leg is fixed in this position, so that these animals walk on the soles of both the fore and hind feet.

CHAPTER II.

JOINTS AND MUSCLES.

General Observations on the Articulatory and Muscular Systems.

A Joint or Articulation is the junction or union of any two adjacent parts of the body. Most usually the term is employed to signify the connection established between contiguous bones. It is by the joints that the various bones are knit together to form the skeleton. Joints may be either *immovable* or *movable*.

The immovable joints are divided into the *synchondroses* and the *sutures*. A *synchondrosis* is the junction of two bones by the interposition of an intermediate plate of cartilage; the fibrous membrane or periosteum which invests the bones being prolonged from one bone to the other over the surface of the cartilage. A *suture* is the connection of two bones by the interlocking of adjacent toothed margins; the periosteal fibrous membrane is prolonged from one bone to the other, and is also interposed between their adjacent margins. In a young skull the basi-occipital and post-sphenoid are united by synchondrosis, but junction by sutures is the mode of union which prevails in the bones of the head. In old persons the sutures become obliterated by the ossification of the



Fig. 12.—Vertical Section through a Synchondrosis. *b*, *b*, the two bones; Sc, the interposed cartilage; *l*, the fibrous membrane which plays the part of a ligament.

intermediate fibrous membrane, and the bones are permanently fused together. The cranial sutures may conveniently be arranged in three groups: *a*, *Median longitudinal*, consisting of the frontal suture, which connects the two halves of the frontal bone, and the sagittal suture, between the two parietal bones; *b*, *Lateral longitudinal*, consisting, on each side of the head, of the fronto-nasal, fronto-maxillary, fronto-lachrymal, fronto-ethmoidal, fronto-malar, fronto-sphenoidal, parieto-sphenoidal, parieto-squamous, parieto-mastoid sutures; *c*, *Vertical transverse*, consisting of the coronal or fronto-parietal, the lambdoidal or parieto-occipital, the sphenoido-malar, sphenoido-squamous, and occipito-mastoid sutures (fig. 6). As the skull grows by ossification of the membranous vault, and of the cartilage of the base, the direction of growth

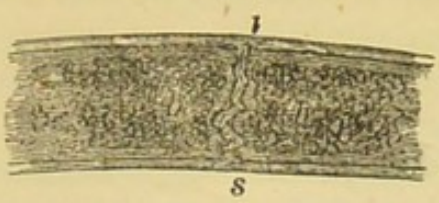

FIG. 13.—Vertical Section through a Cranial Suture. *b*, *b*, the two bones; *s*, opposite the suture; *l*, the fibrous membrane, or periosteum, passing between the two bones, which plays the part of a ligament, and which is continuous with the interposed fibrous membrane.

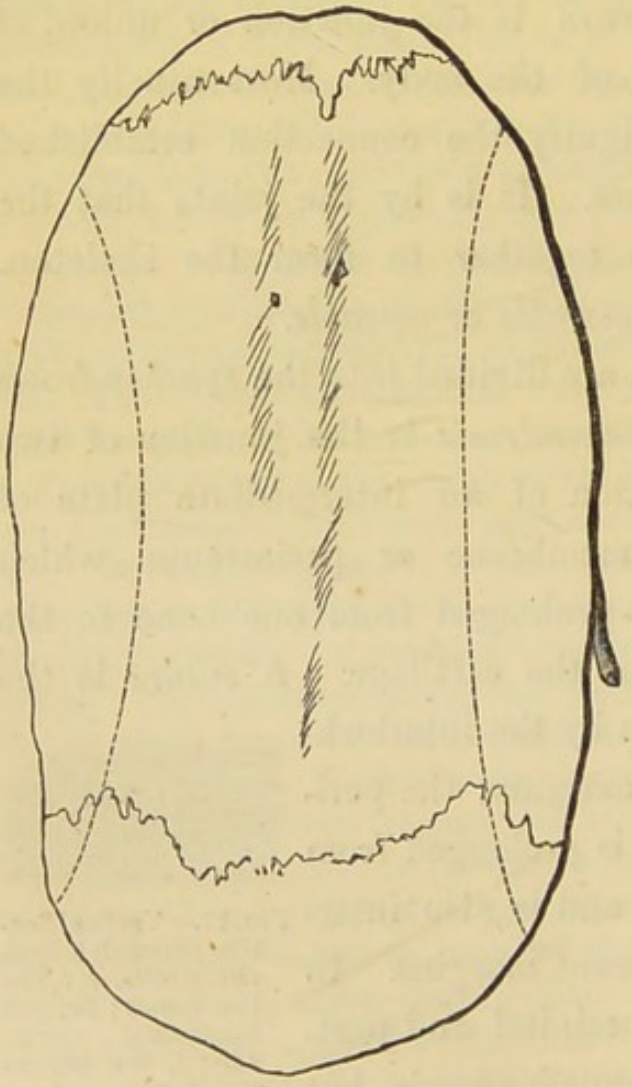

FIG. 14.—Vertex View of a Boat-shaped or Scaphocephalic Skull, showing the complete disappearance of the sagittal suture.

is perpendicular to the margins of the bones and the sutures and synchondroses which connect them together. The growth of the skull in length is therefore at right angles to the basi-cranial synchondrosis and the vertical transverse group of sutures; its growth, in breadth, to the median longitudinal group, and in height to the lateral longitudinal group. So long as any of the cartilage or membrane between the margins of the bones remains unossified, bone may continue to form, and the skull may increase in size. It sometimes happens that the cartilage or membrane is prematurely ossified in a particular locality, and the further growth of the skull put a stop to in that region; if the brain is still growing, the skull must increase in other directions to allow the necessary expansion of the cranial cavity, and deformities of the skull are thereby occasioned. One of the most usual of these deformities is due to premature closure of the sagittal suture, causing stoppage of the growth of the skull in breadth, and, by way of compensation, great increase in its length, so as to produce a very elongated and somewhat boat-shaped cranium (fig. 14).

The movable joints are divided into the *amphiarthrodial* and the *diarthrodial* joints. An amphiarthrosis or half-joint has only a feeble range of movement. It consists of two bones, each of which has its articular surface covered by a plate of cartilage, and these plates are firmly connected together by an intermediate disc of fibro-cartilage. The centre of this disc is soft, or may even be hollowed out

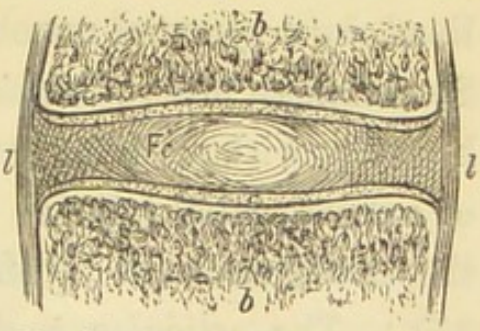

FIG. 15.—Vertical Section through an Amphiarthrodial Joint. *b*, *b*, the two bones; *c*, *c*, the plate of cartilage on the articular surface of each bone; *Fc*, the intermediate fibro-cartilage; *l*, *l*, the external ligaments.

into a cavity, lined by a smooth synovial membrane, and containing a little fluid. Ligamentous bands, continuous with the periosteum investing the bones, invest the fibro-cartilage, and assist in binding the bones together. The best examples of amphiarthrodial joints are furnished by the articulations between the bodies of the true vertebræ.

A diarthrosis admits of more perfect movement. In it the two articular surfaces are each covered by a plate of encrusting cartilage, the free surface of which is smooth and polished; between these surfaces is a cavity of only a capillary lumen, containing a viscid fluid, the *synovia*, for lubricating the smooth surfaces of the cartilage and facilitating the movements of the joint (fig. 16). This cavity is enclosed by ligaments, which are attached to the bones, and usually inhibit or check excessive movement in particular directions; the inner surface of these ligaments is lined by a synovial membrane which secretes the synovia. Sometimes a plate or *meniscus* of fibro-cartilage is interposed between, without being attached to the encrusting cartilages of a diarthrodial joint, so as more or less perfectly to divide the cavity enclosed by the ligaments into two spaces (fig. 17). The articular surfaces of diarthrodial joints are retained in apposition with each other, sometimes by investing ligaments, at others by surrounding muscles and tendons; at others by atmospheric pressure, aided by the viscidity of the interposed synovia.

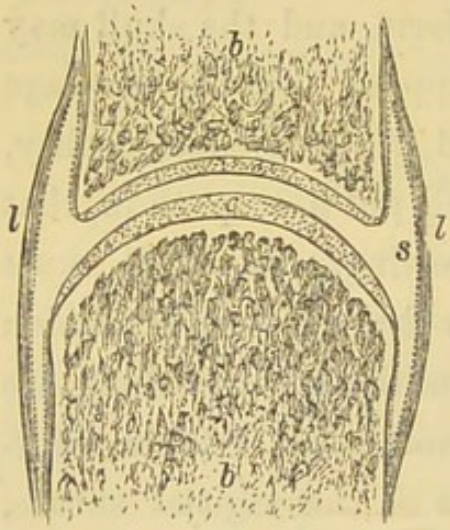

FIG. 16.—Vertical Section through a Diarthrodial Joint. *b*, *b*, the two bones; *c*, *c*, the plate of cartilage on the articular surface of each bone; *l* *l*, the investing ligament, the dotted line within which represents the synovial membrane. The letter *s* is placed in the cavity of the joint.

The form of the articular or movable surfaces varies very materially in different examples of these joints, and the modifications in form determine the direction of the movements of the joints. In some, as the carpal and tarsal joints, the surfaces are almost flat, so that they glide on each other; the movement is comparatively slight, and about an axis perpendicular to the moving surfaces: these are called *plane-surfaced joints* or *arthrodia*. In other joints the articular surfaces may be regarded as produced by the rotation of a straight or curved line about an axis lying in the same plane; these are called *rotation joints*, and they present various modifications according to the direction and relation of the rotating line to the axis. One form of a rotation joint is the *pivot joint*, in which the movement takes place about the axis of one of the bones, which is the axis of rotation of the joint; examples of this joint are found in the joint between the atlas and the odontoid process of the axis and in the radio-ulnar joint. Another form is the *ginglymus* or *hinge joint*, in which the axis of rotation of the joint is perpendicular to the axis of the two bones; the movements of the hinge are called flexion when the angle between the two bones is diminished, and extension when the angle is increased. An important modification of the ginglymus is the *screwed-surfaced joint*, an example of which is found in the ankle; here the plane of flexion is not perpendicular, but oblique to the axis of the joint. The *saddle-shaped* and *oblong joints* are also

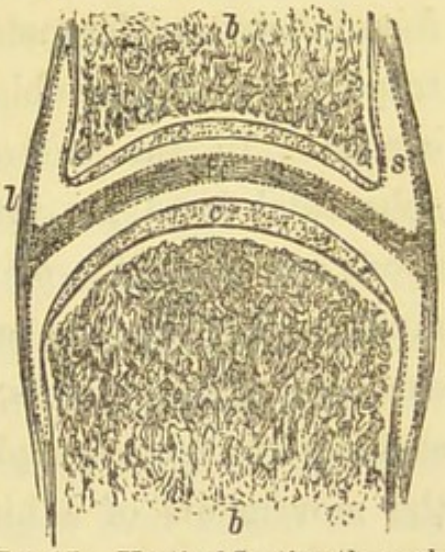

FIG. 17.—Vertical Section through a Diarthrodial Joint, in which the cavity is subdivided into two by an interposed fibro-cartilage or meniscus, *Fc*. The other letters as in fig. 16.

modified hinges, but allow motion about two axes; in the oblong both axes are on the same side of the joint; but in the saddle-shaped there is an axis of rotation on each side of the joint. The best example of the saddle-shaped is found between the metacarpal bone of the thumb and the trapezium; of the oblong between the fore-arm and the carpus. In the *ball-and-socket* or *enarthrodial joint* a spheroidal head fits into a cup, and rotation takes place about any diameter of the sphere; the joint therefore is multi-axial; the hip and shoulder joints are the best examples. Some joints, in which the forms of the articular surfaces are more complex, are called *composite;* in them the movements of a hinge and of a ball-and-socket joint may be combined; the knee may be cited as an example of this form of articulation. In a large number of movable joints only portions of the opposite articular surfaces are in contact with each other at a given time; but, as the joint describes its path of movement, different parts of the surfaces come into contact with each other successively, and it is not unusual to find the articular surface both of the cartilage and the subjacent bone mapped out into distinct areas or facets, which are adapted to corresponding facets on the opposite articular surface in particular positions of the joint. When the corresponding facets on opposite articular surfaces break contact with each other, the space becomes occupied by synovia, or in some joints, more especially the knee, by folds of synovial membrane enclosing clumps of fat, which Goodsir named *synovial pads.* In the simple hinge, in that with screwed surfaces, in the oblong and composite joints, the principal ligaments are situated at the sides of the joint, and are called *lateral;* they not only prevent lateral displacement of the bones,

but, by a tightening of their fibres, check excessive movement forwards or backwards during flexion and extension. In the saddle-shaped and ball-and-socket joints, the joint is included within a bag-like ligament called *capsular*. In the pivot joints the cavity into which the pivot fits is completed by a *transverse* or a *ring-shaped* ligament.

The MUSCLES are the organs which, by their contraction or shortening, move the bones on each other at the joints. The muscles constitute the flesh of the body. They are so arranged as to be capable not only of moving the various bones on each other, but the entire body from place to place. Hence the muscles are organs both of motion and locomotion. As they can be brought into action at the *will* of the individual, they are called voluntary muscles. Some of the muscles are engaged in the movement of other structures than the bones, such as the eye-ball, tongue, cartilages of the larynx, &c. About 400 muscles are usually enumerated, and the names applied to them express either their position, or relative size, or shape, or direction, or attachment, or mode of action. The word muscle is itself derived from the Latin *musculus*, a little mouse, from a fancied resemblance between that animal and some of the most simply formed muscles. It is customary to distinguish in a muscle a central part, or *belly*, and two extremities, one of which is the *head* or the *origin*, the other the *insertion*. The belly is the fleshy part of the muscle, and possesses a deep red characteristic colour; it is the active contractile structure, the source of motor power. The two extremities are called the tendons of the muscle, or sinews; the tendons are bluish white in colour, possess no power of contractility, and are merely, as it were, the ropes by which the belly of the muscle is attached to the bone or

other structure which is moved by its contraction. The term tendon of origin, applied to one extremity of the muscle, signifies the fixed end of the muscle, that to which it draws during its contraction; as a rule this is the end nearest the trunk, the proximal end. The term tendon of insertion is applied to the end which is moved by the contraction; as a rule this is the end most removed from the trunk, the distal end. Entering the substance of each muscle is at least one artery, which conveys blood for its nutrition; this artery ends in a network of capillary blood-vessels, from which a vein arises and conveys the blood out of the muscle again; another small vessel, called a lymphatic, also arises within the muscle, and conveys the fluid lymph out of the muscle. Each muscle also is penetrated by a nerve, by which it is brought into connection with the brain, and along which the nervous impulse, started by the Will, is conducted. The Will is the natural stimulus for exciting muscular action, and the rapidity of transmission of the impulse generated by the Will along the motor nerve is about 110 feet per second.

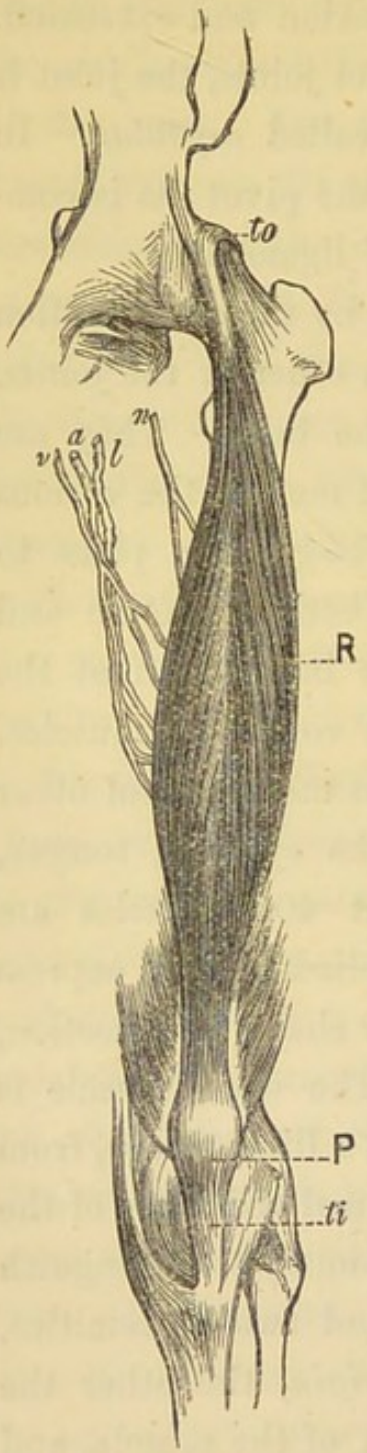

FIG. 18.—The Rectus Muscle of the Thigh; to show the constituent parts of a muscle. R, the fleshy belly; *to*, tendon of origin; *ti*, tendon of insertion; *n*, nerve of supply; *a*, artery of supply; *v*, vein; *l*, lymphatic vessel; P, the patella.

The bones form a series of rod-like levers, and, in study-

ing the mode of action of the muscles, the place of insertion of the muscle into the bone—that is to say, the point of application of the power which causes the movement—and its relations to the joint, or fulcrum, or centre of motion, and to the weight or resistance which is to be overcome, have to be kept in view. The relative positions of fulcrum, point of application of power, and resistance, are not the same in all the bony levers. As a rule, the muscles are inserted into the bones between the fulcrum and the movable point of resistance, and nearer the fulcrum than the movable point, as may be seen in the biceps and brachialis anticus which bend the fore-arm at the elbow-joint (lever of 3d class). Although from the weight-arm of the lever being in these cases much longer than the power-arm, the muscles, as regards the application of the power, act at a disadvantage, yet the movement gains in velocity. Sometimes the muscle is inserted, as is the case in the triceps which straightens or extends the fore-arm, at one end of the lever, and the fulcrum or joint is placed between it and the movable point (lever of 1st class). At other times, as in the case of the depressor digastric muscle of the lower jaw, whilst it is attached to one end of the lever, the fulcrum is at the opposite end (lever of 2d class). When a muscle is so placed that its tendon of insertion is perpendicular to the bone to which it is attached, it acts to great advantage; when placed obliquely or nearly parallel, a loss of power occurs. Many muscles at the commencement of contraction lie obliquely to the bones which they move, but as contraction goes on they become more nearly perpendicular, so that they act with more advantage near the close than at the commencement of contraction. If a muscle passes over only one joint, it acts on that joint

only; but if it passes over two or more joints, it acts on them in succession, beginning with the joint next the point of insertion. A given movement may be performed by the contraction of a single muscle, but as a rule two or more muscles are associated together, and they are not unfrequently so arranged that one muscle initiates the movement, which is then kept up and completed by the rest. Muscles producing movement in one direction have opposed to them muscles which by their contraction effect the opposite movement; when both groups act simultaneously and with equal force, they antagonise each other, and no motion is produced; when a muscle is paralysed or divided, its antagonistic muscle draws and permanently retains the part to its own side. The rapidity of action of a muscle is proportioned to the length of its fasciculi, its power of contraction to their number.

Each muscle is invested by a sheath, the *perimysium*, formed of connective tissue. In the limbs and in the neck not only has each muscle a sheath, but a strong fibrous membrane envelopes the whole of the muscles, and assists materially in giving form and compactness to the region. This membrane is called generally a *fascia* or *muscular aponeurosis*, but special descriptive names are given to it in the different regions—*e.g.*, cervical fascia, brachial aponeurosis, fascia lata or fascia of the thigh. In some localities muscles arise from the fascia, and in others they are inserted into it. The fascia is separated from the skin by a layer of subcutaneous fatty tissue, the *superficial fascia*, and in this layer muscles are in some localities developed. In the fat of the inner border of the palm of the hand a small muscle, the *palmaris brevis*, is found, which arising from the palmar fascia, is inserted into the

skin covering the ball of the little finger; at each side of the neck, also, lies a thin muscle called *platysma myoides*, and the muscles which move the skin of the face and scalp belong to the same category. These muscles form the group of *subcutaneous* or *dermal muscles*, which group except in the localities above referred to, is not represented in the human body, but is well known in the bodies of the mammalia generally as the *panniculus carnosus*.

In arranging the muscles for descriptive purposes, either a morphological, or a topographical, or a physiological method may be pursued. The morphological arrangement is to be preferred when the object is to compare the muscular system in man with that in different animals, and the basis of the arrangement should be into muscles of the axial, of the appendicular, and of the axi-appendicular skeletons, and subcutaneous muscles; a topographical arrangement is most suitable for the purposes of the practical surgeon; a physiological arrangement, when the object is to study the action of the muscles in connection with the movements of the joints.

Joints and Muscles of the Axial Skeleton.

The *Intervertebral Joints* connect the movable vertebræ with each other and the 5th lumbar vertebra with the sacrum. Except the atlas and axis, the other true vertebræ are connected by an amphi-arthrodial joint, a pair of diarthrodial joints, and by special ligaments passing between certain of their processes. The bodies are connected by an amphiarthrodial joint: the fibro-cartilaginous plate or *intervertebral disc* is tough and fibrous in its peripheral part, but soft and pulpy within (fig. 15). Remains of the chorda dorsalis are said to persist in the soft pulp, and sometimes a distinct cavity, lined by a synovial membrane, is found in the centre of the disc, which in the finner whales is expanded into a large central cavity containing many ounces of synovia. An *anterior common ligament*

extends from axis to sacrum, and a *posterior common ligament* from front of foramen magnum to sacrum; the anterior is attached to the front of the discs and margins of the vertebral bodies, the posterior to the back of the same structures. A diarthrodial joint with a *capsular ligament* connects on each side the superior and inferior articular processes of adjacent vertebræ. Elastic yellow ligaments, the *ligamenta subflava*, pass between their laminæ. *Inter-transverse ligaments* between their transverse processes. *Inter-* and *supra-spinous* ligaments connect adjacent spinous processes; in the neck the supra-spinous ligament forms a broad band, the *ligamentum nuchæ*, which reaches the occipital crest and protuberance. In mammals having big heads or heavy horns, this ligament of the back of the neck forms a powerful elastic band for the support of the head. The *Atlo-Axoid joint* is specially modified in connection with the movements of the head on the top of the spine. The intervertebral disc is absent; the articular processes are connected by a *capsular ligament;* a *transverse ligament* retains the odontoid process in place; a *posterior atlo-axoid ligament* passes between the neural arches of atlas and axis, and an *anterior atlo-axoid ligament* from the body of axis to front of atlas. The *Occipito-Atloid joint* consists of *capsular ligaments* uniting the occipital condyles to the superior articular processes of atlas; of an *anterior occipito-atlantal ligament* from foramen magnum to front of atlas, and of a posterior *occipito-atlantal* ligament from foramen magnum to neural arch of atlas. The summit of the odontoid process is connected to the front and sides of foramen magnum by the *check ligaments*, and a vertical band which forms with the transverse ligament a *crucial ligament* passes from the back of the body of the axis to the front of the foramen

magnum. The head rotates along with the atlas about the odontoid or pivot process of the axis; too great movement to one side or the other is prevented by the check ligaments. The nodding movements of the head take place between the occiput and atlas, and are permitted by the size and shape of the occipital condyles and hollow upper articular surfaces of the atlas. These joints are all diarthrodial. The spine is flexible and elastic; except in the atlo-axoid joint the range of movement between any two true vertebræ is very small, but the sum of the movement in the entire spine, owing to the number of bones, is considerable. The elasticity of the spine is partly due to the numerous diarthrodial joints between its articular processes, but more especially to the discs of fibro-cartilage interposed between the bodies of the vertebræ, which act like elastic pads or buffers to prevent shock.

The muscles which move the Vertebræ on each other, and the Head on the Spine, are situated both behind and in front of the spinal column. Those behind are called the *Deep muscles of the Back*, and have their fibres running either longitudinally or obliquely. Those arranged *longitudinally* are the *interspinales*, which pass between the spines of contiguous cervical vertebræ; the *rectus capitis posticus major* from the spine of the axis to the inferior curved line of the occiput; the *rectus capitis posticus minor* from the neural arch of the atlas to the occiput behind the foramen magnum; the *intertransversales* between the transverse processes of contiguous vertebræ; the *rectus lateralis* from the transverse process of the atlas to the jugal process of the occiput; and the *erector spinæ*. The erector spinæ is a great composite muscle which occupies the lumbar region and divides below the level of the last

rib into three longitudinal columns. The external column or *sacro-lumbalis* ascends behind the angles of the ribs into which it is inserted, and from which it receives the *musculus accessorius;* it is prolonged to the 4th, 5th, and 6th cervical transverse processes as the *cervicalis ascendens.* The middle column or *longissimus dorsi* ascends behind the transverse processes of the dorsal vertebræ, into which it is inserted as well as into the ribs between their tubercles and angles; it is prolonged to the 2d, 3d, 4th, 5th, and 6th cervical transverse processes as the *transversalis cervicis,* and to the mastoid-temporal as the *trachelo-mastoid.* The inner column or *spinalis dorsi* ascends from the upper lumbar and lower dorsal spines to the higher dorsal spines. The muscles arranged *obliquely* are subdivided into two groups. In the one group the fibres pass obliquely from *within upwards and outwards.* These muscles are the *obliquus inferior* from the spine of the axis to the transverse process of the atlas; and the *splenius,* which, arising from the ligamentum nuchæ, the 7th cervical spine, and the upper six dorsal spines, and dividing into *S. capitis* and *S. colli,* is inserted partly into the mastoid-temporal and partly into the upper three cervical transverse processes. In the other group the fibres pass obliquely from *without upwards and inwards.* These muscles are the *complexus* arising from the seven highest dorsal transverse processes and the five lowest cervical articular processes, and inserted into the occiput between the two curved lines; the *obliquus superior* from the transverse process of the atlas to the occiput external to the inferior curved line; and the *great oblique rotator of the spine.* This great oblique rotator muscle lies at the side of the vertebral laminæ, and extends from the sacrum to the axis. It is composite, and divided into three

layers, named successively *semi-spinalis dorsi and colli*, *multifidus spinæ*, and *rotatores spinæ*. The semi-spinalis lies in the dorsal and cervical regions, and its fibres pass obliquely upwards and inwards from the transverse processes to be inserted into the spines near their tips; the multifidus reaches from sacrum to axis, and its fibres pass in the same direction from the back of the sacrum, the lumbar mammillary processes, the dorsal transverse processes, and the lower cervical articular processes to be inserted into the vertebral laminæ and side of the spines; the rotatores are confined to the dorsal region, and each passes obliquely from the root of a transverse process to be inserted into the root of the spine of the dorsal vertebra immediately above.

The muscles in front of the spinal column are called *Prevertebral*, and are as follows: *rectus capitis anticus major*, passing from the 3d, 4th, 5th, and 6th cervical transverse processes to the basi-occipital; *rectus capitis anticus minor* from the anterior arch of the atlas to the basi-occipital; the *longus colli* and the *psoas*. The longus colli is a composite muscle, and consists of longitudinal and two sets of oblique fibres, so that it represents in miniature the longitudinal and oblique muscles of the back; the longitudinal fibres pass from the bodies of the three lower cervicals and three upper dorsal vertebræ to the bodies of the 2d, 3d, and 4th cervicals; the lower oblique fibres extend upwards and outwards from the bodies of the three upper dorsals to the 5th and 6th cervical transverse processes; the upper oblique fibres pass upwards and inwards from the 3d, 4th, and 5th cervical transverse processes to the tubercle on the anterior arch of the atlas. The psoas lies in the lumbar region, and extends from the bodies of the last dorsal and the bodies and transverse processes of all the lumbar vertebræ to end

along with the iliacus in the small trochanter of the femur. The *sterno-cleido-mastoid*, which arises from the sternum and clavicle, aids in the movements of the head through being inserted into the mastoid-temporal and superior curved line of the occiput.

The Spine and Trunk can be moved in the antero-posterior plane, in the transverse plane and obliquely. The antero-posterior movements are ventral flexion, extension, and dorsi-flexion, and to produce them the corresponding muscles on the two sides must act together. Ventral flexion or bending forwards is due to the action of the psoæ, the longitudinal fibres of each longus colli, and to the recti abdominis, which draw on the spine owing to their insertion into the 5th, 6th, and 7th ribs. Extension, as in bringing the body to the erect attitude, and dorsi-flexion are due to the interspinales and the erectores spinæ with their subdivisions. Movements in the transverse plane, *i.e.*, flexion either to the right or left, are produced by the intertransversales, erector spinæ, scaleni, serrati postici, and oblique muscles of the abdomen of that side. The oblique movements consist of a rotation or a screwing of the spine either to the right or to the left. To screw the spine so that the trunk may be turned to the right, the left great oblique rotator muscle contracts, the right splenius colli, and the upper oblique fibres of the left longus colli taking their fixed point at the atlas. The opposite muscles contract when the trunk is turned to the left.

The Head is balanced on the summit of the spine, and can be moved in the antero-posterior and transverse planes, and by rotation. The antero-posterior or nodding movements take place at the occipito-atloid joints, and are produced by the corresponding muscles on the two sides

acting together. Nodding forwards is due to the sterno-cleido-mastoidei and the recti antici majores and minores. Nodding backwards is due to the recti postici majores and minores, the splenii capitis, complexi, and superior obliques. The transverse or lateral movements are due to the rectus lateralis and trachelo-mastoid of the same side. Rotation of the head takes place along with the atlas at the atlo-axoid joints, about the pivot-like odontoid process; rotation so that the face is turned to the right is due to the right splenius, right inferior oblique, right rectus posticus major, left complexus, and left sterno-cleido-mastoid. The opposite muscles contract when the face is turned to the left.

In the formation of the walls of the Abdomen proper, bones and joints play but a small part. The lumbar vertebræ behind, the expanded wings of the iliac bones below, and the false ribs above, are the only bones to be considered. Three pairs of greatly expanded muscles—the *external oblique*, *internal oblique*, and *transversales*—lie at the sides and in front; and two pairs of muscles—the *recti* and *pyramidales*—are situated wholly in front. The internal oblique and the transverse muscles are attached above to the ribs, behind to the lumbar spine, below to the iliac crest and to a strong band, *Poupart's ligament* extending from the crest of the ilium to the pubic spine; the external oblique has similar connections above and below, but is not attached behind to the lumbar spine. The muscles all terminate in front in strong expanded tendons, forming the *anterior abdominal aponeurosis*, which blend together in the middle line anteriorly to form the band called *linea alba*, which stretches longitudinally from the xiphi-sternum to the pubic symphysis. These expanded tendons enclose the recti muscles, which pass from the pubic symphysis

and crest upwards to the 5th, 6th, and 7th costal cartilages; and the pyramidal muscles which pass from the front of the os pubis to be inserted into the linea alba. The entire arrangement with the adjunct of the *fascia transversalis* completes the antero-lateral walls of the great abdominal chamber, supports the viscera, and enables the muscles to compress the abdominal viscera, an action which takes place when the contents of the bowels and bladder are being expelled during defæcation and micturition.

Bones and joints play a more important part in the formation of the walls of the thoracic than of the abdominal cavity. The twelve ribs on each side articulate behind with the twelve thoracic vertebræ, and by arching more or less completely forward, the seven upper ribs, through their costal cartilages, articulate with the sternum.

Costo-central Joints connect the head of a rib and the body of one or usually two adjacent vertebræ: in the latter case, an *interarticular ligament* passes from the head of the rib to the intervertebral disc and divides the joint into two synovial cavities. Each joint is closed in anteriorly by a *costo-central* or *stellate* ligament. *Costo-transverse Joints* exist between the tubercle of the rib and the transverse process of the corresponding vertebra except in the floating ribs. The joints are diarthrodial, and possess *posterior*, *ascending*, and *intercosto-transverse ligaments*. The *Costo-sternal Joints* are also diarthrodial (except the 1st costal cartilage, which is united by synchondrosis to the pre-sternum). The 2d costal cartilage to the 7th inclusive are connected to the sternum by capsular ligaments, and the lining synovial membrane is, except that of the 7th cartilage, divided by an interarticular band into two cavities. The cartilages of the 6th to the 9th ribs are also

united together by ligamentous fibres, and synovial membranes lie between these cartilages at their place of union.

The movements of the ribs and sternum at the costo-vertebral and costo-sternal joints are of the utmost importance in the process of breathing. Breathing or respiration consists of two acts with intermediate pauses—breathing in, or *inspiration*, and breathing out, or *expiration*. During inspiration the air rushes through the nose or mouth down the windpipe, and dilates the air-cells of the lungs; as the walls of the chest rise the lungs expand, so that the capacity both of lungs and chest at the end of a full inspiration is nearly doubled. During inspiration the following changes occur: the ribs are elevated and rotated outwards, their cartilages are slightly twisted, and the angle between them and the ribs is widened; the lower borders of their shafts are everted, while their surfaces are at the same time rendered more oblique, and the width of the intercostal spaces is thereby increased; the elevation and rotation of the ribs throw the sternum upwards and forwards, and make the thoracic part of the spinal column straighter; the diaphragm is depressed, and the antero-lateral walls of the abdomen are thrown forward. The muscles engaged in inspiration are as follows:—In each of the spaces between the different ribs a pair of *intercostal muscles* is situated (see p. 607); these elevate and rotate the ribs and the movements are assisted by the *levatores costarum*, and, in the case of the upper and lower ribs, by the *scaleni* and *serrati postici* muscles; and by these agents the transverse and antero-posterior diameter of the chest is increased. The increase in its vertical diameter is due to the action of the *diaphragm* or midriff, aided by the *quadratus lumborum*. The diaphragm forms the floor of the

thoracic and the roof of the abdominal cavity, and constitutes a great arch, with its convexity directed to the cavity of the chest (see p. 610). By the contraction of its fibres, which are inserted into a trefoil-shaped central tendon, it is withdrawn from the walls of the chest; the arch

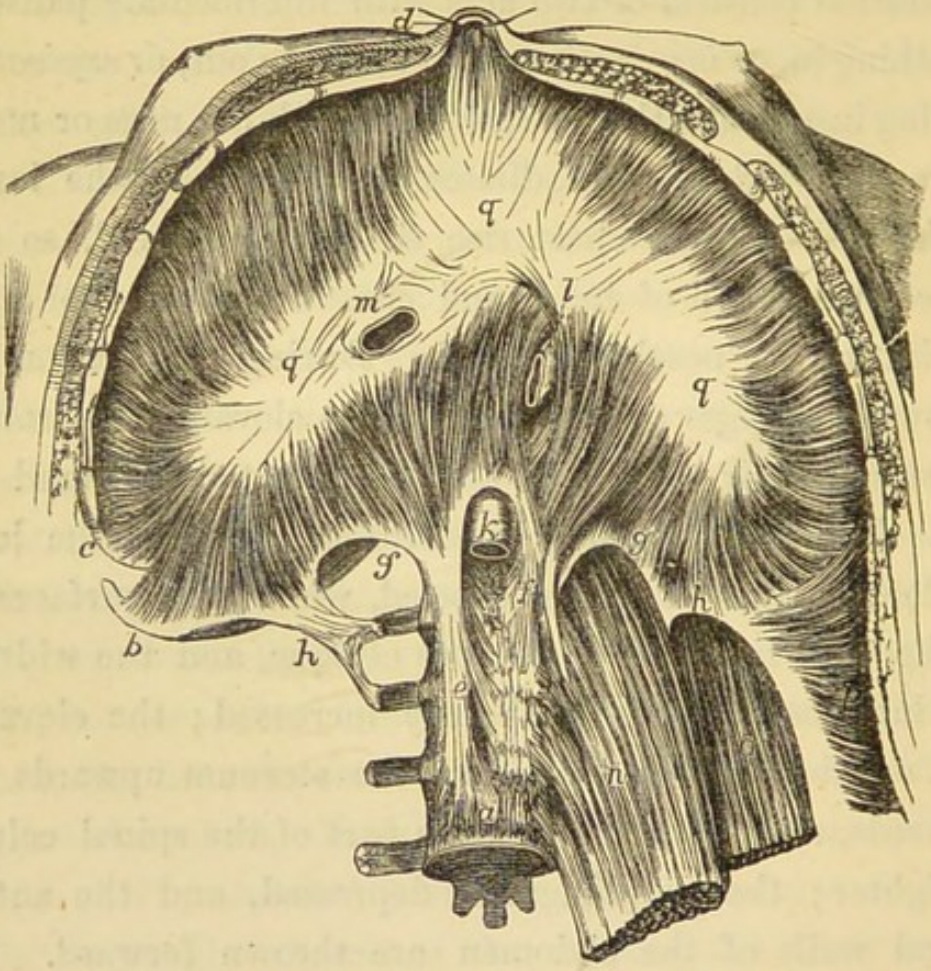

FIG. 19.—The Concave Abdominal Surface of the Diaphragm. *a*, 4th lumbar vertebra; *b*, *c*, 12th and 11th ribs; *d*, xiphi-sternum; *e*, *f*, crura of diaphragm; *g*, *h*, arcuate tendons of origin of diaphragm; *k*, aorta; *l*, œsophagus; *m*, inferior vena cava; *n*, psoas; *o*, quadratus muscle; *qqq*, central tendon of diaphragm, into which the muscular fibres are inserted.

is rendered less convex, and the floor of the chest is thereby depressed. When more powerful efforts of inspiration are needed, the muscles which pass from the walls of the chest to the upper limbs may, by taking their fixed points at the limbs, act as elevators of the ribs. During expiration the ribs are depressed, their lower borders inverted, the width of the intercostal spaces diminished, the sternum

depressed, the spine more curved, and the diaphragm rendered more convex. These movements are principally due to the recoil of the elastic tissue of the lungs previously rendered tense by the inflation of the air-cells, to the weight of the thoracic walls, and to the untwisting of the ribs when the inspiratory muscles cease to elevate and rotate them. Muscular action plays but a small part in quiet expiration, though the *triangulares sterni* depress the ribs; but the expulsion of the air from the lungs may be facilitated by contracting the abdominal muscles, which, by pressing the abdominal viscera against the under surface of the diaphragm, force that muscle upwards.

The *Temporo-maxillary Joints* are, the tympanic ossicles and hyoid joints being excluded, the only diarthrodial articulations in the head. The condyle of the lower jaw on each side is received into the glenoid fossa of the temporal bone; each joint is enclosed by a *capsular ligament*, which is strengthened externally by a band called *external lateral ligament*. The name *internal lateral ligament* is given to a band stretching from the spine of the sphenoid to the border of the dental foramen. Between the articular surfaces is a *meniscus*, which divides the interior of the joint into two cavities, each lined by a synovial membrane. The lower jaw moves simultaneously at both its articulations during mastication and speech, through the action of the several muscles which are *inserted* into it. It is elevated by the *temporales* inserted into the coronoid processes; by the *masseterics*, inserted into the outer surface of the ascending rami and angles, and the *internal pterygoids*, one into the inner surface of each angle. It is depressed partly by its own weight and partly by the action of the *digastrics* and *genio-hyoids*, inserted close to the symphysis;

by the *platysma*, inserted into the outer surface of the body and the *mylo-hyoids*, into its inner surface. The elevators of the jaw are much more powerful than the depressors, for they not only have to overcome the weight of the bone, but during mastication have to exercise force sufficient to cut or break down the food between the teeth. In carnivorous animals, such as the tiger or hyæna, which crack the bones of their prey, these muscles attain a great size. The lower jaw can be projected in front of the upper by the *external pterygoids*, inserted into the neck of the bone and the interarticular meniscus on each side; but excessive movement forward is checked by the action of the *stylo-maxillary ligaments*, which pass from the styloid processes to the angles of the bone: when projected forward, the jaw is drawn back by the posterior fibres of the *temporales*. When the elevator, depressor, protractor, and retractor muscles are successively brought into action, the lateral or grinding movements of the bone, so important in mastication, are produced.

Along with the movements of the lower jaw those of the hyoid bone and larynx must be considered, for the *digastrics*, the *genio-* and *mylo-hyoids*, which, when their fixed ends are at the hyoid, depress the lower jaw, act, when their mandibular ends are fixed, along with the *stylo-hyoids* in elevating the hyoid and larynx. The hyoid and larynx are depressed or drawn downwards by the action of the *sterno-hyoids*, *sterno-thyroids*, *thyro-hyoids*, and *omo-hyoids*. The elevation of the hyoid, when drawn down by its depressor muscles, is also effected by the elastic *stylo-hyoid ligaments* attached to its small cornua, which, by their recoil when the depressor muscles have ceased to contract, draw the bone up to its former position.

Numerous muscles are situated immediately beneath the skin of the scalp and face, and are not of so deep red a colour as the muscles of the trunk and limbs. They arise from the bones of the head, and are inserted into the deep surface of the skin itself, and when they contract they move the skin of the scalp and face. As they are the instruments through which the various passions and emotions are expressed, they are grouped together as the *Muscles of Expression.* The Scalp and Eyebrows are moved by the occipito-frontalis and corrugatores muscles. The *occipito-frontalis* passes from the superior curved lines of the occipital bone over the vertex to the forehead ; when it contracts, the skin of the forehead is wrinkled transversely, the eyebrows are elevated, and an expression of amazement or surprise is produced. Some persons have a greater power over this muscle than others, and by the alternate contraction of its occipital and frontal portions can move the hairy scalp to and fro with great rapidity. A *corrugator supercilii* arises from each superciliary ridge, on the frontal bone, to be inserted into the Eyebrows : they draw the eyebrows downwards and inwards, wrinkle the skin of the forehead longitudinally, and contract with great vigour in the act of frowning. The Auricle of the external ear has three small muscles inserted into it, one behind, the *posterior auricular*, one above, the *superior*, one in front, the *anterior :* in man, as a rule, these muscles are feeble, and have little action ; but in many mammals they are large, and by them the animal pricks its ears to detect the faintest sound of danger. The Eyelids are drawn together, so as to close the eye as in the act of sleep, by the *orbicularis palpebrarum*, the fibres of which lie in the eyelids and on the borders of the orbit, and surround

the fissure between the eyelids. This muscle is a characteristic specimen of the group of *sphincter* muscles, *i.e.*, muscles which surround orifices, and by their contraction close them. When the upper fibres of the muscle alone contract, the upper eyelid is depressed,—a movement which takes place almost involuntarily and with great frequency during our waking hours, so as to wash the tears over the exposed part of the eyeball and keep it moist. In expressing a "knowing wink," the lower fibres alone of the orbicularis contract, and the lower lid is elevated. The elevation of the upper lid, as in opening the eye, is due to the *levator palpebræ superioris*, which, arising in front of the optic foramen, is inserted into the upper eyelid. The Nostrils can be increased or diminished in size, and the passage of air into the nose promoted or impeded. The size is increased by the *levator communis* and *levator proprius* inserted into the ala, or side of the nostril; and during violent exercise or impeded respiration the nostrils are always widely dilated. The levator communis, which also sends a slip down to the upper lip, is the muscle by the contraction of which a sneer is expressed. A partial closure of the nostril can be effected by the *depressores alæ nasi* and *septi narium* and the *compressor alæ nasi* which depress and compress the alæ of the nose: in man these muscles are rudimentary as compared with the seal and other aquatic mammals, in which a powerful sphincter muscle closes the nostrils in the act of diving. The Lips are elevated by the *levatores communis, labii superioris*, and *anguli oris;* they are depressed by the *depressores labii inferioris* and *anguli oris;* they can be protruded or retracted, or the corners of the mouth can be drawn to one side or the other, by the action of the various muscles

which are inserted into them. The *orbicularis oris* is a sphincter muscle, the fibres of which lie both in the upper and lower lips; by its contraction, aided slightly by the *levator menti*, the mouth is closed and the lips pressed against the teeth, as when a firm resolution is intended to be expressed. The Mouth is opened by the elevator muscles of the upper and the depressors of the lower lip; it is widened transversely by the *zygomatic* and *risorius* muscles, which pass to its corners, and which are brought into action in the acts of smiling and laughing. But the muscles of the lips also play an important part in connection with the reception of food into the mouth, and with the act of articulation (p. 646).

The cavity of the Mouth forms the commencement of the alimentary canal, and is lined by a soft mucous membrane. In it the teeth and tongue are situated, and into it the secretion called saliva is poured. It opens behind into the pharynx. The side walls of the mouth are called the cheeks, and into the formation of each cheek a flattened quadrilateral muscle, the *buccinator* (fig. 20, *a*), enters. This muscle is attached above and below to the upper and lower jaw-bones, behind to the pterygo-maxillary ligament, to which the upper constrictor muscle (*d*) is also connected, so that the walls of the mouth and pharynx are continuous with each other, whilst in front the buccinator blends with the structures in the lips. It compresses the cheeks, and drives the air out of the cavity of the mouth as in playing a wind instrument; hence the name, "trumpeter's muscle."

The aperture of communication between the mouth and pharynx is named the *isthmus* of the *fauces*. It is bounded below by the root of the tongue, on each side by the

tonsils, and above by the soft palate. The soft palate is a structure which hangs pendulous from the posterior edge of the hard bony palate. From its centre depends an elongated body, the *uvula*, and from each of its sides two

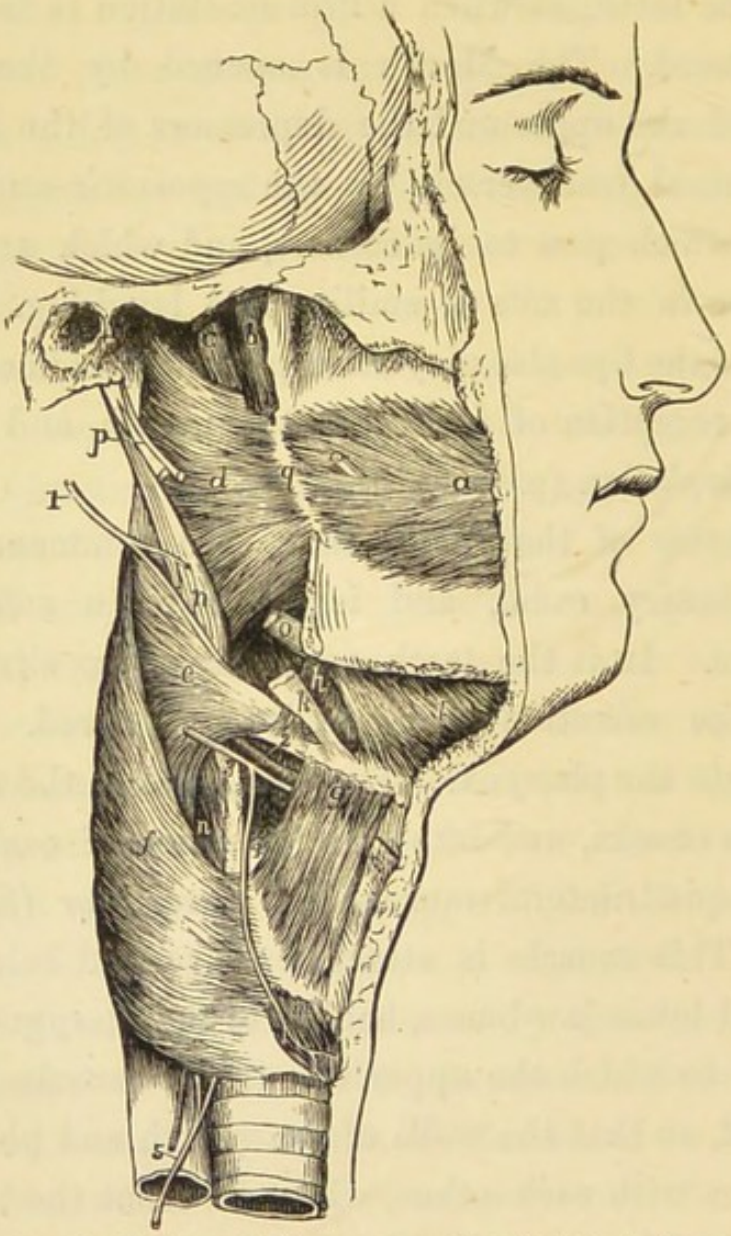

FIG. 20.—Profile of Cheek and Pharynx. *a*, buccinator; *b*, tensor; *c*, levator palati; *d*, *e*, *f*, superior, middle, and inferior constrictors; *g*, thyro-hyoid; *h*, hyo-glossus; *l*, mylo-hyoid; *m*, crico-thyroid; *n*, stylo-pharyngeus; *o*, stylo-glossus; *q*, fibrous band which gives origin to buccinator and superior constrictor; 1, glosso-pharyngeal nerve; 2, superior laryngeal artery; 3, superior laryngeal nerve; 4, its branch to crico-thyroid muscle; 5, inferior laryngeal nerve and artery.

folds extend, one downwards and forwards to the tongue, the other downwards and backwards to the pharynx. These folds are called the *anterior* and *posterior pillars* of

the fauces or palate. Between the anterior and posterior pillar, on each side, the *tonsil* is seated. The soft palate and its pillars are invested by the mucous lining of the mouth and pharynx, and contain small but important muscles (p. 666). The muscles of the soft palate and uvula, termed *levatores palati* and *uvulæ* and *tensores palati*, raise and make them tense during the process of deglutition. The muscles of the posterior pillars, or *palato-pharyngei*, by their contraction, approximate the walls of the pharynx to the soft palate and uvula, whilst the muscles of the anterior pillars, or *palato-glossi*, diminish the size of the fauces.

The Pharynx is a tube with muscular walls, lined by a mucous membrane, which communicates above and in front with the cavities of the nose, mouth, and larynx, whilst below it is continuous with the œsophagus or gullet. It serves as the chamber or passage down which the food goes from the mouth to the œsophagus in the act of swallowing, and through which the air is transmitted from the nose or mouth to the larynx in the act of breathing. It lies immediately behind the nose, mouth, and larynx, and in front of the five upper cervical vertebræ. Its length is from $4\frac{1}{2}$ to $5\frac{1}{2}$ inches; its widest part is opposite the back of the mouth. The muscles in its walls are described on p. 660 (figs. 20, 21). They are arranged in pairs, and are named *superior*, *middle*, and *inferior constrictors*, *stylo-pharyngei*, *palato-pharyngei* with sometimes the *salpingo-pharyngei*.

The action of the muscles of the mouth, palate, and pharynx may now be considered in connection with the *process of Deglutition* or swallowing. When the food is received into the mouth, it is moistened by the secretion of the salivary and other buccal glands, and is broken

down by the grinding action of the molar teeth. The buccinator muscles press it from between the gums and the cheeks, and, along with the movements of the tongue, aid in collecting it into a bolus on the surface of that organ. During the process of mastication the palato-glossi contract

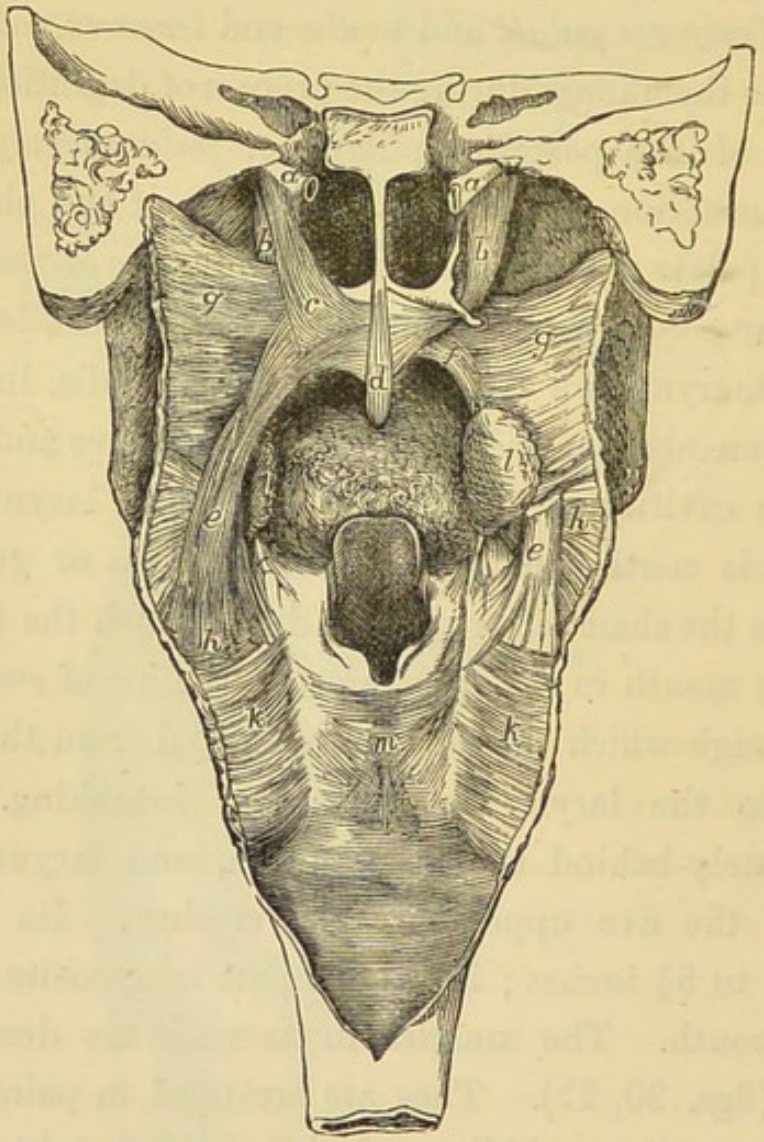

FIG. 21.—Interior of the Pharynx, seen by opening its posterior wall. *a*, *a*, Eustachian tube; *b*, *b*, tensor; *c*, levator palati; *d*, levator uvulæ: *e*, *e*, palato-pharyngeus, cut through on the right side to show *l*, the tonsil; *f*, palato-glossus; *g*, *h*, *k*, the three constrictors.

so as to close the fauces. When the bolus is sufficiently triturated and moistened, the palato-glossi relax, the tip of the tongue is pressed against the roof of the mouth, and by a heave backward of that organ the bolus is pressed through the posterior orifice of the mouth into the pharynx,

where it is grasped by the superior constrictor muscles, and forced downwards by them and the other constrictor muscles into the œsophagus, and thence into the stomach. As both the nose and larynx open into the pharynx, the one immediately above, the other immediately below the orifice of the mouth, it is of great importance that none of the food should enter into these chambers, and obstruct the respiratory passages. To guard against any accident of this kind, two valvular structures are provided,—viz., the soft palate and the epiglottis,—which, whilst leaving the orifices into their respective chambers open during breathing, effectually close them when deglutition is being performed. As the bolus is being projected through the fauces into the pharynx, the soft palate and uvula are elevated and made tense by their muscles, and at the same time the wall of the pharynx is brought into contact with them by the contraction of the palato-pharyngei; the part of the pharynx into which the nose opens is thus temporarily shut off from that into which the mouth opens. If laughter, however, be excited at this time, the tension of the soft palate is destroyed, and part of the food may find its way upwards into the nose. The closure of the larynx by the epiglottis is due partly to the depression of that valve and partly to the elevation of the larynx. The backward heave of the tongue relaxes the glosso- and hyo-epiglottidean ligaments which connect the front of the epiglottis to that organ, and enables the oblique aryteno-epiglottidean muscles to depress that valve and contract the opening into the larynx (p. 601). The elevation of the hyoid and larynx is due to the action of the mylo-hyoid, digastric, and genio-hyoid muscles, which pass from the lower jaw to the hyoid, and of the thyro-hyoids, which pass

from the hyoid to the thyroid cartilage of the larynx; preliminary to their action, the lower jaw must be fixed, which is done by the closure of the mouth prior to the act of swallowing. The aperture of the larynx is thus brought into contact with the depressed epiglottis, which is adapted more exactly to the opening by a change in its form due to the projection of a cushion-like pad from its posterior surface. By these arrangements the nose and larynx are temporarily shut off from the buccal part of the pharynx, and the adaptation of a single chamber to the very different functions of breathing and swallowing is effectively provided for.

Joints and Muscles of the Upper Limb.

The upper limb is jointed to the trunk at the diarthrodial *Sterno-clavicular Joint.* The bones are connected by *anterior* and *posterior ligaments*, and a *meniscus* is interposed between the articular surfaces, so that the joint possesses two synovial membranes. A strong *costo-clavicular* ligament, which checks too great upward movement, connects the clavicle and 1st costal cartilage, and the inner ends of the clavicles are connected by the *inter-clavicular* ligament. The two bones of the shoulder girdle articulate with each other at the diarthrodial *Acromio-clavicular Joint*, which possesses a capsular ligament and a *meniscus;* but, in addition, a strong *coraco-clavicular* ligament, which checks too great displacement of the bones, passes between the clavicle and coracoid. The movements of the upper limb on the trunk take place at the sterno-clavicular joint, and consist in the elevation, depression, forward and backward movement of the shoulder. The movements at the acromio-clavicular joint occur when the scapula is rotated on the clavicle in the act of elevating the arm above the

head. The muscles which act on the sterno-clavicular and acromio-clavicular joints are *inserted* into the bones of the shoulder girdle; the *trapezius* into the clavicle, acromion, and spine of the scapula; the *rhomboids*, *levator anguli scapulæ*, and *serratus magnus* into the vertebral border of the scapula; the *pectoralis minor* into the coracoid process: and the *subclavius* into the clavicle. Elevation of the entire shoulder, as in shrugging the shoulders, is due to the action of the upper fibres of the trapezius, the levator scapulæ and rhomboids; depression partly to the weight of the limb, and partly to the action of the subclavius, the lower fibres of trapezius, and pectoralis minor; movement forward to the serratus magnus and pectoralis minor; and backward to the trapezius and rhomboid. In rotation of the scapula on the clavicle, the inferior angle of the scapula is drawn forward by the serratus and lower fibres of trapezius, and backward by the levator scapulæ, rhomboid, and pectoralis minor.

The *Shoulder Joint* is a ball-and-socket joint, the ball being the head of the humerus, the socket the glenoid fossa of the scapula deepened by the *glenoid ligament*. A large *capsular ligament*, strengthened by the *coraco-humeral band*, encloses the joint. It is pierced by the long tendon of the biceps muscle, and lined by a synovial membrane, and is so loose as to permit a range of movement greater than takes place in any other joint in the body. The muscles which move the upper arm at this joint are *inserted* into the humerus; the *supra-spinatus*, *infra-spinatus*, and *teres minor* into the great tuberosity; the *sub-scapularis* into the small tuberosity; the *latissimus dorsi* into the bottom, and the *teres major* into the posterior border of the bicipital groove; the *pectoralis major* into its anterior border; the *coraco-*

brachialis into the inner aspect of the shaft, and the *deltoid*, which forms the fleshy prominence of the shoulder, into the outer aspect of the shaft. Abduction and elevation, or extension of the arm outwards at the shoulder joint, are due to the supra-spinatus and deltoid; adduction or depression, to the coraco-brachialis, latissimus, teres major, pectoralis major, assisted by the weight of the limb; movement forwards and elevation, to the anterior fibres of the deltoid, pectoralis, and subscapularis; backward movement to the latissimus, teres major and posterior fibres of deltoid; rotation outwards to the supra-and infra-spinatus and teres minor; rotation inwards to the subscapularis, pectoralis, latissimus, and teres major. A combination of abduction, movement forwards, adduction, and movement backwards, produces the movement of circumduction. Certain movements of the upper limb, however, take place not only at the shoulder joint, but between the two bones of the shoulder girdle; for in elevating the arm, whilst the supra-spinatus and deltoid initiate the movement at the shoulder joint, the farther elevation, as in raising the arm above the head, takes place by the trapezius and serratus, which rotate the scapula at the acromio-clavicular joint and draw its inferior angle forward. The free range of movement of the human shoulder is one of its most striking characters, so that the arm can be moved in every direction through space, and its efficiency as an instrument of prehension is thus greatly increased. The movement of

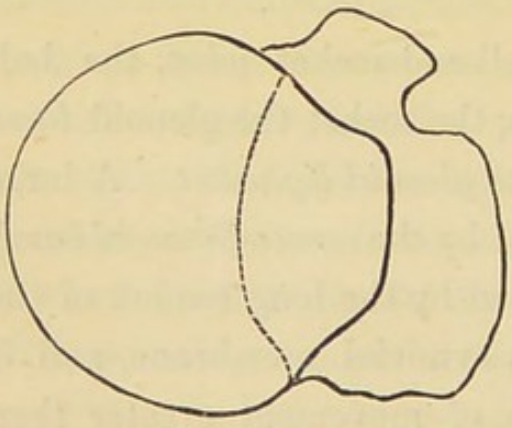

FIG. 22.—Outline Sketch of Human Humerus. The articular area for complete extension lies to the right of the dotted line. (*After Goodsir.*)

abduction, or extension, which elevates the arm in the line with the axis of the scapula, is characteristically human, and a distinct articular area is provided on the head of the humerus for this movement.

The *Elbow Joint* is the articulation between the humerus, radius, and ulna; the great sigmoid cavity of the ulna is adapted to the trochlea of the humerus, and the cup of the radius to the capitellum. The joint is enclosed by a *capsular ligament* divided into *anterior*, *posterior*, *internal*, and *external bands*, and lined by a synovial membrane. Flexion and extension are the two movements of the joint, and the range of movement is limited by the locking at the end of flexion of the coronoid process into the coronoid fossa of the humerus, and at the end of extension of the olecranon process into the olecranoid fossa. The elbow joint is a hinge. The muscles which move the fore-arm at the elbow are *inserted* into the bones of the fore-arm. The flexors are the *brachialis anticus*, inserted into the coronoid of the ulna; the *biceps*, which forms the fleshy mass on the front of the upper arm, into the tuberosity of the radius; the *supinator longus* into the styloid process of the radius. The only extensor is the *triceps-anconeus*, which forms the fleshy mass on the back of the upper arm, and is inserted into the olecranon.

The *Radio-ulnar Joints* are found between the two bones of the fore-arm. The head of the radius rolls in the lesser sigmoid cavity of the ulna, and is enclosed by the *annular ligament;* the shafts of the two bones are connected together by the *interosseous membrane;* their lower ends by a *triangular* fibro-cartilage or *meniscus* and a *capsular ligament* lined by a *sacciform* synovial membrane. The radius rotates about an axis drawn through the centre of

its head and the styloid process of the ulna; rotation of the fore-arm and hand forward is called pronation,—rotation backwards, supination. The direct supinator and pronator muscles are all *inserted* into the radius: the supinators are the *supinator longus*, *supinator brevis*, and the *biceps;* the pronators are the *pronator teres* and *pronator quadratus*. When delicate manipulation is required the fore-arm is semi-flexed on the upper arm, for the cup-shaped head of the radius is then brought into contact with the capitellum of the humerus, and the rotatory movements of the bone can be performed with greater precision.

The Wrist comprises the radio-carpal, inter-carpal, and carpo-metacarpal joints, the carpo-metacarpal joint of the thumb being excepted. The multiplicity of joints contributes to the mobility of the wrist and gives elasticity to the junction of the hand and fore-arm.

The *Radio-carpal Joint* is formed above by the lower end of the radius and the radio-ulnar meniscus, below by the upper articular surfaces of the scaphoid, semi-lunar, and cuneiform bones. A *capsular ligament*, divided into *anterior*, *posterior*, *internal*, and *external* bands, and lined by a synovial membrane, encloses the joint. It is the oblong form of hinge-joint, and possesses two axes, a long and a short; about the long axis movements occur which bend the hand forwards, or extend it on the fore-arm, or bend it backwards; about the short axis the hand may be moved towards the radial or ulnar margins of the fore-arm. The flexors forward of the hand are the *palmaris longus*, inserted into the palmar fascia; the *flexor carpi radialis* into the 2d and 3d metacarpal bones; the *flexor carpi ulnaris* into the pisiform, 5th metacarpal and unciform; the extensors and flexors backwards are the *extensores carpi*

radialis longior and brevior inserted into the metacarpal bones of the index and middle fingers, and the *extensor carpi ulnaris* into the 5th metacarpal bone ; the flexors and extensors of the fingers have also a secondary action on the wrist joint. The flexor and extensor carpi ulnaris draw the hand to the ulnar side, and the flexor carpi radialis, extensor carpi radialis longior and the extensors of the thumb, draw the hand towards the radial border of the fore-arm.

Intercarpal Joints.—The bones are connected by *dorsal ligaments* passing between the dorsal surfaces of contiguous bones, by *palmar* between their palmar surfaces, and by *interosseous ligaments* between the semi-lunar and cuneiform, semi-lunar and scaphoid, os magnum and unciform, os magnum and trapezoid ; *lateral ligaments* also attach the scaphoid to the trapezium, and the cuneiform to the unciform. The pisiform is jointed to the cuneiform by a *capsular ligament* lined by a special synovial membrane.

Carpo-metacarpal Joints.—The trapezoid, os magnum, and unciform are connected to the metacarpal bones of the fingers by *dorsal* and *palmar ligaments ; interosseous ligaments* pass from the adjacent angles of the os magnum and unciform to the adjacent angles of the 3d and 4th metacarpals. The metacarpal bone of the thumb has a saddle-shaped articulation with the trapezium, invested by a *capsular ligament* lined by a distinct synovial membrane, so that its range of movement is extensive.

Inter-metacarpal Joints.—The metacarpal bones of the fingers are connected by *dorsal*, *palmar*, and *interosseous* ligaments at their proximal ends, and by a *transverse ligament* (fig. 23) on the palmar aspect of their distal ends. The metacarpal of the thumb is not jointed to the index.

Metacarpo-phalangeal and Inter-phalangeal Joints.—*Lateral ligaments* pass between the bones; on the *dorsal* aspect is a ligament containing a fibro-cartilage, distinct from the extensor tendon, and on the palmar aspect is a fibro-cartilaginous band.

The muscles which move the thumb act on its carpo-metacarpal, metacarpo-phalangeal, and inter-phalangeal joints, and are *inserted* either into the metacarpal bone or phalanges. They either pass from the fore-arm to the thumb, or are grouped together at the outer part of the palm, and form the elevation known as the ball of the thumb. The thumb is extended and abducted, *i.e.*, drawn away from the index, by the *extensor ossis metacarpi* inserted into the base of the metacarpal, the *extensor primi internodii* into the base of the 1st phalanx, the *extensor secundi internodii* into the base of the 2d phalanx, and, by the *abductor pollicis*, inserted into the radial side of the base of the 1st phalanx: its bones are bent on each other by the *flexor longus pollicis* inserted into the base of the 2d and the *flexor brevis* into the base of the 1st phalanx; it

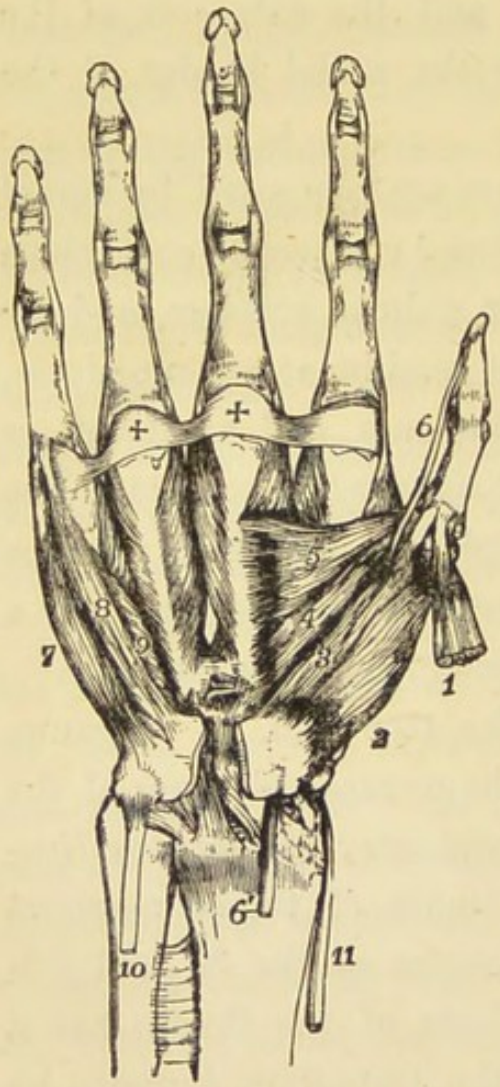

FIG. 23.—Deep Muscles of the Palm of the Hand. 1, abductor pollicis cut short; 2, opponens; 3 and 4, subdivisions of flexor brevis; 5, adductor; 6, 6′, tendon of long flexor of thumb; 7, abductor of the little finger; 8, short flexor; 9, opponens; 10, tendon of flexor carpi ulnaris; 11, tendon of long supinator; ††, transverse metacarpal ligament.

is drawn back to the index by the *adductor* inserted into the ulnar side of the base of the 1st phalanx; and the entire thumb is thrown across the surface of the palm by the *opponens pollicis*, which is inserted into the shaft of its metacarpal bone.

The muscles which move the fingers in flexion, extension, abduction, and adduction act on their metacarpo-phalangeal and inter-phalangeal joints. The 3d or ungual phalanges are bent by the *flexor profundus*, the four tendons of which are inserted into them; the 2d phalanges are bent by the *flexor sublimis*, also inserted by four tendons, one into each

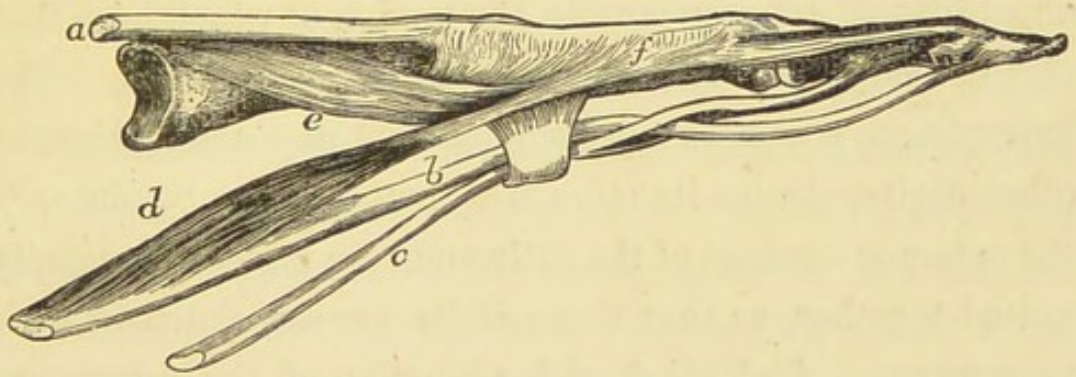

FIG. 24.—Tendons attached to a Finger. *a*, the extensor tendon; *b*, deep flexor; *c*, superficial flexor; *d*, a lumbrical muscle; *e*, an interosseous muscle; *f*, tendinous expansion from the lumbrical and interosseous muscles joining the extensor tendon.

phalanx; these muscles descend from the front of the fore-arm into the palm in front of the wrist, where they are enclosed in a canal along with the flexor-longus pollicis by the *anterior annular ligament*, and their surfaces are invested by a synovial membrane, which facilitates their movements to and fro beneath that ligament; as they pass downwards in front of the fingers they are enclosed in a strong fibrous sheath lined by a synovial membrane, and the tendon of the superficial flexor is pierced by the deep flexor, so that the latter may reach the 3d phalanx. Four rounded muscles, the *lumbricales*, arise in the palm from the deep flexor tendons, turn round the radial borders of

the 1st phalanges, and are inserted one into the extensor tendon on the dorsum of each finger; these muscles bend the 1st phalanges on the metacarpal bones, but from their insertion into the extensor tendons they also extend the 2d and 3d phalanges on the first. The little finger has also a special *flexor brevis minimi digiti* inserted into the ulnar side of the base of the 1st phalanx. The fingers are extended or straightened by the extensor muscles arising on the back of the fore-arm. The *extensor communis* divides into four tendons, one inserted into the back of the 2d and 3d phalanx of each finger. The index and little have each an additional *extensor* muscle, the tendon of which joins that of the common extensor passing to the same finger. The index finger possesses more independent movement than the other digits—hence its more frequent use as a "pointer"; the extensor tendons of the little and ring fingers are usually united together, so that these digits are associated in their movements. Abduction and adduction of the fingers are caused by seven small muscles situated in the intervals between the metacarpal bones,—hence called *interossei;* four of these lie on the dorsum of the hand, three on its palmar surface; they are inserted both into the sides of the first phalanges and the extensor tendons; the dorsal muscles abduct the fingers from a line drawn through the middle finger, the palmar muscles adduct them to that line. The little finger has also a special *abductor minimi digiti* inserted into the ulnar side of the base of the 1st phalanx, and too great abduction is checked by the transverse metacarpal ligament. The little finger has also a special *opponens minimi digiti* inserted into the shaft of its metacarpal bone. The human hand is a perfect instrument of prehension; not only can the individual fingers be bent

into hooks, but the thumb can be thrown across the front of the palm, so that it can be opposed to the several fingers, and objects can therefore be grasped between it and them; but further, this power of opposing the thumb permits objects to be held in the palm of the hand, which may be hollowed into a cup or made to grasp a sphere. The movements of the joints are indicated on the surface of the palm by tegumentary folds,—an oblique fold for the thumb, and two oblique folds for the metacarpo-phalangeal joints of the fingers; the joints of the 2d and 3d phalanges are also marked on the surface by folds.

Joints and Muscles of the Lower Limb.

The innominate bones are connected to the spinal column by the sacro-iliac joints, the sacro-sciatic ligaments, and the *ilio-lumbar ligament*, which passes from the 5th lumbar transverse process to the back of the iliac crest. The *Sacro-iliac Joint* is between the side of the 1st, 2d and 3d sacral vertebræ and the internal surface of the ilium; each auricular surface is encrusted by a plate of cartilage, and between the two plates is an imperfect synovial cavity; *posterior, oblique, and anterior sacro-iliac* ligaments connect the bones. The *Great Sacro-Sciatic* ligament stretches from the ischial tuberosity to the coccyx, sacrum, and postero-inferior iliac spine: the *Small Sacro-Sciatic* from the ischial spine to the sacrum and coccyx. The innominate bones are connected together at the *pubic symphysis*, which is an amphiarthrodial joint. The sacro-iliac joints and pubic symphysis permit only slight movement; that at the former is about an imaginary axis, drawn transversely through the second sacral vertebra, which allows the base of the sacrum to be thrown forward and its apex backward

in the stooping position of the body; but too great movement backward of the apex is checked by the sacro-sciatic ligaments. As the weight of the trunk, or of what may be carried in the arms or on the back, is transmitted through the haunch-bones to the lower limbs, the sacro-iliac ligaments require to be of great strength, because the sacrum, as well as the entire trunk, is suspended by them on the two innominate bones.

The *Hip Joint* is a ball-and-socket joint; the ball is the head of the femur, and the socket the cup-shaped acetabulum in the haunch bone, the depth of the cup being increased by the *cotyloid* and *transverse ligaments* attached around the brim. A large *capsular ligament* encloses the articular surfaces. This ligament consists of circular and longitudinal fibres; the longitudinal fibres form the *ilio-femoral* or *Y-shaped band*, passing from the anterior inferior iliac spine to the anterior inter-trochanteric line; the *ilio-trochanteric band* from the dorsum acetabuli to the root of the great trochanter; the *pubo-femoral band* from the pectineal eminence to the front of the small trochanter; the *ischio-capsular* or *ischio-femoral* from the ischium below the acetabulum to end either in the capsular ligament or in the digital fossa. The capsular ligament is firmly attached to the anterior inter-trochanteric line, but only feebly to the back of the neck of the femur. Within the capsule is the *ligamentum teres* attached to the head of the thigh bone and to the sides of the cotyloid notch. The capsular ligament is lined by a synovial membrane, which invests the neck of the femur and the ligamentum teres. The hip joint has free mobility, and much more stability than the shoulder, owing to the acetabulum being deeper than the glenoid fossa, and the greater strength of its capsular

ligament. The muscles which move the thigh at the hip joint are *inserted* either into the femur or fascia lata, and the great and small trochanters and linea aspera serve as their principal surfaces of attachment. The thigh is bent on the abdomen by the action of the *psoas*, *iliacus*, and *pectineus*, which lie in front of the joint; it is extended or drawn into line with the trunk by the *gluteus maximus* and *medius*; it is abducted or drawn away from the opposite thigh by the *gluteus maximus*, *medius*, and *minimus*, which muscles are of large size, and form the fleshy mass of the buttock. It is adducted or drawn to touch its fellow, or, if slightly bent, drawn in front of its fellow, by the *adductores longus*, *brevis*, and *magnus*, which muscles are inserted into the linea aspera, and form the fleshy mass on the inner side of the thigh; and by the *pectineus* and *quadratus femoris*. The action in succession of these groups of muscles produces the movement of circumduction. It is rotated outwards by the *obturatores* and *gemelli* muscles, the *gluteus maximus*, *pyriformis*, and *quadratus femoris;* and rotated inwards by the *gluteus medius*, *minimus*, and *tensor fasciæ femoris*. In standing erect the hip joints are fully extended, and the mechanical arrangements are such as to check disturbance of the equilibrium of the extended joint both in the antero-posterior and transverse directions. So long as the centre of gravity falls within the basis of support of the body, *i.e.*, the space between the two feet when standing on both legs, the body will not fall. Disturbance of the equilibrium in the antero-posterior direction is checked by the weight of the body in the erect attitude falling behind the joints, so that the strong ilio-femoral bands of their capsular ligaments are made tense, and the body is prevented from falling backwards. If the body is

made to lean forward, then the capsular ligament is no longer tense, and the gluteal and hamstring muscles are put in action to re-extend the trunk on the thigh, and prevent it from falling forward. Disturbance of the equilibrium in the transverse direction, as in falling to one side, is checked by the tension of the ligamentum teres, the pubo-femoral and ischio-femoral bands of the capsular ligament, and the strong *ilio-tibial band* of the fascia lata of the thigh, which stretches from the iliac crest to the external tuberosity of the tibia. The ligamentum teres is tightened when the joint is adducted and rotated, so that it checks rotation of the trunk on the thigh, when standing momentarily on one leg in the act of walking. When, in standing erect either on one or both feet, the balance of the body is disturbed, then various muscles both of the trunk and lower limb are brought into action to assist in preserving the erect position.

The *Knee* is the largest and most complicated joint in the body. The bones are the femur, tibia, and patella. The patella moves up and down the trochlear surface of the femur, whilst the condyles of the femur roll upon the semilunar cartilages and articular surfaces of the tibia. The joint is invested by a strong ligament in which occur the following bands: *external lateral* from head of fibula to outer tuberosity of femur: the *internal lateral* from inner tuberosity of tibia to inner tuberosity of femur; the *posterior* from inner tuberosity of tibia to outer condyle of femur; the *anterior*, which is also the tendon of insertion of the extensors of the leg, from the patella to the anterior tuberosity of tibia. Within the investing ligament the *anterior* and *posterior inter-articular* or *crucial ligaments* pass from the inter-condyloid fossa to the upper surface of

the tibia; and interposed between the tibia and femoral condyles are two *menisci*, the *internal* and *external semilunar cartilages*. The synovial membrane lines the investing ligament, covers the front of the femur for some distance above the trochlea, and forms folds or pads within the joint itself, which in certain movements are interposed between the articular surfaces of the bones. The muscles which move the leg at the knee are *inserted* into the tibia and fibula. The flexors are the three hamstrings on the back of the thigh; they all arise from the ischial tuberosity, but the biceps in addition from the linea aspera, and are inserted—the *biceps* into the head of the fibula, the *semi-tendinosus* and *semi-membranosus* into the upper end of the tibia. The extensors form the fleshy mass on the front and outer side of the thigh; one muscle, the *rectus*, arises from the ilium—the others, the *crureus*, *vastus internus* and *externus*, from the shaft of the femur; they are all inserted by a powerful tendon into the anterior tuberosity of the tibia, and the patella is a sesamoid bone, developed in this tendon (fig. 18). The knee can be bent so that the calf can touch the back of the thigh, and in this position the patella is drawn down in front of the joint, as in kneeling. The articular surface of the patella is divided into seven areas or facets—an internal perpendicular and three pairs of transverse facets (Goodsir). In acute flexion of the knee the internal perpendicular is in contact with a crescentic or patellar facet on the internal condyle of the femur; in passing from the bent to the extended position of the joint, the transverse facets come successively into contact with the trochlear surface of the femur, until, when the leg is fully extended on the thigh, the whole of the patella is raised above the trochlea, except the lowest

pair of transverse facets. In order to provide a smooth surface for the patella in the extended position, the synovial membrane covers the front of the femur above the trochlea, and this membrane is drawn upwards by the action of the *sub-crureus* muscle. At the commencement of flexion a slight rotation inwards of the leg and foot takes place through the action of the *sartorius*, *gracilis*, and *semi-tendinosus*, which are inserted close together into the upper end of the inner surface of the shaft of the tibia, assisted by the *popliteus;* whilst the *extensor* and *biceps* muscles cause, at the completion of extension, a slight rotation outwards of the leg and foot. The movements of flexion and extension are not simply in the antero-posterior plane, but along oblique paths, which are determined by the screwed configuration of the femoral condyles. In complete extension of the leg the joint is "screwed home"; and as this position is necessary for the preservation of the erect attitude, the anterior crucial and the lateral and posterior ligaments are then all tense, and the joint is fixed. The muscles which rotate the leg and foot inwards initiate the act of flexion by unlocking the joint. In complete flexion of the knee the posterior crucial ligament and the anterior ligament are tense and rotation is more freely permitted.

Tibio-fibular Joints.—The *superior* has an *anterior* and a *posterior ligament*, and the synovial membrane is sometimes continuous with that of the knee: the *middle* consists of an *interosseous membrane* between the shafts of the tibia and fibula; the *inferior* has an *anterior* and a *posterior ligament*, a *transverse ligament* which deepens the ankle joint and a strong *interosseous ligament* between the apposed surfaces of the two bones. The movement between the bones is very slight.

The *Ankle Joint* is formed by the convex upper and the two lateral surfaces of the astragalus fitting into the concavity formed by the lower end of the tibia and the two malleoli. An investing ligament, lined by synovial membrane, encloses the joint; the *external* and *internal lateral* bands of this ligament are much stronger than the *anterior* and *posterior*, which are thin membranes.

At the ankle joint movements of flexion and extension take place. The dorsum of the foot is bent towards the front of the leg by the direct action of the *tibialis anticus*, inserted into the ento-cuneiform and metatarsal of great toe, and the *peroneus tertius*, inserted into the base of the metatarsal of little toe. The opposite movement, the so-called extension of the foot, is due to the action of the *gastrocnemius*, *plantaris* and *soleus* the muscles of the calf of the leg, inserted by the Tendo Achillis into the posterior prominence of the os calcis or heel bone. This movement is made at every step in walking or running, and the great size of the calf-muscles is in relation to their use in the act of progression. The foot cannot, however, be drawn so far back as to be brought into direct line with the leg. In standing erect the foot is at right angles to the axis of the leg, the astragalus is locked in between the two malleoli, and the fibres of the lateral ligaments are tense, so as to fix the joint.

Inter-Tarsal Joints.—Interosseous ligaments connect the bones situated in the transverse rows of the tarsus, *e.g.*, the cuboid with the ecto-cuneiform; the meso- with the ecto- and ento-cuneiform; the cuboid with the scaphoid; the astragalus with the os calcis by a powerful interosseous band. No interosseous ligaments pass antero-posteriorly between the bones placed in the internal and external

longitudinal columns of the tarsus. *Dorsal ligaments* connect the three cuneiforms with each other and with the scaphoid and cuboid, the cuboid with the os calcis, and the scaphoid with the astragalus. *Plantar ligaments* as a rule pass between contiguous bones; two between the os calcis and cuboid are very powerful and named *long* and *short plantar ligaments;* the exception is the astragalo-scaphoid joint, the plantar bands for which are the strong *external* and *inferior calcaneo-scaphoid ligaments*, on the latter of which the astragalus rests.

Between the several bones of the tarsus gliding is permitted, especially between the os calcis and cuboid, the os calcis and astragalus, and the astragalus and scaphoid, so that the foot can be inverted or everted, *i.e.*, its inner or outer borders raised from the ground. Inversion is performed by the *tibialis anticus* and by the *tibialis posticus;* the tendon of the tibialis posticus, though inserted chiefly into the tubercle of the scaphoid bone, gives slips to all the tarsal bones except the astragalus; and to all the metatarsal bones except the 1st and 5th. This tendon lies in contact with the plantar surface of the inferior calcaneo-scaphoid ligament, and both it and the tibialis anticus act as slings in preserving the internal arch of the foot. Eversion is performed by the *peronei longus* and *brevis*, situated on the outer side of the leg, the tendons of which pass behind the outer malleolus,—the brevis to be inserted into the base of the 5th metatarsal, the longus into the plantar surface of the 1st and 2d metatarsals and ento-cuneiform.

Tarso-Metatarsal Joints.—Dorsal and *plantar ligaments* pass between the corresponding surfaces of contiguous bones. *Interosseous ligaments* are, one from ento-cunei-

form to 2d metatarsal, one from ecto-cuneiform to 3d and 4th metatarsals; hence the tarso-metatarsal joints have three synovial membranes.

Inter-Metatarsal Joints.—*Dorsal*, *plantar*, and *interosseous* ligaments connect the tarsal ends of the four outer metatarsals; a *transverse metatarsal ligament* connects the distal ends of all five metatarsals. The *Metatarso-phalangeal* and *Inter-phalangeal Joints* are constructed similarly to the corresponding joints in the hand.

The toes are bent on the sole by a number of flexor muscles. *Inserted* into the ungual phalanges are the *flexor longus digitorum*, with its *musculus accessorius*, and the *flexor longus hallucis*. The flexor longus hallucis is the special flexor of the ungual phalanx of the great toe, but its tendon always gives a slip to the tendon of the flexor longus digitorum, which slip goes, along with that tendon, sometimes to the 2d toe only, more frequently to the 2d and 3d, or even the 2d, 3d, and 4th, and rarely to the 2d, 3d, 4th, and 5th toes. *Inserted* into the 2d phalanges of the four outer toes is the *flexor brevis digitorum* the tendons of which are pierced by those of the flexor longus. *Inserted* into the 1st phalanx of the great toe is the *flexor brevis hallucis*, into that of the 5th toe the *flexor brevis minimi digiti*, whilst the *lumbricales*, as in the hand, are inserted into the extensor tendons. The ungual phalanx of the great toe is extended by the *extensor longus hallucis*; its proximal phalanx by the inner division of the *extensor brevis digitorum*, which is therefore an *extensor primi internodii hallucis*. The four outer toes are extended by the *extensor longus digitorum*, and in addition the *extensor brevis* gives tendons to the 2d, 3d, and 4th, but not the 5th, toes to be *inserted* with the longus into the 2d and 3d phalanges. The great toe

is abducted by the *abductor hallucis* and adducted by the *adductor hallucis* and *transversalis pedis*. The little toe is abducted by the *abductor minimi digiti*. Seven *interossei*, arranged generally on the same plan as those in the hand, are present; but a line through the 2d toe is that from or to which they draw. The hallux or great toe is the most important digit; a line prolonged backwards through it to the heel forms the proper axis of the foot, and the sole chiefly rests upon the pads of integument situated beneath its metatarso-phalangeal joint and the heel. The hallux is much more restricted in its movements than the thumb: the configuration of its tarso-metatarsal joint and the attachment to it of the transverse metatarsal ligament prevent the great toe from being thrown across the surface of the sole as the thumb is thrown across the palm in the movement of opposition; an object can, however, be grasped between the hallux and second toe by the action of its adductor muscles, and persons can be trained to write with a pen or pencil held in this position.

The act of walking consists in the movement forwards of the trunk by the alternate advancement of the lower limbs. Suppose a person to be standing erect, with one leg a little in advance of the other; the body, being inclined slightly forwards, is pushed in advance by the extension of the hindmost limb, so that the weight falls more and more upon the advanced leg, which at the same time is shortened by bending the knee and ankle. The heel of the hindmost limb being then raised by the action of the muscles of the calf, the toes press against the ground so as to push the trunk so far in front of the advanced limb as to be no longer safely supported by it; the hindmost limb is then raised from the ground by muscular action, and

allowed to swing forward by its own weight, but guided by the muscles, until the toes touch the ground in front of the opposite limb. A step has now been made, and the limbs are in a corresponding but opposite position from that in which they were when the step commenced: a repetition of the act constitutes another step, and so the alternate action continues. At one moment in each step both feet touch the ground at the same time, *i.e.*, when the hind foot presses against the earth. The act of running consists in a repetition of the movements of walking performed with so much greater rapidity that the feet never touch the ground at the same moment; the heels also are never brought to the ground. The propulsive action is also greatly increased by the extension of the hip and knee joints, so that a succession of small leaps on to alternate feet takes place. In leaping from the standing position the joints of both lower limbs, previously flexed, are suddenly and simultaneously extended, and the body is projected forwards with a rapid impulse.

Development and Homologies of the Voluntary Muscular System.

The voluntary muscles, like the bones and joints with which they are so intimately associated, are developed out of the mesoblast layer of the blastoderm. The muscles of the axial skeleton may be divided into an *epi-skeletal* group situated outside the endo-skeleton, *i.e.*, between it and the integument—and a *hypo-skeletal* or *hæmal* group lying on the ventral surface of the vertebral bodies and within the rib arches. The epi-skeletal muscles, are developed from the *muscle-plates*, which like the vertebræ themselves, are formed from the *proto-vertebræ*, or *primitive mesoblastic somites* (Balfour), and it is probable that the hypo-skeletal group have the same origin. In fishes the epi-skeletal muscles preserve their fundamental arrangement with but little modification. They are disposed in transverse segments or *myotomes*, which equal in number the vertebræ. These myotomes are separated from each other by bands of fibrous tissue, the *inter-muscular septa*. In man and the higher vertebrates the simple transversely segmented

arrangement is to a large extent lost. Traces are preserved, however, in the interspinales and intertransversales muscles, situated in the intervals between the spines and transverse processes of some of the vertebral segments; in the external intercostals and in the recti abdominis muscles, in the last-named of which tendinous bands the *lineæ transversæ* divide the muscle into four or five transverse segments. More usually, the intermuscular septa disappear, and adjacent myotomes become blended into a continuous mass of muscle. In some instances the fibres of a muscle run longitudinally, and the entire mass divides longitudinally into separate and distinct parallel muscles, as in the composite erector spinæ with its several divisions. In other instances the muscles run obliquely; some on the back of the body pass obliquely from below upwards and outwards, as the splenius, and obliquus inferior; others obliquely from below upwards and inwards, as the complexus, obliquus superior, and the composite oblique rotator muscle; others again, as the oblique muscles of the abdomen, extend obliquely from behind forwards to the ventral mesial line.

Of the hypo-skeletal group of muscles, the internal intercostals display the transverse segmentation. As a rule, however, the muscles of this group extend longitudinally, and form the pre-vertebral muscles; though the diaphragm, triangulares sterni, transversi abdominis, and levatores ani, which lie in relation to the inner surfaces of the ribs and visceral cavities, are not longitudinal, but are specially modified in arrangement for functional reasons. The plane of demarcation between the hypo- and epi-skeletal groups of muscles, where they form together the walls of the thorax and abdomen, is marked off by the position and course of the intercostal spinal nerves.

The muscles attached to the appendicular skeleton are either limited to the limbs (purely appendicular, therefore), or pass from the axial part of the body to the limb (axi-appendicular). The axi-appendicular group are prolongations of the axial system of muscles. They are in the upper limb derived from the epi-skeletal division, and form the trapezius, rhomboid, levator anguli scapulæ, latissimus dorsi, subclavius, serratus magnus, and pectoral muscles. In the lower limb they are in part derived from the hypo-skeletal division, and form the psoas and pyriformis; and in part as the gluteus maximus, from the epi-skeletal division. It is not improbable that the purely appendicular muscles are also prolongations of the axial system, and that as the limbs, in their development from their fundamental bud-like lappets, undergo both a transverse and a longitudinal segmentation, so the muscular mass, prolonged into them, differentiates both transversely and longitudinally into a motor apparatus, fitted for the performance of the special functions of each extremity.

CHAPTER III.

ANATOMY OF THE TEXTURES OR TISSUES.

Introductory.

Before proceeding to the description of the other organic systems of which the human body is built up, it may be well to enter into the consideration of the minute or microscopic structure of its constituent parts. These parts may primarily be divided into Fluids and Solids. The fluids are the blood, the lymph, the chyle, the secretions of the various glands, and of the serous and synovial membranes. The solids form the framework of the several organic systems, and assume different appearances in different localities. Sometimes they are arranged in compact solid masses, as in cartilage; at others they are elongated into fine threads or fibres, as in muscle, tendon, nerve; at others they are expanded into thin membranes, as in the fasciæ or aponeuroses, the serous, synovial, and mucous membranes; at others they are hollowed out into distinct tubes for the conveyance of fluids, as in the blood-vessels, the lymph and chyle vessels, and the ducts of glands. To the solids of the body, whatever their form may be, the general name of Tissues or Textures is applied. Each organic system may be regarded as in the main composed of a tissue or texture peculiar to and characteristic of itself. Thus, the bones are essentially composed of the osseous tissue, the

muscles of the muscular tissue, the nervous system of the nervous tissue, fibrous membranes of the fibrous or connective tissue, &c. But though the essential constituent of each organic system is a tissue peculiar to that system, yet in most localities certain other tissues are mingled with that which is to be regarded as the characteristic texture of the part. In a muscle, for example, not only is the muscular tissue present, but mingled with it are connective tissue, nerve tissue, blood-vessels, and lymph-vessels. A gland also consists not only of its proper tissue, the secreting cells, but of more or less connective tissue, nerves, blood and lymph-vessels, and gland ducts. Indeed, there are few localities in which, along with the proper tissue of the part, blood and lymph-vessels, nerves and connective tissue, are not found; and to a part built up of two or more tissues the term ORGAN is applied. Thus the muscular system consists of the series of organs which we call the muscles, the glandular system of the several organs called glands, and so on. Each tissue and each organ, into the construction of which that tissue enters as the characteristic texture, possesses both distinctive structural and distinctive functional properties. Thus the muscular tissue is characterised by the property of contractility, and the muscles, of which it forms the essential texture, are organs of motion or locomotion; the osseous tissue is characterised by its hardness and strength, and the bones, of which it forms the essential texture, are organs of support and protection.

But the study of the textures embraces not only an inquiry into the special structural, and functional properties of each tissue and organ—into the special part which each plays in the animal economy—but the consideration of their

properties as living structures. It would be out of place in this work to enter into a discussion of the meaning of the term LIFE, or LIVING, or to attempt an analysis of the various definitions of the term which have been suggested from time to time by different philosophers. It will suffice for our present purpose to adopt the old Aristotelian definition, and to speak of Life as the faculties of self-nourishment, self-growth, and self-decay. All the tissues, over and above the special properties which they possess, have therefore the power of growing, and of maintaining themselves in full structural perfection and functional activity for a given period of time. After a time they begin to exhibit signs of diminished perfection and activity, they degenerate or decay; ultimately they die, and the entire organism, of which they form the constituent parts, is resolved by the putrefactive process into more simple forms of matter.

GENERAL CONSIDERATIONS ON CELLS.

The simplest form of organic matter capable of exhibiting the phenomena of life is a nitrogenous compound (proteid) called Cyto-blastema or Protoplasm. It is viscous or jelly-like, colourless, translucent, and granulated. The granules express a very minute *intra-protoplasmic network* of very delicate fibrils, in the meshes of which is a homogeneous substance. Protoplasm assimilates nutriment, grows, reproduces its kind, moves and responds to stimuli. It enters in a very important manner into the structure of the bodies of the lower animals. The elongated processes, or *pseudopodia*, to which Dujardin applied the name of *sarcode*, which the Rhizopoda can project from their surface into the surrounding medium, and again withdraw into their substance,

consist of protoplasm, and may be cited as furnishing excellent examples of its motive and contractile power. From the researches of Haeckel it would appear that protoplasm is capable of forming, without the super-addition of any other structure, independent organisms, which are at the lowest grade of organisation, and from their extreme simplicity are named by him Monera. To the group Monera belong the genera Protamœba and Protogenes. Haeckel has referred these simple organisms to a sub-kingdom of PROTISTÆ, which he considers to lie on the confines of both the animal and vegetable kingdoms. To a mass of protoplasm, whether it forms, as in one of these PROTISTÆ, an independent organism, or is merely a portion of the substance of the body of a higher organism, Haeckel has given the general name of a *Cytode* (fig. 25). So far back as 1861, Lionel Beale had described, under the name of *germinal matter* (*Bioplasm*), minute living particles of vegetable protoplasm, and in 1863 he demonstrated extremely minute particles of living matter in the blood. Stricker had also called attention, in the bodies of the higher animals, to minute detached clumps of living protoplasm. When a cytode is a naked clump of soft protoplasm, without a trace of differentiation either on its surface or in its substance, as in the freely-moving Monera, it is a *simple cytode*; when the peripheral part of the cytode hardens, and differentiates into a more or less perfect envelope, as in the genera Protomonas and Protomyxa it is an *encased cytode*.

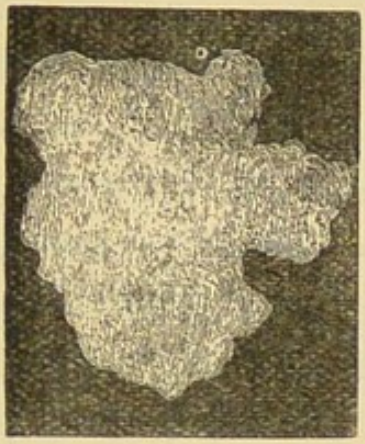

FIG. 25. — Undifferentiated Cytode mass of Protoplasm.

As a rule, however, in both vegetable and animal organisms the specks or clumps of protoplasm assume definite shapes, and show evidence of an internal differentiation. In the midst of a minute clump of protoplasm a definite body called a *nucleus* is found, which has a limiting membrane, and contains an *intra-nuclear plexus* of fine fibrils, but differs from the surrounding protoplasm in not being contractile; sometimes a minute speck, or *nucleolus* exists within the nucleus. When a definite clump of protoplasm contains a nucleus in its interior, whether a nucleolus be present or not, it is called a *Simple Nucleated Cell* (fig. 26). Cells are definite anatomical and physiological units, and exhibit all the phenomena of life. Some of the lowest organisms consist merely of a single cell, others of two or more cells united together, and these are called uni- or multi-cellular organisms. Cells also enter in the most material manner into the constitution of the textures of all the higher forms of plants and animals. Not unfrequently the peripheral part of the protoplasm of the cell differentiates into a distinct investing envelope, technically named a *cell wall* or *cell membrane*, in which case the cell becomes an *encased cell*.



FIG. 26.—A simple form of Nucleated Cell. *P*, protoplasm cell-substance; *N*, nucleus; *Nl*, nucleolus.

In the earlier periods of investigation into the minute structure of cells it was believed that a cell wall was constantly present, and that each cell was a minute microscopic vesicle or bladder, which in its typical shape was globular or ovoid, but capable of undergoing various modifications both in form and chemical composition. The material enclosed by the cell wall was termed the *cell contents*, and

either in the midst of these contents or in contact with the cell wall was the nucleus, which might or might not contain a nucleolus. Schwann believed that the cell wall was the most active constituent of the cell, *i.e.*, possessed the power not only of producing chemical and physical changes in its own substance and in the cell contents, but of separating materials from the surrounding media,—of secreting them, as it were, into the interior of the cell. In this manner he accounted for the formation in some cells of fat, in others of pigment, in others of the characteristic secretion of glands, and so on.

It was then maintained by John Goodsir that the nucleus was the part of a cell which in all probability was concerned in separating and preparing its characteristic cell contents, and in its nutrition. Martin Barry and Goodsir also contended that the reproduction and multiplication of cells were due to self-division of the nucleus, which was thus the source of successive broods of young cells. They gave to the nucleus, therefore, an importance in the economy of the cell greater than had previously been assigned to it.

As the investigations into cell structure became more extended, it was ascertained that a cell wall was by no means always present; that in many of the cells in which it had been supposed to exist it could not satisfactorily be demonstrated, and that in others, more especially in young actively-growing cells, no trace of an investing envelope could be observed. Hence the importance of the cell wall as an essential component of a cell was still further diminished; and Leydig then defined a cell to be a little mass composed of a soft substance enclosing a central nucleus.

But a most important advance in our conceptions of the essential structure of a cell was made when Brücke pointed out that the contents of cells not unfrequently possessed the property of spontaneous movement and contractility, and when Max Schultze determined that the contractile substance termed *sarcode*, which forms so large a part of the bodies of the lower animals, was analogous and apparently homologous with the contents of young actively-growing animal and vegetable cells, before a differentiation of these contents into special secretions or other materials had taken place. As the term "protoplasm" had been introduced by Von Mohl to express the contents of the vegetable cell, which undergo changes in the process of growth, it was adopted by the animal histologist; and Max Schultze suggested that a cell should be defined to be a *nucleated mass of protoplasm*,—a definition which is adopted in this book. Now, as protoplasm, whether it occurs along with a nucleus in the form of a cell, or in independent clumps or cytodes, exhibits not merely the property of contractility, but the power of growing and maintaining itself, it is regarded as the functionally active constituent of the cell. And thus our conceptions as to the part of the cell in which the functional activity resides have passed through three phases. In the first, the cell wall; in the second, the nucleus; in the third the protoplasm cell contents, or cell substance, has been looked upon as the active constituent, not only as regards its nutrition, but the reproduction of young cells. But though the protoplasm can of itself perform these offices, yet there can be no doubt, as Barry and Goodsir were the first to show, that the nucleus of the cell plays a part in the multiplication of cells by self-division.

The details of the changes in the nucleus have been worked out by Strasburger, Flemming, Klein and others. The nucleus loses its limiting membrane. The intra-nuclear network of fibrils becomes more distinct, the fibrils thicker, more separated and more convoluted and the nucleus larger. The fibrils then form long loops, arranged as a wreath or rosette, and the nucleus becomes flattened and is called the *nuclear* or *equatorial plate.* The loops of this plate then arrange themselves so that they radiate from the centre to the periphery of the plate, when a star-like figure or *monaster* is formed. Next this star divides into two stars—*dyaster*—which separate from each other; the fibrils of each of the two stars become convoluted, anastomose, and form a spherical or oval body, around which a limiting membrane is produced and two new nuclei arise. The cell-protoplasm surrounding the original nucleus also divides and a portion arranges itself around each of the two new nuclei, so that two daughter-cells are formed from the single mother-cell.

One of the most characteristic cells is the mammalian ovum. In it a cell wall exists, known as the *zona pellucida* or vitelline membrane; within this envelope is the granular *yelk* or cell contents, in the midst of which is imbedded the nucleus or *germinal vesicle*, which in its turn contains the nucleolus or *germinal spot.* The granules of the yelk are a special metamorphosis of the protoplasmic cell substance.

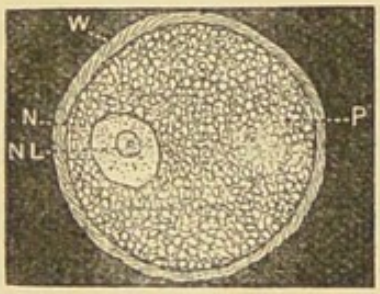

FIG. 27.—Ovum of a Sheep. *W*, cell wall or zona pellucida; *P*, protoplasm or yelk; *N*, nucleus, or germinal vesicle; *Nl*, nucleolus, or germinal spot.

Schwann made the important generalisation that the tissues of the animal body are composed of cells, or of materials derived from cells, "that there is one universal principle of development for the elementary part of organisms, however different, and that this principle is the formation of cells." The ovum is the primordial or fundamental cell, or germ-cell, from which, after being fertilised by the male spermatozoa, the tissues and organs of the animal body are derived. The germinal vesicle loses its

limiting membrane, and whilst a portion of its substance is extruded from the ovum as the *polar cell* or *cells*, the rest remains within the egg as the *female pro-nucleus*. The head of the spermatozoon which enters the ovum forms the *male pro-nucleus*. The male and female pro-nuclei fuse with each other and produce the segmentation nucleus, which divides along with the surrounding yelk protoplasm, first into two, then four, then eight, then sixteen segments, and so on in multiple proportion. Each segment is therefore a nucleated mass of protoplasm—is, in short, a nucleated cell, and the protoplasm of these cells exhibits the property of contractility. The ovum or germ-cell is thus the immediate parent of all the new cells which are formed within it, and mediately it is the parent of all the cells which, in the subsequent processes of development and growth, are descended from those produced by the segmentation of the yelk. The process of development of young cells within a parent cell, whether it occurs in the ovum or in a cell derived by descent from the ovum, is called the *endogenous* reproduction of cells. Another mode of multiplication of cells is by *budding:* little clumps of protoplasm bud out from the protoplasm of the parent cell, become detached, and assume an independent vitality. If a nucleus differentiates in the interior of such a clump, it becomes a cell; if it remains as a mere clump of protoplasm, it is a cytode.

These methods of multiplication are all confirmatory of Schwann's generalisation of the descent or derivation of cells from pre-existing cells. But as the nucleated cell, either with or without a cell wall, is not, in the present state of science, regarded as the simplest and most elementary unit capable of exhibiting vital phenomena, and as these phenomena can be displayed by individual

clumps of protoplasm, without the presence of a nucleus, some modification of the doctrine, as regards the formation of the tissues from nucleated cells, seems to be necessary. For, although there can be no doubt that all the tissues are immediately derived from the ovum or fundamental cell, and that most of the tissues are derived directly from nucleated cells, yet there is reason to think that a differentiation of a cytode clump of protoplasm into tissue may take place, so that the direct formation of such tissue would be, not from a nucleated cell, but from the more simple cytode. Hence a more comprehensive generalisation, to which observers have gradually been led from the consideration of numerous facts, has now been arrived at,—that the tissues and organs of the body, whatever may be their form and composition, are formed of protoplasm, or produced by its differentiation; and that the protoplasm itself is derived by descent from the protoplasm substance of the primordial germ-cell. Some, indeed, have contended that protoplasm, cells, and their derivatives can arise by a process of precipitation or aggregation of minute particles or molecules in an organic infusion, and that living matter may be thus spontaneously generated. But the evidence which has been advanced in support of this hypothesis is by no means satisfactory or conclusive, whilst the theory of the direct descent of protoplasm from pre-existing living protoplasm is supported by thousands of observations made by the most competent inquirers.

Preliminary to the formation of the individual tissues and organs the segmentation cells of the fertilized ovum arrange themselves as the *blastodermic membrane*, which divides in the embryonic area into two layers, *epiblast* and *hypoblast*, forming the *bilaminar blastoderm*. Between these layers a third appears, the *mesoblast*, so that a *trilaminar blastoderm* is produced (fig. 11*). The mesoblast is derived either from

the epiblast or hypoblast, or perhaps from both. In the process of conversion or transformation of the protoplasm of the cells of these three layers into the several tissues and organs, a differentiation of form and structure (*i.e.*, a morphological or histological differentiation), and of composition (*i.e.*, a chemical differentiation) takes place, the result of which is a physiological differentiation, and the tissues and organs become adapted to the performance of special functions. Hence arise the several forms of tissue which occur in the human body and in the higher animals. From the epiblast arise the epidermis and the epithelial lining of the nose, mouth, and salivary glands, the nervous system and the sensory expansions of the organs of special sense. From the mesoblast arise the skeleton, the muscular, vascular and connective tissues, and the urinary and generative organs. From the hypoblast arise the epithelial lining of the digestive tube, of the windpipe and air cells, and of the glands opening into the digestive canal, with perhaps the chorda dorsalis.

Many of the tissues consist exclusively of cells, which present in different parts of the body characteristic modifications in external configuration, in composition, and in properties, as may be seen in the fatty tissue, pigmentary tissue, and epithelium. Other tissues, again, consist partly of cells, and partly of an intermediate material which separates the constituent cells from each other. Here also the cells present various modifications; and the intermediate material, termed the *matrix* or *intercellular substance*, varies in structure, in composition, and in properties in the different textures, as is seen in the connective, cartilaginous, osseous, and muscular tissues.

It is not an easy matter to devise a classification of the tissues, based on their structural characters, which shall be in all respects logically perfect; but a convenient basis of arrangement for descriptive purposes may be found by dividing them into those which consist—1st, of cells suspended in fluids; 2d, of cells arranged on free surfaces; 3d, of cells placed interstitially in a matrix.

FIRST GROUP OF TISSUES.

Cells Suspended in Fluids.

The fluids of the body in which cells or other minute solid particles are suspended are the blood, the lymph, and the chyle. Sometimes cells are found floating in the secretions of glands.

The Blood.

The blood is the well-known red fluid which circulates throughout the blood-vascular system. As its general composition and properties have to be considered in physiological rather than in anatomical works, the solid particles only, which are suspended in the *plasma* or *liquor sanguinis*, will be described here. If a drop of human blood be examined under the microscope, crowds of minute bodies, the blood corpuscles, or blood globules, may be seen in it. These present two different appearances, and are distinguished by the names of red and white blood corpuscles.

The *red corpuscles*, which are by far the more numerous, are circular, biconcave, non-nucleated discs. Their average diameter is about $\frac{1}{3200}$th of an inch, and their thickness about $\frac{1}{4}$th of that measurement; hence they are not spheres, as the old name blood globules would imply. Single corpuscles have a faint fawn-coloured hue, but collectively they give to the blood its characteristic red colour, due to the presence in the corpuscles of *hæmoglobin*. Vierordt and Welcker have estimated that 5,000,000 red corpuscles are present in every cubic millimetre of healthy human blood, and Malassez computes the whole volume of blood to contain 22,500 thousand millions. The red corpuscles

in the blood of all mammals are non-nucleated and biconcave, and in all, except the tribe of camels, they are circular discs; but in the camels they are elliptical. An appearance of nucleation has been seen in exceptional individual cases; for Rolleston saw it in a small proportion of the dried red blood corpuscles of a two-toed sloth; and I have observed in a proportion of the red blood discs of a Hoffmann's sloth an appearance of a central nucleus.

In all birds, reptiles, amphibia, and most fishes the red corpuscles are oval or elliptical, nucleated and biconvex (2, 4, 5, fig. 28). In the Cyclostomatous fishes the red corpuscles are circular discs. The red corpuscles vary materially in size in different vertebrata, and these variations have been especially studied by Gulliver. He has found them to vary in mammals from an average diameter of $\frac{1}{2745}$th of an inch in the elephant, and $\frac{1}{2769}$th in *Orycteropus capensis*, to $\frac{1}{12325}$th in *Tragulus javanicus*, and he concludes that the smallest blood discs occur in the small species of an order or family, the largest in the large species. In birds they are larger than in mammals, and vary in length from an average of $\frac{1}{1455}$ inch in *Casuarius javanicus* to $\frac{1}{2416}$th in *Linaria minor*. In reptiles they are still larger, and vary in length from an average of

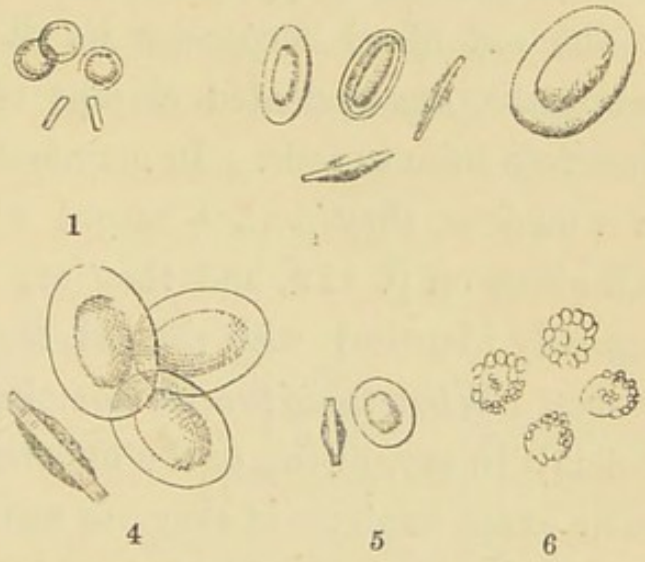

FIG. 28.—1, red corpuscles of human blood; 2, red corpuscles of blood of common fowl, seen on the surface and edgeways; 3, red corpuscles of frog; 4, of *Squalus squatina*; 5, of *Lophius piscatorius*; 6, corpuscles of the blood of a scorpion.

$\frac{1}{1178}$th in *Anguis fragilis* to $\frac{1}{1555}$th in *Lacerta viridis*. In amphibia the largest corpuscles, according to Gulliver, are about $\frac{1}{400}$ inch in length in *Proteus* and *Siren*, though Riddell states that in *Amphiuma tridactylum* they are $\frac{1}{3}$d larger; whilst the smallest, as in the common frog, average in length $\frac{1}{1108}$ inch. In cartilaginous fish the corpuscles are larger than in osseous; *e.g.*, in *Lamna cornubica* Gulliver found their long diameter to be $\frac{1}{923}$ inch; while in the Salmonidæ, which have the largest blood discs among osseous fish, the long diameter in the salmon and common trout is only about $\frac{1}{1500}$ inch.

The red blood corpuscles in all vertebrata, except the mammalia, are nucleated clumps of protoplasm; they are therefore minute cells. In mammals, owing to the absence of a nucleus, they do not accord with the definition of a cell given on p. 119, and they are not therefore morphologically identical with the red corpuscles in other vertebrates. What their precise homology may be is somewhat difficult to say, owing to the obscurity which prevails as to their exact origin. If they are merely clumps of specially modified protoplasm, budded off from the white corpuscles, then they are cytodes. If, as some have supposed, they are the nuclei of the white corpuscles, specially modified in composition, then they are free nuclei. If, again, they are the white corpuscles, the cell substance of which has undergone a special differentiation, and the nucleus has disappeared, then they are potentially cells, though no nucleus is visible. Whatever may be their exact homology, there can be no doubt that the non-nucleated mammalian red corpuscle, and the substance of the nucleated red corpuscle which lies outside the nucleus, are functionally identical with each other; the protoplasm having in both

undergone a special chemical differentiation into hæmoglobin, a proximate principle characterised by containing iron as one of its essential constituents. The action of water, spirit, acids, alkalies, various gases, heat, cold, and electrical currents, on the red corpuscles has been studied by several observers, and the conclusion has been reached that the corpuscles consist of a "stroma," in the interstices of which the coloured part of the corpuscle is placed. The stroma though denser at the periphery than in the centre does not form a definite investing envelope or membrane. When blood is drawn from the vessels the red corpuscles, in about half a minute, run together into piles, like *rouleaux* of coins (fig. 29), which arrange themselves into irregular meshes.

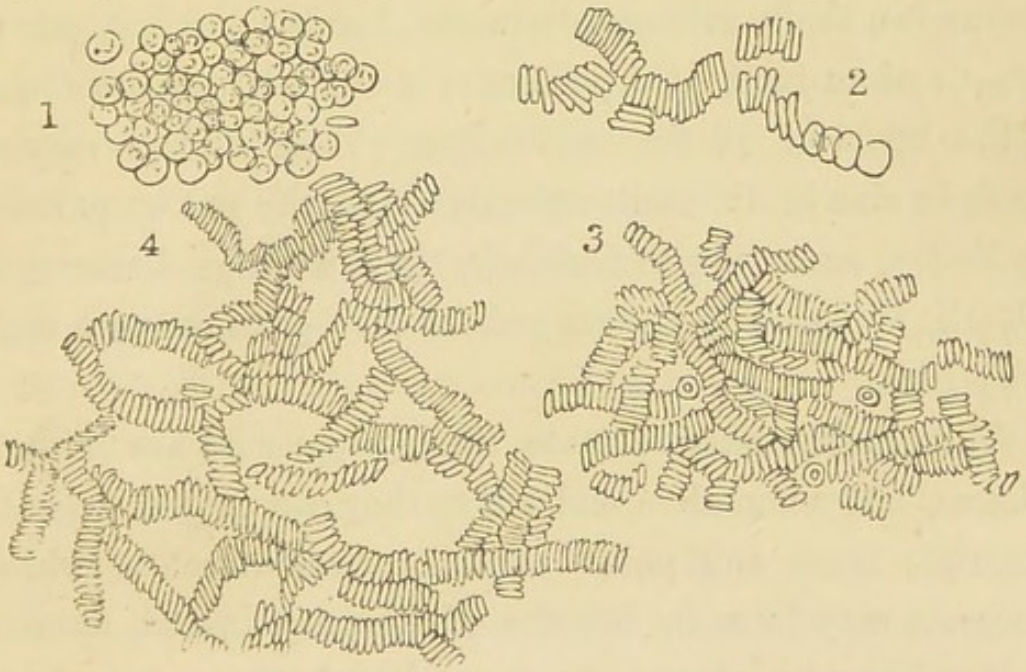

FIG. 29.—1, red corpuscles of healthy human blood; 2, red corpuscles beginning to form *rouleaux*; 3, mesh-like arrangement in healthy blood; 4, mesh-like arrangement in buffy blood, where the meshes are larger than in healthy blood.

In inflammatory diseases, and in the blood of pregnant women, the piles of corpuscles form more readily, and at the same time sink rapidly below the surface of the fluid, so as to cause the "buffy coat" seen in the blood coagulum. In the healthy blood of horses a buffy coat is formed as a natural condition of the coagulation.

The *white* or *colourless corpuscles* are comparatively few in number in the healthy human blood. Welcker has estimated the normal relative number as one white to 335 red; in pregnant and menstruating women the proportion is increased to about 1 to 280. In the disease called leucocythæmia, the proportion is so materially increased that they appear to be almost as numerous as the red. The white corpuscles are minute nucleated clumps of protoplasm without a cell wall, they are therefore simple cells. The protoplasm may be coarsely or finely granulated, and possesses an intra-cellular network of fibrils. The nucleus has a similar network and becomes more distinct after the addition of acetic acid. The white are larger than the red corpuscles, their average diameter being from $\frac{1}{2500}$th to $\frac{1}{3000}$th of an inch. Corpuscles of a similar form are found in the blood of all the vertebrata. They do not vary so much in size in different animals as do the red corpuscles. In *Triton*, according to Gulliver, their average diameter is $\frac{1}{2000}$th, whilst in *Herpestes griseus* they are not more than $\frac{1}{3878}$ inch.

When in the passive state these corpuscles are minute spheres, but when alive and active they can project delicate processes from any point of their circumference, which processes may branch, become greatly attenuated, assume various irregular shapes, or even detach themselves from the body of the corpuscle. These processes resemble the sarcode prolongations which *Amœba* and other Rhizopods can project from various parts of their circumference (fig. 25); and as a white blood corpuscle, like an *Amœba*, can by the movements of the processes change its position, the term "amœboid movements" has been applied to the phenomena in question. Like an *Amœba*, also, a white

corpuscle can by these movements include within its substance, or feed upon, minute particles of solid matter which it may come in contact with in its path. Many years ago W. Addison stated that the white blood corpuscles could pass through the walls of the blood-vessels into the surrounding tissue, where they formed mucus corpuscles, and, under certain pathological conditions, the corpuscles of pus or inflammatory lymph. The passage of white blood corpuscles through the wall of the capillaries was seen in 1846 by A. Waller; and though for many years his observations were ignored, yet the more recent inquiries of Cohnheim and others into the subject have again directed attention to them. It is now admitted that the migration or *diapedesis* of these corpuscles from the blood through the wall of the capillaries into the tissues does take place, and that they then "wander" to and fro, owing to the mobility of their contractile protoplasm. These migrated corpuscles are believed to play an important part in many physiological and pathological processes.

But the blood contains in addition to the red and white corpuscles, smaller particles, inconstant in number. Corpuscles about $\frac{1}{4}$th the size of the white corpuscles and perhaps these in their early stage have been seen. Minute globules have been described by Beale and Max Schultze, which are probably detached fragments of protoplasm budded off from the white corpuscles; and Zimmermann has described, as elementary corpuscles, minute particles, which are apparently derived from broken-up red corpuscles.

Development of Blood-corpuscles.

"In the very young embryo the blood corpuscles, like the capillary blood-vessels themselves, are formed by special differentiation of the mesoblast cells of the vascular area, the nuclei of which multiply by fission and form the embryonic blood corpuscles, which at first are

colourless, but afterwards assume a red colour. In mammals the earliest red blood corpuscles are nucleated and larger than the future red discs, but as development goes on, non-nucleated red corpuscles appear, and as their number increases, both absolutely and relatively with the progress of the fœtus, in course of time all the nucleated red corpuscles have disappeared, and are replaced by non-nucleated discs. In adults the red corpuscles are believed to be derived from the white corpuscles, though the exact process of metamorphosis has not been satisfactorily ascertained. It is also believed that red corpuscles may be new-formed in the spleen, and Neumann has stated that the cells of the red marrow of the bones may serve as a centre of origin for the red blood corpuscles. In the fœtus the liver apparently serves as a centre of origin for the white corpuscles, but its blood corpuscle forming function ceases at the time of birth. Throughout extra-uterine life the spleen and the lymphatic glands are without doubt organs of formation of the colourless corpuscles,—those produced in the lymphatic glands, under the name of lymph corpuscles, being mingled with the blood-stream where the fluid lymph flows into the venous system. When mixed with the blood, the lymph corpuscles become the white blood corpuscles.

Corpuscles are also found in the blood of the invertebrata. They are as a rule colourless, but R. Wagner pointed out that in the Cephalopods they are coloured. They are sometimes round, at others oval or fusiform, and in worms and insects have even branched processes. They are always nucleated.

The Lymph and Chyle.

The Lymph is the fluid found in the division of the vascular system named the lymph-vascular system. It is transparent and colourless, and contains numerous corpuscles floating in it, which correspond, in appearance, structure, and the possession of the property of amœboid movements, to the white corpuscles of the blood. The lymph corpuscles are formed in the lymph-glands situated in the course of the lymph vessels, and are carried away from the glands by the stream of lymph which flows through them.

The Chyle is a milky fluid found during the period of digestion in the delicate lacteal vessels which arise in the

walls of the small intestine. The lacteals join the lymphatics at the back of the abdomen to form the thoracic duct in which the lymph and chyle become mingled together. The chyle contains corpuscles similar to the lymph corpuscles, which are apparently derived from the lymph glands in the mesentery, through which the chyle flows on its way to the thoracic duct. The fluid of the lymph, the chyle, and the blood, in which the corpuscles are suspended, is sometimes described as a fluid intercellular substance. Corpuscles possessing the type of structure of the lymph corpuscles, are named lymphoid cells or *leucocytes*.

Cells are also met with floating free in the Secretions formed in the interior of some of the glands. They are more particularly found in the secretion of mucus from the mucous glands, and of saliva from the salivary glands (fig. 33, B). They are round, colourless, nucleated corpuscles, like leucocytes, and are either formed in the glands, or are migrated white blood corpuscles.

SECOND GROUP OF TISSUES.

Cells Arranged on Free Surfaces.

By the term Free Surface is meant a surface which is not blended with or attached to adjacent structures, but is free or separable from them without dissection. Every free surface is covered by one or more layers of cells. It has been customary to name these cells Epithelium, and to speak of a *simple* or a *stratified* epithelium, according as the cells are arranged in one or in several layers. But it has been suggested by His that the cells lining the inner surface of the wall of the vascular and serous canals an

cavities should be termed Endothelium, whilst the cells covering the mucous surfaces should form the Epithelium properly so-called. The cells situated on the free surface of the skin, though usually termed the epidermis or cuticle, should also be referred to the epithelial structures. Speaking generally, one may say that by the term epithelium is meant the cells situated on free surfaces which are exposed either directly or indirectly to the air; whilst by the term Endothelium is meant the cells situated on free surfaces which are not exposed either directly or indirectly to the air.

Epithelium.

The free surfaces covered by an epithelium are the mucous membranes, and the skin.

The Mucous Membranes secrete mucus, line internal passages and canals, and are continuous at certain orifices with the skin,—*e.g.*, the mucous membrane of the Alimentary canal opens on the surface at the mouth and anus: the mucous membrane of the Respiratory passage opens on the surface at the nostrils, and is continuous in the pharynx with the alimentary mucous membrane—it is also prolonged through the Eustachian tube into the tympanum, and is continuous through the nasal duct with the conjunctiva: the Genito-Urinary mucous membrane opens on the surface at the orifices of the urethra and vagina. Mucous membranes also line the ducts of the various glands which open on the surface either of the skin or the several mucous canals. The epithelial cells are as a rule arranged in layers or strata, and the shape of the cells is not uniform in the different layers. The cells of the deeper strata are smaller, softer, and more recently formed than those of the superficial strata, and in the skin, in the bladder, conjunctiva,

and some other mucous surfaces, they are irregular in size, and elongated into short columns. The cells next the free surface have a tendency to be shed, and they are replaced by the cells of the deeper layers, which become modified in form as they become superficial. Epithelium is distinguished by being devoid of blood-vessels, *i.e.*, it is non-vascular; and also, with some exceptions, devoid of nerves, *i.e.*, non-sensitive. Epithelium is divided into the *squamous*, *columnar*, *ciliated*, *transitional*, *glandular*, and *nervous* varieties.

The epithelial cells, whether arranged in one or several strata, rest upon a subjacent tissue, which, from its relation to the cells, may be called *sub-epithelial*. The sub-epithelial tissue is a form of the fibrous variety of connective tissue, to be subsequently described, and in it lie the nerves, the blood and lymph vessels, and the involuntary muscular tissue of the skin and mucous membranes; hence it is sometimes described as a fibro-vascular tissue or *corium*. It was for a long time believed that, between the deeper surface of the epithelium and the corium, a definite, homogeneous, continuous membrane, named by Bowman a *basement membrane*, intervened, which formed a sharp line of demarcation between the epithelial and the sub-epithelial tissue. Bowman, however, himself admitted that in some of the localities where this membrane was theoretically supposed to exist it could not satisfactorily be demonstrated. Sometimes, however, a layer of flattened cells intervenes between the epithelium and sub-epithelial connective tissue, and assumes a membrane-like appearance (Debove). H. Watney has described in the mucous membrane of the alimentary canal, a delicate reticulum of connective tissue as prolonged between the epithelial cells.

The corium is also the seat of numerous glands, with their blood and lymph vessels and nerves; and the epithelial lining of the glands is continuous at their orifices with the epithelial investment of the corium. The surface both of the mucous membranes and skin is usually more or less undulated—sometimes it is thrown into strong folds or rugæ, at others it is elevated into minute, frequently conical, processes, named in some localities papillæ, in others villi; but in all these cases the epithelium is prolonged as a continuous covering over the undulating free surface. The free surface of all mucous membranes is kept moist by the secretion or mucus which lubricates it.

Squamous, tessellated, pavement, or *scaly* epithelium is usually stratified, and as such occurs on the free surface of the mucous lining of the mouth, pharynx, œsophagus, vestibular entrance to the nose, ocular conjunctiva, vagina, and entrance to the urethra. It forms under the special name of the horny layer of the cuticle or epidermis, the superficial investment of the skin. Its cells are flattened scales, varying in diameter from $\frac{1}{500}$th to $\frac{1}{1000}$th inch, and with flattened nuclei. They have a granular appearance due to the intra-cellular plexus of fine fibrils; a similar plexus exists within the nucleus. The cells are connected together by a cement substance; those in the same layer, being in contact by their edges, form a tessellated, pavement-like arrangement, whilst the cells in contiguous layers have their flattened surfaces in contact with each other. The cells in the deeper layers have often fluted

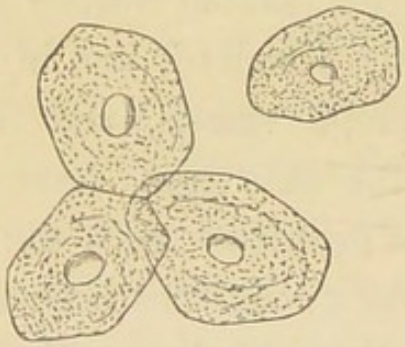

FIG. 30.—Scaly Epithelium from the mucous membrane of the mouth.

surfaces and prickle-like processes, and are called *prickle cells.* In the formation of this epithelium a morphological differentiation of the protoplasm of the cells of the deeper strata into flattened scales, and at the same time a chemical differentiation of their soft contents into a horny material, have occurred.

Columnar or *cylindrical* epithelium is situated on the free surface of the mucous membrane of the alimentary canal, from the œsophageal orifice of the stomach to the anus, and is prolonged into the ducts of various glands which open on the alimentary mucous membrane; it covers the mucous lining of the urethra, vas deferens, mammary ducts, and gall bladder. The cells are elongated columns, about $\frac{1}{500}$th inch long, placed side by side like a row of palisades, and with the long axis perpendicular to the surface on which the cells rest. Sometimes the cells are uniformly cylindrical; at other times they are compressed at the sides; at others they are more conical,—the base or broad end, rounded or polygonal, forming the free surface of the membrane which they cover; the apex or attached end being attenuated and next the sub-epithelial tissue. The nuclei are oval, and both they and the cell protoplasm are granular and contain a network of fine fibrils. The columnar cells have a clear hem or border at their broad free ends, which in the cells covering the intestinal villi is streaked with fine parallel lines (fig. 31, C). Intermingled with the columnar epithelial cells of the intestine are cup-shaped *chalice* or *goblet* cells, which seem mostly empty, or



FIG. 31.—Columnar Epithelium. A, side view of a group of cells; B, larger free end of a group of cells; C, a striated columnar cell from intestinal villus.

contain a colloid substance; their nucleus surrounded by a little protoplasm is near the attached end of the cell. Short *replacement* cells which do not reach the surface, lie between the attached ends of the columnar epithelium cells, in localities where these form only a single layer.

Ciliated epithelium is situated on the nasal mucous membrane, and its prolongations into the cranial air-sinuses, into the nasal duct and lachrymal sac, into the Eustachian tube and tympanum, and the nasal part of the pharynx; on the free surface of the mucous membrane of the windpipe as far as the terminal branches of the bronchial tubes; on the mucous surface of the uterus and Fallopian tubes; on the mucous lining of the commencement of the vas deferens, and on the lining membrane of the ventricles of the brain and central canal of the spinal cord. It consists of columnar cells, which have at their free or basal ends extremely slender, soft, pellucid, hair-like processes, or *cilia*. Beale states that the soft bioplasm (protoplasm) of the body of the cell is prolonged along the axis of each cilium, whilst the periphery possesses the firmer consistence of formed or differentiated material, but Klein regards the cilia as prolongations of the fibrils of the intra-cellular network. During life these cilia move rapidly to and fro in the fluid which moistens the surface of the membrane on which this form of epithelium is situated. In the human body the cilia are not more than from $\frac{1}{2500}$th to $\frac{1}{4000}$th inch in length; but in various marine invertebrata they are both longer and stronger. Sometimes, as in the lining membrane of the cerebral ventricles and on the inner surface of the

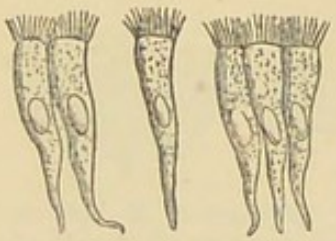

FIG. 32.—Ciliated Epithelial Cells.

membrana tympani, the cells carrying the cilia are flattened and not cylindrical. Cilia occasion currents in the fluid in which they move, and play an important part in the economy of many animals; in some of the invertebrata they serve as organs of locomotion, in others they propel currents over respiratory surfaces, and in others aid in bringing food within the animal's reach.

Transitional epithelium is the name applied to epithelial cells which have a form transitional between either the columnar and squamous epithelia, or the columnar and polygonal. The epithelium of the mucous lining of the bladder is transitional between the columnar and squamous varieties. In many glands the continuity of the epithelial layer from the polygonal cells of the gland-follicles to the columnar cells of the gland-ducts is kept up by interposed transitional cells, often *cubical* in shape.

Glandular epithelium is situated on the free surface of the follicles or ultimate secreting apparatus of glands, and the commencement of gland ducts. The cells are not uniform in shape in the different glands, so that the name glandular applied to this epithelium expresses the locality and not the form of the cell. They are often polygonal, occasionally spheroidal (fig. 33), or columnar, or even ciliated. Their contents are specially differentiated into the secretion of the particular gland in which they are situated.



FIG. 33.—A, polygonal gland cells from the liver; B, spheroidal gland cells from the saliva.

The epithelial cells of a Secreting Gland rest upon a sub-epithelial tissue, which frequently has the appearance of a membrane, the basement membrane of Bowman, or

membrana propria, and consists of flattened endothelial cells. Deeper than this membrane is a delicate connective tissue in which the blood and lymph vessels and the nerves of the gland ramify. The anatomical structures necessary for secretion are cells, blood-vessels, lymph-vessels, and nerves. The blood-vessels convey the blood from which the secretion has to be derived; the cells, as Goodsir showed by a variety of proofs, are the active agents in separating the secretion from the blood; the nerves regulate the size of the blood-vessels and therefore the amount of blood which circulates through the gland, and also exercise some direct influence on the activity of the cells. The function of the lymph-vessels is not so well understood, but the researches of Ludwig and of some of his pupils have shown their relation to the secreting structure of several glands. The connective tissue and the membrana propria are merely supporting structures for the cells, vessels, and nerves. All secreting glands have the same general type of structure, though they differ from each other, as will be pointed out when the individual glands are described, in the degree of complexity in which their constituent parts are arranged. The simplest form of gland is a short tube, or follicle closed at its deep end, whilst the opposite end has a mouth opening on a free surface, as in the tubular glands of the intestine; but in other cases the tube may branch at its deep end, as in the glands of the stomach; or it may become greatly elongated and rolled into a ball, as in the sweat glands; or it may branch, and the branches may form coils and loops, as in the kidney; or the tube may branch, and the branches may dilate into sac-like expansions, gland-vesicles, follicles, or acini, as in the compound racemose group of glands, of

which the salivary glands, the mammæ, the lachrymal glands, and the pancreas are good examples.

Nerve epithelium is the specially modified epithelium on certain sensory mucous surfaces, as the olfactory area of the nasal mucous membrane, the taste area of the mucous membrane of the tongue: also a special arrangement of cells in the retina and membranous labyrinth. The nerve epithelium has intimate relations with the nerves ending in these sense organs, and will be described in Chapter VI.

Development of Epithelium.

Both the epiblast and hypoblast layer of the blastoderm serve as surfaces of origin for epithelial cells, and it is believed that the epithelial covering of the genital mucous membrane is derived from a differentiation of certain of the cells of the mesoblast. The cells of the hypoblast give origin to the epithelium of the alimentary canal below the mouth, and to the epithelium of the various glands which open into this part of the digestive tract; also to the epithelial lining of the windpipe and air cells; also to the epithelial lining of the urinary bladder. The epiblast gives origin to the epidermal covering of the skin, the epithelial cells lining the sweat glands, sebaceous glands, and mammæ, which are in anatomical continuity with the epidermal cells; also to the epithelial lining of the mouth and the salivary glands opening into it; also to the epithelial lining of the nose and of the glands connected with its mucous membrane. But, further, the epithelial cells lining the cerebral ventricles, central canal of the spinal cord, and membranous labyrinth, are primarily derived from the cells of the epiblast. For though these canals and spaces are, when development is completed, shut off from all connexion with the outer surface of the body, yet they are originally continuous with the layer of epiblast, and only become discontinuous with it, when from the great development of the adjacent part of the mesoblast, required for the formation of the bony walls which enclose the labyrinth and cerebro-spinal nervous axis, the original connexion is severed.

Endothelium.

The free surfaces covered by an endothelium are the serous membranes, the inner surface of the wall of the

lymph and blood vessels and of the heart, the synovial membranes of joints, of synovial sheaths and bursæ. The tubes, canals, and cavities lined by an endothelium are shut off from all communication with the external atmosphere. The cells of the endothelium are arranged so as to give perfect smoothness to the surface which they cover. In the blood and lymph vessels this smoothness of surface is in order to facilitate the flow of the blood and lymph in the course of the circulation. The serous and synovial membranes are found covering the surfaces of parts which move on each other, and the smoothness of their respective surfaces, by permitting freedom of movement, diminishes the friction.

Endothelial cells form only a single layer of tessellated scales, cemented together by an albuminous substance, which reduces nitrate of silver. The nuclei usually disappear; but when present they show an intra-nuclear network of fibrils, and the body of the cell an intra-cellular network (Klein). Endothelium, like epithelium, is non-vascular, and, so far as is known, non-nervous.

The endothelial cells rest upon a sub-endothelial tissue, consisting of the fibrous variety of connective tissue.

Here, as in the surfaces covered by epithelium, a basement membrane was at one time supposed to intervene between the cells and the connective tissue; but it is now believed that the cells are in direct contact, by their deeper surface, with the connective tissue itself, which serves as the framework of support for the blood and lymph vessels and the nerves of the part. In the serous membranes, and in the coats of the larger blood-vessels, elastic fibres are present in considerable numbers in the sub-endothelial tissue. In the serous membranes the lymph-vessels are

very abundant in the sub-epithelial tissue, where they form a layer parallel to the free surface of the membrane, from which short vessels pass vertically to open by minute orifices into the serous cavity. The serous membranes are attached by the sub-endothelial connective tissue to the organs which they invest.

Each Serous Membrane consists of a portion which invests the viscus or organ, named the *visceral layer*, and a portion which lines the wall of the cavity in which the organ is situated, named the *parietal layer*. Between these two layers is the *serous cavity*, of only a capillary lumen, the boundary of which is formed by the smooth surface of both the parietal and the visceral layers. The serous membranes are as follows :—The two *pleuræ* situated in the cavity of the chest, one investing each lung, and lining the interior of that part of the thoracic cavity in which the lung is situated; the *pericardium*, which invests the heart, and lines the bag in which the heart is contained; the *peritoneum*, which invests the abdominal viscera, and lines the abdominal cavity; and the *arachnoid* membrane, which invests the brain and spinal cord, and is also regarded by some as lining the membranous dura mater, which encloses these important organs. The smooth free surfaces of the serous membranes are moistened by a limpid fluid, or serum, which facilitates their movement on each other, just as the free smooth surfaces of the synovial membranes are lubricated by the viscid synovia which they secrete.

The endothelium of the Serous Membranes consists of a layer of irregular squamous cells, the edges of which may be smooth or slightly serrated. The cells are closely adapted to each other by their edges, so as to form a continuous smooth layer, which forms the free surface of

the serous membrane. Scattered irregularly over this surface are the minute orifices, or *stomata*, which open into lymphatic vessels. The cells which surround the stomata differ in form and appearance from the ordinary endothelium; they are smaller, and are polyhedral, their contents are granular, and the nucleus is more distinct.

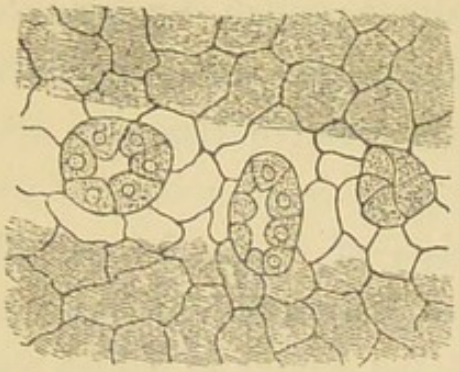

FIG. 34.—Endothelial Cells from the Peritoneal Serous Membrane. Three stomata may be seen surrounded by polyhedral nucleated cells; the one to the right is closed. The light band marks the position of a vertical lymphatic vessel. (*After Klein*).

The endothelium lining the Lymphatic Vessels consists of a layer of flattened cells, which are elongated and sinuous in outline. The endothelium of the lymphatics is continuous with that of the serous membranes through the stomata, so that the cavities of the serous membranes are now regarded as great lymph-sacs.

The endothelial lining of the Blood-Vessels corresponds in general characters with that of the lymphatics. In the small blood capillaries the cells are fusiform; in those of large size more irregular: in the veins they are broader, more irregular, and less distinctly fusiform than in the arteries. The endothelial covering of the endocardial lining of the heart consists of a layer of flattened cells with irregular outlines. The endothelial lining of the blood-vascular system is continuous with that of the lymph-vascular system, at the openings of the thoracic and right lymphatic ducts into the great veins, and thus a continuity of surface is established between the serous membranes and the lining membrane of the blood-vascular system through the lymphatics.

The endothelium of the Synovial Membranes forms a

layer of polygonal, tessellated, squamous cells, on the inner surface of the vascular connective tissue of the synovial capsules. Hüter and Reyher state that the cells do not form a continuous layer, but only occur in patches, and that between these patches the connective tissue forms the free surface. Tillmanns, however, asserts that the endothelial cells form a continuous layer. Villous processes of the sub-endothelial vascular connective tissue called *synovial fringes*, covered by endothelium, project into the cavities of joints and synovial bursæ, and contribute to the formation of the synovia which lubricates the surface of a synovial membrane.

Development of Endothelium.

Endothelium is developed exclusively from the cells of the mesoblast, from which cells also are formed by histological differentiation, the organs to which the endothelium serves as a covering or lining. Between the endothelium and the connective tissue a close genetic co-relationship obviously exists, as the plasma canals between the bundles of connective tissue are lined by flattened endothelial-like cells.

THIRD GROUP OF TISSUES.

Cells placed Interstitially in a Matrix.

The tissues which are constructed on this plan are of great importance, and constitute by far the larger proportion of the tissues not only of the human body, but of the bodies of animals generally. Sometimes these tissues are elongated into delicate threads or fibres, at other times they are expanded into thin membranes, at others they form solid masses of considerable thickness. The matrix substance varies in its character in the different tissues, and sometimes is so abundant as to obscure the cells.

Connective Tissue.

By the term Connective Tissue is meant a group of tissues which, though the members of the group differ from each other, both in naked eye and microscopic characters, yet agree in the property of binding or connecting other tissues or parts of the body, and in serving as a supporting framework for more delicate tissues. This group of tissues is the most extensively diffused of all the textures, for there is no organ in the body which does not contain one or other of its forms. The following varieties, based on modifications in their appearance and structure, may be recognized.

a. Neuroglia. This name, which means nerve glue, has been applied by Virchow to the delicate tissue in the central organs of the nervous system, and in the retina, which supports the nerve cells, nerve fibres, and blood-vessels of those parts. It is homogeneous, or finely granular, or contains a network of fine fibrils, and in it elliptical or ovoid nuclei, or stellate flattened corpuscles are situated. A form of tumour, named Glioma, is sometimes produced by the excessive growth in the brain or retina of the neuroglia.

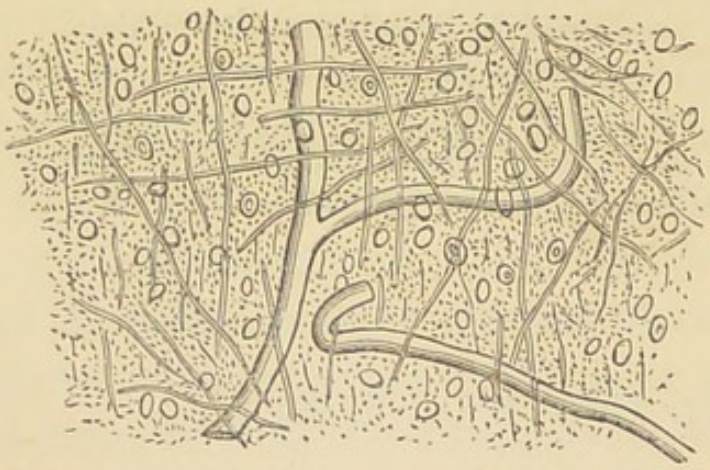

Fig. 35.—Section of the White Matter of the Cerebrum. The nuclei of the neuroglia, nerve fibres, and capillary blood-vessels are represented.

b. Retiform connective tissue constitutes the stroma or supporting framework of the lymphatic glands. It is also found in the solitary and Peyer's glands of the alimentary

canal, in the intestinal villi, the tonsils, at the back of the tongue, in the posterior wall of the nasal part of the pharynx, the palpebral conjunctiva, the thymus gland and the pulp and Malpighian bodies of the spleen. It is usually regarded as consisting of stellate branching cells, the branches of which anastomose with each other, and form a delicate network or reticulum: but it has recently been stated that the network is formed of delicate, homogeneous fibrils, attached to which are flattened nucleated endothelial-like cells, situated more especially at the sides, or points of intersection of the fibrils. Colourless lymph corpuscles occupy the meshes of this network, and in the lymph glands channels for the flow of the lymph fluid occur. The name *adenoid* or *lymphoid* tissue is sometimes given to this tissue, and in some diseased conditions the tissue increases so largely in quantity as to form well-defined Lymphoid tumours (fig. 37).

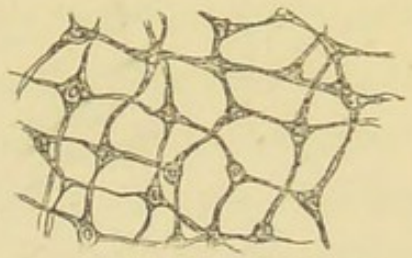

FIG. 36.—Retiform Connective Tissue from a Lymphatic Gland.

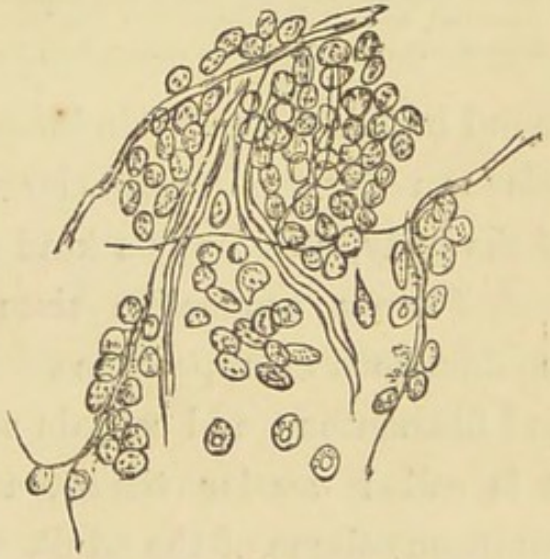

FIG. 37.—Lymphoid Cells, included in a reticular mesh of connective tissue from a lymphoid tumour of the mediastinum.

c. Gelatinous or *mucous* connective tissue (*Schleimgewebe*), forms the connective tissue of the embryo, the vitreous humour of the eye-ball, and the jelly of Wharton which invests the blood-vessels of the umbilical cord. It is soft and jelly-like in consistency. It consists of spindle-like, and stellate anastomosing cells, some of which may be

flattened plates imbedded in a soft mucin yielding intercellular substance. Sometimes the intercellular substance is in part differentiated into short delicate fibres. Rounded colourless cells, like white blood corpuscles, are also found in this tissue. Under some pathological conditions, this form of tissue increases largely in quantity in some parts of the body, and forms a kind of tumour named Myxoma.



FIG. 38.—Gelatinous Connective Tissue. The fusiform, rounded, and stellate cells, and the partial differentiation of the intercellular substance into fibres, are shown.

d. Fibrous connective tissue presents three principal modifications in appearance. It may be loose, flocculent, and filamentous, and contain small spaces or areolæ (when it is called *areolar tissue*), as is well seen in the subcutaneous tissue of the adult, and in the omenta. It may be expanded in the form of a *fibrous membrane*, as in the fasciæ or aponeuroses, and the threads or fibres, strong and well marked, sometimes run parallel, sometimes cross each other at various angles. It may be collected into rounded or flattened bands, as in tendons and ligaments, where it forms the *tendinous* and *ligamentous* tissues. Here also the threads or fibres may be distinctly recognized and seen to run in parallel bundles, so as to connect together the two structures between which the tendon or ligament passes.

In the fibrous connective tissue, both cells and inter

cellular substance, the latter of which is differentiated into fibres, may be recognised. The *cells* are either fixed cells, or wandering cells. The *wandering* cells are leucocytes, like the white corpuscles of the blood. The *fixed* cells are the proper *connective tissue corpuscles.* These corpuscles are not uniform in appearance. When seen on edge they appear elongated or fusiform or caudate, when seen on their surface they are flattened plates, often with branched processes so as to have a stellate form. In tendons they are arranged in definite rows (Ranvier) and appear as rectangular plates, and the cells in the same row are connected together by cement substance. Klein states that these corpuscles frequently consist of two substances; of a hyaline ground plate in which is an oval nucleus containing an intra-nuclear network, and of a granular material containing an intra-cellular network of fibrils. In the rectangular cells of tendons the nucleus is usually placed near one border of the cell, and the nuclei of contiguous cells lie near the borders which are next each other. Lines described by Boll are really projections of the cell in a direction perpendicular to the rectangular plate, which adapt it more precisely to the surface of a bundle of fibres.

The *inter-cellular substance* or matrix consists of fibres, which are not uniform in shape, and are divided into the two groups of white and yellow fibres.

The *white fibres* of connective tissue constitute the most common form, and make up the great bulk of most ligaments, tendons, and fibrous membranes. They consist of excessively delicate fibrils varying from $\frac{1}{25000}$th to $\frac{1}{50000}$th inch in thickness, which are united together in bundles or fasciculi of variable size. The bundles, as well as the fibrils of which they are composed, have a wavy course, and

the fibrils in each bundle lie almost parallel to each other. The bundles also in some cases are parallel, though in others they cross at various angles. The fibrils in each bundle, as well as the bundles themselves, are cemented together; the firmness of the adhesion varies in the different modifications of the fibrous connective tissue, being much more decided in the tendons, ligaments, and fasciæ, than in the lax areolar tissue.



Fig. 39.—Fasciculi of White Fibres of Connective Tissue.

It is important to determine the relation which the cells of the connective tissue bear to the bundles of white fibres, and on this point the researches of Ranvier have thrown much light. He has pointed out that the fixed cell plates occupy the interstices between the fasciculi, and are moulded on the outer surface of the bundles. He, Thin, Axel Key, Retzius, and Mihalkovics have shown that this



Fig. 40.—Cells investing the primary bundles of tendo Achillis of a Sheep. (*From Thin.*)

arrangement applies to the bundles in the lax areolar tissue as well as to those in the firmer tendon, though it does not follow that each bundle has a complete covering of flattened cells.

Microscopic interstices exist between the fasciculi of the connective tissue, which are bounded by the flattened cells moulded on the surface of the bundles. In transverse sections through tendons these interstices assume a stellate appearance and are seen to anastomose with each other,

and they form a system of microscopic juice spaces and canals into which the plasma of the blood penetrates for the nutrition of the connective tissue. The leucocytes or wandering cells of this tissue also pass along these spaces. It is very probable that these interstices serve as rootlets of origin of the lymphatic vessels. For there can be no doubt, as the injections of Ludwig and Schweigger-Seidel have shown, that tendons and fasciæ are well provided with lymph-vessels, arranged as a minute network, consisting in part of polygonal meshes and in part of vessels running longitudinally and parallel to the bundles of connective tissue, and that the walls of these vessels are formed of flattened endothelial-like cells.

But the fixed cells of a tendon are not limited to those moulded on the surface of its constituent bundles. For the outer surface of the tendon itself is also invested by a layer of flattened endothelial-like cells.

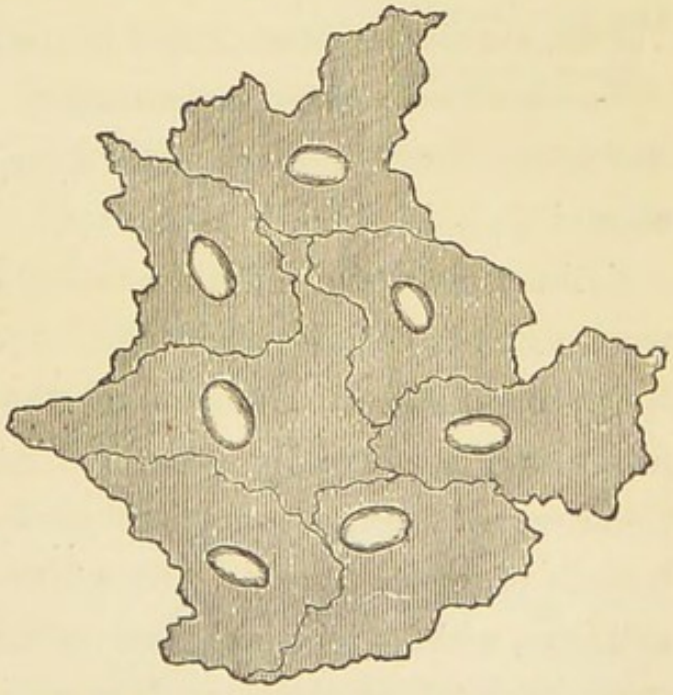

Fig. 41.—Flat Cells on surface of tendo Achillis of a Frog. (*From Thin.*)

The wide diffusion of the connective tissue throughout the body and the great importance of its cellular elements have been especially dwelt on by Virchow as sources of origin of the new cell forms which arise in the course of various pathological processes.

The *yellow fibres* of connective tissue, named *elastic*

tissue from its elasticity, make up the mass of the ligamentum nuchæ, the ligamenta sub-flava, and the yellow elastic coat of the arteries. They are also found mingled with the white fibres, in the fibrous membranes, the skin, the mucous and serous membranes, the areolar tissue, in tendons, and some ligaments. In the ligamenta sub-flava and nuchæ the yellow fibres are arranged in bundles, the individual fibres of which are solid, comparatively broad, with a distinct dark outline. They branch, and their branches readily break across, and the broken end then may curl upon itself. Their diameter is from $\frac{1}{3200}$th to $\frac{1}{4000}$th inch. In the middle coat of the arteries the elastic fibres form an anastomosing network and in the inner coat a perforated elastic membrane. When mingled with the white fibres they are much finer, and sometimes do not exceed $\frac{1}{25000}$th inch in diameter. They possess, however, a distinct and definite outline; they branch and form a network and are often sinuous. Fibres possessing a ring-like, or spiral arrangement wind around the bundles of the white fibres and are usually described as elastic fibres, though some regard them as constrictions of a sheath investing each bundle of white fibres. The white fibres are composed of collagen, which yields gelatine on boiling; the elastic fibres are composed of elastin. The white fibres swell up and become so transparent under the action of acetic acid as to be no longer recognisable. The yellow fibres, again, are not affected by that reagent. Quekett pointed out that the elastic fibres of the ligamentum nuchæ of the giraffe were marked by transverse striæ, and M. Watson has seen a



FIG. 42. — Fasciculus of Fibres of Yellow Elastic Tissue from ligamentum nuchæ.

similar appearance in the elastic pericardiac ligament of the elephant. These transverse striæ are apparently cracks in the fibre; and, as Beale has shown, are not unfrequently seen in the elastic fibres of beef and mutton which have been eaten and passed undigested through the alimentary canal.

The vascularity of the connective tissue varies in different localities. The periosteum and perichondrium are very vascular; and their vessels are concerned in the nutrition both of these fibrous membranes, and of the bone and cartilage which they invest. The sheath of connective tissue which invests a tendon is more vascular than the substance of the tendon itself. As a rule, it may be stated that the fibrous connective tissues are not highly vascular, and that the nutritive changes which take place in them after their growth is completed are not very active. Connective tissue is sparingly supplied with nerves, and their mode of termination in it has not been ascertained.



FIG. 43.—Connective Tissue of the Omentum of the Fœtus, showing the fusiform corpuscles. A capillary blood-vessel crosses the figure, and outside it are several blood corpuscles which have probably migrated from the vessel.

DEVELOPMENT OF CONNECTIVE TISSUE.

The mode of development of the connective tissue has been much discussed by anatomists, and various views have been advanced as to the changes which lead to its production. The neuroglia arises along with the nervous organs to which it belongs in the epiblast, but the other varieties of the connective tissue are produced by a special morphological and chemical differentiation of the protoplasm of the cells of the mesoblast. The degree to which this differentiation may proceed varies with the particular form of the texture. The neuroglia is a granular nucleated protoplasm, though a delicate fibrillation and flattened cells may be seen in it. In the retiform connective tissue

the network is usually regarded as formed of stellate anastomosing cells. In the gelatinous and fibrous forms an intercellular matrix is extensively produced, and exhibits a differentiation into fibres. In the gelatinous form, the cells of the mesoblast become fusiform, caudate, stellate or flattened, and the intercellular matrix is homogeneous or delicately fibrillated. In the fibrous form the matrix is distinctly fibrillated and assumes the characters of the bundles of white fibrous tissue. It has been much disputed whether these white fibres take their rise immediately from the peripheral portion of the cells by a direct differentiation of their protoplasm, or whether this protoplasm is not in the first instance converted into a homogeneous hyaline matrix in which the fibrous differentiation then occurs. There can be no doubt that the fibres are formed by a metamorphosis of the protoplasm of the cells; but whether the metamorphosis takes place directly, or through the intermediate stage of a homogeneous hyaline matrix, is a secondary question, and in all probability both modes of conversion take place at different times and in different localities. As the differentiation into fibres progresses, the tissue becomes firmer and tougher, and the proportion of the cellular to the fibrous element diminishes. Hence, say in a young tendon, the rows of fixed connective tissue cells are not only closer together, but are much more readily seen than in an adult tendon, in which the increased production of fibres obscures the cellular element.

The mode of origin of the Yellow Elastic fibres has also been much discussed. At one time it was believed that they were derived from nuclei, and on this supposition they were named nuclear fibres. But from more recent observations there is reason to believe that they are produced, like the white fibres, by a special differentiation of the protoplasm of the embryonic cells, or of a homogeneous hyaline, or granular matrix derived from that protoplasm. In such localities as the ligamentum nuchæ, where the fibres are both large and numerous, almost the whole of the cell protoplasm appears to become converted directly or indirectly into elastic tissue.

Adipose Tissue.

The Adipose or Fatty tissue varies in its amount in different individuals. It is especially found in the yellow marrow of the bones; as a layer beneath the skin, differing in thickness in different individuals; and collected in the cavity of the abdomen in the folds of peritoneum, known as the mesentery and omenta, in which, and indeed in the

other localities where it occurs, it is intimately associated with the connective tissue. It consists of cells, which vary in size from $\frac{1}{300}$th to $\frac{1}{800}$th inch, usually ovoid or spherical in form, though when collected into masses they may be laterally compressed. These cells are sometimes isolated, though most usually arranged in rows or clusters to form lobules of fat. The number of cells in a given lobule varies with the size of the lobule. The distinctive contents of these cells is a minute drop of oil, which, when examined by transmitted light, presents a bright appearance; so that the fat cells look when seen by reflected light, as Monro *primus* described long ago, like a cluster of pearls. Each fat cell possesses a distinct wall, as can be readily demonstrated by digesting these cells in ether, when the oil is dissolved out and the membranous wall remains. The nucleus of the fat cell is more difficult to demonstrate, and, when seen, is found attached to the inner surface of the cell wall. In the fat of old persons, and in specimens of this tissue which have been removed from the body for a length of time, a stellate group of acicular crystals is not unfrequently to be seen in the interior of the cell, which consist either of margarin or margaric acid, one of the constituents of human fat. The lobules of fat cells lie in the areolæ of the areolar variety of connective tissue, which forms their supporting framework, and they are also surrounded by a network of capillary vessels, which serve to convey to them blood for their nutrition, and aid in retaining them in position.

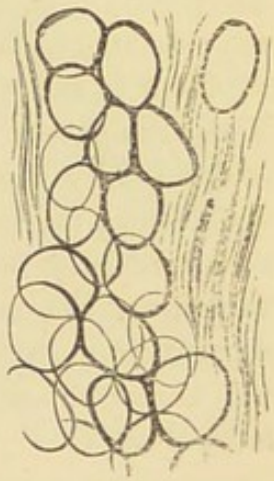

FIG. 44.—Fat Cells and Areolar Tissue.

Development of Adipose Tissue.

The close anatomical relation between the adipose and the connective tissues points to a genetic relationship between them. The fixed connective tissue-cells situated in relation to blood-vessels may be converted into fat cells. The first stage is the appearance of extremely minute drops of oil in the protoplasm of the connective tissue corpuscles of the part; as these run together larger drops are produced, a cell wall at the same time differentiates from the peripheral part of the protoplasm, and as the cell becomes distended with oil, by the conversion into fat of its substance, it swells out into a spherical or ovoid cell, and the nucleus is pushed to the periphery of the cell. Klein has shown that the fatty tissue of the omentum and mesentery is formed by the production of oil drops within the branched cells, which form the reticular tissue that supports the lymphoid cells found so abundantly between these folds of peritoneum. In a lymphoid tumour of the mesentery, which I recently examined, where fatty degeneration had made considerable progress, I found that not only the branched cells, but the lymphoid cells also, had undergone the fatty change.

Pigmentary Tissue.

In some parts of the body a yellow, brown, or black pigment is found in the interior of cells, which gives to the tissue and organ a characteristic colour. In the coloured races of mankind, and in certain parts of the body of the white races, pigment is produced in the cells of the cuticle or epidermis, more especially in the cells of the deeper strata or rete Malpighi. In the connective tissue corpuscles, also, more especially in the dermis of fish, amphibia, and reptiles, pigment is found in considerable abundance. The choroid coat of the eyeball and the choroidal surface of the retina owe the dark brown or black colour to the presence of pigment in the interior of cells. The pigment cells of the choroidal surface of the retina are usually polyhedrons, 5 or 6-sided, and are



Fig. 45.—Group of 6-sided Pigment Cells from the choroidal surface of the retina.

arranged to form a mosaic pattern. In the centre is a nucleus, and the cell substance is occupied by numbers of minute brown granules. In the connective tissue of the choroid itself the pigment is contained in stellate cells. In the skin of fishes and amphibia, the stellate pigment cells branch and the branches divide so as to form highly complex patterns, and the cells are crowded with brown or yellow granules. The production of pigment, either in the interior of epidermal cells, in the polyhedral cells of the choroidal surface of the retina, or in the stellate connective tissue corpuscles, is owing to a special metamorphosis or differentiation of the protoplasm substance of these cells.



FIG. 46.—Stellate Pigment Cells from the skin of a codfish.

CARTILAGINOUS TISSUE.

By the term Cartilage, or cartilaginous tissue, is meant a group of tissues which, though usually found in the form of plates or bars, yet differ in various respects from each other, both in naked eye and microscopic characters. They agree, however, in forming solid textures, opaque when seen in mass, but translucent, pearly, or bluish white, in thin slices, firm in consistence, but easily cut with a knife, endowed with considerable elasticity, and yielding chondrine on boiling. Cartilage is of greater importance in the fœtus, and in the immature condition of the body than in the adult, for in early life the skeleton is in a great measure formed of it. As development and growth proceed, a considerable proportion of the cartilage becomes converted into bone, and is called, therefore, *temporary* cartilage,

whilst the remaining portion continues as cartilage throughout life, and is termed *permanent*. The following varieties of cartilage, based on modifications in structure and appearance, may be recognized :—

Cellular cartilage. — Cells with matrix substance.

Matrix homogeneous. (Hyaline cartilage.) — Matrix fibrous. (Fibro-cartilage.)

White fibro-cartilage. — Yellow fibro-cartilage.

The *Cellular* or *Parenchymatous Cartilage* does not exist in the adult human body, but is found in that of some of the smaller mammals. Thus the cartilaginous framework of the ear of the mouse, the bat, and the rat, is formed of cellular cartilage, the cells of which

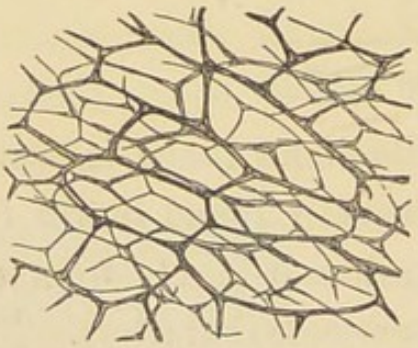

FIG. 47.—Cells of the Chorda Dorsalis of the Lamprey.

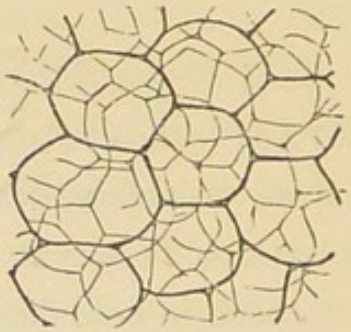

FIG. 48.—Cells of the Cartilaginous Framework of the ear of the Mouse.

are irregularly polygonal, and packed together so closely that the intercellular matrix is scarcely to be recognized. It is customary also to regard the chorda dorsalis or notochord, the axial rod around which the vertebral bodies and intervertebral discs are developed, as formed of cellular cartilage. In all the higher vertebrata the chorda dorsalis disappears as development advances, but in the lower vertebrates it persists throughout life as a

more or less perfect structure. In the lamprey and myxine it forms a continuous rod in the vertebral region. In fish generally, and in the cartilaginous fish especially, it is a jelly-like mass, occupying the concavities between the bodies of the vertebræ. The notochord is at first a solid cord of cells around which a sheath forms. The cells are comparatively large and ovoid or polygonal. The nucleus is often very distinct, though at other times more difficult to detect, and the cell wall is well marked. Subsequently vacuoles form in the cells of the notochord, which enlarge until the chorda becomes formed of large vacuoles separated by membranous septa, which form a reticulum filled with gelatinous material (F. M. Balfour). G. Retzius states that the tissue of the chorda does not contain chondrine.

The *Hyaline Cartilage* consists of cells imbedded in a pellucid or hyaline matrix, which, under some conditions, however, may assume a dimly granulated appearance. The xiphoid and costal cartilages, the encrusting cartilages at the articular ends of the bones, the cartilages of the nose, those of the windpipe, except the epiglottis and cornicula laryngis, belong to this variety, as also the temporary cartilages. In hyaline cartilage the cells are ovoid or polygonal, or even fusiform, and sometimes flattened, the flattened form of cell being found next the surface of the cartilage. They lie singly, or in groups of two, or three, or four; sometimes they are arranged in linear series, at other times they are irregularly grouped together. The cell protoplasm is granular and contains a network of minute

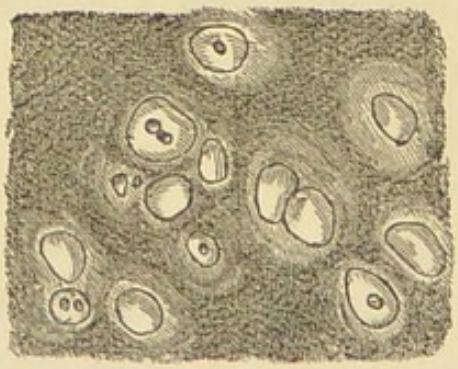

FIG. 49.—Hyaline Costal Cartilage.

fibrils (Flemming), and in old cartilage it is coarsely granular, or even infiltrated with drops of oil. One or more nuclei are present in each cell, and the nuclei contain an intra-nuclear network of fibrils. Heidenhain has shown that powerful induction shocks cause contraction of the protoplasm of the cells towards the central nucleus. The cells lie in cavities in the matrix substance, and the part of the matrix which forms the immediate wall of the hollow is named the *capsule* of the cell. Two or more cells may sometimes lie in the same hollow.

The *matrix* of hyaline cartilage appears to be homogeneous. In some animals it has a concentric arrangement round the cells; and Rollett has stated that by the use of dilute sulphuric acid, or chromic acid, the matrix may be made to split up into concentric layers. Sometimes the matrix appears granulated, or even delicately fibrillated, a change which is very apt to occur in sections of cartilage which have been removed for some time from the body. In the costal cartilages of old persons the matrix becomes distinctly fibrous; and it is by no means uncommon to find in advanced age these bars of cartilage converted into bone.

In the articular or encrusting cartilages the arrangement of the cells is quite distinctive. In a vertical section through this cartilage, the cells next the bone, forming a deep zone, are arranged in parallel rows perpendicular to the surface of the bone on which the cartilage rests; the cells are smaller than those of the costal cartilage, oblong in form, and both the cells in the same row and those in adjacent rows are separated by intermediate granulated matrix. Near the free surface of the cartilage, *i.e.*, in the superficial zone, the cells are flattened, placed parallel to

the plane of the surface, and so closely packed together that the proportion of matrix is much reduced. In the intermediate zone the cells are rounded and lie irregularly in a hyaline matrix. It was from the study of the changes which take place in articular cartilage in disease that Goodsir was enabled to establish the production of new cells by the multiplication of the normal pre-existing cells of the cartilage,—an observation which formed the starting-point of the doctrine of cellular pathology.

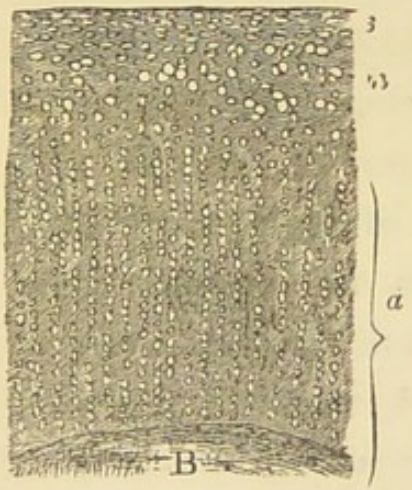

FIG. 50.—Vertical Section through an Encrusting Cartilage; *s*, superficial; *m*, middle; and *d*, deep zones of cells; *B*, the bone on which the cartilage rests.

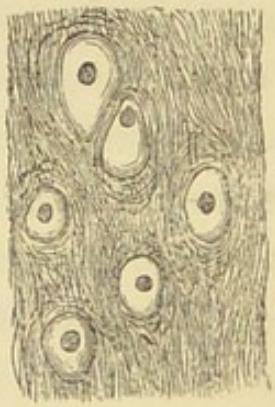

FIG. 51.—White Fibro-Cartilage of an Intervertebral Disc.

Fibro-cartilages are divided into white and yellow. *White* fibro-cartilage forms the connecting medium between the articular surfaces of an amphiarthrodial joint, as in the inter-vertebral discs; or it may form plates in the interior of joints, as in the semi-lunar cartilages of the knee and the menisci in other diarthrodial joints; or it may extend around the margin of the socket of a joint, as in the cotyloid ligament of the hip; or it may invest the surfaces of bones over which tendons have to play, as where the tendons of the peronei muscles play in the groove on the back of the external malleolus. In the intervertebral

discs, which give the best illustrations of the structure of white fibro-cartilage, the cells are ovoid in form and distinctly nucleated. Sometimes two or three are grouped together, but not unfrequently they occur singly. They are separated from each other by fine wavy fibres like those of white fibrous tissue (fig. 51). In these discs the fibrous matrix is always stronger and more distinct in the peripheral than in the central part. White fibro-cartilage is transitional between true hyaline cartilage and connective tissue; *i.e.*, the cells possess the characters of cartilage cells, whilst the matrix, instead of being hyaline, is fibrous, like the matrix of the connective tissue.

The *yellow elastic* fibro-cartilages are the epiglottis, cornicula, and cuneiform cartilages of the larynx, the auricle of the human ear, and the ears of mammalia generally, and the petrous end of the cartilaginous wall of the Eustachian tube. The cells are rounded or ovoid, distinctly nucleated, and usually arranged singly or in pairs. The matrix is distinctly fibrous; the fibres, which form a close intersecting network, branch and anastomose, hence the name *reticular fibro-cartilage* sometimes given. They resist the action of acetic acid like the yellow fibres of connective tissue; and Donders has described a continuity between them and the elastic fibres of the connective tissue, which forms the investing perichondrium of this form of cartilage. The yellow fibro-cartilage has no tendency to ossify.

The bars and plates of cartilage—except the encrusting hyaline cartilages, and the interarticular, marginal, and investing white fibro-cartilages—are surrounded by a fibrous membrane or *perichondrium*. In the adult human body cartilage is not penetrated by blood-vessels, but is nourished

by the vessels which ramify in its investing perichondrium. In the fœtus, however, and in the large masses of cartilage which are found in the skeletons of the cetacea and of the cartilaginous fishes, the cartilage is permeated by canals in which blood-vessels ramify. The encrusting cartilages are nourished by the blood-vessels of the synovial membrane of the joint, which form a ring of capillary loops around the margin of the cartilage; and, both in them and in those white fibro-cartilages that do not possess a perichondrium, the vessels of the bone, to which these cartilages are as a rule connected, assist in conveying nourishment to the attached surface of the cartilage. In the movable joints, after the child has begun to use its limbs, the synovial membrane is not continued over the free surface of the articular cartilage, but stops at its margin at the ring of capillary loops. In the fœtus, however, it has been stated that both blood-vessels and synovial membrane are prolonged over the free surface of the articular cartilage. The termination of nerves in cartilage has not been ascertained.

Development of Cartilage.

In the development of hyaline cartilage the contents of the embryonic mesoblast cells where the cartilage is to be produced, become clear, and a cell wall differentiates around the exterior of the cell. The nuclei in the cells divide and subdivide, so that a multiplication of the cells by endogenous reproduction takes place. Hyaline matrix substance then appears between the cells and forms the cell capsule; it is believed to be produced by a special conversion of successive layers of the cell protoplasm into a substance which yields chondrine on boiling. The fibro-cartilages, both white and yellow, but especially the latter, yield but little chondrine on boiling, for the fibrous matrix of the white fibro-cartilage is a gelatine yielding substance, like the white fibres of connective tissue, whilst the fibres of the yellow fibro-cartilage partake of the nature of elastic tissue. The fibro-cartilages, therefore, form a group which links together the connective and cartilaginous tissues.

Osseous Tissue.

The Osseous Tissue, or Bone, is that which constitutes the hard framework of the skeleton. Each bone consists of a hard, more or less dense, tough, and but slightly elastic material. The elasticity of the bones is more marked in young than in adult and aged persons. From differences in their external configuration, bones are divided into long or cylindrical, *e.g.*, femur; short, *e.g.*, carpal or tarsal bones; flat or plate-like, *e.g.*, scapula; irregular bones, *e.g.*, vertebræ. These variations in shape do not, however, involve differences either in composition or minute structure. Bone consists chemically of an animal and an earthy substance intimately blended together. The animal matter forms about one-third, is identical with collagen, and yields gelatine on boiling; it imparts elasticity and toughness to the bone, and binds together the particles of earthy matter. The earthy matter forms about two-thirds, and is deposited in the animal matter. It consists chiefly of phosphate of lime, which from its abundance in bone, is frequently called "bone earth," but carbonate, chloride and fluoride of calcium and a small proportion of soda and magnesia salts are also present. The hardness of bone is due to the presence of the earthy matter.

Bone presents two different structural characters to the naked eye. The outer part of a bone is its hardest part, and forms a dense external shell, technically called the *compact tissue.* The interior of a bone is much less firm, and is made up of thin delicate plates or bars, or trabeculæ, which intersect each other at various angles, and form a lattice-like arrangement, technically called the *spongy* or *cancellated tissue.* The plates and bars of the spongy

tissue are continuous with the inner surface of the compact tissue. In the long bones the interior of the shaft is hollowed into a canal, named the *medullary canal*, the walls of which are formed by the compact tissue, and the cancellated tissue is found only at the articular ends of these bones; the thickness of the compact tissue in a long bone is always greater at the centre of the shaft, but diminishes towards the articular ends.

If we examine with a pocket lens the outer surface of the compact tissue and the wall of the medullary canal in a *macerated* long bone, multitudes of minute orifices will be seen, which are the mouths of minute tubular passages or canals that traverse the compact tissue. These passages are named *Haversian canals*, and their arrangement may be studied by making thin sections through the compact tissue, and submitting these to microscopic examination, when they will be seen to pass longitudinally or very obliquely through its substance, so as to terminate by rounded orifices both on the outer surface, and on the inner surface which forms the wall of the medullary canal. These canals are connected together at intervals by short transverse or oblique canals. Owing to these communications the dense osseous tissue is permeated by an anastomosing network of Haversian canals, which, as they contain blood-vessels, are *vascular* canals. These canals are circular in transverse section, and vary in diameter from about $\frac{1}{200}$th to $\frac{1}{1000}$th inch. They not unfrequently are dilated at the inner end, which opens into the medullary canal or the spaces of the cancellated tissue. In the compact tissue of all bones is a system of Haversian canals similar to those found in the long bones, but when bone occurs in the form of very thin plates these canals may be absent. In addition

to the Haversian canals, irregular spaces, named *Haversian spaces* by Tomes and De Morgan, may also be seen in sections through the compact tissue : they are met with both in young and adult bones, and are regarded as produced by absorption of the bone in the localities where they occur. In thin sections through bone made transversely to the long axis of the Haversian canals, the dense tissue or matrix of the bone, which surrounds the canals, is seen to be arranged in concentric rings, as if it were built up of a series of *lamellæ* one external to the other, and varying from two or three to half a dozen in number ; they are called the *Haversian lamellæ.* Other lamellæ lie in relation and parallel to the periosteal surface of the bone, and are called *peripheral lamellæ* ; others are in relation to the medullary canal and cancellated spaces, and may be named *central lamellæ* : whilst others again are, as it were, intercalated between adjacent Haversian systems of lamellæ, and are named *intermediate or interstitial.* Sharpey showed that a bone lamella, after the earthy matter has been dissolved out by the action of an acid, was made up of multitudes of fine transparent fibres. De B. Birch states that the fibres in each lamella are in the same plane, and mostly parallel to each other. The peripheral and intermediate lamellæ are perforated by stronger fibres, which pass through them either perpendicularly or obliquely, so as to bolt adjacent lamellæ together. With a little care, these *perforating fibres* of Sharpey may be drawn out of the holes or sockets in which they are lodged. The perforating fibres are derived from the periosteum, and are formed both of white and elastic connective tissue.

When thin sections through a *macerated* and dried bone are examined under the higher powers of the microscope,

the lamellated matrix is seen to exhibit an appearance, which is characteristic of the osseous tissue. Elliptical or irregularly elongated, spaces, called *lacunæ*, are to be seen in considerable numbers. Those which lie in relation to the Haversian lamellæ are concentrically arranged around the Haversian canals, and the lacunæ, the lamellæ, and the Haversian canal which they surround, are named a *Haversian system.* From the ends and sides of each lacuna very minute branching canals, termed *canaliculi*, proceed, which penetrate the lamellæ and anastomose with the canaliculi proceeding from adjacent lacunæ ; the canaliculi belonging to the outermost lacunæ of a Haversian system do not as a rule anastomose with those of a contiguous system, but bend back to join canaliculi in the same system ; whilst the canaliculi, springing from the sides of those lacunæ which lie nearest to the Haversian canal, open on the wall of the canal itself. The lacunæ average in length $\frac{1}{1800}$th inch, and their transverse diameter is about $\frac{1}{3600}$th inch ; the canaliculi vary from $\frac{1}{12000}$th to $\frac{1}{20000}$th inch in diameter. When examined in a dried bone by transmitted light, the lacunæ look like solid, black bodies, and the canaliculi seem to be processes branching off from them, hence they were erroneously called by the earlier observers bone-corpuscles. But if a little turpentine be added to the section, the fluid displaces the air which the lacunæ and canaliculi contain in the dried bone, renders the part more transparent, and

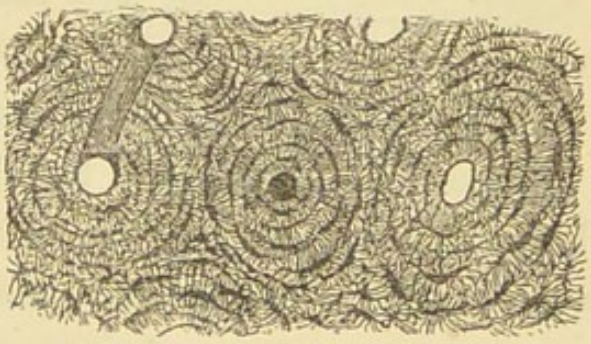

FIG. 52.—Transverse Section through the compact tissue of the shaft of a long bone. The transversely divided Haversian canals, lamellæ, lacunæ and canaliculi are shown.

affords a satisfactory demonstration that they are, in a macerated and dry bone, not solid bodies but a minute system of spaces and anastomosing little canals; and that those which lie in the same Haversian system freely communicate with each other, and either directly or indirectly, with the Haversian canal which they surround.

But a macerated and dried bone, such as one sees in museums and in articulated skeletons, is a bone which has been deprived of several soft tissues by the process of putrefaction, which tissues are of the utmost importance in the economy of the bone in the living animal. A *living* bone is a complex organ, and a macerated bone is only the skeleton of a living bone. It is essential, therefore, in studying the structure of bone, that the attention should not be confined to the appearances presented by the macerated bone, but that the arrangement and structure of its soft tissues should be considered. The soft tissues of a bone are the periosteum and its prolongations, the marrow, the minute masses of nucleated protoplasm which occupy the lacunæ of the bone, the blood and lymph vessels, and the nerves.

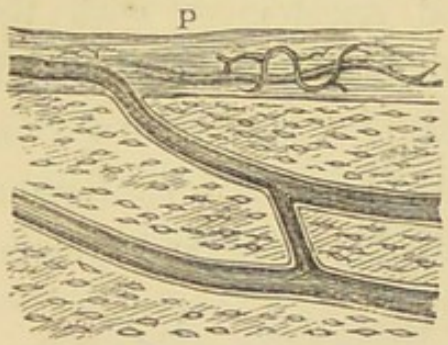

FIG. 53. — Longitudinal Section through the Compact Tissue of a Long Bone, to show the passage of blood-vessels from the periosteum P. into the Haversian canals H H.

The *Periosteum* is a strong fibrous membrane which invests and adheres to all the exterior of a bone, except where the encrusting cartilage is continuous with its articular end. It is divided into two layers: a firm external fibrous layer (fig. 54 SP), and a softer internal or deep layer (DP). The external layer consists of white and yellow fibres of connective tissue, amidst which numerous

small blood-vessels ramify. The internal soft layer is especially well marked in young growing bones. It partly consists of very delicate connective tissue, in which rounded or oval cells are found, which give off slender processes at various points of their periphery, and partly of larger granular cells called *osteoblasts* (Gegenbaur) which lie next the bone itself. In adult bone the osteoblasts are much less numerous than in growing bone. The deep layer is also vascular, and its vessels, along with the soft cellular material which surrounds them, pass into the Haversian canals, in which, as Goodsir pointed out, a layer of cellular substance lies between the wall of the canal and its contained blood-vessel, so that these canals are not, as in macerated bones, empty passages, but are occupied by blood-vessels and the deep cellular layer of the periosteum.

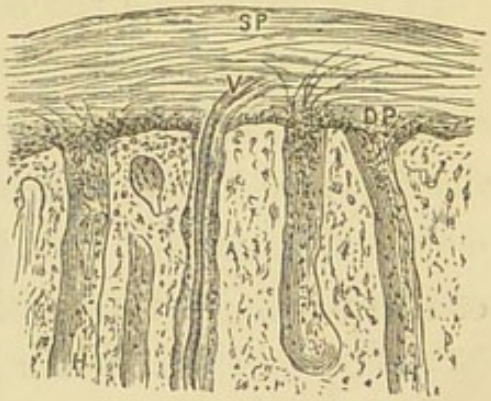

FIG. 54.—Section through the Periosteum and Compact Tissue of a Young Bone. S P, superficial fibrous layer of periosteum; D P, deeper cellular layer prolonged into H H, the wide Haversian canals; V, a vessel of the periosteum entering a canal.

The *Marrow* occupies the medullary canal of a long bone and the spaces in the cancellated tissue of bones generally. It occurs in two forms, red and yellow marrow. Red marrow is found in the bones of the fœtus generally, and in the cancelli of the plate-like, short, and irregular bones at a more advanced period. It consists largely of colossal many-nucleated cells (fig. 56), the *myeloid* cells (*myeloplaxes*) of Robin, also of leucocytes and of cells like red blood corpuscles but nucleated (Neumann and Bizzozero). The cells are supported by a delicate areolar tissue, and are supplied by a network of capillary blood-vessels. Yellow

marrow, again, is composed of fat cells lying in a delicate areolar tissue with accompanying blood-vessels. The areolar tissue, which supports the marrow cells, and lines the medullary canal and cancelli, is named the medullary membrane, or the *endosteum*.

In the fresh bone the lacunæ are not empty spaces as in the macerated bone. They are filled up by nucleated clumps of protoplasm, and are therefore, as Goodsir was the first to show, the seats of little masses of nucleated cells, which cells are the true *bone-corpuscles*. The protoplasm of these cells is apparently prolonged into the canaliculi. Hence the hard part of the osseous texture has within it a system of nucleated cells, some of which occupy the lacunæ and canaliculi, while others form a lining to the Haversian canals.

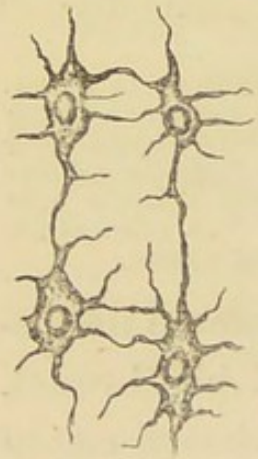

FIG. 55.—Nucleated Branched Cells occupying the lacunæ and canaliculi of a bone.

The blood-vessels of a bone are abundant. It receives its arteries partly from the small arteries which ramify in the periosteum, the fine branches of which enter the Haversian canals, and form within them an anastomosing network of capillaries; partly through a special artery which enters the nutrient canal in the bone, to be distributed chiefly to the marrow; partly through small arteries which enter openings in the compact tissue near the articular extremities. The veins of bones are also abundant. In the cancellated tissue they are large, and leave the interior of the bone partly through foramina situated near the articular ends, and partly by a vein which accompanies the artery that traverses the nutrient canal. In the plate-like bones of the skull the veins lie in distinct channels in the diploë,

and in the bodies of the vertebræ the veins pass out through large holes in the posterior surface. Bones possess lymph-vessels, which pass along with the blood-vessels into the Haversian and medullary canals and cancelli. Fine nerves accompany the arteries which enter the nutrient and Haversian canals, and nerves end also in the periosteum.

It is clear, therefore, that a bone, hard and dense though its texture seems to be, is yet hollowed out by spaces, passages, and canals, which, under the several names of medullary canal, cancellated spaces, nutrient canal, Haversian canals, Haversian spaces, lacunæ, and canaliculi, are occupied by blood-vessels or other soft tissues. By the penetration of blood-vessels into the bone, blood is conveyed both to the medulla, and into the very substance even of the compact tissue; and there can be no doubt that the nucleated masses of protoplasm which occupy the lacunæ and canaliculi, and line the Haversian canals, are, as Goodsir long ago pointed out, centres concerned in the nutrition of the matrix substance of the bone in their immediate neighbourhood. These cells, together with the periosteum, the medulla, and their blood-vessels, are active agents in the development, growth, and nutrition of the osseous tissue.

Development of Osseous Tissue.

In the section on the development of the skeleton, it was stated that the bones are formed by ossification in cartilage and fibrous membrane, so that bones are produced by secondary changes in a pre-existing material. The mode of production of the osseous tissue in the cartilaginous and fibrous tissues will now be considered, and it should be clearly understood at the outset that, in normal ossification, bone is not formed by a mere calcification of the matrix of the pre-existing tissue, and a direct conversion of the cartilage or connective tissue corpuscles into bone corpuscles; but, as the researches of Sharpey, Bruch, H. Müller, Lovén, and Gegenbaur have made known, is due to the development of, and changes in new corpuscles, which Gegenbaur has named *osteo-blasts*, accompanied by an abundant formation of blood-vessels.

Endo-chondral Ossification.—The pieces of cartilage in which bone forms have the same shape as the bones themselves, and each piece of cartilage is invested by perichondrium which in time becomes the periosteum. The perichondrium like the periosteum consists of two layers, an external fibrous and an internal or osteogenetic layer containing numerous osteo-blast cells. When the process of ossification in temporary cartilage begins, a change takes place in the arrangement of the cartilage cells at the centre, or point, or nucleus of ossification. These cells, instead of preserving their irregularly scattered arrangement in the matrix, are now collected into longitudinal parallel rows, not unlike what was described in a previous section, in the deep zone of encrusting cartilage. In each row the cells lie with their long axes transverse, and proliferate by transverse fission. The cells at the end of the rows which lie nearest the centre of ossific change swell out and become more rounded. Calcification of the matrix substance, which separates both the adjacent parallel rows of cells, and the cells in the same row, from each other, then takes place, which calcification includes also the capsules of the cartilage cells. A general opacity of the cartilage is the result of this calcification, and the further progress of ossification is rendered obscure. It is necessary, therefore, to dissolve out by an acid the calcareous matter, in order to follow the steps of the process. Irregular spaces or channels now form in the cartilage through absorption of its calcified matrix and of the capsules of the cartilage cells, and the corresponding cartilage cells themselves at the same time undergo disintegration. These channels are called the *medullary spaces*, and they are bounded and separated from each other by beams or trabeculæ of the calcified cartilage, which has not been absorbed. The medullary spaces are occupied by blood-vessels and quantities of rounded cells, not unlike leucocytes in size and appearance, which constitute the *primary medulla* or *marrow*.

Respecting the source of origin of the cells of this medulla, there have been difficulties in arriving at a correct conclusion. Henke conceived that they might be blood corpuscles migrated from the blood-vessels within the spaces. Others have believed them to be derived by proliferation from the cells of the cartilage which have not undergone disintegration. But the recent observations of Stieda seem satisfactorily to show that the cells of the primary medulla are derived from the osteo-blastic layer of the perichondrium, which is prolonged along with its blood-vessels into the medullary spaces as they form in the ossifying cartilage. But, whatever be their derivation, there can be no doubt that these cells undergo certain modifications which are of the utmost importance in the further stages of the ossific process. A few become elongated into fusiform or stellate corpuscles, like those of connective tissue; others have oil drops forming in their interior, and become the cells of yellow marrow; others become the many-nucleated cells

of red marrow; others, again, which form the osteo-blasts properly so-called, are the direct agents in the production of the osseous tissue itself.

Kölliker has pointed out that the absorption of the calcified cartilaginous tissue which leads to the production of the medullary spaces is in part at least effected through the agency of colossal, many-nucleated cells (*myeloplaxes*), which he named *osteo-klasts*, and believes to be derived from some of the cells of the medulla already described, so that a destruction of the calcified cartilage precedes the formation of the proper osseous tissue. As the absorption of the cartilage goes on, adjacent medullary spaces coalesce and communicate more or less freely with each other. But along with the destructive changes in the cartilage the production of the new osseous tissue takes place. The cells of the medulla, which become the osteo-blasts, form a layer in contact with the trabeculæ of calcified cartilage which form the walls of the medullary spaces, and undergo an important change both in composition and shape. They become granular, their protoplasm hardens from the periphery towards the nucleated centre of the cell, so as to give origin to the dense matrix substance of a bone lamella; but the nucleus, and the protoplasm immediately investing it, do not harden,—they form the soft contents of the lacunæ and canaliculi, *i.e.*, the bone corpuscles, which represent therefore in the adult bone the osteo-blast cells by which the osseous tissue has been produced. In this way a network of osseous trabeculæ appears, the calcified cartilaginous trabeculæ are then absorbed, and embryonal spongy bone is formed. A second layer of osteo-blastic medulla cells then passes through a similar metamorphosis, and a second lamella is formed. By a repetition of this process around the walls of the several medullary spaces, the lamellæ of the bone are produced. Hence it would appear that the dense solid matrix of the osseous tissue is produced by a special hardening of the protoplasm of the osteo-blastic cells in the medullary spaces, and as layer after layer of these cells is ossified successive lamellæ arise. The persistence, however, of the nucleus of each osteo-blast, and of a small portion of its investing protoplasm, preserves within the hard matrix a certain amount of soft material, which being destroyed when a bone is macerated, leaves the lacunary and canalicular system already described. The formation of successive lamellæ, which takes place from the periphery towards the centre of the medullary spaces, necessarily diminishes the size of the spaces, which then form the Haversian canals, and the lamellæ surrounding these canals are the

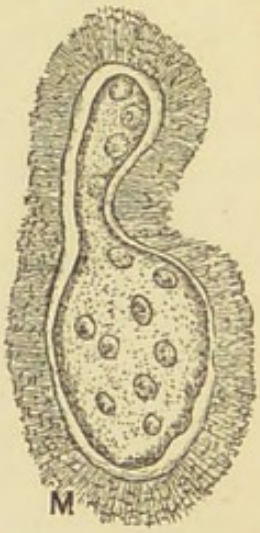

FIG. 56. Colossal many-nucleated Osteo-klast, occupying a cavity in M, the surrounding matrix. (*After Kölliker.*)

Haversian lamellæ. The vascular and cellular contents of these canals are therefore the remains of the contents of the medullary spaces of the fœtal cartilage, and are continuous with the deeper layer of the periosteum.

So long as any cartilage remains in a fœtal or young bone the process of replacement of the cartilaginous tissue by the proper osseous tissue goes on, until none of the cartilage is left, except the thin layer of encrusting cartilage at each articular extremity. Bones grow in length by an ossification in cartilage ; and a provision for their longitudinal increase is furnished up to, and even beyond the age of puberty, by the plate of cartilage which separates the epiphysis from the shaft of a bone. The ossification of this plate of cartilage marks the period when growth ceases in the long axis of the bone. But bones also grow in thickness, and this addition to their girth takes place by an ossification of material situated at their circumference. It has already been pointed out that a bone is invested by a fibrous membrane, the periosteum, which fulfils for it the same purpose as does the perichondrium for the cartilage. The deeper surface of the periosteum like that of the perichondrium has an osteo-genetic layer of osteo-blastic cells, similar to those which lie in the medullary spaces of the fœtal cartilage. These cells pass through a similar series of changes, and produce successive layers of new bone at the periphery, which constitute the peripheral lamellæ. The importance of the periosteum as a centre of origin of new bone has, indeed, long been recognised by both surgeons and pathologists. The parts of this membrane in which the special bone-producing power resides is the deep layer of osteo-blastic cells, whilst the blood-vessels furnish the pabulum for their nutrition. If strips of periosteum be removed, along with the cells of the deeper osteo-blastic layer, from a bone, and transplanted to other parts of the living body, bone will continue to be produced by their agency.



FIG. 57.—Section through a Fœtal Bone to illustrate its development. B, B, the dense osseous tissue, in which the lacunæ, with their soft nucleated contents, may be seen. M, M, the medullary tissue in the medullary spaces. OB, OB, layer of osteo-blastic cells of the medulla, next the osseous tissue, some of which in places are obviously becoming included in it. V, V, transversely divided blood-vessels, surrounded by medulla cells, situated in medullary spaces, which are assuming the form of Haversian canals.

Intra-membranous Ossification.—The formation of bone in fibrous membrane was first recognised by Nesbitt, and has been worked out in most of its details by Sharpey, Kölliker, and Gegenbaur. The tabular bones of the skull offer the best illustration of this mode of ossification. Sharpey has pointed out that a network of minute spicula of bone forms in the fibrous membrane, and extends in radiating lines from the centre of ossification towards the circumference of the bone. The ossifying tissue consists of fibres, of multitudes of granular corpuscles or osteo-blasts, and of blood-vessels. The osteo-blasts invest the fibres, but as the investing osteo-blastic cells calcify, from the periphery towards the nucleus, they assume a stellate configuration, and pass through a series of changes similar to those described in the intra-cartilaginous mode of ossification. The fibres, which are in the first instance soft, also calcify and contribute to the formation of the bone. Here, however, as in the intra-cartilaginous ossification, the active agents in the ossific process are the osteo-blastic cells. The lamellated structure is due to ossification of successive layers of these cells, and the formation of the lacunæ and canaliculi is owing to the persistence of their nuclei with a proportion of unossified investing protoplasm. The increase in thickness of a membrane bone, like that of a cartilage bone, takes place through ossification in a deep periosteal layer of osteo-blasts. Hence it follows that, though the tissue which precedes the appearance of bone in the skeleton is not uniformly the same, in some cases being fibrous membrane, in others cartilage, there is an identity in the ossific process in the two forms of pre-existing tissue, in both of which the osteo-blast cells are the active agents in ossification. The chemical differentiation which takes place in the protoplasm of the osteo-blasts during bone-formation is not merely a calcification, but a coincident production of a gelatine-yielding substance, within which the minute calcareous particles are deposited.

Stress has been laid by some anatomists, in discussing the homologies of the several bones of the skeleton, on the differences met with in the place of their formation. Thus it has been supposed that a bone originally developed in cartilage cannot be homologous with one originally developed in fibrous membrane, and that a fundamental morphological distinction should be drawn between cartilage bones and membrane bones. But when it is considered that, though the place of formation may vary, the method of formation is the same in all localities, it does not appear that so much importance should be attached to the distinction between cartilage and membrane bones as it has sometimes received. Moreover, the differences between these two varieties of bones are, during the growth of the bone, still further diminished, for in both cases increase in thickness takes place in the same kind of

pre-existing tissue, and in the same way, viz., by ossification of the deep periosteal layer of osteo-blasts.

In the description of the development of bone in the fœtus and young person, the formation of medullary spaces was referred to. But the production of spaces in bone is by no means limited to its early stages of growth. The medullary canal in a long bone can scarcely be said to exist in the bones of an infant's limbs. The hollowing out of the shaft of a long bone into a large canal, and the enlargement of the spaces of the cancellated tissue, goes on not only up to the period of adult life, but even to advanced years; so that in an old person the relative size of this canal is greater than in the prime of life. The Haversian spaces also, as Tomes and De Morgan pointed out, are produced by the absorption of the lamellæ of the osseous tissue surrounding the Haversian canals, and the production of these spaces is constantly going on during the life of the bone; portions of the lamellæ which may remain unabsorbed constitute the intermediate lamellæ. But along with the absorption leading to the formation of Haversian spaces, new bone arises through the agency of the osteo-blasts, and when this takes place on the wall of the medullary canal or cancelli, central lamellæ are formed. The air-sinuses in the cranial bones are also formed by the absorption of the diploë, and consequent separation of the two tables of the skull. Bones, therefore, are organs which are continually undergoing change. During growth additions are being made to their length by endo-chondral ossification, and to their thickness by periosteal ossification, and additional lamellæ are being formed in the walls of the medullary and Haversian spaces. At the same time a hollowing out of spaces in their interior is going on, so that an increase in weight commensurate with their growth does not take place. The interstitial absorptive changes, whether occurring during growth or after growth is completed, are due, as Kölliker has shown, to the action of the many-nucleated colossal cells, or osteo-klasts, which line the walls of the spaces where absorption is going on. The changes due to absorption are indeed so extensive that in the course of time the original endo-chondral bone becomes absorbed, and replaced by bone derived from ossification of periosteum. The development, modelling and ultimate configuration of a bone are, therefore, as has been well expressed by Kölliker, the product of the formation of osseous tissue by the agency of the osteo-blasts, and of its absorption or destruction by the action of the osteo-klasts.

From the fact that osseous tissue may be produced either in the cartilaginous or in the fibrous tissues, and that all three contribute to the formation of the skeleton, it is evident that these tissues are closely allied. To express this alliance they have all been grouped together under the common term Connective Substances.

Muscular Tissue.

The muscular tissue is that which is actively concerned either in the movement of parts of the body on each other, or in the movement of the entire body from place to place; it is, from its contractile properties, the active agent, therefore, both in motion and locomotion. It forms a large proportion of the general mass of the body, is the essential constituent of the muscles or flesh, and enters into the formation of the walls of the hollow viscera. It consists structurally of threads or fibres, some of which are distinguished by being marked with transverse stripes or striæ; others have no such markings. Hence it is customary to divide the fibres of the muscular tissue into transversely striped fibres and non-striped fibres. As a rule, the striped fibres are collected together to form those muscles which are under the influence of the Will, so that both the muscles and the fibres of which they are composed are called voluntary. An important exception to this rule is, however, met with in the heart, the muscular fibres of which, though transversely striped, are involuntary; the Will exercises no control over the action of the heart. The muscles of the pharynx and upper part of the oesophagus are also striped, but their action is involuntary. The non-striped fibres, and the muscles into the construction of which they enter, are not subject to the influence of the will; so that they are involuntary.

The *Non-striped* or *Involuntary* fibre, sometimes called pale or smooth muscular fibre, enters into the formation of the walls of the hollow viscera—*e.g.*, stomach, intestines, bladder, uterus—of the walls of the air-tubes, gland-ducts, blood and lymph vessels, of the skin, and various mucous membranes. The fibres are usually collected into bundles

or fasciculi, which are not aggregated together into such compact red masses as in the voluntary muscles, but are of a paler red colour, and are set farther apart, and often cross and interlace with each other in the walls of the tubes and hollow viscera, in which this form of muscle is found. The fasciculi are separated from each other by a delicate, areolar connective tissue, or *perimysium.* The size of the fasciculi varies in different localities; in the hollow viscera they are so large that their arrangement can be observed with the naked eye; but in the skin, the walls of gland-ducts, &c., they can only be seen with the aid of the microscope. If a fasciculus be carefully torn up with needles it can be resolved into its constituent fibres, and the number of the fibres varies with the size of the fasciculus. The non-striped fibres are pale and almost colourless, with soft, ill-defined outlines, from $\frac{1}{3500}$th to $\frac{1}{7000}$th inch in diameter; they are rounded in form or laterally compressed, and are so easily flattened by artificial pressure, that they have erroneously been regarded as flat or ribbon-shaped fibres. When digested for a few hours in dilute nitric or hydrochloric acid, and sometimes even without any reagent, they are seen to be elongated fusiform cells—the *contractile fibro-cells* of Kölliker—which vary in length from $\frac{1}{120}$th to $\frac{1}{600}$th inch, and which taper off usually into attenuated ends. In the middle of each cell is a characteristically elongated, rod-shaped fusiform nucleus within which is a plexus of fine fibrils. The cell protoplasm is finely granular, or faintly longitudinally

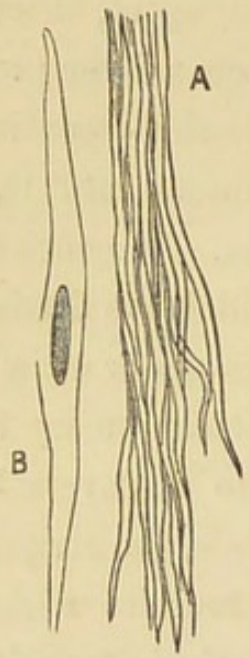

FIG. 58.—A, a fasciculus of non-striped muscular fibre; B, an isolated muscular fibre cell, more highly magnified.

striped, owing to the presence of fine fibrils. Opinions differ as to the existence of a cell wall or sarcolemma. In some localities, as was pointed out by Lister in the minute arteries in the web of the frog's foot, isolated contractile fibro-cells are wound spirally around the wall of the vessel. The cell-substance refracts light doubly.

The *Transversely Striped* fibre is the characteristic tissue of the voluntary muscular system, and is found wherever energetic movements are to be performed. In these muscles the fibres are collected together in fasciculi, and the bundles usually lie parallel to each other, and extend from the tendon of origin to the tendon of insertion. Each muscle is invested by a membranous sheath formed of connective tissue, the *perimysium externum*, which sheath gives off processes that dip into the substance of the muscle, so as to form delicate partitions between the fasciculi, and from these partitions still more slender prolongations of connective tissue, named *perimysium internum*, pass between the fibres. The number and size of the fasciculi vary with the size and texture of the muscle; in some, as the deltoid and gluteus maximus, the fasciculi are large and coarse; whilst in others, as the gracilis and omo-hyoid, they are much finer. The number of fibres in a fasciculus varies with its length and thickness, and the fibres which are contiguous with each other in the same fasciculus lie parallel. The striped fibres themselves are cylindrical or laterally compressed; they usually taper off at their extremities, and apparently do not, even in muscles with long fasciculi, exceed $1\frac{1}{2}$ inch in length. The transverse diameter of the striped fibres varies, in different localities in the human body, from $\frac{1}{400}$th to $\frac{1}{2400}$ inch. Much wider differences in diameter are found in the animal

series; in most insects the fibres being of extreme minuteness, whilst in cold-blooded animals they are much larger than in man and mammals.

A fibre should be carefully separated from a fasciculus, and examined microscopically by transmitted light. As the fibres of the water beetle and some other invertebrates are larger than those of mammalia, they are often employed for this purpose.

Each fibre is invested by a homogeneous elastic membrane, the *myolemma* or *sarcolemma* (Bowman), which being translucent allows the characteristic transverse striæ to be distinctly seen through it. The sarcolemma is so closely incorporated with the periphery of the fibre, that its isolation and demonstration as a distinct membrane in the fibres of the mammalia are attended with some difficulty; but when water is added to the living fibre of frogs and fish, it is absorbed, and elevates the sarcolemma from the sarcous contractile particles. Thin describes the sarcolemma as being covered by a layer of flat cells. If acetic acid be added to a muscular fibre the transverse striæ become less distinct, and a number of oval bodies come into view. These lie in the mammalia in close relation to the inner surface of the sarcolemma, but in many animals they are also deeper in the substance of the fibre. These bodies have long been known as the nuclei of the striped fibre. Each nucleus is imbedded in a little finely-dotted protoplasm, which often extends in a fusiform manner beyond the ends of the nucleus. The nucleus itself contains a network of delicate fibrils (Flemming). These nuclei, with their investing protoplasm, have the anatomical characters of nucleated cells, and are called the *muscle corpuscles*.

The sarcolemma encloses the proper sarcous contractile

substance, which is transversely striped. The transverse striæ are not mere surface marks, but, as Bowman pointed out, pass through the entire thickness of the fibre and indicate that it may be regarded as built up of a pile of discs superimposed on each other. Dobie described in 1848 the discs as consisting of two kinds of sarcous matter, arranged in a definite manner alternately dark and light, and that the dark discs or bands are broader than the light or clear bands. Dobie also described a dark line passing across the light band, so as to subdivide it into two halves, which line Busk and Huxley showed to be dotted; and this appearance has also been figured by Sharpey. Krause regards the line described by Dobie as due to a fine membrane, attached to the sarcolemma, which passes transversely across the fibre: he conceives the fibre as divided by these membranes into *muscle compartments*, each of which contains a dim disc with one half of a clear disc on each of its aspects. Rutherford denies the existence of Krause's membrane, and holds that Dobie's line consists of a single row of highly refracting globules in the feebly refracting clear disc. Dobie, and more recently Hensen, have also directed attention to a slender, feebly refracting stripe passing transversely across the strongly refracting dark disc, so as to subdivide it also into two halves.



FIG. 59.—A transversely striped muscular fibre.

If a piece of muscle be digested in dilute hydrochloric acid, gaps or fissures form transversely in the substance of the fibres (fig. 60), and if the digestion be prolonged the fissures extend completely across the fibre, which may

therefore be split up transversely into its constituent plates or discs, the *muscular fibre discs*, each of which corresponds in its transverse diameter to that of the fibre from which it is derived.



Fig. 60.—A muscular fibre cleaving transversely into discs.

But the transverse striæ are not the only markings seen in a voluntary muscular fibre. Longitudinal lines, not so definite either in extent or arrangement as the transverse bands, pass parallel to its long axis; they are irregular in position, and do not correspond to the whole length of the fibre, or necessarily pass through its whole thickness.

The longitudinal marks in the fibre are best seen by digesting a piece of muscle in strong spirit of wine, or in a solution of chromic acid. If a fibre so treated be teased out with needles, and the thin covering glass be smartly tapped, the fibre will split up longitudinally into multitudes of minute, elongated threads—the *muscular-fibre fibrillæ*. A fibrilla may be regarded as equalling in length the fibre of which it formed a part, and like the fibre is transversely striped; but its breadth is not definite, and depends upon the minuteness with which the fibre has been split up in the longitudinal direction. The fibrillæ lie parallel to each other, in the long axis of the fibre, and are connected together by intermediate cement. Thin describes the fibrillæ as collected into bundles, which are separated from adjacent bundles by spaces lined by flat cells. These spaces he believes to be continuous through holes in the sarcolemma, which admit the nerves, with



Fig. 61.—A muscular fibre cleaving longitudinally into fibrillæ.

lymph spaces outside the sarcolemma, which lie between it and the perimysium.

If in the same fibre the processes of transverse and longitudinal splitting were to go on simultaneously, then the fibre would be resolved into an immense multitude of rectangular particles—the *sarcous elements* of Bowman. If these particles be regarded as the ultimate subdivisions of the fibre, then the *discs* may be conceived to be built up of a number of these sarcous elements possessing similar optical properties, arranged side by side, so as to occupy the entire diameter of the fibre in any transverse plane: whilst the *fibrillæ* are built up of the sarcous elements arranged end to end, so as to correspond to the entire length of the fibre; but in the fibrillæ particles with different optical properties, the one singly refracting, the other doubly refracting, alternate with each other with the utmost regularity.

It is generally believed that the transverse striation indicates that the sarcous substance of the fibre is not a homogeneous material, and that the alternating series of dark and light bands differ from each other physically, chemically, and optically. Brücke pointed out that the light bands refracted the light singly, were *isotropic*; whilst the dark bands refracted the light doubly, were *anisotropic*, and he conceived that this anisotropic material was built up of an aggregation of minute doubly refracting bodies, which he named *disdiaklasts*. By some observers the broader dark bands are regarded as the proper sarcous or contractile portion of the fibre, and the intermediate narrower lighter bands as interstitial material cementing the broader dark discs together. Kühne considers that this interstitial material, to which he gives the name of *muscle plasma*, is

in the living fibre of the consistency of a viscous fluid, and that the anisotropic sarcous elements of the dim discs are suspended in it. Kühne supports this view by an observation in which he saw a living nematode worm, within the sarcolemma of a living fibre, moving from one end of the fibre to the other, and temporarily displacing the sarcous elements. Haycraft has recently advanced another and more simple explanation of the cause of the transverse striation based on the observation that a muscular fibre is not a smooth cylinder, but has a sinuous surface. The transverse striæ correspond with the inequalities of the surface; at the focus usually employed in examining the fibre the dark stripes mark the minute elevations running around the fibre, whilst the light stripes lie in the depressions or valleys between the elevations. The dark and light appearances being due to the thicker and thinner parts of the fibre acting on the rays of light which pass through the fibre, in the one case as a converging lens producing a dark stripe, in the other as a diverging lens producing a light stripe.

Some peculiar modifications of the striped muscular fibre are met with in certain localities. As a rule, this form of fibre does not branch; but in the muscles of the tongue and lip, and other muscles of the face, these fibres usually branch prior to their insertion, and the branches taper off to finely attenuated ends.

In the Heart the fibres branch; and the branches of adjacent fibres anastomose, so that the muscular wall of this organ consists of a compact network of fibres. The individual fibres are smaller than those of the voluntary muscles; they consist of oblong muscle cells, the substance of which is faintly transversely striped, the investing

sarcolemma is not present, and the muscle corpuscles lie in the substance of the fibre.

Some difficulty has been experienced in determining the exact mode of connection of the fibres of the belly of a muscle with those of its terminal tendons. By some it has been supposed that the fibres of the muscle are directly continued into the connective tissue bundles of the tendon (fig. 62). Weismann again has described the muscular fibre as terminating in a sharply-defined, rounded, or pointed extremity, to which the fibres of the tendon are closely apposed, and Ranvier states that the sarcolemma is interposed between the sarcous substance and the tendon.



FIG. 62.—Blending of the bundles of fibrillæ of the muscular fibre of the mouse with the bundles of the tendon. (*From Thin*).

Both the striped and non-striped forms of muscle are well provided with blood-vessels, which ramify in the areolar connective tissue, or perimysium, that separates the fasciculi and fibres from each other. The capillaries form an elongated network, the principal strands of which lie parallel to the muscular fibres, but never penetrate the sarcolemma. Hence, though the belly of a muscle is a highly vascular organ, its individual fibres are extra-vascular. But if Thin's observations be correct, spaces in the interior of the muscular fibres are continuous with the lymphatic system. The vascularity of the fleshy belly is much greater than that of the terminal tendons of attachment, and the nutritive changes are much more active in it than in them. The mode of termination of nerves in muscle will be considered in the chapter on the nervous tissue.

Development of Muscular Fibre.

The contractile fibre-cells of the *non-striped* muscular fibre are formed by the gradual elongation of the cells of the mesoblast into spindle-shaped cells, the oval nuclei at the same time becoming elongated, so as to assume a rod-shaped form and the cell protoplasm differentiating into contracticle fibrils. Usually the spindle cells which lie in the same linear series become cemented together into the smooth fibres of this form of muscle.

The mode of development of the *striped* fibre from the mesoblast cells is more difficult to follow out, and various statements have been made as to the successive stages of its formation. Schwann believed that a fibre was built up of the embryonic cells of the part, which arranged themselves in linear series, coalescing with each other at their surfaces of contact; that the contents of the cells then became transversely striated, and that the cell walls formed the sarcolemma. Savory and Lockhart Clarke maintained that a formation of blastema took place around free nuclei, and that this blastema gradually assumed the striated character. Remak, Kölliker, Wilson Fox, and Frey have, however, by studying the earliest stages of development in the very young embryo, established the fact that the striped fibres are developed from the cells of the embryo, though not in the manner described by Schwann. The process, briefly stated, is as follows: The embryonic cells elongate, the nucleus may remain single, but more usually it divides and subdivides, so that many nuclei appear in the interior of the elongated cell. The nuclei lie in linear series, and may either be separated from each other, or two or more may be in contact, and they may lie either near the periphery of the elongated cell, or in its axis. With this multiplication of the nuclei, the cell increases in length and assumes the form of a fibre. The cell protoplasm, both in the single and many-nucleated fibres, then differentiates into the sarcous particles of the transverse striæ, and as this progresses the fibre assumes its characteristic striped appearance. The whole amount of the protoplasm does not, however, assume the transversely striped appearance, for a small quantity remains around each nucleus and forms with it a muscle corpuscle. The differentiation of the protoplasm occasions an anatomical and chemico-physical change in the fibre, and confers on it the property of energetic contractility. The mode of development of the sarcolemma is still somewhat obscure. By some it is regarded as the wall of the embryonic cells, which have become metamorphosed into muscular fibres; by others it is regarded as a special differentiation of the protoplasm at the periphery of the fibre, which takes place at the time when the transverse striæ are being formed; whilst by others it is considered to be a special modification of connective tissue formed

around the fibre. In the development of the muscular fibres of the heart, the cells of the embryo heart branch and anastomose, and the nuclei multiply. By the transverse striation of the protoplasm of these cells the branched muscular fibres of the heart are produced.

In the growth of a muscle the individual fibres increase in size, so that they are larger in the adult than at the time of birth. The observations of Budge, Weismann, and Beale show that new fibres may also form in a muscle. Weismann believes that this increase may be due to a longitudinal splitting of a pre-existing fibre ; but Beale maintains that the new fibres are produced in the muscle in the same manner as the original fibres of the part.

The Nervous Tissue, the tissues which form the Blood and Lymph Vessels and the Dental Tissues, will be described in the chapters on the Nervous and Vascular systems and on the Teeth.

medullated from non-medullated fibres not with reading

CHAPTER V.

NERVOUS SYSTEM.

THE Nervous System consists of a number of organs which are named respectively Nerve Centres, Nerves, and Peripheral End-organs. The largest and most important Nerve Centres are the brain and spinal cord, which together constitute the Cerebro-Spinal nervous axis, and are lodged in the cranial cavity and spinal canal. But, in addition, numerous small bodies, usually oval in form, technically called Ganglia, are situated in many localities, and form smaller nerve centres. The Nerves are white cords or threads which traverse the different regions of the body, both axial and appendicular, for a greater or less distance, for the purpose of connecting together the other divisions of the nervous system. The Peripheral End-organs are minute structures connected with the peripheral extremities of the nerves. These end-organs are situated in the skin and other organs of sense, in the glands, blood-vessels, and muscles. The nerves establish communications and conduct nervous impulses, either between different nerve centres, or between nerve centres and peripheral end-organs, so as to associate together and regulate the activities of organs often widely separated from each other. Nerves, therefore, are internuncial structures. When a nerve connects two nerve centres together it is *intercentral*. When a nerve connects a nerve centre with a peripheral end-organ, and, under the influence of a stimulus, conducts impulses from the centre to the end-organ, it is a *centro-*

peripheral or *centrifugal* nerve. When a nerve connects a peripheral end-organ with a centre, and, under the influence of a stimulus, conducts impulses from the end-organ to the centre, it is a *periphero-central* or *centripetal* nerve. Owing to the different directions in which impulses are conducted by nerves, the varying nature of their end-organs, and the structural and functional differentiation of the nerve centres, or portions of the nerve centres in which their central extremities terminate, nerves vary so in their functions, that a classification of the nerves, based upon their functional properties, has been proposed. Of the Centro-Peripheral nerves, those which end in, and conduct impulses to the muscles are *motor* nerves; those which end in, and conduct impulses to the muscular coat of the blood-vessels are *vaso-motor* nerves; those which terminate in connection with, and conduct impulses to the secreting cells of a gland, are *secretory* nerves; whilst some physiologists have named nerves, which they believe to terminate in the tissues and to conduct impulses for the regulation of their nutrition, *trophic* nerves. It should be stated, however, that it is not yet absolutely determined that the cell elements of the tissues have special nerves terminating in connection with them, for the purpose of exercising a direct influence over their nutrition. Should these special nerves be non-existent, then the nutritive functions would be influenced solely by the vaso-motor nerves, which regulate the size of the blood-vessels and the amount of blood which flows through a part in a given time. Certain nerves which conduct impulses, by virtue of which the functional activity of a part is arrested or diminished, are called *inhibitory* nerves. Of the Periphero-Central nerves, those which arise in the end-organs in the skin, and terminate in a

nerve centre, so as to induce in it the molecular changes which give rise to the sensation of touch, are *nerves of common sensation;* those which arise in the end-organs in the eye, ear, nose, and tongue, and induce in their appropriate nerve centres the sensations of sight, sound, smell, and taste, are *nerves of special sense;* whilst nerves which conduct impulses from peripheral end-organs to a nerve centre, and, instead of inducing in the latter a sensation, have the impulses reflected to other nerves, are *reflex* nerves. When the impulses are reflected to motor nerves, they are *excito-motory;* to secretory nerves, *excito-secretory;* to inhibitory nerves, *excito-inhibitory.* In some fishes which possess electrical organs, nerves, named *electric* nerves, conduct impulses to, and set in activity the batteries from which electrical shocks are discharged.

The nerve centres, nerves, and peripheral end-organs form two groups or systems—a Cerebro-spinal and a Sympathetic. The Cerebro-spinal nervous system consists of the brain and spinal cord, of the nerves which arise from or terminate in these large centres, of the small ganglia connected with these nerves, and of the end-organs at their peripheral terminations. The Sympathetic nervous system consists of the sympathetic ganglia, with their nerves and end-organs.

Nervous Tissue.

The several parts of the nervous system are not uniform in colour, some being white, others grey. The nerves, at least those of the cerebro-spinal system, are invariably white, and white masses, variable in size, are met with in the brain and spinal cord; they constitute the white matter of the nervous system. In the nerve centres, both of the cerebro-spinal and sympathetic systems, grey matter is

found, sometimes in considerable quantities. This grey colour is so characteristic, that it may be regarded as marking the position of a nerve centre.

The nervous system possesses a characteristic form of tissue—the nervous tissue—which in part consists of fibres (Nerve Fibres), and in part of cells (Nerve Cells). The nerve cells are found in the grey matter—that is, in the nerve centres—and sometimes also in the peripheral end-organs. The nerve fibres constitute the nerves, enter into the nerve centres, and pass into the peripheral end-organs; they form the white matter. But in addition to the characteristic nervous tissue, the nervous system also contains a considerable quantity of connective tissue, numerous blood-vessels, and some lymph-vessels.

Nerve Fibres.—Nerve fibres are of two kinds: *a*, the white, medullated, or dark-bordered fibres, which are the characteristic fibres of the cerebro-spinal nervous system, though they also sparingly occur in the sympathetic system; *b*, the pale, non-medullated, or gelatinous nerve fibres, which are the characteristic fibres of the sympathetic nervous system, though they are also found in the cerebro-spinal system.

Medullated Nerve Fibres.—To examine the structure of these fibres, a portion of a cerebro-spinal nerve may be selected. In the first place, it will be seen to be invested by a sheath of connective tissue, the *perineurium*, which gives off processes that pass into the nerve, and divide it into fasciculi or funiculi. Each fasciculus is in its turn composed of nerve fibres, which are separated from each other by delicate connective tissue, the *endoneurium*, prolonged from the perineurium, in which the nutrient blood-vessels of the nerve ramify. The perineurial connective tissue investing a fasciculus, presents, when treated with

nitrate of silver, polygonal markings, which, as Ranvier showed, are the outlines of a layer of flat endothelial-like cells. The size of a nerve is in relation to the number and size of its fasciculi, and the size of a fasciculus is in relation to the number of its fibres. The fibres and the fasciculi lie parallel to each other in the same nerve; but as nerves branch at intervals, the more external of the fasciculi diverge from the main stem to form the branches. In the white matter of the brain and spinal cord the nerve fibres are not arranged in such definite fasciculi as in a distributory nerve, and the connective tissue between the fibres is the soft, delicate form called neuroglia.

A medullated nerve fibre is an elongated cylinder, which, when examined in the body of a living animal, or immediately after removal from the living body, consists apparently of a soft, homogeneous, or glassy-looking substance enclosed within a limiting membrane. When examined after death, or after the addition of reagents, such as water, spirit, ether, collodion, acetic acid, &c., it loses its homogeneous aspect, and the following structures can readily be distinguished in it (fig. 63): A, an elastic, transparent, investing membrane,—the *primitive membrane*, or neurilemma; C, a delicate thread, extending along the axis of the fibre,—the *axial cylinder* or central band of Remak; B, a substance which lies between the primitive membrane and the axial cylinder,—the white substance of Schwann, or the *medullary sheath*. Within the external outline of the fibre, formed by the investing membrane, is a second line, not quite parallel to the first, and the presence of these two lines gives to the fibre a characteristic double-contoured appearance. The primitive membrane, or neurilemma, not unlike the sarcolemma, is a pellucid,

homogeneous, nucleated membrane. It is believed to be absent from the nerve fibres in the brain and spinal cord, as well as at the peripheral terminations of many nerves. The medullary sheath is a fatty and albuminous substance (myelin), which refracts the light strongly. Not unfrequently it collects into little ball-like masses, and sometimes causes irregular bulgings on the fibre, and produces a knotted, varicose appearance; at other times it becomes granular, and makes the fibre opaque. By gentle pressure it can be squeezed out of the broken end of a fibre, and it leaves behind a framework of a strongly refracting corneous material, in the meshes of which the myelin was contained (Kühne and Ewald). Ranvier has described the medullary sheath as, divided into segments from breaks in its continuity, occurring at intervals in the fibre. These breaks have been called the *nodes*, or constrictions of Ranvier. The axial cylinder is, however, prolonged across the node from one segment to the other, and at the node an annular fold of the primitive membrane is in contact with the axial cylinder. Lantermann has recently described fine indentations passing obliquely across the medullary sheath in the intervals between the constrictions of Ranvier.

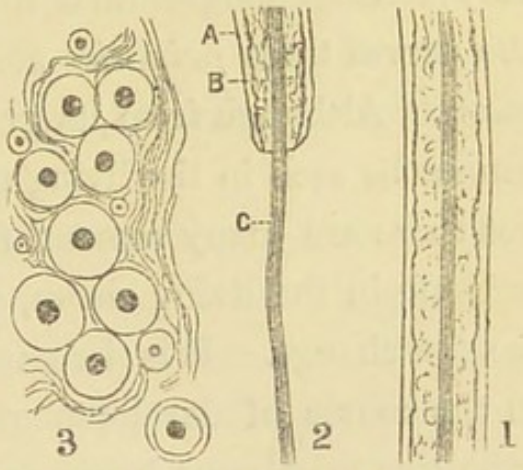

FIG. 63.—1. Medullated nerve fibre, showing the double contour. 2. A similar fibre in which A is the primitive membrane, B the medullary sheath, C the axial cylinder, protruding beyond the broken end of the fibre. 3. Transverse section through the medullated fibres of a nerve, showing the axial cylinder in the centre of each fibre. Between the fibres is the endoneurium or connective tissue.

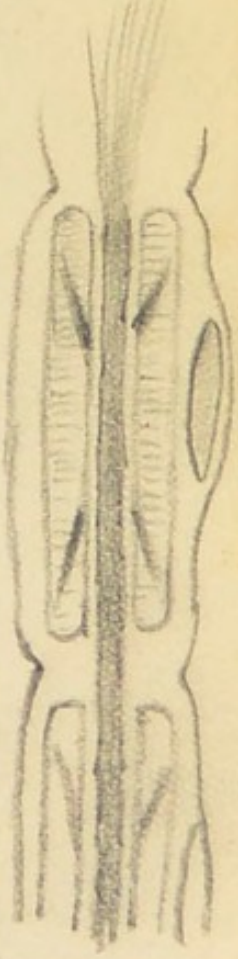

The axial cylinder is a pale, grey, cylindriform band, usually about one-third or one-fourth the diameter of the fibre, which possesses more tenacity than the medullary

sheath, and not unfrequently, as in fig. 63, 2, projects for some distance beyond the broken end of a fibre. Max Schultze showed that it is not homogeneous, but exhibits a very delicate longitudinal fibrillation, and at the ends of the nerves these *primitive fibrillæ* may separate from each other. Although from its great delicacy the axial cylinder cannot be seen in the living fibre of a cerebro-spinal nerve, yet there are many reasons for regarding it as a structure existing in the living nerve, and not the product of a *post mortem* change. It is the part of a fibre which first appears in the course of development—the medullary sheath and primitive membrane being secondary investing structures, superadded as development proceeds. It forms not unfrequently the only constituent of a nerve fibre at its central and peripheral terminations, and is therefore the part of the fibre which is anatomically continuous with the nerve cell, or with the peripheral end-organ. As it is the sole constituent of many nerve fibres at their terminations, and of all nerve fibres in the earlier stage of development, and as it forms the medium of connection between them and the structures in which they terminate, it is obviously of primary importance both anatomically and physiologically, and is believed to be the part of the fibre directly concerned in the conduction of nervous impulses; whilst the investing structures serve the purpose of insulating materials. Lister and I pointed out, in 1859, that essential differences in chemical composition existed between the axial cylinder and the medullary sheath; the former being unaffected by chromic acid, though the latter is rendered opaque and brown, and concentrically striated under its influence; while, on the other hand, the axial cylinder is stained red with great facility by an ammoniacal solution of carmine,

although the medullary sheath is unaffected by it. We further showed that these differences in the mode of action of chromic acid and carmine might advantageously be employed in the demonstration of the structure of nerve fibres. Ranke has subsequently stated that the axial cylinder possesses an acid, and the medullary sheath an alkaline reaction.

Medullated nerve fibres vary materially in diameter in different parts of the nervous system. In the brain, for instance, they are sometimes as fine as the $\frac{1}{12000}$th inch, whilst, in the distributory nerves, fibres of $\frac{1}{1500}$th of an inch in diameter may be seen; though it should be stated that, even in the nerves of distribution, fibres of great minuteness are often placed in the same bundle with those of a larger size. Nerve fibres do not branch in their course, but only at their central or peripheral terminations, and much more frequently at the latter than the former.

Non-medullated Nerve Fibres.—These fibres, which are characterised by the absence of a medullary sheath, are chiefly found in the sympathetic nervous system, but the fibres of the olfactory nerve are non-medullated, so also are the peripheral terminations of the cerebro-spinal nerves, and indeed all nerve fibres in the first stage of their development. In *Petromyzon* it has been stated that all the nerve fibres are distinguished by the absence of a medullary sheath.

This form of nerve fibre consists of pale grey, translucent, flattened bands, from the $\frac{1}{6000}$th to $\frac{1}{8000}$th inch in diameter. They usually appear as if homogeneous or faintly granular; but Schultze showed that, when carefully examined, they present a delicate fibrillated appearance, like that seen in the axial cylinder of a medullated nerve; hence, like that

cylinder, they are supposed to be composed of multitudes of extremely delicate primitive fibrillæ imbedded in a finely granulated material. Sometimes these fibres consist solely of this fibrillated material, at other times they are invested by a sheath similar to the primitive membrane of a medullated fibre. Nuclei are also found both in the substance of the fibre and in relation with the primitive membrane. The presence of multitudes of fibres in the sympathetic nervous system, formed either entirely, or almost entirely, of a material precisely similar in structure to the axial cylinder of a medullated fibre, and by which the proper function of the fibre can alone, therefore, be exercised, is, of course, an additional argument to those previously advanced, in favour of the existence of the axial cylinder as a normal constituent of the fibre, and of its functional importance.

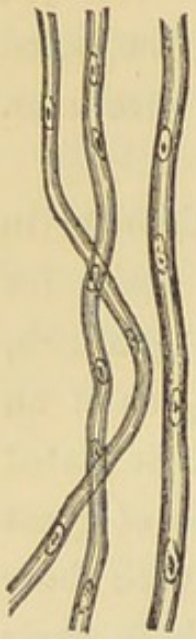

FIG. 64. — Non-medullated Nerve Fibres from the sympathetic system.

Nerve Cells.—Nerve cells constitute an important division of the nervous tissue. They are the characteristic structures in the nerve centres, are susceptible to impressions, or nervous impulses, and are the texture in which the molecular changes occur that produce or disengage the special form of energy named nerve energy, the evolution of which is the distinctive mark of a nerve centre. It was at one time thought that nerve cells were globular in form; but it is now known that, though the body of a cell is not unfrequently globular, one, two or more processes or poles project from it, and are continuous with its substance, and one or more of these processes are also continuous with a nerve fibre or fibres situated in relation to the nerve cell.

Nerve fibres may therefore be regarded as prolongations of the nerve cells with which they are continuous. Nerve cells are distinctly nucleated; the nuclei are usually large, and contain one, and often two distinct nucleoli. The cell substance is granular and fibrillated, like the axial cylinder of the nerve fibres; not unfrequently brown or yellow pigment is collected around the nucleus. A cell wall is sometimes apparently present, though at others it cannot be demonstrated. The nerve cells in the grey matter of the brain and spinal cord are imbedded in the neuroglia. In the smaller nerve centres, as the sympathetic ganglia and the ganglia on the posterior roots of the spinal nerves, the nerve cells are surrounded by a capsule of connective tissue. Fräntzel, Kölliker, and others have described this capsule as lined by an endothelium formed of flattened cells.

Nerve cells with only a single process, called *unipolar cells*, are the characteristic cells in the ganglia on the posterior roots of the spinal nerves of most vertebrates. This process often bifurcates in a T-like manner, and each branch becomes continuous with a nerve fibre (Ranvier).



FIG. 65.—Bipolar Nerve Cell, with two nerve fibres continuous with it, from the spinal ganglion of a skate.

Nerve cells from which two poles or processes proceed are called *bipolar*. Characteristic specimens of these cells, as was first pointed out by Robin and R. Wagner, may be recognised without difficulty in the ganglia on the posterior roots of the spinal nerves of fishes. These cells usually possess a globular body, though sometimes it may be elongated; and from opposite points of the surface of the body a strong process is given off, which is directly

continued into a nerve fibre. The axial cylinder of the fibre is continuous with the cell substance, and Schultze has shown that both exhibit a delicate fibrillated structure. The medullary sheath and the primitive membrane are also usually continued from the fibre over the nerve cell. Hence these bipolar cells seem to be, as Schultze expressed it, nucleated enlargments of the axial cylinder.

A remarkable modification of the bipolar nerve cell, carefully studied and described by Lionel Beale, is found in the sympathetic ganglia of the frog. The cells are pear-shaped, and from the narrow end of the pear two nerve fibres arise, one of which, called the straight fibre, forms, as it were, the stalk of the pear; whilst the other, or spiral fibre, winds spirally round the straight fibre, and then passes away from the cell in the opposite direction. Both fibres are nucleated, and at their origin consist, apparently, of axial cylinder substance only; but in their course they may acquire both a medullary sheath and a primitive membrane. The straight fibre passes into the interior of the cell substance, and Arnold and Courvoisier believe that they have traced it into the nucleus; but the spiral fibre apparently arises nearer the periphery of the cell. The pear-shaped cells are invested by a distinct capsule of connective tissue. The nerve fibres of these cells, although they both arise close together from one end of the cell, represent its poles.

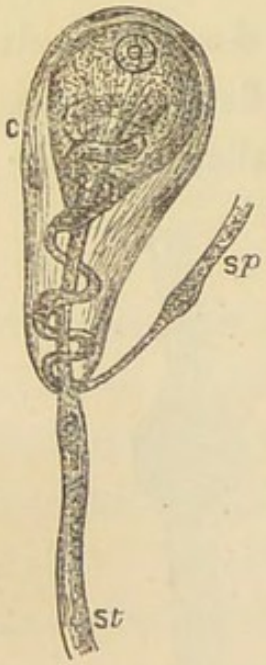

FIG. 66.—Pyriform Nerve Cell. *St*, straight nerve fibre; *Sp*, spiral nerve fibre; C, capsule of connective tissue around nerve cell. (*After Beale.*)

In other localities, as in the sympathetic ganglia of man and many other vertebrates, and in the several divisions of the cerebro-spinal nervous axis, the nerve cells have more than two poles or processes projecting from them. Cells of this kind are called *multipolar*, and in many localities they present characteristic forms. In the grey matter of the spinal cord, more especially in its anterior cornu, they give rise to numerous processes, and have a stellate or radiate form (fig. 68). In the grey matter on the surface of the convolutions of the cerebrum they are pyramidal in shape; the apex is directed to the surface of the convolution, the base towards the white matter (fig. 92); the processes arise from the base, apex, and sides of the pyramid. In the grey matter on the surface of the cerebellum the body of the cell is almost globular; from that aspect of the cell which is directed towards the white matter a slender central process arises; from the opposite or peripheral aspect of the cell two strong, antler-like branching processes extend for a considerable distance (fig. 82). In the human sympathetic ganglia, again, the stellate form

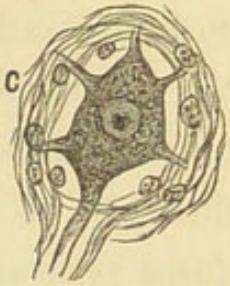

FIG. 67.—Multipolar Cell from human sympathetic ganglion. C, capsule of connective tissue. (*After Schultze.*)

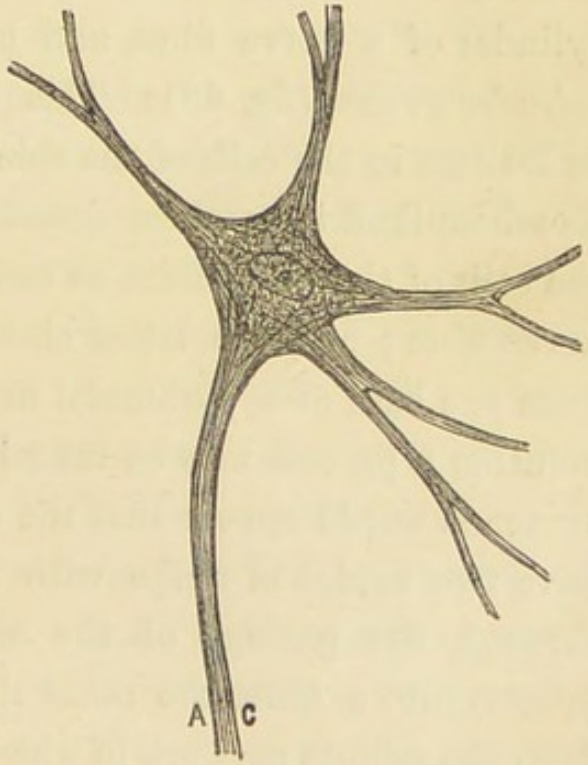

FIG. 68.—Multipolar Cell from the grey matter of anterior cornu in the spinal cord. A C, non-branched axial cylinder process directly continuous with a nerve fibre.

of cell prevails, and the existence of a capsule of connective tissue around the individual cells can be recognised (fig. 67). The processes which arise from a multipolar nerve cell, as a rule, divide and subdivide as they pass away from the body of the cell, until at last they give rise to branches of extreme tenuity. These branching processes apparently consist exclusively of cell protoplasm, and have been called *protoplasm processes.* Gerlach has described the protoplasm processes of the multipolar nerve cells of the brain and spinal cord as forming, by their repeated branching, an excessively minute network, from which minute medullated nerve fibres arise; and F. Boll conceives that a similar arrangement occurs in the cells of the cerebellum. One, at least, of the processes of a multipolar nerve cell does not branch, but becomes directly continuous with the axial cylinder of a nerve fibre, and has been named the *axial-cylinder process* (fig. 68). This process was first recognised by Deiters in the cells of the spinal cord; but Hadlich and Koschennikoff have since described the central process of the cells of the cerebellum as continuous with a medullated nerve fibre; and the latter observer has pointed out, that from the base of a pyramidal nerve cell in a cerebral convolution a process may be traced directly into a nerve fibre. Hence it would appear that the multipolar nerve cells may have two modes of union with nerve fibres—one directly through the passage of the non-branched axial-cylinder process into a fibre, the other through the origin of fibres from the minute network in which the branched protoplasm processes terminate. The branched processes of adjacent nerve cells may also blend with each other, so as to form an anastomosing cell network, though these anastomoses are, in all probability, not so frequent as was at one time

supposed. Schultze has pointed out that the protoplasm substance of the body of a multipolar nerve cell, and both the non-branched and branched processes, possess a fibrillated structure similar to that described by him in the axial cylinder of the nerve fibres.

Peripheral End-Organs or *End Bodies.*—Nerve fibres at their peripheral extremities terminate in connection with peculiar structures, named *end-bodies*, *terminal bodies*, or *peripheral end-organs*, which are situated in the several organs of the body. The motor nerves end in the voluntary and involuntary muscles; the vaso-motor nerves end in the muscular coat of the blood-vessels; the sensory nerves end in the skin, mucous membranes, and organs of special sense; and it is probable that secretory nerves terminate in connection with the ultimate cell elements of the secreting glands. The end-organs, connected with the terminations of the nerves in these textures, possess certain structural peculiarities, which are by no means uniform in the different parts, so that the end-body connected with the peripheral termination of a nerve is distinctive of the organ in which it is situated. It will be a matter of convenience to defer the consideration of the peripheral end-bodies in the skin, organs of special sense, and the several glands, until these organs are described. In this chapter the mode of termination of the motor nerves in the voluntary and involuntary muscles, of the sensory nerves in the mucous membrane, and of the ending of the nerves in the remarkable bodies named Pacinian corpuscles, will alone be examined.

After a nerve has entered a voluntary muscle it ramifies in the connective tissue, which lies between the fasciculi, and at the same time divides and subdivides into smaller branches. These branches interlace with each other and

form plexuses, from which slender nervous twigs, often consisting of only a single medullated nerve fibre, proceed, which ramify in the connective tissue, separating the individual muscular fibres from each other. The single nerve fibres in their turn branch, accompanied by a splitting of the axial cylinder, and these branches usually lose the medullated character. The mode of termination of these very delicate branches has been a subject of much dispute. Beale described them as forming a minute network, situated on the exterior of the sarcolemma, but in contact with it, and the fibres of this nervous network were distinctly nucleated. Other observers have, however, described peculiar bodies, called *motorial end-plates*, at the extremity of these nerves. These end-plates consist of a clump of richly nucleated protoplasm, somewhat oval or perhaps irregular in form, into which the axial cylinder of the nerve fibre penetrates. The exact position of these end-plates in relation to the muscular fibres is difficult to determine. Krause holds that they lie outside the sarcolemma, but adherent to it; whilst Kühne, Margo, and Rouget maintain that the end-plate lies within the sarcolemma, and that the nerve fibre has to pierce that membrane before it can enter the end-plate. After the axial cylinder has entered the end-plate it divides into very minute branches. Two nerve fibres may enter a single end-plate, and a muscular fibre may have more than one end-plate connected with it.

In the non-striped muscles the nerves are distributed in the connective tissue which separates the fasciculi from each other. Here they form plexuses, which, in the coats of the arteries, in the myenteric plexus of Auerbach in the muscular coat of the intestines, in the muscular coat of

the bladder and elsewhere, have collections of nerve cells, forming microscopic ganglia lying in them. From these plexuses fibres arise which divide into delicate non-medullated fibres, possessing nuclei. These delicate fibres form still finer plexuses, which in their turn give origin to minute fibres, which pass between the muscular fibre cells to form a still more minute intramuscular network. Frankenhäuser maintains that the delicate nerve fibrils which arise from this terminal network penetrate the muscular fibre cells, enter the nucleus, and terminate in the nucleolus; but Arnold considers that, after having entered the nucleus, the fibril again gives off a filament, which passes out of the cell to join the intramuscular plexus; the ending of the nerve, therefore, within the nucleus is only apparent, and is rather to be regarded as the nodal point of a fine intra-nuclear plexus.

The termination of the sensory nerves in the mucous membranes has been especially studied in the conjunctiva, the mucous membrane of the soft palate, and the glans of the penis and clitoris. In these parts Krause discovered oval or globular end-bodies, which consisted of a soft, homogeneous substance invested by a nucleated capsule of connective tissue. A nerve fibre pierces the capsule and terminates in the interior of the end-body, which forms a bulbous enlargement at the end of the nerve, and is called the *end-bulb*. After the nerve has entered the end-bulb, it may consist only of the axial cylinder and terminate in a pointed extremity, or it may twist upon itself and form a coil within the end-bulb. When the structure of the skin is described, it will be seen that the ending of the nerves in the cutaneous papillæ bears a general resemblance to their termination in the end-bulbs of a mucous membrane.

In certain of the mucous membranes delicate nerves have been traced into the layer of epithelium, situated on the free surface of the membrane. Petermöller described nerve fibres, continuous with the nerves of the cornea, passing into the layer of conjunctival epithelium on the front of the cornea. Klein recognised an intra-epithelial nervous network in the same locality. Chrschtschonovitsch traced non-medullated nerve fibres proceeding from a subepithelial network into the deeper epithelial layers of the vaginal mucous membrane, and similar nerve fibres have been seen by Elin to end in the epithelial investment of the mucous membrane of the mouth.

Connected with the sensory nerves in some localities are the remarkable bodies named the *Corpuscles of Pacini*, or *Bodies of Vater*, which were the first terminal organs discovered in connection with the peripheral distribution of the nerves. These corpuscles are attached to the cutaneous nerves of the fingers, toes, palm, and sole, to the nerves of the skin of the neck and arm, to the intercostal nerves, to the nerves of the joints and of the periosteum, to the nerves of the penis and clitoris, and to the mesenteric nerves. In cats they are often extremely abundant both in the mesentery and omenta. A Pacinian corpuscle can be seen by the naked eye, and looks like a minute grain from $\frac{1}{10}$th to $\frac{1}{20}$th inch long. It is elliptical in form, and may either be sessile or attached to the nerve stem by a slender stalk. It consists of numerous lamellæ of membrane-like connective tissue concentrically arranged, which form its capsule, and surround a central core of protoplasm. The outermost lamellæ are more widely separated than the innermost, and a clear interlamellar fluid occupies the intervals. Numerous connective tissue corpuscles may be

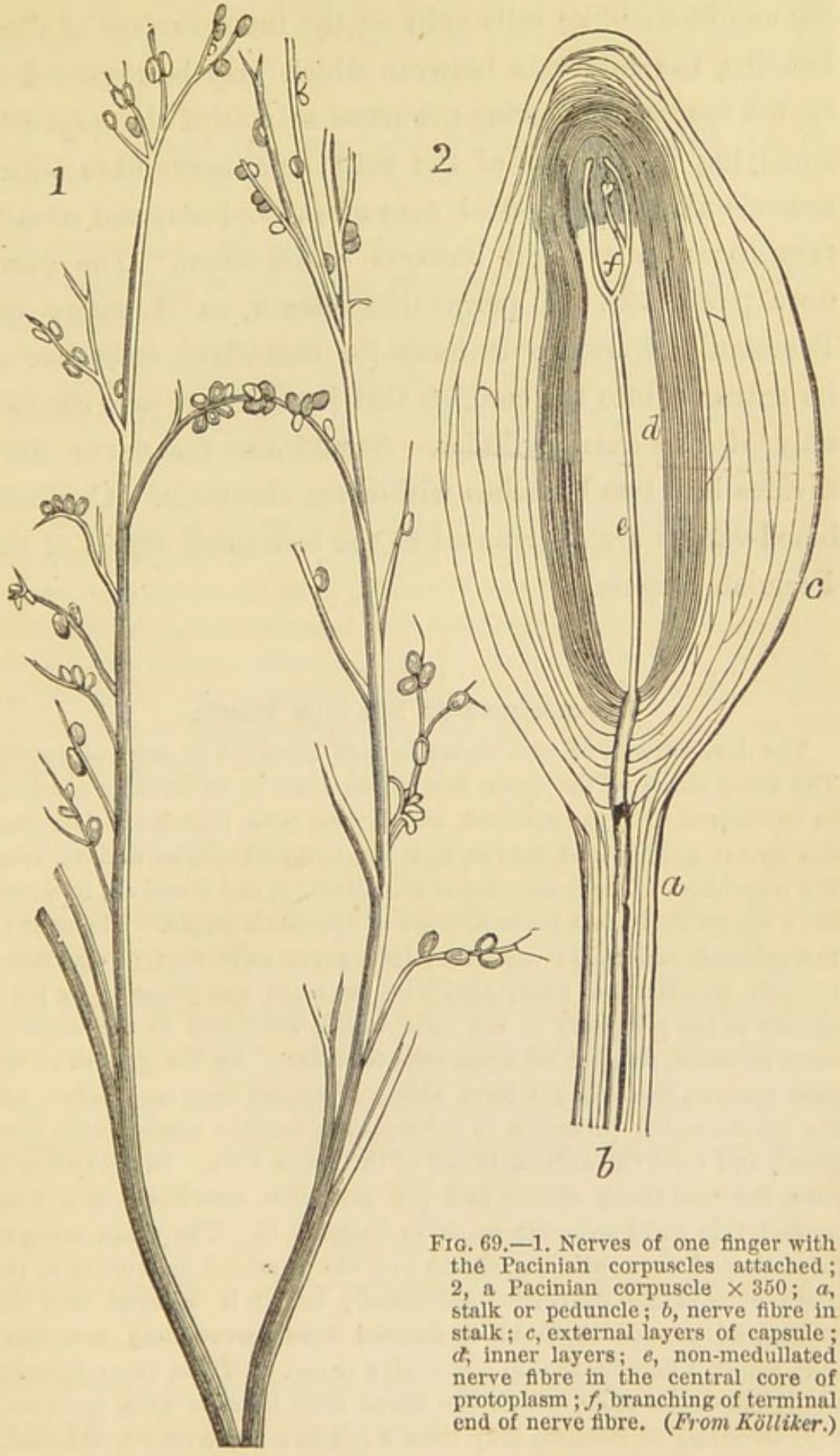

FIG. 69.—1. Nerves of one finger with the Pacinian corpuscles attached; 2, a Pacinian corpuscle × 350; *a*, stalk or peduncle; *b*, nerve fibre in stalk; *c*, external layers of capsule; *d*, inner layers; *e*, non-medullated nerve fibre in the central core of protoplasm; *f*, branching of terminal end of nerve fibre. (*From Kölliker.*)

seen in the concentric lamellæ, and Hoyer has shown that flat endothelial-like cells exist on the inner surface of these lamellæ, the intervals between which may be regarded as lymph spaces. Entering the attached pole of the corpuscle, and lying in the axis of the stalk, is a nerve fibre which extends along the central core of protoplasm, and usually terminates in a slight bulbous enlargement. The nerve fibre parts with its perineurial sheath as it enters the Pacinian corpuscle; it loses its medullary substance at its entrance into the core, so that its terminal part consists only of the axial cylinder. Sometimes the nerve fibre divides into two branches within the corpuscle. Capillary blood-vessels are distributed to the concentric layers of the Pacinian corpuscle.

Development of Nervous Tissue.

The development of this tissue is still involved in some obscurity. The nerve tissue of the brain and spinal cord is universally admitted to be derived from the epiblast, and it has been customary to regard the spinal ganglia and nerves, and the sympathetic, as derived from the mesoblast. The researches of His, Balfour, and Marshall, however, have shown that these parts also are of epiblastic origin. The cells of the epiblast, which are converted into nerve cells, assume characteristically granular and finely fibrillated contents, and processes or poles appear at the periphery of the cells, which, according to the observations of Beale, connect adjacent cells together. As the growth of the part goes on, the cells are more widely separated from each other, and the anastomosing processes in consequence become considerably elongated, and form the axial cylinder of the nerve fibre. In the course of time the medullary sheath and the primitive membrane may form around this axial cylinder so as to insulate it. The exact mode of formation of the medullary sheath and the primitive membrane of the nerve fibre is not properly understood; but it is believed that the perineurial connective tissue is derived from surrounding mesoblast cells which differentiate into connective tissue. Of the two originally contiguous cells from which the nerve fibre is, as it were, spun out, one, according to Hensen, may form a cell in a nerve centre, the other

may differentiate into a peripheral end-organ. The spinal ganglia, the spinal nerves, and the sympathetic, are all anatomically continuou with each other, and through the nerve roots with the spinal cord. At their first appearance they are all composed of elongated cells, continuous with the cells of the involuted epiblast which forms the spinal cord. It is probable that nerve fibres are formed by the fusion of these elongated cells end to end. The young cerebro-spinal nerve fibres are distinctly nucleated, and correspond in appearance and structural characters to the non-medullated nerve fibres of the adult. In the tail of the tadpole the formation and growth of nerve fibres have been studied by Kölliker, and it has been seen that the terminal part of a fibre may have fusiform or tri-radiate cells connected with it, the processes of which cells gradually differentiate into nerve fibres.

If in a young or adult person a nerve be cut across, its conducting power is destroyed ; but after a time it reunites, and its function is restored. The part of the nerve which lies between the place of section and its peripheral extremity, undergoes, as Waller pointed out, degenerative changes. To how great an extent the degeneration affects the various constituents of each fibre it is difficult to determine ; for whilst some experiments would seem to show that only the medullary sheath broke up into granular particles and was absorbed, in others both it and the axial cylinder disappeared. In process of time, however, these parts may be reproduced, and the nerve then recovers its functional activity.

The Cerebro-spinal Nervous System.

In this section the anatomy of the Brain and Spinal Cord, and of the numerous distributory Nerves which arise from them, will be described. The brain and spinal cord are the largest and most important of all the nerve centres. They occupy the cranial cavity and spinal canal, and are continuous with each other through the foramen magnum in the occipital bone. As the arrangement of the structures which compose the brain and spinal cord is extremely complex, and as the names applied to the several parts are numerous and often very arbitrary, it may be well, before commencing a detailed description, to make a few general observations on their mode of development.

Development of the Cerebro-Spinal Nervous Axis.

In the section on the development of the skeleton (p. 54) the formation of the axial, dorsal groove in the embryonic area has been described. The wall of this groove is formed by an involution of the cells of the epiblast, or external layer of the blastoderm, and these involuted cells form the axial *medullary plate.* The groove deepens by the elevation of its walls into the dorsal laminæ (fig. 70), and as these continue to grow they meet mesially and enclose the involuted axial epiblast or medullary plate. The surrounding mesoblast cells then differentiate, in the region in which the vertebral column is to appear, into the proto-vertebræ, and the medullary plate becomes completely severed from the epiblast forming the external layer of the blastoderm, which differentiates into the epidermis. The axial groove is by these changes converted into an axial *neural*, or *central canal*, and the walls of this canal formed by the epiblast cells of the medullary plate (fig. 71), which by repeated multiplication are arranged in several layers, constitute a tube the *medullary* or *cerebro-spinal tube.* This axial canal becomes the central canal of the cerebro-spinal nervous axis. The layer of epiblast cells next the canal differentiates into its epithelial lining, and it is to be noted that this layer though most internal in the involuted epiblast, was originally continuous with the most external layer of the epiblast covering of the embryo. The layers of epiblast cells situated peri-

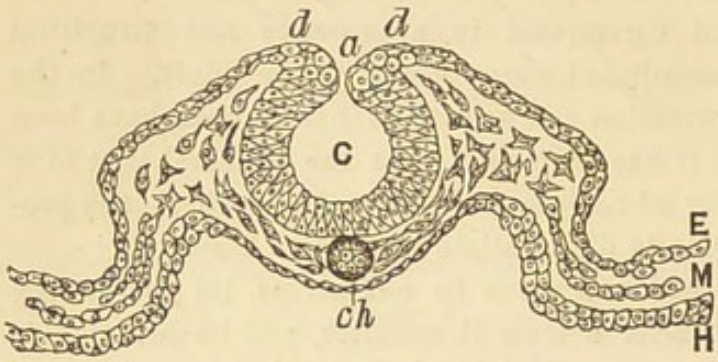

Fig. 70.—Transverse-Vertical Section through the Blastoderm of a Chick at the end of the second day. E, epiblast; M, mesoblast; H, hypoblast. C, the axial groove closing in to form the axial or central canal; *d*, *d*, the elevated sides of the groove or dorsal laminæ, which subsequently blend opposite *a*; *ch*, chorda dorsalis. (*After Schenk.*)

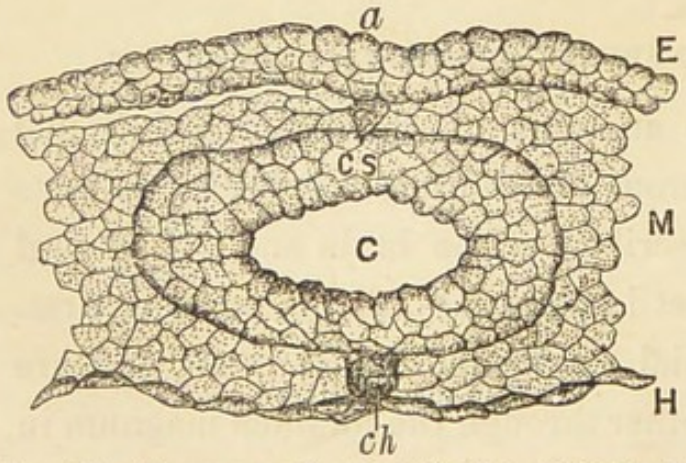

Fig. 71.—Transverse Vertical Section through the Blastoderm of *Bufo cinereus.* C S, the epiblast cells of the medullary tube, forming the embryonic cerebro-spinal nervous axis, which has been cut off from the superficial epiblast, E, by growth of the mesoblast, M. The other letters are as in fig. 70. (*After Schenk.*)

pherally to the epithelial layer differentiate into the nerve cells and fibres of the brain and spinal cord.

In the part of the cerebro-spinal tube which becomes the Spinal Cord the axial canal persists as the *central canal* of the spinal cord, and is lined by a layer of ciliated cylindrical epithelium. The cells outside this epithelium differentiate into the grey and white matter of the cord. The grey matter, which contains the nerve cells, is prolonged into a *crescent shaped body* in each lateral half of the cord, and the horns of each crescent form the *anterior* and *posterior cornua.* Outside the grey matter, and forming therefore the peripheral part of the cord, is the white matter, which is arranged in a series of *longitudinal columns* of nerve fibres. These fibres are derived from the most external cells of the involuted epiblast. The anterior cornua and columns in each half of the cord then increase in size and enclose between them a ventral mesial fissure, the *anterior fissure,* and at the bottom of this fissure the *anterior commissure* is formed. Subsequently a dorsal or *posterior mesial fissure* appears in the whole length of the cord, and its appearance is coincident with a reduction in calibre of the central canal, which is much larger in the embryo than in the adult. At the bottom of the posterior fissure is the *posterior commissure* which along with the anterior commissure connects the two lateral halves of the cord together.

The anterior or cerebral end of the cerebro-spinal tube becomes the Encephalon, or Brain. At first the cerebral part of this tube is uniform in appearance with the spinal part, but it soon expands into three vesicular dilatations—the *Primary Cerebral Vesicles.* These vesicles, named (from before backwards) anterior vesicle or fore-brain, middle vesicle or mid-brain, and posterior vesicle or hind-brain, are separated from each other by transverse constrictions. As each vesicle is an expansion of the cerebro-spinal tube, it is necessarily hollow, and its axial canal is continuous with the central canal of the spinal cord. In the walls of these vesicles the nervous tissues and organs, which form the several divisions of the encephalon, are produced by a differentiation of their epiblast cells. The most internal layer of these cells differentiates into the epithelial lining of the central portion of the axial neural canal, which canal is known from below upwards by the names of central canal of medulla oblongata, 4th ventricle, aqueduct of Sylvius, 3d ventricle, and two lateral ventricles. A curvature takes place in the axis of the encephalon in the region of the mid-brain, by which the fore-brain is bent downwards at an angle with the hind brain. This flexure corresponds with the cranial flexure in the base of the skull in the region of the pituitary fossa, where the notochord ends anteriorly, and where the demarcation takes place between the occipito-sphenoid and the sphenoido-ethmoid parts of the basis cranii. Another

flexure takes place more posteriorly, in the region of the foramen magnum, where the brain and spinal cord become continuous with each other.

The *Posterior Cerebral Vesicle* (hind-brain) undergoes a great thickening of its walls and gives origin to the Medulla Oblongata, Cerebellum and Pons Varolii. The posterior or lower part forms the medulla oblongata, which is continuous with the spinal cord. Shallow anterior and posterior median fissures appear in it, which divide it into two lateral halves, and each lateral half differentiates into grey matter and a longitudinal arrangement of nerve fibres continuous with the columns of the cord. The cerebellum appears as a thickening in the posterior wall of the upper end of this vesicle and, as it grows backward, a deep bend takes place between it and the medulla. It consists at first of a central lobe only, and in the lower vertebrates does not advance beyond this stage. In mammals, including man, two lateral lobes or hemispheres are superadded, and, with their growth, numerous transversely arranged nerve fibres arise, which produce the thickening in the floor of the vesicle called the pons. The axial space in the vesicle lies between the cerebellum and medulla and forms the dilatation called *4th ventricle.* The cerebellum is connected below with the medulla oblongata by the pair of restiform bodies or inferior peduncles, and above with the corpora quadrigemina by the pair of superior peduncles.

The *Middle Cerebral Vesicle* (mid-brain) corresponds to the region of the cranial flexure. Its walls thicken and differentiate, the roof into the Optic Lobes, the floor into the Crura Cerebri, the sides into the Corpora Geniculata Interna, whilst the axial canal becomes the *aqueduct of Sylvius.* At first the optic lobes form a single structure, but about the sixth month of embryo life a median furrow divides this structure into two lateral halves (the *corpora bigemina*), and in the lower vertebrates the development does not proceed beyond this stage ; but in the seventh month of embryo life of the human fœtus each lateral half is subdivided into two by a transverse fissure, so that four bodies (the *Corpora Quadrigemina*) are produced. The crura cerebri form the two cerebral peduncles, which, diverging from each other, pass upwards to the hemispheres of the cerebrum. They consist almost entirely of nerve fibres continuous with the longitudinal fibres of the pons, a few of which go to the corpora quadrigemina, but the greater number ascend to the cerebral ganglia and hemispheres.

The *Anterior Cerebral Vesicle* (primitive fore-brain) is an unpaired vesicle when it first appears. Soon it gives off a bud on each side the *primary optic vesicle.* The primitive fore-brain is then prolonged forwards and divided by an oblique constriction into a posterior part, the Thalamencephalon, and an anterior part, the Prosencephalon.

The Thalamencephalon thickens; in each lateral wall the Optic Thalamus is formed, and the axial canal between the two thalami is the dilatation called the *3d ventricle*. This ventricle is bounded in front by the lamina cinerea or terminalis. In the floor of the thalamencephalon appear the optic nerves and commissure, the tuber cinereum, infundibulum and corpora albicantia. The infundibulum is connected with the pituitary body, or *hypophysis cerebri*, lodged in the pituitary fossa of the sphenoid. The infundibulum forms indeed the posterior lobe of the pituitary body; but its anterior lobe has a very different origin, for it is derived from a prolongation of the epiblast lining of the mouth, which in the course of time becomes severed from the mouth, and enclosed within the cranium by the development of the cartilaginous floor of the skull. In the roof of the thalamencephalon appears the pineal gland or *epiphysis cerebri*, from which two white peduncles run forwards on the sides of the optic thalami. Below this gland the transverse fibres of the posterior commissure pass between the two optic thalami.

The Prosencephalon (*primitive hemisphere vesicle* or *secondary forebrain*) is at first unpaired, and contains a single axial cavity continuous with that of the thalamencephalon or 3d ventricle (His). This unpaired vesicle then, as Mihalkovics has shown, presents a median notch at its anterior part, which gradually deepens into a furrow, as the vesicle increases in size, until at length the vesicle becomes divided into the right and left hemispheres of the Cerebrum and the median furrow forms the great longitudinal fissure of the cerebrum. The production of this fissure is due to the formation of a mesial band of connective tissue, derived from the surrounding mesoblast, which forms the falx cerebri. Each hemisphere is hollow, the cavity in its interior is the *lateral ventricle*, and the two lateral ventricles freely communicate with each other and with the third ventricle through a large primitive foramen of Monro. The roof and sides of each hemisphere are the Mantle, whilst in its floor the Corpus Striatum is formed. As development advances the corpora striata increase in size, project on the floor of the lateral ventricle, and mark off the anterior from the middle or inferior cornu. Nerve fibres form in the wall of the mantle, which become continuous with nerve fibres that have formed in the corpus striatum, they constitute the white core of the hemisphere or the corona radiata. Two parallel folds appear on the inner face of each hemisphere, which project towards the ventricle. The upper fold thickens into the hippocampus major (cornu ammonis), which projects into the inferior cornu of the ventricle. The lower fold elongates and thins into a layer of short cylindrical cells, which form the epithelial covering of the vascular choroid plexus. This epithelial layer is continuous with the wall of the hemisphere, covers the fornix and

optic thalamus, and shuts out the choroid plexus from the interior of the ventricular cavity. About the third month the adjacent inner faces of the two hemispheres partially fuse together, and form a triangular shaped grey expansion, the septum lucidum, whilst the space left between them is the 5th ventricle, which is not, like the other ventricles, derived from the axial canal of the cerebro-spinal tube, but is a portion of the mesial longitudinal fissure enclosed by the imperfect fusion of the adjacent inner faces of the two hemispheres. In the more posterior and lower part of the septum lucidum the transverse fibres of the anterior commissure appear, which pass through the two corpora striata ; also the fibres of the anterior pillars of the fornix, which grow downwards to join the corpora albicantia, and also extend backwards along each hippocampus major as the posterior pillar of the fornix and tænia hippocampi. At the upper and anterior part of the septum lucidum the transverse fibres of the corpus callosum arise, which pass across the mesial plane, form the floor of the great longitudinal fissure, enter the white core of each hemisphere, and end in the grey surface of the mantle.

The grey outer surface of the mantle of each hemisphere is at first smooth, but in the course of time furrows appear, which divide it into convolutions and lobes. The fissura hippocampi appears about the third month, and extends along the inner face of the hemisphere ; it corresponds on the surface to the hippocampus major within the ventricle. Then the calcarine fissure appears, which corresponds on the surface to the calcar avis within the posterior cornu of the ventricle. At the beginning of the fourth month the parieto-occipital fissure is formed, which corresponds to an elevation on the inner wall of the posterior cornu, called by Henle the bulbus cornu posterioris. The Sylvian fissure appears on the outer face of the hemisphere about the fourth month, and the fissure of Rolando at the sixth month.

Springing from the antero-inferior part of each hemisphere is the Olfactory Lobe, which is prolonged forwards as the olfactory peduncle and bulb. The cavity of the lateral ventricle is continued into the peduncle and bulb, but subsequently it disappears, and both bulb and stalk become solid.

Owing to the great development of the mantle of the hemispheres in the human brain, and the size and complexity of the convolutions, the hemispheres grow forward so as to overlap the olfactory bulbs and peduncles, and backward so as to conceal the corpora striata and optic thalami as well as the corpora quadrigemina, crura cerebri, cerebellum, pons, and medulla oblongata ; so that when the human brain is looked at from above, none of these structures can be seen. It is only when the brain is turned over, and its base exposed, that the medulla, pons, cerebellum, and crura are visible ; and before the corpora quadri-

gemina, optic thalami, and corpora striata can be exposed, portions of the hemisphere substance must be removed. The growth backwards of each hemisphere leads also to a prolongation backwards of the lateral ventricle into the occipital lobe and the formation of a posterior cornu.

A vascular membrane, the *Pia mater*, is developed from the mesoblast as an investment of the spinal cord and encephalon, and processes derived from it dip into the fissures between the two halves of the cord, also between the cerebral convolutions and the lamellæ of the cerebellum. A broad band, the *Velum Interpositum*, possesses two marginal fringes, the *choroid plexuses*, which project on the floor of the lateral ventricle and its inferior cornu, but are separated from the cavity of the ventricle itself by the layer of cylindrical cells already described (p. 209) as forming the epithelial covering of the choroid plexus. When the two hemispheres are *in situ*, and the two halves of the fornix are joined together to form the *body* of that structure, the velum interpositum, passes across the mesial plane from one hemisphere to the other, having the fornix and tænia hippocampi above and the optic thalami and corpora quadrigemina below. The interval occupied by the velum is called the *great transverse fissure of the cerebrum.*

Until quite recently it was believed that the Cranial and Spinal Nerves were derived from the cells of the mesoblast, but the researches of F. M. Balfour, Marshall and Hensen have shown that they are really outgrowths of the cerebro-spinal nervous axis, and therefore derived from epiblast cells which differentiate into nerve fibres. The posterior roots of the spinal nerves, with their ganglia, arise in relation to the dorsal aspect of the cord. The anterior roots appear subsequently to the posterior, and grow out of the ventral aspect of the cord ; they join the posterior roots beyond the ganglia. The cranial nerves arise from the dorsal aspect of the cerebral end of the cerebro-spinal tube, so that their relation to the brain at their first appearance resembles that of the posterior roots of the spinal nerves to the spinal cord (Balfour).

The Sympathetic Nervous System was also believed to be of mesoblast origin, but Balfour, Schenk and Birdsell have now shown it to arise in connection with the cranial and spinal nerves. The sympathetic ganglia appear as swellings on the main branches of the spinal nerves in close relation with the ganglia on the posterior roots. They then become removed from them by the growth of intermediate nerve fibres ; but the continuity of the sympathetic and spinal nervous systems is kept up throughout life by the *communicating* branches, which pass from the anterior divisions of the spinal nerves to adjacent sympathetic ganglia.

Membranes of Brain and Spinal Cord.

The brain and spinal cord are invested by three membranes or Meninges, which lie between them and the bones that form the walls of the cranial cavity and spinal canal. The membranes are named from without inwards dura mater, arachnoid mater, and pia mater.

Dura mater.—The most external membrane, named *dura* from its firmness, consists of a cranial and a spinal division. The Cranial division or *endocranium* is in contact with the inner table of the cranial bones; it is adherent along the lines of the sutures and to the margins of the foramina which transmit the nerves, more especially to the foramen magnum, and it gives sheaths to the cranial nerves. It forms, therefore, for these bones an internal periosteum, and the meningeal arteries which ramify in it are the nutrient arteries of the inner table. As the growth of bone is more active in infancy and youth than in the adult, the adhesion between the dura mater and the cranial bones is greater in early life than at maturity. When not adherent to the bones, capillary intervals or *epidural spaces* exist between it and them, and these intervals correspond to the subperiosteal lymph spaces of other bones.

From the inner surface of the dura mater strong flattened bands pass into the cranial cavity, and form partitions between certain of the divisions of the brain. A vertical longitudinal mesial band, named, from its sickle shape, *falx cerebri*, dips between the two hemispheres of the cerebrum, and stretches from the crista galli to the internal occipital protuberance. A smaller sickle-shaped vertical mesial band, the *falx cerebelli*, attached to the internal occipital crest, passes between the two hemispheres of the cerebellum. A large band arches forward in the horizontal

plane of the cavity, from the transverse groove in the occipital bone to the clinoid processes of the sphenoid, and is attached laterally to the upper border of the petrous part of each temporal bone. It separates the cerebrum from the cerebellum, and, as it forms a tent-like covering for the latter, is named *tentorium cerebelli*. A small horizontal band, the *diaphragma sellæ* bridges over the sella turcica, and leaves only a small aperture for the infundibulum.

Along certain lines the cranial dura mater splits into two

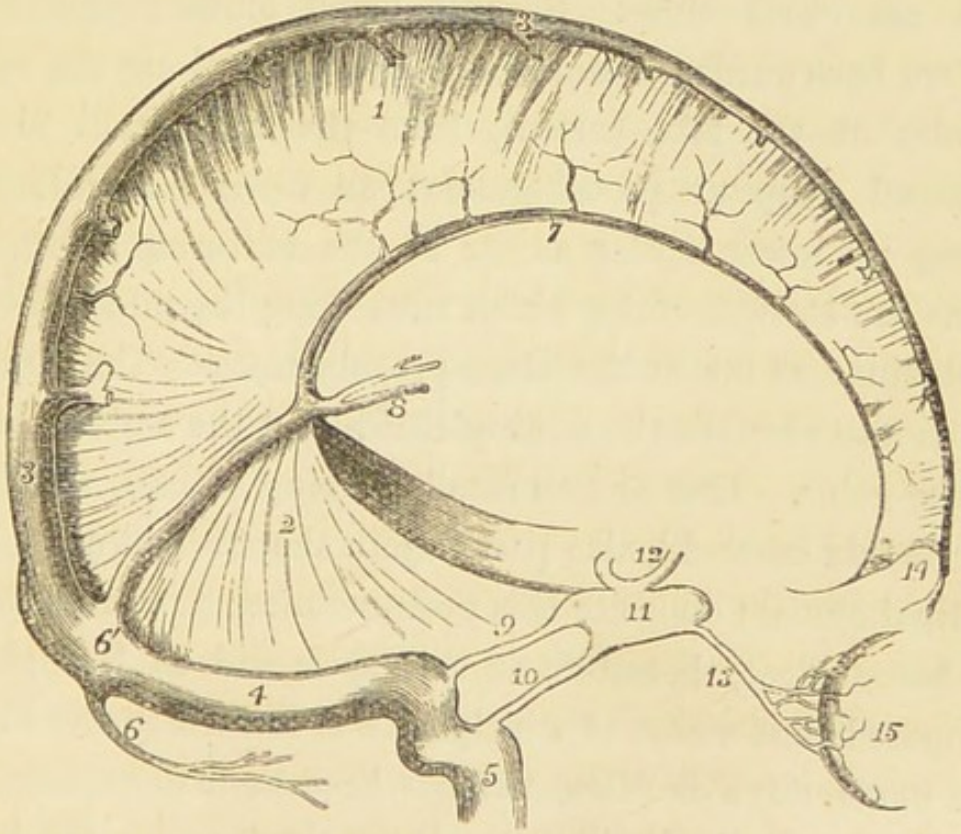

FIG. 72.—Dura Mater and Cranial Sinuses. 1, Falx cerebri; 2, tentorium; 3, 3, superior longitudinal sinus; 4, lateral sinus; 5, internal jugular vein; 6, occipital sinus; 6′, torcular Herophili; 7, inferior longitudinal sinus; 8, veins of Galen; 9 and 10, superior and inferior petrosal sinuses; 11, cavernous sinus; 12, circular sinus, which connects the two cavernous sinuses together; 13, ophthalmic vein, from 15, the eyeball; 14, crista galli of ethmoid bone.

layers, to form tubular passages for the transmission of venous blood. These passages are named the *venous blood sinuses* of the dura mater, and they are lodged in the grooves on the inner surface of the skull referred to in the description of the cranial bones. Opening into these

sinuses are numerous veins, which convey from the brain the blood that has been circulating through it. Two of these sinuses, called *cavernous*, lie at the sides of the body of the sphenoid bone, and receive the ophthalmic veins from the eyeballs situated in the orbital cavities. The two cavernous sinuses are connected by vessels which cross the pituitary fossa in front of and behind the pituitary body, and are called the *circular* sinus. A *spheno-parietal* sinus lies under the lesser wing of the sphenoid and joins the cavernous sinus. Several blood sinuses pass from before backwards: a *superior longitudinal* along the upper border of the falx cerebri, from the crista galli to the internal occipital protuberance; an *inferior longitudinal* along its lower border as far as the tentorium, where it joins the *straight sinus*, which runs along the middle of the tentorium as far as the same protuberance. The straight sinus also receives the *veins of Galen* and the superior cerebellar veins. One or two small *occipital sinuses*, which lie in the falx cerebelli, also pass to join the straight and longitudinal sinuses opposite this protuberance; several currents of blood meet, therefore, at this spot, and as Herophilus supposed that a sort of whirlpool was formed in the blood, the name *torcular Herophili* has been used to express this confluence of these sinuses. From the torcular the blood is drained away by two large sinuses, named *lateral*, which curve forwards and downwards to the jugular foramina to terminate in the internal jugular veins. In its course each lateral sinus receives two *petrosal* sinuses, a *superior* and an *inferior*, which pass from the cavernous sinus backwards along the upper and lower borders of the petrous part of the temporal bone (see p. 510).

The Spinal division of the dura mater hangs loosely in

the spinal canal, and forms a tubular investment for the spinal cord. It does not serve as a periosteum for the vertebræ, which possess a distinct periosteal covering, between which and the dura mater loose fat and a plexus of veins are situated. It gives off no bands like the falx and tentorium from its inner surface, and it does not split into two layers for the lodgment of venous blood sinuses. It extends from the foramen magnum, where it is continuous with the cranial dura mater, to the lower end of the sacral canal, where it ends in a funnel-shaped prolongation. It is pierced laterally by the roots of the several spinal nerves in their passage outwards to the intervertebral foramina, and gives a covering to each, which forms a sheath for the nerve.

Both the cranial and the spinal parts of the dura mater consist of a tough, fibrous membrane, containing numerous elastic fibres; it is flocculent externally, but smooth, glistening, and free on its inner surface. The inner surface has the appearance of a serous membrane, and when examined microscopically is seen to be covered by a layer of squamous endothelial cells, as in fig. 34. Hence the dura mater is sometimes called a fibro-serous membrane. The dura mater is well provided with lymph vessels, which in all probability open by stomata on the free inner surface. Nerves have been traced to the cranial dura mater both from the 5th cranial nerve and the sympathetic. Between the dura mater and the arachnoid membrane is a space of only a capillary lumen, containing a minute quantity of limpid serum, which moistens the smooth inner surface of the dura and the corresponding smooth outer surface of the arachnoid. It is regarded as equivalent to the cavity of a serous membrane, and is named the *arachnoid cavity*,

or, more appropriately, the *sub-dural space.* Schwalbe, Axel Key and Retzius have described the sub-dural space as communicating with the deep lymph-vessels and lymph-glands of the neck; with the sub-dural spaces of the nerve roots and the lymph channels of the cranial and spinal nerves; with the venous sinuses around the Pacchionian bodies and with lymph-channels in the substance of the dura mater.

Arachnoid mater.—The arachnoid is a non-vascular connective tissue membrane of great delicacy and transparency, which envelops both the brain and spinal cord. It is separated from these organs by the pia mater; but between it and the latter membrane is a distinct space, called *sub-arachnoid.* The free surface next the sub-dural space is smooth and covered by a layer of squamous endothelium. The opposite surface is connected to the pia by threads and membranes of delicate sub-arachnoid connective tissue, which traverse the sub-arachnoid space and divide it into numerous loculi freely communicating with each other. The connection is much closer opposite the summits of the convolutions than opposite the sulci between them, for the arachnoid does not dip between the convolutions: it is loose also opposite the interpeduncular space, and around the pons, medulla, and spinal cord, in which localities therefore the sub-arachnoid space is most distinct. The arachnoid is prolonged around the roots of the cranial and spinal nerves, and in the spinal region a mesial membranous band (*septum posticum*) connects the pia and arachnoid in the mesial plane posteriorly. Endothelial cells line the inner surface of the arachnoid, cover the outer surface of the pia, and invest the various bands and membranes which traverse the sub-arachnoid space. This space communicates

with the interior of the Pacchionian bodies; with the ventricles of the brain through the *foramina of Magendie* and *Key* and *Retzius* in the region of the 4th ventricle; with the serous and lymphatic spaces of the organs of sense, and along the nerve roots with a serous system of spaces situated around the entire peripheral nervous system up to its peripheral ramifications (Key and Retzius). The sub-arachnoid space contains a limpid cerebro-spinal fluid, which varies in quantity from 2 drachms to 2 ounces. The fluid is alkaline, of sp. gr. 1·005, contains a little albumen, and a substance which, as I pointed out many years ago, reduces blue oxide of copper to the state of yellow sub-oxide. Some anatomists regard the arachnoid membrane as the visceral layer of a serous membrane, and the endothelial lining of the dura mater as the parietal layer of the same membrane, whilst the sub-dural space is the intermediate serous cavity.

When the skull cap is removed, clusters of granular bodies, often of a reddish colour, are usually to be seen imbedded in the dura mater on each side of the superior longitudinal sinus; these are named the *Pacchionian bodies* or *arachnoidal villi*. When traced through the dura mater they are found to spring from the visceral or proper cerebral arachnoid. Each Pacchionian body consists of a prolongation of the cerebral arachnoid enclosing sub-arachnoid tissue, the loculi of which communicate with the sub-arachnoid space. The observations of Luschka and Cleland have proved that villous processes invariably grow from the free surface of that membrane, and that when these villi greatly increase in size they form the bodies in question. Sometimes the Pacchionian bodies greatly hypertrophy, occasion absorption of the bones of the cranial vault, depressions

on the upper surface of the brain, and project into the lumen of the superior longitudinal sinus.

Pia mater.—This tender vascular membrane consists of delicate connective tissue closely investing the whole outer surface of the brain and cord. It dips into the fissures between the convolutions, and a wide prolongation, named *velum interpositum* and *choroid plexuses*, passes into the interior of the brain. With a little care it can be stripped off the brain without causing injury to its substance, although it gives a funnel shaped sheath around the blood-vessels which pass from it into the convolutions. The pia mater which invests the spinal cord, consists of two layers, with the outer of which the sub-arachnoid tissue is continuous. The inner layer (*pia intima*) is intimately attached to the cord. It sends prolongations into the anterior and posterior fissures of the cord; numerous slender bands pass from its inner surface into the columns of the cord, and it ensheathes the blood-vessels which enter the cord, so that it cannot be stripped off the cord without causing injury to its substance. The pia mater is prolonged on to the roots both of the cranial and spinal nerves, and on to the filum terminale.

In the spinal canal a slender fibrous band projects from the pia mater covering the side of the cord, and, pushing the arachnoid membrane in front of it, is attached by about twenty-two pairs of denticulated processes to the inner surface of the dura mater. It is named *ligamentum denticulatum*, and its teeth-like processes alternate with the successive pairs of spinal nerves.

The arteries of the brain and spinal cord ramify and divide into small branches in the pia mater and sub-arachnoid tissue before they penetrate the nervous substance, and the veins conveying the blood from the nerve centres traverse

these membranes before they open into the blood sinuses of the cranial dura mater, and into the extra-dural venous plexus of the spinal canal. The vessels which pass from the pia mater into the brain and spinal cord are invested by a loose funnel-shaped sheath, which has been described as forming the wall of a peri-vascular lymphatic vessel, but Axel Key and Retzius consider that the space between the blood-vessel and the sheath opens into the sub-arachnoid space, and contains cerebro-spinal fluid. A network of lymph vessels ramifies freely in the pia mater. It is also well provided with nerves, which arise from the posterior roots of the spinal nerves, from the 3d, 5th, 6th cranial nerves, glosso-pharyngeal and accessory of the 8th, and from the carotid and vertebral plexuses of the sympathetic. The epi-cerebral and epi-spinal spaces described by His as existing between the pia mater and the brain and spinal cord are in all probability artificial productions.

Spinal Cord.

The Medulla Spinalis, or Spinal Cord, occupies the spinal canal, and extends from the foramen magnum to opposite the body of the first lumbar vertebra. In the early fœtus it equals in length the canal itself; but as the spinal column grows at a greater proportional rate than the cord, the latter, when growth has ceased, is several inches shorter than the column. The cord is continuous above with the medulla oblongata, whilst it tapers off below into the *conus medullaris*, which ends in a slender thread, the *filum terminale*. The filum lies in the axis of the sacral canal, and is attached, either to the fibrous membrane which closes in the sacral canal below, or to the back of the coccyx. The length of the cord is from 15 to 18 inches.

It approaches a cylinder in shape, but is flattened on its anterior and posterior surfaces, and presents two enlargements which have a greater girth than the rest of the cord The upper, called the *cervical* or *brachial enlargement*, extends from opposite the 3d cervical to the 1st dorsal vertebra, and from it arise the nerves which supply the upper limbs; the lower, called the *crural* or *lumbar enlargement*, is opposite the last dorsal vertebra, and supplies with nerves the lower limbs. Between these two enlargements the cord is of almost uniform girth, and gives origin to the dorsal or intercostal nerves, and is called the *dorsal* part of the cord.

The cord is almost completely divided into a right and a left lateral half by two fissures, named respectively *anterior* and *posterior median fissures*, the anterior of which is wider but not so deep as the posterior. Each half of the cord contains the commissures, the columns, the cornua, and the nerve roots. At the bottom of the anterior fissure are the transverse fibres of the *anterior white commissure*, and at the bottom of the posterior fissure the fibres of the *posterior grey commissure*. By these commissures the two halves of the cord are united together. The posterior commissure consists partly of nerve fibres, and partly of neuroglia called *substantia gelatinosa centralis*. This neuroglia surrounds an axial canal, the *central canal*, which extends along the whole length of the cord, and even passes into the upper end of the filum terminale. This canal is lined by a ciliated columnar epithelium, and expands superiorly into the cavity of the 4th ventricle. The attached ends of these columnar cells are elongated, and project into the neuroglia which surrounds the canal.

Each lateral half of the cord is divided into three

columns, anterior, lateral, and posterior, by the lines of emergence of the roots of the spinal nerves. The anterior nerve roots emerge as separate fasciculi at the *antero-lateral depression*, and between it and the antero-median fissure is the *anterior column* of the cord. The posterior nerve roots emerge from a definite fissure, the *postero-lateral fissure*, and between it and the postero-median fissure is the *posterior column*; whilst the *lateral column* is between the anterior and posterior nerve roots (fig. 73). In the cervical and upper dorsal region the posterior column is subdivided by the *postero-intermediate fissure* into the small *postero-median* column or *band of Goll*, which lies next to the postero-median fissure, and the *postero-external column* or *funiculus cuneatus* (*posterior root-zone* of Charcot), which lies next the posterior nerve root. The division of the cord into columns, cornua and commissures is well seen in transverse sections through its substance.

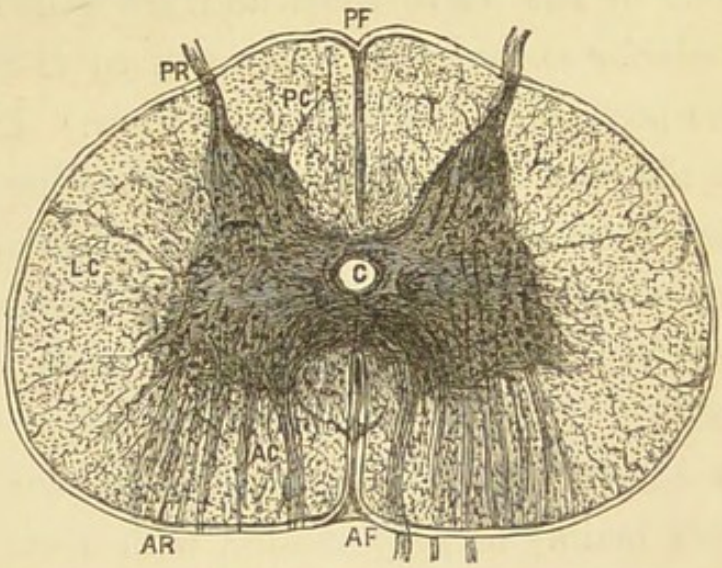

FIG. 73.—Transverse Section through the Lumbar Cord. AF, antero-median, and PF, postero-median fissures; PC, posterior, LC, lateral, and AC, anterior columns; AR, anterior, and PR, posterior nerve roots; C, central canal of cord, with its columnar epithelial lining. The pia mater is shown investing the cord, sending processes into the anterior and posterior fissures, as well as delicate prolongations into the columns. The crescentic arrangement of the grey matter is shown by the darker shaded portion.

The cord is composed of white and grey matter and contains both nerve fibres and nerve cells. The white matter is external, and forms the columns of the cord.

The grey matter is surrounded by the white, and has in each lateral half of the cord a crescentic shape. The horns of the crescent are directed towards the points of emergence of the nerve roots and are called the *anterior* and *posterior cornua*; the anterior horn is thick and rounded; the posterior elongated and narrow. In the dorsal region of the cord a lateral offshoot of the grey matter, about midway between the anterior and posterior cornua, is sometimes called the *intermediate* or *lateral* cornu; it blends in the cervical and lumbar regions with the anterior cornu. The proportion of grey matter to the white varies in different parts of the cord. The conus medullaris consists mainly of grey matter, with a very thin covering of white. In the lumbar swelling the grey and white matter are almost in equal proportion. In the dorsal region the white substance is five times more than the grey; whilst in the cervical swelling it is twice as much as the grey. The absolute amount of grey matter is greater in the cervical and lumbar enlargements, where the nerves of the limbs arise, than in the intermediate dorsal region. The white matter increases in amount from below upwards, so that its absolute quantity is greatest in the cervical part of the cord.

The Grey crescentic portion of the cord contains connective tissue, blood-vessels, nerve fibres, and nerve cells. The connective tissue neuroglia consists partly of a delicate fibrillated material and partly of flattened, stellate corpuscles, the *cells of Deiters.* The nerve fibres in the grey matter are numerous. They are derived from various sources, from the anterior and posterior nerve roots; from the anterior and posterior commissures; from the division of processes of the nerve cells, and in addition fibres run

longitudinally in the grey matter which probably connect groups of nerve cells situated in different transverse planes. The nerve fibres in part at least divide and subdivide, and, as Gerlach has shown, form a narrow-meshed network of extremely minute fibres. The nerve cells are multipolar. Those of the anterior cornu are large, distinct, and stellate (fig. 68), and frequently form two well-defined groups, an *antero-internal* and an *antero-external.* The cells of the posterior cornu are, as a rule smaller, elongated, or spindle-shaped, but with stellate branched processes. They are neither arranged in groups, nor so distinct as in the anterior horn, for the neuroglia is abundant, and forms at the tip of the posterior horn the *substantia cinerea gelatinosa* of Rolando. Sometimes also isolated nerve cells may be seen in the white columns immediately outside the grey matter of this cornu. In the lateral horn, in the dorsal region of the cord, and in the corresponding structure in the cervical and lumbar enlargements are the stellate cells named *intermedio-lateral* group of nerve cells. In the lower dorsal region, from the origins of the 9th dorsal to the 3d lumbar nerve, are the cells forming *Clarke's vesicular column* or *group* of nerve cells. They are situated behind the plane of the central canal at the inner side of the base of the posterior cornu. Stilling has described a similar group in relation to the origins of the 2d and 3d sacral nerves, and another in relation to the origins of the 3d and 4th cervical nerves.

The Columnar, external, white part of the cord consists of nerve fibres, with a supporting reticular framework of connective tissue and blood-vessels derived from the pia mater. But in addition a neuroglia is present, which consists partly of a delicate fibrillated material, and partly of

the flattened stellate cells of Deiters. The nerve fibres of the various columns run longitudinally in the cord and lie parallel to each other, so that in transverse sections through the columns the fibres are transversely divided. The individual fibres vary much in diameter, but the axial cylinder and medullary sheath can be seen.

Some of the longitudinal fibres run from below upwards and conduct either excito-motory impulses to regions in the spinal cord itself, or sensory impulses to the brain. Other fibres again descend from the brain and higher region of the cord to the lower, and conduct motor and vaso-motor impulses from above downwards. Hence the columns of the cord contain distinct tracts of fibres, which perform different functions, and in the upper regions of the cord these tracts are more precisely differentiated than in the lower. Through the researches, more especially of Flechsig, a more definite knowledge of these tracts has recently been obtained. The *Pyramidal tracts*, so named because they are continuous with and form the anterior pyramids of the medulla oblongata, are found both in the anterior and lateral columns. The direct pyramidal tract in the anterior column lies next the anterior median fissure; it is best marked in the cervical region, but may at times be traced as far down as the lumbar; its fibres are probably con-

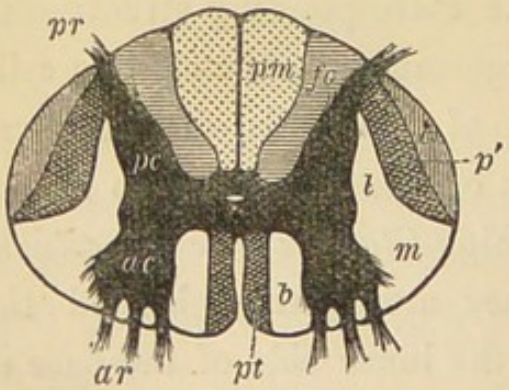

FIG. 73*.—Diagrammatic Transverse Section through the Spinal Cord on the level of the 6th cervical nerve. *ac*, anterior, and *pc*, posterior cornu; *ar*, anterior, and *pr*, posterior nerve roots; *pt*, pyramidal tract of anterior, and *p'*, pyramidal tract of lateral column; *c*, direct cerebellar tract of lateral column; *l*, limiting layer, and *m*, mixed zone of lateral column; *pm*, posterior median division of posterior column; *fc*, funiculus cuneatus or postero-external column; *b*, basis bundle of anterior column.—*Modified from Flechsig.*

nected with the cells of the anterior cornu. The crossed pyramidal tract in the lateral column runs in the posterior half of that column and can be traced as low as the lumbar enlargement; its fibres emerge from the grey matter between the anterior and posterior cornua. The *Direct Cerebellar tract* lies in the lateral column, immediately subjacent to the pia mater, and outside the pyramidal tract, being bounded behind by the posterior nerve root: it may sometimes be traced down to the lumbar enlargement, and it ascends through the restiform body to the cerebellum, increasing in sectional area from below upwards; its fibres probably arise from Clarke's vesicular group of nerve cells. The *Limiting layer* of the lateral column lies between the pyramidal tract and the grey matter. The connections of its fibres are not known, but it is probably continuous above with the formatio reticularis in the substance of the medulla oblongata. The *Mixed zone* of the lateral column lies immediately behind the anterior nerve roots, with which some of its fibres are continuous, whilst others enter the anterior cornu and anterior commissure. It reaches the medulla oblongata, and forms there the formatio reticularis behind and external to the olivary body. The *Basis bundle* of the anterior column lies between the pyramidal tract and anterior cornu; its fibres are apparently continuous with the anterior nerve roots and anterior commissure, and enter the anterior cornu. It is continuous above with the posterior longitudinal fasciculus of the medulla oblongata (pp. 251, 295). The *Postero-median* or *Goll's band* in the posterior column receives fibres from the posterior cornu, and from Clarke's vesicular group of nerve cells; its fibres ascend to the posterior pyramid in the medulla oblongata. The *Funiculus cuneatus* or *postero-external*

part of this column is continuous with the posterior nerve roots and ascends to the restiform body and cerebellum.

The fibres of the Anterior and Posterior Commissures have a horizontal course. Those of the *anterior commissure* pass across the bottom of the anterior median fissure, where they decussate with the corresponding fibres from the opposite side. They consist apparently of fibres of the anterior nerve roots going to the opposite anterior column; of fibres arising in the anterior cornu going to the opposite anterior column; and of fibres from the pyramidal tract of the anterior column passing through the grey matter into the lateral column of the opposite side. The fibres of the *posterior commissure*, more deli-

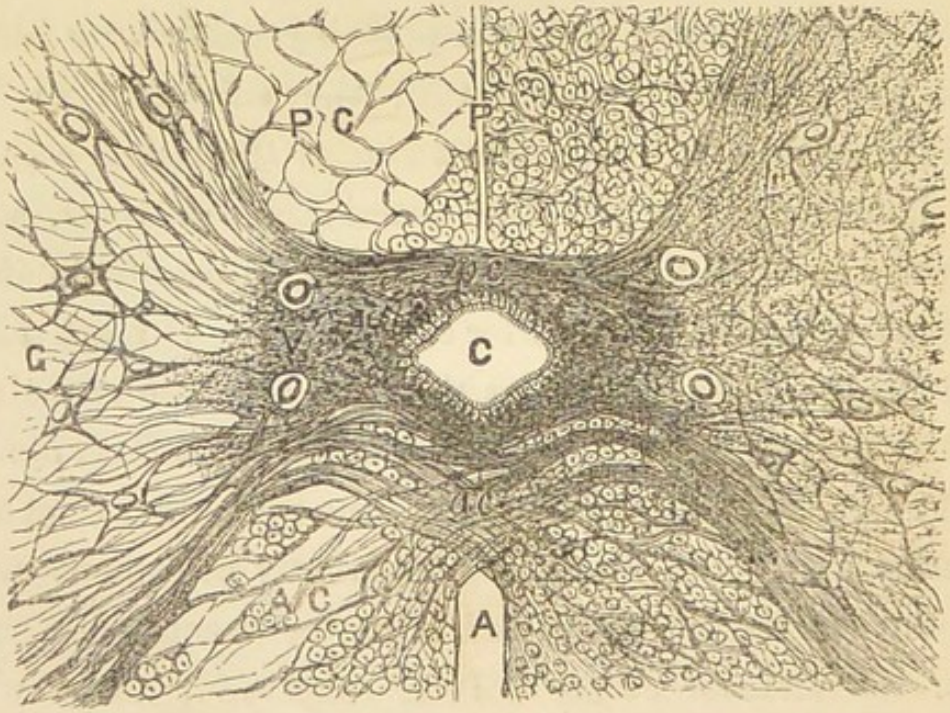

FIG. 74.—Transverse Section through the Central Canal, C, of the Cord, and its surrounding structures. A, anterior, and P, posterior median fissures; A C, anterior, and P C, posterior columns. On the left side the transversely divided nerve fibres are not represented so as to show the framework of connective tissue. *ac*, anterior, and *pc*, posterior commissures; G, grey matter with its nerve cells; V, a pair of transversely divided blood-vessels, probably veins.

cate than those of the anterior, lie both at the bottom of the posterior median fissure, and traverse the neuroglia

surrounding the central canal. They consist both of fibres connecting the grey matter in the posterior cornua of opposite sides, and of fibres of the posterior nerve roots.

The Anterior or Motor Nerve Roots enter the anterior cornu in distinct bundles, and run usually in three directions, and there can be no doubt that a proportion of these fibres is continuous with the axial cylinder processes of the nerve cells. The *internal* fasciculi pass into the antero-internal group of nerve cells, and also into the anterior commissure to reach the opposite anterior cornu or column. The *middle* fasciculi pass into the antero-external group of nerve cells and also backwards into the posterior horn. The *external* fasciculi pass into the antero-external group of nerve cells in which they may end, and these cells may in turn give origin to fibres which pass into the pyramidal tract in the lateral column. The Posterior or Sensory Nerve Roots enter the postero-lateral fissure and divide into two bundles. The *internal* bundle runs longitudinally in the postero-external column of the cord, and may either ascend to the brain, or may at some higher point enter the posterior cornu: fibres have also been traced into Clarke's vesicular group of nerve cells. The *external* bundle enters the apex of the posterior cornu and the fibres radiate horizontally forwards in the grey matter; some reach the anterior cornu of the intermedio-lateral group of nerve cells; others lie in relation to the cells of the posterior cornu; others pass through the posterior commissure to the opposite side of the cord; whilst others ascend towards the brain as the longitudinal bundles in the posterior cornu. It does not appear to have been precisely determined if the posterior root fibres are directly continuous with the axial cylinder

processes of the nerve cells; and it is possible that they may be indirectly continuous with the cells through the plexus of fine fibres formed by the division and subdivision of the processes of the cells (Gerlach).

The spinal cord is well supplied with blood by numerous arteries, which ramify both in the pia mater investing its periphery, and in the processes which dip into the median fissures, more especially the anterior. Small arteries enter the longitudinal columns perpendicular to their free surfaces, ramify in the connective tissue framework, and end in a capillary plexus for the supply of the nerve fibres. Other vessels, somewhat larger in size, pass through the columns into the grey matter, where they also are connected with a capillary plexus. The capillaries are much more numerous in the grey matter of the cord than in the white columns. In transverse sections through the cord a pair of veins may be seen imbedded in the neuroglia of the posterior commissure; these veins lie parallel to and at the sides of the central canal (fig. 74), and collect the blood from the capillaries. Perivascular lymph spaces continuous with the lymphatics of the pia mater ensheath the blood-vessels of the cord.

The structure of the Spinal Cord shows it to be both a nerve centre and a conductor of nervous impulses. The nerve cells in its grey matter give rise either directly, or perhaps through the delicate plexus formed by their branching processes, to nerve fibres, which may either pass out of the cord as the anterior and posterior roots of the spinal nerves, or may ascend to the brain as the columns of the cord. Hence the cord is anatomically continuous, on the one hand, through the nerves which arise from it, with the peripheral end-organs in the skin and in the muscular system in which those nerves terminate; and, on the other hand, it is continuous with the brain. It serves, therefore, to conduct through its white substance the impulses of touch-sensation from the skin upwards to the brain; also the motor impulses from the brain downwards to the muscles. But the roots of the spinal nerves

do not as a rule pass directly to the brain, though it is possible that some may do so. From the observations of Stilling the white matter of the cord opposite the 2nd cervical nerve contains only about half as many nerve fibres as there are in the whole of the anterior and posterior nerve roots collectively. The fibres of the nerve roots end to a large extent in the grey matter, and that grey matter in its turn gives origin to nerve fibres which enter the white substance and ascend to the brain. Motor impulses are conducted downwards by the pyramidal tracts in the antero-lateral columns, or according to Ludwig only by the lateral columns. Sensory impulses are usually regarded as conducted through the posterior columns, though Ludwig places their path of conduction also in the lateral columns. The cord is through its grey matter the great nerve centre concerned in reflex excito-motory actions, or rather it consists of a series of nerve centres, arranged in transverse segments, and corresponding to the transverse segmentation of the spinal nerves ; but the adjacent transverse segments are connected together. The lumbar swelling contains the centres for the nerves of the lower limb ; the brachial swelling the centres for the upper limb. The centre for the nerves of the ball of the thumb has been localised at the origin of the 8th cervical nerve. Some of the vaso-motor nerves probably have their centres in the spinal cord. The *oculo-* or *citio-spinal* centre, situated at the junction of the cervical and dorsal parts of the cord, regulates the vessels of the head, the dilator of the iris, &c., and the fibres pass along the anterior nerve roots into the cervical part of the sympathetic cord. The *genito-spinal* centre, situated in the lumbar swelling is the centre for the bladder, rectum and vasa deferentia. It must, also, be remembered that the two halves of the cord are anatomically continuous with each other through the nerve fibres of the commissures, so that it acts as a single organ, and not as two organs.

Origin, Arrangement, and Distribution of the Spinal Nerves.

The spinal cord gives origin to thirty-one pairs of Spinal nerves, which pass out of the spinal canal through the intervertebral foramina, and have a transversely segmented arrangement. These nerves are arranged in groups, corresponding to the groups of vertebræ, and their formula is as follows : $C_8D_{12}L_5S_5Coc_1 = 31$. Of the eight pairs of Cervical nerves ; the 1st or *sub-occipital* emerges between

the occipital bone and the atlas; the 8th between the 7th cervical and 1st dorsal vertebræ. Twelve pairs of Dorsal or thoracic nerves pass out in relation to the dorsal vertebræ: five pairs of Lumbar nerves in the region of the loins; five pairs of Sacral nerves through either the sacral foramina or the sacro-coccygeal ligament; and one pair of Coccygeal nerves through the sacro-coccygeal ligament. Each spinal nerve-trunk arises from the side of the cord by two *roots*, an *anterior* and a *posterior*. These roots are distinguished from each other both anatomically and physiologically. The posterior root has a swelling or *ganglion*, whilst no ganglion exists on the anterior root, and the posterior root contains more nerve fibres than the anterior. The posterior root is sensory, *i.e.*, its fibres conduct impulses from the periphery into the nerve centre; whilst the anterior root is motor, *i.e.*, its fibres conduct impulses from the centre to the periphery. The ganglion on the posterior root is situated, as a rule, in the intervertebral foramen; but the posterior roots of the lower sacral nerves have the ganglia in the spinal canal. These ganglia contain nerve cells, which are bipolar in fishes, but apparently unipolar in the higher vertebrates. The single pole bifurcates, as Ranvier has shown, like a T, and each branch is continuous with a nerve fibre. One of the fibres probably passes along the nerve root into the cord, the other peripherally into the nerve. The roots of the spinal nerves vary in direction and length. Those of the cervical nerves are short, and run almost horizontally outwards to their respective intervertebral foramina; those of the dorsal are longer and more oblique; whilst the roots of the lumbar and sacral nerves, owing to the cord ending much above the foramina through which the nerves proceed, are very long, and form a leash

of nerves in the lower part of the spinal canal; which leash surrounds the filum terminale, and, from its general resemblance in arrangement to the hairs of a horse's tail, has been named *cauda equina*.

The anterior nerve root joins the posterior immediately outside the ganglion, and by their junction a spinal nerve trunk is formed. This nerve trunk contains a mixture of both motor and sensory fibres, and is compound therefore in function. Almost immediately after its formation the nerve trunk separates into two primary divisions, an anterior and a posterior, and each division, like the nerve itself, contains both motor and sensory fibres.

The *Posterior Primary Divisions* of the spinal nerve trunks, smaller than the anterior, are distributed both to the muscles and skin on the back of the axial part of the body. Their general arrangement is as follows: each division, except the 1st cervical, two lower sacral, and coccygeal, subdivides into an *internal* and an *external* branch. The 1st cervical or *sub-occipital* nerve extends backwards, lying on the neural arch of the atlas, and supplies the posterior recti, the obliqui, and complexus muscles. The two lower sacral and coccygeal unite in a loop-like manner behind the sacrum, and supply the skin. Of the cervical and upper six dorsal nerves the external branches of the posterior primary divisions supply the deep muscles of the back, in the neck and in the upper dorsal regions; the internal branches pierce the muscles close to the spines of the vertebræ, and end in the skin of the same regions; but the internal branch of the 2d nerve, called *great occipital*, and that of the 3d cervical, pass upwards to the skin over the occipital bone. Of the lower six dorsal and lumbar nerves the internal branches supply

the deep muscles of the back in the corresponding regions; the external branches pass to the skin, but those of the upper three lumbar nerves run downwards and end in the skin of the buttock. Of the upper three sacral nerves the internal branches supply the multifidus spine muscle; the external branches form loops with each other and supply the skin over the gluteus maximus.

The *Anterior Primary Divisions* are not so uniform either in arrangement or distribution as are the posterior. They supply the front and sides of the axial part of the neck and trunk, and the extremities. The anterior divisions of the twelve *Dorsal* or *Thoracic nerves* have the most simple arrangement. Each nerve, called from its position an *Intercostal* nerve, runs outwards, immediately below the lower border of a rib, and gives origin to three series of branches, named communicating, muscular, and cutaneous. By the *Communicating* branch each intercostal nerve is connected with an adjacent ganglion on the thoracic portion of the cord of the sympathetic system. By the *Muscular* or motor branches these nerves supply the intercostal muscles, the levatores costarum, and the triangulares sterni, whilst the lower intercostal nerves run forwards and downwards into the wall of the abdomen, and supply the oblique, the transverse, the recti, and

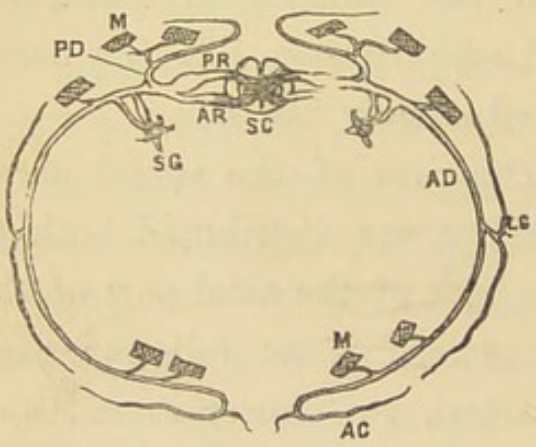

FIG. 75.—Diagram of the arrangement of a pair of Thoracic Spinal Nerves. SC, spinal cord; AR, anterior nerve root; PR, posterior root, with its ganglion; PD, posterior primary division; AD, anterior primary division, or intercostal nerve; SG, sympathetic ganglion, with the communicating branches between it and the anterior division; M, muscles, with the motor branches entering them; LC, lateral cutaneous, and AC, anterior cutaneous branches.

pyramidales muscles. The *lateral cutaneous* nerves which arise about midway between the vertebræ and the sternum, and divide into an *anterior* and a *posterior* branch, supply the skin of the side of the thorax and abdomen; whilst the skin on the front of the trunk is supplied by the *anterior cutaneous* terminations of the intercostal nerves. The lateral cutaneous branches of the 2d and 3d intercostal nerves, comparatively large in size, assist in the supply of the skin of the inner side of the upper arm, and are called *intercosto-humeral* nerves. The 1st thoracic, usually called the 1st *dorsal* nerve, for the most part ascends into the neck, to aid in forming the brachial plexus; only a small branch extends along the intercostal space as the 1st intercostal nerve, and from it no lateral cutaneous branch as a rule arises (fig. 76, 1). The 12th thoracic, usually called the *last dorsal* nerve, runs along the lower border of the 12th rib and gives off its *lateral cutaneous* branch to the skin of the buttock.

In the regions of the neck, loins, and pelvis, the anterior divisions of the spinal nerves do not pass simply outwards to their distribution. In each region adjacent nerves interlace with each other, and form what is technically called a *Nervous Plexus.* When a branch arises from a thoracic nerve, it contains fibres derived from that nerve only; but when a branch arises from a plexus, it may contain fibres, not of one only, but of two or more of the nerves which, by their interlacement, form the plexus. Hence the parts which are supplied by these branches are brought into connection with a greater number of nerves, and consequently with a greater extent of the spinal cord or nerve centre, than are the parts which receive branches from a single nerve only. These plexuses are especially

found in connection with the nerves which supply the extremities, where, owing to the complexity of the muscular movements, the co-ordination of these movements through the nervous system is rendered necessary.

The anterior divisions of the eight cervical nerves are arranged in two plexuses, named cervical and brachial.

The *Cervical Plexus* is formed of the 1st, 2d, 3d, and 4th cervical nerves, which form a series of loops (fig. 76) in front of the transverse processes of the cervical vertebræ, behind the sterno-mastoid and on the middle scalenus and levator scapulæ muscles. Communicating, muscular, and cutaneous branches arise either directly from these nerves, or from the plexus which they form. *Communicating* branches connect these nerves with the superior cervical ganglion of the sympathetic cord, also with the vagus, spinal accessory, and hypoglossal cranial nerves, and with the descendens noni of the hypoglossal, these last from the 2d and 3d cervical being called *communicantes noni.* *Muscular* branches supply the anterior and lateral recti muscles of the neck, the levator scapulæ, the middle scalenus, the diaphragm, and in part the sterno-mastoid and trapezius. The branch to the diaphragm or the *phrenic* nerve, is the most important; it springs from the 3d, 4th, and 5th cervical, and passes down the lower part of the neck, and through the thorax, to supply its own half of the diaphragm; Luschka has described twigs proceeding from the phrenic to the pleura, pericardium, and peritoneum. The *Cutaneous* branches are as follows:—the *occipitalis minor*, a branch of the 2d cervical to the skin of the occiput; the *auriculo-parotidean*, from the 2d and 3d cervical, to the skin over the parotid gland and the adjacent part of the auricle; the *transversalis colli*, also

from the 2d and 3d cervical, to the skin of the front of the side of the neck; the *supra-clavicular* nerves, from the 3d and 4th cervical, to the skin of the lower part of the side of the neck, and upper part of the chest.

The *Brachial Plexus* is formed of the 5th, 6th, 7th, and 8th cervical nerves and of the larger portion of the 1st dorsal nerve (fig. 76), which pass outwards between the anterior and middle scaleni. It is of large size, and is principally for the supply of the upper limb. It presents variations in arrangement. Sometimes the 5th and 6th nerves join to form a large nerve, which is then joined by the 7th, to form the *upper cord* of the plexus. The 8th cervical and the 1st dorsal then join, to form the *lower cord* of the plexus. The cords then pass behind the clavicle and subclavius muscle into the axilla, where they become modified in arrangement. From each a large branch arises, and these two branches then join to form a third cord. The three cords have special relations to the axillary artery; the one which lies to its outer side is named the *outer cord;* that to the inner, the *inner cord;* that behind, the *posterior cord.* At other times the upper cord is formed by the 5th and 6th and a branch of the 7th; the lower cord by the 8th cervical and 1st dorsal; and the posterior cord by a branch of the 7th nerve and by branches from the upper and lower cords. These nerves and the cords formed by them give origin to communicating, muscular, cutaneous, and mixed branches. *Communicating* branches join the middle and inferior cervical and 1st thoracic ganglia of the sympathetic system. *Muscular* branches supply the scaleni, longus colli, rhomboid from the 5th, and subclavius from the 5th and 6th; a *supra-scapular* branch from the 5th and 6th to the supra- and

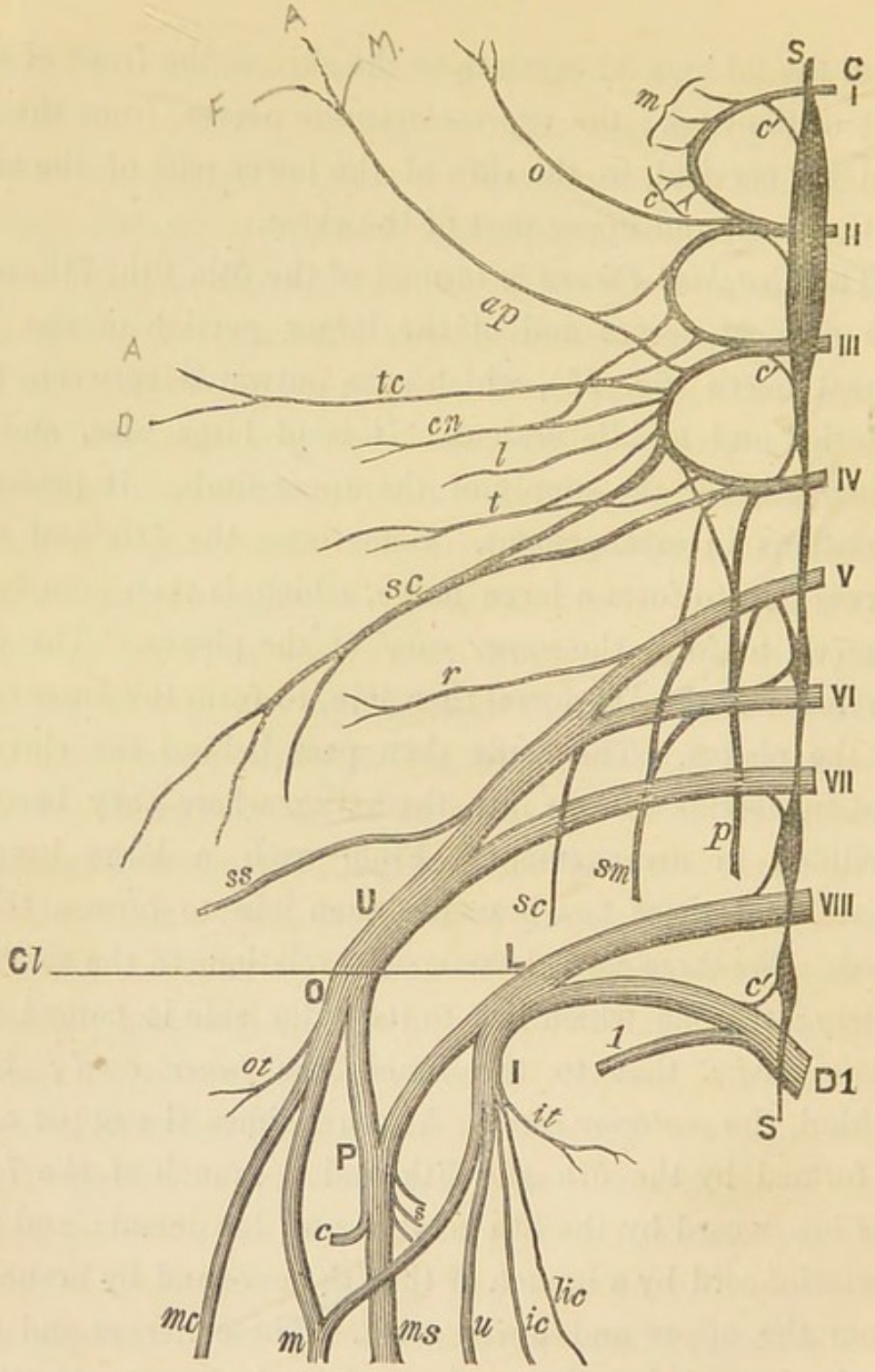

FIG. 76.—Diagram of Cervical and Brachial Plexuses.

CI to IV, Cervical Plexus; *o*, small occipital nerve; *ap*, auriculo-parotidean; *tc*, transverse or superficial cervical; *sc*, supra-clavicular; *m*, muscular branches to recti, &c.; *l*, to levator anguli scapula; *t*, to trapezius and sterno-mastoid muscles; *cn*, communicantes noni; *p*, phrenic nerve; *c*, communicating to vagus and hypo-glossal.

CV to DI, Brachial Plexus; *r*, branch to rhomboid muscle; *ss*, supra scapular nerve; *sc*, nerve to subclavius; *sm*, nerve to serratus magnus; U, upper cord; L, lower cord; O, outer, I, inner, P, posterior cord of plexus; *ot*, outer, and *it*, inner anterior thoracic nerve; *mc*, musculo-cutaneous; *m*, median; *ms*, musculo-spiral; *c*, circumflex; *s*, subscapular; *u*, ulnar; *ic*, internal cutaneous; *lic*, lesser internal cutaneous; 1, first intercostal nerve; *Cl*, line of clavicle; SS, gangliated cord of sympathetic; *c'c'*, series of communicating branches with spinal nerves.

infra-spinatus; a *posterior thoracic* branch from the 5th and 6th to the serratus magnus; two *anterior thoracic* branches, one from the outer and one from the inner cord, to the pectoralis major and minor; three *subscapular* branches, from the posterior cord to the subscapularis, teres major and latissimus dorsi. The *Cutaneous* branches arise from the inner cord, and are the *lesser internal cutaneous*, which ends in the skin of the inner side of the upper arm, and joins the intercosto-humeral; and the *internal cutaneous*, which sends branches to the skin of the upper arm, and supplies the skin of the inner side of the forearm, both on its anterior and posterior surfaces. The *Mixed* branches are large and very important:—*a*, The *Circumflex*, from the posterior cord, supplies *muscular* branches to the deltoid and teres minor, a *cutaneous* branch to the skin over the deltoid, and an *articular* branch to the shoulder-joint. *b*, The *Musculo-Spiral*, which continues downwards the posterior cord, supplies *muscular* branches to the triceps, anconeus, supinator longus and extensor carpi radialis longior; by its *internal cutaneous* branch the skin of the back of the upper arm, and by its *external cutaneous* branch, the skin of the outer side of the back of the forearm. It then divides into the radial and posterior interosseous branches. The *Radial* passes down the forearm to the hand, and supplies the skin on the back of the thumb, index and middle digits, and radial side of the ring digit. The *Posterior Interosseous* pierces the supinator radii brevis, supplies the muscles on the back of the forearm and the carpal articulations. *c*, The *Musculo-Cutaneous* branch of the outer cord supplies the biceps, brachialis anticus, and coraco-brachialis, and ends in an *external cutaneous* branch, which supplies the skin of the

outer side of the forearm, both in front and behind. *d*, The *Ulnar* nerve from the inner cord, passes through the upper arm, enters the forearm between the inner condyle and olecranon, and the two heads of the flexor carpi ulnaris, when it supplies an *articular* branch to the elbow-joint. Here it may easily be compressed, when a pricking sensation is experienced in the course of its distribution. In this spot it is popularly called the "funny bone." In the forearm the ulnar nerve supplies the flexor carpi ulnaris and inner part of the flexor profundus digitorum. In the hand it supplies the palmaris brevis, the muscles of the ball of the little finger, the two inner lumbricales, the interossei muscles, and the adductor and deep part of the short flexor of the thumb. It also supplies a *dorsal cutaneous* branch to the back of the hand, and the back of the little and of the ulnar side of the ring digits. *Palmar cutaneous* branches are also given to the palm and to the palmar aspects of the same digits. *e*, The *Median* nerve arises by two roots, one from the inner, the other from the outer cord of the plexus. It passes down the upper arm, enters the forearm in front of the elbow-joint between the two heads of the pronator radii teres, and supplies, either directly or through its *anterior interosseous* branch, all the pronators and flexors, except the flexors supplied by the ulnar; it is continued to the hand, where it supplies the abductor, opponens, and superficial part of the short flexor of the thumb, and the two outer lumbrical muscles. It also supplies a *palmar cutaneous* branch to the skin of the palm, and gives *digital cutaneous* branches to the thumb, index, and middle digits, and radial side of the ring digit.

The *Lumbar Plexus*, of large size, is situated at the back of the abdominal cavity in the region of the loins, and is

formed by the 1st, 2d, 3d, and 4th lumbar nerves, which form a series of loop-like interlacements in the substance of the psoas muscle and in front of the transverse processes of the lumbar vertebræ (fig. 77). It gives origin to communicating, muscular, cutaneous, and mixed branches. *Communicating* branches join the four upper lumbar ganglia of the sympathetic cord. *Muscular* branches supply the quadratus lumborum muscle, and the psoas. The *Cutaneous* branches are—*a*, *Ilio-hypogastric*, from the 1st lumbar nerve, which gives an iliac branch to the skin of the buttock, and a hypogastric branch to the skin of the abdomen above the pubic symphysis; *b*, *Ilio-inguinal*, also from the 1st lumbar, which supplies the skin of the groin, and by some is said to send a branch to the internal oblique muscle; *c*, *External Cutaneous*, from the 2d and 3d lumbar, which supplies the skin on the outer aspect of the hip and thigh. The *Mixed* branches are as follows:—*a*, *Genito-crural*, chiefly from the 2d lumbar, but partly from the 1st, supplies the cremaster muscle, and a cutaneous branch to the skin of the groin. *b*, *Anterior Crural*, chiefly from the 3d and 4th lumbar nerves, but partly from the 2d, is a large nerve which enters the thigh by passing behind Poupart's ligament, and supplies *muscular* branches to the extensor muscles of the knee-joint, viz., the rectus femoris, crureus, vastus internus and externus, and also to the sartorius, psoas-iliacus and pectineus, which act as flexors of the hip-joint; it also gives off the following *cutaneous* branches:—An *internal cutaneous* to the skin of the inner side of the thigh, a *middle cutaneous* to the skin of the middle of the front of the thigh, and the *long saphenous* nerve, which supplies the skin of the inner side of the knee-joint, the inner side of the leg and of the foot.

c. Obturator, also from the 3d and 4th lumbar nerves, leaves the pelvis through the obturator foramen, and supplies *muscular* branches to the obturator externus, gracilis, three adductor muscles of the thigh, and the pectineus; it also supplies *articular* branches to the hip and knee joints, and not unfrequently gives a *cutaneous* branch to the skin of the lower part of the inner side of the thigh, which joins the internal cutaneous and long saphenous branches of the anterior crural. *d*, An *Accessory Obturator* nerve, also from the 3d and 4th lumbar, is sometimes present, which descends in front of the os pubis and goes to the pectineus, to the hip-joint, and also joins the obturator nerve.

The *Lumbo-sacral Cord* is formed of the 5th lumbar nerve and of a branch from the 4th lumbar (fig. 77). It joins the sacral plexus. Before the junction it gives origin to a communicating and a muscular branch. The *Communicating* branch joins the 5th lumbar ganglion of the sympathetic. The *Muscular* branch, or *superior gluteal* nerve, supplies the gluteus medius, minimus, and tensor fasciæ femoris.

The *Sacral Plexus* is the largest of all the plexuses. It is formed by the junction of the lumbo-sacral cord, the 1st, 2d, 3d, and part of the 4th sacral nerves, and lies in the pelvis as a flattened mass in front of the pyriformis muscle and sacrum (fig. 77). It gives origin to communicating, muscular, and mixed branches. *Communicating* branches join the upper sacral ganglia of the sympathetic cord. *Muscular* branches supply the upper fibres of the gluteus maximus, pyriformis, gemelli, quadratus femoris, and obturator internus. The *Mixed* nerves are as follows:—*a*, *Deep Pudic*, which supplies *superficial perineal* branches

to the skin of the external organs of generation; *muscular* branches to the transversus perinei, erector penis, accelerator

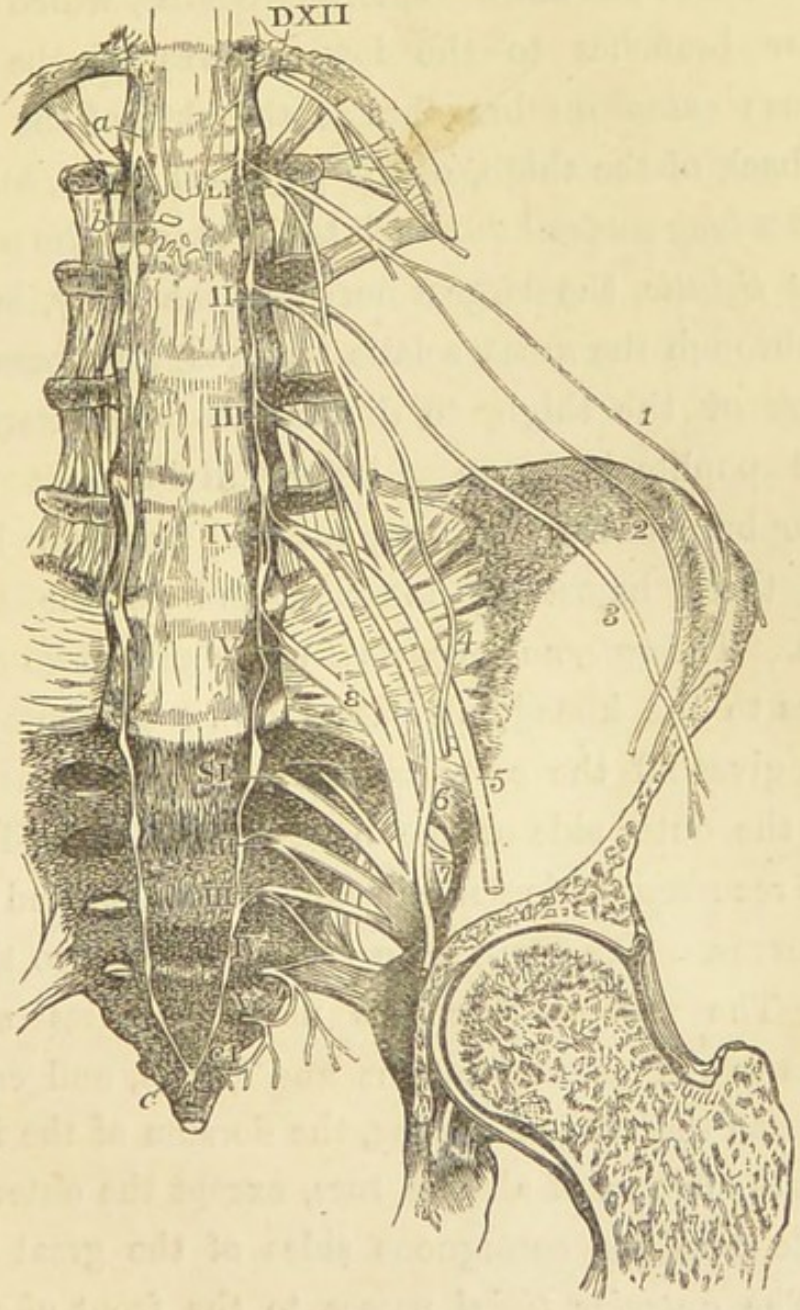

FIG. 77.—Lumbar, Sacral, and Sacro-coccygeal Plexuses. DXII, the lowest thoracic nerve of the intercostal series; LI to IV, the nerves of the lumbar plexus; V, the fifth lumbar, with 8, the lumbo-sacral cord; SI to IV, sacral nerves going to form the sacral plexus; V and CI, the sacro-coccygeal plexus; *a*, chain of ganglia of the sympathetic system, showing the communicating branches with the spinal nerves; *c*, the last of these ganglia, called coccygeal ganglion, or ganglion impar; *b*, position of solar plexus; 1, ilio-hypogastric nerve; 2, ilio-inguinal; 3, external cutaneous; 4, genito-crural; 5, anterior crural; 6, obturator; 7, superior gluteal.

urinæ, compressor urethræ, and levator ani; a *long dorsal* branch to the skin of the dorsum penis, which ends in the

sensitive surface of the glans, and gives a large branch to the corpus cavernosum; *inferior hæmorrhoidal* branches to the skin about the anus. *b*, *Small Sciatic*, which supplies *muscular* branches to the lower fibres of the gluteus maximus; *cutaneous* branches to the skin of the buttock, of the back of the thigh, of the popliteal space, and of the leg, and a *long pudendal* branch to the skin of the perineum. *c*, *Great Sciatic*, the largest nerve in the body, leaves the pelvis through the great sciatic foramen, and passes down the back of the thigh, to divide into the external and internal popliteal nerves. Before dividing it supplies *articular* branches to the hip-joint and *muscular* branches to the three hamstring muscles, and to the adductor magnus. The *external popliteal* nerve gives two *articular* branches to the knee-joint, passes down the outer side of the leg, gives off the *communicans fibularis* branch to the skin of the outer side of the back of the leg, and divides into the recurrent articular, musculo-cutaneous, and anterior tibial nerves. The *recurrent articular* ascends to the knee-joint. The *musculo-cutaneous* nerve supplies *muscular* branches to the peronei longus and brevis, and *cutaneous* branches to the skin of the leg, the dorsum of the foot and the dorsal surfaces of all the toes, except the outer side of the little and the contiguous sides of the great and 2d toes. The *anterior tibial* passes to the front of the leg, supplies *muscular* branches to the tibialis anticus, peroneus tertius, long and short extensor muscles of the toes, tarsal joints, and terminates as the *cutaneous digital* nerve for the contiguous sides of the great and 2d toes. The *internal popliteal* nerve gives three *articular* branches to the knee-joint, and supplies the *communicans tibialis* nerve, which joins the communicans fibularis, and forms with it the *ex-*

ternal saphenous nerve, that passes to the outer side of the foot and little toe. The internal popliteal gives *muscular* branches to the gastrocnemius, soleus, plantaris and popliteus, and ends as the posterior tibial nerve. The *posterior tibial* nerve passes down the back of the leg, supplies *muscular* branches to the tibialis posticus and long flexors of the toes, gives off a *calcanear cutaneous* branch to the skin of the heel, and ends by dividing into the internal and external plantar nerves. The *internal plantar* nerve supplies the skin of the sole and sends *digital* branches to the skin of the great, 2d, 3d, and tibial side of the 4th toes; it also supplies *muscular* branches to the abductor hallucis, flexor brevis digitorum, flexor brevis hallucis, and two inner lumbrical muscles. The *external plantar* nerve supplies *digital* branches to the skin of the little toe and fibular side of the 4th toe, and *muscular* branches to all the muscles of the sole of the foot which are not supplied by the internal plantar nerve.

The *Sacro-Coccygeal Plexus* is the smallest plexus of the anterior divisions of the spinal nerves. It is formed by a part of the 4th and the 5th sacral, and the coccygeal nerves. It lies in front of the 5th sacral and 1st coccygeal vertebræ, and gives origin to communicating, visceral, muscular, and cutaneous branches. *Communicating* branches join the lower sacral and the coccygeal ganglia of the sympathetic cord; *Visceral* pass to the pelvic plexus of the sympathetic, and through it to the bladder and rectum; *Muscular* to the levator ani, coccygeus, and sphincter ani externus muscles; *Cutaneous* to the skin about the anus and tip of the coccyx.

The Brain or Encephalon.

The Brain or Encephalon includes all the central nervous axis contained within the cavity of the skull. It is divided into medulla oblongata, pons, cerebellum, corpora quadrigemina, crura cerebri and cerebrum. The medulla oblongata is directly continuous with the spinal cord through the foramen magnum. The cerebellum lies above, and immediately behind the medulla oblongata, with which it is continuous. The pons lies immediately above the medulla, with which it is continuous. The corpora quadrigemina lie above and in front of the cerebellum. The crura cerebri emerge from the upper surface of the pons. The cerebrum lies above all the other divisions, with which it is either directly or indirectly continuous.

The Posterior Cerebral Vesicle gives origin to the Medulla Oblongata, Pons, and Cerebellum, whilst the 4th Ventricle is the axial canal of the modified vesicle.

medulla oblongata.

The Medulla Oblongata or Bulb rests upon the basi-occipital. It is shaped like a truncated cone; about $1\frac{1}{4}$ inch long, and 1 inch broad in its widest part. It is a bilateral organ, and is divided into a right and a left half by shallow *anterior* and *posterior median fissures*, continuous with the corresponding fissures in the spinal cord. Each half is subdivided into longitudinal tracts of nervous matter; but the tracts are not always the same throughout the whole length of the medulla. Next and parallel to the whole length of the anterior median fissure is the *Anterior Pyramid;* it is continuous below with the pyramidal

tracts in the antero-lateral columns of the cord; and the lower limit of the medulla is marked by the passage across this fissure of three to five bundles of nerve fibres, from each lateral column of the cord to the opposite anterior pyramid; this crossing is called the *decussation of the pyramids* (figs. 78, 79).

The anterior pyramid is bounded externally by a groove, very distinct above, where it separates the pyramid from the olive, and gives passage to the roots of the 9th cranial nerve; but faint below where it is in line with the antero-lateral depression for the anterior spinal nerve roots. The *Olive* is a convex projection, about $\frac{6}{10}$ths inch long, placed immediately external to the upper $\frac{2}{3}$rds of the anterior pyramid. External to the lower third of this pyramid is the *Lateral Tract* of the medulla, which is continuous below with the anterior or mixed zone fibres of the lateral column of the cord. Posterior to the olive is a broad shallow groove, through which the

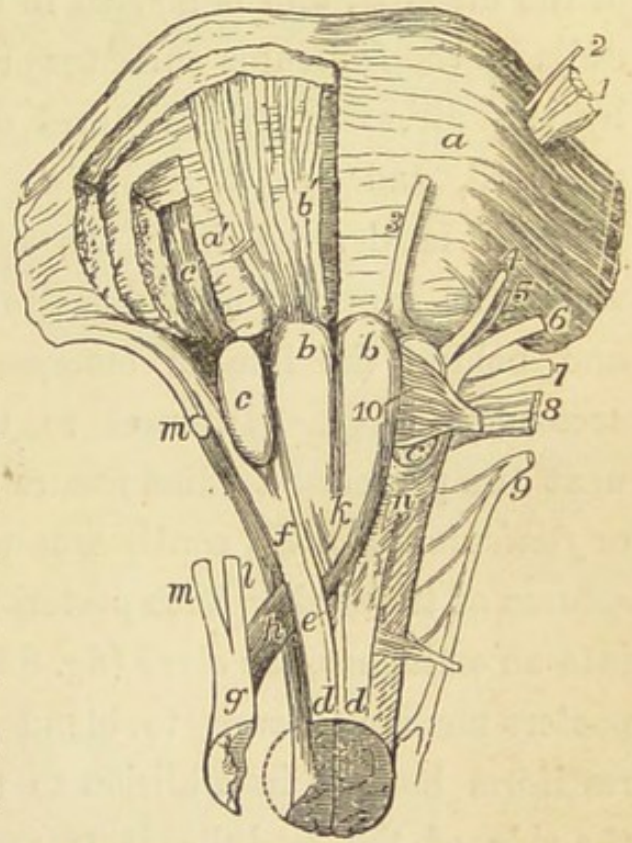

FIG. 78.—Diagrammatic dissection of the Medulla Oblongata and Pons to show the course of the fibres. *a*, superficial, *a'*, deep transverse fibres of the pons; *b*, *b*, anterior pyramids ascending at *b'* through the pons; *c*, *c*, olivary bodies; *c'*, olivary fasciculus in the pons; *d*, *d*, anterior columns of the cord; *e*, pyramidal fibres of the right column joining the outer side of the anterior pyramid; *f*, the outer part passing deeper than the olive; *g*, lateral column of cord; *h*, the pyramidal fibres which decussate at *k*, the decussation of the pyramids; *l*, the direct cerebellar fibres which join the restiform body; *m*, fibres which form the formatio reticularis; *n*, arciform fibres. 1 and 2, sensory and motor roots of fifth nerve; 3, sixth nerve; 4, portio dura; 5, portio intermedia; 6, portio mollis of seventh nerve; 7, glosso-pharyngeal; 8, pneumo-gastric; 9, spinal accessory of eighth nerve; 10, hypoglossal nerve.

roots of the 8th cranial nerve emerge, and this groove separates the olive from the restiform body. The *Restiform Body* or *pedunculus cerebelli* is the largest division of the medulla, and is formed in the lower part of the medulla by the funiculus cuneatus or postero-external column, by the direct cerebellar fibres of the lateral column of the cord, and by the funiculus Rolandi. The *funiculus Rolandi* is derived from the cervical part of the cord about the junction of the lateral and posterior columns, and behind the line of emergence of the roots of the accessory nerve. Internal to the restiform body and next the posterior median fissure is the *Posterior Pyramid* or *funiculus gracilis*, continuous with the posterior median column of the cord. Each posterior pyramid expands above into an eminence, the *clava* (fig. 83), then diverges from the postero-median fissure to blend with the corresponding restiform body. In addition to these longitudinal tracts the side of the medulla is traversed by *transverse fibres*, which spring from the restiform body and reach the anterior pyramid and mesial fissure. The lowest of these transverse fibres arch across the side of the olive and are called *external arciform fibres*; the highest cross immediately below the pons and form the *ponticulus*.

The Medulla Oblongata, like the spinal cord, consists both of grey and white matter. A central canal, continuous with that of the cord, lies in the medulla opposite the decussation of the pyramids, but above that spot it opens out posteriorly into the 4th ventricle. The surface of the medulla is not so exclusively formed of white matter as is the cord, for the grey matter becomes superficial on the floor of the 4th ventricle. As the spinal cord passes into the medulla oblongata a re-arrangement of the *grey matter*

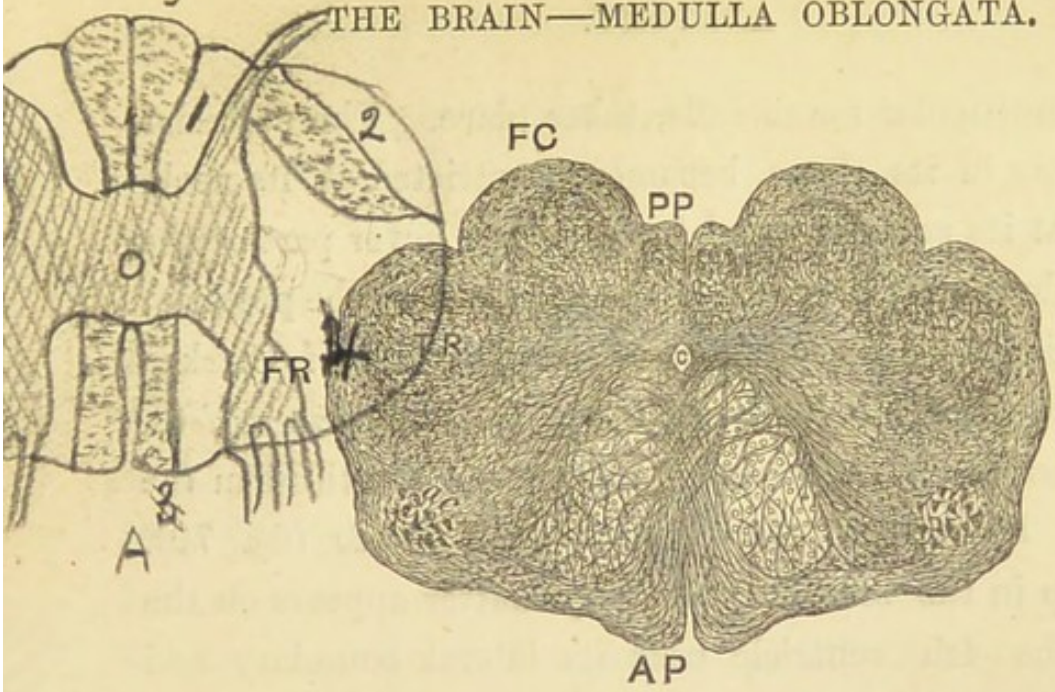

FIG. 79.—Transverse section through the Medulla Oblongata at the decussation of the pyramids below the olivary body. AP. anterior pyramid, showing decussating fibres at the bottom of the anterior median fissure; *c*, central canal; PP, posterior pyramid, containing post-pyramidal nucleus; FC, funiculus cuneatus, containing grey tuberculum cuneatum; FR, funiculus Rolandi containing TR, grey tubercle of Rolando; *ac*, group of nerve cells continuous with the cells of the anterior cornu of the cord; *r*, formatio reticularis.

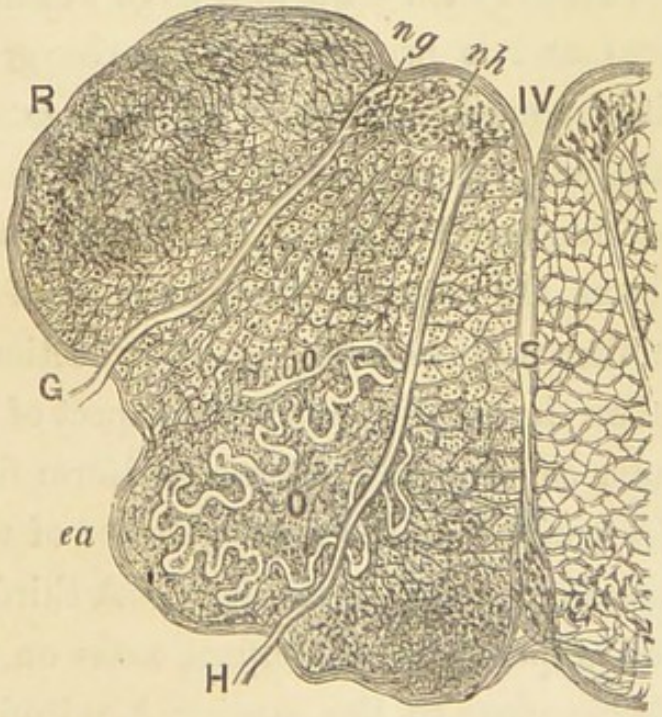

FIG. 80.—Transverse section through the Medulla Oblongata in the plane of the olivary body. AP, anterior pyramid-fibres transversely divided; S, septal commissural fibres or raphe in the anterior median part of which is a group of nerve cells forming the arciform nucleus of the raphe; R, restiform body; O, olivary body; *ao*, outer accessory olive; IV, fourth ventricle; H, hypoglossal nerve; *nh*, nucleus of hypoglossal; G, glosso-pharyngeal nerve; *ng*, nucleus of glosso-pharyngeal nerve; I, inner or white formatio reticularis; *f2*, outer or grey formatio reticularis, *ea* external arciform fibres.

with its multipolar nerve cells, takes place. The posterior cornu alters in its shape, becomes constricted at its neck, expands at its periphery and forms in the lower part of the medulla three grey masses; one in the clava of the posterior pyramid is the *posterior pyramidal ganglion* of Clarke; another in the funiculus cuneatus is the *restiform nucleus*, or the *tuberculum cuneatum* of Schwalbe; the third in the funiculus Rolandi is the *tubercle of Rolando* (fig. 79). Higher up in the medulla this grey matter appears on the floor of the 4th ventricle near its lateral boundary and forms the *nuclei of origin* of the 8th and auditory nerves. The grey matter of the anterior cornu and intermedio-lateral group is very materially modified by the passage through it of the crossed pyramidal tract of the lateral column of the cord on its way from the decussation of the anterior pyramids. This grey matter is to a large extent intersected by these fibres and is broken up into the grey *formatio reticularis*, in the meshes of which network scattered nerve cells are situated. A portion of the grey matter at the periphery of the cornu remains for a time as a compact mass and forms the *antero-lateral nucleus* of Dean (fig. 79 *ac*). Another portion forms small collections of nerve cells situated on the anterior and inner aspect of the anterior pyramid, under cover of the external arciform fibres; these are the *nuclei arciformes*, the most anterior of which is the *anterior pyramidal nucleus* of Kölliker. A third part of the anterior cornu appears as a compact mass on the floor of the 4th ventricle close to the median longitudinal fissure, and forms the *nucleus of origin* of the 9th cranial nerve. In the interior of the olive a mass of grey matter, containing multipolar flask-shaped cells, is folded in a zig-zag manner and forms the *corpus dentatum* or *nucleus* of the

inferior olive. It is arranged as a sort of capsule closed in above, below, and externally, but deficient on its inner side, and through this gap the fibres of the *peduncle* of the *olive* proceed. A little to the inner side of the inferior olive is a smaller collection of nerve cells and grey matter named *inner accessory olive* or *nucleus pyramidalis;* and in relation to its dorsal aspect a similar mass called the *outer accessory olive* (fig. 80).

The nerve tracts of the *white matter* of the medulla oblongata are partly continuous below with the columns of the spinal cord, and partly arise in the medulla itself from the cells of its grey matter. In the ascent through the medulla of the columns of the cord, a re-arrangement of their fibres takes place, just as in a great central railway station, the lines of rails, which enter it in one direction, intersect and are rearranged before they emerge from it in the opposite direction. The posterior pyramid, or funiculus gracilis, consists of the fibres of the postero-median column of the cord, and in its upward passage it blends with the restiform body. The restiform body, or pedunculus cerebelli, is formed chiefly by the junction of the posterior pyramid, the funiculus cuneatus or postero-external column, the funiculus Rolandi, and the direct cerebellar tract of the lateral column; but in addition it receives internal arciform fibres from the region of the olive, and from the formatio reticularis and external arciform fibres from the anterior pyramid. It is customary to state that the fibres of the posterior and lateral columns of the cord, which form so large a part of the restiform body, ascend through it to the cerebellum. But the restiform body contains nerve cells, and it is possible that some, if not the whole of these ascending fibres end in the cells within the corpus

restiforme, and that these cells in their turn give origin to the fibres which reach the cerebellum. Meynert, however, holds that a number of the fibres of the restiform body pass off as the arciform fibres, and cross through the raphe to the opposite side of the medulla. The anterior pyramid is formed in large part of the crossed pyramidal tract of the lateral column of the opposite side of the cord (fig. 78). These decussating tracts, from the opposite sides, form at the bottom of the anterior median fissure the well-known *motor decussating fibres*, and represent, but in an exaggerated form, the fibres of the anterior commissure of the cord, which cross from the lateral column of one side to the opposite anterior column. They form the part of the anterior pyramid, which lies next the anterior median fissure; whilst the outer part of the pyramid contains the direct pyramidal tract of the anterior column. But this pyramid also receives fibres from the posterior cornu and posterior column of the opposite side of the cord (Clarke) which constitute the *sensitive pyramidal decussation* of Meynert, and it contains arciform fibres. The fibres of the anterior pyramid ascend through the pons and crus cerebri to the cerebrum. The external fibres or basis bundle of the anterior column, with fibres of the mixed zone of the lateral column, form the *olivary fillet* or *lemniscus* which ascends to the pons.

The medulla oblongata, in addition to the tracts which form its surface, contains nerve fibres within its substance. Above the decussation of the pyramids a well-marked *raphe* extends mesially from the bottom of the anterior median fissure to the floor of the 4th ventricle. It consists chiefly of commissural fibres crossing between the two sides of the medulla, which are in great part continuous with the in-

ternal arciform fibres. Near the anterior median fissure it contains nerve cells, the *arciform nucleus* of the raphe (fig. 80). Between the raphe and the roots of the 9th nerve, as they pass from their nuclei of origin, is the white *formatio reticularis* formed by internal arciform fibres intersecting the basis bundle of the anterior column; which bundle, as it reaches the medulla, leaves the surface and sinks into its substance to lie on the dorsal aspect of the anterior pyramid (fig. 80). Fibres ascend from it through the pons as the *posterior longitudinal fasciculus*. Between the roots of origin of the 8th and the 9th nerve, and deeper than and external to the olive is the grey *formatio reticularis*, in which fibres of the lateral column of the cord, apparently those of the mixed zone, and internal arciform fibres are commingled with the broken up grey matter of the peripheral part of the anterior cornu. Some of these fibres, together with fibres of the white formatio reticularis from the anterior column form the *fasciculus teres* on the floor of the 4th ventricle (fig. 83). This fasciculus ascends on the back of the pons to the corpora quadrigemina and optic thalamus. *Internal* or *deep arciform fibres* arch across the two halves of the medulla and through the septum. Many of these spring from the funiculus cuneatus and posterior pyramid of the restiform body, and traverse the formatio reticularis, the corpus dentatum of the olive and the accessory olives, and are joined by fibres of the pedunculus olivæ.

The structure of the Medulla Oblongata shows it to be both a nerve centre and a conductor of nervous impulses. The nerve cells of the grey matter on the floor of the 4th ventricle give origin to the hypoglossal nerve, the glosso-pharyngeal, pneumogastric, and in part the fifth, accessory and auditory nerves. It is therefore the centre for the movements of the tongue and for deglutition; it is the respiratory centre, and it regulates the action of the heart. Moreover, an area on

the floor of the 4th ventricle about 3 millimetres above the calamus scriptorius has been localised by Dittmar as the general vaso-motor centre, so that it regulates the blood pressure throughout the vascular system. Further, its nerve cells give origin to fibres which participate in the formation of the arciform and longitudinal tracts of the medulla. As a conductor it transmits impulses both downwards from the higher divisions of the encephalon to the spinal cord, and upwards from the cord to the higher encephalon. Thus the cord is brought into anatomico-physiological continuity through the medulla with the cerebellum, corpora quadrigemina, pons, crura cerebri, and cerebrum.

PONS.

The Pons Varolii or Bridge (fig. 78), is cuboidal in form; its anterior convex surface rests upon the dorsum sellæ of the sphenoid, and is marked by a median basilar groove; its inferior surface receives the pyramidal tracts of the medulla oblongata; from its superior surface emerge the two crura cerebri; each lateral surface is in relation to a hemisphere of the cerebellum, and the *crus cerebelli ad pontem* (middle peduncle) passes from each hemisphere into the pons; the posterior surface forms in part the upper portion of the floor of the 4th ventricle, and in part is connected with the corpora quadrigemina.

The pons consists of both white and grey matter. The nerve fibres of the *white matter* pass both in a transverse and a longitudinal direction. The *transverse fibres* go between the two hemispheres of the cerebellum; some are situated on the anterior surface of the pons, and form its superficial transverse fibres, whilst others pass through its substance and form the deep transverse fibres. The transverse fibres of the pons constitute, therefore, the commissure through which the two hemispheres of the cerebellum are anatomically continuous with each other. By the decussation of these fibres in the mesial plane a

raphe is formed; these commissural fibres may be regarded as a system of arciform fibres similar to those of the medulla oblongata. The *longitudinal fibres* of the pons pass vertically upwards from the medulla oblongata. They consist in large part of the anterior pyramids, which break up into bundles situated between the bundles of deep transverse fibres and then leave the pons as the peduncular fibres of the crusta of the crura cerebri. But deeper in the pons than its pyramidal fibres are other longitudinal fibres which ascend through its substance. On the floor of the 4th ventricle are the *fasciculi teretes* continuous with the same structures in the medulla oblongata (p. 251, fig. 83). To the side of and deeper than each fasciculus teres is the tract named the *lemniscus* or *olivary fillet*. It is continuous below with the formatio reticularis of the medulla, the basis bundle of the anterior column and perhaps the mixed zone of the lateral column. It ascends to the side of the 4th ventricle between the superior and middle peduncles of the cerebellum and passes into the posterior part of the outer side of the corpora quadrigemina. The pons also contains in its substance a *formatio reticularis;* and the roots of the 5th, 6th and 7th cranial nerves emerge from it.

The *grey matter* of the pons is scattered irregularly through its substance, and appears on its posterior surface, but not on the anterior surface. It forms small collections of multipolar nerve cells, *nuclei pontis*, situated in the intervals between the transverse and longitudinal bundles of fibres. Deeper than the deep transverse fibres is the collection of nerve cells named *superior olive;* and in the upper part of the floor of the 4th ventricle are the cells of the *locus cæruleus.*

The Pons is both a conductor of nerve impulses through its nerve fibres, and a centre of origin of nerve fibres from nerve cells. Roots of the facial and auditory divisions of the 7th, and of the 6th and 5th nerves arise in its grey matter. It is possible that some of the peduncular or cerebral fibres end in its nerve cells, and that some of the transverse or cerebellar fibres arise from them.

CEREBELLUM.

The CEREBELLUM, LITTLE BRAIN, or AFTER BRAIN (figs. 81, 91), occupies the inferior pair of occipital fossæ, and, along with the pons and medulla oblongata, lies below the plane of the tentorium cerebelli. It is somewhat ellipsoidal in form, its longer diameter being transverse. It consists of two hemispheres or lateral lobes, and of a median or central lobe, which in human anatomy is called the *vermiform process*. It is connected below with the medulla oblongata by the two restiform bodies, its *inferior peduncles*; above to the corpora quadrigemina by two bands, its *superior peduncles*; whilst the two hemispheres are connected together by the transverse fibres of the pons which form the *middle peduncles* of the cerebellum. On the superior or tentorial surface of the cerebellum the median or vermiform lobe is elevated (fig. 92 *u*) above the plane of the hemispheres, and terminates in front in a slender tongue-like process the *lingula* (p. 261). On its inferior or occipital surface this lobe forms a well-defined *inferior vermiform* process, which lies at the bottom of a deep fossa or *vallecula* (fig. 81); this fossa is prolonged to the posterior border of the cerebellum, and forms there a deep notch which separates the two hemispheres from each other; in this notch the falx cerebelli is lodged. Extending horizontally backwards from the middle cerebellar peduncle, along the outer border of each hemisphere is the *great horizontal fissure*, which divides the cerebellum into

its upper tentorial and lower occipital surfaces. The tentorial surface is subdivided by fissures into two smaller lobes, named *superior anterior* and *superior posterior* (fig. 92). The occipital surface is subdivided into five lobes, *posterior inferior* lobe (*g*), *slender* lobe (*h*), *biventral* lobe (*k*), *flocculus* (*m*) situated immediately behind the middle

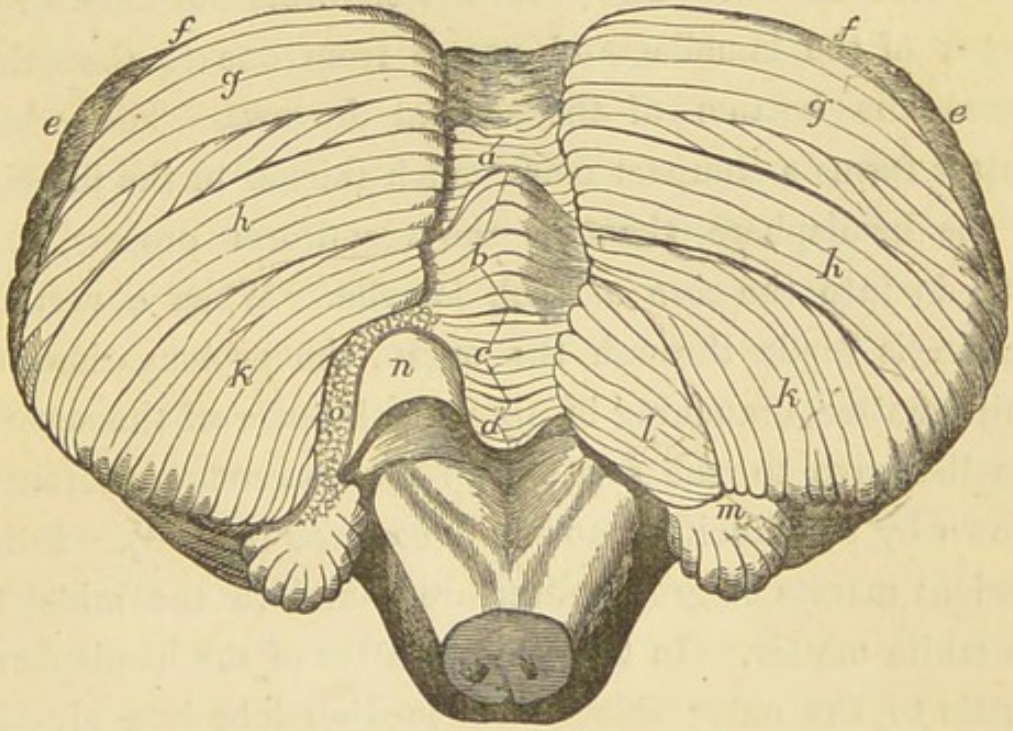

FIG. 81.—Occipital surface of Cerebellum. *a*, vallecula; *b*, pyramid; *c*, uvula; *d*, nodule; *e, e*, margin of tentorial surface; *f, f*, great horizontal fissure; *g g*, posterior inferior lobes; *h, h*, slender lobes; *k, k*, biventral lobes; *l*, tonsil; *m*, flocculus; *n*, posterior medullary velum; *o*, cut surface from which the left tonsil has been detached.

peduncle of the cerebellum, and *amygdala* or *tonsil* (*l*) which forms the lateral boundary of the anterior part of the vallecula, and lies immediately internal to the biventral lobe. The inferior vermiform process is divided into a posterior part or *pyramid* (*b*); an elevation or *uvula* (*c*) situated between the two tonsils; and an anterior pointed process or *nodule* (*d*). Stretching between the two flocculi, and attached midway to the sides of the nodule, is a thin, semilunar plate of white matter, the *posterior medullary velum* (*n*), whilst the layer of grey matter stretching between

the uvula and tonsil on each side is called the *furrowed band.*

The whole outer surface of the cerebellum possesses a characteristic foliated or laminated appearance, due to its subdivision into multitudes of thin plates or lamellæ by numerous furrows. The cerebellum consists both of grey and white matter. The grey matter forms the exterior or cortex of the lamellæ, and passes from one to the other across the bottom of the several furrows. The white matter forms a compact mass, much thicker in the interior of the hemisphere than in the vermiform process, and extends into the core of each lamella. When a vertical section is made through the organ, the prolongations of white matter branching off into the interior of the several lamellæ give to the section an arborescent appearance, known by the fanciful name of *arbor vitæ* (fig. 83). Independent masses of grey matter are found in the midst of the white matter. In the white matter of the hemisphere a little to the outer side of the median lobe is a zig-zag arrangement of grey matter, the *corpus dentatum* of the cerebellum, similar in appearance and structure to the corpus dentatum of the olive in the medulla oblongata; it encloses white fibres, which leave it at its inner and lower side. Immediately to the inner side of each corpus dentatum is a longitudinal wedge-shaped band of grey matter, the *embolus*; to its inner side is a grey layer, the *nucleus globosus.* At the anterior end of the vermiform process and immediately behind the lingula, where it aids in the formation of the roof of the 4th ventricle, are two grey masses, named *roof nuclei* (Stilling). In all these masses are multipolar nerve cells containing yellow pigment, which cells in the nucleus globosus and roof nuclei are

almost twice as large as in the embolus and corpus dentatum.

The *white medullary matter* is for the most part directly continuous with the fibres of the peduncles of the cerebellum. Thus the restiform or inferior peduncles pass from below upwards through the white core, to end in the grey matter of the tentorial surface of the cerebellum, more especially in that of the median lobe; on their way they are connected with the grey matter both of the corpus dentatum and of the roof nuclei. The superior peduncles, which descend from the corpora quadrigemina of the cerebrum, reach the grey cortical matter, more especially on the inferior surface of the cerebellum, though they also form connections with the corpus dentatum. The middle peduncles form a large proportion of the white core, and their fibres terminate in the grey matter of the foliated cortex of the hemispheres. But, in addition to these peduncular fibres, which connect the cerebellum to other divisions of the encephalon, its white matter contains fibres proper to the cerebellum itself. The *fibræ propriæ* have been especially described by Stilling; some, which he has termed the median fasciculi, lie near the mesial plane, and connect the grey matter on the tentorial aspect of the middle lobe with that of the inferior vermiform process, whilst others cross directly the mesial plane to unite opposite and symmetrical regions of the hemispheres. Further, the auditory nerve is said by Foville and Meynert to derive a root through the restiform body from the cerebellum: Meynert also ascribes to a portion of the sensory root of the 5th cranial nerve a cerebellar origin through fibres in the superior cerebellar peduncle.

The *grey matter* of the cortex is divided into two well-

defined layers, an *external grey* or *cellular layer*, and an *inner rust-coloured layer*. The rust-coloured layer is distinguished by containing multitudes of so called "granules," the well-defined nucleus in which, as described by Strachan, is invested by a small quantity of branched protoplasm. These "granules" are, therefore, minute

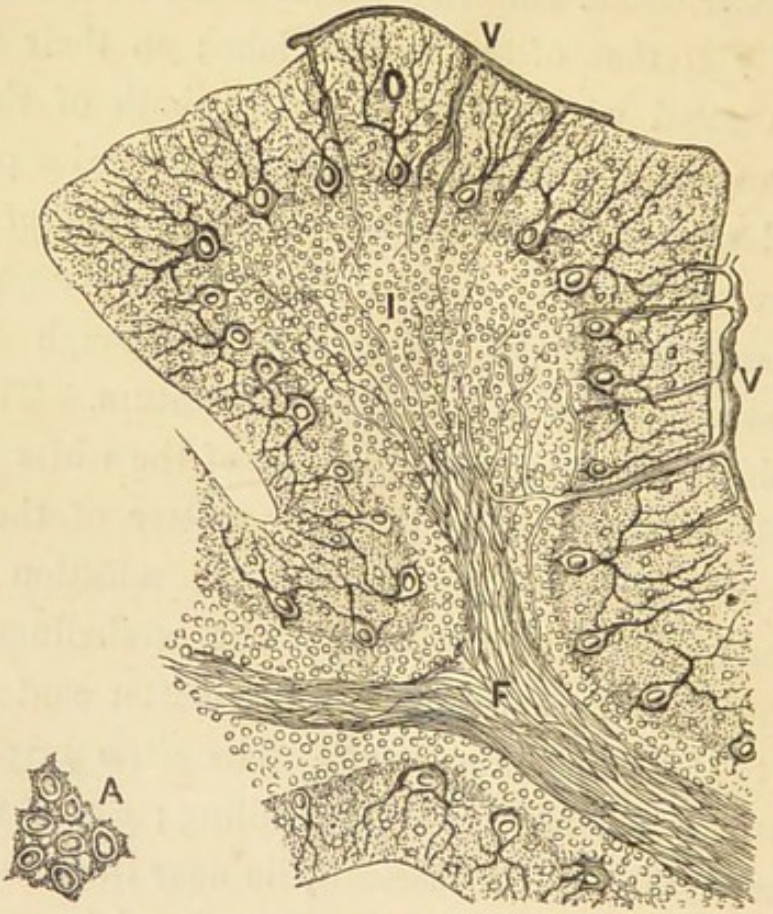

FIG. 82.—Vertical Section through a folium of the Cerebellum. O, outer layer of grey matter in which are the corpuscles of Purkinje; I, inner or rust-coloured layer; F, fibres of the white core; V, V, vessels in the pia mater. A, a more highly magnified view of the "granules" of the rust-coloured layer to show the branched protoplasm

stellate cells. A plexus of very delicate nerve fibres lies in this layer between the granules. The rust-coloured layer is at least twice as thick in that part of each cerebellar leaflet which lies next the surface, as opposite the bottom of a fissure between adjacent leaflets (fig. 82). The characteristic nerve cells of the cerebellum, named the *corpuscles of Purkinje*, are situated in the grey cellular

layer. The body of each cell lies close to the junction of the cellular and rust-coloured layers with each other, and the slender central process arising from each cell enters the rust-coloured layer, and, as the observations of Hadlich and Koschennikoff show, becomes continuous with the axial cylinder of a medullated nerve fibre; for the nerve fibres of the white core enter this layer, divide into minute fibres, and ramify amidst the granules. From the opposite aspect of each cell two peripheral processes arise, and ramify in an antler-like manner in the external grey layer. Obersteiner and Hadlich maintain that the finer branches of these processes curve back towards the rust-coloured layer, where, according to Boll, they form a network of extreme minuteness, from which it is believed that nerve fibres may arise. The substratum of the grey layer, in which the branched processes of the cells of Purkinje lie, consists of a very delicate neuroglia, in which scattered corpuscles are imbedded; but, in the outer part of this layer, delicate supporting connective tissue-like fibres are also met with. The blood-vessels of the investing pia mater pass into the cellular layer of grey matter and form in it a rich capillary plexus. Some pass through the cellular into the rust-coloured layer, where they also form a close capillary network, and from them smaller vessels are prolonged into the white core, the vascularity of which is comparatively feeble.

The Cerebellum is both a conductor of nerve impulses and a nerve centre. Through the nerve fibres of its peduncles it is continuous with the other divisions of the encephalon, and with the spinal cord, and its nerve cells give origin both to peduncular fibres and to some roots apparently of the auditory and 5th cranial nerves. It seems to be the great nerve centre associated with the co-ordination of orderly muscular movements.

Fourth Ventricle.—This ventricle is the dilated central canal of the posterior cerebral vesicle, and it forms a space shaped like a heraldic lozenge. The lower half of the lozenge is on the back of the medulla oblongata, and is bounded laterally by the restiform bodies and posterior pyramids, as they diverge from the postero-median fissure outwards to the cerebellum. The upper half is on the

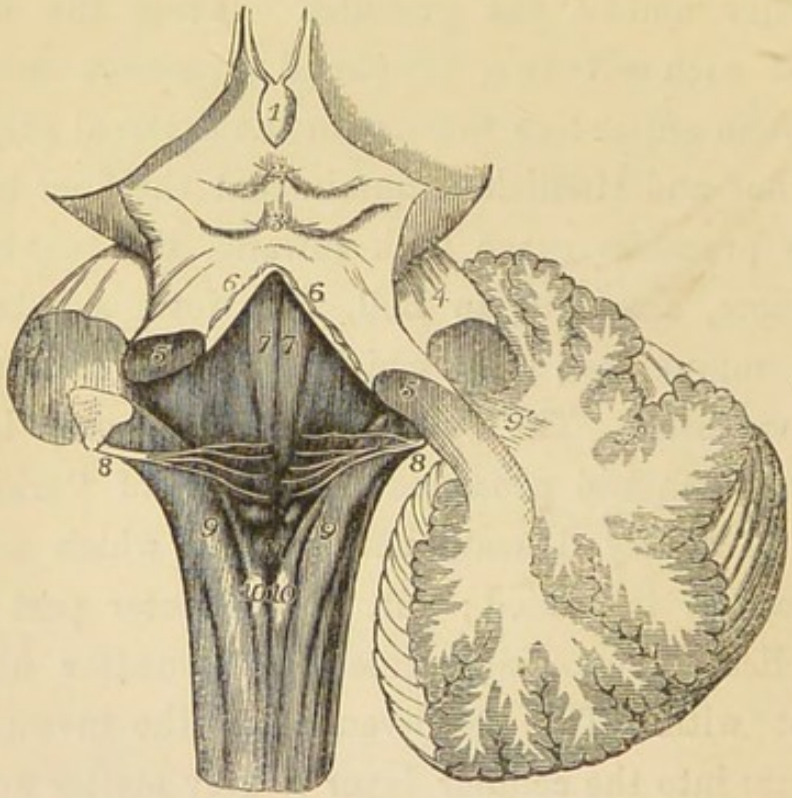

FIG. 83.—Floor of the Fourth Ventricle and adjacent structures. 1, pineal gland; 2, the nates, and 3, the testes of the corpora quadrigemina; 4, 4, middle peduncles; 5, 5, superior peduncles of the cerebellum; 9, 9, inferior peduncles of the cerebellum or restiform bodies, the figures being placed on the funiculus cuneatus; 6, 6, valve of Vieussens divided; 7, 7, fasciculi teretes; 8, 8, roots of the auditory nerves; 9′, corpus dentatum; 10, 10, posterior pyramids, the figures being placed on the clavæ; 11, calamus scriptorius.

back of the pons, and is bounded laterally by the superior peduncles of the cerebellum which converge to the corpora quadrigemina. The inferior angle, *calamus scriptorius*, lies between the clavæ of the two diverging posterior pyramids, and is closed in by a thin layer, of white matter, the *obex*, which passes between the two clavæ. The superior angle communicates with the aqueduct of Sylvius. The lateral

angles are where the restiform bodies branch off to the cerebellum. The floor is divided into two lateral halves by a *longitudinal mesial fissure*, continuous at the calamus with the central canal of the medulla and cord. The floor consists of the grey matter of the medulla and pons, which is continuous with the grey matter of the cord and gives origin to the roots of the cranial nerves from the 5th to the 9th inclusive. The bluish black spot, named *locus cœruleus*, is in the floor close to the entrance to the aqueduct of Sylvius. Its nerve cells, charged with dark pigment, give origin to the sensory root of the 5th, and perhaps to the posterior root of the 4th cranial nerve. On each side of the mesial fissure is the longitudinal elevation, the *fasciculus teres.* White lines, the *striæ acusticæ*, or roots of the auditory nerve, pass from the mesial fissure across the floor to reach the surface of the restiform body. The roof of this ventricle is formed anteriorly of the *valve of Vieussens* or *anterior medullary velum*, which stretches between the two superior peduncles of the cerebellum and reaches the corpora quadrigemina. This velum consists partly of a layer of white matter which is continuous with the white or medullary matter of the vermiform process, and partly of four to five transversely arranged shallow lamellæ of grey matter, projecting into the velum in a tongue like process, *lingula*, and continuous behind with the anterior end of the superior vermiform process. Behind the anterior velum is the *nodule* or anterior end of the inferior vermiform process, with the white medullary core in which the posterior medullary velum is continuous. Behind the nodule and forming the thinnest and most posterior part of the roof is a pair of thin bands of white matter, the *ligulæ*, each of which is continuous with the

inner border of a restiform body and with the obex. The two ligulæ do not meet mesially, and the interval between them is filled up by the pia mater, which helps to form the roof, and is named *tela choroidea inferior.* Projecting from this pia mater towards the ventricle are the vascular folds, the *choroid plexuses* of the 4th ventricle. The surface of the pia and of its choroid plexuses next the ventricle is lined by an epithelium, which, along with the ligulæ and obex constitutes the dorsal wall of the cerebro-spinal tube, where it closes in the lower and back part of the ventricle. The ventricle is lined by an epithelium continuous with that of the central canal of the medulla and cord. Secondary communications, however, arise between the ventricle and the sub-arachnoid space situated behind the tela choroidea inferior. The mesial opening or *foramen of Magendie* is immediately in front of the obex, and the two lateral openings or *foramina of Key* and *Retzius* are situated one near each side of the floor of the ventricle.

The MIDDLE CEREBRAL VESICLE or MESENCEPHALON gives origin to the Corpora Quadrigemina and Crura Cerebri, whilst the Aqueduct of Sylvius is the axial canal of the modified vesicle.

CRURA CEREBRI.

The Crura Cerebri or Peduncles of the Cerebrum emerge from the upper surface of the pons, lie on the base of the brain, and diverging from each other as they ascend, pass, under cover of the optic tracts, into the hemispheres of the cerebrum. On the inner side of each crus is a groove through which the 3rd cranial nerve emerges, and on the outer side is the *sulcus lateralis mesencephali* (Schwalbe),

which demarcates the crus cerebri from the corpora quadrigemina. Between the two crura is a layer of grey matter, *pons Tarini*, perforated by holes for small arteries and called *locus perforatus posticus.*

Each crus cerebri consists for the most part of the pyramidal or peduncular fibres of the pons, medulla, and cord, which form its white surface or *crusta*, and which ascend to the internal capsule of the corpus striatum of the cerebrum. In the substance of the crus is a mass of dark grey matter, *locus niger*, which contains multipolar nerve cells filled with brown pigment. These cells give origin to a root of the 3d nerve. Deeper than the locus niger are the nerve fibres of the *tegmentum*, which are ascending from the lemniscus, fasciculus teres, posterior longitudinal fasciculus, and the superior peduncles of the cerebellum ; most of these fibres ascend to the optic thalamus, though some go to the corpora quadrigemina.

Corpora Quadrigemina.

The Corpora Quadrigemina, or Optic Lobes (fig. 92), lie immediately in front of the superior peduncles of the cerebellum, behind the posterior commissure and 3rd ventricle, between the posterior ends of the two optic thalami, and above the two crura cerebri. They present superficially both a longitudinal mesial fissure and a transverse fissure, which differentiates them into four eminences, an anterior larger pair, the *nates ;* a posterior smaller pair, the *testes* From each testis a tract, the *posterior brachium*, passes forwards, and on it is situated an eminence, the *corpus geniculatum internum*, from the anterior end of which a portion of the optic tract seems to proceed. From each nates a tract, the *anterior brachium*, passes forwards under

cover of the pulvinar of the optic thalamus and gives rise to a portion of the optic tract. Behind the testes the 4th cranial nerves emerge.

The Aqueduct of Sylvius, or passage from the 3d to the 4th ventricle, lies longitudinally and mesially in the substance of the corpora quadrigemina and is lined by a columnar ciliated epithelium continuous with that of the ventricles.

The corpora quadrigemina have on the free upper surface a thin layer of white matter, which is continuous with the

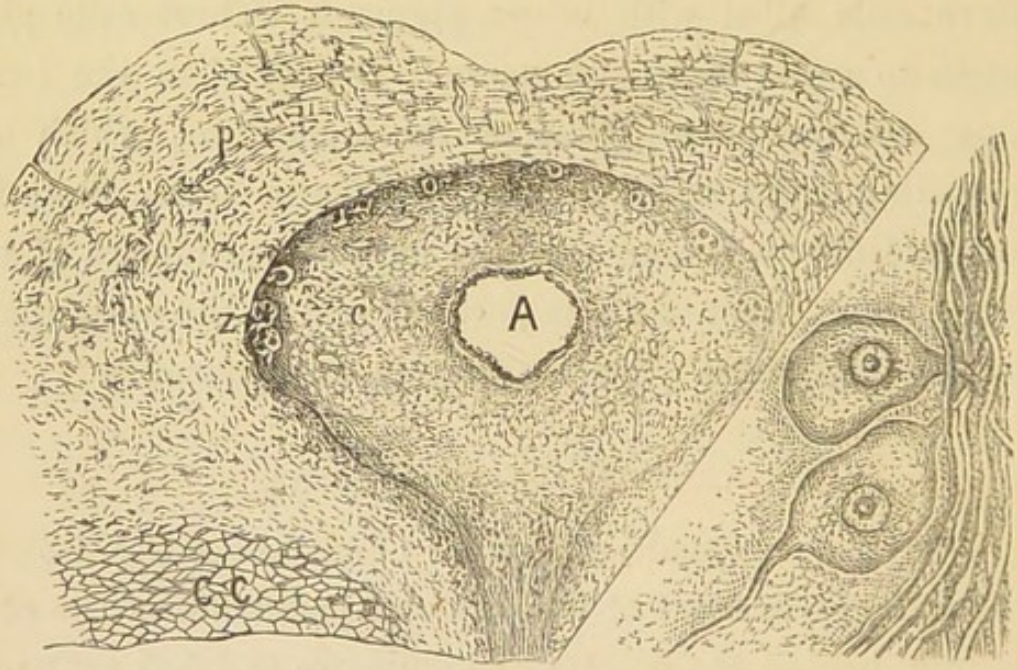

FIG. 84.—Vertical Transverse Section through the Corpora Quadrigemina. A Aqueduct of Sylvius; *p*, peripheral mass of grey matter; *c*, central layer of grey matter; *z*, large nerve cells arranged as a zone around the circumference of the central layer; *C*, *C*, superior peduncle of cerebellum transversely divided. At the right lower corner two cells of the zonular region are represented, highly magnified.

fibres of the posterior brachium. Surrounding the aqueduct of Sylvius is the grey matter of the wall of the axial canal, named the *Sylvian or central layer*, which is continuous with the grey matter of the floor of the 4th ventricle and of the cord. It contains numerous small multipolar nerve cells, and the roots of the 3rd and 4th nerves arise from groups of cells situated near the deeper aspect of the aqueduct. A

remarkable zone-like arrangement of nerve cells lies at the circumference of the dorsal aspect and sides of this central grey layer. In vertical transverse sections (fig. 84) they may be seen to lie singly, but usually in groups of from two to six cells. They are much larger than the ordinary cells of the central layer, and consist of a globular body giving origin to one or two processes. These cells lie in a tract of well-defined nerve fibres, to which they have apparently a relation like that of the cells in a spinal nerve ganglion to the fibres of the posterior root. Outside this zone is the *peripheral layer* of grey matter containing small multipolar nerve cells, which, especially in the nates, give origin through the anterior brachium to many fibres of the optic tract. The corpus geniculatum internum contains small multipolar nerve cells. The nerve fibres of the lemniscus penetrate the corpora quadrigemina between the peripheral and central grey layers, and form a transverse arrangement, and some of these decussate in the mesial plane. Some fibres from the corpora quadrigemina may ascend to the cerebrum. It is now maintained that the superior peduncles of the cerebellum do not end in the corpora quadrigemina but pass upwards to the optic thalami (Forel), or even to the cortex of the hemisphere (Meynert). In their course they decussate and form a horse-shoe shaped commissure or *raphe*, in which a mass of nerve cells, *nucleus tegmenti* is situated (Schwalbe.)

The Crus Cerebri, except in its locus niger, is exclusively for conduction of nerve impulses. The locus niger and the grey matter of the Corpora Quadrigemina are centres of origin for the 3d, 4th, and in part the optic nerve. Other nerve fibres, *e.g.*, those of the posterior brachium and the lemniscus either arise or terminate in this grey matter.

The ANTERIOR CEREBRAL VESICLE gives origin through the Thalamencephalon to the Optic Thalami, and through the Prosencephalon to the Corpora Striata and the convoluted Mantle of the Hemispheres, with their offshoots and subordinate parts. These constitute the CEREBRUM proper, and the third and two lateral ventricles are the axial canal of the modified vesicle.

CEREBRUM.

The CEREBRUM or GREAT BRAIN lies above the plane of the tentorium, and forms much the largest division of the encephalon. It is ovoid in shape, and presents superiorly, anteriorly, and posteriorly a deep *median longitudinal fissure*, which divides it into two hemispheres (fig. 86). If the hemispheres be drawn asunder by opening out this longitudinal fissure, a broad white band, the *corpus callosum*, may be seen at the bottom of that fissure passing across the mesial plane from one hemisphere to the other. The outer surface of each hemisphere is convex, and adapted in shape to the concavity of the inner table of the cranial bones. Its inner surface, which forms one side of the longitudinal fissure, is flat and is separated from the opposite hemisphere by the falx cerebri. Its under surface, where it rests on the tentorium, is concave, and is separated by that membrane from the cerebellum and pons. The base of the brain presents either mesially, or immediately to the side of the mesial line, several objects. Winding round the outer side of each crus cerebri is a flat white band, the *optic tract;* these tracts converge in front, and join to form the *optic commissure*, from which the two *optic nerves* arise. The crura cerebri, optic tracts, and optic commissure enclose a lozenge-shaped region, the *inter-peduncular space*, which includes from behind forwards—*a*, the grey layer, *pons Tarini*, or *locus perforatus posticus: b*, two white mammillæ, the *corpora albicantia: c*, a grey

nodule, the *tuber cinereum:* from which, *d*, the *infundibulum* projects to join the *pituitary body*. Immediately in front of the optic commissure is a grey layer, the *lamina cinerea* or *lamina terminalis* of the 3rd ventricle: in front of this lamina is the antero-inferior end of the *great longitudinal fissure:* between the optic commissure and tract and the inner end of each Sylvian fissure is a grey layer, perforated by small arteries, the *locus perforatus anticus* (fig. 94).

The Mantle or peripheral part of each hemisphere, consists of grey matter, which has a characteristic folded appearance, known as the *convolutions* or *gyri* of the cerebrum. These convolutions are separated from each other by *furrows, fissures*, or *sulci*. Some of the fissures are so deep as to cause corresponding elevations on the wall of the ventricle, *e.g.*, the Sylvian, parieto-occipital, hippocampal and calcarine fissures (p. 210); others are shallower and form indentations only on the surface of the hemisphere. Some of the fissures divide the hemisphere into lobes, whilst others separate the convolutions in each lobe from each other. In each hemisphere of the human brain five lobes are recognised: the temporo-sphenoidal, frontal, parietal, occipital, and the central lobe or insula. The *Sylvian fissure* passes from the locus perforatus anticus obliquely, upwards and backwards, along the outer face of the hemisphere; the temporo-sphenoidal lobe lies below it, and above and in front are the parietal and frontal lobes. A short *ascending branch* passes from its anterior end into the inferior frontal convolution. The elevation in the ventricle corresponding to the Sylvian fissure is the corpus striatum. The *fissure of Rolando* extends from the mesial longitudinal fissure obliquely downwards and forwards on the outer face of the hemisphere almost to the Sylvian

fissure; it separates the frontal from the parietal lobe. The *parieto-occipital fissure*, is about two inches from the hinder end of the hemisphere; it commences at the longitudinal fissure, passes vertically down the inner surface of the hemisphere, and also transversely outwards for a short distance on its outer surface; it separates the parietal from the occipital lobe.

The Outer Surface of the Hemisphere.

The *Temporo-Sphenoidal Lobe* (figs. 85, 87) presents from above downwards three parallel convolutions, the *superior, middle, and inferior temporo-sphenoidal convolutions.* They all blend in front at the tip of the temporo-sphenoidal lobe. Behind, the superior convolution joins the angular gyrus of the parietal lobe, and the middle and inferior join the lowest convolution of the occipital lobe. The fissure which separates the superior from the middle convolution is called the *parallel fissure.*

The *Occipital Lobe* forms the hinder end of the cerebrum,

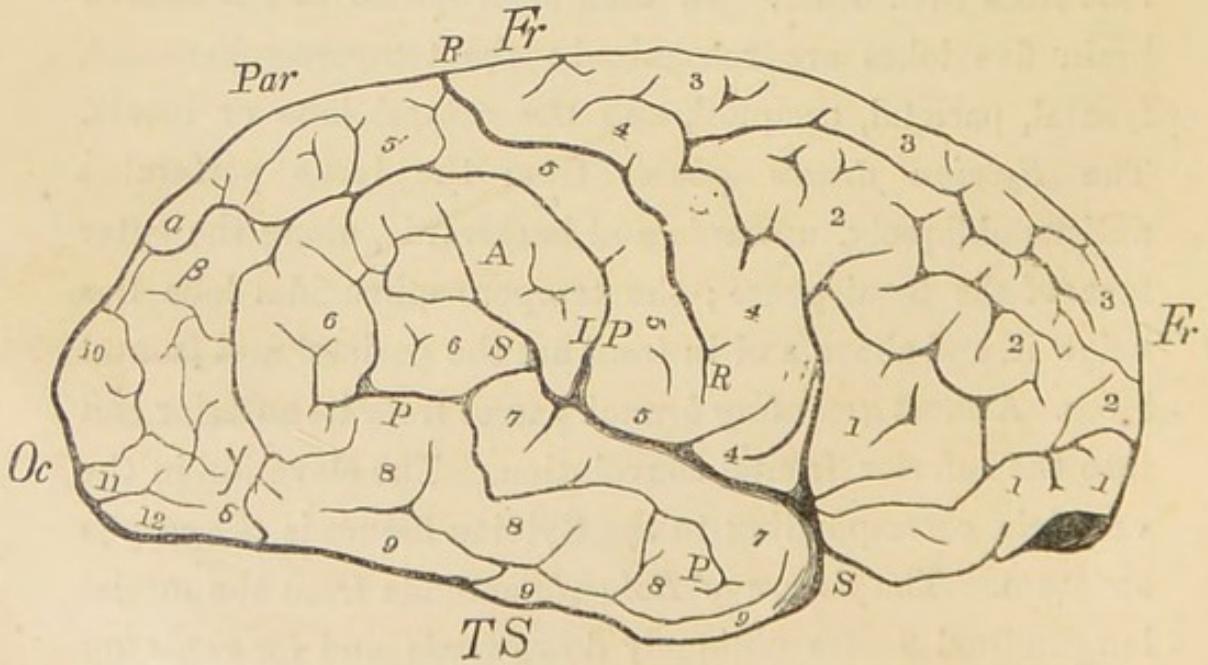

Fig. 85.

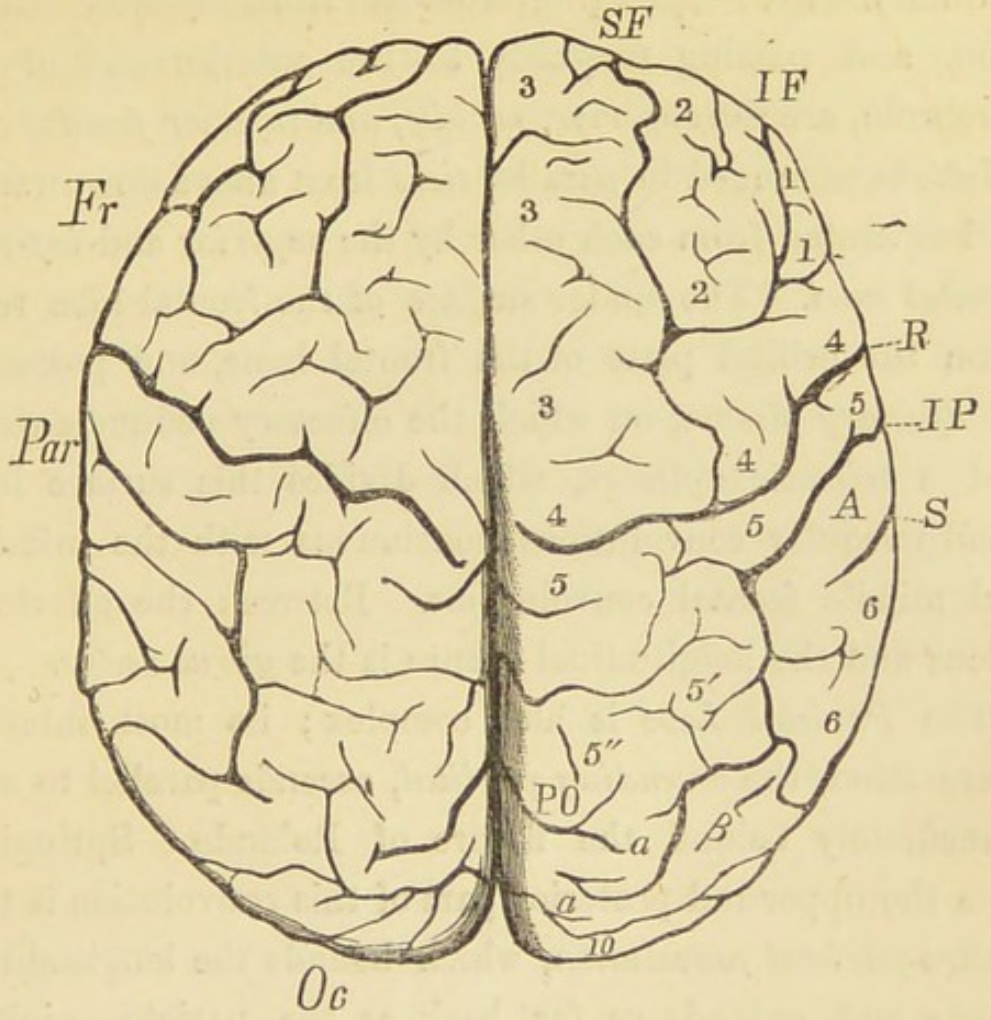

Fig. 86.

FIGS. 85 and 86.—Profile and Vertex Views of Cerebrum. *Fr*, the frontal lobe; *Par*, parietal; *Oc*, occipital; *Ts*, temporo-sphenoidal lobe; *SS*, Sylvian fissure; RR, fissure of Rolando; PO, parieto-occipital fissure; IP, intra-parietal fissure; PP, parallel fissure; SF and IF, supero- and infero-frontal fissures: 1, 1, 1, inferior, 2, 2, 2, middle, and 3, 3, 3, superior frontal convolutions; 4, 4, ascending frontal convolution; 5, 5, 5, ascending parietal, 5′, postero-parietal, and 6, 6, angular convolutions; A, supra-marginal, or convolution of the parietal eminence; 7, 7, superior, 8, 8, 8, middle, and 9, 9, 9, inferior temporo-sphenoidal convolutions; 10, superior, 11, middle, and 12, inferior occipital convolutions; α, β, γ, δ, four annectent convolutions.

and consists, from above downwards, of three parallel convolutions, named *superior, middle, and inferior occipital*, which are separated from each other by two fissures.

The *Frontal Lobe* forms the anterior and upper part of the cerebrum. It begins immediately in front of the fissure of Rolando, in a convolution named *ascending frontal*, which ascends obliquely backwards and upwards parallel and next to the fissure of Rolando, from the Sylvian to the longi-

tudinal fissure. Springing from the front of this convolution, and passing forwards to the anterior end of the cerebrum, are the *superior, middle, and inferior frontal convolutions*, arranged in parallel *tiers* from above downwards, and separated from each other by the *superior* and *inferior frontal sulci.* The under surface of the frontal lobe rests upon the orbital plate of the frontal bone, and possesses an *olfactory fissure*, on which the olfactory peduncle rests, and a *triradiate fissure*, which divides this surface into small irregular convolutions continuous with the inferior and middle frontal convolutions. Between the olfactory sulcus and the longitudinal fissure is the *gyrus rectus.*

The *Parietal Lobe* is also complex; its most anterior convolution, the *ascending parietal*, ascends parallel to and immediately behind the fissure of Rolando. Springing from the upper and posterior part of this convolution is the *postero-parietal convolution*, which bounds the longitudinal fissure and extends as far back as the parieto-occipital fissure. Springing from the lower and posterior part of the ascending parietal convolution is the *supra-marginal convolution*, which forms a part of the upper boundary of the Sylvian fissure; as it occupies the hollow in the parietal bone, which corresponds to the parietal eminence, it may appropriately be named the *convolution* of the *parietal eminence.* Continuous with the convolution of the parietal eminence is the *angular convolution*, which bends round the posterior end of the Sylvian fissure. Lying in the parietal lobe is the *intra-parietal fissure*, which separates the convolution of the parietal eminence from the ascending and postero-parietal convolutions. The occipital is connected with the parietal lobe by two *annectent* or *bridging* gyri, which bridge across the transverse external part of the

parieto-occipital fissure; the depth and extent of this fissure vary in different brains in proportion to the size of these bridging convolutions. The *superior annectent gyrus* passes between the postero-parietal and the superior occipital convolutions, whilst the *second annectent gyrus* connects the middle occipital with the angular gyrus. The convolutions which connect the inferior occipital convolution with the middle and inferior convolutions of the temporo-sphenoidal lobe have sometimes been named 3rd and 4th *bridging convolutions.*

The lobes of the cerebrum, though named after the bones which form the vault of the skull, are not exactly co-terminous with them (fig. 87). The frontal lobe not only lies under cover of the frontal bone, but extends backwards under the anterior part of the parietal; for the fissure of Rolando, which forms its posterior boundary, lies from $1\frac{1}{2}$ to 2 inches behind the coronal suture. The occipital lobe is not limited to the upper tabular part of the occipital bone, but extends forwards slightly under cover of the posterior part of the parietal; for the parieto-occipital fissure is a little in front of the apex of the lambdoidal suture. The temporo-sphenoidal lobe not only lies under the squamous-temporal and great wing of the sphenoid, but passes upwards under cover of the lower part of the parietal; for the Sylvian fissure passes from below obliquely upwards and backwards across the line of the squamous suture near its middle. The area covered by the parietal bone so far then, from being co-terminous with the parietal lobe of the cerebrum, is trenched on anteriorly by the frontal, posteriorly by the occipital, and inferiorly by the temporo-sphenoidal lobe. The convolutions of the parietal lobe itself are grouped around the parietal eminence, and in the interval between it and the sagittal

suture. The inner table of the cranial bones is an almost exact mould of the convolutions of these lobes; but this is not so with the exterior of the skull, the configuration of which is modified by the formation of ridges and processes

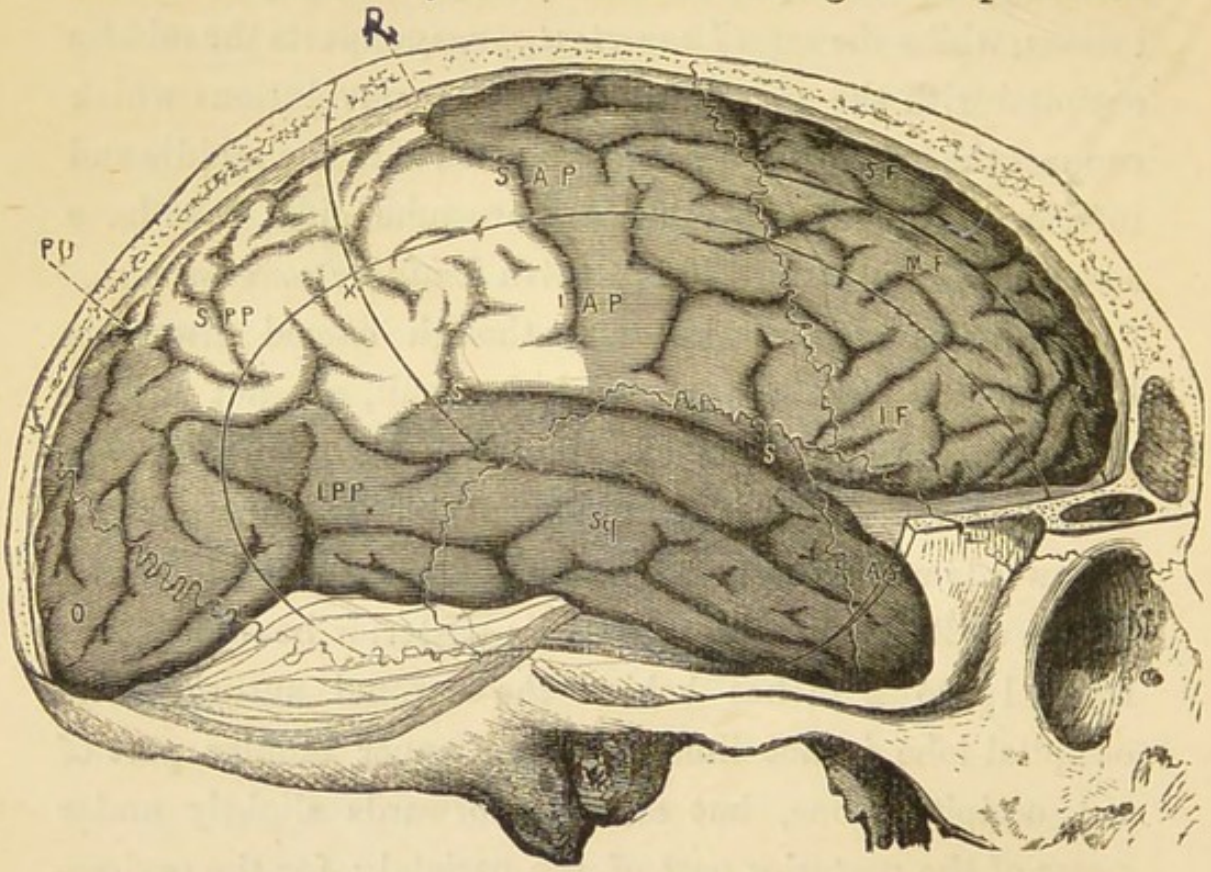

FIG. 87.—Side view of the Brain in the skull.[1]

[1] The above view of the brain *in situ*, shows the relations of the surface convolutions to the regions of the skull. R, fissure of Rolando, which separates the frontal from the parietal lobe. PO, parieto-occipital fissure between the parietal and occipital lobes. SS, fissure of Sylvius, which separates the temporo-sphenoidal from the frontal and parietal lobes. The frontal area lies in front of the coronal suture. SF, MF, IF, the supero-, mid-, and infero-frontal subdivisions of the frontal area of the skull; the letters are placed on the superior, middle, and inferior frontal convolutions; the inferior frontal region is separated from the middle frontal by the frontal part of the curved line of the temporal ridge; the mid- from the supero-frontal by a line drawn backwards from the upper margin of the orbit through the frontal eminence. SAP, the supero-antero-parietal area of the skull; S is placed on the ascending parietal convolution, AP on the ascending frontal convolution. IAP, the infero-antero-parietal area of the skull; I is placed on the ascending parietal, AP on the ascending frontal convolution. SPP, the supero-postero-parietal area of the skull; the

for the attachment of muscles, by variations in the thickness of the diploë, and by the development of the frontal and mastoid air-sinuses. Hence the outer surface of the skull does not precisely correspond in shape to the outside of the brain.

The *Central Lobe* of the hemisphere, more usually called the *Insula* or *Island of Reil* (fig. 88 C), does not come to the surface of the hemisphere, but lies deeply within the Sylvian fissure, the convolutions forming the margin of which conceal it. It consists of four or five short convolutions, which radiate from the *locus perforatus anticus*, situated at the inner end of the Sylvian fissure. This lobe is almost entirely surrounded by a deep fissure, the *sulcus insulæ*, which insulates it from the adjacent frontal and parietal convolutions. The claustrum and nucleus lenticularis are deeper and internal to it. It lies opposite the articulation of the alisphenoid with the parietal and squamous-temporal bones.

If the convolutions on the outer face of the hemisphere be now examined, not so much with reference to their disposition in the individual lobes as to their general arrange-

letters are placed on the angular convolution. IPP, the infero-postero-parietal area of the skull; the letters are placed on the mid-temporo-sphenoidal convolution; the temporal ridge separates the supero- and infero-parietal regions from each other; a vertical line drawn from the squamous to the sagittal suture through the parietal eminence separates the antero- and postero-parietal regions. X, the convolution of the parietal eminence, or supra-marginal gyrus. O, the occipital area of the skull lies below the lambdoidal suture; the letter is placed on the mid-occipital convolution. Sq, the squamoso-temporal region of the skull; the letters are placed on the mid-temporo-sphenoidal convolution. AS, the ali-sphenoid region of the skull; the letters are placed on the tip of the supero-temporo-sphenoidal convolution. The black lines mark the boundaries of the different cranial areas.

ment, and the fissure of Rolando be taken as the starting line, it will be seen that a well-defined convolution extends in the vertical transverse direction immediately in front of, and a second immediately behind, that fissure, from the margin of the longitudinal fissure downwards and outwards to the fissure of Sylvius. These are the ascending frontal and parietal gyri. From the anterior of these gyri the convolutions extend in the postero-anterior direction to the anterior end of the cerebrum, and form the three tiers (more or less distinct in different individuals) of frontal convolutions. From the posterior of these gyri, also, convolutions extend in the antero-posterior direction as far as the posterior end of the cerebrum, but their separation into tiers is not so clearly marked as in the anterior group. Still the postero-parietal convolution, the first annectent gyrus, and the superior occipital convolution, which are

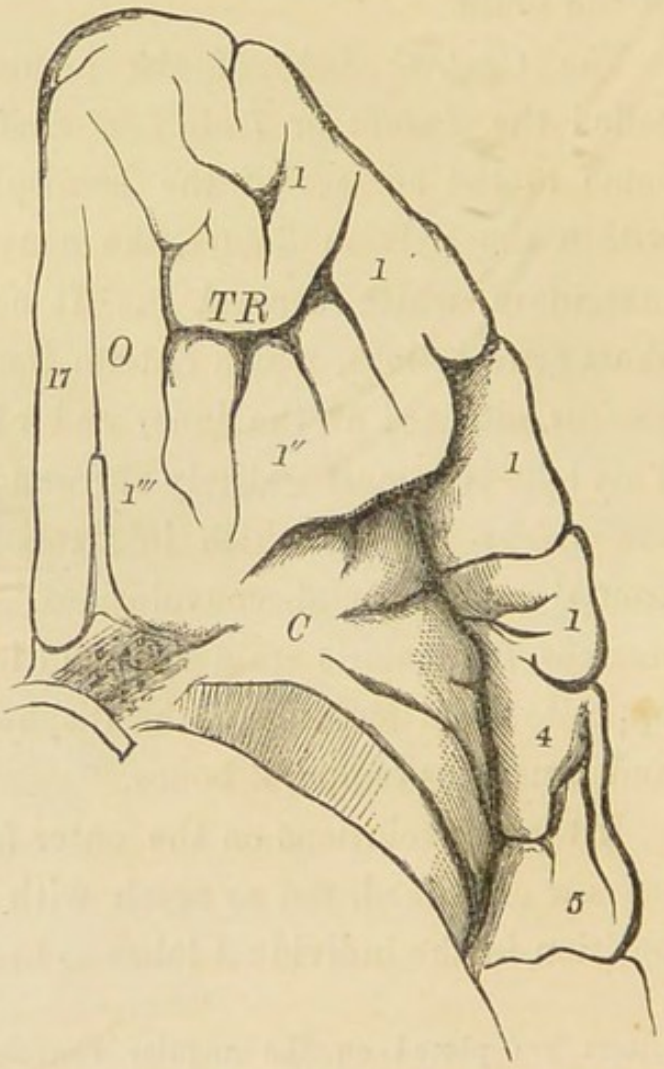

FIG. 88.—Orbital Surface of the Left Frontal Lobe and the Island of Reil; the tip of the temporo-sphenoidal lobe has been removed to display the latter. 17, gyrus rectus; O, olfactory fissure over which the olfactory peduncle and lobe are situated; TR, tri-radiate fissure; 1″ 1‴, convolutions on the orbital surface; 1, 1, 1, 1, under surface of infero-frontal convolution, 4, under surface of ascending frontal, and 5, of ascending parietal convolutions; C, central lobe or insula.

continuous with each other, form collectively a superior tier. The convolution of the parietal eminence, the angular gyrus, the second annectent, and middle occipital gyri, are the members of a second or inferior tier, though their foldings are often so complex as to add materially to the difficulty of determining their continuity. The convolutions of the temporo-sphenoidal lobe, again, are parallel to the horizontal limb of the Sylvian fissure, below which they lie, and as they blend with the angular gyrus of the parietal lobe and with the middle and inferior occipital convolutions, they continue the posterior convolutions of the inferior tier downwards and forwards to the tip of the temporo-sphenoidal lobe.

In this manner the convolutions just referred to are so associated together as to be grouped around, and form, if one may so express it, a cap or hood, which encloses so effectually the convolutions of the central lobe or island of Reil, that it is rare to find any of that structure exposed. It is by the great development of the inferior frontal gyrus, the lower ends of the two ascending convolutions, the convolution of the parietal eminence, the angular and superior temporo-sphenoidal gyri, that the lips of the Sylvian fissure are so closely approximated, and that the island is completely concealed within it.

The Inner and Tentorial Surfaces of the Hemisphere.

The convolutions on these surfaces have no relation to the bones of the cranial vault. They belong in part to the frontal, parietal, occipital, and temporo-sphenoidal lobes, and in part form a special arrangement in relation with the corpus callosum or great transverse commissure, which connects the two hemispheres. The wedge-shaped con-

volution behind the vertical part of the parieto-occipital fissure belongs to the inner surface of the occipital lobe, and forms the *cuneus* or *occipital lobule* (fig. 89). The cuneus is bounded below by the *calcarine fissure* which passes almost horizontally backwards from the lower end of the parieto-occipital fissure: the calcar avis in the posterior horn of the lateral ventricle is the elevation which corresponds to this fissure. Bounding the calcarine fissure below is the *gyrus lingualis*, which also belongs to the occipital lobe. Bounding the gyrus lingualis below is the *collateral* or *occipito-temporal fissure;* it separates that gyrus and the gyrus hippocampi from the *occipito-temporal gyrus.* The convolution which extends forwards from the parieto-occipital fissure along the margin of the longitudinal fissure to the anterior end of the hemisphere, and which then turns back to the locus perforatus anticus, has been named the *marginal convolution.* But this convolution is divided into sections. The part immediately in front of the parieto-occipital fissure belongs to the parietal lobe, and is the *precuneus* or *quadrilateral lobule.* This lobule is separated by the posterior end of the calloso-marginal fissure from the *paracentral lobule,* which belongs mostly to the upper end of the ascending frontal, but partly to that of the ascending parietal convolution. The remainder of the marginal convolution is the median surface of the superior frontal convolution. The *calloso-marginal sulcus* separates the paracentral lobule and median part of the superior frontal convolution from the callosal convolution.

The convolutions on the inner and tentorial surface of the hemisphere, which cannot be referred to any of the previously described lobes, have recently been named by Broca the *great limbic lobe,* but have long been known as

the *gyrus fornicatus*. The *gyrus fornicatus* begins at the locus perforatus anticus, it turns round the knee or anterior end of the corpus callosum, runs backwards parallel to its upper surface, then bends downwards behind its splenium or posterior end, and is prolonged forwards below the

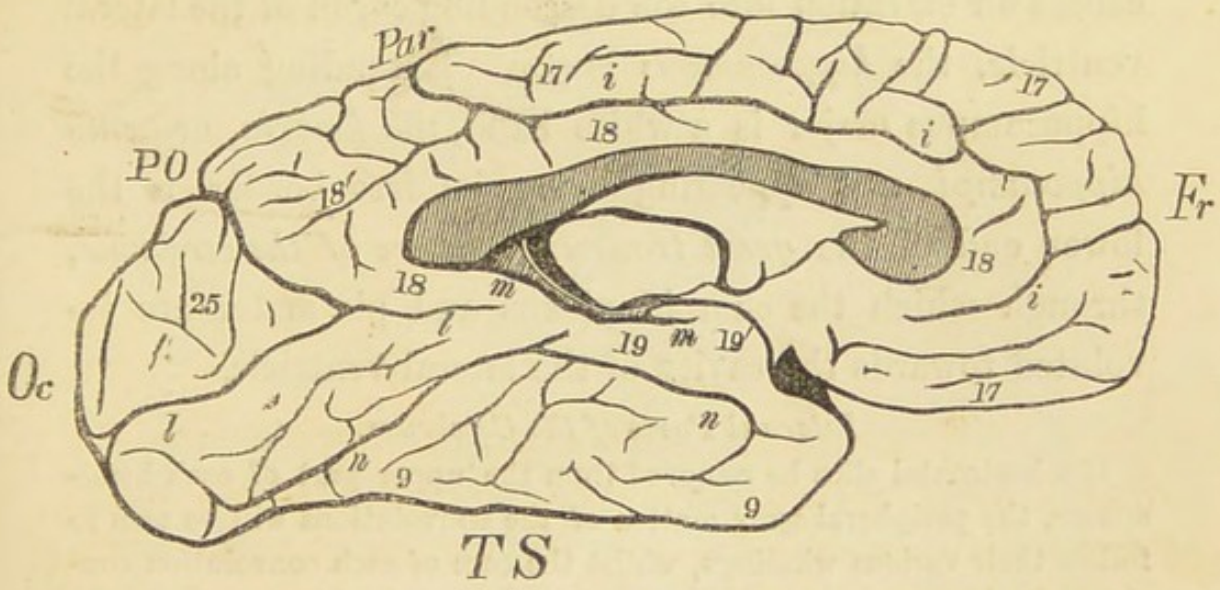

FIG. 89.—Convolutions of the Inner and Tentorial Surfaces of the Left Hemisphere. *i*, *i*, *i*, calloso-marginal fissure; *l*, *l*, calcarine fissure, the letters are on the gyrus lingualis; *m*, *m*, hippocampal fissure; *n*, *n*, collateral fissure, the letters are on the occipito-temporal gyrus; PO, parieto-occipital fissure; 17, 17, marginal convolution; 18, 18, callosal convolution of gyrus fornicatus; 18′, precuneus or quadrilateral lobule; 19, hippocampal gyrus; 19′ uncinate gyrus; 25, cuneus or occipital lobule; 9, 9, inferior temporo-sphenoidal convolution

hippocampal fissure to the tip of the tentorial surface of the temporo-sphenoidal lobe, where it forms a recurved end. The part of this convolution in relation to the corpus callosum is called the *callosal convolution*, or *gyrus cinguli*, the part below the hippocampal fissure is the *gyrus hippocampi*, and the recurved end is the *uncinate gyrus*. Where the callosal and hippocampal convolutions are continuous with each other near the posterior end of the corpus callosum the convolution is somewhat constricted and forms the *isthmus*. The *callosal fissure* intervenes between the callosal convolution and the corpus callosum, and at the bottom of this fissure the grey matter of the gyrus terminates in a well-defined edge. This fissure is

continued behind the splenium into the *hippocampal or dentate fissure*, which forms the upper boundary of the gyrus hippocampi. At the bottom of the hippocampal fissure the grey matter forms a well-defined denticulated edge, the *fascia dentata*, or *dentate gyrus*, and the fissure causes an elevation into the descending cornu of the lateral ventricle, the *hippocampus major*. Extending along the hippocampus major is a white band, the *fimbria*, or *tænia hippocampi*, and appearing below its free border is the lower end of the *great transverse fissure of the cerebrum*, through which the choroid plexus and pia mater are involuted towards the cavity of the lateral ventricle.

Internal Parts of the Cerebrum.

If a horizontal slice be removed from the upper part of each hemisphere, the peripheral grey matter of the convolutions will be seen to follow their various windings, whilst the core of each convolution consists of white matter continuous with a mass of white matter in the interior of the hemisphere (*centrum ovale*). If a slice be now made down to the plane of the corpus callosum, the white matter of that structure will be seen to be continuous with the white centre of each hemisphere.

The *Corpus Callosum* does not equal the hemispheres in length, but approaches nearer to their anterior than their posterior ends (fig. 90). It terminates behind in a free rounded end, the *splenium*, whilst in front it forms a knee-shaped bend, the *genu*, and passes downwards and backwards, as the *rostrum*, as far as the lamina cinerea on the base of the brain. It is thicker behind than in front, whilst the middle part, or *body*, is the thinnest. If the dissection be performed on a brain which has been hardened in spirit, the corpus callosum is seen to be composed of bundles of nerve fibres, which pass transversely across the mesial plane between the two hemispheres; these fibres radiate into the white core and grey matter of the convolutions, and

connect apparently the corresponding convolutions in the opposite hemispheres. Hence the corpus callosum is a connecting or commissural structure, which brings the convolutions of the two hemispheres into anatomical and

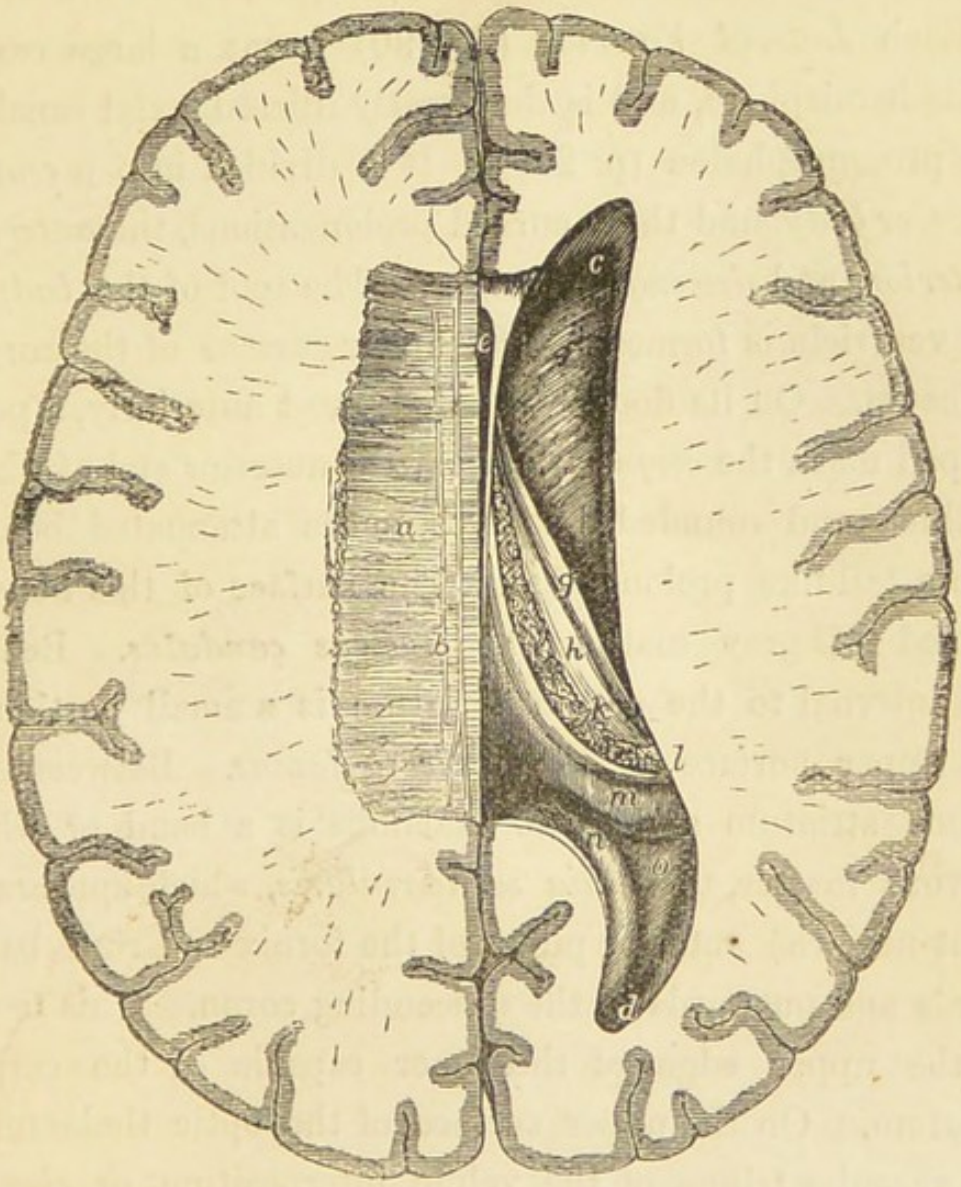

FIG. 90.—To show the right Ventricle and the left half of the Corpus Callosum. *a*, transverse fibres, and *b*, longitudinal fibres of corpus callosum; *c*, anterior, and *d*, posterior cornua of lateral ventricle; *e*, septum lucidum; *f*, corpus striatum; *g*, tænia simicircularis; *h*, optic thalamus; *k*, choroid plexus; *l*, tænia hippocampi; *m*, hippocampus major; *n*, hippocampus minor; *o*, eminentia collateralis.

physiological relation with each other. On the upper surface of the corpus callosum a few fibres, the *striæ longitudinales*, run on each side of the middle line, in the antero-posterior or longitudinal direction; they bend round

the genu and rostrum and form at the anterior perforated spots, the *peduncles of the corpus callosum.* In the middle line itself is a shallow longitudinal furrow, the *raphe.*

If the corpus callosum be now cut through on each side of its mesial line, the lateral, or 1st and 2nd ventricles will be opened into.

Each *Lateral Ventricle* (fig. 90) forms a large cavity in its hemisphere, and is the greatly dilated axial canal of the prosencephalon (p. 209). It is divided into a *central space* or *body*, and three curved prolongations, the *anterior*, *posterior*, and *descending cornua.* The roof of the *body* of the ventricle is formed by the under surface of the corpus callosum. On its floor is situated, most anteriorly, a pear-shaped mass, the *corpus striatum*, the anterior end of which is thick and rounded, but it becomes attenuated behind into a tail-like prolongation. The surface of this body is formed of grey matter, the *nucleus caudatus.* Behind and internal to the corpus striatum is a small portion of the upper surface of the *optic thalamus.* Between the corpus striatum and optic thalamus is a band of white nervous matter, the *tænia semicircularis*, which appears in front near the anterior pillar of the fornix and runs backwards and outwards to the descending cornu. This tænia is the upper edge of the inner capsule of the corpus striatum. On the upper surface of the optic thalamus is the vascular fringe of the velum interpositum, or *choroid plexus*, which appears to lie in the ventricular cavity, but is actually separated from it by an investing layer of epithelium (p. 209). Immediately internal to the choroid plexus is the free edge of the body and posterior pillar of the *fornix*, and the posterior pillar curves outwards to the *hippocampus major.*

The *anterior cornu* extends forwards and outwards into

the frontal lobe, and the head of the corpus striatum projects into it. The *posterior cornu* curves backwards, outwards, and inwards into the occipital lobe. On its inner wall are two curved projections; the lower one, lying next the floor, is the *hippocampus minor*, or *calcar avis*, the elevation corresponding to the calcarine fissure; the upper one, next the roof, is the *bulbus cornu posterioris*. The *descending* or *inferior cornu* curves backwards, outwards, downwards, forwards, and inwards almost to the tip of the temporo-sphenoidal lobe (fig 91). Projecting into this cornu, and following its curvature, is the *hippocampus major*, or *cornu Ammonis*, which terminates below in a nodular end, the *pes hippocampi*. This hippocampus is the elevation which corresponds to the fissura hippocampi. A white band, the *tænia hippocampi*, or *fimbria*, continuous above with the posterior pillar of the fornix, forms, the free border of the hippocampus major. The floor of this cornu forms, with that of the posterior cornu, a triangular area, *trigonum ventriculi*, in which in many brains an elevation exists, the *eminentia collateralis*, which corresponds to the collateral fissure. If the fimbria be drawn on one side the grey matter of the *fascia dentata* or *dentate gyrus* is exposed, and between it and the gyrus hippocampi or *subiculum* is the *fissura hippocampi*. The uncinate gyrus marks the fusion of the gyrus hippocampi with the dentate gyrus and fimbria. Internal to the fimbria is the vascular choroid plexus, situated in the great transverse fissure of the cerebrum. It lies apparently in the descending cornu, but is actually separated from the cavity by an investing layer of epithelium.

The two lateral ventricles communicate with each other and with the 3rd ventricle through the *foramen of Monro*,

which lies behind the anterior pillars of the fornix and opposite the anterior end of each optic thalamus. All three ventricles are lined by an epithelium, usually cylindrical and ciliated, which is continuous with the

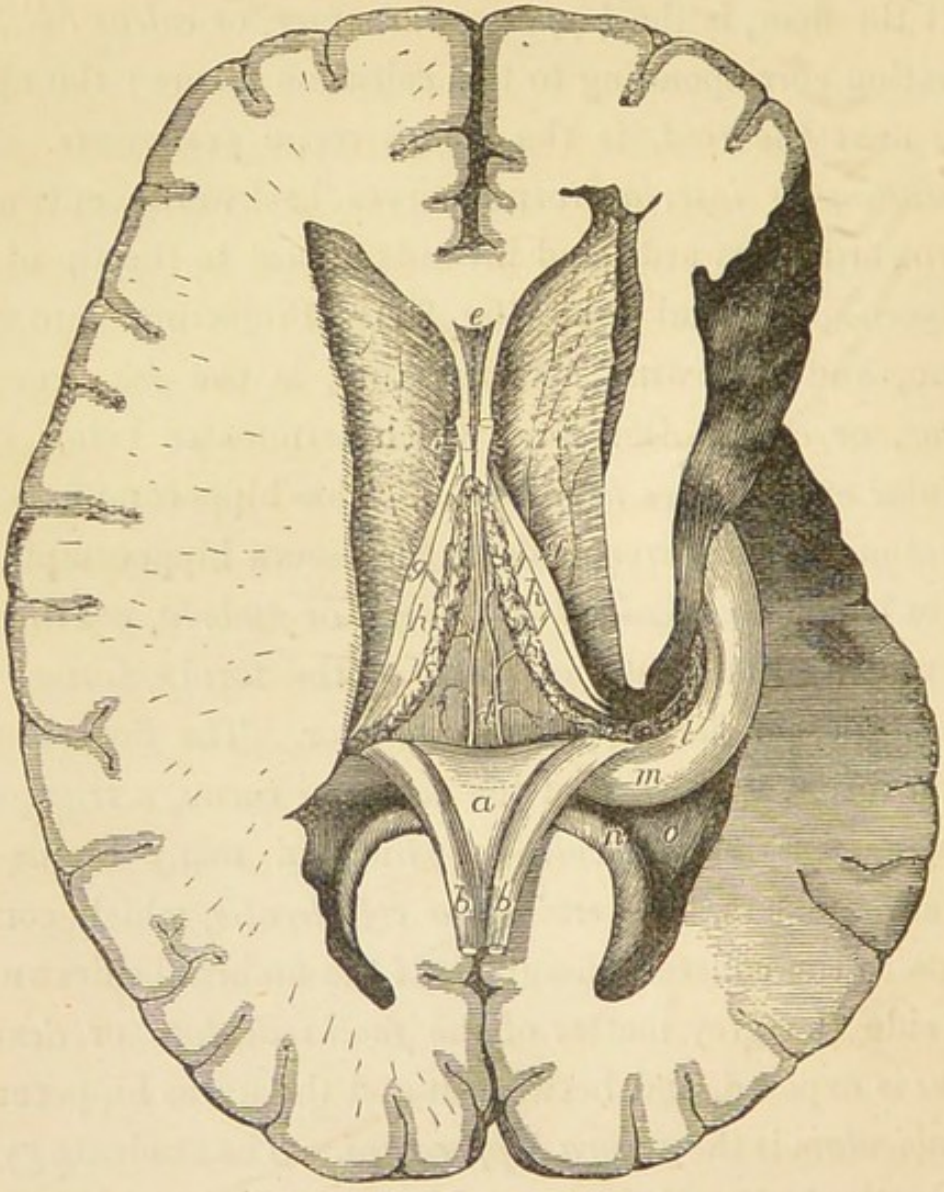

FIG. 91.—A deeper dissection of the Lateral Ventricle, and of the Velum Interpositum. *a*, under surface of corpus callosum, turned back, forming the lyra; *b*, *b*, posterior pillars of the fornix, turned back; *c*, *c*, anterior pillars of the fornix; *d*, velum interpositum and veins of Galen; *e*, fifth ventricle; *f*, *f*, corpus striatum; *g*, *g*, tænia semicircularis; *h*, *h*, optic thalamus; *k*, choroid plexus; *l*, tænia hippocampi; *m*, hippocampus major in descending cornu; *n*, hippocampus minor; *o*, eminentia collateralis.

epithelial investment of the choroid plexuses. The epithelium rests on a layer of neuroglia, and forms with it the *ependyma ventriculorum*. The ventricles contain a little cerebro-spinal fluid.

If the corpus callosum be now divided about its middle by a transverse incision, and the posterior half of this structure be turned back, the body of the fornix on which the corpus callosum rests is exposed. If the anterior half of the corpus callosum be now turned forward, the grey partition, or septum lucidum, between the two lateral ventricles is exposed. When the septum is removed, the anterior part of the fornix is brought into view.

The *Septum Lucidum* fits into the concavity of the knee of the corpus callosum, which bounds it above, in front and below, whilst behind it is bounded by the anterior pillars of the fornix and the anterior commissure. It consists of two thin vertical laminæ, a right and a left, originally continuous with the inner surface of the hemispheres. Each lamina consists of a grey and a white layer, and the fibres of the latter are connected with those of the fornix. The outer white surface of each lamina forms the inner wall of the lateral ventricle in front of the foramen of Monro, and is covered by its ependyma; the inner grey surface bounds the 5th ventricle.

The *Fifth Ventricle* is a mesial cleft-like space, situated between the two laminæ of the septum lucidum. It is not continuous with the other ventricles, and was originally a part of the great longitudinal fissure of the cerebrum, which has been separated from that fissure by the development of the corpus callosum.

The *Fornix* or arch is an arch-shaped band of nerve fibres extending in the antero-posterior direction. It consists of two lateral halves, one belonging to each hemisphere. At the summit of the arch the two lateral halves are conjoined to form the *body;* anterior to the body the two halves separate from each other, and form two rounded *anterior pillars*, which descend in front of the third ventricle and foramen of Monro, and behind the septum

lucidum and anterior commissure, to the base of the cerebrum, where they form the white surface of the *corpora albicantia*, and send fibres into the anterior tubercle of the optic thalamus. The two halves diverge behind the body much further from each other, and form the flattened *posterior pillars;* each of which curves downwards and outwards into the descending cornu of the ventricle, where its fibres, partly spread out on the surface of the hippocampus major, and partly form the *fimbria* or *tænia hippocampi.* The transverse fibres of the splenium of the corpus callosum form, between the diverging posterior pillars, the appearance called the *lyra.*

If the body of the fornix be now divided by a transverse incision, its anterior part thrown forwards, and its posterior part backwards, the great transverse fissure of the cerebrum is opened into, and the velum interpositum lying in that fissure is exposed (fig. 91).

The *Velum Interpositum* is an expanded fold of pia mater, which passes into the cerebrum through the great transverse fissure. It is triangular in shape; its base is in a line with the splenium of the corpus callosum, where it is continuous with the pia mater investing the cerebral convolutions and the cerebellum: each lateral margin is fringed by the *choroid plexus* in the body and descending cornu of the lateral ventricle. Its apex, where the two choroid plexuses blend with each other, lies just behind the foramen of Monro and the anterior pillars of the fornix. The choroid plexuses contain the small *choroidal arteries,* which supply the corpora striata, optic thalami, and corpora quadrigemina; and the blood from these bodies is returned by small veins, which join to form the *veins of Galen* (fig. 91). These veins pass along the centre of the velum, and, as is shown in fig. 72, open into the straight sinus. A pair

of small vascular folds, the *choroid plexuses* of the 3rd *ventricle* project from the under surface of the velum towards the 3rd ventricle, but are separated from that space by an epithelial layer which represents the thinned dorsal wall of the thalamencephalon.

If the velum interpositum be now carefully raised from before backwards, the optic thalami, 3d ventricle, pineal gland, and corpora quadrigemina are exposed.

The *Optic Thalamus* is the large ganglion developed in each lateral wall of the thalamencephalon. It is a somewhat ovoid body, situated behind and to the inner side of the corpus striatum, with which its outer surface is closely united (fig. 92). Its upper surface is partly free in the floor of the body of the lateral ventricle, but is mostly covered by the fornix and velum interpositum; it is formed of white matter, and presents an eminence in front, the *tuberculum anterius.* Its posterior surface is free and possesses a transverse elevation, the inner end of which forms the *pulvinar*, the outer the *corpus geniculatum externum.* Its inner surface forms the side wall of the 3rd ventricle, and consists of grey matter, which is separated from the white upper surface by the *stria medullaris.*

The *Third ventricle* is the axial canal of the thalamencephalon, and occupies the mesial plane between the two optic thalami. Its roof is formed by the epithelium covering the under surface of the velum interpositum and by the velum, whilst above the velum is the body of the fornix; its floor is funnel-shaped and consists from behind forwards of the anterior part of the pons Tarini, the corpora albicantia, tuber cinereum, infundibulum, which is continuous with the pituitary body, and the optic commissure; its anterior boundary, by the lamina cinerea,

anterior pillars of the fornix, and by the *anterior commissure;* and its posterior boundary, by the corpora quadrigemina

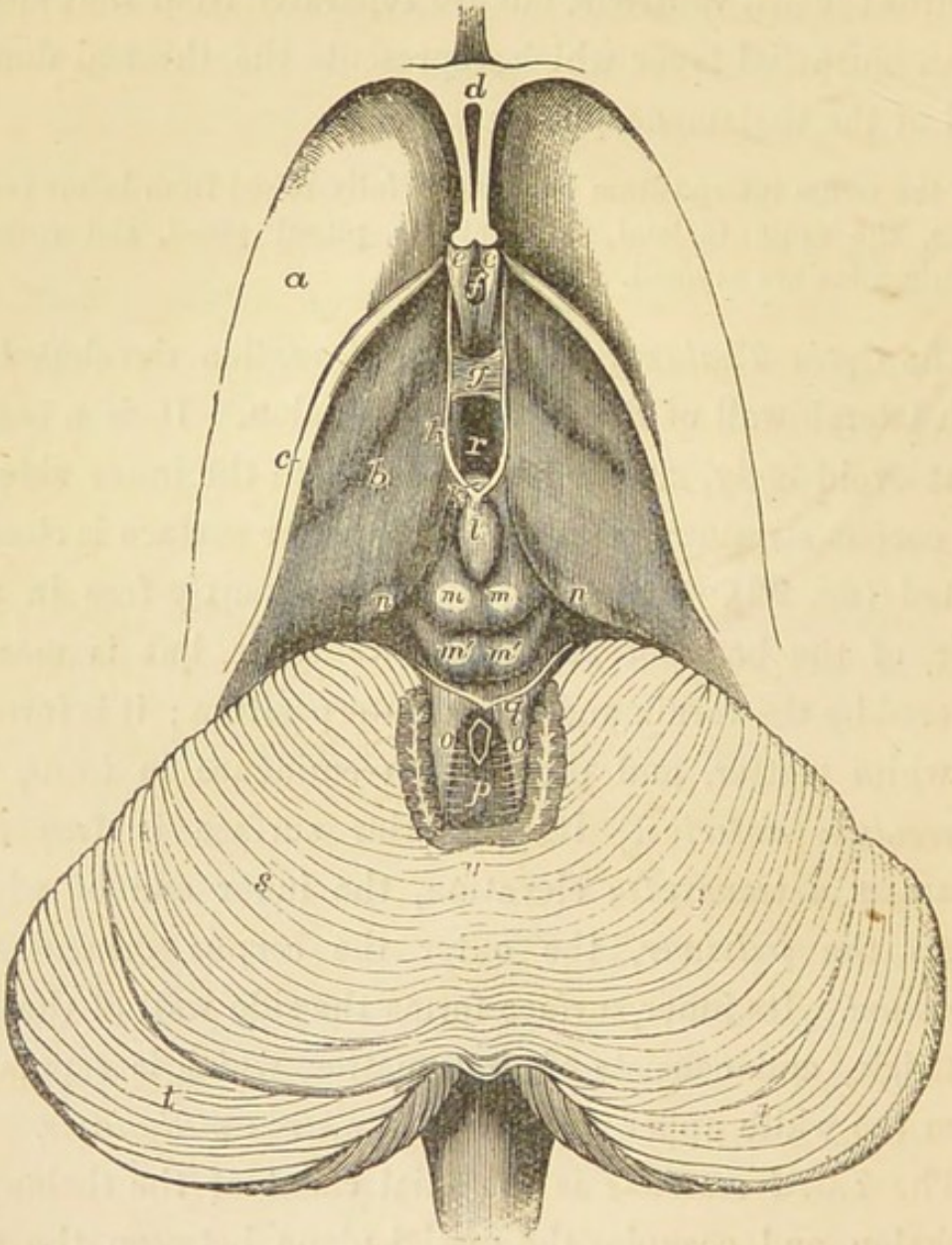

Fig, 92.—A dissection to show the 3d ventricle, Corpora Quadrigemina, and upper surface of Cerebellum. *a*, corpus striatum; *b*, optic thalamus; *c*, tænia semicircularis; *d*, 5th ventricle; *e*, *e*, anterior pillars of fornix; *f*, anterior, *g*, middle, and *k*, posterior commissure; *l*, pineal gland, *h*, its left peduncle; *m*, *m*, nates; *m' m'*, testes; *n*, pulvinar; *o*, *o*, superior peduncles of cerebellum; *p*, lingula of valve of Vieussens; *q*, 4th nerve; *r*, 3d ventricle; *s*, *s*, anterior superior, and *t*, *t*, posterior superior lobes of cerebellum; *u*, upper surface of vermiform process.

and *posterior commissure.* The cavity of this ventricle is of small size in the living head, for the inner surfaces of the two thalami are connected together by intermediate grey matter, named the *middle or soft commissure;* but in

taking the brain out of the cranial cavity this commissure is usually more or less torn through, and the cavity is consequently enlarged. The *posterior white commissure* consists of nerve fibres, which pass transversely between the two thalami, immediately in front of the corpora quadrigemina. The *anterior white commissure* lies transversely in front of the anterior pillars of the fornix and passes through the corpora striata. The 3rd ventricle communicates in front, through the foramen of Monro, with the lateral ventricles, and behind with the aqueduct of Sylvius.

The *Pineal Body*, or Epiphysis cerebri, is a reddish cone-shaped body, enveloped by the velum interpositum, and situated on the nates at the posterior and upper part of the 3rd ventricle. From its anterior end two white bands, the *peduncles of the pineal body*, pass forwards, one on the inner side of each optic thalamus, where they blend apparently with the striæ medullares. Its structure is described on p. 574.

Internal Structure of the Cerebrum.

The Cerebrum or developed Anterior Cerebral Vesicle consists both of grey and white matter; the general relations of these two forms of nerve matter to each other may be seen by making sections through the cerebrum. The determination, however, of their minute structure, and of the relations and connections of the nerve fibres to the nerve cells is, owing to the delicacy of the organ, one of the most difficult departments of anatomical study.

The *Grey Matter* of the cerebrum is disposed in three great groups: *a*, The grey matter of the cortex of the hemispheres; *b*, the grey matter of the ganglia at the base of the cerebrum; *c*, the central grey matter which

forms the wall of the cerebral end of the cerebro-spinal tube.

a, *The grey matter of the cortex of the hemisphere* forms the superficial part of the convolutions, and is known as the *great hemispherical ganglion*, but in some localities, as the *loci perforati antici* and the *septum lucidum*, it has received distinctive names. When a convolution is divided vertically, the grey matter is seen to be confined to the surface and to enclose a white core. The grey matter presents a laminated appearance, and is as a rule divided into five or six layers, which consist of nerve cells, nerve fibres, matrix or neuroglia, and blood-vessels. The neuroglia is present in all the layers and contains multitudes of minute rounded or elliptical corpuscles lying in a finely reticulated matrix, and sometimes small stellate cells with branched processes are found, the protoplasm of which is so pellucid that the nuclei seem as if free (Meynert). The grey cortex is about five times as vascular as the white matter. The arteries and veins, enclosed in a funnel-shaped sheath of pia mater (p. 219), lie vertically in the grey matter. Some arteries end in a rich capillary plexus, within the grey matter; others of larger size give off branches to join the capillaries in the grey matter, and then enter the white matter, where they form a comparatively scanty capillary plexus. The 1st, superficial or *molecular* layer consists largely of neuroglia, in which nerve fibres extend parallel to the surface of the convolutions. The 2nd, or *small pyramidal-cell* layer contains multitudes of pyramidal nerve cells, characteristic of the cerebral cortex; they lie with their long axes vertical to the surface of the convolutions; their apices are directed to the first layer, and according to Cleland are continuous with its horizontal fibres. The

3d or *large pyramidal-cell* layer contains, along with the smaller pyramidal cells, pyramidal cells two or three times larger than those in the 2d layer, and more widely separated from each other (fig. 93). The 4th or *granular* layer contains small elliptical or angular cells, giving off branches from their sides; they appear like transversely divided pyramidal cells. The 5th or *claustral* layer contains fusiform cells, which give off lateral processes. Nerve fibres radiate from the white core of the convolutions into the several layers of grey matter. They are arranged in bundles in the 5th, 4th, and 3d layers, and are more scattered in the 2d and 1st. They have apparently a double connection with the pyramidal nerve cells, partly with the central process from the base of each cell, and partly with the fine network of fibres formed by the branching and anastomosing of the protoplasm processes (p. 198).



FIG. 93.—Vertical Section through the 3d layer of grey matter of the Superior Frontal Convolution. Larger-sized pyramidal nerve cells; the neuroglia, with its corpuscles and some capillary blood-vessels, are represented.

Special modifications in structure occur in several of the convolutions. Betz has described in the *ascending frontal convolution* and in the *paracentral lobule* clusters of from two to seven giant pyramidal cells, about three times larger than the large pyramidal cells of the 3d layer. They are

intermingled with the angular cells of the 4th layer. In the *inferior frontal* or *Broca's convolution*, behind the ascending branch of the Sylvian fissure, he has sometimes found giant pyramidal cells in the 3d layer. Lewis states that they also occur in the *superior* and *middle frontal convolutions*, and sparingly along the anterior aspect of the *ascending parietal convolution* deep in the fissure of Rolando. The convolutions in which these giant pyramidal cells are found are the most important of the motor centres of Ferrier. *Behind* the ascending parietal convolution a six laminated arrangement of the cortical grey matter is described by Lewis, due to the smaller pyramidal cells of the 3d layer forming a distinct layer below the larger pyramidal cells, and at the same time undergoing a numerical increase. The pole of the *occipital lobe*, the *cuneus*, and the *gyrus lingualis*, present a white streak in the grey matter known to Vicq d'Azyr; it is interposed between the layer of smaller (2) and the layer of larger pyramidal cells (3). This white streak is laminated, and consists of two granular layers and of longitudinal nerve fibres, so that eight layers are described in the occipital lobe (Clarke, Meynert, Betz). The grey cortex of the *Island of Reil* has been studied by Major, who states that it agrees with the general arrangement, but the cells of the 3d layer are usually smaller in the insula. Fusiform cells, with the long axis parallel to the surface, form the chief constituent of the grey *claustrum*, which is situated deeper than the grey matter of the Island, and is separated from the outer part of the corpus striatum by a thin layer of white matter. Fusiform cells also occur abundantly in the *nucleus amygdalæ*, a grey mass situated below the corpus striatum, which in some sections seems as if isolated, but in reality is con-

tinuous with the grey matter of the inferior temporo-sphenoidal convolution. The *callosal convolution*, according to Betz, at its commencement near the locus perforatus anticus, consists of little more than two layers, the 1st and 5th, the pyramidal cells of the 2d layer being few and small; but the fusiform cells of the 5th layer are large and lie vertically to the surface of the convolution. At the genu the 2d layer becomes thicker. At the middle of the convolution the 4th layer and the pyramidal cells of the 3d layer appear, but these cells are much smaller than in the other convolutions. The pyramidal and fusiform cells increase in size as they approach the splenium.

The cortex of the *gyrus hippocampi* has on the surface a layer of white matter, derived from the tænia tecta of the cingulum. Below this is a thin layer of neuroglia containing small, scattered corpuscles, the *nuclear lamina*. Below this lamina lies the *stratum reticulare*, in which the apices of the numerous pyramidal cells, which form the next layer, branch and again unite to form a delicate network. This *layer of nerve cells* is prolonged into the hippocampus major, in which it is rolled on itself in a convoluted manner. The free surface (*alveus*) of the hippocampus seen in the descending horn of the ventricle, consists of white matter, viz., the nerve fibres of the fimbria, or tænia hippocampi. But there is in addition a well-marked layer, prolonged also into the fascia dentata, which Meynert has termed the stratum of compressed nerve corpuscles. This layer, however, as was recognized by A. B. Stirling some years ago, resembles the "granules" of the rust-coloured layer of the cerebellum, and may more appropriately be called the *rust-coloured layer* of the hippo-

campus; each granule consists of a well-defined nucleus invested by delicate branched protoplasm.

The grey matter of the *septum lucidum* was originally continuous with the cortex of the inner surface of the hemispheres, and contains both small pyramidal and fusiform cells. The grey matter of the *locus perforatus anticus* contains clusters of minute granules and a compact arrangement of small nerve cells.

b, *The ganglia at the base of the cerebrum* are, on each side, the corpus striatum, the optic thalamus, the corpus geniculatum externum, and the corpus subthalamicum.

The *Corpus Striatum* consists of two masses of grey matter separated from each other by the white peduncular fibres of the inner capsule, which pass upwards through its substance. The upper mass projects into the lateral ventricle, and is called the intra-ventricular portion or *nucleus caudatus*. The lower extra-ventricular portion or *nucleus lenticularis* forms the outer and lower part of the corpus striatum: it is bounded above by the inner capsule, externally by the external capsule of white matter, which separates it from the claustrum, whilst below it is in relation with the locus perforatus anticus. The fibres of the internal capsule traverse both these grey nuclei and give them a striated appearance. Multipolar nerve cells are found in both the caudate and lenticular masses, and in the latter cells of large size have been seen. The *Optic Thalamus* consists largely of grey matter, arranged in three masses, the *anterior*, *inner*, and *outer nuclei*, which are imperfectly separated from each other by a thin layer of white matter. The nerve cells in the grey matter are both stellate and fusiform. The *Corpus Geniculatum externum* consists of grey matter mingled with the nerve fibres of the optic tract.

The grey matter is apparently distinct from the outer nucleus of the thalamus, and contains numerous stellate pigmented nerve cells. The *Corpus Subthalamicum* (Schwalbe) consists of a grey mass situated under the optic thalamus and containing stellate nerve cells. It is separated from the thalamus by a layer of white matter, the *zona incerta* (Forel), which is continuous with the tegmentum.

c, *The central grey matter of the cerebrum* is in series with the central grey layer surrounding the aqueduct of Sylvius. It is situated at the sides and floor of the 3d ventricle. It forms the middle or soft commissure of that ventricle, and the grey surface of the inner wall of the optic thalamus, which is continuous with the inner nucleus. The grey masses situated at the base of the brain between and in front of the crura cerebri, viz., the pons Tarini, tuber cinereum, lamina cinerea, infundibulum, and the grey matter of the pituitary body, belong to the central grey matter and contain nerve cells. Each corpus albicans contains in its interior grey matter with nerve cells. By some anatomists the grey matter of the pineal body is referred to the same category, but Arnold has pointed out that it is separated by its peduncle from the soft commissure; and Meynert is disposed to regard it as a ganglion of origin of the tegmentum. Both the pituitary and pineal bodies contain other structures besides the nervous matter (pp. 573, 574).

The *White Matter* of the cerebrum consists of tracts or fasciculi of nerve fibres, which connect—*a*, the cerebrum with the lower divisions of the encephalon, *peduncular fibres*; *b*, the two hemispheres together, *commissural fibres*; *c*, different structures in the same hemisphere, *association*

fibres; *d*, or serve as fibres of origin for the 1st and 2d cranial nerves, *nerve roots.*

a, *Peduncular Fibres.*—The peduncular fibres are derived from the crura cerebri, more especially from its superficial fibres or *crusta.* They ascend into the corpus striatum and form the white matter of the *inner capsule.* Many bundles enter the nucleus lenticularis and nucleus caudatus and give to them their striated appearance, and a few pass into the optic thalamus. Many of these peduncular fibres, together with fibres arising in the nuclei of the corpus striatum and optic thalamus radiate into the white matter of the hemisphere and form the *corona radiata.* The fibres of the corona pass forwards and upwards to the convolutions of the frontal lobe, upwards to those of the parietal, backwards to the occipital, and as the *stria cornea* backwards and downwards to the temporo-sphenoidal lobe. The direct continuity of many of the peduncular fibres with those of the corona is therefore broken or interrupted by the interposition of ganglia at the base of the cerebrum, which Meynert has named *ganglia of interruption.* The locus niger, nucleus lenticularis, and nucleus caudatus are the ganglia developed in connection with the peduncular fibres of the crust. The peduncular fibres and those of the corona constitute the cerebral portion of the *projection system* of fibres of Meynert, a term devised to express that they conduct upwards to the grey cortex of the hemispheres sensory impulses derived from the external world, the image of which is projected upon the cortex. But it must also be kept in mind, that many if not the majority, of the fibres of this system conduct motor impulses downwards to be propagated along the motor cranial and spinal nerves. The motor tract arises apparently in the giant pyramidal cells

of the paracentral, ascending frontal and parietal convolutions; it forms some of the fibres of the corona radiata and inner capsule of the corpus striatum, also the peduncular fibres of the crusta of the crus cerebri, the longitudinal pyramidal fibres of the pons, the anterior pyramids of the medulla oblongata, the direct pyramidal tract of the anterior column, and the crossed pyramidal tract of the lateral column of the cord. The motor tract leaves the cord as the anterior nerve roots on the side opposite to the hemisphere in which the fibres arise, and terminates in the motorial end plates of the muscular apparatus.

The *tegmentum* forms the posterior or deeper part of the crus cerebri, and is separated from the crusta by the locus niger. It lies between the locus niger and the floor of the aqueduct of Sylvius. Schwalbe proposes to extend the term tegmentum so as to include also the subthalamic region, and the parts of the medulla and pons situated between the floor of the 4th ventricle and the anterior pyramidal or peduncular fibres. The term would therefore comprise the nuclei of the cranial nerves from the 3d to the 9th inclusive, the olives, the corpus subthalamicum, the raphe of the medulla, pons, and mesencephalon, the formatio reticularis in these regions, the fasciculus teres, the lemniscus, superior peduncles of cerebellum, and posterior longitudinal fasciculus. The *posterior longitudinal fasciculus* lies next the mesial plane, in the dorsal part of the formatio reticularis, between the lemniscus and the aqueduct of Sylvius. It arises in the medulla oblongata from the basis bundle of the anterior column and can be traced upwards as high as the posterior commissure, where its termination is doubtful. The longitudinal fibres of the formatio reticularis, the fasciculus

teres, and lemniscus are apparently continuous below with the basis bundle of the anterior column and the mixed zone of the lateral column, whilst superiorly they, as well as the superior peduncles of the cerebellum, for the most part seem to enter the optic thalamus, though some fibres, as those of the lemniscus, go into the corpora quadrigemina. In this respect the fibres of the tegmental region differ from the peduncular fibres of the crusta, the chief destination of which is to the corpus striatum. Some of these tegmental fibres may end in the optic thalamus, but others along with fibres arising within the thalamus radiate into the white matter of the hemisphere, as a part of the corona radiata, and reach the frontal, parietal, occipital, temporo-sphenoidal lobes and the insula. The optic thalamus, corpus subthalamicum, corpora quadrigemina and geniculata, and nucleus tegmenti are the ganglia of interruption of the tegmentum.

The comparison of the human brain with those of different mammals has shown that the development of the hemispheres bears a direct relation to the size of the crusta and its ganglia, but is in inverse relation to the size of the tegmentum and its ganglia.

b, Commissural Fibres.—The largest of these commissures is the *corpus callosum*, which connects apparently corresponding convolutions in the opposite hemispheres. It is found only in mammals. The fibres of the genu radiate forwards and outwards into the frontal lobe. The fibres of the body pass transversely outwards into the parietal lobe, and as they lie on a plane superior to the fibres of the corona radiata, where these emerge from the corpora striata and optic thalami, the two systems of fibres intersect with each other on their way to the convolutions.

The fibres of the splenium radiate into the occipital and temporo-sphenoidal lobes : those for the temporo-sphenoidal and lower part of the occipital are named *tapetum*, and form the upper and outer wall of the posterior and inferior cornua : those for the upper part of the occipital lobe are bent in a peculiar manner and form the *forceps*. The *anterior commissure*, though often described as connecting the two corpora striata, yet, as Spurzheim pointed out half a century ago, passes through these bodies. It occurs also in the lower vertebrates, and is commissural for the two insulæ and the tips of the temporo-sphenoidal lobes. It also gives a root of origin to the olfactory peduncle. The *posterior commissure* passes into the optic thalami. The course of its fibres has recently been studied by Pawlowsky, who states that they proceed from the pineal body, the frontal and temporal lobes, and probably also from the thalamus, and then cross over to the tegmentum of the opposite crus cerebri.

c, Association System of Fibres.—The *arcuate fibres*, or *fibræ propriæ* are situated immediately within the inner surface of the cortex, and connect the grey matter of adjacent convolutions in the same hemisphere. The *fasciculus uncinatus* passes across the Sylvian fissure, traverses the claustrum and nucleus amygdalæ, and connects the convolutions of the orbital surface of the frontal with those of the temporo-sphenoidal lobe. The *cingulum* or *fillet of the gyrus fornicatus* extends longitudinally, partly on the surface and partly within the gyrus fornicatus, from the anterior perforated spot to the gyrus uncinatus. Some of the fibres lie on the surface of the corpus callosum and form its *longitudinal fibres*, *nerves of Lancisi*, *tænia tecta*, and form the white reticular surface of the gyrus hippocampi.

The *longitudinal inferior fasciculus* lies external to the posterior cornu, and connects the occipital with the temporal convolutions. The *longitudinal superior fasciculus* lies in the centrum ovale and connects the convolutions of the frontal with those of the occipital lobe. *Longitudinal septal* fibres lie on the inner surface of the septum lucidum, and extend into the gyrus fornicatus.

The *Fornix* belongs in part to the association system of fibres. Schwalbe holds that it connects the grey matter of the septum lucidum with that of the dentate gyrus, and that these structures together constitute an *internal marginal gyrus*, which bounds the great transverse fissure. Meynert, however, maintains that as the anterior pillars of the fornix emerge from the optic thalami, the fornix forms a part of the peduncular arrangements of that ganglion.

d. Nerve Roots.—The roots of the olfactory and optic nerves will be described in Chapter VI.

Cerebral Organology.

The Cerebrum is both a conductor of nerve impulses through its nerve fibres and a nerve centre. The cerebral ganglia and the central grey matter are important sensory and motor centres and the seats of reflex actions. Of the two great basal ganglia the corpus striatum is associated with motion, the optic thalamus with sensation. The convolutions or hemispherical ganglia, again, are the seat of psychical activity; though there is also reason to believe that they are associated with the discharge of sensori-motor functions. The question has often been put, Are not the individual convolutions distinct organs, each endowed with special functions? and various arguments based on anatomical, physiological, and pathological grounds have been advanced in support of this proposition. In connection with the anatomical branch of the argument it may be stated that the convolutions, not only in man, but in all animals with convoluted brains, have a form, relative position, and arrangement which are characteristic of the species; but specialisation of form, position, and arrangement are not in themselves a sufficient test of specialisation of function. Again, though the convolutions have definite forms they are not disconnected from each

other, for the grey matter forms a continuous layer over the whole surface of the hemisphere. Hence a group of cerebral convolutions differs from a group of muscles, each member of which is undoubtedly a distinct organ, for each muscle is isolated from those around it by a definite investing sheath. As regards internal structure, it has been shown (p. 289) that the convolutions are not all constructed on precisely the same plan, and it has also been pointed out that the convolutions are not all connected in the same way, either with the cerebral ganglia or with each other. These structural modifications unquestionably point to functional differences in the several parts in which they are found. But further, special connections through the commissural and association systems of fibres are established between certain convolutions and not between others, and through the peduncular and tegmental fibres with different regions of the body, and it is possible not only that particular combinations of convolutions through an interchange of internuncial fibres may condition a particular state of psychical activity, but that these combinations may associate various convolutions together in the performance of a given intellectual act, just as in the muscular system several muscles are as a rule associated together for the performance of a given movement. Much light on the special functions of the convolutions will doubtless be thrown by studying their connections with each other and with other parts of the encephalon, just as the action of the members of a group of muscles is ascertained by examining the direction of their fibres and the attachment of their terminal tendons.

Physiological evidence has been obtained that some of the convolutions are especially associated with sensori-motor functions. Ferrier, by stimulating in monkeys the cerebral cortex in those regions in which the giant pyramidal cells, described on p. 289, are found, obtained movements of particular groups of muscles on the opposite side of the body, and by destroying the cortex in these regions, caused paralysis of the same muscles. Hence the convolutions which bound, or are adjacent to, the fissure of Rolando are regarded as centres associated with the production of certain movements. Ferrier also by injuring the cortex of other convolutions, has impaired or destroyed the perception of sensory impressions, and has thus associated the sense of sight with the angular gyrus ; that of hearing with the superior temporo-sphenoidal gyrus ; that of taste with the lower end of the temporo-sphenoidal lobe ; that of touch with the gyrus hippocampi and hippocampus major ; in all these cases the organ, the sensibility of which is lost or impaired, is on the opposite side to the injured convolution. The uncinate convolution again is the centre of the sense of smell on the same side, a relation which is supported by anatomical evidence. Broca and others have also shown that destruc-

tion by disease of certain convolutions impairs or destroys particular functions.

Variations within certain limits in the degree of complexity of arrangement of the convolutions are found in the human brain. The observations of Gratiolet and Marshall on the brains of women of the Bush race have shown that in them a greater simplicity of arrangement prevails, due to the foldings of the surface being less numerous than in the average European brain. Again, the observations of Rudolph and Hermann Wagner on the brains of Gauss and Dirichlet, the eminent mathematicians, show that the convoluted surface was much more tortuous, and the superficial area of the convolutions was considerably greater than in the average European brain. From these and other data, it is evident that a complex arrangement of the convolutions may co-exist with high intellectual powers. But it must also be admitted that men of undoubted intellectual ability have been found to possess brains in which the convolutions had no unusually complex arrangement. In endeavouring to form an estimate of the comparative value of the convolutions in different individuals, not only should the degree of tortuosity of the surface be inquired into, but the depth of the sulci, the thickness of the grey matter, and the quality of the tissue of which the convolutions are composed. A brain with deep sulci, conjoined with a thick layer of grey matter, but with comparatively simple gyri, might present as large a hemispherical ganglion as one the convolutions of which were more tortuous but less deep. That grey matter is presumably the most active which contains the greatest proportion of nerve cells in a given area. From the structural point of view, one may say that those convolutions present the most complex organisation in which with a large proportion of nerve cells, the foldings of the surface are tortuous, the sulci are numerous and deep, and the grey matter possesses relatively considerable thickness.

As regards the convolutions in opposite hemispheres of the same brain, it should be stated that a want of symmetry within certain limits is by no means uncommon.

Mass and Weight of the Brain.

The human brain is absolutely bigger and heavier than the brain of any animal, except the elephant and the larger whales. The brain of the elephant weighs from 8 to 10 lbs., and that of a large finner whale between 5 and 6 lbs. The human brain is also heavier relatively to the bulk and weight of the body than are the brains of the lower animals, except in some small birds and mammals. Considerable variations, however, exist in the size and weight of the human brain, both in the different races of mankind, and in individuals of the same race and in the two sexes. The heaviest brains occur in the white races.

The average weight of the adult European male brain is 49 to 50 oz. (about 3 lbs.), that of the adult female 44 to 45 oz.; so that the brain of a man is on the average fully 10 per cent. heavier than that of a woman. The greater weight of the brain in man as compared with woman is not in relation merely to his greater bulk, but is a fundamental sexual distinction; for, whilst there is a difference of 10 per cent. in the brain weight, the average stature of women is, according to Thurnam's calculations, only 8 per cent. less than that of men. Dr Boyd states that the average weight of the brain in the newly born male infant is 11·67 oz.; in the female only 10 oz. The exact age at which the brain reaches its maximum size has been variously placed at from the 3d to the 8th years by different authors; but it continues to increase in weight to 25 or 30, or as some say even to 40. After 60 the brain begins to diminish in weight; in aged males the average weight is about 45 oz., in females about 41 oz.

In some cases the adult brain considerably exceeds the average weight. The brains of several men distinguished for their intellectual attainments have been weighed: the brain of Cuvier weighed 64½ oz.; of Dr Abercrombie, 63 oz.; of Professor Goodsir, 57½ oz.; of Spurzheim, 55 oz.; of Sir J. Y. Simpson, 54 oz.; of Agassiz, 53·4 oz.; and of Dr Chalmers, 53 oz. But high brain weights have also been found where there was no evidence of great intellectual capacity. Peacock weighed four male brains which ranged from 62·75 to 61 oz.; Boyd, a specimen of 60·75 oz.; and I have in my possession one of a boy of 15, which weighed 60 oz. In the brains of the insane high brain weights have also been observed. Bucknill met with a brain in a male epileptic which weighed 64½ oz.; Thurnam, one which weighed 62 oz.; and in the cases examined in the West Riding Asylum, under the superintendence of Dr Crichton Browne, out of 375 males, the weight of the brain in 30 cases was 55 oz. or upwards, and the highest weights were 61 oz. in a case of senile dementia, 60½ oz. in a case of dementia, and 60 oz. in one of melancholia. No case has as yet been recorded of the weight of the brain in a woman of great intellectual attainments; but Boyd met with a woman's brain as high as 55·25 oz., and many instances of upwards of 50 oz. in women where there was no evidence of high mental endowment. Skae observed in a female monomaniac, a brain which weighed 61½ oz.; and of 300 females examined in the West Riding Asylum the weight of the brain in 26 cases was 50 oz. or upwards, the highest weights being 56 and 55 oz. in two cases of mania. The size and weight of the brain do not, therefore, *per se*, give an exact method of estimating the intellectual power of the individual, and a high brain weight and great intellectual capacity are not necessarily correlated with each other. For it must be remembered that the brain is not only the organ of the mind, but a great centre of

origin for sensory and motor nerves. Moreover it contains tracts of nerve fibres connecting it with the spinal cord and the nerves which arise from the cord, as well as collections of nerve cells belonging to these tracts. Hence it is both a psychical apparatus and a great sensori-motor piece of mechanism.

It seems certain, if the adult human brain, even amongst the most uncultivated peoples, falls below 30 oz., that this low weight is not merely incompatible with intellectual power and activity, but is invariably associated with idiocy or imbecility; so that the human brain has a minimum weight below which intellectual action is impossible. Amongst the more cultivated races the minimum weight-limit of intelligence is, however, in all probability higher than 30 oz. It has been placed by Broca at 32 oz. for the female, and 37 oz. for the male brain; and Thurnam's numbers are almost the same. To how low a weight the brain in the microcephalous idiot may fall is well shown in a case recorded by Theile, where it weighed only 10·6 oz., in Gore's case of 10 oz. 5 grs., and in Marshall's case, 8½ oz. But instances are not wanting in which the brains of idiots have exceeded even 50 oz. Langdon Down observed the brain of a male idiot aged 22, which weighed 59½ oz.; and J. B. Tuke has recently met with a brain of 60 oz. in a male idiot aged 37, the capacity of whose cranium was 110½ cubic inches. In the West Riding Asylum the brain weights in 10 idiots were not less than 34 oz., and in 5 cases exceeded 40 oz.

As yet the opportunities of weighing the brain in the coloured races of men have been but scanty. But from a very extensive series of observations made by Barnard Davis, not on the brains themselves, but on the cubic capacities of crania, from which an approximate estimate of the brain weight may be obtained with a fair measure of accuracy, the following facts are derived:—The average weight of the male brain in the African races is 45·6 oz.; of the female brain, 42·7 oz.: the average weight of the male brain in the Australian races is 42·8 oz.; of the female brain, 39·2 oz.: the average weight of the male brain in the Oceanic races, 46·5 oz.; of the female brain, 43 oz. The conclusions which may legitimately be drawn from an analysis of Barnard Davis's observations are as follows:—1st, That the average brain weight is considerably higher in the civilized European than in the savage races; 2d, That the range of variation is much greater in the former than in the latter; 3d, That there is an absence, almost complete, of specimens heavier than 54 oz. in the exotic races, so that the higher terms of the series are not represented; 4th, That though the male brains are heavier than the female, there is not the same amount of difference in the average brain weight between the two sexes in the uncultivated as in the cultivated peoples.

No reliable determinations have as yet been made of the exact pro-

portion, as regards bulk and weight, which the convolutions bear to the corpora striata, optic thalami, and corpora quadrigemina, but data are obtainable of the relative weight of the pons, cerebellum, and medulla to the entire encephalon. Between the ages of 20 and 70 the ratio of weight of the pons, cerebellum, and medulla, to the entire brain, is as 1 to 7·9, or about 13 to 100, and this relative weight is virtually the same in both sexes. From Peacock's observations the ratio of weight of the cerebellum alone to the entire encephalon is as 1 to 9, or about 11 to 100.

Origin, Arrangement, and Distribution of the Encephalic Nerves.

Several pairs of Cranial or Encephalic Nerves arise from the under surface or base of the encephalon, and pass outwards through foramina situated in the floor of the cranial cavity. Continental anatomists usually enumerate twelve pairs of cranial nerves; but because in one locality two of these nerves lie together and pass through the same foramen; and through another foramen three of these nerves emerge together from the skull, British human anatomists have restricted the number to nine pairs. These nerves are numbered from before backwards, in the order in which they are seen at the base of the brain. The names applied to the individual nerves, and their numerical designations, according to both the Continental and British methods, are given in the following table:—

	Continental.	British.
Olfactory Nerves,.....	1st pair	1st pair
Optic Nerves, ...	2d ,,	2d ,,
Oculo-motor Nerves,.....	3d ,,	3d ,,
Trochlear Nerves,.....	4th ,,	4th ,,
Trifacial or Trigeminal Nerves,.....	5th ,,	5th ,,
Abducent Nerves,.....	6th ,,	6th ,,
Facial Nerves (Portio dura),.....	7th ,,	7th ,,
Auditory Nerves (Portio mollis),...	8th ,,	
Glosso-pharyngeal Nerves,.....	9th ,,	8th ,,
Pneumogastric Nerves (Vagus),....	10th ,,	
Spinal Accessory Nerves,.....	11th ,,	
Hypoglossal Nerves,.....	12th ,,	9th ,,

These nerves may be arranged in three groups according to their function.

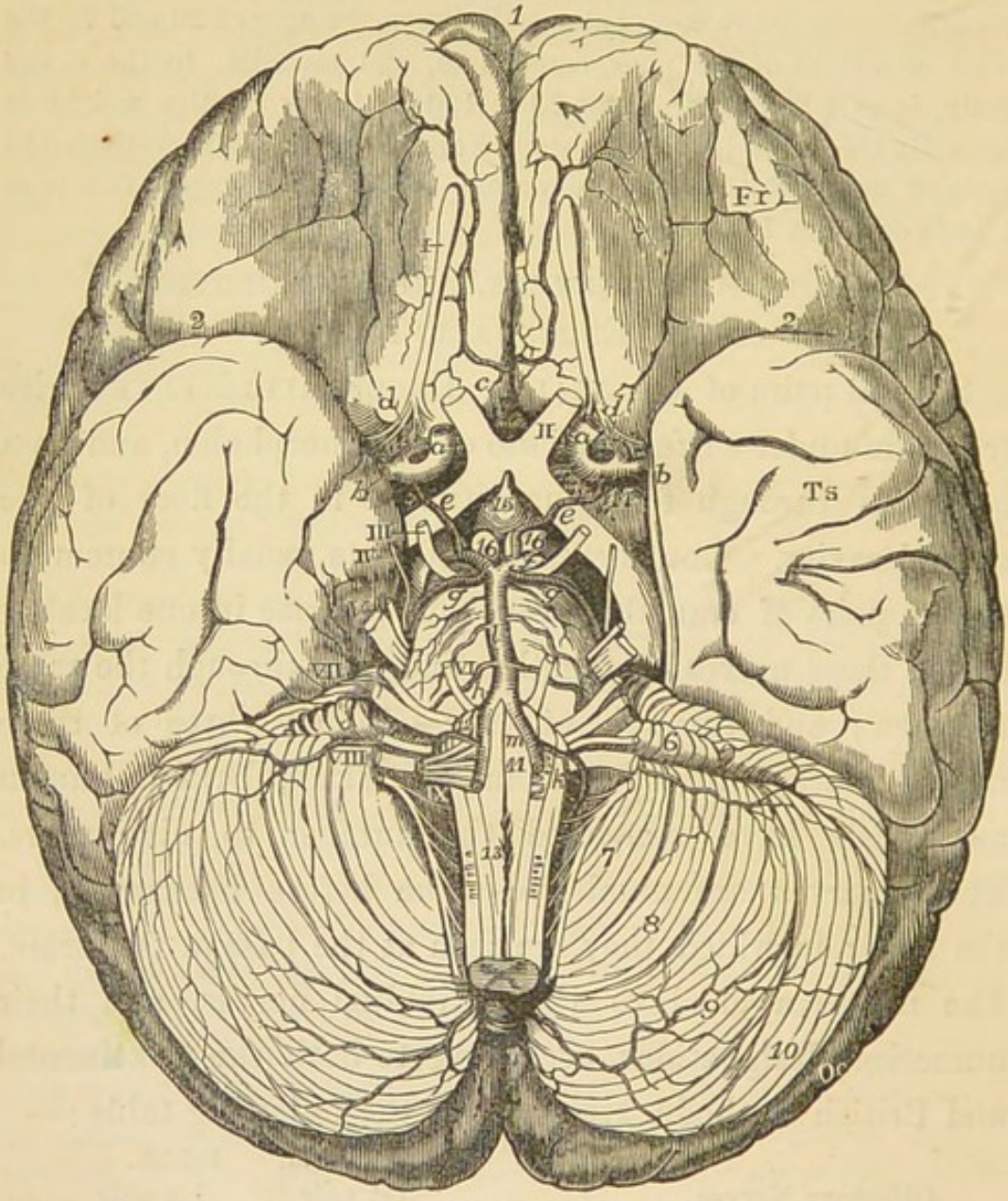

FIG. 94.—Diagram of the Base of the Brain with its nerves and arteries. I. to IX, cranial nerves; *a*, *a*, internal carotid artery; *b*, *b*, middle cerebral; *c*, anterior communicating; *d*, *d*, anterior cerebral; *e*, *e*, posterior communicating; *f*, posterior cerebral; *g*, *g*, superior cerebellar; *h* and *k*, inferior cerebellar; *l*, basilar; *m*, vertebral artery; *Fr*, frontal lobe; *Ts*, temporo-sphenoidal lobe; *Oc*, occipital lobe; 1, great longitudinal fissure; 2, Sylvian fissure; 6, flocculus; 7, tonsil; 8, postero-inferior; 9, slender; 10, biventral lobes of cerebellum; 11, left anterior pyramid; 12, right olivary body; 13, decussation of the pyramids; 14, left locus perforatus anticus; 15, tuber cinereum and infundibulum; 16, 16, corpora albicantia.

First group.—*Sensory* nerves, or nerves of special sense: *a*, olfactory, the nerve of smell: *b*, optic, nerve of sight: *c*, auditory, nerve of hearing.

Second group.—*Motor* nerves: *a*, oculo-motor, the principal nerve of supply for the muscles of the eyeball: *b*, trochlear, the nerve for the superior oblique muscle: *c*, abducent, the nerve for the external rectus: *d*, portio dura, the nerve for the facial muscles of expression: *e*, spinal accessory, the nerve which gives a motor root to the pneumogastric, and supplies the sterno-mastoid and trapezius muscles: *f*, hypoglossal, the nerve for the muscles of the tongue.

Third group.—*Mixed* nerves: *a*, trifacial, distributed to the muscles of mastication, the skin and mucous membranes of the face, and to the antero-lateral surfaces of the tongue: *b*, glosso-pharyngeal, distributed to the pharynx, to certain palato-pharyngeal muscles, and to the mucous membrane of the back of the tongue, where it acts as a nerve of the special sense of taste: *c*, the pneumogastric, conjoined with the internal division of the spinal accessory, is distributed to the pharynx, œsophagus, stomach, larynx, lungs and heart.

The 1st and 2d cranial nerves arise primarily from the anterior cerebral vesicle; the 3d and 4th from the middle cerebral vesicle and the remainder from the posterior cerebral vesicle.

The consideration of the First group of cranial nerves may appropriately be deferred until the organs of sense, in which they terminate, are described.

The anatomy of the Motor Nerves is as follows:—

The *Oculo-motor* or 3d *nerve* springs out of the inner surface of the crus cerebri. Its root fibres pass amidst the nerve cells of the locus niger, and reach the group of nerve cells situated in the corpora quadrigemina below the aqueduct of Sylvius. The nerve runs forwards in the outer wall of the cavernous sinus, divides into an upper and a lower branch, and enters the orbit through the

sphenoidal fissure, and between the two heads of the external rectus. It supplies the levator palpebræ superioris, the superior, inferior, and internal recti muscles, and the inferior oblique. It contributes the short or motor root to

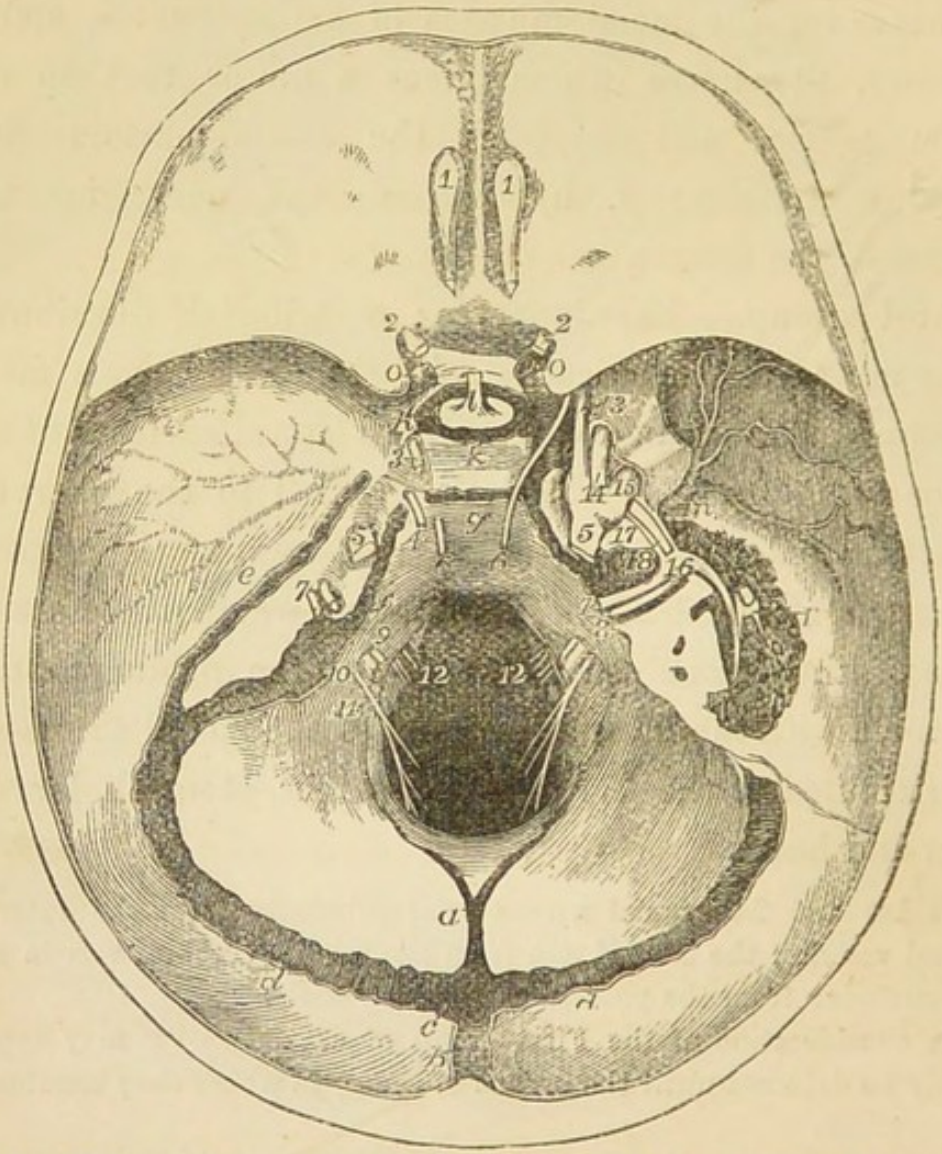

FIG. 95.—Floor of the Cavity of the Skull to show the places of exit of the nerves. 1 to 6, first to sixth cranial nerves; 7, portio dura; 8, portio mollis; 9, glosso-pharyngeal; 10, pneumogastric; 11, spinal accessory; 12, hypo-glossal; 13, 14, 15, first, second, and third divisions of fifth nerve; 16, knee-shaped ganglion of portio dura; 17 and 18, great and small superficial petrosal nerves; *a*, occipital sinus; *b*, superior longitudinal; *c*, torcular Herophili; *d*, lateral sinus; *e*, superior, and *f*, inferior petrosal sinus; *g*, transverse sinus; *h*, cavernous sinus; *k*, circular sinus; *l*, pituitary body; *m*, middle meningeal artery; *n*, *n*, bones of the ear; *o*, *o*, internal carotid artery.

the ciliary ganglion, and through it supplies the sphincter pupilæ of the iris and the ciliary muscle within the eyeball. It also communicates with the cavernous plexus of the sympathetic.

The *Trochlearis* or 4th, the smallest cranial nerve, lies at the outer side of the crus cerebri, and winds backwards, round the side of the superior peduncle of the cerebellum, to sink into the valve of Vieussens, where its fibres divide into three roots: one decussates across the valve with a root of the corresponding nerve on the opposite side; another passes backwards to the locus cæruleus; the third sinks into the corpora quadrigemina and reaches the group of nerve cells, from which the 3d nerve also arises. The 4th nerve runs forward in the outer wall of the cavernous sinus, enters the orbit through the sphenoidal fissure, and passes into the orbital surface of the superior oblique muscle. It also communicates with the cavernous plexus of the sympathetic and receives a twig from the 1st division of the 5th.

The *Abducent* or 6th *nerve* springs out of the groove between the lower border of the pons and the anterior pyramid of the medulla oblongata. Its roots sink deeply into the pons, and arise from the nerve cells of the *nucleus abducens* in the fasciculus teres, which nucleus also gives rise to one of the roots of the portio dura. The 6th nerve runs forward in the inner wall of the cavernous sinus in contact with the internal carotid artery, enters the orbit through the sphenoidal fissure, and between the heads of the external rectus, in which muscle it ends. It communicates with the carotid plexus of the sympathetic and receives a twig from the 1st division of the 5th.

The *Portio Dura* or *motor facial* portion of the 7th *nerve* springs out of the groove between the lower border of the pons and the restiform body. Its roots sink deeply into the pons; some fibres arise from the nucleus abducens, others from the *nucleus facialis*, situated deeper in the

pons close to the superior olive, and others again decussate across the median raphe of the pons. An accessory portion, called *portio intermedia*, which is said to arise from the lateral columns of the cord, joins the portio dura The portio dura enters the internal auditory meatus in the petrous-temporal bone along with the auditory nerve; but at the bottom of the meatus it leaves that nerve and enters the aqueduct of Fallopius, along which it is conducted through the bone to emerge at the stylo-mastoid foramen. When in the aqueduct it forms a *knee-shaped bend*, and expands into the *geniculate ganglion*, which is joined by the *great*, *small*, and *external superficial petrosal nerves*, and sends a twig to the vestibular branch of the auditory nerve. Through the external petrosal it communicates with the sympathetic and receives, probably from it, vaso-motor fibres; through the great petrosal, which subsequently forms a part of the vidian nerve, it communicates with Meckel's Ganglion on the 2nd division of the 5th nerve, and gives to that ganglion branches, which supply through it the levator palati and azygos uvulæ muscles; through the small petrosal it communicates with the Otic Ganglion and with the tympanic plexus of the glosso-pharyngeal nerve, and receives, probably from the latter, branches which pass off in the chorda tympani as its taste branches. The portio dura also communicates with the auricular branch of the vagus, and freely with the 5th cranial nerve. The portio dura gives off in the aqueduct—*a*, a minute branch to the stapedius muscle: *b*, the *chorda tympani*. After it has passed through the stylo-mastoid foramen it gives off—*c*, the *posterior auricular* branch to the occipital belly of the occipito-frontalis and to the retrahens aurem muscle: *d*, the *digastric* branch to the

posterior belly of the digastric and stylo-hyoid muscles; it then runs forwards through the parotid gland, where it expands into the *pes anserinus*, and divides into (*e*) *temporo-facial* and (*f*) *cervico-facial* branches to supply the facial muscles of expression, *i.e.*, the muscles of the scalp and external ear, the orbicular muscle of the eyelids, the muscles which dilate and compress the nostrils, the buccinator, the muscles which approximate and separate the lips, and also the platysma myoides. The Chorda Tympani enters the tympanum and passes, between the handle of the malleus and the long process of the incus, to a small foramen near the Glaserian fissure, through which it goes, and joins the lingual branch of the 5th nerve, which it accompanies. It is complex both in distribution and function. It is said to supply *motor* branches to the inferior lingualis and genio-hyo-glossus; *secretory* branches, through the sub-maxillary ganglion, to the sub-maxillary and sub-lingual glands; *sensory taste* branches to the mucous membrane of the anterior part of the tongue (pp. 316, 384); *vaso-motor* fibres to the vessels of the anterior part of the tongue. The portio dura is also said, through the connection between its small petrosal nerve and the auriculo-temporal in the otic ganglion, to influence the secretion of the parotid gland.

The *Spinal Accessory* is the lowest division of the 8th *nerve.* It springs out of the side of the medulla oblongata, and from the lateral column of the spinal cord as low as the 6th cervical nerve: its roots arise from the intermedio-lateral group of nerve cells in the cervical cord, and from the *nucleus accessorius* in the floor of the 4th ventricle close to the nucleus of the vagus. The spinal fibres of origin enter the skull through the foramen magnum, join

the fibres from the medulla, and leave the cranial cavity through the jugular foramen. This nerve, purely motor in function, is divided into two parts, an internal and an external. The *external* is derived from the spinal roots, it passes obliquely outwards across the side of the neck, pierces and supplies the sterno-mastoid, forms a plexus of communication with the 3d and 4th cervical nerves, and ends in the trapezius. The *internal* has its roots in the medulla oblongata, it joins the upper ganglion of the pneumogastric nerve, of which it forms the motor or accessory root, and is distributed along with it.

The *Hypoglossal* or 9th *nerve* springs out of the groove between the anterior pyramid and olivary body, in series with the anterior roots of the spinal nerves. Its roots pass through the medulla to the floor of the fourth ventricle, to arise from the nerve cells in the *hypoglossal nucleus*, and *nucleus ambiguus*, situated close to the median furrow (fig. 80). The nerve passes out of the skull through the anterior condyloid foramen, and arches across the side of the neck to the tongue. It gives off—*a*, the *descendens noni* branch, which, after being joined by the *communicantes noni* from the 2d and 3d cervical nerves, supplies the omo-hyoid, sterno-hyoid, and sterno-thyroid muscles: *b*, the *thyro-hyoid* branch to the thyro-hyoid muscle: *c*, the *genio-hyoid* branch to the genio-hyoid muscle: *d*, *glossal* branches to the extrinsic and intrinsic muscles of the tongue. It communicates in the neck with the sympathetic, vagus, lingual branch of the 5th and cervical plexus.

The group of Mixed Nerves will now be considered.

The *Trifacial* or 5th is the largest cranial nerve. It springs by two distinct roots out of the side of the pons. The *smaller* or *motor* root arises from the nerve cells of a

grey nucleus in the back of the pons, near the lateral angle of the 4th ventricle. The *larger* or *sensory* root has a complex origin—*a*, from a nucleus of grey matter in the pons to the outer side of the origin of the motor root: *b*, by descending fibres which arise from nerve cells in the substance of the corpora quadrigemina, and from the grey matter of the locus cæruleus (Meynert): *c*, by an ascending root which apparently arises from the grey tubercle of Rolando and ascends in the medulla external to the substantia gelatinosa, and between the restiform body and the corpus dentatum: *d*, probably by fibres from the cerebellum which accompany the superior peduncle of the cerebellum. The large sensory root of the fifth lies on the petrous bone, and expands into the Gasserian ganglion, which resembles in structure the ganglion on the posterior root of a spinal nerve. From this ganglion three large branches arise, named respectively the 1st, 2d, and 3d divisions of the ganglion (fig. 95). The 1st and 2d divisions are purely sensory, but the 3d division is joined by the motor root and becomes a mixed nerve.

The 1*st* or *Ophthalmic division* is the upper sensory nerve of the face, it lies in the outer wall of the cavernous sinus and divides into three branches, which pass into the orbital cavity through the sphenoidal fissure. *a*, Its *lachrymal* branch supplies the lachrymal gland, and the outer part of the skin and conjunctiva of the upper eyelid, and sends a branch to join the subcutaneous malar nerve. *b*, Its *frontal* branch divides into the *supra-trochlear* and *supra-orbital*; the supra-trochlear supplies the inner part of the skin and conjunctiva of the upper eyelid and eyebrow; the supra-orbital passes through the supra-orbital foramen and supplies the skin of the forehead and scalp as

far back as the vertex. *c*, Its *oculo-nasal* branch goes between the heads of the external rectus, lies superficial to the optic nerve, and divides into a *nasal* nerve to the mucous membrane of the nose, and to the skin of the side of the nose, and an *infra-trochlear* nerve to the conjunctiva and integument of the eyelids. The oculo-nasal nerve gives off *long ciliary* nerves directly to the eyeball. Also the *long* or *sensory* root of the small *Ciliary ganglion*, which lies in the cavity of the orbit, external to the optic nerve, and which receives also a *motor* root from the 3d nerve, and a sympathetic root from the cavernous plexus. This ganglion gives origin to the *short ciliary* nerves for the ciliary muscle and iris.

The 2*d* or *Superior Maxillary division* is the sensory nerve for the middle part of the face. It leaves the skull by the foramen rotundum, passes across the spheno-maxillary fossa, and through the spheno-maxillary fissure, then lies in the canal in the floor of the orbit, from which it emerges on the face through the infra-orbital foramen as the *infra-orbital* nerve. It gives off—*a*, a small *orbital* branch which divides into a *temporal* branch for a small part of the skin of the temple, and a *subcutaneous malæ* branch for the skin over the check bone : *b*, *posterior* and *anterior dental* branches to the teeth in the upper jaw : *c*, *spheno-palatine* branches ; *d*, *palpebral* branches to the skin and conjunctiva of the lower eye-lid : *e*, *nasal* branches to the skin and mucous membrane of the nose : *f*, *labial* branches to the skin and mucous membrane of the upper lip. The spheno-palatine branches arise in the spheno-maxillary fossa and form the *sensory* root of the *Spheno-palatine* or *Meckel's ganglion.* This ganglion receives a *motor* root through the great petrosal nerve from the knee-

shaped bend of the portio dura, and a *sympathetic* root from the carotid plexus, which runs along with the great petrosal, and forms with it the *Vidian* nerve. The ganglion gives origin to—*a*, an *orbital* branch, which supplies a layer of non-striped muscular fibres, described by H. Müller and myself as developed in connection with the periosteum of the orbit, where it covers the spheno-maxillary fissure: *b*, *upper nasal* and *naso-palatine* branches to the mucous membrane of the nose and anterior part of hard palate: *c*, *descending palatine* branches to the mucous membrane of the hard and soft palate, and through them the fibres of the portio dura conveyed by the Vidian to Meckel's ganglion are transmitted to the levator palati and azygos uvulæ: *d*, *pterygo-palatine* to the mucous membrane of the upper part of the pharynx.

The 3*d* or *Inferior Maxillary division* passes out of the skull through the foramen ovale, and as it does so is joined by the whole motor root of the 5th nerve. By the junction a mixed nerve is formed, which is the sensory nerve for the lower part of the face, and the skin of the temple, and the motor nerve for the muscles of mastication. Immediately after passing through the foramen this nerve divides into a smaller and larger division, in each of which motor and sensory fibres are found. The *smaller division* supplies *motor masticatory* branches to the masseter, temporal, external and internal pterygoid muscles. It also gives off a *long buccal* branch, which, though often described as the motor nerve for the buccinator muscle, is really a sensory nerve for the skin and mucous membrane of the cheek: the sensory nature of this nerve is proved, both by physiological and pathological experiments, and by tracing its fibres through the buccinator muscle to the mucous

membrane. I have also observed two cases in which the long buccal nerve arose as a branch of the sensory superior maxillary nerve. The *larger division* separates into three branches—*a*, *auriculo-temporal*, which ascends to supply the parotid gland, the temporo-maxillary joint, and, as the *superficial temporal* nerve, supplies the skin of the auricle, external meatus, and temple: *b*, *inferior dental*, which enters the dental canal in the lower jaw, supplies the lower set of teeth, and, emerging through the mental foramen, as the *mental* nerve, supplies the skin and mucous membrane of the lower lip; the inferior dental also gives off a *mylo-hyoid* branch to the mylo-hyoid and anterior belly of the digastric muscle: *c*, *lingual* or *gustatory*, which, accompanied by the chorda tympani, runs forward along the side of the tongue to end in the filiform and fungiform papillæ of its mucous membrane. The lingual branches are sensory nerves of touch, and many physiologists believe that they are also nerves of taste. Connected with the branches of the inferior maxillary division are two small ganglia, which, like the ciliary and spheno-palatine ganglia, are of a greyish colour, contain nerve cells, and receive roots from motor, sensory, and sympathetic nerves. The *Submaxillary ganglion* lies under cover of the mylo-hyoid muscle, and receives a root from the chorda tympani which contains the *secretory* fibres of that nerve, a root from the *sensory* lingual, and a *sympathetic* root from the plexus on the facial artery. It gives branches to the sub-maxillary and sublingual salivary glands. The *Otic ganglion* lies close to the Eustachian tube, and in front of the middle meningeal artery. It receives a *motor* root from the nerve to the internal pterygoid, a *sensory* root from the auriculo-temporal, and a *sympathetic* root from the plexus on the middle

meningeal. It also receives the *small petrosal* nerve, through which it obtains roots from the knee-shaped bend of the portio dura and the glosso-pharyngeal nerve. It supplies the tensor tympani and tensor palati muscles, and sends a twig to the chorda tympani. The branches of the three divisions of the 5th cranial nerve, which pass to the skin of the temple, forehead, and face, freely communicate with the branches of the portio dura, which supply the muscles situated in those regions.

The *Glosso-pharyngeal* or uppermost division of the 8th nerve springs out of the side of the medulla between the olivary and restiform bodies; its roots arise from a grey nucleus in the floor of the 4th ventricle (fig. 80) in common with one root of the vagus. It leaves the skull through the jugular foramen, and possesses two small *ganglia*, the *jugular* and *petrous*. It then runs across the side of the neck, in relation to the stylo-pharyngeus, and gives off *carotid* branches along the internal carotid artery: *pharyngeal* branches to the mucous membrane of the pharynx: *muscular* branches to the stylo-pharyngeus and perhaps the middle constrictor: *tonsilitic* branches to the tonsil and soft palate: *glossal* branches to the base of the tongue and the circumvallate papillæ, which branches are unquestionably nerves of the special sense of taste. Through the petrous ganglion the nerve communicates with the vagus and sympathetic. The petrous ganglion gives off the *tympanic* branch or *nerve of Jacobson*, which enters the tympanic cavity, and forms a plexus on the promontory: it supplies the mucous membrane of the tympanum and Eustachian tube, and gives off three communicating branches—one to the carotid plexus of the sympathetic: a second to the great petrosal, and through it to the knee-

shaped bend of the facial, which may be the path of taste fibres continued through the facial to the chorda tympani: a third to the small petrosal and otic ganglion, and through the latter to the auriculo-temporal of the 5th, through which connection the glosso-pharyngeal may act as the *secretory* nerve for the parotid gland. From the petrous ganglion a branch arises which forms a loop with the digastric branch of the portio dura and perhaps conveys motor fibres to the glosso-pharyngeal from the portio dura.

The *Pneumogastric* or *Vagus*, the middle division of the 8th cranial nerve, springs out of the side of the medulla between the olivary and restiform bodies; its roots arise from the *nucleus pneumogastricus* in the floor of the 4th ventricle, from the *nucleus ambiguus* situated deeper in the medulla, and from the *solitary* or *respiratory fasciculus*, which descends in the formatio reticularis and lateral column of the cord, as far as the cervical enlargement, where it comes into relation with the origin of the phrenic nerve. It goes through the jugular foramen, is joined by the inner division of the spinal accessory, which is its motor root, then passes down the side of the neck within the carotid sheath, enters the thorax, inclines behind the root of the lung, reaches the outer wall of the œsophagus, accompanies that tube through the diaphragm, and terminates in the wall of the stomach. The left nerve lies on a plane anterior to the right: it crosses in front of the arch of the aorta, and is distributed to the anterior wall of the stomach, whilst the right nerve supplies the posterior wall. Each nerve possesses two enlargements, the *upper* and *lower ganglia*. The upper ganglion lies in the jugular foramen; it communicates with the sympathetic and glosso-pharyngeal, and gives origin to the *auricular* branch,

which traverses a small canal in the petrous temporal, and emerging through a hole behind the external meatus ends in the skin of the back of the auricle. The lower ganglion is high in the neck: it communicates with the sympathetic and hypoglossal, and gives origin to—*a*, two *pharyngeal* branches which form with the glosso-pharyngeal and sympathetic nerves the pharyngeal plexus, which supplies the muscles of the pharynx: *b*, the *superior laryngeal*, which divides into an *external* branch to supply the crico-thyroid muscle, and an *internal*, which pierces the thyro-hyoid membrane, supplies the mucous lining of the larynx and the mucous covering of the epiglottis and root of the tongue. From the nerve trunk arise—*a*, the *recurrent laryngeal*, which on the right side turns round the subclavian artery, and on the left round the ductus arteriosus and arch of the aorta; it ascends between the trachea and œsophagus, supplies their muscular and mucous coats, and enters the larynx to end in its intrinsic muscles except the crico-thyroid: *b*, *cardiac* branches, which arise from the nerve trunk both in the neck and chest, and from the recurrent laryngeal nerves; they join the great cardiac plexus and furnish inhibitory nerves for the heart: *c*, *pulmonary* branches, which arise in the chest, and form along with the sympathetic an *anterior pulmonary plexus* in front of, and a *posterior pulmonary plexus* behind the root of the lung; they enter the lung and supply the bronchial muscles and mucous membrane: *d*, *œsophageal* branches form a plexus, and supply the coats of the œsophagus; *e*, *gastric* branches, which supply the coats of the stomach, send branches to the liver and to the solar plexus of the sympathetic, through which it influences the small intestine, spleen, pancreas, kidneys, and supra-renal capsules.

The Sympathetic Nervous System.

The Sympathetic Nervous System consists of a pair of gangliated cords, situated one on each side of the spinal column; of three great gangliated prevertebral plexuses situated in the thoracic and abdominal cavities; of numerous smaller ganglia lying more especially in relation with the thoracic and abdominal viscera; of multitudes of fine communicating and distributory nerves, which apparently possess sensory, motor, vaso-motor, secretory and inhibitory functions.

Each *Gangliated Cord* of the sympathetic extends along the side of the spine from the base of the skull to the coccyx. In the neck it lies in front of the transverse processes of the vertebræ; in the thorax, upon the heads of the ribs; in the abdomen, on the sides of the vertebral bodies; and as it descends in front of the sacrum it approaches its fellow, so that in front of the coccyx the two are united in the single ganglion, the *ganglion impar* (fig. 77, *c*). Each cord consists of a number of ganglia united into a continuous chain by intermediate nerves. As a rule, the ganglia equal in number the vertebræ of the region. Thus, in the sacral region there are five ganglia, in the lumber five, and in the thorax twelve; but in the neck there are only three, named superior, middle, and inferior; of these the superior is very large, lies opposite the 2d and 3d cervical vertebræ, and represents without doubt four smaller ganglia. From the superior cervical ganglion the cord is prolonged upwards by an *ascending* or cranial offshoot, through the carotid canal into the cranial cavity, and forms a plexus around the internal carotid artery, both in the carotid canal, named the *carotid plexus*,

and in the inner wall of the cavernous sinus, named the *cavernous plexus.*

From the gangliated cord and its ascending or cranial prolongation a communicating and a distributory series of branches are derived.

By the *Communicating* branches this portion of the sympathetic is connected with most of the cranial and with the anterior divisions of all the spinal nerves, so as to bring the cerebro-spinal and sympathetic systems into close anatomical and physiological relation with each other. It is important also to observe that each communicating branch contains both non-medullated nerve fibres from the sympathetic system to the cerebro-spinal nerves, and medullated fibres from the cerebro-spinal to the sympathetic, so that a double interchange takes place between the two systems. The superior cervical ganglion, with its cranial prolongation, communicates with the 3d and 4th cranial nerves, with the Gasserian, ciliary and spheno-palatine ganglia of the 5th, with the 6th, the portio dura of the 7th, the glosso-pharyngeal and pneumogastric of the 8th, with the 9th cranial nerve, and with the anterior divisions of the four upper cervical spinal nerves. The middle cervical ganglion is in relation with the inferior thyroid artery, and communicates with the 5th and 6th cervical nerves; the inferior cervical ganglion is in relation with the vertebral artery and communicates with the 7th and 8th cervical nerves: the twelve thoracic ganglia communicate with the series of intercostal nerves; the five lumbar ganglia with the series of lumbar spinal nerves; the sacral and coccygeal ganglia with the sacral nerves and the coccygeal nerve.

The *Distributory* branches of the gangliated cord are as

follows :—*a*, *Pharyngeal* branches from the superior cervical ganglion, which join the pharyngeal branches of the glosso-pharyngeal and pneumogastric nerves, to form the *pharyngeal plexus*, which supplies the muscles and mucous membrane of the pharynx. *b*, *Articular* branches from the upper thoracic and the lumbar ganglia to the articulations between the adjacent vertebræ. *c*, *Pulmonary* branches from the 3d or 4th thoracic ganglia, which join the posterior pulmonary plexus. *d*, *Vaso-motor* branches or *nervi molles*, which supply the muscular coat of the arteries : those which arise from the cranial prolongation of the superior cervical ganglion supply the internal carotid artery and its branches to the brain and eyeball : those which arise from the superior cervical ganglion itself supply the external carotid artery and its branches ; from the branch accompanying the facial artery the submaxillary ganglion derives its sympathetic root ; from that accompanying the middle meningeal artery the otic ganglion derives its sympathetic root : the vaso-motor nerves which arise from the middle cervical ganglion supply the inferior thyroid artery, and pass to the thyroid gland : the vaso-motor branches of the inferior cervical ganglion supply the vertebral and basilar arteries and their several branches, which pass to the spinal cord and the hinder part of the encephalon. Vaso-motor nerves also arise from the thoracic ganglia, which pass to the thoracic aorta, from the lumbar ganglia to the abdominal aorta, and from the sacral ganglia to the middle sacral artery ; the ganglion impar gives branches to a peculiar vascular structure, named the *coccygeal body*, developed in connexion with the end of the middle sacral artery ; a body of similar structure, called *intercarotic body*, situated in the angle of bifurcation of

the common carotid artery, receives branches from the superior cervical ganglion. *e, Cardiac* branches from the superior, middle, and inferior cervical and the 1st thoracic ganglia, which pass to join the prevertebral cardiac plexus in the thorax. *f, Splanchnic* branches as follows :—*great splanchnic nerve*, by the union of branches from the thoracic ganglia, the 3d to the 10th inclusive ; it pierces the crus of the diaphragm, and joins the semilunar ganglion in the prevertebral solar plexus ; *small splanchnic nerve*, also to the solar plexus from the 10th or 11th thoracic ganglia ; *smallest splanchnic nerve*, from the 12th thoracic ganglion to the renal plexus. *g, Hypogastric* branches, from the lumbar and sacral ganglia to the prevertebral hypogastric plexus.

The *Prevertebral Cardiac plexus* is situated at the base of the heart, and is divided into a *superficial* part, which lies in the concavity of the arch of the aorta, and a *deep* part between the aorta and trachea. It receives the cardiac branches of the pneumogastric and the cervical ganglia of the sympathetic. It contains collections of nerve cells and a dense plexiform arrangement of nerve fibres. It gives off branches to the heart, which wind around the surface of that organ and penetrate its muscular substance : on these branches minute ganglia are found which regulate its rhythmical movements. Through these branches and the cardiac plexus the heart is brought into connection with both the cerebro-spinal and sympathetic systems of nerves. The sympathetic apparently regulates its contraction, for when this nerve is stimulated the action of the heart is accelerated. The pneumogastric again exercises an inhibitory or restraining influence on the contraction of the organ, for when this nerve is irritated the activity of contraction is diminished, but when divided it is greatly increased.

The cardiac plexus also sends offsets to the *anterior* and *posterior pulmonary plexuses* for the supply of nerves to the lungs.

The *Prevertebral Solar or Epigastric plexus* is situated at the pit of the stomach around the cœliac axis, a branch of the abdominal aorta. It receives the great and small splanchnic nerves from the thoracic ganglia of the sympathetic, and some of the terminal branches of the pneumogastric nerve. It contains large collections of nerve cells, which form the two *semilunar ganglia*, and a dense plexiform arrangement of nerve fibres. It gives origin, either directly or indirectly, to numerous plexiform branches, which accompany, and are named after, the abdominal aorta and its various branches given off to the walls and viscera of the abdomen proper. In this manner, not only do the arteries which supply the abdominal viscera receive their vaso-motor nerves, but also the muscular and mucous coats of the stomach, intestines, gall bladder, bile ducts, ureters, and seminal ducts, the glandular structures of the liver, pancreas, kidneys, testes, and the spleen and suprarenal capsules. It is important also to observe that these plexuses of distribution not unfrequently contain small ganglia, and the branches which supply the muscular coat of the stomach and intestines have minute microscopic ganglia, with stellate nerve cells lying amidst them. The distribution of the pneumogastric nerve to the stomach, and its connection with the solar plexus, enables that nerve to stimulate its peristaltic contraction, and, according to some experimenters, that of the small intestine also; but the precise action of the sympathetic on these organs is still a disputed question, though some physiologists hold that it is the inhibitory nerve for those organs.

The *Prevertebral Hypogastric plexus* is situated in front of the last lumbar vertebra. It receives branches from the lumbar ganglia of the sympathetic, and from the plexus surrounding the abdominal aorta. It divides into two parts, which lie one on each side of the rectum, and are called the *pelvic plexuses;* these plexuses are joined by branches from the sacral ganglia of the sympathetic, and from the 3d and 4th sacral spinal nerves, and contain small gangliform collections of nerve cells. From the pelvic plexuses numerous plexiform nerves arise, which accompany the internal iliac artery and its branches to the walls and viscera of the pelvis, and are named after them. These nerves supply not only the vaso-motor nerves for these blood-vessels, but also the muscular coat and mucous membrane of the bladder, rectum, and urethra, besides the prostate gland in the male, and the uterus and vagina, and in part the ovary, in the female; in connection with their distribution to these viscera, minute ganglia are found lying amidst the nerves, the nerve cells in which act undoubtedly as centres of reinforcement for the origin of additional nerve fibres.

From the distribution of the branches of the gangliated cord of the sympathetic, and of the gangliated prevertebral plexuses, it will be seen that this nerve is especially associated with the blood-vessels and the thoracic and abdominal viscera. As the cerebro-spinal system is engaged in the supply of nerves to the voluntary muscles, the sympathetic is the medium of supply for the involuntary muscular apparatus, both in the coats of the vessels and in the walls of the hollow viscera. But though the vaso-motor nerves branch off from the sympathetic ganglia, it must not be supposed that they have no connection with

the cerebro-spinal system. The communicating branches between the sympathetic ganglia and the anterior divisions of the spinal nerves establish a connection between them and the cerebro-spinal nervous axis. By recent experiments, the tract of transmission of the vaso-motor fibres has been traced along with the anterior roots of the spinal nerves, through the lateral columns of the cord to the medulla oblongata, in which the vaso-motor nerve centre lies a little to one side of the mesial plane, above the calamus scriptorius. In the distribution of the sympathetic to the glandular viscera, it is important to attend to their terminations in the muscular coat of the blood-vessels of the glands, and the termination of the nerves in connection with the secreting cells themselves must be taken into consideration. The communications between the cerebro-spinal and sympathetic systems, through both the spinal nerves, and the pneumogastric, are to be kept in mind in considering the effects produced by varying mental conditions on the secretions of the glands.

CHAPTER VI.

ORGANS OF SENSE.

THE Organs of Sense are the organs through the intermediation of which the mind becomes cognisant of the appearance and properties of the various objects in the external world. These organs are severally named nose, eye, ear, tongue, and skin. For the excitation and perception of a sensation three sets of structures are necessary: *a*, a peripheral end-organ; *b*, a sensory nerve; *c*, a central organ. The peripheral end-organ is the part of the apparatus to which the stimulus necessary for the production of the sensation is applied. This stimulus causes nervous impulses to be propagated from the end-organ along the fibres of the sensory nerve to the central organ, in which that nerve terminates at its central extremity. These nervous impulses occasion molecular changes in the nerve cells of the brain, and the mind becomes conscious of a sensation. The shape and construction of each organ of sense is adapted to the application of the stimulus required for the production of the particular sensation to which the organ is subservient. Each organ of sense possesses its own characteristic form of end-organ. The touch corpuscles of the skin, the end bulbs found in several mucous membranes, and the Pacinian corpuscles, are the end-organs

occurring in their several localities; the peripheral ends of the sensory nerves pass into their substance, and the axial cylinder of the nerve fibre ends in their interior. The rods and cones of the retina, the organ of Corti in the cochlea, the olfactory cells of the nose, and the gustatory bodies in the tongue, are the end-organs belonging to their several organs of sense; the sensory nerve fibres which terminate in relation with them have not yet, however, been traced into actual continuity with their substance. A stimulus, whatever may be its nature, applied to any organ of sense can excite only that kind of sensation for the production of which the organ is subservient. Thus a stimulus applied to the eye, whether it be the natural stimulus of the waves of light, the mechanical stimulus of a blow, or an electric stimulus, can only excite the sensation of light. Stimuli applied to the ear can only excite the sensation of sound, and in like manner with the other senses. In studying the anatomy of the organs of sense the arrangement of numerous accessory structures, which assist either in conducting stimuli or in modifying their effects, the arrangement and structure of the peripheral end-organs, and the origin, course, and distribution of the sensory nerves, will have to be considered.

The Nose.

The Nose or organ of smell is a large cavity situated in the face, between the orbits, above the mouth, and below the cribriform plate of the ethmoid bone. It communicates by the *anterior nares*, or nostrils, with the external atmosphere, by the *posterior nares* with the pharynx, and through it with the larynx, trachea, and lungs. It is not only the organ of smell, but is the proper entrance to the respiratory

passage, is accessory to the production of the voice, aids in the sense of taste, and forms one of the most important features of the face. It is divided into a right and a left chamber by a vertical mesial partition, the *septum nasi*, so that the nose is a double organ in the same sense as the eyes or ears are double. The walls of the cavity of the nose are formed partly of bone and partly of cartilage. The osseous walls are referred to on page 35. The cartilages form the point, the alæ, and a part of the septum nasi. The *mesial* or *septal cartilage* is triangular in shape, and fits into the interval between the vomer, the mesial plate of the ethmoid, and the nasal spine of the superior maxilla (fig. 7). Anteriorly and inferiorly its border is free, projects on the face, and forms the *columna* of the nose. The *lateral cartilages* form the tip and alæ. On each side is an *upper lateral cartilage* attached by its outer margin to the free edge of the nasal bone and superior maxilla, whilst by its inner it is continuous with the anterior border of the septal cartilage. The *lower lateral cartilage* curves inwards upon itself, touches its fellow in the mesial plane at the tip, and forms the anterior and lateral boundary of the orifice of the nostril. It is connected by fibrous membrane above to the upper lateral cartilage, and behind to the anterior edge of the superior maxilla. In this membrane two to five small cartilaginous plates, called the *epactal cartilages*, are often found imbedded. The skin of the nose, which covers the lower lateral cartilage, contains numerous sebaceous follicles, which open by comparatively large orifices on the surface. It is closely connected to these cartilages, and to the muscles of the alæ. The lower lateral cartilage forms the wall of the *vestibule* or entrance to the nasal chamber, and the vestibule is lined by a pro-

longation of the integument, studded with numerous short hairs or *vibrissæ* which possess large sebaceous glands. Each nasal chamber is lined by a mucous membrane called the *pituitary* or *Schneiderian* membrane, which is prolonged into the meatuses and the air sinuses opening into them; posteriorly it is continuous with the mucous lining of the pharynx, and anteriorly it blends with the cutaneous lining of the vestibule. The pituitary membrane is thick and soft, and diminishes the size of the meatuses and the openings of the air sinuses as seen in the skeleton. The mucous membrane is divided into a respiratory and an olfactory region. The *respiratory region* corresponds to the floor of the nose, to the inferior turbinated bone, and to the lower third of the nasal septum. It is covered by a ciliated columnar epithelium, and contains numerous racemose glands for the secretion of mucus or *pituita*. It is also vascular, and the veins which ramify in it have a plexiform arrangement. The mucous lining of the air sinuses is also ciliated, but almost devoid of glands, except in the antrum, in which region the glands sometimes dilate into cystic tumours.

The *olfactory region* is the seat of distribution of the olfactory nerve and of its peripheral end-organs. It corresponds to the roof of the nose, to the superior and middle turbinals, and the upper $\frac{2}{3}$ds of the septum. The mucous membrane is thick, soft, easily destroyed, of a yellowish-brown colour, and blended with the periosteum. When vertical sections through this membrane are examined microscopically, the tubular glands discovered by Bowman may be seen in its vascular connective tissue layer. These glands contain roundish secreting cells, with yellowish-brown pigment-stained contents. The epithelium is

columnar, but not usually ciliated, though patches of ciliated epithelium cells are said to occur in man. Long, slender, and even branched processes proceed from the deeper end of each cell towards or even into the subepithelial connective tissue. The cells usually contain pigment granules. Between the epithelium cells the characteristic olfactory cells of Schultze are situated. Each *olfactory cell* (fig. 96) consists of a globular or fusiform body, from which two long processes arise: one, the *peripheral process*, passes vertically between the adjacent columnar epithelium cells to the free surface of the mucous membrane: in amphibia, reptiles, and birds it projects beyond the plane of the epithelium as a simple hair-like structure, or divided into several slender "*olfactory hairs;*" in fish and mammals, man inclusive, it ends, without forming a hair-like prolongation, on the general plane of the mucous surface. The second or *central process* of the olfactory cell extends towards the sub-epithelial connective tissue: it is finer than the peripheral process, and has not unfrequently a varicose appearance like a nerve fibre. In the intervals between the central processes of the olfactory cells and the cylindrical epithelium cells are small globular or elongated *basal* or *replacement cells*, which are probably an early stage of columnar epithelium.



FIG. 96. — Section through the Olfactory Mucous Membrane. *e*, epithelium cell; *o*, olfactory cell; *c*, its central varicose process; and *p*, its peripheral process. (*After Schultze.*

In the description of the development of the brain (p. 210), the origin of the OLFACTORY BULB and PEDUNCLE from the hemisphere vesicle was referred to. In the adult

brain the *olfactory peduncle* is in relation with the olfactory sulcus on the under surface of the frontal lobe (fig. 88). It is a white band, which passes back to the *trigonum* or *tuber olfactorium*, situated immediately in front of the locus perforatus anticus, where it divides into its so-called roots. The *external* or *long root* passes outwards to the uncinate gyrus, which is the convolutionary centre of the sense of smell (Ferrier). The *internal* or *short root* has been traced into the anterior end of the gyrus fornicatus. The *middle* or *grey root* is continuous with the locus perforatus anticus. Broca has also described a *superior root* continuous with the white matter of the adjacent part of the frontal lobe. But further, the peduncle receives some fibres from the anterior commissure, which are more numerous in those animals that possess a strong sense of smell and a large olfactory lobe. The *olfactory bulbs* rest on the upper surface of the cribriform plate of the ethmoid, one on each side of the crista galli. Each bulb consists both of grey and white matter, and sometimes retains the central cavity lined by a ciliated epithelium. The grey matter contains fusiform and pyramidal nerve cells imbedded in neuroglia (the *stratum gelatinosum* of L. Clarke). Between it and the central cavity is the white matter formed of nerve fibres interspersed with "granules," similar to those seen in the rust-coloured layer of the cerebellum. Between the grey matter and the surface is the *stratum glomerulosum* of Meynert, which apparently consists of coils of the olfactory nerve fibres with interspersed "granules." The *olfactory nerve fibres* form the first pair of cranial nerves or nerves of smell; they leave these coils in from 15 to 25 bundles, and enter the roof of the nose through the holes in the cribriform plate; they lie in

grooves in the bones of the olfactory region, and form a network from which bundles of fine non-medullated fibres arise that enter the mucous membrane and run between the glands into the epithelial layer. These nerves have a varicose appearance, and though their terminations have not been precisely ascertained, it is believed that they are connected with the varicose central processes of the olfactory cells, which cells are therefore regarded as the peripheral end-organs of the olfactory nerve fibres. The mucous membrane of the nose also receives nasal branches from the 1st and 2d divisions of the 5th cranial nerve. Their mode of termination in that membrane is not known, but they are associated with the sense of touch, and not with the special sense of smell.

Development of Nose.

The nose appears on the face of the embryo in the form of a little depression in the epiblast, the *nasal pit*, which by the growth forward of the mesial trabecular cartilage becomes divided into two nasal fossæ. Each fossa is superficial to the olfactory bulb, which is prolonged forward from the corresponding hemisphere vesicle. From the fronto-nasal process the integument and facial part of the nose are formed. At first the rudimentary nasal chambers freely communicate with the cavity of the mouth ; but by the growth inwards, to the mesial line of the palate of the palatal processes of the maxillo-palatine lobes, the cavity of the mouth is shut off from the nose, except where the incisive canals remain pervious in the anterior part of the upper jaw bones. As the nasal pits are lined by an involution of the epiblast, the epithelial lining of the nose, including the olfactory cells, is derived from the epiblast cells. The osseo-cartilaginous framework of the nose is produced by a differentiation of the mesoblast cells of the embryo head.

The Eyeball.

The Eyeball, globe or apple of the eye, or organ of vision, is a complex optical apparatus situated in the cavity of the orbit, imbedded to a large extent in loose fat, and

with several muscles attached to it. Its form approximates to the spheroidal, but it actually consists of segments of two spheres, the posterior of which is the larger.

The eyeball consists of three coats or tunics, which enclose three translucent refracting media. The first, or external, or fibrous coat consists of a posterior, white,

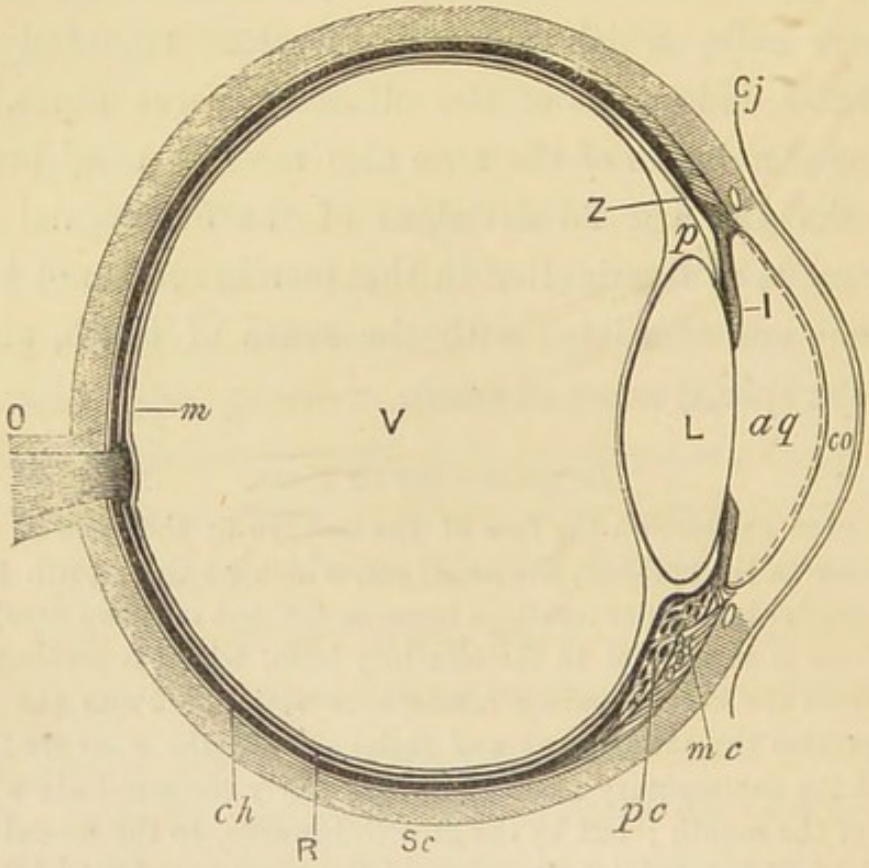

FIG. 97.—Diagrammatic section through the Eyeball. *cj*, conjunctiva; *co*, cornea; Sc, sclerotic; *ch*, choroid; *pc*, ciliary processes; *mc*, ciliary muscle; O, optic nerve; R, retina; I, iris; *aq*, anterior chamber of aqueous humour; L, lens; V, vitreous body; Z, zonule of Zinn, the ciliary process being removed to show it; *p*, canal of Petit; *m*, macula or yellow spot. The dotted line behind the cornea represents its posterior epithelium.

opaque part, the *sclerotic*, which corresponds in its area with the posterior larger segment of the eyeball, and of an anterior, translucent part, the *cornea*, which corresponds in its area with the anterior smaller segment of the eyeball. Piercing the sclerotic coat is the optic nerve, which enters the globe about $\frac{1}{8}$th or $\frac{1}{10}$th inch to the nasal or inner side of its antero-posterior axis. The second or middle coat,

or tunica vasculosa, consists of the *choroid*, the *ciliary processes*, and the *iris*. The third or internal or nervous coat is named the *retina*, and in it the optic nerve terminates. The enclosed refracting media occupy the axis of the globe, and are named from before backwards, the *aqueous humour*, *crystalline lens*, and *vitreous body*.

The External or Fibrous Tunic.

The *Sclerotic coat*, called from its white appearance the white of the eye, is a firm, unyielding fibrous membrane, which forms the posterior $\frac{5}{6}$ths of the outer coat, and gives form to the eyeball. It is thicker behind than in front, and where pierced by the optic nerve it has a cribriform structure, as the bundles of nerve fibres do not pass through one large, but several small openings. Its inner surface is flocculent, and brown (*lamina fusca*) from contact with the choroid. The sclerotic consists of the white fibrous tissue, intermingled with a small proportion of elastic fibres. The bundles of white fibres lie in two directions; some pass in the meridian of the globe from the optic nerve towards the cornea, others lie parallel to its equator. The sclerotic is joined by accessory fibres behind, derived from the perineurium of the optic nerve, where the nerve pierces it; and in front from the tendons of the recti and obliqui muscles, which are inserted into it. It is not very vascular. In the cetacea the sclerotic possesses extraordinary thickness. In fish and amphibia it consists largely of cartilage, and in birds a ring of bone is developed around its anterior margin.

The *Cornea* forms the translucent anterior $\frac{1}{6}$th of the outer coat of the eyeball. It is almost circular in form, and is blended at its circumference with the anterior border

of the sclerotic. Its anterior surface is convex, and covered by the conjunctival epithelium. The forward projection of the cornea is always greater in young than in aged persons. Its posterior surface is concave, and bounds the chamber in which the aqueous humour is contained; if the chamber be punctured, and the humour evacuated, the cornea loses its translucency, tension, and forward convexity, and becomes flaccid and opaque. It has considerable thickness, and can be readily split up into laminæ. When antero-posterior sections are made through it and the epithelium on its anterior and posterior surfaces, four distinct series of structures may be seen, viz., the anterior epithelium, the proper tissue of the cornea, the posterior elastic lamina, and the posterior epithelium.

The *anterior epithelium* of the cornea, often called the conjunctival epithelium, is stratified. The deepest layer, which lies next the cornea, is formed of columnar cells, placed vertically to the plane of the surface of the cornea. The more superficial layers are squamous cells, often with fluted surfaces and prickle-like edges. The intermediate layers are irregular in shape, and often possess, as Cleland pointed out, long digitate processes, which interlock with those of the adjacent cells. The nuclei of the cells contain an intra-nuclear network (Klein).

The *proper tissue of the cornea* is a modified form of connective tissue. When examined fresh it appears as if perfectly homogeneous, but after a time, and more especially if hardened in alcohol, chloride of gold, and other reagents, it is seen to consist of cells and an intercellular matrix. The cells consist of two kinds,—those which belong to the cornea, and those which have migrated into it. The proper cornea cells or *cornea*

corpuscles were first seen by Toynbee, and have now been carefully studied. They are large stellate, flattened cells, and lie with their surfaces parallel to the surfaces of the cornea; they possess branching thread-like processes, and the processes of adjacent cells anastomose to form a cell network (fig. 98). Each corpuscle consists of a hyaline ground plate containing an oval nucleus, which is surrounded by protoplasm. Both the protoplasm and the nucleus possess a close reticulum of fibrils (Klein). In vertical sections through the cornea the corpuscles seem as if shaped like elongated spindles. The *migrating cells* of the cornea were first seen by Von Recklinghausen. They resemble white blood corpuscles, and possess active amœboid movements, so that they can wander through the lacunæ and lymph spaces of the cornea. In a healthy cornea they have migrated out of the marginal blood-vessels; but in an inflamed cornea, where their number is greatly increased, they are in part white corpuscles derived from the blood, and in part produced by proliferation of the proper cornea corpuscles. The *intercellular matrix* of the cornea consists of a laminated substance; the lamellæ are arranged parallel to the surfaces of the cornea, but contiguous lamellæ anastomose with each other. The lamellæ consist of extremely delicate filaments, collected into bundles. The adjacent lamellæ are cemented together, and in the cement substance the branched lacunæ of the cornea are situated. The lacunæ anastomose with each

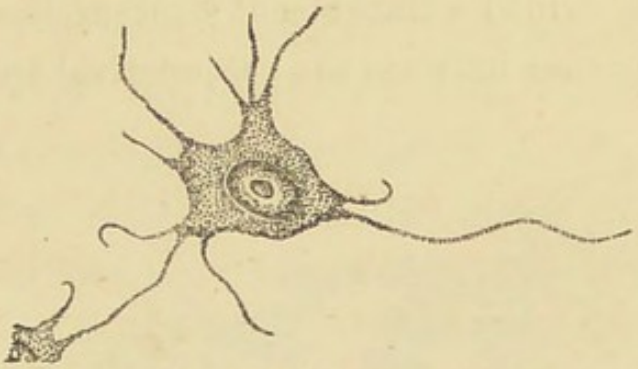

FIG. 98.—Stellate Cell from the centre of the Cornea of an Ox. (*From Thin.*)

other and contain the flat cornea corpuscles. Immediately under the anterior epithelium the bundles decussate with each other, and at the circumference of the cornea they run into the connective tissue of the sclerotic. Bowman described a translucent structureless layer or *anterior elastic lamina* between the conjunctival epithelium and the cornea proper, but it is doubtful if this layer exists as a constant arrangement. Bowman and other observers have injected tubular spaces in the cornea which are apparently situated between the lamellæ. The exact nature of these spaces is somewhat doubtful, but Thin believes them to be lymph-vessels traversing its substance, for he has seen a lining of flat cells similar to the endothelial cells lining the lymphatics (fig. 99), and he states that they communicate with the lacunæ. It is probable that these spaces serve as channels for the migrating corpuscles to wander through.



FIG. 99.—Cornea treated by nitrate of silver to show the lacunæ and a lymph-space. *a*, lymph-vessel; *b*, line separating two of the cells forming its lining; *c*, communication between the vessel and a lacuna surrounding a cornea corpuscle; *d*, matrix of the cornea; *e*, lacuna of the cornea. (*From Thin.*)

The *posterior elastic lamina* forms a distinct, translucent,

structureless layer adherent to the back of the proper tissue of the cornea, from which it may be stripped off without much difficulty. When torn across, the edges curl inwards towards the corneal tissue. It is from $\frac{1}{2000}$ to $\frac{1}{3000}$th inch thick, and resists the action of various reagents. This lamina thins off at its circumference and splits into fibres, which become continuous with the pectinate ligament of the iris.

The *posterior epithelium* of the cornea, also called the epithelium of the aqueous humour, forms a single layer of polygonal cells on the back of the posterior elastic lamina. It is continuous with the epithelial covering of the pectinate ligament and of the anterior surface of the iris.

The cornea is not in the adult traversed by blood-vessels, though in the fœtus a layer of capillaries lies near its anterior surface. In the adult, however, the margin of the cornea is penetrated by a zone of capillary loops derived from the arteries of the conjunctiva; these loops, according to Lightbody, are invested by perivascular lymph spaces. The *canal of Schlemm* runs round the circumference of the cornea, at the junction of its deeper layers with the sclerotic. Leber states that it is not a simple canal, but a plexiform arrangement of veins, whilst Schwalbe regards it as a lymph canal. The nerves of the cornea, first seen by Schlemm, have been carefully examined

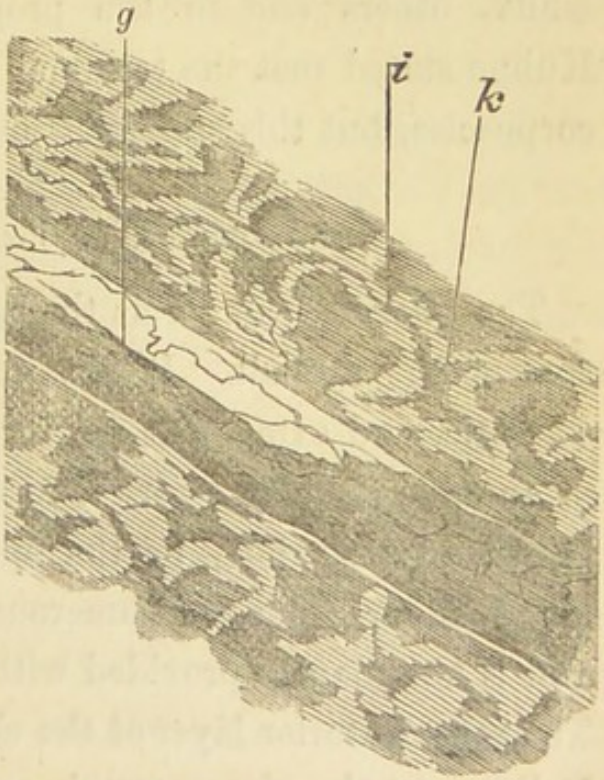

FIG. 100.—Cornea treated with nitrate of silver and chloride of gold. *i*, anastomosis between two cornea corpuscles; *k*, stellate cornea corpuscle; *g*, nerve fibre lying in a lymphatic canal. (*From Thin.*)

by recent observers. They arise from the ciliary nerves, and enter the margin of the cornea in from twenty to forty fasciculi, which run from the circumference to the centre and to the anterior surface of the cornea, and give off numerous branches. Thin states that the nerves lie free in the lymph spaces and canals, and that between them and the flat cells lining the canals is the fluid-filled space in which the migrating corpuscles can wander. The nerve fibres soon lose their medullary sheath, and branch; adjacent branches then communicate, and form plexuses which possess nuclei at the points of intersection of the nerves. From these plexuses delicate branches again arise, some of which penetrate between the cells of the anterior epithelium, whilst others end in the proper tissue of the cornea. Kühne stated that the terminal fibres ended in the cornea corpuscles, but this statement has not been confirmed.

The Middle or Vascular Tunic.

The *Choroid coat* forms the largest portion of the middle coat of the eyeball. It lies immediately internal to the sclerotic, and extends as far forward as the corpus ciliare, or annulus albidus, where it forms the ciliary processes; it is pierced posteriorly by the optic nerve. It has a deep black colour, from the numerous pigment cells it contains, and is abundantly provided with blood-vessels and nerves. The most anterior layer of the choroid is the *lamina vitrea*. It lies next the pigmentary layer of the retina, and forms a translucent membrane, described by some as structureless, but by Kölliker as faintly fibrous, which is intimately connected with the stroma of the choroid. The *stroma* consists of a plexiform arrangement of bundles of connective tissue, with numerous, flattened, stellate, pigment cells, which give to the entire thickness of the choroid its black

appearance. This stroma connects the outer surface of the choroid with the inner surface of the sclerotic, and forms the *lamina fusca.* In the stroma are lymph spaces, blood-vessels, and nerves. Non-striped muscle cells have also been described as arranged in a meridional direction. The vessels of the choroid are arranged in two layers. Next the lamina vitrea is a plexiform capillary layer, the meshes of which are so minute, and the vessels so close together, as to give the appearance of a vascular membrane, long known as the *membrana Ruyschiana.* The capillaries radiate like minute stars from the terminal twigs of the choroidal arteries and veins, which form a layer external to the capillaries, *i.e.*, next the lamina fusca. Between the layer of capillaries and the layer of choroidal arteries and veins is the *elastic layer* of Sattler, and an endothelial membrane. The arteries are the short posterior ciliary branches of the ophthalmic artery, which pierce the sclerotic close to the entrance of the optic nerve, and, running forwards in a tortuous manner, divide dichotomously before ending in capillaries. The veins of the choroid are arranged in a series of remarkable whorls, named the *venæ vorticosæ*, which receive the blood not only from the capillaries of the choroid proper, but from those of the iris and ciliary body ; they discharge their blood by means of from 4 to 6 veins into the ophthalmic vein.

The *Corpus ciliare*, or annulus albidus, is a greyish-white ring, which surrounds the anterior border of the choroid close to the junction of the sclerotic and cornea. It consists of two portions—an external, the *ciliary muscle*, which lies next the sclerotic, and an internal, the *ciliary processes.* The ciliary processes, about 80 in number, are folds of the middle tunic separated from each other by furrows, which extend forwards in the meridional direction

as far as the iris, and form collectively a zone-like plated frill around the circumference of the iris. At the one border, they are continuous with the vasculo-pigmentary structures of the choroid; at the other, with the vasculo-pigmentary structures of the iris. The *ciliary muscle* is the greyish-white structure which forms the outer part of the ciliary body. It was at one time called the ciliary ligament, but its muscular nature was discovered almost simultaneously by Bowman and Brücke. It consists of smooth involuntary muscle, the fibres of which are arranged in two layers. The outer and thicker part of the muscle consists of fasciculi, which arise from the ligamentum pectinatum, opposite the junction of the sclerotic and cornea, and radiate from before backwards in the meridian of the eyeball, between the ciliary processes and the sclerotic. The inner part of the muscle forms a ring-like arrangement of fasciculi close to the circumference of the iris, and is often called the *annular muscle* of Müller. Iwanoff has shown that in long-sighted persons (hypermetropic) the annular muscle is strongly developed; whilst in short sighted (myopic) eyes its fasciculi are very feeble. The *Ciliary Processes* have on their inner surface a black pigmentary layer of cells or *uvea*. The vitreous layer is also present, but according to H. Müller is no longer smooth but reticulated. The stroma does not contain so large a proportion of stellate pigment cells as the choroid. The arteries are the long posterior ciliary branches of the ophthalmic, and the anterior ciliary of the muscular branches of the ophthalmic. They pierce the sclerotic, run forwards, and at the anterior border of the ciliary muscle form by their anastomoses the *circulus arteriosus*, which gives origin to the arteries for the ciliary processes and the iris. The arteries for the ciliary processes are short, and divide into

tortuous branches, which frequently anastomose, and form highly complex vascular plexuses, from which veins arise that join the venæ vorticosæ. Before the long ciliary arteries contribute to the formation of the arterial circle they send branches to the ciliary muscle, and recurrent branches to the anterior part of the choroid coat.

The *Iris* is a circular, flattened disc-shaped diaphragm, situated behind the cornea, in front of the crystalline lens, and bathed by the aqueous humour. By its circumference or ciliary border, the iris is continuous with the ciliary processes, and is also connected by fibres, termed *ligamentum pectinatum*, with the posterior elastic lamina of the cornea and with the sclerotic. The iris is the structure which gives the characteristic colour to the eye—blue, grey, brown, hazel, as the case may be. It is perforated at, or immediately to the inner side of, its centre by a circular aperture, the *pupil*, the size of which is regulated by the contraction or relaxation of the muscular tissue of the iris.

The iris has its anterior surface covered by a layer of cells continuous with the epithelium of the aqueous humour. This layer is continuous at the pupillary border with a thick layer of cells filled with black pigment granules, the *uvea*, which covers the posterior surface of the iris, and is continuous at its ciliary border with the pigmentary layer of the ciliary processes. The connective tissue stroma of the iris also contains stellate pigment cells. The variations in colour of the iris in different eyes depend upon the distribution and amount of the pigment in the uvea and the stellate cells : in dark-coloured eyes, both are filled with dark pigment granules ; whilst in light-coloured eyes the stellate cells of the stroma are either devoid of pigment or only faintly coloured. The iris contains numerous fasciculi of involuntary or non-striped muscular

fibre arranged in two directions. Circularly arranged fibres surround the aperture of the pupil, and form the *sphincter pupillæ*, by the contraction of which the size of the pupil is diminished. Smooth muscular fibres also radiate from the pupillary to the ciliary border of the iris and form the *dilatator pupillæ*. The muscular nature of these fibres in the human iris was long disputed, but was satisfactorily demonstrated in 1852 by Lister. Jeropheef has also described circular fasciculi surrounding the ciliary border. In birds and reptiles the muscular tissue of the iris consists of transversely striped fibres. The arteries of the iris arise from the circulus arteriosus, and run radially forwards towards the pupil, where they anastomose and form the *circulus iridis minor*. They possess relatively thick external and muscular coats. The capillaries form a plexus not so compact as that of the choroid coat. The veins of the iris end in the venæ vorticosæ. In the fœtus the pupil is closed in by a delicate membrane, *membrana pupillaris*, into which the blood-vessels of the iris are prolonged. This membrane disappears by absorption during the later months of embryo life. The nerves of the middle coat of the eyeball are the long ciliary branches of the ophthalmic division of the 5th and the short ciliary branches of the ciliary ganglion. They pierce the sclerotic near the optic nerve, and run forward in the lamina fusca of the choroid. They give off branches to the choroid and form in it a plexus, in which H. Müller found nerve cells. From this plexus delicate branches pass to the muscular coat of the choroidal arteries. The ciliary nerves then enter the ciliary muscle, and form plexuses with interspersed nerve cells, from which branches pass to the muscular fibres. Other branches of the ciliary nerves enter the iris, and form plexuses, from which branches proceed to the muscular tissue.

The Inner or Nervous Tunic.

The *Retina* is the delicate nervous coat of the eyeball which lies immediately internal to the choroid, and extends from the place of entrance of the optic nerve as far forward as the ciliary processes, where it forms a jagged border, the *ora serrata.* In the living eye it is translucent and of a purple-red colour, but shortly after death it becomes grey: it is soft and so easily torn that it is difficult to display it in a dissection without injury. Its inner or anterior surface, concave forwards, is moulded on the vitreous body, and presents the following appearances:— Almost exactly in the antero-posterior axis of the eyeball is a transversely oval *yellow spot* (*macula lutea*), about $\frac{1}{20}$th inch in its long diameter, which amongst mammals is found only in man and apes, though, as Knox and Hulke have shown, it exists in reptiles; in the centre of this spot is a depression, the *fovea centralis;* about $\frac{1}{8}$th inch to the inner side of the yellow spot is a slight elevation, the *papilla optica,* which marks the disc-like entrance of the *optic nerve* into the retina; here the fibres of the nerve radiate outwards and forwards to the ora serrata, and branches of the *arteria centralis retinæ* accompany them.

The retina is highly complex in structure, and consists of nerve fibres and cells, of peripheral end-organs, of connective tissue, and of blood-vessels, arranged in several layers. Max Schultze, the chief authority on the subject, recognised ten layers, and included among these the layer of pigment cells up to that time described as the inner pigmentary layer of the choroid. These layers are, from before backwards, as follows:—(1) membrana limitans interna; (2) layer of optic nerve fibres; (3) layer of ganglion cells; (4) internal molecular or granulated layer; (5) internal granule or nuclear layer; (6) external molecular

or granulated layer; (7) external granule or nuclear layer; (8) membrana limitans externa; (9) bacillary layer; (10) pigmentary layer (fig. 101).

The nervous elements of the retina will first be considered. The *optic nerve fibres* (2), where they pierce the sclerotic, as a rule lose the medullary sheath, and radiate outwards from the optic disc to the ora serrata as axial cylinders, immediatly behind and parallel to the membrana limitans interna. These fibres vary greatly in size, and are frequently varicose. When any optic nerve fibres retain the medullary sheath the retina is there rendered opaque. Immediately behind the nerve fibres is

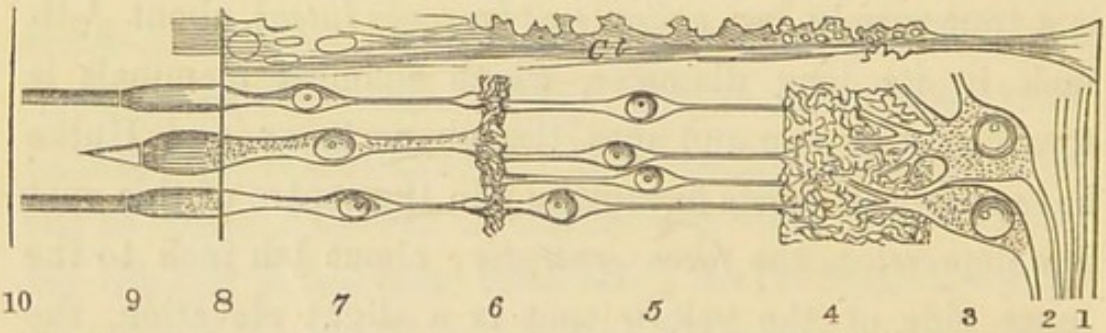

Fig. 101.—Diagrammatic antero-posterior section through the Retina to show the several layers which are numbered as in the text. *Ct*, the radial fibres of the supporting connective tissue. (*Modified from Schultze*).

the *layer of ganglionic nerve cells* (3). These cells are either bipolar or multipolar. In the living eye the cell substance is hyaline and the nucleus transparent, but after death the substance both of the body of the cell and the processes assumes a fibrillated appearance, like the axial cylinder of an optic nerve fibre. One process, the central process, extends into the layer of optic nerve fibres; and one or two branched peripheral processes into the internal molecular layer. The *internal molecular* or *granulated layer* (4) contains a reticulum of very fine fibrils, into which the branching processes of the nerve cells penetrate. The reticulum is partly nervous tissue and partly connective tissue. The *internal granule* or *nuclear layer* (5) contains

numerous fusiform cells, with relatively large nuclei, the so-called internal granules, arranged in superimposed strata; from each fusiform cell a fibre proceeds in two directions, one centrally into the internal molecular layer, and one peripherally into the external molecular layer. These fibres possess varicosities, and resemble the optic nerve fibres. The *external molecular* or *granulated layer* (6) is very thin, and consists of an expanded network of minute fibres, with nuclei situated at the points of intersection of the fibres. Krause has called it the *membrana fenestrata.* The *external granule* or *nuclear layer* (7) contains numerous fusiform cells with relatively large nuclei, the so-called external granules, arranged in superimposed strata: from each enlargement a fibre proceeds in two directions, one centrally into the external molecular layer, and one peripherally through the membrana limitans externa into the bacillary layer, where it becomes continuous with the anterior end of either a rod or a cone, as the case may be. Hence these fibres of the external granule layer are called by Schultze rod and cone fibres, and the external granules are nuclei in these fibre-like cells. The fibres possess varicosities like those of the internal nuclear layer. In man the nuclei of the cone fibres are transversely striped and close to the membrana limitans externa, and those of the rod fibres are clear and in the deeper strata.

The *bacillary layer* (9), or membrane of Jacob, consists of multitudes of elongated bodies arranged side by side like rows of palisades, and vertically to the surfaces of the retina. Some of these bodies are cylindrical, and are named the *rods* of the retina; others are flask-shaped, and named the *cones* of the retina: the rods equal in length the entire thickness of the bacillary layer; the cones are shorter than the rods, and are interspersed at regular intervals

between the rods; the apex of each cone is directed towards, but does not reach, the plane of the posterior or choroidal surface of the retina. The posterior or outer end of each rod rests against the pigmentary layer. The anterior or inner ends of both rods and cones are continuous with the rod and cone fibres of the external granule layer, as already described. Each rod and cone is divided into an outer strongly refractile and an inner feebly refractile segment. By the action of various reagents the outer segments both of the rods and cones exhibit a transverse striation, and ultimately break up into discs. Hensen has described a longitudinal striation in the outer segments, and Ritter has stated that both in the outer and inner segments of the rods an axial fibre exists. Max Schultze has also seen the inner segments of both rods and cones longitudinally striped on the surface. Ewart has traced a varicose fibrilla, which he believes to be nervous, from the external granule layer into the inner segment of a cone (fig. 102). Modifications in the relative numbers and appearances of the rods and cones have been seen in the eyes of various vertebrata. In birds, for example, the cones are much more numerous than the rods, whilst the reverse is the case in mammals generally. In the cartilaginous fishes the cones are entirely absent; so also, as Schultze has shown, in the bat, hedge-hog, and mole; whilst in reptiles the bacillary layer is exclusively composed of cones. In all the vertebrata, except the mammalia, the twin or double cones described by Hannover probably exist. In the amphibia and some birds (fig. 102), lens-shaped bodies have been described in the inner seg-

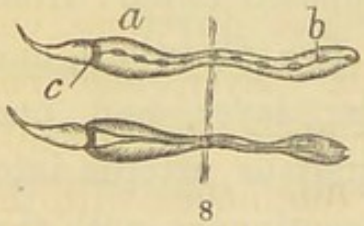

FIG. 102.—Cones of the Retina of a Hen. *a*, inner segment of a cone; *b*, external granule, containing a varicose fibrilla, which is prolonged into the inner segment; *c*, lenticular body at junction of the outer and inner segment; 8, membrana limitans externa. (*From Ewart.*)

ments of the cones. The purple colour of the retina resides in the outer segments of the rods.

The rods and cones are the peripheral end-organs in connection with the fibres of the optic nerve, and their apparent relation to these fibres is as follows:—The optic nerve fibres are continuous with the central processes of the ganglion cells of the retina, the peripheral branching processes of which pass into the internal molecular layer, where they may possibly become continuous with the central processes of the inner nuclear layer. The peripheral processes of the inner nuclear layer enter the external molecular layer, but it is difficult to say whether or not they become continuous with the central processes of that layer. There can, however, be no doubt that the peripheral processes of that layer are directly continuous with the rods and cones of the bacillary layer. The entire arrangement is sometimes called the *radial nervous fibres* of the retina.

In addition to the nervous structures just described, the retina contains a delicate supporting connective tissue composed of a reticulum of fine fibrils. It forms the *radial supporting fibres* of Müller, and penetrates the different nervous layers between the fibres, cells, and so-called granules, and it constitutes the two limitary membranes of the retina.

The *membrana limitans externa* (8) is excessively thin, and appears in vertical sections through the retina as a mere line between the bacillary and external nuclear layers, continuous on the one hand with the radial supporting tissue which lies between the rods and cones, and on the other with the supporting tissue framework of the external nuclear layer (fig. 101),

The *membrana limitans interna* (1) is formed by the expanded anterior end of the fibres of Müller. It covers

the anterior surface of the retina, and lies next the vitreous body. Its anterior or hyaloid surface possesses a mosaic appearance, due to the presence of a layer of flat epithelial cells (Ewart).

The *pigmentary layer*, or *uvea* (10), lies next the choroid, and consists of a mosaic of pentagonal and hexagonal cells usually containing pigment (fig. 45). These cells send delicate processes of contractile protoplasm between the rods of the bacillary layer. In the eyes of Albinos the cells contain no pigment, and in those animals that have the beautiful iridescent lustre, known as the *tapetum lucidum*, the pigment is also absent in the uvea, so that they are translucent. In ruminants and the horse the iridescence is due to the reflection of the light by the bundles of the connective tissue of the choroid, and in the dog and cat to polygonal cells which contain double refracting crystals (Schultze).

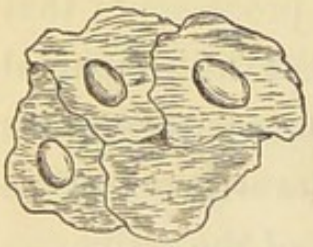

FIG. 103.—Flat Cells on the anterior surface of the Retina of the Sheep. (*From Ewart.*)

The *yellow spot* exhibits some structural differences from the rest of the retina. It owes its colour to the presence of yellow pigment diffused between the elements of the retina. Except at its central depression, the fovea centralis, it is thicker than the surrounding parts of the retina; but it is much softer, a condition which is due to the almost complete absence of the layer of optic nerve fibres, and a diminution in the amount of the supporting connective tissue; the membrana limitans interna is, however, relatively stronger. In the *fovea centralis* itself the rods of the bacillary layer have entirely disappeared, and are replaced by cones, which are distinguished by their close arrangement, and the more slender form and increased length, especially of their outer segments. The

external nuclear layer is well marked, and the central fibres belonging to it, instead of passing vertically forwards, incline very obliquely or almost horizontally outwards to the internal nuclear layer, which, together with the layers anterior to it, is so thin as almost to have disappeared. In the yellow spot *surrounding the fovea*, the bacillary layer is also composed of cones which are not, however, so slender or so long as in the fovea itself. The layer of nerve cells and the inner part of the external nuclear layer are thicker than in the rest of the retina. The yellow spot is the part of the retina most sensitive to light.

At the *ora serrata*, or anterior border of the retina, the nervous layers, including the rods and cones, cease to exist. The radial connective tissue and internal limiting membrane are present; from the radial tissue a layer of cells is prolonged forward in contact with the deep surface of the ciliary processes as the *pars ciliaris retinæ*.

The retina is supplied with blood by the arteria centralis, which, traversing the axis of the optic nerve, reaches the retina at the optic disc. In the retina it branches dichotomously in the nerve fibre layer, avoiding, however, the yellow spot, and its terminal twigs reach the ora serrata. The capillaries form in the more anterior layers of the retina a distinct network, which does not enter the external granule and bacillary layers, but penetrates the yellow spot, though not the fovea centralis. The blood is conveyed from the retina by the central vein which accompanies the artery in the optic nerve, and opens either into the ophthalmic vein or directly into the cavernous sinus. The veins and capillaries of the retina have been described by His as completely invested by perivascular lymphatic sheaths, whilst the arteries only possess such sheaths for a limited part of their course. These lymphatics leave the

eyeball along with the bundles of the optic nerve through the lamina cribrosa in the sclerotic.

The Optic Nerve itself passes from the orbit through the optic foramen into the cranial cavity, where it arises from the *optic chiasma* or *commissure*. This commissure is a flattened band formed by the junction of the two *optic tracts*. Each tract winds backwards at the outer side of the tuber cinereum and crus cerebri, and divides posteriorly into three roots: the primary root goes to the corpus geniculatum externum and optic thalamus; a second goes over the surface of the corpus geniculatum internum to the corpora quadrigemina; the third gives an offshoot to the corpus subthalamicum, but is mainly prolonged through the pons and medulla to the decussation of the pyramids and spinal cord (Stilling). This nerve arises primarily from the thalamencephalon, and secondarily from the middle and posterior cerebral vesicles. Ferrier localises the cerebral centre for visual perception in the angular gyrus, but Munk places it in the occipital lobe, from which fibres are regarded as passing into the optic thalamus, corpora quadrigemina, and geniculata. In the commissure an interchange takes place between the fibres of opposite nerves and tracts, so that an optic nerve contains fibres derived from the tract on its own side as well as from the opposite tract; and it even has been stated that fibres pass across the commissure from one optic nerve to the other nerve, and from one optic tract to the other tract.

The Refracting Media.

The *Aqueous Humour* is a limpid watery fluid, containing a little common salt in solution, which occupies the space between the cornea and the front of the crystalline lens. In this space the iris lies, and imperfectly divides it into

two chambers, an anterior and a posterior, which communicate with each other through the pupil. The *anterior chamber*, of some size, is situated between the iris and cornea; but as the iris is in contact with the front of the lens, the *posterior chamber* is reduced to a mere chink between the circumference of the iris and that of the lens.

The *Crystalline Lens* is situated behind the iris and pupil, and in front of the vitreous body. It is a transparent bi-convex lens, with its antero-posterior diameter $\frac{1}{3}$d less than the transverse, its posterior surface more convex then the anterior, and with its circumference rounded. It consists of a capsule, which encloses the body of the lens. The *lens capsule* is a transparent, smooth, striated and very elastic membrane, about twice as thick on the anterior as on the posterior surface of the lens. It is non-vascular in the adult, though in the fœtus a branch of the central artery of the retina, which traverses the vitreous humour, ramifies in its posterior portion. A single layer of polygonal cells lies between the body of the lens and the anterior portion of the capsule. The *lens body* is softer at its periphery than in its centre. It is built up of concentric layers united by interstitial cement substance; and on both the anterior and posterior surfaces lines are to be seen radiating from the central pole of each surface towards the circumference of the body. The radiated pattern varies in different animals. In the human fœtus there is usually a star of three rays, but in the adult the rays are more numerous. The rays on one surface do not lie immediately opposite those on the other, but are intermediate. By the action of strong spirit and other reagents the body of the lens can be split up from the periphery towards the centre in the direction of these lines, so that they mark the edges of apposition of its concentric laminæ. Each lamina

consists of numerous hexagonal fibres, about $\frac{1}{5000}$th inch wide, which extend from one surface to the other over the circumference of the lens, so that a fibre which begins at the polar end of a radius on the one surface terminates at the circumferential end of a radius on the opposite. The edges of the fibres are sinuous in man, but denticulated in many animals, especially fishes, so that the fibres, not only in the same, but in superimposed layers, are closely interlocked. The lens fibres are nucleated, a structural fact which gives a clue to their true nature, and they are now regarded as peculiarly modified elongated cells. Babuchin states that he can trace the transition from the cells of the layer between the lens-body and capsule to the proper lens fibres. The lens-body is non-vascular and non-nervous. The surfaces of the lens become more flattened in old age, and its substance hardens and is less transparent.



FIG. 104.—The larger flat cells in this figure are from the surface of the Hyaloid membrane. The smaller cells are from the substance of the vitreous humour. (*From Ewart.*)

The *Vitreous Body* is the most bulky of the refracting media, and occupies the largest part of the space enclosed by the tunics. Anteriorly it is hollowed out to receive the posterior convexity of the lens, but posteriorly it is convex, and the retina is moulded on it. It is as translucent as glass, jelly-like in consistency, and when punctured a watery fluid drains out. Its minute structure is difficult to ascertain, but as it, like the subcutaneous tissue of the embryo, contains rounded, stellate, and flattened cells, it is customary to refer it to the gelatinous form of connective tissue; concentric lamellæ, and even a radiated arrangement of fibres, have also been described. Most observers regard the vitreous humour as invested by a

delicate structureless membrane, the *hyaloid membrane*; immediately within which small amœboid cells have been described by Ciaccio and Ivanoff. Huschke and others have described a layer of epithelial cells as present on the surface of the hyaloid membrane. Almost opposite the ora serrata the hyaloid membrane passes forwards from the vitreous body, in relation to the deep surface of the ciliary processes, but separated from them by the pars ciliaris retinæ, and then inclines inwards to become attached to the anterior surface of the capsule of the lens close to its circumference. It is named the *suspensory ligament of the lens*, or *zonule of Zinn*, and contains fibres, which run in the meridional direction. Where it leaves the vitreous body a narrow space is enclosed between it and that body, which space surrounds the circumference of the lens, and is called the *canal of Petit*. From the relation of the suspensory ligament to the ciliary processes it has a plicated surface, aud when these processes are torn away from it, a portion of the pigment of the processes is often left behind, so that the zonule is sometimes named the *ciliary processes of the vitreous body*.

In addition to the lymphatics of the cornea and retina already described, the recent researches of Schwalbe have shown that spaces exist within the eyeball which communicate with the lymphatic system. The slit-like interval between the sclerotic and choroid, or *perichoroidal space*, is regarded as a receptacle for lymph lined by an endothelium; from it lymphatics arise, which pierce the sclerotic alongside the veins, and communicate with the space of Tenon which lies between the exterior of the eyeball and its investing tunic of fascia. The lymph formed in the iris and ciliary processes is believed to be poured into the anterior chamber, and from it into the

canal of Schlemm; the canal of Petit, which is believed to be a lymph-space, opens also into the anterior chamber by a series of fissures in the zonule of Zinn.

The Eyeball is an optical instrument, constructed on the plan of the camera obscura. The sclerotic forms the wall of the chamber. The choroid represents the black lining for absorbing the surplus rays of light. The cornea, aqueous humour, lens, and vitreous body are the translucent refracting media which, like the glass lens of the camera obscura, bring the rays of light to a focus. The retina is the sensitive plate on which the optical picture is thrown. In considering the relation of the retina to the visual rays, it must be kept in mind that the place of entrance of the optic nerve is insensible to light, and that the most sensitive part of the retina is the yellow spot, with its fovea centralis, where the optic nerve fibres are absent, but where the bacillary layer reaches its maximum size. It is clear, therefore, that the rods and cones of this layer, and not the optic nerve fibres, are the structures in the retina which are stimulated by the light; and it is probable, as was suggested many years ago by Goodsir, that these rods and cones are impressed by the light, not as it enters the eye directly, but as it is reflected backwards from the choroid coat along their axes. The iris is the diaphragm which, by opening or closing the pupil, admits or cuts off the rays of light. The ciliary muscle represents the adjusting screw of the camera; through its attachment to the ciliary processes and their relation to the suspensory ligament of the lens, it is able to act upon the lens and modify the curvature of its anterior surface; for when the eye is to be accommodated to the vision of near objects, the anterior surface of the lens becomes more convex than when distant objects are being examined.

Development of Eyeball.

The primary optic vesicle is an outgrowth of the epiblast of the thalamencephalon, with which it is connected by a hollow peduncle continuous with the cavity of the thalamencephalon. This peduncle subsequently thickens and solidifies and becomes the optic nerve tract. This optic vesicle is covered by the epiblast investment of the embryonic head, which thickens and becomes involuted superficial to the vesicle, so as to produce a hollow in its front, which gradually deepening forms a cup or pocket, the *secondary optic vesicle* or cup, in which the involuted part of the epiblast is lodged. This cup has double walls, an anterior and a posterior, the former of which becomes the retina proper, the latter the layer of hexagonal pigment cells on its choroidal surface, also the pars ciliaris retinæ, and the uvea of the ciliary processes and iris. The cavity between these walls, originally continuous through the canal in the optic nerve with the cavity in the hemisphere, becomes obliterated, so that the retina proper and the pigment layer come into contact with each other. The part of the epiblast lodged in the cup severs its connexion with the superficial epiblast or epidermis, and forms the crystalline lens. It becomes closed in in front by a growth superficial to it, both of mesoblast and epiblast; the mesoblast layer forms the cornea, whilst the superficial epiblast layer forms the anterior epithelium of the cornea, or conjunctival epithelium. Through a want of uniformity in the growth of the wall of the secondary optic vesicle, a fissure, called the *choroidal fissure*, exists on its under surface, through which the mesoblast passes between the lens and the retina, and forms the vitreous humour, and perhaps the capsule of the lens. This fissure then closes up so that the connexion between the vitreous humour and the surrounding mesoblast is severed. The mesoblast immediately surrounding the optic vesicle then differentiates into the vascular, muscular and connective tissue structures of the choroid, ciliary processes and iris, and into the sclerotic coat. The sclerotic is continuous in front with the mesoblast, out of which the cornea is formed, so as to complete the external tunic of the eyeball, and a band, the *funiculas scleræ* (Hannover), which traverses the adult sclerotic opposite the *fovea centralis*, marks the position of the fissure in the embryonic eye.

Accessory Parts to the Eyeball.

In relation to the eyeball are several accessory parts.

The *Eye-Brows* are projections of the integument, from which short, stiff hairs grow.

The *Eye-Lids*, or *Palpebræ*, are two movable curtains, an

upper and a lower, which protect the front of the globe. Between each pair of lids is a horizontal fissure, the *palpebral fissure.* From the free margins of the two lids project short hairs, the *eye-lashes* or *cilia:* the upper set curve downwards and forwards, the lower set upwards and forwards; they also protect the front of the globe. Each eyelid consists externally of skin, with sebaceous glands and sweat glands; immediately beneath the skin are the fibres of the *orbicular sphincter muscle;* a thin plate of fibro-cartilage, the *tarsal cartilage,* lies beneath the sphincter; to the inner end of this cartilage a fibrous band, the *tendo palpebrarum,* is attached, which springs from the ascending process of the superior maxilla; into the cartilage in the upper eye-lid the tendon of the levator palpebræ superioris is inserted. Lining the inner surface of the eye-lid is the *conjunctiva.* Between the conjunctiva and the tarsal cartilage is a layer of glands, the *Meibomian glands;* each gland consists of a short duct, which expands at its sides into small sacculi. The sacculi contain short columnar cells; these secrete a sebaceous material, which escapes through the orifice of the duct at the border of the eye-lid, and by greasing the edge of the eye-lid prevents the overflow of the tears, except when lachrymation is profuse.

The *Conjunctiva* is a mucous membrane, which forms the posterior layer of the eye-lid, and is reflected on to the anterior part of the sclerotic. At the inner angle of junction of the eye-lids is a soft reddish elevation of the conjunctiva, the *caruncula lachrymalis,* and immediately external to it is a vertical fold, the *plica semilunaris,* the rudiment of the third eye-lid seen in many mammals, or the *membrana nictitans,* so well developed in birds. The palpebral conjunctiva has small papillæ scattered over its surface; its epithelium is stratified, with scaly cells on the

free surface and columnar cells in the deepest layer. In the sub-epithelial tissue are small branched mucous glands, which are numerous in the caruncula. Little masses of adenoid tissue (p. 145) with lymphatic vessels are also found in it, and the conjunctiva of the front of the eyeball is thinner than the palpebral part. It is not glandular, and its nerves terminate in end-bulbs (p. 201). The palpebral conjunctiva, and in part that of the eyeball, receive their blood-vessels from those of the eye-lids, but the portion of the conjunctiva next the cornea is supplied by the arteries of the sclerotic coat.

The *Lachrymal Apparatus* is engaged in the secretion of the tears, and in conveying them away from the front of the globe. The *lachrymal gland* occupies a depression in the outer part of the roof of the orbit. It is smaller than an almond, is divided into lobules, and belongs to the group of compound racemose glands. It consists of the ramifications of short ducts, which terminate in clusters of small sacculi. The wall of each sacculus consists of a delicate membrana propria, and the cavity contains the polyhedral secreting cells. Outside the membrana propria is a capillary network derived from the lachrymal artery,

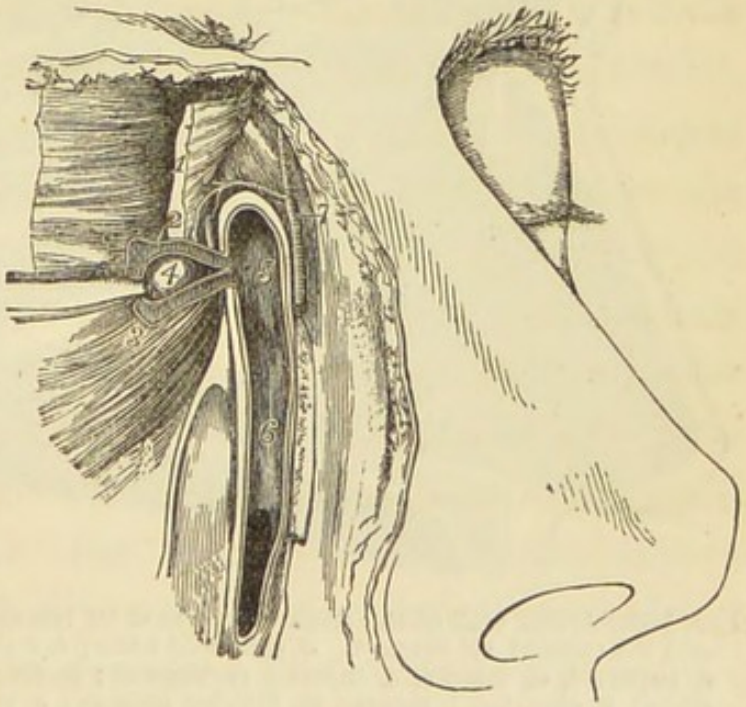

FIG. 105.—Lachrymal Canals and Duct. 1, orbicular muscle; 2 and 3, lachrymal canals; 4, caruncula; 5, lachrymal sac; 6, lachrymal duct; 7. angular artery.

but Giannuzzi and Boll have recently described a space between this network and the membrana propria which they believe to be continuous with the lymphatic system. Pflüger has described nerves as terminating in connection with the secreting cells. The excretory ducts of the gland are from six to eight in number, and open on the back of the upper eye-lid, and the tears are washed over the surface of the globe by the involuntary winking of this lid.

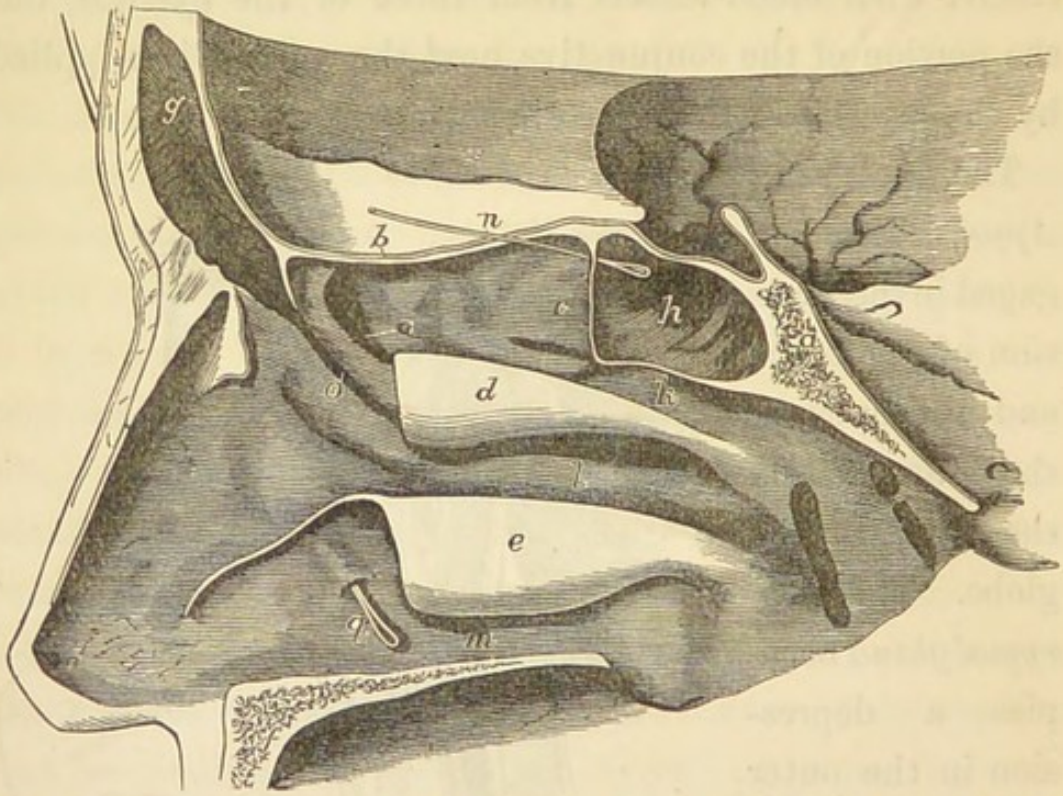

FIG. 106.—Outer wall of the Right Nose, to show the openings of the Nasal Duct and the Cranial Air Sinuses. *a*, sphenoid bone; *b*, cribriform plate of ethmoid; *c*, superior, *d*, middle, *e*, inferior turbinated; *g*, frontal sinus; *h*, sphenoidal sinus; *k*, superior, *l*, middle, *m*, inferior meatus; *o*, passage from frontal sinus into middle meatus; *q*, opening of nasal duct.

When the secretion is increased in quantity, in the act of crying, the tears flow over the cheek, but in ordinary circumstances they are conveyed away by two slender tubes, the *lachrymal canals*, which open by minute orifices, the *puncta lachrymalia*, one at the inner end of the free border of each eye-lid. These tubes open at their opposite ends into a small reservoir, the *lachrymal sac*, situated in a hollow in the lachrymal bone. From this sac a duct, the

nasal or *lachrymal duct*, proceeds, which opens into the inferior meatus of the nose, and here the tears mingle with the mucous secretion of that cavity.

Muscles of the Eyeball.—The sclerotic coat of the eyeball has six muscles inserted into it. Four *Recti* muscles, situated one *superior*, one *inferior*, one *external*, another *internal* to the globe. They all arise from the rim of bone which bounds the optic foramen, and the external rectus has two heads. The external and internal muscles are inserted vertically into the sides of the sclerotic, but the superior and inferior recti have oblique insertions into its upper and lower aspects. The two other muscles are called *Obliqui*. The *superior oblique* arises along with the recti, passes to the inner end of the upper border of the orbit, where its tendon goes through a pulley, and is directed backwards and outwards, to be inserted, between the superior and external recti, obliquely into the upper and outer part of the sclerotic. The *inferior oblique* arises from the inner end of the lower border of the orbit, runs outwards and upwards, to be inserted obliquely into the sclerotic close to the superior oblique. These muscles roll the eyeball in the orbit, and, without entering into a minute analysis, their action may be stated generally as follows :—The internal rectus rolls it horizontally inwards, the external outwards, about its vertical axis ; the superior rectus rolls it upwards, the inferior downwards, about its transverse horizontal axis, though from the obliquity of their insertions the superior also gives it a slight inward, the inferior also a slight outward movement ; the superior and inferior oblique roll the globe about its antero-posterior or sagittal axis, the superior upwards and inwards, the inferior downwards and outwards.

Periosteal Muscle of the Orbit.—The periosteum of the

orbit contains, as H. Müller and I have described, a layer of non-striped muscular fibre in the part which covers over the spheno-maxillary fissure. In man it is rudimentary, but in the sheep, deer, elephant, &c., where the osseous wall of the orbit is deficient, this muscle forms a well-defined structure. It has been suggested that it acts as a protractor muscle of the globe.

The Ear.

The Ear, or organ of Hearing, is a complex acoustic apparatus, placed in connection with the temporal bone. It is divided into three parts, named external, middle, and internal ear.

External Ear.

The *External Ear* consists of the pinna or auricle and the external auditory meatus. The *auricle* is the oblong convoluted body situated at the side of the head. Its incurved outer border is named the *helix*. Within this lies a curved ridge, the *anti-helix*, in front of which is a deep hollow, the *concha*, which leads into the external meatus. The concha is bounded in front by a prominence, the *tragus*, and behind by a smaller prominence, the *anti-tragus;* below the anti-tragus is the *lobule*, which forms the most dependent part of the auricle. The framework of the auricle is formed of yellow elastic fibro-cartilage invested by integument, except the lobule, which consists merely of a fold of integument containing fat. Attached to the cartilage are the three auricular muscles referred to on page 85, and smaller rudimentary muscles called the proper muscles of the pinna. Thus the *greater muscle of the helix* is placed on its anterior border; the *lesser muscle of the helix* is situated where it arises out of the concha; the *muscle of the tragus* lies on the front of that prominence; the *muscle of the anti-tragus* is placed on the back of its

prominence; the *transverse muscle* on the posterior or cranial surface of the auricle.

The *External Meatus* leads from the bottom of the concha into the temporal bone, and is separated from the tympanum or middle ear by the membrana tympani. It is a crooked passage $1\frac{1}{4}$ inch long, inclined at first forwards and upwards, then downwards and inwards. The wall of the outer end of the passage is formed of fibro-cartilage

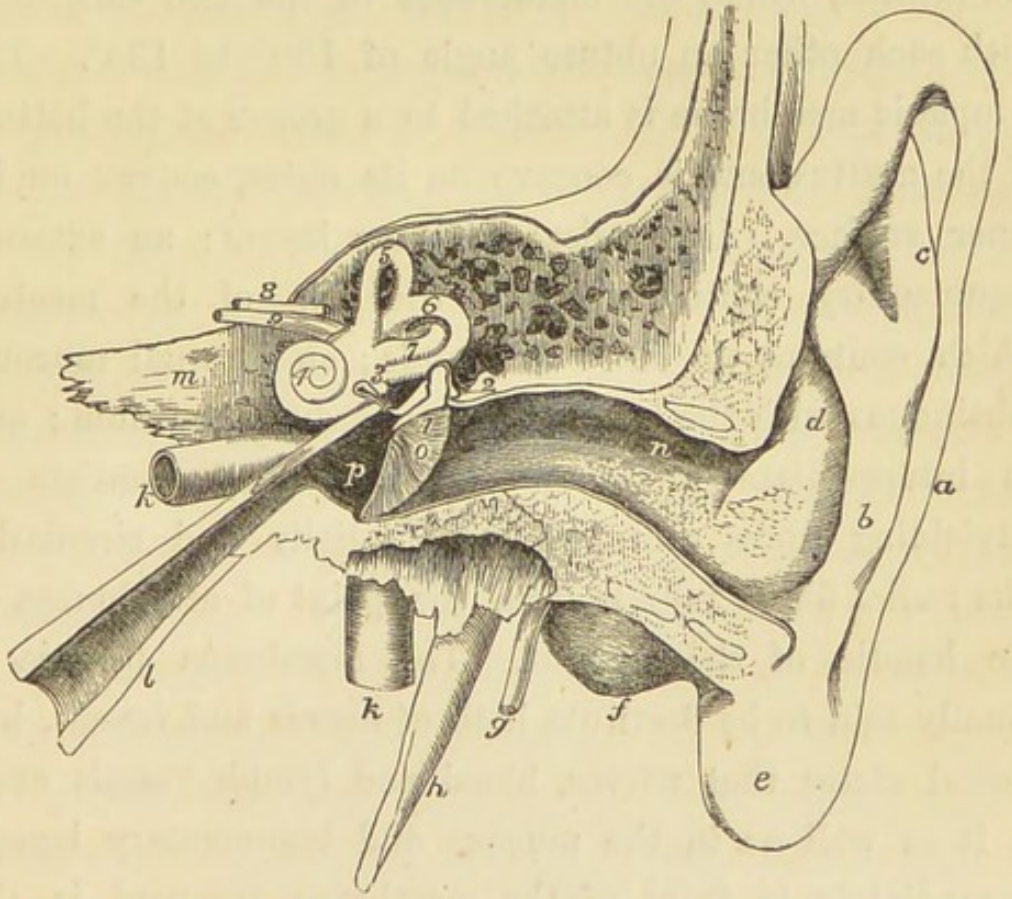

FIG. 107.—The Ear as seen in section. *a*, helix; *b*, anti-tragus; *c*, anti-helix; *d*, concha; *e*, lobule; *f*, mastoid process; *g*, portio dura; *h*, styloid process; *k*, internal carotid artery; *l*, Eustachian tube; *m*, tip of petrous process; *n*, external auditory meatus; *o*, membrani tympani; *p*, tympanum; 1, points to malleus; 2, to incus; 3, to stapes; 4, to cochlea; 5, 6, 7, the three semicircular canals; 8 and 9, portio dura and portio mollis. (*After Arnold.*)

continuous with the cartilage of the auricle, whilst that of the deeper end is formed of the plate-like tympanic part of the temporal bone. The passage is lined with integument continuous with the skin of the auricle, in which are situated numerous hairs, together with ceruminous glands which secrete the well-known yellow "wax."

Middle Ear.

The *Tympanum*, or *Drum*, or *Middle Ear*, is a chamber irregularly cuboidal in form, situated in the temporal bone between the bottom of the meatus and the internal ear (fig. 107). It is a specially differentiated air sinus. The outer wall is formed of the *membrani tympani*, which inclines obliquely downwards and inwards at the bottom of the external meatus, at an angle of 55° to the axis of the meatus, whilst the membranes in the two ears form with each other an obtuse angle of 130° to 135°. The tympanic membrane is attached to a groove at the bottom of the meatus, and is concave on its outer, convex on its inner surface. It consists of three layers: an external tegumentary, continuous with the skin of the meatus, which contains no hairs or glands; an internal mucous, continuous with the mucous lining of the tympanum; and an intermediate membrana propria, which consists of unyielding fibres arranged both radially and circularly. The radial fibres radiate from the point of attachment of the handle of the malleus. The membrana propria is usually said to be destitute both of nerves and vessels, but Kessel states that nerves, blood and lymph vessels exist in it as well as in the mucous and tegumentary layers. Immediately in front of the membrana tympani is the Glaserian fissure. The inner wall separates the tympanum from the labyrinth, and presents the following appearances: a rounded elevation or *promontory* caused by the first turn of the cochlea, on the surface of which promontory are grooves for the lodgment of the tympanic plexus of nerves; above the promontory is an oval opening closed in by a membrane, the *fenestra ovalis*, which lies next the vestibule; behind and below the promontory is a round opening closed in by a membrane, the *fenestra rotunda*, which lies

next the tympanic passage in the cochlea. The floor of the tympanum is a narrow chink between the inner and outer walls; and the roof is formed by the antero-superior surface of the petrous-temporal bone. At its anterior wall the tympanum opens into the *Eustachian tube*, a canal which communicates with the nasal compartment of the pharynx immediately behind the inferior turbinal. The wall of the tympanic end of this tube is formed of bone, that of the pharyngeal end of a curved plate of hyaline cartilage, which is connected to the bone by fibro-cartilage; its pharyngeal orifice is dilated into a trumpet-shaped mouth; through this tube the ciliated mucous membrane of the nasal part of the pharynx is prolonged into the tympanum. The cartilaginous wall of the tube does not completely surround it, but is completed by a fibrous membrane, and a layer of voluntary muscle, named by Rüdinger the *dilatator tubæ*. Above the tympanic end of the Eustachian tube, and separated from it by the *processus cochleariformis*, is a fine *canal*, through which the tensor tympani muscle enters the tympanum. At its posterior wall the tympanum communicates with the air-sinuses in the mastoid temporal; here also is found a small hollow eminence, the *pyramid*, through a hole at the apex of which the tendon of the stapedius muscle passes; and a foramen which transmits the chorda tympani nerve from the aqueduct of Fallopius.

The tympanum communicates in the macerated bone with the external meatus, the vestibule, cochlea, mastoid cells, and Eustachian tube, but as the first three are closed in by membrane, the only communications left in the living head are with the mastoid cells and Eustachian tube.

The tympanic cavity contains three small bones, named malleus, incus, and stapes, which form an irregular chain across the cavity from the outer to the inner wall.

The *Malleus*, or hammer, is the most external bone. In it may be recognised a *head* separated by a constricted *neck* from an elongated *handle*. Close to the junction of the neck and handle a long *processus gracilis* projects downwards and forwards to be inserted into the Glaserian fissure, and near the root of the long process a *short process* projects outwards. By its handle the malleus is intimately connected with the centre of the membrana tympani; by its head it articulates with the incus, whilst ligamentous fibres pass from it upwards, forwards, outwards, and backwards to the tympanic walls. The *Incus*, or anvil-shaped bone, possesses a *body* and two *processes;* on the anterior surface of the body is a saddle-shaped hollow into which the head of the malleus fits; the *short* process projects almost horizontally backwards, and is attached by a ligament to the posterior wall of the tympanum; the *long* process extends at first downwards and then inwards, to end in a rounded projection named *os orbiculare*, through which it articulates with the stapes.

The *Stapes*, or stirrup-shaped bone, possesses a *head* and *neck*, a *base* and two *crura;* the head articulates with the os orbiculare of the incus; from the constricted neck the two crura curve inwards to the base, which is attached to the fenestra ovalis. The joint between the malleus and incus is diarthrodial and saddle-shaped, and the articular surfaces are enclosed by a capsular ligament. The joint between the incus and stapes is also diarthrodial, and has a capsular ligament. Toynbee and Rüdinger have described the base of the stapes and the margin of the fenestra ovalis as each invested by hyaline cartilage. Between these plates plexiform elastic fibres extend, and the intervals between them are occupied by fluid; the joint seems, therefore, a modified amphiarthrosis.

The bones are moved on each other at these joints by small muscles. The *tensor tympani* arises from the apex of the petrous temporal, the ali-sphenoid and the cartilage of the Eustachian tube; it enters the tympanum through the canal in its anterior wall, and is inserted into the handle of the malleus near its root. The *laxator tympani* arises from the spine of the sphenoid, and the cartilage of the Eustachian tube; it enters the tympanum through the Glaserian fissure, and is inserted into the neck of the malleus. The *stapedius* arises within the pyramid, enters the tympanum through the hole at its apex, and is inserted into the neck of the stapes. The tympanum is lined by a mucous membrane, continuous with that of the Eustachian tube, which also invests the tympanic ossicles, ligaments, and muscles, and is prolonged backwards so as to line the mastoid air-sinuses. The epithelium covering this membrane, on the floor and the adjacent part of the anterior, posterior, and internal walls, is ciliated and columnar; but the epithelium on the roof, the promontory, the membrani tympani, and the tympanic ossicles, is tessellated. In the sub-epithelial connective tissue the blood and lymph vessels and nerves of the tympanum ramify.

The auricle and external meatus are well adapted for collecting and transmitting sound-vibrations inwards to the middle ear and labyrinth. These vibrations strike the membrana tympani, and are propagated by the chain of bones across the tympanic cavity to the labyrinth. The pressure of the vibrations on the tympanic membrane forces that membrane inwards, so that its inner surface presses on the handle of the malleus, the effect of which is to rotate the hammer about its axis. By the ligamentous attachment of the malleus to the tympanic walls and to the incus, and, as Helmholtz has shown, by the inter-

locking of cog-like processes connected with the articular surfaces of the two bones, the range of movement is so limited that the pressure on the malleus is transmitted through the incus upon the stapes, which presses, therefore, on the membrane of the fenestra ovalis; so that the movements of the membrana tympani are thus transmitted to fluid within the labyrinth. The tensor tympani muscle tightens the tympanic membrane by drawing the handle of the malleus inwards, and still further adapts the structures for the transmission of sound-vibrations. The laxator tympani is considered to be the antagonistic muscle to the tensor tympani. The stapedius draws the head of the stapes backwards, so that the posterior border of the base will press against the fenestra ovalis, and the anterior border will be raised from it.

Internal Ear.

The *Internal Ear*, named the *Labyrinth*, from its complex construction, is the part of the auditory apparatus in which the nerve of hearing is distributed, and where the peripheral end-organs are situated. It is enclosed within the petrous bone, and is divided into three parts, viz., vestibule, semicircular canals, and cochlea, each of which consists of an osseous and a membranous portion.

The *Vestibule* lies immediately internal to the tympanum, between it and the bottom of the internal auditory meatus; behind the vestibule are the semicircular canals, and in front is situated the cochlea. It is the part of the labyrinth which first appears in animals, and is therefore the most constant part of the organ. In the myxinoid fishes a single semicircular canal is superadded to the vestibule, in the lamprey two canals, but in other fishes and in the higher vertebrates three canals exist. In amphibia, reptiles, and

birds the cochlea is small and rudimentary in comparison with its development in mammals. The osseous vestibule is an ovoid chamber about $\frac{1}{5}$th inch in diameter. In its outer or tympanic wall is the *fenestra ovalis*; in its inner is the *fovea hemispherica* pierced with small *auditory foramina*, which transmit from the internal meatus the vestibular branches of the auditory nerve; behind these holes, and separated from them by the *crista vestibuli*, is the opening of a minute canal, the *aqueductus vestibuli;* in the roof is the *fovea hemi-elliptica*; its anterior wall opens into the *scala vestibuli* of the cochlea; on its posterior wall open the five orifices of the three semicircular canals.

The *Semicircular Canals* are named *superior*, *posterior*, and *external*. The superior and posterior are sometimes called the vertical canals, and the external the horizontal canal; but, as Crum Brown has shown, the superior and posterior lie in planes nearly equally inclined to the mesial plane of the head, and the external is in a plane at right angles to the mesial plane. Further, the canals in the two ears have definite relations to each other; for whilst the superior canal in each ear is nearly parallel to the posterior canal in the other, the external canals in both ears lie nearly in the same plane. The canals are bent, forming nearly $\frac{2}{3}$ds of a circle, and would have had six openings into the vestibule had not the contiguous ends of the superior and posterior blended together to open by a common orifice. The opposite end of each of these canals and the outer end of the external canal dilate close to the vestibule to twice their usual diameter, and form an *ampulla*. The osseous vestibule and semicircular canals are lined by a periosteum invested by a tessellated epithelium, and contain a little fluid, the *perilymph*. In this fluid the membranous labyrinth is suspended.

The osseous vestibule communicates in the macerated bone with the tympanum, internal meatus, aqueductus vestibuli, cochlea, and semicircular canals, but as the first three are occupied by membrane, the only communications left in the living head are with the semicircular canals and scala vestibuli of the cochlea.

The membranous vestibule is formed of two small sac-like dilatations, the walls of which are directly continuous with each other, though the cavities are separated by an intermediate partition. The upper and posterior dilatation occupies the fovea hemi-elliptica, and is named *utriculus;* it is larger than the lower and anterior, named *sacculus*, which lies in the fovea hemispherica. The sacculus is continuous with the *ductus cochlearis* of the membranous cochlea, and both sacculus and utriculus communicate by slender tubes with a short diverticulum lodged in the aqueductus vestibuli, to which the name of *ductus vestibuli* may be given (fig. 109). The membranous semicircular canals are about $\frac{1}{3}$d the diameter of the osseous. Their walls are continuous with that of the utriculus, and they open by five orifices into it. Each has an ampulla within the ampulla of the osseous canal. The sacculus, utriculus, and membranous semicircular canals are attached by delicate ligamentous bands to the periosteal lining of the osseous vestibule and semicircular canals. The wall of the membranous vestibule and canals consists of a delicate fibrous membrane lined by a tessellated epithelium. The inner part of this membrane has a vitreous or hyalin lustre, and gives origin in the canals to short papillæ which project into the lumen. The membranous vestibule and canals are distended with the fluid *endolymph.* The sacculus, utriculus, and ampullæ are specially modified in connection with the peripheral termination of the vestibular branches of the auditory nerve. The membranous wall forms in each of these dilatations a projecting ridge, the *macula*,

or *crista acustica*, to which calcareous particles, the *otoliths*, which may be either amorphous or crystalline, are adherent. The epithelial investment of the crista is elongated into columnar cells, and intercalated between them are fusiform cells, the *auditory cells*, each of which, as Schultze and other observers have described, possesses a peripheral and a central process. The *peripheral* process projects beyond the plane of the free surface of the endothelium into the endolymph as the *auditory hair*. A hyaline cuticle covers the epithelium and auditory cells, and is pierced by the auditory hairs (Pritchard). The *central* process extends into the sub-epithelial tissue, where the nerve plexus belonging to the terminal branches of the auditory nerve ramifies, and with which it is probably continuous (fig. 108). These auditory cells are, therefore, the peripheral end-organs of the vestibular branches of the auditory nerve, and their general arrangement is not unlike that of the olfactory cells of the nose.

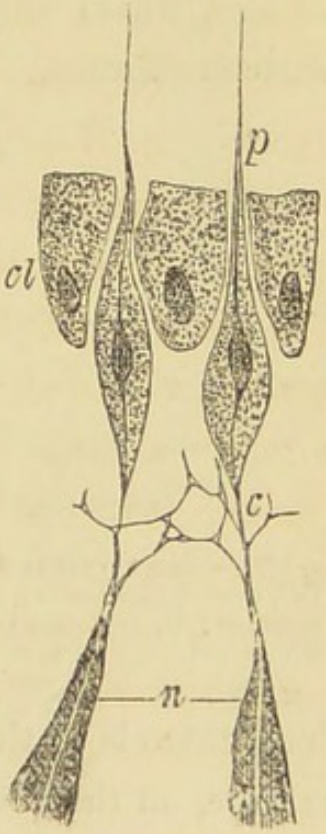

FIG. 108.—Ending of the Vestibular Nerve. *cl*, columnar cells covering the *crista acoustica*; *p*, peripheral, and *c*, central processes of auditory cells; *n*, nerve fibres. (*After Rüdinger.*)

The *Cochlea* is by far the most complex part of the labyrinth. It is about $\frac{1}{4}$th inch long, and shaped like the shell of a common snail; its base lies near the internal meatus, and its apex is directed outwards. The osseous cochlea is a tube wound spirally two and a half times round a central pillar or *modiolus*. Both the pillar and the tube diminish rapidly in diameter from the base to the apex of the cochlea. The tube is imperfectly divided into two passages

by a plate of bone, the *osseous spiral lamina*, which, springing from the modiolus, winds spirally around it, and projects into the tube. When the membranous cochlea is in its place, the division is completed by a membrane, the *membranous spiral lamina*, or *basilar membrane*, which bridges across the interval between the free edge of the osseous spiral lamina and the outer wall of the tube, to the latter of which it is attached by the *spiral cochlear ligament*, which contains elastic fibres radiating from the basilar membrane. These passages are called *scala tympani* and *scala vestibuli*. The vestibular border of the free edge of the osseous spiral lamina terminates in a denticulated spiral crest, the *limbus* or *crista spiralis*. From the basis of this crest arises the *membrane of Reissner* which extends to the spiral ligament at the outer wall of the tube, on the vestibular aspect of the basilar membrane, so as to enclose a passage between it and the basilar membrane, called *scala intermedia* or *ductus cochlearis*. The membrane of Reissner is formed of delicate vascular connective tissue, with an epithelial layer on each of its two surfaces. The scala tympani or lower passage, widest at the base of the cochlea, begins at the inner wall of the tympanum, into which it would have opened through the fenestra rotunda, had not the fenestra been closed up by a membrane. The scala vestibuli or upper passage, also widest at the base, communicates with the cavity of the osseous vestibule. At the apex of the cochlea these two

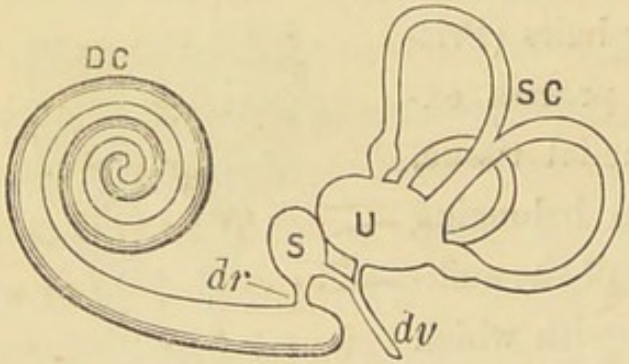

FIG. 109.—Diagram of the Membranous Labyrinth. DC, ductus cochlearis; *dr*, ductus reuniens; S, sacculus; U, utriculus; *dv*, ductus vestibuli; SC, semicircular canals. (*After Waldeyer.*)

scalæ communicate with each other through a small hole, the *helicotrema*. As the scala vestibuli opens into the osseous vestibule, the perilymph is continued into it, and through the helicotrema into the scala tympani. The ductus cochlearis is the *membranous cochlea*, and its walls

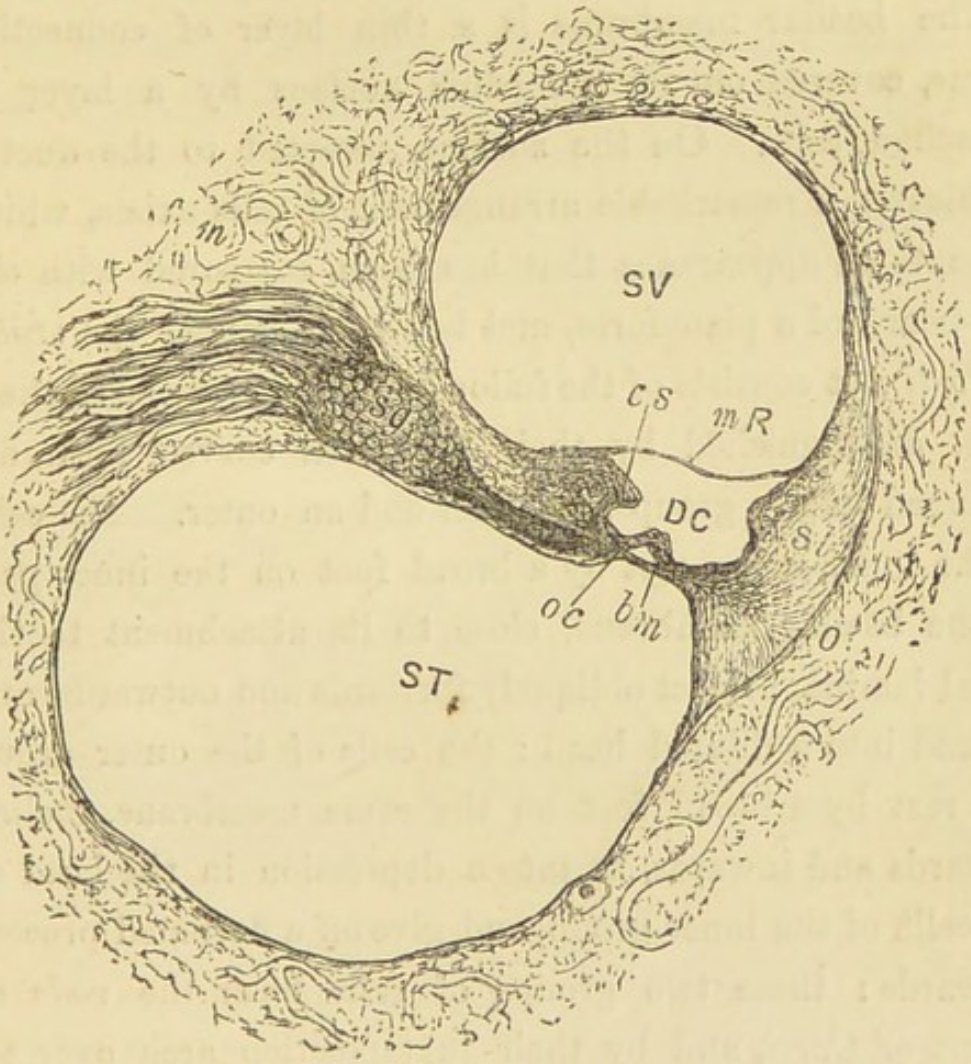

FIG. 110.—Tranverse section through the tube of the Cochlea. *m*, modiolus; O, outer wall of cochlea; SV, scala vestibuli; ST, scala tympani; DC, ductus cochlearis; *m*R, membrane of Reissner; *bm*, basilar membrane; *cs*, crista spiralis; *sl*, spiral ligament; *sg*, spiral ganglion of auditory nerve; *oc*, organ of Corti.

are formed of the basilar membrane next the scala tympani, of the membrane of Reissner next the scala vestibuli, of the spiral ligament next the outer wall of the cochlea, and of the crista spiralis next the osseous spiral lamina. It follows the spiral windings of the cochlea, terminates at the apex of the spiral in a closed end, whilst at the base it

communicates with the sacculus of the membranous vestibule by a slender tube, the *canalis reuniens;* hence the membranous cochlea contains endolymph. The termination of the cochlear branches of the auditory nerve and the arrangement of the peripheral end-organs in relation to them are to be looked for in the basilar membrane.

The basilar membrane is a thin layer of connective tissue, covered on its tympanic surface by a layer of branched cells. On the surface, directed to the ductus cochlearis, a remarkable arrangement of cells exists, which presents an appearance that has been compared with the key-board of a pianoforte, and has been named the *organ of Corti;* it consists of the following parts :—Some of these cells, distinguished by their elongated curved form, are arranged in two groups, an inner and an outer. The cells of the inner group rest by a broad foot on the inner part of the basilar membrane, close to its attachment to the spiral lamina, project obliquely forwards and outwards, and expand into a dilated head : the cells of the outer group also rest by a broad foot on the same membrane, incline forwards and inwards, fit into a depression in the head of the cells of the inner group, and give off a flattened process outwards : these two groups of cells form the *rods* or *pillars of Corti*, and by their juxtaposition arch over an excessively minute canal, enclosed between them and the basilar membrane, which may be named the *canal of Corti.* The inner rods are more numerous, but not so long as the outer, and Pritchard has shown that the rods increase in length from the base to the apex of the cochlea. A nucleated mass of protoplasm is in contact with both the foot and head of both the inner and outer rods. Immediately internal and almost parallel to the inner group of these rods, and adjacent therefore to the crista spiralis, is a single

row of compressed conical cells, which possess at their anterior ends short stiff hair-like processes; they are the *inner hair cells* of Deiters. Internal to these are elongated *supporting cells* continuous with those covering the crista spiralis. Immediately external and almost parallel to the outer group of rods of Corti are four, five, or even six rows of haired cells, the *outer hair cells*. Each consists of a deeper part attached to the basilar membrane, and of a

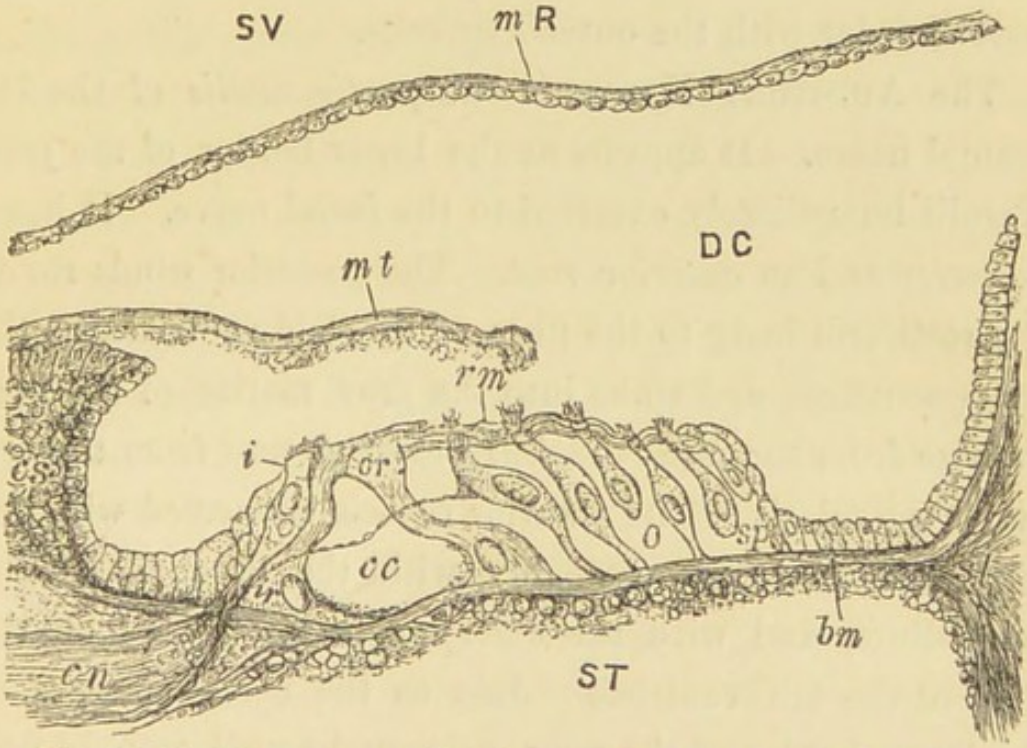

FIG. 111.—Vertical transverse section through the Crista Spiralis, Basilar membrane and organ of Corti. *bm*, *cs*, *sl*, &c., as in fig. 109; *i*, inner hair cell; *ir*, inner, and *or*, outer rod of Corti; *o*, outer hair cells; *sp*, supporting cells; *cn*, cochlear nerve; *cc*, canal of Corti; *rm*, reticular membrane; *mt*, membrana tectoria, torn through at its outer end. (*Adapted from Waldeyer.*)

superficial part from which a brush of hairs projects through the reticular membrane. The outer hair cells are, according to Waldeyer, relatively of large size in man. The *reticular membrane* of Kölliker is a delicate framework perforated by rounded holes. It extends parallel to the basilar membrane from the inner rods of Corti to beyond the external row of outer hair cells, and through the holes in it the hairs of the outer hair cells project. It obviously acts as a support for the anterior ends of these cells, and

binds together these important elements of the organ of Corti. The interval between the outer hair cells and the spiral ligament is occupied by cells of a more or less columnar form, the *supporting cells* of Hensen. Covering over the organ of Corti, and separating it from the endolymph of the ductus chochlearis, is the *membrana tectoria*, which springs from the crista spiralis close to the attachment of the membrane of Reissner, passes outwards superficial to the membrana reticularis, and apparently blends at its outer border with the outer hair cells.

The AUDITORY NERVE is the *portio mollis* of the 7th cranial nerve. It appears at the lower border of the pons Varolii immediately external to the facial nerve. It has a *posterior* and an *anterior root*. The posterior winds round the restiform body to the floor of the 4th ventricle, as the striæ acusticæ, and sinks into the grey matter of the floor to arise from the *inner nucleus acusticus* and from the formatio reticularis. The anterior root is connected with the restiform body, and probably with the flocculus of the cerebellum, and with the *outer nucleus acusticus* on the floor of the 4th ventricle. Just as the nerve emerges at the lower border of the pons, as may be well seen in preparations by A. B. Stirling, collections of very vascular grey matter containing groups of multipolar nerve cells lie between the bundles of the nerve, and from their processes re-inforcing fibres are added to the nerve. The auditory nerve passes down the internal meatus, and divides into a vestibular and a cochlear division. The *vestibular* division enters the vestibule, and divides into five branches for the sacculus, utriculus, and three ampullæ of the membranous semicircular canals. Each branch enters a crista acustica and forms a plexus, in the meshes of which nerve cells are imbedded. From this plexus fine non-medullated fibres

arise, which enter the layer of cells on the surface of the crista, where they anastomose and form a very delicate plexus, from which fibres spring that in all probability join the central processes of the auditory cells (fig. 108).

The *cochlear* division enters a canal in the axis of the modiolus, and gives off lateral branches, which pass into the canals situated in the osseous spiral lamina. Here they radiate outwards to the membranous spiral lamina, and have connected with them collections of nerve cells forming the spiral ganglion. Beyond the ganglion they form a flat plexiform expansion, from which non-medullated fibres pass through a gap in the edge of the osseous lamina into the organ of Corti. In this organ the nerves, as Gottstein and Waldeyer have described, are arranged in two groups of fibres: the inner group become continuous with the deep end of the inner hair cells; the outer group pass across the canal of Corti and end in the outer hair cells (fig. 111). Hence these cells are the peripheral end-organs of the cochlear branch of the auditory nerve, and may be called the *auditory cells of the cochlea.*

The perilymph of the labyrinth is set in vibration by the movements of the tympanic ossicles and the fenestra ovalis; motion is thus communicated to the membranous labyrinth and the endolymph which it contains. The auditory hairs and cells would thus be set in motion, and the vestibular branches of the auditory nerve would be stimulated to conduct sound-impulses to the brain. The movements of the perilymph in the scala tympani, and of the endolymph in the ductus cochlearis, would set in vibration the basilar membrane and the auditory cells resting on it, through which the cochlear branches of the auditory nerve would be stimulated to conduct sound-impulses to the brain. It has been customary for physiologists to

regard the vestibule as the part of the labyrinth by which sound or mere noise is determined; the cochlea, as the part which determines variations and degrees of sound, as musical notes or harmony; the semicircular canals, as determining the directions from which sound proceeds. But within the last few years experiments and arguments have been advanced almost simultaneously by Breuer, Mach, and Crum Brown, in favour of the view that the semicircular canals act as peripheral end-organs for the sense of rotation, by which sense the axis about which rotation of the head takes place, the direction of that rotation, and its rate, are determined.

Development of Ear.

In the account of the development of the skull, p. 58, it was stated that the external meatus, tympanum, and Eustachian tube are the remains of the 1st visceral cleft of the embryo; that the malleus and incus are formed in the 1st and 2d visceral arches, and that the stapes and petrous bone are ossified in the periotic cartilage. The membranous labyrinth arises as an invagination of the epiblast into the mesoblast, near the upper end of the 1st visceral cleft, and the invaginated fold then closes in, by the growth of the surrounding mesoblast, and forms a shut sac, the *primary auditory vesicle*. The cavity of this vesicle enlarges, thickening of its walls takes place, and in this manner arise modifications in its form, from the condition of a simple closed sac, until the membranous vestibule, the semicircular canals, and the cochlea are produced. From the epiblast lining of the vesicle, the organ of Corti, and the special apparatus connected with the termination of the auditory nerve in the vestibule and semicircular canals, together with the general epithelial lining of the membranous labyrinth, are derived. The fibro-membranous wall of the labyrinth, and the periotic cartilage which subsequently ossifies into the petrous bone, are produced by a differentiation of the mesoblast surrounding the auditory vesicle. The space filled by perilymph, between the membranous and osseous labyrinth, is apparently due to a splitting of this surrounding mesoblast. The auditory nerve arises from the neural crest of epiblast from which the cranial nerves generally proceed. In the course of time its central end unites with the part of the brain from which it derives its roots, and its peripheral end extends into the epiblast lining of the labyrinth, which forms the peripheral end organs of the auditory apparatus.

The Tongue.

The Tongue, situated on the floor of the cavity of the mouth, is the chief organ provided for the excitation of the special sense of taste, but the under surface of the soft palate is said to participate to some extent in this property.

The tongue is also highly endowed with the sense of touch. The structures concerned in the excitation of taste and touch are situated in the mucous membrane which envelopes the tongue. The tongue is also a muscular organ, and plays an important part in articulation, mastication, and deglutition. Its shape is flattened from above downwards, so that it presents an upper surface or dorsum, and a lower surface. Its posterior part is broad, forms the base or root of the organ, and is attached to the hyoid bone. Its anterior extremity or tip is more or less pointed, and its lateral margins or sides are rounded.

The muscles connected with the tongue are arranged in pairs, and form three distinct groups, viz., accessory, extrinsic, and intrinsic muscles. The *Accessory* muscles are the stylo-hyoid, digastric, mylo-hyoid, genio-hyoid, omo-hyoid, sterno-hyoid, and thryo-hyoid, already referred to on page 84, which act upon the hyoid bone, and thus indirectly are concerned in the movements of the tongue. The *Extrinsic* muscles pass from adjacent parts into the substance of the tongue, and are as follows :—The *stylo-glossus* arises from the tip of the styloid process and the stylo-maxillary ligament ; it runs forwards along the side of the tongue to the tip.—The *hyo-glossus* is divided into three parts : *a*, *basi-glossus*, which arises from the body of the hyoid ; *b*, *cerato-glossus*, from the great cornu of the hyoid ; *c*, *chondro-glossus*, from the small cornu of the hyoid. The fibres of the three parts ascend into the side of the tongue.

The *genio-hyo-glossus* arises from the upper tubercle of the symphysis of the lower jaw, its fibres radiate into the substance of the tongue along its whole length from base to tip; this muscle is separated from the corresponding muscle of the opposite half of the tongue by a mesial septum of fibrous tissue. The *palato-glossus* arises in the substance of the soft palate, and descends to the tongue in the anterior pillar of the fauces. The *intrinsic* muscles lie in the substance of the tongue itself, and are as follows: The *lingualis superior* (noto-glossus), consisting of longitudinal fibres, which extend from the base to the tip beneath the mucous membrane of the dorsum; the *lingualis inferior*, consisting of longitudinal fibres, which extend from the base to the tip, along the under surface, between the hyo-glossus and genio-hyo-glossus; *transverse muscular fibres*, which spring from the mesial fibrous septum and curve outwards and upwards to the sides of the tongue; *vertical fibres*, which pass through the substance of the tongue from the dorsum to the under surface. The extrinsic and intrinsic muscles can not only move the entire tongue within the cavity of the mouth, protrude it between the lips, and again retract it, but can modify its form; thus the dorsum can be flattened, made convex or concave, the margins can be raised or depressed, and the tip elevated or depressed.

The mucous membrane of the tongue forms a part of the general mucous lining of the mouth; it covers the dorsum, tip, sides, and under surface; is reflected from the under surface to the floor of the mouth, where it forms the *frænum linquæ*, or bridle of the tongue, is reflected from the base of the tongue to the epiglottis as the *fræna* of the epiglottis, as well as over the tonsils, and from the sides of the tongue to the soft palate as the anterior palatine pillars

or palato-glossal folds. Immediately in front of each palato-glossal fold are several transverse folds of the mucous membrane, which form a series of lamellæ. They are sometimes called the papillæ foliatæ, but are more appropriately named *gustatory lamellæ*.[1] The free surface of the mucous membrane of the tongue is generally elevated into multitudes of fine processes, called the papillæ of the tongue, some of which are simple, others compound. The *simple papillæ* are short, simple, conical elevations of the membrane, and are situated on the back part of the dorsum and the under surface of the mucous membrane, as well as scattered between the compound papillæ. The *compound papillæ* are arranged in three groups, named filiform, fungiform, and circumvallate papillæ. The compound character of each of these papillæ is due to the presence of several small secondary papillæ projecting from it. The *filiform papillæ*, elongated and thread-like, are the smallest and most numerous, and cover the dorsum in front of the circumvallate papillæ. The *fungiform* or club-shaped papillæ are scattered over the anterior and middle parts of the dorsum, and at the tip and sides. The *circumvallate papillæ*, seven to twelve in number, are arranged in a V-shaped manner on the dorsum towards its base; a depression in the mucous membrane, called *foramen cæcum*, marks the apex of the V: they are the largest papillæ; each is sunk in a vallum or trench-like depression of the mucous membrane, which isolates it from the surrounding surface. The epithelial covering of the filiform papillæ is characterised by the peculiar modification which the tessellated epithelium of the mouth has undergone; the cells have become cornified and elongated into dense,

[1] The gustatory lamellæ can be seen to great advantage in the tongue of the rabbit.

imbricated brush-like processes. In the carnivora the epithelium is hardened so as to form sharp spines, with the points turned backwards, which give to the tongues of these animals a rough prickly character. In the fungiform and circumvallate papillæ the inequalities between the projecting secondary papillæ are filled up by tessellated epithelium, so that the surface of the compound papillæ has a smooth appearance. Both the simple and compound papillæ are highly vascular, for the lingual artery supplies both the muscular substance of the tongue, and many branches to the mucous membrane, which end in simple

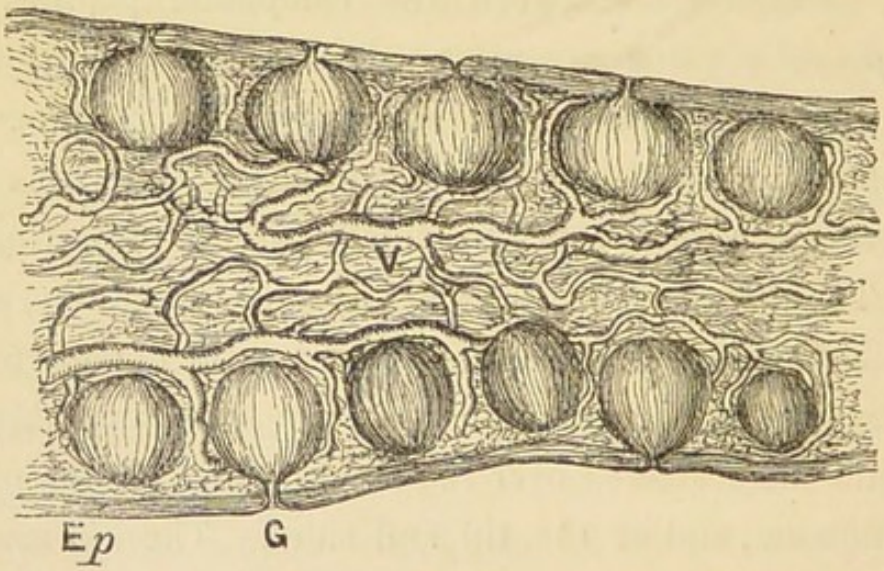

FIG. 112. Section through a Gustatory lamella of the Rabbit's Tongue. *G*, gustatory bulbs in relation to *Ep*, the epithelial layer of the mucous membrane; V, capillary blood-vessels in the sub-epithelial connective tissue.

capillary loops in the simple papillæ, but in the compound papillæ the capillaries are so multiplied that each secondary papilla has a capillary loop within it.

The tongue is provided with several nerves, viz., the hypo-glossal, glosso-pharyngeal, lingual branch of the 3d division of the 5th, and the chorda tympani of the portio dura of the 7th. The hypo-glossal nerve supplies its muscular structure, but the inferior lingualis and genio-hyo-glossus are said to receive branches from the chorda tympani of the facial. The glossal branch of the glosso-

pharyngeal is distributed to the mucous membrane of the dorsum of the root of the tongue, to the circumvallate papillæ and the gustatory lamellæ. In connection with its terminal branches, peculiar flask-shaped organs, called *gustatory bulbs* or *bodies*, have been described by Lovén, Schwalbe, and Engelmann, in the sides of the circumvallate papillæ, and in the gustatory lamellæ. When sections are made through one of these lamellæ, or through a circumvallate papilla and the trench which surrounds it, numerous flask-shaped gustatory bulbs may be seen in the epithelium, which covers the side of the lamella or of the papilla and the opposite side of its trench. The bottom of each flask is next the sub-epithelial tissue, whilst its short neck opens on the surface by a mouth, the *gustatory pore;* similar bodies, though in much smaller numbers, have also been seen in the fungiform papillæ. Each gustatory body consists of two different forms of cells, named *covering cells* and *gustatory cells.* The outer covering cells are elongated, flattened, and nucleated; arranged in layers, which form the envelope of each gustatory bulb, and reach from the bottom of the flask to its mouth; they enclose the gustatory cells. The inner gustatory cells occupy the axis of the gustatory bulb. They are homogeneous, highly refractile; and are attenuated either into delicate spindles or rods, and the peripheral end of the rod is sometimes forked. Each cell has an elliptical nucleated body with two processes, a central and peripheral. The peripheral process, broader than the central, sometimes ends in a short hair-like tip, which almost reaches the gustatory pore; the central process extends to the base of the flask,



FIG. 113.—*s*, superficial covering cells of a Gustatory bulb; G, gustatory cell, with *p*, its peripheral, and *c*, its central process.

and often divides into small branches. This process is varicose, and not unlike the axial cylinder of a nerve fibre. The branches of the glosso-pharyngeal nerve, which are distributed to the back of the tongue, enter the circumvallate papillæ, the outer wall of the surrounding trench, and the gustatory lamellæ, and form a minute plexus, with groups of nerve cells interspersed in it, from which bundles both of medullated and non-medullated fibres pass to the base of the gustatory bulbs. It is believed that the finest non-medullated fibres are continuous with the central processes of the gustatory cells, which are therefore regarded as the peripheral end-organs of the nerve of taste, and by the excitation of these bodies gustative or taste sensations are produced. As the glosso-pharyngeal is the nerve distributed to the circumvallate papillæ, where these gustatory bulbs are especially found, it is therefore the special nerve of taste. The gustatory bulbs are not penetrated by blood-vessels, but the vascular sub-epithelial tissue is prolonged upwards along the sides of the bulbs almost as far as the plane of the gustatory pore (fig. 112).

Gustatory bulbs have also been described in the fungiform papillæ, but it is not known if these are supplied by the glosso-pharyngeal nerve. In these papillæ the nerves have been described (Krause) as ending both in a pencil-like brush of non-medullated fibres, and in small end-bulbs. The lingual branch of the 3d division of the 5th is distributed to the mucous membrane of the tip, sides, anterior part of the dorsum, and the under surface of the tongue. It supplies the compound filiform papillæ, but its exact mode of ending in them has not been definitely ascertained. It is a nerve of common sensation, though some have also regarded it as a nerve of taste for the anterior part of the tongue. Distributed, in part at least, along with the

lingual nerve is the chorda tympani, which is also believed to be associated with the sense of taste. It is doubtful if it derives its taste fibres directly from the 7th; for it may receive them from the glosso-pharyngeal through the connections of the tympani branch of that nerve with the superficial petrosal nerves, and of these with the geniculate ganglion of the portio dura of the 7th. The cerebral centre for the sense of taste has been placed by Ferrier in the tip of the middle temporo-sphenoidal convolution.

The mucous membrane of the tongue contains numerous small tubular or branched glands, more especially on the dorsum near its root, which secrete mucus. Depressions also occur in this part of the mucous membrane, around which lymphoid cells are collected in the sub-epithelial connective tissue; these cells are arranged as in the adjacent tonsils, and form an adenoid or lymphoid tissue.

Development of Tongue.

The tongue arises as a bud-like process on the floor of the mouth of the embryo. It consists of mesoblast covered by the epiblast layer which lines the buccal chamber. From the epiblast is produced the epithelial covering, and in all probability the gustatory bulbs, whilst the mesoblast gives rise to the muscular, fibrous, vascular, and nervous structures.

The Skin.

The Skin, or Integument, invests the entire outer surface of the body, and contains structures by the excitation of which the properties of things are determined by the sense of touch. The skin also contains accessory structures, as the nails, hairs, sebaceous glands, and sweat glands. The skin consists of a non-vascular cuticle or epidermis, and of a vascular and sensitive corium, or cutis vera.

The *Cuticle*, *Epidermis*, or *scarf skin*, forms the outer covering of the skin, and protects the cutis. It is a laminated structure, and consists of numerous layers of cells

superimposed on each other. As these cells cover a free surface exposed to the air, they belong to the group of epithelial tissues. The thickness of the cuticle varies in different localities from $\frac{1}{10}$th to $\frac{1}{200}$th inch; where the skin is frequently exposed to pressure, as in the soles of the feet, the cuticle is the thickest and hardest; and the hands of those accustomed to manual labour have a hard and horny cuticle. The increase in thickness in these localities is for the purpose of protecting the highly sensitive cutis from injury. The outer surface of the cuticle in many parts of the body, especially the palm of the hand and the fingers, is marked by ridges and furrows; the ridges indicate the position and arrangement of the papillæ of the cutis, whilst the furrows are due to the sinking of the cuticle into the spaces between the rows of papillæ. The mouths of the sweat glands open on the surface of these ridges. The cuticle is divided into two strata. The *superficial horny stratum* consists of many layers of flat, polygonal horny scales like a tessellated epithelium; the cells in these layers firmly adhere to each other by their surfaces, and in vertical sections this stratum presents a fibrous appearance; but the cells may be readily isolated by digestion in a caustic alkali. The deepest layer of the horny stratum, sometimes called *stratum lucidum*, consists of closely packed scales, and often has a bright appearance. The *deeper* or *mucous stratum*, or *rete Malpighii*, lies next the cutis, and closely follows the undulations of its papillary surface. The cells forming the layer next the cutis are short columns, those in the layers immediately succeeding are polyhedral and possess prickle-like processes projecting from them; hence the name, *prickle cells*, employed by Schultze. The prickles of adjacent cells do not apparently interlock, but are continuous with each other at

their apices, so that lymph channels lie between the cells for the transmission of a nutrient pabulum. The colouring matter of the skin is found in the cells of the mucous stratum, which in the fair races of men form the isolated coloured spots called freckles and moles, but in the dark races the pigment granules are uniformly distributed throughout the cells of this stratum. The superficial cells of the horny stratum of the cuticle are constantly being shed, so that the cells of the deeper layers gradually approach the surface, and new cells are continually being formed in the deeper part of the rete Malpighii by horizontal division of the layer of short columnar cells. The cuticle is closely adherent to the cutis in the healthy living skin, but on the application of a blister, or when putrefaction sets in after death, they separate from each other.

The *Cutis vera.*—When the cuticle is removed the surface of the cutis is seen to be studded with multitudes of minute elevations, the papillæ of the skin. These papillæ are either simple conical structures, or compound with two or three branches. They are largest in the palm and sole, being from $\frac{1}{100}$th to $\frac{1}{200}$th of an inch high, and are arranged in ridges, but more usually they are much shorter and irregularly distributed. The cutis is formed of connective tissue, in which stellate connective tissue corpuscles and elastic fibres are abundant. The deeper surface of the connective tissue of the cutis is reticulated, and is continuous with the bundles of connective tissue that form the areolar subcutaneous tissue. In the papillæ themselves the fibres of the connective tissue are not so well marked, and the surface of the papillæ possesses more of a homogeneous aspect, which gives rise to the appearance described as a basement membrane. The cutis is highly vascular; the small arteries which go to the skin give off

branches to the lobules of fat in the subcutaneous tissue, then penetrate the cutis and form a plexus from which capillaries arise, which enter the papillæ, and form vascular loops within them. The lymphatic vessels of the skin are numerous; they form a plexus in the cutis, which lies beneath the vascular plexus and forms, as Neumann's injections

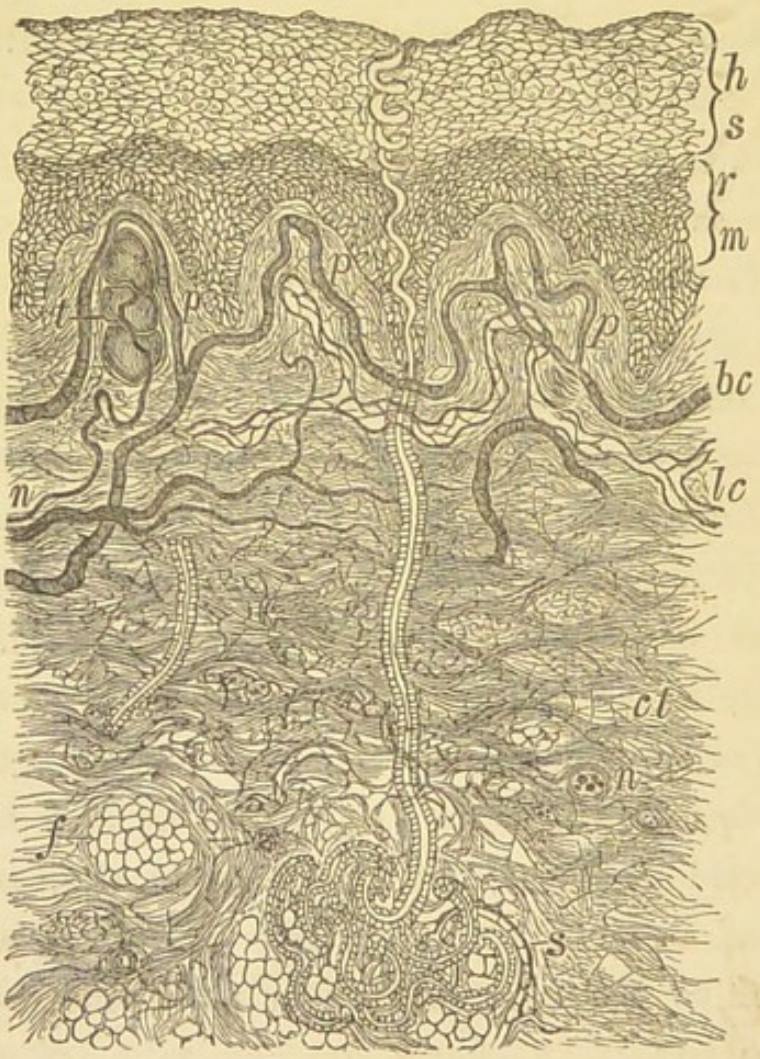

FIG. 114.—Vertical Section through the Skin and Subcutaneous Tissue. *hs*, horny stratum, and *rm*, rete Malpighii of cuticle; *pp*, papillæ of cutis; *t*, a touch corpuscle, with *n*, a nerve fibre; *bc*, a blood, and *lc*, a lymph capillary; *ct*, connective subcutaneous tissue; *f*, fat lobule; *s*, a sweat gland with its duct.

show, a network around both the sebaceous and sweat glands, and gives off capillary loops into the papillæ.

The nerves of the skin are the cutaneous branches both of the spinal and of certain of the cranial nerves, the origin and distribution of which have already been described. They run through the subcutaneous tissue, and enter the

deep surface of the cutis, where they divide into branches. As these pass towards the papillæ they unite to form a nerve plexus, from which smaller branches arise to enter the papillæ, and terminate, more especially in the skin of the palm of the hand, fingers, and sole, which are the surfaces most sensitive to touch impressions, in the *tactile* or *touch corpuscles.* The touch corpuscles discovered by Wagner and Meissner are the peripheral end-organs of the nerves of touch (fig. 114). They may be single or compound, and are usually ovoid in form, not unlike a minute fir cone. Each corpuscle has an investing capsule of connective tissue, the nuclei in which are arranged transversely or obliquely. The capsule encloses a soft, delicate, granulated material which forms the substance of the corpuscle. Each single corpuscle and each division of a compound corpuscle is penetrated by at least one medullated nerve fibre. The sheath of the fibre joins the capsule of the corpuscle. Within the corpuscle the nerve fibre may branch, or run spirally, or divide into a bunch of non-medullated fibres, which, Krause says, may end either in points or in bulbous extremities. Virchow and other German observers have stated that the papillæ which contain capillaries do not contain nerves or touch corpuscles, and *vice versa;* but Dalzell and Thin have shown that certainly the majority of papillæ that contain nerve fibres and touch corpuscles are also vascular papillæ. Non-medullated nerve fibres pass through the cutis into the rete Malpighii between the cells of the mucous layer (Langerhans). The hippocampus major and the gyrus hippocampi are apparently the cerebral centres for tactile impressions.

Nails.—On the back of the last phalanx of each thumb, finger, and toe is situated a firm horny curved plate, the nail. Each nail rests on a bed, the surface of which is

formed of the cutis, which also overlaps the side and root of the nail; thus the nail fits into a groove formed of the cutis something after the manner in which a watch-glass fits into its rim. A nail is merely a special modification of the cuticle, the cells of the superficial stratum of which are more horny, harder, and more firmly adherent to each other than in the cuticle proper. Deeper than the horny stratum is the rete Malpighii of the nail, the cells of which are soft, as in the cuticle itself. The cutis forming the bed of the nail is studded with vascular papillæ, which are arranged in almost parallel rows. Nails grow both in length and thickness: the increase in thickness is due to the formation of cells on the bed of the nail; the increase in length takes place through the formation of nail cells at the root, and as the nail is thus slowly pushed forward it requires to be cut at intervals. At the root, sides, and below the free border of the nail, the cuticle is continuous with the substance of the nail itself.

Hair.—Projecting from the surface of the skin are multitudes of elongated cylindrical horny structures, the hairs. In the skin of the scalp, the armpits, and the pubis they are long and numerous; but in the eye-brows, eye-lashes, vibrissæ of the nostrils, and surface of the body generally, they are short. They are stronger and thicker in the skin of man than of woman, more especially on the cheeks, lips, and chin. Hairs do not grow from the skin of the palms and soles, the back of the ungual phalanges, and the surface of the upper eye-lids. Each hair is partially imbedded in a depression of the skin, called a *hair follicle.* The deeper end of the follicle is somewhat dilated, and has in its fundus a papilla, the *hair papilla.* The wall of the hair follicle is formed of the constituent structures of the skin; the outer part of the wall belongs

to the cutis, and has been described as arranged in three layers, the external, middle, and inner layer of the hair follicle. The external and middle layers are formed of connective tissue, with blood-vessels; whilst the inner, sometimes called the *vitreous layer*, is transparent and homogeneous, and continuous with the so-called basement membrane of the cutis. The inner part of the wall of the hair follicle, or the *root-sheath*, belongs to the cuticle, and consists of two layers, the outer and inner root-sheaths. The *outer root-sheath* is continuous with the rete Malpighii, and consists of layers of cells similar to those of that stratum. The *inner root-sheath* is continuous with the horny stratum of the cuticle, and consists of layers of cells; those of its outer layer are flattened and non-nucleated; those of its middle layer, which form the *sheath of Huxley*, are polyhedral and nucleated, whilst those of the inner layer are non-nucleated, elongated, and flattened.

A hair possesses a root, a shaft, and a tip; the root is imbedded in the hair follicle, whilst the shaft and tip form the free projecting part of the hair. The hair is invested by imbricated scale-like cells, which form the *hair cuticle*. The substance of the human hair is composed of a *fibrous*-looking horny material, which by the action of strong sulphuric acid is resolved into elongated, closely compacted, fusiform cells, which in coloured hairs contain pigment granules. In the thicker hairs the cells in the axis of the hair are polygonal, contain air, and form a central pith or *medulla*. In different animals the size and relative proportion of the cells of the cuticle, medulla, and fibrous part of the hair present many modifications. The wool of the sheep has its cuticle scales, with well-defined serrated margins, so that the hair of this animal is well adapted for felting into cloth; in the bat, also, the cuticle cells ar

largely and strongly serrated. The bristles of the pig, again, have the fibrous part of the hair largely developed. In the deer tribe the hair consists of polygonal medulla-like cells, which contain air. The root of the hair dilates at its deeper end into a bulb which embraces the hair papilla. It is softer in texture than the shaft, so that the cellular structure of the hair is more easily seen. Next the papilla the cells are like those of the rete Malpighii, but in the shaft they are differentiated, both in structure and composition, into the proper hair cells. The hair papilla bears to the hair the same relation as a papilla of the cutis has to its investing cuticle, so that a hair is a specially modified cuticular structure. The human hair papilla is vascular. Nerves have been traced into the wall of the hair follicle, but not into the hair papilla. In the tactile hairs of the mammalia, however, nerves have been traced into their papillæ.

The bristles, feathers, claws, hoofs, the horny envelope of the horn cores in the hollow horned ruminants, and various tegumentary spines and scales, present in many animals, are, like hairs and nails, special modifications of the tegumentary system.

Each hair follicle has opening into it the excretory duct of one or more small glands named *Sebaceous Glands*. Each gland consists of an excretory duct, and of from two to twenty grape-like saccular expansions or acini which open into the duct. The wall of the sacculi and of the duct is continuous with the vitreous layer of the outer wall of the hair follicle. Capillary blood-vessels and lymph-vessels are distributed on the outer wall of the sacculi. The sacculi are almost entirely filled with polygonal cells containing drops of fat, which cells are continuous with the epithelial lining of the gland duct and the cells of the

outer root-sheath. These glands secrete a fatty material, which lubricates the surface of the hair.

One or two bundles of involuntary smooth muscular fibres extend from the deep surface of the cutis to be inserted into the lower third of the outer layer of the wall of the hair follicle (Kölliker). These muscles, named *arrectores pili*, by their contraction erect the hairs, that is, cause them to become more prominent, and produce the condition of skin called *cutis anserina* or goose skin, well known to occur when cold is applied to the surface of the body.

Sweat Glands, or sudoriparous glands, are found generally distributed throughout the skin, but are most abundant in the palms and soles, where they number 2500 to 3000 in each square inch. In the skin of the back, again, there are only between 400 and 500 in the square inch. Each gland consists of a ball-like body lying in the subcutaneous tissue, from which a tubular duct proceeds through the skin to open on its free surface (fig. 114). The ball is composed of a convoluted tube continuous with the tubular duct, and terminating in a blind end. The wall of the gland tube consists of a delicate nucleated membrane lined by short columnar secreting cells. External to this membrane is a layer of involuntary muscles consisting of short fusiform cells; and outside it, again, is an adventitia of connective tissue containing capillary blood-vessels and lymph-vessels. As the gland-duct pierces the cutis it passes between the papillæ; in its course through the cuticle it pursues a spiral direction, and has its walls formed, not of a distinct membrane, but of the cuticle cells themselves. The epithelial lining of the duct is continuous with the cells of the rete Malpighii of the cuticle. The mouths of the sweat ducts, or *sweat pores*, open on the skin of the hand and

fingers on the summit of the delicate ridges, where they may be seen with a pocket lens. In the axilla and groin the sweat glands are much larger than in the skin generally.

Development of Skin.

The Cutis, its vessels and nerves, and the peripheral end organs connected with the nerves of touch, are produced by a differentiation of the cells of the mesoblast. The two layers of the Epidermis, with the cellular prolongations into the hair follicles, sebaceous glands, and sweat glands, are differentiations of the cells of the epiblast.

The Sweat Glands arise as flask-shaped pouches of the rete Malpighii projecting into the cutis, which in course of time become elongated into tubes, and the cells contained in these tubes become the secreting cells of the gland.

Hairs are developed about the 4th month of embryo life, within depressions in the cutis, which form the future hair follicles, filled with cells similar to, and continuous with the epiblast cells of the rete Malpighii. A papilla forms at the bottom of this depression, around which the cells become arranged in a bulbous expansion. The cells, in line with the bulb, elongate and harden, and group themselves so as to form the shaft of the young hair, which at this stage is completely buried within the follicle. A rapid production of new cells takes place at the bulb, the hair consequently increases in length, and is pushed outwards through the superficial horny stratum of the cuticle, which had closed in the mouth of the depression or follicle in which the hair is produced. At the same time, the more external cells within the follicle are pushed outwards towards its wall, and form the cells of the root-sheath. When a hair is pulled out of its follicle the cells of the root-sheath are drawn out along with it. A new hair will be developed at the bottom of a follicle from which the hair has been shed as long as cells continue to be formed around the papilla. When the growth of cells ceases and the hair follicles and papillæ atrophy, then permanent baldness is the result.

The Sebaceous Glands are developed as bud-like offshoots from the hair follicles, filled, like the follicles themselves, with cells continuous with the epiblast cells of the rete Malpighii. Instead of the cells in these buds differentiating into a hair, they become filled with fatty particles, and the wall of the bud assumes the characteristic sacculated form of the gland.

CHAPTER VII.

VASCULAR SYSTEM.

The human body and the bodies of all the more highly organized animals are traversed by a system of closed, branching tubes or pipes, technically called Vessels, some of which in man are nearly an inch in diameter, others so small as to require a microscope for their examination, others again of every intermediate size. In connection with the vessels is a central organ, the Heart. The heart and the vessels collectively constitute the Vascular System. When examined after death the vessels are frequently found to be empty, but during life they contain fluids. Some contain Blood, and form the Sanguiferous or Blood-vascular system; others contain Lymph, and form the Lymph-vascular system. The lymph-vascular system is not distinct from and independent of the blood-vascular system, but communicates with it at several points. The vascular system is a hydraulic apparatus, possessing a pump, pipes, and valves. The heart is the pump, which works, not by the movements of a piston, but by the contraction of its muscular walls; the vessels are the pipes which convey the contained fluid, and they are provided in certain localities with valves for directing its flow.

Blood-Vascular System.

The blood flows through the blood-vascular system in a given direction, and its movement is called the *circulation of the blood.* In man and the higher vertebrates the heart is a double organ, *i.e.*, it consists of a right and a left portion, intimately united to, but not directly communicating with, each other. The blood which flows from its right side passes through vessels which traverse the lungs, and is conveyed to the left side of the heart: this is called the *pulmonary circulation.* The blood which flows from the left side passes through vessels which traverse the body generally, and is conveyed to the right side of the heart: this is called the *systemic circulation.* The complete circulation, *i.e.*, the passage of a drop of blood, from one side of the heart, back again to the same side, can only be effected by passing through both the pulmonic and systemic circulations. Hence the complete circulation is sometimes called a *double circulation.*

The vessels which carry the blood away from the heart are called *arteries.* The arteries branch and terminate in a network of vessels of microscopic size called *capillaries.* The vessels which convey the blood back to the heart are *veins,* and the veins arise from the capillaries. The arteries and veins do not communicate directly with each other, but centrally through the intermediation of the heart, and peripherally through the intermediation of the capillaries. Hence, both in the pulmonary and systemic circulations, the blood in its passage from the arteries into the veins must go through capillaries. The blood which flows from the left side of the heart into the systemic arteries is

bright red, pure or arterial blood; as it traverses the systemic capillaries it parts with certain of its constituents to nourish the organs and tissues, and as it also receives from them waste products it becomes impure blood; in which condition it flows back to the right side of the heart by the systemic veins as dark red, or venous blood; hence the right side of the heart is often called the venous side. The blood which flows from the right side of the heart along the pulmonary artery is this dark-red, venous blood; as it traverses the pulmonary capillaries it is purified by the action of the air in the lungs, it parts with carbonic acid, takes up oxygen, and is changed into arterial or pure blood, in which condition it flows back by the pulmonary veins to the left side of the heart, which consequently is called the arterial side. The object of the pulmonary circulation, therefore, is to reconvert into pure blood the blood which has been rendered impure during its passage through the systemic capillaries.

The anatomy of the heart, and of the pericardium, the bag in which it is enclosed, will first be described.

THE PERICARDIUM.

The Pericardium is a bag which envelopes the heart. It is situated in the cavity of the thorax, and occupies the middle division of the space called *mediastinum*, between the two lungs; it lies therefore behind the sternum, and in front of the spinal column, but projects more to the left than to the right side of the mesial plane. Laterally the pericardium is in relation to the lung, pleura, and phrenic nerve; but the lungs, when inflated during inspiration,

overlap the pericardium, and lie between it and the sternum and costal cartilages. The pericardium is separated from the spine by the contents of the posterior mediastinum. It is attached below to the central tendon of the diaphragm, and blends above with the sheaths of the great vessels which pass to and from the heart. Two fibrous bands, the *sterno-pericardiac ligaments* of Luschka, are connected to its anterior surface; the *superior ligament* springs partly from the back of the manubrium, and is partly continuous with the cervical fascia; whilst the *inferior ligament* proceeds from the inner side of the base of the xiphisternum.

Structure.—The pericardium is formed externally of a strong fibrous membrane, which is attached by areolar tissue to the diaphragm, the wall of the œsophagus and the attached surface of the two pleuræ.

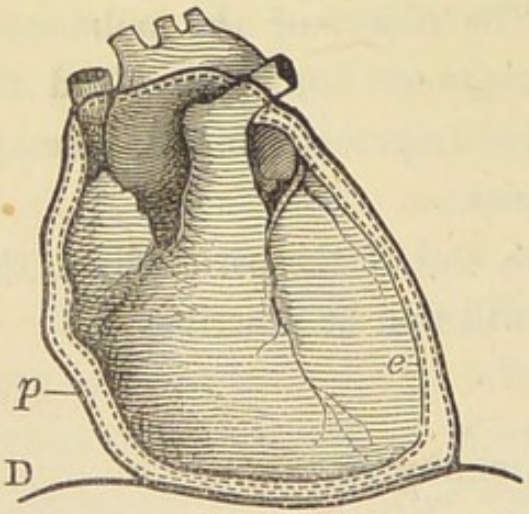

Fig. 115.—The Heart within the Pericardium. The dotted line represents the arrangement of the serous layer; *e.* the epicardium; *p*, the pericardium; *D*, the diaphragm.

When the pericardium is cut open its inner surface is seen to possess a smooth, free, glistening, serous aspect, similar to the inner surface of the dura mater. This is due to the interior of the bag being lined by a single layer of squamous endothelium. Where the fibrous membrane of the pericardium is prolonged on to the aorta, the pulmonary artery and veins, and the venæ cavæ, the serous endothelial lining of the bag

is reflected as a covering upon those great vessels, and is continued from them over the exterior of the heart itself, so as to give it a covering, possessing a smooth, free, glistening serous surface, which is called the visceral layer of the pericardium, or the *epicardium*. The serous lining does not form a separate covering for the aorta and the pulmonary arterial trunk, but encloses them in a common sheath; each of the great veins has its own investment, though the covering given to the inferior cava is very short, as that vein opens into the right auricle immediately on piercing the fibrous membrane of the pericardium. A fold of the pericardium, named by Marshall the *vestigial fold*, is situated between the left pulmonary artery and immediately subjacent pulmonary vein. This fold marks the position of a vessel present in the embryo heart, and known as the left superior vena cava, or duct of Cuvier. The free surface of the epicardium glides upon the serous lining of the bag during the movements of the heart, and the two surfaces are lubricated by a little serous fluid; which under certain pathological conditions may increase in quantity, and produce dropsy of the pericardium.

THE HEART.

The Heart is a hollow muscle enclosed in the pericardium, and lying in the thoracic cavity in the middle division of the mediastinal space between the two pleural membranes. It is the great motor organ for the circulation of the blood, and, though varying in its dimensions with the amount of blood that it contains, may be said to be of much the same size as the fist of the individual. It

measures about five inches in length, by three and a half in its greatest breadth, and is about two and a half inches in thickness. Its weight is from nine to ten ounces.

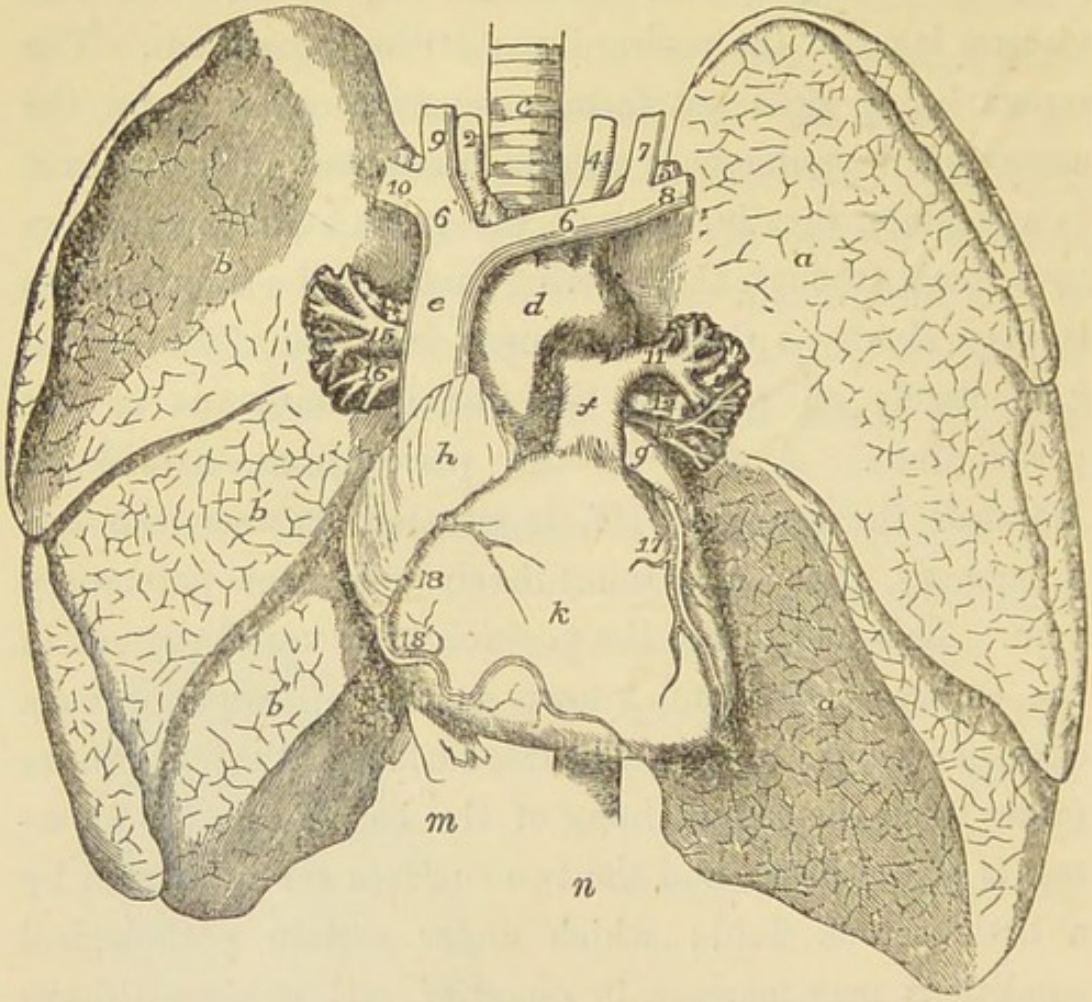

FIG. 116.—The Thoracic Viscera.

In this diagram the lungs are turned to the side, and the pericardium removed to display the heart. *a*, upper, *a'*, lower lobe of left lung; *b*, upper, *b'*, middle, *b''*, lower lobe of right lung; *c*, trachea; *d*, arch of aorta; *e*, superior vena cava; *f*, pulmonary artery; *g*, left, and *h*, right auricle; *k*, right, and *l*, left ventricle; *m*, inferior vena cava; *n*, descending aorta; 1, innominate artery; 2, right, and 4, left common carotid artery; 3, right, and 5, left subclavian artery; 6, 6, right and left innominate vein; 7 and 9, left and right internal jugular veins; 8 and 10, left and right subclavian veins; 11, 12, 13, left pulmonary artery, bronchus, and vein; 14, 15, 16, right bronchus, pulmonary artery, and vein; 17 and 18, left and right coronary arteries.

The heart is frequently compared in shape to a blunt cone, and is directed obliquely from above downwards, from right to left, and from behind forwards. For descriptive purposes it may be regarded as possessing a base, an

apex, an anterior and a posterior surface, a right and left border. The base lies backwards, upwards, and to the right, opposite the 4th to the 8th dorsal vertebræ. The apex is directed downwards, forwards, and to the left, opposite to the interval between the 5th and 6th left ribs, where it comes into relation with the anterior wall of the chest about $1\frac{1}{2}$ inch below the nipple, and $3\frac{1}{2}$ inches from the middle line of the sternum. The anterior surface is convex, and in relation to the back of the lower half of the sternum, of the 3d, 4th, 5th, and 6th left costal cartilages, and the 3d, 4th, and 5th right costal cartileges. The pleuræ and lungs overlap this surface of the heart, being separated from it by the pericardium. The posterior surface is flattened, and in relation to the diaphragm. The right border is thin when compared with the left border, which is shorter and more rounded. About two-thirds of the heart are situated to the left of the mesial plane of the thoracic cavity.

The outer surface of the heart is marked by grooves, which indicate externally its division internally into four chambers or cavities. One of these grooves, called the *auriculo-ventricular groove*, runs around the heart, both on the anterior and posterior surfaces, from border to border, and marks off the two auricles from the two ventricles. This groove is more distinct on the back than on the front of the heart, for it is concealed anteriorly by the origins of the aorta and the pulmonary artery. Two longitudinal grooves extend from the base to the apex of the heart, one on the anterior surface, the other on the posterior. They indicate the separation of the heart into a right and left portion or side. The right side consists of the right auricle and right ventricle, the left side of the left auricle

and left ventricle. The two longitudinal grooves are most distinctly marked on the ventricular portion of the heart, where they are called the *ventricular grooves.* The *anterior ventricular groove* is nearer to the left than to the right border, whilst the *posterior ventricular groove* is nearer to the right border. The two grooves become continuous with each other immediately to the right of the apex of the heart. In one mammal, viz., the dugong, the ventricular grooves are deepened at the apex into a wide cleft, extending between the two ventricles.

To study the chambers of the heart incisions should be made through the walls of the auricles and ventricles, when all these chambers will be seen to be lined by a smooth membrane, the *endocardium,* which is continuous on the one hand with the lining membrane of the several veins, and on the other with the lining membrane of the arteries, which communicate with the chambers.

The *Right Auricle* occupies the right part of the base of the heart. It consists of a large dilated portion, the *sinus venosus,* and of a small ear-shaped appendage, the *auricula.* Its muscular wall is smooth internally, except in the auricula and adjacent anterior wall of the sinus venosus, where it is thrown into parallel ridges, like the teeth of a comb, named *musculi pectinati.* Into the sinus venosus open the great systemic veins or venæ cavæ. The *superior vena cava* conveys to the auricle the systemic blood that has been circulating in the body above the diaphragm; it opens by a patent mouth into the upper and back part of the sinus venosus. The *inferior vena cava* conveys to the auricle the blood that has been circulating in the parts of the body below the diaphragm; it opens into the lower and

back part of the auricle, and at its mouth is the *Eustachian valve.* The valve of Eustachius is a crescent-shaped fold of the endocardium, situated in front of the mouth of the inferior cava: its anterior cornu is continuous with the annulus ovalis on the auricular septum, its posterior cornu is lost on the outer wall of the auricle. The valve in the adult is often perforated with holes, or is so rudimentary as to be functionless, but in the fœtus it is a large and important structure. Close to the orifice of the inferior cava is the mouth of another large vein, the *coronary venous sinus,* which returns most of the blood from the walls of the heart itself; this orifice also possesses a small crescent-shaped valve, the *coronary* or *Thebesian valve.* Several minute openings, the *foramina Thebesii,* scattered over the inner wall of the auricle, are the mouths of small veins ramifying in the wall itself. Through these various orifices the venous blood pours into the auricle, and then flows into the right ventricle through a large orifice, the *right auriculo-ventricular opening,* which lies at the lower part of the auricle in front of the inferior cava. The right auricle is separated by a partition, the *auricular septum,* from the left auricle. On the surface of this septum is a depression, the *fossa ovalis,* surrounded by a raised border, the *annulus ovalis,* with which border the inner end of the Eustachian valve is continuous. Before the birth of the child the septum is perforated by a hole, called *foramen ovale,* through which the blood directed by the Eustachian valve flows from the inferior vena cava into the left auricle. This foramen closes up after the birth of the child, but sometimes a small orifice, directed obliquely through the septum, persists even in the adult.

The *Right* or *Anterior Ventricle* forms the right border, a large part of the anterior surface, but only a small part of the posterior surface of the heart. It is shaped somewhat like a flattened cone, its apex being directed downwards towards the apex of the heart, its base to the

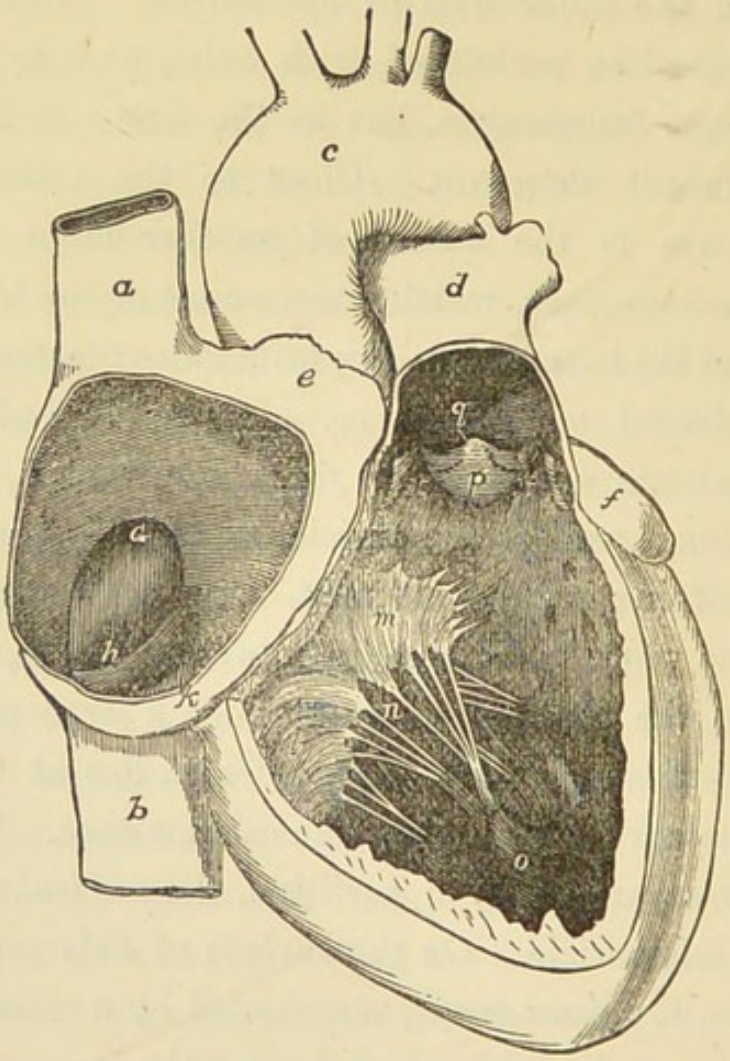

FIG. 117.—Cavities of the right side of the Heart.

a, superior, and *b*, inferior vena cava; *c*, arch of aorta; *d*, pulmonary artery; *e*, right, and *f*, left auricular appendage; *g*, fossa ovalis; *h*, Eustachian valve; *k*, mouth of coronary vein; *l*, *m*, *n*, cusps of the tricuspid valve; *o*, *o*, papillary muscles; *p*, semilunar valve; *q*, corpus Arantii; *r*, lunula.

corresponding auricle. The inner surface of its muscular wall is very irregular, owing to the muscular bundles being elevated into strong reticulated ridges, called *columnæ carneæ*. Two, or it may be three, of these fleshy columns

project like nipples or big papillæ into the cavity of the ventricle, and are called *musculi papillares*. Attached to the free apex of each papillary muscle are several fibrous threads, the *chordæ tendineæ*, which, by their opposite extremities, are connected to the segments of a large valve situated around the opening between the right auricle and ventricle. The right auriculo-ventricular opening, situated at the base of the ventricle, is sufficiently large to admit three fingers, and possesses a valve, which consists of three large pointed segments or cusps (hence the name *tricuspid* given to it), between which three small intermediate cusps lie. One of the large cusps is opposite the anterior wall of the ventricle, another opposite the posterior, whilst the third is to the left between the auriculo-ventricular opening and the conus arteriosus. The cusps are flattened triangular folds of the endocardial membrane connected by their bases around the opening; when the valve is not in action the apex of each cusp hangs pendulous in the ventricle: one surface is smooth, and looks to the cavity of the ventricle, the other surface is rough, and is directed to its wall; to this rough surface, to the apex, and to the edges of the cusp, the chordæ tendineæ are attached. As the musculi papillares, from which the chordæ tendineæ spring, are opposite the intervals between the cusps, the chordæ tendineæ from any given papillary muscle divide themselves into two groups, one for each of the two cusps between which it is situated. In the mammalian heart, and as Rolleston has shown in the the heart of the bird, a band not unfrequently passes from the base of the anterior papillary muscle to the septal wall of the ventricle. As it prevents over-distension of the

ventricle, it has been named the *moderator band.* In the bird the right auriculo-ventricular valve is a muscular structure.

The base of the right ventricle forms to the left and in front of the auriculo-ventricular opening, a funnel-shaped prolongation, the *conus arteriosus,* from which the *pulmonary artery* arises, through the intervention of a strong fibrous ring. Surrounding the mouth of this artery is a valve called *semilunar,* which consists of three semilunar segments. Each segment is attached by its convex border to the artery where it springs from the ventricle. The opposite border is free, and possesses at its centre a minute nodule, the *corpus Arantii,* from which slender fibrous threads curve outwards at the free border and in the substance of the valve to strengthen it. A thin lunated portion lies immediately within the free border. One surface of the valve is convex, and directed to the lumen (*i.e.*, the space contained by the walls) of the artery; the other is concave, and directed to the wall of the artery, and between it and the wall is a pouch named *sinus of Valsalva.* The pulmonary artery extends upwards and to the left for about $1\frac{3}{4}$ inch, and then divides into two branches, one for each lung. The right ventricle is completely separated from the left by the *ventricular septum,* which passes obliquely from left to right, and from before backwards, so that it forms the posterior wall of the right ventricle and the anterior wall of the left. The apex of the septum is at the apex of the heart, its base or highest part is between the two auriculo-ventricular openings. Thurnam pointed out that the highest part is not formed of muscular fibres, but of the endocardial membrane, strengthened by fibrous

tissue. This part is called *pars membranacea septi.* In very rare cases it is defective, and then an opening of communication exists between the two ventricles.

The *Left Auricle* is situated at the posterior and left part of the base of the heart, and, like the right auricle, consists of a dilated *sinus venosus* and an ear-shaped appendage, the *auricula.* Its muscular wall has a smooth surface internally, except in the auricula, where the comb-like *musculi pectinati* occur. Opening into the posterior part of the sinus venosus are the orifices of the four *pulmonary veins,* two from the right, two from the left lung; these orifices are without valves. At the lower part of the auricle is the large *left auriculo-ventricular orifice* of communication between it and the base of the left ventricle. The auricular septum is marked by a slight depression, which indicates the position of the foramen ovale in the fœtal heart. The auricular appendix is somewhat longer than on the right side, and curves forward by the side of the pulmonary artery.

The *Left* or *Posterior Ventricle* forms the left border, the apex, a large part of the posterior surface, but only a small part of the anterior surface of the heart. It is conical in form, its apex is at the apex of the heart, the base at the corresponding auricle. As in the right ventricle, the inner surface of its wall is elevated into fleshy columns, two of which project like nipples into the cavity and form large *musculi papillares,* which have *chordæ tendineæ* connected with them. The left auriculo-ventricular opening, situated at the base of the ventricle, is large enough to admit two fingers. It possesses a valve, which consists of two large pointed segments or cusps, hence it is called the

bicuspid valve; and as these cusps are placed one in front of the other like the segments of a bishop's mitre, the name *mitral valve* is often given to it. The cusps agree in shape, general arrangement, and mode of attachment with those of the tricuspid valve, but they are stronger. The more posterior segment lies in relation to the posterior wall of the ventricle: the more anterior segment lies obliquely between the auricular and aortic orifices, and is characterized by being smooth on both its surfaces. At the angles between the bases of attachment of the two large cusps of this valve two small intermediate cusps are situated. The *chordæ tendineæ*, springing from each musculus papillaris separate, as on the right side, into two groups, one for each of the two cusps.

From the base of this ventricle the great systemic artery or *aorta* arises through the intervention of a strong fibrous ring. The mouth of the aorta is surrounded by a three-segmented *semilunar valve*, similar in form, mode of attachment, and structure to the semilunar pulmonary valve, but with thicker and stronger segments, and possessing more strongly marked *sinuses of Valsalva.* The segments are placed, one in relation to the posterior wall of the aorta, and two to its antero-lateral wall. The base of each ventricle has therefore two openings in it, one for communication with the auricle, the other with the great artery arising from the ventricle. The auriculo-ventricular openings are the most posterior, and almost in the same transverse plane; the aortic opening lies in front of the interval between the two auriculo-ventricular, and the pulmonary opening is in front of the aortic.

The relation which these openings have to the anterior

wall of the chest is of importance in connection with the diagnosis of disease of the valves. The pulmonary opening lies behind the articulation of the third left costal cartilage with the sternum, and the trunk of the pulmonary artery ascends, prior to its bifurcation, as high as the level of the second left costal cartilage. The aortic opening, somewhat lower down than the pulmonary, and posterior to it, is situated behind the left border of the sternum, on a level with the third intercostal space. The right auriculo-ventricular or tricuspid opening, lies behind the sternum, on a level with the fourth pair of costal cartilages. The left auriculo-ventricular or mitral opening is on the same plane as the right tricuspid opening, but to its left side.

Structure.—The walls of the cavities of the heart are chiefly formed of striped muscular fibre, over the contractions of which the Will exercises no control; but, in addition, connective tissue, a little fibro-cartilaginous tissue, the endocardium, and vessels and nerves are also found.

The muscular fibres are collected into fasciculi, which have a reticulated arrangement, and the fibres themselves branch and again unite to form a complicated network. The fibres of the walls of the auricles are distinct from those of the ventricles, so that the auricular and ventricular compartments are connected together, not by an interchange of muscular tissue, but by an intermediate ring-like arrangement of fibres of connective tissue, known as the *auriculo-ventricular rings.* The muscular fasciculi of the auricles are arranged in two strata. The deeper stratum consists of fibres proper to each auricle, some of which run obliquely in the wall, others surround the auricula, and others are prolonged in rings into the coats of the venæ

cavæ and pulmunary veins, whilst fibres extend longitudinally and obliquely along the wall of the coronary venous sinus. The superficial stratum consists of fasciculi, which run obliquely from one auricle to the other on both the anterior and posterior surfaces, and are said to be prolonged into the auricular septum.

The muscular wall of the ventricles is much thicker than that of the auricles, and the wall of the left ventricle is about three times thicker than the right. The fibres vary in their direction in different parts of the thickness of the ventricular walls. The superficial external fibres run on the anterior surface of the ventricles obliquely from above downwards, and from right to left, and dip into the anterior ventricular groove to enter the septum, whilst on the posterior surface they extend across the posterior ventricular groove. At the apex of the heart they turn inwards in a whorl-like manner, and, as was known to Lower and Gerdy, become continuous with superficial fibres on the inner wall of the ventricle. At the base of the ventricles, some of the superficial external fibres are attached to the auriculo-ventricular and arterial rings, but the greater number turn round the border of the auriculo-ventricular openings, and, as Pettigrew has shown, become continuous with the superficial internal fibres, which run obliquely in the reverse direction. The internal fibres are also prolonged into the musculi papillares, the chordæ tendineæ springing from which serve therefore as tendons of insertion of these muscles. Deeper in the substance of the wall the fibres are arranged in different degrees of obliquity, and about the centre of the thickness of the wall are seen to lie in the horizontal plane. Various anatomists have

described these fibres of the ventricles as arranged in layers. Lower recognised two layers spirally crossing each other; Haller, three; Wolff, three in the right and six in the left ventricle. Pettigrew at one time believed he could dissect nine layers, but has subsequently reduced the number to seven—three external, a fourth or central, and three internal. He conceives that the fibres of the three external layers run in a spiral direction from left to right downwards, the first layers being more vertical than the second, and the second than the third, whilst the fibres of the fourth or central layer are horizontal. The three internal layers also run spirally, but in the reverse direction from the external, with which they become continuous both at the base and apex. The subdivision of the ventricular wall into such precise and determinate layers as is implied in the descriptions of Pettigrew is, however, an artificial procedure. There can be no doubt, as his dissections so beautifully show, that the direction of the fibres in the ventricular wall varies at different depths; but owing to the reticulated arrangement of the fibres, not only are those connected together which lie in the same plane in one of the so-called layers, but they also anastomose with the fibres in the layers immediately superjacent and subjacent to it. Hence when one layer is peeled off, that immediately subjacent exhibits, not a smooth face, which it would have done had the definition of the layers been distinct, but a rough appearance, due to the rupture of intermediate connecting muscular fibres. The fasciculi form, therefore, a network, the strands of which are arranged in two directions, one parallel to the surfaces of the ventricles, the other passing from the inner to the outer surface of

the wall. Owing to these connections the substance of the wall of the ventricle, as Henle's dissections show, may, with the exception of the superficial internal and superficial external fibres, be split up into lamellæ, which extend either horizontally, obliquely, or in an arched manner through the wall between its two surfaces; and the surfaces of those lamellæ are not parallel to the wall of the ventricle, but are directed upwards and downwards.

The connective tissue of the heart is only small in quantity between the muscular fasciculi. At the base of the ventricles it is collected in a ring-like arrangement around the auriculo-ventricular and arterio-ventricular openings, and forms the auriculo-ventricular and arterial fibrous rings. These rings are in part composed of a tissue resembling white fibro-cartilage and in part of elastic fibres. In some animals, as the ruminants, a bone, the *os cordis*, is developed in the interval between the aortic and auriculo-ventricular openings. The rings give origin to some of the muscular fibres of the ventricles and auricles, and send bundles of fibrous tissue into the auriculo-ventricular and aortic valves, whilst the arterial rings are prolonged into the middle coats of the aorta and pulmonary artery. Owing to the close relation between the base of the anterior cusp of the mitral orifice and the aortic orifice, the fibrous rings of these two openings become blended together.

The endocardium consists of connective tissue and elastic fibres, with a layer of endothelium on the free surface; and Schweigger-Seidel has also described smooth muscular fibres in it. Hence, as Luschka has stated, the endocardium represents not merely the inner coat of the blood-vessels but all the structures of the vascular wall. Purkinje de-

scribed fibres beneath the endocardium, which are now regarded as imperfectly formed striated muscular fibres. The valves are folds of the endocardium, enclosing fibres continuous with those in the fibrous rings; the cuspidate auriculo-ventricular valves receive fibres from the chordæ tendineæ, and muscular fibres, continuous with those of the auricles, are prolonged for a short distance into the cusps. The semilunar and cuspidate valves are vascular; fine arteries, derived from the coronary, pass between the two layers of each valve, and terminate in a capillary plexus.

The heart is well supplied with blood, not by the blood which flows through its cavities, but by two special coronary arteries which ramify in its walls, and end in numerous capillaries lying between the fibres. From these capillaries the coronary veins arise, which join to form the coronary venous sinus. Lymphatic vessels occur both in the endocardium and pericardium, and apparently ramify in the muscular wall. The nerves of the heart have been dissected especially by Scarpa, Remak, Lee, and Pettigrew, and numerous small ganglia described in connection with them (p. 317).

The blood flows from the capillary networks along the great veins into the auricles; the systemic veins convey it into the right auricle, the pulmonary veins into the left. The blood is then propelled by the contraction of the muscular walls of the auricles through the auriculo-ventricular openings, the valves of which open outwards, into the ventricles. When the ventricles are distended, their muscular walls contract and force the blood into the arteries—the right ventricle into the pulmonary artery, the left into the aorta—the valves at the mouth of each artery opening

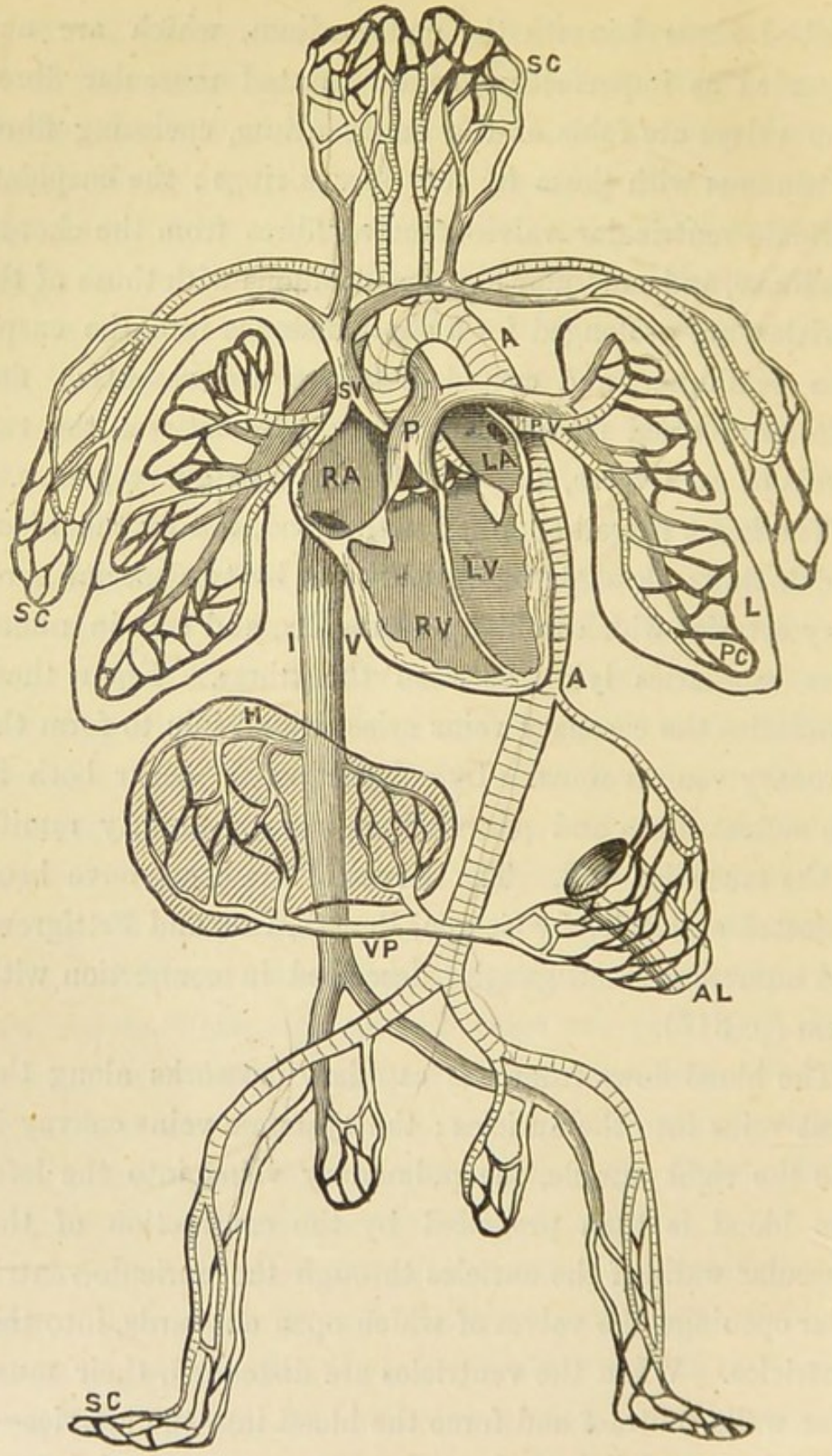

FIG. 118.—Diagram of Blood-vascular system. AA, aorta; P, Pulmonary arterial trunk; PV, left pulmonary vein; SV, superior cava; IV, inferior cava; PC, pulmonary capillaries; SC, systemic capillaries; RA and RV, right auricle and ventricle or pulmonic heart; LA and LV, left auricle and ventricle or systemic heart; H, hepatic vein in the liver; AL, alimentary canal; VP, portal vein; L lung.

outwards to allow of the free passage of the fluid. To prevent, during the ventricular contraction, the regurgitation of blood into the auricles, the auriculo-ventricular valves are floated away from the sides of the ventricle across their respective openings, and by the apposition and slight overlapping of their edges temporarily close the opening. The tilting upwards of the valves into the auricle is prevented by the contraction of the musculi papillares and their connection with the cusps of the valve through the chordæ tendineæ. Pettigrew has shown that casts of the ventricular cavities, more especially of the left, have the form of a double cone, spirally twisted from right to left, and has described the blood as forced in spiral streams against the under surface of the segments of the valve, which are twisted and wedged into each other so as to prevent regurgitation. The propulsion of the blood into the arteries distends the elastic wall of those tubes; but when the ventricular contraction has ceased, the elastic wall recoils, and the blood is propelled onwards into the capillaries in the course of the circulation. The regurgitation of the blood from the arteries into the ventricles is prevented by the closure of the semilunar valves, the segments of which are thrown across the arterial orifices through the pressure exercised by the elastic rebound of the arterial walls on the column of the blood in the lumen of the artery and in the sinuses of Valsalva.

If we commence, therefore, at the pulmonary capillary system, where the blood becomes pure or arterial, we find that it flows, as arterial blood, successively into the pulmonary veins, left auricle, left ventricle, aortic system of arteries, and systemic capillaries. In the systemic capil-

laries it becomes venous blood, and in that condition flows into the systemic veins, right auricle, right ventricle, pulmonary system of arteries, and pulmonary capillaries.

THE ARTERIES.

These vessels were named arteries by the older anatomists, on the supposition, now known to be erroneous, that they contained air. The term artery is now employed to express a blood-vessel, which, arising either directly or indirectly from the heart, conveys blood away from that organ into a network of capillaries. Arteries divide and subdivide into smaller vessels in their course, and to the individual branches descriptive names are applied. Some of these names express the position of an artery, as subclavian, axillary; others, the organ in which it is distributed, as pulmonary, hepatic; others a peculiarity in its course, as circumflex, coronary. The branches of arteries may be either *collateral* or *terminal*. The collateral branches arise from the sides of the parent artery either at an acute, a right, or an obtuse angle. Terminal branches arise at an acute angle by the bifurcation of the parent artery, which is the most common form, or by the breaking up of the artery into a cluster of branches. An artery does not diminish in calibre from the origin of one branch to the origin of the next succeeding branch. The calibre of each branch is less than that of the stem from which it arises, but the sum of the calibre of the different branches is greater than that of the stem from which they spring.

Branches which arise either from the same artery or

from different arteries may be distributed in a common locality, may there unite together, and form what is called an *inosculation* or *anastomosis*, so that the blood from one artery may thus flow from it into another. The inosculations of the branches of the same or of adjacent arteries are of great importance with reference to the mode in which a part receives its supply of blood when the main artery is obstructed, for through these anastomoses secondary channels are provided along which the blood may flow to a part. The most common anastomosis is by the formation of loops between adjacent branches; but sometimes, as when the two vertebral arteries join to form the basilar, a convergence of two almost straight arteries takes place; and in other cases, as where the two anterior cerebral arteries are joined together by the anterior communicating, a connecting branch passes transversely across the mesial plane. A more complex form of anastomosis is when an artery (and a similar arrangement is sometimes found in veins) rapidly subdivides into numerous branches, which may again join to form a trunk either with or without the formation of a plexus. This is called a *rete mirabile*, an arrangement not uncommon in the cetacea, and also found in the internal carotid arteries of ruminants, in the mesenteric arteries of the pig, in the arteries of the limbs of the sloths and lemurs, in the caudal arteries of the armadillo, and in the arterial system of fishes. The only examples of a rete in the human body are the glomeruli, or convoluted Malpighian tufts of the kidney, and the arterial distribution in the coccygeal and intercarotic bodies.

PULMONARY GROUP OF ARTERIES.

The pulmonary group of arteries consists of the trunk of the pulmonary artery and of its branches. (Fig. 116, f. 11, 15.)

The TRUNK of the PULMONARY ARTERY arises from the conus arteriosus of the right ventricle. It is about two inches long, and passes upwards, backwards, and to the left as high as the level of the second left costal cartilage, when it divides into the right and left pulmonary branches. In its course it lies at first in front of the origin of the aorta, and then passes to the left of the ascending part of the aortic arch, to bifurcate into its two terminal branches immediately below the transverse part of the arch. It is attached to the aorta by areolar tissue, and the two are invested by a common envelope of the serous layer of the pericardium.

The RIGHT PULMONARY ARTERY passes to the right almost transversely behind the ascending aorta and the superior vena cava to the root of the right lung, where it lies between the right pulmonary vein and the bronchial tube.

The LEFT PULMONARY ARTERY is shorter than the right. It runs in front of the descending aorta to the root of the left lung, where it lies above the bronchus and pulmonary vein. A fibrous cord, the remains of the ductus arteriosus, is attached on the one hand to the left pulmonary artery close to its origin, and on the other to the lower surface of the transverse part of the aortic arch. In the fœtus the ductus arteriosus is a short wide vessel, which conveys blood directly from the pulmonary artery into the aorta. After the birth of the child it is no longer required,

and shrivels up into a fibrous cord. The distribution of the pulmonary arteries in the lungs will be afterwards described.

AORTIC OR SYSTEMIC GROUP OF ARTERIES.

This group consists of the aorta and of the branches, which arise either directly or indirectly from it.

The AORTA is the great systemic arterial trunk, and lies in the cavities of the thorax and abdomen. It arises from the base of the left ventricle of the heart, and forms above the root of the left lung an arch, the *arch of the aorta;* it then descends in close relation to the thoracic spine, as the *descending thoracic aorta;* it next passes through the aortic opening in the diaphragm, enters the cavity of the abdomen, and becomes the *abdominal aorta.* In the abdomen it descends in front of the bodies of the lumbar vertebræ as low as the fourth, where it is usually described as dividing into the two terminal branches, the common iliac arteries. At the angle of bifurcation, however, a long slender artery, called the *middle sacral,* is prolonged downwards in front of the sacrum to the end of the coccyx. In animals with long tails this artery can be recognised as a direct continuation of the aorta, prolonging it downwards in front of the caudal vertebræ, whilst the iliacs are seen to be collateral branches; but in man, where the coccyx is rudimentary, and the lower limbs largely developed, the iliac arteries, which supply those limbs, are so big as to obscure the true signification of the middle sacral artery, and appear themselves to be the terminal branches of the aorta.

The ARCH OF THE AORTA springs from the base of the left ventricle on a level with the third pair of intercostal spaces

in front, and the sixth dorsal vertebra behind. It passes behind the sternum obliquely upwards and to the right, as the *ascending aorta*, or *ascending part* of the arch, to the level of the second right costal cartilage. It then changes its direction, and passes from right to left and from before backwards as the *transverse part* of the arch of the aorta. It is often stated that the transverse part of the arch reaches the left side of the spine on a level with and close to the left of the body of the second dorsal vertebra, but John Wood has pointed out that it approaches the spine at the lower border of the left side of the body of the fourth dorsal vertebra, and first touches the spine at the disc between the fourth and fifth dorsal vertebræ. Here it again changes its direction and runs vertically downwards, as the *descending part* of the arch, in close contact with the left side of the body of the fifth dorsal vertebra as far as its lower border, when it becomes the *descending thoracic aorta*.

The ascending aorta is enclosed within the bag of the pericardium, and has at its origin the three semilunar valves with the sinuses of Valsalva. The pulmonary arterial trunk is at first in front of and then to its left side; the right auricular appendage and superior cava are to its right side, and the structures going to the root of the right lung lie behind it.

The transverse part of the arch lies behind the sternum, left pleura, and left lung, and is crossed by the left phrenic, pneumogastric, and superficial cardiac nerves. It is placed in front of the trachea, œsophagus, and thoracic duct, and the left recurrent laryngeal nerve hooks round its lower surface and behind it. Its lower surface is in relation to

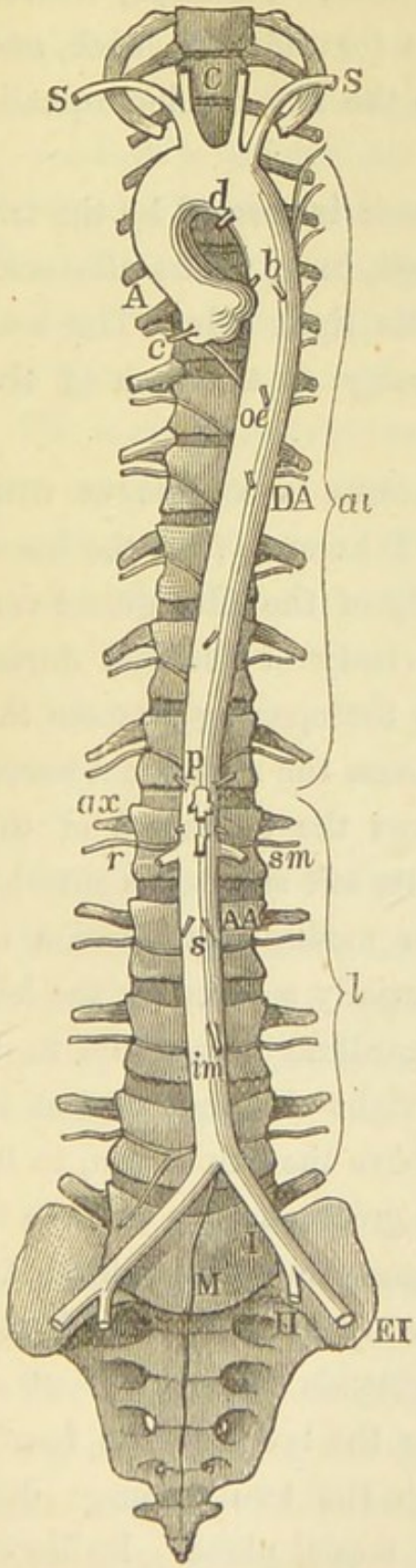

FIG. 119.—The Aorta in its relations to the spine:—A, ascending part of arch of aorta; DA, descending thoracic aorta; AA, abdominal aorta; M, middle sacral artery; S S, subclavian arteries; C, is placed on the 2nd dorsal vertebra between the two carotid arteries; I, common iliac artery; EI, external iliac; II, internal iliac artery; *c*, coronary artery; *d*, obliterated ductus arteriosus; *b*, bronchial artery; *oe*, œsophageal artery; *ai*, series of aortic intercostal arteries; *l*, series of lumbar arteries; *p*, between the two phrenic arteries; *ax*, points to the cœliac axis; *r*, points to the two renal arteries, immediately above which are the small capsular arteries. Between the two renals is the superior mesenteric, *sm*; *s*, is placed between the two spermatic arteries; *im*, inferior mesenteric artery.

the pulmonary artery at its bifurcation, and has connected to it the obliterated ductus arteriosus. Its upper surface gives origin to the three arteries for the head, neck, and upper limbs, and is in relation to the left brachio-cephalic vein.

The descending part of the arch is covered by the left pleura and overlapped by the left lung, whilst the œsophagus and thoracic duct are to its right side. The root of the left lung lies in the concavity of the arch of the aorta.

The Descending Thoracic Aorta is continuous with the descending part of the arch. It extends from the lower border of the left side of the body of the fifth dorsal vertebra, as far as the front of the body of the last dorsal vertebra, where it passes through the opening between the pillars of the diaphragm and becomes the abdominal aorta. It is in contact with and follows the curvature of the thoracic spine, and inclines from its left side to its anterior surface. It lies in the posterior mediastinal division of the interpleural space, and is partially covered by the left pleura. The left lung and pericardium are anterior to it. The œsophagus is at first to its right side, but crosses in front, so as to lie, immediately above the diaphragm, to its left side. The thoracic duct and greater azygos vein are to its right side, but the smaller azygos vein passes behind it.

The Abdominal Aorta is directly continuous with the descending thoracic aorta. It extends from the front of the last dorsal vertebra as far as the body of the fourth lumbar, where it bifurcates into the two common iliac arteries, a little to the left of the mesial plane. It lies on the bodies of the upper four lumbar vertebræ and discs, and

is separated from the anterior abdominal wall by the stomach, pancreas, transverse colon, transverse part of duodenum, mesentery, and coils of small intestine: the splenic artery, and the splenic and left renal veins are also in relation to its anterior surface. It is to a great extent surrounded by the aortic nervous plexus of the sympathetic. The inferior vena cava, greater azygos vein, and thoracic duct are in contact with its right side. Lymphatics, veins and glands lie on the spinal column in close relation to it.

The aorta gives direct origin to numerous branches, which may be arranged in four groups.—1st, Branches for the supply of the viscera of the thorax and abdomen proper; 2d, branches for the walls of the thorax, abdomen, and pelvis; 3d, branches for the head, neck, and upper limbs; 4th, branches for the lower limbs, pelvic walls and viscera.

FIRST GROUP.—VISCERAL BRANCHES OF THE AORTA.

The branches of the aorta which supply the viscera may be arranged in two groups,—those which pass to the thoracic viscera, and those which pass to the viscera of the abdomen proper.

The branches of the aorta which supply the Viscera of the Thorax are the coronary, the œsophageal, the bronchial, and the pericardial arteries.

The CORONARY arteries, two in number, are the first branches of the arch of the aorta, and arise, opposite the right and left antero-lateral segments of the semilunar valve, from the wall of the aorta, where it dilates into the sinuses of Valsalva. The *right coronary* artery runs in

the auriculo-ventricular groove to the right border and posterior surface of the heart, and gives off branches to the right auricle and ventricle. A long branch descends in the posterior ventricular groove to supply the ventricles. The *left coronary* artery runs behind the pulmonary artery to the auriculo-ventricular groove, and then round the left border of the heart to its posterior surface. It supplies the left auricle and ventricle, and sends a long branch to the apex of the heart in the anterior ventricular groove. According to some observers, the mouths of the coronary arteries are covered by the opening outwards of the aortic valves during the ventricular contraction; whilst the elastic recoil of the aorta following that contraction would, it is said, not only close the aortic orifice, but drive the blood into the coronary arteries. As these arteries break up into branches in the muscular walls of the heart, a sudden turgescence of its walls would, according to Brücke and A. H. Garrod, result from the filling of these vessels, and be the cause of the dilatation of the ventricular cavities. Hyrtl and Ceradini have, however, raised important objections to this theory; they more especially urge that the valves do not close the orifices of the coronary arteries during the ventricular contraction, and that the capacity of the ventricles is diminished and not increased by the filling of these arteries.

The BRONCHIAL arteries are two in number. They may arise from the descending thoracic aorta, either by a common trunk, or independently; or the right bronchial may spring from the first aortic intercostal artery: one artery accompanies each bronchial tube, branches along with it, and supplies the tissues of the lung.

The Œsophageal arteries, four or five in number, arise from the descending thoracic aorta, and supply the coats of the œsophagus.

The Pericardial branches are very small arteries, which arise either from the descending thoracic aorta or the œsophageal arteries, and supply the back of the bag of the pericardium, and the lymphatic glands and loose tissue of the posterior mediastinum.

The branches of the aorta which supply the Viscera of the Abdomen proper arise either singly or in pairs. The single arteries are the cœliac axis, the superior mesenteric, and the inferior mesenteric, which arise from the front of the abdominal aorta; the pairs are the two capsular, the two renal, and the two spermatic or ovarian, which arise from its sides. The single arteries supply viscera, which are either completely or almost completely invested by the peritoneum, and the veins corresponding to them are the roots of the vena portæ. The pairs of arteries supply viscera developed behind the peritoneum, and the veins corresponding to them are rootlets of the inferior vena cava.

The Cœliac Axis is the first visceral branch of the abdominal aorta. It arises from the front of that vessel between the two pillars of the diaphragm, above the pancreas, and is surrounded by the solar plexus of the sympathetic. It is a thick, short artery, which almost immediately divides into the coronary, hepatic, and splenic branches.

The *Coronaria ventriculi* artery is the smallest branch, and passes upwards and to the left to the cardiac orifice of the stomach, where it subdivides into an *œsophageal* branch

for the lower end of the œsophagus, and a *gastric* branch for the coats of the stomach. The gastric branch runs along the lesser curvature, and supplies the anterior and posterior walls of the stomach.

The *Hepatic* artery passes upwards and to the left between the two layers of the gastro-hepatic omentum to

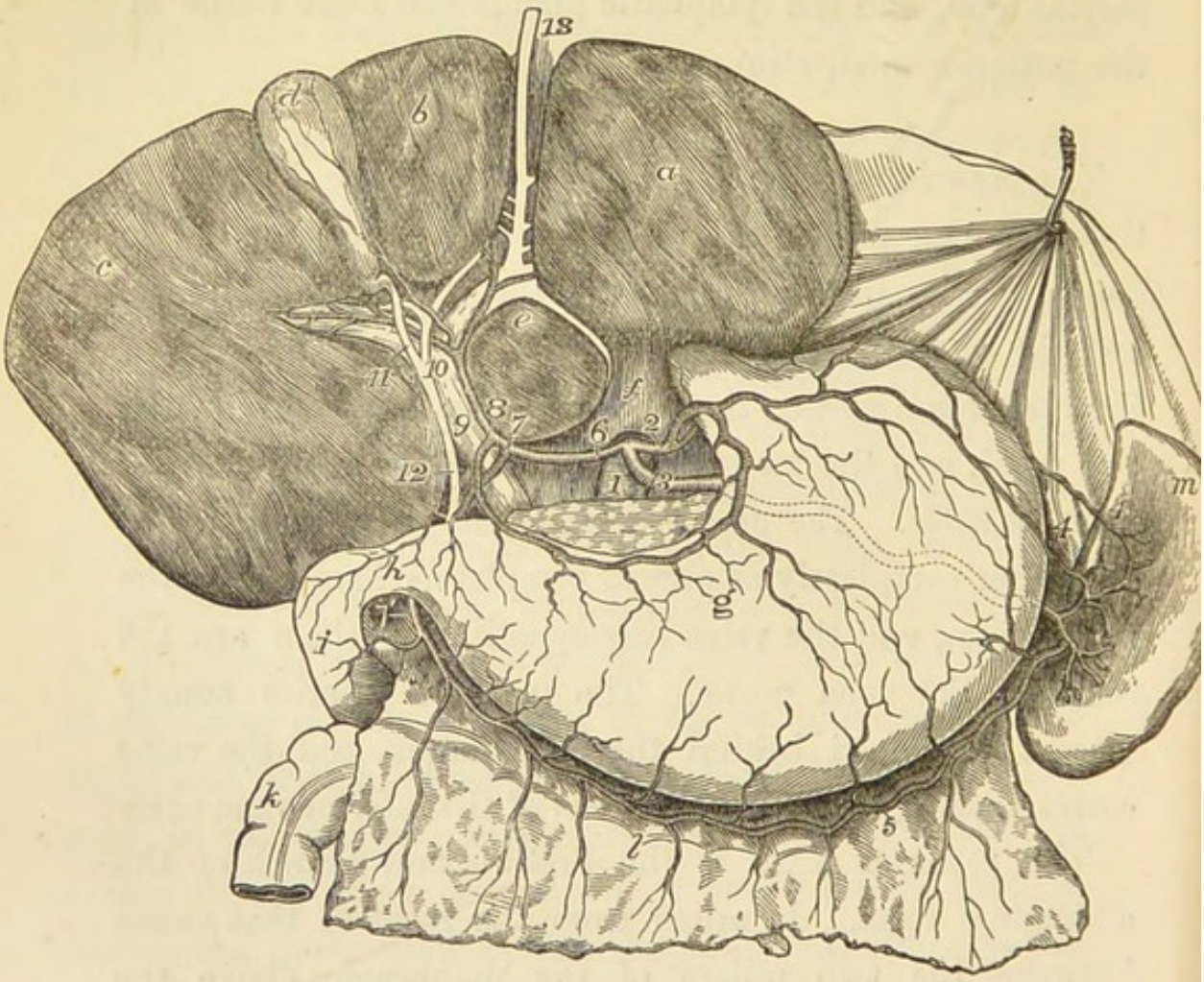

FIG. 120.—The Cœliac Axis and the chief Viscera supplied by its branches.

1, Cœliac axis; 2, coronary artery; 3, splenic artery; 4, its terminal branches; 5, left gastro-epiploic; 6, hepatic artery; 7, gastro-duodenal artery; 7′, right gastro-epiploic; 8, pyloric branch; 9, portal vein; 10, hepatic duct; 11, cystic duct; 12, common bile duct; 13, round ligament; *a*, left lobe of liver; *b*, lobulus quadratus; *c*, right lobe; *d*, gall bladder; *e*, Spigelian lobe; *f*, cardiac orifice of stomach; *g*, stomach; *h*, pylorus; *i*, duodenum; *k*, ascending colon; *l*, great omentum; *m*, spleen.

the transverse fissure of the liver, where it terminates, by dividing into two branches—the one for the right, the

other for the left lobe of the liver. In its course it gives off *a*, the *pyloric* branch, which passes to the pyloric end of the lesser curvature of the stomach: *b*, the *gastro-duodenal* branch which descends behind the duodenum, when it divides into a *superior pancreatico-duodenal*, which supplies the pancreas and duodenum, and a *right gastro-epiploic* branch, which runs along the greater curvature of the stomach to supply branches to its anterior and posterior walls, and to the omentum: *c*, the *cystic* branch which supplies the coats of the gall bladder: *d*, the *terminal* right and left *hepatic* branches, which supply the tissues of the liver.

The *Splenic* artery is the largest branch of the cœliac axis. It passes to the left behind the stomach, and is lodged in a groove on the upper border of the posterior surface of the pancreas. It gives off *a*, *pancreatic* branches to supply the pancreas: *b*, *vasa brevia*, which pass to the fundus of the stomach: *c*, the *left gastro-epiploic* artery, which runs along the greater curvature of the stomach, and supplies its anterior and posterior walls and the omentum: *d*, the *terminal splenic* branches, which enter the spleen at the hilus.

The Superior Mesenteric artery arises from the aorta a little below the cœliac axis. It lies at first behind the pancreas, then crosses in front of the duodenum, and descends between the two layers of the mesentery, inclining towards the right iliac fossa. It gives off *a*, the *inferior pancreatico-duodenal* branch, which supplies the pancreas and duodenum: *b*, the *intestinal* branches, about twelve in number, which arise from the left aspect of the artery, and descend in the mesentery to the coils of the jejunum

and ileum; in their course they bifurcate, and the branches of bifurcation of adjacent arteries inosculate to form arterial arcades, three or four series of which may be found in the mesentery; from the series next the intestine branches pass to the wall of the bowel: *c*, *ileo-colic* branch, which passes to the right iliac fossa to supply the lower end of the ileum, cæcum, and ascending colon: *d*, *right colic* branch, which runs to the ascending colon to supply it: *e*, the *middle colic* branch, which passes between the layers of the meso-colon to the transverse colon to supply it. All these colic arteries bifurcate, anastomose, and form arterial arcades after the manner of the branches to the small intestine.

The INFERIOR MESENTERIC artery arises from the aorta a short distance above its bifurcation. It lies behind the peritoneum covering the posterior wall of the abdomen, and passes downwards to the left iliac fossa, where it enters the meso-rectum, and takes the name of *superior hæmorrhoidal artery*, and supplies the coats of the rectum. It gives off *a*, the *left colic* branch, which runs to the descending colon to supply it: *b*, *sigmoid* branch, which runs between the two layers of the meso-colon to the sigmoid flexure to supply it; these branches bifurcate, anastomose, and form arterial arcades as on the right side.

The arteries which supply the coats of the alimentary tube from the œsophagus to the rectum, anastomose freely with each other in the wall of the tube, or in its mesenteric attachment, and the anastomoses are usually by the formation of arches or loops between adjacent branches. Thus the œsophageal branches of the aorta anastomose with each other and with the œsophageal branch of the

coronary artery, which again anastomoses with the gastric branch of the same artery. This gastric branch anastomoses along the lesser curvature of the stomach with the pyloric branch of the hepatic. Along the greater curvature the left gastro-epiploic of the splenic anastomoses with the right gastro-epiploic of the gastro-duodenal branch of the hepatic, and in the walls of the stomach, branches from these arteries of the curvatures anastomose with each other and with the vasa brevia of the splenic. Along the curve of the duodenum, the superior pancreatico-duodenal of the gastro-duodenal of the hepatic anastomoses with the inferior pancreatico-duodenal of the superior mesenteric. The intestinal branches of the superior mesenteric anastomose not only with each other in the series of arterial arcades already described, but with the inferior pancreatico-duodenal and ileo-colic branches of the same artery. In the large intestine the ileo-colic anastomoses with the right colic, and the right colic with the middle colic branch of the superior mesenteric. The middle colic anastomoses with the left colic of the inferior mesenteric, the left colic with the sigmoid, and the sigmoid with the superior hæmorrhoidal artery. The superior hæmorrhoidal anastomoses in the coats of the rectum, near its lower end, with the middle hæmorrhoidal branch of the internal iliac and the inferior hæmorrhoidal branch of the pudic. Through this chain of anastomoses, provision is made for equalizing the distribution of blood to the coats of the several divisions of the alimentary canal, and of providing secondary channels for the conveyance of blood to any division, in the event of the proper artery for that part being obstructed,—a point of great importance in connection with

the glandular or secreting function of the alimentary mucous membrane.

The CAPSULAR arteries, small in size, arise from the sides of the aorta above the renal arteries, and run outwards, to end in the supra-renal capsules.

The RENAL arteries arise from the sides of the aorta, and pass outwards, one to each kidney. They send branches to the supra-renal capsule and ureter. In the substance of the kidney they give off small *perforating* branches, which pierce the capsule of the kidney, and are distributed in the surrounding fat.

The SPERMATIC arteries are two long slender arteries, which arise from the aorta close to the renal arteries. They descend one on each side, behind the peritoneum, to the internal or deep abdominal ring, where each comes into relation with the vas deferens, and assists in forming the spermatic cord, which passes into the scrotum to the testicle. The corresponding arteries in the female, called the OVARIAN, do not leave the abdomen; they supply the ovaries.

SECOND GROUP.—PARIETAL BRANCHES OF THE AORTA.

The branches of the aorta which supply the walls of the thorax, abdomen, and pelvis, are the intercostal, the lumbar, the phrenic, and the middle sacral arteries.

The INTERCOSTAL arteries arise from the back of the thoracic aorta, and are usually ten pairs. They run along the sides of the vertebral bodies as far as the commencement of the intercostal spaces, when each divides into a *dorsal* and a *proper intercostal* branch; the dorsal branch passes to the back of the thorax to supply the deep muscles

of the spine, and gives a *spinal* branch to the spinal cord through the inter-vertebral foramen. The proper intercostal branch runs outwards in the intercostal space close to the lower border of the upper of the two ribs, and gives off a collateral branch which runs parallel to the upper border of the lower rib; they supply the intercostal muscles, and the lower pairs of intercostals also give branches to the diaphragm and wall of the abdomen.

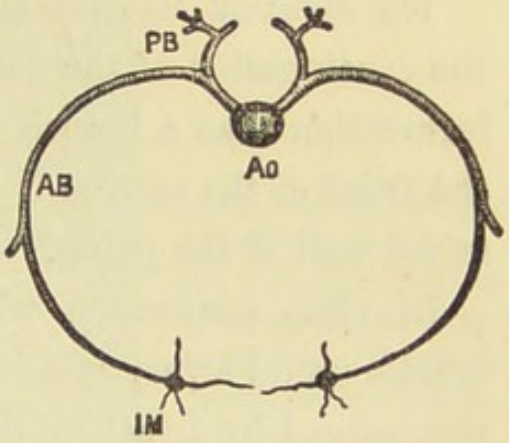

FIG. 121.—Diagram of a pair of Intercostal arteries. Ao, the aorta transversely divided, giving off at each side an intercostal artery; PB, the posterior or dorsal branch; AB, the anterior or proper intercostal branch; IM, a transverse section through the internal mammary artery, the anterior intercostal branch of which anastomoses with the aortic intercostal.

The LUMBAR arteries arise from the back of the abdominal aorta, and are usually four pairs. They run along the sides of the lumbar vertebræ, under cover of the psoas muscle, and divide into a *dorsal* branch, which supplies the deep muscles of the back of the loins, and an *abdominal* branch, which runs outwards behind the quadratus lumborum muscle to supply the wall of the abdomen. From the dorsal branch, a small *spinal* branch passes through the inter-vertebral foramen into the spinal canal to supply the nerve roots, membranes, and vertebræ. The distribution of the lumbar and intercostal arteries exhibits a transversely-segmented arrangement of the vascular system in the walls of the abdomen and thorax, similar to the transversely-segmented arrangement of the bones, muscles, and nerves observed in these localities, especially in the thoracic region.

The PHRENIC arteries, two in number, arise from the aorta close to the crura of the diaphragm; the right phrenic passes behind the inferior cava, the left behind the œsophagus, to supply the diaphragm; they also give branches to the supra-renal capsules.

The MIDDLE SACRAL artery, as already stated, is rather the continuation of the aorta downwards from the place of bifurcation than a branch of that vessel. As it runs down the front of the sacrum it gives transverse branches to the sacral wall of the pelvis.

In close connection with the terminal twigs of the middle sacral artery is a body, about the size of a small pea, named by Luschka the *coccygeal gland*. This body, now more usually called the *coccygeal body*, is not a gland, but, as Julius Arnold pointed out, is composed principally of the dilated and tortuous twigs of the middle sacral artery, the middle or muscular coat of which is greatly thickened. But, in addition, a laminated arrangement of cells is found within the dilatations. The body is invested by connective tissue in which nerve cells are embedded. Branches of the ganglion impar of the sympathetic pass to the coccygeal body.

Important anastomoses take place in the walls of the thorax and abdomen between the parietal branches of the aorta and branches of other arteries which pass to the parietes. If we go from the upper to the lower parts of the walls of the chest and belly, the following arteries may be seen to run from behind forwards, the superior intercostal branch of the subclavian in the first and second intercostal spaces; the intercostal branches of the aorta in the other intercostal spaces; the lumbar branches of the aorta in the muscular

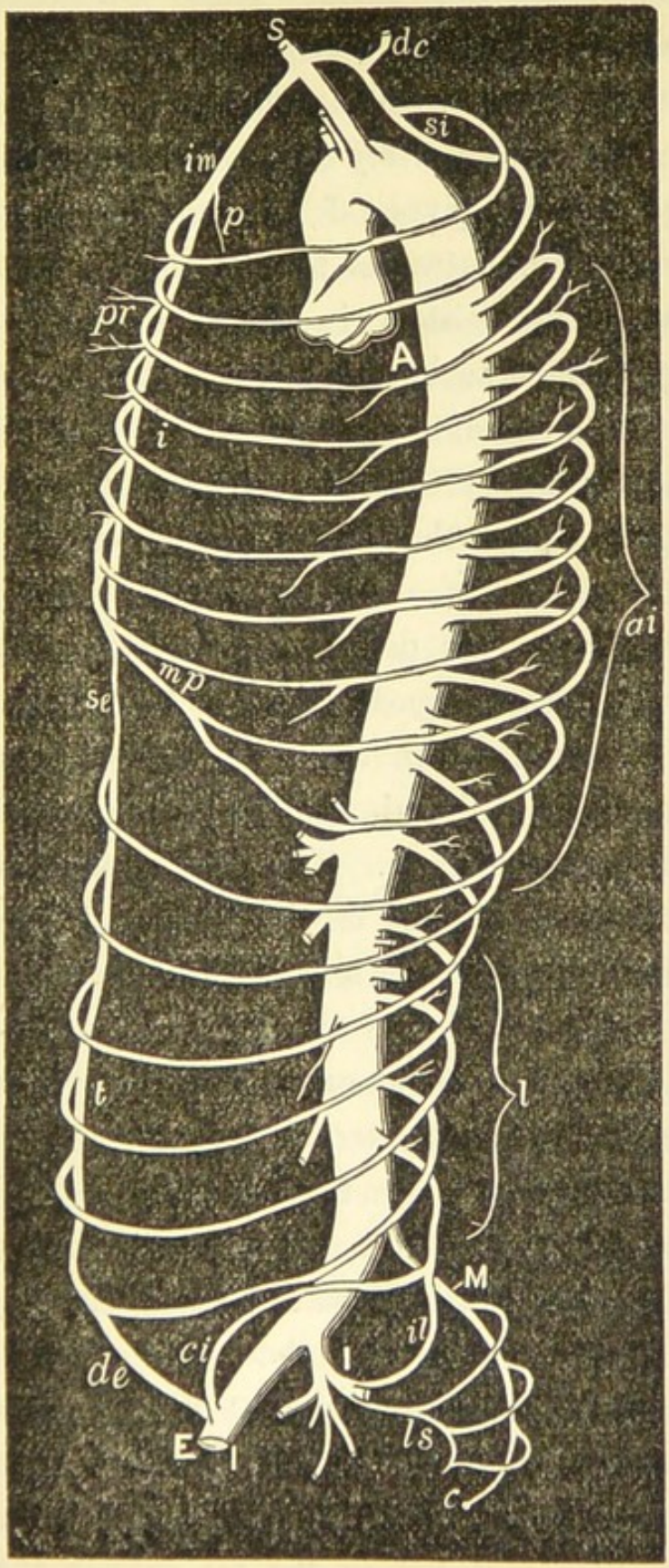

FIG. 122.—Arteries of the left wall of the Thorax and Abdomen. *A*, aorta; *E*, external iliac; *I*, internal iliac; *M*, middle sacral artery; *S*, subclavian; *si*, superior intercostal; *dc*, deep cervical; *im*, internal mammary; *p*, its phrenic; *pr*, its perforating; *i*, its anterior intercostal; *mp*, its musculo-phrenic, and *se*, its superior epigastric branch; *ai*, aortic intercostals; *l*, lumbar arteries; *de*, deep epigastric; *t*, its transverse branches; *ci*, circumflex iliac artery; *il*, ilio-lumbar artery; *ls*, lateral sacral artery; *c*, coccygeal body.

wall of the abdomen, and the ilio-lumbar branch of the internal iliac artery in the iliac fossa. These inosculate with the branches of three arteries which run from before backwards in the same parietes. Thus the internal mammary branch of the subclavian artery descends behind the cartilages of the ribs, and gives off the anterior intercostal branches, which run outwards to join the superior intercostal and aortic intercostals in the thoracic wall; also the musculo-phrenic branch which inosculates in the diaphragm with the aortic intercostals and the phrenic branches of the aorta; whilst the internal mammary terminates in the anterior wall of the abdomen by inosculating with the deep epigastric artery. From the external iliac artery arise two branches—the deep epigastric and deep circumflex iliac. The deep epigastric ascends behind the rectus abdominis, inosculates with the superior epigastric of the internal mammary, and with the lower intercostal and lumbar branches of the aorta. The deep circumflex iliac runs outwards along the line of the iliac crest, and inosculates with the lumbar arteries and the ilio-lumbar of the internal iliac. In the region of the pelvis the transverse branches of the middle sacral artery inosculate with the lateral sacral branches of the internal iliac.

The statement has frequently been made that the visceral and parietal branches of the aorta do not anastomose with each other, but injections which I made some years ago proved that, both in the thoracic and abdominal cavities, slender anastomosing communications exist between the two sets of branches. In the abdominal cavity a wide meshed plexus of small arteries, which I have named the *sub-* or *extra-peritoneal* plexus, lies in the fat outside the

peritoneum. On the one hand, it communicates with the perforating branches of the renal arteries and with slender branches of the capsular, spermatic, colic, and pancreatic arteries, and in the region of the diaphragm with the capsular branches of the hepatic artery. On the other hand, it communicates with the phrenic arteries, the lower intercostals, the lumbar branches of the aorta, and with the ilio-lumbar, circumflex iliac, and epigastric branches of the iliac arteries, which also go to the wall of the abdomen. In the pelvis also the visceral superior hæmorrhoidal artery anastomoses with the middle and lateral sacral arteries. The extra-peritoneal plexus supplies the gangliated cord of the sympathetic and the fat and lymphatic glands lying outside the peritoneum, and it also gives origin to *vasa vasorum* for the coats of the aorta and vena cava. This plexus may, when the visceral branches of the aorta are obstructed, aid in an important manner in carrying on the circulation. In a subject examined by J. Chiene, in the dissecting-room of the University of Edinburgh, where the cœliac axis and the superior and inferior mesenteric arteries were obliterated at their origins, the blood flowed from the parietal arteries, into these visceral arteries and the viscera they supplied, through a great enlargement of the arteries of the extra-peritoneal plexus. In the thoracic cavity a similar plexus, which I have named the *extra-pleural* plexus, lies between the pleura and pericardium; it communicates, on the one hand, with the phrenic and mediastinal branches of the internal mammary arteries, and on the other passes in front of the root of the lung to join the bronchial system of vessels. Another portion of this plexus joins, on the one hand, the intercostal arteries

near the dorsal vertebræ, and on the other passes to the lung behind its root.

THIRD GROUP.—BRANCHES OF THE AORTA FOR THE HEAD, NECK, AND UPPER LIMBS.

The branches for the head, neck, and upper limbs arise as three large arteries from the upper surface of the transverse part of the aortic arch; they are named in the order in which they arise from right to left, arteria innominata, left common carotid, and left subclavian.

The ARTERIA INNOMINATA, or BRACHIOCEPHALIC artery, is the largest branch of the arch of the aorta, and springs from the commencement of its transverse part. It passes upwards and to the right, to the root of the neck, on a level with the right sterno-clavicular articulation, and then divides into the right common carotid and the right subclavian artery. It lies in the upper part of the chest behind the manubrium sterni and in front of the trachea. The right brachio-cephalic vein and right pleura are to its right, the left common carotid artery is to its left, and the left brachio-cephalic vein crosses between it and the sternum. It gives off, as a rule, no collateral branches.

Subclavian System of Arteries.

This system consists of the large artery of supply for the upper extremity, and of the branches, which arise either directly or indirectly from it. This artery bears different names in its course. It is called *subclavian*, as it passes across the root of the neck and under the clavicle;

when it enters the armpit, it becomes the *axillary* artery; by that name it extends as far as the posterior fold of the axilla, when it enters the upper arm, takes the name of *brachial* or *humeral* artery, and courses as far as the bend of the elbow, where it bifurcates into the *radial* and *ulnar* arteries.

The SUBCLAVIAN artery arises on the right side at the bifurcation of the innominate artery; but on the left side directly from the arch of the aorta, being the last of the three branches of the transverse part of the arch. The right subclavian arches across the root of the neck, and passing behind the clavicle and subclavius muscle, reaches the outer border of the first rib, where it becomes the axillary artery. The left subclavian has to ascend through the upper part of the thorax into the neck, before it arches across the root of the neck. In its course each subclavian artery goes behind the scalenus anticus muscle, so that it is customary to divide this artery into three parts; a first part internal to the scalenus, a second part behind that muscle, a third part to its outer side.

The relations of the first part of the subclavian are not the same on the right and left sides, owing to the difference in origin of the two vessels. The first part of the left subclavian is longer than that of the right; it is overlapped by the left pleura and lung, and is crossed by the left innominate vein; it lies in front of the œsophagus and thoracic duct; whilst to its right side are the trachea, left common carotid artery, left vagus, and recurrent laryngeal nerves. The first part of the right subclavian is covered by the platysma, sterno-mastoid, sterno-hyoid and sterno-thyroid muscles, and by the cervical fascia; it is crossed by

the vertebral and internal jugular veins, the cardiac branches of the sympathetic and the right vagus nerve. The right recurrent laryngeal nerve hooks behind it. The right subclavian vein lies below it, and the right pleura is below and posterior to it.

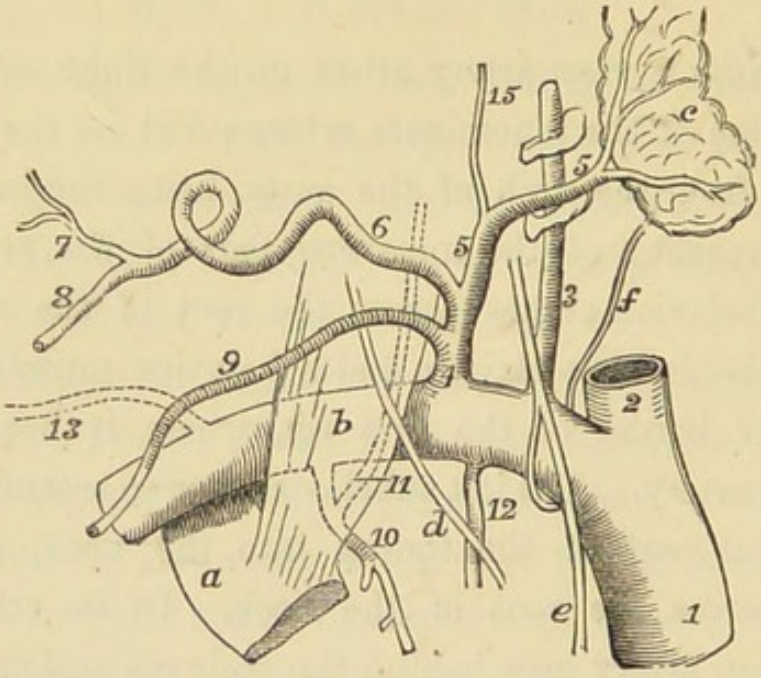

FIG. 123.—The Right Subclavian Artery and its Branches.

1, Innominate artery; 2, common carotid; 3, vertebral branch of subclavian; 4, thyroid axis; 5, inferior thyroid branch; 6, transversalis colli; 7, superficialis colli; 8, posterior scapular; 9, supra scapular; 10, superior intercostal; 11, deep cervical; 12, internal mammary; 13, in dotted outline shows the occasional origin of the posterior scapular from the third part of the subclavian; 15, ascending cervical artery. *a*, 1st rib; *b*, scalenus anticus; *c*, thyroid gland; *d*, phrenic nerve; *e*, pneumo-gastric nerve; *f*, recurrent laryngeal nerve.

The relations of the second and third parts of the subclavian arteries are the same on both sides. The second part lies upon the scalenus medius, and has the scalenus anticus, sterno-mastoid, cervical fascia, and platysma superficial to it; it is separated by the scalenus anticus from the subclavian vein and phrenic nerve; above it are the nervous cords of the brachial plexus, and below is the pleura.

The third part of the subclavian artery lies partly in the supra-clavicular triangle—a region bounded by the pos-

terior belly of the omo-hyoid, the sterno-mastoid muscle, and the clavicle—and partly under cover of the clavicle and subclavius muscle. It is covered by the skin, platysma, and cervical fascia, and is crossed by the external jugular vein, the nerve to the subclavius, and the descending cutaneous branches of the cervical plexus. It rests on the scalenus medius and the grooved upper surface of the first rib. The cords of the brachial plexus are above and the subclavian vein below it. From the subclavian artery branches arise in the following order :—

a. Vertebral, which arises from the first part of the artery. It enters the foramen at the root of the transverse process of the sixth cervical vertebra, ascends through the corresponding foramina in the vertebræ above, lies in a groove on the arch of the atlas, pierces the dura mater, and enters the skull through the foramen magnum, where it joins its fellow to form the *basilar* artery. It is accompanied by vaso-motor branches from the inferior cervical ganglion of the sympathetic, and by the vertebral vein, and in its ascent through the series of foramina, it lies in front of the cervical nerves. It gives off *muscular* branches to the deep muscles of the neck : *spinal* branches, which enter the intervertebral foramina and pass to the spinal cord : a *posterior spinal* branch, arises on a level with the medulla oblongata, and descends on the back of the cord to anastomose with the spinal branches which enter the intervertebral foramina : an *anterior spinal* branch arises on the same level, descends in front of the cord, anastomoses with its fellow, and forms the *anterior median* artery of the cord, which artery anastomoses in its descent with the spinal branches from the vertebral, inferior thyroid, intercostal and

lumbar arteries, so as to form a long slender artery, situated in front of the cord in its entire length, which supplies the cord and the pia mater: *meningeal* branches to the dura mater: an *inferior cerebellar* branch to the under surface of the cerebellum. The *Basilar* artery, formed by the junction of the two vertebrals, extends from the lower to the upper border of the pons Varolii; it gives off collaterally *transverse* branches to the pons: *auditory* branches which accompany the portio mollis to the internal ear: *inferior cerebellar* branches to the under surface of the cerebellum: whilst it breaks up into four terminal branches, viz., two *superior cerebellar* to the upper surface of the cerebellum, and two *posterior cerebral* which supply the convolutions on the tentorial aspect of the temporo-sphenoidal lobes, those of the occipital lobes, and the posterior convolutions of the parietal lobes of the cerebrum: *perforating* branches pass from the posterior cerebral artery to the locus perforatus posticus. The third cranial nerve on each side appears between the superior cerebellar and posterior cerebral arteries.

b. Thyroid Axis, a short branch, which immediately divides into the *inferior thyroid*, the *supra-scapular*, and the *transversalis colli* branches. The *Inferior Thyroid* ascends on the longus colli muscle, and then turns inwards behind the sheath of the carotid vessels and the gangliated cord of the sympathetic to be distributed to the thyroid body; it gives off an *ascending cervical* branch to the muscles of the neck, which also sends small *spinal* branches to the spinal cord: a *laryngeal* branch which accompanies the inferior laryngeal nerve to the larynx: *œsophageal* branches to the œsophagus. The *Supra-scapular* runs outwards behind the sterno-mastoid muscle and the clavicle,

reaches the upper border of the scapula, and passes over the supra-scapular ligament to the dorsum of the scapula, where it ramifies in the supra and infra spinous fossæ, and supplies the muscles on the dorsum scapulæ. The *Transversalis Colli* passes outwards behind the sterno-mastoid and above the clavicle; it then goes under cover of the trapezius, and divides into the *superficial cervical* and *posterior scapular* branches; the superficial cervical ends in the trapezius and levator scapulæ muscles; the posterior scapular runs parallel to the posterior border of the scapula, supplies the muscles attached to that border, and gives branches to the dorsal and ventral surfaces of the scapula. The *transversalis colli* artery varies in its arrangement in different individuals; it not unfrequently ends in the trapezius, and represents in its distribution the superficial cervical branch; in these cases the posterior scapular branch arises directly from the subclavian.

c. Internal Mammary arises from the lower surface of the first part of the subclavian, passes into the thorax behind the cartilage of the first rib, and descends behind the internal intercostal muscles and costal cartilages as far as the sixth intercostal space, where it divides into the *musculo-phrenic* and *superior epigastric* branches. The costal pleura lies immediately behind the upper part of the artery, but its lower part is separated from the pleura by the triangularis sterni muscle. In its course the following branches arise:—*arteria comes nervi phrenici*, which accompanies the phrenic nerve to the diaphragm: *mediastinal* branches to the thymus gland, pericardium, and areolar tissue of the mediastinal space: *perforating* branches, which pierce the internal intercostal and greater

pectoral muscles, and supply the skin of the front of the chest; the second and third perforating arteries pass to the mammary gland: *anterior intercostals* run outwards in the upper five or six intercostal spaces, and inosculate with the aortic intercostals: *musculo-phrenic*, one of the two terminal branches, runs outwards along the line of origin of the diaphragm, and assists in supplying that muscle: *superior epigastric*, the other terminal branch, descends in the wall of the abdomen in the sheath of the rectus, and supplies that muscle.

d. Superior Intercostal arises from the back of the second part of the subclavian; it descends into the back of the cavity of the chest in front of the neck of the first rib, and ends in two branches, one for the first, the other for the second intercostal space. Before it enters the chest it gives off the *deep cervical* artery, which passes backwards between the transverse process of the seventh cervical vertebra and the neck of the first rib, and then ascends on the back of the neck between the complexus and semi-spinalis colli muscles to supply them. It is equivalent to the dorsal branch of an aortic intercostal, and sometimes arises directly from the subclavian.

The branches, which arise either directly or indirectly from the subclavian artery, may be arranged, according to their distribution to the parts which they supply, in three groups:—

1*st.* To neck, thyroid gland, windpipe, brain, and spinal cord: vertebral, inferior thyroid, ascending cervical, superficial cervical, deep cervical arteries;

2*d.* To walls of trunk: internal mammary, superior intercostal arteries;

3*d*. To scapular region: transversalis colli, supra-scapular arteries.

The AXILLARY artery is the direct continuation of the subclavian; it commences at the outer border of the first rib and passes through the axilla, in close relation to the outer wall, as far as the lower border of the tendon of the teres major muscle, where it becomes the brachial artery. In this course it lies in relation to the inner aspect of the head and upper part of the shaft of the humerus. It is covered, in addition to the skin and fasciæ, by the costo-coracoid membrane, pectoralis major and minor muscles, but where it lies on the teres major it passes from under cover of the greater pectoral. It is in relation behind to the serratus magnus, subscapularis, latissimus dorsi, and teres major muscles. The axillary vein lies to its inner side, and it is crossed at its upper end by the cephalic vein. The axillary plexus of nerves is at first to its outer side; then the plexus is disposed with one cord to the outer side of the artery, another to the inner side, and a third behind it; whilst lower down the branches arising from these cords are so arranged about the artery that the median and musculo-cutaneous nerves are to its outer side; the ulnar, internal cutaneous and lesser internal cutaneous are to its inner side, and the circumflex, musculo-spiral, and subscapular are behind it.

The branches of the axillary artery are as follows:—

a. *Short Thoracic* arises above the pectoralis minor, and runs inwards to the upper part of the lateral wall of the chest.

b. *Thoracic Axis* arises close to the upper border of the pectoralis minor, and almost immediately divides into the

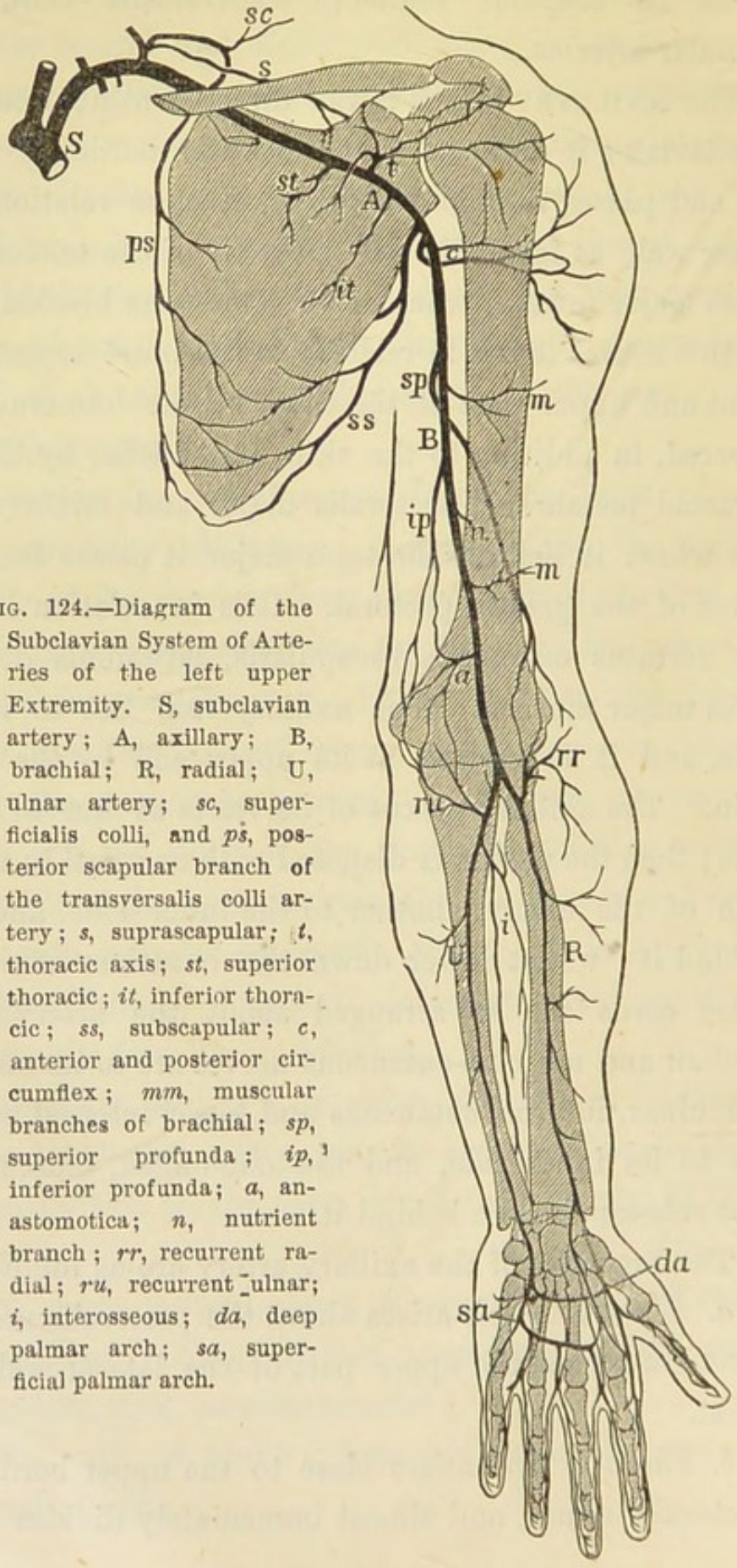

FIG. 124.—Diagram of the Subclavian System of Arteries of the left upper Extremity. S, subclavian artery; A, axillary; B, brachial; R, radial; U, ulnar artery; *sc*, superficialis colli, and *ps*, posterior scapular branch of the transversalis colli artery; *s*, suprascapular; *t*, thoracic axis; *st*, superior thoracic; *it*, inferior thoracic; *ss*, subscapular; *c*, anterior and posterior circumflex; *mm*, muscular branches of brachial; *sp*, superior profunda; *ip*, inferior profunda; *a*, anastomotica; *n*, nutrient branch; *rr*, recurrent radial; *ru*, recurrent ulnar; *i*, interosseous; *da*, deep palmar arch; *sa*, superficial palmar arch.

following branches; *acromial thoracic*, which passes outwards to the deltoid and the region of the acromion: *humeral thoracic*, which descends, at the side of the cephalic vein, between the deltoid and greater pectoral muscles to which it gives branches: *pectoral thoracic*, which supplies the two pectoral muscles: *clavicular thoracic*, which supplies the subclavius muscle.

c. Long Thoracic, or *External Mammary*, runs parallel to the lower border of the lesser pectoral muscle to the lateral wall of the chest, and in woman supplies the mammary gland.

d. Alar Thoracic, a short branch to the fat and lymphatic glands of the axilla: it sometimes arises from the subscapular or long thoracic arteries.

e. Subscapular arises opposite the lower border of the subscapularis, along which it runs to the inferior angle of the scapula and lateral wall of the chest; it supplies the serratus magnus and the muscles of the posterior wall of the axilla: it gives off a large *dorsal* branch, which turns round the axillary border of the scapula, in the triangular space bounded by the teres minor, teres major, and long head of the triceps, which branch ramifies on the dorsum of the scapula to supply the teres minor and infra-spinatus.

f. Anterior Circumflex, a small branch, which runs outwards in front of the humerus to the bicipital groove, where it sends a branch along with the tendon of the biceps to the shoulder joint, and terminates in the deltoid muscle.

g. Posterior Circumflex, a large branch, which winds round the back of the humerus, along with the circumflex nerve, in the quadrilateral space bounded by the teres minor, teres major, long head of the triceps and shaft of

the humerus : it ends in the deltoid muscle, for which it is the principal artery of supply.

The branches of the axillary artery may be arranged according to their distribution in three groups :—

1*st*. To walls of thorax : short thoracic, long thoracic, pectoral thoracic, terminal branches of subscapular artery.

2*d*. To scapulo-humeral region : acromio-thoracic, clavicular thoracic, humeral thoracic, anterior and posterior circumflex, and dorsal branch of subscapular artery.

3*d*. To fat and glands of axilla : alar thoracic artery.

The branches to the walls of the thorax anastomose with the superior intercostal of the subclavian, the aortic intercostals and the anterior intercostals of the internal mammary. The branches to the scapulo-humeral region inosculate with the posterior scapular and supra-scapular branches of the subclavian. Both series of inosculations enlarge, and form secondary channels for the conveyance of blood to the upper limb, when the third part of the subclavian artery is tied.

The BRACHIAL or HUMERAL artery is the direct continuation of the axillary. It commences at the lower border of the tendon of the teres major, and passes down the upper arm to a little below the bend of the elbow, where it divides into two terminal branches, the radial and ulnar arteries. In this course it lies at first to the inner side of the shaft of the humerus, but lower down it inclines to the front of that bone. It is covered by the skin and fasciæ, and at the bend of the elbow it is crossed by the thin tendon of the biceps, which is inserted into the fascia of the fore arm. It is in relation behind to the long head of the triceps, but is separated from it by the musculo-spiral nerve

and superior profunda artery, whilst lower down it rests on the tendon of insertion of the coraco-brachialis, and on the brachialis anticus muscle. At first the coraco-brachialis, and then the inner border of the biceps, are to its outer side, and in muscular arms it is overlapped by the latter muscle, the inner border of which forms a definite guide to the position of the artery. It is accompanied by two venæ comites; and the basilic vein, separated by the brachial aponeurosis, is superficial to it, whilst at the bend of the elbow the median basilic vein is separated from it by the thin tendon of the biceps. The median nerve is at first to its outer side, then crosses over it, but at and immediately above the bend of the elbow it is to its inner side.

Not unfrequently the brachial artery divides into the radial and ulnar arteries in the upper arm, and the division may in some cases take place as high as the axilla. In those instances in which a supra-condyloid process and foramen are developed (p. 41), the brachial artery and median nerve are deflected from their usual course to pass through the foramen, though occasionally the foramen only transmits the median nerve.

The branches of the brachial artery are as follows :—

a. Muscular branches pass outwards from the brachial artery to supply the biceps, coraco-brachialis, and brachialis anticus muscles.

b. Superior Profunda arises from the upper portion of the brachial; it winds downwards, backwards, and outwards, along with the musculo-spiral nerve in the musculo-spiral groove of the humerus, passes between the heads of the triceps, then pierces the external inter-muscular septum of the upper arm to reach the interval between the

brachialis anticus and supinator longus muscles, and to end at the outer side of the elbow; it is the artery of supply for the triceps.

c. Inferior Profunda arises opposite the coraco-brachialis, and descends along with the ulnar nerve to the interval between the inner condyle of the humerus and the olecranon.

d. Anastomotic arises from one to two inches above the elbow, and divides into two branches—the smaller branch descends on the brachialis anticus in front of the elbow; the larger pierces the internal inter-muscular septum, and reaches the interval between the inner condyle and the olecranon.

e. Nutrient enters the nutrient canal in the shaft of the humerus to supply the medulla of the bone.

The branches of the brachial artery may be arranged according to their distribution in four groups :—

1*st.* To muscles alone : muscular branches.

2*d.* To muscles and region of elbow : superior profunda, inferior profunda, anastomotic arteries.

3*d.* To bone : nutrient artery.

4*th.* Terminal : radial and ulnar arteries.

The ULNAR artery, the larger of the two terminal branches of the brachial extends down the ulnar side of the front of the fore arm to the wrist, where it crosses in front of the anterior annular ligament, and reaches the palm of the hand; it then curves outwards towards the thumb, and anastomoses with the superficial volar and radial index branches of the radial artery to form the SUPERFICIAL PALMAR ARTERIAL ARCH. In the fore arm the ulnar artery passes at first behind the pronator teres, flexor

carpi radialis, palmaris longus, and flexor sublimis digitorum muscles, and then descends, covered only by the skin and fasciæ, close to the radial border of the flexor carpi ulnaris, as far as the radial side of the pisiform bone, when it passes under cover of the palmaris brevis muscle and the palmar fascia and forms the superficial palmar arch. It rests when in the fore arm for a short distance on the brachialis anticus, and then on the flexor profundus digitorum; at the wrist it lies on the anterior annular ligament; in the hand on the flexor tendons of the fingers, and the branches of the median and ulnar nerves. It is accompanied by the deep ulnar veins. The median nerve is separated from the commencement of the artery by the deep head of origin of the pronator teres. About the junction of the upper and middle thirds of the fore arm the ulnar nerve comes into relation with the artery, and passes along with it to the hand, the nerve being close to the inner side of the artery.

The ulnar artery in the fore arm gives origin to the following branches :—

a. Anterior Ulnar Recurrent arises close to the origin of the ulnar, and ascends in front of the brachialis anticus to anastomose with the anastomotic artery.

b. Posterior Ulnar Recurrent arises close to the anterior, and passes upwards and backwards to the interval between the inner condyle and olecranon. It and the anterior recurrent supply the muscles in front, and to the inner side of the elbow joint.

c. Interosseus is the largest branch of the ulnar, and arises high in the fore arm; after a course of about an inch it divides into the anterior and posterior interosseous branches. The *anterior interosseous* artery passes down the

fore arm, lying on the interosseous membrane, and between the flexor longus pollicis and flexor profundus digitorum muscles, as far as the pronator quadratus muscle, when it divides into two terminal branches—one to reach the front of the carpus, the other and larger pierces the interosseous membrane to reach the back of the carpus. It is accompanied, when in front of the interosseous membrane, by the anterior interosseous branch of the median nerve. It supplies *muscular* branches to the deep muscles of the fore arm; a *median* branch, which is occasionally an artery of considerable size, accompanies and supplies the median nerve, and descends with it to the palm of the hand; *nutrient* branches, to enter the foramina in the shafts of the radius and ulna. The *posterior interosseous* artery passes backwards through the interosseous space, and between the supinator brevis and extensor ossis metacarpi pollicis muscles to supply the muscles on the back of the fore arm; it gives off the *posterior interosseous recurrent* branch, which ascends under cover of the anconeus to the interval between the outer condyle and the olecranon.

d. Muscular branches to muscles of fore arm.

e. Posterior Ulnar Carpal, a small and inconstant branch, arises opposite the wrist, and forms an arch with the posterior radial carpal on the back of the carpus, and supplies the articulations.

f. Anterior Ulnar Carpal, also small and inconstant, is covered by the flexor tendons, and forms an arch with the anterior radial carpal on the front of the carpus, the articulations of which it supplies.

The palmar portion of the ulnar artery, or superficial palmar arch, gives origin to the following branches :—

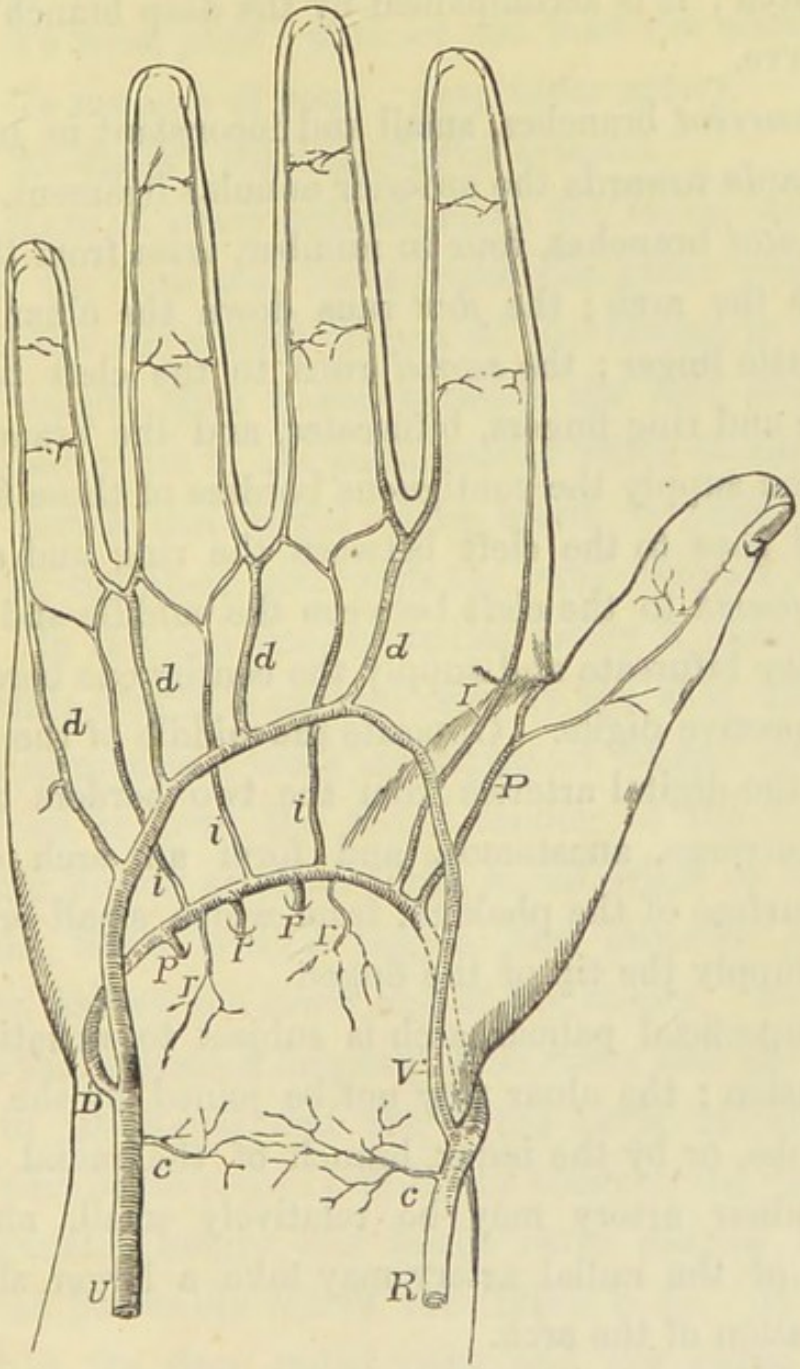

FIG. 125.—Diagram of the Arteries of the Hand.

R, radial artery; V, superficial volar; P, arteria magna pollicis; I, artery of the radial side of the index; U, ulnar; D, its deep branch; *c*, *c*, ulnar and radial anterior carpal branches; *d*, *d*, *d*, *d*, digital branches from the superficial palmar arch; *i*, *i*, *i*, interosseous branches from the deep arch; *p*, *p*, *p*, perforating branches; *r*, *r*, recurrent branches.

g. Profunda or *deep* branch arises just beyond the pisiform bone, and dips between the flexor brevis and ab-

ductor minimi digiti into the deep part of the palm, where it inosculates with the radial artery to form the deep palmar arch; it is accompanied by the deep branch of the ulnar nerve.

h. Recurrent branches, small and inconstant in number, run upwards towards the anterior annular ligament.

i. Digital branches, four in number, arise from the convexity of the arch; the *first* runs down the ulnar border of the little finger; the *second* runs to the cleft between the little and ring fingers, bifurcates, and the branches of bifurcation supply the contiguous borders of those fingers; the *third* goes to the cleft between the ring and middle, and the *fourth* to the cleft between the middle and index, where they bifurcate and supply the contiguous borders of their respective digits. Opposite the middle of the ungual phalanx the digital arteries from the two borders of each finger converge, anastomose and form an arch on the palmar surface of the phalanx, from which small branches arise to supply the tip of the finger.

The superficial palmar arch is subject to variations in its formation; the ulnar may not be joined by the superficialis volæ, or by the index branch of the radial artery, or the ulnar artery may be relatively small, and the branches of the radial artery may take a larger share in the formation of the arch.

The branches which arise either directly or indirectly from the ulnar may be arranged according to their distribution in six groups :—

1*st.* To muscles of fore arm : muscular and interosseous.

2*d.* To bones : nutrient artery.

3*d*. To elbow joint: anterior and posterior ulnar recurrent, posterior interosseous recurrent artery.

4*th*. To wrist joint: anterior and posterior ulnar carpal.

5*th*. To muscles of hand: deep ulnar artery.

6*th*. To digits: the four digital arteries.

The RADIAL artery extends down the radial side of the front of the fore arm, turns round the outer side of the wrist, below the styloid process of the radius, to the back of the hand; then passes between the first and second metacarpal bones to the palm, across which it runs as far as the fourth metacarpal bone, where it joins the deep branch of the ulnar, and forms the DEEP PALMAR ARTERIAL ARCH. In the fore arm the radial artery is placed so near the surface that it is covered only by the skin and fasciæ, though in muscular arms the supinator longus overlaps it. It lies on or over the radial tendon of the biceps, the supinator brevis, pronator teres, radial origin of the flexor sublimis, flexor pollicis longus, and pronator quadratus muscles, and on the lower end of the radius. To its outer side is the supinator longus; to its inner side the pronator teres in the upper, and the flexor carpi radialis in the lower part of its course; as it lies between the tendons of the supinator longus and flexor carpi radialis, its pulsations can be readily felt in the living body. It is accompanied by the deep radial veins, and the radial nerve is close to its outer side in the middle third of the fore arm.

At the wrist and back of the hand the radial artery is crossed by the three extensor tendons of the thumb, and rests on the external lateral ligament of the wrist and the back of the carpus.

As it enters the palm it goes between the two heads of

the abductor indicis muscle, and, as the deep palmar arch it is covered by the flexor brevis pollicis and the flexor tendons of the fingers ; it rests on the interossei muscles and the metacarpal bones.

The radial artery in the fore arm gives origin to the following branches :—

a. Radial Recurrent arises just below the elbow, and ascends in front of the brachialis anticus to the interval between that muscle and the supinator longus.

b. Muscular branches to muscles of fore arm.

c. Anterior Radial Carpal arises close to the wrist, and forms with the anterior ulnar carpal an arch in front of the carpal joints.

d. Superficial Volar arises close to the wrist, and descends to the ball of the thumb, where it supplies the muscles and inosculates with the ulnar artery to assist in forming the superficial palmar arch.

At the wrist and back of the hand arise—

e. Posterior Radial Carpal, which runs across the back of the wrist, and forms an arch with the posterior ulnar carpal ; from this arch arise the *dorsal interosseous* branches for the third and fourth metacarpal spaces.

f. 1*st Dorsal Interosseous* descends superficial to the second dorsal interosseous muscle as far as the cleft between the index and middle fingers.

g. Dorsal branches for Thumb, two in number, descend on the radial and ulnar borders of the back of the metacarpal bone of the thumb.

h. Dorsal branch for Index descends on back of metacarpal bone of index finger.

In the palm of the hand the radial artery and the deep arch which it forms give origin to—

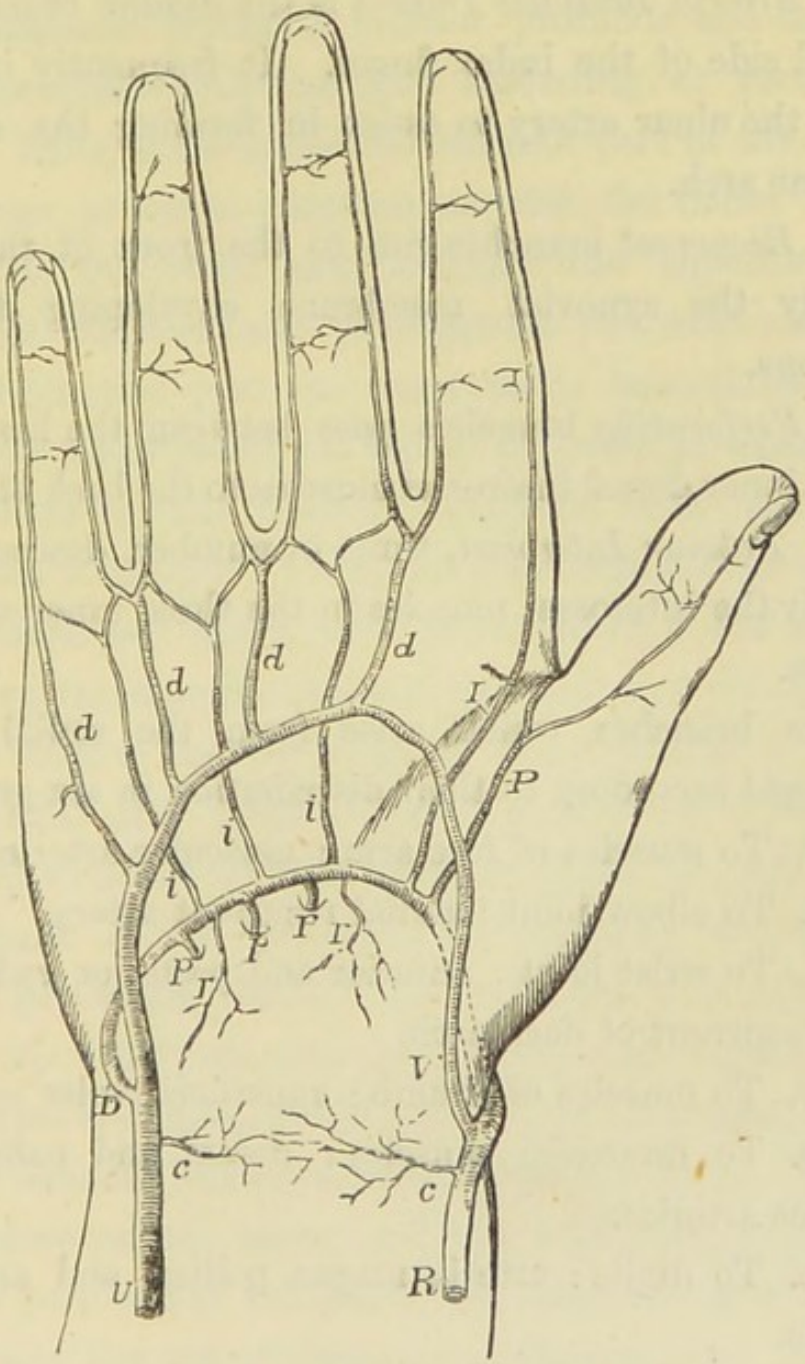

FIG. 126.—Diagram of the Arteries of the Hand.

R, radial artery; V, superficial volar; P, arteria magna pollicis; I, artery of the radial side of the index; U, ulnar: D, its deep branch; *c*, *c*, ulnar and radial anterior carpal branches; *d*, *d*, *d*, *d*, digital branches from the superficial palmar arch; *i*, *i*, *i*, interosseous branches from the deep arch; *p*, *p*, *p*, perforating branches; *r*, *r*, recurrent branches.

i. Arteria Magna Pollicis, which runs close to the metacarpal bone of the thumb, and divides into two *digital*

branches, one for each of the two borders of the thumb on its palmar aspect.

j. Arteria Radialis Indicis is the *digital* branch for the radial side of the index finger. It frequently inosculates with the ulnar artery to assist in forming the superficial palmar arch.

k. Recurrent branches run to the front of the wrist to supply the synovial membrane enveloping the flexor tendons.

l. Perforating branches pass between the heads of the three inner dorsal interossei muscles to the back of the hand.

m. Palmar Interossei, three in number, descend on and supply the interossei muscles in the three inner metacarpal spaces.

The branches which arise from the radial may be arranged according to their distribution in six groups—

1*st.* To muscles of fore arm : muscular arteries.

2*d.* To elbow joint : radial recurrent artery.

3*d.* To wrist joint : anterior and posterior radial carpal and recurrent of deep arch.

4*th.* To muscles of thumb : superficial volar artery.

5*th.* To interossei muscles : dorsal and palmar interosseous arteries.

6*th.* To digits : arteria magna pollicis and art. radialis indicis.

Inosculations take place freely in the upper limb between the branches of the different arteries. Around the shoulder the scapulo-humeral set of branches of the axillary anastomose with each other, and with the posterior and suprascapular branches of the subclavian. In the upper arm anastomoses take place between the muscular branches of the brachial and the circumflex

branches of the axillary. Around the elbow joint the three descending branches of the brachial artery, viz., the superior profunda, inferior profunda and anastomotic, inosculate with the four ascending or recurrent arteries. Thus, at the outer and anterior part of the joint, the superior profunda anastomoses with the radial recurrent, and at the outer and posterior the superior profunda with the posterior interosseous recurrent; at the inner and anterior part the anastomotic inosculates with the anterior ulnar recurrent, and at the inner and posterior the anastomotic and inferior profunda with the posterior ulnar recurrent. If the brachial artery were tied or occluded from any cause, these anastomoses would enlarge and convey the blood into the arteries of the fore arm.

In the front of the fore arm the short muscular branches of the radial and ulnar arteries anastomose with each other, and with the anterior interosseous of the ulnar; and on the back of the fore arm, the posterior interosseous with the perforating branch of the anterior interosseous. Around the wrist joint not only are there the inosculations of the carpal arches, but the anterior carpal arch anastomoses with the anterior interosseous and the recurrent branches of the deep palmar arch; and the posterior carpal arch with the perforating branch of the anterior interosseous. In the hand the anastomoses are numerous; not only does the ulnar artery itself join the volar and index branches of the radial artery to form the superficial palmar arch; and the radial artery itself join the deep branch of the ulnar to form the deep arch; but the palmar interosseous branches of the deep arch anastomose with the digital branches of the superficial arch; again the two digital

arteries passing along the borders of each digit anastomose on the palmar surface of the ungual phalanx, and the perforating branches of the deep arch anastomose on the back of the hand with the metacarpal and posterior carpal arteries. Owing to the multiplicity and freedom of the inosculations in the hand, wounds of the arteries are apt to occasion troublesome hæmorrhage. If in the development of the arteries of the hand any one of the vessels has not reached its ordinary dimensions, in order to compensate for its reduced size, one or more of the arteries which inosculate with it is more largely developed, so as to convey to the part the amount of blood that is required for nutrition; from this circumstance variations in the relative size of the arteries are not unfrequently found in the hand.

Carotid System of Arteries.

This system is composed of the arteries of supply for the neck and head, and consists of the common carotid artery, of its two branches of bifurcation, the internal and external carotids, and of their several branches.

The Common Carotid artery varies in its origin on the two sides of the body. On the right side it arises from the arteria innominata opposite the right sterno-clavicular joint; on the left it arises from the transverse part of the arch of the aorta between the arteria innominata and the left subclavian artery, but nearer to the former than to the latter. Both common carotids run up the neck by the sides of the windpipe, and when they reach the level of the upper border of the thyroid cartilage they divide into the internal and external carotid arteries.

The left common carotid is longer than the right; it is placed at first in the upper part of the thorax, in which it ascends as far as the left sterno-clavicular joint; it is covered by the manubrium sterni and the remains of the thymus gland, and is crossed by the left innominate vein. It lies at first in front of the trachea, and then in front of the œsophagus and thoracic duct.

In the neck each common carotid artery is enclosed along with the internal jugular vein and vagus nerve in a sheath, formed of the cervical fascia; it is covered in the lower part of the neck by the sterno-thyroid, sterno-hyoid, and sterno-mastoid muscles, cervical fascia, platysma, and skin; it is crossed opposite the cricoid cartilage by the anterior belly of the omo-hyoid muscle, above which it lies in the anterior triangular space, where it is overlapped by the inner border of the sterno-mastoid, which forms a definite guide to the position of the artery, and is covered by the cervical fascia, platysma and skin. It rests behind on the cervical vertebræ, the longus colli, and rectus anticus major muscles, and the inferior thyroid artery crosses behind its sheath. To the inner side of the artery are the trachea, larynx, thyroid body and pharynx, and the thyroid body when enlarged overlaps the artery. The greater width of the larynx than of the trachea causes the two carotids to be further asunder in the upper than the lower part of their course. A chain of lymphatic glands lies in the neck parallel to the common carotid, and when enlarged they sometimes overlap the artery. The internal jugular vein descends close to the outer side of the artery in the same sheath, whilst the superior thyroid vein, which joins the internal jugular, crosses the upper part of the artery, and

the anterior jugular vein, which joins the subclavian, crosses its lower part. The descendens noni and communicantes noni nerves lie in front of the carotid sheath; the vagus nerve is within the sheath, parallel to but behind and between the carotid artery and internal jugular vein; the cord of the sympathetic lies behind the sheath, between it and the pre-vertebral muscles; the recurrent laryngeal branch of the vagus ascends to the larynx obliquely behind the lower part of the artery.

From the common carotid artery no collateral branches arise, but in addition to the terminal internal and external carotids, it gives off at and near its bifurcation some fine twigs, which form the *intercarotic ganglion* or *intercarotic body*. This body is sometimes referred to the sympathetic nervous system, but, as Julius Arnold has shown, it is principally formed, like the coccygeal body, of tortuous and dilated arterial twigs. The walls of the dilatations are not so thick as in the coccygeal body, the muscular coat is said to be absent, but the dilatations contain layers of polygonal cells. Branched nerve cells are found in the connective tissue which envelopes the body.

The INTERNAL or DEEP CAROTID artery, one of the two terminal branches of the common carotid, begins opposite the upper border of the thyroid cartilage; it ascends in the neck at the side of the pharynx and tonsil, as high as the base of the skull, then enters the carotid canal in the petrous-temporal, leaves that canal at its upper orifice and enters the cranial cavity, where it lies in a groove on the side of the body of the sphenoid bone; here it forms a sigmoid curve, and terminates close to the anterior clinoid process by dividing into the anterior and

middle cerebral arteries. At its origin in the neck it lies in the anterior triangular space, and is covered only by the skin, platysma, and cervical fascia; but as it ascends it becomes more deeply placed, and the posterior belly of the digastric and stylo-hyoid muscles, the hypoglossal nerve, the external carotid and occipital arteries, the parotid gland, the stylo-glossus and stylo-pharyngeus muscles, stylo-hyoid ligament, glosso-pharyngeal nerve and pharyngeal branches of the nervus vagus are between it and the surface. It lies in front of the rectus capitis anticus major muscle and the cervical vertebræ. To its outer side is the internal jugular vein, whilst the vagus nerve and the cord of the sympathetic are behind it.

In the carotid canal and cranial cavity the artery is accompanied by the ascending prolongation of the gangliated cord of the sympathetic, which forms the carotid and cavernous plexuses around the artery. On the side of the body of the sphenoid it lies on the inner wall of the cavernous blood sinus, and has the sixth cranial nerve in contact with its outer surface; whilst the third and fourth cranial nerves, and the ophthalmic division of the fifth lie in the outer wall of the cavernous sinus. Close to the anterior clinoid process it pierces the dura mater, and becomes covered by the visceral arachnoid prior to its termination.

No branch arises from the internal carotid in the neck. In the carotid canal a small *tympanic* branch arises, which enters the tympanum. When in the inner wall of the cavernous sinus minute branches, named *arteriæ receptaculi*, pass to the walls of the sinus; but the chief branches of the internal carotid are to the eyeball and other contents of the orbit, and to the brain.

The *Ophthalmic* branch arises close to the anterior clinoid process, enters the orbit, along with the optic nerve, through the optic foramen and runs forwards and inwards above the optic nerve to end in branches to the nose and forehead. It gives origin to the following branches: *lachrymal*, which runs forwards in relation to the outer side of the roof of the orbit, and supplies the lachrymal gland, conjunctiva, and eyelids: *arteria centralis retinæ*, which passes into the optic nerve, enters the eyeball along with it, and supplies the retina: *ciliary* branches, which accompany the optic nerve and pierce the sclerotic coat to ramify in the choroid coat, ciliary processes, and iris: *muscular* branches to the muscles: *anterior* and *posterior ethmoidal* branches, which pass through the ethmoidal foramina, and supply the adjacent part of the dura mater: *palpebral* branches to the two eye-lids: *nasal* branch to the root of the nose: *supra-orbital* branch, which passes through the supra-orbital notch to the skin and muscles of the forehead: and a *frontal* branch, which is distributed to the forehead, internal to the supra-orbital.

The branches of the internal carotid for the supply of the brain are the middle and anterior cerebral and the posterior communicating.

The *Middle Cerebral* artery extends outwards into the Sylvian fissure, divides into branches in the pia mater, and supplies the island of Reil, the orbital convolutions, the inferior and ascending frontal convolutions, and the convolutions of the parietal and temporo-sphenoidal lobes: it also gives *perforating* branches through the locus perforatus anticus to the corpus striatum, and sends a *choroid* branch to the choroid plexus of the velum interpositum

The *Anterior Cerebral* artery runs forward in the longitudinal fissure, then turns upwards in front of the corpus

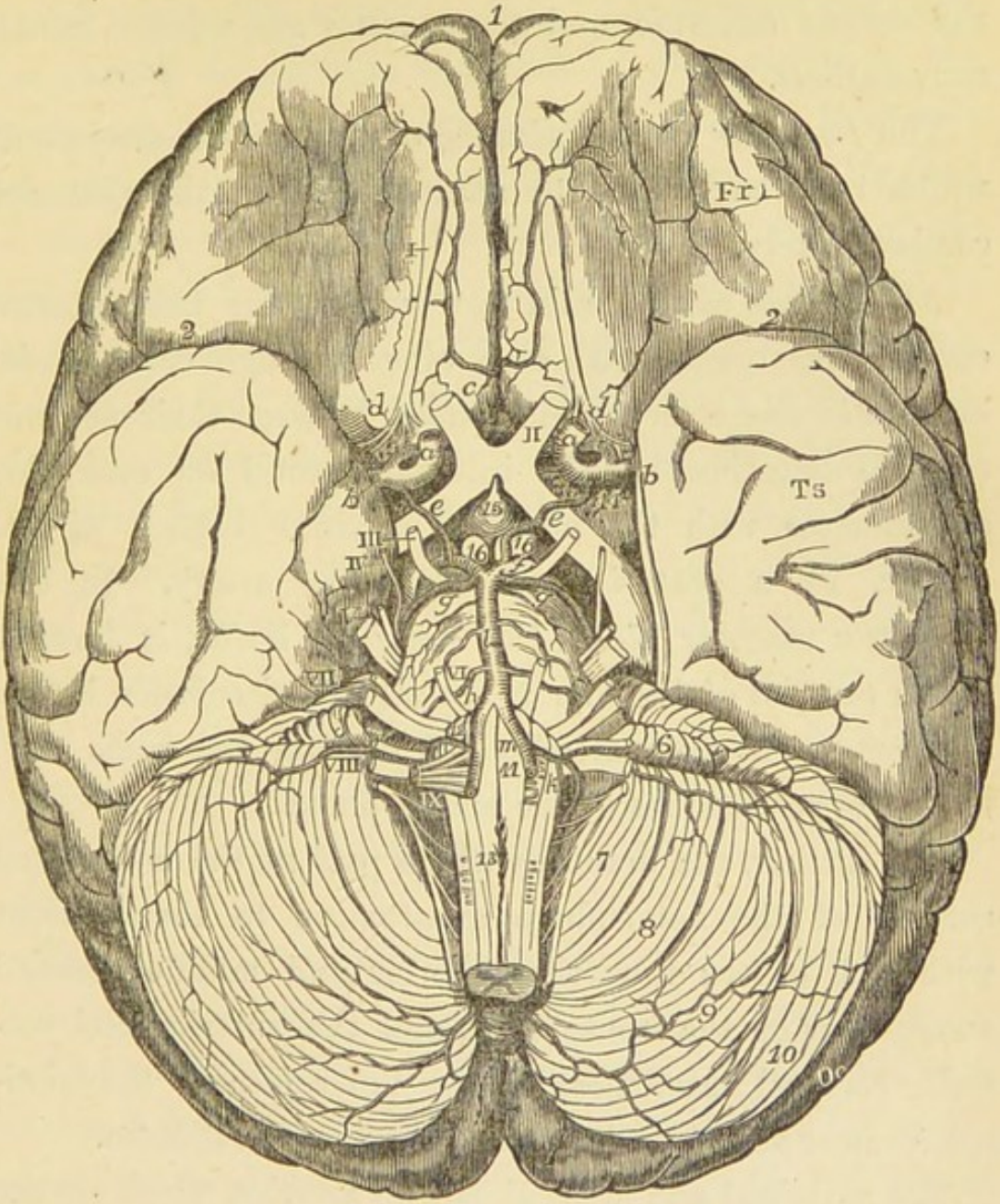

FIG. 127.—Diagram of the base of the Brain with its arteries. I. to IX. cranial nerves; *a a*, internal carotid artery; *b b*, middle cerebral; *c*, anterior communicating; *d d*, anterior cerebral; *e e*, posterior communicating; *f*, posterior cerebral; *g g*, superior cerebellar; *h* and *k*, inferior cerebellar; *l*, basilar; *m*, vertebral artery; *Fr*, frontal lobe; *Ts*, temporo-sphenoidal lobe; *Oc*, occipital lobe; 1, great longitudinal fissure; 2, Sylvian fissure; 6, flocculus; 7, tonsil, 8, postero-inferior; 9, slender; 10, biventral lobes of cerebellum; 11, left anterior pyramid; 12, right olivary body; 13, decussation of the pyramids; 14, left anterior perforated space; 15, tuber cinereum and infundibulum; 16, 16, corpora albicantia.

callosum, and then passes backwards in close relation to its upper surface: it supplies the convolutions of the inner

face of the hemisphere from the anterior end of the frontal lobe as far back as the internal parieto-occipital fissure, also the corpus callosum, and the superior and middle frontal convolutions.

The *Posterior Communicating* artery is a slender branch which runs backwards to anastomose with the posterior cerebral artery.

At the base of the brain not only do the two internal carotids anastomose with each other through the *anterior communicating* artery, which passes between their anterior cerebral branches, but the internal carotid on each side anastomoses with the posterior cerebral branch of the basilar, by a *posterior communicating* artery. In this manner a vascular circle, the *circle of Willis*, is formed, which permits of freedom of the arterial circulation by the anastomoses between arteries not only on the same side, but on opposite sides of the mesial plane.

But further, the branches which pass to the convoluted surface of the hemisphere anastomose to some extent with each other; thus the anterior and middle cerebral anastomose on the frontal lobe, and the anterior and posterior cerebral anastomose on the inner face of the hemisphere near the posterior end of the corpus callosum.

The vertebral and internal carotid arteries, which are the arteries of supply for the brain, are distinguished by lying at some depth from the surface in their course to the organ, by having curves or twists in their course, whereby the force of the flow of blood is retarded, and by the absence of large collateral branches. Further, as the ophthalmic artery is a branch of the internal carotid, the circulation in the eyeball is in sympathy with that in the brain.

The EXTERNAL CAROTID artery is the more superficial of the two terminal branches of the common carotid: it begins opposite the upper border of the thyroid cartilage, and ascends to opposite the neck of the condyle of the lower jaw, where it divides into two terminal branches, the temporal and internal maxillary arteries. At its commencement it lies in the anterior triangular space of the neck internal to the internal carotid artery, overlapped by the sterno-mastoid, and covered by the skin, platysma, and fascia; but as it ascends it reaches a plane superficial to that artery, and is crossed by the hypoglossal nerve and the posterior belly of the digastric and the stylo-hyoid muscles. It then enters the substance of the parotid gland, where it is crossed by the facial nerve and external jugular vein. In the upper part of its course it is separated from the internal carotid artery by the stylo-hyoid ligament, stylo-glossus and pharyngeus muscles, glosso-pharyngeal nerve, and pharyngeal branches of the nervus vagus.

The external carotid gives origin to a number of branches, of which the superior thyroid, lingual, facial, and internal maxillary run forwards and inwards; the occipital and posterior auricular run backwards and outwards; and the ascending pharyngeal and temporal run almost directly upwards.

a. Superior Thyroid artery arises from the external carotid close to its origin; it runs downwards and inwards in relation to the superior cornu of the thyroid cartilage, and ends in the substance of the thyroid body. From it arise a *hyoid* branch, which runs inwards below the hyoid bone: a *sterno-mastoid* branch which runs downwards and

outwards, superficial to the carotid sheath, to supply the sterno-mastoid muscle: a *superior laryngeal* branch, which pierces the thyro-hyoid membrane, along with the superior laryngeal nerve, and supplies the mucous membrane

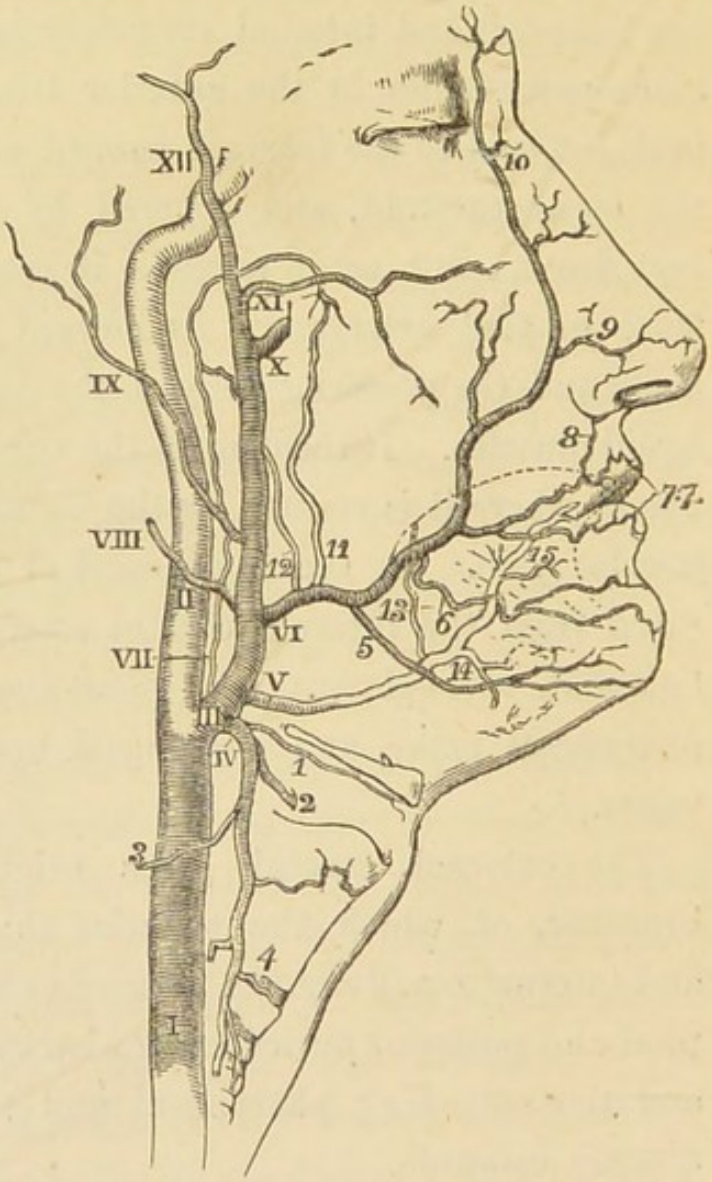

FIG. 128.—Diagram of the Carotid arteries. I. common carotid; II. internal, and III. external carotid; IV. superior thyroid; V. lingual; VI. facial; VII. ascending pharyngeal; VIII. occipital; IX. posterior auricular; X. internal maxillary; XI. transverse facial; XII. temporal. 1, hyoid branch of superior thyroid; 2, superior laryngeal branch; 3, sterno-mastoid branch; 4, terminal branches; 5, submental branch of facial; 6, inferior labial; 7, coronary; 8, septal branch; 9, lateral nasal; 10, angular termination of facial; 11 and 12, tonsillary and ascending palatine branches of facial.

and muscles of the larynx: a *crico-thyroid* branch, which runs inwards superficial to the crico-thyroid membrane, and forms by anastomosing with the opposite crico-thyroid artery an arterial arch. The *terminal thyroid* branches supply the lateral lobe of the thyroid body, and inosculate with the inferior thyroid of the subclavian; a branch also

runs along the upper border of the isthmus to join the opposite superior thyroid.

b. The *Lingual* artery arises just above the superior thyroid artery, and runs upwards and inwards, above the great cornu of the hyoid bone to the under surface of the tongue. It passes between the hyo-glossus and middle constrictor muscles, and then between the mylo-hoid and genio-hyo-glossus, when it assumes the name of *ranine* artery. From it arise a *hyoid* branch, which runs inwards in relation to the upper border of the hyoid bone : a *dorsalis linguæ* branch, which supplies the muscular substance and mucous membrane of the dorsum of the tongue ; this branch is usually represented by a number of small branches : a *sublingual* branch, which supplies the sublingual gland and the adjacent muscles. The *ranine* termination of the lingual artery runs along the under surface of the tongue as far as the tip to supply its muscles and mucous membrane.

c. Facial artery arises above the lingual, but sometimes along with it by a common trunk. It runs upwards and inwards through the digastric triangle, then mounts over the horizontal ramus of the lower jaw, close to the anterior border of the masseter muscle, and ascends in a tortuous manner across the side of the face, close to the angle of the mouth, the angle of the nose, and the inner angle of the eye. It is crossed immediately after its origin by the stylo-hyoid and posterior belly of the digastric muscles, and when in the digastric triangle it is enclosed by the submaxillary gland. On the face it is covered by the platysma and zygomatic muscles, and lies on the buccinator, levator anguli oris, and levator labii superioris. The

artery when on the face is crossed by the branches of the facial nerve, but the facial vein is not in close relation to it. From it arise an *ascending palatine* branch, which ascends between the stylo-glossus and stylo-pharyngeus muscles to supply the wall of the pharynx, tonsil, and soft palate: a *tonsillar* branch to the tonsil and side of the tongue: *glandular* branches to the sub-maxillary gland: a *submental* branch, which runs below the lower jaw to the chin: *posterior facial* branches, which run backwards to the masseteric region: *inferior labial* branch, which runs forward to the skin and muscles of the lower lip: two *coronary* branches, one to run along the free margin of each lip immediately beneath the mucous membrane,—each inosculates with the corresponding artery of the opposite side, and forms an arterial arch, and from the superior coronary arch the *septal* artery ascends to the nasal septum: *lateral nasal*, a branch distributed to the side of the nose. The terminal part of the facial is the *angular* artery, which anastomoses at the inner angle of the orbit with the nasal branch of the ophthalmic artery.

d. Occipital artery arises from the posterior surface of the external carotid, and passes upwards and backwards to the occipital region. It goes under cover of the posterior belly of the digastric, and is crossed by the hypoglossal nerve; it then reaches the mastoid-temporal and occipital bones, where it is covered by the sterno-mastoid, splenius, and often by the trachelo-mastoid muscle, whilst it rests on the complexus and superior oblique. It then passes through the occipital origin of the trapezius, along with the great occipital nerve, and is distributed to the back of the scalp. From it arise a *sterno-mastoid* branch to the

sterno-mastoid muscle: a *meningeal* branch, which ascends through the jugular foramen to the dura mater: *princeps cervicis* branch to the deep muscles of the back of the neck: *occipital* branches to the scalp.

e. Posterior Auricular artery arises from the external carotid in the substance of the parotid gland. It ascends behind the ear, and supplies *auricular* branches to the back of the auricle of the ear; *cranial* branches to the scalp adjacent to the ear: and a *stylo-mastoid* branch, which enters the stylo-mastoid foramen.

f. Ascending Pharyngeal artery arises close to the origin of the external carotid, and ascends in relation to the wall of the pharynx to supply it, the tonsil, and soft palate; its size is in inverse ratio to that of the ascending palatine branch of the facial. It also gives *meningeal* branches through the jugular foramen to the dura mater.

g. Temporal artery, one of the two terminal branches of the external carotid, arises in the parotid gland. It ascends superficially to the root of the zygoma, and in front of the ear to the scalp, where it divides into two branches, an *anterior* and a *posterior temporal* artery, which supply the scalp of the side of the head and the anterior surface of the auricle: in old persons the temporal branches become very tortuous. The temporal artery, whilst in the parotid, gives origin to the *transverse facial* artery, which runs forwards to the face superficial to the masseter, and immediately below the zygoma: the transverse facial sometimes arises directly from the external carotid.

h. Internal Maxillary artery, the larger of the two terminal branches of the external carotid, arises in the substance of the parotid gland, and passes forwards and

inwards under cover of the ascending ramus of the lower jaw as far as the spheno-maxillary fossa, where it divides into six terminal branches. In this course it lies at first below the external pterygoid muscle, and between the jaw and the internal lateral ligament; then it crosses over the external pterygoid, between that muscle and the coronoid insertion of the temporal, though it not unfrequently pierces the external pterygoid, or even goes behind it; and lastly it dips between the two heads of the external pterygoid, and enters the spheno-maxillary fossa. Its branches are numerous, and are usually arranged in three sets.

The first set of branches arise between the jaw and the internal lateral ligament, and in their course enter foramina or fissures in the bones of the head. They are as follows:—*tympanic* branch passes through the Glaserian fissure to supply the mucous membrane of the tympanum: *middle meningeal* branch ascends under cover of the external pterygoid muscle to the foramen spinosum in the ali-sphenoid, and ramifies extensively in the dura mater to supply it and the inner table of the cranial bones; it gives off a *small meningeal* branch, which enters the skull through the foramen ovale: *inferior dental* branch, which accompanies the inferior dental nerve along the dental canal in the lower jaw, and supplies the teeth; when opposite the mental foramen it gives a *mental* branch to the structures of the chin.

The second set of branches arise from the internal maxillary as it lies in contact with the external pterygoid, and are distributed to muscles. They are as follows:—*masseteric* branch to the masseter: *pterygoid* branches to the two pterygoid muscles: *buccal* branch to the bucci-

nator: *deep temporal* branches which enter the deeper surface of the temporal muscle.

The third set of branches arise in the spheno-maxillary fossa, and enter foramina or fissures in the bones of the head. They are as follows:—*superior maxillary* branch runs downwards and forwards on the upper jaw, supplies the gum, and sends *superior dental* branches through small foramina in the upper jaw, which accompany branches of the superior dental nerve to the pulps of the upper teeth: *infra-orbital* branch enters the infra-orbital canal, and emerges on the face, along with the infra-orbital nerve, at the infra-orbital foramen; it supplies the lower eyelid and adjacent parts of the face: *descending palatine* branch runs down the posterior palatine canal along with the descending palatine nerve, and emerges at the posterior palatine foramen on the back of the hard palate to supply the palatal mucous membrane: *spheno-palatine* branch runs inwards to the nose, along with the spheno-palatine nerve, and supplies the nasal mucous membrane; one branch runs down the nasal septum, and appears on the roof of the mouth at the anterior palatine foramen: *vidian* branch passes backwards by the side of the vidian nerve through the vidian canal, and supplies the Eustachian tube and adjacent part of the pharynx: *pterygo-palatine* branch runs backwards, along with the pterygo-palatine nerve, through the pterygo-palatine canal to the roof of the pharynx.

The branches of the external carotid artery may be arranged according to their distribution in five groups:—

1*st*. To thyroid body and larynx: superior thyro artery.

2*d*. To tongue: lingual artery.

3*d*. To palate and face: facial artery.

4*th*. To scalp and auricle: occipital, posterior auricular and temporal arteries.

5*th*. To pharynx, palate, deep parts of face, teeth, nose, and membranes of brain: ascending pharyngeal and internal maxillary arteries.

Important anastomoses take place not only between the branches of the carotid arteries, but also between them and those of the subclavian. The principal anastomoses may be arranged as follows:—

1*st*. Between the external and internal carotids of the same side: *a*, temporal with supra-orbital and frontal; *b*, angular termination of facial with nasal branch of ophthalmic.

2*d*. Between branches of external carotid of the same side: *a*, temporal with posterior auricular and occipital; *b*, facial with transverse facial and with buccal, infra-orbital and mental branches of internal maxillary; *c*, ascending palatine of facial with ascending pharyngeal, and with descending palatine of internal maxillary.

3*d*. Between branches of external carotids of opposite sides: *a*, facial with facial; *b*, temporal with temporal; *c*, occipital with occipital; *d*, superior thyroid with superior thyroid.

4*th*. Between branches of internal carotids of opposite sides: anterior cerebral with anterior cerebral, through the anterior communicating.

5*th*. Between the subclavian and external carotid of the same side: *a*, deep cervical with princeps cervicis of occipital; *b*, vertebral with occipital; *c*, inferior thyroid with superior thyroid.

6th. Between the subclavian and internal carotid of the same side: vertebral through the basilar and posterior cerebral with the posterior communicating of the internal carotid.

7th. Between branches of subclavians of opposite sides. The two vertebrals with each other to form the basilar artery.

The anastomoses of the branches of the external and internal carotid with those of the subclavian enlarge, and form secondary channels for the conveyance of blood to the face, head, and the upper part of the neck when the common carotid artery is obstructed by the application of a ligature.

FOURTH GROUP—BRANCHES OF THE AORTA FOR THE LOWER LIMBS AND PELVIS.

This group consists of the iliac system of arteries, which are produced by the so-called bifurcation of the abdominal aorta.

Iliac System of Arteries.

This system is composed of the arteries of supply for the pelvis and lower limb, and consists of the common iliac, the external and internal iliac arteries and their several branches.

The COMMON ILIAC artery springs from the abdominal aorta, at its so-called bifurcation, opposite the body of the fourth lumbar vertebra. It passes downwards and outwards for about two inches, and bifurcates opposite the side of the lumbo-sacral joint into the external and internal

iliac arteries. Each common iliac lies behind the peritoneum covering the posterior wall of the abdomen, and is overlapped by the small intestine. Each is crossed by the ureter and the branches of the sympathetic cord to the hypogastric plexus, and the left in addition by the inferior mesenteric vessels. Each is in front of the bodies of the two lower lumbar vertebræ, but the two common iliac veins are interposed between the right artery and the last lumbar vertebra, whilst the left common iliac vein lies below its corresponding artery. No collateral branches arise from the common iliac.

The EXTERNAL ILIAC artery is the commencement of the great arterial trunk for the lower limb; it is the larger of the two branches of bifurcation of the common iliac, and passes downwards and outwards within the cavity of the abdomen as far as Poupart's ligament, where it becomes the femoral artery. It lies behind the peritoneum covering the posterior wall of the abdomen, and is overlapped by the intestines. It rests on the fascia covering the inner border of the psoas muscle close to the pelvic inlet. The external iliac vein lies behind the upper end of the artery, but on the same plane and internal to its lower end, where it receives the deep circumflex iliac vein, which crosses in front of the artery. The genito-crural nerve is at first external and then anterior to it; lymphatic glands and vessels run close to its anterior and inner aspects. Its only branches are distributed to the muscles of the abdominal wall, and are as follows :—

a. Deep Epigastric artery arises just above Poupart's ligament and ascends, immediately to the inner side of the internal or deep abdominal ring, to the anterior wall of the

abdomen between the fascia transversalis and the peritoneum; it then enters the sheath of the rectus abdominis, and, continuing to ascend, supplies that muscle and inosculates with the superior epigastric branch of the internal mammary artery. As it lies to the inner side of the internal or deep abdominal ring, the vas deferens, which passes through the ring in its course to the pelvis, turns behind the artery. It gives off *transverse* branches, which pass outwards to inosculate with the lower aortic intercostal, lumbar, and deep circumflex iliac arteries: a *cremasteric* branch to the coverings of the spermatic cord; a *pubic* branch runs inwards to the back of the pubes, inosculates with the obturator artery, and sometimes enlarges so as to form the origin of the obturator artery.

b. Deep Circumflex Iliac artery arises from the external iliac close to Poupart's ligament: it runs outwards behind that ligament to the iliac crest, supplies the muscles attached to the crest, also the iliacus, and inosculates with the lumbar, ilio-lumbar, and deep epigastric arteries.

The FEMORAL artery is the direct continuation of the external iliac: it commences at Poupart's ligament, runs down the anterior and inner aspects of the thigh, as far as the opening in the tendon of the adductor magnus muscle, where it becomes the popliteal artery. In this course the artery passes at first through the triangular space of Scarpa, from the middle of its base to its apex, and is covered by the skin, superficial fascia, and fascia lata, but at the base of the triangle it has an additional investment from the femoral sheath. Near the apex of Scarpa's triangle the artery goes under cover of the sartorius muscle, behind which it descends to its termination. For about three

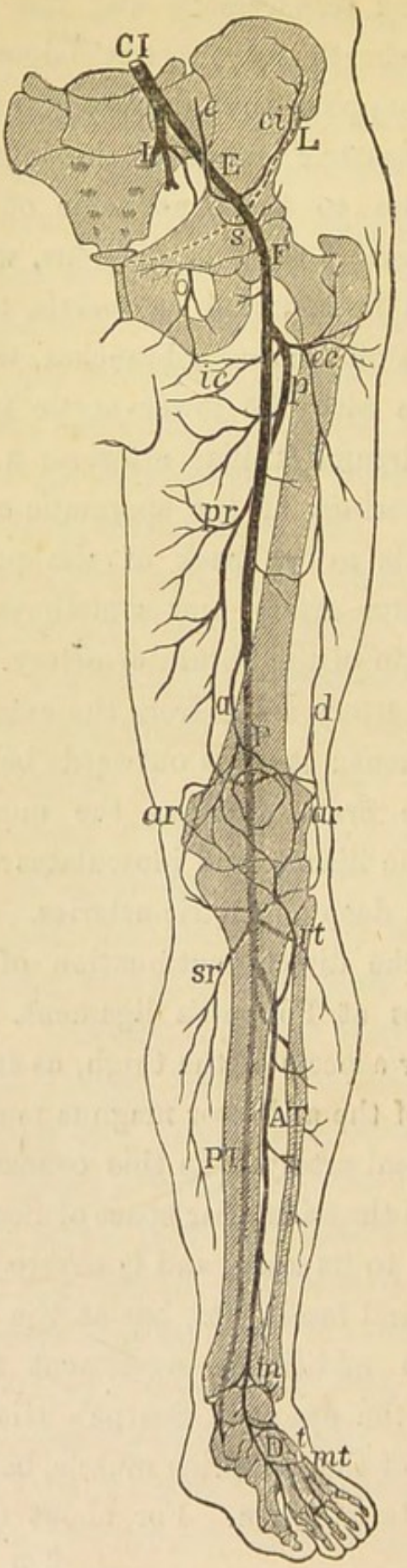

FIG. 129.—The Arteries of the Lower Limb. CI, common iliac; I, internal iliac, and E, external iliac artery; F, femoral artery; P, popliteal; PT, posterior tibial; AT, anterior tibial artery; D, dorsal artery of foot; *e*, deep epigastric, and *ci*, deep circumflex iliac arteries; *o*, obturator artery: *s*, superficial branches of femoral; *p*, profunda artery; *ec*, external circumflex; *ic*, internal circumflex, and *pr*, perforating series of branches; *a*, anastomotic artery; *d*, descending branch of external circumflex; *ar ar*, articular arteries; *rt*, recurrent tibial branch; *sr*, sural branch; *m*, malleolar arteries; *t*, tarsal, and *mt*, metatarsal branches: L, Poupart's ligament.

inches above the opening in the tendon of the adductor magnus it lies in Hunter's canal—a canal bounded externally by the tendon of the vastus internus, posteriorly by the tendons of the adductor longus and magnus, and anteriorly by a fibrous prolongation from the tendon of the vastus to those of the two adductors. When in this canal the artery is in close relation to the inner surface of the middle third of the femur. Close to the apex of Scarpa's triangle it is in relation to the inner border of the sartorius muscle, which forms a definite guide to the position of the artery. Behind the artery is the psoas muscle, by which it is separated from the capsule of the hip joint and the head of the thigh bone; lower down the artery is in front of the pectineus, but separated from it by the deep femoral vessels, and still lower the artery has the tendons of the adductor longus and magnus posterior to it. The femoral vein is at first on the same plane and internal to the artery, and is enclosed along with it and the femoral lymphatics in the femoral sheath; about the apex of Scarpa's triangle the vein sinks behind the artery, and remains posterior to it as far as the popliteal space. The long saphenous vein is superficial, and to the inner side of the artery, and separated from it by the fascia lata. The anterior crural nerve is to the outer side of the artery near the base of Scarpa's triangle; of its several branches the internal cutaneous nerve crosses the artery near the apex of the triangle: the internal saphenous accompanies the artery into Hunter's canal, but when the artery leaves the canal to enter the popliteal space, the nerve perforates its fibrous wall, and becomes cutaneous near the inner side of the knee joint. The branches of the femoral artery are as follows:—

As the artery lies in the femoral sheath, it gives origin to three superficial branches, which pierce the fascia lata, and end in the skin, superficial fascia, and lymphatic glands of the groin.

a. Superficial Circumflex Iliac, which runs outwards to the anterior superior iliac spine.

b. Superficial Epigastric, which ascends in front of Poupart's ligament to the wall of the abdomen.

c. Superficial Pudic usually consists of two branches—a superior and an inferior, which run inwards and end in the skin of the external organs of generation.

d. Muscular branches small in size, which run outwards into the muscles of the thigh.

e. Anastomotic arises near the lower end of Hunter's canal; it divides into three branches: a *cutaneous*, which runs along with the long saphenous nerve behind the sartorius to the inner side of the knee: a *muscular*, which passes into the substance of the vastus internus, and is distributed as low down as the knee: an *articular*, which descends directly to the knee on the tendon of the adductor magnus inserted into the internal femoral condyle.

The largest and most important branch of the femoral is

f. The *Profunda*, or *Deep Femoral* artery, which arises in Scarpa's triangle from the posterior and outer part of the femoral from one and a half to two inches below Poupart's ligament. It descends behind the femoral artery and the tendon of the adductor longus, and pierces the substance of the adductor magnus muscle. It has the iliacus, psoas, pectineus, adductor brevis and adductor magnus muscles behind it, and the femoral and profunda veins lie between it and the femoral artery. From it arise the following

branches: *external circumflex*, which passes outwards behind the rectus and sartorius and between the branches of the anterior crural nerve to divide into ascending, transverse and descending branches; the *ascending* passes under the tensor fasciæ femoris to anastomose with the gluteal artery; the *transverse* enters the substance of the vastus externus, and the *descending* passes downwards and outwards on and in the vastus externus, partly to supply that muscle, and partly to reach the outer side of the knee. Sometimes the external circumflex arises directly from the femoral, and sometimes its ascending, or its ascending and transverse branches arise from the femoral, whilst the descending branch springs as an independent branch from the profunda. The *internal circumflex* arises from the inner side of the profunda opposite the origin of the external circumflex: it runs backwards first between the psoas and pectineus, then between the adductor brevis and obturator externus, then between the adductor magnus and quadratus femoris to reach the back of the thigh; it supplies the muscles between which it passes, also the hip joint. The *perforating* branches, usually three in number, and named, from above downwards, *first*, *second*, and *third perforating*, pass to the back of the thigh to supply the hamstrings; the first and second pierce the short and great adductors. The second perforating gives origin to the small *nutrient* artery which enters the nutrient canal in the femur to supply the medulla of the bone. The *terminal* part of the profunda, sometimes called the *fourth perforating* artery, not only supplies the adductor magnus, but gives branches to the short head of the biceps.

The branches which arise either directly or indirectly

from the femoral artery may be arranged according to their distribution as follows :—

1*st.* To glands, fat, and skin of groin : superficial pudic, epigastric and circumflex iliac arteries.

2*d.* To muscles : muscular branches, profunda artery.

3*d.* To bone : nutrient artery.

4*th.* To hip joint : external and internal circumflex arteries.

5*th.* To knee joint : anastomotic and descending branch of external circumflex artery.

The profunda artery with its branches is the great muscular artery of the thigh. Occasionally in the upper limb an arrangement similar to the profunda in the thigh occurs, when the circumflex, subscapular, superior and inferior profunda arteries arise by a common trunk from the axillary artery.

By some descriptive writers the part of the femoral prior to the origin of the profunda is called common femoral ; which is then said to divide into a superficial femoral and a deep femoral artery, the deep femoral being looked upon therefore as a terminal branch of bifurcation, and not as a large collateral branch.

The POPLITEAL artery is the direct continuation of the femoral artery ; it commences at the opening in the adductor magnus, passes down the popliteal space, or ham, as far as its inferior angle, and reaches the lower border of the popliteus muscle, where it divides into two terminal branches, the anterior and posterior tibial arteries. It lies immediately behind the back of the lower end of the femur, the posterior ligament of the knee joint, and the popliteus muscle, so that it is in close relation to the floor of the popliteal space, and is separated from the surface of

the back of the limb by a considerable interval. To its outer side in the upper half of the space is the biceps, and in the lower half the outer head of the gastrocnemius and the plantaris. It enters the space by passing in front of the semi-membranosus, and then has that muscle with the semi-tendinosus to its inner side in the upper half of the space, and the inner head of the gastronemius in its lower half : as the two heads of the gastrocnemius approach each other at the lower angle of the space they overlap the artery. The popliteal vein lies immediately posterior to the artery, at its upper part being a little to its outer side, at its lower part a little to its inner side. The internal popliteal nerve is also posterior to the artery, but nearer to the surface of the region ; like the vein it is at first somewhat external, but in the lower part of the region it lies to the inner side of the artery.

The branches of the popliteal artery are distributed to the knee joint, to the muscles around it, and to the skin of the popliteal space.

a. Superior Muscular pass to the lower end of the hamstring muscles.

b. Inferior Muscular or *Sural*, to the heads of the gastrocnemius and to the plantaris.

c. Superior Internal Articular turns round the femur above the inner condyle, and under cover of the adductor magnus tendon and the inner hamstrings, to reach the inner side of the knee.

d. Superior External Articular turns round the femur immediately above the outer condyle, and under cover of the biceps to reach the outer side of the knee.

e. Inferior Internal Articular runs inwards below the

internal tuberosity of the tibia and under cover of the internal lateral ligament to the inner side of the knee.

f. Inferior External Articular runs outwards under the outer head of the gastrocnemius and the external lateral ligament, and above the head of the fibula to the outer side of the knee.

q. Azygos Articular pierces the posterior ligament of the knee, and is distributed to the crucial ligaments and synovial membrane.

h. Cutaneous branch or branches arise either from the popliteal or from its muscular arteries to supply the skin of the popliteal space and calf of the leg.

The ANTERIOR TIBIAL artery is the smaller of the two terminal branches of the popliteal. It passes at first directly forwards between the tibia and fibula, then descends on the front of the leg as far as the front of the ankle, where it becomes the dorsal artery of the foot. As it passes forwards it lies above the upper end of the tibialis posticus and the interosseous membrane. On the front of the leg it rests on the front of the interosseous membrane for about its upper two-thirds, but for the rest of its course on the front of the tibia. In the upper part of the leg it is deeply placed between the muscles, with the tibialis anticus on its inner side, and the extensor communis digitorum and extensor longus hallucis on its outer side. Above the ankle, where it rests on the tibia, it is covered by the anterior annular ligament of the fascia of the leg, and is crossed by the tendon of the extensor longus hallucis. It is accompanied by the two venæ comites, and the anterior tibial nerve lies in close relation to it. Its branches are as follows :—

a. Muscular to the muscles of the front of the leg.

b. Recurrent Tibial Articular arises as soon as the anterior tibial has passed to the front of the leg, and ascends in the substance of the tibialis anticus to the knee.

c. External Malleolar runs outwards to the region of the external malleolus, behind the long extensor of the toes.

d. Internal Malleolar runs inwards to the region of the internal malleolus behind the tibialis anticus. The malleolar arteries supply the ankle joint.

The DORSAL ARTERY OF THE FOOT is a direct continuation of the anterior tibial artery; it runs forwards from the front of the ankle to the first metatarsal space, where it enters the sole of the foot to join the external plantar artery and assist in the formation of the plantar arch. It rests on the inner row of tarsal bones and lies between the extensor longus hallucis and the extensor communis digitorum; it is crossed by the innermost tendon of the extensor brevis digitorum, and is covered by the skin and fascia of the dorsum of the foot. It is accompanied by two venæ comites, and the anterior tibial nerve is immediately to its outer side. Its branches are as follows:—

a. Tarsal branch runs outwards under cover of the extensor brevis digitorum to supply it and the tarsal joints.

b. Metatarsal branch arises in front of the tarsal, and passes outwards under cover of the extensor brevis. It supplies the tarso-metatarsal joints, and gives off *interosseous* branches to the three outer interosseous spaces to supply the dorsal interossei muscles, which branches are prolonged on the dorsum of the toes.

c. Marginal branches to the skin of the inner border of the foot.

d. Dorsalis Hallucis arises as the artery dips into the first metatarsal space, and runs along the dorsal surface of the great toe.

e. First Digital branch arises in the sole and runs along the inner border of the plantar surface of the great toe.

f. Second Digital branch also arises in the sole, and dividing into two, supplies the adjacent sides of the great and second toes.

The Posterior Tibial artery is the larger of the two terminal branches of the popliteal, and continues the course of that artery down the back of the leg as far as the inner ankle, where it divides into its two terminal branches, the internal and external plantar arteries. In the upper two-thirds of its course, it is placed deeply in the limb under cover of the great muscles of the calf, but in the lower third it lies to the inner side of the tendo Achillis, and is covered by the skin and fasciæ; immediately prior to its termination, however, it passes under cover of the origin of the abductor hallucis. It rests from above downwards on the tibialis posticus, flexor longus digitorum, the tibia, and ankle joint; at the inner ankle it has the tendons of the tibialis posticus and flexor longus digitorum between it and the inner malleolus, and the tendon of the flexor longus hallucis to its outer or calcaneal side. It is accompanied by two venæ comites. The posterior tibial nerve is at first to its inner side, and then crosses behind to descend on the outer side of the artery. Its branches are as follows :—

a. Muscular branches to muscles of back of leg.

b. Nutrient branch to shaft of tibia.

c. Calcaneal branch to skin of heel.

d. Peroneal, a large branch, which descends under cover of the soleus and flexor longus hallucis, and in close relation to the fibula as far as the lower end of the leg when it passes to the outer ankle, where it terminates. It supplies *muscular* branches to the muscles of the back and outer side of the leg: a *nutrient* branch to the fibula: an *anterior peroneal* or *perforating* branch pierces the interosseous membrane, and descends to the outer side of the front of the ankle: a *communicating* branch runs transversely behind the lower end of the tibia, and joins the posterior tibial artery. It is not uncommon to find the peroneal artery much larger than the posterior tibial is below the origin of the peroneal, in which case the communicating branch is also enlarged, and through it the blood flows into the lower end of the tibial and the plantar arteries.

The INTERNAL PLANTAR artery is the smaller of the two terminal branches of the posterior tibial artery. It passes forwards close to the inner border of the sole of the foot as far as the root of the great toe, and is accompanied by the internal plantar nerve; it is covered by the abductor hallucis muscle. It supplies *marginal* branches to the skin of the inner border of the foot, and *muscular* branches to the abductor hallucis and flexor brevis digitorum.

The EXTERNAL PLANTAR artery, the larger of the two terminal branches of the posterior tibial, inclines forwards and outwards from the inner ankle as far as the base of the fifth metacarpal bone, and is accompanied by the external plantar nerve; it then runs inwards and forwards through the deepest part of the sole as far as the first metatarsal space, where it joins the dorsal artery of the foot, and forms

the PLANTAR ARTERIAL ARCH. The artery is at first covered by the skin, plantar fascia, and abductor hallucis, and rests on the os calcis, it then passes between the flexor brevis digitorum and musculus accessorius, and when it runs forwards

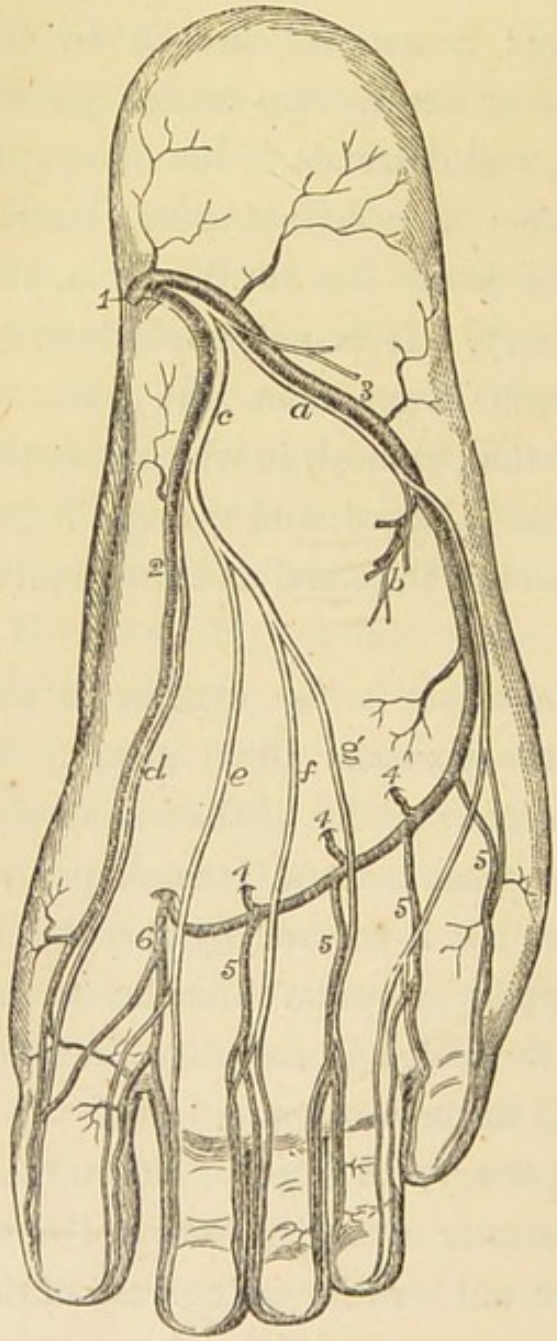

FIG. 130.—Outline Diagram of the Plantar arteries and nerves. 1, Posterior tibial artery; 2, internal plantar; 3, external plantar; 4, 4, 4, posterior perforating branches; 5, 5, 5, 5, digital branches; 6, dorsal artery of foot appearing in the sole; *a*, external plantar nerve; *b*, its deep branch; *c*, internal plantar nerve; *d*, *e*, *f*, *g*, its digital branches.

and inwards in the deep part of the sole, it is covered by the flexor tendons, the lumbricales and the adductor hallucis, and it rests on the metatarsal bones and the interossei

muscles. It supplies a *cutaneous* branch to the skin of the heel: *muscular* branches to the muscles of the sole: *marginal* branches to the skin of the outer border of the foot. From the plantar arch arise three *posterior perforating* branches, which pass between the heads of the dorsal interossei muscles and inosculate with the interosseous branches of the metatarsal artery: four *digital* branches, of which the *first* supplies the outer side of the little toe; whilst the *second*, *third*, and *fourth* divide at the clefts between the toes, and supply the contiguous borders of the fifth and fourth, fourth and third, third and second toes; from the digital arteries *anterior perforating* branches pass at the clefts between the toes to the dorsum of the foot, to inosculate with the branches of the metatarsal artery prolonged on to the dorsum of the toes.

The INTERNAL ILIAC artery, the smaller of the two terminal branches of the common iliac, commences at the lumbo-sacral joint, sinks into the cavity of the pelvis, and after a course of about one inch and a half, divides opposite the great sacro-sciatic foramen into several branches. It lies behind the peritoneum, and is crossed by the ureter. It is in front of the psoas, the upper origin of the pyriformis, the internal iliac vein and the lumbo-sacral nerve, and at its termination is situated in the loose areolar tissue which separates the peritoneum from the pelvic fascia.

In the fœtus the internal iliac artery is a more important vessel than it is after the birth of the child, for by it the impure blood of the fœtus is conveyed to the placenta. Accordingly it does not end in the pelvis, but runs along the side of the upper part of the bladder, and the back of the anterior wall of the abdomen as far as the

umbilicus, under the name of the *hypogastric* artery. At the umbilicus it passes out of the abdomen, forms one of the constituents of the umbilical cord, and is called the *umbilical* artery. When the child is born the function of the hypogastric artery ceases, and it shrivels up into a

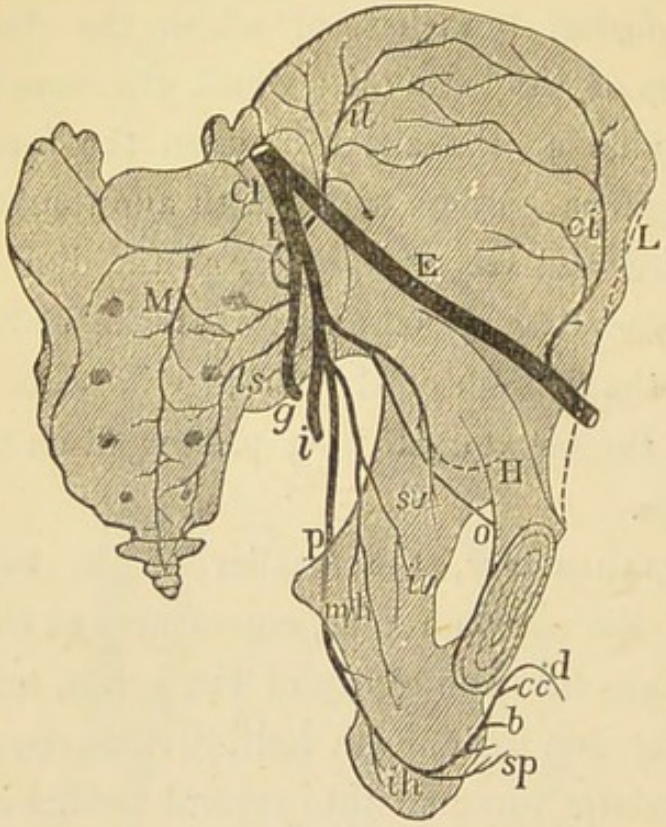

FIG. 131—Diagram of the Internal Iliac artery. CI, common iliac; E, external, and I, internal iliac; H, obliterated hypogastric. M middle sacral artery. *ci*, deep circumflex iliac artery; *i l*, ilio-lumbar; *ls*, lateral sacral; *g*, gluteal; *i*, ischiatic; *o*, obturator; *sv*, superior vesical; *iv*, inferior vesical; *mh*, middle hæmorrhoidal; *p*, pudic; *ih*, inferior hæmorrhoidal; *sp*, superficial perineal; *b*, artery to bulb; *cc*, artery to corpus cavernosum; *d*, dorsal artery of penis. L, Poupart's ligament.

fibrous cord, which may be seen in the adult on the side of the bladder and on the wall of the abdomen.

It is customary to speak of the internal iliac artery as terminating in the adult in two divisions, from each of which particular branches arise, but as these branches are variable in their origin, it is better to arrange them according to their distribution into five groups of branches. 1st, to viscera of pelvis: superior and inferior vesical and middle hæmorrhoidal. 2d, to walls of pelvis: lateral sacral, ilio-lumbar. 3d, to external organs of generation: in-

ternal pudic. 4th, to muscles of buttock: gluteal and sciatic. 5th, to hip-joint and external obturator muscle: obturator

a. Superior Vesical artery arises from the beginning of the hypogastric portion of the internal iliac artery, which has not altogether become obliterated; it passes to the upper part of the bladder, which it supplies; it gives a branch to the vas deferens.

b. Inferior Vesical artery runs to the lower part of the bladder, supplies it and the vesiculæ seminales; one branch, also passes to the side of the prostate gland. From its distribution to the prostate, this branch is sometimes called the *vesico-prostatic* artery.

c. Middle Hæmorrhoidal artery supplies a portion of the rectum in relation to the base of the bladder. It is often a branch of the inferior vesical artery.

In the female, from the absence of the vesiculæ seminales and prostate, the corresponding branches are absent; but in their stead are two arteries not present in the male, viz., a *Uterine* branch, which reaches the neck of the uterus, and ascends between the two layers of the broad ligament, to supply the uterus; also, a *Vaginal* branch, which is distributed to the walls of the vagina, the bladder, and rectum.

d. Lateral Sacral artery usually consists of two branches which pass to the front of the sacrum, supply the pyriformis muscle, and send twigs into the sacral canal through the anterior sacral foramina.

e. Ilio-lumbar artery passes outwards behind the psoas into the iliac fossa, where it divides into a *lumbar* branch, which ascends to supply the muscles of the loins, and an *iliac* branch, which supplies the iliacus and gives a *nutrien*

branch to the ilium through the nutrient foramen in its ventral surface.

f. Internal or *Deep Pudic* artery pierces the pelvic fascia, passes out of the pelvis through the great sacro-sciatic foramen, and appears in the buttock below the pyriformis muscle, where it lies on the spine of the ischium. It then goes through the small sacro-sciatic foramen, runs forwards along the outer wall of the ischio-rectal fossa, in close relation to the inner surface of the obturator internus muscle, and ensheathed by the obturator or parietal layer of the pelvic fascia; it continues its course forwards behind the triangular ligament of the urethra, and in close relation to the side of the pubic arch, then pierces the triangular ligament, and terminates by dividing into the dorsal artery of the penis and the artery for the corpus cavernosum. It is accompanied by the deep pudic vein, and the pudic nerve. Its branches are as follows: *inferior hæmorrhoidal* arises in the outer wall of the ischio-rectal fossa, passes through the fat in that fossa, and is distributed to the lower end of the rectum, the sphincter ani, and the skin around the anus: *superficial perineal* arises in the outer wall of the ischio-rectal fossa, and runs forwards to supply the fascia and skin of the scrotum: *transverse perineal*, a small branch to the structures between the anus and the bulb of the urethra: *artery of the bulb*, a short but important artery which arises behind the triangular ligament of the urethra, passes transversely or obliquely inwards, then pierces the ligament to enter the back of the bulb; sometimes the artery of the bulb arises nearer the ischio-rectal fossa, and runs very obliquely forwards in order to reach the bulb; were the lateral operation of

lithotomy to be performed in such a case the artery would in all probability be cut through: *artery* of the *corpus cavernosum* enters the crus penis, and is distributed in the erectile structure of the corpus cavernosum penis: *dorsal artery* of the penis pierces the suspensory ligament of the penis, runs forward in the subcutaneous fascia on the dorsum of the organ, sends branches into the corpus cavernosum, and ends in the glans penis and prepuce.

In the female the internal pudic artery is much smaller than in the male, owing to the small size of the clitoris as compared with the penis. It gives off a similar set of branches, but the *superficial perineal* is distributed to the labium, the *artery to the bulb* supplies the bulbus vestibuli, and the *terminal* branches supply, the one the crus and corpus cavernosum of the clitoris, the other the dorsum and glans of the clitoris.

g. Gluteal artery, the largest branch of the internal iliac, pierces the pelvic fascia, and passes out of the pelvis through the great sacro-sciatic foramen in close relation to its upper or iliac boundary, and appears in the buttock immediately above the pyriformis muscle, where it divides into a superficial and a deep branch. The *superficial* branch runs between the gluteus medius and maximus, and enters the maximus to supply the upper portion of that muscle. The *deep* branch divides into two parts, one curves outwards along the border of attachment of the the gluteus minimus to the superior curved line, the other runs straight between the gluteus medius and minimus muscles, along with the superior gluteal nerve; both divi sions of the deep branch reach the tensor fasciæ femoris

muscle, and supply it and the gluteus medius and minimus.

h. Sciatic artery pierces the pelvic fascia, and passes out of the pelvis through the great sacro-sciatic foramen, and appears in the buttock, immediately below the pyriformis muscle, along with the great and small sciatic nerves. It gives off a *coccygeal* branch, which pierces the great sciatic ligament, supplies the origin of the gluteus maximus muscle from that ligament, and ends in the skin about the coccyx: a *comes nervi ischiatici*, a small branch, which accompanies the great sciatic nerve; *terminal* branches, which for the most part end in the lower half of the gluteus maximus, though some snpply the rotator muscles in the buttock. Not unfrequently the sciatic and pudic arteries arise from the internal iliac by a common trunk, which divides as it enters the buttock into the two arteries.

i. Obturator artery passes forwards between the peritoneum and pelvic fascia, along the side wall of the pelvis as far as the upper part of the obturator foramen, through which it passes into the thigh, where it divides into its terminal branches. It gives off in the pelvis a *pubic* branch, which anastomoses with the pubic branch of the deep epigastric artery. The *terminal* branches pass to the obturator externus, gracilis, and adductor muscles, and a branch enters the hip joint through the cotyloid notch. The obturator artery varies in its origin. In 361 cases examined by R. Quain, it arose in two-thirds from the internal iliac: in one case out of three-and-a-half from the deep epigastric; in a very small proportion, partly from the internal iliac, and partly from the epigastric, and in an

equally small proportion from the external iliac artery. Its origin from the epigastric is due to a great increase in the size of the pubic branch of that artery. When the obturator arises from the epigastric it enters the pelvis behind its pubic wall, and in its course passes usually to the outer side of, more seldom to the front and inner side of the crural ring; a point to be kept in mind in connection with the anatomy of the parts concerned in femoral hernia.

Important anastomoses take place not only between branches belonging to the iliac system of arteries, but between some of these branches and those of other arteries.

In the wall of the abdomen, as already described, the deep epigastric and circumflex iliac of the external iliac, and the ilio-lumbar of the internal iliac, anastomose with the internal mammary of the subclavian, and with the lower intercostal and lumbar branches of the aorta. At the sacral wall of the pelvis, the lateral sacral of the internal iliac anastomoses with the middle sacral of the aorta, and with the superior hæmorrhoidal termination of the inferior mesenteric artery. At the anterior wall of the pelvis behind the os pubis, the pubic branch of the deep epigastric anastomoses with the pubic branch of the obturator.

In the lower limb the following inosculations take place around the hip joint: in the buttock and region of the trochanter major the gluteal and sciatic branches of the internal iliac with the external and internal circumflex branches of the profunda; in the region of the trochanter minor the obturator of the internal iliac with the internal circumflex of the profunda. These inosculations enlarge and form

secondary channels for conveying the blood to the lower limb when the external iliac artery is tied. In the substance of the thigh, more especially in the hamstring and adductor magnus muscles, the several perforating branches of the profunda anastomose with each other, with the circumflex branches of the profunda, with the comes nervi ischiatici branch of the sciatic, and with the superior muscular branches of the popliteal. These anastomoses enlarge and form secondary channels when the femoral artery is tied. Around the knee joint the five articular branches of the popliteal anastomose with each other, with the anastomotic branch of the femoral, with the descending branch of the external circumflex, and with the recurrent articular branch of the anterior tibial. In the front of the leg the muscular branches of the anterior tibial anastomose with each other. In the back of the leg the muscular branches of the posterior tibial and peroneal inosculate with each other, and the communicating branch of the peroneal with the posterior tibial. Around the ankle joint the internal and external malleolar branches of the anterior tibial inosculate with the anterior perforating and terminal branches of the peroneal, and with the tarsal branch of the dorsal artery of the foot. In the foot itself the dorsal artery inosculates with the external plantar artery to form the plantar arterial arch; its tarsal and metatarsal branches inosculate not only with each other, but at the outer border of the foot with the marginal branches of the external plantar, and at the inner border of the foot with the marginal branches of the internal plantar artery. The perforating branches of the plantar arch inosculate with the interosseous and digital branches of the metatarsal arte-

ries, and the collateral arteries to each toe anastomose with each other on the plantar aspect of the terminal phalanx.

Structure of the Arteries.

As a general rule, each artery is surrounded by a *sheath*, formed of connective tissue, which is attached to the outer wall of the artery by slender fibres, and the attachment is so loose, that when the artery is cut across it retracts within its sheath. The wall of the artery consists of several coats, which are distinguished from each other not only by differences in the direction of the fibres of which they are composed, but by structural differences. Some

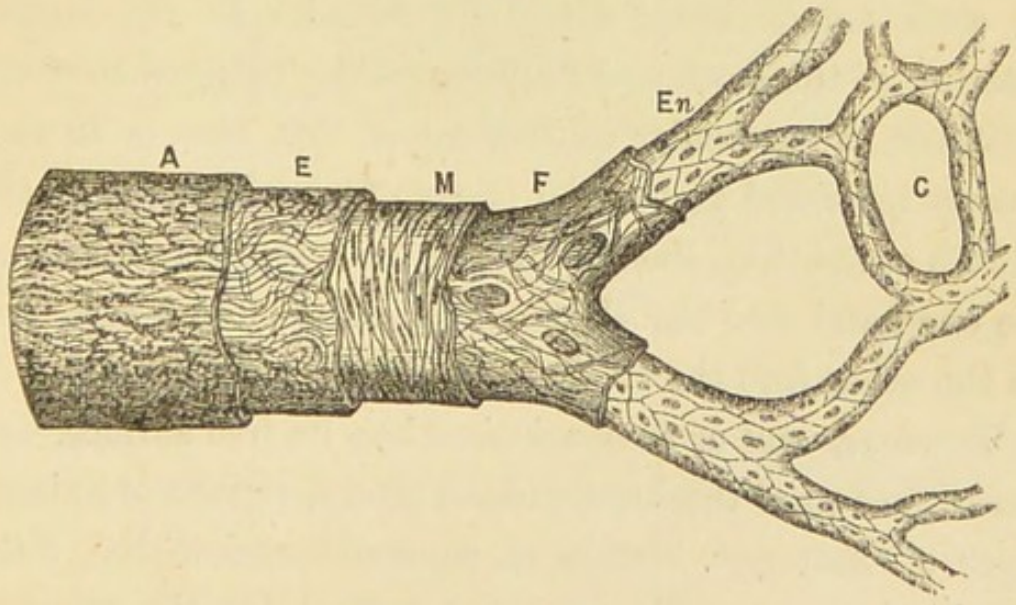

FIG. 132.—Diagram of the Structure of an Artery. A, tunica adventitia; E, elastic layer; M, muscular coat; F, fenestrated layer; En, endothelium continuous with the endothelial wall of C, the capillaries.

anatomists name these coats outer, middle, and inner, but others apply to them the names of fibrous coat, elastic coat, muscular coat, fenestrated coat, and endothelial coat, a nomenclature based on their structural characters.

The *outer* coat of the artery, or *tunica adventitia*, consists of interlaced bundles of white fibrous tissue mingled with elastic fibres. In the larger arteries, the proportion of elastic tissue increases in the deeper part of this coat, so as to form an *elastic layer*. In some arteries, as the aorta, splenic, and renal arteries, bundles of non-striped muscular fibre arranged longitudinally or obliquely, have been described in the deeper part of the outer coat.

The *middle* coat consists in medium-sized arteries chiefly of non-striped muscular fibres, arranged transversely to the long axis of the artery, so that this coat is sometimes named the *circular* or *muscular* coat. The muscular coat forms several layers, which may be peeled asunder. Between the layers, as well as between the muscular fibres in each layer, elastic fibres are found. In the largest arteries, as the aorta and pulmonary, the proportion of the elastic to the muscular constituent of this coat is so very greatly increased as to form layers of elastic tissue in the middle coat. The elastic fibres of the middle coat pass on the one hand into the elastic layer of the outer coat, and on the other into the elastic layer of the inner coat.

The *inner coat* or *tunica intima* has its free surface, *i.e.*, the surface next the lumen of the artery, formed of a single layer of flattened, elongated, squamous endothelial cells, which give a smooth glistening surface for the blood to flow over. Outside the endothelium is an extra-endothelial layer, consisting of a delicate connective tissue in which stellate corpuscles are situated : outside this layer is the elastic or fenestrated layer, which forms the chief thickness of the inner coat. The *fenestrated* layer consists of an elastic membrane, which may be slit up into several strata.

It contains a network of elastic fibres, with spaces or perforations in it, which give it a fenestrated appearance. The inner coat may be peeled off the middle coat as a brittle film, which curls upon itself when detached from the artery. The inner coat is always cut through by the surgeon when he ties a ligature around an artery, and the middle coat is usually divided along with it; the toughness of the external coat, however, enables it to resist the application of the ligature.

The wall of an artery is nourished not by the blood which flows along the tube, but by small arteries distri-

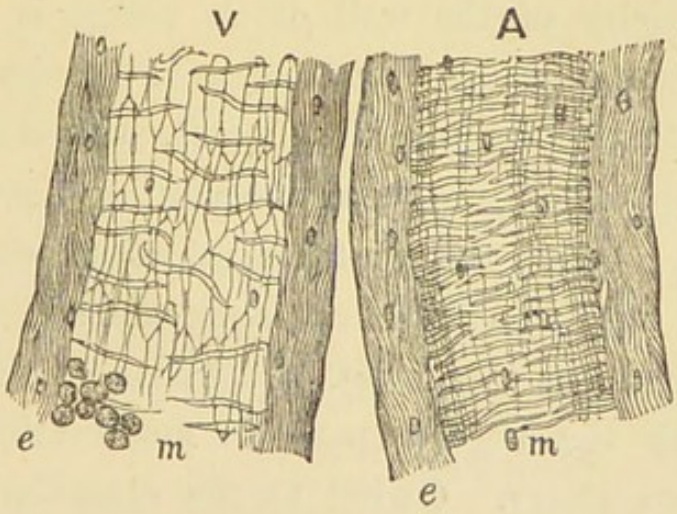

FIG. 133.—Structure of a Minute Artery A and Vein V. *e* External coat or adventitia; *m*, transversely arranged muscular tissue of the middle coat. In the vein the endothelial lining may be seen through the thin middle coat. × 300 diam.

buted in its coats, which arise either from the artery itself, or from adjacent arteries. They form a network on the surface of the artery before entering its wall, and they ramify in the external and middle coat; but it is doubtful if any vessels pass into the inner coat. They end in capillaries from which veins arise. The vessels of the

wall of an artery are named *vasa vasorum*. Lymph-vessels are said to be situated in the outer coat. Nerves, chiefly derived from the sympathetic, are distributed to the muscular coat; they form the peripheral distribution of the vaso-motor nerves.

The smallest arteries, or *arterioles*, are of microscopic size. They possess an endothelial lining, a muscular middle coat, and an external adventitia; but the elastic fenestrated coat is absent (fig. 133). The muscular coat is reduced to a single layer of circularly arranged fibre-cells; but in the frog, as Lister has shown, these fibre-cells are spirally arranged around the wall of the artery.

The elasticity of the wall of an artery is one of its most important physical characters, as it permits the artery to become distended under the pressure caused by the propulsion of the blood into the arteries during the ventricular contraction. When the ventricle ceases to contract the elastic wall recoils on the blood, and causes a continuous stream through the capillaries. Pulsation, or the pulse, is produced by the regular periodic modifications in the calibre of an artery. Owing to the muscularity of the arterial wall, the lumen of the tube can be lessened by the contraction of the circular muscular coat, and the amount of blood supplied to a part can be diminished. When cut across the divided end of an artery is open or gapes.

THE BLOOD CAPILLARIES.

The blood capillaries are the minute tubes which connect together the terminal branches of the arteries and the rootlets of the veins. They vary in diameter from $\frac{1}{1500}$ to $\frac{1}{3500}$ inch, and the finest capillaries are so narrow that only a single blood corpuscle can lie in the transverse diameter of the tube. The structure of the wall of a capillary blood vessel is very simple. It consists of a single layer of elongated, squamous endothelial cells, united together by their somewhat crenulated margins, so as to form the wall of the tube. The outlines of these cells can be demonstrated after the addition of a solution of nitrate of silver. The nuclei of the cells are coloured by carmine, or can be seen after the addition of acetic acid. Minute spots are sometimes seen between the cells, which have been interpreted as orifices or *stomata* in the capillary wall, but the accuracy of this interpretation is very doubtful. The endothelial wall of the capillaries is continuous with the endothelial lining of the arteries and veins, so that a continuity of the walls of the blood tubes is ensured. In many localities, as the lymph-glands and follicles, the spinal cord, the ovaries, &c., the endothelial wall is invested by a delicate coat of connective tissue, which forms a *tunica adven-*

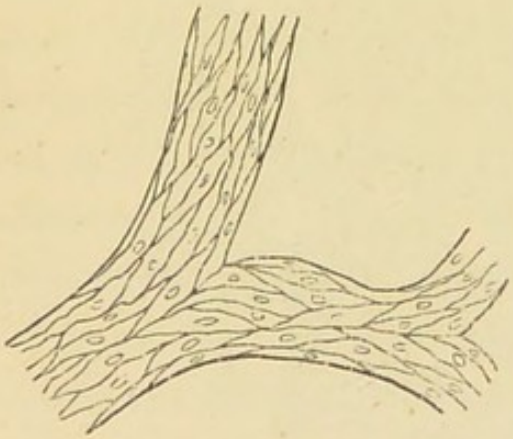

FIG. 134.—The endothelial wall of the capillaries of the retina. The outlines of the cells are stained with nitrate of silver. ×300 diam.

titia for the capillary. This coat is continuous with the connective tissue of the organ in which the capillaries are situated, and also with the adventitia of the small arteries and veins which the capillaries connect together. Capillaries have no muscular coat, and the appearance of muscular fibre cells in the vascular wall indicates the passage from a simple capillary either into a minute artery or a minute vein. The endothelial wall is therefore the simple fundamental form of the blood tube, and the fenestrated, the

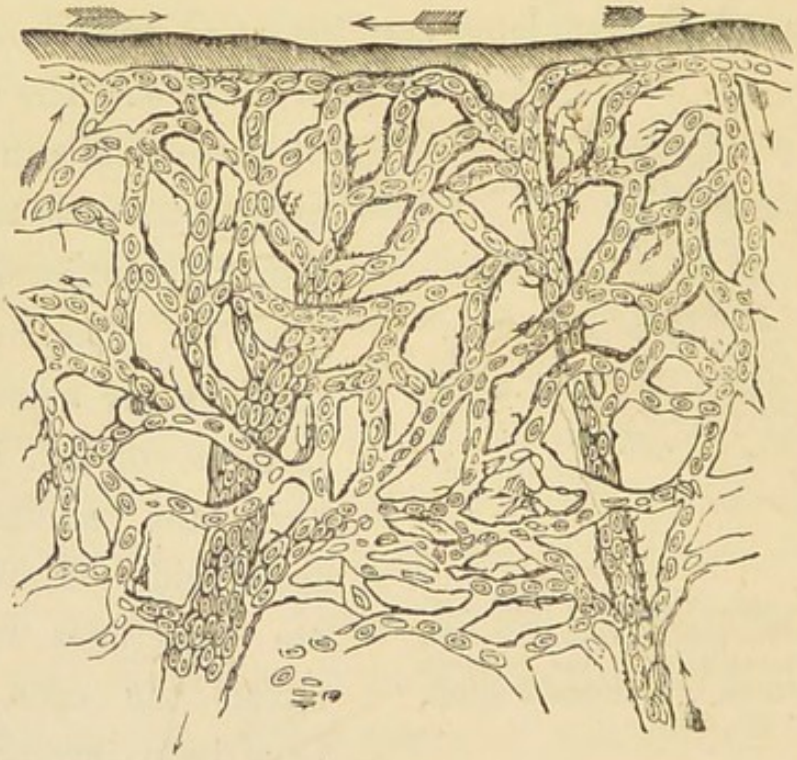

FIG. 135.—Capillary Network in the Web of the Foot of the Frog (from Allen Thomson).

muscular and the external coats are layers superadded as the blood tube increases in structural complexity.

Capillaries have a network like or plexiform arrangement in the organs of the body, but the form of the network varies in different localities, and is to some extent regulated by the

arrangement of the tissues of the organ itself. In muscles, for instance, the strands of the capillary network are elongated, parallel to and between the muscular fibres and fasciculi: in most glands the network is irregularly polygonal: around the lobules of adipose tissue the spaces of the network are more rounded: in papillary projections, like those of the skin, or mucous membranes, or placental villi, the capillaries are arranged in the form of loops, which either may, or may not, be united into a network.

The capillaries lie in the interstices between the proper tissues of the part or organ, and do not penetrate into the interior of the cells or fibres of which the tissues are composed. Organs vary considerably in their vascularity, and the vascularity of an organ depends upon the relative proportion of the capillaries that it contains to the proper substance of the tissue of the organ. The vascularity of an organ is in relation to its degree of functional activity, and in infancy and youth when parts are actively growing, their vascularity is greater than in adult life, when the growth has ceased. Some structures, as adult cartilage, the cornea, epithelium, hairs, nails, cuticle, and endothelium, have no capillaries passing into their substance, and are therefore non-vascular.

THE VEINS.

The veins are the vessels which convey the blood from the capillaries back to the heart, and in their course increase in size, by junction or anastomosis with each other. The rootlets of the veins spring from a network of capillary vessels; they communicate with each other and form a venous plexus, from which larger veins arise. The veins in the body are more numerous than the arteries, and possess collectively a greater capacity than the arteries. In most of the veins delicate valves are found, which possess a semilunar form, and are usually arranged in pairs, and a pouch-like dilatation of the wall of the vein is opposite each segment of the valve. When the blood flows along the veins towards the heart, the valves lie against the wall of the vessel; but if pressure be applied to a vein so as to obstruct the onward flow of the circulation, then the blood passes into the pouches between the wall of the vein and the valve adjacent to the seat of pressure, so as to force the segments of the valve across the lumen of the vein and stop the regurgitation of the blood. The valves are found especially in the veins of the limbs, where the circulation is likely to be interfered with either by the pressure of the muscles on the veins during their action, or by the pressure of blood caused by gravity, and are usually seated at the points of confluence of veins.

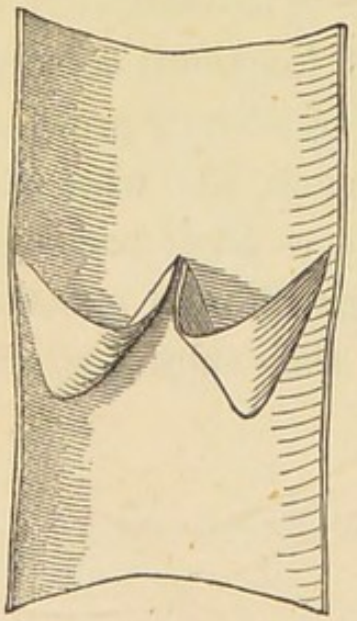

FIG. 136.—A Vein cut open to show a pair of valves.

They are absent in the veins of the lungs, of the brain, in the venæ cavæ and hepatic vein, and in the veins of several of the abdominal viscera. Some of the veins lie in the subcutaneous fat, and are called *superficial veins*, others lie amidst the muscles, and form the *deep veins*. The deep veins usually accompany the arteries, and are named after them; in many localities an artery is accompanied by two veins, termed its *venæ comites*. Some of the deep veins, as the cranial venous sinuses, do not however run along with arteries. The superficial veins do not accompany arteries. Frequent anastomoses take place between the superficial and deep veins.

The veins are arranged primarily into two groups—the Pulmonary veins and the Systemic veins.

PULMONARY GROUP OF VEINS.

The pulmonary group of veins consists of the veins which convey the arterial blood from the lungs to the left auricle of the heart.

Two PULMONARY VEINS are formed in each lung by the coalescence of the venous radicles, which arise from the pulmonary capillary plexus. They run to the root of the lung, where they are placed anterior to the pulmonary artery and bronchial tube, and end by opening into the back of the left auricle. The pulmonary veins anastomose with each other in the substance of the lung. They are devoid of valves, and do not possess a greater capacity than the pulmonary arteries.

SYSTEMIC GROUP OF VEINS.

The Systemic group of veins consists of the coronary venous system; the system of the superior vena cava; the system of the inferior vena cava; and associated with the inferior vena cava is the portal venous system.

Coronary Venous System.

The Coronary venous system consists of the veins of the heart, or the cardiac veins.

The CARDIAC VEINS arise from the capillaries of the coronary arteries in the substance of the muscular wall of the heart. Those which arise in the ventricles run on the anterior and posterior surfaces, from the apex to the auriculo-ventricular groove, where they open into the *great coronary vein*, and possess valves at their orifices. This vein runs in that groove on the back of the heart, where it dilates into a sinus—the *coronary venous sinus*—which opens into the right auricle, between the mouth of the inferior cava and the right auriculo-ventricular orifice. Veins from the wall of the left auricle open into the great coronary vein, but the veins from the wall of the right auricle for the most part open directly into its cavity at the foramina Thebesii. One vein which passes obliquely from the wall of the left auricle into the sinus is the remains of the left superior vena cava of the embryo.

System of the Superior Vena Cava.

The SUPERIOR or DESCENDING VENA CAVA collects and conveys to the right auricle of the heart the blood which circulates in the head, neck, upper limbs, and the walls of

the chest. It is situated in the cavity of the thorax, and is formed by the junction of the two brachio-cephalic veins, about opposite the sternal end of the first intercostal space. It descends on the right of the ascending aorta, pierces the fibrous layer of the pericardium, and opens into the upper and posterior part of the right auricle. Immediately above the pericardium it is joined by the azygos vein (fig. 137). No valve exists either in its course or at its auricular orifice.*

The AZYGOS vein collects the blood which has been conveyed by the intercostal arteries to the posterior part of the walls of the chest. It consists in the lower part of the thorax of two veins, the right and the left azygos. The *right azygos*, or *azygos major*, is connected below with the right lumbar veins of the wall of the abdomen; it enters the thorax through the aortic opening in the diaphragm, ascends on the bodies of the dorsal vertebræ to the right of the thoracic duct and the descending thoracic aorta, and receives in its course the series of right intercostal veins. Opposite the 6th or 7th dorsal vertebræ it is joined by the *left azygos* vein, and higher in the thorax it receives the *œsophageal* veins, the *right bronchial vein*,

* As an exception to this statement, I may mention that in the year 1868 I dissected the heart of a man in which a semilunar valve was placed at the mouth of the superior cava. Shortly afterwards P. D. Handyside published an account of the heart of a male fœtus, æt 6½ months, in which a semilunar valve was present at the auricular orifice of the superior cava. In 1839 A. F. J. C. Mayer described two semilunar valves situated close together in the anterior cava of the dromedary. Vulpian and Philipeaux had seen a valve at the mouth of the right anterior cava in the heart of the elephant, and a similar observation was afterwards made by one of my former assistants, M. Watson, on an elephant's heart dissected in the practical anatomy rooms of the University of Edinburgh.

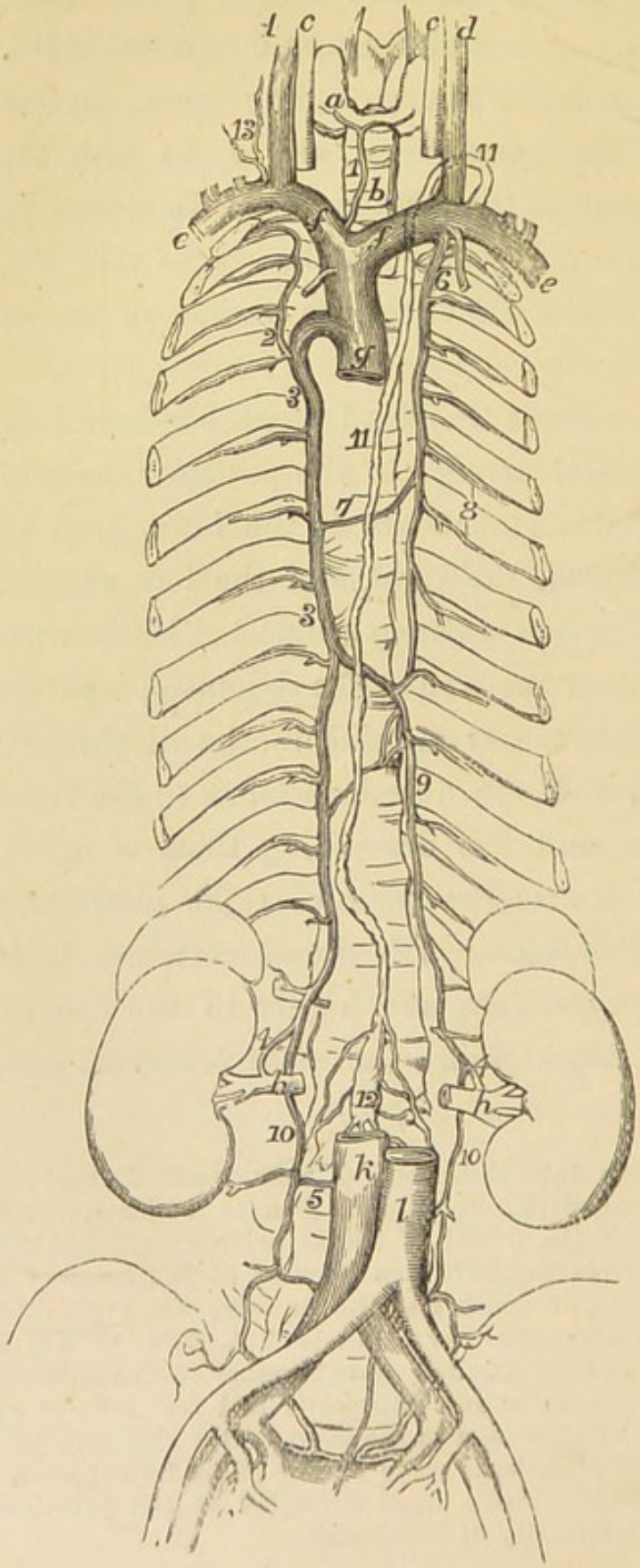

FIG. 137.—The Great Systemic Veins. *a*, thyroid body; *b*, trachea; *c*, *c*, common carotid arteries; *d*, *d*, internal jugular veins; *e*, *e*, subclavian veins; *f*, *f*, innominate veins; *g*, superior vena cava; *h*, *h*, renal veins; *k*, inferior vena cava; *l*, abdominal aorta. 1, inferior thyroid vein; 2, right superior intercostal vein; 3, 3, vena azygos; 4, origin f vena azygos from right renal vein, and from lumbar vein 5; 6, left superior intercostal vein; 7, communicating branch with vena azygos 8, 8, intercostal veins 9, lesser vena azygos; 10, origin from renal and lumbar veins 11, 11, thoracic duct 12, receptaculum chyli; 13, right lymphatic duct.

and sometimes the *right superior intercostal* vein. When on a level with the upper border of the root of the right lung, the azygos vein arches forwards above the root and joins the superior cava. The *left azygos*, or *azygos minor*, is connected below with the left lumbar veins, or the left renal; it enters the thorax through the aortic opening in the diaphragm, ascends in front of the bodies of the lower five or six dorsal vertebræ, receives the corresponding intercostal veins, and runs behind the aorta to join the right azygos vein. Owing to the connection below of the azygos veins with the lumbar veins, the systems of the superior and inferior venæ cavæ are anatomically continuous with each other (fig. 137). The azygos vein is provided with valves.

The intercostal veins of the two or three upper spaces of the right side join to form the *right superior intercostal* vein, which opens into the right brachio-cephalic vein, though sometimes they join the azygos vein. The intercostal veins of the upper four or five spaces of the left side join to form the *left superior intercostal* vein, which usually opens into the left brachio-cephalic vein, though it may join the left azygos vein. The *left bronchial* vein ends in the left superior intercostal vein.

The BRACHIO-CEPHALIC or INNOMINATE veins are two in number, a right and a left. Each is formed by the junction, opposite the inner end of the clavicle, of the subclavian and internal jugular vein of its own side. The right vein is short, and descends to the right of the arteria innominata as far as the sternal end of the first intercostal space, where it is joined by the left brachio-cephalic vein to form the superior cava. The *left* vein, much longer than the right, crosses obliquely

from left to right behind the manubrium sterni, between it and the three great arteries arising from the transverse part of the aortic arch. These veins have no valves. Each brachio-cephalic vein has opening into it: *a*, the *inferior thyroid* vein, which descends from the thyroid body, in front of and by the side of the trachea, and receives the *inferior laryngeal* vein: *b*, the *internal mammary* vein, which is formed by the junction of the venæ comites of the internal mammary artery; these venæ comites receive small veins corresponding to the several branches of the artery: *c*, the *superior intercostal* vein, except in those cases in which this vein joins the azygos (fig. 137).

The subclavian vein is a large trunk, formed by the junction of the superficial and deep veins of the upper limb, which are arranged as follows:—

The *superficial* veins of the hand commence at the tips and sides of the fingers, from whence they proceed to the back of the hand, beneath the skin of which they may be distinctly seen. They then ascend along the fore-arm, forming three large veins: the *radial*, on the outer side; the *ulnar*, on the inner; and the *median*, in the middle of the front of the fore-arm. At the bend of the elbow the median divides into two branches, of which one, named *median-cephalic*, joins the radial to form the *cephalic;* the other, named *median-basilic*, joins the ulnar to form the *basilic* vein. Into one or other of these two branches the surgeon generally makes an opening when he is desirous of drawing blood from the veins of the arm. The cephalic vein ascends along the upper arm, and a little below the clavicle pierces the fascia to join the axillary vein. The basilic pierces the fascia about the middle of the upper arm, and joins the

brachial veins to form the axillary vein. The communications between the superficial and deep veins are not, however, confined to the point of termination of the former, but occur at various parts of their course, more especially at the bend of the elbow, where a *deep median* vein connects the median with the deep veins of the fore-arm.

The *deep* veins of the hand commence at the tips of the fingers, and pass as *digital* veins on the sides of the fingers to the palm of the hand, in which two venous arches, corresponding to the arterial arches of the palm, are situated; from these arches the veins extend upwards along the front of the fore-arm, as far as the bend of the elbow; two veins closely accompanying each of the arteries of the fore-arm, and receiving numerous small veins corresponding to the branches of these arteries. At the bend of the elbow two *brachial* veins result from the junction of the *deep radial* and *deep ulnar* veins of the fore-arm. The *brachial* veins pass up the inner side of the upper arm, closely accompanying the brachial artery as far as the arm-pit, where they join to form, along with the superficial basilic vein, a single large axillary vein: they receive in their course small veins which correspond to the branches of the brachial artery.

The AXILLARY vein is a large vessel which ascends to the inner or thoracic side of the axillary artery, and passes behind the clavicle and the subclavius muscle, to become the subclavian vein. It receives not only the veins which correspond to the branches of the axillary artery, but, just before passing behind the subclavius muscle, it is joined by the superficial *cephalic* vein. Valves occur in it and in the other veins in the upper limb.

The SUBCLAVIAN vein is the direct continuation of the axillary; it courses upwards and inwards across the root of the neck, and joins the internal jugular, to form the brachio-cephalic vein. It lies anterior and inferior to the subclavian artery, and rests in a groove on the upper surface of the first rib, in front of the scalenus anticus muscle, which separates it at that spot from the artery. It receives the *vertebral* vein, which descends at the side of the vertebral artery, in the vertebrarterial foramina in the transverse processes of the cervical vertebræ, as far as the sixth vertebra, and then enters the subclavian vein: it receives various *spinal* veins and the *deep cervical* vein.

The subclavian vein also receives two of the superficial veins of the neck, the *anterior* and *external jugular* veins.

The ANTERIOR JUGULAR vein commences by the junction of small rootlets in the superficial fascia of the submaxillary region: it descends close to the anterior middle line of the neck, and joins either the subclavian vein directly, or the external jugular vein. The opposite anterior jugulars are frequently connected together by a transverse branch which passes across the middle line, above the sternum, and superficial to the trachea.

The EXTERNAL JUGULAR vein commences in the substance of the parotid gland, by the junction of the temporal, internal maxillary, transverse facial, posterior auricular, and sometimes the occipital veins, all of which correspond to branches of the external carotid artery. It passes obliquely downwards and backwards under the platysma; but superficial to the cervical fascia and sterno-mastoid muscle, and a little above the clavicle, pierces the fascia and enters the sub-

clavian vein: after it has pierced the fascia, it receives the *suprascapular* and *transversalis colli* veins corresponding to those branches of the subclavian artery. A bisegmented valve occurs in the course of the external jugular vein, and a similar valve at its junction with the subclavian. J. Struthers has shown that the transversalis colli and suprascapular veins possess valves, but not the anterior jugular: also that no valves occur in the subclavian vein, except immediately external to the point of entrance of the external jugular; but at the junction with the brachio-cephalic vein a two segmented valve is found.

The INTERNAL JUGULAR vein is the large vein which collects the blood from the brain, the face, and certain parts of the neck. It begins at the jugular foramen, where it is continuous with the lateral cranial blood sinus in the dura mater, and descends to the outer side of the internal carotid and the common carotid arteries, but within the same sheath; behind the inner end of the clavicle, it joins the subclavian vein, to form the brachio-cephalic vein. J. Struthers has described a bi-segmented valve as constantly present, either at or close to the mouth of the internal jugular vein. It receives—

a. The *Facial* vein, which runs down the side of the face, posterior to and a little distance from the facial artery, and enters the internal jugular a little below the posterior belly of the digastric muscle: the facial vein is joined by the veins which correspond to the branches of the facial artery, as well as by the *frontal* vein from the forehead. A *communicating* vein connects the facial with the temporal veins, and, in cases where the external jugular vein is small, allows the blood from the veins,

corresponding to the cranial branches of the external carotid artery, to flow into the internal jugular vein.

b. The *Lingual* vein conveys the blood from the tongue into the internal jugular vein.

c. The *Pharyngeal* vein corresponds to the ascending pharyngeal artery, and joins the internal jugular.

d. The *Occipital* vein sometimes joins the internal, at others the external jugular vein.

e. The *Superior Thyroid* vein proceeds from the thyroid body, and is joined by the *superior laryngeal* vein before it enters the internal jugular.

f. A *Middle Thyroid* vein is sometimes seen passing from the thyroid body to the internal jugular vein.

The Cranial Venous Blood Sinuses are veins situated between two layers of the dura mater lining the interior of the cranial cavity. Their general arrangement has been described in the section on the membranes of the brain, p. 217. It may, however, be further stated that these sinuses are situated, some in the mesial plane of the cavity, as the *superior longitudinal* sinus, *inferior longitudinal* sinus, *straight* sinus and *occipital* sinus : others laterally to that mesial plane, as the *cavernous* sinus, the *superior* and *inferior petrosal* sinuses and the *lateral* sinus : others across the mesial plane, as the *circular* sinus, which courses around the pituitary body, and opens on each side into the cavernous sinus lying at the side of the body of the sphenoid bone ; and the *transverse* sinus which passes across the upper surface of the basi-occipital and connects the two inferior petrosal sinuses (figs. 138, 139). The cranial blood sinuses receive blood from the brain, orbit, and veins of the diploë of the cranial bones, also small veins from the

dura mater immediately adjacent to each sinus. They are without valves; but the superior longitudinal sinus has an irregular inner surface, owing to the projection of fibrous bands into its lumen.

The VEINS OF THE BRAIN ramify in the pia mater, and are arranged in a superficial and a deep group:—

The *superficial* veins of the cerebrum pass out of the convolutions into the pia mater covering the outer surface

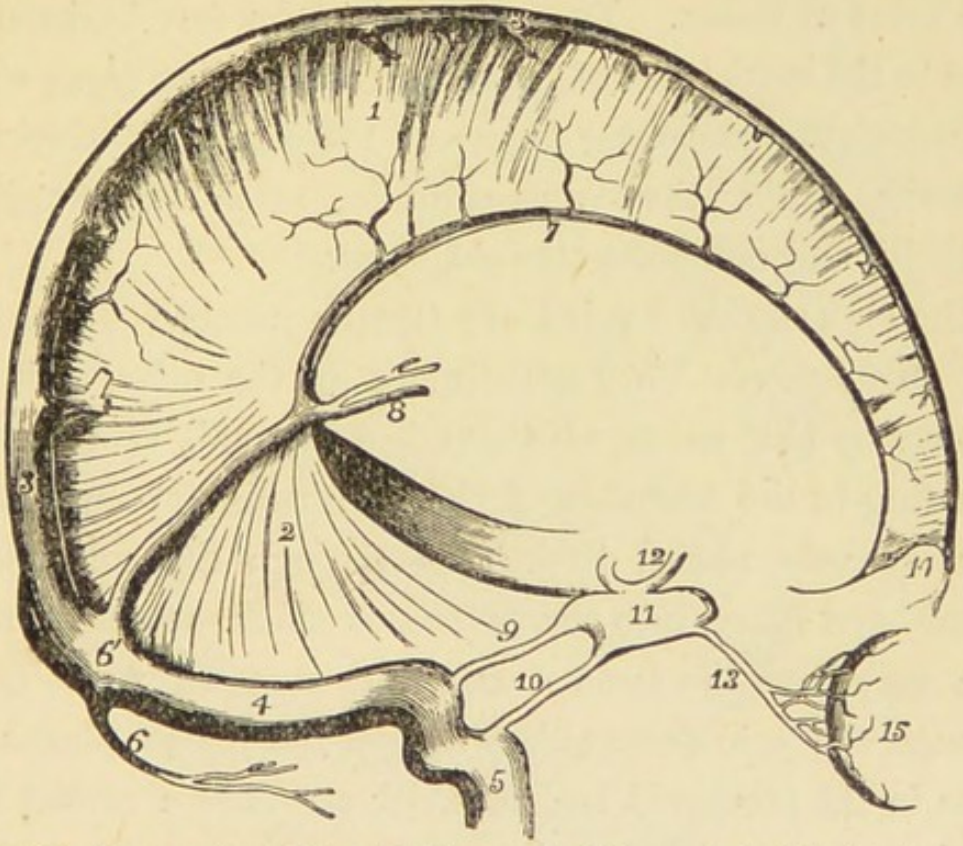

FIG. 138.—Dura mater and Cranial Sinuses. 1, Falx cerebri; 2, tentorium; 3, 3, superior longitudinal sinus; 4, lateral sinus; 5, internal jugular vein; 6, occipital sinus; 6', torcular Herophili; 7, inferior longitudinal sinus; 8, veins of Galen; 9 and 10, superior and inferior petrosal sinuses; 11, cavernous sinus; 12, circular sinus, which connects the two cavernous sinuses together; 13, ophthalmic vein from 15, the eyeball; 14, crista galli of ethmoid bone.

and the inner face of the cerebral hemispheres, and open into the superior longitudinal sinus, though some of the veins of the inner face open into the inferior longitudinal sinus. The veins from the convolutions on the lateral and under surfaces of the cerebrum open into the cavernous,

petrosal and lateral sinuses. The veins of the upper surface of the cerebellum open into the straight sinus, those of the under surface into the lateral and occipital sinuses.

The *deep* veins of the cerebrum emerge from the corpora striata and optic thalami, enter the choroid plexuses which form the fringe of the velum interpositum, and converge to the middle of the velum, where they form the two veins of Galen. The *veins of Galen* run backwards close to the mesial line of the velum, and passing along with it through the transverse fissure of the cerebrum below the posterior end of the corpus callosum, reach the tentorium cerebelli, and enter the straight sinus.

The OPHTHALMIC veins are two in number, a *superior* and an *inferior*. They are situated in the orbit, and are formed by the union of a number of small veins corresponding to the branches of the ophthalmic artery. The superior vein passes backwards through the sphenoidal fissure, and opens into the cavernous sinus. The inferior vein may have the same course, but more usually it goes through the spheno-maxillary fissure, and joins a plexus of veins in the pterygoid region, which serves as a rootlet for the internal maxillary vein. The *vena centralis retinæ* usually opens directly into the cavernous sinus. The superior ophthalmic vein communicates with the veins of the forehead and with the *angular* vein, one of the rootlets of the facial vein, at the inner angle of the orbit.

The VEINS OF THE DIPLOË are contained in canals in the diploë of the cranial bones; those which lie in the parietal and occipital bones communicate not only with the lateral and occipital sinuses, but with the temporal and occipital

veins, whilst the veins in the diploë of the frontal bone open into the frontal or supra-orbital vein.

Though the intra-cranial blood for the most part leaves the skull through the lateral sinuses and internal jugular

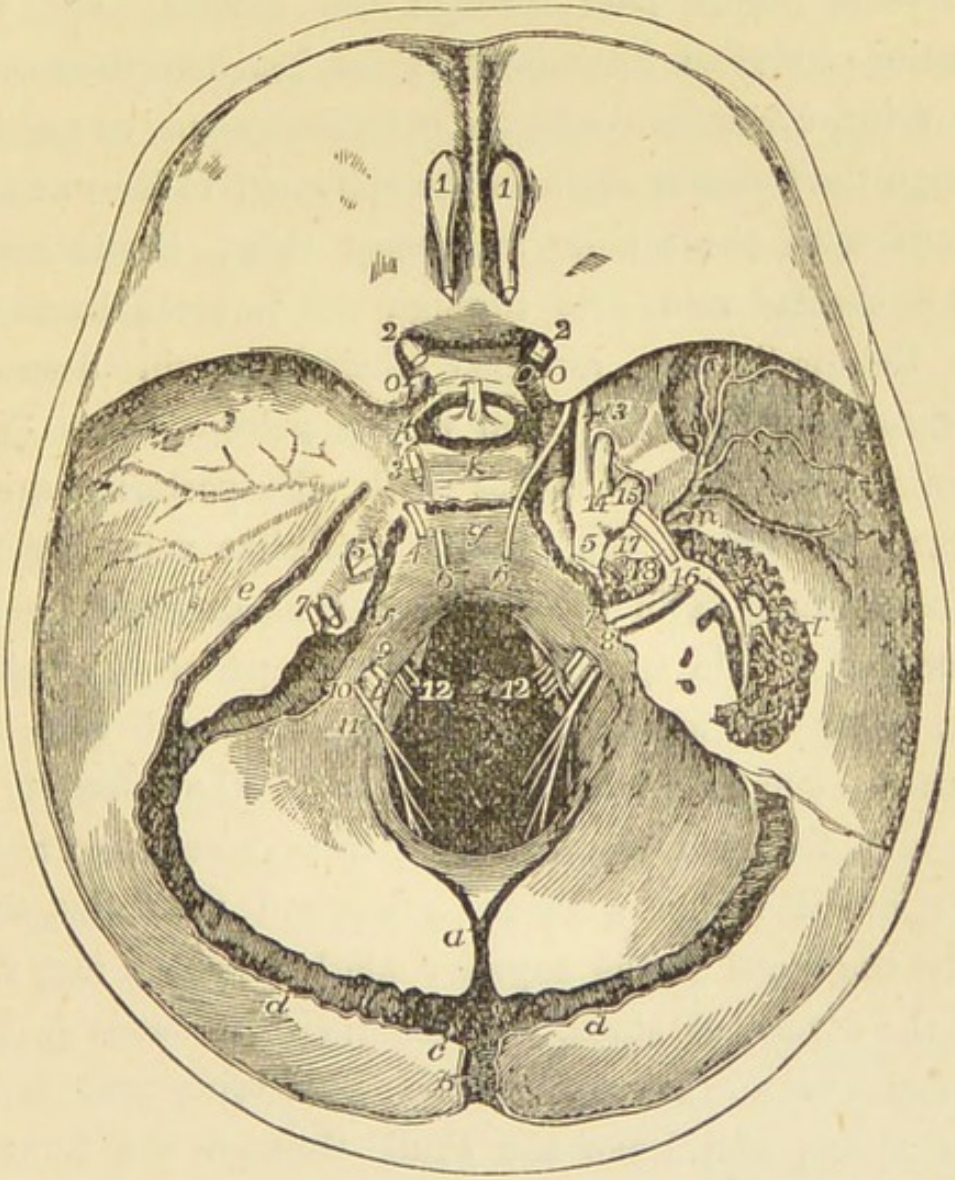

FIG. 139.—Floor of the cavity of the skull to show the Cranial Nerves and Blood Sinuses. 1 to 6, first to sixth cranial nerves; 7, portio dura; 8, portio mollis; 9, glosso-pharyngeal; 10, pneumogastric; 11, spinal accessory; 12, hypo-glossal; 13, 14, 15, first, second, and third divisions of fifth nerve; 16, knee-shaped ganglion of portio dura; 17 and 18, great and small superficial petrosal nerves; *a*, occipital sinus; *b*, superior longitudinal; *c*, torcular Herophili; *d*, lateral sinus; *e*, superior, and *f*, inferior petrosal sinus; *g*, transverse sinus; *h*, cavernous sinus; *k*, circular sinus; *l*, pituitary body; *m*, middle meningeal artery, *n*, *n*, bones of the ear; *o*, *o*, internal carotid artery.

veins, yet certain accessory communications exist between the cranial sinuses and the veins on the outside of the head. Thus the superior longitudinal sinus communicates

with the veins in the parieto-occipital region of the scalp by two small *emissary* veins, which pass through the parietal foramina; and each lateral sinus communicates with the veins at the back of the head through the *emissary* veins which pass through the mastoid and the posterior condyloid foramina. Nuhn has described *emissary* veins, continuous with the cavernous sinus, as passing through the foramen ovale in the sphenoid to become continuous with the middle meningeal vein; Henle states that a similar vein goes through the foramen lacerum; and Rektorzik has recorded a similar vein descending through the carotid canal in the petrous bone. The occipital sinus communicates with the posterior spinal plexuses of veins; the inferior cerebellar veins, or the petrosal sinuses, join the venous plexus surrounding the upper end of the spinal cord. The superior ophthalmic vein, by its communication, on the one hand with the cavernous sinus, and on the other with the veins of the face and forehead, connects the intra-cranial with the extra-cranial venous systems. Seseman maintains that, whilst the blood of the superior ophthalmic vein may flow into the cavernous sinus, yet that its chief outlet is into the facial vein. The *middle meningeal* veins arise in the dura mater, and leave the skull through the foramen spinosum to serve as rootlets for the internal maxillary vein.

The Veins of the Spine are arranged in relation to both the spinal column and the spinal cord.

The *Veins of the Spinal Column* ramify on the exterior of the vertebræ, in the substance of the vertebral bodies, and in the interior of the spinal canal. The *extra-spinal* or *dorsal veins* form a plexus on the back of the neural

arches and spines. The *veins of the bodies* of the *vertebræ* lie in canals in the spongy substance of the vertebral bodies, and leave the bone through foramina on its surface, of which the one that opens on the posterior surface of the body is the best marked. The veins within the spinal canal lie in the fatty tissue which separates the dura mater from the bony walls of the canal, and are arranged in an anterior and a posterior longitudinal group; the *anterior longitudinal spinal* veins lie behind the bodies of the vertebræ in the whole length of the spinal canal; the *posterior longitudinal spinal* veins form a plexus in the whole length of the canal immediately in front of the neural arches.

The *Veins of the Spinal Cord* ramify in the pia mater investing the cord, in which they form plexuses.

The spinal veins freely anastomose with each other. The veins of the cord communicate with the veins within the canal through small veins, which run with the nerve roots to the foramina in the dura mater, through which the roots proceed; whilst at the upper end of the canal they join the vertebral and the inferior cerebellar veins, and perhaps the petrosal sinuses. The veins of the vertebral bodies communicate with the anterior longitudinal veins. The anterior longitudinal communicate with the posterior longitudinal veins, with which they form a venous plexus; this plexus is united to the dorsal spinal veins by veins, which pierce the ligamenta subflava, and pass between the vertebral laminæ; it freely communicates also with the lumbar veins, the intercostal veins, and the vertebral veins, by veins which pass outwards through the intervertebral foramina.

System of the Inferior Vena Cava.

The Inferior or Ascending Vena Cava collects and conveys to the right auricle of the heart the blood which circulates in the lower limbs, in the abdominal and pelvic walls and viscera. It is chiefly situated in the cavity of the abdomen, and is formed by the junction of the two common iliac veins on the right side of the body of the fifth lumbar vertebra (fig. 140); it ascends to the right, close to the abdominal aorta, for some distance; when it reaches the under surface of the liver it lies in a fossa in that organ, and is separated from the aorta by the right crus of the diaphragm; it then pierces the tendon of the diaphragm and the fibrous layer of the pericardium, and opens into the lower and posterior part of the right auricle. Except the Eustachian valve at its auricular orifice, it is without valves.

Several veins, corresponding to branches of the abdominal aorta, open directly into the inferior vena cava; as follows:—

The Middle Sacral vein joins either the commencement of the cava, or the left common iliac vein.

The Lumbar veins collect the blood from the posterior wall of the abdomen, and open into the posterior wall of the inferior cava. As already described (pp. 503, 505), these veins also communicate with the azygos vein.

The Spermatic veins ascend from the testicles, one in each spermatic cord, in which it forms a plexiform arrangement. At the internal or deep abdominal ring it runs upwards behind the peritoneum and opens on the right side into the inferior cava, on the left into the left renal vein.

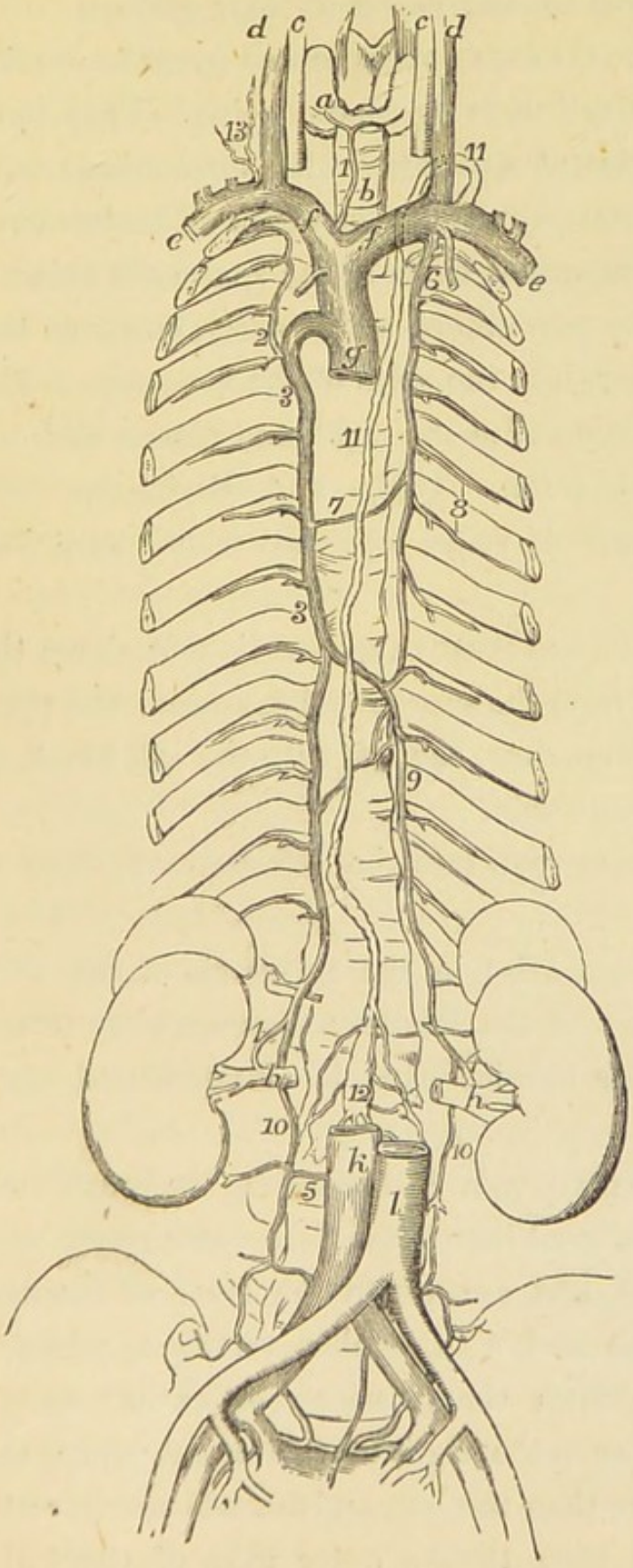

FIG. 140.—The Great Systemic Veins, *a*, thyroid body; *b*, trachea; *c*. *c*, common carotid arteries; *d*, *d*, internal jugular veins; *e*, *e*, subclavian veins; *f*, *f*, innominate veins; *g*, superior vena cava; *h*, *h*, renal veins; *k*, inferior vena cava; *l*, abdominal aorta. 1, inferior thyroid vein; 2, right superior intercostal vein; 3, 3, vena azygos; 4, origin of vena azygos from right renal vein, and from lumbar vein 5; 6, left superior intercostal vein; 7, communicating branch with vena azygos; 8, 8, intercostal veins; 9, lesser vena azygos; 10, origin from renal and lumbar veins; 11, 11, thoracic duct; 12, receptaculum chyli; 13, right lymphatic duct.

They possess valves, and, according to Rivington, both spermatic veins have usually valves at their orifices.

In the female the OVARIAN veins ascend from the ovaries and terminate like the male spermatic veins. They form in each broad ligament a plexus, which anastomoses with the veins of the uterus. Rivington observed their valves to resemble in arrangement those of the spermatic veins.

The RENAL veins pass almost transversely, one from the hilus of each kidney, into the sides of the vena cava. The left renal vein is longer than the right, and crosses in front of the abdominal aorta. Crisp and Rivington have observed valves in these veins, especially where they join the inferior cava.

The SUPRA-RENAL or CAPSULAR veins lie just above the renal, and proceed from the supra-renal capsules; the right opens into the inferior cava, the left into the left renal, or sometimes the phrenic vein.

The PHRENIC veins open into the inferior cava, close to the diaphragm.

The HEPATIC veins arise in the substance of the liver from the capillaries of the lobules; they converge to the fossa in which the inferior cava is situated, and open into it.

The COMMON ILIAC vein is formed by the junction of the external and internal iliac veins. It commences near the sacro-iliac joint, and ascends to the level of the disc between the fourth and fifth lumbar vertebræ, when it joins its fellow to form the inferior vena cava. As the junction takes place to the right of the mesial plane, the right vein is shorter than the left, and ascends nearly vertically behind, and then to the outer side of the right

common iliac artery ; the left vein is at first to the inner side of its artery, and then ascends behind the right common iliac artery.

The INTERNAL ILIAC vein is formed in the cavity of the pelvis by the junction of a number of veins which correspond to the branches of the internal iliac artery. It lies in front of the sacro-iliac joint, and opposite the brim of the pelvis joins the external iliac to form the common iliac vein. The iliac veins are without valves.

The veins which correspond to the visceral branches of the internal iliac artery form, in relation with their respective viscera, complicated venous plexuses. The *prostatic venous plexus* surrounds the prostate gland, and receives at its anterior part the *dorsal vein* of the penis, which enters the pelvis by piercing the sub-pubic ligament and does not end in the deep pudic vein. The prostatic plexus communicates behind with the *vesical venous plexus*, which is arranged on the outer aspect of the muscular coat of the bladder, and is especially well marked at the base of the bladder. The vesical and prostatic plexuses communicate with the *hæmorrhoidal venous plexus*, which is arranged in and around the wall of the lower end of the rectum and anal orifice. The hæmorrhoidal plexus communicates with the superior hæmorrhoidal vein, which forms one of the rootlets of the portal system of veins ; it also gives rise to the middle and inferior hæmorrhoidal veins, which join the deep pudic vein of the internal iliac, and is thus brought into connection with the system of the inferior vena cava. In the female a *vaginal venous plexus* surrounds the wall of the vagina, and a *uterine venous plexus* is arranged on and in the wall of the uterus, and between

the two layers of the broad ligament. The several venous plexuses in relation to the pelvic viscera are apt to become enlarged and gorged with blood, especially in old people, and the veins of the lower end of the rectum and around the anus are apt to undergo varicose dilatations, named hæmorrhoids or piles.

The EXTERNAL ILIAC vein is directly continuous with the femoral vein, ascends in close relation to the external iliac artery, and joins the internal iliac to form the common iliac vein. It receives immediately above Poupart's ligament the *deep epigastric* and *deep circumflex iliac* veins.

The FEMORAL vein is formed by the union of the superficial and deep veins of the lower limb, which are arranged as follows:—The superficial veins of the dorsum of the foot are separated from the deep veins by the deep fascia. They commence by very fine rootlets arising from the capillaries of the skin. At the sides of the toes they form the *digital* veins, and on the dorsum of the foot the digital veins form an arch, from the inner side of which a vein, called the *long saphenous*, arises. This passes upwards along the inner side of the leg and thigh, increasing considerably in size in its course, owing to a number of veins joining it from the extensive surface of the skin of the limb. It terminates, at the upper part of the thigh, by passing through the saphenous opening in the fascia lata, and joins the femoral vein. From the outer side of the venous arch on the dorsum of the foot arises the *external saphenous* vein, which runs behind the outer ankle and on the back of the leg to the ham, where it pierces the popliteal fascia to join the popliteal vein. The deep veins begin both on

the dorsum of the foot and in the sole. Those which arise on the dorsum of the foot form the *anterior tibial* veins, and accompany the anterior tibial artery; they receive a considerable number of branches in their upward course, which proceed from the mass of muscles lying on the front of the leg. The veins which begin in the sole of the foot accompany the plantar arteries, form the *plantar* veins, and then pass upwards, along the inner ankle, to reach the back of the leg, along which they ascend as the *posterior tibial* veins, closely accompanying the posterior tibial artery, and receiving in their course numerous small veins that proceed from the muscles of the back of the leg, and the *peroneal* veins. At the upper part of the leg the anterior tibial veins pass to the back of the leg, and join the posterior tibial veins. The large *popliteal* vein, formed by their junction, ascends behind the knee-joint, lying in the ham, along with the popliteal artery. At the upper part of the popliteal space it passes to the inner side of the thigh, ascends as the *femoral* vein, alongside of the femoral artery, as far as Poupart's ligament, when it enters the cavity of the abdomen and becomes the *external iliac* vein. At the upper part of the thigh the femoral receives the *profunda* vein, corresponding to the profunda artery of the thigh, which conveys the blood that has been carried by that artery to the numerous large and important muscles of the thigh. The femoral vein is also joined near this spot by the superficial long saphenous vein, into which the *superficial epigastric*, *pudic* and *circumflex iliac* veins open immediately before its termination. Valves exist in the femoral and the other veins in the lower limbs.

The Portal Venous System.

The portal system of veins is supplementary to the system of the inferior vena cava, and is formed by the veins of the intestine, which correspond to the inferior and superior mesenteric branches of the abdominal aorta, and by veins corresponding to the branches of the cœliac axis which go to the stomach, spleen, pancreas, and gall bladder. It collects and conveys the blood from those viscera and from the several divisions of the intestinal tube (fig. 141).

The INFERIOR MESENTERIC vein arises, as the *superior hæmorrhoidal* vein, from the hæmorrhoidal plexus of veins around the lower end of the rectum; it ascends behind the rectum, and is then joined by the *sigmoid* vein. In its further ascent the inferior mesenteric receives the *left colic* vein, and lies behind the peritoneum to the left of the inferior mesenteric artery; it then passes behind the pancreas and ends in the splenic vein.

The SUPERIOR MESENTERIC vein is formed by the junction of the *ileo-colic*, *right colic*, and *middle colic* veins; it receives the *intestinal* veins corresponding to the intestinal branches of the superior mesenteric artery and the *right gastro-epiploic* vein. It ascends in the mesentery to the right side of the superior mesenteric artery, goes in front of the duodenum, and behind the pancreas, to join the splenic vein and so form the portal venous trunk (fig. 141).

The SPLENIC vein commences in the substance of the spleen, from which it emerges at the hilus in five or six divisions, which unite in the gastro-splenic omentum into a single vein. The splenic vein runs to the right along with the splenic artery and behind the pancreas, and joins

the superior mesenteric vein to form the portal venous trunk. It receives in its course the *short gastric* vein from the stomach, the *left gastro-epiploic* vein, *pancreatic* and *duodenal* veins, and the *inferior mesenteric* vein. E. Crisp has described valves in both the splenic and mesenteric veins.

The CORONARY vein runs along the small curvature of the stomach and joins the portal venous trunk near its origin.

The CYSTIC vein proceeds from the gall bladder, and joins either the portal venous trunk near the liver, or its right branch of bifurcation.

The PORTAL VENOUS TRUNK, or PORTAL VEIN, is formed by the union, behind the pancreas, of the splenic and superior mesenteric veins. It passes obliquely upwards and to the right, between the two layers of the small omentum, behind and between the hepatic artery and common bile duct, to reach the transverse fissure of the liver, where it divides into a right and a left branch. These branches enter the right and left lobes of the liver, in which they divide and subdivide after the manner of an artery, and end in the intra-lobular capillary plexus, from which the rootlets of the hepatic vein arise.

Although the portal venous system is sometimes regarded as distinct from the system of the inferior cava, except through the channel of communication provided by the hepatic vein, yet anastomoses between the two systems, do undoubtedly occur in connection with certain of their peripheral ramifications. It has already been stated (p. 519) that the hæmorrhoidal plexus is continuous with the rootlets of both systems. The elder Retzius observed

small veins from the duodenum opening into the inferior cava, also veins from the left colon opening into the renal

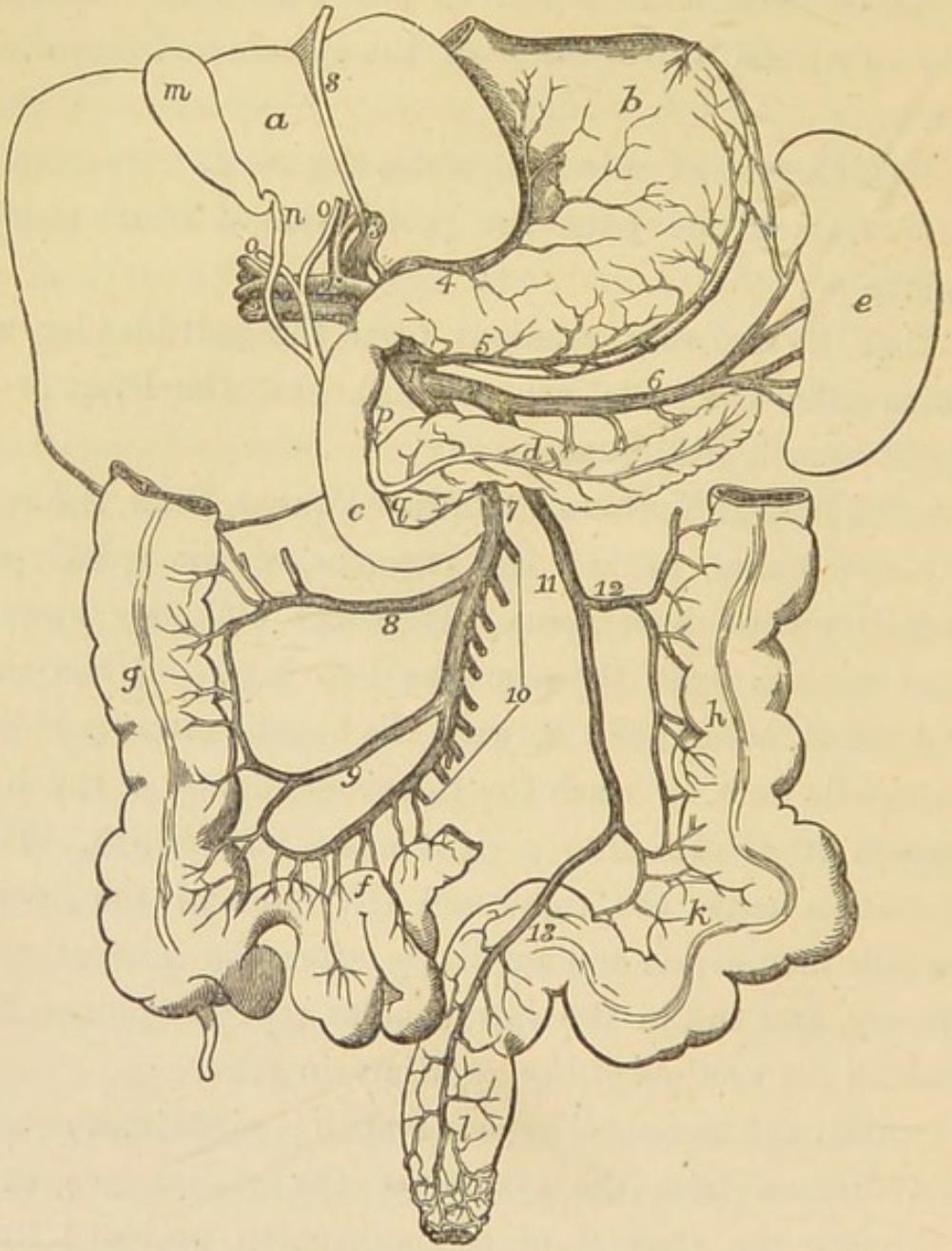

FIG. 141.—Diagram of the Portal Venous system. 1. Portal vein; 2 and 3, its right and left branches; 4, gastric vein; 5, right gastro-epiploic vein; 6, splenic vein; 7, superior mesenteric vein; 8 and 9, right and middle colic veins; 10, intestinal veins; 11, inferior mesenteric vein; 12, left colic vein; 13, superior hæmorrhoidal vein; *a*, liver; *b*, stomach; *c*, duodenum; *d*, pancreas; *e*, spleen; *f*, coils of small intestine; *g*, ascending colon; *h*, descending colon; *k*, sigmoid flexure; *l*, rectum; *m*, gall bladder; *n*, cystic duct; *o*, *o*, hepatic ducts; *p*, where common bile duct pierces wall of duodenum; *q*, pancreatic duct; *r*, hepatic artery; *s*, round ligament.

vein. Moreover, he described a network of small veins lying in the areolar tissue outside the peritoneum, which communicated on the one hand with the veins of the colon, and on the other with the renal veins, the pelvic veins, and other rootlets of the inferior vena cava. This network evidently corresponds with the extra-peritoneal arterial network, which I have injected and described in the same locality (p. 433), as connecting together the parietal and visceral branches of the abdominal aorta. Schiff and Luschka have also described, by the name of *vena parumbilicalis*, a small vein, which is connected on the one hand with the deep epigastric vein, a rootlet of the external iliac, and on the other with the portal vein; this vein ascends to the liver along with the round ligament. Cases of occasional enlargement of this vein have been described by Monro, Rokitansky, Champneys, and others. The inosculations described on p. 515 between the spinal veins and the lumbar and intercostal veins, establish a communication between the circulation in the spinal cord and that in the parietes of the chest and abdomen. These venous and arterial anastomoses have an interest and importance in connection with the practice of local blood-letting by cupping or leeching the abdominal wall.

Structure of the Veins.

Veins, like arteries, are enclosed in a fibrous sheath. The thickness of the wall of a vein is considerably less than that of an artery of equal size. The thinness of the venous wall enables the colour of the blood to be seen through it, so that veins have a bluish-purple colour. Veins have three coats,—an outer, middle, and inner.

The *outer* coat, or *tunica adventitia*, is formed by an interlacement of white and yellow elastic fibres of connective tissue; it possesses considerable strength, though it has no great thickness. In some veins, more especially those of the abdominal cavity, non-striped muscular fibres are found in this coat, arranged as a longitudinal network.

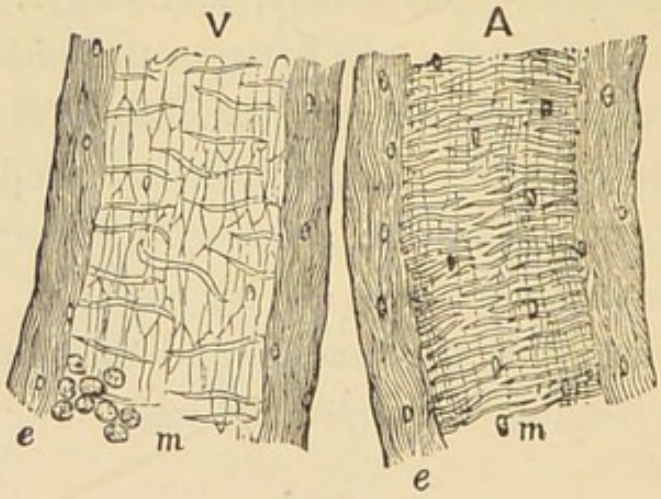

FIG. 142.—Structure of a Minute Artery A and Vein V. *e*, external coat or adventitia; *m*, transversely arranged muscular tissue of the middle coat. In the vein the endothelial lining may be seen through the thin middle coat. ×300.

The *middle* coat consists of non-striped muscular fibres, arranged transversely around the vein, and mingled with these muscular fibres are white and yellow elastic fibres of connective tissue, which mostly run in a longitudinal

direction. This coat is much thinner than the middle coat of a corresponding artery; but in some veins, especially those of middle size, it is thicker in proportion than in the largest sized veins. On the other hand, the veins of the pia mater, the venous sinuses in the dura mater, the veins of bones, of the retina, and the dilated veins of the corpora cavernosa, have no proper middle coat, and are without muscular fibres in their walls. In the smallest veins the venous rootlets, or *venules*, possess muscular fibres arranged transversely, but they are so scattered as not to form a continuous middle coat, and thus the venules present a marked contrast to the arterioles (fig. 142). Ranvier indeed considers that no definite middle coat exists in any of the veins, and that they have only an inner and an outer coat, in the latter of which non-striped muscular fibres, varying in number and direction, may be present.

The *inner* coat, or *tunica intima*, possesses a layer of endothelium next the lumen of the vein, the cells of which are polygonal scales, shorter and broader than those of an artery. Outside the endothelium is an extra-endothelial layer of connective tissue, and outside that again a network of elastic fibres, which does not possess the fenestrated character. This coat is not so thick as in the corresponding arteries. In the pulmonary vein it is said to contain non-striped muscular fibres. The valves of the veins are continuous with the inner coat; they are covered by a layer of endothelium; the cells on the surface of the valve, situated next to the lumen of the vein, are, according to Ranvier, elongated in a direction corresponding to the long axis of the vessel, whilst those on the opposite

surface of the valve are elongated transversely. Beneath the endothelium are bundles of connective tissue with elastic fibres, which are most distinct at the attached border of the valve.

Veins have not the elasticity of arteries, and do not pulsate. All veins which have muscular fibres in their coats are contractile. Veins, like arteries, possess vasa vasorum, and vaso-motor nerves are distributed to the muscular tissue in their walls. When a vein is empty or cut across, it does not gape like an artery, but collapses. H. Hoyer has recently pointed out that at the tip of the digits some of the small arterial twigs open directly into venous radicles, the communicating vessels being tortuous like a small glomerulus.

Lymph-Vascular System.

The lymph-vascular system is an appendage of, and supplementary to the blood-vascular system, and consists of small tubes or vessels, the Lymphatic Vessels, and of collections of Lymphoid or Adenoid Tissue, which form Lymphoid Organs. It is sometimes called the Absorbent System, as it plays an important though not an exclusive part in absorbing materials which have to be transmitted to the blood, but the blood capillaries themselves are also directly concerned in absorption.

LYMPHATIC VESSELS.

The Lymph Vessels, or Lymphatics, are tubes with delicate transparent walls, which convey the fluid called lymph and chyle. They arise, in the form of microscopic networks, in the connective tissue on the surface and in the substance of the parts and organs of the body, and they terminate by joining the large veins at the root of the neck, so that their contained fluid flows into the blood towards the heart. They resemble veins in having a course from periphery to centre; in possessing valves, which are generally two in number and semilunar in shape, and in being divided into *superficial* and *deep lymphatic* vessels. In the limbs and axial parts of the body the superficial lymphatics are situated, like the superficial veins, in the subcutaneous tissue; whilst the deep lymphatics accompany the arteries and deep veins. But the internal viscera also possess a superficial and a deep set of lym-

phatics, the superficial being situated next the investing coat of the organ, whilst the deep are situated along with the blood-vascular trunks in its substance. Lymphatics differ from veins in possessing in their course glandular enlargements, the lymph glands; in having thinner coats; in being almost uniform in size and much smaller than the veins; in not as a rule uniting into larger vessels as they pass onwards in their course; and in conveying lymph and not blood. They are for the most part fine thread-like tubes, and their main trunk, the thoracic duct, is not bigger than a crowquill. From the number of valves in these vessels, they present, when distended with fluid, a beaded or moniliform appearance. The lymph-vessels are divided into lacteal or chyle vessels and proper lymphatic vessels.

Distribution of the Lacteal or Chyle Vessels.

The LACTEAL or CHYLE VESSELS are limited to the intestine and its mesenteric folds, and are named from the milk-like chyle which they contain. They principally arise in the minute processes called *intestinal villi*, which project from the free surface of the mucous membrane of the small intestine into the canal of the bowel. The lacteals from adjacent villi unite and form a network in the submucous coat of the intestine, from which larger lacteals arise, which pierce the muscular coat. Immediately beneath the serous coat a longitudinal network exists, which communicates with the deeper lacteals. From these networks larger lacteals proceed, which enter the mesentery and ascend between its folds to its root of attachment at the posterior wall of the abdomen, where,

opposite the body of the first lumbar vertebra, they enter the receptaculum chyli or dilated commencement of the thoracic duct.

As the lacteals ascend in the mesentery they pass through a number of bodies, about the size of, or somewhat larger than, flattened peas, called the *mesenteric glands*, and as they unite in their ascent, they diminish in numbers and form larger vessels than when they emerged from the coats of the bowel.

Similar vessels, though fewer in number, arise in the mucous membrane of the large intestine, but not in intestinal villi. They also ascend to join the thoracic duct, and pass through glands similar to those within the mesentery.

Distribution of the Proper Lymphatic Vessels.

The Proper Lymphatic Vessels are situated in the other parts of the body than the intestine and its mesenteric folds. By their junction with each other they form two lymphatic trunks, named the thoracic duct and the right lymphatic duct.

The THORACIC DUCT commences in the cavity of the abdomen about opposite the body of the first or second lumbar vertebra, where it forms a dilatation, the *receptaculum chyli*, which receives not only the lacteal vessels, but the lymphatics from the other abdominal viscera, from the abdominal walls, and from the lower limbs. The thoracic duct passes through the opening in the diaphragm which transmits the aorta, ascends in front of the bodies of the dorsal vertebræ, at first to the right of the aorta, and

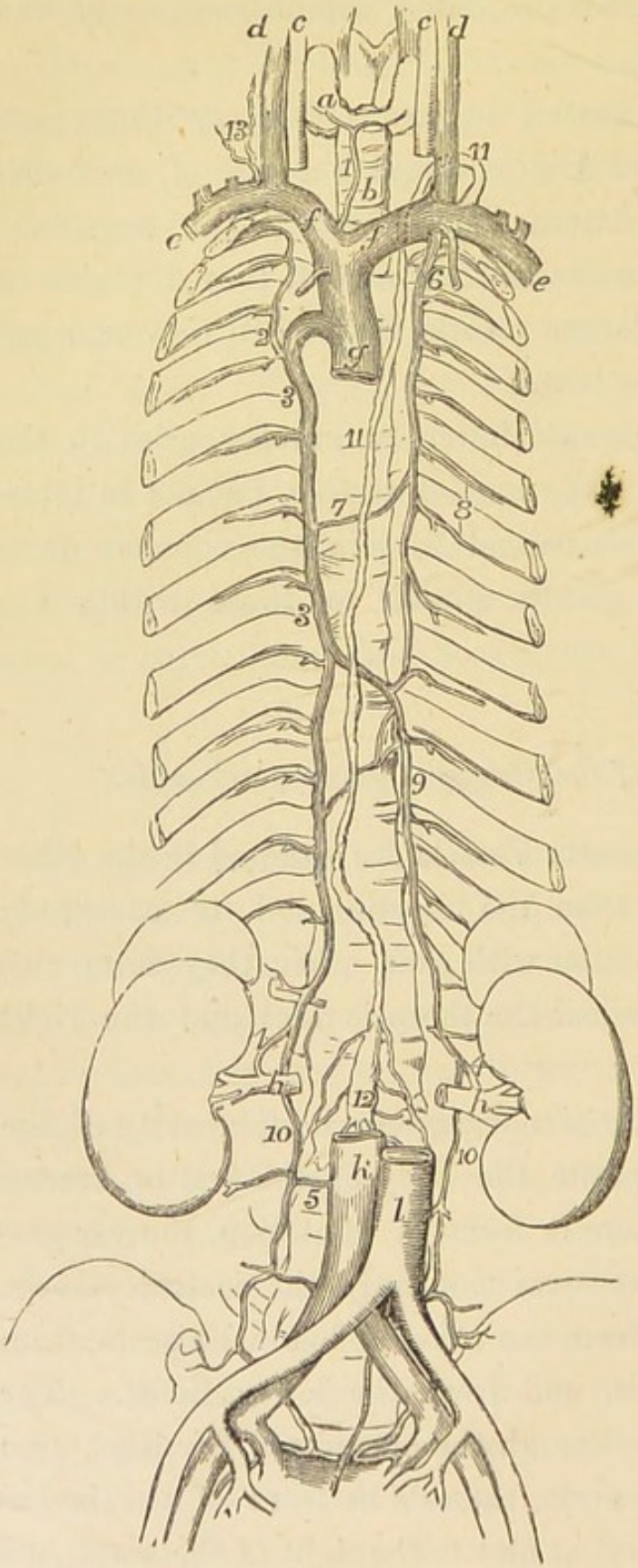

FIG. 143.—The Great Systemic Veins. *a*, thyroid body; *b*, trachea; *c*. *c*, common carotid arteries; *d*, *d*, internal jugular veins; *e*, *e*, subclavian veins; *f*, *f*, innominate veins; *g*, superior vena cava; *h*, *h*, renal veins; *k*, inferior vena cava; *l*, abdominal aorta. 1, inferior thyroid vein; 2, right superior intercostal vein; 3, 3, vena azygos; 4, origin of vena azygos from right renal vein, and 5, from lumbar vein; 6, left superior intercostal vein; 7, communicating branch with vena azygos; 8, 8, intercostal veins; 9, lesser vena azygos; 10, origin from renal and lumbar veins; 11, 11, thoracic duct; 12, receptaculum chyli; 13, right lymphatic duct.

then inclines behind the arch and reaches the left side of the œsophagus, at the side of which it ascends to the root of the left side of the neck. In its course in the thorax it receives the deep lymphatics of the left half of the chest, and at the root of the neck on the left side it is joined by the deep and superficial lymphatics of the left upper limb and left side of the head and neck, and opens into the internal jugular or the subclavian vein, or at the angle of junction between them. This duct conveys, therefore, the chyle during digestion, and the lymph contained in the lymph-vessels below the diaphragm and in the lymph-vessels situated to the left side of the mesial plane in the parts of the body above the diaphragm. The thoracic duct contains numbers of valves in its course, and a two-segmented valve occurs at its junction with the jugular vein, which prevents the blood from flowing from the vein into the duct.

The RIGHT LYMPHATIC DUCT is much smaller than the thoracic duct. It is situated on the right side of the root of the neck, and is formed by the junction of some of the lymph-vessels of the right half of the thoracic cavity, with those of the right upper limb and right side of the head and neck. It joins the great veins at the angle of union of the right internal jugular with the right subclavian, and a two-segmented valve, which prevents the flow of blood into it, is situated at its orifice.

The LYMPHATICS OF THE UPPER LIMB are arranged in a superficial and a deep set. The *superficial* lymph-vessels arise in the fingers as digital lymphatics, and from the

skin of the back of the hand and palm. From the hand they ascend to the fore arm, and then run along the upper arm to the axilla, where they enter the axillary glands. In the superficial fascia, immediately above the internal condyle of the humerus, one or two lymphatic glands are found in the course of the superficial lymph vessels.

The *deep* lymphatics ascend from the palm and accompany the radial, ulnar and interosseous arteries in the fore arm. In the upper arm they accompany the brachial artery, and with it enter the axilla. The *axillary lymph-glands*, about twelve in number, lie in the fat of the axilla, and to them the deep and superficial lymph-vessels of the upper limb proceed. Along the course of the deep brachial lymphatics some small lymphatic glands are sometimes seen. In addition to the lymph-vessels of the upper limb, the axillary glands receive superficial lymphatics from the anterior thoracic wall and the mammary gland, and the superficial lymphatics of the back. From the axillary glands lymph vessels proceed, which accompany the subclavian artery and join on the left side the thoracic duct, on the right side the right lymphatic duct.

The Lymphatics of the Head and Neck are arranged in a superficial and a deep set. The *superficial* lymphatics of the face accompany the facial vein to the submaxillary region; whilst the superficial lymphatics of the cranium run along with the occipital and temporal blood-vessels to the back and side of the neck. *Deep* lymphatics accompany the internal maxillary vein from the deep parts of

the face; deep lymphatics proceed from the pia mater and arachnoid membrane and leave the skull along with the internal jugular vein. In the neck *superficial* lymphatics are placed beneath the skin, and deep lymphatics proceed from the pharynx, larynx, tongue, &c. The lymphatics, both of the head and neck, converge towards the region of the sterno-mastoid muscle, and communicate with numerous cervical lymphatic glands arranged so as to form a chain connected by interglandular lymph-vessels, and termed the *glandulæ concatinatæ.* These glands lie under cover of the sterno-mastoid, and from their lower ends lymph-vessels proceed which join on the right side the right lymphatic duct; on the left side the thoracic duct. Lymphatic glands occur in the submaxillary region, also superficial to the parotid gland, and in close relation to the occipital artery, where it pierces the trapezius to reach the back of the scalp.

The LYMPHATICS OF THE THORAX are situated in both the thoracic walls and in the viscera. The *superficial* lymphatics of the walls pass, as already stated, into the axilla, to enter the axillary glands. The *deep* lymphatics of the walls accompany the internal mammary and intercostal arteries, and in their course pass through lymphatic glands. Those which accompany the internal mammary arteries are in connection with the *sternal* or *anterior mediastinal glands*, and end on the right side in the right lymphatic duct, on the left side in the thoracic duct. Those which accompany the series both of right and left intercostal arteries end in the thoracic duct.

The *Lymphatics of the Lungs* form a *superficial* set

beneath the pleura, and a *deep* set accompanying the bronchus and the pulmonary blood-vessels. They pass from the lung at its root and enter the *bronchial glands*, which form a large cluster, both at the root of the lung and in the angle of bifurcation of the trachea. From the bronchial glands lymph-vessels proceed, which on the right side join the right lymphatic duct, on the left the thoracic duct.

The *Lymphatics of the Heart* accompany the coronary blood-vessels, and form at the base of the heart a right and a left trunk, each of which ascends in relation to the trachea; the right to end in the right lymphatic duct, the left in the thoracic duct. In their course they pass through lymphatic glands.

The *Lymphatics of the Œsophagus* are said to form only a single set, situated in the submucous coat; they leave the œsophagus and pass through lymphatic glands situated around the tube, and end in the thoracic duct.

The *Lymphatics of the Thymus* gland are numerous in infancy and childhood, and have been traced by Astley Cooper into the internal jugular veins.

The LYMPHATICS OF THE ABDOMEN are situated in both the abdominal walls and in the viscera.

The *superficial* lymphatics of the anterior abdominal wall descend to join the *inguinal lymphatic glands* situated in the groin immediately below Poupart's ligament.

The *deep* lymphatics of the wall run along with the internal and external iliac arteries and their branches;

they have numerous *iliac lympatic glands* connected with them. They ascend alongside of the aorta and inferior vena cava, passing through numerous *lumbar lymphatic glands* in their course, diminish in number but increase in size, and opposite the second lumbar vertebra unite to form the commencement of the thoracic duct. The iliac and lumbar lymphatic glands receive numerous lymph-vessels from the pelvic walls, the iliac fossæ, and the muscles of the loins.

The *Lymphatics of the Abdominal Viscera* proceed from the stomach, spleen, pancreas, liver, supra-renal capsules, kidneys, bladder, prostate gland, vesiculæ seminales and testicles, and in the female from the ovaries, uterus, and vagina.

In the *hollow viscera*, as the stomach and uterus, they are arranged in two sets, a *superficial* beneath the serous coat, a *deep* in the submucous coat. The lymphatics of the stomach leave that organ along with the blood-vessels; some join the lymphatics from the spleen, others the lumbar lymphatics, others one of the larger lacteals before it enters the receptaculum chyli. The lymphatics of the uterus receive those from the ovaries and vagina; whilst some accompany the ovarian arteries to join the lumbar lymphatic glands, others pass to the glands and lymph-vessels which accompany the internal iliac artery. The lymphatics of the bladder and vesiculæ seminales also enter the internal iliac glands and lymph-vessels.

In the *solid viscera* the lymphatics are arranged in two sets. The *superficial* are situated in relation to the tunica propria of the organ; the *deep* accompany the blood-vessels which pass into its substance. The lymphatics of

the pancreas join those from the spleen, and the splenic lymphatics accompany the splenic artery, and join the lumbar lymphatics. The lymphatics of the liver have different modes of termination; those from the upper surface communicate with the lymphatics which accompany the internal mammary arteries; those from the under surface join the commencement of the thoracic duct; whilst the deep lymphatics leave the liver at the transverse fissure and join one of the larger lacteals before it opens into the receptaculum chyli. The lymphatics of the supra-renal capsules join those of the kidneys, and the renal lymphatics open into the lumbar chain of lymphatic glands. The lymphatics of the testicles ascend along with the spermatic blood-vessels, and enter the lumbar chain of glands.

The Lymphatics of the Lower Limb are arranged in a superficial and a deep set. The *superficial* lymph-vessels arise in the toes, and on the dorsal and plantar surfaces of the foot; they ascend to the leg, and accompany the internal and external saphenous veins. Those which run up the back of the leg in part pierce the popliteal fascia along with the external saphenous vein, and join the deep popliteal lymphatics; but the others extend to the inner side of the knee, and ascend along with the superficial lymphatics, which accompany the internal saphenous vein, on the anterior surface of the thigh as far as the groin, where they enter the femoral group of lymphatic glands. The *superficial glands* of the *groin* are eight or ten in number, and lie in the superficial fascia. It is customary to arrange them in two groups: an inferior, lying parallel

to the internal saphenous vein, named *femoral* glands, and a superior, lying parallel to and immediately below Poupart's ligament, named *inguinal* glands. The femoral glands receive the superficial lymph-vessels which ascend along the thigh. The inguinal glands receive the superficial lymph-vessels from the outside of the thigh, the anterior abdominal wall, and the organs of generation. From both sets of glands lymph-vessels proceed which perforate the fascia lata, at and near the saphenous opening, and join the deep lymphatics of the limb.

The *deep* lymph-vessels of the lower limb ascend from the sole and dorsum of the foot, along with the anterior and posterior tibial and the peroneal arteries. In the popliteal space they enter lymphatic glands situated in close relation to the popliteal artery. From these glands efferent vessels emerge, and ascend along with the femoral artery to reach the deep lymphatic glands of the groin, where they are joined by the efferent vessels from the superficial glands. They then ascend on the inner side of the femoral vein, through the crural canal, or innermost compartment of the femoral sheath, enter the abdominal cavity, and become continuous with the deep lymph-vessels and glands which accompany the external iliac artery.

Structure of the Lymphatic Vessels.

The lymphatic vessels consist of vessels that can be seen with the naked eye, and of lymph capillaries.

The *Larger Lymphatics* have in many respects the structure of veins, and like them possess three coats. The *outer* coat consists of white fibrous tissue, intermingled with elastic fibres, and a few bundles of non striped mus-

cular fibre. The *middle* coat is formed of circularly arranged non-striped muscular fibre, intermingled with elastic fibres. The *inner* coat consists on its free surface of a layer of elongated, flattened, endothelial cells, outside which is a layer of elastic fibres arranged longitudinally. The valves of the lymphatics are simple folds of the inner coat. They usually consist of two semilunar segments, lying side by side. They occur much more frequently than in the veins, and as the wall of the lymphatic has a slight sinus or bulging opposite each valve, the vessel, when distended, has a beaded or moniliform appearance.

The *Lymph Capillaries* lie between the tissues of the organs in which they are situated. They are arranged in a network or plexiform manner, the meshes of which are polygonal. The capillary wall is formed of a single layer of elongated, flattened, endothelial cells, the outlines of which can be stained on the addition of a solution of nitrate of silver. The lymph capillaries, where they pass into the larger lymph-vessels, differ from the blood capillaries in possessing indications of a beaded or varicose appearance, due apparently to an imperfect valvular arrangement in the interior of the tube.

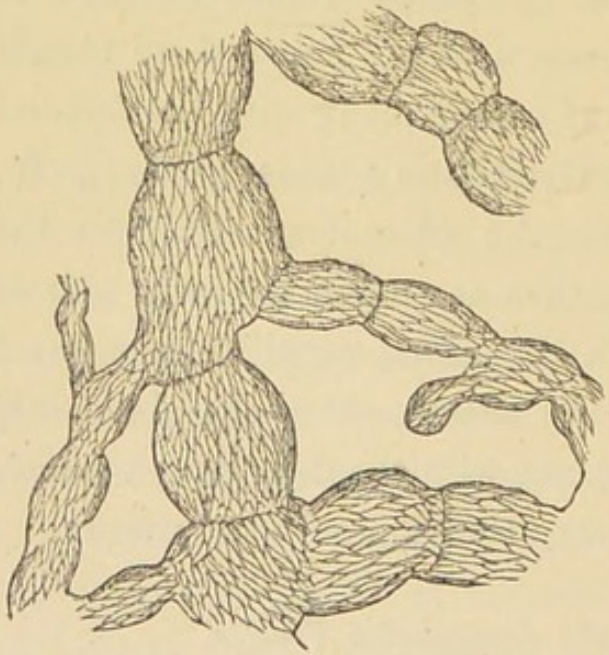

FIG. 144.—Lymph Capillaries and finer lymphatic vessels, from the lymphatic network beneath the peritoneal covering of the diaphragm. From a preparation made by Klein. × 80 diam.

Origin of the Lymphatic Vessels.

The mode of origin of the lymphatic vessels is a difficult subject of study, and has long been a disputed question amongst anatomists. In the intestinal villi they are capillary tubes, which come apparently to a blind termination near the free end of the villus, though some observers have supposed that they are continuous with a minute network in the basis substance of the villus, and through it with the deeper ends of the epithelial cells covering the villus.

In the skin, the mucous and submucous tissues, the tendons, and other forms of connective tissue, lymph-capillaries form at their origin a compact polygonal network, which is apparently continuous with spaces in the connective tissue, situated either between its bundles or surrounding the connective tissue corpuscles. These spaces have been termed the *juice* or *plasma canals;* they are not vessels in the proper sense of the word, but, as it were, microscopic chinks in the tissue. They communicate freely with each other, and apparently with the lymph capillaries. It is an open question if these plasma passages possess any other boundary than that of the elements of the tissue in which they are situated, though some observers have described them as lined by a layer of endothelium. These plasma passages provide an arrangement by means of which the tissues can be permeated by a nutritive fluid derived from the liquor sanguinis, and afford room for the wandering colourless corpuscles which have migrated out of the blood-vessels. T. A. Carter has injected from the blood-vessels an extremely minute net-

work in the tissues, the strands of which are not more than $\frac{1}{4300}$ to $\frac{1}{8600}$th of an inch in diameter; he names it the *diaplasmatic network*, and it is apparently the juice passages just referred to.

By Virchow and others it has been thought that the connective tissue corpuscles are continuous with the lymph capillaries, and these also have been named juice canals.

In some localities, as around the solitary and Peyer's glands, as well as around the glands of Brunner and other acinous glands, the lymph capillaries at their origin have not the form of cylindrical tubes, but are dilated into irregularly-shaped spaces, lined by an endothelium. Around the arteries of the pia mater, both external to and in the substance of the brain and spinal cord, are situated lymph-spaces, in the form of hollow cylinders, and termed the *peri-vascular canals;* and a similar arrangement has been seen around the small vessels at the border of the cornea.

In the sub-endothelial tissue of the serous membranes a close network of lymph capillaries is situated, which, as Recklinghausen pointed out, communicate with the serous cavity through small openings, or stomata, on its surface. These openings, as has already been described (p. 140), are surrounded by polygonal, distinctly nucleated cells, with granular contents, which differ in appearance from the ordinary endothelial covering of the serous membrane. The serous

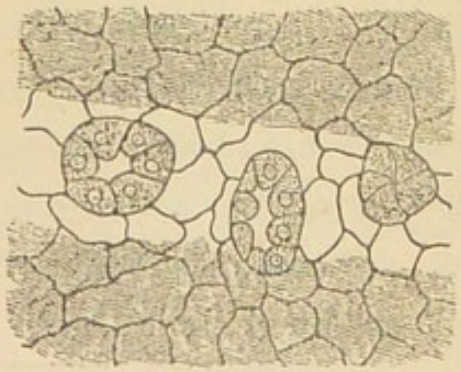

FIG. 145.—Endothelial cells from the peritoneal serous membrane. Three stomata may be seen surrounded by polyhedral nucleated cells; the one to the right is closed. The light band marks the position of a vertical lymphatic vessel. (*After Klein.*)

cavities have, therefore, been regarded as great lymph spaces freely communicating with the lymph-capillaries. But the fluid which the serous cavities contain is not lymph in the proper sense of the word, but a thin serum, in which a few lymph corpuscles may be suspended. In the view that the serous cavities are lymph spaces they may be regarded as affiliated to the lymph-lacunæ of the lower vertebrata. In the frog, for example, spaces exist in the subcutaneous region, which communicate with the lymphatic system, and in the same animal the aorta and other large arteries are enclosed in perivascular lymph spaces.

The thoracic duct and the right lymphatic duct are, as already described, the great channels of communication between the lymphatics and the veins, but other smaller connections have also been described in the human body. Wutzer saw in one subject two offshoots from the thoracic duct opening into the vena azygos. Nuhn has observed lymph-vessels opening into the renal veins and inferior cava; and Petrel has seen lymphatics communicating with the portal vein, renal veins, and vena azygos. It is possible that these smaller communications may enlarge and serve as important channels for the flow of lymph and chyle into the blood, in cases where the thoracic duct has become obliterated by pressure from an aneurism of the thoracic aorta.

It may be stated, that in amphibians, reptiles, and some birds, pulsating vesicles, with muscular walls, named *lymphatic hearts*, occur in connection with the termination of the lymph-vessels in the venous system, and, by their contraction, drive the lymph into the veins. No lymph hearts have, however, been found in the mammalia.

Two sets of capillary vessels occur in the tissues and organs, the blood capillaries and the lymph capillaries. The network of lymph capillaries is not continuous with or even in contact with the network of blood capillaries, but the lymph capillaries lie in the meshes of the blood capillary network, and are separated from them by intervening tissue elements. The blood which flows into the blood capillaries from the arterial system is for the most part conveyed directly onwards into the veins; but from the pressure to which the blood is subjected, in part its liquor sanguinis, with perhaps some white corpuscles, transudes through the delicate coats of the capillaries into the tissues. That which is required for the nutrition of the tissue is applied to that purpose. That which is not needed would accumulate in the tissues, were it not that a drainage system is provided by means of the plasma channels, whch convey it into the lymph capillaries, and from them it is transmitted into the larger lymph vessels. Hence, while there is only one channel, viz., the arterial, for conveying pabulum to the tissues of an organ, there are two channels, viz., the venous and lymphatic, for conveying

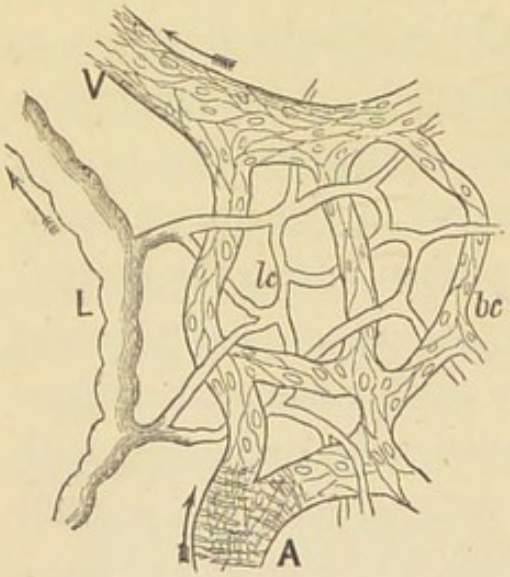

FIG. 146.—Diagram of the relation of the Blood and Lymph Capillaries amidst the tissues. A, small artery; *bc*, blood capillary network; *lc*, lymph capillary network; *v*, vein; L, lymphatic. The arrows indicate the course of the blood and of the lymph stream. The spaces between the capillaries of the two networks are occupied by the tissue of the part.

the unemployed part of that pabulum back to the central part of the circulatory apparatus. Under some pathological conditions, the blood serum transudes in such quantities into the tissues that it cannot be conveyed away by the drainage system, so that it occasions an œdema, or a dropsical accumulation in the part.

LYMPHOID ORGANS.

In many parts of the body round, colourless cells, resembling the corpuscles of lymph, or the white corpuscles of the blood, are either infiltrated into the meshes of the connective tissue, or are collected into masses visible to the naked eye. These may appropriately be called Lymphoid Organs. Not unfrequently these organs are situated as node-like swellings in the course of the lymphatic vessels, and are invested by definite capsules, when they are known as *Lymphatic Glands*. At other times they are not separated from the surrounding connective tissue by a definite capsule, and apparently are not situated in the direct course of lymphatic vessels, though a network of lymph-capillaries may lie around them, when they are termed *Lymph Follicles*.

LYMPH FOLLICLES.

The Lymph Follicles are especially found in connection with the mucous lining of the alimentary canal, and occur in the mucous membrane of the back of the dorsum of the tongue, in the tonsils, the wall of the pharynx, as the solitary glands of the œsophagus, stomach, and intestines, and as the Peyer's glands in the small intestine: their characteristic tissue is also infiltrated into the basis substance of the intestinal villi, and into the connective tissue which separates the tubular intestinal glands from each other. But the lymph follicles are not confined to the alimentary mucous membrane. They are situated in the conjunctiva, where they form the trachoma glands, in the mucous membrane lining the Eustachian tubes, in the laryngeal, tracheal and bronchial mucous membrane, and they have also been seen in the mucous membrane of the urinary bladder and in that of the vagina. They are developed also in large numbers in the spleen, and form its Malpighian bodies. They constitute the structure of the thymus gland. Lymph follicles have also been described in relation to the pleura and the great omentum. The presence of lymph-follicles in the respiratory and intestinal mucous membranes is of interest in relation to the frequent formation of tubercle, under certain pathological conditions, in those localities.

The characteristic tissue of the lymph follicles has been variously named *lymphoid tissue*, *lymph-follicular tissue*, and *adenoid tissue*. It consists essentially of two structural elements: first, of colourless corpuscles resembling those of the lymph and blood; second, of stellate branch-

ing cells, the processes of which anastomose freely with each other, so as to form a network or reticulum of the retiform connective tissue (fig. 147). These cells are distinctly nucleated. This reticulum forms a sustentacular or supporting framework for the lymph corpuscles, which fill up the interstices of the meshwork. When this lymphoid tissue is developed so abundantly in a locality as to form definite masses, or follicles, they usually possess a spheroidal or ovoid form, such as one sees in the solitary glands, in the individual glandules of a Peyer's patch, in the trachoma glands of the conjunctiva, the faucial and pharyngeal tonsils, and the Malpighian bodies of the spleen. At other times the tissue is not aggregated into masses, but is uniformly diffused throughout a particular locality, as is the case in the basis substance of the intestinal villi, in the interglandular connective tissue of the intestinal mucous membrane, and in the sheath and outer coat of the branches of the splenic artery. It not unfrequently happens, as in the tonsils and the conjunctival mucous membrane, that not only is the lymphoid tissue aggregated into definite masses or follicles, but that lymph corpuscles are infiltrated or diffused throughout the connective tissue, which surrounds the individual follicles.

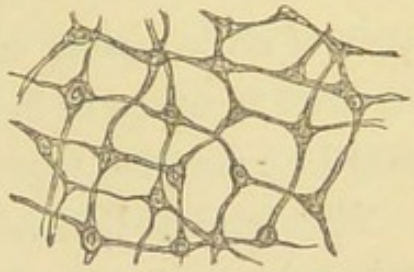

FIG. 147. — Retiform connective tissue from a lymphatic gland, × 300.

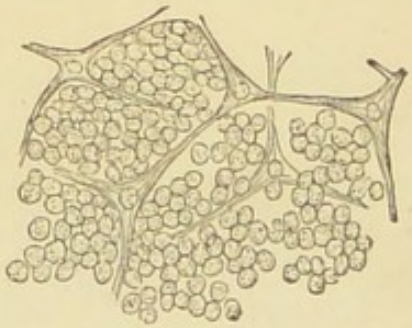

FIG. 148.—Lymphoid tissue, with the lymph cells situated in the interstices of the reticulum formed by the stellate retiform cells × 450.

The lymphoid tissue in the centre of a lymph follicle has a more open meshwork than at the periphery, where the retiform tissue is more compact and often simulates the appearance of an investing capsule. When a number of follicles lie close together, as in a Peyer's patch, the separate follicles may be connected together by intermediate retiform tissue.

The lymph follicles possess considerable vascularity. Not only do the blood-vessels form a network around the follicles, but, as may easily be seen in injected solitary and Peyer's glands, capillaries pass from the periphery to the centre of each follicle, and form in it a wide meshed plexus, the strands of which are in relation to the sustentacular framework.

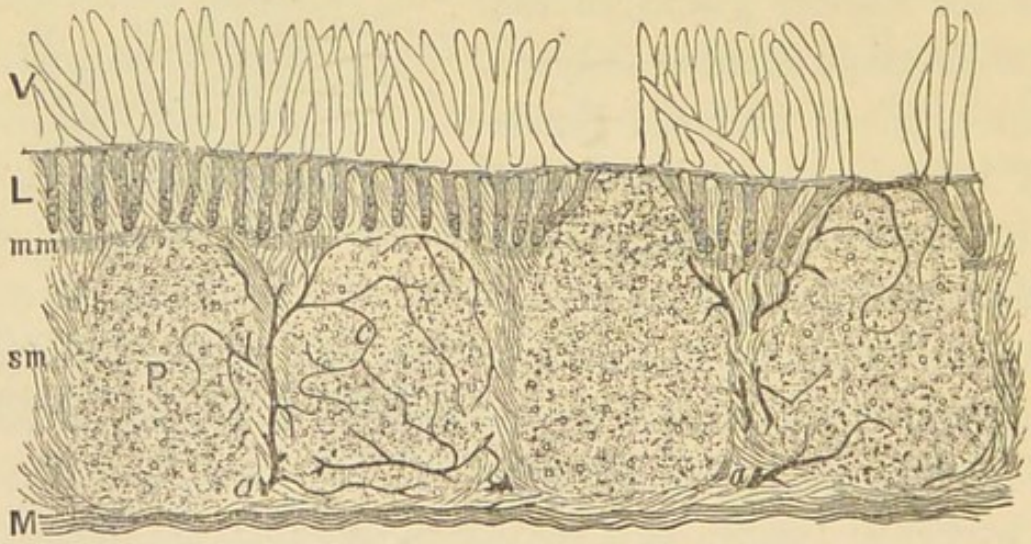

FIG. 149.—Vertical section through a Peyer's patch in the wall of the small intestine. V, the intestinal villi; L, the layer of Lieberkühn's glands; *mm*, the muscularis mucosæ; *sm*, the connective tissue of the submucous coat; P, the follicles of a Peyer's patch. The two to the right are completely divided from the cupola to the base; the two to the left are cut through to one side of the apex; *aa*, small arteries in the submucous coat, which enter the follicles of Peyer, and form *c*, a capillary network; M, muscular coat. Slightly magnified.

Lymphatic vessels have a close relation to the lymph follicles. In the solitary and Peyer's glands of the intestine, where their arrangement has been chiefly studied, a network of lymph capillaries has been seen around the peri-

phery of the follicles. Frey has described the bases of these follicles as invested by a system of spaces or passages, continuous with and capable of being injected from the lymphatic system. It is possible that these spaces communicate with the meshwork of the retiform tissue of the follicle, but the communication has not been definitely ascertained. There can be no doubt, however, that the lymph follicles are appendages of the lymph-vascular system, and are the seats of production of lymph corpuscles. Nothing is known of the arrangement of the nerves in relation to the lymph-follicles.

Lymphatic Glands.

The Lymphatic Glands are nodal swellings occurring in the course of the lymphatic vessels. They are abundantly distributed throughout the body, and are found in clusters in the groin, axilla, neck, chest, abdomen, &c., as has been described in the section on the distribution of the lymphatic vessels. They often are arranged as a chain of glands connected together by intervening lymph vessels. They are round or oval in shape, and vary in size from a small shot to a kidney bean. It is not uncommon for the glands to enlarge and for adjacent glands to become fused together. Each gland receives at one end several lymphatic vessels called *vasa afferentia*, and from it lymphatic vessels, called *vasa efferentia*, emerge; which in their onward course may become afferent vessels for glands situated higher in the course of the lymphatic vessels (fig. 150). Where the efferent vessels pass out of a gland a depression on its surface, named the *hilus*, is often seen.

Each lymphatic gland is surrounded by a *capsule*, which consists of interlacing bundles of connective tissue intermingled with non-striped muscular fibres, which in some animals, as the ox, are very numerous. When a section is made through a gland it is seen to consist of an external, yellowish-red, rtical part, and of a central, more deeply red, medullary part, which, however, reaches the surface at the hilus.

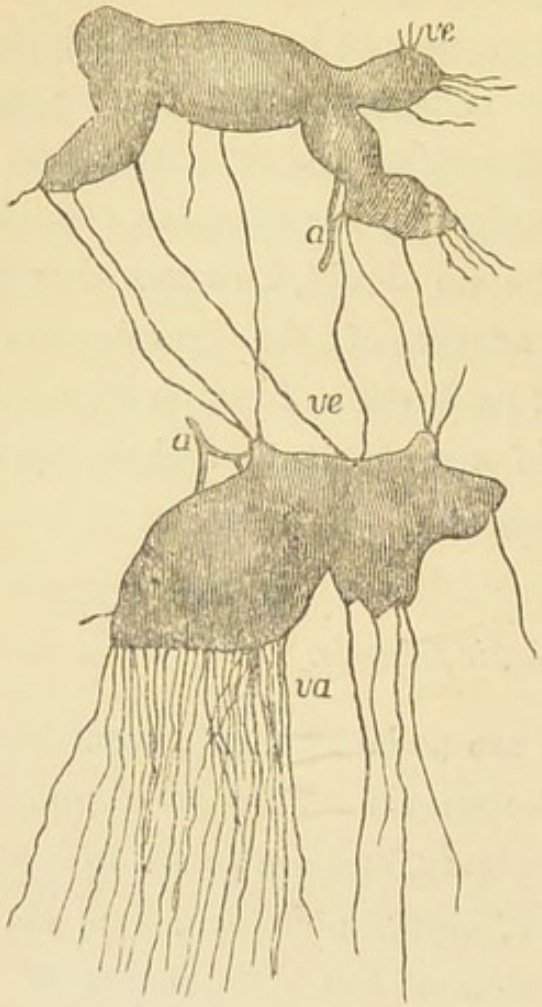

FIG. 150.—Cluster of Lymphatic Glands of the groin, between some of which fusion has taken place. *va*, vasa afferentia; *ve*, vasa efferentia; *a*, *a*, small arteries. Natural size

From the capsule thin laminæ pass into the *cortical* substance and form in it a trabecular framework, which divides the cortex into a number of compartments or alveoli. These alveoli contain rounded nodules, consisting of the proper glandular or follicular tissue of the lymphatic gland, which is arranged therefore as a number of follicles, called the follicles of the cortex. As the trabeculæ do not form perfect partitions between adjacent follicles, the tissue of one follicle is to some extent continuous with that of those which lie around it. These follicles are formed of lymphoid tissue, resembling in structure the lymphoid follicles already

described, and the meshes of the reticulum are crowded with lymph corpuscles. Surrounding each of the follicles, and bounded by the trabeculæ, is a space traversed by a reticulum of the retiform connective tissue, the stellate

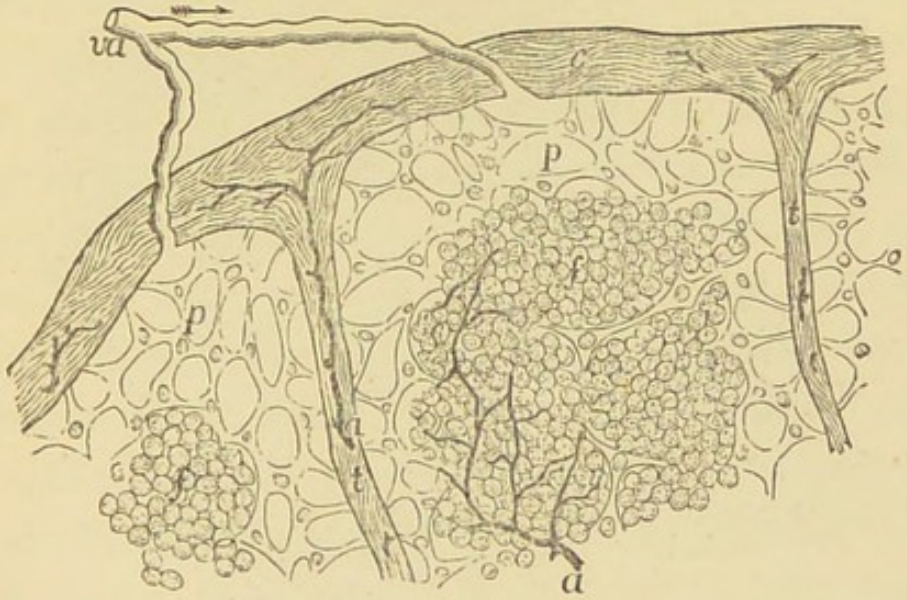

FIG. 151.—Semi-diagrammatic view of the structure of the cortex of a Lymphatic Gland. *c*, capsule; *t*, *t*, trabeculæ; *p*, lymph passage with retiform tissue; *f*, lymph follicle; *v a*, vas afferens communicating with lymph passages; *a*, arteries and blood capillaries. Highly magnified.

cells of which are continuous on the one hand with the retiform tissue of the follicle, and on the other with the trabecular framework of the cortex. This space contains lymph corpuscles, which are easily washed out, and it obviously resembles the lymph spaces or passages which invest the bases of the follicles of a Peyer's patch. It communicates with the vasa afferentia, from which it can be injected. Owing to the continuity between the tissue of adjacent follicles, their surrounding lymph spaces are also continuous with each other, and form an anastomosing set of lymph passages within the cortex of the gland.

The *medullary* part of the lymphatic gland is also

traversed by a trabecular framework continuous with that of the cortex. The trabecles are arranged in a cylindriform manner, and enclose alveoli, which contain lymph follicles that possess a cylindrical form. Here also, as in the cortex, the lymphoid tissue of the follicles within adjacent

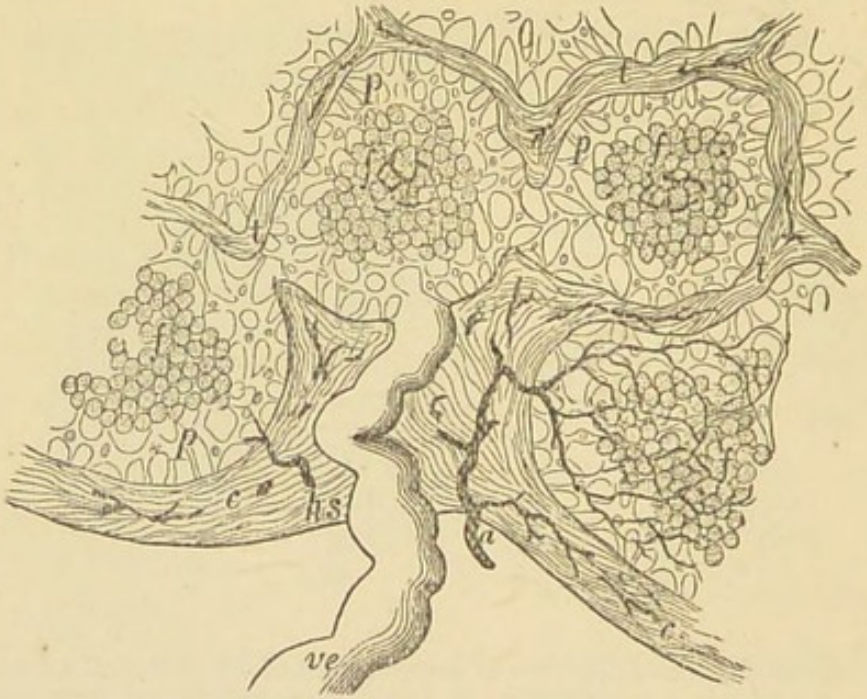

FIG. 152.—Semi-diagrammatic view of the medullary part and the hilus of a Lymphatic Gland. *hs*, stroma of hilus; *ve*, vas efferens; *a*, artery ending in capillaries; *c*, capsule; *tt*, trabeculæ; *pp*, lymph passage; *f*, follicles, highly magnified.

alveoli is continuous through gaps in the intervening trabecular wall. The medullary lymph follicles are surrounded by lymph passages, continuous, on the one hand, with the lymph passages in the cortical part of the gland, and on the other, with the vasa efferentia, with which the medullary substance comes into direct relation at the hilus. The medullary lymph passages can be injected from the vasa efferentia. The surfaces of the trabeculæ which bound the lymph passages both in the cortex and medulla are covered by a layer of endothelial cells con-

tinuous with the endothelium of the vasa afferentia and efferentia.

Through the researches of His, Frey, and Recklinghausen, it has now therefore been established that a lymphatic gland is permeated by an anastomosing system of lymph passages or channels, continuous with the afferent and efferent vessels. These channels surround the follicular masses of lymphoid tissue, and as the stream of lymph flows through the gland, it washes lymph corpuscles out of the meshes of this lymphoid tissue, which corpuscles mingle with the lymph stream and are carried onwards in its flow. The lymphatic glands are the seats of production of lymph corpuscles, and are the great centres of origin therefore of the white corpuscles of the blood.

Each lymphatic gland receives at least one small artery, which enters at the hilus, and breaks up into branches that in part ramify in the capsule and trabecular framework, and in part pass directly to the follicular tissue. Capillaries are distributed in the follicular tissue in which they form a plexus; they supply the pabulum for the nutrition and production of the lymph corpuscles: veins arise from this plexus and pass out of the gland at the hilus.

In many lymphatic glands a quantity of fibrous connective tissue, named by His the *hilus-stroma*, is situated at the hilus, and surrounds the artery, vein, and vasa efferentia. It also not unfrequently contains a collection of fat cells. Vaso-motor nerves accompany the blood-vessels into the gland, and supply not only their muscular coat, but the muscular tissue of the capsule and trabeculæ. Nerve-cells have also been described on these nerves by some observers.

The Ductless Glands.

In several parts of the body soft, vascular, glandular-looking organs are found, which differ from secreting glands in not possessing an excretory duct, and, in consequence of this anatomical character, have long been known as the DUCTLESS GLANDS, or GLANDS WITHOUT DUCTS. The spleen, thyroid gland, thymus gland, supra-renal capsules, pineal gland, and pituitary body are all distinguished by this peculiarity. From recent observations on their structure and functions, it has been ascertained that some of the ductless glands have a physiological relation to the blood-vascular system, and they have consequently been called the BLOOD-VASCULAR GLANDS. As two of these glands, viz., the spleen and thymus, contain large quantities of lymphoid tissue, and are the seats of production of lymph corpuscles, they have been named BLOOD-LYMPH-VASCULAR GLANDS. It is possible that the thyroid gland, the pituitary and pineal glands, and the supra-renal capsules, may have a physiological relation to the vascular system, but as their structure differs in some particulars both from each other, and also from that of the spleen and thymus, their exact function is even yet involved in much obscurity. It may also be stated, that by some observers the coccygeal and intercarotic bodies have been referred to the blood-vascular glands, but their structure more closely approaches that of a modified rete mirabile. I have preferred, therefore, to group these glands together by the term Ductless Glands, which expresses an anatomical character common to the whole series, rather than to employ the term Blood-Vascular Glands, used by many writers,

which implies that all these organs possess a special relation to the blood-vascular system.

THE SPLEEN.

The Spleen is the largest of the ductless glands. It lies in the costal zone of the abdomen, and is so deeply placed in the left hypochondrium that, when the abdomen is opened, it is not seen until the stomach is drawn on one

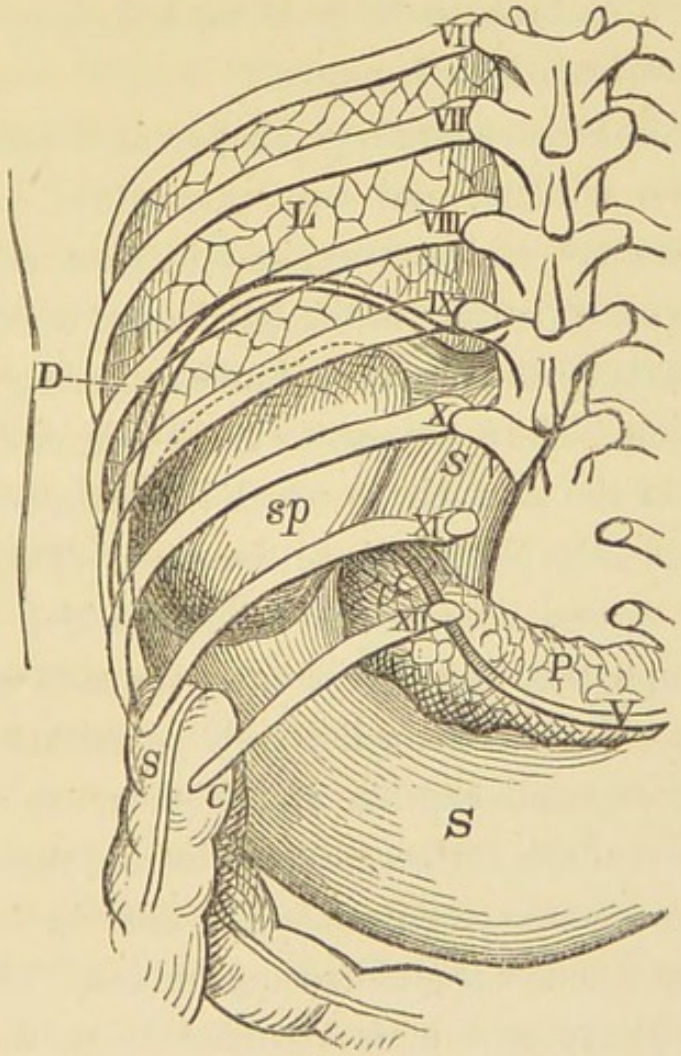

FIG. 153.—View of the Spleen and Stomach from behind, after the removal of the intercostal and lumbar muscles. VII to XII, the lower seven ribs; L, the lung; SS, stomach; *sp*, spleen; P, pancreas; V, splenic vein; SC, splenic flexure of colon; D, diaphragm; the black line immediately below which is the fundus of the stomach. Modified from Luschka.

side, for it is situated between the diaphragm and the posterior surface of the stomach. It lies obliquely from

above downwards and forwards, and as Luschka has pointed out, is in front of and follows the curvature of the ninth, tenth, and eleventh ribs. Its inner and upper end, when the spleen is of average size, is about 1 inch from the spinal column, its outer and lower end reaches to about $1\frac{1}{2}$ inch from the tip of the eleventh rib. It varies much in size in different individuals, and at different times in the same person, but its average length is from 5 to 6 inches, and its breadth from 3 to 4 inches, whilst its weight varies from 5 to 7 ounces.

The spleen is elongated in shape, and possesses two surfaces, two borders, and two extremities. The *outer surface* is smooth and convex, and in close contact with the concave under surface of the left half of the diaphragm; the movements of which muscle it follows during inspiration and expiration. The *inner surface* is concave, and in relation to the back of the stomach, to which it is attached by a fold of peritoneum, the *gastro-splenic omentum*. This surface is marked by several depressions through which the blood-vessels, lymphatics, and nerves enter the substance of the spleen; these depressions collectively constitute the hilus. The left supra-renal capsule and kidney are in relation to a small part of this surface, situated behind the attachment of the gastro-splenic omentum. The *anterior border* often presents a notched or crenulated appearance. The *posterior border* is thicker and more rounded than the anterior. The *upper* and *inner extremity* is attached to the diaphragm by a fold of the peritoneum, named the *suspensory* or *phrenico-splenic ligament*. The *lower* and *outer end*, more pointed than the upper and inner end, is in relation to the splenic flexure of the colon and the phrenico-colic ligament.

The great increase which not unfrequently takes place in the bulk of the spleen, leads to an extension of its relations to surrounding parts; and in these cases it may be seen appearing at the side of the great curvature of the stomach, or even projecting, obliquely downwards and forwards, into the lumbar or umbilical regions of the abdomen. Occasionally also portions of spleen substance are detached, and form *accessory spleens*, situated in the great omentum, or in the gastro-splenic omentum. More rarely the spleen is divided into a number of perfectly distinct lobes; a condition which is normally found in some animals, as the pilot whale.

Structure.—The spleen is a solid organ of a bluish-purple colour, and so soft in its texture that it is easily ruptured and torn. It possesses two coats,—a serous and a fibrous.

The *serous* or *external coat* is a part of the peritoneal membrane. It invests the spleen, and is reflected from it to the diaphragm as the suspensory ligament, and to the stomach as the gastro-splenic omentum.

The *fibrous coat*, or *tunica propria*, is immediately subjacent and intimately united to the serous coat. It is composed of white fibrous tissue with elastic fibres; in many animals, as the ox and dog, it contains a large proportion of non-striped muscular tissue, but in man the muscularity is only feeble. At the hilus it passes into the interior of the spleen along with the vessels and nerves, for which it forms sheaths. From the whole extent of the inner surface of the tunica propria processes pass into the substance of the spleen, which interlace freely with each other so as to form a network, the *trabecular framework* of the spleen. The individual beams, or

trabecles of this framework, possess a similar fibro-elastic and muscular structure to that of the fibrous coat. The blood-vessels ramify in the interior of the spleen in close relation to the trabecles. The intervals between the trabecles are irregular in form and size, and are occupied by a soft reddish substance, the *spleen pulp*. If a section be made through the spleen, and a current of water be directed on the surface of the section, the spleen pulp is easily washed out of these intervals, and the trabecular framework is left.

The examination of the more minute structure of the spleen is attended with many difficulties, more especially as regards the mode of termination of the splenic artery, the commencement of the vein, and the relation of the splenic blood-vessels to the spleen pulp. When the pulp is examined microscopically, it is seen to contain fine blood-vessels, spheroidal bodies called the Malpighian corpuscles, numerous cells, and a delicate reticulum of connective tissue. By one set of observers, as W. Müller and Frey, it is believed that the blood in passing from the splenic artery into the splenic vein flows into channels, which have no continuous tubular walls, so that it comes



FIG. 154.—The trabecular framework *t*, *t*, of the Spleen after the spleen pulp has been washed out; *c*, *c*, the fibrous coat seen in section. Natural size.

into direct relation with the cells and reticulum of the spleen pulp. By other observers again, as Billroth and Kölliker, it is held that the continuity of the vascular wall from the splenic artery to the splenic vein is preserved, and that the reticulum and pulp-cells lie outside the wall of the blood-vessels.

The following description, though agreeing in its main features with the descriptions of W. Müller and Frey, is chiefly based on my own observations on the structure of the human spleen and that of the rat.

The reticulum of the spleen pulp has been named the *intervascular network:* it is situated in the intervals between the trabecles, and consists of a retiform connective tissue, such as makes up the framework of a lymph follicle. The strands of this framework are composed of stellate and nucleated connective tissue cells, the processes of which anastomose with each other, but fusiform cells are intermingled with them. The interstices between these stellate cells are occupied by lymphoid and other colourless corpuscles, and by red blood corpuscles, and intervene between the capillary terminations of the arteries and the commencement of the veins, so that they are channels for the blood to flow through. They constitute a special modification of the circulatory apparatus, and are a sort of cavernous rete mirabile, not enclosed within an endothelial wall, and the stellate cells themselves form a supporting frame-

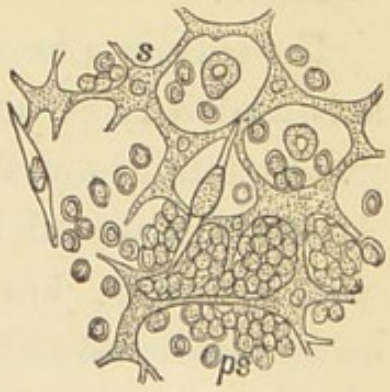

FIG. 155.—Cells of the pulp of the human Spleen. *s*, the stellate retiform cells; *ps*, colourless corpuscles of the spleen pulp. × 450.

work for the blood-corpuscles and the lymphoid corpuscles of the spleen pulp. The colourless lymphoid corpuscles have distinct nuclei, relatively large to the size of the cells, and with them are a few cells, also with distinct nuclei, but with a larger proportion of protoplasm, and somewhat polygonal in shape. In addition to the red blood corpuscles possessing the normal appearance, shrivelled red corpuscles and pigment granules are also seen, together with large cells containing several red corpuscles or pigment granules. Frey supposes that these large cells are colourless corpuscles, which have taken into their interior either entire red corpuscles, or portions of their substance, which present the appearance of clumps of yellow pigment. Owing to the elasticity of the fibrous coat and trabecles of the spleen, and the free communication of the blood-vessels with these interstices, they at times become engorged with blood: if the splenic artery be artificially injected, they are easily distended by the injection.

The splenic artery is the largest branch of the cœliac axis, and is large in relation to the size of the spleen. It divides into five or six branches before entering the hilus. After it has passed into the spleen it continues to divide and subdivide, branching dichotomously, without any anastomoses between its branches. When traced down to its finest ramifications it breaks up into clusters of branches or *penicilli*, which are usually compared in their arrangement to the hairs of a paint brush, though Frey regards them as more like the branches of a willow tree deprived of its leaves. The branches of the artery are enclosed in a sheath continuous at the hilus with the

fibrous coat of the spleen. An important metamorphosis takes place in the structure both of the sheath, and of the tunica adventitia of the smaller branches of the artery, which lose their fibro-elastic character, and become transformed into lymphoid tissue.

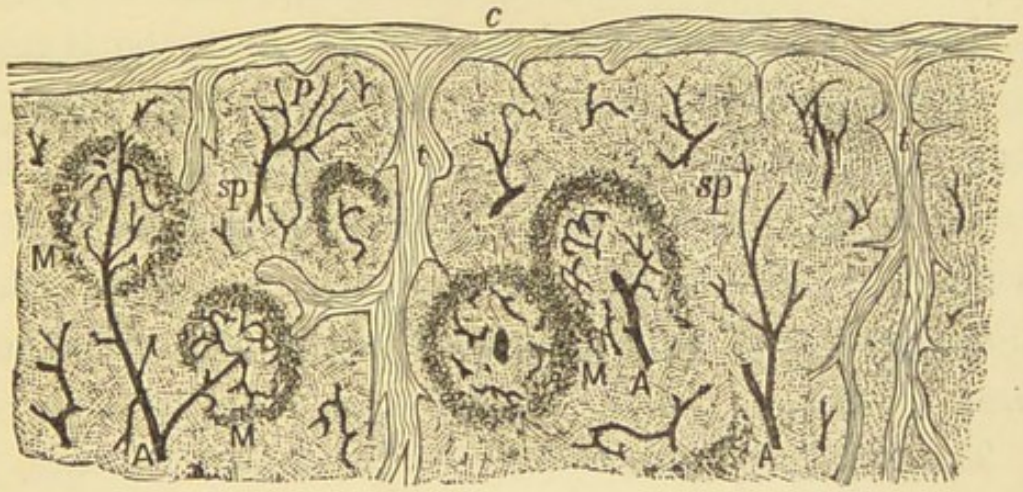

FIG. 156.—Vertical section through the Spleen to show the Malpighian corpuscles. *c*, the fibro-muscular coat; *t*, *t*, trabeculæ; M, M, M, Malpighian corpuscles; A, A, A, arteries of the spleen; *p*, penicilli; *sp*, *sp*, spleen pulp. × 80.

In many localities this lymphoid tissue increases so much in amount, as to form minute spheroidal or elliptical bodies—the *spleen-follicles*—just visible to the naked eye, and long known as the *Malpighian bodies* or *corpuscles*. Each of these bodies is therefore developed in relation to the wall of an artery. When the development takes place around the entire circumference of the wall, the Malpighian body is penetrated by the artery, which seems to form therefore its peduncle or stalk; the passage of the minute arteries into and through the Malpighian bodies was first pointed out by W. R. Sanders; when the formation of the Malpighian body is limited to one aspect only of the wall of the artery, then it is sessile on the vessel. At one time it was thought that each Malpighian

body possessed a definite capsule which separated it from the surrounding spleen pulp, but it is now known that the appearance of a capsule is due to only a greater density of the peripheral layers of the lymphoid tissue, of which the Malpighian body is composed. The meshes of the lymphoid tissue of the Malpighian body are infiltrated with colourless lymph cells. Busk and Huxley showed that the retiform tissue which forms the supporting framework of these lymph cells is continuous with the retiform tissue of the pulp. Capillaries are distributed within the Malpighian bodies, which may arise either from the arteries that penetrate them, or may enter them from without.

The capillary terminations of the finest branches of the splenic artery, both in the Malpighian bodies and in the surrounding spleen pulp, do not end directly in veins, but, according to W. Müller and Frey, open into the interstices of the intervascular network already described. The wall of the capillary, it is said, loses its tubular form, and its endothelium becomes continuous with the stellate cells of the retiform connective tissue of the pulp. Schweigger-Seidel and W. Müller state, that whilst some of the capillaries possess simple walls, others have distinct sheaths, consisting of a delicate connective tissue with round or elongated nuclei, and Frey has pointed out, that as this sheath approaches the arterioles, it assumes the characters of lymphoid tissue.

If the splenic artery be carefully injected, the injection passes out of the capillaries, and forms an anastomosing stellate network, situated between the colourless corpuscles of the spleen pulp. At first sight it appears as if the

stellate corpuscles of the reticulum had been filled with injection, so closely does the injected network resemble in form the intervascular network of stellate cells (fig. 155); but it is more probable that the reticulum merely guides the course of the injection, which lies outside the stellate cells, and not within them (fig. 157). The injected stellate network is well marked in the peripheral part of the Malpighian bodies, and is continued into their interior, so that the network within the Malpighian body is continuous with that in the surrounding spleen pulp.

The veins of the spleen do not arise directly from capillaries, but from the interstices of the intervascular network. The venous radicles are arranged as a close plexus, and possess simple walls, formed apparently of only a single layer of fusiform endothelial cells, so that they were named by Billroth *capillary veins*. Where they come into relation with the intervascular network, it is said that the continuity of their walls is interrupted, their endothelial cells are separated from each other, and assume the character of the retiform connective tissue, and their lumen communicates with the interstices of that network.

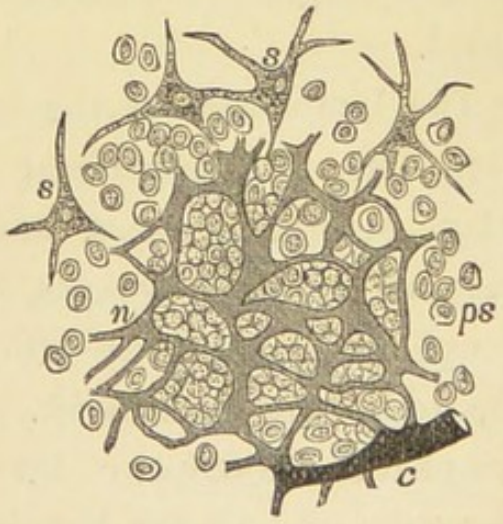

FIG. 157.—The injected stellate network in the human Spleen pulp. *c*, an injected capillary; *n*, the injected intervascular stellate network tinted grey in the figure; *s*, stellate cells; *ps*, the lymphoid corpuscles of the spleen pulp. × 450.

From the plexus of capillary veins the proper tubular veins arise, which join together to form larger trunks,

that leave the spleen at the hilus, along with the branches of the splenic artery. It seems now to have been established that the blood of the splenic artery flows into capillaries; but before it enters the veins, it has to traverse the interstices of the intervascular network of the spleen pulp, in which interstices quantities of lymphoid cells are situated, which cells are washed into the blood stream, and are conveyed into the splenic vein; so that the spleen pulp serves as a centre for the production of white blood corpuscles, and the blood of the splenic vein contains a larger proportion of white blood corpuscles than that of the splenic artery. The spleen, therefore, may be compared with a lymphatic gland, but with this difference, that while in the latter the stream which flows through the organ and collects the lymph corpuscles is lymph, in the former organ it is blood.

The lymphatics of the spleen form a superficial and a deep set. The superficial lymphatics were injected by Alex. Monro, *secundus*, and form in the ox's spleen a network of large vessels with distinct valves. Deep lymphatics, continuous with the superficial set, ramify in the trabecular framework. According to Tomsa, deep lymphatics accompany the arteries, and probably form networks around the Malpighian corpuscles. It has also been surmised that they arise from the lymphoid tissue in the coat of the smaller arteries.

Nerves from the solar plexus accompany the splenic artery and its branches throughout the substance of the spleen. Ganglion cells have been described on these nerves.

THYMUS GLAND.

The Thymus Gland is found in all animals which breathe by lungs, though it has no physiological connection with them. It is a fawn-coloured, lobulated body, situated in the upper part of the thorax, and in the lower part of the neck of infants and children. It lies for the most part in the anterior mediastinum, but is prolonged upwards into the neck in close relation to the trachea as far as the lateral lobes of the thyroid body. Its thoracic part is immediately behind the sternum, and in front of the pericardium, the left innominate vein, the aortic arch, and its three large branches. The thymus consists of two lateral lobes, somewhat triangular in form, but of unequal size. The broader part of each lobe lies in the thorax, and the narrower end forms the cervical prolongation. The two lobes are closely attached to each other by intermediate connective tissue, so that at first sight they seem to constitute a single organ. The gland reaches its maximum size about the end of the second year; after which it remains stationary for some years. About the eighth year it begins to undergo fatty degeneration, and at the time of puberty it forms two elongated lobes of fatty tissue, situated in the anterior mediastinum, in which condition it is found during the rest of life. In rare cases the thymus may retain its proper structure until after puberty; I have seen it in the adult hartebeest and nylghau preserving its normal structure.

Structure.—Each lobe of the thymus gland is invested by a capsule of connective tissue, which is prolonged into the substance of the lobe and divides it into *lobules*.

The lobules are arranged as if grouped around an axia spirally twisted stem, in which the vascular trunks of the gland are situated. By some observers the stem is believed to be hollowed out into a *central canal.* The lobules are still further subdivided into numerous *thymus follicles.* Each thymus follicle is formed of lymphoid tissue corresponding in structure to the lymph follicles already described (p. 547). The thymus follicles may either be separated from each other by distinct capsules; or the infiltration of lymph corpuscles into the meshes of the connective tissue may be so great that adjacent follicles appear to have run together. Bodies presenting a concentric appearance, the *concentric corpuscles* of Hassall, also occur, and, in the later stages of growth, cells containing oil drops, which mark the commencing fatty degeneration of the gland, are also present. The lobules of the thymus frequently contain a space in the centre, which some observers regard as normally present, though others consider it to be produced artificially by the breaking down of the lymphoid tissue of the centre of the lobule.

The thymus gland receives its supply of blood from the thymic branches of the internal mammary, and from the superior and inferior thyroid arteries. They pass to the stem of each lobe, and send off lateral branches to the lobules, which end in a capillary network within the thymus follicles. The veins which arise from the capillaries, pass out of the lobes to end in the internal mammary and innominate veins.

Lymphatics are situated in the connective tissue between the lobules and follicles, but their relation to the lymphoid

tissue of the follicles has not been traced. They leave the thymus along with the blood-vessels, and join the lymphatic glands in the anterior mediastinum. Fine nerves pass to the thymus along with the arteries, and offsets of the cardiac plexus are said to enter it.

The lymphoid tissue of the thymus gland may serve as the centre of production of the large lymphoid intrathoracic tumours, sometimes developed in the anterior mediastinum.

THYROID GLAND.

The Thyroid Gland, or Thyroid Body, is a very vascular organ, of a reddish-brown colour, situated in the anterior part of the neck, in close relation to the sides and front of the windpipe. It consists of two lateral lobes united together by an intermediate median lobe or isthmus. Each *lateral lobe* is about two inches long, one inch wide, and three-quarters of an inch in thickness. The lateral lobe lies in close relation to the side of the thyroid and cricoid cartilages, and extends as far down as the fifth or sixth ring of the trachea; and it is connected to the laryngeal and tracheal cartilages by areolar tissue. The *median lobe* or *isthmus* varies in its vertical diameter from $\frac{1}{4}$ to $\frac{3}{4}$ inch; it passes transversely across the front of the trachea opposite its third and fourth rings, and connects together the lower ends of the two lateral lobes.

The thyroid gland is covered by the sterno-hyoid, sterno-thyroid, and omo-hyoid muscles, and its posterior border comes into relation with the common carotid artery.

Occasionally, though Luschka says in every third

person, a prolongation of the gland, named the *pyramid*, ascends from the upper border of the isthmus, in front of the cricoid and thyroid cartilages, as far even as the hyoid bone. A muscle, called *levator glandulæ thyroideæ*, is often seen passing from the pyramid, or the adjacent part of the gland, to the hyoid bone. The gland is normally bigger in women than in men. It often undergoes a pathological enlargement, named bronchocele or goitre. In many mammals, as the camel, alpaca, nylghau, hartebeest, dog, warthog, porcupine, and kangaroo, the isthmus is wanting, and the two lateral lobes are quite disconnected; whilst in the feline carnivora the isthmus is very small in relation to the size of the lateral lobes.

Structure.—The thyroid gland is closely invested by a thin capsule of connective tissue, and is not divided into definite lobules, capable of separation from each other. When sections are made into its substance it is seen to be made up of numbers of closed vesicles, separated from each other by intermediate connective tissue, which is continuous with the investing capsule. These vesicles are just visible to the naked eye, and are spherical or ovoid in form (fig. 158). Each vesicle is said to be bounded by a delicate hyaloid membrane, lined on its inner surface by a single layer of somewhat cubical epithelial cells; but Peremeschko thinks that no hyaloid membrane is present, and that the cells rest directly on the surrounding connective tissue. The vesicles contain a translucent, viscous fluid, which coagulates by the action of heat, alcohol, or nitric acid. The enlargement of the gland in goitre is due to a distension of the vesicles, and an accumulation of the glairy colloid fluid in their interior.

The thyroid gland is abundantly supplied with blood by the superior and inferior thyroid arteries, which freely anastomose with each other in its substance. Occasionally an additional artery, the *arteria thyroidea ima*, a branch of the innominate artery, ascends to the thyroid gland in front of the trachea. The capillaries, in which the arteries terminate, form a compact polygonal network in the connective tissue immediately surrounding the closed vesicles. The veins which proceed from the capillary network form plexuses at the surface of the gland, and give rise to the superior, middle, and inferior thyroid veins. Lymph-vessels arise in the connective tissue between the closed vesicles and by anastomosis form larger vessels, which leave the gland at its surface, where they form a dense network. The nerves form a superior and an inferior thyroid plexus, which accompany the corresponding arteries. They arise from the middle and inferior cervical ganglia of the sympathetic, and have nerve cells interspersed in their course.

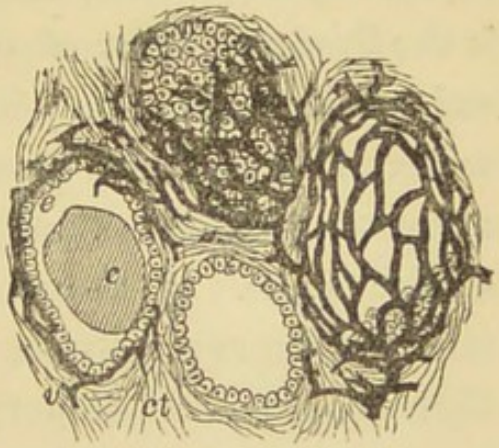

FIG. 158. Section through the injected Thyroid gland of a lion, to show the gland vesicles and the intervesicular connective tissua. *e*, the epithelia lining of a vesicle; *v*, the blood capillary vessels surrounding the vesicles *c*, colloid mass in one of the vesicles.

SUPRA-RENAL CAPSULES.

The Supra-renal Capsules or Glands, or Adrenals, are two bodies situated in the cavity of the abdomen, one in relation to the upper end of each kidney. Each gland lies at about the level of the twelfth dorsal vertebra, and is in contact with the fleshy part of the crus of the diaphragm by its posterior surface. In front of the right gland is the liver; in front of the left gland are the pancreas and spleen. Each gland has been compared in shape to a cocked hat, and the lower concave surface fits on the upper end of the kidney, to which it is attached by areolar tissue. A fissure, named the *hilus*, which transmits the supra-renal vein, exists in the anterior surface. Each gland measures on the average about $1\frac{1}{2}$ inch in its vertical diameter, 1 inch in its transverse, and $\frac{1}{4}$ inch in thickness. Relatively to the size of the entire body, these glands are somewhat larger in new-born children than in adults.

Structure.—The supra-renal gland is invested by a thin capsule of connective tissue; it sends processes into the interior of the gland, which form a trabecular arrangement, in the meshes of which cells are situated. If the gland be cut across, it is seen to be divided into an external, firm cortical part, of a yellow colour; and a central, soft, medullary part, of a deep brown colour.

The *cortical* part consists of cells imbedded in a trabecular framework of connective tissue, and is described by Julius Arnold as if arranged in three zones. The outer layer, or *zona glomerulosa*, is thin, and its connective tissue surrounds roundish spaces or alveoli, occupied by

groups of roundish or ovoid nucleated cells. The middle layer, or *zona fasciculata,* is relatively thick, and its connective tissue is arranged in longitudinal meshes, perpendicular to the surface of the gland; the spaces or alveoli of the meshwork are elongated, and occupied by groups of polyhedral cells, arranged in parallel columns, so that this layer presents a striated appearance. The inner layer, or *zona reticularis,* is thin, and its connective tissue forms a small meshed network occupied by groups of polyhedral cells. The cells of the several layers of the cortex are distinctly nucleated; the protoplasm is coarsely granular, and in those of the inner layer contains pigment granules; sometimes delicate protoplasm processes jut out from the periphery of the cells. In all the layers the spaces of the meshwork, occupied by the groups of cells, are traversed by a very fine reticulum of connective tissue, which separates the individual cells in each group from each other.

The *medullary* part is so soft as to be easily broken down. It is separated from the cortical part by connective tissue, and is traversed by a trabecular stroma of connective tissue, which forms a network, in the meshes of which the medulla cells are lodged. These cells are polyhedral in form, with a clear nucleus, and finely granular protoplasm, free from fat and pigment. Delicate processes not unfrequently jut out from the periphery of the cells, and give them a stellate form. Henle showed that they are stained deep brown by chromic acid, or bichromate of potash, which is not the case with the cortical cells.

The supra-renal glands are supplied with blood by the capsular branches of the aorta, and by the capsular branches of the phrenic and renal arteries. They pierce

the investing capsule, and end in a capillary plexus, which is distributed in the trabecular framework of connective tissue; and the meshes of the capillary plexus correspond in their general arrangement with that of the connective tissue in which they ramify. Arnold states that they form glomeruli in the zona glomerulosa, elongated meshes in the zona fasciculata, and a fine network in the zona reticularis and in the medulla. In the medullary part the large capsular vein arises, and smaller veins spring from the capillaries of the cortical part. Lymph vessels have been seen to leave the supra-renal glands, but their distribution in them is not known. Nerves are very abundantly distributed to the gland: they are derived from the renal, capsular, and phrenic plexuses of the sympathetic, and from the phrenic and pneumogastric nerves; so abundant are they, indeed, that Bergmann and Luschka consider the glands to be more intimately associated with the nervous system than with any of the other organic systems. They traverse both the cortical and medullary parts of the organ, and have nerve cells associated with them. Small detached accessory supra-renal glands are sometimes seen.

The function of the supra-renal glands is not fully ascertained. A curious correlation between pathological changes in these bodies and a bronzed hue of the skin, accompanied by emaciation and debility, has been pointed out by Addison.

PITUITARY GLAND.

The Pituitary Gland, or Hypophysis cerebri, is a small body, about the size of a pea, situated in the pituitary fossa in the upper surface of the body of the sphenoid bone. It is attached to the base of the brain by the funnel-shaped process, or *infundibulum*. It is divided into two lobes, an anterior and a posterior. The anterior is the larger, is invested by a capsule, and is divided by a framework of connective tissue into a number of small alveoli, which are occupied by groups of polygonal cells arranged in the form of columns. Blood-vessels pass into the connective tissue framework, in which is found a capillary plexus. The posterior lobe possesses a framework of connective tissue, intermingled with varicose nerve fibres, and small cells, some of which are polygonal, others fusiform. A plexus of capillaries lies in its connective tissue stroma. The anterior lobe corresponds in its type of structure with the supra-renal capsules, whilst the posterior lobe is an appendage of the brain.

The pituitary body is larger in proportion in the fœtus than in the adult, and the cavity of the third ventricle is prolonged into it through the infundibulum. Though its function has not been ascertained, it is found throughout the vertebrata at the base of the brain.

PINEAL GLAND.

The Pineal Gland, Conarium, or Epiphysis cerebri, is a reddish body, shaped somewhat like a minute fir cone, which is enclosed within the velum interpositum of the pia mater. It lies on the anterior pair of the corpora quadrigemina of the cerebrum, under cover of the posterior end of the corpus callosum. Attached to its anterior surface are two white bands of nerve fibres, which pass forwards on the inner sides of the optic thalami, and are named the peduncles of the pineal gland. It is invested by a capsule, and is divided by an internal framework of connective tissue into small alveoli, which contain roundish lymphoid cells, spindle-shaped cells, and multipolar cells. The stroma contains a network of capillary blood-vessels and medullated nerve fibres. The multipolar cells are larger than the lymphoid and spindle-like cells, and are believed by some observers to be nervous. It is often hollowed out into one or two cavities, which contain not only an inspissated fluid, but amylaceous and gritty calcareous particles, termed brain sand. It is developed in relation to the upper part of the third ventricle, and is present throughout the vertebrata. Its function is unknown.

Development of the Vascular System.

The vascular system is formed in the middle or mesoblast layer of the germinal membrane of the early embryo.

The *Blood-vessels* first appear in that part of the mesoblast which forms the vascular area. The cells of the mesoblast lose their original spherical form and become stellate, the processes of adjacent cells unite together and form a network, and the nuclei rapidly increase in numbers. The peripheral part of the protoplasm of the stellate cells differentiates into a wall of nucleated protoplasm, and forms the wall of the primary embryonic blood-vessel, the central part of the protoplasm liquefies and forms vacuoles in the cells, and the nuclei in this liquefied protoplasm become the blood-corpuscles. If the vessel remains as a capillary, its wall assumes merely the character of a single layer of endothelial cells. If it becomes an artery or a vein, the mesoblast cells, lying immediately external to the primary blood-tube, apply themselves to the exterior of its wall, and differentiate into the muscular and elastic coats and the tunica adventitia. A similar mode of development of the blood-vessels apparently takes place within the body of the embryo itself. The formation of blood-vessels in the healing of wounds, and in some pathological processes, is also from the cells of the part in which the blood-vessels arise.

The *Lymph-vessels* also arise in a manner closely resembling the origin of blood vessels. The cells of the part branch and anastomose with each other. According to Klein, vacuoles appear in these cells, so as to form a cavity, and the vacuoles of adjacent cells in time communicate with each other, and form an anastomosing series of lymph capillaries. The nucleated protoplasmic wall of the cells forms the nucleated endothelial wall of the capillaries, and from this wall portions of the protoplasm may separate off into the lymph-tube and form lymph corpuscles.

The *Heart* begins to form in the body of the early embryo at the same time that the blood-vessels appear in the vascular area. It is placed at the cephalic end of the embryo, close to the cephalic fold of the amnion, and arises in the splanchno-pleure layer of the mesoblast. It is at first attached to the primitive pharynx by a delicate membranous fold. It has been customary to regard it as developed out of a solid mass of cells, the central part of which mass liquefies to form blood and blood corpuscles, whilst the peripheral

cells arrange themselves so as to form the wall of a single tube. The cells of the wall are contractile, and in the course of time differentiate into muscular tissue and an endocardium. But from the recent observations of Kölliker, on the early stages of development of the mammalian embryo, it would appear that the single tube is preceded by a stage, in which there are two tubes situated side by side, which, however, soon fuse together and then form a single tube. This tube receives at its posterior end two *omphalo-mesenteric veins* from the vascular area. It gives off anteriorly two arteries, the *ventral aortic roots*, which run forwards at the sides of the primitive pharynx ; they then arch towards the embryonic spine, run backwards below the primordial vertebræ, and form the two *primitive dorsal aortæ*, from which arise the omphalo-mesenteric arteries that pass into the vascular area. Two transverse constrictions then appear in the wall of the simple heart tube, which indicate a differentiation into three chambers—a posterior or *primitive auricle ;* an anterior, the arterial bulb or *truncus communis arteriosus ;* and an intermediate chamber or *primitive ventricle*. At the same time, a sigmoid bend takes place in the tube, which becomes doubled on itself, so as to throw the primitive auricle on the dorsal surface of the primitive ventricle. This condition of the heart in the human embryo is found at about the third week of development, and it represents the permanent condition of the organ in fish. A few cases have been recorded in which the development of the human heart had not passed beyond this stage, and the child was born with only a single auricle and a single ventricle.

Changes then begin to take place in the interior of the three chambers into which the tube has become divided, which result in the conversion of the single auricle into two auricles, of the single ventricle into two ventricles, and of the truncus communis arteriosus into the ascending aorta, and the trunk of the pulmonary artery.

The conversion of the *primitive ventricle* into two ventricles is due to the formation of a muscular septum in the ventricular chamber. It appears at about the sixth week in the human heart, and grows from the apex to the base of the ventricle. The apex of the ventricle then becomes the apex of the heart, and a groove, on the anterior and posterior surfaces of the ventricular part of the heart, marks the position of the two borders of the septum. The base of the septum, and the bases of the ventricles, are directed to the auricles and the orifices of the great arteries. The septum is complete about the eighth week, and the two ventricles then form

two distinct chambers. In rare cases the development of the septum stops short before its base is finished, and then the two ventricles have a permanent direct communication with each other. This malformation of the human heart corresponds with the normal construction of the heart in the Chelonia and Scaly Reptiles.

The *primitive auricle* is larger in size than the primitive ventricle, and, before its division takes place, two pouch-like projections, the right and left auricular appendages, appear on its walls. The conversion of the primitive auricle into two auricles is due to th formation of a septum in the auricular chamber. This septum appears about the eighth or ninth week, and not until the ventricular septum is completed. It springs as a muscular septum from the anterior and upper wall of the auricle and the base of the ventricular septum, and grows into the auricular chamber, in the direction of the mouths of the great veins. About the end of the sixth month the septum has grown so much that the anterior parts of the two auricles are separated from each other, but they freely communicate posteriorly, and the great veins open therefore into the common cavity. These veins are now three in number, and constitute the inferior vena cava, the right superior cava, and the left superior cava, the last of which subsequently becomes modified into the coronary sinus. A crescentic membranous fold, which grows towards the upper and lower boundaries of the auricle, then arises from the left wall of the inferior cava. At the same time it projects into the auricular chamber, and approximates to the muscular part of the septum, but between the two a hiatus, called the *foramen ovale*, exists, during the whole of intra-uterine life. With the growth of the membranous part of the septum, the orifice of the inferior vena cava, which at first opened towards the left half of the auricular chamber, is directed into the right auricle ; but up to the birth of the child the blood of the inferior cava flows through the foramen ovale into the left auricle. Some days after the child is born, the number of which varies in different instances, the foramen ovale closes up by the union of the anterior and posterior parts of the auricular septum, and the two auricles are then completely separated from each other. In some cases the closure of the foramen is not complete, and a small valvular opening remains in the septum throughout life ; more rarely the opening is large, and allows of a mixture of the blood of the two sides of the heart. From the right wall of the inferior cava, a membranous fold, the *Eustachian valve*, arises, which grows to the border of the anterior part of the auricular septum, where it forms the annulus ovalis, or

anterior boundary of the foramen ovale. It directs the blood of the inferior cava through this foramen into the left auricle.

The auriculo-ventricular valve arises around the aperture of communication between the auricle and ventricle as a semilunar fold of the endocardium. These folds then become connected with the muscular trabeculæ of the ventricular walls, which differentiate into the musculi papillares, whilst the chordæ tendineæ are produced by the depending border of the valve assuming a fenestrated appearance.

The conversion of the *truncus communis arteriosus* into the ascending aorta, and the trunk of the pulmonary artery, is due to the formation of a longitudinal septum in the single arterial trunk. This septum begins to form about the same time as the ventricular septum, and consists of two folds projecting one from each side of the inner surface of the common arterial trunk. These folds meet about the eighth week, and the vessel is then divided into the trunk of the pulmonary artery and the ascending aorta. The pulmonary artery becomes continuous with the now differentiated right ventricle ; at its lower end it lies in front of the aorta, and then winds round it to its left side. The ascending aorta, again, becomes continuous with the left ventricle, and, though situated at its commencement behind the pulmonary trunk, it subsequently appears anterior to it and to the right side. That part of the arterial septum is last formed which lies nearest the base of the ventricles ; and in connection with this circumstance it may be mentioned, that some cases of malformation of the human heart have been seen, in which the aorta and pulmonary artery directly communicated with each other, through a deficient formation of this part of the septum.

It has already been stated that the truncus communis arteriosus bifurcates anteriorly into the two ventral aortic roots, which lie at the sides of the primitive pharynx, and then arch backwards, parallel to the rudimentary spine, as the two primitive dorsal aortæ. The arches formed by these two vessels form the 1st pair of *Vascular Arches.* As the neck of the embryo elongates, these arches also elongate, and in their concavity four additional pairs of *vascular arches* form, successively from before backwards, and are named the 2nd, 3rd, 4th, and 5th pairs of vascular arches. All five pairs, however, are not present at the same time, for before the 5th pair appears, about the fourth or fifth week in the development of the human embryo, the 1st and often the 2nd pair have disappeared. The first pair of vascular arches are as far forward as the 1st visceral

arch, in which the lower jaw is developed, and the 2nd, 3rd, and 4th pairs are in the corresponding visceral arches. The 1st, 2nd, and 3rd pairs spring from the ventral aortic roots ; the 4th pair from that part of the truncus communis which subsequently becomes the ascending aorta, and the 5th pair from the part of the truncus communis which becomes the trunk of the pulmonary artery. All five pairs of arterial arches join the primitive dorsal aortæ, and form, at their junction with it, the *dorsal aortic roots.* The primitive dorsal aorta is at first two distinct vessels lying parallel and close to each other ; they subsequently coalesce in the dorsal and lumbar regions of the embryo, and form the descending thoracic and abdominal portions of the aorta, which is thus, as was demonstrated by Allen Thomson, a secondary vessel formed by the fusion of two originally distinct arteries. Two or three cases have been seen in which the fusion between the two primitive vessels has not been completed, and the aorta has been divided into two canals by a longitudinal septum. The descending thoracic and abdominal part of the aorta have numerous branches developed in connection with them, which supply the parietes of the thorax and abdomen, the pelvis, and the lower limbs. But further, two arteries are developed in the wall of the allantois, which become continuous through the iliac arteries with the abdominal aorta. During the later period of embryonic life they attain a large size, convey the blood to the placenta, and are named the hypogastric or umbilical arteries.

The vascular arches in the early human embryo have a general resemblance to the arrangement of the branchial arteries in the gills of fish and amphibia, but in man and the higher vertebrates gills are not formed in connection with them. In reptiles, birds, and animals they have a similar arrangement to what has just been described in the human embryo. In man, and all the higher vertebrates, the vascular arches undergo a metamorphosis as the development of the embryo advances. Some of the arches, as the 1st and 2d, atrophy and disappear, whilst others undergo a great increase in size, and give rise to those arteries which are known in human anatomy as the arch of the aorta, the right and left pulmonary arteries and ductus arteriosus, the innominate artery, the common, internal, and external carotid arteries, and the subclavian arteries.

In man, and all the other mammalia, the 4th left arch, and the part of the dorsal aortic root which connects the 4th and 5th left arches, undergo a great increase in size, in correspondence with the growth of the embryo, and forms the transverse part of the arch of the aorta, which arches above the root of the left lung, and consti-

tutes what is called a left aorta. The 4th right arch also increases in size, though not to the same extent as the left, and forms the innominate artery, and the first and second parts of the right subclavian artery of human anatomy; whilst the third part of this artery, with the axillary, seems to be a lateral twig, from the dorsal aortic root, that connects the 4th and 5th vascular arches. The left subclavian again is apparently in its whole extent a lateral branch of the dorsal aortic root, connecting the 4th and 5th vascular arches. The common carotid artery is formed by a great

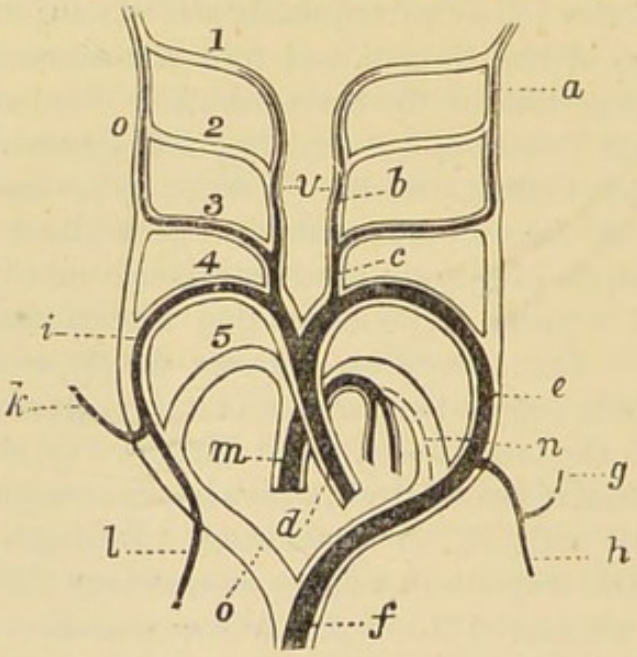

Fig. 159.—Diagram of the Vascular Arches, to illustrate their conversion into the great arteries (after Rathke.) 1 to 5, the five pairs of vascular arches; *v*, the two ventral aortic roots; *oo*, the right dorsal aortic root; *a*, internal carotid; *b*, external carotid; *c*, common carotid; *d*, the part of the truncus communis which developes into the ascending aorta; *e*, transverse part of arch of aorta; *f*, descending aorta; *g* and *h*, left vertebral and subclavian arteries; *i* and *l*, right subclavian; *k*, right vertebral; *m*, the part of the truncus communis which developes into the trunk of the pulmonary artery; *n*, the 5th left arch which gives off the right and left pulmonary arteries, and forms the ductus arteriosus represented by the dotted line in the figure. The shaded parts indicate the permanent vessels, whilst those left in outline, atrophy, and disappear.

increase in size of the ventral aortic root, which joins the 3rd and 4th vascular arches: the external carotid is a dilatation of the more anterior part of the same root connecting the 3rd with the 2nd, and the 2nd with the 1st vascular arch. The internal carotid artery is produced by a great increase in the size of the 3rd vascular arch, and of the dorsal aortic root between the 3rd and 2nd, and 2nd and 1st vascular arches. The descending thoracic aorta, as already stated, is formed by the fusion of the two dorsal aortic roots; whilst the ascending aorta is one of the two vessels into which the truncus communis is divided.

The trunk of the pulmonary artery is the other division of the truncus communis arteriosus. It is continuous with the 5th pair of vascular arches. Of these the 5th right arch atrophies, and disappears at an early period of embryonic life. The 5th left arch again increases in size, forms the *ductus arteriosus*, or Botalian duct, and conveys the blood directly from the trunk of the pulmonary artery into the aorta, immediately beyond the origin of the left subclavian artery. From the 5th left arch two collateral twigs arise, the one of which passes to the root of the right lung, the other to that of the left lung, and form the right and left branches of the pulmonary artery. After the birth of the child, when respiration by the lungs commences, the ductus arteriosus begins to close, and in the second or third week has shrivelled up into a fibrous cord ; the right and left pulmonary arteries also increase in size, so as to convey all the blood of the right or pulmonic side of the heart into the lungs.

In birds and reptiles, the right pulmonary artery is developed from the right 5th vascular arch, and the left pulmonary artery from the left 5th vascular arch, so that in these animals there are two Botalian ducts during fœtal life, and in some families of reptiles these are found even in the adult.

In birds the arch of the aorta is developed from the 4th right vascular arch and right dorsal aortic root, and arches above the right bronchus, so that the aorta in this class is a right aorta. Sometimes in the human body the arch of the aorta follows the avian and not the mammalian type of development, and a right and not a left aorta is present.

In reptiles, again, both 4th vascular arches, with the corresponding parts of the dorsal aortic roots, persist, so that the aorta is a double aorta, an arch existing both on the right and left sides. A few cases have been seen in man in which the aorta possessed this reptilian arrangement.

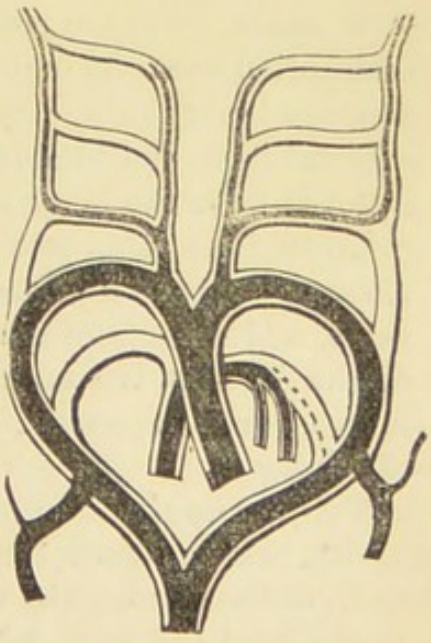

Fig. 160. Scheme of the mode of formation of a double arch of the aorta, through the persistence of both fourth vascular arches, and the immediately adjacent dorsal aortic roots.

But the vascular arches and aortic roots may undergo other metamorphoses than those above described, which may lead to the production of other variations in the

arrangement of the great arteries, examples of which are occasionally seen in the human subject. It would be out of place in this elementary work to enter further into this matter, but I may refer for more complete information to my memoir on this subject in the *British and Foreign Medico-Chirurgical Review*, 1862.

The *Veins* that first appear in the development of the human embryo are the *omphalo-mesenteric* veins, which arise in the vascular area situated in the wall of the umbilical vesicle. These veins unite into a single trunk which opens into the primitive auricle. As the allantois grows out from the pelvic region of the body of the embryo to reach the chorion, and assist in the formation of the fœtal placenta, two umbilical veins appear in its wall in about the fourth week of utero-gestation. In the fifth week one of these veins has disappeared, and the remaining one enlarges and forms the umbilical vein, which conveys the blood from the placenta to the embryo throughout the rest of fœtal life. It joins at its proximal end the omphalo-mesenteric vein. As the umbilical vein lies in one part of its course in the region occupied by the liver, it becomes connected with the veins of the liver. The veins developed in connection with the spleen and abdominal portion of the alimentary canal are the splenic, gastric, and mesenteric veins, which, by their union, form the portal vein, and the portal is in direct communication with the umbilical vein. Veins develope in the rudimentary lower limbs, and in the pelvis, which become the femoral, external iliac, and common iliac veins, whilst the internal iliac are believed to be the lower ends of the two cardinal veins. The two common iliac veins join to form the inferior vena cava, which, as it ascends to the liver, receives the renal, capsular, and spermatic veins, and veins from the parietes of the abdomen. In the region of the liver it is connected to the umbilical vein by the *ductus venosus*, and it receives the hepatic veins. It opens into the auricle of the heart.

Two *cardinal* veins are developed in the thoracico-abdominal cavity, which return the blood from the Wolffian bodies and the walls of the trunk; and two *primitive jugular* veins are developed in the head and neck, which return the blood from these regions. The primitive jugular and cardinal vein on each side join in the cervico-thoracic region to form a vein called the *duct of Cuvier*, and the two ducts of Cuvier open into the auricle of the heart. The upper part of the primitive jugular subsequently becomes the external jugular vein. At its lower end the primitive jugular on each side is joined by veins, which become the internal jugular and sub-

clavian veins. The conjoined right jugular and subclavian veins form the right innominate vein. A *transverse communicating* vein is developed, which connects the right innominate with the conjoined left jugular and subclavian, and forms the left innominate vein. The two innominate veins are continuous below with the right duct of Cuvier, which has undergone a commensurate enlargement, and forms the right or persistent superior vena cava. The left duct of Cuvier does not undergo a commensurate increase in size, but almost entirely disappears, except at its lower end, which forms the coronary sinus, and opens into the right auricle. Traces of the vessel, however, as was pointed out by Marshall, exist in a small vein, which passes obliquely from this sinus along the wall of the left auricle, and in the vestigial fold of the pericardium.

The upper end of the right cardinal vein becomes the part of the vena azygos which joins the superior cava. The upper end of the left cardinal vein becomes the left superior intercostal vein, which usually joins the left innominate vein. The lower ends of the cardinal veins, as already stated, form the internal iliac veins. The intermediate portions of the cardinal veins are said to atrophy, and their place is taken by two *posterior vertebral* veins, which receive the intercostal veins, and form the left azygos vein, and the lower part of the right azygos, which afterwards become continuous with the upper end of the azygos developed from the right cardinal vein.

In birds, and in some mammals, the left duct of Cuvier persists, and forms a left superior cava. A few cases have also been seen in man in which the left duct of Cuvier had not atrophied, and a right and a left superior vena cava opened into the right auricle; in these cases, the transverse communicating, or left innominate vein, was either altogether absent or only feebly developed.

Whilst these changes are going on in the heart, and in the arrangement of the great vessels, the position of the heart is also altered. With the formation and elongation of the neck, the heart is further removed from the head, in close proximity to which it had first appeared, and becomes enclosed, by the development of the ribs and sternum, in the thoracic cavity. The carotid arteries and jugular veins at the same time become greatly elongated. As the pneumogastric nerves, which supply branches to the heart, accompany these vessels, they become elongated likewise. In the early embryo each pneumogastric gives off its recurrent laryngeal nerve opposite the fifth vascular arch, around which the nerve turns in its ascent to the larynx. When the fifth right arch com-

pletely disappears, the nerve then turns around the first part of the subclavian, which represents the 4th right arch. As the fifth left arch, however, persists throughout life as the obliterated ductus arteriosus, the left recurrent nerve bends immediately below it before it ascends behind the transverse part of the arch of the aorta.

Owing to the progressive changes which take place in the heart during its formation, the circulation of the blood through it is necessarily much modified in the course of its development. When the heart is in its primitive stage of single cavities, the blood flows from the veins successively into the auricle, ventricle, and truncus communis arteriosus, as a single stream. But when the ventricle is divided into two chambers, each communicating with a distinct artery, derived from the division of the truncus communis, then the blood is divided in these parts of the heart and great vessels into two streams. As the division of the auricle into two chambers takes place at a later period than that of the ventricle, the subdivision of the blood into two streams does not take place so early in that cavity. In the later stages of intra-uterine life, when the left duct of Cuvier has atrophied, the superior and inferior venæ cavæ have attained their proportional size, and the auricular septum has become developed, though with the foramen ovale patent, the circulation of the blood through the heart is as follows :—

The blood of the inferior cava, which consists not only of the impure venous blood from the infra-diaphragmatic parts of the body, but of the blood of the umbilical vein from the placenta, flows into the right auricle, but is at once directed by the Eustachian valve through the foramen ovale into the left auricle. It then flows into the left ventricle and the ascending and transverse parts of the aorta, from which it principally proceeds through the carotid and subclavian arteries into the head, neck, and upper limbs, only a small proportion apparently passing into the descending aorta.

The blood of the superior cava again is solely venous, which is returned by this great vein from the head, neck, upper limbs, and walls of the chest. It flows into the right auricle, where it may acquire a slight admixture with the blood of the inferior cava. By this auricle it is propelled into the right ventricle, and thence into the pulmonary artery. Only a small part of this venous blood passes into the right and left pulmonary arteries ; the greater part flows through the ductus arteriosus into the descending aorta, by which it is distributed, not only to the infra-diaphragmatic parts of the body, but by the hypo-gastric and umbilical arteries to the placenta. In the fœtus, therefore, the blood which circulates

through the heart and arteries is mixed blood. The precise differentiation of the blood of the two sides of the heart into a right venous side, and a left arterial side does not take place until after the birth of the child, when the pulmonary respiration being established, the ductus arteriosus becomes obliterated, and the foramen ovale becomes closed.

The *Ductless Glands* for the most part, though not entirely, are developed from the mesoblast.

The *Spleen* arises from a mass of cells situated in connection with the meso-gastric fold of the stomach. These cells belong to the mesoblast, and form originally, as Peremeschko has shown, a mass common to both spleen and pancreas. A constriction then forms which separates the mass into a left, or splenic, and a right, or pancreatic portion. Into the pancreatic portion a prolongation of the hypoblast lining of the primitive alimentary canal passes, but not into the splenic portion. An artery grows into the spleen mass from the aorta, and the collection of cells differentiates into the proper textures of the spleen.

The *Supra-renal capsules* arise, as was pointed out by Goodsir, from a mass of cells situated between the two Wolffian bodies. These cells belong to the mesoblast layer of the embryo. Kölliker considers that the two capsules are originally one organ, which subsequently separates into two lateral portions. At first the supra-renal capsules are larger than the kidneys, but their subsequent growth is not so rapid, so that the kidneys soon surpass them in size.

The *Thymus* arises, according to Simon, in a membranous substance situated parallel and close to the carotid arteries. This membrane is probably derived from the mesoblast.

The *Thyroid* arises from a rounded mass of mesoblast cells situated in relation to the first pair of vascular arches. W. Müller states that a prolongation of the hypoblast lining of the pharynx is continued into it. It is probable, therefore, that, whilst the vascular connective tissue of the thyroid is of mesoblast origin, the cellular lining of its vesicles is derived from the hypoblast. This difference in the origin of the thyroid, as compared with the thymus and spleen, is an additional argument to that derived from their structural differences, against the physiological identity of these organs.

The *Pituitary gland* consists of two lobes developed from very different parts. The posterior lobe is a downward prolongation of the floor of the third cerebral ventricle, with which it is continuous through the infundibulum; it is derived therefore from the epi-

blast. The anterior lobe, as has been shown by the recent observations of W. Müller, Götte, and Mihalkovics, is an upward prolongation from the upper part of the back of the embryo mouth, in front of the anterior end of the chorda dorsalis. This buccal prolongation is continuous with the epiblast lining of the mouth, but is subsequently cut off from it by the growth of the cartilaginous floor of the skull. The two lobes then fuse together into a single organ, which is lodged in the pituitary fossa of the sphenoid bone.

The development of the *Pineal gland* has not been definitely ascertained; but from its relation to the optic thalami it evidently arises in connection with the thalami from the thalamencephalon, or posterior division of the anterior cerebral vesicle. As it is so closely invested by the pia mater, some have supposed that it might be developed in connection with that membrane.

CHAPTER VIII.

THE LARYNX, OR ORGAN OF VOICE.

The Larynx, or Organ of Voice, is the upper end of the windpipe, which, whilst performing the function of a respiratory tube, is especially modified in its construction for the production of the voice.

The larynx lies in the middle of the anterior part of the neck, in front of the pharynx, and immediately below the hyoid bone. It passes downwards to opposite the body of the sixth cervical vertebra, where it becomes continuous with the trachea. It is covered by the sterno-hyoid, sterno-thyroid, thyro-hyoid, and omo-hyoid muscles, cervical fascia and skin; and the lateral lobes of the thyroid body, with the upper ends of the two common carotid arteries, lie at its sides. It forms a tube, the wall of which is composed of a framework of cartilages, jointed together and movable on each other by the action of special muscles. Within the tube are the vocal cords, by the vibrations of which the voice is produced. It is lined by a glandular mucous membrane, and is supplied by blood-vessels and nerves.

Cartilages of the Larynx.

The cartilages of the larynx are nine in number, and form its framework. They consist of three single cartilages, the thyroid, the cricoid, and the epiglottis; and of three pairs of cartilages, the two arytenoid, the two cornicula laryngis, and the two cuneiform cartilages.

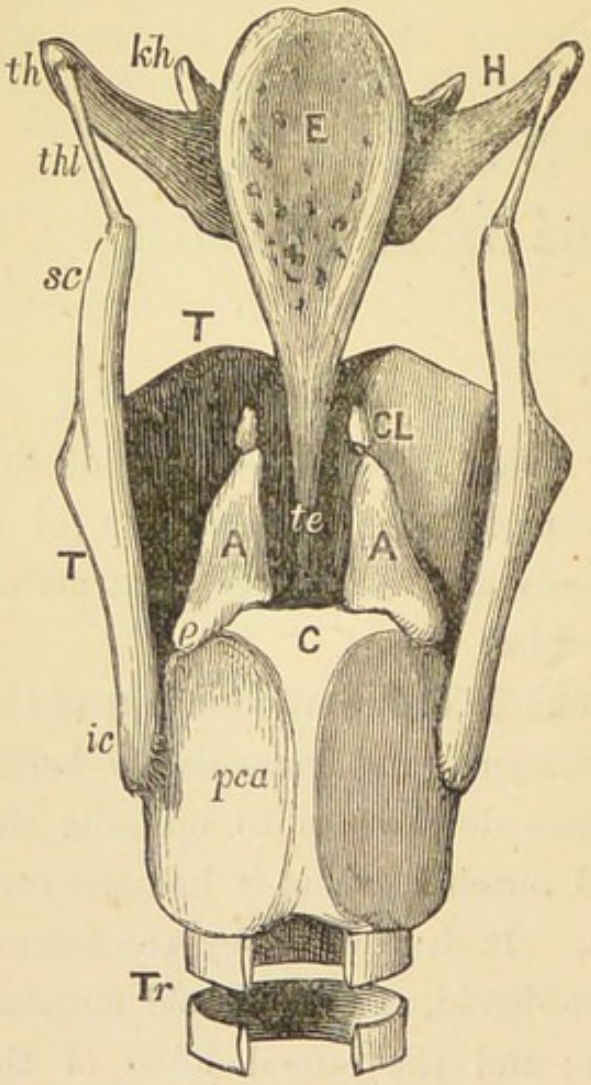

FIG. 161.—Cartilages of the Larynx seen from behind. E, epiglottis; T, thyroid cartilage; C, cricoid cartilage; AA, arytenoid cartilages; Cl, cornicula laryngis Tr, trachea; H, hyoid bone; *kh*, keratohyoid or small cornu; *th*, thyro-hyoid, or great cornu; *thl*, thyro-hyoid ligament; *sc*, superior cornu, and *ic*, inferior cornu of thyroid cartilage; *te*, thyro-epiglottidean ligament; *e*, external process of arytenoid cartilage; *pca*, surface of origin of posterior crico-arytenoid muscle.

The THYROID, or shield-like cartilage, is the largest of the cartilages of the larynx. It is situated anteriorly, and laterally, and consists of two quadrilateral plates or *alæ*, which are united together by their anterior borders, where they form, especially in the neck of a man, a projecting angle, or prominence in the middle line of the front of the neck, familiarly known as Adam's apple, the *pomum Adami* (fig. 168). From this border of union the plates project

backwards, diverging from each other to form a retreating angle, and enclosing the smaller cartilages of the larynx. Each plate is marked on its outer surface by an oblique ridge for the attachment of the thyro-hyoid and sterno-thyroid muscles, whilst the inner surface is smooth, and for the most part covered by mucous membrane. The upper border of each plate is attached to the hyoid bone by a broad fibro-elastic membrane, the *thyro-hyoid membrane*, and the lower border is united to the upper border of the cricoid cartilage by the *crico-thyroid membrane*. The posterior border gives attachment to the palato-pharyngeus and the stylo-pharyngeus muscles, and is prolonged into two cornua. The superior cornu is attached to the tip of the great cornu of the hyoid by a rounded elastic band, the *thyro-hyoid ligament*, in which a nodule of cartilage, *cartilago triticea*, is often situated; the inferior cornu is short, and articulates with the side of the cricoid cartilage by a movable joint.

The Cricoid, or ring-like cartilage, is the lowest cartilage of the larynx, and completely surrounds the tube. Its vertical diameter posteriorly is about one inch, but anteriorly not more than $\frac{1}{4}$ inch. Its outer surface possesses posteriorly a mesial vertical ridge, to the side of which is a depression for the origin of the posterior crico-arytenoid muscle (fig. 161). On each lateral aspect of the cartilage is an articular facet for the inferior cornu of the thyroid cartilage, anterior to which is a surface for the attachment of the crico-thyroid muscle. The inner surface of the cricoid cartilage is smooth, and lined by mucous membrane. Its lower border is almost horizontal, and is attached by membrane to the first ring of the trachea.

Its upper border slopes from behind downwards and forwards, and possesses a pair of articular facets posteriorly for the two arytenoid cartilages; whilst in front of these facets it gives attachment to the crico-thyroid membrane and lateral crico-arytenoid muscle. The cricoid cartilage is connected to the thyroid by a pair of crico-thyroid joints and the crico-thyroid membrane. The *crico-thyroid membrane* is a fibro-elastic structure attached below to the upper border of the cricoid cartilage; it consists of a mesial and of two lateral portions; the mesial part is attached above to the lower border of the middle portion of the thyroid cartilage; whilst each lateral portion runs upwards in close relation to the mucous lining of the larynx, and terminates in a thin free superior border, the inferior or true vocal cord; as the anterior end of this cord is attached to the middle of the retreating angle of the thyroid cartilage, and the posterior end to the anterior or vocal process at the base of the arytenoid cartilage, it may be more precisely called the *inferior crico-thyro-arytenoid ligament* (fig. 162). The *crico thyroid joint* is formed on each side between the inferior cornu of

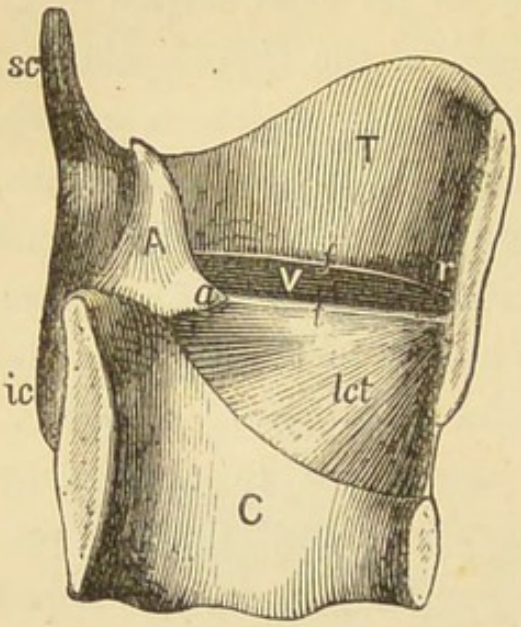

FIG. 162.—View of the interior of the left half of the Larynx, after the removal of the mucous membrane. T, thyroid cartilage; *sc*, its superior, and *ic*, its inferior cornu; *r*, its retreating angle; A, arytenoid cartilage; *a*, its anterior or vocal process; *t*, true, and *f*, false vocal cord; V, the position of the ventricle; C, cricoid cartilage; *lct*, lateral crico-thyroid membrane or crico-thyro-arytenoid ligament.

the thyroid and the side of the cricoid cartilage, between which is a diarthodial joint, enclosed by a *capsular ligament*, and lined by a synovial membrane.

The EPIGLOTTIS is a leaf-like plate of yellow fibro-cartilage situated in front of the upper opening of the larynx. Its elongated stalk passes vertically downwards behind the body of the hyoid, and the projecting angle of the thyroid cartilage to be attached to the inner surface of this angle by the *thyro-epiglottic ligament* (fig. 161). The blade of the leaf is ovoid in form, and projects upwards behind the tongue. Its surfaces are directed forwards and backwards, and are covered by mucous membrane, which is prolonged from the anterior surface to the back of the tongue as the *glosso-epiglottidean* folds; beneath these folds is an elastic membranous band, the *glosso-epiglottidean ligament*, which stretches from the root of the tongue to the anterior surface of the epiglottis; and on a still deeper plane is the *hyo-epiglottidean ligament*, an elastic membrane, which attaches the front of the epiglottis to the body, and great cornua of the hyoid. The posterior surface, concave from side to side, is free, and possesses a prominence called the *cushion* (figs. 163, 164). The upper border is free and rounded; but from the lateral borders the mucous membrane is prolonged downwards and backwards, as far as the cornicula laryngis and arytenoid cartilages, to form a pair of folds, the *aryteno-epiglottidean folds of mucous membrane*, which form the lateral boundaries of the superior opening of the larynx. The cartilage of the epiglottis is pitted by numerous depressions, in which mucous glands are lodged.

The ARYTENOID, or pyramidal cartilages, two in number, are placed on the posterior part of the upper border of the cricoid cartilage. Each is a three-sided pyramid, about half an inch in height, and a quarter of an inch in width. The base articulates with the cricoid, and two of its angles are prolonged into well-marked processes: the *external* or *muscular* process is directed backwards and outwards, and gives attachment to the tendons of insertion of the lateral and posterior crico-arytenoid muscles; the *anterior* or *vocal* process is directed forwards, and gives attachment to the true vocal cord. The apex of the cartilage is directed upwards, and articulates with the corniculum laryngis. The posterior surface is concave, and gives attachment to the arytenoid muscle: the inner surface is smooth, and covered by the mucous membrane; the anterior surface gives attachment to the superior or false vocal cord, and to the thyro-arytenoid muscle. The base of the arytenoid cartilage is connected to the cricoid by a *capsular ligament*, lined by a synovial membrane, and a band of fibres extending from the back of the arytenoid to the back of the cricoid has been named the *posterior crico-arytenoid ligament.* The *false vocal cords*, or *superior thyro-arytenoid ligaments*, pass from the anterior surface of each arytenoid cartilage to the retreating angle of the thyroid; and the *true vocal cords*, or *inferior thyro-arytenoid ligaments*, pass from the anterior vocal process of the arytenoid to the retreating angle of the thyroid cartilage (fig. 162).

The CORNICULA LARYNGIS, or Cartilages of Santorini, are two small nodules articulated to the apices of the arytenoid cartilages, the connection being effected by a *cap-*

sular ligament, lined by a synovial membrane (figs. 161, 163.) The cornicula are formed of yellow fibro-cartilage.

The CUNEIFORM cartilages, or Cartilages of Wrisberg, are two thin plates of yellow elastic cartilage, placed one in each aryteno-epiglottidean fold of mucous membrane.

Interior of the Larynx.

The tube of the larynx, or the glottis, communicates above with the pharynx, and below with the trachea. The *superior opening* of the larynx is somewhat triangular in form, with the base in front and the apex behind. It is bounded in front by the epiglottis; on each side by the aryteno-epiglottidean fold of mucous membrane; behind by the cornicula laryngis, the apices of the arytenoid cartilages, and the fold of mucous membrane passing between them. The *inferior opening* is circular in form, like the tube of the trachea, with which it is continuous.

The mucous lining of the larynx is elevated into folds, which correspond in position to the false and true vocal cords; the arrangement of the cords may be seen when the larynx is looked into through its superior opening, or when a mesial incision is made longitudinally through the posterior wall, and the two sides of the tube slightly separated from each other (fig. 163). Two pairs of vocal cords may then be seen extending, one above the other, at the sides of the mesial plane, in the antero-posterior direction from the thyroid to the arytenoid cartilages. The *superior pair*, or the *false vocal cords*, consist of thin fibres attached anteriorly to the retreating angle of the thyroid cartilage, and posteriorly to the anterior surface of the arytenoid cartilage: these fibres are covered by a fold of the mucous

membrane, which presents a convex contour on the surface next the mesial plane of the larynx, whilst the opposite surface bounds the laryngeal pouch. The *inferior pair*, or *true vocal cords*, have a sharp straight border superiorly,

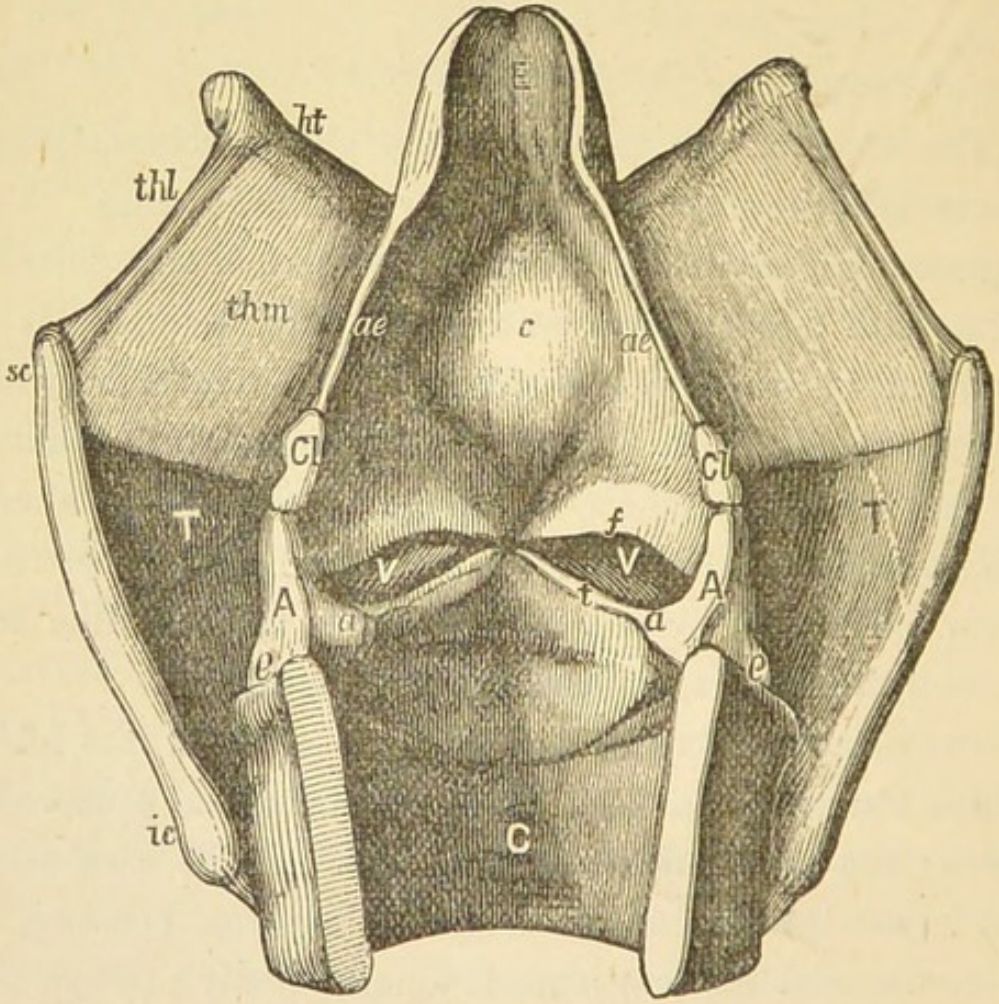

FIG. 163.—View of the interior of the Larynx, obtained by making a mesial vertical incision through the posterior wall. E, epiglottis; *c*, its cushion; *ht*, great cornu of hyoid; *thm*, thyro-hyoid membrane; *thl*, thyro-hyoid ligament TT, alæ of thyroid cartilage; *sc*, its superior, and *ic*, its inferior cornu; AA arytenoid cartilages; *Cl Cl*, cornicula laryngis; *a e*, *a e*, aryteno-epiglottidean folds of mucous membrane; C, cricoid cartilage; *f*, false vocal cord; V, ventricle of larynx; *t*, true vocal cord; *a*,*a*, anterior or vocal processes of arytenoid cartilages; *ee*, external or muscular processes.

whilst their inner surfaces are flattened. They consist of fibres extending from the retreating angle of the thyroid to the anterior vocal process of the arytenoid cartilage, and each is so blended with the lateral portion of the crico-

thyroid membrane as to form its free upper border. The mucous membrane which covers them is thin and free from glands. The slit between the two true vocal cords and the inner surfaces of the two arytenoid cartilages, is in the mesial plane, and is named the *rima glottidis*, or *chink* of the larynx. That part of the rima which lies between the vocal cords has been called the *vocal glottis*, whilst that situated between the arytenoid cartilages is the *respiratory glottis* (fig. 166). The long or antero-posterior diameter of the rima is nearly 1 inch in the larynx of a man, and about $\frac{3}{4}$-inch in that of a woman. Its width or transverse diameter varies with the position of the vocal cords, and the variations in its width modify its shape. When the cords are separated to the greatest extent, the rima is lozenge-shaped ; when they are moderately asunder, it is an elongated triangle, with the base behind and the apex in front; when they are brought in contact with each other the rima is closed.

Between the superior and inferior vocal cord on each side is an elongated deep depression, the *sinus*, or *ventricle* of the larynx, which is lined by mucous membrane ; the floor of this ventricle is concave immediately to the outer side of the true vocal cord. A prolongation of the ventricle, named the *pouch of Morgagni* or *saccule of the larynx*, passes upwards, to the outer side of the superior vocal cord, as high as the level of the upper border of the thyroid cartilage; the pouch is lined by mucous membrane continuous with the mucous lining of the ventricle of the larynx, and in its outer wall is the thyro-arytenoid muscle.

If a vertical transverse section be made through the larynx immediately in front of the arytenoid cartilages the

vocal cords are transversely divided, and it will be seen, as was pointed out by J. Wyllie, that the interior of the larynx possesses the form of two wedge-shaped spaces (fig. 164). The upper wedge extends from the superior orifice of the larynx to the ventricles of the larynx: the lower wedge from the lower orifice of the larynx to the true vocal cords. Experiments made by Wyllie have shown that the glottis can be closed, during an inspiratory effort, not only by the action of the muscles which bring the true vocal cords into apposition with each other; but by the pressure of the column of air, in the upper wedge-shaped space of the larynx, on the concave floor of the ventricles, immediately external to the true vocal cords. Whilst closure of the glottis, during an expiratory effort may be occasioned by the pressure of the column of air in the lower wedge-shaped space, inflating the pouches of the larynx, and forcing the false vocal cords together. The larynx contains in its interior therefore two valves, one of which can control the entrance, the other the exit of air.

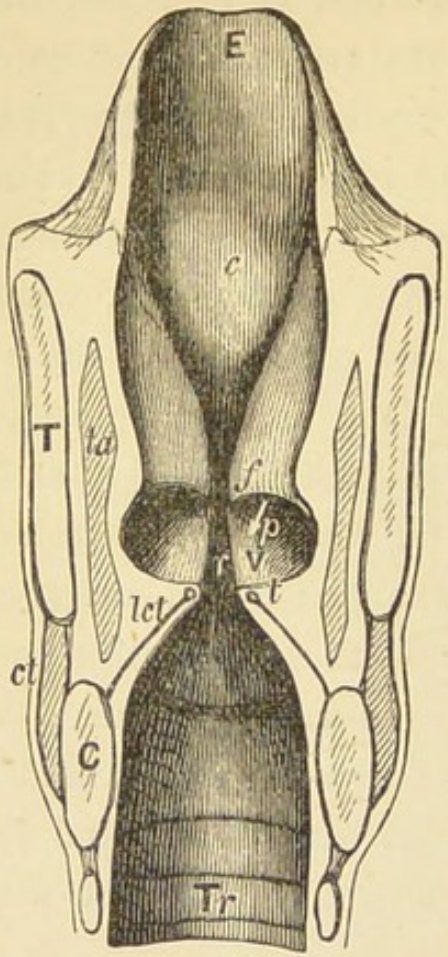

FIG. 164.—Vertical transverse section through the Larynx. E, epiglottis; *c*, its cushion-like prominence; T, left ala of thyroid cartilage; *ta*, thyro-arytenoid muscle; C, cricoid cartilage; *ct*, crio-thyroid muscle; *f*, false vocal cord; *t*, true vocal cord; *v*, ventricle of larynx; *p*, points upwards into laryngeal pouch; *r*, rima glottidis; *lct*, lateral crico-thyroid membrane seen in section; *Tr*, trachea.

Muscles of the Larynx.

The muscles of the larynx are arranged in two groups, an extrinsic and an intrinsic.

The *extrinsic* muscles are divided into a supra-hyoid and an infra-hyoid group. The supra-hyoid muscles are the digastric, stylo-hyoid, mylo-hyoid, and genio-hyoid. The infra-hyoid are the omo-hyoid, sterno-hyoid, sterno-thyroid, and thyro-hyoid. These muscles act on the entire larynx through their insertion into the hyoid bone, and through the attachment of that bone to the thyroid cartilage. Their description naturally comes, therefore, into that of the muscles acting on the hyoid. As the sterno-thyroid and thyro-hyoid muscles have a direct attachment to the alæ of the thyroid cartilage, they will be described here.

Sterno-thyroid arises from the back of the manubrium sterni, and the first costal cartilage; it ascends in front of the trachea, and is inserted into the oblique line on the outer surface of the thyroid cartilage.

Thyro-hyoid arises from the lower border of the great cornu and the body of the hyoid bone, and is inserted into the same oblique line to which the sterno-thyroid is attached.

From the attachment of these muscles to the thyroid cartilage, they can fix it, and put it in a better position to serve as a surface of origin for those intrinsic muscles of the larynx, which arise from it.

The *intrinsic* muscles of the larynx arise from and are inserted into the cartilages of the larynx, and by their action diminish or increase the tension of the vocal cords, diminish or increase the size of the rima glottidis, or affect the position of the epiglottis and the size of the superior

aperture of the larynx. These muscles should be examined with reference to their action on the crico-thyroid joints, the crico-arytenoid joints, and the epiglottis.

The muscles which act on the crico-thyroid joints are the pair of crico-thyroid muscles and the pair of thyro-arytenoid muscles.

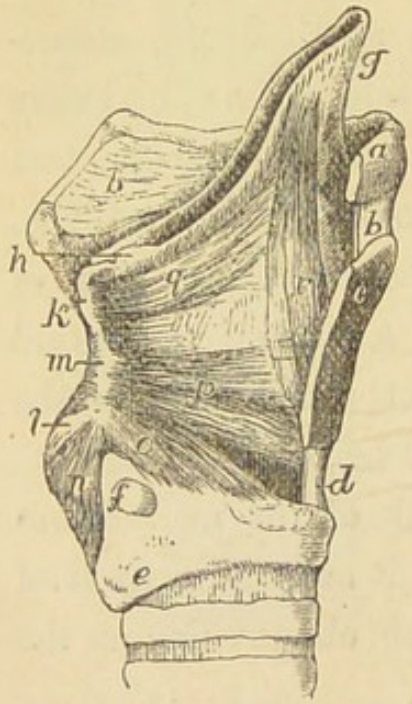

FIG. 165.—The muscles of the Larynx as seen after the removal of the right ala of the thyroid cartilage. *a*, hyoid bone; *b*, *b*, thyro-hyoid membrane; *c*, thyroid cartilage; *d*, middle crico-thyroid membrane; *e*, cricoid cartilage; *f*, surface of articulation with thyroid; *g*, epiglottis; *h*, cuneiform cartilage; *k*, corniculum laryngis; *l*, muscular process of, *m*, the arytenoid cartilage; *n*, posterior and *o*, lateral crico-arytenoid muscles; *p*, thyro-arytenoid muscle; *q*, oblique arytenoepiglottidean muscle; *r*, thyro-epiglottidean muscle.

The *Crico-thyroid* muscle arises from the side of the cricoid cartilage as far forward as its anterior middle line; its fasciculi pass backwards and upwards, and are inserted into the lower border of the thyroid cartilage and the anterior border of its inferior cornu. The two crico-thyroids diverge from each other, and leave uncovered the middle division of the crico-thyroid membrane.

The *Thyro-arytenoid* muscle arises from the inner surface of the thyroid cartilage close to its retreating angle: it passes almost horizontally backwards in close relation to the outer wall of the pouch of the larynx and to the true vocal cord, and is inserted into the vocal process at the base of the arytenoid cartilage, into the anterior surface of the same cartilage, and by a few fibres into the true vocal cord.

The crico-thyroid muscles increase the tension of the vocal cords. As to the mode in which this tension is occasioned there is a difference of opinion. It is usually believed that the crico-thyroid muscles rotate the thyroid cartilage about a transverse axis, passing horizontally through the two crico-thyroid joints, and depress the anterior border of the thyroid cartilage so as to elongate the vocal cords in front. But some anatomists hold that the thyroid cartilage is fixed by the action of the thyro-hyoid muscles, that the crico-thyroid muscles then rotate the cricoid cartilage on the thyroid, by drawing the front of the cricoid cartilage upwards, which depresses the back of the cricoid and the arytenoid cartilages, and

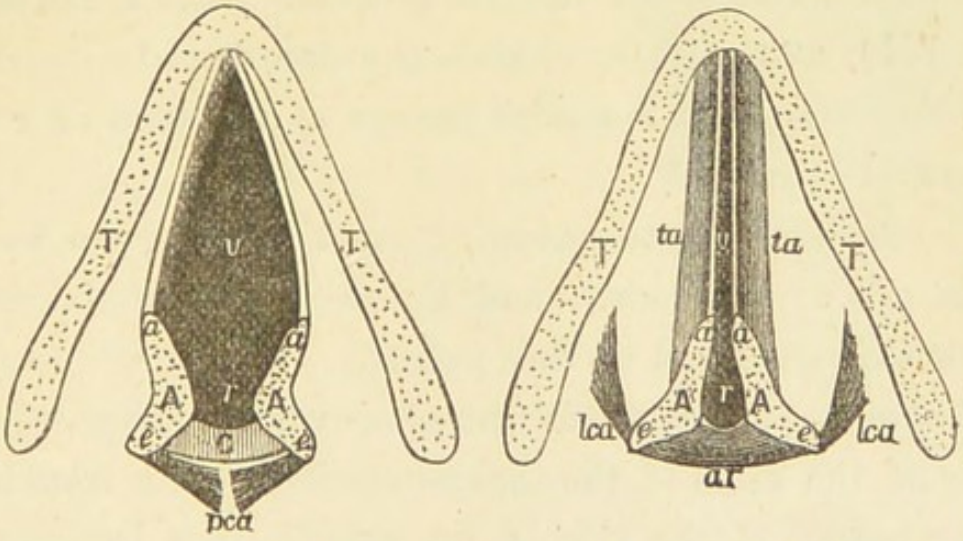

FIG. 166.—Diagram of the Rima Glottidis, to illustrate the action of the muscles on it. A transverse section has been made through the larynx on a level with the true vocal cord and the bases of the arytenoid cartilages. TT, alæ of thyroid cartilage; AA, arytenoid cartilages; *aa*, their vocal, and *ee*, their muscular processes; *v*, vocal, and *r* respiratory part of glottis. In the right hand figure the rima is shown as almost closed by the action of *lca* the pair of lateral arytenoids and *ar*, the arytenoid muscle, *ta*, *ta*, the pair of thyro-arytenoid muscles. In the left hand figure the rima is shown widely open by the action of *pca*, the pair of posterior crico-arytenoid muscles; C, the upper border of the cricoid cartilage.

elongates the posterior ends of the vocal cords. The thyro-arytenoid muscles approximate the opposite ends of the vocal cords, and thus relax them, by drawing the thyroid

cartilage upwards and backwards, but owing to the attachment of some fibres to the vocal cord, local tension may be given to certain parts of it. The fibres attached to the anterior surface of the arytenoid cartilage may roll it inwards so as to bring the two cords together, and narrow the rima glottidis.

The width of the rima glottidis is altered by the movements of the arytenoid cartilages, which rotate about a vertical axis passing through the crico-arytenoid joints. The cartilages are rotated outwards, the vocal processes and vocal cords are separated from each other, and the rima glottidis is widened by the pair of

Posterior crico-arytenoid muscles, which arise from the depressed surfaces on the back of the cricoid cartilage (fig. 161), and pass upwards and outwards to be inserted into the external or muscular process at the base of each arytenoid cartilage.*

The arytenoid cartilages are rotated inwards, the vocal cords are approximated, and the vocal part of the rima glottidis is narrowed by the pair of

Lateral crico-arytenoid muscles, which, being under cover of the sides of the thyroid cartilage, arise from the upper border of the side of the cricoid, pass backwards and upwards to be inserted into the external or muscular process at the base of each arytenoid cartilage.

The arytenoid cartilages are drawn together, and the width of the respiratory part of the rima glottidis is narrowed, by the single

* Merkel described a small *Kerato-cricoid* muscle as occasionally extending, but on one side only, from the lower part of the back of the cricoid cartilage to the inferior cornu of the thyroid. I found it to be present 7 times in 32 subjects, and to be occasionally present on both sides.

Arytenoid muscle, which arises from the posterior concave surface of one arytenoid cartilage, passes transversely across the mesial plane, to be inserted into the corresponding surface of the other cartilage.

The epiglottis is drawn backwards and depressed by the pair of oblique aryteno-epiglottidei, and the thyro-epiglottidei muscles.

The *Oblique aryteno-epiglottidei* muscles consist of the oblique fibres situated superficial to the arytenoid muscle. They arise near the external or muscular tubercle at the base of the arytenoid, pass obliquely upwards across the mesial plane to the apex of the opposite arytenoid cartilage, and then ascend in the aryteno-epiglottidean fold of mucous membrane. The oblique aryteno-epiglottidean and arytenoid muscles are arranged around the superior orifice of the larynx like a sphincter, and by their contraction the size of this opening is diminished.

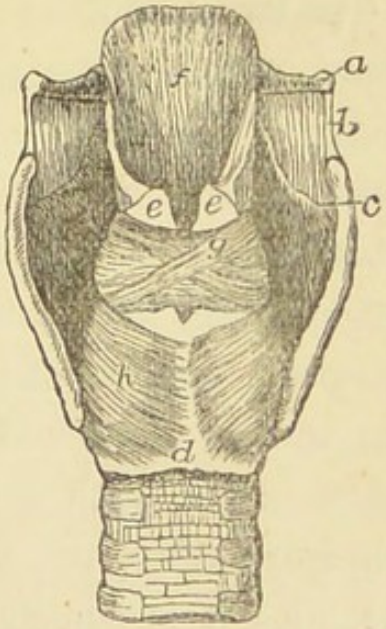

FIG. 167.—The posterior muscles of the Larynx. *a*, hyoid bone; *b*, thyro-hyoid ligament; *c*, thyroid cartilage; *d*, cricoid cartilage; *e*, *e*, arytenoid cartilages; *f*, epiglottis; *g*, oblique aryteno-epiglottidean muscles; *h*, posterior crico-arytenoid muscle.

Thyro-epiglottidei consist of fibres which arise from the inner surface of the thyroid cartilage near the retreating angle, and ascend to the side of the epiglottis.

The glottis is shut, during the act of swallowing, not only by the depression of the epiglottis, as described on p. 89, but by the closure of the rima glottidis, due to the approximation of the arytenoid cartilages and the true vocal cords.

The free edges of the vocal cords are thrown into vibrations in the production of the voice. The modifications which take place in their degree of tension, and in the size of the rima in connection with the production of the notes, and the elevation or lowering of their pitch, are questions which are more appropriately discussed in works on physiology.

Mucous Membrane of the Larynx.

The larynx is lined by a mucous membrane, continuous above, through the superior opening, with the mucous lining of the pharynx, and below, through the inferior opening, with that of the trachea. It is thin, especially where it covers the true vocal cords, but in the aryteno-epiglottidean folds it is thicker and the sub-mucous tissue is looser: it does not possess a high degree of vascularity. Its surface is covered by a ciliated columnar epithelium, intermingled with goblet-shaped cells; except near its superior orifice, and over the true vocal cords, in which localities it is squamous. The sub-epithelial connective tissue of the mucosa contains a quantity of elastic fibres. Numerous racemose glands are found opening on the surface of the laryngeal mucous membrane. They are very abundant on the back of the epiglottis, in which they are lodged in small pits, and in the walls of the laryngeal pouches. Collections of lymphoid tissue are also found in the subepithelial tissue of the mucosa.

Vessels and Nerves of the Larynx.

The larynx receives its supply of blood from the superior laryngeal branches of the superior thyroid arteries, which pierce the thyro-hyoid membrane; from the crico-thyroid branches of the same arteries, which form an arch on the crico-thyroid membrane, and from the inferior laryngeal branches of the inferior thyroid arteries, which pass to the lower and posterior part of the larynx. Veins correspond to these different arteries. Lymphatics are distributed in the mucous and submucous tissues.

The nerves of the larynx are the superior and inferior laryngeal branches of the pneumogastric. The superior laryngeal nerve divides into an external and an internal branch. The external branch is small, and descends to supply the crico-thyroid muscle. The internal branch pierces the thyro-hyoid membrane, and divides into two parts; the upper or epiglottic branch supplies the mucous covering of the epiglottis, the aryteno-epiglottidean and hyo-glossal folds of mucous membrane; the lower part supplies the mucous lining of the middle and lower parts of the larynx, and gives a branch to the arytenoid muscle. The inferior or recurrent laryngeal nerve supplies branches to all the intrinsic muscles of the larynx except the crico-thyroid. It also communicates with the superior laryngeal nerve, and gives some small twigs to the mucous membrane.

CHAPTER IX.

RESPIRATORY SYSTEM.

THE Respiratory System is composed of organs, which are engaged in the interchange of gases between the blood and the atmospheric air. Through their instrumentality, the blood acquires oxygen from the air, imparts to it carbonic acid and watery vapour, and becomes changed from impure venous into pure arterial blood. In man and the higher vertebrates the interchange of gases is effected through the medium of a long branching tube, called the Windpipe, and of two vascular spongy organs, the Lungs. But as the windpipe has no direct communication with the exterior of the body, and opens superiorly into the pharynx, the atmospheric air has to pass, through either the nose or mouth into the pharynx, before it can enter the windpipe. The nose is the proper passage for its transmission, and constitutes therefore a part of the respiratory apparatus. As the nose is also an organ of sense, its anatomy has been described under that head (p. 322).

The process of respiration consists of two acts, with intermediate pauses—breathing in and breathing out. Breathing in, or Inspiration, consists in drawing air into

the lungs, so as to expand those organs. Breathing out, or Expiration, consists in the expulsion from the lungs of a portion of the air which they contained. By the regular alternation of these two acts, during extra-uterine life, the air in the lungs is constantly being renewed, and fresh portions of air are brought into relation with the stream of blood, as it is propelled through the capillaries of the lungs by the action of the right, or pulmonic side, of the heart. The movements of respiration are in a great measure effected by the agency of numerous muscles acting on the osseo-cartilaginous framework of the thorax. A general description of the action of these muscles has been already given on p. 78.

As the lungs occupy a large portion of the cavity of the chest, and have important relations to its walls, it will be advisable, before describing them, to give an account of the construction, shape, and size of the thorax, and to point out the regions into which it is customary to divide it.

Thorax.

The Cavity of the Thorax or Chest is intermediate in position, in size, and in the extent of mobility of its walls to the cavities of the cranium and abdomen. It contains not only the two lungs and the terminal part of the windpipe, but the heart, with the great blood-vessels which pass to and from it, some large nerves, the œsophagus, and the thoracic duct. It is very completely walled in by bones, cartilages, muscles, membranes, and skin.

Thirty-seven bones enter into the formation of the osseous walls of the thorax, viz., 12 dorsal vertebræ,

12 pairs of ribs, and the sternum. The dorsal vertebræ are situated in the middle of its posterior wall. Their bodies are united together by the intervertebral discs, and anterior and posterior common ligaments; their articular processes by capsular ligaments; their laminæ by the ligamenta subflava; and their spines by the supra and inter spinous ligaments. The sternum is situated in the middle of the anterior wall of the chest. It consists of three pieces, which ultimately fuse together into a single bone. The twelve ribs on each side are articulated behind to the dorsal vertebræ. They project at first backwards, downwards, and outwards; they then arch downwards, forwards, and inwards, and are continuous at their anterior ends with the costal cartilages. The first costal cartilage prolongs the first rib downwards and inwards to the side of the manubrium sterni. The second continues the second rib horizontally inwards to the side of the joint between the manubrium and body of the sternum. The cartilages of the third rib to the tenth inclusive slope upwards and inwards, and become gradually more vertical in their direction, as one passes downwards in the series. The cartilaginous termination of the seven upper ribs, on each side articulate with the side of the sternum. The cartilaginous terminations of the eighth, ninth, and tenth ribs do not reach the side of the sternum; but as they are jointed together, and as the eighth cartilage is jointed with the seventh, the seventh to the sixth, and the sixth to the fifth, they are indirectly connected to that bone, and the movements of the ribs, of which they are the terminations, can thus influence the movements of the sternum. The cartilaginous terminations of the eleventh and twelfth ribs

come to free ends in the muscles of the wall of the abdomen.

The ribs are all jointed behind by their heads to the bodies of the vertebræ, and they all, except the eleventh and twelfth, possess tubercles, which are jointed to the transverse processes of their corresponding dorsal vertebræ. The intervals between the ribs, or intercostal spaces, are occupied by the external and internal intercostal muscles, and by an anterior and a posterior intercostal fibrous membrane. The intercostal spaces are eleven in number on each side of the thoracic wall. Each space is not of equal width in its entire length, for the borders of the ribs which bound it are not parallel with each other. They are the widest opposite the junction of the osseous and cartilaginous part of the costal arch, but from this spot they diminish in width from before backwards. The width of the upper series of spaces is greater than that of the middle and lower. The lower two intercostal spaces, however, remain of equal width throughout.

The *External* or *Superficial Intercostal* muscle forms a layer extending, from the tubercles of the ribs posteriorly, as far as, or almost as far as, the junction of the osseous and cartilaginous part of the rib anteriorly. Its fasciculi are short; they arise from the lower border of one rib, and pass obliquely downwards and forwards to be inserted into the upper border of the rib situated immediately below.

The *Internal* or *Deep Intercostal* muscle forms a layer extending from the anterior ends of the costal cartilages as far back as the angles of the ribs. Its fasciculi arise from the inner margins of the lower border of the rib and

costal cartilage, and pass obliquely downwards and backwards to be inserted into the upper border of the rib situated immediately below.

The *Anterior Intercostal Fibrous Membrane* stretches between the lower border of one costal cartilage, and the upper border of the cartilage immediately below it. It lies superficial to the intercartilaginous part of the internal intercostal muscle. In the case of the sternal ribs, the membrane reaches from the anterior border of the external intercostal muscle to the side of the sternum, whilst in the case of the a-sternal ribs, it connects their cartilages without reaching the sternum.

The *Posterior Intercostal Fibrous Membrane* stretches between the lower border of the neck and shaft of one rib and the upper border of the neck and shaft of the rib immediately below. It reaches from the posterior border of the internal intercostal muscle as far as the head of the rib; it is in relation to the inner surface of the posterior fibres of the external intercostal muscle, and between the two are the intercostal vessels and nerve.

The *Triangulis Sterni* muscle lies behind the costal cartilages of the lower true ribs. It arises from the side of the xiphi-sternum and the sternal ends of the sixth and seventh costal cartilages; it passes obliquely upwards and outwards in separate digitations to be inserted into the costal cartilages, from the second to the fifth inclusive, at their junction with the bony part of the rib.

The *Intra-* or *Sub-costal* muscles are irregular in number and size. They are situated on the inner surface of the ribs in the region of the angles, and are chiefly found attached to the lower ribs. Their fibres run obliquely

downwards and backwards, like those of the internal intercostals, and correspond in length to two intercostal spaces.

The thorax is usually compared in shape to a truncated cone, the apex of which is above, the base below. It is rounded at the sides, but flattened both in front and behind. The truncated apex, or thoracic inlet, is bounded behind by the first dorsal vertebra, laterally by the first pair of ribs, and in front by the manubrium or pre-sternum. As the vertical diameter of the sternum is less than that of the series of dorsal vertebræ, the upper end of the sternum does not reach so high as the first dorsal vertebra, and the plane of the thoracic inlet slopes obliquely from above downwards and forwards. In expiration the upper border of the manubrium is opposite the body of the third dorsal vertebra, or the disc between it and the second dorsal vertebra; in inspiration it is raised to opposite the body of the second vertebra. Through the thoracic inlet the trachea, œsophagus, and some large veins, and nerves descend into the thorax, and the great arteries and thoracic duct ascend into the neck. Owing to the obliquity of the plane of the thoracic inlet, the parts in the middle of the lower part of the neck, though above the sternum, lie anterior to the bodies of the first and second dorsal vertebræ.

The base of the thorax is much more capacious than the apex. It slopes from the xiphi-sternum downwards, outwards, and backwards along the cartilages of the seventh, eighth, ninth, and tenth ribs, as far as the cartilaginous tip of the eleventh rib, and then slopes upwards, backwards, and inwards along the twelfth rib to the twelfth dorsal verte-

bra. The point of the xiphi-sternum is opposite the body of the twelfth dorsal vertebra in expiration, but in inspiration is raised to opposite the body of the eleventh vertebra.

The base of the thorax is filled in by the diaphragm, which forms the floor of the thorax and the vaulted roof of the abdomen. At the end of an expiration, the summit of the diaphragm mounts as high as the level of the sternal end of the fourth intercostal space on the right side, but not quite so high on the left; from this summit level it slopes downwards and backwards to the costal origins of the muscle. The thoracic surface of the diaphragm is therefore convex. The diaphragm is perforated to allow of the passage of the œsophagus, nervi vagi, aorta, and sympathetic nervous cords downwards into the abdomen, and of the thoracic duct, vena azygos and inferior vena cava upwards into the thorax.

The antero-posterior diameter of the thorax is less than either the transverse or vertical diameters. The antero-posterior diameter in the mesial plane, *i.e.*, the sterno-vertebral diameter, though it increases from above downwards, is less than it is on one side of the sternum, for the projection forwards of the bodies of the dorsal vertebræ, and the backward slope of the posterior ends of the ribs, cause a considerable hollow at the side of the vertebral bodies, in which the posterior border of the lung is lodged. The transverse diameter rapidly increases from the first to the 6th or 7th ribs, and then diminishes somewhat down to the 12th rib. The vertical diameter is much greater, owing to the more backward slope of the diaphragm at the costo-vertebral than at the costo-sternal wall. All the diameters

increase during the inspiratory, and diminish during the expiratory movements. The capacity of the thorax in men is greater than in women. In women, during respiration, a greater range of movement takes place in the upper part of the thoracic walls than in men, in whom the lower part of the chest passes through a wide range of movement. In young children again the diaphragm, much more than the thoracic walls, is concerned in inspiration, and the abdominal viscera are therefore much depressed, and the anterior abdominal wall is pushed forwards. Modifications of the natural form of the thorax may arise from congenital malformations of its walls: from external pressure artificially applied, as tight lacing: from diseases of its walls, as in curvatures of the spine: or from diseases of the viscera contained in its cavity, as from pleuritic effusions, emphysema, aneurisms or other tumours, &c.

When the bones of the shoulder girdle, and the great muscles which pass from them to the walls of the chest are in position, and when these are covered by the fascia and skin, the external configuration of the chest is very materially modified. The outward projection of the shoulders, more especially in men, causes the transverse diameter to be greater at the upper part of the chest than lower down; and the pectoral and scapular muscles add materially to the thickness of the anterior and posterior walls of the chest. In order to assist in localising precisely the position of the important organs within the chest, it is customary to map out the surface of the integument into certain areas or regions, and to apply to these regions descriptive names. Thus, the region corresponding to the sternum is the *sternal*

region, and it is divided into an *upper sternal* and a *lower sternal* by a line drawn across the front of the bone on a level with the upper border of the third pair of costal cartilages. The fossa immediately above the manubrium sterni is the *epi-* or *supra-sternal* fossa. The region corresponding to the inner half of the clavicle is the *clavicular* region: that which lies immediately above it is the *supra-clavicular* region, and that which extends downwards from the clavicle to the lower border of the third rib is the *infra-clavicular* region. The region which extends from the lower border of the third rib to the lower border of the sixth rib is the *mammary* region, and that which extends downwards from the lower border of the sixth rib to the inferior limit of the thoracic wall is the *infra-mammary*. The clavicular, infra-clavicular, mammary and infra-mammary regions are bounded internally by a line corresponding to the outer border of the sternum, and externally by a line drawn vertically downwards from the middle of the clavicle to the inferior limit of the thoracic wall. In the mammary region are situated the mammary gland and nipple. In women the mamma occupies almost the whole of the mammary region, and the nipple usually lies superficial to the fifth rib, and about $4\frac{1}{3}$ inches from the middle line of the sternum. In men the mamma is a rudimentary organ, and the position of the nipple is more variable. Luschka found in 60 men examined, that it was placed 44 times between the fourth and fifth ribs, 6 times on the fifth rib, 8 times on the fourth rib, and twice between the fifth and sixth ribs; whilst Gruber found it in 95 males, 43 times on the fifth rib, 31 times on the fourth intercostal space, 12 times on the fourth rib, and 9 times on the fifth intercostal

space. It varies also in position on the two sides of the same chest. As a rule, it lies in men about $3\frac{3}{4}$ inches from the middle line of the sternum.

At the lateral wall of the chest are the axillary and infra-axillary regions. The *axillary* extends from the apex of the axilla to a line corresponding to the lower border of the sixth rib; and the *infra-axillary* from that line to the edge of the false ribs, where they limit the thoracic wall inferiorly.

Several regions are placed on the posterior wall of the chest. The *scapular* region corresponds to the scapula, and in its vertical diameter reaches from the second to the seventh or eighth rib: the *infra-scapular* region extends from the inferior angle of the scapula to the twelfth rib: the *inter-scapular* region lies between the vertebral borders of the two scapulæ; it varies in its transverse diameter with the position of the arms; for, when they are drawn forwards, the vertebral borders of the two scapulæ are further asunder, than when the arms hang pendulous at the sides, or are pushed backwards: the *supra-scapular* region extends from the upper border of the scapula to a little above the level of the first rib. The size of both the supra-scapular and infra-scapular regions is modified with the elevation or depression of the shoulders.

The portion of the anterior wall of the chest which lies superficial to the heart is called the *cardiac* region. It comprises the whole of the lower sternal region and portions of the right and left mammary regions. Owing to the greater portion of the heart being situated to the left than to the right of the mesial plane of the thoracic cavity, it projects more into the left than into the right mammary

region. The right ventricle corresponds to the lower sternal region, but on the one side passes slightly into the right mammary region, and on the other more extensively into the left mammary. The right auricle is also in the right mammary and lower sternal regions, but the left auricle and ventricle correspond to the left mammary region. The vertical diameter of the cardiac region is from the level of the upper border of the third pair of costal cartilages to that of the sixth pair; its transverse diameter is from a line somewhat internal to the left nipple to a finger's breadth to the right of the sternum. The relations of the aortic and auriculo-ventricular openings to the wall of the chest has already been given on p. 407. It may further be stated, that the relation of the heart to the walls of the thorax varies slightly with the position of the body, with the quantity of blood in the heart, and with the stage of the respiratory process. In a full inspiration the heart is depressed about half an inch, owing to the descent of the diaphragm.

The Windpipe.

The Windpipe is the tube which transmits the atmospheric air from the pharynx into the lungs. It is divided into the larynx, the trachea, and the two bronchi. As the larynx has been described in Chapter VIII., the trachea and bronchi now require description.

The Trachea is situated in the middle of the anterior part of the neck, and in the upper part of the back of the thoracic mediastinum. It is continous above with the

cricoid cartilage of the larynx, and extends from opposite the body of the 6th cervical vertebra to the level of the body

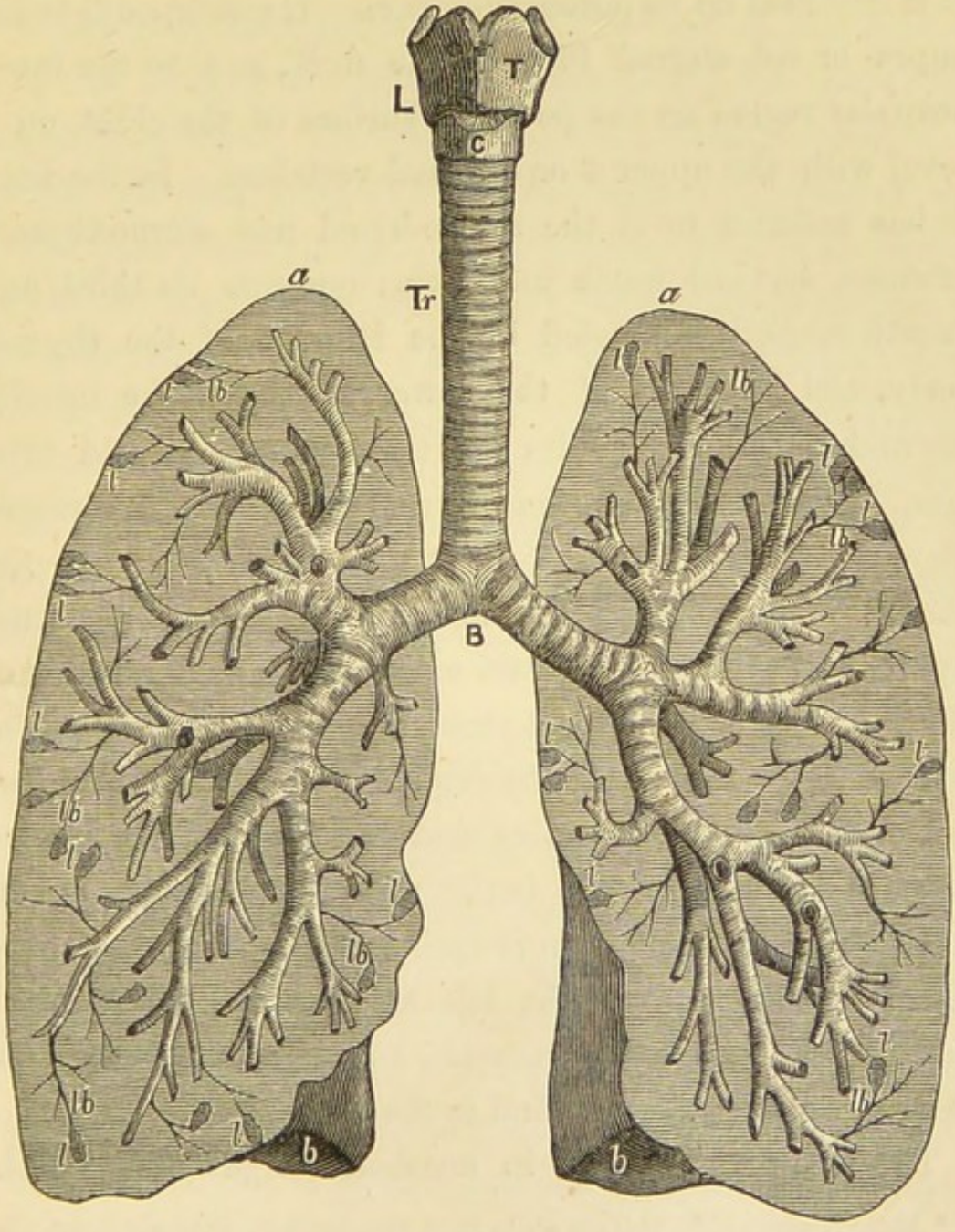

FIG. 168.—The Windpipe and Lungs. L, larynx; T, thyroid cartilage; C, cricoid; *Tr*, trachea; B, bifurcation into bronchi; *a*, apex, and *b*, base of each lung. The ramifications of the bronchi within the lungs are shown; *lb*, *lb*, lobular bronchial tubes; *l*, *l*, *l*, lobules.

of the 4th or sometimes the 5th dorsal vertebra, where it

bifurcates into the two bronchial tubes.* It is between four and five inches long, and is nearly an inch in its greatest width. Anteriorly and laterally it is cylindrical in form, but it is flattened on its posterior surface. It corresponds to the supra- or epi- sternal fossa in the neck, and to the interscapular region on the posterior surface of the chest, on a level with the upper 4 or 5 dorsal vertebræ. In the neck it has anterior to it the sterno-hyoid and sterno-thyroid muscles, cervical fascia and skin; opposite its third and fourth rings, it is crossed by the isthmus of the thyroid body, and in front of the lower rings are the inferior thyroid veins : at its sides are the common carotid arteries, lateral lobes of the thyroid gland, and recurrent laryngeal nerves ; behind it is the œsophagus. In the thorax it lies behind the manubrium sterni, the sterno-hyoid, and the sterno-thyroid muscles, the fatty remains of the thymus gland, the left innominate vein, the transverse part of the aortic arch, the origins of the innominate and left common carotid arteries, and the deep cardiac plexus of nerves ; on each side is the pleural membrane, but in addition on the right side is the termination of the innominate artery, and on the left side are the left common carotid and subclavian arteries, and the left vagus with its recurrent branch : behind is the œsophagus.

The Bronchi are two in number, a right and a left.

* Many descriptive writers state that the trachea extends from the 5th cervical to the 3d dorsal vertebra. The observations of Braune, on sections through the neck in frozen bodies, show that the cricoid cartilage lies opposite the 6th cervical vertebra. The bifurcation also takes place lower down than the 3d dorsal vertebra. But it should be remembered that the position of the trachea is modified by changes in the position of the head. When the head is thrown back the trachea is drawn up ; when the chin is approximated to the sternum the trachea is depressed.

They proceed from the bifurcation of the trachea, and pass obliquely downwards and outwards to the roots of their respective lungs. The left bronchus is longer and more oblique than the right, and enters the back of the root of the left lung, below the pulmonary artery, but above the pulmonary vein. The right bronchus, though shorter, is wider than the left, and enters the back of the root of the right lung above the pulmonary artery. The vena azygos arches forwards immediately above the right bronchus to join the superior cava; whilst the left bronchus lies within the arch of the aorta. In the angle formed by the bifurcation of the bronchi is a cluster of lymphatic glands. The bronchi correspond to the interscapular region on the posterior surface of the thoracic wall, on a level with the fifth and sixth dorsal vertebræ.

Structure of the Trachea.

The wall of the trachea is formed of cartilage, fibro-elastic membrane, muscular tissue, a submucous coat, and a mucous membrane. The *cartilage* is arranged in the form of imperfect rings, from sixteen to twenty in number, separated by narrow intervals. Each ring is about two-thirds of a circle, and is placed at the front and sides of the trachea, but is absent posteriorly (fig. 161). Sometimes a cartilage divides into two branches, at other times two adjacent cartilages fuse together at their posterior ends. The lowest tracheal cartilage has a process prolonged backwards, at the angle of bifurcation into the two bronchi.

The *fibro-elastic membrane* connects together the upper and lower borders of adjacent cartilages, also the upper

tracheal cartilage with the cricoid cartilage, and completes the wall of the trachea posteriorly by passing between the posterior ends of the cartilaginous rings.

The *muscular tissue* consists of non-striped fibres, which lie in the posterior wall of the trachea, under cover of the fibro-elastic membrane. They pass for the most part transversely, and not only extend between the posterior ends of the cartilaginous rings, but lie also opposite the intervals between them.

The *submucous coat* is distinguished by containing, especially in the posterior wall of the trachea, longitudinal bundles of elastic fibres. In this coat are situated numerous compound racemose glands, the branches of which on section are like cylindrical tubes: they are lined by a columnar epithelium, and the excretory duct opens on the free surface of the mucous membrane.

The *mucous membrane* lines the inner surface of the trachea, and is elevated on the posterior wall into longitudinal folds, which correspond to the bundles of elastic fibres in the submucous coat. The free surface of the mucous membrane is covered by a layer of ciliated columnar epithelium, amidst which goblet-shaped cells are interspersed. Between the deeper ends of the ciliated epithelium, smaller spindle-shaped, or rounded, cells are found in considerable numbers. Deeper than the epithelium is a muscular layer, the muscularis mucosæ. Lymphoid tissue is also found diffused throughout the sub-epithelial tissue of the mucous membrane, and occupying the intervals between the vesicles of adjacent racemose glands.

The trachea is supplied with blood by branches from the laryngeal branches of the inferior thyroid arteries. Lym-

phatic vessels form plexuses in the mucous and submucous coats. Fine nerves, derived from the pneumogastric and sympathetic, are distributed to it, in connection with which microscopic ganglia have been seen.

The Pleuræ.

Each lung is situated in, and occupies the greater part of, one lateral half of the cavity of the thorax. It is invested by a serous membrane, the Pleura; and the wall of the chest, bounding the space in which the lung is contained, is lined by a prolongation of the same serous membrane. Like the serous membranes elsewhere, the pleura consists, therefore, of a *visceral part* investing the organ, and a *parietal part* lining the wall of the cavity in which the organ is lodged. The pleural investment of the lung is called the *pulmonic pleura*. The pleural lining of the cavity has different names applied to different portions of its extent. That which lines the inner surface of the ribs, costal cartilages, and intercostal muscles, is the *costal pleura;* that which covers the upper surface of the diaphragm is the *diaphragmatic pleura:* that which is prolonged for one inch, or rather more, above the level of the first rib into the root of the neck, is the *cervical pleura;* that which covers the lateral surface of the pericardium, and forms the lateral boundary of the mediastinum, is the *mediastinal pleura;* whilst a fold of the pleura, prolonged downwards from the root of the lung to the diaphragm, forms the broad ligament of the lung, *ligamentum latum pulmonis*. These several terms simply express topographical divisions of one and the same membrane: thus the pleura costalis

is continuous above with the cervical pleura, and below with the diaphragmatic pleura. Where the costal cartilages articulate with the sternum, the costal pleura comes in contact with the back of that bone, and is then reflected backwards, as the mediastinal pleura, on the outside of the pericardium, from which it is prolonged in front of the root of the lung to become continuous with the pulmonic pleura. Where the ribs articulate behind with the spine, the pleura is prolonged on the sides of the vertebral bodies, from which the right pleura is reflected forward on the back of the root of the lung, to become continuous with the pulmonic pleura; but the left pleura, before it reaches the back of the root of its lung, is prolonged over the left aspect of the descending thoracic aorta.

The cervical prolongation of the pleura forms the dome-shaped summit of the parietal pleura. It corresponds to the apex of the lung, and is in relation by its outer surface to the scalenus anticus muscle and the subclavian artery.

The parietal part of the right pleura is more extensive than that of the left, for not only does it pass behind the sternum up to the mesial line of that bone, or sometimes even to the left of that line; but owing to the greater projection of the heart to the left than to the right of the mesial thoracic plane, it covers a larger proportion of the upper surface of the diaphragm. The costo-parietal part of the left pleura, again, whilst it reaches the left border of the upper part of the sternum, does not pass so far forward as the lower part of the body of that bone. The costal pleuræ do not reach quite so far down as the costal origins of the diaphragm, so that these origins, as well as

the surface of the diaphragm, to which the pericardium is attached, are not covered by the pleural membranes.

The two pleural membranes are perfectly independent of each other, and although they both extend towards the mesial plane of the thorax, they do not come in contact with each other, except in some cases, where they touch immediately behind the body of the sternum. The interval between the two pleural membranes occupies the mesial plane, or sterno-vertebral diameter of the thoracic cavity, and is named the *mediastinum*, *mediastinal space*, or *interpleural space*. The mediastinum is bounded laterally, therefore, by the two pleuræ; it is not an empty space, but is occupied by the heart and pericardium, and by certain structures situated both in front of and behind the pericardium. The heart and pericardium fill up the greater portion of the interpleural space, and the region they occupy is called the *middle mediastinum*. Owing to the projection of the heart to the left, the middle mediastinum extends more to the left than to the right of the mesial plane. As the phrenic nerves lie between the sides of the pericardium and the mediastinal pleura, they are also placed in the middle mediastinum. The narrow interval between the front of the pericardium and the back of the sternum is the *anterior mediastinum*, which inclines from above downwards to the left of the mesial plane. It contains the left triangularis sterni muscle, the origins of the sterno-hyoid and sterno-thyroid muscles, in the infant and child the thymus gland, and in the adult the lobes of fat into which the gland has degenerated; also some loose areolar tissue. The wider interval between the back of the pericardium and the front of the bodies of the vertebræ

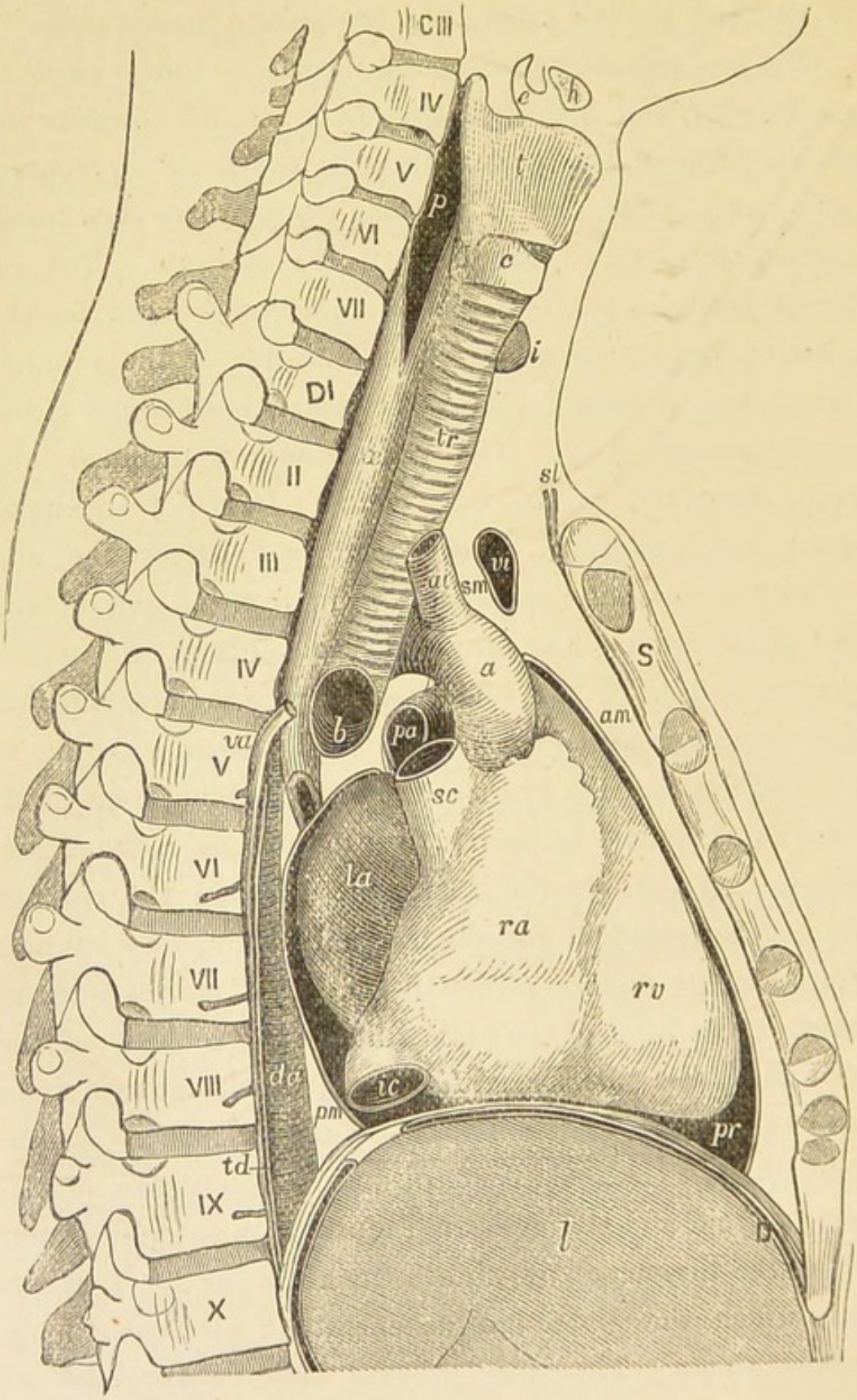
CIII
IV
V
VI
VII
DI
II
III
IV
V
VI
VII
VIII
IX
X
va
e
h
t
p
c
i
tr
sl
vt
at
sm
a
S
am
b
pa
sc
la
ra
rv
ic
pr
da
pm
td
l

FIG. 169.—View of the Sterno-vertebral region of the chest, or the Mediastinum Thoracis. S, sternum; D, diaphragm; CIII to VII, cervical vertebræ; DI to X, dorsal vertebræ; *am*, anterior mediastinum; *pm*, posterior mediastinum; *sm*, superior mediastinum. The middle mediastinum is occupied by the pericardium, *pr*, and by the heart, of which the following parts are shown; *ra*, right auricle; *rv*, right ventricle; *la*, left auricle; *sc*, superior vena cava; *ic*, inferior vena cava; *a*, ascending aorta; *ai*, innominate artery; *pa*, right branch of pulmonary artery. In the posterior mediastinum are shown *da*, descending thoracic aorta; *va*, vena azygos; *td*, thoracic duct; *œ*, æsophagus. *tr*, trachea; *vi*, left innominate vein; *st*, sterno-hyoid and sterno-thyoid muscles. *p*, pharynx; *t*, thyroid cartilage; *c*, cricoid; *e*, epiglottis; *h*, hyoid bone; *i*, isthmus of thyroid body; *l*, liver.

is the *posterior mediastinum.* It contains the descending thoracic aorta, the œsophagus, and nervi vagi, the vena azygos, thoracic duct with lymphatic glands, and the splanchnic nerves. As the pericardium does not extend so high as the level of the top of the sternum, the inter-pleural space between the manubrium sterni and the higher dorsal vertebræ lies above the pericardium, and J. Struthers has suggested that the name *superior mediastinum* should be given to it. It contains the two innominate veins, the innominate, left common carotid, and left subclavian arteries, the upper thoracic portion of the phrenic, pneumo-gastric and cardiac nerves, a part of the left recurrent laryngeal nerve, the trachea, and the upper thoracic part of the œsophagus and thoracic duct.

The pleura, like other serous membranes, possesses two surfaces, an attached surface and a free surface. By its attached surface the pleura is connected by areolar tissue to the ribs, intercostal muscles, diaphragm, pericardium, and lung. The free surface of the parietal pleura is smooth, and in apposition with the corresponding free surface of the pulmonic pleura. These two free surfaces glide on each other as the lungs and thoracic walls rise and fall during inspiration and expiration; and, as the surfaces are lubricated by a little serous fluid, the movement is facilitated. This fluid occupies a scarcely appreciable interval between the free surfaces of the parietal and visceral pleuræ, which interval forms the so-called *pleural cavity.* The pleural cavity becomes distinct when any cause operates to push the lung from the wall of the chest; such as the introduction of air into the pleural cavity, either through an external wound, or from rupture of the lung;

or the effusion of fluid into the cavity, in the course of inflammation of the pleura; either of these causes would push the lung backwards towards the spine, and occasion a great interval between the pulmonic and parietal parts of the pleura. But even in the healthy chest a modification in the relations of the pulmonic to the parietal pleura takes place in some localities. For as, during expiration, the lung does not pass either so far forwards or downwards, as during inspiration, the lung leaves the parietal pleura along its line of reflection from the ribs to the diaphragm, and from the sternum to the side of the pericardium, so that at the end of an expiration the smooth surface of the diaphragmatic and the mediastinal pleura is in apposition along these lines with the smooth surface of the costal pleura.

The pleura is supplied with blood by the intercostal, internal mammary, and bronchial arteries, which ramify in the sub-endothelial layer of connective tissue. Lymphatic vessels form fine networks in the same layer, and communicate through microscopic stomata with the pleural cavity. Nerves pass to the pleura both from the phrenic nerve and from the thoracic ganglia of the sympathetic cord.

It is not uncommon to find along the line of reflection of the pleura from the ribs to the diaphragm, and from the diaphragm to the side of the pericardium, folds of the pleural membrane containing lobules of fat; and on the costal wall of the chest large lobules of fat are often developed beneath the parietal pleura. These folds have been called *pleural villi*, and they resemble the appendices epiploicæ, to be afterwards described, in the abdominal cavity.

THE LUNGS.

The Lungs are two in number and are situated one in each cavity of the thorax. Each lung is usually described

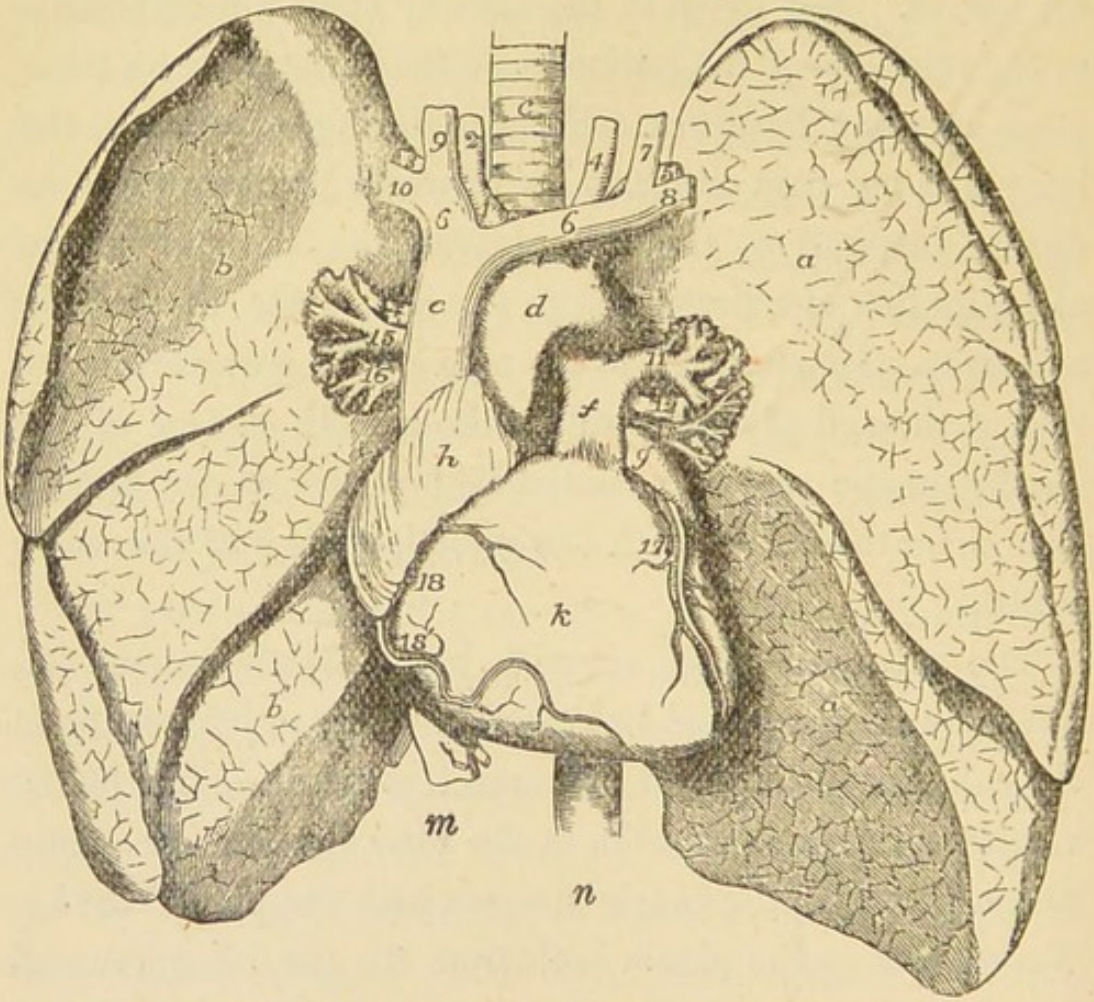

FIG. 170.—The Thoracic Viscera. In this diagram the lungs are turned to the side, and the pericardium removed to display the heart. *a*, upper, *a'*, lower lobe of left lung; *b*, upper, *b'*, middle, *b''*, lower lobe of right lung; *c*, trachea; *d*, arch of aorta; *e*, superior vena cava; *f*, pulmonary artery; *g*, left, and *h*, right auricle; *k*, right, and *l*, left ventricle; *m*, inferior vena cava; *n*, descending aorta; 1, innominate artery; 2, right, and 4, left carotid artery; 3, right, and 5, left subclavian artery; 6, 6, right and left innominate vein; 7 and 9, left and right internal jugular veins; 8 and 10, left and right subclavian veins; 11, 12, 13, left pulmonary artery, bronchus, and vein; 14, 15, 16, right bronchus, pulmonary artery, and vein; 17 and 18, left and right coronary arteries.

as having a conical form; it possesses a base, an apex, an outer surface, an inner surface, an anterior border, a posterior border, and an inferior border.

The *base* of the lung is concave, rests on the convex

upper surface of the diaphragm, and reaches much lower down behind than in front: the *apex* is rounded, and reaches into the root of the neck from one inch to one and a half inch above the first rib. The *external* or *costal surface* is much the larger of the two surfaces; it is convex, and adapted to the curvature of the ribs: the *internal* or *mediastinal surface* is concave, and adapted to the convex lateral surface of the pericardium; about the middle of this surface, but much nearer to the posterior than to the anterior border, is situated the root of the lung. The *anterior* or *sternal border* is thin, and fits in between the back of the sternum and the front of the pericardium: the *posterior* or *vertebral border* is thick and rounded, and occupies the deep hollow at the side of the vertebral bodies; this border possesses a longer vertical diameter than any other part of the lung. The *inferior* or *diaphragmatic border* forms the boundary between the base and the external and internal surfaces of the lung: in the greater part of its extent it fits between the ribs and the costal origins of the diaphragm. On all its aspects the exterior of the lung is in close relation to the parietal pleura, which relation it always preserves in the healthy chest, as it rises in inspiration, or falls in expiration. The contact of the lung with the parietal pleura is ensured by the pressure of the column of air in the windpipe and air-cells.

Each lung is divided into two *lobes* by a deep fissure, which, beginning at the posterior border about three inches below the apex, and on a level with the vertebral end of the third rib, extends through its substance, obliquely downwards and forwards, as far as the anterior border, or the anterior end of the inferior border. The *upper lobe* is

smaller than the *lower lobe*, and, from the direction of the oblique fissure, lies both above and in front of it. The apex and the whole, or the greater part, of the anterior border belong to the upper lobe: the greater part of the posterior border and of the base to the lower lobe. In the right lung a second fissure, which does not exist in the left lung, is also present. It commences at the oblique fissure, runs almost horizontally forwards to the anterior border of the lung, and separates the lower part of the upper lobe as a distinct lobe, called the third or *middle lobe* of the right lung. The right lung is still further distinguished from the left by being more hollowed out at its base, owing to the arch formed by the right half of the diaphragm being higher than that of the left, so that the vertical diameter of the right is not so long as that of the left lung. But the transverse diameter of the right lung is more than that of the left, for the greater projection of the heart and pericardium, to the left than to the right of the mesial plane, causes the mediastinal surface of the left lung to be more concave than the corresponding surface of the right lung. The anterior border of the right lung is much more nearly straight than that of the left, in which this border presents a semilunar notch below the level of the fourth rib, which corresponds to the position of the heart.

The lungs have extensive relations to the walls of the chest, and even to structures at the root of the neck. The apex of each lung lies in the supra-clavicular and supra-scapular regions, and is marked by a slight groove corresponding to the position of the subclavian artery, from which it is separated by the cervical prolongation of the

pleura. The bulk of the upper lobe is placed in the clavicular, infra-clavicular, mammary, axillary, and scapular regions. The middle lobe of the right lung is in the right mammary region. The lower lobe of each lung is in the infra-mammary, infra-axillary, scapular, and infra-scapular regions. The anterior border of each lung overlaps the front of the pericardium, and extends into both the upper and lower sternal regions, but the anterior border of the left lung does not pass so far into the lower sternal region as the corresponding border of the right lung. The posterior borders of the two lungs lie in the interscapular region. During inspiration the anterior border passes further forwards into the upper and lower sternal regions than during expiration, and the base of each lung, with the descent of the diaphragm, extends further down into the infra-mammary, infra-axillary, and infra-scapular regions. As the base of the lungs rests on the diaphragm they are necessarily brought into relation, through that muscle, with viscera situated in the costal zone of the abdomen; thus the right lung is in relation to the liver, and the left lung to the liver, stomach, and spleen.

The *Root* of the lung is composed of the important structures, which pass into, or emerge from, the interior of the lung. It consists of the large air tube, or bronchus, of the pulmonary artery, and the pulmonary veins, the bronchial artery and bronchial vein, the pulmonary nerves, the pulmonary lymphatic vessels, and the bronchial lymphatic glands. The bronchus is placed at the back of the root of each lung; in the root of the right lung it is the highest object, but in the root of the left lung it lies below the pulmonary artery. It is accompanied by the bronchial

artery and vein, by nerves and lymphatics. The pulmonary veins are anterior and inferior to the pulmonary artery in the

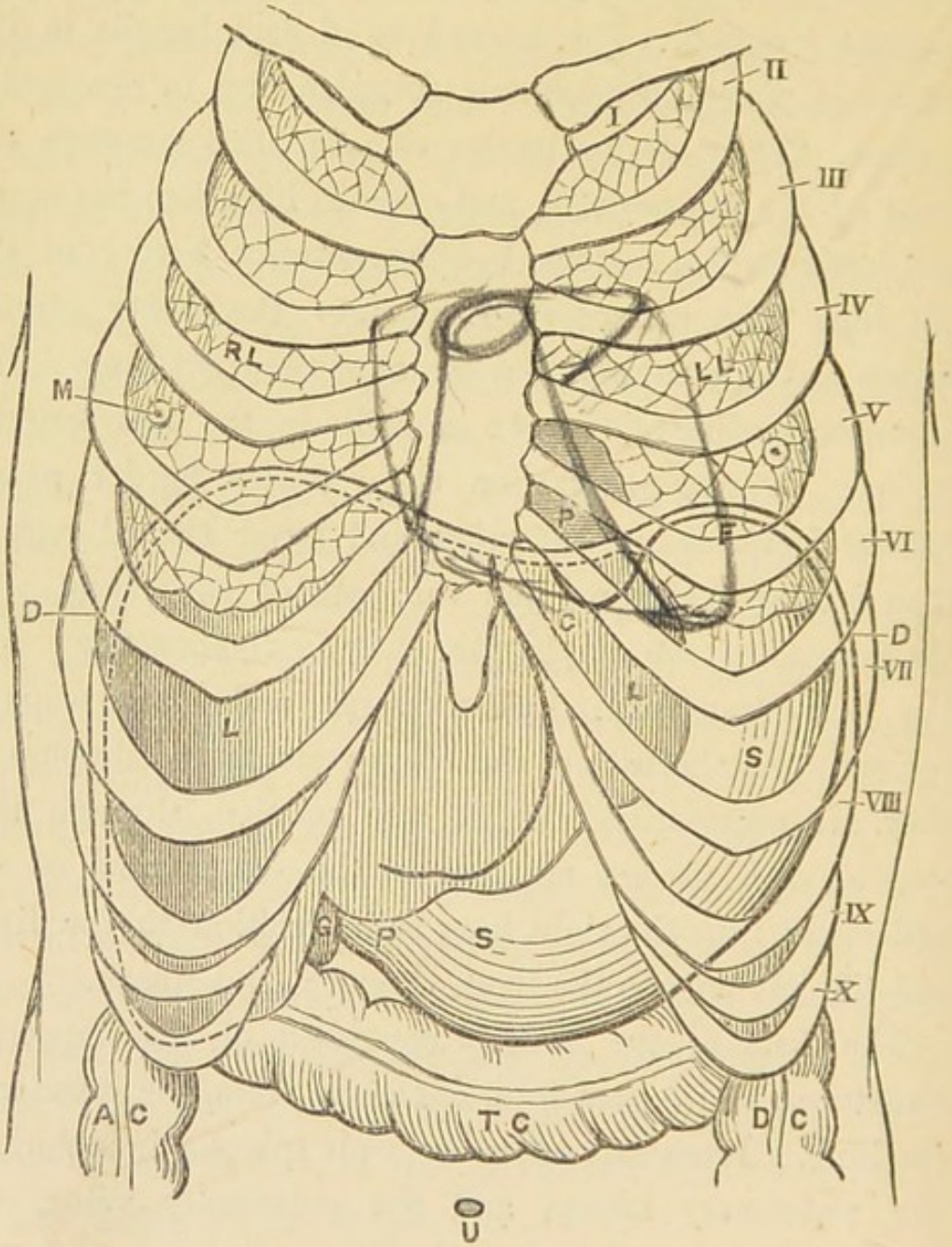

FIG. 171.—The Lungs and their relations to the diaphragm, liver, and stomach. II, to X, second to tenth ribs; DD, diaphragm; RL, right, and LL, left lung; P, pericardium; S,S, stomach; F is placed superficial to its fundus; P, its pylorus; C is over the cardiac orifice; L,L, the liver; G, gall bladder; AC, ascending, TC, transverse, and DC, descending colon; U, umbilicus; M, right nipple. Modified from Luschka.

root of each lung. The posterior pulmonary nervous plexus lies at the back of the root, and the anterior pulmonary

nervous plexus is at the front of the root of the lung. Some areolar tissue connects these various objects together, and the whole are surrounded by the pleural membrane, as it passes from the region of the mediastinum to become continuous with the pulmonic pleura.

The vena azygos arches above the root of the right lung: the aorta above that of the left. The phrenic nerve passes in front of the root of each lung, but the root of the right lung has also the superior vena cava in front of it. The nervus vagus descends behind the root of each lung, but the root of the left lung has also the descending thoracic aorta behind it.

The lungs are light, spongy organs, and contain, after the child has begun to breathe, a quantity of air, so that they float on water. When roughly handled they crepitate, or emit a crackling sound, owing to the air being squeezed out of the air vesicles by the pressure of the fingers. Before the birth of the child they are dense and compact, and sink in water. They are highly vascular, and in the child possess a pink colour. In the adult they are bluish-grey, or slate-coloured, or even mottled with black spots, owing to the formation or deposition of colouring matter in their substance. Their size varies not only with the period of life, but with the degree of inflation with air. Their weight after death also varies, in relation to the amount of blood or mucus they may contain. The average weight of both lungs is about 40 oz., and the right lung is somewhat heavier than the left.

Structure of the Lungs and Bronchi.

The Lung is composed of the ramifications of the bronchial tube, of its terminal apparatus the air-cells or pulmonary vesicles: of the branches of the pulmonary artery, the pulmonary capillaries, and pulmonary veins: of the ramifications of the bronchial artery and vein: of nerves and lymphatics. These several structures are bound together by connective tissue, and the entire organ is invested by the pulmonic pleura.

The *pulmonic pleura* forms the external or serous coat of the lung. It closely envelopes the lobes of the lung, and gives to them a smooth, glistening surface. The free surface of the pulmonic pleura is covered by a single layer of endothelial cells. Klein has pointed out that whilst the endothelium covering the costal pleura consists of polygonal scales, like those of serous membranes generally, the cells of the pulmonic pleura are flattened only during inspiration: during expiration, again, they are polyhedral, or even columnar, their contents are distinctly granular, and the nucleus is more spherical in shape. The sub-endothelial tissue of the pulmonic pleura consists of bundles of white fibrous connective tissue intermingled with elastic fibres. Klein has shown that in some animals, more especially the guinea pig, bundles of non-striped muscular fibres form a network immediately beneath the sub-endothelial connective tissue.

Lobules of the Lung.—The pulmonic pleura is so translucent that the surface of the lung may be seen through it to be mapped out into multitudes of small polygonal areas,

the *lobules* of the *lung*. These lobules are not limited to the surface, but are found in great numbers throughout its entire substance, where they are so closely packed together that their boundaries are indistinct. The lung may therefore be regarded as built up of many thousands of lobules. In the human fœtus, but more readily in fœtal sheep and calves, the lobules may be teased asunder without much difficulty, by tearing through the intermediate connective tissue. In the adult lung they are more closely united together, but their boundaries are often rendered distinct by the formation of pigment in the intermediate connective tissue. The lobules are about the size of peas; they are irregularly pear-shaped, the broader end being directed towards the surface of the lung, whilst the narrow end receives a terminal branch from the bronchial tube.

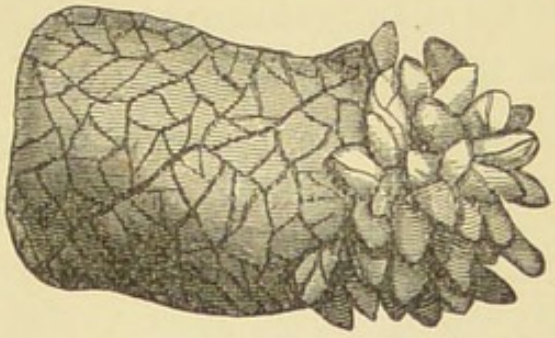

FIG. 172.—Portion of the Lung of a fœtal calf, to show the division into Lobules. At the right border of the figure the individual lobules have been separated from each other. Natural size.

The *connective tissue* of the lung not only separates the lobules from each other, but forms a layer beneath the pulmonic pleura, which is on the one hand continuous with the interlobular connective tissue, and on the other with the sub-endothelial connective tissue of the pleura. Connective tissue also surrounds the bronchus and blood-vessels at the root of the lung, and is prolonged along with the vessels and bronchus, as their tunica adventitia, into the substance of the organ, where it becomes continuous with the interlobular connective tissue. The interlobular

and sub-pleural connective tissue is the seat in the adult lung of the colouring matter, which gives the lung its dark colour. As a lobule of the lung is a miniature lung, it consists of the structures which characterise the lung itself.

The *bronchial tube*, before it enters the lung, resembles in form and structure the trachea. After it has passed in at the root, it immediately begins to divide into smaller bronchi. The process of division and sub-division goes on, usually in a dichotomous manner, as the bronchi extend into the lung substance, until at last minute bronchi are produced, which pass to the lobules of the lung, and are called *lobular bronchial tubes* (fig. 173). A lobular bronchial tube divides within the lobule into two or more terminal branches, which end by dilating into a number of minute chambers, called the *pulmonary vesicles*, *air-vesicles*, *alveoli*, or *air-cells*.

The larger bronchial tubes within the lung correspond generally in their structure to the trachea, though with some modifications in the arrangement of the constituent tissues. The *cartilage* is not in the form of rings, but of irregularly-shaped plates arranged at intervals around the sides of the tube, which is cylindrical in form, and not, like the trachea, flattened posteriorly. These plates diminish in size and frequency in the smaller bronchi, and finally disappear when the bronchi attain a diameter of not more than about $\frac{1}{20}$th of an inch. The cartilaginous framework in both the bronchi and trachea keeps the air-tube open, and allows the free ingress and egress of air. The *fibro-elastic membrane* connects the cartilaginous plates together; it diminishes in strength and thickness as it extends into

the smaller bronchi. The *muscular tissue* forms a definite layer of circular fibres around the entire bronchus not only

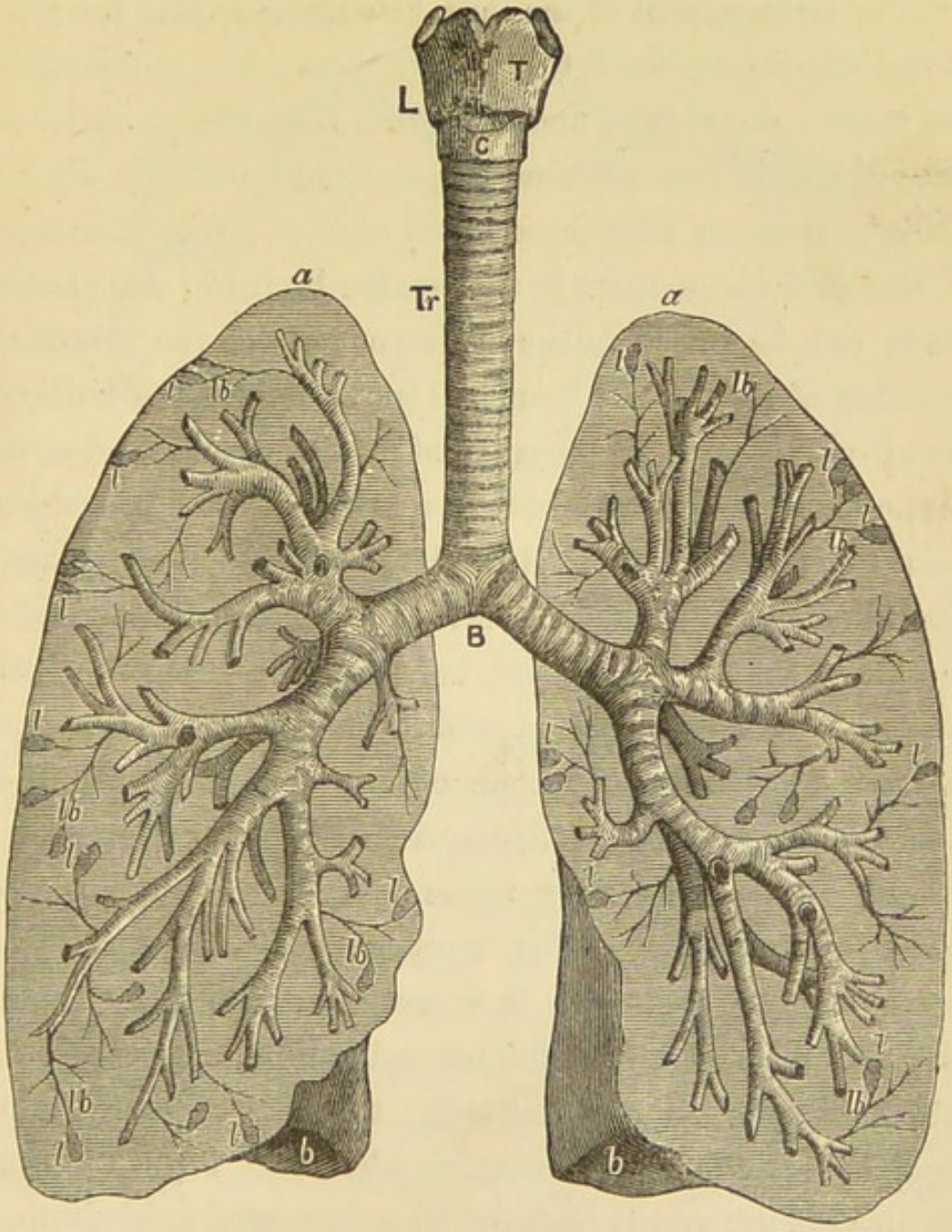

FIG. 173.—The Windpipe and Lungs. L, larynx; T, thyroid cartilage; C, cricoid; Tr, trachea; D, bifurcation into bronchi; *a*, apex, and *b*, base of each lung. The ramifications of the bronchi within the lungs are shown; *lb lb*, lobular bronchial tubes; *l*, *l*, *l*, lobules.

where there are cartilaginous plates, but in the intervals be-

tween them: the muscular layer is between the cartilaginous plates and the mucous membrane: it disappears in the lobular bronchi, where they form the lobular passages. The circular arrangement of the muscular tissue around the wall of the bronchi enables it to constrict these tubes, and modify the ingress of air into, and its egress from the air-vesicles. The *submucous coat* contains longitudinal bundles of elastic tissue continuous with those in the trachea; they diminish in size and distinctness in the smaller bronchi; but elastic tissue can be traced in the walls not only of the terminal branches of the lobular bronchial tubes, but in the walls of the air-vesicles. The presence of longitudinal bundles of elastic tissue in the walls of the bronchi and trachea enables these tubes to be elongated, and to recoil to their former dimensions when the tension is removed. Racemose glands lie outside the muscular layer, between it and the bronchial cartilage: slender ducts proceed from them, which pierce the muscular layer, and open on the free surface of the mucous membrane. Collections of lymphoid tissue are situated in the connective tissue immediately external to the muscular layer. The *mucous membrane* lines the interior of the bronchi. It is covered on its free surface with a layer of ciliated columnar epithelium, amidst which goblet-shaped cells are scattered: the ciliated epithelium disappears in the lobular bronchi, when they begin to form the air-vesicles, and is replaced by a tesselated epithelium.

The *terminal* branches of a lobular bronchial tube lose the cylindrical form of the bronchus, and dilate both laterally and terminally into the *alveoli*, or *air-vesicles*. The collection of air-vesicles surrounding any given terminal bronchus is called a *primary lobule*, or an *infundibulum*

from its funnel-shaped form, whilst the lumen of the terminal bronchus is named the *lobular*, or *alveolar passage* The relation of the air-cells to the lobular passage is not

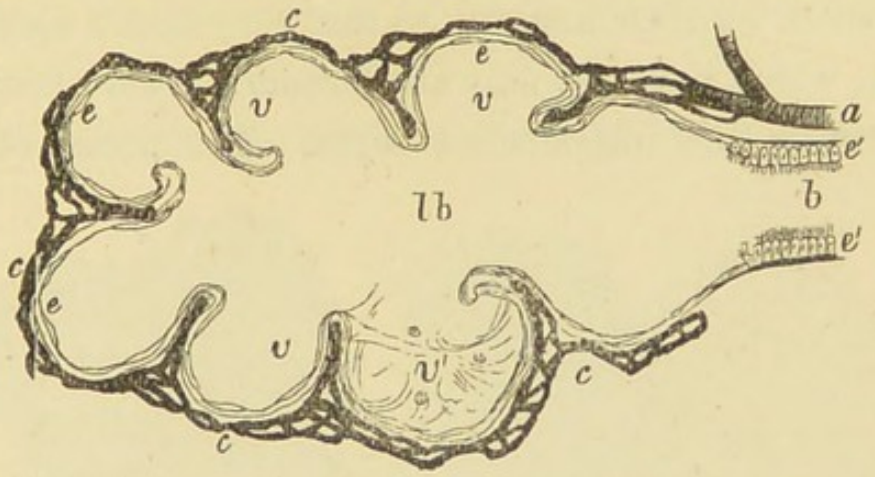

FIG. 174.—Semi-diagramatic longitudinal section through an Infundibulum. *b*, terminal bronchial tube; *lb*, lobular passage; *vv*, air-vesicles; in *v'* the nucleated elastic membranous wall of a vesicle is shown; *a*, pulmonary artery; *c*, *c*, pulmonary capillaries; *e'*, ciliated epithelium; *e*, *e*, tesselated epithelium lining air-cells.

unlike that of a number of small chambers opening into a common corridor. The air-vesicles have an average diameter of about $\frac{1}{100}$th of an inch, though they not unfrequently are larger in size, and are always bigger at the end than at the commencement of an inspiration. The air-vesicles in the same infundibulum are separated from each other by septa, or partitions, so that they do not communicate directly with each other, but only through the common corridor, or lobular passage: it should be stated, however, that these partitions sometimes break down, and permit contiguous air-vesicles to communicate. The air-cells in adjacent infundibula do not communicate at all, but are separated by a thin layer of intermediate connective tissue, and by the pulmonary capillaries.

The structure of the wall of the air-vesicles and lobular

passages is much more simple than that of the bronchi. It consists of a very thin and delicate fibro-elastic membrane, covered on its free surface by a single layer of pavement epithelium. The epithelial cells are polygonal scales, in contact by their margins, so that they form a continuous layer, which lines not only the bottom of the air-vesicles, but covers the intermediate septa. The nuclei of these

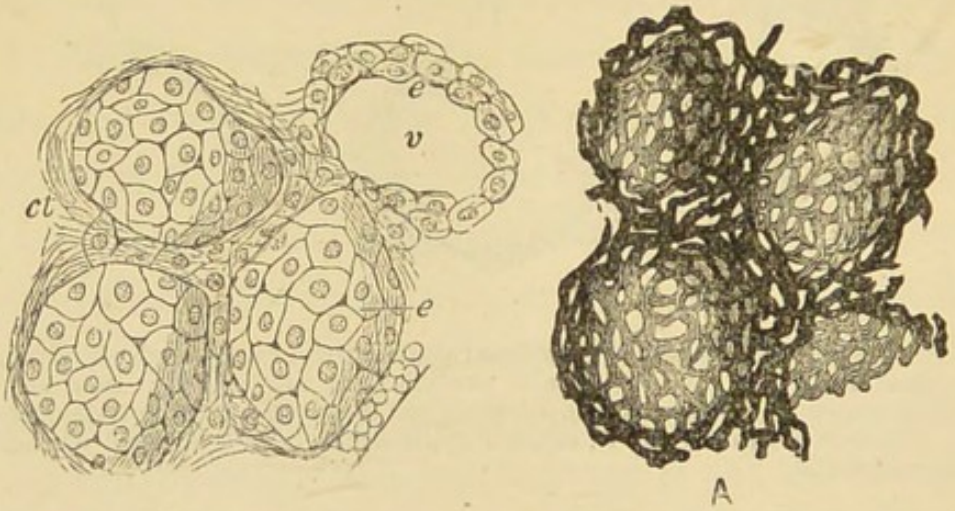

FIG. 175.—A, the pulmonic Capillaries in the walls of the air-vessels; B, the tesselated epithelium *e*, lining the air vesicles of the cat's lung; at *ct*, the elastic fibres in the wall are shown; *c*, a capillary with its blood corpuscles, the size of which may be compared with that of the epithelium cells. × 450.

cells are rounded and granular, so that they are much more easily recognised than the surrounding very translucent protoplasm of the cell substance. This pavement epithelium is in the same morphological plane as the ciliated epithelium of the bronchi. The fibro-elastic membranous wall consists of a very delicate connective tissue in which a few corpuscles are imbedded. Its elastic fibres are distinct, and though few in number at the bottom of an air-vesicle, are more numerous in the intermediate septa, and form apparently a ring-like arrangement around the mouth of the air-vesicle where it communicates with the lobular passage. This elastic tissue permits the air-vesicles to

expand during inspiration, and to recoil during expiration; but breathing having once begun, the air-vesicles are never empty of air. F. E. Schulze states that the septa between those vesicles, which are next the bronchial tube, contain non-striped muscular tissue, which is absent, however, in the proper walls of the alveoli.

The *pulmonary artery* enters the lung at its root, and

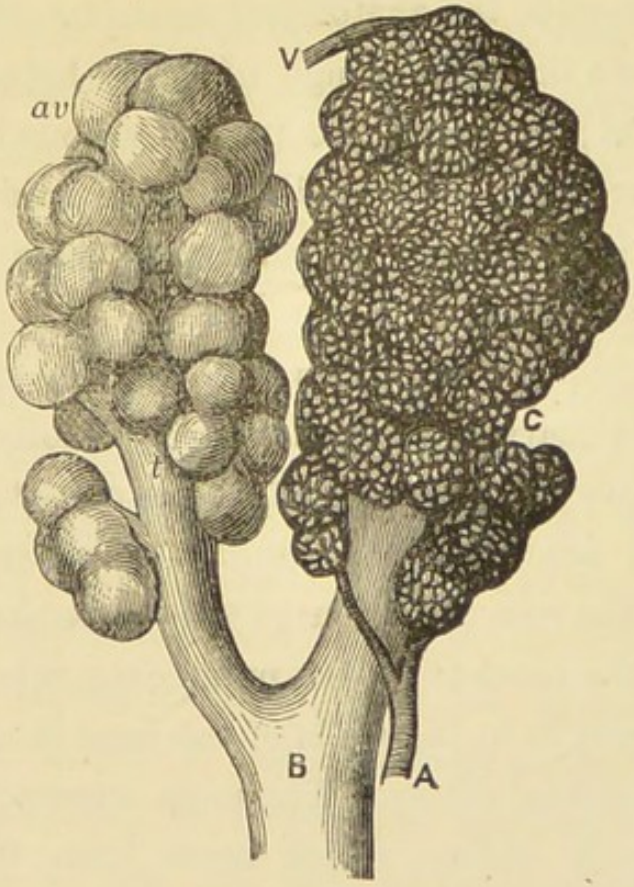

FIG. 176—The outer surface of two of the Infundibula in a lobule of the lung. B, lobular bronchus; *av*, air vesicles ; A, pulmonary artery; *c*, pulmonary capillaries: V, pulmonary vein.

divides and subdivides, without anastomoses, even more frequently than the bronchus, which it closely accompanies. Its finer branches pass to the lobules, along with the lobular bronchi, and within the lobules end in the *pulmonary capillary plexus.* This plexus is dis-

tributed in the fibro-elastic membranous wall of the air-vesicles, passes into the intermediate septa, and forms a ring-like arrangement around the mouths of the air-cells. Its constituent capillaries are very fine, and form an extremely close polygonal meshwork, so that the lung is one of the most vascular of all the organs. The capillaries lie immediately beneath the lining epithelium of the air-vesicles, and are separated by it alone from the air in the air-cells, the anatomical arrangement being such as to facilitate the interchange of gases between the air and the blood; by which the impure venous blood of the pulmonary artery is converted into pure arterial blood, in which state it flows into the pulmonary veins back to the left side of the heart.

The *pulmonary veins* arise in great part by small rootlets from the pulmonary capillary plexus. The rootlets from adjacent pulmonary infundibula, and lobules unite to form larger veins, which accompany the pulmonary artery and leave the lung at the root as two large venous trunks. To some extent also the rootlets of the pulmonary veins arise from a capillary plexus in the walls of the finer bronchi derived from the bronchial artery. The most superficial twigs of the pulmonary veins, which arise from the capillary plexus on the air-vesicles near the surface of the lung, ramify for some distance in the sub-serous connective tissue, when they either join the pulmonary vein at the root of the lung, or sink into its substance to open into some of the more deeply placed pulmonary veins.

The *bronchial* or *nutrient artery* of the lung arises either from the thoracic aorta, or from an intercostal artery, and enters the lung along with the bronchial tube. It is in

part distributed to the lymphatic glands, connective tissue, and the walls of the great vessels at the root of the lung: in part it accompanies the bronchial tube, and breaks up into small arteries, which end in a capillary plexus for the supply of the bronchial mucous membrane and the racemose glands connected with it; in part it is distributed to the interlobular and sub-serous connective tissue. The capillaries which supply the finer bronchi communicate with the pulmonary capillary plexus, and with some rootlets of the pulmonary vein, so that this plexus and the pulmonary veins can be injected from the bronchial artery.

Some years ago I injected a *supplementary* set of *nutrient arteries* for the lungs, consisting of fine branches of the internal mammary and intercostal arteries, which formed an extra-pleural plexus under the mediastinal pleura, and then passed to the lung, both in front of and behind the root, as well as between the folds of the ligamentum latum pulmonis. Having reached the lung, some of these branches entered its substance along with the bronchial tube, whilst others ramified in the sub-serous connective tissue. The extra-pleural plexus keeps up an anastomosis between the arteries of the lung and those of the thoracic wall.

The *bronchial vein* is situated at the root of the lung, and receives venules corresponding to branches of the bronchial artery distributed to both the superficial and deep parts of the lung. It does not, however, convey all the blood which the bronchial artery has carried into the lung, as that artery also communicates through its capillaries with the pulmonary veins. The *lymphatics* of the lung are arranged in a superficial and deep set. The

superficial, or *sub-pleural* lymphatics, form a network beneath the pleural membrane, and communicate, as Klein has shown, with the pleural cavity through microscopic stomata between the endothelial cells. The deep lymphatics arise, according to Klein, in two localities. First, from the walls of the air-cells by means of irregular lacunæ and anastomosing canals, which give origin to lymphatic vessels, that accompany the pulmonary artery and vein, and have been called *perivascular* lymphatics. Second, from the walls of the bronchi by irregular lacunæ and anastomosing canals, situated both in the mucosa and tunica adventitia of the air-tube: they give origin to lymphatic vessels, and form a network in the adventitia of the bronchi, which Klein has named the *peribronchial* lymphatics. The superficial and deep lymphatics enter the bronchial glands at the root of the lung.

The *nerves* of the lung are derived from the pneumogastric and sympathetic branches, from which form at the root of the lung the anterior and posterior pulmonic plexuses, from which fine nerves pass into the substance of the organ with the bronchus, and branch and are distributed along with it. Remak and Julius Arnold have both described minute ganglia on the course of these nerves; and W. Stirling has recently shown that microscopic ganglia are situated on the finer branches of the nerves which lie in the walls of the bronchial tubes.

CHAPTER X.

ORGANS OF DIGESTION.

The Organs of Digestion, Digestive Apparatus or Chylopoietic Viscera, are situated in the axial part of the body. They are for the purpose of receiving the food, or aliment, of converting that portion of the food, which is digestible, into chyle, so that it may be absorbed and applied to the nourishment of the body; and of transmitting that which is indigestible onwards to be excreted. The digestive organs consist of an elongated tube, the Alimentary Canal; of numerous Glands, which pour their secretions into the alimentary canal; and of a hard masticatory apparatus, the Teeth.

Alimentary Canal.

The Alimentary Canal is a tube about 28 feet long, which traverses almost the entire length of the axial part of the body. In man and all other vertebrates, it lies in relation to the ventral surface of the bodies of the vertebræ. It commences on the face at the orifice of the mouth, and terminates on the surface of the lower part of the trunk at the orifice of the anus. It is divided into

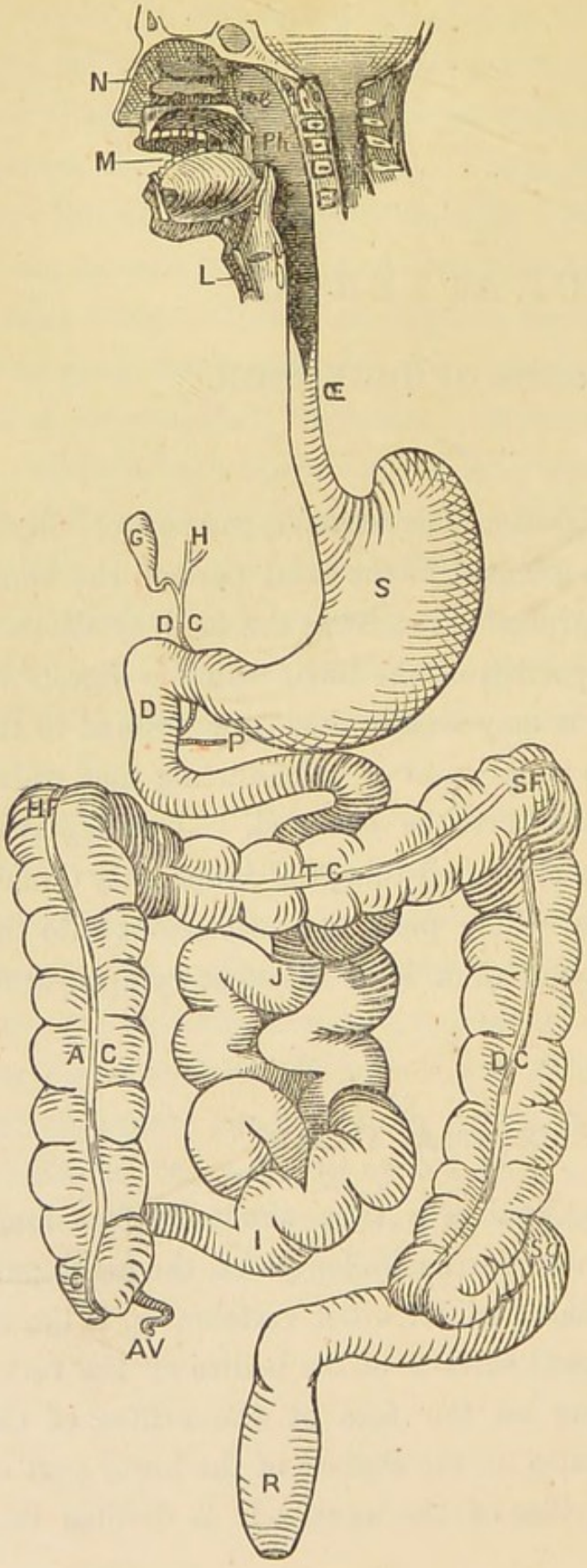

FIG. 177.—Diagram of the several Divisions of the Alimentary Canal. M, mouth; Ph, pharynx; Œ, œsophagus; S, stomach; D, duodenum; J, jejunum; I, ileum; AV, appendix vermiformis; AC, ascending colon; HF, hepatic flexure; TC, transverse colon; SF, splenic flexure; DC, descending colon; Sg, sigmoid flexure; R, rectum; L, larynx; e, Eustachian tube; G, gall bladder; H, hepatic duct; DC, common bile duct; P, pancreatic duct.

a series of segments, or compartments, which communicate with each other, from above downwards, in the longitudinal axis of the canal. These compartments are named mouth, pharynx, œsophagus, stomach, small intestine (subdivided into duodenum, jejunum, and ileum), and large intestine (subdivided into cœcum, colon, and rectum). The canal is lined by a mucous membrane, called the alimentary mucous membrane, which is continuous with the nasal mucous membrane, with the respiratory mucous membrane, and at the anal and oral orifices with the integument. Outside this mucous membrane is the submucous coat, and external to it is the muscular wall of the canal. By the contraction of the muscular wall the food is propelled along the canal from above downwards. Opening on the surface of the mucous membrane are the orifices of the ducts of numerous glands, the secretions of which mingling with the food, act chemically on it, so as to render it soluble and capable of being absorbed.

THE MOUTH.

The Mouth, Oral cavity, or Buccal cavity, is the dilated commencement of the alimentary canal, in which the food is masticated and mingled with the secretion of the salivary and mucous glands. It is situated in the face, and extends from the lips in front, to the pharynx behind. It is bounded above by the hard and soft palate, with the uvula; below by the lower jaw, the mucous membrane of the floor of the mouth, and the tongue; on each side by the cheek; and in front by the lips, between which is the aperture of communication with the surface of the face. Behind it freely communicates with the pharynx through the isthmus faucium, posterior buccal, or pharyngo-oral orifice.

The muscles which enter into the formation of the walls of the mouth are situated in the lips, cheeks, floor of the mouth, tongue, and soft palate.

The muscles of the Lips are as follows :—

Orbicularis, or *Sphincter oris*, surrounds the orifice of the mouth, and forms a large part of the muscular substance of the lips. The fasciculi form a series of ellipses, of which those next the margins of the lips are finer and paler than those that lie further from the margins. The fasciculi in the upper lip are prolonged into those in the lower round the corners of the mouth. The outer border of the muscle blends with the other muscles of the lips : in the upper lip this border is attached by a slip to the septal cartilage of the nose, and by two other slips to the incisive fossæ in the upper jaw; in the lower lip it is

attached by two slips to the lower jaw opposite the canine teeth. The sphincter oris approximates the lips and closes the mouth.

Levator communis arises from the upper part of the nasal process of the superior maxilla; it descends by the side of the nose and divides into two slips, the one of which ends in the ala of the nose, the other blends in the upper lip with the orbicularis oris. From its double insertion and action this muscle is often called *levator labii superioris alæque nasi.*

Levator labii superioris proprius arises from the superior maxillary and malar bones, where they form the lower border of the orbit; it descends into the upper lip to blend with its muscular fibres.

Levator anguli oris arises from the canine fossa of the superior maxilla: it passes downwards and outwards to the angle of the mouth to blend with the other muscles situated there.

Zygomaticus minor, a slender muscle, arises from the anterior end of the zygomatic arch: it passes downwards and forwards, and usually joins the levator labii superioris.

Zygomaticus major arises from the zygomatic arch behind the *minor*: it passes downwards and forwards to the angle of the mouth.

Risorius muscle of Santorini consists of scattered fasciculi, which arise from the fascia covering the masseter muscle: it passes transversely inwards to the angle of the mouth, and is often described as a part of the platysma.

Depressor labii inferioris arises from the front of the inferior maxilla between the symphysis and mental fora-

men, ascends to the lower lip, and blends with the orbicularis oris. From its four-sided form it is sometimes called the *quadratus menti* muscle.

Depressor anguli oris has a broad origin from the external oblique line of the lower jaw; it ascends to the angle of the mouth, where it blends by a narrow insertion with the other muscles which pass there. From its form it is sometimes called *triangularis oris.*

Levator menti, or *levator labii inferioris*, arises from the incisor fossa of the lower jaw : its fibres radiate downwards and forwards to end in the skin of the chin.

The muscle of the Cheek is the *Buccinator*, a flat four-sided muscle, which arises by its upper and lower borders from the outer surface of the upper and lower jaws, a short distance from the alveolar edge, and by its posterior border, from the pterygo-maxillary ligament. From these lines of origin the fibres pass forwards to the anterior border which blends at the angle of the mouth with the other muscles in that region : to some extent the fibres of the upper part of the muscle go into the lower lip, those of the lower part into the upper lip. The *pterygo-maxillary ligament* is a slender fibrous band which stretches from the internal pterygoid plate of the sphenoid to the back of the mylo-hyoid ridge of the lower jaw : as the buccinator arises from it in front and the superior constrictor of the pharynx behind, it forms the bond of union between the muscles of the pharynx and cheek, and ensures the continuity of the walls of these divisions of the alimentary canal.

The muscles of the Floor of the Mouth are the pair of *Mylo-hyoid* muscles, which are situated immediately

beneath the mucous membrane. Each arises from the mylo-hyoid ridge of the lower jaw: the fibres pass downwards and inwards to be for the most part inserted, along with the opposite muscle, into a tendinous median raphe which extends from the symphysis menti to the body of the hyoid bone; the most posterior fibres are, however, inserted directly into the body of the hyoid. The name of *diaphragma oris* has been applied to the muscular floor formed by the two mylo-hyoid muscles.

The muscles of the Tongue have been described, as a part of that organ, on p. 376: those of the Soft Palate will be described on p. 666. The action of the muscles of the mouth has been described on p. 84 *e.s.*

The mouth is lined by a red-coloured mucous membrane, which becomes continuous at the posterior buccal orifice with that of the pharynx, and at the margins of the lips with the skin of the face. The mucous membrane covering the alveolar portions of the jaws, and surrounding the necks of the teeth, is called the *gum*. From the outer surface of each jaw it is reflected to the inner surface of the cheeks and lips. A narrow band passing from the symphysis of the lower jaw to the lower lip is the *frænum labii inferioris*, and a similar band from the upper jaw to the upper lip is the *frænum labii superioris*. From the inner surface of the lower jaw the mucous membrane is reflected to the floor of the mouth, and a broad band, called *frænum linguæ*, is prolonged to the middle line of the under surface of the tongue. From the back of the dorsum of the tongue three slender folds of the mucous membrane, the *frœna epiglottidis*, are prolonged to the front of the epiglottis. From the soft palate on each side two folds of

mucous membrane proceed; the one extends downwards and forwards as the *anterior pillar of the fauces* to the side of the tongue, and encloses the palato-glossus muscle; the other runs downwards and backwards, as the *posterior pillar of the fauces*, to the wall of the pharynx, and encloses the palato-pharyngeus muscle. In the interval between these pillars is the *tonsil*.

In its structure the mucous lining of the mouth consists of a stratified pavement epithelium, and a sub-epithelial fibro-vascular corium, possessing numerous vascular papillæ. The superficial strata of the epithelium covering the mucous surface of the cheeks and lips are formed of squamous cells, whilst those which lie next the corium are elongated in a direction perpendicular to its surface. Some of the squamous cells have fluted surfaces; others prickle-like edges, by the junction of which adjacent cells anastomose together. From the surface of the corium numerous conical vascular papillæ project into the epithelial layer. At the margin of the lip the mucous membrane becomes continuous with the integument, and the transition from the tegumentary to the mucous surface is marked by the disappearance of the hair follicles and sebaceous glands, by the greater translucency of the epithelial covering and by the greater vascularity of the corium. Klein has described bundles of fibres of the sphincter orbicularis oris muscle passing into the corium of the mucous lining of the lip, as far as the base of the papillæ, and in close proximity to the epithelium.

The mucous membrane of the gum is characterised by its density and toughness, due to the numerous strongly developed bundles of connective tissue in the corium,

many of which are continued into the fibrous tissue of the periosteum, which covers the alveolar surface of the jaw. The free surface of the corium of the gum possesses numerous broad papillæ, and is covered by a stratified pavement epithelium similar to that in the lips and cheeks. The mucous membrane of the hard palate is also tense and tough, though not so much so as the gum; and the fibrous fasciculi of its corium blend with the connective tissue of the subjacent periosteum. The mucous lining of the mouth is a sensitive membrane, and receives its nervous supply from the fifth cranial nerve. The superior maxillary division of that nerve gives branches to the hard and soft palate, upper gum, and mucous lining of the upper lip: the inferior maxillary division to the mucous lining of the cheek and lower lip, lower gum, and floor of the mouth. Krause has described end bulbs, in connection with the terminal branches of the nerves, in the mucous membrane of the lips, floor of the mouth, and soft palate.

The mucous membrane of the mouth is specially modified in some localities by the development of collections of Lymphoid Tissue in the sub-epithelial connective tissue. This is particularly the case in connection with the mucous membrane of the dorsum of the tongue in the interval between the circumvallate papillæ and the epiglottis; and in the substance of the tonsil.

The Tonsils are two almond-shaped bodies, situated, one on each side of the posterior orifice of the mouth, in the fossa between the anterior and posterior pillars of the soft palate. One surface of each tonsil is free, and covered by the epithelium of the mucous membrane; the other is attached to the inner surface of the superior constrictor

muscle of the pharynx. They lie in a plane a little above the angles of the lower jaw. Their normal size is not bigger than a hazel nut, but they are very apt to enlarge, grow inwards across the posterior aperture of the mouth, and diminish the size of that opening. The free surface is marked by several rounded holes, which lead into shallow pits or crypts, which may be either simple or branched, in the substance of the tonsil. The pits are lined by the epithelial covering of the mucous membrane, into which minute papillæ project. In the sub-epithelial connective tissue of the walls of the crypts numerous follicles of lymphoid tissue are situated, and lymph cells are infiltrated in great numbers in the connective tissue between the follicles. Interspersed amidst the crypts are small racemose mucous glands. The tonsils are very vascular, and receive their arteries from the descending palatine branch of the internal maxillary, the ascending pharyngeal of the external carotid, the dorsalis linguæ of the lingual, and the tonsillar and ascending palatine branches of the facial. Capillary blood-vessels are distributed in connection with the papillæ, the lymphoid tissue, and the racemose glands. The tonsillar veins form a plexus in relation to the attached surface of the tonsil. Lymph-vessels are found in the tonsils; they form networks

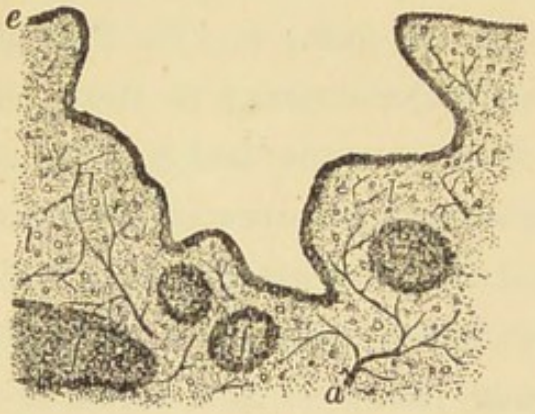

FIG. 178.—Vertical section through one of the Tonsils, to show a pit vertically divided. *e*. Its epithelial lining; *f*, *f*, lymph follicles; *l*, *l*, *l*, lymph cells diffused in the connective tissue; *a*, small artery ending in capillary blood-vessels. Slightly magnified.

between and around the follicles of lymphoid tissue. Branches of the glosso-pharyngeal nerve, and the descending palatine branches of Meckel's ganglion, pass to the tonsil.

MUCOUS AND SALIVARY GLANDS OF THE MOUTH.

The ducts of numerous glands engaged in secreting mucus and saliva open on the free surface of the mucous membrane of the mouth. Their secretion not only keeps the mouth moist, and aids therefore in articulation, but by mingling with the food assists in mastication, deglutition, and the digestive process. Each gland is characterised by being divided into small lobules, and by possessing a duct or ducts, which branch off in an arborescent manner in the substance of the gland, and finally end in the minute lobules. They all belong to the Compound Racemose group of glands; other examples of which are found in the pancreas, Brunner's glands, the mammæ, the lachrymal glands, Cowper's and Bartholini's glands.

The MUCOUS GLANDS OF THE MOUTH are situated beneath its mucous lining in the following localities:—*a*, *labial* glands in the upper and lower lips, but absent at the angles of the mouth: *b*, *buccal* glands scattered on the inner surface of the cheek from the lips to the opening of the parotid duct: *c*, *palatine* glands on the oral surface of the hard palate, in the uvula, on both surfaces of the soft palate and in the tonsils: *d*, *molar* glands, close to the last lower molar tooth on each side: *e*, *lingual* glands, extending backwards from the tip of the tongue along its margin, and also on the dorsum between the circumvallate papillæ and epiglottis. Blandin and Nuhn

have described a cluster of glands at the tip of the tongue, between the genio-hyo-glossus, stylo-glossus and lingualis, opening by four or five ducts on the under surface of the tip.

Structure.—The ducts of these mucous glands consist of a delicate membrane lined by a single layer of columnar epithelial cells. The terminal branches of the ducts, which enter the lobules, end in a series of saccular dilatations, the *acini*, *alveoli*, or *gland vesicles*, which contain rounded or polygonal secreting cells. A collection of such vesicles forms a lobule. The lobules are bound together by intermediate connective tissue, in which the blood-vessels divide into a capillary network, that ramifies on the outer surface of the delicate membrane forming the wall of the gland vesicles.

The SALIVARY GLANDS OF THE MOUTH are the parotid, submaxillary, and sublingual glands.

The *Parotid gland* is the largest salivary gland, and occupies the parotid hollow between the ascending ramus of the lower jaw, the mastoid process of the temporal bone, the external auditory meatus, and the zygoma. Its anterior border overlaps the masseter muscle, and the excretory duct emerges out of this border. A prolongation of gland substance, the *socia parotidis*, frequently accompanies the duct for a short distance. By its deep surface the gland passes as far as the styloid process, the parotid fossa in the temporal bone, the digastric muscle, internal carotid artery, and internal jugular vein. The gland is enclosed in a capsule formed of the cervical fascia. Passing into the gland is the external carotid artery, which gives off in it the occipital, posterior auricular, temporal and

internal maxillary branches: from the posterior auricular and temporal branches arise the small arteries which supply the parotid gland with blood. Emerging from the gland is the external jugular vein, which is formed in it by the junction of the temporal, internal maxillary, posterior auricular and transverse facial veins. Piercing the gland are the facial and auriculo-temporal nerves.

The excretory duct of the gland, called *Stenson's duct*, passes forwards superficial to the masseter muscle, then pierces successively the fat of the cheek, the buccinator muscle and the mucous membrane, and opens on the inner surface of the cheek opposite the second upper molar tooth. The duct is between two and three inches long, and about the thickness of a crow quill.

The *Submaxillary gland* is situated in the submaxillary triangular space, and rests against a shallow fossa on the under surface of the horizontal ramus of the lower jaw. It lies for the most part on the mylo-hyoid muscle, but sends a process, along with the excretory duct, round the posterior border of the muscle, which process lies between the mylo-hoid and the hyo-glossus muscles. The gland is enclosed in a capsule formed of the cervical fascia, and is separated from the parotid gland by a deep process of that fascia named the stylo-maxillary ligament. The facial artery, as it ascends to the face, passes through the substance of the gland and gives off glandular branches to supply it with blood.

The excretory duct of the gland, called *Wharton's duct*, runs forwards for two inches between the mylo-hyoid and the hyo-glossus and genio-hyo-glossus muscles, and ends by opening on the floor of the mouth by the side of the frænum linguæ.

The *Sublingual* is the smallest of the salivary glands, and lies under the mucous membrane of the floor of the mouth, close to the genio-hyo-glossus muscle and the line of attachment of the frænum linguæ. It is concealed by the mylo-hyoid muscle, and receives, as its arteries of supply, the sublingual branch of the lingual artery and small branches of the submental branch of the facial artery. Instead of having, like the parotid or the submaxillary gland, only a single excretory duct, it possesses from ten to twenty small ducts, the *ducts of Rivinus*, some of which join Wharton's duct, though the greater number open directly into the floor of the mouth near the frænum linguæ.

Structure.—The ducts of the salivary glands branch and terminate in the lobules; each terminal duct ending in a series of saccular dilatations, the *acini, alveoli*, or *gland-vesicles*, the wall of which, formed apparently of a membrana propria, is continuous with the simple membranous wall of the terminal duct. The terminal ducts are lined by a layer of squamous epithelium. The wall of the larger ducts is formed of white and yellow fibrous tissue, with, in some instances, contractile muscular fibre-cells, and is lined by a columnar epithelium.

The gland vesicles contain the secreting cells, which present two different histological appearances. The cells which lie in the centre of the alveolus approach the spheroidal in form, though with the sides often flattened; their protoplasm is granulated, though it may clear up, apparently from a mucous change in its substance; their nucleus is distinct, and usually close to the circumference of the cell. The cells which lie next the wall of the vesicle are smaller, with a more granulated protoplasm, and on

section present a semilunar form; they were first described by Gianuzzi as the semilunar body. Lavdowsky states that the semilunar cells are connected together by a network of exceedingly delicate threads of protoplasm. Though some have supposed these two forms of cells to be quite distinct, it is not improbable that the peripheral, so-called semilunar cells are merely a younger stage of the central secreting cells, which have not yet undergone a mucous change. Both kinds of cells are found in the submaxillary and sublingual glands; but in the parotid, the secreting cells exhibit a uniform granulated protoplasm, and do not undergo the mucous change. Heidenhain has pointed out that, when the submaxillary gland has been stimulated for some time, the central cells lose their clear transparent appearance, and assume the characters of a granulated protoplasm, a change which is doubtless due to the contained "mucus" being poured out in the secretion. Boll has described the membrana propria of the gland-vesicles as consisting of anastomosing connective tissue cells, and an anastomosing reticulum of connective tissue corpuscles has been said to exist between the cells situated within the vesicles. Pflüger has described minute channels, or intercellular passages between the secreting cells, which communicate with the lumen of the duct, and serve as the passages along which the salivary secretion flows out of the vesicle. Schlüter and Pflüger have described smooth muscular fibre-cells, arranged either solitarily, or in fasciculi, in the connective tissue framework of the salivary glands.

The blood-vessels are distributed in the interlobular connective tissue, and form a capillary network on the wall of the gland-ducts, and on the wall of the gland vesicles.

Gianuzzi has described lymphatics, in the interlobular connective tissue, and around the arteries and veins of the glands. The submaxillary and sublingual glands receive their nervous supply from the chorda tympani branch of the facial nerve, and from the third division of the fifth cranial and sympathetic through the submaxillary ganglion. The parotid gland is supplied by the small superficial petrosal branch of the facial and by the sympathetic. The nerves pass into the interlobular connective tissue, branch in their course, and sometimes are connected to minute ganglia. Pflüger states that medullated fibres can be traced up to the gland vesicles, where they perforate the membrana propria, and then lose the medullary sheath, whilst the axial cylinder is prolonged into the protoplasm of the secreting cells. Other medullated fibres, he says, pierce the walls, of the gland ducts, and after losing their medullary sheath, the axial cylinders branch, and become continuous with the columnar epithelial lining of the duct. He has also described multipolar cells, which he believes to be nervous, directly continuous by their processes with the secreting cells. Pflüger's observations, however, on the direct continuity of the nerve fibres and cells with the secreting cells of the salivary glands have not been generally accepted.

THE PHARYNX.

The Pharynx is an irregularly dilated canal, which forms a common passage, connecting the mouth with the œsophagus, and the nose with the larynx, so as to be subservient to the processes both of deglutition and respiration. It is situated in the upper part of the neck, and extends from the basi-cranial axis, which forms its upper boundary, as low down as the level of the sixth cervical vertebra, where it becomes continuous with the œsophagus. It lies in front of the six upper cervical vertebræ, with their prevertebral muscles, from which it is separated by some loose areolar tissue. It is placed behind the nose, mouth, and larynx, all of which communicate with it through openings in its anterior wall. Its length is from $4\frac{1}{2}$ to $5\frac{1}{2}$ inches; the transverse diameter is greater than the antero-posterior, and it is wider opposite the back of the mouth and the great cornua of the hyoid bone, than opposite the back of the nose, or larynx; at its lower end it assumes a tubular form, where it becomes continuous with the œsophagus. Its walls are composed of muscles and membrane, which are arranged so as completely to wall in the tube laterally and posteriorly, but to permit of free communication in front with the nose, mouth, and larynx. If the pharynx be opened by a longitudinal incision through the posterior wall, two structures, viz., the soft palate and epiglottis, will be seen to project into it from the anterior wall. The soft palate, with the uvula depending from its lower border, inclines downwards and backwards, and divides the upper or nasal part of the pharynx from the

middle or buccal portion. The epiglottis projects upwards immediately in front of the orifice of the larynx, and marks the boundary between the buccal part of the pharynx and the superior orifice of the larynx.

Seven openings communicate with the interior of the pharynx (fig. 181). Into the upper or nasal portion are the two posterior nares, separated from each other by the posterior edge of the nasal septum; and the trumpet-shaped mouths of the two Eustachian tubes open, one on each side, in line with the posterior end of the inferior turbinated bone of the same side. Below the soft palate is the posterior orifice of the mouth; behind the epiglottis is the superior aperture of the larynx; opposite the sixth cervical vertebra the pharynx communicates with the œsophagus.

Structure.—The wall of the pharynx consists of three coats, an external muscular, an internal mucous coat, and an intermediate fibrous membrane, which blends with the submucous coat.

The *muscular coat* consists of three pairs of circularly arranged muscles, the constrictors of the pharynx; and of two pairs of longitudinally-arranged muscles, the stylo-pharyngei and palato-pharyngei, with occasionally a third pair, the salpingo-pharyngei. The constrictor muscles extend from the lateral wall to the middle line of the posterior wall of the pharynx, and are named from below upwards the inferior, middle, and superior constrictors; they lie on three different planes, so that the inferior constrictor overlaps the middle, and the middle the superior.

Inferior constrictor, or *laryngo-pharyngeus* muscle, arises from the side of the cricoid cartilage of the larynx,

from the oblique ridge on the outer surface, and the upper and lower borders of the lateral plate of the

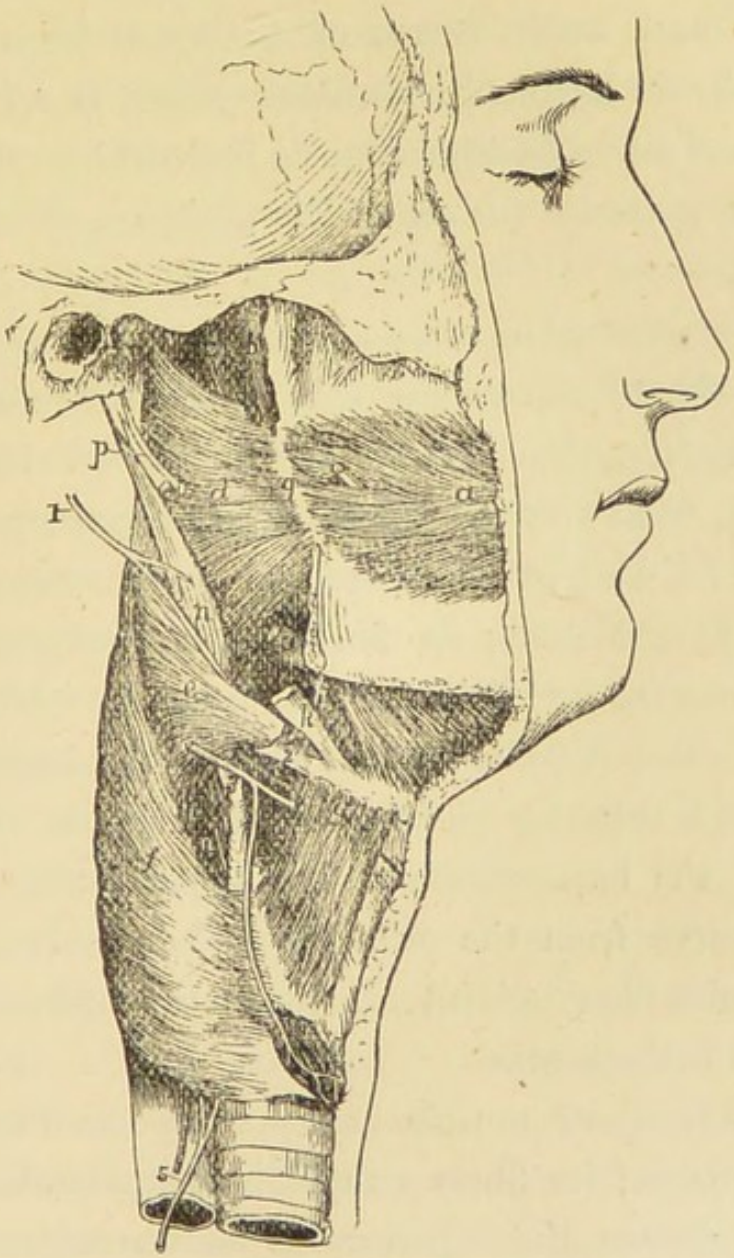

FIG. 179.—Profile view of Cheek and Pharynx showing the Constrictor Muscles. *a*, buccinator; *b*, tensor; *c*, levator palati; *d*, *e*, *f*, superior, middle, and inferior constrictors; *g*, thyro-hyoid; *h*, hyo-glossus; *i*, mylo-hyoid; *m*, crico-thyroid; *n*, stylo-pharyngeus; *o*, stylo-glossus; *q*, pterygo-maxillary ligament which gives origin to buccinator and superior constrictor; 1, glosso-pharyngeal nerve; 2, superior laryngeal artery; 3, superior laryngeal nerve; 4, external laryngeal branch to crico-thyroid muscle; 5, inferior laryngeal nerve and artery.

thyroid cartilage; its fibres curve backwards, to be inserted into the middle line of the posterior surface of the pharynx,

where it joins its fellow of the opposite side. Its lower fibres are in relation to the upper fibres of the œsophagus.

Middle constrictor, or *hyo-pharyngeus* muscle, arises from the great and small cornua of the hyoid bone and from the stylo-hyoid ligament; its fibres radiate in a fan-shaped manner, and curve backwards to be inserted into the middle line of the posterior surface of the pharynx, where it joins its fellow.

Superior constrictor, or *gnatho-pharyngeus* muscle, arises from the side of the tongue and adjacent buccal mucous membrane, from the back of the mylo-hyoid ridge of the lower jaw, from the pterygo-maxillary ligament, and the lower third of the posterior border of the internal pterygoid plate of the sphenoid; its fibres curve backwards to be inserted into the middle line of the posterior surface of the pharynx, where it joins its fellow; but the highest fibres are inserted into the pharyngeal tubercle on the under surface of the basi-occipital. The upper border forms a concave curve from the origin to the insertion, and the fibrous tunica pharyngis interna fills up the interval between it and the basis-cranii.

Stylo-pharyngeus muscle arises from the root of the styloid process: its fibres run obliquely downwards and inwards, between the superior and middle constrictors, to be inserted partly into the posterior border of the thyroid cartilage, and partly to blend with the adjacent part of the muscular wall of the pharynx.

Palato-pharyngeus muscle arises in the soft palate, where it decussates across the mesial plane with the corresponding muscle of the opposite side: its fibres pass downwards in the posterior pillar of the fauces, and spread

out in the muscular wall of the pharynx from the posterior border of the thyroid cartilage, back to and even across the middle line of the pharynx posteriorly.

Salpingo-pharyngeus muscle, when present, arises from the cartilage of the Eustachian tube; its fibres descend in the postero-lateral wall of the pharynx, to be inserted along with the palato-pharyngeus.

The muscular wall of the pharynx is enveloped by a fibrous membrane, the *tunica pharyngis externa*, which is continuous superiorly with the fibrous membrane covering the buccinator muscles. Between the muscular and mucous coats of the pharynx is the *tunica pharyngis interna*, which forms in the posterior wall of the nasal part of the pharynx a well-defined fibrous membrane. It is attached above to the petrous-temporal, the basi-sphenoid, and the pharyngeal tubercle of the basi-occipital. From this tubercle a slender band passes longitudinally down the middle line of the posterior wall of the pharynx and forms a common insertion for the three pairs of constrictors. As the tunica interna descends in the wall of the pharynx it becomes thinner, and is finally lost in the submucous coat.

The *mucous coat* of the pharynx lines the canal, and is continuous through the several openings with the mucous membrane lining the Eustachian tubes, nose, mouth, larynx, and œsophagus.

The epithelium covering the mucous membrane of the nasal part of the pharynx is columnar and ciliated over a considerable surface, but elsewhere the pharyngeal epithelium is tesselated and stratified; and in the latter localities, vascular papillæ project into the epithelial

layers. Small racemose glands, similar to the mucous glands of the mouth, or to Brunner's glands, lie beneath the mucous membrane, which is pierced by their ducts to open on the surface (fig. 180): they are most numerous



FIG. 180.—Vertical section through the mucous membrane of the Pharynx to show the racemose glands. *e*, the epithelium; *ct*, subjacent connective tissue; *g*, racemose gland; *d*, its duct; *a*, artery ending in a capillary plexus on the gland vesicles. × 40.

in the nasal part of the pharynx. Collections of lymphoid tissue are found in the sub-epithelial connective tissue, more especially in the nasal part of the pharynx, where it forms a mass, extending across the posterior and upper wall, between the openings of the two Eustachian tubes, which Luschka has called the *pharyngeal tonsil*. A network of lymphatic vessels exists both in the submucous coat, where it lies in relation to the lymphoid tissue, and between the tunica pharyngis externa and muscular coat; lymphatic glands are in connection with the latter part of the network. The arteries of the pharynx are derived

from the ascending pharyngeal branch of the external carotid, the ascending palatine and tonsillar of the facial, and the palato-pharyngeal and descending palatine branches of the internal maxillary. The motor nerves of the pharynx are derived from the pharyngeal branches of the vagus, the external laryngeal nerve and the glosso-pharyngeal nerve. The sensory nerves arise from the pharyngeal branches of the glosso-pharyngeal, and from the pharyngeal branch of Meckel's ganglion, which latter supplies the mucous lining of the nasal part of the pharynx. Sympathetic nerve fibres pass to the pharynx from the superior cervical ganglion. The motor, sensory, and sympathetic nerves unite to form the pharyngeal plexus situated behind the middle constrictor muscle.

The SOFT PALATE forms an inclined plane, which projects, downwards and backwards into the pharynx, from the posterior border of the hard palate. It is less dependent at the sides than in the mesial plane, where it forms an elongated body, the *uvula*. From its position it is in relation both to the mouth and the pharynx. Its anterior or oral surface is smooth, and gives origin on each side to a fold, which curves downwards to the side of the root of the tongue, to form the *anterior pillars of the palate or fauces*. Its posterior or pharyngeal surface, also smoooth, gives origin on each side to a fold, which, springing from the base of the uvula, curves downwards and backwards to be lost in the side walls of the pharynx; this pair of folds forms the *posterior pillars of the palate or fauces*.

Structure.—The soft palate is complex in structure, and consists of muscles, mucous membrane, glands, blood and lymph vessels, and nerves. The muscles of the soft

palate are arranged in two groups, those which elevate and make it tense, and those which constrict the fauces.

The tensors and elevators are as follows :—

Levator palati arises from the front of the under surface

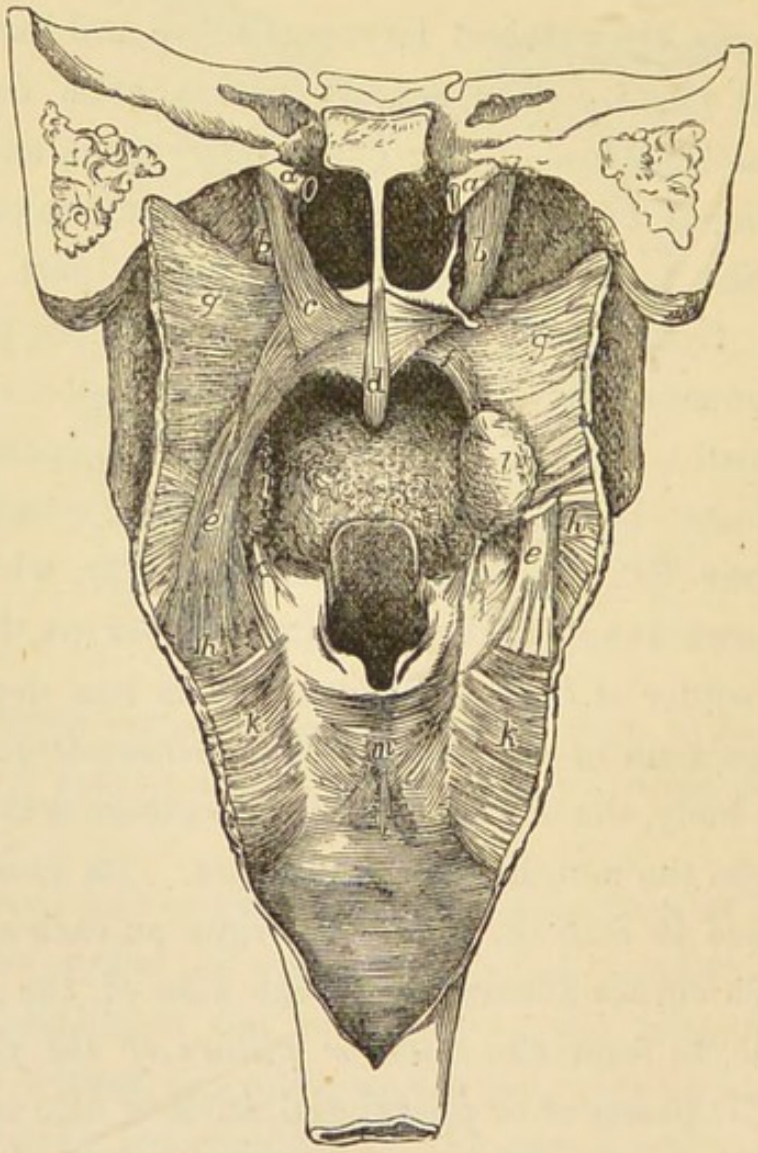

FIG. 181.—Interior of the Pharynx exposed by cutting through its posterior wall. The mucous membrane has been removed, and the muscles of the Soft Palate are exposed. *a*, *a*, Eustachian tube; *b*, *b*, tensor; *c*, levator palati; *d*, levatores or azygos uvulæ; *e*, *e*, palato-pharyngeus, cut through on the right side to show, *l*, the tonsil, and *f*, the palato-glossus; *g*, *h*, *k*, the three constrictors.

of the petrous temporal, and from the membrano-cartilaginous wall of the Eustachian tube : it passes through the wall of the pharynx above the upper concave border of the superior

constrictor, and enters the soft palate in the posterior part, in which it may be traced up to the mesial plane.

Levatores or *Azygos uvulæ* consist of two fasciculi, one on each side of the mesial plane of the uvula, which arise from the spine of the palate plates of the palate bones, and descend into the uvula towards its tip.

Tensor or *Circumflexus palati* arises from the scaphoid fossa at the root of the internal pterygoid plate, and from the outer third of the wall of the Eustachian tube: it descends in the pterygoid fossa, and ends in a tendon which hooks round the root of the hamular process, and pierces the wall of the pharynx between the pterygoid and pterygo-maxillary origins of the superior constrictor; it enters the soft palate and expands into an aponeurotic tendon, which blends in the mesial plane with that of the corresponding muscle, and is attached to the under surface of the palate plate of the palate bone.

The constrictors of the fauces are as follows:—

Palato-glossus forms, along with its fellow, a sphincter arrangement in the soft palate, anterior palatine pillars and tongue. It lies in the soft palate in close relation to the mucous membrane of the anterior surface, descends in the anterior pillars to the sides of the root of the tongue, into the substance of which it enters. By its contraction it constricts the pharyngo-oral orifice.

Palato-pharyngeus has been described on p. 662.

The action of the muscles of the soft palate and pharynx in connection with the process of deglutition has been described on p. 88. From their attachment to the wall of the Eustachian tube, the tensor and levator palati muscles can, when the soft palate is fixed, act on the tube. The

tensor palati is believed to be a dilator of the tube. The levator palati is also regarded by some as a dilator, but Cleland maintains that it acts as a constrictor by approximating the membranous to the cartilaginous wall of the tube.

The mucous membrane of the soft palate is continuous with that of the mouth and pharynx. The epithelium covering the anterior or oral surface is a stratified pavement epithelium. That on the posterior or pharyngeal surface appears to vary at different periods of life; for whilst Klein found in the infant a laminated cylindrical and ciliated epithelium, with isolated areas of pavement epithelium, in adults the surface generally was covered by a laminated pavement epithelium. Numerous racemose mucous glands lie beneath the mucous membrane, but much more abundantly on the oral than on the pharyngeal aspect. Collections of lymphoid tissue, similar to those found in the tonsils, are also met with. The arteries are the descending palatine branches of the internal maxillary, the inferior palatine of the facial, and palatine branches of the ascending pharyngeal. The veins of the soft palate often assume a dilated character, and are continuous with the pharyngeal veins. Lymphatics are also distributed beneath the mucous membrane.

There are difficulties in determining with precision the motor nerves of the soft palate. A branch from the otic ganglion of the third division of the fifth nerve passes to the tensor palati. The levator palati and azygos uvulæ are by some considered to be supplied by the pharyngeal branches of the vagus, though others regard them as supplied by the large superficial petrosal of the facial,

which goes to Meckel's ganglion, and sends branches to the palate in the descending palatine branches of that ganglion. The palato-pharyngeus and palato-glossus are probably supplied by the pharyngeal branches of the vagus. The sensory nerves to the mucous membrane are derived, from the second division of the fifth, through the descending palatine branches of Meckel's ganglion. Sympathetic nerve fibres also probably accompany the descending palatine nerves.

ŒSOPHAGUS.

The Œsophagus, or Gullet, is an almost cylindrical tube, about 9 or 10 inches long, which transmits the food from the pharynx to the stomach. It commences in the neck opposite the body of the sixth cervical vertebra, where it is continuous with the pharynx. It passes down the lower part of the neck, traverses the cavity of the thorax, pierces the diaphragm at the œsophageal opening, enters the abdomen, and becomes continuous with the cardiac end of the stomach close to that opening. It lies in front of the bodies of the vertebræ, and follows the antero-posterior curvatures of the spine, but, at the lower part, both of the neck and thorax, it inclines somewhat to the left of the mesial plane. It is placed behind the trachea, the arch of the aorta, the heart, and pericardium. In the thorax it is situated in the posterior mediastinal division of the interpleural space, with the vena azygos to its right, and the descending aorta at first to its left and then behind it. It is closely accompanied in the greater part of its course by the pneumogastric nerves, which form a plexus around it.

Structure.—The wall of the œsophagus consists of three

coats, named, from without inwards, muscular, sub-mucous, and mucous coats.

The *muscular* or *external coat* is divided into two layers, an external and an internal. The *external* layer is composed of fibres arranged *longitudinally* in the wall. They are collected into three bundles; one springs from the back of the cricoid cartilage and descends in the anterior wall, the others are situated at the sides of the œsophagus; as they reach its lower end the fibres are no longer collected into three bundles, but form a uniform layer around the tube. The *internal* layer consists of fibres arranged in a series of rings around the tube, which lie sometimes horizontally, at others obliquely. The muscular coat in the upper fourth of the œsophagus is red, and its fibres are transversely striped; in the second fourth numerous non-striped fibres are mingled with the striped; whilst in the lower half the coat consists exclusively of non-striped fibres. By the contraction of the fibres of the muscular coat the food is propelled downwards into the stomach. Hyrtl described in 1844 muscular slips as occasionally found passing from the œsophagus to the pleura and left bronchus. D. J. Cunningham, who has recently examined this arrangement, states that the *pleuro-œsophageal muscle* arises from the left pleura, where it lies over the thoracic aorta, and joins the left margin of the œsophagus; it is always present. The *broncho-œsophageal* muscle is not so constant; it springs from the back of the left bronchus, and blends with the longitudinal fibres of the œsophagus.

The *sub-mucous coat* connects the muscular and mucous coats with each other. It consists of bundles of white fibrous tissue intermingled with elastic fibres, and the

nerves and blood-vessels passing to the mucous coat ramify in it.

The *mucous* or *internal coat* lines the interior of the tube, is continuous above with the mucous lining of the pharynx, and below with that of the stomach. When the œsophagus is empty it is thrown into longitudinal folds. Its free surface is covered by a thick layer of stratified squamous epithelium, which terminates abruptly at the cardiac orifice of the stomach in an irregular line. Projecting into the epithelium are multitudes of minute conical papillæ. Opening on the surface of the membrane are the ducts of numerous small racemose glands similar to those in the pharynx (fig. 180). Collections of lymphoid tissue, forming solitary follicles, are also found in the mucous membrane. The deep surface of the mucous membrane consists of a layer of non-striped muscular tissue, the bundles of which run longitudinally; it forms the muscular layer of the mucous coat, or *muscularis mucosæ*.

The œsophagus is supplied with blood by the inferior thyroid artery, the œsophageal branches of the thoracic aorta and the ascending branch of the coronary artery of the stomach. The nerves are derived from the pneumogastrics, which form plexuses containing nerve cells, not only in the muscular coat, but in the muscularis mucosæ. A network of lymphatic vessels also occurs in both the mucous and sub-mucous coats.

Abdominal Cavity and Peritoneum.

As the remaining portions of the Alimentary Canal are situated in the Abdominal Cavity, it will be advisable, before describing their anatomy, to give an account of the form and boundaries of that cavity, of its division into regions, and of the general arrangement of the peritoneum, which constitutes its lining membrane.

The Abdominal Cavity, Abdomen, or Belly, is the largest of the three great cavities of the body. It occupies about the lower two-thirds of the trunk, and extends from the diaphragm above to the pelvic floor below. As its walls, except in the pelvic region, are chiefly formed of muscles and of fibrous membrane, they are much more distensible than those of the thorax, and permit considerable modifications in the size of the viscera, contained within the cavity, to occur.

The abdomen is elongated in form: its vertical diameter is greater than either the transverse or the antero-posterior diameter. The superior boundary is formed by the concave vault of the diaphragm, and by the seven lower pairs of ribs and costal cartilages: in this boundary occur the opening through which the œsophagus passes into the abdomen; also the apertures for the transmission of the great blood-vessels, the nerves and the thoracic duct. The inferior boundary is formed by the levatores ani and coccygei muscles, and the pelvic fascia: in relation to this boundary are the termination of the rectum and anal orifice, the termination of the urethra, and in the female that of the vagina also. The anterior boundary is formed above by the muscles of the anterior abdominal wall and

the fascia transversalis: the linea alba occupies its middle line, and about the middle of the linea alba is the umbilicus or navel: the anterior wall below is formed by the two pubic bones with the symphysis. The lateral walls, or flanks, are formed above by the flat muscles of the abdominal wall and the fascia transversalis, and below on each side by the ilium and ischium with the muscles attached to them. The posterior wall is formed by the lumbar spine, sacrum, and coccyx, and by the muscles attached to these bones with their accompanying fasciæ.

The abdomen is primarily divided into the *pelvis* and *abdomen proper*. The *pelvis* is subdivided into the *false pelvis*, or part above the pelvic brim, and *true pelvis*, or part below the pelvic brim.

The *abdomen proper* is subdivided into nine regions, the boundaries of which are not regulated by anatomical structures, but by certain lines drawn upon the surface of the body, which are supposed to be prolonged through the cavity in imaginary planes. An upper horizontal line is drawn on a level with the most prominent part of the ninth pair of costal cartilages, and a lower horizontal line on a level with the summit of the iliac crest. Through these lines the abdomen is divided into three zones, an upper or *costal*, a middle or *lumbar*, a lower or *iliac*. Each of these zones is subdivided into three regions by two vertical lines drawn perpendicularly upwards from the middle of Poupart's ligament. The costal zone is subdivided into two lateral regions, the *right* and the *left hypochondrium*, and a middle or *epigastrium*; the epigastrium lies immediately below the xiphi-sternum, in the interval of divergence between the costal cartilages of

opposite sides, and is sometimes called the pit of the stomach; whilst the hypochondriac regions are under cover of the lower ribs and costal cartilages. The lumbar zone is subdivided into two lateral regions, the *right* and the *left lumbar* regions, or the loins, and a middle or *umbilical* region; in the middle of the umbilical region is the navel, which is placed opposite the body of the fourth lumbar vertebra. The iliac zone is subdivided into two lateral regions, the *right* and the *left iliac* regions, and a middle or *hypogastrium;* the hypogastrium is situated immediately above the pubic symphysis and the bodies of the two pubic bones, and opposite the bodies of the sacral vertebræ. The position of the viscera in these regions will be given in the account of their descriptive anatomy.

The PERITONEUM is the largest and most complicated serous membrane in the body. Like the other serous membranes, it not only lines the walls of the cavity in which it is situated, but gives a more or less complete investment to the contained viscera. It is arranged, therefore, so as to form a *parietal* and a *visceral* part, which are continuous with each other in the various regions, where the part lining the wall is reflected as a covering upon the viscera. A space or cavity, called the *peritoneal cavity*, is enclosed between the parietal and visceral layers. This cavity, as in other serous membranes, is a closed or shut sac, without any communication externally, except in the female, where the two Fallopian tubes open into it. Through these openings the mucous membrane lining the tubes becomes continuous with the serous membrane, and a communication is established between the lumen of each tube and the peritoneal cavity. That surface of both the

parietal and visceral portion of the peritoneum, which lies next to the cavity, is free, smooth, covered by an epithelium, and lubricated by a little serous fluid, which under some pathological conditions may be greatly increased in quantity, so as to cause abdominal dropsy. The moistening of the two free surfaces by the serum permits them to glide smoothly on each other, during the movements of the viscera, and the changes which take place in their size and position. The opposite surface of the peritoneum is attached—that of the parietal part to the fasciæ situated internal to the abdominal muscles—that of the visceral part to the subjacent coat of the several organs.

The attached surface of the parietal part is connected to the abdominal fasciæ by areolar tissue, which is usually so loose as to permit the peritoneum to be stripped off with out difficulty. In some localities, as the region of the kidneys, the iliac fossæ and the inguinal regions, fatty tissue, often in considerable quantities, is developed external to the peritoneum. To this fat, and the areolar tissue in which it lies, the name of sub-peritoneal fat and areolar tissue is usually applied, but the name *extra-peritoneal* would more appropriately express its position. It is in this fat and areolar tissue that the extra-peritoneal vessels, already referred to (pp. 432, 525), ramify.

The parietal part of the peritoneum is in some localities elevated into folds, or dimpled into fossæ. In the middle of the anterior abdominal wall, is a longitudinal fold extending from the fundus of the bladder to the navel, and marking the position of the obliterated urachus. On each side of, and somewhat removed from, this mesial fold is a lateral fold, also extending towards the navel, and mark-

ing the position of the obliterated hypogastric artery; and outside this again is a slight fold along the course of the deep epigastric artery. Between the urachal and hypogastric folds is a dimple-like fossa: between the hypogastric and epigastric folds is a similar depression. Immediately external to the epigastric fold is a depression corresponding to the internal or deep abdominal ring—the entrance to the inguinal canal. Immediately below the inner end of Poupart's ligament, another depression may sometimes be seen, which marks the crural ring, or entrance into the crural canal. The inguinal and crural fossæ are of great surgical interest in relation to the seats of inguinal and femoral herniæ.

In the posterior abdominal wall, immediately to the left of the junction of the duodenum and jejunum, and on a level with the left side of the 2nd lumbar vertebra, a pocket-like involution of the peritoneum, about the size of a walnut, is sometimes seen. The entrance to this pocket is marked by a crescentic fold of the peritoneum continuous with the meso-colic fold. Coils of the small intestine have been known to become incarcerated in this pocket, a condition which has been named retro-peritoneal hernia, though the name intra-peritoneal, as suggested by J. Chiene, would be more appropriate. A pocket-like involution of the peritoneum sometimes exists behind and below the cœcum; and another in the peritoneal fold at the junction of the sigmoid flexure of the colon with the rectum, both of which may become the seats of an intra-peritoneal hernia.

Special names are applied to the folds or duplicatures of the peritoneum, which pass from the wall of the abdomen

to the viscera. In the case of the liver, spleen, bladder, and uterus, these folds are named *ligaments*, whilst the corresponding folds which pass to the intestine have received the name of *mesenteries*. Folds of peritoneum also pass between certain of the viscera themselves, and these are called *omenta*.

To understand the disposition of the peritoneum in relation to the viscera, it will be necessary to follow it from the wall to the different viscera, and from one viscus to another. If we commence with the roof of the abdomen, we find that the peritoneum is reflected from the under surface of the diaphragm to the liver, to form the *suspensory*, *coronary*, and *lateral ligaments* of that organ; also from the diaphragm to the spleen as its *suspensory ligament;* also from the diaphragm to the stomach at its junction with the œsophagus as the *gastro-phrenic ligament;* also from the diaphragm to the splenic flexure of the colon as the *phrenico-colic ligament*. The liver is invested by the peritoneum, which is reflected from the lips of its transverse fissure to the lesser curvature of the stomach, as the two layers of the *gastro-hepatic* or *small omentum*. The anterior layer of this omentum is prolonged over the anterior surface of the stomach, and the posterior layer over its posterior surface, as far as the greater curvature. Both layers then leave the stomach and form the descending layers of the *great omentum*, which hangs pendulous, like an apron, in front of the coils of the small intestine, and forms a free border below. At its left border the great omentum becomes continuous with the gastro-splenic omentum, and at its right border it reaches the hepatic flexure and upper end of the ascending colon. At the

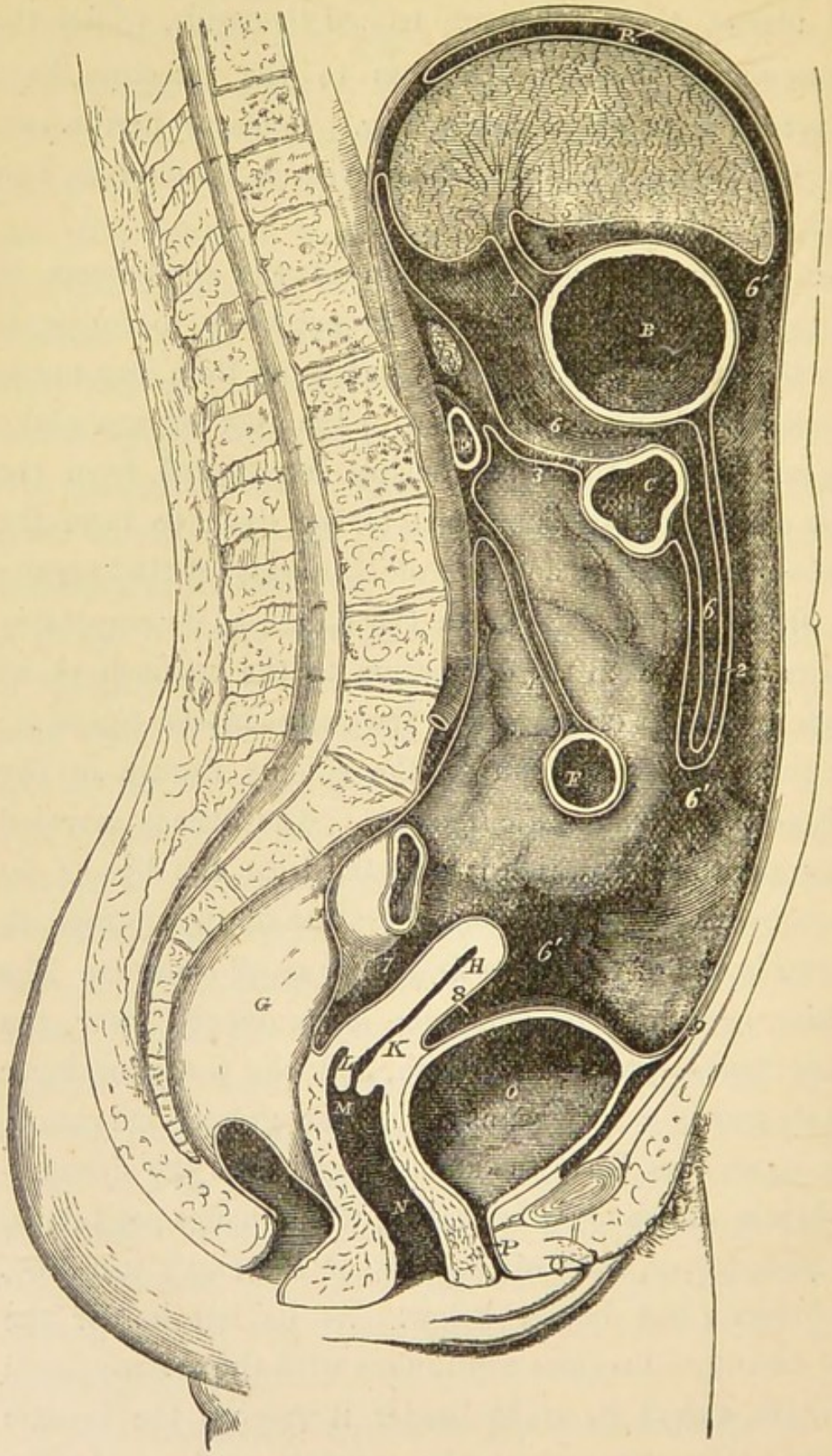
R
A
B
C
F
G
H
K
M
N
O
P
1
2
3
6
6'
7
8

FIG. 182.—Diagram of Peritoneum as displayed in a vertical section through the abdominal cavity and viscera of a female subject. A, liver; B, stomach; C, transverse colon; D, pancreas; E, duodenum; F, ileum; G, rectum; H, uterus; K, cervix uteri; L, posterior lip of os uteri; M, os uteri; N, vagina; O, bladder; P, urethra; Q, clitoris; R, diaphragm; 1, small omentum; 2, great omentum; 3, transverse meso-colon; 4, mesentery; 5 points to foramen of Winslow; 6 6, lesser cavity of peritoneum; 6′ 6′ 6′, greater cavity of peritoneum; 7, recto-vaginal pouch; 8, utero-vesical pouch; 9, parietal layer of peritoneum.

lower free border of the great omentum, these descending layers bend upwards as the ascending layers of the great omentum, and in their ascent meet the transverse colon, when the two ascending layers separate from each other in order to enclose the transverse colon. After enclosing it, they again come together, and pass backwards to the spine as the *transverse meso-colon.** The two layers of the transverse meso-colon then separate from each other. The one ascends in front of the pancreas to the diaphragm, where it becomes continuous with the posterior layer of the coronary and left lateral ligaments of the liver. The other descends as the *anterior layer* of the *mesentery*, reaches the coils of the jejunum and ileum, is prolonged around the wall of the gut, and then ascends to the spine, as the *posterior layer* of the *mesentery*. The line of attachment of the two layers of the mesentery to the front of the spine is called the *root of the mesentery*. From this line the peritoneum spreads out laterally; on the right side of the abdomen it covers the anterior and lateral surfaces of the cœcum and ascending colon, but not the posterior surface; on the left side of the abdomen it has a similar relation to the descending colon, but it forms a complete investment for the sigmoid flexure of the colon, and is reflected to the left iliac fossa as the *sigmoid meso-colon*.

From the root of the mesentery the posterior layer

* This account of the relation of the omentum to the transverse colon and meso-colon is in conformity with the arrangement one sees in the adult body, and accords with the description usually found in the text books. But it should be stated, that observations have been made by various anatomists which prove that, in the fœtus, the transverse meso-colon is a fold of the peritoneum quite distinct from the ascending layers of the great omentum, and that the arrangement seen in the adult is due to a secondary fusion of these peritoneal folds with each other.

descends in front of the aorta and lumbar spine into the pelvis, where it invests the upper end of the rectum and forms the *meso-rectum*. It only partially covers the second part of the rectum, and is reflected from it to the base and sides of the bladder to form the *posterior false ligaments* of the *bladder*. Between the bladder and the rectum the peritoneum forms a well-defined pouch, the *recto-vesical pouch*. In the female the uterus and vagina being interposed between the rectum and bladder, the disposition of the pelvic part of the peritoneum is modified as follows:— The membrane passes from the rectum to the upper end of the back of the vagina, and is then prolonged over the posterior surface of the uterus, the fundus uteri, and Fallopian tubes, and over about the upper two-thirds of the anterior surface of the uterus. From the sides of the uterus it is reflected to the sides of the pelvic cavity as the *broad ligaments* of the uterus, and from the front of the uterus to the back of the bladder. In both sexes the bladder has no peritoneal covering on its anterior wall, for the membrane is reflected from its sides to the pelvic wall, as the *lateral false ligaments*, and from its fundus along the line of the urachus to the anterior abdominal wall, as the *superior false ligament*.

The spleen is invested by the peritoneum, which is reflected from its hilus to the stomach, as the two layers of the *gastro-splenic omentum*, which again becomes continuous with the great omentum. The vessels and nerves which pass to the spleen lie between the two layers of the gastro-splenic omentum; those which go to the stomach between the two layers of the gastro-hepatic omentum, also between the two descending layers of the great omentum;

those which go to the liver between the two layers of the gastro-hepatic omentum. The vessels and nerves of the jejunum and ileum are between the anterior and posterior layers of the mesentery, and those of the transverse colon, sigmoid flexure, and rectum, between their respective mesenteric folds. Between the layers of the omenta, and those of the mesenteric folds, fatty tissue is developed, often in considerable abundance.

The general cavity of the peritoneum consists of two compartments, which communicate with each other through a constricted passage, the so-called *foramen of Winslow*. The larger of these compartments, or greater cavity of the peritoneum, is opened, when the anterior abdominal wall, and the parietal layer of peritoneum, which lines it, are cut through. It extends from the diaphragm above to the pelvis below, is in front of the stomach, great omentum, and intestine, and is the best known of the peritoneal compartments. The smaller compartment or *lesser cavity of the peritoneum*, lies behind the gastro-hepatic omentum and the stomach, and is prolonged downwards between the descending and the ascending layers of the great omentum as the *sac of the omentum*. Its posterior boundary is formed by the layer of peritoneum, which ascends in front of the pancreas to the diaphragm, to become continuous with the posterior layer of the coronary and the left lateral ligaments of the liver. It is closed in below by the omentum, transverse colon, and transverse meso-colon, and above by the liver, diaphragm, and coronary ligament. It is walled in on the left by the spleen and gastro-splenic omentum, whilst on the right it communicates with the greater cavity of the peritoneum through the foramen of Winslow.

This so-called foramen is not a hole, or break in the continuity of the peritoneal membrane, but a constricted passage, situated behind the right free border of the small omentum, where the portal vein, hepatic artery, and bile duct are ascending to the transverse fissure of the liver. The passage

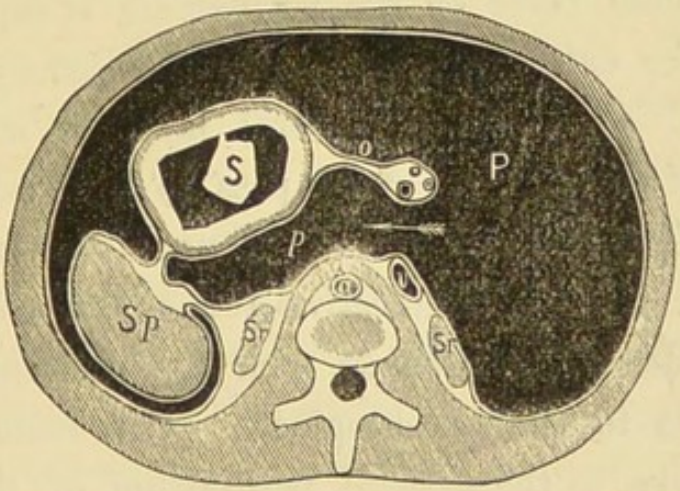

FIG. 183.—Diagram of a transverse section through the Abdomen and Peritoneum in the region of the lesser cavity of the peritoneum and of the Foramen of Winslow. *s*, stomach; *sp*, spleen. The stomach and spleen are attached together by the gastro-splenic omentum, *sr*, *sr*, supra-renal capsules; *d*, diaphragm; *a*, aorta; *i*, inferior vena cava; *o*, small omentum, with the portal vein, hepatic artery, and bile duct, transversely divided; *p*, lesser cavity of peritoneum; P, the greater cavity of peritoneum, the letter being placed in the position of the liver. The arrow is placed in the foramen of Winslow.

is bounded posteriorly by the peritoneal membrane covering the inferior vena cava; above it is bounded by the Spigelian lobe of the liver, and below by the duodenum. Through it not only does the greater cavity of the peritoneum communicate with the lesser, but the membrane lining the greater is continuous with that of the lesser cavity. The foramen is sufficiently large to admit of the passage of two fingers, and through their agency the extent of the lesser cavity may be examined. But a fuller view of this cavity may be obtained by detaching the great omentum from the greater curvature of the stomach and then drawing the stomach forwards. The prolongation of the lesser

cavity, as the sac of the omentum, between the ascending and the descending layers of the great omentum, is seen most readily in young persons ; for in adults it is not uncommon to find these layers fused together, or even riddled with numerous holes.

The parietal layer of the peritoneum is supplied with blood by the extra-peritoneal arterial plexus already described (p. 433). The visceral layer is supplied by branches of the arteries, which pass to the viscera that it invests. Lymphatic vessels form networks in the subendothelial layer of connective tissue, and communicate through microscopic stomata with the peritoneal cavity. Nerves pass to the diaphragmatic peritoneum from the phrenic nerve, to the parietal peritoneum of the lumbar regions from the lower intercostals, and to the pelvic peritoneum from some of the sacral nerves. Twigs from the sympathetic plexus apparently pass to the visceral peritoneum.

STOMACH.

The stomach is the bag-like dilatation of the alimentary canal, connecting the œsophagus with the duodenum, in which the food is mingled with the gastric juice, and converted into a pulpy substance—the chyme. The stomach is situated in the costal zone of the abdominal cavity; three-fourths of its volume, according to Luschka, being contained in the left hypochondrium, whilst the remaining fourth extends into the epigastrium. About five-sixths of the organ lies to the left of the mesial plane, and one-sixth to the right. The stomach varies in size, shape, and somewhat in position, according as it is empty or full of food. When moderately full it is about one foot in length, whilst its greatest transverse diameter is four to five inches. Its general shape is pyriform, and it may be described as possessing two extremities, two surfaces, and two borders. The larger extremity, called the *fundus*, *cardiac extremity*, or *great cul-de-sac*, is directed upwards so as to be in contact with the under surface of the diaphragm, whilst the smaller end, *pyloric* or *duodenal extremity*, is directed downwards, curves to the right, and becomes continuous with the duodenum. The *surfaces* form the *anterior* and *posterior walls* of the stomach. When the organ is empty, the walls are flattened, and in apposition with each other by their inner surfaces; but when it is distended they are curved; the anterior convex surface, directed forwards and upwards, is in relation with the anterior abdominal wall, the diaphragm, and the under surface of the liver; the posterior surface, also convex, directed

backwards and downwards, is in relation with the diaphragm, pancreas, transverse part of the duodenum,

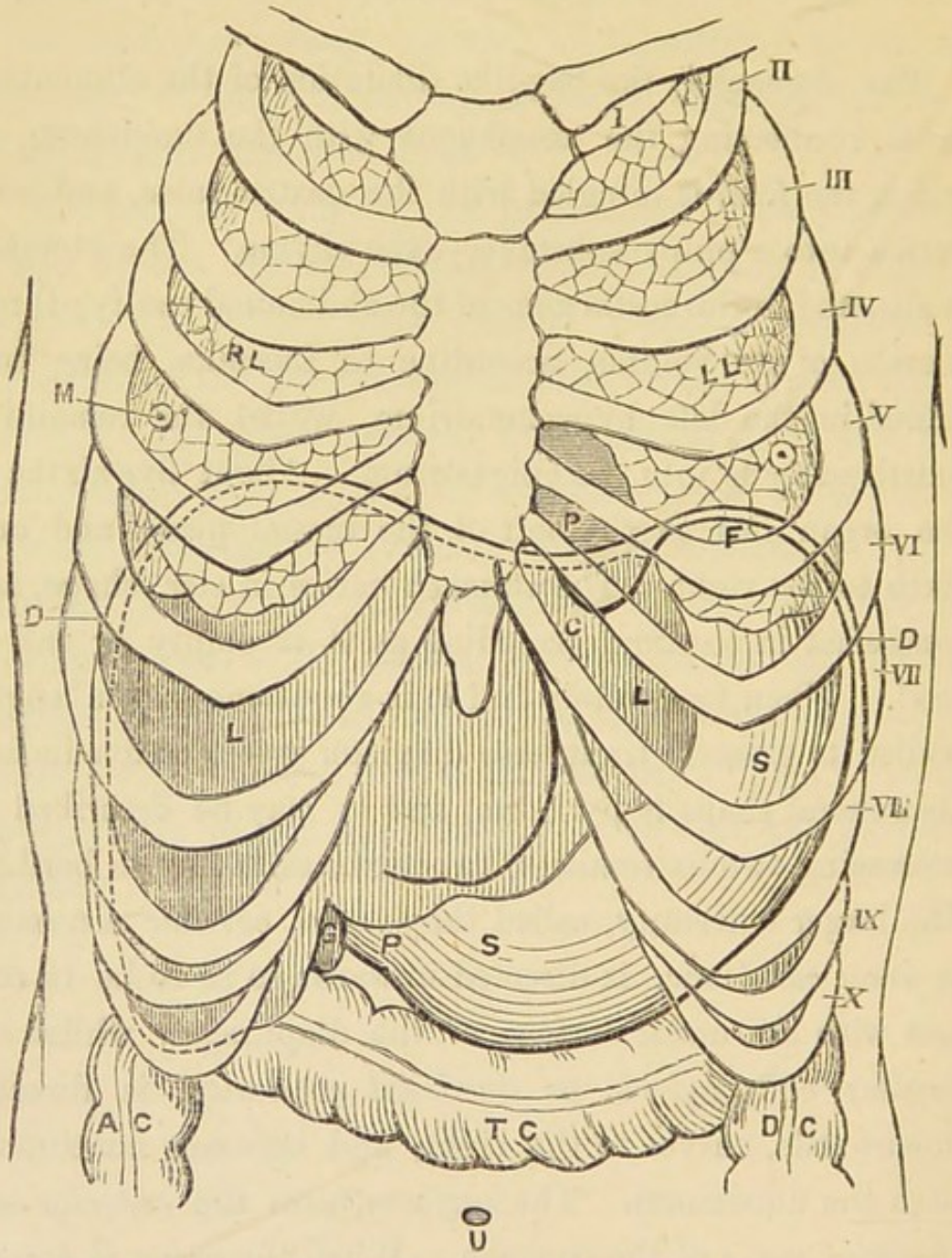

FIG. 184.—The Lungs and their relations to the Diaphragm, Liver, and Stomach. II, to X, second to tenth ribs; DD, diaphragm; RL, right, and LL, left lung; P, pericardium; S,S, stomach; F is placed superficial to its fundus; P, its pylorus; C is over the cardiac orifice; L,L, the liver; G, gall bladder; AC, ascending, TC, transverse, and DC, descending colon; U, umbilicus; M, right nipple. Modified from Luschka.

spleen, left kidney, and supra-renal capsule. The *borders* of the stomach are curved and unequal in size; one is convex, about three times as long as the other, and

is named the *greater curvature;* the other is concave, and forms the *lesser curvature.* The curvatures are so arranged that the greater has its convexity directed downwards and to the left, where it lies in relation to the transverse colon and the splenic flexure of the colon. The lesser curvature has its concavity directed upwards and to the right; for the most part it is to the left side of the spinal column with which it is almost parallel; it lies in relation to the cœliac axis. The œsophagus opens into the stomach at the upper end of the lesser curvature, and the cardiac orifice lies behind and opposite to the sternal fourth of the seventh left costal cartilage. Above this orifice the stomach expands into the fundus, which is situated in the highest part of the left hypochondrium, and occupies therefore the summit of the vault of the left half of the diaphragm. At the lower and right end the two curvatures lie almost horizontally in the epigastrium and terminate at the pylorus, where the stomach becomes continuous with the duodenum. The pylorus, or gate of the stomach, is situated in the epigastrium about three fingers' breadth below the ensiform cartilage, and immediately to the right of the mesial plane. The junction of the stomach with the duodenum is marked by a circular constriction externally, called the *pyloric constriction*, and by a valve internally, the *pyloric valve.* At its pyloric end the stomach presents a small bulging, the *lesser cul-de-sac*, or *antrum pylori.* Occasionally another constriction surrounds the stomach between its pyloric and œsophageal portions, so as to give it the appearance of an hour-glass, and imperfectly to separate it into two chambers.

The stomach does not, as has often been stated, lie

transversely across the abdominal cavity, but, as has been clearly pointed out by Luschka, is for the most part placed vertically in the left hypochondrium, so that the fundus is the uppermost part of the organ; whilst the pylorus, which curves to the right into the epigastrium, forms its lower extremity. Owing to the vertical direction of the stomach in the left hypochondrium, the 5th, 6th, 7th, 8th, and 9th ribs, separated of course by the diaphragm, arch in front of it, for a greater or less distance; and its fundus, the diaphragm intervening, is in relation to the base of the left lung, the heart, and pericardium. When greatly distended the stomach acquires more extensive relations. It may push the transverse colon to one side, and may reach into the umbilical, left lumbar, or even the left iliac region. Its fundus also may press upwards the left half of the diaphragm, interfere with the descent of that muscle during deep inspiration, and affect the position and action of the heart. In the distended condition the greater curvature of the stomach is thrown forward, so as to lie in relation to the anterior abdominal wall.

The stomach is retained in position, partly by its connections with the œsophagus and duodenum, partly by the pressure of the surrounding abdominal walls and viscera, and partly by folds of peritoneum which pass from it to the adjacent structures. These folds are as follows:— The *gastro-phrenic ligament* extends from the diaphragm to the stomach in the angle between the œsophagus and the cardiac extremity: the *gastro-hepatic*, or *small omentum*, passes from the lesser curvature of the stomach to the lips of the transverse fissure of the liver; the *gastro-splenic omentum* from the cardiac end of the stomach to the

spleen; the *gastro-colic*, or *great omentum*, descends from the greater curvature of the stomach in front of the coils of the small intestine, and then ascends to enclose the transverse colon.

Structure of the Stomach.

The wall of the stomach consists of four coats, named from without inwards, serous, muscular, sub-mucous, and mucous coats.

The *external* or *serous coat* is that part of the peritoneal membrane which encloses the stomach; one layer covering the anterior, the other the posterior surface. It leaves the stomach at the curvatures, where it forms the great and small omenta, and along these borders the two layers enclose between them the blood-vessels and nerves which supply the organ. The serous coat is loosely united to the subjacent muscular coat by areolar tissue, which is sometimes called the *sub-serous coat.*

The *muscular coat* consists of non-striped fibres arranged in three layers from without inwards. The outer layer consists of *longitudinal* fasciculi, which are continuous with the external longitudinal layer of the œsophagus. They form scattered fasciculi extending longitudinally over the surface of the stomach from cardia to pylorus, but along the two curvatures, more especially the lesser, they are collected into stronger bundles, and at the pylorus become continuous with the longitudinal fibres of the duodenum. The middle layer consists of *circular* fasciculi, which form a ring-like arrangement transversely to the long axis of the stomach. These fasciculi are comparatively thin and scattered at the cardiac end, but as they approach

the pylorus, they become more closely aggregated, so as to form a thick layer, which at the pylorus extends into the pyloric valve, and forms the *sphincter pylori* muscle. The circular fibres of the stomach are in the same morphological plane as the circular fibres of the œsophagus and duodenum. The inner layer consists of *oblique* fasciculi, which are not found over the entire organ ; the greater number spring from the left side of the cardiac orifice, and radiate on the anterior and posterior surfaces towards the pylorus and greater curvature. Henle and Pettigrew have described a group of short oblique fasciculi as spreading from the right side of the cardiac orifice over the anterior and posterior surfaces of the fundus, and the latter author has described oblique fibres investing the pylorus ; Pettigrew indeed considers that the circular layer consists of very oblique fibres intersecting each other in figure of eight loops. These oblique fibres by their contraction approximate the cardia to the pylorus, the great curvature to the smaller, and the anterior to the posterior wall : they are thus the true grinding muscles of the stomach, and have been compared to the muscular gizzard of the bird. From the relation of the two groups of oblique fibres to the cardiac orifice they probably close that opening during gastric digestion. The longitudinal and circular fibres occasion a longitudinal shortening and transverse constriction of the stomach. By the action of the muscular coat the food is churned about in the stomach, so as to become thoroughly intermingled with the gastric juice. The contraction of the sphincter pylori closes the pyloric orifice, and prevents the passage of the food into the duodenum, before it is converted into chyme.

The *submucous coat* lies immediately subjacent to the oblique layer of the muscular coat, and forms the bond of union between that coat and the mucous membrane. It consists of the areolar variety of connective tissue, mingled with elastic fibres, and in it the blood-vessels ramify before they pass into the mucous membrane.

The *mucous* or *internal coat* lines the cavity of the stomach, and is continuous with the mucous membrane of the œsophagus and duodenum. It is a soft, pulpy mem-

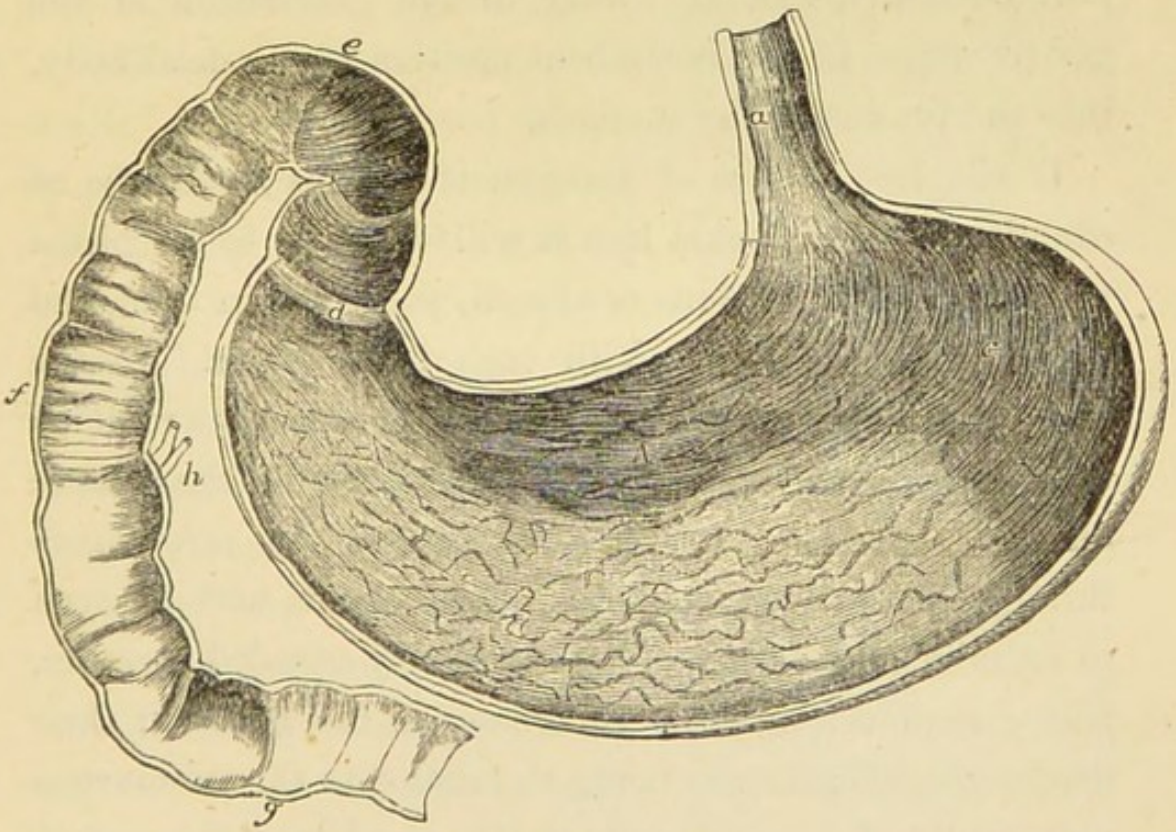

FIG. 185.—The mucous coat of the Stomach and Duodenum, showing the rugæ of the stomach and the valvulæ conniventes of the duodenum. *a*, œsophagus; *c*, cardiac end of stomach; *d*, pyloric valve; *e*, ascending, *f*, descending, and *g*, transverse parts of duodenum; *h*, biliary and pancreatic ducts.

brane, of a pink colour, which becomes redder during digestion, owing to turgescence of the blood-vessels. At the pyloric end it is often stained yellow or green with bile, and in old people it has a brown colour, from formation of pigment. In the empty stomach it is thrown into

folds or *rugæ*, which have usually a longitudinal direction, but when distended the rugæ are obliterated, and the surface of the mucous membrane is smooth. This membrane is usually said to be thicker at the pyloric end than in the fundus; but Brinton, who had opportunities of examining the stomach of healthy young adults immediately after death, found the cardiac mucous membrane to be more than twice as thick as the pyloric: he ascribes the thinning of the cardiac mucous membrane to the effects of post-mortem digestion, owing to the gravitation of the gastric juice, in the recumbent position of the dead body, into the fundus of the stomach.

If the free surface of the gastric mucous membrane be examined with a pocket lens it will be seen to be pitted with shallow depressions or alveoli, polygonal in form, and varying from $\frac{1}{100}$th to $\frac{1}{200}$th inch in diameter. In the sides and bottom of each of these pits numerous rounded orifices may be seen, which are the mouths of the gastric secreting glands. If vertical sections be now made through the mucous membrane, these glands will be seen to be tubular in form. They are closely crowded together, and extend through the thickness of the mucosa; their deeper closed extremity being in relation to the submucous coat, whilst the open mouth of the gland is at the surface of the mucous membrane.

In the human stomach the tubular glands are, for the most part, simple, almost straight cylinders, and possess an average length of $\frac{1}{25}$th inch, and a breadth of about $\frac{1}{350}$th inch. They are somewhat dilated at their orifices, and at their closed ends give rise to cœcal pouches. The wall of the tubes consists of a condensation of the inter-

glandular connective tissue, which forms a membrana propria; flat stellate cells are said to occur in it. For about the upper fourth or fifth of their length the tubes are lined by a single layer of columnar epithelium, continuous with the columnar epithelium covering the free surface of the gastric mucous membrane. In these columnar cells the nucleus is situated close to the attached end of the cell. In the rest of the gland-tube Brinton found two kinds of cells. The one consisted of the so-called *peptic cells*, about $\frac{1}{1200}$th inch in diameter, and of an ovoid or somewhat polygonal form, which lay next to the wall of the gland. The other kind, somewhat cubical in form, lined the very narrow central canal of the gland, and formed an *axial layer*, which was continuous above with the columnar epithelium lining the upper end of the tube. Brinton stated that this dimorphous structure of the gastric glands exists throughout the vertebrata.

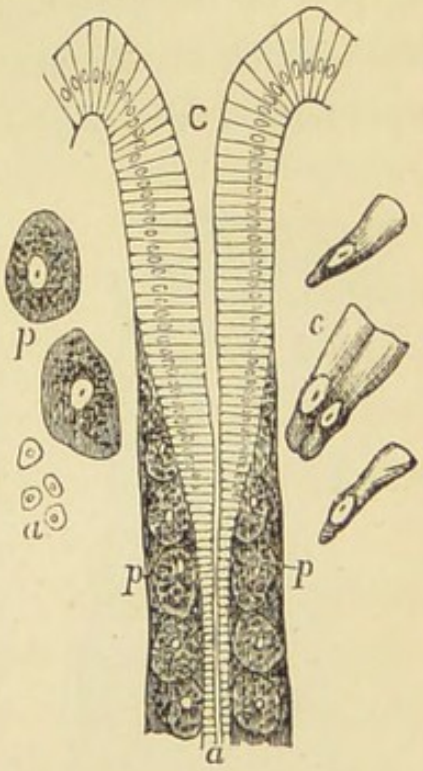

FIG. 186. — Upper part of a gastric gland from the middle of the human Stomach. *c*, columnar epithelium; *a*, axial cells; *p*, peptic cells. × 200. More highly magnified views of these cells when isolated are also given. From Brinton.

It is in the dog and cat, however, that the structure of the gastric mucous membrane has especially been studied, and two kinds of glands have been described. The one, situated especially in the region of the pylorus, consists for the most part of simple tubes, which may however

branch at their deeper end: they have been called the *mucous glands.* They are lined by a columnar epithelium, the cells of which at the deeper end of the gland are more cubical in form, and have a clouded granular appearance. The other kind of gland is situated in the remaining part of the gastric mucous membrane, and consists of tubes which divide usually into four branches; they have been named the *peptic glands.* The cellular lining of these peptic glands closely corresponds with the dimorphous arrangement in the human stomach already referred to. The two forms of cells in the deeper branched part of the gland were first observed by Kölliker in the dog, and have since been specially studied by Heidenhain, Rollett, and Frey. According to the last two observers, the axial layer of cells is absent in a certain extent of the gland tube, below the place where the columnar epithelium ceases, and the cellular lining consists merely of a continuous layer of peptic cells. In the deeper part of the gland again, both kinds of cells occur. Heidenhain states that in a fasting dog the glands are shrunken, and the axial cells are transparent, whilst during digestion the peptic glands are swollen out and the cells are clouded and granular.



FIG. 187. — Vertical section through the Gastric mucous membrane of a cat, to show the tubular pepticg lands. *c*, columnar epithelium near the gland mouth; *p*, peptic cells; *m*, interglandular muscular band; *v*, vessels surrounding tubular gland. *mm*, muscularis mucosæ; *sm*, submucous coat.

The gastric glands are separated from each other by slender prolongations of the muscularis mucosæ, and by the vascular interglandular connective tissue, which is soft, delicate, and contains a small proportion of lymphoid corpuscles diffused in it. In some localities the lymphoid tissue may be collected into solitary follicles, forming the *lenticular* glands of the stomach. Beneath the glands is a well defined *muscularis mucosæ*, arranged in two layers, which gives off bundles that pass between the gastric glands.

The gastric mucous membrane is highly vascular: small arteries enter it from the submucous coat, and terminate in a capillary plexus, situated in the interglandular connective tissue surrounding the gastric glands; a vascular capillary ring surrounds the orifice of each gland.

The *pyloric valve* is the name given to the circular fold, situated at the junction of the stomach and duodenum, which surrounds the pyloric orifice. This fold is covered on its free surface by mucous membrane, which encloses the submucous coat and the circular layer of the muscular coat, but not the longitudinal layer, or the serous coat. That portion of the mucous membrane which covers the gastric surface of the valve possesses the structure of the mucous membrane of the stomach; whilst that which covers the duodenal surface is studded with villi, and possesses the structure of the intestinal mucous membrane.

The arteries of the stomach are the coronary branch of the cœliac axis, and branches of the hepatic and splenic arteries. They form, as already described (p. 427), arterial arches along the greater and lesser curvatures, and

anastomosing arrangements in the anterior and posterior walls of the stomach. The veins of the stomach are rootlets of the portal vein. The lymphatics are numerous, and form a superficial and a deep set. The superficial run along the curvatures. The deep lymphatics arise in the gastric mucous membrane, where they form a network between the glands: they pierce the submucous and muscular coats, and join the superficial lymphatics. The nerves of the stomach are derived from the epigastric plexus of the sympathetic and from the pneumogastric nerves. The right vagus ends in the posterior wall of the stomach, the left in the anterior wall. Nerve cells are met with in relation to the nerves both in the muscular and submucous coats.

INTESTINAL CANAL.

The Intestinal Canal, Intestine, Gut, or Bowel, is situated in the abdominal cavity, and extends from the pyloric opening, or gate, of the stomach to the orifice of the anus, where it opens on the surface of the body in the region of the perineum. In it the chyme becomes mingled with the bile, the pancreatic fluid, and the secretions of the intestinal glands, and is converted into chyle. In it also the absorption of the chyle takes place, and the insoluble part of the food is passed onwards to be excreted in the form of fæces. The intestine is the longest division of the alimentary canal, and measures on an average about twenty-five feet. It is primarily divided into two parts, called small intestine and large intestine; the length of the small is about twenty feet, that of the large about five feet.

The SMALL INTESTINE is the upper of the two divisions of the canal, and consists of a convoluted, almost cylindrical tube, which reaches from the pylorus to the cœcum, or commencement of the large intestine. It is sub-

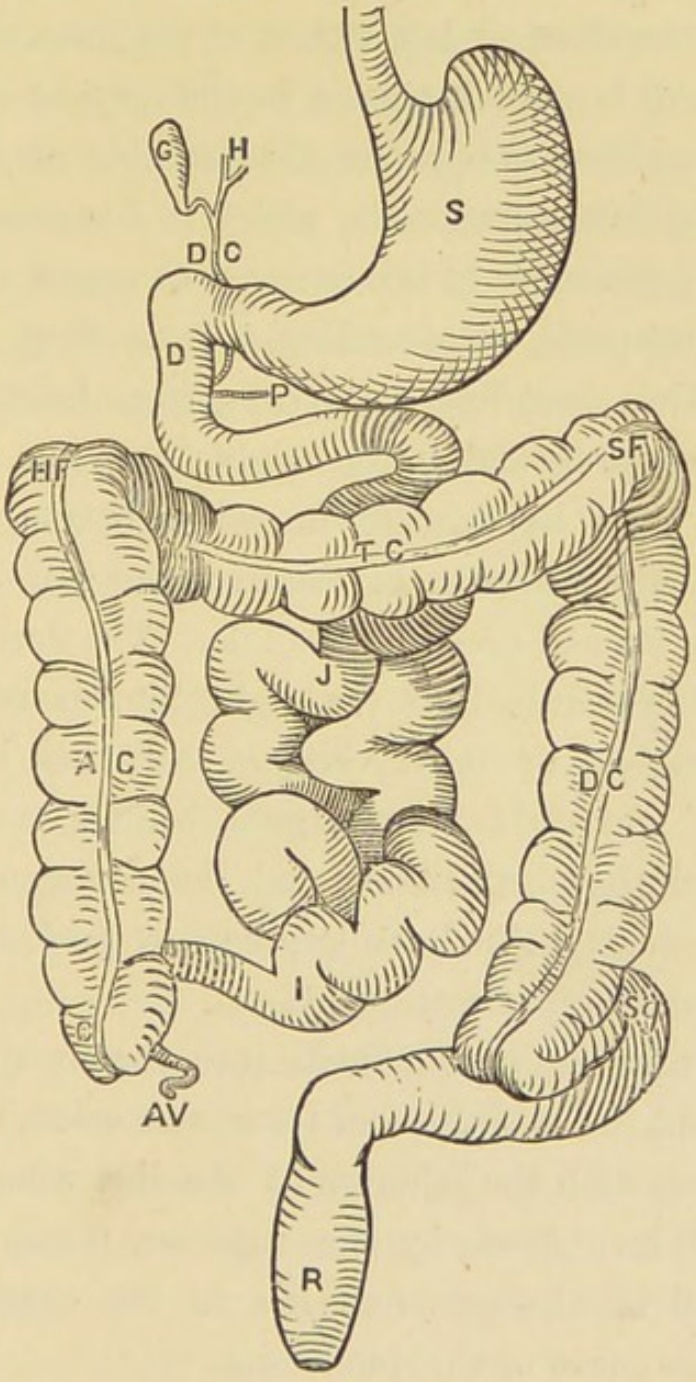

FIG. 194.—Diagram of the abdominal part of the Alimentary Canal. S, stomach; D, duodenum; J, jejunum; I, ileum; AV, appendix vermiformis; AC, ascending colon; HF, hepatic flexure; TC, transverse colon; SF, splenic flexure; DC, descending colon; SG, sigmoid flexure; R, rectum; G, gall bladder; H, hepatic duct; DC, common bile duct; P, pancreatic duct.

divided into three portions, named duodenum, jejunum, and ileum.

The DUODENUM is the commencement of the small intestine, and has received its name from its length being regarded as about equal to the breadth of twelve fingers. It forms the shortest and widest of the three sub-divisions of the small bowel; it curves, in the form of a horse-shoe, from the pylorus to opposite the left side of the body of the second lumbar vertebra, where it becomes continuous with the jejunum. It is customary to regard it as consisting of three parts, an ascending, a descending, and a transverse. The ascending part runs from before backward slightly upwards and to the right, from the epigastrium into the right hypochondrium, where it comes in contact with the under surface of the liver and gall bladder, and is usually stained green by the bile. The descending part passes downwards into the right lumbar region, as far as the second or third vertebra. It lies between the pancreas and right kidney, goes behind the transverse colon and the meso-colon; and the common bile duct, running down behind its left border, perforates its wall along with the pancreatic duct.

The transverse part extends into the umbilical region, lies behind the stomach and transverse colon, and becomes continuous with the jejunum at the line where the small intestine is crossed by the superior mesenteric artery. The head of the pancreas lies in the concavity of the horse-shoe curve of the duodenum.

The duodenum is that part of the small intestine which is most fixed in its position. Its ascending part is connected to the liver by a fold of peritoneum, sometimes

called the *hepatico-duodenal ligament*, and its descending and transverse parts are attached to the right kidney and posterior wall of the abdomen by connective tissue. But in addition a *suspensory muscle*, composed of non-striped fibres, has been described by Treitz as extending from the region of the cœliac axis and superior mesenteric artery to the transverse part of the duodenum.

The duodenum is distinguished from the rest of the small intestine by having the ducts of the liver and pancreas opening into its canal, by containing in its wall a collection of compound racemose glands, named the glands of Brunner, and by being developed from the primitive fore-gut, and not, like the jejunum and ileum, from the primitive middle gut (p. 774). Like the stomach, it should be regarded as a distinct segment of the alimentary canal.

The JEJUNUM and ILEUM form by far the longest part of the small intestine, and are not separated from each other by any sharp line of demarcation : the upper two-fifths being called jejunum, on account of its being usually empty after death, the lower three-fifths being termed ileum, from its convoluted arrangement. They occupy the umbilical, hypogastric, right and left iliac regions of the abdomen, in which they are arranged in a series of coils or convolutions ; one or two coils of the ileum sometimes lie in the cavity of the pelvis, between the bladder and rectum. The coils are attached to the posterior wall of the abdomen, along a line from the body of the first lumbar vertebra to the right sacro-iliac joint, by the fold of peritoneum called the *mesentery*. Owing to the extent of the mesentery, the coils of the jejunum and ileum can

be freely moved about in the abdominal cavity, so that they are apt to be displaced from their natural position, and, when a rupture occurs, to become the most usual contents of the hernial sac. The lower end of the ileum passes into the right iliac fossa, where it becomes continuous with the large intestine, at the junction of the cœcum and ascending colon. Though the line of demarcation between jejunum and ileum is an arbitrary one, yet the upper end of the jejunum may be distinguished from the lower end of the ileum by being wider, and having a thicker mucous membrane, in which the folds called *valvulæ conniventes* are larger and more numerous.

There is occasionally found projecting from the lower third of the ileum a short prolongation of that tube, which forms an elongated hollow process, terminating at its free end in a *cul-de-sac*. It is named *diverticulum ilei*. It may vary in length from half-an-inch to six or seven inches, and usually projects from the convex aspect of the circumference of the bowel. On rare occasions it has been seen to be attached to the wall of the abdomen in the region of the navel by a slender band of fibrous tissue. The diverticulum is of interest as representing a persistent condition of the omphalo-mesenteric or vitello-intestinal duct, which in the embryo connects the umbilical vesicle with the primitive intestine.

Structure of the Small Intestine.

The wall of the small intestine consists in the greater part of its extent, of four coats, named from without inwards, serous, muscular, submucous, and mucous coats.

The *serous*, or *external coat*, derived from the peritoneum, forms a complete investment for the jejunum and ileum, and is continuous with the mesentery along a line of attachment, named the mesenteric border of the intestine. The ascending part of the duodenum also has a complete serous coat, but the serous covering of the descending and transverse portions is limited to their anterior surface. The serous coat of the small intestine is loosely united to the subjacent muscular coat by areolar tissue, which is sometimes called the *subserous coat*.

The *muscular coat* consists of non-striped fibres arranged in two layers from without inwards. The outer layer consists of *longitudinal* fasciculi, which form a thin layer parallel to the long axis of the intestine. The inner layer consists of *circular* fasciculi arranged around the gut transverse to its long axis : this layer is thicker, stronger, and more highly coloured than the longitudinal layer. By the contraction of the muscular coat, the peristaltic or vermicular movement is produced, which propels the ingested materials along the intestine.

The *submucous coat* lies immediately subjacent to the circular layer of the muscular coat, and forms the bond of union between that coat and the mucous membrane. It consists of areolar connective tissue, and in it the blood-vessels ramify before they pass into the mucous membrane.

The *mucous*, or *internal coat*, is a soft, velvety-looking membrane, which lines the wall of the small intestine, and possesses a complex appearance and structure. The inner surface is not smooth, but is thrown into strongly-marked folds, the *valvulæ conniventes*, which are not obliterated

during distension of the gut. The folds are placed transversely to the long axis of the bowel, and run around its inner wall for one-third or one-half, or two-thirds of its circumference (fig. 185). They project into the lumen of the intestine, and the largest are about one-third of an inch in depth. They are first seen about the commencement of the descending part of the duodenum, are very numerous in the transverse part of the duodenum and upper half of jejunum, then decrease in size and numbers, until at the lower end of the ileum they have disappeared. Each *valvula* consists of a fold of the mucous membrane with its submucous coat. Owing to their presence, the extent of the mucous surface is much greater than if it were a plane-surfaced membrane.

In its more minute structure the mucous coat may be regarded as composed of projecting bodies, a glandular layer, and a muscular layer.

The projecting bodies are the intestinal *Villi*, which jut out into the lumen of the intestine from the free surface of the mucous membrane, not only of the valvulæ, but of the intermediate surface. They are delicate minute processes, varying in length from a fourth to half a line, and in number amount to several millions.

They are best examined when the mucous surface is placed in water or spirit, when they may be seen with the naked eye, or still better, with a pocket lens; when the chyle-vessels or blood-vessels are injected, they become erected, and stand out more prominently from the surface. They vary in form, being filiform, or cylindrical, or conical, or club-shaped, or leaf-shaped. They are more numerous in the duodenum and jejunum than in the

ileum, and to their presence is due the velvety appearance of the mucous surface. They are not found elsewhere than in the small intestine.

As they are the parts of the mucous membrane directly concerned in the absorption of the chyle, their structure is interesting and important. Each villus is invested by a cap of epithelium continuous with the general epithelial covering of the mucous membrane. The epithelium consists of a single layer of *columnar cells*, compactly arranged side by side. The deep attached end of the cell is frequently attenuated into a slender filament. The broad free end, as was first figured by Goodsir, possesses a border distinct from the general body of the cell. Kölliker and Funke recognised in this border vertical striæ, which they regarded as minute canals, for the transmission of the particles of the chyle, but which are probably nothing more than a peculiar vertical arrangement of the cell-protoplasm at the border of the cell (fig. 31, C). Occupying the intervals between the attenuated ends of the

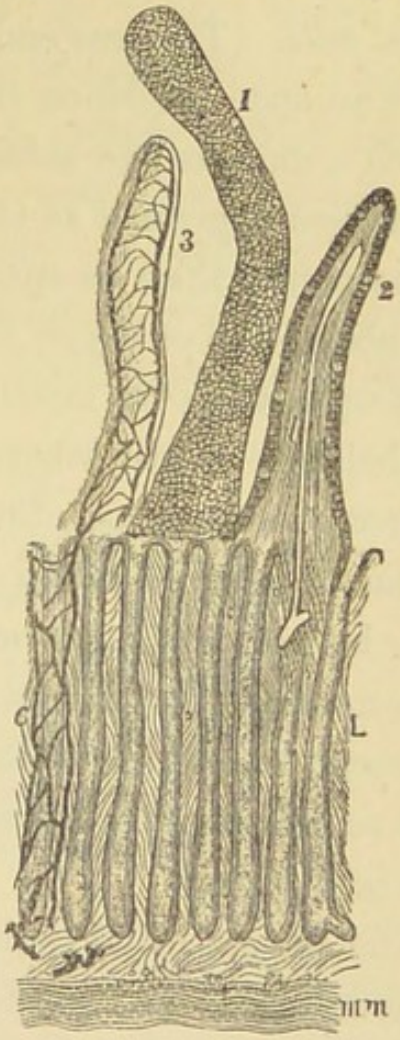

FIG. 189.—Vertical section through the mucous membrane of the Small Intestine, showing the villi and glands of Lieberkühn. 1, villus covered by epithelium; 2, vertical section through a villus, showing the lacteal; 3, blood vessels of the villus; L, the layer of glands of Lieberkühn; *c*, capillaries surrounding one of these glands; *m*,*m*, muscularis mucosæ. × 40.

attached cells are minute *supplementary cells*, sometimes globular in shape, at others elongated and somewhat caudate. Scattered amidst the columnar cells are cells which possess the form of microscopic goblets, and are named *goblet cells*. The free end of each goblet cell appears to have an open mouth on the surface of the villus, through which a mucous-like substance exudes. Various opinions have been expressed as to the nature of these goblet cells. Some regard them as special structures engaged either in the absorption of chyle, or the secretion of mucus : others look upon them as merely modifications of the columnar epithelium : whilst others again consider them to be *post-mortem* productions, due to the swelling out of the columnar epithelium by the imbibition of fluid. There can be no doubt, however, that they are not specially concerned in the absorption of chyle, as cells of the same character are found in the respiratory mucous membrane, and on other surfaces, where the absorption of chyle does not take place.

The sub-epithelial tissue of a villus forms its matrix or basis substance, and consists of the sub-epithelial connective tissue of the mucous membrane. When thin sections through a villus are examined, the matrix is seen to be composed not of areolar tissue, but of a delicate retiform tissue, which forms a network, between the periphery of the matrix and the wall of the chyle vessel, and in the meshes of this network numbers of colourless lymphoid corpuscles are imbedded. These cells were described and figured by Goodsir, as the absorbing cells or vesicles of the villus. Immediately beneath the epithelium, the matrix appears, from Krause's observations, as if its corpuscles were flat-

tened into irregular scales. H. Watney states that a delicate reticulum continuous with the most superficial layer of corpuscles of the connective tissue is prolonged between the epithelium cells. In the axis of the villus one, or perhaps two, minute lacteals or chyle vessels are situated, which serve as rootlets of origin of the lacteal division of the lymph vascular system. The lacteal is a capillary tube, which ends near the apex of the villus, as a dilated microscopic *cul-de-sac*. By its opposite extremity it becomes continuous with a plexus of lacteals in the submucous coat. When treated with nitrate

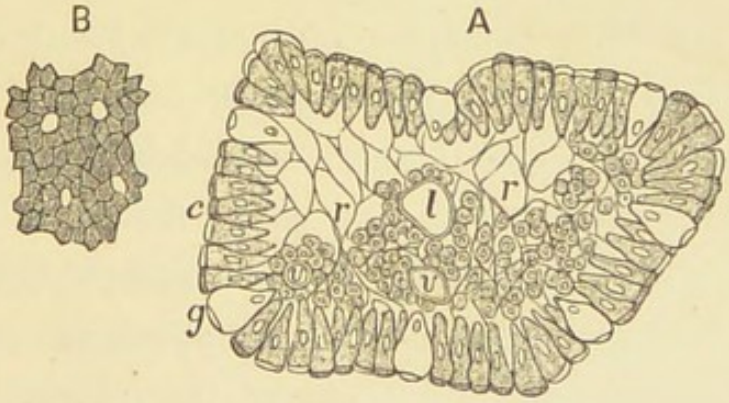

FIG. 190.—A transverse section through an intestinal Villus A, showing its epithelial investment and the matrix of Lymphoid tissue; *c*, columnar epithelium; *g*, goblet-shaped cell; *l*, lacteal; *r*, *r*, lymphoid retiform tissue; *v*, *v*, transversely divided blood-vessels. B, free ends of columnar epithelium, with mouths of four goblet-shaped cells. × 300.

of silver, its wall is seen to consist of flattened endothelial cells, which are connected with the retiform tissue of the matrix substance. In the matrix substance, around the lacteal vessel of the villus, is a layer of non-striped muscular fibro-cells, which is continuous with the general muscular layer of the mucous coat, and extends as far as the apex of the villus. By the contraction of this layer the chyle during absorption is propelled along the lacteal

vessel, and a wrinkled or puckered condition of the villus, sometimes seen after death, is occasioned. The villus also contains blood-vessels ; a small artery enters at its attached base, and terminates in a capillary plexus, situated in the peripheral part of the matrix, close to the cap of epithelium ; from the plexus a vein arises, which leaves the villus at its base, and joins the veins in the sub-mucous coat.

Various theories have been put forward to account for the mode of passage of the chyle, during digestion, from the lumen of the intestine into the lacteal vessels of the villi ; but the question cannot even yet be regarded as definitely settled. The appearance of a network of minute tubules within the matrix, extending from the epithelial investment to the lacteal, which Letzerich supposed to be the channels along which the chyle flowed, is doubtless produced by the arrangement of the strands of the retiform tissue. There seems little doubt, that both the cells of the epithelial investment, and those of the retiform tissue of the matrix, become distended with the particles of chyle previous to its passage into the lacteal. The view advanced by Schäfer, that the corpuscles in the meshes of the retiform tissue may serve as carriers of the fatty particles of the chyle into the lacteals, is but another mode of expressing the function of these cells advocated thirty years ago by Goodsir.

The mucous membrane of the small intestine is abundantly provided with secreting glands, named the glands of Brunner and of Lieberkühn.

Brunner's glands are confined to the duodenum ; they belong to the compound racemose group of glands, and

resemble generally in structure the mucous and salivary glands. The minute lobules of these glands lie in the submucous coat, and the excretory duct pierces the mucous membrane to open on the surface. The wall of the duct is formed of connective tissue lined by columnar epithelium. The finest branches of the duct are continuous with the acini or gland vesicles, and W. Krause states that their membrana propria consists of a layer of polygonal flattened cells. The gland vesicles contain the secreting cells, which are columnar in form: and Schwalbe has described inter-cellular passages, between these cells which communicate, as in the salivary glands, with the excretory duct. A plexus of capillary blood-vessels is distributed outside the membrane propria of the gland vesicles, and lymphatic vessels lie around the lobules. Into the duodenum, about the junction of its descending and horizontal portions, the duct of the pancreas, and the bile duct from the liver, open by a common orifice. These glands may be regarded therefore as accessory glands to this portion of the small intestine.

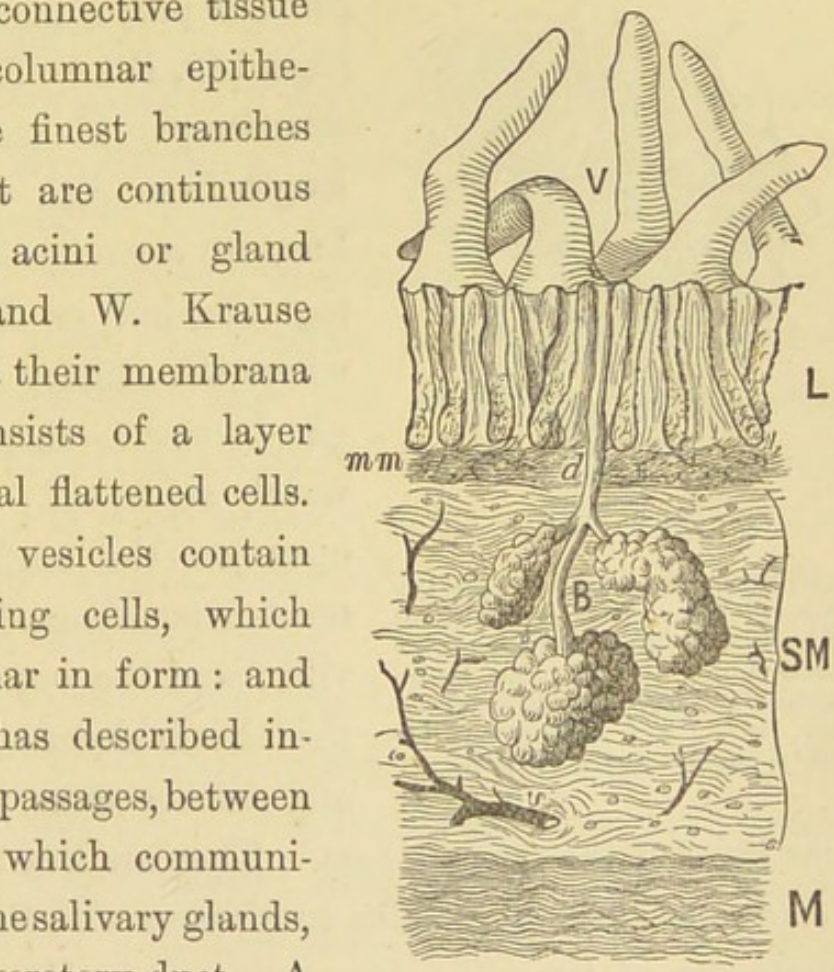

FIG. 191.—Vertical section through the wall of the duodenum, showing the Glands of Brunner. V, intestinal villi; L, layer of glands of Lieberkühn; *m*, *m*, muscularis mucosæ; B, a Brunner's gland, *d*, its excretory duct; SM, submucous coat; M, muscular coat; *v*, a small artery. × 40.

The *glands of Lieberkühn* are distributed throughout the whole length of the mucous coat of the small intestine. They are simple tubular glands, in form like test tubes, which lie vertically in the mucous membrane, and form its proper glandular layer (figs. 189, 191.) The tubes are microscopic in size, vary in length from $\frac{1}{10}$th to $\frac{1}{30}$th of a line, are sometimes closely set together, but in the localities where the solitary and Peyer's glands occur, they are more widely separated. The glands open on the surface of the mucous membrane between the villi; and the opposite end of the tubes is closed and rounded, and reaches close to the muscular layer of the mucous coat. They are lined by a layer of columnar epithelium cells, continuous with the epithelial investment of the villi; supplementary and goblet cells, similar to those described on the villi, are situated between the columnar cells. The glands are separated from each other by retiform connective tissue, in the meshes of which colourless lymphoid corpuscles exist in considerable numbers; the plexus of capillary blood-vessels, which is distributed outside the membrana propria of the gland tube, lies in this connective tissue.

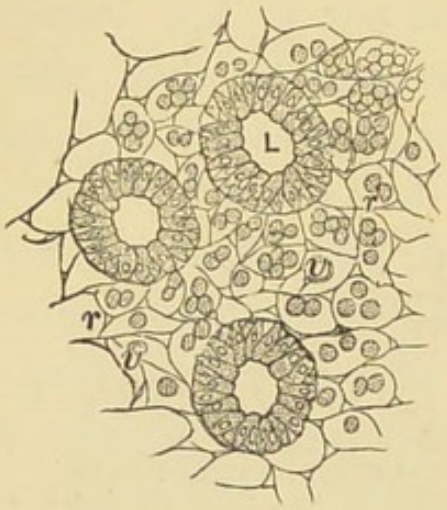

FIG. 192. — Horizontal section through the mucosa of the small intestine, to show the Glands of Lieberkühn, L, and the interglandular retiform lymphoid tissue, *r*, *r*. *v*, *v*, transversely divided blood vessels. × 300.]

The connective tissue of the mucous coat is characterised generally by its retiform character, and by the diffusion of colourless lymphoid corpuscles in the meshwork. But

in some parts of the mucosa these corpuscles, with their supporting framework of retiform tissue, are collected into distinct masses or follicles, visible to the naked eye, and known in descriptive anatomy as the solitary and Peyer's glands or follicles.

The *solitary glands* are scattered throughout the whole length of the intestinal mucous membrane. They are about the size of millet seeds, and vary in number and distinctness in different individuals. They are globular or ovoid in form, and occasion a slight elevation of the mucous membrane. One pole of the gland, sometimes named the cupola, lies next the free surface of the mucous membrane, and is in relation to the columnar epithelium covering the mucosa, whilst the opposite pole, or base, rests on the submucous coat.

Peyer's glands, or the *agminated glands*, consist of an aggregation of solitary glands or follicles, which are crowded together, so as to form distinct elongated patches, which may vary in length from one quarter inch to three or four inches. The long axis of each patch corresponds to the long axis of the intestine, and the patches are placed opposite to the mesenteric attachment of the bowel. Villi either may, or may not, be situated on the surface of the patch, in the intervals between the individual follicles, but Lieberkühnian glands are always found opening on the surface, and frequently forming a ring of orifices around each follicle. Peyer's patches are most abundant in the lower end of the ileum, but diminish in size and numbers in its upper end and in the jejunum, and are absent in the duodenum.

These follicles are lymphoid organs, and are composed of

lymphoid tissue, as has been described on p. 548, where an account of the arrangement of their blood-vessels and lymph-vessels has also been given. The solitary and Peyer's glands, as is the case generally with the lymphoid organs, are more distinct and perfect in structure in infancy and childhood, than in adults or in advanced age.

Peyer's glands are the seats of tubercular formation in tubercular disease of the intestine; and they become swollen and ulcerated in the typhoid form of continued fever. The changes which take place in these glands in the course of typhoid ulceration is due, as was pointed out by Goodsir, to the great development of cells within the constituent follicles of a patch, which in consequence burst and give rise to an ulcerated surface.

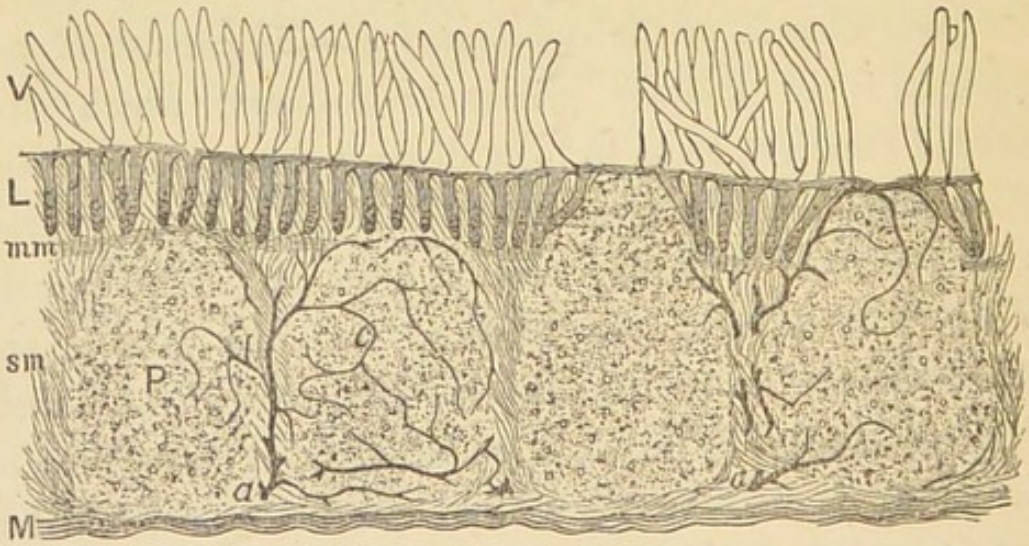

FIG. 193.—Vertical section through a, Peyer's patch in the wall of the small intestine. V, the intestinal villi; L the layer of Lieberkühn's glands; *mm*, the muscularis mucosæ; *sm*, the connective tissue of the submucous coat; P, the follicles of a Peyer's patch. The two to the right are completely divided from the cupola to the base; the two to the left are cut through to one side of the apex; *aa*, small arteries in the submucous coat, which enter the follicles of Peyer, and form, *c*, a capillary network; M, muscular coat. Slightly magnified.

The *muscular layer* of the mucous membrane lies next to the submucous coat. It was discovered by Brücke, and

consists of non-striped fibres which lie parallel to the surface of the membrane. It passes also into the substance of the villi, and lies around the closed end of the glands of Lieberkühn; but, where the solitary and Peyer's glands are situated, it is perforated, to allow the base of the follicle to reach the submucous coat.

Of the *blood-vessels* of the small intestine, the arteries enter the wall of the jejunum and ileum at its attached or mesenteric border, and are branches from the arcades of the superior mesenteric artery; whilst the arteries for the duodenum are the superior pancreatico-duodenal of the gastro-duodenal branch of the hepatic artery, and the inferior pancreatico-duodenal branch of the superior mesenteric. They run in the sub-serous tissue around the wall of the intestine; then pierce the muscular coat and supply it; they then enter the sub-mucous coat, and form a network from which branches pass into the mucous coat. The veins accompany the arteries, and form rootlets of the superior mesenteric vein.

The *Lymph-vessels*, or *lacteals*, may be traced into the wall of the intestine at the mesenteric border; they form a network in the muscular coat, and then enter the sub-mucous coat, where they are very abundant; from this sub-mucous layer offshoots pass through the retiform tissue, which lies between the Lieberkühnian glands, into the villi. Where the solitary and Peyer's glands are situated the lacteals, as Frey has pointed out, form a system of anastomosing vessels around the base and mesial part of each follicle.

The *nerves* are derived from the plexuses of the sympathetic, which accompany the branches of the superior

mesenteric artery. They form between the two layers of the muscular coat an important plexus, named after its discoverer, Auerbach's plexus, in which large stellate nerve-cells are intermingled with nerve fibres, and a similar nervous plexus is found in the muscular coat of the other divisions of the alimentary canal. It supplies and regulates the movements of the muscular coat. In the submucous coat is found a nervous plexus, named Meissner's plexus, after its discoverer, in the strands of which nerve-cells are collected into gangliform masses, and a similar plexus is found in the submucous coat of the other divisions of the alimentary canal. Auerbach's plexus is connected with Meissner's plexus by intercommunicating fibres; and fibres pass from Meissner's plexus to the muscularis mucosæ, to the glandular layer of the mucous coat, and to the attached base of the villi.

The LARGE INTESTINE, though not nearly so long as the small intestine, is of much greater diameter. It reaches from the end of the ileum to the orifice of the anus, and is divided into the cœcum with the appendix vermiformis, the colon, and the rectum; whilst the colon is subdivided into the ascending colon, the hepatic flexure, the transverse colon, the splenic flexure, the descending colon, and the sigmoid flexure.

The CŒCUM is the commencement of the large intestine, and lies below the ileum. It occupies the right iliac fossa, and is attached by areolar tissue to the fascia covering the iliacus muscle. Sometimes it is displaced from this position and hangs down into the true pelvis; more rarely it is elevated into the right lumbar region. It is the most

dilated part of the large intestine, and forms a large *cul-de-sac*, closed in below, but communicating freely above with the ascending colon. Opening on the inner and posterior wall of the cœcum is the *Appendix vermiformis*, which is a slender hollow prolongation of the bowel, varying in length from three to six inches. It has the calibre of the stem of a common tobacco pipe, and ends in a free closed extremity, so that, like the cœcum, it is a *cul-de-sac*. It possesses a peritoneal fold or small mesentery, by which it is sometimes tied to the adjacent wall of the abdomen, though at other times it may be freely movable. It is not generally found in mammals, but is present in man, the orang, certain lemurs, and the marsupial wombat.

The Ascending or Right Colon is continuous below with the cœcum and above with the hepatic flexure. It occupies the right lumbar region, and is attached by areolar tissue to the fascia covering the quadratus lumborum muscle and to the front of the right kidney.

The Hepatic Flexure of the Colon is a bend in the large intestine, forming almost a right angle, continuous on the one hand with the ascending colon, and on the other with the transverse colon. It lies in the right hypochondriac region in contact with the under surface of the liver.

The Transverse Colon connects the hepatic and splenic flexures, and curves across the abdomen from the right hypochondrium, through the umbilical region to the left hypochondrium. It forms the arch of the colon, the convexity of which is directed downwards and forwards, and the concavity upwards and backwards. It lies immediately below the great curvature of the stomach, and is

connected with the posterior layer of the great omentum. Owing to the length of the *transverse meso-colon*, which forms its peritoneal attachment, it not unfrequently undergoes some change in its position, and may hang down-

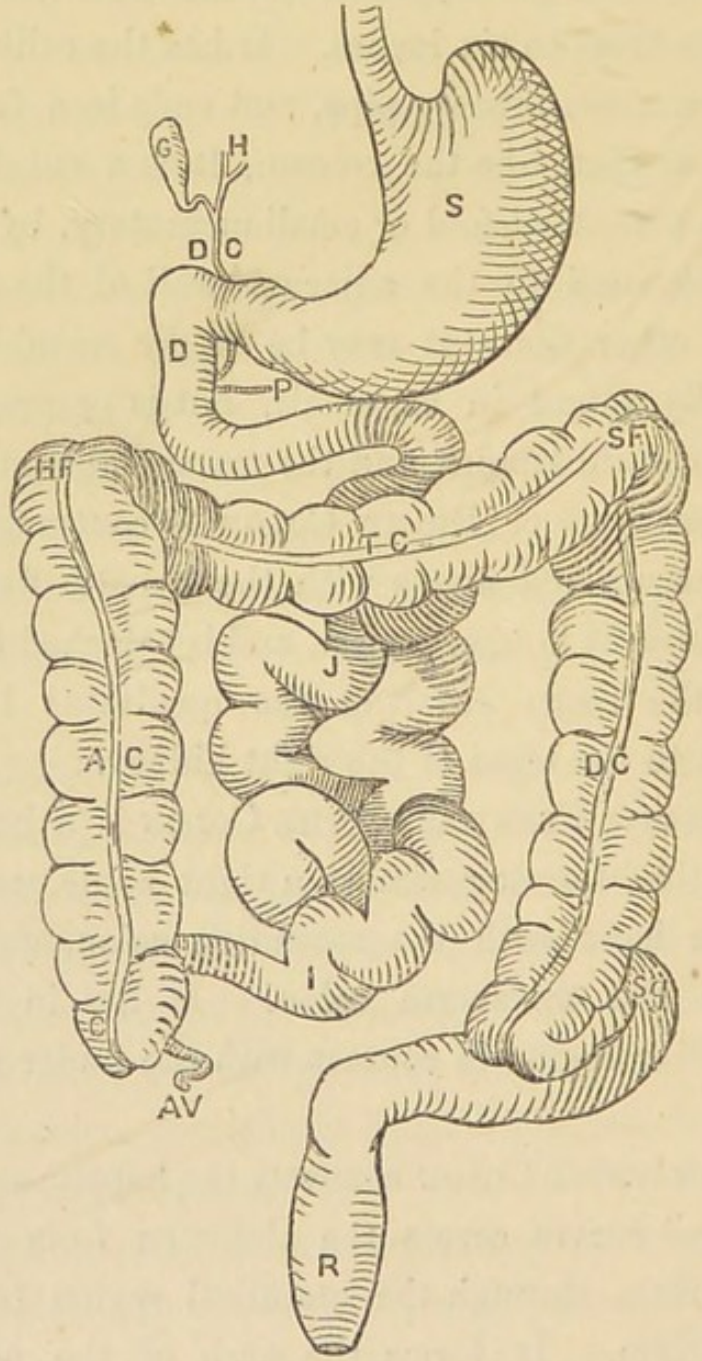

FIG. 194.—Diagram of the abdominal part of the Alimentary Canal. S, stomach; D, duodenum; J, jejunum; I, ileum; AV, appendix vermiformis; AC, ascending colon; HF, hepatic flexure; TC, transverse colon; SF, splenic flexure; DC, descending colon; SG, sigmoid flexure; R, rectum; G, gall bladder; H, hepatic duct; DC, common bile duct; P, pancreatic duct.

wards towards the pelvis, or be elevated in front of the stomach, or thrown to the right or left side. This tendency to displacement of the transverse colon should be kept in mind in the diagnosis of diseases of the abdominal viscera.

The Splenic Flexure of the Colon is continuous on the one hand with the transverse colon, and on the other with the descending colon, and is attached to the diaphragm by the *phrenico-colic* fold of peritoneum. It lies in the left hypochondrium in close relation to the spleen.

The Descending or Left Colon connects the splenic and sigmoid flexures, and occupies the left lumbar region. It is attached by areolar tissue to the left kidney near its outer border, and to the fascia covering the left quadratus lumborum. As low as the level of the 3rd lumbar vertebra it is in relation to the outer border of the quadratus, but from that level to the ilium the quadratus muscle lies behind the descending colon. Owing to its position, and the absence of a peritoneal covering posteriorly, the surgeon opens into this segment of the bowel when he wishes to form an artificial anus.

The Sigmoid Flexure of the Colon connects the descending colon with the rectum. It lies in the left iliac fossa, but as the *sigmoid meso-colon*, which forms its peritoneal attachment, is of some length, it is freely movable, and not unfrequently hangs into the pelvis, or even extends across into the right iliac fossa.

The Rectum is the terminal segment of the large intestine, and extends from the sigmoid flexure to the orifice of the anus. It occupies the cavity of the pelvis. It commences opposite the left sacro-iliac joint, and passes at first

obliquely downwards and to the right until it reaches the middle line of the sacrum; secondly, it closely follows the curvature of the sacrum and coccyx, lying in relation to their anterior surface; thirdly, when it reaches the tip of the coccyx its terminal or third part inclines downwards and backwards for about one inch and a half to the anal orifice. The upper end, or first part of the rectum, is invested by peritoneum, and is attached to the front of the sacrum as far down as its 2nd or 3rd vertebra by the peritoneal fold, termed *meso-rectum*. The second part extends from the 2nd or 3rd sacral vertebra to the tip of the coccyx, is attached to the bone by areolar tissue, and is in relation also to the pelvic fascia. The peritoneum does not form a complete investment for the second part of the rectum; at first it covers it anteriorly and laterally, lower down only anteriorly, and still lower it leaves it, to be reflected, in the male on the back of the bladder, in the female on the back of the vagina. The third part of the rectum is in relation to the pelvic fascia and the levatores ani muscles, by which parts it is supported and retained in position. In the male the bladder, vesiculæ seminales, and prostate gland are in front of the rectum; but in the female its anterior surface is in relation to the uterus and vagina, to the latter of which it is intimately connected. The anus opens on the surface of the middle line of the perineum, midway between the two ischial tuberosities, and the skin surrounding the orifice is thin and wrinkled when the opening is closed. Immediately beneath the skin is the *sphincter ani externus muscle*, which forms a thin layer of fasciculi, arranged in a series of ellipses around the orifice. It is attached behind to the tip of the coccyx, surrounds the

opening as it passes forwards, and extends as far as the so-called central tendinous point of the perineum, where it often joins the acceleratores urinæ and transversi perinei muscles. The sphincter in its normal condition of contraction simply closes the opening, but, under the influence of the will, a more powerful contraction can be induced, so as to resist the entrance of foreign bodies into the rectum.

As the *Levatores ani* muscles are in such intimate relation to the rectum, they may now be described. They form a pair of symmetrically arranged muscles, which descend from the pelvic wall to its perineal outlet. Each arises anteriorly from the back of the body and of the horizontal ramus of the os pubis, posteriorly from the ischial spine, and between these attachments from the pelvic fascia, where it splits into its parietal and recto-vesical layers. The muscle passes downwards and inwards to the middle line of the floor of the pelvis to be inserted as follows: most posteriorly into the side of the tip of the coccyx; from the tip of that bone to the anus into the median raphé of the perineum, where it joins its fellow; then into the lower end of the rectum in close relation to the external sphincter; whilst the most anterior fibres descending by the side of the prostate reach the median raphé of the perineum in front of the anus, and blend, on the perineal aspect of the prostate, with the corresponding muscle of the opposite side. Owing to the relation of the anterior or pubic fibres of origin of the levator ani to the prostate gland in the male, they are sometimes named the *levator prostatæ muscle.* In the female the pubic fibres of origin lie in relation to the side

of the vagina. The pair of levator muscles not only assist in forming the pelvic floor, but can draw upwards the organs which lie in relation to it.

On the same plane as, and continuous with the posterior border of each levator ani, is the *Coccygeus muscle*, which arises from the spine of the ischium, and descends as a thin triangular muscle, to be inserted into the side of the lower end of the sacrum and the side and front of the coccyx. It acts as an elevator of the coccyx. The two pairs of coccygei and levatores ani constitute the *pelvic diaphragm*. They and the external sphincter are supplied by the fourth and fifth sacral and the coccygeal nerves.

The large intestine is arranged in the abdominal cavity in the form of an arch, the summit of which is the transverse colon, whilst the cœcum and rectum are the right and left piers. Within the concavity of this arch the coils of the jejunum and ileum are situated. The large intestine is not, except in the rectum, a cylindriform tube, but is dilated into three parallel and longitudinal rows of sacculi, which rows are divided from each other by longitudinal muscular bands, whilst the sacculi in each row are separated externally by intermediate constrictions. In the rectum the sacculi have disappeared, and the intestine assumes a cylindrical form, but at its lower end it dilates into a reservoir, in which the fæces accumulate prior to being excreted.

At the junction of the large with the small intestine a valvular arrangement, termed the *ileo-cæcal* or *ileo-colic valve*, is found. This valve is due to the peculiar manner in which the ileum joins the cœcum and colon. If these portions of the large intestine be opened into, it will be

seen that the orifice of the ileum is not circular, but elongated in a direction nearly transverse to the long axis of the large intestine.

The opening is bounded by two semi-lunar folds, which project into the large bowel. These folds are the two segments of the valve; one situated above the opening is the *ileo-colic segment*, the other, below the opening, the *ileo-cœcal*. The two segments become continuous with each other at the ends of the elongated opening, and are prolonged for some distance around the inner wall of the large intestine as two prominent ridges, named the *frœna* of the valve. Each segment consists of the mucous and submucous coat, and of the circular layer of the muscular coat of the ileum, which are, as it were, pushed into the canal of the large bowel, at the place of junction, so as to form the prominent folds which have been described. The longitudinal muscular layer and the serous coat of the ileum are prolonged

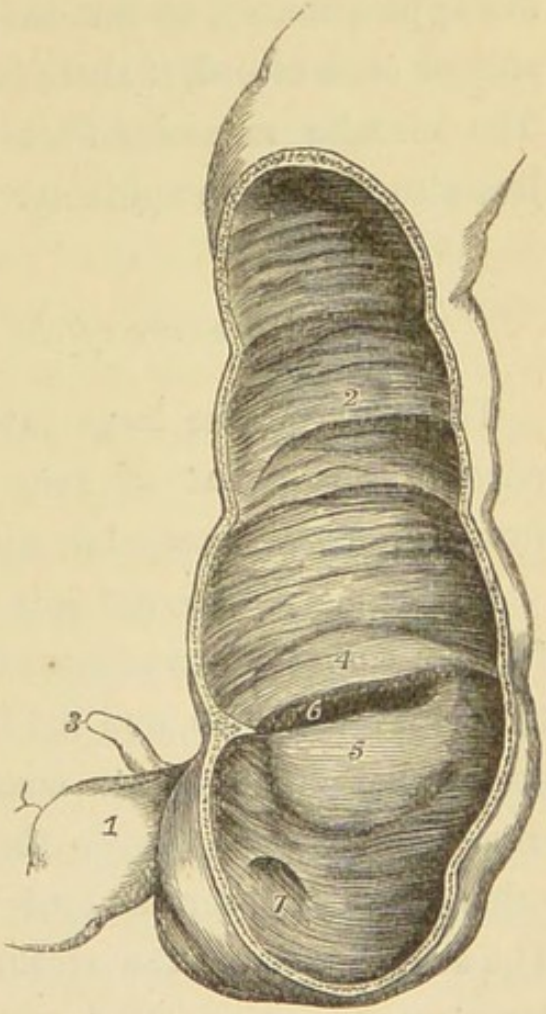

FIG. 195.—View of the interior of the cœcum and ascending colon, to show the Ileo-colic valve. 1, Ileum; 2, ascending colon; 3, appendix vermiformis; 4, Ileo-colic segment, and 5, Ileo-cæcal segment of valve; 6, opening of Ileum; 7, mouth of appendix vermiformis.

directly from the ileum to the wall of the large intestine, and do not enter into the segments of the valve. The use of the ileo-cœcal valve is to impede or prevent the reflux of the contents of the large into the small intestine. When the cœcum and colon are distended the frœna of the valve are put on the stretch, and the two segments are approximated, so that the opening is reduced to a mere slit, or even closed, if there is great distension of the bowel. The circular muscular fibres in the segments will doubtless also exercise a sphincter action on the orifice.

Structure of the Large Intestine.

The wall of the large intestine consists in the greater part of its extent of four coats, named from without inwards, serous, muscular, submucous, and mucous coats.

The *serous* or *external coat* derived from the peritoneum, forms a complete investment for the flexures of the colon, the transverse colon, and the first part of the rectum. The cœcum has sometimes a complete serous coat, but more usually, it, together with the ascending and descending colon, have the serous coat only anteriorly and laterally. The second part of the rectum has only a partial serous investment, and the third part has no serous coat. Numerous pedunculated processes invested by the serous membrane, and containing lobules of fat, named *appendices epiploicæ*, are attached to the large intestine. The serous coat is loosely united to the subjacent muscular coat by areolar tissue, which is sometimes called the *subserous coat.*

The *muscular coat* consists of non-striped fibres arranged

in two layers from without inwards. The outer layer consists of longitudinal fasciculi, which are not as a rule distributed uniformly in the wall, but in the cœcum and colon are collected into three longitudinal bands, which start from the cœcum, where it is joined by the appendix vermiformis, and extend along the colon to the rectum. One band extends along the meso-colic or attached aspect of the bowel, another along the anterior aspect, whilst the third is situated on the inner aspect of the ascending and descending colon, and the under aspect of the transverse colon. As these bands are not so long as the colon itself, they occasion the puckering or constrictions in the wall which separate the sacculi, so that when the bands are cut through the sacculi disappear. The colon then becomes more elongated and cylindriform.

In the appendix vermiformis the longitudinal layer is not collected into bands, but arranged uniformly along the wall. In the rectum, also, the longitudinal layer is spread uniformly along the wall, and forms a well-defined red-coloured layer. Slender fasciculi have been described as passing from this layer to the adjacent pelvic fascia, and to the subcutaneous tissue about the anus, and Luschka has traced some bundles into the anterior sacro-coccygeal ligament.

The inner layer of the muscular coat consists of *circular* fasciculi distributed around the wall of the large intestine. In the rectum this layer increases in thickness, and in proximity to the anus forms a circular muscle, the *sphincter ani internus*, which is a strong band, about half an inch broad, around the lower end of the rectum. In the large, as in the small intestine, the muscular coat

occasions the peristaltic movements, and its increased thickness in the rectum is for the purpose of expelling the fæces.

The *submucous coat* has similar relations and structure to the corresponding coat in the small intestine.

The *mucous*, or *internal coat*, is not thrown into valvulæ conniventes, but presents a series of well-marked permanent ridges, lying transversely or somewhat obliquely to the long axis of the gut, and corresponding internally to the constrictions, which, on the outer surface of the colon, separate the sacculi from each other (fig. 195). These ridges are also found in the rectum, though in diminished numbers. Of the rectal folds, three have been especially described by Houston—one, the lowest, is about $1\frac{1}{2}$ inch from the anus; another, the highest, is near the sacral promontory, whilst the third is somewhere intermediate. The transverse folds are formed not only of the mucous and submucous coats, but of the circular layer of the muscular coat. Near the anal orifice the mucous coat is folded longitudinally, and forms the *columnæ recti* of Morgagni. The mucous membrane of the large intestine is covered by a layer of columnar epithelium. It is devoid of villi, and consists of a glandular and a muscular layer. The secreting glands of the glandular layer have the form and structure of the Lieberkühnian glands of the small intestine (fig. 189, 191); they open on the free surface of the mucous coat, and, owing to the absence of villi, their mouths are more closely set together than is the case with the corresponding glands in the small intestine; the tubular glands are separated by a retiform tissue containing lymphoid corpuscles. Solitary glands, similar to those

in the small intestine, are also present; but no Peyer's patches. The muscularis mucosæ resembles generally that of the small intestine.

Of the *blood-vessels* of the large intestine, the arteries are principally derived from the colic branches of the superior mesenteric and the several branches of the inferior mesenteric artery; but the lower end of the rectum receives the middle hæmorrhoidal branches of the internal iliac, and the inferior hæmorrhoidal branches of the pudic. The veins which correspond to these arteries for the most part join the superior and inferior mesenteric veins, and are consequently rootlets of the portal vein. But the veins which belong to the middle and inferior hæmorrhoidal arteries form a plexus about the anal orifice, which partly joins the superior hæmorrhoidal vein, and through it the portal vein, and is partly connected through the middle and inferior hæmorrhoidal veins with the internal iliac vein, and through it with the inferior vena cava. The veins about the anus are very apt to become varicose, and to form the excrescences termed hæmorrhoids or piles. The *lymph vessels* are arranged as in the small intestine, except that they are not prolonged into villi. Nervous plexuses with ganglion cells are found in both the muscular and submucous coats. They proceed from the superior and inferior mesenteric plexuses, but the rectum receives branches from the hypogastric plexus, and from the third and fourth sacral spinal nerves.

The Liver.

The Liver is the biggest of the abdominal viscera, and the largest gland in the body. It is the organ in which the secretion of bile takes place, and is the chief seat in the body of the formation of glycogen, a substance like dextrine, which readily undergoes conversion into sugar. It lies in the costal zone of the abdomen, fills up the greater part of the right hypochondrium, and extends, through the epigastrium, into the left hypochondrium. In its long or transverse diameter it averages about 12 inches, in its antero-posterior diameter about 6 inches, in the vertical diameter of its thickest part about 3 inches. Relatively to the size of the body the liver is bigger and heavier in the fœtus than in the adult; soon after birth the relative weight declines, and that of the left lobe diminishes much more rapidly than the right lobe. Frerichs states that the relative weight of the healthy liver fluctuates in adults between $\frac{1}{24}$th and $\frac{1}{40}$th that of the body, and the absolute weight varies from 1·8 to 4·6 pounds avoird. During the digestion of the food the liver increases both in size and weight, partly from the greater quantity of blood flowing through it, and partly from the new material in the secreting cells; whilst after a long fast it becomes smaller and lighter.

For descriptive purposes the liver may be regarded as having two surfaces, two borders, and two extremities. The *superior* or *diaphragmatic surface* is smooth and convex, and in close contact with the under surface of the vault of the right half of the diaphragm, with its central

tendon, and with a portion of the left half of the muscle, also with the anterior abdominal wall in the upper part of the epigastrium. It is attached to the diaphragm and epigastric wall of the abdomen by a fold of the peritoneum, called the *falciform* or *suspensory ligament*, which extends along the upper surface from the anterior to the posterior border of the liver, and marks the division into a large right and a small left lobe. From the close relation of this surface of the liver to the diaphragm it follows the movements of that muscle, being depressed during inspiration, elevated during expiration. The highest part of the surface of the liver lies at the end of an expiration opposite the 4th right intercostal space, a little to the inner side of the right nipple, from which spot it rapidly slopes downwards to the right about as low as the 11th right rib, whilst it inclines much more gradually to the left almost on a line with the junction of the ensiform cartilage with the meso-sternum. The 5th, 6th, 7th, 8th, 9th, and 10th ribs, separated by the diaphragm, arch superficially to its right lobe, whilst the left lobe is arched over by the cartilages of the 6th, 7th, and 8th ribs. The summit of the right lobe is in relation, the diaphragm intervening, with the base of the right lung; that of the left lobe with the heart, pericardium, and a portion of the base of the left lung. The upper surface of the liver is sometimes marked by furrows extending in the antero-posterior direction, which, when the organ is *in situ*, are occupied by folds of the diaphragm. These depressions have usually been ascribed to tight lacing, the pressure of the stays being supposed to have forced the ribs and diaphragm into the liver. But as I have seen these furrows almost as fre-

quently in men as in women, I regard them, and the coincident depression of the ribs, as congenital, and not as artificially produced.

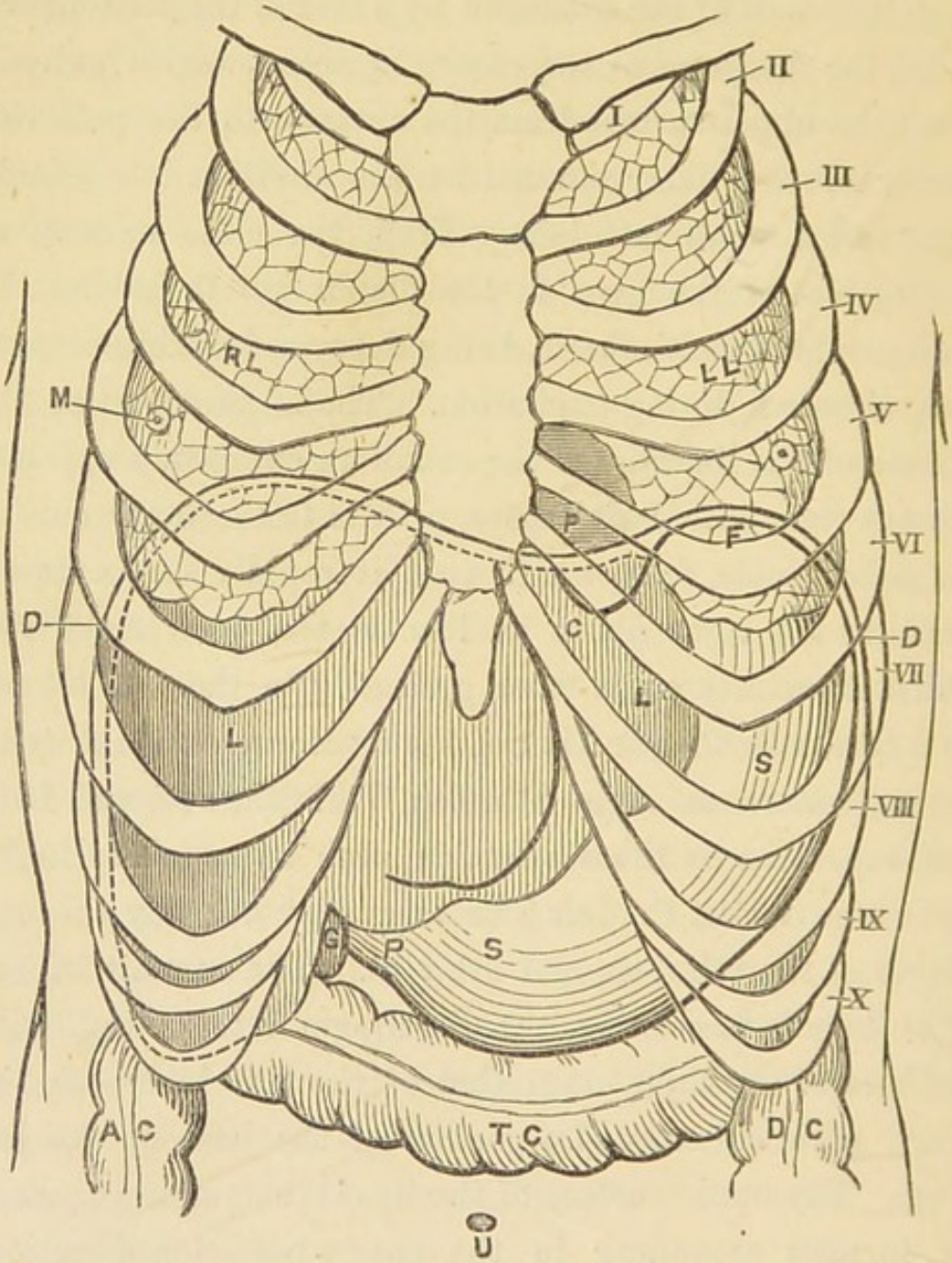

FIG. 196.—The Lungs and their relations to the Diaphragm, Liver, and Stomach. II, to X, second to tenth ribs; DD, diaphragm; RL, right, and LL, left lung; P, pericardium; S,S, stomach; F is placed superficial to its fundus; P, its pylorus; C is over the cardiac orifice; L,L, the liver; G, gall bladder; AC, ascending, TC, transverse, and DC, descending colon; U, umbilicus; M, right nipple. Modified from Luschka.

The *posterior* or *vertebral border* of the liver is thick, and rounded at its right extremity, but comparatively thin at

the left. It is attached by areolar tissue to the diaphragm, and a fold of peritoneum called the *coronary ligament*, passes from it to the under surface of that muscle. The coronary ligament expands at its extremities into the *right* and *left lateral ligaments*, and becomes continuous with the posterior border of the falciform ligament opposite a slight depression which marks the separation of the right from the left lobe of the liver. The posterior border is notched for the lodgment of the inferior vena cava.

The *anterior border* of the liver is unattached, thin, and attenuated, and is marked by a deep notch, opposite the anterior edge of the falciform ligament, which lodges the *round ligament* of the liver. This notch marks the separation of the right from the left lobe. To the right of this round ligament is a shallow notch in the anterior border, at which the fundus of the gall bladder may be usually seen to project; at this spot the liver overlaps the ascending part of the duodenum.

Of the two *extremities* of the liver the *right* is thick and massive, and lies deep in the right hypochondrium, in contact with the diaphragm; the *left* is thin and attenuated, and overlaps the œsophageal opening and fundus of the stomach.

The *inferior* or *visceral surface* of the liver is much more complex in form than the upper.

The *longitudinal* or *umbilical fissure*, continuous with the notch in the anterior border of the liver, and much nearer to the left than the right extremity of the gland, divides it into a large right and a small left lobe. In the anterior part of the fissure the *round ligament* formed by the obliteration of the *umbilical vein* of the fœtus is lodged;

whilst the posterior part contains a slender fibrous cord formed by the obliteration of a vein of the fœtus, named *ductus venosus.* The longitudinal fissure is often bridged across by a band of liver substance called *pons hepatis.* The under surface of the left lobe is smooth, and overlaps the anterior surface of the stomach. The under surface of

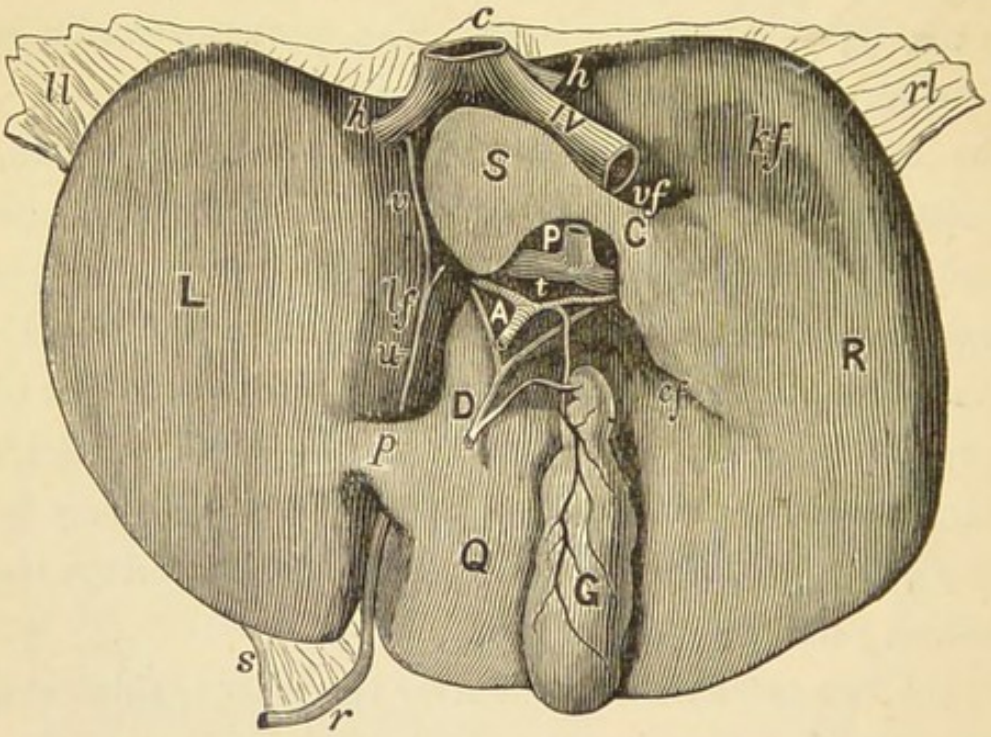

FIG. 197.—Under surface of the Liver. R, right, L, left lobe; Q, lobus quadratus; S, lobus Spigelii; C, lobus caudatus; *p*, pons hepatis; *lf*, longitudinal fissure; *t*, transverse fissure; *cf*, caudate fissure; *vf*, fossa for vena cava; *kf*, fossa for right kidney; G, gall bladder in its fossa; *u*, obliterated umbilical vein; *v*, obliterated ductus venosus; IV, inferior vena cava; *h*, *h*, hepatic veins; *p*, portal vein; A, hepatic artery; D, bile duct; *c*, coronary ligament; *ll* and *rl*, left and right lateral ligaments; S, suspensory ligament; *r*, round ligament.

the right lobe is divided into smaller lobes by fissures and fossæ. Starting from about the middle of the longitudinal fissure is the *portal* or *transverse fissure,* which extends for from three to four inches across the under surface of the right lobe. It is the gate (*porta*) of the liver, the *hilus* or fissure of entrance into the organ of the portal vein,

hepatic artery, hepatic duct, hepatic nerves, and lymphatics. A short distance to the right of that part of the longitudinal fissure in which the round ligament lies, is the *fossa for the gall bladder*, which is a depression on the under surface of the right lobe extending from the anterior border to the transverse fissure : in it the gall bladder lies. Extending somewhat obliquely from the posterior border of the liver, towards the transverse fissure, is a deep *fossa for the inferior vena cava*, which lodges this great vein before it pierces the diaphragm. Sometimes the vena cava is bridged across by a prolongation of the liver substance. Opening into the vena cava as it lies in this fossa are the trunks of the large hepatic veins from the substance of the liver. A portion of liver substance, which is bounded by the gall bladder, the longitudinal fissure, the transverse fissure, and the anterior border, forms a four-sided lobe called *lobus quadratus*. Another portion, bounded by the transverse fissure, the posterior border, the vena cava, and the longitudinal fissure, is the *lobus Spigelii*. A thin prolongation of liver substance continuous with the lobus Spigelii, and running obliquely between the fossa for the inferior cava and the transverse fissure, is the *lobus caudatus*. The lobus caudatus is rudimentary in the human liver, but, as W. H. Flower has pointed out, attains a considerable magnitude in many mammals. He has named the fissure, which separates it from the adjacent part of the right lobe, the *fissure of the caudate lobe*. To the right of the fossæ for the gall bladder and inferior cava are two shallow depressions on the under surface of the right lobe; the more anterior marks the position of the hepatic flexure of the colon, the more posterior, the upper end of the right

kidney and supra-renal capsule. As the liver is a solid organ, the sound which is elicited by percussing the wall of the abdomen superficial to it is a dull sound. But as the liver has three resonant structures in relation to it, viz., the lung above, and the hepatic flexure of the colon and the stomach below, the dull sound is necessarily modified in the regions occupied by those organs. As the heart is in relation to a portion of the upper surface of the liver, the line of demarcation in that locality between the two organs is with difficulty discriminated by percussion.

Structure of the Liver.

The liver is a solid organ, of a brownish-red colour. It is composed of the ramifications of the portal vein, of the portal capillaries, the hepatic vein, the hepatic artery, the hepatic duct, of secreting cells, nerves, and lymphatics. These several structures are bound together by connective tissue, and the organ is invested by the peritoneum. The liver possesses two coats, a serous and a fibrous.

The *serous* or *external coat* is a part of the peritoneal membrane, and forms an almost complete investment for the liver. Where the gall bladder and inferior cava lie in contact with the under surface it is prolonged over those bodies; it is reflected from the transverse fissure as the gastro-hepatic omentum, and from the upper surface and the posterior border as the falciform, coronary, and right and left lateral ligaments.

The *fibrous coat*, or *tunica propria*, is immediately subjacent to the serous coat, and is so closely adherent to it as

to be separated from it with difficulty; but along the lines of reflection of the ligaments from the liver, at the transverse fissure, and at the fossæ for the gall bladder and inferior cava, it can be readily recognised as a definite fibrous membrane. When carefully raised from the liver delicate processes of areolar tissue may be seen to pass from its deep surface into the substance of the organ. At the transverse fissure it is prolonged into the liver as a very distinct sheath, enveloping the portal vein, hepatic artery, hepatic duct, nerves, and lymphatics. This sheath is named the *capsule of Glisson*, and is prolonged throughout the substance of the organ, along the ramifications of the portal vein, and the structures that accompany it.

Lobules of the Liver.—To the naked eye the substance of the liver does not present a homogeneous aspect, but is mottled, and mapped out into multitudes of small areas or lobules,—the *hepatic lobules* or *leaflets*. The lobules of the liver are irregular polygons, and vary in size from $\frac{1}{20}$th to $\frac{3}{20}$th of an inch. In man and the mammalia generally, the lobules are imperfectly separated from each other by the interlobular vessels and duct, and a scarcely appreciable quantity of areolar connective tissue. In the pig, as is well known, each lobule is circum-

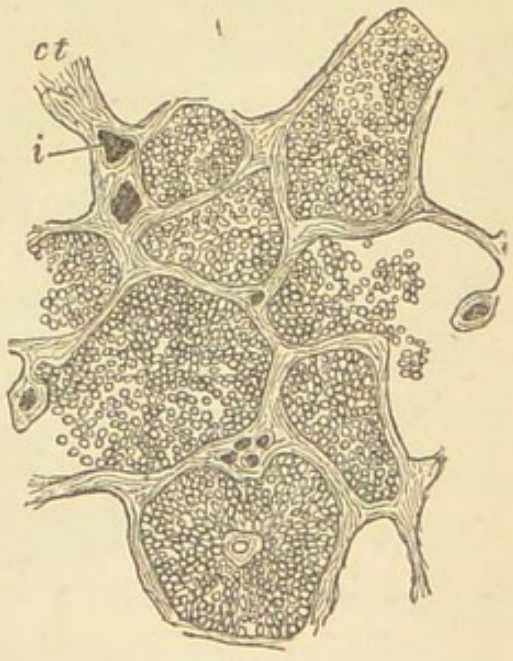

FIG. 198.—Section through the liver of a Camel, to show the lobules. *ct*, capsule of connective tissue; *i*, divided interlobular vein. × 10.

scribed by a definite capsule of connective tissue, and the capsules of adjacent lobules blend with each other. In the camel the observations of Goodsir showed that the capsules of connective tissue were thicker and more distinct than in the pig. In the polar bear, Johannes Müller has described the lobules as distinct and easily separable from each other; and Hyrtl has observed a similar appearance in the liver of the South American rodent, *Octodon Cumingii*. The capsule of connective tissue is continuous with Glisson's capsule, which invests the interlobular vessels, and, in the case of the lobules lying next the surface of the liver,

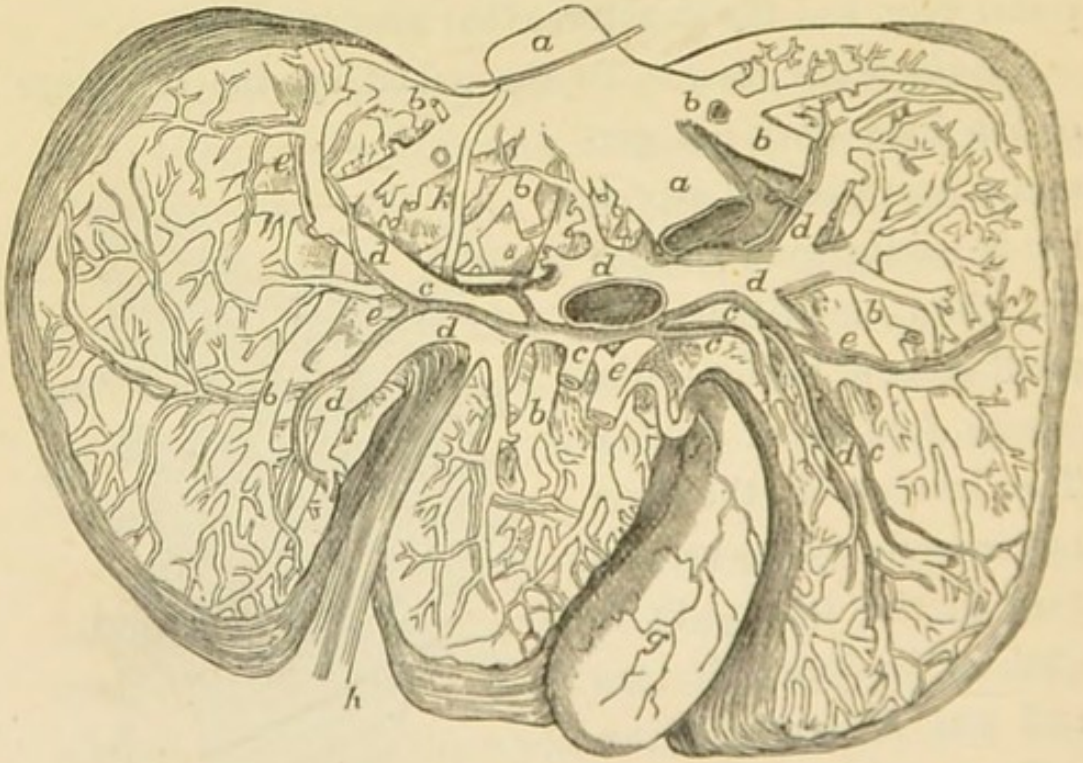

FIG. 199.—The under surface of the Liver, dissected to show the ramifications of the vessels in its substance. *a*, inferior vena cava; *bb*, hepatic veins; *c*, *c*, hepatic artery; *dd*, portal vein; *e*, *e*, hepatic duct; *g*, gall bladder; *h*, round ligament.

with the delicate processes of the fibrous coat which pass into the substance of the organ.

As a lobule of the liver is a liver in miniature, and as the structure of the entire liver is the sum of the structure of its constituent lobules, it will be necessary to examine with care the constituent parts of a lobule, and the arrangement of the vessels, duct, and nerves which pass to and from it. A hepatic lobule is composed of blood-vessels, secreting cells, and bile ducts, with perhaps nerves and lymphatics. The blood-vessels will first be considered. The liver receives its supply of blood through two vessels, the portal vein and hepatic artery, and the blood brought by both these vessels leaves the liver through the large hepatic vein.

The *portal vein* conveys to the liver the venous blood from the stomach, spleen, pancreas, gall bladder, and small and large intestine. It ascends to the transverse fissure, and before it enters the liver divides into two branches, one for the right and one for the left lobe. In its course, within the liver, the portal vein divides and subdivides after the manner of an artery. It is closely accompanied by the hepatic artery and duct, and, along with them, is invested by the fibrous sheath, called Glisson's capsule. The terminal branches of the portal vein run between the lobules, and are named, from their position, the *interlobular* branches. The interlobular branches lie around the circumference of a lobule, and anastomose with each other. They partly terminate directly in a capillary network situated within the lobule, and partly give off fine branches, which enter the lobule before they end in the capillary network. The *intralobular capillaries* form a close network, which converges from the periphery of the lobule, where they spring from the interlobular

branches of the portal vein, to the centre of the lobule, where they terminate in the *intralobular* or *central vein*, one of the rootlets of the hepatic vein. In man, where the lobules are not separated from each other by a distinct capsule, the capillaries of one lobule to some extent communicate with those of adjacent lobules.

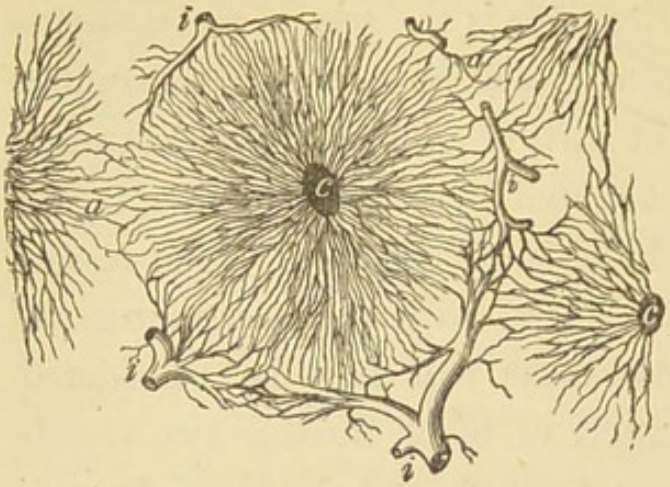

FIG. 200.—Transverse section through the hepatic Lobules. *i*, *i*, *i*, interlobular veins ending in the intralobular capillaries. *c*, *c*, central veins joined by the intralobular capillaries. At *a*, *a*, the capillaries of one lobule communicate with those adjacent to it. From an injection by T. A. Carter.

The *hepatic artery*, a branch of the cœliac axis, closely accompanies, as already stated, the portal vein, and divides into two branches, for the right and left lobes. It enters the transverse fissure and ramifies, along with the portal vein, through the substance of the liver. It is the nutrient artery of the liver, and gives off three series of branches: *a*, *vaginal branches*, which are distributed to the walls of the portal vein, the hepatic duct, and to Glisson's capsule, probably also to the wall of the hepatic vein. They end in a capillary network in these structures, from which *vaginal veins* arise that terminate in the portal vein. *b*, *capsular branches*, which are distributed to the fibrous coat of the liver and end in a capillary network, from which arise *capsular veins* that join the portal vein. The capsular branches anastomose with the diaphragmatic arteries, in the areolar tissue which attaches the posterior border of the liver to the diaphragm, and sundry offshoots which pass

between the layers of the suspensory ligament, anastomose with the epigastric branch of the internal mammary artery. *c, interlobular branches* of the hepatic artery lie along with the interlobular branches of the portal vein, and end in the capillary network within the lobules.

The *hepatic vein* arises within the substance of the liver from the intra-lobular capillaries. In the centre of each lobule is the *intra-lobular* or *central vein.* It traverses the axis of the lobule, and leaves it to join a small vein running immediately under the bases of adjacent lobules, which, from its position, is named the *sub-lobular vein.* Adjacent sub-lobular veins then join together, and form larger vessels which are the *trunks* of the *hepatic vein*, or the *hepatic venous canals.* These trunks run towards the posterior border of the liver, and open into the inferior vena cava. The sub-lobular veins and hepatic venous trunks differ from the branches of the portal vein in the following particulars:—They are not accompanied by other vessels; they are not invested by Glisson's capsule, and are more or less closely adherent to the surrounding lobules; they gape, and do not collapse when the liver is cut through; their coats are so thin that

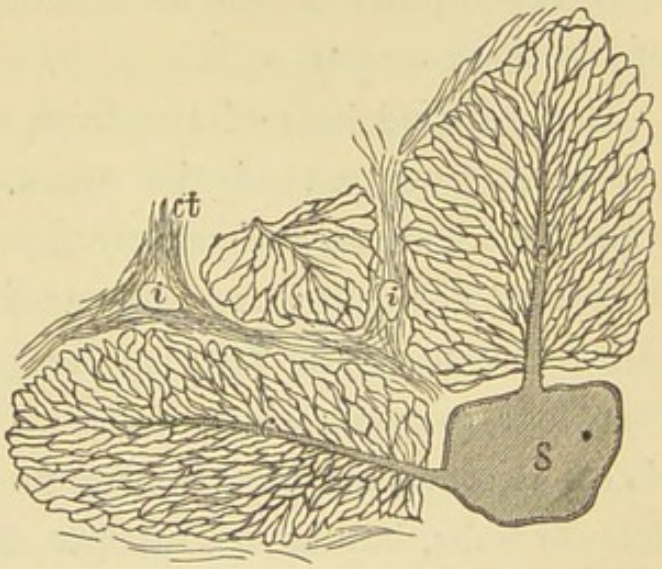

FIG. 201.—Vertical section through two hepatic Lobules of a pig. *c, c,* central veins receiving the intra-lobular capillaries. *s,* sub-lobular vein. *ct,* interlobular connective tissue forming the capsules of the lobules; *i, i,* interlobular veins. From an injection by T. A. Carter.

the lobules can be seen through them; they have no relation to the transverse fissure.

From this description of the vascular arrangements within the liver, it will be seen that the intra-lobular capillaries are continuous with three vascular trunks, two which carry blood to them, the portal vein and the hepatic artery; one which conveys the blood away from them, the hepatic vein. The communication in each case is so free that the capillaries can be artificially injected from any one of these vessels.

The *secreting cells* of the liver, *hepatic cells*, form the proper parenchyma of the organ. They are situated within the lobules, and occupy the spaces of the capillary network. The cells vary in diameter from $\frac{1}{840}$th to $\frac{1}{1030}$th inch; they have the form of irregular polyhedrons, with from four to seven sides, and with the angles sometimes sharp, at others rounded. They do not appear to possess definite walls, but have a distinct nucleus. The cell protoplasm is granular, and usually contains fat drops and yellow particles, apparently bile pigment. Colourless granules, believed to be glycogenic, are also infiltrated through the protoplasm. Amœboid movements have been observed to take place in these cells, when isolated from each other. W. Krause states that fusiform cells sometimes lie between the polyhedral cells. The general arrange-



FIG. 202.—Transverse section through Lobules of human liver to show the columns of secreting cells. *c,c*, central veins; *i*, interlobular vein with a fine sheath of connective tissue. × 10.

ment of the cells is in rows or columns, and when sections are made through a lobule, transverse to the long axis of the central vein, the columns of cells are seen to converge from the periphery to the centre of the lobule, and to form a network.

By many observers the cells are regarded as in contact with the intra-lobular capillaries, without the intervention of an intermediate membrane.

By others, and more especially by Lionel Beale, the secreting cells are regarded as enclosed in a tubular network, the wall of which is formed by a basement membrane. Beale states that the diameter of the network is usually about $\frac{1}{1000}$th of an inch in most mammals. According to this view, the cells are not in direct contact with the capillary blood-vessels, but separated from them by the basement membrane. In some parts of the lobule Beale has been able to demonstrate the basement membrane as distinct from the wall of the capillaries, but usually they are incorporated together. At the periphery of the lobule the membrane becomes continuous with the wall of the interlobular duct. I have seen in the liver of the camel delicate bars of connective tissue, prolonged from the capsule of the lobule between the columns of secreting cells, so as to form a sustentacular tissue quite distinct from the network of blood capillaries.



FIG. 203.—Portion of the lobule of a camel's liver. *ct*, capsular connective tissue; *ct'*, intralobular prolongations of the capsule between the columns of cells. × 300.

The *hepatic*, or *bile duct*, is the tube that conveys the bile out of the liver. It leaves the transverse fissure as two branches, one from the right, another from the left lobe, which almost immediately unite at an acute angle. As already stated, it closely accompanies within the liver the ramifications of the portal vein and hepatic artery, and its terminal branches pass between the lobules to form the *interlobular branches* of the duct. If the hepatic duct be injected, not only does the injection fill the interlobular ducts, but it flows into a set of excessively minute passages within the lobules themselves. These passages are arranged so as to form a polygonal network, which may appropriately be called the *intralobular biliary network*. This network has a most intimate relation to the polyhedral hepatic cells, for the passages lie between the flattened sides of adjacent cells, so that each cell is enclosed in a mesh of the network.

The German observers, who first directed attention to these passages, named them *bile-capillaries*, and Macgillavry, Frey, and Eberth supposed that they possessed an independent wall, distinct from the hepatic cells between which they are situated. But it is doubtful if such a wall exists, and it seems much more probable that they are merely intercellular passages bounded by the protoplasm of the hepatic cells.

The intra-lobular biliary network differs from the intra-lobular blood capillary network, not only in the character of the fluid conveyed, but in other important particulars. The bile passages have a transverse diameter of about $\frac{1}{10}$th that of the blood capillaries: the passages are in relation to the sides of the cells, the blood capillaries to

their angles, so that the two systems of networks are not in contact with each other, but are separatedby intervening hepatic cell substance; the passages have not, in all probability, an independent wall, such as is possessed by the blood capillaries.

As these passages can be injected from the hepatic duct, and as they convey bile from the interior of the lobule into the duct, it is obvious that they must be continuous with the lumen of the interlobular branches of the duct, at the periphery of the lobules. The wall of an interlobular duct consists of a membrana propria, lined by columnar epithelium. From this duct fine branches enter the periphery of the lobule, and the epithelial lining abuts on and assumes the character of the rows of hepatic cells, whilst the intercellular passages of the biliary network become continuous with the lumen of the duct.

The wall of the larger bile ducts is formed of a fibro-elastic tissue, with a proportion of non-striped muscular fibre: it is lined by a columnar epithelium. Opening into the larger ducts are numerous orifices, which communicate with branched cœcal tubes and follicles, situated within and clustered around the walls of the larger ducts, often in considerable numbers. Some of these appendages to the duct doubtless serve as glands for the secretion of mucus, but others are probably, as Beale supposed, mere diverticula of the duct, in which the bile may be temporarily retained, as in the gall bladder.

The hepatic duct also gives origin to some *aberrant ducts*, which were described by Kiernan and Henle as passing into the left lateral ligament of the liver, and into the fibrous bands, which sometimes bridge over the

fossa for the vena cava and the fissure for the umbilical vein. They anastomose freely with each other in these localities, and have blind terminations; they are not surrounded by hepatic lobules. They are lined by columnar epithelium.

The *lymphatics* of the liver form a superficial and a deep set. The superficial set ramifies beneath the serous coat, where it forms a network. Each capsular branch of the hepatic artery is, according to T. A. Carter, accompanied by a pair of lymphatics, which are connected together at intervals by short transverse branches, so that the artery is more or less ensheathed by lymphatics. The deep lymphatics accompany the portal vein and hepatic artery as far as the intervals between the lobules, where they form *interlobular lymphatics*, which, like the corresponding branches of the portal vein, run around the lobule. Carter has traced into the lobule towards its centre minute branches of the interlobular lymphatics; Macgillavry considers that the intra-lobular capillaries are surrounded by lymph spaces; A. Budge has injected lymph-vessels in the wall of the central vein of the hepatic lobules, and Kölliker has observed lymphatics surrounding the hepatic vein. Kisselew has described lymph-follicles in relation to the interlobular lymphatics of the pig.

The *nerves* of the liver arise from the cœliac plexus of the sympathetic and from the left pneumogastric. They accompany the portal vessels in their distribution, and supply the muscular coats of the vessels. According to Pflüger, nerves may be traced to the secreting cells within the lobules.

The *obliterated umbilical vein*, to which reference has

been made in the description of the round ligament of the liver, is an important vessel in the fœtus. It conveys the blood from the placenta, enters the abdominal cavity at the umbilicus, and ascends to the longitudinal fissure on the under surface of the liver. Here it divides into three branches; one joins the portal vein, and conveys the blood through that vessel into the intra-lobular capillaries and hepatic vein; another enters the liver, and divides into branches, which terminate in the intra-lobular capillaries; the third continues in the longitudinal fissure under the name of *ductus venosus*, and joins directly the inferior vena cava. The blood of the umbilical vein ultimately reaches, therefore, the inferior cava, either directly or by passing through the hepatic circulation. When the umbilical cord is tied after the birth of the child, the connection with the placenta is severed, and the umbilical vein and ductus venosus shrivel up into fibrous cords.

The GALL BLADDER is a reservoir for the bile, situated in a fossa on the under surface of the right lobe of the liver, and in a notch in its anterior border (fig. 197). It is pyriform in shape, its larger end, or fundus, projects beyond the anterior border; its opposite end, or neck, gives origin to the *cystic duct*, which is directed towards the transverse fissure; after a course of $1\frac{1}{2}$ inch, it joins the hepatic duct, and forms the common bile duct, *ductus communis choledochus*. At its neck, the gall bladder bends on itself in a sigmoid curve. The gall bladder is three or four inches long, and can hold from one to two oz. of bile. It is attached to the liver partly by areolar tissue, and partly by the peritoneum, which is reflected over its free surface.

Structure.—In addition to its partial *serous coat*, the gall bladder has a fibrous and mucous coat. The *fibrous coat* consists of interlacing bands of connective tissue, with which non-striped muscular fibres are sparingly intermingled. The *mucous membrane* lining the gall bladder is deeply bile-stained, and presents on its free surface an alveolar appearance, due to the presence of multitudes of minute folds, which form a reticulum with intermediate depressions. This surface is covered by columnar epithelium. The mucous lining of both the neck of the gall-bladder and cystic duct is thrown into folds, which in the duct have an oblique direction, and form the spiral valve. Racemose glands, for the secretion of mucus, occur in the wall of the gall bladder, cystic duct, and common bile duct. The gall bladder is supplied with blood by the cystic branch of the hepatic artery. It receives lymphatics and nerves continuous with those which belong to the liver.

The *Common Bile Duct*, formed by the junction of the cystic and hepatic ducts, is about 3 inches long, and conveys the bile into the duodenum. It lies in the gastro-hepatic omentum between its two layers, having the hepatic artery to its left, and the portal vein behind it. It then inclines behind the duodenum to the inner side of its descending part, where it comes into relation with the pancreatic duct. The two ducts then run together in an oblique direction through the wall of the duodenum, and open on the summit of a papilla, by a common orifice, about the junction of the descending and transverse portions of the duodenum.

The Pancreas.

The Pancreas is an elongated gland which lies in relation to the posterior wall of the abdomen, in front of the first lumbar vertebra, and extends obliquely from the right lumbar region through the epigastrium into the left hypochondriac region. It is from 6 to 8 inches long, and whilst its dilated right extremity, or *head*, occupies the horse-shoe curve of the duodenum, and is attached by areolar tissue to the descending and transverse portions, its attenuated left extremity, or *tail*, is in relation to the spleen. Anterior to the pancreas is the pyloric end of the stomach and a portion of the posterior surface of that organ, but between the stomach and pancreas is the lesser cavity of the peritoneum, and the anterior surface of the pancreas is covered by the layer of peritoneum, which forms the posterior boundary of that cavity. It is attached behind by areolar tissue to the crura of the diaphragm, the splenic and superior mesenteric vessels, the portal vein, the aorta, inferior vena cava, left kidney, and supra-renal capsule. A prolongation of the gland, named the *accessory* or *lesser pancreas*, usually surrounds the superior mesenteric artery at its origin.

Structure.—The pancreas is one of the compound racemose glands, and resembles generally in structure the mucous and salivary glands of the mouth and the glands of Brunner (fig. 191). It is sometimes called the abdominal salivary gland, and its secretion flows into the duodenum, and assists in the process of chylification. It has a yellowish creamy colour, and is divided

into distinct lobules by septa of connective tissue. The excretory duct, or *duct of Wirsung*, is completely surrounded by the lobules, and extends from the tail to the head of the gland, receiving in its passage the numerous secondary ducts, and increasing gradually in size. It leaves the head of the gland, comes into relation with the common bile duct, and with it pierces obliquely the posterior wall of the descending part of the duodenum, to open by a common orifice about the junction of the descending and transverse portions. Sometimes the duct from the accessory part of the pancreas opens independently into the duodenum, a little above the common hepatico-pancreatic orifice. The finest ducts within the gland terminate in the *acini*, or *gland vesicles* of the lobules. These acini contain the secreting cells, which have a somewhat cubical form. Minute channels or intercellular passages have been described by Saviotti, between the secreting cells, similar to those already referred to in the acini of the salivary glands. The ducts are lined by a columnar epithelium, and mucous glands are situated in the mucous membrane lining the duct of Wirsung. The pancreas receives its supply of blood from the pancreatic branches of the splenic artery, the inferior pancreatico-duodenal of the superior mesenteric, and the superior pancreatico-duodenal of the gastro-duodenal of the hepatic. Its veins join the splenic and superior mesenteric veins, and through them contribute to the formation of the portal vein. Its blood capillaries are abundantly distributed on the walls of the gland vesicles. Lymph vessels are found in the connective tissue between the lobules. The nerves are derived from the solar

plexus, and accompany the arteries; they are believed by Pflüger to have a similar mode of termination to that described by him in the salivary glands (p. 658).

The Teeth.

The Teeth are calcified organs developed in connection with the mucous membrane of the mouth. Their primary use is that of biting and grinding the food; but in man they serve as aids to speech, and in many animals act as instruments of offence and defence.

Arrangement and Form of the Teeth.

Teeth are present in the greater number of the mammalia, in which class they are implanted in sockets in the alveolar arches of the bones of the upper and lower jaws, and form only a single row in each arch. In a few mammals, as the toothed whales and the sloths, only one generation of teeth is produced, and when these drop out, they are not replaced by successors; these animals are called Monophyodont. In the majority of the mammalia, however, there are two generations of teeth; a temporary or milk set, which are deciduous, and are replaced by a permanent or adult set; these animals are called Diphyodont. But in speaking of two generations of teeth it is not to be supposed that all the teeth in the adult jaw have had temporary predecessors, for the molar or back teeth have only a single generation. A few mammals, as the toothed whales, have the teeth uniform in size, shape, and structure, and are named Homodont;

but, in the majority of the mammalia, the teeth in the same jaw vary in size, form, and structure, and are therefore called Heterodont. In every Heterodont mammal, possessing a complete dentition, four groups of teeth are found, which are named incisor, canine, premolar, and molar teeth. Each of these teeth possesses a *crown*, which projects into the cavity of the mouth, and a *fang* lodged in the socket in the jaw; at the junction of the crown and fang there is usually a constriction named the *neck* of the tooth.

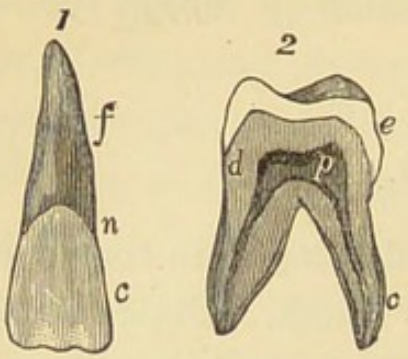

FIG. 204.—1, A human upper incisor Tooth. *c*, the crown; *n*, neck; *f*, the fang. 2, a section through a molar tooth; *e*, cap of enamel; *c*, cement; *d*, dentine; *p*, pulp cavity.

In Man the dentition is Diphyodont and Heterodont. The single row of teeth in each alveolar arch of the human jaw is characterised by the crowns of the teeth being of almost equal length, and by the absence of any great interspace, or *diastema*, between the different teeth, or of irregularities in the size of the interspaces, so that the teeth form an unbroken series in each jaw. The span of the upper dental arch is slightly bigger than that of the lower, so that the lower incisors fit within the upper, and the lower molars, being inclined obliquely upwards and inwards, are somewhat overlapped by the upper molars. The upper and lower dental arches terminate behind in line with each other, and the teeth are equal in number in the two jaws.

Man possesses 32 teeth in his permanent dentition, arranged in four groups, viz.—8 incisors, 4 canines, 8

premolars or bicuspids, and 12 molars. The number and arrangement of the teeth in the two jaws is expressed in the following formula :—

Formula of Permanent Dentition.

$$\frac{\begin{matrix}\text{m.} & \text{pm.} & \text{c.} & \text{in.}\\ 3 & 2 & 1 & 2\end{matrix}}{\begin{matrix}3 & 2 & 1 & 2\end{matrix}} \Bigg| \frac{\begin{matrix}\text{in.} & \text{c.} & \text{pm.} & \text{m.}\\ 2 & 1 & 2 & 3\end{matrix}}{\begin{matrix}2 & 1 & 2 & 3\end{matrix}} = 32.$$

Man possesses only 20 teeth in his milk or temporary dentition, and their arrangement is expressed in the following formula :—

Formula of Temporary Dentition.

$$\frac{\begin{matrix}\text{m.} & \text{c.} & \text{in.}\\ 2 & 1 & 2\end{matrix}}{\begin{matrix}2 & 1 & 2\end{matrix}} \Bigg| \frac{\begin{matrix}\text{in.} & \text{c.} & \text{m.}\\ 2 & 1 & 2\end{matrix}}{\begin{matrix}2 & 1 & 2\end{matrix}} = 20.$$

If the temporary and permanent formulæ be compared with each other, it will be seen that, while the incisors and canine teeth correspond in numbers in both dentitions, in the temporary dentition there is an absence of premolars, and the molar teeth are only 8, instead of 12 in number.

The characters of the permanent teeth will now be considered.

The *Incisor Teeth*, eight in number, are lodged in the front of the jaws, two on each side of the mesial plane. The upper incisors project downwards and forwards, the lower are directed almost vertically upwards. The oblique direction of the upper incisors in the Negroes, Caffres,

and Australians adds to the prognathic form of the face possessed by these races. The central pair of upper incisors are larger than the lateral: whilst the lateral pair of lower incisors are larger than the central pair, which are the smallest incisor teeth. The crowns of the incisor teeth are chisel-shaped, and adapted for biting and cutting the food; the anterior or labial surface is convex, the posterior, palatal, or lingual surface is concave. When the crown is first erupted the cutting edge is minutely serrated, but the serrations soon wear down by use. The fangs are long and single; being in the upper incisors round and fusiform, in the lower laterally compressed, and sometimes marked by a longitudinal groove. Although the human incisors are, as the name implies, cutting, chisel-shaped teeth, in many mammals the incisors are greatly modified in form, as for example in the tusks of the elephant. The determination of the incisor teeth does not depend, therefore, on their form, but on their position in the jaws. The name incisor is given to the teeth situated in the pre-maxillary portion of the upper jaw, and in the anterior end of the lower jaw, whatever their shape may be.

The *Canine* or *Unicuspid Teeth*, four in number, one on each side of the mesial plane of each jaw, are placed next the lateral incisors. They are bigger than the incisor teeth, and the upper canines, which are sometimes called the eye-teeth, are larger than the lower; the fangs of the upper canines are lodged in deep sockets in the superior maxillæ, which extend towards the floor of each orbit. The crowns of these teeth are thick and conical, convex on the labial surface, concave on the lingual; the fangs

are long, single, conical, compressed on the sides where they are marked by a shallow groove. In many mammals these teeth are developed into large projecting tusks.

The *Premolar* or *Bicuspid Teeth*, eight in number, two on each side of the mesial plane of each jaw, lie immediately behind the canines, and the upper bicuspids are somewhat larger than the lower. The crown is quadrilateral in form, and convex both on the inner and outer surfaces. It possesses two cusps, of which the outer or labial is larger and more projecting than the inner, palatal, or lingual cusp. The fangs of the upper bicuspids are single and laterally compressed; often bifid at the point into an outer and an inner segment; in the lower bicuspids the fangs are rounded, and taper to a single point.

The *Molar* or *Multicuspid Teeth*, twelve in number, are placed three on each side of the mesial plane of each jaw. They are the most posterior teeth, are the largest of the series, and as a rule decrease in size from the first to the last; the crowns of the lower molars are somewhat bigger than those of the upper molars. The last molar tooth does not erupt until the end of puberty, and is called *dens sapientiæ* or *Wisdom Tooth*. The crowns are broad, quadrilateral, and convex both on the inner and outer surfaces. The first and second upper molars have four cusps projecting from the angles of the grinding or masticating surface, and an oblique ridge often connects the large anterior internal cusp with the posterior external cusp; in the upper wisdom teeth, the two inner or palatal cusps are frequently conjoined. The first lower molar has five cusps, the fifth being interposed between the

two posterior cusps; in the second lower molar the fifth cusp is usually absent, or only rudimentary in size, but in the lower wisdom tooth it is often present. The fangs of the first and second upper molars are three in number, and divergent; two on the outer or buccal side, one on the inner or palatal side; in the upper wisdom the fangs are frequently partially conjoined, though trifid at the point. The fangs of the first and second lower molars are two in number, an anterior and a posterior, of which the anterior is the larger; they usually curve backwards in the jaw: in the lower wisdom the fangs are usually conjoined, but bifid at the point.

The crowns of all the teeth become more or less flattened by use, so that the incisors lose their sharp cutting edge, and the cusps of the premolars and molars are worn away.

The temporary or milk teeth are smaller than the permanent teeth. They are more constricted at the neck, where the crown joins the fang, especially in the milk molars, the fangs of which also diverge more widely than in the permanent set. The second temporary molar is bigger than the first. The crown of the first upper molar has three cusps, two buccal, one palatal: that of the second four cusps. The crown of the first lower molar has four cusps; that of the second five, three of which are buccal, two lingual. The temporary teeth lie more vertically in the jaws than the permanent.

The alveolus, or socket for the lodgment of the single fanged teeth, is a single socket; in the multi-fanged teeth, the socket is divided into two or three compartments, according to the number of fangs. The socket is lined by the

alveolo-dental periosteum, which is continuous at the mouth of the socket with the periosteal covering of the jaw and with the deeper fibrous tissue of the gum, where it embraces the neck of the tooth. At the bottom of the socket the alveolo-dental periosteum may be seen to have the character of a distinct layer of retiform connective tissue, on the one hand connected with the surface of the cement, on the other with the more fibrous periosteum lining the bony wall of the socket (fig. 207). Higher up the socket, the retiform character of the periosteal connective tissue gradually disappears, but nearer the mouth of the socket it reappears, and the stellate cells form a continuous network with similar cells in the deeper fibrous part of the gum. The alveolo-dental periosteum is vascular, its vessels being continuous with those of the gum, the pulp-vessels, and the bone. It receives nerves from those going to the pulp. The fang fits accurately in the socket, and through a hole at the tip of the fang the blood-vessels and nerves of the tooth pass into the pulp-cavity of the tooth.

Structure of the Teeth.

Each tooth is composed of the following hard structures —dentine, enamel, and cement, or crusta petrosa; occasionally other substances, named osteo-dentine or vaso-dentine, are present. In a tooth which has been macerated, an empty space exists in its interior, called the pulp-cavity, which opens externally through the hole at the tip of the fang; but in a living tooth this cavity contains a soft, sensitive substance named the pulp.

The *Dentine* or *Ivory* makes up the greater part of each

tooth ; it is situated both in the crown, where it is covered by the enamel, and in the fang, where it is invested by the crusta petrosa ; whilst the pulp cavity in the centre of the tooth is a cavity in the dentine. The dentine is composed of an intimate admixture of earthy and animal matter in the proportion of 28 of the animal to 72 of the earthy. The animal matter is resolved on boiling into gelatine ; the earthy matter consists mostly of salts of lime.

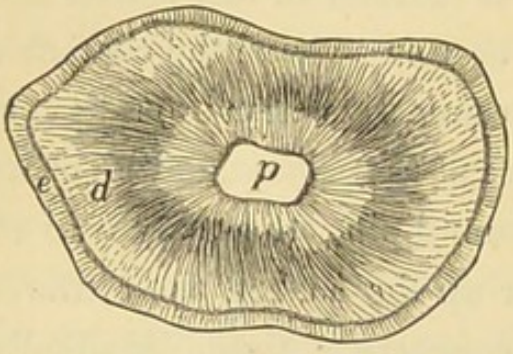

FIG. 205.—Transverse section through the crown of a tooth. *p*, pulp cavity; *d*, dentine; *e*, enamel. × 6.

If thin slices through the dentine of a macerated tooth be examined microscopically, it will be seen to consist of a hard, dense, yellowish white, translucent *matrix*, penetrated by minute canals, called *dentine tubes.* The dentine tubes commence at the pulp cavity, on the wall of which they open with distinct orifices. They radiate in a sinuous manner from the pulp cavity through the thickness of the dentine, and terminate by dividing into several minute branches ; this division takes place in the crown of the tooth immediately under the enamel, and in the fang of the tooth immediately under the crusta petrosa. In their course the dentine tubes branch more than once in a dichotomous manner, and give off numbers of extremely minute collateral branches. The transverse diameter of the dentine tubes near the pulp cavity is $\frac{1}{4500}$th inch, but that of their terminal branches is much more minute. When transverse sections are made through the tubes, they are seen to be bounded by a distinct circular line, which is

regarded as the sheath of the dentine tube; for each tube is believed to have a definite wall, not formed of the matrix substance, though coalesced with it. By many observers the sheath is regarded as a calcified membranous tube.

If the dentine be examined in a fresh tooth, the tubes will be seen to be occupied by soft delicate, thread-like prolongations of the pulp. The passage of processes of the pulp into the dentine tubes was first seen by Owen in the examination of the tusk of an elephant; but the soft contents of the dentine tubes have been made the subject of special investigation by J. Tomes in the human and other mammalian teeth, and have been named the *dentinal fibrils*. Sharpey has pointed out that the dentine possesses a laminated structure; the lamellæ being arranged parallel to the wall of the pulp cavity. This laminated arrangement indicates the mode of formation of the dentine, as will be described on p. 762.

In sections through the dentine of dried teeth, it is not uncommon to find, near its periphery, irregular, black spaces containing air. These spaces freely communicate with each other. As the dentine which forms their boundary has not unfrequently the appearance of globular contours, they were named by Czermak the *interglobular spaces*. In a fresh tooth they are not empty, but are occupied by a soft part of the matrix, which is traversed in the usual manner by the dentine tubes. This matrix is apparently imperfectly calcified dentine, which shrinks up in a dried tooth, and occasions an air containing space. A layer of small irregular spaces situated in the peripheral part of the dentine in the fang, immediately under the

crusta petrosa, and sometimes named the *granular layer*, is apparently of the same nature as the interglobular spaces.

The *Enamel* is the brilliant white layer which forms a cap on the surface of the crown of a tooth. It is thickest on the cutting edge or grinding surface of the crown, and thins away towards the neck, where it disappears. It is not only the hardest part of a tooth, but the hardest tissue in the body, and consists of 96·5 per cent. of earthy and of 3·5 per cent. of animal matter. The earthy matter consists almost entirely of salts of lime. The great hardness of the enamel admirably adapts it as a covering for the cutting edge, or grinding surfaces, of the crowns of the teeth.

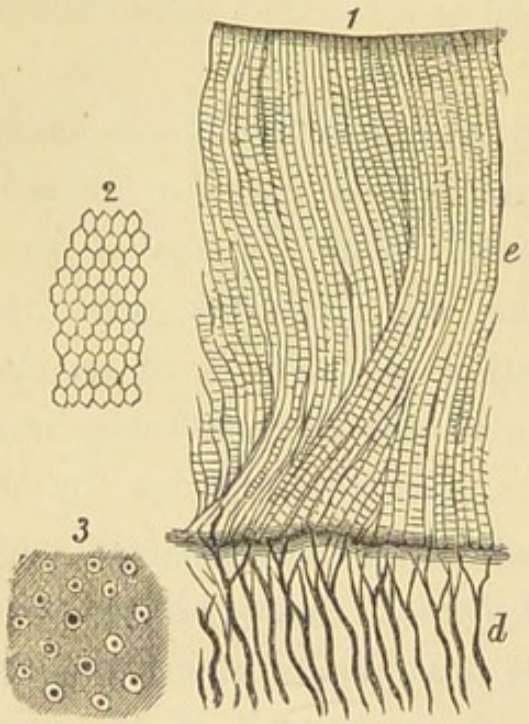

FIG. 206.—1, Vertical section through the Enamel and immediately subjacent Dentine. *e*, enamel rods; *d*, branched termination of dentine tubes. 2, transverse section through the enamel rods. 3, transverse section through dentine tubes and matrix. × 300.

When sections are made through the enamel perpendicular to the surface of the crown, it is seen to be composed of microscopic rods, named the *enamel fibres*, or *enamel prisms*. These rods are set side by side in close contact with each other; one end of each rod rests on the surface of the dentine, the other reaches the free surface of the crown. The rods do not all lie parallel to each other, for whilst some are straight, others are sinuous, and the latter seem

to decussate with each other. The rods are marked by faint transverse lines: they are solid structures in the fully formed enamel, and are polygonal in form. When cut across transversely, they are seen to be hexagonal or pentagonal, and about $\frac{1}{5000}$th inch in diameter. Fissures are often seen extending into that surface of the enamel, which rests on the dentine; and I agree with Tomes's statement, that dentine tubes may sometimes be seen to enter the deep surface of the enamel.

The free surface of the enamel of an unworn tooth is covered by a thin membrane, named the *cuticle of the enamel*, or *Nasmyth's membrane*. This membrane can be demonstrated by digesting an unworn tooth in a dilute mineral acid, when it separates as a thin flake from the free surface of the crown. It is a horny membrane, which resists the action of acids. Waldeyer states that when treated with a solution of nitrate of silver, it presents the appearance of figures like large epithelial cells. Its deep surface is pitted for the ends of the enamel rods. As the crown of the tooth comes into use, Nasmyth's membrane is worn off, and the enamel itself by prolonged use is thinned and worn down. In persons who live on hard food, that requires much mastication, it is not uncommon to find the grinding surface of the crowns of the molar teeth worn down quite flat, and the dentine exposed.

The *Cement*, *Crusta petrosa*, or *Tooth bone*, forms a thin covering for the surface of the fang of a tooth, and extends upwards to the neck. It is of a yellowish colour, and is usually thickest at the point of the fang; though in the multifanged teeth it sometimes forms a thickish mass at the point of convergence of the fangs. It possesses the

structure of bone, and consists of a lamellated matrix with perforating fibres, lacunæ and canaliculi. The lacunæ are irregular in size and mode of arrangement, and vary also in the number of the canaliculi proceeding from them. Sometimes the canaliculi anastomose with the branched terminations of the dentine tubes. In the thin cement situated near the neck of the tooth the lacunæ are usually absent. If the jaw with its contained teeth be softened in acid, and sections be made so as to show the teeth *in situ*, there is no difficulty in recognising the cellular masses of nucleated protoplasm within the lacunæ, which resemble

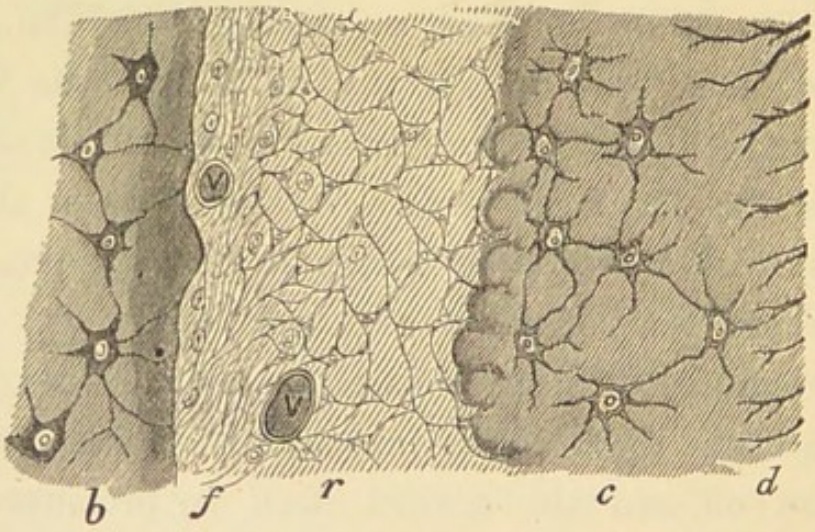

FIG. 207.—Section through the socket and fang of a Tooth. *b*, the bony wall of a socket, its lacunæ contain the bone corpuscles; *f*, the fibrous, and *r*, the reticulated portion of the alveolo-dental periosteum, in which transversely divided vessels, v,v, may be seen; *c*, the cement, the lacunæ of which contain the bone corpuscles; *d*, the dentine. × 450.

in appearance the corresponding structures in the adjacent bone. Haversian canals are only found in the cement, when it acquires unusual thickness. In old teeth the cement thickens at the tip of the fang, and often closes up the orifice into the pulp cavity; the passage of the nerves and vessels into the pulp is thus cut

off, and the nutrition of the tooth being at an end, it loosens in its socket and drops out. When the tooth is in its socket, the reticulated connective tissue of the alveolo-dental periosteum is closely attached to the outer surface of the cement.

Osteo-dentine and *Vaso-dentine* do not exist as normal structures in human teeth, though they occur in various animals. They may appear, however, as abnormalities in the human teeth, and are found on the inner wall of the pulp cavity. Osteo-dentine is a mixture of dentine structure, with lacunæ and canaliculi. If vascular canals, like the Haversian canals of bone, are formed in it, then the name vaso-dentine is applied.

Tue *Pulp* of the tooth is one of its most important constituents. It is a soft substance occupying the cavity in the dentine, or the pulp cavity, and is destroyed in a macerated and dried tooth. It consists of a very delicate gelatinous connective tissue, in which numerous cells are imbedded. Those which lie at the periphery of the pulp are in contact with the dentine wall, and form a layer, named by Kölliker the *membrana eboris*. As the cells of this layer play a part in the formation of the dentine, similar to that performed by the osteoblast cells in the formation of bone, Waldeyer has named them *odonto-blasts*. The odontoblasts are elongated in form, and their protoplasm gives off several slender processes : some enter dentine tubes to form the soft dentinal fibres already described ; another passes towards the centre of the pulp, to become connected with more deeply-placed pulp cells, whilst others are given off laterally to join contiguous cells of the odontoblast layer. The pulp contains the

nerves and blood-vessels of the tooth, which pass into the pulp, through the foramen at the point of the fang. The vessels form a beautiful plexus of capillaries. The nerves are sensory branches of the fifth cranial nerve. They enter the pulp as medullated fibres, which divide into very fine non-medullated fibres, that form a network in the peripheral portions of the pulp. Boll detected delicate branches of this network passing outwards between the odontoblast cells, but no twigs were seen to enter the dentine tubes. The pulp of the tooth is the remains of the formative papilla, out of which the dentine or ivory has been produced. In adult teeth changes that lead to the production of osteo-dentine and vaso-dentine may take place in it. Through the dentinal fibres an organic connection is preserved between the dentine and the pulp, and the sensitiveness exhibited by the dentine in some states of a tooth is not necessarily due to the passage of nerves into it, but to its connection with the sensitive dentine pulp.

Development of the Teeth.

In studying the development of the teeth, not only has the mode of formation of the individual teeth to be examined, but the order of succession of the different teeth both in the temporary and permanent series.

The teeth are developed in the mucous membrane or gum, which covers the edges of the jaws of the young embryo, and their formation is due to a special differentiation in the arrangement and structure of portions of the epithelial and sub-epithelial tissues of that membrane. The enamel

is produced from the epithelium, and the dentine, pulp and cement from the sub-epithelial connective tissue.

The *development of the temporary teeth* will first be considered. If a vertical section be made through the mouth of a young human embryo about the 6th or 7th week, its cavity may be seen to be lined by a stratified epithelium, continuous with the layer of stratified epiblast forming the cuticle of the face. Along the edge of the gum, corresponding in position to that of the future jaws,

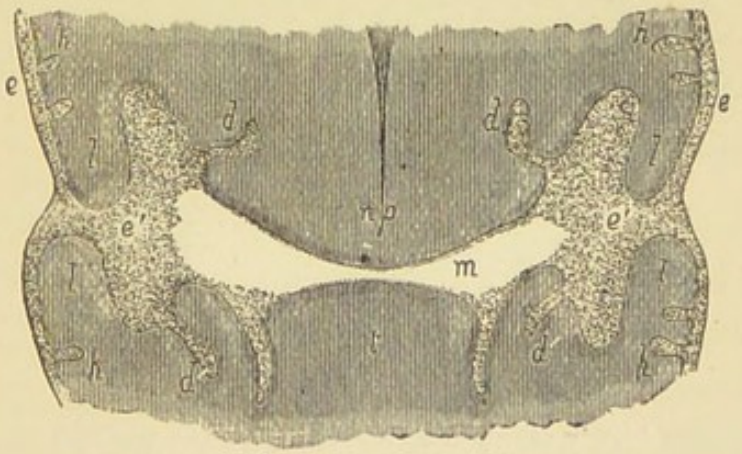

FIG. 208.—Vertical transverse section through the Mouth of a young Human embryo. *np*, naso-palatine region; *t*, tongue; *m*, mouth; *l*, *l*, *l*, *l*, lips; *d*, *d*, primitive dental grooves with epithelial contents in upper gum; *d'*, *d'*, similar structures in lower jaws; *e*, *e*, cuticular epiblast; *h*, *h*, hair follicles; *e'*, epiblast prolonged into the mouth.

the epithelium is of some thickness, and an involution of the epithelium into the subjacent connective tissue has taken place. Owing to this involution a narrow furrow or groove in the connective tissue is produced, which constitutes the *primitive dental groove* of Goodsir. This groove is not, however, an empty furrow, but is occupied by the involuted epithelium. The sub-epithelial connective tissue is soft and gelatinous, and abounds in corpuscles, which are especially abundant in the connective tissue at the

bottom of the groove, where the *dental papillæ* are produced. These papillæ form, at the bottom of the groovse by an increased development and growth of the corpuscles of the subjacent connective tissue. The base of each papilla is continuous with the subjacent connective tissue, and the

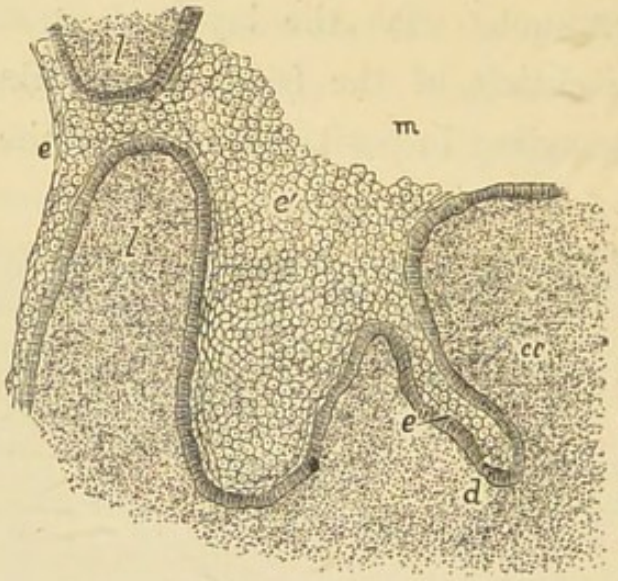

FIG. 209.—A more highly magnified view of a section through the same jaw as fig. 208; *ct*, sub-epithelial connective tissue of the gum; *d*, primitive dental groove; *e''*, its epithelium; *e'*, epithelium lining *m*, the cavity of the mouth; *l*, *l*, lips; *e*, the epiblast cuticle. The deepest layer of the epithelium consists of columnar cells.

apex projects into the deeper part of the involuted epithelium. As a papilla increases in breadth and length, the groove widens and deepens, and the involuted epithelium increasing in quantity, expands over the apex and sides of the papilla, so as to form a hood-like covering or cap for it. The cap of epithelium constitutes the *enamel organ*, whilst the papilla is the *formative pulp* for the dentine and permanent pulp. Whilst these changes are taking place in the epithelium and the connective tissue at the bottom of the groove, no commensurate widening occurs at its upper part, which remains for a time relatively narrow, but retains within it

a narrow string of epithelial cells, continuous on the one hand with the epithelial lining of the mouth, and on the other with the enamel organ. This epithelial string forms the *neck of the enamel organ.* After a time, however, the growth of the connective tissue, forming the lips of the primitive groove, causes the neck of the enamel organ to atrophy, so that all communication between the enamel organ and the superficial epithelium is cut off; the connective tissue on the opposite lips of the groove becomes continuous, and the embryo tooth, being now completely enclosed in a cavity or sac, formed by the gelatinous connective tissue of the gum, has entered on what Goodsir termed its *saccular* stage of development.

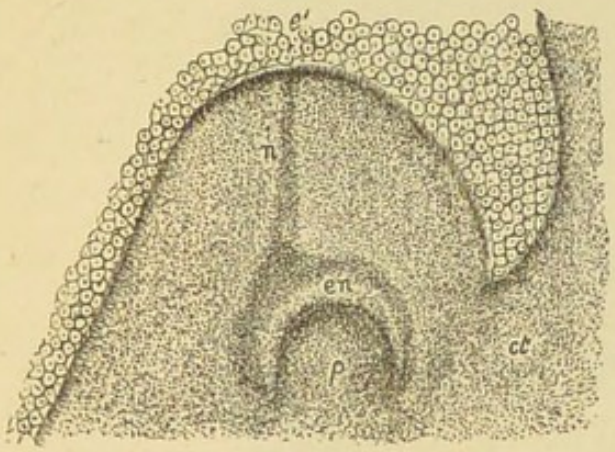

FIG. 210.—Vertical section through the gum to show the formation of the Dental Papilla. *e'* the epithelium covering the gum; *n*, the neck of *en*, the enamel organ; *p*, the dental papilla; *ct*, sub-epithelial connective tissue. Magnified.

When enclosed in its sac the embryo tooth, though perfectly soft, acquires a shape, which enables one to recognize to what group of teeth it belongs. After a time it begins to harden and to exhibit the characteristic tooth structure.

The dental papilla is more vascular than the surrounding connective tissue, from the blood-vessels of which its vessels are derived. The papilla abounds in cells which are, in the first instance, rounded and ovoid in shape. Changes then take place in the cells situated at its periphery, which become elongated and branched, and form layers of cells, which Waldeyer has appropriately named *odonto-*

blasts. Calcification of the protoplasm of these odonto-blasts then occurs, and the peripheral layer of the dentine

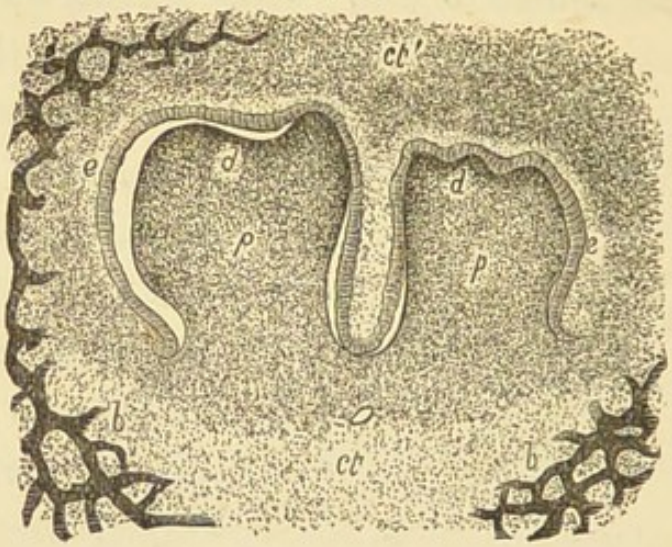

FIG. 211.—Sacculated stage of development of two molar teeth in the Cat. *ct*, *ct*, connective tissue forming the sacs for the teeth; *p*, *p*, dental papillæ; the opaque bands *d*, *d*, mark the commencement of calcification of the dentine; *e*, *e*, internal enamel epithelium; the outer enamel epithelium was not recognisable. *b*, *b*, the bony walls of the alveoli are beginning to form. Magnified.

is produced. In contact with the inner surface of the thin film of dentine, a second layer of odontoblast cells is then arranged, which in its turn calcifies, and as the process goes on in successive layers of odonto-blasts, the entire thickness of the matrix of the dentine and the dentinal sheaths are produced. It is owing to this circumstance that the dentine may exhibit the laminated arrangement referred to on p. 753. But the process of calcification does not apparently take place throughout the whole thickness of the protoplasm of the odonto-blasts, for, as Waldeyer pointed out, the axial part of the cells remains undifferentiated, as the soft dentinal fibrils of the dentine tubes. As these changes are going on in the peripheral layers of the odonto-blasts, the central part of the papilla

increases in quantity, apparently by a proliferation of its cells; nerve fibres are developed in it; it does not undergo calcification, and persists as the pulp of the tooth. The papilla of the tooth has essentially, therefore, the same

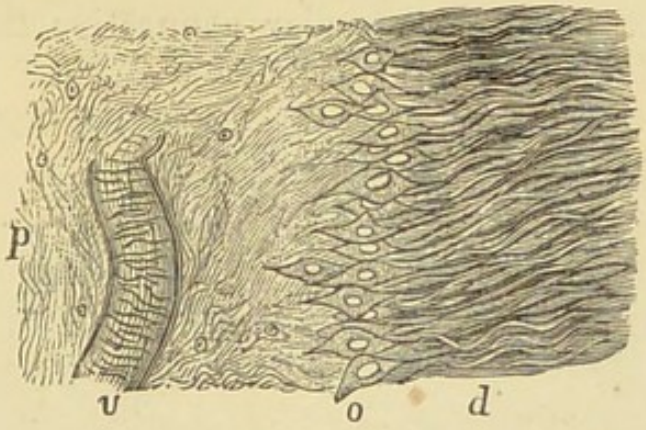

FIG. 212.—Section through the dentine and pulp cavity of a young tooth. *p*, the pulp, with *v*, one of its vessels, and *o*, layers of odonto-blast cells giving off processes into *d*, the dentine. × 450.

relation to the formation of dentine that the cellulo-vascular contents of the medullary spaces, in intra-cartilaginous ossification, have to the formation of bone. In both instances the hard matrix is due to a special differentiation of the protoplasm of the formative cells; the dentinal fibrils are the equivalent structures to the soft contents of the lacunæ and canaliculi, and the persistent pulp is equivalent to the cellulo-vascular contents of the Haversian canals.

Prior to the embryo tooth becoming sacculated, changes had taken place in the enamel organ. Those cells of the enamel organ, which lie next the dental papilla, are continuous through the neck of the enamel organ, with the deepest layer of cells of the oral epithelium, which cells are elongated columns set perpendicularly to the surface on which they rest. Similarly the cells of the deepest

layer of the enamel organ are columns set perpendicularly to the surface of the dental papilla. They undergo a greater elongation, and form six-sided prismatic cells, which Kölliker has named the *internal* or *enamel epithelium*. The cells of the most superficial layer of the enamel organ lie in contact with the vascular connective tissue, which

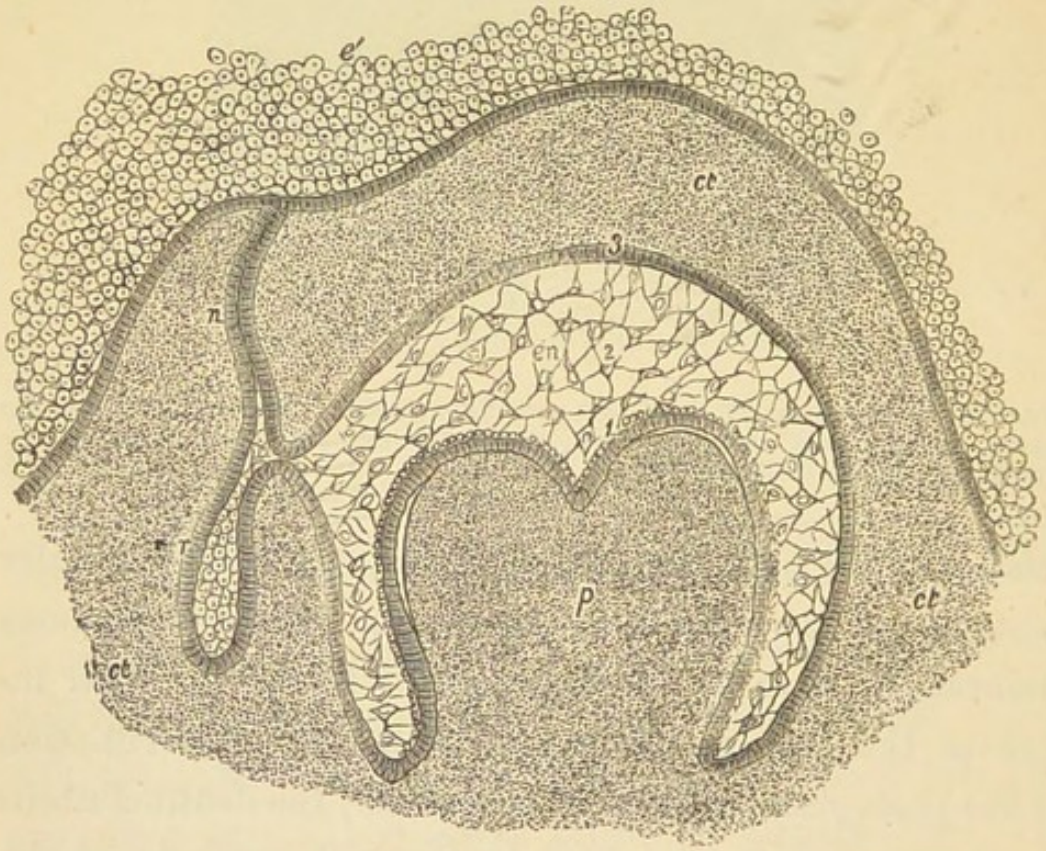

FIG. 213.—Vertical section through gum of Sheep in the region of the molar teeth. *p*, the papilla of a milk molar; 1, the inner, 2, the middle, and 3, the outer layers of the enamel organ; *n*, the neck of the enamel organ; *e'*, the superficial epithelium; *ct*, *ct*, *ct*, the sub-epithelial connective tissue which subsequently forms the sac of the tooth; *r*, the cavity of resere occupied by epithelium, in connection with which the permanent successional tooth is formed. × 300.

encloses the embryo tooth. They form the *external epithelium* of the enamel organ, and slender papillary prolongations of the connective tissue frequently project into this epithelial layer. The cells of the enamel organ, situated between its external and its internal epithelium, become

stellate, and form with each other an anastomosing network of cells like those sometimes seen in the gelatinous connective tissue.

After the tooth has become sacculated, and coincident with the transformation of the odonto-blast cells of the dental papilla into dentine, calcification begins in the elongated prismatic cells of the internal or enamel epithelium; their protoplasm becomes calcified, and they become the rods or prisms of the enamel. As the hardening takes place from the periphery to the centre of each cell, the axial portion may, as Tomes pointed out, remain soft for some time in the axis of the enamel rod. With the increase in length and with the calcification of the cells of the enamel epithelium, the stellate gelatinous cells disappear, and the outer ends of the enamel rods come in contact with the cells of the external enamel epithelium. By some observers the external epithelium is supposed to disappear without undergoing any special differentiation, but by others it is believed to undergo conversion into Nasmyth's membrane.

In this manner the crown of a tooth is formed, and it is lodged in a membranous sac formed by the differentiation into a fibro-vascular membrane of the surrounding connective tissue. Whilst within its sac the crown of the tooth possesses the characteristic form of the group of teeth to which it belongs. After the calcification of the enamel rods is completed, it can undergo no further change either in shape, or in increase of size.

Whilst the crown of the tooth is being formed, ossification of the jaws has been going on, and the tooth, with its membranous sac, has become lodged in an alveolus or

socket in the jaw, which alveolus is closed in by the gum. In order that the crown of the tooth may come into use as a masticatory organ, it has to be elevated to the level of the gum, which is absorbed by the pressure, and the crown then erupts into the cavity of the mouth. The process of eruption is due to the development of the fang, which, as it grows in length, elevates the crown of the tooth and forces it outward. The dentine of the fang is developed from the odonto-blast cells of the pulp in a manner similar to that already described for the development of the dentine of the crown. The cement or crusta petrosa is developed from the connective tissue lining the alveolus, which forms the alveolo-dental periosteum. It is therefore an ossification in membrane.

As the temporary or milk teeth precede the permanent

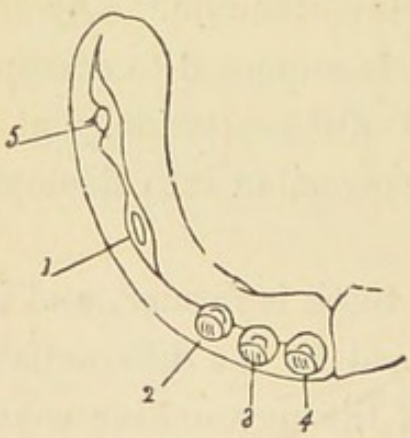

FIG. 214.—One-half the lower jaw of a fœtus about the 11th or 12th week, showing the dental papillæ in the order of their appearance. 1, the first milk molar; 2, the canine; 3 and 4, the two incisors; 5, the second milk molar.—From Goodsir.

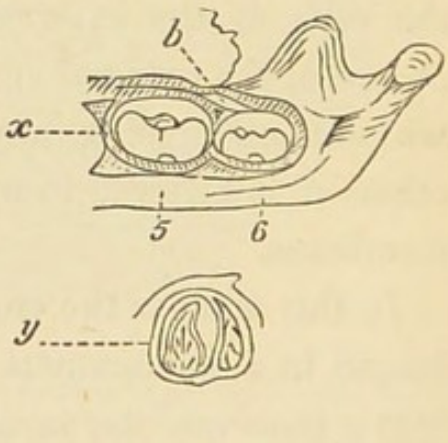

FIG. 215.—Posterior part of the lower jaw of a child at birth. 5, the crown and sac of the posterior milk molar; 6, the crown and sac of the first permanent molar; *b*, the cavity in connection with which the papilla of the second permanent molar ultimately forms. *y*, shows a temporary and permanent incisor from the same fœtus. —From Goodsir.

teeth, their papillæ are naturally the first to form. The

series of milk-papillæ are not, however, simultaneously produced. From the observations of Goodsir, it has been shown that the milk-papilla of the anterior molar in the upper jaw appears about the seventh week, then the canine papilla, the two incisor papillæ, and the posterior molar papilla are successively formed, the last making its appearance about the end of the tenth week. The dental papillæ in the upper jaw immediately precede the papillæ of the corresponding teeth in the lower jaw.

The eruption of the milk teeth into the mouth does not begin to take place until the latter half of the first year of extra-uterine life, and is not completed until between the second and third year. Though variations occur in the date of eruption of each tooth in different children, it may be stated that the incisors usually appear from the seventh to the ninth month; the anterior molars from the twelfth to the sixteenth month; the canines during the seventeenth or eighteenth month; the posterior milk molars from two to two and a half years. The milk teeth begin to be shed about the sixth year by the dropping out of the incisors. The last to be shed are the canines, which do not fall out until the tenth or eleventh year. The shedding of the milk teeth is preceded by the absorption of the fangs. This is effected, as was satisfactorily shown by J. Tomes, by the agency of a group of cells situated at the bottom of the sockets. As these cells occasion absorption of the tooth tissue, similar to that occurring in the bone tissue from the action of the large, many nucleated osteo-klast cells (p. 172), they may appropriately be called *odonto-klasts*.

The *development of the permanent teeth* will now be considered. In the description of the arrangement of the

teeth it has been pointed out that the number of teeth in the permanent set exceeds that of the temporary set. The permanent incisors and canines come into the place of the temporary incisors and canines; the permanent bicuspids succeed the temporary molars, but the permanent molars have no milk predecessors, and are superadded at the back of the dental series.

The development of the *successional permanent teeth*, which are the ten anterior teeth in each jaw, will first be examined. Prior to the period when the lips of the primitive dental groove meet, to produce the saccular stage of dentition of the several temporary teeth, an indentation, or furrow, takes place in the connective tissue adjoining the string of epithelial cells, forming the neck of the enamel organ. This furrow constitutes what Goodsir termed the *cavity of reserve*, and it is filled up by epithelial cells continuous with the epithelium of the neck of the enamel organ. As a cavity of reserve is formed immediately behind, *i.e.*, on the lingual side of, each milk tooth, they are ten in number in each jaw, and, except that for the anterior molar, are formed successively from before backwards.

The cavities of reserve are concerned in the production of the permanent successional teeth, and each temporary tooth is replaced by the permanent tooth formed in connection with the cavity of reserve situated immediately behind it (fig. 213). The cavities of reserve become elongated, and widened, and pass above the temporary teeth in the upper jaw, and below those in the lower jaw. At the bottom of each a dental papilla forms, the apex of which indentates and becomes covered by the epithelium

contained in the cavity, which forms a cap for the papilla, and constitutes the enamel organ for the permanent tooth. The cavity becomes completely closed by the growth of the surrounding connective tissue, and the embryo permanent tooth becomes sacculated. The process of calcification then goes on, in both the enamel organ and dental papilla, in a manner similar to that already described in the temporary teeth. The permanent teeth then become lodged in sockets in the jaw distinct from those of the temporary teeth. The sac of each permanent tooth remains connected with the fibrous tissue of the gum by a slender fibrous band, or *gubernaculum*, which passes through a hole in the jaw immediately behind the corresponding milk tooth. Before the successional permanent tooth erupts, not only should the temporary tooth be shed, but the bony partition between their respective sockets must be absorbed.

The *superadded permanent teeth*, or permanent molars, three in number on each side, lie behind the successional

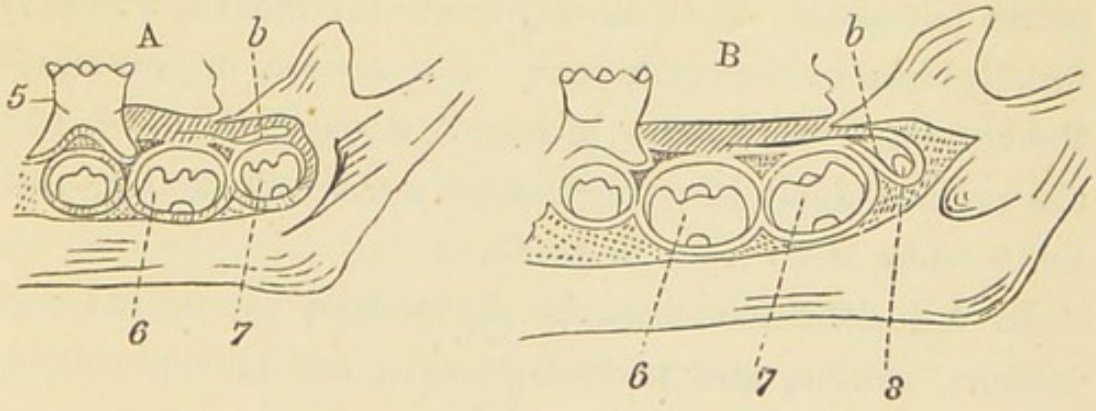

FIG. 216.—A, the lower jaw of a child between four and five years old. 5, the last milk molar, with the successional bicuspid tooth in the cavity of reserve immediately below it; 6 and 7, the first and second permanent molars in their sacs; *b*, the cavity in connection with which the wisdom tooth is formed. B, the lower jaw of a child about six years old; 6 and 7, the first and second permanent molars; 8, the papilla of the wisdom tooth developed in connection with its cavity *b*.—From Goodsir.

teeth. Their mode of origin is similar to that of the

temporary teeth. The primitive groove, occupied by an involution of the epithelial covering of the gum, is prolonged backwards. Three dental papillæ successively appear at the bottom of this groove, and the epithelium covering each papilla forms its enamel organ. Legros and Magitot, however, state that the 2nd permanent molar arises in connection with a diverticulum (cavity of reserve) proceeding from the epithelial string of the enamel organ of the 1st permanent molar, and that the wisdom tooth is formed in connection with a similar diverticulum from the 2nd permanent molar. The embryo tooth becomes sacculated, and goes through the process of calcification similar to what has been described in the other teeth.

The germ of the 1st permanent molar appears about the sixteenth week of embryo-life: that of the 2nd permanent molar not until about the seventh month after birth, whilst that of the wisdom tooth is not formed until about the sixth year. The crown of the first molar is the first of the permanent teeth to erupt into the mouth, which it usually does in the sixth year. The incisors appear when the child is 7 or 8; the bicuspids when it is 9 or 10; the canines about 12; the second molars about 13; and the wisdom teeth from 17 to 25.

In his dentition man is diphyodont as regards his incisors, canine, and premolar teeth; but monophyodont in the molar series.

From the description of the development of the teeth, it will have been seen that a tooth is an organ composed of three hard tissues, enamel, dentine and cement, and of the soft vascular and nervous pulp. These tissues are not developed from one layer only of the blastoderm. The

enamel is of epiblast origin, whilst the dentine, cement, and pulp are derived from the mesoblast. A tooth in its fundamental development, as was long ago pointed out by Goodsir, must be referred to the same class of organs as the hairs and feathers. The enamel of the tooth, like the hair, is produced by a differentiation of the involuted epithelium of the epiblast, whilst the dentine and pulp resemble the papilla of the hair, in proceeding from the mesoblast. The tooth-sac, like the hair follicle, is also of mesoblast origin. Whether the cement, as Robin and Magitot have described, be developed by means of a special *cement organ*, in the interior of the tooth-sac, or is formed, as has been stated in this description, by the alveolo-dental periosteum, it is derived from the mesoblast. As to the origin of Nasmyth's membrane, there is a difference of opinion; some regard it as a special cornification of the external cells of the enamel organ, in which case it would be from the epiblast; whilst others consider it to be continuous with, though structurally different from, the cement—homologous, therefore, with the layer of cement, which in the horse, ruminants, and some other mammals, covers the surface of the crowns of the teeth. As to the membrana preformativa, which some writers have described between the enamel organ and the dentine papilla, and others between the enamel and the enamel organ, I have not been able to see it in any of the developing teeth which I have examined: I therefore agree with C. S. Tomes in believing it not to be present.

The tissues of a tooth have not all the same importance in the structure of a tooth. The dentine is apparently always present, but the enamel, or the enamel and cement,

may be absent in the teeth of some animals. For example, the tusks of the elephant and narwhal, and the teeth of the Edentata, are without enamel, and, in the Rodentia, enamel is present on only the anterior surface of the incisors. But though the enamel is not developed, or forms only an imperfect covering for the crowns of these teeth, yet an enamel organ is formed in the embryo jaws. In 1872 I described a structure homologous with the enamel organ in relation with each of the dental papillæ in the lower jaw of a fœtal narwhal; but this organ did not exhibit a differentiation into the three epithelial layers, such as occurs in those teeth in which enamel is developed. Since then C. S. Tomes has seen an enamel organ in the embryo armadillo, and has also pointed out that, in teeth generally, enamel organs exist, quite irrespective of whether enamel subsequently does or does not form.

But further, the involution of the oral epithelium, and the coincident formation of a primitive groove, take place not only where the teeth subsequently arise, but along the whole curvature of the future jaws; whilst the production of dental papillæ is restricted to the spots where the teeth are formed. Hence I am disposed to consider the inflection of the oral epithelium as not so essential to the development of a tooth, as the formation of a papilla. The inflected epithelium marks only a preliminary stage, and it may or may not be transformed into tooth structure. But that which is essential to the formation of a tooth is the production of the papilla which appears at the bottom of the primitive groove.

Development of the Digestive and Respiratory Systems.

The Digestive and Respiratory Systems are for the most part developed from the mesoblast and hypoblast layers of the blastoderm, the epiblast having but a limited share in their formation.

When the differentiation of the blastoderm into three layers has taken place, its deepest or hypoblast layer lies in contact with the yolk, and is in the course of time prolonged over it to form the epithelial layer of the wall of the umbilical vesicle. As the axial part of the body of the embryo rises up from the surface of the yolk (through the occurrence of those changes in the epiblast and mesoblast which lead to the formation of the nervous axis, the chorda dorsalis, and the protovertebræ (p. 211), a fold takes place at both the cephalic and caudal ends of the embryo. At the same time the hypoblast, both anteriorly and posteriorly, becomes folded so as to form the anterior and posterior ends of a tube, whilst the intermediate part of the hypoblast continues to invest the yolk as the wall of the *umbilical vesicle.* The hypoblast tube, owing to the folding at its anterior and posterior ends, forms, in front and behind, a *cul-de-sac;* but its intermediate part relatively has the form of a wide furrow, and communicates freely with the yolk sac. Subsequently, as the hypoblast assumes the tubular shape, in the intermediate part likewise the communication becomes constricted, and forms the *omphalo-mesenteric duct.* The tube in its whole length is the *Primitive Alimentary Canal.*

At the same time important changes are going on in the mesoblast on each side of the protovertebræ. It splits into two layers, one of which, named the *somato-pleure layer*, adheres to the epiblast, and forms with it the ventral wall of the body of the young embryo ; for as it increases in size it grows towards the ventral surface of the body, and encloses the future thoracic and abdominal cavities. At the umbilicus, however, an opening remains in the mesial ventral line, which permits the structures constituting the umbilical cord, to pass out to the placenta. The other layer of the mesoblast, named the *splanchno-pleure layer*, adheres to the hypoblast, and along with it forms the primitive alimentary canal, and the several viscera which are developed as diverticular offshoots from that canal. Owing to the extension of the somato-pleure, with its cuticular covering of epiblast, to the ventral mesial line of

the embryo, the splanchno-pleure and hypoblast are included within the thoracico-abdominal chamber. The splitting of the mesoblast into two layers occasions a cavity between the somato-pleure and splanchno-pleure, which cavity forms the *pleuro-peritoneal cavity*.

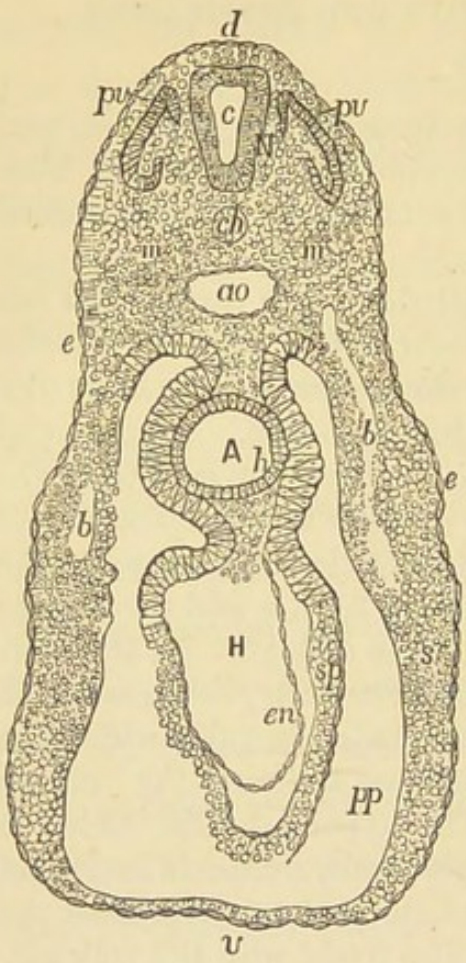

FIG. 217.—Transverse section through the body of an embryo Chick about the 3rd day. *d*, dorsal, and *v*, ventral surface of embryo; N, neural axis; *c*, central canal; *ch*, chorda dorsalis; *pv*, protovertebræ; *m*, *m*, mesoblast; *e*, *e*, epiblast; *ao*, aorta; A, primitive alimentary canal; *h*, hypoblast; H, heart; *en*, endocardium; *sp*, splanchno-pleure; *s*, somato-pleure; *pp*, pleuro-peritoneal cavity; *b*, *b*, divided vessels in the wall of the body.—Modified from Schenk.

The *Primitive Alimentary Canal* is a straight, or almost straight tube, and lies in relation to the ventral surface of the chorda dorsalis, and the bodies of the vertebræ which are developed around the chorda. From its anterior closed end, or the *fore-gut*, are developed the pharynx, œsophagus, stomach, and duodenum. From its posterior closed end, or the *hind gut*, are developed the rectum, and sigmoid flexure of the colon. From its intermediate part, or the *middle gut*, are developed the jejunum and ileum, the cœcum, and the greater part of the colon.

In the differentiation of the walls of the primitive tube, which leads to the formation of these different divisions of the alimentary canal, the cells of the hypoblast are transformed into the epithelium situated on the surface of its mucous membrane, whilst the muscular and connective tissues, the vascular and nervous structures in the wall of the several divisions of the canal, are differentiated o m the cells of the mesoblast.

The *primitive pharynx* is the most anterior part of the primitive alimentary canal, and is enclosed by the visceral and vascular arches in the head of the embryo. As the pharynx lies in the embryo head, the splitting of the mesoblast into the two definite layers of somato-pleure and splanchno pleure, is not seen in con-

nection with it, but that part of the mesoblast, which differentiates into the muscular coat, and into the several layers of connective tissue entering into the formation of the pharyngeal wall, is continuous with the splanchno-pleure layer belonging to the other divisions of the alimentary canal. Its anterior end is closed, and has at first no communication with the mouth, which is not developed from the primitive alimentary canal.

The *mouth* is formed on the facial aspect of the early embryo, by an involution of the epiblast and of the immediately subjacent mesoblast, so as to form a pit, or depression, situated between the superior maxillary plates and the mandibular or first pair of visceral arches. This pit deepens, and widens into the buccal cavity. At first it freely communicates with the embryo nasal chamber, but is subsequently cut off from it by the formation of the hard palate, though the anterior palatine foramina, which in many animals remain patent, keep up the original communication between the oral and nasal chambers. The lining epithelium of the mouth is therefore of epiblast origin, and is continuous with the epiblast cuticle at the margins of the lips (fig. 208). An aperture of communication is formed in the course of time between the mouth and pharynx, so that they become continuous with each other, the communication being established at the fauces or pharyngo-oral aperture.

The *œsophagus* is the part of the primitive canal which immediately succeeds the primitive pharynx, and when the formation of the visceral chambers is completed, it lies successively in the neck, thorax, and abdomen.

The *stomach* is at first a straight, and but little dilated part of the canal, lying vertically in the visceral chamber, and connected to the ventral surface of the spinal column by a fold of the mesoblast, named the *mesogastrium*. As the stomach dilates and assumes its curvatures, it turns over on its right side, so that the original left surface becomes anterior, and the right surface posterior. This change in position explains why the left vagus supplies the anterior wall of the stomach, and the right vagus the posterior wall. The mesogastrium becomes the great omentum.

The *duodenum* is the last part of the alimentary canal developed from the fore-gut. It also loses its straight direction, and forms a horse-shoe curve.

The *jejunum* and *ileum* are at first a simple loop of the primitive middle gut, which is connected to the ventral surface of

the spine by a fold of the mesoblast, named the *mesentery*. This loop at first protrudes out of the abdominal chamber through the umbilical opening, along with the allantois and the vessels of the umbilical cord, but it is soon withdrawn into the abdomen. The portion of the loop which becomes the ileum was originally continuous with the umbilical vesicle through the *omphalo-mesenteric*, or *vitello-intestinal duct;* but this duct atrophies, and in the course of time disappears. As the jejunum and ileum increase in length, they become more and more convoluted, and produce the coils of the small intestine.

A blind sac appears in the course of the middle gut beyond the place of union with the omphalo-mesenteric duct. This sac is the rudimentary *cæcum*, or commencement of the large intestine. The remaining part of the middle gut forms a portion of the colon. The cœcum undergoes a great expansion, except at its lower part, which remains of small calibre and forms the *appendix vermiformis*. The colon also expands into the large intestine, and is continuous with the rectum, formed by a growth and dilatation of the primitive hind gut. The cœcum and colon lie in their early stage to the left of the mesial plane, but, as they increase in length, they pass into the right hypochondrium, and then descend through the right lumbar region into the right iliac fossa. In some cases the descent of the cœcum does not take place, and it then remains in the adult in the right lumbar region, or even in the right hypochondrium, where I have occasionally seen it. In other cases it descends lower down into the pelvis.

The *rectum* and apparently the *sigmoid flexure of the colon* are produced by growth and expansion of the primitive hind gut. The posterior end of the hind gut is at first a *cul-de-sac*, but the mesoblast and epiblast wall of the body, opposite the end of the gut, becomes involuted and absorbed, and the gut then opens into a fossa called the *cloaca*, common to it and to the external orifices of the genital tube and the urethra. In the course of time the intestinal orifice becomes completely separated from the genito-urinary, by the growth of integument, and the *anal orifice* is formed. The imperforate anus, sometimes found in new-born children, is due to the communication between the blind end of the rectum and the surface never having been established.

From the terminal part of the primitive hind gut a diverticulum, called the *allantois*, sprouts out, the several stages of the development, and atrophy of which will be described in connection with the development of the genito-urinary apparatus.

In the wall of the alimentary canal are developed numbers of racemose glands, of tubular gastric glands, and of tubular Lieberkühnian glands. The epithelial cells lining the ducts of the *mucous and salivary glands* opening into the mouth are involutions of its lining epiblast epithelium, and the secreting cells within the gland vesicles are probably derived from the same layer, whilst the connective tissue, vessels, and nerves of these glands are developed from the mesoblast.

The epithelium of all the *tubular glands* situated in the wall of the stomach and intestine is of hypoblast origin. The epithelial lining of the ducts of *Brunner's glands*, and of the *racemose glands* in the wall of the pharynx and œsophagus, is derived from the hypoblast, but there is a question how far the secreting cells within the gland vesicles are of hypoblast or of mesoblast origin. The *lymphoid follicles* and *lymphatic glands* are developed from the mesoblast.

The *Pancreas* is developed along with the spleen from a clump of mesoblast situated in connection with the wall of the duodenum. A diverticulum of the hypoblast lining of the duodenum grows into it, which gives rise to the epithelial lining of the pancreatic duct; but as to the cellular contents of its gland vesicles, as well as those of Brunner's glands, it is not yet determined whether they are derived from mesoblast or hypoblast.

The *Liver* arises from one or two masses of mesoblast situated in connection with the wall of the duodenum. A diverticulum from the hypoblast lining of the duodenum is prolonged into it, which branches and forms the epithelial lining of the bile ducts and gall bladder. Columns of cells then arise in the embryonic organs, which come into relation with the branched divisions of the diverticulum from the hypoblast. These columns form the secreting cells of the liver, but there is a difference of opinion as to whether they are produced from the mesoblast cells, or from the hypoblast diverticula. The vessels, nerves, and connective tissue, both of the liver and pancreas, are produced by differentiation of their mesoblast cells.

The Organs of Respiration are developed in connection with the wall of the primitive alimentary canal.

The *Lungs* arise as two bud-like projections in the wall of the primitive fore gut, in the region of the primordial heart and liver. These buds are hollow, and consist of collections of mesoblast cells, into which a diverticulum of the hypoblast lining of the fore gut is prolonged. Growth and thickening of the anterior or ventral wall

of the fore gut takes place, which differentiates into the *larynx* and *trachea*. From the lower end of the trachea the two *bronchi* proceed, which become continuous with the hollow space in the embryo lungs. The characteristic lung substance is produced by repeated divisions and subdivisions of the bronchial tube, and by growth within the lung, which produces the lobular and vesicular structure of the air cells. The hypoblast cells form the epithelial lining of the windpipe and air cells ; whilst the mesoblast cells differentiate into the connective tissue of the lungs, its vessels and nerves, and the cartilaginous, muscular and fibrous structures in the walls of the bronchi and air cells. In its general mode of development the lung closely corresponds with that of a racemose gland; but the alveoli or air vesicles of the lung are not occupied by secreting cells as are the vesicles of the racemose glands.

The trachea is formed in relation to the ventral aspect of the œsophageal part of the fore gut, and the larynx to the pharnygeal part ; the larynx opens into the pharynx. At the ninth week of intra-uterine life the cartilages of the larynx are formed, and the cartilage of the epiglottis, up to about the sixth month, has the structure of hyaline and not of yellow fibro-cartilage.

The *pleuro-peritoneal cavity*, situated between the somato-pleure and splanchno-pleure layers of the mesoblast, becomes lined by an endothelium, produced by a differentiation of the mesoblast cells situated next to the free surface of each layer. As the splanchno-pleure layer differentiates into the outer coats of the several viscera which have just been described, the cells covering its free surface form the endothelium of the visceral layer of the serous membrane enveloping the viscera; whilst the cellular covering of the somato-pleure layer forms the endothelium of the free surface of the parietal part of the serous membrane. The pleuro-peritoneal cavity on each side of the body of the embryo is one chamber, but, by the development of the diaphragm, the pleura and lung become shut off from the peritoneum and abdominal viscera. Occasionally, the development of the diaphragm is incomplete, and a communication remains between the pleural and peritoneal chambers. Through the gap the abdominal viscera may project into the pleural sac and occasion a diaphragmatic hernia. The heart was originally in relation to the pleuro-peritoneal space, but becomes shut off from it by the development of the fibro-serous wall of the pericardium.

CHAPTER XI.

URINARY SYSTEM.

The Urinary Organs are for the purpose of separating from the blood, and conveying out of the body, certain materials, such as urea and uric acid, formed by the oxidation within the body of its nitrogenous constituents. These materials are dissolved, along with various salts, in a large proportional quantity of water, and the solution constitutes the Urine. The secretion is formed in a pair of glands, the Kidneys. The excretory apparatus for conveying it from the kidneys to the surface of the body, consists of a duct from each kidney, the Ureter; of a reservoir, the Urinary Bladder, into which these ducts open; and of a single duct, the Urethra, leading from the bladder and opening on the surface of the body.

The Kidneys.

The kidneys are two in number, and are placed in relation to the posterior wall of the abdominal cavity, one on each side of the mesial plane. They are situated in the right and left lumbar regions, and reach, from about

the level of the upper border of the 12th dorsal vertebra, downwards to the level of the 3rd lumbar. Luschka

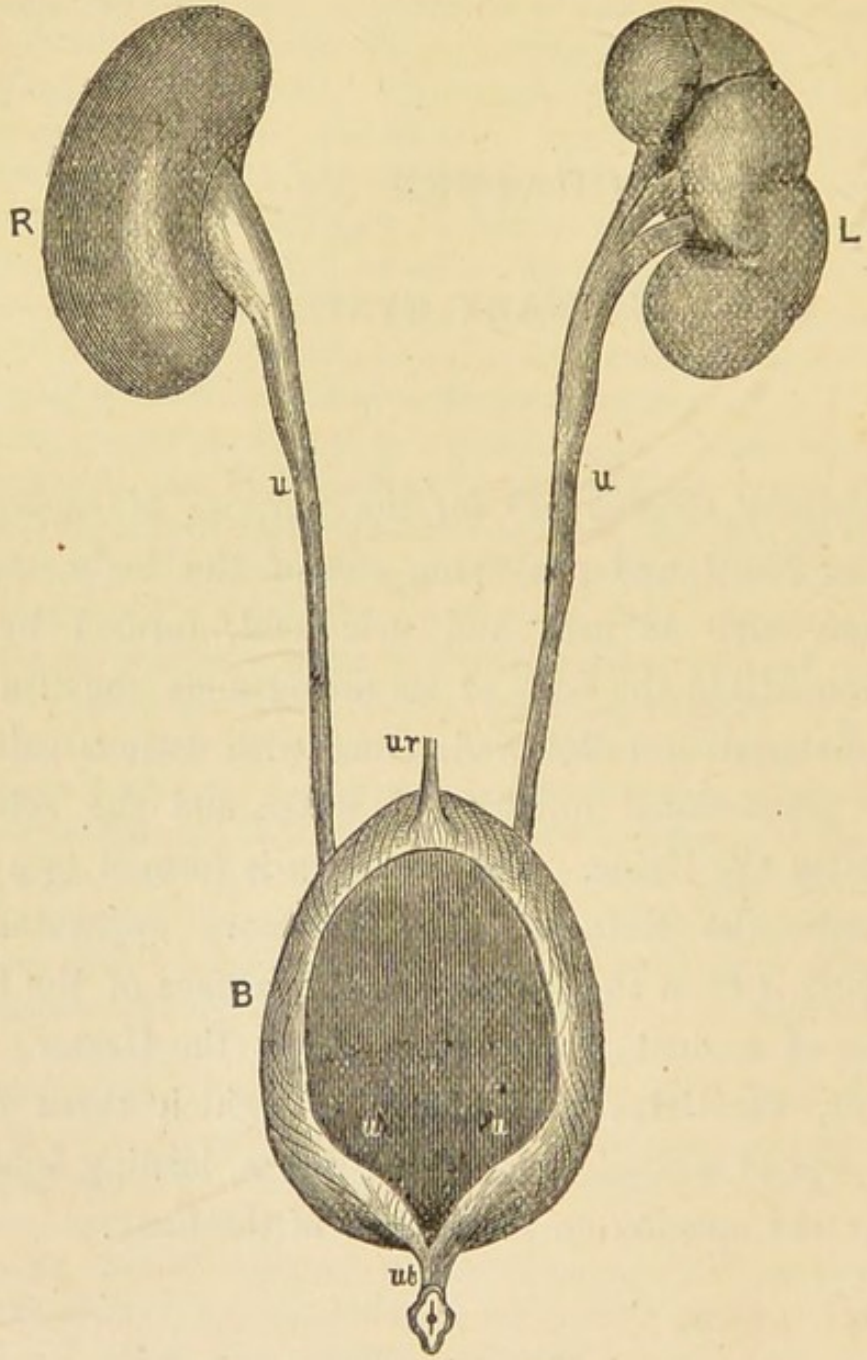

FIG. 218.—The Urinary Organs in the female. R, the right, and L, the left kidney; the left kidney is drawn with fissures on its surface, such as are sometimes seen marking its separation into lobules; U, U, the ureters; B, the bladder, in which are *u*, *u*, the openings of the ureters; *ut*, the urethra; *ur*, the urachus.

states that they may reach as high as the level of the middle of the 11th dorsal vertebra. As a rule, the left

kidney is a little higher than the right. The hilus of the kidney is opposite the 1st lumbar vertebra. The kidneys lie behind the peritoneum, and are surrounded by a mass of fat and loose areolar tissue.

Each kidney is about 4 inches long, 2 to 3 inches wide, and from 1 to $1\frac{1}{2}$ inch in thickness. The average weight is between 4 and 5 oz.

The shape of the kidney is characteristic. It possesses two surfaces, two borders, and two extremities. The *anterior surface* is convex, and looks forwards and outwards; on the right side it is in relation to the duodenum and ascending colon, on the left side to the descending colon. The *posterior surface* is flattened, and rests on the crus of the diaphragm, and on the fascia covering the quadratus lumborum and psoas muscles: on a plane still more posterior to the upper part of this surface, are portions of the 11th and 12th ribs. The *outer border* is convex, and directed towards the postero-lateral wall of the abdomen. The *inner border* is concave, and directed forwards towards the spine: the deep fissure in this border is called the *hilus*, and allows of the passage of the vessels, nerves, and ureter into or out of the kidney. The *upper extremity* is thicker and more rounded than the lower, and has the supra-renal capsule in relation with it. The upper end of the right kidney, and the immediately adjacent part of the anterior surface, are in relation to the liver; the corresponding parts of the left kidney are in relation to the spleen. The *lower extremity* is smaller and thinner than the upper, and does not reach so low as the level of the crest of the ileum.

In rare cases one kidney has been known to be con-

genitally absent. Occasionally the upper ends of the two kidneys have been seen to be united together by an intermediate portion of kidney substance, situated in front of the abdominal aorta, when the conjoined organs formed a horseshoe-shaped kidney.

Structure of the Kidney.

The kidney, though situated in the abdomen, does not possess a serous coat. In rare instances, however, the peritoneum has been seen to invest it more or less completely, and in these cases the kidney was not a fixed, but a movable organ, known as a *floating kidney.*

The *proper coat* of the kidney is a fibrous membrane completely investing the organ. It can be readily stripped off the surface, and in doing so very delicate processes of connective tissue may be seen passing from its deep surface into the substance of the kidney. It is also continuous at the hilus with the sheaths of the various structures, which enter the gland. The inner layer of the proper coat contains a wide-meshed network of non-striped muscular fibres. When the fibrous coat is stripped off, the surface of the kidney is seen to be quite smooth, and of a brownish-red colour. In infants and children it is not unfrequent to find fissures extending for some distance into the substance of the kidney, a condition which indicates the lobular construction of the gland. In some mammals, as the ox, the bear, the cetacea, the lobules can be readily separated from each other, and the organ is divided into numerous independent *renules;* but in the human

kidney, that of the sheep, and of mammals generally, the lobules become fused together into a single organ.

To obtain a knowledge of the structure of the gland, it will be necessary to make longitudinal sections through the organ from the convex border to the hilus. When this is done, the ureter will be seen to enter the kidney at the hilus, and to dilate into a wide *pelvis*, which divides, either directly or indirectly, into several short, truncated

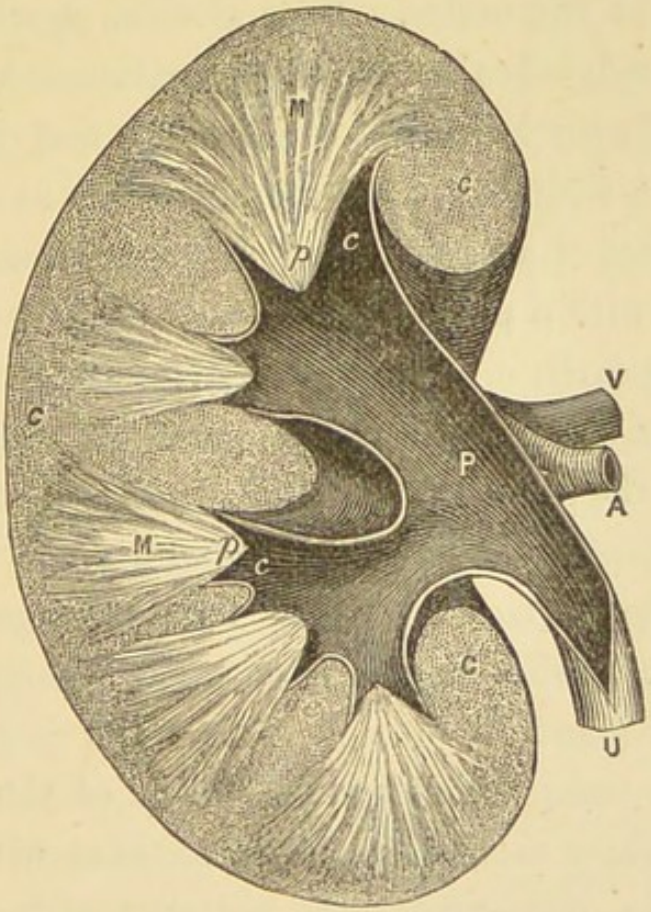

FIG. 219.—A longitudinal section through the kidney. C, C, C, the cortical substance; M, M, the medullary pyramids; *p*, *p*, the papillæ; *c*, *c*, the calyces of the ureter; P, the pelvis; U, ureter; A, renal artery; V, renal vein.

branches, the *calices*, or *infundibula*. The substance of the kidney itself consists obviously of two parts, an external highly vascular part forming the surface of the kidney, and named the *cortical portion;* and an internal or central part, next the calices and pelvis, named the

medullary portion. As prolongations of the cortex, named the *columns of Bertin*, dip into the medullary part, they divide the latter into from ten to eighteen distinct masses, each possessing a pyramidal form; they are named the *medullary pyramids*, or *pyramids of Malpighi.* The base and sides of each of these pyramids are directed to, and bounded by the cortex: the apex forms a *papilla*, which projects into one of the calices, produced by the branching of the pelvis of the ureter. Each of these pyramids, with the cortical substance in immediate relation to it, forms one of the primary lobules of the kidney, and is homologous therefore with one of the renules of the ox's kidney.

If the surface of a section through one of these pyramids be examined with a pocket lens, it will be seen to possess a striated appearance, and the striæ radiate from the papillary apex to the base of the pyramid. These striæ indicate that the pyramid is principally composed of tubes, the *tubuli uriniferi.* The urinary tubules commence at the papilla, on the surface of which the openings of about twenty of these tubes may be seen. The kidney is therefore a tubular gland.

In order to trace out the arrangement of the tubes, it will be necessary to examine thin sections with higher powers of the microscope. If we start with a tubule, where it opens on the surface of a papilla, as the *ductus papillaris*, and trace it into a medullary pyramid, we find that in its course it bifurcates repeatedly at acute angles into smaller branches, which slightly diverge from each other, and ultimately reach the base of the pyramid. These branching tubes are called the *straight* or *collecting* tubes; they then enter the cortex in bundles, which are

named the *medullary rays*, or the *pyramids of Ferrein*. In the cortex the tubes extend towards the surface of the kidney preserving their straight course, when they again branch, and the branches, which are at first dilated and tortuous, are named the *intermediary* or *junctional* tubes. Each intermediary tube then diminishes in calibre, and descends for a variable distance into the medullary pyramid, where it turns on itself, forms a loop, known as the *looped tube* of Henle, and reenters the cortex as the ascending limb of the looped tube. In the cortex the ascending tube becomes continuous with a dilated and very tortuous tube, which opens, as was clearly shown by Bowman, into a dilated and closed sac, named *Bowman's capsule*. The junction of this capsule with the tortuous tube is marked by a constricted *neck*, and the tortuous tube is called the *convoluted* tube.

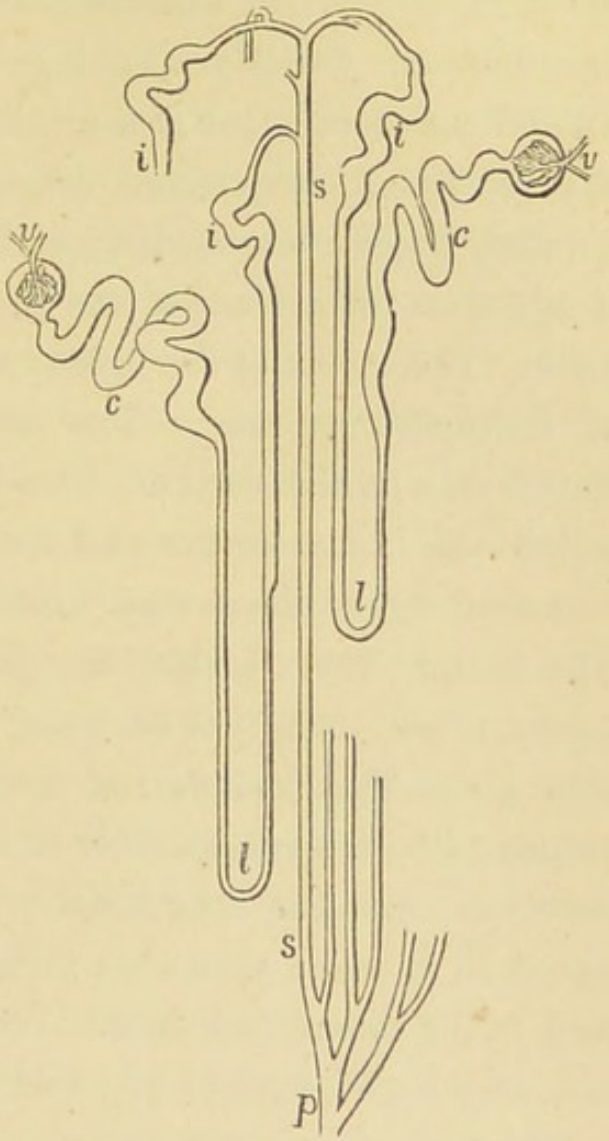

FIG. 220.—Scheme of the arrangement of the Urinary tubules. *p*, the ductus papillaris *s*, the branching straight tubes; *i*, *i*, intermediary tubes; *l*, *l*, looped tubes with ascending and descending limbs; *c*, *c*, convoluted tubes ending in Bowman's capsules; *v*, *v*, vas afferens and efferens.—From Ludwig.

The convoluted tubes and Bowman's capsules occur only in the cortex of the kidney; and they, with their contents, are the characteristic structures seen in it on microscopic examination. Strictly speaking, Bowman's capsule is the dilated commencement of a urinary tubule, which possesses the long and complicated course described as the convoluted, looped, intermediary and straight tubules, before it opens on the surface of the papilla at the ductus papillaris. The cortex of the kidney contains many thousands of Bowman's capsules. The intermediary tubes are also found only in the cortex. The looped and straight tubes occur both in the cortex and in the medullary pyramids. The diameter of the several kinds of tubes is not uniform. The straight tubes within the papilla are from $\frac{1}{240}$th to $\frac{1}{450}$th of an inch, that of their branches $\frac{1}{600}$th, which is also about the diameter of the convoluted tubes. The looped tubes are considerably smaller, and the limb, which descends from the intermediary tube into the medullary pyramid, is wider than that which ascends from the pyramid to the convoluted tube. Bowman's capsules vary in diameter from $\frac{1}{120}$th to $\frac{1}{250}$ each.

The wall of each tube is formed of a delicate membrane, or tunica propria. Generally speaking, the membrane is extremely thin and homogenous, with occasional nuclei, but Frey states that in the looped and convoluted tubes it is thicker than in the straight tubes; and in the ductus papillaris, the tunica propria is said to be absent. The tubes are lined by an epithelium, which varies in its character in different localities. In the ductus papillaris the epithelium consists of low columns. In the straight tubes it is much more distinctly columnar. In the inter-

mediary and convoluted tubes, it consists of a clouded mass of nucleated protoplasm, which presents a very imperfect differentiation into individual cells; this mass so fills up the tube as to leave a very small lumen. In the looped tubes the epithelium is flattened, and with distinct ovoid nuclei, which project towards the lumen of the tube; but from the observations of W. Pye, cubical epithelium occurs in the wider parts of the looped tube, and where the tube joins the intermediary tube, the cells are more elongated, and the lumen of the tube is diminished.

The intervals between the tubes both in the medullary and cortical parts of the kidney, are occupied by connective tissue and blood-vessels. The connective tissue stroma within the kidney was first described by Bowman and Goodsir. In the medullary region this tissue is distinctly fibrillated, but in the cortex the fibrillated tissue is very sparing, and the connective tissue stroma of the gland consists essentially, as Arnold Beer pointed out, of spindle-shaped and stellate corpuscles.

The blood-vessels of the kidney consist of the renal artery and renal vein, with their capillaries.

The renal artery arises from the side of the abdominal aorta, and runs transversely outwards to the hilus of the kidney, where it divides into several branches before entering the gland. Sometimes two, or even three, renal arteries arise independently from each side of the aorta. The branches of the renal artery enter the hilus between the calices of the ureter; they penetrate and divide into smaller branches within the columns of Bertin, or prolongations of cortical substance that lie between the sides of the medullary pyramids. When they reach the level of

the bases of the pyramids, they arch between them and the cortex, and form a series of arterial arcades, which have but little communication with each other. From these arterial arches numerous branches pass outwards into the cortex. They run almost straight towards its free surface,

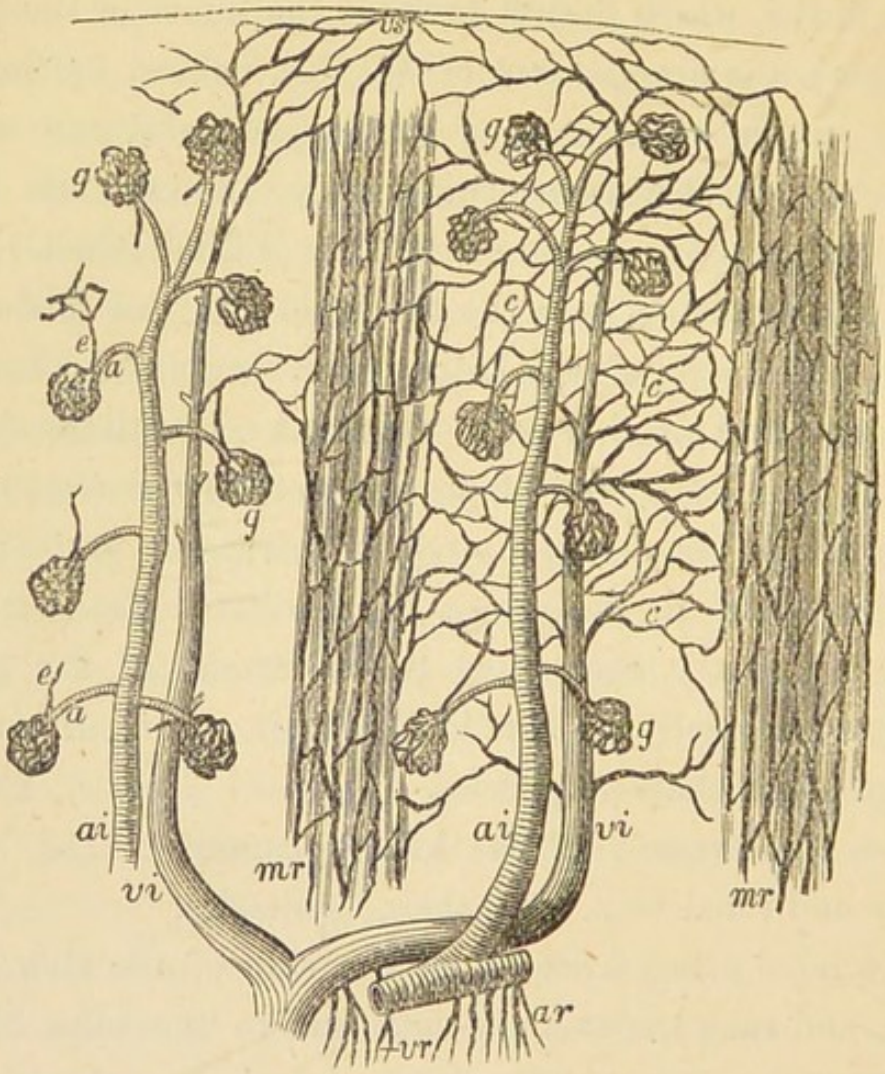

FIG. 221.—Vertical section through the cortex of the Kidney. *ai*, *ai*, interlobular arteries; *a*, *a*, vasa afferentia; *g*, *g*, glomeruli; *e*, *e*, vasa efferentia; *c*, *c*, *c*, capillaries of the cortex, partly surrounding the convoluted tubules, and partly surrounding the straight tubules of the medullary rays, *mr*, *mr*; *vs*, stellate vein on the surface of the cortex; *vi*, *vi*, interlobular veins; *ar*, the straight arteries, and *vr*, the straight veins of the medullary pyramids.—From an injection by T. A. Carter. + 40.

and lie in the intervals between adjoining medullary rays. They are named *interlobular arteries*, and give off both collaterally and terminally short branches, called *vasa afferentia*, and at the surface of the kidney supply small

branches to its fibrous coat. Each vas afferens, invested by its sheath of connective tissue, passes to a Bowman's capsule in its immediate neighbourhood, the wall of which it appears to perforate at one pole. It divides in the capsule into from four to eight branches, which subdivide into capillaries, and form a vascular tuft or *glomerulus*, called the *Malpighian tuft*, situated opposite to the junction of the capsule with the urinary tubule. From the capillaries of the tuft a vessel arises, which

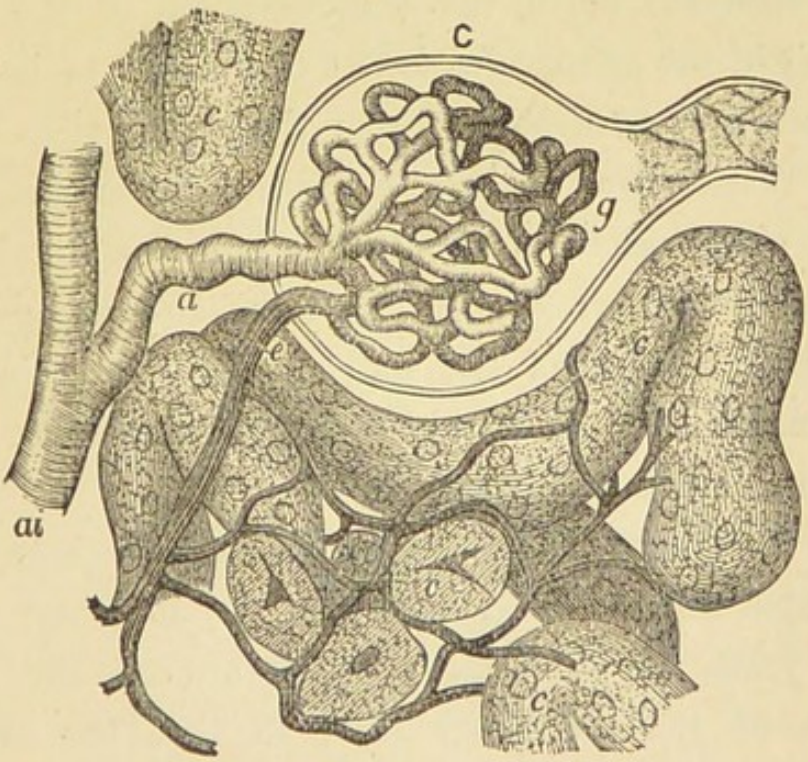

FIG 222—Section through the cortex of the kidney. *C*, Bowman's capsule containing *g*, a glomerulus; *ai*, interlobular artery; *a*, vas afferens, and *e*, vas efferens; *c*, *c*, *c*, convoluted tubules surrounded by a capillary plexus springing from the efferens. In order to show the glomerulus, the cellular contents of Bowman's capsule have not been represented. × 300.

passes out of Bowman's capsule as the *vas efferens*. It usually emerges quite close to the vas afferens, but at once diverges from it, and after a short course ends in a network of capillaries, distributed between and around the convoluted tubules (fig. 222).

The wall of Bowman's capsule is extremely thin, and according to Ludwig consists of a layer of flattened cells, on the outer surface of which is a little connective tissue. These cells form the lining epithelium of the capsule. The glomerulus occupies the interior of the capsule, but is not adherent to its wall. By most observers it is believed that the epithelial lining of the capsule is reflected on the surface of the glomerulus, to form a covering for it, consisting of granulated cells, smaller and somewhat thicker than those of the epithelial lining of the capsule. By other observers again, the demonstration of the cellular covering of the glomerulus is not considered to have been satisfactorily established. From the observations of Seng and of Walter Pye, not only the entire glomerulus, but the several subdivisions of the tuft, are in the fœtal kidney invested by epithelial cells. As Bowman's capsule is produced by a folding of the wall of the fœtal tubule over the glomerulus, the cells which cover the tuft are the epithelium of the fœtal urinary tubule.

The capillaries, which lie in the stroma between the convoluted tubules, form a network around these tubules, which joins the capillary network around the straight tubules of the medullary rays, so that the capillaries form a continuous plexus throughout the cortex. According to Ludwig, lacuniform spaces, often filled with fluid, intervene between the wall of the capillaries and that of the urinary tubes. Minute veins arise from this capillary plexus. Those that arise from the capillaries surrounding the tubules at the free surface of the cortex, are arranged in a star-like manner, and form the *venæ stellatæ*, which also receive small veins from the fibrous

coat. The stellate veins give origin to larger veins, which pass through the cortex towards the medulla, along with the interlobular arteries, and receive in their course numerous small veins from the cortical capillary plexus. They unite near the bases of the medullary pyramids into larger veins, which form venous arcades (fig. 221).

But the renal artery also gives branches to the medullary pyramids of the kidney, and *perforating* branches, which pierce the fibrous coat, and anastomose in the surrounding fat with the extra-peritoneal system of arteries (p. 433). The branches to the pyramids are named *arteriæ rectæ*, and in part arise directly from the branches of the renal artery, situated near the sides and bases of the pyramids, and in part consist of vasa efferentia, proceeding from those glomeruli in the cortex, which lie close to the medulla. In the pyramids the arteriæ rectæ divide into capillaries, which form a plexus in the stroma and surround the straight and the looped tubes. To some extent, therefore, but not altogether, the circulation of blood to the medullary pyramids is independent of that in the cortex. Veins called *venulæ rectæ* correspond to the arteriæ rectæ, and run from the apex to the base of a pyramid, where they end in the larger veins of the cortex. These join to form the venous trunks, which accompany the arteries in the columns of Bertin to the hilus, where they unite to form the renal vein, which lies in front of the artery, and opens into the inferior cava.

Lymphatic vessels emerge from the hilus of the kidney and from its fibrous coat. The superficial lymphatics arise, according to Ludwig, from lymph-spaces, situated between the convoluted tubes of the cortex. The origin

of the deeper lymphatics is not known. Nerves accompany the blood-vessels into the kidney: they arise from the renal plexus of the sympathetic nerve, which is joined by the smallest splanchnic nerve.

THE URETERS.

The Ureters are two tubular ducts, which convey the urine from the kidneys to the bladder. Each ureter arises at the hilus of its kidney from the dilated pelvis formed by the junction of the calices. The ureter is about fifteen inches long, and descends behind the peritoneum covering the posterior wall of the abdomen into the pelvis, where it runs forward to reach the base of the bladder, the wall of which it pierces obliquely before opening into its cavity by a slit-like orifice (fig. 218).

Structure.—The ureter possesses several coats. The external is a tunica adventitia formed of connective tissue: within this is a muscular coat of non-striped fibre arranged in three layers, of which the internal and external layers are longitudinal, and the middle layer is circular. The internal coat is a mucous membrane, and between it and the muscular coat is the submucous coat. The epithelium covering the mucous coat resembles that of the bladder to be immediately described. Where the calices embrace the papillary apices of the medullary pyramids of the kidney, the tunica adventitia of the cortex is continuous with the adjacent fibrous coat of the kidney, and the mucous lining is prolonged upon the surface of the papilla. The longitudinal muscular fibres disappear near the attached border

of the calyx, but the circular fibres have been described by Henle as forming a circular muscle around the papilla, where the mucous membrane is reflected on it.

The coats of the ureter receive blood through small branches of the renal, spermatic, and inferior vesical arteries. Nerves from the spermatic and hypogastric plexuses also pass to them.

URINARY BLADDER.

The Urinary Bladder is the reservoir in which the urine collects prior to being expelled along the urethra. It varies in size, shape, and consequently in position, with the amount of urine it contains. When quite empty it lies in the cavity of the pelvis, behind and above the pubic bones and symphysis. When moderately full it rises slightly above the pubic symphysis into the hypogastrium, and, as its distension increases, it ascends still higher into this region. The empty bladder is flattened in form; when moderately full it is rounded; when much distended it is ovoid, and its longest axis is directed from above, downwards and backwards.

The following parts may be recognized in a well-distended bladder, a base, an apex, an anterior a posterior and two lateral *surfaces*, and a cervix or neck. Its *base* or *fundus* is directed backwards towards the second part of the rectum, from which it is separated, in the male, by the vesiculæ seminales, and the recto-vesical layer of the pelvic fascia. Its *apex* is directed forwards to the hypogastrium, and from it a fibrous cord, the obliterated *urachus*, proceeds towards, and often as far as the navel. The

anterior surface, directed downwards and forwards, is in relation to the pubic bones and symphysis, and to the anterior wall of the abdomen, in the region of the hypogastrium, to all of which it is attached by loose areolar tissue. The *posterior surface*, directed upwards and backwards, is covered by peritoneum, and is separated from the first part of the rectum by the recto-vesical pouch, in which some coils of the small intestine may be lying. The *lateral surface* is partially covered by peritoneum, and has the vas deferens and obliterated hypogastric artery running along it. The *neck* is situated immediately in front of the base, and gives origin to the urethra; it is the lowest or most depending part of the bladder, and in the male is embraced by the base of the prostate gland.

Passing to the bladder are two important membranes, which, together with its vessels and ducts, retain it in position. These membranes are the peritoneum and the pelvic fascia.

The *Peritoneum* forms the *false ligaments* of the bladder, and is arranged with reference to it as follows:—The peritoneum is reflected from the rectum to the posterior surface of the bladder as two folds, named the *posterior false ligaments*, which form the lateral boundaries of the recto-vesical pouch, or pouch of Douglas. Having reached the bladder the peritoneum covers its posterior surface, and extends for a variable distance over the base or fundus; in the empty bladder the peritoneal covering for the base is more extensive than when the bladder is distended. The peritoneum passes over the sides of the bladder as far as the obliterated hypogastric arteries, when it is reflected to the side walls of the pelvis as the *lateral false ligaments*.

It also extends to the apex of the bladder, where it is reflected to the anterior wall of the abdomen, along the line of the urachus, as the *superior* or *false ligament.* The anterior surface of the bladder is not covered by the peritoneum, so that when the bladder rises above the pubes it can be opened without injuring that membrane. The cervix likewise has no relation to the peritoneum. The absence of a peritoneal covering, on the anterior part of the base of the bladder, enables the surgeon to puncture the bladder from the rectum without injuring the serous membrane.

The *Pelvic Fascia* gives rise to the *true ligaments* of the bladder. As this important fascia is intimately related, not only to the bladder, but to all the other pelvic viscera, it will be advisable to examine its arrangement generally. The pelvic fascia is attached to each side of the pelvic brim, and to the back of the bodies of the pubic bones; it descends into the pelvis on the inner surface of the internal obturator muscle, is prolonged downwards as far as the spine and tuberosity of the ischium, to both of which it is attached, and is often called the obturator fascia. Behind the spine of the ischium the fascia is prolonged backwards as a thin membrane on the anterior aspect of the pyriformis muscle, sacral plexus of nerves, and great sciatic foramen. It lies behind the internal iliac artery and its branches, and is pierced by the gluteal, sciatic, and pudic arteries in their course to the great sciatic foramen. From the relation of this part of the fascia to the anterior, lateral, and posterior part of the pelvic wall, it may appropriately be called the *parietal* division of the pelvic fascia.

On a line with the spine of the ischium and the back of

the pubis the fascia gives rise to a strong band, which passes inwards to the pelvic viscera, and may appropriately be called the *visceral* division of the pelvic fascia. Where this visceral band is given off the fascia is whiter and more opaque, and is known as the *white line.* The most anterior part of the visceral division of the fascia passes backwards, in the male, to the upper surface of the prostate gland, forming the *pubo-prostatic ligament*, and is then reflected on the front of the bladder as its *anterior true ligament.* The lateral portion of the visceral division passes inwards, and, in the male, splits into three layers, the most superior of which reaches the side of the bladder to form its *lateral true ligament;* the middle layer goes between the base of the bladder and the rectum as the *recto-vesical* layer of the fascia; whilst the most inferior layer forms the *rectal* layer, which passes under the second and third parts of the rectum and ensheaths the levator ani. The pubo-prostatic ligament gives rise to the fibrous capsule of the prostate gland, and the recto-vesical layer ensheaths the vesiculæ seminales, and the corresponding parts of the vasa deferentia, which lie between the rectum and bladder.

The *Urachus*, which is prolonged from the apex of the bladder to the anterior wall of the abdomen, is a fibrous cord, representing, in the adult, an embryonic canal, connecting the bladder with the extra-abdominal part of the allantois. As development advances the allantois disappears and the urachus shrivels up into a fibrous cord, sometimes called the *middle vesical ligament.* Cases sometimes occur in which the urachus remains pervious for a short distance, and communicates with the bladder.

Structure of the Bladder.

The Bladder possesses four coats—serous, muscular, sub-mucous, and mucous.

The *serous* or *external coat* furnishes only a limited investment to the bladder, as has already been described.

The *muscular coat* is formed of fasciculi of non-striped fibres arranged in three layers. The fasciculi of the *external longitudinal* layer arise from the posterior surface of the body of the two pubic bones, and from the adjacent part of the prostate gland and its capsule; they reach the anterior surface of the bladder, ascend as far as its apex, and then pass downwards on its posterior surface and base, as far as the neck of the bladder and the under surface of the prostate. This layer has been named the *detrusor urinæ* muscle. The *circular layer* lies next the external longitudinal layer, and consists of fasciculi which, though to some extent placed transversely to the long axis of the bladder, are for the most part arranged obliquely. At the neck of the bladder they increase in numbers and form the *sphincter vesicæ* muscle. Pettigrew has described the external longitudinal and circular layers as forming together a series of figure-of-8 spiral loops. The *internal longitudinal* layer was first described by Ellis, and consists of slender fasciculi arranged longitudinally in relation to the sub-mucous coat. The muscular coat by its contraction expels the urine from the bladder into the urethra. In cases where the urethra is obstructed by stricture, or by enlargement of the prostate, the muscular coat becomes greatly hypertrophied.

The *sub-mucous coat* forms a layer of vascular connnective tissue between the muscular and mucous coats. It is

almost absent in the region of the trigone of the bladder. The *mucous* or *internal coat* is thrown into folds or rugæ in the empty bladder, owing to the laxity of the sub-mucous coat, but, when the bladder is distended, the mucous coat is smooth. The mucous lining of the base of the bladder is, however, smooth, even in the contracted bladder, over a triangular surface, bounded behind by a line drawn transversely between the two uretral openings, and on each side by a line drawn from the uretral orifice to the opening of the urethra. This triangular surface is called the *trigone* of the bladder, and it corresponds, internally, to a triangular region on the outside of the base of the bladder, bounded on each side by the vesicula seminalis and vas deferens, in front by the prostate gland, and behind by the line of reflection of the peritoneum from the rectum to the bladder.

The free surface of the mucous membrane is covered by a stratified epithelium, the cells of which are multiform in

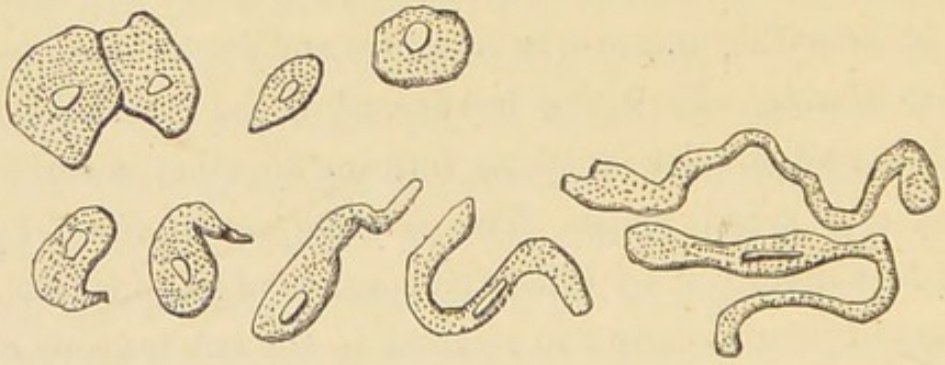

FIG. 223.—Epithelial cells from the mucous membrane of the Bladder. Those in the upper row are the superficial squamous cells; those in the lower row are the peculiar cells of the middle stratum.

shape. The superficial stratum consists of large flattened cells with large distinct nuclei; the middle stratum consists of pear-shaped cells, the broad ends of which are in

contact with the deep surface of the cells of the superficial stratum, whilst the narrow end is prolonged between the cells of the deepest stratum, which are irregularly oval or rounded cells, with sometimes a slender process prolonged between the narrow ends of the pear-shaped cells. Small racemose glands open on the surface of the mucous membrane, especially in the region of the cervix; their excretory ducts are lined by columnar epithelium.

The *arteries* which supply the bladder with blood are the superior vesical branch of the hypogastric artery, and the inferior vesical branch of the internal iliac, which are distributed in the muscular coat, and give rise to a capillary network in the mucous membrane. The veins pass to the vesical venous plexus. *Lymphatics* occur in the walls of the bladder, especially in the trigone, in which region solitary lymph follicles are also found; the lymph vessels join the lymphatics which accompany the internal iliac artery. The nerves proceed from the hypogastric plexus of the sympathetic and from the sacro-coccygeal plexuses. F. Darwin has traced slender plexuses with nerve cells accompanying the blood-vessels.

THE URETHRA.

As the Urethra in the *male* is the excretory duct for both the urine and the secretion of the genital glands, the consideration of its anatomy will be deferred until the next chapter.

The urethra in the *female*, conveys only the urine. It is a tube about $1\frac{1}{2}$ inch long, which, arising as a funnel-shaped tube from the neck of the bladder, passes downwards and forwards under the pubic arch to open on the vulva, between the nymphæ, immediately above the orifice of the vagina, and about an inch below the clitoris. It is imbedded in the anterior wall of the vagina, and is in a part of its course surrounded by the fibres of the compressor urethræ muscle. It is lined by a mucous membrane, continuous with that of the bladder, which is elevated into longitudinal folds. This membrane is covered by a stratified squamous epithelium, and mucous glands open on its surface. The wall of the urethra, external to the mucous membrane, is very vascular, and contains large veins; the vessels are mingled with connective tissue and a circular layer of non-striped muscular fibres.

CHAPTER XII.

REPRODUCTIVE SYSTEM.

The Reproductive System consists of organs, the office of which is to provide for the perpetuation of the race. These organs differ from each other in the two sexes : but, both in the male and female, the materials essential for the reproductive process are the products of two genital glands, and are conveyed along a system of tubes and passages.

Male Organs of Reproduction.

The essential organs of Reproduction in the male are the Testicles, or *genital glands*, in which the semen is secreted. From each testicle a duct proceeds, called Vas Deferens, which conveys the semen to the Urethra. The male urethra is for the greater part of its extent contained in the Penis, or organ of copulation. Certain accessory structures to the male generative apparatus are named Vesiculæ Seminales, Prostate Gland, and Cowper's Glands.

THE TESTES AND SPERMATIC CORDS.

The Testes or Testicles are two glands situated in the Scrotum, and the Spermatic Cord is the collection of vessels, nerves, and the excretory duct connected with each testis. As the testicle and the cord in the scrotum are invested by several structures, technically called their *coverings*, these will first be described.

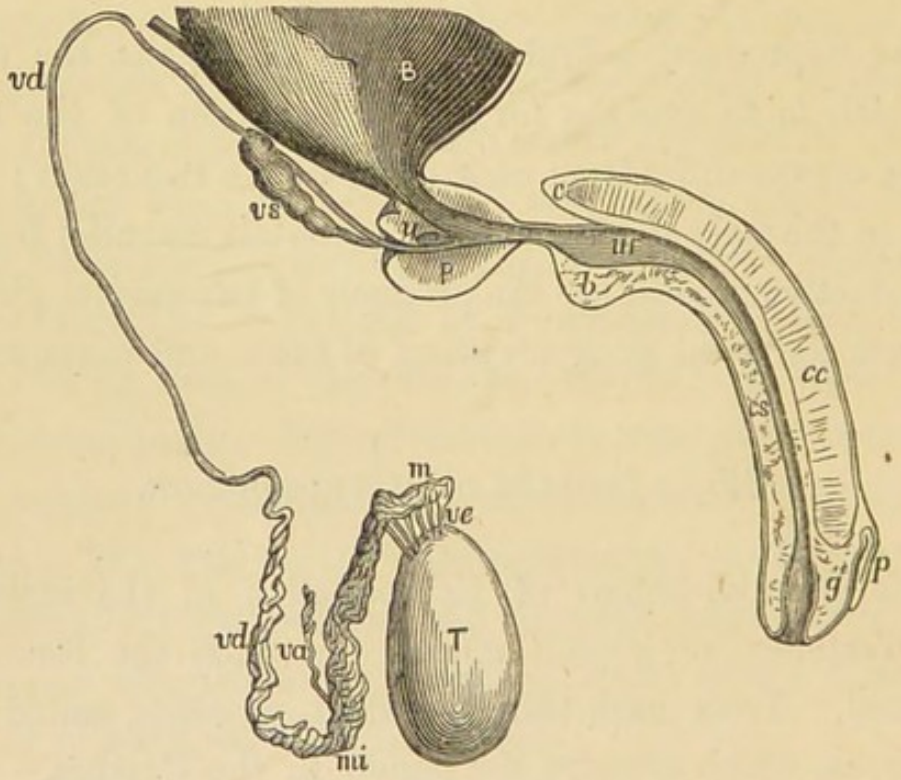

FIG. 224.—General view of the Male organs of generation. T, testicle; *ve*, vasa efferentia; *m*, globus major, and *mi*, globus minor of epididymis; *va*, vas aberrans; *vd*, *vd*, vas deferens; *vs*, vesicula seminalis; *p*, prostate gland, with *v*, the vesicula prostatica and the common ejaculatory duct piercing it to open into the urethra; *ur*, the urethra; *b*, the bulb; *cs*, corpus spongiosum; *cc*, corpus cavernosum; *g*, glans penis; *p*, prepuce; B, bladder.

The SCROTUM consists of a purse-like fold of the integument, which hangs pendulous between the two thighs. Its skin is coloured by pigment, and is covered with hairs;

it presents a wrinkled appearance, though it may become smooth and lax in hot weather, and in a debilitated state of the body. Beneath the skin is a thin layer of superficial fascia of a pale reddish tint, which contains a large quantity of non-striped muscle, and is devoid of fat. This layer is called the *dartos muscle*, and through its contraction the corrugated condition of the skin of the scrotum is produced. The scrotum is divided into two lateral halves, by a median septum, into which the dartos fibres are prolonged. The position of this septum is marked, on the surface of the scrotum, by a median line or raphé, which is continuous behind with the raphé of the perineum. Each half of the scrotum contains a testicle and a spermatic cord, and each testicle with its cord is enveloped by four special coverings, which are arranged from without inwards, as follows :—

The *spermatic fascia* is a thin fibrous membrane, continuous above with the flattened tendon of the external oblique muscle of the abdomen, at the external or superficial abdominal ring. The *cremaster muscle* consists of fasciculi of striped muscle, continuous above with the internal oblique muscle of the abdomen : the fasciculi form a loop-like arrangement over the testicle and spermatic cord, and are attached together by intermediate areolar tissue, so as to form the cremasteric covering or fascia. The *infundibuliform fascia* is a very delicate layer of fibrous membrane, continuous above with the fascia transversalis of the abdomen, at the internal or deep abdominal ring. The *tunica vaginalis* is a serous membrane, the outer surface of which is connected by areolar tissue to the infundibuliform fascia. Its inner surface is smooth, and

covered by a layer of endothelium, which is reflected on the testicle, so as to form a smooth visceral layer, similar to the serous epicardium which envelopes the heart. The visceral layer of the tunica vaginalis reaches the testicle at its posterior border, where it is in contact with the epididymis: it partially invests the epididymis, and forms a pouch between that body and the testicle. The tunica vaginalis is also prolonged for a short distance upwards along the spermatic cord, where it forms a closed sac. Sometimes a thread-like band may be seen in the cord above the tunica vaginalis, and extending upwards towards the peritoneum. This band indicates the position of a tubular connection, at one time existing between the peritoneum and tunica vaginalis.

To understand why the testicle and spermatic cord possess these several coverings, it should be stated that the gland is originally formed in the abdomen, where it has a peritoneal envelope; but that it descends through the wall of the abdomen into the scrotum, and carries along with it a covering from each of the structures in that wall, with which it comes in contact in the course of its descent.

Owing to its development in the abdomen, it derives its vessels and nerves from the vascular and nervous trunks situated in that cavity. As it descends through the wall of the abdomen into the scrotum, these structures are elongated, and descend with it, and together with the vas deferens, or excretory duct of the testicle, form the spermatic cord. The cord, after it has passed through the wall of the abdomen, like the testicle, is enveloped by the spermatic, cremasteric, and infundibuliform fasciæ. The

cord consists of the spermatic artery, a branch of the abdominal aorta: of the spermatic veins, which form a well-marked plexus, called the *pampiniform plexus:* of lymphatics, which communicate with the iliac and lumbar lymphatics: of nerves which are derived from the aortic plexus of the sympathetic, and accompany the spermatic artery, and of the vas deferens. But the vas deferens has a small special artery accompanying it, a branch of the superior vesical artery, and the coverings of the cord receive the cremasteric branch of the epigastric artery. The genital branch of the genito-crural nerve supplies the cremaster muscle.

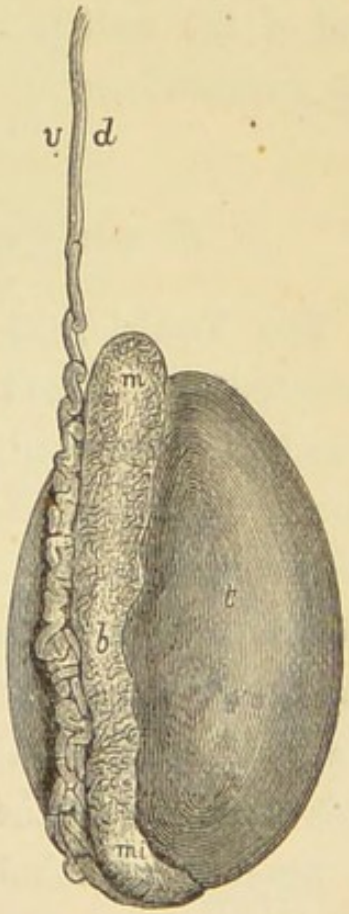

FIG. 225.—The Testicle, as seen from behind; *m*, globus major; *b*, the body, and *mi*, globus minor of epididymis; *vd*, vas deferens.

The testicle is suspended by the spermatic cord and its coverings in the scrotum, in which it lies obliquely; the left testicle being usually a little larger and more dependent than the right. It is ovoid in form, compressed laterally; and possesses two lateral surfaces, two borders, and two extremities. It is about $1\frac{1}{2}$ inch in its vertical diameter, $1\frac{1}{4}$ inch in its antero-posterior diameter, and half an inch from side to side. The whole of the exterior of the gland, except the posterior border, is smooth, and invested by the visceral layer of the peritoneum. The

posterior border gives attachment to the epididymis, which is the convoluted commencement of the vas deferens. The *epididymis* consists of an upper end, the *globus major*, or head of the epididymis ; a lower end, or *globus minor*, and an intermediate part, the *body* of the epididymis. From the globus minor the vas deferens proceeds. The epididymis is to a large extent covered by the visceral layer of the tunica vaginalis, but at its upper and lower ends it is closely united to the testicle. Between the globus major of the epididymis and the upper end of the testicle is a small pedunculated body, called the *pedunculated hydatid of Morgagni.*

Structure of the Testis and Epididymis.

The Testicle, in addition to its serous envelope, is invested by a dense fibrous coat, the *tunica albuginea*, which gives off along the posterior border of the gland a strong prolongation into its interior, named the *corpus Highmorianum* or *mediastinum testis.* But, in addition, slender processes arise, generally from the inner surface of the tunica albuginea, which pass inwards to the mediastinum testis, and collectively form the *septa testis.* Through this arrangement the interior of the gland is divided into a number of lobular compartments, occupied by the seminal tubes. The tunica albuginea, the mediastinum testis, and the septa testis are formed of connective tissue. Kölliker states that non-striped muscular tissue occurs in the tunica along its posterior border, and in the septa testis. Blood-vessels, continuous with the spermatic artery and veins, are also distributed over its inner surface,

and along the septa, so as to form what Astley Cooper called the *tunica vasculosa*.

The *tubuli seminiferi*, or seminal tubules, constitute the proper secreting substance of the testicle. They are lodged in the intervals between the septa testis, and

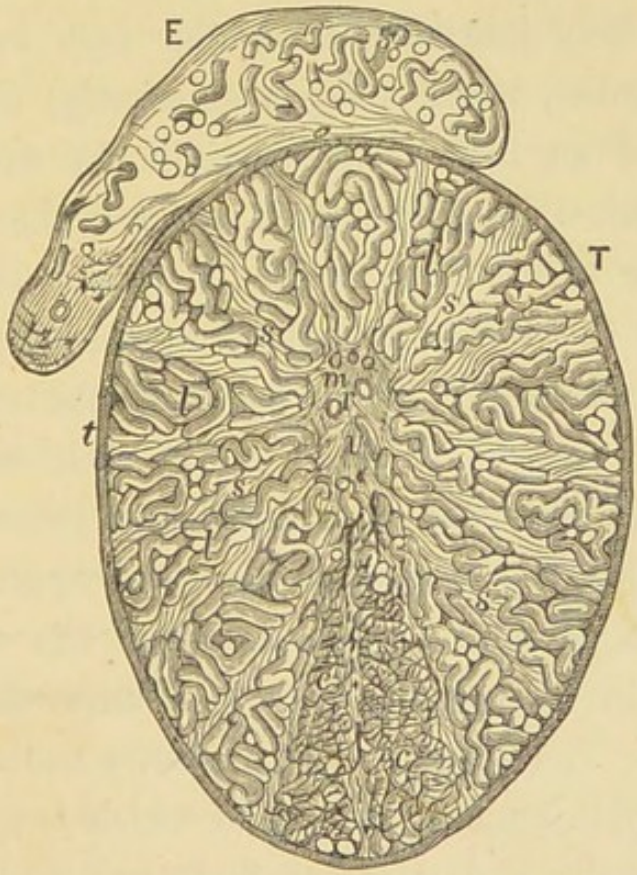

FIG. 226.—Transverse section through the Testicle and Epididymis of an infant. T, the testicle; *t*, tunica albuginea; *s*, *s*, septa testis; *l*, *l*, lobes of testis containing seminal tubules; *m*, mediastinum; *v*, vasa recta; *r*, rete testis; *c*, capillaries surrounding seminal tubules; E, epididymis. × 6.

form conical masses of a reddish-yellow soft material, named the *lobes* of the testis. Each lobe is composed of from two to four or six highly convoluted tubules; and as there are from 250 to 400 lobes in the testis, the number of seminal tubules ranges probably from about 800 to 1000. The convoluted tubules in a lobe are connected together by delicate areolar tissue and capillary blood-

vessels. When these are torn down by dissecting with needles under water or spirit, the tubes may be untwisted and seen to have an average length of $2\frac{1}{4}$ feet, and a diameter of from $\frac{1}{150}$th to $\frac{1}{200}$th of an inch. The tubes begin either with blind ends or anastomosing loops. They become straighter as they approach the mediastinum, where they join and form the *vasa recta*, about twenty in number, which possess an average diameter of about $\frac{1}{80}$th of an inch. When within the mediastinum the straight tubes unite to form a network, the *rete testis*. From the rete testis from twelve to twenty tubes arise, which pierce the tunica albuginea, at the upper end of the testicle under cover of the head of the epididymis, and form the *vasa efferentia*. As in each vas efferens the tube again becomes convoluted, and forms a conical mass, the name *coni vasculosi* has been applied to the series of vasa efferentia. The length of the convoluted vas efferens in each conus is, when unravelled, about seven inches. The several vasa efferentia unite together to form the epididymis ; the tube of which is coiled upon itself to form the globus major, body and globus minor of that canal. From the tube in the globus minor the vas deferens arises. The length of the tube of the epididymis, when unravelled, is about twenty feet, and its diameter varies from about $\frac{1}{70}$th to $\frac{1}{90}$th inch.

The tubuli seminiferi, within the lobes of the testis, have a wall, or membrana propria, formed of layers of polygonal, nucleated, flattened cells. Outside this wall is a very delicate areolar tissue, in which is situated, not only the network of blood capillaries surrounding the seminal tubes, but the lymph-spaces and lymph capillaries

that give origin to the lymphatics of the testicle. The bundles of intertubular connective tissue are, according to Mihalkovics, invested by flat endothelial-like cells, and the chinks between these bundles are apparently the lymph-spaces. The wall of the vasa recta and rete testis also consists of flattened cells. The wall of the vasa efferentia is thicker and more highly differentiated, for it consists not only of connective tissue, but of non-striped muscle, arranged both circularly and longitudinally. The wall of the epididymis possesses a similar structure.

The tubuli seminiferi are occupied by cells. Before the period of puberty these cells are inactive: their protoplasm is granulated and possesses nuclei, but the outlines of the individual cells are obscure. When the testicle is actively engaged in the secretion of semen, the contents of its tubes assume other characters, and give rise to the formation not only of the fluid part of the semen, but of the peculiar spermatic filaments or spermatozoa.

The *spermatozoa* are microscopic thread-like filaments from $\frac{1}{400}$th to $\frac{1}{500}$th inch long. At one end the thread is dilated into an ovoid or pear-shaped body, about $\frac{1}{600}$th inch long, called the head of the spermatozoon, whilst the rest of the structure forms the body and filamentous tail. The spermatozoa are developed within the specially modified sperm cells or *spermato-blasts*, occupying the seminal tubes, the nuclei of which have greatly increased in numbers. From the recent observations of Neumann and Krause, it would appear that the spermato-blasts consist of a network of nucleated protoplasm, in part attached to the wall of the seminal tube, and in part projecting into its

lumen, so as to form a series of projecting columns of nucleated protoplasm. From the free ends of these columns long filaments protrude, which look at first like cilia, but are seen on further examination to be the attenuated tails of the spermatozoa. The protoplasm of the spermato-blasts is colourless, granulated, and easily torn. The nuclei, situated near the attached ends of the columns, are large and oval, and contain a nucleolus. Those nuclei which lie near the free ends of the columns are specially modified to form the heads of the spermatozoa, and the protoplasm immediately surrounding them becomes continuous with the nucleus, and differentiates into the body and filamentous tail of the individual spermatozoa. As the development proceeds, the spermatozoa liberate themselves from the spermato-blasts, and become free in the seminal tube. In the meshes of the network formed by the spermato-blasts, numerous distinct cells, capable of being separated from the network, are situated. They are often globular in form, and contain one or more nuclei. The precise function of these cells has not been determined, and they have been named indifferent sperm cells; it is not improbable that they are spermato-blasts in the earlier stages of formation. It is not until the spermatozoa reach the rete testis, or the vasa efferentia, that they become entirely free from the protoplasm of the spermato-blasts, in connection with which they were formed, when they then assume a power of active movement.

The indifferent sperm cells and the spermato-blasts represent the epithelium of the seminal tubes in the lobes of the testis and in the rete testis. In the vasa efferentia and epididymis, as far as the globus minor, the seminal ducts

possess a distinct lining of columnar and ciliated epithelial cells, but the cilia disappear in the globus minor.

The blood and lymph vessels and the nerves of the testicle are continuous with those to which reference has been made in the description of the spermatic cord. According to Letzerich, the nerve fibres pierce the proper wall of the seminal tubules, and end in clumps of protoplasm, having a direct relation to the sperm cells.

Haller described a tubular diverticular prolongation from the globus minor of the epididymis by the name of *vas aberrans*. It varies in length from 1½ inch to 14 inches, and lies parallel to and between the epididymis and the vas deferens, and is convoluted like the former tube. In structure it resembles the vas deferens.

Giraldès discovered in 1857 a small body situated beneath the tunica vaginalis, covering the front of the spermatic cord, immediately above the head of the epididymis, which has been named the *parepididymis*, or *organ of Giraldès*. It varies in size from a mere speck to a body 4 or 5 lines long, and consists of small convoluted tubes lined with a squamous epithelium.

The VAS DEFERENS is the tubular duct, about two feet in length, which conveys the semen from the epididymis to the urethra. It arises from the globus minor of the epididymis, with the convoluted tube of which it is continuous. It is tortuous at its commencement, and ascends behind the epididymis, then enters the cord, and is continued upwards, behind the spermatic vessels, through the inguinal canal, as far as the internal or deep abdominal ring. Here it leaves the spermatic vessels, curves round the outer side of the deep epigastric artery, and sinks into

the pelvis. It then reaches the side of the bladder, along which it descends to reach the base of the bladder; in its course it crosses the obliterated hypogastric artery, and goes between the ureter and the bladder. At the base of the bladder it inclines to the inner side of the vesicula seminalis, and, near the base of the prostate gland, it joins the duct of the vesicula to form the common ejaculatory duct. The vas is sacculated and tortuous at the base of the bladder, but in the greater part of its extent it is a cylindrical tube, with dense, firm walls, so that it feels like a piece of whip-cord.

It possesses an external coat of connective tissue; within which is a thick coat partly formed of fibro-elastic tissue and partly of non-striped muscle, arranged both longitudinally and circularly. It is lined by a mucous membrane, which is covered by columnar epithelium. The fibro-muscular coat of the sacculated part of the vas is much thinner, and branched tubular glands open on the mucous surface. Owing to the thickness of its wall in the greater part of its extent, the vas deferens possesses a comparatively small lumen.

The Vesiculæ Seminales are two sacculated reservoirs for the semen, situated between the base of the bladder and the rectum. Each vesicula is about 2 inches in length, and consists of a convoluted tube, about 6 inches long, which forms at one end a *cul-de-sac*, but at the opposite end becomes attenuated into a slender duct, which joins the vas deferens, to form the common ejaculatory duct. When the convoluted tube of the vesicula is unravelled, it is seen to possess several short diverticula opening into it. The structure of the wall of the vesicula

corresponds with that of the sacculated portion of the vas. The tubular glands in its wall pour their secretion into it, so that its fluid contents consist not only of semen, but of the special secretion of these glands.

The Common Ejaculatory Ducts are two in number, each being formed by the junction of the vas with the duct of the vesicula of its own side. Each common duct is about one inch long. They lie close together, and pass forwards, between the middle and lateral lobes of the prostate gland, to open in the prostatic part of the urethra, on the summit of the colliculus seminalis, one on each side of the mouth of the prostatic vesicle. Their walls are much thinner than those of the vesiculæ seminales, the diminution being especially marked in the fibro-elastic coat.

The excretory apparatus of the testicle, known by the several names of vasa efferentia, epididymis, vas deferens, and common ejaculatory duct, is characterized by the extraordinary length and convoluted character of its tube. Whilst the actual distance between the testicle and the prostatic part of the urethra, in which the excretory apparatus ultimately opens, is not more than a few inches; the length of the tube which conveys the secretion into the urethra amounts to many feet. The inference which may naturally be drawn from this arrangement is, that the secretion of the testis passes but slowly from the gland to the vesiculæ seminales and urethra, and probably undergoes a considerable amount of elaboration in its course.

The Prostate Gland.

The Prostate Gland is a muscular and glandular body which surrounds the commencement of the urethra (fig. 224). It is shaped like a chestnut, and measures $1\frac{1}{4}$ inch from base to apex, $1\frac{1}{2}$ inch in its transverse diameter, and something less than an inch in thickness. It lies behind the symphysis pubis, and in front of the rectum. Its direc tion is obliquely from above downwards and forwards, and its base, or highest part, is in relation to the neck of the bladder and the common ejaculatory ducts, whilst, from its depending truncated apex, the membranous part of the urethra emerges. Its anterior surface is attached to the pubes by the pubo-prostatic ligaments of the pelvic fascia, and the anterior parts of the lateral true ligaments of the bladder; whilst the most anterior fibres of the levator ani muscle passes to each of its sides, and form the *levator prostatæ* muscle.

The prostate is divided into three lobes, a median and two lateral. The lateral lobes make up the chief part of the gland, and are separated behind by a median notch. The middle lobe is of small size, and lies below the prostatic part of the urethra and between the prostatic vesicle and the neck of the bladder.

Structure.—The prostate gland is invested by a fibrous capsule continuous with the pubo-prostatic ligaments. Beneath the capsule is the prostatic venous plexus, which receives the dorsal vein of the penis, and joins the vesical venous plexus. The substance of the organ is composed partly of muscular and partly of glandular tissue. The

muscular tissue is both non-striped and striped. The non-striped muscle forms a portion of the anterior part of the gland in front of the urethra, as well as a considerable proportion of the base of the organ, where it is continuous with the sphincter vesicæ muscle. It forms a ring-like sphincter arrangement around the commencement of the urethra, by the division of which, in the lateral operation of lithotomy, the urethra and prostate can be dilated so as more readily to admit the forceps into the bladder.

The striped muscle of the prostate has been especially described by Kohlrausch and Henle. It is best seen at the apex of the prostate, where it is directly continous with the striped fibres of the constrictor urethræ muscle which surround the membranous part of the urethra. It surrounds the urethra at the apex of the prostate, and doubtless acts as a sphincter muscle for it, so that Kohlrausch has named it *sphincter uretræ prostaticus*. Fasciculi continuous with this muscle also pass backwards as far as the sides of the neck of the bladder.

The glandular substance of the prostate consists of short branching acinous glands, which unite into a number of excretory ducts, that for the most part open on the floor of the urethra on each side of the colliculus seminalis. Both the ducts and the acini are lined by a columnar epithelium. Concretions are apt to form in old men in the ducts of these glands.

The prostate is penetrated by the urethra, the common ejaculatory ducts, and the prostatic vesicle.

The prostatic part of the urethra is the dilated commencement of that tube. It is about $1\frac{1}{4}$ inch long, is continuous behind with the bladder, and in front with

the membranous part of the urethra. It is nearly half an inch wide about the middle of the prostate, somewhat less where it opens into the bladder, and about a quarter of an inch in width at the apex of the gland, but it is capable of being more widely distended under pressure. It lies in front of the middle lobe of the prostate, and nearer its anterior than posterior surface. It is lined by a mucous membrane, which forms at the opening into the bladder a transverse fold, the *uvula vesicæ*. In front of the uvula a longitudinal fold about $\frac{3}{4}$ inch long, and $\frac{1}{8}$th of an inch in its greatest height, extends forwards along the floor of the prostatic part of the urethra; it is called *colliculus seminalis*, or *verumontanum*, or *crest of the urethra*. On each side of this crest is a longitudinal depression, the prostatic sinus, into which many of the ducts of the glands of the prostate open. At the summit of the crest are three minute orifices, a mesial and two lateral: the mesial is the mouth of the prostatic vesicle, the lateral are the openings of the common ejaculatory ducts. The free surface of the colliculus is formed by the mucous lining of the urethra, beneath which, as Henle has shown, is a network of elastic fibres with interspersed non-striped muscle; cavernous tissue, capable of erection, occupies the spaces of this network.

The *vesicula prostatica*, or *utriculus*, or *uterus masculinus*, is a pouch from $\frac{1}{4}$ to $\frac{1}{2}$ inch long, which opens by a narrow slit on the middle of the summit of the colliculus seminalis. It inclines backwards and upwards, between the lateral lobes, and below the middle lobe of the prostate, and though dilating somewhat in its course terminates in a cul-de-sac at its posterior free end. It is lined by a mucous membrane, covered by a stratified pavement epithelium, and its wall

contains fibro-muscular tissue, and some small tubular glands, which open on the free surface of its mucous lining. The ejaculatory duct is placed, for the terminal part of its course, in the wall of the prostatic vesicle. The vesicula prostatica is of great anatomical interest as representing in the male the uterus and vagina. In some mammals it possesses considerable size; in the horse and ass it is several inches long, and in the goat it divides into two horns posteriorly.

COWPER'S GLANDS.

Cowper's Glands are a pair of yellowish bodies, about the size of small peas, situated in the perineum, behind the anterior layer of the triangular ligament, and below the membranous part of the urethra. From each gland a duct proceeds, which runs forwards for about an inch, and opens into the bulbous dilatation of the urethra. The glands are composed of lobules, and have the compound racemose type of structure. Each gland is supplied with blood from a branch of the artery to the bulb.

THE URETHRA.

The Male Urethra is the excretory duct for the urine and seminal fluid. It extends from the neck of the bladder to the opening at the end of the glans penis. Its average length is from 8 to 9 inches, and it varies in length with the size and condition of the penis. In the erect state of the penis it forms a continuous curve, with the concavity directed towards the pubic arch. In the flaccid penis it makes, at first, a curve with the concavity directed towards the pubic arch; but when it reaches the penis it changes its direction, and forms a second curve, with the concavity directed downwards. It is lined by a mucous membrane continuous at one end with that of the bladder, and at the other with the tegumentary covering of the glans. The epithelial covering of the prostatic part of the mucous membrane is, near the bladder, laminated and with an arrangement of cells similar to the epithelium of the bladder, but in the rest of the urethra, as far forwards as the fossa navicularis in the glans penis, the epithelium is columnar. At the external orifice again it is stratified and squamous. Beneath the mucous membrane is the submucous coat, in which, in addition to the fibres of connective tissue, there are non-striped muscular fibres arranged both longitudinally and circularly. Ellis has shown that the longitudinal fibres are continuous with the internal longitudinal muscular fibres of the bladder.

As the external relations of the urethra vary in different parts of its extent, it is divided into three parts, the prostatic, membranous, and spongy portions. The prostatic

part of the urethra has already been described; the spongy part will be considered along with the penis; the membranous part will now be examined.

The *membranous part of the urethra* curves, with the concavity directed forwards, under the pubic arch, from the apex of the prostate gland to the bulbous portion of the spongy part of the urethra. It is the shortest part of the canal, measures about $\frac{3}{4}$ inch along its anterior wall, and about $\frac{1}{2}$ inch along its posterior wall. It is the narrowest part of the urethra, and in some cases apparently is not more than about $\frac{1}{2}$ inch in circumference, but it is capable of being more widely distended. It pierces the triangular ligament of the urethra before it joins the bulb, and diminishes somewhat in calibre as it passes through it; the fibrous membrane of this ligament supports and gives an investment to the membranous part of the urethra. It is also surrounded by the constrictor urethræ muscle. It is lined by mucous membrane, and its wall not only contains the nonstriped fibro-muscular elements met with generally throughout the urethra, but a vascular, cavernous venous plexus. A few racemose glands open on the free surface of its mucous lining.

The *Compressor* or *Constrictor Urethræ* is a striped muscle passing across the pubic arch, to the sides of which it is attached. In its course it completely surrounds the membranous part of the urethra, to which it acts as a sphincter muscle. It is quite distinct from the non-striped circular muscular fibres, in relation to the submucous coat of the urethra.

THE PENIS.

The Penis, or organ of copulation, is situated in the perineum in front of the triangular ligament and the pubic arch. It consists of a root, a body, and of the glans penis. By its root it is attached to the sides of the pubic arch: its body forms the bulk of the organ, whilst the glans is the terminal part in which is situated the orifice of the urethra. The base of the glans possesses a rounded border, or *corona*, behind which is a constricted *cervix*. The body of the penis possesses an upper flattened surface or dorsum, two lateral rounded surfaces, and an inferior rounded surface principally formed of the corpus spongiosum.

The penis is invested by thin, freely movable skin, destitute of fat and hairs. Anteriorly the skin forms a loose fold, the *prepuce* or *foreskin*, which may either cover the glans, or be drawn backwards from it. The inner layer of the prepuce is reflected over the surface of the glans, and behind and below the urethral orifice forms a thin fold, the *frænum preputii*. The inner layer is smooth, thin, and moist, and has a muco-tegumentary character. Opening on its surface, more especially near the cervix, are the ducts of numerous sebaceous glands, the glands of Tyson, in which a peculiar odoriferous secretion is formed. The skin of the glans itself is covered with vascular and highly sensitive papillæ, and is firmly attached to the subjacent spongy tisssue of the glans. At the root of the penis the integument is continuous with the hairy skin of the pubes and scrotum, and beneath the

skin is the *suspensory ligament*, which forms a triangular band passing from the symphysis pubis to the dorsum of the penis.

When the loose integument is removed from the penis, it is seen to consist of three longitudinal and parallel columns, the two corpora cavernosa, and the corpus spongiosum urethræ. The *corpora cavernosa* are the proper erectile parts of the penis, and form its dorsum, sides, and root. In the body of the penis they are closely united together, but at its root they diverge from each other and form the *crura penis*, which are attached to the sides of the pubic arch in front of the triangular ligament. Each crus is attenuated at its attached end, but in front of its place of attachment it dilates into the bulb of the corpus cavernosum. On the dorsum penis is a shallow groove, which marks the line of union of the corpora cavernosa on this aspect of the organ : on the under surface is a deep furrow, in which the corpus spongiosum is lodged. Each crus penis, and the part of the corpus cavernosum immediately continuous with it, is connected with the erector penis muscle. The *erector penis*, or *ischio-cavernosus* muscle, arises from the inner surface of the ischial tuberosity : it passes forwards in close contact with the under surface of the crus, and is inserted into the fibrous coat of the corpus cavernosum.

Structure.—The corpora cavernosa possess a dense white coat of fibro-elastic tissue, the *tunica albuginea*, which is not only prolonged from one cavernous body to the other, but forms a mesial septum between the two. This septum is perforated by numerous slits, which lie parallel to each other, so as to give it a comb-like appearance, hence the

name *septum pectiniforme* applied to it. From the inner surface of the external coat and from the septum numerous bands, or trabeculæ, arise, which intersect in various directions; they subdivide the space enclosed by the fibrous coat into numbers of small compartments, which are lined by an endothelium, continuous with that of the venous vascular system, and form a cavernous arrangement of veins. The trabeculæ are composed not only of fibro-elastic tissue, but of non-striped muscle, which is also prolonged over the inner surface of the tunica albuginea. The compartments between the trabeculæ freely communicate with each other in the same corpus cavernosum, and also through the slits in the septum with those in the opposite cavernous body.

The corpora cavernosa are supplied with blood by the cavernous branches of the two pubic arteries, which enter the crura penis, and by branches of the dorsal artery of the penis, which pierce the fibrous coat. They branch and run along the trabeculæ. They may terminate either in capillaries, or in the peculiar curling twigs described by J. Müller as the *helicine arteries*. The capillaries open directly into the venous intertrabecular spaces. The helicine arteries are chiefly found in the crura penis, and are apparently small convoluted arteries, which may end either in capillaries, or may form a blind termination. The veins of the corpora cavernosa arise from the cavernous venous spaces, by the distension of which with blood the erection of the penis is produced. The veins join to form not only the dorsal vein of the penis, but likewise the veins which accompany the cavernous arteries.

The *corpus spongiosum penis* is the part of the organ

which contains the urethra, and is situated on the inferior or perineal surface of the penis. It commences behind in the dilatation called the *bulb*, from which it passes forwards as a cylindriform body, and terminates in front in the expanded structure known as the *glans penis*. Its bulbous commencement is in contact with the perineal surface of the triangular ligament, and receives an investment from it. The bulb, and the part of the corpus spongiosum immediately continuous with it, are invested by the accelerator urinæ muscle.

The *accelerator urinæ* or *bulbo-cavernosus* muscle may either be regarded as a single muscle, the two lateral halves of which are united together by a mesial tendinous raphé, or as a pair of muscles. It arises from a point in the perineum, to which the levatores ani and transverse muscles of the perineum converge, also from the mesial tendinous raphé; the greater number of its fibres pass round the bulb and adjacent part of the corpus spongiosum to the perineal surface of the triangular ligament; but the most anterior fibres run outwards around the side of the corpus cavernosum, either to be inserted into the dorsum penis, or to end in a fibrous layer prolonged over the dorsum.

Structure.—The corpus spongiosum possesses a fibrous envelope, with trabeculæ and with intertrabecular venous compartments, but its coat is thinner, and the compartments are fewer and less distensible than those of the corpora cavernosa. The bulb receives a pair of special arteries, the arteries to the bulb, one from each internal pudic artery, which run forwards in the body of the corpus spongiosum; the dorsal arteries of the penis end in the glans

penis. These arteries branch, and the branches for the most part end in capillaries, which open into the inter-trabecular venous compartments, but in the bulb helicine arteries are found. Veins arise in the corpus spongiosum, some of which join the dorsal vein, whilst others form veins corresponding to the arteries of the bulb.

The distinctive character of the corpus spongiosum is the presence of the urethra in it. The *spongy part of the urethra* is about six inches long. It is continuous behind with the membranous part, and when it enters the bulb presents a dilatation. In front of the bulb the urethra diminishes in calibre, and remains of uniform diameter until it enters the glans penis, when it again dilates into the *fossa navicularis*. The fossa terminates anteriorly at the constricted orifice at the end of the glans. The urethra, as seen in transverse section through the body of the corpus spongiosum, is widest transversely; in the fossa navicularis it is widest vertically, which is also its greatest diameter at the external orifice.

The mucous lining is covered, except near the orifice, by columnar epithelium, and opening on its surface are the ducts of numerous small racemose glands. Depressions or lacunæ also open on its surface, one situated in the roof of the fossa navicularis, and named the *lacuna magna*, being most conspicuous. External to the mucous membrane is a layer of non-striped muscle, together with a venous plexus.

The penis is well provided with lymphatics, which form networks in the glans, the prepuce, and around the mucous membrane of the urethra. They communicate with the inguinal glands in the groin. Nerves go to the skin of

the penis from the superficial perineal and long pudendal nerves, and to the substance of the organ from the cavernous and dorsal branches of the pudic nerve. The dorsal branch ends in the glans. Branches of the hypogastric plexus of the sympathetic accompany the arteries.

Female Organs of Reproduction.

The essential organs of reproduction in the female are two genital glands, thedOvaries, in which are found the Ova, or Germ-cells. In close relation to the ovaries are the Fallopian tubes, the Uterus, and Vagina, along which the ova are conveyed. Should an ovum become impregnated, it remains lodged in the uterus until the development of the embryo is completed. When the child is ready for birth, it is expelled from the uterus along the vagina. The Fallopian tubes, uterus, and vagina constitute the genital tubes and passages. The Fallopian tubes are the excretory ducts of the ovaries, but are not anatomically continuous with them. Certain accessory organs, named the Par-ovaria, the Clitoris, the Nymphæ, the Vestibular Bulb, and the Mammæ, are also present.

The Ovaries.

The Ovaries are two flattened oval bodies, in which the ova or eggs are found. They are situated in the pelvis, in connection with the posterior surface of the broad ligaments of the uterus (fig. 231). From their relation to that organ they necessarily change their position along with it, so that, when it enlarges during pregnancy, they rise with it into the abdomen proper. Each ovary is about $1\frac{1}{2}$ inch long, $\frac{3}{4}$ inch wide, and $\frac{1}{2}$ inch in thickness. It is attached to the broad ligament by its anterior border, which is sometimes called the *hilus*, for it transmits the vessels and nerves into and out of the organ. Its inner end is attenuated and attached to the upper lateral angle of the uterus, by the *ligament of the ovary*, into which the non-striped muscular fibres of the wall of the uterus are prolonged. Its outer end, posterior border, and its two surfaces are free; but to its outer end one of the fimbriæ of the Fallopian tube is often attached.

Structure of the Ovary.

The surface of the ovary is partly smooth and partly marked with small cicatrices, which indicate the spots where the surface has given way to allow of the escape of the ova. The ovary is a solid gland, and consists of a surface epithelium, of a vascular stroma, of Graafian follicles, and of ova.

The *surface epithelium* forms a layer continuous with the endothelial cells covering the broad ligament of the

uterus, but is quite different in the shape of its cells. Instead of consisting of squamous cells, it is composed of short columnar cells, which have granular contents, so that the surface of the ovary has a duller appearance than that of the surrounding peritoneum. This columnar epithelium is the remains of the germ epithelium, covering the ovary in the embryo, from which the ova are derived. The line of demarcation between the columnar epithelial covering of the ovary, and the squamous endothelium of the peritoneum, is marked by a whitish, and often an elevated, line surrounding the attached border of the ovary.

The *stroma* of the ovary consists for the most part of connective tissue, in which numerous spindle-shaped connective tissue corpuscles are situated. Immediately beneath the surface epithelium the stroma forms the cortical layer, which at one time was described as a tunica albuginea, but is not now regarded as a separate coat. The stroma at and near the hilus has been named the medullary substance, and is very vascular; both the connective tissue and the vessels radiate from the hilus into the cortical layer. The medullary part of the stroma also contains bundles of non-striped muscle, which, as Waldeyer states, lie around the branches of the ovarian artery: they do not apparently enter the cortical layer.

The *Graafian follicles*, *ovi-sacs*, or *ovi-capsules*, are situated in the cortical layer of the ovary, and vary much in appearance with their stage of development. If a follicle in an advanced stage be examined, it will be seen to possess an external envelope of connective tissue, continuous with the stroma of the ovary, and containing a network of capillary blood-vessels. This forms the sac or wall of the

follicle, and the inner part of the wall is not so strongly fibrous as that which lies next the surrounding stroma. The inner surface of the wall of the sac is lined by some layers of cells which constitute the *membrana granulosa*, or so-called *epithelium* of the *Graafian follicle*. These

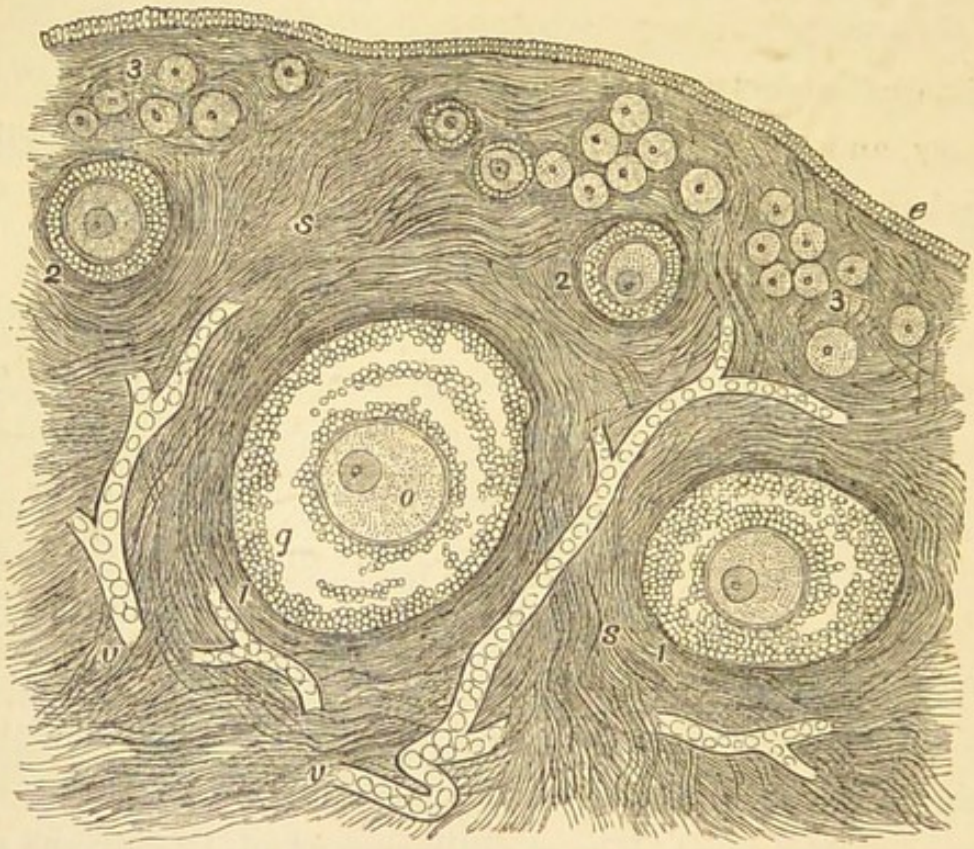

FIG. 227—Section through the cortical part of the Ovary; *e*, surface epithelium; *s*, *s*, ovarian stroma; 1, 1, large-sized Graafian follicles; 2, 2, middle sized, and 3, 3, smaller sized Graafian follicles; *o*, ovum within Graafian follicle; *v*, *v*, blood-vessels in the stroma; *g*, cells of membrana granulosa.

cells are columnar, and possess elliptic nuclei: they have no cell wall, and are very delicate and soft in texture. At one spot they form a little mass called the *cumulus*, or *discus proligerus*, in which the ovum is imbedded. The Graafian follicle contains some liquid, secreted doubtless through the agency of these cells, and, as the secretion accumulates, the follicle approaches the

surface of the ovary by causing absorption of the surrounding stroma. The surface of the ovary then gives way, the wall of the follicle bursts, and the ovum and the liquid, with some of the cellular contents of the follicle, are discharged into the mouth of the Fallopian tube. The largest Graafian follicles can be readily seen with the naked eye, and measure from $\frac{1}{5}$th to $\frac{1}{20}$th inch in diameter. Graafian follicles of middle size have an average diameter of about $\frac{1}{50}$th inch, and contain a much smaller amount of follicular fluid. The smallest Graafian follicles are arranged in large numbers in the cortex immediately subjacent to the surface epithelium. They are about $\frac{1}{100}$th inch in diameter, contain no follicular fluid, and are lined by a single layer of the cells of the membrana granulosa, which are interposed between the ovum and the wall of the follicle. In rare cases two ova occur in a single follicle.

These modifications in the size of the Graafian follicles are especially seen during the sexually active period of life. In children they are almost uniformly of small size, and number, in all probability, between 30,000 and 40,000 in each ovary. After puberty, from twelve to twenty or thirty, may be seen at one time expanding into follicles of the largest size, a change in condition which indicates that in them the ova are becoming mature. After an ovum is discharged, through rupture of the wall of the follicle, the chink on the surface of the ovary heals, and forms a scar, and the Graafian follicle becomes occupied by a yellowish mass, called a *corpus luteum.*

The corpus luteum is a lobulated body closely invested by the wall of the follicle, which possesses about its centre an irregularly elongated greyish band, which is softer than

the surrounding lobules. The yellow mass is composed of cells, the protoplasm of which is finely granulated. Some of the cells are spherical in shape, but the greater number are elongated, and uni- or bi-caudate, in the latter case forming thick spindles; sometimes the caudate processes branch. The yellow mass is very vascular, its vessels being continuous with and derived from those in the wall of the follicle. The larger vessels lie between the lobules, and give rise to an abundant capillary network. The cells of the corpus luteum are derived from the cells of the membrana granulosa, which rapidly multiply and increase in size after the discharge of the ovum. In the course of time the corpus luteum shrivels up and disappears. Where an ovum has become impregnated, the corpus luteum remains for a much longer period than when impregnation has not taken place: the persistence being probably due to the greater flow of blood to the generative organs in the pregnant state, keeping up for a longer period the nutrition of the yellow body.

The *ovum* or *germ cell* is a globular body which attains a diameter of about $\frac{1}{120}$th inch prior to being extruded from the Graafian follicle. The mature mammalian ovum is an example of a well-formed cell. It possesses a colourless envelope, the *zona pellucida* or *vitelline membrane*, which represents the cell wall: the zona usually seems to be perfectly pellucid; but a finely striated appearance has been described in it, which is believed to indicate the presence of minute pores. Within the zona is the *yelk protoplasm*, or cell contents, which contains numerous fatty granules. Imbedded in the yelk is the germinal vesicle or nucleus, about $\frac{1}{700}$th inch in diameter, which

contains, not only a minutely granulated material, but a dark definite spot, the germinal spot or nucleolus, about $\frac{1}{3000}$th inch in diameter. The zona pellucida is apparently formed by a differentiation of the peripheral part of the yelk protoplasm.

The ovary receives its supply of blood from the ovarian artery which enters it at the hilus. It divides into small branches in the fibrous medulla, which pass outwards to the cortex, and form capillary plexuses in the walls of the Graafian follicles. The veins which leave the ovaries form a well-marked plexus, called the pampiniform plexus, between the layers of the broad ligament. Lymphatics also pass out at the hilus: they form within the ovary a capillary plexus, and are continuous with lymph spaces situated around the Graafian follicles; according to His they pass into the substance of the corpora lutea. The nerves proceed from the sympathetic plexus which accompanies the ovarian artery, and have been traced towards the Graafian follicles, but their mode of termination is not known.

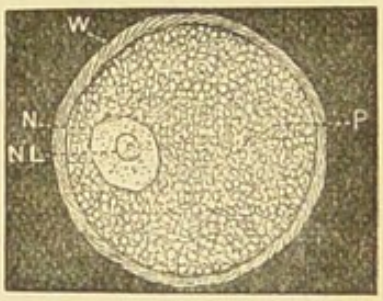

FIG. 228.—Ovum of a Sheep. W. cell wall or zona pellucida; P, protoplasm or germ yelk; N, nucleus or germinal vesicle; NL, nucleolus or germinal spot.

Development of the Ovary and Ova.

From the observations of Waldeyer, it would seem that the ovary appears as a thickening, or small eminence, on the median aspect of the Wolffian body in the early embryo. It consists of two parts, a superficial epithelium, and a

subjacent tissue abounding in corpuscles, which projects from the interstitial tissue of the Wolffian body, and subsequently becomes the vascular stroma of the ovary. Both the epithelium and the vascular stroma of the ovary are differentiations of the cells of the mesoblast.

The superficial epithelium is named by Waldeyer the *germ epithelium*, for from its cells the ova are produced. It consists of columnar corpuscles, arranged side by side so as to cover the free surface of the ovary. Each germ epithelium corpuscle consists, as has been pointed out by J. Foulis, of an elongated, columnar-shaped nucleus, invested by so thin and delicate a layer of protoplasm, that the nucleus forms the most noticeable part of the corpuscle The corpuscles are from $\frac{1}{2000}$th to $\frac{1}{2500}$th inch in their long, and about $\frac{1}{3500}$th in their short diameter. Waldeyer showed that changes then took place in some of these germ epithelial corpuscles; the nucleus swelled out into a spherical body, the protoplasm around the nucleus increased considerably in quantity, a nucleolus appeared within the nucleus, and the corpuscles assumed a spherical form, and formed a primordial ovum. At the same time involutions of the columnar germ epithelium into the substance of the ovary are taking place on various parts of its surface, and some of the corpuscles of this involuted epithelium pass through modifications in form and structure similar to those seen in the epithelium on the free surface of the ovary, so that spherical corpuscles, or primordial ova, appear also in it. The sub-epithelial tissue, or ovarian stroma, now contains multitudes of fusiform connective tissue corpuscles, with some capillary blood-vessels. A coincident growth takes place in it, so that

it penetrates between and around the spherical corpuscles, and separates them from the columnar corpuscles on the outer surface and in the involuted germ epithelium. Collections of these spherical cells then become enclosed in the substance of the stroma of the ovary, and form the egg-chains and egg-clusters described by Pflüger and Waldeyer. As the examination of the developing ovary is made by means of vertical sections into its substance, the egg-chains appear as if enclosed in tubes, and have led to

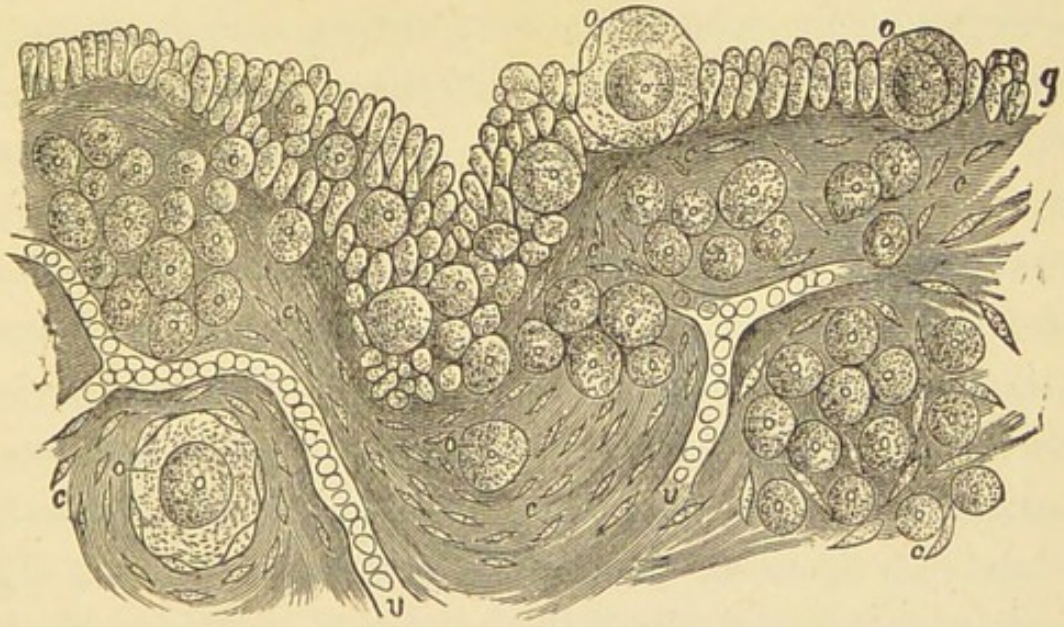

FIG. 229.—Vertical section through the Ovary of the Human fœtus. *g*, *g*, germ epithelium, with *o*, *o*, developing ova in it; *s*, *s*, ovarian stroma, containing *c*, *c*, *c*, fusiform connective tissue corpuscles; *v*, *v*, capillary blood-vessels. In the centre of the figure an involution of the germ epithelium is shown; and at the left lower side a primordial ovum, with the connective tissue corpuscles ranging themselves round it.—After Foulis.

the impression that the ovary was a tubular gland. But, from Foulis's observations, it would appear that these so-called tubes are produced by sections through furrows and depressions between irregular prominences on the surface of the ovary, which prominences are owing to the expansion of egg-clusters situated under the germ epithe-

lium. Waldeyer believed that of the cells in the imbedded egg-clusters, some developed into ova, whilst others greatly multiplied in numbers and formed the cells of the membrana granulosa, whilst the surrounding vascular stroma formed the wall of the Graafian follicle. Hence he regarded both the ova and the follicular epithelium as derived from the germ epithelium. The researches of J. Foulis have led to a modification of this opinion. The primordial ova undoubtedly arise from imbedded spherical cells of the germ epithelium. But Foulis has traced delicate processes of the connective tissue stroma, with its characteristic fusiform corpuscles, penetrating between the individual cells of the egg-clusters, so as to separate these cells from each other, and to give to each cell a special envelope of stroma tissue. The connective tissue corpuscles of the stroma are closely applied to the peripheral part of the yelk protoplasm of the primordial ovum, so as to dimple its surface. The vascular stroma surrounding each primordial ovum then forms the wall of the Graafian follicle, whilst the fusiform connective tissue corpuscles rapidly proliferate into the cells of the membrana granulosa, which originally form only a single layer. According to this view, therefore, whilst the ova are specially modified germ epithelium cells, the cells lining the Graafian follicle are derived from the corpuscles of the connective tissue stroma. With the increase in the number of the cells of the membrana granulosa they become arranged in several layers, and the discus proligerus is produced; as the expansion of the follicle goes on, the liquor folliculi is secreted. The cells of the membrana granulosa have a diameter of about $\frac{1}{3000}$th inch.

The primordial ovum is converted into the mature ovum, not only by growing larger, principally by an increased formation of the yelk protoplasm, but by the yelk becoming infiltrated with fatty granules. An investing envelope or zona pellucida is also produced. Reichert and many other observers supposed that the zona was formed from the cells of the membrana granulosa immediately surrounding the ovum, but it is more probably produced by a special differentiation of the peripheral layer of the yelk protoplasm. The germinal vesicle is the modified nucleus of a germ-epithelial corpuscle, and as this nucleus, not only in the unmodified germ epithelium cell, but in the early stage of growth of the primordial ovum, greatly preponderates in size over its investing protoplasm, it seems at first to be the most important constituent of the cell. About the time of the maturation of an ovum the germinal vesicle has apparently completed its function, for when the Graafian follicle has burst, and the ovum has escaped into the Fallopian tube, the vesicle can no longer be distinguished. The formation of primordial ova from the germ epithelium corpuscles comes to an end before the third year of extra-uterine life. Of the many thousands of primordial ova in each ovary, only a comparatively small number come to maturity, and the maturation of the ova ceases when the function of menstruation terminates.

PAR-OVARIUM.

The Par-ovarium, or Organ of Rosenmüller, is a small body situated between the two layers of the broad ligament in the interval between the ovary and the Fallopian tube. It consists of a group of short convoluted tubules, from twelve to twenty in number, arranged in a radiated manner, with the base towards the Fallopian tube, and with the apex towards the ovary, but having no connection with either structure (fig. 231). At the base a longitudinal tube often unites the convoluted tubes together. This longitudinal tube is developed in the sheep, cow, and pig into a canal, which extends along the side wall of the uterus and vagina to open near the orifice of the urethra, where it is named the canal or duct of Gaertner. The tubes of the par-ovarium are lined by epithelium.

FALLOPIAN TUBES.

The Fallopian tubes, or Oviducts, are not anatomically continuous with the ovaries, but are intimately connected with the supero-lateral angles of the uterus. They are two in number, and are placed one along the upper free border of each broad ligament. Each oviduct is from 3 to 4 inches long; at its uterine or attached end it is slender and cord-like, but it expands towards its outer or free end, and terminates in a number of delicate processes or *fimbriæ*, one of which is often attached to the surface of the ovary. These fimbriæ surround the mouth of the oviduct, which, though constricted at the orifice, opens into the wide, trumpet-shaped outer end of the tube.

The oviduct possesses four coats. The external or *serous coat* is continuous with the peritoneum forming the broad ligament. The *muscular coat* consists of an external longitudinal, and an internal circular layer of non-striped fibres, continuous with the muscular wall of the uterus. Beneath the muscular coat is the *submucous coat*, formed of vascular connective tissue. The internal or *mucous coat* lines the Fallopian tube, and is continuous with the mucous lining of the uterus. It is elevated into longitudinal folds, and is covered on its free surface with a ciliated columnar epithelium; glands do not exist in the mucous membrane. At the external orifice the ciliated columnar epithelium is prolonged upon the inner surface of the fimbriæ, and on these processes it passes into the squamous endothelium of the peritoneum.

Though the oviduct is not directly continuous with the substance of the ovary, yet when ova are being shed, through rupture of the wall of the Graafian follicles, the fimbriated end of the Fallopian tube embraces the surface of the ovary, so that the ova can enter its mouth. The ovary therefore differs from glands generally in not having its excretory duct directly continuous with its secreting structure. The ovum is propelled along the duct, partly by the movements of the cilia, and partly doubtless by a peristaltic contraction of the muscular coat.

THE UTERUS.

The Uterus is the important organ which receives the ovum, and after impregnation retains it during embryonic life, until its development being sufficiently advanced, the period of parturition arrives, when the fœtus is expelled from the uterus. In the non-impregnated state the uterus lies in the cavity of the pelvis, between the rectum and the bladder, and is about 3 inches long, 2 inches broad at the widest part, and not quite 1 inch thick. When the ovum is impregnated, the uterus increases greatly in size, rises into, and occupies a considerable part of, the cavity of the abdomen proper.

The uterus is compared in shape to a pear, and possesses a fundus, a body, and a neck. The *fundus* is the

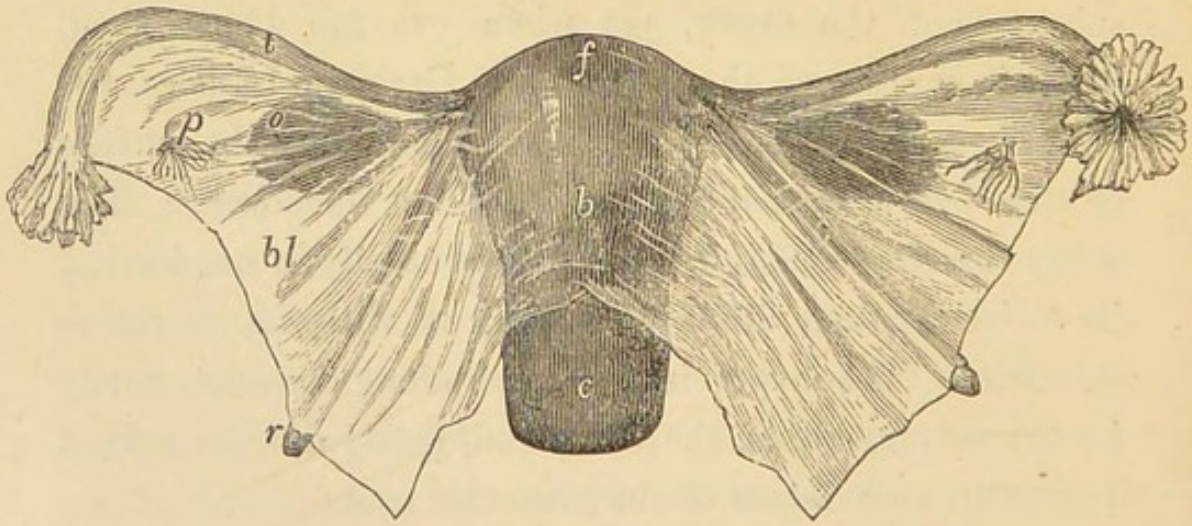

FIG. 230.—The anterior surface of the Uterus and broad ligaments. *f*, fundus; *b*, the body, and *c*, cervix uteri; *bl*, broad ligament; *r*, round ligament; *t*, Fallopian tube; *p*, par-ovarium; *o*, ovary shown through the broad ligament.

broad, free, convex upper end, and projects slightly beyond the place of attachment of the two Fallopian tubes. The *body* is elongated, with its anterior and posterior surfaces

slightly convex, and with its side nearly straight. The *neck* or *cervix uteri* is the lower, somewhat constricted end, about one inch in length, the wall of which is continuous with that of the vagina.

The non-gravid uterus lies obliquely in the cavity of the pelvis, the fundus is directed upwards and forwards, the cervix and os downwards and backwards. The body is not quite straight, but is slightly curved, with the concavity towards the bladder, the convexity towards the rectum. The vagina forms an angle with the uterus at their place of junction, so that, whilst the axis of the uterus is in that of the pelvic inlet, the axis of the vagina lies almost in that of the pelvic outlet.

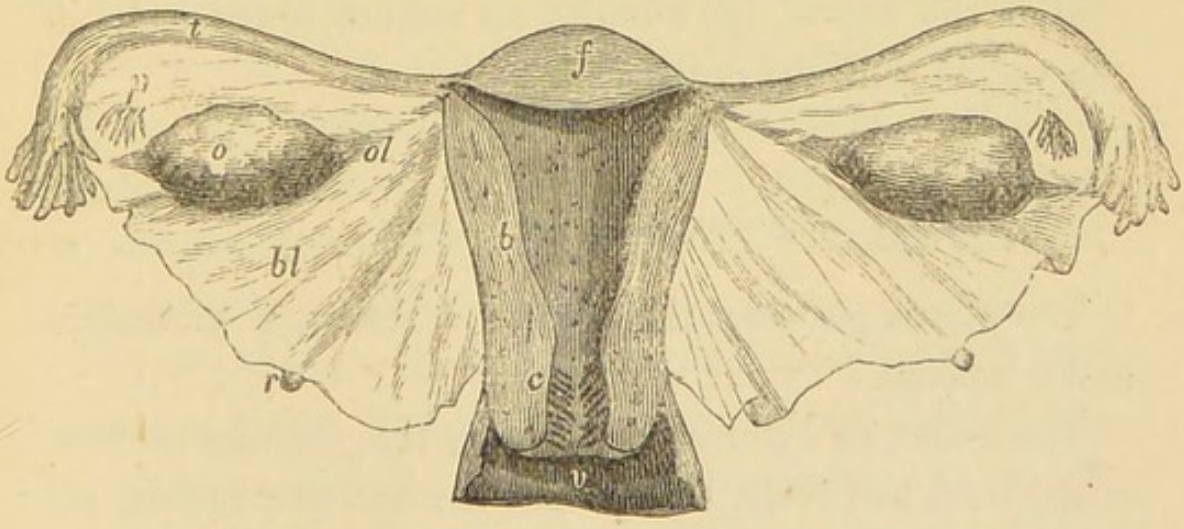

FIG. 231—The posterior surface of the broad ligaments and the cavity of the Uterus. *f*, fundus; *b*, body, and *c*, cervix uteri; *v*, vagina; *bl*, broad ligament; *t*, Fallopian tube; *o*, ovary; *ol*, ovarian ligament; *p*, par-ovarium; *r*, round ligament.

The uterus possesses a wall of considerable, but not of uniform, thickness: for the posterior wall both of the body and cervix is somewhat thicker than their anterior wall, whilst the sides of the uterus, at the junction with the

Fallopian tubes, are generally thinner. The body of the uterus is hollowed out into a triangular cavity, which communicates at its base with the Fallopian tubes. The base of the triangular cavity is at the uterine fundus, the opposite end is at the cervix, where it communicates with the canal in the cervix by a circular constricted opening, named the *os uteri internum.* The cavity of the cervix is elongated and somewhat fusiform. The aperture of communication between the cervix and the vagina is transversely elongated, and named the *os uteri externum.* The os externum is bounded by two thick lips, the posterior of which is longer than the anterior, because the posterior wall of the vagina is prolonged higher on the uterus than is the anterior wall. From the oblique direction of the uterus, the anterior lip reaches lower down in the vagina than the posterior lip.

Structure of the Uterus.

The uterus possesses three coats, a serous, a muscular, and a mucous.

The *serous*, or external coat, covers the posterior surface of the neck and body, the fundus, the anterior surface of the body, but not the anterior surface of the neck of the uterus : it is also prolonged from the back of the cervix uteri on that part of the posterior wall of the vagina, which lies behind the posterior lip of the os uteri. It is reflected from the sides of the uterus, as the *broad ligaments*, which are prolonged to the sides of the pelvis : in front it is reflected to the bladder as the two *utero-vesical folds*, whilst behind it is reflected to the rectum as the two *utero-rectal folds* of

peritoneum. The interval between the uterus and the bladder, bounded laterally by the utero-vesical folds is the *utero-vesical pouch* of the peritoneum, whilst the interval between the uterus and rectum, bounded laterally by the utero-rectal folds, is the *utero-rectal pouch*, or pouch of Douglas. Both the utero-vesical and utero-rectal folds of peritoneum contain fasciculi of non-striped muscle, continuous with the muscular coat of the uterus. Those in the utero-rectal folds are most distinct, and extend backwards to the rectum in the region of the second sacral vertebra. Luschka conceives that they can draw the uterus backwards, and has named the arrangement the *musculus retractor uteri.*

The broad ligaments of the uterus are expanded folds of the peritoneum, which not only serve as lateral ligaments for the organ, but enclose the Fallopian tubes, the ovarian, and round ligaments, the par-ovarium and the vessels and nerves of the uterus and ovaries. The ovaries also are attached by their anterior borders to the posterior surface of the broad ligaments.

The *round ligament*, or *ligamentum teres*, is a round cord about five inches long, attached to the upper angle of the uterus, below and in front of the Fallopian tube. It passes forwards and outwards to reach the internal or deep abdominal ring; it then enters the inguinal canal, along which it passes, and leaves it at the external or superficial abdominal ring to end by becoming continuous with the subcutaneous tissue of the pubic region. The round ligament is chiefly composed of non-striped muscular fibres continuous with the muscular wall of the uterus, and some of these fibres spread out between the layers of the

broad ligament. Sometimes a prolongation of the peritoneum, named the *canal of Nuck,* accompanies the round ligament into the inguinal canal.

The *muscular coat* consists of non-striped muscle intermingled with areolar tissue, arranged so compactly as to form the thick, dense wall of the unimpregnated uterus. In the impregnated uterus the muscular wall expands and becomes less compact, during the growth of the organ, and the muscular coat is then seen to be arranged in three sets of fibres. The external set forms a thin layer immediately beneath the peritoneum, the fibres of which extend from the cervix over the body and fundus, and are prolonged into the round ligament, the ovarian ligaments, the wall of the Fallopian tubes, between the layers of the broad ligaments, the utero-rectal and utero-vesical folds. The middle set of fibres consists of longitudinal and transverse fasciculi, which intersect in various directions, especially at the sides of the uterus, where they surround the arteries and veins of the organ. The inner set of fibres forms the thickest part of the muscular coat. They are arranged in concentric rings around the sides of the fundus, from the place of junction of the Fallopian tubes to the middle of the body. In the cervix and around the external and internal os, they are arranged circularly, and form the sphincter muscles of those regions. The increase in size of the muscular coat during pregnancy is due to the formation of additional fasciculi, and to a considerable increase in size of the muscular fibre-cells.

The *mucous membrane* lining the uterus presents different appearances in the cervix and in the body of the organ. In the cervix it is elevated into two longitudinal

ridges, one on the anterior and the other on the posterior wall, to which a number of shorter ridges, directed obliquely downwards, converge, the whole forming an appearance known as the plicæ palmatæ or *arbor vitæ*. The epithelial covering of the mucous lining of the cervix is not at all times the same. In the virgin it consists of ciliated columnar cells, which extend as far as the os externum, where a squamous and stratified epithelium, like that of the vagina occurs. After the first pregnancy the ciliated epithelium is confined to the upper half or two-thirds of the cervical canal, whilst the lower part is lined with stratified squamous cells. In the lower part of the cervix vascular papillæ project into the epithelium. Simple and branched mucous follicles, lined by a ciliated columnar epithelium, open into the cervix, and in addition clear vesicles, filled with a yellowish fluid, and named the *ovula Nabothi*, are also found. In the pregnant uterus the glands of the cervix secrete a tenacious mucous, which plugs up the os and cervix.

The mucous lining of the body of the uterus is smooth and thin, and so closely set on the muscular coat that a definite submucous coat can scarcely be said to exist. It is covered by a ciliated columnar epithelium, the cells of which are not very elongated. Numerous small openings exist on the free surface of the mucosa, which are the mouths of the utricular glands. When vertical sections are made through the uterine wall, the utricular glands are seen to be elongated tubes, which branch once or twice in the course of their extent. It is not unusual to see two neighbouring glands join close to the free surface of the mucosa, and open by a common aperture. The glands do

not lie vertically to the free surface, as is represented in the well-known diagram by E. H. Weber, but run obliquely, or even in a slightly convoluted manner, so that in vertical sections they are often cut across, and only portions of the length of any single gland can usually

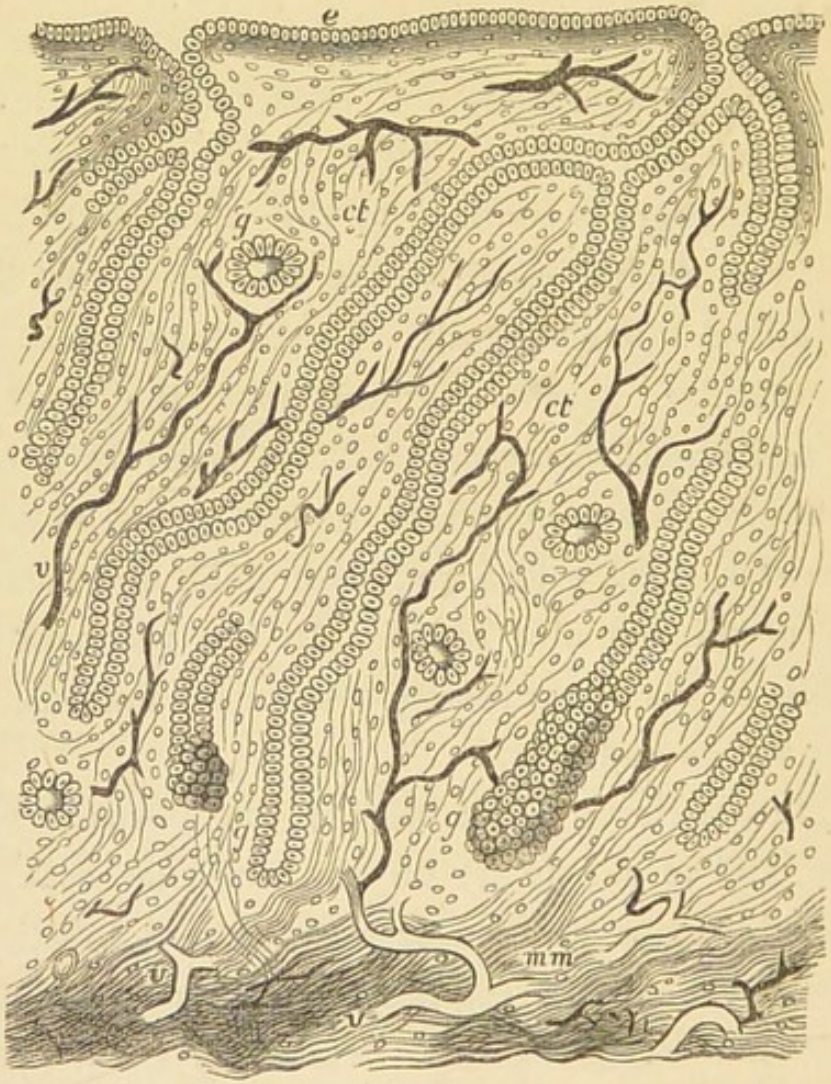

Fig. 232.—Vertical section through the mucous membrane of the Human Uterus. *e*, columnar epithelium—the cilia are not represented; *g*, *g*, utricular glands; *ct*, *ct*, interglandular connective tissue; *v*, *v*, blood-vessels; *m*, *m*, muscularis mucosæ. × 450.

be seen. The closed ends of the glands reach as far as the innermost layer of the muscular coat, which sends prolongations around the deep end of the gland, and repre-

sents therefore, as J. Williams has stated, the muscularis mucosæ of the alimentary mucous membrane. The glands are lined by a columnar epithelium. In 1846 Allen Thomson observed, though he did not record the fact, that the epithelial lining of the uterine glands in the sow was ciliated. In 1852 Leydig published an account of the ciliated epithelium of the glands in this animal. Since that time Lott has recognised it in the cow, sheep, rabbit, mouse, and bat, and more recently Friedländer and J. Williams have observed it in the human female. The interglandular connective tissue contains multitudes of oval and elliptical corpuscles, which from their number give a marked character to the structure. In this tissue are distributed small arteries and veins, united together by a capillary plexus, which is distributed around the tubular glands.

The uterus receives its supply of blood from the two ovarian branches of the aorta and the two uterine branches of the internal iliac arteries. The uterine arteries reach the uterus at the sides of the cervix, and ascend in relation to the borders of attachment of the broad ligament, giving off numerous branches into the muscular wall. The ovarian arteries enter the folds of the broad ligaments, and not only give branches to the ovaries and Fallopian tubes, but send each a large branch to the side of the uterus, which supplies its wall in the region of the fundus, and freely inosculates with the uterine artery. The branches of the arteries in the muscular wall are tortuous, and the number and tortuosity of the branches increase greatly during pregnancy. The uterus is provided with numerous veins, which are thin walled, without valves,

and lie in close relation to the muscular fasciculi. They freely communicate with each other and give rise to the uterine and ovarian plexuses of veins. During pregnancy the veins within the muscular coat increase greatly in size, and form a cavernous-looking arrangement in the muscular wall. Lymphatic vessels form a network in the muscular wall, from which larger lymphatics proceed, that pass between the layers of the broad ligaments. From the observations of Leopold, it would appear that lymph spaces exist between the bundles of connective tissue of the mucosa, the walls of which spaces are formed of the flattened endothelial cells investing those bundles, and that similar endothelial sheaths invest the glands and blood-vessels. The nerves of the uterus arise from the hypogastric and spermatic plexuses of the sympathetic, and from the 3rd and 4th sacral nerves. Their arrangement and distribution have been investigated by Tiedemann, Robert Lee, Snow Beck, and Frankenhäuser. They form numerous plexuses, in which both medullated and non-medullated nerve fibres and nerve cells are found. They are distributed in the muscular wall, and Frankenhäuser states that the fibres can be traced into the nuclei of the contractile muscular fibre-cells. By some authors the nerves are said to increase in size during pregnancy.

THE VAGINA.

The vagina is the tube which extends from the uterus to the vulva. It is about 5 inches long, and curves from above downwards and forwards. Posteriorly it is related to the rectum, from which it is separated, in the greater part of its extent, by the thin recto-vaginal layer of the pelvic fascia, whilst between its upper end and the rectum is the bottom of the pouch of Douglas, lined by the peritoneum. Anteriorly it is related to the bladder and urethra, the latter of which is imbedded in the anterior wall of the vagina. Laterally, the levatores ani muscles and the visceral layer of the pelvic fascia are attached to it. This fascia gives a thin prolongation in front of the vagina, which at the same time encloses the urethra. The upper end of the vagina embraces the cervix uteri, and extends in a marked degree higher up behind than in front, so that the protrusion of the posterior lip of the os uteri into the vagina is much greater than that of the anterior lip. The lower end of the vagina opens in the vulva, at the bottom of the vestibule between the two nymphæ, and behind the orifice of the urethra; the diameter of this opening is somewhat less than that of the tube of the vagina.

Structure.—The vagina possesses an external coat of connective tissue derived from the pelvic fascia. Beneath this coat is the muscular coat, formed of fasciculi of non-striped muscle, arranged both longitudinally and circularly, which are continuous above with the muscular wall of the uterus. The inner coat is formed of the

mucous membrane which is elevated in the virgin into two longitudinal folds, one on the anterior, the other on the posterior wall, and into numerous transverse folds; these folds almost entirely disappear in women who have borne several children. The free surface of the mucosa is covered by a stratified squamous epithelium, into which numerous papillæ project. The ducts of numerous small mucous glands and follicles open into it; lymph corpuscles and lymph follicles are also scattered through it. It is supplied with blood by branches of the uterine, vesical, and vaginal arteries, derived from the internal iliac. The veins corresponding to these arteries form a vaginal plexus around it. Lymphatic vessels form plexuses in its wall. Its nerves, derived from the hypogastric plexus of the sympathetic, and from the 4th sacral and pudic nerves, also form plexuses in which are numerous microscopic ganglia.

The external orifice of the vagina is, in the virgin, to a large extent closed up by a fold of the mucous membrane, named the *Hymen*. This membrane does not form a complete partition, but is usually semilunar in shape, with the concave free border directed towards the pubes. At times the hymen passes completely round the orifice of the vagina, when it is pierced by a circular opening near the centre. In rare cases the hymen is imperforate. The hymen is ruptured in the act of copulation, and its remains form some papillary elevations around the orifice of the vagina called *carunculæ myrtiformes*.

The *Bulbo-cavernosus muscle*, or *compressor bulbi*, surrounds the orifice of the vagina and the wall of the vestibule. It is formed of striped muscle, which arises from

the central tendinous point of the perineum and from the perineal septum, to which are also attached the sphincter ani, transversi perinei, and levatores ani muscles. Its fasciculi run forwards and embrace the bulb of the vestibule, and are inserted into the crus clitoridis and into the upper part of the bulb. As its most anterior fibres are in relation to the urethra in the vaginal wall, Luschka regards it also as a sphincter of the urethra (fig. 233).

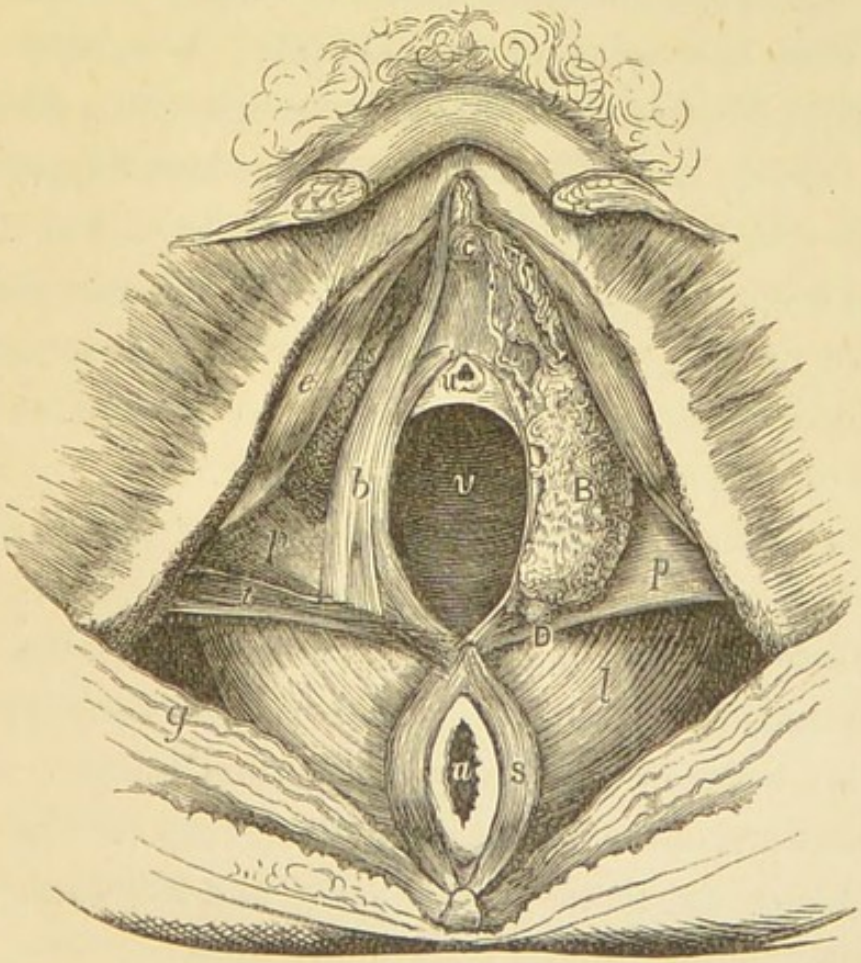

FIG. 233—Dissection of the female Perineum. *a*, anus; *v*, vagina; *u*, urethra; *s*, sphincter ani externus; *l*, levator ani; *g*, gluteus maximus; *p*, *p*, perineal septum; *t*, transversus perinei muscle; *b*, bulbo-cavernosus muscle; B, vestibular bulb; D, gland of Duverney; *c*, clitoris; *e*, erector clitoridis muscle. Modified from Savage.

The VESTIBULE is the interval between the nymphæ, in which the orifices of the urethra and vagina are situated.

At the orifice of the urethra are some slight folds of the mucous membrane. The *Nymphæ*, or labia minora, are two muco-tegumentary folds, which lie one on each side of the vaginal orifice, and form the lateral walls of the vestibule. When they are removed the bulbo-cavernosus muscle is exposed, and situated partially under cover of each half of this muscle is a highly vascular structure, the *Bulb* of the vestibule. The vestibular bulb is about one inch long, and consists of a complicated venous erectile network, the veins from which communicate with the vaginal plexus of veins and with the veins of the clitoris. A smaller venous plexus in front of the bulb has been named by Kobelt the pars intermedia. The two vestibular bulbs represent, in the female, the two halves of the erectile part of the bulb in the corpus spongiosum penis. The muco-tegumentary surface of the nymphæ is covered by a squamous and stratified epithelium, and opening on its surface are the ducts of numerous small mucous glands.

Two glands, named the *Glands of Bartholini, or Duverney*, or the *vulvo-vaginal* glands, open each by a long duct into the vestibule close to the orifice of the vagina. These glands vary in size from a pea to a small almond, and lie between the transversi perinei muscles and the posterior end of the bulbus vestibuli. They are homologous with Cowper's glands in the male, and like them possess the compound racemose type of structure.

At the anterior part of the vestibule is situated the *Clitoris*, a structure about $1\frac{1}{2}$ inch long, which represents in the female the penis of the male, but has no urethra enclosed in it. It is attached to the sides of the pubic arch by two crura, which become the corpora cavernosa

clitoridis and form the body of the clitoris. The anterior end of the clitoris forms a small and imperforate glans, which is invested on its superior surface by a preputial fold of the integument. The clitoris resembles in structure the penis. Each crus clitoridis is covered by an erector clitoridis muscle, that arises from the ischial tuber, and is inserted into the corpus cavernosum.

The clitoris, nymphæ, vestibule, and the orifices of the urethra and vagina are enclosed between two folds of the integument named *Labia majora*, or labia pudendi, which unite in front and behind at the anterior and posterior commissures. Immediately in front of the posterior commissure is a transverse muco-tegumentary fold named the *fourchette*. In front of the labia, the skin is elevated in front of the pubes into an eminence, the *mons Veneris*. The mons and the outer surface of the labia are covered with hairs.

THE MAMMARY GLANDS.

The Mammary Glands are accessory structures to the Reproductive system, and, at the termination of utero-gestation, are engaged in the secretion of milk for the nutrition of the infant. They are two in number, and are situated one in each pectoral region. They form the rounded eminences named the breasts, and occupy in woman, when gravid or nursing, the region from the 3rd to the 6th ribs, and from the side of the sternum to the axilla. From about the centre of each breast the nipple projects, the base of which is surrounded by a pigment-stained ring or areola. The superficial surface of the gland

is in relation to the skin and subcutaneous fatty fascia; its deep surface rests on the aponeurosis covering the greater pectoral muscle.

The mammary gland is divided into primary lobes, separated from each other by lobules of fat. Each primary lobe is sub-divided into secondary lobes, and these again into lobules, whilst the lobules consist of rounded acini or gland vesicles. From these lobules slender branched ducts arise, and the ducts from adjacent lobules join together to form larger ducts, these again join to form still larger ducts, until at length from 15 to 20 large-sized milk ducts are formed, which converge to the nipple to open on its surface by as many orifices. Prior to entering the nipple the ducts dilate into sinuses, in which the milk collects during lactation.

The mamma is a compound racemose gland. The ducts are lined by an epithelium composed of short columnar cells. In the virgin the secreting cells within the acini are also columnar, but during lactation they swell out into polyhedral cells, and the gland vesicles at the same time become more dilated.

The gland is supplied with blood by the perforating branches of the internal mammary artery, the aortic intercostals, and the external mammary branch of the axillary artery, which end in capillary plexuses around the gland vesicles. Corresponding veins accompany these arteries. The anterior and lateral cutaneous nerves give branches to it.

In the male the gland is rudimentary, and the nipple, though small, is always present. Cases have been known in which the male mamma has developed so as to secrete

milk. Sometimes in young men at the time of puberty the mamma swells out a little and secretes a little thin fluid. Supernumerary mammæ in the human subject have been recorded by W. Gruber, P. D. Handyside, and other anatomists.

Development of the Urinary and Reproductive Systems.

The Urinary and Reproductive Organs have close relations to each other, not only after their formation is completed, but in the region of their development.

In the early embryo the following structures are found in the abdominal region on each side of the mesial plane:—A Wolffian body; an excretory duct of the Wolffian body; a small body situated at the summit of the Wolffian body; a genital gland; a slender tube named the Müllerian duct lying on, but not communicating with, the Wolffian body.

The *Wolffian bodies* appear in the human embryo about the 3rd week as thickenings of the mesoblast lying in relation to the ventral surfaces of those protovertebræ, which correspond in position to the abdominal region. The mesoblast cells, out of which they proceed, lie between these protovertebræ and the line of division of the mesoblast into somato-pleure and splanchno-pleure, where they form a mass named the *intermediate cell-mass.* In the cell mass a tube or duct appears, from which diverticular offshoots arise, as a series of short convoluted tubes with vascular glomeruli, not unlike the structure of the kidney. From this resemblance in structure the Wolffian bodies are often called the *primordial kidneys.* The duct of each Wolffian body opens into the cloaca. After fulfilling until about the 6th or 7th week of embryonic life the office of kidneys, the Wolffian bodies atrophy, so that at the time of birth scarcely any trace remains. In the adult male the body known as the organ of Giraldès and the vas aberrans are the representatives of the Wolffian body; whilst in the adult female some fragments of tubes, called the grains of Folin, near the par-ovarium, are its persistent representatives.

The *permanent kidneys* arise from a mass of mesoblast cells situated in relation to the dorsal aspect of the Wolffian duct. As this mass increases in size it becomes hollowed out into minute tubes, the rudiments of the uriniferous tubes, which, as growth and development proceed, elongate and form the characteristic tubular structures of the kidney. These tubes then communicate with a tube, arising apparently in connection with the mesoblast, which becomes the ureter.

The *urinary bladder* is formed by a dilatation of that part of the allantois, which, by the development of the abdominal walls, be-

comes enclosed within the abdominal cavity. The allantois itself appears as a hollow bud-like diverticulum from the primitive hind gut, and grows not only into the pleuro-peritoneal cavity, but beyond the body cavity, so as to come into contact with the outer envelope of the ovum, and assist in the formation of the secondary or persistent chorion. The wall of the allantoic bud consists externally of cells derived from the mesoblast, which develop into a vascular connective tissue, and internally of cells derived from the hypoblast, which form the epithelial lining of the sac of the allantois, and are continuous with the hypoblast epithelial lining of the primitive hind gut. As the development of the walls of the abdomen advances, the part of the allantois connecting its extra-abdominal and intra-abdominal portions becomes attenuated into a slender peduncle, until finally, in the human subject, all communication between the two disappears. The intra-abdominal part of the sac becomes the urinary bladder, and the attenuated peduncle forms the urachus.

The *Genital Glands* in the two sexes arise in close relation to the Wolffian body from the same intermediate cell mass. The development of the *ovary* and *ova* has already been described (p. 832), and it has been shown that the ova arise by an involution and subsequent development of the germ-epithelium corpuscles covering the surface of the intermediate cell mass, in the seat of development of the ovary ; whilst the vascular stroma of connective tissue, the walls of the Graafian follicles, and the cells of the membrana granulosa, proceed from the subjacent structures continuous with the interstitial tissue of the Wolffian body.

The *Testicle* is also produced in the same locality, but its tubular gland structure apparently proceeds from a differentiation of the cells of the subjacent interstitial tissue, and not from the superficial germ-epithelium, which loses its columnar form and probably becomes the squamous endothelium of the visceral layer of the tunica vaginalis testis. In the human embryo the sexual distinctness of the genital glands is said to be apparent about the 7th and 8th week, and, from Kölliker's observations, the tubes of the testicle can be recognised about the 10th week. Subsequently they grow longer, branch, assume their characteristic arrangement and structure, and form the tubuli seminiferi of the lobes of the testis, the vasa recta, and the rete testis. The more superficial parts of the interstitial tissue differentiate into the connective tissue of the tunica albuginea.

The small body situated at the summit of the Wolffian body

was first recognised as distinct from the Wolffian body by J. Cleland, and its structure has been investigated both by him and by W. M. Banks. It is formed of tubes, 12 to 18 in number, which run transversely from without inwards, and are slightly wavy in their course. Their outer ends are connected together by a common tube. This body does not contain glomeruli such as are formed in the Wolffian body. According to Banks, this body is converted in the male into the vasa efferentia, coni vasculosi, and globus major of the epididymis, and its tubes become continuous with those of the rete testis. In confirmation of this opinion of Banks's, I may refer to a congenital malformation that I described in 1865, in which the globus major was absent, and the testicle was not continuous with the body and globus minor of the epididymis. In this case the genital gland and the duct of the Wolffian body had been developed, but the small body at the summit of the Wolffian body had either not been developed, or had atrophied, so that the communication between the testicle and epididymis had not been established. In the female the small body becomes converted into the par-ovarium.

The *excretory duct of the Wolffian body* becomes dissociated from the proper tubes of that structure. In the male it is converted into the body and globus minor of the epididymis, the vas deferens, and the common ejaculatory duct, whilst the vesicula seminalis arises as a diverticular prolongation from it. The vas aberrans is probably a persistent portion of the tubular structure of the Wolffian body, which preserves its communication with the excretory duct, now converted into the tube of the epididymis. The tube of the body of the epididymis becomes continuous with that of the globus major. In the male, therefore, the excretory duct of the Wolffian body is converted into an important part of the genital apparatus. In the female, again, this duct almost entirely disappears, but it forms in certain animals the tubes called the *canals of Gaertner*.

The *Duct of Müller* is a slender tube, which is formed by an involution of the epithelium covering the intermediate cell mass, along a line immediately internal to the duct of the Wolffian body. The Müllerian duct opens at its anterior end into the peritoneal cavity, and as it passes backwards it lies in close relation to the Wolffian duct. The Müllerian and Wolffian ducts of the two sides become incorporated into a cord, named by Thiersch the *genital cord*, in which each tube is at first distinct. After a time the two Müllerian ducts become fused together posteriorly, and

form a common passage for a considerable distance ; but at their anterior ends they always remain distinct. The further development of the Müllerian ducts varies materially in the two sexes. In the male they almost entirely disappear, and are represented in the adult by the pedunculated hydatid of Morgagni, situated at the summit of the testicle, which is the persistent remains of the anterior end of the duct, and by the vesicula prostatica, which is the conjoined portion of the posterior ends of the two ducts that had coalesced in the genital cord. Banks is of opinion that the small cysts, sometimes situated alongside of the epididymis, may also be remains of the anterior part of the Müllerian duct.

In the female the ducts of Müller become greatly developed, and form the genital tubes and passages. The anterior end of each duct remains distinct, and becomes the Fallopian tube, whilst the posterior coalesced portions are converted into the uterus and vagina. The greater or less extent of this coalescence accounts for the production of the simple uterus, or the several varieties of double uteri that occur in different mammals, or that are found as variations in the human female. The tissue of the genital cord, which surrounds and connects together the Wolffian and Müllerian ducts, becomes converted in the male into the prostate gland, and in the female into the intermediate tissue between the urethra and vagina.

In both sexes the genital, urinary, and intestinal tubes open on the perineal surface of the embryo by a common outlet, or *cloaca*, up to the seventh or eighth week of embryo life. A partition then forms in this cloaca, which divides it into a posterior or anal part, and an anterior part, named the *uro-genital sinus*, which serves as a common space for the termination of the urinary Wolffian and Müllerian ducts. The female urethra and the prostatic part of the male urethra, situated above the vesicula prostatica and the orifices of the ejaculatory ducts, are formed from that part of the urogenital sinus which lies above the orifices of the Müllerian and Wolffian ducts ; whilst the lower part of this sinus ultimately forms the vestibule in the female, and the lower part of the prostatic and the membranous part of the urethra in the male.

A fold appears at the front of the uro-genital sinus, named the *genital eminence*, which differentiates into the penis or clitoris. In the male it is grooved on its under surface, and this uro-genital groove, by the development of a pair of folds, which grow together to meet below in the mesial line, subsequently closes in to form

the corpus spongiosum urethræ. In the female this closure does not occur, but the folds grow downwards and increase in size to form the nymphæ. The urethra has therefore no relation to the clitoris, but opens independently into the vestibule, or persistent lower part of the uro-genital sinus. The bulbs of the vestibule represent the bulbous part of the male corpus spongiosum, but from the absence of a corpus spongiosum urethræ in the female, they do not meet in the mesial line and remain as independent bilateral bodies.

At the sides also of the uro-genital sinus folds of integument arise. In the female they form the labia majora, and are separated from each other by the vertical fissure which communicates with the vestibule ; whilst in the male the two folds meet in the middle line of the perineum to form the scrotum, the line of union being permanently marked by the raised raphé of the scrotum.

In the development of the external organs of generation the female does not present so perfect a mesial union of the originally bilateral folds as takes place in the male, so that the female does not make so great an advance, but preserves certain arrangements which represent a transitional stage in the male development. The development of the internal organs in the two sexes shows much more important divergences. Thus in the formation of the male genital passages, whilst the Müllerian duct takes no part, the Wolffian duct is of primary importance. In the female, again, the genital passages are dilatations of the Müllerian ducts, and the Wolffian ducts do not contribute to their production. The genital glands, again, though arising in both sexes from the intermediate cell mass, yet owe their essential constituents to different portions of that mass of cells. For whilst the ova are special differentiations of the corpuscles of the germ epithelial layer on its surface, the seminal tubes, with their contents, are derived from the subjacent sub-epithelial tissue.

Owing to these differences in the development of the sexual apparatus in the male and female, the possibility arises of individuals being produced, possessing in a more or less strongly marked degree the characters of the two sexes. For example, the want of union of the two halves of the scrotum in the mesial line of the perineum would cause a mesial vertical cleft between the two lateral folds of integument ; if this were conjoined with the want of union of the two lateral halves of the uro-genital groove, the urethra would open, not at the end of the penis, but in the vertical mesial cleft. Externally, therefore, the individual might appear to have the

characters of a female, although the testicles might be present in the divided scrotum, and the ovaries and uterus be absent.

Again, in an individual otherwise possessing the characters of a male, if the Müllerian ducts were not to atrophy, but to undergo a certain commensurate enlargement, the prostatic vesicle would not appear as a rudimentary structure, but would exhibit, to a greater or less degree, the external characters of a vagina and uterus, situated between the rectum and the bladder.

The difference in the mode of development of the testicle and ovary also lends countenance to the possibility of both kinds of glands being produced in the same individual, a condition which has occasionally been seen in certain fish, as the codfish and herring, but examples of the occurrence of which have not been so definitely ascertained in the higher vertebrates.

It may, however, be stated that a structure sometimes found closely attached to the outer surface of the human testicle, and named by Luschka the non-pedunculated hydatid of Morgagni (to distinguish it from the pedunculated hydatid of Morgagni near the head of the epididymis), is, by the recent researches of Fleischl, in all probability the rudimentary *ovarium masculinum*. Its outer surface is covered by a cubical or short cylindrical epithelium, distinct from the squamous endothelium of the surrounding tunica vaginalis, which is involuted to some extent into its substance. Its proper substance consists of connective tissue, with convoluted canals, lined by a cubical or short cylindrical ciliated epithelium. Hence in the male a rudimentary representative of the ovary may be present, though functionally inactive.

The *Mammary glands* are developed in connection with the integument of the pectoral region. It has been customary to regard the epithelial lining of the ducts and gland vesicles as arising from an involution of the cells of the cuticular epiblast, whilst the ducts and the vascular connective tissue of the lobes proceed from the subjacent mesoblast. From the recent observations of C. Creighton, it would appear that the acini of the gland arise at many separate points quite independent of the ducts, and develope from the same kind of cells which give origin to the fatty tissue. The ducts themselves are formed by the aggregation of embryonic cells along certain lines, and are formed before the acini, with which they subsequently become continuous. Creighton's observations on the development of the mamma support Goodsir's view of gland development, according to which a gland is originally a mass of nucleated cells, the progeny of one or more parent cells;

whilst the membrane in connection with the embryo gland may, or may not, be prolonged in the form of a hollow cone into the mass; but, whether this happens or not, the extremities of the ducts are formed as closed vesicles, and then nucleated cells are formed within them, and are the parents of the epithelium cells of the perfect organ.

CHAPTER XIII.

THE PLACENTA.

THE impregnated ovum undergoes within the cavity of the uterus those structural changes which lead to the development of the embryo, and the formation of the placenta. The placenta is the organ that serves as the medium of connection, during intra-uterine life, between mother and fœtus, and in which the physiological processes take place that are concerned in the nutrition of the fœtus.

The placenta is a compound organ, and consists of two series of structures, the one belonging to the fœtus, the Fœtal Placenta; the other to the mother, the Maternal Placenta. In the diffused form of placenta occurring in the Pig, Mare, Zebra, Cetacea, Manis, Lemurs, and Camels, and in the Cotyledonary form of placenta of the typical Ruminants, the fœtal and maternal parts of the placenta can be readily separated from each other. But in the zonary form of placenta occurring in the Carnivora, Hyrax, and the Elephant; in the dome-shaped placenta of the Sloths and in the discoid placenta of the Rodentia, Insectivora, Cheiroptera, Quadrumana, and the Human female, the fœtal and maternal structures are much more intimately blended with each other.

The FŒTAL PLACENTA is formed of certain membranes,

named chorion, amnion, allantois, and umbilical vesicle, the mode of formation of which will now be considered.

When the ovum becomes fertilised by the penetration of spermatozoa through the zona pellucida, developmental changes take place in it, which lead to the production not only of the embryo, but of the fœtal membranes. The yelk undergoes cleavage, and becomes subdivided into multitudes of minute cells, each consisting of a nucleated clump of protoplasm. These cells form, immediately within the zona pellucida, a cellular membrane, the blastoderm, which surrounds the undifferentiated central part of the yelk, assumes a vesicular form, and is named the *blastodermic vesicle.* At one part of the blastoderm a roundish white spot then appears and forms the *area germinativa,* or area of formation of the future embryo. Commencing at the area germinativa the blastoderm splits into two layers, an outer, epiderm or epiblast, and an inner, hypoderm or hypoblast. Subsequently a third or intermediate layer is formed, the mesoderm or mesoblast.

Whilst these changes are taking place in the cells derived from the differentiation of the yelk, the zona pellucida, which was at first quite smooth, gives rise, at least in the dog and rabbit, to numerous short, simple villi, which form the villi of the *primitive chorion.* Whether or not similar villous outgrowths project from the zona pellucida of the human ovum has not yet been determined. These villi are, like the zona itself, perfectly structureless, and their apparent object is to attach the ovum in the early stage of gestation to the surface of the uterine mucous membrane. In a short time the primitive chorion disappears, and is replaced by the secondary or

permanent chorion, which forms the outer envelope of the embryo, and is the proper medium of attachment to the wall of the uterus.

The mode of origin of the *secondary* or *persistent chorion* has now to be considered.

From the margin of the area germinativa a delicate fold arises, which, by becoming more and more elevated, gradually extends itself above the back of the young embryo, until at last the folds from opposite sides meet in the middle line, become continuous with each other, and form the membrane of the *amnion*. Between the amnion and the back of the embryo is a space, the cavity of the amnion, which increases in size by the secretion of the liquor amnii into it. The amnion consists of two layers, an outer and an inner, and as it is derived from the area germinativa it is necessarily continuous with the blastoderm. The inner layer of the amnion, which lies next the amniotic cavity, consists of tessellated epithelial cells, is derived from the epiblast, and is continuous with the cuticular layer of the embryo. The outer layer of the amnion is a thin stratum, continuous with the somatopleure layer of the mesoblast, and formed of stellate and spindle-shaped cells, like the corpuscles of embryonic connective tissue. The amnion is the most internal of the fœtal membranes, and forms an ovoid bag in which the fœtus and liquor amnii are contained.

But before the amniotic folds meet to become continuous with each other, the free edge of each fold is bent outwards, and, by a continuous process of growth, gradually spreads around the ovum, immediately within the zona pellucida, so as to form a layer, which was named by Von

Baer the serous envelope of the ovum, but which may more appropriately, from its position within the zona, be named the *sub-zonal membrane.* When the union of the amniotic folds has taken place, the sub-zonal membrane becomes completely severed from the proper amnion, and constitutes one of the layers of the secondary or persistent chorion. The sub-zonal membrane consists essentially of a layer of cells, which was originally continuous with the cellular layer lining the inner surface of the proper amnion, and through it with the epiblast cells forming the cuticular covering of the embryo. But it is not unlikely that, along with this cell-layer, a thin prolongation of the layer of stellate connective tissue corpuscles of the somato-pleure layer of the mesoblast is present. Between the sub-zonal membrane and the proper amnion a space exists, continuous with the general pleuro-peritoneal cavity of the embryo, which is of interest, in connection with the formation of the permanent chorion, as the space into which the allantois grows and expands.

Whilst the changes in the epiblast and somato-pleure, which lead to the formation of the amnion and sub-zonal outer layer of the persistent chorion, are taking place, the hypoblast and adjacent splanchno-pleure gradually extend over the undifferentiated part of the yelk, which they enclose in a sac, the *yelk-sac,* or *umbilical vesicle,* and at the same time they form along the ventral surface of the embryo an elongated tube, the alimentary canal. This canal at first freely communicates with the yelk-sac, but as the walls of the alimentary canal thicken and become more closed in, the communication narrows, until at length the omphalo-mesenteric duct forms the only channel

of communication between the umbilical vesicle and the intestine. In the splanchno-pleure forming the wall of the umbilical vesicle, and in the corresponding wall of the alimentary tube, blood-vessels are developed. As that pole of the umbilical vesicle, which lies opposite the omphalo-mesenteric duct reaches, and is, and at an early period of its development, in contact with a limited area of the sub-zonal membrane, the blood-vessels in the wall of the vesicle may be, and in some mammals are, conveyed by it up to the sub-zonal membrane.

In some mammals, as in the Pig, Mare, Cetacea, and Ruminantia, the umbilical vesicle disappears as development advances, so that no trace of it can be seen in the membranes of an advanced embryo. In others, as the Human subject, it persists, according to Schultze, even up to the end of intra-uterine life, as a minute vesicle at the placental end of the umbilical cord. In the Carnivora and Pinnipedia again it forms a well-defined sac, in relation to the abdominal aspect of the fœtus, situated between the allantois and amnion, and prolonged laterally into two horns. In the Bitch I have seen its vessels persistent, and forming a well-defined plexus in its wall, though they did not reach the chorion. In the Rabbit, and probably also in other Rodentia, the umbilical vesicle reaches the chorion, and forms a large sac in contact with a considerable portion of that membrane, to which it conveys blood-vessels: but the discoid placenta of the rabbit apparently derives its fœtal vessels only from that part of the chorion which receives its vascular supply from the allantois.



An important change also takes place at the pelvic end

of the alimentary tube. The small vesicular outgrowth, named the *allantois*, rapidly increases in size, grows into the space between the umbilical vesicle, amnion and sub-zonal membrane, and becomes more or less intimately united with these structures, but more especially with the sub-zonal membrane, and its extra-abdominal part forms a dilated bag, the sac of the allantois, which contains the allantoic fluid. This sac keeps up its continuity with the urinary bladder by a slender tubular stalk, the urachus, which passes through the abdominal wall at the umbilicus. The wall of the sac of the allantois, having reached the inner surface of the sub-zonal membrane, spreads itself over the whole, or a great part of that surface, and forms the inner layer of the permanent chorion. The allantois is lined by an epithelium continuous with the hypoblast epithelial lining of the intestine, whilst external to the epithelium is a layer of connective tissue, continuous with and derived from the splanchno-pleure layer of the meso-blast. In this connective-tissue layer blood-vessels are developed, which are continuous with the abdominal ves-sels of the embryo. When the sac of the allantois reaches the sub-zonal, or external, layer of the permanent chorion, the blood-vessels are necessarily brought there at the same time, and, as the allantois grows to form the inner layer of the chorion, its blood-vessels become the vessels of the permanent chorion, or the vessels of the fœtal placenta. These vessels increase in size and numbers with the growth of the chorion, their trunks become the umbilical arteries and vein, they enter into the formation of the umbilical cord, and pass into the abdominal cavity, at the umbilicus, to join the aorta and inferior vena cava.

There are thus four structures, of which one is developed at the periphery of the ovum, whilst the remaining three

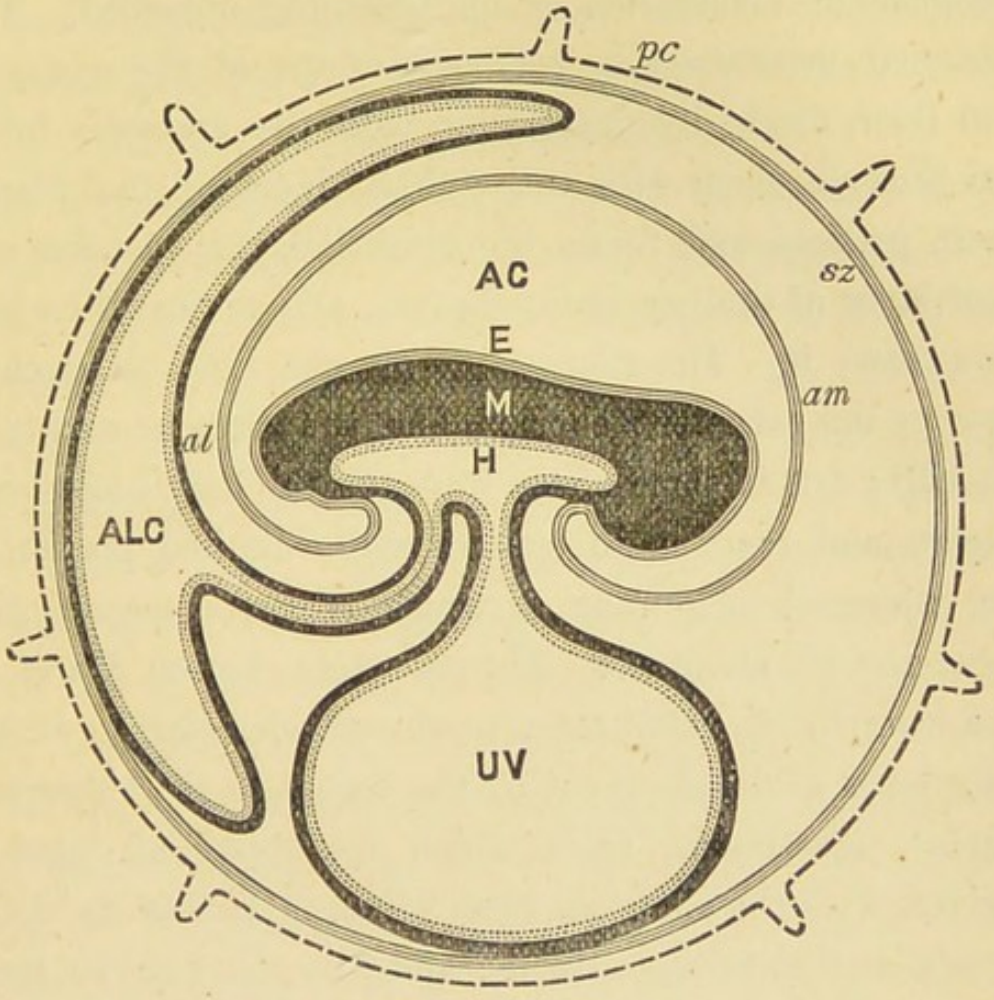

FIG. 234.—Diagram of the Fœtal Membranes. Structures which either are, or have been at an earlier period of development, continuous with each other are represented by the same character of shading. *pc*, primitive chorion with its villi; *sz*, sub-zonal membrane; E, epiblast, or cuticular covering of embryo continuous with *am*, the amnion; M, mesoblast forming the bulk of the body of the embryo, and prolonged into the wall of the sac of the Allantois *al*, and into the wall of the Umbilical Vesicle UV. H, hypoblast forming the epithelial lining of the intestinal tube and prolonged into the wall of the sac of the Allantois and of the Umbilical Vesicle; AC, cavity of Amnion; ALC, cavity of Allantois.

ultimately reach the periphery, which from their position may enter into the formation of the persistent chorion, or outer envelope of the fœtus: viz., the zona pellucida, the sub-zonal membrane, the allantois, and the umbilical vesicle. The structureless zona, with its simple structureless villi, which together form the primitive chorion, very early dis-

appears, either by becoming incorporated with the sub-zonal membrane, so as no longer to be recognised as an independent membrane, or by becoming absorbed. The sub-zonal membrane, or serous envelope of the ovum of Von Baer, originally continuous with the amniotic folds, and through them with the epiblast layer of the blastoderm, persists, and forms the epithelial, non-vascular epiblast layer of the persistent chorion, and of the villi which grow from it. The allantois forms the inner or vascular layer of the persistent chorion, and the vascular matrix of the villi; but in some of the Rodentia, the umbilical vesicle reaches and remains in contact with a limited portion of the sub-zonal membrane, to which it conveys connective tissue and blood-vessels. The persistent chorion, therefore, is a compound membrane, produced secondarily during the process of development by the union of the sub-zonal, epiblast membrane, from which its epithelial layer is derived, with the allantois, from which it derives its blood-vessels and connective tissue; and like the embryo itself it arises from the layers of the blastoderm.

The allantois undergoes considerable modifications in both size and general disposition in the different orders of mammals. In many mammals, as the Pachydermata, Ruminantia, Cetacea, Carnivora, Pinnipedia, the Lemurs, and the Scaly Anteaters (*Manis*), the sac of the allantois persists as a distinct chamber, and contains a considerable quantity of allantoic fluid. Of the opposite walls of the sac, the one lines, to a greater or less extent, the inner surface of the permanent chorion, which is coated therefore by the epithelial lining of the allantois; the other invests, to a greater or less extent, the outer surface of

the amnion, which is covered therefore, in whole or in part, by the wall of the sac of the allantois. As a consequence of this arrangement, the bag of the amnion in these mammals is altogether, or in great part, separated from the inner surface of the permanent chorion.

So large and persistent is the sac of the allantois in the ordinary Ruminantia, in the Camelidæ, Tragulidæ, Solipeda, and cloven-hoofed Pachydermata, that M. H. Milne-Edwards has grouped them together as *Megallantoids;* whilst he has placed the Carnivora and Pinnipedia, from the smaller size of the sac of the allantois, in a *Mesallantoid* legion of mammals. The Rodentia, Insectivora, Cheiroptera, Quadrumana, and Man are characterised by the small size of the sac of the allantois, or even by its complete disappearance as an independent chamber: hence Milne Edwards has grouped them together in a *Micrallantoid* legion. The disappearance of the allantois as a distinct sac is correlated with the great expansion of the amnion, and increase in the amount of amniotic fluid. As the bag of the amnion expands it grows outwards towards the chorion, and in the Sloths, the Apes, and the Human Female, reaches, and adheres, through the intermediation of a gelatinous connective tissue, to the inner surface of that membrane, so that when the chorion is cut through, the amnion is at once exposed.

The chorion is the most external of the fœtal membranes. When first formed, it is globular or ovoid in shape. In uniparous mammals, as the Sloths, the Apes, and the Human Female, where the uterus is single, it preserves, with but little alteration, this form throughout intra-uterine life; but in most uniparous mammals, where the uterus

possesses two horns, the chorion becomes greatly elongated, and extends as far as the ends of both horns.

In the Human ovum all trace of the zona pellucida has disappeared before the 10th day, and the secondary chorion, as Reichert's observations show, is then an epitheliated membrane, with unbranched villi projecting from, but not completely covering, its outer surface. At the 2nd week the chorion is covered with villi, which at the 3rd week are branched, and about the 4th week have acquired blood-vessels, from the growth into them of the vessels of the allantois. About the 6th week some of the villi begin to atrophy, and at the end of the 2nd month, when the ovum has attained the size of a hen's egg, the villi have disappeared from one pole, and are arranged over a discoid surface, which represents the placental area throughout the remaining period of gestation. In the mature placenta the villi are very arborescent, and extend from the chorionic to the decidual surface; the terminal branches, which lie next the decidua, being attached to the placental surface of that membrane. The chorion and the basis substance of each villus are formed of a gelatinous connective tissue continuous with a similar tissue in the umbilical cord. In it the branches of the umbilical vessels ramify, and the capillaries form simple or sometimes double loops in the collateral terminal branches of the villi. Each villus is invested by a layer of cells, which have been recognised by anatomists since Dalrymple figured them upwards of thirty years ago, and to which Goodsir gave the name of the external cells of the villus. These cells are somewhat flattened, though not squamous, are rectangular in outline, and closely applied to each other

by their margins, so that they form a continuous layer. This layer of cells can be peeled off the villus, and belongs, as was stated by Goodsir, to the cellular structure of the decidua, which has become adherent to the villi in the course of the development of the placenta.

The MATERNAL PLACENTA is formed by a special modification of the uterine mucous membrane.

When the fertilised ovum is received into the cavity of the uterus the mucosa undergoes important changes. It swells up, becomes thicker, softer, and more vascular. Its epithelial covering loses its columnar form; its glands enlarge, and their orifices become more distinct; the interglandular tissue increases largely and rapidly in quantity, by a multiplication, not only of the cells of the surface-epithelium, but by a proliferation of the corpuscles of the sub-epithelial connective tissue, so that the glands are separated from each other by a much greater amount of interglandular tissue than in the non-gravid state; the blood-vessels not only increase in numbers but in size. At the same time the free surface of the modified mucosa becomes divided into a number of irregular areas by furrows, and on the free surface of these areas, more especially near the furrows, the mouths of the utricular glands may be seen to open in considerable numbers. The modified mucosa constitutes the *decidua vera* or *uterina*.

The fertilized ovum attaches itself to the surface of one of these areas; and the decidua, immediately surrounding the place of attachment, grows around the ovum so as to enclose it and to form the *decidua reflexa* or *decidua ovuli;* the place of junction of the decidua, growing up from opposite sides of the attached border of the ovum being

marked by a pellucid spot named the umbilicus or scar. The ovum is thus enclosed in a distinct chamber, the *ovigerous* or *ovular chamber*, and the decidua reflexa shuts off the ovum from the general cavity of the uterus. The free surface of the decidua reflexa, except at and close to the scar, is perforated by the mouths of the enlarged utricular glands. Dilated veins continuous with those in the decidua uteri are prolonged into the decidua reflexa.

The portion of the decidua uterina, forming the surface of the area to which the ovum becomes attached, undergoes a great development, forms the maternal part of the placenta, and is named the *decidua placentalis* or the *decidua serotina*. In two specimens which I examined at about the 3rd or 4th week of utero-gestation, I found the surface of the decidua serotina next the ovular chamber to be subdivided into shallow irregular spaces, occupied by the villi of the chorion. The decidua was nearly $\frac{2}{10}$ths inch in thickness, and had a loose spongy appearance. On making vertical sections it was seen to contain numerous cells, some of which were polygonal, others rounded, and of large size, and with large nuclei ; others were caudate, and between the cells was a delicately fibrillated connective tissue. Amidst this cellulated tissue numerous dilated vessels were also seen in section, many of which were entirely, or to a large extent, filled with blood corpuscles. These dilated vessels were neither arteries nor veins, but dilated capillaries, for they possessed merely a simple cellular wall, fused with that of the tissue in which they were situated. At this early period of gestation, therefore, the capillaries of the uterine mucosa in the placental area exhibited a sinus-like dilatation. Here and there an utri-

cular gland might be seen either longitudinally or transversely divided, but the number of glands in a given area was much fewer than in the non-impregnated mucosa, so that the increase in area of the decidua was obviously due to a great increase in the amount of interglandular connective issue.

The villi of the chorion were intimately adherent to both the surface of the decidua reflexa and the serotina forming the wall of the ovular chamber. This adhesion was due to an up-growth of the decidua between and surrounding the villi, so that the fixing and interlocking of the fœtal and maternal structure seem to be due to a coincident growth both of villi and decidua, whereby the villi, even at this early stage of placental development, are ensheathed by the cell structures of the decidua.

It has been customary for anatomists to state that the attachment of the villi to the decidua, not only in the human placenta, but in placentæ generally, is due to the penetration of the villi into the tubes of the dilated utricular glands. The researches made by Ercolani and by myself, during the last few years, on the various forms of placenta in different groups of mammals, have however shown that the villi are not lodged in these glands, but are received in crypt-like depressions on the surface of the mucous membrane, formed during gestation by a hypertrophy and folding of the mucous surface. For not only are the glands much fewer in number than the villi and the crypts which contain the villi, but in many mammals, as the pig, the mare, the lemurs, and the true ruminants, the glands can be seen to open on the free surface of the uterine mucous membrane in areas quite distinct from the crypts.

This arrangement applies also to the human placenta; for the utricular glands, which open, on the free surface of the decidua serotina, into the ovular chamber, are much fewer than the villi of the chorion attached to that surface of the chamber; whilst the uterine glands in the decidua reflexa open on that surface of the decidua which is next the general cavity of the uterus. The up-growths of the decidua around the villi of the human chorion are comparable therefore with the foldings of the uterine mucosa, which in the cat, pig, cow, and other mammals constitute the walls of the crypts in which the villi are lodged.

But the interlocking of the fœtal and maternal parts of the human placenta may be advantageously studied at a later stage of development. About the 5th month, when the decidua reflexa and the villi connected with the non-placental area of the chorion have atrophied, whilst the villi in the placental area have undergone a great increase, both in length and in the number of branches, the placenta has then assumed a definite discoid form. Well-marked bars or dissepiments of decidua serotina pass through the thickness of the placenta as far as the chorion, and divide it into lobes or cotyledons. Numbers of more slender decidual bands pass into the substance of each lobe, partly from the surfaces of the dissepiments, and partly from the general surface of the serotina between the dissepiments. These bands give rise to still more delicate offshoots, which form a microscopic intraplacental trabecular arrangement in the interspaces of which the villi are lodged. These intraplacental prolongations of the decidua are applied to the stems and branches of the chorionic villi, and the interspaces containing the villi are comparable to the cavities

of the crypts in the placenta of the pig, fox, bitch, sheep, and other mammals.

The bands of decidua principally consist of large, distinctly nucleated, rounded or polygonal cells, lying in a delicately fibrillated connective tissue. The more slender offshoots contain, at their origin, similar cells, but to a large extent are made up of delicate fibrillated connective tissue containing scattered corpuscles. Although this tissue is often in close apposition to the villi, it may be separated from it by appreciable intervals, and, from its extreme delicacy, has the appearance as if it were being so attenuated by the growth and expansion of the placenta, that it is undergoing atrophy. The maternal blood-vessels, the capillaries of which, as already stated, have dilated into sinuses, are also prolonged into the placenta, along with the cellular structures of the decidua serotina, so that the dilated vessels of the modified uterine mucous membrane are brought into relation with the vascular villi of the fœtal chorion.

In the placenta, at and near the full time, the growth and expansion of the organ have made so great an advance, that the original relations of its fœtal and maternal constituents have become greatly modified, so that some observers have questioned, though erroneously, if maternal structures enter at all into its internal construction.

The Mature Placenta presents the appearance of a disc-shaped spongy cake, from 7 to 9 inches in diameter, and about 1 inch thick about its centre, where the umbilical cord is continuous with its chorionic surface; towards its circumference it is always somewhat thinner. Its inner or chorionic surface shows the ramifications of the umbilical

vessels, and is closely covered on its fœtal side by the amnion, whilst from its placental side multitudes of arborescent vascular villi arise. Some of these villi are comparatively short, but the greater number are so long that their terminal branches reach, and are often attached to, the placental surface of the decidua serotina.

The outer, attached or uterine surface of the placenta, is formed by the placental decidua, decidua serotina, or modified uterine mucosa of the placental area. The placental decidua is continuous at the margin of the placenta with the decidua vera, and it usually turns over the border of the placenta on its chorionic surface, and forms a more or less strongly marked band extending around its circumference. When separated from the uterus the outer surface is seen to be covered by a layer of the decidua serotina, which presents a flocculent appearance where it has been torn away from the uterine wall. It is marked by furrows, and bands of the decidua pass into the substance of the placenta at these furrows, and extend through its substance up to the chorion, so as to divide it into lobes or cotyledons. As these inter-lobular dissepiments are often imperfect, the lobes are not completely shut off from each other. Slender processes of the decidua serotina proceed both from the surface of the dissepiments, and from the placental surface of the serotina generally, into the interior of the lobes, but they can only be traced for a short distance, as they do not form a continuous framework of maternal tissue, such as exists in the placenta at the fifth month. Delicate threads of decidua may, however, occasionally be seen passing between the villi, and connecting them not only with each other, but with the decidual dis-

sepiments, or with the general surface of the serotina. These threads are without question the remains of that intra-placental arrangement of decidua, occurring so abundantly at the fifth month, but which has become attenuated and atrophied, in the fully formed placenta, in correlation with the great expansion of the intra-placental maternal sinus system.

A number of peculiarly tortuous arteries, continuous with the convoluted uterine arteries in the muscular wall, and named the *curling arteries* of the placenta, pierce the decidua serotina, and open on its placental surface by obliquely directed mouths situated between the terminal branches of the villi attached to the decidua serotina. The decidua serotina is also traversed by dilated *utero-placental veins*, which communicate with the venous sinuses in the muscular wall of the uterus. The utero-placental veins form in the decidua serotina a system of intercommunicating sinuses. Some of these veins are prolonged into the decidual dissepiments between the placental lobes; others lie in the thickened border of the decidua surrounding the circumference of the placenta, where they form the so-called circular sinus of the placenta. Not only the circumferential, but the other utero-placental veins freely communicate with the interior of the placenta, but their mode of opening into it is peculiar. Instead of possessing large patent mouths, the wall of the vein, where it lies in relation to the interior of the placenta, is perforated by one or more small apertures, so that it possesses a cribriform appearance; and not unfrequently a terminal offshoot of a placental villus may be seen to protrude through one of these small holes in the venous coat into the lumen of the vein.

It is clear, therefore, that the curling arteries and utero-placental veins open into the interior of the placenta, so that a stream of maternal blood flows through the placenta in its passage from the curling arteries to the utero-placental veins.

In a placenta still attached to the uterus, the spaces in its interior, through which the maternal blood circulates, may be injected either from the uterine arteries or veins; and in a separated placenta, if an injecting

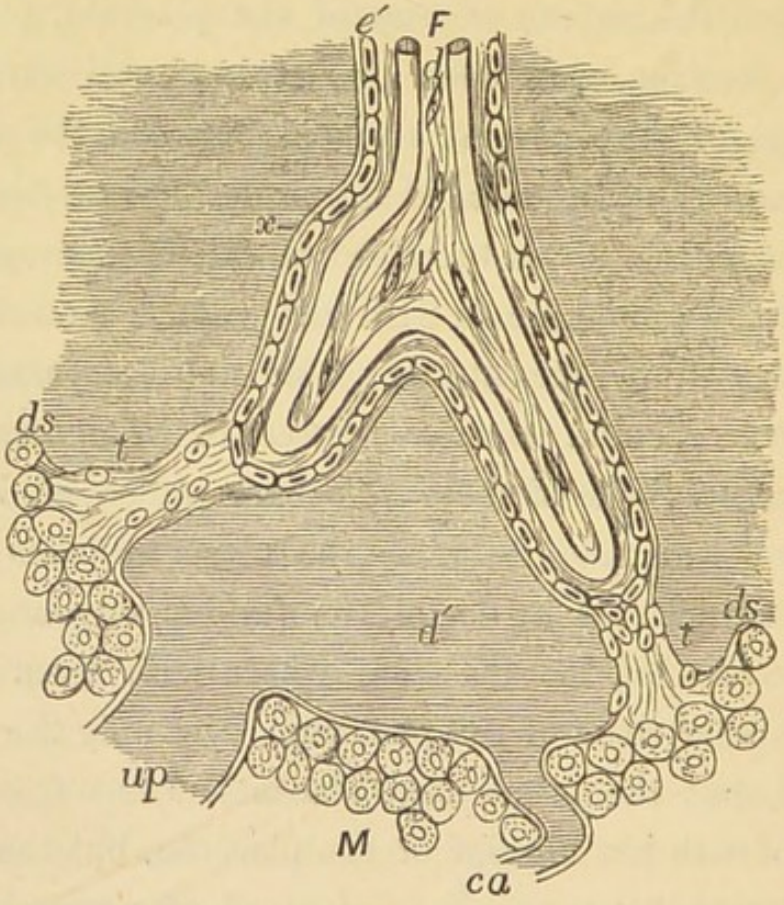

FIG. 235.—Diagram of the minute structure of the Human Placenta. F, the fœtal placenta represented by V, a chorionic villus; *d*, the fœtal capillaries within the villus; *e'*, the cellular investment of the villus derived from the decidua serotina; M, the maternal placenta; *ds*, *ds*, the cells of the decidua serotina; *t*, *t*, trabeculæ or slender offshoots of the serotina passing to the fœtal villus; *ca*, curling artery: *up*, utero-placental vein; *d'*, the shaded space to represent the intra-placental maternal sinus system; *x*, a thin layer superficial to the cellular investment of the villus to represent the wall of the maternal sinus vessel.

pipe be introduced into one of the lobes of the organ,

the utero-placental veins may be injected from it. The spaces in the interior of the placenta for the transmission of the maternal blood have been variously termed the cavernous spaces, the placental sinuses or lacunæ, the cells of the placenta, the intervillal spaces, and the placental bag or sac; they freely communicate with each other, not only in the same lobe, but in adjacent lobes, through imperfections in the interlobular dissepiments. These spaces belong to the maternal vascular system, and they are obviously an expansion of the dilated capillaries to be seen in the decidua serotina as early as the first month of gestation. Owing to the expansion of the intra-placental maternal capillaries into these irregular sinuses, a thinning and expansion of the vascular wall has at the same time taken place, so that it cannot, as a rule, be recognised as a distinct layer bounding the maternal sinus; but one may sometimes see a layer of great delicacy on the exterior of the villus, between its cellular covering, already described, and the maternal blood space, which from its position represents the wall of the intra-placental maternal vessels.

As to the cellular investment of the villus, at first sight it may appear to be only its proper epithelial covering derived from the outer epithelial layer of the chorion. But the cells are not squamous; they differ therefore from the epithelial covering of the chorion, and can readily be stripped off the villi. I am of opinion that they are derived from the intra-placental prolongations of the decidua. Through the expansion of the maternal sinuses, the cells of the decidua, situated superficially to the dilated capillaries, have been pressed so closely to the villi as to become incorporated with them, and apparently to form a part of their

texture. This opinion is based not only on the examination of the human placenta, but on the study of the comparative anatomy of the organ in a considerable number of mammals. For in every case a layer of maternal epithelium, derived from the uterine mucosa, was found interposed between the fœtal vessels of the chorionic villi and the vessels of the maternal part of the placenta; whether the maternal vessels were simple capillaries, as in the diffused and cotyledonary forms of placenta, or dilated capillaries, as in the zonary placenta, the dome-shaped placenta of the sloth, or the discoid placenta of the ape and the human female.

As regards the function of this layer of epithelium throughout the placental series, I agree with Ercolani in regarding it as a secreting epithelium, which separates and prepares from the maternal blood a secretion, to be absorbed by the vessels of the chorionic villi, and applied to the nutrition of the fœtus. The passage of material from the maternal to the fœtal system of vessels is not a simple percolation or diffusion through their walls, but is occasioned by the action of cells. The placenta, both in its function and in the relative arrangement of its constituent textures, is therefore a specially modified secreting gland, the excretory apparatus of which is represented, not by a system of ducts, but by the blood-vessels of the fœtal villi.

INDEX.

PAGE

Abdominal aponeurosis, . 77
Abdominal cavity, . . 672
Abdomen proper, . . 673
Aberrant ducts of liver, . 739
Acarus folliculorum, . . 390
Accessory spleens, . . 557
Acromion, ... 39
Acetabulum, . . . 45
Adenoid tissue, . . 144, 546
Adipose tissue, . . . 152
Air vesicles, . . . 634
Allantois, . . . 776, 866
Alimentary canal, . . 643
Ampulla, ... 366
Anatomy, definition of, . 1
,, divisions of, . . 1
,, special of human body, 3
Amphiarthrosis, . . . 65
Anal orifice, . . . 776
Analogues, ... 54
Annulus ovalis, . . . 401
Antibrachium, . . . 37
Anterior cerebral vesicle, . 213
Anterior commissure, 292, 212, 223
Antrum, ... 31
Anterior elastic lamina, . 332
Anterior intercostal fibrous membrane, . . . 608
Anterior nares, . . . 322
Appendicular, ... 6
Appendicular skeleton, . 936
Appendix vermiformis, 713, 776
Aponeurosis, . . . 73
Aqueduct of Sylvius, 213, 260, 281
Aqueous humour, . 329, 347
Arachnoid mater, . . 219
Arbor vitæ, . . . 256
Arciform fibres, . . . 246

PAGE

Areolar tissue, . . . 145
Area germinativa, . . 862
Arrectores pili, . . . 390
Arteries, ... 414
Arteries, structure of, . . 493
Arteries, description of—
abdominal aorta, . . 417
acromial thoracic,. . 443
alar thoracic, . . 443
anastomotic artery, 446, 476
aorta, . . . 407, 417
aortic or systemic group, of arteries, . . 417
arch of the aorta, . . 417
arteria innominata, . 434
articular, . . . 476
arteriæ receptaculi, . 459
anterior cerebral, . . 461
anterior circumflex, . 443
anterior communicating, 462
anterior and posterior ethmoidal, . . . 460
anterior interosseus, . 447
anterior intercostals, . 440
anterior median, . . 437
anterior perforating, . 485
anterior peroneal, . . 483
anterior radial carpal, . 452
anterior spinal, . . 437
anterior tibial, . . 480
anterior ulnar carpal, . 448
anterior ulnar recurrent, 447
ascending cervical, . 438
ascendingaorta, . . 418
ascending pharyngeal, . 467
ascending palatine, . 466
auditory, . . . 438
angular, . . . 466

PAGE

Arteries, description of—
auricular, . . . 467
axillary, . . . 441
azygos articular, . . 488
basilar, . . . 430
brachial, . . . 444
bronchial, . . 422, 640
buccal, ... 468
of the bulb, . . . 488
calcaneal, . . . 482
capsular, . . . 428
centralis retinæ, . . 460
choroid, . . . 460
ciliary, ... 460
circle of Willis, . . 462
clavicular thoracic, . 443
coccygeal, . . . 490
cœliac axis, . . . 423
collateral, . . . 414
communicating, . . 483
common carotid, . . 456
common iliac, . . 471
comes nervi ischiatici, . 490
coronary branches, 421, 466
coronaria ventriculi, . 423
cranial, ... 467
crico-thyroid, . . 464
curling, . . . 877
cutaneous, . 476, 480, 485
deep cervical, . . 440
deep circumflex iliac, . 473
deep epigastric, . . 472
descending palatine, . 469
descending thoracic aorta, 417, 418
digital, . . . 450, 485
dorsal, ... 489
dorsal artery of the foot, 481
dorsal branch for index, 452
dorsal branch for thumb, 452
dorsalis hallucis, . . 482
dorsal interosseous, . 452
dorsalis linguæ, . . 465
external carotid, . . 463
external circumflex, . 477
external iliac, . . 472
external malleolar, . 481
external plantar, . . 483
extra-peritoneal plexus, 432
extra-pleural plexus, . 433
facial, ... 465
femoral, . . . 473
first digital, . . . 482
frontal, ... 460

PAGE

Arteries, description of—
gastro-duodenal, . . 425
glandular, . . . 466
gluteal, . . . 498
hepatic, . . 424, 734
humeral thoracic, . . 443
hyoid, ... 463
hypogastric, . . . 486
ileo-colic, . . . 426
iliac, ... 487
ilio-lumbar, . . . 487
inferior dental, . . 468
inferior cerebellar, . 438
inferior external articular, 480
inferior hæmorrhoidal, . 488
inferior internal articular, 479
inferior labial, . . 466
inferior mesenteric, . 426
inferior muscular or sural, 479
inferior pancreatico-duodenal, . . . 425
infra-orbital, . . . 469
inosculation or anastomosis, . . . 415
intercostal, . . . 428
internal carotid, . . 458
internal circumflex, . 477
internal iliac, . . 485
internal malleolar, . 481
internal mammary, . 439
internal maxillary, . 467
internal plantar, . . 483
internal or deep pudic, . 488
inferior profunda, . . 446
inferior thyroid, . . 438
inferior vesical, . . 487
interosseous, . . 447, 481
intestinal, . . . 425
lachrymal, . . . 460
laryngeal, . . . 438
lateral nasal, . . 466
lateral sacral, . . 487
left colic, . . . 426
left coronary, . . 422
left gastro-epiploic, . 425
left pulmonary, . . 416
lingual, ... 465
long thoracic, . . 443
lumbar, . . . 429, 487
magna pollicis, . . 453
marginal, . . 481, 485
masseteric, . . . 468
median, ... 448
mediastinal, . . . 439

E

Arteries, description of—
meningeal, . 438, 467, 460
mental, ... 468
metatarsal, . . . 481
middle cerebral, . . 460
middle colic, . . . 426
middle hæmorrhoidal, . 487
middle sacral, . 417, 430
muscular, 437, 445, 448, 460, 476, 481, 482, 483, 484
musculo-phrenic, . . 439, 440
nasal, ... 460
nutrient, 446, 448, 477, 482, 483, 487
obturator, . . . 490
occipital, . . 466, 467
œsophageal, . . 423, 438
ophthalmic, . . . 460
ovarian, . . 428, 831
palmar interossei, . . 454
palpebral, . . . 460
pancreatic, . . . 425
parietal branches of aorta, 428
pectoral thoracic, . . 443
pericardial, . . . 423
perforating, 438, 439, 454, 460, 477
peroneal, . . . 483
phrenic, . . . 430
plantar arterial arch, . 484
popliteal, . . . 478
posterior auricular, . 467
posterior cerebral, . 438
posterior circumflex, . 443
posterior communicating, 462
posterior facial, . . 466
posterior interosseous, . 448
posterior interosseous recurrent, . . . 448
posterior perforating, . 485
posterior radial carpal, 452
posterior scapular, . 439
posterior spinal, . . 437
posterior tibial, . . 482
posterior ulnar carpal, . 448
posterior ulnar recurrent, 447
princeps cervicis, . . 467
profunda or deep femoral, . . . 449, 476
pterygoid, . . . 468
pterygo-palatine, . . 469
pulmonary, . . 404, 639
pulmonary group of arteries, . . . 416

PAGE

Arteries, description of—
pyloric, . . . 425
radial, . . . 451
radialis indicis, . . 454
radial recurrent, . . 452
ranine, . . 465
recurrent, . . 450, 454
recurrent tibial articular, 481
renal, . . . 428, 787
right colic, . . . 426
right coronary, . . 421
right gastro-epiploic, . 425
right pulmonary, . . 416
sciatic, . . . 490
second digital, . . 482
septal 466
short thoracic, . . 441
sigmoid, . . . 426
spermatic, . . 428, 805
spheno-palatine, . . 469
spinal, . . . 437, 438
splenic, . . 425, 560
sterno-mastoid, . . 463
stylo-mastoid . . 467
sub-clavian, . . . 435
sub-lingual, . . . 465
sub-mental, . . . 466
sub-scapular, . . 443
superficial cervical, . 439
superficial circumflex iliac, . . . 476
superficial epigastric . 476
superficial palmar arterial arch, . . 446
superficial perineal, 488, 489
superficial pudic, . 476
superficial volar, . . 452
superior cerebellar, . 438
superior dental, . . 469
superior epigastric, . 439
superior external articular, . . . 479
superior hæmorrhoidal, 426
superior intercostal, . 440
superior internal articular, . . . 479
superior laryngeal, . 464
superior maxillary, . 469
superior mesenteric, . 425
superior muscular, . 479
superior pancreatico-duodenal, . . 425
superior profunda, . 445
superior thyroid, . . 463

PAGE

Arteries, description of—
superior vesical . . 487
supra-orbital, . . 460
supra-scapular . . 438
tarsal, . . . 481
temporal, . . 469, 467
terminal . . 414, 478
thoracic axis, . . 441
thyroid axis, . . 438
thyroidea ima, . . 569
tonsillar, . . . 466
transverse, . . 438, 477
transversalis colli, . . 438
transverse facial, . . 467
transverse perineal, . 488
tympanic, . . 468, 459
ulnar, ... 446
umbilical, . . 486, 867
uterine, . . 487, 845
vaginal, . . . 487
vasa brevia, . . 425
vasa vasorum, . . 433
vertebral, . . . 437
vesico-prostatic, . . 487
vidian, ... 469
visceral branches of the aorta, . . . 421
Arterioles, ... 496
Articulations, . . . 63
Aryteno-epiglottidean folds, 591
Arytenoid cartilages, . . 592
Atlantal, ... 6
Auditory cells, . . . 367
Auricle, ... 358
Auriculo-ventricular rings, . 407
Auricular septum, . . 401
Axial, ... 6
Axial cylinder, . . . 194
Axial cylinder process of nerve fibre, . . . 202
Axial skeleton, . . . 910
Axillary, ... 613
Axillary lymph-glands, . 534

Bacillary layer, . . . 343
Ball and socket joint, . . 68
Bartholini, glands of, . . 850
Bicuspid valve, . . . 406
Bile capillaries, . . . 738
Bile duct, ... 737
Bioplasm, ... 114
Bipolar nerve cells, . . 198
Bladder, ... 793
,, false ligaments of, . 794

PAGE

Bladder, true ligaments of, . 795
,, structure of, . . 797
Blastodermic vesicle, . . 862
Blood, ... 121
Blood capillaries, . . . 497
Blood-lymph vascular glands, 554
Blood vascular glands, . . 554
Blood vascular system, . 394
Blood vessels, . . . 575
Bone corpuscles, . . . 168
Bones, description of, . 10
astragalus, . . . 52
atlas, ... 12
axis, ... 13
bones of Bertin, . . 25
calcaneum, . . . 52
carpus, bones of, . . 42
clavicle, . . 37, 59
coccyx, . . . 15
cuboid, . . . 52
cuneiform, . . 43, 52
ethmoid, . . 26, 57
femur, . . 50, 60
fibula, . . 52, 60
foot, bones of, . . 52
frontal, . . 27, 57
hand, bones of, . . 42
humerus, . . 40, 60
hyoid, ... 33
ilium, ... 46
incus, ... 362
inferior maxilla, . 32, 58
inferior turbinated, . 32
interparietal, . . 23
ischium, . . . 48
lachrymal, . . . 32
malar, ... 32
malleus, . . . 361
mes-ethmoid, . 26, 57
metacarpus, bones of, . 43
metatarsus, bones of, . 53
nasal, ... 32
occipital, . . 23, 57
os innominatum, . 45, 60
os intermedium, . . 43
os magnum, . . . 43
palate, . . 31, 57
parietal, . . 28, 57
patella, . . . 50
pelvis, . . . 49
phalanges, . . 44, 53
pisiform, . . . 43
pubis, . . . 47
radius, . . 41, 60

PAGE

Bones, description of—
ribs, . . 18, 55
sacrum, . . . 15
scaphoid of carpus, . 43
,, tarsus, . 52
scapula, . . 38, 60
semilunar, . . . 43
sphenoid, . . 23, 57
stapes, . . . 362
sternum, . . 18, 55
superior maxilla, . 30, 157
tarsus, bones of, . . 52
tibia, . . . 51, 60
temporal, . . 28, 57
trapezoid, . . . 43
trapezium, . . . 43
ulna, . . 42, 60
unciform, . . . 43
vertebræ, . . 10, 54
vertebra prominens, . 13
vomer, . . . 31, 58
Bowman's capsule, . . 785
Brachium, ... 37
Brain, ... 245
Branchial arches, . . 57
Bronchi, ... 616
Bronchial artery, . . . 640
,, glands, . . 536
,, tubes, . . . 634
,, vein, . . 641
Brunner's glands, . . 706
Buccal glands, . . . 653
Budding of cells, . . . 118
Bulb of vestibule, . . 850

Calamus scriptorius, . . 260
Canalis reuniens, . . . 370
Canine teeth, . . . 748
Capillary veins, . . . 563
Cardiac region, . . . 613
Cartilaginous tissue, . . 155
Cartilages of larynx, . . 588
Cartilago triticea, . . 589
Carunculæ myrtiformes, . 848
Cavernous sinuses, . . 217
Cellular cartilage, . . 156
Cell wall, ... 115
Cells, general consideration of, 112
Cells imbedded in solid tissue, 142
Cells suspended in fluids, . 121
Cement, ... 755
Central canal, . . 212, 224
Centrifugal nerves, . . 190
Central lobe of cerebrum, . 269

PAGE

Cerebellum, ... 254
Cerebrum, ... 261
Cerebro-spinal nervous axis, 210
,, ,, ,, system, 210
Chorda dorsalis, . . 54, 211
Choroid coat, . . . 335
,, plexuses, 215, 261, 275
Chordæ tendineæ, . . . 405
Chyle, ... 128
Chyle vessels, . . . 530
Ciliated epithelium, . . 134
Ciliary processes, . . 329, 335
Circulation of the blood, . 394
Circulus arteriosus, . . 338
,, iridis minor, . . 339
Claustral layer, . . . 284
Clitoris, ... 850
Cloaca, . . . 776, 857
Coccygeal body, . . 316, 430
Cochlea, ... 368
Cœumœ, ... 776
Concentric corpuscles of thymus, ... 566
Concha, ... 358
Condyles of femur, . . 50
,, of humerus, . . 40
,, of lower jaw, . . 33
Colourless corpuscles, . . 123
Columnar epithelium, . . 133
Columnæ carneæ, . . 402
Common bile duct, . . 742
Connective tissue, . . 142
Conjunctiva, . . . 354
Contractile fibro-cells, . . 179
Conus arteriosus, . . . 404
Coracoid, . . . 39, 60
Corium, ... 131
Cornea, . . . 329, 330
,, corpuscles, . . 331
Cornicula laryngis, . . 592
Corona radiata, . . . 289
Corpora albicantia, 213, 262, 277
,, bigemina, . . 213
,, quadrigemina, . . 213
Corpus Arantii, . . . 404
,, callosum, . . 214, 261
,, ciliare, . . . 335
,, dentatum, . . 251, 256
,, striatum, . . . 214
Corpuscles of Purkinje, . 259
Cranial nerves, . . . 300
Cranium, ... 20
Crico-thyroid membrane, . 590
Crista acoustica, . . 367

PAGE

Crura cerebri, . . 213, 262
Crusta, ... 290
Crystalline lens, . . 329, 348
Cuneiform cartilages, . . 593
Cuticle, ... 382
Cutis anserina, . . . 390
,, vera, ... 384
Cytode, ... 11
Cyto-blastema, . . . 112

Decidua reflexa, . . 872
,, serotina, . . 872
,, uterina, . . 871
,, vera, . . . 871
Decussation of pyramids, . 245
Dentine, ... 751
Dentition, formula of permanent, ... 747
Dentinal fibrils, . . . 753
Development of vascular system, ... 576
Diaplasmatic network, . 545
Diarthrosis, . . . 62
Diastema, ... 745
Digestive system, development of, ... 773
Diphyodont, . . . 745
Diverticulum ilei, . . 700
Dolicocephalic, . . . 34
Dorsal, ... 6
,, aortic roots, . . 579
,, groove, . . . 210
Douglas, pouch of, . . 841
Ductless glands, . . 554, 585
,, venosus, . . 741
Ductus arteriosus, . . 581
,, cochlearis, . . 366
Ductus vestibuli, . . 366
Ducts of Rivinus, . . 656
Duodenum, . . 698, 775
Dura mater, . . . 216
Duverney, glands of, . . 850

Ear, ... 358
Elastic tissue, . . . 147
Eminentia collateralis, . 215
Enamel, ... 754
Encephalon, . . . 245
End-bulb, ... 205
Endo-cardium, . . . 400
Endogenous cell production, 118
Endolymph, . . . 367
Endosteum, ... 168
Endothelium, . . . 138

PAGE

Epactal cartilages, . . 323
Epicardium, . . . 397
Epiblast, ... 210, 862
Epididymis, . . 806, 808
Epidermis, ... 382
Epiglottis, ... 591
Epithelium, . . . 103
Erect position of man, . 4
Eustachian tube, . . 361
Eustachian valve, . 401, 577
External meatus, . . 358
Eye-ball, ... 328
Eye-brows, ... 353
Eye-lids, ... 353
Eye-lashes, ... 353

Face, ... 20
Fallopian aqueduct, . . 30
,, tube, . . . 836
Falx cerebelli, . . . 216
,, cerebri, . . . 216
Fascia, ... 73
Fasciculus teres, . . 246
Fauces, ... 86
Femoral glands, . . . 539
Ferrein, pyramids of, . . 784
Fibræ propriæ, . . . 257
Fibro-cartilage, . . 159
Fibrous tissue, . . . 145
,, membrane, . . 145
Filum terminale, . . 223
Fimbriæ, ... 836
Fission of cells, . . . 118
Fœtal placenta, . . . 862
Foramen cœcum, . . 378
,, of Monro, . . 214
,, of Winslow, . . 682
Foramina, ovale, . . 401, 577
,, Thebesii, . . 401
Foregut, ... 774
Formatio reticularis, . . 251
Fornix, ... 291
Fourchette, ... 851
Fourth ventricle, . . 212, 259
Fossa ovalis, . . . 401
Fovea centralis, . . . 341
Frœna epiglottidis, . . 649
Frænum labii, . . . 649
,, linguæ, . . . 649
Frontal lobe, . . . 263
Funiculus cuneatus, . . 225

Gall bladder, . . . 741
Gaertner's canals, . 836, 856

	PAGE
Ganglia of base of cerebrum,	286
,, post-pyramidalia,	251
Gangliated cord,	314
Ganglion impar,	314
Gastro-splenic omentum,	556, 681
Gelatinous tissue,	144
Genital cord,	856
,, eminence,	857
,, glands,	801, 855
Germinal matter,	114
,, vesicle,	117
Ginglymus,	67
Glandulæ concatinatæ,	535
Glaserian fissure,	29
Glenoid fossa,	39
Glisson, capsule of,	731
Globus major,	806
,, minor,	806
Goblet cells,	704
Goll, band of,	225
Grains of Folin,	854
Gum,	649
Gustatory bulbs,	379
Gyri of cerebrum,	262
Gyrus fornicatus,	271
,, hippocampi,	271
Hair,	387
Hair follicle,	387
Hæmoglobin,	122
Haversian canals,	163
Head,	20
Heart,	397, 575
Helicotrema,	370
Helix,	358
Hemisphere vesicles,	213
Hepatic artery,	734
,, cells,	736
,, flexure of colon,	713
,, vein,	735
Hermaphroditism,	858
Heterodont,	746
Hindgut,	774
Hinge joint,	67
Hippocampus major,	215, 275
,, minor,	275
Homodont,	745
Homologues,	54
Huxley, sheath of,	389
Hyaline cartilage,	157
Hymen,	848
Hypoblast,	210, 862
Iliac lymphatic glands,	537
Ileo-colic valve,	718
Ileum,	699, 775
Immovable joints,	63
Incisor teeth,	747
Incisive foramen,	31
Inferior vena cava,	400
Infra-axillary region,	613
,, mammary,	612
Infundibulum,	213, 262, 573
Infundibuliform fascia,	803
Inguinal lymphatic glands,	536
Intercarotic body,	316
,, ganglion,	458
Intercellular substance,	147
Intercentral nerves,	189
Interglobular spaces,	753
Intermedio-lateral nerve cells,	227
Intermediate cell mass,	854
Intermuscular septa,	108
Internal ear,	364
Internal structure of cerebrum,	281
Intestine, large,	712
,, small,	697
Intestinal canal,	696
Intestinal villi,	530
Iris,	335
Jejunum,	699, 775
Joints, definition of,	63
Joints, description of—	
acromio-clavicular,	90
ankle,	104
carpal,	94
carpo-metacarpal,	94
coraco-clavicular,	90
costo-transverse,	78
costo-sternal,	78
costo-vertebral,	78
cranio-vertebral,	75
crico-thyroid,	590
elbow,	92
hip,	99
interclavicular,	90
interphalangeal,	95
intervertebral,	74
knee,	101
metacarpo-phalangeal,	95
metatarso-phalangeal,	106
pubic symphysis,	99
radio-carpal,	94
radio-ulnar,	93
sacro-iliac,	99
sacro-sciatic,	99
shoulder,	91

	PAGE
Joints, description of—	
sterno-clavicular,	90
tarsal,	104, 105
temporo-maxillary,	80
tibio-fibular,	103
wrist,	94
Kidney,	779
,, structure of,	782
Labia majora,	851
Labial glands,	653
Lacteal vessels,	530
Lacunæ of bone,	165
Lachrymal apparatus,	354
Lamellæ of bone,	164
Lamina cinerea,	231
Lamina fusca,	336
,, vitrea,	336
Large intestine,	712
Larynx or organ of voice,	587
Lateral ventricle,	214
Leaping,	107
Left auricle,	405
,, colon,	715
,, or posterior ventricle,	405
Leuco-cytes,	129
Lieberkühn, glands of,	708
Life, definition of,	112
Ligaments, description of,	55
annular,	96
glosso-epiglottidean,	591
hepatico-duodenal,	699
hyo-epiglottidean,	591
inferior crico-thyro-arytenoid,	590
ligamentum denticulatum,	222
ligamentum latum pulmonis,	619
ligamentum pectinatum,	335
phrenico-splenic,	556
posterior crico-arytenoid,	592, 600
pterygo-maxillary,	648
pubo-prostatic,	796
thyro-epiglottic,	591
thyro-hyoid,	589
Limbs, development of,	59
Linea alba,	77
Lingual glands,	653
Liver,	724, 777
,, lobules of,	731
,, lymphatics of,	740
,, nerves of,	740
Liver, structure of,	730
Lobes of cerebellum,	255
,, cerebrum,	263
Lobus caudatus,	729
,, quadratus,	729
,, Spigelii,	729
Lobules of Lung,	632
Locus cœruleus	253
Lower limb,	44
Lung, development of,	777
,, lobes of,	627
,, position and form of,	626
Lumbar lymphatic glands,	537
Lymph,	128
,, capillaries,	540
,, follicles,	546
,, follicular tissue,	546
,, vessels,	575, 711
,, vascular system,	529
Lymphatic hearts,	543
,, vessels,	529
Lymphatics of—	
abdomen,	536
abdominal viscera,	537
bladder,	779
head and neck,	534
heart,	536
lower limb,	538
lung,	535, 641
œsophagus,	536
spleen,	564
stomach,	696
thorax,	535
thymus,	536
upper limb,	533
uterus,	846
Lymphoid organs,	545
,, tissue,	546
Malpighi, pyramids of,	783
,, rete,	383
Malpighian bodies,	561
Malleolus,	51, 52
Male organs of reproduction,	801
Mammæ,	851
Mammæ, development of	859
Marrow,	167
Mass and weight of brain,	296
Maternal placenta,	871
Matrix substance of tissues,	120
Meckel's cartilage,	57
Meatuses of ear,	358
,, of nose,	35
Mediastinum,	395, 621

	PAGE
Mediastinum testis,	806
Medullated nerve fibres,	192
Medulla spinalis,	223
,, oblongata,	212, 245
Medullary canal,	163
,, sheath,	194
,, spaces of bone,	171
Megallantoids,	869
Meiboamian glnds,	354
Membranes of brain and spinal cord,	216
Membrana propria,	135
,, pupillaris,	339
,, Ruyschiana,	337
,, tympani,	360
Meniscus,	67
Mesallantoids,	869
Mesentery,	680, 699, 776
Mesenteric glands,	531
Mesial line and plane,	6
Mesoblast,	210, 862
Mesogastrium,	775
Meso-rectum,	716
Micrallantoids,	869
Middle cerebral vesicle,	212
,, gut,	774
Migrating cells,	331
Mitral valve,	406
Mixed nerves,	302
Moderator band,	404
Modiolus,	368
Molar glands,	653
,, teeth,	749
Monophyodont,	745
Mons veneris,	851
Morgagni, hydatid of,	806
Motorial end-plates,	204
Motor nerves,	300
Mouth,	646, 775
Moveable joints,	63
Müllerian duct,	856
Mucous glands of mouth,	653
Multipolar cells,	200
Muscles,	69
Muscles acting on intervertebral joints,	75
abdomen,	77
acromio-clavicular joint,	90
ankle,	104
carpal joints,	95
cranio-vertebral,	76
digits,	95
elbow,	92
hip,	100
knee,	102
radio-ulnar,	93
ribs and sternum,	78
shoulder,	91
sterno-clavicular,	90
tarsal,	105
wrist,	94
Muscles, description of—	
accelerator urinæ,	823
arytenoid,	601
broncho-œsophageal,	670
buccinator,	648
bulbo-cavernosus,	823, 848
ciliary,	335
coccygeus,	718
constrictors of pharynx,	660
compressor bulbi,	848
cremaster,	803
crico-thyroid,	598
dartos,	803
deglutition, muscles of,	87
detrusor urinæ,	797
dermal,	73
depressor anguli oris,	648
depressor labii inferioris,	647
diaphragm,	79
diaphragma oris,	649
epi-skeletal muscles,	107
expression, muscles of,	82
external or superficial intercostal,	607
eyeball, muscles of,	356
hyo-pharyngeus,	662
hypo-skeletal muscles,	108
internal or deep intercostal,	607
intra- or subcostal,	608
laryngo-pharyngeus,	660
larynx, muscles of,	597
lateral crico-arytenoid,	600
laxator tympani,	363
levator anguli oris,	647
levator ani,	717
levator communis,	647
levator glandulæ thyroidei,	568
levator labii superioris proprius,	647
levator menti,	648
levator palati,	666
levator prostatæ,	717
levatores or azygos uvulæ,	667
mastication, muscles of,	81

PAGE

Muscles, description of—
mylo-hyoid, . . . 648
oblique aryteno-epiglottidei, ... 601
oblique muscles of eyeball, ... 357
orbicularis, . . . 646
palato-glossus, . . 667
palato-pharyngeus, 662, 667
panniculus, . . . 73
pelvic diaphragm, . 718
periosteal muscle, . . 357
platysma, ... 73
pleuro-œsophageal, . 670
quadratus menti, . . 648
recti muscles of eyeball, 356
retractor uteri, . . 841
risorius, ... 647
salpingo-pharyngeus, . 663
sphincter muscles, . 83
sphincter ani externus, . 716
sphincter ani internus, . 721
sphincter uretræ prostaticus, ... 815
sphincter vesicæ, . . 797
stapedius, . . . 363
sterno-thyroid, . . 597
stylo-pharyngeus, . . 662
tensor palati, . . 667
tensor tympani, . . 363
thyro-arytenoid, . . 598
thyro-epiglottidei, . 601
thyro-hyoid, . . . 597
triangularis sterni, . 608
zygomaticus major, . 647
zygomaticus minor, . 647
Muscle rods, . . . 183
,, corpuscles, . . 184
Muscular-fibre discs, . . 182
,, fibrillæ, . . 182
Muscular tissue, . . . 177
Musculi papillares, . . 405
,, pectinati, . 400, 405
Myeloid cells, . . . 168
Myotomes, ... 108

Nails, ... 386
Nasal fossæ, . . . 34
,, pits, ... 327
Nasmyth's membrane, . . 755
Nerves, description of—
abducent, . . . 304
accessory obturator, . 240

PAGE

Nerves, description of—
anterior crural, . . 240
anterior interosseous, . 239
anterior primary divisions, ... 233
anterior thoracic, . . 238
articular, . . . 315
auriculo-parotidean, . 235
auriculo-temporal, . 310
brachial plexus, . . 236
cauda equina, . . 232
carotid plexus, . . 314
cardiac, . . . 313, 316
carotid, ... 311
cavernous plexus, . . 314
centripetal, . . . 190
cervico-facial, . . 306
cervical plexus, . . 235
chorda tympani , . . 305
ciliary ganglion, . . 308
circumflex, . . . 238
communicans peronei and tibialis, . . . 243
communicating branches, 315
communicantes noni, . 235
cutaneous, . . . 238
dental, ... 309
descending palatine, . 309
digastric, . . . 305
distributory, . . . 315
eighth cranial, 306, 311, 312
electric, ... 191
excito-motory, . . 191
external cutaneous, . 240
fifth cranial, . . . 307
first cranial, . . . 306
fourth cranial, . . 303
gastric, ... 313
genito-crural, . . 240
glossal, ... 311
glosso-pharyngeal, . 311
great sciatic, . . . 243
hypogastric, . . . 317
hypoglossal, . . . 307
ilio-hypogastric, . . 239
ilio-inguinal, . . . 240
inferior dental, . . 310
inferior maxillary of 5th, 309
infra-orbital, . . . 309
infra-trochlear, . . 308
inhibitory, . . . 191
intercosto-humeral, . 234
internal cutaneous, . 238

	PAGE
Nerves, description of—	
jugular ganglia,	311
labial,	309
lachrymal,	308
lateral cutaneous,	234
lesser internal cutaneous,	238
lingual or gustatory,	310
long buccal,	310
lumbar plexus,	239
lumbo-sacral cord,	240
malar,	309
median,	239
Meckel's ganglion,	309
motor masticatory,	310
motor,	190
musculo-cutaneous,	239
musculo-spiral,	238
nasal,	309
nerves of common sensation,	191
nerve of Jacobson,	312
nervous plexus,	243
nerves of special sense,	191
ninth cranial,	307
obturator,	240
occipitalis minor,	235
oculo-motor,	302
oculo-nasal,	308
œsophageal,	313
olfactory,	325
ophthalmic division of 5th nerve,	308
otic ganglion,	311
palpebral,	309
peroneal,	243
petrous ganglion,	311
petrosal,	305
pharyngeal,	311, 313, 315
phrenic,	235
pneumogastric,	312
popliteal,	243
posterior auricular,	305
posterior interosseous,	238
posterior primary divisions,	232
posterior thoracic,	238
portio intermedia,	305
portio dura,	304
portio mollis,	372
prevertebral cardiac plexus,	317
pterygo-palatine,	309
pudic,	242
pulmonary,	313
radial,	238
recurrent laryngeal,	313
reflex,	191
sacro-coccygeal plexus,	244
sacral plexus,	240
saphenous,	241, 244
second cranial,	347
secretory,	190
seventh cranial,	304
sixth cranial,	304
small petrosal,	311
small sciatic,	243
spheno-palatine,	309
spinal accessory,	306
spinal,	231
splanchnic,	316
sub-occipital,	231
submaxillary ganglion,	311
subscapular,	238
superior gluteal,	241
superior laryngeal,	313
superior maxillary of 5th,	308
supra-clavicular,	236
supra-scapular,	236
supra-trochlear,	308
temporo-facial,	306
third cranial,	302
tonsillitic,	311
transversalis colli,	236
trifacial,	307
trochlearis,	303
trophic,	190
tympanic,	312
ulnar,	239
vagus,	312
vaso-motor,	190, 316
vidian,	309
Nerve cells,	198
,, fibres,	192
Nervous system,	189
,, tissue,	192
Neural arch,	11
,, laminæ,	211
Neuroglia,	143
Nodes of Ranvier,	195
Non-medullated nerve fibres,	196
Non-striped fibre,	178
Nose,	322
Nuck, canal of,	842
Nucleus,	114
,, amygdalæ,	285
Nymphæ,	850

PAGE

Obliterated umbilical vein, . 740
Oblong joints, . . . 68
Occipital lobe, . . . 263
,, sinuses, . . . 218
Odonto-blasts, . . 757, 762
Odonto-klasts, . . . 767
Œsophagus, . . 669, 775
Omenta, ... 677
Omphalo-mesenteric duct, 773, ... 776, 865
Optic lobes, . . . 213, 281
„ nerves, . 213, 262, 341
,, thalami, . . 213, 278
Olivary body, . . . 246
Olfactory bulb, . . . 214
,, cells, . . . 325
,, hairs, . . . 325
„ region, . . . 324
,, nerve, . . . 326
,, peduncle, . 214, 325
Os cordis, ... 410
Osteo-dentine, . . . 757
Osteo-blasts, . . . 170
Osteo-klasts, . . . 172
Osseous spiral lamina, . . 368
,, tissue, . . . 162
Os uteri, ... 840
Otoliths, ... 367
Ora serrata, . . . 340
Organs of digestion, . . 643
,, of reproduction, 801, 825
,, of respiration, . . 604
,, of sense, . . . 321
Organ, definition of, . . 111
Organ of Giraldès, . 811, 854
,, of Rosenmüller, . 836, 856
,, of voice, . . . 587
Ovarium masculinum, . . 859
Orbit, ... 34
Oviduct, ... 836
Ovigerous chamber, . . 872
Ovula Nabothi, . . . 843
Ovum, . . . 117, 830, 862

Pacchionian bodies, . . 221
Palatine glands, . . . 653
Palpebral fissure, . . 353
Pampiniform plexus, . 805, 831
Papilla optica, . . . 341
Parieto-occipital fissure, . 263
Parietal lobe, . . . 264
Pancreas, . . . 743, 777
Parotid gland, . . . 654
Par-ovarium, . . 836, 856

PAGE

Pars membranacea septi, . 405
Pelvis, ... 673
Pelvic fascia, . . . 795
„ girdle, . . . 49
,, plexuses, . . . 310
Penicilli, ... 565
Perforating fibres of bone, . 166
Peribronchial lymphatics, . 642
Perineurium, . . . 195
Periosteum, . . . 163
Peripheral end-organs, . 202
Peritoneum, ... 674
Pericardium, . . . 395
Perichondrium, . . . 160
Perimysium, . . 72, 179
Peri-vascular canals, . . 542
,, lymphatics, . 642
Permanent cartilage, . . 156
Petrosal sinuses, . . . 218
Peyer's glands, . . 548, 709
Pharynx, . . . 86, 659
Pharyngeal tonsil, . . 664
Pia mater, . . . 215, 221
Pigmentary tissue, . . 154
Pineal gland, 213, 280, 574, 586
Pituita, ... 324
Pituitary body, 213, 262, 573, 585
Pivot joint, ... 67
Placenta, ... 861
Plane surfaced joints, . . 67
Plasma canals, . . . 541
Pleuræ, ... 619
Pleural cavity, . . . 624
,, villi, . . . 625
Pleuro-peritoneal cavity, 774, 778
Pomum Adami, . . . 588
Pons Tarini, . . . 262
Pons Varolii or bridge, . 252
Portal vein, ... 733
Posterior commissure, . . 212
,, cerebral vesicle, . 212
,, epithelium of cornea, 333
„ elastic lamina, . 333
,, intercostal fibrous membrane, . . 608
,, nares, . . . 322
Pouch of Morgagni, . . 595
Poupart's ligament, . . 77
Premolar teeth, . . . 749
Prevertebral cardiac plexus, 317
,, hypo - gastric plexus, . 318
,, solar plexus, . 317
Prickle cells, . . . 384

	PAGE
Pimary cerebral vesicles,	212
Primitive alimentary canal,	774
,, chorion,	862
,, dorsal aortæ,	576
,, membrane of nerve fibre,	194
,, pharynx,	774
Primordial kidneys,	854
Protistæ,	113
Protovertebræ,	54, 108
Protoplasm,	112
Protoplasm processes of nerve cells,	201
Pterygo-maxillary fissure,	34
Pulmonary artery,	639
,, capillaries,	639
,, veins,	405, 640
,, vesicles,	634
,, pleura,	632
Pulp of the tooth,	757
Pyloric valve,	687
Rectum,	715, 776
Receptaculum chyli,	531
Red corpuscles of blood,	121
Regions of abdomen,	673
,, head,	266
,, heart,	613
,, thorax,	612
Reproductive system,	801
Restiform body,	246
Respiratory system, development of,	773
Respiratory glottis,	595
,, region of nose,	324
,, system,	604
Rete mirabile,	415
Retina,	213, 329, 340
Retiform connective tissue,	143
Right colon,	713
,, lymphatic duct,	533
,, or anterior ventricle,	402
Rima glottidis,	595
Rods of Corti,	371
Roof nuclei,	256
Rolando, fissure of,	263
Rotation joints,	67
Root of lung,	629
Rouleaux,	125
Running,	107
Sac of omentum,	682
Sacculus,	366
Saddle-shaped joint,	68
Salivary glands of mouth,	654
Sarcolemma,	184
Sarcous elements,	183
Sarcode,	112, 116
Scapular arch,	37
Schneiderian membrane,	324
Sclerotic coat,	329
Screwed surface joints,	68
Scrotum,	802
Secondary chorion,	863
Semicircular canals,	365
Semilunar ganglia,	318
,, valve,	404, 406
Seminal tubes,	807
Sensory nerves,	300
Septum lucidum,	214
,, nasi,	323
Serous membranes,	139
Shoulder girdle,	37
Sheath of Huxley,	389
Sigmoid cavity,	42
,, flexure of colon,	715, 776
,, meso-colon,	680
Sinus venosus,	400, 405
,, of Valsalva,	404
Skeleton, appendicular,	9
,, axial,	9
,, definition,	8
,, forms of,	8
,, development of,	54
,, homologies of,	54
Skin,	382
Skull,	20, 56, 58
,, age, character of,	35
,, sexual character of,	34
Small intestine,	697
Socia parotidis,	654
Soft palate,	664
Solitary glands,	709
Somato-pleure layer,	773
Spermatic cord,	802
,, fascia,	803
Spermato blasts,	809
Spheno-maxillary fossa,	34
,, ,, fissure,	34
Spheroidal epithelium,	135
Spine,	10
Splanchno-pleure layer,	773
Splenic flexure of colon,	714
Spleen, position and form,	555
,, development of,	585
Spleen-follicles,	561
,, pulp,	558
Stomata,	140, 497

PAGE

Stenson's duct, . . . 655
Sternal mediastinal glands, 535
Sterno-pericardiac ligaments, 396
Striæ longitudinales, . . 273
,, medullares, . . 246
Stomach, . . . 685, 775
Structure of stomach, . . 689
Styloid process, . . . 42
Sub-arachnoid cavity, . 219
Sub-dural space, . . . 219
Sub-lingual gland, . . 656
Sub-maxillary gland, . . 655
Sub-pleural lymphatics, . 647
Substantia gelatinosa, . . 222
Subzonal membrane, . . 864
Sulci of cerebrum, . . 262
Superficial glands of groin, . 538
Superior vena cava, . . 400
Suplementary cells, . . 704
Supra-renal capsules, . 570, 585
Supra-condyloid foramen, . 41
Supra-sternal fossa, . . 612
Suture, ... 63
Sweat glands, . . . 391
Synchondrosis, . . . 63
Sympathetic nervous system, 313
Sylvian fissure, . . . 263
Synovial fringes, . . 141
Synovia. 66

Tactile corpuscles, . . 386
Tænia hippocampi, . . 214
,, semicircularis, . . 214
Tegmentum. . . . 290
Teeth, ... 745
,, structure of, . . 751
,, arrangement and form of, ... 745
,, development of, . 758
Temporary cartilage, . . 156
Temporo-sphenoidal lobe, . 263
Temporal fossa, . . . 34
Tendinous tissue, . . 145
Tentorium cerebelli, . . 217
Tessellated epithelium, . 132
Testicle, ... 802
Thebesian valve, . . . 401
Third ventricle, . . . 213
Thoracic duct, . . . 531
Thorax, ... 18
Thymus, . . . 565, 585
,, follicles, . . 566
Thyroid cartilage, . . 588
,, gland, . . 567, 585

PAGE

Thyro-hyoid membrane, . 589
Tissues or textures, . . 110
Tongue, ... 376
Tonsil, ... 86, 650
Torcular Herophili, . . 218
Trachea, ... 614
Trabecular framework, . 557
Transitional epithelium, . 136
Transversely striped fibre, . 180
Transverse meso-colon, . 714
,, colon, . . 713
Trapezium, ... 252
Tricuspid valve, . . 403
Trigone, ... 798
Trochanters, . . . 50
Truncus communis arteriosus, 576, 578
Tubuli uriniferi, . . . 783
Tunica pharyngis externa, . 663
Tunica vaginalis, . . . 803
Tympanum, . . . 360

Umbilical region, . . . 674
Umbilical vesicle, 700, 773, 864
Upper limb, . . . 36
Urinary bladder, . . . 793
,, development of, . . . 854
Urinary system, . . . 779
Uro-genital sinus, . . 857
Urethra, female, . . 800
,, male, . , . 818
Utero-placental veins, . 877
Uterus, position and form, . 838
,, structure, . . 840
,, development, . . 857
,, ligaments of, . . 840
Urachus, . . 796, 855, 864
Ureters, ... 792
Uterus masculinus, . 816 857
Utriculus, ... 366
Uvea, ... 338
Uvula, ... 664

Vagina, ... 847
Vallecula, ... 254
Valve of Vieussens, . . 260
Valvulæ conniventes, . . 700
Vascular arches, . . . 578
Vascular system, . . . 393
Vas aberrans, . . 814, 854
Vaso-dentine, . . . 757
Veins, description of, . . 500
angular, . . . 512

PAGE

Veins, description of
- anterior jugular, . . 508
- anterior longitudinal spinal, . . . 515
- anterior tibial, . . 521
- axillary, . . . 507
- azygos, . . . 503
- azygos major, . . 503
- brachial, . . . 507
- brachio-cephalic or innominate, . 505
- ,, brain veins of, 511
- cardiac, . . . 502
- cardinal, . . . 582
- cavernous sinus, . . 510
- cephalic, . . . 507
- circular sinus, . . 510
- circumflex iliac, . . 521
- common iliac, . . 518
- communicating, . . 509
- coronary, . . . 523
- coronary venous sinus, . 502
- coronary venous system, 502
- cranial venous blood sinuses, . . . 510
- cystic, ... 523
- deep cervical, . . 508
- deep circumflex iliac, . 520
- deep epigastric, . . 520
- digital, . . . 520
- diploë, veins of, . . 512
- dorsal, ... 519
- duct of Cuvier, . 397, 582
- ductus venosus, . . 582
- duodenal, . . . 523
- emissary, . . . 514
- external iliac, . 520, 521
- external jugular, . . 508
- external saphenous, . 520
- extra-spinal or dorsal, . 514
- facial, ... 509
- femoral, . . . 521
- frontal, ... 509
- great coronary, . . 502
- Galen, veins of, . . 512
- hæmorrhoidal venous plexus, . . . 519
- hepatic, . . 518, 735
- ileo-colic, . . . 522
- internal iliac, . . 519
- internal jugular, . . 509
- inferior laryngeal, . 506
- inferior longitudinal sinus, 510
- inferior mesenteric, . 523

PAGE

Veins, description of—
- inferior thyroid, . . 506
- inferior vena cava, . . 516
- internal mammary, . 506
- intestinal, . . . 522
- lateral sinus, . . 510
- left azygos vein, azygos minor, . . 503, 505
- left bronchial, . . 505
- left colic, . . . 522
- left gastro-epiploic, . 523
- left superior intercostal, 505
- lingual, . . . 510
- long saphenous, . . 520
- lumbar, . . . 516
- middle colic, . . 522
- middle meningeal, . 514
- middle sacral, . . 516
- middle thyroid, . . 510
- median-basilic, . . 506
- median-cephalic, . . 506
- median, . . . 506
- occipital sinus, . . 510
- occipital, . . . 510
- œsophageal, . . . 503
- omphalo-mesenteric, 576, 582
- ophthalmic, . . . 512
- ovarian, . . . 518
- pancreatic, . . . 523
- peroneal, . . . 521
- hparyngeal, . . 510
- phrenic, . . . 518
- plantar, . . . 521
- popliteal, . . . 521
- portal venous system, . 522
- portal venous trunk or portal vein, . 523, 733
- posterior longitudinal spinal, . . . 515
- posterior tibial, . . 521
- primitive jugular, . . 582
- profunda, . . . 521
- prostatic venous plexus, 519
- pudic, ... 521
- pulmonary, . . 501, 640
- radial, ... 506
- renal, . . . 518, 891
- right bronchial, . . 503
- right gastro-epiploic, . 522
- right superior intercostal, 505
- short gastric, . . 523
- sigmoid, . . . 522
- spinal, . . . 508, 514
- splenic, . 522, 563

	PAGE
Veins, description of—	
spermatic,	516
straight sinus,	510
structure of the veins,	526
subclavian	508
superficial epigastric,	526
superficial of the hand,	501
superior hæmorrhoidal,	522
superior and inferior petrosal sinus,	510
superior intercostal,	506
superior longitudinal sinus,	510
superior laryngeal,	510
superior mesenteric,	522
superior thyroid,	510
superior vena cava,	502
supra-renal or capsular,	518
suprascapular,	509
systemic group of veins,	502
transversalis colli,	509
transverse communicating,	583
transverse sinus,	510
ulnar,	506
umbilical,	582, 867
uterine venous plexus,	519
utero-placental,	877
vaginal venous plexus,	519
vena centralis retinæ,	512
venæ comites,	501
vena parumbilicalis,	525
vertebral,	508, 583
vesical venous plexus,	519
Velum interpositum,	215, 221
Venæ vorticosæ,	337
Venæ stellatæ,	790
Ventral aortic roots,	576
Venous blood-sinuses,	217
Vertebral column,	10
Vertebræ,	10
Vestibule,	365, 849
Vestigial fold,	397, 583
Venules,	527
Vibrissæ,	324
Villi,	702
Vitello-intestinal duct,	700, 776
Vitreous body,	329, 349
Vocal glottis,	595
Vulvo-vaginal glands,	850
Walking,	106
Wharton's duct,	655
White matter of cerebrum,	289
Windpipe,	614
,, development of	778
Wirsung, duct of,	744
Wisdom teeth,	749
Wolffian bodies,	854
,, duct of,	856
Yelk,	117, 830, 862
Yelk sac,	864
Yellow elastic fibro-cartilage	160
,, ,, tissue,	147
Yellow spot,	340
Zona pellucida,	117, 830, 862
Zonule of Zinn,	350
Zygomatic fossa,	34

PRINTED BY NEILL AND COMPANY, EDINBURGH.