

**Injuries of the eye, orbit, and eyelids : their immediate and remote effects /
by George Lawson.**

Contributors

Lawson, George, 1831-1903.
Royal College of Physicians of Edinburgh

Publication/Creation

London : Longmans, Green, 1867.

Persistent URL

<https://wellcomecollection.org/works/rr93uyqx>

Provider

Royal College of Physicians Edinburgh

License and attribution

This material has been provided by This material has been provided by the Royal College of Physicians of Edinburgh. The original may be consulted at the Royal College of Physicians of Edinburgh. where the originals may be consulted.

This work has been identified as being free of known restrictions under copyright law, including all related and neighbouring rights and is being made available under the Creative Commons, Public Domain Mark.

You can copy, modify, distribute and perform the work, even for commercial purposes, without asking permission.



Wellcome Collection
183 Euston Road
London NW1 2BE UK
T +44 (0)20 7611 8722
E library@wellcomecollection.org
<https://wellcomecollection.org>




12/6

615:9

R34797





INJURIES
OF
THE EYE, ORBIT, AND EYELIDS.

LONDON
PRINTED BY SPOTTISWOODE AND CO.
NEW-STREET SQUARE

INJURIES
OF
THE EYE, ORBIT, AND EYELIDS :

THEIR IMMEDIATE AND REMOTE EFFECTS.

BY

GEORGE LAWSON, F.R.C.S. ENG.

ASSISTANT SURGEON TO THE ROYAL LONDON OPHTHALMIC HOSPITAL, MOORFIELDS, AND
TO THE MIDDLESEX HOSPITAL; LATE ASSISTANT SURGEON, RIFLE BRIGADE.

LIBRARY
COLL. REC.
MED. EDIN.

LONDON :
LONGMANS, GREEN, AND CO.
1867.

THE NEW YORK PUBLIC LIBRARY

ASTOR LENOX AND TILDEN FOUNDATIONS

1897


1897

TO

MY FATHER,

IN GRATEFUL REMEMBRANCE OF HIS UNVARIED KINDNESS,

I Dedicate this Book.



PREFACE.

IN the work which I now offer to the profession I have endeavoured to group together all the most important points relating to injuries of the eye, orbit, and eye-lids. My aim has been to produce a book of reference in which will be found not only a description of the injury and its primary treatment, but also the best methods of dealing with those changes and deformities which, however remote, may be more or less consequent on the accident.

I have illustrated, as far as I have been able, each form of injury with characteristic cases, feeling that the truthful record of what has been, makes a more lasting impression on the mind than the mere detail of what may be. In my report of the cases I have had frequent occasion to refer to Jaeger's Test-types as a means for ascertaining the acuteness of the patient's vision. I have therefore for the convenience of reference added at the end of the book a set of test-types, printed so as to correspond with Jaeger's, but with the addition of No. 15, as it appeared to me that the leap from the letters marked 14 to those

numbered 16 was too great, and that an intermediate link was wanting.

At the close of the last chapter I have printed an abstract from the Surgical Report of the Royal London Ophthalmic Hospital for the past year, 1866. It forms a good index of the different diseases of the eye, and it gives also a fair approximation of the relative frequency of each.

In alluding to the tension of the eye in the different cases, I have adopted the symbols first suggested by Mr. Bowman for recording accurately its varying degrees of increase and diminution. I quote the account given by him, as reported in the British Medical Journal, October 11, 1862:—

“T represents *tension* (‘t’ being commonly used for ‘tangent,’ the capital T is to be preferred); Tn, *tension normal*. The interrogative, ?, marks a *doubt*, which in such matters we must often be content with. The numerals following the letter T on the same line indicate the *degree of increased tension*; or, if the T be preceded by —, of *diminished tension*, as further explained below. Thus:

“T 3. *Third degree, or extreme tension*. The fingers cannot dimple the eye by firm pressure.

“T 2. *Second degree, or considerable tension*. The finger can slightly impress the coats.

“T 1. *First degree. Slight but positive increase of tension*.

“T 1 ? *Doubtful if tension increased*.

“Tn. *Tension normal*.

“—T 1? Doubtful if tension be less than natural.

“—T 1. First degree of reduced tension. Slight but positive reduction of tension.

“—T 2 } Successive degrees of reduced tension, short of
“—T 3 } such considerable softness of the eye as allows the
finger to sink in the coats. It is less easy to define these
by words.”

Parts of some of the chapters have already appeared as short papers in the medical periodicals, but from the rapid progress of ophthalmic surgery I have had occasion either to re-write them or to add much new material.

To my colleagues both at the Ophthalmic and the Middlesex Hospitals I return my warmest thanks for the use they have allowed me to make of their cases, and for the information which they have at all times readily afforded me.

I am also greatly obliged to my friend Dr. Workman for the assistance he has kindly rendered me in revising the proof sheets as they have passed through the press.

The drawings of the different instruments are by Mr. Dearle, and those of the eye by Mr. Stecher.

12 HARLEY STREET, CAVENDISH SQUARE, W.

March, 1867.

...the ... of ...

...the ... of ...

...the ... of ...

...the ... of ...

...the ... of ...

CONTENTS.



CHAPTER I.

SUPERFICIAL INJURIES OF THE EYE.

Introduction—Foreign Bodies on the Eye, or on the Inner Surface of the Lids
—Symptoms of a Foreign Body on the Eye or on the Conjunctiva of the Lids
—How to examine an Eye which is suspected to be suffering from the Presence of a Foreign Body on its Surface—How to remove a Foreign Body if lodged in the Cornea either superficially or deeply—Blows on the Eye without any Lesion of Structure—Concussion of the Eye—Subconjunctival Hæmorrhage—Lacerations of the Conjunctiva—Traumatic Ophthalmitis—Its Symptoms, Treatment, and Results PAGE 1

CHAPTER II.

INJURIES TO THE EYE FROM BURNS, SCALDS, AND CHEMICAL AGENTS.

General Effects of Escharotics on the Eye—The Effects produced by, and the Treatment for Injuries to the Eye from Quick Lime, Mortar, Lime-Plaster, and other Combinations of Lime—Scalds and Burns of the Eye—Treatment of Fungoid Granulations after a Burn—The Effects caused by, and Treatment of, Injuries from strong Sulphuric and Nitric Acids, Vinegar and Dilute Acetic Acid, and strong Alkalis 28

CHAPTER III.

PENETRATING WOUNDS OF THE EYE, AND OTHER INJURIES OF THE CORNEA AND IRIS.

Penetrating Wounds of the Cornea and Sclerotic—Repair of Wounds of the Cornea—Treatment of Wounds of the Cornea—Diffuse Suppurative Corneitis—Abrasions of the Cornea—Fistula of the Cornea—Leucoma and Nebula of the Cornea—Operations for Artificial Pupil—Opacity of the Cornea from Lead Deposit—Staphyloma of the Cornea, partial and complete—Abscission

of the Staphyloma—Ciliary Staphyloma—Operation of Iridectomy—Prolapse of the Iris, Treatment of—Coredialysis—Laceration of the Iris without Rupture of the External Coats of the Eye PAGE 57

CHAPTER IV.

TRAUMATIC CATARACT.

Traumatic Cataract with Rupture of the External Coats of the Eye—Traumatic Glaucoma following a Wound of the Lens: Cases of—Traumatic Cataract without Rupture of the External Coats of the Eye: Cases of—Treatment of Traumatic Cataract: First, if the Cataract is uncomplicated with Prolapse of the Iris; Second, if it is complicated with Prolapse of the Iris; Third, if complicated with Injury to Iris and Protrusion of Lenticular Matter through the Wound—Operations for the Removal of a Traumatic Cataract: Rules for Guidance in the selection of the Operation—Linear Extraction of Cataract—Suction Operation for Cataract—Cases of Traumatic Cataract suitable for Linear Extraction or Suction—The Traction Operation—Cases suited for the Traction Operation—Von Graefe's Linear Extraction Operation for Cataract—Liebreich's Eye-bandage 126

CHAPTER V.

CAPSULAR OPACITIES AND DISLOCATIONS OF THE LENS.

Capsular Opacities following the Loss of the Lens—Simple Opacity of the Lens Capsule—Defect of Sight after an Extraction of the Lens from a Wrinkling of the Capsule—Opacity of the Capsule, with Particles of Lens Matter between its Layers—Opacity of the Capsule blended with Inflammatory Exudations—Degenerative Changes of the Lens Capsule—Treatment of Capsular Opacities—Needle Operations for Opaque Capsule—Removal of Opaque Capsule with Canular Forceps—Dislocations of the Lens: First, into the Anterior Chamber, Treatment of; Second, into the Vitreous, Prognosis and Treatment of; Third, beneath Conjunctiva, Prognosis and Treatment of—Partial Dislocations of the Lens 176

CHAPTER VI.

FOREIGN BODIES WITHIN THE EYE.

The Lodgement of a Foreign Body within the Eye—How to examine an Eye suspected to have a Foreign Body within it—The Dangers of a Foreign Body within the Eye—The Severity of the Symptoms influenced by the Size of the Foreign Body and the Part of the Eye in which it is embedded—Exceptional Cases in which a Foreign Body within the Eye excites little or no irritation—Treatment of Foreign Bodies within the Eye: When lodged between the Iris and Lens; on the Iris; in the Lens; or in the Vitreous: Cases illustrative of—Foreign Bodies suspected to be within the Eye, but not actually seen: Cases of 213

CHAPTER VII.

TRAUMATIC INTRAOCULAR HÆMORRHAGE AND RUPTURE OF
THE GLOBE.

Traumatic Intraocular Hæmorrhage: Definition of—Division into Anterior and Posterior Intraocular Hæmorrhage—Hæmorrhage into the Anterior Chamber: Causes, Prognosis, and Treatment of: Cases of—Deep or Posterior Intraocular Hæmorrhage: First, between Choroid and Retina, Cases of; Second, between Choroid and Sclerotic, Cases of; Third, Hæmorrhage into the Vitreous, Cases of—Prognosis and Treatment of Deep or Posterior Intraocular Hæmorrhage—Rupture of the Globe, Causes of—Usual Seat of the Rupture, Prognosis and Treatment of—Cases of Ruptured Globe—Operation for Excision of the Globe—Directions for wearing an Artificial Eye . PAGE 236

CHAPTER VIII.

GUNSHOT INJURIES OF THE EYE.

The Effects produced by the Explosion of Gunpowder near the Eye—Squib Accidents—Lodgement of Grains of Powder on the Cornea and within the Eye—Treatment of Gunpowder Injuries—Accidents from cheap Percussion Caps—Injuries from Small Shot—First, Spent Shot—Second, Glancing Shots—Third, Penetrating Shots—Gunshot Injuries of the Eye in Military Practice—First, from Shot and Shell—Second, from the Explosion of Magazines—Injuries from Gravel and Dust thrown up by the Explosion of Shells and Magazines—Treatment of Gunshot Injuries 282

CHAPTER IX.

SYMPATHETIC OPHTHALMIA.

The Primary Cause of Sympathetic Ophthalmia—Two Forms of the Disease—Sympathetic Irritation and Sympathetic Ophthalmia—Symptoms of—Its Nature, and the way in which it invades the different Tissues of the Eye—Tension of the Eye—Sympathetic Ophthalmia not excited by a Suppurative Inflammation of the Injured Eye—Influence of Age on the Disease—The Period at which it may come on after an Injury—The Causes of Sympathetic Ophthalmia—First, from Wounds of the Eye—Second, from the Lodgement of Foreign Bodies within the Globe—Third, from the Irritation excited by Degenerative Changes taking place in Eyes already lost—Treatment of Sympathetic Ophthalmia—General Conclusions 304

CHAPTER X.

INJURIES OF THE ORBIT.

The Lodgement of Foreign Bodies in the Orbit—First, the immediate Effects they may produce—Second, the secondary Effects which may result from them

- Treatment of Foreign Bodies in the Orbit—Penetrating Wounds of the Orbit—Fracture of the Bones of the Orbit—Abscess of the Orbit, Acute and Chronic: Causes of, Symptoms, and Treatment PAGE 341

CHAPTER XI.

INJURIES OF THE EYELIDS.

- Ecchymosis of the Lids: Treatment of—Abscess of the Eyelid—Wounds of the Eyelid—Symblepharon: Operations for the Relief of—Anchyloblepharon—Traumatic Entropion—Operation for Excision of the Eyelashes—Traumatic Ectropion—Operations for the Relief of Ectropion 367

-
- ABSTRACT OF THE SURGICAL REPORT OF THE ROYAL LONDON OPH-
 THALMIC HOSPITAL, MOORFIELDS, 1866 401
- JAEGER'S TEST-TYPES 407
- INDEX 413

INJURIES OF THE EYE.

CHAPTER I.

SUPERFICIAL INJURIES OF THE EYE.

INTRODUCTION—FOREIGN BODIES ON THE EYE, OR ON THE INNER SURFACE OF THE LIDS—SYMPTOMS OF A FOREIGN BODY ON THE EYE OR ON THE CONJUNCTIVA OF THE LIDS—HOW TO EXAMINE AN EYE WHICH IS SUSPECTED TO BE SUFFERING FROM THE PRESENCE OF A FOREIGN BODY ON ITS SURFACE—HOW TO REMOVE A FOREIGN BODY IF LODGED IN THE CORNEA EITHER SUPERFICIALLY OR DEEPLY—BLOWS ON THE EYE WITHOUT ANY LESION OF STRUCTURE—CONCUSSION OF THE EYE—SUBCONJUNCTIVAL HÆMORRHAGE—LACERATIONS OF THE CONJUNCTIVA—TRAUMATIC OPHTHALMITIS—ITS SYMPTOMS, TREATMENT, AND RESULTS.

To RIGHTLY APPRECIATE the results of injuries to the eye, it will be necessary to bear in mind the excessive delicacy of the textures of which it is composed, and the fact that the integrity of each is absolutely requisite to perfect vision; hence it is, that an injury which in itself is slight, may, if it happen to the eye, be productive of the most hurtful consequences. The fundus of the eye may be sound and capable of receiving and transmitting impressions, but if the cornea from an accident has been rendered opaque, the eye is blind; or the reverse may occur, the retina from an injury may have been detached, and though the brilliancy of the cornea may be unimpaired, yet the result is the same, the image is not received and the eye is useless.

A departure from health of any of the structures of the

eye is always more or less prejudicial to vision, no matter whether induced by injury or disease. My present purpose is to confine myself to the consideration of the effects which *injuries* may produce, either in a primary or secondary manner, on the different tissues of the eye and eyelids, and of the treatment which should be adopted in each case. Exposed and liable to accidents as the eye appears to be, special protection has yet been afforded to keep it from harm. Embedded in a quantity of fat, contained within a bony cavity (the orbit), the eye rolls in its varied movements on its bed, which acts as a soft and elastic cushion to deprive blows upon it of a large portion of their force. The prominent bony ridge of the orbit, but especially the overhanging frontal portion, guards the eye, and wards off injuries which might otherwise prove most destructive. But in addition to this, one eye is watchful for the safety of the other: rapidly appreciating objects as they flit past towards the other eye, it gives imperceptible but timely notice, sufficient to warn its fellow to close its lid, or by a rapid movement of the head to escape the threatened danger. Such must be the explanation of the frequent occurrence of injuries to the one eye after the other from any cause has been lost; deprived as it were of its vigilant guardian, it often falls a victim to accidents from which its companion in health would have warned it to escape.

FOREIGN BODIES ON THE EYE OR ON THE INNER SURFACE OF THE LIDS.—The difficulty of removing a foreign body from the surface of the eye, or from the conjunctiva lining the lids, depends upon the nature of the object, and the part of the eye on which it has become impacted. The instant a foreign body, such as a particle of coal, iron, or dust, or of any other hard material, is deposited on the

eye, the branch of the fifth nerve which supplies the lachrymal gland is stimulated; a copious flow of tears immediately follows, and the foreign body, if free, is washed by the current to the inner canthus, where it will be often found lying on the caruncle.

The chance, however, of being thus speedily relieved of the foreign body is frequently prevented by the patient himself, for the instant he feels that something "has gone into the eye," he almost instinctively gives it a rough rub with the back of his hand, which he repeats several times in rapid succession, until, if the foreign body has any sharp edges, he has succeeded either in embedding it in the cornea, or in the conjunctiva of the upper lid, from which it has to be removed by some skilled hand. The proper mode of proceeding, if the patient can have the resolution and presence of mind to do it, is, the instant he feels that something has flown on to the eye, or has gone between it and the upper lid, to gently close the eye, and seize with his finger and thumb the integument of the upper lid, and pull it forwards so as to draw the lid away from the globe, giving it at the same time two or three slight shakes. By this simple manœuvre the foreign particle if free, or even if loosely attached, is disengaged from its hold, and then washed away in the flow of tears to the inner angle of the eye.

The part of the eye on which the foreign body is impacted determines very materially the amount of irritation which is induced by it. If it has penetrated the conjunctiva covering the sclerotic, and lodged itself in the subjacent cellular tissue, the irritation it sets up is slight, and may after a while completely cease; it may remain then for years without giving any annoyance.

I have frequently seen fine spicula of iron or fragments of stone in the eyes of millstone-grinders, which have thus

become embedded beneath the ocular conjunctiva, and which, after the slight irritation excited by their first introduction, have never caused any trouble.

The next *least* sensitive part of the eye is the oculo-palpebral fold, the reflection of the mucous membrane as it passes from the upper lid on to the globe. In this soft fold foreign bodies of even a large size will often remain for a very long period without causing much discomfort, or at any rate without producing sufficient uneasiness to cause the patient to trouble himself to seek for advice. An old man applied to me at the Royal London Ophthalmic Hospital complaining of an irritation in one eye which had continued for about five or six months: at first he had not suffered much inconvenience from it, but lately it had become worse, and caused him considerable annoyance. It came on, he said, whilst he was pruning some apple-trees, and he fancied that something had flown into the eye, but beyond bathing it with tepid water he had taken no notice of it. On everting the lid, I found the green bud of a leaf lying embedded in the posterior tarsal fold of conjunctiva of the upper lid, and around it the mucous membrane had become quite granular. The removal of it afforded him immediate relief. In another case, a girl came under my care on account of slight pain and redness in one eye from which she had been suffering for five or six weeks. On everting the upper lid, I found a grain of canary seed lying in the oculo-palpebral fold of mucous membrane.

In each of these cases the symptoms the patients suffered from were very slight, when compared with the excessive irritation which is excited by the finest particle of grit or dust on the cornea, or inner surface of the upper lid.

The cornea is the most sensitive part of the surface of

the eye, and the impaction of a foreign particle on it gives rise to the most acute pain and lachrymation.

Almost as troublesome to the patient, is the lodgement of a foreign body on the conjunctiva lining the upper eyelid, and especially that region of it which corresponds to the cornea; the frequent up and down movements of the lid cause it to grate each time against the corneal epithelium, and to induce a most painful set of symptoms.

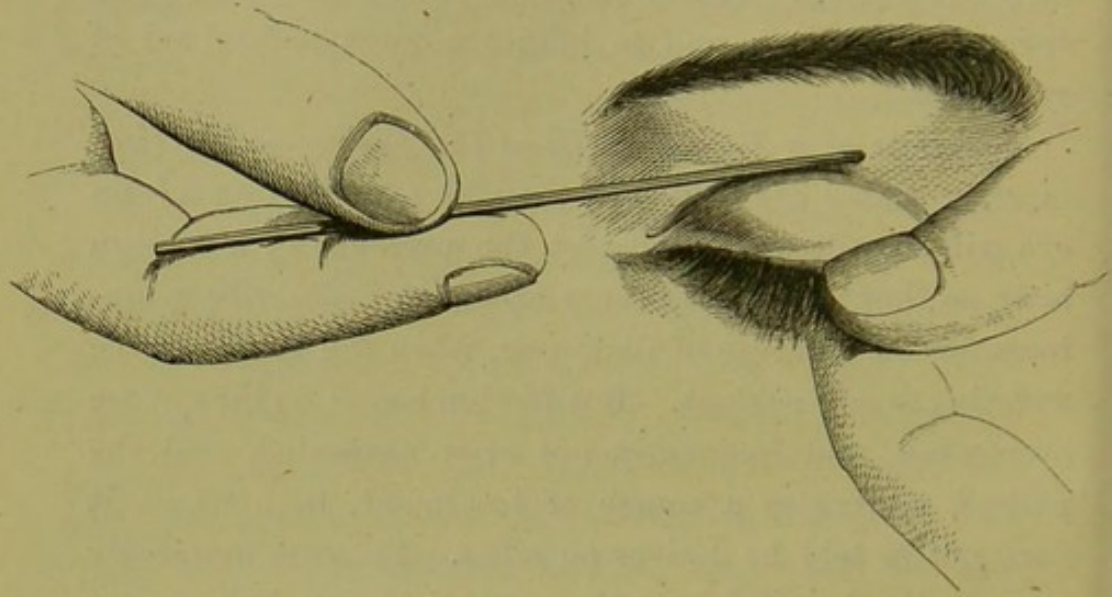
Symptoms of a Foreign Body on the Eye, or on the Conjunctiva lining the Lids.—A careful examination of an eye will usually at once detect the presence of a foreign body, so that it hardly appears necessary to describe symptoms for the purpose of diagnosis, when the cause of the suffering is self-evident. But foreign bodies on the eye are overlooked, and frequently not even suspected, and the patient undergoes a course of treatment, from which it need not be told he derives no relief. Patients frequently come to the hospital from the country having been under treatment for some weeks previously without benefit, when a careful examination of the eye at once shows that the cause of all their suffering has been a foreign particle, either embedded in the cornea, or else lodged in the conjunctiva of the upper lid.

Great irritability of the eye accompanied by a copious flow of tears, an almost absolute inability to raise the upper eyelid and face the light, and a distinct feeling of grittiness as if something were in the eye, are the symptoms which usually indicate the presence of a foreign body. The suddenness of the attack, and the exposure to which the patient has subjected his eye, are also points to be noted.

To examine an eye which is suspected to be suffering from the presence of a foreign body on its surface, the patient

should be made to sit in a chair with his face towards a window, so that a good light may fall upon the eye. The lower lid should be first drawn down, and if any particle of dust or chip of iron is seen, it can be readily removed. Next the cornea should be carefully scanned

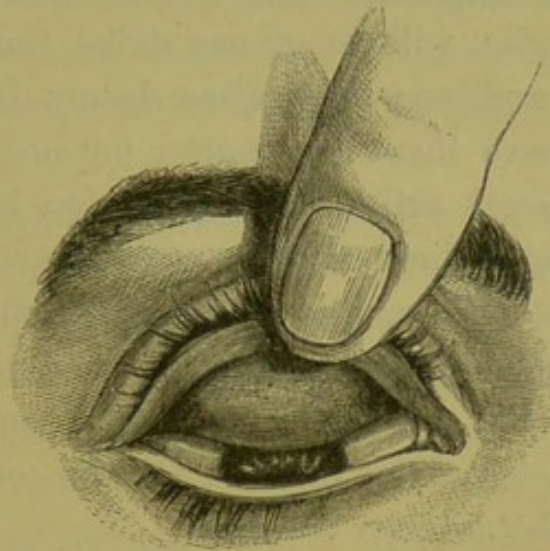
FIG. 1.



over, by turning the head in different positions, so as to cause the light to fall obliquely on the eye, first on one part of its surface, and then upon another; or by using a two inch focus convex lens a column of light may be directed over the cornea, so as to illumine each portion of it in succession. Often it is exceedingly difficult to detect a fine spiculum of steel, or a fragment of glass, or indeed any minute shining substance which may have been impacted on the cornea. In cases of doubt or difficulty the question may be settled by taking the patient into a darkened room and examining the corneal surface by oblique illumination with ophthalmoscopic light. Should the cornea be free, the under surface of the upper lid should be then examined. To do this, the surgeon, standing behind the head of the patient, seizes with his left finger and thumb the

lashes of the eyelid, and drawing them slightly away from the globe, he at the same moment with his right hand presses the end of a probe on the integument of the lid downwards and forwards, so as to tilt the upper edge of the cartilage of the lid downwards, and by this manœuvre to evert it (fig. 1). One finger of the left hand is then made to press gently the tarsal edge of the lid against

FIG. 2.



the brow, to maintain it in its everted state, and the patient is told to look down so as to expose as fully as possible the fold of mucous membrane which extends from the posterior edge of the cartilage on to the eye (the oculo-palpebral fold)—(fig. 2.) The under surface of the lid thus exposed may be then carefully inspected, and the cause of the irritation, if any is found, be removed. It is of importance to look well to this fold at the posterior margin of the tarsal cartilage, as minute particles will be often lodged there and escape observation. The best instrument for removing foreign bodies from the front of the eye, or from the under surface of the lids, is what is called a spud (fig. 3). It is flat on its front surface, whilst posteriorly it is rounded and bevelled towards its end.

By gently inserting the extremity of this instrument beneath the object to be removed, it can be lifted easily from its bed without disturbing the neighbouring parts.

FIG. 3.



Often, however, the foreign body is more or less embedded, and then a fine or a broad needle, as the case may require, will be best suited to dislodge it.

Sharp spicula of iron from striking rivets, or minute fragments of steel from turning, or of stone or granite, will sometimes strike the cornea with force, and bury themselves deeply in its texture, so that to remove them is a matter not only of difficulty, but often of great skill. If the foreign body is merely sunk in the epithelium which covers the cornea, it may be dug out with the spud or a broad needle; but if it is deep in the corneal tissue, it must be dealt with differently, as, in the endeavour to pick it out, it may be made to penetrate the posterior lamina of the cornea and fall into the anterior chamber.

If the foreign body is buried deeply in the corneal tissue, a broad needle should be passed into, but without penetrating, the cornea; inserting it just by the side of the object, it should be made to traverse the corneal lamellæ until the broad part of the blade is behind the foreign body, when, by thus giving a firm support upon which to act, another needle may be fearlessly used to pick gently from the surface until it reaches the object, which can then be lifted away. Should, however, the foreign body have so deeply penetrated the cornea, that it is feared any attempts to reach it from its surface may end in pushing it into the anterior chamber, a broad needle should be passed into the anterior chamber, and pressed against the inner surface of the cornea immediately behind the foreign body, and carefully and steadily held in this position, whilst

the surgeon, with another needle, scrapes through the cornea, layer after layer, until he reaches it.

Having succeeded in removing the foreign body, the eye as a rule rapidly recovers itself, and no further inconvenience is experienced; but this is not always the case, for occasionally a certain amount of irritation remains which will require treatment. The endeavour to remove the foreign body from the cornea may have caused some abrasion of its epithelium, and this has to be repaired, and in such cases, even under favourable circumstances, the eye will continue more or less painful and irritable to light for a few days.

Immediately after removing the foreign body from the cornea, one or two drops of olive or castor oil dropped into the eye will generally afford considerable relief, and this may be repeated if the patient derives comfort from it. The eyes should not be used for two or three days; they should be allowed a short rest from all work, such as reading or writing, and strong light should be strictly avoided. If there is pain, two or three leeches may be applied to the temple, and one or two may be repeated after an interval of twenty-four hours, if relief is not obtained. Fomentations of hot water, poppy heads, or belladonna may be had recourse to whilst the eye looks red and irritable. Usually after two or three days' treatment the eye is restored to its healthy state.

When the foreign body has been allowed to remain for some days embedded in the cornea, it frequently lights up a halo of inflammation around it, which may extend until it includes the whole or the greater part of the corneal tissue. The epithelium of the cornea immediately around the foreign particle becomes first whitened and swollen, the foreign body is loosened from its bed, and if not buried too deeply in the corneal tissue, may

be detached, and washed away by the tears, to the inner corner of the eye. But while these changes are going on in the cornea, the vascularity of the eye is increased, a zone of red vessels is seen around the cornea, and the eye is very intolerant of light. Generally all these symptoms subside after the foreign body has been removed, whether it be by the surgeon, or, as in some cases, by the natural reparative efforts of the eye; but occasionally the inflammation of the cornea, which the foreign body has lighted up, is severe and difficult to arrest, and even when cured leaves behind it nebulosities which impair the vision of the eye.

It occasionally happens that a small foreign body, having been driven against the cornea with great force, lodges itself in the lamellated tissue just beneath the epithelium. For the first two or three days it creates little or no inconvenience, as, being covered by the epithelium, it offers no sharp point to grate against the inner surface of the upper lid; but as it becomes partially detached from its nidus, it projects slightly from the corneal surface, and gives rise to all the painful symptoms of a foreign body on the eye.

It is useless to enumerate the many different substances which find their way between the lids, or get impacted in the cornea. The most common are spicula of the different metals, particles of dust, of coal and stone.

Patients frequently allow them to remain unmolested for many days, until the irritation they produce compels further notice to be taken of their presence. It is often astonishing to find the length of time during which a patient will endure the pain of a foreign body on the eye, or on the inner surface of the lids, before he will seek for advice, attributing all his suffering to some other cause.

The following case is an illustration of a foreign body having been lodged in the cornea, without producing any irritation, until the fourth day, and then exciting a halo of inflammation around it. The eye rapidly recovered after the foreign body was removed.

CASE I.—*A chip of metal lodged in the cornea without producing any irritation until the fourth day.*

John H., æt. 27, a farrier, applied to the Ophthalmic Hospital on April 11, 1865, suffering from a foreign body in the eye. He states that four days ago, whilst at work, a chip of metal lodged itself on the cornea. It buried itself beneath the epithelium in the lamellated tissue, in the central part of the cornea, to the outer side of the pupil. For the first three days it produced no annoyance; it was so buried that it presented no rough surface to the conjunctiva of the upper lid. This morning on getting up the eye was so painful and irritable that he was unable to go to work. The chip of metal had excited a little halo of inflammation in the cornea around it, and had become loosened from its bed, so that now it projected slightly beyond the corneal surface, and acted as a local irritant to the conjunctiva of the upper lid each time it closed over it. The speck of metal was lying in a little pit, quite loose, and the epithelium around it was whitened and swollen. It was easily removed by the spud. He was ordered to apply two leeches to the temple, and to bathe the eye frequently with the poppy-head fomentation. The patient shortly recovered.

CASE II. is an example of a general inflammation of the cornea, following the lodgement of a chip of iron which had been allowed to remain undisturbed for four days.

A minute chip of iron lodged in the lamellated tissue of the cornea, followed by general keratitis.

Edward S., æt. 21, came to the Hospital on April 18, 1865, a small chip of iron having been lodged in the cornea four days previously.

On examining the eye a minute speck of metal was seen embedded deeply in the lamellated tissue of the cornea. The whole cornea was dull; the general haze extending from the black speck of iron near its centre to towards its circumference. The eye was very painful and red; the whole globe being much injected. After a little difficulty I succeeded in removing the foreign body. Two leeches were applied to the temple, and he was ordered to bathe his eyes frequently with the belladonna lotion. Under this treatment the man soon recovered from all effects of the injury.

In the next case a foreign body, the fragment of a wing of a beetle, was lodged in the cornea, and was allowed by the patient to remain there, without any attempt even being made at its removal. Severe inflammation followed, which ended in the complete loss of the eye.

CASE III.—*Destructive inflammation of the right eye from a foreign body having been allowed to remain embedded in the cornea.*

Ann W., æt. 48, was admitted as in-patient of the Royal London Ophthalmic Hospital on September 30, 1864.

History.—Twelve months ago she was struck in the right eye by a flying beetle, and a part of the hard wing of the insect was left sticking in the cornea. This was allowed to remain untouched for three months, when it came away of itself. Severe inflammation of the eye then ensued, and all sight was destroyed. The eye had con-

tinued very painful ever since the accident ; and her sole object in applying to the Hospital was to obtain relief from the pain, as she said she knew her sight was irreparably lost.

Present state.—The cornea is staphylomatous and opaque ; there is no perception of light ; the eye is red and irritable. She complains of almost constant pain in the eye, which is worse at intervals.

As the eye was quite destroyed for all visual purposes, and was giving the patient much suffering, I removed it. After the operation she slept well, and on October 3rd she was able to leave the Hospital entirely relieved of all pain, and attend as an out-patient.

BLOWS ON THE EYE WITHOUT ANY LESION OF STRUCTURE are frequently the source of considerable suffering, and sometimes of actual danger to the eye. In chopping wood, a piece flies up and strikes the eye ; or in getting the cork from a soda-water, ginger-beer, or bitter ale bottle, it flies out, and the bottle being held carelessly in the wrong direction, hits the eye ; or in a variety of other ways sharp and sudden blows may be given to the eye. They may be so severe as to cause a laceration of its external coats, or a detachment of the iris from its great circumference ; but I refer now only to those blows which injure the eye without producing any visible lesion. The immediate result of such an injury is pain in the eye, redness of its surface, a flow of tears, and some dread of light. These symptoms may be merely temporary and pass off in a few hours, but if the blow is severe it may be many days before the general congestion it has caused begins to subside. The eye continues weak, it will not face the light, and the globe has a pinkish tinge. The patient will tell you that his eye is more irritable than painful, but that he is unable

to do any work with it. This state of the eye requires careful watching and treatment, as what at first seems to be mere irritation may drift almost imperceptibly into active inflammation. It is seldom that a blow on the eye which produces no laceration of any of its structures terminates unfavourably, but occasionally it is productive of serious symptoms which it is well always to anticipate. A less frequent, but at the same time more severe result of a blow, is

CONCUSSION OF THE EYE.—Simple concussion means literally a shake which is followed by a loss of the functions of the eye, without any appreciable change in any of its component parts. The eye receives a blow, not sufficient in force to lacerate or contuse any of its external coats, yet it is followed immediately by an abeyance of the functions of the retina. The pupil is dilated and the sight impaired, and this impairment of vision may vary from great dimness to complete blindness; but as a rule it is only temporary, and in a short time the retina recovers itself and vision is restored. When blindness follows a blow, and continues for more than one or two hours, the prognosis is very unfavourable. It very rarely happens, however, that the sight is completely and permanently destroyed by simple concussion. In such cases there is usually some laceration of the tissues at the fundus of the eye to account for the sudden destruction of vision; probably some deep intra-ocular hæmorrhage.

Sometimes in concussion of the eye, the pupil instead of being completely dilated, is only partially so, or dilated only in one direction so as to give it an oval shape. The latter condition would indicate that only the ciliary nerves of one side were affected by the blow, or certainly that those of one side of the eye were more involved in the injury than those of the other.

A case of concussion of the eye may terminate favourably in a few hours by the patient recovering his sight; but, on the other hand, the blow which produced it may have so disturbed the parts within, that grave inflammatory symptoms may arise which will jeopardise the eye.

Treatment of injuries to the eye from blows without lesion of structure.—If the blow on the eye has been a sharp one, it is well to act in anticipation of any symptoms which may occur, and to apply at once two leeches to the temple of the injured eye, and to repeat them in twenty-four hours if the pain in the eye either continues or increases.

The same treatment should be adopted in all cases of concussion of the eye.

The local abstraction of blood soon after an injury to the eye is of the greatest service, and oftentimes the single application of a few leeches to the temple will give immediate and permanent relief. But, in addition, the eye should be fomented every two or three hours with a warm decoction of poppy heads, and in the intervals a fold of wet lint or linen should be laid over the lids, and kept moistened from time to time with a little cold water. All use of the eyes for reading, writing, or fine work of any kind should be forbidden, and if there is any dread of light the room in which the patient resides should be darkened. The continuance of this plan of treatment for a few days is generally sufficient to restore the eye to health; but if, instead of improving, the pain in the eye increases, and the pupil becomes sluggish and irregular in its action, and the aqueous humour turbid, and other symptoms of a general inflammation of the globe show themselves, further treatment must be adopted. (*See* 'Ophthalmitis,' p. 19.)

If, however, the injury inflicted by the blow on the eye is very slight, it will not be necessary to apply leeches to

the temple. In many cases twenty-four hours' rest without the use of any local remedies will enable the eye to recover itself completely; but as a rule the application of cold, either in the form of some mild evaporating lotion, or of a fold of wet lint laid over the eye, is grateful to the patient and expedites his cure.

At the third meeting of the *Ophthalmological Society* at Heidelberg, 1865, a report of which, by Dr. Hasket Derby, appeared in the *Boston Medical and Surgical Journal* of October 5, 1865, the following cases were cited.

“ Dr. Testelin, of Lille, related five cases of impaired vision from blows on the eye, without corresponding ophthalmoscopic symptoms.

“ 1st.—A severe blow had been received over the eye. Only a limited portion of the retina retained its functions, the remainder having lost perception of light. No external or internal change was visible.

“ 2nd.—The same cause. The pupil was dilated and immovable; vision greatly impaired. The interior of the eye appeared normal. Three months later marked atrophy of the papilla was found to exist.

“ 3rd.—Immediately after pressure on one eye everything appeared to be seen through a red mist. A month afterwards *Jaeger*, No. 20, could be made out, only, however, with the inner portion of the field of vision. Later there was less vision. No objective change.

“ 4th.—A stone had been thrown against the eye. The case was seen three months after the accident. The pupil was so far dilated that hardly a trace of the iris was visible. No perception of light. The ophthalmoscope revealed nothing.

“ 5th.—The eye had been struck by a cricket ball. Vision was much impaired: the pupil dilated and sluggish. On ophthalmoscopic examination in the inverted

image, a small prominence, like a pea, was seen above and to the inside of the papilla. In a month this projection had disappeared, leaving a simple spot. Vision had very slightly improved.

“ Von Graefe, who was present, remarked that he had seen such cases, and admitted them to be very difficult of explanation. He thought, however, that analogous paralyses of the motor nerves might be adduced, that, for example, where the arm becomes temporarily paralysed, from resting the head on it in sleep. Perhaps the sudden shock caused some change either in the molecular system, or in the walls or calibre of the vessels.”

SUBCONJUNCTIVAL HÆMORRHAGE.—An effusion of blood beneath the conjunctiva may be caused by a blow, or by the rupture of a small vessel from coughing, or during any violent exertion. The appearance is quite characteristic. If the eye is seen shortly after the accident, the effused blood appears as a bright red mark, which is generally abruptly limited to a portion of the conjunctiva. The blood is usually quickly absorbed; but as it disappears, the colour first loses its intensity and then passes through a variety of shades, from a brownish red to a light yellowish brown, which diffuse themselves over the front of the eye, each succeeding shade being of a lighter tint than the one which preceded it, until at last the sclerotic whiteness of the eye is restored.

When the effusion of blood beneath the conjunctiva is uncomplicated with any injury to the eye, it need never be the source of any alarm; in no instance have I ever seen any ill effects follow it.

Treatment.—A few days' rest is generally all that is required for the blood to be absorbed, and the eye to regain its normal appearance. In these cases cold applications

are generally grateful, and may therefore be used, either by allowing the patient to sponge his eye with cold water three or four times during the day, or by prescribing for him some cool evaporating lotion, with which he may frequently bathe his eyes, the eyelids being kept closed.

LACERATIONS OF THE CONJUNCTIVA covering the eye, but without any other injury to the eye or eyelids, are occasionally met with, and, indeed, in hospital practice, are not very infrequent. The accident is generally occasioned either by the patient striking his eye against some sharp projecting object which catches the conjunctiva and tears it as the head is moved away; or else by some second person running a shutter, or a pole, or whatever he may be carrying, against the eye. The injury is usually followed by swelling of the lids and conjunctiva, often sufficient to render it difficult to make a thorough examination of the eye a few hours after the accident.

Treatment.—The eye should be closed, some water dressing should then be laid over the lids, and fastened in its place by one turn of a roller. It is very rarely necessary to apply any sutures to keep in situ the torn edges of the conjunctiva, as they usually fall together of their own accord; and there is seldom afterwards any sufficient strain to draw them apart, or prevent union. An exceptional case might occur in which sutures would be called for; thus, if a flap of the conjunctiva was torn from the globe, so that it was reflected back on itself, one or two fine stitches would be required to hold it, after it had been restored to its proper position. When all the swelling of the lids and conjunctiva has completely subsided, if there is some muco-purulent discharge, a lotion of sulphate of zinc, gr. j. or gr. ij. to the ounce of water, may be used, and two or three drops of it be dropped into the eye twice a day.

Lacerations of the conjunctiva, when uncomplicated with injury to the globe, generally get rapidly well.

CASE IV.

Extensive laceration of the conjunctiva covering the globe.

James F., æt. 21, applied to the Hospital on August 1, 1865, suffering from an injury he had that morning received to the left eye. Whilst at work in the street, a man carrying an iron shutter bar ran against him, and struck his left eye with one end of it.

State on admission.—The lower eyelid was much swollen and ecchymosed, and on drawing it down so as to expose the eye, a long lacerated and contused wound was seen in the conjunctiva covering the globe. The wound was nearly one inch in length, and extended almost the length of the eye, running horizontally a little beneath the lower margin of the cornea. The external tissues of the lid were not in any way torn. The sclerotic coat appeared uninjured, the wound being apparently confined to the ocular conjunctiva. Two leeches were ordered to be applied to the temple, and cold water dressing to be kept continuously to the eye.

Severe conjunctivitis followed this injury, with a good deal of muco-purulent discharge; but after a few days' treatment with cold water applications, he was allowed to use a lotion of Zinci Sulph. gr. j. ad Aquæ ℥ j. The wound soon cicatrized, and the eye completely recovered from the injury.

TRAUMATIC OPHTHALMITIS, OR GENERAL INFLAMMATION OF ALL THE TISSUES OF THE EYE, may be induced by any form of injury. It is one of the most severe affections to which the eye can be subjected, or which an injury can produce. It may follow a blow on the eye,

or an injury to the superficial parts, such as an abrasion or a laceration of the cornea; or it may be excited by a burn or scald of that structure from hot fluids or metals. Any injury to the eye accompanied with rupture of its external coats may give rise to it; but the lodgement of a foreign body within the globe is specially prone to produce it. All the tissues of the eye are involved in the one general inflammation, and in many cases it appears to commence simultaneously in each of them. If ophthalmitis follow an injury, it may undoubtedly originate in the injured part; but the inflammatory action spreads rapidly from tissue to tissue, and the whole globe is speedily involved.

Symptoms.—Great vascularity of the eye, both of its conjunctival and sclerotic vessels. The ciliary zone of vessels around the cornea is fully injected and markedly seen. There is more or less œdematous swelling, with redness of the upper lid, which usually bears some proportion to the acuteness of the attack and the stage to which it has advanced.

The Aqueous Humour at the beginning of the attack is transparent, but yellow and serous; it then becomes turbid from corpuscular lymph or pus, and there is hypopion or a deposition of lymph or pus at the bottom of the anterior chamber. The secretion of the aqueous is often increased, and the anterior chamber is very considerably deepened, by the iris being thrown backwards by the excess of fluid anterior to it, whilst the posterior chamber is probably diminished to a corresponding extent.

The Iris seen through the yellow aqueous at the commencement of the attack appears changed in colour, but as the disease advances, it loses its brilliancy and striation from effusion of lymph on its surface and into its texture. The pupil, at first somewhat contracted and sluggish in its

action, becomes afterwards irregular from points of adhesion between it and the anterior capsule of the lens, and so paralysed as to be unaffected by atropine. At a later stage of the disease complete synechia or union of the entire pupillary border of the iris to the capsule of the lens, is very apt to occur; and that portion of the lens capsule which is within the pupillary area becomes more or less covered with lymph.

The Cornea soon becomes dulled, and in parts roughened, and oftentimes an irregular sloughing looking ulcer appears on its surface; or it may be that pus or lymph is infiltrated between its laminae; a condition which is recognised by the name of onyx or corneal abscess.

Such are the visible changes which are rapidly induced by an attack of ophthalmitis, but mischief is also going on at the same time in the posterior or deeper parts of the eye.

The Ciliary Processes become coated with lymph and matted to each other.

The Vitreous Humour grows turbid, and lymph and pus are effused within it. The same effusions also take place on the surface of the retina, and in some cases between the retina and choroid, and between the choroid and sclerotic, all of which tissues may be covered with morbid deposits, and even separated the one from another by them.

Pain.—The pain of ophthalmitis is always very severe. It is supra-orbital, extending up the side of the head; it is around the orbit and down the side of the nose, and in the eye itself. At first neuralgic in character, sometimes acute, at others dull and aching, but, as the disease advances, hot and throbbing. The pain is usually sufficient to destroy sleep and to produce severe constitutional symptoms.

Prognosis.—Ophthalmitis may under judicious treatment combined with other favourable circumstances gradually

subside, and a useful, although it may be to a certain extent a damaged eye, will remain. On the other hand, the activity of the disease may continue unabated, and not expend itself until all the tissues of the eye are involved in one general suppuration. Sometimes the sudden giving way of the cornea from ulceration appears to arrest the further progress of the disease, for, after this casualty, an improvement will often seem to commence, and the inflammatory symptoms subsiding, the eye will become quiet and recover itself, but its efficiency as an organ of vision will be greatly impaired, if not completely destroyed.

Treatment.—What are the best means of combating an inflammation so acute, involving so many tissues, and running its course so rapidly? The treatment must be local and constitutional.

The Local Treatment.—At the commencement of the attack leeches should be applied, two or three in number, to the temple, and these may be once repeated if they give relief. All applications to the eye should be warm and soothing, and none are better than the frequent fomentation with the decoction of poppy heads, or with a solution of the extract of belladonna of the strength of ℥ j. of the extract to a pint of boiling water. A solution of atropine gr. j. ad Aquæ ℥ j. may also be dropped into the eye twice or three times a day. The patient should be kept in a darkened but well ventilated room, into which no candle or lamp should be admitted, and all use of the eyes should be strictly prohibited.

Constitutional Treatment.—The bowels should be freely acted on at the commencement of the attack, and sleep, if the patient is restless, should be produced and the pain relieved by opium. Opium in these cases is usually of the greatest service; it assuages the pain in the eye and the neuralgia around the brow and down the side of the nose;

and at the same time it tranquillizes the patient, and places him in a more favourable condition for recovery. Often it is advantageous to add a grain of calomel each night with the opium, which may be given either by itself, or in the form of Dover's powder. It is never necessary to give mercury so as to affect the gums, for patients who suffer from ophthalmitis as the result of an injury will not bear much depressing. At the commencement of the attack salines and diaphoretics may be prescribed, but these must soon give place to quinine or bark with the mineral acids. The strength of the patient should be maintained by a liberal strong beef tea diet with a moderate allowance of wine or brandy. But if the inflammation goes on, and the cornea becomes ulcerated, or infiltrated with pus; or if there is hypopion with the eye very painful, tapping the anterior chamber with a broad needle and letting off the aqueous will sometimes afford very considerable relief, and materially benefit the eye. The activity of the disease is frequently sensibly diminished after one such operation. It is not, however, a proceeding which should be undertaken rashly, as, when it fails to do good, it often seems to irritate the eye and increase the urgency of the symptoms. In some bad cases of ophthalmitis which have been under my observation, I am satisfied that the ultimate destruction of the eye has been hastened by an injudicious paracentesis of the cornea. When the operation gives ease, it may be repeated at intervals of twenty-four or thirty-six hours if the pain and acute symptoms recur; but if, after once tapping the anterior chamber, the pain in the eye is increased, it should not again be attempted.

Paracentesis of the Cornea may be performed as follows. The patient being seated in a chair or lying on a couch as may be most convenient, with his face towards the light,

the lower lid is to be drawn down by the finger of an assistant, whilst the upper lid is slightly raised by the operator. A broad needle is made to puncture the cornea towards its lower margin, the point being kept well forwards towards the cornea to avoid wounding the lens, when, by suddenly turning the flat of the blade on to its edge, so as to render patulous the opening it has made, the aqueous is allowed to run off. As soon as the iris closely approaches the cornea, which it will do when the aqueous has nearly escaped, the blade of the needle should be again turned on the flat, and quickly withdrawn from the eye.

If, however, all treatment has failed to arrest the progress of the disease, and suppuration of the globe has actually set in, one of two plans of treatment may be selected.

1st. The eye being now lost for all visual purposes, the suppuration should be encouraged with the hope of bringing the case to as speedy a termination as possible. An incision across the cornea may be made with a cataract knife to give vent to the pus and at the same time to relieve pain; a warm linseed meal poultice should then be applied over the eye, which should be fomented each time the poultice is changed with hot water or a decoction of poppy heads. Opium should be given at night to relieve pain, and the patient should have a liberal meat diet with wine or beer. As the suppuration diminishes, water dressings may take the place of the poultices. Gradually the globe will shrink, and in the end it will form a convenient stump upon which to rest an artificial eye.

2nd. Suppuration of the globe having commenced, and the eye being now irreparably lost, it may be excised. The process of suppuration of the contents of the globe is a long and often a very painful one, extending over from one

month to six weeks before a stump is formed, and cicatrization completed. The patient suffers severely, and always becomes much pulled down from the long suppuration and the necessary confinement it entails. In such cases I usually recommend the removal of the eye. The great argument in favour of leaving an eye to suppurate, is, that a good stump will probably be formed on which an artificial eye can be placed, and that the movements of it in association with the sound eye will then be perfect. On the other hand we must consider the length of time which has to elapse and the suffering the patient has to endure before the happy result of a good stump is effected. I would always advise the eye to be excised if possible before the globe has given way, and the pus has found an exit; but it may be performed even after the cornea has sloughed and when pus is freely escaping from the globe, if the circumstances of the case demand it; although at that period it often happens that the eye is nearly free from pain, and, therefore, one of the objects of the operation is done away with. On several occasions I have excised eyes which have supplicated from injuries they have received, and on afterwards examining them have found embedded in them fragments of metal, which were known to have struck the eyes, but not suspected to have lodged within them. In these patients excision of the eye was the only proper treatment, for a foreign body in the stump of an eye which it has caused to suppurate, may induce sympathetic inflammation many years after in the other eye. (*See "Sympathetic Ophthalmia."*)

In my own practice I have never had any unfavourable symptoms follow the excision of a suppurating eye. In one case, however, which came under my observation, as the patient was under the care of one of my colleagues, orbital cellulitis with rather severe head symptoms set in

on the third day after the operation, but the patient ultimately completely recovered.

For the mode of performing the operation of excision of the eye, see the article on that subject.

Results of Ophthalmitis.—1st. Under a combination of favourable circumstances the eye may recover. In some instances, but these are certainly exceptional, the recovery is complete; the transparency of the cornea is quite restored, the parts within the eye reassume their normal state, and perfect sight is regained; but in the majority of cases, traces of the disease for ever after remain, either in a slightly hazy cornea, or in a small leucoma marking the site of an ulcer, or in adhesions of portions of the iris to the anterior capsule of the lens: still the eye may be a good and a very useful one.

2nd. If the disease has been more severe, or perhaps not so soon arrested, the markings it will leave will be probably deeper and more extensive. A dense leucoma may occupy the place of a large portion of the cornea which has been destroyed by ulceration, and involved in the cicatrix may be a piece of the iris, that part of it which temporarily filled the gap when the cornea gave way, and which afterwards became adherent to the new cicatricial tissue thrown out to repair the breach. The pupil may be thus partially or even completely obliterated, or if only distorted it may be so hidden behind the leucoma that no light can pass through it to the retina, and so for all useful purposes the eye will be blind. There may, however, be a portion of transparent and healthy cornea beyond the leucoma; and if in addition there is a fair space between it and the iris, a small anterior chamber, a very useful eye may be restored to the patient by the making of an artificial pupil. (*See "Leucoma."*)

3rd. The whole cornea may have been destroyed and its

place supplied by cicatrix tissue, and lying in close contact with it will be the iris altered in appearance and structure. There will be no anterior chamber or space between the cornea and iris.

4th. The new tissue which has thus replaced the cornea is often incapable of resisting the outward pressure of the parts within the eye, and gradually yielding to the force, thins, and forming a prominent bulge becomes what is called a staphyloma. (*See "Staphyloma."*)

5th, and lastly, the tissues of the eye may have been so disorganised by the destructive inflammation to which they have been subjected, that, although suppuration has not taken place in any one of them, yet still their integrity has been so much disturbed that they are unable to recover themselves even when all the activity of the disease has ceased. The eye slowly subsides into a quiet state; the sight instead of improving diminishes; the tension of the globe is lessened, and gradually gets softer; ultimately sight becomes quite extinct, and the eye shrinks. The vitreous in such cases atrophies, diminishes in bulk, loses its consistency, and becomes serous and fluid as water. With this shrinking of the vitreous, the retina becomes detached; for, losing its anterior support, it falls forwards and separates itself from the choroid, retaining only its connexion with the sclerotic at the optic nerve entrance and the ora serrata.

Whilst all these changes are going on, the sclerotic case gradually accommodates itself to the wasting of the parts within it, and shrinks to a corresponding degree, contracting itself upon the atrophic remnants of the eye.

CHAPTER II.

INJURIES TO THE EYE FROM BURNS, SCALDS, AND
CHEMICAL AGENTS.

GENERAL EFFECTS OF ESCHAROTICS ON THE EYE—THE EFFECTS PRODUCED BY, AND THE TREATMENT FOR INJURIES TO THE EYE FROM QUICK LIME, MORTAR, LIME-PLASTER, AND OTHER COMBINATIONS OF LIME—SCALDS AND BURNS OF THE EYE—TREATMENT OF FUNGOID GRANULATIONS AFTER A BURN—THE EFFECTS CAUSED BY, AND TREATMENT OF, INJURIES FROM STRONG SULPHURIC AND NITRIC ACIDS, VINEGAR AND DILUTE ACETIC ACID, AND STRONG ALKALIS.

IN CONSIDERING the injuries inflicted on the eye from burns, scalds, and chemical agents, it will be noticed that there is a certain similarity in the effects they each produce on the tissues with which they are brought in contact, and that the process of repair which follows is also in each very identical. There are, however, certain peculiarities which usually serve to distinguish the agent by which the injury has been caused, and to demand for it some special treatment. The severity of the injury may vary from a mere irritation of the eye, to an actual destruction of the part upon which the escharotic has acted; and between these two extremes every gradation may be met with.

When the injury is confined to the ocular or palpebral conjunctiva, if it does not reach deeper than the epithelial layer, though it is sufficient to dull and whiten the surface, the damaged epithelium will be ultimately shed, but it will be again reproduced, and little if any indication will be left to mark the site of the wound. The same may also be said

if the injury is limited to the epithelial layer of the cornea, except that there is then a greater risk of it lighting up a general inflammation of the eye than when the conjunctiva covering the sclerotic is the part only affected.

If, however, the injury extends deeper than the epithelium, so as to include the connective tissue on which it rests, the whole thickness of the mucous membrane will be destroyed, and a slough will form, which will slowly separate before any attempt is made to repair the gap. When such complete destruction of the part ensues, the space is not filled up by a growth of new tissue, but the wound is gradually closed by a drawing together of its sides, and a contracted cicatrix is formed. This contraction is one of the terrible results which follow a large loss of the conjunctival membrane, and it is the cause of the serious deformities which are so common after burns, or scalds, or injuries from lime of the mucous membrane of the eye and eyelids. But when the cornea is the part deeply burnt or deeply injured by lime, or some other chemical agent, the result is still more severe. A slough of the entire thickness of the cornea may destroy the eye; or a tedious ulceration with inflammation of the true corneal tissue may follow, which may terminate by the formation of a dense leucoma on one part of the cornea, whilst the rest of its surface may be rendered hazy by interstitial deposits.

Another very frequent and distressing result of this class of injury to the eye is *Symblepharon*, or union of the inner surfaces of the eyelids to the globe. (*See* article "*Symblepharon*."

QUICK LIME, or lime before it has been slaked by the addition of water, is the most destructive agent that can come in contact with the surface of the eye. If it is in

sufficient quantity, and is allowed to remain long enough in apposition, absolute destruction of the part ensues, a slough follows, and complete loss of the eye is a not infrequent result. In the smallest quantity it is a most powerful irritant: a spasmodic contraction of the orbicularis tightly closing the lids upon the globe, and a copious flow of tears, follow the introduction of even a particle of lime into the eye. The rapid secretion of tears, which is always excited by the presence of a foreign body on the surface of the eye, is, as a rule, beneficial in helping to dislodge and wash it towards the inner canthus; but in the case of lime, the tears slake what lime is yet unslaked, and so tend to increase the rapidity with which it carries on its work of destruction. The lime absorbs rapidly all moisture from the conjunctival surface of the lids or globe with which it is in contact, and as it slakes acts as a most powerful escharotic. The epithelium is at once whitened and destroyed, and a sharp clear line will indicate the boundary of the part which has been affected by it; outside this boundary the conjunctiva is excessively red and more or less chemosed; and the lids, if the injury is severe, are œdematous.

If the epithelium only is destroyed, it will be replaced, and no markings of the injury will remain; but it is seldom, if ever, that the action of unslaked lime is thus limited; the whole thickness of the tissue with which it comes in contact is usually destroyed by it, and dense contracted cicatrices are the result.

The effect of lime upon the cornea is most disastrous: if it is allowed to continue one or two minutes in contact with it, immediate death of its entire thickness follows, a slough forms, and the eye is lost; but, even when its action is less severe, and the direct damage it inflicts is comparatively superficial, affecting the epithelial layer and involving only

to a slight extent the true corneal tissue, still the ultimate result is often complete loss of, or irreparable damage to, the eye; an acute or a subacute form of corneitis is set up, which may not subside until after the cornea has given way by ulceration, or a portion of its surface has sloughed; or the inflammation which has been excited may extend backwards and involve the deeper tissues of the eye, causing a general ophthalmitis. If the eye is not destroyed, a dense leucoma may mark the site of a partial destruction of the true corneal tissue, or the cornea may have become nebulous either from superficial ulceration, or from interstitial deposits resulting from the attack of keratitis which the lime had induced.

Treatment.—The first course to be adopted is, to remove as quickly as possible every particle of lime from the eye, and at the same time to arrest the further destructive action of any fragments which may be still sticking to the conjunctival epithelium. For this purpose a little sweet oil should at once be dropped into the eye, and the upper and lower lids being everted in turn, the bits of lime should be gently lifted away with a fine spatula or spud. Having removed all that can be seen, the upper lid being everted and the lower one drawn down by the finger of an assistant, a stream of tepid water should be gently syringed over the front of the eye and the inner surface of the lids, so as to wash away any small pieces which may have escaped notice; but before closing the lids, two or three more drops of oil should be dropped in. The oil seems to afford ease by lubricating the surface, and, for the time, taking the place of the epithelium which has been destroyed.

The application of oil to the eye may be repeated during the next twenty-four hours at intervals of two, three, or four hours if it gives comfort to the patient. A fold of

linen dipped in cold water should then be placed over the eye, and kept moist by being wetted with a sponge as often as necessary to prevent its becoming hot or dry. If the patient is seen by the surgeon *very early* after the accident, the eye may be syringed out with a little weak vinegar and water, or the dilute acetic acid and water, about the strength of one drachm to one and a half ounces of water. An acetate of lime is thus formed, which is innocuous; but for this treatment to do good, it must be resorted to immediately after the introduction of the lime; and as such a chance is rarely afforded the surgeon, I think the use of olive oil in the first instance will generally be found preferable. For the first two or three days after the injury soothing applications are best suited, and the cold water dressings to the eye should be continued, or a lotion of belladonna may be substituted if the eye is very painful. Opiates should be given at night if the pain prevents sleep.

The treatment which will have to be continued will depend very much on the extent of damage the eye has sustained. If it has been confined to the conjunctiva of the lids or globe, and has not affected this tissue very deeply, there will be more or less conjunctivitis with a muco-purulent discharge, which will require after a few days, the use of some mild astringent, as a solution of Argenti Nitratis gr. j. ad Aquæ ℥j., a few drops of which should be dropped into the eye twice or three times daily; or a lotion of Zinci Sulphatis gr. j. ad Aquæ ℥j., or of Aluminis gr. iij. ad Aquæ ℥j., may be used to wash the eye with frequently, allowing a little each time to run into the eye. The margins of the lids should be anointed every evening with a little unguent. cetacei to prevent their gumming together. But if the destruction of the conjunctiva has been more severe, and sloughing or suppuration is threatened, or if the cornea has been involved and there is

inflammation of the corneal tissue, or if, as is not unfrequent, the whole eye is painful and inflamed, soothing applications are best suited, and these may be applied either hot or cold according as they afford the greatest relief to the patient. Those parts which have had their vitality actually destroyed by the lime will become sloughs, and will have to be detached from the living tissues before repair will commence. The increased vascular action which accompanies this process of the separation of the sloughs, will not allow of any stimulating application to the eye.

As the tendency of severe injuries to the eye is to produce great prostration, the patient should, from the very beginning of the treatment, be well supported, not necessarily by stimulants, but certainly with a liberal meat diet. If there is much pain and restlessness, opiates should be given to procure sleep.

One of the most distressing cases of injury to the eyes from lime which ever came under my care, and, at the same time, one which illustrates well its terrible escharotic effects, occurred under the following circumstances. The patient was an engineer in a large brewery, and as he was walking along heedlessly, he casually passed a vat which was being cleansed out with some lime and water. Just at that moment the lime which had caked was being stirred up with a stick, and the person who had the stick in his hand gave it a flick to detach a mass of lime which was clinging to it. By a strange combination of circumstances, portions of this mass of lime struck the engineer, and entered each of his eyes. He came under my care on the following day: both eyes were irreparably lost, both corneæ were destroyed. He continued under treatment, and both eyes suppurated. The lime, no doubt, when it entered the eyes, was in the act of slaking.

CASE V.—*Injury to the eye from lime, followed by suppuration of the cornea and complete loss of the eye.*

Thomas M., æt. 12, a plasterer's boy, was admitted into the Hospital on June 5, 1863. One month previously a boy threw a handful of lime at him, and a portion of it entered the right eye. The eye at once became very painful and inflamed, and ever since it has been getting steadily worse.

State on admission.—The parts chiefly affected by the lime are the cornea, and the conjunctiva immediately beneath its lower margin. The whole cornea is suppurating, and looks as if it would slough; and there is a large slough of the conjunctiva near the lower border of the cornea which has not yet separated.

June 9.—The cornea has sloughed, and the eye is consequently lost.

June 12.—As the boy was suffering considerable pain, Mr. Bowman excised the lost eye. The boy soon recovered from the operation, and was able in a few days afterwards to leave the Hospital.

MORTAR, LIME, PLASTER, and the other combinations of lime used for building purposes, differ only in degree from lime in the way in which they affect the eye. Their action is not quite so rapid or so acute as unslaked lime; still, if they are allowed to remain a sufficient time in contact with the eye or with the conjunctiva of the lids, similar results are produced; sloughs may be formed, and suppuration ending in complete destruction of the eye may follow.

The same nebulous and whitened state of the cornea, and the same contracted cicatrices of the conjunctiva, and union of the lining membrane of the lids to the surface of the globe, follow the introduction of these materials into

the eye as in the cases of unslaked lime ; but, as their action is slower, the injury they inflict is usually less severe. Fresh made and moist mortar or lime plaster is much more deleterious than dry or old.

CASE VI.—*Large superficial burn of the conjunctiva of the eye from lime plaster used in making the ceiling of a room.*

James D., æt. 26, a bricklayer, came to the Hospital on Aug. 1, 1865, suffering from an injury he had received to the eye ten days previously. He was at the time of the accident engaged plastering a ceiling when a large piece of the fresh lime plaster fell into the left eye.

Present state.—The epithelium of the conjunctiva of the globe is whitened and swollen to the extent seen in

FIG. 4.

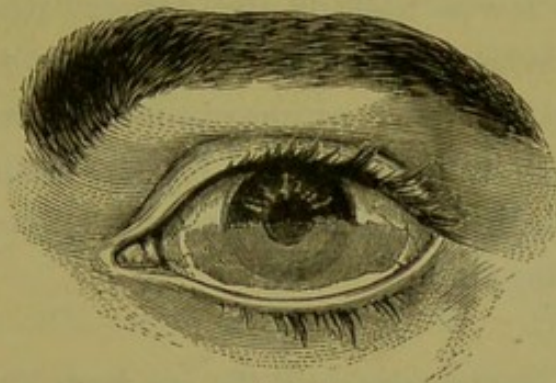


fig. 4. A clear sharp line marks the exact extent of the injury, both above and below. Within these lines all the epithelium of the conjunctiva is of a greyish white, with here and there minute spots of ecchymosis ; beyond these boundary lines both above and below, the conjunctiva is excessively red, its capillary network being fully injected. The conjunctiva of the lower lid is not affected, the injury being entirely confined to that which covered the lower half of the eye. The lower half of the cornea has completely lost its brilliancy, and is whitish and semi-

opaque. The eye is excessively painful. The pupil, part of which only can be seen, acts well.

He was ordered a lotion.

Glycerine ℥j.
Aque destillat. ℥viij. M. ft. lotio.

To bathe the eye frequently with the lotion, and to allow each time a little of it to run into the eye.

August 4.—The eye still very painful. To continue the lotion, and to apply over the brow of the injured eye

Extract. belladonnæ ℥iij.
Glycerine ℥j. M. ft. liniment.

and to take pil. saponis c. opio gr. v. every night, if in much pain. Under this treatment the eye gradually recovered, and on

August 25, the report states; there is an irregular nebula of the lower half of the cornea, which has now recovered its brightness, and in parts, its transparency. A broad cicatrix of the conjunctiva marks the seat of the injury. The epithelium is restored, but the conjunctiva looks puckered and tight. There is no symblepharon, or union of the lids to the globe.

CASE VII.—*Severe injury to the eye from fresh mortar.*

George P., æt. 8, was brought by his mother to the Hospital on March 18, 1865, having the day previously received a severe injury to his left eye from some fresh made mortar.

History.—Yesterday he was climbing up a ladder placed against a house which was being repaired, when a mortar boy called to him to get off; but as he did not immediately comply with his order, he pelted him with some fresh mortar which he had by him, and some of it entered the left eye. The boy immediately suffered great pain in the

eye, and hastened home. His mother washed away the mortar from the front of the eye as well as she could, and dropped in some sweet oil.

On examination, the conjunctival surfaces of the lower half of the globe, and of the lower lid, seemed quite destroyed; the epithelium was of a yellowish-white, and looked in a sloughing state. Nearly the upper and outer half of the cornea was clear and uninjured, but the remainder of it was bluish-white, and semi-opaque. A portion of the conjunctiva of the upper lid was also involved in the injury. A good deal of mortar was still sticking to the surface of the eye, and lying beneath the lids.

All the loose mortar was carefully lifted from the eye with a fine scoop, and the surface of the eye washed with a gentle stream of tepid water.

The mother was told to repeat the drops of olive oil into the eye three or four times daily, and to keep a fold of linen wet with a lotion of

Glycerine ℥jss.
Aqueæ ℥vjss. M. ft. lotio.

March 22.—The eye is less painful. There is a large superficial slough of the conjunctiva of the lower lid, which has not yet separated. The conjunctiva of the lower half of the globe is still whitened.

April 6.—Sloughs of conjunctiva have separated from the lower lid and from the lower half of the eye, and union has already commenced between the opposed surfaces of the lower lid and globe.

April 10.—From the contraction and cicatrization which are taking place on the inner surface of the lower lid, which is now nearly united to the globe, the eyelashes have been drawn completely inwards, so as to brush against

the cornea. For the relief of this entropion, I excised the whole row of lashes. From this operation great relief was obtained.

From this date the lad progressed favourably, and made a much better recovery than might have been anticipated; for the injury, though very severe, did not involve the tissues very deeply. He was discharged the Hospital with a useful eye.

FIG. 5.

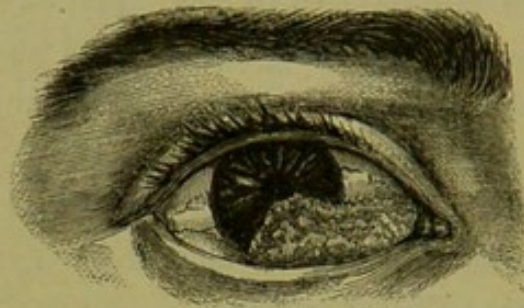


Fig. 5 represents the state of the eye when the boy left the Hospital. There is a large fleshy cicatrix of the conjunctiva which extends from the caruncle on to the cornea, the lower and inner third of which is covered by it. The rest of the cornea is clear. There is a good circular pupil which acts well. The lower lid, the eye-lashes of which I excised on account of the entropion, is united to the globe.

BURNS AND SCALDS OF THE EYE.—Hot fluids, according to the intensity of their heat, redden, vesicate, or even destroy the conjunctival surface of the eye or lids with which they come in contact. They produce the same immediate effect on the conjunctiva of the eye as they do on the skin covering the body; but the delicacy of the textures of the eye, and the importance of the integrity of each for the well doing of the whole, render what would be a slight scald elsewhere, a severe injury to the eye.

A SCALD, if at all severe, whitens the surface, vesicates the epithelium, and induces a general redness of the conjunctiva of the eye and lids.

If it is slight, a mere reddening of the part with some conjunctivitis will follow, which will in all probability terminate favourably in a few days. When the scald is more severe, the epithelium is whitened and destroyed, vesicated, and afterwards detached; but if the burn extends no deeper, it will be replaced. In all severe scalds there is a risk of an extension of the superficial conjunctival inflammation to the deeper tissues of the eye. But if the scald should have gone beyond the epithelium and involved the subjacent connective tissue, the injury will be necessarily more severe, not only in its direct effects, but in the subsequent cicatrization and contraction which must follow.

It is, however, comparatively seldom that hot fluids affect deeply the tissues of the eye: the rapid flow of tears which follows their introduction speedily cools and dilutes them, and prevents that severe mischief which would otherwise ensue.

When the cornea is scalded, the danger to sight as well as the chance of an extension of the inflammation to the deeper parts of the eye is increased. The most frequent sources of scalds are from boiling water, and splashes of hot fat or oil in cooking.

BURNS OF THE EYE are frequently met with in the Royal London Ophthalmic Hospital practice. They usually occur amongst the men who work in the iron ship building yards, amongst engineers, boilermakers, or men employed in metal casting. They are a frequent complication of other injuries: thus, in turning a bar of heated iron which has to be welded or hammered out, the hot end may acci-

dentally strike the eye with considerable force; a burn is thus inflicted, but this is often secondary in importance to the damage done by the blow. Sometimes the eye is struck with a small fragment from a red-hot rivet, which lodges between the eye and the lower lid; and in such a case the eye often suffers an injury quite independent of, but in addition to, the burn.

Burns, however, are very commonly quite uncomplicated; scales of hot iron will fly off whilst being struck with the hammer, or sprays of molten metal in casting will strike the eye, and become lodged between the globe and the lower lid, and produce an eschar of the tissues with which they are brought in contact. I have frequently had to remove beads of metal which had evidently been brought against the eye in a fluid state, and gravitated to the sulcus in which I found them. The injuries which splashes of hot metal inflict, although sometimes very severe, are often wonderfully slight. One would reasonably expect that if even a small quantity of molten or red-hot metal was brought into contact with the eye, the heat would be so great as either to burn through the conjunctiva and sclerotic, and cause an immediate death of the entire thickness of the external coats of the eye; or else certainly that such a burn would be inflicted that a local superficial slough of the sclerotic would follow. But such is by no means the general rule: the copious flow of tears which is excited the moment the hot metal touches the eye rapidly cools it, and to this may be partly attributed the limited action it seems generally to exert on the surface with which it is brought into contact; but it is also probable that, as has been suggested, the hot metal immediately converts the first drop of moisture which meets it into steam, and that a thin film of steam is thus at once interposed between the metal and the surface of

the globe, and by it the action of the hot metal on the eye is considerably retarded.

One of the most remarkable cases on record of this kind is that related by Mr. Hutchinson in the Royal London Ophthalmic Hospital Reports, vol. i., p. 217. The subject of this case was an out-patient who came under Mr. Hutchinson's care when he was on duty for Mr. Dixon. "He was a very healthy man, employed in an iron foundry. It appeared that whilst at work some of the molten metal (at a white heat) had been spurted into his left eye. It had struck the globe over the lower edge of the cornea and the adjacent part of the sclerotic. One of his fellow-labourers removed the metal, after it had solidified, with some difficulty, on account of its adhering firmly to the charred tissues. It had in cooling been accurately moulded upon the surface of the globe and the edge of the lower eyelid. So severe a burn might have been expected to induce serious consequences. The affected parts of the cornea and sclerotic, which included the greater part of the thickness of each, but without actual perforation, sloughed off, as also did some of the palpebral mucous membrane. The globe itself, however, did not inflame. In the healing of the scar, the pupil was drawn downwards by puckering of the iris at its attached margin, but perfect vision was retained." . . . "Some adhesions between the globe and the lower lid resulted, but they do not constitute any material deformity or occasion the man much inconvenience."

It is seldom that so large an eschar separates without perforation of the sclerotic, or without inducing such an inflammation of the eye as to end in its complete destruction. When a slough of the entire thickness of the sclerotic follows a burn, causing a complete aperture in that coat, loss of the eye is generally the result; but even to this there

may be an exception, and the following very interesting case occurred in my practice at Moorfields.

The burn, which was very severe, was caused by a large triangular piece of red-hot iron becoming wedged between the lids at the inner angle of the eye. The inner third of both lids were so burnt that their vitality was destroyed, and that portion of them became detached as sloughs. The point of the hot metal which rested against the sclerotic caused a slough of the entire thickness of that coat, which became detached, and an aperture of the size of a small pea was made, through which the black choroid could be seen shining. The conjunctiva of the inner third of the globe was completely destroyed, but at no other point than that mentioned was the sclerotic affected. The eye, notwithstanding this severe injury, did not become generally inflamed, and the sight continued good both during and after the separation of the slough of the sclerotic. As far as I could judge, by closely examining the aperture in the sclerotic from day to day, no attempt at closure of the wound was made by that structure. The edges of the aperture did not appear to granulate, but they continued to look sharp and clean, as if the opening had been punched out with a small punch.

The wound was eventually filled in by granulations from the lower lid, which united with those on the surface of the globe, and so gradually closed around the gap, and one granulation could be seen projecting into it.

As cicatrization proceeded, the opening in the sclerotic became completely closed by symblepharon, or union of the lids to the globe; but the eye became so much drawn inwards and fixed that it was rendered comparatively useless, as, excepting at one point, the man had double vision. The eye was so much inverted that the cicatrix of the lids slightly encroached upon the pupil. It was quite im-

moveable, and was permanently stationary at about one line to the inner side of the mesial line of the orbit. In consequence of the contraction of the cicatrix of the lids, he was able to open them to a limited extent.

On March the 6th of this year the patient came to show himself to me, and with that eye he was able to spell words of No. 8 of Jaeger's test-types.

The impairment of sight seemed to be dependent partly on the effort he had to make to open the lids and adjust the eye to the object, causing a flow of tears, which obscured greatly his vision.

The following are the notes of the case, from my case book :—

CASE VIII.—*Severe burn of the eye and both eyelids, involving both the external and conjunctival surfaces of the lids—Slough of the sclerotic, and afterwards closure of the aperture in the globe by union of the sclerotic with the granulations of the wound of the lower eyelid.*

James S., æt. 21, a riveter, came to the Hospital on December 19, 1865, suffering from an injury he had two days previously received to the left eye. He was striking a red-hot rivet, when a triangular piece of it, of the exact size and shape represented in fig. 6, became detached and lodged itself at the inner angle of the eye. It was wedged in, the point being pressed firmly against the globe, and the broad end against each eyelid and the side of the nose close to the caruncle.

FIG. 6.



Both eyelids were œdematous, and there was an ash-coloured slough involving the inner third of the integument of each lid, which extended to the side of the nose for about one-quarter of an inch beyond the caruncle.

On examining the eye, the cornea was found perfectly

clear and transparent; but at about a quarter of an inch below the lower and inner margin of the cornea there was a severe burn of the eye, extending inwards as far as the caruncle, and involving the corresponding conjunctival surfaces of both eyelids. The patient progressed favourably, and on December 28 the sloughs had separated from the external and internal surfaces of the lids, and left healthy granulating wounds. The burnt portion of the conjunctiva of the globe had also sloughed; at one point, a little below the lower and inner margin of the cornea, where the end of the hot metal had rested, the burn had extended deeper, and a slough of the sclerotic of the size of a small pea, not yet detached, was now seen.

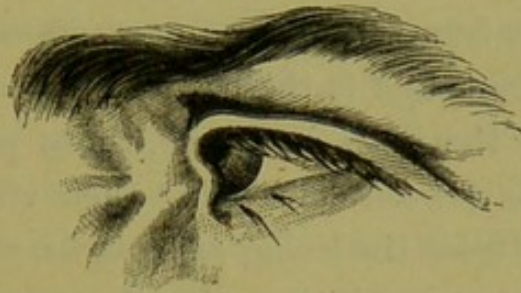January 1.—The slough in the sclerotic has separated, and through a nearly circular aperture, about the size of a small pea, the choroid is seen, on a level with, but not bulging through the wound. The eye shows no signs of inflammation, and the sight is good.

January 5.—The granulations of the palpebral surfaces of the lids are uniting to those of the globe, and those of the lower lid appear to be gradually contracting round the aperture in the sclerotic; one of the granulations is seen projecting into it. There is no irritation of the eye.

January 9.—The sclerotic is now united to the palpebral surfaces of the upper and lower lids to about the inner third of their extent. The wound in the sclerotic cannot be seen; the lower lid seems to have so completely united to the globe as to have closed it. The external wound of the lids has nearly healed. There is already a considerable contraction inwards and drawing together of the eyelids, diminishing to a great extent the palpebral aperture. The sight of the eye is good. He is able to read No. 4 of Jaeger's test-types.

March 6.—The man came to the Hospital to show himself. The contraction of the cicatrix of the lids has caused the eye to be drawn inwards to a line within the mesial line of the orbit, and to be permanently fixed in this position. The cicatrix of the lids slightly encroaches on the pupil. The palpebral aperture is much diminished

FIG. 7.



in size, and on attempting to read and fix the eye on the object, there is a considerable flow of tears which impedes his sight. With difficulty he is able to spell words of No. 8 of Jaeger's test-types.

The description which has been given of the effects resulting from scalds will apply also to burns, except that injuries from burns are usually more severe, and the burnt part immediately after the accident generally exhibits a drier surface. A slight burn will redden and vesicate as in a scald, but a severe one will char the surface, and leave it whitened and dried. The injury from burns usually extends deeper than in scalds, and there is consequently more suppuration and more frequent sloughing of the injured parts.

As the destruction of tissues is more complete in burns than in scalds, so the deformities which follow are greater; and bad cases of contracted cicatrices, drawing the lids from their normal relation to the eye, or uniting their inner surfaces to the globe, are the common sequencies of extensive burns.

Treatment of Burns and Scalds.—The same principles which guide the treatment of burns and scalds in other parts of the body, are applicable to similar injuries to the eyes and lids. I have associated the treatment of the eyes and lids together, as they are very frequently involved in the one injury.

1st. In the early treatment of a burn or scald, it should be remembered that whatever application excludes the air most completely from the injured part, affords the greatest ease to the patient, and is the best for his well doing.

2nd. That if the burn is severe, those portions of the tissues which have been deprived of their vitality will have to be separated from the living as sloughs, and that during this stage soothing applications are the most called for.

3rd. The sloughs having separated, a granulating surface is exposed, and during this, the last or healing stage, stimulating applications do the most good.

1st stage.—When the patient is first seen, a few drops of olive oil should be dropped into the eye, and the lids then gently closed, and some cotton-wool laid loosely over them, which should be kept in its place by a single turn of a light bandage.

The dropping of oil into the eye may be repeated two or three times during the day, and each time the bandage is removed, the eye and lids should be washed free of any discharge which may have accumulated, with a lotion of

Glycerine ℥ij.
Aqtæ Rosæ ℥ij.
Aqtæ destillat. ad ℥viiij. Ft. lotio.

If the lids are severely burnt or scalded, previously to applying the cotton-wool, lint soaked in carron oil, or equal parts of lime-water and linseed oil, should be laid over them; but if the burn or scald is only slight, a little ung. cetacei on lint will be sufficient. Opiates should be

given internally if the patient is suffering much pain: they not only give ease and procure sleep, but they exercise a specially beneficial control over the suppurative action which has to follow.

2nd stage.—If the burn of the eye has been severe, and sloughs of the burnt tissue are beginning to separate, the cotton-wool pad may be left off, and soothing applications will be found to do good. The eye should be frequently bathed with the glycerine lotion, so as to keep it free from discharge, or, if it is very painful, it may be fomented with the decoction of poppy heads; or, if there is no granulating wound of the external surface of the lids, a fold of linen repeatedly wetted with a belladonna lotion, of the strength of three or four grains of the extract to the ounce of water, may be laid over the eye. If the lids have been badly burnt, and the sloughs are separating, a warm linseed poultice is the best application to hasten their detachment; or, if this cannot be conveniently worn, a little water dressing covered with oil silk is a good substitute.

3rd stage.—When the sloughs have separated from the eye, or from the mucous surface of the lids, or if the burn or scald has not been so severe as to have caused sloughs, but a conjunctivitis is present with a free muco-purulent discharge, stimulants are required; of these, a lotion with one grain of sulphate of zinc or one grain of the nitrate of silver to the ounce of water may be used. The best application to a granulating wound of the lids after the sloughs have separated, is an ointment of equal parts of the unguentum resinæ and unguentum cetacei, spread on lint and applied to the surface. Any mild stimulating ointment or lotion will, however, usually answer very well.

The following cases are illustrations of burns of the conjunctiva of the lid and globe from hot metal.

CASE IX.—*Burn of the conjunctiva from the lodgement of a piece of a red-hot rivet between the eye and the lower lid.*

George S., æt. 30, a boiler maker, engaged at iron ship building, applied to the Hospital on June 26, 1865, suffering from an injury he had that morning received to the right eye. Whilst striking a red-hot rivet a fragment of it, about the size of a small pea, flew off, and lodged itself at the inner angle of the eye between the globe and the conjunctiva of the lower lid.

The conjunctiva of the lower lid near the inner angle, and the corresponding portion of the conjunctiva of the globe and the caruncle, the parts with which it had come in contact, were quite white, and the epithelium destroyed. Both the upper and lower lids of that eye were so œdematous that he was unable to open them. A fellow workman removed the piece of metal immediately after the accident. A copious flow of tears followed the lodgement of the foreign body.

He was ordered to bathe the eyes frequently with a lotion of

Glycerine ℥ij.
Aquæ ℥vj. Ft. lotio,

and to apply two leeches to the temple.

The man continued his attendance as an out-patient, and in a few days a superficial slough of the burnt parts separated, and a healthy granulating surface was left, which soon cicatrized. The cicatrix which resulted drew the inner portion of the lower lid rather closer to the eye than normal, but not so much so as to cause the patient any inconvenience. The sight of the eye was unaffected.

CASE X.—*Burn of the conjunctiva from molten lead.*

John V., æt. 37, applied to the Hospital on July 23, 1865. He was engaged working on board a ship at the Isle of Dogs, when a plumber, who was employed in a compartment just over his head, dropped some molten lead which he was running into a joint. It fell on his head; but as he suddenly turned his face upwards, a small quantity of it ran into the left eye, burning the portion of the conjunctiva of the lower lid and the globe, with which it came in contact. The cornea escaped injury, but on the burnt portion of the conjunctiva the epithelium was quite destroyed, and its surface was whitened.

The man was ordered to use frequently a lotion of

Glycerine ℥ij.
Aquæ ℥vj. Ft. lotio.

A little of the lotion on each application is to be allowed to run into the eye, and a fold of linen wet with it, is to be laid over the closed lids.

In eight days the burnt portion of the conjunctiva separated as a slough, and left a granulating surface, which soon healed. The man recovered with a good eye, but a cicatrix remained which approximated the lower lid a little more closely to the globe than normal. The sight of the eye was unaffected.

CASE XI.—*Burn of the eye from molten lead.*

Richard P., æt. 21, a plumber, applied to the Hospital on April 25, 1865, suffering from an injury he had received the day before to the right eye. He was carrying a pot of melted lead, when his foot slipped over a piece of wood and some of the molten metal splashed up into the eye. He removed a piece of lead of the exact

FIG. 8.



shape and size of that represented in the woodcut, which was moulded to the part of the eye against which it rested.

Present state.—The injury is confined to the outer side of the eye. The epithelium of those parts of the conjunctiva of the upper and lower eyelids with which the metal came in contact is quite white, and apparently destroyed; so also is the epithelial surface of the conjunctiva, just along the outer margin of the cornea; and the outer and lower third of the cornea is dulled and whitened.

The patient complained of the eye being very painful.

He was ordered

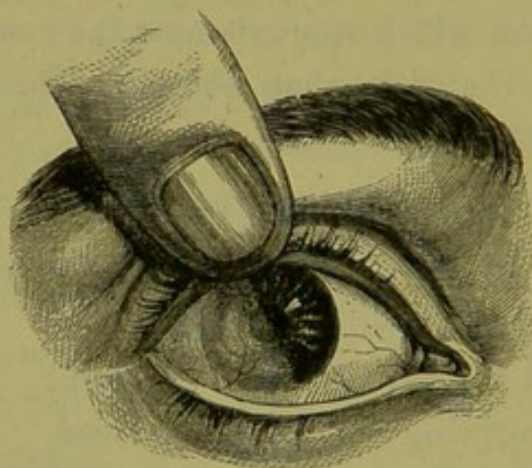
Glycerine ℥ij.
Aquæ ℥vj. Misc. Ft. lotio.

To bathe the eye frequently with the lotion. Pil. Saponis c. Opio gr. v. to be taken every night if in pain.

Under this treatment the patient progressed very satisfactorily.

The burn was more superficial than at first appeared; the epithelium of the conjunctiva of the lids and eye became

FIG. 9.



detached, and over the injured part of the cornea there was left an uneven cloudy surface, on a lower level than

the rest of the cornea. This gradually filled up, and the eye now presents the appearance represented in the fig. 9.

The outer half of the cornea is leucomatous, there having been a superficial loss of the true corneal tissue; but the inner half of the cornea is quite clear. There is no symblepharon, and the movements of the eye are perfect.

In drawing the woodcut, the finger was made to raise the upper lid so as to show the full extent of the injury to the cornea.

FUNGOID GRANULATIONS AFTER A BURN.—Occasionally in burns of the eye or mucous membrane of the lids, after cicatrization and contraction have ceased, there remains a fungous-looking granulation. This is often a source of great annoyance to the patient: it keeps up a constant muco-purulent secretion, which astringent lotions will not arrest. The treatment is simply to snip it off close to the conjunctival surface with a fine pair of scissors, and afterwards to use a slightly astringent lotion for a few days, such as a weak solution of alum and zinc; three or four grains of the former and one of the latter to the ounce of water.

CASE XII.—*Burn of the conjunctiva of the lower lid and the globe from the lodgement of a piece of hot iron; fleshy granulation of the cicatrix.*

Samuel H., æt. 31, engaged at some iron-works, came to the Hospital July 24, 1865, suffering from the effects of a burn he had received to the left eye. He stated that about last Easter he was working with a steam hammer, when a fragment of hot iron flew into the eye, and became lodged between the lower lid and the conjunctiva of the globe, close to the external canthus. It was in contact with the eye for several minutes before it was removed by a fellow

workman. Immediately on the introduction of the foreign body there was a great flow of tears, so that when the piece of metal was removed it was quite cold. The injured parts have now healed, but a dense cicatrix remains, which draws the lower lid at that point closely towards the globe. The object of his present application to the Hospital was to get relieved of a large fungous granulation which was growing from the cicatrix. This I removed with a snip of a pair of scissors. The part at once healed, and he ceased his attendance as an out-patient.

STRONG SULPHURIC AND NITRIC ACIDS act chemically on the tissues of the eye, and if in sufficient quantity cause disorganisation of the parts with which they are brought in contact, producing superficial or deep sloughs. If the opposed surfaces of the palpebral and ocular conjunctiva are thus destroyed, deformity from the contraction of the cicatrices, and from symblepharon, will occur after the same manner as I have related in cases of burns from hot metals, quick lime, or any other escharotic.

The action of a strong acid on the eye, even in the smallest quantity, is that of a powerful irritant; it produces great pain and smarting, more or less œdema of the lids, and a constant flow of tears with intolerance of light, which may last for many days afterwards, even though the actual injury inflicted does not extend beneath the epithelium of the ocular conjunctiva.

The rapid flow of tears, however, which the irritation of the acid instantly excites, quickly dilutes it; and if it is only a drop or a small splash which has entered the eye, the injury which it inflicts is comparatively slight and completely remediable.

When the cornea is injured by nitric or sulphuric acid, if its action extend beyond the epithelium to the lamellated

corneal tissue, a suppurative corneitis is very apt to follow, which will greatly damage if it does not entirely destroy the eye.

Sulphuric acid, on account of its well-known burning properties, is often selected as an agent of revenge, and is thrown over the dress or in the face of the offending person, and not unfrequently the eyes are injured by it; or occasionally in chemical works, splashes of nitric or sulphuric acid accidentally fly into the eye.

In injuries to the face from strong acids, the eyelids are more liable to suffer than the eyes; large portions of the integuments of the lids are often destroyed, and become detached as sloughs; great contraction accompanies the process of cicatrization which follows, and the worst and most intractable forms of ectropion are produced. In such cases the lost integument is not replaced by a complete regrowth; the wound is partially healed by a thin cicatrix tissue, but principally by a gradual contraction or pulling together of its edges, borrowing as it were from the skin in the immediate vicinity, by drawing upon it to effect a closure of the gap. In one patient under my care, whose case I have cited in the article on Ectropion, the integument of the right upper eyelid was in a great measure destroyed by strong nitric acid; a slough formed, and as cicatrization afterwards advanced, the upper eyelid became completely everted, its tarsal edge being drawn upwards to within a quarter of an inch of the eyebrow, with which it was parallel.

Treatment of injuries from strong acids.—If the patient is seen very shortly after the accident, the eyes should be gently syringed out with some weak alkaline solution, such as Potassæ Bicarb. or Sodæ Sesquicarb. gr.v., Aq. destillat. ℥j., to neutralise any acid which may yet remain; or if this cannot be at once obtained, tepid water should be used.

A little olive-oil should be then dropped into the eye, and this may be repeated two or three times a day if it gives ease. The lids being now closed, a layer of cotton-wool should be laid loosely over them, and a single turn of a bandage passed round the head to keep it in its place. The after treatment should be conducted in the same manner as that described for burns of the eye from hot metal, lime, &c. As long as the eye is irritable, and unable to bear the light, only soothing applications should be used; but when all irritation has passed away, if there is any conjunctivitis with a muco-purulent discharge, the use of a mild astringent will be found beneficial.

When the lids are much burnt with a strong acid, an alkaline dressing should be used for the first twenty-four hours, and lint dipped in a mixture of Cretæ preparat. ʒj., Ol. Lini ʒj., should be laid over them, then a layer of cotton-wool, and a turn of a bandage over the whole to keep them in situ. The ordinary carron-oil, or equal parts of lime-water and linseed-oil, may be afterwards substituted for the chalk dressing, and continued until the sloughs begin to separate. The after treatment to be pursued should be the same as that recommended for burns.

CASE XIII.—*Injury to both eyes and the integuments of the face from strong nitric acid.*

S. R., æt. 25, by profession a wizard, applied to the Hospital May 12, 1865, on account of an accident he had met with the day previously, whilst preparing a galvanic battery for the performance of some of his tricks. He was filling a porous pot with some strong nitric acid when the sides of the jar suddenly gave way, and the acid was splashed up into his face, some of it going into each eye. A copious flow of tears immediately followed, and

the lids soon became swollen, and since then he has been unable to open the eyes.

Present state.—Both lids are much swollen and œdematous, so as to prevent his opening them; and there are two or three small superficial yellow eschars, from the action of the nitric acid on them. There are also several yellow eschars on different parts of the face. On drawing apart the lids so as to examine the eyes, there is seen an œdematous conjunctivitis of both eyes; but in the right eye the cornea is steamy and rough, evidently from a drop of the nitric acid having come in contact with it, and destroyed a portion of its epithelium. In the left eye the cornea has escaped, the acid only having affected the conjunctiva of the globe and lids. The injury to both eyes is, however, quite superficial, and has effected no serious damage. This must be explained by the abundant flow of tears which followed the instant the acid entered the eyes, causing it to be so rapidly diluted that its caustic properties were at once destroyed, and it was thus made to act only as a powerful irritant.

He was ordered to bathe the eyes frequently with a lotion of

Glycerine ℥j.
Aquæ destillat. ℥vij.,

and to apply to the right temple two leeches.

To the burns about the face he was ordered to apply lint soaked in carron-oil.

May 16.—Very much better. Has no pain in the eyes. There is some muco-purulent discharge from the eyes, but the cornea of the right is regaining its natural transparency. The swelling of the lids has diminished, but there is still some œdema, preventing his keeping them open.

From this date he progressed uninterruptedly. A lotion of Zinci Sulph. gr. j. ad Aquæ ℥j. was ordered, to arrest the

slight muco-purulent discharge which continued for a short time.

VINEGAR, DILUTE ACETIC ACID, *or any of the weak or dilute acids* act as irritants to the eye; and although they do not immediately destroy any of the tissues with which they may be brought into contact, yet they often give rise to an ophthalmia which is the cause of much suffering, and in some instances even of danger to the eye. The primary treatment recommended in the cases of injury from strong acids is equally applicable to those occasioned by the weak or the dilute. If seen early, the alkaline solution should be used, and afterwards, either soothing or astringent applications, according to the directions already given in the treatment of burns from quicklime, hot metal, &c. In all injuries to the eyes from chemical agents, a solution of the antidote should be first used if the patient is seen sufficiently early to render its application of service. As in the cases of injury from an acid an alkaline solution was recommended, so in those from a strong alkali, such as caustic potash or soda, an acid solution of ℥j. of vinegar or of the dilute acetic acid to the ounce of water should be syringed over the front of the eye and palpebral surfaces of the lids.

CHAPTER III.

PENETRATING WOUNDS OF THE EYE, AND OTHER INJURIES
OF THE CORNEA AND IRIS.

PENETRATING WOUNDS OF THE CORNEA AND SCLEROTIC—REPAIR OF WOUNDS OF THE CORNEA—TREATMENT OF WOUNDS OF THE CORNEA—DIFFUSE SUPPURATIVE CORNEITIS—ABRASIONS OF THE CORNEA—FISTULA OF THE CORNEA—LEUCOMA AND NEBULA OF THE CORNEA—OPERATIONS FOR ARTIFICIAL PUPIL—OPACITY OF THE CORNEA FROM LEAD DEPOSIT—STAPHYLOMA OF THE CORNEA, PARTIAL AND COMPLETE—ABSCISSION OF THE STAPHYLOMA—CILIARY STAPHYLOMA—OPERATION OF IRIDECTOMY—PROLAPSE OF THE IRIS, TREATMENT OF—COREDIALYSIS—LACERATION OF THE IRIS WITHOUT RUPTURE OF THE EXTERNAL COATS OF THE EYE.

WOUNDS OF THE CORNEA AND SCLEROTIC.—A simple puncture of the cornea with a fine sharp-pointed instrument, provided no other texture of the eye is involved, is almost harmless: it rapidly heals, and no inconvenience is experienced. The same indeed may be said of a simple puncture of the sclerotic with a fine needle; but such punctures are rarely produced by accident, and it is only the experience of the surgeon, who has to make them for the purpose of operating on the parts within the eye, which enables him to speak of the remarkable freedom from danger of these wounds. When the result of accident, they are very generally complicated either by injury of the deeper structures of the eye or by a certain amount of contusion.

A wound of the cornea, even though the lens or the iris be implicated, is less fatal to the eye than a similar wound in the sclerotic. In the former the hæmorrhage, if the iris is

wounded, is into the anterior chamber, and the blood mixing with the aqueous is speedily acted on by it, and in a few days absorbed; whereas in the latter, if hæmorrhage ensues, it is into the vitreous, and frequently also between the choroid and retina. Blood is very slowly absorbed by the vitreous, whilst the function of the portion of retina displaced by a clot is irreparably destroyed. In addition to this, wounds of the sclerotic are sometimes difficult to heal, and this especially if the cut is at a distance from the margin of the cornea. They will occasionally remain patulous, and show no attempt at union. Wounds of the cornea on the contrary heal very rapidly. The peculiarly unyielding nature of the sclerotic may in a great measure account for this difference in the capacity for primary union in the two structures. The cornea is specially soft and pliable, and capable of accommodating itself rapidly to the altered condition of the globe, when rendered soft by a sudden partial evacuation of its contents; whilst the sclerotic maintains its cup-like shape, and adapts itself but slowly to a diminution of the parts within: hence it is that in wounds of the sclerotic where only a small quantity of vitreous has escaped, there is a tendency for the lips of the wound not to come accurately together, and a consequent inability for primary union. If, however, you can succeed in bringing the edges correctly in contact, union will take place as quickly as in the cornea. This fact was exemplified in two cases which came under the care of Mr. Bowman at the Royal London Ophthalmic Hospital. In the first patient there was a wound in the sclerotic which had remained patulous for three days; and in the second, no attempt at union had taken place one week after the accident, yet, in each case, immediate union followed after the edges of the wounds had been brought

into accurate apposition by a single fine thread suture. That wounds in the sclerotic will heal readily when their margins are in accurate apposition is witnessed in the frequent results of the operation of iridectomy, where the incision is made in the sclerotic, though only at a short distance from the cornea. The wound seldom gives any trouble, but unites by primary union.

Occasionally a cystoid cicatrix is formed, but this I believe is generally due to the edges of the wound from some cause or another not coming into close contact, and in consequence a too abundant formation of cicatrix tissue, which gradually yields before the outward pressure of the parts within the eye, and becomes thinned and bulging.

The cicatrix tissue of a wound in the sclerotic is semi-transparent as in tendon.*

CASE XIV.—*Wound of the sclerotic; escape of vitreous; closed by a single stitch; favourable result.*

John M., æt. 25, was admitted into the Hospital October 31, 1863, under Mr. Bowman, on account of an injury he had received to the left eye three days previously. He was at work with an iron punch when a small fragment of it flew off and struck the sclerotic on the inner side of the cornea close up to its margin. The piece of metal stuck in the wound, and was pulled out by one of his fellow workmen.

State on admission.—There was a small horizontal wound in the sclerotic at the inner side of the cornea about $\frac{1}{6}$ inch in length. The edges of it were not in apposition, and through it vitreous was oozing. The anterior chamber was excessively deep—about three times its natural depth; and the plane of the iris was sloping backwards. The aqueous was serous. The tension of the globe was—T 3,

* Bowman on the Eye.

and was daily diminishing. He could count fingers at from six to seven feet.

Fig. 10 shows in outline the position and size of the wound.

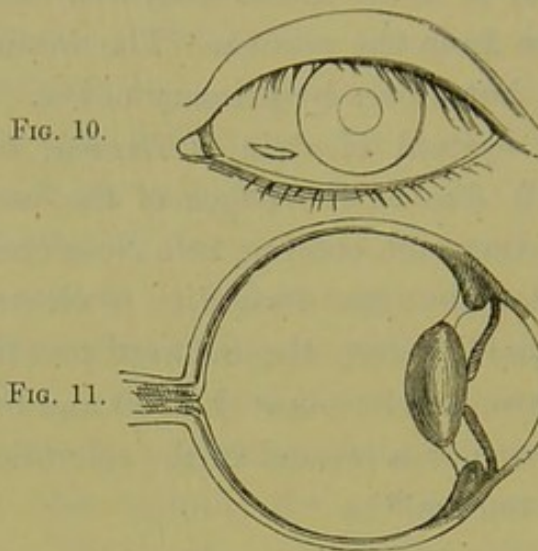


Fig. 11 is an imaginary vertical section of the same eye, showing how the iris and lens were drawn backwards, and the anterior chamber deepened by the escape of a large portion of the vitreous.

Before operating Mr. Bowman pointed out the following symptoms of the case:—

The tension of the globe was diminished—T 3. The anterior chamber was very deep; the iris appeared discoloured (greenish), and pushed back into close contact with the lens. The pupil was slightly dilated, and the aqueous chamber occupied by serum. Close to the inner side of the cornea, almost reaching up to its margin, was a linear wound of the sclerotic, through which the vitreous was slowly draining away.

He remarked that if no operation was performed, but the usual remedies, a dark room, leeches, &c., only resorted to, the integrity of the eye being destroyed, the organ would most likely be lost.

He therefore proposed first to stitch up the wound, so

as to prevent any further escape of vitreous. Secondly, to perform iridectomy, so as to establish a free communication between the anterior and posterior chambers. A small incision was accordingly made with an iridectomy knife at the edge of the cornea and sclerotic, on the inner side. As soon as the opening was made the fluid in the anterior chamber squirted out; the tension being minus behind, but plus in front of the iris. The iris was prolapsed into the wound, and the pupil became contracted, and changed from its greenish colour at once to blue. The wound was slightly enlarged with a pair of scissors, and a portion of the iris removed.

The edges of the wound in the sclerotic were then brought together by a very fine suture—the needle being made to pass through each lip of the wound from within outwards; using, in order to accomplish this, a fine silk thread with a needle attached at each end; one needle to pass through one edge of the wound, and the second needle through the other.

November 4.—The man had a good deal of pain the second night after the operation, but it was relieved by the application of a leech to the temple. The lens has come forward; the iris has resumed its proper place; the aqueous is slightly serous. The tension of the globe is normal. The thread has come away. He can see letters of 16 Jaeger's types.

The patient continued to progress favourably, and when he left the Hospital (November 25) he could read letters of No. 10.

CASE XV.—*Gaping wound of the sclerotic, closed by a suture one week after the accident; good result.*

Mary S., æt. 9 months, was brought to the Hospital on July 7, 1863, suffering from an injury to the left eye. A piece of china in falling off a shelf struck the eye, and

inflicted a small wound in the sclerotic, close to the corneal margin. The wound (notwithstanding that a week had passed since the accident had occurred) was still a gaping one; the edges of it not being in apposition. Mr. Bowman applied a single suture, and with it brought the lips of the wound accurately together.

No irritation followed; and on July 21 the child ceased its attendance at the Hospital, the eye being quite well.

THE REPAIR OF WOUNDS OF THE CORNEA.—Mr. Bowman, in his well-known “Lectures on the Parts concerned in the Operations on the Eye,” has shown “that simple punctures and incisions of the cornea are followed in general by speedy reunion of the divided parts, without suppuration or sloughing;” that, although the wound is in a structure which contains no blood-vessels, yet “there is speedily an increased quantity of blood in the vessels that are nearest to the wounded part, viz., in those of the conjunctiva and those of the sclerotica; and thus the materials from which the breach is to be made good are brought in greater abundance to the part that requires them. We cannot doubt that as these vessels, comparatively so remote, are thus affected, so the part of the corneal tissue intervening between them, and the exact seat of injury, is pervaded by a corresponding change, of which the general expression is this,—that it is one of exalted nutritive vigour; the play of forces, and the interchange of material, which mark the nutritive function, being more energetic and more rapid than before. . . . The breach being filled, the new material is gradually transformed into products resembling those tissues among which it has been poured; the blood-vessels, at the border of the cornea, resume their size, and at length, in the most favourable instances, all vestige of the wonderful process which has taken place vanishes

away. . . . But it will readily be conceived that, in cases of wounds with loss of substance, or attended with extensive division of parts, the demands on a tissue so feebly nourished must exceed its limited powers. The result will then oftentimes be the failure of the adhesive process, with the establishment of a temporary ulcer or open breach, or with an actual sloughing of the lips of the wound. The reparative actions then advance more slowly, and in a modified form, by a species of granulation very similar to that which obtains in corresponding states of the skin or mucous membrane." *

The new material which is thus often added to unite a wound in the cornea, or to fill up the gap caused by a loss of substance or the inaccurate apposition of its edges, has not the true lamellated corneal structure. Like all cicatrix tissue, it has a lower development than that which it replaces. Mr. Bowman says it "is fibrous instead of being lamellated, and opaque instead of being translucent. It contains a quantity of yellow tissue, intimately mixed with the white, and both most irregularly interwoven and ill-developed." † Its vitality is less than the true corneal tissue, and it is the part which first gives way, either by ulceration or softening, if the eye is exposed to any severe asthenic inflammation. In after years it is very apt to degenerate, and to become the seat of earthy or fatty deposits.

We may therefore say that, in cases of simple incised wounds of limited extent, and punctures of the cornea, where the edges fall into accurate and close apposition, union will take place without the intervention of a new material—that it will be direct, and after a time no scar will remain to mark the spot of the injury. The proof of

* Bowman's Lectures on the Parts concerned in the Operations on the Eye, pp. 28-30.

† *Ibid.*, p. 36.

this fact is seen daily in the perfect union of wounds made in the cornea by surgeons for operations on the parts within the eye. The small punctures with a needle, the limited incisions in the cornea for the introduction of the curette or syringe in linear or suction extraction, and also for other operations, often so completely re-unite that no trace of the wound can afterwards be detected. If the wound is beyond a certain size this will not then happen, as complete and accurate apposition of its margins cannot take place. A cicatrix in such cases marks the line of the injury, and this scar is as permanent as the cicatrices in the other tissues of the body.

True it is that for some time after the wound has been closed the cicatrix will contract, and thus diminish in size; but this only goes on to a certain point, and having reached this limit, no treatment will further obliterate it.

It is also certain that much of the cloudiness of the cornea which surrounds the wound during the reparative process is afterwards cleared away; but this is, probably, as Mr. Bowman has explained, "due to a quantity of fresh material of that kind which denotes an over-activity of the nutritive function, and which, not being employed for conversion into permanent tissue, will, in due course, be absorbed."

Complications of Wounds of the Cornea.—Wounds of the cornea may be complicated, 1st, *by contusion, or laceration, or by both.* A contused and lacerated wound of the cornea will generally be found, after twenty-four hours, with its edges looking swollen and whitened, and not lying in accurate apposition. Direct or primary union in such a case cannot take place, but if repair follows it must be by granulation. A severe injury of this class often leads to sloughing, which may be either superficial and limited to one or other of the margins of the wound; or it may be

deep and involve a large portion of the cornea, and ultimately cause a complete loss of the eye.

2nd. The danger of a wound of the cornea will be immensely increased if it extends through its circumference into the sclerotic—into that portion of the eye known as the ciliary region. The risk to the injured eye is very great; but the chief danger is the chance of the other eye becoming involved in a Sympathetic Ophthalmia. (*See chapter on “Sympathetic Ophthalmia.”*)

3rd. Wounds of the cornea are very frequently complicated with prolapse of the iris and wound of the lens, either singly or combined. Each of these complications will be found treated under the respective headings of “Prolapse of the Iris” and “Traumatic Cataract.”

Treatment of Wounds of the Cornea uncomplicated with injury or prolapse of the iris, or with wound of the lens.

The treatment must be local and constitutional.

1st. *The Local treatment.*—In all cases the primary treatment must be soothing. The exclusion of strong light both from the sound as well as from the injured eye is essential, and as complete rest as possible should be given to the eyes by ordering the patient to abstain from reading, writing, and all close work. In wounds of the cornea, whether there is contusion or not, it is wise in the first instance to close the eye and apply a cotton-wool compress over the lids, which should be replaced night and morning so as to ensure uniform pressure. The perfect repose which is afforded to the eye by the closure of the lids, gives the best chance for an immediate union of the wound. The after applications to the eye must depend on the progress of the case. Two or three leeches should be applied to the temple, thus anticipating any excessive action which may arise, rather than waiting for it to light up. From

the very commencement of the treatment, one or two drops of the solution of Atropine, of the strength of gr. j. ad Aquæ ℥j., should be dropped into the eye twice daily, each time the compress is readjusted, so as to keep the pupil fully under its influence, as it often exerts a peculiarly soothing and beneficial effect upon the injured eye. If the wound is a simple incised one, it will probably, under this treatment, soon unite, and the eye, in a short time, will be restored to health; but if there is much contusion or laceration of the margins of the wound, a protracted inflammation will follow, which, although perhaps only reparative in its action, will yet cause the patient much irritation and suffering. The compress may have to be discontinued, and warm or cold applications to the eye may be substituted in accordance with the feelings of the patient. Belladonna may be used in the form of a cold lotion applied continuously to the eye by a fold of linen wetted with it, and laid over the closed lids; or if warmth is preferred, the belladonna fomentation can be substituted.

2nd. *The Constitutional treatment* will vary somewhat with the condition of the patient. It must, however, be remembered that affections of the cornea, even though they are traumatic, will not bear much depletion. The inflammation which follows such injuries is reparative in its action, and requires to be watched and kept from exceeding its proper limits, rather than that means should be taken completely to check it, as the part may perish from a want of vital action, as well as from an excess of energy.

If the patient is robust, a brisk purgative may be prescribed, with some saline or diaphoretic medicine. A regular antiphlogistic course is seldom if ever required. A moderate, well-regulated diet, the avoidance of more stimulants than the case demands, and rest both to the

eyes and body, place the patient in the condition most favourable for recovery. Pain in the eye sufficient to prevent sleep should be relieved by opiates, taking care at the same time that there is a regular daily action of the bowels.

In delicate and feeble patients it may be necessary to order from the very commencement a liberal diet and a certain amount of stimulants ; and to prescribe tonics, such as the mineral acids with cinchona, or quinine, combining a few minims of *Liq. Opii* with each dose, to allay the constant irritability which injuries to the cornea often excite in such patients ; or the opiate may be given in one full dose at bedtime. In all cases the constitutional treatment of the patient must be regulated by the symptoms which are present ; but it should not be forgotten that it is far easier to pull down than to build up, though the latter operation is the one more frequently called for.

DIFFUSE SUPPURATIVE CORNEITIS is generally the result of a contused or lacerated wound of the cornea ; but in exceptional cases it may be caused by a simple contusion from a blow on the eye, even though it is unaccompanied with any rupture of the corneal tissue. It may follow any operation on the eye in which the cornea is involved ; and it is one of the most fatal terminations of the operation for cataract. The state of health of the patient at the time of the injury determines very much the form of the inflammation which may arise from it. A simple incised wound or an abrasion of the cornea, from which a strong healthy person would probably recover without an untoward symptom in a few days, happening to an unhealthy patient or to one enfeebled by dissipation or disease, might be sufficient to induce a diffuse suppurative corneitis which would destroy the eye.

Symptoms.—The whole cornea becomes involved in a general inflammation ; its surface looks dull and steamy, and pus is effused between its lamellæ. A small quantity of pus is usually first seen between the corneal layers at its lower margin, but this is by no means a general rule, for it may first be effused into the central or even into the upper part of the cornea. If the inflammation continues, the pus between the lamellæ of the cornea increases in quantity, and gradually diffuses itself throughout its entire structure. By the time the disease has reached this stage, the deeper parts of the eye have usually participated in the inflammatory action, and the aqueous has become turbid and serous, and there is hypopion, or an effusion of pus or corpuscular lymph into the aqueous at the lower part of the anterior chamber. The pus which has been infiltrated into the substance of the cornea has now to make for itself an outlet, and this it will do by ulceration either towards the external surface, or else backwards into the anterior chamber. By far the more frequent course is forwards towards the surface of the cornea. Large effusions of pus between the lamellæ of the cornea are never absorbed ; it is only the small collections of pus, or probably corpuscular lymph, which are often seen at the lower margin of the cornea, and to which the name of onyx is commonly applied, that are thus disposed of.

When the whole cornea is involved in a diffuse suppuration, complete loss of the eye must follow, but by careful treatment its progress may be often arrested ; and if only a small portion of clear cornea can be saved, much may be done afterwards by altering the position of the pupil to make the eye a very useful one.

Treatment of diffuse Suppurative Corneitis.—Warm and soothing applications are here specially called for ; they

are the only local remedies which afford ease to the patient and benefit the eye.

Of these, the belladonna fomentation, made with ℥j. of the extract of belladonna to one pint of water, and applied hot to the eye by means of a cupped sponge, will give the greatest relief; or simple hot water, or a decoction of poppy-heads, may be used in a similar manner. The fomentation may be frequently repeated, and in the intervals a fold of linen wet with the belladonna lotion may be laid over the eye. A question will naturally suggest itself—whether, as there is pus between the lamellæ of the cornea, it would not be wise to make an incision into the cornea to give an exit to it? Experience has decided that it is best to leave the cornea alone. A cut into it will fail to give vent to the pus: it is so thick, and so infiltrated into the corneal tissue, that it will not run out through any artificial opening, and the wound which would have to be made would be an additional injury, without producing any corresponding good. The only operation which is beneficial is paracentesis—tapping the anterior chamber with a broad needle, and allowing the aqueous slowly to escape. The tension of the cornea is thus temporarily diminished, and great relief is often experienced. It is an operation which may be repeated every second day for three or four times, if it is found to act beneficially. There are, however, many cases of diffuse suppurative corneitis in which this as well as all other treatment fails to do any good: the disease progresses, and the eye is lost. An incision into the cornea may then be made with the view of relieving pain, and this it will usually do by anticipating the exit which the pus would have caused by ulceration. No sudden burst of pus will follow, a bead or two may escape; but the complete relief of corneal tension which will be given, will ease very much the sufferings of the patient.

With regard to the constitutional treatment, the recommendations which are made at p. 66 on the treatment of wounds of the cornea are applicable also to this form of inflammation.

As in all cases of suppuration, no matter where it occurs, the strength of the patient must be maintained, and depletory remedies do positive mischief. Diffusible stimulants, such as ammonia, and chloric ether combined with bark, are suitable during the early stages of diffuse suppurative corneitis, whilst in the later, quinine and iron are generally called for.

The excessive pain should be relieved by opium, either given in full doses at bedtime, or in repeated small doses during the day.

The term *onyx* is often indefinitely used to signify a collection of pus between the lamellæ of the cornea; but as I understand it, it is only applicable to those small effusions at the lower part of the cornea, from the peculiar resemblance of which to the lower part of the finger-nail it has derived its name. *Abscess of the cornea* and *onyx* are by many regarded as synonymous terms; but as the word "onyx" indicates the appearance and locality of the disease rather than the disease itself, the term "abscess" should be considered as applicable to those larger effusions of pus between the corneal lamellæ into which onyx occasionally passes; or to the diffused purulent infiltrations which are the result of diffuse suppurative corneitis.

ABRASIONS OF THE CORNEA.—An abrasion of the cornea is the forcible removal of a small portion of the epithelium from its surface.

The impact of a foreign body as it flies rapidly past the eye, the rebound of the twig of a tree or of a hedge, or the finger-nail of another person, may produce it. Mothers

and nursemaids are specially liable to this accident; the child they are nursing often unconsciously claws at the eye, and scratches the cornea, tearing off with its nail the epithelium with which it comes in contact. At the first glance the injury may appear slight, but it is very frequently the cause of much suffering, and sometimes of severe inflammation.

Symptoms of Abrasion of the Cornea.—Immediately after the accident there is photophobia, great lachrymation, and conjunctival redness, with a feeling as if a foreign body were in the eye. On examination of the eye before a good light, and with the patient so placed that the light may fall obliquely on the cornea, the injury which has been sustained will be manifested by the glistening facet which will be seen where the cornea has been denuded of its epithelium.

Prognosis.—If it is a simple abrasion without contusion, and in a strong and healthy patient, the eye will soon recover from the injury. The abraded surface will first become cloudy, the sharp edge of the facet will be smoothed down, the epithelium will be restored, and the transparency of the part regained. This accident, however, frequently occurs in mothers who are suckling; and as the period of lactation is unfavourable for the repair of injuries, very troublesome results often follow.

The irritation which the scratch first excited may pass into a local inflammation, and pus between the lamellæ of the cornea may be formed, or a tedious ulceration in the site of the original injury may continue for many weeks. The prognosis in these cases must be therefore guarded; for although, under proper treatment, they generally soon recover, yet the fact that it is not uncommon for them to give much suffering and anxiety to the patient, should cause them not to be too lightly esteemed.

Treatment of abrasions of the cornea.—If there is a simple abrasion of the cornea, and the patient is seen soon after the accident, a drop of castor or olive oil, or cream dropped into the eye, will often give temporary relief, and may be repeated every two or three hours for the first day or two. Gently closing the eye and applying over it a cotton-wool compress with a single turn of a soft roller will give great ease, by effectually excluding the eye from light, and by preventing the up and down movements of the lid, which serve to irritate the abraded surface. If the eye is very painful, the bandage may be removed three or four times during the day, whilst the eye is bathed with hot water, or with a decoction of poppy-heads, and two leeches may be applied to the temple. This local abstraction of blood, even in a feeble patient, is often of the greatest service, and may be repeated once or twice if necessary. In an ordinary case this simple treatment will be sufficient; but if untoward symptoms come on, such as ulceration or abscess of the cornea, or if a general ophthalmitis is threatened, more energetic measures will be required. Warmth and soothing remedies are still best suited. A warm belladonna fomentation may be used, frequently applying it to the eye with a hollow sponge, so as to steam it, and thus relax and soothe the inflamed parts. In addition to this, two or three drops of a solution of Atropine, gr. j. ad Aquæ ℥j., may be dropped twice a day into the eye. If the abrasion becomes converted into an ulcerated surface, and the cornea grows dull, and the aqueous turbid, and hypopion follows, tapping the anterior chamber with a fine needle, and letting off the aqueous, will often do good.

When abrasions of the cornea take on these unfavourable symptoms, as they frequently do, it is usually on account of some condition of the patient's health spe-

cially unfavourable for the repair of injuries. Too great plethora, a constitution broken by drink and rough living, anæmia, or one enfeebled from some exhausting cause, such as suckling, may retard recovery or induce symptoms dangerous to the eye. Such conditions of system must regulate our constitutional treatment. In the one class of cases moderate antiphlogistic treatment will be called for, whilst in the other, the patient must be propped up by stimulants, and all irritation be allayed by sedatives. Opiates in these cases are of the greatest service, and a few minims of the Liq. Opii Sedativ. combined with Liq. Cinchonæ given three or four times a day will sometimes completely change the character of the inflammation, and induce a healthy action and a speedy recovery. If it should be preferred to give the opiate in one dose at night, it should be sufficient in quantity to produce sleep, as a single moderate dose will excite rather than tranquillise.

CASE XVI.—*Abrasion of the cornea, followed by ulceration, keratitis, and hypopion.*

Elizabeth F., æt. 30—married—a pale and anæmic woman, with a languid look and small pulse, came under my care on April 25, 1865, on account of the severe pain she had been suffering in the right eye consequent on an injury she had received a fortnight since. Her husband accidentally thrust his finger into her eye, and with his nail tore away a portion of the epithelium from the surface of the cornea. Immediately after the accident she had great pain and lachrymation, which have continued up to the present time, the tears feeling, she says, hot and scalding. The pain at times has been most intense. Her appetite has been bad, and she has been unable to obtain much sleep.

Present State.—A central patch of the cornea, from

which the epithelium has been abraded, presents an irregular ulcerated surface covered with pus. The cornea for some distance around the abrasion is cloudy. The aqueous is turbid, and there is hypopion. The injected conjunctival vessels form a complete network, and the ciliary zone around the cornea is very distinct. She has no appetite, and sleeps very badly. Before the accident, she states that she had been for some time out of health. Ordered Fofus Belladonnæ; and

Liq. Cinchonæ ℥xv.

Liq. Opii sedativ. ℥vij.

Aquæ ℥j. Ft. Haust.

To be taken three times a day.

Under this treatment the eye at once began to improve. The pain was relieved by the repeated doses of opium, and the ulcerated surface of the cornea assumed a healthy action. The patient recovered with a good eye, but the site of the injury was marked by a diffused haziness.

CASE XVII.—*Abrasion of the Cornea followed by corneo-iritis.*

Margaret F., æt. 46, suckling a child fourteen months old, came to the Hospital on August 18, 1865. Three days previously the child she was nursing accidentally struck her eye with the blade of a table-knife, which he had unseen taken into his hand, and with it had abraded the surface of the cornea, scratching away a portion of its epithelium. She at once suffered great pain, and the eye became intolerant of light, a flow of tears following the slightest exposure; the eye has ever since continued in the same painful and irritable state.

On examining the eye, an irregular abrasion of the epithelial surface is seen about the centre of the cornea, and around this there is a slight diffused haziness. There is hypopion and iritis. She was ordered to wean the child,

and to apply the Lotio Belladonnæ to the eye; and to take

Acid. Nitric. dilut. ℥x.
Liq. Cinchonæ ℥xv.
Aquæ ℥j. Ft. Haust.

Three times a day.

Under this treatment the patient soon recovered from all effects of the injury.

A FISTULA OF THE CORNEA is a small opening in the cornea, which has little or no tendency to close, and through which the aqueous humour is constantly oozing. It is the occasional result of a penetrating wound, or of a penetrating ulcer of the cornea. The original wound or ulcer cicatrises up to a certain point, and then, from some special cause, the process of repair ceases, and a minute opening through the cornea remains, through which the aqueous slowly dribbles. Oftentimes the fistula is so minute as to escape a superficial examination.

Symptoms.—The presence of a fistula is suspected when, for some weeks or months after a wound or an ulcer of the cornea has apparently healed, the eye continues irritable, and with a shallow, or in some instances a scarcely perceptible anterior chamber, the iris lying almost in contact with the cornea. A careful examination will, if a fistula exists, detect it, by noticing that the smallest possible drop of aqueous keeps exuding from its orifice, and that this may be increased by a little pressure with the finger on the eye. One useful method of diagnosing a fistula of the cornea is, to separate the eyelids with the fingers from the globe, and having dried the suspected spot of the cornea with a piece of blotting paper, to notice if the surface again becomes moist whilst the eye is kept open.

The causes which tend to produce fistula of the cornea are—

1st. *A contused and lacerated Wound of the Cornea.*—

After such an injury, perfect union of the entire length of the wound may fail, either from the contused and lacerated edges of the wound preventing their accurate apposition, or from some loss of substance occasioned by sloughing or ulceration.

2nd. *A Wound of the Cornea accompanied with a Wound of the Lens may be the cause of a fistula of the cornea.*—The lens, cataractous and swollen from the imbibition of the aqueous, by its pressure on the posterior surface of the iris, keeps up an irritable state of the eye, diminishes the anterior chamber by pushing forwards the iris, causes a constant drain of the aqueous through the wound, and may thus delay its perfect union.

3rd. *A glaucomatous state of the eye.*—An increased intraocular pressure coming on, as it occasionally does, after a penetrating wound of the eye, is sufficient to prevent an entire union of the lips of the wound, and thus to establish a fistula. When once formed, the increased tension of the globe will keep up a constant drain of aqueous through the fistula and hinder its closure.

4th. Occasionally a fistula of the cornea is due to the presence of a foreign body within the eye. The corneal wound through which it entered fails to unite completely, and a fistula is formed which is uninfluenced by treatment.

Treatment.—When a fistula of the cornea is the result of a penetrating wound of the cornea with or without contusion and laceration, but *unaccompanied* with a cataractous lens, or any increased tension of the eyeball, the application of a compress to the eye is often beneficial. The eye should be closed, and a cotton-wool compress evenly applied over the lids, and kept in situ either by a knitted bandage or by a turn of a roller: if the fistula is of recent date, this plan of treatment will often succeed. A solution of Atropine of the strength of gr. j. ad Aquæ ℥j.

may be dropped twice daily into the eye. It will act as a sedative to the eye, and help to allay the irritation which is so commonly associated with fistula of the cornea, and by maintaining a dilatation of the pupil keep the iris from pressing forwards towards the cornea.

Another plan of treatment is the application of the nitrate of silver to the fistulous orifice in the cornea. A very fine camel's hair brush, having been moistened in water, is to be drawn a few times across a stick of nitrate of silver, so as to become coated with it. The hair of the brush is then to be screwed to a fine point, and the mouth of the fistula touched with it. This application may be repeated three or four times, at intervals of two days, if it does not excite undue irritation.

If both these modes of treatment, after fair trials, fail, the removal of a portion of the iris by an iridectomy is almost certain to cause a closure of the fistula. It has been recommended that the iridectomy should be performed near to the fistula, or directly opposite to the fistula; but I do not conceive that the exact spot in which it is made is of much consequence, as in any part it will equally accomplish its object.

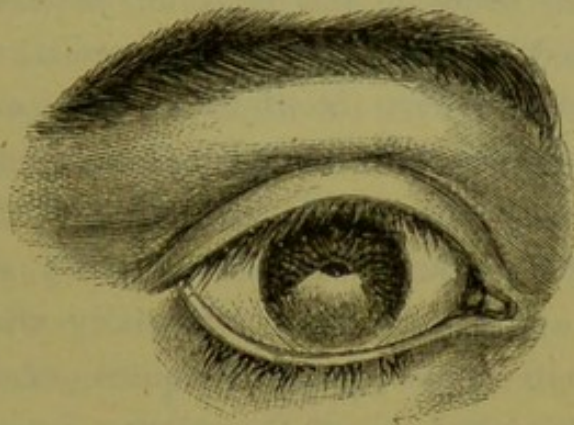
The choice of the site should be rather with reference to the part of the cornea which will be most suited for the artificial pupil which the iridectomy will make, as where a fistula exists there is usually more or less corneal opacity. If the fistula is apparently caused and kept up by the irritation produced by a swollen cataractous lens pressing against the uveal surface of the iris, the lens should be at once removed; and this may be accomplished either by linear extraction or suction, or by first removing a portion of the iris by an iridectomy, and then extracting the lens. The special circumstances of the case will indicate the choice of the operation. (*Vide* "Traumatic Cataract.")

When the fistula is the result of a glaucomatous state of the eye, supervening on a wound of the cornea, there can be no hesitation about the propriety of at once performing an iridectomy, as, until the tension of the eye is restored to its normal standard, the fistula is sure to continue, and at present we know of no certain means of reducing increased intraocular pressure except by this operation. But this glaucomatous state of the eye with fistula of the cornea is oftentimes associated with, and dependent on, traumatic cataract. In such a case, if the lenticular matter has *not been thoroughly macerated* by the aqueous, but is gummy and tenacious, it will be wise to remove a piece of the iris to relieve the tension, and to leave the cataract to be dealt with at a future period. If, however, after the excision of a portion of the iris, the lens is found to be soft and diffuent, it is best at once to remove it with a suction curette, or to let it run off through the wound on an ordinary curette, as in linear extraction.

LEUCOMA OF THE CORNEA.—A leucoma is a dense white opacity of the cornea, caused by the loss or destruction of a part of its substance, the gap thus made being replaced by cicatrix tissue, which is opaque and white, instead of transparent and colourless, like healthy cornea. It is often the result of an injury, but more frequently it is occasioned by inflammation and deep ulceration induced by other causes. It is irremediable. No medicinal agent will transform the opaque into transparent tissue. Many remedies have been tried and recommended, but none are of any avail. You might as well attempt by local applications to obliterate the scar of a severe burn on the surface of the body, as to restore transparency to a leucoma. I have merely alluded to it, as the surgeon is often consulted as to whether some means cannot be

adopted to remedy such a deformity. In all cases where it exists, the patient ought to be well satisfied that his eye has made such a comparatively good recovery ; for it is indicative of the severe inflammation and consequent danger to which it has been exposed. With the leucoma there is often some alteration in the shape of the pupil, from a portion of the iris having become adherent to the cicatrix ; in such cases the ulcer which had caused the leucoma had penetrated the cornea, and when the aqueous escaped through the aperture, either the iris had been dragged into

FIG. 12.



A LEUCOMA OF THE CORNEA, COPIED FROM DALRYMPLE'S PLATES.

the wound, or else, falling forwards, its anterior surface had contracted adhesions to the granulations, which were afterwards to be converted into the cicatrix tissue. Like all cicatrices, a leucoma after its formation undergoes a certain amount of contraction, and a corresponding diminution in size. This takes place slowly, and may extend over two, three, or more years. If the leucoma is near the margin of the cornea, and the space opposite the pupil is clear, the sight will be but slightly affected by it, although as a rule a certain cloudiness of the cornea usually extends beyond the leucomatous patch ; but if the leucoma is central, so as directly to interfere with vision, an artificial pupil may be made in that part of the cornea which

is the clearest, and of the most normal curvature. One evil result of a leucoma is the effect it sometimes has in altering the curvature of the cornea: by changing the curve of that portion of the cornea which is transparent, in either the vertical or the horizontal meridian, it renders the eye astigmatic—a defect which may now be neutralised to a great extent by a cylindrical glass.

NEBULA OR CLOUDINESS OF THE CORNEA is one of the results of an injury which has caused a traumatic keratitis, although a similar state may follow inflammation of the cornea brought on by other causes. A nebula may be limited to a portion of the cornea, or it may be irregularly diffused over its whole surface, one part of it, however, being usually more hazy than another. When it is directly over the pupil, even though the nebulosity is slight, and the pupil can be distinctly seen, yet the sight of the eye will be very materially affected by it, oftentimes to an extent apparently quite out of proportion to the opacity. Nebula of the cornea, in many cases, is due to an interstitial deposit of lymph in the true corneal tissue; whilst in other instances, it is produced by the reparation of a breach, caused by a superficial ulceration and the formation of a layer of cicatricial tissue, which, from being extremely thin, is semi-transparent, and thus differs in appearance from the dense white leucoma. The former kind of nebula is often much ameliorated by time and treatment, but the latter is unaffected by any local applications.

In the treatment of nebula of the cornea no stimulating application is of any service whilst the eye is irritable, or so long as there is any degree of photophobia. Soothing treatment must be adopted until all irritation has passed away; and the eye should be allowed to remain for at least

five or six months perfectly quiet before any local remedies are employed. It is often astonishing to witness how much clearing of the cornea will be effected by the natural restorative power of the patient, if it is unthwarted by drops into the eye; but this will only go on for a certain time, and then the opacities will appear to become stationary, and no further improvement will take place. It is at this period that medicinal treatment is often of use, by exciting a renewal of that reparative action which has already done so much. Numerous remedies are vaunted as of service for removing or diminishing nebulæ of the cornea, but I believe that none are specific, and that the benefit which may result from the use of any of them is solely due to their acting as a slight irritant, and by their stimulating the absorbent vessels of the cornea to an increased activity.

The applications to the eye which I have found of the most service have been:

1st. A weak solution of the Hydrarg. Bichlorid., of the strength of gr. j. ad Aquæ ℥ viij.; two or three drops to be dropped into the eye twice a day. This remedy is often a powerful irritant; and if the eye resents its use by becoming inflamed, or painful, it should be at once stopped for a time.

2nd. Drops of the Ol. Terebinth. c. Ol. Olivæ. I have often seen much good follow the use of these drops. At first they should be used very weak—Ol. Terebinth. ʒss. Ol. Olivæ ʒvj.—ʒviij.—but if the eye is found tolerant, the strength may be materially increased.

3rd. The dusting of calomel into the eye, every or every other morning, in many cases exerts a beneficial influence over the nebula. It acts as a slight irritant for a short time after its introduction into the eye; but this soon passes away, and it then ceases to give the patient any annoyance for the rest of the day.

4th. I have seen decided improvement take place under the steady use of a slight stimulating application, such as *Zinci Sulphatis* gr. ij. ad *Aquæ* ℥j. ; or of *Argenti Nitratis* gr. j. ad *Aquæ* ℥j. The drops should be dropped into the eye night and morning. Care should be taken that the solution of the nitrate of silver to the eye is not continued for too long a time, as its persistent use, even when very diluted, is apt to cause discoloration.

5th. A solution of the iodide of potassium has long enjoyed a reputation for the influence it has over opacities of the cornea. I have often used it, but I think that the power which is ascribed to it is very problematical. There are many other remedies for the treatment of nebula of the cornea, which I will only allude to. Their use has the sanction of good names, and may be therefore considered in some cases as worthy of trial.

Dr. Mackenzie, of Glasgow, speaks highly of the vapour of hydrocyanic acid. He says: "I have witnessed good results from its use in many cases of speck, especially in nebula consequent to corneitis. It is to be applied by opening the eye for a few minutes into a small phial, the mouth of which is shaped as an eye-cup, a few drops of the concentrated acid being previously placed at the bottom of the phial." *

The *vinum opii* has been recommended to be dropped into the eye two or three times daily. A solution of the Sulphate of Cadmium (gr. j.-iv. ad *Aquæ* ℥j.), † or of the Sulphate of Copper (gr. ij. ad *Aquæ* ℥j.), have been spoken of with favour, but especially the former.

The *hydrarg. nitric. oxyd.* is said to be very useful in cases of nebula of the cornea.

* Mackenzie on the Diseases of the Eye, 4th edition, pages 639 and 428.

† Lawrence on Diseases of the Eye; edited by Isaac Hays.

It has been prescribed in two ways, as a powder and as an ointment.

As a powder it is recommended to be diluted with loaf sugar—from half a drachm to a drachm of the Pulv. Hydrarg. Nitric. Oxyd. to one ounce of finely-powdered loaf sugar.* A little of this powder is to be dusted or blown into the eye once every, or every other day.

When used in the form of an ointment, it should be of the strength of Pulv. Hydrarg. Nitric. Oxyd. gr. iij.-v.; Unguent. Cetacei ʒj. A small piece of this ointment, about the size of a large pin's head, should be introduced between the lids, on the end of a probe, about three times a week. There are yet other remedies which have been extolled, but I have named sufficient for an ample selection if the one first tried should fail.

In some cases of nebula of the cornea, the cloudiness is limited to the central portion, so as to be opposite the pupil, whilst the rest of the cornea is perfectly clear. In such eyes great improvement of sight will be derived from making an artificial pupil, so as to bring the new pupil opposite that part of the cornea which is transparent and healthy.

ARTIFICIAL PUPIL.—To gain the full benefit which an artificial pupil will afford in properly selected cases, the cornea should be first very carefully examined, and, if necessary, by oblique illumination with ophthalmoscopic light, to determine the part opposite to which an artificial pupil will be the most effective. In examining the cornea, the two points to be noted are, first, its transparency, and next, its curvature:—that part should be selected which is the most transparent, and which has the most normal curve.

* Mackenzie on the Eye.

In cases of leucoma or nebula of the cornea, one of the following operations may be performed for the formation of an artificial pupil, according to the special indications which the eye may present.

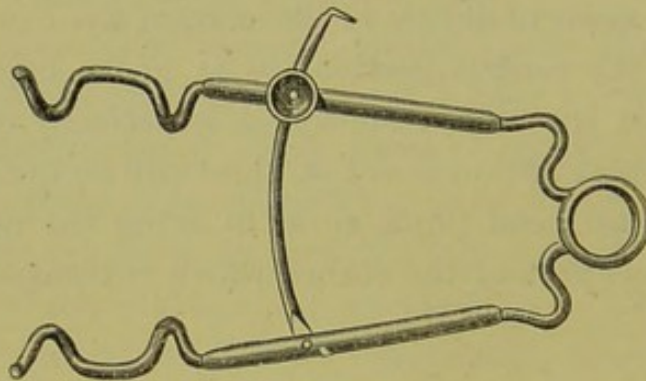
1st. By the removal of a portion of the iris.

2nd. By the operation of iridodesis or ligature of the iris.

3rd. By incision of the iris.

1st. *To make an Artificial Pupil by the removal of a piece of Iris.*—The patient lying on a couch, a spring stop speculum, fig. 13, is to be introduced between the lids, so as to keep them apart. The operator, standing behind the head of the patient, with one hand seizes the conjunctiva and submucous tissue of the eye with a pair of forceps, so as to

FIG. 13.



steady it, whilst with the other he makes an opening in the extreme margin of the cornea with a broad



needle, fig. 14. Having completed the incision, the broad needle is to be withdrawn, and the eye being still held by the forceps, a Tyrrell's hook, fig. 15, is to be passed *sideways* through the corneal wound, into the anterior chamber, and onwards across the iris to the pupil, when it is to be turned with the hook downwards, so as to catch the pupillary edge of the iris, and then to be slowly



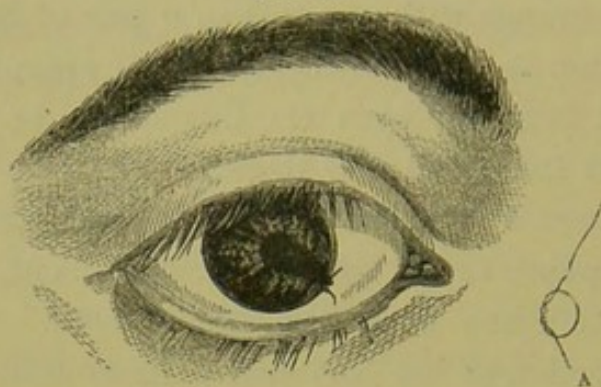
and carefully withdrawn from the eye. When the hook approaches the opening at the margin of the cornea, it must be again turned on its side, or a difficulty will be experienced in getting it out of the eye. As soon as the iris is drawn from the eye, the assistant should cut it off close to the cornea with one snip of a pair of fine scissors. The operation is now finished, and the speculum should be removed from the eye; the lids should be closed, and a fold of wet linen laid over them.

This operation is only applicable to those cases where there is a pupil, or at least a portion of one, to the free edge of which the hook can fasten itself. When the pupillary portion of the iris has been so drawn into the leucoma, that the pupil is either obliterated, or made so small that it would be difficult for the hook to catch its free margin, a different proceeding should be followed. The opening in the cornea should be made sufficiently large, either with a broad needle or with a lance-shaped iridectomy knife, for a pair of iris forceps to be *easily* introduced through the wound. When within the anterior chamber, the blades of the forceps should be opened, and made to grasp a portion of the iris, which should be then drawn out through the corneal incision, and cut off with a pair of fine scissors.

To make an Artificial Pupil by Iridodesis, or Ligature of the Iris.—This operation was first suggested and practised by Mr. Critchett, who published an account of it in the Royal London Ophthalmic Hospital Reports, vol. i. page 220. It may be performed as follows:—The patient lying on his back, a spring stop speculum is placed between the lids, and the operator with one hand lays hold of the conjunctiva of the eye with a pair of forceps, to fix it, whilst with the other he makes an opening with a broad needle through the extreme margin of the cornea. A

sufficiently large incision having been made for the introduction of the hook, or the forceps, or whatever instrument is to be used to seize the iris, the broad needle is withdrawn, and a small loop of fine silk, A, fig. 16, is then laid

FIG. 16.



over the wound. If the hook, fig. 15, is the instrument selected, it is introduced by the corneal wound into the anterior chamber, passing through the loop of silk; and having been made to catch the pupillary edge of the iris, it is slowly and carefully drawn out of the eye, dragging with it the piece of iris it has hold of into the loop of silk, which had been placed over the incision at the margin of the cornea. As soon as the piece of iris is within the loop, the assistant, with a pair of cilia forceps, fig. 17, in

FIG. 17.



each hand, seizes hold of its two ends and draws them firmly together, so as to cause the strangulation of the protruded portion of iris, and at the same time to prevent its slipping back, through the incision, into the anterior chamber. The two ends of the ligature may now be cut off, but one end should be left longer than the other, for the convenience of catching hold of it with a pair of for-

ceps, if, with the resecretion of the aqueous, it should be drawn within the corneal wound.

It is a matter of importance not to make the incision in the margin of the cornea too large, as although at the time it facilitates the operation, yet, as the aqueous is restored, the piece of iris, with the ligature on it, may be sucked back into the anterior chamber. I have seen this accident happen two or three times, but on each occasion one end of the ligature had been left so long, that it was easily caught with the forceps, and drawn out of the eye, and no unpleasant symptoms followed.

It is often a question whether a hook, or a pair of iris forceps, should be used to seize hold of the iris, prior to drawing it out through the incision at the margin of the cornea. In many cases, the choice of the instrument is immaterial, either will answer equally well; but occasionally it is desirable only to enlarge the old pupil, and to leave the pupillary border uninjured. In such cases the iris or the canular forceps should be used, as they can be made to grasp the iris with accuracy near the margin of the cornea, and to draw out only just sufficient of it to be fastened by the ligature. In this manner the shape and position of the pupil may be changed, without interfering much with its free pupillary edge. It is, indeed, to those cases where it is desired to leave as much of the pupillary edge as possible, that the operation of iridodesis is specially fitted.

For the majority of cases where an artificial pupil is required in leucoma or nebula of the cornea, I prefer making it by the removal of a piece of iris close up to the extreme margin of the cornea.

To make an Artificial Pupil by Incision of the Iris.—This operation is only suited to a special class of cases: those eyes in which no trace of a pupil remains, the iris appear-

ing as a plane surface stretched tightly from the cicatrix to the circumference of the cornea, and in which there is *no lens*. Such a condition of eye is occasionally met with after a penetrating wound of the cornea, which has involved the lens, and also caused a sufficiently large prolapse of the iris to draw the pupil into the wound ; or occasionally it is seen after an ordinary corneal flap extraction of cataract, which has been followed by a prolapse of the iris ; or after an operation for cataract, in which a large piece of the iris has been excised, but which has terminated unfavourably from subsequent inflammation closing the pupil, and causing the iris to be drawn up to the cicatrix in the cornea.

A broad needle is to be passed through the cornea into the anterior chamber, and along the plane of the iris, to the point where it is desired to make the new pupil ; it is then to be turned with its edge and point towards the iris, when, by suddenly depressing the hand, the needle is made to penetrate the iris, and to cut a small slit across its fibres. The needle is then to be withdrawn, and if the iris is healthy, the edges of the incision will at once retract, and a good pupil will be formed. If, however, owing to the iris having lost its natural elasticity, the edges of the cut should fail to retract so as to form a new pupil, a Tyrrell's hook should be introduced through the opening in the cornea already made with the broad needle, and having caught one edge of the incision in the iris, it should be gently drawn out of the eye, and the piece of iris it brings with it cut off with a pair of fine scissors.

OPACITY OF THE CORNEA FROM LEAD.—This is a form of opacity of great importance to recognise, as it admits of very considerable relief, and in many cases of complete cure. It may be said to be the result of treatment rather than of injury or disease. It is occasioned by the use of

a lead lotion when the cornea is ulcerated or abraded; the lead is deposited on the surface as a carbonate, producing a milky-white patch, which is often sufficiently opaque to occlude either the portion of iris or the pupil which lies behind it.

The treatment consists in removing the layer of lead deposit which has coated the abraded surface of the cornea. This may be done with a small knife curved convexly on its cutting edge, as in fig. 18. A speculum being introduced between the lids, the operator with one hand fixes the eye with a pair of forceps, whilst with the other he gently scrapes the whitened surface of the cornea with the knife, until, having detached the epithelium, he comes down to the thin coating of lead; steadily but gently scraping, he will generally succeed in de-

FIG. 18.

taching all that is required. Where the lead is rather thickly deposited it will chip off in filmy scales, but where it is very thin it has to be scraped off as fine powder. It is well, if possible, to remove the whole of the lead deposit from the cornea, though in some cases this cannot be readily accomplished; but care should be always taken to clear thoroughly that portion of the cornea which is opposite to the pupil. When the operation is completed, a few drops of olive oil should be dropped into the eye, and a fold of wet lint laid



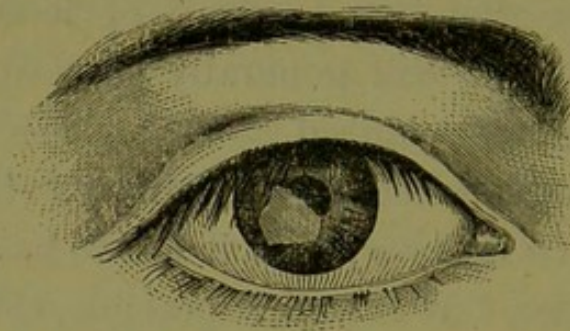
over the closed lids. The oil may be afterwards dropped two or three times a day into the eye if it gives ease. The operation should be performed under chloroform, as it is exceedingly painful, and perfect stillness on the part of the patient is absolutely necessary. A certain amount of irritation will follow the operation; but if it is carefully performed the case is almost certain to do well. If the eye should continue for several days painful and irritable, two

leeches to the temple, and a lotion of belladonna to the eye, will generally suffice to remove all discomfort.

The following case is a good illustration of an opacity from lead.

CASE XVIII.—A bricklayer came under my care at the Middlesex Hospital, January 9, 1866, on account of a dense white patch on the cornea of the right eye. It was irregular in outline, of milky whiteness, and occluded entirely the lower and outer half of the pupil, and that portion of the iris in front of which it was placed.

FIG. 19.



The history the man gave was, that on the 4th of November previously, some chalk lime was splashed in his eye. The eye was very painful, and he obtained for it some white lotion, which was undoubtedly one containing lead, and this he had sedulously applied ever since.

From the man's account it may be fairly concluded, that after the introduction of the lime into the eye the cornea became ulcerated, and in his steady perseverance in the use of the white lotion, he succeeded in depositing on the abraded surface a coating of lead.

On January 10, I performed the operation I have described, and succeeded in removing the whole of the white patch. A portion of it chipped off in fine white scales; the rest was removed by steady scraping. The eye continued

irritable for five or six days afterwards, but he was able to leave the hospital, and resume his employment on January 23.

A STAPHYLOMA OF THE CORNEA is a projecting forwards or bulging of the whole or a part of the cornea, or of the new tissue which supplies its place when a part or the whole of it has been destroyed by injury or disease. We have an example of a simple staphyloma of the cornea in what is called conical cornea, where the centre of the cornea, becoming thinned from disease, yields before the pressure from within, and assumes a projecting conicity.

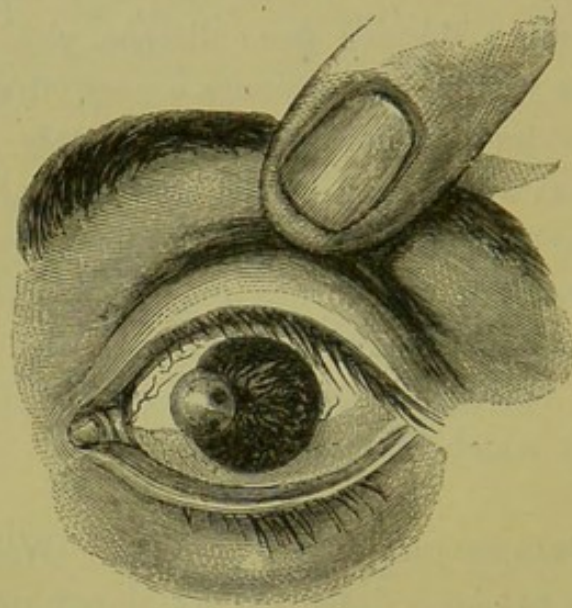
Our present inquiry, however, includes only those forms of staphylomas which may be the result of injury, though similar staphylomas may also be occasioned by disease.

A staphyloma of the cornea may be either partial or complete; that is to say, it may be limited to a small portion, or it may involve the whole of the cornea or the new structure which represents it.

PARTIAL STAPHYLOMA OF THE CORNEA.—When a portion of the cornea has been destroyed by sloughing or ulceration, its place is made good by cicatrix tissue, which is more or less white and opaque, and in many cases incapable of resisting the normal outward pressure of the parts within the eye; slowly yielding, it bulges and forms an unsightly prominence on the cornea, fig. 20. A partial staphyloma of the cornea differs both in its formation and appearance from what is called a leucoma, although a leucoma may become staphylomatous. In the formation of a true leucoma, there is often a great loss of corneal tissue, and very frequently perforation; but the perforation is generally very small, a mere pin-hole, through which the aqueous escapes, and to which point the iris, having

fallen forwards, becomes adherent ; but it does not usually bulge through the aperture, or, if it does, it is to a very trifling extent : there is no absolute prolapse. The internal or posterior elastic lamina of the cornea is but little affected in the formation of leucoma, excepting at the mere point of perforation ; so that, though a large piece of the cornea may have been destroyed, yet the gap which has been made is somewhat funnel-shaped, and the sides are bevelled to the

FIG. 20.



PARTIAL STAPHYLOMA OF THE CORNEA, COPIED FROM DALRYMPLE'S PLATES ON THE EYE.

point of perforation at the bottom of the ulcer. The strength of the cornea in such a case is comparatively but little weakened ; a new tissue is developed, and a dense white leucoma is formed, which is even with the surface of the cornea, and assumes, to a certain extent, its curvature. Such a leucoma does not bulge and become staphylomatous.

In partial staphyloma the case is different. By ulceration or sloughing, an aperture is made in the cornea ; the internal opening is large, and the iris, falling forwards with the gush of aqueous, either prolapses, or else bulges so as to fill up the wound to the level of the external surface of

the cornea. An effort to repair now follows; the protruded iris is coated with lymph, which is ultimately converted into a cicatrix tissue, and the wound is closed; not, however, by a dense cicatrix, as in leucoma, but by iris coated externally by the thin membrane which has been organised from the lymph which covered it. Such a structure is inelastic, and has not the resisting power of the portion of cornea which it has replaced; it yields before the pressure from within the eye, and becomes staphylomatous. As the bulge increases in size, it drags the iris with it, drawing also upon the iris which is at a distance from the cicatrix, and approximating it towards the cornea. Between the leucoma, which remains stationary as a white patch on the surface of the cornea, and the partial staphyloma I have described, there are many gradations, from the mere elevation of the surface to the actual staphylomatous bulging, which continues to increase, and ultimately to interfere with the free motions of the lids over it. I believe that these different conditions may in a great measure be accounted for—1st, by the size of the perforation made in the cornea; 2nd, by the extent to which the posterior elastic lamina was involved; and 3rd, by the amount of iris which was prolapsed; but some allowance must also be made for the reparative powers of the patient, as the condition of health always exercises an important influence on the formative process.

Treatment of partial Staphyloma.—In the large majority of these cases, the iris being involved in the staphyloma to a greater or less extent, the pupil is drawn towards it; or, if the staphyloma is near the centre of the cornea, the pupil may be almost directly behind it. The sight of the eye is therefore always seriously affected, and in some cases all vision, except the perception of light and dark, destroyed by it.

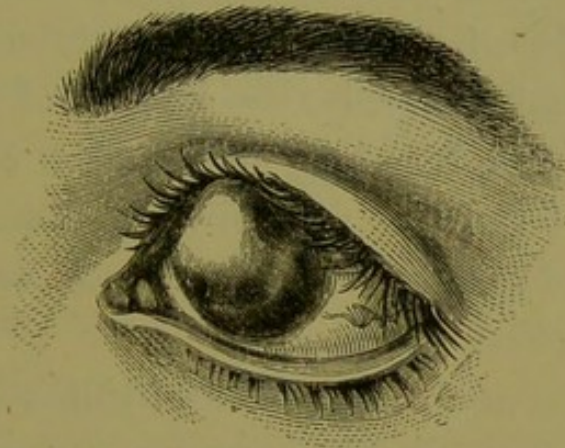
The objects to be accomplished in the treatment of partial staphyloma are : 1st, to arrest the progress of, and, if possible, to diminish the bulge ; and 2nd, to restore some of the lost sight to the eye. Both of these conditions may be often attained by the operation of iridectomy :—by the removal of a piece of iris opposite to that portion of the cornea which is in the most healthy state, an artificial pupil is made, and if the fundus of the eye is sound, and the transparency and curvature of the cornea opposite the new pupil tolerably good, useful sight will be regained. But the removal of a piece of the iris by iridectomy exercises an important influence in diminishing the tension of the globe, and to this must be attributed the beneficial effect which this operation so frequently produces on the staphyloma. In cases of partial staphyloma which have occurred in my own practice, and in others which I have witnessed in Mr. Bowman's and Mr. Critchett's, where an iridectomy has been performed, the bulging has certainly not increased after the operation ; and in some instances it has decidedly receded. Undoubtedly the great success of the operation depends upon its being performed at an early date—as soon as possible after the first indications of staphyloma have become manifest, but not until the eye is in a perfectly quiescent state, and all symptoms of irritability have completely passed away.

No attempt should be made to shave off the staphyloma, as if it succeeds in reducing the prominence, it will fail in restoring any sight to the eye, and it may prevent the possibility of any future operation to regain vision by the formation of an artificial pupil.

COMPLETE STAPHYLOMA OF THE CORNEA is a bulging of the entire structure which has replaced the original cornea after it has been destroyed by ulceration or sloughing,

induced either by accident or disease. When the cornea has been thus destroyed, the whole plane of the exposed iris may be seen coated with a film of lymph; this, after a while, will become organised and converted into a bluish-white cicatrix tissue, to which the iris will be firmly adherent, and the breach will thus be closed. One of two events will now happen; either the eye will gradually shrink, and cease for a time to give trouble, or it will become staphylomatous. If the case is seen at a very early date, immediately after the cornea has been de-

FIG. 21.



A COMPLETE STAPHYLOMA OF THE CORNEA, COPIED FROM DALRYMPLE'S
PLATES ON THE EYE.

stroyed, the lens will be often found lying in the centre of the pupil, perfectly transparent, and projecting slightly forwards; unless, as indeed frequently happens, it has been shot out from the eye at the moment that the cornea gave way. If this has not taken place, it is always wise to remove the lens by gently lifting it away with the point of a needle, as after the lens has gone, the cicatrisation will be more rapid, and the probability of a staphyloma following, will be materially diminished. Should the eye be first seen at a later period, when the staphylomatous bulging is recent, and the new tissue which occupies the corneal space is yet but imperfectly formed, it is still a wise

course to endeavour to remove the lens, and this may be done by an operation lately suggested by Mr. Bowman, and practised by him in several cases with success. A broad needle is passed through the most prominent part of the staphyloma in the direction of the lens, so as to penetrate its capsule, and the lenticular matter is freely broken up. The needle is then withdrawn, and through the aperture it has made, a curette is introduced, and as much of the lens matter as is sufficiently soft and diffuent is allowed to escape from the eye along its groove. The puncture made with the broad needle may be repeated every two or three days until the prominence of the staphyloma is reduced. Under this treatment the staphyloma will gradually subside, the cicatrix of the cornea will become a firm and resisting one, and a certain amount of shrinking of the eye will probably follow, so that the patient will in due time be able to wear an artificial eye without any further operation.

The formation of a complete staphyloma is thus seen to be greatly influenced by the presence of the lens within an eye, in which the whole or greater part of the cornea has been destroyed by sloughing or ulceration; the eye having lost much of its anterior support, the pressure from behind causes the lens to bulge forwards, and in this position it prevents the formation of the firm contracted cicatrix, which would, as a rule, take place if it were removed. The new tissue which is developed over the lens and iris to occupy the place of the cornea, is incapable of resisting the pressure which is made upon it from within the eye; its entire surface soon begins to yield, and an unsightly staphylomatous projection is gradually formed, which will often continue to increase until it seriously impedes the free motions of the lids.

A complete staphyloma of the cornea may, and occasionally does, occur after the lens has been removed; but the

tendency to its formation is greatly lessened by its removal.

After a staphyloma of the cornea has been fully formed, the extraction of the lens will not exert any beneficial influence in diminishing its size.

For the production of a complete or general staphyloma of the cornea, it is not necessary that the whole of the cornea should have been destroyed; it is often sufficient if the central two-thirds have given way. A large central staphyloma will be formed, which will so drag on the marginal portion of the cornea that it will become blended in the general prominence, and the small circumferential margin of free iris will be drawn into close contact with that part of the cornea which is not absolutely involved in the disease, and all appearance of the anterior chamber will thus become obliterated.

Oftentimes in staphyloma of the cornea, that portion of the sclerotic which surrounds the cornea, and is known as the ciliary region of the eye, becomes thinned, staphylo-matous, and drawn into the general bulging of the new corneal tissue, so that it seems to be continuous with it. To this condition of the eye, the term corneo-sclerotic staphyloma has been applied.

Treatment of Complete Staphyloma of the Cornea.—The eye for all visual purposes is for ever lost, and the patient seeks advice, either to be relieved of the unsightly prominence which, if the staphyloma is large, keeps up a continual annoyance by the impediment it offers to the up and down movements of the lids; or else, on account of the disfigurement it occasions, he desires to have it so reduced that he may be able to wear an artificial eye. The question, then, resolves itself into whether it is better to abscise the front of the eye after the manner recommended by Mr. Critchett, or to remove the eye altogether?

For a complete staphyloma of the cornea, the operation of abscission is appropriate, as it should only be performed on those lost eyes, in which it may be hoped that the fundi are healthy. Where there is pre-existing disease of the choroid or retina, deep hæmorrhage is likely to follow the removal of the front of the globe, which may necessitate the immediate excision of the rest of the eye; or if the operation is completed, and the bleeding arrested, a troublesome suppuration of the stump is almost certain to follow. If the operation of abscission is properly performed, and the case does well, a good stump is formed on which an artificial eye may rest, and the deception becomes almost complete, for the natural fulness of the orbit is preserved, and the movements of the artificial eye in concert with the sound one are perfect. But, on the other hand, it must be considered that in leaving the whole of the posterior part of the globe, we have left behind a sclerotic cup, containing portions of the vascular tissues of the eye, the retina and choroid; and that those destructive changes which so commonly take place between these structures in lost eyes, after the lapse of many years, may also occur here, and eventually prove a source of much suffering, if not of actual danger, to the other eye.

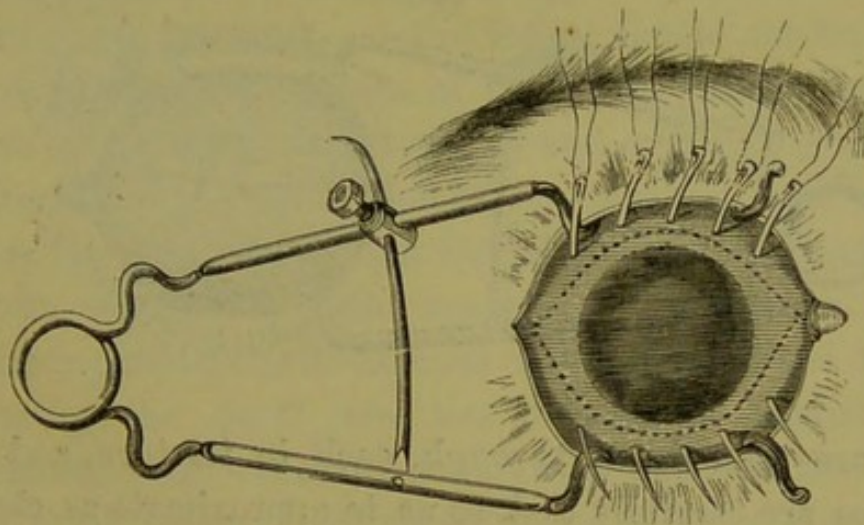
My own feeling is, that to the wealthy, where personal appearance is a source of serious moment, the operation of abscission is most valuable, as the patient can keep a watch over the stump, and seek medical aid the moment any unpleasant symptoms arise; so that if at any time it should give trouble or become dangerous to the other eye, it can immediately be removed. To the poor, however, where safety stands so much before symmetry, and where neglect of early symptoms is the rule rather than the exception, it is better to remove the staphylomatous eye entirely, rather than to abscise the front of it.

The recovery from the operation of excision of the eye is more rapid than after abscission, and the patient is able sooner to wear, with good effect, an artificial eye.

The operation of abscission of the eye was first described by Mr. Critchett, in the 1st chapter of vol. iv. of the Royal London Ophthalmic Hospital Reports. I quote his own description of the mode of performing it. "The patient being placed under the influence of chloroform, the staphyloma is freely exposed by means of a wire speculum; a series of four, or rather five, small needles, with a semi-circular curve, are passed through the mass, about equidistant from each other, and at such points as the lines of incision are intended to traverse, fig. 22.

"These needles are left in this position, with both extremities protruding to an equal extent from the staphyloma. The advantages gained by this part of the proceeding

FIG. 22.

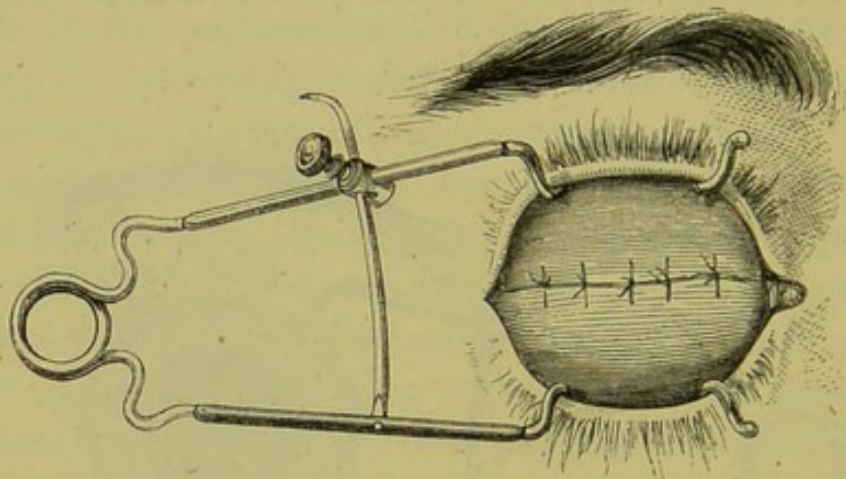


THE DOTTED LINES INDICATE THE LINE OF THE INCISION TO BE MADE AFTER THE NEEDLES HAVE BEEN INTRODUCED.

are:—1st. That a small quantity of the fluid parts of the distended globe escapes, thus diminishing pressure, and preventing a sudden gush of the contents when the anterior part is removed. 2nd. That the points of emergence indicate

the line of incision. 3rd. That the presence of the needles prevents or rather restrains, to some extent, the escape of the lens and vitreous humour, after the anterior part of the staphyloma has been removed. The next stage of the proceeding is to remove the anterior part of the staphyloma. This requires some judgment and modification in size and form, in accordance with the extent of the enlargement, so as to leave a bulb. My usual plan is to make an opening in the sclerotic, about two lines in extent, just anterior to the tendinous insertion of the external rectus, with a Beer's knife. Into this opening I insert a pair of small probe-pointed scissors, and cut out an elliptical piece just within the points where the needles have entered and emerged. The needles, armed with fine black

FIG. 23.



silk, are then drawn through, each in its turn, and the sutures are carefully tied, so as to approximate as closely as possible the divided edges of the sclerotic and conjunctiva, fig. 23. The operation is now finished; the speculum may be removed so as to allow the lids to close, and wet lint may be applied to keep the parts cool."

Unless this operation is carefully performed, there is apt to be a projecting corner, at one or both of the extremities of the cicatrix. Such a result is a serious impediment to

the proper fitting of an artificial eye, and may require a second operation to remedy it.

Treatment of Staphyloma of the Cornea by Seton.—For the purpose of reducing the bulge of the staphyloma, so that an artificial eye may be worn, Von Graefe has recommended that a silk thread seton should be passed through the most prominent part of the staphyloma, with the view of inducing a suppurative inflammation, and a subsequent shrinking of the globe.

The following is an abstract from Von Graefe's article entitled "The setting up of a suppurative choroiditis for the preservation of the globe,"* in which the operation is described:—An ordinary double silk thread is passed through the vitreous humour, so as to include the coats of the eyeball, for the width of four or five lines within the suture. It should not be drawn tight, so as to cut the tissues and allow a gradual escape of the intra-ocular fluid, but only tied in a slack loop to keep the thread in position. . . . The thread should not be passed through thinned portions of the coats, because in those parts the choroid is atrophied, and will not give a fit material for the production of suppuration. . . . As to the direction of the thread, it is most convenient to run it parallel to the margin of the cornea. The counter-puncture is thus most easily made, and in this situation the parts are less disposed to conjunctival chemosis than when the puncture is made farther back. But the direction of the thread is not of much importance. The ends of the silk are to be cut off close to the knot, and the lids kept closed by a piece of strapping or a lightly applied compress. In from sixteen to thirty-six hours an acute choroiditis is set up, with chemosis and enlarge-

* Archiv für Ophthal., vol. ix. part ii. pp. 106-109.

ment of the globe, and the seton is then to be withdrawn. Fomentations and poultices may be applied to relieve uneasiness. In from three to eight days a diminution of the symptoms will occur, and atrophy of the globe will shortly follow.

CILIARY STAPHYLOMA, OR STAPHYLOMA OF THE SCLEROTIC, as it is commonly called, is a staphylomatous projection of the sclerotic in the ciliary region of the eye. It consists of a series of grape-like bulgings, with such a thinning of the sclerotic coat, that the dark colour of the ciliary processes with which it is in contact is distinctly seen through it. It may be limited to a part, or it may involve the whole of the ciliary region of the eye.

Ciliary staphyloma may be the result of injury, or disease. In the majority of cases it is dependent on a chronic form of choroido-iritis, accompanied with a gradual wasting of the sclerotic in the immediate vicinity of the ciliary processes, so that it loses its normal power of resisting the outward pressure from within the eye, and, slowly yielding, a dark irregular nodulated prominence is developed.

As the result of an injury to the eye, ciliary staphyloma may be produced in two ways.

1st. It may be the *direct* sequence of a rupture of the sclerotic, and especially when there is also associated with it an extensive prolapse of the iris and choroid. After such an accident, it frequently happens that the margins of the wound are prevented from falling into apposition by the prolapse which bulges between them. Over the surface of this, lymph is subsequently effused and afterwards organised; a thin cicatrix tissue is ultimately formed over the protruded iris and choroid with which it is blended, but a staphylomatous projection is left in the immediate site of

the wound, which seldom recedes, if it does not afterwards increase.

2nd. Ciliary staphyloma may occasionally be the *indirect* result of an injury to the eye. The chronic choroido-iritis, with thinning of the sclerotic in the ciliary region, which has been the immediate cause of the staphyloma, may have originated in some distant injury. The acute inflammatory symptoms which were primarily induced, instead of completely subsiding, may have drifted into that low form of choroido-iridic inflammation, which so often ends in blindness and deterioration of the tissues of the eye.

The prognosis of ciliary staphyloma is always most unfavourable; even when slight, there is considerable impairment of vision; but the danger to be apprehended is that it will increase, and as it enlarges all sight will be destroyed.

Treatment.—For the ciliary staphyloma which is produced by a rupture of the sclerotic, I know of no remedy. The sight which such an eye retains, even when the staphyloma is small, is usually very limited; but if it is sufficiently large to interfere with the free movements of the lid over it, the eye is generally blind. When an eye thus completely lost for all visual purposes is unseemly in appearance, and troubles the patient, the best treatment is to excise it. If, however, a ciliary staphyloma is dependent on disease, no matter whether it has originated from constitutional causes, or from some remote injury to the eye, it may frequently in its early stages be arrested by the operation of iridectomy. It is the only remedy from which I can really feel satisfied that I have seen any decided benefit; and although in some cases it may fail in accomplishing the desired end, yet it is certainly the most successful of all the remedial agents I have known practised for the relief of this disease. By reducing the

tension of the eye, the tendency of the staphyloma to increase is certainly diminished, and in some instances completely stopped. It should be remembered that even though the tension of the eye at the time of the operation may be normal, yet the resisting power of the sclerotic has been lowered by disease, and that by lessening the tension which exists, the condition of the eye is improved.

CASE XIX.—*Ciliary staphyloma following a rupture of the sclerotic, with a dislocation of the lens beneath the conjunctiva.*

Frances L., æt. 40, was admitted into the Ophthalmic Hospital, July 10, 1866, under the care of Mr. Bowman, suffering from a severe injury to the left eye. Ten days previously she received a blow on that eye.

Present state.—In the ciliary region, at the upper part of the eye, the lens is seen dislocated beneath the conjunctiva; and through it a rent in the sclerotic can be discerned. About the lower half of the cornea retains its normal curvature, but the upper part is bent forwards. The aqueous humour is yellow: she is suffering no pain.

July 13.—Mr. Bowman made an incision through the conjunctiva and sub-conjunctival tissue over the lens, which he then removed in its capsule. Behind the lens there was some vitreous, which had escaped through the rent in the sclerotic.

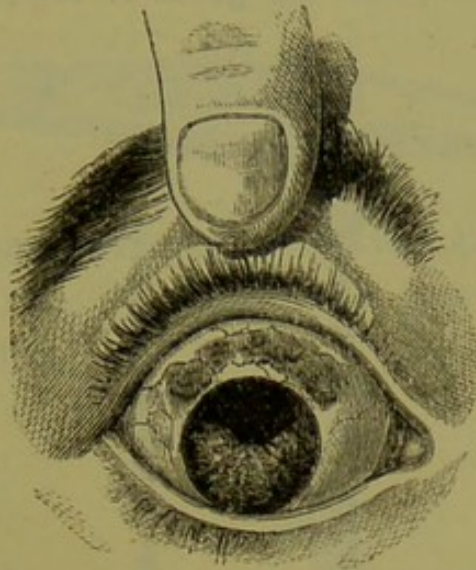
July 14.—No pain or swelling of the lids.

July 18.—Good perception of light. There is a curtain of blood across the area of the pupil.

July 20.—The fundus of the eye cannot be lighted up with the ophthalmoscope. The cornea has almost resumed its natural curvature. The tension of the globe is —T 1. The iris is tremulous.

July 27.—Wound in the sclerotic healed; she can discern a hand moving.

FIG. 24.



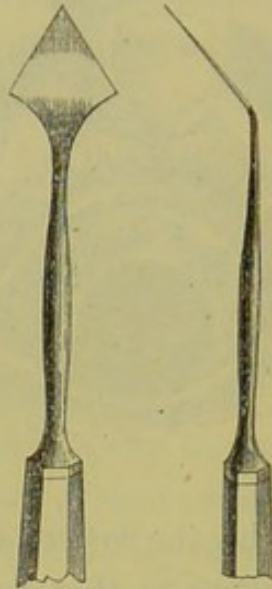
September 14.—To-day the patient called at the Hospital. The appearance of the eye is that represented in fig. 24. There is a rather large ciliary staphyloma in the immediate site of the rent in the sclerotic.

Examined with the ophthalmoscope, there is still seen some blood in the vitreous, in the upper part of the eye, in the vicinity of the wound. With a 3-inch convex glass she is able to make out 20 Jaeger's test types.

THE OPERATION OF IRIDECTOMY.—The patient lying on a couch, a spring stop speculum is to be introduced between the lids to open them to the desired extent. The operator, standing behind the head of the patient, seizes with a pair of forceps in his left hand the conjunctiva and subjacent fascia of the eye, at a part near the cornea, opposite to that at which he is about to introduce the point of the iridectomy knife; whilst with his right hand he makes an incision in the sclerotic with a

lance-shaped knife (fig. 25) at about one line from the margin of the cornea, so that the point of it may enter the anterior chamber just in front of the ciliary attachment of the iris. As soon as the point of the knife is seen in

FIG. 25.

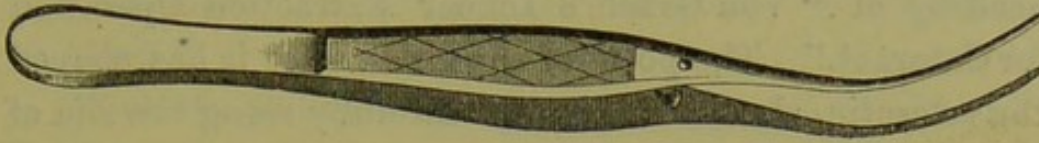

A FRONT AND SIDE VIEW OF A LANCE-SHAPED IRIDECTOMY KNIFE, SHOWING THE ANGLE AT WHICH THE BLADE IS SET TO THE SHAFT OF THE INSTRUMENT.

the anterior chamber, the blade should be directed onwards in front of the iris, until the required opening has been made. In doing this, it is necessary to keep the point of the instrument slightly forwards, so as to avoid the risk of wounding the lens, taking care at the same time that it does not scratch the inner surface of the cornea. The knife should be then steadily and cautiously withdrawn from the eye, so as to allow the aqueous to flow gently away, and thus to avoid the sudden gush which usually follows a too rapid withdrawal of the blade. The incision having been completed, the operator now hands over the forceps, which fixed the eye, to his assistant, who, if necessary, rotates the globe a little downwards, and steadies it whilst he excises a portion of the iris. If the iris is already

prolapsed, as often happens, he at once seizes it with a pair of iris forceps (fig. 26), or if not, he introduces the blades of the forceps through the wound, and makes them

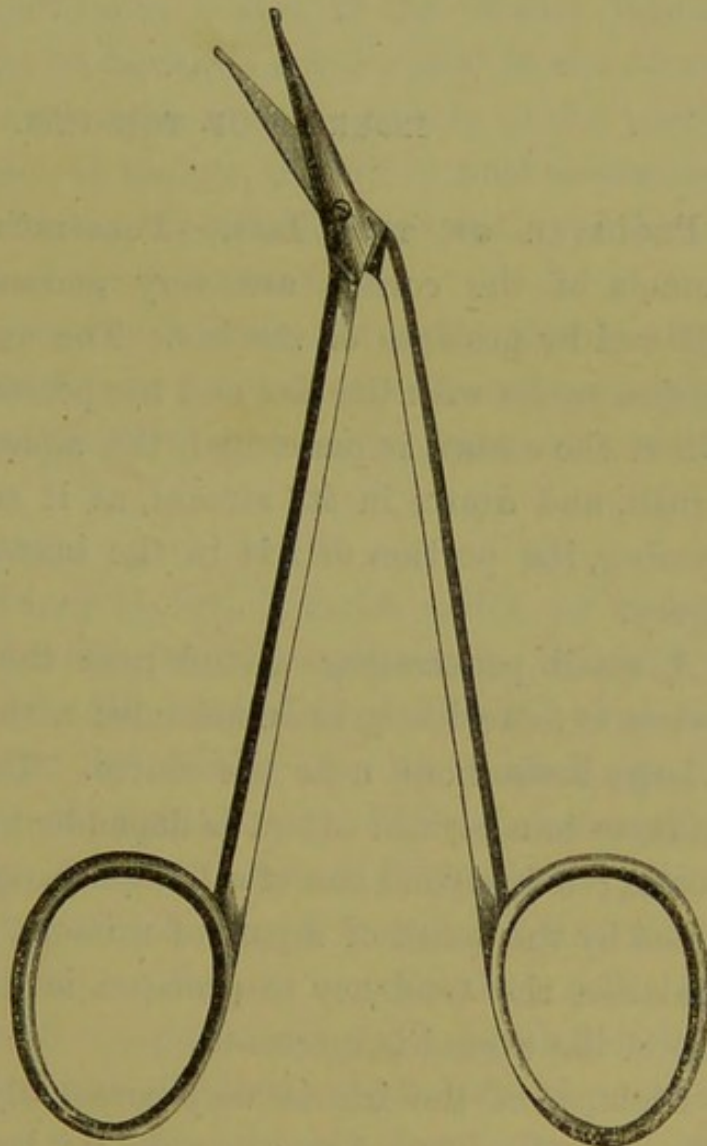
FIG. 26.



grasp the iris near the pupillary border, and then, drawing a portion of it out of the wound, he first cuts it through

with a pair of fine scissors (figure 27) on one side of the forceps, from its ciliary margin to the pupil, and then drawing on the free end of the iris, which is still within the grasp of the forceps, he separates as much of it from its ciliary attachment as he desires to excise, and cuts it off with a pair of scissors.

FIG. 27.



When from any cause the anterior chamber is so shallow that the iridectomy knife

cannot be used without incurring the risk of wounding the lens, the incision in the sclerotic should be made with an ordinary cataract knife, or with Von Graefe's linear extraction knife, a drawing of which is seen under the heading of "Von Graefe's Linear Extraction Operation for Cataract." The point of the knife, after it has pierced the sclerotic, should be directed carefully along the rim of the anterior chamber for a distance in accordance with the desired size of the incision, and then, making the counter-puncture, it should cut its way out, as in the ordinary flap extraction for cataract.

INJURIES OF THE IRIS.

PROLAPSE OF THE IRIS.—Penetrating and incised wounds of the cornea are very generally immediately followed by prolapse of the iris. The extent of the protrusion varies with the size and the position of the wound. When the cornea is punctured, the aqueous escapes with a rush, and draws in its stream, as it runs through the opening, the portion of iris in the immediate site of the injury.

A small penetrating wound near the margin of the cornea is more likely to be attended with a prolapse, than a large incised one near the centre. The amount of the prolapse to a certain extent is dependent on the size of the wound; but beyond one of a limited range, such as is produced by the point of a pair of scissors, or the blade of a penknife, the tendency to prolapse is diminished as the size of the wound is increased.

Prolapse of the iris is very commonly associated with injury to the lens; but as a rule, we have first to direct our attention in the treatment of the case to the prolapsed

iris, leaving the traumatic cataract to be dealt with at a future period. There are, however, cases where the injury to the lens materially influences the treatment to be pursued for the protrusion of the iris. These complications are considered in the article "*Treatment of Traumatic Cataract.*"

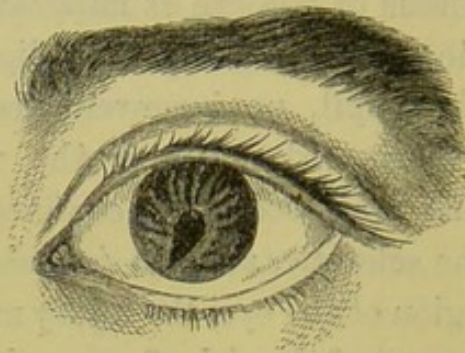
When the prolapse of the iris is small, and produced by a clean, sharp, but small cut near the margin of the cornea, and no other tissue of the eye is implicated, the case is almost certain to do well, and beyond a slight alteration in the shape of the pupil, no inconvenience will probably hereafter be experienced. But if the wound through which the iris has prolapsed is not confined to the cornea, but runs into the sclerotic, so as to include in it a portion of the ciliary region of the eye, the injury must be seriously regarded, on account of the risk of sympathetic ophthalmia to which the sound eye is exposed.

The following case is an illustration of a small prolapse of the iris, produced by a small clean cut at the margin of the cornea, but without injury to any of the other tissues of the eye.

CASE XX.—Sydney O., æt. 7, came under my care on June 11, 1866, having two days previously received an injury to the left eye. He was amusing himself by breaking an earthenware pot by striking it with a stick, when a piece of it flew up and hit the eye. When I first saw him there was a clean sharp cut wound at the lower part of the cornea, through which a small portion of the iris was prolapsed. The lens, as far as I could then make out, was clear. A small compress was applied over the closed lids, and a lotion of belladonna was ordered to bathe the eye with three or four times a day. The lad progressed towards recovery without an untoward symptom,

and on September 18, when he came to show himself at the Hospital, the eye presented the appearance seen in fig. 28. The pupil was drawn downwards, but the cornea in front of it was transparent, and the lens was clear. He could see as well with that eye as with the other. He read No. 1 of Jaeger's test types with ease.

FIG. 28.



If the patient is seen very shortly after the accident, before any adhesion can have commenced between the protruded iris and the edges of the wound, it has been recommended to expose the eye suddenly to a strong light, with the idea that the rapid contraction of the pupil will draw the prolapsed iris back again within the chamber of the eye. This mode of treatment is simple, and may be tried; but my own experience is that it will never succeed. Since the introduction into ophthalmic practice of the Calabar bean, we have at our disposal the means of causing a rapid contraction of the pupil, and of maintaining this state as long as it may be deemed desirable. This drug has been used with success in certain cases of prolapse of the iris, seen by the surgeon very shortly after the accident which caused it. The steady and continued contraction of the pupil has succeeded in some instances in drawing the iris out of

the wound; whilst in other cases the success has been partial, and the prolapse has been diminished. As a rule, however, the patient is not seen sufficiently early to allow of this treatment being followed.

In treating prolapse of the iris, we have first to consider the best means of dealing with the prolapse itself; and next what general treatment should be adopted to favour the recovery of the eye.

The prolapse of the iris may be treated in four different ways:—

1st. By a compress applied externally over the closed lids.

2nd. By removing with a pair of fine scissors the prolapsed iris.

3rd. By frequent puncturings of the prolapsed iris with a fine needle.

4th. By applying a fine ligature to the prolapsed iris.

The general treatment must be strictly soothing, and great care should be taken of the eye for at least six months after a wound followed by prolapse of the iris, even though the lens may have escaped all injury. Both eyes should be shaded, and all strong lights should be carefully excluded. The room in which the patient resides should be darkened, and when he goes out of the house, the eyes should be protected from glare by spectacles with dark neutral tint glasses. The spectacles should be provided with large curved glasses, so bowed as to shut off lateral light; or a pair of goggles may be used.

Soon after the accident two or three leeches should be applied to the temple of the injured eye; and three or four times during the day the eye should be bathed with a belladonna lotion; or it may be fomented with a warm de-

coction of poppy heads, but then a few drops of the solution of the Sulphate of Atropia gr. j. ad Aquæ ℥j. should be also dropped into the eye twice a day, as it is of importance to keep the eye under the influence of belladonna for the first two or three days at least after the accident. If a compress is applied over the eye, it should be removed three times daily, to allow of the eyes being bathed with the lotion; but if one of the other plans of treating the prolapse be adopted, in addition to bathing the eye, a fold of linen wet with the lotion may be laid over the closed lids.

No prolapse of the iris should be very lightly regarded; for I have seen almost complete blindness follow from what has appeared at first a comparatively slight injury.

I. *Treatment of Prolapse of the Iris by a Compress.*—In a large majority of cases of prolapse of the iris following an injury, it is best at the onset to leave the prolapse alone, and to be guided by the progress of the case as to the ulterior measures to be resorted to. The patient should be directed to gently close both eyes, and a little cotton wool, or charpie, should be evenly placed over the injured one, so as to form a compress, which is to be kept in its place by a turn of a roller. To do good, the pressure on the eye must be uniform, and steadily maintained by a readjustment of the bandage and padding as often as necessary. This method of treatment often affords considerable comfort to the eye; it artificially supports the relaxation of the parts within, caused by the sudden evacuation of a portion of the contents of the globe; it tends to prevent an increased prolapse of the iris; and it effectually excludes all light.

So long as a compress contributes to the ease of the patient, it may be worn; but if from its first application it

is complained of as hot and annoying, it should be discontinued. This treatment should generally be resorted to in the early stage, when the indications which call for it are manifest; but it may have to give place to, or be used in concert with, some other remedy as the case advances. Thus, if after wearing the compress for a few days, the eye is found on examination to be tolerably quiet, and the prolapse covered with lymph, it may be deemed advisable to snip it off with a pair of scissors, or to puncture it with a fine needle, and again to continue the pad. In a very large number, however, of cases of prolapse of the iris, no surgical treatment of the prolapse will be required. The prolapsed portion of iris will be strangulated in the wound, and becoming detached, a smooth cicatrix will be formed.

CASE XXI.—*Large wound of the cornea with a small prolapse of the iris—Treated by compress—Good result.*

Edward O., æt. 34, a boiler-maker, came to the Hospital August 22, 1864, suffering from an injury he had received to the left eye a few hours previously. He was striking a piece of iron, when a fragment flew off and struck the eye. On examination, a vertical slit was seen in the centre of the cornea, extending to within a sixteenth of an inch of the margin at each extremity. The iris was lying in contact with the cornea, all the aqueous having escaped; and projecting through the wound at the lower part, was a small portion of the iris. The lens was wounded.

A cotton-wool compress was applied to the eye, and kept in situ by a turn of a roller, and two leeches were ordered to the temple.

August 23.—The man has not had much pain in the eye. The wound is closed, and there is a fair anterior chamber.

Ordered to use a belladonna lotion two or three times daily.

The man continued to do well, and on August 30th the report states that the eye is quiet. There is a good deep anterior chamber. The outer margin of the pupil is adherent to the cicatrix of the cornea, but the inner half is free and circular, and acts well. The lens is quite opaque.

In this patient, although the wound was very large, the prolapse of the iris was very slight. The compress acted as a support to the eye, and favoured the rapid union of the corneal wound by keeping its edges in apposition, and by excluding air and light.

II. *Removing, with a pair of fine scissors, the Prolapsed Iris.*—From the very slight amount of irritation which follows the operation for artificial pupil, when an opening is made at the margin of the cornea, and a piece of iris is drawn out and cut off, it might reasonably be inferred that the snipping off of a piece of iris which has bulged through a small wound made accidentally instead of intentionally, would be followed by no more severe results. The cases, however, are not exactly parallel. In the one case, the wound is a simple incised one, made with a clean sharp-cutting instrument, its edges falling into accurate apposition immediately after the iris has been cut off, and primary union speedily resulting. In the other, the wound is nearly always a punctured one, inflicted with a considerable amount of force, and producing a certain amount of contusion; hence, instead of a direct union of the edges, the wound is apt to remain more or less patulous, and after the prolapsed portion of iris has been snipped off, the constant drain of the aqueous will often cause an additional protrusion to follow, and thus render the subsequent displacement of the pupil greater than that

caused by the primary injury. There are, however, cases where this line of treatment is judicious, but they require to be selected. Those to which it might be applied are—

1st. Where the wound is small, and has been made by a fine, sharp instrument; where there is little or no contusion of the corneal tissue, and the prolapse is not large.

2nd. In certain cases where there is a portion of iris lying between the lips of a large wound across the cornea. The removal of the iris allows the edges of the cut to fall into apposition, and favours primary union.

3rd. It may be often resorted to with advantage at a later period in the treatment of a case of prolapsed iris, when the protruded portion has become coated with a film of lymph, and the edges of the wound through which it bulges are evidently sealed to the iris which fills it.

CASE XXII.—Large wound of the cornea with a knife—Prolapse of the iris—Injury to the lens—Abscission of the prolapsed iris.

W. L., æt. 8, was brought to the Hospital on September 3, 1864, having, three hours previously, met with the following accident:—He was cutting a piece of string with a carving knife, when the string suddenly giving way, the blade of the knife struck with full force the cornea of the left eye, inflicting a large wound, which extended from near the upper and outer margin to close to the lower and inner border.

Condition on coming to the Hospital.—There was a long cut across the cornea of the size above indicated, and projecting through the lips of the wound was a small portion of iris, with some lens matter. The anterior chamber was full of blood.

Treatment.—The small protruding portion was snipped off with a pair of scissors. He was ordered

Two leeches to the temple.

Fotus Belladonnæ to be applied continuously to the eye.

Pulv. Calomel c. Jalap gr. viij. at bed-time.

September 6.—Has slept well each night since the accident. The whole globe is much injected, but a portion of the blood has been absorbed, sufficient to see that there is a good anterior chamber, and that the lens is opaque. The wound of the cornea has united, and retains the aqueous within the chamber.

September 13.—Has continued to do well. The eye is quiet. All the blood has been absorbed. The portion of iris which was prolapsed and removed with the scissors was very small, and a long narrow pupil, free above the wound, remains, but the lower part of the iris is adherent to the edge of the cicatrix. The lens is quite opaque, and particles of lenticular matter are seen in the anterior chamber.

This case is quoted as illustrative:—

1st. Of a small prolapse occurring through a very large wound of the cornea.

2nd. Of the mode of treating the prolapse by cutting it off with scissors.

III. *Frequent puncturing the prolapse with a fine needle* is a plan of treatment suggested by Mr. Bowman in certain cases, and one from which I have seen the most satisfactory results. It is specially applicable to large prolapses of the iris, near the margin of the cornea:—that form, indeed, which is very intractable to other treatment. In the smaller prolapses, puncturing is often of the greatest service, but such cases admit of other and apparently milder measures, and do well. The class of injury in which I have seen so much benefit accrue from judiciously

pricking from time to time the protruded iris, is where a large wound with a tendency to gape, has been made near the margin of the cornea; where the piece of iris prolapsed is large; and where, from the appearance of the wound, it is evident that snipping it off will only be followed by an additional protrusion, and that without some energetic treatment, the prolapse will probably increase and give rise to great irritation.

The portion of iris which protrudes through the wound is usually a fold, bulged to its fullest extent by the aqueous behind; the hollow of the fold communicating directly with the anterior chamber, which it continues to do, until the opposed surfaces of the bag of iris are compressed by the falling together of the edges of the wound.

The object of the operation is twofold. 1st. By pricking the prolapsed iris, to allow the aqueous which fills it out to escape and cause it to collapse, and at the same time to permit the edges of the wound to close upon it, and come into more immediate apposition.

2ndly. To excite sufficient local action to produce adhesion of the edges of the wound to the iris, and of the opposed surfaces of the iris to each other. The wound is thus closed, and the portion of iris beyond the cornea, cut off from its vascular supply, withers away.

CASE XXIII.—*Large prolapse of the iris treated by frequent prickings with a fine needle—Good result.*

L. B., æt. 5, was brought to the Hospital on account of an injury she had received in her right eye the day previously. Her brother, playing with a bow and arrow, shot an arrow into her right eye.

It penetrated the globe at the inner margin of the cornea close to its junction with the sclerotic, and stuck in the eye. It was withdrawn by the child, and immediately

an extensive prolapse of the iris took place. When first seen there was a wound about one-eighth of an inch in length at the site above mentioned, and through it was protruding a large portion of iris, nearly one-sixth of its entire circumference.

The point of the arrow appears to have passed simply into the anterior chamber, and not to have touched the lens, or otherwise to have disturbed the parts within the eye. The lens, as far as could be made out, was quite clear, and the sight was good.

With the exception of the large bulging portion of iris, the eye looked very much as if an iridectomy had been performed. Some recent lymph coated the protruding iris. The prolapse was too large to admit of a ligature being placed round it as in iridodesis; for the wound, a gaping one, still remained, and if the bulging part was diminished in size, fresh iris would probably prolapse. For the same reason, cutting it off with scissors was unadvisable, as the large open wound would still remain, and another bulge would certainly take place. Mr. Bowman saw the child, and punctured with a fine needle the protruded iris at four or five points, allowing the aqueous which swelled it to escape. This treatment he recommended to be repeated once or twice a week, according to the condition of the eye.

The child was brought to the Hospital regularly twice a week for about a month, and on each occasion I repeated the puncturings. They produced but little annoyance, the slight action which followed each operation being limited to the prolapsed iris and the wound. The case progressed uninterruptedly, the bulging portion of the iris became strangulated, a firm cicatrix resulted, and the child has a good and useful eye.

IV. *Treatment of Prolapse of the Iris by Ligature.*—In

cases where a small prolapse occurs close to, or at the circumferential margin of the cornea through a *small but clean cut wound*, the placing a ligature of very fine silk round the protruded iris is a mode of treatment which may be adopted.

It strangulates and cuts off the bulge, and excites sufficient local action to close the wound ; but this treatment is only applicable to a limited class of cases, as, if the wound is large, the diminishing suddenly the size of the protrusion by a ligature soon after the accident, would either favour an additional prolapse, or else, as the aqueous was re-secreted, would allow the prolapsed iris, with the ligature, to be sucked back within the anterior chamber. The latter accident occasionally occurs after the operation of iridodesis, if the opening in the margin of the cornea is made too large.

COREDIALYSIS is a detachment of the iris from its ciliary border, by which a new pupil is frequently formed. It is generally caused by sharp blows on the eye, such as with the handle of a whip; with the cork from a bottle of soda water, or an accidental back blow from the hand of another person, or indeed from any sharp sudden violence. Core-dialysis may be associated with rupture of the external coats of the eye, but in the majority of cases it has not this severe complication. The separation of the iris from its ciliary connection is always immediately followed by free bleeding, often sufficient in quantity to fill the whole of the anterior chamber with a blood clot. The extent of the coredialysis varies very much : in some cases the detachment is so small as scarcely to be visible after all the blood has been absorbed ; whilst in other instances, as in Case XXIV., fig. 29, a third or even more of the iris may be loosened from the ciliary body.

The pupillary border of the iris corresponding to the dialysis is paralysed from a tearing through of the ciliary nerves which supply it, and that part of it is uninfluenced by the action of light and shade. The complete circle of the pupil is thus destroyed—a defect which is most observable when the pupil is dilated. This paralysis of a limited portion of the iris is often in slight cases of coredialysis the only indication, after the blood has been absorbed, of the nature of the injury the eye has sustained. The detachment of the iris from its ciliary border may have been small, or perhaps a mere loosening or partial separation may have happened, sufficient in extent to cause a rupture of some of its nerves and vessels, and consequent hæmorrhage, and limited paralysis, but not enough to form a new pupil.

The prognosis of cases of coredialysis when there is no rupture of the external coats of the eye is favourable. When the patient is first seen, if it is shortly after the accident, the blood in the anterior chamber will generally prevent a correct diagnosis of the extent of the injury being formed; but in a few days the clot will have become absorbed, and a careful examination can then be made. A guarded opinion should be always given, as the blow which has force enough to cause a coredialysis may also inflict such an injury on the lens as to produce a cataract.

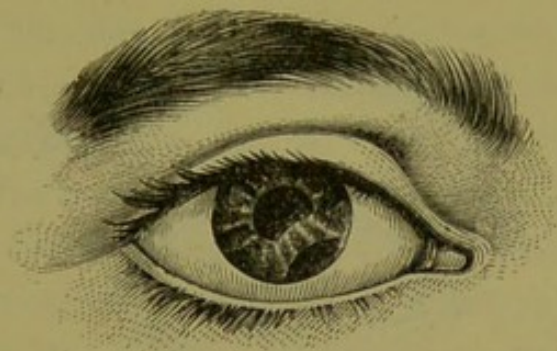
If the eye recovers from the injury, the second pupil will interfere but very slightly with vision: provided the lens is clear, and the choroid and retina sound, perfect vision may be afterwards enjoyed, even though the second pupil is one of considerable size. This fact is illustrated in the following case, where, although a third of the iris was detached, the patient was afterwards able to read No. 1 of Jaeger's test types.

CASE XXIV.—*Large detachment of the iris from its ciliary circumference, occasioned by the bursting of a squib close to the eye.*

Eliza B., æt. 21, was sitting in her garden on November 5, 1861, when a squib, thrown over the wall by a child, burst within a few inches of the right eye. The eye was struck as it exploded. Immediately she suffered great pain, and very shortly afterwards she found that the eye was quite blind. She came under my care on the following day. The eye was then very painful and inflamed; the anterior chamber entirely occupied by a clot of blood, so as to render it impossible to distinguish any of the internal structures.

Leeches were applied to the temple, and a fold of linen wet with cold water was laid over the lids. Under this

FIG. 29.



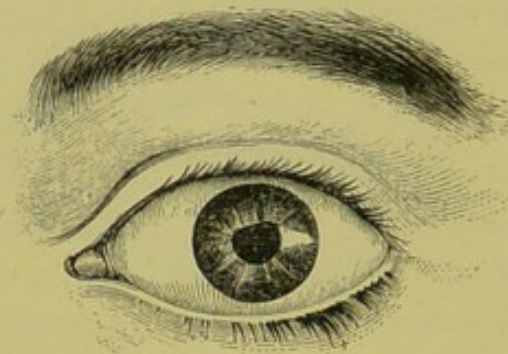
treatment the pain and redness of the eye subsided; and after eight days (on November 14) the blood was sufficiently absorbed for an exact examination to be made. It was then found that at the lower and inner part, an extensive detachment of the iris from its ciliary attachment (coredialysis) had taken place; but as far as could be then ascertained, the lens was clear. The case progressed most satisfactorily. The blood in a fortnight was

quite absorbed; but the aqueous continued of a yellow colour for many weeks afterwards, giving to the iris a greenish tinge. The hæmorrhage, as the result proved, was limited entirely to the anterior chamber; and the coredialysis was the only injury the eye sustained. The patient, three months after the accident, was able to read No. 1 of Jaeger's test types. The detachment of the iris from its marginal circumference was so extensive that a distinct second pupil was formed, through which, with the ophthalmoscope, the fundus of the eye could be clearly seen. The vision, however, with that eye, was single.

CASE XXV.—*Coredialysis occasioned by a blow on the eye with a cork from a bottle of soda-water.*

T. W., æt. 45, came to the Hospital on May 23, 1865, having half an hour previously received a blow on the eye

FIG. 30.



from the cork of a soda-water bottle. He was about to open a bottle of soda-water; and, whilst speaking to a person near him, the cork unexpectedly flew out and struck him on the eye. There was some hæmorrhage into the anterior chamber, sufficient to form a thin clot across the lower third of the iris, but not to occlude the pupil. At the upper circumferential margin, there was a separation

of the iris from its ciliary attachment to the extent of about one-quarter of an inch. The pupil opposite the detachment was paralysed. He was ordered to have two leeches applied to the temple; and a fold of linen, wet with the belladonna lotion, to be laid over the eye.

May 26.—The blood was quite absorbed. The portion of iris which had been torn from its ciliary border was loose and tremulous. The lower margin of the pupil acted well, but the upper and outer was paralysed. The case did well.

For the directions concerning the treatment of core-dialysis, see the article "Hæmorrhage into the Anterior Chamber," in which, under the heading of "Treatment," the subject is fully discussed.

LACERATIONS OF THE IRIS WITHOUT RUPTURE OF THE EXTERNAL COATS OF THE EYE.—Such injuries are quite distinct from the detachments of the iris (coredialysis) described in the last article. I refer now to those rare cases of injury in which the structure of the iris is torn by a blow on the eye, but without any rupture of the sclerotic or choroid. From a sharp blow I have seen the pupil present the appearance as if it had been notched, a small tear having been made by it through the pupillary margin of the iris, and yet there was no laceration of the external coats of the eye, nor wound of the lens. A very remarkable instance of this kind of injury was seen in a patient under the care of Mr. Critchett. The following are the notes of the case.

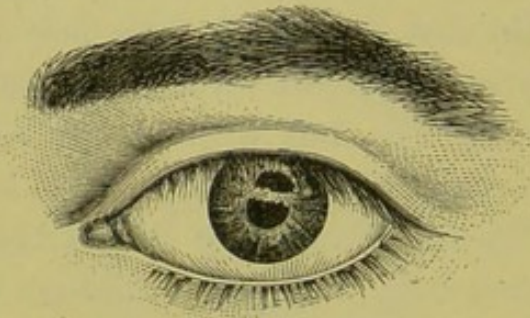
CASE XXVI.—*A laceration of the iris without injury to any of the external coats of the eye from the splash of a bullet, after it had hit the target, striking the eye.*

Wm. P., æt. 41, a marker at a rifle butt, came under the

care of Mr. Critchett May 23, 1865, having met with the following extraordinary injury. Eleven days ago he was engaged marking off as the volunteers fired, when a splash from one of the bullets came into the mantelet where he was sitting, and struck the left eye. He felt at the time that he was struck, but he did not take any notice of it until the firing had ceased, although he said he was quite blinded (probably from hæmorrhage into the anterior chamber).

On examining the eye the following curious condition is seen. On the outer part of the cornea is a slight unevenness of the epithelial surface, but there is no opacity or any mark to indicate the point which received the blow. The whole of the external coats of the eye are entire, and there are no indications of there ever having been any rupture of them. On looking, however, within the

FIG. 31.



eye, two distinct pupils are at once seen, the one immediately above the other; the lower is separated from the upper one by a bridge of iris; and the upper pupil is bounded by a border of iris, so that it is distinct from and does not encroach on the ciliary attachment of the iris. The margins of the new pupil when carefully examined are found to be slightly lacerated and irregular. With the ophthalmoscope the fundus of the eye can be seen through either pupil, though the media appear slightly

hazy. The upper border of the old pupil is paralysed, and has lost its circular outline, but the lower border is normal in shape, and acts freely. He is able to read No. 18 Jaeger's test types.

It is difficult to imagine how this injury to the iris can have been effected. At first sight it looks as if a piece of the iris had been punched out, but this evidently is only apparent, for there had been no rupture or penetration of the coats of the eye. It is probably simply a rent in the iris, occasioned by the force of the blow, the edges of which, owing to the iris maintaining its normal elastic and contractile power, have opened out, and so formed a new pupil. But another curious point in the case is, how could the iris have received such an injury, and yet the lens have escaped apparently unscathed?

Eleven days since the accident, and yet the lens is still sufficiently transparent for the patient to read No. 18 Jaeger, and for the fundus of the eye to be examined with the ophthalmoscope. The case is altogether an exceptional and remarkable one.

CHAPTER IV.

TRAUMATIC CATARACT.

TRAUMATIC CATARACT WITH RUPTURE OF THE EXTERNAL COATS OF THE EYE—TRAUMATIC GLAUCOMA FOLLOWING A WOUND OF THE LENS: CASES OF—TRAUMATIC CATARACT WITHOUT RUPTURE OF THE EXTERNAL COATS OF THE EYE: CASES OF—TREATMENT OF TRAUMATIC CATARACT: FIRST, IF THE CATARACT IS UNCOMPLICATED WITH PROLAPSE OF THE IRIS; SECOND, IF IT IS COMPLICATED WITH PROLAPSE OF THE IRIS; THIRD, IF COMPLICATED WITH INJURY TO IRIS AND PROTRUSION OF LENTICULAR MATTER THROUGH THE WOUND—OPERATIONS FOR THE REMOVAL OF A TRAUMATIC CATARACT: RULES FOR GUIDANCE IN THE SELECTION OF THE OPERATION—LINEAR EXTRACTION OF CATARACT—SUCTION OPERATION FOR CATARACT—CASES OF TRAUMATIC CATARACT SUITABLE FOR LINEAR EXTRACTION OR SUCTION—THE TRACTION OPERATION—CASES SUITED FOR THE TRACTION OPERATION—VON GRAEFE'S LINEAR EXTRACTION OPERATION FOR CATARACT—LIEBREICH'S EYE-BANDAGE.

TRAUMATIC CATARACT, or cataract the result of an injury to the eye, may occur either with or without a rupture of the external coats of the eye.

1st. *Traumatic Cataract with Rupture of the External Coats of the Eye.*—One of the most frequent complications of a wound of the cornea is an injury to the lens. Wounds of the lens terminate almost invariably in cataract. The point of injury is within twenty-four hours indicated by an opaque patch, and this opacity gradually increases until the whole lens becomes opaque. The rapidity of the formation of the cataract will depend partly on the extent of the injury inflicted on the lens and its capsule, and partly also on the age of the patient. If the rent in the capsule is large, and the lenticular matter has also been broken into, the aqueous humour will be rapidly brought into contact

with the lens substance, and its transparency will be quickly destroyed; but if the tear of the lens capsule is very small, although cataract will as a rule follow, its formation and progress will be much more slow than in the former case. It occasionally happens, but it must be considered as exceptional, that a small wound of the lens capsule produces only a limited opacity, which does not extend so as to pervade the whole lens, but remains stationary. So fortunate a termination to such a severe injury of the eye as a wound of the lens capsule is more likely to happen to an old than to a young patient. In the young, the lens is soft, and becomes more rapidly cataractous from an injury than in the aged, where it is more dense and has a firm nucleus. A wound of the lens is very commonly associated with a prolapse or laceration of the iris, or with both: indeed it is more usual for it to be accompanied with some lesion of the iris than for the injury to be confined to the lens.

The immediate effect of a wound of the lens is the admission of the aqueous within its capsule. This is imbibed by the lens tissue, each part of which becomes opaque, and rapidly swells as it is brought under its influence; so that the swelling of the lens increases with the opacity until the whole is opaque. The lens thus swelling frequently presses on the posterior or uveal surface of the iris, bulging it more or less towards the cornea, and often exciting great irritation: hence it is of the greatest importance, after an injury to the eye in which it is suspected that the lens has been implicated, that the iris should be kept fully under the influence of atropine, in order that a wide dilatation of the pupil may afford space for the swelling lens, and prevent as far as possible its encroaching on the iris.

The irritation which is excited by the pressure of a

swollen lens on the posterior surface of the iris is greater and more apt to occur in the adult and aged person than it is in the child. Von Graefe, in a clinical lecture on traumatic cataract, says, "On the one hand the lens is softer and causes less mechanical irritation when the patient is young; and on the other the iris becomes progressively more irritable as age advances. . . . Whilst rapid swelling of the whole lens is generally well borne by children, we find that slow and limited expansion of the cortex is sufficient to excite dangerous inflammation in old people."*

The most serious symptom which the pressure of a swollen lens on the back of the iris is apt to produce is a glaucomatous hardness of the globe—a condition known as "traumatic glaucoma." It is ushered in with increased pain and irritation; the anterior chamber is diminished in size from the lens having pressed the iris forwards towards the cornea; the eye has a pinkish tinge from a general fulness of the sclerotic vessels, but especially of those which form the zone around the cornea; and the globe, examined with the fingers, is found to be increased in tension. That this glaucomatous state of the eye is due to the injury of the lens is proved by the fact, that it will occasionally come on the day following the needle operation for breaking up the lens, in the first stage of the operation for the linear extraction of a congenital cataract, and that the removal of the broken down lens will generally at once cause an abatement of all the symptoms.

The following cases are examples of glaucomatous symptoms supervening on an injury to the lens.

* Extract from a Clinical Lecture on Traumatic Cataract by Professor v. Graefe, translated in the Ophthalmic Review, vol. ii. p. 142.

CASE XXVII.—*Congenital cataract of the right eye—Linear extraction—Great irritation and glaucomatous hardness of the globe the day after breaking up the lens with a needle—Relieved by at once removing the lens.*

W. H., æt. 24, came to the Hospital on Sept. 3, 1864, with a soft cataract in the right eye. On that day I broke up the anterior two-thirds of the lens capsule with a fine needle, and freely comminuted the lenticular matter, a great portion of which floated forwards into the anterior chamber. A solution of atropine was dropped into the eye, and the pupil was kept as widely dilated as possible.

He passed a restless night, and on the following morning he was in great pain; the tension of the eye was increased to T. 1.; the iris was close up against the cornea. In my absence the patient was seen by Mr. Hulke, who at once removed the lens, by making an opening into the cornea with a broad needle, and then letting off as much of the lenticular matter as would flow away on the curette.

Sept. 6.—The patient has had but little pain in the eye since the last operation; it is much more quiet. Ordered to continue the atropine drops. This patient completely recovered with a good eye.

CASE XXVIII.—*Wound of cornea involving the iris and lens; followed by glaucomatous hardness of the globe.*

J. N., æt. 42, came under my care, Nov. 19, 1860, having the previous evening met with the following accident. Whilst hammering a mass of metal a piece flew off and struck the left eye. On examination a wound is seen extending from about the centre of the cornea outwards towards its circumferential margin. The iris has been cut through, and the lens wounded. The lens is opaque,

much swollen, and pressing on the iris, which is bulged forwards against the cornea. The whole globe is intensely injected and painful. He cannot distinguish shadows. Ordered Hirudines iv. to the temple; warm poppy fomentation; Sol. Atropiæ gr. j. ad Aquæ ℥ j. to be dropped into the eye three times daily.

Nov. 21.—The eye still very painful. The tension of the globe is much increased, T. 3. The iris is bulged against the cornea. There is great chemosis of the conjunctiva; he has no perception of light. I performed an iridectomy, excising a large piece of iris upwards and outwards, and then removed with a curette as much of the opaque lens as would come away.

Nov. 22.—States that within one hour after the operation all pain had left him. The eye is more quiet. Ordered to smear belladonna over the brow.

Nov. 26.—He was discharged from the Hospital at his own request and made an out-patient. An anterior chamber has been restored, and floating in it are some loose and opaque pieces of lens matter. He can just see shadows.

The man continued to improve; the eye became quite quiet, and the pupil clear. Examined afterwards with the ophthalmoscope, the eye would not illumine. He was able only to distinguish shadows.

This case is illustrative of glaucomatous tension coming on after an injury to the eye involving the lens, which was relieved by iridectomy and the removal of the swollen cataractous lens. The loss of sight was probably due to some posterior hæmorrhage having occurred at the time of the accident.

2nd. *Traumatic Cataract produced without Rupture of the External Coats of the Eye.*—Without any rupture of the external coats of the eye, the lens, or the capsule enclosing the lens, may be so injured that cataract may speedily

follow, and so shortly indeed after the accident that the relation between the cause and effect cannot be doubted. If, for a moment, we glance at the structure of the lens, we find that it consists of delicate albuminoid fibres arranged in an exceedingly complex manner, and enclosed in a thin and brittle capsule, the anterior half of which is lined by a single layer of nucleated cells. It is dependent for its nutrition on the integrity of its capsule and the layer of cells which line it anteriorly; and for the even distribution of this supply, it is essential that the exact normal relationship between its component fibres should be maintained. For the perfect transparency of the lens, its due nutrition is absolutely necessary; when from any cause this fails, cataract follows.

In certain diseases in which the nutrition of the body is below the standard of health, we find a predisposition for cataract; thus it is frequently met with in diabetes and in albuminuria. Now as the source through which the lens derives its support is very frail, it is also liable to be seriously influenced by external injuries to the eye, which may be comparatively slight, and certainly insufficient to cause rupture of either the cornea or the sclerotic. A sudden jar or a blow on the eye may, without even injuring the lens capsule, so disarrange the internal structure of the lens that its nutrition will become diminished, and as a result its transparency will be ultimately destroyed.

Again, sudden violence applied to the parts about the head, or to the eye itself, may cause, without any rupture of the external coats of the eye, a rent in the capsule of the lens, sufficient to allow the aqueous to permeate its interior and to render it cataractous. The form of cataract which is usually thus produced, is a diffused opacity; a portion of the lens first becomes nebulous, and this nebulosity increases until the whole lens is opaque. In a clinical lecture on

Traumatic Cataract* Von Graefe noticed the fact, that traumatic cataracts do occur after simple contusions of the eye. He stated that in such cases, "the capsule seems generally to be ruptured, but the tear is found at the periphery of the lens, where the thick anterior passes into the thin posterior capsule, or within the area of the latter, and never in the middle of the anterior capsule. Owing to this circumstance the opacity of the lens forms far less rapidly, and is attended by much less swelling than when the anterior capsule is widely divided, and the wound thus allows free access of the aqueous humour to the cortical layers of the lens."

The following cases are examples of traumatic cataract produced by blows on the eye, but without rupture of its external coats.

CASE XXIX.—*Cataract from a blow with a whip, without rupture of the external coats of the eye, but causing laceration of the capsule of the lens.*

A coachman came under my care at the Hospital in February 1862, in consequence of rapidly failing sight of the right eye. Three weeks previously he had received a blow with a whip. It produced some uneasiness at the time, but that was all. He is positive that up to that date he could see well; since then the sight in that eye has become impaired, and is daily getting worse.

Examined with the ophthalmoscope. The central portion of the lens is nebulous, and a small piece of the central part of the capsule is opaque, showing that a rent had taken place.

* Von Graefe on Traumatic Cataract, translated in the Ophthalmic Review, vol. ii. p. 138.

CASE XXX.—*Traumatic cataract coming on immediately after a blow on the eye, without visible rupture of the lens capsule, or of any of the external coats of the eye.*

December, 1863.—C. W., æt. 10. One week ago, whilst walking into the school-ground where the game of tip-catt was being played, a boy struck the catt and it flew with violence against his right eye. An hour or so afterwards, he discovered that the sight was dim. The dimness increasing, caused his father to bring him to the Hospital.

Present State.—The pupil is unevenly dilated, being more dilated at the outer than the inner side. The part of the eye struck by the catt was the outer, and here the iris is partially paralysed. The whole globe is considerably injected, but he is perfectly free from pain. He can just count fingers. The lens is cataractous—a diffuse nebulosity. Examined with the ophthalmoscope, the lens is too cloudy to allow the fundus to be seen. No rent in the capsule of the lens can be detected.

CASE XXXI.—*Cataract from a blow, with rupture of the capsule of the lens, but without injury of the external coats of the eye.*

In January of 1863, B. C., æt. 21, from Woolwich, applied to the Hospital for advice concerning his left eye. A large piece of opaque capsule occupied the pupillary area. All lenticular matter had been absorbed.

His story was, that three years previously, whilst chopping wood, a fragment flew up and struck his eye with considerable force. The external coats of the eye were uninjured, but a fortnight afterwards he found that he was nearly blind with that eye. He continued in this state for some time, when he again began to see, but he never recovered his proper sight.

In this patient, the capsule of the lens had no doubt been lacerated, and the free admission of the aqueous had produced a gradual solution and absorption of the lenticular matter, and left only the opaque capsule now occupying the pupillary space.

CASE XXXII.—*Cataract from a blow producing laceration of the capsule of the lens, without rupture of the external coats of the eye.*

C. C., æt. 13, a shoemaker, from Northampton, applied to the Hospital, December 1862. He stated that six weeks ago whilst closing a pair of shoes his hand slipped, and the knuckle of the right hand struck his left eye. He suffered comparatively little pain at the time and has had none since, but he noticed that the sight of that eye soon became very misty, and in two or three days afterwards he was unable to distinguish even large objects with it.

Present Condition.—The eye is quite quiet; its tension normal. The lens is cataractous, and through the rent in the capsule a large portion of lenticular matter has escaped, and is floating in the anterior chamber.

CASE XXXIII.—The following case occurred in the practice of my friend Dr. Buzzard, and is a good example of how a cataract may be produced *without* any direct blow on the eye itself, but simply by a propagation of the force from the part struck to the eye, causing a disarrangement of the lenticular matter, without even rupturing the lens capsule.

J. C., æt. 23, a healthy young man, was in the train on the North London Railway, which met with a collision near the Kentish Town Station on the evening of September 2, 1861, when an engine, tender, and several carriages ran into a ballast train, and rolled down the steep embankment. He was with his wife and infant in a second class carriage next to the tender of the engine.

When removed from the *débris* he was bleeding from several wounds on the head, especially from those about the left temple, the brow and the outer angle of the orbit. The eye itself was in no way injured externally. He was taken to University College Hospital, where he remained for a week. I first saw him, says Dr. Buzzard, on September 27, 1861. The wounds were then nearly all healed, and but faint scars indicated their site. He complained of feeling much shaken, and looked ill. Until the accident his sight in both eyes was perfect; of this fact he was quite positive. Since the occurrence, he has found the sight of the left eye becoming hazy and confused.

Examined with the ophthalmoscope, the following was the condition:—The pupil large, sluggish, of an oval shape, being produced downwards and outwards; the sector of the lens corresponding to this pupillary lesion, opaque. The opacity affects the superficial fibres only, and has a shining satin-like appearance. The rest of the lens is transparent; no tear in the capsule was observed. He spells words of No. 16 with pain, slowly.

TREATMENT OF TRAUMATIC CATARACT.—There are so many circumstances which influence the mode of dealing with a traumatic cataract, that it will be necessary to consider them somewhat in detail, and then to draw up some general conclusions which may help to clear away many of the difficulties which beset the management of these cases.

1st. *If the cataract is uncomplicated with injury to the iris, and has been caused by a needle, or some fine sharp-pointed instrument penetrating the cornea, the probability is that the case will do well. As the iris is not involved in the injury, and the corneal wound is slight, there is good reason to hope for a favourable result. A*

solution of Atropine (gr. j. ad Aquæ $\bar{\zeta}$ j.) should be dropped twice or three times a day into the eye, to dilate the pupil fully, and thus to keep the iris out of the way of the lens, which will gradually swell, as the aqueous permeates it and renders it opaque. The lids having been closed, a compress of cotton-wool should be placed over the eye, and kept in its place by a single turn of a light bandage; or if it is more comfortable to the patient, a fold of linen wet with cold water may be kept laid over the eye. If there is any pain in the eye, or around the orbit, two leeches should at once be applied to the temple. The patient should be kept in a darkened room.

Under this treatment the early symptoms of irritation will probably soon pass away; the corneal wound will heal, a good anterior chamber will be re-established, and the eye having become perfectly quiet, will present a simple traumatic cataract, which will require to be afterwards dealt with. Frequently in such a case, the wound which has caused the cataract, has also completed the first step towards the getting rid of it. The rent in the lens capsule caused by the prick of the instrument which penetrated the cornea, has admitted the aqueous, and this, acting on the lenticular matter, will cause its gradual solution, and ultimately its complete absorption, leaving only some semi-opaque capsule within the pupillary area.

If after all the irritation occasioned by the injury has subsided, a gradual absorption of the lens matter is found to be going on, it is wise not to meddle with the cataract, but to keep a careful watch over the eye, and be prepared to treat symptoms as they arise, being guided by them in the future management of the case.

The following cases are examples of complete absorption of the lens following a wound of its capsule.

CASE XXXIV.—*Wound of the cornea, involving the lens, from the point of a pair of scissors—Absorption of the lens.*

Mary H., æt. 11, was brought to the Ophthalmic Hospital in January 1860, having eleven days previously run the point of a pair of scissors into the cornea of the left eye. The wound extended from near the upper edge of the cornea, downwards and outwards to close upon its lower margin. There was a large rent in the capsule of the lens, the whole of which was quite milky. There was very little irritation of the eye, and the child complained of no pain. The iris was adherent to the cicatrix in the cornea. She was unable to make out the outline of objects, but she had good perception of light. Ordered a fold of wet linen to be laid over the eye, and the pupil to be kept dilated by dropping two or three drops of the solution of Atropine, gr. j. ad Aquæ ℥j., into the eye twice a day.

The lenticular matter was gradually absorbed, and without a bad symptom the child recovered a useful eye.

CASE XXXV.—*Penetrating wound of the cornea with a penknife, involving the iris and lens; followed by absorption of the lens.*

Samuel G., æt. 12, was brought to the Ophthalmic Hospital in December 1861. The history of the accident was, that eight years ago he was playing with a penknife, when he thrust the blade of it into the right eye, through the cornea. From the present state of the eye, it is evident that he then cut the iris, and wounded the lens. No prolapse apparently followed, but a sharp notch at the lower border of the pupil shows that the knife had divided its circular fibres.

There is now a linear cicatrix in the cornea of about one eighth of an inch in length, to which a tag of the iris

is inherent. The whole of the lens has been absorbed, and a piece of semi-opaque lens capsule occupies the pupillary space. The free portion of the iris acts well.

CASE XXXVI.—*Wound of the cornea and lens—Complete absorption of the lens.*

Timothy D., æt. 23, came under my care at the Ophthalmic Hospital on Feb. 14, 1865.

Eight years ago the right eye was struck by a stone, which inflicted a large central wound of the cornea. The lens appears also to have been involved in the injury.

Present state.—There is an oblique linear cicatrix in the cornea, to which the outer edge of the pupil is adherent. The inner part of the pupil acts sharply and fully. All lenticular matter has been absorbed, and a piece of semi-opaque lens capsule occupies the pupillary space. This was torn through with a single needle, and the man recovered with a good useful eye.

2nd. *If the wound in the lens is complicated with injury to or prolapse of the iris*, attention must first be directed to the iris, which, if prolapsed, will require to be treated in one of the ways recommended under the heading “Prolapse of the Iris.” Frequently in cases of wound of the cornea with prolapse of the iris, the anterior chamber is so filled with blood, that it is impossible to form an immediate opinion as to whether the lens has sustained any injury. At this early stage of the treatment it is not of much consequence, for in a few days the blood will be absorbed, and a more correct examination can then be made; but in the meantime the prolapsed iris will require to be carefully attended to. Soothing applications to the eye, leeches to the temple, and absolute rest from work, with the exclusion of all strong light, must be prescribed; and if no untoward symptoms arise, the cataractous lens must be

left untreated until the eye has quite recovered from the primary shock the injury has inflicted.

3rd. *If the injury to the lens is complicated with a lacerated and contused wound of the cornea, with prolapse and contusion of the iris, and with lenticular matter protruding between the lips of the corneal wound,* active treatment is at once called for. A very careful examination should be made of an eye which has sustained such a complicated and severe injury; and if the patient is a young child, chloroform should be administered to enable this to be thoroughly done.

Such an accident is often induced by a blow on the eye with some semi-blunt instrument; I have seen it occur from a fragment of a rivet, from the eye being struck with a child's arrow, and from a common table fork. Sometimes in addition to the contusion and laceration of the parts mentioned in the heading, the force of the blow has been sufficient to cause a rupture of the hyaloid by pushing the lens backwards partially into the vitreous, and one or more beads of vitreous may be then mixed with the lenticular matter which is presenting at the corneal wound. The primary treatment should be as soon after the injury as possible, before any inflammatory products have been effused to mask the condition of the wounded parts.

The contused and lacerated iris should be snipped off with a pair of fine scissors, and all the lenticular matter which is lying between the lips of the corneal wound should be carefully removed with a curette, or sucked away with a cataract syringe. If any vitreous presents, it should be cut away with a few clips of a pair of scissors. The lids should now be closed over the eye, and a cotton-wool compress be applied, either with a single turn of a roller, or with the knitted bandage. If twelve or twenty-four hours have elapsed after the injury before the patient is

seen by the surgeon; and if, in endeavouring to remove the lenticular matter from between the margins of the corneal wound, the rest of the lens looks soft and diffuent, as much of it *as will easily come away* may be withdrawn by the syringe; but this operation should not be attempted except the patient is young, and there is reason to believe that the lens matter is sufficiently soft to be easily removed.

Leeches should be applied to the temple in anticipation of any undue action which may arise. The compress should be continued for at least twenty-four hours, when, if it is found to be hot and uncomfortable, a fold of linen wetted with a belladonna lotion may be laid over the eye in the place of it.

Opiates should be given if the patient is in pain or restless. All exposure of the eyes to light should be forbidden, and the room in which he resides should be darkened.

When the eye has so far recovered that the wound of the cornea has closed and the aqueous has again occupied the anterior chamber, a solution of Atropine (gr. j. ad Aquæ ℥j.) may be dropped twice daily into the eye. But it is useless to use it immediately after the injury, as it does not act upon the iris until after the aqueous is held within the anterior chamber. The repeated dropping of Atropine into the eye often excites irritation, when it fails from mechanical causes to dilate the pupil.

The following case is an illustration of this severe form of injury to the eye.

CASE XXXVII.—*Penetrating wound of the cornea with a fork; laceration and prolapse of the iris, and protrusion of lenticular matter through the wound.*

Thos. G., æt. 17, came under my care at the Ophthalmic

Hospital on Aug. 12, 1864, suffering from an accident he had received five days previously to the right eye. His mother stated that she accidentally jerked a kitchen fork which she was using out of her hand, and it struck her son's eye; one of the prongs tore through the cornea, dragging with it in its exit a part of the iris and wounding the lens.

Present State.—The eye is very red and painful; a jagged lacerated wound extends obliquely across the cornea from the upper and inner border to the lower and outer margin. Involved in the wound and bulging through it, so as to keep its margins from falling together, is a large portion of the iris with some glutinous lens matter; the whole prolapse being glazed over with some recently effused lymph. The anterior chamber is filled with blood, so that the extent of the lesion of the iris cannot be ascertained.

The protruding iris and lens matter were at once snipped off with a pair of fine scissors, so that the edges of the wound were then able to come into closer apposition, and he was ordered two leeches to the temple, and Lotio Belladonnæ for the eye.

Aug. 16.—The eye is more quiet and less painful. The wound of the cornea appears to be closed. The blood is being absorbed.

Aug. 19.—Nearly all the blood has been absorbed, and the injury to the iris can be now distinctly made out. There is a very extensive detachment of the iris from its ciliary border. About two-thirds of the iris has been drawn out of the eye; the only part of it remaining is the upper and inner third.

Aug. 26.—The eye is free from pain, and quiet,—all the blood has been absorbed. Some opaque lens matter and lens capsule are seen; but the greater portion of the lens escaped

from the eye at the time of the injury. The patient has only perception of light. From this date the eye progressed steadily, and recovered from all the active inflammation induced by the injury ; but on September 9, when he ceased his attendance, the vision of that eye was limited to a mere perception of light and dark. It is probable that at the time of the accident there was posterior hæmorrhage in addition to the other injuries the eye sustained.

OPERATIONS FOR THE REMOVAL OF A TRAUMATIC CATARACT.—In considering what operation is most fitted for removing a traumatic cataract, it is necessary to carefully enquire into the nature of the cataract, with which we have to deal.—1st, Whether it is a soft cataract or one with a hard nucleus but with circumferential soft matter? and 2nd, Whether the whole lens is opaque, or whether the opacity is confined to a portion only of its substance?

1. *Whether the cataract is soft or has a hard nucleus with circumferential soft matter?*—By far the greatest number of traumatic cataracts are occasioned by a direct wound of the capsule of the lens, involving also the lens substance : the aqueous is thus freely admitted, and its action on the lens tissue occasions the opacity. It macerates, softens, and renders opaque all the lens fibres with which it comes in contact. In the soft lens of a young person this process, which commences on the surface, rapidly extends throughout the whole until a complete soft cataract is formed. Under the ages of from 35 to 40 years, a wound of the lens will induce a soft cataract, for the nucleus of the lens is not yet so dense but that it is easily acted on by the aqueous humour. After that period of life, although a cataract is rapidly formed from an injury to the lens, yet the lenticular matter is not macerated and softened down in the same rapid manner by

the aqueous; and although the circumferential part of the lens may become soft, yet there remains behind a nucleus more or less hard, upon which the aqueous can only slowly exert its solvent power. Now as the large majority of accidents to the eye happen to young people, certainly in patients under from 35 to 40 years of age, it may be safely asserted that the majority of cases of traumatic cataract are soft. It is always of importance to distinguish whether the cataract is completely soft, or whether it has a hard nucleus; for the operation which would be applicable to the one would be unsuited for the other. When the cataract is completely soft, it may be treated by either a linear extraction, or a suction operation; but when the nucleus is hard, either of these operations would be improper, and a traction operation would be better suited.

2. *Whether the whole lens is opaque, or whether the opacity is confined to a portion only of its substances?*—The answer to this question will materially influence the preliminary steps of the operation. When the opacity is limited to a part of the lens, we can only deal with precision with that which is opaque and visible to our eyes. If in such a case an attempt should be made to remove the lens at one operation by linear extraction or suction, a quantity of transparent lens matter will be left behind, the amount of which must be to a great extent conjectural. But this is not the only difficulty which a partial opacity creates, for the transparent lenticular matter before it has been acted on by the aqueous and rendered opaque, is gummy and tenacious, it adheres to the lens capsule and it cannot be completely disengaged from the eye; whereas the opaque portion which has undergone a certain amount of maceration, is diffuent and non-adherent, and readily escapes along the groove of the curette or up the tubular portion of the syringe. It is advisable therefore that the whole

lens should be opaque before an attempt is made to remove it.

If a linear extraction or suction operation is called for when the opacity of the lens is found to be limited, a needle operation should be first performed, and a few days' interval allowed in order to make opaque and diffuent that portion which is still transparent and sticky.

In describing the operations which may be resorted to for the removal of a traumatic cataract, it will be convenient first to consider the different methods employed for the treatment of a soft or congenital cataract. Each is applicable to the traumatic form, but the choice of the operation must depend on the special circumstances which almost seem to individualise each case.

LINEAR EXTRACTION OF CATARACT.—The operation known as Gibson's, from the late Mr. Gibson of Manchester having first suggested and performed it, is now recognised and practised with some slight modifications, under the name of linear extraction.

It is well adapted to a large majority of the cases of soft cataract, but it is an operation which requires great care, and great delicacy of manipulation. The whole chance of success depends on the manner in which the different steps are performed, and on the careful fulfilment of every detail. It has been said that this operation is not nearly so successful as that known as keratonyxis, or solution of the lens by allowing the aqueous to permeate its interior through a small puncture of its capsule. Possibly there may be truth in this assertion, but I believe that a large amount of the failures have depended on a want of a due appreciation of the difficulties which beset linear extraction, and a consequent neglect of the precautions necessary for a proper performance of it.

The operation may be divided into two stages :

1st. To break up the anterior capsule of the lens, so as freely to allow the aqueous to act on the lenticular matter.

2nd. To remove, by a small opening in the cornea, the broken-down lens from within the eye.

Prior to performing the operation, the pupil should be fully dilated with atropine, so that the whole of the lens may be under the observation of the operator, and the iris may be drawn away as far as possible from the chance of injury.

The first stage of the operation is to break up with a fine needle two-thirds of the anterior capsule of the lens ; and by carefully moving the needle through the soft lenticular matter, so to comminute it that every portion of it may be brought into contact with the aqueous.

1st. Great care must be taken not to injure the posterior layer of the capsule of the lens, as by so doing the hyaloid membrane will be ruptured, and the vitreous mixing with the particles of the lens will materially interfere with the due action of the aqueous humour on them, and also render more difficult the second part of the operation.

2nd. In breaking up the anterior capsule with the needle, there is danger, if it be tough, of rupturing the suspensory ligament of the lens, so that the lens with its capsule will be freely moved at the point of the needle.

3rd. It is of the *utmost* importance not to bruise the iris in the frequent movements of the needle.

4th. The aqueous humour must be maintained within the anterior chamber, until the termination of the operation.

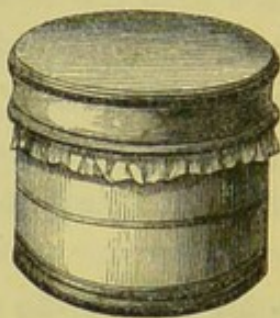To fulfil all these objects, this, the first part of the operation, may be performed as follows.

The patient should lie on a couch, with his face towards the window, the pupil of the eye to be operated on having been previously thoroughly dilated with atropine. The

surgeon should stand behind the head of the patient. The needle, fig. 32, to be used should be a fine one, FIG. 32. with a short spear-shaped point, to allow of an easy entrance. The shaft should be perfectly cylindrical and slightly conical—that is to say, slightly thicker two or three lines from the point than at the point itself, and highly polished. Tried upon the drum, fig. 33, it should perforate without sticking, and on attempting to withdraw it, should raise the leather with it. In short it should fill the aperture which it makes in the cornea so completely, that no aqueous humour can escape until its withdrawal from the eye at the finish of the operation.



FIG. 33.



The lids being kept apart by a spring speculum, the needle is made to perforate the cornea obliquely, one or one and a half lines within its margin, so that during its movements, it may not in any way injure the iris. Mr. Bowman is very urgent on the advisability of penetrating the cornea well within its margin, and of the great importance of keeping the iris untouched during the operation. The distance within the cornea, at which the needle should enter, will depend partly on the extent of dilatation of the pupil, as if it is not very widely dilated, the needle should be made to perforate nearer the centre.

Different operators follow different plans of breaking

up the anterior layer of the capsule of the lens. The object to be attained is, to tear up the anterior two-thirds of the lens capsule, without inflicting any injury on its posterior layer; to destroy in fact that portion of it which occupies the pupillary area, even when the pupil is slightly dilated.

One method is, after having introduced the needle, to endeavour to destroy a given portion of the anterior layer of the capsule, within the pupillary space, by a series of movements of the point of the instrument from the circumference towards the centre, thus tearing it through by a number of radiating lines, and then by a semi-rotatory or stirring motion to break up the lenticular matter, and urge it as it were forwards into the anterior chamber.

A second mode of proceeding is to act first on the central portion of the anterior layer of the capsule, and to proceed gradually towards its circumference.

A third method is merely to prick the capsule very freely at many points, first making a series of punctures around the circumferential border, and then two or three in the central part, so as to allow the aqueous to well in, and act upon the lens matter.

The first action of the aqueous humour on the lenticular matter is to render all that which is transparent opaque; and in so doing to cause it to swell and occupy more space; then it acts as a solvent, gradually melting it down, prior to its absorption.

After the operation is completed, the needle is withdrawn from the eye; and the pupil is to be kept widely dilated with atropine. The patient should be in a darkened room, but not in bed, and a solution of Atropine of the strength of gr. ij. ad Aquæ ℥j., should be dropped into the eye twice a day.

As a rule, no urgent symptoms follow the first stage of

the operation of linear extraction. Frequently some little irritation exists for a few days, but oftentimes the eye remains so quiet, that one can hardly imagine that any operation has been performed. Still on the other hand, grave symptoms occasionally arise and require to be actively dealt with; for an eye with a congenital cataract is usually below the standard of strength, and succumbs quickly to sharp inflammatory action.

Supposing the operation to have been well conducted, and the case apparently a good one, the great cause of untoward symptoms arising is the pressure of the swollen lens itself, or of some of its particles, on the posterior surface of the iris. Large pieces of lens matter may float freely in the anterior chamber,—may even apparently almost fill it, and fragments may lie on the anterior surface of the iris, without producing any unpleasant symptoms; but the pressure of even a portion of the lens on its posterior surface, may act as such an irritant as to kindle an amount of inflammatory action sufficient to destroy the eye. To avoid as far as possible the chance of such a contingency, the pupil should be kept widely dilated with atropine, so that the particles of lens matter, as they swell and detach themselves from the capsule, may float through the widely dilated pupil into the anterior chamber. Sometimes, although the capsule has been freely broken on its anterior surface, yet if the lenticular matter has not been sufficiently comminuted, the lens, as it becomes swollen by the aqueous, may be unable to discharge itself by fragments into the anterior chamber, and may press by its entire surface on the back of the iris, and thus become the source of great irritation.

The reverse of this may however take place. The lenticular matter may have been freely broken up, but the aperture in the lens capsule may not have been made

sufficiently large to allow of the ready escape of the particles after they have become swollen by the aqueous, and so the enlarged lens may press on the posterior surface of the iris.

The symptoms which would be present in such cases would be those of great irritation; severe neuralgia over the brow, around the orbit, and in the eye itself, with a considerable amount of photophobia: the eye more red than normal, and the ciliary zone of vessels manifest; the aqueous muddy, and the pupil at first sluggish, then quite inactive, and unaffected by atropine. Such symptoms as these call for immediate treatment; if they commence a few hours after the operation, or on the following day, it will be well to apply one or two leeches to the temple, and repeat them in twelve or twenty-four hours if necessary. This local abstraction of blood often affords a most speedy relief, and at once arrests all excessive irritation. Act freely on the bowels with some moderate purgative, and keep the eye cool with a piece of linen moistened with cold water applied over it, and let the room in which the patient resides be kept darkened. If no abatement follows this treatment, but the symptoms of irritation continue, it is then advisable to remove at once the lens, or as much of it as possible, by performing the second part of the operation of linear extraction.

The second stage of linear extraction consists in removing the broken-down lens through a small linear opening in the cornea. Before it is attempted, if nothing has happened since the first operation to necessitate its immediate performance, sufficient time should be allowed to elapse for all the transparent portions of the lens to become opaque, and somewhat macerated by the aqueous. From three to six days will be about the time required for the

desired changes to take place, but much depends on the condition of the cataract at the time of the operation, and upon the extent to which the capsule has been torn, and the lenticular matter broken up. This stage of the operation requires great caution.

1st. As to the part of the cornea through which the broad needle should be introduced, and the mode in which the opening should be made in the cornea.

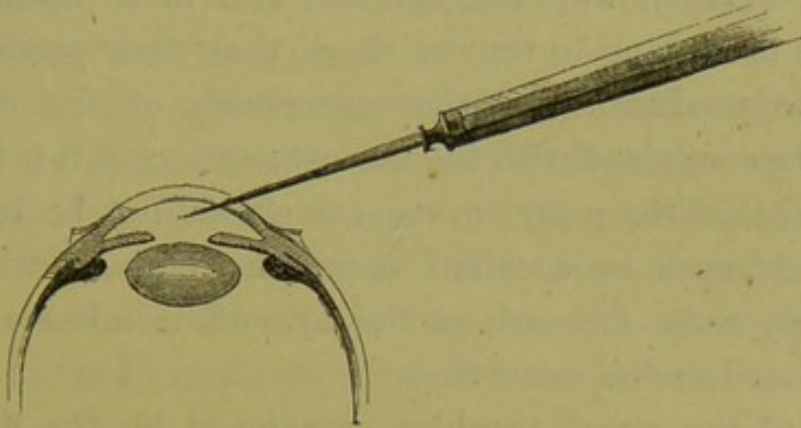
2nd. In allowing the lens which is now diffuent to run off on a curette, taking care not to bruise or in any way to injure the iris, or the posterior layer of the lens capsule.

The patient should lie on his back on a couch, with his face towards the light; the eye should be kept open by a spring speculum, and steadied by the operator with a pair of forceps. The broad needle should be used in the right hand of the surgeon for the right eye, and in the left hand for the left eye, to make the linear opening in the cornea. The outer portion of the cornea is the most convenient, and the part usually selected in each eye for the incision about to be made.

With reference to the opening to be made in the cornea.—The pupil being widely dilated with atropine, the needle should be made to perforate the cornea at the point just external to where the pupillary margin of the iris is seen, and instead of penetrating it directly from before backwards, it should be made, as Mr. Bowman has suggested, to pass obliquely inwards, through the lamellæ of the cornea, as in fig. 34, and then by a slight cutting motion in its withdrawal, to enlarge the opening to its necessary size. The aperture thus made will be valve-shaped, the external opening in the cornea being nearer to the circumferential margin than the internal, the object being, that the curette in and after its introduction shall not

press at all upon the iris; but in making the many movements which are required, shall rest solely on the inner lip of the valve-shaped orifice in the cornea. Frequently before withdrawing the broad needle, it may be well to dip it towards the lens, and break up more completely any


FIG. 34.



large fragments which may remain. Another advantage in thus making the opening well within the margin of the cornea is, that prolapse of the iris does not occur; whereas, when the linear incision is made close to the corneal margin, a protrusion of the iris is very apt to follow the aqueous, as it runs off with the soft lens on the curette.

A sufficient opening having been made, the curette, fig. 35, is next to be introduced, and this should be done with a gentle lateral motion. The eye being still held by the surgeon with a pair of forceps in the most convenient position, the curette is moved gently from side to side, pressing slightly on the mouth of the wound, to permit the aqueous with the softened lens to flow down its groove. When the largest portion of the lenticular matter has escaped, small opaque pieces will occasionally be seen which have not flowed away in the stream; these may be followed by the curette, and on the

FIG. 35.



point of it being dipped beneath them, they will also escape along its groove.

When the pupillary space is clear, it is advisable not to be too eager to get away every little bit of opaque soft matter which may be left, as oftentimes some small fragments will be seen still lying on the front of the iris, difficult to reach with the curette; and more harm may be done in seeking to remove them, than their presence is likely to produce. All the movements of the curette should be conducted with the utmost caution, as it is highly essential that the posterior capsule should not be broken, for should such an accident occur, the vitreous will immediately come forward, as the hyaloid membrane must be ruptured at the same time.

One of the great troubles occasioned by the flowing forwards of the vitreous is, that mixing with the opaque portions of the lens which have evaded the curette, it becomes often next to impossible to remove them, as, coated with the tenacious vitreous, they elude the point of the curette, and instead of falling into its groove, and escaping by it, they are pushed about the anterior chamber in front of it.

The lens having been removed, or as much of it as will readily flow away, the patient is to be sent to bed in a darkened room, and the pupil is to be kept under the influence of atropine. This is generally necessary, as it is very common to leave behind some soft matter, which not having been acted on by the aqueous, remained transparent at the time of the operation, and so escaped the notice of the operator. If towards evening there is pain, one or two leeches should be applied to the temple, and may be repeated if it continues. This small abstraction of blood has often a most beneficial effect in arresting any untoward symptoms which may present themselves at this early period after the operation.

The pain in the eye increasing will call for warm and soothing applications, and of these the belladonna fomentation will afford the most comfort. If the eye should become hard, its normal tension being increased, a puncture of the cornea may be made with a broad needle, so as to allow the aqueous to escape. It frequently gives immediate relief, and may be repeated if the glaucomatous symptoms recur.

Iritis is the affection most to be dreaded after this operation. Its presence is suspected by a continuance of pain in and around the eye, but an examination of the eye itself will at once confirm or refute the suspicion. The serous aqueous, the muddy iris, and the ciliary zone of vessels around the cornea give evidence of internal inflammation.

There is an *acute* and a *chronic* form of iritis, which occasionally follows the operation of linear extraction.

The acute iritis may run its course in a few days and destroy the eye, or it may gradually subside to a certain point, and then become chronic.

The chronic form, as a rule, commences from one to three weeks after the operation, and is the cause of great trouble to both the surgeon and patient. It is always accompanied with photophobia and lachrymation, and the edges of the lids often become puffy, thickened, and excoriated. The aqueous continues serous, and the striation of the iris indistinct. The pupil is but slightly and irregularly acted on by atropine, and there is a slow dull pain in the eye. This chronic condition will last frequently many weeks, and it yields but slowly to treatment. Counter-irritants behind the ear repeated from time to time sometimes do good, but as a rule, all applications to the eye should be soothing, and the treatment tonic.

Belladonna in one form or another should be applied to the eye to relieve pain, and to keep the pupil dilated, and occasionally a moderate mercurial inunction may be necessary.

EXTRACTION OF SOFT CATARACT BY SUCTION.—This method of removing a soft cataract was reintroduced by Mr. T. Pridgin Teale, Junr., of Leeds, who suggested the operation, and performed it with success in December 1863, on a young man who had a traumatic cataract, quite unconscious at the time of the antiquity of the proceeding he was adopting, or even of the operation having been ever practised before by other hands.

Mr. Teale has since published a pamphlet on "The Extraction of Cataract by Suction," and also a paper on the same subject in the Royal London Ophthalmic Hospital Reports, vol. iv. p. 197, in both of which he has given a short account of the operation, and of the previous attempts to apply the principle of suction to the extraction of cataracts. He states that:—

"According to Avicenna a similar proceeding (viz., excision of cataract, by opening in the cornea and drawing out the cataract by means of a needle) was practised by the Persians in the 4th century, and Albucasis reports that the procedure was gradually displaced by the 'suctions-methode,' in which the cataract was sucked out through a hollow needle." ("Arlt. Krankheiten," vol. ii. p. 352. Prag. 1863.)

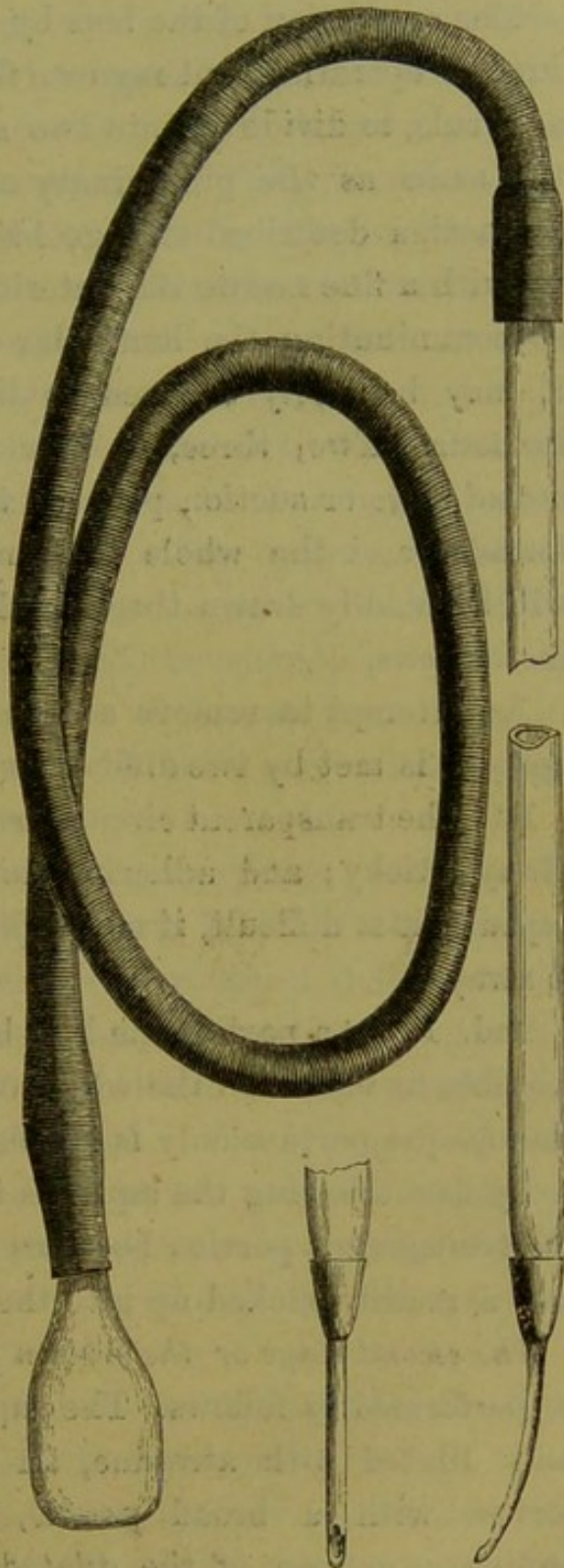
In an American edition of Lawrence's Treatise on Diseases of the Eye, 1854, pp. 733, edited by Isaac Hays, M.D., there is the following notice of a suction operation:—

"*Operation by suction.*—M. Blanchet has lately promulgated a new method of operating upon soft cataracts, which

he denominates the operation of suction (*par suspiration*). The pupil having been dilated with belladonna, he punctures the cornea with a large cataract needle toward its circumference, in order that the opacity which follows may not occur in the field of vision. Through this opening, he introduces a small tube with a flageolet-like mouth, attached to an Anel's syringe, with which he pierces the capsule of the lens, and if the cataract is soft, he pumps it out through this tube by working the piston of the syringe; but if, on the contrary, the lens is hard, or the capsule is dense and opaque, he then has recourse to depression."

In the instrument devised by Mr. Teale, fig. 36, the suction power is applied by the mouth of the operator. It consists of a glass tube of the exact size as that represented in the drawing, to one end of which is

FIG. 36.



fastened a tubular curette, whilst to the other extremity is attached a piece of india rubber tubing with a glass mouthpiece.

The extraction of the lens by suction may be completed in one operation, but my own feeling is that it is better, as a rule, to divide it into two stages. The *first stage* is the same as the preliminary needle operation for linear extraction described at page 145. It consists in tearing up with a fine needle the anterior capsule of the lens, and so comminuting the lenticular matter, that every part of it may be freely exposed to the action of the aqueous humour. Two, three, or four days having elapsed, the *second stage* or suction part of the operation may be performed, and the whole lens, now opaque and diffuent, will be readily drawn through the tubular curette of the instrument.

An attempt to remove a lens which is not completely opaque, is met by two difficulties:—

1st. The transparent circumferential portion of the lens is always sticky; and adhering to the inner surface of the capsule, it is difficult, if not impossible, to get the whole of it away.

2nd. From a part of the lens being transparent it is impossible to say when the whole of it has been removed, as the opaque portion only is visible to the operator.

By first allowing the aqueous to act on the lens matter, the transparent portion becomes opaque, loses its tenacity, and is readily sucked up into the tube.

The second stage or the suction part of the operation may be performed as follows. The pupil having been previously fully dilated with atropine, an opening is made in the cornea with a broad needle, immediately within the pupillary margin of the dilated pupil, sufficient in size to allow of the *easy entrance* of the tubular curette. A

delicate manipulation of the instrument is required to move it from point to point, so as to place the open mouth of the curette in the most favourable positions for sucking in the lens matter, without in any way injuring the iris. The suction power must be carefully regulated by the operator, who is able to arrest it instantly if necessary.

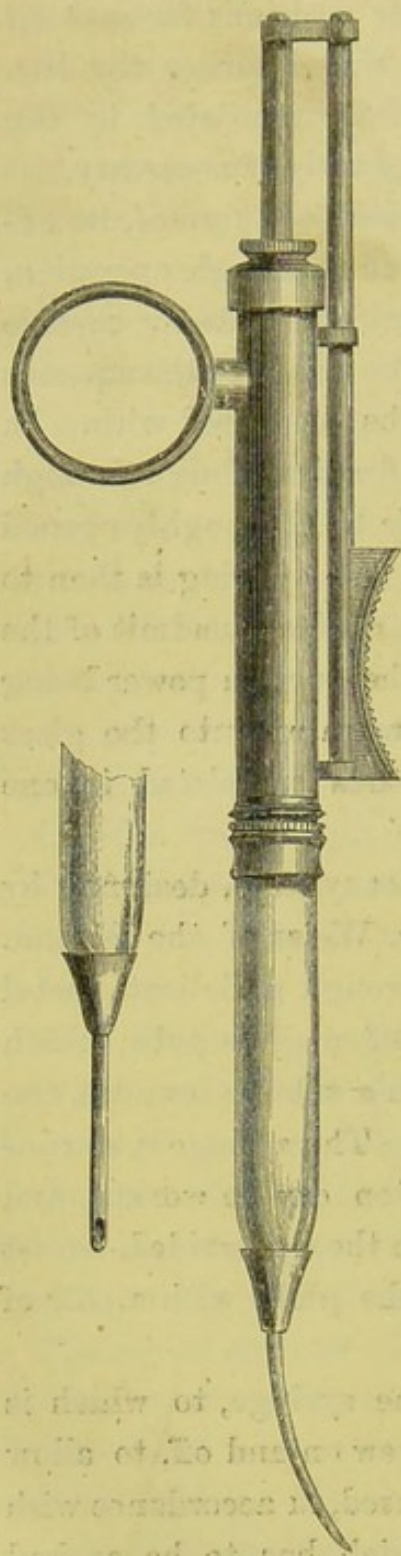
Should the cataract be *very soft and fully formed*, its extraction by suction may be completed in a single operation, and the preliminary stage of opening the anterior capsule and submitting the lens matter to the action of the aqueous for a certain number of days may be dispensed with. In such a case a fine needle should be first introduced through the cornea, and the anterior capsule be thoroughly opened and the lens matter broken up. A free opening is then to be made in the cornea with a broad needle, to admit of the easy entrance of the curette, and the suction power being applied, the opaque lens may be drawn up into the glass tube, and the operation may be thus completed in one sitting.

Fig. 37 is a very excellent cataract syringe, designed by Mr. Bowman and made by Messrs. Weiss of the Strand. The suction power is obtained through a delicate metal syringe placed at one extremity of a glass tube, which is furnished at the other end with a tubular curette, the aperture of which is countersunk. The syringe is so contrived, that with one hand the piston can be worked, and the movements of the curette within the eye guided, whilst the other hand is left free to fix the globe with a pair of forceps.

The glass tube at the end of the syringe, to which is fastened the curette, is made to screw on and off, to allow of currettes of different sizes being used, in accordance with the consistence of the cataract which has to be sucked out.

The drawing differs in one respect from the instrument

FIG. 37.



used by Mr. Bowman in having a ring attached to its side, through which the index finger can be passed, so as to steady the syringe, whilst the thumb on the concave rest moves the piston rod.

In applying the operations of linear or suction extraction to the treatment of traumatic cataracts, the state of the opaque lens will determine whether its removal can be completed in one operation, or whether it will be best to divide it into two stages.

If the capsule of the lens has been already ruptured by the injury, and the whole lens is opaque, having been well macerated by the aqueous, it will be unnecessary to perform the first stage of linear extraction. An attempt may be at once made to remove the lens, either by means of the curette, or with the suction syringe.

But if notwithstanding that the capsule has been torn and a large portion of the lens is opaque, it is evident, on a careful examination, that much remains which is transparent:—in such a case, the needle operation must be performed, and an

interval of some days be allowed to elapse before an attempt is made to extract the lens.

The operations of linear or suction extraction may be performed in the following cases of traumatic cataract, provided there is no reason to expect that the opaque lens has a hard nucleus.

1st. If all the acute symptoms occasioned by the injury have subsided, but a chronic irritable state of the eye continues, and it is probable that this is kept up by the presence of the swollen lens constantly pressing on the iris; then it is best to remove it without delay. By thus getting rid of the source of the irritation the eye will be placed in a condition more favourable to recovery.

I believe that it is always wise, if possible, to wait until the eye has recovered from all the shock occasioned by the primary injury, before making any attempts to remove the cataract; until, in fact, all dread of light and all redness of the conjunctiva have subsided. It is only when special symptoms arise which may be attributable to the presence of the swollen lens acting injuriously on the eye, that this rule should be departed from.

2nd. If, after all irritation of the eye has ceased, little or no progress is being made towards the absorption of the cataractous lens, it is advisable to adopt some operation for its removal, and either linear extraction or suction may be had recourse to. It is better as a rule in such cases to get away what remains of the lens rather than to perform a needle operation with the hope that the process of absorption will be thus rekindled.

The frequent lighting up of an increased vascular action within the eye by repeated pricking operations, and the long continuance of this extra-vascular state during the somewhat slow process of solution and absorption, are very apt to produce more ultimate mischief than the one larger

operation, which at once disposes of the opaque lens, and removes from the eye the great source of anxiety.

There are, however, certain cases of traumatic cataract where neither linear extraction nor the suction operation are suitable, but which may be well treated either by the traction operation or by an operation in which an iridectomy is first performed, and then the softened lens or what remains of it is removed either by the curette or by the cataract syringe.

THE TRACTION OPERATION is one which has been very largely employed and with great success during the last four years for the removal of the ordinary senile cataract, and for certain other cases of cataract in which complications have rendered the extraction by a large corneal flap inadmissible. As in the two former operations, linear and suction extraction, I will first describe the mode of performing the operation, and then briefly classify the cases which seem to me to be specially fitted either for it or for a modification of it.

In the traction operation the object is, to draw the opaque lens out of the eye through a slit-like opening, in preference to the large incision with a corneal flap, which was made in the old extraction operation. A portion of the iris is removed at an early stage of the operation, so as to avoid that contusion or laceration of its structure to which the introduction of instruments within the eye for the withdrawal of the lens would expose it.

This operation was first originated by Von Graefe for those forms of traumatic cataract where the nucleus was too dense to be easily removed by linear extraction. His assistant, Dr. Schuft (now Waldau), extended the application of this operation to cases of ordinary cataract, and designed a series of scoops for the drawing out of the

opaque lens from the eye. His description of the operation is published in the Royal London Ophthalmic Hospital Reports, vol. iii. page 159, under the title of "*The Out-scooping of Cataract.*"

Since then the details of this operation (now known as the traction operation) have been modified, and two very clear descriptive papers have been written on the subject by Mr. Critchett and Mr. Bowman in vol. iv. of the Royal London Ophthalmic Hospital Reports.*

The Operation.—The patient having been placed on a couch with his face towards the light, a spring stop speculum is introduced between the lids, so as to separate them to the proper extent. The operator stands at the head of his patient, and with his left hand he fixes the eye with a pair of forceps, which he makes take firm hold of the conjunctiva and subjacent fascia, just below the centre of the lower margin of the cornea, at the point directly opposite to that where he wishes to introduce the point of his triangular knife. With the right hand he makes the incision into the upper border of the cornea with a lance-shaped iridectomy knife, fig. 25, p. 106, causing it to enter that structure at the corneo-sclerotic junction, and passing it downwards, and very slightly forwards across the anterior chamber, nearly up to the extremity of the broad end of the blade, taking care on the one hand not to wound the lower border of the iris, or, on the other, to scratch the inner surface of the cornea. The opening should always be made sufficiently large to allow of the easy introduction of the scoop, and the ready escape of the lens. The failing in this requisite is one of the commonest

* On the Removal of Cataract by the Scoop-method, or the Method by Traction, by George Critchett: Royal London Ophthal. Hosp. Reports, vol. iv. p. 315.—On Extraction of Cataract by a Traction Instrument, with Iridectomy; with Remarks on Capsular Obstructions and their Treatment, by William Bowman, F.R.S.: Royal Lond. Ophthal. Hosp. Reports, vol. iv. p. 332.

causes of failure of success in this operation. If the aperture is found on the withdrawal of the knife not to be ample enough, it should be enlarged laterally by a pair of scissors. The size of the opening should be determined by the nature of the lens to be extracted from the eye; an old and hard lens requiring a more free incision than one with a hard nucleus, but with a soft surface. The opening into the cornea may be made at any part of its circumference; but it should always, if possible, be in the upper border, so that the iridectomy may be made directly upwards, as in this direction the deformity of the pupil will be covered by the upper lid, and by it the size of the pupil for the admission or exclusion of light will to a great extent be regulated.

The operator should now let go his hold of the forceps which fixed the globe, and hand them over to his assistant to rotate the eye a little downwards if necessary, and to keep it steady whilst he excises a portion of the iris. This he does by introducing a pair of iris forceps (fig. 26, p. 107) through the wound, and seizing the iris with them near its pupillary border draws out a portion of it, and cuts off as much as he desires with a pair of fine scissors. If the iris has already prolapsed through the corneo-sclerotic incision, as it frequently does, he has only to take hold of it with the iris forceps, whilst he removes a piece of it with the scissors.

If there is any bleeding into the anterior chamber either from the cut iris or from blood trickling in through the wound from the divided conjunctiva, it is well to wait for a few minutes, and to get it away before proceeding to the second step of the operation. This may be easily accomplished before it is coagulated. In most cases the mere introduction of the point of the curette between the lips of the corneal incision is sufficient to cause the fluid blood to

flow from the anterior chamber. If this, however, fails, the plan sometimes adopted by Mr. Bowman is almost certain to succeed. He introduces the end of the curette just within the corneal section, and with it presses slightly on the sclerotic edge of the wound, whilst at the same time he seizes the tendon of the inferior rectus and gently pulls upon the globe, so as to exercise a slight pressure.

The second stage of the operation is to tear through the capsule of the lens. This is to be done with an ordinary pricker, fig. 38, or with Von Graefe's fleam-cystotome, fig. 39.

The point of the instrument should be introduced sideways through the section, so as to avoid the chance of

FIG. 38.



THE ORDINARY PRICKER.

FIG. 39.



GRAEFE'S FLEAM-CYSTOTOME.

its catching in the wound, or scratching the inner surface of the cornea, and then turning it upon itself, so that its point comes into contact with the lens, the capsule should be freely torn.

The third stage of the operation is the withdrawal of the lens from the eye. This is to be done by gently introducing the traction instrument through the wound, using scarcely any perceptible force, but urging it as it were onwards, if it seems inclined to hitch; by one or two slight lateral movements, directing it at the same time first a

little backwards, so as to insinuate its extremity between the posterior surface of the lens and its capsule, and then downwards and slightly forwards, allowing it almost by its own weight to follow the posterior curvature of the lens. Having secured the lens within its grasp, the instrument is to be gradually withdrawn, slightly depressing its handle during this movement, so as to draw the lens with it out of the eye. If the whole lens, as occasionally happens, is brought out with the first withdrawal of the instrument, the operation is completed. Generally, however, some soft lenticular matter is left behind, and sometimes some fragments of the nucleus which have become detached. A cataract spoon must now be used to bring away all the lens matter which remains. It is always advisable to remove as much as possible of that which has been left behind, and especially any hard or chippy fragments; but if a little soft sticky lenticular matter is seen occupying the pupillary area, and one or two endeavours have failed to catch it in the spoon, it is better to leave it rather than to run the risk of doing injury by the too frequent attempts to get it away. The fewer times the spoon is introduced within the eye the better for the patient. Before finally closing the eye, see that the edges of the corneal wound lie well in apposition, and that no particles of lens matter are in the angles of the wound or between its lips. The lids may now be closed, and a light pad with a knitted bandage should be fastened across the eyes.

The instruments which are requisite for the withdrawal of the lens from the eye in the 3rd stage of the traction operation are :

1st. A traction instrument to pass between the posterior surface of the lens and its posterior capsule, with which the nucleus and generally a large portion also of the remainder of the lens are brought away on its first withdrawal from the eye.

2nd. A small spoon for the removal of any soft lenticular matter which may remain after the nucleus has been taken away.

For the accomplishment of the first object, Mr. Critchett has devised one and Mr. Bowman two instruments, all of which perform the work required of them very well. FIG. 40.

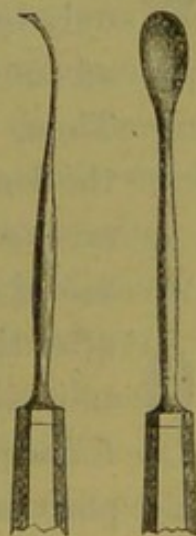
Fig. 40 shows the front view of Mr. Critchett's spoon. It consists of a thin oval plate of silver at the end of a stem, slightly curved from end to end to enable it to accommodate itself during its introduction to the posterior curve of the lens. Its extreme edge is bent upon itself so as to form a thin wedge, which not only facilitates the passage of the instrument, but on withdrawing it causes it to fix itself by its free edge into the part of the lens with which it is brought into contact, and thus to hold it firmly whilst the instrument is being withdrawn from the eye.



Mr. Bowman has designed two instruments, which he employs under different circumstances in the traction operation.

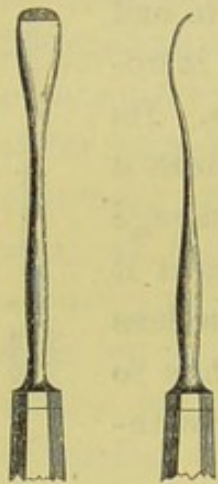
The following is the description of them given by Mr. Bowman in his paper on "The Extraction of Cataract by a Traction Instrument," published in the Royal London Ophthalmic Hospital Reports, vol. iv. p. 350. FIG. 41. FIG. 42.

Figs. 41 and 42 represent a front and side view of one of the spoons. "The body of the spoon is very nearly flat from side to side, a little concave forwards from end to end; and the incurvation of the extreme end is in fact a continuation of this concavity, though inclined to it at an obtuse angle. Where the end joins the sides of the spoon, this incurvation gradually



ceases, and the sides, except towards the end, have no edge above the general level. The whole is as thin as possible consistent with due rigidity, and the breadth about half or a third of that of the lens. The stem is slightly curved, to adapt it to the position of the brow, across which it has to work in the ordinary iridectomy upwards."

FIG. 43. FIG. 44.



Figs. 43 and 44 are the front and side view of the other spoon Mr. Bowman has devised, and which he considers preferable "where, from the entire absence of soft matter, there is the least room for the insinuation of an instrument between the lens and its capsule, and where therefore it should occupy the least possible space. This form is nearly flat from side to side, and but slightly concave from end to end. The end has a very thin, though not a sharp edge, only slightly incurved, and the concave surface at the end is roughened by transverse lines. It is thus fitted to insert itself readily between the nucleus and



posterior capsule, particularly if poised, as it were, only by the thumb and a single finger, and made to advance with a gentle laterally wriggling motion. Then, when the handle is lowered, its end rises in the lens-substance beyond the nucleus, and obtains an excellent hold on it for its extraction." For the removal of any soft lenticular matter which may remain after the nucleus has been taken away, one of Schuft's (now Waldau's) smallest spoons (fig. 45) will be found very convenient. Mr. Bowman, however, for this purpose generally uses one of his own spoons (figs. 41 and 42), with which he often commences and completes the operation of drawing out the lens.

The cases of traumatic cataract which are specially suited for the traction operation, or for an operation in which an iridectomy is performed previous to the use of the curette or the syringe, are :

1st. Traumatic cataracts occurring in patients after 35 or 40 years of age. At this period of life the nucleus becomes more dense, and is not so easily acted on by the aqueous as in younger people. It is best therefore to perform such an operation, that should the nucleus be found too firm to come away by suction or to escape on the curette, it may be easily lifted out by a cataract scoop.

2nd. Where the iris has been involved in the injury and only a very small pupil remains, one margin of it perhaps adherent to the lens capsule, and the other to the cicatrix in the cornea; where indeed an artificial pupil would be necessary both for the convenient extraction of the lens, and also for the improvement of sight after the lens has been extracted.

3rd. In eyes which are suffering from what may be called traumatic glaucoma, a condition which occasionally comes on after a severe injury in which the lens has been implicated. The tension of the globe becomes increased, and the iris is pushed forwards by the swollen lens. In such an eye the removal of the enlarged lens would probably arrest the symptoms, as indeed I have seen it do on several occasions; but if the iris has been carried much forwards, so as to lie close to the cornea, it is almost impossible to extract the lens without inflicting some injury to the iris. One of two courses may then be followed: either perform an iridectomy and leave the extraction of the lens to a future period, or else, after having removed a portion of the iris, complete the operation by getting away the lens, if it is sufficiently soft, with a curette or suction instrument; or if there is a dense nucleus, with a cataract spoon.

4th. In cases of fistula of the cornea associated with traumatic cataract, an iridectomy should be made opposite that portion of the cornea which is the least affected by the injury, and the opaque lens may be then removed by one of the methods already described.

Lastly. When a wounded lens is rapidly swelling and causing great irritation of the eye, but the whole of it is not opaque, an iridectomy should be performed, and that portion of the iris should be excised which appears to be most pressed upon by the swollen lens. The extraction of the opaque lens should be deferred until a future period, when the eye has completely recovered from the shock of the injury.

VON GRAEFE'S MODIFIED LINEAR EXTRACTION OPERATION FOR CATARACT.—The following is an extract from a translation of Von Graefe's paper on this subject* by Dr. A. Samelson of Manchester, which appeared in the Ophthalmic Review, vol. iii. p. 7. †

“The patient being placed on the couch, the lids separated by an adjustable speculum—I prefer the one re-
 FIG. 46. commended by Critchett—and the eyeball drawn downwards by spring forceps, which are applied immediately below the cornea, the operation is commenced.



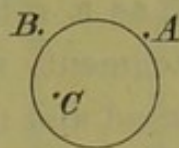
“STEP I. *The Incision.*—The point of a small knife (fig. 46), the cutting edge being directed upwards and the surface forwards, is inserted at the point *A* (fig. 47), so as to enter the anterior chamber as peripherally as possible. In order to widen the extent of the inner wound, the point should at first not be directed towards *B*, *i. e.* the point of counter-puncture, but rather towards *C*; only when the

* Archiv für Ophthalmologie, 1865, xi. Jahrgang, 3. Band, p. 1.

† “This translation has been revised by Professor v. Graefe.—Eds. of O. R.”

knife has advanced fully three lines and a half within the visible portion of the anterior chamber should the handle be lowered, and the instrument directed along the scleral border, on to *B*. As soon as the resistance to the point is felt to be overcome, showing the counter-puncture to be accomplished, whether the uplifted conjunctiva be transfixed or not, the knife must immediately be turned steeply forwards, the back of it being almost directed to the centre of the ideal sphere of the cornea, when the incision is to be continued in this plane, first by boldly pushing the knife onwards, and then, after its length is exhausted, drawing it backwards. Should this latter movement, though generally sufficient, fail completely to divide the scleral border, the sawing manoeuvre must to a less extent be repeated. As soon as the last bridge of the scleral border is cut through, the knife lies freely moveable under the uplifted conjunctiva, which, in order to avoid the formation of too long a flap—the proper height is $1\frac{1}{2}''$ – $2''$ —must now be divided by a sawing movement horizontally forwards, or even forwards and downwards.

FIG. 47.



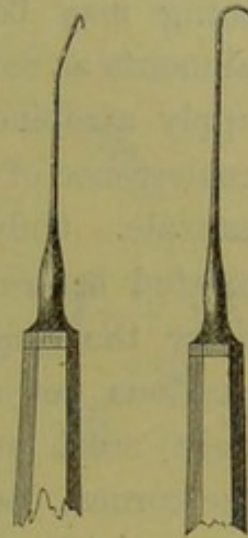
“STEP II. *The Iridectomy*.—The holding forceps having been handed to an assistant, with a straight pair of iridectomy forceps—I use a very small pattern—we lift the conjunctival flap off the prolapsed iris; the former, merging as it does into the limbus, and there being, from the previous extensive loosening, no further resistance sideways, is easily reflected down over the cornea, when the iris appears perfectly bare. Hereupon the prolapse of the iris is seized with the same forceps at its central and most vaulted portion; it is gently pulled upon so as to make it present a triangular shape, and excised at its base from one corner of the wound to the other, to which end usually two slight strokes of the scissors are required.

“STEP III. *Dilaceration of the Capsule.*—The operator, having resumed the fixing forceps, now with a cystotome properly bent, and which is armed with a fleam, opens the capsule by two successive rents, beginning from the lower edge of the pupil, and ascending successively along its nasal and temporal margins, near to the upper equator of the lens.

“STEP IV. *Evacuation of the Lens.*—The mode of evacuating the lens varies according to the amount of soft surface matter. Where there is plenty of it, the delivery is, as a rule, effected without the introduction of any instrument, merely by external pressure. The back of a broad and moderately arched spoon is, close to the centre of the incision, gently pressed against the sclera, so that the wound is made to gape. Thus, cortical masses are caused to escape, and the vertex of the nucleus presents itself. In order to promote as much as possible the thorough exit of the latter, the back of the spoon is made to glide along the sclera, first with an equable degree of pressure laterally towards the corners of the wound, and, thereupon, withdrawing it from the wound, upwards with a continuous increase of pressure. If during these movements the diameter of the nucleus presents itself, the pressure is more and more abated, and the delivery may be completed by applying the end of the spoon to the projecting edge of the nucleus. If there be but a thin stratum of soft cortex, the recommended ‘slide manœuvre’ may likewise be tried, but ought to be abandoned as soon as we observe that during the lateral movements no presentation ensues; in this event the hook must be resorted to, which in the case of hard cataract is required *ab initio*. The blunt hook which I am in the habit of employing has the form represented in fig. 48, and has its stem bent in such a manner (fig. 49) as to enable it to be readily pushed under the nucleus. It is first laid flat on the opening made in

the capsule, thereupon drawn back over the near edge of the nucleus, when, by a suitable elevation of the handle, it is brought in the direction of the posterior cortex, along which it is then pushed forward on the flat until it has passed the posterior pole of the nucleus. The instrument is now between the fingers rotated around its axis, so that the plane of the curved extremity of the hook exchanges its horizontal for the vertical position, or, should resistance be felt, an oblique one, and the nucleus, or, as the case may be, the whole lens is by a gentle traction carried towards the incision.

FIG. 48. FIG. 49.



“STEP V. *Clearing of the Pupil and Coaptation of the Wound.*—If, as happens in the majority of cases, after extraction of the nucleus, cortical masses remain, they must be evacuated by gentle pressure and friction, exercised with the finger-ends through the medium of the lids, and in accordance with the well-known rules for the same purpose observed in flap-extraction. Only in exceptional cases may a small spoon be introduced for the removal of isolated cortical fragments, which may be particularly adherent to the capsule. Very delicate coatings of the capsule, if their evacuation be difficult, are better left behind; but, on the whole, as complete a removal as possible of the cortex should be insisted on. Finally, the wound is to be cleared with forceps from any adherent iris pigment or coagula, and the conjunctival flap replaced in its proper position.

“Regarding the after-treatment I may be brief. The usual compressive bandage must be applied, and first renewed five or six hours after the operation, afterwards twice (or even once) a day. In regard to light, the habitual cautions must be observed. Rest is to be recom-

mended, but less rigorously than after flap-extraction. If necessary, the patient may pass even the first days following the operation out of bed. Respecting the diet, everything may be allowed excepting stimulants and such aliments as require mastication. From the second day I apply atropine (usually twice a day), chiefly to prevent coalescence of the two corners of the sphincter with the capsule. Only where copious conjunctival secretion either existed before or became apparent after the operation, I defer the application. If anything untoward occurs, a cautious yet accurate examination (always by artificial light) must decide whether it originate from the wound, the cornea, the iris, or the capsular cells, when the proper measures have to be taken in accordance with the customary rules. On the whole, departures from the normal course are but rarely observed."

The favourable reports of Von Graefe concerning the results of "the modified linear extraction" have been confirmed by Dr. Liebreich of Paris, and by others who have practised it. I have not myself had any experience of the operation in the treatment of traumatic cataracts; but in those cases where the patient is advanced in years, and the probability is in favour of the nucleus being very dense, the modified linear extraction will, I have no doubt, be found a very useful operation.

I have made no reference in this chapter to the ordinary flap extraction for cataract, as although it is a most admirable operation, and in many cases the best which can be selected for a senile cataract, yet it is not applicable to the traumatic form.

Liebreich's Eye Bandage.—After all operations on the eye, but especially after an extraction of cataract, the comfort of the patient is increased, and the prospect of success improved, by an easy, well-adjusted bandage. The one now

in use at the Royal London Ophthalmic Hospital fully accomplishes its purpose : it was introduced by Dr. Liebreich about three years ago when on a visit to the Hospital.

FIG. 50.

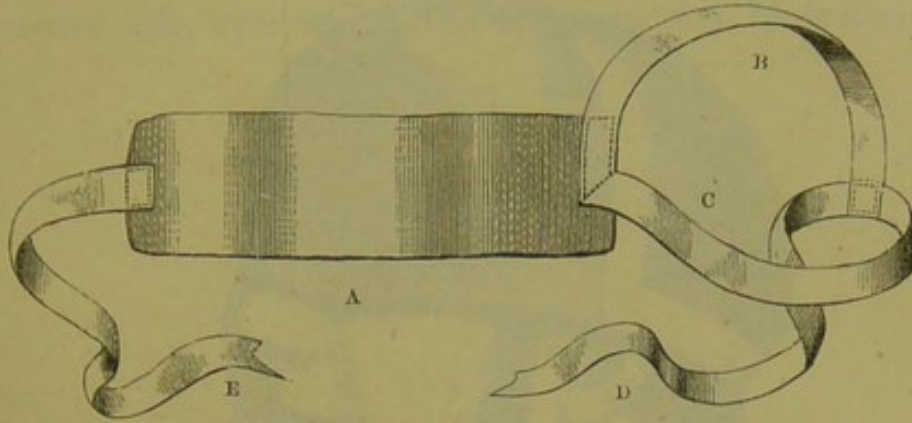
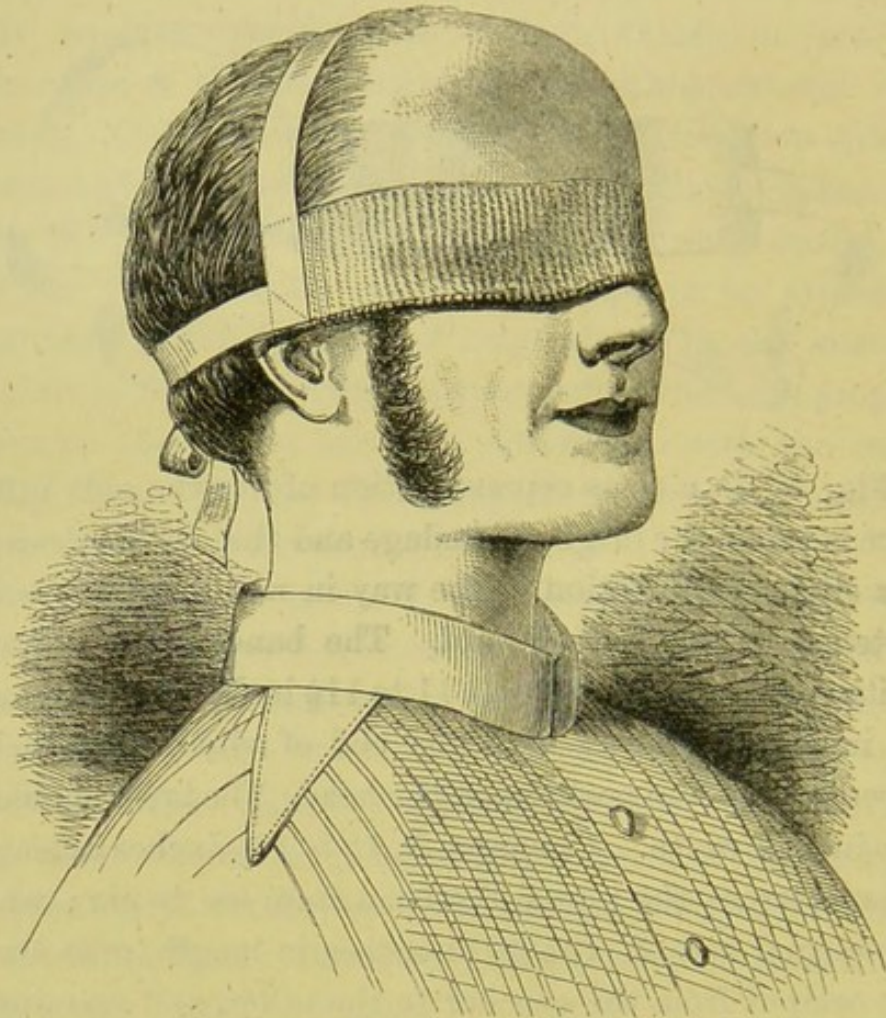


Fig. 50 is a close representation of it : the only difference between the original bandage and that in the drawing is a slight modification in the way in which the tapes are fastened to the knitted band. The bandage consists of a knitted cotton band, *A*, from 11 to 11½ inches in length, and 2½ inches in width ; at either end of which are attached tapes to keep it in position on the head. The tapes should be one inch in width. One tape, *B*, 12 to 12½ inches in length, passes across the top of the head from ear to ear ; whilst the second tape, *C*, 10½ to 11 inches in length, goes across the occiput from the one ear to the other, and terminates in a free end, *D*, by which it is tied to the tape *E*, and fastened on the head.

Fig. 51 shows the way in which the bandage should be applied. The patient having been told to gently close the lids of both his eyes, a small single square of fine linen is laid over the one which has been operated on ; upon this is placed a little cotton-wool, and over the whole and across both eyes the bandage, which is to be tied on the side of the head *opposite* to the eye which has undergone the

operation. The advantages which this bandage has over the many different methods which are practised for keeping the eyes closed after operations are :

FIG. 51.



It is easily applied, and fits accurately without slipping ; it can be unfastened quickly and the eye examined without disturbing the patient, or without requiring him to sit up if he is lying down. It is also very easy to the patient, and it does not exclude the use of moist applications to the eye, as they can be applied through the bandage.

I have lately had the bandage made with a linen instead of a knitted band, and in some respects I prefer it, as it is

not so hot to the eyes; and if water dressings or lotions have to be used, they can be more conveniently applied through the linen than the knitted cotton. When moist dressings are required, the cotton-wool should be omitted, and in its place a double fold of linen should be laid upon the closed lids, over which the bandage is to be fastened.

CHAPTER V.

CAPSULAR OPACITIES AND DISLOCATIONS OF THE LENS.

CAPSULAR OPACITIES FOLLOWING THE LOSS OF THE LENS—SIMPLE OPACITY OF THE LENS CAPSULE—DEFECT OF SIGHT AFTER AN EXTRACTION OF THE LENS FROM A WRINKLING OF THE CAPSULE—OPACITY OF THE CAPSULE, WITH PARTICLES OF LENS MATTER BETWEEN ITS LAYERS—OPACITY OF THE CAPSULE BLENDED WITH INFLAMMATORY EXUDATIONS—DEGENERATIVE CHANGES OF THE LENS CAPSULE—TREATMENT OF CAPSULAR OPACITIES—NEEDLE OPERATIONS FOR OPAQUE CAPSULE—REMOVAL OF OPAQUE CAPSULE WITH CANULAR FORCEPS—DISLOCATIONS OF THE LENS: FIRST, INTO THE ANTERIOR CHAMBER, TREATMENT OF; SECOND, INTO THE VITREOUS, PROGNOSIS AND TREATMENT OF; THIRD, BENEATH CONJUNCTIVA, PROGNOSIS AND TREATMENT OF—PARTIAL DISLOCATIONS OF THE LENS.

CAPSULAR OPACITIES FOLLOWING THE LOSS OF THE LENS.

—After the lens has been removed, whether by absorption following an injury in which its capsule has been torn, or by an operation for its extraction, some density of the originally transparent capsule which has been left is very apt to occur, and to greatly mar the excellence of vision which the patient would otherwise possess. The degree of opacity which so frequently follows varies very much, and is dependent on different circumstances.

1st. *The simplest form of opacity of the capsule* is that which often occurs after an operation for the removal of the lens, especially after linear or suction extraction. Its formation is unaccompanied with any inflammatory action; the eye after the operation may have progressed most favourably, and the iris have resumed its activity in dilating and contracting the pupil under the influence of light and shade, but yet the acuteness of vision is dimmed.

The patient may be able to read No. 10 or 12 of Jaeger's test types, but he is unable to discern a word of No. 1 or No. 2. If such an eye is examined with the ophthalmoscope, a film of capsule will probably be found occupying the pupillary space, not actually opaque, but with its transparency sufficiently dulled to interfere with the due passage of the light to the fundus of the eye.

In a paper by Mr. Bowman on Capsular Obstructions* he has shown that the capsule, which remains after the lens has been removed, may cause a serious imperfection of sight *without* becoming opaque, but by assuming a wrinkled and folded state, so as to produce an unequal refraction of light in its passage through it, and a consequent confusion of the image on the retina. A careful examination by lateral focal illumination will detect this crumpled condition of the capsule.

The second form of opacity of the capsule which is frequently met with, is where the membrane itself is semi-opaque, but its opacity is considerably increased by bits of the soft lenticular matter having become enclosed between parts of the anterior and posterior layers of the capsule, so that the aqueous is unable to exert its solvent influence on them. In such a case, if the pupil be dilated with atropine, the opacity of the capsule will be seen to vary in density in different points of its area, according to the quantity of lens matter which has been enclosed between its layers. This condition is a very frequent result of penetrating wounds of the eye, in which the lens has been wounded, and absorption of the greater part of it has subsequently followed, but where, owing to the rent in the lens capsule having been small, the aqueous has failed to act completely on every part of its substance. The op-

* Royal London Ophthalmic Hospital Reports, vol. iv. p. 358.

posed layers of the lens capsule have then closed upon the little remaining lenticular matter, and by thus shutting off the aqueous have prevented its further maceration and absorption. This form of opacity is not necessarily accompanied with any inflammatory action.

Dr. Schweigger of Berlin has shown that the opacity of the lens capsule may also be increased by an imperfect growth of those of its lining of intra-capsular cells, which from some cause have escaped the action of the aqueous on them.

The third form of opacity of the capsule is always associated with iritis, following the wound of the lens. Lymph is effused on the surface of the capsule, and adhesions more or less extensive take place between it and the iris. The capsule itself becomes opaque, and blending with the lymph upon its surface grows tough, and almost fibrous in its structure, losing all its natural elasticity. This state of the capsule is very frequently combined with some soft opaque lens substance shut in between its layers; indeed in many cases it is due to the irritation which has been excited from some lenticular matter having been left behind at the time of the operation for the extraction of the lens. The pupil in these cases is generally contracted, and its margin adherent either at points or often in its entire circumference to a dense membrane, composed of lymph and opaque capsule, enclosing between its layers fragments of the lens substance.

It is this form of membranous opacity which frequently undergoes after a lapse of time a degeneration of structure: in some cases, losing the toughness it at first acquired, it becomes brittle and friable, allowing a needle or a pair of iris forceps to pass through it like tinder; or in others, in after years becoming the seat of earthy deposits. The second form of capsular opacity I alluded to, where a

portion of lenticular matter is enclosed between the layers of the capsule, is also liable to degenerative changes, and to have earthy salts deposited in the vestiges of the lens between its folds.

TREATMENT OF CAPSULAR OPACITIES.—In treating opacities of the capsule after the lens has been removed, it may be taken as a rule which should never, if possible, be departed from, that no operation should be performed so long as the eye is red or irritable.

All irritation from the previous operation should have passed away, and the sclerotic should have regained its normal white appearance. The rekindling of an inflammation which has not quite subsided is more dangerous to the eye than a completely fresh attack excited by a second operation some weeks or months after the eye has perfectly recovered from the effects of the first. At the same time it should be remembered that too long an interval should not be allowed to elapse before a needle operation is performed to break through the semi-opaque capsule. It is apt after a while to become tough and to lose some of its elasticity; so that it will not tear so easily before the needle, and when torn the sides of the rent will not so readily separate. From two to three months after the extraction of the lens is usually sufficient for the eye to recover itself, and to fit it for a needle operation, should one be required; but in some cases even a longer period than this may be necessary.

Needle operation for opaque capsule.—A single needle is usually sufficient to tear an opening through the semi-opaque or wrinkled capsule which is often found after an ordinary operation for cataract, but two needles should be in readiness in case a second is required. The needles should be carefully selected, as much of the facility in per-

forming the operation, and sometimes even the success of it, depends on their being properly made. Each needle should be after the pattern described at page 146, with a fine cutting point and the stem slightly cylindrical, so as to hold accurately the aqueous within the chamber until the operation is completed.

Before commencing the operation, the pupil should be fully dilated with atropine. A spring speculum should be then introduced between the lids to hold them apart, and the eye, if very mobile or inclined to roll upwards, may be fixed with a pair of forceps held in the left hand of the operator; but this is not generally necessary, for as soon as the needle has entered the cornea, the eye is entirely under command.

The needle should penetrate the cornea obliquely about one or one and a half lines from its circumference, and passing across the pupil to the opposite side it should puncture the capsule close to the iris, and, by then slightly depressing the hand, the needle is made to dip a little into the vitreous, and to cut its way through the capsule. In some eyes one or two dips of the needle will suffice to make a clear opening in the capsule, whilst in other cases they have to be repeated many times. When such is the

Fig. 52. case, the incursions of the needle should be in lines radiating from the circumference to the centre of the pupil. Great care should be taken not to pass the needle too deeply into the vitreous, as the unnecessary breaking up of that structure acts very prejudicially to the eye. To avoid the risk of doing this, Mr. Bowman some years ago devised a stop needle, fig. 52, which is prevented from penetrating too far by an abrupt increase in the thickness of the stem at a certain distance from its point. This instrument will be found very useful in the hands



of those who have not had much practice in such operations.

Occasionally it happens that after the needle has made an opening through the capsule, an adherent film remains, stretching across the pupil, which a single needle fails to divide. A second needle should then be used, after the manner first recommended by Mr. Bowman. It should be introduced by the other hand through the cornea at a point nearly opposite to the first; and passing its point *behind* the band, whilst that of the first needle remains *in front* of it, so that their points cross, the one needle is made to revolve a few turns over the other, until the band of capsule is torn; or if this does not readily follow, the two needles may be then slightly but slowly separated; a proceeding which will seldom fail in breaking it through. By this simple manœuvre, each needle will obtain a hold on the band of capsule, which each revolution of the needle will tighten. In using the two needles, the one needle should be kept still whilst the other revolves, until each has a fold of capsule around its end, when by gently drawing them apart, the band is pulled asunder without dragging upon the iris.

In cases where there is some lens matter enclosed between the anterior and posterior layers of the capsule, a needle operation such as has been already described will generally be sufficient. The breaking up of the capsule will expose the particles of lens matter to the action of the aqueous, and they will usually be quickly absorbed.

A more troublesome class of cases to deal with is where there has been iritis, and the pupil is closed with a dense membrane to which it is completely adherent. In such eyes, the mere tearing through of the capsule to make a new pupil is not enough, as some iritis is almost certain to follow, and the pupil will again become closed. It is

generally necessary after the capsule has been torn through to remove a portion of the iris and make a false pupil. One of two plans may be adopted.

1st. To use two needles to tear through the opaque capsule and open out the pupil. One needle is to be introduced through one side of the cornea, and be passed into the centre of the capsule upon which the pupil is contracted and adherent. The second needle is to penetrate the opposite side of the cornea and to be inserted also into the capsule close to the first. The points of the two needles are now to be dipped downwards a little into the vitreous, and to be drawn slowly in opposite directions, so as to tear through the capsule, and at the same time to pull open the pupil. Having done this, the needles are to be withdrawn, and according to the size of the pupil which has been formed must depend the necessity of making an artificial pupil by removing a piece of iris. If the new pupil does not open out sufficiently, it will be well at once to make an opening in the cornea with a broad needle, and with a Tyrrell's hook, fig. 15, p. 84, to draw out a piece of the iris and cut it off.

2nd. Another mode of proceeding in such cases is to introduce a broad needle through the cornea at about a line from its lower border, and passing it upwards, and then through the opaque capsule, to dip its point into the vitreous and at the same time to draw it slightly downwards, so as to cut through the capsule and the lower circular fibres of the iris. If the pupil thus made does not open out, but remains as a slit, it will be advisable to remove a piece of iris with the Tyrrell's hook, and snip it off with a pair of scissors.

The most difficult cases, however, of all to treat are those in which there is a piece of tough milky white looking lens capsule occupying the pupillary area, and to

which the iris is adherent at points, though at one part of its circumference it may be perfectly free. The normal elasticity of such a portion of capsule has been lost, and oftentimes some of the earthy salts are found to be incorporated with it, or with the remains of the little lenticular matter which has been enclosed between its layers. A needle operation here would do no good.

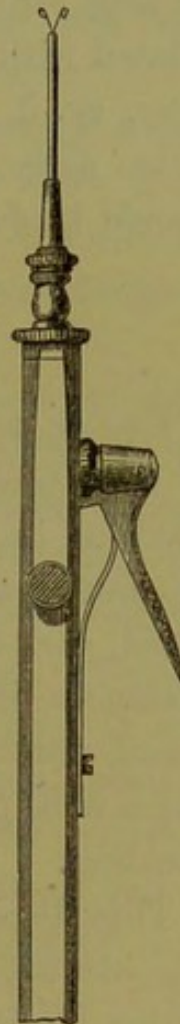There are two modes of dealing with such cases.

1st. Having fully dilated the pupil with atropine, detach the opaque capsule from its adhesions to the iris by a fine needle introduced through the cornea.

Having done this, the fine needle is to be withdrawn, and the opening it has made is to be enlarged with a broad needle to allow of the introduction within the anterior chamber of the canular forceps, fig. 53, with which the piece of capsule is to be seized and drawn out of the eye. If, on drawing out the opaque capsule through the aperture in the cornea, a point of it is found still adherent to the iris, that which has been withdrawn should be snipped off with a pair of scissors, but no attempt should be made to detach it by force. This operation is a *very hazardous one*, though the result, when success follows, is very brilliant. The great danger consists in the dragging upon the iris and the ciliary processes. I have occasionally seen suppuration of the globe follow this operation.

The second plan which may be adopted, and in many cases it is a very safe and efficient one, is first to make an iridectomy of a moderate size, selecting that part of the iris which is either free, or has the least adhesions to the capsule in the pupillary

FIG. 53.



space. A piece of opaque capsule will be then seen occupying the greater part of the area of the new pupil. Through the wound in the cornea the blades of a pair of fine iris scissors may be introduced, and passing one blade in front of the opaque capsule, and the other behind it, with two clips a triangular piece may be cut out, which may be lifted away by a pair of forceps. A clear space may thus be made for the free passage of light into the eye with far less danger than by forcibly removing the opaque capsule entire.

After all operations for capsular opacities, the eye should be kept for at least three or four days with the pupil fully dilated with atropine. A few drops of a solution of Atropine, gr. ij. ad Aquæ ℥j., should be dropped into the eye twice daily, and the room in which the patient resides should be darkened.

DISLOCATIONS OF THE LENS.

DISLOCATION OF THE LENS INTO THE ANTERIOR CHAMBER is most frequently occasioned by a blow on the eye, or on the head in the vicinity of the eye. Occasionally it may be produced under special circumstances by any violent effort, such as excessive retching or coughing; but in such instances, if careful inquiry is made, it will generally be found either that the eyes were unsound ones, or that there were peculiar causes which predisposed them to this accident.

This displacement of the lens is very serious, both as regards the effect it has on vision, and the danger to which it exposes the eye. To produce it a sharp blow is required which may, and frequently does, involve other parts of the eye in the injury, so that this accident is often complicated by lesions of other structures; but indepen-

dently of this, the mere change of position which the lens has assumed incurs a serious risk to the eye.

Symptoms.—The lens from some cause has been separated from its attachment to the suspensory ligament, and has been forced through the pupil, and lies in the anterior chamber. It may be enclosed *in its capsule*, which may be either entire or torn at some point; or it may be dislocated *out of its capsule* into the anterior chamber.

Under this latter heading I would include only those cases in which the firm nucleus of an adult or aged lens has burst from its capsule into the anterior chamber, and not the mere escape of a large quantity of soft lenticular matter, following a wound of the lens capsule.

A dislocation of the lens forwards is usually accompanied with more or less hæmorrhage, so that if the patient is seen immediately after the injury, the anterior chamber being filled with coagulum, no correct diagnosis can be made.

After a lapse of some days, when the blood has been absorbed, the lens, if dislocated, will be seen lying in the anterior chamber, and if transparent, will present a peculiar and characteristic appearance. It will look like a large drop of oil lying at the back of the cornea, the margin of it exhibiting a brilliant yellow reflex. The iris is pushed backwards, and the anterior chamber is thus greatly deepened. The lens in this abnormal position acts as a foreign body. It is productive of great irritation, which often passes into active inflammation, and of severe pain. The inflammation which so frequently follows this accident may be partially due to other parts of the eye having suffered from the primary injury; but much must also be attributed to the pressure of the lens on the iris, forcing it backwards, and thus altering, by the compression of a portion of the most vascular tissue of the

eye, the relative circulation of all the parts within it; whilst at the same time the lens, jammed against the iris, must act as an irritant to the nerves which supply it.

The pain which accompanies this displacement of the lens is usually severe and neuralgic in character, oftentimes more severe than the state of the eye would lead us to anticipate; but the pressure on the iris, and consequently on the ciliary nerves, is sufficient to account for its severity.

The state of the pupil is always more or less dilated in proportion to the amount of pressure the lens exerts upon the iris. The lens, if enclosed in its capsule entire, may retain its transparency for a time; but as a rule, it will ultimately become opaque. If, however, the capsule has been torn, the lens will very rapidly become cataractous.

Although active irritation and pain are the common sequences of dislocation of the lens into the anterior chamber, still they do not invariably follow. Mr. Lawrence mentions the case of a man who "visited the London Ophthalmic Infirmary with the lens surrounded by its capsule in the anterior chamber, where it had been for twenty-eight years."*

Treatment of dislocation of the lens into the anterior chamber.—If the lens is acting as a foreign body, and giving rise to irritation, it should undoubtedly be removed, and as soon as possible: the irritation will probably continue and increase if it is allowed to remain in its abnormal position. This rule should be followed in all cases, whether the patient is a child, a young adult, or an aged person. But if the lens, although lying in the anterior chamber, is not acting as an irritant, and the eye, when seen by the surgeon, is perfectly quiet and free from

* Lawrence on the Eye, edited by Isaac Hays.

undue vascularity, what course should be pursued? To answer this question, it is necessary first to consider what are the present, and what are likely to be the ultimate effects of such an accident. For visual purposes, even if the lens continues transparent, the sight is greatly impaired; but the chances are largely in favour of its becoming cataractous, and a still further loss of sight will then ensue. There are, however, two results which generally follow the long-continued presence of the lens in the anterior chamber, viz., paralysis and atrophy of the iris: both of these are due to the one cause, pressure of the lens on the iris. They are not the immediate results of a dislocated lens, but they are the sequences of the prolonged pressure which is kept up by the lens against the iris, when it has been allowed to remain for many months or years in contact with it. Now although the eye when first seen may be quiet and free from all vascular excitement, yet it is impossible to say how long this quiescent state may last. An outbreak of acute inflammation may occur at any time without any special assignable cause beyond the abnormal pressure of the lens on the iris. Again, the presence of the lens in the anterior chamber is very apt to give rise to a glaucomatous state, under which the tension of the globe becomes suddenly increased, and the pain very severe. This condition is always one of peculiar danger to the eye, and calls at once for active treatment.

The glaucomatous state may not be induced immediately or even within a certain number of days or weeks after the accident; but it may occur at any subsequent period, even though sufficient time may have elapsed for the eye to have lost all perception of vision.

Considering then all the many casualties which may happen to an eye with a dislocated lens lying in its anterior chamber, I believe it is advisable in all cases to get

rid of it; but the manner in which it is best to accomplish this end must depend on a variety of contingent circumstances. The choice of the operation to be performed for the removal of the displaced lens will be influenced partly by the age of the patient, and partly also by the condition of the eye at the time of the operation.

I. In the very young, a suction operation or a modified linear extraction may be performed. The lens capsule must be first freely opened with a fine needle, and the lenticular matter be thoroughly comminuted; and then the operation may be completed by making an opening in the cornea with a broad needle sufficiently large *to admit easily* the tubular curette of the syringe, and sucking out the broken down lens; or else by introducing a curette, and allowing it to escape from the eye down its groove.

In the ordinary suction and linear extraction operations it is always advisable, if the circumstances will permit of it, to wait an interval of two, three, or more days after the first needle operation before attempting to remove the broken down lens, so as to allow the lenticular matter to be well acted upon by the aqueous, and to become diffuent; but in an operation for the removal of a lens dislocated into the anterior chamber, it is different. The lens is so jammed between the iris and the cornea, that even if the capsule were freely torn, the aqueous would be unable to permeate its substance, and no good result would follow. In a child with a congenital dislocation of the lens into the anterior chamber, I lacerated the capsule with a fine needle, and at the end of a week the only effect was a slight white mark at the point at which the needle had entered. I repeated the operation twice, at intervals of two and three weeks; but the lens did not become generally opaque, and only those parts of it were affected with which the point of the needle was actually brought into

contact. On two occasions in children, I have seen Mr. Bowman successfully remove the displaced lens in a single operation; in the first patient by a linear extraction, and in the second by a syringe; in each case first breaking up thoroughly the lenticular matter with a fine needle, but completing each operation at one sitting.

II. If the lens is dislocated into the anterior chamber in its capsule, and the patient is either an adult or a person advanced in years, so that there is reason to believe that it has a firm nucleus, the best operation is extraction through a large section in the cornea. The selection as to whether it shall be an upper or a lower section must depend very much on the special circumstances of the case. Often the lower section will be difficult to perform on account of the lens lying in close contact with the cornea, and being thus directly in the course the blade of the knife would have to take. During the operation an escape of vitreous will probably occur, as the suspensory ligament must have been torn to allow of the lens being dislocated, and this could hardly have been accomplished without at the same time some rupture of the hyaloid membrane.

III. In certain cases where there is a glaucomatous tension of the globe, it will be advisable to perform an iridectomy as a preliminary to the extraction of the lens, which may then be accomplished either with a syringe; or with a scoop as in the traction operation; or with an ordinary curette as in linear extraction, according to its consistency. Even in eyes which are not glaucomatous it may be often advisable to perform a "traction operation" for the removal of the dislocated lens.

IV. Lastly, if in an old person the lens has been dislocated *out of its capsule* into the anterior chamber, it should be extracted. The nucleus will take very long to absorb, if it is ever absorbed; and it is almost certain

sooner or later to create great irritation, which may pass into a destructive inflammation of the eye.

CASE XXXVIII.—*Dislocation of the lens into the anterior chamber ; excessive pain two years after the injury, and loss of sight ; extraction of the lens, followed by immediate posterior hæmorrhage.*

Richard W., æt. 55, a wheelwright, applied to the Ophthalmic Hospital April 21, 1865, on account of the excessive pain he suffered in the left eye, which had been injured by an accident two years previously, dislocating the lens into the anterior chamber.

His story was—Two years ago he was working at a steam-sawing-machine, and was engaged feeding the saw, when a piece of wood jumped up and struck the eye, dislocating the lens into the anterior chamber. For some time after the accident he suffered great pain, and lost nearly all sight, but retained sufficient for twelve months to be able to guide himself about with that eye. Since that period he has only been able to see shadows. In March of this year the eye began to trouble him severely, and since then he has suffered so much pain in it that he came up from Malton to the Hospital for the purpose of obtaining relief, and was willing to submit to any treatment which would afford it to him.

Present state.—The globe is much injected ; the sclerotic of a dingy colour, with enlarged ciliary veins. The tension of the eye is increased to T 2. A completely opaque lens in its capsule entire is lying in the anterior chamber, pushing the iris backwards. The pupil is widely dilated, so that a mere rim of iris can be seen. He says he has perception of light ; but from a careful examination it must be very slight, as he is unable to tell with any certainty whether

the eye is shaded or not, although he contends that with that eye he could point out the window of the room.

The man was naturally anxious to save the eye if possible, but he was willing at the same time to submit to any operation to gain relief from the pain he had lately been suffering. Although the eye was evidently very unsound, and in a state of glaucomatous tension, I determined to extract the lens, and to be guided by the result as to what other treatment should be adopted, as, if this failed, the last resource—the removal of the eye—could be performed.

The man was admitted as an in-patient, and I extracted the lens by an upper section. It came away readily in its capsule, but a quantity of perfectly fluid vitreous escaped with it. He immediately complained of agonizing pain in the eye, and in a few minutes the whole globe was filled with blood. It was evident what had happened. The sudden alteration in the tension of the globe by the removal of the lens and partial escape of the fluid vitreous had deprived the vessels of the choroid (probably already weakened by disease) of their support, and becoming thus overdistended, some of them had given way, and extensive hæmorrhage had ensued. I determined therefore at once to remove the eye, and save the poor fellow a long and painful course of suppuration. For this purpose he was put under the influence of chloroform, and the eye removed. On making an examination of it immediately afterwards, the following was the condition:—The hæmorrhage had taken place from the vessels of the choroid, and blood had been poured out between it and the sclerotic, sufficient to detach the entire choroid from the sclerotic. The retina was in close contact with the choroid, but of course carried forwards with it. The whole of the fluid vitreous had been squeezed out of the eye by the blood clot.

This case is specially interesting as illustrating two

important facts. 1st. The danger of leaving a dislocated lens in the anterior chamber. In its new position it acts as a foreign body; and although in exceptional cases it may not produce much irritation, yet, in the majority, loss of sight and destruction of the eye is the result. Like a foreign body it may remain for a time without giving rise to any dangerous symptoms, but its presence in the anterior chamber pressing upon the iris keeps the eye in constant jeopardy, as, sooner or later, it is almost certain to kindle an inflammation which will probably destroy it. 2nd. It confirms what was, I believe, first pointed out by Mr. Hulke, viz., that hæmorrhage immediately after the extraction of the lens in an unsound eye takes place from the posterior choroidal vessels, and that the blood clot is between the sclerotic and choroid.

DISLOCATION OF THE LENS INTO THE VITREOUS.—This accident may occur either with or without rupture of the external coats of the eye. The blow, however, which is required to produce this displacement of the lens, is often sufficient to rupture at the same time the sclerotic, and hence it is not very uncommon in cases of ruptured globe to find that the lens has been dislocated into the vitreous. An injury so severe and complicated is almost certain to be fatal to the eye.

The lens is usually dislocated enclosed in its capsule, which may be either entire or partially lacerated by the blow which produced the injury. If the capsule has been torn, the lens will soon become cataractous; but even if it is entire, it is liable after some months to become opaque on account of its due nutrition being interfered with.

Symptoms.—If the patient is seen early after an accident which has dislocated the lens into the vitreous, the diagnosis of the injury is generally masked by the presence of

blood in the anterior chamber; for to produce this displacement, the capsule of the lens has to be separated from its suspensory ligament, and this can hardly be effected without some injury to the ciliary processes or iris. In the hæmorrhage which ensues, the blood either trickles into the vitreous, or running into the anterior chamber forms a clot which entirely occludes the parts behind it. Some days must, therefore, elapse before a satisfactory examination can be made.

After the clot has been absorbed, the patient will complain of great defect of vision, and this even if there has been no damage to the choroid and retina, for the lens being out of the field of vision, all power of focusing the eye will have been lost.

1st. If the dislocation has been complete, the plane of the iris will not be materially altered. The lens having sunk in the vitreous below the level of the lower border of the pupil, there will be no pressure on the posterior surface of the iris; but the iris, having lost the support of the lens, will rather fall backwards towards the vitreous, and thus slightly increase the depth of the anterior chamber, and occasionally it will be found tremulous, its whole surface vibrating with the movements of the eye.

2nd. If the dislocation has not been complete, but, as is usually the case, some shreds of the suspensory ligament still connect the lens in its capsule with the upper region of the globe, then the lower surface of the iris against which the lens presses will be bulged towards the cornea, whilst the plane of the upper part will be unaltered. This bulging forward, however, of the iris is often not sufficient to strike an inexperienced observer. The upper border of the lens may in some cases occupy the lower part of the pupillary area, whilst in others it may have sunk below the lower margin of the pupil. When the lens is thus

suspended, it may be sometimes seen by the unaided eye, but always by focal illumination, hanging by filmy shreds from the upper surface of the globe, and swaying to and fro with the motions of the eye.

State of the pupil.—There is always more or less dilatation of the pupil. This is probably chiefly due in most cases to the injury which the ciliary nerves have sustained in the accident, although it may also be partly accounted for by the pressure which the displaced lens often exerts on the lower segment of the iris.

The general symptoms are those of great irritation. There is increased vascularity with dread of light, lachrymation, and pain. The eye from the first effects of the injury becomes actively inflamed, but this under treatment may gradually subside. It is, however, generally succeeded by a low form of choroido-iritis or choroido-retinitis, which is kept up by the irritation caused by the abnormal position of the lens. In this stage a glaucomatous state frequently supervenes, and the tension of the eye becomes greatly increased; with the increase of tension all the symptoms become aggravated; and unless the lens, the source of the irritation, is removed, the loss of the eye is certain. This glaucomatous condition is liable to occur in all the dislocations of the lens *within* the eye. I alluded to it in the cases of dislocation of the lens into the anterior chamber, but it is more prone to follow those in which the lens is either partially or completely displaced behind the iris than where it is thrown in front of that structure.

Prognosis and treatment of dislocation of the lens into the vitreous.—When this displacement of the lens is associated *with rupture of the globe*, the eye may as a rule be considered lost: it is seldom that it recovers with any power of sight after such a severe injury. But *without rupture* of the external coats of the eye, dislocation of the lens into the

vitreous must still be regarded very unfavourably. The blow which is required to displace the lens is so severe that other parts of the eye are usually involved in the injury : thus hæmorrhage into the vitreous from rupture of some of the ciliary processes, or hæmorrhage between the choroid and retina, are not unfrequently associated with it. If the dislocation of the lens is apparently uncomplicated with injury of the deeper structures, and the eye recovers from the first shock of the injury, still the abnormal position of the lens keeps the eye in jeopardy. Deep-seated inflammation may come on at any time, and ultimately cause its destruction. The vitreous may become fluid, the eye soft, and the retina more or less displaced.

In the treatment of dislocation of the lens into the vitreous the first indication is to remove the lens, the source of all the irritation. This is best done by a traction operation. (See page 160.) There are, however, certain difficulties which beset this operation when performed for the extraction of a dislocated lens from the vitreous. It is often impossible to seize hold of the iris to draw it out of the wound preparatory to excising a portion of it ; for, having lost the support of the lens, it will sometimes fall backwards and get so behind the cut edge of the sclerotic that the forceps cannot be made to grasp it. This difficulty is increased by an escape of vitreous which almost invariably takes place immediately on the withdrawal of the knife from the eye, and is dependent on a rupture of the hyaloid at the time of the accident, which has allowed the vitreous to fall forwards. If, therefore, at this stage of the operation the attempt to seize and draw out a piece of iris is unsuccessful, it is better at once to abandon it, and to go on with the operation, as the repeated introduction of the forceps within the eye will cause a large and unnecessary amount of vitreous to be

lost. The next step is the removal of the lens, and this is to be accomplished by introducing a middle-sized lens scoop through the wound into the vitreous chamber, passing it downwards and slightly backwards until it gets behind the lens, when it must be gently pressed forwards so as to get the lens within its grasp, and then be slowly drawn out of the eye. If this manoeuvre is cleverly performed, a single introduction of the scoop will suffice to remove the lens. During the operation the vitreous will continue to escape; but if all the instruments have been previously placed ready at hand so that there is no unnecessary delay, and the operation is performed skilfully and expeditiously with a light hand, the loss of vitreous will be far less than might be anticipated, and certainly not sufficient of itself to exert any very prejudicial influence on the eye. After the operation the lids should be gently closed, and a cotton-wool compress applied by means of a knitted bandage.

The two following cases are examples of dislocation of the lens into the vitreous. In both of them the lenses were removed by the operation I have described.

CASE XXXIX.—*Dislocation of the lens into the vitreous from a blow on the eye with a piece of wood.*

Charles B., æt. 46, came under my care in January, 1865, suffering from the following injury to the left eye. On the 20th of October previously he was at his saw-mills speaking to one of his men, when a wooden ruler which was lying on one of the benches was caught in the teeth of a circular saw and jerked up against the left eye endways.

He had been under treatment ever since the accident, but without gaining any relief. The pain had continued, and the sight was now so impaired that he could only see large objects. On examining the eye, the lens was seen

to be displaced downwards and backwards into the vitreous. It was lying below the lower edge of the pupil, which was widely dilated; but it was prevented from completely resting on the fundus of the eye by some ligamentous shreds which passed from it to the upper part of the globe. The eye was very painful, greatly inflamed, and its tension slightly increased.

On February 8 I removed the lens by making a free opening in the corneo-sclerotic junction with an iridectomy knife, and then, passing a cataract spoon through the incision into the vitreous, lifted it away in its capsule entire. The pupil was so widely dilated, and the iris so much pressed backwards by the vitreous which escaped as soon as the section was completed, that I was unable to seize a portion of the iris with the forceps, and I therefore introduced the scoop through the dilated pupil, without performing an iridectomy.

Feb. 9.—He had some pain in the evening, but it was relieved by the application of two leeches to the temple.

Feb. 10.—The eye looks well. He states that he is more free from pain than he has been for two months.

From this date he gradually recovered, and on March 1 he was able with a $2\frac{1}{2}$ -inch focus convex glass to read No. 16 of Jaeger's test types.

The sight, however, has not continued: with the subsidence of the long-continued inflammation to which the eye was subjected, atrophy and shrinking of the vitreous commenced. When I last saw the patient a few months ago the eye was quite blind, but he was perfectly free from pain. The globe was soft, and the retina was partially detached.

CASE XL.—*Dislocation of lens into the vitreous, following a blow on the eye with a piece of wood.*

Caleb R., æt. 41, was admitted into the Hospital on March 14, 1865, under Mr. Bowman.

Seven weeks previously he was chopping a piece of wood when a fragment of it flew up and struck the left eye.

State on admission.—The eye is over-vascular, the ciliary veins large. There is a staphylomatous bulging for about three-quarters of an inch in the ciliary region above the cornea, between it and the superior rectus. It has just the appearance as if a rent had been made in the sclerotic in the line of the bulging. The pupil is slightly dilated, but the plane of the iris is in no way altered. The tension of the globe is = T 2. His vision is very defective. He is unable to make out letters of No. 20 of Jaeger's test types, and he can only see imperfectly large objects in front of him. His sole reason for coming to the Hospital was to obtain relief of the constant pain he was suffering, as he considered that his eye for visual purposes was irreparably lost.

On further dilating the pupil with atropine the lens was seen dislocated into the vitreous: it was apparently resting by its lower margin on the fundus of the eye, and below the level of the lower border of the pupil. It in no way pressed on the iris. Connected with its upper border were shreds of the suspensory ligament, which still remained attached to it and kept it partially suspended, so that it swayed backwards and forwards with the movements of the eye. The lens was already cataractous.

Mr. Bowman decided at once to extract the lens, and thus to remove the source of irritation, and to relieve at the same time the increased tension of the globe.

He first performed an iridectomy in the upward direction, and then passed a large scoop into the vitreous chamber behind the lens; then pressing it gently forwards, and at the same time drawing it towards the wound, he extracted it in its capsule entire.

Some vitreous was necessarily lost during the operation, but not as much as might have been anticipated. The man progressed favourably. All pain in the eye ceased, and on March 31 he stated that his sight was decidedly improved. With a convex glass he was able to count fingers, and to guide himself about the room.

In the museum of the Royal London Ophthalmic Hospital is a preparation (A 14) of an eye in which the lens had remained dislocated into the vitreous for thirteen years. It was excised by Mr. Dixon on account of its having become painful, and a source of irritation to the other. The following is from the Hospital note-book:—

“ R. W., æt. 36, a patient of Mr. Dixon’s. Thirteen years ago he received a blow from the fist on the left outer supra-orbital edge. Within two months from the receipt of the injury vision with the left eye was reduced to a mere perception of light.

“ Six months ago the eye became painful, and has been so occasionally since.

“ *State of both eyes when the man was admitted into the Hospital.*—*Left eye*: no perception of light. Tension of the eye increased to T 1; no conjunctival redness. The central portion of the cornea slightly opaque. The anterior chamber very large; the iris flat and tremulous; the pupil, medium-sized, acts sluggishly. Examined with the ophthalmoscope, a whitish well-defined substance (the lens) is seen behind the pupil, lying fixed at the most depending part of the vitreous space.

“ *Right eye*: weakened by the state of the left.

“ The left eye was excised.

“ Examined afterwards the following was the state of the eye:—

“ The sclera, choroid, and retina were in apposition.

The vitreous space was occupied by transparent fluid. The whitish well-defined substance seen with the ophthalmoscope behind the pupil, and fixed at the most depending part of the vitreous space, was the greyish white and opaque lens in its capsule. It had fallen backwards, breaking through the hyaloid fossa, and had formed slight adhesions to the hyaloid. The suspensory ligament and the membrane which forms the hyaloid fossa hung in shreds in the vitreous space."

DISLOCATION OF THE LENS BENEATH THE CONJUNCTIVA can only occur in cases where the sclerotic has been ruptured, but the conjunctiva over the rent has remained entire. The lens, separated by the violence of the injury from its ciliary attachment, is forced out of the eye through the wound, and, as the conjunctiva has not been lacerated, it will be seen lying beneath it. The dislocation is almost invariably upwards, or upwards and inwards, as it is in the upper region of the eye, between the insertion of the recti muscles and the margin of the cornea, that the split of the sclerotic coat most frequently occurs.

Symptoms.—This displacement of the lens is always accompanied with severe injury to other parts of the eye. The choroid must be torn at the point where the sclerotic is ruptured, and the lens in its escape from the eye usually drags with it more or less of the iris which is prolapsed into the wound. There is consequent hæmorrhage, which may occasionally be confined to the anterior chamber; but more frequently the blood is effused also into the vitreous, and more or less between the structures at the fundus of the eye, the retina, the sclerotic, and the choroid.

The lens will be seen lying beneath the conjunctiva, forming a small roundish, semi-transparent swelling. If the anterior chamber is clear, the altered shape of the

pupil, probably also the tremulous state of the iris, and the presence of a sub-conjunctival tumour, will be sufficient evidence of the nature of the accident. The lens is nearly always dislocated enclosed in its capsule; but owing to the rough manner in which it is squeezed through the aperture in the sclerotic, the capsule is often lacerated, and the lenticular matter frequently somewhat comminuted.

The prognosis of these cases is very unfavourable; but still, if the rent in the sclerotic has not been very large, and the other parts of the eye have not suffered very severely, there is always a hope that the eye may so recover that some vision may be regained. There are many such instances recorded.

Treatment.—When the lens is seen lying beneath the conjunctiva, it should be removed; and this may be done by making a small incision through the conjunctiva either with a cataract knife or with a pair of fine scissors, and then, if the lens is entire in its capsule, by at once lifting it out; or if its capsule has been broken and its substance comminuted, carefully taking it away piecemeal with a small scoop, paying special regard that fragments of it are not left between the lips of the wound of the sclerotic to interfere with its primary union. The lids should be then closed, and a cotton-wool compress with a light bandage be applied to the eye.

It will be well, as a precautionary measure, to apply two or three leeches to the temple, and for a few days to keep the patient on a slightly antiphlogistic regimen.

A good example of a dislocation of the lens beneath the conjunctiva is related in Case XIX., in the article “Ciliary Staphyloma,” p. 104. The rent of the sclerotic was in the upper region of the eye, and the lens was seen lying immediately over it, but beneath the conjunctiva. The lens was removed, and the patient recovered with sufficient sight to

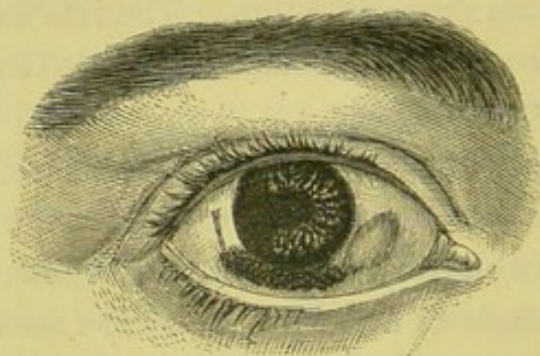
be able to read with a 3-inch focus convex glass No. 20 of Jaeger's test types.

The following is a very remarkable case of dislocation of the lens beneath the conjunctiva. The lens was shot out of a wound of the sclerotic on the outer side of the eye, and travelled beneath the conjunctiva to the opposite point. By what agency this movement of the lens was accomplished, it is difficult to imagine, except that the constant motion of the lids upon the eye, and of the eye against the lids, may have caused it to be gently pressed onwards through the loose cellular tissue beneath the conjunctiva in which it was lying. This case is also an instance of very useful sight remaining after so severe an injury as rupture of the globe from a blow, complicated as it was by a dislocation of the lens.

CASE XLI.—*Dislocation of the lens beneath the conjunctiva through a rupture of the sclerotic.*

Caroline C., æt. 53, came under my care on Feb. 13, 1866. She had received the following injury seven weeks previously. Whilst engaged at her usual household work

FIG. 54.



she struck the right eye with the handle of a fire shovel. The eye was at once blinded, and for some days she suffered severe pain; but this had passed off, and the eye was quiet, at the time of her application to the Hospital.

Present state.—The eye presents a very extraordinary appearance. At the outer side of the cornea is the cicatrix of a wound of the sclerotic through which a large portion of iris had evidently been prolapsed; for a large piece of about one-sixth of its circumferential portion was wanting, and the eye looked as if an iridectomy had been performed. On the other side of the cornea (the lower and inner), and almost directly opposite the rent in the sclerotic, was a prominent tumour of the conjunctiva, of about the size and appearance represented in the diagram; and in a line extending from the lower edge of the cicatrix to this swelling the conjunctiva was discoloured from recent ecchymosis.

The tumour was evidently the lens which had been shot out of the eye at the time of the injury, and had been left lying beneath the conjunctiva; and the line of ecchymosis which was seen beneath the lower margin of the cornea was the trail of the course which the lens had taken in its travel from where it was first lodged to the position it now occupied. As it burrowed its way beneath the conjunctiva, the delicate areolar tissue which connects that membrane with the sclerotic became torn, and no doubt some conjunctival vessels ruptured; slight hæmorrhage consequently followed, and thus as the lens travelled onwards an ecchymosis was formed in its wake.

With a pair of fine scissors I snipped the conjunctiva and exposed the lens, which I at once removed. It was quite opaque: there was a large circumferential portion of soft matter, and a firm nucleus.

Feb. 29.—The eye is very much better. It is less vascular and much less painful, and the sight has much improved. There is a good field of vision, and the patient is able to count fingers in all directions.

PARTIAL DISLOCATIONS OF THE LENS may occur from blows on the eye or the side of the head, when a portion only of the suspensory ligament is detached, and consequently a limited or only partial displacement of the lens ensues.

1st. The lens may be dislocated either partially upwards or partially downwards, and in either position it may continue permanently fixed.

2nd. The suspensory ligament may have been torn or partially detached at one part of its circumference; and although no immediate displacement of the lens may have followed, yet, owing to this loosening or partial detachment of its ligament, it may have become what is called a moveable or swinging lens, swaying backwards and forwards with the movements of the head or the eye—the amount of its mobility being dependent on the extent of its separation from the suspensory ligament. In certain postures of the head, as in looking downwards or in stooping forwards, a partial dislocation of the lens through the pupil may take place; whilst with the head erect, as in looking directly forwards or upwards, the lens may sink back behind the pupil to apparently its normal position. Independently of the intra-ocular symptoms which such a swinging lens is liable to excite, a serious defect in vision will be produced by the frequent changes in the position of the lens, such as to render the eye not only comparatively useless, but a source of very considerable annoyance and even of danger to the patient in causing him to misjudge and confuse objects with which he may come in contact in his daily work.

General symptoms.—Partial displacements of the lens are generally accompanied by grave symptoms. The blow required to produce such an injury must be one of considerable force, and the mere laceration of the suspensory

ligament, irrespective of the irritation which the mal-position of the lens may give rise to, is sufficient to place the eye for a time in some danger. But when all the first symptoms which may be attributed to the blow have passed away, there often remain severe neuralgic pains in the eye and around the orbit, which in some instances are persistent, though varying in intensity, whilst in other cases they are recurrent, with intervals of perfect ease. The sight is always materially affected, as in proportion to the tilting forwards of the lens the patient becomes myopic. The lens may continue transparent for a long time after the injury, but the general rule is for it sooner or later to become cataractous.

The most alarming condition which a partially displaced lens is likely to produce is a state of glaucoma, which may come on at any period after the accident. In such cases the glaucomatous symptoms are generally more or less recurrent; for the increased tension of the eye being dependent on the pressure of the lens on the back of the iris, it is produced when it falls forwards and rests against that structure, and it gradually subsides when this pressure is removed by a change of the position of the lens. A frequent repetition of this glaucomatous condition will, however, speedily induce such changes, that unless means are adopted to arrest it, total loss of sight must in the end be the result.

Treatment of partial displacements of the lens.—If the patient is seen soon after the injury, the first indication is to treat any inflammatory symptoms the blow may have excited by applying two or three leeches to the temple, and by using fomentations of either hot water, poppy heads, or of belladonna to the eye. If the lens is seen partially dislocated, the pupil should be kept fully under the influence of atropine, so as to avoid as far as possible

any pressure on the posterior surface of the iris. The important question in these cases is, whether the displaced lens shall be removed, and if so, at what period after the injury? The answer to this question is influenced by many varying conditions.

1st. If the early inflammatory symptoms have appeared to be rather the result of the blow than of the misplaced lens, and if these under proper treatment have subsided, and the eye has become quiet and painless, it is best to leave it alone, but to keep a careful watch over the patient, in order to treat at once any unfavourable symptoms should they arise. So long as the lens remains fixed in its new position and continues transparent, with the eye free from pain and of its normal tension, no operation should be performed.

2nd. If the lens from partial detachment of its suspensory ligament is a swinging or moveable one, and is causing personal inconvenience from frequently dropping partially through the pupil and thus producing a confusion of the patient's vision, even though there is no pain, its extraction should be advised.

3rd. If the lens has become opaque, an operation for its removal may be performed, but it should be delayed until the cataract is fully formed.

4th. If glaucomatous symptoms come on, the removal of the lens becomes an absolute necessity for the safety of the eye, and an operation for its extraction should be performed with as little delay as possible.

The choice of the operation for the removal of the lens in these cases lies between the ordinary extraction with a large corneal flap and the traction operation. In either operation a certain amount of vitreous must be lost, as, with the rupture of the suspensory ligament, the hyaloid is certain to have been broken, and a portion of the vitreous

will necessarily escape either immediately before or else directly following the exit of the lens from the eye. If the lens is only slightly displaced and fixed in its new position, provided the eye is otherwise sound, the patient a quiet person in good health, without cough and with full control over his emotions, the ordinary operation for extraction of the lens with a large corneal flap may be performed. In such a case there is every probability of a good result following. But if, on the other hand, the lens is a moveable one, or, if fixed, is very much displaced, it is better to perform a traction operation. For this purpose the opening should be made at the corneo-sclerotic junction, and of *a full size*, so as to insure the removal of the lens without the risk of breaking it. A piece of iris being then excised, a large scoop is to be introduced through the section into the eye, and being gently passed behind the lens is made to draw it out in its capsule entire. In all cases in which a glaucomatous state has followed a displacement of the lens, the traction operation should be performed, as the excision of a portion of the iris will help to restore the eye to its normal tension. But, in addition to this, the lens will be removed through a comparatively small opening, and the risk of posterior hæmorrhage, which is always great when the ordinary flap extraction is performed on glaucomatous eyes, will be thus prevented. The traction operation should also be selected in all cases where the patient has not full control over himself, or where from other causes it is desirable that he should take chloroform.

In a very interesting paper by Mr. Bowman in the Royal London Ophthalmic Hospital Reports, chap. i. vol. v., he has shown that in partial displacements of the lens there is a peculiar tendency for the eye to assume the glaucomatous state, and that although this condition is consequent on the mechanical pressure of the lens on the

iris, yet it need not occur as an immediate result of the injury, but may come on at almost any period after the accident. He has there related three cases of partial dislocation of the lens, in each of which glaucomatous symptoms supervened. In the first case there was no apparent injury, but the displacement seems to have originated during "the developmental period" of the eye; whilst in the two others an injury was the cause—in the one a blow with a chip of wood, and in the other a blow from the blunt end of a child's arrow. In the remarks which Mr. Bowman appends to these cases, he states that "whatever the explanation, the fact is remarkable, that iridectomy, with the removal of the lens as the original exciting cause of the whole, put an end to the whole series of morbid phenomena, and restored permanently the healthy state of the vessels, and the proper balance of tension."

The following is one of the three cases which he quoted.

"CASE XLII.—*Partial dislocation of the lens from a blow followed by glaucomatous symptoms—Extraction of the lens followed by immediate relief and ultimate recovery.*

"A clergyman, æt. 37, who had hypermetropia $\frac{1}{2}$ in each eye, and who had formerly been successfully operated on for internal strabismus, chanced to have the right eye hit by a morsel of wood, which was being chopped. After the immediate pain of the blow had subsided by simple treatment, he seemed to be recovering, and did not apply for aid until March 4, 1864, three weeks after the accident. Great pain had suddenly come on four days before, and had lasted ten hours. The tension of the eye was augmented, = T 1. Field complete. Could only see No. 18 of Jaeger's test types. The cornea and vitreous were rather hazy, but the ophthalmoscope gave a fair reflex, and though the optic disc was not visible, there was no

manifest hæmorrhage. The pupil was much dilated, and the lens, though quite behind the iris, was seen to have dropped somewhat downwards and inwards, so that its upper and outer edge crossed the pupil above, leaving an interval through which a portion of the vitreous humour appeared to project into the anterior chamber. The capsule of the lens was unruptured, and the lens was transparent; but as the light fell in different directions from the ophthalmoscope, dark striæ (which I call *striæ of refraction*, as distinct from *striæ of opacity*) were seen, indicating some derangement of the marginal fibrous laminæ. Such striæ I have very often seen, and I suppose they must have been seen by others, as a condition that long precedes, in certain cases, the opaque or cataractous degeneration of the lens. Here they were probably due to the mechanical injury.

“ Under strict rest and antiphlogistic measures, with the use of atropine, some improvement occurred, and on the 10th he could see No. 14, and with $\frac{1}{12}$, letters of No. 6 of Jaeger's test types. But the tension continued T 1.

“ *March 17.* T 1. Ciliary vessels injected; front of sclerotic red. Eye weak, watering, and intolerant of light. With $\frac{1}{12}$, No. 8 of Jaeger.

“ *March 21.* T 2. With $\frac{1}{12}$, No. 10 of Jaeger. Cornea and fundus duller; lens more advanced, pushing the iris slopingly forward, so as to render the anterior chamber shallow. The eye was more painful. He had also now, for the first time, iridizations; a candle was surrounded by an orange, yellow, and blue halo, the colours not being bright.

“ I now determined, as in the preceding case, to attempt relief by operation. Under chloroform, a marginal incision of two lines was made upwards and outwards by a Sichel's knife, and a bead of vitreous, which at once pro-

truded, apparently in the hyaloid tunic, was snipped off. A spoon was now passed behind the lens and its capsule, and the lens, rupturing in the attempt, was withdrawn in two or three portions; but as it was transparent, some fragments were probably left. More rather solid, clear vitreous protruding, in all about five or six minims, was now snipped off by scissors, and the eye closed. No iris was removed, as the instruments failed to take hold of it; the vitreous folding it backwards above and behind the corneal section, as usual in such cases. It will be seen that it would have been better if it could have been excised at the time. After operation, —T 2.

“*March 22.*—No pain; but some swelling of the lids, Tn. Two leeches were applied.

“*March 23.*—More pain; the swelling of the lids extends to the temple, and the leech bites are suppurating. Some chemosis. Goulard lotion.

“After this the tumefaction subsided gradually. The tension of the eye was then found normal. On the 26th he could see the hand, but could not count fingers. The next day he could count fingers held close; the following day at 4'. On the 30th, with $\frac{1}{2}$, No. 15 of Jaeger. The centre of the section gaping, and the iris protruding there, was snipped off on the 31st. On April 11th the eye continued red, but pain had quite ceased. On May 10th, redness nearly gone, but returned on use. Tn, with $\frac{1}{2}$, No. 8 of Jaeger. After this the eye became strong, and the vision still improved when he was last heard of in January, 1865.”

Mr. Bowman, in his remarks on this case, states that “the glaucomatous hardness of the eye seemed to originate in the traumatic displacement of the lens and pressure on the iris. It increased as the iris was more pushed forwards towards the cornea; and it was similarly at once

relieved by the operation, though the removal of the lens only, with some vitreous humour, sufficed for the result."

The following case is a good illustration of a partial dislocation of the lens, and the woodcut shows well the appearance which such a misplacement presents.

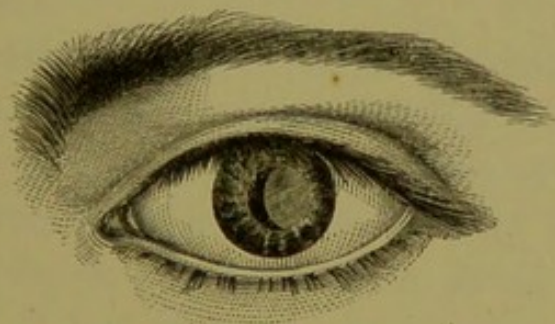
CASE XLIII.—*Partial displacement of the lens from a blow on the eye with a stone.*

Eleanor L., æt. 45, came under my care at the Ophthalmic Hospital on October 10, 1865, having met with the following accident. Two months previously she was walking down the street in which she lived, when a stone thrown by a boy struck the left eye. She at once suffered great pain, which has continued up to the present time.

Present state.—She complains now of severe pain extending from the eye upwards over the brow and along the side of the head. The pupil is rather dilated, and acts sluggishly and irregularly. The tension of the globe is increased to T 1.

Examined by oblique illumination, the eye presented the appearance represented in fig. 55. The lens was dis-

FIG. 55.



placed outwards, and a little tilted, so as to present its inner edge slightly forwards. It was already very cloudy, and was rapidly becoming cataractous. With the move-

ments of the head the lens was seen to vibrate. I strongly urged the necessity of an operation for the removal of the displaced lens, as the tension of the globe was increased, and she was suffering severe pain. Unfortunately, the patient was very nervous and fearful, and the mere idea of an operation caused her at once to leave the Hospital.

CHAPTER VI.

FOREIGN BODIES WITHIN THE EYE.

THE LODGEMENT OF A FOREIGN BODY WITHIN THE EYE—HOW TO EXAMINE AN EYE SUSPECTED TO HAVE A FOREIGN BODY WITHIN IT—THE DANGERS OF A FOREIGN BODY WITHIN THE EYE—THE SEVERITY OF THE SYMPTOMS INFLUENCED BY THE SIZE OF THE FOREIGN BODY AND THE PART OF THE EYE IN WHICH IT IS EMBEDDED—EXCEPTIONAL CASES IN WHICH A FOREIGN BODY WITHIN THE EYE EXCITES LITTLE OR NO IRRITATION—TREATMENT OF FOREIGN BODIES WITHIN THE EYE: WHEN LODGED BETWEEN THE IRIS AND LENS; ON THE IRIS; IN THE LENS; OR IN THE VITREOUS: CASES ILLUSTRATIVE OF—FOREIGN BODIES SUSPECTED TO BE WITHIN THE EYE, BUT NOT ACTUALLY SEEN: CASES OF.

THE LODGEMENT OF A FOREIGN BODY WITHIN THE EYE is one of the most serious injuries which can happen to that organ, and the importance of ascertaining correctly, as soon as possible after the infliction of an injury, whether there is a foreign body within it, cannot be over estimated. The prognosis of the case rests entirely on the elucidation of this one point.

Every penetrating wound of the globe should be specially examined with reference to the possibility of there being a foreign body within the eye. The history of the accident should be carefully gone into, an inquiry being closely made concerning the fragment which struck the eye; of what material it was composed, whether it was large or small; and by what force and in what direction it was propelled against the eye. The eye itself should be then examined, first superficially over its surface, so as to make

out the nature of the wound, and to estimate, if possible, by its character whether the foreign body which has inflicted it has penetrated the globe. The size and appearance of the wound often afford very important information, when viewed in *conjunction* with the nature of the agent which caused it: thus a small clean-cut wound penetrating directly the eye, without any tail to its ends, and produced by some small spiculum of metal, would be presumptive evidence of the foreign body having become lodged within the eye, even though it could not be seen.

On the other hand, a similar wound might be occasioned by some sharp-pointed instrument, such as the point of a penknife or of a pair of scissors; but the knowledge of the instrument which caused it would at once relieve all anxiety concerning the probability of the lodgement of a foreign body. In some instances when the foreign body cannot be seen, the shape of the wound *alone* may be a valuable guide in forming an opinion whether a foreign body is within the eye. The wound may be what is called a glancing one, that is, one which, commencing with a superficial cut, gradually deepens until it penetrates, and then tapers off again to the surface, so that the deep wound may be said to have as it were a tail at each extremity, the internal aperture being small when compared with the external cut. Such an injury would be inflicted by a foreign body striking the eye as it passed it in a rapid flight, and such a wound would lead one to believe that *no* foreign body was within the eye, even though it could not be found.

The deeper parts of the eye should then be carefully scanned over. *And first the iris.* A foreign particle may sometimes be detected lying on its surface or partially buried in its structure; or if the iris has been penetrated, a small rent may indicate the point through which it has

passed. In thus exploring the surface of the iris, oblique illumination will be of great assistance, and should always be used unless the case is one beyond doubt.

The lens has next to be examined.—If possible, the pupil should be widely dilated with atropine, so as to expose a large area of the lens. Here oblique illumination is absolutely necessary, to determine whether it has been penetrated, or if a foreign particle has been lodged in its substance. If the lens has been injured, the importance of making an early examination is manifest, as it will soon become turbid, and not only prevent any foreign body within itself being seen, but will shut off the whole of the fundus from the eye of the observer.

In one patient under my care the examination of the lens on the day following the injury enabled a correct diagnosis to be made. A small cut in the sclerotic, not more than the sixteenth of an inch, indicated the point where the eye had been struck. It was a question whether a foreign particle was lodged within the eye, or whether it had glanced off after it had inflicted the wound. The pupil was dilated with atropine, and the lens examined by oblique illumination; and at its posterior and upper surface, in a line corresponding to the wound, there was a slight nebulosity, sufficient, however, to show that the lens at this point had been grazed, and to render conclusive, as there was no aperture of egress, that the foreign body was within the eye.

The ophthalmoscope should now be used, and the whole fundus of the eye thoroughly explored, directing the patient to look in different directions, so as to bring each part of it in succession into view.

It is often impossible to make any deep examination of the eye when the patient comes first under treatment, as the anterior chamber may be filled with blood. In such a

case, unless the evidence in favour of a foreign body being within the eye is conclusive, we must wait until the blood in the anterior chamber has been absorbed, before forming a prognosis. In many cases, even when the anterior chamber and the lens are clear, we can only obtain negative evidence that a foreign body is within the eye. I would say that in the majority of cases it is impossible to see the object which has been lodged in the eye; and we can only arrive at a tolerably definite conclusion by a careful analysis of the history of the accident, and by a minute examination of the superficial and as far as practicable of the deep parts of the eye.

There are many causes, either singly or combined, which prevent a foreign body being detected within the eye. If the patient is not seen soon after the accident, inflammatory changes may dull one or other of the transparent media of the eye, and either interfere with or entirely prevent a proper examination. The cornea may become steamy and dull; the aqueous turbid from corpuscular lymph or pus; and the lens, if it has been injured by the accident, may be cloudy. But suppose the lens and the parts in front of it are clear, and the foreign body is not there, hæmorrhage from the ciliary processes into the vitreous may prevent an ophthalmoscopic examination of the fundus; or hæmorrhage between the choroid and the retina, throwing the latter forward, may equally frustrate the attempt to find the object. All these causes may however be absent, and still we may fail to detect it. It may be hidden from our view, and lie either between the iris and lens, or be buried in the ciliary processes, or in some part of the margin of the fundus out of the field of ophthalmoscopic view. The fact of our not being able to see the foreign body is no proof that it is not there, and other evidence in favour of its having entered the eye

should receive due weight, and make the prognosis of the case a guarded one.

It will be useless to enumerate all the different materials which may be lodged within the eye, as the fragment of any hard substance driven with a certain amount of force will penetrate the globe and bury itself in one or other of its deeper tissues. Chips of iron, minute particles of steel, bits of stone, and fragments of percussion caps are the foreign bodies which most frequently enter the eye—so frequently, indeed, that at no time of the year is the Moorfields Ophthalmic Hospital without one or more in or out-door patients suffering from the effects of these destructive agents.

The class of men in London whose eyes are injured most frequently from these accidents are the boiler-makers and engineers, but especially the former, who cut and strike rivets. Scales of iron, or even large fragments, will often become detached from the rivet under the blows of the hammer, and fly off with great velocity. If they come in contact with the eye, they will frequently penetrate it, and in many cases after having first passed through the upper eyelid. The wound is usually a severe one, and will often lead to the ultimate loss of the eye, if it be not completely destroyed at the time of the accident.

Although amongst this class of mechanics penetrating wounds of the eye are so frequent, and so many eyes are yearly lost by them, yet it is impossible to persuade them to use the simple precaution of wearing efficient protectors. When working on the inside of boilers I believe many of them do use a wire gauze protector, but not so when employed in the workshop or out of doors.

Engineers in turning steel in a lathe frequently get minute spicula lodged in the eye—small fragments being

detached either from the chisel they are using or from the metal they are turning. The injury is usually less severe than in the case of the boiler-makers, as the particle which strikes the eye is much smaller, and the wound of less extent.

Millstone-makers often come to the Hospital with a small bit of stone in the eye, or a minute chip of the chisel with which they were working it. I need hardly say that all men who thus expose their eyes to danger ought to be made to wear protectors, but the prejudice is strong against them, both on the part of the employers and employed.

The dangers of a foreign body within the eye are—

1st. The risk of the eye being completely destroyed by the inflammation which its presence may excite.

2nd. If the eye has been destroyed by the inflammatory action which the foreign body has induced, the stump or that which remains of the eye will be liable to repeated attacks of inflammation so long as it continues embedded in it; and with each attack there will be an increased danger of the other eye becoming affected with sympathetic ophthalmia.

1st. *The risk of the eye being completely destroyed by the inflammation which the presence of the foreign body may excite.*—The primary danger of a foreign body within the eye is acute inflammation, which may run on rapidly to suppuration and destroy the eye within a week or ten days after the receipt of the injury. But the inflammation may be less severe, though equally fatal in its results. It may drag its course over a longer period; and although it may not destroy the eye by suppuration, yet plastic exudations into its different tissues may so disorganize them that total loss of sight will ensue.

In some instances the inflammation which follows the

lodgement of a foreign body in the eye rapidly abates, and it is hoped that the eye having recovered from the primary shock will suffer no further annoyance: but after a few weeks or months it again becomes painful and inflamed; and though under treatment it may again recover, yet there is always a strong disposition for the inflammation to recur, so long as the foreign body remains to act as an irritant within the eye. These recurrences of inflammation may take place at variable intervals. In some cases no long period of repose is allowed, but one attack succeeds rapidly upon another until the eye is lost; whilst in others the intermissions may be much longer. After each relapse the sight becomes more impaired, and ultimately the eye is destroyed. In all these cases there is a special danger of the other eye becoming involved sympathetically, and therefore each recurrence of inflammation should be regarded with the greatest anxiety.

The severity of the symptoms which follow the introduction of a foreign body within the eye is influenced by its size, and by the part of the eye in which it has buried itself. A large substance entering the eye is necessarily far more dangerous than a small one, not only because its presence will excite a greater amount of irritation, but on account of the greater destruction of the different coats of the eye which must follow its entrance. In many cases the lacerations of the several structures of the eye, and the consequent hæmorrhage, are so great that the eye when first seen may be pronounced as irreparably lost.

The part of the eye in which the foreign body has lodged is also of great importance. The irritation which it excites depends very much on the locality in which it is embedded, as some parts of the eye are more tolerant than others. The lens, the iris, and the space in front of it (the anterior chamber), and I might also add the vitreous

humour, will bear the presence of an extraneous particle better than if it were embedded in the ciliary processes, the choroid, or the retina. I have seen a particle of steel remain for years buried in the iris; a fragment of stone in another case, and a portion of a gun-cap in a third, rest for many years in the lower part of the anterior chamber, lying between the iris and the cornea, without producing any untoward symptoms. In a patient of Mr. Bowman's a fragment of a gun-cap floated in the vitreous close upon the retina without exciting any inflammatory action. In the lens a small particle may be lodged; and although cataract will certainly follow, yet it may remain there for many years without destroying the eye, and may ultimately be removed with the opaque lens. Although one part of the eye is more tolerant of a foreign body than another, yet great danger is incurred by its presence in any of its structures—a risk which always continues, even though the eye may for a time remain quiet. But, in addition, the situation of the foreign body determines the possibility of its removal.

2nd. *The repeated attacks of inflammation to which the stump or the remains of the lost eye will be subjected if a foreign body remains within it.*—A lost eye, with a foreign body within it, is a constant source of danger. Generally such an eye shrinks, and an unsightly stump remains; but whether it shrinks or not, it contains within it an irritant, which sooner or later will be a source of much suffering and annoyance to the patient. It will be always liable to attacks of inflammation, which are not only painful, but dangerous to the sound eye. In one or other of these recurrences of inflammation the sound eye may sympathise, and be either greatly impaired or its vision entirely destroyed by that terrible disease now so well known as sympathetic ophthalmia. As long as a foreign body remains within the stump of a lost eye, it is a constant peril to the sound

one. There is but one line of treatment to be adopted in such cases, and that is to remove the stump or what remains of the lost eye.

An attempt to search in the dark for the foreign body will probably only end in not finding it; or if we should succeed in obtaining it, a troublesome inflammation and even suppuration may follow, whereas if the lost eye is removed, all source of irritation is at once disposed of.

CASE XLIV.—*Lodgement of a chip of metal in the eye three years ago—Complete loss of vision—Recurrences of inflammation.*

Leonard S., æt. 16, works at iron shipbuilding and boiler-making. He applied to the Hospital April 18, 1865, on account of the continued pain in the right eye, which had suffered from an injury three years previously. All sight was gone; he had not even perception.

He stated that three years ago his mate was knocking in a cotter to draw together two iron plates, when a fragment of it flew off and struck the right eye, and, he thinks, entered it. Very shortly after the accident he was quite blind with that eye. He has suffered from repeated attacks of inflammation; and although the eye is quiet, he says he has *always pain in it*, and that the sound eye is becoming affected. When he attempts to read, the sound eye waters, and the type soon becomes confused, and he is obliged to desist. It always feels weak, and he is unable to use it much by candle light or in strong light.

State of the injured eye.—The eye is smaller than the sound one, very soft, —T 3, and shrunk to about one-sixth. It is perfectly quiet, and at present free from irritation. The cornea is clear, and there is a deep anterior chamber, but the aqueous is yellow and serous. The lens is cataractous, and the pupil adherent to its capsule.

As the eye was a lost and shrinking one, always painful, liable to recurrences of inflammation, and acting prejudicially on the other, I advised him to have it excised, particularly as there was reason to believe that a foreign body was lodged within it. He consented, and I accordingly removed the eye.

An examination of it afterwards showed the following condition. In the sclerotic, one-eighth of an inch from the outer border of the cornea, was a small puckered cicatrix. On making a section of the globe through the optic nerve, the choroid was seen lying in contact with the sclerotic, but the retina was entirely detached, adherent only at the optic nerve and at the ora serrata, and the space between filled with a yellowish limpid fluid. The lens was opaque. The ciliary processes on the inner side of the eye, and opposite to the cicatrix in the sclerotic, were coated with lymph, and lying buried in them was a small scale of metal. At the cicatrix of the sclerotic, the choroid and a portion of the ciliary processes were firmly adherent. All vitreous had disappeared except a small portion, which seemed to hang as a film around the ciliary processes.

There are, however, cases which, though several in number when collected from the experience of many years, must still be considered as exceptional, in which the presence of a foreign body within the eye has given but little, if any annoyance.

In some instances the eye has suffered severely immediately after the accident, but in a few days all the active inflammatory symptoms have subsided, and the eye has remained for many years afterwards a perfectly useful organ. In other cases the introduction of the foreign body has created at the time only a temporary sense of uneasiness, and has never since given the patient the slightest discomfort. It may be, as has been suggested,

that in some cases the foreign body becomes coated with lymph, and thus encysted it has been isolated from the rest of the eye, and the primary irritation which its presence first excited having abated, it afterwards ceased to give any trouble. This explanation may be applicable to a few cases, but it certainly is not to the majority, as I have seen chips of metal, small splinters of wood and of stone which have remained in the eye for many years without causing any irritation, and yet not the smallest film of lymph could be detected on their surface.

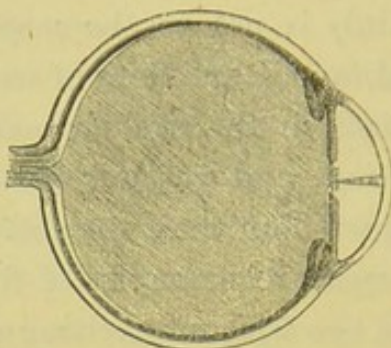
The following cases are examples of foreign bodies remaining within the eye without exciting any irritation.

CASE XLV.—*Lodgement of a thorn in the anterior chamber of the eye for nearly five months—No irritation after the first few days.*

Abraham S., æt. 10 years, came under the care of Mr. Critchett at the Ophthalmic Hospital May 2, 1865, on account of an injury he had received to his left eye a fortnight before Christmas, nearly five months ago. He was running across a walk to the school when a projecting bough of the hedge struck him in the left eye. His eye at once became very painful, and in a few days he found the sight of it dim. The pain in the eye ceased in two or three days, but the sight became worse, and about a month after the accident he could not do more than discern shadows. During the last three or four weeks, he says, his vision has materially improved. On examining the eye, the cause of all the symptoms he has suffered is manifest. At the time of the accident a thorn had penetrated the cornea, and traversing the anterior chamber, the point of it became fixed in the lens, and in this position it has ever since remained. It can now be seen, by looking sideways at the eye, stretching across the anterior chamber,

with the base of the thorn against the inner surface of the cornea, and its apex stuck into the lens capsule as represented in fig. 56. The lens had speedily become cata-

FIG. 56.



ractous after the accident, but the soft lenticular matter had been in a great measure absorbed, and there now remains a piece of opaque capsule with some lens matter occupying the pupillary space.

The eye is quiet, and in no way seems to resent the presence of the foreign body. It might, however, slip from its site, and with its change of position excite an ophthalmitis which might be destructive of the eye. Mr. Critchett therefore decided to remove it.

CASE XLVI.—A fragment of stone lodged in the anterior chamber four years without producing any irritation.

W. B., æt. 54, applied to the Hospital, Aug. 23, 1864, on account of a slight injury he had the day previously received to the right eye. On examining it, a large fragment of some foreign substance was seen lying on the iris at the lower and outer part. His story was that the foreign body within the eye was the result of an old injury and gave him no trouble, and did not interfere with his sight. Four years ago whilst striking a stone with a hammer a fragment of it flew off and struck the globe, and entered

the eye through a small wound in the cornea, the cicatrix of which was plainly visible. At first he suffered from the eye being much inflamed, but after a few weeks it became quite quiet, and has remained so ever since. The iris acts well, except at the point on which the piece of stone rests, where it is perfectly motionless. The vision is good.

In the Royal London Ophthalmic Hospital Reports, vol. i. p. 264, Mr. Critchett relates the following case of "a foreign body for sixteen years loose in the anterior chamber."

CASE XLVII.—"In June, 1856, a young farmer applied to me for advice under the following circumstances. He stated that whenever in reading or writing he leant his head forward, he felt something glide along in his left eye in such a way as to get in front of his sight and obscure the object. On examining the eye, when the head was bent forward, a small piece of glass could be seen on the inner surface of the cornea, and as the head was raised it could be seen gradually to slip back, and to rest in the sulcus formed by the ciliary attachment of the iris and the sclerotic. When in that situation it became invisible, but could be made to rest upon any part of the surface of the cornea by altering the position of the head. The history given by the young man was as follows:—About sixteen years previously he was amusing himself with a small glass toy, the object of which was to produce a slight explosion when held in a candle. He felt a small fragment of the glass strike his eye. This was followed by some slight inflammation, which speedily subsided, leaving the symptoms above described. The eye had been subject from time to time to slight attacks of inflammation, and generally felt weak; this, together with the dimness of vision, induced him to seek relief.

“The patient having been seated in a chair, a broad needle was passed into the anterior chamber close to the ciliary attachment of the iris, and the aqueous humour was allowed to flow out. The minute and transparent particle of glass was not seen, but it either escaped through the wound or became entangled in it, as it never occasioned any further inconvenience.

“The eye was examined more than a year afterwards ; it was perfectly healthy, and vision was good. Nothing had been seen or felt of the foreign body since the operation.”

“The remarkable feature in this case would seem to be the residence of a foreign body in the eye for so many years, and in a constant state of movement, with such slight irritation, and with no injury to the organ.”

TREATMENT OF FOREIGN BODIES WITHIN THE EYE.—In all cases of foreign body within the eye the treatment undoubtedly is, if it can be seen and the removal of it is practicable, to take it away. But the object may be so placed that it can be seen, yet from its situation an attempt to remove it will incur a risk of loss of the eye, or from the difficulty of reaching it will probably fail : how then should we act? My answer to this is—

1st. If it is creating much irritation, endeavour to remove it, as, though failure may be the result, yet a chance has been afforded to the eye, which, had it been successful, might have saved it. An eye inflamed and painful from the presence of a foreign body within it is certain to be ultimately destroyed ; an attempt therefore to rescue it is justifiable, notwithstanding it may be accompanied with a risk of immediate loss. As regards the patient it is really for his advantage, if the eye, so far as experience can tell us, is certain to be lost, that it should perish quickly and be removed by the surgeon, rather than be destroyed by the slower but equally sure process of a subacute in-

flammation, which may possibly involve the other eye in a sympathetic ophthalmia, and thus greatly endanger its safety.

2nd. If, however, the foreign body is creating little or no irritation, and there is a fair amount of vision, and an attempt to remove it would greatly hazard the eye, it should be left alone; but the patient should be either kept under constant observation, or be cautioned that as soon as any symptoms of irritation show themselves either in the injured or the sound eye, he must seek the aid of his surgeon.

In all cases where the surgeon deems it right to attempt the removal of a foreign body from within the eye, he ought to have a discretionary power, that if he fail to find it, he may remove the globe whilst the patient is still under chloroform, *if circumstances render it advisable.*

The part of the eye in which the foreign body is lodged materially affects the difficulty and the danger of removing it. If it is a chip of metal or a small fragment of some other material *lying on the iris*, it may often be easily reached with a pair of fine forceps through a small opening made in the cornea with a broad needle, and be drawn away. But if it is *deeply buried in the iris*, or there is any danger of dislodging it, or the iris is likely to be torn in the attempt to remove it, it is best to make an opening in the margin of the cornea with a moderate-sized iridectomy knife, and, having introduced a pair of iris forceps through the wound, seize hold of the iris near the foreign body, and gently draw the portion of it on which the foreign body is lodged out of the eye, and cut it off with a pair of fine scissors. The case is almost sure to do well.

If the foreign body is lodged in the lens, an early attempt should be made to remove it while it can be seen, for the

lens having been injured will soon become cataractous, and then it will be hidden from view. Frequently patients do not present themselves until some days or weeks after the receipt of the injury, and by that time the lens has become quite opaque. In such cases, if there is any evidence of there being a foreign body within the eye, it is well at once to extract the lens, as it may be buried within it; but even if it is not found, the removal of the lens will clear the way for further treatment. In many cases where it is determined to remove a cloudy or opaque lens with the hope of finding a foreign body, it will be expedient to perform an iridectomy as a preliminary to the extraction operation. More space will thus be given to work in, a larger field will be afforded for a visual examination, and the chance of bruising the iris will be much diminished; and as the excision of a piece of iris may be said to be almost devoid of danger, the safety of such an exploratory operation will be increased.

Foreign bodies in the vitreous.—A foreign body may be lodged in the vitreous and remain there for a long period provided it does not exert any injurious pressure on any of the other parts within the eye. The danger is, that with the motions of the eye its position may be shifted, and falling to the fundus may then excite a dangerous ophthalmitis. In a patient under the care of Mr. Bowman at the Ophthalmic Hospital the density of the vitreous appeared to support a fragment of a gun-cap which had been lodged within the eye. The man was engaged in charging percussion caps with the detonating material, when one of them accidentally exploded, and a scale of the copper case penetrated the eye through the sclerotic and buried itself in the vitreous, but without wounding the lens. Examined with the ophthalmoscope the piece of the percussion cap could be seen hung up as it were in the vitreous, and

moving slightly with each up and down movement of the eye. The vitreous seemed to exert a preservative influence over the foreign body, for the piece of copper cap maintained its lustre, and when seen many weeks after it had entered the eye, was still as bright as when it first penetrated.

A very interesting case of a foreign body buried in the vitreous is related by Mr. Dixon in the Royal London Ophthalmic Hospital Reports, vol. i. p. 280, in which he was not only able to detect it with the aid of the ophthalmoscope, but succeeded in removing it, and thus regained for the man a useful eye.

The following is an abstract of his report of the case.

Successful extraction of a foreign body from the vitreous chamber.—“James Perkins, a cooper, aged 24, came to the Hospital December 2, 1858, half an hour after receiving an injury to the left eye. As he was knocking an iron hoop off a cask, the edge of the chisel broke, and a chip of metal flew off and struck the lid. A small vertical wound, a little above the margin of the left upper lid, marked the spot where the chip had penetrated the skin. On everting the lid, I found a corresponding wound in the conjunctiva covering the tarsal cartilage. In the sclerotic, nearly on a level with the upper border of the cornea, and about a line from its inner edge, was a small gaping wound, a line long, surrounded by a patch of blood effused beneath the conjunctiva. A minute vesicle of vitreous humour showed itself in the opening. The pupil was active, and the patient could read large type, but saw all objects through a slight mist.

“I at once dilated the pupil with atropine, and examined the eye with the ophthalmoscope. At the upper and inner portion of the pupil was a clot of blood, behind the lens, hanging down from the wound and slightly waving to and

fro in the vitreous. The rest of the humour was perfectly clear; and as the cornea and lens were also quite transparent, I obtained a good view of the retina. Just below the optic nerve I noticed a small rounded body, looking almost like a minute air-bubble; and it appeared as if this globule were a portion of clear lymph, effused around a foreign body which was assumed to have entered the eye. There was, however, no redness surrounding this little globule; and this absence of vascularity made me doubt that what I saw could really be lymph."

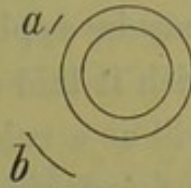
The man was kept under observation, and the report states that "on December 6 the sight was less dim than on the patient's first visit, and he could read a good-sized type pretty easily. The sight continued to improve, and by the 30th all redness of the conjunctiva had disappeared; the little wound in the sclerotic (*a*: fig. 57) presented a hardly traceable grey line; there was no intolerance of light."

At a subsequent examination of the eye Mr. Dixon states that "at a sudden turn of the globe there started from behind the inner portion of the iris an oblong black body, which was instantly recognised as a chip of metal. It was entangled in a few thread-like remains of clot, which kept it suspended in the vitreous humour, and allowed it to move freely backwards and forwards, while its movements outwards were checked by the body of the lens." Mr. Dixon determined to remove it; but as he found that the foreign body sank backwards and disappeared when the patient was lying down, he says "I gave up the intention of using chloroform, which would have rendered the recumbent position necessary."

"The patient being seated in a chair close to a window, I stood behind him; the lids were separated with a spring speculum, and I fixed the globe by nipping up a fold of conjunctiva just above the cornea. Then I thrust a

Jaeger's lance knife through the coats of the eye at *b*, directing the point of the instrument backwards to avoid wounding the lens. Having withdrawn the knife, I passed in a forceps, invented by Assalini for catching the iris in his operation for artificial pupil, which opens when one of the branches is pressed, and closes again by means of a spring when the pressure is relaxed. I could obtain but a dim view of the foreign body, for it was by no means brilliant, and only now and then glanced indistinctly as the light fell upon it. After two ineffectual grasps, I was so fortunate as to catch it by one end and draw it out. The lids were immediately closed with plaster, and cold rags applied for a short time. The foreign body proved to be part of the edge of a chisel: it was about the tenth of an inch long, and weighed a quarter of a grain."

FIG. 57.



"On examining the eye on January 6, I found the pupil circular and its area clear. The patient could read the large type on his bed ticket. The wound *b* made at the operation had drawn together. There was, of course, a small quantity of blood extravasated beneath the conjunctiva, but very little increased vascularity of that membrane.

"*January 13.*—The pupil to-day had recovered from the effects of the atropine, and was round and contractile. There was no intolerance of light, and the patient could read a pica type. The lens was perfectly clear." From this date the patient continued to improve.

A foreign body within the eye suspected, but not actually seen.—All the evidence we can collect may be in favour of there being a foreign body within the eye, yet if we cannot see it, and we have no reason to believe that it is buried within the lens, we must wait for symptoms, and treat them as they arise. Leeches to the temple and soothing

applications to the eye should be ordered. A warm fomentation of belladonna is very grateful, and may be used frequently; or if cold is preferred, a belladonna lotion may be applied to the eye by keeping a fold of linen wet with it laid over the closed lids. The progress of the case will as a rule quickly determine whether there is a foreign body within the eye, although, as I have already shown, in some exceptional instances the foreign body excites but little if any irritation.

The symptoms which strongly favour the presumption that a foreign body is within the eye when a careful examination fails to detect it, are—

I. An increase or a continuance of the inflammation primarily excited by the injury in spite of all the remedial agents which may have been used to arrest it.

II. If the first inflammatory symptoms have subsided, the continuance of a subacute choroido-iritis or choroido-retinitis uninfluenced by proper local and constitutional treatment.

III. The non-union of the corneal wound, when the cornea has been the part of the eye involved in the injury; or the only partial closure of the wound, leaving a fistula through which there is a constant drain of the aqueous, causing the iris to lie in contact with the cornea.

IV. Severe and continued pain in the eye, unproportioned to the apparent existing inflammation, and unalleviated by the ordinary local applications and medicines.

In every case where the eye is destroyed for visual purposes by the inflammation induced by a penetrating wound, and there is reason to believe that a foreign body is lodged within it, the only treatment to be adopted is to excise it. It has ceased to be an organ of vision, and at some future period it may, and very probably will, become a source of much danger to the sound eye.

In the two following cases the eyes were destroyed by large fragments of metal having been lodged within them. Although in each case the foreign body was very large, yet in neither was the evidence at the time of the accident conclusive that it had entered the eye.

CASE XLVIII.—*A large piece of iron, the fragment of a rivet, lodged in the eye, followed by sloughing of the cornea—Excision of the eye.*

Joseph M., æt. 26, a boiler-maker, came under my care at the Ophthalmic Hospital November 27, 1864, on account of an injury he had received a few hours previously to the right eye. Whilst cutting a cold rivet, a fragment of it flew off and struck the right upper lid, making a vertical cut a quarter of an inch in length, which extended through its cartilaginous border, and inflicted on the eye a vertical wound, involving the upper two thirds of the cornea, and running the eighth of an inch through the sclerotic into the ciliary region. The patient was first seen by the house surgeon, who brought the edges of the wound together with a fine pin and twisted suture, and closing the lid, applied over it a cotton-wool compress and bandage, and ordered two leeches to the temple. The man had an impression that the piece of iron which struck his eye was a large fragment, judging from the surface of the rivet from which it had been splintered, and concluded that after inflicting the wound it had glanced off.

Three days after the injury there was great chemosis of the conjunctiva; the cornea looked steamy and opaque, but the eye was not very painful; the large wound of the globe had not closed, and the continued escape of aqueous kept the eye quite soft. The needles were removed, as the edges of the lid had perfectly united.

December 3.—The eye has progressed very unfavour-

ably; the cornea has sloughed. I strongly advised the man to have the eye removed, as it was now useless, and it was also very probable that a chip of metal was buried in the globe which might be the cause of great suffering and annoyance hereafter.

December 7.—I removed the globe, and afterwards, on making a section of it, the following was

FIG. 58.



found: Extensive hæmorrhage had taken place between the choroid and retina, the latter being completely detached, except at one part of the fundus, where, lying upon it and embedded in a mass of lymph, was a large fragment of iron, of the shape and size represented in the wood-cut.

The man did well, and in four days left the Hospital.

CASE XLIX.—*Lodgement of a large piece of iron within the eye for eight months, followed by complete loss of sight, shrinking of the globe, and constant pain.*

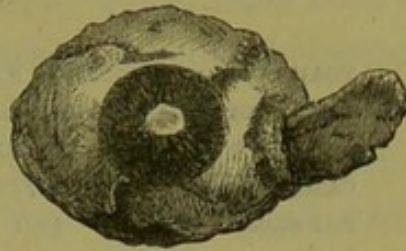
J. L., æt. 40, applied to the Middlesex Hospital on Sept. 6, 1866, for admission as an in-patient. He stated that eight months ago he was engaged cutting a cold rivet, when a piece of the chisel flew off, and striking the left upper lid, passed through it and wounded the eye. He has been under treatment ever since. All sight was lost immediately after the accident. He has suffered constant pain in the eye, and it is now so severe that he is unable to do any work. As he can obtain no relief from medicines, he has come up from Sunderland for the sole purpose of having the eye removed.

State on admission.—The eye was red and irritable; painful to the touch; its tension diminished to $-T 2$, and shrunken about one third. The pupillary space was occupied by opaque capsule, to which the margin of the pupil

was adherent. The movements of the eye were very limited. The right or uninjured eye was now beginning to trouble him. It felt weak and gritty, and would not face the light. From these symptoms I was induced to believe that there was a foreign body within the eye. I therefore at once acceded to the man's request and excised the globe.

Fig. 59 is a good representation of the eye after its removal. It was somewhat flattened and soft, and projecting from the sclerotic some distance from the outer side of the cornea was the large piece of iron which is well shown in the drawing. The piece of iron could be felt extending within the eye to a point below the level of the centre of the lower margin of the cornea.

FIG. 59.



On September 18 the patient left the Hospital, feeling quite well, and relieved of all pain.

In this patient three important points are illustrated.

1st. The non-subsidence of the irritation originally produced by the injury. Eight months after the accident and still the eye was inflamed.

2nd. The constant pain—pain so severe as to prevent his working, and to make him desire that the eye should be removed.

3rd. The commencement of sympathetic symptoms in the sound eye.

Any one of these symptoms might be induced by other causes; but the existence of all three in one patient, coupled with the history of the accident, are so many links in a strong chain of evidence in favour of a foreign body being lodged within the eye.

CHAPTER VII.

TRAUMATIC INTRAOCULAR HÆMORRHAGE AND RUPTURE OF
THE GLOBE.

TRAUMATIC INTRAOCULAR HÆMORRHAGE: DEFINITION OF—DIVISION INTO ANTERIOR AND POSTERIOR INTRAOCULAR HÆMORRHAGE—HÆMORRHAGE INTO THE ANTERIOR CHAMBER: CAUSES, PROGNOSIS, AND TREATMENT OF: CASES OF—DEEP OR POSTERIOR INTRAOCULAR HÆMORRHAGE: FIRST, BETWEEN CHOROID AND RETINA, CASES OF; SECOND, BETWEEN CHOROID AND SCLEROTIC, CASES OF; THIRD, HÆMORRHAGE INTO THE VITREOUS, CASES OF—PROGNOSIS AND TREATMENT OF DEEP OR POSTERIOR INTRAOCULAR HÆMORRHAGE—RUPTURE OF THE GLOBE, CAUSES OF—USUAL SEAT OF THE RUPTURE, PROGNOSIS AND TREATMENT OF—CASES OF RUPTURED GLOBE—OPERATION FOR EXCISION OF THE GLOBE—DIRECTIONS FOR WEARING AN ARTIFICIAL EYE.

TRAUMATIC INTRAOCULAR HÆMORRHAGE must be clearly distinguished from those hæmorrhages within the eye which are so commonly associated with, but secondary to, some special disease, or from that which is seen occasionally in patients who, without suffering from any actual disease, have manifestly a peculiär hæmorrhagic diathesis. It is dependent solely on an injury causing rupture of the vessels of one or more of the vascular coats of the eye, and a consequent effusion of blood. It may occur either *with or without* rupture of the external coats of the eye. For convenience of description, and also with reference to the severity of the results, intraocular hæmorrhage may be divided into *anterior* and *posterior* hæmorrhage.

Anterior intraocular hæmorrhage is the effusion of blood from the more superficial structures of the eye into the chambers anterior to the crystalline lens. It is generally

induced by a less severe injury than that which gives rise to the deep or posterior hæmorrhage, and its results are far less detrimental to the eye.

Although hæmorrhage within the eye is very frequently limited to the chambers anterior to the lens, yet anterior hæmorrhage is also very often associated with the deep or posterior form.

Anterior hæmorrhage may take place from an injury to the iris or the ciliary processes; it may be confined solely to the anterior chamber, or the posterior chamber between the iris, and the lens may also be occupied by the clot. Thus, if the bleeding commence from the ciliary processes, the blood usually trickles through the pupil, and occupies more or less of the anterior as well as the posterior chamber.

Bleeding into the vitreous humour may and frequently does happen from a laceration of the ciliary processes; but this is a more severe injury, and at present we are only considering the anterior form of hæmorrhage.

HÆMORRHAGE INTO THE ANTERIOR CHAMBER.—This is the most common form of intraocular hæmorrhage, and at the same time the least severe. It may vary in extent from a few drops of blood to a quantity sufficient to fill both the anterior and the posterior chambers. Generally, however, when the bleeding arises from an injury to the vessels of the iris, it is confined to the anterior chamber; for, as the blood flows, the iris is pushed backwards towards the lens, and the blood, rapidly coagulating, does not pass through the pupil into the posterior chamber, even though the hæmorrhage be sufficient to form a clot large enough to fill the whole of the anterior space. This, however, is not usually the case when the hæmorrhage occurs from the ciliary processes; for the anterior chamber

of the eye is so much larger than the posterior, that the blood soon finds its way through the pupil, and gravitates to the bottom of the space in front of the iris.

The most usual causes of hæmorrhage into the anterior chamber are either rupture of one or more of the superficial vessels of the iris, or a distinct laceration of its structure; or a detachment of a portion of the iris from its ciliary circumference (coredialysis). The blood, as it is effused from the lacerated vessels of the iris, sinks at once to the bottom of the anterior chamber, quickly coagulates, and, if not much in quantity, may be seen as a small clot occupying its lower part, and moulded as it were to it. If, however, the bleeding be more severe, the whole anterior chamber may be filled with one large coagulum, which will entirely occlude the pupil and iris. This more extensive hæmorrhage is usually owing to a detachment of the iris from its ciliary border, when, on account of the number of vessels necessarily torn through, and also of their larger size, the quantity of blood which is poured out is considerable.

Prognosis.—If the patient is first seen within a few hours, or even on the day following the injury, the clot of blood in the anterior chamber, according to its size, will mask more or less the immediate cause of the hæmorrhage. But after a few days, when the blood has been absorbed, a rent in the iris, or a separation of it from its ciliary connexion, will usually indicate the site from which the blood has been effused. Occasionally the cause of the hæmorrhage has been a simple rupture of some superficial vessel of the iris, in which case the interval of time necessary for the absorption of the blood will probably have obliterated nearly all trace of the injury.

If, on examination, the injury is found to be limited to a detachment or to a laceration of the iris, and none of

the deeper parts are involved, and there is no rupture of the external coats of the eye, the prognosis is favourable; and this even though the detachment of the iris from its circumferential margin be as much as one-sixth or even one-fourth of its entire extent. But if, in addition to the laceration or detachment of the iris, there is a wound of the sclerotic or cornea, the danger of the injury is greatly increased, and the prognosis is much more unfavourable.

The bleeding from a coredialysis, or separation of the iris from its ciliary border, is generally extensive, even though the detachment is small; and it often goes on until the anterior chamber is filled with blood, when the clot seems to arrest the continuance of the flow by pressing on the vessels from which it is being effused. Shortly after the injury, it is very probable that the eye may become inflamed and painful, partly from the contusion which all the tissues of the eye must have suffered from the blow, and partly also from the special injury to the iris itself. If, however, the external coats of the eye have been uninjured or but slightly contused, and the hæmorrhage is limited to the anterior chamber, the prognosis will be favourable.

The clot of blood in the anterior chamber will be first macerated by the aqueous humour, and then become rapidly absorbed; and in from three to eight days after the accident, according to the quantity of blood effused, sufficient progress will have been made to allow the surgeon, by a visual examination, to ascertain the exact extent of the injury. For a long but variable time after the clot has disappeared, the iris presents a greenish appearance, owing to the aqueous having become stained a little yellow from the blood; but this ultimately disappears; and, although a rent in the iris or a coredialysis remains, yet the patient may have a good useful eye. The separa-

tion of the iris from its ciliary attachment may be so extensive as to form another pupil, through which, by an examination with the ophthalmoscope, the fundus of the eye may be clearly seen ; still, if the posterior parts of the eye are sound, good single vision will remain : the second image which will be formed on the retina will not be appreciated. A good illustration of this fact is recorded in Case XXIV., p. 121.

Treatment.—When the hæmorrhage is confined to the anterior chamber, and there is no rupture of any of the external tunics of the eye, the case generally does well. In this, as indeed in all cases of injury, rest to the eyes is essential : all work should for a time be forbidden, and the eyes should be shaded from strong light. If the anterior chamber is occupied by a large clot of blood, great care for the first few days after the injury must be taken of the eye, as, until it has been absorbed or nearly so, a correct diagnosis cannot be arrived at. As the cause of the hæmorrhage is always some violence, it is reasonable to anticipate some contusion ; and to guard against any untoward after-results, such as iritis or ophthalmitis, it is a wise precaution to apply two or more leeches to the temple ; and, if the eye should continue painful, to repeat them in twenty-four or thirty-six hours. Cold applications are the best suited, and afford the most comfort to the eye. A double fold of linen, wet with cold water, may be laid over the eye, and kept in its place with a single turn of a light roller, and moistened from time to time with a little fresh water from a sponge ; or, if the eye be painful, a cold lotion of belladonna may be used in the place of the water-dressing.

A moderate diet and a limited amount of stimulants should be enjoined, as placing the patient in a condition favourable to recovery ; and the bowels, if necessary,

should be acted on with some gentle purgative. The administration of mercury is not necessary, and will do harm; it will not promote absorption, but will depress the patient.

The treatment formerly recommended, of puncturing the anterior chamber to let the blood escape, is wrong both in theory and practice. The object of the puncture is to let the blood escape; but this it must generally fail to do, as the blood, within a few minutes after its effusion, forms a coagulum, and will not run from the eye through an incision in the cornea. Even if the eye could be seen by the surgeon immediately after the infliction of the injury, and before the blood had coagulated, still the treatment would be prejudicial, as it is not the presence of the blood in the anterior chamber which is likely to give rise to untoward symptoms, but the contusion or laceration of the iris which has produced it. The mere removal of the blood will not benefit the eye, whilst the attempt to do so may injure it.

CASE L.—*Hæmorrhage into the anterior chamber from a blow on the eye with the fragment of a rivet.*

Francis P., æt. 31, a shipwright, came to the Hospital on the morning of June 27, 1865, having, about four hours previously, met with an injury to the left eye. Whilst cutting a cold rivet, a fragment, about one-fourth of an inch in size, flew off and struck the eye. On examination, the lower half of the anterior chamber was seen to be occupied by a clot of blood. The eye was red; but there was no abrasion of the cornea, or wound of the conjunctiva. The upper border of the pupil could be seen, but the lower half of it was concealed by the blood. He was ordered fifteen grains of purgative powder at bed-

time; and to apply a fold of linen, wet with the belladonna lotion, over the eye.

June 30.—The blood was nearly absorbed. The pupil could be seen widely and evenly dilated. There was no pain in the eye. He was ordered to continue the lotion.

July 4.—The blood was now absorbed, and the eye free from all pain. No detachment of the iris from its ciliary border could be seen.

It is probable, in this case, that the hæmorrhage was caused by the rupture of some small vessels near the greater circumference of the iris, but that there was no absolute separation or coredialysis.

The man ceased his attendance as an out-patient, having fully recovered the use of his eye.

CASE LI.—*Hæmorrhage into the anterior chamber, following a blow on the eye.*

William N., æt. 34, a shipwright, came to the Hospital on January 18, 1864. He stated that on the previous evening, whilst striking a rivet, a fragment of the size of a pea flew off and struck the eye.

State on admission.—At the lower and inner margin of the cornea there was a small jagged abrasion; and corresponding with it was a small clot of blood lying at the bottom of the anterior chamber, and resting against the iris, but not of sufficient size to reach the pupil. The upper half of the pupil acted well and rapidly; but the lower half was quite stationary, and unacted on by the stimulus of light. The sight was slightly dim. He was ordered two leeches to the temple, and a belladonna lotion to the eye.

Jan. 22.—All the blood was absorbed. The eye was quiet and free from pain.

Jan. 25.—The eye was now well, and the patient was discharged.

In this patient, the hæmorrhage probably took place from a rupture of one or more of the vessels of the iris at its ciliary circumference. The temporary paralysis of the lower portion of the iris was due either to the pressure of the blood-clot, or to some contusion of the ciliary nerves which supply its inferior border.

DEEP OR POSTERIOR TRAUMATIC HÆMORRHAGE, as it is commonly called to distinguish it from the hæmorrhage of the more superficial structures into the part of the eye anterior to the lens, may occur—

1. Between the choroid and retina ;
2. Between the choroid and sclerotic.
3. Hæmorrhage may take place into the vitreous humour.

In the first the retina is separated by the clot from the choroid ; whilst in the second the choroid is detached from the sclerotic. Both forms may, however, be present in the same eye, when the hæmorrhage is caused by great violence.

In considering the first two forms of hæmorrhage, it is a fact of pathological interest to notice, that, though both may and often do occur together in the same eye after a severe injury, yet there are special circumstances which may cause the one kind of hæmorrhage to predominate over the other, and even the one to take place independently of the other. It must, however, be remembered that, in many cases of rupture of the globe, in which posterior hæmorrhage almost invariably occurs, the primary injury is so severe that all the vascular tissues of the eye are included in it, and hæmorrhage from each at once ensues.

1. HÆMORRHAGE BETWEEN THE CHOROID AND RETINA.— This may take place either *with* or *without* rupture of the external tunics of the eye. It is generally caused by blows with the fist or from some large foreign body, or by striking the eye in a fall against a projecting object. The effusion of blood may be limited to a small clot, or it may be so extensive as at once to entirely destroy the eye for all visual purposes. The severity of the injury is very greatly increased when it is accompanied with a rupture of the sclerotic or cornea.

When posterior hæmorrhage is due to a blow on a previously healthy eye, *the external coats of the eye not having been ruptured*, I have generally found that the principal hæmorrhage is between the choroid and retina. The blood has been effused from the anterior surface of the choroid, and has caused a separation of the retina from it, in some cases only partially, in others to its entire extent, from the entrance of the optic nerve as far forwards as the ora serrata. In the severe cases there may be some hæmorrhage between the choroid and sclerotic, and small scattered clots may be seen; but, as a rule, this is not its chief seat, for the principal effusion is between the choroid and the retina. In occasional cases instead of the retina being much detached from the choroid when hæmorrhage takes place between these structures, the blood bursts through the retina, and, if only small in quantity, forms a clot which will be often seen lying on the retina; or, if the bleeding be more extensive, it may force its way through the hyaloid, and become extravasated into the vitreous humour.

In cases where the posterior hæmorrhage is associated *with rupture of the external coats of the eye*, we seldom, if ever, find that the bleeding has been limited to between the choroid and retina, but that it has taken place to a greater

or less extent from different points of all the vascular tissues of the eye which have been involved in the injury. As there is usually an escape of some vitreous at the time of the accident, it is an interesting question to decide whether the hæmorrhage so frequently met with between the choroid and retina is due to a direct rupture of the choroidal vessels from the blow; or whether a primary separation of the retina from the choroid may have been occasioned by the sudden loss of vitreous, and the hæmorrhage is consequent on, but secondary to this detachment? I believe that, in nearly every case, it will be found that the hæmorrhage is due solely to a direct rupture of the choroidal vessels, and that the separation of the retina is brought about by the blood being poured out between it and the choroid.

In examining carefully into the history of these cases, we find that although, in many of the eyes which had been ruptured, the lens and a certain amount of vitreous had escaped through the wound, yet that the loss of vitreous was small at the time of the accident, and certainly not sufficient in a *healthy* eye to produce a detachment of the retina. In some of the cases of ruptured eyes which have come under my care, I am sure that the great bulk of the vitreous which had been lost did not escape at the time of the infliction of the injury, but had drained away afterwards from the pressure of the increasing blood-clot behind the retina squeezing it out of the eye as it occupied itself the vitreous space.

The following case is an example of a limited hæmorrhage between the choroid and retina. The structure of the retina had been torn through; and the remains of, and the site occupied by, the blood-clot were still easily seen by the ophthalmoscope ten months after the receipt of the injury.

CASE LII. — *Blow on the eye ten months previously—
Limited hæmorrhage between the choroid and retina—Rent
of the retina immediately in front of the clot.*

Wm. R., æt. 39, a sailor, came to the Hospital from Sunderland on July 12, 1865. He stated that, ten months ago, he had received an injury to the right eye. One day, whilst on board ship, his foot slipped, and in his fall he struck the right eye against one of the stanchions of the ship. The eye had now recovered from the injury, but his sight was very much impaired. In the immediate axis of vision he was blind; but by turning the eye either way, so as to look laterally, he was able to read letters of No. 16 of Jaeger. When he looked straight at an object, he was unable to see it; but he could discern bodies on either side of it.

On examination with the ophthalmoscope, the cause of his defect of sight was manifest. In the immediate neighbourhood of the yellow spot, and almost in the axis of vision, there was seen a small rent in the retina, the edges of which could be distinctly made out; and lying upon what now represented the choroid in this site was a black deposit, evidently either the remains of a blood-clot with some pigment, or else a deposition of pigment, which had taken place either during or since the absorption of the clot.

In many instances, where hæmorrhage between the choroid and retina has followed as the result of an accident, and the structures in the front of the eye are still clear, and not masked by any anterior bleeding, a diagnosis of the extent of the injury and of the seat of the hæmorrhage may be made with the ophthalmoscope. The red clot may be seen at the fundus of the eye, bulging forward the retina; and oftentimes a careful examination will detect the retinal vessels running over its surface. The following case is an illustration.

CASE LIII.—*Limited hæmorrhage between the choroid and retina, from a blow with a piece of a rivet; the blood-clot being clearly seen by the ophthalmoscope a few hours after the accident.*

James R., a boiler-maker, came to the Hospital on September 9, 1865, on account of an injury he had that morning received to the right eye. Whilst engaged in striking a bolt, a piece of iron flew off and struck his right eye. On the nasal side of the cornea there was considerable ecchymosis of the conjunctiva. The pupil was slightly more dilated than that in the other eye, but, within a limited range, acted sharply. A portion of the field of vision on the outer side was quite destroyed. The anterior chamber and the humours of the eye were clear.

Examined with the ophthalmoscope, a blood-clot was seen at the upper and inner part of the eye, behind the lens, and bulging into the vitreous body. Another smaller clot was also seen on the same side, but nearer the fundus of the eye. The hæmorrhage was probably between the choroid and the retina, bulging the retina forwards. The outline of the clots was evenly defined.

This man continued for nearly five weeks under treatment. When last seen, the ecchymosis of the conjunctiva had quite disappeared, and all the blood within the eye had been absorbed; but the sight had in no way improved. There was a detachment of the retina on the inner side; and the outer part of the field of vision was quite destroyed.

From the frequent opportunities I have had of examining eyes which had been removed on account of their complete loss from deep intra-ocular hæmorrhage, and in many cases accompanied with more or less extensive rupture of their

external coats, I am satisfied that though the seat and extent of the hæmorrhage are greatly determined by the nature of the injury, yet they are also much influenced by the soundness of the eye at the time of its infliction.

The following very interesting case of traumatic hæmorrhage occurring first between the choroid and retina, and afterwards between the choroid and sclerotic in the same eye, but at different times and under different circumstances, is an example of what I have just stated.

The eye, at the time of the original injury, was healthy; and hæmorrhage undoubtedly occurred between the choroid and the retina from a direct rupture of the anterior choroidal vessels. Nine months after the injury the patient came under my care. The eye was then quite blind, and excessively painful, and there was a large ciliary staphyloma. I excised the eye; and, during the operation, the staphylo-matous portion either gave way or was accidentally pricked by the scissors, when some fluid vitreous at once escaped. On examining the eye afterwards, an old blood-clot was seen between the choroid and retina; but recent hæmorrhage had taken place during the operation between the choroid and sclerotic, caused by the sudden withdrawal of vitreous from an eye in an *unsound* state.

CASE LIV.—Susannah W., æt. 40, was admitted into the Hospital on May 22, 1865. She stated that, at the beginning of last September, she accidentally ran in the dark against the door, striking, she thought, the left temple, and inflicting a wound close to the outer edge of the orbit. For the first two months after the injury she did not appear to have had very much pain. Since last January she had suffered from pain in that eye, and during the last three months it had at times been very

intense. It was on account of the pain that she came to the Hospital, as the eye was quite blind.

State on admission.—The shape of the eye was altered in form. Along the upper portion of the ciliary region, behind the upper margin of the cornea, but in front of the insertion of the superior rectus muscle, was a large staphylomatous bulge, which had to the touch a sense of solidity. It extended laterally almost as far as the upper edge of the insertions of the external and internal recti muscles. The eye was quite blind; and the bulging, she said, was rapidly increasing. I recommended the removal of the eye; and she at once consented, on account of the great pain from which she was then suffering. During the operation the staphylomatous portion of the eye was either pricked by the point of the scissors, or from some other accidental cause it gave way, and a portion of the semifluid vitreous escaped.

On making a section of the eye after its removal, the great bulging of the upper part of the ciliary region was seen to be entirely due to a deposition of lymph, nearly three-eighths of an inch in depth, at the most prominent part. It appeared as if the sclerotic had been ruptured, but perhaps not throughout the entire thickness of its structure; and that the film of tissue which had held externally its edges together had yielded before the pressure from within, and become staphylomatous; but that, as it bulged, lymph had been effused, which increased in quantity as the staphyloma increased in size. The retina was seen detached from the choroid throughout its entire extent by the remains of an old blood-clot; and the choroid was completely separated from the sclerotic by fluid blood, evidently recently effused. It was clear that the hæmorrhage between the choroid and sclerotic had taken place during the operation, and was consequent on

the giving way of the staphylomatous bulge, and the sudden escape of vitreous in an unhealthy eye. The vitreous which remained was semifluid.

2. HÆMORRHAGE BETWEEN THE CHOROID AND SCLEROTIC.

—This form of traumatic hæmorrhage, when it occurs singly—that is to say, uncomplicated with hæmorrhage in any other part of the eye—is most commonly produced by an escape of the lens and a sudden loss of vitreous through a wound in an *unhealthy eye*; thus withdrawing unexpectedly the support which the choroid and retina had derived from these structures when, in their entirety, they occupied their normal position within the eye.

In a normal and healthy eye, the lens and a large amount of vitreous humour may be lost through a wound of its external coats, without exerting any very unfavourable influence on the retina or the choroidal vessels. We witness occasionally this fact in the operation for the extraction of cataract, when, either through some fault on the part of the patient in not properly restraining his emotions, or some accidental circumstance in connection with the operation, an escape of vitreous follows the removal of the lens; yet, notwithstanding this, a good and permanently useful eye results.

In a perfectly healthy eye, the vitreous is thick and tenacious; its viscidty being, as Mr. Bowman has shown, most conspicuous in its outer or circumferential part, where, the hyaloid only intervening, it is in contact with the retina; whilst its inner portion, towards the centre of the globe, is of a thinner consistence. When a small quantity of vitreous in such an eye is lost, the anterior segment of the globe only is much affected by it; and the cornea and adjoining sclerotic, being rendered flaccid, fall inwards, whilst the posterior curve of the eye is but little

altered in shape. If a greater quantity of vitreous be lost, the more fluid portion, or that towards the centre of the eye, will escape before the more viscid outer part is interfered with. A thick coating of healthy vitreous will, therefore, still be in contact with the retina, to maintain it *in situ*; so that, even if sufficient vitreous has escaped to cause a temporary folding in of the sclerotic posteriorly, yet no detachment of the retina from the choroid, or choroid from the sclerotic, will follow; for the choroidal vessels will still receive support adequate to prevent their undue distension, until the place of the lost vitreous is supplied with aqueous humour, and the shape of the eye restored.

In an unsound eye, traumatic hæmorrhage between the choroid and sclerotic is very liable to occur. From chronic disease, and the repeated increased vascularity of the eye consequent on it, the choroidal vessels have lost more or less of their proper tone; and their walls, either weakened by recurrent distension, or from some deprivation of the nervous influence of the sympathetic filaments which preside over them, become easily, and on the slightest irritation unduly injected. In such eyes, the loss of the lens, or of a portion of the vitreous, by diminishing the pressure on the choroidal vessels counter to the force of the impulse of the blood within them, will induce a sudden distension and yielding of their coats, which frequently ends in rupture, and hæmorrhage ensues between the choroid and sclerotic.

An increased or glaucomatous tension of the globe is the most frequent predisposing cause of this form of hæmorrhage, and varying in intensity, is frequently associated with chronic disease of the eye. It is not then a primary affection, but is secondary to some preexisting disease, and is often the precursor of a later and even

more unfavourable condition—that of a softening, or *minus* tension of the globe. If such an eye, with its tension above the normal range, from whatever cause it may have been produced, receive a wound, and a loss of the lens or vitreous follow, hæmorrhage between the choroid and sclerotic is almost certain to ensue; the already distended choroidal vessels are incapable of much further distension, and, on the withdrawal of a portion of their anterior support, yield before the pressure of the blood within them, and give way.

It is this form of hæmorrhage which occasionally occurs after an operation for the removal of a cataractous lens from an unsound eye; indeed, it is almost certain to happen, if there be an increased or glaucomatous tension of the eye at the time of operating. In such cases, the hæmorrhage takes place from the posterior surface of the choroid, detaching, sometimes partially, but generally completely, the choroid from the sclerotic, and, forming a large blood-clot, pushes in front of it the choroid and retina, and extrudes more or less of the vitreous from the eye. As before mentioned, the credit of first drawing attention to the fact that the posterior hæmorrhage which sometimes occurs after the operation of extraction of cataract is between the choroid and sclerotic, is due to Mr. Hulke, who first described it in the report of a dissection he had made of an eye removed by Mr. Bowman on account of this accident; and it has since been confirmed by Bowman, White Cooper, and others. One peculiarity of this form of hæmorrhage is the excessive pain which accompanies it. The separation of the choroid from the sclerotic by the clot causes a dragging on the ciliary nerves, and induces the most acute and apparently almost intolerable suffering, accompanied often by a feeling of nausea and faintness. The severity of the pain appears to continue whilst the de-

tachment of the choroid from the sclerotic is going on ; but the pressure of the blood-clot on the ciliary nerves causes a continuance of the suffering, though much less in degree, for some time afterwards. If it happen after the extraction of cataract, it may follow immediately the escape of the lens, or in some cases it may be delayed for some hours, or occasionally even for two or three days. In two cases under my own care, in which it followed the extraction of cataract in unsound eyes, the hæmorrhage ensued very shortly after the escape of the lens. In each it was accompanied with violent and sudden pain ; the cry of the patient being the first indication that all was not right.

In the first case, the operation was concluded, and the eyelids closed, and I was about to leave the room, when the nurse called me back on account of the sudden and violent pain the patient experienced. On undoing the eye, I found the vitreous and a quantity of blood welling from the globe. The pain was very severe. Active inflammation followed, and the eye suppurated.

In the second case, the hæmorrhage followed the extraction of an opaque lens, which had been dislocated two years previously into the anterior chamber. It is recorded as Case XXXVIII., p. 190, under the heading of "Dislocation of the Lens into the Anterior Chamber." I had removed the opaque lens by an upper section ; its escape from the eye was followed by some fluid vitreous ; and, in a few minutes afterwards, the man, who had borne the operation without uttering a word, cried out in the excess of his pain, "that it was unendurable ; it felt as if his eye was being torn from his head."

In the museum of the Royal London Ophthalmic Hospital there is a preparation of a staphylomatous eye, No. A 29, which had been ruptured by a blow, and afterwards excised by Mr. Streatfeild, in which very extensive hæmor-

rhage had taken place between the choroid and sclerotic. The blood-clot occupies the whole vitreous space, carrying in front of it the choroid and retina as far forwards as the iris. The case is specially interesting, as illustrating the influence which the condition of the eye at the time of the injury exercises over the seat of the hæmorrhage. The eye in this patient, previous to the blow which ruptured it, was a damaged one, and had suffered from repeated injuries, first from a wound with an arrow sixteen years ago, and since then from a succession of blows on it, inflicted at different times by his opponents whilst he was engaged with them in the active discharge of his duties as prize-fighter. The eye had become staphylomatous and deprived of sight; and, although it is not stated in his case, yet we may fairly conclude that the vitreous was fluid; and it is also very probable that the tension of the eye at the time of the injury was greater than normal. The last blow he received ruptured the eye. The vitreous and the lens also (if there were one) escaped through the wound; and the chief hæmorrhage which followed was between the choroid and sclerotic. The history of the case, taken from the Hospital Note-book, is as follows.

CASE LV.—“J. W., æt. 30, was admitted into the Hospital, under Mr. Streatfeild, on Feb. 22, 1858. Sixteen years ago his left eye was wounded by an arrow, and its power of vision reduced to a mere perception of objects. During the last ten years he had received repeated blows on this eye. Two years ago he had a severe blow on the left temple, after which the globe began to enlarge. Ten days since he received another blow, which ruptured the staphylomatous portion of the globe.

“*State on admission.*—The *right eye* was normal. The *left eye*—No perception of light; tension = T 1; cornea

transparent; anterior chamber almost full of blood. A bluish red substance beneath the conjunctiva, near the lower corneal edge, made the globe appear irregular and large. Mr. Streatfeild excised the eye; and, on opening the conjunctiva, coagulated blood escaped.

“*Examination of the eye after excision.*—The blood which was seen when the conjunctiva was divided in the operation for the removal of the eye was due to a rupture in the staphylomatous portion of the sclerotic, and had accumulated beneath that membrane. The globe was then divided vertically. The sclerotic was found to be thinned throughout its entire extent. The rupture was in the staphylomatous portion; in the ciliary region at the lower and outer part of the eye. The whole cavity of the globe was filled with dark red coagulated blood. The choroid and retina were detached and pushed forwards to the posterior surface of the iris. The coagulated blood was easily detached from the outer surface of the choroid from which the bleeding appears to have originated. No lens or vitreous could be found.”

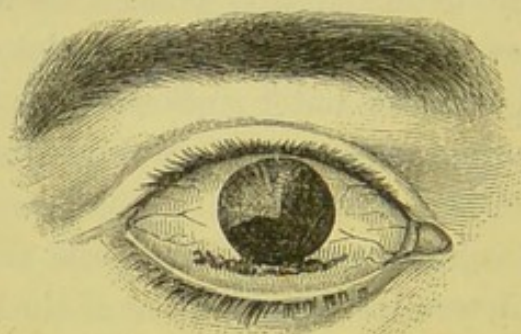
The kind of injury to which the eye is subjected will, however, often determine the chief seat of the hæmorrhage, irrespective of the soundness or unsoundness of the eye at the time of the accident. One of the severe classes of injuries to which men who work at iron shipbuilding are exposed will illustrate this fact. The eye is sometimes literally ripped open by a fragment or a large piece of metal. One extremity of it if it be large, or the whole of it if it be small, strikes the eye in its rapid flight, enters it, and cuts its way out again, drawing with it the iris, lens, and a portion of the choroid—in fact, all the textures with which it comes in contact. In such cases, as all the tissues within the eye suffer a direct injury, the hæmorrhage is probably from all of them; or, as the choroid may be ab-

solutely stripped from the sclerotic, the chief hæmorrhage may be between these structures. The following is an example of this severe form of injury. In this patient it was found, after the eye was removed, that the chief hæmorrhage was between the choroid and sclerotic.

CASE LVI.—*Extensive rupture of the globe from a blow with a large piece of iron—Extrusion of the lens, a portion of the vitreous, two-thirds of the iris, and a portion of the choroid.*

John M., æt. 24, works at iron shipbuilding at Mill-wall. He was brought to the Hospital on the morning of June 9, 1865, having, about two hours previously, met with a severe injury to the right eye. At the time of the

FIG. 60.



accident he was engaged in bringing together two iron plates with a pin and cotter; and, having struck the cotter with a hammer, from some casualty it flew out with great rapidity, and in its flight came in contact with the right eye.

State on admission.—There was a rent in the sclerotic, about three-quarters of an inch in length, running along the lower border of the cornea, fig. 60. One extremity of the steel cotter appeared to have entered the eye, passing through the sclerotic near the lower margin of the cornea, on its nasal side; and to have cut its way out again, inflicting a wound along the lower margin of the cornea,

about three-quarters of an inch in extent. In its exit, it had dragged with it the lens, two-thirds of the iris, and a portion of the choroid, all of which were entangled in, and protruding from, the wound. A large quantity of the vitreous must have escaped at the same time; for the eye was shrunken to at least one-third of its normal size, and its tension was diminished to —T 2.

As the eye was completely lost, with the consent of the man I at once removed it. On making a section of it, the following state was found. Nearly all the vitreous had escaped through the wound, but a little was still left clinging to the remains of the lens and ciliary processes. The whole vitreous space was filled with a coagulum of blood, which had pushed in front of it the choroid and retina. The chief hæmorrhage had thus taken place between the choroid and sclerotic; but there had been also some bleeding from the anterior surface of the iris and ciliary processes, though this was slight, compared to the posterior hæmorrhage.

The man was able to leave the Hospital at the end of the week.

3. HÆMORRHAGE INTO THE VITREOUS.—This may take place in three ways. 1. From rupture of some of the vessels of the ciliary processes; 2. From choroidal hæmorrhage; the blood breaking through the delicate structure of the retina and becoming extravasated into the vitreous; 3. It may ensue from the rupture of a retinal vessel, but this is rare.

We have found that blood effused into the aqueous is rapidly absorbed: this is not the case with blood in the vitreous. It may remain for months, or even in some exceptional cases for years, without being absorbed, and with little or no change in it taking place; although it frequently

happens that, if small in quantity, absorption of it after a few months will ensue. It is always, therefore, a very serious result of an injury to find that there has been hæmorrhage into the vitreous. If the amount effused be small, although the absorption of it is, as a rule, very slow, yet after a few weeks or months it becomes altered in character; it loses its colouring matter, and the clot shrinks; and it is seen, with the aid of ophthalmoscopic light, as a small dark mass, or as filamentous shreddy particles in the vitreous, and in this condition it may remain for years. When the quantity effused is large, loss of the eye is almost certain to follow; not necessarily an immediate loss, but the chronic secondary changes which are the result of it only end in the destruction of all visual power. To allow the blood to be extravasated into the vitreous, the hyaloid has to be ruptured; and wherever the blood forces its way, it breaks down the texture of the vitreous. If, therefore, a large extent of the vitreous space be occupied by blood, the whole of that body as a consequence suffers. From impairment of its nutrition, it atrophies, loses its consistence, and becomes fluid. In these large effusions of blood, although the clot may remain for a few weeks or months unabsorbed, yet, with the changes which take place in the vitreous, it is slowly disposed of. As the vitreous becomes fluid, the clot softens and is gradually dissolved; but it stains the whole of the fluid which occupies the vitreous space to a yellow or brownish-yellow tinge, which colour may last for years. The mischief, however, does not end here; for, as the vitreous becomes fluid, it diminishes in bulk; and the retina, losing the support which it had received from the healthy vitreous, falls forward and becomes detached.

CASE LVII.—*Wound in the sclerotic close to the margin of the cornea, from a fragment of iron detached from a rivet—Large prolapse of the iris—Hæmorrhage into the anterior chamber, and into the vitreous, from injury to the ciliary processes—Excision of the eye three months after the accident.*

William R., æt. 53, a boiler-maker, came to the Hospital on September 26, 1864, suffering from an injury he had received the day previously. Whilst cutting a cold rivet, a sharp-edged fragment of it flew off and struck the left eye, inflicting a wound in the sclerotic nearly a quarter of an inch in length, close to the lower and outer margin of the cornea.

State on admission.—The anterior chamber was full of blood, so as to prevent any of the deeper parts being seen. Through the wound above indicated there was an extensive prolapse of the iris, which was jagged and torn. It was also probable that vitreous had been lost. The protruded lacerated portion of iris was removed with a pair of scissors; a cotton-wool compress was applied to the eye, and two leeches to the temple, to be repeated if necessary; and a belladonna lotion was ordered to bathe the eye with three or four times a day.

September 30.—A large part of the blood in the anterior chamber had been absorbed; and it was now evident that nearly the whole of the lens had escaped through the wound, and that there had been extensive hæmorrhage into the vitreous. A small quantity of opaque lenticular matter still remained; but, behind this, a large clot of blood could be seen in the anterior part of the vitreous space, immediately behind the ciliary processes from which the hæmorrhage had probably ensued. The eye was much inflamed and very painful, and there was chemosis of the conjunc-

tiva. The leeches to the temple were repeated. From this date all active inflammation gradually subsided; and in about six weeks he was able to leave the Hospital. All sight was lost. The blood in the anterior chamber was completely absorbed; but the clot in the vitreous still remained, though diminished in size.

In January of 1865 he was re-admitted into the Hospital, as the lost eye had become inflamed and was giving him pain. It was quite blind, very soft, and shrinking; being already smaller than the sound eye. The blood in the vitreous had quite disappeared, and the retina was detached. Under these circumstances I advised him to have the eye removed; and he having consented, I excised it. On making a section of it, the following was the condition. The lower and outer third of the iris was gone. There was no lens; but an opaque film remained, which was united to the posterior surface of the iris. There was no vitreous. The retina was entirely detached and coarcted, fastened posteriorly around the optic nerve, and anteriorly adherent to the back of the iris. The space between the retina and choroid was filled with a yellow serous fluid. The choroid was *in situ* throughout, and in contact with the sclerotic except at several points where small ecchymoses separated them.

In this patient, it is probable that, in addition to the extensive hæmorrhage into the vitreous from the ciliary processes, there was also some hæmorrhage between the choroid and retina; but the blood in the anterior part of the eye prevented the fundus from being seen. The falling forward and complete detachment of the retina is, however, a result which is often met with after a portion of the vitreous has been lost through a wound of the eye, and the remainder of it has been broken down by an extravasation of blood within it.

Prognosis and treatment of deep Intraocular Hæmorrhage.

—After an injury to the eye which has produced intraocular hæmorrhage, but *without* rupture of its external coats, it is often impossible, on first seeing the patient shortly after the accident, to say whether there has been any deep bleeding; for if the anterior chamber is filled with blood, it hides from view the parts behind the lens, and time must be allowed for it to be absorbed before any positive conclusions can be drawn as to the actual state of the eye. The prognosis of posterior hæmorrhage is always unfavourable. It is only when the hæmorrhage has been slight and limited to a small surface, that even a hope can be held out that a certain amount of useful sight will be retained. Occasionally it happens that as in Case LII. the effusion of blood between the choroid and retina has been small, and only a corresponding portion of the retina has been affected by it. If in such a case the patient progresses favourably, he will probably recover with some valuable sight, but he will not regain that which was destroyed by the blood-clot: one blind spot in his field of vision will indicate the extent of retina which has been detached, and the loss the eye has sustained, though on either side of this he may be able to see with tolerable distinctness. Blood effused into the vitreous, *if small in quantity*, may after a time be absorbed, and good sight be recovered, although the process is usually a slow one: even if this does not happen, in the course of a few months the clot may have become so altered in character and diminished in size that a considerable improvement in sight will have been gained.

When there is extensive posterior intraocular hæmorrhage, the eye for all visual purposes is lost: no matter whether the blood is effused into the vitreous, or between the retina and choroid, or the choroid and sclerotic. If

the eye does not suppurate (and as a rule it does not do so if the external coats are entire), it gradually under treatment subsides into a quiet state, becomes soft, and somewhat smaller than the other. Now although after severe deep hæmorrhage the eye is lost so far as seeing is concerned, still it is always an object to save it, if by so doing it will not endanger the sound eye or prove unsightly to the patient. Immediately after the injury a leech or two may be applied to the temple with the hope of preventing any undue inflammatory action; and a fold of lint or linen dipped in cold or iced water should be placed over the eye, and wetted as often as it becomes dry and hot. Two or three drops of a solution of the Sulphate of Atropia, gr. j. ad Aquæ ℥j., should be dropped into the eye twice a day. It will exert a sedative influence, and also act beneficially on the pupil if any active inflammation comes on. Complete rest should be given to the sound eye by abstaining from all work, and the exclusion of strong light from the room. There are no special applications or medicines which can be given with the view of favouring absorption of the blood which has been effused. The patient must be placed in the condition most favourable for his recovery in the manner just described, and time must be allowed for the full completion of those natural reparative efforts which if unchecked often accomplish so much.

When posterior hæmorrhage is associated *with* rupture of the external coats of the eye, and all sight is lost, it will become a question whether it will not be better at once to excise the eye.

RUPTURE OF THE GLOBE.

RUPTURE OF THE EYE THROUGH THE SCLEROTIC.—This is the most severe injury which can happen to the eye. It either destroys the eye at once, or else so impairs it that it seldom sufficiently recovers to be of much service. It is usually caused by blows on the eye with the fist, or with some blunt or semi-blunt instrument, or by the patient falling and striking his eye against some projecting object. The exact part at which the eye will burst depends partly on the situation of the point which receives the force of the blow; still the locality in which the rupture takes place is so frequently the same that it must depend on more than mere accidental circumstances.

The split in the sclerotic is almost invariably near the margin of the cornea, following somewhat the direction of its curvature, about one-sixteenth to one-eighth of an inch distant from it, and immediately anterior to the insertion of the recti muscles. The rent most commonly occurs in the horizontal diameter and upper region of the eye, in a line extending inwards from between the margin of the cornea and the superior rectus. The next most frequent site is towards the inner side, between the cornea and the internal rectus. It is comparatively seldom that it occurs to the lower or outer side of the cornea. If the rent is either to the inner or the outer side of the cornea, the split is more or less vertical, thus following the curve of the cornea.

In endeavouring to ascertain the reason why the rupture should so invariably take place between the insertion of the recti and the margin of the cornea, we must for a

moment refer to the anatomy of the eye, and at the same time notice the support which the neighbouring parts afford it.

On looking at the sclerotic we shall find that this coat is thickest posteriorly, and that it gradually becomes thinner as it advances forwards, until it is thinnest immediately behind the insertion of the recti, but that between the insertion of the recti and the cornea it increases again in thickness. Now, the whole of the posterior, the strongest part of the sclerotic, derives a material support from the soft cushion of fat on which it rests, whilst its weakest portion is strengthened by the tendons of the recti muscles, so that the only part which may be regarded as completely exposed to the direct impulse of blows is between the insertion of the recti and the cornea.

There is, however, another reason which seems to account for rupture taking place so commonly in this situation.

In blows on the eye, the prominent cornea, the segment of a smaller sphere than that which forms the rest of the eye, is usually sufficiently strong to maintain its own integrity; but driven with force against the sclerotic, on which it is implanted, it acts almost like a wedge, and the part of that coat which is unsupported by the orbital fat, and unprotected by other tissues being superimposed, yields before its impulse and splits. When, however, the sclerotic is ruptured, as in Case LXII., by a large piece of metal, or indeed by any foreign body, striking it with great force in its rapid flight past the eye, the seat of the rupture will be the part struck, and the line of the rent will indicate the direction in which the body was driven.

The cornea itself may be, and is frequently, ruptured by blows on the eye; but the injury when confined to the cornea is usually less severe and the result less disastrous than in the cases we are now considering of rupture of the

eye through the sclerotic. A blow to rupture the sclerotic must be direct or nearly so, and inflicted with great force—whereas a side or glancing one will split the cornea.

In rupture of the sclerotic, the injury is unfortunately not confined to the laceration only of this coat. The force which is required to produce it is so great that all the tissues within the eye suffer more or less. A detachment of the iris to a greater or less extent from its ciliary border commonly occurs, and hæmorrhage takes place into the anterior chamber. A portion of the iris may be prolapsed through the wound, or, in some cases, even the whole iris may be detached and shot out with the lens. The lens is usually dislocated. Most frequently it is jerked out through the wound, and escapes unnoticed.

The ciliary processes are more or less injured, and blood is effused from them into the vitreous. The choroid is nearly always involved in the injury. Some of the vessels being ruptured, hæmorrhage, generally from its anterior surface, ensues, the clot, according to its size, producing a displacement of a portion or the whole of the retina, and a corresponding bulging into the vitreous. Occasionally, either from a rent in the retina produced by the injury or from a breaking through of its substance by the hæmorrhage from behind, blood clots are seen lying on its surface; or if in such a case the hæmorrhage continues, the blood is extravasated into the vitreous, breaking down its substance, and ultimately causing its complete disorganisation. But in addition to this, small filmy clots of blood will be usually found between the choroid and the sclerotic, causing here and there small detachments of the one from the other. Vitreous humour may escape from the wound at the time of the injury, but unless the loss of it is very great, the detachment of the retina and the hæmorrhage between it and the choroid cannot be consi-

dered as consequent on it. The displacement of the retina is in the very large majority of cases secondary to the choroidal hæmorrhage, and occasioned by it.

Such is frequently the condition of an eye after it has been ruptured by a violent blow. All the different textures may not be implicated to the extent described, though it is very usual to find them all more or less involved after such a serious injury. Certain it is, that in the very large majority of cases the eye is irreparably lost.

Prognosis.—Our prognosis in cases of rupture of the eye through the sclerotic must always be very unfavourable; for if we regard the injury only with reference to the rent in the sclerotic, without anticipating any deeper destruction of parts, we must notice that the wound is a contused and lacerated one—the most unfavourable for primary union—and that it is in the ciliary region, the part of the eye worst suited for the reception of injuries. These facts alone would lead us to anticipate the loss of the eye; but when we further consider the force required to produce such an injury, we are led to predict a bad result.

There are, however, cases in which a certain amount of sight is retained after a rupture of the globe through the sclerotic. Under the heading “Ciliary Staphyloma” in Case XIX. the globe was ruptured and the lens dislocated out of the eye beneath the conjunctiva, yet the patient recovered with sufficient sight to be able to read with a 3-inch convex glass 20 of Jaeger’s test types. Again, under the heading of “Dislocation of the Lens beneath the Conjunctiva” in Case XLI. the globe was ruptured through the sclerotic, and the lens also was dislocated beneath the conjunctiva; but sixteen days after the accident the patient was found to have a good field of vision and was able to count fingers in all directions.

Treatment.—When a patient with a rupture of the globe

through the sclerotic first presents himself for treatment, the eye is generally somewhat in the following condition:—A rent is seen in the sclerotic in the locality already indicated. A portion of iris may or may not be prolapsed through the wound. The cornea is probably entire, and the tension of the eye is $-T$ 2 or 3. On looking into the eye, the anterior chamber is probably seen filled by a coagulum of blood. The extent of damage the deeper tissues have undergone can be only surmised. Two or three leeches should be applied to the temple of the injured side, and repeated in twelve or twenty-four hours if the eye is very painful. Soothing applications afford the greatest relief, and a double fold of linen may be laid over the eye and kept wet with a belladonna lotion. The room in which the patient resides should be darkened. If the eye progresses favourably, towards the end of the week the blood in the anterior chamber will have been sufficiently absorbed to allow of a more accurate examination being made. The patient, though unable to discern objects, ought now to have a fair perception of light: failing to possess this, a very unfavourable prognosis must be formed. If the blood in the anterior chamber at the end of the week remains unabsorbed, and no correct diagnosis of the injury can be made, let the patient continue the treatment, and examine the eye from day to day. If, however, after ten days or a fortnight's treatment, or perhaps even longer, the eye is found to be irreparably destroyed for all purposes of vision, what is the best course to pursue? In such a case, even supposing the eye to progress favourably and to give rise to no untoward symptoms, the best we can hope for is, that when all active inflammation has subsided the globe will shrink, and shrink sufficiently to allow of the use of an artificial eye. This process, however, takes time, and at least from six weeks to three months' constant attention

will be required, during which it will be a source of continual anxiety and very often of pain.

But eyes lost from rupture of the sclerotic do not always progress in this quiet manner; they frequently go on to suppuration, and a long, painful, and tedious process is entailed, occupying not less than six or eight weeks, and a still further period is necessary before the remnant of the globe has cicatrised, and the contraction of the stump is completed. The great danger, however, of a severe injury to one eye is the chance of the other becoming involved in a sympathetic ophthalmia, a danger always to be apprehended as long as it continues in a state capable of acting as a source of irritation. My own feeling is, that when, after a careful examination, it has been accurately decided that the eye is lost, it is far the safest and wisest plan to remove it; a long period of certain anxiety is saved, for a man must be anxious who has lost one eye, and knows that the other is, as it were, in the balance; all further suffering is thus put an end to, and the safety of the other eye is insured. Surely these three considerations must weigh well with a sensible man against the simple fact that the stump of a lost eye is a good button upon which to hang an artificial one; for though the deception in such cases is more complete than when the globe has been excised, it is in truth nothing more than balancing the worth of the seemly appearance of an artificial eye against the chance of losing a sound and a living one.

CASE LVIII.—*Rupture of the eye through the sclerotic in a line extending inwards from between the margin of the cornea and the superior rectus.*

Joseph F. came to the Ophthalmic Hospital on April 15, 1860, suffering from an injury he had received to the left eye seven days previously. He was employed unloading

ballast from railway trucks into a barge, and in striking a large piece of wood which he had laid across the rails, it flew up and struck the eye with great force.

State on admission.—There was a rupture of the sclerotic in a line corresponding to the horizontal diameter of the cornea, between its upper margin and the superior rectus muscle. Through this wound the iris, a portion of the choroid and some lens matter were still bulging. The whole eye was softened and somewhat shrunken, acutely inflamed, and intensely painful. The interior, as far as could be seen, was filled with blood and inflammatory effusions. He had no perception of light. The eye was quite destroyed; and to relieve his sufferings and place the sound eye in safety, the injured one was excised.

The man made a quick recovery.

In the following two cases of rupture of the globe the patients recovered, but retained only sufficient sight to be able to distinguish shadows. The woodcuts well represent the appearance of such eyes when they do not become staphylomatous.

CASE LIX.—*Rupture of the globe through the sclerotic in the upper and inner region of the eye, between the margin of the cornea and the line of the insertion of the recti muscles.*

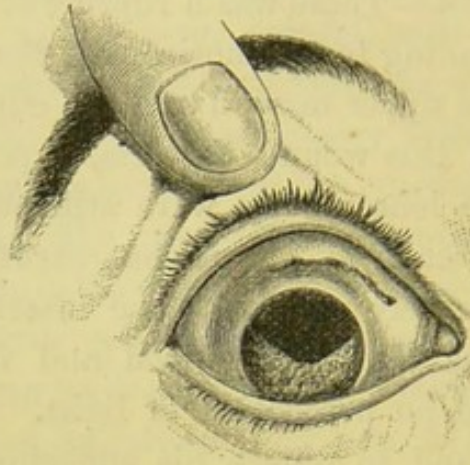
Joseph M., æt. 36, was sent to the Ophthalmic Hospital October, 1866, on account of an injury he had received to the *right* eye. The poor fellow had already lost all sight of the *left* eye, from a blow on it six years ago, apparently rupturing the globe. It was now a soft eye; its tension — T3.

Three weeks since, he accidentally fell on the fender and struck the *right* eye.

Present state.—There is a dark cicatrix in the upper and

inner region of the eye, as shown in fig. 61, marking the extent of a rupture in the sclerotic. The upper half of

FIG. 61.



the iris is wanting, having been carried away by the lens, which was extruded through the rent in the sclerotic at the time of the injury. A clot of blood occupies the pupil, so that the fundus cannot be lighted up for ophthalmoscopic examination. The tension of the globe is normal. The patient has only just perception of shadows.

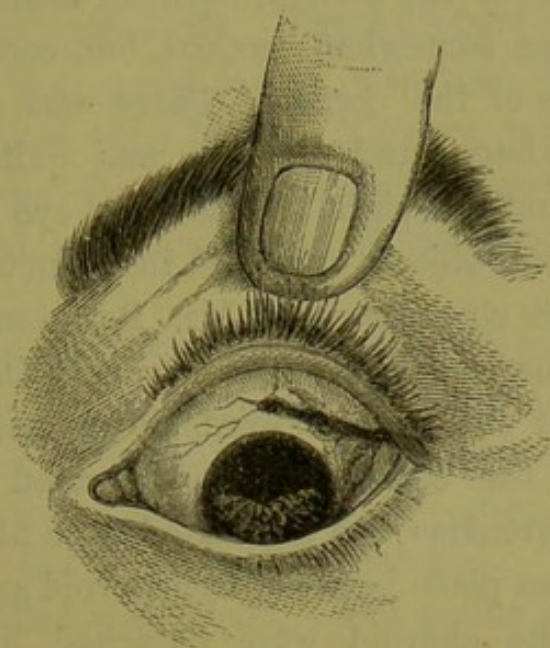
CASE LX.—*Rupture of the eye through the sclerotic from a blow—Contracted cicatrix of the wound.*

Charles C., æt. 42, came as an out-patient to the Ophthalmic Hospital, September 7, 1866, for advice concerning an injury he had received to the left eye. Three weeks previously he was struck on it a very violent blow by a drunken man. He says that he was immediately blinded, and since then he has only recovered sufficient sight to be able to distinguish light from dark.

The eye now presents the appearance seen in fig. 62. The upper half of the iris is wanting. In a line corresponding to the upper and outer border of the cornea, and between it and the insertion of the recti muscles, is a dark

irregular groove in the sclerotic—the cicatrix of the rupture produced by the blow. The tension of the globe

FIG. 62.



is — T 1. Examined with the ophthalmoscope, no lens is seen: it had escaped through the rent in the sclerotic at the time of the injury. The large pupil is occupied by some filmy capsule and blood clot, which prevent the fundus of the eye from being seen.

The next case is an illustration of sympathetic irritation of the sound eye, coming on after a rupture of the globe, and relieved by the removal of the injured one.

CASE LXI.—Rupture of the eye through the sclerotic from a blow with a piece of iron—Escape of the lens and entire iris through the wound—Sympathetic irritation of the other eye.

James L. was admitted as an in-patient of the Ophthalmic Hospital on October 21, 1859, suffering from an injury he had received to the left eye a fortnight previously from

a blow on it with a large piece of iron. He says that immediately after the accident he lost all sight.

State on admission.—There was a rent in the sclerotic on the inner side of the cornea, between it and the internal rectus, in a line somewhat vertical, but corresponding to the curvature of the cornea. There was evidently posterior hæmorrhage, and the eye was quite blind. He complained that the sight of the right eye was dim, and that surrounding objects appeared indistinct.

Under these circumstances Mr. Bowman excised the eye, and the man made a good recovery. On making an examination of the eye afterwards, it was ascertained that the lens and the entire iris had escaped through the wound. The vitreous was infiltrated with blood; hæmorrhage had taken place between the choroid and retina, and portions of the choroid were detached by blood-clots from the sclerotic.

In the following case, the rupture of the sclerotic was in the horizontal diameter of the eye, but *below* the lower margin of the cornea. It was occasioned by the direct impact of a large foreign body driven with great force against it.

CASE LXII.—*Rupture of the globe in a line with the lower margin of the cornea—Protrusion of the whole iris—Posterior hæmorrhage—Excision.*

Fred. F., æt. 34, a boiler-maker, was brought to the Hospital on March 28, 1865, having one hour previously met with a severe injury to the left eye. He says he was driving a steel cotter through a pin to fasten together two iron plates, when the cotter flew out, and struck the left eye.

State on admission.—The globe collapsed more than one third. There was a wound nearly three-quarters of an inch in length in the horizontal diameter of the eye,

running along the lower margin of the cornea, entirely detaching it from the sclerotic, and extending inwards towards the caruncle for nearly a quarter of an inch through the ciliary region. Protruding from this wound, and hanging loosely, was the entire iris. The collapsed eye indicated that there had been great loss of vitreous. The anterior chamber was filled with blood. The eye was irreparably lost. This being the case, I strongly urged the man to have it removed, and having gained his consent, I at once excised it.

On examining it afterwards, the following was the condition:—There was a large wound, as indicated above. The whole iris was prolapsed, having been torn from its ciliary attachment. The lens was also gone, and at least two-thirds of the vitreous had escaped. The anterior chamber was filled with blood. The retina was detached entirely, except at the optic nerve and ora serrata, and bulged forward by a large clot of blood between it and the choroid, which latter was *in situ* with the sclerotic.

The following case is an example of a rupture of the globe through the corneo-sclerotic junction, caused by a sharp blow on the eye with a piece of wood.

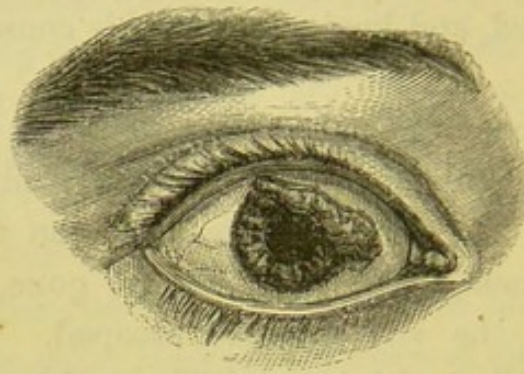
CASE LXIII.—Catherine S., æt. 17, was admitted into the Ophthalmic Hospital on September 11, 1866, having about two hours previously met with the following accident to the right eye. She was chopping some wood, when a large piece of it flew up and struck the eye with great force.

On her admission, the eye presented the appearance which is seen in the woodcut. There was a wound along the upper and inner part of the corneo-sclerotic junction, through which was prolapsed about one-third of the iris,

and a large portion of the choroid, together with lens matter and blood-clot. There was evidently extensive posterior hæmorrhage. She had no perception of light.

She was ordered cold water dressing to the eye; leeches to the temple; and to take Pil. Saponis c. Opio gr. v. every night if in pain.

FIG. 63.



September 14.—The eye has continued very painful since her admission. The lids are now swollen and oedematous, and the conjunctiva of the globe chemosed. The eye is evidently on the verge of suppuration. With her consent I therefore excised the globe. On making a section of it afterwards, the whole vitreous space was found filled with a large blood-clot, and the retina throughout its entire extent was detached.

The night after the operation she slept well, and without a bad symptom has made a rapid recovery. She was able to leave the Hospital on September 22, and attend as an out-patient.

General Conclusions.—The results which may follow a rupture of the globe are:—

1st. The eye may occasionally recover with a certain amount of sight, as in Cases XIX. and XLI.

2nd. Although the eye has been destroyed for visual purposes, it may subside into a quiet state, and become

more or less shrunken and soft, with a healthy contracted cicatrix of the rent in the sclerotic, as in Cases LIX. and LX.

3rd. The eye may recover from the primary inflammation induced by the injury, but a staphylomatous bulging may occur in the immediate site of the rupture. This staphylomatous state may be present, and the eye may still have some sight, as in Case XIX.—“Ciliary Staphyloma.”

4th. Sympathetic ophthalmia of the sound eye may be induced by the irritation of a ruptured globe, as in Case LXI.

5th. The ruptured eye may suppurate.

EXCISION OF THE EYE.—The present mode of removing an eye-ball is one of the greatest improvements in modern ophthalmic surgery. The credit of the operation is due to O’Ferrall * and Bonnet,† who suggested it independently of each other and at about the same time ; to Stoeber ‡ of Strasbourg, who first performed it in 1841 ; and to Critchett, who first excised an eye after this method in London in 1851. It consists in removing the eye from the capsule of fascia in which it is enclosed without encroaching on the cellular tissue of the orbit. The tendons of the muscles and the optic nerve are divided close to the sclerotic, and the only vessels cut through are the ophthalmic artery and the smaller arterial branches just before they perforate the globe. No division of the external commissure of the lids is required ; but through a comparatively small opening in the conjunctiva, made by dividing it and the subjacent fascia around the cornea, the globe is enucleated. The risk of severe hæmorrhage and

* Dublin Journal of Medical Science, vol. xix. p. 355.

† Annales d’Oculistique, tome vii. p. 30. Bruxelles, 1842.

‡ Ibid. p. 31.

the chance of an extension of inflammation along the peri-orbital membrane are thus avoided. The wound soon cicatrizes, and forms a convenient bed on which to place an artificial eye. As all the ocular muscles have been left, they become drawn together and adherent to the cicatrix; and acting in concert with those of the sound eye, they impart a degree of mobility to the artificial one which gives it a life-like appearance it would otherwise fail to possess.

Operation.—The patient should lie on his back on a couch with his face towards the light, and the eyelids be separated by the stop spring speculum. With a pair of fine single-toothed dissecting forceps a fold of the conjunctiva and subjacent fascia is to be seized close to the cornea,

FIG. 64.



and divided with a pair of blunt-pointed



scissors, curved on the flat, as in fig. 65.

Through this opening one blade of the scissors is now to be passed, whilst the other remains external to the eye, and then with a few clips, the conjunctiva and fascia covering the globe are to be cut through in a circle around the cornea. An ordinary strabismus hook, fig. 64, is then to be introduced in turn beneath the tendons of each of the recti muscles, which are to be divided with the scissors close to their insertions in the sclerotic.

Having made certain that the recti muscles are completely divided, one finger of each hand should press back the tissues on either side of the eye, so as to push the globe forwards and to partially dislocate it through the opening which was made in the conjunctiva at the commencement of the operation. By this simple manœuvre, the next step, the division of the optic nerve, is facilitated. The cut end of the tendon

of either the internal or external rectus muscle should now be seized with the forceps, and the eye drawn over to one side, whilst the scissors with the blades shut and the curve towards the globe are passed backwards between it and the surrounding tissues. As they round the posterior curve of the eye, the blades should be opened, when, after gently urging them a little further onwards, the optic nerve will come within their grasp, and by then closing them it will be cut through. The eye may now be lifted with the fingers forwards, and the oblique muscles or any other tissues which may be still adherent cut through with the scissors, and the operation will be completed.

As the operator stands at the head of the patient, if he is not ambidextrous, the optic nerve of the *right* eye is most easily divided by first drawing the globe over to the nasal side and passing the scissors along the outer wall of the orbit; whilst that of the *left* eye is most easily accomplished by rotating the globe outwards and introducing the scissors along the nasal side of the orbit. The right hand will thus be used for either eye to sever the nerve. With the division of the optic nerve there is usually a free flow of blood from the ophthalmic artery, but this as a rule soon stops; no ligature will be required for any bleeding vessel; the hæmorrhage can be completely restrained by keeping the speculum between the lids, and squeezing a small stream of cold water into the orbit from a sponge held a few inches above the face. Whilst doing this the head of the patient should be tilted slightly to one side, and a large sponge placed by the side of it, to catch the water as it runs from the orbit, and thus prevent the bed and clothing of the patient from being wetted. When all the bleeding has ceased, the opening in the conjunctiva, through which the eye has been enucleated, may be closed by drawing it together by a fine thread passed through it at different

points and then tying it. It is a finish to the operation, and gives an appearance of neatness to it at the time. It is not, however, essential, as the parts are afterwards completely drawn together by cicatrization. In the excision of inflamed eyes it is positively prejudicial, as it prevents the free escape of inflammatory exudations, and thus favours orbital cellulitis.

When the operation is completed, it is a wise precaution to leave the speculum between the lids, and after laying a fold of wet lint over the wound, to apply a small sponge as a pad, and fasten it firmly by a single turn of a roller. This may be removed at the end of an hour, when, if all oozing has ceased, the speculum should be taken away, the lids closed, and a fold of wet lint fastened over them by a light bandage. By taking care that all bleeding has ceased before the pressure on the wound is removed, much of the ecchymosis which frequently disfigures the patient for some time after the operation is prevented.

Treatment after excision of the eye.—As a rule the patient recovers so rapidly from this operation that but little after treatment is required. A fold of wet lint should be kept over the lids, and all discharge from the wound carefully washed away from time to time with a little warm water gently syringed into the orbit with a glass syringe. The wound usually cicatrizes in from three days to a week, but a slight muco-purulent discharge from the orbit often continues for two or three weeks afterwards. This may be checked by a lotion of *Aluminis gr. iv. ad vj. Aquæ ℥j.*, which should be used with a syringe three or four times daily. It frequently happens that on looking into the orbit the cause of the continuance of the discharge may be seen in a small fungoid granulation sprouting from the cicatrix of the conjunctiva. This should be removed by a single snip with a pair of curved scissors.

If, however, instead of progressing thus favourably, symptoms of orbital cellulitis should come on, warmth should be applied to the wound by frequent fomentations of hot water or decoction of poppy-heads, and afterwards by a linseed-meal poultice over the lids and brow. If the opening in the conjunctiva has been closed by a suture, it should be at once removed. It is good practice in such a case to make a free incision through the wound in the conjunctiva into the cellular tissue of the orbit, so as to give free vent to all inflammatory exudations as they are effused. By thus encouraging suppuration and favouring the exit of the pus, the urgent symptoms will probably be at once relieved. The bowels should be freely acted on by a purgative, and the patient should be kept very quiet in a darkened room. It is seldom that any untoward symptoms follow the operation of excision of the eye.

After an eye has been removed, one of the first questions asked by the patient is, when can he wear an artificial one? In an ordinary case from six weeks to two months after the operation is the best time for commencing the use of a glass eye. I know that in many cases one is ordered for the patient at the expiration of a week or ten days: I have done so myself, but I have had occasion to regret it. Time should be allowed for complete cicatrization to be effected, and for all swelling and discharge to have subsided, before an artificial eye is introduced within the orbit.

When a lost eye has been removed on account of the sound one suffering from sympathetic ophthalmia, an artificial one should not be allowed until all the sympathetic symptoms have been arrested, and the eye has remained quiet for at least six months.

One of the most frequent inconveniences produced by too soon wearing an artificial eye is a chronic conjunc-

tivitis with a muco-purulent discharge, which is often very troublesome to arrest. Another and a more serious annoyance is an inflammation of the conjunctiva and sub-mucous tissue in the line on which the edge of the artificial eye rests, sometimes going on to ulceration. As the result of this, cicatrices are often formed, which render the adjustment of another eye very difficult, and sometimes impossible.

In fitting an artificial eye, a small one should be first worn for a few days; and when the tissues within the orbit and the lids have accommodated themselves to it, it may be exchanged for one of a larger size. In the anxiety of the patient to make his deception complete, he should be careful not to be tempted to wear an eye over which he cannot comfortably close his lids. A well-fitted artificial eye adds very much to the comfort of the patient by preventing a turning in of the eyelashes, and by affording a support to the lids. It should, however, be remembered that the surface of an artificial eye is apt after some wear to become rough, and that then it will cause not only discomfort to the patient, but often serious injury to the conjunctiva of the lids. When this happens it should be at once laid aside.

The following very excellent rules are given to the patients at the Royal London Ophthalmic Hospital who have had the misfortune to lose an eye.

INSTRUCTIONS FOR PERSONS WEARING AN ARTIFICIAL EYE.—It should be taken out every night and replaced in the morning.

TO TAKE THE EYE OUT.—The lower eyelid must be drawn downwards with the middle finger of the left hand,

and then with the right hand the end of a small bodkin must be put beneath the lower edge of the artificial eye, which must be raised gently forward over the lower eyelid, when it will readily drop out; at this time care must be taken that the eye does not fall on the ground or other hard place, as it is very brittle and might easily be broken by a fall.

TO PUT THE EYE IN.—Place the left hand flat upon the forehead, with the fingers downwards, and with the two middle fingers raise the upper eyelid towards the eyebrow; then, with the right hand, push the upper edge of the artificial eye beneath the upper eyelid, which may now be allowed to drop upon the eye. The eye must now be supported with the middle fingers of the left hand whilst the lower eyelid is raised over its lower edge with the right hand.

After it has been worn daily for six months the polished surface of the artificial eye becomes rough; when this happens, it should be replaced by a new one: unless this is done uneasiness and inflammation may result.

CHAPTER VIII.

GUNSHOT INJURIES OF THE EYE.

THE EFFECTS PRODUCED BY THE EXPLOSION OF GUNPOWDER NEAR THE EYE—SQUIB ACCIDENTS—LODGEMENT OF GRAINS OF POWDER ON THE CORNEA AND WITHIN THE EYE—TREATMENT OF GUNPOWDER INJURIES—ACCIDENTS FROM CHEAP PERCUSSION CAPS—INJURIES FROM SMALL SHOT—FIRST: SPENT SHOT—SECOND: GLANCING SHOTS—THIRD: PENETRATING SHOTS—GUNSHOT INJURIES OF THE EYE IN MILITARY PRACTICE—FIRST, FROM SHOT AND SHELL—SECOND, FROM THE EXPLOSION OF MAGAZINES—INJURIES FROM GRAVEL AND DUST THROWN UP BY THE EXPLOSION OF SHELLS AND MAGAZINES—TREATMENT OF GUNSHOT INJURIES.

GUNPOWDER.—The near explosion of gunpowder may affect the eye in four different ways:—

1st. By the concussion it produces when exploded in close contiguity to the eye.

2nd. From the burning or scorching of the surface of the eye and the lining membrane of the lids.

3rd. From depositing in the external tissues of the eye specks of unexploded powder.

4th. From grains of powder being driven with sufficient force to penetrate the globe.

The most frequent accidents from gunpowder in *civil* practice occur from the explosion of fireworks, and the ignition of small trains or masses of powder by young people for amusement; or in the firing of cakes of powder called “devils,” made by moistening gunpowder with water, pressing it into a cone, and firing it by a light applied to some dry powder dropped into a small hole made in the apex. The effects of concussion and burning

from gunpowder are seen in some of the many accidents which happen yearly on or about the 5th of November, when lighted squibs are thoughtlessly thrown about, and often even held in close proximity to the eyes of passers-by.

The concussion from the explosion of powder close to the eye is a very serious complication. It may light up a general ophthalmitis, which the mere burn or scorching of the surface of the eye would not necessarily produce. In one patient who came under my care a large coredialysis or detachment of the iris from its ciliary circumference, with hæmorrhage into the anterior chamber, was the immediate result. The squib did not touch the eye, but burst within a few inches of it. The case is related at page 121, under the heading of Coredialysis.

The following is one of the most severe squib injuries which has come under my notice. The scorching effects produced by gunpowder when exploded near the eye are here well shown. The entire surface of the eye and the conjunctiva of both the upper and the lower lids were severely burnt. They were whitened and dried as if they had been boiled; and the fragments of powder which were embedded in them gave the whole a mottled appearance. A large quantity of loose unexploded powder, made into a paste by the tears, was lying between the lids and the globe.

CASE LXIV.—*Severe burn of the eye and palpebral surfaces of both eyelids from the explosion of a squib close to the eye, followed by inflammation and suppuration of the globe and conjunctiva of the lids.*

Henry B., æt. 47, came to the Hospital November 6, 1865, having the previous evening met with the following injury to the left eye:—He was walking down a street

where some men were letting off squibs, when one of them held a squib within four inches of his eye, and in that position it exploded. On admission, both eyelids were very œdematous and swollen. On separating them with a speculum, a quantity of loose, unexploded powder, moistened into a thick paste with the tears, was seen lying between them and the globe. The cornea and conjunctival surfaces of the eye, and upper and lower lids, were dried and charred, and looked whitened, just as if they had been boiled. A quantity of unexploded powder was partially adherent to the burnt tissues, and some was embedded in them, giving them a mottled appearance. I removed as much of the loose pasty powder as was possible from between the lids with a small scoop, and a stream of tepid water was gently syringed over the front of the eye to wash away all the detached particles which remained. A few drops of olive-oil were dropped into the eye, some water-dressing was laid over the lids, and one grain of opium was ordered to be taken every six hours.

Nov. 10.—The eye very painful. The lids are œdematous; the whole cornea semi-opaque. There is hypopion, and a free muco-purulent discharge from the conjunctiva of the lids and globe. To continue the treatment.

Nov. 14.—The cornea is opaque, and evidently about to slough. There is a free suppuration of the conjunctiva of the eye and lids.

Nov. 17.—The whole cornea has sloughed and separated, the lens has come away, and the surface of the vitreous and iris is covered with lymph and pus. The conjunctiva of the lids and globe is suppurating.

Nov. 21.—The conjunctiva of both eyelids and of the eye is quite destroyed, and there remain large granulating opposed surfaces. Adhesions have already commenced

between the whole front of the eye and the palpebral surfaces of the lids. The man still complains of pain. Under these circumstances I strongly advised the removal of the eye, and, with the patient's consent, excised it. Had granulation and cicatrization been allowed to go on, a complete symblepharon, or union of the whole anterior surface of the globe to the lids, would have taken place. On examining the eye after it was removed, pus was found in the vitreous; and the retina and choroid were bulged forwards by an accumulation of pus between the choroid and sclerotic.

The next case is an example of an injury to the eye from the lodgement of a number of unexploded grains of powder on its surface. It also illustrates the advantage of removing as many of them as possible soon after the accident. In this patient the cornea was speckled with black dots of powder, but nearly all of them were picked off with a fine needle.

CASE LXV.—*Injury of the eye from gunpowder—Lodgement of some unexploded grains in the cornea and conjunctiva covering the sclerotic—Recovery.*

Robert A., æt. 19, applied at the Hospital November 6, 1865, suffering from an injury he had the evening before received to the right eye. He was engaged with some friends letting off fireworks, when, to increase the effect, several men fired off their Enfield rifles, loaded only with powder and a piece of paper for wadding. The night was very dark, so that they could not distinguish each other at more than a few feet distance, and a rifle was inadvertently fired in a direct line with and scarcely three yards from his face. The pellet came in contact with the malar bone, causing some bruising and abrasion of the skin; but a quantity of the unexploded powder struck the eye, and

lodged itself in the cornea and conjunctiva, covering the sclerotic. In addition to the powder embedded in the cornea, its epithelial surface was abraded. The eye was very painful and intolerant of light, and the lids were puffy and cedematous.

Treatment.—Drawing upwards the upper eyelid, and the lower one being held downwards with the finger of an assistant, I picked away from the cornea with a fine needle all the grains of unexploded powder which it was possible to remove with safety to the eye, and also all that could be easily taken away from the conjunctiva. Two or three grains of powder more deeply embedded in the cornea than the rest were allowed to remain. A little olive-oil was then dropped into the eye, and water-dressing was laid over the lids. Two leeches were ordered to be applied to the temple.

Nov. 10.—The man states that the eye felt much easier after the leeches. The eye, although very irritable, is doing well; the cornea is very hazy. He was ordered to use a belladonna lotion.

Nov. 15.—Decidedly better. There is still some photophobia. The cornea, though cloudy, is clearing. To continue the lotion.

From this date the eye steadily improved, and at the beginning of December the patient ceased his attendance at the Hospital. The sight of the eye was quite restored.

Lodgement of grains of powder in the lens.—It occasionally happens that grains of unexploded powder are driven with sufficient force to penetrate the cornea, and to lodge within the lens. From such an injury cataract will necessarily follow.

Mackenzie states that he has “repeatedly seen grains of powder propelled through the cornea into the lens so as to produce cataract. In one case a grain of powder propelled

through the cornea traversed also the lower part of the iris, in which it left a considerable opening, and striking the lens produced cataract."*

Mr. Pridgin Teale jun. of Leeds has published in his pamphlet on "the Suction Extraction of Cataract" a case of traumatic cataract caused by the lodgement of powder within the lens. "In the summer of 1862, Mr. G. E. D. was engaged in a sham fight, in which a rifleman discharged a blank cartridge within a few feet of his face. The coarse grains of the powder penetrated the right eye and lodged in the lens. After some weeks cataract slowly formed, and last summer (1863) was complete and very opaque, so that he could only distinguish light and shade."

Mr. White Cooper also relates the case of a young gentleman who was under his care on account of an injury to the eyes from the bursting of a small cannon. In one eye three grains of powder had penetrated the cornea and lodged in the lens. The condition of the two eyes was as follows :

"*Right eye.*—The pupil was widely dilated and insensible to light; the lens had escaped, at the time of the accident, through a rent at the upper part of the sclerotic; the retina was detached in a considerable part of its extent, and the eye was perfectly amaurotic.

"*Left eye.*—Three grains of powder had passed through the cornea, and stuck in the capsule of the lens, and to these the pupil was adherent by three tags of lymph; the lens and capsule were opaque and displaced, but the above adhesions retained it somewhat *in situ*. Towards the nasal side there was a chink by the side of the lens, through which there was sight." †

Treatment of Gunpowder injuries.—The first object is to

* Mackenzie on the Eye. 4th edition, page 409.

† Cooper on Injuries to the Eye, page 261.

remove all loose powder, if there is any, from the surface of the eye and from between the lids and the globe. This may be done by everting the lids and gently passing a stream of tepid water over the front of the eye and the conjunctiva of the lids with a syringe or small india rubber bottle, and afterwards by lifting away with a fine spatula or small scoop any particles of powder which may be partially adherent from being entangled with mucus or with the conjunctival epithelium. The cornea should be then carefully examined, and all the unexploded grains which may be found embedded in it should be removed with a fine needle or spud. Their presence in the cornea, if near the front of the pupil, will seriously interfere with vision, not only from the little black speck which is formed by each grain, but also from the slight halo of nebulosity with which each so commonly becomes surrounded. Those granules which are deeply embedded in the true corneal tissue and are out of the field of vision may be left if they cannot be easily lifted away, as more harm will be done by injudiciously picking than their presence can excite.

Those specks of unexploded powder which are lying on the sclerotic surface of the eye may be removed, but no great effort should be made to detach them, as, beyond the slightly unseemly appearance they occasion, they seldom if ever do harm.

Having removed all the unexploded powder, a little castor or olive oil should be dropped into the eye and soothing applications should be used. A lotion of belladonna will relieve pain, and by keeping the pupil dilated act beneficially in case any general inflammation of the eye should follow. The after treatment of the case must depend on the way in which it progresses. If there has been much destruction of the surface of the globe or of the conjunctiva of the lids, partial suppuration will probably

follow, and warm applications will give the most comfort. If, however, after four or five days or a week the eye is steadily improving, but a muco-purulent discharge continues owing to some conjunctivitis which the injury has excited, slight astringents, such as one of those recommended in the treatment of a similar stage after burns from lime, may be advantageously employed.

Percussion caps.—One of the most frequent sources of injuries to the eye from the use of guns, which is met with in *civil* practice, is from fragments of percussion caps flying off when they are exploded by the hammer of the gun. This accident very rarely happens when the caps are of the best quality, such as are sold by respectable gunsmiths for ordinary sporting purposes. It is almost invariably occasioned by toy guns, bought as playthings for children, or used by itinerants at fairs and other places of public resort for firing at a target for nuts. These common percussion caps are sold at a very low price, and are made of a brittle alloy instead of the best copper. In their explosion small scales are detached from them, and driven with such velocity that if they strike the eye they usually penetrate it. Unfortunately, the victim of such accidents is more frequently some by-stander or passer-by than the person who is shooting. In nearly every case total loss of the eye is the ultimate result of the injury, and in several which have come under my care the end has been still more disastrous; the other eye has become affected with sympathetic ophthalmia, and it also has been irreparably destroyed; absolute blindness has ensued.

The following brief abstracts of six cases of injuries to the eye from cheap percussion caps are examples of the danger which accompanies their use. In each patient the eye struck was at once destroyed, and in five, the sound eye after varying intervals of time suffered from sympathy.

Joseph M., æt. 32, applied to the Hospital for relief in February, 1863. Twelve years previously he was out sparrow shooting. Accidentally he let the gun off: the shot went into the air, but a scale from the percussion cap penetrated the eye. He was instantly blinded. The caps used were the cheap ones. He now sought advice on account of sympathetic symptoms coming on in the sound eye. The patient was under the care of Mr. Dixon.

W. F., æt. 7.—In May, 1864, whilst playing with a toy gun which was being fired by another person, a scale of the percussion cap flew off and lodged itself in the right eye. The eye is now blind.

George T., æt. 33, a confectioner, was a patient under my care in September, 1865.—Eight years ago he was striking percussion caps on a stone to make them explode, when a fragment of one of them was blown off and lodged in the left eye. Seven years afterwards the sound eye became sympathetically affected, and he is now practically blind. He can only distinguish shadows. The details of this case are given in the chapter on Sympathetic Ophthalmia.

Rich. P., æt. 41, came under my care in January, 1865, suffering from sympathetic ophthalmia of the left eye, dependent on the irritation excited by the stump of the right eye, which he had lost thirty-three years previously. He was striking a percussion cap on a nail to make it explode, when a scale flew off and wounded the right eye. It became severely inflamed and all sight was destroyed. The other eye is now a very defective one.

Susannah A., æt. 23, came to the Ophthalmic Hospital May 24, 1866, under the care of Mr. Bowman. Ten years

ago, she states, she was at Chesterfield Fair, and whilst looking at some boys who were shooting at a target for nuts, a fragment of one of the percussion caps flew off and lodged itself in her right eye. All sight was lost, and the eye afterwards shrank. She has had frequent pain in the stump of the lost eye, but her chief object in applying to the Hospital was to obtain relief for the sound eye, which was beginning to suffer sympathetically.

Joseph K., æt. 12, applied at the Ophthalmic Hospital, October 16, 1866. Two years ago he was playing at school with another boy with a toy gun, using the cheap percussion caps which had been sold with it. His companion fired the gun, when a scale of the percussion cap flew off and lodged itself in his right eye. Three months after the injury the left eye sympathised, and since then he has lost all sight. He is now in a blind asylum, irreparably blind.

INJURIES OF THE EYE FROM SMALL SHOT, SUCH AS IS COMMONLY USED FOR SPORTING PURPOSES.—The velocity and direction of the shot when it strikes the eye determine very much the extent of the injury which it inflicts.

1st. *Spent shots*.—If the shot is *nearly spent*, it may merely produce a slight concussion with some ecchymosis of the conjunctiva, from which the eye may quickly recover. Usually there is some irritation for a few days, but this, under soothing applications such as have been recommended in the article on “Concussion of the Eye,” will generally suffice to restore it to health again.

Occasionally a spent shot has sufficient force for it to penetrate the conjunctiva, and to lodge itself in the subjacent cellular tissue, but it is unable to travel any farther. A case of this kind came under my notice at the Ophthalmic Hospital. The man whilst pigeon shooting had been

struck on the eye by a shot from a friend's gun, which he believed had entered the globe. He came immediately to the Hospital, and was first seen by Mr. Moss, the house surgeon, who after a careful examination found a shot buried in the sub-conjunctival cellular tissue, from which he at once removed it. The sclerotic coat was uninjured. The man recovered without feeling any ill effects of the injury. But spent shot, though they may not penetrate the globe, may yet cause very serious mischief to the eye. Coredialysis or a separation of a portion of the iris from its ciliary attachment, or hæmorrhage from the ciliary processes into the vitreous, or even between the choroid and the retina, may be occasioned by them. After a sharp rap on the eye with a spent shot cataract may follow:—the opacity of the lens being dependent on causes I have already described in the article on "Traumatic Cataract produced without Rupture of the External Coats of the Eye," p. 130.

Mr. Haynes Walton has kindly given me the following notes of a patient who was under his care on account of a blow on the eye which he had received from a spent shot. A marker at a shooting-ground was more than eighty yards distant from the man who shot at the pigeon. A No. 6 shot struck the outside of the sclerotic of one of his eyes, and caused no further inconvenience than a very slight circumscribed redness. No pain was felt, only a slight tap. In a few weeks the lens became quite opaque.

In all injuries to the eye from spent shot, it is advisable to give a guarded prognosis, as the exact amount of damage it has inflicted may not be manifested until some weeks after the accident.

2nd. *Glancing shots.*—A shot at full speed may strike the eye in its transit without penetrating it, and leave a deep furrow which may very closely resemble a penetrating

wound. Such an injury requires a very careful examination, as it is often extremely difficult to decide whether the shot has really entered the eye, or has merely struck it and passed on. The following case, which was under the care of my friend Dr. Bridgwater, is a very good example of this kind of injury.

CASE LXVI.—A little fellow, A. B. B., æt. 12, was out shooting with his uncles in September, 1866, and was accidentally shot. The two gentlemen turned round suddenly and shot simultaneously at a covey of partridges which rose unexpectedly behind them. The birds were flying low, so that the guns were fired at about breast high, and three partridges were brought down. The lad, who was behind the shooters before they turned round, but just within range of fire, instantly called out that he was hit. It was then found that he must have received the greater part of the charge of one of the guns, as scattered over the body and legs there were about sixty shots. One shot, however, had struck the eye, and for the moment had caused blindness. Ignoring the rest of the shot about the body, the first impulse of the boy was to ask anxiously if his eye was permanently blinded.

On opening the eye, the pupil was seen irregularly dilated, but on raising the upper eyelid, at about 2'' from the margin of the cornea there was a horizontal fissure in the sclerotic with a leaden stain. It appeared just as if the shot had penetrated.

Examining the parts around the eye, there was found a shot hole on the side of the forehead close to the external angle of the orbit. It was clear that the shot must have either first passed through the outer margin of the orbit before it struck the eye, or else have grazed the bone and glanced from it on to the eye; the former seemed the most

261 INJURIES FROM SMALL SHOT.
probable. Great fears were at first felt that the shot had entered the eye. He was, therefore, kept under careful observation. He was placed in a darkened room; leeches were applied to the temple and cold applications to the lids. Under this treatment the eye improved; all pain and irritation ceased, and in a few days the sight was almost as good as it was before the accident. He could read small print, and tell distant objects, but the pupil was still unevenly dilated. On the morning of the ninth day after the accident, the lad feeling some itching at the inner angle of the eye, rubbed it, when to his intense surprise the shot dropped out from between the lids.

In this patient the shot having struck the eye passed onwards, and probably lodged itself in the cellular tissue just beneath the mucous fold at the upper and inner angle of the eye, from which place after nine days it became dislodged.

3rd. *Penetrating shots.*—The lodgement of a shot within the eye will produce all the severe symptoms which have already been described in the chapter on “Foreign Bodies within the Eye.” As a rule the eye may be considered as lost after such an accident. The passage of the shot into the eye generally inflicts such irreparable damage on the different tissues through which it passes, that all sight is at once extinguished. The eye at first becomes acutely inflamed, and occasionally suppurates; but generally the acute symptoms subside, and a low form of deep-seated inflammation sets in, which ends in softening and shrinking of the globe. So long, however, as the shot remains within the eye, even though it is shrunken to a mere stump, it is a constant source of danger, and may at any time give rise to an attack of sympathetic ophthalmia in the sound eye which may cause its destruction. The pain which is oc-

caused by a shot in the eye is the same as that which is produced by the presence of any other foreign body. In a case related by Dr. Mackenzie it was so severe that the patient requested that the globe might be removed. A gentleman whilst shooting was struck by a shot in the left eye from the gun of another person, producing instant blindness. For nearly six years he suffered so much from neuralgic pains, that although two endeavours to find the shot had failed, at his own request Dr. Butter of Plymouth extirpated the globe. "He removed the whole of the left eyeball with the lachrymal gland, and divided the optic nerve close to the foramen opticum, fearing lest he might still miss the object of his pursuit. On a dissection of the extirpated parts, he had the satisfaction to find a duck shot impacted so firmly in that part of the optic nerve which joins the retina, that a considerable effort was required to detach it from its bed, in which it must have been fixed for six years and six months."*

It occasionally happens that a shot passes through the eye and lodges in the cellular tissue of the orbit. Complete loss of the eye would almost certainly follow such an injury, but there would be far less probability of severe after effects than if the shot had remained within the eye. In a patient under the care of Mr. Critchett a shot penetrated the eye through the cornea. Severe ophthalmitis followed, all sight was lost, and sympathetic irritation showed itself in the other eye. He therefore excised the globe, and on making a section of it, the shot was found embedded in the sclerotic at the fundus of the eye.

There are, however, exceptional cases in which a shot has been lodged within the eye, and yet useful sight has been retained. The shot may have penetrated the cornea, but being nearly spent, it has then fallen to the bottom

* Mackenzie on the Eye, page 411.

of the anterior chamber, where it may remain without causing the patient any annoyance. Mr. White Cooper relates such a case as having been under his care. In his account of it he states that "At the first glance the nature of the case was apparent. A shot lay at the bottom of the anterior chamber. A little below the centre of the cornea was the mark of a wound, but this appeared to have closed sufficiently to seal the anterior chamber. The shot had kept the iris back, so that it was not entangled. There was a slight pink tint around the lower portion of the cornea, but the eye was singularly free from inflammation."

"The patient being recumbent, an incision was made through the cornea, and the shot was lifted out by means of a small scoop with facility. No inflammation followed, and the eye was well in a week."*

IN MILITARY PRACTICE gunshot injuries of the eye are generally associated with gunshot wounds of the face. It is very seldom that the eye is the only part involved in the injury.

The importance of the subject of gunshot injuries of the eye may be estimated by the following returns which I have abstracted from the Blue-book of "the Medical and Surgical History of the British Army during the War against Russia." From April 1, 1855, to the termination of the war 573 cases of gunshot wounds of the face are recorded; and of these 14 died. In 43, or rather more than 1 in 13, there was lesion of one of the eyes, and in 2 instances both were destroyed; out of the 14 deaths, 3 were attributed to the injuries of the eye. One was caused by tetanus, the eyeball having been destroyed, and the optic nerve injured; and two by inflammation of the membranes of the brain supervening where one eye had been destroyed.

* Cooper on Injuries to the Eye.

But in addition to these, 4 cases are recorded where a loss of both eyes took place from the explosion of magazines.

For the cases I have to relate of gunshot injuries to the eye during the Crimean war, I am indebted to the admirable reports in the above-mentioned Blue-book. It is to be greatly regretted that the valuable records which that book contains, drawn up as they have been in the most masterly manner, should be rendered comparatively useless from the unwieldy form in which they are printed.

The dangers to which the eyes are exposed in actual warfare are,

I. From shot and shell.

II. From the explosion of magazines.

INJURIES FROM SHOT AND SHELL.—1st. When the eye is struck directly by a shot or a fragment of a shell, it must necessarily be destroyed. But as already mentioned, it is seldom that the eye suffers alone; other parts of the face are usually involved at the same time in the injury.

The following remarkable case is an illustration of a severe injury to the face, in which one eye was completely destroyed. The patient, however, ultimately recovered, and was invalided to England.

CASE LXVII.—“T. O’Brien, 1st Regiment, 2nd Battalion, æt. 22, was wounded on September 8, 1855, and admitted at the Castle Hospital, Balaklava, on September 28. The wound had been inflicted by what turned out to be a grape-shot of the largest size (weight 18 oz.), which had entered the face at the opening of the left eye, had passed through the nasal cavity in a direction downwards, backwards, and to the right side, fracturing the hard palate, and lodged at the back of the pharynx, on the right side, resting on the vertebral column and its muscles, and covered by the posterior arch of the palate. The eye was

completely destroyed, the internal commissure of the eyelids torn to the extent of about half an inch, and the ramus of the inferior maxilla was transversely fractured on the right side, or that on which the ball was lodged. It is strange that the presence of this large foreign body should have escaped observation for twenty days, but it was completely hidden by the posterior arch of the palate behind, slightly below, and to the right side of which it lay. The wound in the face was so small, and the general disturbance so little, that it was supposed to have been inflicted by a fragment of a shell, which had not lodged. The finger, or a curved probe, however, readily detected the shot from the mouth. After slitting transversely the arches of the palate with a probe-pointed bistoury, to as great an extent as was considered safe, it was removed through the mouth, although not without difficulty, by means of one blade of a forceps for the extraction of balls, made on the principle of midwifery forceps. The man recovered without a single bad symptom, the fracture of the lower jaw united, and he was sent to England little or none the worse, with the exception of the loss of the eye, on the 26th January."

2ndly. The sight of the eye may be destroyed by a shot causing an injury to the optic nerve, the globe itself remaining apparently intact. An example of this kind is related in the "Surgical History of the Crimean War," in which the sight of both eyes was destroyed by a musket ball passing through both orbits, but without inflicting any external wound on either of the globes.

CASE LXVIII.—"A man of the 88th Regiment was wounded by a musket-ball, which entered at the inner angle of the left eye, and made its exit close to the lobule of the right ear, passing behind the nasal bones. Neither eye

appeared to have been organically injured, yet the vision of both was irreparably destroyed. On examination, the pupils of both were found to be much dilated, and they did not act to the stimulus of light. No appreciable inflammation of the eyeballs followed, nor could any other change in the shape or appearance of the several structures composing them be detected, but the eyes became at once, and remained, completely amaurotic, the man asserting that he was even unable to distinguish between bright light and total darkness. The wound gave little trouble, and he was invalided to England well, but totally blind, about a month after its receipt, and discharged from the service in this condition."

3rdly. Shot or shell may cause severe injury to the eye without striking the globe itself, but by propelling against it with force materials with which they are first brought into contact. A round shot as it ricochets, or a shell if it bursts after it has struck the ground, throws up the dust or gravel, whichever it may be, with sufficient violence to inflict very serious damage to the eyes if it comes against them. In this manner particles of gravel, sand, and chips of stone walls are often made to penetrate the eyes and to cause their ultimate if not their immediate destruction. In siege operations such accidents are of more frequent occurrence than in engagements in the open field. During the Crimean war the majority of the injuries to the eye were thus produced.

A more rare form of injury is where an article of the dress, or a tooth or the fragment of the skull of a comrade is carried in front of a shot, and hurled by it with sufficient impetus to lodge it within the tissues, if it strikes a man. There are two cases recorded as having occurred during the Crimean war in which the eye was injured by this

curious form of accident. "In one instance the double tooth of a comrade was found embedded in the eye," and in a second case "a portion of another man's skull was removed from between the lids."

The following case is an example of a severe injury to the face and eye from stones and gravel being thrown against the face by the explosion of a shell. The man died of tetanus.

CASE LXIX.—"Private William Hardinge, 1st Battalion Rifle Brigade, was admitted into the Regimental Hospital September 5, 1855, with a severe contusion of the face, and very considerable swelling on the left side of the head. The injury had been inflicted by the explosion of a shell, which drove a quantity of stones and gravel into his face. Much of this was removed. The eyelid of the left eye was found to have been divided, and the eye destroyed. He complained of very great pain of the face and eye, but there were no remarkable constitutional symptoms. On the 7th of September, in syringing out the orbit, a hard substance was felt, and with some difficulty a piece of stone the size of a large walnut, but of angular shape, was extracted, and much gravel in small fragments was afterwards washed out of the orbit. This relieved him, and he was very easy till the 9th, when he complained of twitching about the mouth, and on putting out his tongue it was violently and involuntarily bitten by spasmodic contraction of the temporal and masseter muscles. The sterno-cleido-mastoid muscle was also much affected with spasms. These were increased or brought on by any attempt to protrude the tongue or to swallow.

"The spine was blistered and sprinkled with morphia; calomel frequently given in small doses, and chloroform exhibited; but the tetanic symptoms continued, and be-

came worse, and he died in great pain on the 11th, having remained perfectly sensible the whole time.

“On examination after death it was found that the bony orbit was extensively fractured, including the orbital plates of the frontal, superior maxillary, and ethmoid bones. The sclerotic coat of the eye was torn open and much gravel embedded in its interior, and some fragments had been forced into the substance of the optic nerve.”

Another case is also recorded, “where both eyes were irrevocably destroyed by gravel thrown up by a shell explosion, complicated with extensive bruising and laceration of the face; one testis had been cut away entirely, and more than half the other with a large portion of the integument of the scrotum, by a fragment of shell; and a severe laceration of the fore part of both thighs existed. Both eyes had been penetrated and were collapsed.” Notwithstanding the severe nature of the general injuries, the man “was invalided to England at the expiration of two months, well, but quite blind.”

II. INJURIES FROM THE EXPLOSION OF MAGAZINES.—In accidents from this cause all the severe effects which the explosion of gunpowder can produce are witnessed. The eye may be badly burnt, or it may suffer from concussion, or from dust or gravel being thrown with force against it. Any one of these or the three combined may destroy the eye, or inflict on it an irreparable damage. Four cases of the loss of both eyes are recorded as having occurred during the Crimean war from the explosion of magazines. In two “the coats of the organ had been perforated by fragments of foreign bodies driven against them, and vision was entirely lost, the eyeballs collapsing.”

In one case both eyes were destroyed by the concussion caused by the near explosion of a powder magazine.

The Report states "the eyes seem to have been disorganised by the direct force of the concussion conveyed by the medium of the air. In this case the aqueous humour would appear to have been forced between the layers of the cornea, as though no rupture of the eye existed, and the eyeball was full and retained its natural rotundity, a complete blueish white opacity of the whole of this membrane was found to have taken place within a few hours of the receipt of the injury. In this case the amount of inflammation set up was slight, but vision was completely and permanently destroyed."

TREATMENT OF GUNSHOT INJURIES OF THE EYE.—In the subject of gunshot injuries of the eye are comprised the majority of accidents to which the eye is exposed. Their chief peculiarities are their severity and the agents by which they are produced. It will be needless to describe at length the treatment which should be adopted for each form of injury: I will therefore enumerate the various lesions which are met with, and refer the reader to the special articles which give a full detail of the treatment to be followed.

From the explosion of shells and magazines of powder we have examples of dust, gravel, and other foreign bodies being lodged on the surface of the eye, and in some instances penetrating within the globe. In such cases the eye should be examined both superficially and deeply as soon as the patient is seen by the surgeon, and all foreign particles either upon or within the eye should, if practicable, be removed. (See the article on "Foreign Bodies on the Eye or on the Inner Surface of the Lids," page 2, and also the chapter on "Foreign Bodies within the Eye," page 213.) If the injury is complicated with a burn of the surface of the eye or lids, the treatment recom-

mended at page 46, under the heading of "Treatment of Burns and Scalds," may be advantageously prescribed.

The lodgement of small shot within the eye.—If after a careful examination it is decided that a shot is within the eye beyond the reach of the surgeon, and all sight is lost, there need be no delay—the eye should be excised. The whole interest of the patient is now in the sound eye, and this cannot be pronounced safe so long as the shot remains embedded in the lost one. There is no occasion to wait for urgent symptoms to arise.

Experience has taught, as far as human means are capable of teaching, the risk the patient incurs by waiting, and he will act most wisely who accepts the experience of others in preference to purchasing it himself at his own cost. (See "Treatment of Foreign Bodies within the Eye," page 225.)

When, however, there is doubt as to whether the shot has really lodged within the eye, the patient must be kept for a time under observation, and the progress of the case anxiously watched from day to day. (See the article on "A Foreign Body within the Eye suspected, but not actually seen," page 231.)

If the eye has been *completely destroyed* by a bullet or a fragment of a shell, or from any other cause, it will be wise at once to remove the remains of it. By so doing, a tedious suppuration will be prevented, and the patient will be spared much suffering.

CHAPTER IX.

SYMPATHETIC OPHTHALMIA.

THE PRIMARY CAUSE OF SYMPATHETIC OPHTHALMIA—TWO FORMS OF THE DISEASE—SYMPATHETIC IRRITATION AND SYMPATHETIC OPHTHALMIA—SYMPTOMS OF—ITS NATURE, AND THE WAY IN WHICH IT INVADES THE DIFFERENT TISSUES OF THE EYE—TENSION OF THE EYE—SYMPATHETIC OPHTHALMIA NOT EXCITED BY A SUPPURATIVE INFLAMMATION OF THE INJURED EYE—INFLUENCE OF AGE ON THE DISEASE—THE PERIOD AT WHICH IT MAY COME ON AFTER AN INJURY—THE CAUSES OF SYMPATHETIC OPHTHALMIA—FIRST, FROM WOUNDS OF THE EYE—SECOND, FROM THE LODGEMENT OF FOREIGN BODIES WITHIN THE GLOBE—THIRD, FROM THE IRRITATION EXCITED BY DEGENERATIVE CHANGES TAKING PLACE IN EYES ALREADY LOST—TREATMENT OF SYMPATHETIC OPHTHALMIA—GENERAL CONCLUSIONS.

OF all the different forms of inflammation of the eye, there is not one over which the surgeon has so little control as sympathetic ophthalmia. It is the most insidious in its attack, destructive in its progress, and its results are the most irreparable. It almost defies treatment, and, when once established, often runs its course unchecked, to the complete destruction of the eye as an organ of vision.

The primary cause of sympathetic inflammation is the peculiar relationship the nervous systems of the two eyes bear to one another; the mutual sympathy which exists between the two in health becomes more manifested in disease. Light admitted to one eye will cause the pupil of the other to contract, even though it is shaded; and the pupil of a blind eye will often dilate and contract in unison with that of the sound one when the light is shut off or thrown on. It is a fact of practical importance,

that when it is desirable to limit the amount of light to an injured or a diseased eye, both must be shaded, as the affected one will appreciate and resent the stimulus admitted to the sound eye, almost as much as if it were itself exposed.

There are *two* forms of sympathetic ophthalmia.

The first, from being the slighter of the two, may be called sympathetic irritation.

The second is the severe disease now so well known by the name of sympathetic ophthalmia.

The symptoms which characterise sympathetic irritation cannot be diagnosed from the early stages of sympathetic ophthalmia; still I think they are distinct, and this distinction is often made manifest in cases where, in spite of neglect of all warnings, no irreparable mischief of the sound eye is ultimately produced.

SYMPATHETIC IRRITATION seems to differ from sympathetic ophthalmia only in degree. It consists in attacks of extreme irritability of the sound eye, which may come on whenever the lost or injured one becomes inflamed. There is a slight indistinctness of vision, the objects seem to dance about, and reading tires the eye. The patient may be able to read No. 1 of Jaeger, and to see distant figures rightly; but he cannot do so for any length of time; the effort of accommodation soon fails, and the eye becomes fagged. During the attack the eye is slightly reddened, watery, and irritable: occasionally it is painful; the patient has neuralgic shootings in it, and this may then be the symptom which gives the greatest trouble. The attack generally lasts for some days, or it may even continue for one or two weeks, and then gradually cease; the recovery being frequently coincident with the cessation of the irritation in the injured eye.

The points in which sympathetic irritation differs from sympathetic ophthalmia are :

1st. Although the eye may be subjected to frequent recurrences of the attacks, yet no fibrinous effusions nor disorganising changes of its different tissues take place.

2nd. The excision of the lost or injured eye at once arrests the disease. All sympathetic irritation ceases when the cause which gave rise to it is removed.

The fact of our being unable to diagnose positively whether the symptoms are merely those of simple irritation, or the early stages of the more formidable affection of sympathetic ophthalmia, is of little practical consequence, as in both cases the removal of the injured eye which is acting as the irritant is the first treatment which ought to be adopted.

SYMPTOMS OF SYMPATHETIC OPHTHALMIA.—These may vary from the symptoms of mere irritation just described to those of actual inflammation of the eyeball. The symptoms are of two kinds:—1. Those which relate to the nervous, and, 2. Those which belong to the vascular system of the eye.

The nervous symptoms always show themselves at an early period. Slight photophobia, with some lachrymation, is present in every case, though varying in degree. The dread of light does not become severe until the disease has been thoroughly established, and even then it is not so intense as in many other affections. An inability to define clearly and to read small print without a distinct feeling of discomfort is a symptom so often seen at an early period of the disease, while the humours are still clear, that I believe it is referable to a want of power in the ciliary apparatus to focus the eye correctly for

near objects, and to the consequent imperfect formation of the image on the retina.

The symptoms which arise from a derangement of the vascular system of the eye manifest themselves in a rapid effusion of lymph, capable of speedy organisation.

If the eye at an early period of the disease be examined with the ophthalmoscope, great congestion of all the choroidal vessels will be seen. It is possible that the general arterial congestion may be due to some impaired condition of the sympathetic system of the eye, so that the vessels, losing the control of the sympathetic filaments, which in a normal state exert a powerful influence in maintaining a proper tonicity of their coats, become distended, and this passive engorgement favours the rapid effusions which characterise this disease.

General summary of symptoms.—At the commencement of the attack, the eye is irritable and abnormally sensitive to light; there is some lachrymation, the conjunctiva is a little injected, and the pupil is decidedly sluggish in its action; the power of focusing the eye for near objects is diminished; and the patient is unable to maintain a prolonged accommodative effort. Reading or any fine work quickly induces a fatigue which is followed, first by the words becoming confused and blurred, and, lastly, if the eyes are not rested, by a complete loss of their image. A few minutes' rest and the eye can resume its work, but the same symptoms shortly reappear and oblige it to desist.

If the disease progresses, the globe from sclerotic injection assumes a pinkish appearance, with a distinct ciliary zone around the cornea, showing internal congestion. The pupil contracts adhesions to the anterior capsule of the lens, and becomes stationary; or if atropine is dropped into the eye, it dilates only slightly, irregularly, and parti-

ally. The aqueous becomes serous, and the striation of the iris, at first indistinct, is afterwards completely lost. At the onset of the disease there is generally *no pain*, not even sufficient to draw proper attention to the eye; but in the later stages the globe is tender to the touch, and there is frequently supra-orbital pain. Lymph is speedily effused in large quantities as an infiltration into the different tissues involved in the inflammation; the pupillary area of the capsule of the lens is covered and the iris almost soaked with it. This exudation rapidly becomes organised, and contracts firm adhesions between the posterior surface of the iris and the lens-capsule. Commencing generally in the iris, the disease extends itself back to the choroid, and a form of irido-choroiditis is established, very difficult to arrest.

FIG. 66.

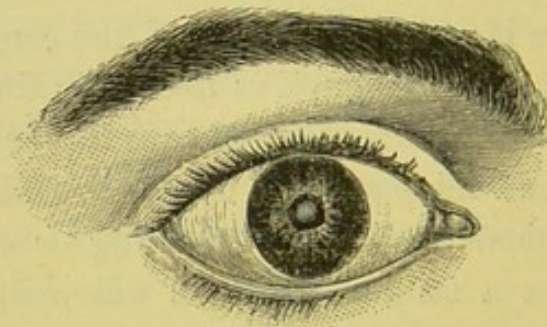


Fig. 66 represents, as well as an engraving can, the appearance of an eye suffering from sympathetic ophthalmia. It was drawn from a young man, *æt.* 18, a glass-blower, who had lost his left eye from an injury he received ten months previously.

Whilst following his occupation of glass-blower, a piece of glass struck the left eye and inflicted a small penetrating wound in the ciliary region of the sclerotic, close to the lower margin of the cornea. The eye became

inflamed, and in five months his sight with it was reduced to a mere perception of shadows.

About six months after the accident, the injured eye became more inflamed, and the right eye began to sympathise. Four months after this, he applied to the Ophthalmic Hospital for relief.

The state of the two eyes was then as follows :

Left eye.—The globe flattened at the site of the injury. Its tension reduced to $-T 3$; the pupil closed; the anterior chamber very shallow, the iris and lens being almost in contact with the cornea. He has bare perception of light.

Right eye suffering from sympathetic ophthalmia. The tension of the globe was $-T 1$. The pupil was of the size seen in the drawing; its margins completely adherent to the lens capsule, the pupillary area of which was covered with a false membrane. The anterior chamber very shallow, the iris and lens being thrown forwards towards the cornea. He was able to see a hand waving in front of him, but could not count fingers.

Sympathetic ophthalmia differs from all other inflammations of the eye—

I. In its nature and the way in which it invades all the different tissues of the eye.

II. In the causes which produce it.

I. *The nature of sympathetic inflammation, and the way in which it involves the other tissues of the eye.*—It is essentially an adhesive or fibrinous inflammation. Seldom if ever does an eye affected with sympathetic inflammation suppurate. Its tendency is to rapid plastic effusions, which soon become organised and incapable of absorption—blending the different tissues together, impairing their textures, and destroying their functions. Repair seldom follows an arrest of the disease; the damage it has in-

flicted remains. Very insidious in its attack, the eye is generally, though not always, invaded by the disease *without having pain* as a warning of its presence. It often creeps on unheeded by the patient, and the first symptom which frequently draws the attention to the apparently sound eye is a slight defect in the ability to define clearly, and a general pinkiness of the globe. In children I have seen the disease thoroughly established before they have been brought by their parents for advice, simply from the fact that the absence of pain induced them to think lightly of it. When once fairly started it is an inflammation very difficult to subdue, and even when arrested *it is liable to frequent recurrence*. The iris, choroid, or ciliary processes are the parts primarily affected by the disease; but the other tissues may and do become secondarily involved. In some cases it seems to originate in and limit itself to the anterior structures of the eye, leaving the fundus healthy, as in a case under the care of Mr. Critchett, where after an arrest of the disease he succeeded in extracting the lens and making a new pupil, and in restoring to the patient a very useful amount of vision. In other patients the choroid and deeper structures become implicated, and total loss of sight ensues. As a rule, the disease commences in the iris, and its progress is backwards to the choroid. It may, however, occasionally commence in the choroid, and extend forwards to the iris.

The peculiar disposition of this inflammation to the rapid effusion of lymph is manifested from the very commencement of the disease. At an early period the pupil is fixed by adhesions between it and the anterior capsule of the lens, and the whole tissue of the iris appears as if it were soaked in lymph. It is not deposited on the surface in nodules, as in syphilitic iritis, but occurs in the

form of an infiltration invading the very texture of the iris. In the synechiæ which are formed, it is not simply the pupillary margin of the iris which contracts adhesions to the capsule of the lens, but the whole of its posterior surface, gluing it down and incorporating it with the lens-capsule; so that if at a future period an attempt is made to form an artificial pupil, and a portion of the iris is torn away, it is common to find the exposed part of the capsule covered with uvea, indicating exactly the extent of adhesion which had existed between it and the posterior surface of the iris.

Early in the disease, when the iris is saturated with lymph, it is soft and rotten; for this is the only word which conveys to the mind its actual condition. Attempt at this stage to remove a portion of it, and the hook will go through it like tinder, or the forceps will only bring away the particle which it holds between the extremity of its blades, tearing it away from the rest. At a later date, when all the acute symptoms have passed away, the iris has become completely changed in its character; it is excessively tough, has completely lost all its elasticity, and is converted into a dense fibrous membrane. In the endeavour to remove a portion of it to form an artificial pupil, the hook is often unable to penetrate its texture, and scissors are required to cut it; but the cut made in it remains only as a slit, no separation or retraction of its edges taking place. The lymph, which in the early stage was infiltrated into its substance, has now become organised and been converted into a fibrous tissue.

Tension of the eye.—The tension of a sympathetically inflamed eye varies with the development of the disease. In the early stages it is usually increased, sometimes to the extent of T 2 or 3, so that the globe cannot be indented

with the fingers. This state of increased tension may continue during many months, or even last beyond a year. It may accompany the acute or subacute symptoms of the disease which precede atrophy. If the disease runs on unabated and unarrested, the increased tension subsides, and the eye gradually becomes softer than normal, and sinks to $-T$ 2 or 3. The vitreous slowly atrophies, loses consistency and diminishes in bulk, and with these changes the eye softens. But, worst of all, as the atrophy of the vitreous proceeds, the retina is deprived of its normal support, and falling forwards becomes first in part, and often at last entirely, detached from the choroid.

Sympathetic ophthalmia is seldom, if ever, excited by a suppurative inflammation of one eye. This fact has been noticed by Von Graefe, and my own experience accords with it. I have never seen a sympathetic inflammation of the sound eye come on during suppuration of the injured one. If, however, a foreign body is within the globe, suppuration does not lessen the danger which its presence in the stump will keep up.

The age of the patient has a remarkable influence on this disease.—The young are much more prone to it than the old, and it runs its course more rapidly in the child or the young adult than it does in the middle-aged or the old. This might be reasonably anticipated, for the excitable nervous energy and quick circulation of the young predispose them to all diseases which depend on irritation of any portion of the nervous system.

The period at which sympathetic ophthalmia may come on after an injury.—It is difficult to assign any date at which sympathetic ophthalmia may be expected, or after which the sound eye may be considered as safe. If the injury is a *penetrating wound*, the most usual time for the early symptoms to appear is from six weeks to three months

after the accident, but I have seen them occur at both a much earlier and later date. So long as the irritation primarily excited by the injury continues, the sound eye may sympathise. The risk cannot be said to have passed away until the injured eye has quite recovered; the sclerotic must have regained its normal whiteness, and all photophobia and lachrymation have ceased.

If the injury *is from a foreign body within the eye*, the sound eye may become sympathetically affected at any time, and after the lapse of any number of years.

II. *The causes of sympathetic ophthalmia* may be classed under three headings:—

1st. Wounds of the eye.

2nd. The lodgement of foreign bodies within the globe.

3rd. The irritation excited by degenerative changes taking place in eyes already lost.

1. *From wounds of the eye.*—One of the most frequent causes of this affection is undoubtedly a wound of one eye, but the situation and class of injury influence very materially the chance of this sympathetic action being started in the other. Penetrating wounds in the ciliary region, or that part which extends for about one eighth of an inch or more backwards from around the cornea, a space in which the ciliary muscle and ciliary processes lie, are peculiarly liable to produce sympathetic irritation in the sound eye.

A simple incised wound of the cornea, even though it be of considerable extent, provided none of the deeper tissues are implicated, will generally speedily heal, and beyond the impairment of vision caused by the scar, no further evil will probably follow; but if the cut extend into the ciliary region, there is good cause for anxiety. The danger of the injured eye is increased, and there is super-

added a serious risk of the sound eye becoming involved in sympathetic ophthalmia.

Wounds of the cornea, accompanied with large prolapse of the iris, are prone to excite irritation in the other eye, and especially if the patient be a young child. This danger is increased if the cut is near the margin of the cornea, and if the prolapse is sufficiently large to pull upon the ciliary processes.

Of all wounds the penetrating ones caused by semi-blunt instruments, such as the points of a pair of scissors, a steel pen, or a crochet-hook, especially if inflicted in the ciliary region, are the most liable to give rise to sympathetic symptoms in the other eye.

CASE LXX.—*Wound of the cornea of the right eye, with prolapse of the iris, from a blow with a stone, followed by sympathetic ophthalmia of the other eye—Frequent recurrence of the disease—Removal of the injured eye ten months after the accident—Relief.*

Mary R., æt. 8, was brought by her mother to the Hospital on April 22, 1864. Five days previously a stone thrown by a boy struck her right eye, and inflicted a wound in the cornea, through which a piece of iris immediately prolapsed.

State on admission.—The eye was very red and irritable, and unable to bear any exposure to light. There was a wound in the cornea at the lower and outer part, extending from just below the margin of the pupil to near its circumferential border. Through this wound the iris had prolapsed, and the bulging portion was covered with lymph. The lens apparently was not wounded, nor did the iris seem to have been cut; it simply bulged through the wound, drawing the pupil towards it. The aqueous, though

a little serous, was transparent, and the striation of the iris quite distinct. Ordered—

Belladonna fomentation.

Pulv. Hyd. c. Cret. c. Rheo, gr. viij. at bedtime,

and to keep in a darkened room.

April 26.—The child is decidedly better. The eye is more quiet. The prolapsed iris is covered with lymph, and the edges of the wound in the cornea appear to have united to it. The prolapsed iris formed a button, which projected considerably, from the aqueous within distending it. This I snipped off with a pair of scissors, and a little aqueous immediately escaped. To continue the belladonna fomentation.

May 2.—The eye is now quite quiet; the redness has almost disappeared: she has no pain. There is a good anterior chamber; the aqueous is clear, and the pupil acts well.

May 12.—The eye apparently well. The patient now ceased her attendance at the Hospital.

June 10.—The child was again brought to the Hospital. The injured eye was slightly irritable; there was some photophobia and slight sclerotic redness. It was for the *left or uninjured* eye for which the mother now sought advice. The cornea was cloudy, the pupil stationary, with complete posterior synechia—the aqueous serous, but clear. The ciliary zone of red vessels around the cornea was distinct; the whole globe had a pinkish appearance, and there was a slight dread of light. The vision was much impaired; she could only read No. 16 of Jaeger's test-types. The child had suffered *no pain whatever* in the eye, and had slept well. The only symptoms the mother had noticed were a slight intolerance of light, and a trifling redness of the eye; but as the eye was evidently getting worse, she sought advice for it. It was about a fortnight

since she first noticed that the eye was not quite well. Ordered—

To be rubbed into the axilla, Ung. Hydrarg. ℥ss. every night; and to take

Quinæ Disulph. gr. $\frac{1}{2}$;
Acid. Sulph. dilut. ℥ v. ;
Aquæ ℥ss. ; three times a day.

And to drop into both eyes a solution of

Atropiæ Sulph. gr. j. Aquæ ℥j. ; three times a day.

She was told to procure a pair of goggles with dark neutral-tint glasses to wear habitually, and the room in which she lived was to be kept darkened.

June 21.—The mouth slightly affected by the mercurial inunction; the eye decidedly better; there is less photophobia and redness. To continue the unguent. hydrarg. every other night, and to repeat the medicine.

June 28.—The eye is more quiet, and there is but little dread of light; the cornea is almost clear, and the aqueous is less serous. To repeat the quinine medicine, but omit the mercurial inunction.

The eye from this date steadily improved; the redness disappeared, and all active disease ceased: but, as the result of the inflammation to which it had been subjected, there was complete posterior synechia, and the lens-capsule within the pupillary area was covered with a film of lymph. The eye was also irritable, and when exposed to a full light, by removing the dark glass goggles which she habitually wore, would flush up. About the second week in July she went into the country, with special injunctions to abstain from all use of the eyes for six months, to continue the use of the dark goggles, and when in the house to keep the room darkened. This arrest of the disease was, however, only for a time; every few weeks the eye would become irritable and inflamed, and she would come to the Hospital for relief. Under soothing and tonic

treatment all irritation would soon cease, and she would discontinue her attendance for a while, but only to return again after a short interval.

In the beginning of February, 1865, a more acute attack than usual brought her to the Hospital; and as the sight of the injured eye was now quite lost, and the irritation in the other very severe, I strongly urged the mother to have the injured eye removed; and to this she consented.

Before the operation, the state of the injured eye was as follows: The globe soft, its tension — T 2; the iris almost in contact with the cornea; on its surface could be seen with the unaided eye large red varicose vessels. There was a cicatrix in the cornea marking the seat of the injury, and to it the lower and outer edge of the iris was drawn. The sclerotic was reddened, and the ciliary zone of vessels distinctly marked. The eye was excised on February 13. After its removal, it was examined by Mr. Hulke and Mr. Bader, and their report is as follows:— Œdema of the retina with fibrillated exudation and swelling of the connective elements, especially the radial fibres; œdema and purulent infiltration of the choroid, with swelling and incomplete disintegration of the hexagonal epithelium. The whole vitreous semi-opaque, and infiltrated with a fibrillated substance.

February 21.—The left eye is decidedly improved since the source of the irritation has been taken away. The globe is less vascular and more tolerant of light; with it she is able to read No. 16 Jaeger's types; tension, normal.

From this date the eye continued quiet, but the sight was in no way improved, as there was complete synechia, and the pupillary area of the lens was covered with a false membrane.

On September 20, 1866, she was readmitted into the

Hospital. I then excised a piece of iris in the upward direction and removed the lens. After the operation she had slight iritis, and the pupil gradually became closed and adherent to the opaque lens capsule behind it. She has now a perfect field of vision, and very good perception of large objects. Another operation will be necessary for the formation of an artificial pupil, which, if successful, will regain for her very useful sight.

In this patient, the insidiousness of the disease, its severity, and its recurrent nature are well marked. From the complete absence of pain, it was not detected by the mother until it had become fully established, and had already committed irreparable damage to the eye, in the sealing-down of the pupillary edge, and a portion of the posterior surface of the iris, to the anterior capsule of the lens. By soothing applications to the eye and a gentle mercurial course, the disease was for a time arrested, but only to recur again and again at short intervals. The excision of the injured eye exercised a specially beneficial influence in allaying the last attack of inflammation; and there is reason to hope that with the removal of the exciting cause the disease may be stopped: certainly the chances of its recurrence are materially diminished.

CASE LXXI.—*Injury to right eye from a punctured wound at the margin of the cornea, extending into the sclerotic, followed by sympathetic ophthalmia of the other eye.*

Kate S., æt. 9 years, came under the care of Mr. Bowman at the Ophthalmic Hospital in February, 1864. She was endeavouring to untie a knot with the point of a pair of scissors, when they slipped; and the point of one blade penetrated the right eye at the lower and inner margin of the cornea, inflicting a wound which extended into the sclerotic. The eye, after a certain amount of in-

flammation, which her mother says did not give her much pain, became apparently well, and in seven or eight weeks she went into the country. About one month after this the injured eye became again inflamed, and at the end of a week from this time the child noticed that the sight of the left (the uninjured) eye was failing rapidly. *She had never suffered any pain in it.* There was a slight dread of light, but not much, and the eye looked a little bloodshot. The child was now seen by Mr. Bowman, who ordered her small doses of the hydrarg. bichlorid. with tinct. cinchonæ, and a belladonna lotion to bathe the eyes with frequently: she was told to wear goggles with dark glasses habitually, and to avoid all exposure of the eyes to strong lights. Under this treatment the irritation of the left eye subsided, but only to recur again and again.

On *March 7, 1865*, the mother brought the child again from the country. The left eye was more irritable than usual. The following was the condition of the two eyes:—

The right eye (the injured one).—A cicatrix at the junction of the lower and inner part of the cornea with the sclerotic; the pupil is small and contracted, the pupillary space filled with lymph; there is complete posterior synechia, and the iris is bulged forwards toward the cornea, so as almost to come in contact with it. The tension of the eye is T 3; with it she can only distinguish shadows.

The left eye.—Irritable and of a pinkish colour; the pupil irregularly adherent to the lens-capsule, and the pupillary area of the capsule of the lens covered with lymph, with the exception of a small spot at the lower and outer part, through which she is able, with her head thrown to one side, to read with difficulty words of No. 1 Jaeger's types. Tension T 2.

Mr. Bowman excised the injured eye, but declined per-

forming any operation for the present on the left eye: he thought it advisable to wait until all irritation had ceased. The left eye decidedly improved after getting rid of the source of the irritation.

In this patient, as in the previous case, the peculiar insidiousness of the disease and its recurrent nature were well marked. The child suffered no pain, and scarcely any photophobia; yet the severity of the inflammation to which the eye has been subjected is evidenced from the results which it has left behind it.

2. *From foreign bodies within the eye.*—The danger of the sound eye sympathising when there is a foreign body in the injured one is very great. It cannot be exaggerated. No lapse of time diminishes the risk: it continues whilst the source of irritation remains. Even the fact that the injured eye has suppurated from the inflammation primarily excited by the accident, does not render the sound one more safe, if the foreign body still lies embedded in the shrunken stump. The length of time which a foreign body has been in the eye without producing any irritation is no guarantee that the danger of its presence has passed. In Case LXXII., in which a portion of a gun-cap was lodged in the eye, suppuration and shrinking of the globe followed. For seven years the stump remained quiet and gave no trouble, but without any apparent cause it then became inflamed, and the sound eye was soon after affected sympathetically. The poor fellow is now practically blind. He can only distinguish light from dark, or the waving of a hand in front of him.

Again in Case LXXIII. the patient lost his right eye from a piece of gun-cap being lodged within it, and for more than thirteen years the lost eye caused him no annoyance. Without any assignable cause it became inflamed, and the left eye was almost simultaneously involved in sympa-

thetic ophthalmia. At the time of his admission into the Hospital he was scarcely able to distinguish his own hand.

Both of these cases tend to prove that accidental circumstances over which the patient has no control may cause a foreign body which has long laid quietly in a lost or shrunken eye, to light up such an amount of irritation that the sound one will at once become affected by it.

CASE LXXII.—*Loss of the left eye from the lodgement within it of a portion of a gun-cap—Inflammation of the stump more than seven years after the injury, followed by sympathetic ophthalmia of the right eye.*

George S., æt. 33, by trade a confectioner.—Eight years ago, by way of amusement, he was exploding some percussion caps by striking them with a hammer on a stone. The caps were cheap ones, which he had procured at what he called a cheap Birmingham shop, in the country, at the price of 25 for a penny. Whilst striking one of the percussion caps a fragment flew into the left eye, and there lodged itself.

The eye inflamed and suppurated, and, after much suffering, shrank to a mere stump; but the foreign body, as far as he knew, still remained in the shrunken remnant of the eye. From that date, for more than seven years, he was completely free from pain; the lost eye gave him no inconvenience. The sight of the right eye was remarkably good, for he was a crack shot at long distances in the volunteer company to which he was attached.

In February 1865, for the first time, the stump of the left eye became painful and inflamed, and soon afterwards he noticed the sight of the right eye was foggy, but he suffered *no pain* in it. This attack continued about three weeks, the sight of the right eye becoming rapidly worse. Under treatment he recovered, but the sight of the unin-

jured eye was much impaired. Since then the stump had been repeatedly inflamed, and with each attack the right eye had sympathised, and on one occasion became acutely affected and very painful.

After each attack the sight of the right eye was materially injured; and although all irritation would for a time subside under treatment, yet he never regained any of the vision he had lost.

On September 22 of the same year he applied to the Royal London Ophthalmic Hospital. The following was the state of the two eyes.

Left eye.—A shrunken and contracted stump, inflamed, and looking red and irritable. Through the centre of some cicatrix tissue, which occupied the place of the cornea, was projecting a metallic point, evidently the extremity of the piece of the percussion cap which had been so long lodged in the eye, and which was now making its way to the surface.

Right eye.—Slightly pink and irritable. The cornea clear. The pupil fully the normal size, but fixed and completely adherent to the lens capsule, and the pupillary area of the capsule of the lens covered with a film of lymph. The striation of the iris very indistinct, and the anterior chamber very shallow, the plane of the iris having been approximated towards the cornea. He is unable to read No. 20 of Jaeger's test types or to count fingers. He can only just make out the hand when held before his eye, or distinguish any large object in front of him.

He was at once admitted into the Hospital, and I removed the stump of the lost eye. On making a section of it, the piece of the percussion cap was seen to have made its way towards the surface, and was projecting by one of its edges through the cicatrix tissue in the front part of the stump.

The deep tissues of the eye were all so matted together as not to be recognised.

The man made a good recovery from the operation, and the right eye has decidedly improved. It is less irritable, and the pink appearance has disappeared.

CASE LXXIII.—*Loss of the right eye from the lodgement within it of a portion of a gun-cap fourteen years previously—Inflammation of the lost eye, and sympathetic ophthalmia of the other, running on to almost complete loss of vision.*

This patient was under the care of Mr. Couper at the Ophthalmic Hospital. His history was as follows:—Whilst shooting in the streets at a target, fourteen years ago, a piece of a gun-cap flew into his right eye. For some time after, he had great pain and inflammation of the eye, which ended in complete loss of sight: he did not even retain perception of light.

The man applied to the Hospital on September 2, 1864. He said that up to six months ago he had suffered no trouble with the lost eye, but about that time it became inflamed and painful, and has continued so ever since. The left eye at the same time was sympathetically affected, and with it he can now scarcely distinguish his own hand.

Mr. Couper excised the right eye; and on making a section of it afterwards, he found a small chip of a gun-cap embedded in lymph and lying on the ciliary processes: the retina was detached.

3. *Sympathetic inflammation dependent on abnormal changes taking place in an eye already lost.*—Eyes which either from injury or disease have ceased to be organs of vision usually undergo a slow process of disorganisation. The original tissues gradually waste, become altered in texture, and new products are often formed. These

changes are, as a rule, very slow. There may be no evidence of their having even commenced until many years after the eye has been lost. Nevertheless, I believe that atrophy and degeneration of the tissues speedily begin in an eye which has ceased to see on account of changes induced by a destructive inflammation, no matter how that inflammation has originated; but it may require years to effect a complete disorganisation or change of structure. The exception to this, I think, is in eyes which have been lost from perforation of the cornea in purulent ophthalmia, or from any disease which blinds by a destruction of the cornea without implicating the deeper parts. These will continue for many years, and indeed for long lifetimes, without giving their owners any annoyance whatever. The fundus in such eyes is healthy; a gradual atrophy takes place from disuse; and they may shrink, but they still remain quiet.

This is not, however, always the case, for the parts within may waste more rapidly than the tunics of the globe by shrinking can accommodate themselves to their lessened contents, and the relative connection of the internal structures thus becomes disturbed. From atrophy of the vitreous, its consistency and bulk are diminished, and the retina, deprived of its natural support, falls forward and becomes separated from the choroid, which may still maintain its normal position with the sclerotic. This space often gets filled up by some adventitious deposit, capable either of becoming organised and forming a new growth, such as fibrous tissue or bone, or at some future period of undergoing degeneration.

The development of bone in eyes which have been long lost is a frequent source of suffering to the patient and of danger to the sound eye. It most commonly occurs in those eyes which have been destroyed by injury, or by

DEGENERATIVE CHANGES IN BONY MATTER

some inflammatory disease. The bony matter is almost invariably seen on the anterior surface of the choroid, between it and the retina which is always detached, and usually coarcted. In some cases a mere ossific film is found lying on the choroid, whilst in others, as in Case LXXIV., there is a thick bony cup, sufficient in size to occupy nearly the entire stump.

It seems very probable that the formation of these bony plates is due to an inflammatory exudation of lymph on the surface of the choroid, which after a lapse of time becomes organised and converted into fibrous tissue. This afterwards undergoes a further change; osseous granules are deposited within it, and it becomes bone, having all the characters, both anatomical and chemical, which distinguish this tissue in other parts of the body. The cup of bone is usually perforated near its centre by a small canal, through which passes a small band of the atrophied retina back to the optic nerve.

Whilst bone is thus being developed in the fundus of the eye, earthy salts, such as the phosphate or carbonate of lime, are frequently at the same time being deposited in the lens, if there is one, and between the laminae of the cornea; or if that has been destroyed, in the cicatricial tissue which has replaced it.

In a report of a specimen of "Bone from the inner surface of the Choroid," by Mr. Hulke, in the *Pathological Transactions*, vol. viii. page 320, he has given the drawings of the microscopical appearances of the sections he examined. He found in them all the elements of true bone—a complete system of vascular canals, with lacunæ and canaliculi. In the mere scales of bone which he has since examined, he has told me that he has been unable to detect any vascular canals, but in all he has seen the lacunæ and canaliculi. This is probably simply due to the

fact that such delicate films of bone were too thin to admit of them. In vol. xi. of the Pathological Transactions, page 227, is a microscopic drawing of a section of a cup of bone removed by Mr. Obrè from an atrophied eye which had been lost from an injury thirty years previously. The account given by him of its structure confirmed that already described by Mr. Hulke. The chronic changes which are taking place in such eyes render them liable to frequent attacks of inflammation; and although these may not be very severe, yet they are peculiarly prone to produce sympathetic ophthalmia in the sound eye.

FIG. 67.

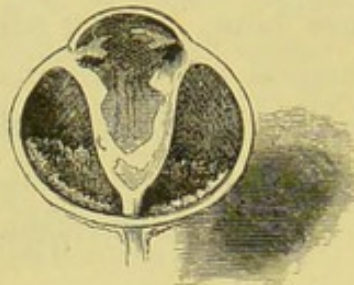


Fig. 67 is the drawing of a section of an eye from a patient, æt. 30. She had lost all sight in it from an injury eighteen years previous to her coming under my care. Until within four or five months it had never given her any trouble. The globe

was shrunk about one-third; at times it was very painful, and it had lately been subject to frequent recurrences of inflammation. But her chief anxiety was about her sound eye, which sympathised whenever the lost one was inflamed. She complained that it became very irritable, and that she was unable to read or work with it. I therefore, with her consent, excised the lost eye.

On making a section of it, the appearance represented in fig. 67 was seen. The entire retina was detached and coarcted; the choroid was *in situ* with the sclerotic; but lying on its anterior surface around the optic nerve was a delicate film of bone.

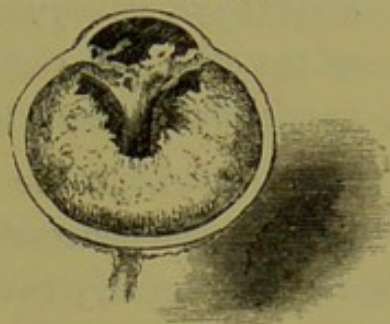
After the operation all sympathetic irritation rapidly subsided.

The next case is a good example of the development of a large cup of bone in the stump of an eye which had been

lost for more than sixty years. It was removed, as it had become very painful, and was exciting sympathetic symptoms in the other eye.

CASE LXXIV.—Mary S., æt. 61, came under my care on account of neuralgic pains in the stump of her lost eye. From her description, her left eye was lost in infancy, before she was twelve months old; the cornea had been destroyed, and its place was supplied by cicatrix tissue, in which was now seen to be deposited a quantity of chalky matter. It then shrank about one-third. She never had any annoyance from it until about four months ago, when it began to give her pain, and since then she has suffered with it severely. The right eye presented all the usual symptoms of sympathetic irritation. I therefore excised the stump of the lost eye.

FIG. 68.



On making a section of it, the appearance well represented in fig. 68 was seen. Nearly the whole of the interior of the stump was occupied by a thick cup of bone. The dark line just within the sclerotic is a section of the atrophied choroid. The bone extends forwards to within a short distance of the cicatrix tissue, which has taken the place of the cornea; and running through the centre of this mass of bone are seen the wasted remains of the retina, folded upon itself, so as almost to resemble a cord.

The patient soon recovered from the operation, and all irritation of the right eye ceased.

The following case is a very instructive one, as it shows the danger of the neglect of frequent warnings. In this patient the lost eye was often a source of pain from the

recurrences of inflammation to which it was subjected. Notwithstanding repeated advice to have the lost eye removed, he refused to submit to an operation until his sound eye became sympathetically involved, and then it was too late, as the result proved, to benefit him.

CASE LXXV.—*Severe sympathetic ophthalmia occurring in the left eye, consequent on repeated attacks of inflammation of the other, the sight of which had been lost twenty years previously—Result, total blindness.*

S. H., æt. 25, came to the Hospital in December, 1862, to seek advice concerning the right eye, the sight of which he had lost nearly twenty years previously. The cornea was nebulous; a portion of the iris had evidently been removed for the purpose of making an artificial pupil, and some opaque capsule occupied the irregular pupillary space. The eye was soft, and as an organ of vision useless; it was liable to attacks of inflammation, which gave him considerable annoyance. As the eye was then quiet, there was no need for active interference; but the patient was strongly advised, if it again became troublesome, to come at once to the Hospital and have it removed, as it was very possible it might act injuriously on the sound eye.

On July 11, 1863, he again came to the Hospital on account of the bad eye being inflamed and painful. Its removal was urged, but in vain; he was treated with belladonna fomentations and tonics, and all active mischief for the time ceased. His great objection to having the eye removed was, that as he was subject to epileptic fits, he did not like to wear an artificial eye.

In November of the same year he was again suffering from a recurrence of the inflammation, but under the use of soothing applications the eye sufficiently recovered to enable him to cease his attendance at the Hospital.

On March 8, 1864, he returned to the Hospital with the right eye again inflamed, and he was strongly urged to part with it, but he positively declined to submit to the operation.

On the 22nd of the same month the left eye began to show symptoms of sympathetic irritation. The whole globe had a pinkish appearance; there was a ciliary zone of redness around the cornea, and a decided dimness of vision. He was unable to define clearly, and it was with difficulty he could read No. 2 Jaeger's types: even then he refused to submit to the removal of the right eye.

On March 28 the symptoms of sympathetic irritation in his left eye were much more manifest, and active deep-seated inflammation was present. The whole eye was very red, the aqueous serous, and the pupil fixed: he was now not only willing, but anxious, to part with the right eye. He was at once admitted into the Hospital, and I removed the eye which had given him so much trouble.

From the operation he made a good recovery; but the disease, which was now thoroughly established in the left eye, was not arrested: unhappily, it steadily progressed. On April 11 he was unable to count fingers, and since then he has become totally blind. Had the patient submitted to the removal of the source of irritation at the commencement of the attack of sympathetic ophthalmia in the good eye, there would have been a much greater chance of his recovery; but the delay in his case unfortunately rendered the operation, though his only chance, too late for success.

Treatment.—In the treatment of sympathetic inflammation of the eye, we must consider—1. How to arrest the progress of the disease; and, 2. How to deal with an eye which remains damaged after the disease has been arrested.

336 TREATMENT OF SYMPATHETIC OPHTHALMIA.
1. *How to arrest the progress of the disease.*—If the sympathetic inflammation of one eye is dependent on injury to the other, and it is clear that the wounded eye is a lost one, or if it arises from the irritation of the remains of an already lost eye becoming inflamed, then there cannot be a moment's hesitation about the propriety of at once removing the exciting cause of the disease, and extirpating the diseased or the injured eye.

The removal of an eye by the present operation is so simple a proceeding, attended with so little annoyance to the patient, and is at the same time generally followed with such decided benefit, that it is the absolute duty of the surgeon to urge it, when necessary, in the strongest manner. Very frequently, after thus getting rid of the primary source of irritation, the sympathetic symptoms in the other eye will rapidly subside.

The importance of removing at an early period an eye which has been so injured as to be useless, and which is exciting irritation in the other, or the inflamed remnant of a lost eye which is acting in the same prejudicial manner, cannot be exaggerated; for though *in the very early stage* of sympathetic ophthalmia the removal of the cause of irritation will and generally does cause its subsidence, yet when the disease has thoroughly taken hold of the sound eye, even the removal of the lost one may fail to arrest its progress.

But suppose the sympathetic irritation is due to a wound in the other eye, and that the injury has not been quite sufficient to destroy sight, how then should we act? In such a case, if I saw the patient suffering with the one eye in the *early stage* of sympathetic ophthalmia, I would unhesitatingly sacrifice the injured eye with the hope of saving the other.

General treatment.—Absolute rest to the eyes is impera-

tively demanded ; all reading, writing, or fine work of any kind, must be forbidden ; when at home, the room should be kept darkened, and, when out, dark neutral tinted glass goggles should be worn. It is impossible to overrate the importance of keeping the patient for a long period in a very subdued light ; it affords the best hope of success, and places the eyes in a position to receive most favourably the influence of any other treatment which may be adopted. However well the patient may progress, the order to rest the eyes and abstain from work should not be rescinded for at least from six to eight months. The disease is very recurrent in its nature, and the too soon exposing the eyes to the stimulus of strong light will increase the chances of relapse.

In some cases I have seen decided benefit from a moderate inunction of mercury, but quinine in one or two-grain doses must be given at the same time.

Local applications.—Belladonna in one form or another affords the most grateful application to the eyes. A solution of atropine, of the strength of one grain to the ounce, should be dropped into the eye three or four times a day. It has a double effect : it is a direct and very excellent sedative to the eye, allays irritability and relieves pain, and sometimes it seems to exert almost a specific action on the disease ; but in addition to this it dilates the pupil, and so helps to destroy recent adhesions, and by maintaining the dilatation tends to prevent the formation of a closed and contracted pupil. The frequent use of a belladonna fomentation also gives great comfort.

At one time I used to think that if an iridectomy was performed on the affected eye at an early stage of the disease, it helped to quiet it, and by the removal of a piece of iris an artificial pupil was established, and a portion of transparent lens was exposed, if lymph had already been effused on the lens-capsule within the pupillary area. Ex-

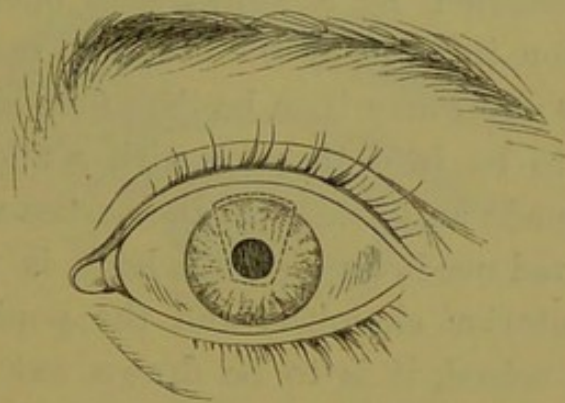
perience has now made me think and act differently. I believe that whilst the eye is actively inflamed, operative interference is positively prejudicial; an iridectomy, if attempted, is performed under very unfavourable circumstances, and is generally indifferently accomplished: for the iris, soaked with lymph, is so friable that it tears before the hook or the forceps, and but a small portion of it can be removed; the irritation of the eye is increased rather than arrested, and fresh lymph speedily fills the space made by the excision of the piece of iris. On this account no attempt to form a new pupil should be made until the disease has been quite subdued and the eye is quiet.

2. *How best to deal with an eye which remains damaged after the disease has been arrested.*—If the disease has been stayed before the deeper parts of the eye have been seriously implicated, and a fair perception of light remains, much may be done to restore useful vision to the eye. The condition of the eye after an attack of sympathetic ophthalmia will vary according to the intensity of the disease to which it has been subjected. But to consider a severe though not an extreme case:—the pupil will be found closed and contracted; its margin, and probably also the greater part of the posterior surface of the iris, bound to the capsule of the lens, and the small pupillary space filled up with a dense false membrane; the iris has been altered in structure and become fibrous, and its elasticity has been destroyed. In such an eye an ordinary iridectomy would fail, partly because it would be difficult if not impossible to get away sufficient iris to form an opening large enough for an artificial pupil; and partly from the portion of lens, which would be exposed if an artificial pupil was successfully made, having its capsule coated with uvea, owing to the adhesions which had existed between it and the posterior surface of the iris. It is generally, therefore, advis-

able in such severe cases to get away the lens at the same time that the operation is performed for making the artificial pupil. The extraction of the lens seems to exert a beneficial influence on the eye, as after it has recovered from the effects of the operation it is much less disposed than it was before to a recurrence of the inflammation.

The plan which has been adopted by Mr. Bowman and Mr. Critchett has given very favourable results. An iridectomy-knife is used to make an opening at the margin of the cornea, as in an ordinary operation for iridectomy; but the point of it is carried beyond the pupil, and made to dip downwards, so as to make a transverse cut in the iris just below the pupil. The blades of a pair of fine scissors are then introduced through the opening at the margin of the cornea, one blade in front of and the other behind the iris; and a cut is made first on one side to join one extremity of the transverse slit below the pupil, and the same proceeding is then repeated on the other side to make a similar cut to join the other end of the transverse incision. The somewhat oblong-shaped piece thus included in the section consists of iris, and a portion of the

FIG. 69.



anterior capsule of the lens adherent to it. The piece is then lifted away by a pair of forceps, and the lens-matter behind removed by a curette or cataract-spoon.

354 TREATMENT OF SYMPATHETIC OPHTHALMIA.

The dotted lines in fig. 69 represent the line of the incision at the margin of the cornea, and the piece of iris which is afterwards excised. In some cases the lens may be removed by first performing an iridectomy, and then extracting it either by suction or the curette; or if there is a firm nucleus, by using a cataract spoon to draw it from the eye, as in "The Traction Operation for Cataract," p. 160.

In the milder forms of sympathetic ophthalmia, where the tissue of the iris has not been so much changed and where the adhesions between it and the lens capsule have not been so complete, an iridectomy alone may be sufficient.

If the portion of lens exposed by the removal of the iris is clear, useful vision will be regained; but if, after the eye has recovered from the operation, the sight of it is very imperfect, and this imperfection is found by focal illumination to be due to a coating of uvea on the lens capsule, the lens should be removed.

After any operation for the extraction of the lens from an eye which has been subjected to sympathetic ophthalmia, a subacute form of iritis is very apt to follow, which frequently ends in closure of the pupil. This may be afterwards remedied by a subsequent operation, when all the irritation induced by the first has completely subsided. A new pupil may then be thus formed:—The false membrane is to be torn through with a fine needle, and after having made an opening in the cornea near its margin with a broad needle, a Tyrrell's hook is to be passed within the anterior chamber, and the pupillary edge of the iris being seized, it is to be drawn out through the wound and cut off. This operation usually succeeds in restoring a good pupil to the eye, when any minor one would probably fail.

The following case was jointly under the care of Mr.

Bowman and myself. When the child was brought to the Hospital, the disease appeared to have subsided; both eyes were perfectly quiet, and had been so for many months. The object of the treatment was to regain, if possible, some useful vision for the eye which had suffered from sympathetic inflammation.

CASE LXXVI.—Thomas S., æt. 8, was admitted into the Ophthalmic Hospital on May 7, 1866, suffering from the results of sympathetic ophthalmia of the right eye.

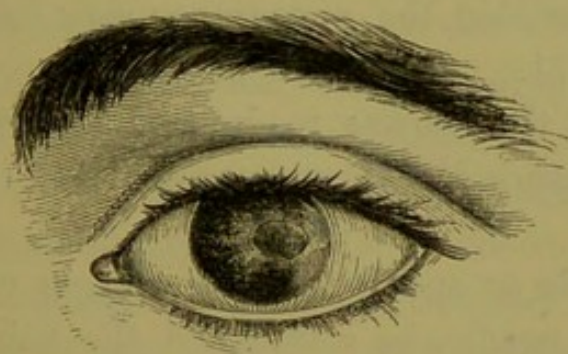
History.—Two years ago, when at play, a boy threw a peg top at him, and the peg struck the left eye, penetrated it, and then fell out again.

The wound was in the outer margin of the cornea, extending into the ciliary region. The eye at first suffered severely; it became much inflamed, and all sight soon after the accident was quite destroyed.

About three months after the injury the right eye became affected with sympathetic ophthalmia.

State on admission.—*The Left* (the wounded eye) presented the appearance which is shown in fig. 70.

FIG. 70.



At the outer part of the cornea there was a diffused leucomatous whitening, indicating the site of the injury. The anterior chamber was very shallow, so as to be scarcely perceptible. The iris had lost all appearance of

striation, and bulging forwards was lying almost in contact with the cornea. The pupil was drawn towards the outer margin of the cornea, and entirely adherent to the opaque lens capsule behind it. With that eye the lad had just perception of light.

The Right (the uninjured eye).—The cornea was clear, the anterior chamber diminished from the iris being thrown forwards towards the cornea. The pupil was slightly contracted, and completely adherent to a piece of milk-white opaque capsule which occupied its area. With it he was able to make out quickly passing shadows; but he could not count fingers or see the hand.

As the disease seemed to have expended itself, the treatment was directed solely to the endeavour to regain some useful vision in the right eye. The injured one was left alone.

On May 12 I performed an iridectomy upwards on the right eye, and extracted the lens, but left the piece of opaque capsule in the pupillary space to be dealt with at a future period.

The eye progressed very favourably, and on May 20, when the boy left the Hospital, it had recovered from the operation, and presented the appearance very correctly represented in fig. 71.

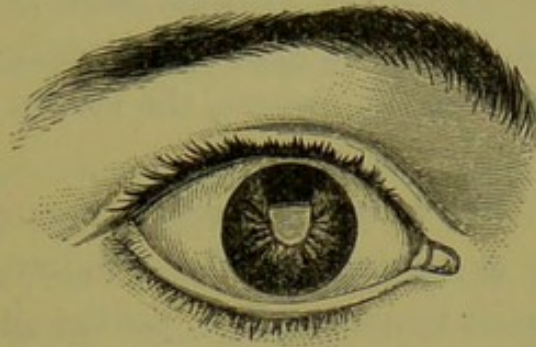
On June 21 the lad was readmitted into the Hospital, and in my absence Mr. Bowman completed the treatment of the case.

Having made an opening in the margin of the cornea with a broad needle, he introduced the points of a pair of fine scissors, and with two snips cut out a triangular piece of the opaque capsule, which he then lifted out of the eye with the canular forceps.

For some hours after the operation there was considerable pain in the eye, but this was relieved by the application of

iced water. The eye did well, and on July 9 he was discharged from the Hospital. He could then count fingers and guide himself about. The sight will probably continue to improve.

FIG. 71.



The next and last case is an illustration of sympathetic ophthalmia which has run its course unchecked, and has terminated, as such cases generally do, in almost total blindness.

CASE LXXVII.—James S., æt. 12, was brought by his mother to the Ophthalmic Hospital from the country to see Mr. Bowman on May 30, 1865. He had met with an injury to the left eye in November 1863. He was endeavouring to look into a pigsty, to see a little pig, and in bending his head to look through a chink in the door he struck his *left* eye against a nail which was projecting from it. The eye was, she believes, ruptured. The child was blind immediately after the accident. After much suffering, extending over between two and three months, the injured eye began to shrink, and continued shrinking until it reached its present state. *The right eye* became sympathetically affected, she thinks, about three months after the primary injury to the left; but she is uncertain as to the exact date, *as he never suffered any pain in it.* The eye at one time looked red, and the lids gummed to-

gether in the morning; and he had a slight pricking sensation in the eye, but beyond this he never complained. The sight, at first dim, steadily but gradually, from day to day, became worse and worse, until in about five or six months he was practically blind.

Present state.—*Left eye* shrunk, and fallen back into the orbit; the lids coming together cover it, so that, unless they are raised with the fingers, the stump of the injured eye is not seen.

The right eye has a very imperfect perception of light. He is just able to distinguish the window, but no more. The eye is soft; its tension — T 2; yet the ciliary veins seen on the surface are large.

The iris is bulged forward, and almost in contact with the cornea. No anterior chamber can be seen. The pupil is completely closed, and the lens is cataractous. The opaque lens also is carried forward with the iris, so as to be almost in apposition with the cornea. Of course no ophthalmoscopic examination could be made, but, judging from the state of the eye and the defect of vision, it is very probable that the retina is more or less detached.

General Conclusions.—The following are the conclusions I have been led to draw from the cases of sympathetic ophthalmia which have come under my care:—

1. That it is a peculiar inflammation of one eye, originating solely from an irritation in the other.

2. That the most frequent causes of sympathetic ophthalmia are:

a. Penetrating wounds of the eye, and especially those which involve the ciliary region.

β. Foreign bodies within the eye.

γ. The irritation excited in the sound eye by degenerative changes taking place in the one already lost.

3. That one of the great peculiarities of sympathetic inflammation is its tendency to the rapid effusion of lymph into all the tissues of the eye which it invades, capable of speedy organisation.

4. That the disease once started is very difficult to arrest; that it is recurrent in its nature; and that, even if the first attack be arrested, a recurrence is almost certain to take place.

5. That it is seldom if ever excited by a suppurative inflammation of the wounded eye.

6. That the removal of the injured eye affords the best chance of arresting the disease; and if this operation is resorted to in its very early stage, there is a good prospect of its doing so.

7. That if the symptoms of sympathetic ophthalmia are fully developed, the removal of the injured eye (the source of the irritation) may fail to arrest the disease, though it will afford a chance which should not be neglected.

8. That in no instance have I seen sympathetic ophthalmia *originate* in an eye after the other had been removed on account of an injury. I have frequently seen it continue its course after the removal of the injured eye, but in each case sympathetic symptoms were manifested before the eye was removed. Hence the importance of diagnosing in what cases of injury sympathetic ophthalmia is likely to follow, and the necessity of at once excising such injured eyes which are prone to produce it, and especially if they are already lost for all visual purposes.

9. That in the treatment of sympathetic ophthalmia, any operation on the eye whilst it is inflamed is positively prejudicial; but that when all the activity of the disease has subsided, much may often be done by some operative procedure to regain for the patient some of the sight he has

lost, and also at the same time to prevent a recurrence of the attacks.

10. That in the early stage of the disease the tension of the globe is often increased to T 1 or 2; but that in the later stage the eye becomes soft from atrophy of the vitreous, causing a diminution in its consistence and bulk, and that this state is often followed by detachment of the retina.

CHAPTER X.

INJURIES OF THE ORBIT.

THE LODGEMENT OF FOREIGN BODIES IN THE ORBIT—FIRST, THE IMMEDIATE EFFECTS THEY MAY PRODUCE—SECOND, THE SECONDARY EFFECTS WHICH MAY RESULT FROM THEM—TREATMENT OF FOREIGN BODIES IN THE ORBIT—PENETRATING WOUNDS OF THE ORBIT—FRACTURE OF THE BONES OF THE ORBIT—ABSCESS OF THE ORBIT, ACUTE AND CHRONIC: CAUSES OF, SYMPTOMS, AND TREATMENT.

FOREIGN BODIES IN THE ORBIT.—The lodgement of a foreign body within the orbit is one of the most dangerous accidents which can be met with in ophthalmic practice, as it not only always involves a serious risk to the eye, but it even places the life of the patient in considerable jeopardy, and in some instances has caused death. It may prove hurtful to the patient both by the immediate and secondary effects it is liable to produce.

The immediate effects which may arise from the lodgement of a foreign body in the orbit are:—

I. In its passage into the orbit, it may either injure the parts within the eye or rupture its external coats.

II. Although the eye itself may escape injury, the optic nerve may be wounded, and absolute blindness follow.

III. It may injure the walls of the orbit, either by penetrating them or by causing fracture.

The secondary effects which a foreign body within the orbit may excite are:—

I. If a foreign body has escaped observation, and has been allowed to remain buried in the orbit, it may excite orbital cellulitis and abscess. This may lead on to a general inflammation of the globe, which may end in great impairment of vision or in complete destruction of the eye from suppuration.

II. As a consequence of the orbital inflammation, a portion of the bones of the orbit may become necrosed.

III. The inflammation may extend backwards along the periosteum lining the orbital walls to the membranes of the brain, and destroy the patient by meningitis, tetanic convulsions, or abscess of the brain.

A foreign body generally enters the orbit somewhere between the upper or inner side of the eye, and the roof or inner wall of the orbit; but cases are frequently met with where it has passed in at other points around the eye. If small, it usually buries itself in the loose cellular tissue of the orbit; but occasionally it becomes fixed by either penetrating the globe, or one or other of the frontal or ethmoidal sinuses, or by becoming in some way wedged between the globe and its external muscles.

It is very strange how often this accident has happened without the patient having been aware of the true nature of the injury he has sustained. Some of the most extraordinary cases which have been recorded in ophthalmic surgery have been the lodgement of large foreign bodies in the orbit without the knowledge of the patient, and in many of them recovery has followed their removal, without any loss or impairment of sight.

In No. 4 of the *Ophthalmic Review*, page 337, Mr. Carter of Stroud has related the following very remarkable case, in which a large piece of an iron hat-peg was impacted in the orbit and remained there for a number of days without the patient being aware of its presence. It was then ex-

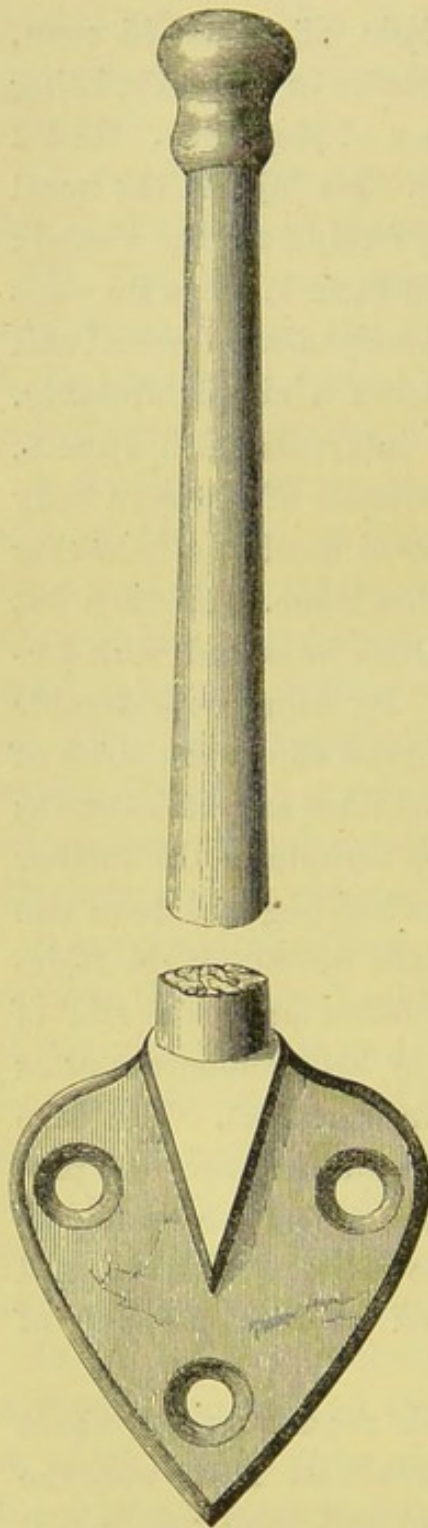
tracted, and the man made a rapid recovery without any impairment of the sight of the eye.

CASE LXXVIII.—“G. W., a hale, vigorous old man, turned 73 years of age, fell down stairs in the dark, being drunk, some time in the last few days of May 1864. He did not lose consciousness from the fall. He injured the nasal side of the right eye, and bled very freely from the wound; but he did not seek medical aid till June 1, when he went to Mr. Clarke, who found a ragged conjunctival wound and much swelling of the lids, and ordered a simple dressing. The patient presented himself at intervals until June 6, when Mr. Clarke discovered the presence of a foreign body in the wound, but deferred its removal until the following day, when he visited the man at his home. He then felt the extremity of a piece of iron, which he seized with forceps and attempted to withdraw. By using considerable force, and after much time, he removed the entire shaft of a cast-iron hat-peg, measuring three inches and three-tenths in length, and weighing twenty-five scruples. On further inquiry, Mr. Clarke found that this hat-peg had been one of a row, screwed to the wall near the bottom of the staircase; so that the man must have fallen upon the end of the peg, and must have broken it by his momentum after it had become completely buried in his orbit. The base of the hat-peg was still in its place in the row, and presented a recently fractured surface fitting accurately to that of the portion removed from the patient. The annexed woodcut represents the hat-peg and its base precisely of their natural size.

“When the question arose with regard to the exact period of impaction, no one could answer it. There were the seven days during which the patient had been under medical observation; but he could not remember on what day

of the week he fell down, and could only say that it was four or five days before he went to the doctor. Four or

FIG. 72.



five, with an illiterate old man, means simply x ; but it may be presumed that the actual period of impaction was between ten and twenty days. The patient recovered without a single unfavourable symptom.

“To-day, November 12, I have made a careful examination of the injured part.

“The hat-peg appears to have lacerated the conjunctiva of the globe a little to the inner side of the cornea, and to have passed between the ocular muscles and the lachrymal apparatus without injury to either. About a line from the corneal margin, and below the horizontal meridian of the eye, there is an excrescence as large as a small hempseed, and resembling the little growths that sometimes follow operations for strabismus. From this excrescence as an apex, a conical patch of vascularity, like a pterygium, extends to the caruncle, and the patient says that a few exceedingly small fragments of bone have worked out. The excrescence probably conceals the opening of a fistula; but I sought vainly for such

an opening with a probe. The vision and movements of the eye are unimpaired, and the lachrymal apparatus is perfect. But the excrescence, by resting on the margin of the lower lid, diverts a portion of the tears from their proper course, and occasions a slight epiphora. This is, indeed, the only inconvenience that the patient has sustained from the injury.

“Mr. Clarke was compelled to use very considerable force to remove the hat-peg, and had to loosen it by lateral movements as well as by direct pulling. Partly from this reason, and partly from his natural astonishment at its bulk and length, he can scarcely be certain of its direction; but, from the relation of its original position to the probable direction of the fall, as well as from anatomical considerations, and from his impression at the time, he thinks that its point must have been received in the antrum of the opposite side. The entire absence of head symptoms, however, must not be taken as conclusive upon this part of the question; since there are cases on record, perfectly authenticated, in which undoubted injuries to the brain have been recovered from without any symptoms that could have revealed their existence.”

The next case, which occurred in the practice of Dr. Nélaton, is, if possible, even more remarkable. It is thus related by Drs. Zander and Geissler (*Verletzungen des Auges*, Bd. i. s. 225). The following translation is by Mr. Carter of Stroud.*

CASE LXXIX.—“A man, 26 years old, applied at Nélaton’s Hospital on account of a lachrymal fistula, and stated that three years previously he had received a blow, in the inner angle of his left eye, from the ivory handle of an umbrella, and that it had rendered him

* *Ophthalmic Review*, No. 4, p. 339.

unconscious for several hours. At that time he was taken to Desmarres' Hospital with a bleeding wound, a centimètre and a half in length, at the place of injury. This wound was examined with a probe, and it was believed that a splinter from the superior maxillary bone had been driven between the eye and the inner wall of the orbit. Various fruitless endeavours were made to remove this supposed splinter, and some small white particles were brought away by the forceps. The globe was unhurt, but its movements towards the nose were impeded, and mydriasis was produced. The suppuration gradually diminished, and the skin contracted and healed, leaving only a fistulous opening to a channel leading to the supposed splinter. Further treatment was then abandoned, and the patient was discharged. On presenting himself to Nélaton, he exhibited slight exophthalmos on the left side, with strabismus divergens; the sclera yellowish, or slightly coloured, as if from ecchymosis; the refracting media normal. Below the inner angle of the eye was a sinus, one centimètre in depth, having an external opening precisely like that of a lachrymal fistula; but the lachrymal sac was healthy, and the tears passed into the nose without impediment. A probe, introduced with some difficulty, struck upon a very hard, smooth, and immovable substance. Lying down at night produced severe pain in the left side of the head, which pain almost entirely subsided in the daytime. Notwithstanding the certainty of the patient that there was no foreign body, and his assertion that the umbrella had not been broken by the blow, Nélaton did not feel satisfied upon the point, and he determined to remove the hard substance, whatever it might be. He made an incision, two centimètres in length, over the inferior margin of the orbit, and through this incision a slight mobility of the substance could be felt. The substance

was then seized with strong forceps, and, to the astonishment of everybody, an ivory handle was withdrawn, cylindrical in shape, four centimètres (one inch and five-eighths) in length, and a centimètre and a half in thickness. The end that had been turned outwards showed where it had been broken from the wood of the umbrella-handle, and presented indentations, produced by the attempts at extraction made by Desmarres three years before. There followed some bleeding from the right nostril, the pains disappeared, and the eye regained its movements inwards. After a few days the patient left the Hospital with his vision improved, and with the fistula nearly healed."

These two cases illustrate the fact that large foreign bodies may become buried in the orbit without the knowledge of the patient, and that recovery with good sight may follow their removal.

I. *In the passage of the foreign body into the orbit, it may either injure the parts within the eye or rupture its external coats.*

The following case is an example of this form of accident. The foreign body as it penetrated the orbit inflicted such an injury to the external coats of the eye that there was immediately complete loss of sight, and the globe afterwards shrank. The patient was under my care at the Royal London Ophthalmic Hospital.

CASE LXXX.—*Lodgement of a piece of iron in the orbit and wound of the eye from the bursting of a railway fog-signal*
—*Complete loss of the eye.*

Joseph C., aged 7 years, was brought to the Ophthalmic Hospital on August 1, 1865, having met with a severe accident to the left eye eight weeks previously. The history the mother gave is as follows:—Living

in the neighbourhood of the Great Eastern Railway, near Shoreditch, her child, like others in that locality, would occasionally pick up a detonating fog-signal, sometimes two or three, and explode them for amusement. Eight weeks prior to her application at the Hospital the lad found a fog-signal, and, unnoticed by the mother, he made it explode by placing it on the ground and striking it with a brick until it went off. The boy was at once knocked down; a large portion of the metal casing penetrated the orbit, inflicting a long wound in the upper eyelid by tearing through its entire structure obliquely from the outer margin of the orbit to its tarsal edge. The lad was seen by a surgeon in the neighbourhood, who brought the edges of the wound together, after removing from the orbit a large piece of tinned iron nearly an inch in length. The wound in the lid united favourably; but the eye, after much inflammation, gradually began to shrink.

State on admission.—A long cicatrix extends obliquely across the upper eyelid. At the upper extremity of it, and immediately beneath the upper edge of the orbit, the small end of a piece of metal can now be seen protruding; it is very firmly fixed, and evidently extends some distance backwards. It is only during the last fortnight that it has made its way through the integument of the lid. The eye is quite lost, and shrunken about three-fourths.

The child was placed under the influence of chloroform, and I excised the shrunken globe, and after some trouble

FIG. 73.



succeeded in removing from the orbit a large fragment of tinned iron, which had become firmly wedged against the superior orbital plate. It was clearly a portion of the fog-signal, and was of the shape and size represented in fig. 73. On examining the eye, it was seen that the sclerotic had been perforated

close to the optic nerve, vitreous had been lost, and posterior intraocular hæmorrhage had followed. Since the removal of the eye and the foreign body, the boy has made a good recovery.

II. *In the passage of the foreign body into the orbit the globe may escape injury, but the optic nerve may be wounded by it.*—This fact has been already exemplified in Case LXVIII., p. 298, in which the sight of both eyes was destroyed by a musket ball which entered at the inner angle of the left eye and made its exit close to the lobule of the right ear, passing behind the nasal bones.

For the following notes of a very interesting case of sudden and immediate loss of sight from the lodgement of the head of a bulrush within the orbit, I am indebted to Dr. Way and Mr. Bowman, under whose care the patient at different times placed himself. From the history of the accident, the sudden blindness which immediately followed, and the size of the foreign body which was afterwards removed, I think there can be little doubt that the optic nerve was wounded by the spike of the bulrush.

CASE LXXXI.—The Rev. T. B., æt. 30, was out shooting in one of the Isles of Scilly on October 27, 1858, when he stooped quickly to pick up a bird which had fallen amongst some bulrushes. Whilst doing so, he suddenly felt a sharp pain in the right eye; some bleeding ensued, and he at once found that the sight of it was completely lost. Dr. Way saw him in consultation about ten days after the accident. There was then much pain in the eyeball, swelling of the lids, and ecchymosis of the ocular conjunctiva. The lower lid was everted, and there was a serous discharge from the orbit, from a small sinus beneath the globe. No foreign body was detected, though its existence within the

orbit was suspected and sought after. Under treatment the inflammation greatly subsided, but the pain continued very severe; the patient slept badly at nights, and suffered from irritative fever. One night, about a month after the receipt of the injury, he discovered a small hard point projecting from beneath the eyeball, which he seized hold of and withdrew. In doing this he said he felt sharp pain "like fire," and he found that he had drawn out of his orbit the head of a bulrush about one inch and a half in length.

There was about one quarter of an inch of the stem of the rush—the remainder was the flower. The local disturbance subsided in a few days, when he came to town and consulted Mr. Bowman, who has kindly given me the following notes which he then made of the case.

December 8, 1858.—After briefly giving the history of the accident as already described, it is stated:—"The pupil of the *left* (the injured) eye is widely dilated. Examined with the ophthalmoscope the lens and humours clear. Optic disc a little enlarged, and the edge pearly. The eye is much drawn inwards, and cannot be brought up to the middle line.

"There is a cicatrix between the sac and the eye: no epiphora—the puncta clear.

"His pulse was 40 after the accident with sickness, and continued so for a month.

"The *right* eye reads well and bears light.

"The accident was attended with no flash or motes.

"*November 9, 1859.*—*Left* eye perfectly dark: in natural position, and moves with the other. Optic disc, white and flat. *Right* eye reads No. 1 Jaeger."

III. *The foreign body may injure the walls of the orbit either by penetrating them or causing fracture.*—In all those remarkable cases which have been related of large substances

having been lodged in the orbit, it is certain that one of the orbital walls must have been penetrated, probably the inner or the lower; one extremity of the foreign body must have been partially projected either into the cavity of the nares or else into the antrum, or it may in some instances have entered the ethmoidal or frontal cells. The size of the orbit forbids the idea that many of the foreign bodies which have been extracted from it should have been contained absolutely within its walls. In Case LXXVIII., in which nearly $3\frac{1}{2}$ inches of a hat-peg was driven into the orbit, it was the opinion of Mr. Clarke, the gentleman who attended the patient, that "its point must have been received in the antrum of the opposite side." Again in Case LXXIX. it is stated that when M. Nélaton extracted the foreign body there was some bleeding from the right nostril, showing that the inner wall of the orbit must have been penetrated by it, and that one extremity of it was probably resting in the posterior nares.

In some instances where the foreign body is not very large, that part of the orbital wall against which it impinges may be fractured without being penetrated by it.

The following case illustrates one of the primary as well as some of the secondary results which may be produced by a foreign body in the orbit. The patient was under the care of Mr. Hulke in the Middlesex Hospital. She had been injured by a fragment of wood from a clothes prop having been impacted in the orbit. From the very first the case seems to have done badly; on the eleventh day she was admitted into the Hospital with tetanic symptoms, and she died on the twelfth day after the accident. From the post mortem examination it was found as a *primary* result of the accident that the eye had been

severely injured by the blow on it from the clothes prop as it entered the orbit, causing extensive hæmorrhage into the vitreous.

As secondary results, there had been orbital cellulitis, which had terminated in abscess. The periosteum of the outer orbital wall had been destroyed, and the bone was in actual contact with the pus. Had the patient lived, it is probable that a portion of the bone would have become necrosed. Lastly, the patient died of tetanus, undoubtedly brought on by the irritation of the nervous system excited by the foreign body in the orbit.

In the chapter on "Gun-shot Wounds of the Eye" (page 300) there is also recorded in Case LXIX. a death from tetanus occasioned by a quantity of stones and gravel having been driven into the face of the patient by the explosion of a shell. The eye was destroyed, and some stones and gravel were lodged in the orbit. Tetanic symptoms showed themselves on the fourth day, and the man died on the sixth day after the injury.

CASE LXXXII.—Jane E., æt. 21, a charwoman, was admitted an in-patient of the Middlesex Hospital under Mr. Hulke on Aug. 17, 1866.

History.—The account given by the mother of the girl was, that eleven days previously she was struck on the right eye with a clothes prop, and the eyelid immediately became greatly swollen. Two or three days afterwards she complained of an uneasiness in the throat, which was shortly followed by rigidity of the lower jaw, and for the last two or three days she had been unable to swallow. Before her admission she had been under medical treatment.

State on admission.—The right upper lid was red and swollen; in the centre of it there was a small notch. The

eyeball was advanced in front of the plane of its fellow. The conjunctiva was œdematous, and there was a mucopurulent discharge. No opening could be detected with a probe. The cornea was semi-opaque, and at the lower part of its circumference there was a sloughy ulcer. There was fulness in the temporal and masseteric regions, and rigidity of the lower jaw, which could be only separated about a quarter of an inch from the upper. The tongue was swollen; the breath fœtid, and the saliva ran profusely from the mouth, probably from mercurial salivation.

She articulated very indistinctly and with much difficulty: her breathing was tranquil, her colour pale; and when asked if she was in pain, she always pointed to the upper part of the throat. The right side of the face was flaccid from paralysis of the portio dura.

Aug. 18.—At about mid-day the patient was seized with tetanic convulsions accompanied with extreme dyspnœa: her head was drawn back on her shoulders, her body bent forward, her knees drawn up, and the supra-clavicular spaces deeply tucked in. There was extreme lividity of the countenance, and almost complete insensibility. This paroxysm lasted for about ten minutes, and then slowly subsided. From this time twitchings of the muscles of the neck on the left side frequently recurred, and were excited whenever a current of cold air fell on her, or when she was touched. Later in the afternoon she had three or four attacks similar to the one described, and she died at 7 P.M. in a state of syncope.

Post mortem examination nineteen hours after death.—Rigor mortis strongly marked. After taking off the skull-cap the dura mater was found normal: the surface, interior, and base of the brain were healthy. On removing the roof of the orbit, a thin film of extravasated blood was seen at its apex, upon the ocular surface of the periosteum.

The orbital cellular tissue was œdematous and matted, especially along the outer and upper angle of the orbit. On cutting into the cellular tissue an abscess was opened between the outer wall of the orbit and the eyeball, which contained an irregular piece of wood, about one inch long and a quarter of an inch wide, and several other smaller pieces. The periosteum of the outer wall of the orbit corresponding to the abscess had sloughed, and the bone was in actual contact with the pus.

After making a section of the eyeball, a clot of blood was seen in the anterior part of the vitreous; the hæmorrhage having apparently taken place from the ciliary processes. Blood had also been effused into the vitreous posteriorly from rupture of some of the retinal vessels.

TREATMENT OF FOREIGN BODIES IN THE ORBIT.—Whenever it can be clearly established that a foreign body is impacted in the orbit, the treatment is to endeavour to remove it as soon as possible. Its presence is always a source of danger to the eye, and may even, as in the cases already quoted, cause the death of the patient. To this rule, however, there are exceptions; and these are, when the foreign body is a small shot, or a fine scale of metal which may have flown off from a rivet and passed into the orbit without injury to the eye. The almost impossibility of finding a small object in a mass of cellular tissue forbids the attempt to hunt after it. If it can be easily felt with a probe introduced through the wound, it should be removed, but no lengthened exploratory operation should be attempted with the view of seeking for it. Such a proceeding would probably excite more irritation than would arise from the presence of a small metallic body in the orbit. It should also be remembered that small masses of metal may be often embedded in the cellular tissue of any

part of the body without producing a symptom of irritation, and that they may remain there for many years without causing any disturbance.

Having ascertained by a careful investigation into the history of the case and by an examination of the wound that a foreign body either is, or is in all probability, embedded in the orbit, the following operation for its removal may be performed.

The outer canthus should be freely divided, either by a pair of scissors or with a scalpel, to allow of the upper lid being completely turned up, or the lower one drawn down, according to the locality in which the foreign body is lodged. If it has entered the orbit *above* the globe, the upper lid is to be raised, and the reflection of conjunctiva between the lid and the eye is to be divided over the spot where the foreign body is suspected to be lying. A probe or the little finger may then be passed through the wound into the orbit by the side of the eye; and having felt the object, it may be seized and drawn out with a pair of sequestrum forceps. When the foreign body has entered the orbit *below* the globe, the lower lid must be drawn down and the lower oculo-palpebral fold of conjunctiva must be divided, but the remaining steps of the operation are the same as those already described.

If the foreign body has become entangled with one of the recti muscles, or from any other cause one of them should interfere with its easy withdrawal from the orbit, it is better at once to divide the muscle with a pair of scissors as close as possible to the globe, rather than to use any force to overcome the resistance it may be causing.

In an operation for the extraction of a foreign body from the orbit, it is always of importance to avoid making the external opening into the orbit through the skin of the

upper or lower eyelid. In the cicatrization which will follow such a wound, not only will a very unsightly scar be produced, but there will most probably be some drawing inwards towards the orbit of the cicatrix of the lid, and a consequent ectropion, or turning outwards of the lashes. Both of these deformities will be prevented by the division of the external canthus, and by making the incision, as already recommended, through the oculo-palpebral fold of conjunctiva.

Having completed the operation, the cut edges of the outer canthus should be accurately brought together either with a *very fine* pin and twisted suture, or else with one or two fine wire or silk stitches. A fold of wet lint should be laid over the closed lids and brow. If there has been much tearing of the orbital cellular tissue, or from any other cause sharp inflammatory action is expected, ice in an india-rubber bag should be kept constantly applied over the wet lint.

After severe surgical operations I have frequently had reason to be well satisfied with the influence which cold thus applied over the wounded parts has had in restraining undue inflammatory action. It generally affords comfort to the patient, and so long as it does so, it may be continued; but should he complain that the cold is painful, the ice-bag should be at once removed. As a rule, cold applications do good for the first day or two after an operation; but when suppuration has commenced, warmth is the most agreeable and beneficial to the patient.

After the foreign body has been removed from the orbit, the patient usually makes a rapid recovery. If there is much suppuration, warm poultices should be applied, and the wound should be kept open by occasionally passing a probe between its lips, so as to afford a free exit for the

pus. As the discharge diminishes, water dressings may take the place of the poultices.

In the majority of cases where the eye has been uninjured either in the entrance, or by the presence of the foreign body in the orbit, no injury results to it from the operation. Even a large foreign body may be often taken away without in any way impairing the functions of the eye: still there is always a greater or less risk of the loss of the organ, either immediate or secondary, with which the patient should be made acquainted.

FRACTURES OF THE BONES OF THE ORBIT.—As we have seen in the previous article, fracture of the inner and lower walls of the orbit is frequently caused by the impaction within its cavity of a large foreign body, one extremity of it passing through the orbital walls into the antrum or the posterior nares. When a fracture of the orbit extends into the frontal or ethmoidal cells, there is generally emphysema of the cellular tissue of the lids and the surrounding parts. This arises from the patient forcibly driving the air through the broken cells when he blows his nose. Fracture of the walls of the orbit and especially of its roof is often associated with fracture of other portions of the skull, and in such cases it frequently happens that the contusion or laceration of the brain produced by the blow is sufficient to cause death, independently of the injury which the cranial bones have sustained.

There is, however, one form of fracture which is confined to the walls of the orbit, and which is very fatal. It is caused by direct violence, and is commonly produced by a forcible thrust in the eye with a sharp or semi-blunt pointed instrument, such as the points of a pair of scissors, the end of an umbrella or foil, or by

the stem of a long tobacco-pipe. The orbit is penetrated, and the end of the stick, or whatever it may be, is thrust against its roof or the upper part of its inner wall, which it in some cases fractures, whilst in others it breaks its way through the bone and penetrates the substance of the brain. From such an injury the patient seldom recovers: even when the bones are broken, but not penetrated, the sharp splinters usually create such irritation of the brain and its membranes that a fatal result ensues. One peculiarity of this accident is, that its severe nature is apt to be often overlooked; the external wound may be small, the immediate symptoms may be trifling, and the patient, if a mechanic, may be able to continue his work for some hours, or it may be for two or three days, before his condition obliges him to desist. Symptoms of inflammation and suppuration may then come on, coupled with those of cerebral or meningeal irritation; the patient may pass rapidly from slight delirium to complete coma, and die in a period varying from a few days to two or three weeks.

The following case is a good illustration of this form of accident. The man received a thrust in the orbit from the ferrule end of an umbrella. Cerebral symptoms began to show themselves two days afterwards, when he was admitted into the Hospital, and he died in a state of coma on the twenty-third day after the accident.

CASE LXXXIII.—William K. was admitted into the Middlesex Hospital under the care of Mr. De Morgan on October 6, 1866. The history given was that two days previously he had been “prodded” in the left eye with the ferrule end of an umbrella. On admission the patient presented a lacerated wound of the left upper eyelid. He appeared very drowsy, but was aroused by being loudly spoken to, when he answered questions rationally, and nar-

rated clearly the circumstances of the injury, but relapsed immediately into his previous drowsy and semi-conscious state. A few days after his admission he was attacked with an erysipelatous inflammation around the wound, which was accompanied with delirium. Under treatment these symptoms gradually subsided. The man rallied from his delirium and became rational, but he continued very drowsy until a few hours before his death, when he sank into a state of profound coma, in which he died, on the twenty-first day after his admission into the Hospital.

Post-mortem examination.—A jagged wound about three-quarters of an inch in length was seen in the *left* upper eyelid, with considerable swelling of the surrounding parts. After removing the skull-cap and raising the anterior lobes of the brain, a piece of bone rather larger than a sixpenny piece was found to have been broken out of the orbital plate of the frontal bone, which had pierced the dura mater and been thrust into the substance of the brain.

On making a section of the brain, the wound of its anterior lobe was found to communicate with the *left* lateral ventricle, which contained a quantity of pus. The *right* ventricle contained some serous fluid, but no pus. The other organs of the body were healthy.

Treatment of fractures of the orbit.—Fracture of the orbit requires the same treatment as fracture of any other portion of the bones of the skull, with the exception that even if there is reason to believe that a fragment of one of the orbital bones may be pressing injuriously on the brain, no operation can be attempted to raise it. Absolute rest, both mental and bodily, should be enjoined in all cases where a fracture of the orbit is suspected. The patient should be kept in bed, and cold water dressings or an india-rubber bag of ice should be laid over the eye and brow of the in-

jured side; and the bowels should be freely acted on by a brisk purgative. All stimulants should be forbidden, and a limited diet should be ordered. If there is much pain in the head, six or eight leeches should be applied to the temple, and these may be repeated in twenty-four hours if the symptoms become more urgent. In severe head injuries I have on several occasions found decided benefit follow the local abstraction of blood from near the seat of the injury: the relief has been so immediate that the good effect of the remedy could not be doubted. In many cases the existence of a fracture of the orbit can be only conjectural, and in such the treatment must be expectant.

PENETRATING WOUNDS OF THE ORBIT should be always regarded seriously. The exact injury which has been inflicted can often be only surmised, and time is required for the manifestation of symptoms before either a correct diagnosis or prognosis of the case can be formed. The instrument which has caused the accident should be examined to see if any fragment of it has been broken off and left behind in the orbital cellular tissue, and the direction in which it penetrated the orbit should be noted. The patient should be kept under careful supervision for some days, so as to enable the surgeon to treat from the onset any unfavourable symptoms that may arise. Even when no injury has been inflicted to the bones of the orbit, orbital cellulitis and abscess are very apt to ensue.

ABSCESS OF THE ORBIT may be caused by blows on the eye; by penetrating wounds of the orbit; or by any violence producing fracture of its bony walls; by the lodgement of a foreign body in the orbital cellular tissue; or

occasionally by the extension backwards of a suppurative inflammation of the lids or of the tissues in immediate contiguity with the eye, no matter how induced. Inflammation of the cellular tissue of the orbit (orbital cellulitis) brought on from any cause may terminate in abscess of the orbit. Caries, necrosis, or orbital periostitis may likewise lead to orbital abscess, but our present inquiry is devoted only to those cases in which it arises either directly or indirectly from injury.

Abscess of the orbit may be either *acute* or *chronic*. In the former the inflammatory symptoms generally rapidly follow the injury; they are sharp and quick in their progress; pus is soon formed; and independently of the history of the case, unmistakable evidence of its presence is afforded by the pain, heat, redness, and swelling. Occasionally, however, there is a variable interval of a week or more of perfect quiet and freedom from pain after the injury, before any premonitory symptoms show themselves; but when once started, their course is equally acute and rapid. In one case of abscess of the orbit which came under my care, eleven days elapsed between the receipt of the injury and the commencement of inflammatory symptoms. The history given by the mother was, that the child had received a blow on the eye from a fall; her foot tripped as she was running, and in falling she struck her right eye against the edge of the door step. The lids and the parts around the eye immediately became much ecchymosed and swollen, but no other apparent injury was inflicted. The discoloration and swelling of the tissues gradually subsided, and the child seemed well. About eleven days after the accident the eyelids began to swell, and look red, and in a day or two afterwards the mother noticed that the eye seemed to project. The child now suffered severe pain in the eye and orbit, sufficient to pre-

vent sleep and to destroy her appetite. The swelling of the lids increased until the upper one was drawn tightly over the eye, and could not be raised by the patient. She was now brought to me at the Ophthalmic Hospital, and her condition was then as follows.

The upper eyelid was red, tense, and shining, and completely closed over the eye, which was projected forwards beyond the orbit about three-quarters of an inch, and turned slightly downwards and outwards. Along the upper and inner border of the globe, between it and the edge of the orbit, was a distinct prominence and feeling of fluctuation. I accordingly made a free opening at this point, and gave vent to a large collection of pus. The child received immediate relief, the eye gradually receded to its normal position, and she recovered without the slightest impairment of sight.

Symptoms of acute abscess of the orbit.—Deep-seated pain in the orbit extending around the brow, worse at one time, better at another, but never absent, and steadily increasing in severity. Any pressure on the eye, or even moving it, aggravates the pain. The eyelids become red, shining, and œdematous; and the conjunctiva of the lids and globe vascular, swollen, and chemosed. The eye is now observed to protrude slightly beyond the level of the other, and this protrusion increases as the disease advances and the pus makes its way to the surface. The displacement is usually not directly forwards, but more or less downwards and outwards; it being dependent on the situation of the abscess within the orbit and the part of the eye on which it presses. With the increasing protrusion of the globe the sight becomes more or less impaired from the strain which is being exerted on the optic nerve. The orbital fold of skin above the lid becomes obliterated, and the upper lid so swollen and stretched in front of the

bulging eye that it cannot be raised by the patient. Over the most prominent part of the swelling a careful examination with the fingers will detect fluctuation. The most usual spot for the matter to point is rather to the inner side of the interval between the supra-orbital ridge of the orbit and the upper border of the globe. Occasionally the suppuration may be more or less confined to one or other side of the orbit, and this will in a great measure determine the site at which the pus will endeavour to make its exit: either the inner, the outer, or lower side of the eye may then be the part selected. When the abscess is a small and limited one, there may be little or no displacement of the eye.

With all these local symptoms there is always considerable constitutional disturbance. The skin is hot and dry, the patient has occasional rigors, he is restless, and his sleep is broken from pain.

In chronic abscess of the orbit the symptoms are different; they are often masked by the very slowness with which they develop themselves, and by the absence of any severe pain. It frequently happens that the patient does not even seek advice until an increasing protrusion of the eye and a somewhat corresponding diminution in vision excite alarm.

Chronic abscess of the orbit is often most difficult to diagnose, and may easily be confounded with a medullary, or recurrent fibroid, or some soft orbital tumour, the elasticity of which closely resembles fluctuating. The exciting cause of the abscess may have been an injury inflicted at some distant period, which has been forgotten, and from which the patient thought he had completely recovered; or the slow progress of the disease, and the comparative and in many cases complete absence of pain during its early stages may make it difficult, if not impossible, for the pa-

tient to give a correct account of how or when it commenced. When doubt exists as to the true nature of the case, an exploratory incision should be made into the tumour, and the surgeon should be prepared to act at once on the information it will afford him. If it is an abscess, the incision should be enlarged sufficiently to give a free exit to the pus; but if, on the other hand, it should prove an orbital tumour, it should, if practicable, be removed without any further delay.

The practice of making exploratory punctures by thrusting a grooved needle into tumours of the orbit or elsewhere to aid in their diagnosis is a bad one: frequently it is useless, and oftentimes dangerous. If the tumour is a chronic abscess, and the pus is thick and curdy, the small opening made by the grooved needle fails to let any escape, whilst it effectually admits the air, which causes its decomposition.

Treatment of abscess of the orbit.—As soon as it is clear that pus has formed, and that the protrusion of the eye, if there is any, is due to its presence in the orbit, a free opening should be made for its escape. The site for making the incision will generally be determined by the place at which the pus has a tendency to point: it should be at that spot where there is the most distinct swelling and fluctuation. Whenever it is possible, it is well to avoid making an incision through the upper eyelid; but in many, and especially in the acute cases no choice is left for the surgeon. When the eye is bulged forwards, with the upper lid red and swollen drawn tightly over it, and a fluctuating swelling is felt between the upper ridge of the orbit and the globe, an incision should then be made through the upper eyelid with a fine sharp knife, and a free exit be given to the pus. In chronic abscess of the orbit, as there is frequently but little if any swelling of the upper

lid, even though the eye may have been considerably protruded, a free escape may be given to the pus without making any incision through it. The upper eyelid should be raised with the finger, and a Beer's cataract knife should be passed through the conjunctiva just above the upper border of the globe into the orbit, taking care that the point of the instrument is directed slightly upwards to avoid the risk of wounding the eye.

After a free vent has been given to the pus within the orbit, a warm linseed-meal poultice should be applied, and care should be taken that the wound is kept open by examining it daily, and, if necessary, by passing a probe along the course of the incision to prevent the cut edges from uniting. It not unfrequently happens after an abscess of the orbit that the wound from the incision only partially closes, and the space lately occupied by the pus is not completely obliterated, and thus a long sinus remains from which a slight purulent discharge continues to drain. When this is the case, and when no fragment of necrosed bone can be detected by a probe to account for it, the use of a stimulating injection, such as *Zinci Sulphat. gr. ij. ad Aquæ ʒj.*, thrown into the sinus with a glass syringe twice a day, will often prove of great benefit. If, however, a portion of dead bone is felt with the probe, time must be given to allow of its becoming detached, or at least partially loosened from the living structure; and then, after enlarging the orifice of the sinus, it may be removed with a pair of sequestrum forceps, first using, if necessary, a gouge, or an elevator, or a pair of fine cutting bone forceps to separate any portion of bone which may be holding it. The presence of pus in the orbit frequently leads to a superficial necrosis of a portion of the orbital plate with which it is in contact; whilst, in other cases, the reverse may occur, and necrosis, perhaps following fracture, or the result of some constitutional taint, may be the cause of the abscess.

The protrusion of the eye which was noticed as one of the frequent symptoms of abscess of the orbit will gradually recede as the pus escapes, and in a few days the eye will have retired to its normal position ; but, in addition, the sight it had lost on account of the stretching of the optic nerve will be almost if not completely restored.

CHAPTER XI.

INJURIES OF THE EYELIDS.

ECCHYMOSES OF THE LIDS: TREATMENT OF—ABSCESS OF THE EYELID—
WOUNDS OF THE EYELID—SYMBLEPHARON: OPERATIONS FOR THE RELIEF
OF—ANCHYLOBLEPHARON—TRAUMATIC ENTROPION—OPERATION FOR EX-
CISION OF THE EYE-LASHES—TRAUMATIC ECTROPION—OPERATIONS FOR
THE RELIEF OF ECTROPION.

ECCHYMOSES OF THE EYELIDS, or as it is commonly called "a black eye," is an effusion of blood into the cellular tissue of the lids and of the parts surrounding them. It may be limited to one or both eyelids, or it may extend to the cellular tissue of the face around the orbit. The blood is generally absorbed in the course of a week or ten days, during which time the discoloration gradually fades away, but, in doing so, passes through a variety of shades which must be familiar to all. If an ordinary black eye is uncomplicated with fracture of the orbital bones, or with any laceration of the integuments, it soon gets well. It is very rare that any suppuration follows.

A black eye is occasionally complicated with fracture of one or more of the frontal or ethmoidal cells. This casualty is recognised by an emphysematous state of the eyelids and of the cellular tissue around the orbit. When the patient blows his nose, air is forced through the fissured bone into the neighbouring cellular tissue. In no case have I ever seen emphysema of the lids productive of any harm, though the discomfort it occasions is always great. The patient should be cautioned not to blow his nose for some days; the fissured bone will

then soon become closed ; and if no fresh air is forced into the cellular tissue, that which is already there will rapidly disappear. Pricking the integument with a fine needle to give vent to the air is seldom if ever necessary, and should not be resorted to except in cases of extreme tension of skin, a condition which is not likely to occur from a simple fracture of a frontal or an ethmoidal cell.

Treatment.—There are many specifics for the relief of a black eye, each of which is extolled for the rapidity with which it takes away the colour which is so distasteful to the sufferer and his friends. No doubt the application of cold immediately after the blow will limit the effusion of blood, and so diminish the extent of the after discoloration, and may therefore, shortly after the receipt of the injury, be advantageously used. This is best done by cold evaporating lotions ; or by applying ice in an india-rubber bag to the eye ; or by a fold of wet linen being laid over the eye, and frequently moistened with iced water. The practice of puncturing the swollen parts, as recommended and frequently adopted by prize-fighters, is essentially wrong. It may and no doubt does afford a temporary relief to the swelling when it is great, but it renders the part liable to supuration and erysipelas, neither of which would have been anticipated if the skin had not been cut. A remedy which has for many years received considerable credit is a poultice of the black-bryony root. It is “ made by mixing some of the black-bryony root scraped finely with a little crumb of bread. This is placed in a muslin bag over the palpebræ for several hours together ; and usually it has an excellent effect in promoting the action of the absorbent vessels.” * It is, however, a drug which cannot be always procured : the best place to seek for it is from one of the herbalists in Covent Garden Market. The tincture of Arnica Mon-

* Tyrrell on Diseases of the Eye, vol. i. p. 200.

tana has also acquired a great repute for the power it is supposed to possess of favouring the absorption of blood in cases of ecchymosis. It may be applied pure over the part with a camel's-hair brush, or it may be used as a lotion. I have frequently used the Tincture of Arnica in such cases, and have been well satisfied with it.

The following formula is a very good one.

Ph. Lond.

Tinct. Arnicæ Montan. ℥iv.

Liq. Ammon. Acetat. ℥j.

Sp. Rosmarini ℥iv.

Mist. Camphoræ ad ℥viij. M. : ft. lotio.

A fold of lint wet with the lotion to be laid over the lids, and moistened as often as it becomes hot or dry.

ABSCESS OF THE EYELID.—From contusion or laceration of the integument of the lid, acute inflammation and suppuration of the subjacent cellular tissue may follow. The eyelid becomes red, swollen, and shining, and unmistakable evidence of pus is soon manifested. The treatment is the same as for an abscess in any other part of the body. As soon as it is clear that pus has been formed, an incision should be made to give vent to it, and a warm poultice should be afterwards applied. The only point which requires special notice is the way in which the abscess should be opened. The incision should be made with a fine sharp knife in the horizontal direction, and in a line with the orbital fold of skin just beyond the lid. The cicatrix will be then a mere line, and from its situation it will be scarcely observable.

WOUNDS OF THE EYELIDS may be divided into two classes.

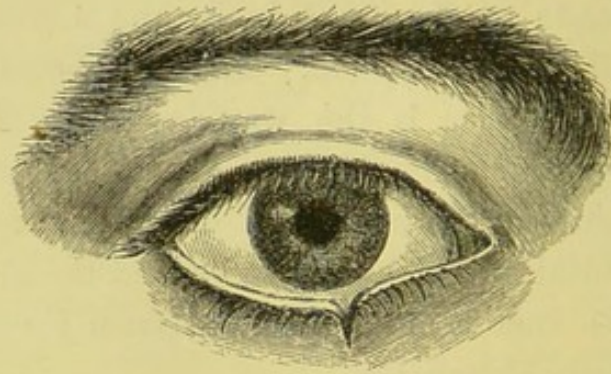
- I. Those which involve only the skin of the lid.
- II. Those which have cut through its tarsal border.

I. *Wounds which involve only the skin of the lid* require the same treatment as similar wounds in any other part of the integument of the body; but from the delicacy of the skin in this locality, and the importance of avoiding as far as possible an unseemly scar, more careful manipulation is needed to bring its edges into accurate apposition. Fine needles and the finest silk, such as are sold by Messrs. Weiss for eye operations, should be used. When all bleeding has ceased, the margins of the wound should be carefully brought together by as many sutures as may be necessary, and a small compress of wet lint should be then laid over the lids, and fastened in its place by a single turn of a light roller. It is of the utmost importance to secure, if possible, primary union. The sutures should be removed on the third or fourth day.

II. *Wounds which have cut through the tarsal border of the lid.*—In lacerations of the eyelid, there are two forms of injury to which its tarsal margin is exposed.

1st. The cartilaginous border of the lid may be cut or torn through at any part, as in fig. 74.

FIG. 74.



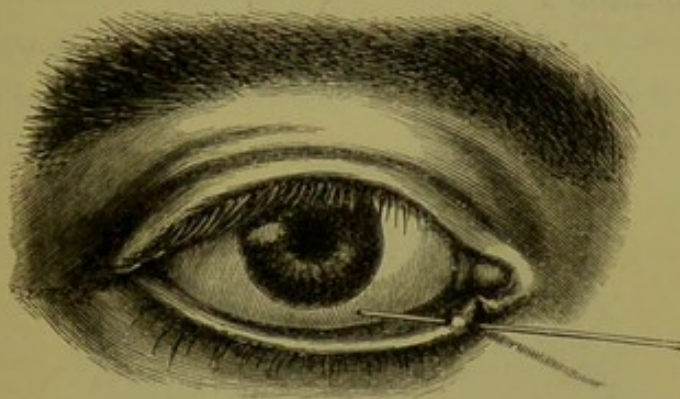
2nd. The rent may pass through the canaliculus, tearing it away from the punctum lachrymale, which may still remain intact at the extremity of the cartilage, as in fig. 75.

1st. *Where the cartilaginous border of the lid has been cut,*

the edges of the wound become slightly drawn apart, and an unsightly notch is formed. If the wound has been a clean incised one, the divided ends of the cartilage should be very accurately fitted together and fastened *in situ* by a pin and twisted suture.

The pin should be a very fine one, such as is used by entomologists for pinning the smaller insects. It should be made to pass through the cartilage of the lid so close to its free edge, that the silk when twisted on the pin will slightly overlay the tarsal margin. By attending to these

FIG. 75.

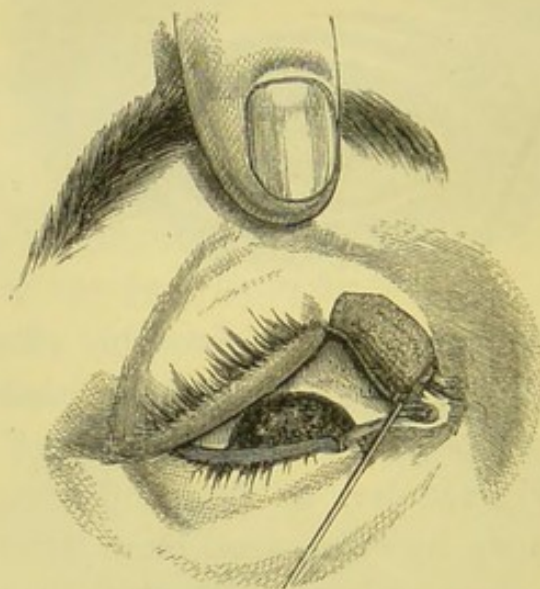


details accurate union will be probably effected, without leaving any notch or irregularity of the border of the lid. When, however, the edges of the wound of the cartilage are jagged or irregular, as frequently happens if the lid has been torn by some semi-blunt instrument, it is better first to pare them smooth with a sharp scalpel before bringing them together with the pin and twisted suture.

If after a wound of the cartilaginous border of the lid no treatment has been adopted, the edges of the gap are apt to become more widely separated, and occasionally a certain amount of eversion is also produced. The extent of the deformity will necessarily depend very much on the depth of the wound.

CASE LXXXIV.—In August 1866, a Russian sailor came under my care at the Ophthalmic Hospital with the hope of gaining some relief from a deformity of the upper lid of the right eye, the result of an injury. Two years previously in a quarrel with one of his shipmates he was stabbed in the eye through both lids with a broad knife. The eye for all visual purposes was at once destroyed. The border of the upper lid was so deeply cut as apparently to extend through the greater part of the breadth of the inner portion of the tarsal cartilage, and the lower lid was also slightly notched. No treatment had been adopted since the accident.

FIG. 76.



On his admission into the Hospital, the upper eyelid presented the curious appearance which is very correctly represented in fig. 76.

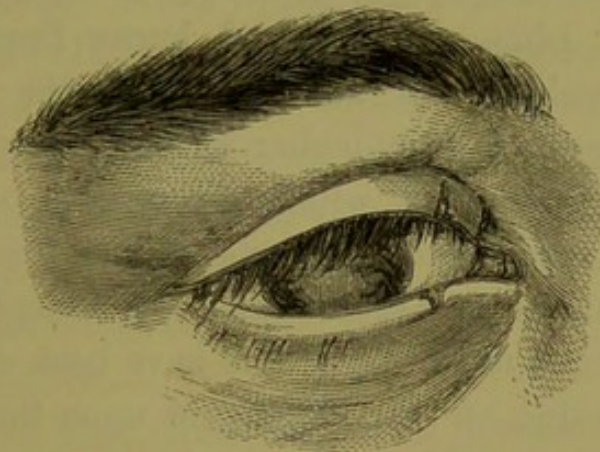
The part of the lid to the inner side of the notch was completely everted, and greatly stretched, so that its conjunctival surface was presented externally.

In the drawing a probe has been passed into the punctum, to show its position on the everted part of the lid.

The man complained that from being unable to close the lid, "the wind and weather came against his eye," and subjected it to repeated attacks of inflammation. I therefore determined to endeavour to restore the lid as far as possible to its normal condition.

With a fine scalpel I first deepened the notch, and freely pared its edges so as to remove the superfluous integument which the long stretching of the inner portion had produced, and then brought the cut ends of the cartilage into apposition by a fine pin and twisted suture. Immediate union followed the operation, and at the end of a week the man left the Hospital, with the eyelid having the appearance which is represented in fig. 77, a drawing of it having been made the day before he went away.

FIG. 77.

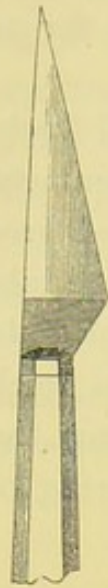

2nd. *When the canaliculus has been torn through and detached from the punctum*, as in fig. 75, a search should be first made for the divided end of the tear-duct. It is of course impossible so to adjust the torn parts that the punctum and the canaliculus can again be made to communicate with each other. If therefore the open end of the divided canaliculus can be detected, a small director, fig. 79, such as was first designed by Mr. Critchett, should

be passed up it, and with a cataract knife, fig. 78, it should

be slit up into the lachrymal sac.

FIG. 79.



The closed tube will thus be converted into an open canal, along which the tears may afterwards flow into their proper channel. The torn parts may then be brought into their normal position and fastened *in situ* with one or two fine silk sutures.

SYMBLEPHARON is an adhesion of the lids to the globe. It is usually produced by an injury which has caused either a destruction or an ulceration of the opposed conjunctival surfaces of the lid and globe, and their subsequent union by granulation. Lime, mortar, and burns from hot metals or scalds from hot fluids are the most frequent causes of symblepharon, but it may be produced by any agent which either destroys or abrades the corresponding parts of the lids and globe. Most of the very severe cases of symblepharon which have come under my notice have been due to lime. The action of this escharotic upon the surface of the eye and lids has been already described at page 30. If the injury it has inflicted is severe, it is absolutely impossible to prevent the union of the lids to the globe. All endeavours to keep the opposed granulating surfaces apart will fail. The contraction which goes on during the process of cicatrization draws the lid and globe into close apposition, and direct union will ensue in spite of all efforts to stop it.

The trouble which symblepharon causes the patient varies necessarily with the extent and position of the adhesions ;

but even in slight cases considerable annoyance is experienced from the limitation of the movements of the eye, and from the epiphora it often excites from the alteration of the position of the punctum with respect to the globe.

Symblepharon is said to be *complete* when the entire inner surface of one lid is adherent to the globe, and *partial* when the adhesion is limited to only a part of the opposed surfaces. Both eyelids may be often seen partially attached to the globe, or the lower lid may be completely united to it; but it is exceptional to meet with complete symblepharon of both the upper and lower lids of the same eye. The lower eyelid is much more frequently affected by symblepharon than the upper.

An example of partial adhesion of both lids to the globe is recorded in Case VIII., p. 43. It was the result of a very severe burn, which was followed by sloughing. Case LXXXVIII., p. 382, is an illustration of complete symblepharon of both the upper and lower eyelids. It was, however, associated with anchyloblepharon, or union of the margins of the lids to each other.

Two forms of symblepharon may be recognised:—

1st. Membranous bands or frena passing between the lids and the globe.

2nd. Direct and close adhesions between the opposed surfaces of the eye and lids.

1st. *Membranous bands between the lids and globe.*—This is the simplest and most remediable kind of symblepharon. It is due to a less extensive and more superficial injury than that which produces the second form:—generally to some *limited* ulceration or abrasion of the corresponding parts of the eye and lids. During the healing process the granulations of the opposed surfaces become united, but the constant pull which is exerted upon them by the movements of the globe will often so stretch the recent

adhesions that they will become elongated into membranous bands.

2nd. *Direct and close adhesions between the opposed surfaces of the eye and lids.*—These are caused by an absolute destruction of corresponding portions of the conjunctiva of the eye and lid. Deep ulceration or sloughing follows the injury, and opposed granulating surfaces are left, which ultimately become firmly adherent and blended with each other. During the cicatrization, the contraction of the surrounding conjunctiva draws the lid and globe into such close contact, that the movements of the eye cannot stretch the bond of union, and the lid and globe remain for ever afterwards firmly bound together.

Treatment.—All operations for the cure of symblepharon are as a rule very unsatisfactory: in the severe cases they generally fail to effect any good; and in the milder ones the relief which is afforded is comparative. It is only in the slight cases that positive good will be found to follow surgical treatment:—those in which small membranous bands or tags of adhesion pass between the eyelids and the globe. When these are insulated, so that a probe can be passed beneath them, and the oculo-palpebral fold of conjunctiva still exists entire, much benefit will be derived from an operation.

There are two ways in which these narrow membranous bands may be treated.

1st. They may be simply divided by a scalpel or a pair of fine scissors; and by daily passing the end of a probe dipped in a little sweet oil between their cut ends, reunion may generally be prevented. This mode of treatment is, however, only applicable to the very mild cases, where a simple tag of adhesion ties the lid to the globe.

2nd. If the bands are small, they may be first cut off close to the globe, and the edges of the wound which is

thus made in the conjunctiva are to be drawn together and united by one or two fine stitches. The other extremity of the band is then to be severed from its attachment to the lid. As in the first operation, careful daily dressing will be required to prevent a rejunction of the ends of the band, as unless the wound in the conjunctiva closes by immediate union, which it may fail to do, the tendency for them to become again united is very great.

The following case of symblepharon which was under my care is an example of the good resulting from the simple division of a membranous band passing between the conjunctiva of the lid and the globe.

CASE LXXXV.—Moses T., æt. 16, came to the Ophthalmic Hospital on December 16, 1864, suffering from slight symblepharon of the right eye. He stated that one day last May a man threw some mortar at him, some of which went into the right eye. He suffered from severe conjunctival inflammation, which resulted in the formation of bands of adhesions between the conjunctiva on the inner side of the globe, and the margins of the eyelids.

On examining the eye, two membranous bands about an eighth of an inch in width were seen extending from the globe to the edge of the lids, one to the upper and the other to the lower eyelid, each of which was attached just external to the punctum lachrymale. The eye was thus tied inwards, by a frenum above and below, so as to give it a strong internal strabismus. On looking outwards the boy could not evert the eye beyond the mesial line of the orbit. As a probe could be passed beneath each of the frena, I cut them through with a pair of fine scissors close to the globe. The eye at once gained more power of eversion; but as there was still a considerable internal squint, the

following week I divided subconjunctivally the internal rectus muscle. This had a very satisfactory result; the free motions of the eye were regained, so that he could turn it outwards until the external margin of the cornea reached the outer canthus, and the squint was cured.

In those cases of symblepharon where there are *direct and close adhesions between the eye and the lids*, many different plans of treatment have been tried, most of them without much success. It is only where the extent of the conjunctival surfaces involved is small, that even amelioration can be hoped for. The lid may be generally easily separated from its union with the globe by a careful dissection, but we have no means at our command by which we can prevent their again uniting. Plates of metal have been interposed between the granulating surfaces, but with very indifferent success. Mr. Tyrrell states in his book on the Diseases of the Eye, vol. i. p. 192, that "in two cases, after excising the band or frenum, I kept a very thin and smooth piece of silver constantly between the eyelid and globe, so as effectually to prevent inosculation of granulations as the surfaces healed. When perfectly healed, much good appeared to have been effected; but in less than six months, contraction had taken place of the new formed matter, and frena were developed as bad as, or worse than those which I had removed."

At the Royal London Ophthalmic Hospital we have tried glass shields, very similar in shape to an artificial eye, but perforated with an aperture opposite to the cornea. They were placed on the eye after the adhesions between it and the lid had been completely severed. The success, however, which attended their use was so unsatisfactory that they are now seldom resorted to.

It is true the granulations of the opposed surfaces cannot

communicate when the glass shield is on the eye; but as the primary efforts of cicatrization consist in a contraction of the tissues around the wound, the glass shield is gradually extruded from between the lids, after this contracting process has advanced to a certain stage.

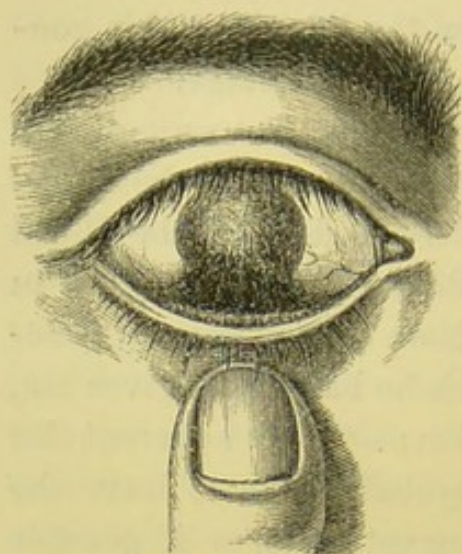
Mr. T. Pridgin Teale, jun., of Leeds, has suggested a plastic operation in cases of symblepharon, which he speaks of very favourably. He first described it in the Royal London Ophthalmic Hospital Reports, vol. iii. p. 253, in which he has cited cases which have been materially benefited by it. In a short note which he has kindly given me, he thus describes the operation:—"The adherent lid having been dissected off the eyeball so as to leave the globe perfectly free in its movements, one, or if possible two flaps of conjunctiva are dissected from the sound part of the eyeball, and transplanted into the gap. If any portion of the adherent lid is united to the cornea, the separation of the lid is commenced at the *margin* of the cornea, leaving the apex of the lid still *in situ* as an opaque spot on the cornea."

There are, however, very many cases of symblepharon where no operation should be attempted. The extent of the adhesions may be so great that it would be worse than useless to endeavour to divide them. The following is an illustration of such a case of symblepharon, caused by the action of mortar on the eye.

CASE LXXXVI.—The patient, who was a plumber, was engaged glazing a sky-light, when a labourer who was throwing up some mortar to a bricklayer near him unintentionally sent some of it into his eye. The accident happened nine months previous to his coming under my care at the Ophthalmic Hospital. The eye had been carefully treated elsewhere, but for all useful purposes it was a lost one.

The cornea was opaque, and broad bands of adhesions, as represented in fig. 80, passed from the lower half of the

FIG. 80.



cornea to the conjunctiva of the lower lid. These bands were best seen by drawing the lid slightly downwards with one of the fingers.

ANCHYLOBLEPHARON is the union of the margins of the eyelids to each other. They may be either partially or completely united. It is, however, seldom that the adhesion

extends throughout the entire length of the lids. The inner third of the two lids are more frequently joined than the outer or middle portions. In nearly all cases of ankyloblepharon, whether partial or complete, a fistulous opening is left at the inner canthus, through which some of the tears find their way on to the face. The union between the lids may be either direct, the two edges being completely adherent, or they may be united by membranous bands passing from the one to the other.

The causes of ankyloblepharon are lacerated wounds of both eyelids, or injuries to them from escharotics. Any accident which causes an abrasion of the corresponding surfaces of the tarsal edges of the eyelids renders them liable to become united. The probability of this deformity occurring after an injury to the eyelids is considerably increased by the habit which many persons, and especially the poor, have of binding up the eye with a handkerchief immediately after the accident, and making no attempt for several days to separate the lids.

Treatment.—When the union between the lids is direct,

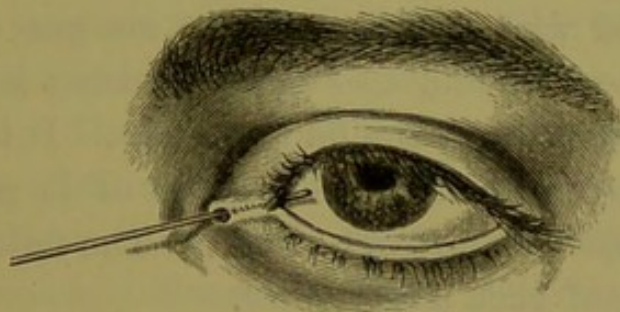
and a fistula exists at the inner canthus, a small director should be passed behind the adherent margins, and out at the fistulous orifice, and upon it the adhesions may be severed with a pair of scissors; or if this cannot be readily accomplished, the lids may be dissected apart with a sharp scalpel.

If a membranous band is the bond of union between the two lids, it should be divided on a director passed beneath it, first close to the margin of one lid, and then be cut off close to the edge of the other. The chance of success following either of the operations depends very much on the daily dressing of the wound: special care should be taken to keep the lids from reuniting during the process of cicatrization.

This may be generally accomplished by daily separating them, and anointing the granulating surfaces with a little sweet oil.

The following case is a good example of simple anchylo-

FIG. 81.



blepharon. The drawing (fig. 81) shows very well the position of the fistula which is so frequently met with when the inner portions of the lids are united.

CASE LXXXVII.—Mary R., æt. 21, came to the Ophthalmic Hospital on November 7, 1865, to obtain relief of a deformity of the right eyelid.

Between nine and ten years ago she fell down and struck the inner angle of the eye against one of the whalebones of an umbrella. The inner canthus and the inner extremities of both the eyelids were torn. The patient has partial anchyloblepharon. The inner margins of the upper and lower lids are united to about one third of their extent. A small fistula exists at the inner angle of the eye, through which the tears flow. There are no adhesions between the lids and the globe. Fig. 81 represents the appearance of the eye when the patient first applied to the Hospital. A probe has been passed through the fistula, to indicate its exact position.

Having passed a director beneath the united portions of the lids, and through the fistula, Mr. Bowman divided the adhesions with a pair of fine scissors. The lids were at once completely opened, and after a few days the wound cicatrised, and the patient left the Hospital.

Anchyloblepharon and symblepharon are often associated: indeed with the union of the margins of the lids it is very general to find also some adhesion between the conjunctival surfaces of the lid and globe. It is, however, rare to find in one eye a complete union of the globe to the lids, and of the lids to each other. The following case is an example of such a deformity.

CASE LXXXVIII.—A patient came under the care of Mr. Critchett at the Ophthalmic Hospital in November 1865, suffering from the effects of an injury he had received to his left eye and eyelids about four years previously.

He stated that a Roman candle had been accidentally allowed to burst near his eye. The whole surface of the globe and the conjunctiva lining the lids were severely

burnt. His sight was completely lost, and the lids and globe eventually became adherent to each other.

State on admission.—There was complete anchyloblepharon, and apparently complete symblepharon also. The lids were firmly united along their tarsal margins. There was not even a fistula at the inner canthus through which the tears could escape. The eye could be felt beneath the lids, but the upper lid could not be made with the finger to glide over the globe. The upper eyelid near the brow was bulged forwards by a fluctuating swelling, evidently fluid, and probably formed by a pent up accumulation of tears.

The patient having been placed under chloroform, Mr. Critchett first punctured the swelling of the upper lid, from which a large quantity of tears escaped. He then divided the lids along the line of union of their tarsal borders, hoping to find the globe free beneath them; but this was not the case—the inner surfaces of the lids were closely adherent to it. He endeavoured by dissection to separate the lids from the eye; but in doing so, he found there was no true cornea, and that whilst he was raising the upper lid from the globe, he was exposing the iris and lens. The cornea had probably sloughed after the accident; or if this had not happened, it had become so intimately incorporated with the inner surface of the lid as to be completely blended with it. The lens was transparent, and the vitreous was healthy and clear.

As no good could result from further dissection, and as no operation would enable the patient to wear an artificial eye, Mr. Critchett closed the wounds to allow the parts again to unite.

ENTROPION, OR AN INVERSION OF THE EYELASHES, is a not infrequent result of injuries of the conjunctiva of the

lids from burns or scalds, from lime, mortar, strong acids, or any other escharotic which may have caused destruction of a portion of that membrane.

As cicatrization proceeds, a contraction of the surrounding tissues goes on to help to close up the gap occasioned by the escharotic, and the margin of the lid with its lashes often becomes inverted and drawn towards the globe. This folding in of the lashes is a source not only of great discomfort to the patient, but of danger to the eye. The continued brushing of the lashes against the cornea in every movement of the eye is apt to induce a troublesome form of corneitis with ulceration, and will invariably after a time render the cornea nebulous and vascular.

Treatment.—There are many operations recommended for the cure of entropion; but when it is dependent on cicatrization following a loss of substance of the conjunctiva of the lids, there is only one way of efficiently dealing with it, and that is by dissecting out the entire row of lashes. Any other mode of treating this deformity will be only temporary, and after a while the lids will again become inverted. As soon as it is noticed that the margin of the eyelid is folded inwards, and the lashes are in contact with the eye, an operation for their removal should be performed, as delay will only give time for the cornea to become injuriously affected by them.

Operation for the removal of the eyelashes.—This consists in first splitting the tarsal cartilage, and then excising the thin wedge of it in which the bulbs of the lashes are embedded.

The lid being drawn tense by one hand of the operator, with the other he makes a long incision with a cataract knife along the inner or ocular edge of the lashes, and of a sufficient depth for the point of the knife to pass beyond the roots of them. The lid is now to be relaxed, and a

second incision is to be made just behind, but parallel to, the row of lashes on the outer surface of the lid, so as to cut through the integuments and the margin of the cartilage just behind their roots: the depths of the two incisions will thus meet, and the whole row of lashes will be excised.

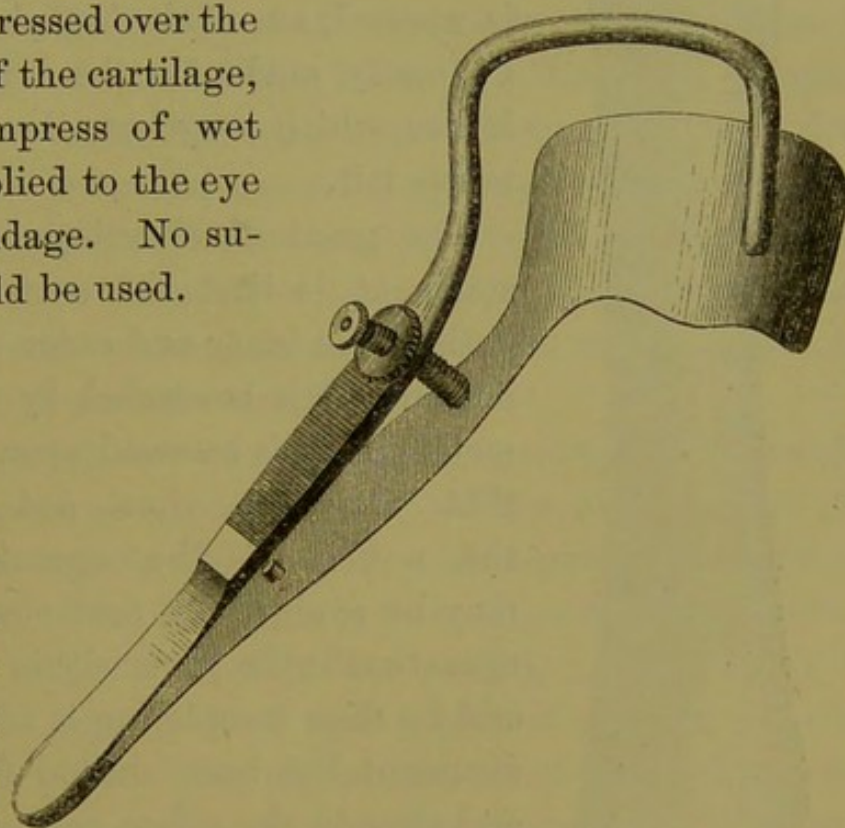
The cut surface of the cartilage should now be carefully scanned over, so that if any of the bulbs of the lashes have escaped excision they may be removed; should any be left, new lashes will sprout again from them, and the object of the operation will not be completely fulfilled, as a single eyelash brushing against the cornea may cause a great amount of suffering, and produce considerable irritation. The bulbs of the lashes may be recognised by their appearing as fine black dots.

Lastly, the skin should be gently pressed over the cut edge of the cartilage, and a compress of wet lint be applied to the eye with a bandage. No sutures should be used.

By this operation the lid is not shortened, for the edge of the cartilage is simply split, and

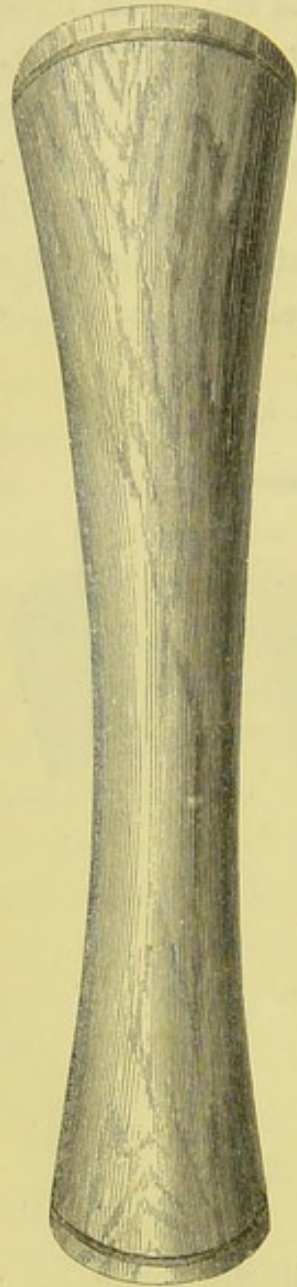
the thin wedge of it removed in which the lashes are implanted.

FIG. 82.



To facilitate the performance of this operation, either Snellen's eyelid forceps (fig. 82) or the horn spatula (fig. 83) may when practicable be used. If Snellen's forceps are selected, the lower blade should be gently insinuated beneath the upper eyelid as far as it will pass, and then, with a few turns of the screw, a metallic clamp

FIG. 83.



is made to compress firmly the circumference of the lid with the exception of its tarsal border, which is left free for the operator.

The advantages which this instrument offers are—1st. That the operation, which is usually accompanied by sharp hæmorrhage, is rendered by it an almost bloodless one; and 2ndly. That as all bleeding is arrested whilst the clamp is applied, an efficient exploration can be easily made for the bulbs of any lashes which may have been inadvertently left.

The great disadvantage of this instrument is that the extreme lashes, both at the inner and outer part of the lid, are often concealed by the rim of metal which is screwed upon them, and that they are thus apt to evade the notice of the operator. This may be avoided by first confining the operation to the parts within the clamp, and by then completing it after the instrument has been shifted first to one and then to the other extremity of the eyelid.

Snellen's forceps are made right and left handed, ac-

ording to the lid for which they have to be used. They are only applicable to operations on the upper eyelid.

When the horn spatula (fig. 83) is used, it should be held by an assistant after one of its extremities has been passed beneath the eyelid. It will serve to support and extend the eyelid during the operation.

There are, however, many cases of traumatic entropion where it is impossible, on account of a partial union of the lids to the globe, to use either Snellen's forceps or the horn spatula. In such cases the plan recommended of making the lid tense by drawing upon it with one of the fingers must be adopted.

There is one form of entropion which frequently follows an injury to the eye, and seems to be dependent on a spasmodic contraction of the orbicularis muscle. It may be met with after any injury to the eye which is followed by much photophobia and lachrymation. The inversion of the lashes is confined to the lower lid. From the constant overflow of tears, its tarsal edge becomes red and excoriated; and from the repeated spasmodic contractions of the orbicularis muscle, the edge of the lid becomes curled inwards—sometimes to such an extent that the eyelashes cannot be seen without first everting the tarsal margin by drawing it down with the finger.

For the treatment of this form of entropion, it is sufficient to remove a narrow strip of the skin, and of the orbicularis muscle, close up to and nearly the length of the margin of the lid. This is to be done by first pinching up a fold of the skin in a line with the lid by a pair of forceps, and cutting it off with a pair of scissors. A corresponding piece of the orbicularis is then to be seized with the forceps and excised in a similar manner. No sutures will be required; but when all the bleeding has ceased, the edges of the wound should be gently pressed together, and

a light pad of wet lint fastened over them with a bandage. Complete union will be effected in two or three days.

There are very many operations for the relief of entropion to which I have not even referred, as they are not applicable to the traumatic form.

ECTROPION, OR EVERSION OF THE EYELIDS, may be induced by either injury or disease. The worst and most intractable cases are those which are the result of injury either to the eyelid or to the tissues in its immediate vicinity. When the ectropion is caused by disease, such as long-continued ophthalmia, the lower lid is the most frequently everted; but when it is the result of accident, the upper lid suffers equally with that of its fellow.

The deformity which ectropion produces is very great: the peculiar and often hideous appearance which an everted eyelid gives to the patient is such that he is generally eager to undergo an operation for its relief. But independently of this, ectropion is the cause of much annoyance, if not of actual suffering. In all except the very slight cases, the eye, having lost a part of its natural protection, is liable, from undue exposure, to attacks of recurrent inflammation of its conjunctival surface. It also becomes what is commonly called a watery eye:—owing to the eversion of the eyelid, the punctum is drawn away from the globe, and some of the tears are constantly flowing over the lid on to the cheek.

Lastly, after the lid has been long everted, the conjunctiva is very apt to become changed in appearance and character. In some instances it grows almost cuticular, whilst in others it becomes so hypertrophied and granular as to acquire somewhat the look of a fungoid excrescence.

Traumatic ectropion may be produced—

I. By the cicatrization following destruction of a part or the whole of the skin of the eyelid.

II. By the cicatrization of a wound in the neighbourhood of the eyelids.

III. By abscesses in the cellular tissue at any point near the margin of the orbit.

In the cicatrization which follows an absolute destruction of a portion of the integument, the loss is not replaced by a regrowth, but the breach is chiefly repaired by a drawing together of the surrounding parts, borrowing as it were from the abundance of skin in the neighbourhood to close the gap which has been occasioned by the injury. The wound is thus greatly diminished in size, and that which yet remains to be closed in is covered over by the development of a cicatrix tissue, which closely resembles the true skin which has been destroyed, but differs from it in its want of elasticity, softness, and vitality.

If the wound is in the vicinity of the orbit or in the integument of the lid, the contraction which accompanies this healing process draws upon its tarsal edge, and gradually everts it. This contraction of the neighbouring skin towards the seat of the injury is not confined to the actual period of cicatrization, but continues for many months afterwards, increasing the extent of the ectropion whilst it diminishes the size of the cicatrix.

Where the ectropion is caused by an abscess near the margin of the orbit, very little if any of the skin may have been involved in the suppuration. The ectropion is dependent on a portion of the cellular tissue having been destroyed by sloughing, and the skin becoming as a consequence puckered in and adherent to the parts beneath it, instead of gliding smoothly over them. With the contraction of the skin towards the cicatrix of the subjacent cellular tissue, a pull is exerted upon the eyelid,

which will first draw down its tarsal edge, and then gradually evert it.

Two forms of ectropion may be recognised, either of which may be produced by the same cause, the difference being only in degree.

1st. Where there is a partial eversion of the eyelid, with a thickened and fungoid condition of the conjunctiva.

2nd. Where the eyelid is entirely everted, its conjunctival surface being completely exposed.

The first form is most frequently caused by the cicatrization of a wound in the neighbourhood of the eyelids; whilst the second is generally the result of an absolute destruction of a portion or the whole of the skin of the lid itself.

Treatment of ectropion.—In considering what are the best means of restoring to its normal condition an eyelid which is deformed by ectropion, it is necessary to determine accurately the relative changes which have been produced by it in the different parts of the lid. 1st. The eyelid is more or less everted. 2nd. As a consequence of this, the punctum lachrymale is displaced: it is drawn away from its proper relationship with the globe, so that it has ceased to act as a conduit for the tears. 3rdly. The tarsal edge of the lid is more or less elongated, according to the extent of the eversion. 4th. In many cases the exposed conjunctiva is hypertrophied and thickened.

In a mild case of ectropion these defects will be only slightly marked, and possibly one or other of them may be absent; but where there is a great eversion of the lid, they will probably be all present and distinctly seen. In treating of each of these defects, I will take them in the order in which it would be wise to proceed in an operation for their relief.

1st. *If the punctum lachrymale is displaced, and drawn*

away from the globe, the canaliculus should be slit up so as to convert it into a canal along which the tears may flow into the sac. This is readily accomplished by a little knife designed by Wecker of Paris, fig. 84. It consists of a fine blade of the exact shape and size as that represented in the woodcut, with a very minute button at its extremity. This is introduced into the punctum, and run along the canal, when, by slightly raising the hand and giving to the blade a cutting movement, it is made to divide the canaliculus to the extent required. FIG. 84.

Another way of laying open the canaliculus is by dividing it on a fine director (fig. 79) with a cataract knife, as described in pp. 373-74; or the same end may be attained by slitting up the duct with a pair of very fine-bladed scissors.

2nd. *If the exposed conjunctiva is much thickened and hypertrophied*, the prominent excrescent looking portion should be excised. This is most easily done by seizing with a pair of fine-toothed forceps the piece of conjunctiva which is to be removed, and cutting it off with a pair of small scissors curved on the flat. The contraction which accompanies the cicatrization of the conjunctiva draws the edge of the eyelid inwards, and helps very materially to restore it to its natural position.

3rd. *When the tarsal edge of the lid is elongated*, it must be shortened before the lid can be restored to its proper position. This lengthening of the tarsal margin is due to the constant pull which has been exerted upon it during the contraction and cicatrization of the wound which has caused the ectropion. To remedy this defect, a V-shaped piece of the edge of the lid, as in fig. 85, may be excised with a fine scalpel. The lips of the wound are then to be brought together with fine pins and twisted sutures, taking



care that one of the needles is inserted close to the tarsal edge, as in fig. 86, so that an accurate apposition of the corresponding surfaces is secured.

A portion of the tarsal cartilage may thus be removed from any part of its length; but in most cases it is advisable to make the excision from the extreme end close to the outer canthus, taking away at the same time sufficient from the edge of its fellow-lid to form a raw surface with which it may be united. This is illustrated in figs. 87 and 92. The edges of the wound are brought more easily and accurately together than when the part excised is near the centre of the lid, and the scar which is left is

FIG. 85.

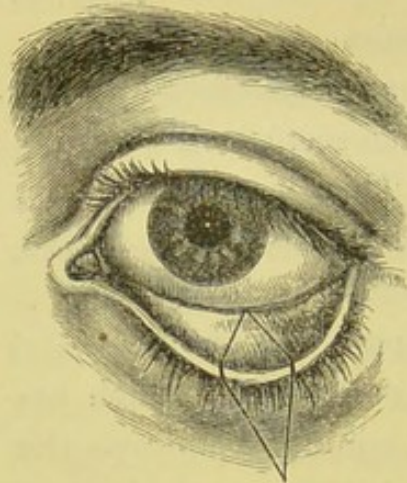
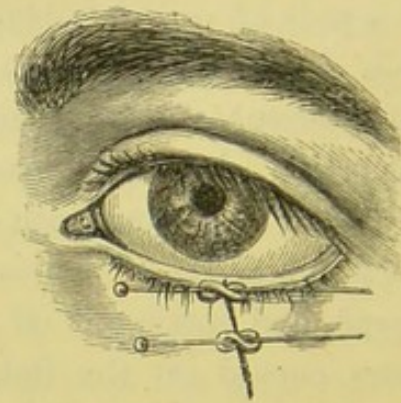


FIG. 86.



much less noticeable. In shortening the lid it is always necessary to take away a piece of sufficient size, so as to reduce the palpebral aperture to a little below its normal dimensions.

4th. *To relieve the eversion of the eyelid*, many operations have been suggested and practised. When the ectropion depends, as it generally does in traumatic cases, upon a cicatrix, either of the skin in the neighbourhood of the orbit or of the lid itself, the first endeavour should be to free the eyelid from the influence of the scar which binds

it down. This can be often readily accomplished: the great difficulty is to prevent a reunion of the parts, and a return of the deformity.

Where there is complete or partial ectropion dependent on a cicatrix at a short distance from the lid.—For convenience of description, I will deal with a case in which the lower lid is the one affected: the same plan of treatment, modified according to circumstances, will be applicable to ectropion of the upper lid. If the ectropion is partial, and due to a small cicatrix which is only adherent to a very limited area of the cellular tissue beneath it, while around the scar the skin will glide easily over the subjacent tissues, it will be sufficient first to free the deep adhesions of the cicatrix by subcutaneous division. A tenotomy knife is to be introduced beneath the integument, at a short distance from the scar, and by a few semi-circular sweeps the union between it and the cellular tissue will be parted. If this is satisfactorily accomplished, the skin will now glide with freedom over the parts to which it was before adherent. The tarsal edge of the lid should now be shortened in the manner already described; and if the exposed conjunctiva is much thickened, a portion of it also should be excised. By these means the lid will be restored to its normal position, and as the scar will be lifted from its original site, the chance of its reuniting to the parts from which it has been severed will be diminished. In the daily dressing of the wounds, the lid should be well supported with a pad of lint, to prevent the cicatrix being again drawn down to its former position.

If the ectropion is severe, and the cicatrix which has caused it is dense and firmly attached to the subjacent cellular tissue, a different proceeding must be adopted. One very excel-

lent mode of treatment is by including in a V-shaped incision the cicatrix, which is to be separated by a few strokes of the scalpel from all its adhesions to the underlying parts, as is well shown in fig. 87.

FIG. 87.

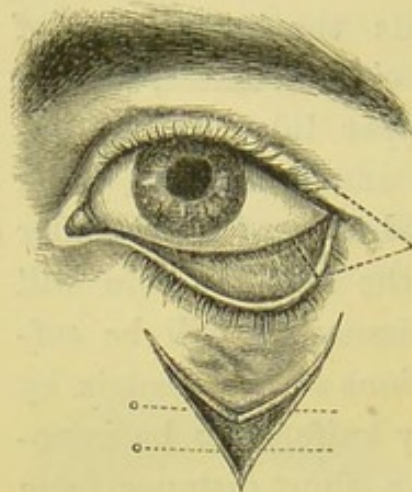
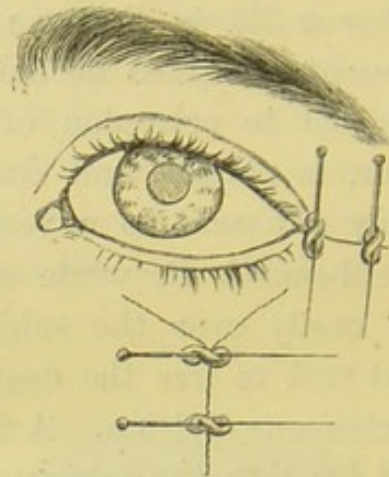


FIG. 88.



The triangular-shaped piece of skin in which is the cicatrix is then to be pushed upwards, whilst the lower edges of the V wound are united by two pins and twisted sutures, in the situation marked by the dotted lines in the woodcut, so as to convert the V, when the parts are brought together, into a Y. The everted lid will thus be raised; but in order to keep it in position, its tarsal edge should be shortened at the outer canthus, removing at the same time a small piece of the margin of the upper lid, to which the lower one should be united by pins and twisted sutures. If the conjunctiva is much thickened, a portion of it may be excised before shortening the lid.

Fig. 88 shows the appearance the eye will present after the operation is completed.

The following operation was the one recommended and performed by Dieffenbach for the relief of ectropion of the

lower lid, which had been caused by a cicatrix at a short distance beneath it.

He first dissected out the cicatrix by including it in a triangular incision, fig. 89, the base of which corresponded with the tarsal margin of the lid. Having removed this tri-

FIG. 89.

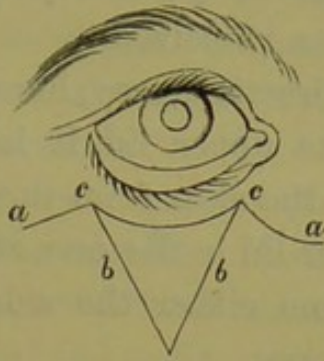
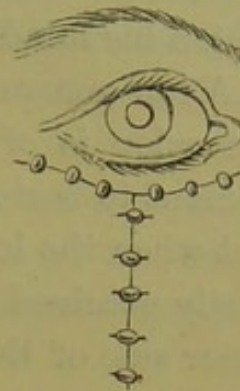


FIG. 90.



angular flap of skin, he then extended the cut *cc* to *ca*, *ca*, to allow of the ready approximation of the sides *b*, *b*; which having been first raised from the subjacent parts by a few strokes of the scalpel, he brought together and united by sutures, as in fig. 90. The two lateral incisions *ca*, *ca*, he then fastened by sutures to the integument beneath the lower lid in the line *cc*. Fig. 90 represents the appearance after the operation was completed.*

In those cases where *much of the integument of the eyelid has been destroyed*, and *complete eversion of it* has followed, it is seldom that the lid can be permanently restored to its natural position without some plastic operation. After the lid has been dissected from the adhesions which bind it down, and has been replaced over the eye, a large granulating surface will be left, which, unless covered over by new skin borrowed from a neighbouring part, will again become drawn from the eye and everted.

I will not attempt to describe the different operations which have been either suggested or performed for the making of a new eyelid. Each case presents peculiarities of its own, for which no special directions can be given.

* Review of Zeis' Handbuch der plastischen Chirurgie, British and Foreign Medical Review, vol. vii. p. 406, from which the woodcuts have been copied.

The result of the operation depends very much on the ingenuity of the surgeon in designing one fitted for the case, and on his dexterity in carrying out neatly the details which his mind has conceived.

A few general directions may, however, be useful. If the ectropion is of the upper lid, it is generally most convenient to borrow the skin from the side of the forehead; but when the lower lid is the one affected, it may be most easily obtained from either the side of the cheek or the inner side of the nose.

1st. Before attempting a plastic operation for the formation of a new eyelid, sufficient time should be allowed to elapse after the injury for the skin in the neighbourhood of the eye to have recovered as far as possible its healthy elasticity and softness. All thickening and induration of the subjacent cellular tissue should have passed away, and the skin should glide readily over the parts beneath it.

2nd. After having by dissection restored the lid to its proper position, the size of the surface to be covered with the borrowed skin should be accurately noted; and the piece which has to be taken from the temple, or elsewhere, should be of larger dimensions than is apparently required, as the skin contracts about one sixth when detached from the part it originally occupied. It must also be remembered that even if it is a little too large, a further contraction of it will take place during the healing process, which will reduce it to its required size.

3rd. Great care should be taken to leave a good pedicle through which the vascular supply of the new lid may be maintained until it has become united with the parts beneath it, and a fresh source of nourishment has been established. It is also advisable, in adapting the skin to

the lid, to avoid twisting the pedicle on itself more than is absolutely necessary.

4th. Before uniting the edges of the new lid to the surrounding skin, all bleeding should be arrested. Nothing tends more to delay primary union than a clot of blood between the opposed surfaces.

In nearly all cases where a plastic operation is required, it will be well to shorten the tarsal margin of the lid in the manner already described, so as to slightly diminish the size of the palpebral aperture.

If the exposed portion of the conjunctiva is much thickened and granular, a portion of it also should be removed with a pair of curved scissors.

Having completed the operation, a layer of wet lint should be laid over the lids, upon which a light compress of cotton wool should be fastened with one or two turns of a roller, for the purpose of keeping the parts in apposition and of maintaining a certain amount of warmth.

In the following case of ectropion of the upper lid, in which its outer half was *completely* everted, I succeeded in restoring it to its normal position without forming a new lid from the neighbouring skin.

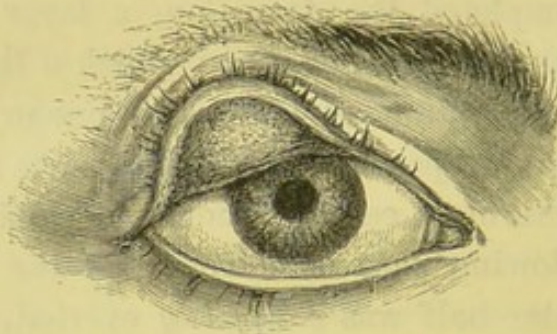
CASE LXXXIX.—Edward O., æt. 19, an assistant at a wholesale chemist's, met with the following accident in January, 1865. He was carrying a Winchester quart of the strongest nitric acid down the warehouse stairs when his foot slipped, and he fell down them; the bottle was broken in the fall, and its contents were thrown over him. The right side of the head and face was completely washed with the acid, as also were large portions of both arms and both legs. He was at once seen by Mr. Stewart, under whose care, considering the severity of the injury, he made a very excellent recovery. Where the integuments

were deeply acted on by the acid, sloughs formed; but as most of these were small and superficial, no contractions of the limbs were produced.

The only deformity which remained after his recovery was a very severe ectropion of the right upper eyelid, with some rigid contractions of the skin about the right side of the face.

The skin of the upper eyelid had been severely burnt by the acid, and the outer half of it was detached as a slough. During the cicatrization which followed, the lid was gradually everted, and ultimately drawn up, as is well represented in fig. 91.

FIG. 91.



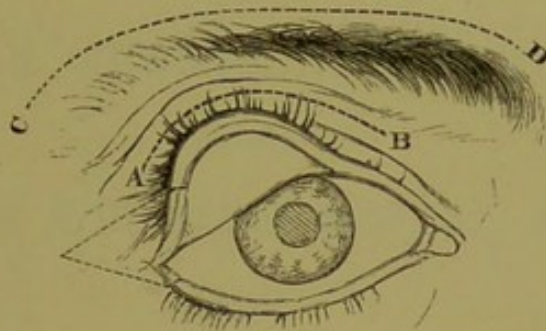
At Mr. Stewart's request I saw the patient frequently with him, and I decided, when the proper time came, to endeavour to relieve this defect by an operation. The patient was sent into the country with the eye covered to protect it from exposure, and no attempt was made to restore the lid to its natural position until March 1866. The object of thus waiting nearly fifteen months was to allow the integuments in the neighbourhood of the lid, which had been severely burnt, to recover as much as possible their normal elasticity and mobility over the subjacent cellular tissue.

The operation which I then performed was the following:—First making an incision along the line *AB*, fig. 92,

I dissected through the adhesions which the everted lid had formed until I was enabled to fold it down over the eye. I then shortened the tarsal margin of the upper lid by excising the portion marked in the dotted lines in the woodcut, and removed a small piece of the edge of the lower lid, to which I fastened the cut end of the upper one by a pin and twisted suture.

The lid was now restored to its natural position; but as the whole of its outer half presented a raw surface, it would probably become again everted during the process of cicatrization. I therefore made a long incision, *c d*, immediately above the eyebrow, and then freely dissected beneath it, so as to be able to lower the brow, which

FIG. 92.



had been drawn slightly above the level of its fellow, to a closer proximity with the eye.

The wound in the line *c d* I then plugged with lint, with the intention of keeping it open until the lid had healed, thinking that the integument on the nasal side of the lid, with that of the brow, would afford sufficient material for the granulating surface of the outer half of the lid to draw on during its cicatrization and contraction. The result was most successful. The lid cicatrized, and remained in the position in which I had replaced it, and afterwards the wound above the brow completely healed. About two months after the operation, as I noticed a

slight tendency to eversion, I excised a portion of the conjunctiva which had been exposed when the lid was everted, and had never completely recovered from the granular state which it had then assumed. This completed the cure, and from that time the eyelid ceased to give any annoyance.

ABSTRACT
OF
THE SURGICAL REPORT
OF THE
ROYAL LONDON OPHTHALMIC HOSPITAL, MOORFIELDS.
1866.

IN-PATIENTS FOR 1866.

Requiring Operation	749
Not requiring Operation	102
Total In-Patients	<u>851</u>

OUT-PATIENTS FOR 1866.

Total Out-Patients	18,953
Total Attendances of Out-Patients	94,765

ABSTRACT OF DISEASES OF OUT-PATIENTS IN 1866.

	New Cases.
Inflammation of Conjunctiva—Acute and Chronic	1,881
" " Catarrhal	1,483
" " Pustular	634
" " Strumous	147
" " Purulent (Infants)	166
" " " (Adults)	25
" " with Granular Lids	234
Ecchymosis	37
Inflammation of Sclerotic	20
Cyclitis	5
Inflammation of Cornea	735
Ulcers of do.	810
Opacity of do.	514
Staphyloma of do.	58
Pannus	25
Corneo-Iritis	69
Injuries of Cornea from wounds and abrasions	160
Conical Cornea	12
Inflammation of Iris—Chronic and Recurrent	326
" " Syphilitic	54
" " Rheumatic	8
Closed Pupil and Synechia	54
Cataract (idiopathic)	400
" (congenital)	47
" (trauatic)	35
Dislocation of Lens into anterior chamber	4
Inflammation of Retina	54
Apoplexy of do.	6
Detachment of do.	15
Musæ	69
Choroiditis	39
Choroido-Iritis	20
Atrophy of Optic Nerve	97
Impaired Vision (cause not stated)	381
Amaurosis	71
Carried forward	<u>8,695</u>

ABSTRACT OF DISEASES OF OUT-PATIENTS IN 1866—*continued.*

	<i>Brought forward .</i>	New Cases.
Glaucoma, acute and chronic	8,695	70
Hypermetropia		401
Asthenopia		186
Myopia		269
Astigmatism		15
Presbyopia		111
Amblyopia		59
Diplopia		38
Nyctalopia		11
Hemeralopia		8
Hebetudo		59
Photophobia		21
Paralysis of 3rd Nerve		23
" 3rd " with 6th		6
" 6th "		4
" 5th "		1
Ptosis		23
Mydriasis		13
Strabismus (Convergent and Divergent)		329
Spasm of Orbicularis		4
Tumours, or Cysts of Eyelids		226
" of Orbit		2
Tinea Ciliaris		943
Lippitudo		47
Trichiasis		29
Entropion		45
Ectropion		14
Injuries to Eyelids from wounds, burns, &c.		39
Abscess of Eyelids		69
Inflamed Eyelids and Hordeolum		196
Inflammation of Lachrymal Sac		24
Abscess of do.		54
Obstruction of Lachrymal Passages		78
Fistula Lachrymalis		6
Injuries of Eyeball from fragments of metal, blows, &c.		883
Disorganised Globe, from inflammation, wounds, &c.		111
Malignant Disease		3
Proptosis		3
Nævus		3
Pterygium		15
Injury to Eyeball from Escharotics		41
Epiphora		121
Blepharitis		31
Tylosis		1
Diseases not peculiar to the Eye		100
Abscess of Eyebrow		6
" of Orbit		9
Corneal Fistula		2
Sympathetic Ophthalmia		14
Molluscum		33
Intraocular Tumour		9
Growths on Conjunctiva		12

Carried forward 13,515

ABSTRACT OF DISEASES OF OUT-PATIENTS IN 1866—*continued.*

	New Cases.
<i>Brought forward</i>	13,515
Cyst of Iris	1
Casual Cases	119
Cases seen by House Surgeon after visit of Surgeons	360
	<hr/>
	13,995
Renewals (after three months' attendance)	4,958
	<hr/>
	18,953

ABSTRACT OF OPERATIONS ON IN AND OUT PATIENTS
IN 1866.

For Cataract, viz. :	
By Extraction by Large Flap	60
" " " with Iridectomy	3
" " by Graefe's method	36
" " by Traction Instrument with Iridectomy	91
" " by Curette (Soft Cataract)	5
" " by Suction Syringe	47
" Solution	99
	<hr/>
	341
For Capsular Obstruction of the Pupil, viz. :	
By Two Needles	60
" One Needle	28
" Broad Needle	4
" " and Canular Forceps	5
	<hr/>
	97
For Glaucoma, Acute	18
" " Sub-acute	20
" " Simple	26
" " (not noted)	10
" Recurrent Iritis	38
" Choroido-Iritis	10
" Corneo-Iritis	11
" Traumatic Keratitis	5
" Ulcer of Cornea	10
" Staphyloma	3
" Artificial Pupil	100
" Conical Cornea	8
" Ophthalmitis and Hypopion	14
	<hr/>
	273
For Conical Cornea, by Iriddesis	4
" Juvenile Camellar Cataract by Iriddesis	4
Artificial Pupil, by Iriddesis	25
	<hr/>
	33
	<hr/>
<i>Carried forward</i>	744

ABSTRACT OF OPERATIONS ON IN AND OUT PATIENTS
IN 1866—*continued.*

	<i>Brought forward</i>	744
For Displaced Lens	2	
„ Detached Retina, by two Needles	8	
„ Abscess of Frontal Sinus	2	
„ Removal of Tumour of Orbit	3	
„ „ „ „ Upper Eyelid	5	
„ „ „ „ Eyebrow	2	
„ Nævus on Upper Eyelid	8	
	—	30
Excision of the Eyeball, viz. :		
For Melanosis	2	
„ Destructive Inflammation	54	
„ Injury	25	
„ Staphyloma of Cornea and Sclerotic	4	
„ Sympathetic Ophthalmia	3	
	—	88
Abcission of the front of the Globe	18	
Removing Foreign Bodies from within the Eye	6	
	—	24
For Strabismus, viz. :		
Internal: One Eye (in children under 10)	32	
„ both Eyes „ „	54	
„ one Eye (in adults)	52	
„ both Eyes „ „	94	
External: One Eye (in children under 10)	1	
„ both Eyes „ „	1	
„ one Eye (in adults)	10	
„ both Eyes „ „	3	
	—	247
Entropion	38	
Ectropion	7	
Trichiasis	19	
Pterygium	9	
Removal of Fleishy Growths from Conjunctiva	5	
Peritomy	8	
Minor Operations, as Slitting up Canaliculi, removing Tarsal Cysts, &c., amongst the in and out patients	368	
Staphyloma (Seton passed through Cornea)	2	
Ptosis	5	
	—	461
		<hr/>
Total Operations on In and Out Patients		1,594
Inoculation for the cure of Granular Lids		6
		<hr/>
		1,600

THE HISTORY OF THE

1875

1875

1875

1875

1875

1875

1875

1875

1875

1875

1875

1875

1875

1875

1875

1875

1875

1875

1875

1875

1875

TEST-TYPES.

THE UNIVERSITY OF CHICAGO

TEST-TYPES,

CORRESPONDING TO THE "SCHRIFT-SCALEN" OF
PROF. EDW. JAEGER, OF VIENNA.

No. 1.—*Diamond.*

A Fox being caught in a trap, was glad to compound for his neck by leaving his tail behind him; but upon coming abroad into the world, he began to be so sensible of the disgrace such a defect would bring upon him, that he almost wished he had died rather than come away without it. However, resolving to make the best of a bad matter, he called a meeting of the rest of the Foxes, and proposed that all should follow his example. "You have no notion," said he, "of the ease and comfort with which I now move about: I could never have believed it if I had not tried it myself; but really when one comes to reason upon it, a tail is such an ugly, inconvenient, unnecessary appendage, that the only wonder is that, as Foxes, we could have put up with it so long. I propose, therefore, my worthy brethren, that you all profit by the experience that I am most willing to afford you, and that all Foxes from this day forward cut off their tails." Upon this one of the oldest stepped forward, and said, "I rather think,

No. 2.—*Pearl.*

my friend, that you would not have advised us to part with our tails, if there were any chance of recovering your own." A Man who had been bitten by a Dog was going about asking who could cure him. One that met him said, "Sir, if you would be cured, take a bit of bread and dip it in the blood of the wound, and give it to the dog that bit you." The man smiled, and said, "If I were to follow your advice, I should be bitten by all the dogs in the city." He who proclaims himself ready to buy up his enemies will never want a supply of them. A certain man had the good fortune to possess a Goose that laid him a Golden Egg every day. But dissatisfied with so slow an income, and thinking to seize the whole treasure at once, he killed the Goose; and cutting her open, found her—just what any other goose

No. 4.—*Minion.*

would be! Much wants more and loses all. A Dog made his bed in a Manger, and lay snarling and growling to keep the horses from their provender. "See," said one of them, "what a miserable cur! who neither can eat corn himself, nor will allow those to eat it who can." A Viper entering into a smith's shop began looking about for something to eat. At length, seeing a file, he went up to it, and commenced biting at it; but the File bade him leave him alone, saying, "You are likely to get little from me whose business it is to bite others." A Cat, grown feeble with age,

No. 6.—*Bourgeois.*

and no longer able to hunt the Mice as she was wont to do, bethought herself how she might entice them within reach of her paw. Thinking that she might pass herself off for a bag, or for a dead cat at least, she suspended herself by the hind legs from a peg, in the hope that the Mice would no longer be afraid to come near her. An old Mouse, who was wise enough to keep his distance, whispered to a friend, "Many a

No. 8.—*Small Pica.*

bag have I seen in my day, but never one with a cat's head." "Hang there, good Madam," said the other, "as long as you please, but I would not trust myself within reach of you though you were stuffed with straw." Old birds are not to be caught with chaff. As a Cock was

THE HISTORY OF THE

REIGN OF CHARLES THE FIRST

BY JOHN BURNET

BOOK THE FIRST

The first part of this history contains the reign of Charles the First, from his accession to the throne in the year 1625, to his execution in the year 1649. The second part contains the reign of Oliver Cromwell, from his death in the year 1658, to his death in the year 1659.

BOOK THE SECOND

The second part of this history contains the reign of Oliver Cromwell, from his death in the year 1658, to his death in the year 1659. The third part contains the reign of Richard Cromwell, from his death in the year 1659, to his death in the year 1660.

BOOK THE THIRD

The third part of this history contains the reign of Richard Cromwell, from his death in the year 1659, to his death in the year 1660. The fourth part contains the reign of James the Second, from his accession to the throne in the year 1685, to his death in the year 1702.

BOOK THE FOURTH

The fourth part of this history contains the reign of James the Second, from his accession to the throne in the year 1685, to his death in the year 1702. The fifth part contains the reign of Anne, from her accession to the throne in the year 1702, to her death in the year 1714.

BOOK THE FIFTH

The fifth part of this history contains the reign of Anne, from her accession to the throne in the year 1702, to her death in the year 1714. The sixth part contains the reign of George the First, from his accession to the throne in the year 1714, to his death in the year 1727.

No. 10.—Pica.

scratching up the straw in a farm-yard, in search of food for the hens, he hit upon a Jewel that by some chance had found its way there. Ho! said he, you are a very fine thing, no doubt, to those who

No. 12.—English.

prize you; but give me a barley-corn before all the pearls in the world. The Cock was a sensible Cock; but there are many silly people who despise what is precious only

No. 14.—Great Primer.

because they cannot understand it. A Man who kept a Horse and an Ass was wont in his journeys

No. 15.—2-line English.

**to spare the Horse,
and put all the bur-
den upon the Ass's**

No. 16.—2-line Great Primer.

**back. The Ass, who had been
some while ailing, besought
the Horse one day to relieve**

No. 18.—Canon.

**him of part of his load;
For if, said he, you
would take a portion,**

THE END OF THE WORLD

**I shall soon get well
again; but if you**

No. 20.—8-line Roman.

REFRESH

PROTESTANT

ROYAL SOCIETY
OF LONDON
PRINTED BY
J. B. ROBERTSON
AT THE PRESS OF
THE UNIVERSITY OF
CAMBRIDGE

INDEX.

A

ABRASIONS. See CORNEA, ABRASIONS OF

ABSCESS. See CORNEA, EYELID, ORBIT, ABSCESS OF

ABSCISSION OF THE EYE

Critchett's operation for, 99, 100

when advisable, 98. See CORNEA, COMPLETE STAPHYLOMA OF

ACIDS

effect of, on the eye, 52, 53

eyelids often suffer from, more than eyes, 53

strong, injuries from, 53, 56

may cause symblepharon, 52

or anchyloblepharon, 380

suppurative corneitis, 53

ectropion, 53

case of, 397

entropion, 384

treatment of, 53, 54

case of, 54

weak, injuries from, 56

may cause ophthalmia, 56

treatment of, 56

ANCHYLOBLEPHARON, 380

causes of, 380

treatment, 381

case of, 381

often associated with symblepharon, 382

case of, 382

ARTIFICIAL EYE

when may be first worn after excision of eye, 279

after excision for sympathetic ophthalmia, 279

inconveniences from wearing too soon, 279, 280

cautions as to fitting of, 280

directions of Ophthalmic Hospital as to wearing, 280, 281

when new one required, 281

ARTIFICIAL PUPIL

- general points to be observed in making, 83
- three operations for making, 84
 1. by removal of a piece of iris, 84, 85
 - in what cases this applicable, 85
 2. by iridodesis (Critchett's operation), 85
 - cautions in this operation, 87
 3. by incision of the iris, 87
 - in what cases this applicable, 87
- how best made in leucoma or nebula of cornea, 87
- after extraction of the lens in sympathetic ophthalmia, 334

B

BANDAGE, LIEBREICH'S EYE, 172

BLOWS ON THE EYE, 13

- when no lesion of structure, effect of, 13
- treatment of, 15
- cases of impaired vision caused by, 16
- may cause subconjunctival hæmorrhage, 17
 - treatment of, 17, 18
- laceration of conjunctiva, 18, 19
 - treatment of, 19
- traumatic ophthalmitis, 20
- coredialysis, 119
- traumatic cataract, 131, 132, 139
- dislocation of the lens, 184, 196, 197, 200, 204
- hæmorrhage into the anterior chamber, 241, 242
 - between choroid and retina, 244
 - between choroid and sclerotic, 255, 256
 - into the vitreous, 259
- rupture of the globe, 263
- abscess of the orbit, 360

BURNS

- general effect of on the eye, 29, 38, 39
- may cause symblepharon, 29, 42, 44
 - or anchyloblepharon, 380
 - or entropion, 384
- frequently complicate other injuries, 39
- from splashes of melted metal, 40
- of the eye, cases of, 41, 46
- treatment of, 46, 47
- fungoid granulations after, 51
 - treatment of, 51
- from acids, See ACIDS
- from explosion of gunpowder, 283. See GUNPOWDER
- of the conjunctiva, cases of, 48, 49. See ENTROPION

C

CANULAR FORCEPS, 183

CAPSULE

OPACITY OF, FOLLOWING LOSS OF LENS, 176

- First form (membrane semi-opaque) no inflammation, 177*
 - often follows linear or suction extraction of lens, 176
 - may arise from capsule being wrinkled, though not opaque, 177

CAPSULE

OPACITY OF, FOLLOWING LOSS OF LENS—*continued*

Second form (membrane semi-opaque, but opacity increased by enclosure of bits of lenticular matter), 177

diagnosis of, 177

often follows penetrating wounds of eye, 177

not necessarily inflammatory, 178

Third form (capsule opaque, and inflammatory exudations), 178

always associated with iritis, 178

diagnosis of, 178

frequently degeneration of structure follows, 178

general treatment of, 179, 184

needle operation for, 179, *et seq.*

Bowman's stop needle, 180

when there has been iritis, 181

where iris adherent to milky white capsule, 182

1. detachment by fine needle and then drawn out of the eye, 183

but this hazardous, 183

2. iridectomy and removal of part of capsule by cutting out a piece with scissors, and drawing it out with canular forceps, 183

this safe, 183

general treatment after operations for, 184

removal of, with lens in sympathetic ophthalmia, 333

CATARACT. See TRAUMATIC CATARACT

following injury from spent shot, 292

hæmorrhage between choroid and sclerotic, following removal of, 192, 252

operations for removal of congenital, 144

linear extraction (Gibson's operation), 144

Von Graefe's modified, 168

suction operation (Teale's), 154

traction operation, 160

use of Liebreich's eye bandage after, 172

knife, 374

CELLULITIS. See ORBIT, ABSCESS OF, PENETRATING WOUNDS OF

CILIARY STAPHYLOMA. See SCLEROTIC, STAPHYLOMA OF

CONCUSSION OF THE EYE, 14

effect of, 14

treatment of, 15

sight seldom permanently destroyed by simple, 14

from explosion of gunpowder, 283, 301

CONJUNCTIVA

covering sclerotic, foreign body in, may give no annoyance, 3

lining the upper lid, foreign body in, otherwise, 3

subconjunctival hæmorrhage, 17. See HÆMORRHAGE

BURNS of, cases of, 48, 49, 51

LACERATIONS of, 18

treatment of, 18

case of, 19

CONJUNCTIVITIS

from injuries by acids, 54

COREDIALYSIS, 119

generally caused by sharp blows on the eye, 119

COREDIALYSIS—*continued*

- effect of, 119, 120
- prognosis favourable when no rupture of external coats of the eye, 120
- the formation of second pupil interferes only little with vision, 120
- treatment of. See HÆMORRHAGE INTO THE ANTERIOR CHAMBER
- cases of, 121, 122
- common cause of hæmorrhage into anterior chamber, 238
- following explosions of gunpowder near eye, 121, 283. See GUNPOWDER

CORNEA

- ABRASIONS of, 70
 - how caused, 71
 - symptoms and prognosis, 71
 - treatment of, 72, 73
 - cases of, followed by ulceration keratitis and hypopion, 73, 74
 - followed by corneo-iritis, 74, 75
- abscess of, distinguished from onyx, 70
- conical. See CORNEA, STAPHYLOMA OF
- FISTULA OF, 75
 - symptoms of, 75
 - caused by contused or lacerated wounds of, 75
 - or wound of cornea accompanied with wounds of lens, 76
 - or glaucomatous state of eye, 76
 - or foreign body within the eye, 76
 - treatment of, 76, 77
 - iridectomy may be advisable, 77, 168
- FOREIGN BODIES ON SURFACE OF, 5. See FOREIGN BODIES
- deeply buried in, 8. See FOREIGN BODIES
- LEUCOMA OF, 78
 - distinction between partial staphyloma and, 91, 92
 - irremediable, 78
 - effect of, 78, 80
 - sometimes alters curvature of cornea, 80
 - making artificial pupil sometimes useful in cases of, 79, 83. See ARTIFICIAL PUPIL
- NEBULA OF, 80
 - treatment of, 80
 - no remedy specific, 81
 - various useful applications for, 81, 83
 - making artificial pupil often useful in cases of, 83. See ARTIFICIAL PUPIL
- OPACITY OF, FROM LEAD, 88
 - caused by use of lead lotion when cornea abraded, 89
 - may be cured by removal of the layer of lead, 89
 - operation for this purpose, 89
 - case of, 90
- PARACENTESIS OF, how to perform, 23, 24
 - when advisable in traumatic ophthalmitis, 23
 - diffuse suppurative corneitis, 69
- STAPHYLOMA OF, 91
 - simple, or conical cornea*, 91
 - partial*, 91
 - how caused, 91
 - how it differs from leucoma, 91, 92

CORNEA—*continued*STAPHYLOMA OF—*continued**partial—continued*

always seriously affects the sight, and sometimes destroys vision,
93

treatment of, 93

iridectomy often useful in, 94

complete, 94

removal of the lens will check tendency to, 97

but will not diminish when formed, 97

Bowman's operation for, 95

causes total loss of vision, 97

treatment of, 97

whether the eye should be excised or abscised, 98

recovery quicker after excision than abscission, 99

Critchett's operation for abscission of the eye, 99

caution in performing, 100

treatment by seton (Von Graefe's), 101

corneo-sclerotic, 97

WOUNDS OF, 57

simple puncture almost harmless, 57

contrasted with wounds of sclerotic, 57, 58

repair of, 62

complete in simple incised, 63

otherwise when beyond a certain size, 64

complications of, 64

contusion or laceration, 64, 67. See CORNEITIS

extension into sclerotic, 65. See SYMPATHETIC OPHTHALMIA

prolapse of the iris caused by, 108. See IRIS, PROLAPSE OF

wound of the lens, 135, 136. See TRAUMATIC CATARACT

uncomplicated, local treatment of, 65, 67

constitutional treatment of, 66, 67

CORNEITIS, SUPPURATIVE, 67

may follow injuries from acids, 53

generally caused by contusion or laceration of cornea, 67

other causes of, 67

symptoms of, 68

treatment of 68, 70

paracentesis useful in, 69

CYSTOID CICATRIX, 59. SEE SCLEROTIC, WOUNDS OF.

D

DISLOCATIONS. See LENS, DISLOCATIONS OF

E

ECTROPION

may arise from injury by strong acid, 53

induced by injury or disease, 388

distinctions between, 388

consequences of, 388

traumatic, usual causes of, 389

two forms, partial and complete, 390

treatment, 390

1. if punctum lachrymale displaced, 390

2. if exposed conjunctiva thickened and hypertrophied, 391

3. if tarsal edge of lid elongated, 391

ECTROPION—continued

- operations to relieve, 392
 - dependent on cicatrix at short distance from lid, 393
 - of lower lid (Dieffenbach's operation), 394
 - when much integument of eyelid destroyed, and complete eversion, 395
 - case of, 397
- plastic operations for relief of, 395
 - general directions for performance of, 396

ENTROPION, 383

- frequently arises from burns or scalds of conjunctiva of the lids, 383
- treatment of, 384
- operation for removal of eyelashes, 384
- spasmodic, 387
 - treatment of, 387

EYELASHES

- inversion of. See ENTROPION
- removal of, operation for, 384
 - use of Snellen's entropion forceps in, 386

EYELIDS

- abscess of, 369
 - directions as to opening, 369
- adhesion of to globe. See SYMBLEPHARON
- union of margins together. See ANCHYLOBLEPHARON
- eversion of. See ECTROPION
- operations for making new, 395—397
- ECCHYMOSES OF (black eye), 367
 - occasional complication of, 367
 - treatment, 368
- WOUNDS OF, 369, *et seq.*
 1. involving skin of lid, 370
 2. cutting through tarsal border, 370
 - a. cartilaginous border of lid cut, 370
 - case of, 372
 - b. canaliculus torn through, and detached from punctum, 371, 373

EXCISION OF THE EYE

- history and advantages of present operation for, 275
- operation for, 276
 - treatment after, 278, 279
 - in traumatic ophthalmitis, 24, 25
 - complete staphyloma of cornea, 98, 99
 - ciliary staphyloma, 103
 - cases of foreign bodies within the eye, 221
 - rupture of globe, 267, 268
 - after injury from explosion of gunpowder, 285
 - in cases of gunshot injuries, 295, 303
 - sympathetic irritation, 306
 - sympathetic ophthalmia, 330

F

FIREWORKS, INJURIES FROM. See GUNPOWDER

FISTULA. See CORNEA, FISTULA OF

FORCEPS

- canular, 183
- Snellen's, 385

FOREIGN BODIES. See GUNSHOT INJURIES

ON THE EYE, OR INNER SURFACE OF THE LIDS, 2

- ordinary effects produced by, 3
- course to be pursued by patient in cases of, 3
- may remain for years without giving annoyance if lodged in conjunctiva covering sclerotic, 3
 - or in oculo palpebral fold, 4
 - but not if on cornea or conjunctiva lining the upper lid, 5
- symptoms of, 5, 9
- how to examine eye suspected of, 5, 7
- how to remove from front of eye or under surface of lids, 7, 8
- buried in corneal tissue, 8
 - symptoms of, 9
 - how to remove, 8, 9
- lodged in lamellated tissue, may occasion no inconvenience for some days, 10, 11
 - cases of, 11, 12

WITHIN THE EYE, 213, *et seq.*

- general symptoms of, 232
- all penetrating wounds of globe to be examined for, 213
- method of examination for, 214
- on the iris, 214
 - lens, 215
- causes of difficulty of detection, 216
- most common causes of, 217, 218
- dangers of, 218
 1. acute inflammation destroying the eye, 219
 - this may be intermittent, 219
 - case, 221
 - the foreign body may sometimes remain long without causing injury, 220, 222
 - cases, 223, 224
 2. after eye is lost, may cause inflammation, affecting sound eye, 221. See SYMPATHETIC OPHTHALMIA
 - in such case lost eye to be removed, 221
- may cause traumatic ophthalmitis, 20
 - or fistula of cornea, 76
- treatment of, 226
- on or in the iris or in the lens, 227
- in the vitreous, 228
 - case, 229
- suspected, but not seen, 231
 - cases, 233, 234
- penetrating shot, 394, *et seq.*

IN THE ORBIT, 341, *et seq.*

- most serious injury, 341
- patient often ignorant of severe injury from, 342
- extraordinary cases of, 343, 345
- immediate effects of, 341
 1. parts within the eye injured, or external coats ruptured, 341, 347
 - case of, 347
 2. globe uninjured, optic nerve wounded, 341, 349
 - cases of, 298, 349
 - loss of sight immediate, *ibid.*

FOREIGN BODIES—*continued*IN THE ORBIT—*continued*immediate effects of—*continued*

3. walls of the orbit injured, 341, 350
- case, showing primary and secondary effects of, 351, 352
- tetanus following, 300, 352
- secondary effects of, 341, 352
- treatment of, 354
 - when removal inadvisable, 354
 - operation for removal of, 355
 - recovery usually rapid after, 356
- may cause abscess of the orbit, 360

G

GLAUCOMA. See LENS, TRAUMATIC GLAUCOMA

GLOBE. See FOREIGN BODIES WITHIN THE EYE

RUPTURE OF THE, 263. See LENS, DISLOCATION OF, INTO VITREOUS
through the sclerotic, 263, et seq.

is usually near margin of cornea anterior to insertion of recti
muscles, 263

why so situated, 263, 264

more serious than rupture of cornea, 265

nature of injuries caused by, 265

may cause ciliary staphyloma, 103, 275

prognosis very unfavourable, 266

cases of recovery, 104, 202

treatment, 266, 267

when excision of eye advisable, 268

cases of, 104, 202, 268, 269, 270, 271, 272

through the cornea, 264, 273

case of, 273

general conclusions as to, 274

adhesion of eyelids to. See SYMBLEPHARON

GUNPOWDER

injuries to eye from, 282

explosion of, near eye, general results of, 282

may cause ophthalmitis, 283

or coreodialysis, 121, 283

cases of, 121, 283, 285

lodgment of on surface of eye, 285

in the lens, 287

may produce cataract, 287

treatment of injuries from, 287, 288

GUNSHOT INJURIES TO THE EYE, 291, *et seq.*

SMALL SHOT, injuries from, 291

1. *spent shot*, 291

cataract may follow injury from, 292

2. *glancing shot*, 292, 293

case of, 293

3. *penetrating shot*, 294

generally fatal to the eye, 294

sometimes lodge in cellular tissue of orbit, 294

GUNSHOT INJURIES TO THE EYE—*continued*SMALL SHOT, injuries from—*continued*3. *penetrating shot*—*continued*

may remain in anterior chamber and can then be removed, 295
excision of eye, when advisable, 295, 303

IN MILITARY PRACTICE, 296

eye seldom the only part involved, 296

1. *shot and shell*, injuries from, 297

eye struck, case of, 297

optic nerve destroyed, globe intact, 298

case of, 298

materials propelled by shot against eye, 299

case of, 300

2. *explosion of magazines*, 301

treatment of, 302

H

HÆMORRHAGE. See BLOWS ON THE EYE

SUBCONJUNCTIVAL

may arise from blows on the eye, 17

TRAUMATIC INTRAOCULAR, 237

two classes, 237

a. *into anterior chamber*, 237. See COREDIALYSIS

usual causes and prognosis, 238

treatment, 240

cases of, 241, 242

following rupture of sclerotic, 265

following explosion of gunpowder near eye, 283

b. *deep or posterior hæmorrhage*, 243

three forms, which are sometimes all coincident, 243

seat of, how determined, 255

1. *between choroid and retina*, 244

caused by blows of large foreign body, 244

external coats not ruptured, 244

external coats ruptured, 244, 245

is then seldom limited to between choroid and retina,
245

cases of, 245, 246, 247

2. *between choroid and sclerotic*, 250

caused by escape of lens and loss of vitreous in an *unhealthy*
eye, 248, 250, 251

a glaucomatous tension of globe predisposes to this form of
hæmorrhage, 251

sometimes follows removal of cataract from an *unsound* eye,
252, 253

cases of, 190, 248, 253, 254, 256

3. *into the vitreous*, 257

causes of, 257

always serious injury, and may cause loss of eye, 258

case of, 259

prognosis and treatment of, 261

without rupture of external coats of eye, 261

with such rupture, 262

I

IRIDECTOMY. See the separate headings

- in wounds of sclerotic, 61
- fistula of cornea, 77, 78
- partial staphyloma of cornea, 94
- ciliary staphyloma, 103
- traumatic glaucoma, 130, 167
- traumatic cataract, 168
- opaque capsule, 183
- dislocation of the lens into anterior chamber, 189
- sympathetic ophthalmia, 333, 334
- operation of, 105, 108

IRIDODESIS. See ARTIFICIAL PUPIL

IRIS

DETACHMENT OF. See COREDIALYSIS

following rupture of sclerotic, 265

LACERATIONS OF, without rupture of the external coats of the eye, 123

distinct from core dialysis, 123

remarkable case of, 123-5

PROLAPSE OF, 108

caused by penetrating and incised wounds of cornea, 108

following rupture of sclerotic, 265

often associated with injury to lens, 108, 127. See LENS, and

TRAUMATIC CATARACT

always serious injury, 112

prognosis, 109

case of, 109, 110

use of the Calabar bean in, 110

general treatment of, 111

four methods of treatment of, 111

1. *by a compress*, 112, 113

case of, 113

2. *by abscission*, 114, 115

when applicable, 115

case of, 115

3. *by frequent puncturing with a fine needle*, 116

when applicable, 117

twofold object of operation, 117

case of, 117

4. *by ligature*, 118

when applicable, 119

IRITIS, 153

often follows linear operation for cataract, 153

acute, 153

chronic, 153

treatment of, 154

associated with opaque capsule, 178

J

JAEGER'S TEST TYPES, 407, *et seq.*

L

LACERATIONS

of conjunctiva, 18. See CONJUNCTIVA, BLOWS ON THE EYE
 as complications of wounds of cornea, 64. See CORNEITIS
 may cause fistula of cornea, 75
 of eyelids may cause anchyloblepharon, 380

LENS

CAPSULAR OPACITY OF. See CAPSULE, OPACITY OF

DISLOCATIONS OF, 184

into anterior chamber, 184

symptoms, 185

lens enclosed in capsule, or dislocated out of capsule, 185

treatment of, 186

paralysis and atrophy of iris generally follow, 187

sometimes also glaucoma, 187

removal of, generally advisable, 187, 188

1. patient young, suction operation, or modified linear extraction, 188

two stages unnecessary, 188

2. patient adult, lens *in* capsule, nucleus firm, extraction through section of cornea, 189

3. glaucomatous condition, iridectomy to be first performed, 189

4. patient adult, lens *out of* capsule, extraction, 189

case of, 190

into vitreous, 192

not uncommon when globe ruptured, 192

generally in capsule, 192

symptoms, 192, 193, 194

dislocation complete, 193

incomplete, 193

state of pupil, 194

prognosis and treatment, 194

removal of lens, 195

difficulties in, 195

cases of, 196, 197, 199

beneath the conjunctiva, 200

symptoms, 200

prognosis unfavourable, 201

treatment, 201

case of, 104, 202

partial, 204

general symptoms, 205

peculiar tendency to produce glaucoma, 205, 207

treatment, 205

extraction of lens in cases of, 207

cases, 208, 211

accompanying rupture of sclerotic, 265

lodgment of gunpowder in, may cause cataract, 287. See GUNPOWDER injury to, associated often with prolapse of the iris, 108. See IRIS,

PROLAPSE OF

removal of. See CORNEA, STAPHYLOMA OF, SYMPATHETIC OPHTHALMIA, TRAUMATIC CATARACT

LENS—*continued*

WOUNDS OF

- frequent complication of wounds of cornea, 126
- almost invariably end in cataract, 126. See TRAUMATIC CATARACT
- often associated with prolapse or lacerations of iris, 127
- effect of, 127
- importance of use of atropine in, 127
- may cause traumatic glaucoma, See TRAUMATIC GLAUCOMA

LEUCOMA. See CORNEA, LEUCOMA OF

LIEBREICH'S EYE BANDAGE, 172

LIME. See QUICK LIME

M

MORTAR, PLASTER, &c. See QUICK LIME

N

NEBULA. See CORNEA, NEBULA OF

O

ONYX, 70. See CORNEA, ABSCESS OF

OPERATIONS. See the separate headings

- removal of foreign bodies from the eye, 6, 9
- paracentesis of cornea, 23
- artificial pupil, 83
- for removing the layer of lead in cases of opacity of cornea from lead deposit, 89
- removal of lens in complete staphyloma of cornea, 96
- abscission of the eye, 99
- for treatment of staphyloma of cornea by seton, 101
- excision of the eye, 275, *et seq.*
- iridectomy, 105, 108
 - in sympathetic ophthalmia, 333, 334
- in cases of prolapse of the iris, 114, 115, 116, 118
- for removal of traumatic cataract, 142, *et seq.*
- linear extraction of cataract, 144, *et seq.*
 - von Graefe's modified, 168, *et seq.*
- suction operation, 154, *et seq.*
- traction operation, 160, *et seq.*
- needle for opaque capsule, 179, *et seq.*
- where iris adherent to opaque capsule, 181, *et seq.*
- in cases of dislocation of lens into anterior chamber, 188, 189
 - into the vitreous, 195
 - partial dislocation of lens, 206, *et seq.*
- for removal of foreign bodies within the eye, 227
 - within the orbit, 355, 356
- in cases of symblepharon (Teale's), 379
- removal of eyelashes, 384
- in cases of ectropion, 392-395
- for making new eyelids, 395-397

OPHTHALMIA, SYMPATHETIC. See SYMPATHETIC OPHTHALMIA

OPHTHALMIC HOSPITAL, ROYAL LONDON, LIST OF CASES TREATED AT,
401, *et seq.*

OPHTHALMITIS

TRAUMATIC, 19

- may arise from any form of injury, 19
- may be caused by explosion of gunpowder, 283
- but specially produced by foreign body within globe, 20
- symptoms of, 20, 21
- treatment of, 22-26
 - paracentesis of cornea for, 23
- treatment of, after suppuration of globe, 24, 25
 - excision of the eye when proper, 25
- recovery from, rarely complete, 26
- general results of, 27, 28

ORBIT

ABSCESS OF, 360, *et seq.*

- how caused, 360
- acute*, 361
 - case of, 361
 - symptoms of, 361, 362
 - usually rapid, 361
- chronic*, 363
 - symptoms, 363
 - often slowly developed, 363
 - with what liable to be confounded, 363
 - practice of exploratory punctures condemned, 364
- treatment of, 364-366
- may cause ectropion, 389

FOREIGN BODIES IN. See FOREIGN BODIES

FRACTURES OF, 357

- usually fatal, though immediate symptoms often trifling, 358
- case of, 358
- treatment of, 359

PENETRATING WOUNDS OF, 360

- orbital cellulitis and abscess apt to follow, 361

P

PARACENTESIS OF CORNEA

- how to perform, 23, 24
- in cases of traumatic ophthalmitis, 23
- diffuse suppurative corneitis, 69

PERCUSSION CAPS

- injuries from, 289
- cases of, 290, 321

PROLAPSE OF THE IRIS. See IRIS, PROLAPSE OF

PUPIL. See ARTIFICIAL PUPIL

SYMPATHETIC OPHTHALMIA—*continued*treatment of, 329, *et seq.*

1. *how to arrest the disease*, 330
 - when excision advisable, 330
 - general and local treatment, 330, 331
 - operative interference prejudicial while eye actively inflamed, 332
 2. *how to deal with damaged eye when disease arrested*, 332
 - iridectomy and removal of lens, 333
 - case of, 335
- case of unchecked, ending in blindness, 337
 general conclusions as to, 338—340

T

TENSION OF EYE

Bowman's symbols for, vi.

TEST TYPES, JAEGER'S, 407, *et seq.*

TRAUMATIC CATARACT

may occur under two conditions, 126

1. with rupture of the external coats of the eye, 126
 - cases of, followed by traumatic glaucoma, 129
 2. without rupture of the external coats of the eye, 130
 - may be caused by sudden blows on the eye or parts of the head 131, 132
 - cases of, 132, 133, 134
 - following injury from spent shot, 292
- treatment of, 135
1. if uncomplicated by injury to iris and caused by sharp instrument penetrating cornea, prognosis favourable, 135, 136
 - cases of, 137, 138
 2. if complicated with injury to or prolapse of iris, 138
 3. if complicated with lacerated wound of cornea and prolapse of iris, &c., 139, 140
 - case of, 140
- operations for removal of, 142
 - preliminary enquiries before performing, 142
 - if cataract soft, linear extraction or suction operation, 143
 - if lens not wholly opaque, 143
 - difficulties in such case, 143, 156
 - then needle operation should be first performed, 144
 - if nucleus hard, traction operation, 143
 - use of Liebreich's eye bandage after, 172
- application of linear extraction or suction operation to, 158—160
 1. when acute symptoms caused by injury subsided, but swollen lens source of irritation, 159
 2. when irritation ceased but cataractous lens not absorbed, 159
- when traction operation specially suited to, 167
 1. patients older than 35 or 40, 167
 2. iris involved in injury, 167
 3. cases of traumatic glaucoma, 167
 4. fistula of cornea associated with traumatic cataract, 168
 5. lens rapidly swelling but not opaque, 168

TRAUMATIC CATARACT—*continued*

Four operations for the removal of,

LINEAR EXTRACTION (Gibson's operation), 144, *et seq.*

well adapted for soft cataract, 144

1st stage of the operation (*breaking up the lens*), 145—147

cautions in performing, 145

subsequent symptoms, 148, 149

2nd stage of the operation (*removal of broken up lens*), 149—152

Bowman's suggestions, 151

cautions in performing, 152

iritis often follows, 153. See IRITIS

if lens dislocated two stages unnecessary, 188

VON GRAEFE'S MODIFIED LINEAR EXTRACTION, 168, *et seq.*

step 1 (incision), 168

2 (iridectomy), 169

3 (dilaceration of capsule), 170

4 (evacuation of the lens), 170

5 (clearing of the pupil, and coaptation of the wound), 171

after treatment, 171

useful in patients of advanced years, 172

SUCTION OPERATION (Teale's), 154, 156

may be completed in one operation, but two stages generally better, 156

though not in dislocation of lens, 188

stage 1, same as in linear extraction, 156

stage 2, 156

when stage 1 may be dispensed with, 157

Teale's suction tube, 155

Bowman's cataract syringe, 157, 158

TRACTION OPERATION, 160, *et seq.*

originally introduced by Von Graefe, and modified by Waldau, Bowman, and Critchett, 160, 161

stage 1 (incision of cornea), 161, 162

common cause of failure in, 161

stage 2 (laceration of capsule), 163

stage 3 (withdrawal of lens), 163, 164

instruments used in, 164, *et seq.*

Critchett's cataract spoon, 165

Bowman's, 165, 166

Waldau's, 166

cases suited for, 167, *et seq.*

may be caused by lodgment of gunpowder in the lens, 287

or injury from spent shot, 292

TRAUMATIC ECTROPION. See ECTROPION

TRAUMATIC ENTROPION. See ENTROPION

TRAUMATIC GLAUCOMA

may follow wounds of the lens, 128

symptoms of, 128

sometimes follows the first stage of operations for linear extraction of congenital cataract, 128

cases of, 129

traction operation for cataract in, 167

may follow certain dislocations of the lens, 187, 205

TRAUMATIC INTRAOCULAR HÆMORRHAGE. See HÆMORRHAGE

TRAUMATIC OPHTHALMITIS. See OPHTHALMITIS

TYRRELL'S HOOK, 84


used in making artificial pupil, 84, 334

needle operation for opaque capsule, 182

LONDON

PRINTED BY SPOTTISWOODE AND CO.

NEW-STREET SQUARE





afE

