

**Injuries and diseases of the jaws : the Jacksonian prize essay of the Royal College of Surgeons of England, 1867 / by Christopher Heath.**

**Contributors**

Heath, Christopher, 1835-1905.  
Royal College of Physicians of Edinburgh

**Publication/Creation**

London : J. Churchill, 1868.

**Persistent URL**

<https://wellcomecollection.org/works/qhwg7y8m>

**Provider**

Royal College of Physicians Edinburgh

**License and attribution**

This material has been provided by This material has been provided by the Royal College of Physicians of Edinburgh. The original may be consulted at the Royal College of Physicians of Edinburgh. where the originals may be consulted.


This work has been identified as being free of known restrictions under copyright law, including all related and neighbouring rights and is being made available under the Creative Commons, Public Domain Mark.

You can copy, modify, distribute and perform the work, even for commercial purposes, without asking permission.



Wellcome Collection  
183 Euston Road  
London NW1 2BE UK  
T +44 (0)20 7611 8722  
E [library@wellcomecollection.org](mailto:library@wellcomecollection.org)  
<https://wellcomecollection.org>







Li 3. 353











INJURIES AND DISEASES

OF

THE JAWS.



*BY THE SAME AUTHOR.*

---

PRACTICAL ANATOMY.

A MANUAL OF DISSECTIONS.

WITH NUMEROUS ILLUSTRATIONS.

8vo, 10s. 6d.

---

A MANUAL OF MINOR SURGERY AND BANDAGING,

FOR THE USE OF HOUSE-SURGEONS, DRESSERS, AND JUNIOR PRACTITIONERS.

WITH WOODCUTS.

Third Edition. 8vo, 5s.

# INJURIES AND DISEASES

OF

## THE JAWS:

THE JACKSONIAN PRIZE ESSAY OF THE ROYAL COLLEGE OF  
SURGEONS OF ENGLAND, 1867.

BY

CHRISTOPHER HEATH, F.R.C.S.

ASSISTANT-SURGEON TO UNIVERSITY COLLEGE HOSPITAL, AND TEACHER OF OPERATIVE  
SURGERY IN UNIVERSITY COLLEGE, LONDON.

LATE ASSISTANT-SURGEON TO, AND LECTURER ON ANATOMY AT, THE WESTMINSTER HOSPITAL.



WITH NUMEROUS WOOD ENGRAVINGS.

LONDON:

JOHN CHURCHILL & SONS, NEW BURLINGTON STREET.

M DCCCLXVIII.

[All rights of Translation and Reproduction are reserved.]



THE JAWB

THE JAWB

THE JAWB

THE JAWB

THE JAWB



THE JAWB

LONDON :  
SAVILL, EDWARDS AND CO., PRINTERS, CHANDOS STREET,  
COVENT GARDEN.

## PREFACE.

---

"THE Injuries and Diseases of the Jaws, including those of the Antrum, with the treatment by operation or otherwise," having been announced as the subject for the Jacksonian Prize of 1867, I prepared an essay upon the subject, to which I had for some years devoted considerable attention; and having been successful, I have printed it with but slight alterations. My very best thanks are due to those gentlemen (whose names will be found in the following list) who, by generously placing valuable preparations of disease at my disposal, enabled me to study the pathology of the subject more successfully than I could otherwise have done, and also to those who have kindly given me notes of interesting cases under their charge, or have lent me valuable illustrations, of which due acknowledgment has been made in each instance. I venture to hope that the information thus brought together may be of service to those under whose care similar cases may be placed.

CHRISTOPHER HEATH.

9, CAVENDISH PLACE,  
*September, 1868.*

# THE

OF

THE

OF

OF

OF



# TABLE OF CONTENTS.

CHAP.	PAGES
I. FRACTURE OF THE LOWER JAW . . . . .	1— 14
II. COMPLICATIONS OF FRACTURE OF LOWER JAW . . .	15— 32
III. TREATMENT OF FRACTURED LOWER JAW . . . . .	33— 51
IV. FRACTURES OF THE UPPER JAW . . . . .	52— 61
V. GUNSHOT INJURIES OF THE JAWS . . . . .	62— 78
VI. DISLOCATION OF THE JAW . . . . .	79— 93
VII. INFLAMMATION, ABSCESS, PERIOSTITIS . . . . .	94—103
VIII. NECROSIS OF THE JAWS . . . . .	104—117
IX. REPAIR AFTER NECROSIS; TREATMENT . . . . .	118—130
X. HYPEROSTOSIS . . . . .	131—136
XI. CYSTIC DISEASES OF THE ANTRUM . . . . .	137—155
XII. CYSTS OF TEETH; DENTIGEROUS CYSTS . . . . .	156—167
XIII. CYSTS IN THE LOWER JAW . . . . .	168—180
XIV. TUMOURS CONNECTED WITH TEETH . . . . .	181—188
XV. DISEASES OF THE GUMS; EPULIS . . . . .	189—205
XVI. TUMOURS OF THE HARD PALATE . . . . .	206—209
XVII. GROWTHS WITHIN THE ANTRUM . . . . .	210—214
XVIII. FIBROUS, FIBRO-CELLULAR, AND RECURRENT FIBROID TUMOURS OF THE UPPER JAW . . . . .	215—226
XIX. MYELOID AND VASCULAR TUMOURS OF THE UPPER JAW	227—233
XX. CARTILAGINOUS AND OSSEOUS     "     "     "	234—254
XXI. CANCEROUS TUMOURS     "     "     "	255—260
XXII. DIAGNOSIS AND TREATMENT OF     "     "     "	261—271
XXIII. FIBROUS, RECURRENT, FIBROID, AND FIBRO-CELLULAR TUMOURS OF THE LOWER JAW . . . . .	272—294
XXIV. MYELOID, CARTILAGINOUS, AND OSSEOUS TUMOURS . .	295—304
XXV. CANCEROUS TUMOURS . . . . .	305—310
XXVI. DIAGNOSIS AND TREATMENT OF TUMOURS OF THE LOWER JAW . . . . .	311—317
XXVII. CLOSURE OF THE JAWS . . . . .	318—341
XXVIII. DEFORMITIES OF THE JAWS . . . . .	342—347
APPENDIX OF CASES . . . . .	348—408

## LIST OF PREPARATIONS.

- | No. in Museum<br>Catalogue. |   |
|-----------------------------|---|
| 1.— 484 A.                  | Fracture of alveolus removed ; containing left incisors and canine teeth. ( <i>Author.</i> )        |
| 2.—2902 A.                  | Skull with fractures from discharge of a pistol. ( <i>Author.</i> )                                 |
| 3.—                         | Dissected specimen of dislocation of the jaw artificially produced. ( <i>Author.</i> )              |
| 4.— 720 A.                  | Necrosis of jaw, the sequestrum including both temporary and permanent teeth ( <i>Mr. Martin.</i> ) |
| 5.— 720 B.                  | Necrosis of the jaw after scarlet fever. ( <i>Mr. Tracy.</i> )                                      |
| 6.— 720 C.                  | Necrosis of condyle and coronoid process. ( <i>Mr. Lawson.</i> )                                    |
| 7, 8, 9.—1007 B.            | Cysts of teeth. ( <i>Mr. E. H. King.</i> )  |
| 10.—1033 C.                 | Dentigerous cyst of lower jaw. ( <i>Mr. Fearn.</i> )  |
| 11.—1031 A.                 | Epulis. ( <i>Author.</i> )  |
| 12.—1031 B.                 | Giant-celled epulis. ( <i>Mr. Wilkes.</i> )   |
| 13.—                        | Epithelial epulis. ( <i>Mr. Hutchinson.</i> )   |
| 14.—                        | Epithelioma of jaw. ( <i>Mr. W. Adams.</i> )  |
| 15.—1052 B.                 | Fibroid disease of antrum. ( <i>Author.</i> )   |
| 16.—1046 A.                 | Enchondroma of upper jaw. ( <i>Mr. Square.</i> )  |
| 17.—1053 A.                 | Medullary cancer of upper jaw. ( <i>Mr. Craven.</i> )   |
| 18.—1053 B.                 | Ditto ditto ditto ( <i>Mr. Craven.</i> )  |
| 19.—1059 E.                 | Scirrhus of right upper jaw with portion of lip. ( <i>Mr. Coates.</i> )                             |
| 20.—1059 D.                 | Ditto of left jaw of same patient. ( <i>Mr. Andrews.</i> )  |
| 21.—1040 B.                 | Fibrous tumour of the lower jaw. ( <i>Mr. Spencer Wells.</i> )                                      |
| 22.—1040 C.                 | Ditto ditto ditto ( <i>Mr. Shillito.</i> )  |
| 23.—1040 D.                 | Ditto ditto ditto <i>Salisbury Infirmary.</i>   |
| 24.—1041 A.                 | Osteo-sarcoma of lower jaw. ( <i>Author.</i> )  |
| 25.—1052 C.                 | Myeloid tumour of lower jaw. ( <i>Mr. Craven.</i> )   |
| 26.—1052 D.                 | Myeloid tumour (2) from lower jaw ( <i>Author.</i> )  |
| 27.—1057 A.                 | Medullary tumour (2) of lower jaw ( <i>Author.</i> )  |
| 28.—1058 B.                 | Scirrhus of lower jaw. ( <i>Mr. Coates.</i> )   |
| 29.—1058 A.                 | Ditto ditto ( <i>Mr. Wilkes.</i> )  |
| 30.—1057 B.                 | Medullary tumour of lower jaw. P.M. ( <i>Author.</i> )  |
| 31.—                        | Wedge removed from lower jaw. ( <i>Author.</i> )  |
| 32.—                        | Wedge removed, with two exfoliations of the cut surfaces ( <i>Author.</i> )                         |
| Cast 1.—1001 A.             | Fracture and dislocation of tooth, which is attached to the cast. ( <i>Mr. Margetson.</i> )         |



## ILLUSTRATIONS.

FIG.		PAGE
1.	Fracture with over-lapping. . . . . after <i>Malgaigne</i>	8
2.	„ with displacement . . . . . „	10
3.	„ of condyles and coronoid process . . . . . <i>Fergusson</i>	11
4.	Fracture united at an angle, from St. George's Hospital Museum . . . . . <i>Original</i>	21
5.	Ditto ditto (Hepburn). . . . . „	21
6.	Ditto ditto „ . . . . . „	21
7.	Displacement with fibrous union . . . . . after <i>Malgaigne</i>	24
8.	Fibrous union, from University College Museum . . . . . <i>Original</i>	29
9.	Ununited fracture after gunshot injury . . . . . <i>Cox Smith</i>	31
10.	Ditto ditto ditto . . . . . „	31
11.	Four-tailed bandage for lower jaw . . . . . <i>Original</i>	33
12.	Gutta-percha splint . . . . . <i>Erichsen</i>	34
13.	Ditto ditto . . . . . „	34
14.	Hamilton's apparatus . . . . . after <i>Hamilton</i>	35
15.	Wheelhouse's method . . . . . .	36
16.	Hayward's mouth-piece . . . . . <i>B. Hill</i>	39
17.	Gunning's interdental splint . . . . .	40
18.	Ditto ditto . . . . .	41
19.	Ditto ditto . . . . .	42
20.	Ditto ditto . . . . .	43
21.	Bean's apparatus . . . . . after <i>Hamilton</i>	45
22.	Lonsdale's apparatus . . . . . <i>B. Hill</i>	47
23.	„ „ modified . . . . . „	48
24.	Fracture of upper jaw . . . . . <i>Salter</i>	53
25.	Plate for ditto . . . . . „	53
26, 27.	Gunshot fracture of upper jaw . . . . . <i>Cox Smith</i>	67
28.	Gunshot injury of face . . . . . <i>Debout</i>	69
29, 30.	Ununited gunshot fracture . . . . . <i>Cox Smith</i>	74
31.	Gunshot injury of face . . . . . <i>Debout</i>	75
32.	„ of jaw . . . . . „	75
33.	Silver chin . . . . . „	76
34.	Dissection after loss of jaw . . . . . „	76



FIG.		PAGE
35.	Dislocation of jaw . . . . . <i>Astley Cooper</i>	81
36.	Ditto ditto . . . . . after <i>Malgaigne</i>	82
37.	Dissection of dislocation of jaw . . . . . <i>Original</i>	83
38.	Dislocation of jaw . . . . . <i>Fergusson</i>	84
39.	Ditto old . . . . . <i>R. W. Smith</i>	85
40.	Ditto „ . . . . . <i>J. Couper</i>	87
41.	Stromeyer's forceps . . . . . after <i>Goffres</i>	91
42.	Necrosis of intermaxillary bones . . . . . <i>Bryant</i>	108
43.	„ of upper jaw . . . . . <i>Hart</i>	110
44.	Portrait of patient . . . . . „	110
45.	Hyperostosis, portrait . . . . . after <i>Howship</i>	132
46, 47.	Ditto „ . . . . . <i>Fergusson</i>	136
48.	Antrum Highmorianum . . . . . <i>Cattlin</i>	137
49.	Ditto ditto . . . . . „	137
50.	„ „ of normal size . . . . . „	138
51.	„ „ of large size . . . . . „	139
52.	„ „ of very small size . . . . . „	140
53.	Antra of unequal sizes . . . . . „	140
54.	Antrum prolonged into malar bone . . . . . „	141
55.	„ with vertical septum . . . . . „	141
56.	Ditto ditto . . . . . „	142
57.	„ subdivided (with perforation) . . . . . „	142
58.	Ditto ditto . . . . . „	143
59.	Ditto ditto . . . . . „	143
60.	Distension of antrum . . . . . <i>Fergusson</i>	145
61.	Ditto ditto . . . . . „	152
62.	Cyst of antrum (W. Adams) . . . . . <i>Original</i>	154
63.	„ „ . . . . . after <i>Giraldès</i>	154
64, 65, 66.	Cysts of teeth . . . . . <i>Original</i>	156
67.	Inverted tooth . . . . . <i>Tomes</i>	160
68, 69.	Dentigerous cyst (Fearn) . . . . . <i>Original</i>	162
70.	Ditto ditto . . . . . <i>Forget</i>	163
71.	Ditto ditto (Underwood) . . . . . <i>Original</i>	164
72.	Calcified cyst (Cartwright) . . . . . <i>Cattlin</i>	164
73.	Dentigerous cyst . . . . . <i>Forget</i>	167
74, 75, 76.	Cyst of lower jaw . . . . . <i>Fergusson</i>	171, 172
77.	Skeleton of cyst of lower jaw (St. Bartholomew's) . . . . . <i>Original</i>	173
78.	Multilocular cyst of lower jaw . . . . . <i>R. Adams</i>	175
79.	Ditto ditto . . . . . <i>Cusack</i>	176
80.	Misplaced tooth . . . . . <i>Forget</i>	182
81.	Ditto ditto . . . . . „	182
82.	Mass of dentine (Fergusson) . . . . . <i>Tomes</i>	184
83.	Ditto ditto . . . . . <i>Forget</i>	185
84.	Cemental tumour . . . . . „	187
85.	Exostosis of tooth . . . . . <i>Tomes</i>	187

FIG.			PAGE
86.	Papillary tumour (Fergusson)	<i>Salter</i>	191
87, 88, 89.	" "	"	192
90.	Epulis (Hutchinson)	<i>Original</i>	193
91.	" myeloid (Hutchinson)	"	194
92.	" giant-celled (Wilkes)	"	195
93.	Epithelioma of gum	<i>Fergusson</i>	196
94.	Epulis (Author)	<i>Original</i>	200
95.	Ditto	<i>Liston</i>	201
96.	Ditto	"	202
97.	Saw	<i>Fergusson</i>	204
98.	Cross-cutting forceps	"	204
99, 100.	Bone-forceps	"	205
101.	Fibroid disease of antrum (Author)	<i>Original</i>	213
102.	Fibrous tumours of upper jaw	<i>Liston</i>	217
103.	Ann Struther before operation	"	218
104.	" " after operation	"	218
105.	Mrs. Frazer	"	219
106.	Myeloid of upper jaw	<i>Canton</i>	228
107.	Large recurrent enchondroma	<i>Original</i>	238
108, 109.	Osseous tumour (Dupuytren)	after <i>V. de Cassis</i>	245
110.	" " (Fergusson)	<i>Original</i>	247
111.	" " (Duka)	<i>Pathological Society</i>	251
112.	Medullary tumour (Craven)	<i>Original</i>	257
113.	Ditto ditto	"	258
114.	Double medullary tumour (Author)	"	260
115.	Gensoul's incision	<i>Fergusson</i>	263
116, 117.	Lizards' "	"	264
118.	Scar of face	"	265
119.	Ditto	<i>Liston</i>	266
120.	Saw	<i>Fergusson</i>	267
121.	Lion forceps	"	267
122.	Fibrous tumour of lower jaw (University College)	<i>Original</i>	272
123, 124.	Ditto ditto ditto	<i>Spencer Wells</i>	273, 274
125.	Fibrous tumour between plates (King's College)	<i>Original</i>	275
126.	Large fibrous tumour (Fergusson)	"	276
127.	Upper jaw of ditto	"	277
128.	Recurrent fibroid of lower jaw	<i>Lawson</i>	280
129.	Ditto ditto	"	281
130.	Large osteo-sarcoma of lower jaw	<i>Syme</i>	287
131.	Patient, after its removal	"	287
132.	Large osteo-sarcoma of lower jaw (Author)	<i>Original</i>	288
133.	" " after removal	"	289
134.	Cystic sarcoma of lower jaw (Hutton)	<i>R. Adams</i>	292
135.	Myeloid tumour of symphysis (Craven)	<i>Original</i>	296
136.	" section of " "	"	296



FIG.			PAGE
137.	Myeloid tumour of lower jaw . . . . .	<i>Fergusson</i>	298
138.	„ „ of both sides of jaw (Author) . . . . .	<i>Original</i>	299
139.	Patient, after operations . . . . .	„	299
140.	Ivory exostosis of lower jaw (South) . . . . .	„	304
141.	Girl, after removal of cancer of lower jaw (Author) . . . . .	„	306
142.	Incision for removal of lower jaw . . . . .	<i>Fergusson</i>	314
143.	Tumour of centre of lower jaw . . . . .	„	315
144.	Incision for removal of lower jaw . . . . .	„	315
145.	Closure of jaws by cicatrices (Author) . . . . .	<i>Original</i>	330
146.	Effects of Esmarch's operation . . . . .	„	330
147.	Closure of jaws and cicatrix of cheek (Author) . . . . .	„	331
148.	Effects of operations . . . . .	„	331
149.	Shields for application to gums (Clendon) . . . . .	„	334
150.	Patient to whom these had been fitted (Holt) . . . . .	„	335
151.	Deformity of maxilla from cicatrix of burn . . . . .	<i>Tomes</i>	344
152.	Deformity of jaws from cancrum oris . . . . .	<i>Harrison</i>	345
153.	Same patient after operation . . . . .	„	346
154.	„ „ after second operation . . . . .	„	347



THE  
INJURIES AND DISEASES OF THE  
JAWS.

---

CHAPTER I.

FRACTURE OF THE LOWER JAW.

FRACTURE of the lower jaw is usually the result of direct violence, though Professor Pancoast met with a case in which fracture of the neck of the bone had resulted from a violent fit of coughing in an old man upwards of seventy years of age. (Gross's "Surgery," p. 964.) Blows received on the jaw in fighting or a kick from a horse are the most common causes of the accident; but falls from a height upon the face also produce some of its most serious forms, owing to the comminution resulting. The unskilful application of the dentist's "key" has been known to produce a complete fracture of the bone, but more frequently in former years than at the present time, when that instrument has been almost entirely superseded by the forceps. Fractures of the alveolus, however, are often unavoidable during the extraction of the molar teeth, even in the most skilful hands, since the position assumed by the fangs is occasionally such that extraction without displacement of the bone to some extent is impossible.

These cases ordinarily give, however, little inconvenience, since the removal of the alveolus only hastens the absorption which must necessarily ensue upon the removal of the teeth, unless indeed the fracture should be so extensive as to affect



the alveoli of the neighbouring teeth, in which case exfoliation of a troublesome character may be produced.

On this subject, which is of considerable interest to those practising dental surgery, I may quote a passage from a paper in the "Dental Cosmos," by Dr. J. Richardson, which illustrates the difficulty which may be met with. He says:—

"I have never come to regard extracting teeth as an operation free from liability to grave complications. I seize hold of a tooth to-day with more misgiving, with more caution, than I did the first year of my practice. Eleven years' experience may be supposed to have given me some confidence and expertness in this operation, yet with each year's added experience the operation grows in importance, and dictates greater vigilance and prudence. I feel my way through the operation with more and more caution, guard every movement with greater circumspection, and magnify my skill more and more with every success. Through eleven years my experience has been free from serious accident, but the catastrophe came at last when I had no possible reason to expect it.

"Within the past two months I fractured the inferior jaw severely in attempting to remove the anterior right inferior molar. It was in this way. The patient was a lady about twenty-five years of age. The crown of the tooth was much decayed, but I had a firm hold upon the neck. Alternate lateral traction was made upon the tooth, moderately at first, but increasing at every movement of the forceps. There seemed to be complete immobility of the tooth until the instant of its giving way, which it did with the outward movement of the forceps. I comprehended instantly, from the enlargement of the gum below the processes, that a fracture of the maxilla had occurred. On examination I found the detached portion adhering firmly to the fangs of the tooth, and extending antero-posteriorly about an inch and a quarter, and in depth about three-fourths of an inch or more. I made no further attempts to remove either the tooth or fragment of bone, but pressed them firmly back to their places, and directed the patient to keep



the mouth persistently closed. I hoped for a reunion of the fractured parts."—*British Journal of Dental Science*, August, 1863.

Gunshot injuries of the face may produce the most terrible injuries of the lower jaw by splintering and removing large portions of it; and the mere explosion of gunpowder in its immediate neighbourhood, as when a pistol is fired into the mouth by a suicide, will produce a fracture of the bone. (See chapter on "Gunshot Injuries.")

Fractures of the lower jaw are remarkable for the fact that they are almost always *compound* towards the mouth, though the skin is rarely involved except in gunshot injuries. The fibrous tissue of the gum being very inelastic, tears readily when the bone is broken across, and thus the saliva and the air come in contact with the fractured surfaces. This statement only applies, however, to fractures of the body of the bone, for when the ramus, or still more the coronoid process or condyle are broken, the bone is too deeply seated for the injury to extend into the mouth.

Fracture may occur at various points in the lower jaw, and the body of the bone is the portion most frequently injured (in 24 out of 25 cases recorded by Hamilton); the ramus from its position and coverings being much less liable to injury except from extreme violence, such as the passage of a wheel over the face or a gunshot injury. The coronoid process is occasionally broken off obliquely, and the neck of the jaw has been repeatedly broken on one or both sides of the bone in cases subjected to great violence.

In the body of the jaw the fracture appears to occur most frequently in the neighbourhood of the canine tooth, this position being determined probably by the greater depth of its socket, and the consequent weakness of the bone at that point; but the fracture may happen at any other point, and has been known to occur exactly at the symphysis in cases too old to admit of separation of the two portions of the bone. Of the twenty-four cases of fracture of the body recorded by Hamilton, one was perpendicularly through the symphysis, twelve were through the body, and five through



the angle; and of the whole number no less than eleven were examples of double and triple fractures.

The line of fracture, except at the symphysis, is usually oblique, and according to Malgaigne (Packard's translation, p. 306), the thickness of the bone is also divided obliquely, so that generally the fracture is at the expense of the outer plate of the anterior fragment and the inner plate of the posterior fragment, though this rule is not without exception.

It is impossible to gather any reliable details respecting the position of the fractures of the lower jaw occurring in the London hospitals; and as this fracture is rarely a fatal accident *per se*, the hospital museums contain comparatively few specimens. An examination of those, however, yields the following results:—

*The College of Surgeons* possesses no specimen of recent fracture of the lower jaw, and only a doubtful one of united fracture near the angle (2903).

*St. Bartholomew's Hospital* possesses no specimen of fracture of the lower jaw.

*St. Thomas's Hospital* has one recent and moist specimen (27) — “A comminuted fracture of the lower jaw. The bone is fractured near the symphysis and near to both angles, so as to expose the nascent pulps of the last molar teeth. The inferior maxillary nerves are not lacerated.”

*Guy's Hospital* has only one specimen (1091,70) — “A lower jaw having a doubtful fracture (united) on the left side at the angle.”

*King's College Museum* is very rich in recent fractures, having no less than four.

1. A fracture between the incisor teeth, running obliquely to the left at the expense of the external plate of the left segment. The right coronoid process is broken off obliquely downwards from the sigmoid notch, and the necks of both condyles are fractured obliquely. This is the preparation figured by Sir William Fergusson in his “*Practical Surgery*,” p. 521, and was taken by him from a patient who fell from a great height, and received fatal injuries. (Fig. 3.)

[This preparation corresponds very closely to that de-



scribed by M. Houzelot, where, in consequence of a fall from a height, there were produced fractures of the symphysis, of both condyles, and of *both* coronoid processes. (Malgaigne, p. 323.)]

2. Is an example of double fracture of the body of the jaw. On the right side the fracture runs between the lateral incisor and the canine tooth obliquely backwards at the expense of the external plate of the posterior fragment. On the left side the fracture extends from the posterior socket of the third molar tooth (which was broken at the time, leaving the anterior fang *in situ*) obliquely backwards, at the expense of the outer plate of the anterior fragment.

This was from a man who was struck on the jaw with the fist, and died of *delirium tremens* in King's College Hospital in 1857, whilst I was Sir William Fergusson's house-surgeon.

3. Is an example of double fracture of the body, and of fracture of both condyles. On the right side there is in front of the last molar tooth a fracture running obliquely forwards and then backwards, thus >, the upper division being at the expense of the outer plate of the posterior fragment, and the lower at the expense of the outer plate of the anterior fragment. On the left side a very oblique fracture runs forward from the front of the second molar tooth, which is broken. A part of the external plate has been broken off and is wanting. The necks of both condyles are broken obliquely downwards and inwards.

The preparation is from a woman who threw herself out of window and fell forty feet.

4. Is an example of comminuted fracture at and to the right side of the symphysis. The left half of the bone is cut nearly vertically through the socket of the left lateral incisor. The right half is cut very obliquely from the canine tooth at the expense of the inner plate, and the fragments would complete the missing portion of alveolus.

*University College Museum* is also very rich in injuries of the jaw, having four specimens of recent fractures; one of bony union; and one of fibrous union. All the recent specimens show a fracture in the neighbourhood of the sym-



physis, which no doubt influenced Mr. Erichsen in the opinion he has expressed as to the usual position of fracture: "I have seen fractures most frequently in the body of the bone near the symphysis, extending between the lateral incisors, or between those teeth and the canine. The symphysis itself is not so commonly fractured, the bone being thick in this situation. The angle is frequently broken, but the neck and coronoid process rarely give way." ("Science and Art of Surgery," p. 224.)

1. Is a vertical fracture through the symphysis, with a horizontal fracture running through the alveolus on the right side, separating the portion containing the right lateral incisor, canine, and first bicuspid teeth.

2. Shows a fracture running at first vertically, and then slightly obliquely to the left through the socket of the left lateral incisor. The neck of the left condyle is broken off obliquely and very low down, so that the fissure runs downwards and backwards in a line with the posterior border of the coronoid process.

3. Is a vertical fracture through the symphysis, with a portion of dried integument adhering. Both condyles are broken off obliquely.

4. Is a remarkable example of multiple and comminuted fracture. One fracture runs obliquely forwards in front of the left first molar tooth into the mental foramen. A second fracture runs vertically between the right incisor teeth. A third fracture runs very obliquely from the last molar on the right side down to the lower border of the bone opposite the canine tooth. This is met by a fourth fracture running obliquely backwards in front of the first molar tooth of the same side. The lower border of the bone in the mental region is broken off and comminuted into numerous fragments, one of which contains the mental foramen of the right side. The left condyle is also broken off obliquely.

5. Is an example of united fracture of the jaw in the right molar region, with loss of all the teeth on the right side except the last molar. The fracture was apparently oblique, and is somewhat irregularly united by bone, with



the result of contracting the alveolar arch, so that the left lower teeth have been thrown inside those of the upper jaw; and both having been exposed to extra attrition, owing to the absence of teeth on the opposite side, are much worn away, the lower on their outer and the upper on their inner surfaces.

6. Is a wet preparation, showing fibrous union of the jaw beyond the right canine tooth, a great part of the body of the bone in that situation being wanting. Hence it was probably a case of comminuted fracture, with exfoliation of a portion of bone. (Fig. 8.)

*St. George's Hospital Museum* contains one remarkable specimen of united fracture of the lower jaw (i. 38). The fracture has taken place to the right of the symphysis, and there has been a loss of substance, from comminution probably, so that the two halves of the body of the bone meet at an acute angle, all the teeth of the right side in front of the bicuspid being wanting. There are small outgrowths of bone both in front and behind in the neighbourhood of the fracture, which is irregularly united, leaving a hole on the middle of the union like the socket of a tooth. The right mental foramen is much smaller than the left, the line of fracture being apparently close in front of it. The sigmoid notches of this jaw are unusually large. (Fig. 4.)

In the catalogue of *St. George's Museum* is an account of a lower jaw fractured through the base of the coronoid process and through the neck of the condyle, in which the lower fragment had been displaced into the meatus auditorius externus, separating the cartilaginous from the osseous portion for nearly half its circumference. The preparation has, however, unfortunately disappeared.

The *London Hospital Museum* contains one specimen of recent fracture of the lower jaw. A fracture extends obliquely backwards between the second and third molar teeth of the *left* side, the external and internal plates of the bone being equally involved. There is also an oblique (downwards and backwards) fracture of the neck of the *right* condyle.

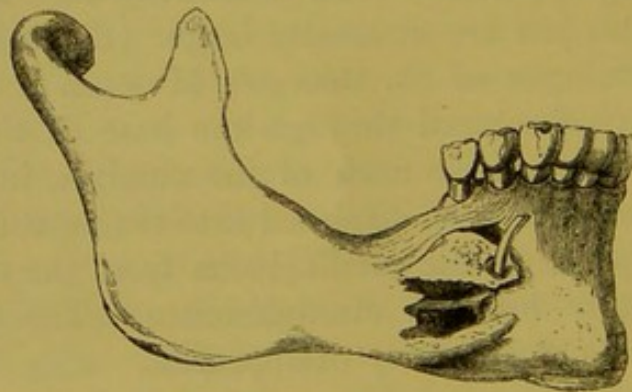


The Museums of Westminster, Middlesex, Charing Cross, and St. Mary's Hospitals contain no specimens of fractured lower jaw.

*Symptoms.*—These are ordinarily well marked. Since even in simple vertical fracture of the symphysis the patient will be conscious of pain and slight crepitus on pressing the jaws together, and the surgeon will readily perceive the irregularity of the teeth due to the alteration in the level of the fragments. The position of a patient with fracture of the jaw is very characteristic, since he endeavours to support and steady the fragments with his hands in the most careful manner, and his anxiety for relief is often most ludicrously complicated by his inability to explain by word of mouth what his ailment is. Where the laceration of the gum has permitted displacement of the fragments, manipulation on the part of the surgeon is unnecessary for the establishment of the diagnosis; but when any doubt exists he should grasp the jaw on each side with the forefingers introduced into the mouth, and will have no difficulty in perceiving the movement and crepitus between the fragments.

When a single fracture occurs on one side of the median

FIG. 1.



line, the smaller fragment is liable to displacement by muscular action, being drawn outwards and at the same time a little forwards so as to overlap the larger fragment. This is due to the action of the temporal and masseter muscles, but principally to the latter, and is favoured by the generally oblique direction of the line of fracture and consequent



tendency of the bones to override, as pointed out by Malgaigne. (Fig. 1.) This is well seen in the fracture of the left side in specimen 3 of the King's College collection, and during life the deformity was well marked. Mr. Lawson was good enough to show me a case recently in which union of a similar fracture had taken place, and in which, notwithstanding every care, very considerable permanent displacement of the fragments had occurred. An instance of the obliquity of the fragments being reversed is given by Dr. Kinloch in the *American Journal of Medical Sciences* for July, 1859. Here the patient, who was fifty years of age, met with a compound fracture of the right side of the jaw, in front of the masseter muscle. "The line of fracture divided the bone obliquely through its thickness, the obliquity being at the expense of the external plate of the small posterior fragment and of the internal plate of the large or anterior fragment. The displacement was singular and marked. The small fragment projected inwards and slightly upwards into the cavity of the mouth. The large fragment rode the small one, having retreated downwards and backwards, and its extremity, which was somewhat pointed, could be felt externally under the integument."

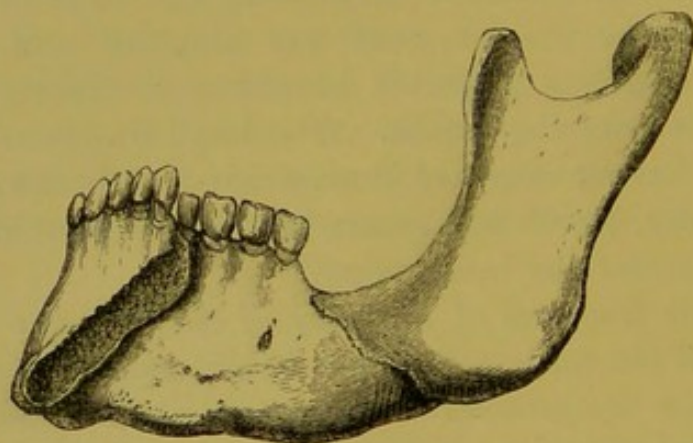
In double fractures of the body of the jaw, one being on each side of the median line, the displacement is necessarily greater, since the muscles attached to the chin tend to draw the central loose piece downwards and backwards towards the hyoid bone, whilst both lateral portions are drawn forwards and outwards, as described in the previous paragraphs. When, as is probably the case in most instances of the kind, the obliquity of the fracture is the same on the two sides, *i.e.*, at the expense of the outer surface of both extremities of the central fragment, no difficulty is experienced in reducing the fracture, and it is only necessary to see that the posterior fragments are sufficiently approximated to it; but when, as in specimen 2 of King's College, the obliquity is different on the two sides, the fracture being at the expense of the outer plate of the posterior fragments on the right side, and the reverse on the left side (consequent no



doubt upon the blow having been struck to the left of the median line), it is obvious that great difficulties will be encountered both in reducing and maintaining the apposition of the fragments, as indeed was the case with the patient in question.

Malgaigne records an almost similar case in which reduction could not be effected. "The middle fragment, which was strongly drawn downward and backward, was easily brought forward nearly to a level with the other two, but when it came close to that on the right side it seemed to catch against its posterior surface, as is seen in the figure (fig. 2), and no effort could disengage it. On post-mortem examination the right fragment in its upper half was bevelled at the expense of the external surface, the middle one at the

FIG. 2.



part corresponding at the expense of its internal face. This bevelled edge opposed an almost insurmountable obstacle to its disengagement; there was an overlapping of the edges of which one would have no idea. And even after death we found that to effect the reduction, it was necessary to carry the middle portion downward and forward, so as to carry it first below and then in front of the other."

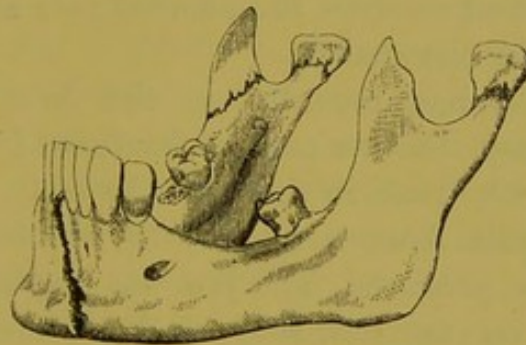
An extraordinary example of double fracture of the jaw was brought before the Edinburgh Medico-Chirurgical Society on 20th November, 1861, by Dr. Struthers, being from a man, æt. 19, who in Australia was caught by the coulter of his plough, when a great part of his jaw was



broken off and torn away. The specimen embraced the entire body of the bone, and more than half of the right ramus, which had been fractured obliquely backwards and downwards from the root of the coronoid process to the middle of the posterior edge. On the left side the fracture extended obliquely across the angle from behind the socket of the second molar tooth to just in front of the angle. The patient recovered. (*Edinburgh Medical Journal*, December, 1861.)

Fracture of the ramus is usually produced by some crushing force, such as the wheel of a carriage, as in a case recently under my care, and the bruising of the soft parts is therefore considerable. But little displacement ordinarily occurs, owing to the deep situation of the bone, and the fact that it is well supported on each side by the masseter

FIG. 3.



and internal pterygoid muscles. In the case alluded to under my own care, the patient was a boy of 12, and the prominent symptom was the projection of the lower incisors beyond the upper jaw, with slight displacement towards the injured side. But when there is much laceration and loss of substance, as in gun-shot injuries, the upper fragment is apt to be tilted forward by the temporal muscle, as was noticed in a case under my own care, which will be found in the Appendix (Case IV.). Pain is referred to the part, and on passing the finger well back into the fauces, irregularity and crepitus may be detected when the patient moves the jaw.



Fracture of the neck of the condyle is not so rare an accident as has been stated by some authors, judging from the number of museum specimens of the accident which exist. Fig. 3, from Sir William Fergusson's "Practical Surgery," shows very well the ordinary appearance of the fracture, though in some specimens the line of fracture is more obliquely placed. This is well seen in specimen 3 in University College Museum, where the left condyle is broken off so obliquely and so low down that the line of fracture runs downwards and backwards from the middle of the sigmoid notch. The cause in all the recorded cases is the same, viz., a fall from a considerable height. The symptoms are obscure, there being pain and difficulty of movement on the affected side, and crepitus perceived by the patient. The condyle is drawn inwards and forwards by the pterygoideus externus, as can be ascertained by passing the finger into the mouth, and the jaw-bone is apt to become slightly displaced, so that the chin is turned *towards* the affected side and not *from* it, as is the case in dislocation.

Dr. Fountain has recorded in the *New York Medical Journal*, January, 1860, a case of fracture of the neck of the left condyle with fracture through the body on both sides, caused by a fall from a height, in which the following symptoms were present. The jaw was displaced backwards, and laterally on the left side—a displacement which was temporarily rectified as long as traction was made at the symphysis, which the connexions of the middle fragment with the membranous and muscular tissues permitted. As soon as this traction was removed, the lateral deformity was reproduced, and every contrivance resorted to failed to maintain a permanent reduction of the fracture of the neck until the upper and lower teeth were wired together so as to keep up traction on the lower jaw. The case did well, and recovered without any deformity.

When double fracture of the neck occurs, the violence must have been so great, as in most cases to lead shortly to fatal results, but M. Bérard has recorded a case in which the double fracture did not at first lead to any displacement,



but on the fifth day convulsions ensued, which led to considerable displacement and subsequent death.

Watson, of New York, has moreover recorded a case of recovery in the person of a man who fell from the yard-arm of a vessel, breaking his thigh and arm bones and *both* condyles of the lower jaw, with the following symptoms :—“ His face was somewhat deformed by the retraction of the chin ; the mouth could not be opened so as to protrude the tongue to any great extent beyond the teeth, and the teeth of the upper and lower jaw could not be brought into contact. In attempting to move the jaw the patient experienced pain and crepitation just in front of the ears ; the crepitation could be easily felt by placing the fingers over the fractured condyles. Nothing was done for the fractures of the jaw. In a few weeks the rubbing of the broken surfaces and attendant soreness ceased to trouble him ; but the shape of the jaw and difficulty of opening the mouth to any great extent still remained unaltered. (*New York Journal of Medicine*, October, 1840.)

Reduction of a fracture of the neck of the jaw, should complete displacement have occurred, can only be effected by acting upon the condyle and the jaw at the same time. The finger carried far back in the mouth should throw the condyle out, whilst the jaw is brought into its proper relation with the other hand. The fragments must then be pressed firmly together, and against the glenoid cavity, with a bandage. Ribes, to whom this plan is due, applied it with success. (Malgaigne.)

Fracture of the coronoid process is a rare accident. Thus Hamilton says that Houzelot's case is the only one which he has found. Curiously enough, however, he employs the illustration from Fergusson's "Practical Surgery" a few pages before, in which a fracture of the coronoid process is seen, and which is taken from specimen 1 in King's College. The fragment would no doubt be drawn upwards and backwards by the temporal muscle, and might be felt in its new situation, though this displacement would probably be limited by the very tough and tendinous fibres which are so closely

connected with the bone forming the insertion of the temporal muscle, and reach down to the last molar tooth. According to Sanson, fractures of the coronoid process do not admit of union.

Considerable inflammation frequently follows a fracture of the jaw, even of a simple kind, particularly if it has been neglected or overlooked for some hours. The face becomes swollen, and the tissues beneath the chin infiltrated with serum, which is sometimes converted into pus, giving rise to troublesome abscesses.



## CHAPTER II.

## COMPLICATIONS OF FRACTURE OF THE LOWER JAW.

*Wounds of the face* are rare accompaniments of fracture of the lower jaw, except in cases of gun-shot injury, and when found are usually the result of a kick from a horse. The wound itself requires treatment on ordinary principles, and is of little moment as regards the fracture (which is doubtless "compound" also into the mouth), except as interfering with the application of the necessary retentive apparatus. In a case of extensive fracture of the lower jaw, the result of a kick from a horse, which I saw in the Westminster Hospital, under Mr. Holthouse's care, the lip and chin were extensively torn; and in a case of Mr. Berkeley Hill's, in University College Hospital, the result of a fall, the wound beneath the chin very much interfered with the application of a modified form of Lonsdale's apparatus, which it was found necessary to employ.

*Hæmorrhage*, beyond that resulting from laceration of the gums, is rarely met with, since, although theoretically one would imagine that the inferior dental artery would frequently be torn across, this appears not to be the case; a result due, no doubt, to the fact that the elasticity of the artery allows of its stretching sufficiently to avoid rupture. In the *Lancet* of 12th October, 1867, a case of fractured jaw is reported, under the care of Mr. Maunder, in which severe hæmorrhage into the mouth occurred, through a fissure in the gum behind the last molar tooth. This was effectually controlled by digital compression of the carotid artery, which was maintained for two hours and a half, after which no further bleeding occurred. Secondary hæmorrhage has also been met



with, for Stephen Smith, of New York, reports a case of double fracture in which about a pint of blood was lost from the seat of fracture on the twentieth day. Injury of the soft parts about the jaws may give rise to severe hæmorrhage, requiring prompt treatment; thus Mr. Lawson has reported (*Medical Times and Gazette*, 1862,) a case in which it became necessary to lay open the face in order to secure the facial and transverse facial arteries, torn by the wheel of a cart, which had fractured both the upper and lower jaws.

*Dislocation and fracture of the teeth* are not unfrequently met with, the former being the direct result of a blow, or the consequence of the fracture running through the socket, and the latter the result of direct violence, or, in the molar region particularly, in consequence of indirect force through the neighbouring teeth; or from the teeth being forcibly driven against those of the upper jaw. (Tomes.) Where the fracture has passed through the socket, the tooth may fall between the edges of the bone and prevent their proper coaptation, and this should be borne in mind where a tooth is missing and difficulty is experienced in setting a fracture, since Erichsen mentions a case where union was prevented until the tooth was removed. In the molar region the crown of the tooth may be broken off, one fang remaining *in situ* and the other dropping into the fracture, as was the case with the patient under my own care, from whom specimen 2 of the King's College Museum was taken. Teeth which are merely *loosened*, generally become reattached and useful, and should therefore not be removed.

In the Appendix will be found a case (No. 1) for which I am indebted to Mr. Margetson of Dewsbury, in which double fracture of the jaw occurred with dislocation of several of the teeth, and fracture of the left second bicuspid, the crown of which was imbedded for more than two years in the tissues of the mouth, behind the incisor teeth. Mr. Margetson removed the crown from its abnormal position and also the fang; and both, together with a plaster cast, showing very well the deformity resulting from the fracture of the jaw,



were sent in with this essay, and are in the Museum of the College of Surgeons. (1001 A.)

The front teeth may be broken off, with the portion of the alveolus containing them, by a horizontal fracture, either alone or in combination with a vertical fracture through the thickness of the bone. Specimen 1 of University College shows a vertical fracture through the symphysis, with a horizontal fracture running through the alveolus on the right side, separating the portion containing the right lateral incisor and canine and first bicuspid teeth. Such a fragment may be made to re-unite if treated at once, but when some days have elapsed and the fragment is only attached by a portion of gum, removal must necessarily be performed. A case of the kind was recently under my own care, in the person of a man aged sixty, who had had a blow on the left side of the jaw six days before I saw him. I found a loose piece of alveolus three-quarters of an inch in length, and containing the left incisors and canine teeth, which was merely held by a portion of gum, there being no other injury to the jaw.

The preparation accompanied this essay, and is now in the Museum of the College of Surgeons. (484 A.)

In fracture of the lower jaw in children—a very rare accident—when the fracture happens to involve the cavity in which a permanent tooth is being developed, exfoliation of the tooth, with a portion of the alveolus, is almost certain to ensue, as was noticed by Mr. Vasey in a case occurring in St. George's Hospital.

*Paralysis and neuralgia* from injury to the inferior dental nerve may be the immediate result of the accident, or be caused at a later period by some pressure arising from the development of callus. In by far the greater number of cases no injury of the nerves accrues, and this may be partly explained, as Boyer originally pointed out, by the fact that "the greater part of these fractures takes place between the symphysis and the foramen by which the nerve comes out."

A case of paralysis of the inferior dental nerve, from a gunshot wound of the ramus, which was under my care



some years ago, will be subsequently referred to; and Malgaigne describes a specimen, in the Musée Dupuytren, also the result of gunshot injury, in which the dental nerve was ruptured, and its canal obliterated at the seat of fracture. (See Fig. 7.)

Temporary paralysis of the inferior dental nerve must be of rare occurrence, since Malgaigne did not meet with it; and Hamilton thinks that "the explanation may be found in the fact that the fragments seldom overlap to any appreciable extent, and that even the displacement in the direction of the diameters of the bone is generally inconsiderable, or, if it does exist, it is easily and promptly replaced." He thinks, moreover, that temporary anæsthesia of the chin might not improbably be overlooked at first, and would have ceased by the time the apparatus was removed. A. Bérard saw a case of vertical fracture without displacement between the second and third molar teeth, in which complete temporary anæsthesia of the lip and chin as far as the median line existed (*Gazette des Hôpitaux*, 10th August, 1841). A case of temporary paralysis of the dental nerve, from fracture, is mentioned also by Robert (*Gazette des Hôpitaux*, 1859, p. 157), occurring in a woman, aged sixty-four, who was run over by a carriage, and who also suffered from fracture and displacement of the malar bone, with *permanent* anæsthesia of the infra-orbital nerve.

The cases of convulsions coincident with fracture of the jaw, recorded by Rossi and Flajani, would appear to have been due to injury of the brain, the result of the original accident and unconnected with the fracture, but it may happen that direct injury may be inflicted on the skull by the broken jaw. Thus Dr. Lefèvre (*Journal Hebdomadaire*, 1834) gives the case of a sailor, aged twenty-two, who fell from a height upon his chin with the following result. There was almost complete inability to open the mouth, the jaws being tightly closed and the lower drawn backwards and a little to the left. There were tenderness and ecchymosis in the left temporo-maxillary region, and a little blood flowed from the left ear. The



case was diagnosed to be one of fracture of the neck of the condyle. The man died six months after with brain symptoms, and on opening the head, the left glenoid cavity was found driven in, with a starred fracture of the temporal bone, between the fragments of which the condyle of the jaw was found. There was a large abscess in the brain.

Similarly in the Museum of St. George's Hospital, there is a temporal bone with the unbroken condyle of the inferior maxilla driven through the glenoid cavity, producing a fracture of the middle fossa of the base of the skull in a case where there was an extensive comminuted fracture of the jaw itself, which, however, is not preserved. In contrast with this, may be mentioned another case which also occurred in St. George's Hospital, and the details of which will be found in the Appendix (Case II.), where the neck of the condyle and the base of the coronoid process having been broken through, the lower fragment was displaced and had produced laceration of the meatus auditorius externus, separating the cartilaginous from the osseous portion for nearly half its circumference. In this case considerable serous discharge flowed from the ear, leading to the suspicion of injury to the skull, but there were no brain symptoms, and the patient dying with *delirium tremens*, the skull, the membranes, and the brain were found perfectly healthy.

In connexion with these cases may be mentioned those recorded by M. Morvan (*Archives Générales*, 1856), who gives two cases of his own, and one by Montezzia, where a blow on the chin was followed by bleeding from the ear; and one case by Tessier, where a double fracture of the jaw from a kick by a horse was followed by bleeding from both ears. In all these instances the patients recovered.

An instance of neuralgia, consequent upon old fracture of the lower jaw, occurred in St. Bartholomew's Hospital in 1863. Mr. Wormald, under whose care the patient was, opened up the dental canal and excised a portion of the inferior dental nerve with the most satisfactory result. (*Medical Times and Gazette*, April 4th, 1863.)



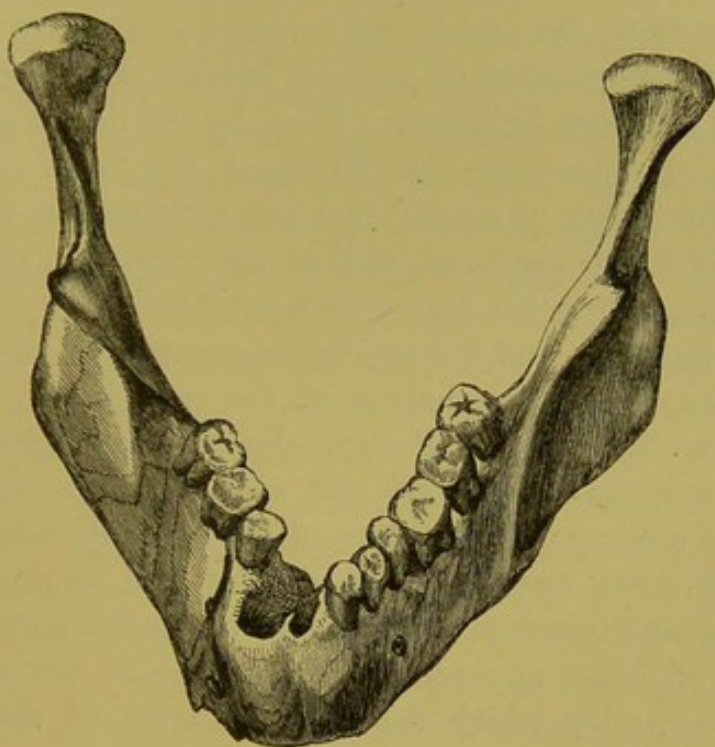
*Abscess* is a not very uncommon complication of severe injuries of the jaw, the matter pointing below the jaw, and being in some cases probably as much the result of injudicious pressure by retentive apparatus as of the injury. A certain amount of pus commonly finds its way into the mouth through the lacerated gum in all cases of severe fracture, but the exit is usually sufficient to prevent the occurrence of abscess within the mouth. In neglected cases of fracture, the abscess may be connected with necrosis, and may open at some distance down the neck, and remain patent for many months; thus in the Appendix will be found a case (Case III.), for which I am indebted to Mr. Margetson of Dewsbury, where, in consequence of a neglected fracture (which from the twisting of the face to the left side would appear to have been one of the neck of the left condyle), three years after the receipt of the injury there was still a fistulous opening on the left side of the neck, about two inches below the angle of the jaw.

*Salivary fistula* may result from a compound fracture of the lower jaw, or from an abscess bursting externally in the case of a simple fracture. The treatment would of course be that for salivary fistula arising from other causes, such as necrosis, &c. In the Appendix will be found a case (Case IV.) which occurred under the author's care, in which a salivary fistula was connected with necrosis and false joint in the ramus of the jaw, following a gunshot injury, and which was successfully closed.

*Necrosis* to the extent of small portions of the alveolus not unfrequently follows fracture of the jaw, and without any permanent deformity occurring, but when the necrosis affects the whole thickness of the bone, as may happen when the fracture is comminuted, and a portion becomes so detached as to lose its vitality, the consequent deformity may be very great. Of this a specimen in St. George's Hospital Museum (fig. 4) affords a good example, a loss of substance to the right of the symphysis having occurred, leading to the union of the halves of the bone at an acute angle. A still better example of the same kind of deformity,



FIG. 4.



and from a similar cause, is seen in fig. 5, taken from a model lent to me by Mr. Hepburn. The patient several years ago received a kick from a horse, which produced a compound comminuted fracture of the lower jaw. The central portion became necrosed and was removed by the late Mr. Aston Key, and appears to have extended from the second

FIG. 5.

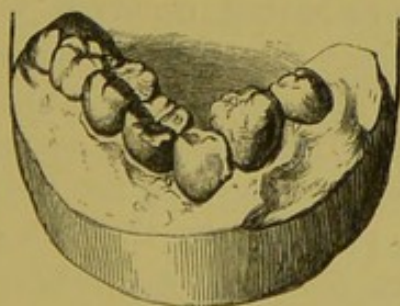
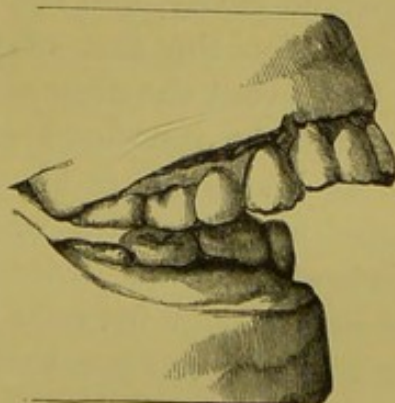


FIG. 6.



bicuspid tooth of the right side to the first molar on the left, the intervening teeth being wanting. The result, as seen in the model, is that the two halves of the jaw



are united at an angle, of which the second bicuspid tooth forms the apex, the jaw being so much contracted that that tooth is three-quarters of an inch behind the upper incisor, as can be well seen in fig. 6. Here, by the skilful adaptation of artificial apparatus, Mr. Hepburn has been enabled to restore the power of mastication and articulation, which was previously much impaired, so that the patient (a clergyman) is able to perform his duties with satisfaction.

A remarkable, and I imagine unique case of necrosis and exfoliation of the two halves of the symphysis menti occurred to Mr. Henry Power, who has been good enough to give me the details of the case. Here the patient sustained a compound fracture of the symphysis by a severe fall, and some months after, during the whole of which time profuse suppuration was going on in the part, two thin lamellæ of bone, apparently the surfaces of the symphysis, came away, after which rapid solidification of the fracture ensued.

Boyer, in his lectures, mentions having extracted from a fistula in the meatus auditorius externus, the necrosed condyle of a man who had had a fracture of the neck of the bone seven or eight months before.

*Dislocation.*—I have been able to find in the standard authors, the records of only two cases of fracture of the body of the jaw complicated by dislocation of the condyle from the glenoid cavity, and the accident must of necessity be a rare one, for the fact of fracture having occurred would tend to prevent the dislocation, since the leverage necessary would thus be interfered with. The cases in question are given by Malgaigne in his work on "Dislocations," one being recorded by Delamotte, who saw a fracture of the body of the jaw with double dislocation, produced by the kick of a horse in a girl of between eleven and twelve years. The other was a more remarkable case, recorded by Robert, who saw a dislocation of the left condyle *outwards*, with fracture of the jaw in front of the right ramus, in a man who was knocked down on his left cheek, the wheel of a carriage passing over the right.



A third case, however, is reported by Mr. Croker King (*Dublin Hospital Gazette*, 1855), and occurred in a boy of eight, who suffered a fracture at the symphysis with dislocation of the left condyle upwards and backwards. There was bleeding from the ear, and the chin was much retracted and turned to the left; the mouth was open, but could be closed, and it was then observed that the lower molars overlapped the upper, but that the lower incisors were at least one inch *behind* the upper. Reduction was easily effected, and the case did well. (Owing to an obscurity and apparent contradiction in the report, this case has been put down by Weber as an instance of unusual dislocation *without* fracture.)

A fourth case of the kind is also briefly referred to by Mr. Gunning, of New York, in his paper on "Interdental Splints." (*New York Medical Journal*, 1866.) "The patient was thirty-six years old; the jaw was fractured through the symphysis and the right condyle dislocated *outward* and *backward*, February 10th, 1866, in falling downstairs and striking the chin on a small desk." The dislocation was reduced before Mr. Gunning was called in.

The case of fracture of the glenoid cavity by the displaced condyle in St. George's Hospital, already referred to, cannot be regarded as one of true dislocation. The treatment in these cases would of course be reduction of the dislocation before setting the fracture.

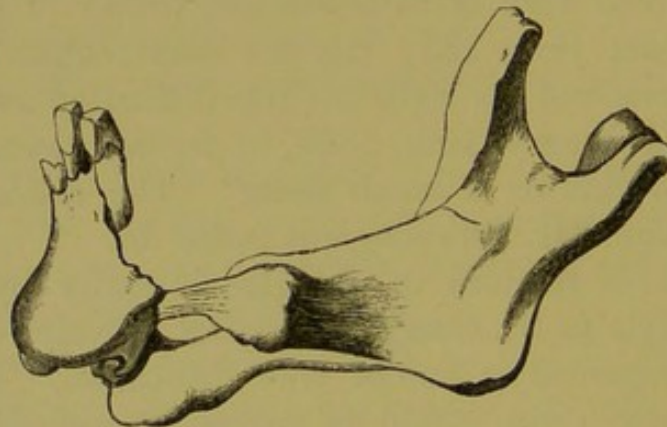
In fractures of the neck of the condyle the condyle has been found displaced. Thus Holmes Coote (in his article on Injuries of the Face, Holmes' "System of Surgery," vol. ii.) mentions that Bonn, writing in 1783, gives an account of a case of the kind. There was a longitudinal fracture in the middle of the bone, and at the same time the right condyle was broken off and dislocated forwards and inwards, lying united by callus near the foramen ovale. The pointed upper extremity of the neck of the lower jaw articulated with the glenoid cavity, and the separated head with the lateral part of the tubercle of the temporal bone. There was motion in the false joint. The same author mentions a case of fracture and dislocation of both condyles of the lower jaw, in a



young man who had numerous injuries and lived five weeks. The condyles were found to be broken off, and fixed near the foramen ovale on either side.

*Irregular Union.*—Where the displacement of the fragments has been great, it may be impossible to keep them in proper position, and the result may be an irregular union of the bone, interfering more or less with its functions in after life. This is particularly liable to occur in cases of double fracture, where the central portion of the jaw is much displaced by the muscles attached to it; and Maligne gives a drawing from a specimen in the Musée Dupuytren (fig. 7) of the kind, in which the middle fragment

FIG. 7.



is displaced downwards and backwards, and has also undergone such a change of position that its lower border is inclined forward, and its anterior surface looks almost directly upwards, the union on one side being partly fibrous.

An almost precisely similar state of things existed in a case of double fracture which came under Mr. Bickersteth's care, and which will be found in detail under the head of "Treatment of Ununited Fracture," the central portion of the jaw having become much depressed, and united on one side, so that when the molars were in contact the incisor teeth were separated more than half an inch, the opposite fracture being still ununited. Here Mr. Bickersteth remedied the deformity by sawing through the bone at the seat



of the united fracture, and replacing the fragment in its proper position.

The specimen of united fracture in University College Museum illustrates very well the effect of irregular union upon the teeth, and the masticatory power of the jaw. The fracture was in the right molar region, and appears to have led to the loss of all the teeth on that side except the last molar. The irregular union has resulted in a contraction of the alveolar arch, so that the left teeth have been thrown within those of the upper jaw, with the result of wearing away the opposed surfaces of the two sets—viz., the lower teeth on their outer and the upper on their inner surfaces. Hamilton expresses an opinion, “that time and the constant use of the lower jaw in mastication will gradually effect a marked improvement in the ability to bring the opposing teeth into contact.” The specimen above referred to illustrates the only mode in which such an improvement could, in my opinion, occur.

The deformity resulting from loss of a portion of the bone near the symphysis, has been already referred to under the head of “Necrosis.” Loss of substance in other parts of the jaw is apt to result in fibrous union or false joint, and this is especially the case in gunshot injuries.

*Non-union and False Joint.*—Fractures of the lower jaw ordinarily unite with great rapidity and certainty, notwithstanding the difficulties often met with in maintaining perfect apposition of the fragments. Hamilton has noticed one instance, in an adult person, in which the bone was immovable at the seat of fracture on the seventeenth day, and says that in no instance under his own observation has the bone refused finally to unite, although union has been delayed as long as eleven weeks. Cases of non-union and false joint have, however, been recorded and treated by Physick, Dupuytren, and others; and a case has already been referred to which occurred under my own care, in which false joint followed a gunshot injury of the ramus of the jaw. (See Appendix, Case IV.) The liability of the lower jaw to false joint as compared with other bones, may



be gathered from a table of 150 cases drawn up by Norris (*American Journal of Medical Sciences*, January, 1842). Of these 150 cases 48 occurred in the femur, 48 in the humerus, 33 in the leg, 19 in the forearm, and 2 in the lower jaw.

Non-union may be simply the result of neglect of treatment, and union may take place readily as soon as the parts are placed under favourable circumstances. Thus a patient was under Mr. Wormald's care who, five weeks before admission into St. Bartholomew's Hospital, had fractured his jaw between the canine and bicuspid teeth on the left side, for which he had not been treated. There was some little necrosis, and sinuses had already formed beneath the chin; but under appropriate treatment the bone thoroughly united in five weeks. (*Medical Times and Gazette*, Jan. 17, 1863.) And yet, on the other hand, fracture of the jaw has no doubt been occasionally overlooked, and still has united. Thus Boyer saw consolidation occur, though not without deformity, in a water carrier who would not endure any dressing, nor abstain from either speaking or chewing when the pain did not prevent him. Notwithstanding the most careful treatment, however, the jaw may fail to unite if the case has been complicated in any way. Thus Mr. Berkeley Hill mentions a case (*British Med. Journal*, March 2, 1867,) of double fracture, where great difficulty was experienced in adapting suitable apparatus, and where one fracture united perfectly, but the other remained ununited. And again, on the other hand, over-solicitous attention appears occasionally to interfere with union; for A. Bérard relates the singular case of a child whose fracture made no progress toward recovery till the apparatus, an ordinary bandage, was removed; and Mr. Hill's case, mentioned above, illustrates the same point, for he informs me that the second fracture became consolidated without any treatment.

The occurrence of necrosis at the point of fracture is the most probable cause of non-union, and a small amount of this may prevent, or at least delay, the union taking place; as in Mr. Power's case, where two thin lamellæ exfoliated



from the symphysis; and, moreover, callus is not thrown out so copiously for the repair of fractures of the jaw as it is in the long bones. Gunshot injuries seem especially liable to produce ununited fractures of the lower jaw, probably by inducing necrosis; and of this an example under the author's care has been already alluded to. On this subject the late Dr. Williamson, of Fort Pitt, has made the following observations in his work on "Military Surgery:" p. 22—

"Ununited fracture of the lower jaw does not seem to have been of such frequent occurrence amongst the wounded from the Crimea as those from India. Six were admitted from India with fracture of the lower jaw. Of these three were invalided, two sent to duty, and one to modified duty. Of these six cases, three were instances where the fracture remained still ununited, though the ends of the bone were in contact. In one case the ball struck one side of the lower jaw, and was cut out on the opposite side one month after, fracturing the bone on both sides. In one, the ball was cut out from below the tongue. In one case, from a shell wound, there was a double fracture, one on the right side of the ramus, and also another near the symphysis, with great laceration of soft parts, and resulting deformity; the first-named fracture remained ununited. In another case there was a double fracture from a musket ball; the fracture at the entrance of the ball still remains ununited; that at the exit has become united. In one case, from round shot, the whole of the left ramus of the lower jaw had been extracted at the time, or came away by exfoliation, leaving a large chasm and great deformity on this side of the cheek from laceration of the soft parts. In one case there was a fracture on the left side, at the angle of the jaw, still ununited.

Attempts were made to excite action in the ends of the bone by forcibly rubbing together, and afterwards keeping the two fractured ends at rest by wire round the teeth, and a piece of cork placed between the teeth of the posterior fragment and that of the upper jaw, but without success.



It was not thought advisable to try the effects of a seton or other means of inducing the effusion of new bone."

Rokitansky, in his "Pathological Anatomy" (Sydenham Society's Translation, iii. p. 216), describes the unnatural joints resulting from fracture as of two kinds; "one more or less resembling a synarthrosis, the other like a diarthrosis, and accordingly, in its proper sense, a new joint. In the former case, the fractured ends of the bone are held together by a ligamentous tissue. Either a disc of ligament the thickness of which may vary, is interposed between them, and allows\* of but little movement, or, as occurs when there has been loss of substance either from injury, absorption of the fractured ends, or otherwise, ligamentous bands connect the fragments, and allow them to move freely on each other. The connecting tissue appears to be nothing more than the intermediate substance, which has failed to become transformed into the secondary callus and remains in its first state.

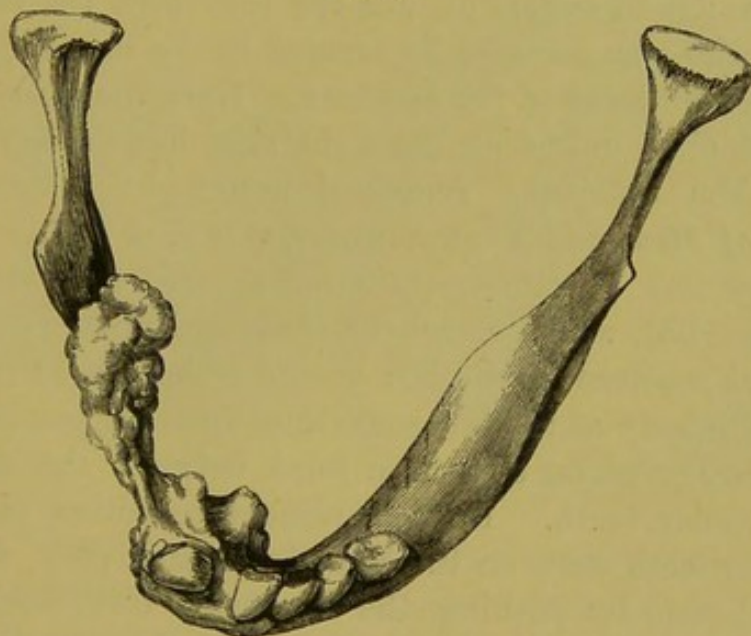
In the second case, a ligamentous articular capsule is formed, and is lined by a smooth membrane which secretes synovia. The fractured surfaces adapt themselves to each other and become covered with a layer of tissue which is fibro-ligamentous, or more or less fibro-cartilaginous, or which resembles and sometimes (Howship) really is cartilage. They may articulate immediately with one another, or may have between them an intervening layer of ligament which corresponds to an interarticular cartilage; and their movement upon each other is more or less free, according to the size of the articular capsule and the form of the articulating surfaces. These last are sometimes horizontal (plane?) and smooth; they glide over each other, and allow of restricted motion; sometimes one surface becomes convex and the other concave; sometimes both are rounded off, and lying within a capacious articular capsule far apart, they come in contact only during particular movements. The articulating capsule is the product of the inflammation of the soft parts; the cartilaginous layer which covers the ends of the bone is secondary callus arrested in its meta-



morphosis and converted into a fibroid tissue. The other ligamentous cords which are sometimes present, and the structures resembling an interarticular cartilage, are remnants of the intermediate substance. Both forms of new joint, but more particularly the synarthrodial form, have an analogue in the lateral new joints sometimes formed between the masses of callus thrown out around two adjoining fractured bones."

The only museum specimen of ununited fracture of the lower jaw I have met with is in University College, (fig. 8) and

FIG. 8.



belongs to Rokitsansky's first division, since it is a good example of fibrous union filling the interval between the right canine tooth and the ramus of the jaw, there having evidently been considerable loss of bony substance at the seat of fracture. I have no doubt, however, that the other form, the true false joint, does occur in the lower jaw both as the result of violence (and particularly in the ramus of the jaw) and as the result of operative interference, having had the opportunity of watching the formation of a false joint in two cases in which I performed Esmarch's operation for closure of the jaws, which will be referred to in another part of this essay.

The amount of inconvenience which the patient expe-



riences from an ununited fracture of the jaw will vary according to the position of the false joint. In the ramus it appears to give very little, if any inconvenience, the new joint performing the function of the temporo-maxillary articulation; and the same may be said, according to my experience, of the false joints purposely made for the relief of closure of the jaws, although in the body of the bone, since the portion of the jaw posterior to the joint is immovably fixed by the cicatrices. When, however, a false joint occurs in the body of an otherwise natural bone great inconvenience results, the patient being unable to masticate properly; and his health is apt to suffer, as was the case with Dr. Physick's patient, who was successfully treated by the use of the seton eighteen months after the accident. Here the fracture, originally double, united on the right side, but the left, which was broken obliquely, remained ununited. (*Philadelphia Journal of Med. and Phys. Sciences*, vol. v. p. 116.) A case is related also by Horeau (*Journal de Médecine*, par Corvisart, x. p. 195), which shows the inconveniences experienced. A colonel received a gunshot wound which broke the right side of the body of the jaw some lines from its junction with the ramus, resulting in a false joint between the first and second molar teeth. In the ordinary condition of things these two teeth were on the same level, and they were not deranged even by pushing the fragments from behind forward or from before backward. But if the posterior fragment was raised and the anterior depressed, the second molar tooth was several lines above the level of the first. The result was great difficulty in chewing on the injured side, and consequently the food was habitually carried to the left molar teeth, and its trituration was neither easy nor complete. The digestion became impaired, and the patient suffered from pain after food, &c.

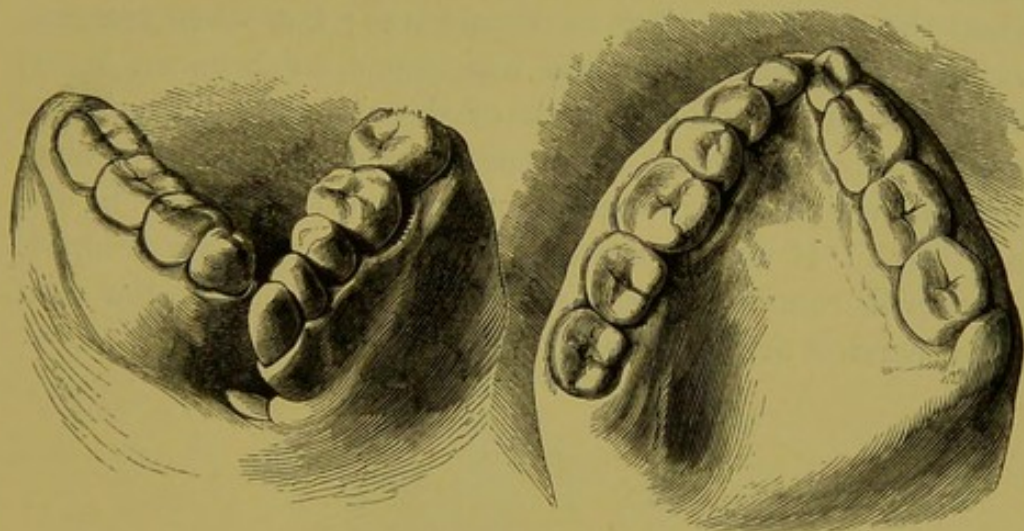
A remarkable case of ununited fracture in the mental region, the result of gunshot injury in the Crimea, is recorded by Mr. John Cox Smith, of Chatham (*Dental Review*, 1858-9), and was satisfactorily treated by apparatus by that gentleman. The full particulars of the case will be found



in the Appendix (Case V.); but the condition of the parts was briefly as follows:—The symphysis with the incisors, right canine, and one bicuspid tooth, having been carried away, the jaw was divided into two unequal portions, which fell together when at rest; but upon opening the mouth the left only was fully acted upon by the muscles, and the right rode over it, as shown in the illustration (fig. 9). Much pain was caused by any attempt to separate the two fragments so as to make them correspond to the teeth of the

FIG. 9.

FIG. 10.



upper jaw, hence mastication was impossible, articulation was much interfered with, and the patient could only sleep on his back, since lying on either side caused displacement of the corresponding section of the jaw. Fig. 10 shows the model first taken by Mr. Smith, and its resemblance to cases of united fracture with loss of substance in the incisor region previously described, will be at once noticed. The treatment of this interesting case will be referred to under another section.

The case of ununited fracture successfully treated by Dupuytren was also the result of a gunshot injury, and the following was the condition of the parts when the patient came under that surgeon's care, four years after the receipt of the injury (Dupuytren's *Leçons Orales*, vol. iv.). The ball had struck the right side of the jaw just in front of the



masseter, and had carried away a portion of the bone at the junction of the body with the ramus. The posterior fragment which contained the wisdom tooth was twisted so that the tooth looked towards the tongue, and at the same time it was drawn outwards into the cheek. The anterior fragment formed by the remainder of the bone was displaced so that its fractured end was carried to the right side and below the other, an interval of an inch intervening, corresponding to the first and second molar teeth which had been carried away. The riding of the fragments was so great that the second bicuspid tooth was in contact with the wisdom tooth when the parts were left to themselves; but when traction was made a space of an inch was produced between them. Of course therefore the teeth of the two jaws did not correspond, and there was consequently great difficulty of mastication, which was increased by the want of power in the jaw itself. If unsupported by a bandage the jaw dropped, the mouth remained open, and saliva dribbled out, the chin being carried over to the right side.

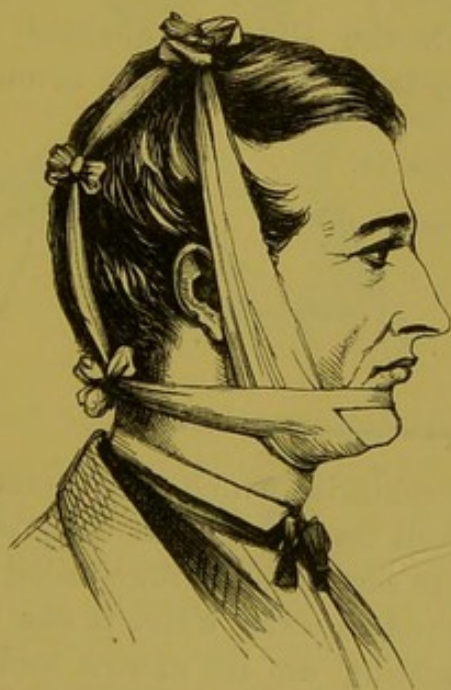

## CHAPTER III.

## TREATMENT OF FRACTURED LOWER JAW.

THE treatment of fractured lower jaw after the reduction of any displacement (the occasional difficulties of which have been alluded to in a previous section) is usually of a simple character; but cases sometimes arise in which the most carefully adapted mechanical contrivances fail to effect a good union. The apparatus employed for the maintenance of the fractured portions in apposition may be conveniently

FIG. 11.



divided into two classes, external and internal to the mouth, though it may be necessary to combine the two methods in a few cases.

The simplest form of external apparatus consists of the ordinary four-tailed bandage or sling, with a slit for the chin to rest in (fig. 11). This is made of a piece of bandage



about a yard long and three inches wide, which should have a slit four inches long cut in the centre of it, parallel to and an inch from the edge. The ends of the bandage should then be split to within a couple of inches of the slit, thus forming a four-tailed bandage with a hole in the middle. The central slit can be readily adapted to the chin, the narrow portion going in front of the lower lip, and the broader beneath the jaw; and the two tails corresponding to the lower part of the bandage are then to be carried over the top of the head, while the others are crossed over them and tied round the nape of the neck. The ends of the two bandages may then be knotted together as seen in the illustration.

A single roller may be employed to support the jaw, as recommended by the American surgeons Gibson and Barton; but this is more difficult of application and is more apt to become disarranged.

Combined with the sling a moulded splint of either pasteboard or gutta-percha may be often advantageously

FIG. 12.

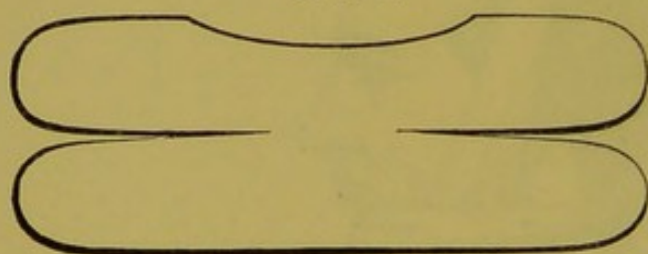
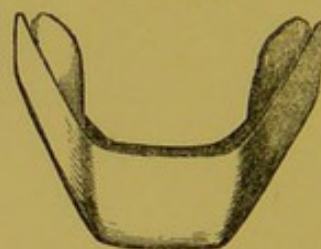


FIG. 13.



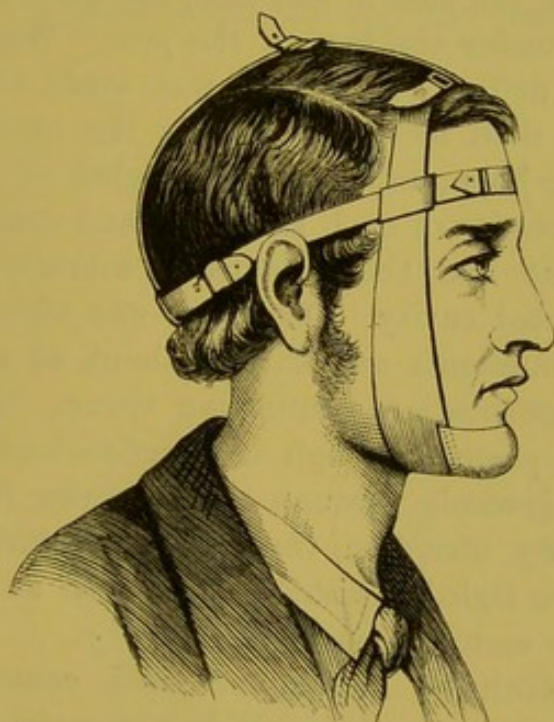
employed. The material which is selected being cut long enough to pass well up the sides of the jaw, is to be divided at the ends, so as to resemble the four-tailed bandage (fig. 12). Being then softened in warm water it can be adapted to the jaw, the chin resting on its centre and the sides being doubled around and beneath the bone, as in fig. 13.

Hamilton states that he has frequently noticed the tendency of the sling as ordinarily constructed to carry the anterior fragment backwards, especially when there is a double fracture. He has devised a special form of apparatus (fig. 14) for which he claims the following:—"The advantage of this



dressings over any which I have yet seen consists in its capability to lift the anterior fragment vertically; and at the same time, it is in no danger of falling forwards and downwards upon the forehead. If, as in the case of most other dressings, the occipital stay had its attachment opposite to the chin, its effect would be to draw the central fragment backwards. By using a firm piece of leather as a

FIG. 14.



maxillary band and attaching the occipital stay above the ears, this difficulty is completely obviated."

Ligature of the teeth with silk or wire is a method which has frequently been employed for the treatment of fractured jaw, but is unsatisfactory from the loosening of the teeth and irritation of the gums which are apt to be produced. When employed, care should be taken to select if possible perfectly sound teeth around which to apply the ligature, which should be prevented from sinking down to the neck of the tooth so as to cut the gum. An astringent wash should be frequently employed during the treatment to maintain the healthy firmness of the gums themselves.



Suture of the jaw itself has been employed from time to time both for the treatment of recent and old fracture, and to insure the union of the two halves of the bone after its division for removal of the tongue by Syme's method. Dr. Kinloch of Charleston treated, July 30th, 1858, a case of compound oblique fracture of unusual form, which has been already referred to (p. 9), by this method after other means had failed. "A semi-lunar incision, about two inches long, was made upon the side of the face, the middle of the incision reaching under the base of the jaw. With Brainard's smallest-sized drill a perforation was made through each fragment, the drill being entered on the outside, close to the base of the bone, and about one-eighth of an inch from the rough extremity of each fragment, and made to traverse the bony tissue and the mucous membrane covering it within the buccal cavity. The drill was afterwards thrust between the fragments and turned about, so as to slightly lacerate the intermediate connecting tissue. A stout silver wire was then passed through the perforations in the bone, from without inwards through the posterior fragment, and in the contrary direction through the anterior one; and their ends were tightly twisted together, so as to bring the fragments into secure apposition.

"By the 26th of September good consolidation was effected, and the suture, which had occasioned but little suppuration, was untwisted and removed. On the 15th of October the patient left the hospital, with the fistulous opening healed and a good use of the jaw."—*American Journal of Medical Sciences*, July, 1859.

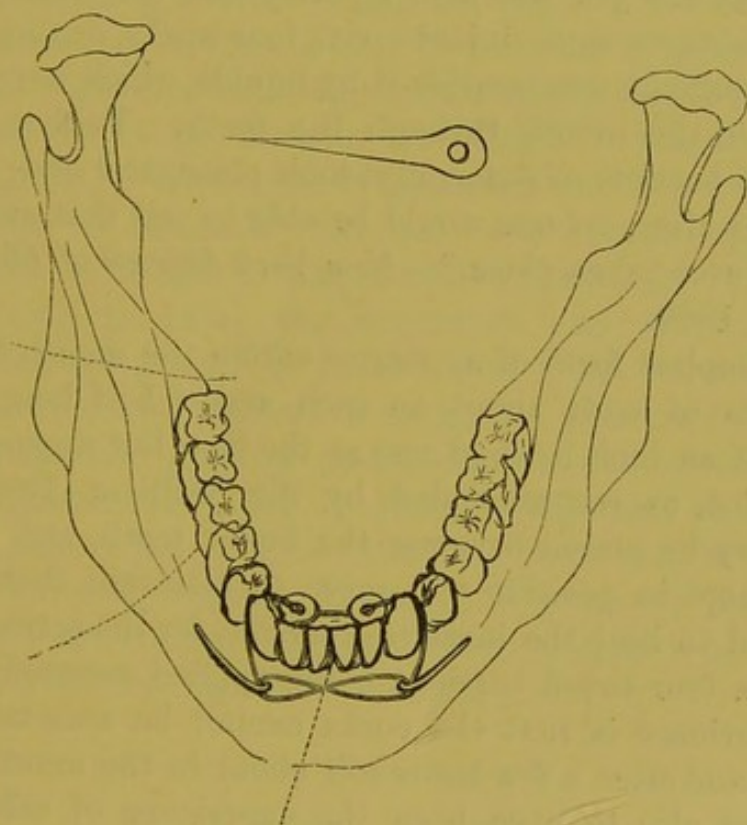
Mr. Hugh Thomas of Liverpool has recently advocated the use of the wire suture in the treatment of recent fractures, and two of his illustrative cases, which had most satisfactory results, will be found in the *Lancet*, 19th January, 1867.

Still more recently (*Lancet*, 17th August, 1867) Mr. Wheelhouse of Leeds has recommended the following plan, which has proved successful in a case of triple fracture (fig. 15), but which presents no great advantage over the ordinary wire:—



"Two silver pins were made with flat, circular, and perforated heads, each pin being about an inch and a quarter in length. Two holes were bored with an Archimedian drill through the substance of the jaw-bone—one between the roots of the outer incisor and canine teeth of the unbroken side, and the second between the roots of the same teeth of the fractured side. Through these holes the two pins were passed from *behind forwards*, the perforated heads threaded with a good stout silk ligature, resting upon the

FIG. 15.



floor of the mouth under cover of the frænum of the tongue. Having been well thrust forward through the drill-holes, the points were bent in opposite directions, the loose fragment was placed in good position, the ligature was brought forward over the teeth, and a figure-of-8 suture was then made round the reversed ends of the pins."

According to Malgaigne, Guillaume de Salicet advised not merely to tie the adjacent teeth together, but to fasten them to those of the upper jaw. The necessity for



such a contrivance must be very rare, but Dr. Fountain treated a case of double fracture and fracture of the left condyle which has been already referred to (page 12), successfully by a somewhat similar method. "Holes were drilled through a front incisor of each jaw, and a double strand of fine annealed jeweller's iron wire was passed through and twisted so as to keep the parts in exact apposition, the central fracture, which gave no trouble, being supported by a pasteboard splint. In ten days the wires gave way, and a cord was inserted composed of four of the same wires; and in this way the jaw was held securely and immovably until all the fractures were united—viz., four weeks, during which time the patient was nourished by liquids, which were easily drawn into the mouth through the teeth. Perfect union, without a particle of deformity, took place, and now, nearly four years after, no one would be able to tell that any fracture had ever taken place."—*New York Journal of Medicine*, January, 1860.

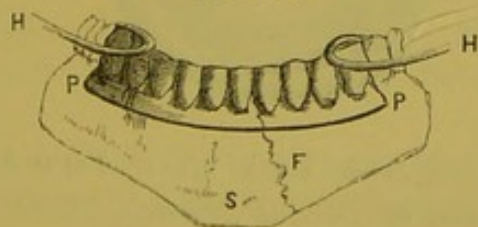
The simplest form of apparatus *within* the mouth consists of wedges of cork about an inch and a half long and a quarter of an inch in thickness at the base but sloping away to a point, as recommended by Sir William Fergusson. These may be placed between the molar teeth, and if they can be kept in position will serve to maintain their regularity and to keep the incisors separated for the introduction of food, a four-tailed bandage being applied externally. My own experience is that the corks cannot be maintained in position, and after a few hours roll about in the mouth; and this I find also to have been the experience of other surgeons, including Sir William Fergusson, with whom also I fully agree, that the majority of cases do well with merely the simple bandage not very tightly applied.

Wedges of gutta-percha, introduced warm into the mouth, so as to become moulded to the teeth and gums, are highly recommended by Hamilton, both as supports and, in some degree, as lateral splints for the fracture. Mütter's clamp, consisting merely of a plate of silver, folded over the tops and sides of two or more teeth adjacent to the fracture, is a



contrivance which, in its original form, can have been but of little service, but as modified by Mr. Tomes and others, is a very efficient method of treating fractures of the body of the jaw. The modification consists in making the silver cap fit accurately to the teeth, for some distance on each side of the fracture, by moulding it to a plaster cast of the jaw. The cap is then lined with gutta-percha, which, being warmed when the apparatus is applied, fills up interstices and fixes the cap, the fragments being maintained in position whilst the application is being made. Although the assistance of a dentist would be required for the proper preparation of the cap, it may not be out of place to notice the best method of obtaining a satisfactory model upon which the cap is to be formed, for which I am indebted to Mr. Tomes. When the displacement of the fragments is great (as is invariably the case where such apparatus is required), it is best to take a cast of the jaw in wax, without attempting to bring the fragments into proper relation. Into this the plaster is poured, and when set a fac-simile of the displaced fracture is of course produced. By now sawing out the piece of plaster between the extremities of the fragments, these can be brought together, and a model of the perfect jaw will be produced, upon which the metal can be carefully fitted. When all is prepared, by carefully adjusting the fracture the cap will of necessity fit, and will maintain the fracture in its normal position.

FIG. 16.



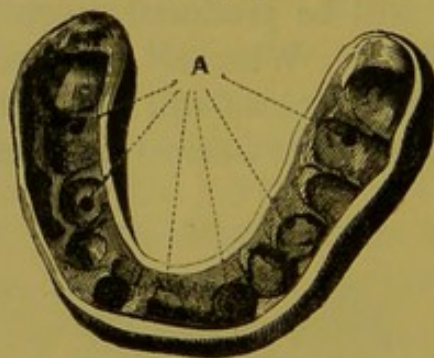
Mr. Howard Hayward has been very successful in treating cases of fracture of the jaw, of both recent and old date, by silver caps, fitted accurately to the teeth on each side of the fracture, and also over the gum, to the depth of half an



inch in front and a quarter of an inch behind them (fig. 16.) To the upper surface of the plate two pieces of stout curved wire are soldered, so as to turn round the angles of the mouth without touching them, and these are attached to a simple gutta-percha splint, moulded externally to the jaw, and retained in position by an ordinary four-tailed bandage. Holes drilled in the metal cap, opposite the point of fracture, permit of the exit of any discharge, but this is usually insignificant in quantity when the fracture is once properly set. Mr. Hayward prefers metal to vulcanite or gutta-percha for the cap, on account of its small bulk, and the consequent small interference with the natural closure of the mouth—a point of some importance, on account of the retention of the saliva.

Mr. Barrett, dental-surgeon of the London Hospital, has kindly shown me models of cases in which he has obtained most satisfactory results, by both metal and vulcanite interdental splints, secured in the mouth by small screws passing between the necks of the teeth. One of his cases was in a child, and here the delicate temporary teeth suffered no damage from the screws.

FIG. 17.



Mr. Gunning, of New York (*New York Medical Journal*, and *British Journal of Dental Science*, 1866), has contrived a form of interdental splint, composed of the vulcanite-rubber now in common use among dentists, which has yielded very satisfactory results in his hands, and of which the following is a condensed description.

“ Fig. 17 represents the inner surface of a splint which in-

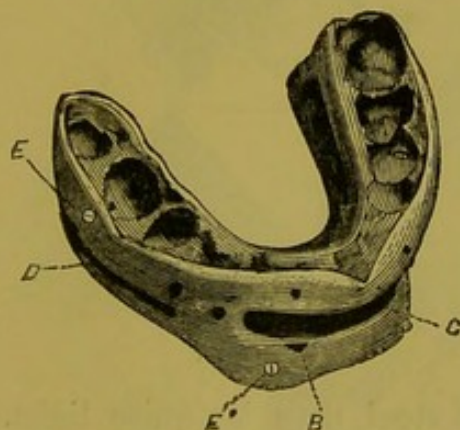


closes all the teeth and part of the gum of the lower jaw, and merely rests against the upper teeth when the jaws are closed. This splint is adapted to the treatment of all cases, which have teeth on both sides of the fracture, except those with *obstinate* vertical displacement. The holes marked A go through the top of the splint for the purpose of syringing the parts within with warm water during treatment. The dark round spots in all the cuts represent holes for similar purposes.

Mr. Gunning has generally used this splint without any fastenings, but in children, or even adults, it is sometimes advisable to secure it by packthread, wire screws passing into or between the teeth, or by the wings and band of Fig. 20.

In cases with obstinate vertical displacement, the splint, in addition to fitting the teeth and gum of the lower jaw,

FIG. 18.



must also inclose the upper teeth, as shown in fig. 18, where screws may be seen opposite both the lower and upper teeth.

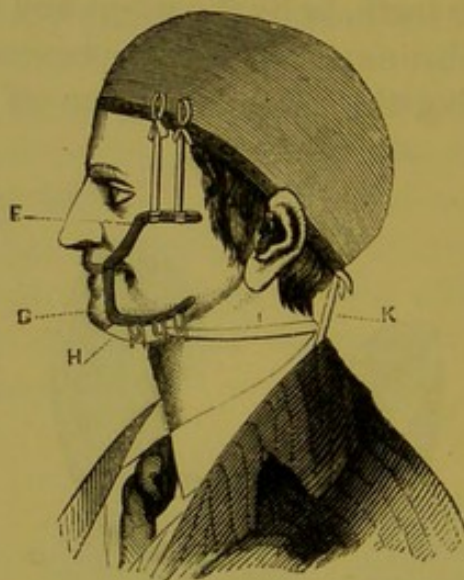
By this arrangement the fragments of the lower jaw are secured, not only relatively to each other, but also to the upper jaw. B, is a triangular opening, of which one side corresponds to the cutting edge of the lateral incisor, which stood in the end of the fragment most displaced before the splint was applied. C, an opening for food, speech, &c. D, a channel for the saliva from the parotid gland to enter



the mouth, its fellow being seen on the other side of the splint. E', a screw opposite the lower canine tooth, the head of the first screw being just discernible. E, the head of screw opposite upper first molar tooth, the end of its fellow being seen on the other side.

Fig. 19 shows the wings for cases *having no teeth in either jaw*—the ends of the wings within the mouth being imbedded in a vulcanite splint similar in principle to that of Fig. 18. F, upper wing. G, lower wing. H, mental band to hold the jaw up in the splint. I, neck strap to keep the band back. K, balance strap to hold the cap in place.

FIG. 19.



Wings made of steel may be quite light. They should have fine teeth along the edges where the bands and tapes bear to prevent slipping, and small holes every half-inch to hold the strings, lacing, &c. The arch of the wings should be high enough to give the lower lip room to go well up. The wings for each side of the jaw are in one piece, and the parts within the mouth pass back in the line of the upper gum. They are thinned down and pierced with holes, that the rubber in which they are imbedded may hold them firmly.

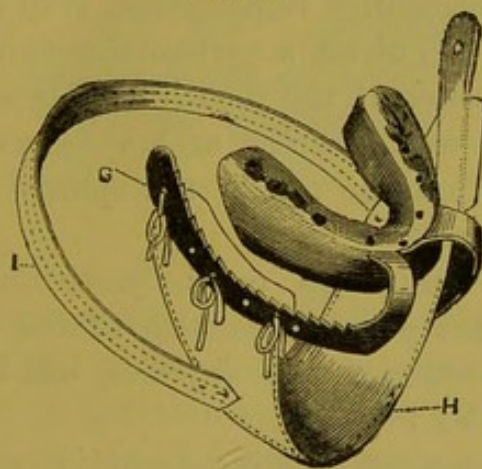
The tape strings pass from the cap inside and under the upper wings, then up between them and the tape lacings (fig. 19) which keep the strings from slipping, to the cap



whence they started. The mental band passes up between the sides of the lower jaw and the wings where it is tied by the strings, which pass through the holes. The band is cut off to show this; but when worn it should be turned down on the outside and pinned just below the wings. The neck strap should be sewed to the mental band on one side and pinned on the other, and worn tight enough to keep the band from slipping forward over the chin.

The jaw and splint are supported by the cap in front of its centre. This is counterbalanced by the elastic strap which passes from the back of the cap down around a non-elastic, and much heavier, strap, extending across and fastened to the shoulders by elastic ends. The balance strap returns to the cap, and is buckled tight enough to hold the jaw up. At night it may be slackened to do this with the neck flexed. It slides on the shoulder strap as the head inclines to either side."

FIG. 20.



In order to meet the case of practitioners out of reach of a dentist, Mr. Gunning has suggested a splint made of tin and lined with gutta-percha (fig. 20) very much resembling Mr. Hayward's metal cap. Six or eight sizes are to be cast and kept ready for use, from which one could be selected suitable for the jaw. The wings are of malleable iron, tinned to prevent rusting and for more readily soldering. Three sizes would probably be sufficient to select from.



“The splint should have a handle in front, that it may be used as a cup to take the impression of the jaw—the holes being useful to allow a small probe to be pressed through the wax down to the teeth, thus allowing air to enter to facilitate the removal of the impression, and when in use as a splint giving entrance to warm water, thrown from a syringe, to keep the parts clean.

The splint should be made to fit well by bending, cutting off the edges and rounding them up smooth. When a tooth projects so as to keep the splint from fitting, a hole may be cut to let the tooth through, if the metal cannot be hammered out. This should all be done before taking the impression, as a well-fitted cup assists greatly in this important matter.

(The adaptability of this splint is shown in the fact that the one from which the cut was taken had been used successfully on two different jaws, so unlike that the first was a quarter of an inch wider, where the ends of the splints rested, than the second. When fitting it to the second jaw, it was necessary to cut off a part of the right wing, to keep it clear of the corner of the mouth. This accounts for the difference in the width of the arches as seen in the cut. The indentations on the top of the splints were made by the boys in eating.)”

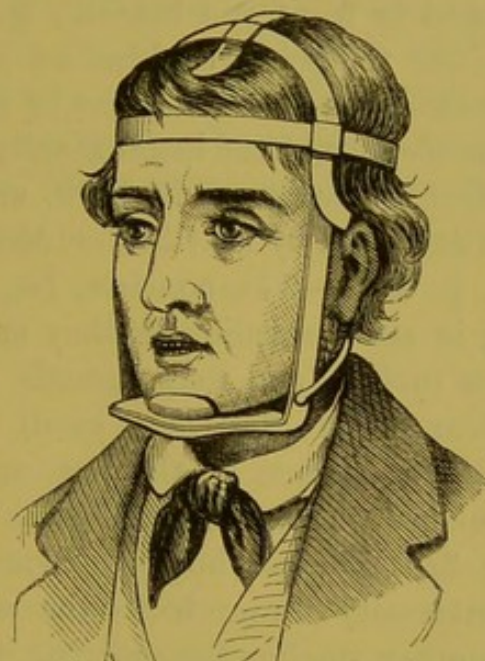One of Mr. Gunning's cases, particularly interesting from the important political position of the patient, no less than the serious nature of the injuries, will be found in the Appendix (Case VI.)

Mr. J. B. Bean of Atlanta, Georgia, appears to have employed a vulcanite interdental splint very similar to Mr. Gunning's, but with the addition of a mental compress, with great success among the wounded soldiers of the Confederate army, and his apparatus is very favourably reported upon by Inspector-General Covey. (*Richmond Medical Journal* and *British Journal of Dental Science*, 1866.) Hamilton also speaks well of the apparatus in the third edition of his work on “Fractures,” and gives an illustration, from which the accompanying drawing (fig. 21) is taken.



Dr. Covey writes:—"The adjustment of the splint to the fracture is very simple. It is inserted into the mouth of the patient; the fragments drawn forward, and the teeth adjusted to their corresponding indentations. The jaws are then closed and held firmly in position by the application of the mental compress and occipito-frontal bandage; this prevents any displacement of the splint or motion of the jaws.

FIG. 21.



The mental compress is designed for retaining the teeth, in their indentations of the splint, by upward pressure applied to the base of the mental process, counteracting thus the traction of those muscles which most tend to cause displacement. There is an advantage also in relieving the parts from the lateral pressure produced by the four-tailed bandage or double-cross roller bandage, generally applied to these cases.

The compress is composed of a light piece of wood, which is four and a half inches in length, three-sixteenths of an inch in thickness, and one inch and a half in width in the middle, tapering to seven-eighths of an inch, and round at the ends; to each of which is attached a metallic



side-piece four or five inches in length, and from three quarters to one inch in width ; also a shallow cup fitting the apex of the chin. Encasing these side-pieces are the temporal straps made of stout cloth, and secured by a strong cord at the base of each piece.

The occipito-frontal bandage is composed of a band passing around the head, from the forehead to the occipital protuberance behind, and secured by a buckle one inch to the right of the median line behind ; of another strap secured to the band in front and behind ; and a third strap extending from the temporal buckles on either side, and secured to the middle strap at the point of crossing."

A combination of external and internal splints was invented by Rutenick, a German surgeon, in 1799, and improved by Kluge. It is thus described by Dr. Chester (*Medico-Chirurgical Review*, vol. xx. p. 471)—"It consists, 1st, of small silver grooves, varying in size according as they are to be placed on the incisors or molars, and long enough to extend over the crowns of four teeth ; 2nd, of a small piece of board, adapted to the lower surface of the jaw, and in shape resembling a horse-shoe, having at each horn two holes, one on either side ; 3rd, of steel hooks of various sizes, each having at one extremity an arch for the reception of the lower lip, and another smaller for securing it over the silver channels on the teeth, and at the other end a screw to pass through the horse-shoe splint, and to be secured to it by a nut and a horizontal branch at its lower surface ; 4th, of a cap or silk nightcap to remain on the head ; and 5th, of a compress corresponding in shape and size with the splint. The net or cap having been placed on the head and the two straps fastened to it on each side, one immediately in front of the ear and the other about three inches farther back, which are to retain the splint in its position by passing through the two holes in each horn ; a silver channel is placed on the four teeth nearest to the fracture, on this the small arch of the hook is placed, and the screw end having been passed through a hole in the splint, is screwed firmly to it by the nut, after a compress has been placed between



the splint and the integuments below the jaw. If there is a double fracture, two channels and two hooks must of course be used."

Bush invented a similar apparatus in 1822, and Houzelot in 1826; since which the apparatus has been variously modified by Jousset, Lonsdale, Malgaigne, and perhaps others.

Lonsdale's apparatus, as Mr. Berkeley Hill remarks, (*British Medical Journal*, March 2, 1867,) "is only suited to cases of fracture between the incisors, as its ivory cap is too short to reach far along the arch of the teeth. It is also very cumbrous; and causes great pain by the pressure under the chin necessary to keep the fragment in place, and by the jogging of the vertical part against the sternum."

FIG. 22.

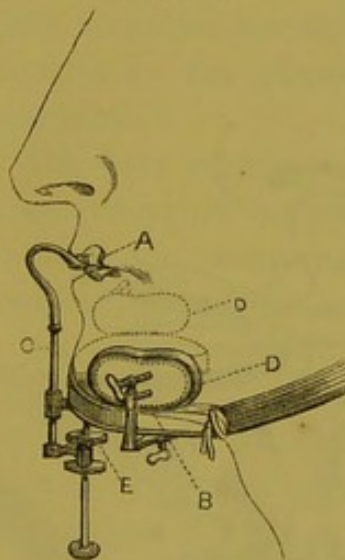


Fig. 22 shows this apparatus somewhat modified by Mr. Hill, to whom I am indebted for the illustrations. In the ordinary Lonsdale's apparatus, the rod carrying the ivory cap (A) for the incisors slides freely up and down a bar projecting downwards from the chin-piece (B), and, when in the required position, is fixed by a pin. Mr. Hill has had a screw-thread cut on the bar, on which a nut (E) travels so as to force down the rod carrying the cap (A),



and thereby approximate the cap on the incisors and the chin-piece.

When this apparatus is to be applied, the fragments are placed in position by the hands, the ivory cap set on the incisors, and the chin-piece, which should be well padded with lint or wool stitched in wash-leather, brought up into place under the jaw and the two made fast. The two cheek-pieces are then adjusted so as to press lightly on the jaw at each side, to prevent the apparatus from swaying aside out of place; and a tape is fastened to a hole at each end of the horse-shoe, and carried behind the neck, to keep the instrument from slipping forwards. So applied, Lonsdale's apparatus permits opening of the mouth for eating and speaking; and, if the fracture be single and between the incisors, it keeps the fragments in position very fairly.

FIG. 23.

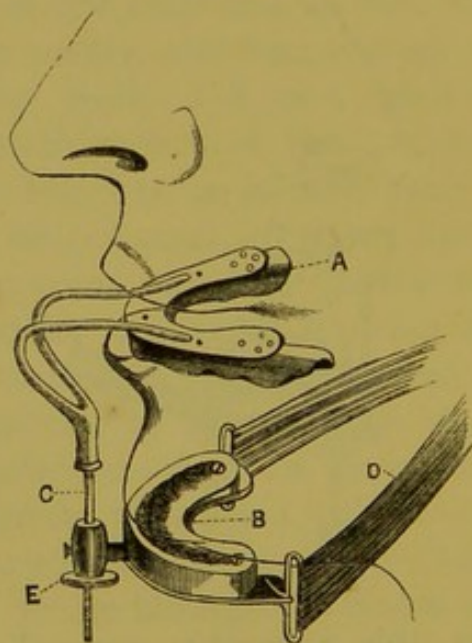


Fig. 23 represents the modification of Lonsdale's splint, contrived by Mr. Berkeley Hill, for the treatment of a complicated case of double fracture in University College Hospital in 1866, the ivory cap of the incisors being replaced by a metal mould of the alveolar arch, and the lateral pads removed.

Lonsdale, in his work on "Fractures," gives the details



of several successful cases of treatment by this apparatus, but the great difficulty always is the tendency of the support for the chin to produce abscess and ulceration by pressing upon the sharp border of the bone; and the cases in which a simple metallic interdental splint would not effect a cure must be few and far between.

The treatment of fracture of the neck of the lower jaw, in those rare cases where the patient survives the injury and the nature of the accident is recognised, is sufficiently simple when there is no displacement, since the ordinary bandage will in most cases suffice. When, however, the condyle is displaced by the action of the pterygoideus externus, reduction must be effected as recommended by Ribes, by drawing the jaw horizontally forwards, and at the same time pushing the condyle outwards with the finger introduced far back into the mouth. Reduction being accomplished, the jaw must be pressed upwards and backwards to fix the condyle in the glenoid cavity, after which a bandage may be applied.

Gross says that the best means to counteract the tendency of the external pterygoid to produce displacement is "to confine a thick graduated compress behind the angle of the bone, the treatment being in other respects the same as in fracture of the body of the jaw." (Gross' "Surgery," p. 967.)

*The Treatment of Ununited Fracture of the Jaw.*—The causes of non-union of a fractured jaw have been described in a previous section. When the delay is due to a superficial necrosis, time for exfoliation to take place is all that is required; when, however, the necrosis is extensive, or the loss of substance great, it is not desirable to produce union between the fragments, since thereby an unsightly deformity will be induced, which can be avoided by the use of apparatus to retain the parts in their normal relation. This subject will be referred to more particularly under the head of "Gunshot Injuries."

Dupuytren, in 1818, treated a case of ununited fracture, the result of a gunshot injury, in the person of a Russian



officer (*vide* p. 31), three years after the receipt of the injury, by resecting the extremity of one fragment and rasping the other. In order to maintain the fragments in position the dentist Lemaire was called in, and devised the following plan, the fracture being on the right side of the jaw:—"First, to carry the posterior fragment inward, he united by means of a platinum wire the wisdom tooth in this fragment to one of the bicuspid of the other side; then, to carry the anterior fragment forward and lessen the overlapping as much as possible, a second wire was stretched from the first lower bicuspid on the right side to the first upper bicuspid on the left; and a third bound together the two canine teeth on the left side." (*Vide* Malgaigne, and for the entire case Dupuytren's *Leçons Orales*, vol. iv.) A cure was accomplished at the end of two months, but one of the wires had nearly bisected the tongue; and as it had gradually become imbedded the flesh had closed over it, and it had to be cut and withdrawn.

Dr. Physick in 1822 treated a case, two years after the receipt of the injury, by the introduction of a seton between the ends of the bones. This was left *in situ* for three months, and induced suppuration and the discharge of fragments of necrosed bone, with an ultimate cure. (*Philadelphia Journal of Medical and Physical Sciences*, vol. v. p. 116.)

Suture of the fragments of bone would appear to offer the readiest means for keeping the two portions in apposition, and this plan has been successfully carried into execution by Mr. Bickersteth, of Liverpool, who, in his paper read before the Medico-Chirurgical Society in 1864, narrated two cases in which he had succeeded in producing union by fastening the two fragments together by means of a drill, or some similar contrivance.

The first case was a fracture of the lower maxilla, where the bones had united in such a position as to render the patient a most unsightly object. As the incision that would have been necessary in this instance for the purpose both of putting the bone into proper position and removing the



deformity of the soft parts, would not have allowed the use of external splints or supports, and as it was found impracticable to effect this object by fixing the teeth by an appliance within the mouth, it was absolutely necessary that some means should be devised by which the divided portions of the jaw could be securely fixed ; and it occurred to Mr. Bickersteth that pegs or nails would answer the purpose, especially as he had already observed their presence caused so little inconvenience. Accordingly, at the operation the apposition of the fractured portions was secured by means of two round-headed nails. They most effectually answered their purpose, and no external splint or bandage was required. The case did well, no undue action being set up. On the twenty-second day after the operation one of the nails came away. The patient left the infirmary perfectly well, the jaw being firmly united in its proper position, and the deformity of the soft parts removed. One of the nails remained in, and the last accounts state that its presence caused no inconvenience. The second case recorded was one that presented many points in common with the one just narrated. No external incision was made, and ordinary drill-heads were substituted for nails. The result was everything that the operator could have wished.

Dr. Cooper, of San Francisco, treated successfully an ununited fracture of the lower jaw by silver sutures. In the report of the case the exact seat of the fracture is not given, but it was evidently in the body of the bone. The periosteum was dissected up, the ends of the bone bared, after which they were carefully united, and the case did well. (*Philadelphia Medical and Surgical Reporter*, 1862, and *Medical Circular*, July 23, 1862.)



## CHAPTER IV.

## FRACTURES OF THE UPPER JAW.

FRACTURES of the upper jaw are not nearly so common as those of the lower, though their results are often more serious, owing to the great violence necessarily undergone. As in the lower jaw, fractures of the alveolus may result from the extraction of teeth, and particularly from the use of the "key;" and so well ascertained was this fact, that in former days even when the key was recommended and employed extensively, Mr. Thomas Bell ("On the Teeth," p. 301) proscribed its use in extracting the upper wisdom teeth on account of the danger of producing fracture of the tuberosity of the maxilla, against which the fulcrum would rest. A fracture thus produced may extend to the palatine process, and even to the palate bone, and might, if extensive, give rise to necrosis and subsequent exfoliation of large portions of bone.

Fractures of the upper jaw may be produced indirectly by falls on the face; thus Liston ("Practical Surgery," p. 55) narrates the case of a man who, slipping on a slide in the street, fell and struck the *malar* bone of the left side; he had sustained a vertical fracture through the orbital process of the superior maxilla.

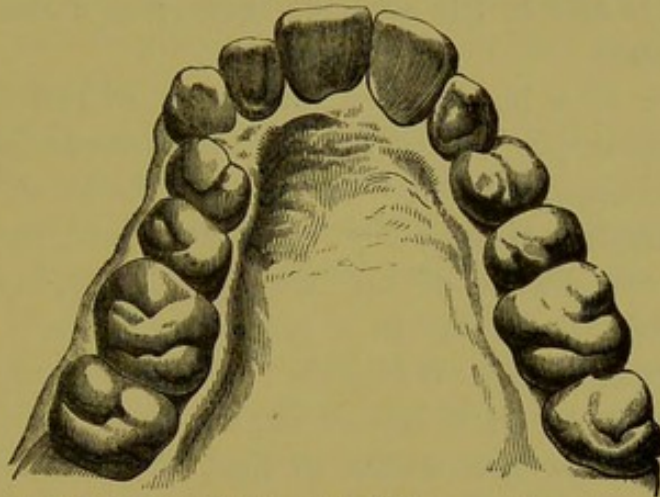
Direct blows upon the bone itself are, however, the most frequent causes of fracture, and these, from the nature of the injury, are often compound.

Mr. James Salter has recorded a case (*Lancet*, June 16, 1860,) of a young gentleman who sustained fracture of the upper jaw from violent contact with a fellow-cricketer's forehead. Here fortunately none of the incisor teeth were knocked out, as so frequently happens in accidents of the



kind; but a fracture of the bone was produced immediately behind the right canine tooth, which extended backwards so as to include the alveoli of the bicuspid and first molar teeth, which were driven inwards towards the median line, to the extent of about one-third of an inch, as seen in the drawing (fig. 24). There was a corresponding depres-

FIG. 24.



Drawing from the plaster cast of the upper jaw, inverted.

FIG. 25.

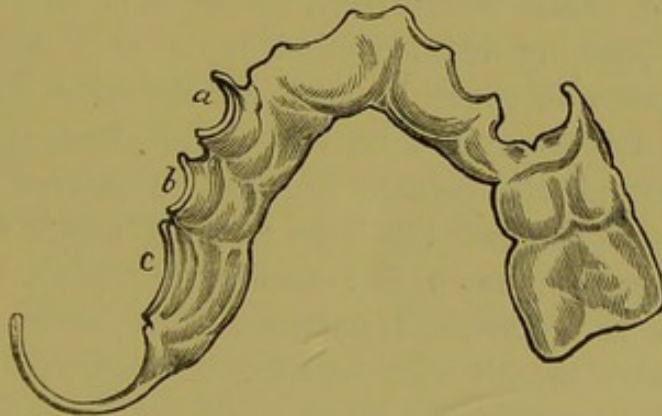


Illustration of the gold plate or splint; *a*, *b*, and *c* corresponding to the first and second pre-molars and first molar respectively.

sion on the outer side of the jaw, and this was somewhat apparent also on the face. Very little swelling followed the injury, and there was not much pain except on manipulation. The principal inconvenience was due to the want of proper apposition of the teeth of the two jaws, and the mouth consequently could not be closed satisfactorily. On



endeavouring to force the displaced bone into its proper situation, considerable pain was produced; it could not be completely reduced, and resumed its former position as soon as pressure was withdrawn. Distinct crepitus was felt during this manipulation.

Mr. Salter succeeded in overcoming the tendency of the fragments to displacement by the adaptation of a gold plate (fig. 25) to it and to the adjacent teeth, and a complete cure was the result.

The kick of a horse often inflicts most serious injuries upon the upper jaw, and of this the classical case recorded by Richard Wiseman, in his "Chirurgical Treatise" (1794), is a good example. Here a boy, eight years old, received such a blow on the middle of his face that he appeared at first dead, and afterwards lay in a prolonged coma. "When I first saw him," says Wiseman, "he presented a strange aspect, having his face driven in, his lower jaw projecting forward; I knew not where to find any purchase, or how to make any extension. But after a time he became sensible, and was persuaded to open his mouth. I saw then that the bones of the palate were driven so far back that it was impossible to pass my finger behind them, as I had intended, and the extension could be made in no other way. I extemporized an instrument, curved at its extremity, which I engaged behind the palate, and having carried it a little upward used it to draw the bone forward, which I did without any difficulty; but I had hardly withdrawn the instrument when the fractured portions went back again. I then contented myself with dressing the face with an astringent cerate to prevent the afflux of the humours; I likewise prescribed bleeding; and some hours afterwards I had an instrument better constructed to reduce the large mass of displaced bone to its proper position. I had it held by the child's hand, by that of its mother, or of an assistant, each for a certain time. Nothing else was done. Thus by our united attention the tonicity of the parts was maintained; the callus was developed, and in proportion as it became solidified the parts became stronger, the face assumed a good



appearance, certainly better than could have been hoped for after such marked displacement, and the child was entirely cured."

The most frightful injury to the face (except from gunshot wounds) I ever witnessed, was from the passage of a waggon wheel over the face of a man who fell in the street. Here the bones were completely shattered, and the maxillæ were torn from one another, and death was instantaneous. A cast of this frightful deformity is in the museum of the Westminster Hospital.

A case very nearly as desperate at first, but which fortunately recovered, was admitted into the same hospital in 1860, and resulted from the overturn of a cab upon the face of its fare, who at the moment was leaning out of window to direct the driver. Here, in addition to a fracture of the lower jaw a little to the left of the median line, there were two fractures of the superior maxilla, about an inch on either side of the median line; the nasal bones were broken; both malar bones were loose and separated from their attachments, and the left bone was fractured, as also the external angular process of the frontal bone. Though not positively ascertained, the vomer was no doubt fractured, and probably the vertical plate of the ethmoid too. In Dr. Fyffe's report of the case (*Lancet*, July 18, 1860), which I can confirm by personal observation, it is well noticed,—“It was remarkable to observe how moveable the bones of the face were. On watching the patient's profile whilst he was in the act of swallowing food, the whole of the bones of the face were observed to move up and down upon the fixed part of the skull as the different parts were brought into motion; it appeared as if the integuments only retained them in their position. It was a curious feature in the case, that notwithstanding the very extensive injury done, and the violent character of the force which caused them, not a single tooth was fractured or misplaced.” This patient made a perfect recovery, and his treatment will be alluded to under another section.

Fracture of the upper jaw extending into the antrum



may give rise to subsequent suppuration in that cavity, as remarked by Liston, but this is by no means a necessary consequence. A remarkable case of transverse fracture of the upper jaw which communicated with the nose and with both antra was recently under Mr. Hutchinson's care in the London Hospital, which perfectly recovered without exfoliation of any part of the bone, although the alveolus containing all the teeth was completely separated and depressed about half an inch. Here the injury was the result of a "jam" between a "lift" and a cross bar. (*Medical Circular*, February, 1867.) A very similar case occurred to Dr. Guentha, when a workman was struck in the face by the angle of a large mass of stone. Here there was complete separation of the alveolar process of the upper jaw, the entire arch in an unbroken state lying on the lower jaw, only suspended by some shreds of the gum and soft palate. This man also made a perfect recovery. (*British and Foreign Quarterly Review*, October, 1860.)

In cases such as these, when there is obvious displacement there can be no difficulty in the diagnosis of the fracture, but cases have no doubt frequently occurred where a fracture without displacement has been overlooked. Dr. A. Guérin has elaborately investigated this subject (*Archives Générales de Médecine*, July, 1866), and has shown from a preparation taken from a fatal case and from experiments upon the dead body, that violent blows below the orbits fracture not only the maxillary bones, but that the fracture usually extends to the vertical portion of the palate bone and the pterygoid process of the sphenoid without producing the slightest displacement. The diagnosis of the injury cannot be established by any external manipulation, but by carrying the finger into the mouth and pressing against the internal pterygoid plate, pain will be produced and mobility of the process will be ascertained. The diagnosis was confirmed in one of Dr. Guérin's cases which recovered by an ecchymosis beneath the mucous membrane of the palate. In his fatal case he found fracture of the vertical plate of the ethmoid in addition to the other injuries.



The nasal process of the superior maxilla has been fractured by blows which have also driven in the nasal bones, and in these cases emphysema of the cellular tissue of the face is not uncommon, and is best checked by the application of collodion. A complication of this form of fracture which has been met with, is permanent obstruction of the nasal duct, leading to subsequent troublesome epiphora.

Separation of the two maxillæ in the median suture has been seen in cases of fatal injury to the face, &c., on many occasions, but Malgaigne gives a case of the kind where the patient recovered. The patient, a man aged twenty-one, owing to a fall from a height sustained, in addition to other injuries, "a separation of the upper maxillary and palate bones in their median suture to the extent of nine millimetres, with depression of the entire left side of the face without any alteration of the soft parts." The parts came together spontaneously and the patient recovered without deformity.

Hamilton, however, quotes (p. 102) a case from Harris, of New York, in which a child, two years of age, had separation of the maxillary and palate bones in the median line, the separation being sufficient to admit the little finger, and here the bones were still open six weeks after the accident.

*Complications.*—The teeth of the upper jaw may be broken or dislocated in the case of fracture of the lower jaw; but if merely loosened, should never be removed, as they will probably become again firmly attached.

Splintering of the bone is much more common in the upper than the lower jaw, particularly after gunshot injuries, and here modern experience has shown the advisability of leaving the fragments to become consolidated, as they almost invariably do, and the non-necessity for the performance of dangerous operations of resection of the fragments—a subject which will be again referred to.

Hæmorrhage is much more frequent and copious in fractures of the upper than in those of the lower jaw, as might be anticipated from the greater vascularity of the part. A case of fracture of both upper and lower jaws, where profuse hæmorrhage was caused by division of the facial artery,



has been already referred to, but the hæmorrhage not unfrequently comes from the internal maxillary vessel and may be immediately fatal. Secondary hæmorrhage in cases of severe injury to the upper jaw is by no means uncommon, and according to the Surgeon-General of the American Army (Circular No. 6, Washington, November 1, 1865), was the principal source of fatality in these cases, ligature of the carotid artery having been frequently performed with the result of only postponing for a time the fatal event.

*Nervous Affections.*—Injury to the infra-orbital nerve and its branches must necessarily ensue in cases of severe fracture and comminution of the superior maxilla, and consequent numbness or modification of sensation will be the result. A lady, recently under my care, who fell down a flight of stairs and sustained severe injuries to the head and face, although no fracture of the jaw could be detected, suffers from partial anæsthesia and a pricking sensation in the skin below the orbit. Robert mentions (*Gazette des Hôpitaux*, 1859, p. 157) the case of a woman who was run over and sustained a fracture with permanent paralysis of the infra-orbital nerve. Serious brain symptoms may ensue when the fracture runs back to the sphenoid bone as described by M. Guérin (p. 56), since the fissure may extend to the cranium, and this is especially likely to happen when the whole of the septum narium is driven back with the jaws.

*Treatment of Fracture of the Upper Jaw.*—Fractures of the upper jaw require but little treatment compared with those of the lower jaw, since the part is naturally so much more fixed that there is little difficulty in keeping the fragments in position. The hæmorrhage, which is often free, must be arrested by cold, the application of styptics, and as a last resource, the actual cautery. The operation of deligation of the carotid artery in these cases has yielded such unsatisfactory results as to render the surgeon unwilling to resort to it except under the most desperate circumstances, and he would in my opinion be justified in laying open the face and removing large fragments of bone so as to apply



the cautery more satisfactorily, rather than resort to a dangerous and doubtful operation. When, as is most commonly the case, the soft tissues of the face are lacerated and the hæmorrhage arises from them, the bleeding vessels must be secured with ligatures in the ordinary manner.

All authorities are agreed as to the non-advisability of removing the fragments of a broken upper jaw, since, owing to the vascularity of the part, they almost invariably unite readily. Malgaigne says, "In compound fractures of the upper jaw there is one principle which surgeons cannot too carefully bear in mind; that is, that all splinters, however slightly adherent, should be scrupulously preserved, as they become reunited with wonderful facility. This remark was made by Saviard; Larrey has strongly insisted on it, and we have seen that M. Baudens, who so much urges the extraction of splinters, has likewise made a special exception of these cases." (Packard's translation, p. 304.) Hamilton remarks that the experience of American surgeons during the war confirms these observations. "Owing to the extreme vascularity of the bones composing the upper jaw, the fragments have been found to unite after the most severe gunshot injuries with surprising rapidity, the amount of necrosis and caries being usually inconsiderable compared with the amount of comminution" (p. 106).

Notwithstanding this, however, Hamilton gives a lengthy account of a case of fracture of the upper jaw, in which he, in conjunction with Dr. Potter, thought it necessary to remove a fragment which included the floor of the antrum and which had been drawn down and displaced in an attempt to extract a loose tooth. "The time occupied in this operation was at least one hour, during which we were every moment in the most painful apprehension lest we should reach and wound the internal carotid artery, which lay in such close juxtaposition to the knife that we could distinctly feel its pulsation. After its removal the hæmorrhage was for an hour or more quite profuse, and could only be restrained by sponge compresses pressed firmly back into the mouth and antrum" (p. 103). Such dangerous opera-



tions are much to be deprecated, and cases already quoted prove that even after greater separation the bone will thoroughly reunite.

Mention has been made of the difficulty Wiseman experienced in reducing the fragments to their proper position in his case and the means he adopted to overcome it. In the majority of cases the finger introduced into the mouth and passed around the alveoli will readily restore any irregularity, being aided, if necessary, by the introduction of a strong elevator or pair of dressing forceps into the nostril. The teeth in adjacent fragments may be advantageously wired together to keep them in position, or where there is great comminution and irregularity of the alveoli a piece of soft gutta-percha may be adapted to them so as to hold and support the fragments. The lower teeth should not be allowed to come in contact with this until it is thoroughly hardened, or they would become imbedded and then lead to its displacement. In very complicated cases, as in examples of fractures of both jaws, the vulcanite interdental splints of Mr. Gunning (described under Fractures of the Lower Jaw) might be employed, these having an aperture for the introduction of food.

Graefe employed an apparatus, of which the following description is given by Malgaigne (Packard's translation, p. 301). "A curved steel spring properly padded, is applied over the forehead, and kept in place by a strap buckled around the occiput. This steel has at each side a hole with a screw for making pressure; and a steel brace to which it affords a *point d'appui*, for acting steadily on the dental arch. Now these braces descending to the level of the free edge of the upper lip, curve backward so as to go around the lip without wounding it; getting thus at the dental arch, they again curve so as to apply themselves to it. But as the pressure of the braces should have the effect of keeping the detached teeth in proper relation with the rest, a silver trough duly padded is made to fit over both to a sufficient length; and upon this trough the braces exert their pressure. It is easy to see how, by altering their height as



regards the spring over the forehead, the pressure may be regulated to the right degree."

A somewhat similar apparatus, but with the addition of a pad which can be applied externally so as to support the cheek, was brought before the Surgical Society of Paris, in September, 1862, by M. Goffres.

In the rare cases of separation of the maxillæ, a spring passing behind the head and making pressure upon the maxillæ after the manner of Hainsby's hare-lip apparatus, might be advantageously employed.



## CHAPTER V.

## GUNSHOT INJURIES OF THE JAWS.

GUNSHOT injuries of the jaws have necessarily been incidentally referred to in considering fractures of those bones separately, but it will be convenient to class the injuries of the two maxillæ by fire-arms together, since these accidents affect both bones in the majority of cases. Laceration of the soft tissues and consequent hæmorrhage are almost constant accompaniments of wounds of the face, and the fatality attending them is high, both from the immediate effects of the injury, and from the frequent occurrence of secondary hæmorrhage. The effects of the modern arms of precision contrast unfavourably in this respect with those of the round bullet of the old fire-lock, for though the latter frequently lodged in one of the cavities of the face for an indefinite time, the irregular mass of metal driven with tremendous velocity by the modern rifle commits greater havoc, splintering the bones and lacerating the soft tissues most extensively.

The Surgeon-General of the American army reported in November, 1865 (Circular No. 6, Washington), that from the commencement of the war to October, 1864, of 4167 wounds of the face reported to him, there were 1579 fractures of the facial bones; and of these 891 recovered and 171 died—the terminations being still to be ascertained in 517 cases. Secondary hæmorrhage was the principal source of fatality in these cases, and the carotid had frequently been tied with the result of postponing for a time the fatal result.

The Crimean returns from the 1st April, 1855, to the



end of the war, show 533 wounds of the face, of which the bones were injured in 107 instances. 445 patients returned to duty, 74 were invalided, and 14 died.

Of 21 cases of wounds of the face with injury to the bones from the Indian Mutiny reported by Dr. Williamson, six were examples of fracture of the lower jaw, and of these three remained ununited.

The following extract is from the official "Medical and Surgical History of the British Army in the Crimea," vol. ii. p. 305, and illustrates the experience of that war, which has been largely confirmed by that of the recent American war:—"Wounds of the face, though presenting often a frightful amount of deformity, are not generally of so serious a nature as their first appearance might lead the uninitiated to expect. The reason of this, apart from the fact that the face contains no vital organ, seems obviously to be the very free supply of blood which this part receives. From this cause the fleshy structures readily heal, and even the bones are so supplied that extensive necrosis rarely happens. The bone tissues, also, are softer than the long bones of the extremities, and we therefore but seldom here meet with long fissures and extensive necrosis as a result of concussion of bone, so often seen in them. This leads us to the very important practical inference, not in this situation, as a rule, to remove bony fragments, unless the comminution be great, or the fragment completely detached from the soft parts. Even partially detached teeth will often be found not to have lost their vitality, and, if carefully re-adjusted, will become useful. There is indeed no great object beyond, perhaps, the present comfort of the patient to be attained in removing either fragments of bone or loosened teeth in the great majority of instances. If they die, they become loose, and are readily lifted away without trouble to the surgeon, and but little pain to the patient. This observation is especially applicable to fractures of the lower jaw. Surgeons in this war have seen so many cases of badly-fractured instances of this kind unite, and that with a very small amount of deformity, that men of ex-



perience are now excessively chary of removing any portion of this bone, unless it has become dead, or the fragment is so situated as to interfere considerably with the adjustment of the remainder, or the bone so much comminuted as to give no probable hope of its becoming consolidated, or so sharply angular as to threaten further injury to the soft parts, or to interfere materially with their adjustment and retention *in situ*. In these fractures of the lower jaw, much less support and adjustment than we are in the habit of thinking advantageous in ordinary cases of fracture of it, will frequently be found necessary, or even admissible. A complicated apparatus cannot be borne at first, on account of the condition of the soft parts, and the application of slight support by a gutta-percha or Startin's wire splint, and a split bandage, is all that can be done. Any attempt at ligaturing the teeth is very generally not only useless, but injurious, and it is surprising how the parts often as it were adjust themselves, with but little aid from the surgeon. An abstract of one interesting case is appended (Case VII.), where the whole of the bone, from angle to angle, was so comminuted by gunshot that no choice was left but to remove the fragments. The injury to the soft parts was very considerable, and one difficulty, occasioned by the loss of all support in front, viz., the tendency of the tongue to fall backwards and close the opening of the glottis, well illustrated. The man, however, generally remedied this himself with his fingers, and nothing was done, or required to be done, on this account beyond carefully watching him. He naturally, as it were, adopted a position on his side, resting mainly on his forehead, so as to have the face as much in the prone posture as possible, and thus the weight of the organ assisted in keeping it in position."

Gunshot wounds of the upper jaw through the mouth, are usually of suicidal origin, and of this a specimen accompanied this essay, and is now in the Museum of the College of Surgeons (2902 A.), being the skull of a man who fired a pistol into his mouth. The red lines on the preparation mark the outline of the fracture, and it will be seen that a



great part of the hard palate was driven in, and that the bullet, after fracturing extensively the base of the skull, carried away a considerable portion of the vault of the cranium. The malar bone, with the outer wall of the antrum, is broken off on the right side, and the malar bone on the left is separated from the maxilla at the articulation. In a second case of the kind, which I also had the opportunity of examining immediately after death, the injuries were similar in extent.

In the preparation referred to there is an oblique fracture of the lower jaw on the left side, running backwards through the socket of the first molar tooth, and an oblique crack has been produced on the inner surface of the right side of the bone, in an exactly corresponding position. Fracture of the jaw had occurred also in the second case alluded to, and has been frequently noticed under similar circumstances, the fracture depending upon the concussion of the explosion and the rapid development of gas within the mouth. This is not without exception however, since, in the University College Museum, there is the skull of a man who fired a pistol into his mouth, in which the palate is extensively damaged but the lower jaw perfect. When the bullet actually enters the mouth the injury is usually immediately fatal, but Otto Weber has recorded (*Handbuch der Allgemeinen und Speciellen Chirurgie*, Part III. 1866) a case of recovery:—"The patient, through despair, arising from pecuniary embarrassments, determined to shoot himself in the churchyard. He held the pistol before his open mouth, and, after firing, fell senseless to the ground. After some time he came to himself, looked for his spectacles, which had fallen off his face, and made the gravedigger bring him to me. The palatal vault was simply perforated, and the ball, completely flattened, was sticking in the body of the sphenoid bone, where it could be felt by the index finger, introduced into the hole by which it had entered. After some fruitless attempts to extract it, it fell into the patient's throat and he spat it out. Subsequently the hole in the palate completely closed up again, and the patient



recovered both physically and morally." In this case the lower jaw does not appear to have suffered, but Mr. Barrett has shown me the model of a case where a pistol bullet, fired at the open mouth, glanced off on an incisor tooth and ran up the side of the face, emerging near the malar bone, and where nevertheless the lower jaw was broken by the explosion.

I was recently called in by Dr. Whitmarsh, of Hounslow, to see a patient who had fired a pistol, loaded with small shot, into his mouth, smashing the palate and fracturing the lower jaw in two places by the explosion, but who eventually made a good recovery.

Because a bullet has entered the mouth, and inflicted injury upon the bones of the palate, &c., it does not necessarily lodge there; thus, in the "Medical and Surgical History of the Crimea," is the case of John Collins, 97th Regiment, who was wounded on the 8th September, and sent to hospital on the 14th, having been struck by a musket-ball, which had entered the mouth, slightly cutting the upper lip, and had comminuted the palate plate of the superior maxilla, and appeared to be lodged somewhere among the ethmoid cells. There was but little constitutional disturbance. All the incisor teeth of the upper jaw became dead and had to be removed, as well as some fragments of the palate plate, but the wound slowly healed, and finally filled up, leaving the man but little the worse, except for the loss of his teeth. Various careful examinations, made at different times, failed to detect the presence of any foreign body, and the man himself afterwards stated that he had always fancied the bullet fell out during his progress from the trenches to the regimental hospital.

Injuries of the palate may also be produced by wounds of the face; thus Mr. Cox Smith, of Chatham, records the case of a soldier who came under his care, in whom the jaw and palate had been extensively fractured, and the incisor teeth driven in, as seen in fig. 26, so that the patient was unable to masticate or speak. By extracting these teeth (fig. 27), Mr. Smith was able to adapt a set of artificial teeth, so as to restore to the patient the use of his mouth for all pur-



poses. The case will be found in detail in the Appendix (Case VIII.).

Missiles, striking from without, occasionally lodge for a considerable time in the antrum or nose, and, sometimes, without their presence being suspected. In the "Medical and Surgical History of the Crimean War" will be found the case of a soldier who received a severe wound of the face. A grapeshot, weighing seventeen ounces, lodged in the jaw, having displaced the palate, with a portion of the maxilla and all the molar teeth of the right side, into

FIG. 26.

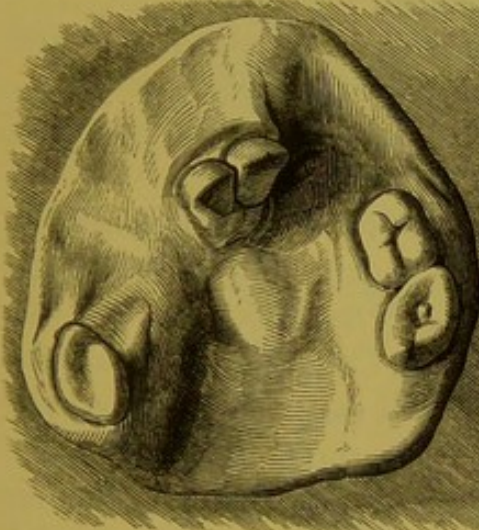
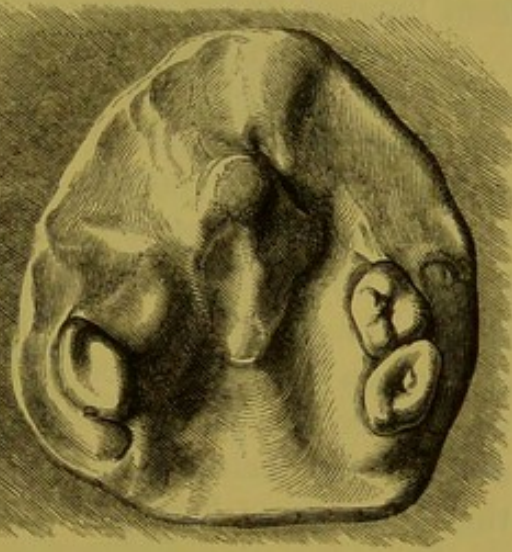


FIG. 27.



the mouth. Here it was found necessary to enlarge the wound and remove the fragments (contrary to the general rule of practice) before the ball could be extracted, but the patient made a good recovery, notwithstanding severe secondary hæmorrhage. Still more remarkable, however, are cases which have occurred in civil practice: where the breech of a burst fowling-piece has lodged for years in the antrum. A remarkable case of this kind was reported in the *Edinburgh Medical Journal*, of September, 1856, by Dr. Fraser, of Newfoundland, who removed a piece of metal, weighing more than four ounces, and measuring nearly three inches in length, from the jaw of a man who had suffered from the accident seven years before. A still more extraordinary case is recorded in the Museum of Guy's Hospital, which possesses a



model of the breech of a gun which had been lodged in the face of a man for twenty-one years! "The patient was shooting birds when the gun burst, the right eye was knocked out, and the roof of the orbit destroyed, and through it the brain protruded; the latter sloughed, and, after a long illness, the man recovered. At the latter end of 1856 he was suddenly seized with symptoms of choking, as from a foreign body in the throat, and, on putting his finger in his mouth to remove it, he drew forth the breech of a gun, much oxidized and covered with purulent matter. It is supposed that the piece of iron broke through the floor of the orbit and had been lodging in the antrum ever since."

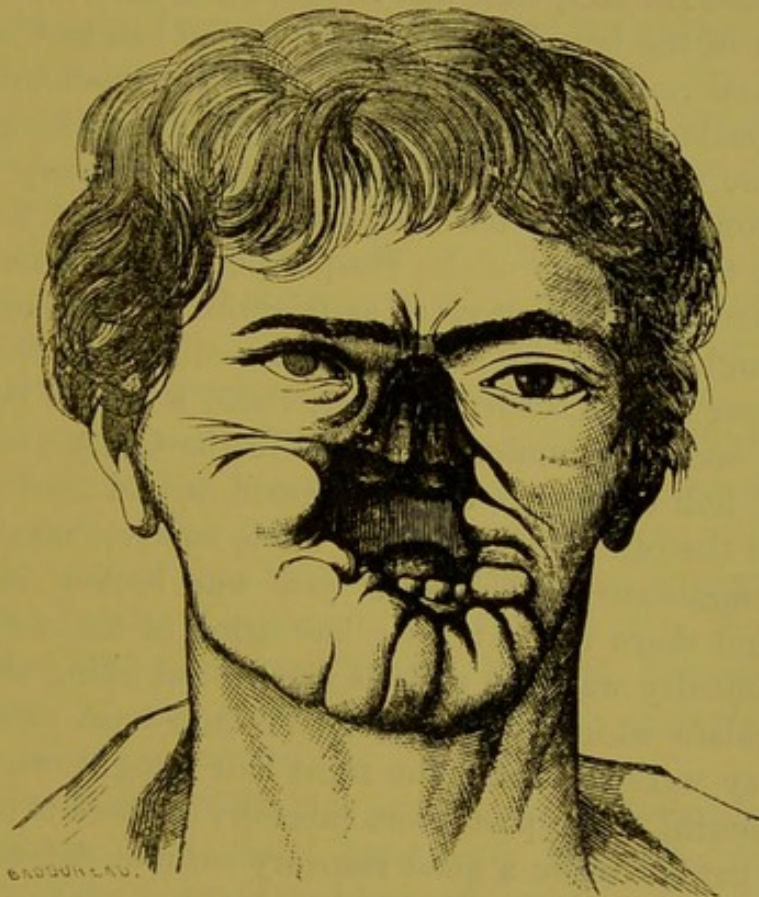
In connexion with this subject may be mentioned the case of a knife-blade lodged in the antrum for forty-two years, and finally coming out of the nostril, reported in the *Bulletino di Bologna*, May, 1864.

Cannon shot, striking the face, inflict the most frightful injuries upon the jaws, which are usually fatal; thus Professor Longmore mentions (Holmes' "System," vol. ii.) the case of an officer of Zouaves in the Crimea, who had the whole face and jaw carried away by a cannon ball, the eyes and tongue being included, so that there remained only the cranium. The patient survived for twenty hours. Guthrie also relates a very similar case, as having occurred at the siege of Badajos. The wars of the first Napoleon afforded some frightful examples of injury to the jaws, which the unfortunate patients survived for years, in one of the military asylums of Paris. The accompanying drawing (fig. 28), taken from an able paper by M. Emile Debout, "On the Mechanical Restoration of the Maxilla" (*British Journal of Dental Science*, April, 1864), shows the condition of a corporal who was struck by a cannon-ball, at the siege of Alexandria, in 1800. The shot carried away the greater part of the face, including three-fourths of the lower jaw and part of the tongue, and the man was thought to be dead. Under the solicitous care of Baron Larrey, he recovered however, and lived for more than twenty years. "It can be seen at a glance that speech and mastication were



impossible. Poor Vauté concealed the deformity by wearing a mask, gilt inside, and imitating the colour of the skin outside. He could even by means of this cover make himself a little understood, but his greatest distress arose from the incessant escape of the saliva, which was so great as to saturate in succession a number of linen compresses in the course

FIG. 28.



of the day. After supporting his misfortune heroically for so many years, he put an end to his misery in 1821. In order to complete the history of a case in which he had felt so deep an interest, Larrey, on learning the death of Vauté, procured his head, the state of which he described.

The loss of substance occasioned by the ball was limited to the elliptic segment seen in the portrait. The left malar bone had been carried away. The arch of the palate and the nasal fossæ down to the ethmoid had been destroyed. The inferior and internal orbital walls, down to the base of



the skull, had been also destroyed. Two thirds of the lower jaw were wanting. The right half of the middle portion of this bone, with three of the teeth, was found adherent to a part of the surface of the right branch, which had been fractured. The portion supporting the coronoid process and the condyle was considerably depressed backwards to meet the other fragments of this bone; but as they were not in sufficiently close contact, they had not grown to each other. All the edges of the bones broken away by the ball had become thinned and rounded, forming, with the corresponding soft parts, a puckered, irregular border surrounding the gulf in the middle of the face. To perpetuate the history of the case, Baron H. Larrey has had the preparation of the head placed in the museum of the Hospital of Val de Grâce."

Fragments of shell produce as frightful injuries as round shot, though the results are not so immediately fatal. Professor Longmore recorded (*Lancet*, 1855) a case of injury of the kind occurring under his notice in the Crimea, in which the right half of the palate was jammed in, and fixed at right angles to the other half, and the whole superior maxilla was much comminuted. The lower jaw was broken in three places, and there was extensive laceration of the soft parts. Great difficulty was met with at first in unlocking the parts of the palate which had been driven into each other, and when they were separated the right half hung down loosely in the mouth. The parts were carefully restored to position, and the patient made a good recovery without deformity.

In the Appendix will be found the report of a case (No. IX.) of extensive injury to the jaws by a piece of shell, in which Dr. D. Lloyd Morgan, R.N., (to whom I am indebted for the report), was obliged to tie the common carotid artery for secondary hæmorrhage, with success, as far as the operation was concerned, though the patient died of cholera some time after.

A charge of small shot, if fired near enough to the face to do more than lodge in the skin or jaw-bone (of which there is a good example in the Middlesex Hospital Museum), will produce as serious injuries to the jaws as a bullet. In



the *Lancet* of 10th November, 1860, is the report by Mr. Swete, of Wrington, of a case of very severe injury to the jaws from a charge of "dust shot," fired at a distance of four feet from the patient, a boy aged nine years. The charge entered the left side of the face, and passed out in front of the right ear, carrying away with it the greater part of the lower lip and jaw, and the whole of the chin. Several pieces of bone and teeth were picked up in an adjoining field, at a distance of ten yards. There was an extensive ragged wound of the face, extending nearly to the ear, the right half of the upper lip being destroyed, and the teeth and alveolus of the same side carried away. The lower jaw was shot away at the angle on the right side, and on the left about an inch of the body of the jaw, and one molar tooth remained. Mr. Swete trimmed the ragged edges of the jaw and brought the lacerated parts together, and, contrary to expectation, the patient recovered, and, by means of a plastic operation, was restored to a condition of considerable comfort.

Fracture of the lower jaw alone may be produced by bullets, and in this case the hæmorrhage is often severe from the divided facial artery, which vessel is generally involved. In the *Edinburgh Medical Journal*, Sept. 1860, Dr. John Brown, of the Bengal Medical Service, records four cases of the kind which are good examples of the variety of injury inflicted by a bullet:—

1. Was a gunshot injury of the jaw, attended by profuse hæmorrhage. The facial artery was secured, and a large portion of the comminuted bone removed. The patient did well.

2. Was a gunshot wound at the symphysis. There was a depression in the bone at the spot, but the ball had not perforated it. Did well.

3. Occurred in Lucknow. A Sikh was shot in the right side of the lower jaw; there was great arterial hæmorrhage from the facial artery, with a small wound over the angle and a larger one over the symphysis. Both were laid into one, fragments were removed, and the facial artery tied. Died twelfth day.



4. Ball traversed the mouth and fractured both sides of the lower jaw near the angles. Died from pyæmia on twenty-first day.

The Catalogue of the Surgical Section of the United States Army Medical Museum (1866) contains numerous records of injuries of this kind, from which the following may be quoted as most remarkable:—

“3350. The right half of the inferior maxilla fractured by a musket-ball, a small portion of which is attached. The missile entered the mouth, struck the alveolar ridge at the molar teeth, comminuting it, and causing oblique fracture of the body of the bone. The patient died the same day from hæmorrhage, from rupture of the internal maxillary artery.

“1451. Wet preparation of the right side of the body of the inferior maxilla, fractured and comminuted by a musket-ball at the angle. A fragment containing the molar teeth is driven inward, and other fragments remain *in situ*, the total amount of bone shattered being two inches. The ball lodged in the thyroid cartilage, causing death by suffocation on the nineteenth day.

“3542. The inferior maxilla fractured and comminuted by a musket ball. The alveolar ridge and the teeth are entirely removed; there is a horizontal fracture of the left ramus passing through the inferior dental foramen; on the right side there is a transverse fracture of the body of the bone at the last molar, and an oblique vertical fracture at the symphysis. The patient died from the effects of the wound of the tongue, causing hæmorrhage, for which the left common carotid was ligated.”

The experience of English surgeons in the Crimea, already referred to, has so completely settled the question of operative interference in cases of gunshot wounds of the lower jaw, that few military surgeons would be inclined to follow the example of M. Baudens (see Guthrie's “Commentaries,” p. 501) in laying open the cheek and removing or rounding off all fragments. Where spicula are much displaced, or where a bleeding vessel is to be reached, it may be occa-



sionally necessary to enlarge the wound, as in one of the cases already quoted, but this must be considered the exception rather than the rule.

A fracture may possibly be produced indirectly without the bullet actually striking the jaw; of this the following extraordinary instance occurred at the battle of Balaclava. A man of the 4th Light Dragoons received a compound fracture of the lower jaw by a grape-shot striking the flat of his sabre while at the slope, and driving it against the side of his face and head. The blade was bent, but not broken, and the missile did not touch the man.

Fragments of the jaw have been driven into other parts of the body, and even into that of a neighbour. In the "Medical and Surgical History of the Crimean War" is reported the case of a soldier who was shot in the right cheek, the ball glancing downwards and lodging in the neck, from which it was extracted. Subsequently a foreign body was detected behind the right clavicle, which was cut down upon and proved to be a portion of the lower jaw. Hamilton, also, in his "Military Surgery" (p. 255), mentions the case of a Confederate soldier who was kneeling and bending forward when he received a rifle ball upon his four lower incisor teeth. The ball and teeth disappeared, but were subsequently removed from beneath the skin at the top of the sternum.

The frequent occurrence of a false joint after gunshot injuries of the lower jaw has been already adverted to in the section upon False Joint. Since in gunshot cases a loss of substance has usually taken place which renders the union of the remaining portions an impossibility, some mechanical contrivance should be adapted by the dentist to hold the parts in their proper position and enable the patient to masticate. A case of false joint near the symphysis, treated in this manner most successfully by Mr. Cox Smith, has been already referred to, and will be found in the Appendix. Figs. 29 and 30 show the effects of mechanical treatment in separating the fragments and the filling of the gap by artificial teeth, and should be contrasted with figs. 9 and 10. The



sooner such apparatus is adapted after the receipt of the injury the better, since, as will be presently shown, the muscles have a constant tendency to draw the two sides of the jaw together. Not only is this effect produced upon the lower jaw, but there appears to be a secondary effect produced in these cases upon the upper jaw, the alveolar arch of which becomes gradually contracted from want of proper antagonism.

FIG. 29.

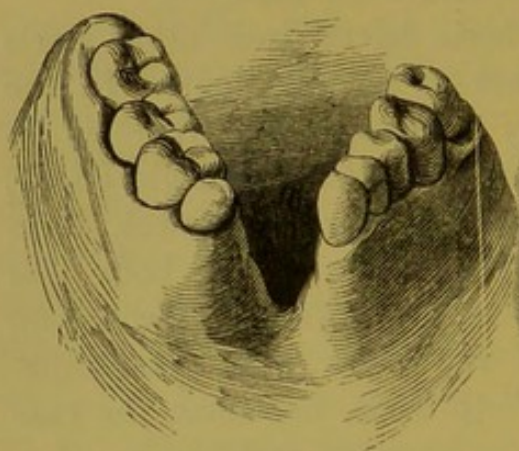
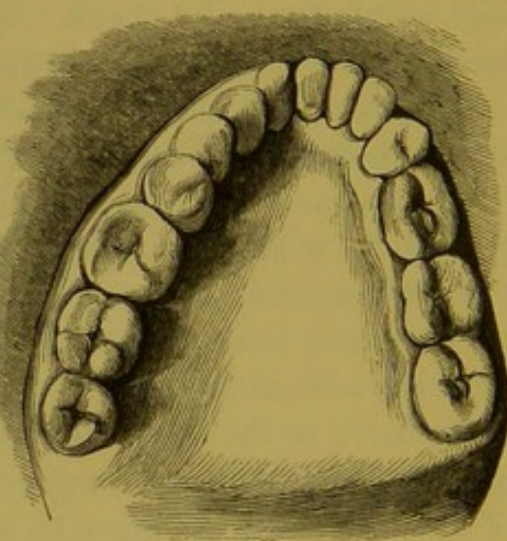


FIG. 30.

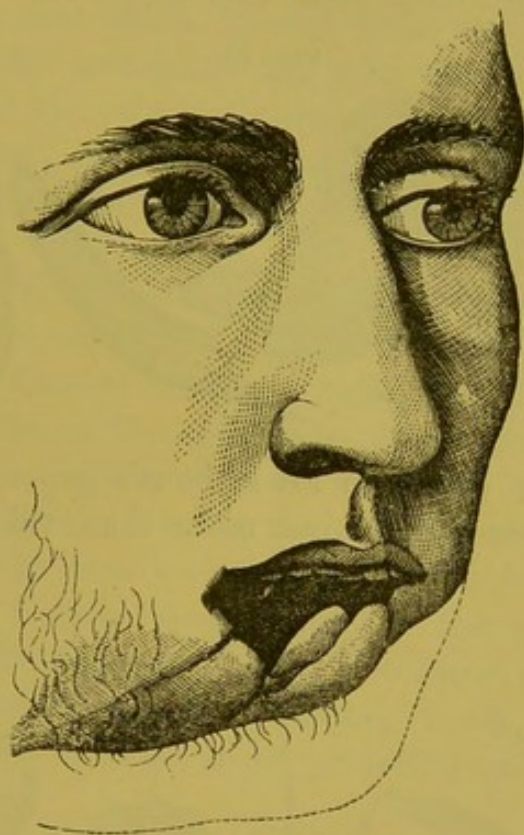

M. Debout, in the paper already referred to, gives the case of a French corporal, who, during the Italian campaign, was wounded by a fragment of shell, which fractured the lower jaw and severely lacerated the integuments. The comminuted fragments were removed, and the soft parts brought together with sutures, so as to restore as far as possible the floor of the mouth. All that could be obtained, however, was to form a sort of channel concealed by the beard, as shown in fig. 31, by which the saliva flowed in great abundance. When the patient arrived at the Val de Grâce he was placed under the care of Professor Legouest, at whose request M. Preterre, the dentist, was called in. The latter gentleman, before making any attempt to remedy the mutilation by restoring the lower jaw, thought it necessary first of all to have an apparatus made for the purpose of preventing the contraction of the dental arch. Fig. 32 shows



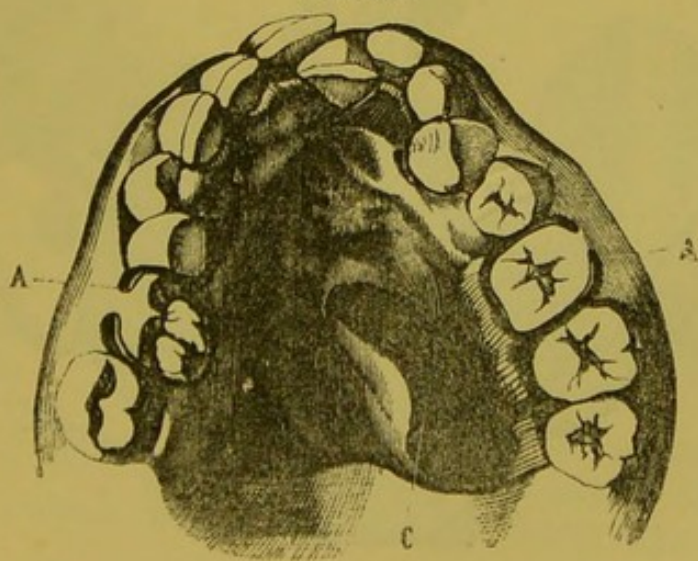
the apparatus in its place, A, c pointing to the position in which the alveolar border was when the case was first

FIG. 31.



seen. The completion of the case was prevented by the patient quitting the hospital.

FIG. 32.





Complete or nearly complete destruction of the lower jaw by a cannon-ball has more than once occurred, the patients surviving for many years, and the deformity being palliated by the use of a silver chin (fig. 33). The accompanying

FIG. 33.

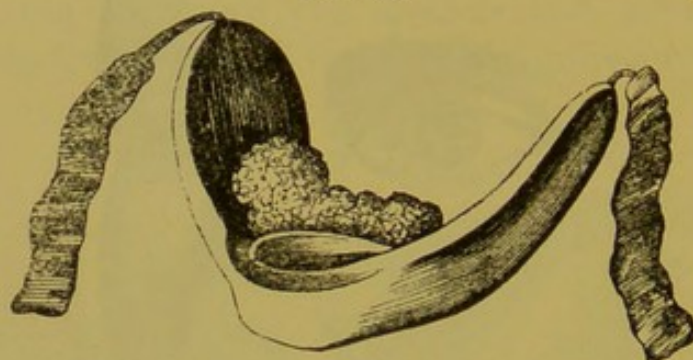
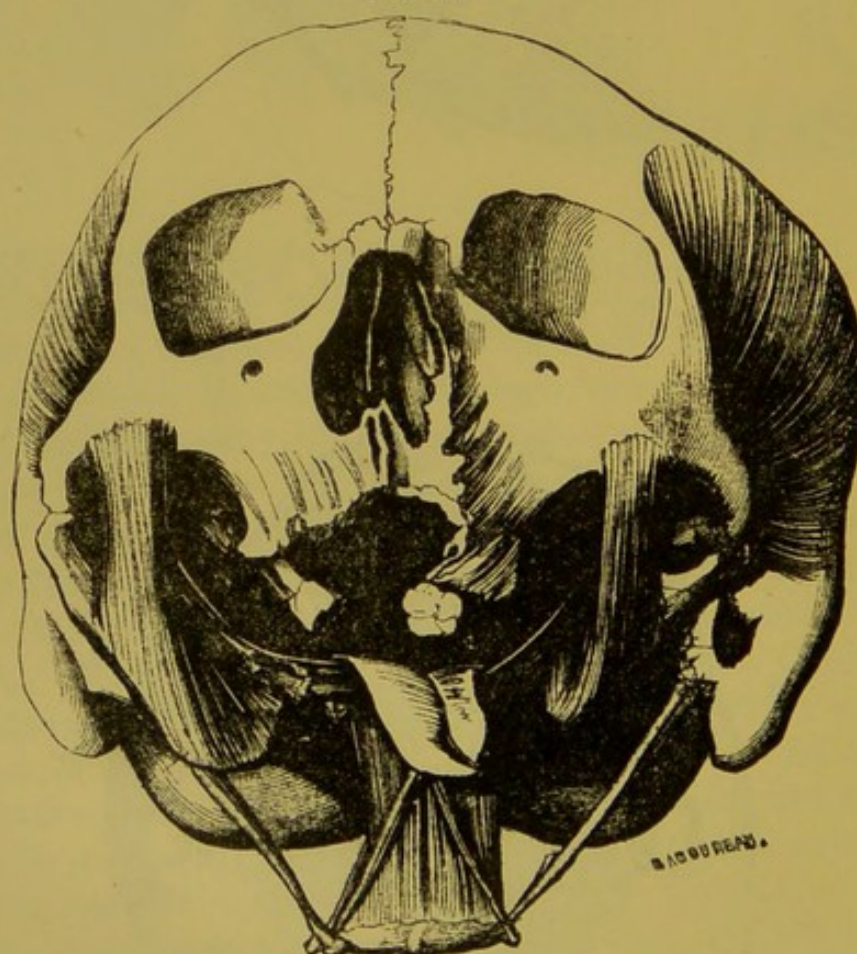


illustration (fig. 34) from M. Debout's paper, shows the dissection of a case of the kind more than thirty years after

FIG. 34.





the receipt of the injury, the history being as follows:—At the battle of Jena, Vernet had the body and left ramus of the lower jaw carried away by a cannon-ball. The soft parts, bruised and torn, hung down in front of the neck, and the tongue was much injured from the tip along the left side. At the ambulance the parts were adjusted as well as possible, and the dressing completed. An abundant supuration ensued; splinters were detached from the extremities of the bones, and the whole was healed in three months.

Ribes, in 1818, describes thus the condition of the parts when Vernet had attained the age of forty-four. "The soft parts and loose flaps of the lips, chin, and cheeks have become agglutinated at the upper part of the neck, above and to the side of the larynx at the root of the tongue, where they form by their adhesion divers folds and cicatrices. The opening—the mouth—is situated beneath the arch of the palate; the tongue lies concealed in the soft parts, and retracted towards the pharynx; the lower part of the tongue is closely adherent, and in a manner fixed to the parts beneath it, so that the tip can be projected only to the left, and not forwards.

"The patient wears a silver double chin, with which he can speak pretty distinctly; but is much inconvenienced by the incessant escape of the saliva."—(Dict. des Sciences Médicales, vol. xxix. p. 425.)

Vernet lived twenty years longer; and some years before his death the mouth-opening became so narrow that, instead of being obliged to change the cloths or sponges into which the saliva used to flow five or six times a day, he scarcely wetted one.

In this case the steady contraction of the cicatricial tissues of the mouth had a beneficial tendency. The effect produced upon the teeth of the upper jaw is well seen in the illustration.

In the United States Army Museum is a remarkable specimen of attempted bony repair of a nearly as extensive injury, which is thus described:—"1162. The inferior



maxilla, probably fractured by a musket-ball. The body of the bone has been removed nearly to the angle on each side, and an irregular plate of new bone, measuring two inches in length, three-fourths of an inch in width, and one half inch in thickness has formed anteriorly, and is connected to the rami on either side by ligamentous bands. The patient died one hundred and one days after the receipt of the injury."



## CHAPTER VI.

## DISLOCATION OF THE JAW.

DISLOCATION of the lower jaw may be unilateral or bilateral, the latter being the more frequent variety, since of 28 cases of dislocation given by Giraldès, 15 were of both condyles; and of 76 cases given by Malgaigne, 54 were the same, 31 of these last being in women. Bilateral dislocation occurs most frequently in middle age, though it is not unknown in youth and old age; thus Sir Astley Cooper gives the case of a child who experienced the accident from forcing an apple into his mouth, and both Nélaton and Malgaigne have met with it in old people of sixty-eight and seventy-two years of age. The possibility of dislocation of the jaw following traction on the chin with the finger or hook in delivery need be only alluded to, since the occurrence must be unknown, or nearly so, in the case of living children. The less frequent occurrence of the accident in the extremes of age may be explained, partly by the smaller liability of children and old people to external violence, and also by the fact that owing to the obtuseness of the angle formed between the ramus and the body of the bone at those ages the leverage of the jaw is diminished, and the muscles do not act in such vertical lines as in middle age. The explanation offered by M. Nélaton—viz., that in youth the coronoid processes are too short, and in old age directed too far back, to impinge upon the malar process of the upper jaw—appears to be untenable, and will be referred to in describing the pathology of dislocation.

The causes of dislocation are yawning, vomiting, or shouting, in all of which actions the patient's mouth is opened



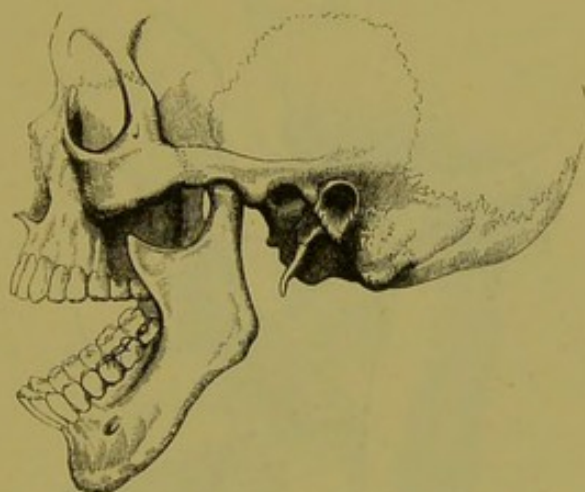
to its fullest extent; or it may result from blows or the kicks of animals, and this is particularly the case with the unilateral form of the affection. Causes acting within the mouth may also produce dislocation—*e.g.*, the introduction of an apple, as in Sir Astley Cooper's case, already alluded to, or the introduction of the stomach-pump. Extraction of teeth, even in the most skilful hands, has been known to produce the accident, and recently Dr. Guignier, of Montpellier, has reported (*Abstract of Medical Sciences*, vol. ii. 1866) an example of complete dislocation occurring during the laryngoscopic examination of a lady, aged thirty-eight, in whom reduction was readily effected.

The pathology of dislocation of the jaw has been a subject of considerable discussion and investigation from the earliest days of surgery to the present time, and various views respecting it have been brought forward by different authorities. When the mouth is opened to its fullest extent, each condyle of the jaw leaves the true glenoid cavity and rests against the articular eminence and the inter-articular fibro-cartilage, which is drawn forward by the pterygoideus externus, the same muscle which advances the jaw itself. The articular eminence is covered by articular cartilage, and by the synovial membrane reflected between it and the cartilage, and a second synovial membrane being placed between the cartilage and the condyle of the jaw, the necessary freedom of movement is insured. A cavity is thus left immediately behind the condyle, which can be readily felt in the healthy living subject, and which is only exaggerated in cases of dislocation. When the jaw is in this position, but a very slight force is needed to carry the condyle over the articular eminence and produce a dislocation, and this is brought about, either by a force applied to the chin, when, owing to the length of the lever, the result is readily induced; or by a spasmodic contraction of the external pterygoid muscles, which, as has been stated, are already in action. The lateral ligaments of the joint have no power to check this, and the few fibres which surround the synovial membrane and form a loose capsule are easily



stretched, but never tear. The accompanying illustration, from Sir Astley Cooper's work on "Dislocations," shows the position of the bone at this period, but is wanting in the ligaments and inter-articular cartilage, which latter is ordinarily carried forward with the condyle. Immediately that the condyles are dislocated the masseter and internal pterygoid muscles contract and draw the jaw forwards and upwards so as to produce the projection of the chin characteristic of the accident. This last muscular action was originally described by Petit, and has been denied, but has recently been confirmed by Heinlein and Busch, who found

FIG. 35.



experimentally on the dead body, that by replacing the muscles by india-rubber bands acting in the same direction as the muscles, the luxation could be invariably maintained and the characteristic deformity produced.

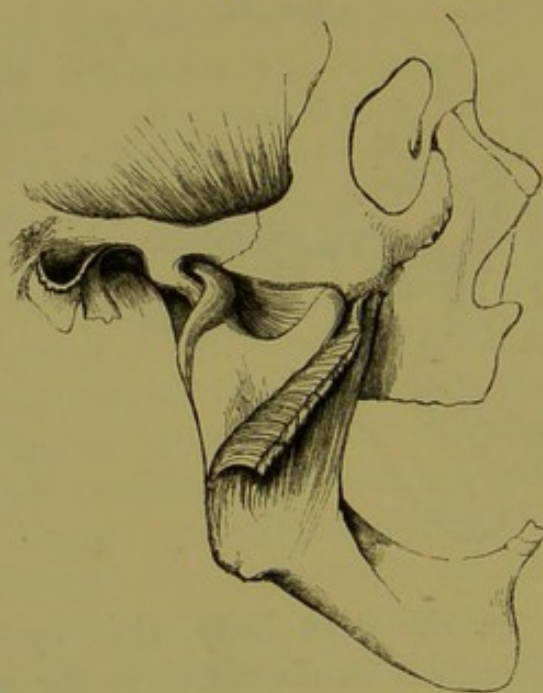
Both Maisonneuve (*L'Union Médicale*, 1863), and Otto Weber (*op. cit.*), have experimented upon the dead body, and have succeeded in producing dislocation of the jaw by imitating the three movements already described, and the following is the condition of the parts found upon dissection:—The condyles are in front of the root of the zygoma, the coronoid processes are completely surrounded by the tendons of the temporal muscle, and are quite below, and scarcely ever touch, the malar bone. The capsular ligament



is tense, but not ruptured; the external lateral ligament is tense, and passes from behind forwards instead of from before backwards; the internal lateral and stylo-maxillary ligaments are stretched, and this is increased by raising the chin. The inter-articular fibro-cartilages are attached to and follow the motions of the condyles. According to Maisonneuve, the temporal muscles are only stretched; but Weber says that some of the fibres are usually torn off the coronoid process.

The fixation of the dislocated jaw has received a different

FIG. 36.

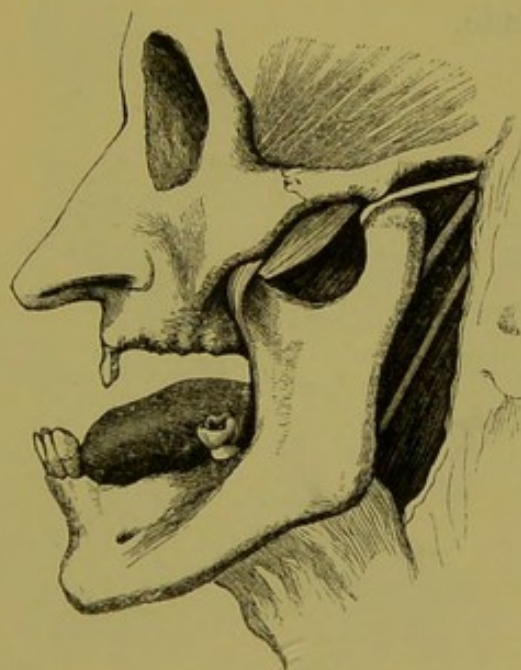

explanation, and has been attributed to the catching of the coronoid process against the malar bone, or the malar process of the superior maxilla. This view was originally maintained by Fabricius ab Aquapendente, by Monro, and more recently by Nélaton (*Revue Médico-Chirurgicale*, tom. vi.), who is followed by Malgaigne in his treatise on "Dislocations" (1855). Nélaton maintains that in his experiments on the dead body, he constantly found the coronoid process fixed against the malar bone; and he appeals also to a unique preparation of a pathological dislocation which he



dissected and presented to the Musée Dupuytren. The accompanying illustration (fig. 36), reduced from Malgaigne's Atlas, is from the preparation in question. The coronoid process in this certainly touches the malar bone, and the relations of the inter-articular cartilage and external lateral ligament are well seen. Ribes and Monteggia agree with Maisonneuve and Weber in believing that in most jaws the coronoid process is not long enough to reach the malar bone; and the last-named author mentions that Roser was unable to reduce an old dislocation of eight weeks' standing, even after cutting through both coronoid processes from within the mouth, by means of bone forceps.

FIG. 37.



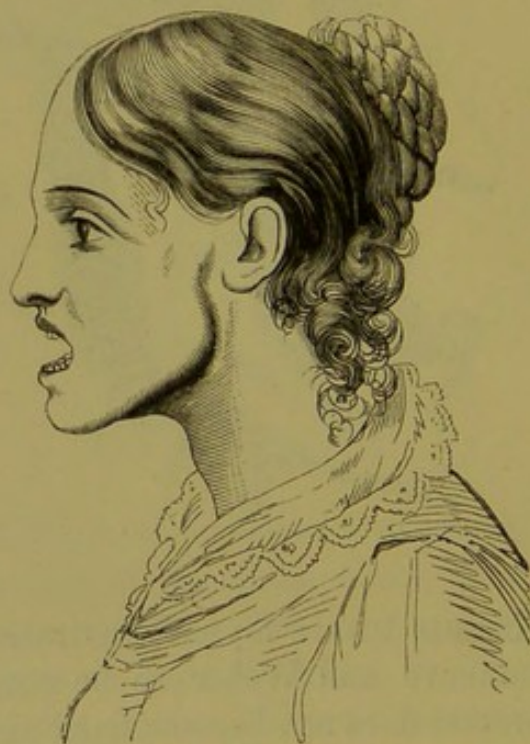From experiments I have myself instituted, I believe the view of Maisonneuve and Weber to be correct—viz., that the coronoid process does not become fixed against the malar bone. In the macerated skull it is easy to dislocate the condyle so far in front of the articular eminence as to cause the coronoid process to be hooked against the malar bone; but this is by no means easy on the subject, even when the parts are dissected, and can only be accomplished



by tearing the structures of the joint very considerably. Besides, the position the jaw assumes when the condyles are so driven forward, is not that of the ordinary form of dislocation, the jaws being too widely separated, and the chin drawn back instead of being advanced. Were the coronoid processes fixed against the malar bones, it would be impracticable to effect reduction by elevating the chin, as is frequently done; and, moreover, the gradual improvement noticed in old-standing cases of dislocation would be impossible.

A preparation, illustrating the anatomy of dislocation, which was dissected for me by my friend and pupil Mr. Beck, accompanied this essay, and is now in the Museum of the College of Surgeons. From one side of it the drawing (fig. 37) was made.

FIG. 38.

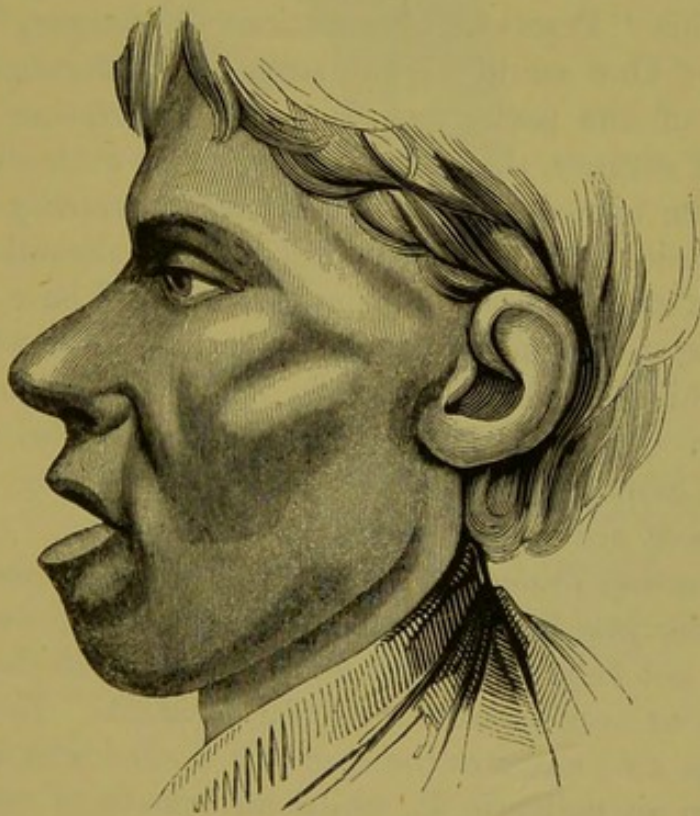


*Symptoms of Dislocation.*—When the dislocation is bilateral, the deformity is so evident as at once to attract attention. The mouth is open and the jaw fixed, with the lower teeth carried beyond those of the upper jaw, as seen



in fig. 38, from Fergusson. Speech and deglutition are much interfered with, since the lips cannot be approximated; and, for the same reason, the saliva dribbles from the mouth. On examining the neighbourhood of the temporo-maxillary joint, a distinct and unusual hollow will be seen immediately in front of the ear, and the condyle may be both seen and felt in front of this. The coronoid process forms a projection immediately behind and below the malar bone, and may be readily felt in its abnormal position from the mouth. The masseter is firmly contracted and strongly prominent. R. W. Smith, in his work on "Fractures and

FIG. 39.



Dislocations," has also specially called attention to a prominence immediately *above* the zygoma, which has not been usually described, and which he believes is due to the condyle pressing forward and stretching the posterior fibres of the temporal muscle, but which I believe to be caused by their spasmodic contraction. The accompanying drawing (fig. 39),



taken, by permission, from the work referred to, illustrates both these points.

In dislocation of one condyle only, the signs are less manifest, and may possibly be overlooked or misinterpreted. The chin is usually directed towards the *sound* side instead of towards the *injured* side, as is the case in fracture of the neck of the bone; the hollow in front of the ear is equally visible in this as in the double form of dislocation, and speech and deglutition are similarly to some degree interfered with. The obviousness of the direction of the chin to one side will depend in some degree upon the original prominence of that feature in the individual, and too much stress must not be laid upon the symptom: thus Hey, in his "Practical Observations in Surgery" (1814), remarks—"One would expect, from a consideration of the structure of the parts, and from the description given in systems of surgery, that the chin should be evidently turned towards the opposite side: but I have repeatedly seen the disease (accident) where I could discern no alteration in the position of the chin. The symptom which I have found to be the best guide in this case is, a small hollow which may be felt behind the condyle that is dislocated, which does not subsist on the sound side." R. W. Smith also mentions that, in a case of luxation of the right condyle, he had seen the efforts at reduction applied to the left side.

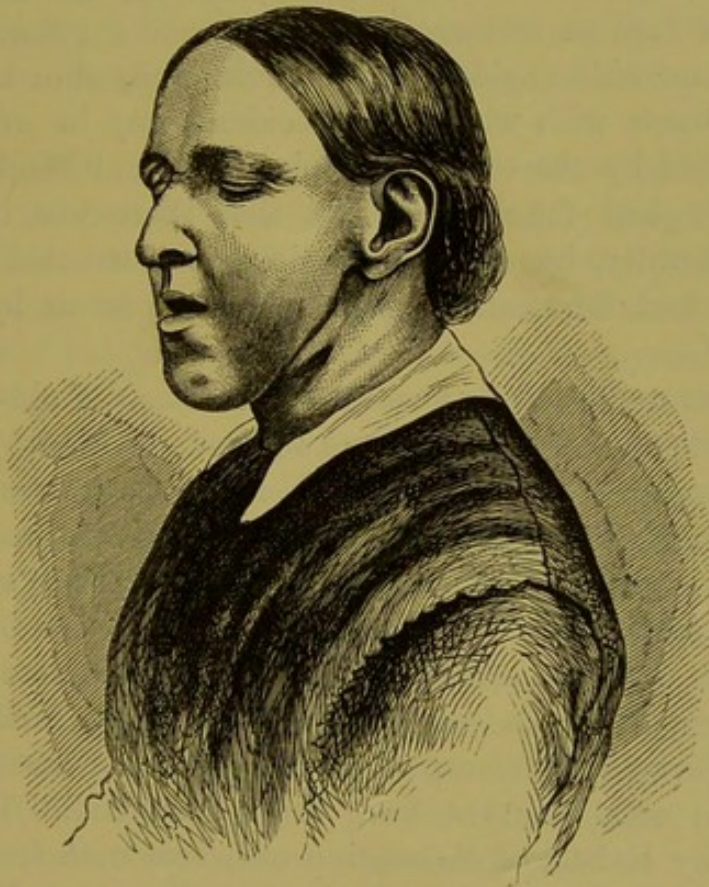
*Old-standing Dislocations.*—From various causes dislocations of the jaw have been from time to time overlooked, and have not been brought under the notice of the surgeon for weeks or even months after the accident. Thus R. W. Smith (*op. cit.*) narrates the case of a woman who dislocated her jaw in an epileptic fit, whilst an inmate of one of the Dublin hospitals, but the accident escaping notice the bone remained unreduced. The drawing in Mr. Smith's work represents the condition of the patient one year after the accident, and it is to be remarked that though the signs of dislocation are sufficiently obvious in the hollow in front of the ear and the projection of the chin, yet that the patient was able to close the lips so as to retain the saliva and



speak intelligibly, but was able to open the mouth only to a limited extent.

Mr. John Couper has recorded an equally interesting case in the *London Hospital Reports*, vol. i. p. 262. More than three months before, the patient had dislocated her jaw bilaterally (for the second time) whilst yawning, and when seen, she presented the appearance shown in the illustration (fig. 40), for which I am indebted to the editors of the *Reports*. Mr. Couper found that the jaw had re-

FIG. 40.



covered a certain amount of mobility, so that the incisors of the two jaws could be approximated to within an inch, and separated to an inch and a half, the molar teeth being nearly in contact during extreme closure. The chin was depressed and carried forward, and the hollow in front of the ear was well marked. The patient's utterance was slightly, if at all, impaired, and the labial consonants were



pronounced as distinctly as other sounds, and the saliva was retained. Mr. Couper made attempts, under chloroform, both with levers and forceps, to reduce the dislocation but without success, but the effect of the operation was to increase the range of motion of the jaw.

A second case of old double dislocation of the jaw occurred in the London Hospital in the year following Mr. Couper's, and being of only two months' standing was reduced with some little difficulty by Mr. Hutchinson, who says (*London Hospital Reports*, vol. ii: p. 33): "The woman was unable to shut her mouth, and her chin stuck forward, giving her face an awkward, lantern-jawed expression; but there was no wide gaping and she could easily shut her lips." The readiness with which the accident may be overlooked is illustrated by the concluding observation of Mr. Hutchinson—"We had fancied at first that there was but little facial deformity, but this impression was corrected at once when we had her natural expression before us by way of contrast."

Other examples of the successful reduction of old-standing dislocations have been from time to time recorded. Thus Sir Astley Cooper ("Fractures and Dislocations") gives a case in which Mr. Morley reduced a dislocation after a month and five days. Stromeyer had a similar case. Spät was successful in a case fifty-eight days old: Demarquay in one of eighty-three days (Weber, *op. cit.*), and Donovan in one of even ninety-eight days (*Dublin Medical Press*, May, 1842).

*Rare Forms of Dislocation.*—A few cases of rare forms of dislocation with fracture have been described. The cases recorded by Robert of dislocation outwards with fracture on the opposite side, and by Mr. Croker King and Mr. Gunning of New York, of dislocation outwards and backwards with fracture of the symphysis, have been already referred to under the head of "fracture complicated by dislocation." It might be supposed from the anatomy of the parts that dislocation backwards would be impossible without fracture of the front wall of the meatus auditorius externus or of the glenoid cavity, and the specimen in St. George's Museum



(i. 28) is an instance in point. In Mr. King's case there can be little doubt that there was some injury to the meatus from the hæmorrhage which occurred.

*Congenital Dislocations.*—Cases of congenital dislocation of the lower jaw, with more or less malformation, have been recorded by Guérin (*Gazette Médicale de Paris*, 1841) and R. W. Smith ("On Fractures in the Vicinity of Joints"), who gives elaborate drawings of the dissections of the case. Mention may be made also of the cases of congenital smallness and arrest of development recorded respectively by Langenbeck (*Archiv für Klin. Chir.*, i.) and by Mr. Canton (*Pathological Society's Transactions*, vol. xii.); but these subjects do not properly come within the scope of this essay.

*Sub-luxation* of the jaw was first described by Sir Astley Cooper, and has been generally recognised by surgical writers since his time. It is an affection occurring principally in delicate women, and appears to depend upon relaxation of the ligaments of the joint permitting a too free movement of the bone and possibly (though this is conjectural) a slipping of the inter-articular cartilage. The accident usually occurs during yawning, and the symptoms are sudden inability to close the mouth and pain in one temporo-maxillary articulation, the condyle being more prominent than usual. The accident is usually readily overcome by a slight lateral movement of the jaw, but its recurrence must be combated by the use of tonics, and small blisters over the affected joints. Hamilton says that he frequently suffered from the affection when a youth, but that as he became older the annoyance ceased without any special treatment.

*Treatment of Dislocation.*—Although ordinarily requiring the assistance of the surgeon, dislocations of the jaw have been known to become reduced spontaneously, or with the aid of the patient alone. Nélaton mentions a case of spontaneous reduction occurring in his own practice; and Sir Astley Cooper mentions the case of a lady who reduced a dislocation of one side, induced by sea-sickness, with the help of an oyster-knife. Levison also gives the case of an old



man who, suffering from recurring dislocation, especially when waking from sleep, "would pull his jaw and press it backwards, when, after about half an hour's work, bang it seemed to go, and all was right again."

In recent cases of dislocation, reduction may usually be accomplished with facility by various methods of manipulation, but cases of long standing may require some instrumental assistance. The simplest mode is for the head of the patient to be held firmly against the breast of an assistant, when the operator, having protected his thumbs with lint or a towel twisted round them, passes them as far back as possible upon the molar teeth, grasping the jaw at the same time with his fingers. Pressure is then made downwards and backwards, so as to free the condyles from the articular eminence, and as soon as this is done the chin is elevated and the condyles slip into place. This plan may be advantageously modified by reducing the condyles successively though at the same operation, care being taken that the condyle first reduced is not again dislocated, as has happened more than once. The proceeding is thus rendered easier, because one condyle forms a point of support or fulcrum for the other, so that the entire jaw is used as a lever, instead of the thumbs forming the fulcra, as in the other method. This latter method also obviates the danger of the jaw suddenly closing upon the thumbs, though this is probably somewhat exaggerated.

Sir Astley Cooper recommends the introduction of two corks (or one in the case of single dislocations) between the molar teeth to act as fulcra, the chin being then drawn upwards; and narrates a case of a madman, where, for his own safety, he used two table-forks with a handkerchief wrapped round them to act as fulcra. The same method was originally employed by Ambrose Paré, only using wedges of wood instead of cork, and his example has been followed by numerous surgeons. Mr. Pollock employed this method successfully in 1866, in a case of dislocation of four months' standing, a gag being placed between the molar teeth, and the strap of an ordinary tourniquet being




applied round the head and beneath the jaw, so that the screw might exert its power upon the dislocated bone. (*St. George's Hospital Reports*, vol. i.)

Instead of mere fulcra having been inserted between the molar teeth, levers have been employed to depress the lower jaw in cases of difficulty; thus Sir Astley Cooper narrates that Mr. Fox, the dentist, "placed a piece of wood a foot long upon the molar tooth of one side, and raising it at the part at which he held it, depressed the point at the jaw on that side, and succeeded in reducing the condyle. He then did the same on the other side, and thus replaced the bone." Here, of course, the upper jaw formed the fulcrum, and the advantage of acting upon one condyle at a time is seen. This method is not invariably successful, however, for in the case of old dislocation under Mr. Couper's care, already related, that gentleman employed levers of pine wood six inches long without success.

A more powerful leverage action is obtained by the forceps invented by Stromeyer, which is shown in the illustration (fig. 41). The forceps consists of two blades expanded

FIG. 41.



at the extremities, so as to fit pretty accurately the dental arches of the upper and lower jaws, and covered with leather. A spring between the handles tends to keep the blades closed, and a screw and nut acting upon the handles, is able to close them so as to make the blades diverge forcibly; at the same time a movable pin loosens this, so that the blades may be closed again the moment they have done their work. The blades being closed, and introduced between the teeth as far as possible, are then separated by means of the nut and screw, until the condyles are disentangled from the articular eminences, when, being suddenly closed, they are



withdrawn, an assistant at the same time pressing the jaw backwards, so as to bring the condyles into the glenoid cavities. In this way Stromeyer reduced a dislocation of thirty-five days' standing.

Nélaton, whose view with regard to the locking of the coronoid processes against the malar bones has been already referred to, advocates acting directly upon these processes, in order to force them and the condyles backwards. The surgeon may stand in front of the patient, and, with his thumbs pressing against the coronoid processes, either within or without the mouth, grasp the mastoid processes with his fingers, and thus have a firm *point d'appui* to act from; or, sitting behind the patient, he may place his thumbs on the nape of the neck, and endeavour to draw the jaw backwards with his fingers.

Maisonneuve, though differing from Nélaton with regard to the pathology of the affections, agrees with him in the propriety of acting upon the coronoid processes. The following were the conclusions he arrived at from numerous experiments on the dead body:—Blows on the cheeks or chin (which have been recommended in bygone days) were useless; pressure with the thumbs on the back teeth, combined with elevation of the chin, succeeded only a few times; depression of the chin at the same time that the thumbs pressed away the masseters from the interior of the mouth was rather more successful; depression of the chin and pressure on the coronoid processes from before backwards, with the thumbs in the mouth, effected reduction constantly and with ease.

In all cases of dislocation the administration of chloroform will facilitate the reduction, but it is not necessary in recent cases. In old-standing cases it should invariably be had recourse to, since the operation will necessarily be both painful and prolonged, in consequence of the formation of fibrous adhesions.

When reduction has been effected, the precaution should be taken to limit the movements of the jaw for a week or two by the use of the four-tailed bandage, used in cases of



fracture of the jaw. In individuals liable to recurring dislocation of the jaw (like the woman mentioned by Putégnat, whose jaw was dislocated once a month), some elastic support for the chin should be employed, and care be taken not to open the mouth too widely.



## CHAPTER VII.

## INFLAMMATION—ABSCESS—PERIOSTITIS.

INFLAMMATION of the periosteum leading to necrosis, and inflammation in connexion with carious teeth leading to abscess, appear to be common to both jaws, but there is a form of inflammation to which the lower jaw alone is subject and which requires notice. The inferior maxilla differs from the superior in consisting of two plates of compact tissue (of which the outer is the thinner) separated by cancellous bone, through which runs a canal for the passage of the inferior dental nerve and vessels, each of which gives an offset to each dental fang. When from the irritation of unsound teeth inflammation is excited, it rapidly spreads up the jaw, leading in a few hours to an amount of effusion into the cancellous structure which distends it and forces out the external plate of the bone. This effusion, as I have had the opportunity of observing in my own person, is at first of discoloured serum, which by pressure on the jaw can be made to exude by the side of, or through, the hollow tooth which was the original cause of the mischief. If the source of irritation be allowed to remain, plastic effusion now takes place leading to the formation of a distinct tumour, usually in the neighbourhood of the offending tooth. This is slowly absorbed on the early removal of the tooth, but if the irritation be allowed to continue, the effusion will become organized into fibrous tissue, and a very serious affection may thus be produced. From an attentive examination of numerous examples of fibrous tumour of the lower jaw both before and after removal, I feel sure that the majority originate in the manner here described.



I had in the summer of 1867 a patient under my care—a boy aged fourteen—who was suffering from an enlargement of the lower jaw, due to an expansion of its wall by a growth evidently connected with a carious permanent first molar tooth. I had the peccant tooth extracted, but the enlargement of the jaw continued. In August some suppuration occurred, and an abscess broke behind the angle of the jaw, but this soon healed, and in November he was perfectly free from pain and able to open the mouth thoroughly. I was anxious to perforate the jaw from the mouth so as to give exit to any fluid contained in it and extract any solid material which might exist, but the parents would not consent to any surgical interference. The face has now (May, 1868) considerably diminished in size, but there is still a difference between the two sides. Stanley, in his work on the Bones (p. 20), says, "I believe that a bone once enlarged by the expansion of its tissue will permanently remain so;" but this rule does not hold good with the lower jaw, which bone can most certainly undergo very considerable expansion and yet recover its original form.

*Abscess.*—Inflammation, the result of diseased teeth, may lead to suppuration and abscess, and this may occur either as the ordinary Alveolar Abscess or Gum-boil, or as an abscess in the substance of the jaw, either upper or lower, which is a more serious affection. In ordinary Alveolar Abscess (*parulis*) the mischief begins at the apex of the fang of a carious tooth by an effusion of plastic material, around which, according to Salter (Holmes' "Surgery," vol. iv.), a little cavity is formed by the absorption of the alveolus, often accompanied by some amount of absorption of the fang itself. A portion of this lymph becomes converted into pus, and the remainder forms a kind of sac around it, so that it occasionally happens that on the extraction of the peccant tooth the sac and abscess are brought away with it. So soon as matter is actually formed, rapid absorption of the surrounding bone takes place, and the pus makes for the surface, finding an exit either at the side of the tooth, or by perforating the socket and burrowing in the



soft tissues. The direction which the pus of an alveolar abscess may take is very variable. According to Salter the commonest position for the matter to point is "on the outer surface of the jaw at a point corresponding, as nearly horizontally as may be, with the extremity of the fang of the affected tooth, and *piercing the gum within the mouth.*" But the matter may find its way on to the face, beneath the chin, or into the antrum, and, according to Tomes (Dental Surgery), "collections of matter, formed about the wisdom teeth, pass between the muscles and bone and escape at the angle of the jaw." Both Tomes and Salter mention the tendency of pus derived from an upper incisor tooth to burrow between the bone and periosteum of the hard palate and open upon the surface of the soft palate. The former also states that occasionally the pus separates the periosteum from one side of the hard palate and forces it down to a level with the teeth.

Abscess connected with the upper incisor teeth may also point within the nostrils by small orifices presenting little teat-like elevations, which will be at once detected on a careful examination of the nostrils. The patient's attention will have probably been directed to the occasional discharge of pus from the nose, and the case may, without care, be erroneously treated as one of ozæna.

The early symptoms of alveolar abscess are those of inflammation of the periosteum lining the alveolus, and of the peridental membrane of the tooth itself. There is a dull, obscure pain, relieved by biting upon the tooth, which appears to be raised slightly from the socket. The pain soon becomes of an acute, throbbing kind, and the constitutional symptoms are occasionally severe, amounting to high fever and delirium. The local symptoms are swelling and tenderness of the gum, and, according to Tomes, an early but evanescent symptom is a well-defined red ring encircling the neck of the tooth. The jaw becomes rapidly swollen and the face consequently distorted, and the acute symptoms continue until the pus has found an exit, and then as rapidly subside.



*Treatment.*—In the early stage, if the affected tooth has been recently stopped, and more particularly if the nerve-pulp has been destroyed with arsenic, the stopping should be immediately removed, or a hole drilled into the pulp-cavity through the side of the tooth, so as to give exit to any accumulated fluid. (See paper on Rhizodontresis, by Mr. Hulme: *British Journal of Dental Science*, April, 1865.)

Where there is no obvious exciting cause for the inflammation, the application of one or two leeches to the gum by means of a leech-tube, and the subsequent fomentation of the part by means of hot water held in the mouth, may give relief; but if this is not the case, extraction of the tooth, or stump of a tooth, should be immediately performed. There is a popular notion, which has received some support at the hands of some members of the profession, that extraction of a tooth must not be performed during the stage of active inflammation of the alveolus. I know of no ground for this statement, which is entirely devoid of truth.

When matter has formed, and is finding a precarious exit by the side of the tooth which is certainly dead, and will only prove a source of irritation, its immediate extraction is the best practice; but when, as frequently happens, the matter has perforated the alveolus, and passed into the substance of the gum so as to produce an elastic fluctuating tumour between the teeth and the cheek, a free incision into it is the best and only mode of treatment; and in these cases, if the hole in the alveolus is sufficiently large to give free exit to the pus, the tooth may be eventually saved. I know of no reason for delaying the incision until the gum has become distended with pus, though the practice has its advocates. So soon as inflammatory swelling takes place, an incision will do good by relieving congestion and giving exit to exudations; and I have never seen reason to regret an early and free incision in such cases. A sharp scalpel or small bistoury is the best instrument for the operation, the ordinary gum-lancet being an unsuitable and inconvenient instrument for the purpose.



In cases of abscess arising from the upper incisor teeth and extending along the palate, a free and early incision is even more necessary than in the ordinary form of abscess, since extensive necrosis and exfoliation of the hard palate, with consequent perforation, may not improbably result from the delay. The same rule holds good also in all cases of matter pointing within the cavity of the mouth; but where, as has already been mentioned, the matter shows a tendency to point on the skin of the face or neck, every means should be taken to avert if possible the opening in this situation, and to insure an exit for the matter within the mouth. In order to fulfil the latter indication, which is most essential, the tooth or stump which has been the cause of the mischief should be immediately extracted, and a deep incision made through the gum near the spot where the matter points. It may be well to notice here, that the cause of the abscess in these cases is not unfrequently overlooked, owing to the distance between the tooth and the point where the matter appears, and that in all cases therefore of abscess about the jaws or neck it is well to investigate carefully the state of the mouth.

No greater mistake can be made than to encourage the pointing of an alveolar abscess on the surface of the skin by poulticing. During the early and acute stage of the inflammation, the warmth of a poultice may be grateful to the patient, and if applied for a few hours will do no harm, though I should myself greatly prefer the application of extract of belladonna and glycerine (ʒij to ʒss); but continued poulticing will merely lower the vitality of the part, and tend to the very result which is to be avoided if possible. Even when the skin is already reddened and adherent to the bone, its breaking may be avoided (provided a free exit for the discharge of matter into the mouth has been secured) by painting the surface with iodine and avoiding all warm applications.

The sinuses left after an alveolar abscess has burrowed through the integuments, remain open so long as the cause of irritation remains untouched, and the orifice though con-



tracted never closes, being surrounded by granulations which sometimes grow to a large size. I recently had under my care a girl who was brought to me for the supposed growth of a horn from her chin, and the appearance was not unlike one of the horn-like growths of cuticle occasionally met with. It proved to be nothing more than a growth of epithelium on the top of long granulations around a fistulous opening, due to the presence of a stump in the lower jaw, the bone having been perforated by the abscess. The successful treatment of these sinuses, like those dependent upon the presence of dead bone elsewhere, can only be insured by the extraction of the offending tooth or stump. In these cases the fang is necrosed and forms a sequestrum in the same way as a piece of bone, and will keep up irritation so long as it is allowed to remain.

Abscess may form in the substance of the upper or lower jaw as a consequence of decayed teeth, but differing from ordinary alveolar abscess in the absence of any tendency to find an exit by the socket of the tooth. In the upper jaw this affection has been confounded with the so-called "abscess of the antrum," which is more properly an empyema, and which will be subsequently discussed; but Otto Weber (*Allgemeinen und speciellen Chirurgie*) strongly maintains that abscess may form in the wall of the antrum, but perfectly separated from it both by the periosteum and the mucous membrane, or sometimes by a plate of bone.

Abscess in the substance of the lower jaw has been more frequently met with: thus Mr. Annandale, of Newcastle, met with a case of chronic abscess in the left side of the lower jaw of a boy aged ten, resulting apparently from repeated blows upon the part. Owing to the great thickening of the bone the abscess was not diagnosed, and the half of the jaw was removed, the boy making a good recovery. The tumour was of the size of a hen's egg, and extended from the first bicuspid tooth to the articulation. On section, the bone was found to be very dense, and contained a cavity of the size of a horse-bean, filled with pus and lined by a distinct



membrane of some thickness. (*Edinburgh Medical Journal*, December, 1860.)

Mr. Henry Lee, also, in his paper on Abscess in Bone ("Pathological Observations," p. 52), says, "At King's College Hospital a case lately presented itself where a circumscribed abscess had formed in the lower jaw, the bone around being greatly condensed and thickened."

Another mode in which abscess may be formed in both the upper and lower jaws is by the suppuration of a "dentigerous cyst" connected with non-developed or imperfectly-developed teeth. A remarkable case of this kind is reported by Weber (*op. cit.*), in which a woman, aged 25, shortly after the partial eruption of a wisdom-tooth, found a tumour forming on the left side of the jaw, which in a year extended from the mental foramen to beyond the angle. The bone gave a crackling sound when pressed upon, and in one or two situations appeared to be entirely absorbed. An incision was made over it and the tissues turned aside, and on opening the tumour three ounces of thick flaky pus poured out. Part of the wall was removed, and the patient made a good recovery. The case will be found in detail in the Appendix. (Case X.)

Probably the case described by Liston in his "Elements of Surgery" (p. 419), in which he mentions that osteo-sarcoma may supervene on "spina ventosa" of the lower jaw, is an instance in point. The case was that of a young man, aged 21, who had an abscess of the lower jaw in the molar region, which was evacuated through the mouth, and by means of a seton. Two years after, the abscess refilled, and again after another year; osteo-sarcoma then developed, necessitating the removal of half the jaw.

A remarkable specimen is in the Museum of King's College, of a large abscess of the lower jaw, for which half the bone was removed by Sir William Fergusson. The specimen has been divided, and one-half put up wet, showing the immensely thickened wall of the cavity; the other having been macerated, shows merely the shell of expanded and partially absorbed bone. The disease had



followed an attack of erysipelas of the face and tooth-ache, and continued to increase for eleven years, discharging at intervals offensive matter. This may also be taken as an example of chronic abscess in the jaw, but whether originating in a cyst, or merely the consequence of inflammatory action, it is impossible now to decide. This I have reason to believe is the specimen referred to by Mr. Henry Lee.

*Periostitis.*—The jaws, no less than other bones of the skeleton, are subject to periostitis, which may be of the acute or chronic variety. The acute form may arise from the irritation of decayed teeth, or in young subjects from cutting the permanent teeth; from mechanical injury; or may be induced by a specific poison, such as that of the exanthemata, of mercury pushed to salivation, or the vapour of phosphorus. In strumous children, however, periostitis may occur without any obvious cause, except a constitutional taint, which leads, as we frequently see, to periostitis in other parts of the body.

Mr. Stanley, in his work on "Diseases of the Bones" (p. 71), alludes to cases of this kind, though he does not appear to connect them with a strumous diathesis. He says, "A large portion of the lower jaw in young persons occasionally perishes without any previous derangement of health, local injury, or other apparent cause. But in some cases an aching in the bone has preceded the death of it. Such examples of necrosis usually occur in early life, between the fourth and twentieth years, but rarely later."

The symptoms of periostitis are pain, which is aggravated at night, heat of the part, with considerable swelling of the face, and constitutional disturbance; the teeth are found to be raised somewhat from their sockets and loosened, and the least pressure upon them gives excruciating pain.

In all these cases the tendency of the inflammation to run on to suppuration, and thus induce necrosis of the bone, is so great that the disease is often not recognised in its early stage, but should it be so, the treatment relied upon in other parts of the body would be applicable here—viz., local depletion by leeches, a free incision through the



affected periosteum to give exit to effusion, followed by poppy fomentations, and the exhibition of salines and sedatives.

The more chronic form of periostitis is usually of syphilitic origin, and leads to the formation of nodes here as in other parts. The palate is especially liable to these swellings, which are due to effusion between the periosteum and the bone, and which, if left untreated, will as surely lead to necrosis as the more acute forms. Mercury is inadmissible in these cases, but iodide of potassium in full doses will rapidly remove the swelling, and restore the periosteum to a healthy state.

The simple form of periostitis which will lead to abscess, and perhaps necrosis, is sometimes very insidious in its approach, and the intermittent pain recurring usually at night, may mislead as to the original cause of the attack, the examination of the teeth being neglected, and the attention concentrated on a supposed constitutional diathesis. It is well, therefore, in all cases of supposed periosteal inflammation, to examine the condition of the teeth, both with the eye and by striking them pretty forcibly, and any tender tooth should be removed, since, according to Tomes, a greater or less degree of exostosis of the tooth itself is pretty certain to have taken place, which will keep up the irritation.

*Caries* of the jaws of idiopathic origin may be said to be unknown, for, as pointed out by Fergusson, the term caries ought not to be applied to the ulcerations met with in connexion with the formation of abscesses or the separation of sequestra. In cases of ulceration and extensive destruction of the tissues of the face by syphilis or lupus, the jaw-bones are sometimes involved and become carious, producing the most frightful deformity, or in the case of syphilis (probably mercurio-syphilis in former years), the disease may begin in the palate and gradually destroy it, laying the mouth and nose into one, and passing forward to the face.

In the *Archiv für Pathologische Anatomie*, xviii. 347, Dr. H. Senftleben has given an elaborate description of what



he terms *acute rheumatic periostitis* of the lower jaw, which appears, however, to differ in no essential particular from the ordinary form of acute periostitis following exposure, &c. He says that it attacks perfectly healthy and robust individuals with good teeth, after severe cold, commencing with violent toothache along one side of the lower jaw, considerable and often very intense fever, swelling of the cheek and gums, difficulty in chewing, &c. Active depletion is recommended, and an early incision if matter forms, but necrosis is a very frequent consequence. (*Sydenham Society's Year Book*, 1863, p. 259.)



## CHAPTER VIII.

## NECROSIS.

THE jaws are specially liable to necrosis consequent upon inflammation, but there is a difference in the frequency with which the upper and lower jaw is attacked. According to Stanley ("Diseases of the Bones," p. 69), the order of frequency of necrosis of the bones of the skeleton is as follows:—Tibia, femur, humerus, flat cranial bones, *lower jaw*, last phalanx of finger, clavicle, ulna, radius, fibula, scapula, *upper jaw*, pelvic bones, sternum, ribs; and the greater immunity enjoyed by the upper as compared with the lower jaw is due, no doubt, partly to its less exposed position, but more especially to the fact that necrosis occurs less frequently in cancellous than in compact bone. The great difference in the supply of blood to the two bones must also have an influence, the upper jaw being supplied by very numerous branches of the internal maxillary arteries, which inosculate freely from side to side, whilst the lower jaw is supplied by two small branches only, which do not anastomose.

The causes and early symptoms of necrosis are usually those of periostitis, and have been described under that heading. When the inflammation fails to be arrested, the plastic effusion between the periosteum and the bone becomes rapidly converted into pus, and this, by separating the membrane from the bone, soon leads to the death of the latter. In long bones, where there is a medullary canal abundantly supplied with blood, or in the upper jaw where the vascularity is great, the bone is able to resist this necrotic action for some time, and even to recover, although bared of periosteum for a short time; but in the lower jaw



this cannot be expected, and it is found that a very few hours after suppuration has been excited, the bone is in great part necrosed. This action does not extend, however, of necessity to the whole thickness of the jaw, for the disease almost invariably attacks the outer side of the bone first, and if timely relief be afforded to the pent-up matter, the periosteum in the inner side will escape injury, and that portion of the bone will be preserved. Or even if the disease affect the whole thickness of the bone, it may still be confined to the alveolar border, which may exfoliate, leaving the base of the jaw intact. Of this an excellent example is preserved in the Museum of the College of Surgeons in Dublin, where an unbroken exfoliation of the entire alveolar arch of the lower jaw, with the teeth still in it, closely resembles a set of artificial teeth. In the upper jaw also the disease may attack one part of the bone, the rest being intact, and thus a sequestrum may be formed from either the alveolus or the palatine plate, or occasionally from both, of which examples will be subsequently given. When the pus resulting from the inflammation is unrelieved by timely incision, it tends to gravitate and find an exit for itself at the most easily reached surface. Thus, in the case of the upper jaw the tendency of the matter is to burst into the mouth, and it is the exception to find openings on the face, except when the whole of the bone is involved. In the case of the lower jaw, on the contrary, the matter finds numerous openings for itself along the lower margin of the bone, on its outer aspect, and even at some distance down the neck.

The effects of necrosis of the jaw upon the teeth is easily seen, since in cases of entire necrosis they become loose and discoloured, and even in partial necrosis they cannot bear the least pressure, owing to the pain produced. In the majority of cases of necrosis the loose teeth prove such an annoyance to the patient that they are extracted if they do not drop out of their own accord; but cases have been met with, which will be subsequently referred to, in which the teeth remained *in situ* long after the bone was both necrosed and had been removed. In the case of young subjects, ex-



tensive necrosis of the jaw will ordinarily destroy the germs of the permanent teeth as well as the temporary teeth already cut, and of this a good example is to be seen in the Museum of St. Mary's Hospital, in a sequestrum of the lower jaw from a girl of from 3 to 4, after small-pox. The necrosis involves the whole of the right side of the body of the bone and a portion of the ramus, including five temporary teeth and the half-developed permanent teeth, and reaching beyond the symphysis, includes a portion of the outer plate of the left incisive region. But it has occasionally happened, after repair of the bone in young subjects, that the permanent teeth have been cut, thus leading to the supposition of a reproduction of the teeth as well as of the bone. Mr. Tomes has pointed out, that in these cases the sequestrum did not involve the pulps of the permanent teeth, although encroaching upon them, and they therefore remained *in situ*, whilst the new bone was formed around them, and the teeth, when fully developed, made their appearance in the ordinary way.

From a consideration of these cases Mr. Tomes draws the following valuable practical deductions as regards the treatment of necrosis of the young jaw, which may be usefully referred to at this point:—"I think all will agree that it is desirable in those cases where necrosis of the jaw occurs during the presence of the temporary teeth, that the sequestrum should be allowed to remain until it is perfectly detached both from the contiguous bone and soft parts, before its withdrawal is attempted; and that its removal should be effected with the least possible injury to the latter, so that the permanent teeth, if not destroyed by the disease, may be placed under the most favourable circumstances for their future growth and evolution." ("Dental Surgery," p. 75.)

Quite recently Mr. Oliver Chalk brought before the Odontological Society some cases which in his opinion proved that a fresh development of teeth might occur even after the jaw, together with the germs of the second set, had been removed by necrosis. Having had the opportunity, however, of hearing the paper in question, and of examining Mr. Chalk's preparations, I must remain of my previous opinion,



which coincides with that of Mr. Tomes—that such an event is impossible, and that the germs of any subsequently cut teeth must have been preserved, and become enclosed in the reparative material of the jaw. (See *British Journal of Dental Science*, Feb. 1868.)

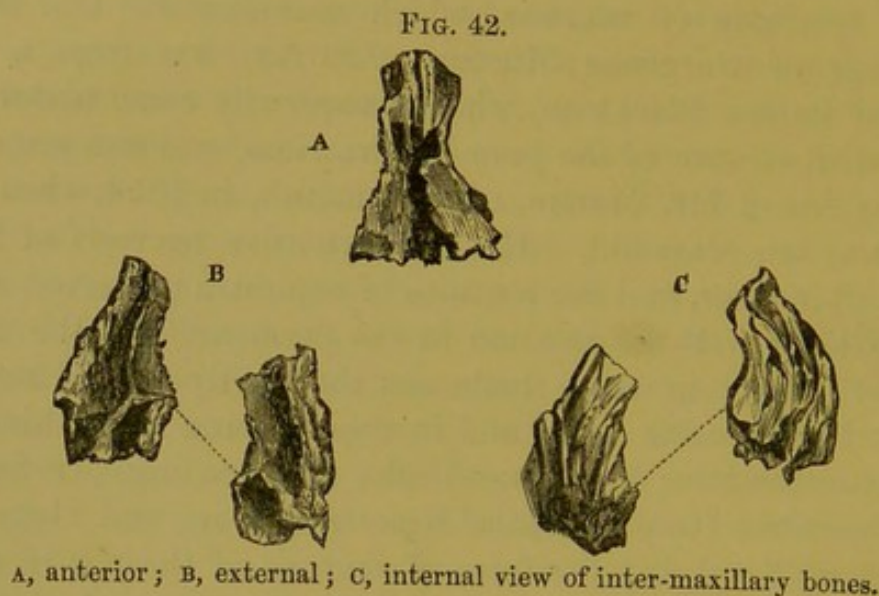
A specimen of necrosis, which accompanied this essay (College of Surgeons Museum, 720 A.), was from a boy named Barton Blackman, who subsequently came under my care with closure of the jaws by cicatrices, and was removed by my friend Mr. Martin, of Portsmouth, in 1856, when the boy was ten years old. He had extensive necrosis of both jaws after fever, and the portions of sequestra preserved show exceedingly well the relation of the permanent to the temporary teeth; in some instances the partly-formed second tooth having come away, and in others being left behind.

*Exanthematous Necrosis.*—Under this heading, Mr. Salter has described (*Guy's Hospital Reports*, vol. iv., and Holmes's "Surgery," vol. iv.) the form of necrosis of the jaw in children, which depends upon the poisonous effects of some of the exanthematous diseases, and especially scarlet fever. Mr. Salter claims to have been the first to call attention to this form of necrosis, and to trace it to its cause, but there can be little doubt that the disease has long been recognised, although not formally indicated. Mr. Salter has met with over twenty instances of the affection, and, in the *Pathological Society's Transactions* (vol. xi.), has described and figured seven specimens of the exfoliation—four after scarlet fever, two after measles, and one after small-pox. The disease appears to occur most frequently about the age of five or six years, when each jaw contains the whole of the first set and the germs, more or less advanced, of the second set of teeth, but Mr. Bryant has recorded (*Pathological Transactions*, vol. x.) a case of exfoliation of the intermaxillary bones after measles, in a child of three (fig. 42), and the boy Barton Blackman, already referred to, is an instance of the kind, at the age of ten.

The disease first shows itself a few weeks after the occurrence of the feverish attack, in tenderness of the mouth and



fœtor of the breath, and the gum is seen to be separated from the teeth and alveolus. The disease is remarkably symmetrical, appearing almost simultaneously on both sides of the jaw and rapidly denuding the bone, and leading to



necrosis and subsequent exfoliation of considerable portions of it. These usually include the whole depth of the alveolus, together with the partially-developed permanent teeth, but no case has been met with where the lower border of the jaw was involved.

I am indebted to Mr. N. Tracy, of Ipswich, for a preparation of necrosis following scarlet fever, in a girl of thirteen, which accompanied this essay (College of Surgeons Museum, 720 B). The disease was, as usual, symmetrical, but the right side was more deeply involved than the left. On the right side the sequestrum,  $1\frac{5}{8}$  inch in length and  $\frac{5}{8}$  in depth, contained the permanent first molar and the uncut permanent bicuspid teeth, besides a temporary molar, and involved part of the socket of the second permanent molar behind, and the canine in front. On the left side the disease involved only a portion of the alveolar border, including a temporary molar tooth. A model, taken three years later, showed the permanent gap left between the canine and the first molar teeth on the right side.



It is possible that this disorder might be confounded with *cancrum oris* in its early stage, but the absence of ulceration of the gum would at once distinguish it.

Mr. Salter regards necrosis after continued fever as of rare occurrence. In the Guy's Hospital Museum, however, is a portion of lower jaw (1091, 7), consisting of condyle, angle, and part of the body of the bone, separated by necrosis after fever, from a boy of fourteen. He recovered with comparatively trifling deformity, and the skin remained sensitive, although a large part of the trunk of the nerve must have been destroyed. In St. George's Hospital Museum also there are specimens (II. 91 and 95) of necrosis of the lower jaw and clavicle in fever.

A case of very extensive necrosis occurring after fever, under Mr. Stanley's care, will be referred to further on.

The repair of extensive necrosis of the alveolus of this character, in young persons, is a subject of some interest. In the lower jaw no repair of the gap is necessary, since, fortunately, the disease leaves the strong lower border of the bone untouched, which preserves the contour of the face, and forms a base for artificial teeth at a later date. In the case of the upper jaw, however, a development of tough fibrous tissue takes place, which gradually fills up pretty completely the cavity left, and thus, to a great degree, prevents the falling in of the cheek and consequent deformity, which would otherwise occur. In the Museum of King's College is a preparation of a nearly entire upper jaw of a child which became necrosed, as a consequence of small-pox, and was removed by Mr. Partridge, when surgeon to the Charing Cross Hospital, some thirty years ago. By the kindness of Mr. Canton, I have had access to a photograph of this patient, taken within the last few years, which shows the very slight deformity now present, in consequence of this repair of the original mischief.

This statement, respecting the repair of a necrosed superior maxilla, is, at first sight, in opposition to the opinion of Stanley ("On Diseases of the Bones," p. 72), who says, "under whatever circumstances the necrosis has occurred, it



is not, as I believe, ever followed by the slightest reproduction of the lost bone." This I believe to be the case *quoad* the reproduction of actual bone, and in the case of adults, but the filling up of the cavity by fibrous tissue I have witnessed in young subjects after the removal of tumours.

The case upon which Mr. Stanley founds the above observation is a remarkable one, from the apparent want of cause for the extensive mischief that ensued. The patient was a man aged thirty, who, twelve months before he applied to Mr. Stanley, began to suffer pain in his upper jaw, soon after which the teeth fell out of their sockets, and matter was discharged into the mouth. When the dead bone was sufficiently loosened, Mr. Stanley drew away the greater part of both superior maxillæ.

A very similar case occurring in a strumous man, aged forty, is recorded by Mr. Ernest Hart, in the *Lancet*, 19th

FIG. 43.

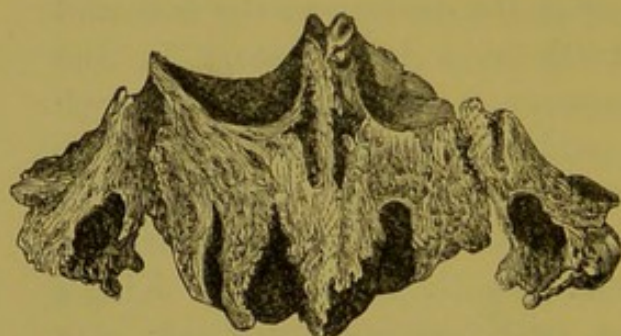
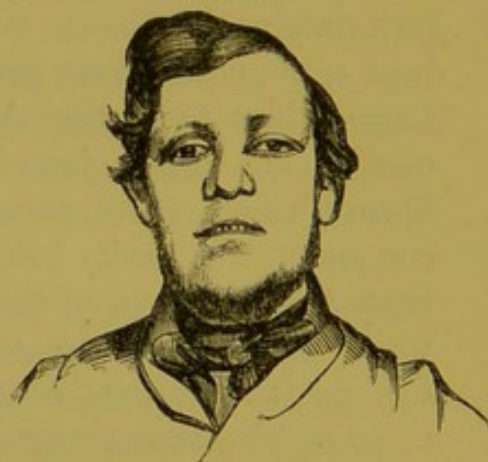

FIG. 44.



July, 1862, and, by the kindness of that gentleman, I am enabled to reproduce the drawings of the bones when removed, and of the patient after the operation.

A second case, very similar to the above, as respects the absence of cause for the disease, has been recently under my notice, the report of it having been kindly furnished to me by Dr. Garnham, of the Peninsular and Oriental Company's Service. The patient, aged forty, was an engineer in the Company's service, and enjoyed perfectly good health in the



tropics for some years, but soon after his return to England his mouth became sore, sloughing of the gums took place, and, when I first saw him, very large portions of the alveolus of the lower jaw were necrosed, and lying exposed in the mouth. Subsequently these came away or were removed by Dr. Garnham, and the patient having been reduced to an edentulous condition, as regards the lower jaw, it became necessary to apply to Mr. C. J. Fox, the dentist, for artificial aid. Dr. Garnham attributes the disease to depression of the vital powers, owing to long residence in warm climates.

Any ulcerative affection of the mouth may lead to necrosis of the jaw: thus it has been met with during scurvy, after cancrum oris, and after mercurial salivation. A very extensive sequestrum resulting from cancrum oris is preserved in Guy's Museum (1091, 5), consisting of the symphysis and horizontal rami of the lower jaw, together with the first two molar teeth. Four years after its removal, an osseous growth was found to have taken the place of the original portion of the lower jaw, the power of mastication being good and the sense of feeling nearly perfect. Profuse salivation from mercury being now of rare occurrence, necrosis from this cause is but rarely met with; but in former years the remedy seems sometimes to have been worse than the disease: thus Mr. Key presented to Guy's Museum a sequestrum consisting of two-thirds of the alveolar processes of the lower jaw, the disease having been induced by the use of mercury for ovarian dropsy. The exfoliation of the entire alveolus in the Museum of the Dublin College of Surgeons, already described, was also due to the exhibition of mercury. In the *American Medical Times* of February 23, 1861, Dr. E. S. Cooper records the case of a child, aged seven, in whom necrosis involving the left half of the lower jaw, including the coronoid and condyloid processes, had been produced by the administration of calomel. After removal of the sequestrum, reproduction of the jaw took place, the reproduced bone being at first very much larger than the natural bone, but gradually improving in shape.



Mr. Stanley mentions (p. 72), and gives a drawing of a sequestrum preserved in St. Bartholomew's Museum (I. 102), embracing nearly the whole body of the lower jaw, which suffered necrosis after the administration of a few grains of calomel in a case of fever. It might be doubted whether the necrosis was not due as much to the fever as to the calomel in this case, but that Mr. Stanley mentions that the patient had excessive salivation and severe inflammation in the gums and cheeks.

*Syphilitic poison* frequently produces necrosis of the jaws; and here we find the observation of Stanley hold good as in other parts of the body. He says (p. 76), "Syphilis produces its effects mostly upon the compact osseous textures, and in portions of bones which have thin soft coverings, as the flat cranial bones;" and it is in the compact tissue of the palatine plate of the superior maxilla, which is thinly covered by mucous membrane, that we find the ravages of syphilis most frequent. Occasionally the disease leads to necrosis of portions of the compact tissue of the lower jaw, but rarely attacks the body of the upper jaw, except in those cases of extensive tertiary ulceration of the face, in which the bones become secondarily affected.

In connexion with the subject of necrosis of the palate, usually of syphilitic origin, a caution may be given against any attempt on the part of the surgeon or patient to fill the gap in the roof of the mouth by any form of plug fitting into the hole left. The proper treatment is to close the aperture by a properly fitting plate of metal or vulcanite attached to the teeth and arching immediately below the palate, but making no pressure upon the edges of the hole itself. The effect of a plug is to enlarge the aperture by absorption, so that its size has to be constantly increased in order to make it effectual. A preparation in St. Bartholomew's Museum shows the extent to which this absorption may be carried in process of years. The following is the description given in the Museum Catalogue:—

"The base of a skull from an elderly woman, who appeared to have been long in the habit of wearing a plug to



close an opening in the palate. The opening gradually enlarging attained such a size that nothing remains of the palatine portions of the superior maxillary and palate bones, and the alveolar border of the jaw is reduced to a very thin plate, without any trace of the sockets of the teeth. The antrum is on both sides obliterated by the apposition of its walls, its inner wall having probably been pushed outwards as the plug was enlarged to fit the enlarging aperture in the palate. Nearly the whole of the vomer also has been destroyed, and the superior ethmoidal cells are laid open. The plug is preserved; it is composed of a large circular cork, with tape wound round it, and measures an inch and three quarters in diameter, and an inch in depth. The history of the patient is unknown. She was brought from a workhouse to the dissecting rooms, with the plug tightly and smoothly fitted in the roof of the mouth."—*St. Bartholomew's Catalogue*, I. 232.

Even the employment of a piece of softened gutta-percha is not unattended with risk: thus several years ago I saw, with Mr. Lawson, a case in which the patient had thrust a considerable quantity of softened gutta-percha through an aperture in the palate and into the nostril, where it formed a hard mass, which was extracted only with the greatest difficulty and at the expense of tearing one of the alæ.

*Phosphorus-Necrosis*.—This, which is perhaps the most formidable form of necrosis of the jaw, is a disease of modern time, having been called into existence only since the introduction of lucifer-matches, into the inflammable material of which phosphorus largely enters. The earliest mention by British writers of disease in connexion with the manufacture of lucifers, appears to have been by Dr. Wilks, in the *Guy's Hospital Reports* of 1846-47; but a paragraph from a German author upon the subject is quoted in the *Lancet* of August 29, 1846. The notice in the *Guy's Hospital Reports* is of a case of disease of the lower jaw with exfoliation, occurring in a lucifer-match maker; and the remark is made that the disease had been noticed to be common among workers in lucifer manufactories—a branch of in-



dustry which had then been introduced into London some ten years. In Germany, however (where lucifer manufactories were started some years earlier than in England), phosphorus-necrosis was recognised as early as 1839 by Lorinser, who published a paper upon the subject in 1845, and was followed by Strohl, Heyfelder, Roussel and Gendrin, and Sédillot, in 1846. In 1847 Drs. Von Bibra and Geist, of Erlangen, published a work ("Die Krankheiten der Arbeiter in den Phosphorzündholzfabriken, ins besondere der Leiden der Kieferknochen durch Phosphordämpfe"), which forms the basis of our present knowledge of the subject, and the conclusions of which further experience has fully confirmed.

In London the lucifer manufactories being principally at the East-end, cases of phosphorus-necrosis are most common in St. Bartholomew's, the London, and the Borough hospitals, and their museums, especially that of St. Bartholomew's, are very rich in specimens. The medical officers of these institutions having thus had special opportunities of study, have not failed to record their experience, and reference may be made to valuable clinical lectures upon the subject by Mr. Simon (*Lancet*, 1850), Mr. Paget (*Medical Times and Gazette*, 1862), and Mr. Adams (*Medical Times and Gazette*, 1863); and to the essay on Surgical Diseases connected with the Teeth, by Mr. J. Salter (Holmes' "Surgery," vol. iv.).

The cause of the disease is unquestionably the fumes of the phosphorus which are inhaled by the operatives during the process of "dipping" the matches, and in a lesser degree during the counting and packing them. When the disease first showed itself in Germany, it was thought that it depended upon the admixture of arsenic with the phosphorus; and it is curious that in the Museum of St. Bartholomew's there are some bones of cows from the neighbourhood of Swansea, which, under the influence of arsenical vapour, have become enlarged and covered with a new bone formation closely resembling that around phosphorus-necrosis. It has been proved, however, that arsenic has nothing to do



with the disease; and if proof positive were wanting that phosphorus alone is the deleterious agent, it is supplied by a case quoted by Mr. Paget, in the lecture referred to, of a man who induced necrosis of his jaws by inhaling fumes of phosphoric acid as a quack remedy for "nervousness."

Lorinser and the earlier writers considered the disease to consist in blood-poisoning, the necrosis of the jaw being consequent thereupon, and Mr. Adams (*loc. cit.*) thinks that the theory of blood-poisoning should not be altogether discarded, since the local disease would not account for the constitutional symptoms experienced. The majority of surgeons agree, however, in considering the affection essentially a local one, the constitutional symptoms being only consecutive.

It is found that the phosphorus fumes produce no injurious effects so long as the teeth and gums of the workers are sound, but so soon as the teeth become carious, or if a tooth is extracted so as to leave an open socket, the disease rapidly develops itself. The experiments upon animals by Geist and Von Bibra, are amply confirmatory of this view, since they found that rabbits exposed to phosphoric fumes suffered no injury so long as the teeth and jaws were uninjured, but that if the teeth were extracted or the jaw broken periostitis and necrosis rapidly resulted. On the other hand, it may be mentioned that a case has been recorded by Grandidier (*Journal für Kinderkrankheiten*, 1861), of necrosis of the upper jaw from phosphorus fumes in a child but six weeks old, and in whom therefore the teeth were not developed.

The liability of the two jaws to the disease appears to be about the same, or perhaps with a slight preponderance in favour of the lower jaw. Of 52 cases given by German authorities, 21 were of the superior maxilla, 25 of the inferior maxilla; in 5 both jaws were involved, and one case is uncertain. (*British and Foreign Medico-Chirurgical Review*, April, 1848.) Mr. Salter (*loc. cit.*) says, "In five cases which I have witnessed, the lower jaw was diseased in four, and the upper in one; whereas four which occurred



in the practice of a surgical friend, were confined to the upper jaw. In seventeen instances of which I have obtained particulars or seen specimens, nine were connected with the superior, and eight with the inferior maxilla. The disease is therefore pretty evenly balanced between the two jaws." The St. Bartholomew's Hospital Museum contains excellent specimens of both jaws affected by this form of disease.

The *Symptoms of Necrosis* of the jaws, from whatever cause, are much the same, but as they present themselves in the most marked degree in phosphorus-necrosis, it will be convenient to describe them under this head.

Pain referred to the teeth is one of the earliest symptoms of the disease, and this, which was intermittent at first, becomes at length continuous. The teeth become loose, and pus is seen to exude from their sockets. At the same time the gums become swollen and tender, and are detached to a greater or lesser degree from the alveoli, giving constant exit to a purulent discharge. In all cases of necrosis the face is swollen, so that if only one side of the jaw is affected a peculiar lop-sided effect is produced. In the cases of phosphorus-necrosis, however, the swelling of the face is much more marked, the soft tissues around the bone being infiltrated and puffy to an extent which is not witnessed in other forms of the disease. One or more openings now form externally, through which pus constantly exudes, and the probe introduced through these, readily reaches bare and dead bone.

The patient's general health has by this time become seriously affected, owing both to the actual suffering he has undergone, and to the interference with his nutrition which the state of his mouth necessarily involves, it being impossible for him to take any but fluid or semi-fluid food, and that in small quantities. The constant presence of most offensive discharges in the mouth, and mixing with the food, must have an injurious effect upon the patient, though this is questioned by Salter, who remarks that these patients swallow daily many ounces of pus "without any obvious



detriment to health." The necrosed portions of bone project more or less into the mouth, and give the patient great inconvenience, and in very severe cases of phosphorus-necrosis gangrene of the cheeks and lips ensues with a rapidly fatal termination. In less severe cases, the patient may drag on a wretched existence for months, and sink at last from exhaustion, or may occasionally recover with considerable loss of bone and deformity.



## CHAPTER IX.

## REPAIR AFTER NECROSIS—TREATMENT OF NECROSIS.

It has been already remarked under the head of Exanthematous Necrosis, that in young subjects a development of fibrous tissue takes place after loss of substance in the upper jaw. This is not the case when loss of part of the superior maxilla takes place in adult life, except in rare instances, it being remarkable that the periosteum of the upper jaw ordinarily makes no effort at repairing, by effusion, the mischief which has taken place. M. Ollier, of Lyons, in his recently published (1867) work "*La Régénération des Os*," gives a case of phosphorus-necrosis of the upper jaws where a certain amount of new bone was produced, and also one of necrosis of the upper jaw from other causes, in which a development of osteo-fibrous tissue took place in a young woman of nineteen. He quotes also from the practice of Bilroth, of Zurich, the case of a man, aged twenty-seven, in whom, after phosphorus-necrosis, a development of plates of bone took place. These cases must be regarded, however, as quite exceptional, Trélat in his thesis (1857) having failed to discover a case of osseous reproduction of the superior maxilla. In the lower jaw, however, the case is very different, the periosteum and the surrounding tissues being very active in producing new bone to take the place eventually of that which is necrosed. So soon as the periosteum is separated from the jaw by the formation of pus around the sequestrum, it appears to take on an active condition which leads to the effusion of plastic lymph. This becomes rapidly converted into fibro-cartilage and then into bone, which forms a more or less complete shell around the necrosed portion.



Through the *cloacæ* or openings in this new shell of bone which correspond to the external apertures on the chin, and also from the mouth, the dead bone or *sequestrum* can be readily examined with the probe, and when sufficiently detached and loosened to be readily extracted, it should be removed if possible through the mouth so as to avoid deformity from an external wound. It is of importance that this removal should not be undertaken until the shell of new bone is sufficiently organized to maintain the shape of the original bone, for if otherwise the reproduction of the bone will be interfered with, and perhaps prevented. So soon as the sequestrum is removed from the interior of the shell of new bone, the space thus left becomes rapidly filled with granulations springing up from the whole surface of the cavity, and these are soon converted into a fibrous mass which is ultimately developed into bone.

In the *St. Bartholomew's Hospital Reports*, vol. i. (1865), a very remarkable case of restoration of the lower jaw is described by Mr. Thomas Smith, to whom I was indebted for the original drawing of the preparations in the hospital museum which accompanied this essay. The case was one of necrosis of the entire lower jaw in a lucifer-match maker, but *not* presenting the peculiar pathological condition of pumice-stone deposit upon the sequestrum which is characteristic of the phosphorus disease and will be afterwards referred to. Mr. Smith removed the sequestrum of the entire jaw in two pieces, and the patient went out of the hospital at the end of six weeks, but died suddenly the next day.

The following is Mr. Smith's description of the preparation:—"The new bone was situated in front of and on a lower plane than the bone it replaced; it was distinctly embedded in the soft parts between the anterior layer of the periosteum of the old jaw and the integuments of the face. The relative position of the old and new bone is shown in the drawing. On the posterior aspect some of the fibrous texture of the gum has been left so as to show a groove in the soft parts that was originally occupied by the dead bone. This groove had very greatly diminished in size before the



patient's death, and has still further shrunk by maceration in spirit.

"The temporal muscle was found attached to the coronoid process; the masseters were blended with the outer surface of the angle and ramus of each side; while behind the symphysis there may still be seen in the specimen the remains of the genio-hyoid, genio-hyoglossi, and digastrici. No other muscles were found attached to the bone. The inferior dental nerves were found lying in the fibrous texture of the old gum. There is apparently no provision for them in the new jaw, from which they lay quite separated by both layers of the periosteum of the necrosed jaw.

"The new bone consisted chiefly of three portions, of which two are formed by the coronoid process and condyle together, of either side; whilst the third and largest portion represents the right ascending ramus, the angle, horizontal ramus, and symphysis, and extends as far as the position of the eye-tooth on the left side. The part of the jaw that is wholly deficient in bony structure is included between the position of the eye-tooth and last molar of the left side. The parts in which most bone is found being apparently those points where ossification commenced, on the coronoid processes, the angles, and especially the neighbourhood of the symphysis, where the bone is more abundant, denser in its structure, and more perfectly formed than elsewhere.

"The newly-formed jaw, on microscopic examination, shows all degrees of development, from a finely fibro-nuclear matrix up to perfect bone. The bone differs from ordinary compact bone in being excessively vascular, the Haversian canals being very large, near together, freely anastomosing, and here and there in their wall presenting fusiform and pouch-like dilatations, in fact, resembling in their outlines veins slightly varicose.

"The bone is thickly studded with lacunæ, and these are peculiar in being very large in their cavities, less uniform in their general outline, and bearing fewer canaliculi than is usual in well-formed bone. In the newest parts of the bone



the lacunæ are merely irregularly-formed cavities without distinct canaliculi.

"From the relation of the dead bone to the soft parts, lying as it did in a fossa formed by the gaping gums, from the relation of this fossa to the new bone, as seen in the specimen, it is evident that the regeneration of bone in this case did not take place from the osseous surface of the periosteum, but rather from the fibrous structure of the gum in front of the original jaw. The only portion of bone in this case formed directly from the detached periosteum, was removed at the time of the operation, and may be seen in the necrosed jaw adhering to the ramus and angle of the left side. It formed no part of that system of bone formation which eventually reproduced the jaw."

This case is remarkable in more ways than one. In the first place, the absence of the pumice-like deposit upon the sequestrum would appear to exclude it from the category of phosphorus-necrosis, but the patient was undoubtedly exposed to the action of phosphorus, and it will be shown at a later period that this is not of necessity in any way connected with phosphorus. The second notable point is, that according to Mr. Smith's description the reparative material was formed not around, but entirely in front of or below the sequestrum. The third point, still more remarkable, is, that if Mr. Smith's observation is correct, the new structure was entirely *outside* the periosteum of the jaw, and was derived entirely from the surrounding soft parts.

Mr. Smith is too accurate an observer to have been deceived by the appearances, and we must conclude, therefore, that not only was the bone killed by the action of the poison, but that the periosteum also lost its vitality to such an extent that it was unable to secrete that pumice-like bone usually found in these cases, or to assist in any way to form reparative material. That the surrounding soft parts should under these circumstances have assumed the reparative function to the extent they did, is a remarkable instance of the adapting powers of nature.

In commenting upon the above case, Mr. Smith expresses



an opinion that "of late the office of the periosteum as an osteogenic membrane has been much magnified at the expense and to the disparagement of other sources of bone reproduction." M. Ollier, on the other hand, whose physiological researches on the nature of periosteum are well known, in his recent work already alluded to, strongly maintains the bone-producing power of the periosteum, and advises its preservation where possible; giving cases where this has been followed by the reproduction of bone, as has been frequently witnessed in England. The question of the so-called subperiosteal resection will be discussed under the head of Treatment of Necrosis.

Whatever the tissue from which the bone is reproduced, there can be no question as to the facts of its reproduction in the majority of instances of necrosis of the lower jaw. Even when the condyle with a large portion of the ramus of the jaw is necrosed, complete repair has been found in young subjects. Stanley quotes a case of this kind from Desault, as one "of the least frequent examples of the reproduction of bone consequent on necrosis," and refers to one recorded by Mr. Syme. As additional examples may be quoted one by the late Mr. H. Gray (*Pathological Transactions*, vol. ii.), which occurred in the practice of Mr. Keate, and one by Dr. Cooper, of San Francisco, which has been already referred to. A case of subperiosteal resection of one half of the jaw by M. Maisonneuve, in which complete repair took place, will be referred to further on. On the other hand it should be remarked that several instances of non-repair of lost bone have been recorded. Thus Stanley mentions a case under the care of Mr. Perry, which will be referred to again, in which no repair took place; and three similar cases are to be found in South's *Chelius*. Also in the *Lancet* (25th January, 1862) it is mentioned that a patient from whom Mr. T. Wakley removed an extensive necrosis in 1857 was at that time to be seen about the streets exhibiting himself for a livelihood, and everting his mouth to show that his lower jaw was absent.

A remarkable feature in Mr. Perry's case, already men-



tioned, was, that though the entire jaw was necrosed and removed, yet "nearly all the teeth remained in the mouth, and were kept together by their connexion with the gum;" and according to Mr. Stanley the patient "chewed her food by a movement of the upper jaw (?), aided by the action of the tongue in rubbing the morsel against the teeth." Extraordinary as it appears, that the teeth should thus remain *in situ*, the fact is undoubted, and is confirmed by other examples: thus Mr. Sharp, of Bradford (*Medico-Chirurgical Transactions*, vol. xxvii.), removed a large sequestrum from a young woman, aged twenty, through an incision beneath the skin, and all the teeth remained firm. In the *Medical Times and Gazette* of October 30, 1858, also, it is mentioned that Mr. Skey brought before the students of St. Bartholomew's a young man of twenty, from whom four months before, he had removed a sequestrum including the entire left side of the jaw from the ramus to the symphysis, and the right side as far as the last molar tooth. The sequestrum showed the sockets of twelve teeth—viz., all those of the left side, and the incisors, canine, and first bicuspid of the right side; but the whole of the alveolar border of the right side was not present in the sequestrum. Instead of coming away with the bone, the incisors, canine, and first bicuspid of the right side, and even the left centre incisor had remained in the gum. The patient now applied to Mr. Skey to have these teeth removed, as, although they evidently possessed vitality and were firmly attached to the gums, they had sunk in position so as to be irregular and inconvenient.

An observation of Mr. Salter's (Holmes' "Surgery," vol. iv.) deserves notice, and it received confirmation from one of the cases recorded by Mr. Chalk in the paper already referred to. He says, "Though it has not been stated in books, this repair of the lower jaw is but temporary, for after a time—often a considerable time—the new bone diminishes by absorption to a mere arch, and ultimately there is scarcely enough bone to keep out the lower lip, and the chin is utterly lost. I have had an opportunity of examining this state of parts after the lower jaw had been removed



ten years. How far this loss, by absorption of supplemental bone, may be prevented by supplying it with a function through the means of artificial teeth, is a question of theoretical interest and of practical importance."

One almost constant pathological peculiarity in cases of phosphorus-necrosis has been already alluded to and deserves special notice; it is the deposit of a peculiar pumice-like bony material around the necrosed portions of the lower jaw, for it is not found in cases of disease of the upper jaw. This is doubtless derived from the periosteum, although so closely adherent to the sequestrum as to be invariably brought away with it, and though resembling true bone in some particulars it is decidedly of a lower development.

According to Von Bibra (*op. cit.*), who has laboriously investigated the subject microscopically, "the Haversian canals exhibit in part a larger diameter than those of normal bone, and are empty except where the deposit appears smooth and compact, and is partially covered with periosteum. They are *not parallel* with the general direction of the bone, but are placed *at right angles* to the latter; they interlace with one another, sometimes expanding to form sacs, sometimes contracting, and end with open mouths on the surface. Their mouths are more minute in the most recent deposit, and appear larger in older layers. The bone corpuscles are rounded off or angular, and their circumference is less decided; during the progress of the formation of the deposit they are very large and their contour proportionably undefined. They appear filled and dark-coloured; at first they are lighter and they have ramifications like those of normal bone, which increase in number with the age of the deposit. The fundamental structure of the deposit is laminated, and several layers are distinctly seen resting upon one another. It exhibits rents with which the ramifications of the corpuscles are connected, and which may therefore be considered as continuations of the latter. Spots are also visible here and there, which Von Bibra looks upon as accumulations of earthy matter. This matrix of the new deposit is at first very brittle; after the deposit has been exposed to



the process of absorption it shows a powdery appearance, as if sprinkled with a coarse powder."

This description of the microscopic appearances may be advantageously contrasted with that of the new bone in Mr. T. Smith's case of restoration of the jaw (p. 120), of which the Haversian canals were parallel to those of the original bone instead of being at right angles to them, which is such a marked peculiarity of the pumice-like deposit.

It appears, however, that cases of necrosis other than those due to phosphorus occasionally lead to a deposit of pumice-like bone upon the sequestrum. Mr. Perry's case of necrosis of the entire lower jaw, already alluded to (and which will be found *in extenso* in the *Medico-Chirurgical Transactions*, vol. xxi.), is a case in point, the sequestrum, as may be seen from the drawing given of the preparation in St. Bartholomew's Museum, being thickly encrusted with new bone, closely resembling that seen in phosphorus cases. The disease in this case was attributed to rheumatism, and corresponds very closely to the description given by Dr. Senftleben of the later stages of acute rheumatic periostitis. (See p. 102.) He says, "Spontaneous separation of the sequestrum rarely ensues; it remains to some extent in organic connexion with the osteophytes, and ultimately, after a number of months, a year or even more, an operation has to be performed, in which both the sequestrum and the osteophytes are removed together." So far as I am aware the new bone in Mr. Perry's case has not been submitted to microscopic examination.

A preparation (720 C) which accompanied this essay bears upon the same question. It is a portion of the lower jaw of a girl æt. ten, consisting of the condyle and part of the ramus and the coronoid process (separate), for which I am indebted to Mr. Lawson. The symptoms were those of necrosis, there being abscess, &c.; and in December, 1866, that gentleman cut down upon the seat of the disease and removed those portions which were separated from the rest of the bone. The preparation shows the ramus of the jaw at the lower part of normal thickness and apparently necrosed,



but at the upper part there is around it a deposit of new bone very closely resembling the pumice-stone deposit of phosphorus-necrosis. A portion of this has been detached, but it may be observed that the articular cartilage is perfect, and the periosteum near it healthy, although, owing to the new deposit, the condyle and neck of the jaw are greatly altered in shape. This appears to me to have been a case of Ostitis rather than Periostitis, the deposit resembling that found under such circumstances; and the fact of the deposit taking place beneath the apparently healthy periosteum, would appear to point to the same solution of the question.

*Treatment of Necrosis.*—In the early inflammatory stage of the disease it is obviously of the first importance to get rid of any local cause which may be exciting or keeping up irritation, and therefore any diseased teeth or stumps should be immediately extracted and the patient should be removed from the action of any local irritant such as the fumes of phosphorus. Local abstraction of blood by leeches, both externally and internally, and by scarification of the gums, will relieve the congestion; and the application of emollient poultices externally and of poppy fomentations in the mouth will relieve the pain. The bowels having been cleared, iodide of potassium should be had recourse to in full doses, according to the age of the patient, combined with opium if there is much pain and restlessness.

By these means the disease may be prevented from proceeding beyond the stage of periostitis, but if from the swelling of the parts about the jaw it is to be feared that the destruction of the bone is probable, free incisions should be made within the mouth down to the bone to give exit to effusion, and thus, if possible, avert the death of the bone; after which the treatment above recommended should be pursued with assiduity. When necrosis has actually taken place and pus has formed around the jaw, its tendency to the surface is so great that if free exit for it is not made within the mouth it will cause sinuses externally and give rise to great disfigurement. Free incisions should therefore



be made through the gum, but without disturbing the efforts at repair if they are already in progress. As all hope of arresting the disease must now be abandoned, it is useless to continue the administration of drugs except as general tonics, and at the same time every effort must be made to support the patient's strength by suitable diet. Since it is impossible that the patient should masticate solid food, it is important that animal food should be prepared in a suitable manner, and this may be attained by making use of soups or essences of meat, and by reducing well-cooked meat to a mash with pestle and mortar. Milk and eggs form very suitable articles of food, and must be supplemented with wine or, better, stout.

The offensive discharges constantly present in the mouth must be combated with detergent gargles of chlorinated soda or permanganate of potash, and when the patient is unable to cleanse his mouth satisfactorily by his own efforts, it should be mopped out with small sponges affixed to a handle, assisted by the use of a syringe.

Most British surgeons agree in counselling non-interference with the sequestra in cases of necrosis until the shell of new bone around is sufficiently developed to maintain the form of the jaw; they are then to be extracted through the mouth, if possible, and if not, through incisions, placed so as to cause as little subsequent deformity as possible. When the sequestrum, although partially detached, is not ready for removal, and greatly inconveniences the patient, a part may be clipped off with the bone forceps, so as to present a smooth surface, and if the teeth are loose and troublesome they had better be removed at once, but if firm they should be left, since, as has been shown, they occasionally become useful. The caution already given against interfering with the permanent set of teeth in cases of necrosis in children should be borne in mind.

Some continental surgeons, however, interfere at any early date, and among them Professor Billoth, who, according to the report of the meeting of the Medical Congress at Zurich in 1861 (*Medical Times and Gazette*, June 8, 1861),



“penetrates immediately, with one incision, which he makes parallel to the necrotic part, through the skin down to the bone; he then scrapes off the periosteum with its bony layers upwards and downwards, by means of a raspatorium, and saws smaller or larger pieces of bone out of the jaw; or he nips those pieces off by means of bone-pincers. In a few cases it appeared advisable to disarticulate at once one or both coronoid and condyloid processes of the lower jaw, which was very easily done, as the joint had become very loose in consequence of the long suppuration. Of the six cases shown by the Professor, two were healed, and amongst them was one of total resection of the jaw in a woman of thirty-five years. This case was in so far remarkable, as two apparently healthy teeth had remained in the periosteum, which had become partly ossified, and in the gums, which had remained healthy; and these have now been used for seven months. Mastication is not impaired, and the woman has a much healthier appearance. The second case in which the resection of one-half of the jaw was performed, is also well healed; but the mouth is, of course, crooked. Two cases in which a partial resection has been made, are progressing favourably; in another case the treatment with mercury and iodine has been commenced.”

When the whole lower jaw is necrosed it is necessary to divide it before it can be extracted. This may be done, as in Mr. Perry's case, by making a section with the saw near the angle on each side, or, better, by dividing with the saw at the symphysis, either without external incision, as in Mr. T. Smith's case, or after reflecting flaps of skin, as in a case of Mr. Paget's, which will be found in the *Lancet*, 1862. In a case of necrosis of the entire lower jaw, from phosphorus, which was in the London Hospital, under Mr. Adams' care, that gentleman preferred to divide the symphysis with a mallet and chisel, and the case is moreover remarkable from the unusual occurrence of secondary hæmorrhage, for which ligature of the common carotid became necessary—the patient eventually recovering. The case will be found in detail in the *Medical Times and Gazette*, 1863.



Under the name of "Sub-periosteal Resection," operations have been described by foreign surgeons, which in no respect differ from the extraction of sequestra as ordinarily practised, of which the following case, extracted from the *Lancet*, of 1863, is a good example:—"M. Rizzoli, of Bologna, submitted to the Surgical Society of Paris a case of necrosis of the lower jaw, from the fumes of phosphorus, in a man aged fifty-six years, in which the sequestra were removed through the mouth. M. Rizzoli made incisions on either side of the gums, scraped the thickened periosteum with a spatula from the dead bone, and removed the latter piecemeal. The preserved periosteum generated new bone in the place of the portions taken away, which comprised the body and part of the ramus on each side. It was, however, soon found that the upper part of the ramus and the condyle were also diseased; these portions of bone were also removed through the mouth with the same precautions, and the periosteum again acted in the same way. Eventually the man was able to use his jaw, and masticate, though deprived of teeth. M. Forget, who reported on the case, observed very justly that there was nothing new in this action of the periosteum in necrosis of bone, surgeons having long acted upon this periosteal property in such cases. M. Flourens had pointedly said, 'Take away the bone, preserve the periosteum, and the preserved periosteum will restore the bone'; but this applies less to cases of necrosis of bone than to cases of experiments on animals and operations performed on healthy bone and periosteum. And even in these cases it should be remembered that osseous substance is reproduced, but not the actual bone as it existed before the resection." In some cases, however, incisions have been made at a comparatively early stage, before the shell of new bone has been formed, and the sequestrum immediately extracted, with good results. It may be doubted however, whether there is any real gain in such procedures, either in time or result, since the repair is no more rapid than if the sequestrum were left, and there is the additional risk both of the actual operation, and of the deformity which may result from the



premature withdrawal of the sequestrum. A case from the practice of M. Maisonneuve, illustrating the practice in the lower jaw, will be found in the *Comptes Rendus*, April, 1861. In his recently-published work, "*La Régénération des Os*," M. Ollier, of Lyons, gives two cases of subperiosteal resection, one of the upper and one of the lower jaw, for necrosis, in neither of which was there any osseous development, and which cannot, therefore, be regarded as very satisfactory examples of a proceeding whose great aim is the development of new bone.

With regard to the prevention of phosphorus-necrosis, the following extract, from Mr. Simon's report to the Privy Council (1863), may be quoted with advantage, as giving the results of Dr. Bristowe's careful investigation of the subject:—"The dangers to which I have adverted, as belonging to the phosphorus industry, belong exclusively to working with common phosphorus. Working with amorphous phosphorus is unattended with danger to health. Since, however, it appears that with reasonable precautions the use of common phosphorus for match-making need not be an unwholesome occupation, I cannot say that, in my opinion, the substitution of amorphous for common phosphorus in the manufacture is, for sanitary purposes, an object to be unconditionally insisted on. Yet having regard to the fact that amorphous phosphorus not only is manufactured without danger to the worker, but that its use in lucifer boxes also involves infinitely less danger of fire than belongs to common lucifer matches, I think that the substitution is altogether one to be desired. And, of course, with reference to any restriction which the legislature might think of imposing on the utilization of common phosphorus, it would deserve to be remembered that manufacturers would have at their option the alternative of using, without restriction, the innocuous amorphous material."



## CHAPTER X.

## HYPEROSTOSIS.

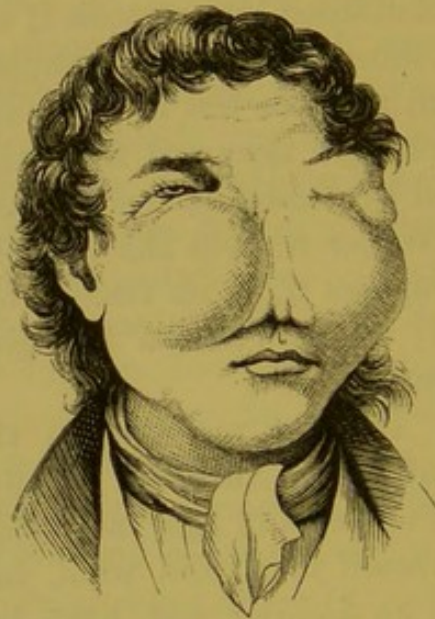UNDER the head of diffused hyperostosis it will be convenient to group together those remarkable examples of hypertrophy of the maxillæ, and more or less of other bones of the face and cranium, which have occurred from time to time, and have been recorded by Howship, Gruber, Astley Cooper, and Bickersteth. O. Weber regards the disease as the result of erysipelas, and compares it, in its results, to elephantiasis of the soft structures; whilst Virchow has given it the name of "leontiasis ossea."

Mr. Howship's case is recorded in that gentleman's "Practical Observations in Surgery" (1816). The patient, when about forty-five years of age, and apparently in perfect health, was exposed to a cold wind, immediately after which he perceived an itching and heat in his eyes, and swelling of the face rapidly supervened. A small tumour formed just below the inner angle of each eye, which burst, and, after twelve weeks, he was able to resume his employment. He suffered from inflammatory attacks in the tumours, with much pain in the head, on more than one occasion, and consulted many medical men, but no treatment relieved the disease or retarded the growth of the tumours, which increased slowly and were of stony hardness. The eyes were projected from the orbits by the tumours, and the right eye inflamed and burst, whilst the left was accidentally ruptured by a blow. The patient lived to over sixty years of age, and died of apoplexy, having been occasionally maniacal during the last two years of his life. The accompanying portrait (fig. 45) is taken from Mr. Howship's



work. The skull of this patient is preserved in the College of Surgeons (3236 A.), and shows, as might be anticipated from the portrait, two large masses of almost exactly symmetrical form and arrangement, which have partially coalesced in the median line. The growths are as hard as ivory, and consist of a very close cancellous structure. They project more than three inches in front of the face, and an inch beyond the malar bones on each side; they completely

FIG. 45.



fill both orbits, the cavities of the nose, and, probably, both antra, and they extend as far backwards as the pterygoid plates of the sphenoid bone. In the Catalogue of the Museum it is stated that the man attributed the growths to repeated blows received on the face in fighting, but Mr. Howship makes no mention of this, and the information was probably derived from Mr. Langstaff, in whose collection the preparation originally was.

A skull of a Peruvian, also in the Museum of the College of Surgeons (3093), exhibits the same form of disease, but of a more diffused character, all the bones of the face, as well as the frontal and the adjacent parts of the sphenoidal and parietal bones, being enlarged and thickened in a



remarkable manner. The nasal fossæ and orbits are nearly closed, the superior maxillary bones, and the orbital portions of the malar and frontal bones, having grown into great knobbed and tubercular masses, in which their original form can be hardly discerned. The hard palate is similarly diseased. The lower jaw is enormously enlarged at its right angle, and in the greater part of its right half it measures upwards of five inches in circumference, and all but three of its alveoli are closed up. A section of the lower jaw shows that its interior is composed of an almost uniformly hard and compact, but finely porous, bone. There is no history attached to the specimen.

Sir Astley Cooper's patient was a Billingsgate fish-woman, long remarkable for her hideous appearance, who died of apoplexy in St. Thomas's Hospital, in the museum of which institution the skull is preserved. (C. 195.) In connexion with each superior maxilla is a rounded bony growth, extending from the lower margin of the orbit to the roots of the alveolar processes. The cavity of each antrum is occupied by the growth, which by its projection, has encroached upon the nasal fossæ, and filled the frontal and ethmoidal sinuses. The case, therefore, closely resembles Mr. Howship's specimen.

Mr. Bickersteth's very remarkable specimen was exhibited to the Pathological Society of London in April, 1866, by Dr. Murchison, and its description in the *Society's Transactions* is illustrated with admirable lithographic drawings.

The patient, who died at the age of thirty-four, first noticed an enlargement of the bones of the face when a boy of fourteen. The swelling of the face gradually increased, and thirteen years after its commencement a similar hard swelling appeared along the course of the left fibula. About two years before death, he began to suffer severe pain, which continued to his death, which was the result of emaciation, consequent upon the encroachment of the disease upon the mouth. All the bones of the head are more or less involved in the disease, with the remarkable exception of the occipital bone. The malar bones are de-



veloped into dense globular masses, the size of an orange. The palatal processes of the superior maxillæ are also greatly diseased, a rounded mass projecting down on each side so as to fill up the cavity of the hard palate to a level with the alveolar ridge. The lower jaw is enormously thickened in every direction, the right side more so than the left. Little trace can be seen of a condyle, coronoid process, or sigmoid notch, the whole being fused into one uniform globular mass.

A very elaborate account of the specimen, with measurements and microscopical appearances, will be found in the 17th vol. of the *Pathological Society's Transactions*, from which the above is condensed.

A fourth specimen is preserved in the Musée Dupuytren, in which both upper and lower jaws are extensively affected.

In all these specimens the external surface of the bones affected is more or less coarsely tuberculated; the tissue is hard and dense, and minutely perforated for the passage of bloodvessels. In the case of the lower jaw of the Peruvian skull, the interior is composed of an almost uniformly hard and compact, but finely porous bone. Traces of the original walls of the jaw are discernible nearly an inch beneath the surface of the most enlarged part, but its medullary cavity is filled up with the same kind of osseous substance as that which is outside the trace of the wall.

A microscopical examination of the St. Thomas's Hospital specimen "shows it to consist of two kinds of bony matter; one firm and compact, whilst the other is more or less soft and spongy. In the former, Haversian canals occur, having concentric laminæ around them, but in the spongy portion cancelli only are present, and the bone exhibits a granular structure, with numerous bony cells arranged in no definite order."

In Mr. Bickersteth's specimen, "The compact structure is traversed in every direction by large branching and communicating vascular canals, forming in some places a close net-work. . . . The spaces between the canals are filled up by bone-tissue of ordinary character. The lacunæ



are in general very numerous, but they are small, and for the most part elongated. Very few traces of true Haversian systems are to be seen."

It is stated in the report upon the last specimen, that the microscopical appearances are nearly identical with those of the Peruvian skull in the Hunterian Museum.

The disease appears to consist primarily in some inflammatory affection of the periosteum, which leads to the deposit of new bone, and the expansion and filling up of the original osseous structure. It appears to be entirely unconnected with syphilis or struma, and to be completely beyond the control of remedies, though the continued exhibition of iodine (a drug unknown when these cases were in their early stage) might possibly be of benefit. The resemblance these cases bear to one another is very remarkable, and there was a few years back an attendant at Somerset House who might have sat for the portrait of Mr. Howship's patient.

In the Museum of St. Bartholomew's Hospital, is a specimen (I. 62), showing obliteration of the antra, due to hypertrophy of the bone of the same character as in the specimen described above, but in an earlier stage. When the disease affects only one of the maxillæ, which is its favourite seat, operative interference will be advisable. Mr Stanley ("On Diseases of the Bones," p. 297) gives the case of a girl of fifteen years, in whom enlargements of the nasal process of the superior maxillæ had been observed for eight years, and was increasing. There was no external deformity, but it was thought advisable to interfere at an early date, when it was found that obliteration of the antrum had already taken place, as in the preceding case. The entire jaw was removed, but the patient unfortunately died of erysipelas.

In the Museum of King's College is another specimen (1201), which shows well the obliteration of the antrum by hypertrophy of its walls. The tumour was removed in 1842, by Sir William Fergusson, from a girl of twelve, in whom some enlargement of the face had been noticed from



the age of four, and whose portrait is shown in fig. 46, taken by permission, from that gentleman's "Practical Surgery." The patient made a perfect recovery, and the particulars of the case will be found in *The Lancet* of February and March, 1842. Fig. 47 shows her portrait after recovery from the operation.

FIG. 46.

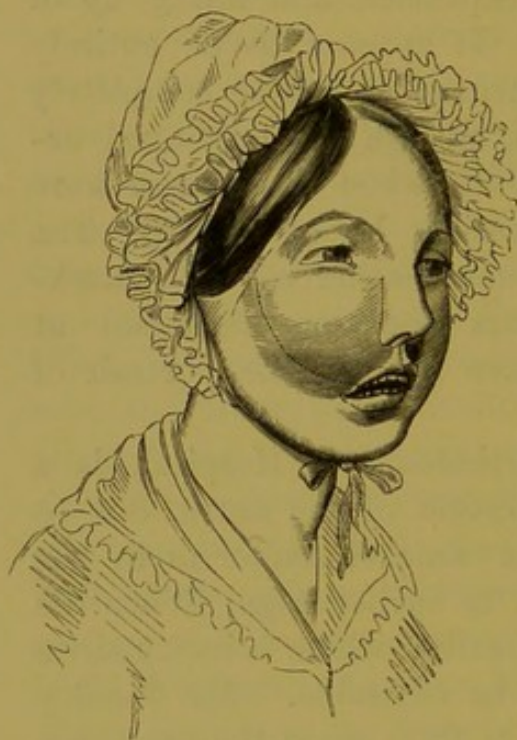
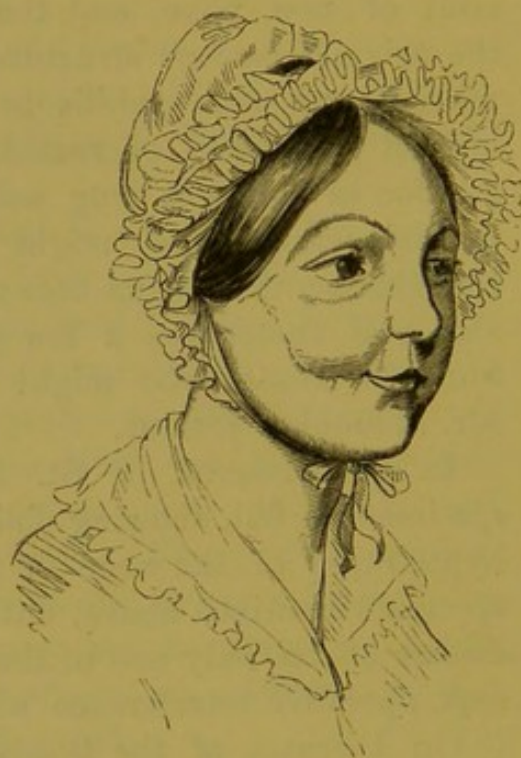
FIG. 47.



In the same museum is a specimen of the disease in the ramus of the lower jaw, removed by the same surgeon from a girl of thirteen, by sawing in front of the molar teeth and disarticulating. The patient made a good recovery.



## CHAPTER XI.

## CYSTIC DISEASES OF THE ANTRUM.

BEFORE entering upon the consideration of the diseases of the antrum, it will be convenient to say a few words respecting the anatomical relations of that cavity. Known as early as the time of Galen, but connected inseparably with the name of Highmore, who described it as "conical and somewhat oblong," and from whose work figs. 48 and 49 are

FIG. 48.

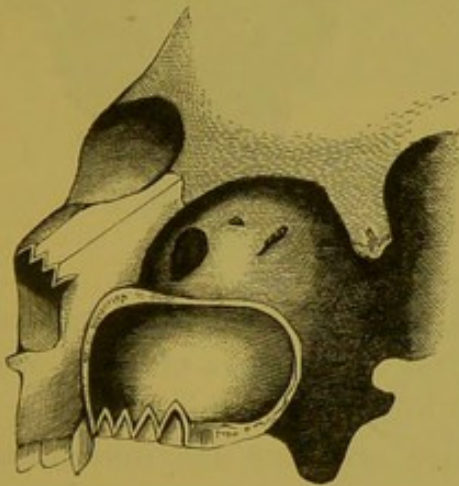
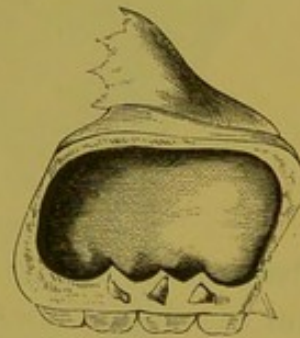


FIG. 49.

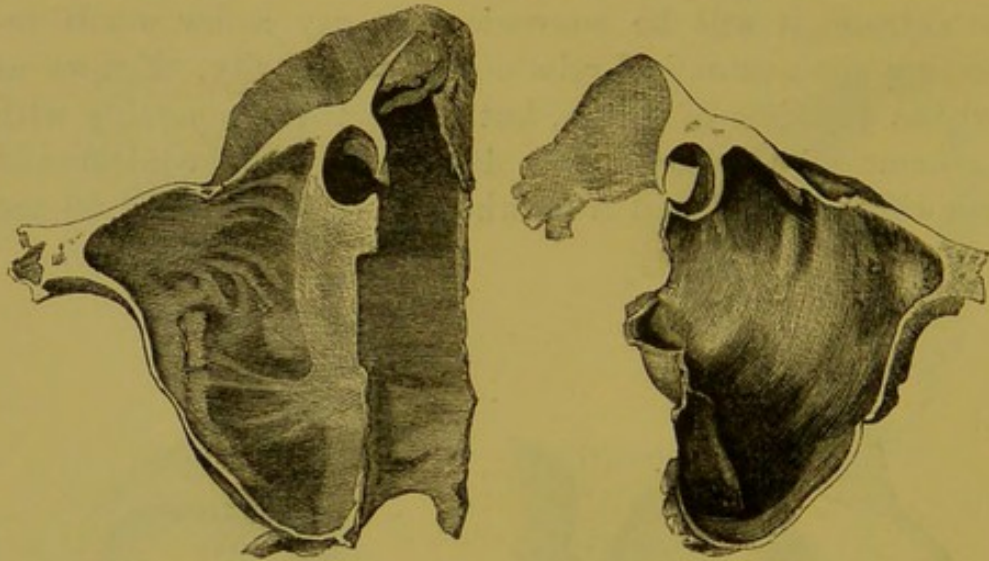


taken, the antrum has been more or less correctly described by all modern anatomists. Holden compares it correctly enough to "a triangular pyramid, with the base towards the nose and the apex towards the malar bone;" and mentions the occurrence of "thin plates of bone which are often found extending across the antrum." The most comprehensive account, however, of the antrum in modern times is to be found in a paper by Mr. W. A. N. Cattlin, F.R.C.S., in vol. ii. of the *Transactions of the Odontological Society of London*, and by the kindness of that gentleman I am enabled to reproduce his valuable illustrations.



As the result of the examination of a hundred specimens, Mr. Cattlin finds that, as a rule, the antrum is larger in the male than in the female, and that it diminishes in size with extreme age. In the young subject, likewise, the cavity is small, and its walls comparatively thick. Fig. 50 shows in a transverse section both the roof and floor of an adult antrum of the common shape and size, capable of containing two and a

FIG. 50.

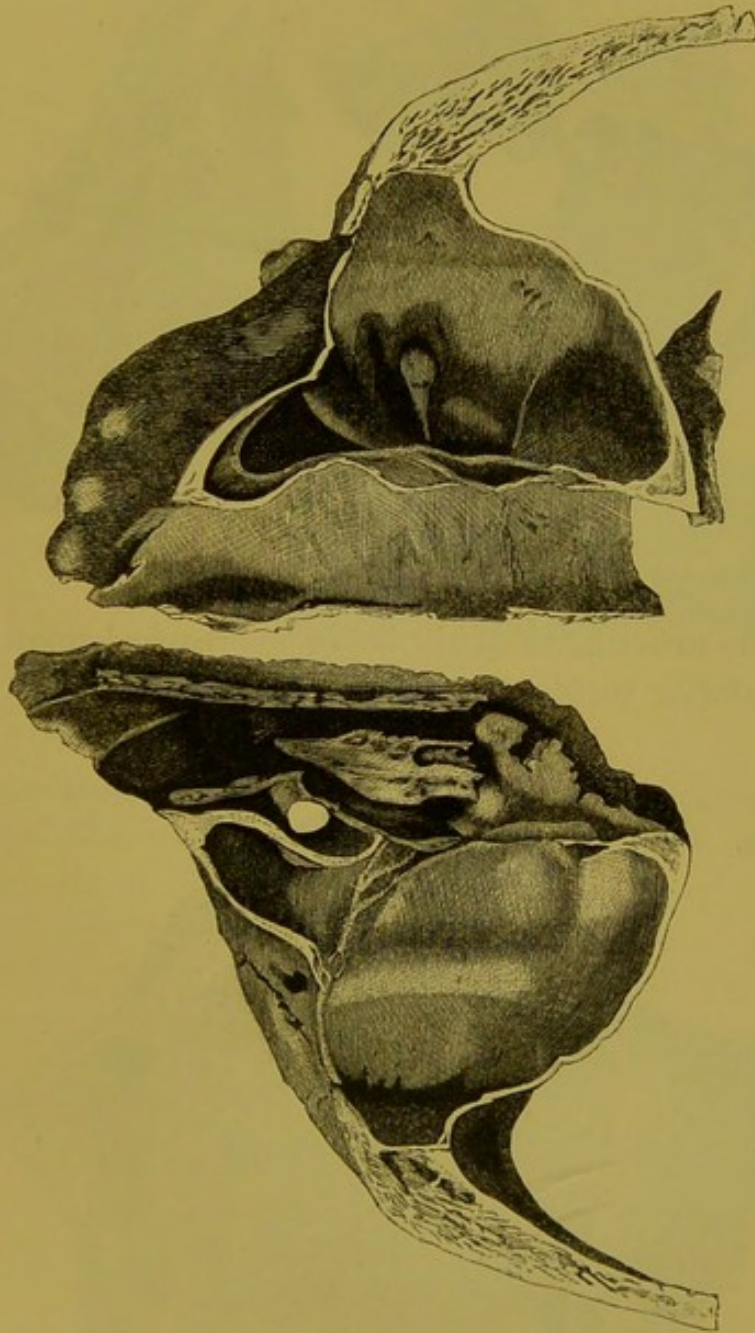


half drachms of fluid. Fig. 51 is a drawing of a large adult antrum capable of containing eight drachms of fluid, whilst fig. 52 shows a small adult antrum containing only one drachm of fluid. The two antra are often unsymmetrical in size and shape; thus fig. 53 shows a much larger and deeper cavity on one side than on the other. The antrum may even extend irregularly into the malar bone, forming a supplementary cavity there, as seen in fig. 54 (where the view is taken from the nasal cavity). The most remarkable variation, however, is due to the development of the ridges of bone already mentioned, which subdivide the cavity; these are very variable in size and shape. Fig. 55 is an example of an antrum divided by a thin plate of bone, and fig. 56 of one divided by a thick ridge of bone. Fossæ of considerable depth are often found in the floor of the antrum, particularly at the anterior and posterior extremities, of which



fig. 57 is a good example, showing on one side a perforation by an alveolar abscess. A rare form is when fossæ or cells

FIG. 51.



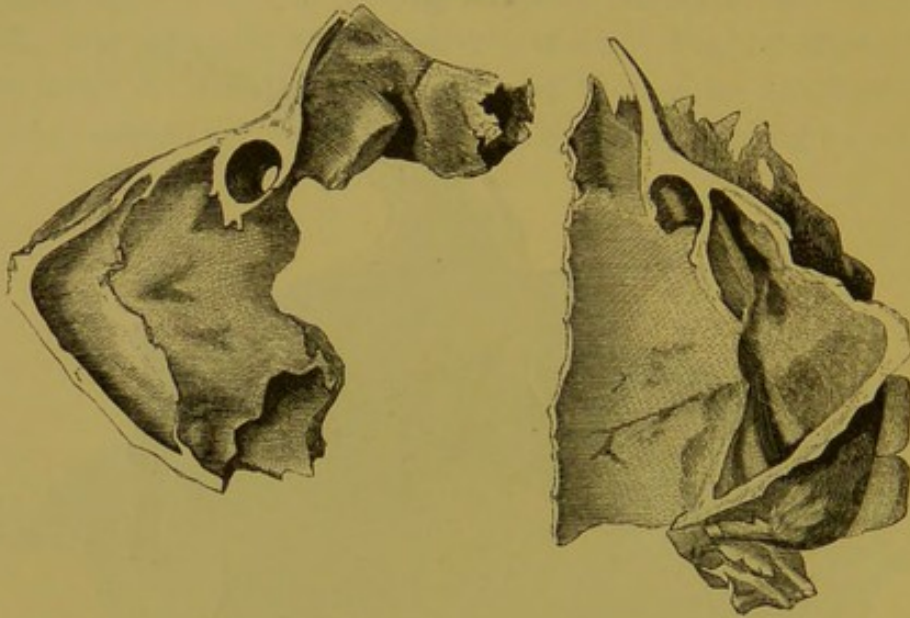
are developed beneath the orbital plate (fig. 58), or a *cul de sac* is formed close to the lachrymal groove (fig. 59).

The position and size of the opening between the antrum and the middle meatus of the nose are points of some im-



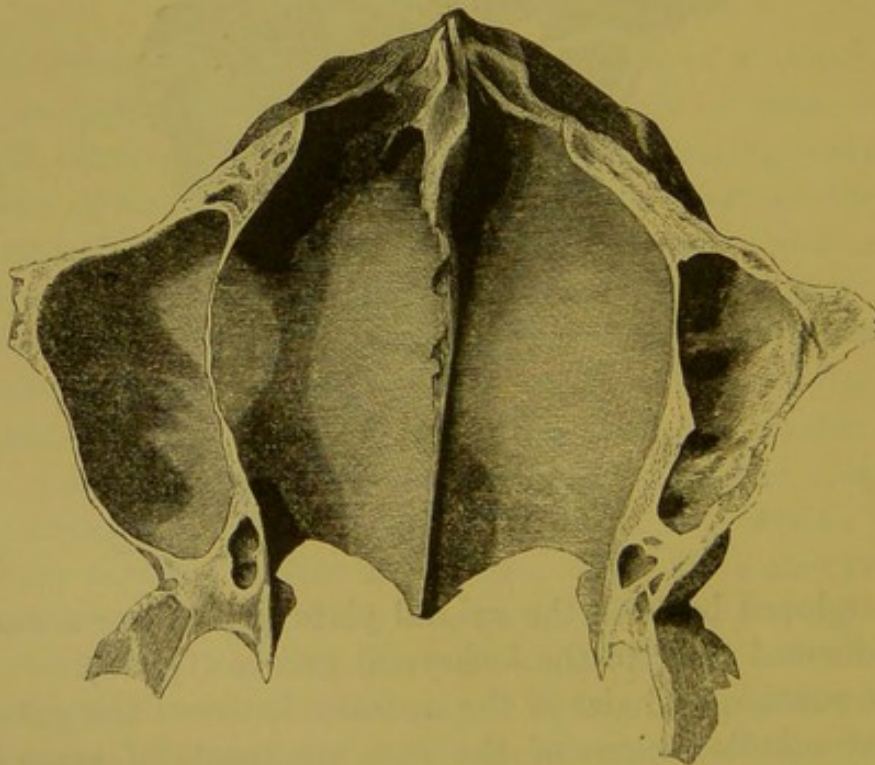
portance. The size of the aperture found in a macerated superior maxilla gives a very exaggerated idea of the open-

FIG. 52.



ing in the articulated skull, being encroached upon by the palate, inferior turbinate, and ethmoid bones, which narrow

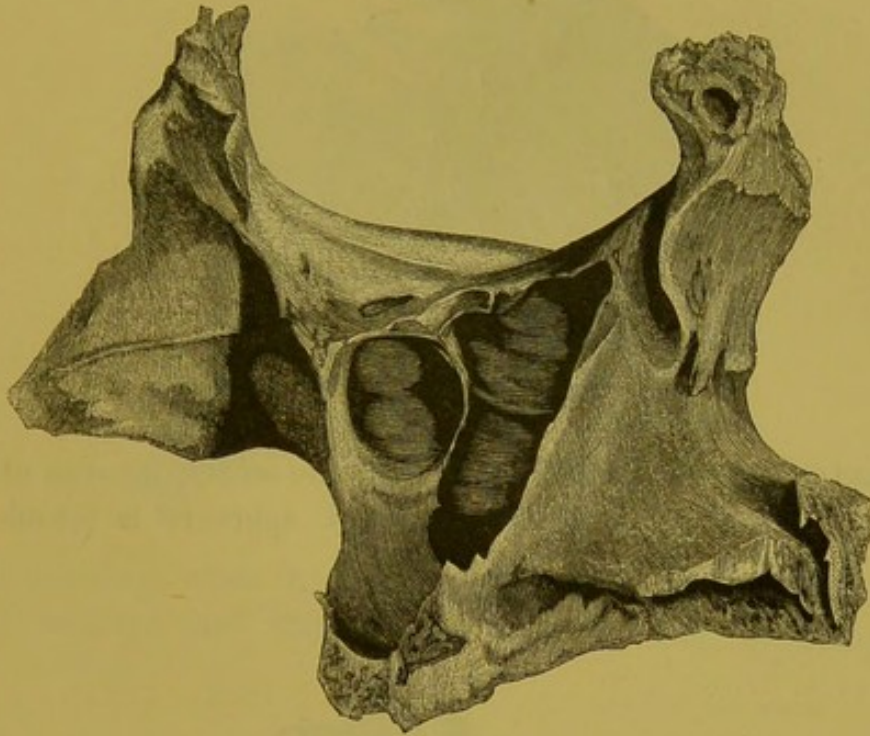
FIG. 53.





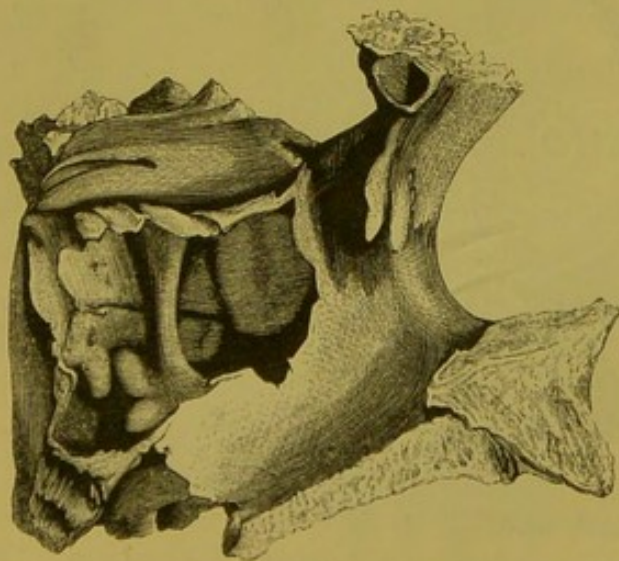
and subdivide the opening into two. In the recent subject these are covered in by the mucous membrane of the nose,

FIG. 54.



so that ordinarily there is only a small oblique aperture left in front of the unciform process of the ethmoid, and close

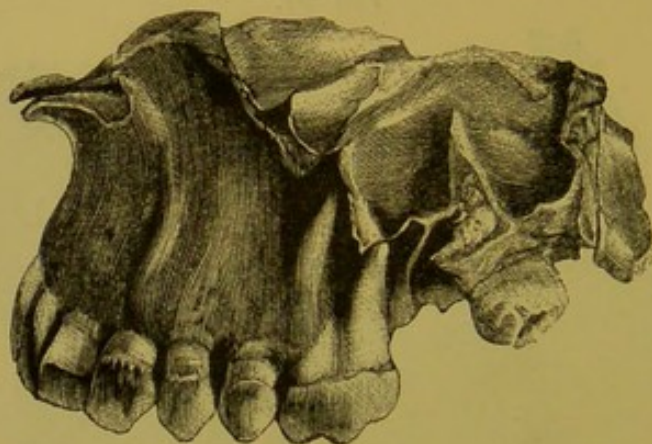
FIG. 55.





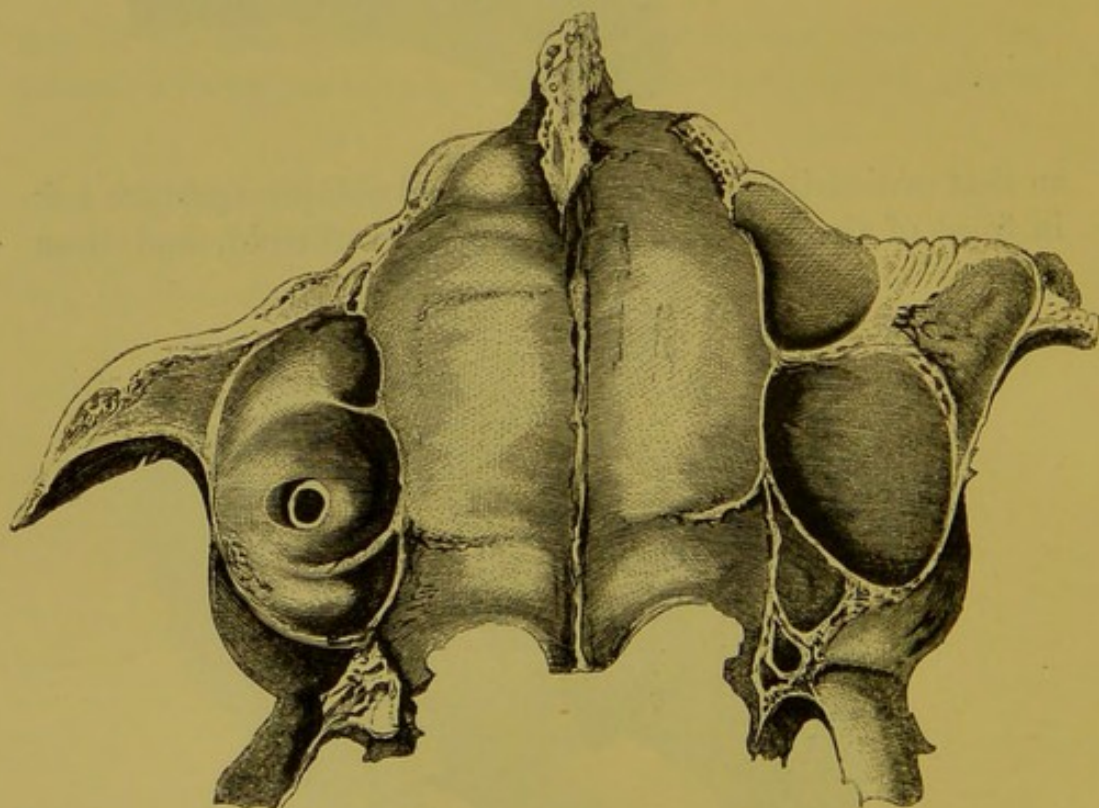
behind the infundibulum. It should be observed, that this opening is at the upper part of and not near the floor of

FIG. 56.



the antrum, and that it opens into the *middle* meatus of the nose. Occasionally a second small aperture is found be-

FIG. 57.

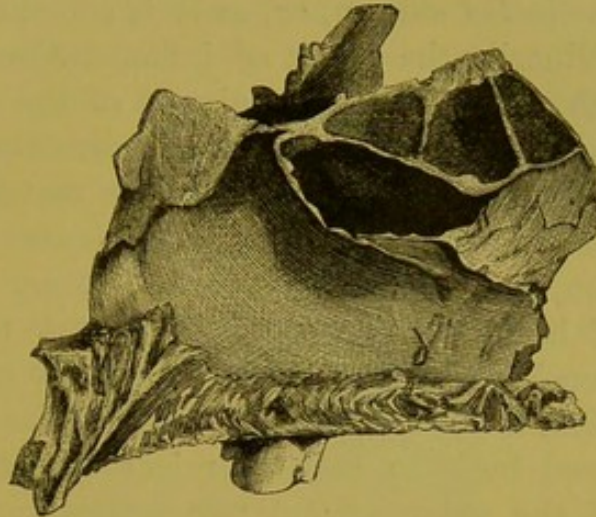


hind this, and nearer to the floor of the sinus, which has been always regarded as a natural formation. M. Giraldès,



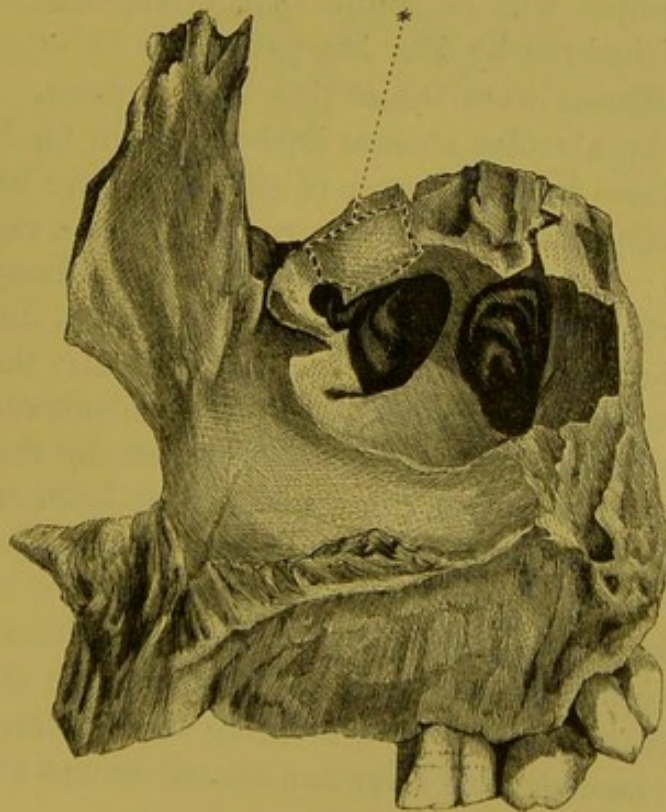
however, in his "*Recherches sur les Kystes Muqueux du Sinus Maxillaire*" (Paris, 1860), maintains that the pos-

FIG. 58.



terior opening, when it exists, is always the result of pathological change, and that the anterior opening is into the

FIG. 59.





infundibulum, and not into the meatus itself. I believe that slight variations in the position of the opening exist; but it is undoubted that the aperture is very minute, and quite inaccessible from the nose.

*Suppuration in the antrum*, or, as it is sometimes termed, *abscess*, is ordinarily the result of inflammation, extending from the teeth to the lining membrane of the cavity; and the disease might therefore be not incorrectly termed an empyema, as proposed by O. Weber. The roots of the first and second molar teeth often form prominences in the floor of the antrum, and when these teeth become carious, the thin plate of bone covering their fangs not unfrequently becomes affected, and disease is set up in the cavity. The fangs of the first molar tooth are occasionally found in health to be uncovered by bone, and to project beneath the lining membrane of the antrum; and under these circumstances, irritation and inflammation would be still more likely to occur. But an abscess may be formed in the alveolus, and eventually burst into the antrum, though connected originally with teeth not usually in relation with the cavity. Of this an example will be found in the Appendix, in a case (XI.), furnished me by Mr. Margetson, of Dewsbury, where the teeth affected were the canine and incisors. This perforation of an alveolar abscess is seen also in fig. 57.

Other causes besides disease of the teeth have been known to induce suppuration in the antrum, such as a violent blow on the face; and Dr. Rees has recorded an example, in an infant a fortnight old, as the result of pressure during birth (*Medical Gazette*, vol. iv.). It is probable also that the disease may result from catarrhal or other inflammation of the lining membrane; and it has been excited by the entrance of foreign bodies either from without or from within the mouth, after the extraction of a tooth communicating with the cavity.

The symptoms are at first simply those of inflammation of the lining membrane—dull, deep-seated pain shooting up the face and to the forehead, swelling and tenderness of the cheek, with considerable fever and constitutional disturbance.



A slight rigor may usher in the formation of matter, which may find its way into the nostril when the patient is lying on his sound side, either through the normal opening, or through an opening caused by absorption, as maintained by M. Giraldès. This is rare, however, and generally the pus, not finding an exit, distends the antrum, causing partial absorption of the walls, and thus both bulging out the cheek and thrusting up the floor of the orbit. Fig. 60 shows the prominence of the cheek thus produced in

FIG. 60.



a patient under the care of Sir William Fergusson. Under these circumstances the affection is readily recognised by the peculiar crackling which is perceived when the thinned bone is pressed upon, and the matter, if not evacuated, will shortly find a way out for itself, either by the side of the teeth, through the front wall of the antrum, or through the floor of the orbit; in either of which cases considerable necrosis and ultimate scar are likely to be the consequences.

The elevation of the floor of the orbit already described



may simply displace the eyeball and render it temporarily blind, as in a case recorded by Mr. J. Smith, of Leeds (*Lancet*, 14th Feb. 1857), or it may lead to permanent amaurosis—a point to which Mr. Salter called especial attention in the *Medical and Chirurgical Society's Transactions* for 1863. Mr. Salter's patient, a young woman, twenty-four years of age, was attacked with violent toothache in the first right upper molar, which was followed by enormous swelling of the side of the face and intense pain. The eyeball then became protruded, and she soon after perceived that the eye was blind. Shortly after the establishment of these symptoms, "abscess" of the antrum pointed at the inner and then at the outer canthus, and a large discharge of pus at both orifices followed; these orifices soon closed, but the general symptoms of the part continued unchanged—the swelling of the face, protrusion of the globe, and blindness. This state of things lasted for about three weeks, when the patient was sent to Guy's Hospital, and admitted. At this time the patient exhibited hideous disfigurement from swelling of the face, œdema of the lids, and lividity of the surrounding integument. Upon examining the mouth, it was found that the carious remains of the first right upper molar appeared to be associated with, and to have caused the disease. Together with the other contiguous carious teeth, this was removed, and led by an absorbed opening into the floor of the antrum. The hæmorrhage which followed the operation was discharged partly through the nose and partly through the orifices in the cheek, as well as from the tooth-socket, showing a common association of these openings with the antrum. The condition of the eye constituted the most important symptom, and the most distressing. The sight was utterly gone; the globe prominent and everted. There was general deep-seated inflammation of the fibrous textures of the eye. The pupil was large and rigidly fixed; it did not move coordinately with the other under any circumstances. Some abatement of the symptoms followed the extraction of the tooth; but it was soon found that there was a considerable sequestrum of dead bone, which was removed. The necrosis



involved the front part of the floor of the orbit, the upper cheek portion of the superior maxilla, and the infra-orbital, and a large plate of bone from the inner (nasal) wall of the antrum. The removal of the dead bone was followed by the immediate and complete cessation of all inflammatory symptoms; but the eye remained sightless, and the pupil rigidly fixed. About five weeks after the removal of the dead bone, it was noticed that the pupil of the affected eye moved with that of the other, under the influence of light, though vision in it had not returned. Mr. Charles Gaine, of Bath, has recorded (*British Medical Journal*, 30th Dec. 1865) a very similar instance in a young woman of twenty-two. In Mr. Salter's paper will be found the case of a gentleman, aged thirty-five, under the care of Mr. Pollock, who had amaurosis following inflammation without abscess, and one by Dr. Brück, where amaurosis followed abscess, in the person of a man of forty-five. Sir Thomas Watson, in his "Lectures on Physic," alludes also to two cases of temporary amaurosis, the result of diseased teeth in the upper jaw.

But even more serious results have followed neglected suppuration in the antrum, for Dr. Mair, of Madras, has recorded, in the *Edinburgh Medical Journal* for 1866, the case of a gentleman in whom suppuration in the antrum was followed by death in sixteen days from suppuration within the cranium, accompanied by epileptic convulsions. The full details of the case, with the most interesting post-mortem appearances, will be found in the Appendix (Case XII.).

The treatment of suppuration of the antrum consists, in the first place, in the extraction of all decayed teeth or stumps in the affected jaw, and with this object in view those teeth which are apparently sound should be tested by a sharp knock with some metal instrument, when, if tender, they should be extracted. If the cause of the mischief is removed in time the inflammation will subside under fomentation and the application of a leech to the gum; but if matter has formed it must be evacuated without delay. If the extraction of a tooth is followed by the flow of pus, the



enlargement of the aperture in the socket by the introduction of a trocar is at once the readiest and simplest mode of evacuating the matter; but if all the teeth are apparently sound it will be advisable to extract the first molar in order to puncture through one of its outer sockets. The first molar is to be preferred for extraction, both on account of the depth of its socket and also because, as mentioned by Salter, it is more liable to decay than the other teeth. In puncturing through the socket of a tooth with a trocar it is well to gauge the resistance likely to be encountered and the depth to which the instrument may safely go, lest injury should be unwittingly inflicted on the orbital plate by the trocar entering unexpectedly. When the teeth are all sound, some surgeons prefer to perforate the alveolus above the gum with a trocar or strong pair of scissors, and similar treatment would be required in the rare case of suppuration occurring after loss of the teeth in old people.

Whatever method may be adopted for emptying the antrum, it is important that the cavity should be thoroughly cleansed by the injection of warm water. For this purpose a curved canula, fitting the syringe ordinarily employed for injecting hydrocele, answers very well; or I have satisfactorily employed an ordinary Eustachian catheter for the purpose, to which an india-rubber injecting-bottle can be readily adapted. After thoroughly cleansing, some detergent and slightly astringent lotion should be injected, to restore the healthy condition of the mucous membrane, and for this purpose weak solutions of permanganate of potash or sulphate of zinc answer admirably. Care must be taken that particles of food do not gain admission to the antrum, and this may be accomplished by plugging the hole with cotton wool, or, as suggested by Salter, by fitting a metal plate to the mouth with a small tube to fill the aperture, which can be corked at pleasure, and will serve as a pipe for injection.

The possible subdivision of the floor of the antrum by bony septa, already described, must be borne in mind in operating upon this cavity, and especially if there is reason to suspect the



presence of any foreign body which may be keeping up irritation. In his paper already referred to, Mr. Cattlin narrates the case of the fang of a tooth lodging in one of these subdivisions, from which it was extracted with difficulty.

Suppuration in the antrum may assume a more chronic form than that above described, and from the slow expansion of the jaw which results may be mistaken for a solid growth. Weber describes a form of chronic subperiosteal abscess proceeding from a tooth, which is surrounded by an osseous plate or shell formed from the periosteum, while it is separated from the antrum by the maxillary wall itself; and believes that the occurrence of suppuration commencing in the bone, either from this cause or from the suppuration of a dentigerous cyst, is much more common than in the antrum itself. The diagnosis of these several forms of abscess is by no means easy, and errors have been made by excellent surgeons in mistaking them for solid growths: thus, Liston mentions ("Practical Surgery," p. 303) having seen a surgeon have his hands covered with purulent matter in attempting to remove a supposed tumour of the jaw. This is more especially likely to happen when, as is sometimes the case, considerable hypertrophy of the osseous wall has taken place in consequence of the irritation the bone has been subjected to. Stanley (p. 285) mentions a case of the kind which occurred in the practice of Mr. Lawrence:—"A woman, aged twenty-four, was admitted with a large, hard, round swelling of the cheek in the situation of the antrum; it was free from pain, and the soft parts covering it were healthy; such was the solidity and hardness of the swelling that it was supposed it might be an osseous growth from the antrum, and the history appeared to confirm this view of its nature, as the woman stated that about five months previously she had received a blow on the cheek, and that soon afterwards the swelling commenced and had slowly increased to its present magnitude, which was about that of a middle-sized orange. A scalpel was thrust into the tumour immediately above the sockets of the molar teeth, and healthy pus flowed from the opening; the discharge continued in gradually decreasing



quantity, and the swelling subsided as the walls of the antrum receded to their natural limits."

This thickening of the bone may remain permanently, long after the cure of the abscess, and may necessitate operative interference; thus, in 1850, Sir William Fergusson met with a case of osseous tumour of the size of a pigeon's egg, projecting from the superior maxilla of a man aged fifty, who had been the subject of abscess, and whose antrum was still distended though containing no fluid. Here it became necessary to remove the tumour with the anterior wall of the antrum, by which the deformity was quite got rid of. The case will be found in the *Lancet*, June 29, 1850. A case, under the care of Mr. Henry Smith, in which an abscess consequent on necrosis of a portion of the jaw closely simulated a tumour of the antrum, will also be found in the *British Medical Journal*, March 2, 1867.

*Hydrops Antri*, or "dropsy of the antrum," is an old name for a disease which has long been recognised, though, within the last few years doubts have arisen as to the exact pathology of the affection. The history of these cases is one of gradual, painless dilatation of the upper jaw, until its outer wall becomes so thin as to crackle like parchment upon pressure being made, or at certain points being so absorbed that fluctuation is readily perceptible. At the same time the other walls of the antrum yield to the persistent pressure, the palate becoming flattened, and the nostril blocked by the bulging of the internal wall. On the extraction of a molar tooth, and perforation through its socket, as described under the previous section, a quantity of clear, or yellowish serous fluid is evacuated, which frequently contains flakes of cholesterine floating in it. After the evacuation of the fluid the swelling ordinarily slowly subsides, the maxilla resuming its normal relations, and the serous discharge, which continues to flow for some time, gradually ceases, the aperture in the alveolus closing.

The old explanation of these phenomena was, that the aperture between the antrum and the nostril having become accidentally obstructed, the mucous secretion, which was pre-



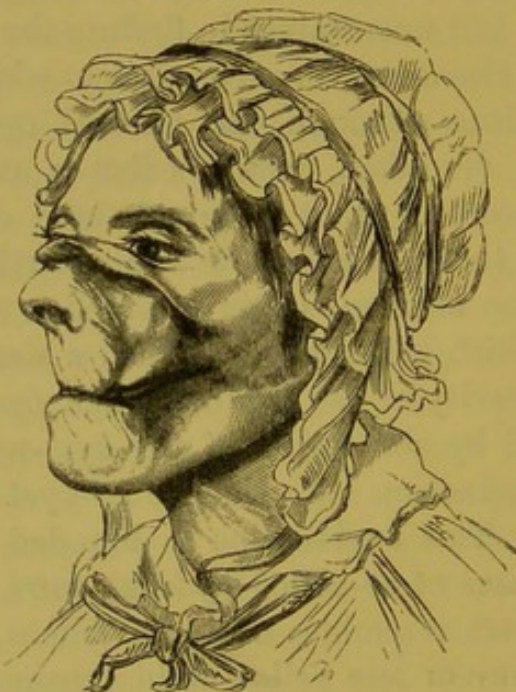sumed to be constantly taking place within the cavity, was thought to be imprisoned, and, by its gradual accumulation, to produce the symptoms which have been described. Following up this idea, we find surgeons, and among others Jourdain, of Paris (1765), who very accurately described the affection, recommending the restoration of the nasal orifice by probing—a useless operation still described in many foreign manuals of operative surgery (see Guérin's "Elémens de Chirurgie Opératoire," 1855). Bordenave, in his "Observations on Diseases of the Maxillary Sinus" (Sydenham Society's translation, 1848), gives full details of this method of probing and injecting, but, after showing that there is great difficulty and uncertainty in finding the natural orifice, remarks that "there are very few cases in which the employment of injections through the natural openings, in the manner above described, would effect a complete cure." It is certain, however, that some of these cases, and very probably all of them, originate in the growth of a cyst, or cysts, within the antrum, or in connexion with the fangs of the teeth, which either grow to such a size as to be mistaken for the cavity of the antrum when opened, or break into the antrum by absorption of the cyst-wall, so that on subsequent examination no evidence of cyst formation can be discovered. This explanation is founded upon the fact that in these cases of so-called *hydrops antri*, the contained fluid in no respect resembles ordinary mucus, but is invariably a clear, more or less yellow fluid, frequently containing cholesterine in considerable quantity. In these respects it closely resembles that found in well-marked cases of cystic growth, which have been examined in various stages of development.

A remarkable case of distension of the antrum is narrated by Sir William Fergusson, and the preparation is preserved in the King's College Museum. It was taken many years ago from a subject in the dissecting room, and from the person of an old woman. The tumour, which was of very large size, had burst shortly before death, leaving the remarkable deformity shown in fig. 61 (taken by permis-



sion from Sir W. Fergusson's work on Surgery), which is due to the complete absorption of the front wall of the antrum and its collapse, by which a prominent horizontal ridge of bone, formed by the upper wall of the antrum, has been left immediately below the orbit. The preparation shows great distension of the antrum, the diameter of which varies in different parts from two to two and a half inches, and the bony wall so thinned out as to resemble parchment. The gums are edentulous. There is no communication between the nose or mouth and the cavity, which is lined with a

FIG. 61.



membrane covered with laminated deposit. (For these particulars I am indebted to Dr. Trimen, the late Curator.) Whether this was originally a case of cystic growth, or a chronic abscess, it is impossible now to decide, but it is, so far as I am aware, a unique post-mortem specimen of this distension.

Numerous instances of distension of the antrum by clear fluid in living patients, have been recorded from time to time, and occasionally mistakes have been made by the surgeon in regarding the tumour as of a solid nature. A



very remarkable case, in which a distended antrum closely simulated a solid growth, occurred in the practice of Sir William Fergusson, in 1850, and the details of the case will be found in the Appendix (Case XIII.). Here the surgeon made an exploratory puncture before commencing the more serious operation; but a case has occurred within my own knowledge in which a very able surgeon removed the upper jaw before discovering the error of his diagnosis.

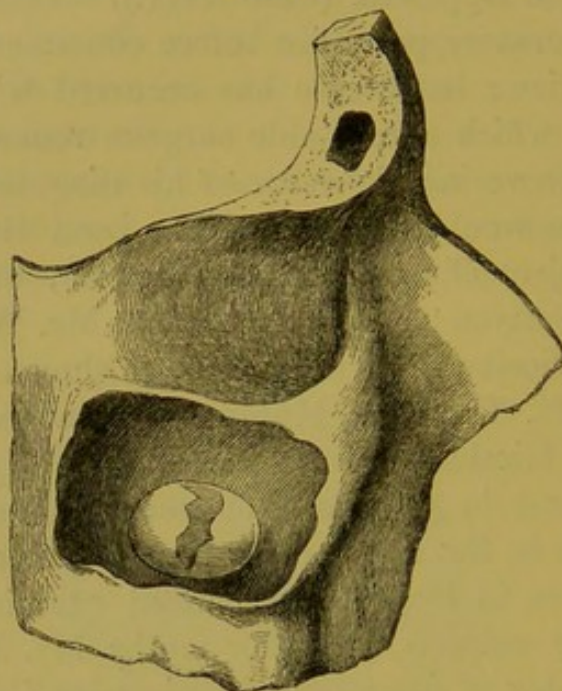
M. Giraldès would appear to have been the first author upon the subject of cysts of the antrum, and his thesis gained the Montyon prize in 1853; but Mr. W. Adams may fairly claim priority of investigation, as shown by specimens preserved in St. Thomas's Museum—as indeed is acknowledged by M. Giraldès. Luschka subsequently investigated the subject, and in sixty post-mortem examinations found cystic growths in the antrum five times, some of them being two centimetres in length. A careful examination of the antra of thirty subjects, made for me by Mr. Marcus Beck, the Demonstrator of Anatomy of University College, during the winter of 1867–68, failed to discover an instance of the kind.

Mr. Adams' specimens, from one of which the drawing (fig. 62) was made, show each a cyst of oval outline, attached to the inner wall of the antrum, and measuring rather more than an inch and three-quarters of an inch respectively in their long diameters. These, of course, are too small to have produced any symptoms during life. The specimens given by M. Giraldès in his "*Recherches sur les Kystes Muqueux du Sinus Maxillaire*," from one of which the illustration (fig. 63) is taken, show very varying degrees of cystic growth in the mucous membrane of the antrum. In one instance there is a single cyst at the floor of the antrum, into which an opening has been made, whilst in the others the cysts are very numerous and of very variable sizes, depending, apparently, upon a cystic degeneration of the entire mucous membrane. M. Giraldès explains the formation of these cysts as being due to the dilatation of the glandular follicles of the mucous membrane, and urges that



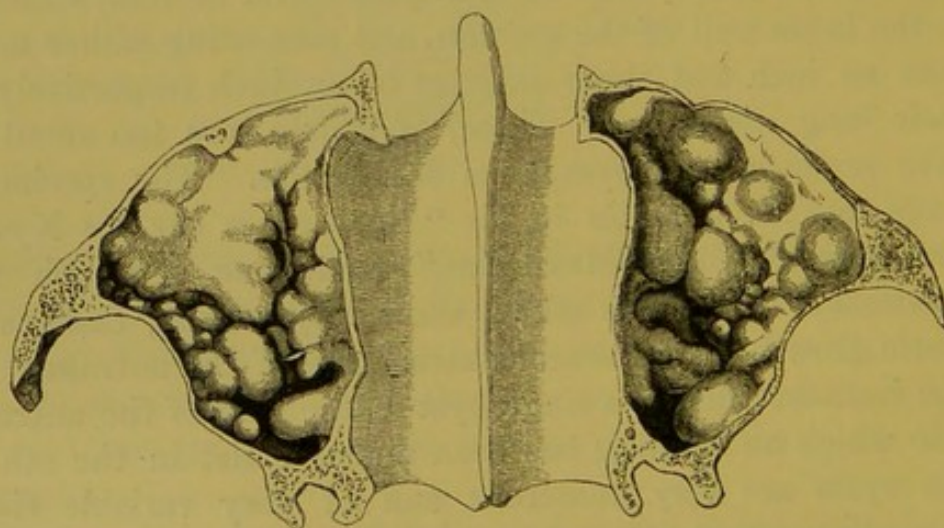
the ordinary operation of tapping the antrum would be useless in such cases, but that it would be necessary to open

FIG. 62.



up the antrum, so as to get at the seat of the disease. Fortunately these numerous cysts appear to be of slower

FIG. 63.



growth than the single cysts, for it would be impossible to extirpate such numbers, as are here seen (fig. 63), without removing the entire jaw.



The contents of these cysts appear to be at first clear fluid, but of a viscid nature; when more fully developed, the fluid becomes flaky, from the presence of cholesterine, and occasionally assumes a greenish tint; it may also become purulent, and Maisonneuve has recorded (*Gazette des Hôpitaux*, 6th Jan., 1855) a case where pressure on the cheek produced a flow of butter-like fluid from the nose in a young woman who, for a year, had suffered from a tumour of the right upper jaw, which had been pronounced malignant, the face being enlarged and the nostril obstructed. Here puncture from the nostril, combined with pressure and injections, effected a cure, and the case must be considered as one of cyst of the antrum, but whether a mucous cyst, the contents of which had undergone solidification, or a separate formation, must remain doubtful.



## CHAPTER XII.

## CYSTS OF TEETH—DENTIGEROUS CYSTS.

CYSTS in connexion with the teeth may be classed under two heads:—1st, cysts connected with the roots of fully developed teeth, and 2ndly, cysts connected with imperfectly developed teeth—to which the term “Dentigerous cysts” has been applied in modern times. Both kinds may occur in either jaw, and, in the case of the upper jaw, may be confounded with collections of fluid in the antrum, or may secondarily involve that cavity.

Cysts, of small size, in connexion with the fangs of permanent teeth, are frequently found on their extraction, but give rise to no symptoms demanding surgical interference. Occasionally, however, they grow to a large size, in which case they produce absorption of the containing alveolus, and give rise to a prominent swelling.

Three specimens of cyst connected with the fangs of teeth

FIG. 64.

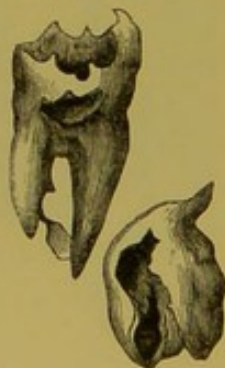

FIG. 65.

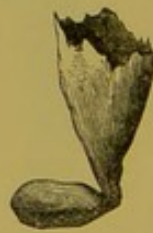

FIG. 66.



accompanied this essay, and are now in the College of Surgeons (1007 B). Two of them (figs. 65, 66) are quite small



(one being remarkable for its pedicle), the third (fig. 64) is of the size of a hazel-nut, and was partly torn in extraction. I am indebted for the specimens to Mr. E. H. King.

Dupuytren remarks that "morbid changes in the roots of the teeth give rise to the formation of serous cysts, which are most frequently met with in the alveoli of the upper canines, and in some instances acquire a very large size, even equal to that of the antrum. In such cases the root of the tooth is found diseased and inclosed within the cyst, which adheres to the alveolar cavity and (when small enough) usually accompanies the tooth in its extraction; but if left behind, a suppurative process is established, which continues for a long time. The fluid yielded by these cysts is sometimes very thick, and in other instances of a serous character, and their inner surface is as smooth as that of the serous membranes" ("On Diseases of Bone," Sydenham Society's translation, p. 440).

Of this kind probably also was the case mentioned by Mr. Paget ("Surgical Pathology," p. 402), of a woman, aged thirty-eight, who had a tumour simulating a collection of fluid in the antrum, but which projected beneath the mucous membrane of the upper jaw above the teeth, and had existed six years. An incision evacuated an ounce of turbid brownish fluid, sparkling with crystals of cholesterine, and it then appeared that there was no connexion with the antrum, but that it rested in a deep excavation in the alveolar border of the jaw. So also the case mentioned by the same author in connexion with the incisor teeth.

Delpech relates a case in which a membranous cyst contained three ounces of fluid, but its interior bore no resemblance to the interior of the antrum; and Stanley (p. 300) narrates a case of Mr. Lawrence's of large cyst, projecting in the situation of the antrum, and containing a glairy fluid with shining particles in it, both which he regards as instances of these cysts connected with the teeth, although it appears more probable that they were cases of cyst in the antrum, which have been already described.

A case, which I have little doubt originated in a cyst



in connexion with the incisor teeth, but in which the antrum had become secondarily involved, has lately been under my own care. The patient, a woman, aged forty, had a fluctuating swelling, which had been noticed for two years, immediately above the incisor teeth, which were decayed even with the gum. On incising it, a quantity of yellowish glairy fluid exuded, and a probe, when introduced, evidently passed into the antrum. From the position of the cyst, and its close proximity to the incisor teeth, I have no doubt it originated from them, and found its way into the antrum by absorption of the bony wall. The patient would not consent to any operation for the cure of the disease, which gave her little inconvenience.

Fischer, of Ulm (Gurlt's "Jahresbericht," 1859, p. 154), has narrated three cases of cyst connected with the fangs of teeth, in one of which he had the opportunity of making a post-mortem examination. After the removal of the facial wall of the antrum, there appeared a cyst connected with the apex of the posterior molar tooth, which filled the whole antrum, without, however, adhering to the mucous membrane. This consisted of a perfectly closed serous bag of  $\frac{1}{8}$ " thickness, with a smooth inner surface, and containing a yellowish serous fluid, which grew from the periosteum of the apex of the root of the tooth.

*Cysts in connexion with undeveloped teeth, or dentigerous cysts,* may occur in either jaw. These, as already mentioned, may suppurate and give rise to abscess which may be confounded with suppuration within the antrum, or may project into the antrum, filling the cavity or communicating with it.

Dentigerous cysts arise in connexion with teeth which from some cause have remained within the jaw, and have undergone a certain amount of irritation. They are almost invariably connected with permanent teeth, though Mr. Salter mentions a case in connexion with a temporary molar occurring in the practice of Mr. Alexander Edwards, late of Edinburgh; and in a remarkable specimen belonging to Mr. Cartwright, which will be afterwards referred to, the



tooth is a supernumerary one. Mr. Tomes explains the formation of cysts in connexion with retained teeth by referring to the fact that when the development of the enamel of a tooth is completed, its outer surface becomes perfectly detached from the investing soft tissue, and a small quantity of transparent fluid not uncommonly collects in the interval so formed. This fluid ordinarily is discharged when the tooth is cut, but when from some cause the eruption of the tooth is prevented, it increases in quantity, gradually distending the surrounding tissues in the form of a cyst.

Mr. Salter, in his article on "Diseases connected with the Teeth," has collected several cases of dentigerous cyst, which were recognised and treated during life. Thus Jourdain records three cases, one in a girl of seventeen, in whom the first and second right upper permanent molars were inverted and the surrounding cyst had involved the antrum; a second in a man of sixty, connected with a bicuspid tooth of the upper jaw; and the third in a girl of thirteen connected with an upper lateral incisor. Dupuytren and Bransby Cooper each met with a case in the upper jaw. Dupuytren's case, which was shown to him by M. Loir, being a remarkable instance of a cyst developed between the plates of the palatine process of the upper jaw (see Dupuytren "On Diseases of Bone," Sydenham Society's translation, p. 438).

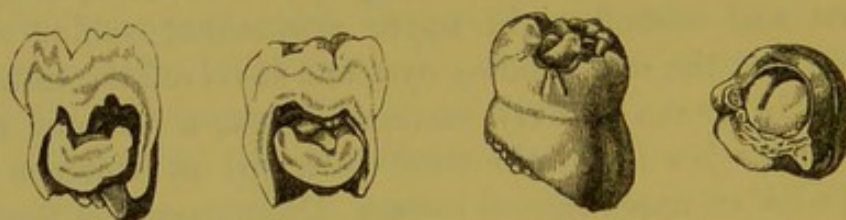
Professor Baum also met with an extraordinary case in a woman aged thirty-eight, both of whose antra were enormously dilated by cysts, from one of which a canine tooth, and from the other a molar tooth, was removed. Mr. Salter gives two cases of his own, which will be found at length in the "Guy's Hospital Reports, 1859," one depending upon the impaction of a wisdom tooth in the lower jaw of a man, aged twenty-two, and the other in a girl of eighteen, who had an elastic fluid containing tumour in the incisive region of the upper jaw connected with a permanent incisor tooth, the fang of which was not developed, and whose place was occupied by a temporary tooth.

Inversion of the tooth appears to be a frequent accom-



paniment, or rather the cause of these cysts, and occurred in one of the cases narrated by Jourdain, and in those of Dupuytren and Bransby Cooper. Mr. Tomes ("Dental Surgery") has recorded a similar case in a girl of sixteen, who had a swelling around the second molar tooth of the lower jaw, which proved to be a cyst. After being tapped, the cyst suppurated, and the extraction of the tooth became necessary, when the inverted crown of the third molar was found lodged between the expanded fangs of the second molar tooth, the two being united by dentine, and having one common pulp-cavity, as seen in the accompanying drawing, fig. 67, from Mr. Tomes' work. The case will be found in detail in the Appendix (Case XIV.).

FIG. 67.



When dentigerous cysts occur in the lower jaw they form more isolated and prominent tumours than in the case of the upper jaw, and in some cases the projecting bony wall has been removed. In St. Bartholomew's Museum is a specimen of the kind (L. 119), consisting of a portion of a bony cyst, which was removed by Mr. Earle from the external and lateral part of a lower jaw. The cyst is lined with a thick and soft membrane, which has been in part separated from it. The cavity of the cyst was filled with a glairy fluid, and at the bottom of it a canine tooth of the second set was adherent to the lining membrane. The case is referred to by Stanley, who gives an accurate drawing of the preparation. In the Museum of the College of Surgeons, there is a very similar preparation (1033 B.) showing a bony cyst of oval shape, one inch in its long diameter, containing an imperfectly formed bicuspid tooth, which was removed by Mr. Wormald from the lower jaw of



a female, aged seventeen, whose case will be found in the *Lancet*, 22nd June, 1850.

Cases of dentigerous cysts may be mistaken for solid tumours. Thus Gensoul, of Lyons, has recorded the case of a girl of thirteen, whose antrum was distended with a large collection of yellow fluid and contained a canine tooth attached to its wall, in whom he had made the incisions necessary for the removal of the tumour before he discovered its nature. Mr. Syme also has related (*Edinburgh Medical and Surgical Journal*, 1838) the case of a woman, æt. thirty-one, on whom he operated for a tumour of the upper jaw of four months' standing, by laying open the cheek and removing the tumour with the bone-forceps. "The tumour was found to consist of a dense cyst lined throughout with earthy matter in a crystalline form, and containing a clear glairy fluid, together with the crown of a tooth, apparently the lateral incisor." In a cavity beyond the tumour, was found a fully formed canine tooth, encrusted with a thin plate of bone. The teeth are said to have belonged to the temporary set.

When the cyst occurs in the lower jaw, and is less prominent than in the two cases already mentioned, giving rise rather to a general expansion of the bone than a distinct tumour, the disease may be mistaken for a solid tumour of the lower jaw. A case of this kind occurred to that excellent surgeon, Mr. S. W. Fearn, of Derby, who has had the courage and honesty to publish the case (*British Medical Journal*, Aug. 27th, 1864), and to whom I am indebted for the very valuable preparation which accompanied this essay (College of Surgeons Museum, 1033 C), from which the drawings, figs. 68 and 69, were made.

Mr. Fearn's patient was a girl of thirteen, who had a large resistant tumour of the left side of the lower jaw, which had been growing six months. There was some enlargement also of the right side, and the teeth there were very irregular. The teeth on the left side had been extracted, with the exception of the second molar and a temporary molar. No opening could be detected in the tumour, though there was



a constant offensive discharge from its surface. Mr. Fearn removed the left half of the jaw from the symphysis to the articulation, and on division of the bone with the saw, a quantity of fœtid pus escaped. The tumour (fig. 68) proved to be a bony cyst formed by the expansion of the two plates of the jaw, which extended for some distance to the right of the symphysis (a very unusual occurrence). The cavity is lined with a thick vascular membrane, and at the

FIG. 68.

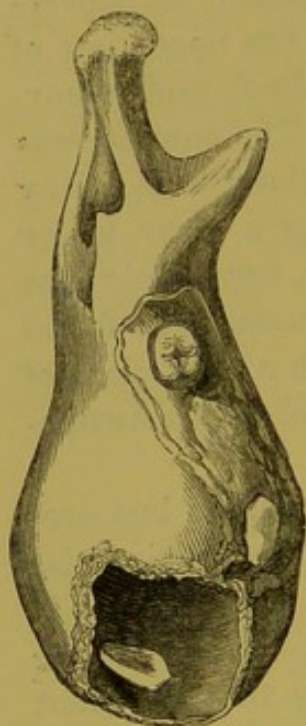
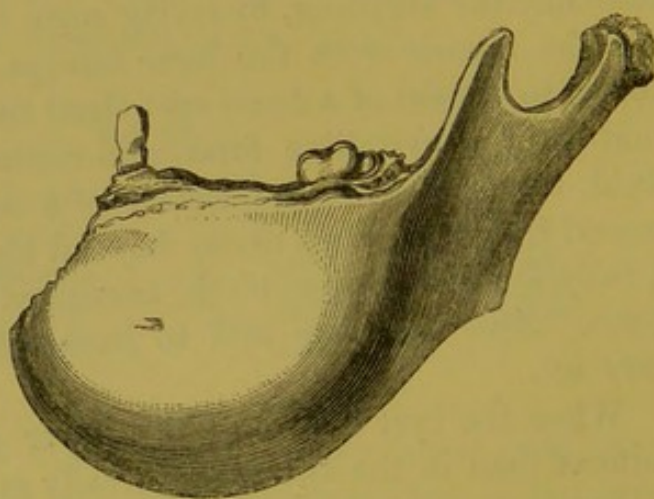


FIG. 69.



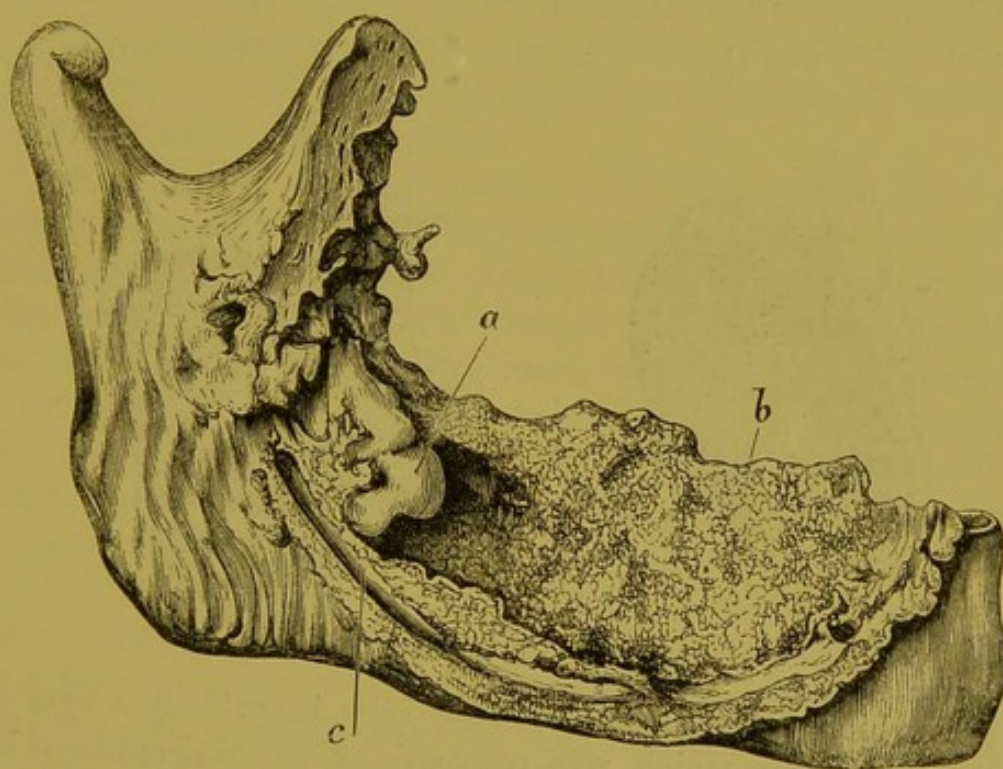
bottom the canine tooth will be seen projecting from the wall. The case was evidently therefore one of dentigerous cyst, due to the non-development of the canine tooth, the contents of which had, from some cause, become purulent. The mental foramen, with the nerve emerging, is still visible in the preparation and drawing (fig. 69). The patient made a good recovery.

A very similar case is recorded by Dr. Forget, in his essay on "*Les Anomalies Dentaires et leur influence sur la production des Maladies des Os Maxillaires*," 1859, which is translated by Mr. R. T. Hulme, in the *Dental Review*, 1860. The patient was a woman, aged thirty, who had a



tumour on the right side of the lower jaw, of the size of a hen's egg, extending from the lateral incisor to the base of the coronoid process, which had been growing ten years. M. Lisfranc removed half the jaw, and the patient made a good recovery. An examination of the tumour showed it to be a cyst, at the bottom of which lay the wisdom tooth, the crown projecting downwards into it, the fang being inverted and fixed in the base of the coronoid process. In the illustration (fig. 70) (for which I am indebted to Mr.

FIG. 70.



Hulme), the cyst has been opened, the internal wall, *b*, being left; *a* marks the position of the tooth, and *c* the inferior dental canal, which has been opened to show its non-communication with the cyst.

M. Legouest brought a very similar case under the notice of the Société de Chirurgie de Paris, in 1862, which had the peculiarity of pulsating at one point synchronously with the radial pulse. The supposed tumour proved to be a dentigerous cyst, containing two teeth, the pulsation having been due to the great vascularity of the membrane covering



it, and the great pain which had been experienced, to the fact that the dental canal was opened, and the nerve pressed upon by the cyst. (*Gazette des Hôpitaux*, Aug. 7th, 1862.)

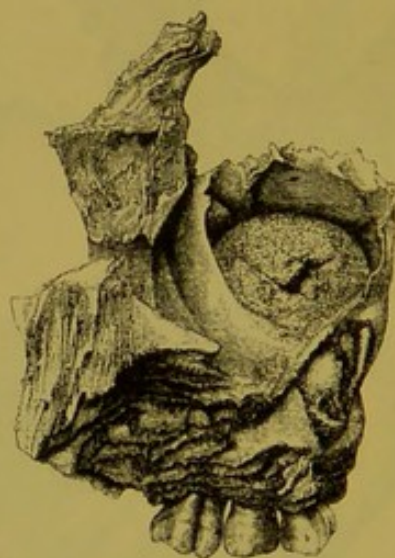
In the *Annali Universali di Medicina* for May, 1867, Sig. Bottini, of Novara, has recorded a case of "subperiosteal and sub-capsular disarticulation" of the left half of the lower jaw of a woman, æt. twenty-three, for what proved a dentigerous cyst in connexion with the wisdom tooth.

Mr. Underwood has allowed me to have the accompanying drawing (fig. 71), taken from the model of a prepara-

FIG. 71.

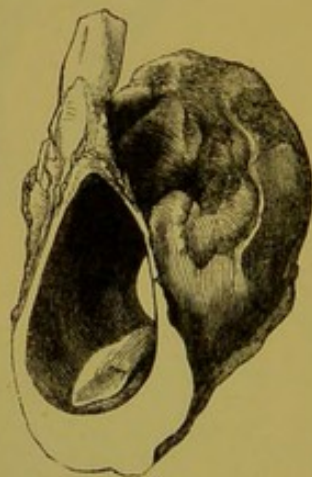

FIG. 72.



tion which he possesses, showing very beautifully a cyst of the lower jaw, which was removed by M. Maisonneuve by sawing through the bone at two points. The canine tooth is seen lying horizontally at the bottom of the cyst. The patient, aged fifty-six, had a swelling in the lower jaw near the chin, and an opening formed behind one of his front teeth, from which a saline fluid escaped. The man made a good recovery from the operation. (Vide *British Journal of Dental Science*, 1862, p. 562.)

Dentigerous cysts, like other cysts, may undergo alteration, not only of the contents, but of the cyst-wall. The opportunities for recognising such changes are exceedingly



rare, and the only known specimen of the kind is one in the possession of Mr. Samuel Cartwright, which shows calcification of the cyst-wall. The preparation (a reduced drawing of which (fig. 72) is taken from Mr. Cattlin's paper on the Antrum) is one of the right superior maxilla, which, having been opened, shows a bony cyst within the antrum, and attached to its floor, but unconnected with it elsewhere. The cyst has been opened, and contains a *supernumerary* tooth loose in its cavity, though no doubt originally attached to its base. This is clearly a case of dentigerous cyst which has undergone calcification, and which, had it been expanded to a greater degree before this change took place, would in all probability have been inseparably united with the walls of the antrum.

The diagnosis of dentigerous cysts from other cysts is exceedingly difficult until they are opened, as indeed is the recognition of any form of cyst. A careful examination of the mouth may reveal the absence of a permanent tooth, or, as in one of Mr. Salter's cases, may show a temporary tooth occupying a permanent position, and this would direct the mind of the surgeon to the possible existence of a dentigerous cyst. On the other hand, however, it must be remembered that teeth may be wanting without being connected with any disease; thus I am acquainted with a family who have the hereditary peculiarity of a single bicuspid tooth on each side. When a cyst is sufficiently expanded for the wall to yield under the finger with the characteristic parchment-like crackle, there can be no difficulty in its recognition, but without this it is impossible in all cases to distinguish between a cyst and a slow-growing solid tumour. Under these circumstances, it is well to insist upon the propriety of making an exploratory puncture in all cases which are not obviously solid growths, and have sprouted so that their nature can be certainly recognised. The puncture being made within the mouth, will be of no moment should a more severe operation subsequently be necessary.

*Treatment.*—The treatment of distension of the antrum



with fluid is the same as that for suppuration within the cavity—extraction of the first molar tooth and perforation through one of its sockets, or perforation of the wall of the antrum immediately above the alveolus. Similar treatment would be applicable to cases of cyst whether in the upper or lower jaw, and where a tooth is contained in the cyst it should of course be extracted. For the cure of many of these cases simple puncture will not suffice, and it will be necessary to remove a portion of the front wall of the antrum or of the cyst wall, and to fill the cavity with lint so as to induce granulation and gradual obliteration. Sir William Fergusson has accomplished this in some cases without any incision of the integuments, and in other more extensive cases by simply dividing the lip, and carrying the incision into the nostril.

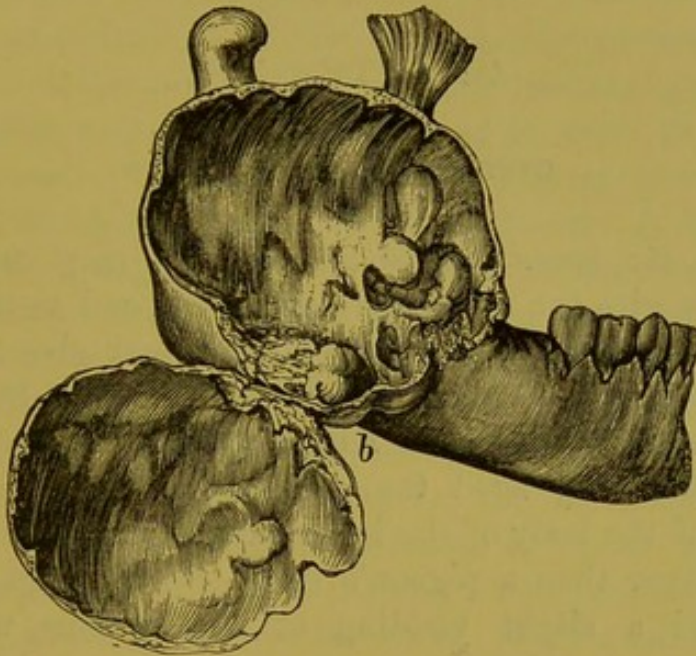
In cases where a permanent opening into the antrum is not required, it will be sufficient to turn up a sort of trap-door, as suggested by O. Weber, the periosteum serving as the hinge, so that it may be replaced after the removal of the contained cysts. It can but rarely happen that such an extensive mutilation can be requisite as is shown in a preparation in Guy's Hospital Museum (1087), consisting of the outer wall of the antrum and the palatine plate, containing all the teeth of the left side except the central incisor, which was removed by Mr. Key from a case of very greatly distended antrum.

In the case of dentigerous cysts of the lower jaw it will, after removal of a portion of the wall, be advisable to squeeze the plates together as far as possible, and in the case of the upper jaw pressure by pads and bandages, as recommended by Liston, will do much to restore the parts to their usual form. Dr. Forget relates the case of a woman, of about thirty, with a hemispherical tumour of the right side of the lower jaw, which was produced by the bulging of the external plate of the ramus of the jaw, the internal having preserved its usual position. M. Nélaton exposed the tumour, and making a hole in the outer wall found a tooth projecting into the cyst. The tooth was extracted with



some difficulty, and the patient perfectly recovered, and was well ten years after. The accompanying illustration (fig. 73) represents the relation of the parts, *b* pointing out

FIG. 73.



the position of the tooth. (*Dental Review*, 1860.) The cases in which Mr. Earle and Mr. Wormald removed the cysts, leaving the jaw entire, have been already described.

Whenever it is possible, the cyst should be reached by dividing the mucous membrane within the mouth, and without incising the cheek; and when necessary, a single line of incision should be made, so that as little after-deformity as possible may be produced.



## CHAPTER XIII.

## CYSTS IN THE LOWER JAW.

*Cysts in the lower jaw* (spina ventosa) may originate in connexion with the fully-developed teeth, and as in the case of dentigerous cysts, already described, may give rise to the suspicion of a more severe affection. In April, 1867, a case of the kind occurred in King's College Hospital in the person of a boy aged ten, who appeared to have a solid tumour of the body of the lower jaw, and on the right side, rather larger than a pigeon's egg. Sir William Fergusson discovered a slight yielding of the osseous wall which crackled upon being pressed, and upon extracting a neighbouring tooth a quantity of glairy fluid escaped. The treatment was completed by cutting away a part of the expanded outer plate of the bone and making the wound heal from the bottom.

But cysts occur in the lower jaw apparently without any immediate connexion with the teeth, though very possibly some irritation connected with these organs may have been the original cause of the mischief. The patient finds that he has a slowly-growing tumour of the jaw, which is painless, and gives him no trouble except from the deformity. The outer plate yields ordinarily to the pressure of the growing cyst, and thus a prominent, smooth tumour is formed, over which the skin is freely moveable. When the bony wall is sufficiently attenuated, the peculiar crackling already described may be produced on pressure, and if the disease is still unchecked the bone becomes entirely absorbed, and nothing but a membranous cyst, with particles of osseous matter imbedded in it, remains. Of this a



most remarkable specimen (II. 150) is to be seen in St. George's Museum (see description in Appendix, Case XV.), of which a drawing would have been appended to this essay but that the permission granted by the School-committee was withdrawn at the instance of Mr. Pollock, who had already had a drawing of this and other preparations made for a work of his own. The cyst is for the most part single, and contains merely fluid, which may be clear or more or less coloured. Dupuytren narrates several cases of the kind ("Diseases of Bone," Sydenham Society, p. 437), from some of which only reddish-coloured serum escaped on their being opened, whilst in others a fibroid growth, and in one osseous nodules, were found within them. There is a good example of a single cyst for which a piece of the entire thickness of the lower jaw was excised in St. George's Museum, of which the following are the particulars:—The patient had had a tumour, supposed to be an epulis, removed from the same spot two years before, and the disease had been growing since that time. When admitted the tumour was found to be a firm oval growth, about the size of an orange, connected with the outer surface of the right inferior maxilla. It was evidently cystic, and there was an indistinct sensation of fluctuation. The tumour, as well as the portion of bone from which it grew, was removed by an incision in the median line. The extent of lower jaw removed was from the lateral incisor tooth on the left side to the angle of the jaw on the right.

It may happen, however, that the cyst may be multilocular or may contain other cysts within it, but this latter condition must be a rare one, for I can find only two examples. One is a congenital cystic tumour in an infant of six months, who was under Mr. Coote's care in 1861, and of which the following brief facts are extracted from the *Lancet* of Aug. 31st, 1861:—"The right half of the lower jaw was enormously enlarged, and occupied a prominent position in the neck, extending downwards as far as the chest. It appeared to invade the entire bone, but was really confined to the right side. Its increase had been rapid since birth, and as



it was still enlarging, it became necessary to do something to afford a chance for life, as, if left alone, suffocation would have ensued in a short time. Accordingly, chloroform being given, an incision was made by Mr. Coote upon its outer part, and a thin shell of the expanded jaw-bone reached. This was opened, and the interior was found to be filled with a regular nest of cysts, one placed within the other, all of which were removed, and the cavity closed with lint. Very little blood was lost during the operation, and for a few days afterwards the child improved very much in health, although necessarily weak, and the great swelling of the neck was much diminished. Suppuration became freely established, and the drain shortly after began to tell upon the system, for the child became weaker and weaker, although well supplied with wine and good nourishment, and finally died from exhaustion."

Here we have an example of the proligerous cyst with an endogenous formation of smaller cysts, but this case being one of congenital disease can hardly be classed in the same category as the ordinary cysts of bone.

The other case is mentioned by Mr. Syme (*Lancet*, March 10th, 1855) who quotes the case of a woman who had a large cystic tumour of the lower jaw, in whom he three times opened the cyst and stuffed it, with temporary benefit. He was obliged eventually, however (five years after the first operation), to remove one-half of the bone, when the cyst was found to be compound, there being four cavities, the walls of which were studded with smaller cysts.

Although the cyst as ordinarily met with in the lower jaw, resembles in many respects that found in connexion with the antrum of the upper jaw, their mode of formation is, I believe, essentially different. In the case of the upper jaw, the cysts originate in the glandular structures of the lining membrane of the antrum, as has already been described. In the lower jaw, on the other hand, there is no mucous membrane lining a cavity, but we have loosely cancellated bone lined with the ordinary endosteum, placed between the two plates of compact bone. It is in these

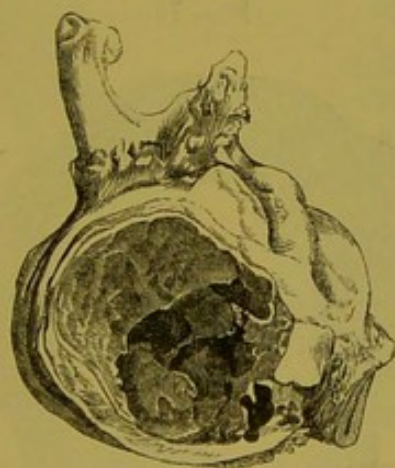


cancelli that the development of the cysts described takes place—a cancellus expanding and producing gradual absorption and obliteration of its neighbours until a cyst of considerable size is produced. What first determines the morbid action it is impossible to say, but it seems not unreasonable to attribute it to some irritation connected with the fangs of the teeth, which are in such close proximity.

A unilocular cyst may occur more than once in the same jaw, provided sufficient cancellous tissue has been left intact in the first instance. In the Appendix will be found the case (No. XVI.) of a woman aged forty-eight, whom Mr. Paget successfully treated for a large cyst of the lower jaw of eight years' growth by removing the anterior wall. Two years after another small cyst had formed, and was operated on; and again, two years after that, another cyst formed, for which a large portion of the jaw was removed.

The accompanying drawings show a case of unilocular cyst of the lower jaw, for which Sir William Fergusson re-

FIG. 74.



moved a large portion of the bone. Fig. 74 shows the growth, and figs. 75 and 76 the patient before and after the operation. (See "Practical Surgery," p. 666.)

*Multilocular cysts* are also found in the lower jaw, and in most cases in direct connexion with teeth or stumps. In the *Guy's Hospital Reports* for 1847 is the notice of a case of the kind by Dr. Wilks, in a girl of eighteen, in whom



FIG. 75.



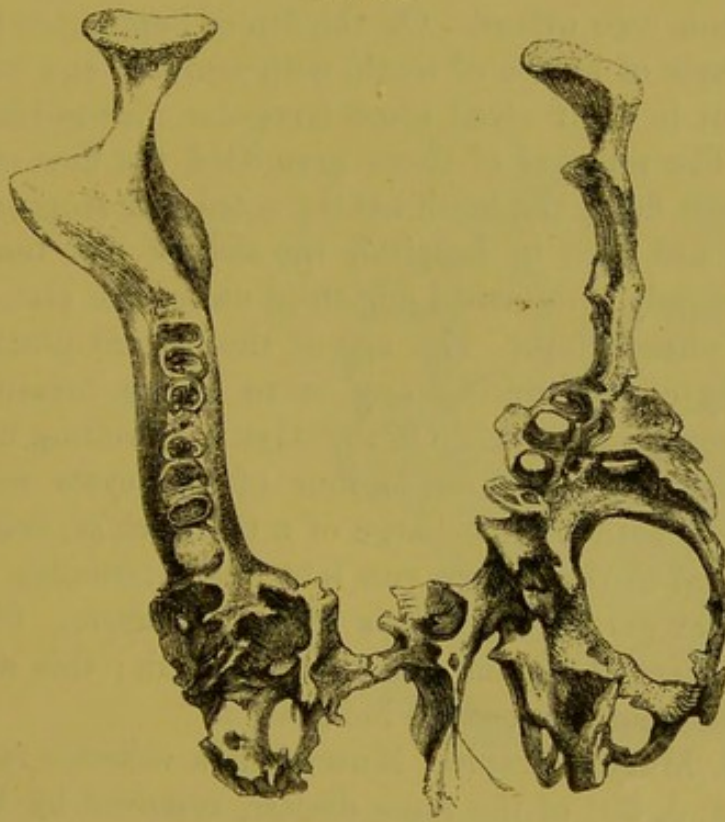
FIG. 76.





there had been an enlargement of the right side of the lower jaw for twelve years. The tumour, on removal, proved to be a cystic growth: "There being four or five large cells between the internal and external plates of bone, which appeared like expanded alveoli, all of them containing fangs of teeth. The cells contained a glairy fluid." Very considerable alteration in the form of the maxilla may be produced by growths of this kind, of which a good example is seen in the drawing (fig. 77) from a macerated specimen in

FIG. 77.



St. Bartholomew's Museum (I. 308). Here the bone is irregularly expanded in great part to form septa between cysts. These, which were independent of one another, had their origin in the interior of the bone, were lined by a highly vascular membrane, and contained thin serous or grumous blood-tinged fluid. The walls of some of the cysts were thin and yielding, but others were thick and resisting, and this was particularly the case with the most



posterior cyst on the left side, which had pressed upon and caused absorption of the left ramus and coronoid process. The preparation was taken after death from an old man aged seventy-five, who had noticed the enlargement for five years when he came under Mr. Coote's care in St. Bartholomew's Hospital in 1857. The following brief account of the case is taken from the *Lancet* of Oct. 10th, 1857:—"The origin of the affection Mr. Coote attributed to the irritation produced by the stumps of decayed teeth. He punctured some of these cysts with a trocar, and gave exit to a sero-purulent fluid from one, and fluid like the white of egg from two others. On the 5th of September he pulled out a couple of bodies of teeth, with scarcely any remains of fangs, but in their stead some irregular fibrous-like projections. The removal of these permitted the flow of a sero-albuminous fluid, the teeth having acted like stoppers. Since the man had been in hospital, the size of the tumour had most certainly diminished one-third under the plan of treatment of puncturing. The age of the patient precluded the possibility of attempting any more severe measures than those already adopted. On the 21st the swelling had somewhat increased, and three or four of the cysts were again punctured, with the discharge of a thick, clear, yellow fluid, and several of these were run into one internally. This was done under partial anæsthesia from chloroform. One of the cysts discharged a good deal in the mouth; this was partly swallowed, and had caused indigestion."

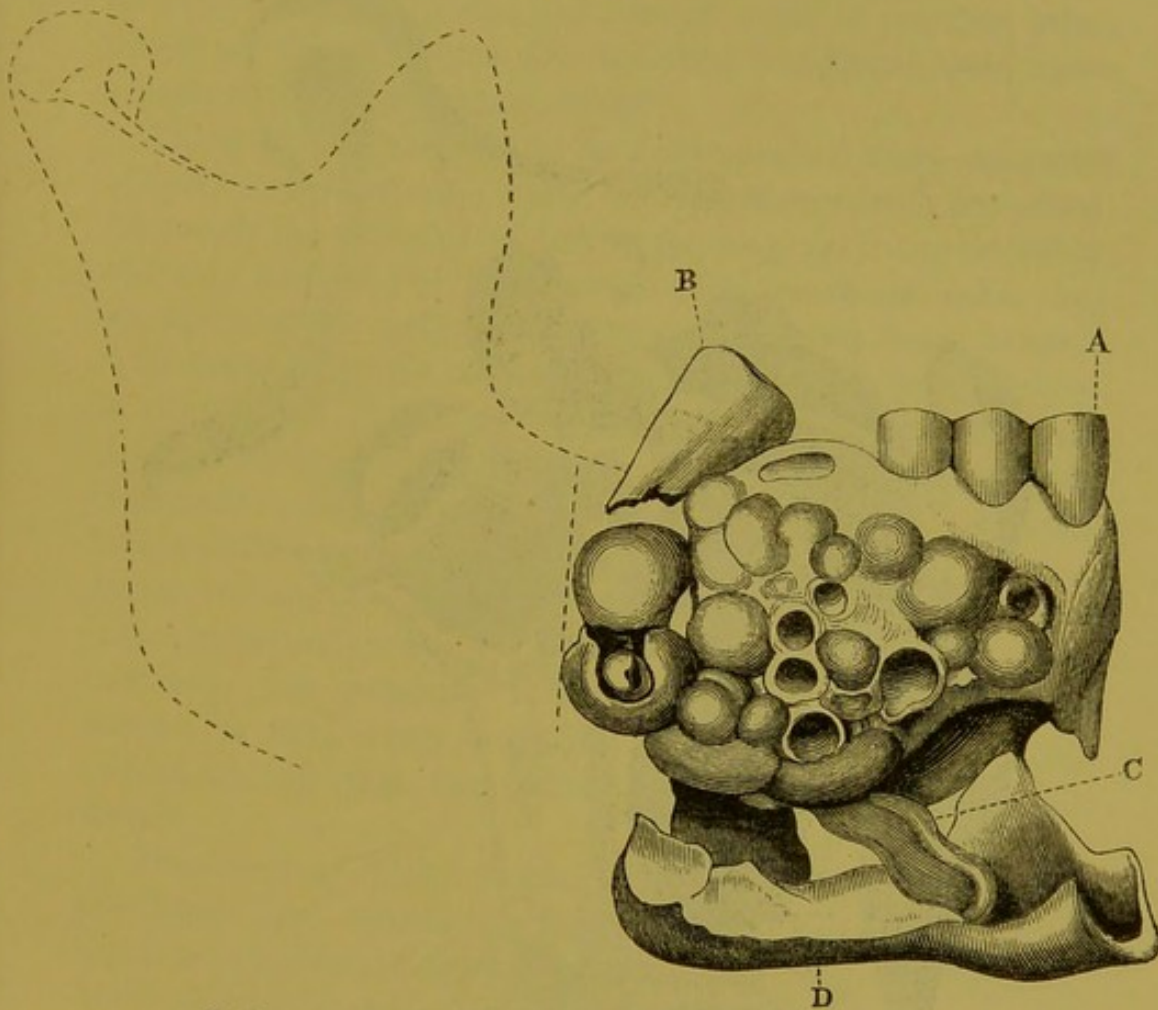
In St. Mary's Hospital Museum is a valuable recent specimen (A. d. 50) of the same disease, removed by Mr. Lane. Here the growth was of seven years' duration, and involved the left side of the body of the lower jaw. A longitudinal section shows the cystic structure, the cells of which were filled with dark gelatinous fluid, and occupied the whole thickness of the bone.

The cells may, however, be of much smaller size; thus Dr. Robert Adams records, in the *Dublin Hospital Gazette* for 1857, the case of a man from whom he removed a portion of the body of the jaw from the symphysis to the molar



teeth, about two inches in length. "The mucous membrane covering it was here and there raised into small rounded eminences of the size of peas, though some were larger and purple in colour. The tumour was composed of bony cells

FIG. 78.



A, Canine; B, Second molar; C, Anterior portion of dental nerve;  
D, Remains of the basis of horizontal branch of jaw excavated on its  
upper surface, on which lay the tumour.

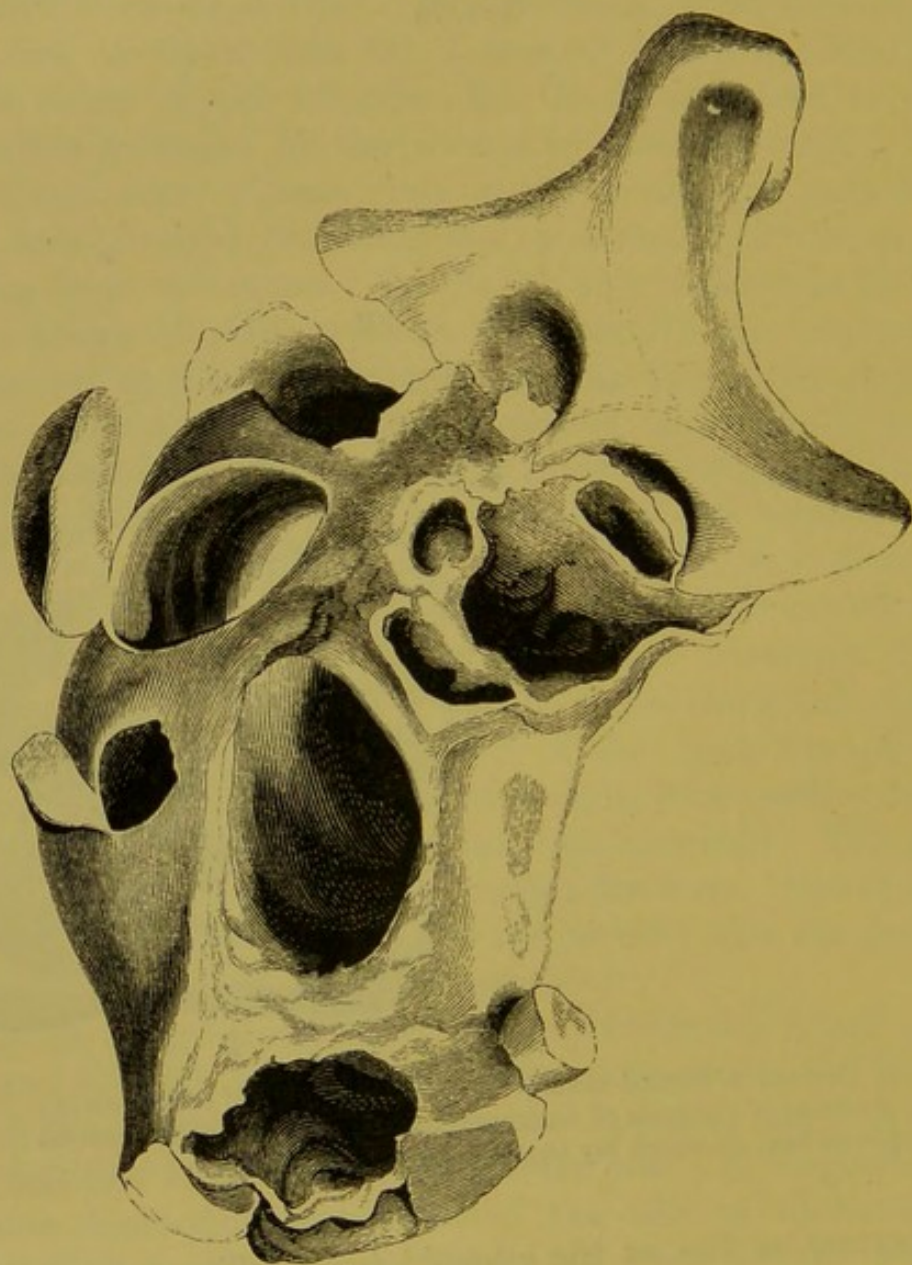
of a texture as fine as the ethmoid bone. The cells generally were of such a size that each might be capable of receiving within it a garden-pea. They communicated with each other, and amounted to no less than twenty-six in number. They were all lined by a pulpy, very red, vascular membrane, and contained an albuminous fluid tinged of



a reddish colour, apparently from blood held dissolved in it."

Again, in cases of long-standing disease, the cysts become

FIG. 79.



greatly distended, and the septa, in great part, absorbed, so that the cysts communicate very freely.

Of this kind was a tumour (fig. 79) removed by Mr. Cusack, in 1826, from a woman named Kenny, whose case will be



found in detail in Mr. Cusack's well-known essay in the *Dublin Hospital Reports*, vol. iv. Dr. Adams, in his paper already referred to, supplies an account of the tumour in this case. "The portion of bone removed comprises the entire right half of the lower jaw. The horizontal ramus is expanded into an oblong hollow shell with bony walls, and its interior is subdivided into many cells of various sizes, which are all lined by a fine polished membrane, and communicate freely with each other."

Cases of this kind are to be distinguished from examples of cystic osteo-sarcoma, which will be subsequently described. Although the contents of the cysts may vary considerably, and may occasionally be so dense as to be almost solid, they are still *contents* only, and the cysts surround them, whereas in the case of cystic sarcoma a growth springs from the jaw, in which cysts of various sizes may be developed. The distinction is important, both on account of prognosis and treatment. In the cases of cysts, whether uni- or multi-locular, the disease is of slow growth, and there is no tendency to fungous excrescences, so that the patient suffers little inconvenience. In the fibro-cystic growths, on the contrary, the progress is comparatively rapid, and the patient is soon worn out with pain and discomfort. The treatment of the two affections also is entirely different.

*Treatment of Cysts in the Lower Jaw.*—Single cysts in the lower jaw, containing fluid, whether connected with a tooth or not, demand the same treatment. The neighbouring teeth should be extracted, since the fluid may be evacuated through their sockets spontaneously; or, if this is not the case, the alveolus may be readily cut through, so as to reach the interior of the cyst. A free opening into the cyst is necessary, in order that it may granulate from the bottom; and, where the wall has become much attenuated, it should be forcibly crushed in, so as to diminish the size of the cavity. Dupuytren (*op. cit.*) has given several cases in which he effected a cure by making a free *external* incision into cysts of the lower jaw, and one which he treated by a



seton. Injections used after the cyst has been laid open have been found of service by many surgeons, but to inject an osseous cyst with stimulating fluids through a small opening, in hope of causing its contraction, is both useless and dangerous. In the case quoted from Sir William Fergusson (p. 171), it is mentioned that the patient nearly lost his life from a proceeding of this kind.

Mr. Butcher, of Dublin, has for some years treated cases of cyst of the lower jaw through the mouth, by dividing the mucous membrane over the cyst freely, and then with gouge and bone-forceps removing the expanded external plate of the bone, with the contents and lining membrane of the cyst. In this operation, the teeth are interfered with as little as possible, and appear to remain firm. Granulations rapidly spring up from the denuded bone, and fill the wound made in the mouth; the cheek resumes its ordinary appearance, and no deformity or scar is left. In his work on "Operative and Conservative Surgery," Mr. Butcher narrates three cases treated in this manner, and remarks, that "the proceeding according to this plan is troublesome and difficult, but its value to the patient in having no deformity left is priceless." A valuable caution is here given respecting the facial artery, which might, without care, be divided from within the mouth in a position where it would be very difficult to secure it. Mr. Butcher also narrates and gives a drawing of a case in which, finding the disease too extensive to be treated from the mouth, he adopted Dupuytren's external incision, and then levelled the projection to the line of the healthy bone with the best results, the incision being completely hidden behind the bone.

Dr. Mason Warren has recently (*Boston Medical and Surgical Journal*, 1866) written upon the treatment of cysts of the jaws, and strongly recommends a milder and even more conservative practice than that followed by Mr. Butcher, which he thus summarizes:—"The treatment consisted in the puncture of the sac within the mouth, evacuating its contents, and at the same time obliterating its cavity by crushing in its walls; and lastly, in keeping up, by injec-



tions, &c., a sufficient degree of irritation to favour the deposition of new bone."

One of Dr. Warren's illustrative cases will be found in the Appendix (Case XVII.), which contrasts favourably with the more severe operation of Mr. Butcher, and still more with cases treated by excision of the portion of the jaw containing the cyst.

Multilocular cysts of the lower jaw in an early stage admit of the same treatment as the unilocular variety, since the septa between the cysts can be readily broken down, and the contents of the cyst evacuated. When far advanced, so that the bone has become completely altered in shape, and is hollowed out into numerous cysts, it will be hardly possible to effect a perfect cure without removing the portion of the jaw affected. Palliative treatment may be adopted, as in Mr. Holmes Coote's case, already referred to, where the cysts were punctured from time to time, but soon re-filled; but had the patient's age admitted it, amputation would have been performed.

In his well-known essay on Diseases of the Jaw (Calcutta, 1844) Mr. O'Shaughnessy narrates a case of large cystic disease of the jaw which would appear to have been originally a multilocular cyst in which the septa had undergone almost complete absorption, so that "the tumour after maceration was found to be a hollow shell of bone, containing in its centre a quantity of a gelatinous and fluid substance, and a few particles of bone like pieces of honeycomb. The coronoid process was hollowed out like the rest of the bone, and so thick, that it must have completely filled the temporal fossa, which accounts for the difficulty experienced in trying to divide the temporal muscle."

This difficulty of clearing the coronoid process has been noticed also in cases where the bone has been expanded by a solid growth within it, or is wedged in by a portion of tumour springing from the ramus. Dr. Robert Adams narrates (*Dublin Hospital Gazette*, April 15th, 1857) a case of the former kind, and Mr. Cusack (*Dublin Hospital Reports*,



vol. iv.) two cases of the latter, in all of which the difficulty was overcome by sawing through the ramus of the jaw, and subsequently removing the coronoid process and condyle. The possible occurrence of this difficulty is to be borne in mind in cases of cystic growth requiring disarticulation; and I experienced it in a case of very large solid tumour of the lower jaw, which will be subsequently referred to.



## CHAPTER XIV.

## TUMOURS CONNECTED WITH THE TEETH.

IRREGULAR development of the teeth is of little interest in a surgical point of view, except when, from their abnormal positions, they give rise to tumours of the jaw. The relation of cysts to undeveloped teeth has been discussed under the head of "Dentigerous Cysts," but the solid growths directly connected with the teeth also require investigation.

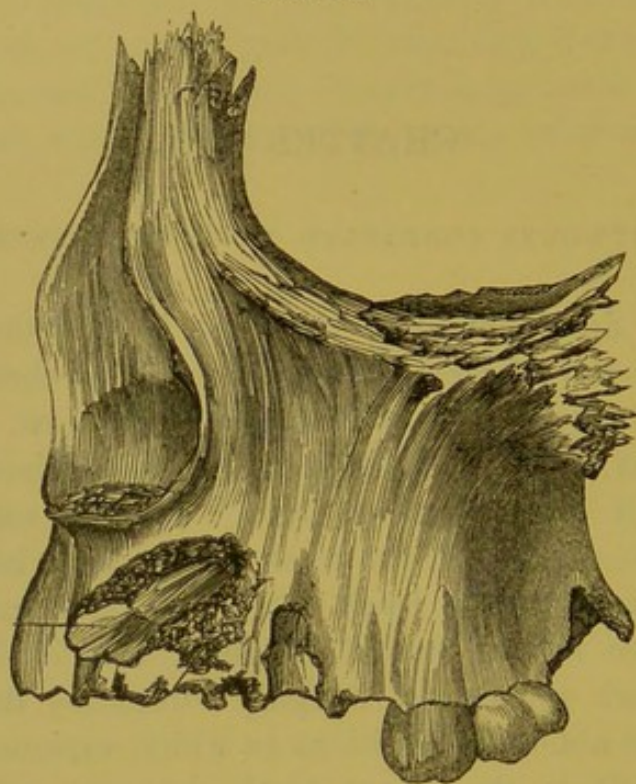
The irregularities of teeth which are fully cut come into the province of the dental surgeon, and in Mr. Tomes' valuable work on Dental Surgery numerous drawings are given of the abnormal positions in which various teeth have appeared. It is the uncut teeth, however, which are of interest surgically, and these may be divided into two classes. In the first, the tooth which has deviated from its normal position is still contained within the alveolus, where by its presence it may give rise to a more or less distinct tumour. Of this, fig. 80 gives an example from the work of Dr. Forget on Dental Anomalies, for permission to use which I am indebted to Mr. R. T. Hulme, the translator of Dr. Forget's papers in the *Dental Review* of 1860. In the second class of cases the misplaced tooth is situated in a part of the jaw more or less distant from the alveolus, and of this fig. 81 presents an example, the canine tooth being placed horizontally in the floor of the nasal fossa, in the interior of which it formed a considerable projection.

The molar teeth of the upper jaw, and particularly the wisdom teeth, seem especially liable to misplacement. Mr. Tomes (*op. cit.*) gives numerous illustrations of this irregularity, and in the Museum of the College of Surgeons is



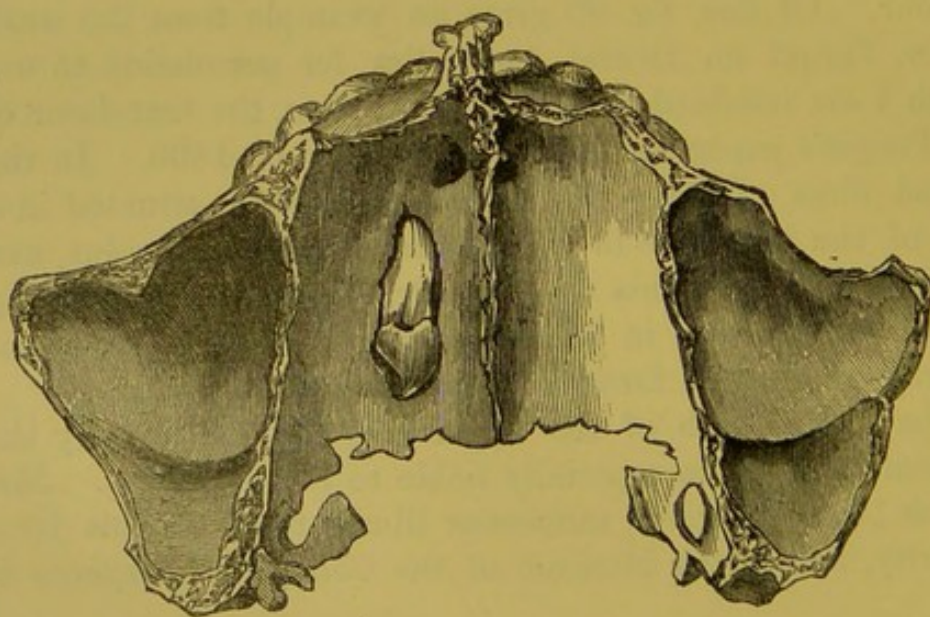
a cast of a case in which a wisdom tooth projected through the cheek. The wisdom teeth of the lower jaw are also

FIG. 80.



prone to assume an abnormal position in relation to the coronoid process, and in either position a tumour may be

FIG. 81.





formed which may be difficult of diagnosis. Dr. Forget (*op. cit.*) quotes the case of a woman who had a tumour of the form and size of a nut on the left side of the hard palate which reached beyond the median line and extended from the canine tooth to the soft palate. Blandin, on attempting to remove it, discovered it to be caused by two dwarfed and abnormally-placed molar teeth, which had penetrated the inner plate of the alveolus and were lodged beneath the mucous membrane of the palate. On the removal of these the tumour subsided. Still more remarkable is the case narrated by Mr. Tellander, of Stockholm, before the Odontological Society, in December 1862, of supernumerary teeth imbedded in the upper jaw, causing a hard, painless tumour, which appeared about the age of twelve.

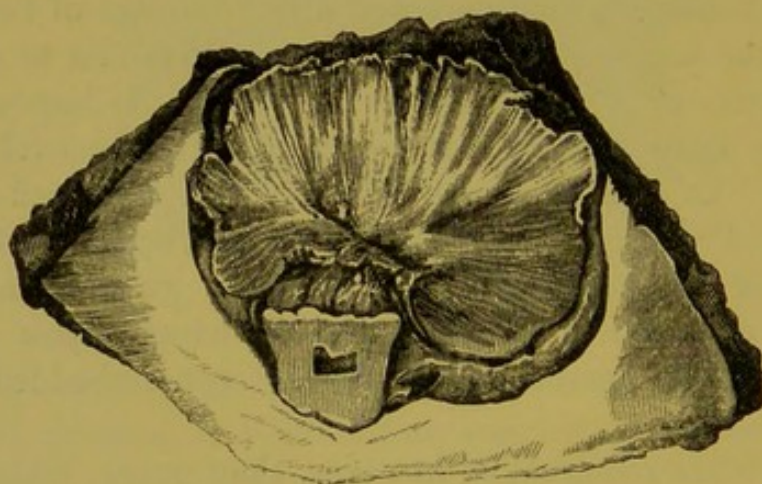
But the malposition of a tooth may give rise to a dense osseous tumour of the upper jaw, in which it is impossible to recognise the source of mischief until after removal of the tumour. Of this kind was a case which occurred to Sir William Fergusson, in 1856, in a girl, aged thirteen, in whom for three years there had been growing a dense tumour of the left superior maxilla, which, upon section after removal, proved to contain a tooth imbedded in its centre.

Even more remarkable, however, than mere malposition are certain modifications which the molar teeth occasionally undergo during their development, giving rise to most remarkable tumours of the jaw. There are, I believe, but three cases of the kind recorded, and these all occurred in the lower jaw. The first case occurred some years back, in the practice of Sir William Fergusson, by whom the tumour was removed with a portion of the jaw, and is described by Mr. Tomes ("Dental Surgery," p. 224), from whose work a drawing of a section of the tumour is taken (fig. 82). "The second molar of the lower jaw was represented by an irregularly flattened mass, composed of enamel, dentine, and cementum, thrown together without any definite arrangement, by which the wisdom tooth was held down. The dental mass, when removed from its receptacle in the bone,



presented no resemblance to a tooth. Little beads of enamel here and there projected from the surface, which was generally rough and irregular. The naked-eye appearance of the section is accurately given in the wood-cut, the radiate character in which shows the arrangement of the component tissues, which, by the aid of the microscope, are seen at places to alternate. The alternation is mainly effected by the dentine and cementum, and these, indeed, form the great bulk of the mass . . . The appearances presented, prior to the operation, consisted in enlargement of the jaw posterior to the first permanent molar tooth, with a hard,

FIG. 82.



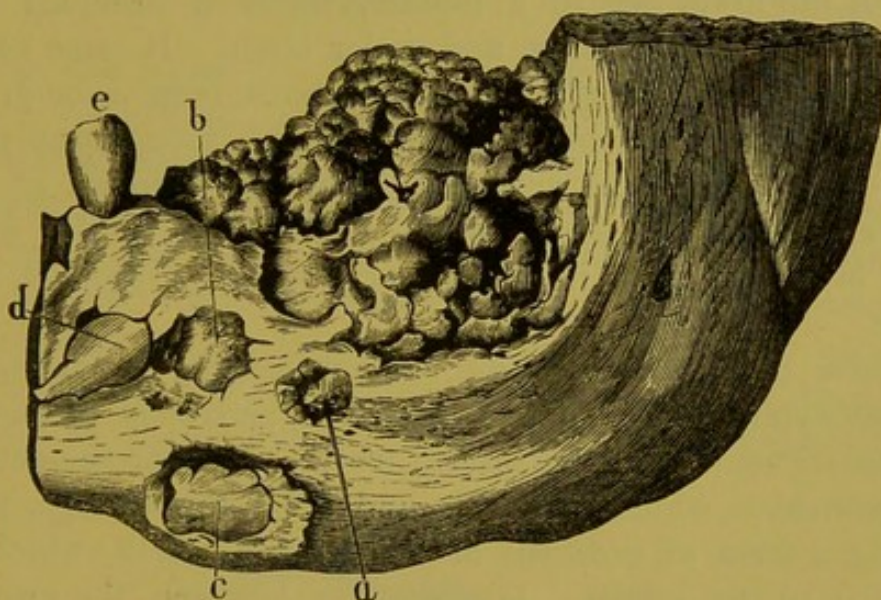
brown-looking body projecting but slightly from the surface of the gum. This projecting portion was, in fact, the upper surface of the aberrant tooth; and the nodules of enamel were, for the most part, situated in this part of the mass."

The second case occurred to Dr. Forget (*op. cit.*), in the person of a young man, aged twenty, who presented himself in 1855 with a disease of the lower jaw, from which he had suffered since he was five years old. Upon looking into the mouth, a round, smooth tumour, hard and unyielding, was seen occupying nearly the whole of the left side of the jaw. None of the teeth beyond the first bicuspid were present. Dr. Forget removed the portion of the jaw involved by sawing through it in front of the bicuspid tooth, and also through



the ramus at the level of the inferior dental foramen. The portion removed is seen in the accompanying drawing (fig. 83). "An examination of the portion which had been removed showed that the portion of the jaw between the ramus and the first bicuspid tooth was converted into a cavity, which was occupied by a hard oval mass, of the size of an egg, having an uneven surface covered here and there with minute tubercles, which were invested by a layer of enamel, penetrating into the substance of the bone, and easily recognisable by its shining appearance and peculiar colour. A

FIG. 83.



section of the tumour showed that it consisted of a compact tissue of the consistence of ivory, of a greyish-white colour, in the interior of which it was possible to perceive, with the naked eye, a kind of regular arrangement of the elements which entered into its composition. Between the tumour and the osseous cyst was a thick membrane, apparently of a fibro-cellular structure. At the anterior extremity of the base of the tumour was a depression in which the crown of an inverted molar tooth was wedged in between it and the maxilla. This tooth is seen in fig. 83, *c*, where a portion of bone has been cut away; *a* and *b* mark portions of the



tumour projecting through the jaw, and *d* is the second bicuspid tooth lying below the first, *e*.

The microscopic examination of the tumour showed it to be composed principally of dentine with enamel on the surface, and dipping into the crevices, at the bottom of which, as well as in other parts, portions of cementum were found. Dr. Forget regards the case as one of fusion and hypertrophy of the last two molars.

The third case of the kind was brought under the notice of the Odontological Society of Great Britain, in December, 1862, by Mr. W. A. Harrison, F.R.C.S. The specimen closely resembled those already described, and came from the left side of the lower jaw of a lunatic, where it occupied the space between the incisor and molar teeth. It came away spontaneously, leaving a long deep groove, large enough to receive the last joint of the thumb, which soon granulated and contracted. The specimen is in the Museum of the Dental Hospital, Soho Square. Cases of a similar kind have been met with in the lower animals, especially the horse.

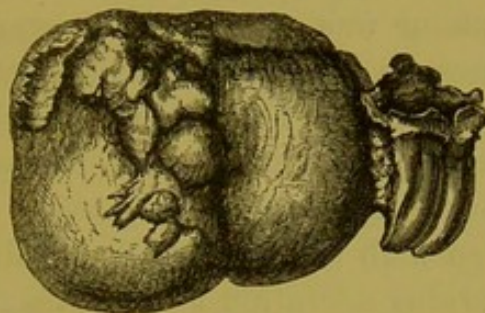
Quite distinct from these, but presenting a somewhat similar external tumour, are cases of hypertrophy of one of the constituents of a fully formed tooth. It is the cementum or tooth-bone which ordinarily undergoes this change, producing a form of exostosis of the fangs of teeth, which is familiar to the dentist. Occasionally, however, the growth is so large as to produce a distinct tumour of the jaw, for which the surgeon is consulted, and this may be due either to an exostosis connected with the apex of the fang, or to one springing from the neck of the tooth. In the Museum of the College of Surgeons is a specimen of large exostosis, due to hypertrophy of cementum. It projects from the neck of the tooth, and forms a process almost as large as the implanted portion of the tooth.

A still larger specimen in connexion with the side of a molar tooth is given in fig. 84, from a case recorded by Dr. Forget (*op. cit.*). It occurred in the practice of M. Maison-neuve, and in the person of a man aged forty. The tumour



occupied the left side of the lower jaw, causing both its surfaces to project, but especially the outer. At the smaller end of the tumour was a decayed molar tooth, and upon extracting this the tumour came away with it. The growth,

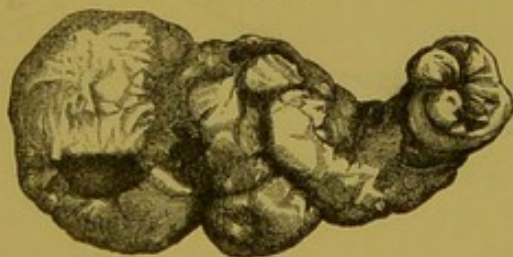
FIG. 84.



which was larger than a pigeon's egg, was attached to the tooth by a kind of pedicle, a section showing a line of separation between it and the root of the tooth. Under the microscope the specimen was seen to contain no dentine, but to consist exclusively of osseous tissue (cementum).

In April, 1863, Mr. Tomes exhibited to the Odontological Society an extraordinary specimen of exostosis, which is shown in the illustration (fig. 85), which I have been permitted to borrow from the *Transactions of the Odontological*

FIG. 85.



*Society*, vol. iii. The molar tooth, to which it is attached, was removed by Mr. Hare, of Limerick, from the upper jaw of a man, aged forty-one, who had long suffered pain in the jaw, from which a fistulous passage led through the cheek. The growth is more or less hollowed out; and on this account it has been suggested that it may possibly be an instance of calcified dental cyst rather than an example of



exostosis. Whatever its nature, it must, from its size, have either invaded or obliterated the antrum.

It will be obvious, from a consideration of the preceding cases, that every effort should be made to extract the osseous tumour from the jaw without removing any portion of the bone itself. In the case of dentinal mass recorded by Mr. Harrison, the tumour was enucleated spontaneously, and in the other two cases its removal was readily effected after the containing portion of jaw had been excised. Where the growth is connected with a tooth, as in the case of exostosis, the rule of removing all neighbouring teeth which may possibly be connected with it should be invariably followed before any more serious operation is undertaken.



## CHAPTER XV.

## DISEASES OF THE GUMS.—EPULIS.

*Hypertrophy of the Gums* is a by no means common affection. Mr. Salter has recorded (Holmes, iv.) a remarkable case which occurred in St. George's Hospital in 1859, in a girl of eight years, in whom there was precocious development of the teeth, accompanied by hypertrophy of the gums. A large pink and smooth mass projected from the mouth, slightly corrugated or indistinctly lobed, which consisted of an expansion of the alveolus, immense hypertrophy of the fibrous gum, and an exuberant growth of the papillæ of the mucous membrane. Dr. Gross has narrated a very similar case in his "System of Surgery" (1862). In April, 1867, I had the opportunity of seeing a case of the kind, under the care of Mr. Erichsen, in University College Hospital. A child of two and a half years, had hypertrophy of the gums, which were prolonged in front of and behind the teeth so as almost to conceal them. The disease affected only the incisive portions of both jaws, and it was remarkable that the temporary teeth had undergone hypertrophy also, being considerably larger than normal. The affection first showed itself at the age of seven months, when the teeth began to appear, the gums increasing in size and bleeding on the least touch. Mr. Erichsen removed the exuberant growth, extracting some of the teeth, and freely cauterized the cut surfaces. In Mr. Salter's case it was necessary to clip away portions of the alveolus as well. The excised portions in Mr. Erichsen's case were examined by Mr. A. Bruce, who has favoured me with the following report upon them:—"On section the mass was found to



consist of a firm fibrous stroma, containing much glandular tissue in its interstices, and covered on its surface by very large and vascular papillæ. The epithelial layer was of unusual thickness, but no abnormal epithelial structures were found in the growth, which was an example of true hypertrophy." These characters agree closely with those observed by Mr. Salter, and it may be remarked, that though in his case the temporary teeth do not appear to have been hypertrophied, yet that the permanent teeth exposed in the alveoli by the operation were excessively large, especially the superior central incisors.

*Polypus of the gum* is the name given to a simple hypertrophy of the portion of gum between two teeth which is ordinarily dependent upon the irritation caused by those organs. It is often connected with accumulations of tartar around the necks of the teeth, and with a generally unhealthy condition of the mouth, and yields readily to astringent lotions or the application of nitrate of silver, provided the irritating tooth be extracted. Mr. Salter describes a condylomatous form of disease of the gum which is of a syphilitic character.

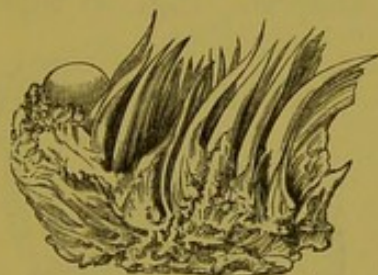*Vascular growths* are occasionally met with in connexion with the gum, and especially in the region of the incisor teeth. These bleed freely when rubbed with the tooth-brush, and may if neglected grow to some size, resembling a nævus in their colour and appearance. Stanley, in his work "On Diseases of the Bones," has narrated and drawn a case in which there was a vascular growth in the region usually occupied by these growths, but in that case the tumour sprang from the interior of the jaw and necessitated removal of a portion of it.

Mr. Tomes has successfully treated the three or four examples of the disease he has met with by the frequent application of powdered tannin. Mr. Salter narrates in Holmes' "System," a case in which the growth was of the size of a marble, and gave rise to hæmorrhage, which he successfully treated by excision and the application of the actual cautery after having failed to effect a cure with the ligature.



*Papillary Tumour of the Gum.*—Under this name Mr. Salter has, in the *Guy's Hospital Reports* (1866), called attention to a rare form of disease in connexion with the jaws, which appears to consist essentially in an hypertrophy of the papillæ of the mucous membrane. The disease was first noticed by Sir William Fergusson, in the lower jaw of an old man of eighty, and “looked like vegetable matter or greatly elongated papillæ,” as described in some clinical observations on the case by that surgeon in the *Lancet*, September 6th, 1862. It was removed by Sir William Fergusson, and is described by Mr. Salter as “a curious white mass, consisting of coarse detached fibres, pointed and free at one extremity and attached at the other; in fact, it was a mass of papillæ, many of them nearly an inch long, and similar in shape to the ‘filiform’ papillæ of the

FIG. 86.

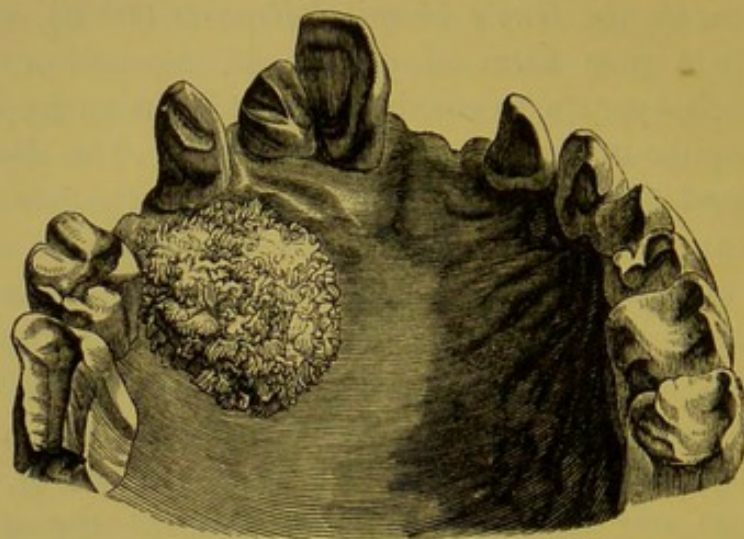


tongue; their surface was shreddy and broken; among these elongated processes were a few rounded eminences like ‘fungiform’ papillæ, and these had a smooth unbroken surface.” The accompanying drawing (fig. 86), for which, as well as for those that follow, I am indebted to Mr. Salter, represents a portion of the tumour of the natural size. Microscopically the mass consisted almost entirely of epithelium.

Mr. Salter met with a second case in the practice of Mr. Cock, at Guy's Hospital. It consisted in a growth of the size of a split chestnut attached to the hard palate of the right side, and extending from the edge to near the median line, as seen in fig 87, and had been growing about eight months. Mr. Cock successfully extirpated the growth, which consisted of a hard mass of fibrous tissue, surmounted

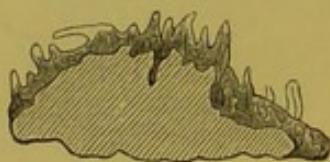

FIG. 87.



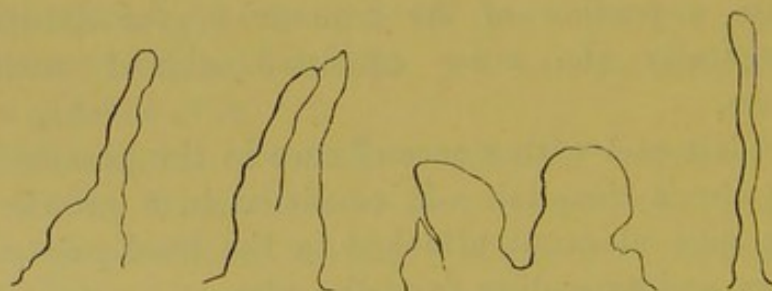
by papillæ, mainly composed of dense coherent epithelium, and met with considerable difficulty in arresting the free hæmorrhage which ensued. Fig. 88 represents a section of

FIG. 88.



the growth of the natural size, and fig. 89 shows outlines of some of the papillæ enlarged six diameters, from Mr. Salter's paper.

FIG. 89.

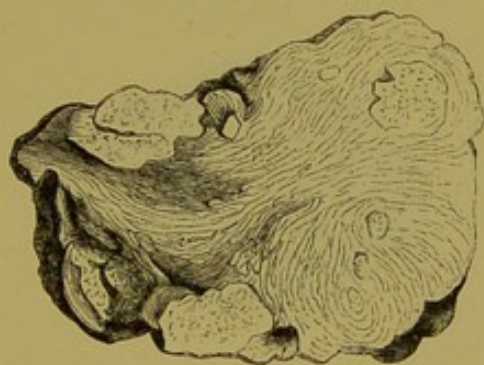

*Epulis*.—The growths connected more or less closely with the gums vary somewhat in their nature, but are conve-



niently classed together under the term epulis. The ordinary form of the disease is a firm fibrous tumour, of slow growth, in which, in many instances, some fibro-plastic cells are intermingled. The accompanying drawing (fig. 90), for which I am indebted to Mr. Jonathan Hutchinson, gives a good idea of the naked-eye appearance presented by a section of an epulis of large size. This form of the disease is closely connected with the fibrous gum, and also with the periosteum of the alveolus, and very generally small spicula of bone are prolonged into it from the maxilla; the mucous membrane of the gum is stretched over the growth. Occasionally a development of true bone takes place in distant parts of the growth, as in the specimen drawn above; so

FIG. 90.



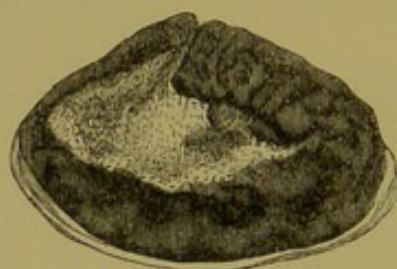also in a large epulis which I removed from the upper jaw of a young woman, and which accompanied this essay (College of Surgeons Museum, 1031 A), a nodule of bone of considerable size is developed near the surface of the growth, and quite unconnected with the alveolus. Mr. Caesar Hawkins mentions (*Medical Gazette*, 1846) a similar occurrence in a case where the epulis was pedunculated. Mr. De Morgan also met with a similar instance, but in that case the isolated piece of bone was found to be entangled in, rather than adherent to, the fibrous tissue which composed the mass; and Mr. Tomes ("Dental Surgery," p. 521) thinks that its microscopic character "fully justified the assumption that it had at one time formed a portion of the subjacent alveolus, and that its detachment had been effected by absorption; and fur-



ther, that when so detached it had formed a source of irritation, and thus led to the development of the epulis." This certainly was not the case in the specimen removed by myself, for microscopic examination showed the ossific matter developed in the fibrous tissue in the most unmistakeable manner.

The softer and more vascular form of epulis is composed of a small quantity of fibrous tissue, holding in its meshes the true polynucleated myeloid cells, or "myelo-plaxies." The drawing from which fig. 91 was taken (also given me by Mr. Hutchinson), showed the vascular appearance of such a tumour on section, the one in question having formed a large overhanging mass upon the lower jaw, which was excised by Mr. Curling in 1864. Mr. Hutchinson has

FIG. 91.



also described a similar case, of somewhat smaller size, and has given drawings of its microscopic characters in the eighth volume of the *Pathological Society's Transactions*. This form of epulis is more commonly connected with the interior of the alveolus than the fibrous variety; and this fact may possibly account for its being more closely allied to the endosteal than the periosteal structures. It is this form which, when irritated and ulcerated, presents an appearance somewhat resembling malignant disease. Irregular nodules of bone may be scattered through the myeloid as through the fibrous variety.

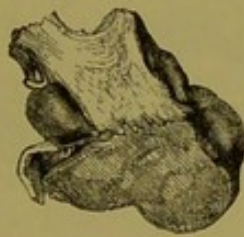*Giant-celled Epulis.*—Mr. Wilkes, of Salisbury, recently forwarded me a very interesting specimen of epulis, which accompanied this essay (1031 B), and a section of which is represented in fig. 92. The tumour consists of a semi-



globular firm elastic mass attached by its base to the margin of the alveolus, from within which it springs. Its surface is smooth and uniform, and of a dark grey colour, mottled with purplish spots. On section it can be traced into the bone, the cut surface being for the most part of a greyish yellow, with patches of pink and purple. The microscopical examination shows interspersed among the fine fibrous tissue some large irregular disc-like cells, containing numerous bead-like nuclei, and the growth may therefore be considered similar to that described by Otto Weber, as "giant-celled sarcoma," and by Wedl as a "fibrous form of cancer arising from bone." The structure would place it in an intermediate position between fibro-cellular and myeloid tumours.

A form of epulis possessing some of the characters of epithelioma is occasionally met with. A specimen which

FIG. 92.



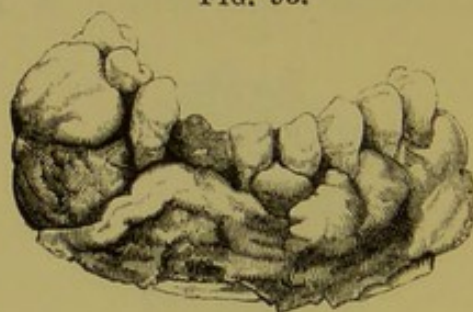
accompanied this essay was sent to me in a perfectly fresh state by Mr. Hutchinson, who had removed it from the lower jaw of a lady, aged fifty-five, where it had been growing a year. I requested Mr. Bruce to make a careful examination of it, and he has kindly furnished me with the following report:—"The surface of the tumour is covered with healthy mucous membrane. The interior of the tumour is whiter, firmer and more compact than the surface; but there is no line of demarcation between the tumour and its mucous covering. The structure of the growth is distinctly glandular, very much resembling some forms of compact adenoid tumour of the breast." [This confirms an observation of Mr. Birkett's, mentioned by Paget—viz., that he has found the glands of the gum much developed in some instances of epulis.]



"At the point of attachment of the tumour to the parts beneath, a remarkable transformation of the glandular into the epitheliomatous structure is seen. In one part of the section may be seen the cut ends of gland tubules, whilst in their immediate neighbourhood are most distinct nests of true epithelioma, consisting evidently of concentrically arranged cells compressed from the centre outwards."

This interesting observation shows that epithelioma may be developed in the gum as on other mucous surfaces. Probably the case recorded by Sir William Fergusson in his "Practical Surgery" (p. 657), from which the accompanying drawing (fig. 93) is taken, was a more advanced example of the same kind.

FIG. 93.



In the *Lancet* (Jan. 5th, 1861), and in the *Pathological Society's Transactions* (vol. xii.), Mr. William Adams has recorded a case of epithelioma of the lower jaw, apparently commencing in an epulis; and by the kindness of that gentleman the preparation accompanied this essay. Mr. Adams found it necessary to remove the right half of the lower jaw, and the patient was relieved; but the disease re-appearing in the skin, he died eleven months after.

The tumour was submitted to the Pathological Society on Oct. 23rd, 1861, and described by Mr. Adams as an example of epithelial cancer, and in a further report of the specimen, made at the request of the Society by Dr. Wilks and Mr. Holmes, this opinion was confirmed. The tumour was of soft consistence, more or less lobulated in form, and on section presented a uniform white colour, its structure



being traversed by dense fibrous bands, having an irregular reticulate arrangement, forming meshes in which the soft tissue was contained. The arrangement was obvious to the naked eye, and still more so under a low magnifying power. Microscopically examined, the soft tissue, whether taken from the central portion or near to the surface, exhibited the ordinary characters of epithelial cell formation — *i.e.*, epithelial cells of all forms and sizes, masses of clear polygonal cells, with round or oval nuclei in some parts, and in other portions small round or oval nuclei, best seen after the addition of acetic acid. Good specimens of the laminated capsules, met with in epithelioma, were not obtained, but some rounded masses resembling these were present. No myeloid cells were seen, even in the portions of the morbid growth which extended into the interior of the horizontal ramus of the jaw. The fibrous bands consisted of simple fibrous tissue, as well as of nucleated fibres.

The tumour was intimately connected with the bone, and not only extended outwards, but had eaten its way into the substance of the jaw, entirely destroying the bone from the angle to within an inch of the symphysis, where it filled the cavity of the bone. In the operation, some portions of the bone were found nearly detached, and broke away; and this condition had probably given rise to much of the common inflammatory mischief and the abscess, which tended to obscure the diagnosis of the precise nature of the morbid growth. The bone was quite healthy where sawn through near to the symphysis.

Epulis appears to be connected with the presence of teeth, and in some cases to depend upon the irritation caused by them. The simplest form is often found growing between two perfectly sound teeth, and in these instances the pedicle attaching the growth may be so slender as to be broken by the tongue of the patient or the finger of the surgeon, of which Sir William Fergusson gives examples. The teeth may be unsound and broken, and in these cases the growth often completely envelopes the stumps and hides them from view, or in the progress of the growth a fang of a tooth may be



*Tabular Statement of Twenty-eight Cases of Epulis.*

No.	Sex.	Age.	Duration.	Position.	Result.	Remarks.
1	F.	35	...	Upper.	Recovered.	
2	M.	39	15 months.	...	Recovered.	
3	F.	60	7 months.	Upper.	Recovered.	
4	F.	50	3 months.	Upper.	Died.	Rigors followed the operation, and death from pyæmia on the 15th day.
5	M.	16	3 years.	Lower.	Recovered.	
6	F.	60	20 years.	Upper.	Recovered.	Very large indeed. It had returned after removal 8 years before.
7	F.	26	9 months.	Lower.	Recovered.	Large, ragged, and fungating. It was fibro-cartilaginous.
8	M.	36	...	Upper.	Recovered.	It was thought after removal to be of cancerous nature.
9	M.	27	7 years.	Upper.	Recovered.	The tumour was thought to be cancerous after removal.
10	F.	28	6 years.	Lower.	Recovered.	The tumour consisted of hardish bone, and had encapsuled completely the stumps of two teeth.
11	F.	11	...	Lower.	Recovered.	
12	F.	36	18 months.	Lower.	Recovered.	Caused by a decayed tooth.
13	M.	24	...	...	Recovered.	
14	F.	30	...	Upper.	Recovered.	
15	F.	23	14 months.	Lower.	Recovered.	Two bicuspid teeth were buried in it. It was of myeloid structure.
16	F.	22	2 years.	...	Recovered.	It involved two teeth.
17	M.	16	1 year.	Lower.	Recovered.	It involved the last bicuspid and first molar.
18	F.	31	...	Lower.	Recovered.	The tumour was soft and fungoid.
19	F.	30	...	Lower.	Recovered.	
20	M.	9	...	...	Recovered.	
21	F.	22	...	Lower.	Recovered.	
22	M.	40	...	...	Recovered.	
23	M.	40	...	...	Recovered.	It was ulcerated, and considered to be malignant.
24	M.	10	...	Lower.	Recovered.	As large as a walnut.
25	M.	51	...	Upper.	Recovered.	
26	F.	47	5 months.	Upper.	Recovered.	
27	F.	24	...	Lower.	Recovered.	The bleeding which followed required the actual cautery for its arrest.
28	F.	73	...	...	Recovered.	The tumour was pedunculated, and was removed by ligature.



pushed forward and be eventually found imbedded in its centre, as narrated by Mr. Tomes.

The statistics respecting epulis (p. 198), founded upon twenty-eight cases observed in the London hospitals, are taken from the *Medical Times and Gazette*, Sept. 3rd, 1859.

"Of these twenty-eight cases in which tumours growing from the gum were of the character usually designated as 'Epulis,' we may make the following summary:—In but one instance did the operation cause the death of the patient, whilst in all the others the parts implicated are stated to have healed soundly. It would appear that the female sex is more liable to this disease than males, in the proportion of 5 to 3, the numbers in the list being 17 females and 11 males. This may perhaps be explained by reference to the fact, that stumps of decayed teeth are by far the most frequent exciting causes of these growths. Now, women are, for several reasons, more likely to retain useless stumps of teeth than men. They are far more patient as regards severe, unavoidable pain, such as that of toothache, and at the same time much more afraid of surgical pain, as that of tooth extraction; besides, it must be remembered, that the conditions either of pregnancy or lactation prevent many women from having their decayed teeth taken out at the times when they ache.

"As it regards *age*, we find that the youngest patient was a boy of 9, and the next to him a girl of 11, whilst the oldest was a woman of 73, and the next to her another woman of 60. Five were under the age of 20; eight between those of 20 and 30; seven between 30 and 40; three between 40 and 50; two between 50 and 60; and three above 60. The average of the whole is 33."

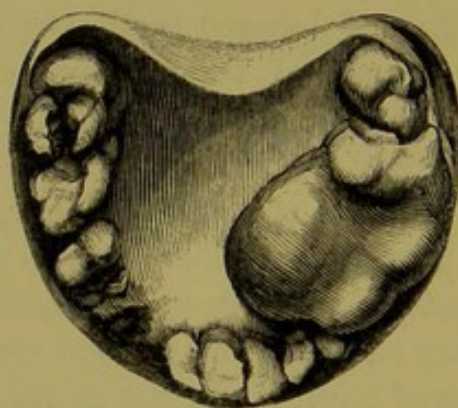
The two jaws appear to be equally liable to the disease; but its position and extent are subject to great variation. In the simplest form it may be connected with only the outer plate of the alveolus, or may be attached at a slight depth within the socket of a tooth. In other instances it is attached solely to the posterior plate of the alveolus, and protrudes the teeth or appears behind them; in the more severe



cases it involves the whole thickness of the jaw, and either envelopes or carries the teeth before it. Of this a case of Dr. Fleming's (*Dublin Quarterly Journal*, Feb. 1866), gives a good example at an unusually early age, the boy being between five and six, and the disease occurring between the first and second temporary molar teeth of the lower jaw, both of which were displaced and imbedded in the morbid growth.

When the tumour attains a moderate size, if it be on the upper surface of the alveolus it is apt to be pressed upon by the teeth of the opposite jaw, and this not only gives rise to pain and inconvenience, but causes also indentations and

FIG. 94.



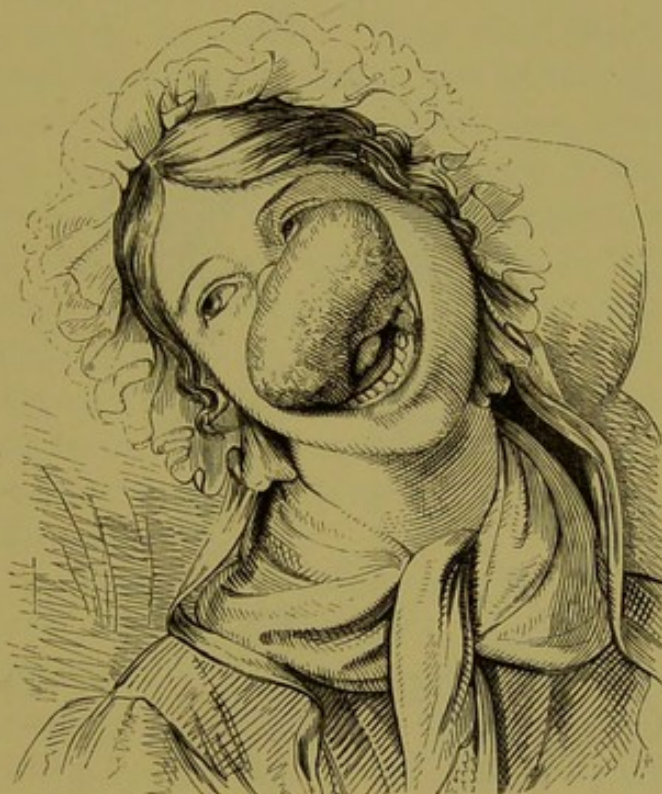possibly ulcerations on its surface. Fig. 94 is reduced from a cast of the upper jaw of a young woman, a patient of Mr. Warn of the Highgate-road, from whom I removed a large epulis containing bone which has been already referred to. The patient was twenty-seven years of age, and the growth had existed two years, and it will be seen that the surface is grooved and indented by the teeth of the lower jaw. In this case the fangs of the first and second molar teeth were found in the alveolus beneath the epulis.

An epulis, if allowed to grow to a large size, will produce external deformity of the face, and although attached to the upper jaw may hang down so as to simulate disease of the lower jaw. This was well seen in a woman, aged twenty-seven, who had an epulis of the upper jaw of seven years'



growth, which hung down to the level of the angle of the jaw, and who was under the care of Mr. Erichsen, by whom the tumour was removed in 1861, with perfect success. Perhaps the most remarkable case of epuloid growth on record, however, is Mr. Liston's well-known patient, Mary Griffiths, from whom, in October, 1836, he removed the growth shown in the accompanying drawing (fig. 95). The case is reported at length in the *Lancet*

FIG. 95.



of November 5th, 1836, and is also referred to in Mr. Liston's "Practical Surgery," from which work both the illustrations are taken. The following summary of it is from a note to Mr. Liston's paper on Tumours of the Jaw in the *Medico-Chirurgical Transactions*, vol. xx.

"The patient had laboured under the disease for eight years, and had been subjected to a partial removal of the growth when of inconsiderable size. The tumour was of the same nature as those of the third and fourth cases related in the paper (*i.e.*, fibroid), as regards its disposition, form,



and intimate structure. It differed somewhat, however, in outward appearance, in consequence of its exposed situation. The growth sprang originally from the gums and sockets of the incisors and canine tooth of the left side; at an early period it protruded from the mouth unconfined and uninfluenced by the pressure of the lips or cheek. It had assumed a most formidable size and appearance, concealed the palate and pharynx, and gave rise to great inconvenience and continued suffering. The surface had been broken by ulcera-

FIG. 96.



tion, but upon a close inspection of the projecting part and of that covered by the cheek, it was found to possess a firm consistence, and to present the same peculiar botryoidal arrangement of its parts as the others of a simple and benign nature. The operation proved perfectly successful." Fig. 96 shows the after condition of the patient, the scars in the upper lip being the result of the previous unsuccessful attempt to remove the disease. The preparation is in the Museum of the College of Surgeons (1032).



*Treatment of Epulis.*—No treatment less radical than removal of the growth is of the slightest advantage. In the case of a small epulis growing between or close to the incisor teeth, after removal with the knife an attempt may be made to check the reproduction of the disease by the application of nitrate of silver, but usually without success. As has been already said, the growth is connected with the periosteum, and will be reproduced from it. It is essential then to remove the periosteum, and this may be done with a chisel or gouge, by which a small scale of the alveolus with its covering can be cut away. Those who object to such a proceeding may produce the same result by the application of such a powerful caustic—either potassa fusa, nitric acid, or the hot iron—as shall destroy the surface of the bone and cause its exfoliation, but with some tediousness and inconvenience to the patient. When the epulis is connected with the lining membrane of the socket of a tooth no superficial operation can effect a cure, and it is in this class of cases that repeated reproductions are often met with. The neighbouring teeth, although sound, must be sacrificed under these circumstances, and the alveolus be cut away with bone forceps. The same treatment will be advisable in cases where the disease springs from the posterior plate or from the interior of the alveolus; and in all these cases, and especially the last, I make an invariable practice of applying the actual cautery to the surface of bone exposed by the operation, which has the advantage of stopping hæmorrhage and of causing the exfoliation of any diseased portions of bone which may have been left. In all operations of the kind, any roots of decayed teeth which may be discovered at the time of the operation should be extracted with the forceps or elevator, and the surface of the bone rendered as smooth as may be.

When the epulis is very extensive, it may be conveniently removed with the alveolus to which it is attached, by making a vertical incision with a small saw (fig. 97) at each extremity of the disease, and then connecting the cuts by a horizontal one with cross-cutting bone forceps (fig. 98).

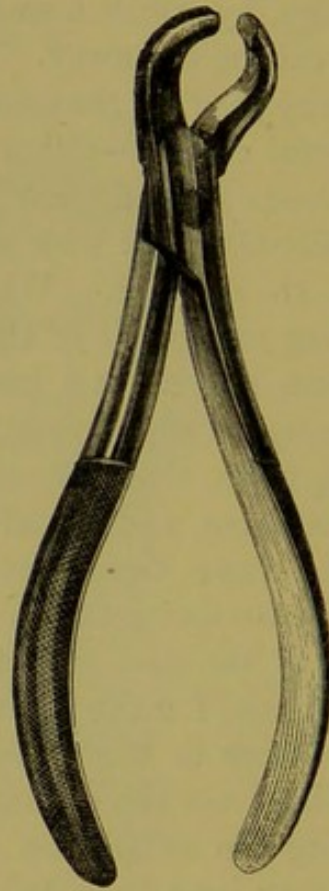


Fig. 93 shows a portion of the lower jaw removed in this manner by Sir William Fergusson. Under no circumstances can it be necessary, I believe, to cut through the whole thickness of the lower jaw, since it has been shown repeatedly that epulis never involves the base of the bone, and the contour of the face depends so much upon its preservation that it should not be interfered with.

FIG. 97.



FIG. 98.



When the growth is of large size and situated at the side of the mouth, some difficulty may be experienced in extirpating it, but with properly made angular and semicircular bone-forceps (figs. 99 and 100) this may generally be overcome. It may be necessary, however, to incise the face, and if so, the suggestion and practice of Sir William Fergusson ("Lectures on Progress of Surgery," p. 239) cannot be too strictly followed—viz., to restrict the incision to the

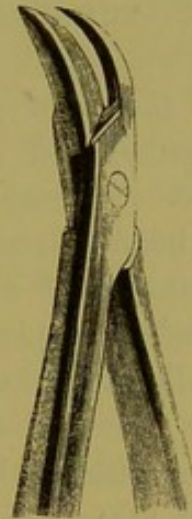


middle line of the lip, which will ordinarily give abundance of room ; or if not, to carry it into the nostril of the affected side, by the stretching of which so much additional room will be gained as to render any incision at the angle of the mouth perfectly unnecessary. When this limited incision is adhered to the scar is so slight as to be imperceptible

FIG. 99.

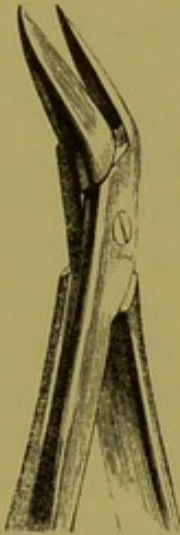

FIG. 100.



except upon the closest investigation. In instances of such enormous growths as in the case of Mary Anne Griffiths, more extensive incisions, resembling those for excision of the jaw, would be required ; but such cases are nowadays few and far between. Mr. Liston considered it necessary to remove the left and a portion of the right maxilla, but subsequent examination showed that these bones, though overlain by the disease, were not implicated in it except at their alveolar borders.



## CHAPTER XVI.

## TUMOURS OF THE HARD PALATE.

*Tumours of the hard palate* are for the most part closely allied to epulis, and may therefore be conveniently considered here. A case of papillary tumour of the hard palate has been already described under the section of Papillary Tumour of the Gum. In the Museum of St. Bartholomew's Hospital is a preparation (XXIII. 6), to which the following description is appended—"An elongated oval tumour removed from the palate, to which it appears to have been attached by a broad base. It is composed of a firm, very closely-textured, obscurely-fibrous substance, with interspersed specks of bone, like the epulis which more commonly grows from the gums."

Of this same character was a tumour of the hard palate removed by Mr. Keat<sup>\*</sup>, which Mr. Cæsar Hawkins speaks of as essentially the same as epulis. Mr. Syme also narrates a case (*British Medical Journal*, April 19th, 1862) occurring in a woman, aged forty-six, which had been growing two years, was of a circular form, and "presented a convex surface extending from side to side and stretching from the anterior third of the palate to the posterior edge of its hard portion." The growth was soft at its centre, but hard at the base and evidently connected with the bone. Unfortunately no more detailed account of the structure of the growth is given in the lecture in question.

Tumours of the palate of a softer consistence have been met with, however; thus in St. Bartholomew's Museum (XXIII. 22) are sections of a tumour removed from the palate, to which it was attached by a base of much less



extent than its circumference. Its surface is covered by thick, but apparently healthy, mucous membrane, and its interior appears composed of lobules of fatty matter.

Encysted tumours of the palate have also occurred, thus Dr. Cabot showed to the Boston Society for Medical Improvement a small round tumour which he had removed from the roof of the mouth of a soldier. It had existed for eighteen months, and was situated on the posterior and left part of the hard palate, extending as far as, but not involving, the gum. Although the patient had suffered severe pain in the left side of the face and temple of a neuralgic character, yet he was not sure that it had its origin in the tumour. It was somewhat tender on pressure, but not painful. The capsule which contained it being incised, it was easily shelled out. It was two-thirds of an inch in diameter, of a yellowish-white colour, and mostly smooth; but in one part it had a watery appearance.

The palate, no less than other parts of the jaw, appears to be liable to cancerous disease, and this may be of a medullary or of an epithelial character. In the Museum of King's College is a specimen of the former kind, in which the greater part of the right side of the hard palate is involved in a soft tumour, the surface of which is very irregular and broken down, whilst the soft palate appears to be free from disease. This was removed from the body after death, and no history is appended to it.

A case of epithelial tumour of the palate in a young woman, aged sixteen, occurred in the London Hospital in 1856, under the care of Mr. Curling, who successfully removed the growth with a large portion of the jaw, the details of which will be found in the *Lancet*, July 26th, 1856.

Dr. Andrew Clark's report of the tumour is as follows:—  
“The tumour is about the size and of the shape of a hen's egg. It is invested by a condensed layer of areolar tissue, and loosely connected with the periosteum of the adjacent bones. At one point—the posterior and inferior edge of the zygomatic surface of the superior maxillary bone—it had a limited but distinct osseous attachment. The tumour



therefore might have been shelled out at all points but this. The tumour lies between the naso-palatine portion of the right maxilla and the mucous membrane. The mucous membrane over the tumour is hypertrophied, and exhibits an oval ulcer with thick, rounded, white margins, and a reddish, smooth base. The naso-palatine part of the superior maxilla is elevated and thinned; the periosteum is loosely attached to it, and at one point the bone is a little 'opened up' in texture. The tumour is soft, slightly elastic, and vascular. The cut surface is of a dead-white colour, distinctly granular, like rough honey, crumbly-looking, and studded with red or pink blotched parts sunk below the general level. On further examination, it appears to be permeated by a kind of glairy substance (colloid matter), which helps seemingly to give coherence to the tumour. To the naked eye the tumour resembles, in some respects, a cephaloid or myeloid mass. To the latter it bears the greatest resemblance in general character, seat, and structure. The microscopic characters are those of epithelial cancer; epithelial cells in all stages of development and of the most various forms, together with a few nest-cells and fat. The mucous membrane over the tumour, though not continuous with it, presents the same structural characters. This decides the doubt between the epithelioma and myeloma. The tumour has been wholly removed." (*Lancet*, July 26th, 1856.)

*Treatment.*—When the disease is of the epuloid character the treatment should be the same as for that disease,—viz., complete removal and destruction of the periosteum, from which the growth springs. When the bone is implicated too deeply for the disease to be effectually removed with the gouge, the plan adopted by Mr. Syme in the case already referred to may be adopted. He removed the growth and the subjacent bone with a trephine large enough to embrace the whole tumour, leaving an aperture with healthy edges, which granulated and was much contracted when the patient was dismissed. When the disease is too extensive to be dealt with in this way, it will be necessary to remove a



portion of the jaw, as in Mr. Curling's case. Under these circumstances the limited incision already insisted upon for cases of epulis should be had recourse to, and the jaw should be divided horizontally immediately above the palatine plate, so as to do as little damage as possible to the appearance of the face.



## CHAPTER XVII.

## GROWTHS WITHIN THE ANTRUM.

THE cystic forms of disease occurring in the antrum having been already considered with other cystic diseases of the jaws (p. 137), this section will be confined to those solid growths which spring directly from the antrum, as distinguished from tumours of the upper jaw, though the line of demarcation between the two is in many cases drawn with difficulty.

*Polypus*.—This is not a common affection, though by no means so very rare as stated by Paget. Luschka has investigated the subject (Virchow's "Archiv," Bd. viii. p. 419), and found polypi five times in sixty subjects, some being two centimetres in length. He gives a drawing showing a large number of these polypoid growths in an antrum, which he considers to be hypertrophies of the sub-mucous connective tissue, covered with mucous membrane. Billroth also describes a good example of large polypus of the antrum with a long pedicle, and regards it as a very rare affection.

These polypi are closely allied apparently to the small cystic growths in the mucous membrane of the antrum described by Giralaldès (*vide* p. 153). Both affections consist essentially in hypertrophy of some elements of the mucous and sub-mucous tissues. When the connective or areolar tissue predominates, the fleshy polypus is produced; when the glandular element is especially affected we have the cystic form produced. Intermediately when the fibrous element is very loose and we have some glandular hypertrophy, the semi-gelatinous polypus is produced, which closely resembles the nasal polypus.



Polypi of the antrum are well supplied with blood-vessels, and bleed freely when interfered with. In some instances they appear to have a malignant character, or at least are the forerunners of malignant disease occurring in the antrum and jaw. Vidal de Cassis, who (*Traité de Pathologie Externe*, tom. iii. p. 492) totally denies the existence of any true polypoid growths in the antrum, says that what have been mistaken for them most frequently are colloid tumours of the periosteum, but believes that many of the examples are cases of cystic growth. Syme also, following the example of John Bell, maintains that polypi in the antrum always intrude from the nose and are never developed in the antrum itself. (*Lancet*, March 10th, 1855.)

The symptoms of polypi, no less than of cysts of the antrum, only become developed when the growth is of sufficient size to encroach upon the neighbouring cavities or produce distension and absorption of the front of the antrum. The most common situation for the polypus to show itself is, as might be expected, the nose, since the tumour readily induces absorption of the thin nasal wall of the antrum. Here it closely resembles the ordinary nasal polypus, and Sir William Fergusson mentions (*Practical Surgery*, p. 561) two cases of the kind in which this had occurred, one being in his own practice. In that instance he soon found that he had attacked a tumour of the antrum, which, in consequence of its deep and firm attachment, and the great hæmorrhage attending it, he did not entirely remove. The disease returned, and he again operated, on this occasion using great force, and wrenched out the whole mass, not without some fear of the consequences. The case, however, did well, and after ten years the disease had not returned.

In the *Medical Times and Gazette*, March 18th, 1860, is a report of another case in which the same surgeon removed a vascular fibrous polypus of the antrum which had projected into the nostril, by laying open the front wall of the cavity and with strong forceps tearing out the tumour bit by bit.



I had, during 1866, the opportunity of watching the case of a patient who had had a polypus partially removed by the nose on several occasions, and from whom Mr. Holt-house removed an entire growth a year and a half before that date. He reappeared with a swelling of the jaw, evidently due to distension of the antrum by some soft growth, and he had also a soft tumour on the forehead. These were doubtless cancerous, for his strength failed, and he sank after some months, but unfortunately his relations would not permit a post-mortem examination to be made.

Hypertrophy of the glandular tissue of the mucous membrane appears capable of producing tumours of a friable description, which may fill up the antra on both sides, as in a case recorded by M. Demarquay (in the *Gazette Médicale de Paris*, November 14th, 1857). Here the patient had a large tumour on each side of the nose, the passages of which were completely obstructed, and his right eye was protruded from the orbit. M. Demarquay removed the front walls of the antra and extirpated two masses of very friable tissue of a greyish-white colour, in which the vascular tissue was not abundant. M. Robin, who examined the growths, pronounced them to be the result of an hypertrophy of the glandular element of the mucous membrane of the antrum.

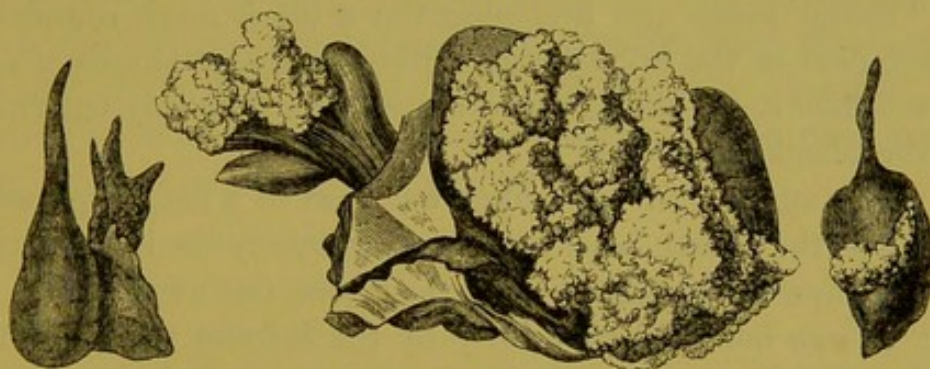*Fibroid Disease of the Antrum.*—Allied to polypus is a form of disease of the lining membrane of the antrum which I do not find described by any author, but of which I have myself met with an instance. In September, 1866, Dr. Whitmarsh, of Hounslow, brought to me a gentleman who, two years before, had perceived some growth in the right nostril, which gave no pain but kept up a constant discharge, especially at night. In the early part of the year this had been removed in part by a surgeon, and since that the discharge had much increased. There was a fungous growth in the right nostril, and the whole right maxilla was swollen, and discharged thin pus at one or two points near the eye. There was a fungous-looking growth in the molar region, and a probe passed by its side into the antrum.



I removed the disease on September 23rd, clearing away the whole of the growth, which was very friable, and leaving the posterior wall of the antrum and the infra-orbital plate untouched. In the course of the operation I found a distinct polypoid growth filling the posterior nares, which I removed. The patient rallied well from the operation, but unfortunately got congestion of the lungs and died on the fifth day. The case will be found in detail in the Appendix (Case XVIII).

The preparation is in the College of Surgeons' Museum (1052 B.), and the appearance of a part of the disease is shown in fig. 101. It will be seen that the interior of the antrum is covered with a remarkable papillary or villous growth,

FIG. 101.



resembling some forms of cauliflower excrescence. A quantity of broken down loose fibroid tissue lies at the bottom of the bottle of the preparation, and a portion of it, with the adjacent mucous membrane, is given in the sketch; the other portion being the polypoid growth extracted from the posterior nares. Mr. Bruce has favoured me with the following report upon the specimen:—

“It appears to consist of a fine soft fibrous stroma, in which very numerous nuclear bodies and a few elongated fibre-cells are distributed. Its structure resembles that of the upper strata of a mucous membrane, from which it is probably an outgrowth. It consists of newly-formed fibrous tissue, and of the elements from which fibrous tissue is developed, and may therefore be classed among the simple



fibro-plastic growths, as distinguished from the true myeloid tumours."

A curious, and I believe unique, case of falling in of the antrum, recorded by Mr. White Cooper, may be conveniently mentioned here, since the depression of the wall of the cavity depended, no doubt, upon some alteration going on in its interior—possibly the absorption of some fluid which had previously induced thinning of the bones. The patient was brought before the Medical Society of London in 1851, and Mr. Cooper has kindly given me the following details of her case:—

"I first saw Margaret Ryan (aged twenty-seven) May 22nd, 1849.

"Complained of the tears running over the left cheek. First perceived about a week previously.

"Seven years ago first observed a black mark round the lower part of the left eyelid; without pain, weakness of eye, or toothache. Gradually and almost imperceptibly flattening of the cheek came on.

"The appearance presented was that of a deep depression between the malar bone and nose, precisely as if a portion of the superior maxillary bone had been cut away.

"It was bounded superiorly by the inferior margin of the orbit, which partook of the depression; inferiorly, by the base of the alveolar process; and externally by the malar bone. As compared with the other cheek, the dimensions were as follows:—From bridge of nose over deepest point of depression, one inch four-tenths, or nearly an inch and a half; right side to corresponding point, just one inch.

"There was a peculiar dusky hue about the depression, especially towards the upper part. The cuspid and bicuspid teeth were removed with considerable difficulty, the roots showing thickening of periosteum.

"No change was visible at the expiration of twelve months."



## CHAPTER XVIII.

## TUMOURS OF THE UPPER JAW.

*Fibrous, Fibro-cellular, and Recurrent Fibroid Tumours.*

WITH regard to the statistics of tumours of the upper jaw, I shall content myself with quoting O. Weber, who has collected 307 cases from the following sources:—183 cases tabulated by Heyfelder; 36 recorded by Lücke from Langenbeck's clinique; 17 reported in the *Medical Times and Gazette* (Sept. 3rd, 1859), and 71 cases either observed by himself in Wutzer's clinique or occurring in his own practice. Of the above cases there were:—

Osseous tumours . . . . .	32
Vascular tumour . . . . .	1
Fibrous tumours . . . . .	17
Sarcomatous tumours . . . . .	84
Enchondromatous tumours . . . . .	8
Cystic tumours . . . . .	20
Mucous polypi . . . . .	7
Carcinoma . . . . .	133
Melanosis . . . . .	5
	—
	307

In commenting upon this table, Weber very justly remarks that doubtless the list of cancerous cases is exaggerated, and suggests that a fair estimate would be gained by allotting rather more than a third of the whole number to sarcomatous (simple) tumours; less than one-third to the cancerous, and the remainder to the osseous tumours, cysts, &c.



It will be observed that in this classification no mention is made of the myeloid tumour, which undoubtedly occurs in the upper jaw.

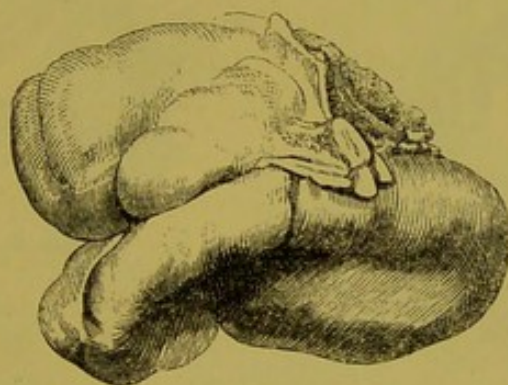
*Fibrous Tumours.*—These closely resemble the fibrous tumours found in other parts of the body, and especially in connexion with the uterus. They are dense in structure but are not unfrequently lobulated, and on section, slender bundles of intersecting fibres may occasionally be traced in them, of which there are good examples in the Museum of the College of Surgeons. The fibrous tumour usually springs from one of two situations, either the interior of the antrum or from some portion of the alveolus. In both cases it is intimately connected with the periosteum, in this respect resembling epulis. The fibrous tumour grows slowly, but surely, involving in its progress the surrounding structures. When arising in the antrum, it first expands the walls of that cavity, bulging out the face and forming tumours in the palate and floor of the orbit, and subsequently produces absorption of the osseous walls and spreads unchecked in all directions. The following description of a specimen in St. George's Hospital Museum gives a good idea of the ravages of such a tumour, and reference may be made to a similar specimen in the Museum of the College of Surgeons (1050):—"Fibrous tumour growing from the antrum, and making its way by the absorption of the walls of that cavity in different directions. It projects upwards into the orbit, destroying the floor of that cavity, and protruding from its inner margin forwards on to the cheek. It has also destroyed the anterior wall of the antrum, and displaced the malar bone forward and outward; inwards it projects into the nose beneath the middle turbinated bone, and downwards it makes its appearance on the under surface of the alveolar process in the form of a rounded mass, destroying the floor of the antrum in the neighbourhood of the front molar tooth. Behind, the tumour appears in the zygomatic fossa by the absorption of the outer part of the tuberosity of the superior maxillary bone. The tumour is composed of circular nuclei



of various size, and spindle-shaped fibres. The patient from whom the specimen was taken, William H., died of arachnitis, and softening of the corresponding part of the brain.” —*Catalogue of St. George's Hospital Museum*. (II. 160).

When it arises from the alveolus, a fibrous tumour may encroach on both the facial and the palatine surfaces of the jaw, crushing in the antrum although not involving its interior. Of this a good example is seen in a preparation (1048) in the College of Surgeons, of an upper jaw removed by Mr. Liston. Here the tumour, which is affixed to the alveolar border, near the molar teeth, extends inwards so as to cover the palatine portion of the jaw, and outwards so as to conceal all the bicuspid and molar teeth, with the

FIG. 102.



exception of the last. The walls of the antrum are pressed inwards, but its interior is healthy. The patient was a woman, thirty years old, and the tumour was observed four years before its removal, which was successful. On the other hand, fibrous tumours, though commencing in the alveolus, may secondarily involve the antrum when they have attained considerable size, producing complete absorption of its walls, and projecting into the nose and through the palate. Of this a preparation in the College of Surgeons Museum (1046), of an upper jaw, also removed by Mr. Liston, affords a good example. Here the patient was only twenty-one, and the growth first appeared on the outer side of the gum of the left upper jaw four years before



the operation. It was cut off six months after its first appearance, but returned, and eighteen months after was removed, with a portion of the alveolar process, but reappeared in a few weeks. Fig. 102, from Liston's "Practical Surgery," shows the growth after its removal, and figs. 103 and 104 show the patient before and after the operation. It may be noticed here, as in the case of a large epulis, that disease of the upper jaw often closely resembles, externally, a tumour of the inferior maxilla.

FIG. 103.



FIG. 104.



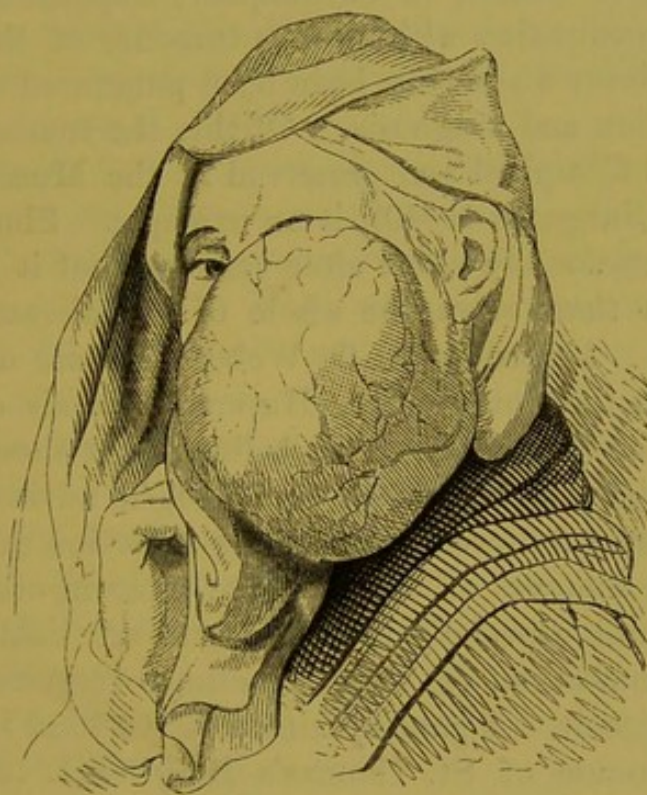The case is given by Mr. Liston in his paper on Tumours of the Jaw, in the *Medico-Chirurgical Transactions*, vol. xx.

The enormous size to which fibrous tumours of the upper jaw may grow without destroying the patient, is well seen in the accompanying drawing (fig. 105) of Mr. Liston's celebrated case of Mrs. Frazer, from whom that eminent surgeon successfully removed the growth. The tumour is preserved in the Museum of the College of Surgeons (1051), and its diameters are, vertically, seven inches, transversely, seven inches, from before backwards, nearly



six inches. Contrary to the ordinary practice, a portion of the integument was removed with the tumour, measuring twelve inches in length and ten in breadth, and this left a gap in the skin of the face upon the patient's recovery, a point which will be again referred to. The growth of this tumour was connected apparently in a curious way with the performance of the uterine functions. The patient was forty years old, and the tumour began to grow six years before its removal, in consequence of a blow in the region

FIG. 105.



of the antrum. Its progress at first was slow and not painful, but at the end of two years a distinct tumour was felt in the cheek. During the next two years it grew rapidly, especially during a period of gestation, but still without much pain. In the fifth year of its growth she bore a second child, after which the catamenia ceased to flow, and the tumour was subject to monthly augmentations of its vascularity, and slight hæmorrhages occurred from its inner, though not ulcerated, surface, and from the adjacent



parts of the gum. The case is given in detail in Mr. Liston's paper already referred to.

A remarkable feature, noticed in a case of fibrous tumour of the antrum, in a young man of eighteen, under the care of Mr. Paget in 1860, was a distinct pulsation in a portion of the tumour which projected into the orbit. The pulsation was slight but decided, and was synchronous with the radial pulse. The case was clearly not one of malignant disease, but proved to be an ordinary fibrous tumour upon removal. No satisfactory explanation seems possible of the case, which I believe to be unique. Suppuration has occurred in connexion with fibrous tumours of the jaw, but only, I believe, when they have been punctured with a view to exploration and diagnosis. Of this the tumour removed from Janet Campbell and preserved in the Museum of the College of Surgeons (1049), is an example. Simple fibrous tumours occasionally recur after removal, but it is doubtful whether in these cases the whole of the disease has been eradicated. According to O. Weber they are usually connected with the lining of the Haversian canals of the surrounding bone, and though he believes that these processes may sometimes be effectually detached, he advises the practice ordinarily followed of removing a portion of bone.

Fibrous tumours of the jaw, like those in other parts of the body, and especially in the uterus, are liable to calcareous degeneration, or, as is sometimes incorrectly stated, to ossific deposit. A good specimen of the kind is preserved in the Museum of St. Thomas's Hospital (I. 18), which is thus described in the Museum catalogue:—

“An osteo-fibrous tumour of the antrum, removed by Mr. Solly. The tumour entirely filled the cavity of the antrum, the bony parietes of which have been absorbed to a considerable extent; it protruded the cheek anteriorly, projected into the fauces posteriorly, pressed down the palate inferiorly, and extended to the septum nasi internally. Its firmest point of attachment is to that part of the antrum corresponding to the roots of the first molar, canine, and incisor teeth. The tumour is of a rounded form,



and has a smooth external surface; its section presents very much the appearance of a fibrous tumour of the uterus of slow growth, and contains an abundance of bony deposit.

"From a boy, æt. seventeen. The existence of the tumour was discovered only ten months previous to its removal, when the face began to swell, the swelling being accompanied by pain. No untoward circumstances followed the operation, and the boy left the hospital quite well. The deformity was very slight. Five years after the operation the boy was in capital health." More complete details of the case will be found in Mr. Solly's "Surgical Experiences," lecture 41.

A thin section of this tumour has been dried and preserved, in order to show the amount and distribution of the calcareous matter (I. 19).

With regard to the causes giving rise to fibrous tumours of the upper jaw there is much obscurity, though there is little doubt that they in many cases originate in some irritation due either to a blow, or more frequently to the presence of diseased teeth; and the latter may give rise to a tumour commencing in the alveolus itself or within the antrum, the lining membrane of which is irritated by the fangs of the diseased teeth. Bordenave strongly insisted upon this, and since his time most surgeons have taken the same view. Stanley mentions a case which occurred to Mr. Luke, in which a black carious tooth was found imbedded in a fibrous tumour of the upper jaw, and other cases of the kind have occurred, although the event is more common in the case of the lower jaw.

*Fibro-cellular tumour*, or osteo-sarcoma, is a softer variety of fibrous tumour which is frequently found in connexion with the upper jaw. It is usually of a yellower colour than the fibrous tumour, owing to the admixture of the cellular element, and of softer consistence, and on section it exudes a serous fluid with which it is infiltrated. The cells may be seen in various stages of development into fibre, and scattered among the fibres may be found numerous cells and nuclei. Under the name of "albuminous sarcoma" Mr. Liston has described a case which appears to



be of this kind, in the *Lancet*, Nov. 26th, 1836, which proved fatal after removal of the tumour. The patient was twenty-four years of age, and the disease appeared to have originated in a blow, and grew with tolerable rapidity. The tumour, which is preserved in the College of Surgeons Museum (1052), is oval in form, its chief diameters being about three inches by two inches, and contained spaces in which was a glairy fluid coagulable by heat. Mr. Lane successfully removed, in 1861, *both* upper jaws, together with the vomer, &c., which were involved in an "albuminous sarcoma," from a man aged forty-eight, whose case will be found in the *Lancet*, Jan. 25th, 1862. The tumour implicated both superior maxillary bones and filled both nostrils. It formed an extensive convex irregular swelling in the mouth which pressed down the tongue. Very little bony material could be distinguished in the position of the palatine processes of the maxillary or palate bones, and the growth which occupied their place was soft and elastic, and was ulcerated in two or three spots of the size of a fourpenny piece. The growth first showed itself within the left nostril three or four years previously, presenting the appearance of a nasal polypus, and was removed three times.

In the same number of the *Lancet* is the report of a case of tumour, also removed by Mr. Lane, from a child of nine years, which presented much the same characters. The report states that portions of the growth, placed under the microscope, presented the characters of a fibro-nucleated structure, being composed of minute fibres, in which were disseminated numerous small oval nuclei about the size of blood globules, measuring from the four-thousandth to the three-thousandth part of an inch in diameter.

In the *Lancet* for Aug. 31st, 1861, is the report of a remarkable case of fibro-cellular tumour of the jaw, under the care of Sir William Fergusson, in which the patient was the subject of two tumours, one situated in the right cheek, the other in the antrum and roof of the mouth. The growths were, however, perfectly distinct from one another, and both were removed at a single operation, which was



attended with the best results. Sir William Fergusson had seen the patient twelve months before, and the disease then presented so malignant an aspect that he dissuaded her from undergoing any operation. Some months later, the disease in the mouth was found to be an ulcerated, sloughy-looking mass, and the finger could be readily passed alongside of it into the antrum. Perceiving that its progress had been slow, and that it was within the reach of surgical aid, he thought he would give her a chance, more especially as there was no development of disease in any other situation, and the tumour in the cheek was quite distinct from that in the jaw.

The report states that the softer part of the disease appeared, on microscopical examination, to consist mainly of a fibro-granular matrix, containing numerous corpuscles, round, regular, of uniform size, granular, and with no appearance of nuclei. The much firmer tumour of the cheek contained corpuscles of a similar character, with a large proportion of the fibrous element.

The tendency to ulceration which was exhibited in this case is a marked feature of this form of disease, and not unfrequently leads to difficulty in solving the question of malignancy. It is seldom that in the case of the upper jaw the skin becomes involved in the disease, but in the lower jaw this frequently happens, and large fungous protrusions occur which may be mistaken for open cancer. The history of the case, together with the absence of any enlargement of the lymphatic glands, is sufficient to mark the nature of the growth.

In his paper on osteo-sarcoma, in the fourth volume of the *Dublin Hospital Reports*, Sir Philip Crampton says that "in the earlier stages of the disease the tumour consists of a dense elastic substance resembling fibro-cartilaginous structure, but the resemblance is more in colour than consistency, for it is not nearly so hard, and is granular rather than fibrous, so that it '*breaks short*.' On cutting into the tumour the edge of the knife grates against spicula, or small grains of earthy matter with which its substance is beset." The tumours described above correspond very closely to this



definition, especially that of Mr. Liston, which is said to be "chiefly composed of a firm substance like fibro-cartilage, with spicula of bone."

Fibro-cellular tumours, like fibrous tumours of the jaw, appear to be often connected with diseased teeth, and like them also are liable to calcareous degeneration. The following account of a tumour removed by Mr. Carr Jackson, illustrates both these points:—

"Examined by Mr. Hulme, the tumour presents the following histological characters:—It was the size of a turkey's egg, involving and infiltrating the greater part of the left superior maxillary bone, and extending upwards into the antrum, its upper and posterior surface having a nodulated or mammillated appearance, and its anterior portion being marked by the under surface of the orbital plate. On section, the structure of the tumour appeared of a dense, homogeneous, somewhat fibro-cartilaginous substance, encased by a thin shell of bone sending processes into its interior, which consisted of a hard bony mass, having a radiated appearance, the fang of a molar tooth being imbedded in its substance. The upper mammillated substance was soft and free in the antrum, covering the central bony structure on its surface. Microscopically the softer parts consisted of elongated cells, having a tendency to form fibre—a tendency especially evident at the thin edge of a section, which showed the fibroid cells very clearly, their nuclei being rendered evident on the addition of dilute acetic acid. Calcareous matter was deposited along the course of the fibres, and the central hard portion of the growth consisted of earthy salts, converting it into a stony mass. The tumour may thus be regarded as a fibrous (fibro-cellular) growth undergoing calcareous degeneration."—*Lancet*, Jan. 24th, 1863.

In his work on the "Diseases of the Bones" (p. 282), Mr. Stanley mentions "fatty" tumours of the superior maxilla. He refers (p. 104) to a specimen in St. Bartholomew's Hospital Museum (I. 151), of which the following is the description:—

"Sections of a tumour which occupied the situation of the



superior maxillary bone, and was removed by operation. The whole of the natural structure of the superior maxillary bone has disappeared. The mucous membrane which covered the palatine surface of the bone extends over a part of the tumour. The morbid growth consists of a moderately firm fatty-looking substance, with minute cells and spicula of bone dispersed through it.

"From a man aged forty-six. The disease returned after the operation, and the patient died in consequence of hæmorrhage from ulceration of the internal carotid artery, which became involved in an extension of the disease."

This, as far as can be judged, would appear to have been an example of fibro-cellular tumour or osteo-sarcoma, which had undergone fatty degeneration; and the same may, I imagine, be said of the cases referred to by Von Siebold as osteo-steatomata. The disease would appear to be a rare one, as it is not mentioned by most authors.

*Recurring Fibroid Tumour* occurs, I believe, occasionally in the upper jaw. It is an undoubted fact that fibrous tumours do recur in the upper jaw after complete removal; and of this Mr. Liston's series of specimens, already referred to, gives more than one example, and it is probable that careful microscopic examination would prove that some of them exhibit the peculiar "oat-shaped nucleated cells," described by Mr. Paget as characteristic of the recurrent tumour. It is not surprising that these tumours should have been considered as examples of the ordinary fibrous tumour, since Mr. Paget himself observes, in speaking of a well-marked specimen, "without the microscope, I should certainly have called it a fibrous tumour."

In connexion with this subject I may quote the following extract from the report upon diseases of the jaw, in the *Medical Times and Gazette*, Sept. 3rd, 1859:—"The only example which we have to quote of recurrent fibroid tumour developed in connexion with the jaws is one in which the diagnosis of that variety of tumour and true cancer is by no means positive. It is that of a woman, aged thirty-four, under Mr. Cock's care, in Guy's Hospital, at different times,



for two or three years (1854 and 1856). The growth occupied the right antrum, and extended into the nose; on several occasions Mr. Cock dissected up the cheek in front, laid bare the cavity, and gouged out the tumour and the bone to which it was attached. The parts always healed quickly, but the disease soon returned. The tumour had the microscopic features of a recurrent fibroid, as distinct from those of a true cancer, and the fact that it continued to recur in the same place, but did not cause disease of the glands, is confirmatory of that diagnosis. The woman was very pallid and cachectic, but her cachexia did not exactly resemble that of cancer. We lost sight of her towards the end of 1856, and do not know the final result of her case. Probably she has since died of her disease."

In March, 1867, I had the opportunity of seeing a patient of Mr. Lawson's, a lady, aged thirty-three, from whom, in the preceding May, that gentleman had removed a recurrent fibroid tumour of the left orbit. From this operation she perfectly recovered, but, four months before I saw her, the patient had found a small hard swelling of the left side of the hard palate. This rapidly increased, spreading backwards into the soft palate, and forwards so as to press upon the incisor teeth. The swelling was irregular in outline, but with a perfectly smooth surface, and was so soft and elastic that it conveyed the impression of fluid, and had been punctured. Mr. Lawson removed the whole of the left side of the hard palate and as much of the soft palate as was involved in the disease, and the patient made a perfect recovery. Four months afterwards the patient again appeared, the disease having recurred on the right side of the hard palate. There was also a fibroid tumour in the parotid region, which had been present some years, and had now begun to increase in size. Mr. Lawson removed the tumour of the palate with the gouge, including all the periosteum involved by the growth, and excised the parotid tumour. The patient recovered, and has had no further return up to the present time. The growths gave unmistakeable microscopic evidence of their recurrent fibroid nature.



## CHAPTER XIX.

TUMOURS OF THE UPPER JAW—(*continued*).*Myeloid and Vascular Tumours.*

*Myeloid Tumours* are found in the upper as well as in the lower jaw, in which latter position the specimen first described by Mr. Paget arose. The occurrence of myeloid cells in specimens of epulis has been already referred to, and it might naturally be expected therefore that the same characters might be discovered in tumours of the jaw. In fact Dr. Eugène Nélaton, in a valuable treatise, published in 1860, "*Des Tumeurs à Myéloplaxes*," says, "*la siége d'élection des tumeurs à myéloplaxes est, sans contredit, dans les os maxillaires, particulièrement au niveau de leur bord alvéolaire*," and supports his statement by quoting twenty-nine cases of the disease in this situation.

In order to avoid the confusion which has arisen between the so-called myeloid or fibro-plastic tumours of Lebert, and the tumours with large myeloid cells described by Paget and Robin, Dr. E. Nélaton proposes to use the term "*myeloplaxic*" for the latter class, but the word "*myeloid*" is now so fully established, in England at least, that it would only lead to confusion to attempt to alter it.

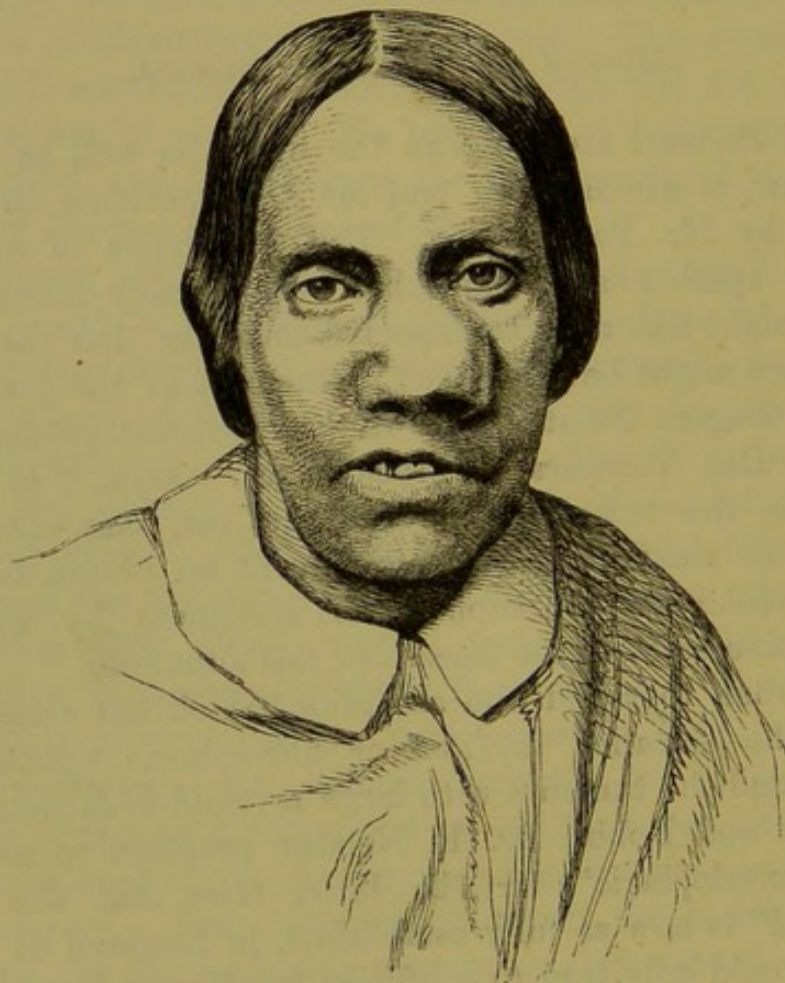
The diagnosis of myeloid tumours of the jaw is by no means easy, since the bone is slowly expanded, much as it would be by a cyst, or by any benign tumour. If the disease originate on the exterior of the bone, or when springing from the interior, if sufficient absorption of the bone have taken place to allow the tumour to appear beneath the mucous membrane, the characteristic dark maroon colour of the tumour may be perceived. Cysts occasionally form in the substance



of a myeloid tumour, and an exploratory puncture of these may yield fluid in which the characteristic myeloid cells may be discovered microscopically.

Myeloid disease occurs mostly before the age of twenty-five. Mr. Paget ("Surgical Pathology," p. 524) quotes two cases of Sir William Lawrence's, occurring in the upper jaws of women, of twenty-one and twenty-two years of age,

FIG. 106.



the latter of which will be quoted in the Appendix (Case XIX.), since it illustrates extremely well the recurrence of myeloid growths (of which there can be no question), and also the very curious fact that a tumour on the opposite side to that removed, and which presented appearances exactly corresponding to it, spontaneously subsided.

Fig. 106 shows a patient from whom Mr. Canton removed a myeloid tumour in 1864. She was thirty-five years old,



and the tumour appeared to have followed a blow. It had been twice removed before she came under Mr. Canton's care, and that gentleman successfully removed the left superior maxilla with the tumour, a portion of which hung down into the pharynx. The tumour was brought before the Pathological Society of London, in December, 1865, and the following is the description of the tumour, given by Messrs. Bryant and Adams, to whom the specimen was referred:—"The parts placed in our hands for examination consisted of the left superior maxillary bone, including its orbital plate, from the inferior surface of which appeared to grow a large tumour, which filled the cavity of the antrum, and projected forwards and inwards into the nasal cavity. There was also a second and loose portion, the size of a walnut, which appeared to have been broken off during the operation, and was said to have projected posteriorly towards the pharynx. The external wall of the antrum was not expanded so fully as is usually found in tumours of the antrum. The tumour, which had been some time in spirit, was of a firm fibrous nature, and irregularly lobulated, and it had a dense capsule. On section, the structure presented a large amount of fibrous tissue, arranged in a curvilinear form, intermixed with other tissue not easily broken up. Microscopically examined, the tumour consisted of an abundance of fibrous tissue, which formed the stroma, containing in its meshes innumerable cells, generally of a circular or ovoid form, varying from two to three diameters of a blood-corpuscle, and some of a still larger size. The cells were all nucleated, usually containing several nuclei, and frequently presenting a granular appearance. Large compound cells were abundant in the posterior and softer lobe of the tumour, and a few elongated cells were seen amongst the fibrous tissue. These large compound cells presented very much the appearance of the polynucleated cells met with in myeloid tumours."—*Transactions of the Pathological Society*, xvii.

Mr. Canton has obliged me with the portrait and history of a case of still more marked myeloid disease of the upper



jaw, which has been more recently under his care. The patient was forty-six years of age, which is decidedly advanced for the disease, and the tumour grew with unusual rapidity. Mr. Canton removed the jaw in Dec. 1866, and I had the opportunity of seeing the patient in Jan. 1867, when he was quite well, but had still a small fistulous opening on the face. Dr. Tonge carefully examined the tumour (which is preserved in the Museum of Charing Cross Hospital), and has kindly furnished me with the following able report upon it and upon the microscopic appearances it presented:—"The tumour was about the size and shape of a large hen's egg, that had been flattened slightly in the transverse direction, and measured (after being in moderately strong spirit for some days) about two and three-quarter inches in length, from one and three-quarters to two inches transversely, and about one and a half inch in thickness. It was of firm consistence throughout, and on section presented a whitish appearance, with a small pink patch or two, and a whitish, creamy-looking juice could be scraped from the cut surface. The microscopical appearances of a portion of a thin section of the tumour, that had been preserved in glycerine and coloured with carmine, are represented in the accompanying drawing, which was taken with the aid of the camera lucida. The fibrous element was much less abundant than the cellular, and consisted of white fibrous tissue, with numerous fine curling fibres of yellow elastic tissue, and many small oval and rounded nuclei were imbedded in the fibrous structure. The greater portion of the tumour seemed to be composed of cells. These were mostly of an irregularly-rounded form, often with pointed processes, and some shuttle-shaped and spindle-shaped, of a somewhat trapezoidal form, were not uncommon, while a few cells presented the character of those distinctive of myeloid tumours. All the cells contained one, and often two, very large and generally oval nuclei, with one, two, or three nucleoli, and a variable number of oil globules. The myeloid cells observed were of irregular outline, and contained from three to five nuclei, with single or double nucleoli—one



very large cell (not represented in the drawing) contained six nuclei.

"These cells were not very numerous, but appeared sufficiently so to justify the application of 'myeloid' to the tumour, though, to the naked eye, and on a superficial microscopical examination, it presented many of the appearances of cancer."

*Vascular Tumours* of a non-malignant character, but closely resembling erectile tumours in other parts of the body, have been occasionally met with in the upper jaw. Mr. Liston successfully removed a specimen of the kind in 1841, which is preserved in University College, from a young man aged twenty-one. The tumour was of more than three years' growth, and projected into the nares and pharynx, forming a tumour beneath the cheek; but the preparation shows that the alveolus and all the lower and anterior part of the maxilla were not involved in the disease. The tumour was not painful, but frequent hæmorrhages had taken place from its surface. The case will be found in the *Lancet*, Oct. 9th, 1841. Mr. Liston removed the jaw, cutting completely beyond the disease, and remarks concerning it (*Lancet*, Oct. 26th, 1844), "It was a curious-looking tumour, and it struck me that it was of a fibrous character, not growing from the jaw, but involving it. Mr. Marshall some months afterwards discovered that the whole mass was erectile. . . . You will see that it is as complete and beautiful a specimen of an erectile tumour as any that I have yet shown you."

M. Gensoul also met with an erectile tumour springing from the antrum, in one of the cases in which he successfully extirpated the upper jaw.

Mr. Butcher, of Dublin, has described ("Operative and Conservative Surgery," p. 249) a case of successful removal of the right upper jaw, on account of a large fibro-vascular tumour springing from the antrum of a lad of sixteen. Nine months before admission, he had had a polypoid growth removed from the nostril giving rise to severe hæmorrhage. It reappeared in a month, and increased, so that when he came under Mr. Butcher's care there was considerable deformity



of the face, and the nostril was filled with the tumour, which projected behind the soft palate. After the boy had been in hospital a few days, the tumour suddenly increased with great rapidity, and interfered so much with respiration and deglutition that Mr. Butcher at once removed the jaw, and the patient made a good recovery.

The following is the description given of the tumour:—  
“The structure of the tumour presented many interesting peculiarities. Its attachment and origin sprang from the outer part of the antrum. Not only was it incorporated with the lining membrane, but it likewise implicated the osseous wall. The surface from which it sprang in the recent state was softened, vascular, and pulpy; the upper surface of the tumour was lobulated where it encroached upon the orbit, and elevated its floor; the lobules were of various sizes—some very small, but each consistent in structure, and invested by a dense capsule in a similar way to the larger masses of the growth. The entire tumour was remarkable for its great vascularity, which was more particularly confined to the posterior and upper surface; while on section the structure was dense by comparison, pale, eminently firm, and partaking of a fibrous, matted nature. This integral arrangement was very manifest under close examination with the microscope, and cleared away the suspicion which, on superficial inspection, might have been created of encephaloid disease being the synonyme most applicable to the growth. There was a total absence of all nucleated cells, either globular, caudate, or spindle-shaped; and, above all, the section of any part only yielded a minute quantity of serum or blood on pressure, and not the true succus of cancerous tissue. The tumour, though destructive to the neighbouring parts by pressure, yet did not appropriate or incorporate them in its structure. This peculiarity of non-malignant growths was strikingly manifest in the present instance; for by pressure, producing interstitial absorption, the cancellated structure of the ethmoid and inferior spongy bones was attenuated and removed; and by the same process the vomer was detached from its position—a



few shreds of it being spared and hanging loosely on the sinistral surface of the tumour. The vascularity of the growth, though remarkable on the surface, yet did not permeate its texture; hence a tendency to degenerate by assumed depravity of action was lessened. Again, the vascularity of the surface will readily account for the repeated and profuse losses of blood—a point of great practical value, because placing the surgeon on his guard as to the importance which should be attached to those repeated losses in constituting a diagnostic feature confirmatory of malignant disease.”



## CHAPTER XX.

TUMOURS OF THE UPPER JAW—(*continued*).*Cartilaginous and Osseous Tumours.*

*Cartilaginous Tumours* of the upper jaw are of uncommon occurrence, but the jaw may become involved in cartilaginous tumours springing from other bones of the face. Of this there is an example in St. George's Hospital Museum (XVII. 66), taken from a young woman who, seven years before her death, began to suffer from soft elastic tumours on the inner side of the orbits. Two years after, the right maxillary bone was fuller below the orbit than the left, and the right half of the bony palate was larger and more depressed than the other; but in neither of these parts was there any softening. Gradually the eyeballs were protruded, and the sight was lost. Two years later, it was noticed that the superior maxillary bones projected nearly an inch beyond the inferior, so that she had some difficulty in masticating. A portrait of this patient is preserved in St. George's Museum. The tumour was found to project into the cranium, the orbits, the antra, and the nasal, zygomatic, and pterygo-maxillary fossæ. All the fossæ were quite filled up by the growth, and the bones of the face and orbits extensively absorbed. The hard palate was pressed downwards, so that the teeth on the two sides deviated from their natural line, and the left central incisor crossed that of the right side. Microscopical examination of the tumour showed it to be composed principally of cartilage.

In the Museum of St. Bartholomew's Hospital is another post-mortem specimen of cartilaginous tumour of the face,



from a lad of sixteen (XXXV. 47), occupying the situation of the superior maxillary bones, which are completely absorbed. Above, the tumour has extended through the left side of the base of the skull into its cavity, where it forms a large projection in the situation of the anterior lobes of the cerebrum; below, it is united to the soft palate; in front, it protrudes and distends the left nostril, and has caused the ulceration of a part of the integuments of the face. The outer surface of the tumour is nodulated, its interior, shown by the section, is formed of close-set nodules and masses of cartilage, partially and irregularly ossified, and in some parts intersected by layers of a softer, probably fibrous tissue. A portion of its external surface projecting below the left nostril has sloughed. This case is drawn in Mr. Stanley's illustrations to his work on "Diseases of the Bones;" and both it and the preceding preparation illustrate very well the tendency of cartilaginous tumours to invade all the surrounding structures, and fill the several cavities.

Mr. Paget, in his "Surgical Pathology," refers to a solitary specimen of enchondroma of the upper jaw alone, in Guy's Hospital Museum, the history of which is given by Mr. Morgan, in the *Guy's Hospital Reports*, vol. i., under the name of "exostosis"—a term very vaguely applied by Sir Astley Cooper and other pathologists of that date. The patient was a man, aged twenty-four, and the tumour occupied the right superior maxilla, and was of nine years' growth. The tumour was large, and the deformity very great. Mr. Morgan removed it, and the patient made a good recovery; but the tumour returned, and the patient died seven years after. In *Guy's Hospital Reports* for 1842, is a picture of a cast taken of this patient immediately after his death, showing an enormous tumour of the right side of the face, having every external appearance of enchondroma. The description of the first tumour removed is as follows:—"A section of the tumour proved that it was composed of an outer hard, thin shell of bone, completely enclosing a morbid growth of spongy cancellated structure, devoid of all appearance of carcinomatous or fungous disease."



Probably the largest enchondroma of the upper jaw ever submitted to operation is one recorded by Mr. O'Shaughnessy, in his essay on Diseases of the Jaws (1844). The patient was a Hindoo, aged twenty-one, who had a tumour of the upper jaw, of a year's growth (?) which had attained an enormous size, as shown in the illustrations of the work in question, looking nearly as big as the patient's head. Mr. O'Shaughnessy successfully removed the tumour, which weighed four pounds, and was nearly globular in form, having at its inferior surface a deep groove into which the lower jaw sank. On section it proved to be dense fibro-cartilaginous structure, surrounded by a thin shell of bone in the greater part of its extent. The case (XX.) will be found in detail in the Appendix.

These cases will serve to illustrate the leading features with regard to enchondroma. The disease appears ordinarily early in life, springing from the surface of the bone, or from the antrum, and then making steady progress either externally, as in the last-mentioned case, or internally, as in the former ones. It produces absorption of the bone of the maxillæ in its progress, and protrudes beneath the skin, which, however, it rarely, if ever, involves. Its rate of increase is ordinarily slow, and there must, I fancy, be some error in the statement of Mr. O'Shaughnessy's patient, since it is difficult to imagine that a growth of that enormous size could have been produced in one year. In the early stage, the enchondromatous tumour may possibly be got rid of by absorbent applications; thus, Mr. Stanley (p. 147) mentions the case of a female, aged twenty-eight, who had a round tumour of the size of a hazel-nut on the front of the maxilla, which had been growing some months. This was ascertained, by the introduction of a needle, to be composed of cartilage with particles of bone dispersed through it. Under the local use of iodine two-thirds of the growth disappeared in the course of a few weeks.

Such a result cannot be hoped for when the tumour has attained any size, but provided it is still confined to the maxilla, a cartilaginous tumour is a favourable one for re-



moval, owing to its solidity and rounded form, and the ease with which it is isolated. The first case in which M. Gensoul removed the superior maxilla was for a tumour of this kind. Ordinarily perfect immunity from return is obtained, provided the whole disease has been extirpated, but Sir William Fergusson has recorded (*Pathological Transactions*, vol. i.) a case of recurrence of a cartilaginous growth.

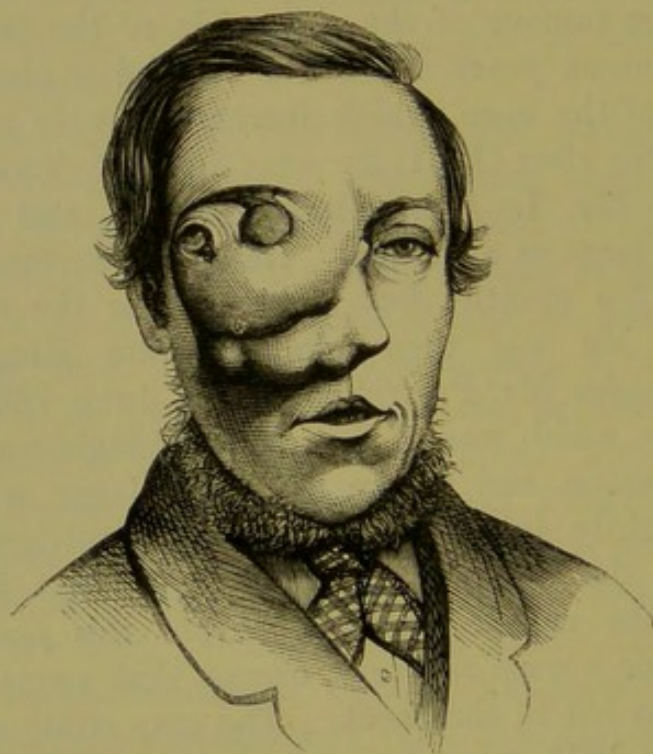A remarkable case of recurrent cartilaginous tumour of the face, originating in the upper jaw, has also recently been under my own care, of which the following are the particulars:—The patient, aged thirty-four, was admitted into University College Hospital on the 1st of January, 1868, with a large tumour of the right side of the face. When about seventeen years of age he noticed a pimple on the right side of the nose, which increased pretty rapidly, and three months after (1851) he went into St. Thomas's Hospital, when Mr. Le Gros Clark operated, and removed a tumour as large as a walnut. He quite recovered, and was well for a few months, but within a year the tumour had returned. He was then admitted into King's College Hospital, under Mr. Partridge, who, in June, 1852, removed the tumour, which was of an osteo-cartilaginous character, oblong in shape, and of the size of a large walnut, projecting slightly into the antrum, and involving the nasal process of the superior maxillary bone, but in no way involving the mouth or orbit. From this operation the patient made a good recovery, except that a small fistulous opening was left in the cheek. The man continued in good health until 1857, when he went to America, and soon after arriving there he found the tumour beginning to appear again, and in 1860 Professor Gunn operated at Anne Harbour, in the State of Michigan, and removed the entire right upper jaw, with the greater part of the tumour, but left a portion at the inner side of the orbit. This soon began to grow again rapidly, and the tumour projected on the face. The surgeons at Maple-rapids, where he lived, wanted to operate again, but the patient declined, and returned to England in 1865. Soon after this an abscess formed in the



upper part of the tumour, which was lanced with great relief, but the incision thus made has never closed, owing to the stretching of the skin by the tumour.

The patient's appearance on admission was most unsightly (fig. 107), the right side of the face being greatly disfigured by a large tumour, by which the eye was thrust completely aside, but without loss of vision. Immediately to the inner side of the eye was an open granulating sore of the size of a florin, the result of the incision for the evacuation of matter already referred to. The tumour appeared externally to con-

FIG. 107.



sist of two portions, separated by a horizontal sulcus, at the bottom of which the fistulous opening resulting from the second operation was still visible. The upper and more prominent portion had invaded the orbit, reaching to its upper border, and extending beyond the middle line of the nose. A small portion of this had within the previous two months projected through the left nasal bone. The lower portion of the tumour involved the ala of the nose and adjacent portion of the cheek, both of which were much dis-



torted; on a small projecting portion of this the skin was adherent. Both nostrils were completely blocked, and had been so for months. Within the mouth it was seen that the whole of the right side of the hard palate had been removed; and in its place there was a smooth, red, oval mass, coming down to the level of the teeth of the opposite side. The scars in the middle line of the lip and on the cheek, resulting from former operations, were still visible. The tumour was solid and not tender to the touch, the most prominent point being apparently osseous. There was no enlargement of the glands in the neck or elsewhere, and the man appeared in good health. The tumour had made decided progress within the previous few months, and he was anxious to have it removed, to which, after a consultation with my colleagues, I agreed.

On Jan. 8th, under chloroform, I made a curved incision below the eye to the side of the nose, from the extremity of which a vertical incision was carried down the face and round the ala of the nose; and the lip was divided in the cicatrix of a former operation. The flap was then dissected back, and with it a hard prominent nodule of bone, which became detached from the bulk of the tumour. The tumour being thus exposed, I proceeded to enucleate it with the fingers, and by successive efforts removed in this way the upper part of the growth. The portion projecting into the mouth was found to be held by a firm band of tissue in the position of the gum, and after dividing this I was able to tear out the growth, and also a portion projecting through the posterior nares into the pharynx. The wound having been well sponged out and the hæmorrhage having abated, the portion at the inner side of the orbit was removed, and was found to project into the frontal sinuses, which (particularly the right) were considerably expanded. With one of Langenbeck's palate spatulæ I carefully cleared these out, scraping the walls, and then introduced a pledget of lint covered with a paste of chloride of zinc (to which a string was attached), in order to destroy any remaining portion. This was the only part from which the growth appeared to have arisen,



the remainder of the huge cavity left by the removal of the growth being smooth and healthy. The septum narium was found to be completely pushed over to the left, and to have been destroyed at the upper part by a projecting lobule of the growth which had pushed through the nasal bone. The ala of the nose included a small portion of the growth, which was removed, and also the bony nodule attached to the flap, the upper corner of which, being very thin and closely involved in the growth, was cut off. The wound was sponged out with solution of chloride of zinc, and, all hæmorrhage having ceased without the application of any ligatures, the lip was brought together with hare-lip pins, and the remainder of the wound with wire sutures. The edges of the gap caused by the opening of an abscess some months back were brought together, but finding that this prevented the patient closing his eye, I subsequently removed these sutures. Collodion was painted over the wound, and the patient, who had a good pulse, was carried to bed.

The patient made an uninterruptedly good recovery from the operation. The wound was kept clean by syringing with Condyl's fluid; the plug of lint in the frontal sinus was removed on the third day after the operation, and the sutures on the eighth day, the incision being well united. The right eye, which had been much displaced, began gradually to recover its proper position. A fortnight after the operation the patient was up and about the ward, and on Feb. 1st he went out for a walk. On Sunday, Feb. 2nd, he again went out, the house-surgeon not being aware that there was a bitter east wind. This he felt a good deal, and the next day his face was noticed to be swollen and red. This had increased on the following day, when I saw him, and it was evident that an attack of erysipelas was coming on. The patient was at once placed in a separate ward, and active treatment adopted. The erysipelas spread, however, and affected the throat, so that on Feb. 7th he was able to swallow but little, and was becoming rapidly exhausted. By the use of the stomach-pump, however, nourishment was introduced into the stomach, and he rallied for a day or two.



Symptoms of pyæmia, however, now manifested themselves, and the patient rapidly lost ground, and, after lingering for a week, died on Feb. 17th.

At the post-mortem examination, the incisions in the face were cicatrized; but the site of the tumour was granulating, and encrusted with mucus in parts. On removing the brain, it and the membranes were found perfectly healthy; but the plate of bone between the frontal sinus and the cranial cavity was so thin that it broke in the removal of the brain. There was no appearance of any remnant of tumour either in the frontal sinus or elsewhere, the walls of the large cavity left by its removal being healthy. In the thorax there was abundant evidence of pyæmia, the lungs being filled with pyæmic abscesses. The tumour weighed nine ounces, and consisted of a loose cartilaginous material enclosed in a bony cyst, from which spicula were sent into the interior. At two points, and particularly at the most prominent portion of the tumour, the bone was of considerable thickness. The tumour was exhibited at the Pathological Society, and was referred to a committee of investigation, which pronounced it to be an enchondroma undergoing ossification, and presented the following report upon it:—"The portions examined consisted of a thin incomplete bony shell, coated by a fibrous membrane, and enclosing a soft tissue penetrated by bony spicula. The external membrane is composed of wavy bundles of common connective tissue, interwoven in planes generally parallel to the surface of the underlying bone, and enclosing groups of fat cells. Beneath this outer stratum there is a deeper layer, immediately resting upon the bone, composed chiefly of small, closely-packed cells, evidently the equivalent of the osteogenic layer of periosteum, and ministering as this does to the growth of the bony shell. This latter is lamellated parallel to its outer surface, and it has a true osseous structure. The enclosed soft tissue consists in greatest part of cartilage, the characters of which, though varying considerably, are everywhere unmistakeable. The cartilage capsules in some situations are very large, and so crowded as nearly



to exclude the intercellular substance, approximating to a colloid structure, while in other parts the two tissues exist in nearly equal quantities, and here many of the capsules exhibit the concentric rings indicative of successive layers, which are not uncommonly seen in old and slow-growing enchondromata. The tumour belongs no doubt to the category of enchondromata."

Enchondroma is liable to two forms of transformation, the fibrous and the osseous. In many cases of enchondroma a certain amount of fibrous tissue is found mixed with the cartilage, but in some cases, particularly those of slow growth and of long standing, the fibrous has, to the naked eye, almost replaced the cartilaginous element. Of this an enchondromatous tumour, removed by Mr. Square of Plymouth, in November, 1866, and kindly given me by that gentleman, is an excellent example.

The tumour was of the size of an orange, and occupied the right superior maxilla of a woman, aged forty-seven. It had been growing ten years, and Mr. Square successfully removed it. The preparation now in the Museum of the College of Surgeons (1046 A), and of which a section has been made, shows a surface closely resembling a fibrous tumour, but in which cartilage cells are readily found under the microscope. The preparation shows a deep groove in the buccal surface of the tumour caused by the teeth of the lower jaw.

The ossific deposit, beginning at several separate points, which is not unfrequently found in connexion with enchondromata of other parts of the body, may take place in enchondroma of the upper jaw. A recent and very excellent example of this has been published by Mr. Maurice Collis of Dublin (*Dublin Quarterly Journal*, Aug. 1867), and the appearance of the patient is well shown in the lithographic illustrations which accompany that paper. The patient was fifty years of age, and the disease dated from his fourteenth year. It grew slowly at first, but latterly had increased with considerable rapidity. The tumour was firm and hard, but painless until recently, when brow-ague was complained



of. The sight of the left eye was lost, the left nostril occluded, and hearing on that side somewhat dull. The tumour had expanded the cheek, pushed up the floor of the orbit, and depressed the hard palate. Mr. Collis successfully removed the growth, and the patient made a rapid recovery. The following is Mr. Collis's description of the tumour:—

“Much of its posterior part was removed piecemeal, but what remained was composed of two kinds of bone. The centre, which may be supposed to correspond to the antrum, is remarkably hard and close—white, with fine concentric rings, like ivory, which it also resembled not a little in its hardness. All round this, except above, lay a much larger mass of bone, distinctly and coarsely laminated, softer in texture, and enveloped in a very thin and strong layer of hard bone. This external mass was divided into two by a fissure which ran in an oblique curve upwards and outwards into a very small, irregular space, filled with a mass of lining membrane, gathered up and jammed together. These two masses evidently corresponded to the middle and inferior spongy bones; and the fissure and cavity represented that portion of the nostril which normally lies between these two bones. The growth commenced in the antrum, filled it, implicated its walls, extended to the spongy bones, developed itself layer over layer, until the entire nasal cavity was filled. It then continued to grow, producing the immense deformity already described. Originally it had probably been an enchondroma, but as years advanced it ossified, beginning from the centre. The outer layers of the new growth were probably the most recent, as they contained some fragments of imperfect or degenerate cartilage. The whole was enclosed within a real bony layer, derived from the proper tissue of the spongy bones and of the walls of the antrum.”

In St. Thomas's Hospital Museum is a section of a skull (C. 196), showing a large tumour in connexion with the superior maxilla, which appears to be an ossified enchondroma. Superiorly the growth encroaches considerably upon the cavity of the orbit, and posteriorly it fills nearly the



whole of the zygomatic fossa, extending as far back as the glenoid cavity. On the inner side it has involved the upper part of the nasal and the lower part of the sphenoidal sinuses; whilst below it projects through the hard palate into the cavity of the mouth.

During the winter session of 1867-68, Mr. Beck, the Demonstrator of Anatomy at University College, found in the antrum of a subject an osseous mass filling up the cavity and attached to its outer wall, but giving rise to no external tumour either on the face or in the nares. On section the bone was white and dense, and upon microscopic examination Mr. Bruce considered it to be an instance of ossified enchondroma, the calcareous matter being more granular than in ordinary osseous growths, and the lacunæ and canaliculi imperfectly developed. The preparation is in my possession, and will serve to elucidate some points in connexion with osseous tumours to be subsequently referred to.

*Osseous Tumours.*—The simplest form of osseous tumour of the upper jaw is an hypertrophy of the whole or of some portion of the bone. A case of Sir William Fergusson's has already been referred to (p. 183), in which this result was due to the presence of a tooth imbedded in the jaw; but the same thing may happen without obvious cause. The tumour is slow of growth and painless, and upon removal shows no deviation from the ordinary structure of healthy bone. An example occurring in a girl of sixteen, from whom Sir William Fergusson successfully removed a growth of the kind, will be found in the *Lancet*, July 26th, 1856.

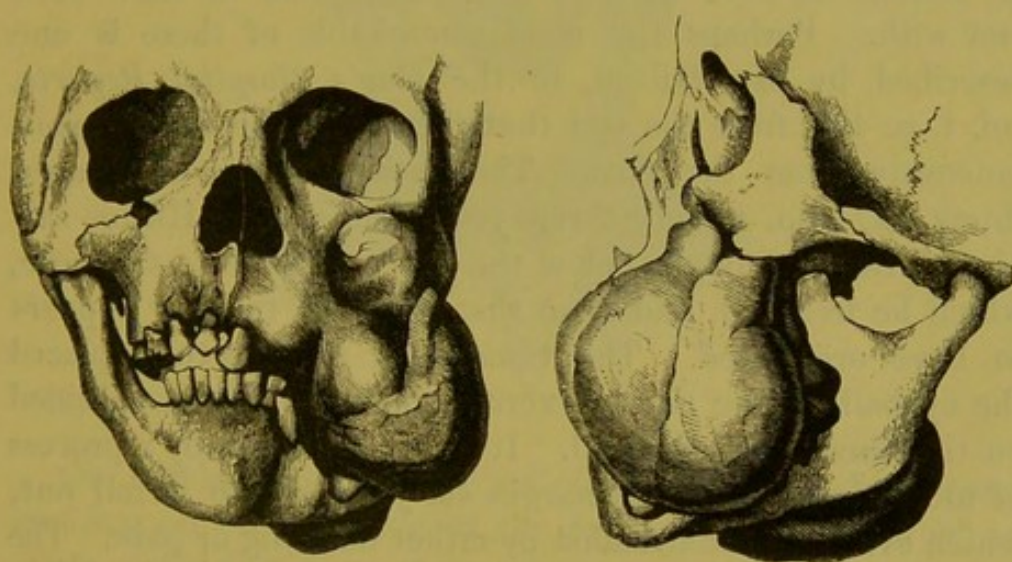
In the Museum of Charing Cross Hospital is a remarkable specimen of osseous tumour of the upper jaw, removed by Mr. Hancock. The whole jaw seems expanded anteriorly, and the outer compact plate is perfect, except at the part immediately below the infra-orbital foramen, where it has given way, and the cancellous structure forming the interior of the tumour is seen. Mr. Hancock, in referring to this specimen (*Lancet*, Jan. 13th, 1855), specially calls attention to the fact that the bone yielded to pressure to such an extent as to lead to some doubt as to its osseous nature.



A still more remarkable specimen of the same kind is preserved in the Musée Dupuytren at Paris, which is shown in figs. 108 and 109 from the "*Traité de Pathologie Externe*," by M. Vidal de Cassis. It is connected with the left superior maxilla, being limited internally by the intermaxillary suture, behind by the pterygoid process, above and externally by the malar bone. The tumour encroaches considerably upon the cavity of the mouth, and reaches back as far as the front of the spine. Its form is bilobed, and in the deep sulcus between the lobes can be seen a molar tooth. All the other teeth of the jaw have disappeared,

FIG. 108.

FIG. 109.



and there is no trace of their alveoli. The left orbit and nasal fossa are not sensibly diminished in size, but the cavity of the mouth is almost entirely occupied by the posterior lobe of the tumour. The lower jaw has, in this case, undergone several remarkable alterations. It must at first have pressed upon the growth and produced the deep sulcus between the lobes, but in its turn the tumour has reacted upon the lower jaw with the following effect:—It has caused a double luxation of the jaw, the left condyle resting against the root of the zygoma and the glenoid cavity being filled with soft material. The teeth of the left side of the lower jaw have disappeared, and absorption of part of the coronoid



process and the whole of the alveolus has taken place, so that only the base of this part of the bone is left. The outer surface of the tumour is smooth and presents numerous vascular grooves of good size; at many points it is perforated with holes. The vascularity of the other bones of the face does not appear augmented.

In the Museum of Netley Hospital, which includes the preparations formerly at Fort Pitt, Chatham, there is a specimen of large osseous tumour of the upper jaw closely resembling that last described, but of smaller size.

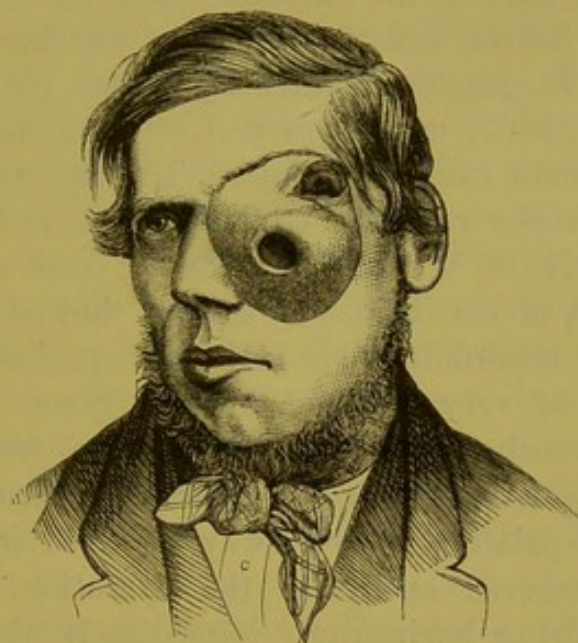
Besides this form of bony tumour, due apparently to an increase of the cancellous structure of the bone, specimens of tumour as hard as ivory have from time to time been met with. Perhaps the most remarkable of these is one described by Mr. Hilton, in the *Guy's Hospital Reports*, vol. i. p. 493, from the fact that the tumour separated spontaneously from the face. The patient was a man, aged thirty-six, who, twenty-three years before Mr. Hilton saw him, noticed a pimple below the left eye, close to the nose, which he irritated, and from that spot the tumour appears to have originated. The tumour in its growth displaced the eyeball, giving rise to excruciating pain, which subsided on the bursting of the ball. It began to loosen by a process of ulceration around its margin six years before it fell out, which event was unattended by either bleeding or pain. The tumour weighed  $14\frac{3}{4}$  ounces. It was tuberculated externally, and an irregular cavity existed at the posterior part. A section presented a very hard polished surface resembling ivory, and exhibited lines in concentric curves enlarging as they were traced from the posterior part. The huge cavity left by the tumour was bounded below by the floor of the nose and antrum, above by the frontal and ethmoid bones, internally by the septum nasi, and externally by the orbit, which had been considerably encroached upon by the tumour.

A case in many respects resembling Mr. Hilton's case was recently under the care of Sir William Fergusson, whom I had the opportunity of seeing operate upon it.



The patient was a young man of twenty-one, who had first noticed the swelling on the left side of the face twelve years before. It grew for six or seven years, and then remained stationary. Two years before he had consulted a quack, who attempted to destroy the growth with caustic, and produced the large hole seen in the lower part of the tumour.

FIG. 110.



On admission into King's College Hospital there was a swelling on the left side of the face about the size of an apple, extending from the eyebrow to a line less than one inch above the mouth. Internally, it encroached upon the nose, displacing it a little, the nasal bone being pushed forwards and the left ala flattened on the columna; the mass was felt by the finger in the mouth above the gums. The nostril on the same side was perfectly blocked up, the patient being totally unable to breathe through it. The right nostril, however, was quite free. Outwards, the tumour extended to the angle of the orbit; the arch was, however, not displaced, but the tumour extended slightly above it. The floor of the orbit seemed displaced. The eyeball was seen imbedded in the most prominent and central part of the tumour, and removed more than an inch from its natural position in the



orbit, which was entirely blocked up by the mass. There was no extension into the pharynx. The tumour was everywhere hard, with a slight blush over the surface. In its centre was a round opening, produced by the caustic applied two years previously, of about the size of a shilling, deep, and displaying on its floor black necrosed bone, and discharging pus. The patient said he had suffered neither headache nor pain in the tumour since its commencement twelve years before, and that his sight had been unaffected. Sir William Fergusson operated upon this patient on November 30th, 1867, and succeeded in removing the whole of the prominent tumour, weighing  $10\frac{1}{2}$  oz., which consisted in all its anterior part of nodulated bone as hard as ivory, and posteriorly, of very dense ordinary bone mixed with a small amount of cartilage. A section showed an ivory-like mass closely resembling Mr. Hilton's specimen, connected with a mass of very much condensed bone. The tumour sprang apparently, as in the former case, from the upper part of the maxilla, and had invaded the antrum, orbit, and nostril. The palate was in no way involved in the growth, and was preserved entire at the operation, Sir William Fergusson sawing horizontally immediately above it. Unfortunately the patient sank rather suddenly from inflammation of the lungs on the fourth day.

At the post-mortem examination, after removal of the brain, it was found that the affection of the bone involved the base of the skull, there being a projection of the size of a hazel-nut from the sphenoid near the optic foramen. This involved the foramen and extended along the sphenoidal fissure, the optic, third, and fourth nerves passing through the condensed bone of which it was composed. The brain was unaffected (vide *Lancet*, Feb. 8th, 1868).

This specimen was exhibited to the Pathological Society of London and was reported upon by a committee. The report of this committee, drawn up by Mr. Hulke, which will be found *in extenso* in vol. xix. of the *Pathological Transactions*, expresses an opinion that "the hard part of the tumour has been directly formed by the exogenous



growth of successive layers of dense bony tissue under the periosteum, which opinion is confirmed by the absence from the hard tissue of the regular Haversian system so characteristic of secondary bone."

The reporters "did not find anywhere along the meeting line of the hard and spongy bony tissues anything resembling cartilage, and are disposed to regard the splitting of the tumour along this line as the result of violence, the place of the separation being determined by the different resistances of the two kinds of bony tissue. The intrusion of masses of the spongy tissue with the hard along the meeting line, and the occurrence of minute specks of spongy tissue in the midst of the hard tissue, suggest the direct continuity of the two tissues, and the microscopic appearances prove not only that this actually occurs, but also that the spongy tissue is formed by the rarefaction of the hard. For near its deep limits absorption spaces begin to appear in the hard tissue, and these, increasing in number and size and coalescing, produce large medullary spaces and cancelli. These are filled with a soft medulla carrying blood-vessels, and their walls consist of remnants of the hard primary bone and of new lamellæ formed from the young medulla."

It seems to me difficult to imagine that the condensed bone which extended into the skull, could at any time have been of an ivory nature, as this report implies. Presuming the ivory-like growth to have been deposited from the periosteum on the surface of the original maxilla, it is conceivable that the same action which led to this result may have led to a thickening and induration of the subjacent bone, which, in process of years, by simple extension, may have reached the sphenoid bone.

In both these cases the tumour appears to have taken its origin in the upper wall of the antrum and to have grown forwards; but tumours of the same kind have been found completely within the superior maxilla, the anterior wall of which has been merely expanded by the growth behind it. Of this two cases reported within the last few years by M. Michon and Dr. Duka are good examples, and they will



be elucidated by reference to a case recorded by M. Demarquay.

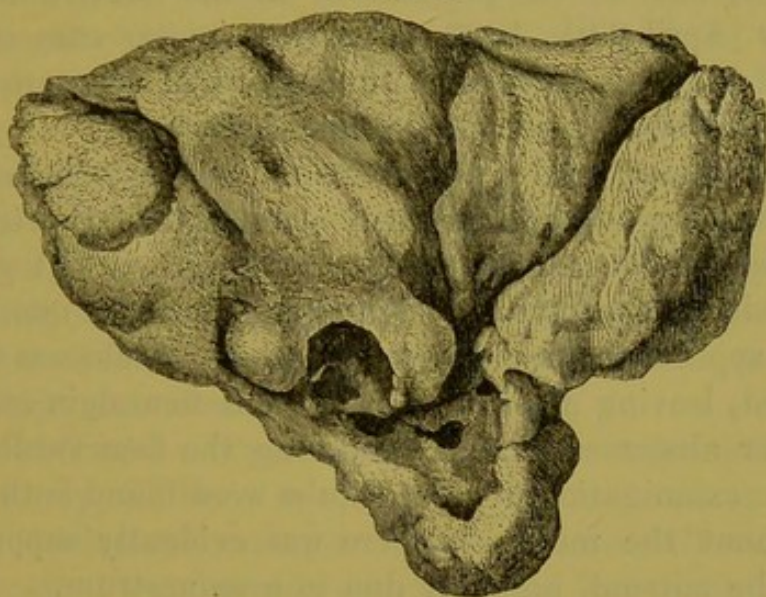
M. Michon's case is reported in the 2nd volume of the *Mémoires de la Société de Chirurgie de Paris* (1851); his patient being a man of nineteen, who had a large tumour of the right upper jaw, which had existed for three years. The tumour was rounded and hard, and had pushed up the eyeball considerably, and closed the right nostril, but the palate was not affected. M. Michon operated in Jan. 1850, by turning up a triangular flap of skin. He had intended to have removed the entire upper jaw, but having with considerable difficulty removed the front wall of the antrum, he found the tumour lying in the cavity, and connected only with the floor of the orbit and the vomer. After an operation extending over an hour and six minutes, and without anæsthetics, the tumour was at length removed. The whole of the vomer and a part of the maxilla came away with the tumour, which was a flattened sphere, or somewhat resembled a heart in shape. It weighed 120 grammes (1800 grains), and was deeply lobulated, particularly on the posterior aspect. A section showed concentric markings upon a surface of ivory, and microscopic examination demonstrated the lacunæ and canaliculi of true bone. The patient made a good recovery.

Dr. Duka's case is reported in the *Pathological Society's Transactions*, vol. xvii., and occurred in a female native of Bengal, aged twenty-six, and on the right side of the face, which was not much deformed. There was a discharge from the right nostril, which was obstructed, and on examination a hard tumour was found within it, *which was moveable*, but could not be extracted, and which had existed six years. Dr. Duka failing to extract the tumour by laying open the nostril, resorted to the somewhat curious proceeding of cutting a wedge out of the hard palate, and thus, after an operation of three quarters of an hour without chloroform, succeeded in removing the growth. The patient recovered. The tumour is preserved in St. George's Hospital Museum, and is figured in the *Pathological Transactions*, from



which the accompanying illustration (fig. 111), is by permission taken. It has an oblong shape, and is not unlike a middle-sized potato, with depressions and elevations passing irregularly over it. The upper part, which is believed to have been in contact with the cribriform plate of the ethmoid bone, exhibits corresponding delicate depressions, with other deeper sulci in front, behind, and on the sides, probably for the passage of blood-vessels. At the

FIG. 111.



lower surface is a large nipple-like process, smooth throughout. This lay in contact with the palatine process, and it has the same dark appearance as the anterior part of the body which presented at the nostril. At the base of this process is a large hole piercing it quite through, and allowing the tip of the little finger to enter it. In this lacuna was a polypoid mass which contained a nucleus of cartilage round and flat, like a small-sized lentil. It was this nipple-like prominence impinging upon the nasal process which prevented the removal of the tumour without interfering with the superior maxillary bone. The whole bony mass, which is of a compact ivory-like character, weighs 1060 grains: its long diameter is nearly three inches, the short one an inch and two lines, and the longest circumference seven inches. The microscope gives evidence of structure



closely resembling that of M. Michon's tumour. There are no distinct Haversian systems, but abundance of lacunæ arranged around vascular canals. In some parts of the tumour the characters are very much those of simple ossified cartilage, clusters of large ossified cells being packed closely together.

This case is remarkable from the fact that the attachment of the tumour had given way, and that it was therefore loose in the antrum. It would have appeared to be unique in this particular, but for the publication in the *Gazette Médicale de Paris* (April 20th, 1867,) of a very similar case of non-adherent exostosis, or osteoid tumour, by M. Demarquay, of which the following are the leading features :—

A gentleman, aged fifty-three, in good health, but who had previously had syphilis, had a swelling of the left side of the face, which had existed for twenty years. It gave no inconvenience except the disfigurement until six months before he applied to M. Demarquay, when an abscess formed and burst, leaving a fistula. After this neuralgia came on, and other abscesses formed, rendering the face swollen and red. On examination, several fistulæ were found both within and without the mouth. There was evidently suppuration within the antrum, probably due to a sequestrum.

At the operation, on Jan. 4th, 1867, it was found impossible to extract the sequestrum, and M. Demarquay therefore removed the entire maxilla, and the patient recovered.

The jaw showed an increase of size and density; the front wall of the sinus was thrown forward, so as to present the segment of a sphere, and was thickened so that its resistance was increased. The posterior part was also enlarged, and had projections upon it, one of which also pushed up the floor of the orbit. There were numerous sinuses in various parts, through which pus escaped.

On section, a white osteo-cartilaginous substance was found filling up the whole cavity of the antrum, but not attached to its walls. In some parts this was of a mere fibrous character, whilst in others it was dense bone. In the centre was a large fragment of bone, of a blackish colour, and



closely resembling a sequestrum. This was surrounded by some smaller portions, and by a cavity containing a quantity of pus, into which the sinuses could be traced. It was impossible to tell from which part of the wall the tumour had sprung.

Here it will be observed that we have apparently an earlier stage of a growth which, if it had continued to increase, would no doubt have developed into a dense osseous tumour, since it consisted in great part of cartilage in which ossification had already partially occurred. Dr. Duka's specimen also had some cartilage mixed with it, and its microscopic appearances showed evidence of ossification of cartilage. The post-mortem specimen of ossified enchondroma within the antrum in my possession, and already referred to (p. 244), shows how slight the attachment of the growth to the wall of the antrum in these cases is.

I think, therefore, it may be concluded that this class of bony tumours depends upon a form of ossification occurring in cartilage or enchondroma.

*Osteoid Cancer.*—Paget under this name includes the cases described by Müller, as examples of "osteoid tumour," and by Stanley as "malignant osseous tumour;" and it will be convenient to quote his description of their pathology:—"The primary tumour consists chiefly of bone, but has on its surface and in the interstices of its osseous parts, an unossified fibrous constituent as firm as fibrous cartilage; after a time similar growths ensue in parts distant from the seat of the first-formed, and not in bones alone, but in the alveolar tissue, serous membranes, lungs, &c."

This is the disease described by Sir Astley Cooper as "exostosis of the medullary membrane."

A specimen, which I believe is one of the disease in question, is in the Museum of the College of Surgeons (3254 a), of which the history with an accompanying drawing is recorded in Mr. Howship's "Surgical Observations." The specimen has been macerated, and the part which remains consists of an oval mass of light cancellous bone, about five inches in its chief diameter, and very slightly connected



with the remaining bones of the face. At its lowest part it preserves somewhat of the form of the alveolar border of the upper jaw, and the incisor, canine, and bicuspid teeth are implanted in it.

The patient was a woman, aged thirty, who died in the Westminster Hospital from hæmorrhage, consequent upon the extraction of some teeth from the tumour in question, which is described as "fleshy," and of a florid red colour where it appeared in the mouth. The tumour had been growing five years. No details are furnished by Mr. Howship as to the post-mortem examination of this patient, but the skull shows a very important feature—a circular portion of the frontal bone just above the right temple, which is thin and perforated by several small apertures, apparently in consequence of the growth of a tumour from the dura mater. There is thus evidence of a secondary growth within the skull; and, taking the history of the case together with the specimen, I am inclined to regard this as an example of osteoid disease.

O. Weber quotes from Tittman (1757) a remarkable case which he considers of the same kind. The tumour was in a youth of fourteen, and had been growing for four years, and finally occupied the entire face. It had displaced the eye, the nose, and the lower jaw, and projected in such a way into the mouth and fauces that the patient died of inanition. The mass weighed six pounds, and on being cut through was quite white and very hard, and had radiating masses of bone interspersed through its substance.



## CHAPTER XXI.

TUMOURS OF THE UPPER JAW—(*continued.*)*Cancerous Tumours.*

*Medullary Cancer.*—The only form of true cancer invading the upper jaw is, in my experience, the medullary or encephaloid, but scirrhus has occasionally been met with, of which preparation 1059 E., removed by Mr. Coates, of Salisbury, is believed to be a specimen. In the majority of cases the disease begins in the antrum, for the protruding masses which are found in the nose or mouth are but secondary to a formation within that cavity. Mr. Hancock, in a paper read before the Medical Society of London (*vide Lancet*, 1855, p. 4), put forward the view that medullary disease does not commence in the antrum, but in the body of the sphenoid bone, and other bones at the base of the cranium. Though it is quite true that in a few cases medullary disease may involve the base of the skull, there can, however, be little doubt, I think, that it began in the antrum, and proceeded backwards rather than forwards, as Mr. Hancock supposes. That medullary disease does begin in the jaw itself the specimens which accompanied this essay show, and one of Mr. Liston's cases is conclusive on the point, the preparation being preserved in the College of Surgeons (1059), with the following description:—"The greater part of a left superior maxillary bone, with a tumour formed in the antrum, removed by operation. The tumour measures about two inches in its greatest diameter, and projects forwards over the right canine and bicuspid teeth. It is pale, soft, and homogeneous, and the surface of its section



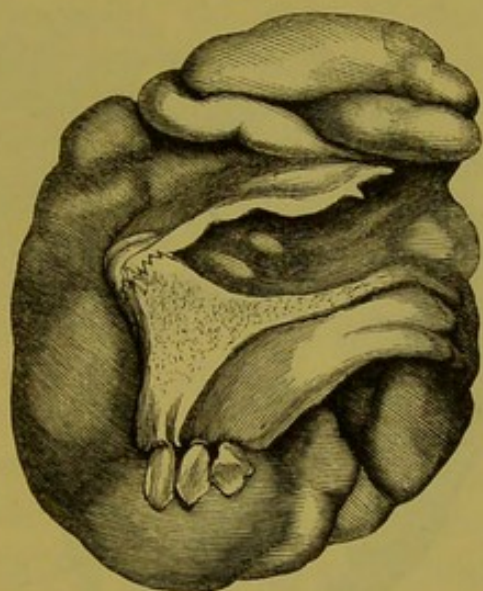
is like that of brain. At the upper part its tissue is broken, and was mixed with blood: in its recent state it was more brain-like. The patient, William Thomson, was sixteen years old. The disease had been observed for two years. He had often suffered pain in the situation of the first molar tooth, which had been in a decayed state for a considerable time previous to his discovering any swelling of the cheek. During the two months preceding the operation the tumour had grown rapidly. Three years and a half after its removal the patient was in good health."—See Liston's paper, *Medico-Chirurgical Transactions*, vol. xx. In this case, which was fortunately submitted to operation at a very early period, the disease was still confined to the antrum, and the removal of the jaw therefore included the whole of it. Unfortunately in too many cases the disease is much more advanced before it is brought under the notice of the surgeon, when therefore the possibility of complete extirpation is much reduced.

Medullary disease in the jaw closely resembles the same disease in other parts of the body. Rapidity of growth, with softness, and a tendency to fungate on the part of the tumour itself, are the main characteristics; but in the more advanced stages, the cancerous cachexia may be established. No lymphatic glandular enlargement takes place in this affection, because there are no lymphatics to the jaw itself, and even to the skin of the face there are very few, so that even when the skin is involved it is unusual, except in very advanced cases, to find any enlargement of the submaxillary or cervical lymphatic glands. The direction which the disease takes and the effects therefore which it produces, will vary in different examples. Frequently it forms a considerable projection on the cheek, causing epiphora from closure of the nasal duct, and œdema of the lower eyelid, and in the later stages enlargement of the facial veins, without the least invasion of the hard palate, and with but slight interference with the nostril. The specimen of medullary disease which accompanied this essay (College of Surgeons Museum, 1053 A), and is represented in fig. 112, illustrates the point, a large tumour being developed externally. The patient was a man, aged



forty-four, who came under the care of Mr. Craven, of Hull, in 1863, with a large rounded tumour of the right cheek, of the size of an orange, extending from the external process of the frontal bone and zygoma above, to the angle of the mouth below (almost completely closing the right eye), and from the side of the nose to the ramus of the lower jaw. The colour of the integument was natural, except at the upper part below the eye, where it presented a rather livid appearance, and several veins, not of large size. It was very firm to the touch, but elastic, especially at the outer part. Pressure and handling caused little or no pain. The

FIG. 112.



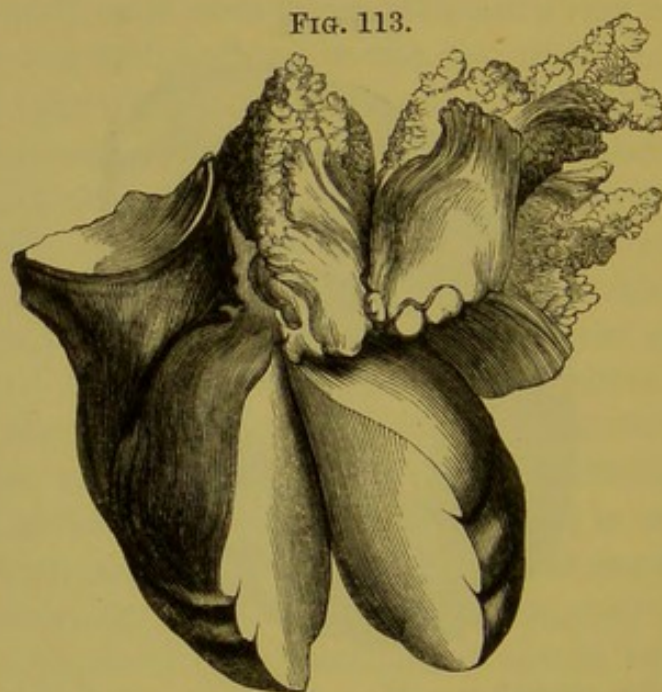
interior of the mouth on the right side, from the alveolar process (which was concealed by the growth or embraced in it) to the inside of the distended cheek, presented a large excavated sore of a greyish sloughy aspect and fœtid odour. This part of the tumour was softer to the touch than that which showed itself externally. It did not encroach on the palate, which was of the natural width. There were no enlarged glands beneath the jaw. The patient seemed a pretty healthy man. The tumour had been growing seventeen weeks. Mr. Craven excised the tumour, and the patient made a good recovery, but died fifteen months afterwards from a recurrence of the disease. The tumour (fig. 112)



was rounded and lobed, especially that part which occupied the pterygo-maxillary fossa; and was firm on section. The cut surface was smooth, becoming slightly granular after prolonged exposure. To the naked eye, the tumour had the appearance of a malignant growth. Under the microscope, the juice scraped off the cut surface showed no fibrous element; but simply a mass of apparently broken-up cells and granular matter.

On the other hand, the disease may at an early period involve the alveolus and palate, or the nose; and it is these cases which are sometimes attributed to the presence of de-

FIG. 113.



cayed teeth, or are mistaken for ordinary nasal polypi. Of this, a preparation (College of Surgeons' Museum, 1053 B.) which is shown in fig. 113, and was also from a patient of Mr. Craven (to whom I was indebted for both valuable preparations), is an instance. Here the disease showed itself first in the gums, where it formed a fungating mass, and soon obstructed the nostril. This last symptom was due to a fungus, almost papillary in appearance, which springs from the nasal surface of the tumour. Mr. Craven removed the tumour in March, 1866, but within a year the disease returned and proved fatal.



Even when the disease is far advanced, so that the tissues of the face and mouth are much involved, it is possible for the surgeon to give relief, if not permanent cure, by completely excising the morbid structures. In the *Lancet*, January 2nd, 1864, will be found a case in which Sir William Fergusson relieved a patient who had been abandoned as incurable some months before by another surgeon, who had declined to proceed after laying open the cheek. Here the patient was very much exhausted and out of health. There was a considerable enlargement on the left side of the face. The eye was protruded, both lids being much swollen, the lower one everted, and the mucous membrane thickened and granular; the sight of the eye was gone. The left nostril was swollen, and there was a thick discharge constantly coming from it. Running across the cheek was the cicatrix of the exploratory incision made some months before. The skin was thickened and unhealthy looking, and there could be felt under the buccinator a large, well-defined, hard tumour. Upon examining the inside of the mouth, there could be seen a large fungous mass, involving the left side of the hard palate, nearly all the soft palate, and the uvula. The disease seemed to have involved the base of the orbit, and extended up under the zygoma. The glands in the neck were not enlarged. The patient suffered most excruciating pain, which was intermittent, and of a neuralgic character.

The disease may extend across the median line, and involve portions of both maxillæ, especially the palatine plates. This is not necessarily a bar to operative interference, provided other circumstances are favourable, but when the disease exhibits the appearance shown in fig. 114, the case is obviously one beyond the aid of surgery. The patient, aged twenty-four, was sent to me in January, 1868, by Mr. Harding, to whom he had applied for the extraction of some teeth, thinking to obtain relief thereby. Four and a half years before he had had a blow on the face from a cocoa-nut, which broke the left canine tooth, and a year before I saw him, the left side of the face swelled up, but subsided



again. In August, 1867, he first noticed a growth below the left eye, which rapidly increased, but even before this the interior of the mouth was tender, and felt swollen and soft to the touch. He had good advice in the country, and subsequently was in a London hospital, but operative interference was declined by the surgeon under whose care he was. When I saw him, some months later, there was a large soft tumour of the left upper jaw, and a smaller one on the right side, which had appeared about four weeks before. The nose was considerably projected by these, the left nostril being completely blocked and the right slightly

FIG. 114.



so. The alveolus was very prominent, so that the incisor teeth sloped backwards, and there were soft masses of disease on each side of the palate. Within a week or ten days of my seeing the patient the lymphatic glands in the neck had become enlarged, particularly on the right side, where a considerable tumour existed. This melancholy case was obviously totally unfitted for operation at the time I saw it, whatever might have been its prospects at an earlier date. I could therefore hold out no hope of alleviation to the unfortunate patient, who returned to the country.



## CHAPTER XXII.

## DIAGNOSIS AND TREATMENT OF TUMOURS OF THE UPPER JAW.

THE diagnosis of tumours of the upper jaw is by no means easy. Even the distinction between fluid tumours due to cystic enlargement of the jaw and solid enlargements, is, as has already been pointed out, not always easy ; and it is still more difficult, and in some cases impossible, to decide as to the malignancy or otherwise of a tumour previous to its extirpation.

The fibrous, fibro-cellular, cartilaginous, and osseous tumours are all of slow growth, painless, and more or less hard to the touch. They do not affect the general health, nor do they show any tendency to involve the surrounding tissues or the skin, except by mechanical interference. The vascular and myeloid tumours are more rapid in their growth and softer than those already mentioned ; both are more vascular in appearance at points where they are covered only by mucous membrane. They occasionally ulcerate, but do not fungate, and may, under these circumstances, discharge blood in considerable quantities. The medullary tumour is the most rapid in its growth, and its tendency to involve surrounding structures is early manifested. Its softness and tendency to fungate and bleed are its chief characteristics, but these must not be relied on too implicitly. This last variety is ordinarily more painful than the others, the patient frequently complaining of neuralgic or gnawing pains in the face and head.

In examining a case of tumour of the upper jaw, a careful inspection should be made of the face, mouth, and nares. The consistency of the projection beneath the cheek should



be tested with the finger both outside and inside the cheek itself. The condition of the hard and soft palate should be particularly investigated, and the finger should be carried behind the soft palate if there is any suspicion that the tumour extends towards the posterior nares. The condition of the nostril will require especial examination, particularly in those cases where the disease shows itself at an early period in that cavity and doubt arises as to its nature. The careful introduction of a probe whilst a good light is thrown into the nostril, will enable the surgeon to decide whether the tumour is merely a polypus springing from the turbinate bones, or whether it is a portion of an antral tumour showing itself in the nostril; or possibly some growth springing from the base of the skull and simulating maxillary disease.

*Prognosis.*—But little can be hoped from medicine in the treatment of tumours of the upper jaw. The application of iodine has been said by Mr. Stanley to have effected the removal of a small enchondroma, and no harm will be done by resorting to such measures and to the internal administration of absorbent medicines for a short time whilst the progress of the disease is watched, provided no chemical agent be applied to the growth itself, by which it might be irritated or caused to inflame. Removal by surgical operation is, however, the only effectual means of treatment, and the sooner an operation is undertaken the better in all cases, since even a benign tumour may, by its size or by its attachments, put a patient's life in danger if allowed to grow unchecked for a series of years. In malignant disease the only hope for the patient is early and complete removal whilst the disease is confined to the bone, and before the surrounding structures have become affected.

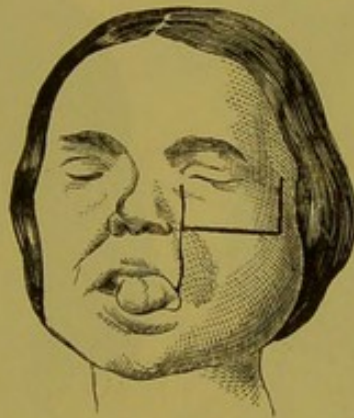
*Operations on the Upper Jaw.*—From early times portions of the upper jaw, and particularly the alveolus, were occasionally removed on account of some disease, and with more or less permanent success. Mr. Butcher, who has laboriously investigated the subject, puts the earliest case in 1693, the operator being Akoluthus, a physician at Breslau. Desault, Garengeot, Jourdain, and others in the last century



removed growths from the jaw, gouging them out with chisels with partial and temporary success, and Dupuytren especially advocated this mode of treatment in his "*Leçons Orales*," and frequently practised it, removing in this manner the greater part of the upper jaw in 1824. Charles White, of Manchester, appears also to have successfully operated on a patient, from whom he removed, piecemeal, nearly the whole of the upper maxilla during the last century.

The late Mr. John Lizars, of Edinburgh, appears to have been the first to propose removal of the entire superior maxilla as a whole in 1826, when, in his "*System of Anatomical Plates*," he showed how, anatomically, it would be possible to remove the bone without injury to important

FIG. 115.



and vital parts, and recommended the previous deligation of the common carotid artery, with a view of preventing hæmorrhage. Mr. Lizars did not have an opportunity of carrying his proposition into effect until December, 1827, when, notwithstanding the ligature applied to the carotid, the hæmorrhage was so fearful as to necessitate a discontinuance of the operation (*Lancet*, 1829-30). M. Gensoul, of Lyons, had, however, forestalled Mr. Lizars quite independently and without being aware of his proposition, for in May, 1827, he removed the entire superior maxillary bone, with a part of the palate, from a boy of seventeen, on account of a large fibro-cartilaginous tumour. The incision employed by Gensoul (fig. 115) was a vertical one from the



corner of the eye to the lip, joined midway at right angles by a transverse incision, which was again met by a small vertical incision ascending to the malar bone. By the employment of the mallet and chisel the jaw, with the tumour, was dislodged and removed by the division of the palate. Although the carotid was not tied the hæmorrhage was not very great, and the patient recovered.—(*Lettre Chirurgicale sur quelques Maladies Graves du Sinus Maxillaire*, par A. Gensoul).

Mr. Lizars operated again in 1829 for a medullary tumour, which was completely removed with the exception of a small portion attached to the pterygoid processes. The

FIG. 116.

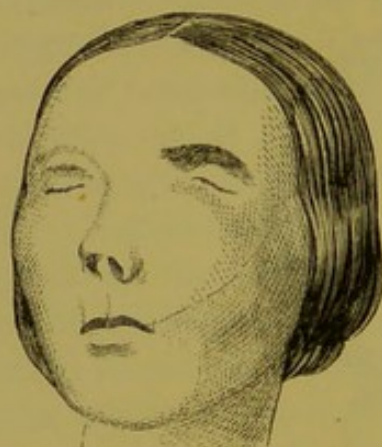
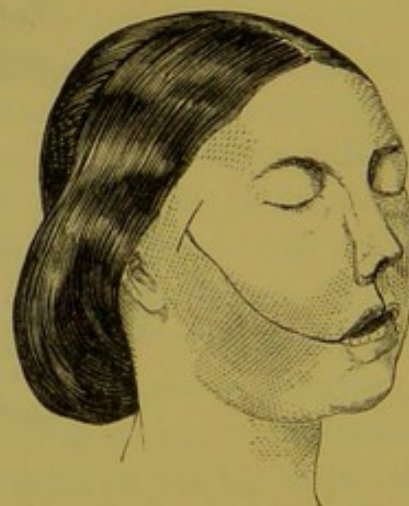
FIG. 117.



patient had become quite convalescent, when she died suddenly on the nineteenth day (*London Medical Gazette*, vol. v. p. 92). His third and successful operation was in 1830 (*Lancet*, 1829–30), and from that time removal of the upper jaw became an established operation in surgery. Mr. Lizars used an incision across the cheek from the angle of the mouth to the malar bone (fig. 116), or, when the tumour was very large, employed in addition an incision through the lip into the nostril with a vertical cut at the malar bone. (Fig. 117.) With the saw and bone-forceps the maxilla was separated from its attachments and removed.

Lizars' example was followed by most of the leading



surgeons of the day, but Mr. Liston requires a special notice, since he performed some of the earliest and most important operations of the kind, and in his essay, which has been frequently referred to (*Medico-Chirurgical Transactions*, vol. xx.), brought the subject and its relation to various forms of disease prominently under the notice of the profession. Mr. Liston seems to have been strongly impressed with the notion that malignant disease of the jaw should not be interfered with, but this idea does not prevail among operating surgeons of the present day, for it is felt that it is better to

FIG. 118.



act upon the principle which guides operations upon cancerous growths in other parts of the body—to remove the growths, if feasible, in the hope of giving at least relief if not a permanent cure.

Syme, Mott, Velpeau, Dieffenbach, O'Shaughnessy, Heyfelder, Fergusson, and Butcher may be mentioned as having performed the operation of excision of the superior maxilla repeatedly and successfully, and to Sir William Fergusson especially is due the proposal of modifications of the greatest



moment in the method of procedure. Noticing the considerable deformity resulting from an incision from the angle of the mouth which necessarily divides the facial nerve (fig. 118), and still more when a flap of skin has been reflected from the face by a double incision (fig. 47), Sir William Fergusson devised the plan of carrying the incision solely through the median line of the lip into the nostril. By dissecting up the tissues of the nose and taking advantage of the stretching of the skin of the nostril, room may

FIG. 119.



thus be obtained for the removal of any tumour not of large size; but supposing this to be found impracticable, it is still open to the operator to prolong the incision round the ala and up the side of the nose, and in the case of large tumours, to carry it in a curve below the orbit to the malar bone, as seen in fig. 119. The great advantages of these methods are that the facial nerve and facial artery are divided at points where their size is of no consequence, and consequently the loss of blood and the subsequent deformity



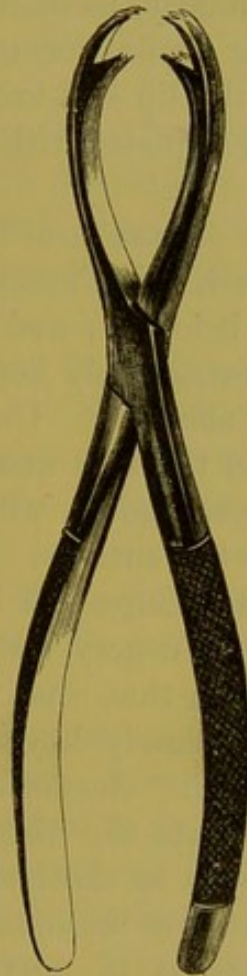
are much diminished; and also that the scars fall in such positions as to be hardly noticeable.

The ordinary method of proceeding when it is necessary to remove the entire upper jaw is as follows:—The skin having been reflected in the manner described above, the incisor teeth of the side to be removed are extracted and a

FIG. 120.



FIG. 121.



narrow saw with a moveable back passed into the nostril. With this the alveolus and hard palate are divided, and a small saw (fig. 120) is then applied to the malar process of the maxillary bone (or, if need be, to the malar bone itself) and to the nasal process of the superior maxilla, so as to notch both these points of bone, the division being completed with the bone-forceps. With the "lion-forceps," de-



vised by Sir William Fergusson for the purpose (fig. 121), the jaw can now be grasped and broken away from the pterygoid process and palate bone, any detaining point being severed with the bone-forceps. Lastly, when the bone is quite loose, the infra-orbital nerve is to be divided and the soft palate dissected off the bone, so as to leave as much of it as possible uninjured. Any remaining portions of disease are then to be removed with the bone-forceps and gouge, and finally, hæmorrhage is to be arrested by ligatures and the application of the actual cautery to the deep tissues, and the lip and incision are to be brought together and carefully adjusted with hare-lip pins and an interrupted suture.

When the disease is of less amount, and the orbital plate is not involved, this should be preserved by carrying a saw horizontally below it; and if the palate is not involved, this may be advantageously kept intact by making a similar cut immediately above it. Under these circumstances the incisions through the skin need only be very limited, and the bone-forceps and gouge will be requisite to clear out all the disease from the antrum.

Sir William Fergusson has recently, in his "Lectures on Anatomy and Surgery," strongly urged the pursuance of a less heroic plan than that which has hitherto been followed, in going completely beyond and not interfering with the diseased tissues. According to this eminent surgeon, it is better to cut into the disease and to clear it out by working from the centre to the circumference, so as not to remove healthy structures unnecessarily, and this may be accomplished by means of curved and angular bone-forceps of various sizes, and by the use of the gouge. Mr. Syme (*British Medical Journal*, Aug. 12th, 1865) has denounced this method as a return to "the old system with its chisels and gouges;" but it remains to be seen which practice gives the best results. Having witnessed both methods and watched their results, it appears to me that there is no greater risk of return of the disease in the more modern practice than in the other.



It has been mentioned that in the earlier operations for removal of the upper jaw, it was customary to apply a ligature to the common or external carotid artery. Although this practice has now been quite abandoned, it has in a few cases been necessary to secure the main vessel after the operation, on account of secondary hæmorrhage. Thus Mr. Field, of Brighton, tied the common carotid two days after removal of the upper jaw, in 1858, and the patient recovered (*Medical Times and Gazette*, Aug. 28th, 1858). In a patient of Mr. Holmes Coote, at St. Bartholomew's, in 1866, the house-surgeon, Mr. Orton, tied the vessel on the nineteenth day, but the patient sank (*Lancet*, Oct. 13th, 1866). In his recent work on Cancer, Mr. O. Pemberton mentions a case which occurred in 1848, when he was house-surgeon at the Birmingham General Hospital, which also proved fatal.

As a rule, however, patients who have been submitted to removal of the upper jaw recover with wonderful rapidity. Of course the primary shock of such an operation is severe, but when this is once got over the convalescence is ordinarily rapid. The table on the following page, from the *Medical Times and Gazette* of Sept. 3rd, 1859, confirms this view, and forms the only available statistical statement on the subject.

Removal of *both* upper jaws has occasionally been performed. A case in which Mr. Lane removed the greater part of both jaws has been referred to in this essay (p. 222), and the operation has been performed by Rogers, of New York (1824), Heyfelder (1844, and twice afterwards), Diefenbach, Maisonneuve, and others. Heyfelder made two incisions from the outer angles of the eyes to the corners of the mouth, and reflected this quadrilateral flap to the forehead, taking the nose with it. He then passed a chain-saw through the spheno-maxillary fissure on each side, and thus separated the jaws and the malar bones. The junctions with the nasal bones and vomer were then divided with bone-forceps, and the soft palate separated from the margin of the hard. Lastly, powerful traction upon the bones was



*Tabular Statement of Resections of the Upper Jaw.*

Number.	Sex.	Age.	Bone affected.	Nature of Disease.	Result.	Cause of Death.	Remarks.
1	...	...	Left.	Malignant.	Recovered.	...	The disease rapidly returned.
2	...	...	...	Fibroid.	Recovered.	...	Believed to be permanently well.
3	...	...	...	Malignant.	Recovered.	...	
4	M.	50	...	Malignant.	Recovered.	...	The disease rapidly returned.
5	F.	53	Right.	Malignant.	Recovered.	...	
6	M.	49	...	Malignant.	Recovered.	...	The disease was believed to be returning.
7	F.	13	Left.	Osseous.	Recovered.	...	Permanent recovery.
8	M.	56	Left.	Osteo-encephaloid, 12 years.	Died.	Commencing pyæmia fifth day.	The tumour was very large.
9	F.	16	Right.	Osseous.	Recovered.	...	Permanent recovery.
10	F.	10	Right.	Tuberculous.	Recovered.	...	
11	F.	23	Left.	Osseous, 7 years.	Recovered.	...	
12	M.	45(?)	Left.	Malignant, 4 months.	Recovered.	...	
13	F.	22	Right.	Fibroid.	Died.	Exhaustion 1 day.	The tumour was very large.
14	F.	55	Right.	Malignant.	Recovered.	...	
15	F.	42	Right.	Malignant.	Died.	Erysipelas, &c., 2 weeks.	In good health at time of operation.
16	M.	18	Left.	Polypoid.	Recovered.	...	The polypus grew by a broad base from the skull itself.
17	M.	43	Left.	Polypoid.	Recovered.	...	The polypi occupied the antrum.



exerted, and the bones were displaced. Dieffenbach, Maison-neuve, and others, employed a median incision, beginning at the root of the nose and ending in the median line of the lip, so as to divide the skin of the face into two lateral flaps. This appears an unnecessary complication, however, since division of the lip and free dissection of the nostrils would afford sufficient room for the removal of the jaw in two halves.

Accompanying this essay were two preparations which are now in the Museum of the College of Surgeons (1059 D, 1059 E), and are the two superior maxillæ of a patient suffering from scirrhus, which were kindly sent to me by Mr. Coates, of Salisbury.

Jane F., aged twenty-one, was admitted into the Salisbury Infirmary, July 24th, 1858, for a tumour of the left upper jaw. The operation of removal of the left upper jaw was performed by Mr. Andrews, and she was made an out-patient Aug. 28th, 1858. She was readmitted on Oct. 1st, 1859, under Mr. Coates, having a fortnight before perceived a small growth occupying the edge of the alveolar process at the site of the left upper incisor, which became rapidly exquisitely painful and involved the alveolus of the right side and also the upper lip. Mr. Coates removed the remaining right superior maxilla under chloroform, Oct. 13th, 1859. The portion of the lip covering the small tumour (which was about the size of a hazel-nut) was also removed, and found to be infiltrated with malignant disease. The patient was discharged cured Nov. 5th, 1859, and has been heard of lately, being in perfect health and having been recently confined.

The operators in this case acted in strict accordance with the rules of surgery of the time in removing the entire bones which were affected; but in the present day, and after the experience and teaching of Sir William Fergusson, it may be doubted whether as successful a cure could not have been achieved at a less expense of healthy tissue, the disease involving little more than the alveolus.



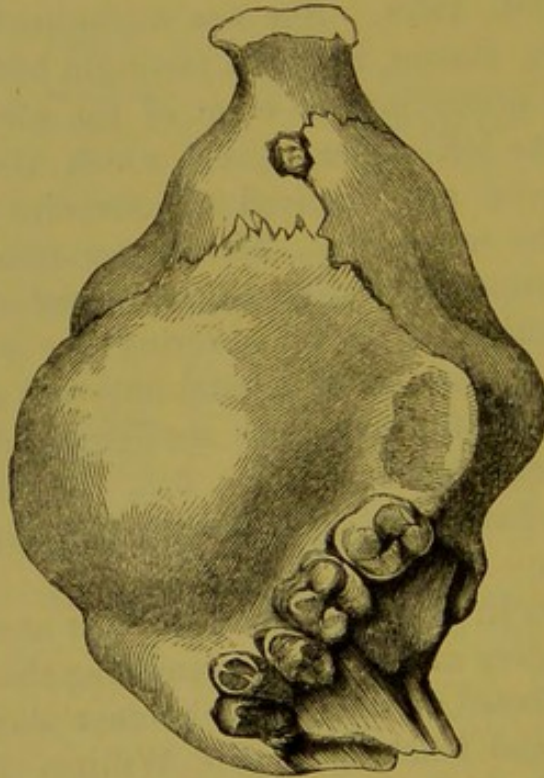
## CHAPTER XXIII.

## TUMOURS OF THE LOWER JAW.

*Fibrous, Recurrent Fibroid, and Fibro-Cellular Tumours.*

*Fibrous Tumour* is the commonest form of growth in the lower jaw, and, as pointed out by Paget, this may take the *endosteal* or *periosteal* form. The formation of fibrous

FIG. 122.

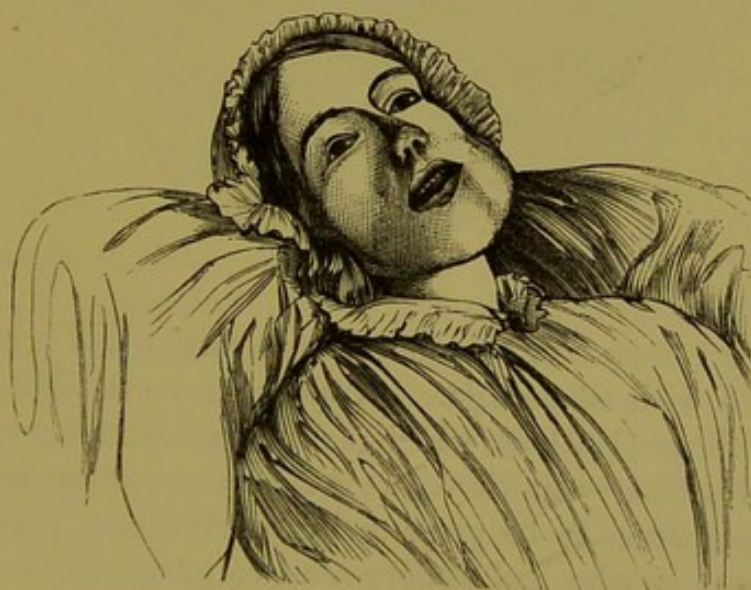

tumours between the plates of the lower jaw has been already referred to under the head of Inflammation (p. 94), and originates, I believe, in the majority of cases in some



inflammatory deposit due to the irritation of decayed teeth. By the slow growth of the tumour the jaw is expanded, the outer plate yielding more readily than the inner, and, if allowed to continue long enough, absorption of the bone will take place and a fungoid mass will project into the mouth. This is well illustrated by a preparation of Mr. Liston's, in the College of Surgeons (1040), the tumour having existed three years, and destroyed the front wall of the jaw. In the description of this preparation it is mentioned that, prior to Mr. Liston's operation, the portion projecting into the mouth had been cut off, and the surface cauterized—it need hardly be said without any good result. A preparation in University College Museum (fig. 122) illustrates the greater expansion of the outer than the inner plate by the contained tumour, already referred to; and shows also a curious transportation of the wisdom tooth close up to the condyle of the jaw by the growth of the tumour, which was probably connected with it in some way.

FIG. 123.



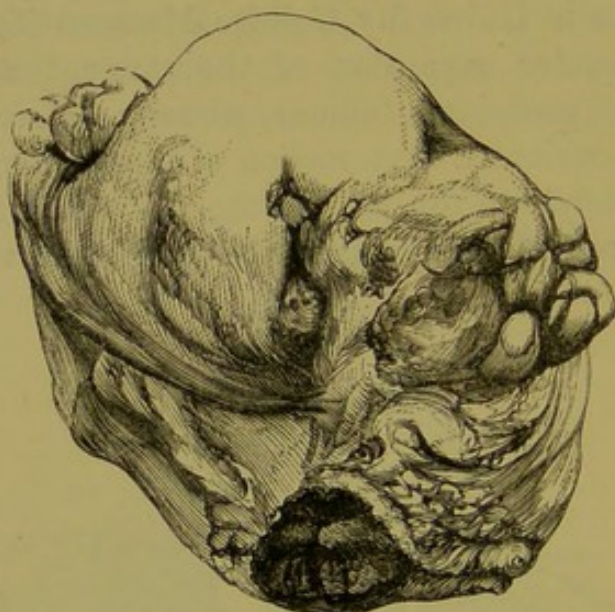
Accompanying this essay was a good specimen of endosteal fibrous tumour (College of Surgeons Museum, 1040 B), which Mr. Spencer Wells removed with the jaw from the symphysis to the angle in a woman, aged twenty-seven, whose condition



at the time of the operation is represented in fig. 123, from a photograph by Dr. Wright. The tumour occupied the left side of the lower jaw, and had existed for four years, being connected with decayed teeth, one of which on being extracted shortly before the operation brought a small portion of the tumour away with it. Fig. 124, also by Dr. Wright, shows the tumour in the recent state (see *Pathological Society's Transactions*, vol. xii.).

It may I think be doubted whether a milder treatment than that of removal of the whole thickness of the bone

FIG. 124.

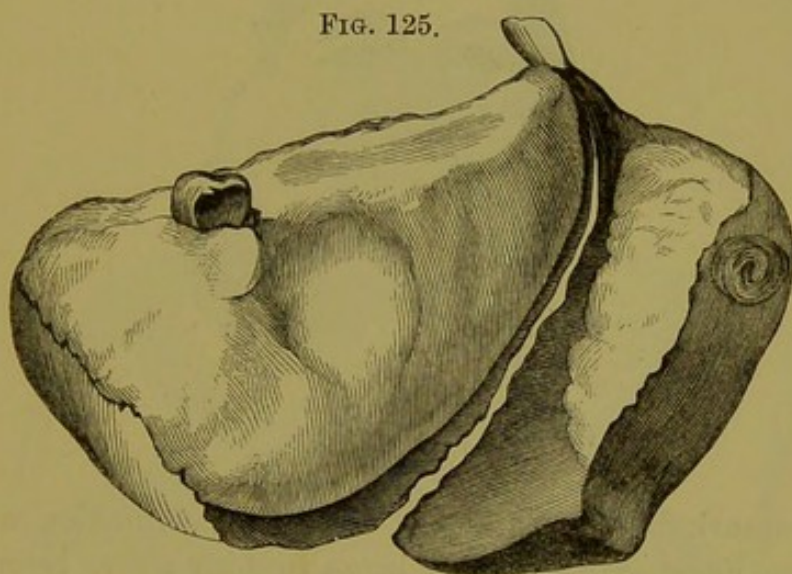


containing tumours of this description might not sometimes be adopted with advantage. A specimen in the Museum of King's College (1321-9), which is represented in fig. 125, admirably illustrates this view. It is a fibrous tumour removed, when I happened to be present, by Sir William Fergusson, from a woman who had undergone two previous operations. Having sawn the jaw partly through on each side of the tumour, the operator applied the bone-forceps to complete one of the sections, when the outer plate of the jaw, with the greater part of the tumour, came away, leaving only a small portion of it adhering to the inner plate. Owing to



the jaw being already divided, it was considered better to complete the operation as originally intended, and the patient made a good recovery. The advantage of not breaking the line of the lower jaw has been already insisted upon in connexion with epulis of an epithelial character, and the same advantage would be gained by preserving the inner plate of the jaw in cases of tumour. The preparation referred to illustrates also the connexion of the teeth with fibrous tumours, a diseased molar tooth being implanted in the upper part of the tumour.

FIG. 125.

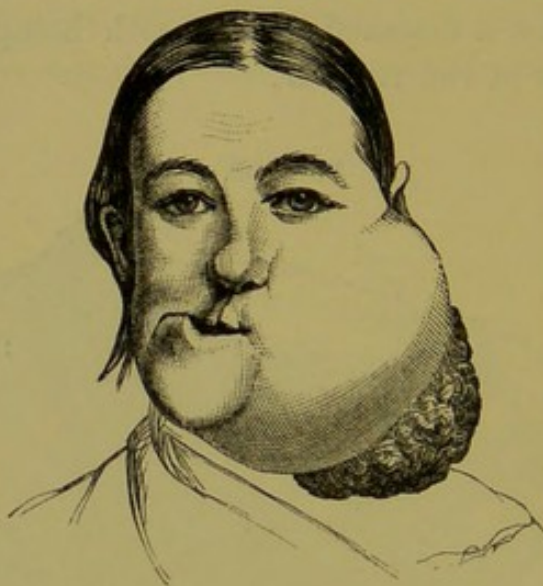

Though of slow growth under ordinary circumstances, a fibrous tumour of the jaw, if irritated by the injudicious application of useless remedies with the view of producing absorption of the growth, may assume enormous proportions, and destroy life by the irritation and continuous discharge it gives rise to. A preparation in King's College Museum, shows a fibrous tumour of large size, involving nearly the whole of the left side of the lower jaw. Its interior is hollowed out into a large cavity with sloughing walls, and there is a large aperture communicating with it surrounded by healthy skin. The patient's portrait, taken about six weeks before her death, is seen in fig. 126, and the case will be found in detail in the Appendix (Case XXI.) The case was



evidently one of ordinary fibrous tumour depending originally upon diseased teeth, which, by dint of incisions and injections of iodine into the growth, followed by a seton introduced through the skin, was brought into such a condition that upon the receipt of a blow it rapidly brought the patient to her death-bed.

FIG. 126.



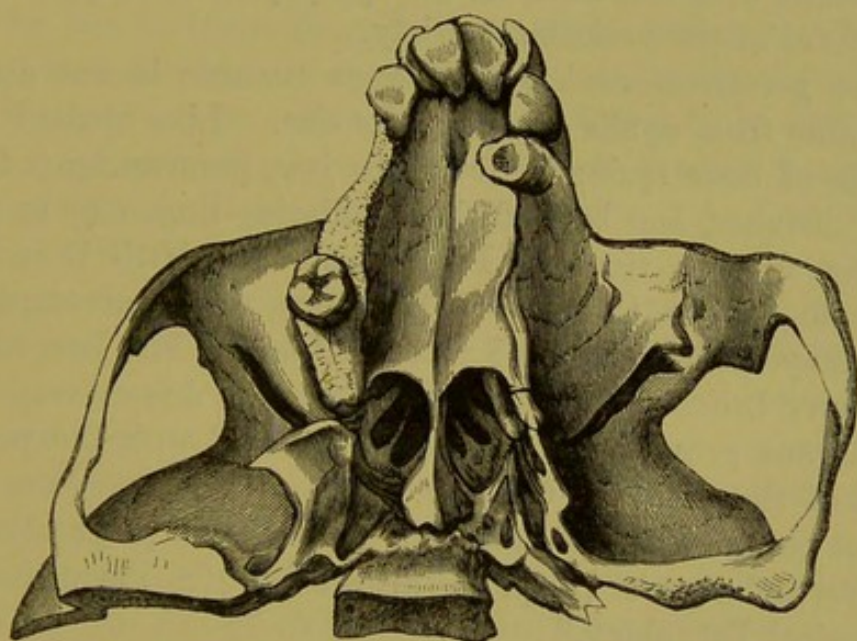
A remarkable and unique feature in connexion with Sir William Fergusson's case of large tumour above referred to, is seen in fig. 127, which shows the front of the base of the skull of the patient. The long-continued pressure of the tumour of the lower jaw has given rise to a remarkable contraction of the hard palate and alveolus, the teeth being crushed together so as to overlap one another, and at the same time an expansion of the malar bone and zygoma has ensued, which is accurately shown in the figure.

A specimen which accompanied this essay, and which is now in the Museum of the College of Surgeons (1040 C), and for which I am indebted to Mr. Buxton Shillito, shows an early stage of the same form of disease. The case is reported, with drawings, in the *Pathological Transactions*, vol. xvi., and the tumour was removed by Mr. Shillito from near the angle of the lower jaw of a young woman,



aged twenty-six, where it had been growing fifteen months, being of the size of a walnut. It was removed by reflecting a flap of skin from its surface, cutting through the thin shell of bone, and enucleation. It left a perfectly smooth cavity into which the fang of the second molar tooth projected, which doubtless was the original cause of the mischief. The tumour was gritty on section, and furnished an example of calcification, to which change fibrous tumours of the lower jaw are liable no less than those of the upper jaw.

FIG. 127.



A large tumour of the same kind, weighing eighteen ounces, which has encroached upon the condyle and coronoid process, and projected into the mouth as well as on the surface, is preserved in University College Museum (3593), and was removed by Mr. Liston in 1846.

Fibrous tumour is most frequently developed in the side of the lower jaw, where the space between the plates is larger than elsewhere, and may occupy the dental canal, as in a case of Mr. Cock's, in which the dental nerve passed through the tumour, necessitating its removal in two parts. (Guy's Hospital Museum, 1091,25.) Occasionally, however, fibrous tumour invades the symphysis, and here, owing to



restricted amount of expansion of which the bone is capable, absorption of the anterior surface takes place at an early date, and the tumour projects, involving also the adjacent bone. A preparation in University College shows the symphysis affected in this way, which was removed, with a portion of healthy bone on each side, by Mr. Liston. A section shows the structure very well, and at the lower part a small cyst has been developed. In connexion with this subject, another preparation in the same museum is deserving of notice, being a fibrous tumour, of the size of an orange, connected with the back of the symphysis, and apparently, therefore, of the periosteal variety.

The *periosteal variety* of fibrous tumour is not distinguishable from epulis except by its size. Like epulis it has spicula of bone springing from the jaw, permeating it for a short distance, and beyond them radiating lines may be seen in the fibrous tissue. Preparation No. 1040 D in the Museum of the College of Surgeons, which accompanied this essay, and for which I was indebted to Mr. Lee, of the Salisbury Infirmary, illustrates this form of disease very well, the fibrous growth being closely connected with the periosteum of the front of the jaw. The disease may, however, almost completely surround the jaw, as the preparation in St. Bartholomew's Hospital, drawn by Mr. Paget in his "Surgical Pathology."

*Recurrent Fibroid Tumour.*—I am acquainted with but two well-marked cases of this disease, one of which I had the opportunity of watching. It occurred in the Westminster Hospital, under the care of Mr. Holt, in 1858, in a young woman aged eighteen, who had a soft fungoid mass covering the molar teeth of the right side of the lower jaw, of ten weeks' duration. It apparently sprang from the angle of the jaw or the base of the ascending ramus, and had pushed the mucous covering before it. The molar teeth were firmly fixed in their sockets; the wisdom tooth was covered with gum. The rapid growth of the fungus, and the absence of any material pain, led to the conclusion that it was probably a form of epulis of a malignant type. Mr.



Holt, therefore, thought it advisable to remove the whole mass, and examine the bone prior to removal of the jaw itself. This being done, its attachments were found to be connected with the posterior part of the body and anterior part of the ascending ramus, the bone being hard and of its ordinary density. Mr. Holt did not feel warranted in doing that which he was prepared to do—namely, remove the bone at its articulation at this time—but preferred removing with the cutting pliers all the bone to which the growth had been attached. Mr. Clendon having then extracted the molars and wisdom tooth, Mr. Holt cut through half the thickness of the jaw corresponding to those teeth, and, going further back, included the coronoid process, with more than half of the sigmoid notch. The disease was found to be intimately connected with the periosteum, which readily peeled off, leaving the bone somewhat roughened. (See *Lancet*, Jan. 28th, 1858.)

The disease reappeared in a few weeks, when Mr. Holt was compelled to remove it again, including this time the remaining part of the ramus of the jaw. The disease now was not confined to the covering of the bone, but extended into the pharynx, and was evidently attached to the mucous lining of the whole of one side of the mouth.

The poor girl left the hospital and went to Reading, and died on the 3rd of February. An autopsy was performed by Mr. Walford, the particulars of which are given in his own words:—

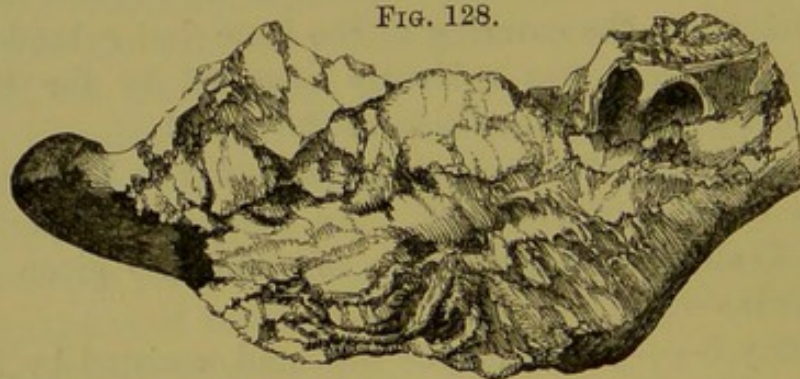
“Fanny S—— died on the 3rd, and, assisted by Mr. G. May, jun., and Mr. Fernie, I made a post-mortem examination. I did not open the head. The thoracic and abdominal viscera were free from disease. I dissected out the tumour, which, had the whole of it been there, would have completely encircled one side (one half) the lower jaw; it extended up to the zygomatic arch and downward into the neck. The gullet was free, and it evidently grew into (not from) the pharyngeal region. We could not satisfactorily discover its origin. The portion of lower jaw-bone left after the operation was sawn through at the symphysis, and ex-



hibits the margins of the tumour on the periosteum, which, I think, must be considered its starting-point, and that, as regards treatment, would be practically the bone." (See *Lancet*, March 6th, 1858.)

The second case occurred at the Great Northern Hospital, in the practice of Mr. George Lawson, who performed three operations with the hope of eradicating the disease, which, however, eventually proved fatal, as in the preceding instance. The patient was a young woman, aged seventeen, and the first operation was performed Oct. 4th, 1858. She had then what might be termed a large epulis growing from the anterior and inner surface of the ascending ramus of the lower jaw of the left side, extending from a point near the angle to close upon the condyle. Mr. Lawson removed the tumour with bone-forceps, cutting away apparently all its bony attachments. About six weeks after the first operation, a small elastic mass appeared in the temporal fossa of the affected side, but the jaw was apparently free. This Mr. Lawson excised, but found that the

FIG. 128.



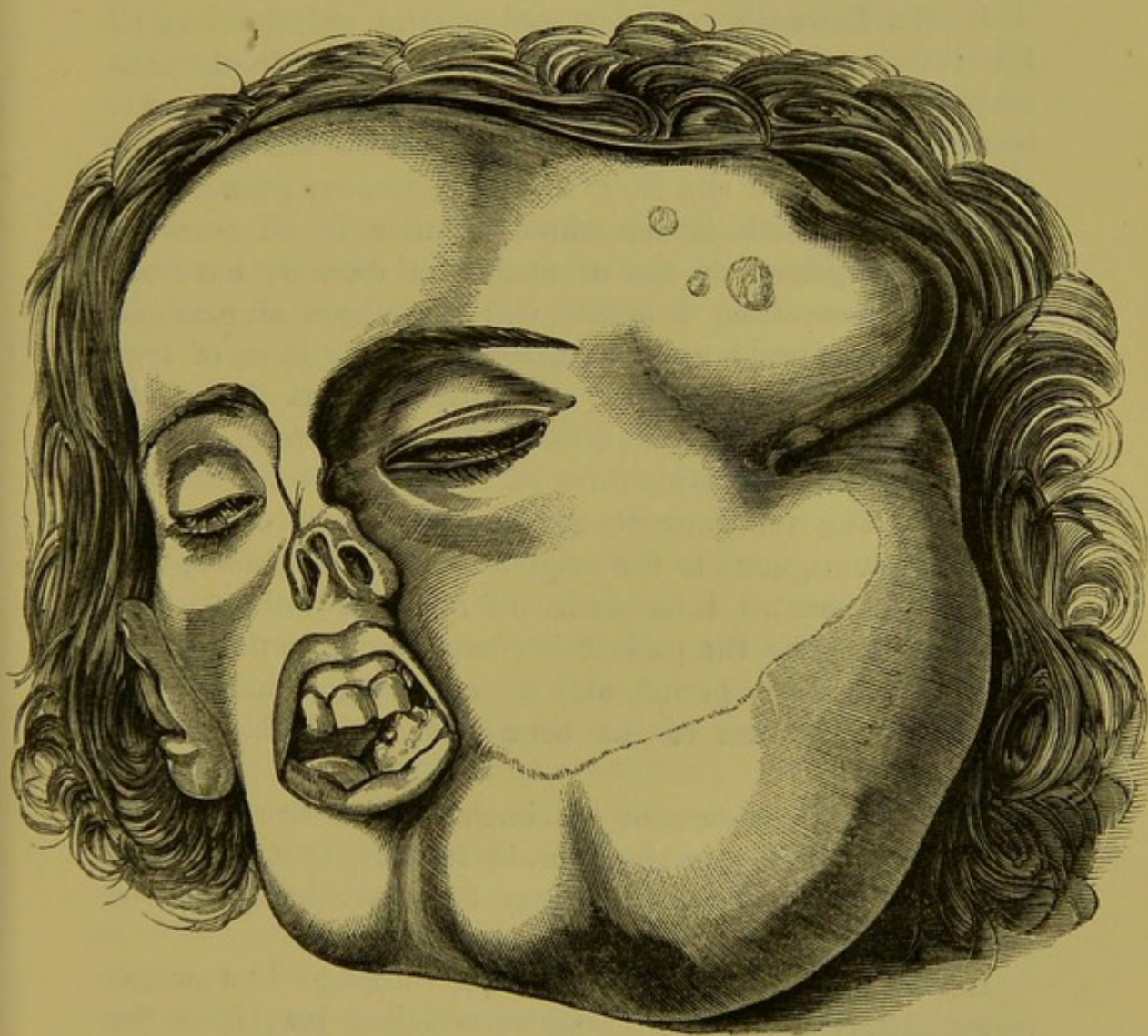
growth had evidently sprung from its original site, and extending upwards, had passed beneath the zygoma into the temporal fossa. The third operation was in June, 1859, when, in consequence of the great size the tumour had attained, the inability of the girl to open her mouth, and the great difficulty she experienced in deglutition, Mr. Lawson removed a portion of the inferior maxilla, sawing through the bone in front of the angle, and then disarticulating. Upon the removal of this portion of bone (fig. 128),



it was found that the tumour had formed so many attachments to the periosteum of the bones forming the base of the skull, that the operator was compelled to leave some of the disease behind.

By the end of November, 1859, the tumour had again grown to a large size, and from the space it occupied in her

FIG. 129.



mouth interfered much with her taking nourishment. It now began to soften and to ulcerate on its surface, both externally and within the mouth, and occasionally very alarming hæmorrhage would take place, so as to threaten imme-



diate dissolution, but from all these she rallied; within the mouth large sloughs would occasionally separate, allowing her to recruit her health by enabling her to take additional nourishment. She died early in 1860, worn out and greatly emaciated. The drawing (fig. 129), for which I am indebted to Mr. Lawson, shows the terrible deformity as seen after death. The preparation is in the Museum of the College of Surgeons (1052 A). (See *Pathological Transactions*, xi.)

In Mr. Lawson's case, repeated careful examinations of the tumour showed it to be of the recurrent fibroid character, and the rough and thickened condition of the periosteum covering the portion of bone which was removed, showed clearly the site from which the tumour grew. Mr. Holt's case, which is remarkably similar in all essential points, is reported as one of malignant disease; but from personal observation, I believe it to have been an example of recurrent fibroid disease, rather than any form of true cancer. The two cases are as nearly alike as they could possibly be, and were doubtless of the same nature.

The treatment of this form of disease must be unsatisfactory. The tendency to invade the tissues continuous with and contiguous to the original seat of the disease, renders any operative interference of doubtful utility. Still the only hope for the patient is complete extirpation of the disease at an early period, and the operation should include the entire thickness of the bone from which the growth arises.

The following museum specimens, which are probably examples of the recurring fibroid tumour, though microscopic evidence is wanting, may be conveniently noticed here.

In the Museum of the College of Surgeons is a preparation (1041) of the right side of a lower jaw, from the angle to the bicuspid tooth, which, with a tumour upon it, was removed by Mr. Liston. The tumour, which measures about two inches in its greatest diameter, is situated almost entirely on the anterior surface of the jaw, projecting forwards and upwards, and extending along nearly the whole



length of the portion removed. The greater part of the tumour consists of a pale, firm, and compact substance: at its base it is osseous, and so closely attached to the anterior surface of the jaw, from which it appears to have risen, that the outline of the latter can scarcely be discovered. The patient was a woman of thirty, who had had a blow on the cheek nine years before the tumour appeared. Its growth was accompanied by lancinating pain in the jaw and continual headache. It was removed five months after its first appearance. No portion of the disease appeared to have been left, but the disease reappeared in the ramus and necessitated its removal by disarticulation ten months afterwards (1042).

In St. Bartholomew's Hospital Museum is a specimen (I. 149) of fibrous tumour, for which the right side of the jaw from the angle to the symphysis was removed. The morbid growth consists of a grey, dense, fibrous substance, originating from the alveolar border, and from the outer surface of the jaw. Part of the alveolar border of the jaw has been absorbed; and in this situation the morbid growth appears to extend into the bone, which is harder than usual. It was removed from a woman aged thirty. Subsequently a tumour formed in the side of the neck immediately below the seat of the operation, which ultimately proved fatal by the ulceration and sloughing which took place in it. A portion of this was connected with the jaw, and a section shows it to consist of a firm fibrous substance.

*Fibro-cellular Tumour, or Osteo-sarcoma.*—This form of growth frequently attacks the lower jaw, and may prove fatal, by obstruction either to respiration or deglutition, if allowed to grow unchecked for many years. Some of the earliest cases of removal of portions of the lower jaw were for growths of this description which had attained a large size, and the names of Crampton, Cusack, and Syme are connected with these operations. The Museum of the College of Surgeons of Ireland, is especially rich in tumours of this class, and possesses also a cast of the head of a patient who died with a large tumour of the lower jaw, which has been injected and



divided. The following is the description of this preparation (I. a. 361), kindly extracted for me by Dr. Barker, the Curator:—"A singularly beautiful preparation of the osteo-sarcoma of the lower jaw, of which the preceding cast gives an outline. The patient was a middle-aged woman. The disease commenced as a fungus in the alveoli of the front teeth. This fungus was removed by operation at an early period, but speedily grew again, and in the course of about two years had acquired its size, which is equal to that of an infant's head, without bursting at any part. It was firm, but elastic to the feel, and inconvenienced the patient more by its bulk than by its malignancy. The woman, who was naturally of a delicate frame, gradually sank from exhaustion. No preparation could exhibit more satisfactorily the circumscribed local nature of this affection than that here shown. It is globular, four inches in diameter, and enveloped in an osseous wall which has connexion, exclusively, with the front central portion of the lower jaw, and which completely insulates the disease. The maxillary bone is perfectly sound beyond the points of adhesion of the tumour. The centre of the tumour is divided by bony partitions into several chambers, the surfaces of which are lined by a pulpy vascular membrane, which has received injection in great profusion. The contents of these chambers were various—some gelatinous, some bloody, and some of a gristly nature, interspersed with bony stalactites. Plate 11, in the fourth volume of the *Dublin Hospital Reports*, was taken from this preparation.—Professor Wilmot."

The central portion of this tumour is of such a distinctly cystic character that modern pathologists would probably have classed the disease among the cystic sarcomata, but I prefer to leave it in the place assigned to it by the Irish pathologists.

In the same fine museum are the historically interesting tumours removed by Sir Phillip Crampton and Mr. Cusack, in 1824, the details of which cases will be found in the valuable papers by those two gentlemen, in the fourth volume of the *Dublin Hospital Reports* (1827). Sir Phillip



Crampton was the first to insist upon the non-malignancy of this form of osteo-sarcoma, and to distinguish it from the medullary form—up to that time confounded with it. His description of the whole course of the disease, as witnessed in the jaw, is so perfect that I cannot do better than reproduce it:—"The first indication of this formidable disease is the appearance of merely a small swelling or projection of the gum, between two of the teeth. The teeth, however, soon become loose and dislocated, being forced inwards upon the tongue, or outwards against the cheek; as the tumour enlarges it assumes a tuberculated appearance, the tubercles varying in colour from a light pink to a deep purple; they are firm in structure, perfectly indolent, and do not readily bleed even when roughly handled. As the morbid growth extends in all directions, the mouth is soon filled by the tumour, the lower jaw is forced downwards upon the fore part of the neck, the tongue is pushed backwards into the pharynx, the mouth is carried to the side of the face opposite to the tumour, and before the patient sinks under his sufferings, a tumour is sometimes formed which nearly equals the bulk of the head itself. It is gratifying, however, to be able to state that even under such deplorable circumstances life has been preserved, and the hideous deformity removed by an operation which must be considered as one of the boldest and most successful of which modern surgery has to boast. But it is from the *internal structure* of osteo-sarcomatous tumours, as developed in the course of operations undertaken for their removal, or by dissection after death, that the true and distinctive characters of these affections are to be traced. In the benign form of osteo-sarcoma, the local and, I might almost say, the encysted character of the disease is evinced by the distinct line which separates the morbid growth from the soft parts with which it is in contact. It becomes apparent that as the tumour has enlarged, it has pushed the soft parts before it, or insinuated itself into their interstices, and that, so far from becoming incorporated with the surrounding structures, and assimilating them to its own nature (as invariably happens in the advanced stage of



malignant tumours), it has formed attachments so slight, that when the portion of bone from whence the tumour springs is detached, the whole morbid growth may be (as it were) drawn out from the surrounding parts almost without the aid of the knife. The interior of the tumour presents a great variety of structure, but I should say, in general, that the cartilaginous character which the tumour exhibits in its origin prevails to the last. In the early stages of the disease the tumour consists of a dense elastic substance, resembling fibro-cartilaginous structure, but the resemblance is more in colour than in consistency, for it is not nearly so hard, and is granular rather than fibrous, so that it 'breaks short.' On cutting into the tumour the edge of the knife grates against spicula, or small grains of earthy matter, with which its substance is beset. If the tumour acquires any considerable size, it is usually found to contain cavities filled with fluids differing in colour and consistency, but in general the fluid is thickish, inodorous, and of the colour of chocolate. Sometimes the growth of the tumour, or the secretion of fluid within its substance, is so slow that the deposition of bony matter keeping pace with the absorption, the bone becomes expanded into a large and thick bony case, in which the tumour is completely enclosed. There is a beautiful preparation of this form of the disease in the Museum of the Royal College of Surgeons. But in general the walls of the cavity consist of cartilaginous structure mixed with bone, the bone bearing but a small proportion to the cartilage. The extent to which this description of tumour may increase without materially affecting the general health, is one of the most extraordinary circumstances connected with its history." (p. 541.)

The "cartilaginous" appearance here referred to, relates only to the naked-eye appearance of the structure, which is characteristically said to "break short." Microscopic examination, as I have recently had the opportunity of testing in a large tumour of the kind, shows a dimly granular stroma, closely resembling the *matrix* of cartilage, but containing no true cartilage-cells. Though parts of the tumour may show



structure of this kind, the greater part is usually of a distinctly fibro-cellular character.

In 1828 Mr. Syme removed a very large tumour of this description (probably the largest which has ever been removed), weighing  $4\frac{1}{2}$  lbs., which, probably for the reason given above, he refers to in a lecture published in the *Lancet*, Feb. 3rd, 1855, as a fibro-cartilaginous tumour. The patient made a good recovery, and the accompanying illustrations, figs. 130 and 131, for which I am indebted to Mr. Syme, show his condition before and some years after

FIG. 130.

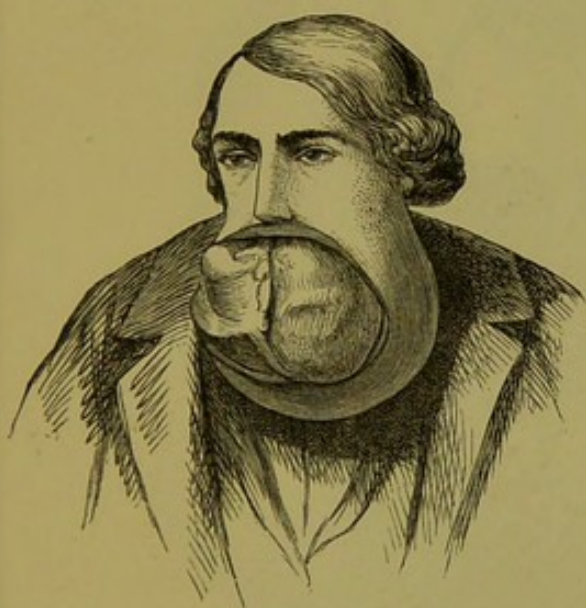



FIG. 131.



the operation, which was one of the earliest of the kind in this country. The case (No. XXII.) will be found in detail in the Appendix.

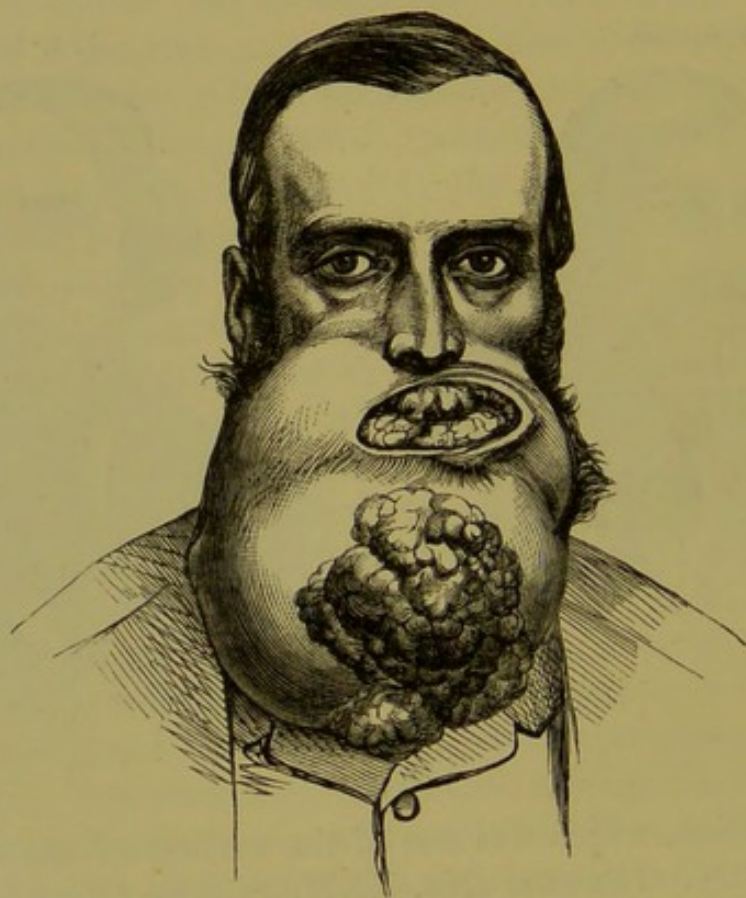
The fibro-cellular tumour, though of a perfectly benign character, will, if its surface be irritated by caustics, &c., throw out fungous masses, which bleed, and may be mistaken for the true, medullary or malignant fungus. Mr. Cusack (*loc. cit.*) gives an example of this result occurring from sloughing of the skin of the face, due to over-distension by the tumour, and I have recently had under my care an extraordi-



nary instance of the kind, where quack applications had produced similar results. Occasional hæmorrhage from such surfaces led to these cases being massed together with cancer as examples of *fungus hæmatodes*, and doubtless Sir William Fergusson's observation is correct—that the rarity of fungus hæmatodes, in the present day, is due to the early treatment to which cases of this kind are submitted.

The portrait of the patient recently under my own care, to whom I have alluded, is shown in fig. 132, taken from

FIG. 132.

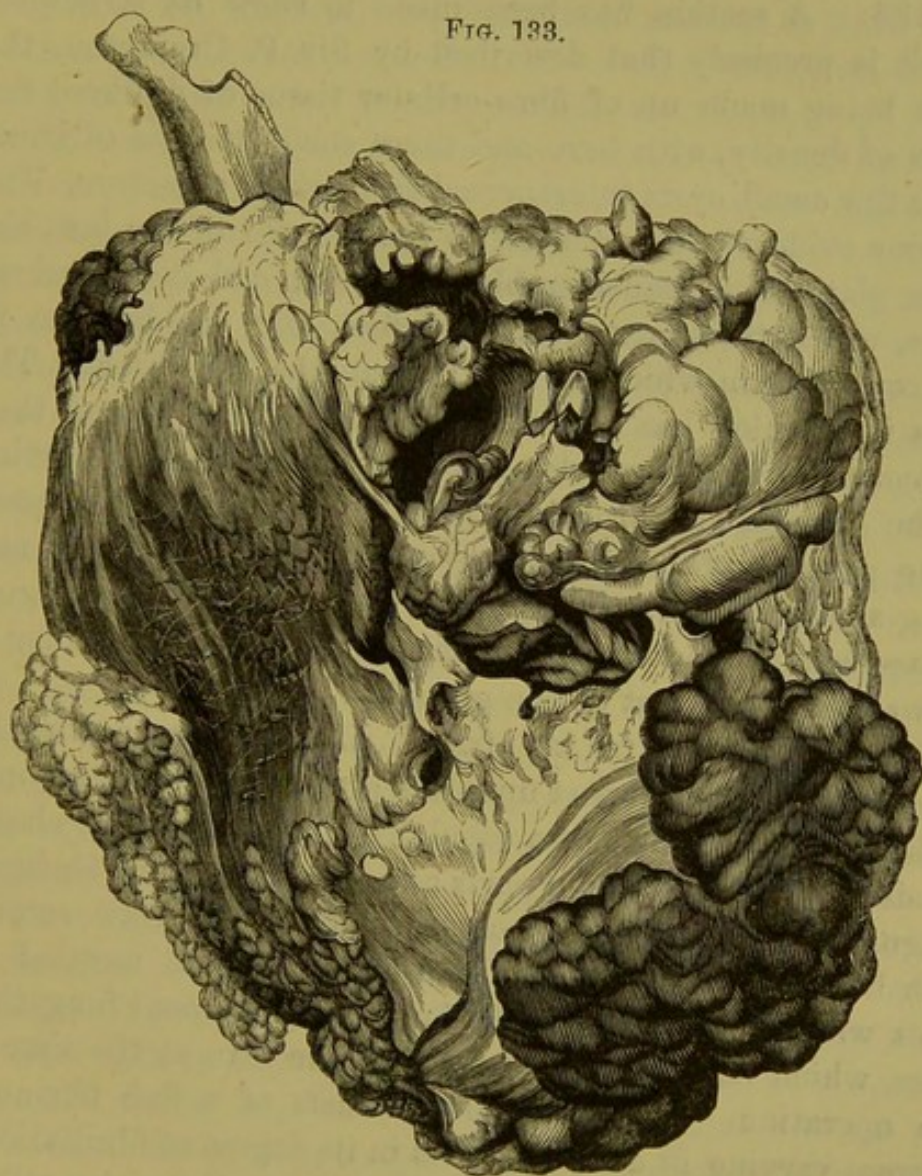


a photograph, and his case will be found in detail in the Appendix (Case XXIII.). The enormous size of the tumour can be best appreciated by the figure, the measurements being as follows:—From the lobule of one ear round the chin to the lobule of the other was  $19\frac{1}{2}$  inches; from the edge of the lower lip over the chin to the *pomum Adami* 13 inches; and the width of the face was 14 inches. The



circumference of the lips was  $9\frac{1}{2}$  inches. The patient was only thirty-two, and the disease appeared to have commenced eleven years before, in a small swelling below the right canine tooth, but the whole of the large growth had taken place within four or five years. The fungous protrusions were, as has been mentioned, the result of the application of

FIG. 133.



quack remedies. The patient, when he came under my notice, was in a miserable condition, being nearly starved, owing to the tumour forming a projecting mass within the mouth, which completely concealed the tongue, and was nearly in contact with the palate. I succeeded in removing



the tumour by sawing in front of the left angle and disarticulating on the right side, with very little loss of blood, but the patient died exhausted on the sixth day. The tumour weighed 4lb. 6oz., and accompanied this essay, being now in the Museum of the College of Surgeons (1041 A). Its appearance (reduced to about one-third) is shown in fig. 133. A section has been made to show its structure, which is precisely that described by Sir P. Crampton, the mass being made up of fibro-cellular tissue of different degrees of density, with here and there small nodules of bone, and a few small cysts interspersed through its structure. The tumour evidently commenced in the interior of the jaw, the outer plate being considerably expanded and destroyed in parts, whilst the inner remains perfect, and can be seen in the condition in which it was left at the operation. The mass in growing has carried up the teeth with it, and they project from it at irregular intervals, a considerable portion of the growth, and probably the most recently formed part, being posterior to them, occupying as it did the mouth and lying among the muscles beneath the tongue. The fungoid masses are covered with granulations, but otherwise differ in no way from the rest of the growth.

I am indebted to my friend Mr. A. Bruce for the following elaborate report upon the structure of this tumour: "The tumour consists of a lobulated mass of soft but elastic consistence, resembling in parts a recent decolorized fibrinous coagulum. It is for the most part of a pale straw colour, with here and there patches of a flesh tint, and mottled in spots with deep crimson. In front is a prominent fungating mass, which had penetrated through the skin at the time of the operation. The structure consists of a fine fibrinous stroma, varying in different parts in its degree of fibrillation; in some portions there are very distinct fibres, in others only imperfect ones, as is frequently seen in rapidly growing parts, whilst in others again the stroma is dimly granular, and closely resembles the matrix of cartilage, but differs from it in its softness; this latter character is limited to the parts in the interior in immediate connexion with the bone.



Embedded in this stroma are numerous cells, lying for the most part with their axes parallel to one another, but in many places without any apparent uniformity in this particular. The cells are small in size, at first sight more resembling elongated nuclei, but in all cases a cell wall may be distinctly traced when a sufficiently high power is employed. The majority are elongated fusiform or fibre cells, with a considerable proportion, however, of oval, rounded, or even polygonal cells. Their size varies from  $\frac{1}{2000}$  to  $\frac{1}{900}$  inch in diameter. The nuclei are proportionately large and prominent, and contain one or two very distinct glistening nucleoli. The cell contents, when any exist, are granular. Some of the rounded and polygonal cells closely resemble those found in malignant growths, especially in the irregularity of their arrangement, and their large eccentric nucleus; one cannot, however, lay much stress upon these characters in the present case, considering the small proportion which these cells bear to the whole mass of the tumour. Fragments of bone and of calcareous matter are found scattered throughout the tumour, and appear to be in part derived from the jaw itself, and in part to be a new development. The general structure of the tumour is that usually described under the head of osteo-sarcoma, and it belongs evidently to the group of simple fibro-plastic tumours, but differs from the myeloid fibro-plastics in the equal proportion existing between the cellular and fibrous elements."

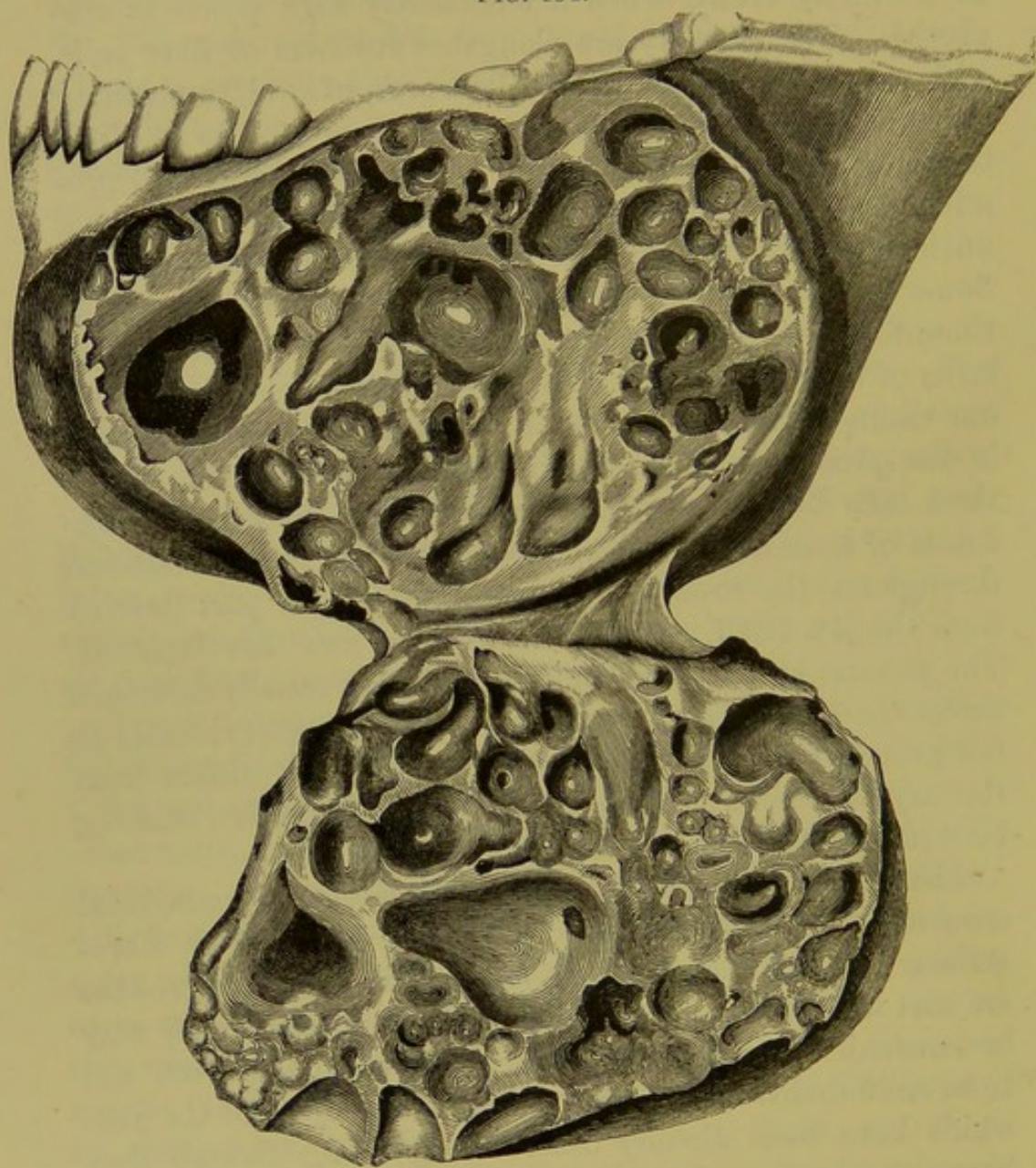
*Fibro-Cystic Tumour, or Cystic Sarcoma.*—The occasional occurrence of cysts containing fluid in fibrous or fibro-cellular tumours has been already referred to, but growths are met with in the lower jaw so full of cysts that they may be conveniently classed together. These tumours are not to be confounded with simple or compound cysts of the jaw, which have been already described (p. 168), though they have some common features—non-malignancy, slow growth, except after irritation, and the sensation of crackling often found from the yielding of remaining portions of the bone beneath the pressure of the finger.

The best example of the disease with which I am ac-



quainted is in the Museum of the Richmond Hospital, Dublin, and was removed by the late Dr. Hutton. It is represented in the accompanying woodcut (fig. 134), for which I am indebted to Dr. R. Adams, and shows very

FIG. 134.



beautifully the development of cysts of various sizes in a growth of a benign character, involving the whole of one side of the body of the jaw and extending to an inch beyond the symphysis. The patient was a young woman of twenty,



and the tumour had existed nine years, but had only recently made rapid progress, and produced great distress by its pressure on the tongue and mouth. Dr. Hutton removed the jaw from the right of the symphysis to the left angle, and the patient made a good recovery (*Dublin Hospital Gazette*, 1860). In this case the disease invaded only the body of the bone, but the ramus is also liable to it, a specimen in King's College Museum, removed by the late Mr. J. H. Green, being an instance in point.

The contents of these cysts vary in consistency and colour; in some cases being clear and limpid, in others almost gelatinous and of a dark colour. The fibro-cellular tissue in which the cells are formed may undergo fatty degeneration, thus constituting Stanley's fourth variety of tumour of the lower jaw, which he thus describes (p. 267): "Fatty substance, in granules, intermixed with cells containing a glairy fluid originating in the interior of the jaw." This description is apparently based upon an examination of a specimen (I. 147) preserved in St. Bartholomew's Hospital, showing a section of a lower jaw expanded by a tumour "consisting of granules of a peculiar fatty-looking substance, partitioned by fibro-cellular tissue and having cells dispersed through it, which cells contain a glairy fluid. The boundaries of some of the cells are thin plate of bone, apparently the remains of the original cancellous texture of the jaw."

A dried specimen of fibro-cystic disease is preserved in the Museum of Guy's Hospital (1091<sup>50</sup>), which is remarkable both for the situation of the disease and the age of the patient. It shows great enlargement of the bone with cysts in it, and includes the whole body of the bone from ramus to ramus. The patient was a boy of thirteen, who was under Mr. Key's care in 1841. He stated that the disease began as a lump two years before, on the anterior part of the lower jaw, and this gradually increased backwards. He never had much pain in it. The jaw was removed by Mr. Key, by sawing through it just below the angles on each side, and the patient recovered.



Instances of fibro-cystic disease, affecting both upper and lower jaw simultaneously, must be very rare. The only case I am acquainted with occurred in the practice of Mr. Skey in 1860, and presented a large uniform swelling about the size of the fist, which was found to consist of a cystic growth involving the outer wall of the upper and lower jaws. Mr. Skey cut away all the diseased portions, and the patient made a good recovery. (*Medical Times and Gazette*, June 2nd, 1860.)

In cases of fibro-cystic tumour the intra-buccal treatment recommended in cases of simple cystic disease is not applicable, and the portion of jaw involved must be removed. At the same time, as the affection is simply of a local character, there is no necessity to remove more than the affected portion, and the bone should therefore be sawn through on each side of it, and removed if possible without opening the articulation.



## CHAPTER XXIV.

TUMOURS OF THE LOWER JAW—(*continued*).*Myeloid, Cartilaginous, and Osseous Tumours.*

*Myeloid Tumour* is frequently met with in the lower jaw, and it was here that the disease occurred in the case from which Mr. Paget drew his description. The case is quoted by Mr. Stanley (*op. cit.* p. 184) as an example of "tumour of bone, composed of a soft, very vascular substance, having the characters of erectile tissue," but his general description corresponds precisely to that of Mr. Paget's. Figs. 1 and 2 of Plate 13 in Mr. Stanley's atlas show the tumour *in situ* and a section of the jaw after removal. "The patient was a boy in St. Bartholomew's Hospital, and the growth occupied the symphysis of the lower jaw, and protruding into the mouth presented a very vascular surface of a mottled red and purple colour, resembling the exterior of some nævi. The tumour was not tender to the touch, and had not been accompanied by pain; it was once destroyed by caustic to the level of the alveolar border of the jaw, but was quickly reproduced; it was then wholly removed with the portion of the jaw in which it originated, and the cure was permanent. The morbid substance was found imbedded in the cancellous texture of the jaw; it was soft, of a dark red colour, *closely resembling the tissue of healthy spleen.*" (Stanley, p. 185.)

Stanley mentions a case very similar to his own recorded by Dupuytren in his *Leçons Orales*, and in the Museum of St. Thomas's there is a very good specimen of myeloid disease, which was described by Sir Astley Cooper ("Surgical Essays") as "a fungous exostosis of the lower jaw, which



formed a large prominence on the chin" with "purple *fungi* of the gums," occurring in a woman, aged thirty-two. The preparation shows at the back part a small portion of firm, healthy bone, having a well-defined margin, and not sending out any spicula, from which the tumour projects. Around its base the tumour is covered with integument; but in front the latter has ulcerated, allowing the growth to fungate through the ulcerated aperture.

FIG. 135.

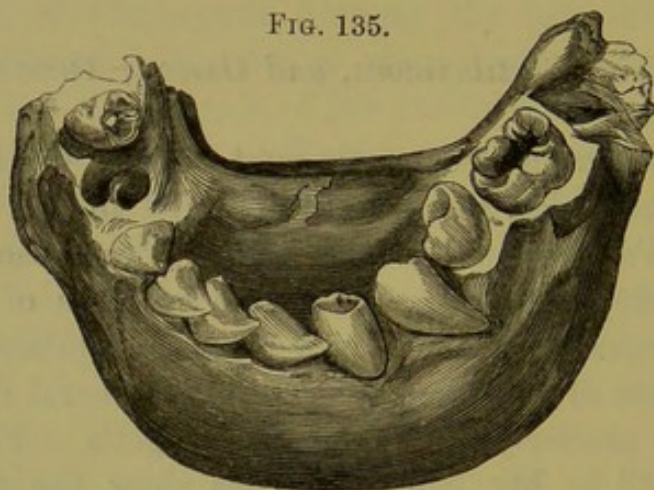
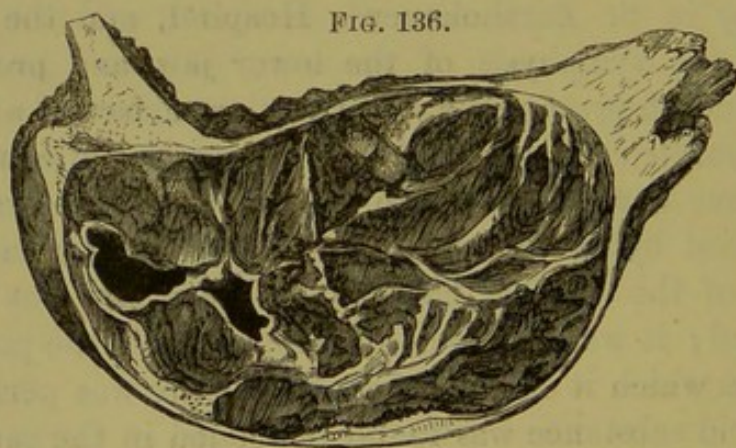


FIG. 136.



Accompanying this essay was a valuable preparation (1052 C) of myeloid tumour of the symphysis and body of the jaw, successfully removed by Mr. Craven, of Hull, from a young woman of eighteen, whose case will be found in the Appendix (XXIV.). Figs. 135 and 136 show very satisfactorily the appearance of the specimen, which has been divided



horizontally. The tumour was of between two and three years' growth, and was covered with healthy mucous membrane. Its section shows a well-marked specimen of myeloid disease imbedded between the plates of the lower jaw; its tissue is of the ordinary friable character resembling spleen, but somewhat decolorized by immersion in spirit, and it is intersected by fibrous septa. Two cysts may be seen in the section; these, as mentioned by the late Mr. H. Gray (*Medico-Chirurgical Transactions*, xxxix.), being of frequent occurrence in myeloid growths. The microscopic examination of Mr. Craven's specimen was unsatisfactory, owing to its previous immersion in spirit, but there can be no question from the naked-eye appearances of the nature of the growth.

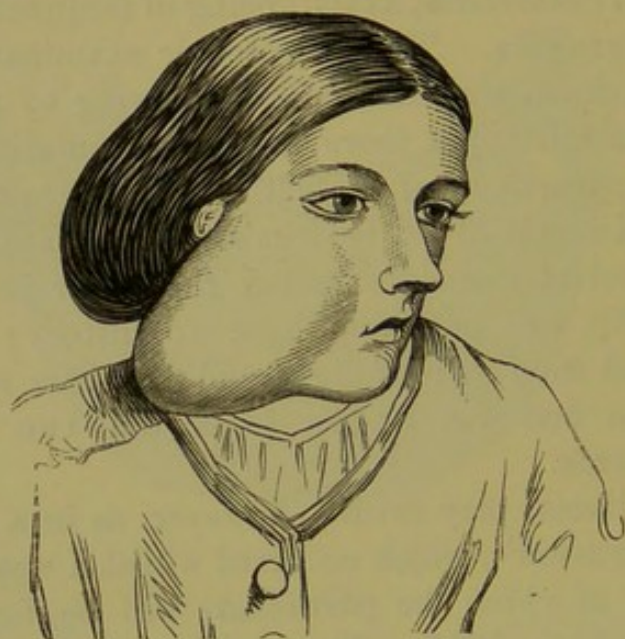In the Museum of St. George's Hospital are four specimens of myeloid disease affecting the lower jaw (II. 166, 167, 168, 169), two of which have no history; the others were removed from girls of eight and five years respectively, of whom the first was known to be well two and a half years afterwards.

Myeloid disease may return, however, as in a case of Sir William Fergusson's, which occurred whilst I was his house-surgeon, and of which the particulars will be found in the *Lancet*, June 13th, 1857. The patient, a young woman of twenty-three, had undergone a previous operation, but it was doubtful if the whole of the disease had then been removed. She presented a tumour of the right side of the lower jaw (fig. 137). Sir William Fergusson removed the tumour by sawing through the jaw at the canine tooth and disarticulating, but the patient unfortunately sank on the following day from exhaustion. The following is a description of the tumour, which proved to be myeloid, extracted from the published report, but it may be remarked that the colour hardly bears out the diagnosis of myeloid disease as ordinarily met with:—"It has been developed within the bone, which it has expanded into a thin envelope of compact bony tissue clothing its exterior. A section showed a surface of a clear white colour, bathed with clear serum (not milky when scraped), of considerable firmness, and present-



ing numerous osteoid deposits.—*Minute structure*: Is neither fibrous nor enchondromatous, as most of the tumours in the lower jaw appear to be. It is almost wholly built up of small cells, whose prevalent form is oval, either free in a dimly granular matrix, or, here and there contained in large parent cells, resembling those of foetal marrow. Very delicate fibres occur sparingly."

FIG. 137.



Another case of myeloid disease of the lower jaw, for which one-half of the bone was excised and which proved fatal from erysipelas, is briefly noticed in the *Medical Times and Gazette* of Sept. 3rd, 1859, as follows:—

"St. Thomas's Hospital, June, 1854.—A man, aged twenty-eight, cachectic and of very nervous temperament, was under Mr. Macmurdo's care for malignant disease developed within the bone. It was growing rapidly and expanding the bone on its exterior. The left half of the jaw was excised; the operation being attended with but little loss of blood. The patient did well for about ten days, when he was attacked by erysipelas, under which he sank about a fortnight after the operation. The tumour after removal proved to be of the fibro-plastic or myeloid class. No examination of the viscera after death was permitted."



A remarkable, and I believe unique, example of disease of both sides of the lower jaw, the microscopic characters of which are decidedly myeloid, has recently been under my own care, of which the following are the brief particulars. The patient, a boy of seven and a half, whose portrait is shown in fig. 138, presented a remarkable enlargement of both sides of the lower jaw, giving his face a very square appearance. The affection had come on gradually and painlessly from the age of a year and a half, and at the time I operated upon him the width of the jaw, as measured with

FIG. 138.



FIG. 139.



calipers, was five inches, the width of an average adult jaw being only four inches. The growths were evidently projections from the outer surfaces of the angles of the jaws, the inner surface of the bone being natural and the mucous membrane of the mouth not interfered with. In September and October, 1867, I removed the right and afterwards the left tumour through incisions behind the margin of the jaw, and without opening into the mouth. The main part of each projection was sawn off the jaw, and they accompanied this essay (1052 D), closely resembling large mussel shells filled with a cartilaginous-looking substance, which however (and especially some darker portions) gave distinct microscopic evidence of myeloid structure. A good



deal of this material, which seemed to fill the interior of the bone, was gouged away, and the symmetry of the face restored as far as possible. The boy made a good recovery, and fig. 139, from a photograph, shows his condition three months after the second operation, and at present there appears to be no tendency to recurrence. The case is given in detail in the Appendix, No. XXV.

*Cartilaginous tumours* of the lower jaw are not common, but they are found of two forms, the endosteal and periosteal, thus resembling the fibrous tumours. The disease generally occurs early in life, and makes slow but steady progress, the periosteal variety acquiring a very large size. A specimen in Guy's Hospital Museum (1019, 15, and 16) shows very well the relation of the endosteal variety to the bone, the growths occupying the space between the plates of the jaw and the teeth being imbedded in it. The specimen was removed by Mr. Key from a woman, aged twenty-nine, in whom it had been growing nine years, by sawing through the bone on each side of the tumour.

A somewhat similar case is recorded by Sir Astley Cooper, in his "Essay on Exostosis," and is remarkable both for the sound pathological views and strictly conservative treatment he therein advocates. The patient was nineteen, and had had a growth in the side of the lower jaw for three years. Sir Astley exposed the tumour and gouged it away, exposing the dental nerve, and the patient made a good recovery. He remarks respecting it (p. 177), "With regard to the cause of the disease, it was evidently the irritation of the decayed tooth, the fangs of which projected into the cartilage, which was effused within the bony cavity, and which, instead of producing suppuration and ulceration, as it frequently does, kept up a degree of irritation that did not pass beyond the stage of adhesive inflammation, and a cartilaginous deposit took place in the first instance, to which succeeded an ossific effusion. As to the treatment of this disease, it consists in first seeking the source of the irritation and removing it as soon as discovered, in order to prevent the further progress of the disease; and, indeed, it may



be probable that the removal of the source of irritation might sometimes, even when the disease has advanced to a considerable extent, succeed in producing a cure, and therefore it is desirable to wait the event before any further operation is undertaken. Should this, however, prove insufficient, it will be necessary that the external shell of the bone be removed by means of a saw, and that the cartilage which it contains be dislodged by an elevator. If the integuments be carefully preserved, little deformity follows; and thus, by a simple operation, destruction otherwise inevitable is prevented."

The periosteal form of enchondroma springs from the membrane covering any portion of the bone, but most frequently affects the body. It grows to an enormous size, and may cause death either by interfering with respiration, as in Sir Astley Cooper's case, or with deglutition, as in the case from which the preparation in the College of Surgeons was taken.

Sir Astley's patient was a girl of thirteen, in whom the tumour had made its appearance near the chin a year before she came under that surgeon's notice. The tumour increased until it measured five inches and a half from side to side, and four inches from the incisor teeth to its anterior projecting part. The circumference of the swelling was sixteen inches. The tongue was thrust back into the throat and to the right side, where it rested in a hollow between the angle of the jaw and the tumour. The epiglottis was bent down upon the rima glottidis so as to produce great difficulty in swallowing and breathing. The mental foramen was large enough to admit the little finger, and owing to the elongation of the bone was directed backwards. The preparation is preserved in the Museum of St. Thomas's Hospital (C. 201), and a section which has been macerated shows very well the ossific spicula from the surface of the bone projecting into the mass.

In the Museum of the College of Surgeons is a still more remarkable specimen of the same disease (1034), the tumour measuring six inches in depth and about two feet in cir-



cumference, and involving the whole of the lower jaw except the right ramus and angle. The patient, when thirty-two, had a small hard tumour on the right side of the lower jaw, just below the situation of the first molar tooth, which had decayed. This gradually increased, and ultimately proved fatal at the end of eight years, by inducing inability to swallow.

A remarkable case of enchondroma, weighing three and a half pounds (German), removed by disarticulation by Chelius, is preserved in the Heidelberg Museum, and is figured by Otto Weber (*op. cit.*).

A little less remarkable one, weighing eight ounces avoirdupois, with a long diameter of  $3\frac{4}{10}$  inches, and a short diameter of  $2\frac{8}{10}$  inches, and involving the whole of the left side of the bone, was successfully removed by W. R. Beaumont, Professor of Surgery in the University of Toronto, Canada, and is reported in the *Medico-Chirurgical Transactions*, vol. xxxiii.

The patient, a child aged seven years, was admitted into the Toronto Hospital, Sept. 17th, 1849. The tumour, on his admission, extended upwards to the zygoma and malar bone, almost covering the temporo-maxillary articulation; it reached downwards to fully an inch below the angle of the jaw, extending inwards into the mouth as far as the mesial plane; backwards beyond the ramus of the jaw, and forwards to the posterior bicuspid. It pushed the tongue quite to the right of the mesial plane, concealed the velum, and almost completely filled the isthmus faucium; the molar teeth of the upper jaw were deeply imbedded in the tumour, which kept the mouth at all times open, with a constant dribbling of saliva, the upper and lower incisors not meeting by fully half an inch. The tumour had been first observed three months before. On Sept. 25th, 1849, Professor Beaumont performed the operation for its removal, commencing by making a curved incision (the concavity upwards), extending from the lobule of the ear to the angle of the mouth, dissecting off the integuments from the tumour. The tumour was firmly wedged in under the malar bone;



the outer wall of the jaw was cut vertically through with a small straight saw; the section was then at one stroke completed with a strong bone-forceps; the condyle was disarticulated by being firmly grasped in a forceps, the joint being opened by dividing the external lateral ligament and capsule. The patient did very well; a small salivary fistula was formed in the cheek, which eventually healed, and on Dec. 1st, 1849, the patient was quite well. The right half of the lower jaw was drawn a very little towards the left side, about an eighth of an inch; the external cicatrix was a mere line.

In cases such as those last mentioned, the most satisfactory mode of treatment is no doubt complete ablation; but milder measures have occasionally been resorted to with success, for Lebert has recorded a case in which a large cartilaginous tumour was successfully removed by Dieffenbach, in instalments, and at three successive operations.

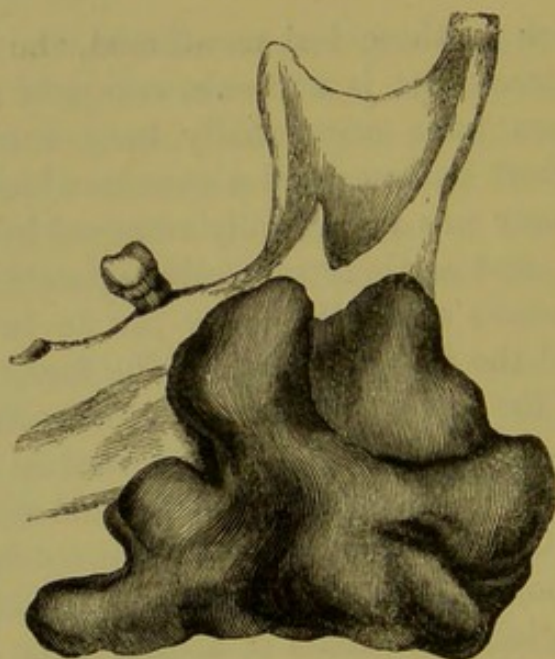
*Osseous Tumours* affect the lower jaw in two forms—the cancellated and the ivory exostosis. The former is no doubt in many cases the result of ossification of enchondroma, as, for instance, a specimen (C. 203) preserved in St. Thomas's Museum, which is of a spongy texture, and which is stated by Sir Astley Cooper to have been removed by Mr. Cline. Occasionally, however, a conversion of the whole thickness of bone into a lobulated mass of spongy bone is met with, of which an excellent example is preserved in St. George's Hospital Museum (II. 185). In this case the tumour, which was of the size of the fist, had been growing for five years, and had been on one occasion partially removed. Mr. Tatum successfully removed the entire portion of jaw affected. The Case will be found in the Appendix (No. XXVI.).

Ivory exostosis appears to affect by preference the angle of the jaw. Of this a good specimen is preserved in St. George's Hospital (II. 191); and O. Weber figures a section of a large ivory exostosis in the same region removed by Chelius. The best example of the kind, however, is in the College of Surgeons (1035), having been presented by Mr. J. F. South. The preparation (post-mortem) shows part of



the right side of the lower jaw, with sections of a large bony tumour at its angle. The angle of the jaw rests in a deep groove on the middle of the upper surface of the tumour, and in some situations their respective substances are continuous. The tumour projects both below and on each side of the jaw, is of irregular shape, measures nearly three inches in its chief diameter, and is deeply nodulated. It is composed throughout of bone, uniform in texture, and as hard and heavy as ivory (fig. 140).

FIG. 140.



When the exostosis forms a distinct and circumscribed growth, whether it be of the cancellous or ivory character, it should be sawn off the bone at the level of the healthy surface, and will in all probability not recur. When, however, the whole thickness of the bone is involved, as in Mr. Tatum's or Mr. South's case, it will be necessary to remove a portion of the bone. A remarkable case of exostosis of the ramus of the jaw, reaching to the styloid process, has been recorded by Mr. Syme, in his "Contributions to the Pathology and Practice of Surgery," in which he removed the ramus of the jaw, with the growth, by an external incision, without opening the cavity of the mouth.



## CHAPTER XXV.

TUMOURS OF THE LOWER JAW—(*continued*).*Cancerous Tumours.*

*Cancer of the Lower Jaw* is of frequent occurrence, and is ordinarily of the medullary form, though scirrhus is sometimes met with. Melanosis has been met with a few times, one case of which was operated upon by Von Gräfe, and is recorded by Müller (on Cancer). Of four hundred and three cases of tumour of the lower jaw, collected from various sources by Otto Weber, one hundred and sixty-two were examples of carcinoma of the soft or hard variety, and two only were cases of melanosis.

Medullary cancer begins usually in the interior of the bone, producing rapid expansion of it, and ultimately breaking through into the mouth, and also through the skin of the face if allowed to proceed unchecked. A specimen in St. Bartholomew's Museum (I. 208), illustrates the early stage of the disease, the bone being expanded by a medullary growth; and the later stages are admirably seen in the series of specimens from Mr. Liston's collection preserved in the Museum of the College of Surgeons. Only one of these (1054) need be particularized, showing, as it does, the extent to which medullary disease of the jaw may involve the surrounding tissues. The tumour extends from the right angle of the jaw to the right canine tooth, and all the intervening portion of the jaw is concealed within it. Anteriorly and below it forms a great nodulated mass, involving the muscles of the tongue and the upper part of the neck; posteriorly and above it projects far into the mouth,



pushing aside the tongue, and pressing backwards upon the larynx. The disease does not appear in this case to have commenced within the jaw, but in a gland which became adherent to the jaw (?) The patient, aged eighteen, died a year after the first appearance of the disease, from suffocation and exhaustion.

I have recently had under my care a very interesting case of medullary disease of the lower jaw, in a little girl, aged five—one of a numerous and healthy family, and who was in perfect health until seven weeks before I saw her. The mother then noticed that the second temporary molar tooth on the right side was loose, and the gum swollen, and a tumour developed so rapidly, that when I saw her the side

FIG. 141.



of the face was considerably enlarged, and a large fungous mass protruded into the mouth. On Sept. 10th, 1867, I removed the right side of the jaw from close to the symphysis to the articulation, and the preparation (1057 A), accompanied this essay. The structure of the growth was distinctly medullary. The child made a perfect recovery and was well for six weeks, when a small growth was noticed within the cheek, which made such rapid progress that in four days, when she was brought up to me again, there was a tumour filling the cheek, and involving the remaining portion of the jaw as far as the canine tooth, and a fungus had been thrown out through a portion of the old cicatrix.



On Oct. 26th, 1867, I removed the whole of the disease again, cutting the jaw on the left side immediately in front of the second molar tooth, and removing the whole of the skin involved in the fungus. The patient made a good recovery, and fig. 141, drawn from a photograph taken seven weeks after the second operation, shows her then condition, which was quite satisfactory, there being no evidence whatever of return, and very slight deformity, considering the amount of jaw removed.

The second growth, which was even more markedly medullary than the first, is preserved with it.

The child continued in perfect health to the end of the year, but early in January, 1868, the disease reappeared, both at the symphysis and in the masseteric region on both sides. Coupled with this, there was loss of appetite, great exhaustion, and irritability of the system; and the poor child gradually sank, and died on Feb. 9th, a little more than six months after the first appearance of the disease. The full particulars of this case will be found in the Appendix (Case XXVII.).

This case appears to me of considerable interest, since it shows the advantage of surgical interference, even under desperate circumstances. If the first growth had not been removed, the patient would have been shortly destroyed by the fungus in the mouth, whereas the operation gave her six weeks' immunity from suffering. The return of the disease was of such a rapid nature, that it would in a very few days have destroyed the patient by hæmorrhage from the true "fungus hæmatodes," which had already begun to form in the skin; but the second operation again relieved her, and restored her to comfort and apparent health for more than two months. When the disease finally appeared on both sides of the face, it was obviously beyond surgical control, and rapidly destroyed the patient. The relief which the operations afforded was, however, gratefully acknowledged by the friends of the little patient.

*Scirrhus of the Lower Jaw* appears to commence usually in the periosteum. The disease is by no means so common



as the medullary form, and few specimens of it are extant. A specimen (1058) in the Museum of the College of Surgeons, though classed among the medullary tumours, must, I imagine, from the history, have been a case of scirrhus. It is the left half of a jaw bone, the body of which has been, to a great degree, destroyed by the growth of a firm cancerous substance, which appears to have been developed on the exterior of the bone, and to have gradually produced ulceration and necrosis of it. At the angle of the jaw, adjacent to the growth, the bone is deeply and irregularly ulcerated, and near the symphysis several portions of it are completely detached. The patient was a man of forty-five, and the disease began in a hard enlargement in the situation of the submaxillary gland. After increasing for a year it extended into the mouth, where a fungous growth protruded, and subsequently the integuments of the cheek sloughed and rapidly ulcerated, and the patient died exhausted. After death cancerous masses were found in the lungs and liver.

By the kindness of Mr. Wilkes, of Salisbury, I was enabled to send in with this essay a specimen of scirrhus, near the angle of the jaw, for which that gentleman amputated one-half of the bone, which was exhibited to the Pathological Society of London, in May, 1862 (1058 A). The patient was a man of fifty, who had a globular mass below the middle of the horizontal ramus of the jaw, adherent to the bone, but moveable. The angle of the jaw was expanded on the outer side. After removal of the half of the jaw the tumour was found to be enclosed in a thick fibrous capsule, connected with the periosteum. On section it had the appearance of ordinary scirrhus, permeated by fibres, and resembling a raw potato, and a milky juice could be scraped from it with the scalpel. At its junction with the jaw, the bone was carious. The case will be found in detail in the Appendix (Case XXVIII.).

Mr. Coates, of Salisbury, has also been kind enough to place at my disposal another specimen of scirrhus connected with the lower jaw, which also accompanied this essay



(1058 B). The patient, a man aged sixty-seven, was admitted into the Salisbury Infirmary in November, 1863, with a tumour of the right side of the lower jaw, for which amputation of one-half of the bone was performed by Mr. Coates. The patient unfortunately sank eleven days after the operation. The tumour is closely connected with the periosteum on the inner surface of the jaw. It is of the size of a chestnut, and on section shows a small cavity in the interior. It appears to be of a scirrhus character.

The question of the necessity for the removal of large portions of bone in cases of cancer of the lower jaw may be here referred to. The two cases last quoted illustrate the doctrine and practice of the majority of surgeons, who maintain that in a case of cancer it is necessary to amputate at the joint above the disease, in order to obtain immunity. Unfortunately both these cases proved fatal at an early date, so that they furnish no information as to the recurrence of disease, yet it must be a subject of regret to have to sacrifice such a large amount of apparently healthy bone for a small extent of disease. If this doctrine is to be carried out fully, the *entire* lower jaw should be removed for disease of one side, for though the bone was originally developed in two halves there is nothing to prevent malignant disease spreading across the symphysis, as was seen in the case of medullary disease under my own care.

It certainly is essential that in dealing with cancer of the lower jaw the surgeon should go beyond the disease, and not meddle with the growth itself. A preparation (1057 B) accompanying this essay is an instance in point. It was removed, post-mortem, from a man who died under my care, with periosteal medullary cancer of the right side of the lower jaw. He had a swelling of the gum in the region of the molar teeth, which was thought by a dentist of repute to depend upon the irritation of some stump of a tooth. The growth was therefore incised, and a prolonged search made for the suspected fang, without result. The effect of this treatment was to excite very considerable action in the parts, the tumour rapidly increased in size, discharging large quantities



of fetid matter, and a considerable piece of necrosed bone could be detected with the probe. The patient, when he came under my notice, was not in a condition to bear any operative interference, and shortly died. The preparation shows a medullary tumour surrounding the greater part of the right side of the jaw, the bone within being in a state of necrosis, and the condyle and part of the coronoid process having entirely disappeared.



## CHAPTER XXVI.

DIAGNOSIS AND TREATMENT OF TUMOURS OF THE  
LOWER JAW.

*Diagnosis.*—The diagnosis of tumours of the lower jaw is easier than is the case in the upper jaw. Slowness of growth, hardness, and isolation point to a non-malignant tumour, and this will be confirmed if there is no tendency to fungate within the mouth, and no enlargement of the neighbouring lymphatic glands. Simple tumours of the lower jaw, if allowed to grow unchecked, may after a time burst through the skin, and thus give rise to a fungating mass, which, however, is of slower growth and more healthy appearance than the medullary fungus. Rapidly-growing tumours, especially if originating within the bone, are almost invariably cancerous, and the only chance for the patient is their early removal, with the portion of bone implicated.

The *prognosis* after removal of tumours of the lower jaw is more favourable than elsewhere, since, owing to the anatomical relations, it is easy to get rid of the whole disease. The question of the return of cancer being influenced by removal of one-half of the bone is, as already mentioned, still an open one.

The successful recoveries following removal of large portions of the lower jaw are very remarkable, operations on the lower jaw being as a rule attended by little constitutional disturbance. Mr. Cusack removed large portions in seven cases, with only one fatal result, which was due to erysipelas and œdema of the glottis. Dupuytren operated in twenty cases, with only one death resulting from the operation, and that from the same cause as in Mr. Cusack's fatal case. The experience of modern surgeons is equally



favourable. When the disease is of ordinary dimensions, and the patient is in fair health, the results are exceedingly satisfactory. The following table, extracted from the *Medical Times and Gazette*, Sept. 3rd, 1859, shows the results of eleven operations of the kind, undertaken in London hospitals.

*Table of Resections of Portions of the Lower Jaw.*

Number.	Sex.	Age.	Bone affected.	Nature of Disease.	Result.	Cause of Death.	Remarks.
1	M.	...	Right.	Malignant, 2 months.	Recovered.	...	The disease returned, and he died in four months.
2	M.	28	Left.	Myeloid.	Died.	Erysipelas, 2 weeks.	The man was in bad health.
3	F.	40	Right.	Fibroid, 3 years.	Died.	Pyæmia, 33rd day.	The woman was in very feeble health.
4	M.	31	Left.	Cystic, 3 years.	Recovered.	...	
5	M.	28	...	Malignant, 1 year.	Recovered.		
6	M.	25	...	Malignant, 9 weeks.	Recovered.		
7	M.	62	Left.	Malignant.	Recovered.	...	A return was feared.
8	F.	23	Right.	Myeloid, 6 years.	Died.	Exhaustion, 1 day.	The tumour was very large.
9	M.	33	Left.	Malignant.	Recovered.	...	It was secondary on cancer of the lip.
10	M.	32	Left.	Syphilitic enlargement.	Recovered.	...	The bone was enlarged and carious.
11	F.	17	Left.	Fibroid recurrent.	Recovered.	...	The tumour grew from the periosteum of the ramus.

*Operations on the Lower Jaw.*—Small tumours, involving the alveolus, may be removed with bone-forceps without any incision through the skin, and even a considerable portion of the central part of the lower jaw may be removed without incising the lip, if the mucous membrane between it and the bone be freely divided and the lip drawn well down. When the tumour is too large to admit of this, a horizontal incision across the chin would allow the lip to be dissected up so as to permit the application of a saw on each side.

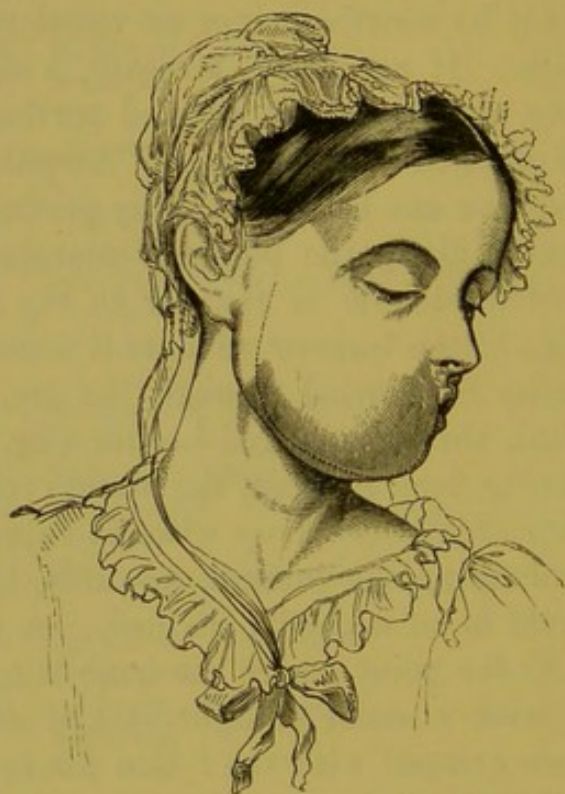

When a large portion of the body and ramus has to be removed, a curved incision may be advantageously carried along the posterior margin of the tumour, so that the scar may be well out of sight afterwards. In this the facial artery will be necessarily divided, and it is advisable to secure both ends immediately with ligatures, or the patient may lose a considerable quantity of blood. The tissues being then dissected off the tumour, a careful examination of it should be made to see if it be possible to extract the tumour by removing the external plate of bone with the gouge and bone-forceps, and no harm can come of such an attempt even if it be abortive, since no vessel of importance is interfered with. If necessary, however, a small saw can be applied above and below the affected portion, which can then be readily isolated and removed. Amputation of one side of the lower jaw can be conveniently performed through an incision running along the posterior margin of the bone from the level of the lobule of the ear to the median line, where, if the size of the tumour renders it necessary, a vertical incision may be carried through the lip, but not, if it can be avoided, through its red border (fig. 142). The facial artery having been secured, the tissues of the cheek and the masseter are dissected up without injuring the flap and without prolonging the incision upwards, by which the facial nerve would be of necessity divided. A tooth having been extracted at the point where the bone is to be divided, this is effected with a small straight-backed saw, and the bone having been grasped with the "lion forceps," is drawn forcibly outwards, whilst the knife is run along its inner side, care being taken to keep close to the bone, so as not to endanger the submaxillary gland or lingual nerve. The internal pterygoid muscle having been carefully separated from the bone, forcible traction is to be made upon the jaw, so as to depress the coronoid process, which by a few touches of the knife is freed from the fibres of the temporal muscle. The joint being now in view, the knife is to be applied to the front of it, when the condyle will be at once dislocated, and the knife can be carried cautiously behind it, so as to



isolate it. A forcible wrench of the bone will now tear through the few remaining fibres of the external pterygoid muscle, and the bone can be removed. In the case of small tumours this proceeding is sufficiently easy, but when the tumour is large it may so completely wedge in the upper part of the bone as to prevent its dislocation. Under these circumstances the best plan is to re-apply the saw and cut off the tumour as high as may be, and subsequently to remove the remaining portion of jaw. Another complication

FIG. 142.



is when the tumour breaks away from the upper part of the jaw during the operation, thus rendering it difficult to dislocate the condyle owing to the want of leverage. The "lion forceps" of Sir William Fergusson is exceedingly useful here, as I have experienced in two cases.

When the central portion of the lower jaw is removed it is well to take precautionary steps to avoid the possibility of the tongue falling back and suffocating the patient. A ligature should therefore be passed through the tip of the



tongue, which will enable a trustworthy assistant to keep it drawn forward until the operation is completed. The ligature should then be attached to one of the hare-lip pins with which the wound is closed, and may safely be cut and removed on the second or third day.

When one-half of the lower jaw has been removed some inconvenience is experienced from the remaining portion being drawn inwards by its muscles. To obviate this, Mr. Nasmyth, of Edinburgh, originally contrived some metallic caps to fit the teeth of the upper and lower jaws, and thus keep the bone in position. Mr. Liston speaks highly of this apparatus, but in my opinion it is unnecessary, as the bone shortly resumes its proper position.

FIG. 143.

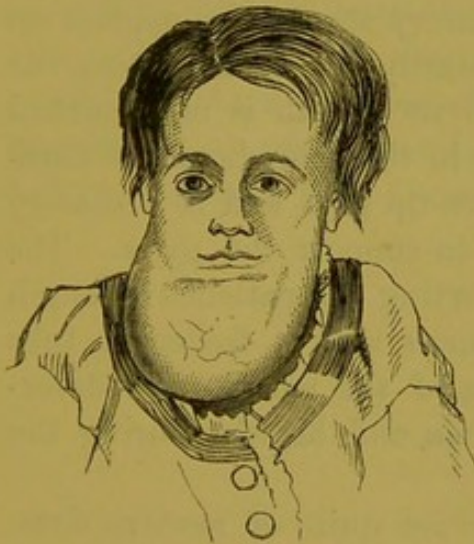



FIG. 144.



In the case of very large tumours, necessitating the removal of the greater part of the lower jaw, the direction of the incision is a matter of considerable importance. Figs. 143 and 144 show the incision recommended by Sir William Fergusson in cases of the kind; the great advantage being the non-interference with the lip (which is dissected up with the integuments of the chin), and the fact that the scar is completely hidden afterwards. On the other hand, this incision necessitates the division of both facial arteries, and if disarticulation on one side is requisite, will not afford good



room for the proceeding without danger to the facial nerve. In a case of very large osteo-sarcoma of the lower jaw, already described, I preferred an incision through the median line of the lip, and was able to dissect the flaps back with great ease and rapidity, and to avoid cutting either of the facial arteries.

The case in which Mr. Syme removed the ramus and condyle of the jaw without opening the mouth through an incision in front of the ear, has been already referred to, and Professor Humphry adopted a similar incision in the case in which he excised the condyle of the lower jaw, which will be found in the *Association Medical Journal* for 1856.

Whatever the operation which has been performed, care should be taken to secure all bleeding vessels, and when there are bleeding points deep in the wound which cannot thus be treated, the actual cautery should be applied to them. The dental artery, necessarily divided in sawing the jaw, is sometimes troublesome if its mouth is not touched with the cautery. The incision in the skin should be carefully adjusted with sutures or hare-lip pins, and if necessary a light bandage may be applied to support the parts. The after-treatment consists in supporting the patient's strength by administering fluid nourishment with a feeder or tube and bottle, and careful syringing of the mouth with detergent washes, so as to keep it clean and healthy during the process of healing.

Operations on the lower jaw are quite of modern date. Anthony White of the Westminster Hospital appears to have been the first surgeon who removed a portion of the lower jaw (1804). He was followed by Dupuytren (1812), Mott and Gräfe (1821), and Sir P. Crampton in 1824. Cusack's celebrated cases of disarticulation occurred immediately afterwards, and the operation became an established one. The names of Liston, Syme, and Fergusson have been prominent in connexion with this operation in this country, whilst abroad Lisfranc, Lallemand, Maisonneuve, Gensoul and other eminent men have given it their support.

It has been already noticed how little deformity often



results from the removal of portions of the lower jaw. Although the bone is never reproduced, a development of firm fibrous tissue takes its place, which affords support to artificial teeth, and to which the muscles gain a firm attachment. In February, 1855, Mr. Spence of Edinburgh brought before the Medico-Chirurgical Society of Edinburgh a preparation illustrating this point in a marked manner. Eighteen years before the patient's death Sir William Fergusson had removed the greater part of the right side of the lower jaw. Five years later Mr. Spence had removed the left side of the jaw from within half an inch of the symphysis to the articulation, and the condition found at death, thirteen years after, is thus described (*Edinburgh Medical Journal*, April, 1855):—"A dense fibrous texture connected the small portion of the ascending ramus of the right side with the remaining portion near the symphysis, whilst on the left side a similar texture occupied the place of the disarticulated bone, on both sides affording firm attachments to the masseters and other muscles, so that the patient during life had considerable use of the mouth."



## CHAPTER XXVII.

## CLOSURE OF THE JAWS.

*Spasmodic Closure of the Jaws*, which may be of several weeks' duration, is almost invariably connected with the eruption of the wisdom teeth of the lower jaw. Owing to want of room between the second molar and the ramus of the jaw, or owing to some malposition of the tooth itself, the wisdom tooth is unable to assume its normal position, and by the pressure which it exerts on the neighbouring structures sets up irritation, which induces a state of tonic spasm of the masseter and internal pterygoid muscles. This fact has long been known to dental surgeons, and is especially alluded to by Mr. Salter in his essay on "Surgical Diseases connected with the Teeth" (Holmes, vol. iv.).

In a discussion which took place at the Odontological Society, in May, 1861, which is reported in the *British Journal of Dental Science* of the same month, Mr. Tomes mentioned a case of the kind which had been allowed to go unrelieved for more than two years, and was immediately cured by the removal of the second molars, so as to allow the wisdom teeth to assume their proper position. Mr. Coleman, Mr. Mummery, and Mr. Ibbetson narrated on the same occasion very similar cases treated in the same manner; and Mr. Drew mentioned a case in which extraction of the half-cut wisdom tooth itself gave immediate relief.

The majority of these cases occur about the age of twenty, when the eruption of the wisdom teeth is to be expected, and the diagnosis is readily made. The treatment is obvious. The mouth must be opened by a screw gag, or



by wedges, under chloroform, and either room must be made for the wisdom tooth by extracting the second molar, or, if it can be reached, the wisdom tooth itself may be removed.

The impeded eruption of wisdom teeth gives rise to various and apparently anomalous symptoms, which are often not traced to their true source; but for a description of these I may refer to Mr. Salter's essay.

*Permanent Closure of the Jaws.*—Cases of permanent closure of the jaw from cicatrices within the mouth, &c., are not of very rare occurrence; but their description and treatment seem to have been very generally neglected by modern English authors. Erichsen, Pirrie, Druitt, Skey, and Pollock make no mention of the affection; and Samuel Cooper, in the last edition of his "Surgical Dictionary," which he revised, merely refers to a case treated by Valentine Mott, who, in 1831, operated on a case of sloughing of the cheek, with subsequent closure of the jaws, by transplanting a piece of skin (see *American Journal of Medical Science* for Nov. 1831); but he enters no further into the treatment. In the new edition of "Cooper's Dictionary," 1861, vol. i., the only passage I can find, bearing on the question, is the following, under the head of "Cicatrization:"—

"In the mouth, after sloughing of the cheek and gums from profuse salivation, the cicatrized surface is so rigid as scarcely to allow of the separation of the teeth, but it becomes more pliant in time." This latter statement, however, is not borne out by general experience.

Sir William Fergusson, in the last edition of his "Practical Surgery," p. 602, says:—

"The lower jaw occasionally becomes so closely bound to the upper, that the teeth cannot be sufficiently separated to admit of solid food. This condition may arise from inflammation and adhesion of the gums, more especially after necrosis of the alveolar processes; sometimes it is the result of chronic contraction of a muscle; occasionally it has been accompanied with ankylosis, both here and in other joints, of which there is a remarkable specimen in the possession



of M. Dubreuil, of Montpellier, in which, however, a similar condition was not present in any other part of the same skeleton; and in certain examples it is difficult to say what is the cause. Some years ago I had a patient with the mouth thus contracted, and in whom there was a portion of the lower jaw in a state of caries; the disease was not in such a condition that I could, with propriety, attempt its entire removal. A portion of bone, however, was excised, but little benefit resulted, and what there was might probably be attributed more to the use of a screw-dilator than to the partial removal of what I considered a source of irritation. Mott has succeeded, in two instances, in relieving such permanent adstrictions; and in the first volume of the *Provincial Medical and Surgical Journal*, there is a case recorded wherein I was fortunate enough to produce a similar effect, by dividing the masseter on one side with a narrow knife, passed from the mouth between that muscle and the skin. If ankylosis be the cause of closure, it is doubtful if the surgeon would be justified in interfering. In the course of my experience I have seen many instances of the kind above referred to, but feel bound to state that most of my attempts at improvement have utterly failed."

By far the most complete account of this affection, however, is given by Dr. Samuel Gross, of Philadelphia, in his large work on surgery, from which I take the following quotation:—

"*Ankylosis or Immobility of the Jaw.* — This distressing affection, which may be produced in a variety of ways, may exist in such a degree as to render the patient entirely unable to open his mouth, or to masticate his food.

"The most common cause, according to my observation, is profuse ptyalism, followed by gangrene of the cheeks, lips, and jaw, and the formation of firm, dense, unyielding, inodular tissue, by which the lower jaw is closely and tightly pressed against the upper. Such an occurrence used to be extremely frequent in our south-western states during the prevalence of the calomel practice, as it was termed, but is now, fortunately, rapidly diminishing.



"Children of a delicate, strumous constitution, worn out by the conjoint influence of mercury and scarlatina, measles, or typhoid fever, are its most common victims; but I have also seen many cases of it in adults and elderly subjects. In the worst cases there is always extensive perforation of the cheeks, permitting a constant escape of the saliva, and inducing the most disgusting disfigurement.

"Secondly, the affection may depend upon ankylosis of the temporo-maxillary joints, in consequence of injury, as a severe sprain or concussion, or arthritic inflammation, leading to a deposition of plastic matter, and the conversion of this substance into cellulo-fibrous, cartilaginous, or osseous tissue. I have met with quite a number of such cases, several in very young subjects.

"Thirdly, the immobility is occasioned by a kind of osseous bridge, extending from the lower to the upper jaw, or from the lower jaw to the temporal bone; such an occurrence, however, is not common, and is chiefly met with in persons who have suffered from chronic articular arthritis.

"Finally, immobility of the jaw may be caused by the pressure of a neighbouring tumour, especially if it occupies the parotid region, so as to make a direct impression upon the temporo-maxillary joint.

"However induced, the effect is not only inconvenient, seriously interfering with mastication and articulation, but it is often followed, especially if it occur early in life, by a stunted development of the jaw, exhibiting itself in marked shortening of the chin and in an oblique direction of the front teeth.

"When complicated with perforation of the cheek and destruction of the lips, the patient has little or no control over his saliva, and is so terribly deformed as to render him an object, at once, of the deepest disgust and the warmest sympathy.

"The treatment of this affection must depend upon the nature and situation of the exciting cause. When the difficulty is in the joint, occasioned by the formation of cellulo-



fibrous adhesions, the only thing that can be done is to break up the adhesions, upon the same principle as in ankylosis of any other joints. For that purpose—the patient being thoroughly under the influence of chloroform—the jaw is forcibly depressed, either by a wedge made of cedar-wood, or by an instrument constructed on the lever-and-screw principle, and figured by Scultetus in his ‘*Armamentarium Chirurgicum*.’

“When the immobility depends upon the presence of inodular tissue, the proper remedy is excision of the offending substance—an operation which is both tedious, painful, and bloody, and, unfortunately, not often followed by any but the most transient relief, owing to the tendency in the parts to reproduce the adhesions, however carefully and thoroughly they may have been removed. There is the same remarkable disposition in these cases to the contraction and regeneration of the inodular tissue as in the case of burns and scalds.

“During my residence in Kentucky I had a large share of such cases; and, although I never failed to make the most thorough work—not unfrequently repeating the operation several times, at intervals of a few months—it is my duty to state that few of them were permanently relieved. After the excision is effected, the patient must make constant use of the wedge, wearing it for months and years so as to counteract the tendency to re-closure.

“Immobility of the jaw, caused by the formation of an osseous bridge, might possibly be remedied by the removal of the adventitious substance by means of the saw and pliers. The great difficulty, however, in such an event, is the obscurity of the diagnosis.”

I must now refer to an essay by Dr. Frederic Esmarch, Professor of Surgery in the University of Kiel, on “The Treatment of Closure of the Jaws from Cicatrices,”\* in which he investigates the pathology of the affection, and describes an operation for its relief, by the formation of an

\* “Die Behandlung der narbigen Kieferklemme durch Bildung eines künstlichen Gelenkes um Unterkiefer.” Kiel, 1860.



artificial joint in the lower jaw—an operation which gave most satisfactory results in two cases under my own treatment.

Professor Esmarch says :

“Injuries to the mucous membrane of the cheek damage the mobility of the lower jaw in a greater or less degree by their cicatrization, as is well known.

“The cause of this ankylosis of the lower jaw is often thought to be a growing together of the inner surface of the cheek with the bones or gums; this is not a correct view, however, and has, in many cases, led to improper treatment. In order to clear up this error it is necessary to examine the conditions which, in health, make movements of the lower jaw within the mouth possible. The cavity of the mouth is divided by the alveoli and teeth into an inner and outer space; the latter is closed in front by the cheeks and lips, which form an elastic dilatable sac; within this the rows of teeth can be separated from each other, even with the lips shut, and much further when the mouth is opened. The inner surface of this sac is covered by a mucous membrane which is also very dilatable and elastic, and which forms a duplicature at the upper and lower boundaries of the outer cavity of the mouth, where it is reflected on to the outer surface of the bone, and ends on the edges of the alveolus as gum. This membrane is so elastic that when the mouth is open to its widest extent it is still by no means put on the stretch; whilst, when the mouth is closed, it presents no folds.

“It is clear that as soon as this dilatable sac shrinks together, loses its elasticity, or is replaced by a rigid substance, the mobility of the jaw must either be injured or entirely cease. This happens most frequently through the formation of cicatrices which follow ulceration or sloughing of the mucous membrane of the mouth, as from mercurial stomatitis or noma.

“The occurrence of what we call secondary cicatrix atrophy, or cicatrix contraction, is sufficiently well known. As soon as the cure commences, the moveable parts of the neighbour-



hood, so far as they can be, are drawn by the shrinking of the newly-formed tissue towards the cicatrizing spot; slowly, it is true, but with almost irresistible power.

"If there are no parts in the neighbourhood which can be drawn together to repair the loss of substance, there necessarily follows a cicatrization of the surface; but the cicatrix remains thin, tender, and stretched to a great extent for some time at least after its formation; it is only after it has existed for a long time that it assumes a more ductile condition, so as to become something more like the natural skin or mucous membrane.

"If, therefore, the mucous membrane of the cheek be completely destroyed from one alveolus to the other, or both, or merely on one side, the resulting cicatrix must necessarily tend to press the jaws more and more closely against one another, the depressor muscles of the lower jaw being quite incapable, as experience has shown, of preventing the contraction of the cicatrix. When cicatrization is complete the elastic ductile mucous sac of the cheek is found to have disappeared, and instead of it the cicatrix tissue stretches so tightly from one alveolar edge to the other that it is scarcely possible to put the finger between it and the rows of teeth; and the teeth themselves can be separated only a little, if at all, or only shifted from side to side very slightly.

"Just the same immobility of the lower jaw follows cicatrization after sloughing involving the whole thickness of the cheek, although here the opening of the mouth is widened as far as the anterior edge of the masseter muscle, or still farther; and in this case, too, the cheek sac is entirely destroyed. In these cases it is the *quasi* lip or posterior margin of the gap which stretches tightly from one jaw to the other. If, in such cases, one is successful in covering the loss of substance by dividing the skin, or by transplantation of a flap, the cicatrization of the inner surface of the flap (being uncovered by mucous membrane) necessarily has the effect of increasing the immobility of the lower jaw.

"As far as is known there are few or no means available to check the shrinking of cicatrices. It is one of Dieffenbach's



great services to surgery that he gave this theory its full value; it was he who first taught us to place a proper value upon this action of nature, and showed how to make it available for operative procedures under certain circumstances. Thus, he first taught how to cure the closure of the mouth by covering the margin with mucous membrane; to form eyelids which do not adhere to the globe or roll inwards after cicatrization; and many other methods which we now consider self-evident in plastic surgery.

“Also, for the treatment of the worst cases of cicatrized contracted jaw, Dieffenbach has given the most rational advice when he suggests, after the separation of the cicatrix from the bones, to lay over the surface of the wound a sound flap of mucous membrane. Unfortunately, in most cases, this cannot be done, because, just in the neighbourhood of the cicatrix, it is impossible to find more healthy mucous membrane. Instead of the mucous membrane one can undoubtedly do as Jaesche did (*Med. Zeitung Russlands*, xxvii. 1858), viz., make use of a flap of skin for a lining; still it is difficult in many cases to get such a flap from the immediate neighbourhood. I would not hesitate, however, in desperate cases—as, for instance, where there is a great deficiency on both sides, to take a flap from the skin of the arm.

“All the hitherto received methods, such as the freeing or cutting through of the cicatrix from the mouth—the separation of the whole cheek, in order to accomplish this perfectly—the extirpation of the mass of cicatrix—the application of mechanical apparatus in order to drag the jaws asunder by degrees, &c. &c., can only be of avail in those cases where, in some angle or other, there is found a remnant of mucous membrane. If one succeeds, after separation of the cicatrix, in preventing, by the application of mechanical means for a long time, the cicatrization in the undesirable direction, the contraction will take place in another direction, and by degrees will drag the remnant of mucous membrane up to the skin. In every case it takes years before such methods can be properly estimated; for, as far as is known,



the secondary shrinking of a cicatrix takes place very late, even after complete or sufficient healing over has occurred. Putting aside the more favourable cases, there still remains a number of patients of this kind, in whom the usual methods produce no lasting cure, just because there is no more old mucous membrane left; and for these cases I recommend the formation of an artificial joint in *front of* the contraction, in order to give, at least, the other half of the jaw some, although a limited motion, and so to lessen considerably the sufferings of those unfortunate patients.

“The formation of an artificial joint in the ramus of the jaw has already been recommended and tried by Dieffenbach (*‘Opérative Chirurgie,’* i. 435), but *behind* the contraction, and naturally without any good result, since the impediment to motion lies more forward, and thus is not removed. Von Brüns has also operated in this manner without success.”

This proposal of Professor Esmarch's to form a false joint in front of the cicatrix was suggested to him by a case which came under his care in 1854, in which considerable destruction of the cheek and contraction of the cicatrix had occurred, together with immobility of the lower jaw and necrosis of a portion of it. The necrosed portion was fortunately in front of the cicatrix. The bone having been removed, it was found that mobility was restored, and a useful amount of movement obtained. Professor Esmarch therefore suggested, at the Congress of Göttingen, in 1855, the removal of a piece of bone in cases of contracted cicatrix; but did not happen to meet with a case suitable for the operation until after it had been successfully performed by Dr. Wilms, of Berlin, in 1858, shortly after which he himself operated upon a case at Kiel, and with the best results. The operation was subsequently performed by Dittl, of Vienna, (*Oest. Zeitschrift für praktische Heilkunde*, vol. v. p. 43, Vienna, 1859); and by Wagner, of Königsberg (*Annali di Medicina di Koenigsberg*, vol. ii. p. 100, 1859).

Shortly after this proposal of Esmarch's, it would appear that Professor Rizzoli, of Bologna, quite independently conceived a somewhat similar idea, but modified the proceeding



by merely cutting through the jaw, without removing any portion of bone. He operated in this way first in 1857, and subsequently had three other successful cases. In Rizzoli's cases no external incision appears to have been made, but the section was accomplished from the mouth with powerful forceps. This proceeding has been followed by Professor Esterle, from whose essay in the *Annali Universali di Medicina* (Omodei, vol. clxxvi.), I have extracted these particulars.

Esmarch's operation appears to me to possess a decided advantage over that of Rizzoli, in the fact that a piece of bone is removed, by which the formation of a false joint is facilitated, as we know by experience in cases of resection of the elbow, &c.; and the external incision can never be a matter of any importance, whilst it admits of the application of the saw, and so avoids risk of splintering the bone.

Mr. Mitchell Henry was, I believe, the first surgeon to put Esmarch's operation into practice in this country, he having performed it a few weeks before myself. The patient was a female, on whom a variety of operations had been performed, and, among others, division of the masseter, and whom I had had under my own care at the St. George's and St. James's Dispensary, two years before, when I divided the cicatrices freely and screwed the mouth open, but without permanent benefit. Mr. Henry employed the chain saw, and removed about half an inch of bone. The patient, unfortunately, sank a few days afterwards, apparently from pyæmia and exhaustion. In my own cases I used an ordinary Hey's saw, in preference to the chain, and was enabled to remove sufficient bone to give free movement, through a small incision along the edge of the jaw.

The subject of the contraction of cicatrices in the mouth, and their treatment, though it has attracted little notice among British authors, in Paris, on the contrary, has attracted much attention, and has furnished the topic of frequent discussions at the Société de Chirurgie. Since the date of the publication of a paper upon the subject by M. Verneuil (*Archives Générales*, 1860), several operations



have been performed by French surgeons, but apparently with but little success, since in cases operated on both by the method of Esmarch and of Rizzoli re-union of the divided jaw has taken place.

Thus, on the 4th February, 1863, M. Boinet brought before the Society a little girl on whom he had previously performed what he terms Esmarch's operation (but which appears to have consisted in the simple division of the jaw, recommended by Rizzoli, and not the removal of a wedge of bone, as originally proposed by Esmarch), and in whom the bone had re-united. M. Deguise thereupon quoted a case in which he had removed a centimetre and a half of bone with the same unsatisfactory result, and expressed a doubt whether a single successful case could be produced. On the 11th February, 1863, M. Deguise brought the case he had alluded to before the Society, and showed that the failure "depended upon the formation of an osseous callus at the level of the resected portion." At the same meeting M. Bauchet showed a young Syrian girl in whom contraction of the left side had taken place, together with a loss of substance of the cheek and commissure of the lips, equalling a five-franc piece in size. In this case a centimetre and a half of the jaw was removed; and though extensive suppuration and necrosis of the jaw ensued, the girl made a good recovery, and at that date (4th February) a very satisfactory amount of movement and power of mastication had been obtained.

On the 29th July, 1863, M. Verneuil communicated to the Société de Chirurgie the histories of several cases operated upon by M. Rizzoli himself, the results of which were most satisfactory. In the first the operation (simple division of the jaw from within the mouth) was performed in 1857, and after six years the boy was able to eat solid food most satisfactorily; the second case, operated upon in the same year, was equally good. In the third case, operated upon in 1858, the mouth could not be widely opened, and the child had some difficulty in speaking. The fourth case, operated upon in 1860, was most satisfactory. M. Verneuil also



mentioned a fatal case which occurred in M. Rizzoli's practice, and alluded to my paper in the *Dublin Quarterly Journal* of May, 1863.

It would appear that M. Rizzoli has adopted the plan of inserting a foreign body, such as a piece of gutta-percha, between the cut surfaces of bone, with the view of preventing their re-union, and the possibility of doing this was roundly denied by one of the speakers at the Société de Chirurgie. There appears to me, however, to be no difficulty in effecting this, provided the section be made from within the mouth and without external incision, as proposed by M. Rizzoli, but I cannot speak with certainty, having no experience of his operation.

One observation of M. Verneuil's is, I think, worthy of special notice, viz.—that all Rizzoli's successful cases have been examples of contraction within the mouth without loss of substance of the cheek, whereas the unsuccessful cases of the operation which have occurred in Paris had suffered considerable damage in the soft tissues; and he suggests that in these cases Esmarch's operation may be more properly applicable. In one of my cases the loss of substance in the cheek had been replaced by a dense cicatrix, which it would have been unwise to interfere with from within the mouth, and at the same time, owing to its firm contraction, it would have been impossible to have performed Rizzoli's operation in the way he recommends, viz.—without any external incision. I therefore resorted to Esmarch's proceeding, with the results of which I have every reason to be satisfied.

The first case in which I performed Esmarch's operation was in a boy, aged fifteen, who was sent to me by Mr. Martin, of Portsmouth, in 1863, with complete closure of the jaws, the result of the contraction of cicatrices within the mouth following extensive necrosis. The cicatrices had been divided, and his mouth screwed open in 1856, but without permanent benefit, and he obtained his food by rubbing it between his teeth, or by putting it through an aperture between the teeth on the right side. The mouth



was finally closed, the teeth overlapping; there was a cicatrix at the right angle of the mouth, and a dense band could be felt within the mouth on the same side. Fig. 145 shows his condition on admission. I made an incision two inches long along the lower border of the jaw, in front of the right masseter, and removed a wedge of bone measuring rather more than a quarter of an inch along the upper, and half an inch along the lower border. The piece contained the mental foramen. The mouth could now be freely opened, and the boy was discharged at the end of a month able to

FIG. 145.

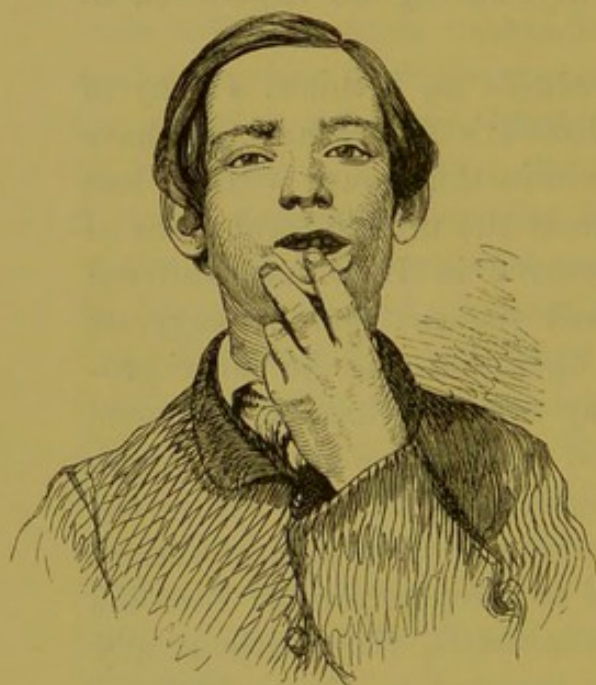
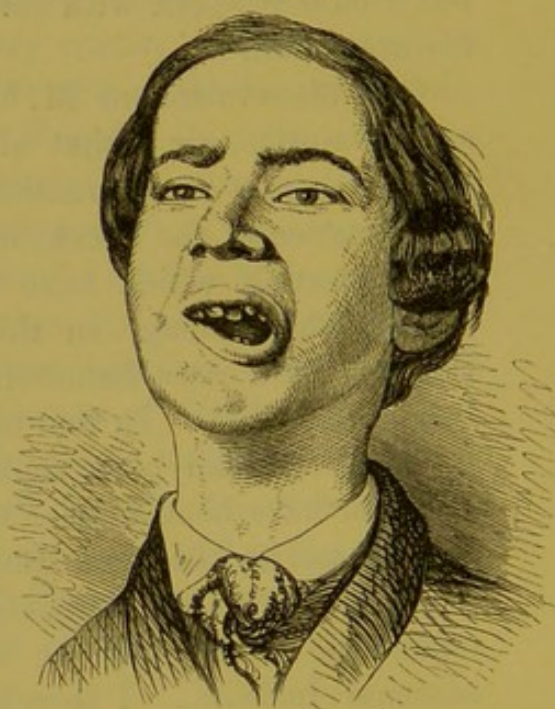


FIG. 146.



open his mouth, as seen in fig. 146; the distance between the teeth being  $\frac{7}{8}$  of an inch. The complete case will be found in the Appendix (Case XXIX.).

The second case in which I operated in the same manner was complicated by the presence of a dense cicatrix occupying nearly the whole of the cheek of the affected side. The angle of the mouth had also given way during a recent attack of fever, and the patient presented the unsightly appearance shown in fig. 147. The patient was twenty-three years old, and the sloughing and contraction occurred at the



age of six. She was sent to me by Mr. Bullen, of the Lambeth Infirmary, in January, 1864. I made an incision along the border of the jaw, and, as in the former case, removed a wedge of bone measuring  $\frac{7}{8}$  of an inch along its lower border. This also contained the mental foramen. The patient's mouth could now be opened to the extent of half an inch. I made two subsequent attempts to remove the deformity of the cheek by plastic operations, but only succeeded in restoring the commissure of the lips, the vitality of the cicatricial tissue being too low to admit of its unit-

FIG. 147.

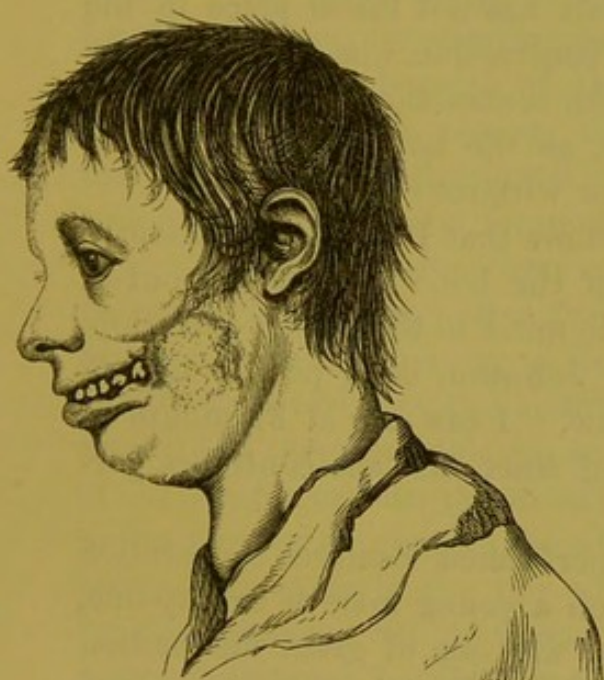
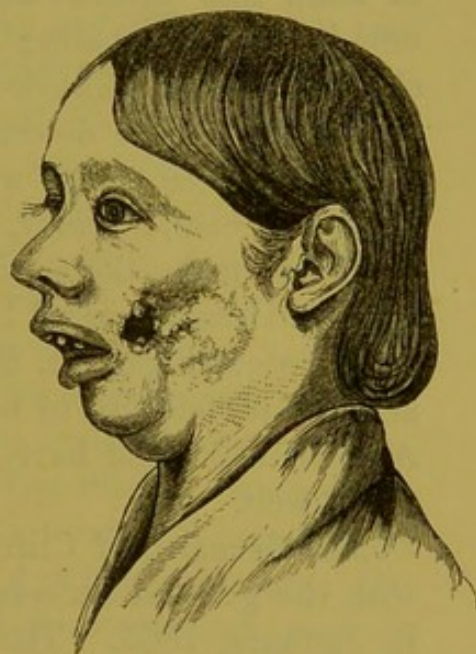

FIG. 148.



ing with other tissues. At the time of her discharge the commissure of the lip was half an inch in breadth; and with a piece of black plaster over the opening which was left behind it, the patient was very comfortable.

Fig. 148 shows her condition at this time with the mouth open. The details of this case will be found in the Appendix (Case XXX.).

With regard to the permanency of the relief afforded in these cases, I may mention that Barton B., the boy on



whom I operated in July, 1862, continues in perfect health, and able to take plenty of nourishment, although the movements of the jaw have very decidedly diminished, owing, apparently, to contraction of the fibrous tissues around the new joint, due, as the patient and his mother believe, in the first instance, to the cold of the severe winter following the operation, from which he suffered considerably.

In March, 1865, I had the boy up from the country, and found that the space between the left molar teeth had diminished from seven-eighths to one-eighth of an inch, and that between the left lateral incisors, from five-eighths to two-eighths of an inch. The movement was still free enough to show that osseous ankylosis has not taken place in the new joint; but whether the contraction was due simply to changes at that point or to the contraction of some band it was impossible to determine, as the boy positively refused all interference, either with or without chloroform.

In this case, however, I believe that I was not sufficiently careful to make the section of the bone entirely in front of the cicatrices, a point I bore in mind in the second operation.

The second patient, Ellen Johnson, is in perfect health, and has perfect use of her jaw. I saw her at Plymouth in August, 1865, and have heard since that she continues perfectly well.

Mr. Bernard, of Clifton, performed Esmarch's operation with the greatest success, upon a young man of twenty-one, in January, 1865. The case was one of great destruction of the cheek by sloughing, and the alveoli of the upper and lower jaw projected considerably through the aperture thus left. Mr. Bernard cut away the alveoli, and then removed a wedge from the lower jaw in front of the contractions with the most satisfactory results.

In connexion with this subject, and to show the pathological result of the proceeding, I may refer to the following account of the post-mortem examination of a case of Esmarch's operation, read before the Société Impériale de Chirurgie, Sept. 5th, 1866.

M. Boinet showed the lower jaw of a girl who had closure



of the jaws from cicatrices resulting from cancrum oris. Rizzoli's operation had been performed at the beginning of 1860, but failed at the end of twelve months. In 1863 a wedge was removed with perfect success. She died of phthisis in 1866:—

“The right ramus of the jaw is deformed, being shorter and broader than on the opposite side. The condyle and the coronoid process are less separated and shorter than on the left side, and the sigmoid notch is shallower. The left temporo-maxillary articulation has lost much of its mobility, and the ligaments are shortened. The sections had been made in the middle of the body of the bone, the angle being intact. The lower border of the jaw presents a difference in length of  $1\frac{1}{2}$  centimetre between the two sides, which corresponds to the breadth of the wedge of bone removed at the operation. The osseous tissue of the ascending ramus appeared reddened, the dental nerve was natural at its entry into the inferior dental foramen. Between the two portions of the jaw there exists a very complete false joint, which is permanent three years after the operation; it is very mobile, and the parts which serve as the hinge are fibrous and sufficiently stretched that the middle portion of the jaw can fall; during life this was sufficient to allow easily the introduction of the forefinger into the mouth. The fibrous tissue which unites the bones occupies the whole interval left between the bones, and extends for the whole depth of the jaw. Its breadth appears to be quite a demi-centimetre, and its strength uniform.”—*Gazette Hebdomadaire*, Oct. 12th, 1866.

The treatment of cicatricial contraction within the mouth by simple division has been proved over and over again to be worse than useless, but when suitable apparatus is adapted to the jaws, so as to prevent re-contraction, a very good result may, with patience, be produced in cases uncomplicated by destruction of the cheek itself.

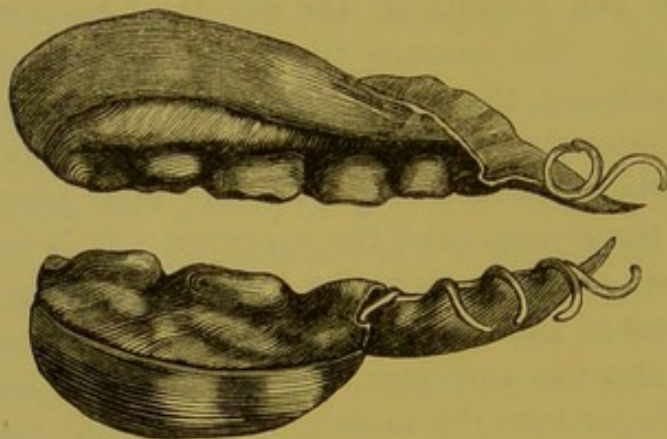
The only drawback to this mode of treatment, and one with regard to which it contrasts unfavourably with Esmarch's proceeding, is the amount of pain which the patient must, of necessity, undergo during the after-treatment. It requires



no small amount of courage on the part of the patient, and some determination on the part of the attendant, to carry out the necessary manipulations within the mouth, more particularly during the first few days after the operation; and even after the shields are fitted to the mouth, they cause some pain and inconvenience, which only those who have arrived at years of discretion will submit to.

Fig. 149 shows the form of the silver "shields" adapted to the upper and lower jaws by Mr. Clendon, late dental-surgeon to the Westminster Hospital, in a case of Mr. Barnard Holt's. The patient was a girl of seventeen, and was under Mr. Holt's care in 1862, having five years before had

FIG. 149.




fever, with an abscess in the cheek, on the right side, which led to such contraction and adhesion of the mucous membrane to the jaw as to cause great difficulty in opening the mouth. Some attempts had been made to open her mouth by the screw, &c., and in 1860 Mr. Holt divided some of the cicatrix with temporary benefit. Mr. Holt now divided the cicatrix within the cheek freely under chloroform, and encountered a firm plate of bone extending between the alveoli of the two jaws, which necessitated the use of a saw for its division. Mr. Clendon subsequently fitted the above-mentioned shields to the teeth, and wedges were gradually introduced between them to separate the jaws. This treatment was continued for three months, when she was able to



open the mouth to the full extent, as seen in fig. 150. The case (No. XXXI.) will be found in the Appendix.

The effect of the use of the shields seems to have been, not merely to prevent adhesions between the inside of the cheek and the alveolus, but to re-establish, to a great extent, the sulcus of mucous membrane at the base of the alveolus, upon which so much stress is laid by Professor Esmarch. Surgical experience in cases of ruptured perineum, &c., shows how soon mucous membrane is reproduced where it has once existed, or even appears on adjacent parts when its presence

FIG. 150.



gives rise to inconvenience; and there can be no question that in this case the mucous lining of the cheek has been reproduced to a great extent, and particularly near the lower alveolus. Esmarch's theory, that there must be some portion of old mucous membrane remaining which afterwards becomes stretched, is certainly untenable as regards this case at least, for without doubt the whole lining of the cheek and the outside of the alveoli were perfectly raw, owing to the division of the firm cicatrices.

The cause of non-success in former attempts at mechanical appliances is to be found, I think, in the fact that they have all been directed simply to keeping the jaws apart, without



any reference to the re-establishment of the mucous lining of the cheek, upon which, as Professor Esmarch says, the movements of the jaw so much depend. That the success in this case depended upon this fact is proved, I think, by the existence of a firm band in the cheek which would effectually control all movement were its extremities attached to the two alveoli; but as it is, it gives no inconvenience, and will, in all probability, atrophy in the course of time.

At the Odontological Society, in June, 1864, Mr. Cartwright narrated a very similar case of contraction (with the exception that there was no bony bridge between the alveoli), in a woman, æt. thirty-eight, which he successfully treated by similar means, using wedges of vulcanized india-rubber affixed to the shields to obtain the necessary distension.

The occurrence of an osseous lamella or bridge between the two jaws is a rare but not unique occurrence. In the *Medical Gazette* of July 4th, 1845, Mr. J. G. French has reported and figured an excellent example of ankylosis produced by a bridge of bone, which occurred under that gentleman's care at the St. James's Infirmary.

The patient was twenty-two at the time of his death, and the closure of the jaws dated from infancy. He was fed through an aperture made by the removal of the incisors on the left side. At the age of fourteen an operation for his benefit had been undertaken by an eminent surgeon, and incisions in the mouth had been made with this object, but without any good result. On post-mortem examination the jaws were perfectly united on the left side, and only the smallest degree of motion was possible on the right; the soft parts were removed and the base of the skull was macerated, when ankylosis was discovered to exist between the upper and lower jaws on the left side, the ramus of the inferior maxilla, immediately internal to the mental foramen, extending upwards by a broad thin plate, and uniting with a corresponding plate of the superior maxilla, a cartilaginous material forming the bond of union. The articulation of the jaw was normal.



Mr. Trueman also mentioned in the discussion which followed the narration of Mr. Cartwright's case (*British Journal of Dental Science*, June, 1864) that he remembered seeing in the Museum at Berlin a very curious case in which cicatrices existed on both sides of the mouth, which were completely ossified, so that the preparation showed the two jaws united by filaments of bone, one on either side of the jaw externally.

Subsequently to Mr. Holt's case, I had under my care a patient with a very severe form of contraction—viz., on both sides of the mouth. The patient was eighteen, and the contraction dated from her fifth year, when she had fever. Various attempts had been made to give her relief by dividing the cicatrices and using wedges, &c., without benefit; and when she came under my care she had no power of separating the jaws at all, and the cheeks were firmly attached to the alveoli from the angles of the mouth. Having secured Mr. Clendon's co-operation, I freely divided the cicatrices, and after repeated trials that gentleman succeeded in fitting in shields resembling those used in Mr. Holt's case, but reaching over both sides. It was found necessary to extract all the teeth, and after more than three months' assiduous care and frequent modification of the shields, the patient being constantly placed under the influence of chloroform for the purpose, a very satisfactory result was obtained, there being exactly one inch between the metal shields in the incisive region, which would have left about half an inch if the teeth had been *in situ*. The case will be found in detail in the Appendix (Case XXXII.).

In order to contrast the permanent results of this method of treatment with that by removal of a portion of the jaw, I may mention that three years after the operations, I ascertained the following facts respecting these patients:—

Frances H., the girl treated by Mr. Holt by internal division and the application of metal shields, wore the shields for some months after leaving the hospital, but discontinued them after some eighteen months. The contraction had returned to some extent, the band which existed in the



cheek having shortened so as to diminish the extent to which she could separate the teeth one-half—viz., from three-fourths to three-eighths of an inch. The cheek was slightly tucked in owing to the contraction; but the girl was perfectly well and comfortable, and would not allow any interference with the parts.

Isabella M'Nab (my patient treated by metal shields), whose case was remarkable owing to the adhesions being present on both sides of the mouth, was seen by Dr. Crockett, of Dundee, in the middle of 1864, and that gentleman has kindly sent me the following report of her condition:—"The jaws can be opened with ease to the extent of half an inch; she has begun to articulate distinctly within the last two months, and within the last fortnight is able to chew a crust of bread, having some lateral motion of the jaw. A fetid muco-purulent discharge continues to come from the mouth, but her general health is much improved."

Having thus shown that cases of closure of the jaws by cicatrices are amenable to two modes of treatment with most satisfactory results, and having had personal experience in carrying out both methods, I shall venture to draw a brief comparison between them.

Esmarch's operation is a comparatively easy proceeding; and in cases where only *one* side of the jaw is affected, restores the patient a very useful, though one-sided, amount of masticatory power in two or three weeks, and with very little suffering or annoyance. One side of the jaw is, however, rendered permanently useless (its previous condition), and there is a necessarily resulting deformity, which is not, however, of a very distressing character. The paralysis, from the division of the nerve, is so slight as not to be worthy of mention.

The treatment by internal division and the use of metal shields, is applicable to all cases in which the entire thickness of the cheek is not involved, and can, with due care and attention, be made to yield most satisfactory results—the patient enjoying the full use of both sides of the jaw, and having no deformity or loss of sensation. On the other



hand, the operation itself is difficult and bloody, and the after treatment is tedious and troublesome; and it is essential for success to have the co-operation of a dental practitioner, fully conversant with the frequent modifications which the metal shields must necessarily undergo. The age of the patient is an important element also, since it would be impossible, I imagine, to carry out the treatment with any hope of success, unless the patient were of an age to assist, or at least not to resist, the surgeon. In my own case chloroform was resorted to on every occasion of real operative interference, but the intermediate treatment was much hindered by the timid character of the patient.

*Closure from Anchylosis of the Temporo-maxillary Articulation* is less common than that due to contracted cicatrices. In his "Practical Observations in Surgery" (1816), Mr. John Howship describes a case of "scrofulous inflammation of the face followed by anchylosis of the jaw" in a man of fifty-six years of age, who dated the origin of the disease from a cold taken at the age of four. The original illustration shows complete bony anchylosis of the lower jaw to the temporal bone. Owing to the habit acquired by the patient of introducing food at the left side of the mouth with his fingers, extensive absorption of both maxillæ had taken place at the part, as will be seen in the drawing referred to.

In Guy's Hospital Museum is the skull of a negro who had disease of the cervical vertebræ, and complete osseous anchylosis of the temporo-maxillary articulation, coming on after a wound in the neck from a fork. The history of the man, with a drawing of the skull, will be found in Mr. Hilton's "Lectures on Rest and Pain." I have recently had the opportunity of watching a case which I fear will terminate in anchylosis of the jaw in a gentleman aged twenty-five, who was sent to me by my friend Mr. Bate. I saw him first in February, 1866, when he told me that he had the measles badly when nine years old, and this was followed by discharge from the left ear, which became deaf. The discharge had ceased for two



years, when in September, 1864, he caught a severe cold, and it recommenced, and at the same time the left temporo-maxillary articulation became swollen and stiff, so that he was obliged to live by suction for some time. The discharge from the ear was very profuse, as much as half a pint at a time, and matter burrowed under the tissues of the face as high as the orbit, where a small opening formed, and down the neck, discharging into the throat for three days. Finding the left lower wisdom tooth cut awry and very far back, I thought that this might possibly be connected with the disease, and therefore had it extracted, with some difficulty, by Mr. Mummery. In the following July I found that he had derived no benefit from the extraction, and the jaws were as firmly closed as before. The space between the incisors was  $\frac{1}{4}$  inch, and rather more between the bicusps on the left side. The mouth did not open so widely as it had done eighteen months before, but he had perceived no difference during the preceding six months. There was no external deformity, but he said he heard a grating sound on moving the jaw which was not audible externally.

This would appear to be a case of inflammation and destruction of the temporo-maxillary articulation, which is undergoing cure by ankylosis, as would happen with other joints under similar circumstances. It cannot be classed with the cases of chronic rheumatic arthritis of the joint, described by Dr. Robert Adams, and Dr. R. W. Smith, of Dublin, since the patient had none of the symptoms of that disorder.

The treatment of cases of the kind is eminently unsatisfactory. Beyond the use of counter-irritation to the neighbourhood of the joint, and the administration of iodide of potassium in the hope of checking periosteal inflammation, little can be done. When the ankylosis has become complete, the question will arise as to dividing the bone or resecting the joint. I should have no hesitation in recommending the former as at once easier and safer, since it would be almost impossible to saw through the articulation itself. Without any external incision through the cheek, it



is quite possible to dissect up the mucous membrane and masseter muscle, so as to introduce a narrow saw or strong bone-forceps, and divide the ramus as high up as convenient, and thus establish a false joint in the manner originally proposed by Dieffenbach, though for another class of cases. Sédillot ("Médecine Opératoire," tom. ii. p. 30) mentions that, in a case of true ankylosis, M. Grube, in 1863, carried a straight chisel through the mouth to the neck of the jaw, which he broke by hammering. Some months after he divided the masseter subcutaneously, and the cure, by the formation of a false joint, was permanent.



## CHAPTER XXVIII.

## DEFORMITIES OF THE JAWS.

THE scope of this essay does not embrace those congenital deformities of the gum and palate which are familiar to the surgeon in combination with hare-lip, but there are certain examples of deformity, the result of disease, which may be conveniently grouped together here.

In describing the tumours of the jaw, mention has been made and drawings given of cases of deformity the result of pressure upon the opposite jaw of some growth of large size; thus, at page 277 will be found an instance of deformity of the upper jaw, due to the pressure of a large fibrous tumour of the lower jaw; and at page 245 an example of deformity of the lower jaw, due to the pressure of a large osseous tumour of the superior maxilla. Tumours within the mouth, unconnected with the jaws, may, however, induce deformity mechanically, hypertrophy of the tongue being the disease most frequently met with, of which several instances will be found in vol. xxxvi. of the *Medico-Chirurgical Transactions*, in papers upon that disease, by Dr. Humphry, of Cambridge, and Mr. Joseph Hodgson. Dr. Humphry's patient was a girl of eleven years, who had had a much hypertrophied and prolapsed tongue for eight years. "Owing to the constant pressure of the tongue on the mental portion of the lower jaw a curvature had taken place in that bone, just in front of the masseter muscles, in such a manner that a wide interval always existed between the incisors and bicusps of the two jaws. Even when the mouth was closed—that is to say, when the corresponding molar teeth were in contact—



this interval between the incisors measured nearly two inches, being increased by the horizontal direction which the inferior incisors and the alveolar process of the lower jaw had assumed. These were so placed as to form a wide channel in which the tongue rested. Moreover, the teeth, especially the two central incisors, were further apart than natural, and encrusted with tartar, which in some measure filled up the spaces between them, and prevented their sharp edges from injuriously pressing upon the tongue." The deformity, therefore, closely resembled that seen in fig. 151, which was due, however, to external causes. Dr. Humphry removed the anterior part of the tongue successfully, and then endeavoured to remedy the deformity of the jaw by fitting a cap of calico and metal to the head, with a hooked bar of iron projecting from it like a horn over the forehead. The bar was attached to the hinder part of the framework of the cap by a hinge and to the forepart by a screw, which enabled the surgeon to alter its elevation according to circumstances. A thick belt of India-rubber passed from the hook beneath the chin, and exerted considerable pressure upon it. The apparatus was worn for several hours at a time. When its use was commenced, on January 18th, four months after the operation on the tongue, the interval between the maxillary alveoli was  $1\frac{5}{8}$  inch, having decreased about a quarter of an inch. On February 22nd it was  $1\frac{1}{4}$  inch, and in August  $\frac{7}{8}$  inch. After this the change took place very slowly, though the deformity was at length almost removed.

A very similar condition of the lower jaw, but in an earlier stage, existed in a child aged three, from whom Mr. Paget successfully removed the hypertrophied portion of the tongue, in February, 1864. (*Lancet*, April 16th, 1864.)

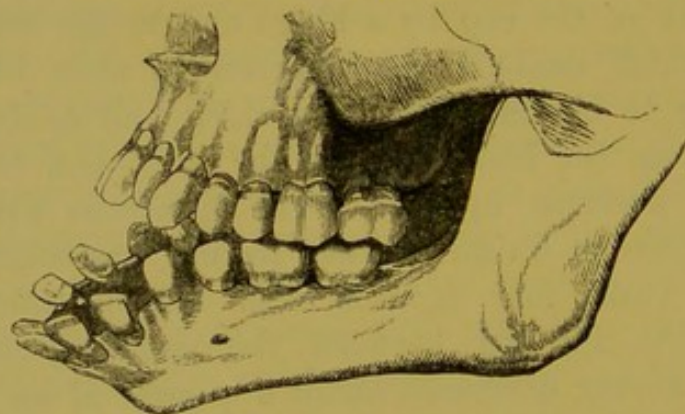
Mr. Oliver Chalk has also narrated, in the *Pathological Transactions*, vol. viii., a case of deformity of the jaw dependent upon enlargement of the tongue, in which he considers that a partial dislocation of the jaw was produced, and where benefit was derived from the use of an elastic support.



The influence of the habit of sucking the thumb upon the position of the front teeth is generally acknowledged, and the practice, if persisted in, may produce very considerable deformity of the jaws. Some drawings illustrating a paper on this subject, by Mr. Vasey, in the *Pathological Transactions*, vol. vi., show the resulting deformity extremely well. Dr. Thomas Ballard has also recently called attention to the deformity resulting from the habit of "tongue-sucking," to which he attributes many of the ailments of children.

The influence of cicatrices outside the mouth in producing deformity of the jaw by their contraction in early life is well ascertained, and every surgeon must have met with painful examples of the kind. Fig. 151, from Mr.

FIG. 151.



Tomes' work, shows the condition of the lower jaw in a young woman twenty-two years of age, her chin having been drawn down towards the sternum by a broad cicatrix, consequent upon a burn received when five years old.


In all these cases the deformity partakes of the same character, and if seen early enough is to some extent amenable to treatment. The slighter cases depending upon thumb-sucking are usually treated by the dental surgeon, who in rectifying the position of the teeth necessarily improves the condition of the jaw. In the more severe cases, constant support by an elastic band making traction upon the jaw will be of much service, as in the cases of Dr.



Humphry and Mr. Chalk. The cases depending upon the contraction of cicatrices can only be relieved by treating the cicatrices, and the pressure of a screw-collar, worn for the purpose of extending these, will do much to restore the shape of the jaw, if the case is not one of too long standing.

Disease originating within the mouth may lead to ultimate deformity of the jaws; thus *cancrum oris*, in addition to leading to closure of the jaws, as described in the previous chapter, may lead to very considerable deformity of the alveoli. A case of closure with deformity thus caused,

FIG. 152.



successfully treated by Mr. Bernard, of Clifton, has been already referred to (p. 332); but a still more remarkable case has recently been under the care of my friend, Mr. W. Harrison, to whom I am indebted for the accompanying engravings of it. The patient, aged thirty-six, had suffered in childhood from *cancrum oris*, which had destroyed the greater part of the right cheek. His appearance is shown in fig. 152, and it will be seen that the lips were widely separated, and that a considerable protrusion of the alveolar processes of both jaws, with their teeth, had taken place



between them. Behind this point the jaws were united by a bridge of bone, and the patient, who was totally unable to open his mouth, fed himself through an aperture between the teeth on the left side. In October, 1867, Mr. Harrison extracted the seven teeth which projected, and reflected the gums from the adjacent alveoli, when as much of them as was thought desirable was removed with the bone-forceps. The molar teeth, which had been driven into the interior of the mouth, were then extracted with some difficulty, when a pillar of bone, about the size of an ordinary lead-

FIG. 153.



pencil, connecting the alveoli was brought into view, but was not interfered with. The gums were brought together with stitches, and the operation was concluded. The appearance of the patient, some weeks afterwards, is shown in fig. 153.

The patient having been transferred to the care of Mr. James Lane, that gentleman proceeded to perform a plastic operation, for the improvement of the condition of the lips. A very long V-shaped incision was made, extending from the extremities of the lips (which were firmly attached to



the alveoli) to a point about an inch in front of the ear, thus embracing within it the cicatrix of the original disease. The tissues were freely dissected from the upper and lower jaws, and were brought together over the old cicatrix. An incision, two inches long, was made along the lower border of the jaw, to enable this to be done without too great tension, and the parts were held together with hare-lip pins and

FIG. 154.



sutures. The operation was perfectly successful, and the subsequent appearance of the patient is shown in fig. 154.

The interesting details of this case will be found in a paper read by Mr. Harrison, before the Odontological Society, in May, 1868 (*British Journal of Dental Science*, May, 1868).



## APPENDIX.

---

CASE I.—*Case of double Fracture of the Jaw with Dislocation of Teeth and Fracture of a Bicuspid Tooth, the crown of which was embedded in the mouth for two years.* By Mr. MARGETSON, of Dewsbury.

THE patient fell from a ladder upon his chin, and fractured his lower jaw in two places, on the right side between the first bicuspid and canine teeth, and on the left between the lateral incisor and canine. The upper front teeth were knocked out, but the jaw not otherwise injured. The two lower central and left lateral incisors were dislodged, and the right lateral loosened, the left second bicuspid was broken at the neck. The fracture united very well, and the man was soon able to masticate. The exfoliation was confined to a small piece of the front alveolus, but although it is more than two years since the accident, there was, until a month ago, suppuration, and a free discharge from the socket of the loose right lateral incisor, and the patient said that about ten months before I saw him he felt a piece of bone forcing its way through the gum behind the incisors. I removed the loose tooth and found behind it, near the floor of the mouth, a small opening, through which I could feel with a probe, what proved to be the crown of the left second bicuspid, which at the time of the accident had been broken at the neck and buried in the soft parts, and according to the statement of the patient had not been suspected either by his surgeon or himself until a few weeks ago. There has not been any injury to the articulation, and the man can use his back teeth as well as ever. A model of the mouth, which was taken immediately after the removal of the buried canine, and the tooth, both crown and root, the latter having been extracted, accompanied this essay.



CASE II.—MR. HOLMES' case of *Fracture of the Neck of the Condyle of the Lower Jaw, with displacement of the lower fragment into the meatus auditorius externus. Serous discharge from the ear.*

J. L., aged fifty, was admitted into St. George's Hospital on July 20th, 1860. It seemed that he had been sleeping in a hay-loft, and being drunk, had walked out of the window during the night. He was found lying on the ground, and was brought to the hospital at half-past four A.M. He was then sensible, but seemed to be stupid from drink. There were several cuts about the face, and one beneath the chin. Blood was flowing from the right ear. There was some ecchymosis about the right temporo-maxillary articulation, and crepitation was detected in that neighbourhood, though not very distinctly. He was unable to move his jaw, and complained of intense pain in trying to do so. The mouth was drawn to the right side. The pupils were natural. On the following day, considerable serous discharge was noticed to flow from the ear. In the evening he was very restless and feverish; but no head-symptoms were observed. Next day (the third) the discharge continued, mixed with blood, and there was great pain in the head. He had considerable difficulty in speaking. On the fourth day from the accident, the symptoms of delirium tremens became more marked, and he sank rapidly, dying in the evening. Other extensive injuries existed of which no mention need be made here. It is sufficient to say that the skull, the brain, and the cerebral membranes were perfectly healthy.

On examining the tympanum, traces of blood were found in the mastoid cells, but hardly a drop in the tympanum itself. A probe passed into the tympanum through the external meatus without resistance, and after dissection a large rent was seen at the upper part of the membrana tympani. This was probably, in great part, produced by the dissection. The meatus externus was full of clotted blood, and serous fluid could be seen exuding from the ear. The temporal bone was carefully examined, but no fracture was found. The lower jaw was fractured in two places—viz., through the base of the coronoid process, separating that process from the rest of the bone, and through the neck of the condyle. The condyle remained in position, and the joint seemed in all respects healthy. The lower fragment was somewhat displaced, and had produced laceration of the meatus, separating the cartilaginous from the osseous portion for nearly half of its circumference. A large quantity of blood lay around the



fracture, and in the neighbourhood of the bone there was some fluid of a sero-purulent appearance. The preparation submitted to the Society consisted of three fragments of the lower jaw, and the greater part of the temporal bone, showing the laceration of the meatus auditorius. In consequence of the dissection that had been undertaken in order to open the tympanum and mastoid cells, the integrity of the petrous portion of the temporal had been destroyed, but the absence of fracture and the course which the blood had taken were still shown by the contrast between the meatus, which was lined with clotted blood, and the mastoid cells and tympanum, in which hardly a trace could be found.—*Transactions of the Pathological Society*, vol. xii.

CASE III.—MR. MARGETSON'S case of *Fracture with Abscess in the neck.*

Mr. S., a builder, was superintending the erection of a house when he was knocked down by a brick, which fell from the second floor upon his head. He found that his jaw and mouth continued very painful after he had recovered from the other effects of the accident, but he does not appear to have complained to his medical attendant, and no examination of the jaw was made at the time. In seven or eight weeks an abscess formed near the angle of the jaw on the right side, for which he consulted a surgeon in a neighbouring town, but singularly enough, he did not think of the abscess as being the result of the accident, and told the surgeon that his jaw had not been injured in any way. Several other abscesses followed, and these were succeeded by troublesome and tedious exfoliations; the whole of the alveolar border and the teeth have been lost, and there is now a discharge from a fistulous opening in the left side of the neck, about two inches below the angle of the jaw. Sequestra are still being thrown off, although more than three years have elapsed since the accident. There seems to have been some injury to the articular surface of the bone on the left side, for when the mouth is opened the symphysis is drawn considerably to the left, and if an attempt is made to open the mouth wider, pain is felt in the articulation. The mouth can never be opened more than half an inch, and sometimes from cold or other causes it cannot be opened more than half that distance. There is not any induration of the muscles apparent, nor any cicatrix to account for the restricted movement.



CASE IV.—*Ununited Fracture and Necrosis of the Lower Jaw, with Salivary Fistula, from old Gunshot Injury. Operation—satisfactory result. Under the care of the Author.*

James P., aged thirty-two, was admitted, August 19th, 1862, into the Westminster Hospital, under the care of the author, for necrosis of the lower jaw.

*History.*—In March, 1860, when in the 64th Regiment, and whilst marching through Central India, he was struck on the right side of the lower jaw by a spent bullet, fired by some hill robbers. He was stunned for a few moments, and had hæmorrhage for half an hour. He went to the rear, but was able to continue the march. The following day he went into camp hospital, under the regimental surgeon, at which time the parts about the wound were much swollen. The wound was bathed with warm water, and the swelling was rubbed with soap-liniment. At this time he was able to open his mouth and eat on the left side without pain; but three weeks afterwards, having attempted to eat on the right side, he felt a grating sensation and much pain, and told the surgeon his jaw was broken; but the surgeon did not believe him. The last molar tooth was found to have been displaced and to be lying horizontally, and attempts were made to extract it, but unsuccessfully. It gave him extreme pain, and the surgeon then admitted that the jaw was splintered. A gutta-percha splint was now moulded on, and a bandage applied for eight days, the wound having by this time closed. On April 9th, 1860, he was admitted into the Kurrachee Hospital, and another splint was applied, and kept on three or four days, when a large abscess formed. It was opened, and a large quantity of matter discharged, and the wound then healed. Another abscess began to form immediately behind the opening, and just below the original wound; and this also was opened and poulticed, and has never closed. The regiment arrived at Dover, on August 6th, 1861, and the man was doing duty; but the cold weather coming on, the wound inflamed and swelled up again, and he was sent into Fort Pitt, on May 14th, 1862. During the whole of the time he felt a numbness over the chin and all round the mental foramen. Various attempts had been made to extract the last molar tooth, which Dr. Longmore removed with some difficulty. After the patient had been in the hospital for twenty-one days, he was, on June 26th, 1862, invalided and discharged from the service.

*Present Condition.*—There is an open sinus on the right angle of the jaw, leading down to dead bone and into the mouth, and



he can blow air through the aperture. He can bite perfectly with the left side, and can open his mouth as wide as most people. He does not complain of any pain in the part, and his general health is good. He has never had syphilis. A small piece of bone has worked out into the mouth since admission. On looking into the mouth, a good deal of swelling about the ramus of the jaws is seen. The second molar tooth is *in situ*, but loose.

*Operation*, Aug. 26th.—Chloroform having been administered, the author proceeded to enlarge the external opening, and removed, with the gouge, several pieces of necrosed bone. He found that the jaw had been fractured, that it had not united, and that the upper fragment was tilted forwards by the temporal muscle, thus causing the projection in the mouth before noticed. The wound was filled with lint, and a compress applied.

28th.—Face considerably swollen, but pain slight; wound discharging freely; can blow air easily through the wound from the mouth.

Sept. 10th.—Wound has much decreased in size; two or three small particles of bone have worked out through the mouth.

20th.—The last molar tooth of the right side being quite loose, was extracted.

28th.—Says that the opening from the mouth has appeared larger since the extraction of the tooth, so that he is unable to hold fluid on that side of his mouth; external wound very much diminished in size.

Nov. 4th.—The wound having degenerated into a small fistula, and there being no evidence of further disease of the jaw, the author determined to attempt to close it. For this purpose, he introduced a narrow knife into the opening, and, by rotating it, pared the surface, including the skin, and then brought the edges together with a curved needle and twisted suture, over which collodion was applied.

7th.—One end of the needle having cut its way out, it was removed altogether. The wound was not united. The edges were now brought together with a strap and pad and bandage.

14th.—Wound much diminished in size; the edges touched with nitrate of silver.

22nd.—No fluid now passes through the fistula, and he says that he can feel with his tongue that the internal wound has healed.

26th.—External wound closed.

Dec. 9th. — Discharged cured. The movements of the



jaw are much freer than they were, and he can eat on the wounded side without pain or inconvenience. The false joint does not appear to affect in any way the powers of mastication or articulation.—*Medical Times*, Jan. 1863.

CASE V.—*Gunshot Injury of Lower Jaw, with loss of Symphysis and False-joint.* By Mr. J. COX SMITH.

William B., private, 55th Regiment, forwarded from St. Mary's, Chatham, for inspection and report. A gunshot wound in the lower jaw, destroying the symphysis and six front teeth—namely, four incisors, one canine, one bicuspid on the right side, together with the ridge as far as the angle of the jaw, the ball finally lodging in the shoulder. Wounds well healed externally, a cicatrix only at points of entrance and exit being observable. The internal condition of the jaw was very peculiar and complicated. It was bisected into two unequal portions, the left containing the dens sapientiæ, second and first molars, bicuspid, and canine teeth perfectly sound and intact.

The right section contained the dens sapientiæ, second and first molars, and second bicuspid, and the extremities of the sections were neatly rounded and covered with firm, healthy gum. The fang of the second bicuspid on the right side was a little exposed, but had the appearance of healthy dentine. The muscular attachments were perfect and motion easy, but the two portions were inclined towards the centre of the mouth, and any attempt made to bring them out in juxtaposition to the upper jaw, caused acute pain in the socket.

The state of this patient's mouth entailed much suffering and privation. Mastication was impracticable in the slightest degree; paper could be drawn from between the jaws, notwithstanding the patient's efforts to the contrary; his articulation was much affected, and his only posture for sleep was on his back, reclining on either side causing luxation of the corresponding section of the jaw. Under different circumstances the relative positions of the two sections varied—the right half following imperfectly the motions of the left. Thus, on opening the mouth, the left portion only would be fully extended, the right riding loosely above it (fig. 9).

The above were the appearances the case presented; and as I could not sketch out any plan of treatment at the time, nor could I possibly obtain any correct model, all that I could do was to note the particulars of the case as well as I could, and appoint another visit. I then succeeded in obtaining impressions



of the jaw by means of two trays cut and bent for the purpose, and inserted a gutta-percha plug moulded to fit the cavity, occupying the space of four teeth. On attempting further separation, so much pain was felt in the socket of the left section that the patient refused to bear it. I next constructed a metal frame-work, separating the parts as much as possible, and capping the teeth freely, but could not succeed in fixing it in consequence of the variable motions of the right side, which instantly unshipped the piece. I then made a metal frame-work, extending the sections and supported by fitting carefully around the necks, and between the teeth, carrying it far back, for the purpose of distributing the strain as much as possible. The space thus gained was filled up by four incisors, soldered to the frame; and the result seemed very satisfactory.

This man had passed the Chelsea Board previous to his being sent to me, and was then waiting for his discharge; so the time at my disposal was limited, or I believe that I could have succeeded in replacing the whole of the six teeth. — *Quarterly Journal of Dental Science*, January, 1859.

CASE VI.—MR. GUNNING'S *Case of Fracture of the Lower Jaw*.

I applied the wings of Fig. 19 in the case of a distinguished statesman in Washington, whose jaw was fractured on both sides between the bicuspid.

The injury was caused by falling from a carriage, April 5th, 1865. Unsuccessful attempts had been made to hold the jaw in place by bandages, and also with ligatures on the teeth, by the surgeons first called to the case. On the 14th the patient, while asleep, was attacked by an assassin, and a cut inflicted which reached from under the right zygoma to the left of the trachea. Steno's duct was severed, and the right fracture laid open externally, the bone being also much exposed in the mouth from the original injury.

In accordance with the letter of April 14th, from Dr. William Whelan, chief of the Naval Bureau of Medicine and Surgery, in answer to one by Surgeon Bache, chief of the Naval Laboratory, suggesting the use of an interdental splint, and telegrams of the 15th, urging me to come on at once, I started for Washington, and reached the patient's house at twelve, noon, on April 16th. Attending-surgeon Basil Norris, U.S.A., informed me that the jaw was fractured on the right side, between the bicuspid teeth, and also in the ramus of same side; that the jaw had been bandaged against the upper gum, but this proving insupportable to



the patient the bandages were removed. Upon examination I found discoloration caused by the accident still remaining on the right side of the face. A cut (inflicted in the attempted assassination) commenced under the zygoma, passed forward about three inches, then downward and backward an equal distance, to the lower border of the jaw, from whence it crossed over the front of the throat to the left of the trachea. On the skin its first direction fell somewhat from a horizontal line, the second passed down at a little less than a right angle to the first, while the third went forward and downward. These three divisions, of nearly equal length, appeared to have been made by one sweep of the knife. Across the throat the wound was superficial, but above the border of the jaw it grew deeper, as it *split* the cheek—the point of the knife making no entrance into the mouth, except so far as it may be considered to have done so by laying open the right fracture externally, the gum being already lacerated internally from the great displacement of the bone following upon the original injury. The knife was evidently aimed at the throat, but the head being thrown over (the right arm being useless) the cheek and jaw received the brunt of the blow. No arteries had been ligatured. The wound was neatly sewed up, and healing by first intention, except immediately under the fracture. The swelling and stiffness made the examination difficult, but the ramus proved to be uninjured. There was, however, a second fracture, but on the other side of the mouth, the jaw being fractured on both sides between the bicuspid. The jaw contained all the ten forward teeth. The right wisdom tooth and root of the left were all that remained back of the bicuspid. The part in front, containing eight teeth, was drawn down out of place, while the right back fragment, with the wisdom tooth and second bicuspid, was drawn up, showing its fractured end white and bare. The fracture was square across, vertical and smooth, and the parts were separated vertically over a quarter of an inch when at rest, sometimes much more. On the left side, the first bicuspid fell forward and downward from the second one quarter of an inch. This fracture passed forward somewhat in descending. Here the bone could not be seen, as the gum had separated from both teeth and lay swollen over it. Pus discharged profusely from both fractures. The gum was pale and flaccid, in keeping with the general condition of the patient. The upper jaw was entirely without teeth. Deeming it important to set the exposed bone in place as early as possible, and also to give the patient time to recuperate—as he had already been subjected, during the morning, not only to a relation of



the President's death, but to much that was said and written upon the subject—I obtained the patient's artificial teeth, intending to cut out the front teeth, and tie the lower natural canines to the upper artificial ones. In this way the back fragments would have been kept down in place, and in return would have held the artificial teeth up against the roof of the mouth. They could have been used therefore to support the front of the lower jaw temporarily, without assistance from bandages, which were not only inadmissible in consequence of the wounds, &c., but would have increased the tendency to necrosis by interfering with the circulation. But the patient's experience with the teeth had not been such as encouraged him that he could bear them in his mouth. It was therefore necessary to leave the parts as they were until the next morning.

In the afternoon, while explaining the treatment proper for the case to Dr. Whelan, I also stated my unwillingness to commence, except with the understanding that I should control it entirely.

April 17th.—Was informed, by Surgeon Norris, that the friends of the patient were unwilling to have the splint fitted to the jaw at present, and that the surgeons agreed with them.

Upon giving my views to the contrary, Dr. Norris came over to my opinion. I consented to wait until the following morning, when it was finally decided not to proceed in the matter. I protested, in vain, but promised to return when sent for.

April 28th.—Arrived in Washington; Surgeon-General Barnes informed me that the jaw was more displaced, but the patient otherwise much improved. I found the sensation of the right side of the forehead, face, and lips deficient. The separation of the inferior dental nerve by the displacement of the bone, and of branches of the facial nerve by the knife, did not seem sufficient to account for it. There was also irregular motion in the right eye. The front of the jaw was lower, and the right back fragment showed its alveolar to a greater extent. There were no indications of any tendency to union on either side. The fragments could be put precisely in place, no splinters or anything else intervening. There was little swelling, but great discharge of pus. Took wax impression of upper jaw, and removed the tartar from lower teeth.

April 29th.—I set the jaw, and held it in place by wire and silk ligatures, as previously described. Took a wax impression of the teeth and gum, and obtained the bite directly from the teeth, &c.\*

\* In doing this and in making the splint, I was assisted by Mr. J. Adams Bishop, who accompanied me from New York.



April 30th.—Patient felt much relieved, as the ligatures held the front of the jaw up well. Tried in a gutta-percha splint: arranged the wings in it, removed it carefully from the mouth, placed the upper and lower casts and female screws in it, and set them in a vulcanizing flask.

Although the front of the jaw containing the eight forward teeth was greatly displaced (before the setting), the silk and wire ligatures held well until May 2nd, when they were removed and the splint applied. It was of hard vulcanized rubber, covered the roof of the mouth and adjacent gum, enclosed all the lower teeth, and went down over the gum on the outside somewhat. The opening in front was seven-eighths of an inch wide, and half an inch high in the centre, the wings preventing any more room sideways, as they were set clear of the commissure of the lips. To have given more room in the height, by depressing the lower jaw, would have made it very difficult to prevent the saliva from overflowing at the lips. Upon putting in the splint, the breathing was very spasmodic for several minutes; but this soon passed off, and I screwed it fast to the lower teeth. They held it against the upper gum for the first night; but after that a cap, with adjuncts, as in Fig. 19, was worn to support the splint. The upper wings only were used, as the lower jaw was held up in the splint by screws passing into the lower canines. The mental band was consequently not applied, although the lower wings were left on in case of need. The upper wings being kept clear of the zygomas, the parts around the jaw and face were left free from pressure—this being important, in order that the vascular and nervous circulation should be unimpeded. After giving the excellent army nurses who were in attendance upon the patient full direction for keeping the splint clean in the mouth, and properly balanced by the cap, which I had fitted to the head, I left Washington, May 3rd.

Arrived in Washington again on the 8th, having received a telegram saying that the patient was suffering much pain. Found him quite comfortable, talking freely, and much encouraged. Saliva had accumulated several times in the cheek, but had been let out by lancing externally. The splint had been kept quite clean, and as everything was going on well I left on the 9th.

June 11th.—Saw the patient again. The left side appeared to be well united, but the right gave no indication of union, although the wound under it was nearly closed, the last of several pieces of bone having been removed some days before. I promised to remove the splint in four weeks from that date to examine the parts.



This splint held the jaw firm for sixty-eight days, when I removed it.

There was good union on the left side, but the right fracture was still ununited. For this, however, I was prepared, as the bone had been exposed so much during the twenty-four days which elapsed before I set it, and the saliva from the right parotid gland had discharged through the fracture from a short time after the attack. These unfavourable conditions, with other depressing circumstances, associated with an enfeebled condition from loss of blood, had been followed by necrosis of the ends of the bone on that side, and several pieces had come away externally during the first six weeks from the time the splint was applied, and also a long piece from the inside of the jaw on the left side.

I now removed the necrosed alveolar of the second bicuspid, but left the tooth in, as it appeared to have healthy connexion with the lower part of its socket. The other teeth had grown firm. The splint had not been off the jaw a moment since its first application, and therefore little examination had been made internally; but external appearances had indicated that the saliva followed the course taken by the point of the knife. At this time, July 9th, Steno's duct proved to be completely closed. I could not pass the smallest probe even into its mouth, and the saliva discharged wholly through the ununited fracture.

Upon removing the first splint, I immediately put another upon the teeth. This splint was ready for application, having been made on a cast taken from the original impression. This second splint was like fig. 17. It covered all the teeth and gum, and was worn from July 9th to August 4th, when I removed it and put on a splint which allowed all the teeth to be seen, except the wisdom tooth on the right and the root on the left side, upon which it rested. This splint was worn screwed to the canines until the beginning of September, four months from the application of the first splint. I saw the patient several times during the month of October. The jaw seemed to be getting firmer on the right side. On the left it was then quite strong, and all precisely in place.

The patient talked freely while wearing the splints, except for a few days at the commencement. From the time the second was applied the jaw has been used for eating.

In letter to me of March 29th, 1866, the patient says—"The whole jaw moves quite well and firmly. Thus at last I begin to regard my cure in that respect complete."

I have not seen it myself since October, 1865; therefore cannot speak of it by personal observation.



CASE VII.—*Badly-comminuted Fracture of Lower Jaw by Grape-shot. Recovery.*

Private Robert Cuthbert, aged nineteen, 31st Regiment, was wounded on 2nd September, by a grape-shot, which struck him in the face, badly fracturing the lower jaw. On removing the bandages which had been placed on the parts in the trenches, the fractured bone, with its muscles, glands, &c., fell down on the cheek, dragging the tongue with it, and exposing the interior of the mouth and throat as far as the root of the tongue, and the wound extended into the anterior triangle of the neck, exposing the carotid artery. The bone was so comminuted that no choice was left but to remove the fragments, and the jagged ends of the bone were sawn even on either side. No part anterior to the angles of the bone could be saved; the soft parts were then brought together, and retained by sutures and a few adhesive strips, and wet lint applied. The patient was now able to lie down, which he could not do before, as the tongue, by falling back, closed the glottis; but even now, when in the recumbent position, he had frequently to lay hold of the tongue and draw it forward, to facilitate breathing. A considerable portion of the injured integuments of the chin sloughed away, but by careful feeding, dressing, and bandaging, the deformity was ultimately much less than could have been expected.

In this case, of course, the food was required to be in the liquid or semi-liquid state, and for a long time great difficulty was experienced in feeding him, but he experienced much comfort from the use of a small pipe, through which he sucked his food. He was sent to England on the 24th November well, and much good might have been expected to result from an operation in remedying a portion of the deformity, as soon as the parts were sufficiently consolidated to warrant such a proceeding. ("Medical and Surgical History of the British Army in the Crimea.")

CASE VIII.—*Gunshot Fracture of Upper Jaw and Palate.*  
By Mr. J. COX SMITH.

John P., private, 75th Regiment. Gunshot wound in the upper jaw, the ball having passed through the right cheek, out under the left eye. The external wounds were well healed; the appearance of the jaw is pretty well indicated by fig. 26.

The ossa palati were broken and disunited, but covered by mucous membrane. Three clumps of teeth were remaining—viz., dens sapientiæ on the right—left central and lateral in the



middle—second molar and dens sapientiæ on the left side; each of these were attached to portions of the upper maxilla, of what size it was impossible to determine, but disconnected with each other, and all very loose. They formed a small irregular triangle, much within the arch of the lower jaw; the two centrals, instead of being in their proper place outside it, were nearly an inch behind it.

The patient was incapable of masticating even the softest diet—in fact, could not hold a piece of paper between his teeth, and his tongue being so efficiently locked in, his attempts at articulation were not more successful. I could not understand whether he intended to say yes or no, to any inquiries I put to him. Thus it will be perceived, that the poor man was, though living in the world, existing as it were apart from it, under circumstances involving severe bodily privation, and it is not much to be wondered at if he felt, as he afterwards was enabled to explain, “that life was a misery to him.” It will be evident nothing could be done without the removal of the front teeth, so very peculiarly placed, and this required extreme care. I dissected out the teeth carefully from the soft parts, and, steadying the loose piece of maxilla with the two fingers of my left hand, successfully removed them, eschewing the aid of either forceps or key, and with no further ill-results than the loss of about a pint of blood. For some time after the bone was quite bare, but by degrees the gum began to granulate, and in about three weeks the mouth was fit (fig. 27) to receive the mechanical appliance. This consisted of a socket of hippopotamus ivory fitted to the upper jaw, bearing strong metal clasps, encircling the molar teeth, and supported by springs to a metal lower frame. Of course the appearance of the piece was exceedingly peculiar, but it does not require further description; experiment only could tell which were the places that would bear pressure. But though every trace of the alveolar ridge was destroyed, and the whole of the surface was newly healed, and almost all soft and yielding, the piece was worn with comfort almost immediately after its insertion. A large cicatrix on the right side of the mouth interfered very much with the action of the spring, the cheek had become attached to a surface which I wished to cover, and any alteration in the frame would have impaired its usefulness. I allowed the spring to work a way for itself; a little sloughing was the consequence, but as a cicatrix is not very vascular, the inconvenience was slight, and my patient was soon discharged from further attendance.

The combined structure, natural and artificial, was exceedingly



firm, and proved a valuable assistant to his otherwise helpless condition. I saw the man a year and a half afterwards; he was, and is now (for anything I know to the contrary) a porter in the Royal Household, Windsor; and a more perfect contrast in the stout, healthy man, whom I should not have recognised, to the disfigured and emaciated military invalid, it is scarce possible to conceive. Perfect union had taken place between the disjointed fragments of palate, and the surface was firm and healthy, though of course very uneven. (*Quarterly Journal of Dental Science*, Jan. 1859.)

CASE IX.—*Extensive Injury to the Jaws by Shell.—Secondary Hæmorrhage.—Ligature of Common Carotid Artery.—Death from Cholera.* By Dr. D. LLOYD MORGAN, R.N. (Notes by Dr. BIRCH, R.N.)

William Howden, aged twenty-six, a marine of H.M.S. *Euryalus*, was in the Japanese war, and was struck on the 15th August, 1862, by a portion of a ten-inch shell. The right side of the neck and face was frightfully shattered, the wound extending from the corner of the mouth as far back as the zygoma superiorly, and the sterno-mastoid a little below the angle of the jaw inferiorly, the mouth being laid open. The body of the jaw on the right side, from within an inch of the symphysis to the angle, was shattered. The zygoma was fractured in two places, and the alveolar process of the upper jaw was crushed at the roots of the first two molar teeth. The fragments which were loose were removed; there was no bleeding from the wound, which was searched in vain for divided vessels; the jagged edges were brought together, and water dressing was applied.

On the evening of the 19th, sudden arterial hæmorrhage came on, and about two pints of blood were lost. The bleeding ceased almost as suddenly as it commenced, only slight oozing continuing.

20th.—Return of bleeding to nearly same extent as before, but ceased under pressure applied to carotid.

21st, four A.M.—The hæmorrhage recurred to an alarming extent, the patient being almost pulseless. Dr. Morgan proceeded to cut down upon and tie the common carotid artery above the omo-hyoid, meeting with considerable difficulty owing to the matting together of the tissues. There was no return of hæmorrhage, and the ligature came away safely on September 3rd, and the patient was doing well, several small pieces of the jaws having come away, when, on the 17th September, he was attacked with symptoms of cholera, and died at midnight.



*Autopsy.*—On reflecting back the soft parts from the chin, several fragments of the lower jaw were found loose, one spiculum projecting downwards, and giving rise to an external swelling, and another containing an incisor and bicuspid tooth. The zygomatic arch was fractured at both extremities. The lower jaw was wanting on the right side from the symphysis to the ramus ; the upper jaw was fractured.

The common carotid was found to have been obliterated about two inches below the bifurcation, a mass of fibro-cellular tissue extending from that spot to the bifurcation, through the upper half of which was a small tortuous canal. A clot extended from the point of ligature down to the bifurcation of the innominata, and another clot extended for three-quarters of an inch into the internal carotid artery. The source of the hæmorrhage was not discovered.

CASE X.—*Case of Suppurating Cyst in the Lower Jaw.*

By OTTO WEBER.

A female, of twenty-five years of age, somewhat subject to chlorosis, but otherwise healthy, observed a year before a tumour of the left side of her lower jaw, which was slowly increasing, but with hardly any pain.

Shortly before a wisdom tooth had just come through, but, though all the rest of the teeth were well developed and sound, this had immediately been attacked by caries. The tumour meanwhile increased more and more in extent, and finally occupied the whole of the maxillary border, from the hinder angle of the jaw almost to the foramen mentale. The consequent distortion induced the patient to seek assistance in the Heidelberg Clinique. The surface of the tumour was tolerably smooth, and the swelling or prominence uniform. It extended all round the jaw, and could everywhere be pressed in with a rustling sound. A few spots consisted apparently only of membrane, and exhibited perceptible fluctuation. Only the inner wall of the jaw was rigid, and offered resistance to pressure. It was open to doubt whether we had to do with a so-called dental cyst, or with a myelogenous cysto-sarcoma, or finally, with an osseous abscess. A slight redness over the tumour, a very trifling elevation of temperature, the rapidity with which the tumour had increased in the course of a year to the size of a goose's egg, and finally, the circumstance that the fourth as well as the last and carious molar tooth appeared somewhat moveable, induced me to diagnose an inflamed cystoma. The operation I performed confirmed



this diagnosis. By an incision lengthwise from the angle of the jaw to the region of the foramen mentale, on the under border of the maxilla, I laid bare the tumour, pushed back the periosteum with the muscles by tearing them off, and then found that a closed osseous cyst was presented, which here and there was no thicker than paper. When I had divided it with the resecting knife, three ounces of a thick, flaky pus, containing much cholesterine, and very fatty, ran out; but it contained no trace of any other elements of the tissues. The cavity extended in the ascending ramus in an upward direction, and on the other side as far as the first molar; and further, it was somewhat uneven in consequence of several projecting osseous ridges. It was completely clothed all round with a large granulated layer, beneath which could be seen the inferior dental nerve, with the vessels in their entire length. Importance must be attached to the relative situation of the fourth and last molar. Both of them stood with their roots directed in a slanting direction outwards, but were surrounded by osseous alveolar walls from which some hard, thorny, osseous spicula projected outwards into the cavity, but which were covered with the membrane of the abscess. The entire inner wall of the jaw was rigid, and was only somewhat thinner near the two teeth. I removed the greatest portion of the bony shell with Liston's forceps, then extracted the two teeth with their prickly alveoli, preserving, nevertheless, the continuity and form of the jaw, and had the satisfaction of seeing the case successfully heal with tolerable rapidity, as the entire periosteum had been preserved.—*Chirurgie*, p. 297.

CASE XI.—*Abscess in the Right Upper Maxilla, communicating with the Antrum.* By Mr. MARGETSON, of Dewsbury.

Mrs. M., aged about forty, called to consult me about an enlargement of the right side of her face.

Found a hard swelling of the gums, extending from the median line to the right canine, and considerable bulging of the palate. She was wearing a badly-made partial set of teeth over the roots of the incisors and left canine; the right canine was the only tooth left in the upper jaw. Three years ago had some swelling after pain in right lateral incisor, and abscess formed in the socket of that tooth. Her medical attendant tried unsuccessfully to extract the roots. The swelling decreased after a time, but never disappeared entirely, and for the last four months it has steadily increased. She has had no pain or tenderness, and only feels a sort of heaviness, and is anxious about the facial disfigurement.



On attempting to remove the root of lateral incisor, it crumbled under the instrument. Trying a second time, and using a little more pressure, in order to seize the root a little higher, the forceps suddenly slipped upwards and were buried to the joint in a cavity in the bone. A gush of thin brownish fluid was the result, and free bleeding from the gum; there was also a discharge from the right nostril. Passing up a probe, I found a cavity extending from the alveolus of the right central incisor, behind the canine, to the position of the first bicuspid—which had been extracted some years. At the posterior extremity of the roof of the cavity there was a pretty large opening into the antrum, through which the probe passed without meeting with any resistance. After satisfying myself that there was no tumour in the antrum, and removing a small piece of dead bone from the lower cavity, I syringed well with warm water, and dismissed my patient.

Aug. 20th (eight days after first visit).—Have seen patient three times since the roots were extracted; she has had very little pain since the operation, the walls of the cavity are contracting, and the face is looking better. There is still a slight discharge. I removed right canine; it was firm, but black and carious. The tooth came away with about an average pull, and brought with it a small piece of adherent alveolus. There was no communication through the socket of this tooth with either the cyst or the antrum.

Aug. 29th.—Very slight discharge from position of right lateral incisor. Face nearly natural.

Sept. 26th.—Discharge ceased, all going on well.

Nov. 22nd.—Mouth quite healthy; considerable depression on right side, requiring the artificial piece to be thicker than usual on that side.

The only treatment required after the extraction of the roots, was syringing with warm water, for three or four days. No stimulating injection was used, showing that there was no disease in the antrum, or alteration in the secretion from the lining membrane.

CASE XII.—*Disease of the Maxillary Antrum, involving the Brain.* By R. S. MAIR, M.D., F.R.C.S.E., Madras.

I was first called to see Mr. J. L., aged thirty years, on the 22nd March, 1861. He complained then, and for some days previous, of a copious fetid discharge from the left nostril, severe pain in the left cheek, extending upwards round the correspond-



ing orbit. There was no swelling over any part of the nose or cheek; the third molar tooth of the left side was loose and painful, and oozing from its side was a free fetid discharge the same as from the nostril.

Suspecting these symptoms to be probably produced by some mischief in the maxillary antrum, the loose tooth was without difficulty removed, and with immediate relief. The discharge from the nostril disappeared, and the pain in the cheek and round the orbit almost entirely ceased.

Four days afterwards (26th) the same severe pain returned, but of distinctly intermittent character; there was still no discharge from the nostril or tooth-socket.

On the following day (27th) the patient had a sharp rigor, followed by fever, which continued for some hours, and the pain in the face and round the orbit continued unabated, notwithstanding the local application of anæsthetic anodynes. On the 28th, in addition to the above symptoms, there was threatening acute inflammatory action in the left eye. Leeches were ordered for this, but were not applied, owing to some prejudice in the minds of the relatives in attendance. Next day (29th) the whole eye was very much inflamed, the conjunctiva of upper and lower eyelids was congested and swollen, and the entire globe of the eye appeared to be fuller than natural.

Two leeches were then applied (the friends would permit no more), but even these, together with the application of ice over the eye, much relieved the pain and reduced the swelling.

On the 30th the former symptoms returned, as severe if not more so than before, and on the following day (31st) the upper and lower eyelids were very œdematous, and the conjunctiva in a state of great chemosis. On raising the upper eyelid the globe was found full, tense, and protruding; the cornea very hazy, and vision almost entirely gone.

On the evening of this day (31st) Dr. J. Shaw saw the case with me, and suspected abscess deep in the cellular tissue of the upper eyelid, behind the eyeball; an incision was made in the upper eyelid close under the supra-orbital ridge, which gave vent to a discharge of some sanguineo-purulent matter.

There was immediate relief to the sense of fulness in the eye; the eyeball could be moved more easily, though vision was not perceptibly improved. The patient slept better that night than he had done for several nights previous, but otherwise, on the following morning (April 1st), his symptoms were most unfavourable. The eyeball was enlarged to nearly double its natural size, and was protruded considerably forwards, while the upper



eyelid was again very much swollen, and the lower one everted, exposing the chemosed conjunctiva, and leaving about one-half of the eye itself uncovered and exposed.

The removal of the tent placed in the wound after the incision was made was not followed by the escape of matter, nor was there any discharge after a probe had been inserted to the bottom of the wound. On the following morning (April 2nd) the general appearance was much the same; if anything, perhaps, the fulness of the eye and swelling of the eyelids were greater.

A probe was again inserted to the bottom of the wound in the upper eyelid in search of matter, but none was found. The original incision was then enlarged, still no matter escaped. Simple soothing treatment was then adopted.

The patient complained of little pain, and remained tranquil up to eleven o'clock forenoon, when suddenly, and without a single premonitory symptom, he had a most violent convulsive fit, of an epileptic form and tetanic character. This fit, which was followed by two others of the same kind on the same day, was preceded by a peculiar scream, or howl, followed immediately by rigidity of the whole body, opisthotonos, foaming at the mouth, and complete unconsciousness. These fits each lasted about five minutes, but consciousness did not return till some time after.

This was the first indication of cerebral complication. It should be here noted that, prior to the first fit, in consequence of the great distension of the eyeball, and as no matter was found in the incision, which was made deep into the cellular tissue of the orbit, a seton was introduced into the left temple, and, subsequent to the fits, a cantharides blister was applied to the nape of the neck.

The case now assumed a most unpromising aspect, and the prognosis was accordingly very unfavourable. The patient remained dull, and sometimes apparently unconscious during the day. Nothing was done on this and the following day (April 3rd and 4th), beyond applying simple cold or tepid water to the eye, as was most grateful to the patient, and administering small doses of calomel. He occasionally appeared cheerful, and talked rationally; at other times he became incoherent, and lapsed into a state of low muttering delirium.

On April 5th the eye continued much swelled, and some pus escaped from the wound over the eyelid. The probe was again introduced to give free vent to the matter, but none came away. During this day the patient had a recurrence of the same fits as before, and while in one of them the pulse flickered and fluctuated so much as to threaten extinction every moment.

On the following day (April 6th) he appeared very little better,



talked now and then, and recognised some of his friends, though there was an evident tendency to lapse into a stupor or semi-comatose state.

He continued in the same condition all the 7th and up till the evening of April 8th, when he became completely comatose. From this he never rallied, but gradually sank, and died early on the morning of April 9th, sixteen days after he first consulted me.

The eye during the last three days of his life remained unchanged; a small quantity of pus escaped from the wound in the eyelid, but there was little or no decrease in the swelling of the globe. The discharge from the nostril ceased after the globe began to swell, and that from the tooth-socket disappeared after the tooth was extracted.

The patient had always enjoyed good health prior to his last illness. He had none of the usual indications of the strumous diathesis, and there was no reason to suppose that he had any syphilitic taint in his constitution.

*Post-mortem appearances.*—Head only examined. Purulent matter in considerable quantity flowed from the cavity of the arachnoid, and from between the hemispheres, on the removal of the falx. There was a layer of more consistent pus on the visceral surface of the arachnoid in some parts of both hemispheres, which, on removal, did not leave the arachnoid roughened.

At the anterior margin of the left hemisphere there was a rugged, excavated, and ulcerated surface, rather larger than a florin, covered with thick purulent matter, and appearing to be the source of the pus found in the arachnoid; but on turning up the anterior edge of the hemisphere from the roof of the orbit, there was found on its lower surface, about an inch from its anterior extremity, a small opening, with dark-coloured edges, from which a thin serous and discoloured fluid was exuding. This opening led to a cavity large enough to contain a good-sized walnut, lined with a dark-greenish investing membrane, of at least half a line in thickness, which could easily be peeled off from the surrounding cerebral substance.

The brain was now removed, and, on being sliced into, presented a larger number of red spots than are usually met with. Otherwise the brain-substance was perfectly healthy, except at the two situations already specified, around which the cerebral substance was of a rose colour.

The left lateral ventricle contained a quantity of a dirty, muddy fluid, with small flakes of purulent matter floating in it, some-



what similar to the fluid found in the peritoneal cavity in some fatal cases of puerperal peritonitis.

The crura and optic thalami presented nothing peculiar.

The examination of the investing membranes, and of the bones of the cranium, was now proceeded with. The roof of the orbit was first carefully examined, but presented no signs of disease, neither was its covering membrane detached at any point. Pus was found on the arachnoid, concreted at two points corresponding to the two abscesses in the brain above mentioned, but the membrane itself was not perforated at these points, and the pus was easily wiped away. A drop of purulent matter surrounded the optic nerve in the optic foramen, but there seemed no continuous flow either into or from the orbit from this channel.

The dura mater was now torn from the bones; it was everywhere adherent, and the bones themselves surrounding the optic foramen, and constituting the orbital roof, were perfectly healthy and of natural colour.

The orbital roof was next removed by two vertical saw-cuts, the inner of which also opened the frontal sinus of the left side. The latter was free from disease, but the orbital contents, the cellular tissue, fat and ocular muscles, were bathed in pus. The globe was flaccid and partially emptied.

On introducing the finger into the orbit, and passing it along its inner boundary, the latter was found diseased—the ethmoid bone crumbling before the finger, which passed readily into the upper part of the nose. Here all the osseous structures yielded readily to the touch of the nail, and portions of the ethmoid bone were removed by it with great facility.

They were in a state of caries, of very fetid odour, and bathed in pus; broken-down scrofulous matter on both.

The contents of the orbit being removed, the antrum was opened from above, when its cavity was found filled with a white, soft substance of the appearance and consistence of firm blanc-mange, and also very fetid. This substance, subsequently examined under the microscope, was found to consist mainly of tuberculous matter, interlaced with very delicate fibres, and showing an abundance of pus-corpuscles. The membrane lining the antrum was entire, considerably congested, and streaked with red lines. The cavity of the antrum did not appear to be enlarged.

*Remarks.*—The form of disease, of which the above case affords an example, is one of uncommon occurrence and of exceptional complications, while it affords much interest, both practical and pathological.



Its apparently simple origin (the first symptom complained of being ozæna), and its rapid progress to a fatal termination, are the most noteworthy features.

The fetid discharge from the nostril, and from the side of the loose undertooth, led me to suspect a morbid state (abscess) of the antrum of Highmore, and induced me to remove the tooth. The opinion then formed was verified by the post-mortem examination. Had the offensive discharge continued from the nostril, or from the socket after the tooth was removed, the indication for further treatment would have been obvious enough—viz., to puncture the antrum and evacuate its contents. But the original symptoms then almost entirely disappeared, the discharge and uneasiness in the cheek ceased, and the patient felt so comparatively well as to be able to attend to his ordinary office duties for five days afterwards, when the other symptoms set in, involving the entire eye and its appendages. These symptoms, which were only partially relieved by treatment, steadily and progressively advanced up till April 2nd, or eleven days after he first consulted me, when the first indication of cerebral complication showed itself by the violent convulsive fit, followed by others of the same kind, which speedily terminated in fatal coma, and put an end to the patient's sufferings.

The examination after death revealed an amount of disease unexpected, and such as could not have been predicted during the lifetime of the patient.

The appearances then found suggest three modes in which the disease may have originated. 1st, by disease in the brain, terminating in abscess—the purulent matter passing through the optic foramen, destroying the ethmoid and other bones of the left cheek, and filling the antrum; 2nd, by caries of the ethmoid bone itself; 3rd, by disease in the antrum.

The history, symptoms, and progress of the case during life, taken in connexion with the morbid appearances found after death, all tend, I think, to point out the last-named as the probable origin of the disease, and the pathological sequence of events was in all likelihood as follows:—Disease of the antrum, originating in degeneration of the mucous membrane lining its cavity, or perhaps connected with the soft tumours which grow from the apex of the tooth, and from the lining membrane of the fang; secondarily involving the ethmoid, lachrymal, palatine, and inferior turbinated bones of the left side, causing suppuration and disintegration; the purulent matter filling the cavity of the antrum, extending towards the left nostril, causing ozæna, and upwards into the orbit, behind the globe of the eye, pushing



the eye outwards and forwards; the matter finding its way through the optic foramen to the anterior surface of the left hemisphere of the brain, there acting as a foreign body, exciting inflammatory action, terminating in cerebral abscess, causing convulsions, coma, and death.

That the disease originated in the antrum, and that it probably commenced there some time previous to his consulting me, there can, I think, be no doubt. 1st. Because all the earlier symptoms pointed to some local mischief in the cheek. 2nd. No symptom indicating cerebral disease showed itself till some time afterwards. 3rd. Because the membrane lining the antrum was found congested and streaked with red lines, and its cavity filled with a *semi-solid substance of a cheesy consistence*.

If the patient had any symptoms previous to my first seeing him, they may have been so slight (perhaps simple toothache) as to pass unnoticed until the offensive discharge from the nostril began.

The morbid matter found in the antrum having a soft, brain-like, or cheesy consistence, and showing, under the microscope, mainly a tubercular appearance, might lead to the suspicion that there was a malignancy about the case sufficient to account for its rapid course and the speedy destruction of tissue.

With reference to treatment, the case just related is suggestive. Were a similar case to occur to me again, I think it would be advisable to puncture the antrum, either through the tooth-socket or through the maxillary bone, inside the mouth. If no matter then escaped, and the symptoms continued, the cavity of the antrum might be freely injected with tepid water, so as to break down and soften the thick curdy or cheesy matter, and permit of its free escape through the puncture.—*Edinburgh Medical Journal*, May, 1866.

CASE XIII.—*Case of Distension of the Antrum by Fluid, closely simulating a solid Tumour.* Under Mr. FERGUSSON.

Marianne P., twenty-six years of age, was admitted into the Adelaide Ward, March 23rd, 1850; was born in Hampshire, and has always lived in the country. Her health has never been strong; she has always been looked upon as delicate, and is subject to severe headaches. Patient has been married eight years, and the youngest of her four children is five months old.

About eight months ago, a swelling appeared on the right cheek, in the situation of the antrum, about three-quarters of an inch external to the right ala nasi, and on a level with that pro-



cess. It came on imperceptibly, without any pain, and when she first noticed the tumour it was about the size of a pea, immovable, and not painful on pressure. Since that time it has gradually increased, but of late somewhat rapidly. On admission the tumour was about the size of a hen's egg, involving the whole of the non-alveolar portion of the superior maxilla on the right side. Externally it formed a large smooth undiscoloured projection, drawing the eye a little downwards. On passing the finger inside the cheek, and along the outside of the teeth, the quantity of gum between the latter and the projection of the swelling was felt to be very small. On looking into the mouth, the right half of the hard palate presented, instead of the normal concavity, a smooth convexity, rather more than an inch long, and half that width, this convexity lying between the median line and the gum of the molars and bicuspid of that side. On pressure, which gives the patient no pain, there is a feeling of some fluctuation, and the hand experiences an elastic tense sensation. When strong pressure is made on the cheek, the patient feels the teeth thrust downwards. The first and third molars and the first bicuspid, are destroyed by caries, and the other teeth are likewise affected; in fact, the patient has always suffered from toothache, and she has hardly a sound tooth in her head. The zygomatici muscles have been so stretched, that they have become paralyzed, and on smiling, the right corner of the mouth, instead of being drawn upwards, is drawn downwards and outwards, the triangularis oris muscle alone acting. The most yielding part of the tumour is the situation where it first appeared. Five days after admission, the patient was attacked with severe inflammation on the *left* side of the face, involving the glands and gums. She was some time before she recovered from this complication, the disease of the antrum remained, however, in the same state as before described. Mr. Fergusson, considering that the time had now arrived to adopt operative measures for this affection, had the patient brought into the theatre on April 27th, and determined to proceed to the removal of the superior maxilla, if the cavity of the antrum were really, as was suspected, found occupied by a solid tumour.

Bearing, however, in mind that the appearances presented *might* be owing to an accumulation of fluid, Mr. Fergusson resolved to make an exploring puncture through the gum, before any further steps were adopted. An exploring needle was therefore passed into the tumour, and when fluid had been seen to escape, Mr. Fergusson took up the scalpel, and made an incision through the gum (the patient having been rendered in-



sensible by chloroform) down to the anterior wall of the antrum, and took out a portion of the same, which was much thinned. By this proceeding, a quantity of glairy fluid, containing flakes of cholesterine, was let out of the antrum, and the nature of the tumour being thus ascertained, no further interference was required, and the patient was removed. The swelling went on diminishing in size for the next few weeks, and the patient was discharged on May 3rd, in a pretty satisfactory condition.—*Lancet*, June 29th, 1850.

CASE XIV.—*Case of Dentigerous Cyst dependent upon an Inverted Tooth.* By Mr. TOMES ("Dental Surgery," p. 204).

A girl of sixteen, the daughter of a tradesman, gave the following history of her case. Nine months since a swelling appeared in the lower jaw, around the implanted portion of the second molar, and was supposed to be produced by a gumboil. At first the pain in the enlarged part was but slight and intermittent, but with a gradual increase in the size of the swelling the amount of discomfort became greater, although it was at no time very severe. I saw her for the first time on Dec. 15th, 1856. There was very considerable enlargement of the alveolar portion of the jaw around the second molar. The tooth, however, was perfectly sound, and although slightly tender when pressed upon by the antagonistic teeth, yet it was not considered by the patient to be the seat of pain. The colour of the tooth was perfectly good, and its implantation firm—indeed, there was a total absence of any indications which would induce a belief that disease had arisen first in it, and subsequently extended to the jaw. The swelling was not confined to the soft parts—the bone was obviously involved. At one point, however, fluctuation could be felt, and the examination did not appear to produce any considerable amount of pain in the part. The absence of active inflammatory symptoms, and the comparative freedom from tenderness, coupled with the large amount of local swelling, rendered the nature of the disease very obscure. Mr. Arnott was kind enough to see the case. He introduced a grooved needle, several drachms of clear yellow fluid escaped, and the swelling of the soft parts to a certain extent subsided, leaving the outline of the enlargement of the bone comparatively distinct. The patient felt relieved by the operation from the sense of tension and weight, which had latterly become distressing. I saw her again on the 26th of the following January. The swelling, she stated, had gradually returned, and with it a dull aching pain. The in-



volved tooth, I found, had in the interval become slightly loose, and was turned a little inwards towards the tongue. The swelling was again punctured, and with results similar to those already described.

On February 5th the patient returned. She stated that after the last operation she suffered great pain, accompanied with constant throbbing in the tumour, and that pus had subsequently been discharged from the orifice made by the needle. The amount of constitutional disturbance was sufficient to confine the patient to her room for some days.

On examination I found that the tooth had become much more displaced than formerly, that it was quite loose, and the surrounding gums were greatly inflamed. Under these circumstances I determined to remove the tooth, although it was by no means clear that it was the primary cause of the mischief. On removal a most curious state of things was manifested. Instead of having the two fangs common to second molars of the lower jaw, the implanted portion of the tooth was dilated into one large concavity, in which was placed the crown of a second tooth, perfectly invested with well-developed enamel and with the masticating surface directed towards the jaw. The two teeth appear to be united by dentine at one point, and to have one common pulp-cavity. The appearances presented by the united teeth are shown in the figures.

The pain from the operation quickly subsided, and within a fortnight all swelling and pain in the soft parts had disappeared; the enlargement of the bone had also sensibly diminished.

CASE XV.—*Encysted Tumour of the Lower Jaw, removed by  
Operation on March 25th, 1830.*

The patient, Ann T., aged forty-five, was admitted March 8th, 1830, with great enlargement of the right side of the lower jaw-bone, extending from the second incisor tooth to the condyle, and forming a large globular tumour, occupying nearly the whole side of the face. The tumour extended downwards over the upper part of the neck, and inwards, displacing the tongue, and thus interfering considerably with speech and mastication, but the principal part of the enlargement was upwards, and outwards, towards the malar bone. In some parts it was of a bony hardness; in others it communicated the sensation of pressing on an elastic gum-bottle. The integument was not discoloured, and there was no enlargement of the neighbouring glands. The disease had been first noticed about eighteen years before her ad-



mission, when it was a small, hard, incompressible lump, just over the angle of the jaw; it gave no pain, and its increase for a long time was extremely slow. Six months before it was not larger than a hen's egg. About that time it began to enlarge very rapidly, and had continued to do so up to the date of admission. The cyst, as may be seen in the preparation, extends from the symphysis to the right condyle of the jaw; its parietes are partly osseous and partly membranous; it is divided into several cells, which contained about four ounces of a transparent, gelatinous fluid. The patient lived fourteen days after the operation. She appeared to sink under the effects of erysipelas and diarrhœa. On examining the body, the lungs presented spots resembling secondary deposits; the other viscera were healthy.—*Catalogue of St. George's Hospital Museum.*

CASE XVI.—*Cystic Disease of the Lower Jaw.* Under the care of Mr. PAGET.

A woman, aged forty-eight, was admitted a few days ago under the care of Mr. Paget for cystic disease of the lower jaw. The disease commenced twelve years before, as a slight swelling of the ascending ramus near the angle. Nothing was done then, and the swelling slowly increased. Eight years from the commencement, however, the disease had increased to such an extent that she was sent to St. Bartholomew's Hospital. The swelling was then as large as the one for which she was last admitted, producing a general enlargement on the right side of the jaw and cheek. Mr. Paget on that occasion considered the propriety of removing the bone, but as he found that the disease then consisted of one large cyst only, he merely removed the anterior wall of the cyst, and filled it with lint and left it to suppurate. By this treatment the disease was so far for a time cured. She remained well for two years, when another smaller cyst was found a little higher than the first. This was treated in the same way, and she again got well, and remained well for twelve months. The disease, however, reappeared and continued increasing until her admission for the third time. It now involved the right lower jaw from the first molar tooth to the angle. Above the angle the bone could scarcely be said to exist, but there were one or two cysts. The zygoma was nearly destroyed, only a small part (two small stumps) being left. Mr. Paget made a vertical incision through the soft parts on the right side of the symphysis, carrying it along the lower edge of the horizontal ramus to the angle. He next cut through the bone, partly by



the saw and partly by the bone-cutting forceps. He divided the parts at the angle, and removed the diseased horizontal ramus. He then cleared out the remains of the cysts which occupied the position of the ascending ramus, pursuing it as high as the zygoma. The vessels requiring ligature were rather numerous. Mr. Paget, in his remarks after the operation, stated that the duration of the disease and the general features of the case clearly showed that the disease was not malignant, otherwise he should long ago have removed the bone.—*Medical Times*, Sept. 1st, 1860.

CASE XVII.—*A Case of Cystic Tumour of the Lower Jaw, treated by Incision through the Mouth.* By MASON WARREN, M.D.

A young woman, aged twenty-five, with light hair, blue eyes, and delicate skin, applied to me, in the spring of 1862, on account of a large tumour involving the whole right side of the jaw above its angle. The tumour was of a globular shape, extended back under the lobe of the ear, forward so as to encroach upon the cavity of the mouth, and upward so as to press upon and somewhat to overlap the zygoma. The external surface of the tumour was smooth and shining, slightly œdematous, and she suffered somewhat from its pressure upon the surrounding organs. It had commenced, some years before, by a swelling at the root of the wisdom tooth of the right side, and the inconvenience caused by its pressure had become so great as to lead her to take measures for its removal.

Upon consultation it was decided that a portion of the jaw would probably require removal, the tumour having been first exposed by an incision made inside of the mouth, to verify its character.

The following operation was performed, under the influence of ether. An incision was made in the most prominent part of the tumour in the mouth, upon which a large quantity of glairy fluid escaped. Upon passing the finger into the opening, it was found that the whole jaw, at this point, with the articulating and coronoid processes, was expanded into a mere shell, at some parts as thin as parchment, and destitute of osseous substance. It was without solid contents. Under these circumstances, and considering the good health and youth of the patient, it was determined to make the attempt to save the jaw. A portion was therefore removed from the sac, and with the fingers the sides of the cavity were made to collapse, so as to come in contact with each other. In order to excite still further irritation, a bit of cotton cloth was forced into the interior, and the end left pro-



jecting into the mouth. A moderate degree of irritation followed, and in a day or two the pledget was removed, suppuration having commenced in the sac. The aperture was dilated from time to time by the introduction either of the finger or of a bougie, and the sac injected with tincture of iodine. In two or three weeks she left the hospital, with the tumour reduced to about half its original size. From that time until the present she has occasionally visited me at my house, and by keeping the external opening free, and occasionally irritating the interior of the sac, a solid mass of bone has been deposited anew, and the jaw has resumed somewhat of its original shape. The sac is in the way of becoming entirely obliterated.

In November, 1863, I again saw the patient, who came to consult me, not about herself, but about a friend. All signs of the tumour were gone, and the jaw had regained almost its natural shape; but a small aperture still existed at the site of the former opening into the mouth, from which a glairy fluid was occasionally discharged. She was quite well, and all the functions of the jaw were perfectly performed.

Subsequently she applied to me with a similar tumour, but of a much smaller size, which had appeared anterior to the site of the first one. It was treated in a similar manner, with a similar result.—*Boston Medical and Surgical Journal*, 1866.

CASE XVIII.—*Fibroid Disease of the Antrum.* Under the care of the AUTHOR.

Mr. W. W——, aged seventy-six, was brought to me on Sept. 18th, 1866, by Dr. Whitmarsh. About two years ago he perceived some growth in the right nostril, which gave no pain, but kept up a constant discharge, especially at night. A surgeon attempted to remove this "polypus" last spring, but only got away parts of it, and since that the discharge had much increased. Two months ago Mr. W. applied to Dr. Whitmarsh with erysipelas of the right side of the face; this has subsided, but the right eye is swollen and inflamed. There is a fungous growth in the right nostril, and the whole right maxilla is swollen, and discharges thin pus at one or two points near the eye. A minute piece of dead bone has worked out. All the teeth on the right side are gone, and there is a fungous-looking growth in the molar region, and a probe passes up easily by its side into the antrum. The patient's general health has given way somewhat lately, and he has an ulcer on the left cornea partly healed. He is taking ammonia, and bark and wine. Believing that the dis-



ease springs from the antrum, and is probably of a non-malignant character, I recommended an immediate operation for its removal.

Sept. 23rd.—Operation. Present, Messrs. Chapman, Whitmarsh, Teevan, and Moore. Dr. Whitmarsh administered chloroform, and I divided the lip, carrying the incision round the right ala and up the side of the nose, and then in a curve below the eye. The facial artery was exposed for a quarter of an inch, and bled freely, and was therefore ligatured at once. The flap being dissected back, the surface of the tumour was exposed, and bled copiously, I therefore at once put a narrow saw into the right nostril and divided the maxilla, and then with forceps divided the nasal process, and removed the remnant of the anterior wall of the antrum, with part of the tumour. The malar bone was next divided, and the greater part of the tumour, which was of a soft friable nature, removed with the forceps. It became necessary now to plug temporarily with a sponge, and administer brandy freely, on account of the failure of the pulse. This having been done, I found that there was a distinct polypoid growth, filling the posterior nares, which I removed, and then, with curved scissors and gouge, removed all traces of the growth, leaving the posterior wall of the antrum and the infra-orbital plate untouched. The actual cautery was freely applied to the deep part of the wound, and the whole sponged out with solution of chloride of zinc—grains 40 ad ʒj. The lip was closed with two hare-lip pins, and a silk stitch at the margin, and the rest of the wound with wire stitches, collodion being painted over the whole. The patient bore the operation (during the latter part of which he was sensible) pretty well, but was rather cold at the termination. The pulse, however, was steady at 60. Stimulants were administered, and hot bottles put to the feet. A stimulant and opiate draught was administered an hour afterwards, and before I left, shortly after, the pulse had improved and was 75, and his general condition satisfactory.

Sept. 24th.—I found the patient very comfortable; pulse full, 100. He takes nourishment well, but is a little troubled with bronchitis, which he had had before the operation. The wound looked healthy, and the incision appears to have united in great part. The stitch in the lip has given way, owing to his having sucked very forcibly.

Sept. 27th.—I received a note from Dr. Whitmarsh, dated last night, and saying that, yesterday, congestion of the lungs had supervened, and that Mr. W. was sinking fast. I could not get down to see him until 3 P.M., when I found that he had died at 10 A.M. The wound was united in its whole



length, and the cavity, as seen from the mouth, presented no appearance of note. There had been no hæmorrhage whatever.

CASE XIX.—*Myeloid Tumour of the Upper Jaw, removed four times by Mr. LAWRENCE.—Return and growth of Tumour in opposite jaw.—Removal of one and spontaneous atrophy of the other.*

A woman, twenty-two years old, was under Mr. Lawrence's care in March, 1851, from the alveolar part of whose right jaw growths, which were regarded as examples of epulis, had been four times removed in the previous thirteen months. In the fourth operation, in August, 1850, the growth was found to extend through the socket of the first molar tooth into the antrum, or into a cavity in the jaw. It was wholly removed (as it was thought), and the wounds healed soundly; but nine weeks afterwards a fresh growth appeared, that seemed to involve or arise from nearly the whole front surface of the right upper jaw bone; it was firm, tense, and elastic, but not painful, projecting far on the face, as well as into the nostril and into the cavity of the mouth, at both the gum and the hard palate. This swelling, under various treatments, rapidly increased; and in December, 1850, a similar swelling appeared at the left canine fossa, and grew at the same rate with that of earlier origin. Of course the co-existence of two such swellings led to the fear, and in some minds to the conviction, that the disease was cancerous; and the more because, at nearly the same time with the second of these, two soft tumours had appeared on the parietal bones. Still the patient's general health was but little impaired; and when the mucous membrane of the hard palate ulcerated over the most prominent parts of the tumours, neither of them protruded, or bled, or grew more rapidly. In April, 1851, the growth of the tumours appeared to be very much retarded, and for the next month was hardly perceptible, and the patient being very urgent that something should be done to diminish the horrible deformity of her face, Mr. Lawrence, in May, cut away the greater part of the front and of the palatine and lower nasal parts of the right upper jaw, and removed from the antrum all that appeared morbid, including doubtless nearly every portion of the tumour. The excised portion of the jaw bone was involved and imbedded in a large, irregularly spherical tumour, composed of a close-textured, shining, soft, and brittle substance of dark greyish hue, suffused and blotched with various shades of pink and deep crimson. It was not lobed, but included portions of cancellous bone, apparently



new-formed, and was very closely adherent to all the surrounding parts. To the microscope it exhibited all the characters of a myeloid growth; and the many-nucleated corpuscles were remarkably well defined and full. They composed nine-tenths of the mass, and were arranged like clustered cells. The patient perfectly recovered from the effects of the operation; and, to everyone's surprise, the tumour on the left upper jaw, which had been in all respects like that removed from the right side, gradually disappeared. It underwent no apparent change of texture, but simply subsided. The swellings on the parietal bones also, the nature of which was not ascertained, cleared away; and when the patient was last seen, a few months after, she appeared completely well, and no swelling could be observed.—Paget's *Surgical Pathology*, p. 524.

CASE XX.—*Fibro-cartilaginous Tumour—Extirpation of the Superior Maxilla.* By Mr. O'SHAUGHNESSY.

Woodey Morrol, aged twenty-one, a Hindoo, of the farmer caste, presented himself at the Gurranhatta Dispensary on Nov. 6th, 1837, under the following circumstances:—

He says that about a year ago, a swelling formed in his left cheek, immediately above the second grinder, about the size of a sparrow's egg, causing much pain and inconvenience. This gradually increased in size, and about four months from its commencement it had attained the bulk of a large orange, when he sought relief from a native doctor, who told him it was an abscess, which he promised to cure as soon as he thought it soft enough to puncture. And accordingly, in three or four days, though the hardness of the tumour had not at all diminished, he commenced his treatment by thrusting a needle into it, but no matter flowed from the wound thus formed; the doctor then set to work to bring it to a head, and for a few days more frequently rubbed it with some mysterious compound, which he appeared to prepare with great skill and care; but this disappointing his expectations also, he gave it up, and absconded. The puncture made into the swelling with the needle produced no ulcer or fungus, though the operation caused great pain and suffering to the patient. From the time the doctor ceased his treatment, the tumour went on increasing; it gradually protruded into the mouth, and six months after its first appearance, it commenced bleeding copiously once or twice a month, and he says the bleeding was more abundant and more certain to return at the full of the moon than at any other time during the month. This pe-



riodical discharge of blood did not produce any salutary alteration, or effect any check on the advancement of this frightful disease; it still continued to increase in pain and bulk, until, after filling the mouth so as nearly to produce suffocation, it at last protruded from that cavity through the lips, and went on rapidly growing up to the day of his admission into the dispensary. He positively says that he never received an injury of any kind in that cheek or jaw, and that he never had a tooth drawn or an unsound one.

On his admission into the dispensary, the tumour presented the following appearance:—An enormous growth completely occupied the left side of the face, rising to a level with the floor of the orbit, and extending a long way below the inferior maxilla, but unattached to it; occupying the whole of the anterior and left side of the mouth, and protruding between the lips, pressing down the lower jaw, so as almost to make the chin touch the throat, and flattening the nose so as to leave but little trace of the natural prominence of that organ. Still there was no difficulty of swallowing, and the patient seemed to breathe without inconvenience through the right nares. That portion of the tumour which protruded through the mouth was of a bright red colour, and covered with mucous membrane, having at its upper part the canine, and the two incisors of its own side, with the central incisor of the opposite maxilla, sticking out of it. The dimensions of this mass were as follows:—From the part near the ear to the most prominent point which protruded from the mouth, exactly twelve inches, and from that part which bulged below the inferior maxilla to the edge of the orbit, about ten inches. It looked as near as may be equal in size to the patient's head. The skin over the tumour was perfectly sound, and not adhering to it, and many of the muscles of that cheek still retained their healthy actions; there was not the slightest trace of ulceration on any part of the tumour, and the principal source of pain to the patient appeared to be from distension and pressure on the surrounding parts. He always hung a cloth upon the tumour, the end of which he kept constantly applied to his mouth for the purpose of collecting the saliva, which was secreted in great abundance, and also to concentrate the sound of the voice when speaking.

Taking everything into consideration, the youth of the patient, and his general good health, and also the benign character of the tumour, and its freedom from any attachment to the lower jaw, I felt not only warranted but in duty bound to offer this poor sufferer the only chance now left for him of escaping a lingering



and frightful death, which of course was only to be hoped for by his submitting to an operation; and he not only willingly but joyfully acceded to the proposal. For the few days he remained in the dispensary before the operation, while I was waiting to have the illustrative drawings executed, he frequently urged that no further delay might be made, as he said he felt the tumour growing larger, and becoming more painful daily. So pressing were his entreaties to have it removed, that I refrained from having a cast of it taken, as that would have caused the delay of an additional day, though I was very anxious to procure one for the Museum of the Medical College.

On the 9th, three days after the patient was admitted into the dispensary, I had him taken to the theatre of the Medical College, where, for the advantage of the pupils, and also as having there better light and room than in any department in my dispensary, I thought it best to operate. The patient being seated in a stout arm chair, and his head supported by Dr. Corbyn, who kindly offered to undertake that charge, while a second assistant, Dr. Goodeve, stood at his left side, prepared to make pressure on the carotid artery, if at any time during the operation the bleeding called for such interference. I commenced the operation by making a cut through the skin over the upper part of the tumour, commencing at the posterior edge of the left malar bone and terminating in the upper lip, which I divided about an inch from the ala of the nose. I then cut from its bony attachments the cartilage of the nose, turned up the left ala, and continued the dissection as far upwards as the edge of the orbit, and back to the zygomatic process of the malar bone, which I laid bare, and with a Liston's bone-nippers divided. I next carefully raised the periosteum of the floor and external side of the orbit with the handle of the knife, and again took the bone-nippers and cut through the malar bone into the sphenomaxillary fissure. I then cut through the orbital process of the superior maxilla with a strong knife, dividing the superior maxillary nerve at the same time; the nasal process of the superior maxilla was next cut, and then, after drawing the second incisor of the opposite side (for the extent of the disease required it), I cut through the alveolar process and hard palate as far back as the palatal process of the palate bone with the bone-nippers; and now all the strong attachments of the tumour being completely severed, I had no difficulty in removing that mass, carefully separating with the knife the palatal process of the superior maxilla from the palatal palate of the palate bone, so as to preserve the soft palate from injury. The whole of the superior



maxillary bone of the left side, part of the alveolar processes and palate plate of the superior maxilla of the opposite side, and also the malar bone of the left side, were involved in the disease.

The tumour weighed four pounds; it was nearly globular in form, having at its inferior surface a deep groove into which the lower jaw sank, and the teeth before mentioned projecting from its anterior and upper part. In making a section right through its axis, it was found to be of a dense fibro-cartilaginous structure, surrounded for three-fourths of its entire extent by a pellicle of bone about the thickness of fine parchment, and where the bone was deficient by condensed cellular membrane. There was no trace of any one of the original processes of the bones involved in this diseased mass; they all appear to have been absorbed, and a case was formed for the tumour by the deposition of new bone.

The patient made a perfect recovery.

CASE XXI.—*Large Fibrous Tumour of the Lower Jaw.*  
Under the care of Sir WM. FERGUSSON.

Mary Anne S., aged forty-two, admitted into King's College Hospital Sept. 1866. Married; had good health except tooth-ache. Nine years ago had a cracked molar in lower jaw, and applied some mercurial stopping. The tooth broke away and painful stumps were left, which were extracted at Cheltenham. Soon after she noticed a small growth below the alveolus, which yielded on pressure and gave no pain. This discharged into the mouth and healed up. Five years ago, after her confinement, she found the left side of the face swollen, and applied at a dispensary, where incisions were made inside the cheek, which were stuffed with medicated dressings, and afterwards, on two occasions, iodine was injected with a syringe from the outside. This made the face swell much more, and gave great pain, which subsided under poulticing. Twelve months after (four years ago) a seton was introduced from the outside, and this was kept in eight months, giving rise to great suppuration and reducing the swelling. No further treatment was adopted, and though there were two large holes in the face, she was very comfortable and in fair health until April, 1866, when she was accidentally struck on the wound. This made it inflame and swell until it got to its present condition, and she was sent up to Sir Wm. Fergusson. There is now enormous deformity, the tumour of the jaw being of great size, and pushing the mouth over to the right. There is a large ulcerated surface on the outside, measuring seven inches



in length, which constantly discharges thin pus. On looking into the mouth there is seen a growth, occupying the lower jaw, behind the left bicuspid teeth, which is smooth and dense, but ulcerated by pressure of the upper teeth.

The patient being in a very feeble state, Sir Wm. Fergusson postponed all operative interference until she had improved under treatment. Unfortunately diarrhœa supervened on Oct. 9th, which still further reduced her. On Oct. 20th the wound in the cheek began to slough, and by the 29th large masses of the disease had come away, and she died exhausted on Nov. 2nd, 1866.

CASE XXII.—*Large Osteo-sarcoma of the Lower Jaw  
removed by Mr. SYME, in 1828.*

Between eight and nine years ago, Robert Penman, from Coldstream, then sixteen years old, noticed a hard swelling of the gum on the outer side of the grinding teeth of the lower jaw. The swelling was not painful, but gradually increased. When it attained the size of an egg he applied to a surgeon of the neighbourhood, who extracted three of the adjoining teeth. It then grew more rapidly, and having at length become so large as an orange, induced him to repair to the Royal Infirmary of this city, where it was removed—*i.e.*, cut off from the bone. The wound did not heal, and the actual cautery was repeatedly applied in vain to make it do so. After remaining eight months in the Infirmary, he returned home; but finding the tumour regularly and rapidly increasing, he, two years afterwards, came again to Edinburgh and consulted a distinguished operating surgeon (now in London), who declined making any attempt towards his relief. He went home with the fearful prospect of a certain lingering and painful dissolution; and it was after three years and a half spent in this miserable state that Dr. Sibbald, of this city, happened to see him. Though the tumour was then nearly three times larger than it was when the patient last quitted Edinburgh, Dr. Sibbald felt persuaded that it was still within the reach of surgery, and therefore encouraged the young man to come once more to town, which he accordingly did. Though prepared for something very extraordinary and frightful, I certainly was astonished at first sight of the patient. The representation may give some notion of what mere words are altogether inadequate to express. The mouth was placed diagonally across the face, and had suffered such a monstrous distension as to measure fifteen inches in circumference. The



throat of the patient was almost obliterated in appearance, there being only about two inches of it visible above the sternum, so that the cricoid cartilage of the larynx was on a level with that bone. When the tumour was viewed in profile, it extended eight inches from the front of the neck. It completely filled the mouth, and occupied all the space below it, from jaw to jaw. The tongue was thrust out of its place, and lay between the teeth and cheek of the right side. The only portion of the jaw not implicated in the disease was the right ramus and base of the same side, from the bicuspid teeth backwards. The tumour, when covered by the integuments, was uniformly very firm, and for the most part distinctly osseous. The part which appeared through the mouth was a florid, irregular fungous-looking mass of firm consistence, from which an alarming hæmorrhage had occasionally occurred; and for the last three or four weeks there had been almost daily a discharge of blood to the extent of one or two ounces. Notwithstanding the great bulk of the tumour, the patient could move his jaw pretty freely in all directions. With the exception of the disease now described, Penman enjoyed good health. He was a tall, well-made, though much emaciated, intelligent young man, and possessed uncommon fortitude.

Having carefully examined the tumour, I undertook to remove it; and this proposal meeting with the approbation of Dr. Abercrombie and Professor Ballingall, was, with the assistance of the latter gentleman, carried into execution on July 7th, in the presence of Dr. Abercrombie, Professor Russell, Dr. Hunter, &c. The patient being seated on a chair—which posture I preferred as being most conducive to the prevention of suffocation from hæmorrhage during the operation—I made an oblique incision by running a sharp-pointed knife through the lip, from the right angle of the mouth to the base of the jaw, where I proposed to divide it—viz., at the second bicuspid tooth, which had been previously removed. Having exposed the external surface of the bone at this part, I divided it partially with a saw, and easily completed what remained by means of the cutting pliers. The inferior coronary artery, which Dr. Ballingall had prevented from bleeding by compressing it in the lip, was then tied. I next made a long semicircular incision from the left angle of the mouth, in the direction of the base and ramus of the jaw, and terminating over the condyle. Having secured the facial artery and two transverse branches of the temporal, I dissected down the large flap thus formed quite to the neck, so as to let Dr. Ballingall feel the carotid lying in the muscular interspace, and ready to be compressed if there should be occasion. I then



made another curved incision in a similar direction, commencing from the mouth, at such distance above the former as to include a portion of the cheek, which was firmly adherent to the tumour; and having dissected up this flap, divided the masseter muscle, so as to expose the whole external surface of the tumour. The next step was to divide the mucous membrane of the mouth. This rendered the tumour much more moveable, and enabled me to expose the coronoid process, divide the temporal muscle, and open the articulation at its fore part. I had then merely to cut closely round the condyle, and detach the pterygoid, mylo-hyoid, and other muscular connexions.

The operation occupied twenty-four minutes; but all this time was not employed in cutting, as I frequently allowed a little respite to prevent exhaustion from continual suffering. The patient bore it well, and did not lose more than seven or eight ounces of blood. His breathing was never in the slightest degree affected. After placing a few folds of lint in the great cavity left by the tumour, which weighed  $4\frac{1}{2}$  lb., I brought the integuments together on the left side of the face, in a triangular form, and retained the edges in contact by the twisted suture. The incision on the right side was dressed in the same way. Two or three turns of a roller were then put round the chin and head, so as to support the relaxed integuments.

The patient made no complaint of any sort after the operation. His pulse for the first two days was about one hundred, but soft, and gradually subsided to the natural standard. He slept well; had an appetite for his food—viz., beef-tea and whey—which were introduced into the pharynx through a funnel with curved tube; and performed his excretions regularly. The whole of the lint was removed by the third day, when the patient sat up, and declared that he felt better than he did previous to the operation.

About two years ago, and consequently seventeen years after this operation, I was stopped in the street by a well-dressed, respectable-looking man, who introduced himself as "Penman." He told me that, after working for several years at home as a boot-maker, he had gone in quest of better wages to New York; that he had spent ten years in America, whence he had just arrived, and that he proposed to return there after a short visit to his native country. I was no less surprised than pleased to see how little the operation had injured either his appearance or articulation. Careful inspection, indeed, was requisite to enable an ordinary observer to detect anything peculiar in either of these respects. — SYME's *Contributions to the Pathology and Practice of Surgery*, p. 13.



CASE XXIII.—*Enormous Osteo-sarcoma of the Lower Jaw—*  
*Removal—Death.* Under the care of the AUTHOR.

W. T., aged thirty-two, was admitted into University College Hospital, Nov. 13th, 1867, with an enormous tumour of the lower jaw. About eleven years before he had a severe pain in the right jaw resembling toothache, and after some little time he perceived a small hard swelling about the size of a nut just below the right canine tooth, which was not decayed, nor were any of the teeth in its immediate vicinity diseased. This swelling continued about the same size for five or six years, during the latter part of which time it was entirely free from pain. Four years before it began to enlarge, and two years afterwards he was thrown from a cart and fell on his face, when he had profuse bleeding from the gums. The tumour now grew rapidly, spreading along its anterior surface, and involving the whole of the right side of the jaw. About twelve months before it began to involve the left side of the jaw, and extended up to the angle. He had been seen by various medical men at his native place, and also by one London hospital surgeon, and the question of an operation had been discussed, but nothing had been done. Two years before, one quack burnt the inside of his mouth with acid, and another put a white ointment upon the surface of the tumour, which caused the skin to give way at the point where the protrusion appeared. About a year before admission, the portion of the tumour near the right angle of the jaw rapidly increased, and in a short time the skin gave way, and a quantity of offensive pus was discharged, but there was no diminution in the swelling. Latterly, owing to the difficulty in swallowing, he had been able to take little but milk and brandy, and this in small quantities at a time, so that he had become much reduced in strength. His family had all been healthy and long-lived.

On admission, the patient presented an extraordinary appearance, the mouth and all the lower part of the face being occupied by an enormous tumour. The measurements of this were as follows:—From the lobule of one ear round the chin to the lobule of the other ear,  $19\frac{1}{2}$  inches; from the border of the lower lip across the chin to the pomum Adami, 13 inches; from the angle of the jaw across to the same point on the opposite side, 14 inches. When the man was sitting, the tumour rested upon the top of the sternum; but it moved freely when he opened and closed the mouth. Between the lips, of which the lower was much stretched, so that the circumference of the



mouth measured  $9\frac{1}{2}$  inches, there was a red granulating mass of disease, which came in contact with the upper lip; but when the mouth was opened, a space intervened through which a second mass, covered with the mucous membrane of the floor of the mouth, could be seen almost in contact with the roof of the cavity, and completely hiding the tongue. Between these two masses some of the teeth could be felt and seen. Fig. 132, taken from a photograph, shows the patient with his mouth shut. From beneath the cheek on the right side a foul, yellowish discharge constantly exuded. An inch below the lower lip was a large red, fungous mass, covered with healthy granulations; this extended to the lower border of the tumour, and the skin was adherent around it. On the right side, just below the angle of the jaw, there was another smaller fungous projection; but the skin on the left side was perfectly healthy, though much stretched. The right ramus of the jaw could not be defined, though the angle could be indistinctly perceived. The articulation, however, was not involved. The tumour, though overlying the neck, in no degree involved its tissues, and there were no enlarged glands either below the jaw or in the neck. On the left side the whole of the ramus and angle could be clearly made out, the disease stopping short of the latter point.

From the time of his admission the patient was well fed with strong beef-tea, milk, eggs, and brandy; and considerably improved in appearance. Mr. Heath's colleagues agreeing with him as to the advisability of an operation, this was undertaken on Nov. 20th, 1867. The patient being seated in a chair, Mr. Clover administered chloroform at first with the ordinary mask, and during the operation with a smaller one, enclosing only the nose. As soon as the patient became partially unconscious he was carefully secured in the chair with bandages, and his head was held firmly against the breast of an assistant. Perfect anæsthesia having been induced, Mr. Heath, standing on the right hand of the patient, divided the lower lip in the median line, and carried the incision round the right side of the fungous protrusion to the lower extremity of the tumour. The skin was then rapidly dissected back with the assistance of Mr. Marshall, who took up the vessels of the flap. Returning to the middle line, Mr. Heath made a second incision on the left side of the fungus, meeting the former one above and below, and dissected back the skin off the tumour as far as the jaw. The bone being isolated with the assistance of Mr. Erichsen, the second molar tooth was drawn, and a narrow saw applied at that point; but before complete division was effected the weight of the tumour



caused it to break away. As had been pre-arranged, Sir H. Thompson then grasped the tongue, which was now seen for the first time, and transfixed the tip with a stout needle and ligature, by which it was held until the operation was concluded. On dividing the mucous membrane beneath the tongue, a large lobulated mass came into view imbedded among the sublingual muscles; and this being dragged forward, the muscles were divided close to the tumour, and one or two bleeding vessels were promptly secured by Mr. B. Hill. The tumour being then turned over to the right side, Mr. Heath carried the knife upwards, so as to clear the coronoid process, which was healthy; but this appeared to be driven forward against the malar bone, and tightly jammed, so that forcible traction made on the tumour failed to clear it. Grasping the process itself with the lion forceps, Mr. Heath succeeded, however, in wrenching it out, when the condyle of the jaw, also healthy, immediately came forward without any dissection. A little dissection round the posterior margin of the tumour now completely disconnected it, and it was removed. About half a dozen bleeding vessels were now tied, none of them of large size, the two facial arteries having been preserved uncut. Finding the bone on the left side where the tumour had broken away rough and irregular, Mr. Heath sawed it cleanly through, close in front of the wisdom tooth.

There was now an enormous gap; the fauces, tongue, and front of the larynx being fully exposed, and the flap of skin on each side being pendulous and superabundant. The right was somewhat ragged, owing to the perforation which had taken place, and also owing to its being so adherent to the tumour that it had been perforated at one or two points; Mr. Heath therefore removed a portion of it, adapting the opposite flap to it. The lip was then brought together with three hare-lip pins and a twisted suture, and the remainder of the incision was held together with four silver sutures, placed some distance apart so as to allow discharge to escape. The thread holding the tongue was next secured to the hare-lip pins, so as to bring the apex of it close to the lip; and some lint was placed in the large cavity, and a bandage externally, so as to check oozing and maintain the shape of the part. The patient was then carried to bed. Not more than three ounces of blood were lost.

Half an hour after the operation the patient had some brandy by the mouth, and one-third of a grain of morphia was injected beneath the skin. He dozed during the afternoon, but was well supplied with beef-tea and brandy both by the mouth and per rectum. He had a second dose of morphia at night, and got



some sleep; being warm and comfortable, and with a fair pulse.

On the two following days the patient's condition was as comfortable as could have been hoped for; he took plenty of nourishment and stimulants by the mouth, and also had nutrient enemata.

On the evening of the third day his breathing and pulse became more rapid, and he had a slight rigor. Mr. Heath now removed the ligature holding the tongue, which was giving him some inconvenience, and ordered him quinine in ten-grain doses.

On the 23rd his condition was more satisfactory again. The pledgets of lint in the chin were removed, and the wound well washed out with Condyl's fluid. He passed a comfortable day, and on Sunday (fifth day) he was apparently gaining ground, and was well enough to write his want of some stout upon a slate, and took plenty of nourishment. In the evening, however, he suddenly became worse, the pulse failing and the skin becoming cold; and notwithstanding the most solicitous attention on the part of the house-surgeon, Mr. Shoppee, he died early on Monday morning (sixth day).

At a post-mortem examination, all the viscera were found healthy, and there was no evidence of pyæmia. The wound had so contracted that the outline of the face was quite restored. The skin at one point was a little discoloured, as by a bruise.

The tumour weighed 4 lb. 6 oz., and was a good example of fibro-cellular growth, springing up between and expanding the plates of the lower jaw. The disease extended from the junction of the body with the ramus of the left side to half-way up the ramus of the right side. The right condyle was perfectly healthy, and the coronoid process had been broken off in the operation. Mr. Heath showed the preparation at the Pathological Society on Dec. 3rd, and a wax model of it in the recent state has been placed in the Museum of University College.—*Lancet*, Dec. 21st, 1867.

CASE XXIV.—*Myeloid Tumour of Body of Inferior Maxillary Bone, removed by Mr. CRAVEN, of Hull.*

Elizabeth Sergeant, aged eighteen, living at Mars Chapel, near Grimsby, was admitted into Hull General Infirmary, April 12th, 1867, with tumour of lower jaw.

There was considerable swelling of the lower jaw, evident from the appearance of the face, and felt within the mouth to extend from the left first molar to the right first bicuspid, consisting



apparently of an enlargement or an exostosis from the bone—everywhere very hard, covered by healthy mucous membrane, and not tender. It had been between two and three years growing; arose spontaneously, and had never been painful; no glandular enlargements; general health good.

May 1st, under chloroform an incision was made from the left angle of the jaw along its lower border to the right of the chin, about an inch beyond the symphysis, and up to within half an inch of the prolabium—very free hæmorrhage occurred, requiring the application of four ligatures; the soft parts were dissected from the body, and the bone was divided with the saw and forceps behind the last molar on the left and the second bicuspid on the right. A tooth was extracted previous to commencing the operation on the right side; any attachments to the soft parts were then separated by the knife, and the mass detached. A double thread was then passed through the tongue to prevent it falling back, and the wound closed with wire sutures. A little charpie was introduced into the mouth for the purpose of support to the lower lip.

The tumour on section appeared to be of a myeloid or marrow-like character, as described by Mr. Paget, having a thin covering or shell, formed of the expanded bone, and its substance consisting of a reddish soft fleshy tissue, divided by fibrous partitions, and containing two cysts with thin fluid. Section, when fresh, very much like the structure of spleen.

No ill effects followed the operation. For the first few days, on account of the difficulty in swallowing, injections of beef-tea and wine were given night and morning. The ligatures came away on the tenth day, when the wound was nearly healed; her general condition at this time excellent. At the end of a fortnight she pronounced herself quite well, and the wound was entirely healed. The thread passed through the tongue was removed five or six days after the operation.

Three weeks after the operation, she came downstairs into the board-room to show herself to several medical men who were assembled at the annual meeting of East Riding and North Lincoln Branch of British Medical Association.

The patient can protrude her tongue perfectly well, and speaks, to my mind, as well and as clearly as before the operation. Without looking into the mouth, it is impossible to tell that so large a portion of jaw has been removed.



CASE XXV.—*Case of Symmetrical Enlargement of both sides of the Lower Jaw—(Myeloid?)* Under the care of the AUTHOR.

William Henry Hogan, aged seven and a half, was brought to me, Feb. 12th, 1867, by Mr. C. J. Fox, with remarkable enlargement of both sides of the lower jaw. When a year and a half old, the mother first noticed an enlargement, first of one side (right?), and then of both, which has been gradually increasing. He has never complained of any pain, but had a good deal of difficulty with his teeth. He was rickety in his legs, and was at Ormond-street Hospital for some time.

He is now a well-nourished boy, with a remarkably broad face, due to the symmetrical development of a tumour on each side of the lower jaw, involving the posterior half of the body on each side. The tumours are smooth on the outer and lower part, but slightly nodulated at the upper. Within the mouth they come up to the level of, but do not encroach upon, the teeth. He has cut his permanent first molar and incisors. The temporary canines and molars are still present, and somewhat decayed.

April 3rd.—He came to University College Hospital. Ordered Ung. Iodin. Co. to apply to one side. The boy attended for a short time at the hospital without improvement, and then ceased to come.

In September I saw him, and found that both tumours had considerably increased, and I persuaded his parents to send him into the hospital, where he was admitted on Sept. 9th, 1867. A photograph and cast were now taken.

*Operation*, Sept. 11th.—I made an incision over the right or larger tumour, and having divided and tied the facial artery, exposed and scraped the periosteum off the tumour. It was bony externally, but felt spongy on pressure. With a narrow saw I then removed the most prominent portion, which cut very easily; then a second slice, and afterwards, with the bone forceps and gouge, removed as much of the semi-cartilaginous structure as I could without interfering with the teeth or opening the mucous membrane. As the surface of the bone bled freely, it was touched lightly with the cautery, and the wound was filled with lint. The growth appeared to be an enchondroma, expanding the outer plate and undergoing ossification, but is pronounced myeloid by Mr. Bruce. The inner plate of the jaw was perfectly even, and at the end of the operation not more than the normal thickness of jaw remained.

The wound suppurated healthily and soon contracted; the boy being about again in a few days.



Oct. 2nd.—I removed the growth on the left side in the same manner as before. This growth appeared of precisely the same character as the other. The boy made a rapid recovery, and was discharged, with the wounds nearly healed, on Oct. 10th.

The boy came to me in December quite well, and a second photograph was then taken. He continues well at the present time.

CASE XXVI.—*Osseous Tumour of the Lower Jaw.*

The patient, Francis E., aged forty-eight, a Spaniard, was admitted into the Hospital on May 1st, 1848. There was considerable deformity of the right side of the face, arising from the presence of a large, hard, nodulated tumour, occupying the whole of the right side of the lower jaw, so that this portion of the inferior maxillary bone appeared surrounded by the growth: it was very irregular on its surface, and uniformly osseous in consistence, the upper part projecting behind the zygoma, and the internal part into the mouth, so as materially to diminish its cavity, and it also encroached much on the fauces; in front it extended nearly to the symphysis of the jaw. There was a large cicatrix in the skin over the outer portion of the tumour, the cicatrix and the surrounding skin being firmly adherent to the tumour below. The patient stated that some five years previous to his admission, he had a tooth extracted from the lower jaw, on the right side, that a growth soon afterwards made its appearance from that portion of the jaw, and gradually increased in size, but was never attended with pain. About two years before his admission, and about three years after the first appearance of the tumour, he was operated on in France, so far, that the part of the tumour which projected externally was removed, but the remainder was not interfered with. Since that operation the growth had continued to increase. The tumour was removed on May 4th. An incision, commencing a little above the temporo-maxillary articulation, on the right side, was carried in a curved direction a little beyond the median line, to about an inch below the lower lip. A second incision was also made, so as to include the whole of the cicatrix of the former operation between the two wounds. The soft parts were then dissected off the tumour, both above and below, and the bone was divided a little to the right of the symphysis, so as not to interfere with the attachment of the genio-hyo-glossus muscle on that side. The facial artery required a ligature. After the division of the jaw, the tumour was forcibly drawn as much as possible outwards and downwards, but it was very difficult to



move it much, in consequence of the irregularities on the inner surface of the tumour projecting into the deep muscles; it was found necessary to cut off with the bone-nippers one projecting portion which ran up under the zygomatic process, and into the temporal muscle, and this very much facilitated the rest of the operation. The jaw was now more easily everted, turning on its articulation; and this being divided with the deeper muscles, the operation was soon completed. The patient left the hospital about two months afterwards, quite recovered. The tumour weighs, after maceration, rather more than seven ounces and a half, and is larger than a man's fist, its largest circumference being between nine and ten inches; its surface is very irregular, nodulated, and fissured deeply at those parts where muscles were attached to the bone. The surface of the bone appears healthy at the bottom of these fissures. The disease does not extend quite to the symphysis, but has almost surrounded the condyle of the jaw; the last molar tooth has been forced partially out just above the angle of the jaw at the posterior edge of the ramus. The tumour consists throughout of bone which is of a spongy character. In a letter received from the patient, April 13th, 1849, he says, "I now feel no inconvenience in mastication, nor the slightest pain, but feel my cheek daily increasing in strength."—*Catalogue of St. George's Hospital Museum*, II. 185.

CASE XXVII.—*Medullary Cancer of the Jaw in a Child—Two successful Operations—Return of the Disease—Death.* Under the care of the AUTHOR.

Miss M. R., aged five, was sent to me by Mr. Edward Randall, of Finsbury-square, on Sept. 9th, 1867, with a tumour of the lower jaw. She was the tenth of a family of eleven healthy children, and her parents are strong and robust. She was fat and well-nourished, though thinner than she had been, and in good health until the last week in July (seven weeks before), when her mother noticed that the second temporary molar tooth on the right side was raised above the others, and the gums looked swollen. Her mother took out the tooth, which was quite loose; but the swelling increased, and the first permanent molar became loose, and was extracted by Mr. Cole, of Ipswich. She was under the care of Mr. Mumford, of Ipswich, who used nitrate of silver lotion without benefit, since the growth continued to increase rapidly, so that she has been unable to eat solid food for a fortnight.

The whole of the lower jaw on the right side was considerably enlarged, and, on opening the mouth, a large, irregular, reddish



mass was seen filling up all the cheek on the right side, the extent of which it was impossible to define. The tumour had a semi-elastic feel, and there were apparently no enlarged glands. There could be no question as to the propriety of, and necessity for, immediate operative interference, which I arranged to undertake on the following day.

On Sept. 10th, 1867, the patient being under the influence of chloroform, I got my finger into the mouth, and then ascertained that the jaw was completely involved in the tumour, the elastic feeling being communicated through the bone. I divided the lower lip in the median line, and carried the incision round the border of the tumour to the level of the lobule of the ear. I then dissected back the flaps, and having divided the facial artery, tied it. Having extracted a loose tooth, I then sawed through the jaw immediately to the right of the symphysis, and detached the tissue on the inner side. On making traction, the tumour came away, leaving a rough, irregular piece of the jaw and a small portion of the tumour behind. These I subsequently extracted, including the condyle and coronoid process, which latter broke off and was removed separately. The internal maxillary artery was not wounded, and there was no great hæmorrhage, four ligatures being applied and cut short. The lip was brought together with two hare-lip pins, and the remainder of the wound closed by wire sutures, a silk suture being put in the red of the lip. Collodion was painted over all. No further dressing was applied. The child rallied, and took some brandy-and-water. In the afternoon she was quite comfortable, and the pulse was good. There was a little oozing from the wound. In the evening she had had some sleep, and had taken a little soup. She drank water frequently. There was no bleeding. The tumour proved to be of soft consistence, and had destroyed all the body of the jaw and a portion of the ramus; the condyle, coronoid process, and upper portion of the ramus being healthy. The point of section of the bone was healthy, and close to it were the canine and first temporary molar. In the upper and posterior part of the growth was the crown of the second permanent molar, carried quite out of position. To the naked eye the tumour presented a loose fibroid appearance. Mr. Bruce kindly examined a portion microscopically for me, and reported numerous fibres, with here and there development of cells, seemingly medullary.

Sept. 11th.—She had had a comfortable night. The mouth syringed out with Condyl's fluid three times. The child took some milk and soup, and was quite comfortable all day.



13th.—Child quite comfortable and happy, and takes liquid food well. I removed the hare-lip pins.

14th.—I removed the sutures. The wound was healed except at the junction of the vertical with the horizontal incision, where there is a minute opening. The patient to be dressed and get up to-morrow.

17th.—Very comfortable and happy. The child eats bread-and-butter easily, and talks quite intelligibly. The interior of the mouth appears to be nearly healed. The left half of the jaw is thrown a little towards the median line.

18th.—She went out in a perambulator.

23rd.—She went home to the country quite well, with the exception of one spot at the angle of the cicatrix, which still discharged slightly.

Oct. 21st.—I heard that she was quite well.

26th.—The child was brought to town on account of a return of the growth. The mother says she first noticed something wrong on the 22nd, when there was a small lump in the mouth. This grew very rapidly, and Mr. Mumford advised her coming up at once.

I found a mass within the mouth on the right side, nearly as large, and of precisely the same appearance, as the former growth. It involved a portion of the jaw left, and extended to the canine tooth on the left side, the incisors being loose. The cicatrix was sound except at the junction of the vertical with the horizontal incision, where the skin was ulcerated and there was a fungous protrusion of the size of a cherry. I explained the serious nature of the case to the parents, and said that an immediate operation was the only hope, as, if left, the growth would rapidly fungate and destroy the child, and they consented to the operation proposed.

On Oct. 27th, 1867, I divided the lip and opened up the old cicatrix to a great extent, surrounding, however, the portion involved in the fungus. I then dissected back the flap, and found the growth extended to what would have been half way up the ramus. I isolated it, and then dissected back the left half of the lip. I next removed the first molar, and sawed the jaw close in front of the second molar. Having put a string in the tongue for safety, I then divided the sublingual muscles, and got the growth and piece of jaw away entire. Two or three large vessels were tied, principally under the tongue, and a few small ones. I washed the entire wound carefully with a solution of chloride of zinc (forty grains to the ounce), brought the lip together with two hare-lip pins, and the remainder of the wound



with sutures, and then fastened the string attached to the tongue to the upper pin in the lip. The child bore the operation very well. In the evening she was cold and restless, but rallied with the use of hot bottles and a little brandy.

A section of the tumour showed a beautiful specimen of soft cancer. Both tumours are now in the Museum of the College of Surgeons.

Oct. 28th.—Patient had had a good night, and was asleep when I saw her at nine o'clock, and warm and comfortable. She passed a quiet day, taking a good deal of milk and a little wine. She was a little distressed by the ligature in the tongue.

29th.—She was comfortable, and took liquid food pretty well. Ordered her mouth to be syringed out.

30th.—Had passed a quiet night. I cut the thread in the tongue, and she was then able to move it about pretty freely. There was no difficulty of respiration. The wound was looking healthy, but the upper part of the old cicatrix was inflamed.

31st.—I removed the hare-lip pins and three of the stitches, leaving those near the angle of the wound for the present. A little pus was pent up in the upper part of the old cicatrix, which I evacuated.

Nov. 1st.—I removed the remaining stitches. The wound was healing well, except at the point where the skin was implicated and removed, and there it gaped.

3rd.—The child was up and dressed. She was able to close her lips and move her tongue very satisfactorily. She takes her food fairly, and has sucked a chicken-bone.

She continued to improve rapidly, and by the 10th, when she returned to the country, the wound was perfectly healed with the exception of a small spot where the portion of skin had been removed. She had perfect control over her tongue and lips, and could move the tissues of the chin very satisfactorily. There was no appearance of any return of the growth at this date.

Dec. 16th.—I heard from the father that the child was perfectly well, and that there was no appearance of return of the growth. He sent me her photograph, from which Figure 141 was taken, to show how little deformity resulted from the double operation.

On Jan. 8th, 1868, I heard from Mr. Mumford that the disease had reappeared at the symphysis, and also in the masseteric region on both sides, there being loss of appetite, exhaustion, and general irritability of system. The poor little patient lingered for a month, and died on Feb. 9th, just five months after I first saw her.



CASE XXVIII.—*Case of Scirrhus-cancer of the Lower Jaw.*

By Mr. WILKES, of Salisbury.

W. M., aged fifty, a native of Dorsetshire, a man of large frame and intemperate habits, who twenty years ago had his right leg amputated for diseased ankle-joint. He for the first time noticed a swelling in the left submaxillary gland seven or eight years ago; this has become painful, and rapidly increased in size during the last two or three months. There is now a globular mass below the middle of the left horizontal ramus of the jaw adherent to the bone, but moveable, giving an obscure feeling of fluctuation. The angle of the jaw is expanded on the outer side. Acute plunging pains pass backwards from the tumour to the ear and side of the head. At a consultation it was decided to remove the tumour, and as much of the jaw bone as might be found to be necessary.

*Operation*, Nov. 11th, 1861.—The patient being under the influence of chloroform, an incision was made downwards from the lobe of the ear to three or four inches down the neck, and another transversely, to meet the symphysis, and one short of the red line of the lip falling into it. The flaps were then dissected upwards and downwards. After the removal of the canine tooth, the bone was divided with a clean section, by means of a common amputating saw, and finally the temporo-maxillary joint was disarticulated. The flaps were brought together by ten hare-lip pins and twisted silk. The wound was frequently brushed with sweet oil. Beef-tea and brandy enemata were administered.

Nov. 12th.—He has had a good night, and swallowed a little milk. The enemata were ordered to be continued; and the alternate pins were removed. The wound was poulticed on account of some redness.

13th.—The remaining pins were removed. Beef-tea and milk were swallowed well, and enemata left off.

14th.—Sutures were removed and the wound found healed, except where the ligatures came out. Speech returned.

16th.—Asked for minced-meat; was placed on full diet and stimulants.

17th.—Sat up; two ligatures came away. He got on very well till the third week, when an abscess formed under the chin, which discharged into the mouth, and subsided in a week. During the fourth week, he had constantly-recurring rigors, with all the symptoms of pyæmia, and sank exhausted on Dec. 11th, 1861. The post-mortem presented the appearances usually



found after death from pyæmia. The heart was large and flabby; the cortical structure of both kidneys was pale and adherent to the capsule; no cancer existed anywhere. Ligamentous structure was found in the site of the removed bone; the wound was perfectly healed.

*Examination of Tumour.*—It is enclosed in a thick fibrous capsule, connected with the periosteum. On section, it has the appearance of ordinary scirrhus, permeated by fibres and resembling a raw potato. A milky juice can be scraped from it with a scalpel. At its junction with the jaw the bone is carious.

*Microscopical Examination by Mr. Tippetts.*—It is composed of nucleated cells chiefly with a few fibres. The cells vary much in size and shape; many being roundish, oval, oblong, caudate or fusiform. The nuclei are large; in some cases well-defined, and generally single. They contain for the most part one or two nucleoli. There is a large quantity of granular matter, both within and without the cells; and also some oil-globules, either free or contained in the cells.—*Pathological Society's Transactions*, vol. xiii.

CASE XXIX.—*Complete Closure of the Jaws by Cicatrices—Esmarch's Operation—Satisfactory Results.* Under the care of the AUTHOR.

Barton B., aged fifteen, admitted July 1st, 1862, into Mark Ward, under the care of the author, with closure of the jaws. In the winter of 1855, the boy, whilst living at Cosham, Hants, suffered from extensive necrosis of the upper and lower jaws, but whether the direct result of a blow or the consequence of fever is doubtful. He came under the notice of Mr. Martin, of Portsmouth, in the beginning of 1856, and that gentleman removed several pieces of bone, including the first permanent molar and undeveloped bicuspid of the upper, and two temporary molars of the lower jaws of the right side, besides several smaller pieces. Contraction of the cicatrices within the mouth supervened, and he was unable to unclosethe jaws. In this state he was sent up to Mr. Fergusson, at King's College Hospital, in July, 1856, and that gentleman divided the cicatrices within the cheek, and screwed the mouth open, but without permanent benefit; for in a fortnight his condition was nearly as bad as before, and he has for the last six years imbibed the whole of his nourishment between his teeth, or by putting soft food through an aperture between the teeth on the right side.

On admission, the mouth was firmly closed, the upper teeth overlapping those of the lower jaw. There was a cicatrix at the



right angle of the mouth, and a dense band could be felt within the mouth on the same side. The boy was feeble, and complained of not being able to fill his stomach with food.

On July 8th, the boy having been placed under the influence of chloroform, the author made an incision, two inches long, at the lower margin of the jaw on the right side, in front of the masseter. The facial artery was divided, and a ligature at once applied; after which the tissues were dissected up, and the jaw exposed. The cicatrix of the lip having been divided so as to give more room, a narrow saw, with a moveable back, was passed through the first incision, and up under the cheek, and a cut made in front of the rigid band of cicatrix and molar teeth. The operator soon found that he was cutting against a tooth imbedded in the jaw, and therefore at once removed it with the elevator, after which the section was rapidly completed. The mouth was now opened, and it was found that the jaw in front of the section was devoid of teeth for half an inch; the saw was therefore applied again immediately behind the canine tooth, and a wedge-shaped piece of bone removed. The hæmorrhage from the dental artery was free for a moment, but was arrested by pressure with the finger. The piece of bone included the entire thickness of the jaw, and measured rather more than a quarter of an inch along the upper and half an inch along the lower border. It contained the mental foramen, and the end of the fifth nerve. The wound was plugged with lint, a bandage applied, and the patient carried to bed. In the evening there was a little hæmorrhage, which was controlled by removing the plug of lint and replacing it with a dry piece. The boy was comfortable, and able to take fluid nourishment. He was ordered twelve ounces of wine, and a morphia draught at night.

July 9th.—Has had a good night. The face and jaw are tender and a little swollen. The plug of lint was removed from the mouth, as it produced pain.

10th.—Wound healthy. Ordered myrrh lotion to wash out the mouth.

14th.—Takes bread, arrowroot, and beef-tea. Is able to masticate readily. Ordered middle diet and extra bread. Can open the mouth to the extent of about an inch. The wound is granulating healthily, and the ligature has come away.

17th.—Ordered hard biscuit to eat, in order to exercise his jaw and keep his teeth in order.

24th.—State of mouth very satisfactory; he is able to open it to the extent of nearly an inch, though the movement is necessarily one-sided. The first molar tooth of the right side was



seen growing into the mouth; it was, therefore, extracted by Mr. Clendon. Wound of face granulating.

Aug. 7th.—Discharged to go to Walton for a month. The movement of the jaw is most satisfactory. Wound healthy, but not yet healed. Health much improved.

Sept. 2nd.—Returned from Walton quite stout, and able to open his mouth most satisfactorily. When open to its extreme limit, the distance between the teeth is seven-eighths of an inch. The amount of lateral movement is more than might have been anticipated, and the new joint gives no inconvenience. The amount of anæsthesia consequent upon the division of the nerve is very small, only extending close around the incision, where he has an occasional numbing pain.—*Lancet*, Oct. 1862.

CASE XXX. — *Complete Closure of the Jaws by Cicatrices — Esmarch's Operation—Good result.* Under the care of the AUTHOR.

Ellen Johnson, aged twenty-three, was admitted into the Westminster Hospital on the 22nd January, 1864, with closure of the jaws from cicatrices.

*History.*—When six years old she had fever, and her mouth was ulcerated, as the patient believes, from the effects of mercury, which her mother told her was rubbed into the soles of her feet. As long as the patient can remember the jaws have been tightly closed; and some years ago Dr. Budd, of Plymouth, removed a small piece of dead bone. Three months before admission she had typhus fever, and whilst ill the left commissure of the lips gave way, causing her present unsightly appearance.

On admission, the lower jaw is firmly held against the upper by dense cicatrix-tissue on the left side, which appears to involve the whole of the buccinator muscle, and to extend to the angle of the mouth, a firm depressed cicatrix occupying the whole of that portion of the cheek. The teeth of the upper jaw on the left side project considerably over the lower teeth; the first molar was extracted by Mr. Bullen, at the Lambeth Infirmary, a short time since, but the bicuspid and canine teeth remain fully exposed to view, the second bicuspid being thrown forward out of its proper position, and being decayed. The commissure of the lips has been divided by the pressure of the teeth, and the extremities of the lips are now half an inch apart. The girl introduces soft food between the teeth on the right side, which is perfectly healthy, and has a very slight power of triturating the



food on that side. She obtains sufficient nourishment, though slowly, and has gained flesh since her convalescence from fever.

In this very unfavourable state of things I determined to perform Esmarch's operation for the formation of a new joint in front of the cicatrix, believing that it would be impossible to obtain any good result by interfering with the cicatrix itself either from within the mouth or by transplantation of skin.

*Operation.*—Jan. 24th, 1864.—The patient being under the influence of chloroform, I extracted the two bicuspid teeth of the upper, and one of the lower jaw. An incision was then made for two inches along the lower border of the jaw, immediately in front of the cicatrix, and the tissues being cleared from the bone, a narrow saw with a moveable back was passed through the wound into the mouth. With this, one cut was made immediately in front of the cicatrix, and slanting backwards; and another cut half an inch in front, and slanting forwards, both going through the whole thickness of the bone. The wedge thus cut was then removed by dividing the few fibres of the mylo-hyoid muscle attached to its inner surface. It was found that the healthy right side of the jaw could now be freely moved, and the teeth of the two jaws separated to some extent. A small piece of sponge was inserted between the cut ends of the bone, and the wound was closed with a couple of sutures, no ligatures being applied.

The piece of bone removed included the whole thickness of the lower jaw, and measured seven-eighths of an inch along its lower border. It contained the mental foramen, with a portion of the nerve.

On the 25th January (following day), there was a little unimportant oozing of blood, and the piece of sponge was removed. Patient quite comfortable.

On the third day, the contracted masseter of the right side having yielded, the patient was able to move the jaw freely. The wound was dressed with water dressing.

By the 10th of February she was ordered soft biscuit to masticate, and so exercise the jaw.

On the 23rd of February (a month after the operation), the wound was nearly healed, and the patient had so much power of mastication that she was ordered meat diet.

March 5th.—Two little exfoliations from the cut surfaces of the bone came away by the mouth, the wound being quite closed and the movements of the new joint free.

It may be mentioned here that it was easy to watch the gradual formation of a new joint from the interior of the mouth; the cut surfaces of the bone becoming gradually rounded and



covered with mucous membrane, continuous with that of the mouth.

On the 23rd of March (just two months after the operation), the false joint being in a perfectly satisfactory condition, I determined to attempt to remedy the deformity of the cheek and angle of the mouth.

The patient being under chloroform, the extremities of the lips were detached from the subjacent bone, and the anterior edge of the cicatrix of the cheek was vivified. A small flap, three quarters of an inch in length, was then marked out in the healthy portion of the cheek, and was dissected up, being attached by a broad base to the extremity of the upper lip. This being drawn down with the end of the lip, fitted well into the gap, and also brought the lips close together at the angle of the mouth. The flap was secured with several wire sutures, and the gap made by the removal of the flap was closed with two hare-lip pins and twisted suture.

The results of this operation were unsatisfactory; the lips failed to unite, and the flap separated from its attachments; after the wounds had healed, however, the upper lip was found to be lower than before, thus offering every probability of a good result in any future operation.

The patient was sent to Walton for a month, and returned on May 30th, with her general health much improved.

On the 3rd of June, I made another attempt to close the aperture in the cheek, under chloroform. The edges of the opening were vivified, and the mucous membrane was removed from both the lips for half an inch from the angle of the mouth. The lips were freed from their attachment to the bones, and they were brought together with a hare-lip pin with a view of forming a new commissure in front of the position of the old one. Another pin was introduced at the posterior part of the wound to keep the parts in position; collodion was painted over all. Straps of plaster were applied to relieve the tension upon the pins.

June 8th.—The pins were withdrawn, having nearly cut their way out. The wound gapes posteriorly; but the lips appear to have united in great part. Straps reapplied.

June 17th.—The new commissure of the lips is quite perfect, and the rest of the wound has contracted considerably, and is granulating healthily. I introduced another hare-lip pin to bring the granulating surfaces together, and increase, if possible, the breadth of the commissure.

July 28th.—The patient was discharged—her personal appearance having much improved owing to the growth of her hair.



The commissure of the lip is half an inch in breadth ; and, with a piece of black plaster over the opening, which is now much reduced in size, the patient is very comfortable, although the saliva flows from time to time through the opening, when the plaster becomes loosened. The space between the incisor teeth, when the mouth is widely opened, is exactly half an inch ; and the movements of the jaw are very free.

CASE XXXI.—*Closure of the Jaws by Rigid Cicatrices and by a Bridge of Bone — Internal Division and subsequent Treatment by Silver Caps and Shields affixed to the Teeth.* Under the care of Mr. BARNARD HOLT, Westminster Hospital.

Frances H., aged seventeen, was admitted July 3rd, 1862, suffering from closure of the jaws. In 1857 the patient had fever, attended with an abscess in the cheek on the right side, which led to such contraction and adhesion of the mucous membrane to the jaw as to cause great difficulty in opening the mouth. This difficulty continued to increase, and attempts were made, by direction of the surgeon under whose charge she was, to force open the mouth with a spoon—frequently used, but to no purpose. Early in March, 1859, she had scarlet fever very slightly, and in the following August she was sent to the Kent and Canterbury Hospital, where several of her teeth were extracted, and an iron screw used to force open the mouth, without permanent benefit.

On November 29th, 1860, she was admitted into the Westminster Hospital, when Mr. Holt divided the bands of the cicatrix (within the cheek) freely ; and by careful dressing, she obtained some power over the jaw, and was discharged in January, 1861.

On being again admitted, July 3rd, 1862, she presented the following condition :—The mouth is contracted on the right side, but not sufficiently to prevent the lips from opening to expose the front teeth. The jaws are firmly closed ; the upper overlapping the lower incisors in the ordinary way, allowing a space of one-sixteenth of an inch between them, through which food is introduced. The right cheek is very dense and rigid, and there is a considerable depression in it. The finger cannot be introduced beyond the canine teeth, owing to the firm adhesions of the cheek to the gums ; while on the left side the mucous membrane of the cheek is free and healthy. The patient's general health is good, as she takes sufficient food, although slowly.

Mr. Holt determined to adopt the plan proposed and success-



fully carried out by Mr. Clendon, dental surgeon to the hospital, in a case under the care of the late Mr. B. Phillips, and also in another of his own in private practice—namely, to operate from the front of the mouth, to separate the cheek freely from all adhesions, and employ mechanical means to prevent the possibility of their reunion.

The operation was performed on the 23rd of July. The patient having been placed under chloroform, Mr. Holt divided the cicatrices freely within the mouth, separating the cheek from the upper and lower jaws, until the finger reached well back to the ramus of the jaw. When this had been effected, the jaw still remained fixed, and it was found that the teeth of the lower jaw, from the bicuspid backwards, had been thrust inwards, and that from the outer margin of the alveolus in this region a firm plate of bone extended to the alveolus of the upper jaw, and effectually prevented any movement. With a narrow saw introduced into the mouth, Mr. Holt succeeded in dividing this, and the mouth could then be opened; after which the remains of the ridge were removed with the bone forceps. The cheek was stuffed with oiled lint to prevent the recurrence of the adhesions, and the patient was put to bed.

July 25th.—There was considerable swelling of the face; the lint was, therefore, removed, and the finger passed freely in every direction; after which the lint was replaced.

28th.—The swelling of the face having somewhat subsided, Mr. Clendon took wax and gutta-percha impressions of the mouth, under chloroform, in order to form the shields to be attached to the teeth, and inserted between the cheek and gums.

30th.—The shields were fitted: they consist of a horizontal portion fitting upon the molar teeth, and fastened with bands to the canine and incisor teeth, and a vertical portion which passes by the side of the alveolus to the bottom of the sulcus between it and the cheek. The edge of this is quite thin, and serves to cut a groove in the adhesions, which are already beginning to fill up the space.

Aug. 7th.—The shields keep thoroughly in their places; but as the cheek is still raw, wet lint is inserted between the gums and the lining of the cheek, and the finger is daily passed freely beneath the cheek to the full extent of the teeth. Two wedges of wood were fitted to the mouth, one on each side, so as to maintain the constant separation of the jaws.

15th.—The condition of the mouth is in every way satisfactory; the gums and cheek are beginning to be covered with mucous membrane, and the discharge is slight. A band in the



middle of the cheek having become rather tense and prominent, it was freely cauterized with nitrate of silver.

Sept. 1st.—The shields and wedges are worn without discomfort, and the girl can open her mouth most satisfactorily. The shields effectually prevent adhesions forming between the gum and the cheek.

From this time the patient's progress was uninterrupted. She recovered perfect use of her jaw and mouth, and all tendency to recontraction seemed to have disappeared. The girl was kept under observation at the hospital many weeks longer than was absolutely necessary for the further carrying out of the treatment, with a view of testing the permanence of the cure, and was finally sent into the country on Nov. 1st, 1862, with the shields still in the mouth, and still wearing one of the wedges, which she had become quite accustomed to.

She returned to the hospital for a few days in December that the progress might be noted, and the portrait (fig. 150—from a photograph) was then taken for the sake of comparison with that given in the *Lancet* of Oct. 25th, 1862, p. 144, showing the result of Esmarch's operation. The shields were removed for five days in order to be stretched, and no apparent change resulted from their non-use; but, for the sake of safety, she is to continue wearing them for the present. The distance between the incisor teeth, when the mouth is wide open, is three quarters of an inch.—*Lancet*, Jan. 24th, 1863.

CASE XXXII.—*Closure and Immobility of the Jaws from Cicatrices on both sides of the mouth—Division and use of apparatus—Good result.* Under the care of the AUTHOR.

Isabella M'N., aged eighteen, admitted into Arden Ward, Dec. 15th, 1862, under the author, with closure of the jaws and mouth from cicatrices.

*History.*—When five years old she had measles (?), and is supposed to have taken mercury; and, a few months after, it was noticed that the cheek was contracting, so that when six years old the jaws were firmly closed. When about seven she was admitted into the Dundee Infirmary, and some operation was performed, by which she was benefited for a short time, but the jaws were soon as firmly closed as before. When about eleven years old she was admitted into the London Hospital, under Mr. Luke, who divided the cicatrices, and opened the jaws with a screw. She was in the hospital three months, and was slightly benefited for a time. Eighteen months after she was again



admitted, and the same operation was repeated, oiled lint being introduced beneath the cheeks, and wedges inserted between the teeth to keep them apart. The parents took considerable pains to keep the wedges in, and to make her move her jaws; but the contractions soon recurred, and for the last two years and a half the jaws have been firmly closed.

*Present condition.*—The mouth is smaller than usual, owing to the contractions at the angles, but she can show the incisor teeth, and the upper ones are seen to be firmly closed over the lower. The cheeks are firmly bound down to the alveoli from the angles of the mouth, and there is no power of separating the jaws at all; but she can move the lower jaw a little from side to side. She introduces her food through an aperture on the right side of the incisor teeth, where a tooth has been lost. She is plump and well nourished, but has not menstruated for five months.

*Operation.*—Dec. 16th.—The patient, having been put under chloroform, the author proceeded to dissect up the cheek from the alveoli, by passing a knife from the mouth. The bands of cicatrix were exceedingly firm, and were found to pass not only between the gum and the cheek, but between the gums themselves; and these required free division before the mouth could be opened at all, and then only by the help of a screw. During the operation a small wedge of wood was extracted from between the teeth, where it had been for some months. Oiled lint was carefully stuffed between the alveoli and the cheek, and the patient put to bed, and given twenty minims of tincture of opium.

18th.—The pledgets of oiled lint were removed, and the mouth well washed out. She can open the mouth for a short distance, but the movements are necessarily painful. Lint, soaked in myrrh lotion, was placed inside the cheek.

20th.—Chloroform having been again administered, Mr. Clendon attempted to take models of the mouth, but found that the aperture was so small, and the space between the teeth so contracted, that it was almost impossible to obtain a satisfactory mould. The teeth appear to have been only partially developed, with the exception of the incisors, which also are so loose as to offer little support to a shield.

22nd.—Mr. Clendon took moulds of gutta-percha of the outer surface of the jaws, as some guide for the formation of temporary shields.

25th.—The house-surgeon was called up last night to the patient, who was bleeding freely from the left side of the mouth. He plugged the cheek with fresh lint, which arrested the hæmor-



rhage. A second hæmorrhage occurred in the afternoon, and the blood came from quite the back of the mouth, between the cheek and alveolus, on the left side. Mr. Beadles (H. S.), finding that a coagulum had formed, which had stopped the hæmorrhage, left it undisturbed.

26th.—The author saw the patient, who was rather reduced by the bleedings, but thought it better not to disturb the clots for another day. Ordered eight ounces of wine and beef tea.

27th.—A severe arterial hæmorrhage occurred this morning, and was arrested by clearing out all clots, and syringing the mouth with cold water. Twelve ounces of wine, beef-tea, eggs.

29th.—No more hæmorrhage has occurred, but the patient has become somewhat anæmic. The author thought it would be safer to postpone any further interference with the case for a week, so as to allow her to recover fully from the loss of blood. The mouth to be simply syringed out with warm water and myrrh lotion.

Jan. 5th, 1863.—The patient having been put under the influence of chloroform, the author carried his finger freely between the cheeks and the alveoli, breaking down the soft adhesions which had begun to form. Mr. Clendon then removed some stumps of teeth and all the incisor teeth (except one of the upper centrals), which were loose; and then succeeded in taking more satisfactory moulds of gutta-percha, from which the shields might be made.

7th.—Under chloroform, silver shields were fitted upon the alveoli, the edges of which passed between the alveolus and cheek. Blocks of gutta-percha were wedged between them, to keep the jaws apart.

10th.—Fresh shields, with deeper sides, were inserted, under chloroform. The remaining incisor tooth came away, and several stumps were removed.

14th.—Bone wedges were fastened on to the shields to keep the jaws apart, and to permit of greater cleanliness than was possible with the gutta-percha. To use a lotion of chlorinated soda frequently.

21st.—Under chloroform, the author made a thorough examination of the mouth, and found everything in a satisfactory condition so far. The sulcus on each side of the mouth has considerably increased in depth, and the finger can be carried between the gum and cheek, as far back as the wisdom teeth, on each side. The mouth is kept well open by the bone wedges, and the absence of incisor teeth gives plenty of room for the introduction of food. Mr. Clendon extracted several stumps, and



then took fresh moulds of the mouth. The old shields and bone blocks were then re-inserted.

28th.—Under chloroform, the shields were removed, and having been relined with soft gutta-percha, were replaced. The mouth opens very satisfactorily, and the soreness is diminishing.

Feb. 4th.—Under chloroform, fresh shields, with deeper edges, were introduced, which kept the mouth widely open.

12th.—Some little swelling about the right eye has come on during the last day or two, but is gradually subsiding under fomentations.

18th.—The patient is able to move the jaw to a slight extent, even with the shields in the mouth, and the case seems to be going on satisfactorily.

28th.—The shields were removed, under chloroform, having been *in situ* three weeks, and were lined with some fresh gutta-percha, so as to fit more accurately to the alveoli. The mouth has increased in size, and the sulci on each side of the alveoli are much deepened.

March 11th.—The shields were removed, under chloroform, and the bone blocks cut off, their places being supplied by moveable wedges of hard gutta-percha, so as to permit the patient's removing them when eating, and thus to exercise the jaw. The granulations in each cheek were touched with nitrate of silver.

25th.—Under chloroform, the adhesions between the lips and the alveoli were divided by the author, and fresh silver shields were then fitted, the edges of which were purposely made deeper in front, so as to free the lips from subsequent contractions.

On the 2nd April I took a careful measurement of the extent to which the jaws could be separated, and found that there was a distance of exactly one inch between the metal shields, in the situation of the incisor teeth. As the shields have some gutta-percha beneath them, and do not, therefore, fit closely upon the gums, it will not be necessary to allow much more than a quarter of an inch for the absent teeth, making the present aperture considerably over half an inch, if the teeth were *in situ*. This must be allowed to be a very satisfactory result so far; and the distance will probably be increased, as the patient has been supplied with beech-wood wedges, which she introduces and wears, between her meals. When the mouth is widely opened, the lining of the cheeks can be seen between the shields, and it is already assuming something of the appearance of mucous membrane. The mobility of the lips, and hence the size of the mouth, have increased considerably since the last operation; and, as far as I can see, this case promises to be as successful as the preceding one.



# INDEX.

---

	PAGE
ABSCCESS after fracture . . . . .	20
„ of jaw . . . . .	95
„ of antrum . . . . .	144
Adams, Mr. W., on cysts of antrum . . . . .	153
„ „ epithelioma . . . . .	196
„ Dr. R., on cysts of lower jaw . . . . .	174
Alveolus, fracture of . . . . .	17, 56
Amaurosis from diseased antrum . . . . .	146
Anchylosis of temporo-maxillary joint . . . . .	339
Antrum, diseases of . . . . .	137
„ suppuration in . . . . .	144
„ dropsy of . . . . .	150
„ cysts of . . . . .	153
„ growths within . . . . .	210
„ polypus of . . . . .	210
„ fibroid disease of . . . . .	212
„ falling in of . . . . .	214
Author's case of fractured alveolus . . . . .	17
„ „ epulis . . . . .	200
„ „ fibroid disease of antrum . . . . .	312
„ „ cartilaginous tumour of upper jaw . . . . .	237
„ „ cancer of upper jaw . . . . .	260
„ „ osteo-sarcoma of lower jaw . . . . .	288
„ „ myeloid of both sides of lower jaw . . . . .	299
„ „ medullary cancer of lower jaw . . . . .	306
„ „ Esmarch's operation for closure . . . . .	329, 330
„ „ closure of jaw treated with shields . . . . .	337
„ „ disease of temporo-maxillary joint . . . . .	339
BEAUMONT, Mr., enchondroma of lower jaw . . . . .	302
Boinet, M., on post-mortem examination after Esmarch's operation . . . . .	332
Bryant, Mr., necrosis of inter-maxillary bones . . . . .	108
Butcher, Mr., on cysts of lower jaw . . . . .	178
„ „ vascular tumour of upper jaw . . . . .	231
CANCER, osteoid, of upper jaw . . . . .	253
„ of upper jaw . . . . .	255
„ of lower jaw . . . . .	305



	PAGE
Cannon-ball, injury to jaws by . . . . .	68, 76
Canton, Mr., myeloid of upper jaw . . . . .	228
Cap for fractured jaw . . . . .	39
Caries of jaw . . . . .	102
Cartilaginous tumours of upper jaw . . . . .	234
"          "          lower jaw . . . . .	300
Cattlin, Mr., on the antrum . . . . .	138
Cemental tumours of teeth . . . . .	186
Chalk, Mr. O., deformity of jaw . . . . .	343
Chin, silver . . . . .	76
Closure of the jaws . . . . .	318
Coates, Mr., scirrhus of lower jaw . . . . .	308
Collis, Mr., enchondroma of upper jaw . . . . .	242
Complications of fractured jaw . . . . .	15
Condyle, fractured neck of . . . . .	12, 19
Congenital dislocation . . . . .	89
Cork wedges for fractured jaw . . . . .	38
Couper, Mr., case of old dislocation . . . . .	87
Craven, Mr., cancer of upper jaw . . . . .	256, 258
"    "    myeloid of lower jaw . . . . .	296
Curling, Mr., epithelioma of palate . . . . .	207
Cysts of antrum . . . . .	153
"    of teeth . . . . .	156
"    dentigerous . . . . .	158
"    in lower jaw . . . . .	168
 DEFORMITIES of the jaws . . . . .	 342
Dentigerous cysts . . . . .	158
Dentinal tumours . . . . .	183
Diagnosis of tumours of upper jaw . . . . .	261
"          "          lower jaw . . . . .	311
Dislocation of teeth . . . . .	16
"    with fracture . . . . .	22
"    of jaw . . . . .	79
"    symptoms of . . . . .	84
"    old standing . . . . .	86
"    rare forms . . . . .	88
"    congenital . . . . .	89
"    treatment of . . . . .	89
Dropsy of antrum . . . . .	150
Duka, Dr., case of ivory tumour of upper jaw . . . . .	250
 ENCHONDROMA of upper jaw . . . . .	 234
"          lower jaw . . . . .	300
Epitheliomatous epulis . . . . .	195
"          hard palate . . . . .	207
 Epulis . . . . .	 192
"    myeloid . . . . .	194



	PAGE
Epulis, giant-celled . . . . .	194
„ epitheliomatous . . . . .	195
„ table of cases of . . . . .	198
„ treatment of . . . . .	203
Esmarch, Professor, on closure of jaws . . . . .	323
FALLING in of antrum . . . . .	214
False joint after fracture . . . . .	25
„ treatment of . . . . .	49
Fearn, Mr., case of dentigerous cyst . . . . .	161
Fergusson, Sir W., case of hyperostosis . . . . .	135
„ case of hydrops antri . . . . .	151
„ cysts in lower jaw . . . . .	171
„ dentinal tumour . . . . .	183
„ epithelioma . . . . .	196
„ ivory tumour of upper jaw . . . . .	247
„ myeloid of lower jaw . . . . .	297
Fibroid disease of antrum . . . . .	212
Fibrous tumours of upper jaw . . . . .	215
„ lower jaw . . . . .	272
Fibro-cellular tumour of upper jaw . . . . .	221
„ „ lower jaw . . . . .	283
Forceps, Stromeyer's . . . . .	91
Forget, Dr., on dentigerous cysts . . . . .	162
„ on dentinal tumour . . . . .	184
Four-tailed bandage . . . . .	33
Fracture of lower jaw . . . . .	1
„ „ museum specimens of . . . . .	4
„ „ symptoms of . . . . .	8
„ ramus of lower jaw . . . . .	11
„ neck of condyle of lower jaw . . . . .	12
„ coronoid process „ . . . . .	13
„ of lower jaw, complications of . . . . .	15
„ of teeth . . . . .	16
„ of alveolus . . . . .	17
„ of glenoid cavity . . . . .	18
„ of lower jaw, treatment of . . . . .	33
„ of upper jaw . . . . .	52
„ complications of . . . . .	57
GENSOUL on cyst of antrum . . . . .	161
Giraldès, M., on cysts of antrum . . . . .	153
Graefe's apparatus for fractured upper jaw . . . . .	60
Gross, Dr., on closure of jaws . . . . .	320
Growths within antrum . . . . .	210
Gums, diseases of . . . . .	189
„ hypertrophy of . . . . .	189
„ polypus of . . . . .	190
„ papillary tumour of . . . . .	191



	PAGE
Gunning's interdental splints . . . . .	40
Gunshot injuries of jaws . . . . .	62
Gutta-percha splint . . . . .	34
„ wedges for fracture . . . . .	38
 HÆMORRHAGE after fracture . . . . .	15, 57
Hamilton's sling for fracture . . . . .	35
Hart, Mr., necrosis of upper jaw . . . . .	110
Hayward, Mr., cap for teeth . . . . .	39
Harrison, Mr., on dentinal tumour . . . . .	186
„ „ deformity of jaws . . . . .	345
Hepburn, Mr., case of angular union . . . . .	21
Hill, Mr. B., modification of Lonsdale's splint . . . . .	48
Hilton, Mr., on ivory tumour of upper jaw . . . . .	246
Holt, Mr., recurrent fibroid of lower jaw . . . . .	278
„ closure of jaws . . . . .	334
Humphry, Dr., prolapse of tongue, producing deformity of jaw . . . . .	342
Hydrops antri . . . . .	150
Hyperostosis . . . . .	131
Hypertrophy of gums . . . . .	189
 INFLAMMATION . . . . .	94
Interdental splint (Gunning's) . . . . .	40
„ „ (Bean's) . . . . .	44
Ivory tumour of upper jaw . . . . .	246
„ „ lower jaw . . . . .	303
 JAWS, gun-shot injuries of . . . . .	62
„ deformities of . . . . .	342
„ dislocation of . . . . .	79
„ inflammation of . . . . .	94
„ abscess of . . . . .	95
„ periostitis of . . . . .	101
„ caries of . . . . .	102
„ necrosis of . . . . .	104
„ „ exanthematous . . . . .	107
„ „ syphilitic . . . . .	112
„ „ phosphorus . . . . .	113
Jaw, upper, fractures of . . . . .	52
„ „ treatment of . . . . .	33
„ „ tumours of . . . . .	215
„ „ fibrous . . . . .	215
„ „ fibro-cellular . . . . .	221
„ „ recurrent fibroid . . . . .	225
„ „ myeloid . . . . .	227
„ „ vascular . . . . .	231
„ „ cartilaginous . . . . .	234
„ „ osseous . . . . .	244



	PAGE
Jaw, upper, tumours of, cancerous . . . . .	255
"    "    diagnosis of . . . . .	261
"    "    operations on . . . . .	262
Jaw, lower, fractures of . . . . .	1
"    treatment of . . . . .	33
"    suture of . . . . .	36
"    cysts in . . . . .	168
"    tumours of . . . . .	272
"    fibrous . . . . .	272
"    recurrent fibroid . . . . .	278
"    fibro-cellular . . . . .	283
"    fibro-cystic . . . . .	291
"    myeloid . . . . .	295
"    cartilaginous . . . . .	300
"    osseous . . . . .	303
"    cancerous . . . . .	305
"    diagnosis of . . . . .	311
"    operations on . . . . .	312
 LAWSON, Mr., recurrent fibroid of upper jaw . . . . .	226
"    "    "    lower jaw . . . . .	280
Ligature of teeth . . . . .	35
Liston, Mr., case of large epulis . . . . .	201
"    fibrous tumours of upper jaw . . . . .	217
Lonsdale's splint . . . . .	47
Lower jaw, fracture of . . . . .	1
"    dislocation of . . . . .	79
"    tumours of ( <i>see</i> tumours).	
 MARGETSON, Mr., case of fracture and dislocation of tooth . . . . .	16
Maisonneuve, on dislocation . . . . .	81
Medullary tumour of upper jaw . . . . .	255
"    "    lower jaw . . . . .	305
Multilocular cysts of lower jaw . . . . .	171
Myeloid epulis . . . . .	194
"    tumour of upper jaw . . . . .	227
"    "    lower jaw . . . . .	295
 NECROSIS of jaw . . . . .	104
"    exanthematous . . . . .	107
"    syphilitic . . . . .	112
"    phosphorus . . . . .	113
"    symptoms of . . . . .	119
"    repair after . . . . .	118
"    treatment of . . . . .	126
"    after fracture . . . . .	20
"    "    of symphysis . . . . .	22



	PAGE
Neck of condyle fractured . . . . .	12, 19
Nélaton, on dislocation . . . . .	82, 92
Neuralgia after fracture . . . . .	17, 58
Non-union of fracture . . . . .	25
OLD-STANDING dislocations . . . . .	86
Operations on upper jaw . . . . .	262
,, lower jaw . . . . .	312
Osseous tumours of upper jaw . . . . .	234
,, lower jaw . . . . .	303
Ossifying enchondroma . . . . .	242
Osteo-sarcoma of upper jaw . . . . .	221
,, lower jaw . . . . .	283
Osteoid cancer of upper jaw . . . . .	253
PALATE, hard, tumours of . . . . .	206
Paralysis of dental nerve . . . . .	17, 58
Periostitis of jaw . . . . .	101
Permanent closure of jaws . . . . .	319
Phosphorus-necrosis . . . . .	113
Polypus of antrum . . . . .	210
RAMUS of lower jaw fractured . . . . .	11
Recurring-fibroid of upper jaw . . . . .	225
Repair after necrosis . . . . .	118
Resections of upper jaw . . . . .	279
,, lower jaw . . . . .	312
Rizzoli, on closure of jaws . . . . .	326
SALIVARY fistula after fracture . . . . .	20
Salter, Mr., case of fractured upper jaw . . . . .	52
,, on exanthematous necrosis . . . . .	107
,, on dentigerous cysts . . . . .	159
,, on papillary tumour of gum . . . . .	191
Scirrhus of upper jaw . . . . .	271
,, lower jaw . . . . .	308
Shillito, Mr. B., fibrous tumour of lower jaw . . . . .	276
Smith, Mr. Cox, case of gun-shot injury of upper jaw . . . . .	66
,, case of injury to symphysis . . . . .	73
,, R. W., on dislocation . . . . .	85
,, Mr. T., on phosphorus-necrosis . . . . .	119
Spasmodic closure of jaws . . . . .	318
Specimens of fractured jaw . . . . .	4
Splint, interdental (Gunning's) . . . . .	40
,, (Bean's) . . . . .	44
,, Lonsdale's . . . . .	47
,, Hill's modification . . . . .	48
,, for lower jaw . . . . .	34







	PAGE
VASCULAR tumours of upper jaw . . . . .	231
Vasey, Mr., deformity of jaw . . . . .	344
Verneuil, M., on closure of jaws . . . . .	328
 WARREN, Dr. Mason, on cysts of lower jaw . . . . .	 178
Wells, Mr. S., fibrous tumour of lower jaw . . . . .	273
Wilkes, Mr., scirrhus of lower jaw . . . . .	308
Wounds of the face . . . . .	15

THE END.



London, New Burlington Street,  
October, 1868.

MESSRS. CHURCHILL & SONS'  
Publications,  
IN  
M E D I C I N E  
AND THE VARIOUS BRANCHES OF  
NATURAL SCIENCE.



"It would be unjust to conclude this notice without saying a few words in favour of Mr. Churchill, from whom the profession is receiving, it may be truly said, the most beautiful series of Illustrated Medical Works which has ever been published."—*Lancet*.

"All the publications of Mr. Churchill are prepared with so much taste and neatness, that it is superfluous to speak of them in terms of commendation."—*Edinburgh Medical and Surgical Journal*.

"No one is more distinguished for the elegance and *recherché* style of his publications than Mr. Churchill."—*Provincial Medical Journal*.

"The name of Churchill has long been a guarantee for the excellence of illustrated works, and it would be superfluous to repeat the admiration that we have several times expressed in this respect, of the spirit with which this firm engages in these costly but valuable series."—*Medical Press and Circular*.

"The typography, illustrations, and getting up are, in all Mr. Churchill's publications, most beautiful."—*Monthly Journal of Medical Science*.

"Mr. Churchill's illustrated works are among the best that emanate from the Medical Press."—*Medical Times*.

"We have before called the attention of both students and practitioners to the great advantage which Mr. Churchill has conferred on the profession, in the issue, at such a moderate cost, of works so highly creditable in point of artistic execution and scientific merit."—*Dublin Quarterly Journal*.



MESSRS. CHURCHILL & SONS are the Publishers of the following Periodicals, offering to Authors a wide extent of Literary Announcement, and a Medium of Advertisement, addressed to all Classes of the Profession.

THE BRITISH AND FOREIGN MEDICO-  
CHIRURGICAL REVIEW,  
AND  
QUARTERLY JOURNAL OF PRACTICAL MEDICINE  
AND SURGERY.

Price Six Shillings. Nos. I. to LXXXIV.

THE QUARTERLY JOURNAL OF  
SCIENCE.

Price Five Shillings. Nos. I. to XX.

THE QUARTERLY JOURNAL OF  
MICROSCOPICAL SCIENCE,  
INCLUDING THE TRANSACTIONS OF THE ROYAL  
MICROSCOPICAL SOCIETY OF LONDON.

Edited by DR. LANKESTER, F.R.S., and GEORGE  
BUSK, F.R.S. Price 4s. Nos. I. to XXXII.  
*New Series.*

THE JOURNAL OF MENTAL SCIENCE.

By authority of the Medico-Psychological  
Association.

Edited by C. L. ROBERTSON, M.D., and HENRY  
MAUDSLEY, M.D.  
Published Quarterly, price 3s. 6d. *New Series.*  
Nos. I. to XXXI.

ARCHIVES OF MEDICINE:

A Record of Practical Observations and Anato-  
mical and Chemical Researches, connected  
with the Investigation and Treatment of  
Disease. Edited by DR. LIONEL S. BEALE,  
F.R.S. Published Quarterly; Nos. I. to VIII.,  
3s. 6d.; IX. to XII., 2s. 6d., XIII. to XVI., 3s.

THE ROYAL LONDON OPHTHALMIC HOSPITAL  
REPORTS, AND JOURNAL OF OPHTHALMIC  
MEDICINE AND SURGERY.

Vol. VI., Part 2, 2s. 6d.

JOURNAL OF CUTANEOUS MEDICINE.

Edited by ERASMUS WILSON, F.R.S.  
Published Quarterly, price 2s. 6d. No. I. to VII.

THE MEDICAL TIMES & GAZETTE.

Published Weekly, price Sixpence, or Stamped,  
Sevenpence.

Annual Subscription, £1. 6s., or Stamped,  
£1. 10s. 4d., and regularly forwarded to all  
parts of the Kingdom.

THE PHARMACEUTICAL JOURNAL,  
CONTAINING THE TRANSACTIONS OF THE PHAR-  
MACEUTICAL SOCIETY.

Published Monthly, price One Shilling.

\* \* Vols. I. to XXVII., bound in cloth, price  
12s. 6d. each.

THE BRITISH JOURNAL OF DENTAL  
SCIENCE.

Published Monthly, price One Shilling. Nos.  
I. to CXLVI.

THE MEDICAL DIRECTORY FOR THE  
UNITED KINGDOM.

Published Annually. 8vo. cloth, 10s. 6d.

THE HALF-YEARLY ABSTRACT OF THE MEDICAL SCIENCES.  
BEING A DIGEST OF BRITISH AND CONTINENTAL MEDICINE,  
AND OF THE PROGRESS OF MEDICINE AND THE COLLATERAL SCIENCES.

Post 8vo. cloth, 6s. 6d. Vols. I. to XLVII.

"American physicians may be congratulated that they are once more favoured with the reprint of 'Ranking's Abstract.' If any doctor is so busy that he can read but a single volume a year, then, assuredly, he should make this his book; for here are collected and condensed the most valuable contributions to periodical medical literature—French, German, British, and American—for the year; and, on the other hand, no physician—it matters not how wide the range of his reading—can fail to find, in this volume, truths that will enlarge his medical knowledge, and precepts that will help him in some of his daily professional needs."—*Cincinnati Journal of Medicine*, April, 1867.

"We have only space to say that this volume is rich in valuable articles, among which there are many on materia medica and therapeutics. Gathered from all sources in the new books and medical journals of Europe and America, this work may be viewed as the cream of that class of medical essays, and is a useful occupant of the physician's office-table, to keep him reminded of the progress of medicine."—*American Journal of Pharmacy*, May, 1867.



a 2



**MEDICINE—continued.**

	PAGE
Budd on Stomach .. ..	11
Camplin on Diabetes .. ..	12
Catlow on Æsthetic Medicine ..	12
Chambers on the Indigestions ..	12
Do. Lectures .. ..	12
Cockle on Cancer .. ..	13
Dale's Practical Medicine .. ..	14
Davey's Ganglionic Nervous Syst.	15
Day's Clinical Histories .. ..	15
Eyre on Stomach .. ..	15
Fenwick on the Stomach .. ..	16
Foster on the Sphygmograph ..	16
Fuller on Rheumatism .. ..	17
Gairdner on Gout .. ..	17
Gibb on Throat .. ..	17
Do. on Laryngoscope .. ..	17
Granville on Sudden Death ..	18
Griffith on the Skin .. ..	18
Gully's Simple Treatment .. ..	18
Habershon on the Abdomen .. ..	18
Do. on Mercury .. ..	18
Hall (Marshall) on Apnoea .. ..	18
Do. Observations .. ..	18
Headland—Action of Medicines ..	19
Do. Medical Handbook .. ..	19
Hooper's Physician's Vade-Mecum ..	18
Inman's New Theory .. ..	22
Do. Myalgia .. ..	22
James on Laryngoscope .. ..	22
Jencken on Cholera .. ..	22
Jones (Bence) on Pathology and Therapeutics .. ..	22
MacLachlan on Advanced Life ..	25
MacLeod on Acoholic Diseases ..	25
MacLeod's Ben Rhydding .. ..	25
Marcel on Chronic Alcoholism ..	25
Macpherson on Cholera .. ..	26
Markham on Bleeding .. ..	26
Morris on Germinal Matter .. ..	26
Meryon on Paralysis .. ..	26
Musket on Apoplexy .. ..	27
Nicholson on Yellow Fever .. ..	27
Parkin on Cholera .. ..	28
Pavy on Diabetes .. ..	28
Do. on Digestion .. ..	28
Pest's Principles and Practice of Medicine .. ..	28
Roberts on Palsy .. ..	31
Robertson on Gout .. ..	31
Sansom on Cholera .. ..	32
Savory's Domestic Medicine ..	32
Sample on Cough .. ..	32
Seymour on Dropsy .. ..	32
Shaw's Medical Remembrancer ..	32
Shrimpton on Cholera .. ..	32
Smee on Debility .. ..	33
Steggall's Medical Manual .. ..	34
Thomas' Practice of Physic .. ..	35
Thudichum on Gall Stones .. ..	35
Todd's Clinical Lectures .. ..	36
Tweedie on Continued Fevers ..	36
Walker on Diphtheria .. ..	37
What to Observe at the Bedside ..	25
Williams' Principles .. ..	38
Wright on Headaches .. ..	39

**MICROSCOPE.**

Beale on Microscope in Medicine ..	8
Carpenter on Microscope .. ..	12
Schacht on do. .. ..	32

**MISCELLANEOUS.**

Acton on Prostitution .. ..	6
Barclay's Medical Errors .. ..	8

**MISCELLANEOUS—cont'd.**

	PAGE
Barker & Edwards' Photographs ..	8
Bascome on Epidemics .. ..	8
Buckle's Hospital Statistics .. ..	11
Cooley's Cyclopædia .. ..	13
Gordon on China .. ..	17
Graves' Physiology and Medicine ..	17
Guy's Hospital Reports .. ..	17
Harrison on Lead in Water .. ..	19
Hingeston's Topics of the Day ..	20
Howe on Epidemics .. ..	21
Lane's Hydropathy .. ..	23
Lee on Homœop. and Hydrop. ..	24
London Hospital Reports .. ..	25
Mayne's Medical Vocabulary .. ..	26
Oppert on Hospitals .. ..	27
Part's Case Book .. ..	28
Redwood's Supplement to Pharmacopœia .. ..	30
Ryan on Infanticide .. ..	31
St. George's Hospital Reports ..	31
Simms' Winter in Paris .. ..	33
Snow on Chloroform .. ..	33
Waring's Tropical Resident at Home .. ..	37
Whitehead on Transmission .. ..	38
Wise's Med. amongst Asiatics ..	38

**NERVOUS DISORDERS AND INDIGESTION.**

Althaus on Epilepsy, Hysteria, &c. ..	7
Birch on Constipation .. ..	10
Carter on Hysteria .. ..	12
Downing on Neuralgia .. ..	15
Hunt on Heartburn .. ..	21
Jones (Handfield) on Functional Nervous Disorders .. ..	22
Leared on Imperfect Digestion ..	23
Lobb on Nervous Affections .. ..	24
Morris on Irritability .. ..	26
Radcliffe on Epilepsy .. ..	30
Reade on Syphilitic Affections of the Nervous System .. ..	30
Reynolds on the Brain .. ..	30
Do. on Epilepsy .. ..	30
Rowe on Nervous Diseases .. ..	31
Sieveking on Epilepsy .. ..	33
Turnbull on Stomach .. ..	36

**OBSTETRICS.**

Barnes on Placenta Prævia .. ..	8
Hodges on Puerperal Convulsions ..	20
Lee's Clinical Midwifery .. ..	24
Do. Consultations .. ..	24
Leishman's Mechanism of Parturition .. ..	24
Pretty's Aids during Labour .. ..	29
Priestley on Gravid Uterus .. ..	30
Ramsbotham's Obstetrics .. ..	30
Do. Midwifery .. ..	30
Sinclair & Johnston's Midwifery ..	33
Smellie's Obstetric Plates .. ..	33
Smith's Manual of Obstetrics .. ..	33
Swayne's Aphorisms .. ..	34
Waller's Midwifery .. ..	37

**OPHTHALMOLOGY.**

Cooper on Injuries of Eye .. ..	13
Do. on Near Sight .. ..	13
Dalrymple on Eye .. ..	14

**OPHTHALMOLOGY—cont'd.**

	PAGE
Dixon on the Eye .. ..	15
Hogg on Ophthalmoscope .. ..	20
Hulke on the Ophthalmoscope ..	21
Jago on Entoptics .. ..	22
Jones' Ophthalmic Medicine .. ..	23
Do. Defects of Sight .. ..	23
Do. Eye and Ear .. ..	23
Macnamara on the Eye .. ..	25
Nunneley on the Organs of Vision ..	27
Power's Illustrations of Diseases of the Eye .. ..	29
Solomon on Glaucoma .. ..	33
Walton on the Eye .. ..	37
Wells on Spectacles .. ..	38

**PHYSIOLOGY.**

Carpenter's Human .. ..	12
Do. Manual .. ..	12
Heale on Vital Causes .. ..	19
Richardson on Coagulation .. ..	30
Shea's Animal Physiology .. ..	32
Virchow's (ed. by Chance) Cellular Pathology .. ..	12

**PSYCHOLOGY.**

Arlidge on the State of Lunacy ..	7
Bucknill and Tuke's Psychological Medicine .. ..	11
Conolly on Asylums .. ..	13
Davey on Nature of Insanity .. ..	15
Dunn on Psychology .. ..	15
Hood on Criminal Lunatics .. ..	21
Millingen on Treatment of Insane ..	26
Murray on Emotional Diseases ..	27
Noble on Mind .. ..	27
Sankey on Mental Diseases .. ..	31
Winslow's Obscure Dis. of Brain ..	39

**PULMONARY and CHEST DISEASES, &c.**

Alison on Pulmonary Consumption ..	6
Bright on the Chest .. ..	10
Cotton on Stethoscope .. ..	14
Davies on Lungs and Heart .. ..	14
Dobell on the Chest .. ..	15
Do. on Tuberculosis .. ..	15
Do. on Winter Cough .. ..	15
Do. First Stage of Consumption .. ..	15
Fenwick on Consumption .. ..	16
Fuller on the Lungs .. ..	17
Do. on Heart .. ..	17
Jones (Jas.) on Consumption .. ..	22
Laennec on Auscultation .. ..	23
Markham on Heart .. ..	26
Peacock on the Heart .. ..	28
Pirrie on Hay Asthma .. ..	29
Salter on Asthma .. ..	31
Skoda on Auscultation .. ..	26
Thompson on Consumption .. ..	35
Timms on Consumption .. ..	36
Turnbull on Consumption .. ..	36
Waters on the Chest .. ..	37
Do. on Emphysema .. ..	37
Weber on Auscultation .. ..	38



**RENAL and URINARY  
DISEASES.**

	PAGE
Acton on Urinary Organs .. ..	6
Beale on Urine .. ..	8
Bird's Urinary Deposits .. ..	10
Coulson on Bladder .. ..	14
Hassall on Urine .. ..	19
Parkes on Urine .. ..	27
Thudichum on Urine .. ..	35
Todd on Urinary Organs .. ..	36

**SCIENCE.**

Baxter on Organic Polarity ..	8
Bentley's Manual of Botany ..	9
Brooke's Natural Philosophy ..	11
Craig on Electric Tension ..	14
Hardwich's Photography ..	19
Hinds' Harmonies .. ..	20
Howard on the Clouds .. ..	21
Jones on Vision .. ..	23
Do. on Body, Sense, and Mind ..	23
Mayne's Lexicon .. ..	26
Noad on the Inductorium ..	27
Pratt's Genealogy of Creation ..	29
Do. Eccentric & Centric Force ..	29
Do. on Orbital Motion .. ..	29
Do. Astronomical Investigations ..	29
Do. Oracles of God .. ..	29
Price's Photography .. ..	30
Rainey on Shells .. ..	30
Reymond's Animal Electricity ..	30
Taylor's Medical Jurisprudence ..	35
Unger's Botanical Letters ..	37
Vestiges of Creation .. ..	36

**SURGERY.**

	PAGE
Adams on Reparation of Tendons ..	6
Do. Subcutaneous Surgery ..	6
Anderson on the Skin .. ..	7
Ashton on Rectum .. ..	7
Brodhurst on Anchylosis .. ..	11
Bryant on Diseases of Joints ..	11
Do. Clinical Surgery .. ..	11
Callender on Rupture .. ..	12
Chapman on Ulcers .. ..	12
Do. Varicose Veins .. ..	12
Clark's Outlines of Surgery ..	13
Collis on Cancer .. ..	13
Cooper (Sir A.) on Testis .. ..	14
Do. (S.) Surg. Dictionary ..	14
Coulson on Stone in Bladder ..	14
Curling on Rectum .. ..	14
Do. on Testis .. ..	14
Druitt's Surgeon's Vade-Mecum ..	15
Fayrer's Clinical Surgery .. ..	15
Fergusson's Surgery .. ..	16
Do. Progress of Surgery ..	16
Gamgee's Amputation at Hip-joint ..	17
Gant's Principles of Surgery ..	17
Heath's Minor Surgery and ..	
Bandaging .. ..	20
Higginbottom on Nitrate of Silver ..	20
Hodgson on Prostate .. ..	20
Holt on Stricture .. ..	21
James on Hernia .. ..	22
Do. on Inflammations .. ..	22
Jordan's Clinical Surgery ..	23
Lawrence's Surgery .. ..	23
Do. Ruptures .. ..	23
Lee on the Rectum, &c. .. ..	24
Liston's Surgery .. ..	24
Logan on Skin Diseases .. ..	24

**SURGERY—continued.**

	PAGE
Macleod's Surgical Diagnosis ..	25
Do. Surgery of the Crimea ..	25
MacLise on Fractures .. ..	25
Maunder's Operative Surgery ..	26
Nayler on Skin Diseases .. ..	27
Nunneley on Erysipelas .. ..	27
Pirrie's Surgery .. ..	29
Pirrie & Keith on Acupressure ..	29
Price on Excision of Knee-joint ..	29
Salt on Rupture .. ..	31
Sansom on Chloroform .. ..	32
Smith (Hy.) on Stricture .. ..	33
Do. on Hæmorrhoids .. ..	33
Do. on the Surgery of the Rectum ..	33
Do. (Dr. J.) Dental Anatomy ..	
and Surgery .. ..	33
Sponder on Ulcers .. ..	34
Squire on Skin Diseases .. ..	34
Steggall's Surgical Manual ..	34
Teale on Amputation .. ..	35
Thompson on Stricture .. ..	35
Do. on Prostate .. ..	35
Do. Lithotomy and Lithotripsy ..	35
Tomes' Dental Surgery .. ..	36
Wade on Stricture .. ..	37
Webb's Surgeon's Ready Rules ..	37
Wilson on Skin Diseases .. ..	39
Do. Portraits of Skin Diseases ..	39
Yearsley on Deafness .. ..	39
Do. on Throat .. ..	39

**VETERINARY MEDICINE.**

Blaine's Veterinary Art .. ..	10
Bourguignon on the Cattle Plague ..	10

TO BE COMPLETED IN TWELVE PARTS, 4to., AT 7s. 6d. PER PART.

PARTS I. & II. NOW READY.

# A DESCRIPTIVE TREATISE ON THE NERVOUS SYSTEM OF MAN,

WITH THE MANNER OF DISSECTING IT.

By LUDOVIC HIRSCHFELD,

DOCTOR OF MEDICINE OF THE UNIVERSITIES OF PARIS AND WARSAW, PROFESSOR OF ANATOMY TO THE  
FACULTY OF MEDICINE OF WARSAW;

*Edited in English (from the French Edition of 1866)*

By ALEXANDER MASON MACDOUGAL, F.R.C.S.,

WITH

AN ATLAS OF ARTISTICALLY-COLOURED ILLUSTRATIONS,

Embracing the Anatomy of the entire Cerebro-Spinal and Sympathetic Nervous Centres and Distributions in their accurate relations with all the important Constituent Parts of the Human Economy, and embodied in a series of 56 Single and 9 Double Plates, comprising 197 Illustrations,

*Designed from Dissections prepared by the Author, and Drawn on Stone by*

J. B. LÉVEILLÉ.



MR. ACTON, M.R.C.S.

I.

A PRACTICAL TREATISE ON DISEASES OF THE URINARY AND GENERATIVE ORGANS IN BOTH SEXES. Third Edition. 8vo. cloth, £1. 1s. With Plates, £1. 11s. 6d. The Plates alone, limp cloth, 10s. 6d.

II.

THE FUNCTIONS AND DISORDERS OF THE REPRODUCTIVE ORGANS IN CHILDHOOD, YOUTH, ADULT AGE, AND ADVANCED LIFE, considered in their Physiological, Social, and Moral Relations. Fourth Edition. 8vo. cloth, 10s. 6d.

III.

PROSTITUTION: Considered in its Moral, Social, and Sanitary Bearings, with a View to its Amelioration and Regulation. 8vo. cloth, 10s. 6d.

DR. ADAMS, A.M.

A TREATISE ON RHEUMATIC GOUT; OR, CHRONIC RHEUMATIC ARTHRITIS. 8vo. cloth, with a Quarto Atlas of Plates, 21s.

MR. WILLIAM ADAMS, F.R.C.S.

I.

ON THE PATHOLOGY AND TREATMENT OF LATERAL AND OTHER FORMS OF CURVATURE OF THE SPINE. With Plates. 8vo. cloth, 10s. 6d.

II.

CLUBFOOT: its Causes, Pathology, and Treatment. Jacksonian Prize Essay for 1864. With 100 Engravings. 8vo. cloth, 12s.

III.

ON THE REPARATIVE PROCESS IN HUMAN TENDONS AFTER SUBCUTANEOUS DIVISION FOR THE CURE OF DEFORMITIES. With Plates. 8vo. cloth, 6s.

IV.

SKETCH OF THE PRINCIPLES AND PRACTICE OF SUBCUTANEOUS SURGERY. 8vo. cloth, 2s. 6d.

DR. WILLIAM ADDISON, F.R.S.

I.

CELL THERAPEUTICS. 8vo. cloth, 4s.

II.

ON HEALTHY AND DISEASED STRUCTURE, AND THE TRUE PRINCIPLES OF TREATMENT FOR THE CURE OF DISEASE, ESPECIALLY CONSUMPTION AND SCROFULA, founded on MICROSCOPICAL ANALYSIS. 8vo. cloth, 12s.

DR. ALDIS:

AN INTRODUCTION TO HOSPITAL PRACTICE IN VARIOUS COMPLAINTS; with Remarks on their Pathology and Treatment. 8vo. cloth, 5s. 6d.

DR. SOMERVILLE SCOTT ALISON, M.D. EDIN., F.R.C.P.

THE PHYSICAL EXAMINATION OF THE CHEST IN PULMONARY CONSUMPTION, AND ITS INTERCURRENT DISEASES. With Engravings. 8vo. cloth, 12s.



DR. ALTHAUS, M.D., M.R.C.P.

ON EPILEPSY, HYSTERIA, AND ATAXY. Cr. 8vo. cloth, 4s.

THE ANATOMICAL REMEMBRANCER; OR, COMPLETE  
POCKET ANATOMIST. Sixth Edition, carefully Revised. 32mo. cloth, 3s. 6d.

DR. MCCALL ANDERSON, M.D.

I.  
PARASITIC AFFECTIONS OF THE SKIN. With Engravings.

8vo. cloth, 5s.

II.

ECZEMA. Second Edition. 8vo. cloth, 6s.

III.

PSORIASIS AND LEPROA. With Chromo-lithograph. 8vo. cloth, 5s.

DR. ANDREW ANDERSON, M.D.

TEN LECTURES INTRODUCTORY TO THE STUDY OF FEVER.

Post 8vo. cloth, 5s.

DR. ARLIDGE.

ON THE STATE OF LUNACY AND THE LEGAL PROVISION  
FOR THE INSANE; with Observations on the Construction and Organisation of  
Asylums. 8vo. cloth, 7s.

DR. ALEXANDER ARMSTRONG, R.N.

OBSERVATIONS ON NAVAL HYGIENE AND SCURVY.

More particularly as the latter appeared during a Polar Voyage. 8vo. cloth, 5s.

MR. T. J. ASHTON.

I.  
ON THE DISEASES, INJURIES, AND MALFORMATIONS  
OF THE RECTUM AND ANUS. Fourth Edition. 8vo. cloth, 8s.

II.

PROLAPSUS, FISTULA IN ANO, AND HÆMORRHOIDAL  
AFFECTIONS; their Pathology and Treatment. Second Edition. Post 8vo. cloth 2s. 6d.

MR. THOS. J. AUSTIN, M.R.C.S.ENG.

A PRACTICAL ACCOUNT OF GENERAL PARALYSIS:  
Its Mental and Physical Symptoms, Statistics, Causes, Seat, and Treatment. 8vo. cloth, 6s.

DR. THOMAS BALLARD, M.D.

A NEW AND RATIONAL EXPLANATION OF THE DIS-  
EASES PECULIAR TO INFANTS AND MOTHERS; with obvious Suggestion  
for their Prevention and Cure. Post 8vo. cloth, 4s. 6d.



DR. BARCLAY.

I.

A MANUAL OF MEDICAL DIAGNOSIS. Second Edition.  
Foolscap 8vo. cloth, 8s. 6d.

II.

MEDICAL ERRORS.—Fallacies connected with the Application of the  
Inductive Method of Reasoning to the Science of Medicine. Post 8vo. cloth, 5s.

III.

GOUT AND RHEUMATISM IN RELATION TO DISEASE  
OF THE HEART. Post 8vo. cloth, 5s.

DR. T. HERBERT BARKER, M.D., F.R.S., & MR. ERNEST EDWARDS, B.A.  
PHOTOGRAPHS OF EMINENT MEDICAL MEN, with brief  
Analytical Notices of their Works. Vol. I. (24 Portraits), 4to. cloth, 24s.

DR. BARLOW.

A MANUAL OF THE PRACTICE OF MEDICINE. Second  
Edition. Fcap. 8vo. cloth, 12s. 6d.

DR. BARNES.

THE PHYSIOLOGY AND TREATMENT OF PLACENTA  
PRÆVIA; being the Lettsomian Lectures on Midwifery for 1857. Post 8vo. cloth, 6s.

DR. BASCOME.

A HISTORY OF EPIDEMIC PESTILENCES, FROM THE  
EARLIEST AGES. 8vo. cloth, 8s.

DR. BASHAM.

ON DROPSY, AND ITS CONNECTION WITH DISEASES OF  
THE KIDNEYS, HEART, LUNGS AND LIVER. With 16 Plates. Third  
Edition. 8vo. cloth, 12s. 6d.

MR. H. F. BAXTER, M.R.C.S.L.

ON ORGANIC POLARITY; showing a Connexion to exist between  
Organic Forces and Ordinary Polar Forces. Crown 8vo. cloth, 5s.

MR. BATEMAN.

MAGNACOPIA: A Practical Library of Profitable Knowledge, commu-  
nicating the general Minutiæ of Chemical and Pharmaceutic Routine, together with the  
generality of Secret Forms of Preparations. Third Edition. 18mo. 6s.

MR. LIONEL J. BEALE, M.R.C.S.

I.

THE LAWS OF HEALTH IN THEIR RELATIONS TO MIND  
AND BODY. A Series of Letters from an Old Practitioner to a Patient. Post 8vo.  
cloth, 7s. 6d.

II.

HEALTH AND DISEASE, IN CONNECTION WITH THE  
GENERAL PRINCIPLES OF HYGIENE. Fcap. 8vo., 2s. 6d.



DR. BEALE, F.R.S.

I.  
URINE, URINARY DEPOSITS, AND CALCULI: and on the  
Treatment of Urinary Diseases. Numerous Engravings. Second Edition, much Enlarged.  
Post 8vo. cloth, 8s. 6d.

II.  
THE MICROSCOPE, IN ITS APPLICATION TO PRACTICAL  
MEDICINE. Third Edition. With 58 Plates. 8vo. cloth, 16s.

III.  
ILLUSTRATIONS OF THE SALTS OF URINE, URINARY  
DEPOSITS, and CALCULI. 37 Plates, containing upwards of 170 Figures copied  
from Nature, with descriptive Letterpress. 8vo. cloth, 9s. 6d.

MR. BEASLEY.

I.  
THE BOOK OF PRESCRIPTIONS; containing 3000 Prescriptions.  
Collected from the Practice of the most eminent Physicians and Surgeons, English  
and Foreign. Third Edition. 18mo. cloth, 6s.

II.  
THE DRUGGIST'S GENERAL RECEIPT-BOOK: comprising a  
copious Veterinary Formulary and Table of Veterinary Materia Medica; Patent and  
Proprietary Medicines, Druggists' Nostrums, &c.; Perfumery, Skin Cosmetics, Hair  
Cosmetics, and Teeth Cosmetics; Beverages, Dietetic Articles, and Condiments; Trade  
Chemicals, Miscellaneous Preparations and Compounds used in the Arts, &c.; with  
useful Memoranda and Tables. Sixth Edition. 18mo. cloth, 6s.

III.  
THE POCKET FORMULARY AND SYNOPSIS OF THE  
BRITISH AND FOREIGN PHARMACOPŒIAS; comprising standard and  
approved Formulæ for the Preparations and Compounds employed in Medical Practice.  
Eighth Edition, corrected and enlarged. 18mo. cloth, 6s.

DR. HENRY BENNET.

I.  
A PRACTICAL TREATISE ON INFLAMMATION AND  
OTHER DISEASES OF THE UTERUS. Fourth Edition, revised, with Additions.  
8vo. cloth, 16s.

II.  
A REVIEW OF THE PRESENT STATE (1856) OF UTERINE  
PATHOLOGY. 8vo. cloth, 4s.

III.  
WINTER IN THE SOUTH OF EUROPE; OR, MENTONE, THE  
RIVIERA, CORSICA, SICILY, AND BIARRITZ, AS WINTER CLIMATES.  
Third Edition, with numerous Plates, Maps, and Wood Engravings. Post 8vo. cloth,  
10s. 6d.

PROFESSOR BENTLEY, F.L.S.

A MANUAL OF BOTANY. With nearly 1,200 Engravings on Wood.  
Fcap. 8vo. cloth, 12s. 6d.

DR. BERNAYS.

NOTES FOR STUDENTS IN CHEMISTRY; being a Syllabus com-  
piled from the Manuals of Miller, Fownes, Berzelius, Gerhardt, Goupp-Besanez, &c.  
Fourth Edition. Fcap. 8vo. cloth, 3s.



MR. HENRY HEATHER BIGG.

**ORTHOPRAXY:** the Mechanical Treatment of Deformities, Debilities, and Deficiencies of the Human Frame. With Engravings. Post 8vo. cloth, 10s.

DR. S. B. BIRCH, M.D., M.R.C.P.

I.

**OXYGEN:** ITS ACTION, USE, AND VALUE IN THE TREATMENT OF VARIOUS DISEASES OTHERWISE INCURABLE OR VERY INTRACTABLE. Second Edition. Post 8vo. cloth, 3s. 6d.

II.

**CONSTIPATED BOWELS:** the Various Causes and the Different Means of Cure. Third Edition. Post 8vo. cloth, 3s. 6d.

DR. GOLDING BIRD, F.R.S.

**URINARY DEPOSITS; THEIR DIAGNOSIS, PATHOLOGY, AND THERAPEUTICAL INDICATIONS.** With Engravings. Fifth Edition. Edited by E. LLOYD BIRKETT, M.D. Post 8vo. cloth, 10s. 6d.

MR. BISHOP, F.R.S.

I.

**ON DEFORMITIES OF THE HUMAN BODY,** their Pathology and Treatment. With Engravings on Wood. 8vo. cloth, 10s.

II.

**ON ARTICULATE SOUNDS, AND ON THE CAUSES AND CURE OF IMPEDIMENTS OF SPEECH.** 8vo. cloth, 4s.

MR. P. HINCKES BIRD, F.R.C.S.

**PRACTICAL TREATISE ON THE DISEASES OF CHILDREN AND INFANTS AT THE BREAST.** Translated from the French of M. BOUCHUT, with Notes and Additions. 8vo. cloth. 20s.

MR. BLAINE.

**OUTLINES OF THE VETERINARY ART; OR, A TREATISE ON THE ANATOMY, PHYSIOLOGY, AND DISEASES OF THE HORSE, NEAT CATTLE, AND SHEEP.** Seventh Edition. By Charles Steel, M.R.C.V.S.L. With Plates. 8vo. cloth, 18s.

MR. BLOXAM.

**CHEMISTRY, INORGANIC AND ORGANIC;** with Experiments and a Comparison of Equivalent and Molecular Formulæ. With 276 Engravings on Wood. 8vo. cloth, 16s.

DR. BOURGUIGNON.

**ON THE CATTLE PLAGUE; OR, CONTAGIOUS TYPHUS IN HORNED CATTLE:** its History, Origin, Description, and Treatment. Post 8vo. 5s.

MR. JOHN E. BOWMAN, &amp; MR. C. L. BLOXAM.

I.

**PRACTICAL CHEMISTRY,** including Analysis. With numerous Illustrations on Wood. Fifth Edition. Foolscap 8vo. cloth, 6s. 6d.

II.

**MEDICAL CHEMISTRY;** with Illustrations on Wood. Fourth Edition, carefully revised. Fcap. 8vo. cloth, 6s. 6d.

DR. JAMES BRIGHT.

**ON DISEASES OF THE HEART, LUNGS, & AIR PASSAGES;** with a Review of the several Climates recommended in these Affections. Third Edition. Post 8vo. cloth, 9s.



DR. BRINTON, F.R.S.

I.  
THE DISEASES OF THE STOMACH, with an Introduction on its Anatomy and Physiology; being Lectures delivered at St. Thomas's Hospital. Second Edition. 8vo. cloth, 10s. 6d.

II.  
INTESTINAL OBSTRUCTION. Edited by DR. BUZZARD. Post 8vo. cloth, 5s.

MR. BERNARD E. BRODHURST, F.R.C.S.

I.  
CURVATURES OF THE SPINE: their Causes, Symptoms, Pathology, and Treatment. Second Edition. Roy. 8vo. cloth, with Engravings, 7s. 6d.

II.  
ON THE NATURE AND TREATMENT OF CLUBFOOT AND ANALOGOUS DISTORTIONS involving the TIBIO-TARSAL ARTICULATION. With Engravings on Wood. 8vo. cloth, 4s. 6d.

III.  
PRACTICAL OBSERVATIONS ON THE DISEASES OF THE JOINTS INVOLVING ANCHYLOSIS, and on the TREATMENT for the RESTORATION of MOTION. Third Edition, much enlarged, 8vo. cloth, 4s. 6d.

MR. BROOKE, M.A., M.B., F.R.S.

ELEMENTS OF NATURAL PHILOSOPHY. Based on the Work of the late Dr. Golding Bird. Sixth Edition. With 700 Engravings. Fcap. 8vo. cloth, 12s. 6d.

DR. T. L. BRUNTON, B.Sc., M.B.

ON DIGITALIS. With some Observations on the Urine. Fcap. 8vo. cloth, 4s. 6d.

MR. THOMAS BRYANT, F.R.C.S.

I.  
ON THE DISEASES AND INJURIES OF THE JOINTS. CLINICAL AND PATHOLOGICAL OBSERVATIONS. Post 8vo. cloth, 7s. 6d.

II.  
THE SURGICAL DISEASES OF CHILDREN. The Lettsomian Lectures, delivered March, 1863. Post 8vo. cloth, 5s.

III.  
CLINICAL SURGERY. Parts I. to VII. 8vo., 3s. 6d. each.

DR. BUCKLE, M.D., L.R.C.P.LOND.

VITAL AND ECONOMICAL STATISTICS OF THE HOSPITALS, INFIRMARIES, &c., OF ENGLAND AND WALES. Royal 8vo. 5s.

DR. JOHN CHARLES BUCKNILL, F.R.S., & DR. DANIEL H. TUKE.

A MANUAL OF PSYCHOLOGICAL MEDICINE: containing the History, Nosology, Description, Statistics, Diagnosis; Pathology, and Treatment of Insanity. Second Edition. 8vo. cloth, 15s.

DR. BUDD, F.R.S.

I.  
ON DISEASES OF THE LIVER.

Illustrated with Coloured Plates and Engravings on Wood. Third Edition. 8vo. cloth, 16s.

II.  
ON THE ORGANIC DISEASES AND FUNCTIONAL DISORDERS OF THE STOMACH. 8vo. cloth, 9s.



MR. CALLENDER, F.R.C.S.

**FEMORAL RUPTURE:** Anatomy of the Parts concerned. With Plates.  
8vo. cloth, 4s.

DR. JOHN M. CAMPLIN, F.L.S.

**ON DIABETES, AND ITS SUCCESSFUL TREATMENT.**  
Third Edition, by Dr. Glover. Fcap. 8vo. cloth, 3s. 6d.

MR. ROBERT B. CARTER, M.R.C.S.

**ON THE INFLUENCE OF EDUCATION AND TRAINING**  
IN PREVENTING DISEASES OF THE NERVOUS SYSTEM. Fcap. 8vo., 6s.  
**THE PATHOLOGY AND TREATMENT OF HYSTERIA.** Post  
8vo. cloth, 4s. 6d.

DR. CARPENTER, F.R.S.

**PRINCIPLES OF HUMAN PHYSIOLOGY.** With numerous Illustrations on Steel and Wood. Sixth Edition. Edited by Mr. HENRY POWER. 8vo. cloth, 26s.

**A MANUAL OF PHYSIOLOGY.** With 252 Illustrations on Steel and Wood. Fourth Edition. Fcap. 8vo. cloth, 12s. 6d.

**THE MICROSCOPE AND ITS REVELATIONS.** With more than 400 Engravings on Steel and Wood. Fourth Edition. Fcap. 8vo. cloth, 12s. 6d.

MR. JOSEPH PEEL CATLOW, M.R.C.S.

**ON THE PRINCIPLES OF ÆSTHETIC MEDICINE;** or the Natural Use of Sensation and Desire in the Maintenance of Health and the Treatment of Disease. 8vo. cloth, 9s.

DR. CHAMBERS.

**LECTURES, CHIEFLY CLINICAL.** Fourth Edition. 8vo. cloth, 14s.

**THE INDIGESTIONS OR DISEASES OF THE DIGESTIVE ORGANS FUNCTIONALLY TREATED.** Second Edition. 8vo. cloth, 10s. 6d.

**SOME OF THE EFFECTS OF THE CLIMATE OF ITALY.**  
Crown 8vo. cloth, 4s. 6d.

DR. CHANCE, M.B.

**VIRCHOW'S CELLULAR PATHOLOGY, AS BASED UPON**  
PHYSIOLOGICAL AND PATHOLOGICAL HISTOLOGY. With 144 Engravings on Wood. 8vo. cloth, 16s.

MR. H. T. CHAPMAN, F.R.C.S.

**THE TREATMENT OF OBSTINATE ULCERS AND CUTA-NEOUS ERUPTIONS OF THE LEG WITHOUT CONFINEMENT.** Third Edition. Post 8vo. cloth, 3s. 6d.

**VARICOSE VEINS:** their Nature, Consequences, and Treatment, Palliative and Curative. Second Edition. Post 8vo. cloth, 3s. 6d.



MR. PYE HENRY CHAVASSE, F.R.C.S.

I.  
ADVICE TO A MOTHER ON THE MANAGEMENT OF  
HER CHILDREN. Ninth Edition. Foolscep 8vo., 2s. 6d.

II.  
ADVICE TO A WIFE ON THE MANAGEMENT OF HER  
OWN HEALTH. With an Introductory Chapter, especially addressed to a Young  
Wife. Eighth Edition. Fcap. 8vo., 2s. 6d.

MR. LE GROS CLARK, F.R.C.S.

OUTLINES OF SURGERY; being an Epitome of the Lectures on the  
Principles and the Practice of Surgery delivered at St. Thomas's Hospital. Fcap. 8vo.  
cloth, 5s.

MR. JOHN CLAY, M.R.C.S.

KIWISCH ON DISEASES OF THE OVARIES: Translated, by  
permission, from the last German Edition of his Clinical Lectures on the Special Patho-  
logy and Treatment of the Diseases of Women. With Notes, and an Appendix on the  
Operation of Ovariectomy. Royal 12mo. cloth, 16s.

DR. COCKLE, M.D.

ON INTRA-THORACIC CANCER. 8vo. 6s. 6d.

MR. COLLIS, M.B.DUB., F.R.C.S.I.

THE DIAGNOSIS AND TREATMENT OF CANCER AND  
THE TUMOURS ANALOGOUS TO IT. With coloured Plates. 8vo. cloth, 14s.

DR. CONOLLY.

THE CONSTRUCTION AND GOVERNMENT OF LUNATIC  
ASYLUMS AND HOSPITALS FOR THE INSANE. With Plans. Post 8vo.  
cloth, 6s.

MR. COOLEY.

COMPREHENSIVE SUPPLEMENT TO THE PHARMACOPŒIAS.

THE CYCLOPŒDIA OF PRACTICAL RECEIPTS, PRO-  
CESSES, AND COLLATERAL INFORMATION IN THE ARTS, MANU-  
FACTURES, PROFESSIONS, AND TRADES, INCLUDING MEDICINE,  
PHARMACY, AND DOMESTIC ECONOMY; designed as a General Book of  
Reference for the Manufacturer, Tradesman, Amateur, and Heads of Families. Fourth  
and greatly enlarged Edition, 8vo. cloth, 28s.

MR. W. WHITE COOPER.

I.  
ON WOUNDS AND INJURIES OF THE EYE. Illustrated by  
17 Coloured Figures and 41 Woodcuts. 8vo. cloth, 12s.

II.  
ON NEAR SIGHT, AGED SIGHT, IMPAIRED VISION,  
AND THE MEANS OF ASSISTING SIGHT. With 31 Illustrations on Wood.  
Second Edition. Fcap. 8vo. cloth, 7s. 6d.



SIR ASTLEY COOPER, BART., F.R.S.

## ON THE STRUCTURE AND DISEASES OF THE TESTIS.

With 24 Plates. Second Edition. Royal 4to., 20s.

MR. COOPER.

A DICTIONARY OF PRACTICAL SURGERY AND ENCYCLOPÆDIA OF SURGICAL SCIENCE. New Edition, brought down to the present time. By SAMUEL A. LANE, F.R.C.S., assisted by various eminent Surgeons. Vol. I., 8vo. cloth, £1. 5s.

MR. HOLMES COOTE, F.R.C.S.

A REPORT ON SOME IMPORTANT POINTS IN THE TREATMENT OF SYPHILIS. 8vo. cloth, 5s.

DR. COTTON.

PHTHISIS AND THE STETHOSCOPE; OR, THE PHYSICAL SIGNS OF CONSUMPTION. Third Edition. Foolscep 8vo. cloth, 3s.

MR. COULSON.

ON DISEASES OF THE BLADDER AND PROSTATE GLAND.

New Edition, revised. *In Preparation.*

MR. WALTER COULSON, F.R.C.S.

STONE IN THE BLADDER: With Special Reference to its Prevention, Early Symptoms, and Treatment by Lithotripsy. 8vo. cloth, 6s.

MR. WILLIAM CRAIG, L.F.P.S., GLASGOW.

ON THE INFLUENCE OF VARIATIONS OF ELECTRIC TENSION AS THE REMOTE CAUSE OF EPIDEMIC AND OTHER DISEASES. 8vo. cloth, 10s.

MR. CURLING, F.R.S.

I.  
OBSERVATIONS ON DISEASES OF THE RECTUM. Third Edition. 8vo. cloth, 7s. 6d.

II.  
A PRACTICAL TREATISE ON DISEASES OF THE TESTIS, SPERMATIC CORD, AND SCROTUM. Third Edition, with Engravings. 8vo. cloth, 16s.

DR. WILLIAM DALE, M.D. LOND.

A COMPENDIUM OF PRACTICAL MEDICINE AND MORBID ANATOMY. With Plates, 12mo. cloth, 7s.

DR. DALRYMPLE, M.R.C.P., F.R.C.S.

THE CLIMATE OF EGYPT: METEOROLOGICAL AND MEDICAL OBSERVATIONS, with Practical Hints for Invalid Travellers. Post 8vo. cloth, 4s.

MR. JOHN DALRYMPLE, F.R.S., F.R.C.S.

PATHOLOGY OF THE HUMAN EYE. Complete in Nine Fasciculi: imperial 4to., 20s. each; half-bound morocco, gilt tops, 9l. 15s.

DR. HERBERT DAVIES.

ON THE PHYSICAL DIAGNOSIS OF DISEASES OF THE LUNGS AND HEART. Second Edition. Post 8vo. cloth, 8s.



DR. DAVEY.

I.  
THE GANGLIONIC NERVOUS SYSTEM: its Structure, Functions,  
and Diseases. 8vo. cloth, 9s.

II.  
ON THE NATURE AND PROXIMATE CAUSE OF IN-  
SANITY. Post 8vo. cloth, 3s.

DR. HENRY DAY, M.D., M.R.C.P.

CLINICAL HISTORIES; with Comments. 8vo. cloth, 7s. 6d.

MR. DIXON.

A GUIDE TO THE PRACTICAL STUDY OF DISEASES OF  
THE EYE. Third Edition. Post 8vo. cloth, 9s.

DR. DOBELL.

I.  
DEMONSTRATIONS OF DISEASES IN THE CHEST, AND  
THEIR PHYSICAL DIAGNOSIS. With Coloured Plates. 8vo. cloth, 12s. 6d.

II.  
LECTURES ON THE GERMS AND VESTIGES OF DISEASE,  
and on the Prevention of the Invasion and Fatality of Disease by Periodical Examinations.  
8vo. cloth, 6s. 6d.

III.  
ON TUBERCULOSIS: ITS NATURE, CAUSE, AND TREAT-  
MENT; with Notes on Pancreatic Juice. Second Edition. Crown 8vo. cloth, 3s. 6d.

IV.  
LECTURES ON WINTER COUGH (CATARRH, BRONCHITIS,  
EMPHYSEMA, ASTHMA); with an Appendix on some Principles of Diet in  
Disease. Post 8vo. cloth, 5s. 6d.

V.  
LECTURES ON THE TRUE FIRST STAGE OF CONSUMP-  
TION. Crown 8vo. cloth, 3s. 6d.

DR. TOOGOOD DOWNING.

NEURALGIA: its various Forms, Pathology, and Treatment. THE  
JACKSONIAN PRIZE ESSAY FOR 1850. 8vo. cloth, 10s. 6d.

DR. DRUITT, F.R.C.S.

THE SURGEON'S VADE-MECUM; with numerous Engravings on  
Wood. Ninth Edition. Foolscap 8vo. cloth, 12s. 6d.

MR. DUNN, F.R.C.S.

PSYCHOLOGY—PHYSIOLOGICAL, 4s.; MEDICAL, 3s.

SIR JAMES EYRE, M.D.

I.  
THE STOMACH AND ITS DIFFICULTIES. Fifth Edition.  
Fcap. 8vo. cloth, 2s. 6d.

II.  
PRACTICAL REMARKS ON SOME EXHAUSTING DIS-  
EASES. Second Edition. Post 8vo. cloth, 4s. 6d.

DR. FAYRER, M.D., F.R.C.S.

CLINICAL SURGERY IN INDIA. With Engravings. 8vo. cloth, 16s.



DR. FENWICK.

I.  
THE MORBID STATES OF THE STOMACH AND DUODENUM, AND THEIR RELATIONS TO THE DISEASES OF OTHER ORGANS. With 10 Plates. 8vo. cloth, 12s.

II.  
ON SCROFULA AND CONSUMPTION. Clergyman's Sore Throat, Catarrh, Croup, Bronchitis, Asthma. Fcap. 8vo., 2s. 6d.

SIR WILLIAM FERGUSSON, BART., F.R.S.

I.  
A SYSTEM OF PRACTICAL SURGERY; with numerous Illustrations on Wood. Fourth Edition. Fcap. 8vo. cloth, 12s. 6d.

II.  
LECTURES ON THE PROGRESS OF ANATOMY AND SURGERY DURING THE PRESENT CENTURY. With numerous Engravings. 8vo. cloth, 10s. 6d.

SIR JOHN FIFE, F.R.C.S. AND MR. URQUHART.

MANUAL OF THE TURKISH BATH. Heat a Mode of Cure and a Source of Strength for Men and Animals. With Engravings. Post 8vo. cloth, 5s.

MR. FLOWER, F.R.S., F.R.C.S.

DIAGRAMS OF THE NERVES OF THE HUMAN BODY, exhibiting their Origin, Divisions, and Connexions, with their Distribution to the various Regions of the Cutaneous Surface, and to all the Muscles. Folio, containing Six Plates, 14s.

DR. BALTHAZAR FOSTER, M.D., M.R.C.P.

THE USE OF THE SPHYGMOGRAPH IN THE INVESTIGATION OF DISEASE. With Engravings. 8vo. cloth, 2s. 6d.

MR. FOWNES, PH.D., F.R.S.

I.  
A MANUAL OF CHEMISTRY; with 187 Illustrations on Wood. Ninth Edition. Fcap. 8vo. cloth, 12s. 6d.

Edited by H. BENGE JONES, M.D., F.R.S., and A. W. HOFMANN, PH.D., F.R.S.

II.  
CHEMISTRY, AS EXEMPLIFYING THE WISDOM AND BENEFICENCE OF GOD. Second Edition. Fcap. 8vo. cloth, 4s. 6d.

III.  
INTRODUCTION TO QUALITATIVE ANALYSIS. Post 8vo. cloth, 2s.

DR. D. J. T. FRANCIS.

CHANGE OF CLIMATE; considered as a Remedy in Dyspeptic, Pulmonary, and other Chronic Affections; with an Account of the most Eligible Places of Residence for Invalids, at different Seasons of the Year. Post 8vo. cloth, 8s. 6d.

DR. W. FRAZER.

ELEMENTS OF MATERIA MEDICA; containing the Chemistry and Natural History of Drugs—their Effects, Doses, and Adulterations. Second Edition. 8vo. cloth, 10s. 6d.

PROFESSOR FRESENIUS.

A SYSTEM OF INSTRUCTION IN CHEMICAL ANALYSIS, Edited by LLOYD BULLOCK, F.C.S.

QUALITATIVE. Sixth Edition, with Coloured Plate illustrating Spectrum Analysis. 8vo. cloth, 10s. 6d.—QUANTITATIVE. Fourth Edition. 8vo. cloth, 18s.



DR. FULLER.

I.  
ON DISEASES OF THE LUNGS AND AIR PASSAGES.

Second Edition. 8vo. cloth, 12s. 6d.

II.  
ON DISEASES OF THE HEART AND GREAT VESSELS.

8vo. cloth, 7s. 6d.

III.  
ON RHEUMATISM, RHEUMATIC GOUT, AND SCIATICA:  
their Pathology, Symptoms, and Treatment. Third Edition. 8vo. cloth, 12s. 6d.

MR. GALLOWAY.

I.  
THE FIRST STEP IN CHEMISTRY. With numerous Engravings.

Fourth Edition. Fcap. 8vo. cloth, 6s. 6d.

II.  
A KEY TO THE EXERCISES CONTAINED IN ABOVE. Fcap.

8vo., 2s. 6d.

III.  
THE SECOND STEP IN CHEMISTRY; or, the Student's Guide to  
the Higher Branches of the Science. With Engravings. 8vo. cloth, 10s.IV.  
A MANUAL OF QUALITATIVE ANALYSIS. Fourth Edition.

Post 8vo. cloth, 6s. 6d.

V.  
CHEMICAL TABLES. On Five Large Sheets, for School and Lecture  
Rooms. Second Edition. 4s. 6d.

MR. J. SAMPSON GAMGEE.

HISTORY OF A SUCCESSFUL CASE OF AMPUTATION AT  
THE HIP-JOINT (the limb 48-in. in circumference, 99 pounds weight). With 4  
Photographs. 4to cloth, 10s. 6d.

MR. F. J. GANT, F.R.C.S.

I.  
THE PRINCIPLES OF SURGERY: Clinical, Medical, and Opera-  
tive. With Engravings. 8vo. cloth, 18s.II.  
THE IRRITABLE BLADDER: its Causes and Curative Treatment.  
Second Edition, enlarged. Crown 8vo. cloth, 5s.

SIR DUNCAN GIBB, BART., M.D.

I.  
ON DISEASES OF THE THROAT AND WINDPIPE, as  
reflected by the Laryngoscope. Second Edition. With 116 Engravings. Post 8vo.  
cloth, 10s. 6d.II.  
THE LARYNGOSCOPE IN DISEASES OF THE THROAT,  
with a Chapter on RHINOSCOPY. Second Edition, enlarged, with Engravings. Crown  
8vo., cloth, 5s.

MRS. GODFREY.

ON THE NATURE, PREVENTION, TREATMENT, AND CURE  
OF SPINAL CURVATURES and DEFORMITIES of the CHEST and LIMBS,  
without ARTIFICIAL SUPPORTS or any MECHANICAL APPLIANCES.  
Third Edition, Revised and Enlarged. 8vo. cloth 5s.

DR. GORDON, M.D., C.B.

I.  
ARMY HYGIENE. 8vo. cloth, 20s.II.  
CHINA, FROM A MEDICAL POINT OF VIEW; IN 1860  
AND 1861; With a Chapter on Nagasaki as a Sanatorium. 8vo. cloth, 10s. 6d.



DR. GAIRDNER.

ON GOUT; its History, its Causes, and its Cure. Fourth Edition. Post  
8vo. cloth, 8s. 6d.

DR. GRANVILLE, F.R.S.

I.  
THE MINERAL SPRINGS OF VICHY: their Efficacy in the  
Treatment of Gout, Indigestion, Gravel, &c. 8vo. cloth, 3s.

II.  
ON SUDDEN DEATH. Post 8vo., 2s. 6d.

DR. GRAVES M.D., F.R.S.

STUDIES IN PHYSIOLOGY AND MEDICINE. Edited by  
Dr. Stokes. With Portrait and Memoir. 8vo. cloth, 14s.

DR. S. C. GRIFFITH, M.D.

ON DERMATOLOGY AND THE TREATMENT OF SKIN  
DISEASES BY MEANS OF HERBS, IN PLACE OF ARSENIC AND  
MERCURY. Fcap. 8vo. cloth, 3s.

MR. GRIFFITHS.

CHEMISTRY OF THE FOUR SEASONS—Spring, Summer,  
Autumn, Winter. Illustrated with Engravings on Wood. Second Edition. Foolsap  
8vo. cloth, 7s. 6d.

DR. GULLY.

THE SIMPLE TREATMENT OF DISEASE; deduced from the  
Methods of Expectancy and Revulsion. 18mo. cloth, 4s.

DR. GUY AND DR. JOHN HARLEY.

HOOPER'S PHYSICIAN'S VADE-MECUM; OR, MANUAL OF  
THE PRINCIPLES AND PRACTICE OF PHYSIC. Seventh Edition, consider-  
ably enlarged, and rewritten. Foolsap 8vo. cloth, 12s. 6d.

GUY'S HOSPITAL REPORTS. Third Series. Vol. XIII., 8vo. 7s. 6d.

DR. HABERSHON, F.R.C.P.

I.  
ON DISEASES OF THE ABDOMEN, comprising those of the  
Stomach and other Parts of the Alimentary Canal, Œsophagus, Stomach, Cæcum,  
Intestines, and Peritoneum. Second Edition, with Plates. 8vo. cloth, 14s.

II.  
ON THE INJURIOUS EFFECTS OF MERCURY IN THE  
TREATMENT OF DISEASE. Post 8vo. cloth, 3s. 6d.

DR. C. RADCLYFFE HALL.

TORQUAY IN ITS MEDICAL ASPECT AS A RESORT FOR  
PULMONARY INVALIDS. Post 8vo. cloth, 5s.

DR. MARSHALL HALL, F.R.S.

I.  
PRONE AND POSTURAL RESPIRATION IN DROWNING  
AND OTHER FORMS OF APNŒA OR SUSPENDED RESPIRATION.  
Post 8vo. cloth, 5s.

II.  
PRACTICAL OBSERVATIONS AND SUGGESTIONS IN MEDI-  
CINE. Second Series. Post 8vo. cloth, 8s. 6d.



MR. HARDWICH.

A MANUAL OF PHOTOGRAPHIC CHEMISTRY. With Engravings. Seventh Edition. Foolsap 8vo. cloth, 7s. 6d.

DR. J. BOWER HARRISON, M.D., M.R.C.P.

I.  
LETTERS TO A YOUNG PRACTITIONER ON THE DISEASES OF CHILDREN. Foolsap 8vo. cloth, 3s.

II.

ON THE CONTAMINATION OF WATER BY THE POISON OF LEAD, and its Effects on the Human Body. Foolsap 8vo. cloth, 3s. 6d.

DR. HARTWIG.

I.

ON SEA BATHING AND SEA AIR. Second Edition. Fcap. 8vo., 2s. 6d.

II.

ON THE PHYSICAL EDUCATION OF CHILDREN. Fcap. 8vo., 2s. 6d.

DR. A. H. HASSALL.

I.

THE URINE, IN HEALTH AND DISEASE; being an Explanation of the Composition of the Urine, and of the Pathology and Treatment of Urinary and Renal Disorders. Second Edition. With 79 Engravings (23 Coloured). Post 8vo. cloth, 12s. 6d.

II.

THE MICROSCOPIC ANATOMY OF THE HUMAN BODY, IN HEALTH AND DISEASE. Illustrated with Several Hundred Drawings in Colour. Two vols. 8vo. cloth, £1. 10s.

MR. ALFRED HAVILAND, M.R.C.S.

CLIMATE, WEATHER, AND DISEASE; being a Sketch of the Opinions of the most celebrated Ancient and Modern Writers with regard to the Influence of Climate and Weather in producing Disease. With Four coloured Engravings. 8vo. cloth, 7s.

DR. HEADLAND, M.D., F.R.C.P.

I.

ON THE ACTION OF MEDICINES IN THE SYSTEM. Fourth Edition. 8vo. cloth, 14s.

II.

A MEDICAL HANDBOOK; comprehending such Information on Medical and Sanitary Subjects as is desirable in Educated Persons. Second Thousand. Foolsap 8vo. cloth, 5s.

DR. HEALE.

I.

A TREATISE ON THE PHYSIOLOGICAL ANATOMY OF THE LUNGS. With Engravings. 8vo. cloth, 8s.

II.

A TREATISE ON VITAL CAUSES. 8vo. cloth, 9s.



MR. CHRISTOPHER HEATH, F.R.C.S.

I.

PRACTICAL ANATOMY: a Manual of Dissections. With numerous Engravings. Fcap. 8vo. cloth, 10s. 6d.

II.

A MANUAL OF MINOR SURGERY AND BANDAGING, FOR THE USE OF HOUSE-SURGEONS, DRESSERS, AND JUNIOR PRACTITIONERS. With Illustrations. Third Edition. Fcap. 8vo. cloth, 5s.

MR. HIGGINBOTTOM, F.R.S., F.R.C.S.E.

A PRACTICAL ESSAY ON THE USE OF THE NITRATE OF SILVER IN THE TREATMENT OF INFLAMMATION, WOUNDS, AND ULCERS. Third Edition, 8vo. cloth, 6s.

DR. HINDS.

THE HARMONIES OF PHYSICAL SCIENCE IN RELATION TO THE HIGHER SENTIMENTS; with Observations on Medical Studies, and on the Moral and Scientific Relations of Medical Life. Post 8vo. cloth, 4s.

MR. J. A. HINGESTON, M.R.C.S.

TOPICS OF THE DAY, MEDICAL, SOCIAL, AND SCIENTIFIC. Crown 8vo. cloth, 7s. 6d.

DR. HODGES.

THE NATURE, PATHOLOGY, AND TREATMENT OF PUERPERAL CONVULSIONS. Crown 8vo. cloth, 3s.

DR. DECIMUS HODGSON.

THE PROSTATE GLAND, AND ITS ENLARGEMENT IN OLD AGE. With 12 Plates. Royal 8vo. cloth, 6s.

MR. JABEZ HOGG.

A MANUAL OF OPHTHALMOSCOPIC SURGERY; being a Practical Treatise on the Use of the Ophthalmoscope in Diseases of the Eye. Third Edition. With Coloured Plates. 8vo. cloth, 10s. 6d.

MR. LUTHER HOLDEN, F.R.C.S.

I.

HUMAN OSTEOLOGY: with Plates, showing the Attachments of the Muscles. Third Edition. 3vo. cloth, 16s.

II.

A MANUAL OF THE DISSECTION OF THE HUMAN BODY. With Engravings on Wood. Second Edition. 8vo. cloth, 16s.

MR. BARNARD HOLT, F.R.C.S.

ON THE IMMEDIATE TREATMENT OF STRICTURE OF THE URETHRA. Third Edition, Enlarged. 8vo. cloth, 6s.



DR. W. CHARLES HOOD.

SUGGESTIONS FOR THE FUTURE PROVISION OF CRIMINAL LUNATICS. 8vo. cloth, 5s. 6d.

DR. P. HOOD.

THE SUCCESSFUL TREATMENT OF SCARLET FEVER; also, OBSERVATIONS ON THE PATHOLOGY AND TREATMENT OF CROWING INSPIRATIONS OF INFANTS. Post 8vo. cloth, 5s.

MR. JOHN HORSLEY.

A CATECHISM OF CHEMICAL PHILOSOPHY; being a Familiar Exposition of the Principles of Chemistry and Physics. With Engravings on Wood. Designed for the Use of Schools and Private Teachers. Post 8vo. cloth, 6s. 6d.

DR. JAMES A. HORTON, M.D.

PHYSICAL AND MEDICAL CLIMATE AND METEOROLOGY OF THE WEST COAST OF AFRICA. 8vo. cloth, 10s.

MR. LUKE HOWARD, F.R.S.

ESSAY ON THE MODIFICATIONS OF CLOUDS. Third Edition, by W. D. and E. HOWARD. With 6 Lithographic Plates, from Pictures by Kenyon. 4to. cloth, 10s. 6d.

DR. HAMILTON HOWE, M.D.

A THEORETICAL INQUIRY INTO THE PHYSICAL CAUSE OF EPIDEMIC DISEASES. Accompanied with Tables. 8vo. cloth, 7s.

DR. HUFELAND.

THE ART OF PROLONGING LIFE. Second Edition. Edited by ERASMUS WILSON, F.R.S. Foolscap 8vo., 2s. 6d.

MR. W. CURTIS HUGMAN, F.R.C.S.

ON HIP-JOINT DISEASE; with reference especially to Treatment by Mechanical Means for the Relief of Contraction and Deformity of the Affected Limb. With Plates. Re-issue, enlarged. 8vo. cloth, 3s. 6d.

MR. HULKE, F.R.C.S.

A PRACTICAL TREATISE ON THE USE OF THE OPHTHALMOSCOPE. Being the Jacksonian Prize Essay for 1859. Royal 8vo. cloth, 8s.

DR. HENRY HUNT.

ON HEARTBURN AND INDIGESTION. 8vo. cloth, 5s.

MR. G. Y. HUNTER, M.R.C.S.

BODY AND MIND: the Nervous System and its Derangements. Fcap. 8vo. cloth, 3s. 6d.

PROFESSOR HUXLEY, F.R.S.

LECTURES ON THE ELEMENTS OF COMPARATIVE ANATOMY.—ON CLASSIFICATION AND THE SKULL. With 111 Illustrations. 8vo. cloth, 10s. 6d.



MR. JONATHAN HUTCHINSON, F.R.C.S.

A CLINICAL MEMOIR ON CERTAIN DISEASES OF THE EYE AND EAR, CONSEQUENT ON INHERITED SYPHILIS; with an appended Chapter of Commentaries on the Transmission of Syphilis from Parent to Offspring, and its more remote Consequences. With Plates and Woodcuts, 8vo. cloth, 9s.

DR. INMAN, M.R.C.P.

I.  
ON MYALGIA: ITS NATURE, CAUSES, AND TREATMENT; being a Treatise on Painful and other Affections of the Muscular System. Second Edition. 8vo. cloth, 9s.

II.  
FOUNDATION FOR A NEW THEORY AND PRACTICE OF MEDICINE. Second Edition. Crown 8vo. cloth, 10s.

DR. JAGO, M.D. OXON., A.B. CANTAB.

ENTOPTICS, WITH ITS USES IN PHYSIOLOGY AND MEDICINE. With 54 Engravings. Crown 8vo. cloth, 5s.

MR. J. H. JAMES, F.R.C.S.

I.  
PRACTICAL OBSERVATIONS ON THE OPERATIONS FOR STRANGULATED HERNIA. 8vo. cloth, 5s.

II.  
ON THE DISTINCTIVE CHARACTERS OF EXTERNAL INFLAMMATIONS, AND ON INFLAMMATORY OR SYMPATHETIC FEVER. 8vo. cloth, 5s.

DR. PROSSER JAMES, M.D.

SORE-THROAT: ITS NATURE, VARIETIES, AND TREATMENT; including the Use of the LARYNGOSCOPE as an Aid to Diagnosis. Second Edition, with numerous Engravings. Post 8vo. cloth, 5s.

DR. JENCKEN, M.D., M.R.C.P.

THE CHOLERA: ITS ORIGIN, IDIOSYNCRACY, AND TREATMENT. Fcap. 8vo. cloth, 2s. 6d.

DR. HANDFIELD JONES, M.B., F.R.C.P.

CLINICAL OBSERVATIONS ON FUNCTIONAL NERVOUS DISORDERS. Post 8vo. cloth, 10s. 6d.

DR. H. BENGE JONES, M.D., F.R.S.

LECTURES ON SOME OF THE APPLICATIONS OF CHEMISTRY AND MECHANICS TO PATHOLOGY AND THERAPEUTICS. 8vo. cloth, 12s.

DR. HANDFIELD JONES, F.R.S., &amp; DR. EDWARD H. SIEVEKING.

A MANUAL OF PATHOLOGICAL ANATOMY. Illustrated with numerous Engravings on Wood. Foolscap 8vo. cloth, 12s. 6d.

DR. JAMES JONES, M.D., M.R.C.P.

ON THE USE OF PERCHLORIDE OF IRON AND OTHER CHALYBEATE SALTS IN THE TREATMENT OF CONSUMPTION. Crown 8vo. cloth, 3s. 6d.



MR. WHARTON JONES, F.R.S.

I.  
A MANUAL OF THE PRINCIPLES AND PRACTICE OF  
OPHTHALMIC MEDICINE AND SURGERY; with Nine Coloured Plates and  
173 Wood Engravings. Third Edition, thoroughly revised. Foolsap 8vo. cloth, 12s. 6d.

II.  
THE WISDOM AND BENEFICENCE OF THE ALMIGHTY,  
AS DISPLAYED IN THE SENSE OF VISION. Actonian Prize Essay. With  
Illustrations on Steel and Wood. Foolsap 8vo. cloth, 4s. 6d.

III.  
DEFECTS OF SIGHT AND HEARING: their Nature, Causes, Pre-  
vention, and General Management. Second Edition, with Engravings. Fcap. 8vo. 2s. 6d.

IV.  
A CATECHISM OF THE MEDICINE AND SURGERY OF  
THE EYE AND EAR. For the Clinical Use of Hospital Students. Fcap. 8vo. 2s. 6d.

V.  
A CATECHISM OF THE PHYSIOLOGY AND PHILOSOPHY  
OF BODY, SENSE, AND MIND. For Use in Schools and Colleges. Fcap. 8vo.,  
2s. 6d.

MR. FURNEAUX JORDAN, M.R.C.S.

AN INTRODUCTION TO CLINICAL SURGERY; WITH A  
Method of Investigating and Reporting Surgical Cases. Fcap. 8vo. cloth, 5s.

MR. JUDD.

A PRACTICAL TREATISE ON URETHRITIS AND SYPHI-  
LIS: including Observations on the Power of the Menstruous Fluid, and of the Dis-  
charge from Leucorrhœa and Sores to produce Urethritis: with a variety of Examples,  
Experiments, Remedies, and Cures. 8vo. cloth, £1. 5s.

DR. LAENNEC.

A MANUAL OF AUSCULTATION AND PERCUSSION. Trans-  
lated and Edited by J. B. SHARPE, M.R.C.S. 3s.

DR. LANE, M.A.

HYDROPATHY; OR, HYGIENIC MEDICINE. An Explanatory  
Essay. Second Edition. Post 8vo. cloth, 5s.

SIR WM. LAWRENCE, BART., F.R.S.

I.  
LECTURES ON SURGERY. 8vo. cloth, 16s.

II.  
A TREATISE ON RUPTURES. The Fifth Edition, considerably  
enlarged. 8vo. cloth, 16s.

DR. LEARED, M.R.C.P.

IMPERFECT DIGESTION: ITS CAUSES AND TREATMENT.  
Fourth Edition. Foolsap 8vo. cloth, 4s.



DR. EDWIN LEE.

I.  
THE EFFECT OF CLIMATE ON TUBERCULOUS DISEASE,  
with Notices of the chief Foreign Places of Winter Resort. Small 8vo. cloth, 4s. 6d.

II.  
THE WATERING PLACES OF ENGLAND, CONSIDERED  
with Reference to their Medical Topography. Fourth Edition. Fcap. 8vo. cloth, 7s. 6d.

III.  
THE PRINCIPAL BATHS OF FRANCE. Fourth Edition.  
Fcap. 8vo. cloth, 3s. 6d.

IV.  
THE BATHS OF GERMANY. Fourth Edition. Post 8vo. cloth, 7s.

V.  
THE BATHS OF SWITZERLAND. 12mo. cloth, 3s. 6d.

VI.  
HOMŒOPATHY AND HYDROPATHY IMPARTIALLY AP-  
PRECIATED. Fourth Edition. Post 8vo. cloth, 3s.

MR. HENRY LEE, F.R.C.S.

I.  
ON SYPHILIS. Second Edition. With Coloured Plates. 8vo. cloth, 10s.

II.  
ON DISEASES OF THE VEINS, HÆMORRHOIDAL TUMOURS,  
AND OTHER AFFECTIONS OF THE RECTUM. Second Edition. 8vo. cloth, 8s.

DR. ROBERT LEE, F.R.S.

I.  
CONSULTATIONS IN MIDWIFERY. Foolsap 8vo. cloth, 4s. 6d.

II.  
A TREATISE ON THE SPECULUM; with Three Hundred Cases.  
8vo. cloth, 4s. 6d.

III.  
CLINICAL REPORTS OF OVARIAN AND UTERINE DIS-  
EASES, with Commentaries. Foolsap 8vo. cloth, 6s. 6d.

IV.  
CLINICAL MIDWIFERY: comprising the Histories of 545 Cases of  
Difficult, Preternatural, and Complicated Labour, with Commentaries. Second Edition.  
Foolsap 8vo. cloth, 5s.

DR. LEISHMAN, M.D., F.F.P.S.

THE MECHANISM OF PARTURITION: An Essay, Historical and  
Critical. With Engravings. 8vo. cloth, 5s.

MR. LISTON, F.R.S.

PRACTICAL SURGERY. Fourth Edition. 8vo. cloth, 22s.

MR. H. W. LOBB, L.S.A., M.R.C.S.E.

ON SOME OF THE MORE OBSCURE FORMS OF NERVOUS  
AFFECTIONS, THEIR PATHOLOGY AND TREATMENT. Re-issue,  
with the Chapter on Galvanism entirely Re-written. With Engravings. 8vo. cloth, 8s.

DR. LOGAN, M.D., M.R.C.P. LOND.

ON OBSTINATE DISEASES OF THE SKIN. Fcap. 8vo. cloth, 2s. 6d.



LONDON HOSPITAL.

CLINICAL LECTURES AND REPORTS BY THE MEDICAL  
AND SURGICAL STAFF. With Illustrations. Vols. I. to IV. 8vo. cloth, 7s. 6d.

LONDON MEDICAL SOCIETY OF OBSERVATION.

WHAT TO OBSERVE AT THE BED-SIDE, AND AFTER  
DEATH. Published by Authority. Second Edition. Foolscap 8vo. cloth, 4s. 6d.

MR. HENRY LOWNDES, M.R.C.S.

AN ESSAY ON THE MAINTENANCE OF HEALTH. Fcap.  
8vo. cloth, 2s. 6d.

MR. M'CLELLAND, F.L.S., F.G.S.

THE MEDICAL TOPOGRAPHY, OR CLIMATE AND SOILS,  
OF BENGAL AND THE N. W. PROVINCES. Post 8vo. cloth, 4s. 6d.

DR. MACLACHLAN, M.D., F.R.C.P.L.

THE DISEASES AND INFIRMITIES OF ADVANCED LIFE.  
8vo. cloth, 16s.

DR. A. C. MACLEOD, M.R.C.P. LOND.

ACHOLIC DISEASES; comprising Jaundice, Diarrhœa, Dysentery,  
and Cholera. Post 8vo. cloth, 5s. 6d.

DR. GEORGE H. B. MACLEOD, F.R.C.S.E.

I.  
OUTLINES OF SURGICAL DIAGNOSIS. 8vo. cloth, 12s. 6d.

II.  
NOTES ON THE SURGERY OF THE CRIMEAN WAR; with  
REMARKS on GUN-SHOT WOUNDS. 8vo. cloth, 10s. 6d.

DR. WM. MACLEOD, F.R.C.P. EDIN.

THE THEORY OF THE TREATMENT OF DISEASE ADOPTED  
AT BEN RHYDDING. Fcap. 8vo. cloth, 2s. 6d.

MR. JOSEPH MACLISE, F.R.C.S.

I.  
SURGICAL ANATOMY. A Series of Dissections, illustrating the Prin-  
cipal Regions of the Human Body. Second Edition, folio, cloth, £3. 12s.; half-morocco,  
£4. 4s.

II.  
ON DISLOCATIONS AND FRACTURES. This Work is Uniform  
with "Surgical Anatomy;" folio, cloth, £2. 10s.; half-morocco, £2. 17s.

MR. MACNAMARA.

ON DISEASES OF THE EYE; referring principally to those Affections  
requiring the aid of the Ophthalmoscope for their Diagnosis. With coloured plates.  
8vo. cloth, 10s. 6d.

DR. MONICOLL, M.R.C.P.

A HAND-BOOK FOR SOUTHPORT, MEDICAL & GENERAL;  
with Copious Notices of the Natural History of the District. Second Edition. Post 8vo.  
cloth, 3s. 6d.

DR. MARCET, F.R.S.

ON CHRONIC ALCOHOLIC INTOXICATION; with an INQUIRY  
INTO THE INFLUENCE OF THE ABUSE OF ALCOHOL AS A PRE-  
DISPOSING CAUSE OF DISEASE. Second Edition, much enlarged. Foolscap  
8vo. cloth, 4s. 6d.



DR. J. MACPHERSON, M.D.

**CHOLERA IN ITS HOME;** with a Sketch of the Pathology and Treatment of the Disease. Crown 8vo. cloth, 5s.

DR. MARKHAM.

**DISEASES OF THE HEART: THEIR PATHOLOGY, DIAGNOSIS, AND TREATMENT.** Second Edition. Post 8vo. cloth, 6s.

**SKODA ON AUSCULTATION AND PERCUSSION.** Post 8vo. cloth, 6s.

**BLEEDING AND CHANGE IN TYPE OF DISEASES.** Gulstonian Lectures for 1864. Crown 8vo. 2s. 6d.

SIR RANALD MARTIN, K.C.B., F.R.S.

**INFLUENCE OF TROPICAL CLIMATES IN PRODUCING THE ACUTE ENDEMIC DISEASES OF EUROPEANS;** including Practical Observations on their Chronic Sequelæ under the Influences of the Climate of Europe. Second Edition, much enlarged. 8vo. cloth, 20s.

MR. C. F. MAUNDER, F.R.C.S.

**OPERATIVE SURGERY.** With 158 Engravings. Post 8vo. 6s.

DR. MAYNE, M.D., LL.D.

**AN EXPOSITORY LEXICON OF THE TERMS, ANCIENT AND MODERN, IN MEDICAL AND GENERAL SCIENCE.** 8vo. cloth, £2. 10s.

**A MEDICAL VOCABULARY;** or, an Explanation of all Names, Synonymes, Terms, and Phrases used in Medicine and the relative branches of Medical Science. Second Edition. Fcap. 8vo. cloth, 8s. 6d.

DR. MERYON, M.D., F.R.C.P.

**PATHOLOGICAL AND PRACTICAL RESEARCHES ON THE VARIOUS FORMS OF PARALYSIS.** 8vo. cloth, 6s.

DR. MILLINGEN.

**ON THE TREATMENT AND MANAGEMENT OF THE INSANE;** with Considerations on Public and Private Lunatic Asylums. 18mo. cloth, 4s. 6d.

DR. W. J. MOORE, M.D.

**HEALTH IN THE TROPICS;** or, Sanitary Art applied to Europeans in India. 8vo. cloth, 9s.

**A MANUAL OF THE DISEASES OF INDIA.** Fcap. 8vo. cloth, 5s.

DR. JAMES MORRIS, M.D. LOND.

**GERMINAL MATTER AND THE CONTACT THEORY:** An Essay on the Morbid Poisons. Second Edition. Crown 8vo. cloth, 4s. 6d.

**IRRITABILITY:** Popular and Practical Sketches of Common Morbid States and Conditions bordering on Disease; with Hints for Management, Alleviation, and Cure. Crown 8vo. cloth, 4s. 6d.



PROFESSOR MULDER, UTRECHT.

THE CHEMISTRY OF WINE. Edited by H. BENCE JONES, M.D.,  
F.R.S. Fcap. 8vo. cloth, 6s.

DR. W. MURRAY, M.D., M.R.C.P.

EMOTIONAL DISORDERS OF THE SYMPATHETIC SYSTEM OF NERVES. Crown 8vo. cloth, 3s. 6d.

DR. MUSHET, M.B., M.R.C.P.

ON APOPLEXY, AND ALLIED AFFECTIONS OF THE BRAIN. 8vo. cloth, 7s.

MR. NAYLER, F.R.C.S.

ON THE DISEASES OF THE SKIN. With Plates. 8vo. cloth, 10s. 6d.

DR. BIRKBECK NEVINS.

THE PRESCRIBER'S ANALYSIS OF THE BRITISH PHARMACOPEIA of 1867. 32mo. cloth, 3s. 6d.

DR. THOS. NICHOLSON, M.D.

ON YELLOW FEVER; comprising the History of that Disease as it appeared in the Island of Antigua. Fcap. 8vo. cloth, 2s. 6d.

DR. NOAD, PH.D., F.R.S.

THE INDUCTION COIL, being a Popular Explanation of the Electrical Principles on which it is constructed. Third Edition. With Engravings. Fcap. 8vo. cloth, 3s.

DR. NOBLE.

THE HUMAN MIND IN ITS RELATIONS WITH THE BRAIN AND NERVOUS SYSTEM. Post 8vo. cloth, 4s. 6d.

MR. NUNNELEY, F.R.C.S.E.

I.  
ON THE ORGANS OF VISION: THEIR ANATOMY AND PHYSIOLOGY. With Plates, 8vo. cloth, 15s.

II.  
A TREATISE ON THE NATURE, CAUSES, AND TREATMENT OF ERYSIPELAS. 8vo. cloth, 10s. 6d.

DR. OPPERT, M.D.

I.  
HOSPITALS, INFIRMARIES, AND DISPENSARIES; their Construction, Interior Arrangement, and Management, with Descriptions of existing Institutions. With 58 Engravings. Royal 8vo. cloth, 10s. 6d.

II.  
VISCERAL AND HEREDITARY SYPHILIS. 8vo. cloth, 5s.

MR. LANGSTON PARKER.

THE MODERN TREATMENT OF SYPHILITIC DISEASES, both Primary and Secondary; comprising the Treatment of Constitutional and Confirmed Syphilis, by a safe and successful Method. Fourth Edition, 8vo. cloth, 10s.

DR. PARKES, F.R.S., F.R.C.P.

I.  
A MANUAL OF PRACTICAL HYGIENE; intended especially for the Medical Officers of the Army. With Plates and Woodcuts. 2nd Edition, 8vo. cloth, 16s.

II.  
THE URINE: ITS COMPOSITION IN HEALTH AND DISEASE, AND UNDER THE ACTION OF REMEDIES. 8vo. cloth, 12s.



DR. PARKIN, M.D., F.R.C.S.

I.  
THE ANTIDOTAL TREATMENT AND PREVENTION OF  
THE EPIDEMIC CHOLERA. Third Edition. 8vo. cloth, 7s. 6d.

II.  
THE CAUSATION AND PREVENTION OF DISEASE; with  
the Laws regulating the Extrication of Malaria from the Surface, and its Diffusion in the  
surrounding Air. 8vo. cloth, 5s.

MR. JAMES PART, F.R.C.S.

THE MEDICAL AND SURGICAL POCKET CASE BOOK,  
for the Registration of important Cases in Private Practice, and to assist the Student of  
Hospital Practice. Second Edition. 2s. 6d.

DR. PATTERSON, M.D.

EGYPT AND THE NILE AS A WINTER RESORT FOR  
PULMONARY AND OTHER INVALIDS. Fcap. 8vo. cloth, 3s.

DR. PAVY, M.D., F.R.S., F.R.C.P.

I.  
DIABETES: RESEARCHES ON ITS NATURE AND TREAT-  
MENT. 8vo. cloth, 8s. 6d.

II.  
DIGESTION: ITS DISORDERS AND THEIR TREATMENT.  
8vo. cloth, 8s. 6d.

DR. PEACOCK, M.D., F.R.C.P.

I.  
ON MALFORMATIONS OF THE HUMAN HEART. With  
Original Cases and Illustrations. Second Edition. With 8 Plates. 8vo. cloth, 10s.

II.  
ON SOME OF THE CAUSES AND EFFECTS OF VALVULAR  
DISEASE OF THE HEART. With Engravings. 8vo. cloth, 5s.

DR. W. H. PEARSE, M.D. EDIN.

NOTES ON HEALTH IN CALCUTTA AND BRITISH  
EMIGRANT SHIPS, including Ventilation, Diet, and Disease. Fcap. 8vo. 2s.

DR. PEET, M.D., F.R.C.P.

THE PRINCIPLES AND PRACTICE OF MEDICINE  
Designed chiefly for Students of Indian Medical Colleges. 8vo. cloth, 16s.

DR. PEREIRA, F.R.S.

SELECTA E PRÆSCRIPTIS. Fourteenth Edition. 24mo. cloth, 5s.

DR. PICKFORD.

HYGIENE; or, Health as Depending upon the Conditions of the Atmo-  
sphere, Food and Drinks, Motion and Rest, Sleep and Wakefulness, Secretions, Excre-  
tions, and Retentions, Mental Emotions, Clothing, Bathing, &c. Vol. I. 8vo. cloth, 9s.



PROFESSOR PIRRIE, F.R.S.E.

THE PRINCIPLES AND PRACTICE OF SURGERY. With numerous Engravings on Wood. Second Edition. 8vo. cloth, 24s.

PROFESSOR PIRRIE & DR. KEITH.

ACUPRESSURE: an excellent Method of arresting Surgical Hæmorrhage and of accelerating the healing of Wounds. With Engravings. 8vo. cloth, 5s.

DR. PIRRIE, M.D.

ON HAY ASTHMA, AND THE AFFECTION TERMED HAY FEVER. Fcap. 8vo. cloth, 2s. 6d.

PROFESSORS PLATTNER & MUSPRATT.

THE USE OF THE BLOWPIPE IN THE EXAMINATION OF MINERALS, ORES, AND OTHER METALLIC COMBINATIONS. Illustrated by numerous Engravings on Wood. Third Edition. 8vo. cloth, 10s. 6d.

MR. HENRY POWER, F.R.C.S., M.B.LOND.

ILLUSTRATIONS OF SOME OF THE PRINCIPAL DISEASES OF THE EYE: With an Account of their Symptoms, Pathology and Treatment. Twelve Coloured Plates. 8vo. cloth, 20s.

DR. HENRY F. A. PRATT, M.D., M.R.C.P.

I.  
THE GENEALOGY OF CREATION, newly Translated from the Unpointed Hebrew Text of the Book of Genesis, showing the General Scientific Accuracy of the Cosmogony of Moses and the Philosophy of Creation. 8vo. cloth, 14s.

II.  
ON ECCENTRIC AND CENTRIC FORCE: A New Theory of Projection. With Engravings. 8vo. cloth, 10s.

III.  
ON ORBITAL MOTION: The Outlines of a System of Physical Astronomy. With Diagrams. 8vo. cloth, 7s. 6d.

IV.  
ASTRONOMICAL INVESTIGATIONS. The Cosmical Relations of the Revolution of the Lunar Apsides. Oceanic Tides. With Engravings. 8vo. cloth, 5s.

V.  
THE ORACLES OF GOD: An Attempt at a Re-interpretation. Part I. The Revealed Cosmos. 8vo. cloth, 10s.

THE PRESCRIBER'S PHARMACOPŒIA; containing all the Medicines in the British Pharmacopœia, arranged in Classes according to their Action, with their Composition and Doses. By a Practising Physician. Fifth Edition. 32mo. cloth, 2s. 6d.; roan tuck (for the pocket), 3s. 6d.

DR. JOHN ROWLISON PRETTY.

AIDS DURING LABOUR, including the Administration of Chloroform, the Management of Placenta and Post-partum Hæmorrhage. Fcap. 8vo. cloth, 4s. 6d.

MR. P. C. PRICE, F.R.C.S.

AN ESSAY ON EXCISION OF THE KNEE-JOINT. With Coloured Plates. With Memoir of the Author and Notes by Henry Smith, F.R.C.S. Royal 8vo. cloth, 14s.



MR. LAKE PRICE.

**PHOTOGRAPHIC MANIPULATION:** A Manual treating of the Practice of the Art, and its various Applications to Nature. With numerous Engravings. Second Edition. Crown 8vo. cloth, 6s. 6d.

DR. PRIESTLEY.

**LECTURES ON THE DEVELOPMENT OF THE GRAVID UTERUS.** 8vo. cloth, 5s. 6d.

DR. RADCLIFFE, F.R.C.P.L.

**LECTURES ON EPILEPTIC, SPASMODIC, NEURALGIC, AND PARALYTIC DISORDERS OF THE NERVOUS SYSTEM,** delivered at the Royal College of Physicians in London. Post 8vo. cloth, 7s. 6d.

MR. RAINEY.

**ON THE MODE OF FORMATION OF SHELLS OF ANIMALS, OF BONE, AND OF SEVERAL OTHER STRUCTURES,** by a Process of Molecular Coalescence, Demonstrable in certain Artificially-formed Products. Fcap. 8vo. cloth, 4s. 6d.

DR. F. H. RAMSBOTHAM.

**THE PRINCIPLES AND PRACTICE OF OBSTETRIC MEDICINE AND SURGERY.** Illustrated with One Hundred and Twenty Plates on Steel and Wood; forming one thick handsome volume. Fifth Edition. 8vo. cloth, 22s.

DR. RAMSBOTHAM.

**PRACTICAL OBSERVATIONS ON MIDWIFERY,** with a Selection of Cases. Second Edition. 8vo. cloth, 12s.

DR. READE, M.B.T.C.D., L.R.C.S.I.

**SYPHILITIC AFFECTIONS OF THE NERVOUS SYSTEM, AND A CASE OF SYMMETRICAL MUSCULAR ATROPHY;** with other Contributions to the Pathology of the Spinal Marrow. Post 8vo. cloth, 5s.

PROFESSOR REDWOOD, PH.D.

**A SUPPLEMENT TO THE PHARMACOPŒIA:** A concise but comprehensive Dispensatory, and Manual of Facts and Formulæ, for the use of Practitioners in Medicine and Pharmacy. Third Edition. 8vo. cloth, 22s.

DR. DU BOIS REYMOND.

**ANIMAL ELECTRICITY;** Edited by H. BENICE JONES, M.D., F.R.S. With Fifty Engravings on Wood. Foolscap 8vo. cloth, 6s.

DR. REYNOLDS, M.D. LOND.

**EPILEPSY: ITS SYMPTOMS, TREATMENT, AND RELATION TO OTHER CHRONIC CONVULSIVE DISEASES.** 8vo. cloth, 10s.

II.

**THE DIAGNOSIS OF DISEASES OF THE BRAIN, SPINAL CORD, AND THEIR APPENDAGES.** 2vo. cloth, 8s.

DR. B. W. RICHARDSON.

**ON THE CAUSE OF THE COAGULATION OF THE BLOOD.** Being the ASTLEY COOPER PRIZE ESSAY for 1856. With a Practical Appendix. 8vo. cloth, 16s.



DR. RITCHIE, M.D.  
ON OVARIAN PHYSIOLOGY AND PATHOLOGY. With  
Engravings. 8vo. cloth, 6s.

DR. WILLIAM ROBERTS, M.D., F.R.C.P.  
AN ESSAY ON WASTING PALSY; being a Systematic Treatise on  
the Disease hitherto described as ATROPHIE MUSCULAIRE PROGRESSIVE.  
With Four Plates. 8vo. cloth, 5s.

DR. ROUTH.  
INFANT FEEDING, AND ITS INFLUENCE ON LIFE;  
Or, the Causes and Prevention of Infant Mortality. Second Edition. Fcap. 8vo. cloth, 6s.

DR. W. H. ROBERTSON.  
I.  
THE NATURE AND TREATMENT OF GOUT. 8vo. cloth, 10s. 6d.  
II.  
A TREATISE ON DIET AND REGIMEN. Fourth Edition. 2 vols.  
12s. post 8vo. cloth.

DR. ROWE.  
NERVOUS DISEASES, LIVER AND STOMACH COM-  
PLAINTS, LOW SPIRITS, INDIGESTION, GOUT, ASTHMA, AND DIS-  
ORDERS PRODUCED BY TROPICAL CLIMATES. With Cases. Sixteenth  
Edition. Fcap. 8vo. 2s. 6d.

DR. ROYLE, F.R.S., AND DR. HEADLAND, M.D.  
A MANUAL OF MATERIA MEDICA AND THERAPEUTICS.  
With numerous Engravings on Wood. Fifth Edition. Fcap. 8vo. cloth, 12s. 6d.

DR. RYAN, M.D.  
INFANTICIDE: ITS LAW, PREVALENCE, PREVENTION, AND  
HISTORY. 8vo. cloth, 5s.

ST. BARTHOLOMEW'S HOSPITAL.  
A DESCRIPTIVE CATALOGUE OF THE ANATOMICAL  
MUSEUM. Vol. I. (1846), Vol. II. (1851), Vol. III. (1862), 8vo. cloth, 5s. each.

ST. GEORGE'S HOSPITAL REPORTS. Vols. I. & II. 8vo. 7s. 6d.

MR. T. P. SALT, BIRMINGHAM.  
I.  
ON DEFORMITIES AND DEBILITIES OF THE LOWER  
EXTREMITIES, AND THE MECHANICAL TREATMENT EMPLOYED  
IN THE PROMOTION OF THEIR CURE. With Plates. 8vo. cloth, 15s.

II.  
ON RUPTURE: ITS CAUSES, MANAGEMENT, AND CURE,  
and the various Mechanical Contrivances employed for its Relief. With Engravings.  
Post 8vo. cloth, 3s.

DR. SALTER, F.R.S.  
ASTHMA. Second Edition. 8vo. cloth, 10s.

DR. SANKEY, M.D. LOND.  
LECTURES ON MENTAL DISEASES. 8vo. cloth, 8s.



DR. SANSOM, M.D.LOND.

I.  
**CHLOROFORM: ITS ACTION AND ADMINISTRATION.** A Hand-  
 book. With Engravings. Crown 8vo. cloth, 5s.

II.  
**THE ARREST AND PREVENTION OF CHOLERA;** being a  
 Guide to the Antiseptic Treatment. Fcap. 8vo. cloth, 2s. 6d.

MR. SAVORY.

**A COMPENDIUM OF DOMESTIC MEDICINE, AND COMPANION TO THE MEDICINE CHEST;** intended as a Source of Easy Reference for Clergymen, and for Families residing at a Distance from Professional Assistance. Seventh Edition. 12mo. cloth, 5s.

DR. SCHACHT.

**THE MICROSCOPE, AND ITS APPLICATION TO VEGETABLE ANATOMY AND PHYSIOLOGY.** Edited by FREDERICK CURREY, M.A. Fcap. 8vo. cloth, 6s.

DR. SCORESBY-JACKSON, M.D., F.R.S.E.

**MEDICAL CLIMATOLOGY;** or, a Topographical and Meteorological Description of the Localities resorted to in Winter and Summer by Invalids of various classes both at Home and Abroad. With an Isothermal Chart. Post 8vo. cloth, 12s.

DR. SEMPLE.

**ON COUGH:** its Causes, Varieties, and Treatment. With some practical Remarks on the Use of the Stethoscope as an aid to Diagnosis. Post 8vo. cloth, 4s. 6d.

DR. SEYMOUR.

I.  
**ILLUSTRATIONS OF SOME OF THE PRINCIPAL DISEASES OF THE OVARIA:** their Symptoms and Treatment; to which are prefixed Observations on the Structure and Functions of those parts in the Human Being and in Animals. On India paper. Folio, 16s.

II.  
**THE NATURE AND TREATMENT OF DROPSY;** considered especially in reference to the Diseases of the Internal Organs of the Body, which most commonly produce it. 8vo. 5s.

DR. SHAPTER, M.D., F.R.C.P.

**THE CLIMATE OF THE SOUTH OF DEVON, AND ITS INFLUENCE UPON HEALTH.** Second Edition, with Maps. 8vo. cloth, 10s. 6d.

MR. SHAW, M.R.C.S.

**THE MEDICAL REMEMBRANCER; OR, BOOK OF EMERGENCIES.** Fifth Edition. Edited, with Additions, by JONATHAN HUTCHINSON, F.R.C.S. 32mo. cloth, 2s. 6d.

DR. SHEA, M.D., B.A.

**A MANUAL OF ANIMAL PHYSIOLOGY.** With an Appendix of Questions for the B.A. London and other Examinations. With Engravings. Foolscap 8vo. cloth, 5s. 6d.

DR. SHRIMPTON.

**CHOLERA: ITS SEAT, NATURE, AND TREATMENT.** With Engravings. 8vo. cloth, 4s. 6d.

MR. U. J. KAY-SHUTTLEWORTH.

**FIRST PRINCIPLES OF MODERN CHEMISTRY:** a Manual of Inorganic Chemistry. Crown 8vo. cloth, 4s. 6d.



DR. SIBSON, F.R.S.  
**MEDICAL ANATOMY.** With coloured Plates. Imperial folio. Fasci-  
 culi I. to VI. 5s. each.

DR. E. H. SIEVEKING.  
**ON EPILEPSY AND EPILEPTIFORM SEIZURES:** their  
 Causes, Pathology, and Treatment. Second Edition. Post 8vo. cloth, 10s. 6d.

DR. SIMMS.  
**A WINTER IN PARIS:** being a few Experiences and Observations  
 of French Medical and Sanitary Matters. Fcap. 8vo. cloth, 4s.

MR. SINCLAIR AND DR JOHNSTON.  
**PRACTICAL MIDWIFERY:** Comprising an Account of 13,748 Deli-  
 veries, which occurred in the Dublin Lying-in Hospital, during a period of Seven Years.  
 8vo. cloth, 10s.

DR. SIORDET, M.B.LOND., M.R.C.P.  
**MENTONE IN ITS MEDICAL ASPECT.** Foolsap 8vo. cloth, 2s. 6d.

MR. ALFRED SMEE, F.R.S.  
**GENERAL DEBILITY AND DEFECTIVE NUTRITION;** their  
 Causes, Consequences, and Treatment. Second Edition. Fcap. 8vo. cloth, 3s. 6d.

DR. SMELLIE.  
**OBSTETRIC PLATES:** being a Selection from the more Important and  
 Practical Illustrations contained in the Original Work. With Anatomical and Practical  
 Directions. 8vo. cloth, 5s.

MR. HENRY SMITH, F.R.C.S.  
 I.  
**ON STRICTURE OF THE URETHRA.** 8vo. cloth, 7s. 6d.

II.  
**HÆMORRHOIDS AND PROLAPSUS OF THE RECTUM:**  
 Their Pathology and Treatment, with especial reference to the use of Nitric Acid. Third  
 Edition. Fcap. 8vo. cloth, 3s.

III.  
**THE SURGERY OF THE RECTUM.** Lettsomian Lectures. Second  
 Edition. Fcap. 8vo. 3s. 6d.

DR. J. SMITH, M.D., F.R.C.S. EDIN.  
**HANDBOOK OF DENTAL ANATOMY AND SURGERY, FOR**  
 THE USE OF STUDENTS AND PRACTITIONERS. Fcap. 3vo. cloth, 3s. 6d.

DR. W. TYLER SMITH.  
**A MANUAL OF OBSTETRICS, THEORETICAL AND PRAC-**  
 TICAL. Illustrated with 186 Engravings. Fcap. 8vo. cloth, 12s. 6d.

DR. SNOW.  
**ON CHLOROFORM AND OTHER ANÆSTHETICS: THEIR**  
 ACTION AND ADMINISTRATION. Edited, with a Memoir of the Author, by  
 Benjamin W. Richardson, M.D. 8vo. cloth, 10s. 6d.

MR. J. VOSE SOLOMON, F.R.C.S.  
**TENSION OF THE EYEBALL; GLAUCOMA:** some Account of  
 the Operations practised in the 19th Century. 8vo. cloth, 4s.



DR. STANHOPE TEMPLEMAN SPEER.

**PATHOLOGICAL CHEMISTRY, IN ITS APPLICATION TO THE PRACTICE OF MEDICINE.** Translated from the French of MM. BECQUEREL and RODIER. 8vo. cloth, reduced to 8s.

MR. J. K. SPENDER, M.B.LOND.

**A MANUAL OF THE PATHOLOGY AND TREATMENT OF ULCERS AND CUTANEOUS DISEASES OF THE LOWER LIMBS.** 8vo. cloth, 4s.

MR. BALMANNO SQUIRE, M.B.LOND.

**CLINICAL LECTURES ON SKIN DISEASES.** Illustrated by Coloured Photographs from Life. Complete in 36 Numbers, price 1s. 6d. each. Nos. I.—XXX. are now ready.

**A MANUAL OF THE DISEASES OF THE SKIN.** Illustrated by Coloured Plates of the Diseases, and by Woodcuts of the Parasites of the Skin. Post 8vo. cloth, 24s.

MR. PETER SQUIRE.

**A COMPANION TO THE BRITISH PHARMACOPŒIA.** Sixth Edition. 8vo. cloth, 8s. 6d.

**THE PHARMACOPŒIAS OF THIRTEEN OF THE LONDON HOSPITALS,** arranged in Groups for easy Reference and Comparison. 18mo. cloth, 3s. 6d.

DR. STEGGALL.

**A MEDICAL MANUAL FOR APOTHECARIES' HALL AND OTHER MEDICAL BOARDS.** Twelfth Edition. 12mo. cloth, 10s.

**A MANUAL FOR THE COLLEGE OF SURGEONS;** intended for the Use of Candidates for Examination and Practitioners. Second Edition. 12mo. cloth, 10s.

**FIRST LINES FOR CHEMISTS AND DRUGGISTS PREPARING FOR EXAMINATION AT THE PHARMACEUTICAL SOCIETY.** Second Edition. 18mo. cloth, 3s. 6d.

MR. STOWE, M.R.C.S.

**A TOXICOLOGICAL CHART,** exhibiting at one view the Symptoms, Treatment, and Mode of Detecting the various Poisons, Mineral, Vegetable, and Animal. To which are added, concise Directions for the Treatment of Suspended Animation. Twelfth Edition, revised. On Sheet, 2s.; mounted on Roller, 5s.

MR. FRANCIS SUTTON, F.C.S.

**A SYSTEMATIC HANDBOOK OF VOLUMETRIC ANALYSIS;** or, the Quantitative Estimation of Chemical Substances by Measure. With Engravings. Post 8vo. cloth, 7s. 6d.

DR. SWAYNE.

**OBSTETRIC APHORISMS FOR THE USE OF STUDENTS COMMENCING MIDWIFERY PRACTICE.** With Engravings on Wood. Fourth Edition. Fcap. 3vo. cloth, 3s. 6d.



MR. TAMPLIN, F.R.C.S.E.

**LATERAL CURVATURE OF THE SPINE:** its Causes, Nature, and Treatment. 8vo. cloth, 4s.

SIR ALEXANDER TAYLOR, M.D., F.R.S.E.

**THE CLIMATE OF PAU;** with a Description of the Watering Places of the Pyrenees, and of the Virtues of their respective Mineral Sources in Disease. Third Edition. Post 8vo. cloth, 7s.

DR. ALFRED S. TAYLOR, F.R.S.

I.

**THE PRINCIPLES AND PRACTICE OF MEDICAL JURISPRUDENCE.** With 176 Wood Engravings. 8vo. cloth, 28s.

II.

**A MANUAL OF MEDICAL JURISPRUDENCE.** Eighth Edition. With Engravings. Fcap. 8vo. cloth, 12s. 6d.

III.

**ON POISONS,** in relation to MEDICAL JURISPRUDENCE AND MEDICINE. Second Edition. Fcap. 8vo. cloth, 12s. 6d.

MR. TEALE.

**ON AMPUTATION BY A LONG AND A SHORT RECTANGULAR FLAP.** With Engravings on Wood. 8vo. cloth, 5s.

DR. THEOPHILUS THOMPSON, F.R.S.

**CLINICAL LECTURES ON PULMONARY CONSUMPTION;** with additional Chapters by E. SYMES THOMPSON, M.D. With Plates. 8vo. cloth, 7s. 6d.

DR. THOMAS.

**THE MODERN PRACTICE OF PHYSIC;** exhibiting the Symptoms, Causes, Morbid Appearances, and Treatment of the Diseases of all Climates. Eleventh Edition. Revised by ALGERNON FRAMPTON, M.D. 2 vols. 8vo. cloth, 28s.

SIR HENRY THOMPSON, F.R.C.S.

I.

**STRICTURE OF THE URETHRA;** its Pathology and Treatment. The Jacksonian Prize Essay for 1852. With Plates. Second Edition. 8vo. cloth, 10s.

II.

**THE DISEASES OF THE PROSTATE;** their Pathology and Treatment. With Plates. Third Edition. 8vo. cloth, 10s.

III.

**PRACTICAL LITHOTOMY AND LITHOTRITY;** or, An Inquiry into the best Modes of removing Stone from the Bladder. With numerous Engravings, 8vo. cloth, 9s.

DR. THUDICHUM.

I.

**A TREATISE ON THE PATHOLOGY OF THE URINE,** Including a complete Guide to its Analysis. With Plates, 8vo. cloth, 14s.

II.

**A TREATISE ON GALL STONES:** their Chemistry, Pathology, and Treatment. With Coloured Plates. 8vo. cloth, 10s.



DR. TILT.

I.  
ON UTERINE AND OVARIAN INFLAMMATION, AND ON  
THE PHYSIOLOGY AND DISEASES OF MENSTRUATION. Third Edition.  
8vo. cloth, 12s.

II.  
A HANDBOOK OF UTERINE THERAPEUTICS, AND OF  
MODERN PATHOLOGY OF DISEASES OF WOMEN. Second Edition.  
Post 8vo. cloth, 6s.

III.  
THE CHANGE OF LIFE IN HEALTH AND DISEASE: a  
Practical Treatise on the Nervous and other Affections incidental to Women at the Decline  
of Life. Second Edition. 8vo. cloth, 6s.

DR. GODWIN TIMMS.

CONSUMPTION: its True Nature and Successful Treatment. Re-issue,  
enlarged. Crown 8vo. cloth, 10s.

DR. ROBERT B. TODD, F.R.S.

I.  
CLINICAL LECTURES ON THE PRACTICE OF MEDICINE.  
*New Edition, in one Volume, Edited by DR. BEALE, 8vo. cloth, 18s.*

II.  
ON CERTAIN DISEASES OF THE URINARY ORGANS, AND  
ON DROPSIES. Fcap. 8vo. cloth, 6s.

MR. TOMES, F.R.S.

A MANUAL OF DENTAL SURGERY. With 208 Engravings on  
Wood. Fcap. 8vo. cloth, 12s. 6d.

DR. TUNSTALL, M.D., M.R.C.P.

THE BATH WATERS: their Uses and Effects in the Cure and  
Relief of various Chronic Diseases. Fourth Edition, revised. Crown 8vo. cloth, 2s.

DR. TURNBULL.

I.  
AN INQUIRY INTO THE CURABILITY OF CONSUMPTION,  
ITS PREVENTION, AND THE PROGRESS OF IMPROVEMENT IN THE  
TREATMENT. Third Edition. 8vo. cloth, 6s.

II.  
A PRACTICAL TREATISE ON DISORDERS OF THE STOMACH  
with FERMENTATION; and on the Causes and Treatment of Indigestion, &c. 8vo.  
cloth, 6s.

DR. TWEEDIE, F.R.S.

CONTINUED FEVERS: THEIR DISTINCTIVE CHARACTERS,  
PATHOLOGY, AND TREATMENT. With Coloured Plates. 8vo. cloth, 12s.

VESTIGES OF THE NATURAL HISTORY OF CREATION.  
Eleventh Edition. Illustrated with 106 Engravings on Wood. 8vo. cloth, 7s. 6d.



DR. UNDERWOOD

TREATISE ON THE DISEASES OF CHILDREN. Tenth Edition,  
with Additions and Corrections by HENRY DAVIES, M.D. 8vo. cloth, 15s.

DR. UNGER.

BOTANICAL LETTERS. Translated by Dr. B. PAUL. Numerous  
Woodcuts. Post 8vo., 2s. 6d.

MR. WADE, F.R.C.S.

STRICTURE OF THE URETHRA, ITS COMPLICATIONS  
AND EFFECTS; a Practical Treatise on the Nature and Treatment of those  
Affections. Fourth Edition. 8vo. cloth, 7s. 6d.

DR. WALKER, M.B.LOND.

ON DIPHTHERIA AND DIPHTHERITIC DISEASES. Fcap.  
8vo. cloth, 3s.

DR. WALLER.

ELEMENTS OF PRACTICAL MIDWIFERY; or, Companion to  
the Lying-in Room. Fourth Edition, with Plates. Fcap. cloth, 4s. 6d.

MR. HAYNES WALTON, F.R.C.S.

SURGICAL DISEASES OF THE EYE. With Engravings on  
Wood. Second Edition. 8vo. cloth, 14s.

DR. WARING, M.D., M.R.C.P.LOND.

A MANUAL OF PRACTICAL THERAPEUTICS. Second Edition,  
Revised and Enlarged. Fcap. 8vo. cloth, 12s. 6d.

II.

THE TROPICAL RESIDENT AT HOME. Letters addressed to  
Europeans returning from India and the Colonies on Subjects connected with their Health  
and General Welfare. Crown 8vo. cloth, 5s.

DR. WATERS, F.R.C.P.

I.

DISEASES OF THE CHEST. CONTRIBUTIONS TO THEIR  
CLINICAL HISTORY, PATHOLOGY, AND TREATMENT. With Plates.  
8vo. cloth, 12s. 6d.

II.

THE ANATOMY OF THE HUMAN LUNG. The Prize Essay  
to which the Fothergillian Gold Medal was awarded by the Medical Society of London.  
Post 8vo. cloth, 6s. 6d.

III.

RESEARCHES ON THE NATURE, PATHOLOGY, AND  
TREATMENT OF EMPHYSEMA OF THE LUNGS, AND ITS RELA-  
TIONS WITH OTHER DISEASES OF THE CHEST. With Engravings. 8vo.  
cloth, 5s.

DR. ALLAN WEBB, F.R.C.S.L.

THE SURGEON'S READY RULES FOR OPERATIONS IN  
SURGERY. Royal 8vo. cloth, 10s. 6d.



DR. WEBER.

A CLINICAL HAND-BOOK OF AUSCULTATION AND PERCUSSION. Translated by JOHN COCKLE, M.D. 5s.

MR. SOELBERG WELLS, M.D., M.R.C.S.

ON LONG, SHORT, AND WEAK SIGHT, and their Treatment by the Scientific Use of Spectacles. Second Edition. With Plates. 8vo. cloth, 6s.

MR. T. SPENCER WELLS, F.R.C.S.

I.  
DISEASES OF THE OVARIES: THEIR DIAGNOSIS AND TREATMENT. Vol. I. 8vo. cloth, 9s.

II.  
SCALE OF MEDICINES FOR MERCHANT VESSELS.

With Observations on the Means of Preserving the Health of Seamen, &c. &c. Seventh Thousand. Fcap. 8vo. cloth, 3s. 6d.

DR. WEST.

LECTURES ON THE DISEASES OF WOMEN. Third Edition. 8vo. cloth, 16s.

DR. UVEDALE WEST.

ILLUSTRATIONS OF PUERPERAL DISEASES. Second Edition, enlarged. Post 8vo. cloth, 5s.

MR. WHEELER.

HAND-BOOK OF ANATOMY FOR STUDENTS OF THE FINE ARTS. With Engravings on Wood. Fcap. 8vo., 2s. 6d.

DR. WHITEHEAD, F.R.C.S.

ON THE TRANSMISSION FROM PARENT TO OFFSPRING OF SOME FORMS OF DISEASE, AND OF MORBID TAINTS AND TENDENCIES. Second Edition. 8vo. cloth, 10s. 6d.

DR. WILLIAMS, F.R.S.

PRINCIPLES OF MEDICINE: An Elementary View of the Causes, Nature, Treatment, Diagnosis, and Prognosis, of Disease. With brief Remarks on Hygienics, or the Preservation of Health. The Third Edition. 8vo. cloth, 15s.

DR. CHARLES T. WILLIAMS, M.B. OXON.

THE CLIMATE OF THE SOUTH OF FRANCE, AND ITS VARIETIES, MOST SUITABLE FOR INVALIDS; with Remarks on Italian and other Winter Stations. Crown 8vo. cloth, 3s. 6d.

THE WIFE'S DOMAIN: the YOUNG COUPLE—the MOTHER—the NURSE—the NURSING. Post 8vo. cloth, 3s. 6d.

DR. WINSLOW, M.D., D.C. OXON.

OBSCURE DISEASES OF THE BRAIN AND MIND. Fourth Edition. Carefully Revised. Post 8vo. cloth, 10s. 6d.



MR. ERASMUS WILSON, F.R.S.

I.  
THE ANATOMIST'S VADE-MECUM: A SYSTEM OF HUMAN ANATOMY. With numerous Illustrations on Wood. Eighth Edition. Foolscap 8vo. cloth, 12s. 6d.

II.  
ON DISEASES OF THE SKIN: A SYSTEM OF CUTANEOUS MEDICINE. Sixth Edition. 8vo. cloth, 18s.  
THE SAME WORK; illustrated with finely executed Engravings on Steel, accurately coloured. 8vo. cloth, 36s.

III.  
HEALTHY SKIN: A Treatise on the Management of the Skin and Hair in relation to Health. Seventh Edition. Foolscap 8vo. 2s. 6d.

IV.  
PORTRAITS OF DISEASES OF THE SKIN. Folio. Fasciculi I. to XII., completing the Work. 20s. each. The Entire Work, half morocco, £13.

V.  
THE STUDENT'S BOOK OF CUTANEOUS MEDICINE AND DISEASES OF THE SKIN. Post 8vo. cloth, 8s. 6d.

VI.  
ON SYPHILIS, CONSTITUTIONAL AND HEREDITARY; AND ON SYPHILITIC ERUPTIONS. With Four Coloured Plates. 8vo. cloth, 16s.

VII.  
A THREE WEEKS' SCAMPER THROUGH THE SPAS OF GERMANY AND BELGIUM, with an Appendix on the Nature and Uses of Mineral Waters. Post 8vo. cloth, 6s. 6d.

VIII.  
THE EASTERN OR TURKISH BATH: its History, Revival in Britain, and Application to the Purposes of Health. Foolscap 8vo., 2s.

DR. WISE, M.D., F.R.C.P. EDIN.

REVIEW OF THE HISTORY OF MEDICINE AMONG ASIATIC NATIONS. Two Vols. 8vo. cloth, 16s.

DR. G. C. WITTSTEIN.

PRACTICAL PHARMACEUTICAL CHEMISTRY: An Explanation of Chemical and Pharmaceutical Processes, with the Methods of Testing the Purity of the Preparations, deduced from Original Experiments. Translated from the Second German Edition, by STEPHEN DARBY. 18mo. cloth, 6s.

DR. HENRY G. WRIGHT.

I.  
UTERINE DISORDERS: their Constitutional Influence and Treatment. 8vo. cloth, 7s. 6d.

II.  
HEADACHES; their Causes and their Cure. Fourth Edition. Fcap. 8vo. 2s. 6d.

DR. YEARSLEY, M.D., M.R.C.S.

I.  
DEAFNESS PRACTICALLY ILLUSTRATED; being an Exposition as to the Causes and Treatment of Diseases of the Ear. Sixth Edition. 8vo. cloth, 6s.

II.  
ON THROAT AILMENTS, MORE ESPECIALLY IN THE ENLARGED TONSIL AND ELONGATED UVULA. Eighth Edition. 8vo. cloth, 5s.



## CHURCHILL'S SERIES OF MANUALS.

Fcap. 8vo. cloth, 12s. 6d. each.

"We here give Mr. Churchill public thanks for the positive benefit conferred on the Medical Profession, by the series of beautiful and cheap Manuals which bear his imprint."—*British and Foreign Medical Review.*

**AGGREGATE SALE, 150,000 COPIES.**

**ANATOMY.** With numerous Engravings. Eighth Edition. By ERASMUS WILSON, F.R.C.S., F.R.S.

**BOTANY.** With numerous Engravings. By ROBERT BENTLEY, F.L.S., Professor of Botany, King's College, and to the Pharmaceutical Society.

**CHEMISTRY.** With numerous Engravings. Ninth Edition. By GEORGE FOWNES, F.R.S., H. BENICE JONES, M.D., F.R.S., and A. W. HOFMANN, F.R.S.

**DENTAL SURGERY.** With numerous Engravings. By JOHN TOMES, F.R.S.

**MATERIA MEDICA.** With numerous Engravings. Fifth Edition. By J. FORBES ROYLE, M.D., F.R.S., and F. W. HEADLAND, M.D., F.L.S.

**MEDICAL JURISPRUDENCE.** With numerous Engravings. Eighth Edition. By ALFRED SWAINE TAYLOR, M.D., F.R.S.

**PRACTICE OF MEDICINE.** Second Edition. By G. HILARO BARLOW, M.D., M.A.

**The MICROSCOPE and its REVELATIONS.** With numerous Plates and Engravings. Fourth Edition. By W. B. CARPENTER, M.D., F.R.S.

**NATURAL PHILOSOPHY.** With numerous Engravings. Sixth Edition. By CHARLES BROOKE, M.B., M.A., F.R.S. *Based on the Work of the late Dr. Golding Bird.*

**OBSTETRICS.** With numerous Engravings. By W. TYLER SMITH, M.D., F.R.C.P.

**OPHTHALMIC MEDICINE and SURGERY.** With coloured Plates and Engravings on Wood. Third Edition. By T. WHARTON JONES, F.R.C.S., F.R.S.

**PATHOLOGICAL ANATOMY.** With numerous Engravings. By C. HANDFIELD JONES, M.B., F.R.S., and E. H. SIEVEKING, M.D., F.R.C.P.

**PHYSIOLOGY.** With numerous Engravings. Fourth Edition. By WILLIAM B. CARPENTER, M.D., F.R.S.

**POISONS.** Second Edition. By ALFRED SWAINE TAYLOR, M.D., F.R.S.

**PRACTICAL ANATOMY.** With numerous Engravings. (10s. 6d.) By CHRISTOPHER HEATH, F.R.C.S.

**PRACTICAL SURGERY.** With numerous Engravings. Fourth Edition. By Sir WILLIAM FERGUSSON, Bart., F.R.C.S., F.R.S.

**THERAPEUTICS.** Second Edition. By E. J. Waring, M.D., M.R.C.P.











R/t



