

Human embryology and morphology / by Arthur Keith.

Contributors

Keith, Arthur, Sir, 1866-1955.
Royal College of Physicians of Edinburgh

Publication/Creation

London : Arnold, 1902.

Persistent URL

<https://wellcomecollection.org/works/yww7sdgp>

Provider

Royal College of Physicians Edinburgh

License and attribution

This material has been provided by This material has been provided by the Royal College of Physicians of Edinburgh. The original may be consulted at the Royal College of Physicians of Edinburgh. where the originals may be consulted.

Conditions of use: it is possible this item is protected by copyright and/or related rights. You are free to use this item in any way that is permitted by the copyright and related rights legislation that applies to your use. For other uses you need to obtain permission from the rights-holder(s).



Wellcome Collection
183 Euston Road
London NW1 2BE UK
T +44 (0)20 7611 8722
E library@wellcomecollection.org
<https://wellcomecollection.org>



R.C.P. EDINBURGH LIBRARY



R28475N0236



W. 30

HUMAN EMBRYOLOGY AND MORPHOLOGY.



Digitized by the Internet Archive
in 2016

HUMAN EMBRYOLOGY AND MORPHOLOGY

BY

ARTHUR KEITH, M.D.(ABERDN.), F.R.C.S.(ENG.)

LECTURER ON ANATOMY, LONDON HOSPITAL MEDICAL COLLEGE
FORMERLY HUNTERIAN PROFESSOR, ROYAL COLLEGE OF SURGEONS, ENGLAND
EXAMINER IN ANATOMY, UNIVERSITY OF ABERDEEN



ILLUSTRATED

LONDON
EDWARD ARNOLD

1902

GLASGOW : PRINTED AT THE UNIVERSITY PRESS
BY ROBERT MACLEHOSE AND CO.

To
THE STUDENTS OF THE LONDON HOSPITAL.



PREFACE.

FIFTY years ago it was possible for a teacher in a Winter course of Lectures to lay all the essential facts of Embryology and Comparative Anatomy before his pupils; to-day fifty courses were not sufficient, so boundless have these subjects grown. Yet, in spite of their rapid growth, they have been retained in Higher Examinations in Human Anatomy by our Universities and Colleges without any principle being laid down to guide teachers and taught as to the scope required. No book dealing with these subjects exists to afford a precedent. The criterion which the Author applied in determining the scope of this work he believes will be accepted by pupils, teachers, and examiners. The course of Demonstrations, of which this book is the substance, was given under the walls of a great hospital to students preparing to work within its wards. Hence, each fact taught the student was necessarily one which was capable of application in his life's work or by the possession of which he became a better workman. The extent to which each subject was dealt with was determined by its practical importance. In brief, clinical utility was the criterion employed. The way to the wards is the road to the examination room,

and the right preparation for the one is the best qualification the student can take with him for the other.

The Author hopes he has prepared a work which will prove useful not only to students proceeding for Higher Examinations in Anatomy and Surgery but also to men actively engaged in practice. Every day conditions come under their notice which can be explained only by a reference to Embryology. He has sought to sketch as briefly and clearly as possible the history of the developing human body. History is the best key to an understanding of the present conditions of a country; the Embryologist and Comparative Anatomist are the dual historians of the human body.

The Author is deeply indebted to Mr. F. G. Parsons for revision of his proofs and numerous suggestions and corrections.


December, 1901.

CONTENTS.

	PAGE
CHAPTER I.	
DEVELOPMENT OF THE FACE, - - - - -	1
CHAPTER II.	
THE NASAL CAVITIES AND OLFACATORY STRUCTURES, - - - -	20
CHAPTER III.	
DEVELOPMENT OF THE PHARYNX AND NECK, - - - - -	28
CHAPTER IV.	
DEVELOPMENT OF THE ORGAN OF HEARING, - - - - -	49
CHAPTER V.	
DEVELOPMENT AND MORPHOLOGY OF THE TEETH, - - - - -	63
CHAPTER VI.	
THE SKIN AND ITS APPENDAGES, - - - - -	70
CHAPTER VII.	
THE DEVELOPMENT OF THE OVUM OF THE FOETUS FROM THE OVUM OF THE MOTHER, - - - - -	80
CHAPTER VIII.	
THE MANNER IN WHICH A CONNECTION IS ESTABLISHED BETWEEN THE FOETUS AND UTERUS, - - - - -	95
CHAPTER IX.	
THE URO-GENITAL SYSTEM, - - - - -	102

	PAGE
CHAPTER X.	
FORMATION OF THE PUBO-FEMORAL REGION, PELVIC FLOOR AND FASCIA, - - - - -	133
CHAPTER XI.	
THE SPINAL COLUMN AND BACK, - - - - -	142
CHAPTER XII.	
THE SEGMENTATION OF THE BODY, - - - - -	155
CHAPTER XIII.	
THE CRANIUM, - - - - -	161
CHAPTER XIV.	
DEVELOPMENT OF THE STRUCTURES CONCERNED IN THE SENSE OF SIGHT, - - - - -	175
CHAPTER XV.	
THE BRAIN AND SPINAL CORD, - - - - -	192
CHAPTER XVI.	
DEVELOPMENT OF THE CIRCULATORY SYSTEM, - - - - -	223
CHAPTER XVII.	
THE RESPIRATORY SYSTEM, - - - - -	249
CHAPTER XVIII.	
THE ORGANS OF DIGESTION, - - - - -	261
CHAPTER XIX.	
THE BODY WALL, RIBS, AND STERNUM, - - - - -	282
CHAPTER XX.	
THE LIMBS, - - - - -	289

HUMAN EMBRYOLOGY AND MORPHOLOGY.



HUMAN EMBRYOLOGY AND MORPHOLOGY.

CHAPTER I.

DEVELOPMENT OF THE FACE.

Processes which form the Face.—About the middle of the first month of foetal life, five processes begin to spring from the base of the primitive cerebral capsule, which, by the end of the second month, have completely united together to form the facial part of the head. In figure 1, a diagrammatic representation is given of the condition of these five processes about the end of the first month. Of the five, one, the **nasal** or **fronto-nasal**, composed of symmetrical right and left halves, is median, and projects beneath the fore-brain; the others are lateral, two on each side, the **mandibular** and **maxillary**. The cavity which these five processes surround is the **stomodaeum** (Fig. 1). It ultimately forms the nasal and part of the buccal cavities. The part of the adult face formed by each process is shown in figure 2.

Malformations of the Face.—These processes may fail to unite in the second month and in this manner malformations of the face are produced. The most common anomaly is a partial failure of the nasal and maxillary processes to fuse, various degrees of **hare lip** and **cleft palate** being thus caused. In **hare lip**, the cleft appears in the upper lip between the middle part formed by the middle nasal processes and the lateral parts formed by the maxillary processes (Fig. 2). In **cleft palate**, the failure of union occurs between the deep parts of the nasal and maxillary

processes (Fig. 8). There is a mesial cleft in the upper lip of hares and rabbits, but it occurs between the two maxillary

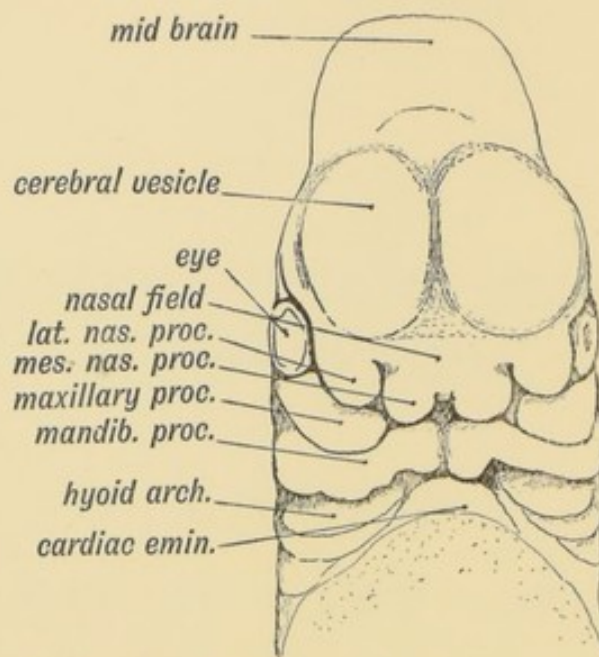


FIG. 1.--Showing the formation of the face by the Nasal, Maxillary, and Mandibular processes in an embryo of the 4th week. (After His.)

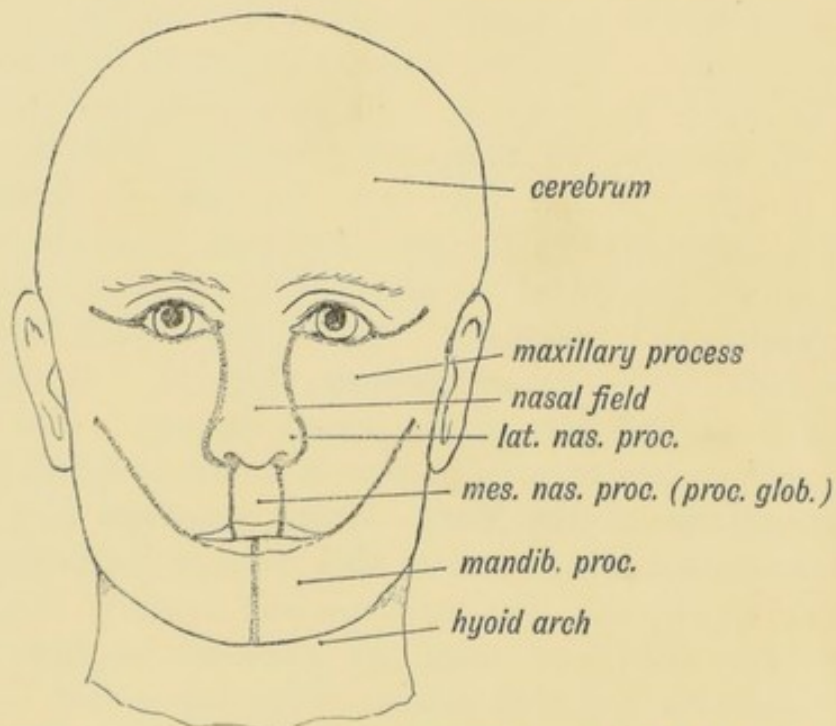


FIG. 2.--Showing the parts of the face formed from the Nasal, Maxillary, and Mandibular processes.

processes, the labial part of the middle nasal process being undeveloped. **Macrostoma** is due to a partial failure of the

mandibular to unite with the maxillary element. Any of these processes may be under or over developed; over-development of the nasal and under-development of the mandibular (micrognathia) are of common occurrence.

THE NASAL PROCESSES.

The nasal process at a very early stage is seen to be divided into **two lateral** processes and **two mesial**, the latter having globular enlargements as tips (Fig. 1). It must be remembered that the lateral and mesial nasal processes are really

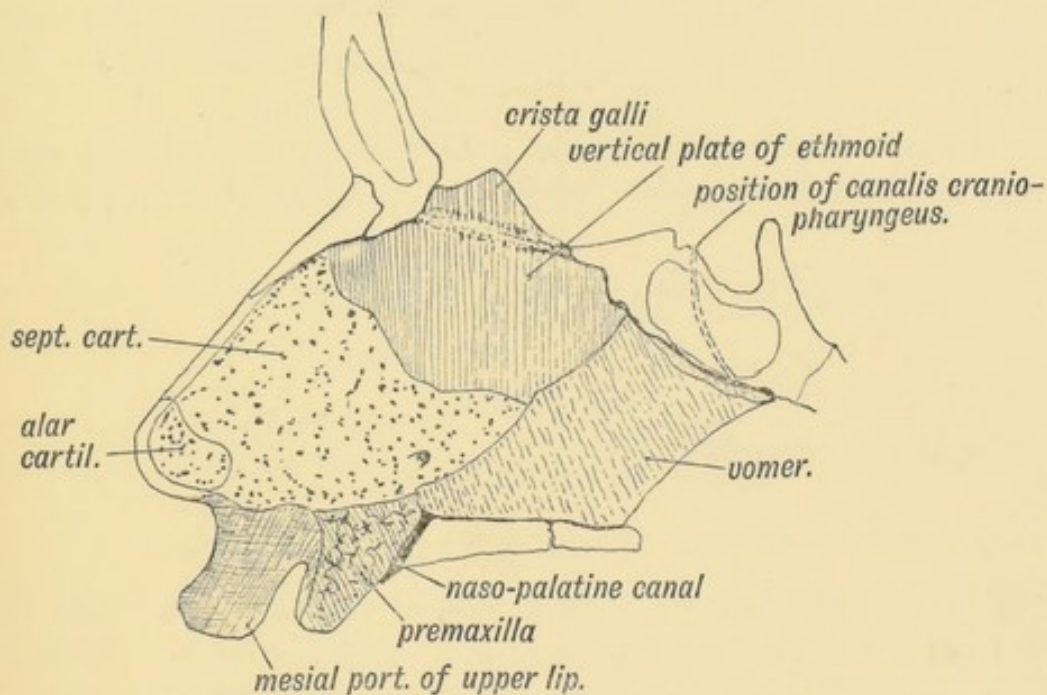


FIG. 3.—Showing the structures formed in the Mesial Nasal Processes.

vertical septa springing from the basis of the primitive capsule of the fore-brain, and the parts seen on the face are the anterior extremities of these septa (see Fig. 8).

What become of the Mesial Nasal Processes.—From the mesial nasal processes, which fuse together, and may enclose epithelial remnants between them, are formed the whole septum of the nose (Fig. 3), the premaxillary part of the upper jaw and the middle third of the upper lip (Fig. 2). It contains a skeletal basis of cartilage, formed by the trabeculae cranii (Figs. 135, 136, p. 168).

Structures formed in the Mesial Nasal Processes.—The

mesial nasal processes fuse together; in their anterior inferior angles are formed the premaxillae. The remainder forms the septum of the nose.

In the mesial nasal processes a laminar plate of cartilage is developed, which is continuous with, and forms part of, the trabeculae cranii (Fig. 136). Part of this cartilage remains as the **septal cartilage** of the nose (Fig. 3). From the septal cartilage, just over the naso-palatine foramina, a small scroll-like or turbinate process is thrown out on each side to form a hood for an isolated piece of olfactory epithelium—the organ of Jacobson. They form the **cartilages of Jacobson**. The cartilages and organ are vestigial in man. In the mesial nasal processes are developed, also, the mesial or septal limbs of the **alar cartilages** of the nose (Fig. 3).

The **Vomer** is developed in the membrane (perichondrium) which covers the primitive septal cartilage. A centre of ossification ap-

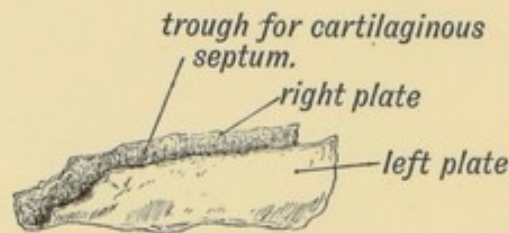


FIG. 4.—Showing the trough-shaped Vomer of the newly born.

pears in the 3rd month at each side of the cartilage; they fuse together under the palatal margin of the cartilage. Thus the vomer forms at first a shallow trough in which the cartilage of the septum appears to be implanted (Fig. 4).

The **Vertical Plate of the Ethmoid** is formed by a direct ossification of the primitive cartilage of the septum. Ossification begins in the 4th month. The crista galli, the intra-cranial part of the septum, is formed in part by the ossification proceeding into the attachment of the falx cerebri.

Premaxillary Bones.—The two premaxillary bones form the sockets of the upper incisor teeth. In the human foetus at birth the suture between the pre-maxilla and maxilla can be seen on the hard palate; it runs on each side from the naso-palatine foramen to the alveolus between the lateral incisor and canine (Fig. 9). On the facial aspect, the premaxilla fuses with the

superior maxilla in the 3rd month of foetal life, the maxillae overlapping and almost completely excluding them from the face. The nasal spine is formed by the premaxillae.

In mammals generally the premaxillae are highly developed and form the snout part of the face. In the higher Primates the face becomes less elongated, less **prognathous** and the premaxillae less developed. In the orang, for instance, the premaxillae are distinctly seen on the face at birth (Fig. 5), but as the permanent canines begin to develop they fuse with the maxillae.

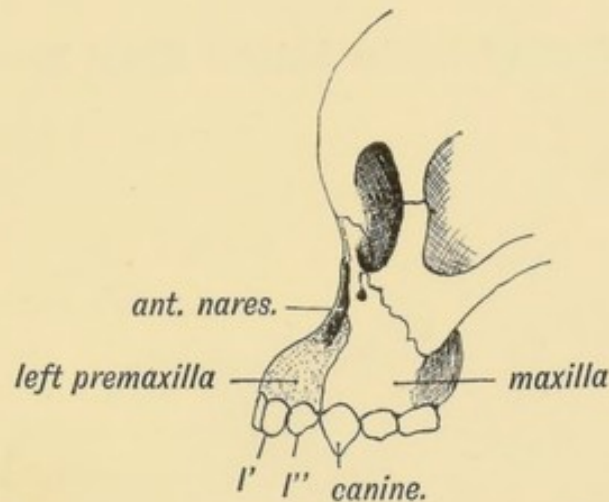


FIG. 5.—Showing the suture on the face between the premaxilla and maxilla in the skull of a young orang.

In man each premaxilla is usually ossified by two centres, placed side by side. Hence it sometimes happens in cleft palate that the fissure appears, not between the canine and lateral incisor, but between the lateral and middle incisor. In such cases the two centres of the premaxilla have failed to unite and the cleft occurs between them. The two premaxillae unite together in the first year after birth. Their vestigial character in man is due to the small size of his masticatory apparatus and consequent retrogression in the development of the facial part of his skull.

Naso-palatine Foramen.—The naso-palatine foramina are formed where the mesial nasal and two maxillary processes unite to form the palate (Fig. 9). In animals with well-developed premaxillae the two naso-palatine (anterior palatine) foramina are large, and through each passes the naso-palatine duct, which allows a communication between the buccal and nasal cavities. The odour of the food within the mouth thus reaches the organ

of Jacobson. In man the upper ends of the ducts remain open; they terminate blindly below, behind the mesial incisor teeth, in the naso-palatine or incisive papilla (see Figs. 9 and 19).

Nasal Duct.—The lachrymal sac and nasal duct, through which tears pass from the eye to the inferior meatus of the nasal cavity, are formed between the lateral nasal and maxillary processes (Figs. 2 and 7). The epithelium of the skin (epiblast) enclosed between the processes, forms at first a solid cord; it afterwards becomes caniculated to form the duct.

Structures Formed in the Lateral Nasal Process.—In each

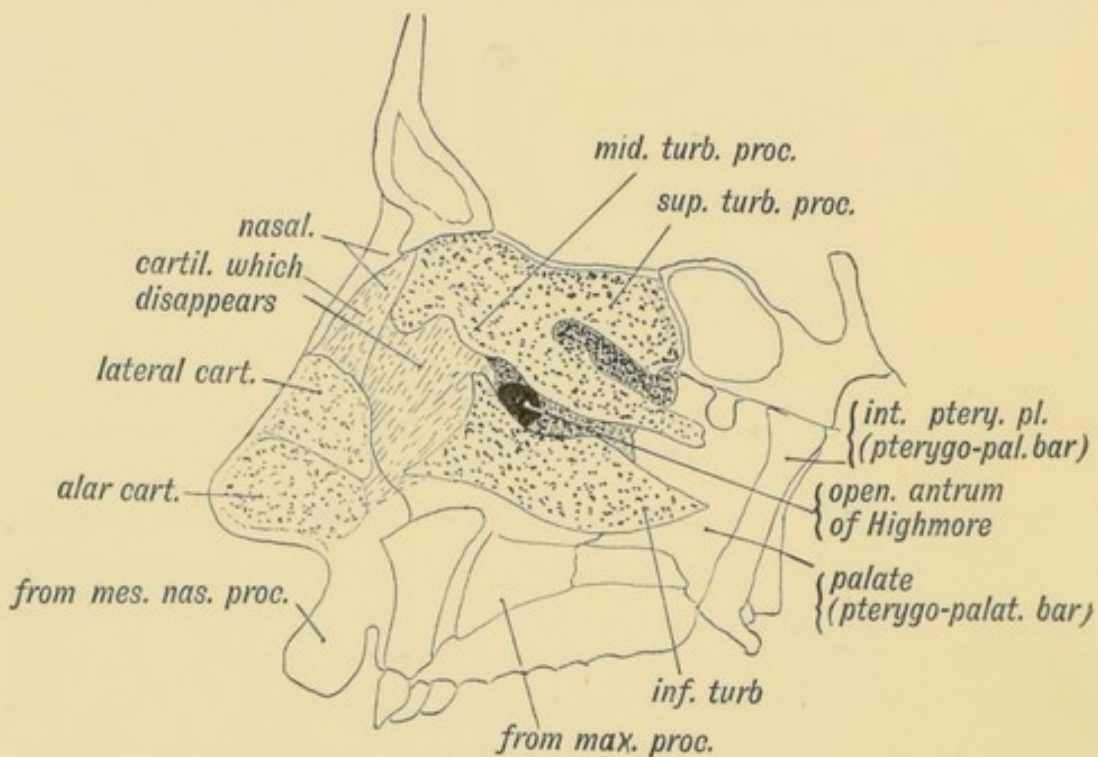


FIG. 6.—Showing the structures formed in the Lateral Nasal Processes.

lateral nasal process a laminar plate of cartilage is developed; it is continuous with, and forms part of, the trabeculae cranii (Fig. 136, p. 168). Its inner or attached margin is continuous with the septal cartilage of the mesial nasal process; it forms on each side the roof and lateral wall of the nasal cavities (Fig. 7).

What becomes of the Cartilage of the Lateral Nasal Process (Fig. 6).—It forms on each side:

(1) The cribriform plate, around the olfactory nerves as they issue from the olfactory bulb;

(2) The lateral mass of the ethmoid, at first merely a plate of cartilage; the superior and middle turbinate processes are developed from the plate (Fig. 7); ossific centres appear in the cartilage of the lateral mass and turbinate processes during the fourth month of foetal life;

(3) The inferior turbinate bone (Fig. 7) (maxillo-turbinal). The body of the superior maxilla is developed on its outer side in the maxillary process (Fig. 7);

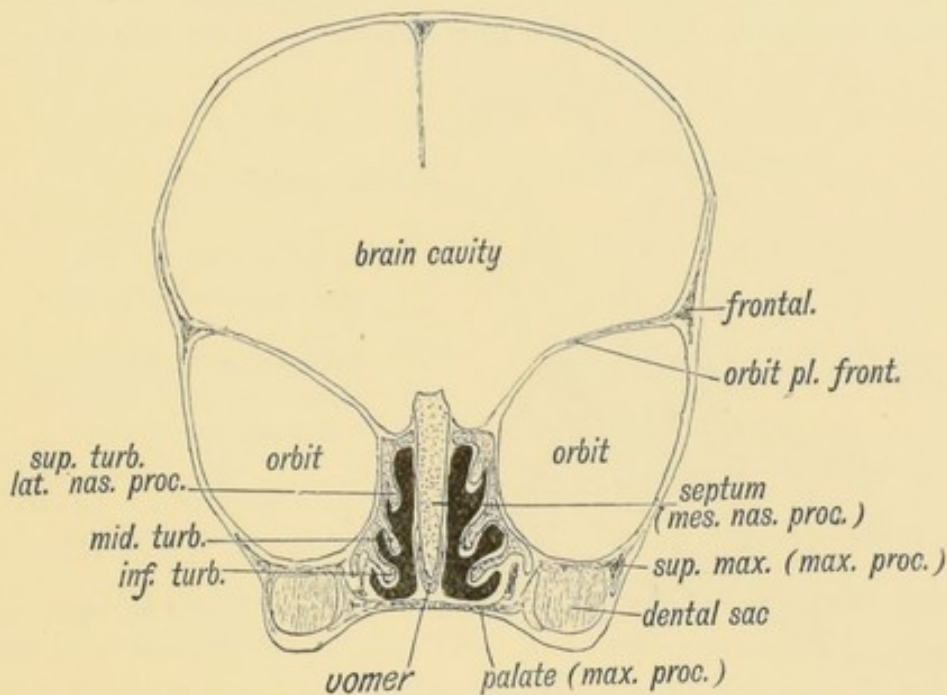


FIG. 7.—Coronal section of the skull of a 7th month human foetus to show the cartilages of the Lateral and Mesial Nasal Processes and the bones formed round them.

(4) The lateral and part of the alar cartilages of the nose;

(5) In the membrane over the cartilage, between the ethmoid behind and the cartilages of the nares in front, are developed the lachrymal and nasal bones, and the ascending process of the superior maxilla. The cartilage beneath these bones disappears after birth (Fig. 6).

Arteries and Nerves of the Nasal Processes.—1. Mesial Nasal Process. The chief artery and nerve of this process are the naso-palatine, but branches also come from the nasal nerve and its accompanying artery, the anterior ethmoidal.

2. Lateral Nasal Process. The lateral nasal nerves are derived from Meckel's ganglion and the descending palatine nerve. Vessels

accompany the nerves from the descending palatine. The nasal nerve and anterior ethmoidal artery supply the process in front.

It will thus be seen that the chief nerves and arteries of both processes are derived from structures in the spheno-maxillary fossa.

MAXILLARY PROCESSES.

The Parts formed from each Maxillary Process.—The maxillary process springs from the base of the mandibular arch and sweeping forwards below the eye separates that structure from

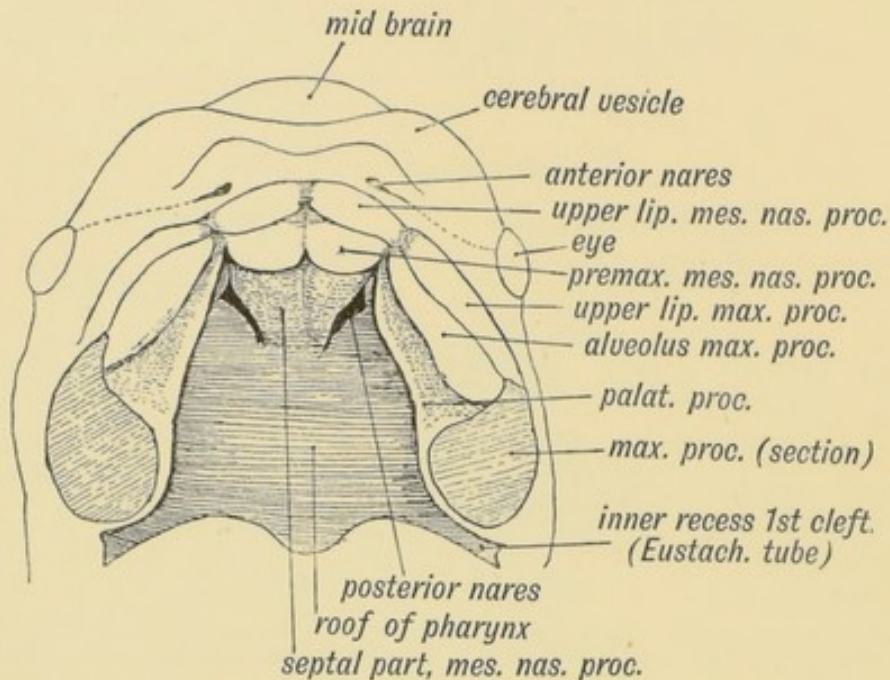


FIG. 8.—Showing the ingrowth of the palatal plates of the two maxillary processes early in the 2nd month. (After Kollmann.)

the mouth (Figs. 1 and 2). In front it comes in contact and fuses with the lateral nasal process which forms the outer wall of the nasal cavity and with the globular process of the mesial nasal which forms the premaxillary part of the palate and the middle part of the upper lip. The part of the face formed by the maxillary process is shown in figure 2. The hard palate (with the exception of the premaxillary part), the soft palate and its muscles, with the uvula, are formed by a **horizontal plate** which grows inwards from the maxillary process and fuses with the plate of the opposite side beneath the septum of the nose, with which the horizontal plates also unite (Figs. 8 and 9). The palatal

processes separate the buccal from the nasal cavities, forming the roof of the one and the floor of the other (Fig. 7). The horizontal palatal plates meet first in front; the process of fusion spreads backwards, and by the end of the second month it is complete.

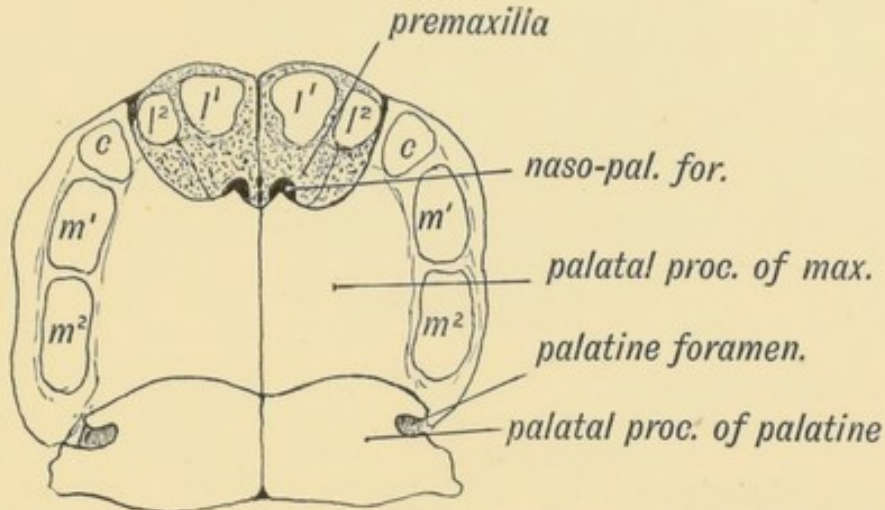


FIG. 9.—Showing the Hard Palate at birth. The premaxillary part is formed from the Mesial Nasal Processes; the remainder by the Palatal Plates of the Maxillary Processes.

The condition of cleft palate is due to a partial or sometimes a complete failure of the process of fusion.

Bones formed in each Maxillary Process.—The zygomatic process of the temporal, the malar, and the greater part of the superior maxillary are formed directly from the connective tissue within the process. They are membrane-formed bones.

Pterygo-palatine Bar.—Two other bones formed in this process have quite a different history. The **internal pterygoid plate**, which is originally a separate bone, and the **palate**, are developed over cartilage. When the maxillary process grows forwards from the base of the mandibular arch, it carries with it a prolongation of the cartilaginous bar which forms the skeletal basis of that arch. The cartilaginous bar is known as the **pterygo-palatine**, and in the membrane over this bar the pterygoid (internal pterygoid process) and palatal bones are developed (Fig. 10 *A, B, C*). From the posterior end of this bar is developed the incus in mammals and the quadrate bone in birds and reptiles. In birds and reptiles the lower jaw articulates with the quadrate bone (Fig. 10 *B*), and on the quadrate the superior maxilla is supported by the pterygoid and palate bones. In amphibians the quadrate, pterygoid and palate form a continuous bar of

cartilage (palato-quadrate). In fishes the **Palato-quadrate** bar forms part of the mandibular arch (Fig. 10 *A*). In mammals the quadrate is completely separated from the pterygoid and, instead

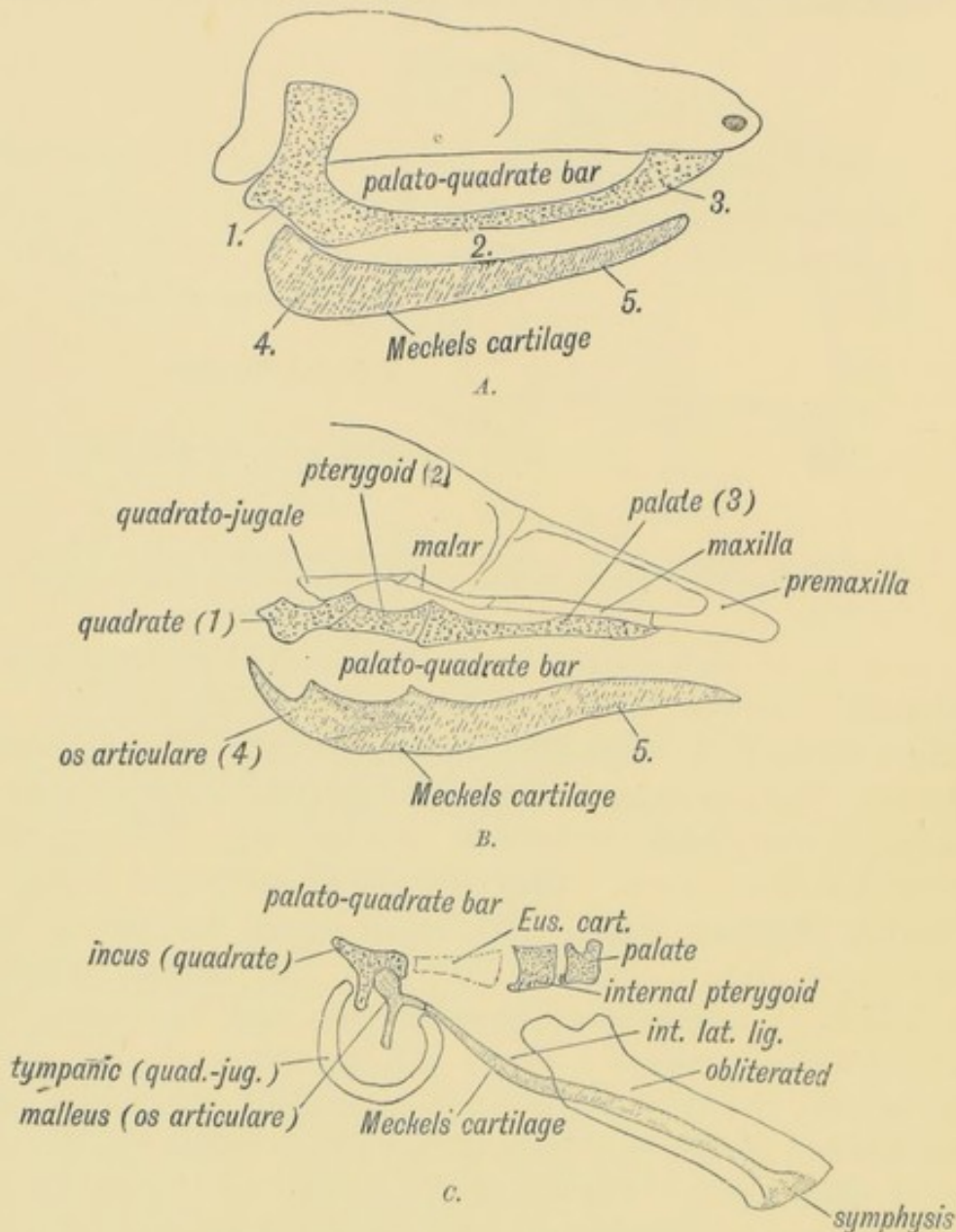


FIG. 10, A, B, C.—Showing what become of the skeletons of the Mandibular Arch (Meckel's Cartilage) and Maxillary Process (Palato-quadrate Cartilage). The numerals indicate corresponding parts.

A. In Fishes and Amphibians. *B.* In Reptiles and Birds. *C.* In Mammals.

of acting as a supporting bone for the lower jaw, as in birds, is subservient to hearing, and known as the incus.

It is difficult to understand, as Dr. Hans Gadow has pointed out, how a bone such as the quadrate, constantly engaged with

the mandible, could have become subservient to hearing, and he has produced good evidence to show that the quadrate does not correspond to the incus but to the tympanic plate, with which the mammalian jaw is still in contact. The incus he believes to

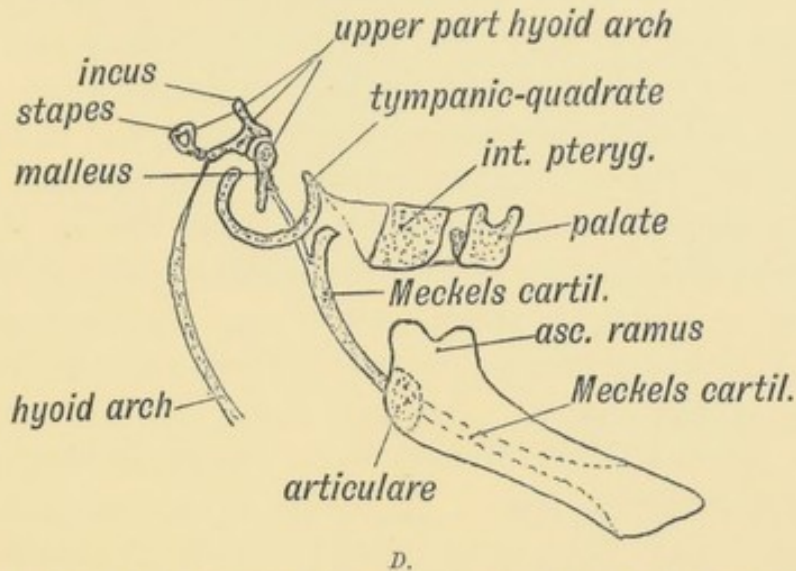


FIG. 10 D.—Illustrating Gadow's view of the origin of the Auditory Ossicles and Tympanic Plate.

be derived from the upper segment of the hyoid arch (see Fig. 10 D).

Nerves and Arteries of the Maxillary Process.—A knowledge of the manner in which the maxillary process is developed explains the distribution and course of its arteries and nerves. The second division of the 5th, represented by the infra-orbital, descending palatine, pterygo-palatine, and Vidian nerves, forms its nerve supply. Its main artery is the internal maxillary. The muscles of the palate are developed in the horizontal palatal processes.

Formation of Foramina and Canals in Bone.—The development of canals and foramina in the bones of the maxillary process illustrates the manner in which these are formed in the skull generally. Many foramina and canals occur originally between separate elements (see page 170). The Vidian nerve lies between the internal pterygoid plate (a separate bone) and the external pterygoid, a plate which grows into the maxillary process as a cartilaginous prolongation of the great wing of the sphenoid. The pterygo-palatine canal is situated between the pterygoid and palate part of the pterygo-palatine bar. The descending palatine

nerves lie between the palate bone and superior maxilla. These are canals formed between different elements. The infra-orbital nerve at first passes forwards in a groove on the orbital aspect of the superior maxilla, but in the later months of foetal life, upgrowths from the malar and nasal centres of ossification of the maxilla meet over the nerve and convert the groove into a canal.

The foramen rotundum and foramen ovale are at first notches on the edge of the great wing of the sphenoid, but in the course of foetal growth the notches are converted into foramina. Hence wherever a nerve foramen or canal is found one may conclude that it marks the junction of two elements, originally distinct, or is originally a groove or notch on the edge of the bone (Bland Sutton). The malar nerves issue between the two centres of ossification of the malar. The two malar centres may fail to unite; the bone is then divided by a suture passing from the orbit to the temporal fossa. It occurs rather more frequently in Japanese and Mongolian skulls, hence the name of **Os Japonicum**.

Palatal Rugae.—In all classes of mammals the mucous membrane on the hard palate is ridged transversely; three or four of these transverse ridges are seen on each side of the palate of the newly born child; they tend to disappear in the adult. Food is triturated between them and the rough papillae on the palatal aspect of the tongue. Their disappearance in man is probably due to the soft nature of his food.

The Antrum of Highmore.—It will be seen from figure 7 that the maxillary process is at first a thin plate, lying between the orbit and mouth, containing the tooth buds. It rests on the outer aspect and covers the cartilaginous basis of the lateral nasal process which forms the outer wall of the nasal cavity (Fig. 7). About the third month of foetal life the mucous membrane in the middle meatus begins to bud outwards, presses before it and bursts through the lateral nasal plate of cartilage and begins to distend the maxillary process. At birth the antrum is only a shallow recess on the outer wall of the middle meatus. It continues to grow until the 25th year, and is the only one of the air sinuses developed from the nasal cavity, which is present at the time of birth. In the years of adolescence the antrum reaches out until it inflates the maxillary part of the malar and

as it grows backwards, presses downward the posterior border of the maxilla and thus brings the permanent molar teeth into

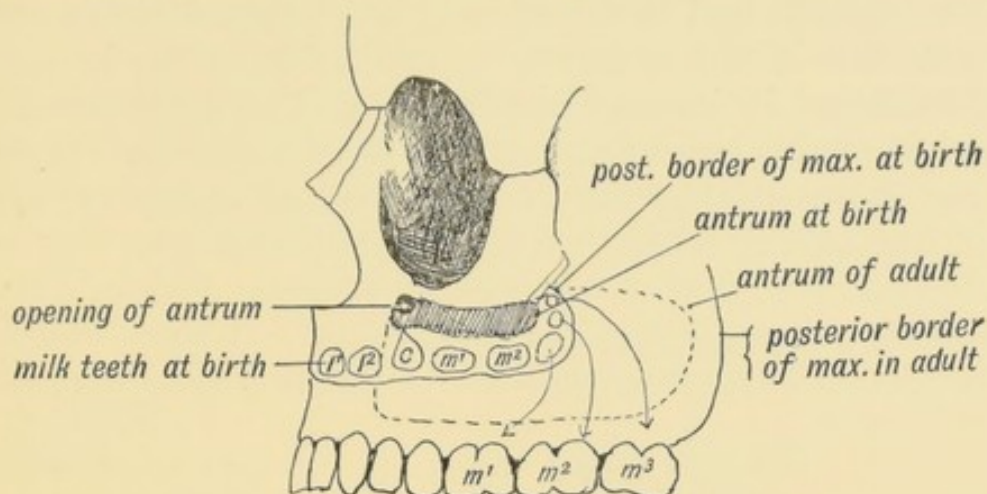


FIG. 11.—Showing the manner in which the development of the Maxillary Antrum affects the size of the palate and position of the molar teeth.

position (Fig. 11). If the process of growth is arrested, the last molar (wisdom) tooth is left on the posterior border of the maxilla, where it may ultimately be the cause of an abscess.

MANDIBULAR PROCESSES AND ARCH.

The two mandibular processes unite in the middle line and form the mandibular or first visceral arch. The arch forms the lower or hinder boundary of the stomodaeum (Fig 1).

Parts formed from the Mandibular Arch.—Besides the lower jaw, there are formed from this arch the soft parts over and under the jaw, the lower lip, the muscles of mastication, the internal lateral ligament and the malleus. The anterior two-thirds of the tongue, the sublingual and submaxillary glands are formed from the floor of the primitive pharynx between the mandibular and the second or hyoid arch. These parts are supplied from the nerve of the mandibular arch, and are therefore probably derived, in part at least, from the substance of the arch.

The Mandibular Arch bounds the stomodaeum behind, and is the foremost of the five visceral arches which encircle and form the walls of the primitive pharynx. **Meckel's cartilage** forms its skeletal basis (Figs. 10 C and 12). The 3rd division of the 5th is its nerve, and its artery is the first aortic arch from which the inferior dental, facial and lingual arteries afterwards arise.

The structures formed from Meckel's cartilage are shown in Figs. 10 *C*, 10 *D*, and 12.

Development and Ossification of the Lower Jaw.—In some animals, such as the kangaroo, the two halves of the lower jaw, each developed in its own mandibular process, never unite. In man ossific union takes place early in the second year. In figure 12 are shown the manner of formation and ossification of the lower jaw, with the changes that take place with age.

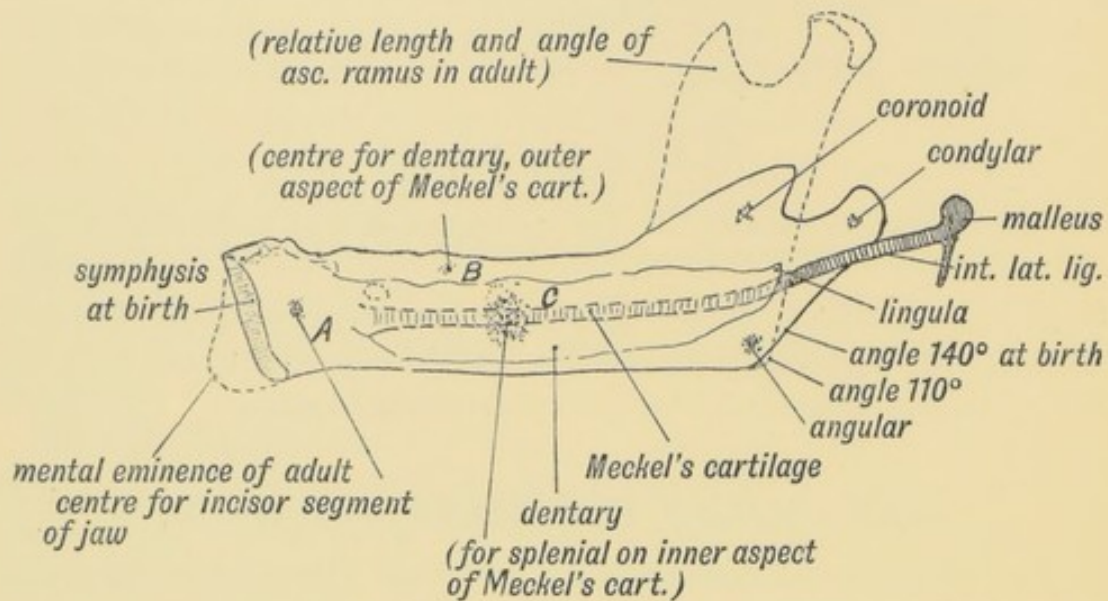


FIG. 12.—Showing the Centres of Ossification and age changes in the Lower Jaw.

The part of the lower jaw (*A*, Fig. 12) is developed directly out of Meckel's cartilage. The dentary centre (*B*) appears in the membrane on the outer side of Meckel's cartilage, and forms the body of the jaw from the mental foramen almost to the angle; the splenic centre (*C*) appears on the inner aspect of the cartilage and between it and the dentary, the canal for the dental nerves and vessels is formed. The ascending ramus, developed in mammals only, is formed from the coronoid and condylar centres which appear in membrane. By the condylar process the lower jaw comes to articulate directly with the skull (squamosal bone).

The growth of the antrum of Highmore, by pushing downwards the body of the lower jaw, leads to an elongation of the ascending ramus, and to its assuming a more vertical position to the body of the jaw (Figs. 11 and 12). In old age, when the teeth drop out and the alveolar margins are absorbed,

the ascending ramus again becomes oblique, to allow the lower jaw to come in contact with the upper during mastication. The **mental eminence** is produced after birth, and is a human characteristic. It gives attachment to the depressores labii inferioris.

The ascending ramus is peculiar to mammals. In other vertebrates Meckel's cartilage forms the skeletal basis of the lower jaw and articulates with the quadrate bone (incus) by its upper articular extremity, the **os articulare** (malleus) (Fig. 10 C). The part of Meckel's cartilage between the malleus and body of the lower jaw forms the internal lateral ligament, and possibly also the interarticular cartilage of the temporo-maxillary articulation.

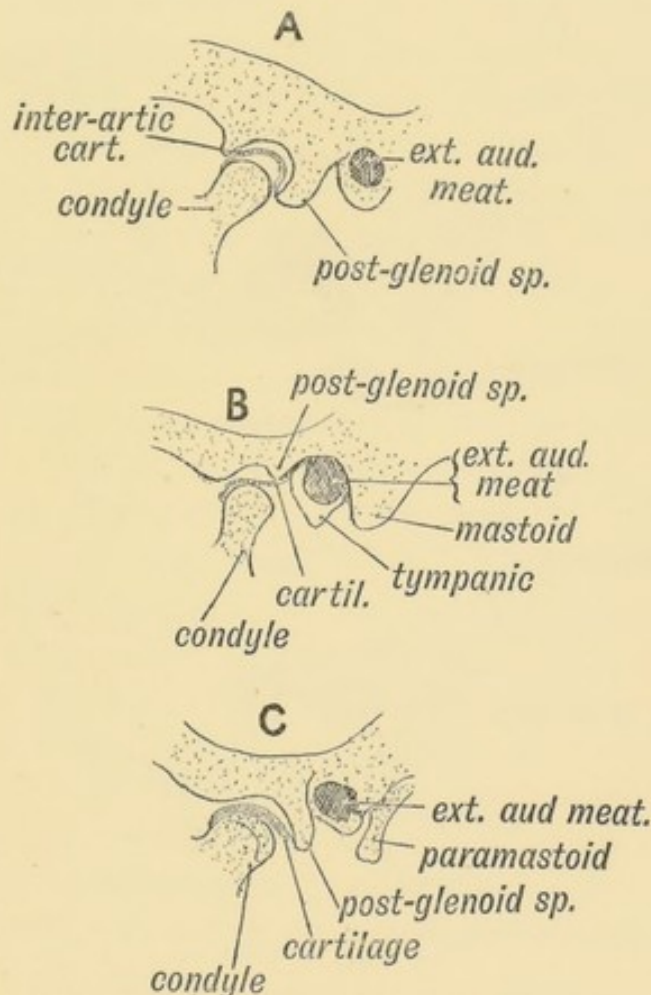


FIG. 13.—The chief types of the Temporo-Maxillary Articulation.
 A. Carnivorous Type. B. Omnivorous Type. C. Herbivorous Type.

Gadow regards the angle of the jaw as the representative of the os articulare.

The Temporo-maxillary Articulation.—Two types of this joint

are found in mammals, one (see figure 13 *A*), exemplified in the carnivora, in which only a hinge action is permitted, and hence the jaws act like scissor blades; the second (see figure 13 *C*), in which

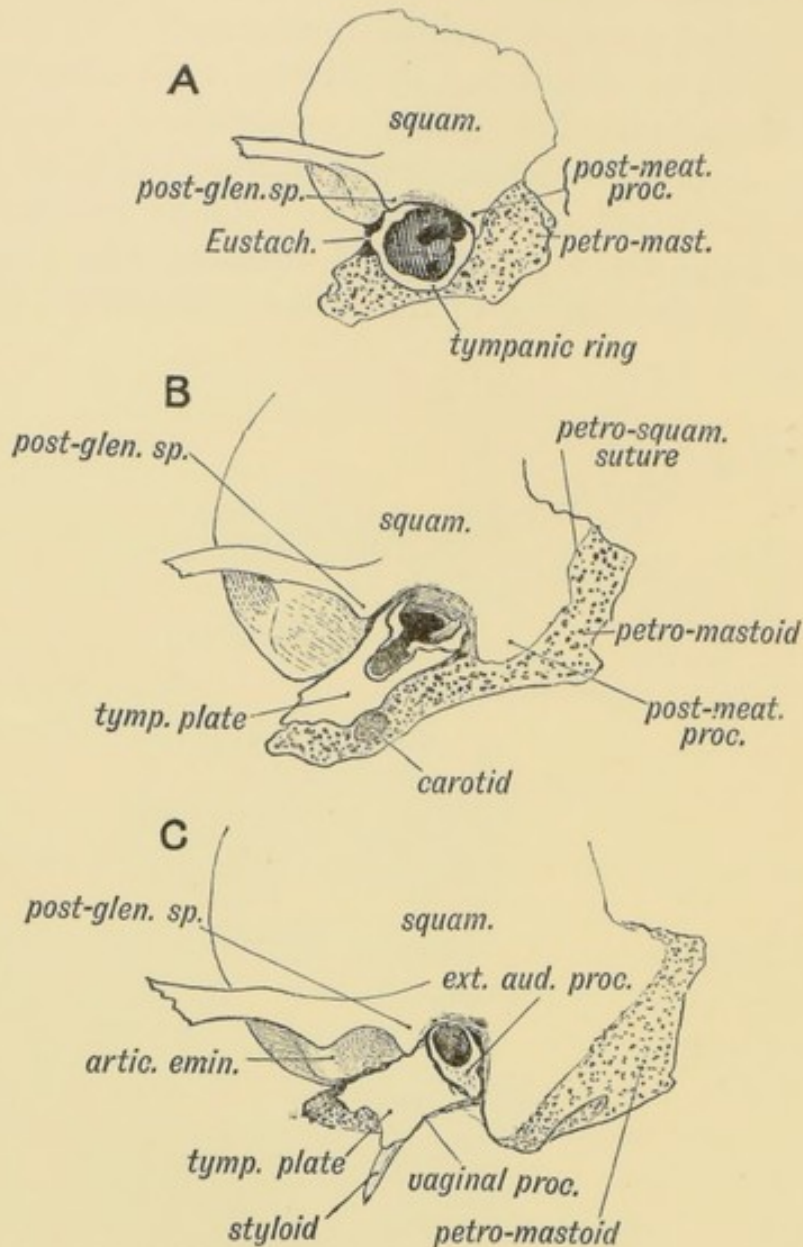


FIG. 14.—Showing the Chief Changes after birth in the form of the Temporo-Maxillary Articulation.

A. At Birth. *B.* At Two Years. *C.* In the Adult.

a gliding movement is allowed, the teeth being thus able to act as grinders. The second type occurs in all vegetable feeders. The human articulation combines the characters of both types (Fig. 13 *B*), the gliding action taking place between the interarticular cartilage and the skull, the hinge action between the cartilage and

the condyle. In rodents the glenoid cavity is a narrow gutter in which the plate-like condyloid process glides backwards and forwards. The interarticular cartilage is developed in all the Mammalia except the monotremes, and one or two marsupials (Parsons).¹ It is probably a derivative of Meckel's cartilage (see Fig. 10 *D*).

Development of the Tympanic Plate and Articular Eminence.—If the chin be depressed the condyle of the jaw moves on to the articular eminence (Fig. 13 *B*); if over-depressed it springs over the eminence, and a dislocation is produced. This is impossible in the early years of life, for at birth there is no eminence and no glenoid cavity (see Fig. 14 *A*). At birth the *membrana tympani* lies exposed on the surface of the skull behind the condyle, supported in a fine osseous hoop, the *tympanic ring*. The ring is imperfect above, and there the flaccid part of the membrane occurs. By the second year the ring has grown into a plate by sending out two processes, which, as they grow out, unite and leave a gap between (Fig. 14 *B*). This, as a rule, is soon filled up. By the 20th year the tympanic plate is three-quarters of an inch long, forming the bony floor of the external meatus and the posterior wall of the glenoid fossa, which in man is remarkably deep. It protects the meatus from the condyle; every year until the 20th the bony meatus gets longer, while the fibro-cartilaginous part becomes relatively shorter. In the adult the bony part forms two-thirds of the meatus. As the tympanic plate grows outwards, the *membrana* becomes less easily accessible to the surgeon (Fig. 14 *C*). The plate also grows inwards to form the floor of the bony part of the Eustachian tube and downwards to form the vaginal process, to which the upper end of the carotid sheath is attached (Fig. 40, p. 54). Gadow regards the tympanic plate as the representative of the quadrate bone of birds and reptiles.

THE STOMODAEUM.

The *stomodaeum* or primitive buccal cavity is the depression or narrow pocket formed between the fore-brain above and the mandibular arch below. It is bounded laterally by the

¹ "Joints of Mammals," *Journ. of Anat. and Physio.*, Vol. XXXIV.

maxillary processes (Fig. 15 *A*) and lined by the covering epithelium of the skin—epiblast. It is blind at first, the floor

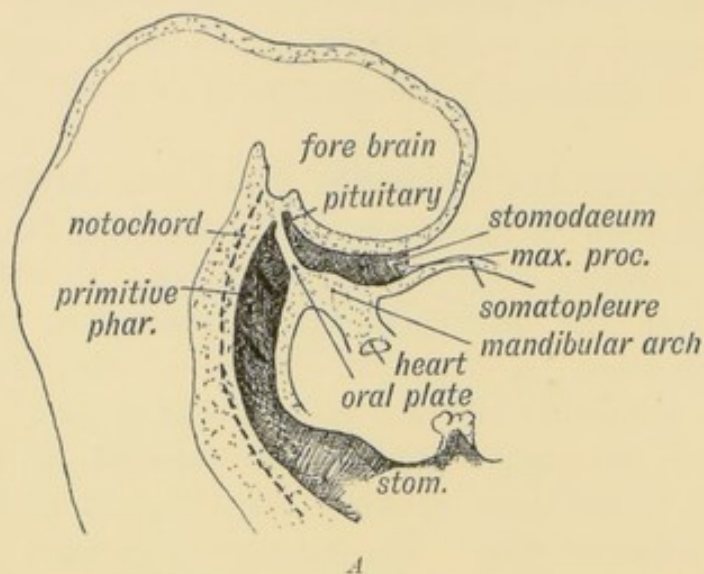


FIG. 15 *A*.—Sagittal Section showing the Stomodaeum and position of the Oral Plate in the 3rd week. (Schematic.)

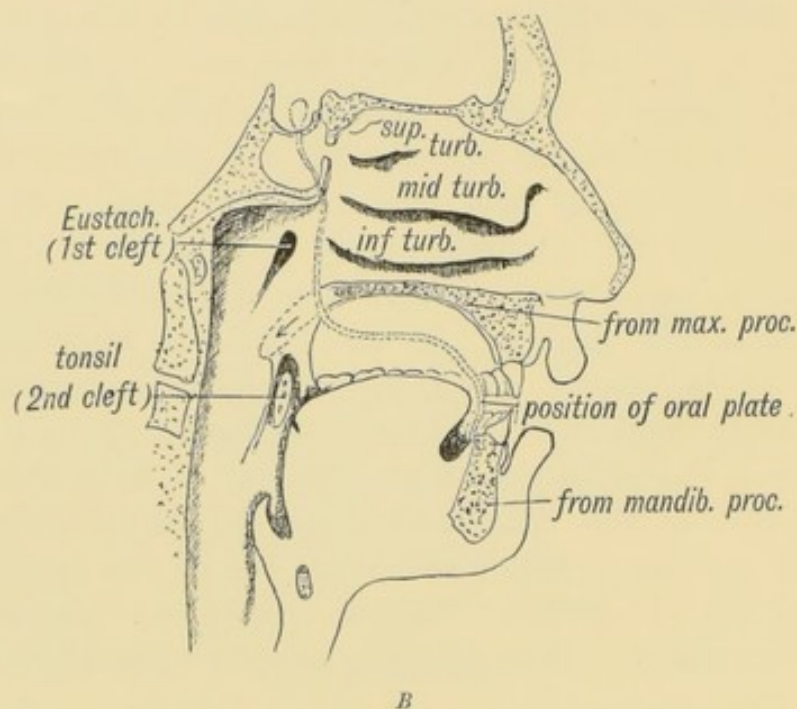


FIG. 15 *B*.—Showing the parts of the Buccal and Nasal Cavities formed from the Stomodaeum. The relative position of the Oral Plate is indicated.

or fundus being formed by the **oral plate**, which separates it from the primitive pharynx (Fig. 15 *A*). The mesial nasal and palatal plates of the maxillary processes divide it into an **upper part**—the nasal cavities—and a **lower**, which forms part

of the permanent buccal cavity (see Fig. 15*B*). The tongue is developed in the floor of the pharynx and the tonsils in the pharyngeal wall, but the lips, teeth, and gums are formed in the walls of the stomodaeum. In the 3rd week of foetal life the oral plate breaks down and the stomodaeum then communicates with the pharynx.

The Origin of the Pituitary Body.—The lining epithelium (epiblast) of the stomodaeum becomes pouched out against the floor of the fore-brain and forms the buccal element of the pituitary (Fig. 15*A* and Fig. 22, p. 30). A process from the floor of the hinder part of the fore-brain (thalamencephalon) meets it and forms the neural part of the pituitary. The buccal evagination is sometimes called Rathke's pocket. With the development of the base of the skull, the stalk of the buccal evagination disappears. A canal may occasionally be seen passing upwards between the basi- and pre-sphenoid, and opening at the olivary eminence, marking the position occupied by the pocket in the foetus (canalis cranio-pharyngeus, Fig. 3). Gaskell, who regards the neural or cerebro-spinal canal as the homologue of the invertebrate alimentary canal, homologises the pituitary evagination of the buccal epiblast with the invertebrate mouth and gullet.

CHAPTER II.

THE NASAL CAVITIES AND OLFACTORY STRUCTURES.

IN tracing the development of structures subservient to the sense of smell, the following elements have to be dealt with :

- (1) The olfactory sense epithelium and olfactory nerves ;
- (2) The parts of the brain concerned with the sense of smell, so far as we know them ;
- (3) The capsule which contains the olfactory epithelium ;
- (4) The respiratory tract of the nasal cavities.

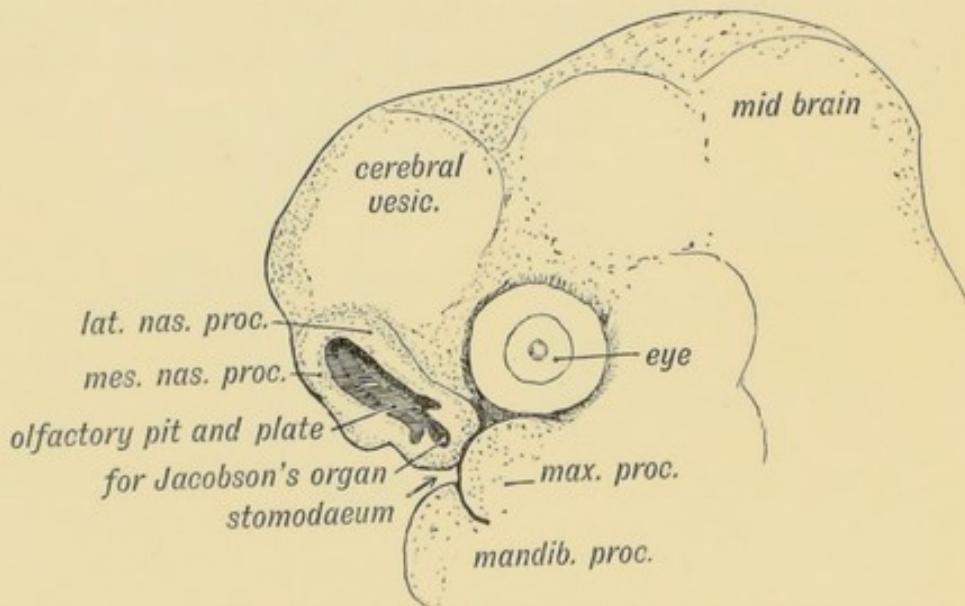


FIG. 16.—The Olfactory Pit and Nasal Processes in a 4th week human embryo
(After Kollmann.)

(1) **Origin of the Olfactory Sense Epithelium.**—A small area of the epiblastic cells, lying under the fore-brain becomes demarcated on each side, to form the **olfactory plates**. Around these two plates the lateral and mesial nasal processes grow up

(Fig. 16), the plates being depressed to form the **olfactory pits**. With the growth of the nasal processes the olfactory plates and pits are thrust into the roof of the stomodaeum, where they form the epithelial lining of the upper third or olfactory area of the nasal cavities. A small island is detached from each plate to form the basis of Jacobson's organ (Fig. 16). The sense epithelia send out nerve processes which form arborescences round the neural cells of the outgrowing olfactory lobe (Fig. 17). The olfactory nerves are thus formed. At first the olfactory plate is directly in contact with the neural tube, and it is probable that neuroblasts may migrate then to the olfactory plate and form the olfactory sense epithelium.

The condition of olfactory pits, a developmental phase in the human embryo, is the permanent form in fishes (Fig. 21*B*); in amphibians and all higher vertebrates the fundus of the pit breaks down and thus the olfactory pits come into communication through the posterior nares with the stomodaeum (Fig. 8).

(2) **The Olfactory Lobe.**—As the olfactory plates are being thrust downwards, the anterior part of the floor of the fore-brain grows out on each side as a hollow protrusion to form the

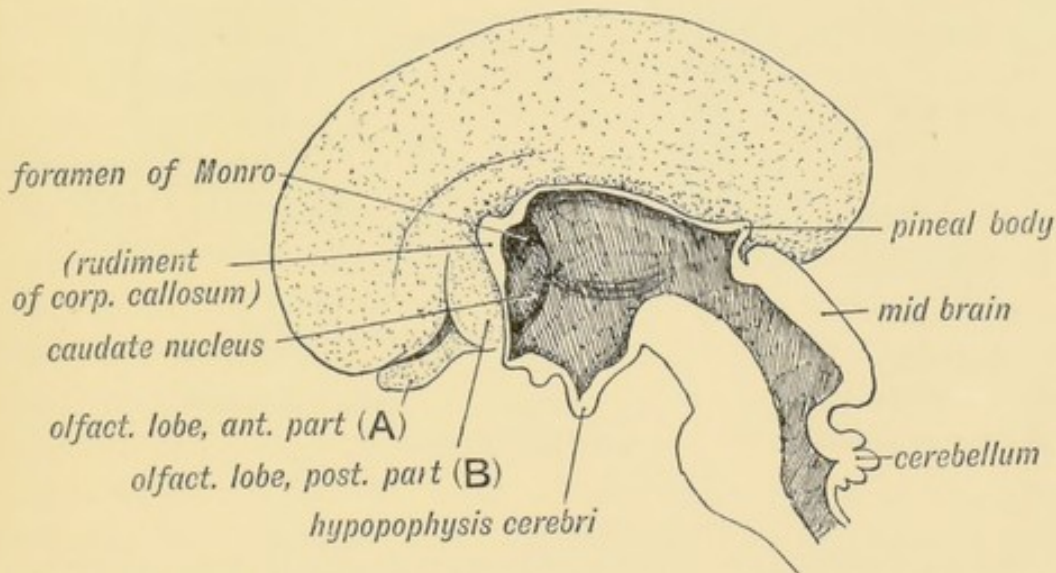


FIG. 17.—The Mesial aspect of the Brain of a human foetus, 3½ months old, showing the Olfactory Lobe.

olfactory lobes (Fig. 145, p. 178). At the end of the 3rd month the olfactory lobe has assumed the form shown in Fig. 17. Its cavity is at first continuous with that of the cerebral vesicle (lateral ventricle), but this connection is soon lost; it becomes

solid and divided into anterior and posterior parts by a transverse fissure (Fig. 17).

The **anterior part**, as is shown in figure 18, becomes (*a*) the olfactory bulb, (*b*) the olfactory peduncle or tract, (*c*) the trigonum olfactorium, lying between the lateral and mesial roots into which the tract divides, and (*d*) the area of Broca. The **posterior part** of the olfactory lobe (*B* in Fig. 17) becomes (*a*) the grey matter of the anterior perforated space, and (*b*) the gyrus subcallosus or peduncles of the corpus callosum (Fig. 18).

Termination of the Olfactory Tract.—As is shown in figure 18, the mesial root terminates in the supra-callosal gyrus and fornix, while the lateral ends in the uncus of the hippocampal convolution. Olfactory nerve fibres also terminate in the trigone and area of Broca. To the parts derived from the olfactory

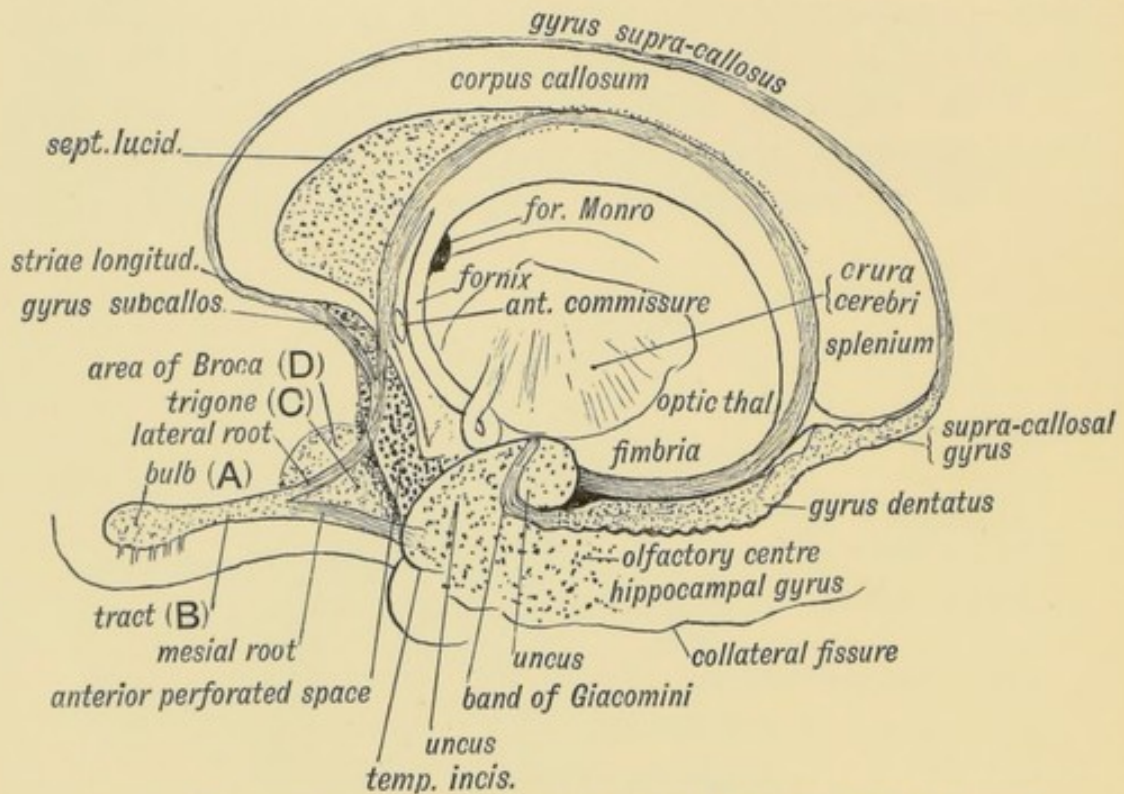


FIG. 18.—Showing the parts formed out of the Olfactory Lobe in the brain of an Adult, and the termination of the Olfactory Roots in the Sub-callosal and Uncinate Gyri. (After Elliot Smith.)

lobe together with the uncus, the fascia dentata, the supra-callosal gyrus, the fimbria, the fornix and septum lucidum (Figs. 18 and 172) the term **Rhinencephalon** is given because these parts are concerned with the sense of smell, and represent the parts first and most highly developed in the brains of lower vertebrates

(Elliot Smith). In man many of these parts are merely vestigial. The higher olfactory centre has been located in the hippocampal gyrus, but no evidence has been given showing any connection between the callosal gyrus and this sense. In animals with a highly developed olfactory sense (carnivora, etc.) these parts of the brain which form the rhinencephalon are well developed. The fornix in its greater part, and the longitudinal striae as association tracts, connect the brain areas which are subservient to the sense of smell (see Fig. 18).

It is important, from a clinical point of view, to remember that the olfactory nerves are surrounded by prolongations of the arachnoid membrane and subarachnoid spaces, and through these spaces infections may spread from the nasal cavities to the meninges. Further, the olfactory tracts rest on the edges of the small wings of the sphenoid, and may be injured in falls on the forehead.

The Nasal Cavities.—The separation of the nasal cavities from the stomodaeum by the downgrowth of the mesial and lateral nasal processes, and the ingrowth of the horizontal plates of the maxillary processes, has been already described (p. 3). These processes also form and bound the anterior and posterior nares.

Development of the Nasal Air Sinuses.—The manner in which the nasal mucous membrane pushes its way through the lateral nasal cartilage into the maxillary process to form the Antrum of Highmore has been already described (page 12). The other air sinuses—the frontal, lachrymo-ethmoidal, anterior, middle and posterior ethmoidal, and sphenoidal sinuses—six in all, arise in the same way as the antrum but at a much later date. Although they begin to bud out about the 3rd year, they assume their active growth in the earlier years of puberty, and reach their full size before the 30th year.

At birth, the lateral mass of the ethmoid is a thin plate, carrying the superior and middle turbinate processes, which almost fill the nasal cavity (Fig. 7). The entire ethmoid is narrow, and hence the proximity of the eyes in children. Beneath the middle turbinate is a thumbnail-like impression—the **hiatus semilunaris** (Fig. 19). The antrum buds out near its posterior end, and the point at which the bud starts becomes its opening. The uncinatè process of the lateral mass of the ethmoid forms the prominent lower margin of the hiatus.

From the upper end of the hiatus a bud of mucous membrane grows upwards to form the **frontal sinus**, gradually works through the ethmoid, and pushes its way into the frontal bone, separating

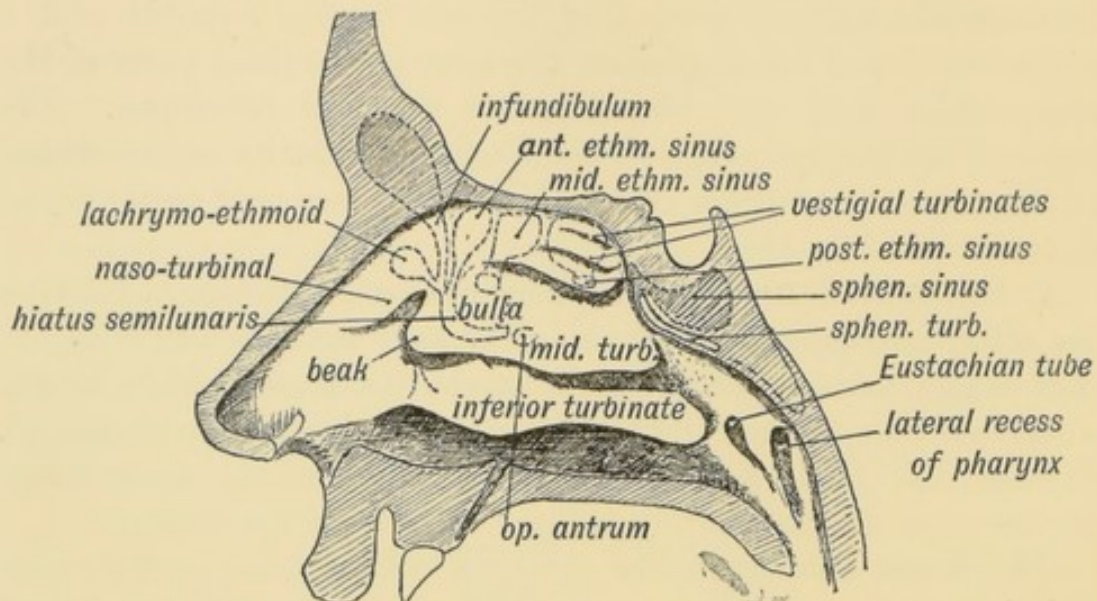


FIG. 19.—A diagram of the Lateral Wall of the Nasal Cavity, showing the position of the Air Sinus. The parts beneath the turbinate processes are indicated by stippled lines.

the outer from the inner lamellae. As a rule, by the 25th year it reaches outwards over the inner two-thirds of the orbital roof, and is an inch or more both in height and depth at its inner part. It is smaller in women than in men, but it may be, and often is, arrested at an early stage of development, or it may be absent altogether. The size of the glabellar prominence is no index to its development.

The stalk of the frontal bud forms the infundibulum, which is narrow, half an inch long, and difficult of catheterization from the nose. Into it open (or sometimes into the hiatus) the **lachrymo-ethmoidal** and **anterior ethmoidal cells** which surround the infundibulum. They are developed as outgrowths from the infundibulum (Fig. 19). Occasionally the antrum of Highmore, as is frequently the case in the gorilla, sends a process to form part of the frontal sinus, and hence there may be a communication between the sinus and the antrum.

The development of the frontal sinuses and supra-orbital ridges lead to a marked change in the face at puberty. By the formation of the frontal sinuses the basal area of the skull, to which the face is attached, is largely increased in extent. Such an

increase is necessary to support the palate, which grows rapidly in size at puberty. Up to the fifth year the upper jaw has to carry only ten milk teeth; in the adult it has to carry sixteen permanent teeth. To support these the face and palate grow rapidly in size. The formation of the frontal sinus gives the necessary increase in the area of the base of the skull for their support. It should be remembered that the growth of the brain and of the cranial cavity is comparatively slight after the fifth year.

Only the gorilla and chimpanzee show an arrangement of frontal and ethmoidal sinuses comparable to that of man.

Above the hiatus lies the **bulla ethmoidalis**, which is inflated by, and commonly carries the opening of, the middle ethmoidal cell (Fig. 19). The posterior ethmoidal sinus opens beneath the superior turbinate process, and is developed from the superior meatus. The **ethmoidal sinuses** are produced in the cartilage of the ethmoidal or lateral nasal plate (Fig. 7). They inflate the ossifying cartilaginous plate until it becomes a cellular mass, thus increasing the breadth of the intra-orbital septum. The **sphenoidal sinus** (Fig. 19) is formed by the mucous membrane growing into and expanding the sphenoidal turbinate bone, which is a small, slightly ossified cartilage lying beneath the pre-sphenoid at birth, and forming the uppermost (sixth) of the nasal turbinate processes. Latterly the sinus grows into and expands the pre-sphenoid and part of the basi-sphenoid, the sphenoidal turbinate remaining as its anterior wall (Fig. 19). The sphenoidal turbinate is a detached part of the ethmoidal (lateral nasal) cartilage.

It will thus be seen that all the nasal air sinuses are produced primarily by a budding outwards of the nasal mucous membrane into the cartilaginous basis of the lateral nasal processes. Disease may readily spread to these sinuses from the nasal cavities. By means of the sinuses the area of the face is increased to support the adult palate bearing the permanent teeth. Most of them open on the respiratory tract of the nasal cavity. They are ventilated with every breath. They act also as resonance chambers.

Vestigial Turbinates.—There is frequently to be seen in the adult one, or even two, secondary meatuses above the superior;

these are constantly present in the chimpanzée and in animals with a keen sense of smell. In the human foetus of four months six turbinates are usually present, besides secondary processes in the meatuses beneath them. The uppermost of these, the sixth, becomes the sphenoidal turbinate; the fifth disappears; the third and fourth may remain separate or become united; the first and second form the inferior and middle turbinate processes. The agger nasi (naso-turbinal, Fig. 19), in front of the attachment of the middle turbinate process, is a vestige of the naso-turbinal, a process well developed in most carnivora and animals with a strong scent. The uncinatè process, which forms the lower border of the hiatus semilunaris, is continuous at its base with the naso-turbinal. Through the hiatus semilunaris acting as a gutter, the antrum may become a cesspool for a suppurating frontal sinus.

Nasal Duct.—Although in no way connected with the sense of smell, the nasal duct is closely related to the nasal cavities.

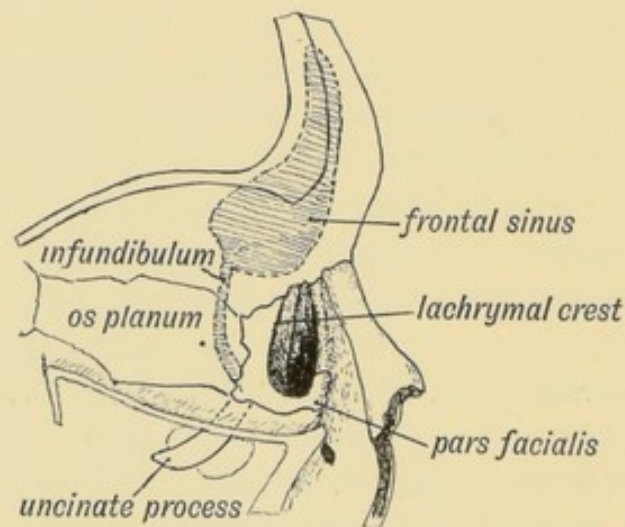


FIG. 20.—Showing on the inner wall of the Orbit (1) the position of the Infundibulum, (2) the pars facialis lachrymalis.

It is formed between the lateral nasal and maxillary processes (Figs. 1 and 7). Three bones bound it: the superior maxilla on the outer side, formed in the maxillary process; the inferior turbinate, formed in the cartilage of the lateral nasal process, and the lachrymal, formed over the lateral nasal cartilage, bound it on the inner side. The formation of the palate cuts the duct off from the mouth. The hamulus of the lachrymal varies much

in size, and is the vestige of a larger process, which in lower primates enters into the formation of the inferior margin of the orbit. This *pars facialis* sometimes occurs in man (Fig. 20). The position of the infundibulum to the lachrymal is shown in Fig. 20; it is seen to lie entirely in the lateral mass of the ethmoid behind the lachrymal. Occasionally the frontal and superior maxillary bones may articulate in an interval between the lachrymal in front and lateral mass of the ethmoid behind.

CHAPTER III.

DEVELOPMENT OF THE PHARYNX AND NECK.

Pharynx of the Embryo.—There is very little resemblance between the pharynx and neck of a human foetus in the third week and that of the adult (Figs. 15 *A* and *B*, p. 18). Indeed, at the third week the human pharynx resembles closely that of a fish (Figs. 21 *A* and *B*). In both the human foetus and fish the pharynx is bounded by **visceral or branchial arches**, which are separated by depressions (human embryos) or clefts (fishes);

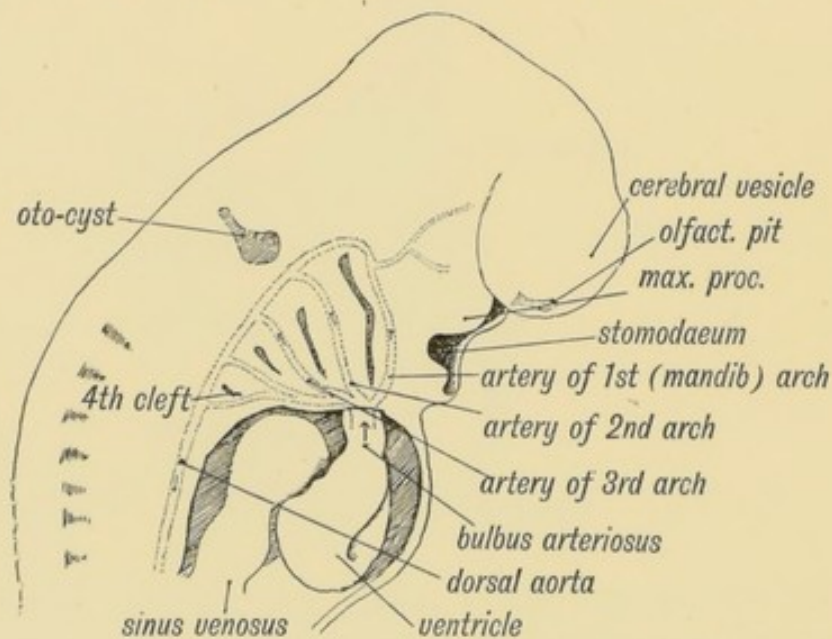


FIG. 21 *A*.—Showing the Visceral Arches and Cleft-depressions in the Pharyngeal Wall of a 4th week human Embryo. Each Visceral Arch contains an Aortic Arch. (After His.)

in both the heart is situated under the pharynx, and from the ventral aorta aortic arches pass up on each side, one in each visceral arch, to terminate in the dorsal aortae. In fishes the aortic arches give

off vessels to the gills, in which the blood is arterialized. In the human embryo the blood passes directly through the aortic arches.

All that part of the human neck lying in front of the vertebral column and between the mouth above and the thorax and clavicles below, with the bounding walls of the adult pharynx, is formed from the foetal visceral arches. A knowledge of the

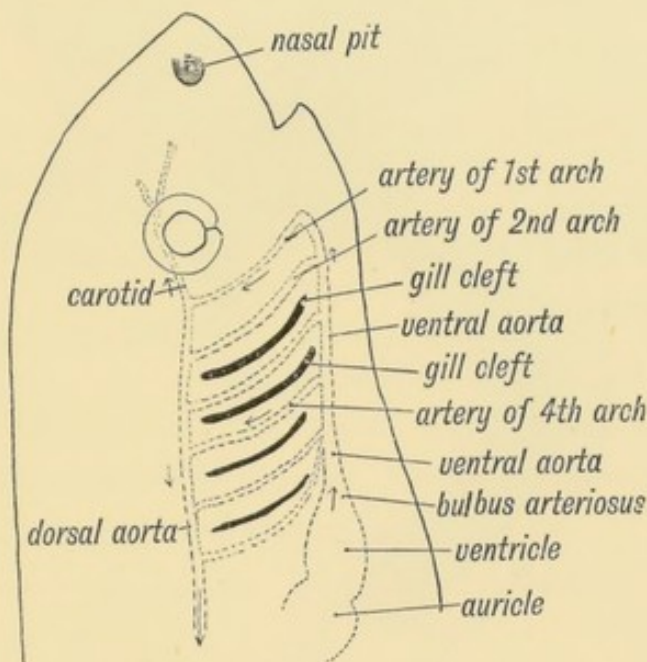


FIG. 21 B.—Showing the position of the Heart, Visceral and Aortic Arches in a fish. (Diagrammatic—after Gegenbaur.)

transformation of the foetal to the adult pharynx is of the utmost practical importance: it explains the occurrence of fistulae and cysts found in the neck; it accounts for the peculiar courses taken by nerves, such as the recurrent laryngeal and phrenic; it explains the peculiar distribution of nerves to the pharynx; and throws light on the nature and anomalies of the thymus, thyroid and tonsil.

The Branchial or Visceral Arches.—The visceral arches bound and form the whole thickness of the wall of the primitive pharynx. Four arches, each bounded behind by a depression, are to be recognised superficially on each side of the pharynx of the fourth week human embryo (Fig. 21 A), but behind the 4th cleft is a fifth arch, perhaps also a sixth which, however, never become raised or superficially differentiated

from the body wall behind. Sagittal and coronal sections of the primitive pharynx (Figs. 22 and 23) give a better idea of the

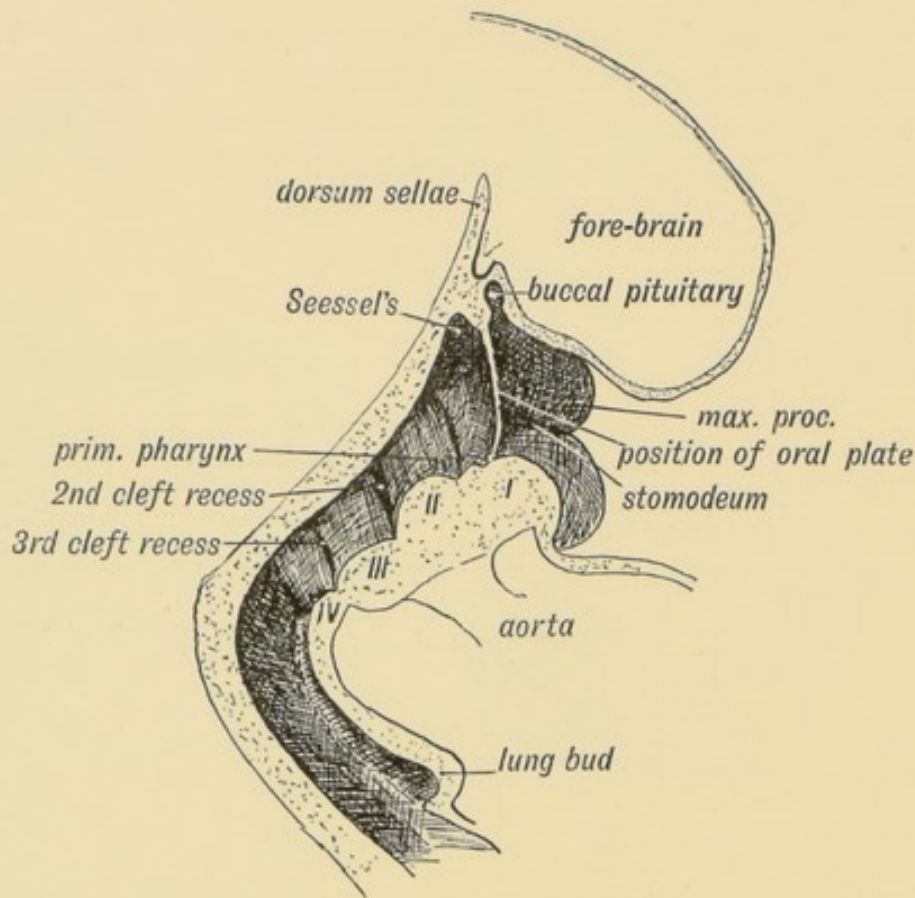


FIG. 22.—Showing the Primitive Pharynx of a 3rd week embryo in sagittal section, bounded by the Visceral Arches. (After His.)

arrangement and constitution of the visceral arches than can be had from a surface view. They are developed round the most anterior part of the fore-gut which forms the lining membrane of the primitive pharynx. The pharyngeal lining membrane, therefore, is the same as that of the alimentary canal from which spring all the organs and glands of digestion and assimilation.

The Visceral Clefts.—The epithelium or **hypoblast**, which lines the primitive pharynx, covers the inner aspects of the arches and passes outwards in the recesses between them and there comes in contact with the epithelial covering of the body (**epiblast**) which dips in to meet it. The membrane thus formed by the union of the epiblast and hypoblast in the recesses between the arches, may be named the “cleft membrane.” It is never ruptured nor disappears in the development

of mammals; in fishes it disappears and real clefts are formed between the arches. On the outer side of the membrane is the

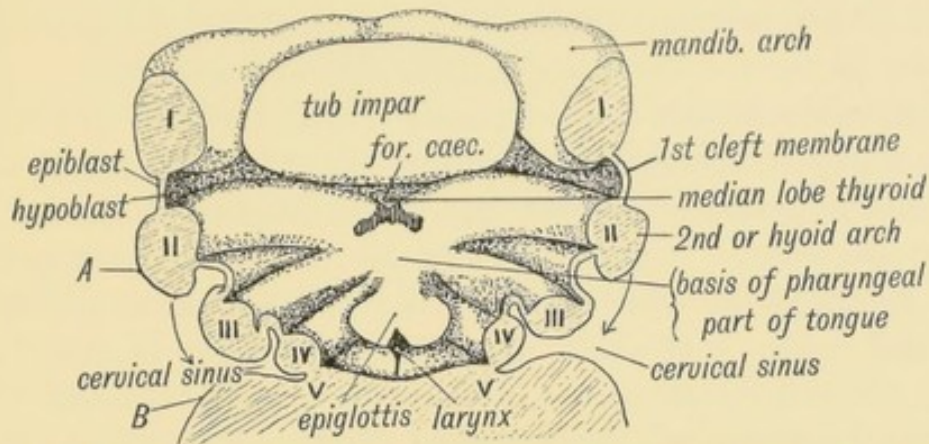


FIG. 23.—Showing the Floor of the Pharynx of a 4th week human embryo. (After His.)

“external cleft depression”: on the inner side, the “internal cleft recess” (Fig. 23). From the hypoblastic lining of these cleft recesses we shall see that the tonsil, thyroid and thymus arise; from the external depressions are formed the various branchial

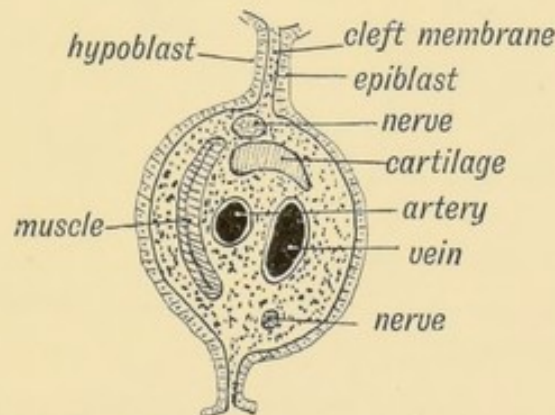


FIG. 24.—Schematic Section of a Visceral Arch.

cysts and fistulae, which occasionally occur in the neck of the adult. Each arch contains, as may be seen from figure 24:

- (a) A skeletal basis of cartilage;
- (b) An aortic arch;
- (c) Vein;
- (d) A larger nerve along its anterior border and a smaller along its posterior;
- (e) A muscle segment.

Formation of the Cervical Sinus.—The first arch especially, and also the second, grow and increase at a much greater rate than the third and fourth. It is observed that the second arch (hyoid) which in fishes forms the operculum for the gills, grows over and buries the third and fourth. As it covers them over and comes in contact with the body wall behind the fifth arch (see *A* and *B*, Fig. 23), the epiblast covering the third and fourth arches and clefts is buried. The epiblast so enclosed forms the lining of the cervical sinus. It usually disappears, but may remain and form a cyst in the neck, which opens some distance above the sternoclavicular joint. If the outer cleft depression in front of or behind the third arch persist, it must open in the cervical sinus.

What becomes of the Visceral Clefts.—By the end of the second month the clefts, or, to be more exact, the representatives

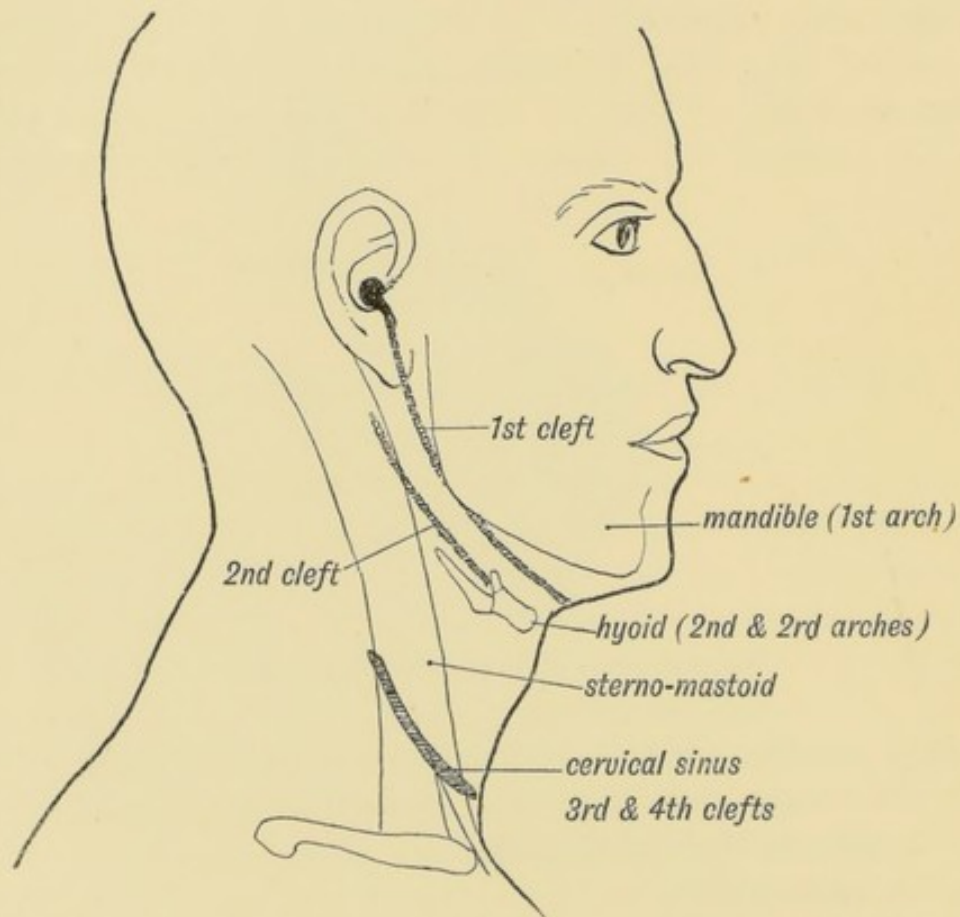


FIG. 25.—Showing the position of the External Cleft Depressions in the Adult.

of clefts in the human embryo, have disappeared, except the upper part of the first which forms :

(1) The external auditory meatus from the external cleft depression ;

(2) The Eustachian tube from the internal cleft recess. These two parts of the first cleft are separated by the cleft membrane which becomes the **membrana tympani**.

If traces of the other clefts remain as fistulae or cysts they will occur in the positions shown in figure 25. Part of the second cleft is marked in the goat by an opening and auricular appendage.

Within the **pharynx** traces of inner cleft recesses are to be seen besides the Eustachian opening (Fig. 33, p. 43). The **tonsil** is developed in the second cleft; the **palato-glossus** in the anterior pillar of the fauces represents the second arch. The **lateral recess of the pharynx** (fossa of Rosenmüller), behind the Eustachian tube, represents the upper end of the second cleft. The **pyriform fossa**, at each side of the laryngeal aperture, represents the fourth cleft (See Fig. 33).

The Cartilages of the Arches.—The history of the skeletal basis of the first arch (Meckel's cartilage) has been already traced (p. 14 and Figs. 10 *C* and 12).

The cartilage of the 2nd or hyoid arch forms (Fig. 26) :

(1) The **tympano-hyal**, which is imbedded in the petro-mastoid.

(2) The **stylo-hyal** (Fig. 26), which ossifies in the early years of life and becomes joined to the tympano-hyal to form the styloid process.

(3) The segment below, the **epi-hyal**, which becomes ligamentous, and forms the stylo-hyoid ligament, but it also may become ossified.

(4) The lowest segment, the **cerato-hyal**, forming the small horn of the hyoid.

The **epi-hyal** lies behind and outside the tonsil, and when ossified has been excised under the belief that it was a foreign body. The body of the hyoid (**basi-hyal**) probably represents the fused ventral parts (copulae) of the 2nd and 3rd arches.

Gadow regards the auditory ossicles as derivatives of the upper or hyomandibular segment of the 2nd arch (Fig. 10 *D*).

It will be seen later that the tongue arises from the floor of the pharynx in the field between the 2nd and 3rd arches. The skeletal bases of the ventral parts of the 2nd and 3rd

arches come to form the bone of the tongue. The skeletal part of the hyoid arch suspends the tongue.

The **great horn** of the hyoid represents the cartilage of the 3rd arch (Fig. 26). The formation of the larynx and lungs from

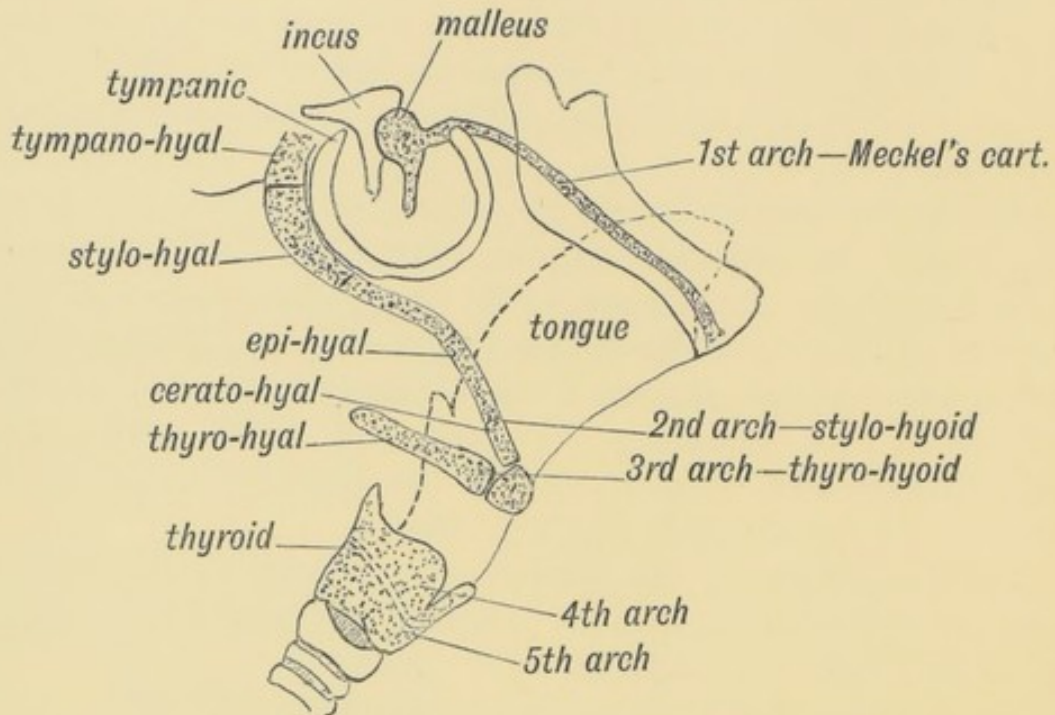


FIG. 26.—Showing what become of the Cartilages of the Visceral Arches.

the ventral part (floor) of the pharynx renders it difficult to say what becomes of the cartilage of the 4th arch, but it probably forms the whole or part of the **thyroid cartilage**. The thyroid in Marsupials is composed of an upper and lower segment, hence it is supposed that it may represent both the cartilages of the 4th and 5th arches. A perforation for vessels near the middle of the thyroid cartilage, on each side, sometimes occurs in man.

The Nerves of the Visceral Arches.—The 3rd division of the Vth nerve is, as has been already seen, the principal nerve of the first or mandibular arch. The nerve for the second or hyoid arch is represented by the 7th and 8th (facial and auditory, Fig. 27). The nerve of the 3rd arch is the glosso-pharyngeal, that for the 4th is the superior laryngeal branch of the vagus, and for the 5th the inferior laryngeal (Fig. 27).

Each nerve of a visceral arch, however, sends a branch to the

posterior border of the arch in front of it. It would be better, perhaps, to describe them as distributed to the clefts rather than to the arches. The anterior branch of the facial (nerve of the

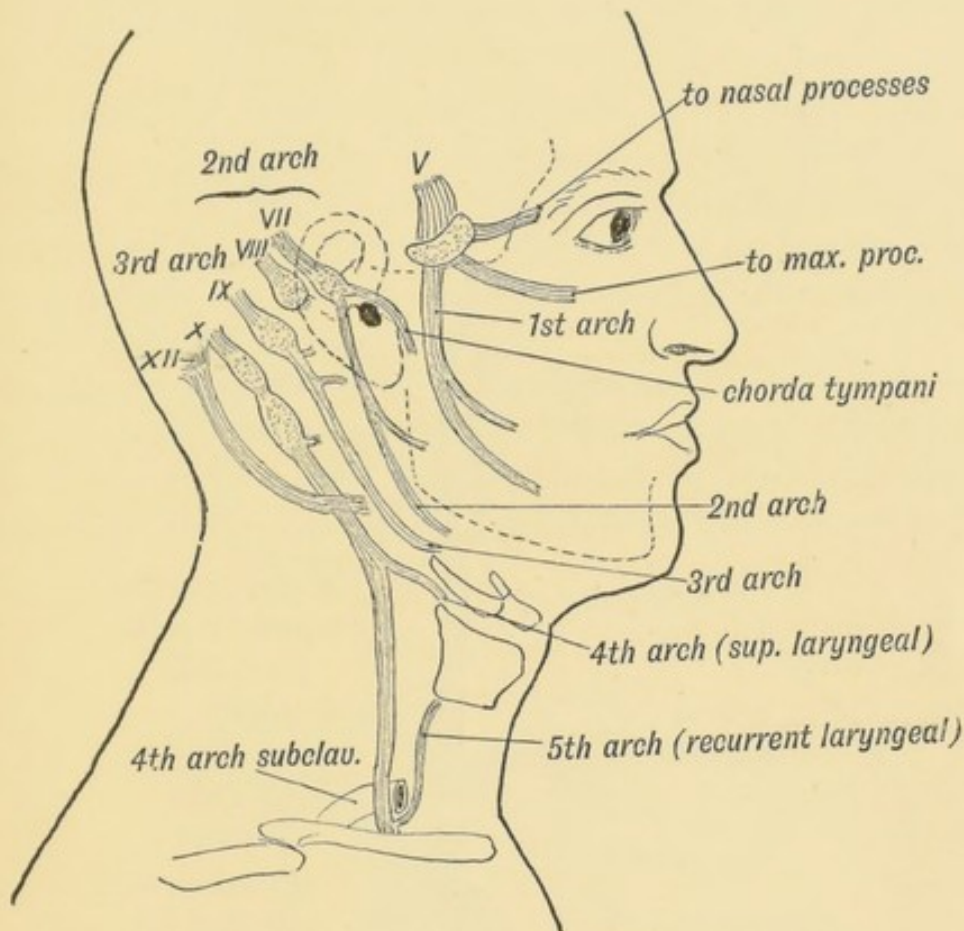


FIG. 27.—Showing what become of the Nerves of the Visceral Arches.

hyoid arch) is represented by the chorda tympani and great superficial petrosal; that of the glosso-pharyngeal by its tympanic branch (Fig. 27).

AORTIC ARCHES.

What become of the Aortic Arches—the Arteries of the Visceral Arches.—In figure 21 is given the foetal arrangement of the aortic arches, and in figure 28 the vessels in the adult which are formed from them. The primitive aorta in the embryo divides into two trunks, which run forwards along the floor of the pharynx, one on each side, lying between the ventral ends of the visceral arches. These may be termed the right and left ventral

aortic stems. From these stems five arteries (aortic arches) pass upwards, one in each visceral arch, to terminate in the right and left dorsal aortae, which run backwards to join together and form

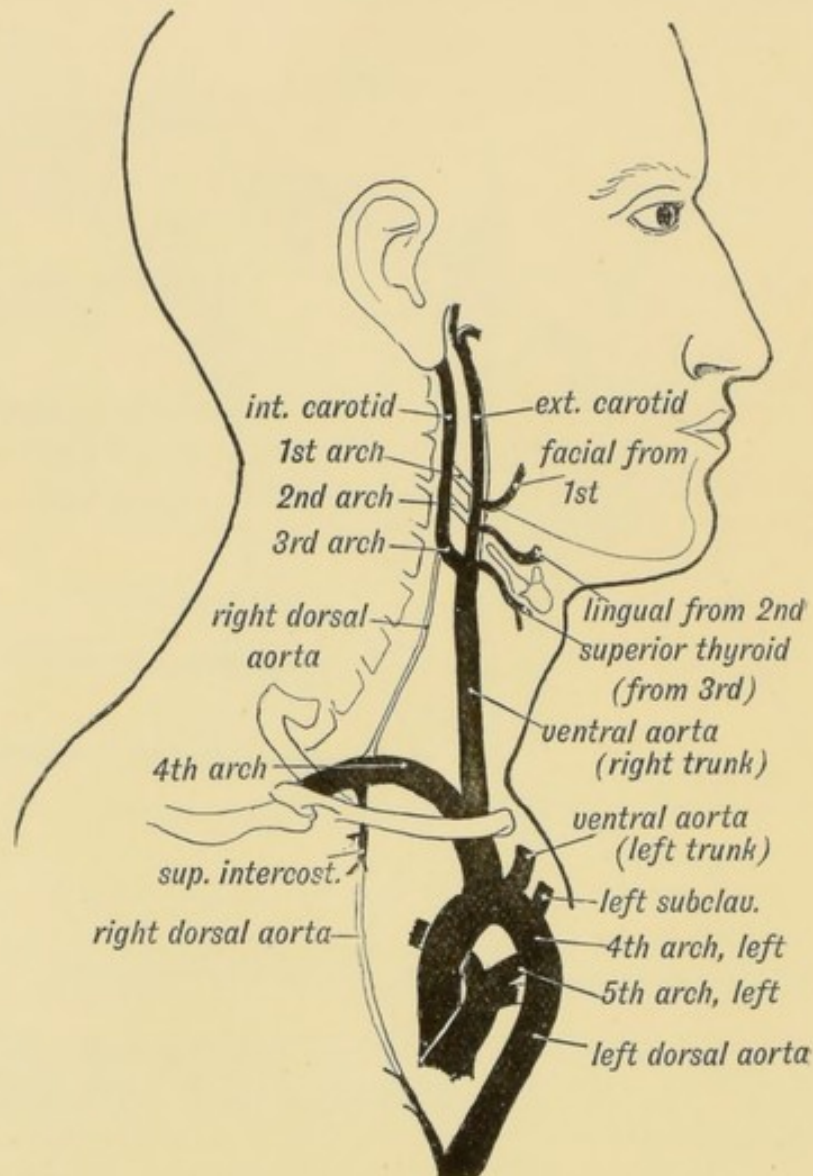


FIG. 28.—Showing what become of the Aortic Arches in the adult. Only the shaded parts persist.

one vessel at the 4th dorsal vertebra—the descending thoracic aorta.

As may be seen from figure 28, the first and second arches disappear; the third remains as the first part of the internal carotid, the fourth forms the 1st and 2nd stages of the right subclavian. On the left side the 4th aortic arch forms that part of the arch of the aorta between the origin of the left carotid

and entrance of the ductus arteriosus. The fifth arch on the left side is represented in its entirety by the pulmonary artery and ductus arteriosus. The fifth arch on the right side disappears, in the greater part of its extent at least. Probably the right pulmonary artery is formed from the inner part of this arch.

All the aortic arches are not present at the same time; some have only a brief period of existence. One of these transient arches is said to appear between what are usually described as the 4th and 5th arches. If this is always the case then the pulmonary arteries should be described as derived not from the 5th but from the 6th aortic arches.

Subclavian Arteries.—The visceral arches with their arteries are well developed before the limb buds appear. When, at the end of the third week, the buds grow out to form the upper extremities, the artery which supplies each bud grows out from

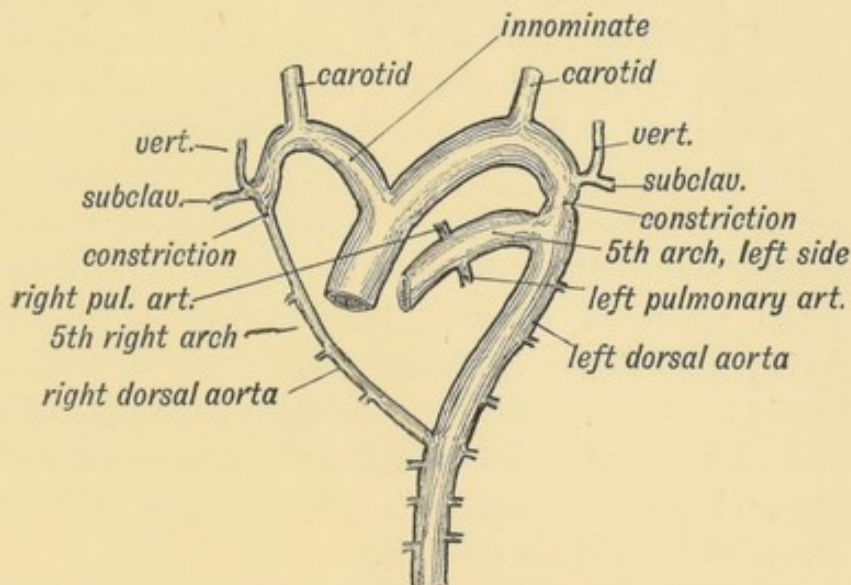


FIG. 29.—The condition of the Right and Left Dorsal Aortae in a 6th week human foetus. (After His.) The right arch disappears beyond the origin of the right subclavian; a constriction may appear at the corresponding point on the left side.

the dorsal aortae opposite the 4th arches (Fig. 29). This artery forms the entire subclavian on the left side, but only its third stage on the right.

The Arch of the Aorta on the Right Side.—In birds it is the 4th right arch which forms the aortic arch, and this occasionally happens in man. In amphibians both the right and left 4th arches persist as aortic arches. The two

dorsal aortae in which they end, unite together, as they do in the human embryo, to form the descending thoracic aorta. Probably a communicating arterial twig which runs in the human body from the origin of the intercostal artery of the 3rd or 4th space to join the superior intercostal of the right side represents the right dorsal aorta between the 4th arch and the descending aorta (see Fig. 28).

Cases are found in which the permanent aorta is very much constricted at or near the point of entrance of the ductus arteriosus (5th arch) (see Fig. 29). It will be noticed that the corresponding part of the right dorsal aorta is obliterated. Such a constriction on the left side is to be regarded as corresponding to that on the right side and indicates a partial attempt to produce a right aortic arch; it may give rise to clinical symptoms.

Dorsal Aortae.—It will be noticed that the parts of the dorsal aortae between the 3rd and 4th arches disappear (Fig. 28). The ventral aortae persist as the innominate, the common carotid and external carotid arteries. It will be observed that, while the 1st, 2nd and 3rd vascular arches have almost retained their foetal position, the 4th and 5th arches have been pulled downwards by the descent of the heart. The 4th, which should lie opposite the upper part of the thyroid cartilage, comes to lie on the 1st rib on the right side and within the thorax on the left, while the 5th dragging the nerve of its arch in front of it (the recurrent laryngeal) is pulled right within the thorax from its foetal position at the thyroid cartilage. With the descent of the heart the ventral aortae between the 3rd and 4th arches are drawn out to form the innominate and common carotid arteries on the right side, and the left common carotid on the left.

Muscles of the Visceral Arches.—All the muscles supplied by the facial nerve—the platysma, muscles of expression, the stapedius, etc.—are derived from the muscle plate of the 2nd or hyoid arch. The muscles of mastication, with the tensors of the palate and tympanum, are derived from the muscle segment of the mandibular arch. The stylo-pharyngeus is derived from the 3rd arch.

The Platysma and Muscles of the Face and Scalp.—The platysma myoides, the muscles of the face, scalp and external ear, are derived from the muscle plate of the second or hyoid arch.

They are supplied by the facial, the nerve of this arch. The muscle bud, from which the whole platysma sheet is developed, is still confined to the area of the hyoid arch at the end of the second month. During the third month the bud spreads out and forms a continuous muscular hood over the head and neck. To this hood or sheet, which is composed of two layers, a deep and superficial, the name of **platysma sheet** may be given. It is developed in the superficial fascia.

In man, the platysma sheet has undergone marked retrograde changes in the neck, scalp and external ear, but over the face it has become more highly specialized and differentiated than in any other animal. From this sheet are derived the epicranial aponeurosis, the occipitalis and frontalis. On the face the platysma sheet forms the muscles round the orbit, nose and mouth. The buccinator and levator anguli oris represent parts of the deeper layer of the sheet. The transversus nuchae, fibres occasionally seen in man passing from the middle line of the neck behind, towards the ear and cheek, represent fibres constantly developed in lower primates, and better still in rodents and carnivores as the *sphincter colli* and *sterno-facialis*.

The muscles supplied by the facial nerve are peculiar in that they are the physical basis into which many mental states are reflected and in which they are realized. Through them mental conditions are manifested. It is found that the differentiation of this sheet into well-marked and separate muscles proceeds *pari passu* with the development of the brain. The more highly convoluted the brain of any primate, the more highly specialized are its facial muscles.

STRUCTURES DEVELOPED FROM THE WALLS OF THE PRIMITIVE PHARYNX.

The Tongue and its Development.—The tongue is developed in the floor of the primitive pharynx between the ventral parts of the 1st, 2nd and 3rd visceral arches (Fig. 31). Two parts are to be recognised in the tongue. The **buccal part** (Fig. 30) is situated in front of the foramen caecum and the V-shaped groove. It is covered by papillae, concerned in mastication and liable to cancer. The second or **pharyngeal part**, bounding the buccal part of the

pharynx in front (Fig. 30), is covered by glandular and lymphoid tissue and concerned with swallowing.

The **buccal part** arises during the 3rd week from the mandibular or 1st arch and the 1st interbranchial space by the upgrowth of a

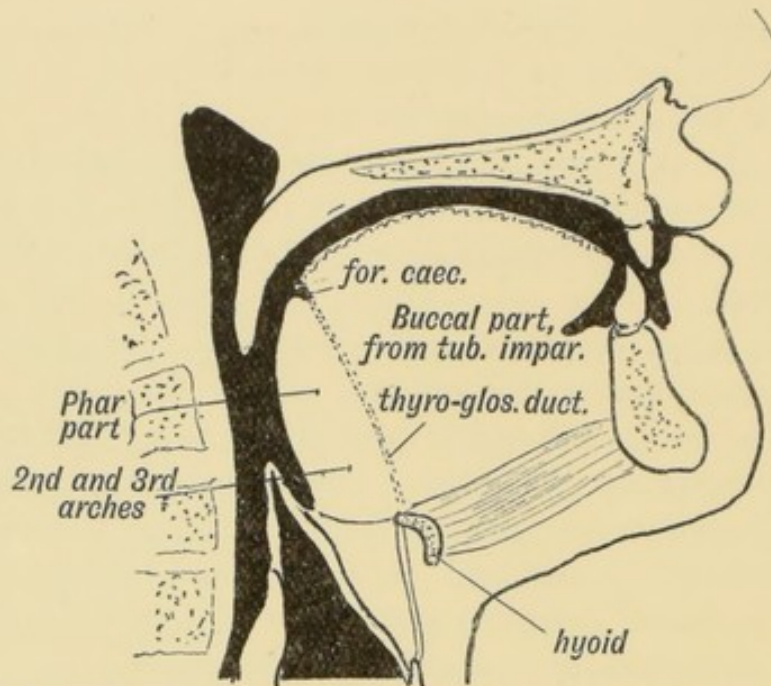


FIG. 30.—Showing the Buccal and Pharyngeal parts of the Tongue.

tubercle, the **tuberculum impar** (Fig. 31). Being mandibular in origin, it is supplied by the mandibular nerve (3rd div. of Vth), and its main attachment is to the mandible. Although its bilateral origin is not apparent during development, the lingual septum, the occasional occurrence of cysts in the middle line and its bifid condition in lower vertebrates and occasionally in man, make it extremely probable that it derives a half from each side of the mandibular arch.

The **pharyngeal part** of the tongue is derived from the fused ventral ends of the 2nd and 3rd arches in which, as we have already seen, the body of the hyoid is developed. The glosso-pharyngeal, the nerve of the 3rd arch, or more strictly of the 2nd cleft, supplies it. The V-shaped groove (*sulcus terminalis*) marks the union of the tuberculum impar with the basal or pharyngeal part. From the hypoblast, which lines the depression between those two parts, arises, by a process of outbudding, the middle lobe or isthmus of the thyroid gland (Fig. 34).

The Musculature of the Tongue.—The muscles of the tongue do not arise within the visceral arches, but are of extraneous origin. It will be shown subsequently that the head is probably composed of nine segments, and it is from the muscle plates of the

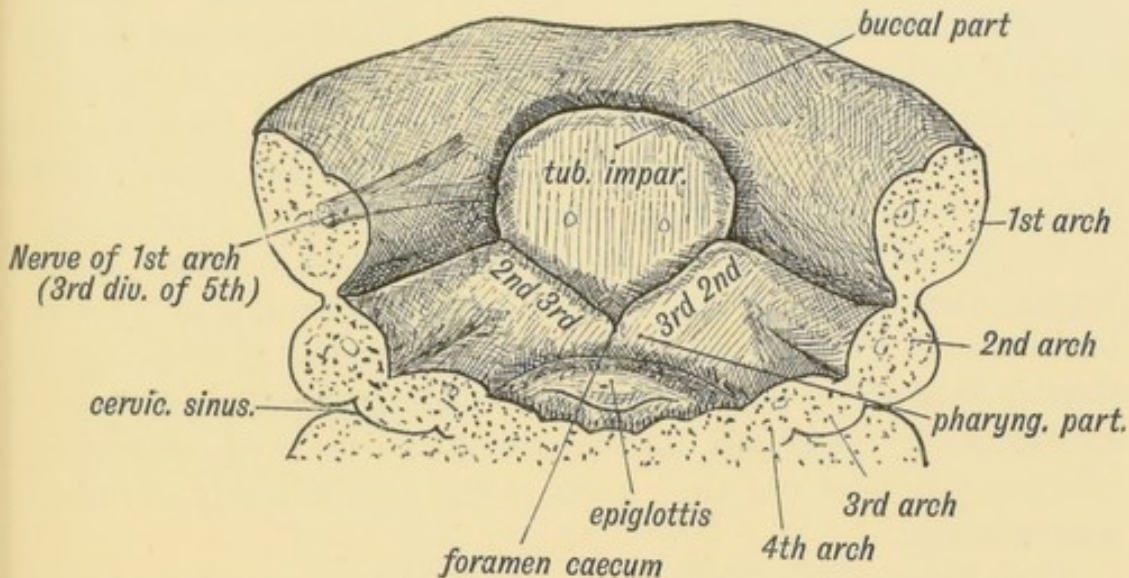


FIG. 31.—Showing the origin of the tongue in the floor of the primitive pharynx. The condition represented is from an embryo in the 6th week. (After His.)

posterior four or five of these segments that the tongue muscles are derived. Processes from the muscle plates of these segments grow downwards and forwards until they reach the basis of the tongue derived from the three visceral arches, carrying their nerves with them—the hypoglossal or 12th cranial nerve, which contains the motor nerve fibres of the posterior segments of the head. Hence, while the sensory nerves of the tongue come from the nerves of the 1st, 2nd and 3rd visceral arches, its motor fibres are derived from the posterior cephalic segments.

Lingual Papillae.—The filiform papillae are the first to appear, then the fungiform, a few of which, along the posterior border of the buccal part, become enlarged and sink to form circumvallate papillae, round the bases of which taste buds are developed. The papillae are confined to the buccal or masticatory part of the tongue. It will be observed that the taste papillae are situated at the brink of the pharynx (Fig. 30), at which the food is seized and carried away by the involuntary muscles. At the lateral margins of the buccal part of the tongue, just in front of the anterior pillars of the fauces, the fungiform papillae are arranged

in a series of laminae, recalling and corresponding to the *papillae foliatae* of low primates and of rodents. Between the *papillae foliatae* occur taste buds. On the under surface of the tongue at birth, on each side of the sublingual papillae and over the position of the ranine artery, are two fimbriated folds of mucous membrane, the *plicae fimbriatae*, vestiges of the tongue-like processes of Lemurs and possibly the entire tongue of lowly Vertebrates. Their function and meaning are unknown, but they may be connected with the sense of taste. A remnant of the *plicae fimbriatae* can commonly be seen in the adult.

The **Lymphatics** of the Tongue, the highways for the spread of lingual cancer, run for the greater part with the lingual vein and terminate in the uppermost of the deep cervical glands, over the jugular vein at the angle of the jaw. Many also terminate in the submaxillary lymphatic glands which lie in and around the salivary glands of the same name. The tongue rarely shows any malformation.

The Epiglottis.—The origin of the larynx, trachea, bronchi and lungs as a depression and bud from the floor of the pharynx, will be dealt with later (page 256); but the origin at the 3rd week of the furcula (Fig. 34), a process from which the epiglottis is derived, may be noted here. It arises from the 4th visceral arch. The upper part of the thyroid cartilage also arises from the 4th. The superior laryngeal is the nerve of the 4th arch, hence it supplies the epiglottis and upper part of the larynx.

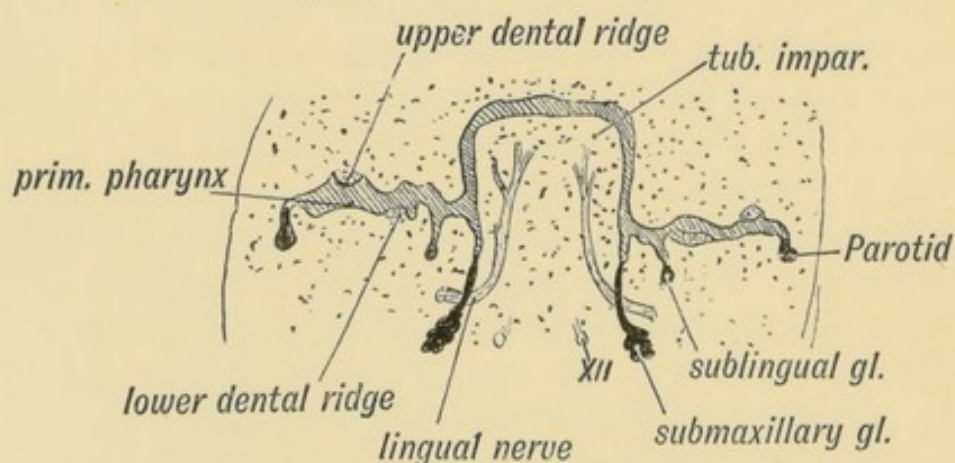


FIG. 32 —Showing the origin of the Submaxillary and Sublingual Glands from furrows between the gum and tongue during the 6th week. (After His.)

Origin of the Salivary Glands.—Between the tongue and gum of the foetus there are two furrows (Fig. 32). From the hypoblast

of the inner, by a process of budding, arises the submaxillary gland; the sublingual arises by a number of buds from the outer groove (Fig. 32). The **parotid gland** springs as a bud from the angle between the mandibular and maxillary processes. It is probably hypoblastic in nature, but it may arise from the epiblast of the stomodaeum, for as yet its exact origin has not been determined. It grows backwards in the connective tissue over the masseter, and at birth is comparatively superficial in position, but as the mandible and external auditory process grow, it sinks inwards to surround the styloid process, pushing the deep cervical fascia beneath it. In this way the stylo-maxillary ligament is formed from the fascia pushed in front of it. Its nerve is derived from the 3rd division of the Fifth (auriculo-temporal).

Seessel's Pocket.—In the middle line of the roof of the pharynx (Fig. 33), just under the basi-occipital, there is a

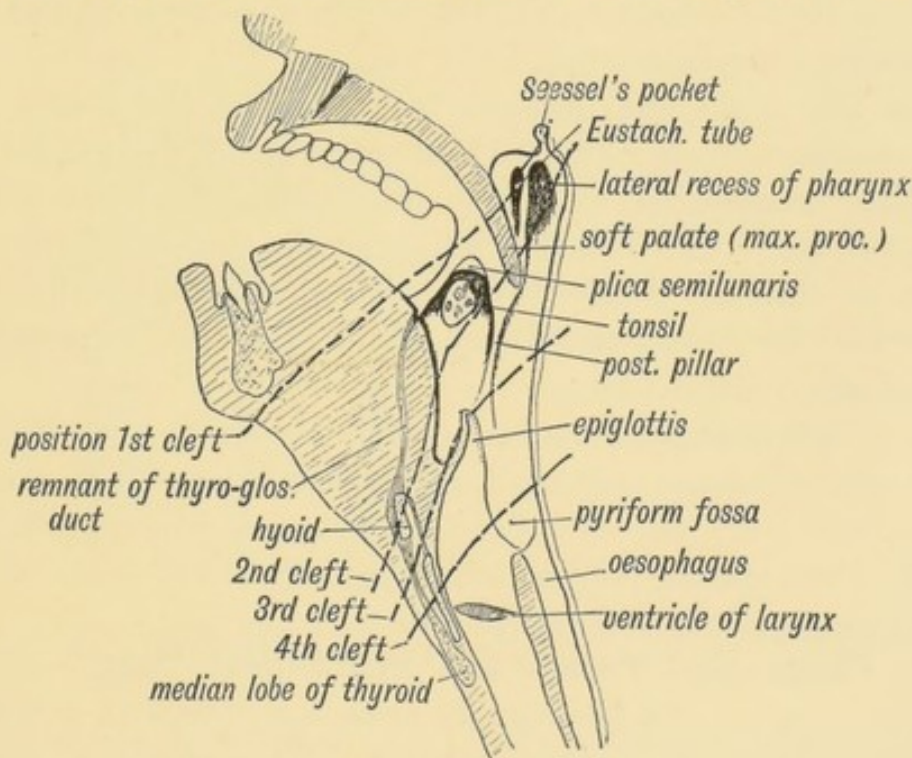


FIG. 33.—Showing the position of the Visceral Clefts in the Adult.

depression or recess of mucous membrane which gets this name. It is of no practical importance, and its embryological significance is doubtful. Lymphoid tissue is developed in its walls and in the mucous membrane round it. It may be a remnant of the pharyngeal opening of the notochord (see page 146). It is developed behind the oral plate.

The Tonsil.—The tonsil arises comparatively late in foetal life. In the 4th month eight or ten isolated buds of hypoblast push out from the second cleft (Fig. 34) into the mesoblastic tissue in the wall of the pharynx above the basal part of the tongue. The buds form the crypts and glandular tissue of the tonsil. Lymphoid tissue—for the tonsil must be regarded as a lymphoid structure—collects round these glandular buds.

Concerning the origin of the lymphoid cells, both of the tonsil and the thymus, there are two quite distinct theories. The more recent (Gulland's) is that the epithelial (hypoblastic) cells, which form the glandular buds of the tonsil, give rise to broods of lymphoid cells; the older, that these lymphoid cells arise from the blood or surrounding connective tissue, creep in and form follicles round the glandular hypoblastic buds. The tonsil rests on the superior constrictor and the pharyngeal fascia, or inner sheath of the constrictor muscles, which surrounds it and forms its capsule.

Over the tonsil and between the pillars of the fauces is the supra-tonsillar recess (Fig. 33), a remnant of the second cleft. The **Plica triangularis** is a fold of mucous membrane which is continued from the anterior pillar of the fauces to the under surface of the soft palate, overhanging the supra-tonsillar recess (Fig. 33). It is well marked in the foetus, but commonly disappears before adult life.

The tonsil is part of a great lymphoid system stationed along the alimentary canal. It reaches its fullest growth in youth, as is the case with the lymphoid system generally; when active growth of the system is over, and especially in the years of decay, it becomes markedly reduced in size.

The Pharyngeal Recess and Pharyngeal Tonsil.—At each side, the roof of the pharynx is produced outwards, behind the Eustachian tube and levator muscles of the palate, to form the **lateral recesses** of the pharynx. They represent the upper ends of the second cleft, the palate (from the maxillary processes) having grown backwards inside the first and second arches and separated the tonsillar part of the second cleft from the pharyngeal recess. In the recess, and especially on the posterior wall of the pharynx between the recesses and round Seessel's pocket, there is developed much lymphoid tissue, the **pharyngeal tonsil**, which may

become hypertrophoid. The lymphoid tissue of the naso-pharynx, when hypertrophied, may press on and obstruct the Eustachian tube and respiratory space (see Figure 33).

The Lingual Tonsil.—That part of the tongue (pharyngeal) produced between the 2nd and 3rd arches is covered by mucous glands which are surrounded by nodules of lymphoid tissue—the collective glandular mass receiving the name of lingual tonsil. It will thus be seen that from the 2nd cleft is produced a circum-pharyngeal ring of lymphoid tissue of great physiological and pathological importance.

The Thymus.—The thymus arises in the same manner as the tonsil, only from the 3rd instead of the 2nd cleft (Figs 33 and 34). The 3rd cleft is represented in the adult by the

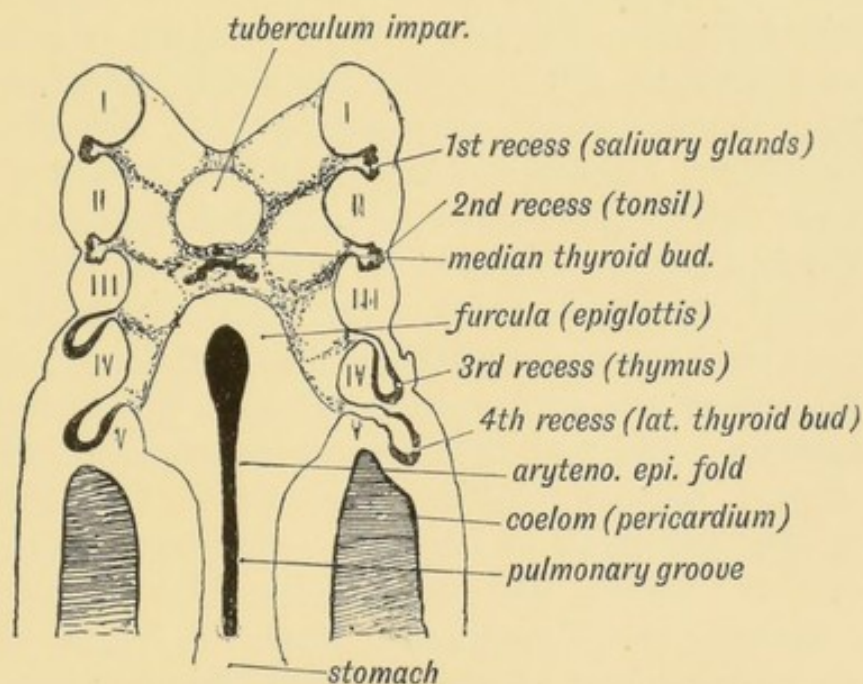


FIG. 34.—Showing the origin of the Tonsil, Thymus, and Thyroid from the Internal Cleft Recesses during the 4th week. (After His.)

space in front, and on each side of the epiglottis. The hypoblast in the 3rd cleft recess thickens, becomes pushed out as a minute pouch, shaped like a Florence flask, between the 3rd (internal carotid) and 4th (arch of aorta) vascular arches. The neck of the glandular hypoblastic pocket disappears. By a species of secondary budding it becomes broken up into islands or separated acini. Either by a production of broods of lymphoid cells within the hypoblastic epithelium or by an invasion of lymphoid cells

from the surrounding mesoblast, the thymus becomes an adenoid structure, the epithelial parts becoming compressed into the corpuscles of Hassall. The surrounding mesoblast supplies its connective tissue stroma and capsule. The lateral lobes come together under the ventral aortae, and in the retrogression of the heart are carried backwards to lie in the superior mediastinum. The pointed upper extremity of each lateral lobe can be traced upwards in the fully developed foetus, under the lateral lobes of the thyroid towards the thyro-hyoid membrane. These apical strands represent the stalk of the thymic buds. In its growth backwards it crosses dorsal to the lateral thyroid buds which arise from the 4th cleft.

The thymus reaches its fullest growth in early childhood (3rd or 4th year), and continues large as long as the body is in a state of active growth. It shrivels up when maturity is reached, and only a remnant is left as a rule, less remaining in men than in woman. It receives its blood supply from the 4th aortic arches through the internal mammary. In manner of origin it resembles the tonsil; indeed it may be regarded as a buried tonsil.

The Thyroid.—At a very early period (4th week), while the buccal and pharyngeal parts of the tongue are appearing as elevations on the floor of the primitive pharynx, the hypoblast in the mesial part of the furrow between those two parts of the tongue thickens. The bud thus formed grows downwards and backwards and soon bifurcates (Fig. 34). The bifurcated extremity, after redivision to form a network of acini, becomes the **isthmus** or **median lobe** of the thyroid. The stalk of the bud becomes the thyro-glossal duct, the lingual opening of the duct remaining as the foramen caecum. It seems probable that this part of the thyroid, at least, was originally a gland which poured its secretion into the mouth. The connective tissue and vessels of the thyroid are derived from the surrounding mesoblast; only the glandular elements arise from the hypoblast of the pharynx.

Thyro-glossal Duct.—In the great majority of subjects the thyro-glossal duct completely disappears; the foramen caecum marks one extremity, while a **pyramid** of thyroid tissue prolonging the isthmus towards the hyoid bone often marks the other extremity. The pyramid of the isthmus may carry on it a

detached part of the thyroid-hyoid muscle—the **levator glandulae thyroideae**. The body of the hyoid bone is developed in the track of the thyro-glossal duct (Fig. 33) and splits it up. Remnants of the duct or of secondary detached acini of the thyroid may persist and form cysts in the base of the tongue above the hyoid, and commonly between the genio-glossus muscles. They may also occur between the hyoid and thyro-hyoid membrane. The supra-hyoid or infra-hyoid bursae may also become cystic, and may be mistaken for thyro-glossal cysts.

The **lateral lobes** of the thyroid are developed from the inner recess of the 4th cleft, the position of which is marked in the adult by the pyriform fossae (see Figs. 33 and 34). These pockets, like the thymic of the 3rd cleft, soon lose their connection with the hypoblastic lining of the pharynx, and become isolated buds which divide and re-divide until a collection of isolated acini is formed. The lateral lobes come in contact as they grow, with the median (lingual) lobe under the laryngeal and tracheal groove in the floor of the primitive pharynx. As they grow outwards the thyroid buds come in contact with the cervical sinus (see page 32), and at one time were supposed to spring from the epiblastic lining of the sinus. They receive their blood supply from the 4th arch (inferior thyroids), while the median lobe is mainly supplied from the ventral aortae, between the 2nd and 3rd arches (superior thyroids). The nerve-supply comes on its arteries from the superior and middle cervical ganglia of the sympathetic. Its nerves appear to have their origin in the upper dorsal segments of the spinal cord.

In the process of development minor buds of the thyroid may become detached. These form **accessory** thyroid bodies.

In manner of origin and growth the thyroid resembles the tonsil and thymus, but unlike these it is not transformed into a lymphoid structure.

Para-thyroids.—These vary in number from three to five on each side (Welsh) and are small bodies of a brownish-red colour, and measuring 6 to 8 mm. in diameter. One or two are situated on the outer side of each lateral lobe amongst the branches of the superior thyroid arteries. They arise with the bud of the thymus from the third cleft. One or two occur constantly on the tracheal aspect of each lateral lobe, amongst the

branches of the inferior thyroid arteries. These are derived from the lateral thyroid buds. In structure they are made up of reticulating columns of cells, with vessels arranged between the columns, thus resembling in structure the carotid body, and probably also in nature and origin the medullary part of the supra-renal. Their presence is essential to the function of the thyroid body.

Carotid Bodies.—The carotid body occurs at the inner side of the fork, between the internal and external carotid arteries. The commencement of the internal carotid represents the artery of the 3rd arch; that of the external carotid, the ventral aortic trunk. The body therefore appears to be developed in the wall of the pharynx at the ventral end of the 2nd cleft. It receives a large supply of nerves from the superior cervical ganglion, and it contains a rich network of vessels. Swale-Vincent regards it as similar in nature and origin to the coccygeal body and medulla of the supra-renal (see p. 259).

CHAPTER IV.

DEVELOPMENT OF THE ORGAN OF HEARING.

The Structures which form the Organ of Hearing.—In figure 35 is shown diagrammatically the derivation of the five elements which unite together to make up the organ of hearing. The five elements are :

(1) **The otocyst**—an area of epiblast (epithelial covering of embryo) above the first branchial cleft which becomes invaginated in a saccular form, and forms the epithelial lining of the membranous labyrinth. Some of its lining cells become differentiated into the auditory epithelium.

(2) A **ganglion** derived from the “neural crest” of the hind brain (Fig. 35). The nerve cells form the cochlear and vestibular ganglia. Each cell sends out two processes, one to become connected with the auditory epithelium of the otocyst, the other to end in groups of nerve cells in the floor of the 4th ventricle, their collective fibres forming the auditory nerve. The development of the auditory nerve thus resembles that of the posterior or sensory root of a spinal nerve.

(3) The otocyst (membranous labyrinth) becomes surrounded by a capsule of cartilage—the **periotic capsule**. This ossifies from several centres, and forms the bony labyrinth and petro-mastoid.

(4) **The dorsal end of the first visceral cleft.**—The inner recess of the 1st cleft forms the Eustachian tube, the tympanum and antrum of the mastoid; the external cleft depression, the external auditory meatus; while out of the cleft membrane is formed the membrana tympani.

(5) The **malleus is derived** from the upper end of Meckel's cartilage, the incus from the posterior end of the palato-quadrate

bar (cartilaginous skeleton of maxillary process), while the stapes is an independent formation developed round the stapedia

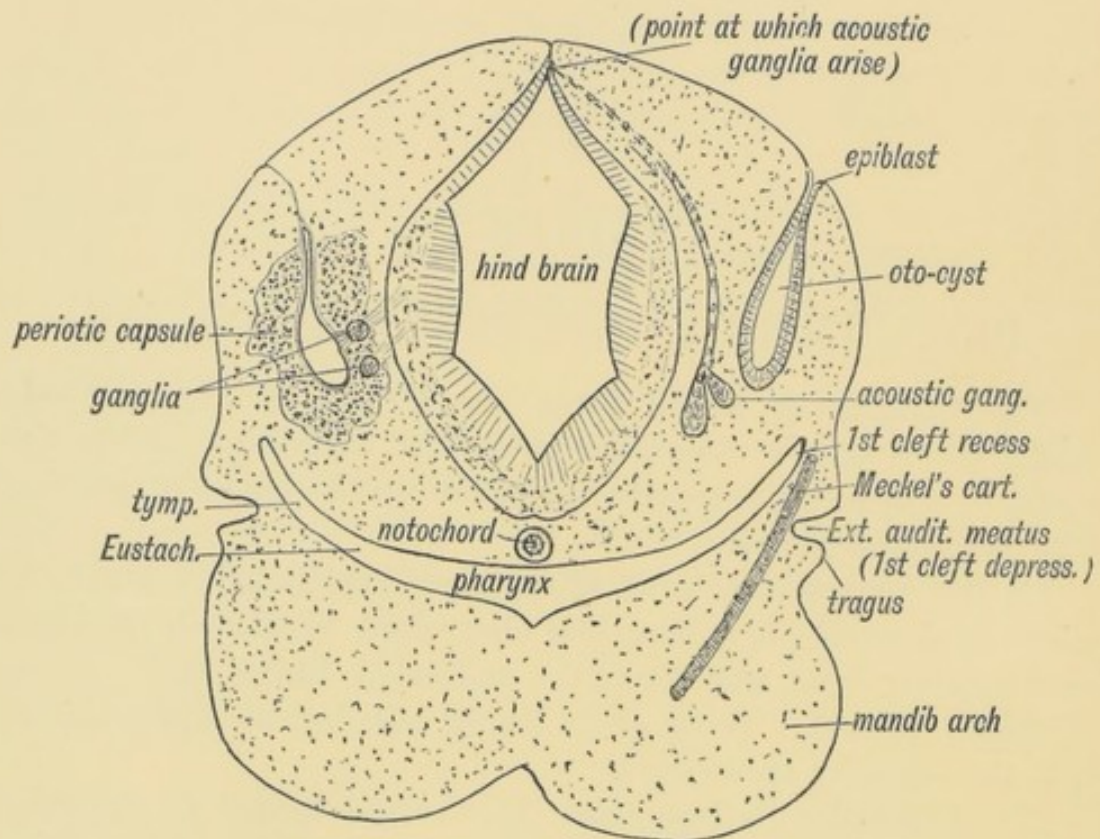


FIG. 35. —Diagrammatic Section through the Cephalic region of an embryo, showing the origin of the Auditory System.

artery. It may be derived, in part at least, from the upper end of the cartilage of the hyoid arch (see also page 10).

In lower fishes the auditory apparatus is composed of elements 1 and 2, and are in them of the simplest form. The other elements are added and specialized in the evolution of the higher vertebrates.

External Auditory Meatus.—The external auditory meatus is derived from the upper part of the first cleft depression. In the adult the meatus is $1\frac{1}{4}$ in. long; at birth it is $\frac{1}{3}$ of an inch, and is surrounded by fibro-cartilaginous and fibrous tissue. In the adult the tympanic ring grows outwards in the fibrous tissue, as we have already seen (page 17) to form the tympanic plate and the inner $\frac{2}{3}$ of the meatal floor. The squamous part of the temporal, which is developed over in its roof, also grows outwards and forms a thick, horizontal plate in the inner two-thirds of

the meatal roof (Figs. 36 *A* and *B*). Over the roof lies the third temporal convolution.

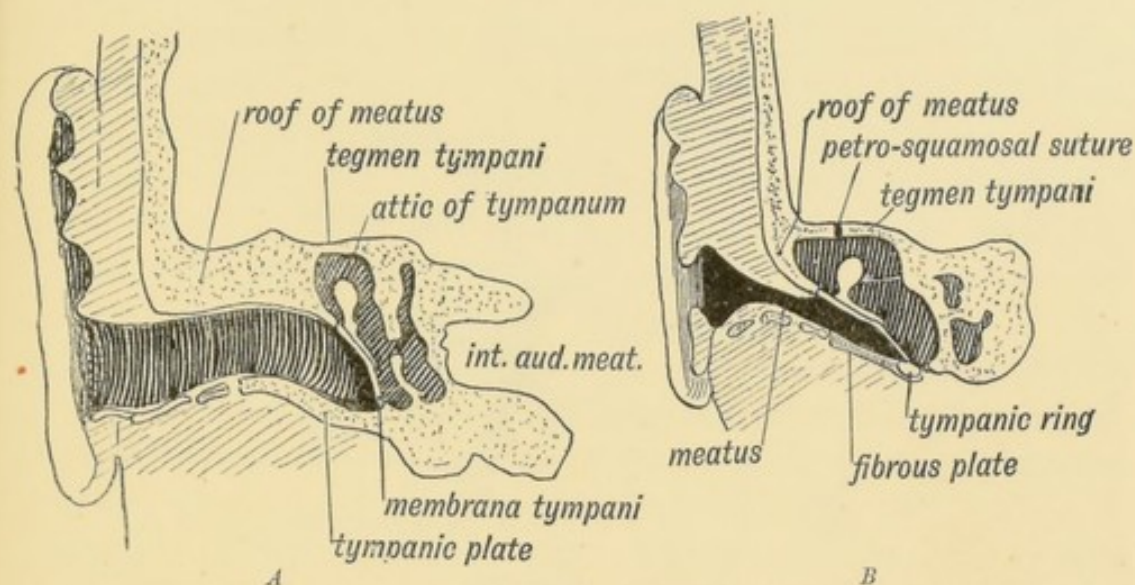


FIG. 36 *A*.—A Section of the External Auditory Meatus of the Adult.

FIG. 36 *B*.—A Section of the External Auditory Meatus at Birth. (After Symington.)

The meatus is supplied in front by the nerve of the mandibular arch (auriculo-temporal branch). Why the vagus should supply it with a branch (Arnold's nerve) is obscure. The vagus is a visceral nerve and supplies the 3rd and 4th clefts by its superior and inferior laryngeal branches. In fishes a branch of the vagus passes backwards beneath the skin on each side and supplies the sense organs of the lateral line. Many regard the auricular branch of the vagus as a vestige of such a branch.

In the newly-born child the membrana tympani is so obliquely set that its outer surface is almost in contact with the meatal floor. With the development in length of the meatus, it becomes more vertical in position. The meatus may be only partly developed or even absent, the upper part of the 1st cleft becoming completely closed like the lower part. In such a case there is commonly a corresponding absence of development of the middle and internal ear.

The External Ear.—Six tubercles appear on the mandibular and hyoid arches round the 1st cleft depression and form the external ear (see Figs. 37 and 38). Two of these tubercles grow from the mandibular arch and form the tragus and crus of the helix; three from the hyoid to form the lobule, antitragus

and antihelix; one above the cleft to form the helix. The posterior margin of the ear is continuous with the lobule, and grows

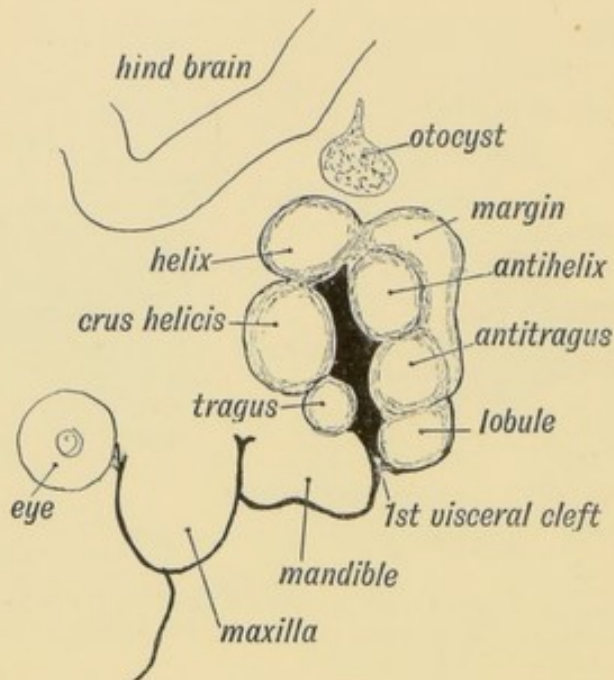


FIG. 37.—Showing the Tubercles which arise round the First Visceral Cleft to form the External Ear.

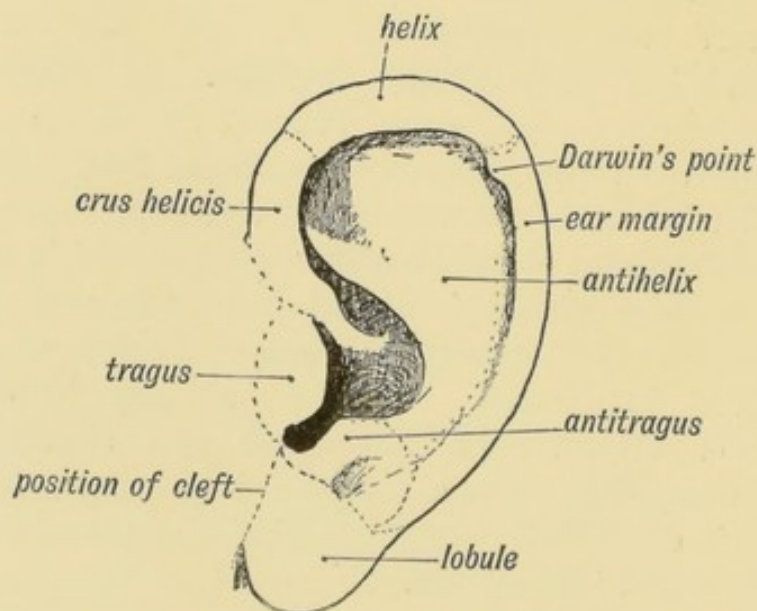


FIG. 38.—Showing the part of the Adult Ear formed by each Tubercle.

from the tissue behind the tubercles which form the antihelix and antitragus. The auricular tubercles may not fuse completely and thus leave fistulae between them. Such fistulae are

commonly seen between the tragus and root of the helix, or between the antihelix and helix. The outgrowth of the ear may be arrested at any stage. The mandibular part is supplied, as one would expect from its origin, by the third division of the 5th, while the sensory fibres of the hyoid part come from the 2nd cervical by the great auricular and small occipital nerves.

Darwin's Tubercle.—The human ear appears to be derived from a form in which the margin was pointed at the posterior superior angle, such as is seen in many of the lower forms of apes and mammals generally. With the retrogression of the posterior border or descending helix and increased development of the antihelix in the human ear, the posterior margin became infolded; hence the tip appears as a tubercle on the inturned posterior margin or welt of the human ear (Fig. 38).

Muscles of the External Ear.—These are derived from the

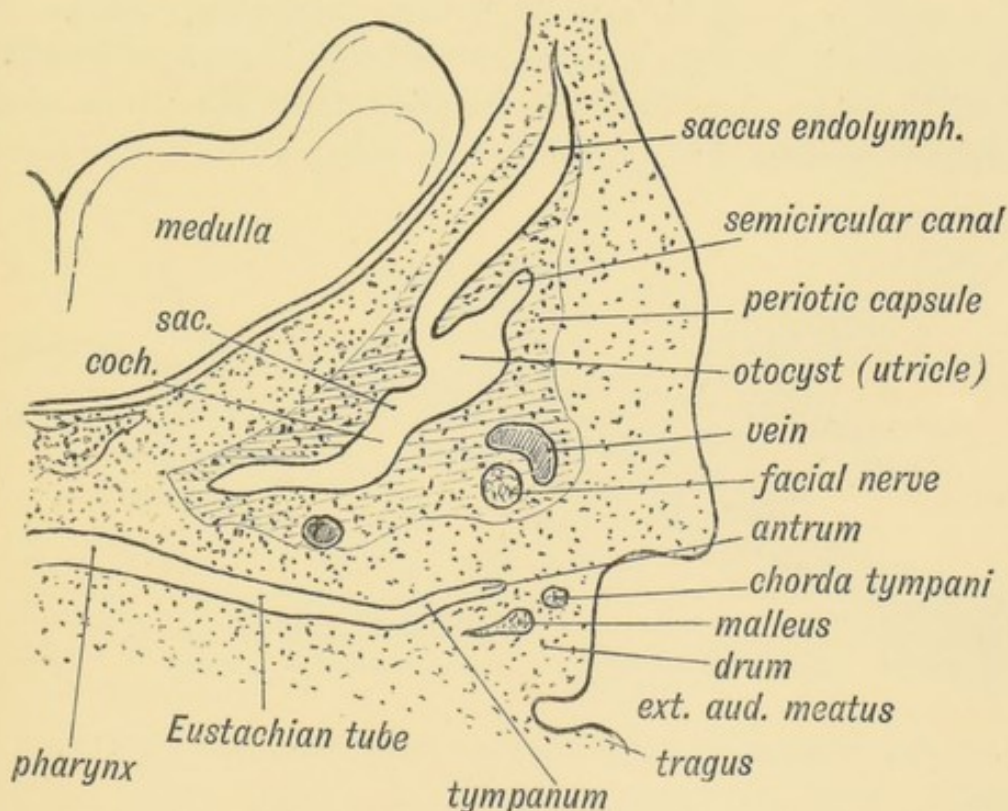


FIG. 39.—Showing the condition of the Auditory Organs in a 6th week human foetus. (After Siebenmann.)

platysma sheet and are supplied by the nerve of that sheet—the VIIth or facial. The ear muscles are not so reduced in man as in some other primates, such as the orang.

The Eustachian Tube.—The Eustachian tube is derived from the first inner cleft recess of the pharynx (Fig. 39) and retains through life the ciliated epithelial lining of the primitive pharynx. It is $1\frac{3}{4}$ inches long. Its inner $\frac{2}{3}$ is bounded behind by a triangular plate of cartilage, which is attached at its inner or pharyngeal end to the internal pterygoid plate, a derivative, with the incus, of the pterygo-palatine bar (Fig. 10 C). The cartilage is developed in the walls of the 1st visceral cleft in the 4th month of foetal life. The tympanic plate grows inwards and forms the floor of its outer third (Fig. 40), while the periotic capsule (petro-mastoid) which is developed above and behind the 1st cleft, grows over and forms the roof of its outer third. The part of the petro-mastoid which grows over it, is the **tegmen tympani**; it also forms the roof of the tympanum and antrum of the mastoid. It forms the roof of all the cavities derived from the inner recess of the first cleft (Fig. 40). The anterior edge of the tegmen tympani appears in the Glaserian fissure. The tensor tympani and tensor palati are developed on the mandibular side of the first cleft and are supplied from the nerve of the mandibular process through the otic ganglion.

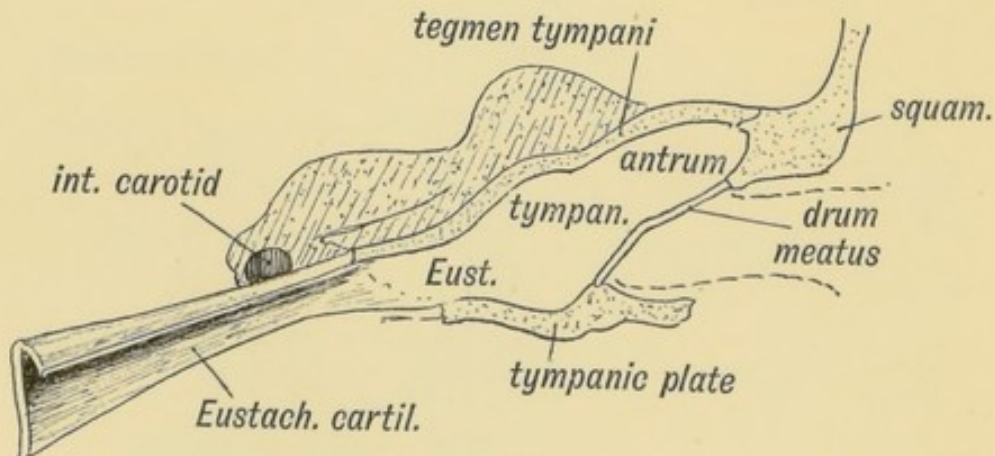


FIG. 40.—Showing the Cavities derived from the Inner Recess of the First Cleft.

The Tympanum.—As may be seen from Fig. 39, the tympanum can scarcely be said to exist at the sixth week of foetal life. The inner cleft recess ends in the jelly-like tissue containing the cartilaginous bases of the malleus and incus. It is directed outwards and backwards between the periotic capsule to its posterior

and inner side and the external cleft depression (meatus) and developing squamosal to its outer (Fig. 39). As the internal recess extends and widens outwards and backwards, the gelatinous tissue is absorbed, so that the malleus and incus and developing stapes, with the chorda tympani, become surrounded by the hypoblastic lining of the inner cleft recess and appear to be situated within the cavity thus formed—the tympanum. The tympanic plate forms its floor, the membrana tympani and squamosal its outer wall, while the petro-mastoid forms its inner wall and roof (Fig. 40). That part of the tympanum which lies above the level of the membrana tympani is named the **attic**, and contains the head of the malleus and body of the incus (Fig. 36).

In carnivora and some other mammals the floor of the tympanum, formed by the tympanic plate, is inflated into a bulla, the tympanic bulla. Its meaning is unknown, but when a bulla is developed the antrum of the mastoid is small or absent.

The Antrum of the Mastoid.—The antrum of the mastoid represents the extreme outer or posterior end of the first cleft recess (Figs. 39 and 40). It is formed at the same time and in

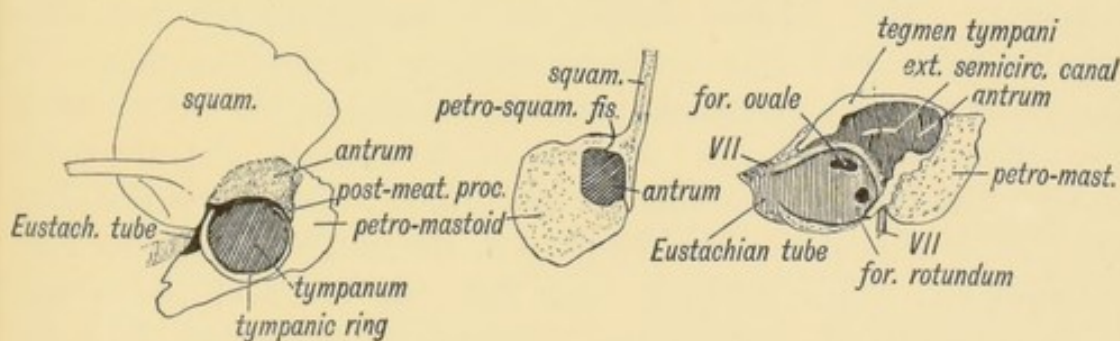


FIG. 41.

FIG. 42.

FIG. 43.

FIG. 41.—The temporal bone at birth showing the formation of the Antrum between the Squamosal and Petro-mastoid.

FIG. 42.—A transverse section showing how the Walls of the Antrum are formed.

FIG. 43.—Showing the outer aspect of the Petro-mastoid at birth after the Squamosal is removed.

the same manner as the tympanum. Its use is unknown, but it has frequently to be exposed by the surgeon to remove the effects of chronic middle ear disease. At birth its outer wall is formed by the thin post-auditory part of the squamosal (Figs. 41 and 42). The squamosal forming its outer wall is then only 2 mm. thick, but every year until the 20th, or later, this plate increases nearly 1 mm. in thickness, so that by the 20th year

the antrum is buried by a plate of bone about 20 mm. thick. There is a great individual variation, however, in the thickness of its outer wall. The antrum lies above and behind the level of the external auditory meatus; the post-auditory spine and supra-meatal triangle formed by the post-auditory part of the squamosal lie over it and serve as surface guides to it. The antrum opens in front into the attic of the tympanum. The tegmen tympani (Fig. 42) forms its roof and the petro-mastoid its floor and inner wall. The aqueductus Fallopii runs down the inner wall of its mouth (Fig. 43), and in its inner wall is situated the external semi-circular canal. The petro-squamous suture in its roof (Fig. 42), and the masto-squamous suture on its outer wall (Fig. 14 *B*), become closed in the second year, and thus the escape of pus from it is rendered more difficult.

The Primitive Jugular Vein.—In the petro-squamous suture a vein or sinus, frequently of considerable size, runs forwards from the lateral sinus, and commonly ends in a tributary of the middle meningeal vein. It receives as it runs along venules from the antrum and attic and may be the means of carrying infection from the middle ear to the lateral sinus or to the meningeal veins (Cheatele). The petro-squamous sinus represents the primitive jugular vein, and may open in man, as it does in mammals generally, at the post-glenoid foramen, situated at the outer end of the Glaserian fissure, near the base of the zygoma. In the early weeks of embryonic development the primitive jugular is the chief vein from the skull, but very soon the internal jugular vein enlarges and takes its place, and thus the blood of the lateral sinus comes to pass out by the jugular foramen instead of by the petro-squamous sinus and temporal canal at the base of the zygoma.

The Membrana Tympani.—As may be seen from Fig. 39, the membrana tympani is of very considerable thickness until the third month. It has an inner covering of hypoblast and an outer of epiblast. In the mesoblastic tissue between the coverings lie parts of the malleus, incus and chorda tympani. As the tympanic cavity expands the mesoblastic tissue is compressed and absorbed, and thus the handle of the malleus and chorda tympani come to appear as if they lie on the membrane, although really within it. The mucous lining of the tympanum covers them. The mem-

brane is supported by the tympanic ring, the age changes of which have already been dealt with (p. 17). The nerves and arteries of the first cleft supply the drum.

The Membranous Labyrinth. **Origin.**—The cells of a certain area of epiblast, situated above the 1st cleft (Figs. 35 and 37), become ultimately sensitive to sound waves. This area is invaginated during the third week, and forms a simple closed pyriform sac, the **otocyst**, which lies above the first visceral cleft in the mesoblastic tissue between the hind brain and the epiblast (Figs. 37 and 39). The sac contains a fluid, the endolymph, and also otoliths are found in it later. The otocyst receives a thin

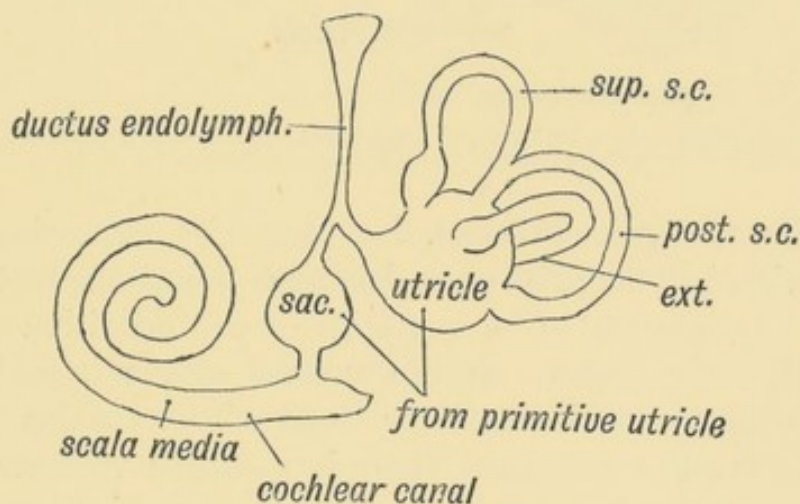


FIG. 44.—Diagram of the Membranous Labyrinth.

coat of mesoblast. The epithelial cells lining it, all of which are originally columnar, soon become flattened, except at the maculae acousticae, where they retain the columnar form and develop hair-like processes. These become connected with the hind brain by the auditory nerve fibres of the cochlear and vestibular ganglia.

In the lower vertebrates, as in the earlier embryonic stages of the higher mammals, the otocyst is of a saccular form with a stalk above—the **ductus endolymphaticus** (Figs. 39 and 45). The simplest form of vertebrate otocyst is seen in the lamprey; the superior and posterior semicircular canals are present, but, as in the mammalian embryo, the primitive cyst is undivided into utricle, saccule, and cochlear canal. The semicircular canals grow out from the cyst as flat, hollow plates, but only the circumferences of the plates persist, the centres disappearing.

The **primitive utricle**, which represents the main part of the

otocyst, subdivides into the saccule and utricle (Fig. 44). The division occurs at the entrance of the endolymphatic canal, which thus comes to open into both saccule and utricle. The endolymphatic canal, which is simply the stalk of the otocyst, is

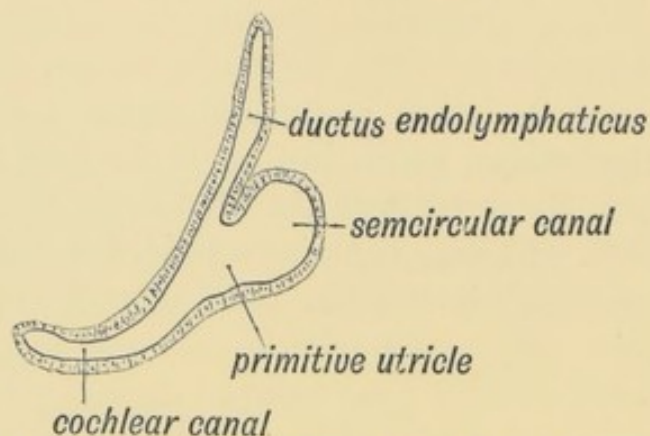


FIG. 45.—The Otocyst in an Embryo of five weeks; it shows a demarcation into the various parts of the Membranous Labyrinth.

enclosed in the petro-mastoid, its extremity appearing at the hiatus vestibuli, where it ends beneath the dura mater in a dilatation. It appears to be a vestige of the primitive mouth of the otocyst, which opens on the surface of the head in many fishes. Lastly, the scala media or canal of the cochlea (Fig. 44) grows out from the saccule. There is merely a rudiment of the cochlea in fishes and amphibians. In reptiles, birds, and monotremes it is a straight canal—the **Lagena**. Only in mammals is it arranged spirally. In it the organ of Corti is developed.

The Petro-mastoid. Origin.—The mesoblast surrounding the membranous labyrinth becomes cartilaginous at the end of the 3rd month of foetal life, forming the periotic capsule (Figs. 35 and 39). The tissue which immediately surrounds the membranous labyrinth does not undergo chondrification, but becomes converted into an open meshwork of cells, the intercellular spaces containing perilymph. The lymphatic space thus formed within the petro-mastoid, containing the saccule and utricle, is the vestibule. The scalae tympani and vestibuli of the cochlea are of similar origin. An oval space on the outer wall of the vestibule is not chondrified; it contains the footplate of the stapes and forms the foramen ovale. The foramen rotundum also remains unchondrified and separates the tympanum from the scala tympani (Fig. 43).

It will be observed that the various structures which serve to transmit the sound waves from the external auditory canal to the brain are drawn from many and very different sources. The *membrana tympani* is the membrane of the first cleft; the *malleus* is the end of the skeleton of the first visceral arch; the *incus* is part of the palato-quadrate bar; the *stapes* is of independent origin or drawn from the cartilage of the second arch; the epithelial lining of the membranous labyrinth is derived from the skin; the petro-mastoid and the perilymph spaces from the mesoblast; the ganglia and nerves from the hindbrain.

Although the derivation of the auditory ossicles given here is the usually accepted one, there are many reasons for supposing that Gadow's views of the nature of the *malleus*, *incus* and *stapes* will turn out to be the right one. He regards all three bones as derived from the upper part of the hyoid arch (see page 11).

The *aqueductus cochleae* is the outlet of the perilymphatic space. It passes from the *scala vestibuli* to the anterior wall of the *jugular fossa*.

Ossification of the Petro-mastoid.—About the end of the 4th month, four ossific centres appear in the periotic capsule; one, the **pteroitic**, gives rise to the *tegmen tympani* which forms the roof of the *antrum*, *tympanum*, and *Eustachian tube*; the petro-squamous suture marks its outer edge; the *hiatus Fallopii* marks its junction with a second centre—the **opisthotic**. This centre forms the posterior half of the petrous bone. The **pro-otic** forms the anterior half; the mastoid part, which appears on the surface of the skull, is developed from the **epi-otic** centre.

The Mastoid.—The mastoid part of the petro-mastoid is flat at birth; about the 2nd year the mastoid process appears as a slight knob, and it gradually grows downwards to form a cephalic lever for the *sterno-mastoid*, *splenius* and *trachelo-mastoid* muscles. The period of its most active growth is marked by the eruption of the permanent teeth. In most mammals the mastoid grows out as a flat wing-shaped process continuous with the occipital crest, and thus increases the basal area of the skull on which the neck muscles are inserted. The post-auditory process of the squamosal forms a considerable part of the mastoid process; it reaches to the apex and forms the anterior border (Fig. 14C). As the mastoid

process grows the diploic spaces within it enlarge into air spaces. Those round the antrum come to open into it, but the more distal remain closed. These spaces occupy the whole of the mastoid part of the temporal, but they also extend forwards in the post-auditory process of the squamosal, and may spread backwards to the occipital. Three varieties of mastoids are recognised :

(1) Dense processes in which the air cells are minute or absent ;

(2) Containing numerous large spaces (pneumatic) ;

(3) An intermediate type with large cells round the antrum, and a few small ones near the surface. The third type is the commonest.

The Floccular or Subarcuate Fossa.—At birth there is a fossa situate on the posterior aspect of the petro-mastoid. It is filled with a process of the dura mater, and over it, but not within it, the flocculus is situated. The posterior semicircular canal surrounds the fossa. This is the condition in most mammals throughout life, but soon after birth the fossa becomes closed in man, merely a remnant being seen above and internal to the hiatus vestibuli in the bone of the adult. Its meaning is unknown.

The Acoustic Ganglia.—It has already been shown (Fig. 35) that the mass of nerve cells which come in contact with the otocyst arise from the neural crest of the hind brain in the same manner as the ganglion of a posterior nerve root. The mass of nerve cells is divided into three groups (*A*, *B*, *C*, see Fig. 46).

One becomes the **geniculate ganglion** (*A*) ; in the formation of the petro-mastoid it is included in the aqueductus Fallopii. Its cells give rise to the great superficial petrosal nerve and chorda tympani in the same manner as the ganglion of a posterior root produces the sensory fibres of a spinal nerve (Dixon). The pars intermedia, in part at least, represents the afferent or ingrowing root of the ganglion.

The second or **cochlear** group (*B*) gives rise to :

(1) The spiral ganglion situated in the lamina spiralis ;

(2) To the cells in the floor of the internal auditory meatus which become connected with the saccule and posterior semicircular canal ;

(3) Another part remains stranded on the restiform body as the accessory and lateral root ganglia (Fig. 46).

Each cell of the ventral acoustic ganglion (group *B*) sends efferent processes to the organ of Corti in the cochlea and the acoustic cells of the saccule and posterior semicircular canal and afferent fibres which form the dorsal or lateral root of the

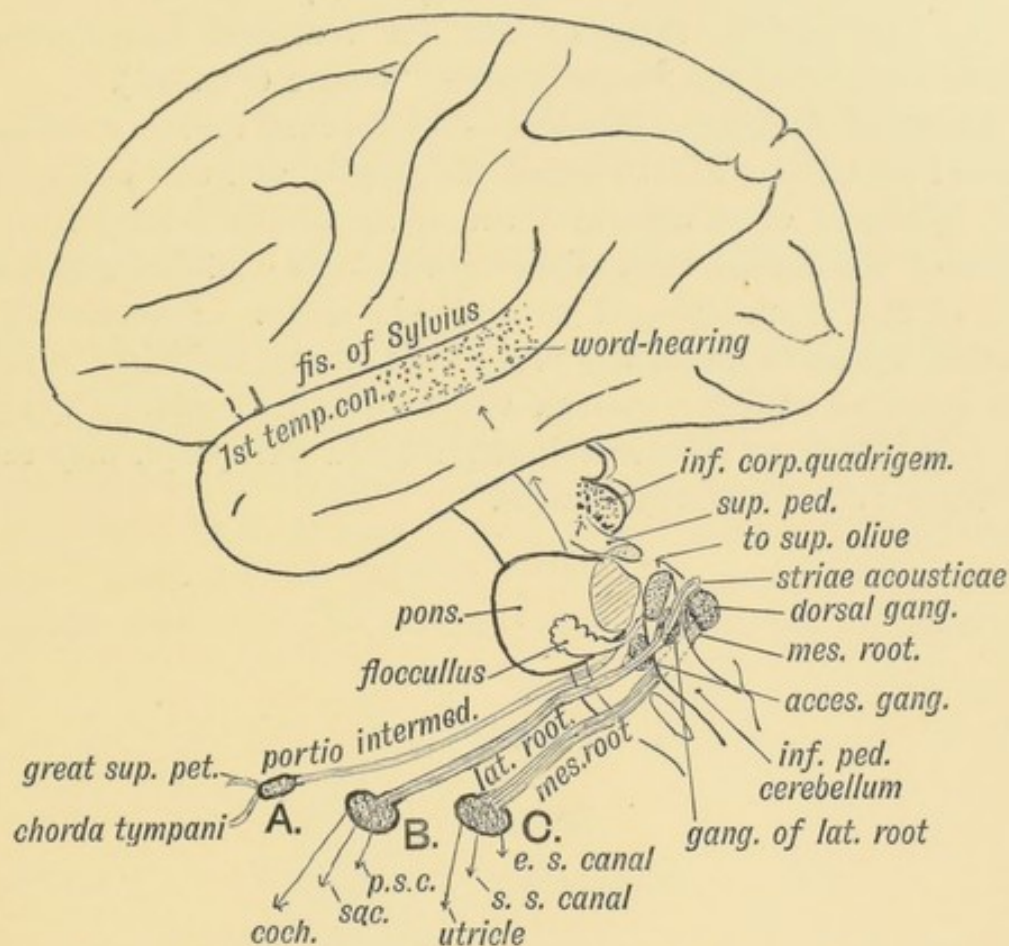


FIG. 46.—Showing the Nerve Structures concerned in the Sense of Hearing.

auditory nerve and run to the nerve cells in the opposite side of the medulla oblongata. Some of these fibres form the striae acousticae.

The third group of cells (*C*, Fig. 46) forms the **vestibular ganglion** in the fundus or floor of the internal auditory meatus. Its cells send efferent fibres to the utricle, external and superior semicircular canals, and afferent fibres which form the mesial root of the auditory nerve. This root passes beneath the restiform body (Fig. 46) to terminate in the nerve cells of the acoustic tubercle and trigone in the floor of the 4th ventricle: These nerve cells and fibres are in no sense auditory, but concerned with the balancing of the body.

By uncertain tracts the central auditory terminations in the medulla are connected with:—

- (1) The cerebellum ;
- (2) The superior olive ;
- (3) The posterior corpora quadrigemina ;
- (4) The middle third of the 1st temporal convolution in which is situated the "word-hearing" centre (Fig. 46).

Internal Auditory Meatus.—The internal auditory meatus is formed round the VIIIth nerve, its ganglia, and the VIIth nerve. The falciform crest separates the fibres of the lateral from the fibres of the mesial root. The meatus also contains a prolongation of the arachnoid and subarchnoid space. Fractures of the base of the skull frequently cross the petro-mastoid in the line of the internal auditory meatus, vestibule and membrana tympani. In such cases the cerebro-spinal fluid and perilymph may escape by the external auditory meatus.

CHAPTER V.

DEVELOPMENT AND MORPHOLOGY OF THE TEETH.

The Structure of a Tooth.—A tooth may be considered as made up of five parts (see Fig. 47):

(1) The **pulp**, situated within (2) a capsule of **dentine**; the exposed part or crown of the dentine is coated by (3) the **enamel**; the imbedded part or root by a layer of bone—(4) the **crusta petrosa**. The root is secured within its socket by (5) the **peridental membrane**, which acts as a periosteum to both the

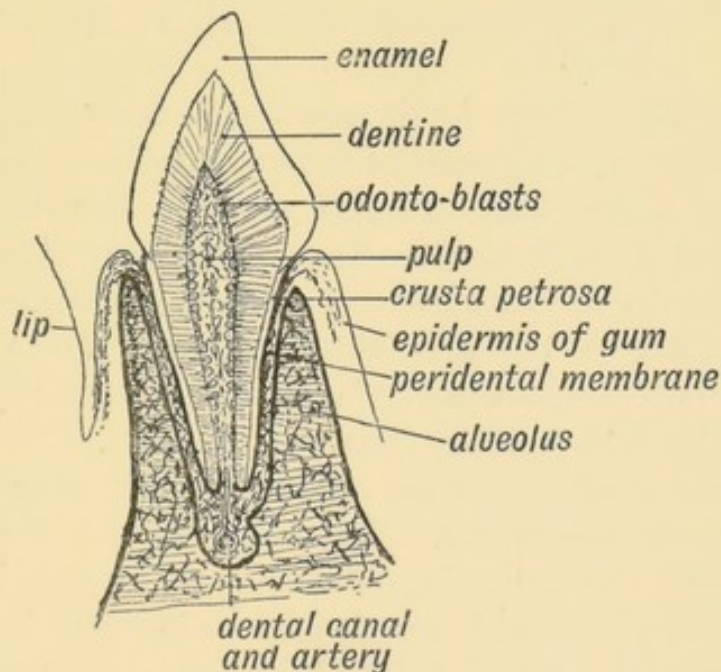


FIG. 47.—Showing the parts of an incisor tooth.

crusta petrosa and bony wall of the tooth socket. An account of the development of a tooth has to deal with the origin of each of these five parts.

(1) **Origin of the Enamel.**—The enamel is formed by the epiblast of the stomodaeum. At the sixth week the epiblast within the labial margin grows downwards so that a narrow semicircular invagination of epithelium is formed. To the plate of epiblast thus infolded the name of **dental shelf** is given; its position is marked superficially by an epithelial crest—the dental

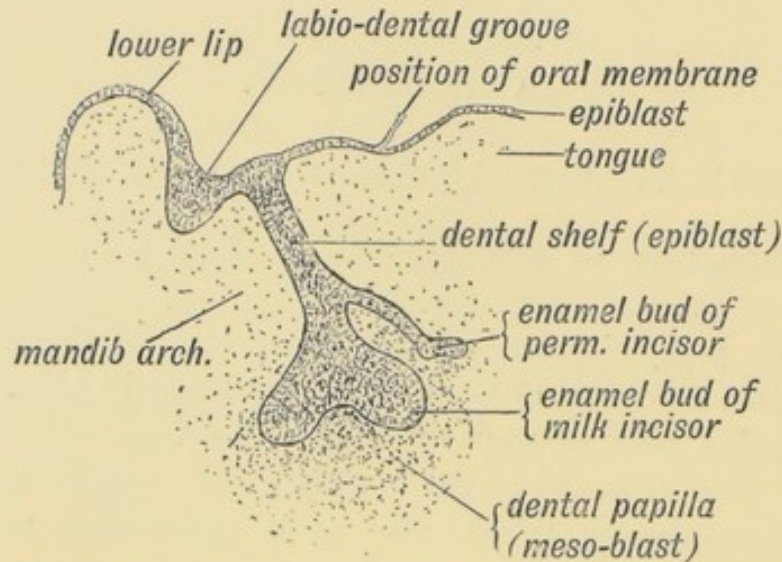


FIG. 48.—Section through the lip and mandible of a foetus in the third month, showing the down-growth of the Dental Shelf.

ridge (Fig. 48). From its ingrowing or deep margin ten epithelial buds arise, both in the upper and lower jaw. Each of these twenty **enamel buds** or **organs** produces the enamel to cover the crown of a milk tooth. Each bud grows downwards and inwards from the surface and comes against a condensed formation in the mesoblast of the jaw—the **dental papilla**. On the papilla the enamel bud becomes partly invaginated, the papilla coming to lie within the invagination (Figs. 48 and 49). The epithelium covering the papilla becomes a layer of columnar enamel-producing cells or **ameloblasts**. The basal part of the ameloblasts are converted gradually into enamel, or to put it somewhat differently, they form and deposit enamel in their bases and thus produce a coating for the dental papilla. Each ameloblast is gradually converted into an enamel fibre, but their more superficial parts are never so converted but persists as the **cuticular membrane** which covers the enamel at birth and is soon afterwards worn off. The enamel of the milk teeth is completely

formed before birth; and that of the first permanent molar is already partly deposited.

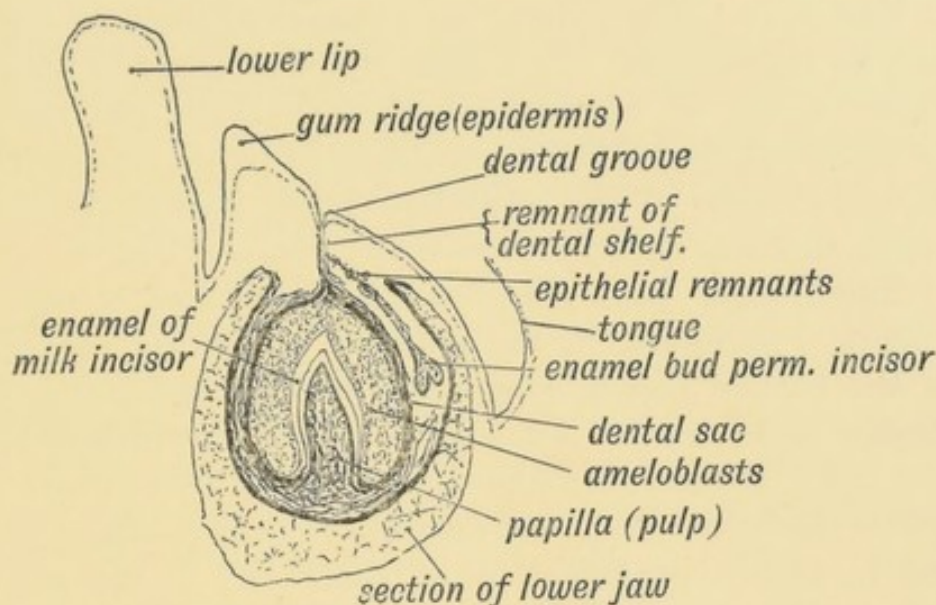


FIG. 49.—Showing the stage of development in an incisor tooth of a foetus of six months.

(2) **Origin of the Dentine.**—The dental papilla, formed from the mesoblast, corresponds to a depressed skin (dermal) papilla, the enamel cells representing its covering of epithelium. The dental papilla determines the shape of the tooth. In its superficial layers it contains numerous cells, **odonto-blasts**, with branched processes radiating towards the enamel epithelium. By the agency of the odonto-blasts a substance is deposited which becomes calcified into dentine or ivory. It is deposited round the processes of the odonto-blasts. The cavities in which the processes are enclosed form the tubules of the dentine. In rodents especially, but also in all mammals, although only to a slight extent in civilized races of mankind, the odonto-blasts react to wear, add new layers of dentine to the wall of the pulp cavity, and thus prevent the pulp from being exposed. The dentine is deposited first in the crown of the tooth beneath the enamel; the neck is laid down next, and then the root, the last point of all to be formed being the narrow canal at the apex of the root by which the dental vessels and nerves reach the pulp cavity. It is the formation of the root that forces the crown of the tooth through the gum. The roots

grow continuously in Rodents. If from any accident to their teeth the normal wear does not take place, the incisors grow into long tusks which may ultimately prevent mastication.

(3) **The Pulp.**—The pulp is the remnant of the dental papilla enclosed by the dentine. It is made up of a matrix of branching cells and is said to have no lymphatics. Thus, like the tissue of the umbilical cord and vitreous humour of the eye, it retains the embryonic form of the mesoblast (Berry Hart). It contains the ramifications of the artery, vein and nerve of the tooth.

(4) **The Dental Sac.**—The foetal tooth, as may be seen from Fig. 49, lies imbedded in the alveolus within the dental sac. When the enamel bud is invaginated on the dental papilla, the **invaginated** layer forms the enamel, while the **invaginating** or parietal layer becomes surrounded by a dense layer of mesoblast and forms the dental sac. Between the enamel (invaginated) and parietal (invaginating) layers, filling the cavity of the sac, lies a mass of epithelium corresponding to the corneous epithelium of the skin.

(5) **The Peridental Membrane.**—The peridental membrane (Fig. 47) is formed by that part of the dental sac which surrounds the fang of the tooth. The part of the dental sac which surrounds the crown is destroyed by the eruption of the tooth (Fig. 49).

(6) **The Crusta Petrosa.**—The peridental membrane is of the nature of periosteum, and contains osteoblasts which deposit the crusta petrosa (bone) on that part of the dentine which forms the fang and also on the inner wall of the alveolus. It may inflame and give rise to an abscess or keep on discharging pus; the tooth then becomes loosened in its socket and drops out.

Origin of the Permanent Teeth.—From the dental shelf, besides the buds for the milk teeth, there grow inwards, so as to lie on the lingual aspect of the milk buds, processes of epiblast which form later the enamel of the ten teeth which replace the milk teeth (Figs. 48 and 49). The three permanent molars of each side arise from a process which prolongs the dental shelf backwards behind the part from which the enamel buds of the milk teeth arise. The first molar is the earliest of all the permanent teeth to undergo development. The permanent teeth are formed in exactly the same manner as the milk set. They develop on

the lingual aspect of the roots of the milk teeth (Fig. 49), and if the milk teeth be roughly extracted the permanent bud may also be torn out.

Dentigerous and other Cysts of the Jaw.—Cysts with epithelial walls, containing fluid, teeth or other dermal contents, occasionally develop in the jaw. They are formed from epithelial remnants of the dental shelf, which normally breaks up and disappear completely, or from detached parts of the enamel buds (see Figs. 48 and 49).

Nature of Teeth.—A tooth must be regarded as an ossified dermal papilla which has received a coating of enamel from the epidermis covering it. In nature they correspond to the placoid scales of the shark's skin. The placoid scales and teeth of the shark are similar in structure, the one series becoming continuous with the other at the margin of the mouth. The dental papilla and enamel bud represent an invaginated or depressed part of dermis and epidermis.

Number of Dentitions.—In many lower vertebrate forms, such as sharks, the dental shelf gives off constantly a series of buds, so that as soon as one tooth is lost another springs up from behind in its place. In mammals generally, as in man, the dental shelf gives off only two series of buds—one for the milk set and another for the permanent set. In marsupials it gives off only one series, so that the first set of teeth is never replaced by a second.

Morphology of Human Teeth.—The crowns of all the human teeth seem to be modifications of the same type, the **tritubercular** a form undoubtedly evolved from the simple conical tooth found in fishes and reptiles (see Fig. 50). The conical peg-like tooth is to be regarded as the most primitive type, and in man vestigial teeth of this type occasionally occur. In the incisor teeth the two outer or labial cusps are represented by the cutting edge of the crown; the inner remains as the heel at the base of the crown. Secondary divisions of the two outer cusps into two or three cuspules may be seen in newly-erupted incisors. In the canine the outer two cusps of the tritubercular type are fused into one while the inner remains slightly marked as a rule, but it may rise up and form a prominent cusp as in the premolars (Farmer). In the premolars or bicuspid the outer

cusps, as may be seen in many of the lower primates, is really double.

In the upper molar teeth, to the three primary cusps which form a cup, a fourth has been added (see Fig. 50 *E*). The two outer or buccal cusps are distinguished as the A.E. cusp (antero-external), the P.E. cusp (postero-external); the two inner as the

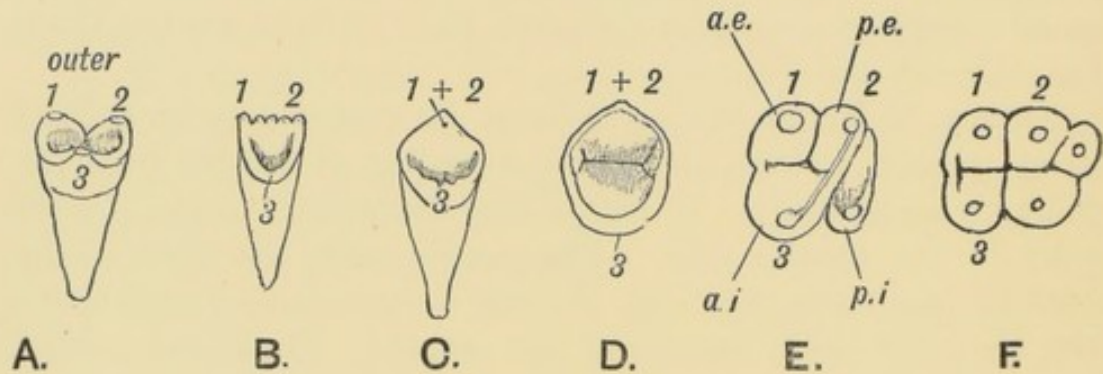


FIG. 50.—*A*. The tritubercular Type of Tooth. The corresponding cusps are shown in the crowns of an Incisor (*B*), Canine (*C*), Bicuspid (*D*), Upper Molar (*E*), and a Lower Molar (*F*).

A.I. (antero-internal) and P.I. (postero-internal). In the upper molars the cusps are situated alternately and the P.E. and A.I. cusps are united by an oblique enamel ridge, which represents the posterior margin of the crown of the primitive tritubercular tooth (Fig. 50 *E*). In the molar teeth of civilized races, especially in their wisdom teeth, the 4th or posterior internal cusp is often absent, the primitive tritubercular tooth thus reappearing. In the lower molars two cusps have been added to the three primary ones, making five in all. The fifth cusp is situated at the posterior border of the crown; the others are arranged in opposite pairs. The fifth cusp has become lost in the 2nd and 3rd lower molars of civilized races.

The Roots.—The upper molar teeth have three roots, two outer and one inner, but in the wisdom teeth, especially of civilized races, the roots are usually fused. The lower molars have two roots, but each root appears to be essentially double in nature. In lower primates the upper bicusps have three roots, but in man these are usually fused so as to form one or sometimes two roots. The lower bicusps have usually one root, but as in lower apes, they may have two.

Eruption of the Teeth.—The eruption of the milk teeth commonly covers a period of eighteen months, beginning in the 6th with the lower incisors and ending in the 24th or 30th with the 2nd milk molars. The eruption of the permanent teeth occupies a period of about eighteen years, beginning with the 1st permanent molar in the 6th year and ending about the 24th with the 3rd molars. In civilized races the third molars or wisdom teeth frequently remain imbedded in the alveolus and may give rise to an abscess. The upper wisdom tooth is developed in the posterior border of the superior maxilla, which bounds the sphenomaxillary fissure in front. The growth backwards of the maxillary antrum converts part of the posterior border of the superior maxilla into the alveolar border, thus bringing the wisdom teeth into position (see page 12 and Fig. 11). The inferior wisdom teeth are developed in the alveolus on the inner aspect of the ascending ramus.

A fourth molar sometimes appears behind the third. A supernumerary incisor or premolar is very rare. The upper lateral incisor may be very small or even absent. If the teeth are too large for the jaw, a not uncommon condition in civilized races, they appear in irregular positions.

CHAPTER VI.

THE SKIN AND ITS APPENDAGES.

The Skin.—Considerable assistance in the understanding of the diseases to which the skin is liable and of the nature of the growths which arise from the epidermis, such as corns, bunions and cancer, is to be obtained by studying the manner in which the skin is developed. At first (see Fig. 51) the human embryo is covered by a single layer of epithelium (**epiblast** or **ectoderm**) as is the case in the adult amphioxus. By the end of the 1st month there are two layers, the lower representing the **germinal** layer; the upper, the **corneous** layer (Fig. 52). In the 4th month intermediate layers appear, from which the stratum mucosum and the stratum lucidum are differentiated (Fig. 53).



FIG. 51.

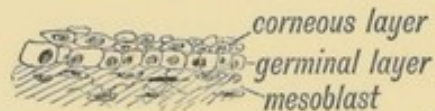

FIG. 52.

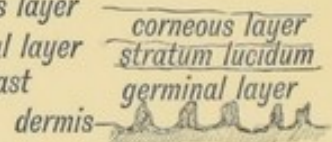


FIG. 53.

FIG. 51.—The strata of the skin during the first month.
 FIG. 52.—The strata of the skin during the second month.
 FIG. 53.—The strata of the skin from the sixth month onwards.

The epidermis rests at first on undifferentiated **mesoblast** or **mesoderm**, consisting of small round cells closely imbedded in a mucoid matrix. This is the normal structure of undifferentiated mesoblast. The superficial mesoblastic cells are subsequently condensed beneath the epidermis to form a corium. They become fibrillated and by the fifth month the mucoid substance has almost disappeared, but even in adult life, when the thyroid is diseased or removed, a mucoid substance may reappear, and a condition

resembling the foetal state be thus produced. In the mucous membranes of the lips, anus and vulva the superficial layer of epithelium does not become cornified.

Formation of Dermal Papillae.—About the fifth month, the dermal papillae, which are grouped in lines and ridges as is well seen in the palm, are formed in the following manner:

Long, linear furrows of epidermis grow down into the dermis (corium) and divide its surface into narrow ridges. These ridges are subsequently subdivided into papillae. The down-growing nature of the epiblastic (epidermal) cells which is here exemplified, is of the greatest clinical importance. The enamel organs, we have seen, arose by a species of downgrowth of the epidermis; so do hairs, sweat glands and sebaceous follicles. Prolonged pressure and friction welds the corneous cells into a solid plate, such as the callosities seen on the palms of manual labourers. Normal desquamation is arrested; the cells produced in the deeper layers, unable to grow to the surface, grow inwards and produce corns. In cancer, the epithelial cells of the skin renew their youth and invade the dermis and deeper tissues.

The papillary lines on the palms and fingers give security of grasp (Hepburn). They are arranged in most variable patterns,

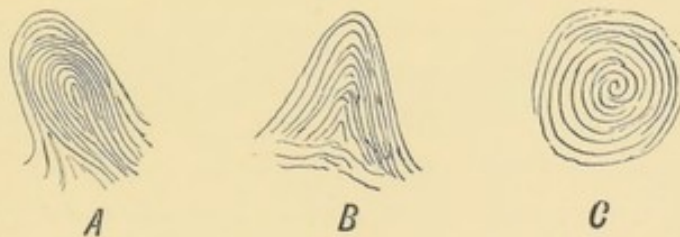

FIG. 54.—The more common patterns formed by the dermal papillae on the tips of the fingers.

A. The Loop Pattern. B. The Triangle Pattern. C. The Whorl Pattern.

but the prevailing types in man are those arranged as loops, spirals or whorls, Fig. 54. So variably are the types arranged on the pulps of the digits, that probably no two people show them in the same sequence counting from thumb to little finger in both hands. Hence the impress of the ten finger tips has been successfully used in the identification of criminals.

The Hairs.—Hairs begin to develop in the 5th month. Morphologically a hair may be regarded as a dermal papilla, which has become sunk in the subcutaneous tissue, and capped by

a process of epidermis. Hairs appear to have been primarily touch organs and are modifications of the touch bodies found in the skin of Reptilia (Gegenbaur). These touch bodies are composed of

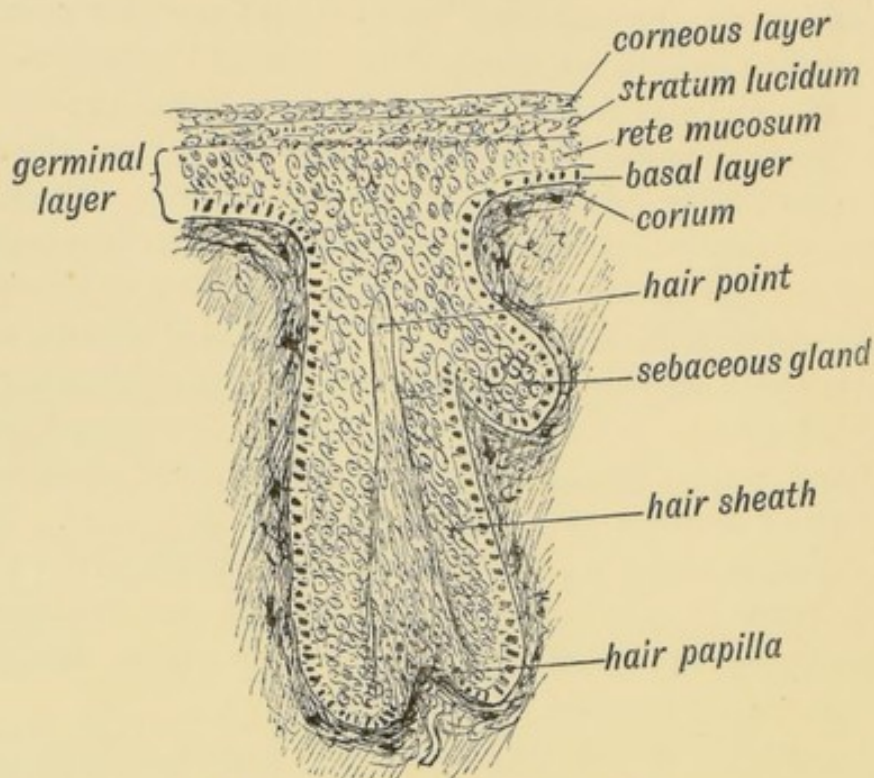


FIG. 55.—Diagram of a Developing Hair.

epithelial cells, having the same shape and arrangement as those which form the taste buds round the circumvallate papillae of the human tongue. The cells which cap the hair papilla evidently represent the primary sensory cells of the touch bodies; they are situated in line, and continuous with the basal or germinal layer of the skin (Fig. 55). They produce the cells of the medulla of the hair which bursts through the epidermis (Fig. 55). The primary function of the hairs as touch organs is seen in the vibrissae round the mouths of carnivora, but the hair of man no longer is subservient to the sense of touch.

The first stage in the development of a hair is the ingrowth of epidermis as a solid bud, which pushes in front of it the dermis to form the papilla on which the hair grows (Fig. 55). Only the two deeper of the primary layers of the epidermis are carried inwards to form the hair sheath and hair root.

The hairs produced at the fifth month are fine in texture (*lanugo*), and by the 7th month the whole body is covered by it.

The production of hair buds goes on until birth, the later buds and hairs being thicker and stronger. After birth, new hairs are constantly reproduced within the sheaths to replace the old. Probably the manner in which new hairs are produced resembles that of teeth, viz.: from processes of the original bud. Hairs appear first on the head and then on other parts of the body. The comparatively hairless condition of man must be regarded as due to an arrest of development; the hair distribution of adult man corresponds to a late foetal condition of the anthropoids. Certain sexual hairgrowths appear on the face, pubes and axilla at puberty. Morphologically the pubic region represents the separated axillary regions, and probably the explanation of sexual hairs in the axilla is due to this correspondence, for there is a persistent tendency towards symmetry of development in the upper and lower extremities. The primitive mammary ridges, also sexual structures, end at the axilla and groin.

The Nails.—The nails are made up of the basal, stratum mucosum, and stratum lucidum layers of the skin (Fig. 56), the

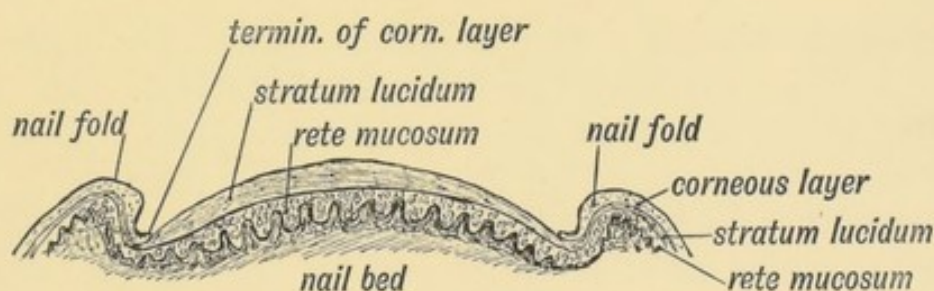


FIG. 56.—Diagrammatic Section across a Nail.

corneous layer being lost after the 4th month of foetal life. They appear first in the 3rd month as fields of thickened epidermis on the tips of the digits, but are afterwards shifted dorsally, carrying their palmar nerves with them, so that the terminal phalanx is wholly supplied from the palmar digital branches. The nail of the little toe, a digit in a retrograde phase of development, is frequently shaped like a claw, probably a reversion to a primitive form. The nail is produced on the scattered papillae (the matrix) at its root. The area of production is marked by the lunule. On the nail bed, in front of the lunule, the papillae are arranged in longitudinal rows. If the nail be pressed, as by the boot, the lateral papillae, under the nail fold (see Fig. 56) are

directed downwards, and their epithelial outgrowths follow the same direction, thus causing ingrowing nail.

About the end of the 7th month the matrix of the nail root becomes differentiated, active growth sets in and the terminal margin of the nails become free; it grows forwards over the corneous layer which covers the terminal row of papillae of the nail bed. The ridge of corneous epithelium under the nail-tip represents the hoof of ungulates.

Sweat Glands.—In the 5th month solid processes of epidermis grow into the dermis and produce sweat glands. They arise at the same time and in the same manner as, and often in common with, the buds of hair roots and sebaceous glands. They are produced within the papillary ridges, and hence the ducts of sweat glands, as may be seen on the palms and fingers, open along the summits of these. The sweat glands in the axillae are peculiar. In section they resemble the acini of the mammary gland, also believed to be highly modified sweat glands. The axillary glands contain much epithelial debris. They appear to be sexual in nature.

Sebaceous Glands.—The sebaceous glands are outgrowths from the more superficial part of hair buds (Fig. 55). Their epithelial lining is derived from the germinal layer. In sheaths which have become occluded from the loss of the hair, or when the mouth of the gland is blocked, the secretion is retained, and a sebaceous cyst or wen, so frequently seen in the scalp, is produced. Round the mouth, on the lips and nose, the sebaceous glands, especially in disorders of the sexual organs, are apt to retain their secretions and become inflamed, small pustules being thus produced. The Meibomian glands in the eyelids are modified sebaceous glands. At birth the child is covered by the *vernix caseosa*, which is composed of desquamated corneous epithelium and the secretion of sebaceous glands.

THE MAMMAE.

The mamma is developed in the same manner in both sexes. At puberty the female breast undergoes a great development, while in the male it retains the infantile form.

The Female Breast.—The mamma of the female is of cutaneous origin, and in its earlier stages of development resembles, and probably corresponds to, a collection of sweat glands arising from a small circular depressed area of skin (Fig. 57 *C*). The manner of its development is the key to its anatomy. The adult female breast is composed of two elements:

(*a*) Glandular tissue derived from the epiblast by a process of inbudding;

(*b*) An intricate arrangement of connective tissue derived from the mesoblastic subcutaneous tissue over the pectoralis major.

I. Origin of the Glandular Tissue.

(1) **The Mammary Line** is a slight ridge of epiblast which stretches along the ventral aspect of the body on each side, from the axilla to the groin, and is the first stage of mammary development in mammalian embryos. In the sow, for instance, mammae are produced along the whole length of the mammary line. Although this stage has not been seen in the human embryo, it probably does occur, for in 5% of bodies a more or less distinct trace of a supernumerary mamma or nipple is to be found, and these occur for the greater part in the inguino-axillary line. Such as occasionally occur on the back or thigh are probably of the nature of dermoid tumours. Supernumerary nipples occur much more frequently in men than in women. This one may expect because the more vestigial the condition of an organ, the greater is the tendency to the production of ancestral (atavistic) forms.

Developmental Stages.—Seven stages may be recognised in the developmental history of the glandular mammary tissue.

Four of these take place **before birth**:

1st (Fig. 57 *A*). The deeper layer of epiblast thickens over the mammary area; this thickening represents a part of the mammary ridge or line. This stage is seen in the 2nd month.

2nd (Fig. 57 *B*). The thickening becomes depressed, thus giving rise to a slight pit on the surface.

3rd (Fig. 57 *C*). From the depression arises a number of buds, exactly similar to those of sweat gland (5th month). The stalks of these buds form the epithelial lining of the lactiferous ducts.

4th (Fig. 57 *D*). The lobular buds, for each bud develops into a lobe, subdivide at their growing extremities. At first solid,

they begin to caniculize (7th to 9th months). At or about birth the pit or depression, from which the lobular buds originated, is raised, evaginated and forms the surface of the nipple (Fig. 57 *D*).

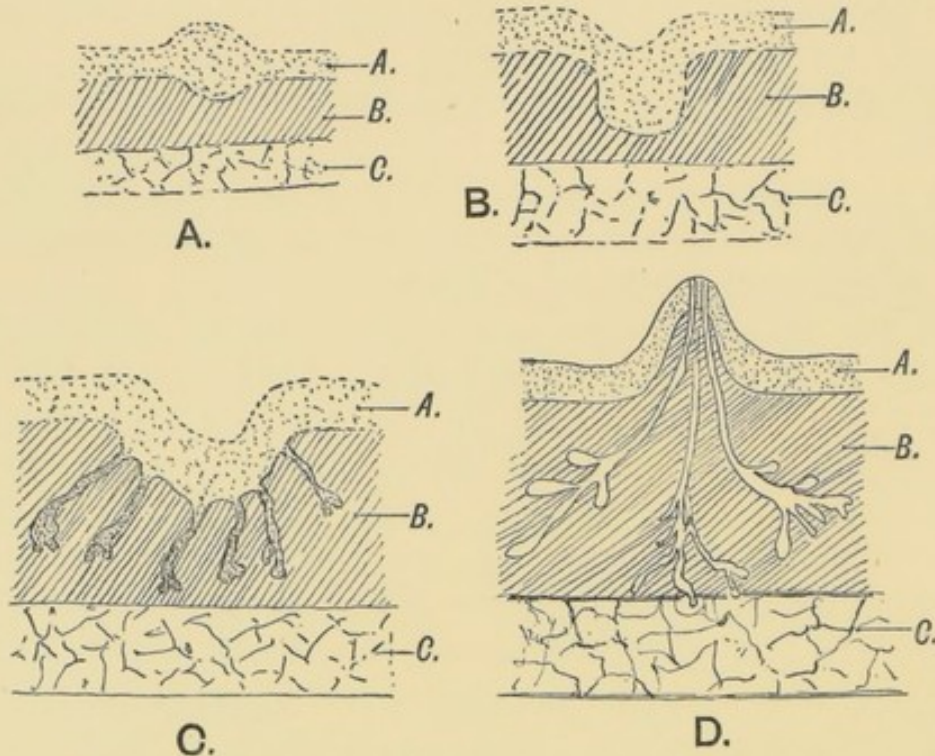


FIG. 57.—Showing the various stages in the development of the Mamma.
A. During the 2nd month. *B.* At the commencement of the 3rd month. *C.* At the 5th month. *D.* At birth.
 A = Epiblast. B = Subcutaneous tissue (mesoblast). C = Pectoralis major.

Thus the ducts come to open on the apex of the nipple. An ampulla is developed in each duct within the base of the nipple. Stage 3 represents the marsupial—the lowest mammalian form of mamma.

Stages after Birth.—Stage 5 occurs at puberty; the latent infantile lobular buds again undergo a rapid growth and give rise to the minor lobules and acini. Stage 6 occurs towards the end of pregnancy and consists of a renewed production of glandular tissue. Stage 7 sets in with the menopause and is characterized by an atrophy of the glandular tissue formed in the later stages of development.

In the process of subdivision, minor buds of adjacent lobes frequently unite together. Hence it is found difficult, during dissection, to separate the gland into its primary lobes. In any

of the three later stages a localized and invading hypertrophy of the cells of the glandular tissue may take place. In this manner cancer is produced. The part played by the lymphatics, which are situated in the mesoblastic tissue of the gland, in the spread of this disease, makes their study important.

II. **Origin of the Capsular or Mesoblastic Part of the Gland.**—As the glandular buds grow out into the subdermal mesoblastic tissue, which reacts and hypertrophies around the invading processes, they divide it (see Fig. 58) into (*a*) superficial, and (*b*) deep layers, these being joined together by (*c*) interstitial septa. The superficial and deep layers are fused in (*d*) the circum-mammary tissue in which the final glandular buds terminate. The processes as they grow outwards also take on (*e*) perilobular and periductal sheaths. The deep and superficial layers are also connected with the anterior sheath of the pectoral muscles and the skin—for they are all parts of the same subdermal or subcutaneous mesoblastic layer.

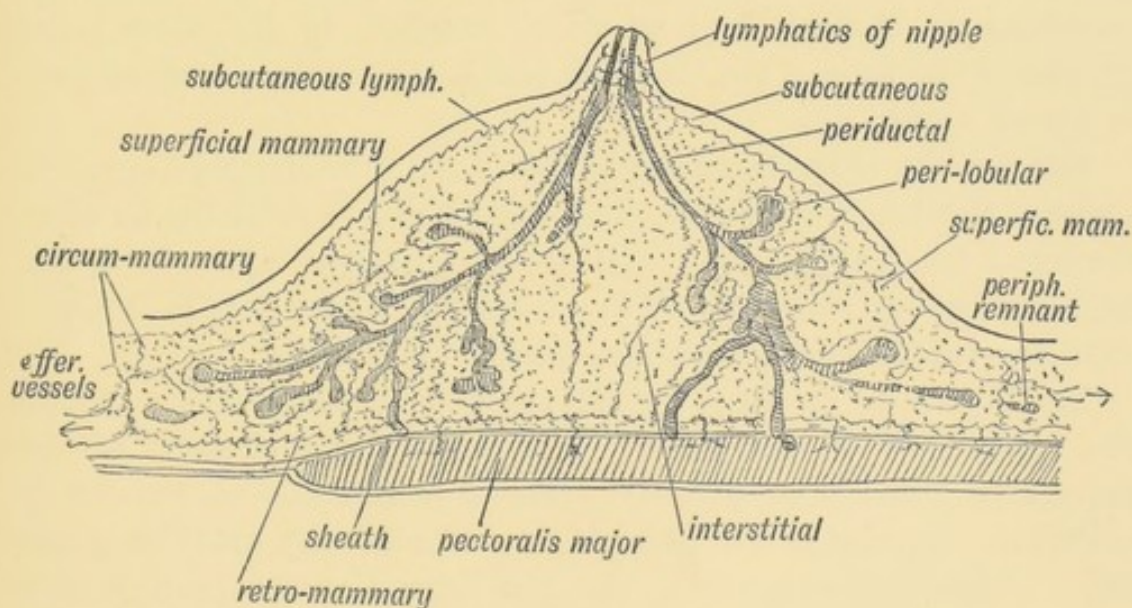


FIG. 58.—Diagrammatic Section of the Breast to show the arrangement of its Capsule and Lymphatics. The lymphatic vessels are represented by thin wavy lines.

Lymphatics.—As each part of the capsule carries a network of lymphatic vessels, into which the glandular lymph passes, it will be seen that the arrangement of the parts of the capsule is an important matter in both the physiology and surgery of the gland. The **periductal** and **perilobular** lymphatics communicate

through the **septal** or **interstitial** vessels with the **superficial mammary** and deep (**retro-mammary**) lymphatics (Fig. 58). The **superficial** communicate with the **subcutaneous**; the deep with those in the **pectoral sheath** and thus it will be seen that mammary cancer may spread to the skin or pectoralis major. The deep and superficial join in the **circum-mammary** lymphatics, and from these pass **efferent vessels** to the **pectoral** and **central** glands of the axilla. The lymph passes from these to the deep axillary and inferior deep cervical glands—all of which are involved in late stages of cancer of the breast. Other efferent vessels pass from the circum-mammary to the **anterior intercostal** glands of the upper four spaces; one or two vessels may go to the **cephalic** gland.

Peripheral Remnants.—Isolated or semi-isolated small masses of glandular substance are found situated in the circum-mammary tissue, beyond the body of the gland. Some may pierce the sheath of the pectoralis major and become a source of recurrent cancer. The presence of glandular remnants is explained by the fact that, when the primary budding takes place, the subdermal mesoblast is shallow and of small extent; in the subsequent growth of the thorax, the tissue in which the mamma is developed, is widely spread out.

The position of the Mammary Gland is as a rule wrongly described. Quite a third lies on the serratus magnus and beyond the anterior border of the axilla. The axillary lobe reaches upwards in the axilla to the upper border of the third rib, where it is in contact with the **central set** of lymphatic glands (Stiles).

Fat begins to be deposited in the subcutaneous tissue during the 5th month of foetal life. It forms a large element of the mammary gland after puberty. The subcutaneous tissue, out of which the capsule of the gland is formed, normally contains much fat. After lactation, when the glandular tissue atrophies to a considerable extent, a growth of fat replaces it. If no fat is deposited or if it be absorbed, then the breast loses its plump form and hangs on the chest.

The mammary nerves (secretory) come from the 3rd, 4th, and 5th intercostals; the nipple is supplied from the same nerves. The nipple contains non-striated muscle and is covered with touch papillae and surrounded by modified sweat and sebaceous glands.

To render the glandular mammary tissue clearly recognisable from the surrounding connective tissue, Stiles adopted the method of immersing the mamma in a 5°/o of HNO₃ for two days. The glandular tissue becomes of a dark yellow tint, and thus can be detected even in minute quantities from the surrounding tissue of mesoblastic origin.

CHAPTER VII.

THE DEVELOPMENT OF THE OVUM OF THE FOETUS FROM THE OVUM OF THE MOTHER.

From the Ovum of one generation to the Ovum of the Next.

—The manner in which the face, neck, pharynx and cutaneous structures of the body are produced having now been traced, it is necessary, before further progress can be made, to turn to the phenomena which mark the opening stages in the development of the embryo. This may best be done by following the cycle of changes which lead to the production of a new generation of germinal cells from the fertilized ovum of a former generation. Every ovum is the offspring of a fertilized ovum, and the fertilized ovum is the intermediary whereby the characters and properties of a race are handed from one generation to the next.

Descent of the Ovary.—In the female human foetus of the fifth month the ovary has reached the iliac fossa (Fig. 59) in the course of its descent from the lower dorsal region where it originated to its permanent position on the lateral wall of the pelvis. The ovary is then long and narrow, with an upper and lower pole; it is three-sided in section—the surfaces being inner, outer and inferior or ventral (Fig. 60). The Fallopian tube, derived from the upper part of the Müllerian duct, lies along the outer side of the ovary in the iliac fossa; its upper fimbriated end terminates at, and is attached to, the upper or cephalic pole of the ovary (Fig. 59). As the parts lie on the iliac fossa, the tube and the ovary are supported each by its own mesentery, the **meso-salpinx** and **meso-ovarium**. The two mesenteries have, however, a common origin or attachment to the posterior abdominal wall and to the common attachment the name of **common genital mesentery** may

be given. The upper end of the common mesentery—the *plica vascularis* (Fig. 59), as it is reflected from the cephalic pole of the ovary and fimbriated extremity of the tube, is continued up towards

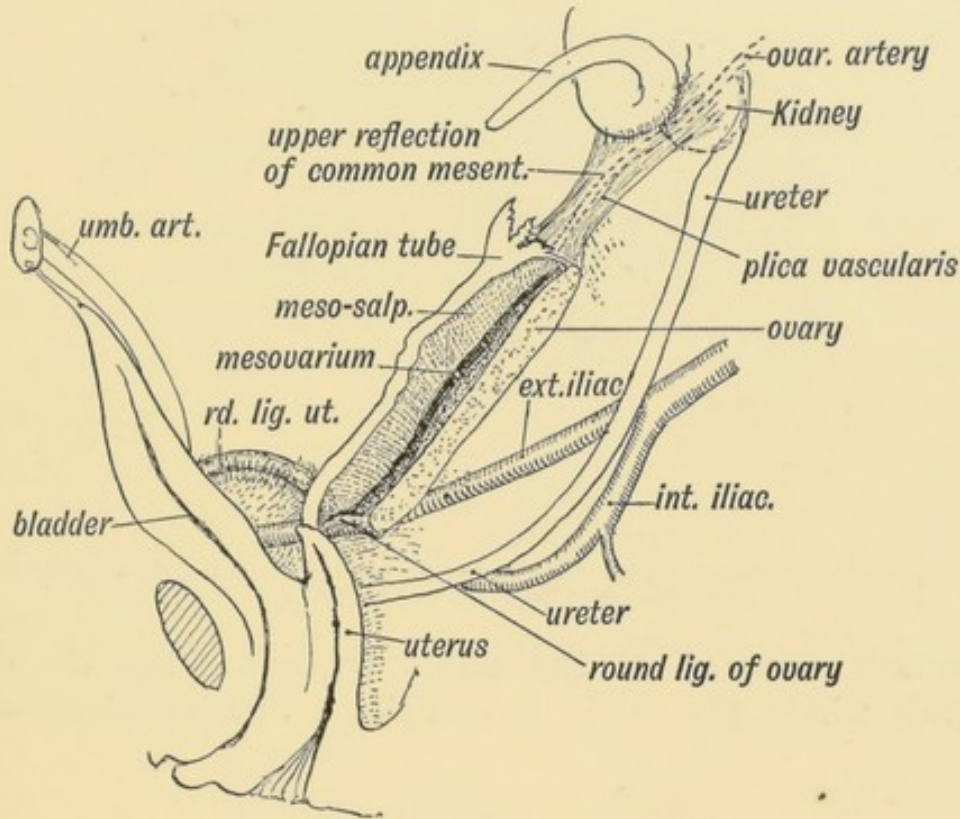


FIG. 59.—The position of the Ovary and Fallopian Tube in the 5th month.

the diaphragm and in it the ovarian vessels and nerves pass to the ovary and tube. The caudal pole of the ovary is joined to the uterus by its round ligament. The round ligament of the uterus, corresponding to the gubernaculum testis of the male, passes from the brim of the pelvis, where it is attached to the horn of the uterus, almost straight to the internal inguinal opening and assists in the descent of the ovary and tube.

By full time the ovary lies at the brim of the pelvis or partly within it; after birth the ovary, uterus and rectum come gradually to occupy their adult positions within the pelvis. This is due to a relatively greater growth in the pelvis itself than in its contents. The ovary, as is more frequently the case with the testicle, may be arrested in its descent.

In Fig. 60 an earlier stage is shown; it represents on section the condition about the end of the second month. The ovary and tube with the remnants of the Wolffian body and duct

occupy the position in which they are developed. Both are suspended by mesenteries from the dorsal wall of the peritoneal cavity, at the side of the mesentery of the gut.

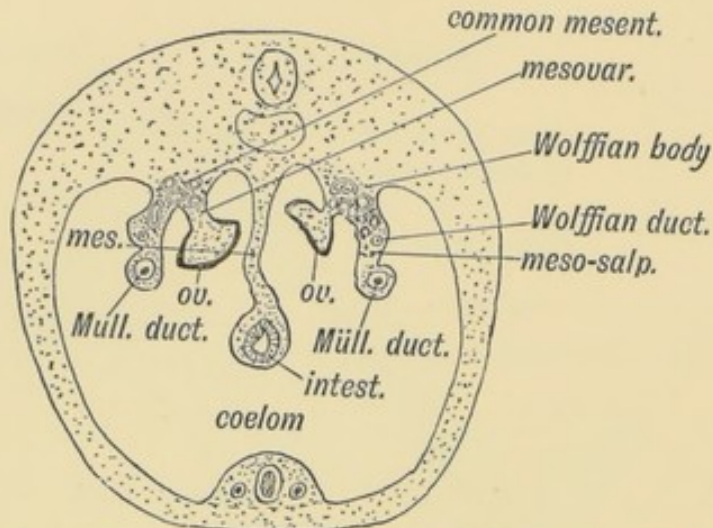


FIG. 60.—Diagrammatic section of a foetus at the end of the 2nd month, showing the Attachments of the Ovary and Müllerian duct.

Normal Position of the adult Ovary.—When the ovary descends within the pelvis it occupies a definite triangle—the

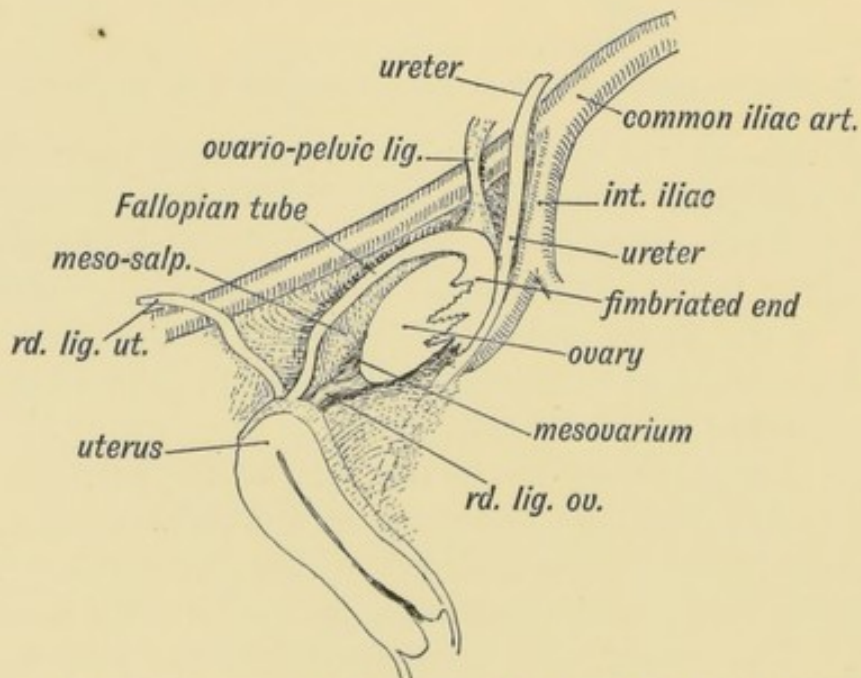


FIG. 61.—Showing the position of the Ovary on the lateral wall of the Pelvis and its relation to the Fallopian Tube.

ovarian triangle—on the lateral wall of the pelvic cavity (Fig. 61). The ovarian triangle is bounded above by the upper half of the

external iliac artery, below and behind by the internal iliac artery, with the ureter lying on the artery; in front by the reflection of the posterior layer of the broad ligament on the side of the pelvis.

The long axis of the ovary is parallel to the ureter and is vertically placed in the standing posture. The peritoneum covering the triangle forms a depression, or occasionally a pouch, for the ovary. It will be seen that, with the descent of the ovary, the mesosalpinx, the mesovarium, and the common genital mesentery have come to form the major part of the broad ligament. The reflection of the common genital mesentery from the upper or cephalic pole of the ovary now forms the ovario-pelvic ligament (Figs. 59 and 61). In the ovarian triangle is also situate the internal iliac group of lymphatic glands, into which most of the pelvic lymphatics drain. The ovarian lymphatics end in the glands of the upper lumbar region near to where the ovary was developed. The ovary brings down with it, too, the ovarian vessels and plexus of nerves. The nerves come through the aortic plexus from the 10th and 11th dorsal segments of the cord.

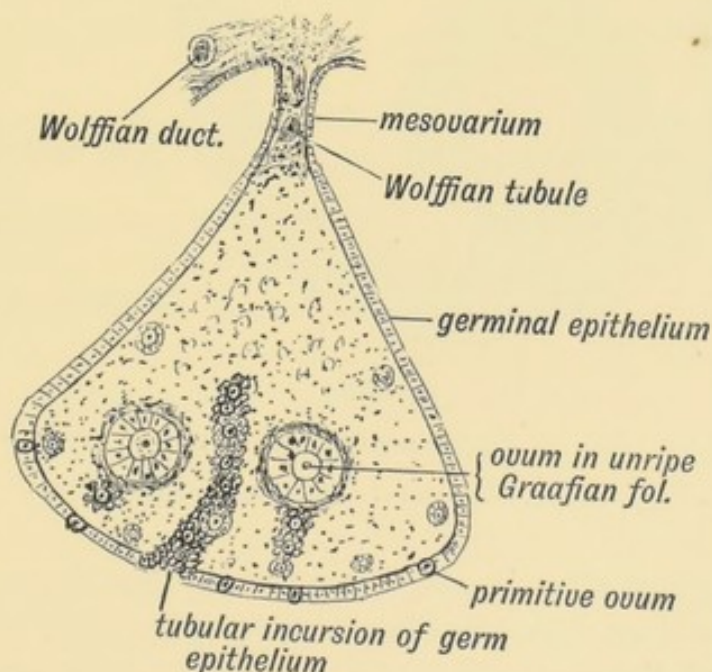


FIG. 62.—Diagrammatic Section of an Ovary to show the manner in which the Primitive Ova are carried in by incursions of the Germinal Epithelium.

An Ovum.—As the infantile ovary descends, it is laden with thousands of ova. Each ovum is surrounded by a capsule com-

posed of a layer of columnar epithelium, which is imbedded in, and surrounded by, the stroma of the ovary. The entire capsule—epithelium and stroma—forms a Graafian follicle (Fig. 62). The ovary is covered by a layer of columnar epithelium, which is named the **germinal epithelium**. Amongst the columnar cells of the germ epithelium during foetal life and for sometime after birth larger cells occur. These are the **primordial ova** from which brood ova arise. The ova are carried within the ovary by tubular ingrowths of germinal epithelium (Fig. 62). These tubular invasions of the ovary become broken up, the isolated masses of the germinal epithelium remaining to form the linings of the Graafian follicles.

Discharge of the Ova.—At puberty, possibly also before it,

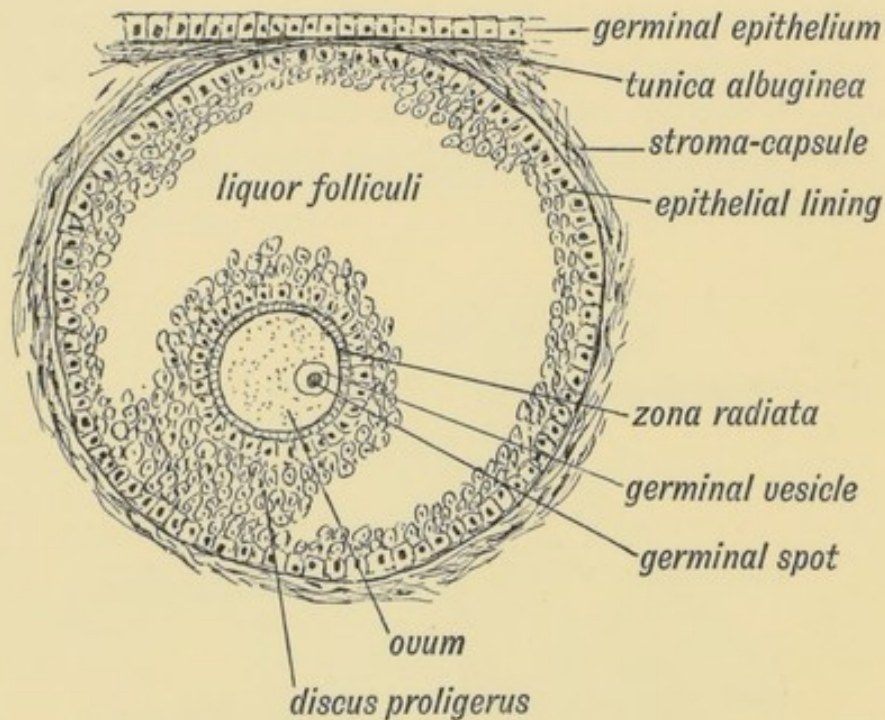


FIG. 63.—Diagram of a ripe Graafian Follicle.

and for 30 years after it, one egg after another ripens; the ovum enlarges; so does the Graafian follicle (Fig. 63). The cells of the epithelial lining proliferate and a cavity appears amongst the cells within the follicle, due to a collection of fluid—the liquor folliculi. The ovum remains attached to the wall of the follicle by a group of epithelial cells, the discus proligerus (Fig. 63). As the fluid collects, the follicle works its way to the surface of the

ovary; the tunica albuginea, which forms a capsule for the ovary, and the germinal epithelium, gradually atrophy over it, and at last it bursts and discharges the ovum.

Two opposite opinions exist among gynecologists as to the period of rupture: (1) That it occurs at the onset of menstruation; (2) that it has no relationship to the menstrual period. The truth is, probably, that both are right. The majority of ova, however, appear to be discharged at the menstrual period. Whether ova are discharged from both ovaries at once, or from only one, and whether one or more than one in a month, are points not yet settled; but the usual opinion is that one ovum is shed each month, and only from one ovary.

The Graafian follicle, after rupture, fills up with blood; a cellular tissue is soon developed within its cavity. If pregnancy occurs this tissue forms a **true corpus luteum**, a large yellow body as big as a pigeon's egg. If pregnancy does not occur, a **false corpus luteum** is formed, a formation which begins to disappear before the next menstrual period. Both forms lead to a cicatrix, which is seen on the surface of the ovary. The ovary of an old person is commonly covered with such scars. The Graafian follicles may become cystic and give rise to enormous ovarian tumours.

The Fallopian Tube.—When the ovum drops from the ovary it cannot easily escape the ciliated fimbriae of the Fallopian tube which surround and clutch the ovary. In Fig. 61 the relationship of the Fallopian tube to the ovary is shown. The tube may be demarcated into three parts: (*a*) the isthmus or arm directed outwards to the wall of the pelvis ($\frac{1}{2}$ to 1 inch); (*b*) the forearm or ampullary part, directed backwards on the lateral pelvic wall above the ovary; (*c*) the hand, infundibular, or fimbriated part, folded backwards and grasping the free border and exposed surface of the ovary. The tube is tethered by one of its fimbriae to the cephalic pole of the ovary.

Course of the Ovum in the Tube.—The cilia on the fimbriae work towards the ostium abdominale, the abdominal mouth of the Fallopian tube, which is situated at the bases of the fimbriae, and carry the discharged ovum through the ostium within the tube. The ostium abdominale is shut when the tube is examined after excision; the closure is probably due to reflex

contraction of the tube muscle, caused by handling and cutting. In the infundibular and ampullary segments of the tube, the mucous membrane is thrown into long plicated folds shown in

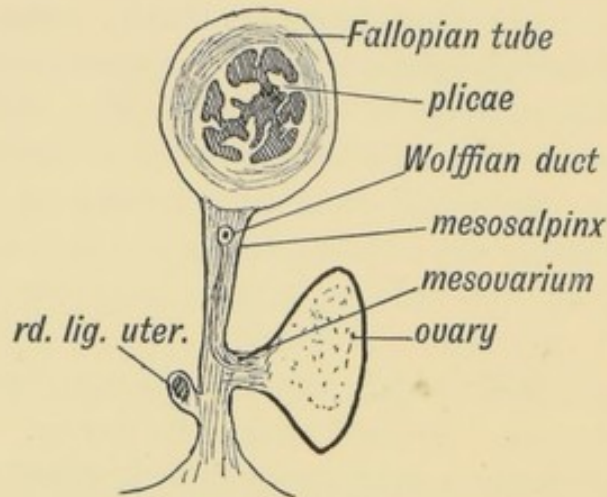


FIG. 64.—Diagrammatic section of the Broad Ligament and Fallopian Tube.

section in Fig. 64. They are covered with ciliated epithelium, which urge the ovum towards the uterus. Within the tube impregnation usually takes place. If an obstruction arrests the fertilized ovum in the tube, perhaps it may be a patch denuded of epithelium and cilia by gonorrhoeal inflammation, a tubular pregnancy is the result. The growing embryo, commonly about the second month, bursts the tube and falls within the broad ligament or into Douglas's pouch (Fig. 64).

The History of the Ovum within the Fallopian Tube.—When the ovum enters the Fallopian tube, it is a cell of very considerable size ($\cdot 2$ mm. = $\frac{1}{12}$ in.) with a cell wall—the zona radiata (Fig. 63), a nucleus—the **germinal vesicle**, and a nucleolus—the **germinal spot**. Then, or before then, the ovum prepares for fertilization by the extrusion from its nucleus of first one, then another **polar body**, and, with the extrusion, the germinal vesicle becomes the **female pronucleus**. The polar bodies, which lie outside the protoplasm of the ovum, but within the zona radiata, are parts of the germinal vesicle, which are extruded with all the display of karyokinesis (Fig. 65 A). The meaning of the process has been much guessed at; the outstanding fact is that two parts of the ovum are segregated and are not involved in the subsequent developmental changes. What

become of the polar bodies in the course of development of the fertilized ovum is not known.

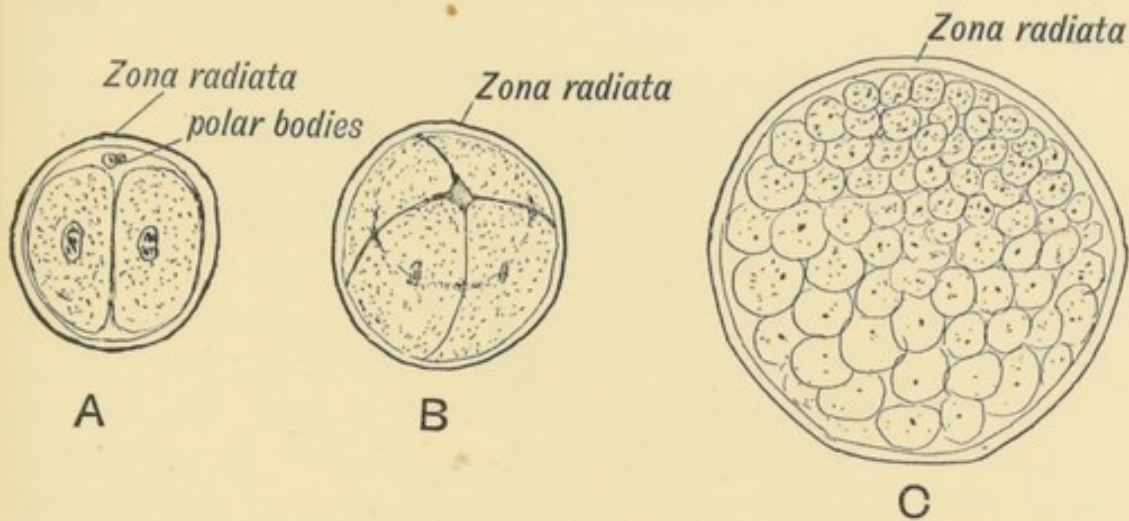


FIG. 65.—Showing the production of the Morula from the Ovum.

A. The ovum after the first division. B. After the second. C. The Morula stage.

In the course of fecundation thousands of spermatozoa are lodged in the genital passage; many stem the adverse current of the uterine cilia, reach and live for days within the interlaminar grooves in the wider parts of the tube. In the course of its descent within one of the grooves the egg may be fertilized. The spermatozoon bursts through the zona radiata, loses its tail, its head enlarges, and forms the **male pronucleus**. The male and female pronuclei unite, and from their union springs the nucleus of the fertilized ovum. This is the centre from which all future developmental changes start. The ovum may be, but rarely is, fertilized in the ovary, or between the ovary and ostium abdominale, the result being a pelvic gestation. The length of time the fertilized ovum takes to reach the uterus is not known exactly, but probably it spends about ten or twelve days within the Fallopian tube, and during that time it passes through the following stages:

1. **The Morula.**—The ovum, with a full display of karyokinetic changes in the nucleus, divides, subdivides, and grows within the zona radiata until a rounded mass of cells is formed—the morula or mulberry mass. The cells are of unequal size and divide at unequal rates (Fig. 65, A, B, C).

2. **The Blastodermic Vesicle.**—This stage is produced from

the morula stage by the collection of fluid within the mass of cells. The cells are then seen to be arranged in two sets—(a) a layer lining the zona radiata and forming the wall of the vesicle

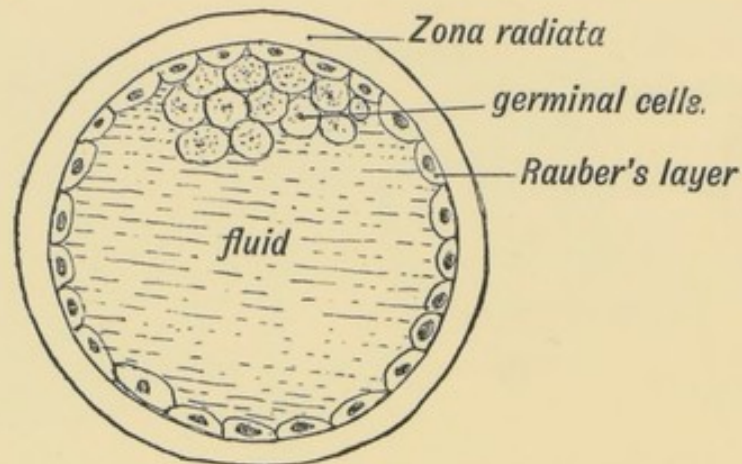


FIG. 66.—Diagrammatic section of a Blastodermic Vesicle.

(Rauber's layer) (Fig. 66), and (b) a group of granular cells within the cavity attached to Rauber's layer at the embryonic pole of the vesicle (Fig. 66). In Vertebrates with huge stores of yolk in their ova, such as birds have, the vesicle is filled by yolk-bearing cells, continuous with Rauber's cells at the vegetative pole, opposite to the granular cells.

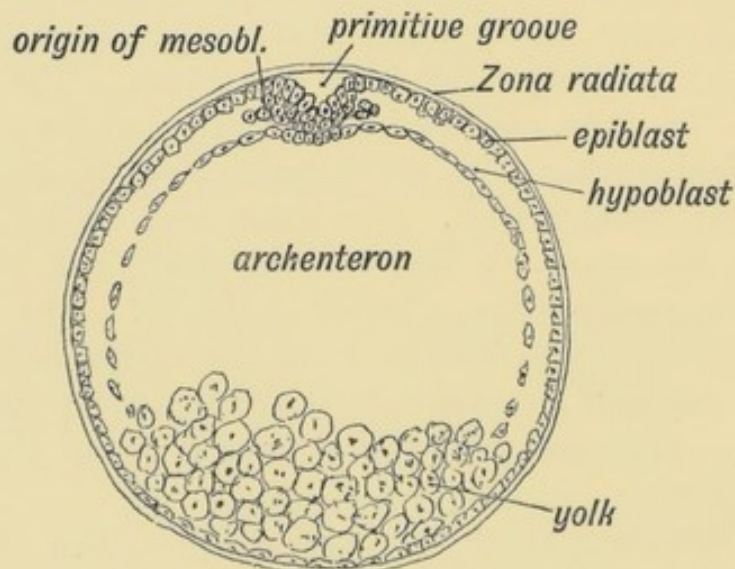


FIG. 67.—A diagrammatic section of a Bilaminar Blastoderm made across the primitive streak.

3. **The Bilaminar Blastoderm.**—This stage is produced by the growth of the group of granular germinal cells within Rauber's layer. At first they arrange themselves in two layers—an outer

which spreads on the inner aspect of Rauber's layer, and absorbs or mixes with it, to form one layer of more or less columnar cells, the **epiblast** or **ectoderm** (Fig. 67); an inner layer also spreads out from the germinal group, and forms a second lining to the blastodermic vesicle, the **hypoblast** or **endoderm** (Fig. 67).

The Primitive Streak and Groove.—In the diagrammatic section of the bilaminar blastoderm, given in figure 67, the hypoblast and epiblast are seen to be fused at one point, and at the point of fusion the epiblast is thickened and somewhat depressed. When the blastodermic vesicle is viewed from the surface, the line along which the fusion of the two layers and thickening of the epiblast take place is marked by the **primitive streak** and **groove** (Fig. 68). At the anterior end of the groove is situated the **blastopore** or neurenteric canal, an opening into the cavity which the hypoblast encloses—the archenteron (see Figs. 67 and 75). Round the blastopore and along the primitive streak the epiblast is continuous with the hypoblast.

The Mesoblast.—The mesoblast or **mesoderm**, the third of the primitive blastodermic layers, is produced from the margins of the primitive streak (Fig. 67). At the line of junction of the

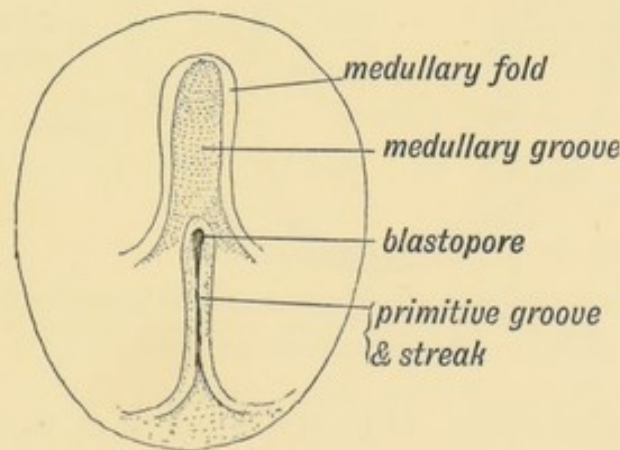


FIG. 68.—Diagram of the Embryogenic area of a Bilaminar Blastoderm viewed from above.

epiblast and hypoblast there is a free proliferation of cells which spreads out between the two primitive layers, and gives rise to a third or intermediate layer—the mesoblast (Fig. 69). In lower vertebrates the mesoblast is entirely produced from the hypoblast.

Neural Canal.—It is at this early stage, while the mesoblastic cells swarm in between the epiblast and hypoblast, and while the

vesicle has not yet reached the uterus, that a grooved strip of epiblast, the **medullary plate**, in front of the primitive streak (Fig. 68) is set aside, by a process of infolding, to form the great central nervous system—the brain, spinal cord, and nerves (Fig. 69).

A medullary fold rises up on each side of what is to be the middle line of the back to enclose the medullary plate. The folds rise until their crests meet, and a tube of epiblast is buried by the fusion of their lips. The blastopore is included within the posterior end of the medullary folds (Fig. 68). Thus, for a short space, the cavity of the yolk sac communicates with the neural canal.

The Notochord.—Beneath the neural tube a similar infolding of hypoblast takes place, and a tube of cells to form the noto-

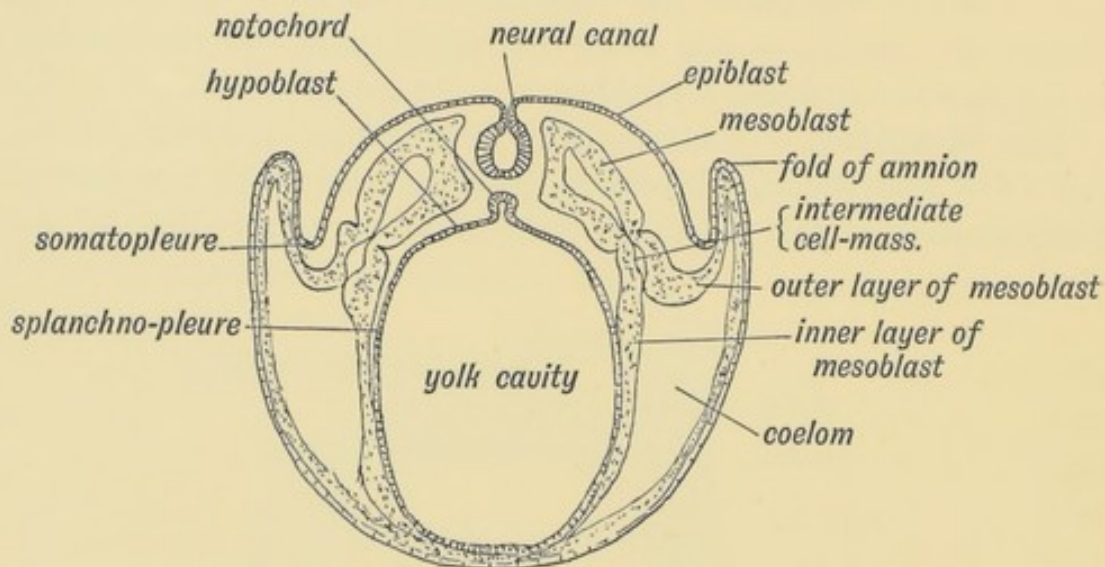


FIG. 69.—Diagrammatic section of a Blastodermic Vesicle showing (1) the origin of the neural canal, (2) the origin of the notochord, (3) the ingrowth of the mesoblast, and (4) the formation of the coelom.

chord is detached (Fig. 69). It forms the first basis of the spinal column.

The Somatopleure and Splanchnopleure.—The mesoblast surrounds both the notochord and neural canal as they are formed—perhaps assists in their formation (Figs. 69 and 70). The solid layer which surrounds these structures is known as the **paraxial mesoblast**. As the mesoblastic cells spread out to cover the outer aspect of the hypoblast and inner aspect of the epiblast, they separate into two layers which enclose between

them a cavity—the **coelom** (Fig. 69). The epiblast, with its accompanying layer of mesoblast, makes up the **somatopleure** which bounds the coelom without; the hypoblast and overlying layer of mesoblast form the **splanchnopleure** which bounds the cavity within.

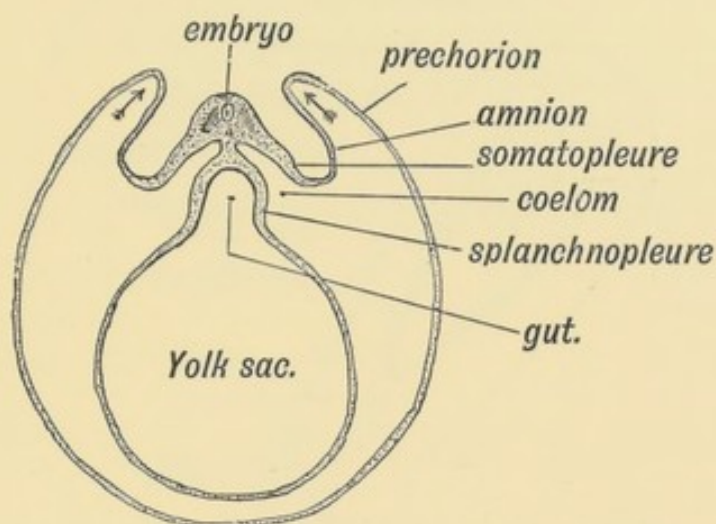


FIG. 70.—Diagram of the Blastodermic Vesicle separating into Embryo and Membranes.

Embryo and Membranes.—During the second week, while the blastodermic vesicle is still within the Fallopian tube and some time before it has reached the uterus, changes take place whereby part of the blastodermic vesicle forms the embryo and part is transformed into the enclosing membranes which contain, protect, and nourish it (Fig. 70). Part also forms the yolk sac.

The Decidua.—When the uterine cavity is reached, the uterine mucous membrane has become hypertrophied, the **decidua** being thus formed. In the formation of the decidua, the uterine glands become elongated and enlarged; the inter-glandular tissue hypertrophied and the mouths of the glands closed, so that the surface layer of the decidua is comparatively solid. The hypertrophy of the mucous membrane is unequal, depressions or pits being formed on its surface. The deeper layer of the decidua is cavernous, the spaces being formed by the distension of capillary veins into venous spaces, and perhaps also by the enlargement of the gland lumina.

When the blastodermic vesicle reaches the uterus, it commonly adheres to the posterior wall near the fundus (Fig. 71). The

decidua forms first a nest for it, and then grows over and buries it, thus forming the outer or decidual membrane of the embryo. The layer which covers the vesicle (see Fig. 71) is the **decidua reflexa**; the part by which it adheres to the uterus, the **decidua serotina**;

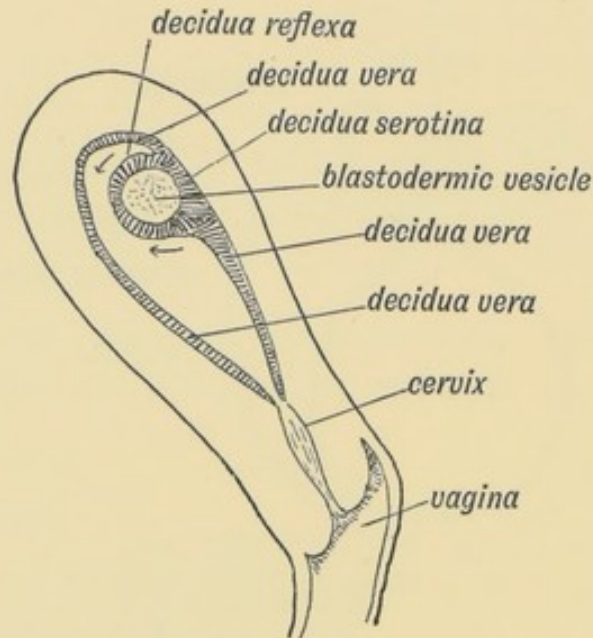


FIG. 71.—Section of the Uterus showing the three parts of the Decidua.

the rest, lining the uterus, the **decidua vera**. As the vesicle grows, it fills the cavity of the uterus, thus bringing the decidua reflexa in contact with the decidua vera; the reflexa disappears when it comes in contact with the vera, which remains as the outermost of the foetal membranes. The serotina takes part in the formation of the placenta.

The Amnion and Chorion.—Only part of the somatopleure of the blastodermic vesicle takes part in the formation of the embryo; the remaining parts of the somatopleure are converted into the amnion and chorion in this manner:

As is shown in Fig. 70, the embryonic area appears to sink within the vesicle; the somatopleure rises up as a wave-like fold right round it, at each side, at the head as well as at the tail end. The folds meet over the embryo and unite, as is shown in Fig. 72. Thus the embryo is wrapped up in a double fold of its own somatopleure. The inner fold or membrane is the **Amnion**, the outer is the **Prechorion** (Fig. 72). The prechorion, in turn, is covered by the decidua reflexa, and at its attached

part by the decidua serotina. Villi containing vessels grow out from the chorion into the decidua.

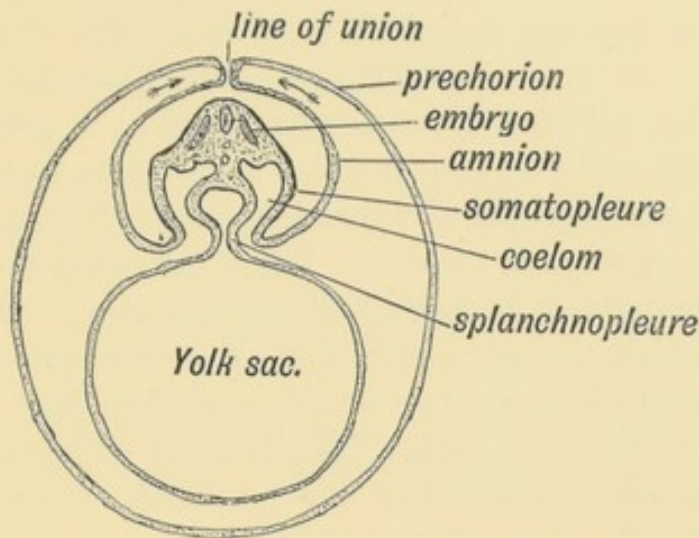


FIG. 72.—Showing the folds of the somatopleure uniting over the embryo and becoming demarcated into Amnion and Prechorion.

Origin of Ova and Spermatozoa.—The cells which give rise to the ova and spermatozoa, according to sex, are derived from the mesothelial lining of the coelom. They appear with the cleavage

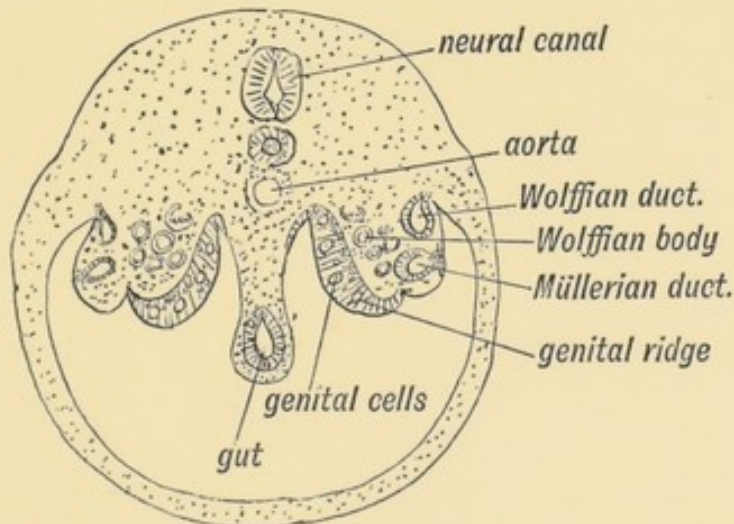


FIG. 73.—Diagrammatic section of the abdominal region of the coelom, showing the position of the Genital Ridges from which the Ovary or Testicle is formed.

of the mesoblast and formation of the coelom. Soon after the coelom is formed (beginning of third week) a ridge—the **genital ridge**—is seen on the roof of the coelom, situated on each side of the attachment of the mesentery of the gut (Fig. 73). The ridge lies over the intermediate cell mass (Fig. 85, p. 111), and is covered

by a layer of columnar meso-thelium, the **germinal epithelium**, which is continuous with the mesothelial lining of the coelom. Some of the columnar cells covering the genital ridge become **primordial ova**, and are set aside to produce ova or spermatozoa, according to the sex. Beard's researches have led him to the conclusion that primordial ova are produced at a very early stage of development, and that they migrate towards the coelom and take up their position amongst the germinal cells covering the genital ridge when that ridge is formed. These cells may stray and give rise in various parts of the body to dermoid tumours (Beard). The manner in which the germ cells and primordial ova grow within the genital ridge to form the ovary or testicle was described at the beginning of this chapter. The cycle of changes which leads to the production of the ova of one generation from the ovum of a former generation have thus been traced.

CHAPTER VIII.

THE MANNER IN WHICH A CONNECTION IS ESTABLISHED BETWEEN THE FOETUS AND UTERUS.

Implantation of the Ovum.—The blastodermic vesicle is represented in Fig. 69. In its course down the Fallopian tube the somatopleure, which forms its outer wall, becomes differentiated into four areas, shown diagrammatically in Fig. 74, by a

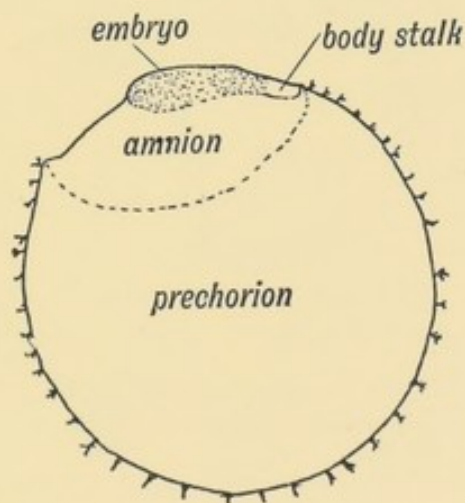


FIG. 74.—Showing what becomes of the Somatopleure of the Blastodermic Vesicle.

series of folding, already described and shown in transverse section in Fig. 72 and in longitudinal section in Fig. 75. The embryo becomes enclosed in a double capsule of somatopleure—the outer the prechorion and the inner the amnion. But, as is shown in Fig. 75, the amnion in man is peculiar in that it forms practically no **tail fold**; the **head fold** grows backwards like a hood until it comes in contact with the caudal pole of the embryo. When

the uterus is reached a third or decidua coat is added by the mucous membrane of the uterus (Fig. 71).

The **serotinal** part of the decidua marks the place where the placenta will be formed. The implantation of the ovum in the decidua is in the posterior wall of the uterus in over 60% of cases; hence the placenta is developed there. It sometimes happens that implantation occurs near the internal os of the uterus, and in such cases the placenta is developed over the os (placenta praevia), a form liable to give rise to a sudden haemorrhage from the uterus during pregnancy.

The Body-Stalk.—When the amnion and prechorion are formed from the human ovum that part of the somatopleure

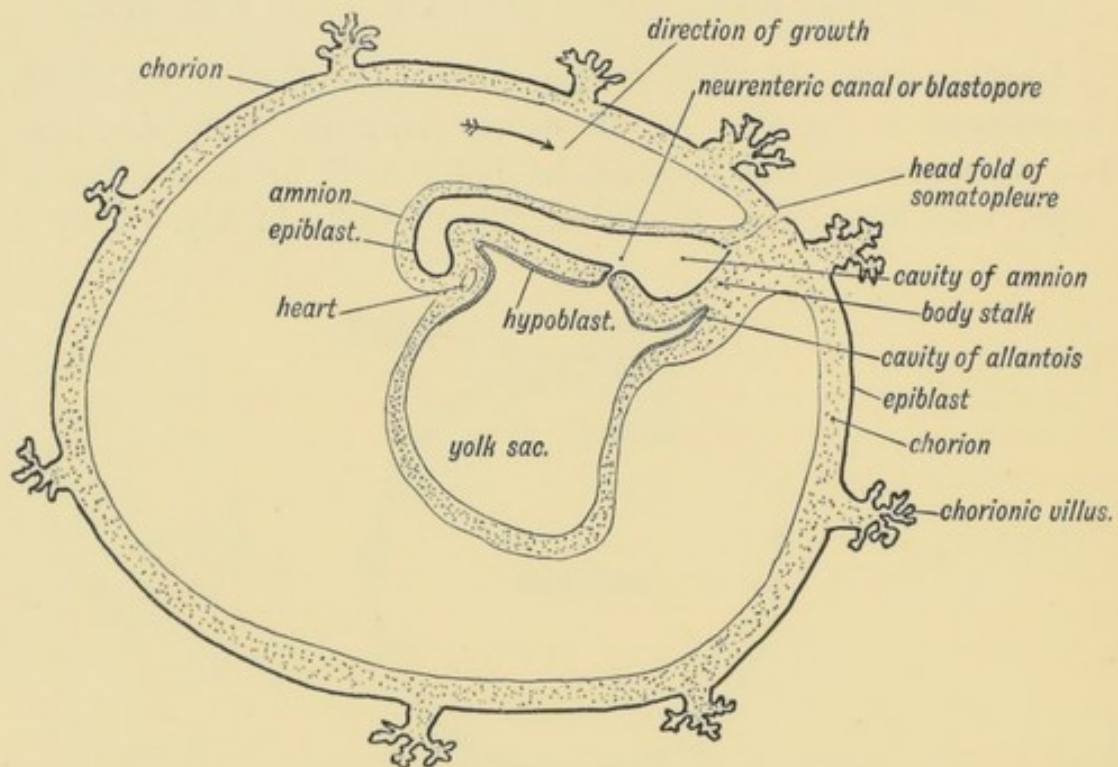


FIG. 75.—Showing the growth backwards of the Somatopleuric Head Fold in the human ovum of 15 days to form the Amnion and Prechorion. The "body-stalk" part of the Somatopleure keeps the embryo attached to the Prechorion. (After Graf Spee.)

lying behind the neural groove, and in which the primitive streak appeared (see Figs. 68, 74 and 75), joins the embryo to the chorion. It is named the **body-stalk**. Through it the allantois—a hollow protrusion from the hind gut (Fig. 75)—grows out to the pre-chorion. Afterwards the body-stalk, with the contained stalk of the allantois, becomes the umbilical cord. The

developmental changes which occur in the body-stalk are of the greatest practical importance (p. 99).

The Chorion and Allantois.—At this early stage a diverticulum has arisen from the hind gut below the caudal part of the embryo (Fig. 75). This ventral evagination of the hind gut, which grows along the body-stalk, carrying the splanchnopleure with it, forms the allantois. The allantoic bud, which is hollow only at its basal part, spreads out on the inner surface of the prechorion, forming a lining to it. The prechorion or false chorion, with the addition of the allantois, forms the **chorion**, or true chorion. The posterior ends of the two primitive dorsal aortae, which terminate until now on the yolk sac, are carried out with the allantoic bud and distributed within the villi of the chorion. The posterior ends of the two dorsal aortae thus become the hypo-gastric and umbilical arteries (Young and Robinson). The veins which return the blood become the umbilical veins. At first there are two of them, and they return the allantoic blood direct to the sinus venosus, afterwards to the ducts of Cuvier, and thus to the heart (Fig. 190, p. 232). In this way the foetal circulation is set up. The heart pumps the blood into the chorionic villi; these are imbedded in the maternal decidual covering; the blood is returned by the umbilical veins (Fig. 76). At this stage, and indeed until the end of the 6th week, the membranes, with the embryo within them, can easily be detached from the decidual nest in the uterus, and then appear as a villous vesicle, the **chorionic vesicle**, about the size of a pigeon's egg. The allantois never forms a free vesicle in man nor in the higher primates. It occurs as a vesicle in other mammals, birds and reptiles, in which it has a double function: 1st, to form a respiratory medium, as is also the case in man; 2nd, to form a receptaculum for the secretion of the kidney.

Formation of the Placenta.—The condition of the membranes in the 3rd month (Fig. 76) differs from that of the 1st month (Fig. 75) by the formation of the placenta. In the first month the chorion is uniformly covered by shaggy villi, which project into the decidua and draw sustenance for the embryo therefrom. This is the permanent condition in low primates (Lemurs). In man the chorionic villi which project within the decidua serotina hypertrophy, while those within the decidua

reflexa atrophy, and in this way the discoidal placenta of man is formed. In lower primates (Monkeys) there are two discs (bi-discoidal), and this form occasionally occurs in man.

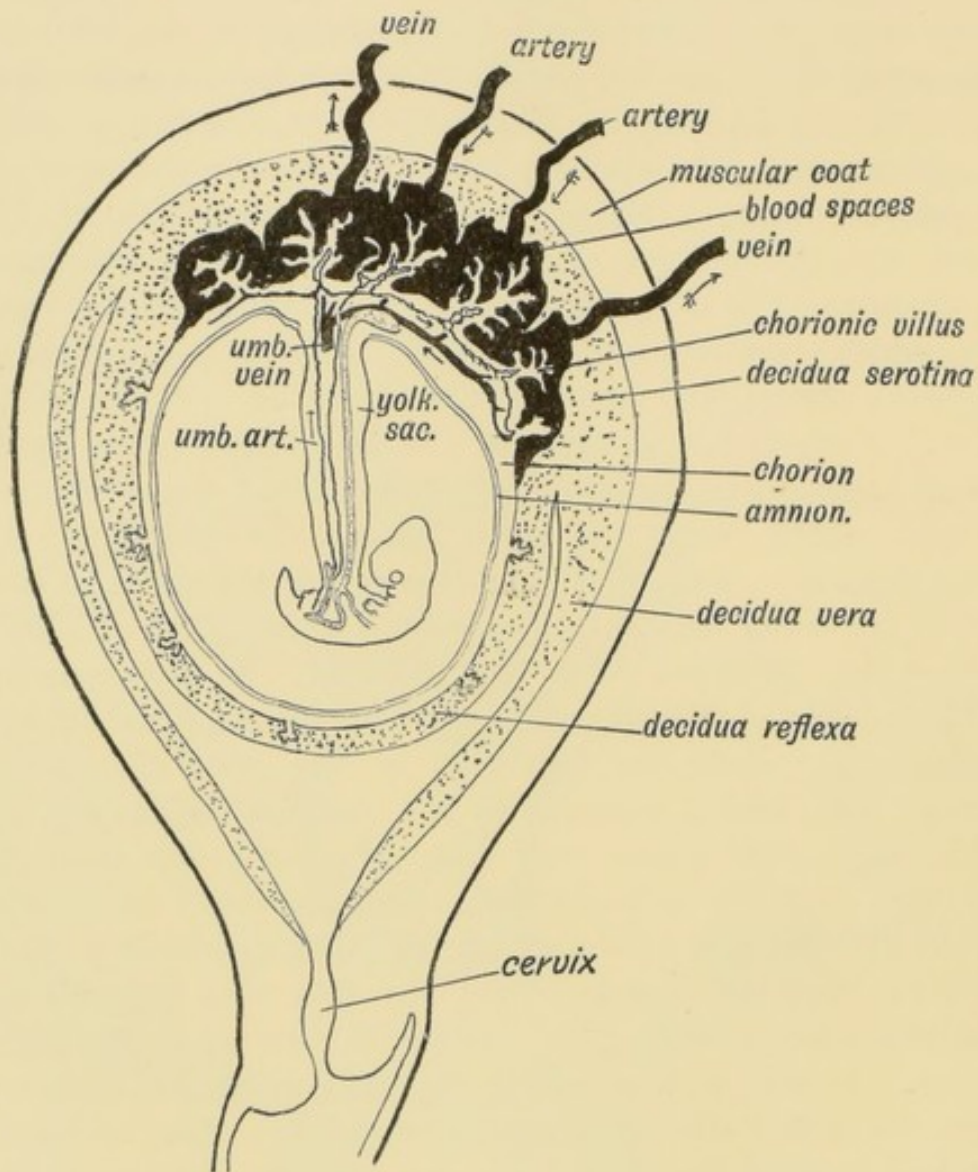


FIG. 76.—Showing the arrangement of the Amnion, Chorion, and Decidua in the 3rd month and the Formation of the Placenta.

The elements entering into the formation of the placenta are diagrammatically shown in Fig. 77. They are :

- 1st. The decidua serotina, formed from the mucous membrane of the uterus.
- 2nd. The prechorion, from the somatopleure.
- 3rd. The allantois from the splanchnopleure.
- 4th. The amnion from the somatopleure.

The amnion is a thin, transparent membrane easily stripped off from the inner surface of the placenta. The serotinal area of the true chorion has become hypertrophied; each villus branches

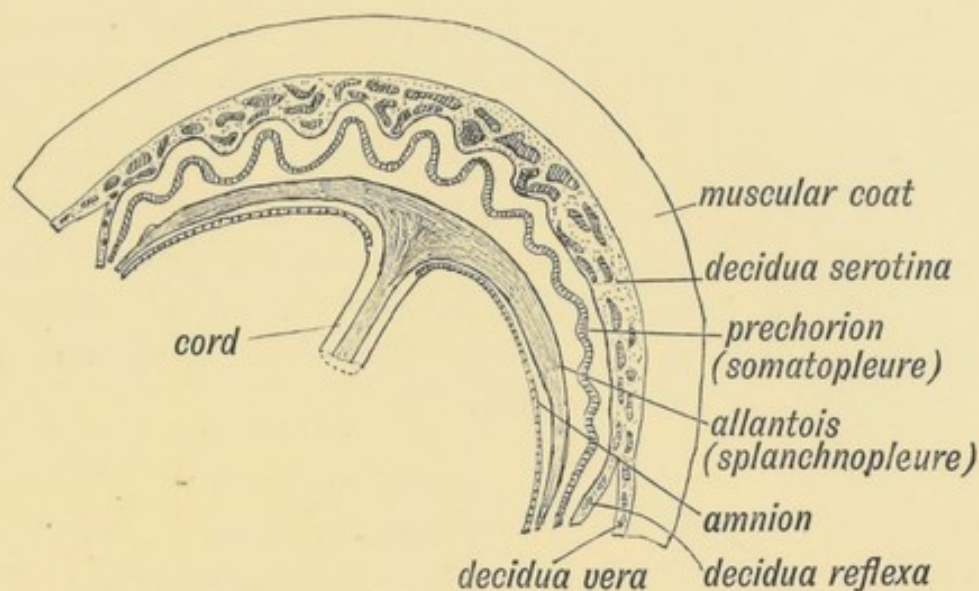


FIG. 77.—Diagrammatic section to show the Elements which enter into the formation of the Placenta.

again and again until it resembles, in the complexity of its ramifications, a miniature beech tree. In these villi the umbilical arteries of the foetus break up into capillaries, which in turn end in the venules of the foetal umbilical vein. The villi project within great blood spaces formed in the decidua serotina (Fig. 76). The ovarian and uterine arteries end in these blood sinuses, and the ovarian and uterine veins begin in them. The blood sinuses are formed:

1st. By the distension of uterine venules in the decidua serotina.

2nd. Possibly by the dilatation of uterine glands.

At full time all the membranes of blastodermic origin come away in the after-birth; also the decidua, except a thin, deep layer next the uterine muscle, which contains the deepest parts of the uterine glands. From this layer the mucous membrane of the uterus is regenerated (Fig. 77).

Formation of the Umbilical Cord and Umbilicus.—The body-stalk, the basis of the cord, is that piece of the embryonic somatopleure situated between the chorion and neural groove (Figs. 74 and 75). The outgrowth of the allantois into the body-stalk adds to it the elements of the splanchnopleure. A

transverse section of the body-stalk shows within it the same elementary structures as are seen in a transverse section of the embryo. The cord must be regarded as a real part of the embryo. The umbilicus, which marks the point of attachment of the cord, is situated in the adult on the ventral surface, but before it was thrust into this position by the development of the caudal and perineal regions of the body, it represented the posterior termination of the embryo (Figs. 74 and 75). The amniotic somatopleure rises from the sides of the body-stalk and encloses it just as it rises from, and encloses, the embryo (Fig. 72), and, as is shown in the next paragraph, the lateral folds of the somatopleure unite in the ventral line of the body-stalk as in the ventral line of the belly (Fig. 78).

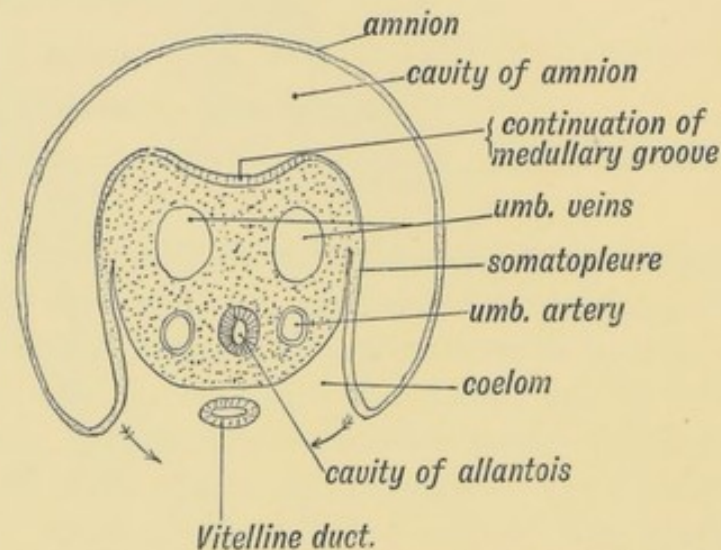


FIG. 78.—Diagrammatic section showing the structures which go to form the Umbilical Cord. (After His.)

Transverse Section of the Umbilical Cord (Fig. 78).—A section of the cord shows:

(1) Two umbilical arteries (continuations of the primitive dorsal aortae).

(2) One umbilical vein, formed by the fusion of the two original veins.

(3) The cavity of the allantois formed from the hind gut. Within the cord its lumen becomes obliterated early.

(4) The vitelline duct, the stalk of the yolk sac, communicating with the intestine and yolk sac. It becomes obliterated in the 3rd month.

(5) Wharton's jelly, a primitive embryonic tissue composed of branching cells in a mucoid matrix.

(6) A covering of epiblast. The amnion is attached round the placental insertion of the cord.

Up to the end of the 4th week the embryo is closely united to the chorion by the short body-stalk (Fig. 75), but in the second month the cord elongates, and in the third month it measures about 12 cm. and about 40 cm. (16 inches) at birth.

Formation of the Umbilicus.—In the adult the umbilicus marks the point where the umbilical cord was attached. It is the point at which the lateral somatopleuric plates fused and thus shut off the intra-embryonic coelom (peritoneal, pleural and pericardiac cavities) from the extra embryonic coelom which is enclosed between the amnion and chorion (Figs. 70 and 72). If these diagrams be examined the yolk sac will be seen to hang free within the great primitive coelom through the umbilicus which, at this stage, is nearly as extensive as the ventral surface of the embryo (Fig. 75). The embryo during the 3rd week is only from 3 to 5 mm. long ($\frac{1}{8}$ - $\frac{1}{2}$ inch); while it grows the umbilicus increases at a slower rate. It thus comes about that when the embryo is an inch (25 mm.) long, the primitive umbilicus, not having kept pace with the body growth, remains comparatively small. The somatic layers gradually contract round the yolk sac and allantoic stalk, the umbilicus and umbilical cord being thus formed. At first the belly end of the umbilical cord is funnel-shaped and a coil of intestine hangs within the umbilicus until the 3rd month of foetal life. After the third month the coil of intestine, probably owing to an increase in the capacity of the abdomen, retreats within the umbilicus, which then contracts round the umbilical vessels. It occasionally happens that the process of development at the umbilicus is arrested at the second month and the child is born with some of its abdominal contents within the umbilicus and upper part of the cord. This condition is known as **congenital umbilical hernia**. Sometimes, too, the stalk of the yolk sac—the vitello-intestinal canal—persists, giving rise to an umbilical faecal fistula. The cavity of the allantois may also remain open, leading to an umbilical urinary fistula. Fistulae at the umbilicus are, however, comparatively rare.

CHAPTER IX.

THE URO-GENITAL SYSTEM.

The Wolffian Body or Meso-nephros.—In lower vertebrates (Fishes and Amphibians) the Wolffian body is the functional kidney; in higher vertebrates (Reptile, Birds, and Mammals) it is

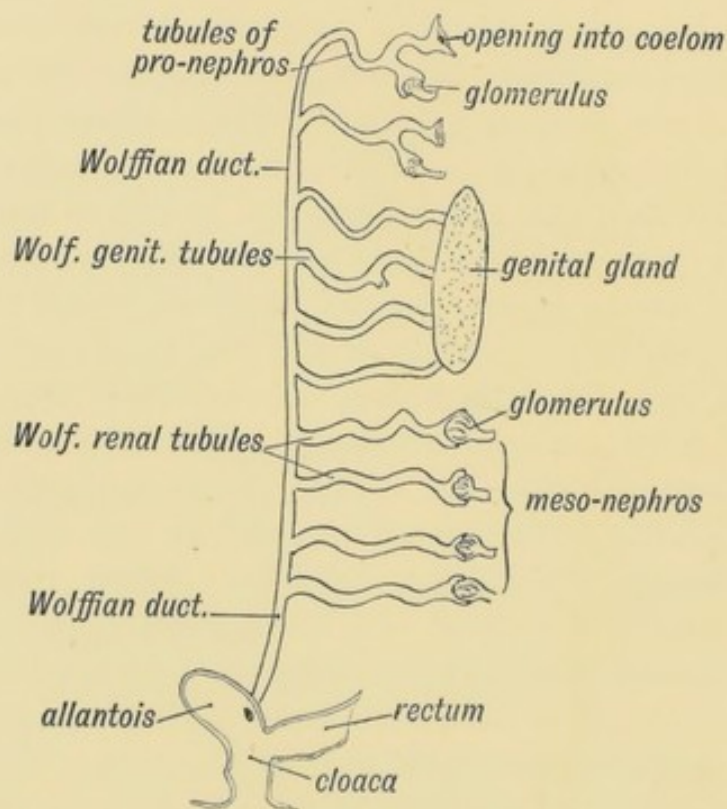


FIG. 79.—Scheme of the Wolffian Body of the right side.

merely a temporary or embryonic structure, the renal function being taken over by the permanent kidney. Nothing is known of how or when the permanent kidney arose and supplanted the

Wolffian Body in the evolution of the vertebrates. Its presence in the human embryo and in the embryonic stages of the three great classes of higher vertebrates, with the presence of many curious stages in the development of their genito-urinary system, can be explained only by the fact that these higher forms are descended from ancestors of the lower.

In Fig. 79 the Wolffian body, such as occurs in the frog, is represented diagrammatically and it corresponds in structure to the Wolffian body which appears in the human embryo. Each body is made up of a main duct and a series of tubules. In the frog, as in the human embryo, the hind gut ends in a dilatation, the **cloaca**. In the cloaca open the rectum, allantois, and the two **Wolffian ducts**—right and left. In the frog, the Wolffian bodies lie on each side of the spine, their anterior ends reaching forwards to the region of the heart. Each duct is joined by numerous convoluted tubules—the **Wolffian tubules**. Each tubule is furnished with a glomerulus at its blind extremity and in most features agrees with a secretory tubule—such as are seen in the permanent kidney. These tubules secrete the urine; the Wolffian duct conveys the urine from the tubules to the cloaca. The anterior tubules, however, lose their secretory function and become associated with the genital gland. In the male frog they convey the spermatozoa to the Wolffian duct, which thus carries both urine and spermatozoa. In the female, the **genital** Wolffian tubules are connected with the ovary but are quite functionless (Fig. 79).

The Wolffian Body in the Human Embryo.—At the beginning of the second month of foetal life, the Wolffian body is well developed: by the end of that month it has become vestigial, the only parts remaining being those connected with the genital organs. It projects as a ridge from the lumbar and dorsal regions on each side of the mesentery, extending, on each side of the spine, from the posterior cervical region, where the diaphragm is developed, to the pelvis behind, where the ridges become approximated (Fig. 80). To its inner side, in the lower dorsal region, lies the **genital ridge**. The genital and the Wolffian bodies have each its own mesentery but these two mesenteries have a common attachment—the common uro-genital mesentery (Fig. 80). On section the Wolffian ridge is seen to be made up of convoluted tubules terminating at

their blind extremities in glomeruli. The tubules open into the Wolffian duct just as in the frog; the duct is situated in the basal or attached part of the ridge. It runs back-

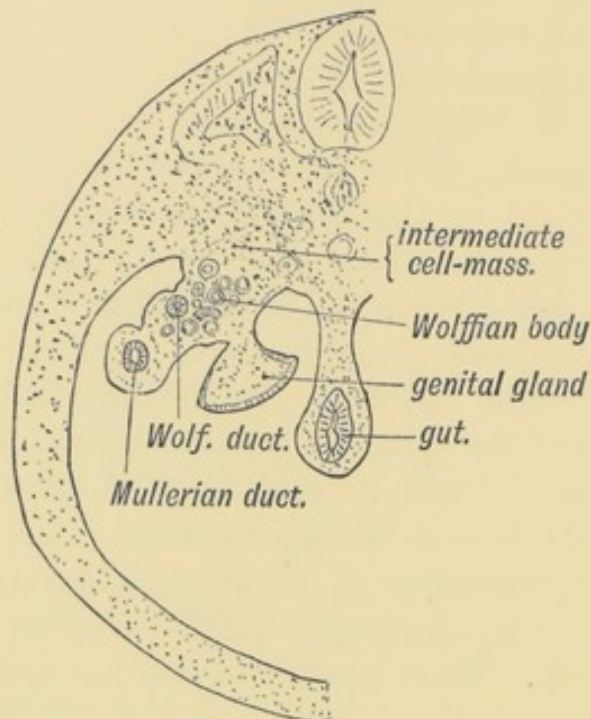


FIG. 80.—Diagrammatic section to show the position of the Wolffian and Genital Ridges on the dorsal wall of the abdomen.

wards in this ridge and turns into the pelvis to end with the Müllerian duct (also situated in the Wolffian ridge) in the cloaca of the hind gut. The whole arrangement is similar to that seen in the frog. Further, as in the frog (Fig. 79), the anterior or genital tubules are connected with the genital glands, and are not, as the posterior are, secretory in nature. If the testis were functional at this time—which it is not—the spermatozoa and urine of the Wolffian body would pass to the cloaca by the Wolffian duct.

Origin of the Wolffian Duct and Tubules.—The tubules which compose the Wolffian body are developed in the **intermediate cell mass** (Fig. 85). At first they are minute transverse vesicles formed by mesoblastic cells in the intermediate mass; these vesicles become tubular; one end opens into the Wolffian duct; at the other a glomerulus is developed.

The origin of the duct has been traced by Kollmann from the epiblast. It arises on the lateral surface of the body by an

invagination of the epiblast and comes to lie subsequently in the intermediate cell mass (Fig. 85). Thus it will be seen that the lining of the Wolffian duct and of the structures formed from it, are epiblastic in nature and liable to all the diseases to which epiblastic structures are subject.

The Pro-nephros (Fig. 79).—Even before the meso-nephros (Wolffian body) there appears to have been another kidney—the pro-nephros. While only permanently functional in some of the lowest fishes and even in them it is partly replaced by the meso-nephros, it still appears transiently in the embryos of vertebrates and is said to occur also in the human embryo. It is developed in the cervical region at the anterior end of the Wolffian ridge. Like the Wolffian body it is composed of a longitudinal duct and tubules; the duct appears to be an anterior prolongation of the Wolffian duct but its tubules are different. They open into the coelom (peritoneal cavity) by trumpet-shaped ciliated ends, and are derived from invaginations of the mesothelial lining of the coelom. They are coiled and terminate in the pro-nephric duct, an anterior continuation of the Wolffian. A glomerulus is developed in the course of each pro-nephric tubule (Fig. 79). The pro-nephric tubules are probably representatives of the segmental (nephridial) tubules of the Vermes.

The Fate of the Wolffian Body (meso-nephros) and Pro-nephros.—(1) In the Female.

In Fig. 81 are shown the various remnants of the embryonic renal formations which may persist in the adult female. The Müllerian duct, the upper part of which becomes the Fallopian tube, is situated in the Wolffian ridge (Fig. 80). Hence when the ovary and tube migrate to the pelvis, the Wolffian mesentery, which comes to form the meso-salpinx, is also drawn within the pelvis and with it all the Wolffian remnants in the female. A hydatid attached to the meso-salpinx (part of the broad ligament) at the fimbriated extremity of the Fallopian tube (Fig. 81) is situated at the anterior end of the Wolffian duct and represents the most anterior (cephalic) of the Wolffian tubules or perhaps the cephalic end of the Wolffian duct, or even the pro-nephros, although it is improbable that this transient embryonic structure should persist (J. H. Watson). It certainly corresponds to the pro-nephric remnant found in the frog. It may become enlarged

or cystic but never to a great extent. The Wolffian duct (Fig. 81) runs towards the body of the uterus in the meso-salpinx; it reaches the side of the uterus and passing down in the superficial

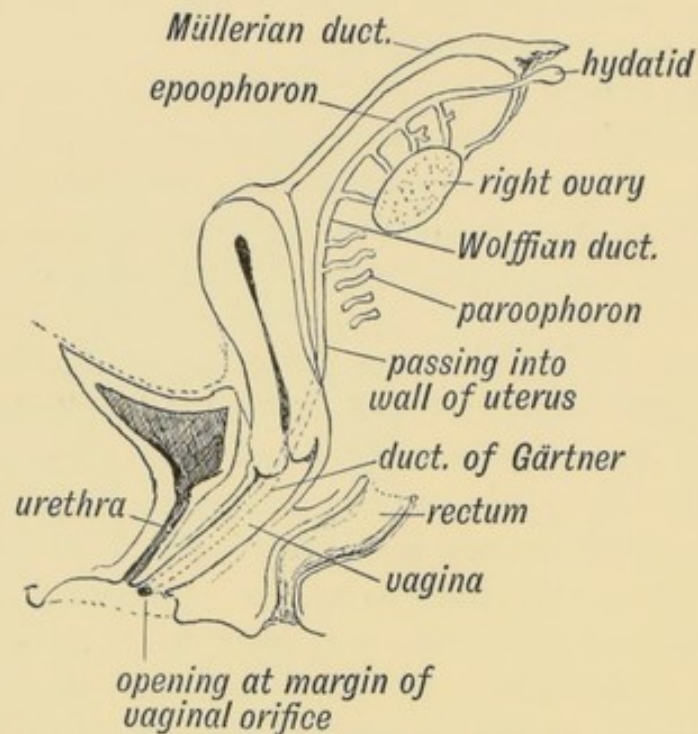


FIG. 81.—Remnants of the Wolffian Body in the Female.

tissue of the cervix and vagina, terminates in the vulval cleft at the outer side of the opening of the vagina near the duct of Bartholin. Only the upper part of the duct (meso-salpingeal part) persists in women. The uterine and vaginal segments disappear. Parts of these may remain; they constantly do so in the sow. The uterine and vaginal segments, if they persist, get the name of **duct of Gärtner**. The **genital** tubules, those attached to or connected with the ovary, persist and form the **epoophoron**, Organ of Rosenmuller, or parovarium (Fig. 81). They frequently become cystic and give rise to large tumours. The **renal** Wolffian tubules—those which acted as renal structures in the embryo, also persist, sometimes unconnected with the duct. They lie between the ovary and uterus and form the **paroophoron** (Fig. 81). They too may form cysts.

2. In the Male.

In the male (Fig. 82) the Wolffian duct forms:

(1) The tube of the epididymis, which is coiled up in the globus major, body and globus minor of the epididymis;

(2) The vas deferens and common ejaculatory duct. The duct opens, as in the female, at each side of the uterus masculinus in the prostatic urethra ;

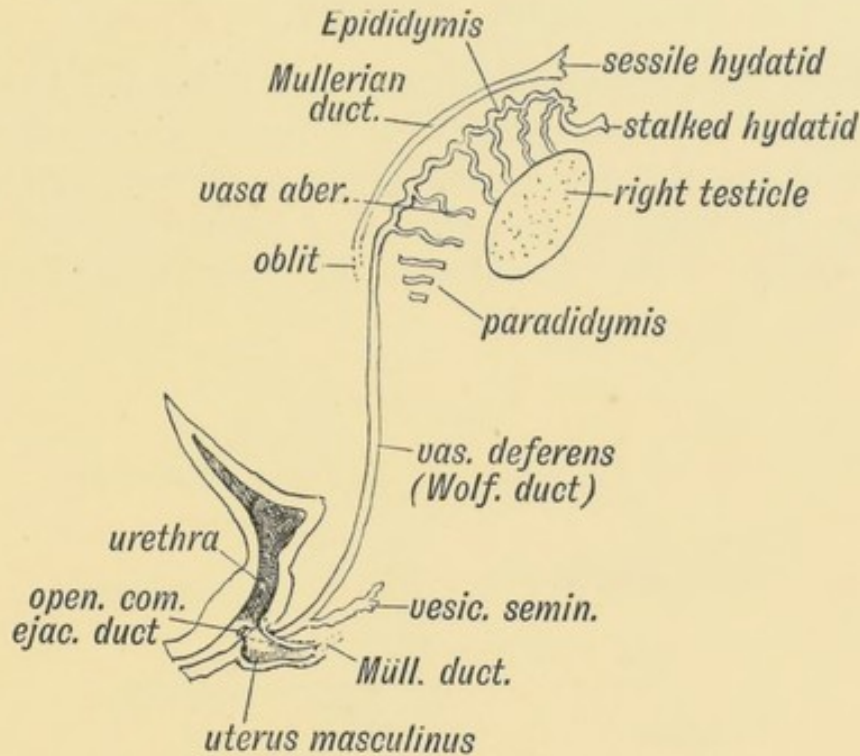


FIG. 82.—Remnant of the Wolffian Body in the Male.

(3) The vesiculae seminales arise from the Wolffian ducts as acino-tubular diverticula.

The stalked hydatid frequently seen on the upper extremity of the testicle corresponds to the hydatid at the fimbriated extremity of the Fallopian tube in the female, and is of similar origin (Figs. 81 and 82).

The **genital tubules** of the Wolffian body become the vasa efferentia and coni vasculosi.

The **renal tubules** of the Wolffian body form :

- (1) The vasa aberrantia found in the globus minor ;
- (2) The paradidymis or organ of Geraldés occasionally situated in the cord above the globus major. All these tubules, both genital and renal of the Wolffian body, are situated originally in the mesentery of the Wolffian body (Fig. 80).

Thus it will be seen that while in the male the Wolffian tubules and duct become part of the genital system, in the female

they become functionless and only of pathological importance. Their presence in the female is due to their being inherited from the male.

THE KIDNEY.

Origin of the Permanent Kidney.—In Fishes and Amphibians the Wolffian body alone acts as a kidney. In Reptiles, Birds and Mammals, the permanent or hind kidney appears and supplants the Wolffian kidney. The kidney appears in the human embryo at the beginning of the second month. It arises

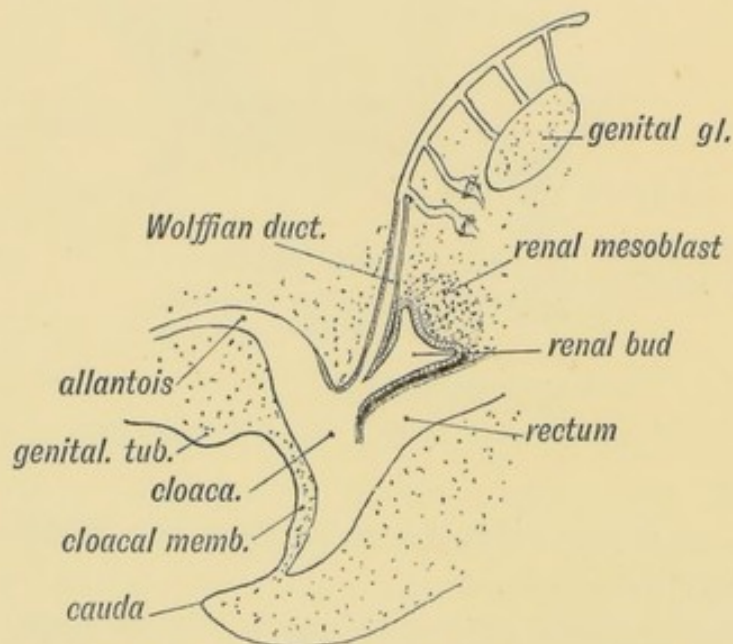


FIG. 83.—The Origin of the Renal Bud (diagrammatic).

(see Fig. 83) as a bud from the dorsal side of the Wolffian duct, near the termination of that duct in the cloaca. At first it is a stalked bud with a narrow lumen; it rapidly extends forwards to the lumbar region behind the Wolffian body and behind the peritoneum. The stalk of the bud forms the ureter. The connection of the stalk with the Wolffian duct is lost; the termination of the ureter migrates along the duct until it reaches that part of the cloaca which afterwards forms the bladder (Fig. 84). The dilated cephalic end of the bud divides into several secondary buds. The dilated terminal part forms the pelvis of the kidney, its infundibula and calyces. The tubules

of the kidney are formed from groups of epithelial cells on the convex margin of the dilated end of the renal bud. They arise as tubular buds which grow out into the intermediate

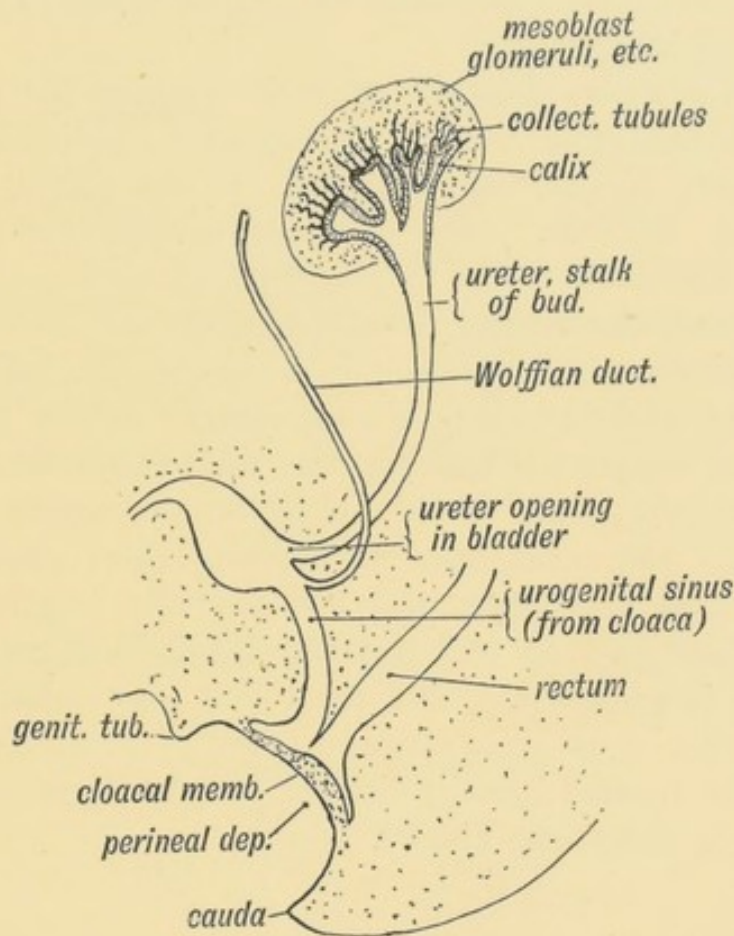


FIG. 84.—The Termination of the Ureter in the Bladder and Sub-division of the Renal Bud.

cell mass, subdividing as they grow out. The tubular buds spring out in groups, each group forming a pyramid. The tubules at first are straight, but as they grow into the intermediate cell mass, each tubule becomes convoluted, and at its blind end a glomerulus, formed in the intermediate cell mass, is developed and comes to project within the tubule. The glomeruli, and perhaps also the convoluted tubules, are produced from the renal mesoblast beneath the capsule, batch after batch being formed as the kidney grows. The loop of Henle is late in appearing. Thus it will be seen that the ureter, the pelvis of the kidney and at least the collecting tubules of the kidney are derived from the epithelial bud which springs from the Wolffian duct; the capsule of the kidney, the intra-renal connective tissue,

the vessels and glomeruli, and possibly the convoluted tubules, are derived from the mesoblast of the intermediate cell mass. It will be remembered that the epithelial lining of the Wolffian duct is epiblastic in origin, and the renal bud which springs from it must also be of a similar nature.

The kidney grows forward until it touches the supra-renal bodies. At the same time it undergoes a rotation so that the hilum, instead of pointing backwards to the pelvis, is directed inwards and forwards. The secretory tubules are grouped in lobules or pyramids. Up to the time of birth and for some time afterwards the lobules remain distinct, and this is the permanent condition in mammals, such as the ox, bear, seal, etc. In man, with the formation of new cortex beneath the capsule, all marks of separation between the surface parts of the renal lobules disappear, only their apices or pyramids remaining distinct. As the renal buds of opposite sides grow forwards, they may come in contact and fuse partially together at their caudal extremities. In this way the condition known as **horse-shoe kidney** is produced. The renal bud may subdivide at its commencement, thus giving rise to **two** or even **three ureters**. Although the ureters remain distinct, the renal parts commonly fuse again to form one kidney.

THE MÜLLERIAN DUCTS.

The **Müllerian Ducts** or **Oviducts** are present in almost all vertebrates, and convey the ova to the surface of the body. In fishes, amphibians, reptiles, birds and lower mammals (Marsupials) the ducts terminate in the cloaca. This is also the case in the embryonic stages of man and all higher mammals. The development of the duct in man is very simple (Fig. 85). It is developed on the outer surface of the Wolffian ridge, below (ventral to) the Wolffian duct, by a tubular invagination of the mesothelium of the coelom. The anterior (cephalic) end remains connected with the coelom and forms the ostium abdominale. As it passes backwards in the Wolffian ridge it lies below and internal to the Wolffian duct and comes in contact with the Müllerian duct of the opposite side in the pelvis (Fig. 87). The Müllerian duct

is formed in the embryo later than the Wolffian duct. In fishes the Müllerian is derived from the Wolffian duct. They

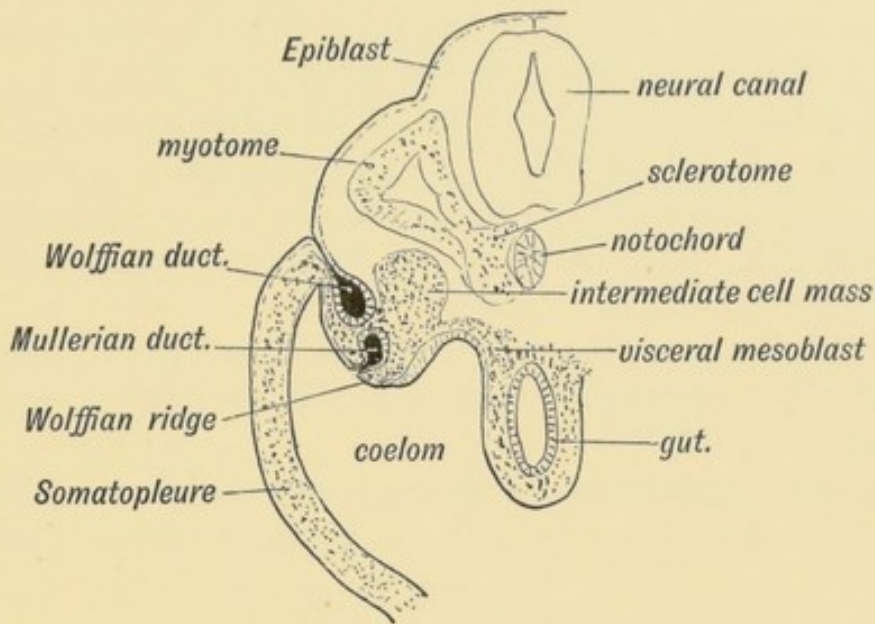


FIG. 85.—A transverse section to show the manner in which the Wolffian and Müllerian Ducts arise, and their position in the Wolffian Ridge. (After Kollmann.)

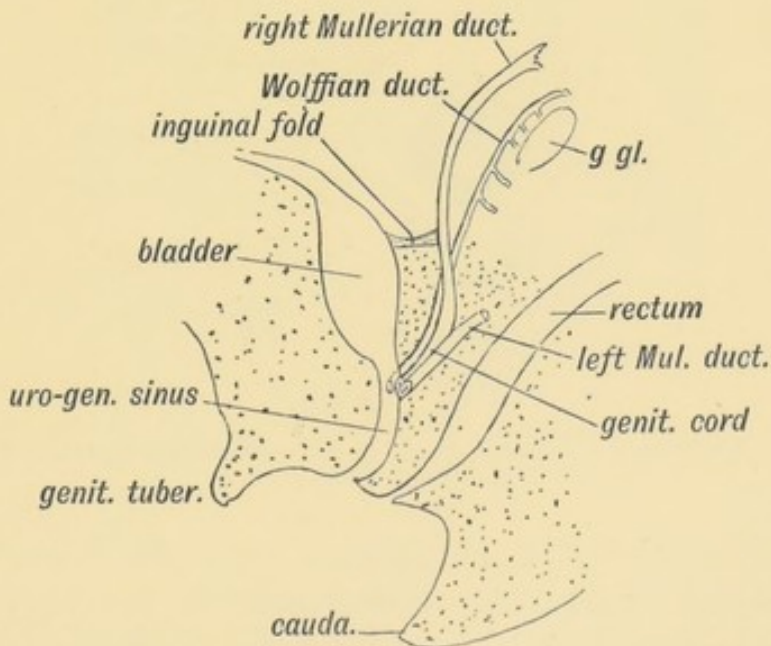


FIG. 86.—Diagram of the Genital Ducts at the commencement of the 3rd month of foetal life. Lateral view.

open in that part of the cloaca which forms the neck of the bladder, between the openings of the Wolffian ducts (Fig. 86). They are developed in the male as well as the female embryo.

The Genital Cord.—During the 3rd month the Müllerian ducts show two distinct stages in their course :

(1) **Lumbar**, which lies in the Wolffian ridge and is suspended from the posterior abdominal wall by the Wolffian mesentery. This stage afterwards forms the Fallopian tube (Fig. 87).

(2) **A pelvic stage**, where it lies in the genital cord. The posterior ends of the Wolffian ridges, with their contents, the Wolffian and Müllerian ducts fuse in the pelvis, and thus form the **genital cord**. The parts of the Müllerian ducts within the cord form the uterus and vagina.

The genital cord of the foetus at the second month shows the two Müllerian and two Wolffian ducts—in the male as well as in the female (Fig. 86).

The Round Ligament of the Uterus is attached to the Müllerian duct on each side (Fig. 87). The point of attachment marks the

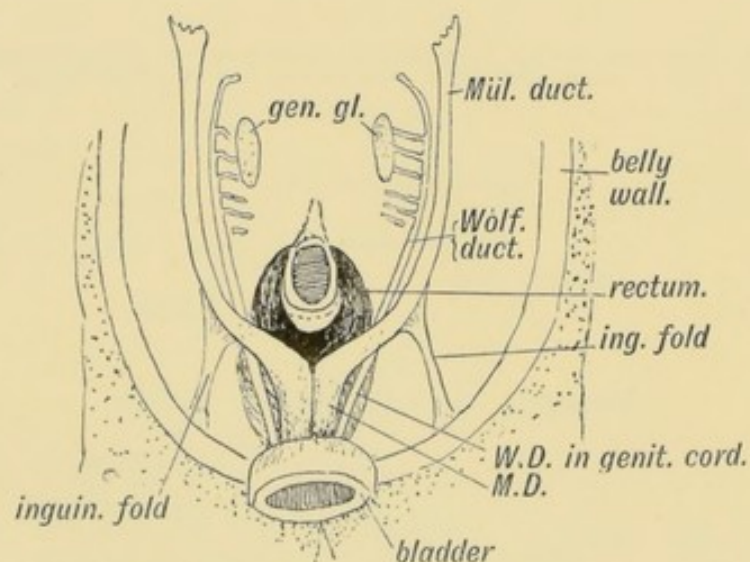


FIG. 87.—Diagram of the Müllerian Ducts at the commencement of the 3rd month. Ventral view.

junction of the uterine and Fallopian segments of the Müllerian ducts. The round ligament corresponds to the gubernaculum testis in the male and its development is similar. Both are developed in the following manner :

Part of the Wolffian ridge is continued backwards as a peritoneal fold to the groin, this part forming the **inguinal fold** (Fig. 87). Into this peritoneal fold muscle cells grow from the rudiments of the transversalis and internal oblique in the abdo-

minal wall and form the round ligament of the uterus. The point from which the ingrowth springs becomes the internal abdominal ring. Others grow out into the labium majus, carrying with them a process of peritoneum—the canal of Nuck. The inguinal canal and external abdominal ring and extra-abdominal part of the round ligament are thus formed.

Formation of Uterus and Vagina.—Within the genital cord the Müllerian ducts fuse and form the uterus and vagina (Fig. 87). In all the members of the vertebrate series below and including

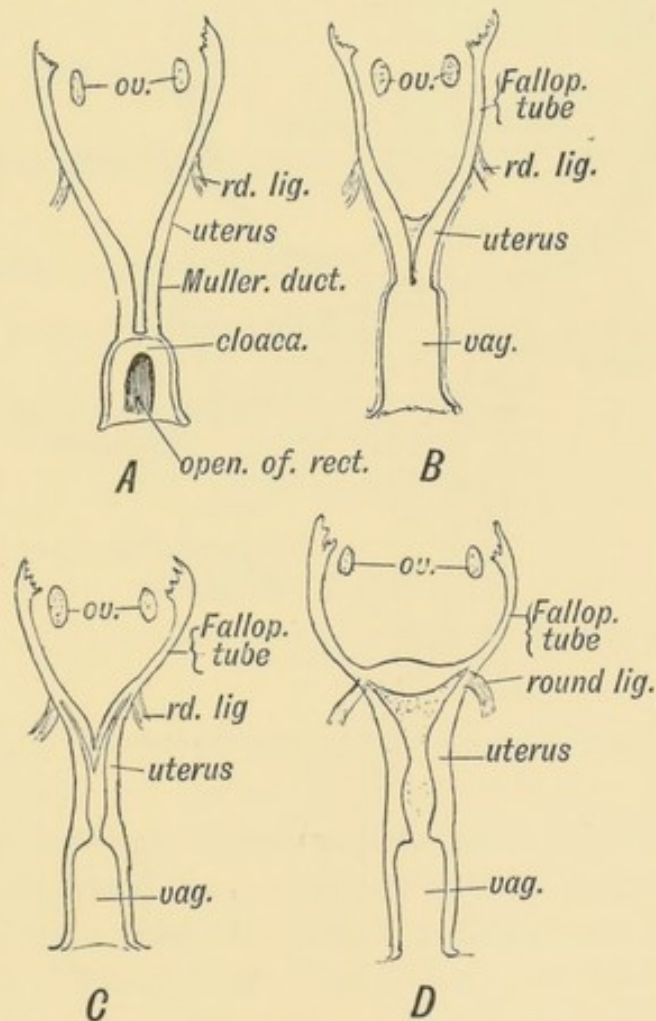


FIG. 88.—Evolution of the Human Form of Uterus.

- A. Form seen in lowest mammals, reptiles, amphibians, fishes, and in the 2nd month human foetus. B. Form of Müllerian Ducts in rodents. C. Form in Carnivora, etc., and in the 4th month human foetus. D. Form found in man and higher primates.

the Monotremes, the Müllerian ducts remain separate and open in the cloaca (Fig. 88 A). The process of fusion begins in the 3rd month. The septum formed by the fused mesial walls (Fig. 89) disappears first in the region of the uterine cervix; the

process may be arrested at this stage—a stage shown by some adult marsupials. Then the lower or vaginal part of the septum disappears; the human uterus then ($3\frac{1}{2}$ months) resembles that of higher mammals (carnivora, etc., Fig. 88 C). It may be arrested at this stage (uterus bicornis). Lastly the upper part of the septum disappears ($4\frac{1}{2}$ months, Fig. 89). The fundus, which is the last part to be developed and is only found in the highest primates, is quite well marked in the child at birth.

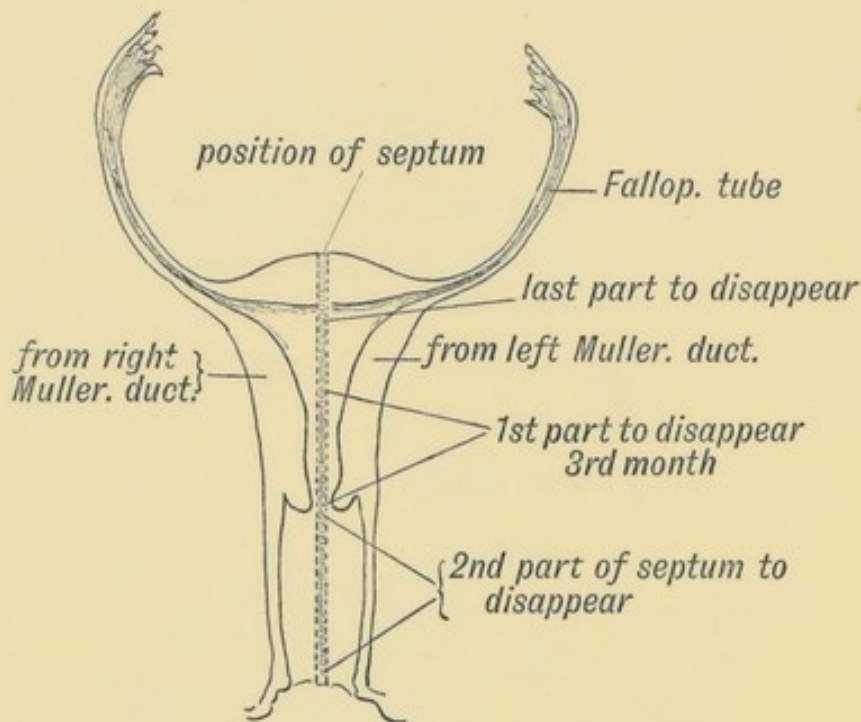


FIG. 89.—Showing the manner in which the Müllerian Ducts fuse to form the Uterus and Vagina.

The lining epithelium of the lower third of the vagina is derived, according to the researches of Berry Hart, from the lower ends of the Wolffian ducts. A solid epithelial bud (epiblast) grows from the end of each duct, and fills the lower part of the united Müllerian ducts. The central cells of the Wolffian buds disappear, while the peripheral form the lining of the lower third of the vagina.

The Müllerian Ducts in the Male.—All that remains of the Müllerian ducts in the adult male are their fused terminal segments forming the sinus pocularis or uterus masculinis in the prostate (Figs. 82 and 90). Its depth is commonly about 3 or 4 mm., but occasionally such a form as is represented in Fig. 91

occurs and shows the real nature of the sinus pocularis. The vagina, uterus, and part of the Fallopian tubes can be recognised (Primrose).

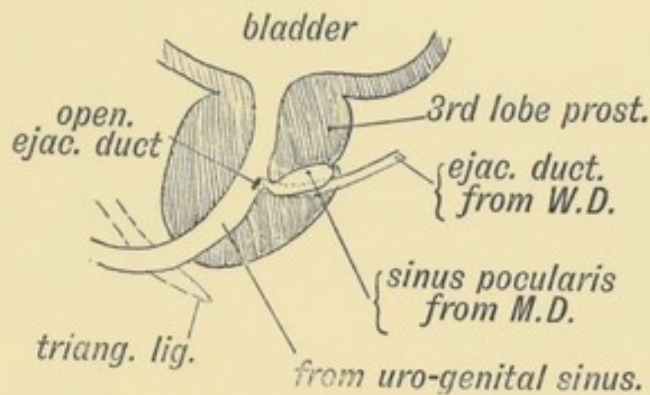


FIG. 90.—A section of the Prostate showing the Remnants of the lower ends of the Müllerian Ducts in the male.

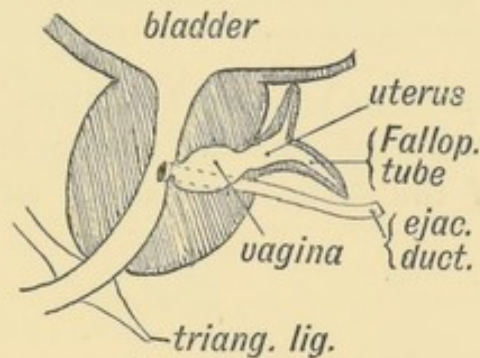


FIG. 91.—A section of a Prostate showing an unusually developed Uterus Masculinus. (After Primrose.)

The fimbriated ends of the Müllerian ducts persist as the sessile hydatids on the testicle (Fig. 82). The intermediate part of the tube becomes greatly stretched during the descent of the testicle and disappears, but a remnant of its upper end can be found in the sharp anterior border of the epididymis until quite a late period in foetal life (J. H. Watson). The mesosalpinx shrinks and completely disappears in the anterior border of the epididymis.

The Uro-genital Sinus or Canal.—The Müllerian ducts open into that part of the cloaca which becomes the neck of the bladder (Fig. 86). That part of the cloaca which serves as a common channel for bladder, Müllerian, and Wolffian ducts is the uro-genital sinus (Figs. 95 *A* and *B*). In the female foetus at the 4th month it is still well marked (Fig. 92 *A*). In all mammals

except man it retains this form. By the beginning of the 6th month in the female foetus (Fig. 92 *B*) it will be seen that the

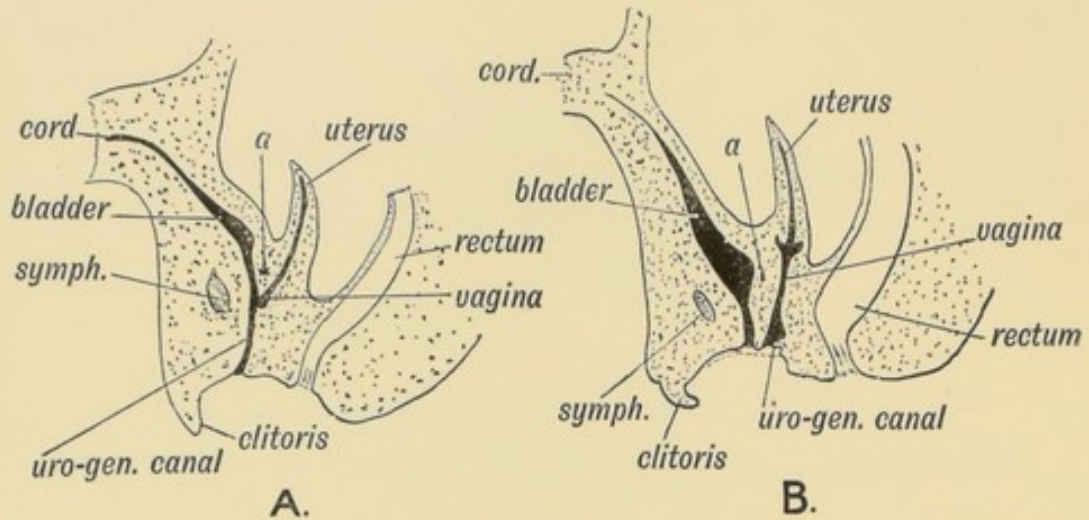


FIG. 92.—Section showing the Uro-genital Sinus.

A. In the 4th month female human foetus. *B.* In the 5th month female human foetus.

vesico-vaginal septum (*a* in Fig. 92) has grown down towards the pudendal cleft, and all that remains of the uro-genital sinus is the small space of the female pudendal cleft from the fossa

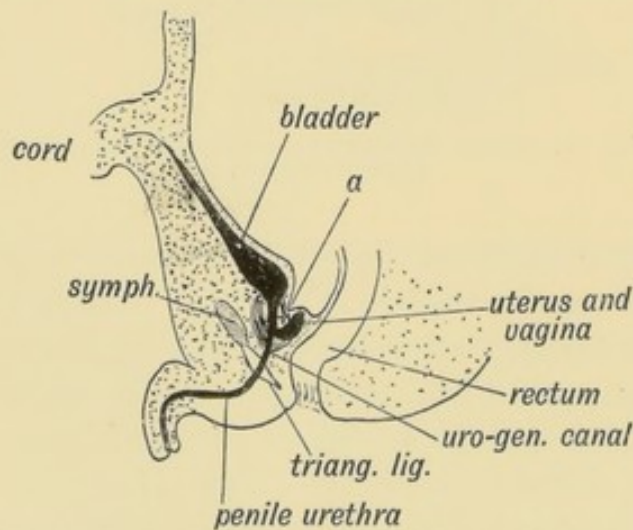


FIG. 93.—Section showing the Uro-genital Sinus in the male foetus.

a indicates the part corresponding to the vesico-vaginal septum of the female. It is occupied by the 3rd lobe of the prostate.

navicularis behind to the vestibule of the vulva in front. The vagina (Müllerian ducts) thus comes to open in the pudendal cleft in the female. In the male (Fig. 93) the early foetal form is retained, and the uro-genital sinus becomes that part of the male urethra between the sinus pocularis and the

anterior layer of the triangular ligament. The female urethra corresponds to the prostatic part of the male urethra above the opening of the sinus pocularis (Figs. 92 and 93).

The Hymen is formed at the junction of the vagina with the uro-genital sinus. The terminal parts of the Müllerian ducts, which form the vagina, are at first solid epithelial cords, the epithelial mass being derived from the bulbous terminations of the Wolffian ducts (Berry Hart). After the Müllerian ducts fuse to form the vagina they become hollowed out, all but the terminal piece, which forms the hymen and it, as a rule, is perforated (Fig. 94).

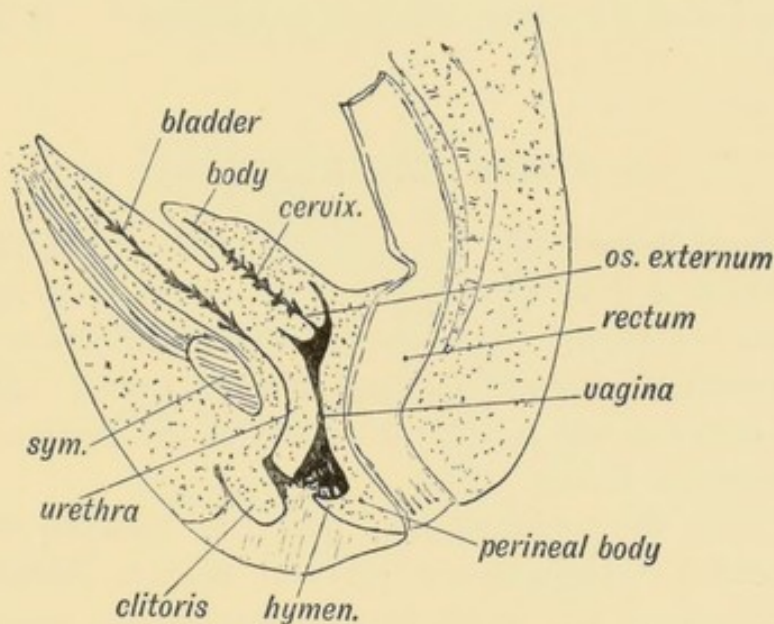


FIG. 94.—A section to show the condition of the Vagina and Uterus at the 7th month of foetal life.

Cases occur in which the hymen is a complete or even thick septum, or occasionally the whole vagina may retain the foetal solid form (atresia vaginae).

The Vagina is at first not only solid, but extremely short; the downgrowth of the vesico-vaginal septum adds greatly to its length (Fig. 92 *A* and *B*). It is separated off from the uterine segment of the Müllerian duct in the fifth month (Fig. 92 *B*) by (1) the growth of the external os and formation of the labia; (2) by its epithelium becoming stratified, while that of the uterus and upper half of the cervix remains columnar.

The Uterus is formed by the fusion of the Müllerian ducts; its muscular walls and thickened mucous lining appear in the 5th

month. By the seventh month (Fig. 94) it is divided into two parts, the cervix or lower segment and body or upper segment. The lower segment or cervix forms then two-thirds of the uterus; its walls are thick and its upper part is lined by columnar non-ciliated epithelium, containing mucous racemose glands. Its mucous membrane is arranged in palmate folds. The upper or uterine segment proper composes only a third of the uterus. It is lined by columnar ciliated epithelium. Uterine glands are developed in it after birth. At puberty the body of the uterus, instead of being half the size of the foetal cervix, becomes larger than it. The cervix takes no part in menstruation nor in containing the foetus; its true function is unknown. It is probably glandular.

THE PERINEUM.

The Perineal Body (Figs. 94 and 95) is the triangular septum of tissue which is developed in the perineum so as to separate the rectum from the vagina. It contains the origin of the sphincters of the anus and vagina, fat and fibrous tissue, and all the structures between the recto-uterine fold of the peritoneum above and the perineum below.

In the male the corresponding part lies between the urethra and the rectum. In man the perineal body is extremely large. By its development the rectal part of the cloaca is separated from that part of it which forms the uro-genital sinus (Fig. 95). The perineal body is formed at the end of the 1st month of foetal life in the following manner:

The allantois grows out from the hind gut; a prolongation of the enteric cavity forms the canal of the allantois (Fig. 75, p. 96). Hence in the 3rd week the hindermost part of the gut is common to allantois and intestine, the common part forming the **cloaca**. There is then no perineal body (Fig. 95 *A*). This is the permanent condition in all vertebrates save the higher mammals—those higher than the Monotremes. The Wolffian ducts open in the cloaca near the neck of the allantois. A cleft appears on each side of the cloaca, and the dorsal or rectal part is separated from the ventral or uro-genital part. The ventral or uro-genital part of the cloaca forms the bladder and uro-genital sinus, which are

thus separated from the rectum by the ingrowth of two lateral cloacal septa.

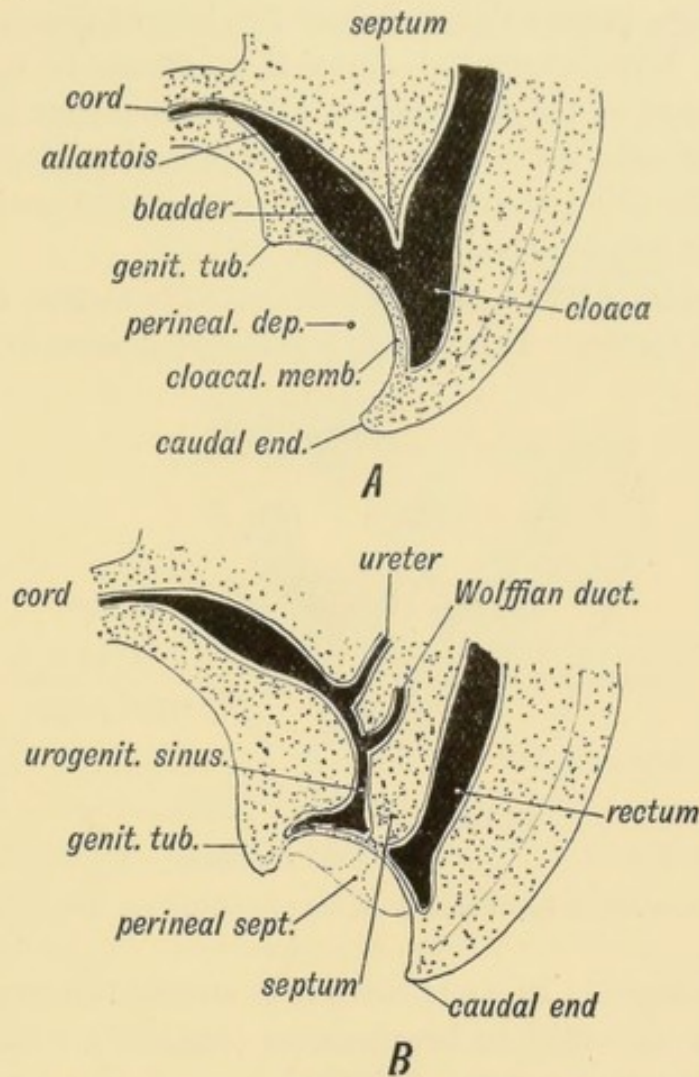


FIG. 95.—The Division of the Cloaca into Rectal and Uro-genital Parts.

- A.* First appearance of the separation of the Cloaca into Rectal and Uro-genital Parts (3rd week).
B. Separation of the Cloaca into Rectal and Uro-genital Parts (5th week).

The Proctodaeum or Primitive Perineal Depression.—Although the main part of the perineal body is formed in the manner just described, a second element, which forms the surface part of the perineal body is formed thus:

Between the caudal protuberance behind, and the genital tubercle in front (Fig. 95 *B*), the epiblast dips in as a median depression to form the proctodaeum or primitive perineal depression. The depressed area comes in contact with the ventral surface of the cloaca (Fig. 95 *A*). By the ingrowth of a perineal septum from each lateral margin of the depression, the proctodaeum is separated into a posterior or anal part, and an anterior or uro-genital part.

The cloacal membrane or plate (Fig. 95 *A*), formed of the applied layers of epiblast and hypoblast between the perineal depression and the cloaca, breaks down before the end of the 1st month of foetal life. The uro-genital sinus then comes to open into the uro-genital part of the depression, while at a rather later date the rectum opens into the anal part. The lateral perineal ingrowths, which divide the proctodaeum into uro-genital and anal parts, complete the perineal body (see Fig. 98).

Imperforate Anus.—This condition occurs not unfrequently, and in many forms. It is due to a mal-development of the cloacal

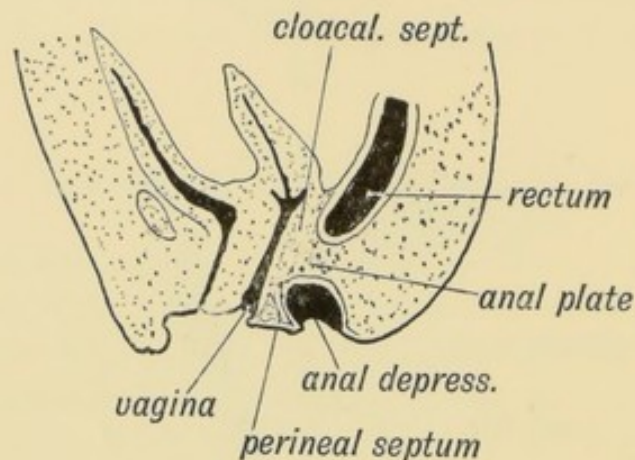


FIG. 96.—A case of Imperforate Anus due to a persistence of the Anal Plate.

and perineal septa. In some cases it is merely the anal part of the cloacal plate that fails to break down (Fig. 96). The white line, situated at the lower ends of the columns of Morgagni, marks the situation of the anal plate and the junction of the epiblast of the anal depression with the hypoblast of the rectum.

In over 50% of cases of imperforate anus the rectum ends blindly two inches or more above the anus. In such cases the lateral septa which divide the cloaca appear to have been mal-placed and included the whole of the cloacal part of the hind gut in the uro-genital canal. On the other hand the cloacal septa may be incomplete, and the uro-genital sinus only partially separated from the rectal. In such cases there is a communication between the rectum and termination of the vagina in the female (Fig. 97), and the part of the urethra formed from the uro-genital sinus in the male (Fig. 93).

Post-anal Gut.—It will be observed that the anus is formed

on the ventral aspect of the hind gut (Fig. 108, p. 136). There is a projection of the gut behind the proctodaeal depression. This is the post-anal gut. It commonly disappears, no trace of

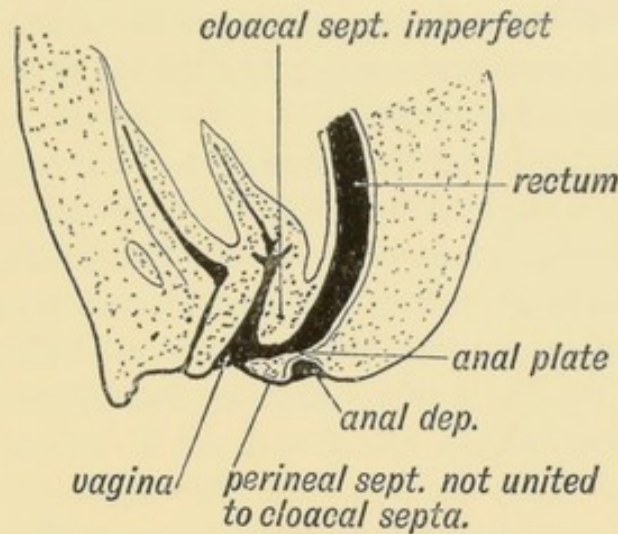


FIG. 97. —A case in which the Rectal part of the Anal Plate has persisted and the Cloacal Septum has failed to fuse with the Perineal Septum.

it being found after the 1st month, but remnants of it are said to give rise to ano-coccygeal tumours and cysts.

The Neurenteric Canal—Ano-coccygeal tumours are also believed to arise from remnants of the neurenteric canal. The neurenteric canal, or blastopore, it will be remembered (p. 89, Figs. 68, 75 and 158) is a communication of the cavity of the hypoblast with the surface of the epiblast. It probably represents the point at which an area of cells was invaginated within the epiblast to form the hypoblast. As it opens at the anterior end of the primitive streak, which afterwards is included in the posterior end of the neural groove, such a canal, if it persisted, might be expected to perforate the coccyx and communicate between the canal of the notochord and filum terminale. No remnant of this canal has been found after the 1st month of foetal life.

The Uro-genital Cleft or Depression is the anterior part of the proctodaeal or primitive perineal depression, cut off from the posterior or anal part by the development of the perineal septa. With the absorption of the cloacal membrane, the uro-genital sinus opens in the cleft (Fig. 95 B). The cleft remains alike in both sexes until the third month. It forms the greater part of

the pudendal cleft of the female. In its anterior angle is developed a prominent tubercle—the **genital tubercle**, the apex of which becomes the glans penis or glans clitoris, according to sex. It is bounded by lateral folds, the **genital folds** (Fig. 98). The genital folds divide in front; the inner division of each runs to the glans and forms the fraenum; the lateral divisions meet over the glans and form the prepuce.

External Genitals of the Female.—In the female the parts retain closely the early foetal form just described. The genital tubercle becomes the glans clitoris. In the genital eminence—of which the tubercle is merely the summit, the corpora cavernosa develop. The lateral genital folds form the labia minora, the prepuce and fraenum. By the junction of the genital folds within the urogenital depression behind, the fourchette is formed. Within the lateral folds or labia minora, are developed the bulbs of the vestibule. The urogenital depression becomes the pudendal cleft. After the third month external genital folds arise and form the labia majora. By their anterior union they give rise to the mons Veneris. Their posterior extremities unite to form the posterior commissure.

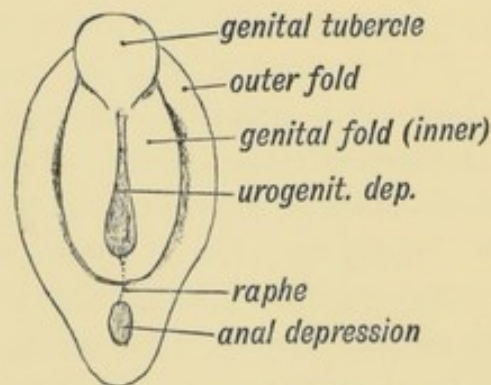


FIG. 98.—The Uro-genital Cleft or Depression and the Genital Tubercle and Folds towards the end of the 2nd month.

External Genitals of the Male.—In the male, at the end of the third month, the lateral genital folds begin to unite from behind forwards, thus closing the urogenital cleft and forming the floor of the penile urethra. While the floor of the penile urethra is formed thus, its roof, corresponding to the vestibule of the female, is derived from an angular forward prolongation of the urogenital sinus. (See Fig. 95 B.) When the genital folds unite

to form the urethral floor, the erectile tissue contained in them, corresponding to the bulbs of the vestibule of the female, also fuses and thus the corpus spongiosum is formed. The part of the urethra within the glans is the last part to be formed, and its development is peculiar. It is formed by a solid rod-like ingrowth of epiblast within the glans which burrows backwards until it reaches the part formed out of the uro-genital cleft. The glans part of the urethra becomes canaliculized a short time before birth. The fossa navicularis and lacuna magna occur at the junction of the part of the urethra formed in the glans and the part formed by the union of the inner genital folds.

The closure of the uro-genital lips to form the floor of the urethra in the penis may be arrested at any stage,

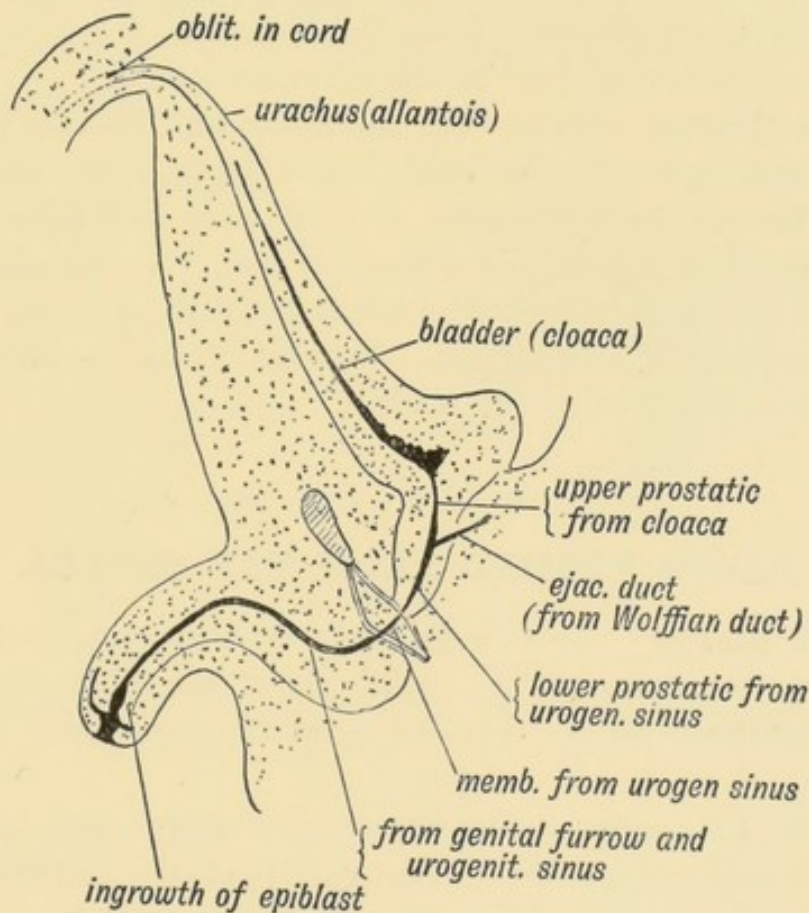


FIG. 99.—A section of the male bladder and urethra at birth, showing the structures derived from the intra-abdominal part of the Allantois and from the Cloaca.

giving rise to the condition of **hypospadias**, a condition normal in the female. It is not very rare to find the terminal half inch of the urethra in a hypospadiac condition. If the

hypospadias is complete then probably the internal sexual organs have been arrested in their development, and the sex of the individual can be determined only by the microscopic examination of the genital glands. The development of the prostatic and membranous parts of the urethra from the uro-genital sinus has been already dealt with (see Figs. 91, 93, and 99).

The Scrotum is formed during the fourth month by the union of the external genital folds (labia majora in the female) between the penis in front and the perineal body behind. The line of union is marked by the raphe.

The Fate of the Allantois (Fig. 99).—The part of the allantois outside the abdominal parietes forms (1) the inner or vascular layer of the chorion (p. 97), and part of the umbilical cord (Figs. 75 and 78). The cavity of the allantois within the cord disappears by the end of the third month.

The intra-abdominal part of the allantois forms:

(1) **The Urachus** between the umbilicus and bladder (Fig. 99). It is reduced to a fibrous cord before birth. It may remain patent in the middle and closed at both ends and thus give rise to a urachial cyst behind the abdominal wall. Or it may open at the umbilicus, or at the bladder or at both, thus giving rise to a urinary fistula at the umbilicus. Urachial cysts are rare.

(2) The apical part of the bladder.

PARTS FORMED FROM THE CLOACA.

(1) **The Bladder.** It was formerly customary to describe the bladder as a derivative of the basal part of the allantois but more recent researches show it to be part of the cloaca (Figs. 95 and 108).

At birth the neck of the bladder lies above and behind the symphysis pubis (Fig. 99). The cavity of the bladder is then fusiform in shape and mostly extra-pelvic in position. It differs from the adult bladder in having a very small trigone and its cavity, therefore, a very short posterior limb in the closed condition.

(2) **The Female Urethra** and the corresponding part in the male, viz., the part between the neck of the bladder and the sinus pocularis.

(3) **The uro-genital sinus** or canal, and the parts derived from it which have been already described (Fig. 93 and page 115).

(4) The terminal part of the rectum.

Ectopia vesicae is as yet unexplained. The condition is shown diagrammatically in Fig. 100 *A*. This condition appears to be produced thus:

(1) The development of the tail in the embryo thrusts the region of the primitive streak, situated on the body-stalk, towards the ventral aspect of the body. The uro-genital part of the perineal depression and the cleft into the uro-genital sinus are formed in the line of the primitive streak (Fig. 158, p. 192). The body-stalk which at first is a direct continuation of the body (Fig. 75, p. 96), is arrested in its migration towards the ventral surface of the body. It is arrested between the rami of the pubes, and prevents the formation of the symphysis.

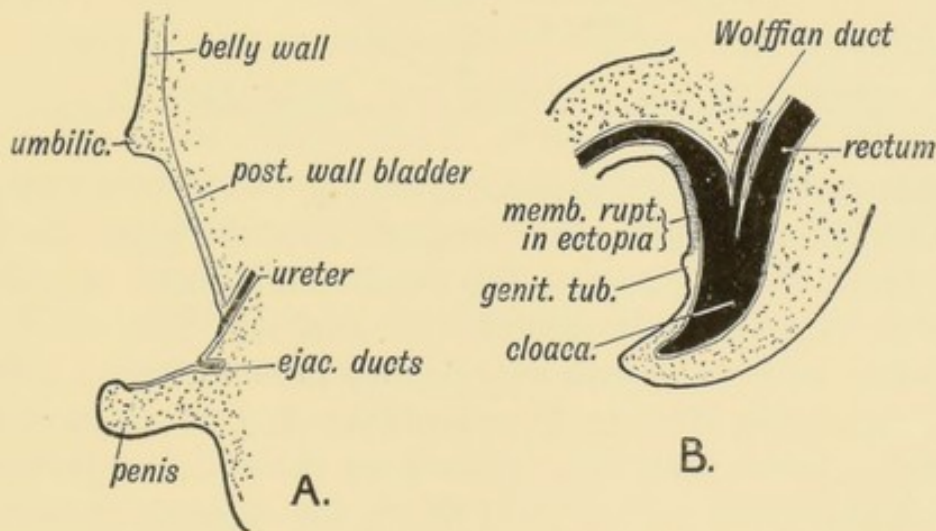


FIG. 100.—*A*. A section to show the condition of parts in Ectopia Vesicae.
B. Section of the pelvis of an embryo (4th week) to show how the condition is probably produced.

(2) The uro-genital cleft is formed in front of and above the genital tubercle instead of below it. The cleft opens thus into the anterior wall of the bladder instead, as it normally does, into the uro-genital sinus (Fig. 100 *B*).

It is also possible that the condition of ectopia vesicae is due to a dropsical condition of the allantois, with subsequent rupture, in the embryonic condition.

THE PROSTATE.

The **Prostate** is developed round the uro-genital sinus. It consists of glandular tissue and stroma.

(1) The **glandular tissue** is composed of tubular glands which open into the prostatic part of the urethra. They are developed in the 4th month, as series of solid buds from the epithelium lining

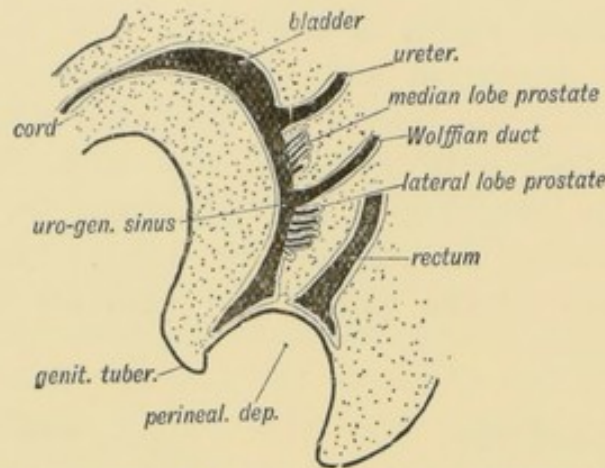


FIG. 101.—A diagram to show the position at which the Prostatic Tubules arise.

the upper part of the uro-genital sinus (Fig. 101). The buds grow out as a right and left lateral mass, and form the glandular tissue of the lateral lobes. At first the two lateral lobes, as in mammals generally, lie separately behind the urethra. Then they fuse behind the urethra; in man only do they meet to form a dorsal or pubic commissure over it. The third lobe (Fig. 91) appears later; the tubular buds which form it rise from the posterior part of the stalk of the bladder (Fig. 101) above the opening of the sinus prostaticus. It is not unfrequently absent or very small.

Skene's tubules, which may be found opening into the urethra of the female, probably represent prostatic tubules.

(2) **The Stroma of the Prostate.**—While the glandular tubes arise in three groups—two lateral and one posterior median—from the epithelium lining the uro-genital sinus, and stalk of the bladder—the muscular and fibrous elements arise from the mesoblastic tissue surrounding the terminal parts of the Wolffian and Müllerian ducts. The stroma surrounds the glandular tissue and forms the peripheral part of the gland. It contains muscular tissue which is especially developed in the pubic commissure.

Probably the stroma is similar in its nature and origin to the uterine muscle, for at a corresponding time of life it is apt to give rise to the same form of fibrous tumours as occurs in the uterus.

As regards **the nature of the Prostate** :

(1) It is purely genital, and develops only in the rutting season in such mammals as manifest a periodical sexual life.

(2) It remains comparatively undeveloped until puberty. At the age of seven it weighs only 30 grains; after sexual life is established it weighs about 300 grains.

(3) It atrophies on castration, a fact which is utilised by the surgeon in cases of prostatic hypertrophy. Castration performed on old men frequently leads to insanity. Atrophy of the prostate is also produced by section of the vas deferens on both sides. In one man out of three over 55 years of age the prostate hypertrophies, both the glandular and fibro-muscular elements participating. Hypertrophy of the third lobe causes a valvular elevation behind the vesical opening of the urethra.

The Glands of Cowper and Bartholin are produced as solid buds from the hypoblast lining the mouth of the uro-genital sinus. Hence in the female the ducts of Bartholin's glands open outside the hymen at each side of the vagina, for the hymen marks the junction of the Müllerian ducts with the uro-genital sinus. In the male the ducts of Cowper's glands open at the commencement of the bulbous part of the urethra. Their function is unknown, but they are certainly sexual in nature. The numerous **glands of Littré**, like Cowper's and Bartholin's glands, are produced by tubular outgrowths during the fourth month. In the male the glands of Littré are produced most numerous along the dorsal aspect of the urethra.

THE TESTES.

Descent and Development of the Testicle.—The position of the testicle in a foetus of the third month is shown in Fig. 102. It is situated in the iliac fossa. The mesorchium, a fold of peritoneum, binds its attached border to the iliac fossa. At its outer side lies the genital part of the Wolffian body which forms the epididymis. It, also, is suspended by a mesentery—the Wolffian mesentery. The two mesenteries have a common base—

the common uro-genital mesentery (see Fig. 80, p. 104). The upper part of the uro-genital mesentery forms the diaphragmatic fold or *plica vascularis* (Fig. 102). This in the female becomes the

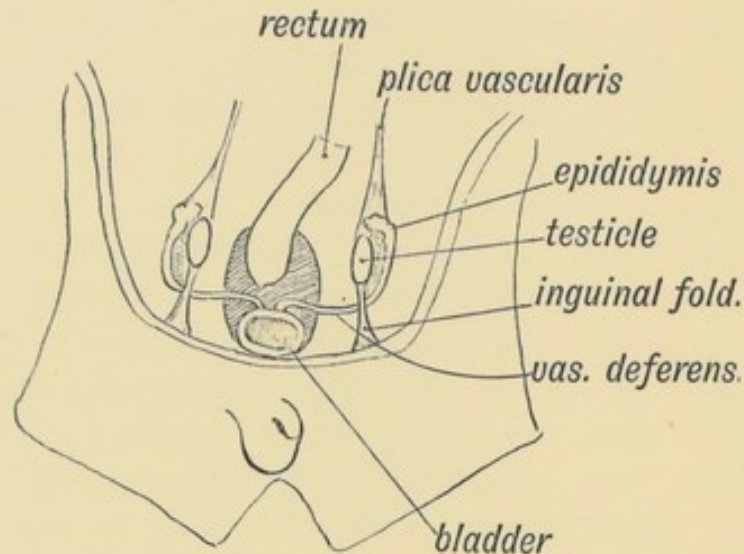


FIG. 102.—The Position of the Testis in a foetus of 2½ months

ovario-pelvic ligament (Fig. 59, p. 81). A fold of peritoneum, the inguinal fold or *plica gubernatrix*, continues the common uro-genital mesentery to the groin (Fig. 102). The gubernaculum testis is developed in the *plica gubernatrix*; in the corresponding fold in the female the round ligament of the uterus appears. The vas deferens (Wolffian duct) turns into the pelvis from the lower end of the epididymis (Wolffian body), and within the pelvis lies in the genital cord (Fig. 87, p. 112). A remnant of the Müllerian duct lies along the outer and ventral aspect of the epididymis.

The Development of the Testis.—Its blood supply comes from the level of the 12th dorsal vertebra; its nerve supply from the 10th dorsal segment of the spinal cord. The testis is therefore developed in the genital ridge between the 10th and 12th dorsal segments. The development of the testis is similar to that of the ovary (Fig. 62, p. 83). The columnar germinal epithelium which covers the genital ridge contain between them larger genital cells—the primordial ova. Tubular buds of germinal epithelium grow into the tissue of the genital ridge and form the epithelial lining of the seminiferous tubules instead of, as in the female, the Graafian follicles. Primordial ova are carried down within the tubes

of enclosing cells and these produce the spermatoblasts. The tunica albuginea is formed from the mesoblastic covering of the genital ridge. The visceral layer of the tunica vaginalis on the testicle is the covering of germinal epithelium which remains after the ingrowth of the genital cells. The vasa efferentia and coni vasculosi are formed from the **genital** Wolffian tubules. The tubuli recti and rete testis are new formations. The epididymis is the elongated upper segment of the Wolffian duct (Figs. 82, 107). The Wolffian elements (see p. 102) are produced within the Wolffian ridge.

Formation of the Gubernaculum Testis.—As shown in Fig. 102 there is no trace of the inguinal canal in the 3rd month;

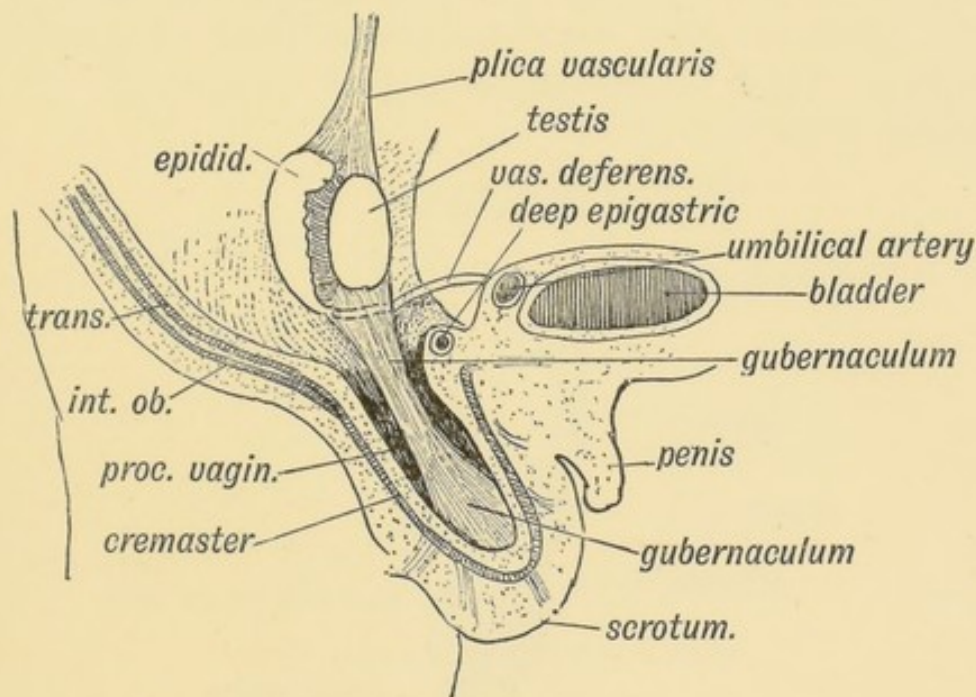


FIG. 103.—Showing the Position of the Testis at the 6th month, and the Formation of the Gubernaculum Testis.

the various layers of the abdominal wall are unbroken. In the fourth month the deep muscular layer of the abdominal wall, composed of the internal oblique and transversalis, buds inwards and expands the plica gubernatrix with muscular and fibrous tissue. The tissue does not stop short at the uro-genital ridge and Müllerian duct as in the female, but grows up and seizes the caudal pole of the testis (Fig. 103). At the same time the tissues in the whole thickness of the abdominal wall bud obliquely inwards towards the scrotum. They are probably carried away by

the downgrowth of the gubernacular bud which pushes its way to the scrotum (Figs. 103 and 104). The gubernaculum grows downwards as a solid fibro-muscular mass, until it reaches the subcutaneous tissue which at that time completely fills the scrotum. Its attachment to the scrotum is slight and easily broken. The gubernaculum, as it grows through the abdominal wall, carries with it:—

- (1) A process of peritoneum (the processus vaginalis);
- (2) The transversalis fascia (the infundibuliform fascia);
- (3) The internal oblique and transversalis muscles to form the cremaster;
- (4) The spermatic fascia from the external oblique;
- (5) The deep layer (Scarpa's) of the superficial fascia of the groin. All these layers are added to the primitive coverings of the scrotum, which until then is made up simply of skin and superficial fascia (Fig. 104).

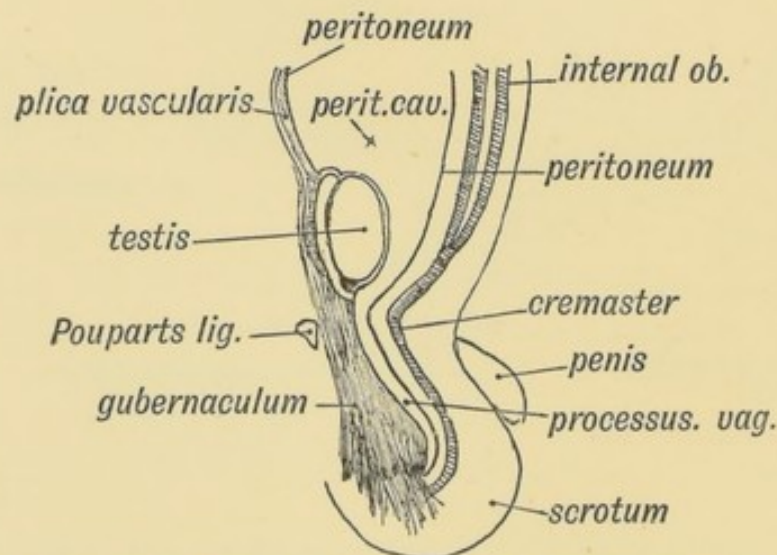


FIG. 104.—The manner in which the structures in the wall of the abdomen are carried out so as to form the Inguinal Canal and Coverings of the Testis.

It will be thus seen that the gubernaculum testis is an actively growing mass of fibro-muscular tissue, which starting from the inner muscular layer of the abdominal parietes in the groin, invades first the plica gubernatrix and then the abdominal wall itself, every layer of which it carries as a prolongation within the scrotum. It is an invading army of cells. It draws with it into the scrotum the peritoneum in the iliac fossa, on which the testis is dragged like a log on a sledge.

The testis spends the seventh month of foetal life in its exodus through the abdominal wall. In the eighth month it leaves the inguinal canal and lies at the external abdominal ring. After birth it reaches the fundus of the scrotum. The atrophy of the gubernaculum pulls it down. A remnant of the gubernaculum can always be found in the adult behind the epididymis and testicle, within the mesorchium (Fig. 105).

The Processus Vaginalis.—The processus vaginalis becomes occluded at two points about the time of birth (Fig. 105). The upper point of occlusion takes place at the internal abdominal

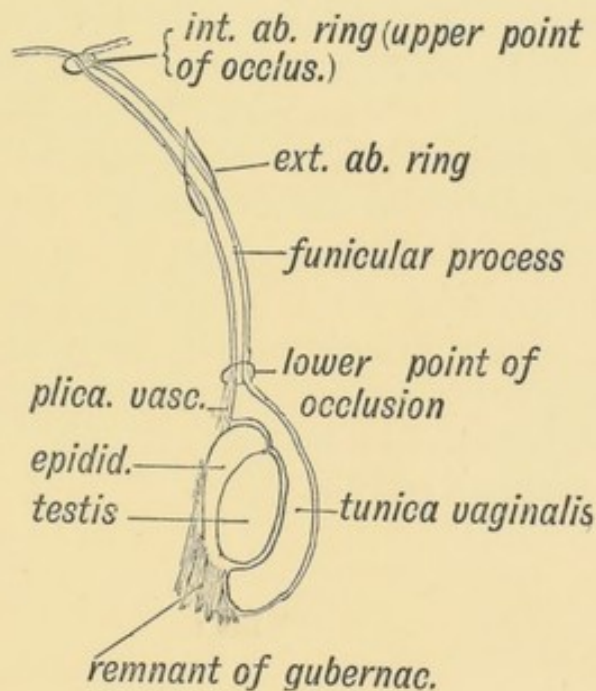


FIG. 105.—A diagram of the Processus Vaginalis.

ring; the lower a short distance above the testicle. The part of the processus vaginalis between the points of occlusion is known as the **funicular process**; the part surrounding the testicle becomes the tunica vaginalis. In quite 30% of children the occlusion takes place at the internal abdominal ring some considerable time after birth or it fails to appear altogether. Occlusion may fail at the upper point, at the lower point, or at both. Or it may close at both points, but the funicular process, instead of disappearing, may remain open and form a cyst (Fig. 105).

Descent of the testicle may be arrested at any stage; often in the inguinal canal; more frequently at the external abdominal

ring. Arrest of descent is commonly a symptom of arrest of testicular development. On the other hand, the testicle may assume an **ectopic** position. The gubernaculum ends in the scrotum principally, but bands of it pass to end on the root of the penis, in the groin and in the perineum. These bands, normally slight, may be big enough to influence the direction of descent of the testicle; hence cases occur in which the testis is found in the groin, by the side of the penis or drawn back in the perineum almost to the anus (Lockwood).

The Mesorchium.—The testis and epididymis were suspended within the abdomen by the common uro-genital mesentery. In the course of the descent of the testis this becomes shortened and binds the testis and epididymis firmly by their posterior borders to the tunica vaginalis. Occasionally the uro-genital mesentery and mesorchium persist; the testicle is then liable to become twisted and strangulated on its mesentery. I have seen three such cases recently. The digital fossa is situated between the mesorchium and mesentery of the Wolffian body.

The meaning of the descent of the testes is unknown. In many animals the testes descend only during the rutting season. The inguinal canal, formed by the descent of the testis, is a source of weakness in man (see p. 133).

CHAPTER X.

FORMATION OF THE PUBO-FEMORAL REGION, PELVIC FLOOR AND FASCIA.

Inguinal and femoral hernia occur so rarely amongst mammals generally that they may be considered human peculiarities. Their

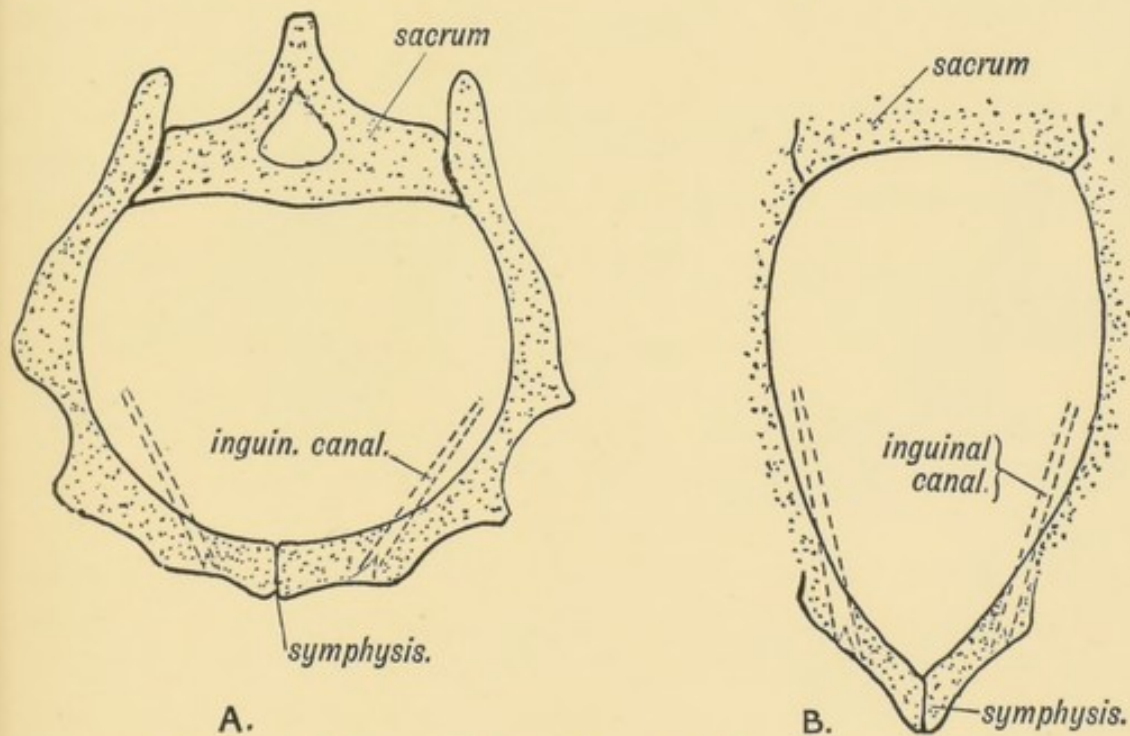


FIG. 106.—A. The form of Pelvis and Inguinal Canal in Man.
B. The corresponding forms in the Lower Primates.

frequency in man is due to certain structural changes in his pubo-femoral region, changes which have resulted mainly from his adaptation to upright progression. His susceptibility to hernia is due to:—

- (1) The unique form of Poupart's ligament in man. It is

scarcely developed in any other animal (Fig. 107). In the orang, for instance, also an upright primate, the external oblique has no attachment to the crest of the ilium, and takes no part in forming the outer part of Poupart's ligament (Fig. 107), but its tendon terminates over and strengthens the region of the inguinal canal. This is the usual termination in the mammalia.

(2) The internal oblique and transversalis (conjoined parts) in the orang, and in all primates except man, arise from the firm tubular sheath of the ilio-psoas, also from the extensive anterior border of the ilium, and arching over the spermatic cord end in a long insertion on the ileo-pectineal line. They act as a powerful compressor or sphincter of the inguinal canal, and thus prevent hernia (Fig. 107 *B*).

(3) The human manner of walking, and the great head of the human child at birth require a wide pelvis. All mammals

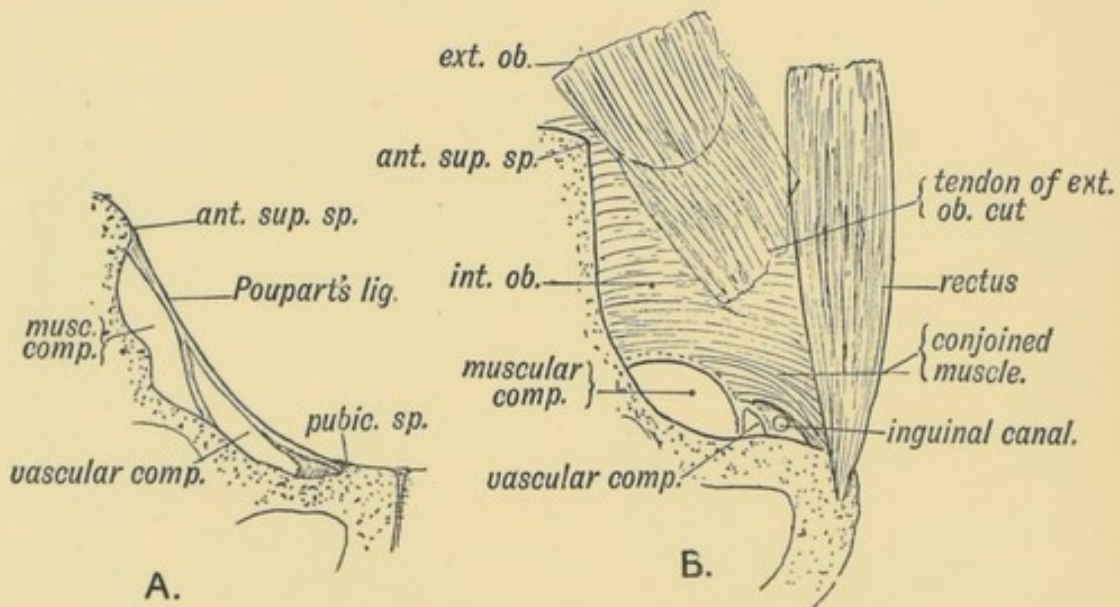


FIG. 107.—*A.* Poupart's Ligament and the Crural Passage of Man.
B. Poupart's Ligament, Crural Passage, and sphincter-like Conjoined Muscle of the Orang.

adapted to the prone posture have a narrow pelvis, and hence a narrow anterior abdominal wall (Figs. 106 *A* and *B*) through which the inguinal canal passes very obliquely. The course of the canal is more direct in man, and therefore offers a greater facility to the escape of the abdominal contents.

(4) The size of the space between the edge of the pelvis and Poupart's ligament (the crural passage) is very much greater in

man than in any other animal (Figs. 107 *A* and *B*). In him, the most internal part of the passage is left unfilled, and this unfilled space forms the femoral or crural canal through which femoral hernia may escape. The crural passage is relatively larger in women than in men, owing to the greater size of the female pelvis, and hence femoral hernia are much more common in women than in men. Some hint as to the method of treatment of hernia in man may be obtained from a consideration of the arrangement of structures which prevent them in other animals.

THE PELVIC FLOOR.

The Coccyx.—It is necessary to consider the coccyx here because the changes which it has undergone in the evolution of the human body are intimately connected with the formation of the pelvic floor.

The coccyx in man is commonly composed of four vertebrae, more or less vestigial in nature, which represent the basal caudal vertebrae of tailed mammals. Evidence of their vestigial or retrograde nature is to be found in:

(1) Only their centra are developed—with the exception of the first, which shows partial formation of transverse processes and neural arches (superior cornua);

(2) Delay in the appearance of the centres of ossification. These, instead of beginning in the 7th week as in a typical vertebra, commence after birth. The centre for the 1st coccygeal vertebra appears in the 1st year, that for the 4th vertebra about the 25th year; the 2nd and 3rd at intermediate periods.

(3) Late in life, between the 40th and 60th year, the vertebrae fuse together, and then unite with the sacrum.

The number of coccygeal vertebrae varies; four is the normal number, but there may be three or five. In the young foetus (2nd month) there are commonly 5, 6 or 7 (Rosenberg). The first coccygeal vertebra may join the sacrum, making 6 sacral vertebrae.

The evidence of the former existence of a **true tail** in the ancestral human stock consists of:

(1) In the second month the coccygeal region of the spine protrudes (Fig. 108).

(2) Vestiges of the extensor and flexor muscles of the tail are frequently found (10% of bodies) on the dorsal and ventral aspects of the sacrum and coccyx.

(3) True tails, consisting of external prolongations of the coccyx, commonly fibrous, rarely containing vertebrae, occasionally occur.

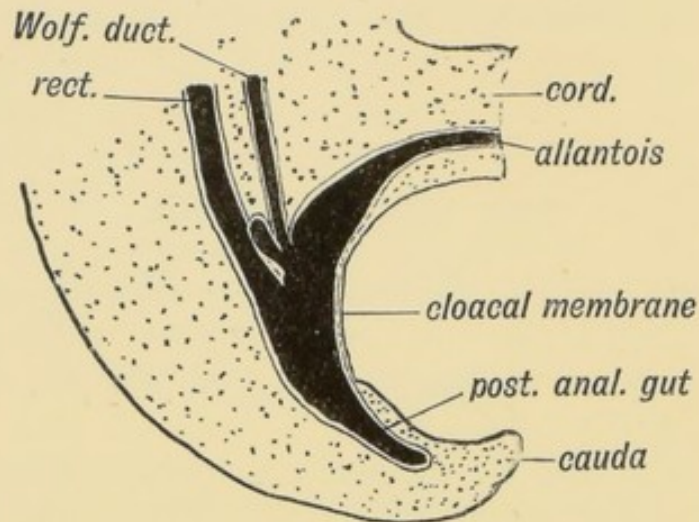


FIG. 108.—The caudal end of the body in a human embryo of the 3rd week.

(4) The post-anal pit, always to be seen in the newly-born child, marks the point at which the coccyx disappears below the surface. In man the coccyx forms part of the perineal floor. Instead of projecting far beyond the gut, as in tailed mammals, it terminates $1\frac{1}{4}$ inches above the commencement of the anal canal.

The Pelvic Floor is peculiarly extensive in man, an adaptation to his upright posture. The floor is formed by the following structures :

(1) The levator ani and its sheath (recto-vesical and anal fasciae) on each side.

(2) The coccyx and coccygeus muscles.

(3) The constrictor urethrae and its sheath (the triangular ligament).

(4) The pyriformis and its sheath may also be included.

Development of the Pelvic Floor.—The pelvic floor has been evolved in man by a transformation of the tail and the caudal

muscles. The arrangement of tail muscles in a four-footed

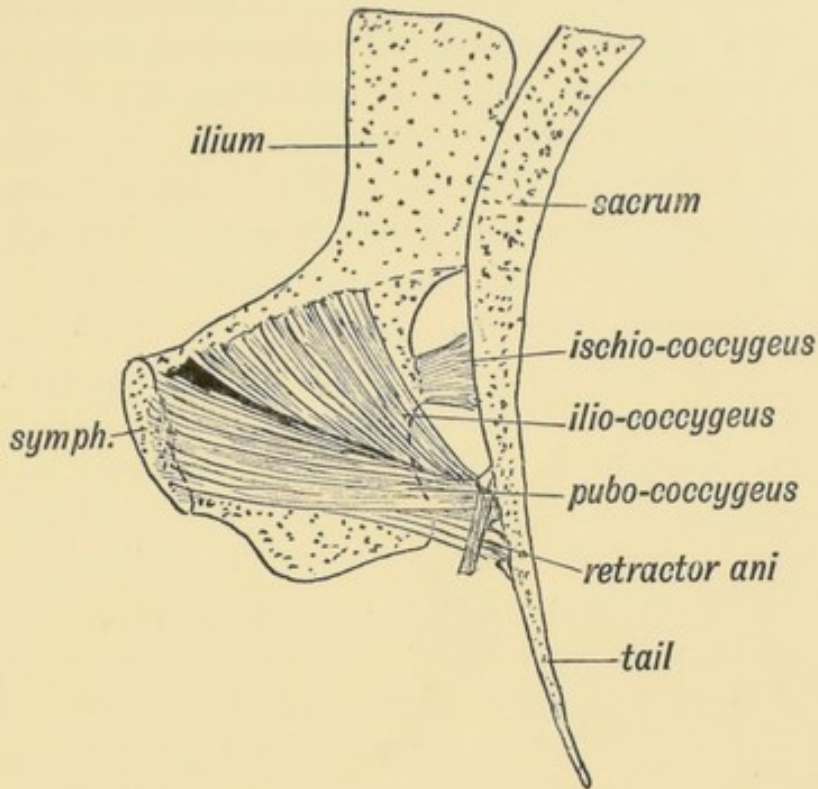


FIG. 109.—The pelvic-caudal Muscles of a Monkey.

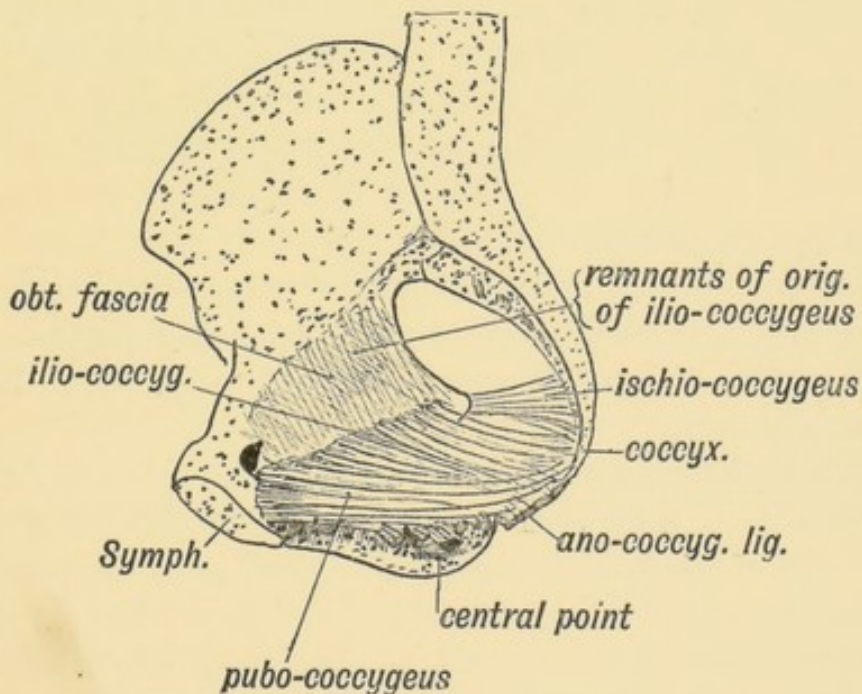


FIG. 110.—The corresponding Muscles of Man.

mammal, such as the monkey or dog, is shown in Fig. 109, and the modification of this form in man in Fig. 110. In mammals

two muscles, the pubo-coccygeus and ischio-coccygeus (Fig. 109), act as depressors of the tail, which in four-footed animals plays the part of a perineal shutter. They are attached to the small V-shaped chevron bones on the under surface of the basal caudal vertebrae. Another muscle, the ischio- or spino-coccygeus, acts as a lateral flexor of the tail (Fig. 109). It is attached to the transverse processes of the caudal vertebrae, and rises from the dorsal border of the ischium. In man the pubo-coccygeus and ilio-coccygeus unite into one sheet and form the levator ani. The shrinkage of the tail leaves the muscle partly stranded on the ano-coccygeal ligament. Other fibres of the pubo-coccygeus lose their primary insertion to the coccyx and become attached to the prostrate, central point of the perineum and to the anal canal. Both muscles, especially the ilio-coccygeus, retain in part their primitive attachment to the coccyx (cauda). The spino-coccygeus, or coccygeus muscle, is partly fibrous in man, its outer laminae forming the small sacro-sciatic ligament; its inner laminae remain muscular and form the coccygeus. In man, too, the origin of the ilio-coccygeus has sunk from the pelvic brim of the ischium on to the obturator fascia (P. Thompson); traces of the primitive origin from the pelvic brim can often be detected. The white line, a structure peculiar to man, marks the new point of origin of the levator ani from the obturator fascia. Further details of changes undergone by the pelvic muscles and fasciae may be found in papers by Dr. P. Thompson in the *Journal of Anatomy and Physiology*, vol. xxxv.

On the dorsal and ventral aspects of the sacrum and coccyx, fibrous or muscular vestiges of the anterior and posterior sacro-coccygeal muscles (elevators and flexors of the tail) are commonly to be found in man.

The Pelvic Fascia and Fasciae in General.—It has been customary to regard fasciae as separate structures forming distinct sheets with devious and complex courses. It is possible by dissection to prepare and display them according to accepted descriptions, but the structures so displayed are artificial and not the true structures with which the surgeon or physician has to deal with in actual practice. Embryology is the best guide to their nature. Take the development of the fasciae seen on making a section of the upper arm, for example. When the

limb bud has appeared, which it begins to do about the end of the 3rd week of development, a section through it reveals a uniform composition of more or less rounded mesoblastic cells with a covering of epiblast (Fig. 111 *A*). Very soon the central cells near the axis of the bud are densely grouped and form the basis of the humerus. Others arrange themselves to form the biceps, triceps and muscles of the arm; others form the walls of vessels and the sheaths of nerves.

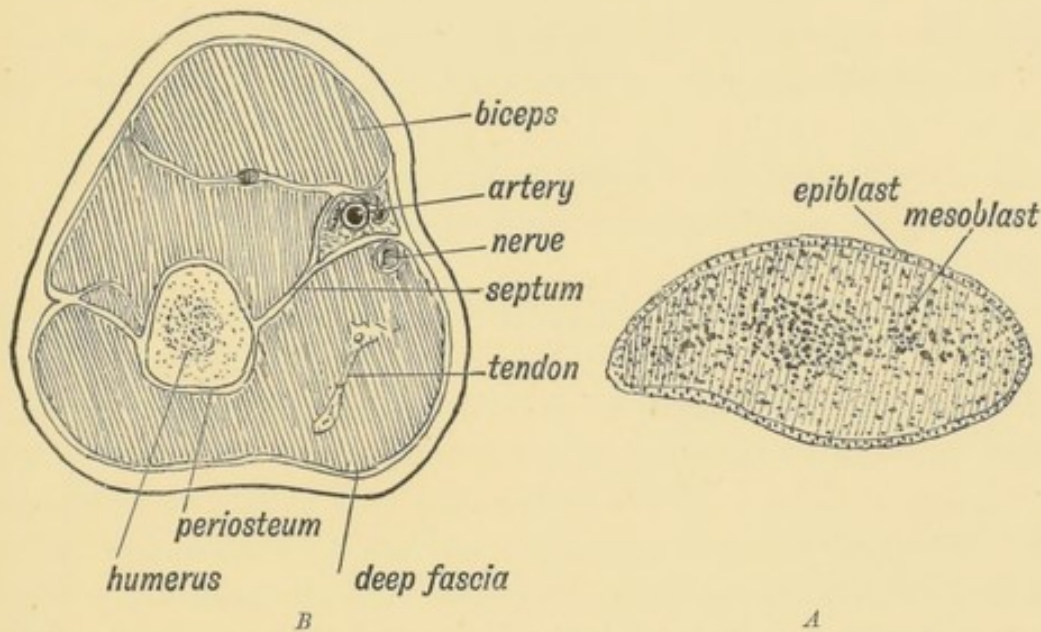


FIG. 111.—*A*. Diagrammatic section of the Arm Bud of an embryo at the commencement of the 4th week.
B. Corresponding section of the Adult Arm.

After these various groups of cells have become differentiated, there are numerous cells left over which form a basis in which the specialized cells and groups of cells are packed and ensheathed. The undifferentiated mesoblast forms the connective tissue or fascial system of the part. From the manner of its origin it is evident that the connective tissue system—the fasciae and septa—must form a continuous formation of sheaths, each being in continuity with that of every surrounding structure. The sheaths of the biceps, triceps and brachialis anticus, the periosteum of the humerus, the deep fascia, internal and external intermuscular septa, the sheaths of the vessels and nerves of the arm, represent the mesoblastic tissue which was left over after the structures which they enclose were differentiated, and are, from the manner of their origin, necessarily in continuity.

They can only be artificially separated from each other. It is more accurate and easier to describe fasciae, then, not as separate structures, but as adjuncts of the structures which they surround or ensheath.

The Pelvic Fascia, which strengthens the pelvic floor, is composed of the sheaths of four muscles:

- (1) The Levator Ani;
- (2) The Obturator Internus;
- (3) The Piriformis;
- (4) The Constrictor Urethrae and deep Transversus Perinei.

The fibrous capsules of the following viscera also form part of it:

- (1) Prostate and Vesiculae Seminales in the male;
- (2) Vagina and Uterus in the Female;
- (3) The Bladder;

(4) The Rectum. Under the title of pelvic fascia these eight elements are combined.

I. **The Obturator Fascia** is the sheath on the inner or pelvic aspect of the obturator internus; the sheath on the outer side of the muscle is formed by the periosteum and obturator membrane. The obturator fascia is attached at the circumference of the muscle. There it becomes continuous with the periosteum of the os innominatum. The part above the white line (supra-linear) is intra-pelvic; the part below (infra-linear) is perineal and situated on the outer wall of the ischio-rectal fossa.

II. **The Recto-vesical and Anal Fasciae.**—The levatores ani form a muscular floor for the pelvis, stretching from the white line of one side to the white line of the other. The sheath on their under surface—on the inner wall of the ischio-rectal fossa—forms the anal fascia. On the upper surface, their sheath forms the greater part of the recto-vesical fascia. The pelvic viscera rest on the upper surface of the levatores ani and the capsules of the viscera are continuous with the sheath on the upper surface of the muscles. The combined visceral capsules and upper sheath of the levatores ani form the recto-vesical fascia.

III. **The Triangular Ligament** is the sheath of the constrictor urethrae muscle (Fig. 112). The inferior transverse fibres of the constrictor form really a separate muscle—the deep transverse perineal. The apex of the prostate rests on the muscle, its

capsule being continuous with the posterior layer of the muscle sheath—the deep layer of the triangular ligament.

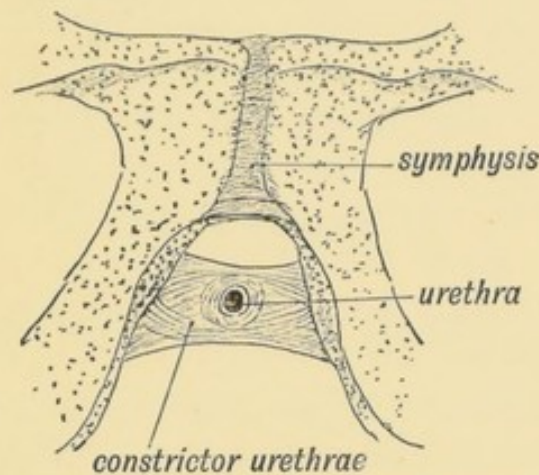


FIG. 112.—The Constrictor Urethrae Muscle.

IV. The inner sheath of the pyriformis forms the **pyriform fascia**. As the muscle arises between the sacral foramina, the sacral plexus lies within the sheath, the iliac vessels on its inner aspect. The coccygeus is continuous with the levator ani and its sheath forms part of the recto-vesical fascia.

The Cervical Fascia.—From what has been said of the pelvic fascia, the nature and arrangement of the cervical fascia will be readily understood. It is composed of (1) the sheaths of the cervical muscles (sterno-mastoid, etc.); (2) of the sheaths of vessels (carotid sheath, etc.); (3) the sheaths of nerves (axillary sheath, etc.); (4) the fascial capsules of viscera, such as the thyroid body, salivary glands, and pharynx.

CHAPTER XI.

THE SPINAL COLUMN AND BACK.

The Pyramids of the Spine.—The spine, when viewed from the front, is seen to be made up of four pyramids: (1) Cervical; (2) upper dorsal; (3) dorso-lumbar; (4) sacro-coccygeal (Fig. 113).

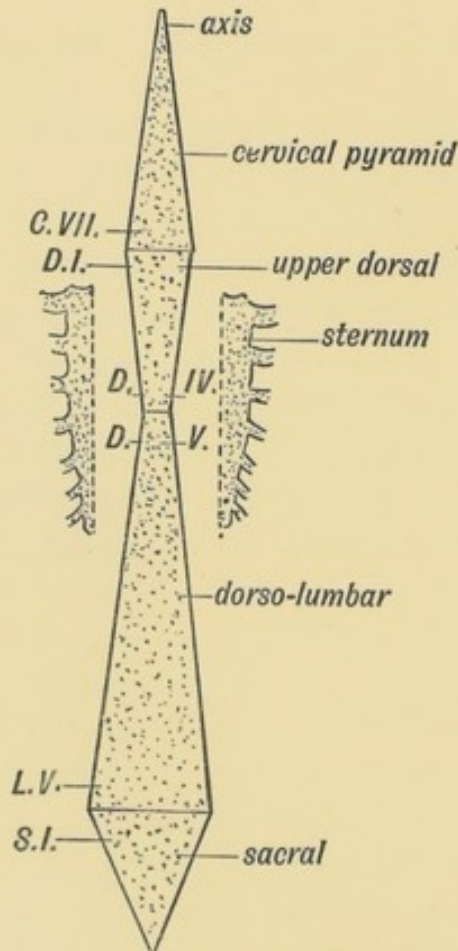


FIG. 113.—Diagram of the Pyramids of the Spine.

The bases of the two upper pyramids meet at the disc between the 7th cervical and 1st dorsal vertebrae; the bases

of the lower two at the disc between the 5th lumbar and 1st sacral vertebrae. The apices of the two middle pyramids meet at the disc between the 4th and 5th dorsal vertebrae, which have therefore the narrowest bodies of the vertebral series. The narrowing in the upper dorsal region is due to the fact that the weight of the upper half of the trunk is partly borne by, and transmitted to, the lower dorsal region by the sternum and ribs which thus relieve the spine to some extent (Fig. 113). At the sacrum the weight is transferred to the pelvis and lower limbs, hence the rapid diminution of the sacrum and coccyx. A well-marked thickening or bar in each ilium runs from the auricular surface to the acetabulum and transmits the weight to the femora.

The Curves of the Spinal Column.—There is only one curve—an anterior concavity—until the 3rd month (Fig. 114 *A*). About

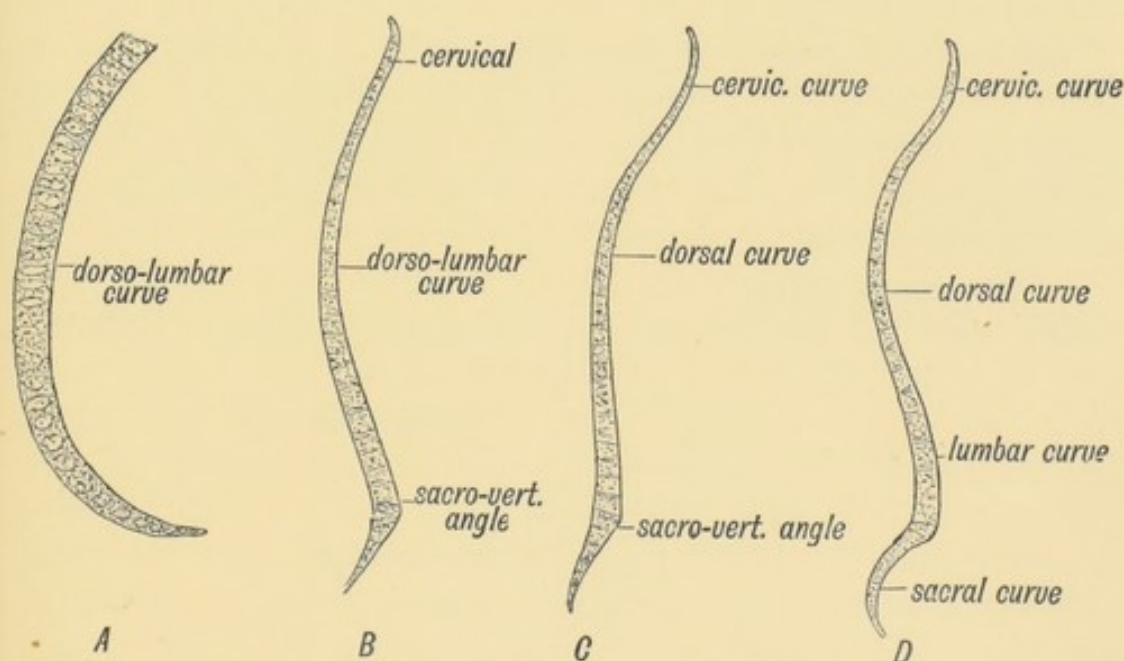


FIG. 114.—Diagram of the Curves of the Spinal Column.

A. At the 6th week of foetal life. *B.* At the 4th month of foetal life. *C.* Curves present at Birth. *D.* Curves present in the Adult.

the beginning of the 4th month the sacro-vertebral angle forms between the lumbar and sacral regions (114 *B*). At birth the cervical and sacral curves have appeared, but the sacral not to a pronounced extent (Fig. 114 *C*). The lumbar curve appears as the child learns to walk. It is produced to allow the body to be brought vertically over the lower extremities. The sacral

and cervical curves also become then more marked (Fig. 114 *D*). The dorsal curvature and the sacro-vertebral angle are the primitive curves and are present in all mammals. The others are adaptations to the upright posture. The lumbar curve is most pronounced in the highly civilized races.

Proportion of Cartilage and Bone.—The inter-vertebral discs form one third of the total height of the spine; the proportion of cartilage is greater in the lumbar than in the dorsal region and greater in the dorsal than in the cervical. The curvatures are due chiefly to the shape of the discs. In the lumbar region, which is convex forwards, only the lower three vertebrae are deeper in front than behind. This is true only for the higher races of mankind, for as Cunningham has shown, in lower races, as in the gorilla, only the lowest lumbar vertebra is deeper in front than behind, and thus helps to maintain the lumbar curvature.

Unstable Regions of the Spine.—In about 90% of men there are 7 cervical, 12 dorsal, 5 lumbar, 5 sacral, and 4 caudal vertebrae, making 33 in all. In the remaining 10% there is some departure from the normal arrangement and these departures affect certain definite regions.

I. **The sacro-lumbar.**—The 25th vertebra in 95% of people forms the 1st sacral; in 1% the 24th, and 3% the 26th.

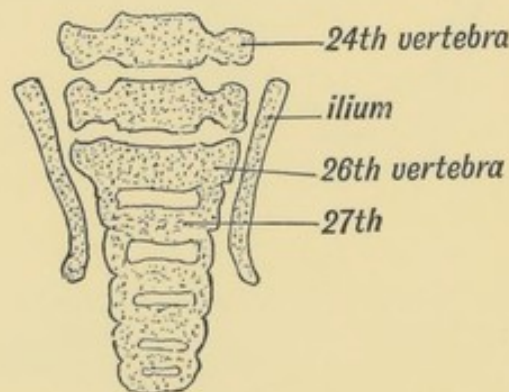


FIG. 115.—A section of the Lumbo-sacral Region of the Spine in a Foetus at the end of the 2nd month, showing the 26th vertebra forming the 1st Sacral. (After Rosenberg.)

These percentages are drawn from the observations of Paterson, Rosenberg, and others who have made researches on this subject. The vertebral formula is not fixed. Rosenberg's investigations showed (Fig. 115) that it is the 26th vertebra that forms the

first of the sacral series in the early embryo; later the 25th throws out great lateral masses, and thus forms a connection with the ilia. In the lower primates (monkeys) the 27th forms the 1st sacral; with the evolution of man the 26th, then the 25th underwent sacral modifications, the trunk being correspondingly shortened. It will be seen that the number is not yet definitely fixed. The anterior point of attachment of the ilium fluctuates from the 24th to the 26th vertebra in man. With the sacral transformation of the 25th and 26th (lumbar) vertebrae, there was a corresponding movement forwards of the sacral plexus.

II. **Sacro-coccygeal.**—The 30th vertebra forms the 1st coccygeal; not uncommonly this vertebra is sacral in type and forms part of the sacrum.

III. **Dorso-lumbar region.**—This region is less liable to variation; the 20th vertebra instead of forming the 1st lumbar, may simulate the last dorsal in the type of its articular processes, and may bear ribs, probably an atavistic form, or, on the other hand, the 12th dorsal vertebra (19th) may not carry ribs. About 2% of bodies show variations of this kind.

IV. **Dorso-cervical.**—The 7th vertebra may carry ribs; rarely the 8th vertebra has no ribs attached to it and is cervical in type.

Evolution and Development of the Spinal Column.—The human spinal column in the process of development passes through three distinct phases:

(1) It is membranous; (2) it becomes cartilaginous; (3) it becomes bony. In the evolution of vertebrates the same three stages are observed. In *Amphioxus* and *Marsipobranchs* (excepting the neural arches), the spinal column is membranous; in *Elasmobranchs* it is cartilaginous; in other fishes and in all other vertebrates it is ossified. In the human embryo, as in every other vertebrate, the spinal column is developed from the mesoblast which surrounds the notochord and neural canal.

The Notochord.—It has already been seen that the notochord is formed at a very early stage (before the 3rd week, Fig. 69, p. 90) by a tubular invagination of the hypoblast under the neural canal. The notochord, with the mesoblastic tissue round it, represents the most primitive type of spinal support. It is hollow—the canal of the notochord runs from end to end, and

into its posterior end the neurenteric canal opens. Afterwards it becomes a solid rod composed of cells of a peculiar type. A sheath is formed round the notochord by cells of the paraxial mesoblast (Fig. 116), which grow inwards and surround it.

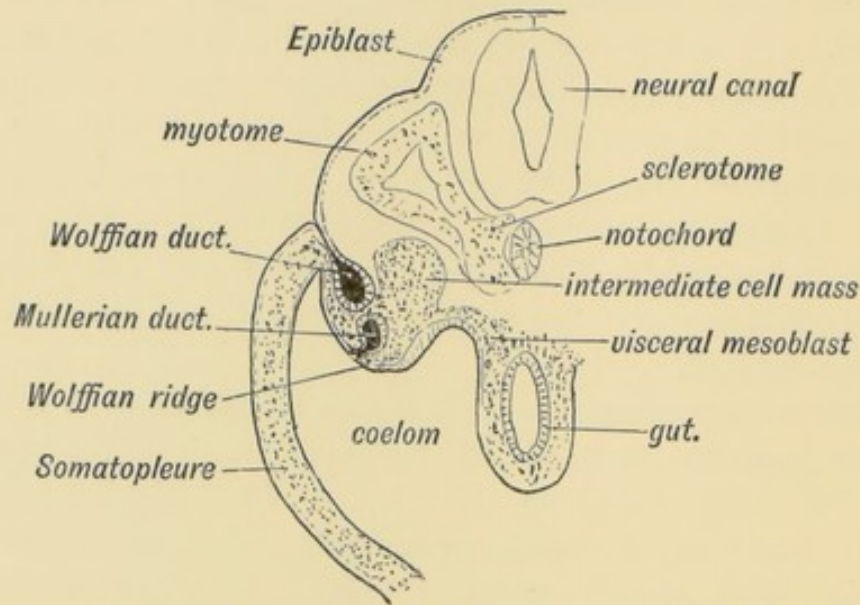


FIG. 116.—Diagrammatic transverse section of a human embryo at the end of the 3rd week.

These cells form the **sclerotome** and spring from the inner parts of the primitive segments (Fig. 116). At the same time the cells of the sclerotome also surround the neural tube. From these cells which grow inwards and surround the notochord and neural canal, the spinal column is formed and also the basi-occipital and part of the basi-sphenoid bones of the skull (Fig. 117).

What becomes of the Notochord.—In the second month of foetal life the notochord begins to disappear; the bodies of the vertebrae and parachordal cartilages form in its sheath and constrict it. The parachordal cartilages form the basi-occipital and basi-sphenoid—the basal part of the skull—behind the pituitary fossa. As they form, the notochord is obliterated between them. Eternod, however, found the anterior part of the notochord on the dorsal wall of the pharynx in the human embryo, so that the parachordal cartilages are evidently developed on its dorsal aspect. The odontoid process represents the body of the atlas and the suspensory ligament the disc between the occipital bone and atlas. A remnant of the noto-

chord is enclosed in the suspensory ligament. The body of each vertebra is formed round the notochord and at first each has an hour-glass canal surrounding the notochord. Within each

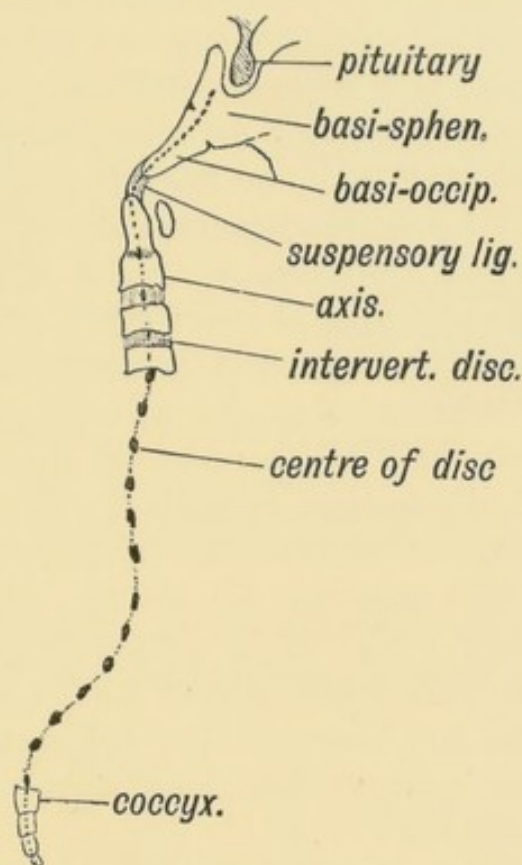


FIG. 117.—Where Remnants of the Notochord may occur in the Adult.

body the notochord ultimately disappears but in the intervertebral discs it swells out and forms much of the central mucoid core which each disc contains. The notochord with its membranous sheath is the earliest form of spinal column known. The real vertebral column, formed out of its sheath, begins to supplant it even in low vertebrates and in the human foetus of the second month this change is also seen to take place.

Proto-vertebrae or Primitive Segments.—Proto-vertebrae are not the forerunners of the vertebrae; they are the primitive segments into which the mass of mesoblast at each side of the neural canal and notochord divides (Figs. 233, p. 289 and 116). The process of division or segmentation begins at the occipital region towards the end of the second week and spreads backwards until 35 or more body segments or somites are cut off. Each segment thus separated forms its own muscles (from its muscle

plate or myotome), has its own nerve (spinal nerve), its own artery (inter-costal), and the basis for its skeletal tissue (sclerotome). The **inter-segmental septum** separates one proto-vertebra or segment from another. Ribs, transverse and spinous processes, are formed in the inter-segmental septa. Hence an intercostal space with its muscles, vessels, and nerves, with the corresponding inter-vertebral structures, represents a differentiated proto-vertebra. In the ventral aspect of the neck and loins, the inter-segmental septa disappear. In the head nine segments are recognised, but their recognition rests on observations made, not on the human embryo, but on the embryos of lower vertebrates.

Recent work on the segmental arrangements of the nerves gives a practical importance to the number and position of the primitive segments and to the part of the body which each forms. Although the epiblast, hypoblast, and walls of the coelom never show any trace of segmentation in the embryo, yet clinically there is evidence that each part belongs to, and was formed from, one definite segment. The upper extremity grows out from the 5th cervical to the 2nd dorsal segments (7 segments in all), and the lower from the 2nd lumbar to the 3rd sacral (7 segments in all). In each limb traces of these seven segments are to be found in the nerve distribution.

Development of a Typical Vertebra,—the 6th Dorsal.—

(1) **Membranous Stage** (3rd and 4th weeks). The vertebra then consists of 1st a body surrounding the notochord, formed from the sheath (Fig. 118 *A*), and 2nd a horse-shoe shaped **vertebral bow** (Fig. 118 *A* and *B*). The bow consists of a hypo-chordal part, and two lateral limbs, united by the hypo-chordal part ventral to the body.

(2) **Cartilaginous Stage** (Fig. 119). It commences in the 4th week. The fibrous basis is transformed into cartilage except the hypo-chordal part of the bow. It should be noticed (Fig. 118 *B*) that the vertebral bodies are formed round the notochord, *opposite* each inter-segmental septum. Hence each vertebra belongs to two segments. The inter-vertebral disc is situated opposite the middle of a segment. The hypo-chordal part of the bow lies also in the segment, and becomes included in the course of development in the disc in front of the vertebra to which it belongs. The lateral limbs of the cartilaginous bow meet behind (dorsal

to) the neural canal in the 4th month, and thus the bow is converted into a ring. The atlas is a permanent representative

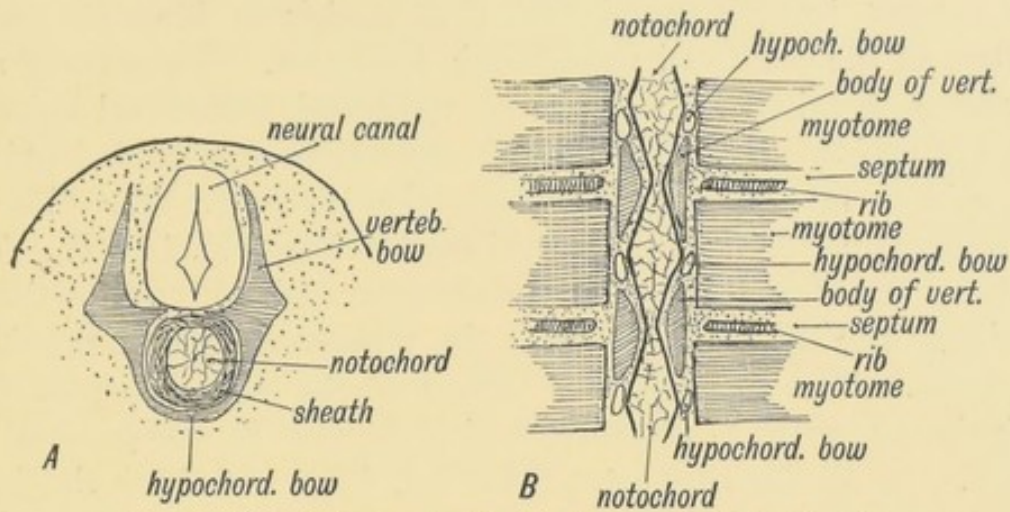


FIG. 118.—The development of the Membranous Basis of a Vertebra.
A. In transverse section. *B.* In horizontal section showing the relation of the vertebra to the Primitive Segments. The section is viewed from the dorsal aspect.

of the ring thus formed. In the atlas only does the hypo-chordal part of the bow become cartilaginous and subsequently ossified ; in

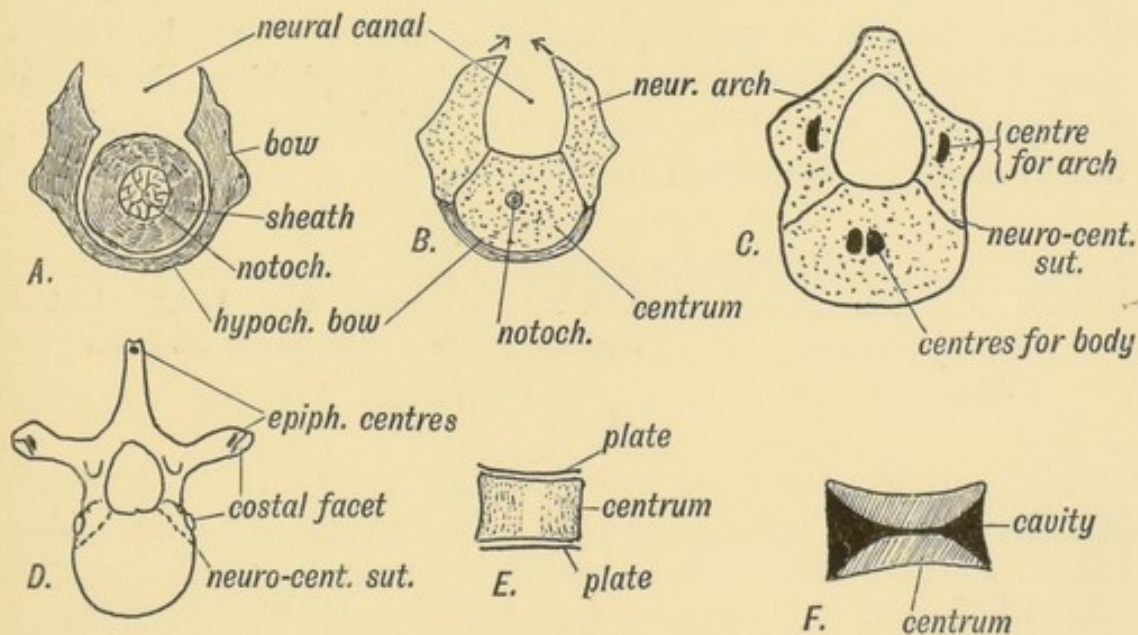


FIG. 119.—Showing the Stages in the Development of a Vertebra.
A. In the Membranous Stage. *B.* In the Cartilaginous Stage. *C.* The appearance of Ossific Points. *D.* The appearance of Secondary Ossific Centres. *E.* The epiphyseal plates of the centra. *F.* Section of an amphicoelous vertebra.

all the other vertebrae it remains as a fibrous strand in the inter-vertebral disc.

(3) **Bony Stage.**—The body and bow parts of the cartilaginous

vertebra fuse and give rise to the condition shown in Fig. 119 *C*. In the 7th week two centres appear in the body, but quickly fuse; one appears in each neural arch (8th week); at birth the ossific centres of the body and neural arch have met. The central and neural ossifications meet at the neuro-central suture and unite at the 4th or 5th year. The neural ossifications fuse behind (where the spinous process is produced) in the 1st year. The ribs are entirely supported from the neural ossifications (Fig. 119 *D*). The spinous and transverse processes are formed by outgrowths of cartilage into the septa between the proto-vertebrae or primitive segments. The ribs are also formed in the septa, each at first articulating with a vertebra, which is also inter-segmental in origin. In all the ribs, except the 1st, 11th and 12th the head is shifted to the inter-vertebral disc in front of its vertebra. Epiphyseal centres for the ossification of the transverse and spinous processes appear about puberty.

The **Bodies of Mammalian Vertebrae** are peculiar (1) in the development of an upper and lower epiphyseal plate; (2) in that no trace of the notochord remains within them. In Fishes, as in the early human or mammalian foetus, the bodies are hour-glass shaped (amphicoelous, Fig. 119 *F*); in Amphibians they may retain a concavity in front (procoelous) or behind (opisthocelous), but in mammals both ends are filled up.

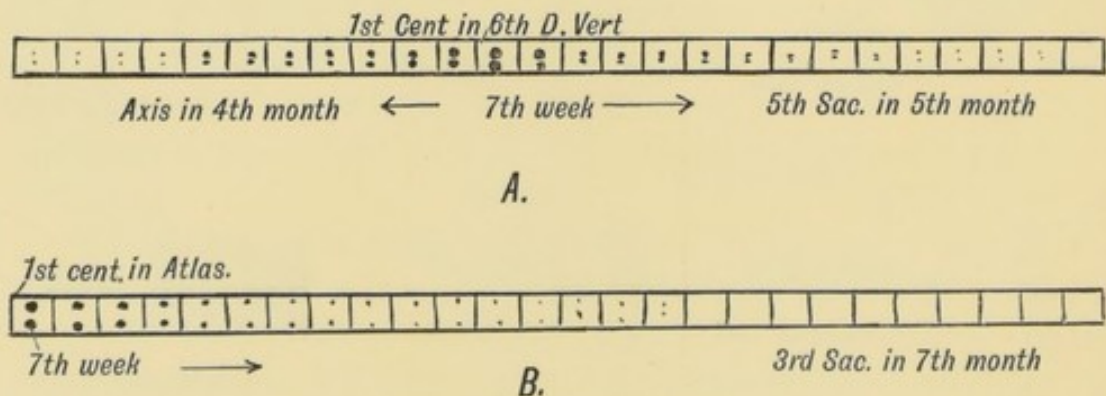


FIG. 120.—The Order in which the Centres of Ossification appear in the Bodies (*A*) and in the Neural Arches (*B*) of the Spinal Column.

It will be observed (Fig. 120 *B*) that the centres of ossification for the neural arches appear first in the anterior end of the spine (1st cervical), the date becoming later the more posterior the vertebra. In the 1st sacral they appear about the 4th month;

in the 2nd sacral in the 5th month or later; in the 3rd they may not appear. In the 4th and 5th sacral and 1st coccygeal vertebrae only vestiges of the neural arches are formed. These vertebrae retain the early foetal type shown in figure 119 *B*. In the remaining coccygeal vertebrae only the centres for the bodies appear. The centres for ossification of the bodies of the vertebrae appear first in the mid dorsal region (6th dorsal). From that point they spread forwards and backwards, the centres for the odontoid process appearing at the 4th month and that for the 5th sacral at the 5th month, while the last coccygeal does not appear until about the 20th or 25th year (Fig. 120 *A*).

The Atlas and Axis.—The atlas represents the completed bow of the 1st cervical vertebra. The body of the vertebra fuses with the body of the 2nd, and forms the odontoid process. A remnant of the disc between the 1st and 2nd vertebrae can

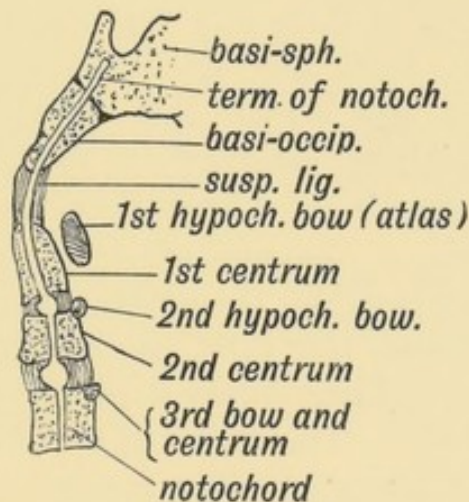


FIG. 121.—A diagrammatic section of the Foetal Axis, Atlas, and Basi-occipital.

sometimes be seen when the odontoid is split open. The suspensory ligament is the representative of the disc between the last occipital segment and the 1st cervical (Fig. 121).

Occipito-atlanto-axial Articulations.—In the intervertebral discs of the cervical region there is at each side, between the lateral lips of the vertebral bodies, a small articular cavity (Fig. 122). It is situated between the parts of the body formed from the neural arches and in front of (ventral to) the issuing spinal nerves. Between the axis and atlas this articulation is greatly enlarged. At it the rotatory movements of the atlas on the axis

take place. The atlanto-occipital joint, which separates the atlas and the last occipital segment is of the same nature. The atlas has neither the upper nor the lower articular processes of the other vertebrae. Hence the 1st and 2nd cervical nerves appear to issue behind the articular processes. At one time the single median

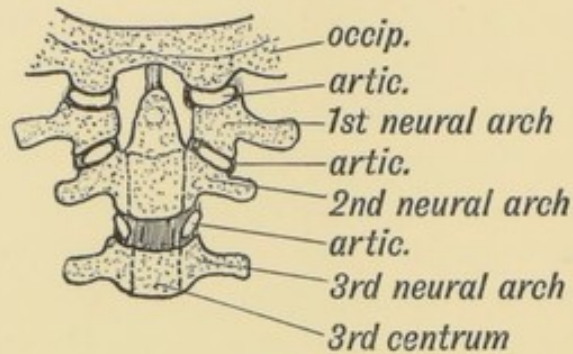


FIG. 122.—The nature of the Atlanto-axio-occipital Articulations.

occipital condyle seen in birds and reptiles was regarded as very different in nature from the double condyles of mammals. Recently Symington has shown that in the lowest mammals (monotremes), the occipital condyles are fused in the middle line, and that foetal mammals show approximations to this condition. In the human skull a remnant of this median fusion of the condyles is frequently seen on the anterior margin of the foramen magnum; it is named the third or **median occipital condyle**. Sometimes the atlas is partly fused with or imperfectly separated from the occipital bone. This seems to be a further manifestation of the process which has led to four segments, which were at one time free body segments, being fused together to form the occipital part of the skull.

The Ribs are developed in the septa between the dorsal primitive segments. At their vertebral ends they come in contact with the vertebral bow (Fig. 118 *B*). In lower vertebrates (birds, reptiles, etc.) each rib has two heads, a dorsal and ventral (Fig. 123). The tuberosity of the human rib represents the dorsal head; the ventral head is well developed in man, as in mammals generally. The rib articulates with the neural arches only (Fig. 119 *D*).

Vestigial Ribs.—Although the ribs are only fully developed in the dorsal region, yet a representative—a **costal element**—is

present in every vertebra. In the **cervical vertebrae** the anterior part of the transverse processes represents a costal process, but only in the 6th (sometimes) and 7th is the costal process formed

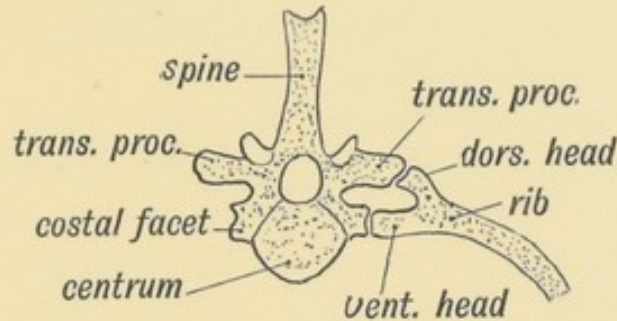


FIG. 123.—The Bicapital Rib of a Lower Vertebrate (crocodile).

by a separate centre of ossification. The costal process of the 7th may develop into a rudiment or even a fully formed rib which reaches the sternum. In the **lumbar vertebrae** only the first shows a separate centre for the formation of the costal process; it fuses with the tip of the transverse process in the later months of foetal life; in the other lumbar vertebrae the tips or perhaps the whole of the transverse processes represent costal processes. The 12th dorsal rib varies widely in size; it may be six inches or ten long or reduced to a mere vestige.

In the **1st, 2nd and 3rd sacral vertebrae** the costal processes are large and have their own centres of ossification. Their cartilaginous bases fuse early to form the greater part of the lateral masses of the sacrum (Fig. 115). The part of the lateral mass

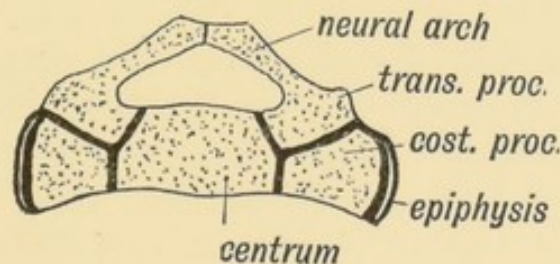


FIG. 124.—A section to show the Nature of the Elements composing the Sacrum.

formed by the costal processes is shown in Fig. 124. The costal processes are absent in the 4th and 5th sacral and all the coccygeal vertebrae. The two lateral epiphyseal plates on each side of the sacrum are new and independent formations.

The Accessory Processes are found in the lumbar and lowest two

dorsal vertebrae. They are developed at the base of the transverse processes and are for the attachment of slips of the longissimus dorsi. The **mammillary processes** are developed on the articular processes of the lower two or three dorsal and all the lumbar vertebrae. They give attachment to tendons of origin of the multifidus spinae.

The Transverse and Spinous Processes grow out from the vertebral bow (Fig. 119 *A*) into the septa between the primitive segments. Each transverse process is pierced, while still in the fibrous condition, by a branch of the corresponding segmental (intercostal) artery. In only the cervical region do those perforating arteries and their foramina persist. In that region the perforating arteries anastomose and out of the chain thus formed is developed the vertebral artery. Thus the foramina for the vertebral artery are formed independently of the costal element in each cervical transverse process. The spines are absent on the 1st cervical, 4th and 5th sacral and coccygeal vertebrae. They are slightly developed and united by ossification of the interspinous ligament in the 2nd and 3rd sacral vertebrae. The 2nd, 3rd, 4th, 5th, and 6th cervical spines are bifid in Europeans; but in lower races, as in anthropoids, the 5th and 6th spines are undivided.

CHAPTER XII.

THE SEGMENTATION OF THE BODY.

Segmentation of the Body.—The human body or trunk consists of 33 or 34 segments. Each segment is fundamentally of the same type, but the resemblance is obscured owing to extensive modifications which they undergo to form the cervical, dorsal (thoracic), lumbar (abdominal), sacral (pelvic) and caudal regions of the body. The outgrowth of the limbs also renders it difficult to recognise in the adult the simple system of segments which can be seen in the embryo at the end of the third week (Fig. 233, p. 289).

Until lately the segmentation of the human body was a matter of only speculative importance, but recent advances in our knowledge of the distribution of nerves, has shown that it has a direct bearing on diagnosis and treatment.

Constitution of a Typical Segment (11th Dorsal).—It is better to study the development of one typical body segment and from that the student will be able to note for himself the modifications which have taken place in the more highly differentiated segments of the body. By the end of the third week, the process of segmentation, which began in the occipital region a few days previously, has spread backwards and separated the 18th body segment (11th dorsal) from the one in front and behind. As already explained, the process of segmentation affects only the paraxial block of mesoblast which lies on each side of the neural canal and notochord. In Figs. 125 and 126 a segment is represented in the adult and in the embryonic condition.

The following elements make up the 11th dorsal segment: (1) Its skeletal basis; (2) Muscular element; (3) Renal element;

(4) Vessels; (5) Nerves; (6) Neural segment. Although the epiblast and hypoblast are never segmented, yet a definite area of each is associated with every body segment. The origin of each element will be taken separately.

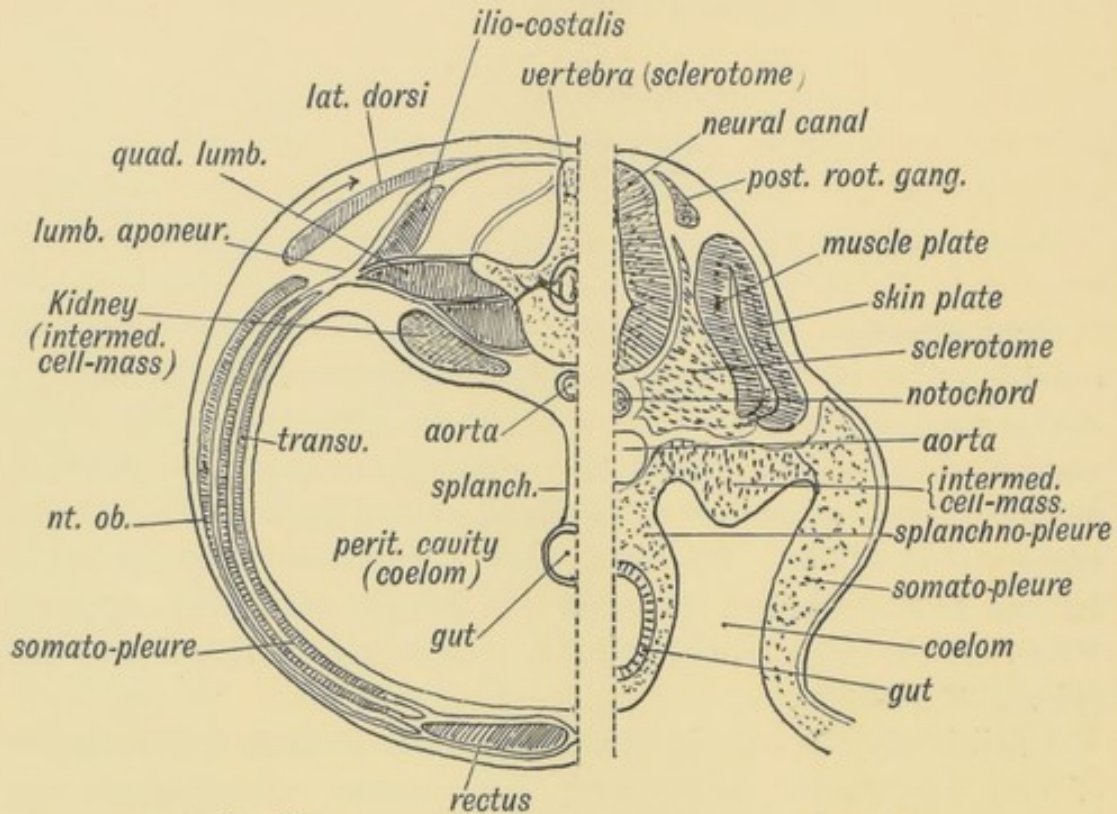


FIG. 125.

FIG. 126.

FIG. 125.—A transverse section showing the Elements of the 1st Lumbar Segment in the Adult.

FIG. 126.—A corresponding section of an Embryo about the end of the 3rd week (diagrammatic).

I. The **skeleton** of the 11th dorsal segment is represented by the adjacent halves of the 11-12 dorsal vertebrae and the disc between them, for, as already pointed out, the vertebrae are inter-segmental in origin (Fig. 126). The transverse processes, the spinous process and 11th and 12th ribs are also formed in the septa in front of and behind the 11th segment. The septum in the rectus muscle a little below the umbilicus represents the inter-segmental septum corresponding to the 11th rib. Sometimes another septum occurs in the rectus, midway between the pubes and umbilicus, marking the lower limit of the 11th segment. The linea alba separates the segments of the two sides.

In the linea alba or ventral median line of the thoracic region, the sternum is developed. The inter-segmental septa are well

marked in the thoracic region; the ribs and their cartilages are developed in them. In the neck the septa are almost lost; the intermediate tendon of the omo-hyoid and the septa occasionally found in the sterno-hyoid and -thyroid, complexus and trachelomastoid muscles are the only representatives of them in the cervical region.

II. The Muscles of the 11th Dorsal Septum.—All the muscles of this segment are developed from the muscle plate of the primitive segment (see Figs. 125 and 126). There is a cavity, which probably arises as a diverticulum of the coelom, in each primitive segment (Fig. 69, p. 90). The cells of the mesoblast on the inner side of the segmental cavity become columnar and form the muscle plate (Fig. 126). Each segment has its own muscle plate. The cells of each plate increase rapidly in number; they spread into the somatopleure, and form the muscles of the body-wall and limbs. Each cell becomes elongated and directed across its segment from septum to septum. The intercostal muscles retain this arrangement, but in the abdominal region the fibres fuse with those of neighbouring segments to form muscular sheets—the external oblique, internal oblique, transversalis and rectus. In fishes the embryonic segmental arrangement of the musculature persists. The manner in which the final groups of muscles are derived from the muscle plates is not known, but in the typical segment with which we are at present dealing it will be seen that the musculature falls into two groups (see Fig. 125): (1) **axial** (acting on the spine—the erector spinae, etc.), and (2) **ventro-lateral** or body-wall muscles (intercostals, rectus, oblique muscles, etc.). The musculature of the limbs is derived from the ventro-lateral group.

Many of the ventro-lateral muscles (trapezius, rhomboids, and latissimus dorsi), migrate dorsalwards over the axial muscles and take origin from the spines of the vertebrae (Fig. 125).

Each muscle fibre is a cell derived from the endothelial cells which make up the muscle plate. The protoplasm of each cell is converted into a living contractile substance (myosin), which reacts to nerve stimuli.

III. The Arteries of the 11th Segment (Fig. 127).—The 11th intercostal is the artery of the segment. It gives off a dorsal branch to supply the axial muscles, the spinal column, spinal cord and

membranes and skin. The segmental artery joins at its termination with a ventral longitudinal vessel, the deep epigastric. The primitive arrangement in vertebrates appears to have been a

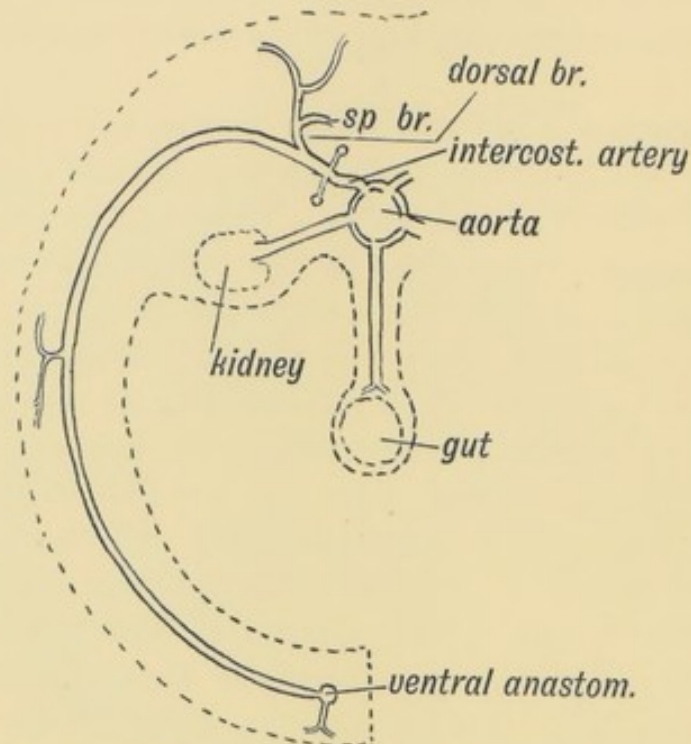


FIG. 127.—The distribution of a typical Segmental Artery.

dorsal and ventral longitudinal vessel, with the segmental artery passing between them. The vertebral, ascending cervical, deep cervical, ascending lumbar and lateral sacral arteries are examples of the anastomoses that may arise between segmental arteries.

Segmental arteries also arise from the aorta to supply the structures formed from the intermediate cell mass (the kidney, testis, ovary, etc., Figs. 125 and 127). As a rule only one renal segmental artery persists, but frequently accessory renals are seen. These are persistent embryonic vessels of the several segments from which the mesoblast of the kidney arose. The splanchnopleure shows no trace of segmentation; hence its vessels (coeliac axis and mesenteric) are not segmental in origin.

IV. The Nerve Elements of the 11th Segment (Fig. 128).—
 (1) Although the spinal cord of the human embryo shows no certain sign during development of being definitely divided into segments corresponding to those of the body, yet from what we know of its condition in embryos of other animals and from clinical

evidence there can be little doubt that such a segmentation does take place, and that it possesses segments corresponding to those of the body. A group of cells in each segment, afterwards those of the anterior horn, sends out processes to all the muscles of the primitive body segment in which it is situated. The anterior root of a spinal nerve is thus formed. Other motor cells send out processes which reach viscera through the white rami communicantes and sympathetic system (Fig. 128).

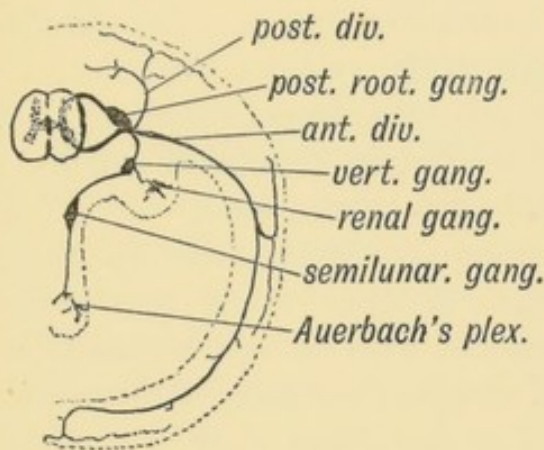


FIG. 128.

FIG. 128.—Diagram of the Nerve System of the 11th Dorsal Segment.

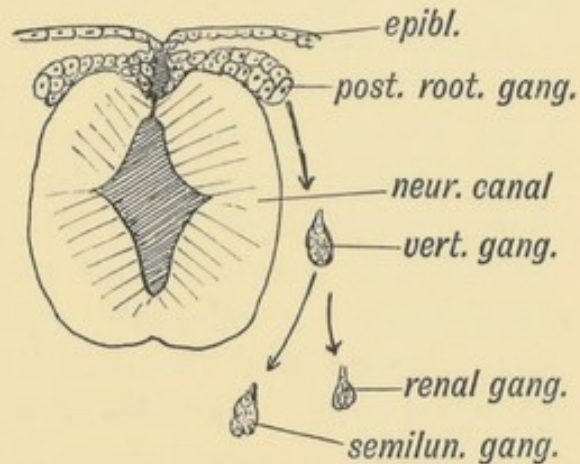


FIG. 129.

FIG. 129.—A diagram showing the derivation of the Parts of the Nerve System of the 11th Segment in the Embryo.

(2) Besides the anterior horn cells, two other nerve groups become connected with each segment. At the point where the medullary plates are cut off from the epiblast to form the neural canal, a crest, **the neural crest**, grows out on each side (Fig. 129) composed of the cells which formed the junctional line between medullary plates and epiblast. A group of these neuroblasts grows into each segment and forms the **posterior root ganglion**. Each neuroblast within the ganglion sends out a process which bifurcates, one branch or fibre growing into the cord and ending in the posterior column and cells of the posterior horn, the other passing to the skin, muscles, etc., of the segment. The posterior nerve root is thus formed by the ingrowing processes of the cells of the posterior root ganglion, and thus the body segment in which the outgrowing processes are distributed is brought into sensory communication with the central nervous system. The anterior and posterior roots unite to form a spinal or segmental nerve. Like the artery it divides into a posterior division for the epaxial part

of the segment and an anterior for the ventro-lateral part (Fig. 128)

(3) A third group of cells, the **sympathetic**, is also connected with each segment. The origin of these cells is not yet certain, but most of the evidence goes to show that the cells are derived, with the posterior root ganglion, from the neural crest and that a group enters each segment. Professor Paterson's research on their origin led him to the conclusion that the nerve cells of the sympathetic arose from the mesoblast. The sympathetic group of nerve cells (Figs. 128 and 129) is broken up into—

(a) The prevertebral ganglion situated on the vertebra (in the gangliated chain), ventral to the exit of the spinal nerve;

(b) A group to the intermediate cell mass (renal ganglion);

(c) Another to the splanchnopleure (in the semilunar ganglia);

(d) To the viscera (cells of Auerbach's plexus, etc.).

Groups (c) and (d) show no trace of segmentation in their arrangement, but, clinically, evidence is to be found that every viscus or part of a viscus is connected with certain segments of the spinal cord. The cells of the sympathetic ganglia throw out axis-cylinder processes, which pass to the spinal cord by a white ramus communicans and posterior root, and act as sensory pathways from the viscera. The distal end of the axis-cylinder process ends in a viscus. In this manner certain segments of the spinal cord are brought into touch with the viscera. The vaso-motor supply of each body segment passes to it from the sympathetic ganglia by a grey ramus communicans.

It will thus be seen that all the parts of a segment—body wall (somatopleure), kidney (intermediate cell mass), and a part of the abdominal or thoracic viscera (splanchnopleure) are connected by nerves to a corresponding segment of the spinal cord. In diseased conditions of any part of the body segment the corresponding spinal segment of the cord is disturbed, the disturbance being reflected from the cord to the segment. The nervous mechanism of the whole segment is affected. Thus, for instance, a stone in the pelvis of the kidney (which is supplied from the 10th, 11th, and 12th dorsal segments) is frequently accompanied by pain referred along the 11th and 12th intercostal nerves. The skin supplied by these nerves may become hyper-aesthetic.

CHAPTER XIII.

THE CRANIUM.

Development of the Skull.—The facial parts of the skull have already been dealt with (Chap. I.). Only those bones which enter into the formation of the cranial cavity and help to form the brain chamber are dealt with here. These bones are the frontal, parietal, occipital, temporal, ethmoid and sphenoid.

Is the Skull made up of Segments?—We have just seen that the body is made up of 33 or more segments. Is the skull made up of a series of segments? The theory supported by Owen and many others that the cranium is really composed of 4 modified vertebrae is now no longer tenable. On the other hand the arrangement of the nerves and muscles, the evidence of development and comparative anatomy, indicate that it is composed of a number of segments, probably nine in number. The four posterior, which form the occipital region of the skull, are recognisable at an early stage of development, but at no period in the development of the embryo have the anterior five segments been seen to be demarcated.

The Primitive Membranous Skull.—The brain is developed in the same manner as the spinal cord from the medullary plates of the neural groove (Fig. 69, p. 90). In the same manner the mesoblast grows under and over the cephalic part of the neural canal, and forms for it a membranous covering. The covering of mesoblast thus formed is the primitive basis of the skull in the embryo.

The Evolution of the Mammalian Cranium.—It is not possible to understand the manner in which the bones of the human cranial cavity are developed without some reference to

comparative anatomy. Only the base of the human skull is developed in cartilage, the rest is developed in membrane. How has that come to be? The brain of amphioxus, if it can be said to possess one, is wrapped in a membranous covering. In fishes with cartilaginous skeletons this embryonic mesoblastic capsule becomes chondrified—plates of cartilage develop in it. As in the spinal column, the process of chondrification begins at the base and spreads slowly round to the crown or dorsum of the head. The cartilaginous cranium is an advance on the membranous stage. In many fishes a further most important element is added. The **dermal** bony plates, to which the placoid scales are fixed, are applied to the cartilage over the sides and dorsum of the skull. Thus to the cartilaginous element of the skull is added a third element—bone formed in membrane. Now in the mammalian skull, and especially in that of man, the cerebral vesicles grow so quickly that long before the process of chondrification has had time to spread in the membranous capsule from the base to the crown, the dermal bones have formed, and thus supplant the cartilage on the calvarium. Hence in the human skull, while the process of chondrification occurs in the base, and afterwards undergoes ossification, the whole calvarium and sides of the skull are formed by bones which, historically, are **dermal bones**, and hence are formed directly in membrane. The dermal bones of the human skull are: (1) the frontal, (2) the parietal, (3) the inter-parietal part of the occipital (the part above the superior curved lines), (4) the squamous part of the temporal.

Thus the calvarial part of the skull passes directly from the membranous to the bony stage, while the base of the skull, like the spinal column, passes through three stages: (1) membranous, (2) cartilaginous, (3) bony. It will be thus seen that the base of the skull, developed in cartilage, is the most ancient part, while the dermal bones, which form the calvarium, represent a later addition.

Development of the Roof (membranous or dermal part) of the Skull.—In the 7th week of foetal life there appear on each side of the membranous cranial capsule four centres of ossification:

(1) For the frontal bone at a point which becomes afterwards the frontal eminence (Fig. 130);

- (2) For the parietal, at the position of the parietal eminence ;
 (3) For the squamosal—at the base of the zygoma (Fig. 130) ;
 (4) For the membranous part of supra-occipital (part above superior curved line).

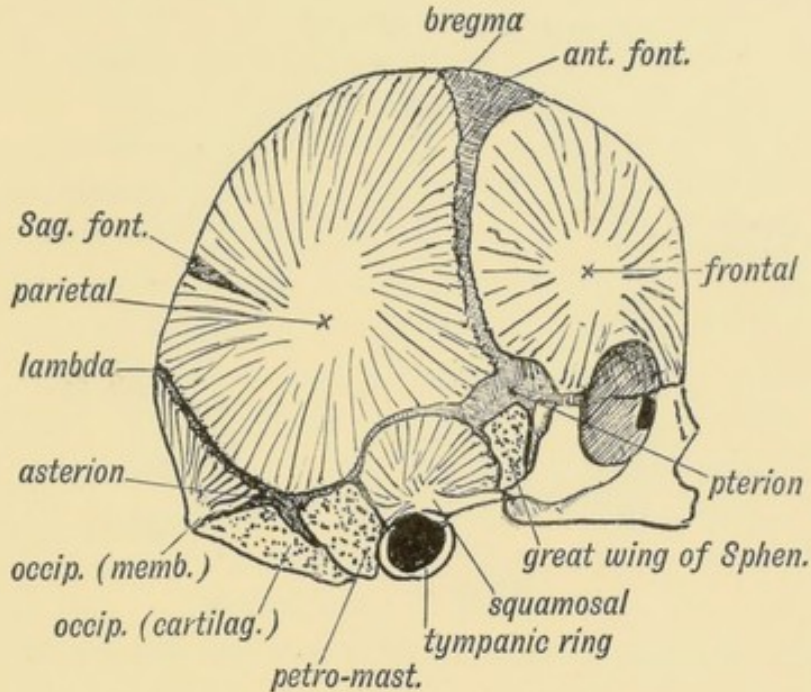


FIG. 130.—The Centres of Ossification for the Dermal Bones of the Skull. The Bones which are formed in Cartilage are stippled.

The two occipital centres fuse early into one at the position of the external occipital protuberance. The two frontal ossifications fuse about the end of the first year; the metopic suture which separates them disappearing then. This suture occasionally persists. The parietal bones fuse together, at the sagittal suture, late in life, commonly between the 35th and 45th year. The squamosal partly covers the petro-mastoid cartilaginous element and fuses with it in the first year, the temporal bone being thus formed.

The Manner in which these Bones are Developed.—In Fig. 131 a vertical section of the skull of a foetus $4\frac{1}{2}$ months old is represented. The coverings of the brain are seen to be then (1) scalp, (2) a stout white fibrous capsule, (3) a fine membrane lining it—the inner layer of the dura mater—(4) the arachnoid covering the brain (not shown in figure). Spicules of bone which form the parietal are seen developing within the fibrous capsule and radiating out from the centre of ossification. Lower down

are seen the ossifying fibres of the squamosal. The base of the skull is formed of cartilage which is covered, or ensheathed, by a perichondrium continuous with the membranous capsule. In the cartilage appear the centres of ossification for the sphenoid.

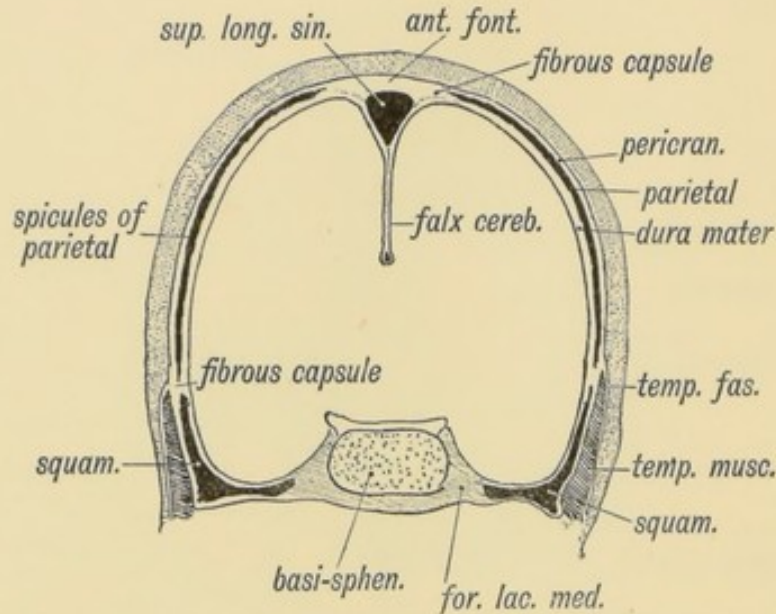


FIG. 131.—A coronal section of the Skull of a Foetus, 4½ months old.

As the bony spicules of the parietal spread out, they divide the primitive cranial capsule into an outer layer—the **pericranium**—and an inner—the **periosteal** layer of the dura mater. At the periphery of the bone and in the sutures the continuity of these two layers persists. The growth of the spicules of bone keeps time with the growing brain which expands the capsule, but there is, at each corner of the parietal bone, until the end of the first year, a part of the primitive cranial capsule left unossified. These unossified parts of the membranous capsule are the **fontanelles**.

The Fontanelles.—There are five fontanelles connected with each parietal bone, one at each of its rounded angles, and one, the **sagittal** (Fig. 130) which occurs between the radiating fibres of the parietal near the posterior end of the sagittal suture. The parietal foramen marks its position in the adult. In about 15% of children this fontanelle is unclosed at birth; a large parietal foramen may permanently mark its situation. The posterior inferior fontanelle, situated at the **asterion** (Fig. 130), the anterior inferior at the **pterion**, and the posterior superior at the **lambda**,

close before or about the time of birth. Separate ossifications, which become Wormian bones, are often developed in the primitive capsule of the skull at those three fontanelles and thus close them. The anterior superior fontanelle, at the **bregma**, cannot be distinctly felt during life after the first year (Warner), but it is not completely closed until the second year is nearly over. This fontanelle is lozenge-shaped, being bounded by four bones, viz., the two parietals and two frontals. The bregmatic or anterior-superior and lambdoid or posterior-superior fontanelles are median and common to both parietals.

The membrane-formed bones consist at first of a thin lamella of osseous fibres radiating out from the point at which ossification commenced. The osteoblasts beneath the pericranium on the outer surface of the lamella and the dura mater on the inner surface deposit bone, and by the 5th year an outer and inner table, with diploic tissue between, are developed. Into the diploe of the frontal bone protrude the growing buds of the two frontal sinuses. As the brain expands new bone is formed at the sutures to increase the capacity of the skull, but the operation of craniotomy to allow the expansion of a confined brain, by the formation of a new suture, is founded on a wrong principle. Expansion of the cranial cavity takes place principally by a deposit on the outer table and an absorption from the inner; for this manner of growth, sutures are unnecessary. The synostosis of the sutures does not necessarily prevent growth; synostosis of the skull bones occurs only when the brain has ceased to expand. If the brain of the infant is arrested in its growth, premature ossification of the sutures occurs, the condition of **microcephaly** resulting therefrom. In **hydrocephalus**, when the ventricles become enormously dilated, the membranous capsule of the cranium expands so quickly that the process of ossification cannot keep up with its rapid growth. Hence in hydrocephalus the fontanelles are enormous. The cartilaginous part of the skull is scarcely affected in this disease. The membrane-formed part of the skull is liable to diseases which do not affect the cartilage-formed part. The dura mater is very adherent to the bones formed in cartilage.

Development of the Cartilaginous part of the Skull.

(1) **The Occipital Bone.**—The occipital bone is developed from

the **parachordal cartilages**, two cartilaginous bars which partly surround the cranial part of the notochord (Figs. 133 and 121). The parachordal cartilages represent in the skull the cartilaginous sheath of the notochord out of which, in the spinal column, the bodies of the vertebrae are developed. Each cartilage throws out a wing (Fig. 134); these meet over the hind brain and form the exoccipitals and cartilaginous part of the supra-occipital,

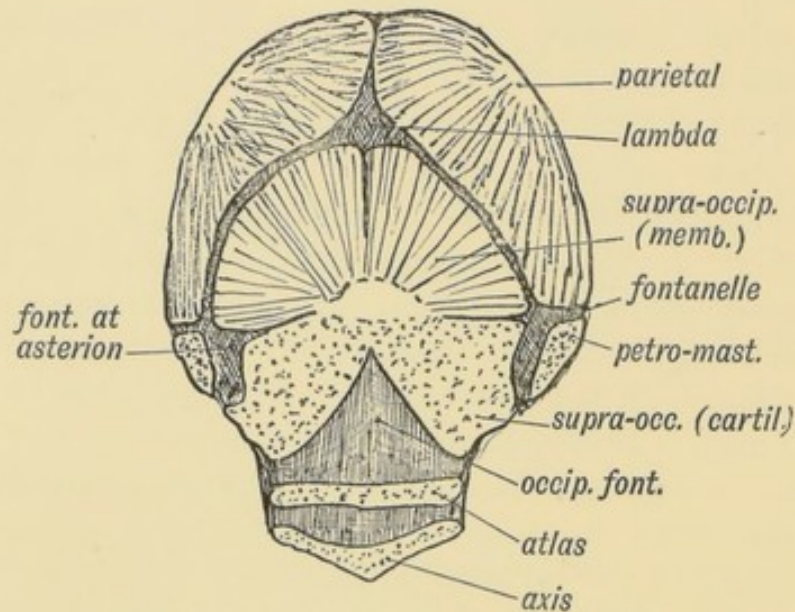


FIG. 132.—The Occipital Region in a Foetus of 5 months.

and thus enclose the foramen magnum. In Fig. 132 the condition of the occipital region is shown in a 5th-month foetus. The supra-occipital parts of the parachordal cartilages have fused. A suture between the membranous and cartilaginous parts is clearly visible—especially near the fontanelle at the asterion. The membranous and cartilaginous parts of the supra-occipital become completely fused soon after birth. It will be observed that the process of fusion between the lateral parts of the cartilaginous supra-occipital is not complete at the 5th month (Fig. 132). The occipital fontanelle (Sutton) projects upwards between them from the foramen magnum (Fig. 132). This fontanelle is filled by a continuation of the posterior atlanto-occipital ligament; and becomes closed soon after birth. It is the most common site of a cerebral meningocele—a saccular protrusion of the membranes of the brain which contains cerebro-spinal fluid, and possibly also a part of the brain.

Separate centres of ossification appear in the parachordal cartilages to form (1) the basi-occipital, (2) the two exoccipitals, and (3) the supra-occipital. The occipital consists of

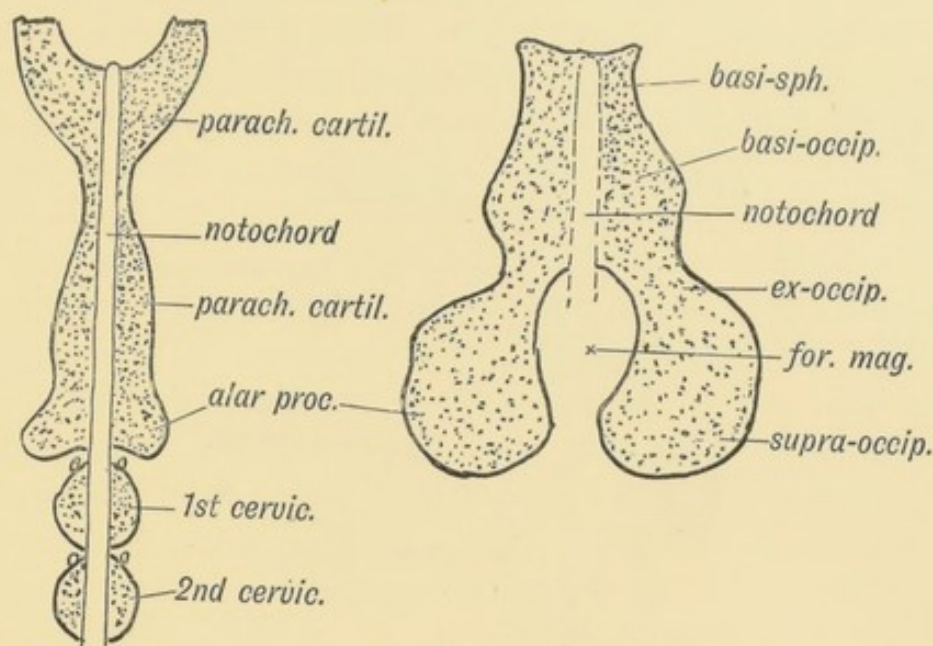


FIG. 133.

FIG. 134.

FIG. 133.—The Parachordal Cartilages out of which the Cartilaginous Parts of the Occipital Bone are formed.

FIG. 134.—The expansion backwards of the Parachordal Cartilages to enclose the Foramen Magnum and form the Supra-occipital.

these four pieces until the fourth year, when synostosis occurs. The occipital condyles are formed from the exoccipitals and basi-occipital, the exoccipital element constituting by far the larger part. The anterior condylar foramen is formed between these two parts. The occipital protuberance is formed by both membranous and cartilaginous parts of the supra-occipital.

(2) **The Petro-mastoid** forms part of the base of the skull. We have already seen that the petro-mastoid part of the temporal bone is developed out of the cartilage which forms the periotic capsule (Figs. 35, p. 50, and 135). The periotic cartilages fuse at points with the parachordal, which form the basis of the occipital bone. Even to a late stage (30th year or later) remnants of these cartilages may be found between the petro-mastoid and occipital bones, especially between the jugular process of the occipital and the mastoid (Fig. 136). The fibro-cartilage in the foramen lacerum medium is a remnant of the periotic cartilaginous capsule. (See also p. 58.)

(3) **Trabeculae Cranii** (Figs. 135 and 136).—The notochord terminates behind the pituitary body and sella Turicæ; the parachordal cartilages develop above and at each side of it (Fig. 135). Two bars of cartilage—the trabeculae cranii—develop in the

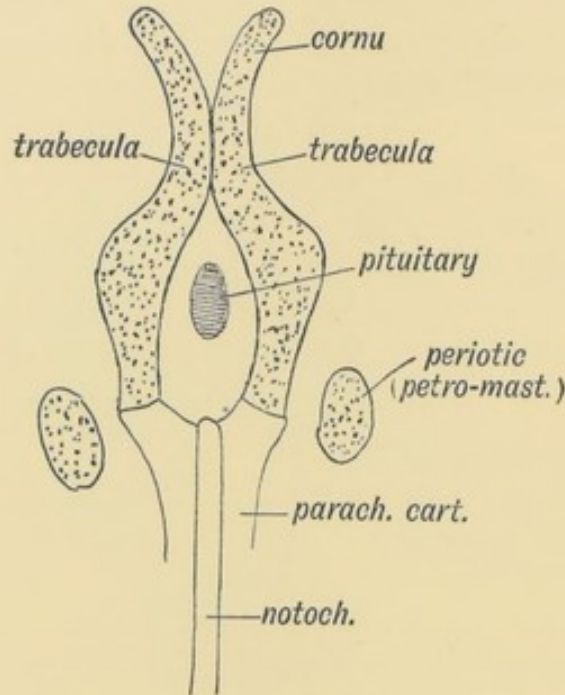


FIG. 135.—Diagram of the Trabeculae Cranii, Parachordal Cartilages, and Periotic Capsules.

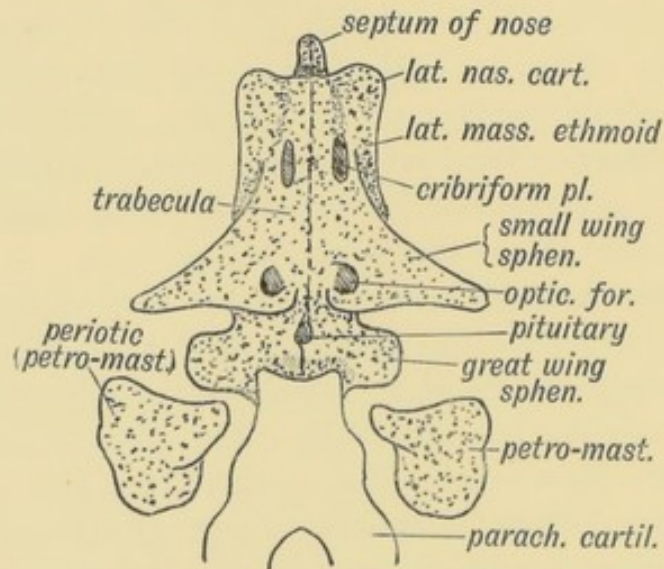


FIG. 136.—Diagram of the structures formed from the Trabeculae Cranii.

membranous basis of the embryonic brain capsule in front of the notochord and on each side of the pituitary body. In Fig. 136 is shown what become of these two cartilaginous bars. Their posterior

extremities fuse round the anterior termination of the notochord with the parachordal cartilages. The buccal part of the pituitary grows into the cranial cavity in front of the notochord and keeps the two cartilages apart; but in front of the pituitary the two bars fuse in the middle line. The mesial fused parts of the trabeculae grow into the mesial nasal processes of which they form the skeletal basis and become transformed into the primitive cartilaginous septum of the nasal cavities (Figs. 136 and 3, p. 3). The posterior segment of the median fused bars forms the cartilaginous basis of the pre-sphenoid and basi-sphenoid (Fig. 136). From the trabeculae four lateral processes or wings grow out on each side (Fig. 136). The **posterior**, which is small at first, forms the great wing of the sphenoid and external pterygoid plate; the **second** is originally large, and forms the small wings (orbito-sphenoids); the **third** and **fourth** outgrowths are closely joined,—they form the lateral masses of the ethmoid and alar cartilages of the nose (Fig. 6, page 6). The nasal bones, the lachrymal and ascending nasal processes of the superior maxilla, develop in the membrane over the lateral nasal wings of the trabeculae, in the same way as the vomer develops over the cartilage of the septum.

Development of the Sphenoid (Fig. 137).—At birth the sphenoid bone, which is developed by ossification of the posterior

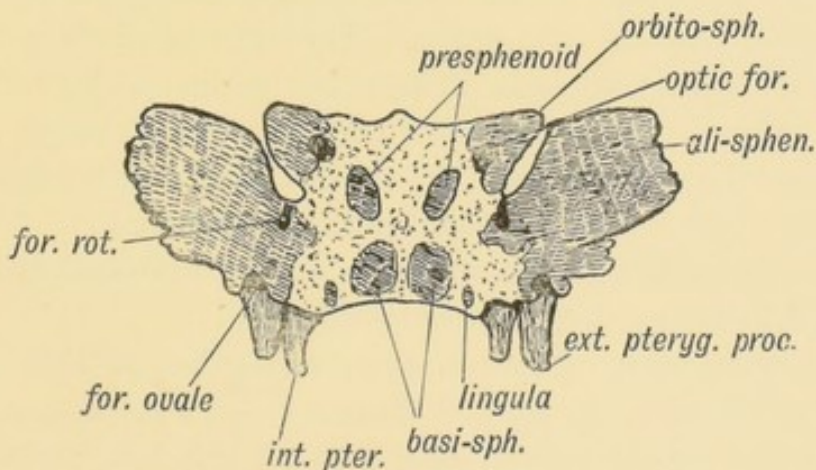


FIG. 137.—The Sphenoid in a foetus of 4 months. The Centres of Ossification are deeply shaded. (After Sappey.)

parts of the trabeculae cranii, consists of three parts, the great wings being separated from the rest of the bone. The sphenoidal turbinate bones, afterwards inflated by the development

of the sphenoidal air sinuses, are then nodules of bone, surrounded by cartilage. They also are separate and form part of the lateral ethmoidal cartilaginous plates. The internal pterygoid plates, formed from the pterygo-palatine bar, become adherent to the external pterygoid plates, which are developed as outgrowths from the ali-sphenoids or great wings. The pre-sphenoid unites with the basi-sphenoid in the 7th month; the great wings unite with the basi-sphenoid soon after birth. The *lingula* which bounds the outer side of the carotid groove (Fig. 137) is ossified from a centre which appears during the 4th month of foetal life. The orbito-sphenoids unite over the pre-sphenoid and cover its cranial aspect.

The Pituitary Body is developed between the trabeculae cranii; the pre-sphenoid is formed in front of it and the basi-sphenoid behind it (p. 19). A canal may remain in the foetal or even adult bone to mark the point of ingress of the buccal part of the Pituitary, Fig. 167, p. 203. The wings of the vomer cover the opening of the pituitary canal on the pharyngeal aspect of the skull, if it be present. On the cerebral aspect it opens at the olivary eminence which also marks the union of the pre- and the basi-sphenoids. The pre-sphenoid and afterwards the basi-sphenoid are much altered by the growth of the sphenoidal sinuses which commence about the 7th year. The great wings support the temporal poles of the brain, their size depending on the development of that part of the brain. They are much larger in man than in any other mammal. The small wings project within the *vallacula Sylvii*. In the early foetus the *dorsum sellae* is enormously developed, and fills the deep and sharp angle between the mid-brain and fore-brain (Fig. 167).

Formation of Foramina in Bone.—The foramina of the skull are formed in one of three ways (Sutton):

(1) By the union of two bones; examples of this form are the jugular foramen, sphenoidal fissure, Glaserian fissure, etc.

(2) By the union of two elements of one bone; the anterior condyloid foramina, optic foramina, the foramen magnum, *aqueductus Fallopii*, etc.

(3) By the enclosure of a notch on the edge of a bone of which the foramen ovale is the best example. This foramen is at first a notch in the posterior border of the great wing of

the sphenoid (Fig. 137); it remains in this condition in all mammals except man. In him the margins of the bone on each side grow out and fuse and thus convert the notch into a foramen. Other examples are the foramen spinosum, the foramen rotundum, parietal foramen, mastoid, etc.

Wormian Bones.—In the six fontanelles which occur at the parietal angles separate ossific centres frequently appear and close them. The fontanelle ossifications form Wormian bones. They occur most frequently at the posterior angles of the parietal (Lambda and Asterion) but they are also common at the Pterion (epipteric Wormian) and rare at the Bregma. The wormian at the last-mentioned point receives the name of os anti-epilepticum. Much confusion has been caused by naming a large wormian, which may occur in the lambdoidal (posterior-superior) fontanelle, the inter-parietal bone.

The Inter-parietal Bone.—It has already been shown that the part of the supra-occipital above the superior curved lines is developed from membrane by two centres of ossification and is at first and almost until birth nearly separated from the lower part developed from cartilage (Fig. 132). The membranous part of the supra-occipital represents the inter-parietal bone. In marsupials, ruminants, and ungulates, the inter-parietals fuse with the parietals and not with the occipital. In rodents they fuse with both occipitals and parietals. In primates and carnivora, as in man, they fuse with the occipital. It is extremely rare to find the whole inter-parietal separate in man, but a large wormian, partly replacing the inter-parietal, is very frequent. Such a wormian bone, if large, is named variously, os epactal, os Incae, os triquetrum, or pre-interparietal.

The Post-frontal does not occur in mammals as a separate bone; in them it has fused with the frontal, and forms that part of the bone which articulates with the great wing of the sphenoid and malar. A wormian bone—the epipteric—which is occasionally developed in the fontanelle at the pterion, may be mistaken for it. Traces of a true post-frontal, partly separated from the frontal, rarely occur in man. The suture round a wormian bone may be mistaken for a fissure or fracture when exposed by the trephine.

The Cephalic Index.—Anthropologists have employed the shape of the head as a character in classifying the races of man-

kind. The **cephalic index** is used to express the shape of the head. It states the proportion that the breadth bears to the length of the skull (Figs. 138 and 139). The length or **long diameter** of the skull is measured from the glabella to the inion (external occipital protuberance); the breadth or widest diameter is measured

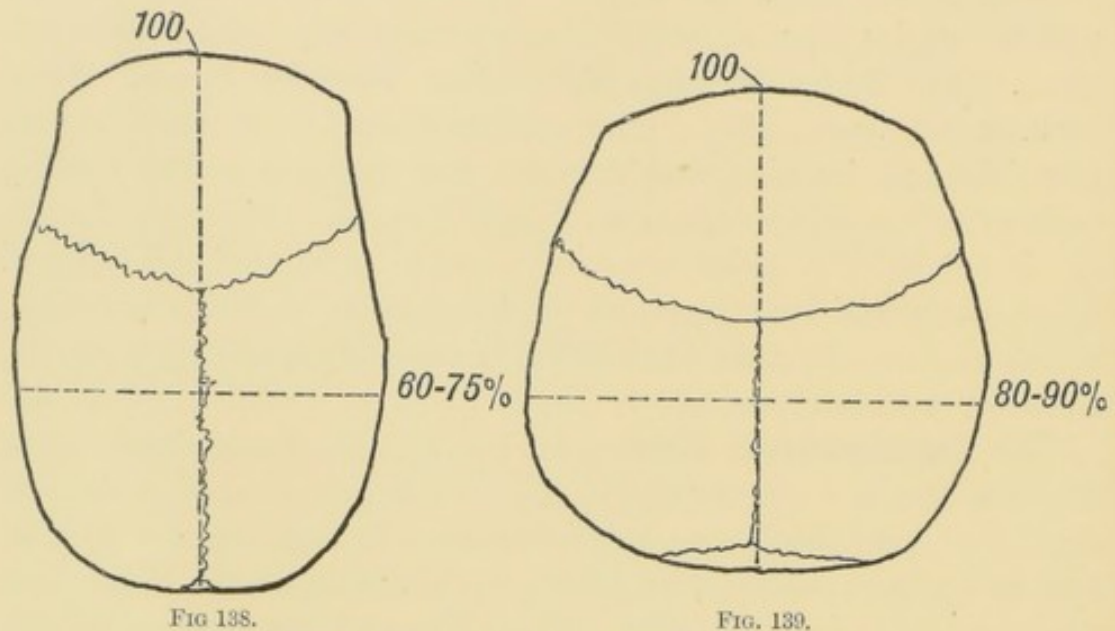


FIG. 138.

FIG. 139.

FIG. 138.—Diagram of a Long-head (Dolichocephalic).

FIG. 139.—Diagram of a Short-head (Brachycephalic).

between the widest points—the parietal eminences. If the length of a skull is 100 mm. and the breadth 75, the cephalic index of that skull is 75, *i.e.* the breadth is 75% of the length. Human races, on an average, are either **Dolichocephalic** (long-headed), the breadth being 75% or less of the length; **Brachycephalic**, in which the breadth is 80% or more of length; or **Meso-cephalic**, in which the breadth is between 75% and 80% of the length.

The English people have an average index of 75, the South Germans 83, but it must be remembered the individuals vary widely. It will be seen that the topography of the brain, worked out by German surgeons, cannot be applied to the longer English heads without modification.

The Facial Angle is the angle at which the face projects from the base of the skull (Fig. 140). The skull consists in man, as in all mammals, of two parts—the facial part, which carries the teeth and is developed according to their size, and the **brain capsule**, which depends on the size of the brain. The smaller the

brain and the larger the face, the more does the face project in front of the skull and therefore the greater is the facial angle, and *vice versa*.

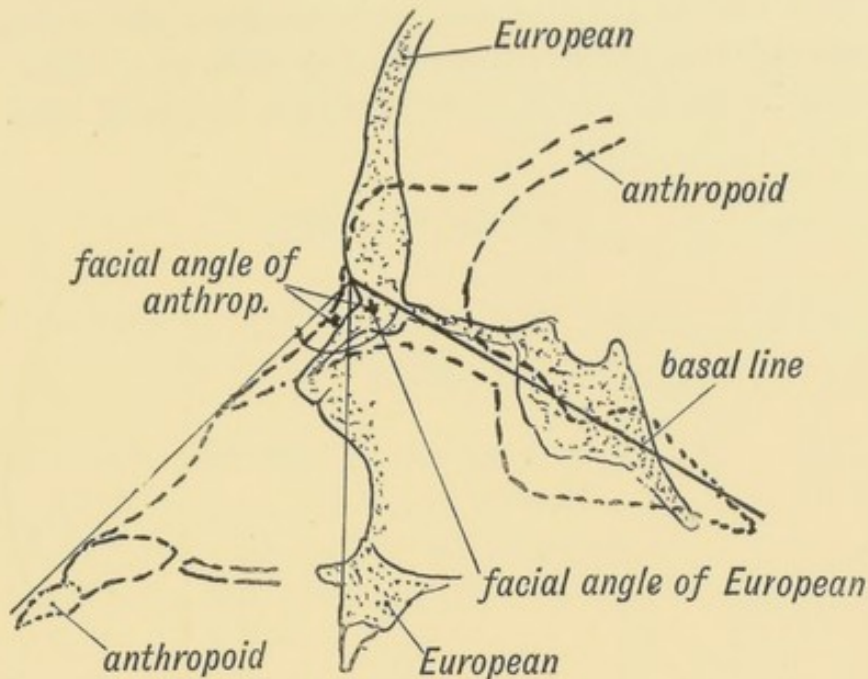


FIG. 140.—The Facial Angle of a European contrasted with that of an Anthropoid.

It will thus be seen that the facial angle is a good index of brain development. It is smallest in the most highly developed races of man; it is larger in the lower races, and larger still in the anthropoids; it increases in size with the advent of the permanent teeth and the necessary increase in the size of the face. It is therefore greater in the adult than in the newly born.

The Para-occipital Process is sometimes present in man, and projects downwards from the jugular process of the occipital bone. The *rectus capitis lateralis* is inserted to it. The process represents the para-occipital process, which is so highly developed in four-footed mammals. The *para-mastoid* process projects from the temporal at its outer side (Parsons).

Upprowth of the Temporal and Occipital Ridges or Curved Lines.—In lower animals, such as the ape or dog, a great increase in the development of the temporal and nuchal muscles takes place with the eruption of the permanent teeth, the area of their origin from the skull being necessarily enlarged. The ridges of bone which mark the limit of attachment of these muscles, the temporal and occipital ridges, ascend on the skull as waves of

bone before the growing muscles. The ridges may meet, as in apes, along the sagittal and lambdoidal sutures and form crests, like that on a fireman's helmet. In man the temporal ridges and superior curved lines of the occipital bone also ascend with the eruption of the permanent teeth, but only to a slight extent. Man retains in the adult the condition seen in young apes.

CHAPTER XIV.

DEVELOPMENT OF THE STRUCTURES CONCERNED IN THE SENSE OF SIGHT.

The structures concerned in the sense of sight are :

- (1) The Eyeball and the Optic Nerve.
- (2) The Eyelids and Lachrymal Apparatus.
- (3) The Orbit, the Muscles, Nerves, and Vessels contained in it.
- (4) The Nerve Centres and Tracts.

The Eyeball.—The condition of the eye in the third week of foetal life is shown diagrammatically in Fig. 141. The three

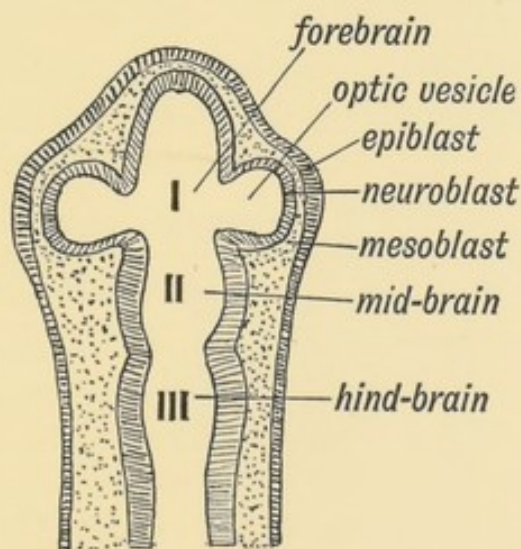


FIG. 141.—Diagram of the Elements which form the Eyeball.

elements which unite to form the eyeball are as yet separate. They are :

- (1) **Epiblast**, which forms (*a*) the epithelium of the cornea, (*b*) the lens, and probably (*c*) the rods and cones of the retina.

(2) **Neuroblast**, which forms (*a*) the optic nerves, (*b*) sensitive retina, (*c*) pars ciliaris retinae, (*d*) uvea (*e*) pigmentary layer of retina.

(3) **Mesoblast**, which forms (*a*) outer tunic (sclerotic and fibrous cornea); (*b*) middle tunic (choroid, ciliary-choroid and iris); (*c*) the vitreous humour and its capsule—the hyaloid membrane; (*d*) the capsule of the lens.

1. **Structures derived from the Epiblast.**—(*a*) **The lens.**—The lens is developed by a saccular invagination of the epiblast situated over the optic vesicle (Fig. 142). It becomes a closed

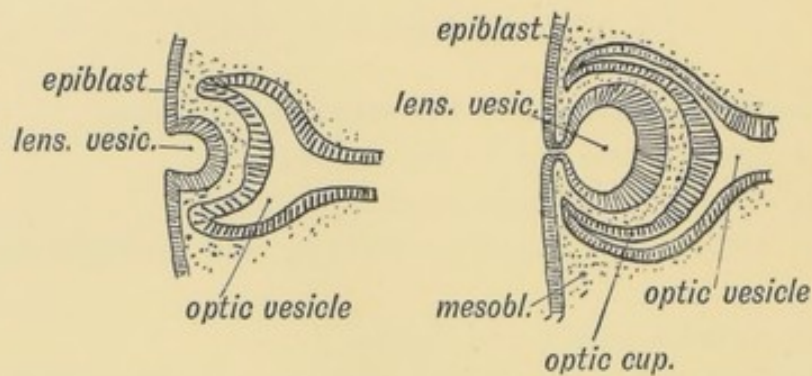


FIG. 142.

FIG. 143.

FIG. 142.—Invagination of the Epiblast to form the Lens Vesicle.

FIG. 143.—The manner in which the Lens Vesicle is severed from the Epiblast.

sac by the severance of its connection with the epiblast, its wall being formed by a single layer of epithelial cells. The cavity of

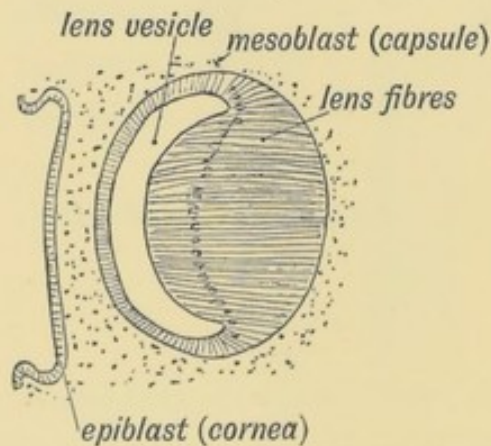


FIG. 144.—The Formation of the Lens Fibres from the Epithelium on the posterior Wall of the Vesicle.

the lenticular vesicle is gradually obliterated by the cells of the posterior wall becoming elongated (Fig. 144) until they reach

the anterior wall. Each elongated cell is transformed into a lens fibre.

The cells of the anterior wall retain their primitive form (Fig. 144). New lens fibres are added by the cells at the margin (equator) becoming multiplied and elongated. The lens reaches its full size in the 1st year of life and then no more fibres are formed. It will thus be seen that the lens is an area of modified epidermis. Like the epidermis, it shows a tendency in the aged to be transformed into keratin. The oldest cells (the central or nuclear fibres) alter first; hence the central position of the cataract which occurs so frequently in old people.

(b) **The cornea.**—The epithelial covering of the cornea is continuous with the epidermis and in some animals (snakes, etc.) it is shed with that structure, rendering the animal blind for the time being. It becomes transparent. The mesoblast which grows in between the lens vesicle and epiblast forms the connective-tissue basis of the cornea and also the capsule of the lens (Fig. 148).

(c) It is probable, although not yet verified, that certain cells from the epiblast grow into the optic vesicle and afterwards form the sensory epithelium of the retina—the **rods** and **cones** (Gaskell). Before the incursion of the mesoblast separates them, the optic vesicle and epiblast are in contact. If this is so, then the rods and cones—the sensory cells of the retina, the olfactory cells, the taste cells, the acoustic cells, are all of similar origin—epiblastic.

2. **Structures formed from the Optic Vesicles (neuroblastic element).**—(a) **The optic nerve** is formed out of the stalk of the optic vesicle. The vesicle is well developed at the commencement of the third week (see Fig. 141); even before the medullary plates have quite met to enclose the cavity of the fore-brain the optic vesicles have commenced as evaginations of those plates. They form a great lateral diverticulum on each side of the fore-brain—a cavity which becomes the third ventricle in the adult. The condition of the optic nerves at the commencement of the second month is shown diagrammatically in Fig. 145. The stalk or neck remains constricted while the vesicle enlarges.

Invagination of the optic vesicle.—Almost as soon as it begins to grow out the optic vesicle becomes invaginated, one half

being pushed within the other. It is invaginated by the lens-bud in the same manner as a schoolboy's fist indents a punctured india-rubber ball. The invaginated vesicle is known as the **optic cup**. The invagination of the vesicle, which takes place in

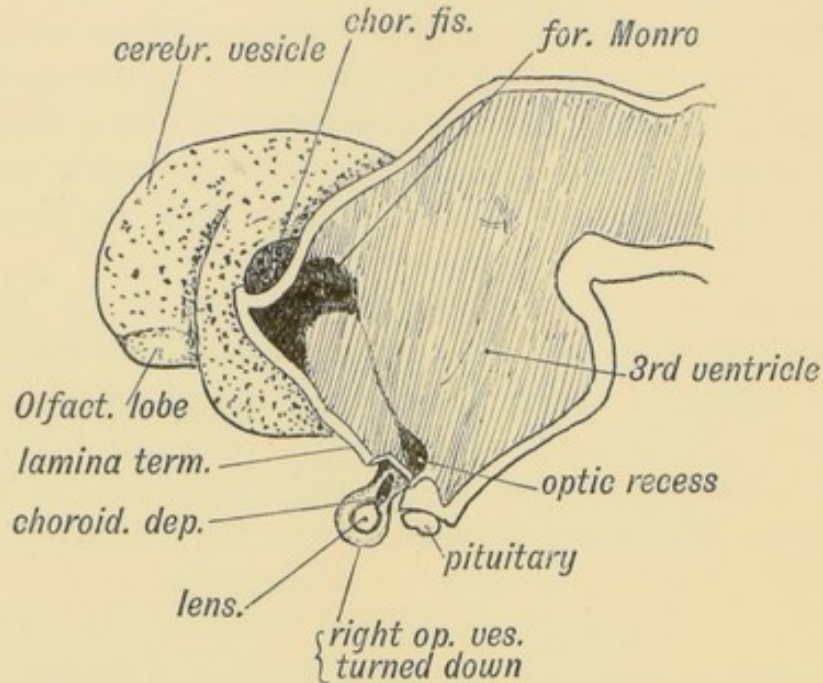


FIG. 145.—Diagram showing the condition of the Optic Stalk and Vesicle at the commencement of the 2nd month. (After His.)

an oblique manner—the pressure being applied from below and behind, leads to the closure not only of the cavity of the vesicle, but also to that of the distal half of the stalk (optic nerve). The mesoblast, surrounding the lens, grows into the invagination and afterwards forms the vitreous humour. The artery, which is folded in with the mesoblast, becomes afterwards the central artery of the retina. Hence the point at which the central artery enters the optic nerve marks the upper limit of the invagination of the optic stalk. By the fourth week the optic vesicle no longer communicates with the cavity of the fore-brain but the recessus opticus, in the floor of the third ventricle, above the chiasma, marks the point at which it entered (Fig. 145). The optic fibres, developed as processes of the neuroblasts of the invaginated layer, grow into the brain from the retina along the optic stalk. They thus form the greater number of the fibres in the optic nerve. The optic fibres also form the chiasma in the floor of the third ventricle and the optic tracts on the wall of the fore-

brain (Fig. 153). It will thus be seen that the optic nerves and vesicles are of the same origin as the cerebral vesicle—both representing parts of the wall of the fore-brain.

(b) **The pigmentary layer of the retina** is formed from the ensheathing or outer layer of the optic cup (Fig. 146). At first the wall of the optic vesicle is composed of a single layer of epithelium; the outer or pigmentary layer of the retina retains this embryonic form.

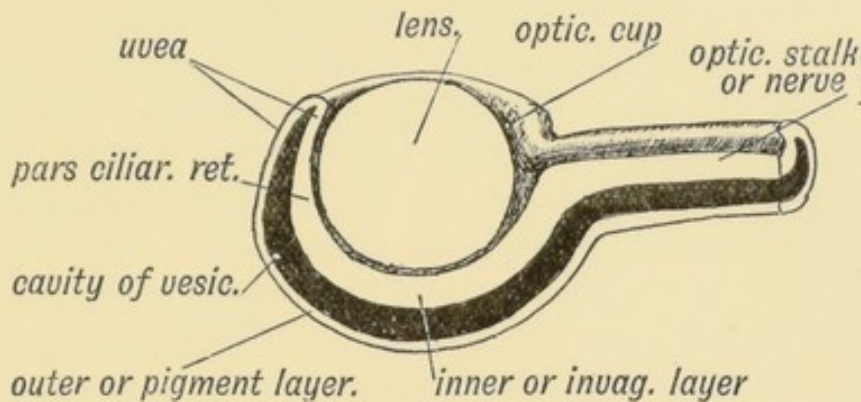


FIG. 146.—Diagrammatic Section of the Optic Cup and Lens.

(c) **The uvea** is the layer of pigmented epithelium which covers the posterior surface of the iris. It is formed out of both outer and inner layers of the optic cup, and represents the rim of the cup (Fig. 146).

(d) **The Pars ciliaris retinae** is formed out of that part of the inner or invaginated layer of the optic cup which lies in the shadow of the iris, and is therefore inaccessible to light rays. It also retains the primitive columnar form of the epithelium. The ora serrata marks the junction of the pars ciliaris retinae and sensitive retina.

Ciliary Processes.—At the commencement of the third month, the pars ciliaris retinae becomes plicated or puckered into 60 or 70 small folds; mesoblast of the middle tunic (choroid) grows into the puckers and forms the ciliary processes. It should be observed that the lens lies within the optic cup and the ciliary processes are formed round the equator or circumference of the lens.

(e) **The Sensitive Retina** is formed out of the inner or invaginated layer of the optic cup (Fig. 146). At first the inner

wall is composed of a single layer of epithelium. The pars ciliaris retinae retains this form. The cells of the sensitive retina elongate, but the process of formation of rods and cones and other structures in the retina has not been fully followed. If Gaskell is right then the matter is simple. He believes that the epithelial cells of the inner layer of the optic cup become transformed into the fibres of Müller; the rods, cones, and ganglionic cells being derived from the cells which grow into the optic vesicle from the epiblast. The ganglionic cells, however, are more probably derivatives of the neuroblasts of the optic vesicle. At any rate an inner layer of ganglionic cells is formed which give off the optic fibres as processes. These fibres converge at the stalk of the vesicle, thus forming the optic disc; they grow inwards on the stalk, which becomes the optic nerve; some at least, perhaps all, cross in the floor of the 3rd ventricle forming the chiasma, and pass round, as the optic tracts, to ganglia situated on the mid-brain. There are also efferent fibres in the optic nerve, which end round the ganglion cells of the retina. The inner ganglionic cells of the retina probably correspond to the cells of a posterior root ganglion. According to Gaskell the optic vesicles arose in the ancestry of the vertebrates as diverticula of their alimentary canal; when the alimentary function of the canal was lost and it became neural, these diverticula became the optic vesicles.

The choroidal Fissure.—Occasionally congenital fissures are seen

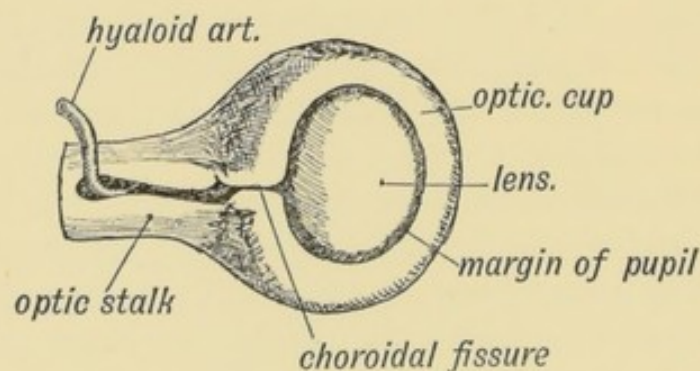


FIG. 147.—The Optic Stalk and Cup, viewed on the lower and lateral aspect, showing the closure of the Choroidal Fissure.

in the lower and outer segment of the iris (coloboma iridis). A white line, due to absence of pigment, may be seen in the corre-

sponding segment of the retina when the interior of the eye is examined. These are due to imperfect closure of the choroidal fissure. The choroidal fissure is the result of the peculiar mode in which the optic vesicle is cupped or invaginated. The lens grows into it from the malar or lower lateral aspect. The lens is lodged in the anterior part of the depression; the posterior part becomes the choroidal fissure (Fig. 147). The margins of the fissure unite, all traces of it normally disappearing. The margin of the cup left after the union of the lips of the choroidal fissure becomes the boundary of the pupil (Fig. 147).

Binocular Vision.—At first the optic vesicles are directed laterally in the human embryo, and in mammals generally the eyes are so directed, each eye having its own field of vision. In the Primates the eyes swing forwards during the second month; binocular vision is thus made possible. With binocular vision and the combination of images appear in the highest primates:—

- (1) A fovea centralis and macula lutea (L. Johnston);
- (2) A partial crossing of the optic fibres at the chiasma;
- (3) Certain alterations in the attachments of the oblique muscles of the eyeball.

The cavity of the Optic Vesicle (Fig. 146) is of some clinical importance. It is obliterated by the invagination of the vesicle; the rods and cones formed in the inner or invaginated layer grow out across the cavity into the outer or ensheathing pigmented layer of the retina. From accident or disease the retina may be detached; the separation takes place between the pigmented epithelium, which remains *in situ*, and the rods and cones, which fall inwards with the nerve layer. Fluid then collects in the site of the primitive cavity of the optic vesicle.

3. Parts of the Eyeball formed from the Mesoblast.—As the lens invaginates the optic vesicle and forms the optic cup, it carries in with it the surrounding mesoblast. Thus the lens is surrounded and the cup filled by mesoblast (Fig. 148).

The structures formed from the mesoblast are:

- (1) **The Capsule of the lens.**—It is developed out of the mesoblast which surrounds the lens. At first the capsule is continuous

in front with the basis of the cornea; behind, it is continuous with the mesoblast of the vitreous humour (Fig. 148).

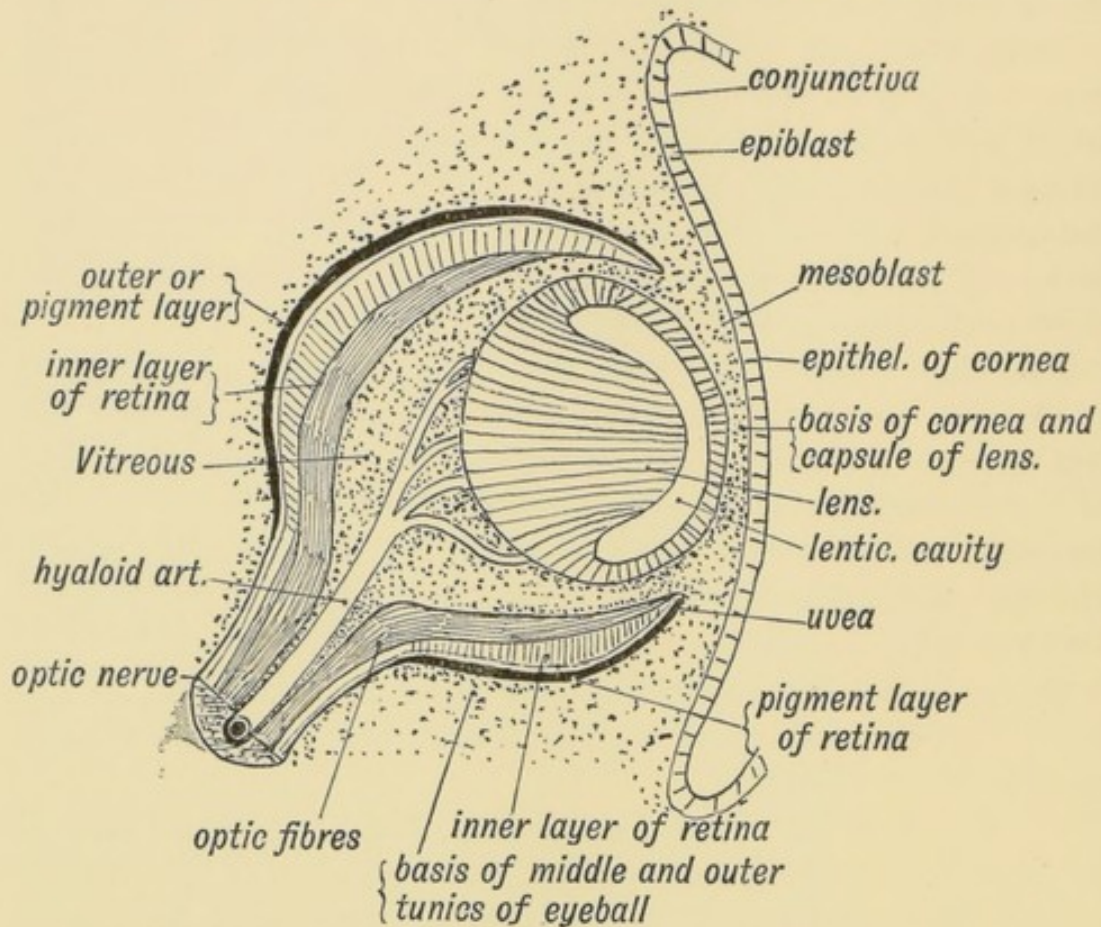


FIG. 148.—Diagrammatic Section of the Eye showing the Parts formed from the Mesoblast. (After His' Model of the eye of a 3rd month human embryo.)

(2) **The vitreous humour.**—This is formed out of the mesoblast which fills the optic cup behind the lens. The closure of the choroidal fissure cuts the vitreous humour off from the mesoblast which covers the outer layer of the optic cup and becomes transformed into the tunics of the eyeball. The vitreous humour—like Wharton's jelly of the umbilical cord—represents an early form of embryonic tissue. It consists of cells imbedded in a jelly-like matrix. All the connective tissues of the body are originally of this type, and remain as such until the fifth month (Berry Hart).

(3) **The hyaloid artery.**—This is the vessel which supplies the mesoblast of the optic cup; it terminates in the capsule of the lens (Fig. 148). In the 7th month foetus a trace of the artery can still be seen passing through the vitreous humour from the optic

disc to the lens. With the gradual obliteration of the artery, the capsule of the lens becomes thin and clears up. A foetus born in the seventh month is blind, because of the vascular and opaque capsule of the lens. The anterior part of the capsule—filling the pupil—is the *membrana pupillaris*. The part of the hyaloid artery within the optic nerve persists as the central artery of the retina. The canal of the artery within the vitreous humour, from the optic disc to the lens, remains as the *hyaloid canal*—a lymph path. The hyaloid artery may persist and cause partial or complete blindness. It disappears some days after birth in cats and rabbits.

(4) The **Aqueous chamber**, a space formed in the mesoblast which lies between the epiblast of the cornea and the lens (Fig. 148). Part of this mesoblast becomes the anterior capsule of the lens; part becomes the connective-tissue basis of the cornea. The aqueous chamber is simply an enlarged lymph space formed between these two parts. Up to the time of birth the lens lies almost in contact with the cornea (Fig. 149).

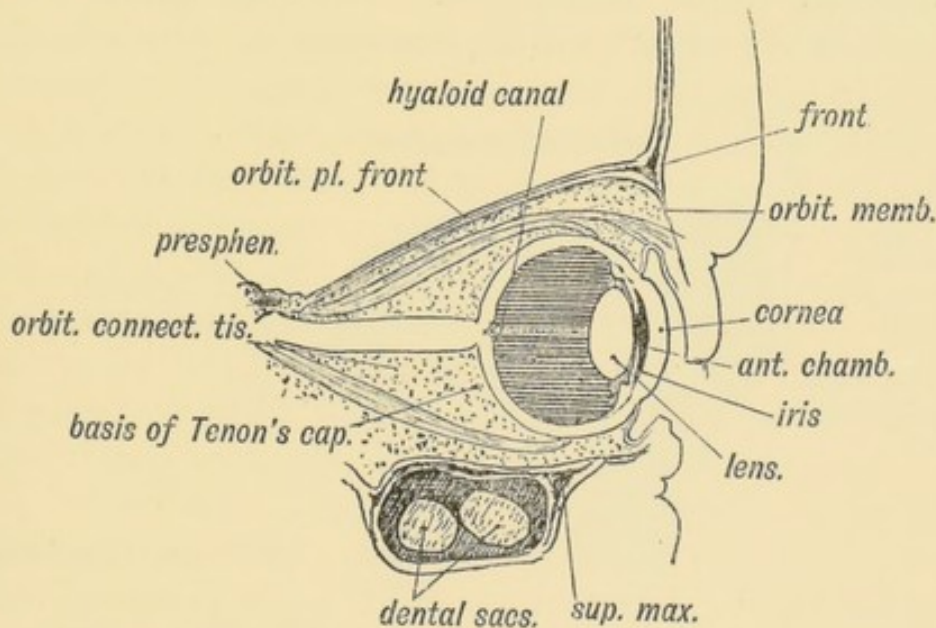


FIG. 149.—Section of the Eye and Orbit at birth.

(5) **The choroid, ciliary processes, and iris.**—These form the middle or vascular tunic of the eye, and are developed out of the mesoblast which covers the optic cup. They form a vascular and pigmented covering through which the optic cup is nourished. The ciliary muscle is formed in this tunic.

(6) **The sclerotic.**—This is the outer covering or tunic of mesoblast. It is continuous in front with the cornea; behind with the optic nerve sheath. In some vertebrates, but not in mammals, plates of bone are developed in the anterior half of the sclerotic.

The Tapetum lucidum is absent in the human and primate eye. It gives the metallic lustre seen on the retinal surface of the eye of the ox, and is formed by a layer of fine fibres which are developed on the retinal surface of the choroid.

(7) **The Capsule of Tenon**, the bursa or connective-tissue socket of the eyeball, and is developed in the mesoblast surrounding the eyeball. A lymph space separates it from the sclerotic, which is but slightly marked until after birth. The **choanoid muscle** (retractor bulbi or Müller's muscle) which surrounds the posterior part of the eyeball as a muscular hood in mammals and vertebrates generally, has disappeared in man and the higher primates. Probably its fibrous remnant helps to form the capsule of Tenon.

Formation of the Orbit (Fig. 150).—The orbit is formed (1) above by the capsule of the fore-brain in which the frontal

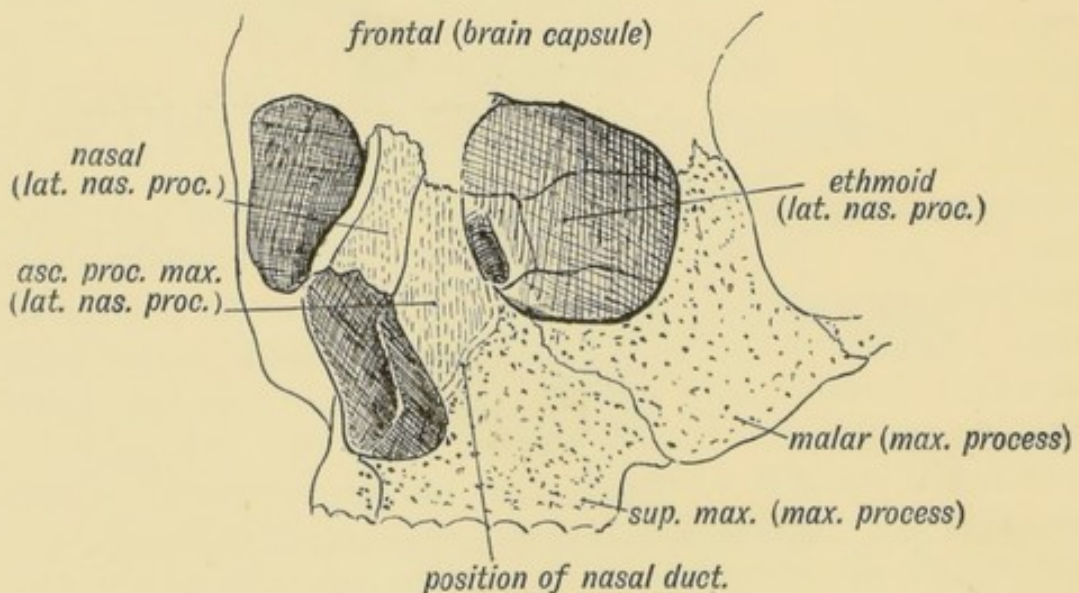


FIG. 150.—The Origin of the Bones entering into Formation of the Orbit.

bone is developed; (2) externally and below by the maxillary process (Fig. 1). In the maxillary process the malar bone and superior maxilla (except the ascending nasal process) are

developed (Fig. 150). (3) The inner wall is formed by the lateral nasal process, in which the nasals, lachrymals lateral mass of the ethmoid, are formed. The optic nerve enters the orbit between the orbito- and pre-sphenoids—derivatives of the trabeculae cranii, both of which help to form the orbit. The great wings of the sphenoid are also derived from the trabeculae (p. 168). The **orbital plate** of the malar cuts the orbit off from the temporal fossa; it is developed in higher primates only. The nasal duct is formed between the maxillary and nasal processes (Figs. 1 and 150). In lower primates and mammals generally the hamular process of the lachrymal appears on the margin of the orbit; the **pars facialis lachrymalis** is sometimes seen in the human skull (Fig 20, p. 26).

The Eyelids are formed by folds or ridges of epiblast which rise above and below the cornea. Mesoblast grows into the folds and forms the tarsal plates. The upper eyelid is formed from the capsule of the fore-brain, the lower from the maxillary process. The epiblast on the deep surface of the folds forms the palpebral conjunctiva. It is continuous with the epiblast of the cornea. The lid-folds meet in front of the cornea during the third month and adhere by their edges. The edges become again separated about the 7th month. From the epiblast between their adherent edges, buds grow into the lids and form the cilia, Meibomian and other glands in the same manner as hairs and sweat glands are developed.

The plica semilunaris (Fig. 151), a fold of conjunctiva in the inner canthus of the eye, is a vestige of the third eyelid (*membrana nictitans*) which is so fully developed in birds and reptiles. It is well seen in the cat, partially crossing the cornea as the lids are shut. The lachrymal papillae rub in the grooves at the outer and inner margins of the fold.

The Lachrymal Gland arises as a number of epiblastic buds which spring from the fornix of the conjunctiva beneath the upper lid and grow into the tissue of the outer and upper segment of the orbit. The outer buds form the orbital part of the gland; the more internal buds form the palpebral part. Smaller lachrymal glands may occasionally be found at the outer angle of the eye. This is the position occupied by the lachrymal glands of birds and reptiles (*Wiedershiem*). The

lachrymal canaliculi and sac and nasal duct are formed out of solid epithelial cords enclosed between the maxillary and lateral nasal processes (Fig. 151).

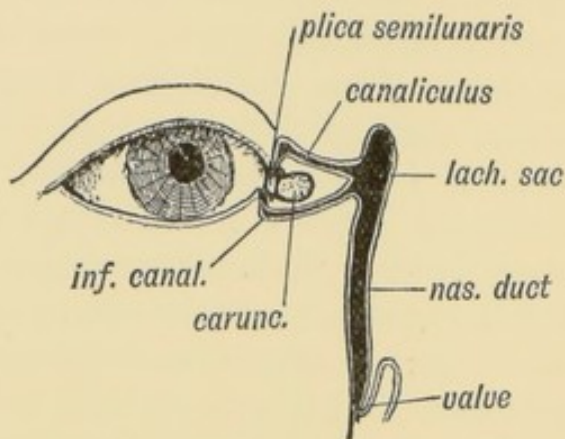


FIG. 151.—Diagram of the Plica Semilunaris and Lachrymal Canaliculi.

The Orbital Muscles.—We have already seen that the head is composed of nine segments, at least four of these being occipital; also, that each segment gives rise to a muscle plate. The muscle plate of the first head segment forms the muscles

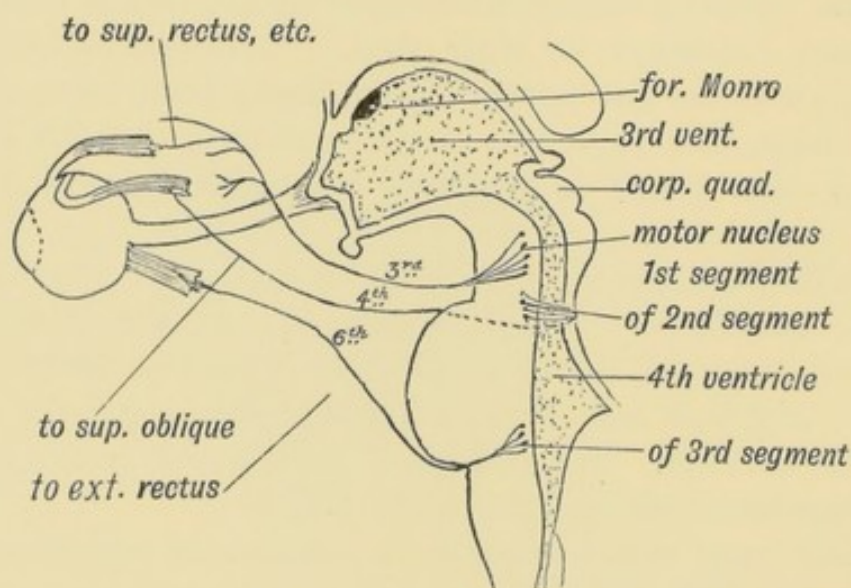


FIG. 152.—Diagram of the Motor Nerves of the Muscles of the Eye derived from the 1st, 2nd, and 3rd Cephalic Segments.

supplied by the third cranial nerve—the motor nerve of the first cephalic segment. The mesencephalon (*crura cerebri*) contains the corresponding segment of the neural canal. The ciliary muscle and sphincter of the iris also belong to this segment and

are supplied by the 3rd nerve (Fig. 152). The muscle plate of the 2nd head segment produces the superior oblique. In the course of evolution the superior oblique of the right side has shifted to the left and the left to the right (Gaskell), hence the decussation of the 4th nerves (the motor nerves of this segment) on the anterior part of the roof of the hind-brain—the valve of Vieussens. The muscle plate of the third cephalic segment gives rise to the external rectus; the 6th nerve is the motor nerve of the segment.

The sensory nerves of these three segments are fused together to form the ophthalmic division of the 5th nerve. The ciliary ganglion is the splanchnic (sympathetic) ganglion of the first segment (see Fig. 180, p. 220). The nerves for the choanoid (Müller's) muscle, the non-striated muscle of the upper eyelid, and the dilator fibres of the iris, issue from the upper three dorsal segments of the spinal cord, and reach the eye by the cervical sympathetic chain and cavernous plexus. The nerve fibres for the orbicularis palpebrarum pass out with the facial, but they arise from cells in the first segment of the neural canal (oculo-motor nucleus). The ophthalmic division of the fifth nerve represents the sensory part of the 1st segment; hence the reflection of pain along this nerve (frontal headache) in disorders of accommodation, the muscle of accommodation being the ciliary, and its nerve, the oculo-motor, both also derivatives of the first segment.

Development of the Nerve Centres concerned with Sight.

—Five parts of the brain are concerned with vision. They are:

- (1) The optic tracts.
 - (2) The basal centres surrounding the termination of the aqueduct of Sylvius in the 3rd ventricle.
 - (3) The optic radiations.
 - (4) The occipital lobes—in part at least.
 - (5) The angular gyrus.
- (1) **The optic tracts** are made up of fibres developed from the ganglionic cells of the retina and also in part of efferent fibres developed from cells of the basal ganglia in which the

optic tracts are seen to terminate. The fibres grow in by the optic stalk, decussate in the floor of the third ventricle between the origins of the optic vesicles, and thus form the chiasma. The optic fibres grow backwards on the surface of thalamencephalon (see Fig. 153) and on the optic thalamus to reach the nerve centres which afterwards form the pulvinar, geniculate

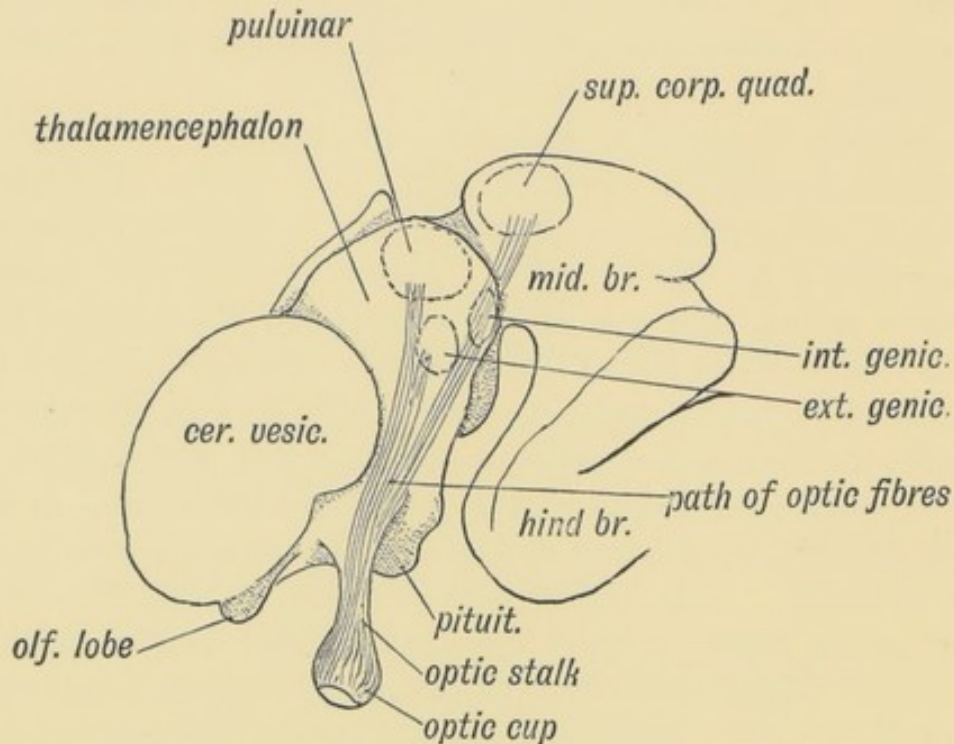


FIG. 153.—Diagram of the Foetal Brain at the end of the 2nd month, showing the Position in which the Optic Tracts are developed.

bodies and the superior corpora quadrigemina. In these centres the optic fibres end. From some of the cells of these ganglia the efferent fibres of the optic tracts are developed.

(2) **The basal ganglia.**—**The corpora quadrigemina.**—Almost in every structure the human embryonic condition resembles the adult condition of lower vertebrates. A good example is seen in the corpora quadrigemina. The human foetus at the commencement of the third month (Fig. 153) shows the corpora quadrigemina represented by a prominent thickening in the roof of the cavity of the mid-brain, which forms subsequently the aqueduct of Sylvius. The thickening is divided into lateral halves by a median sulcus, each half being nearly as large as the cerebral vesicle of that period. In Fig. 154 is shown the condition in an adult lizard; there is

one body on each side—the **optic lobes** or *corpora bigemina*. As the human foetus grows older, each lateral lobe becomes divided into an upper and lower part by the formation of a transverse groove, the upper and lower pairs of the *corpora quadrigemina* being thus formed. The upper pair are connected with sight. In the mole they are vestigial, but in compensation the inferior corpora are well developed as they are connected with the sense of hearing, which is very acute in that animal.

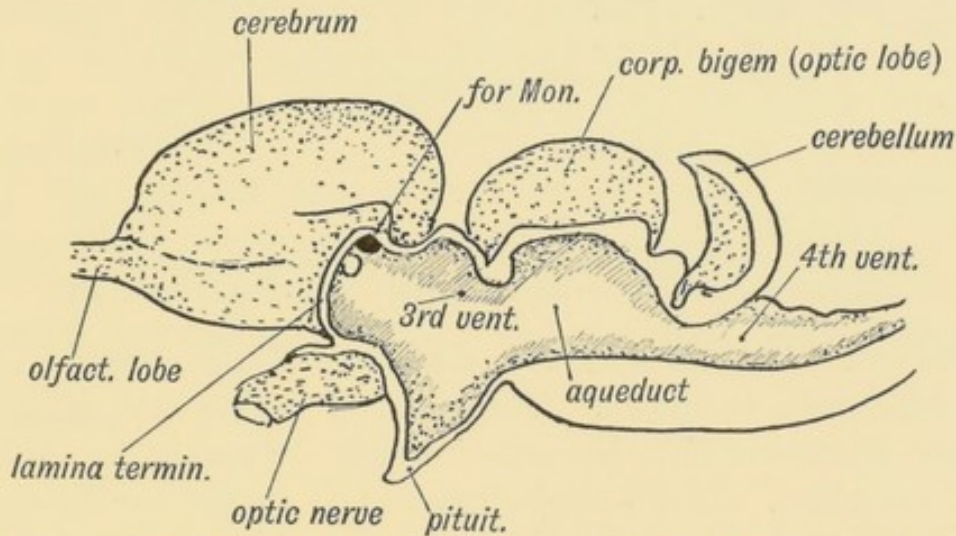


FIG. 154.—Mesial Section of the brain of a Lizard showing the resemblance to the human foetal brain (Fig. 153) especially in the development of the *Corpora Bigemina*.

The **internal geniculate body** also belongs to the mid-brain (mesencephalon); the pulvinar and external geniculate body, in which the upper division of the optic tract ends, are developed on the wall of the 3rd ventricle (thalamencephalon).

(3) **The optic radiations** connect the basal optic centres just named with the mesial surface of the occipital lobes. The fibres join the posterior part of the internal capsule and pass under and round the posterior horn of the lateral ventricle to end in the cortex of the calcarine fissure and neighbourhood.

(4) **The occipital lobe and calcarine fissure.**—A mesial view of the 5th month foetal brain is shown in Fig. 155. The occipital lobe is already well formed; its inner aspect shows the calcarine and parieto-occipital fissures. A section across the occipital lobe is shown in Fig. 156; the posterior horn is large; the calcarine fissure indents its inner wall, giving rise to the *calcar avis* or *hippocampus minor*.

The **calcarine** is one of the first fissures to appear on the brain;

it appears early in the fifth month. It is present in all primates except the very lowest. The optic radiations end in the cortex of

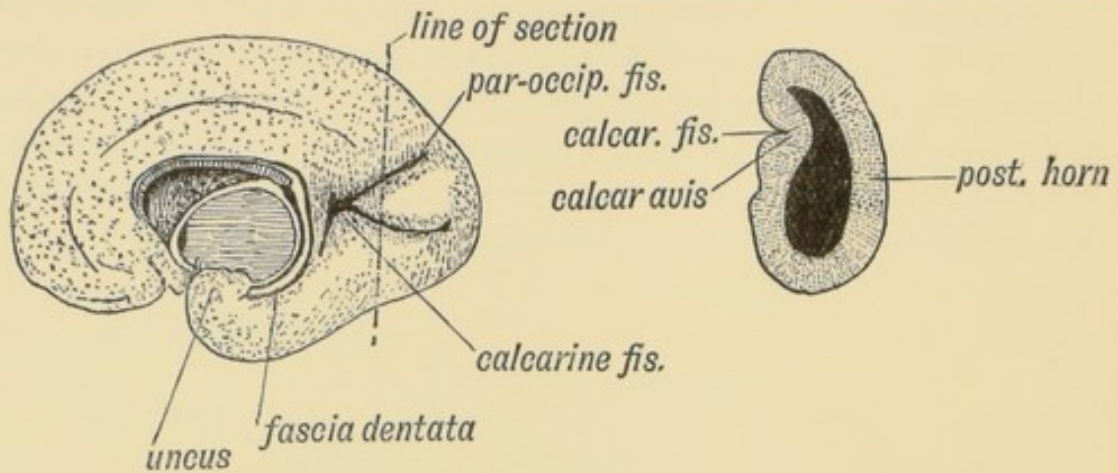


FIG. 155.

FIG. 156.

FIG. 155.—View of the Mesial Surface of the Brain in the 5th month.

FIG. 156.—Section of the Occipital Lobe at the position marked in Fig. 155.

the fissure. In Fig. 157 the condition of the occipital lobe in the 4th week is shown. The cerebral vesicle has arisen as a hollow protrusion from the anterior superior end of the fore-brain (3rd ventricle). The lateral ventricle is as yet undifferentiated into horns and only the rudiment of the occipital lobe is present. The occipital lobe is produced by a backward growth of the cerebral vesicle, the posterior horn being produced as a diverti-

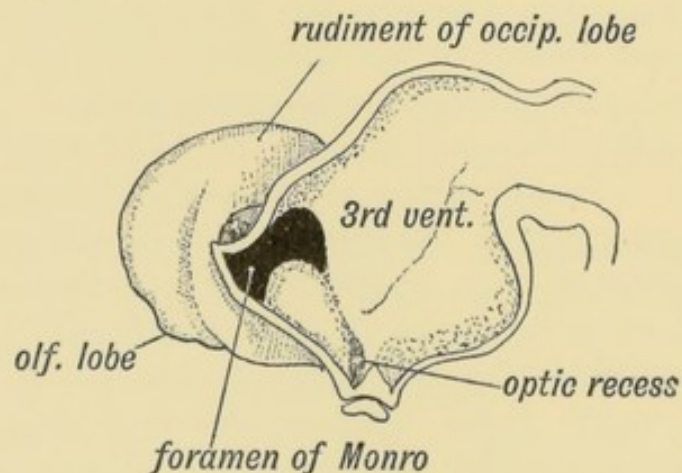


FIG. 157.—Mesial Section of the Brain at the 4th week showing the Rudiment of the Occipital Lobe. (After His.)

culum of the cavity of the vesicle. By the 5th month the occipital lobe has reached far enough back to overlap the cerebellum.

(5) **The Angular Gyrus** is connected with the calcarine region by association fibres. In it is seated the word-seeing and word-understanding centre. It is developed round the posterior end of the 1st temporal or parallel fissure (Fig. 176, p. 214). It is part of the wall of the cerebral vesicle. The first temporal or parallel fissure appears during the sixth month and is one of the primary fissures. It is found in the brains of all primates except the lowest.

Summary.—It will thus be seen that three parts of the neural tube are specialized in connection with sight.

(1) The optic vesicle, an outgrowth from the fore-brain (thalamencephalon).

(2) The occipital end of the cerebral vesicle, which may also be regarded as an outgrowth from the thalamencephalon.

(3) The walls of the 3rd ventricle (thalamencephalon) and mid-brain (mesencephalon), in which the basal optic ganglia are developed.

CHAPTER XV.

THE BRAIN AND SPINAL CORD.

Formation of the Central Canal.—The medullary plates of epiblast, which form the spinal cord and brain, rise up, meet, and enclose a canal—the central canal of the spinal cord and brain (Figs. 158 and 69, p. 90). The lips of the medullary plates meet

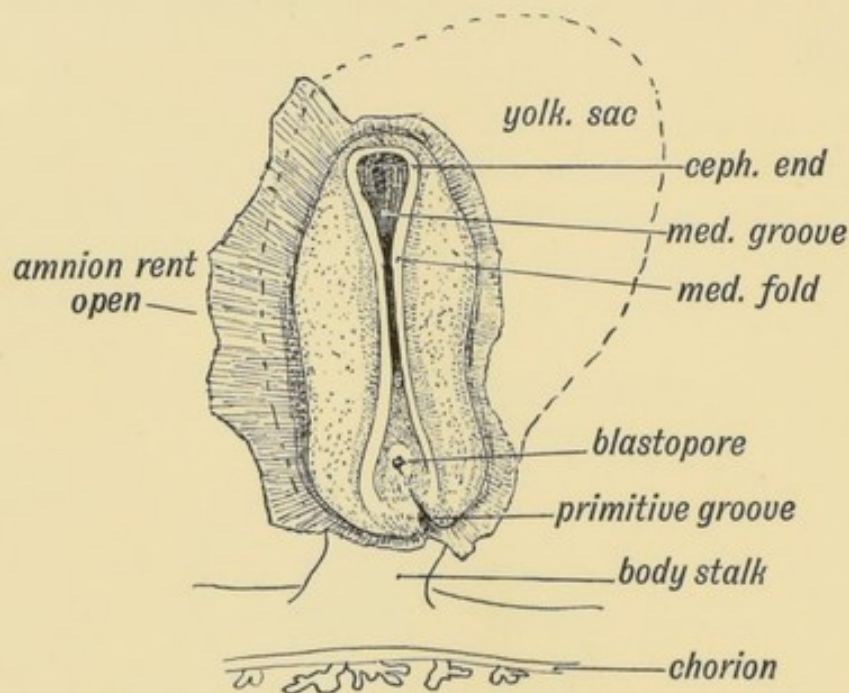


FIG. 158.—Medullary Folds uniting to form the Neural Tube in a Human Embryo of about 14 days. (After Graf Spec.)

and fuse together in the cervical region first (Fig. 158), the process of union spreading forwards and backwards, the last parts to be enclosed being the cephalic and caudal extremities. The optic vesicles start to grow out from the medullary plates before they have united to enclose the cavity of the fore-brain. The canal is completely closed by the middle of the 3rd week.

Divisions of the Neural Canal (Fig. 159).—At the end of the 3rd week the neural tube is divided into four parts. They are:

- (1) An anterior dilatation, the fore-brain, which forms the 3rd and lateral ventricles and their walls.
- (2) The mid-brain, which becomes transformed into the aqueduct of Sylvius and crura cerebri.
- (3) The hind-brain, the basis of the 4th ventricle, pons, cerebellum and medulla.
- (4) The central canal and spinal cord.

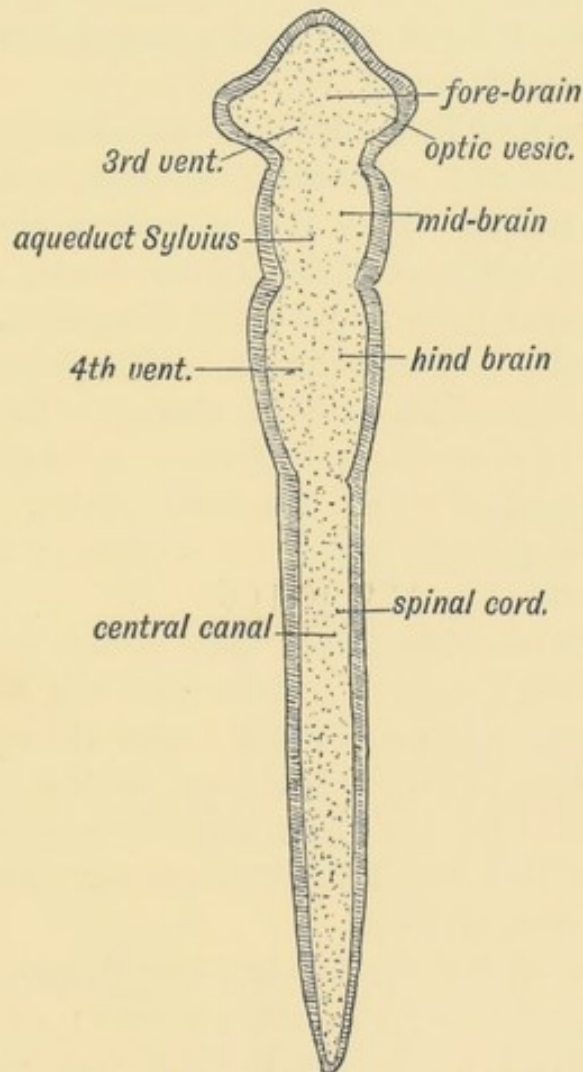


FIG. 159.—Diagram of the Four Primary Divisions of the Neural Tube.

Cerebro-spinal fluid fills the canal. We do not know how it is secreted or absorbed, but under certain abnormal conditions it may collect and give rise to a cystic condition of the neural tube. The expansion may involve the whole tube or only a part of it.

Chick embryos, hatched under abnormal conditions as regards temperature, frequently show a cystic condition of the neural tube, which is also accompanied by a dropsical state of the mesoblastic tissues. If the cystic condition occurs at an early stage it may dilate the fore-brain, or even the whole cephalic part of the tube until it bursts. This is probably the pathology of the condition seen in **anencephalic** foetuses, children born with all the parts of the body developed except the brain and roof of the skull, which are represented merely by a broken mass of tissue. A cystic condition of the lateral ventricles, which are formed as diverticula of the fore-brain, occasionally occurs towards the end of foetal life, and gives rise to the condition known as **hydrocephalus**.

Encephalocele and Spina-bifida.—Localised dilatations of the neural tube may occur. The most common, spina bifida, occurs in the lumbar region, where the medullary plates are last to close. The dilatation may affect the arachnoid and dura mater only; or the neural tube may be also distended. Another site is at the anterior or cephalic end of the tube, where the medullary plates are also late in closing. The encephalocele, or it may be only a meningocele, formed in this site, projects at the root of the nose or within the nasal cavity. A meningocele may also occur at the roof of the 4th ventricle; it projects at the occipital fontanelle (Fig. 132, p. 166).

The Spinal Cord.—The Spinal Cord at first extends the whole length of the spinal column. After the 4th month the spinal column and canal grow more rapidly than the cord, and at birth its lower end has become withdrawn to the level of the 3rd lumbar vertebra. By the third year it only reaches the disc between the 1st and 2nd lumbar vertebrae. The results of this inequality of growth are—

(1) The roots of the lumbar and sacral nerves become enormously elongated, forming the cauda equina; all the nerves are more or less drawn up, except the 1st and 2nd cervical; the origins of the lower cervical nerves are drawn up 2 vertebrae (as indicated by the position of their spines); the upper dorsal, 3; the lower dorsal, 4; the lower lumbar, 5; the coccygeal, 10. These statistics represent a broad expression of the observations made by Professor R. W. Reid.

(2) As the caudal termination of the neural canal is never separated from the epiblast over the coccyx, the posterior end of the cord with its pial covering (mesoblast) is pulled out into a fine string—the *filum terminale*. The neural canal extends for some way into the *filum terminale*, and in the foetus shows there a dilatation or ventricle. The arachnoid and dura mater, mesoblastic sheaths of the cord, do not suffer in the retraction of the cord; they remain widely open to the level of the 2nd sacral vertebra.

Neurenteric Canal.—The caudal ends of the medullary plates fold over and include within the neural canal the blastopore (Fig. 158). The blastopore occurs at the anterior end of the primitive streak and marks the point at which the cavity of the hypoblast (that part which becomes the hind-gut) opens on the epiblast. There is thus set up a communication between the neural canal and the gut to which the name of neurenteric canal is given (see p. 121). The neurenteric canal also opens into the posterior end of the canal of the notochord.

Differentiation of the Spinal Part of the Neural Tube.—When the medullary plates close in about the 14th day to form

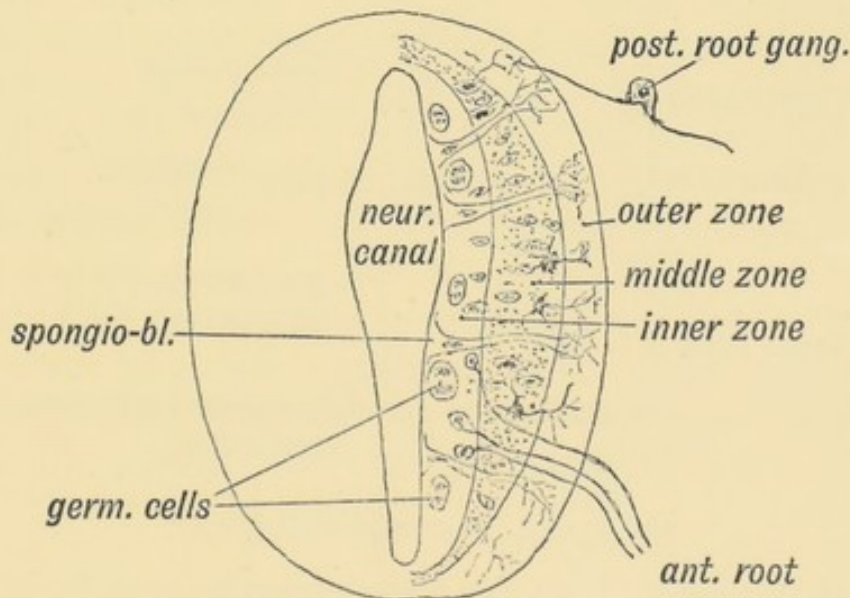


FIG. 160.—Diagrammatic Section showing the three Zones of the Spinal Neural Tube at the 6th week.

the neural tube, they are composed of a layer of elongated epithelial (epiblastic) cells. By the **6th week** these cells have undergone the following changes (Fig. 160):

(1) Some become **neuroglia**, elongated and branched supporting cells; in the **outer zone** of the tube wall they form a mesh-work; in the **inner zone**, round the central canal, they form the ependyma; in the **middle zone** their interstices are filled with neuroblasts.

(2) Some of the cells become differentiated into **neuroblasts**. These are produced from germinal cells lying in or near the inner zone (Fig. 160). Two points should be noted (Fig. 160)—

- (a) That the cells in the **roof** and **floor** scarcely undergo any proliferation—they retain for a considerable time the simple embryonic form.
- (b) That there are two lateral centres of proliferation—a dorsal centre or **lamina**, the cells of which are connected afterwards with the ingrowing fibres of the dorsal root, and a ventral centre or **lamina**, at which the cells of the anterior horn are produced and from which the fibres of the anterior root arise.

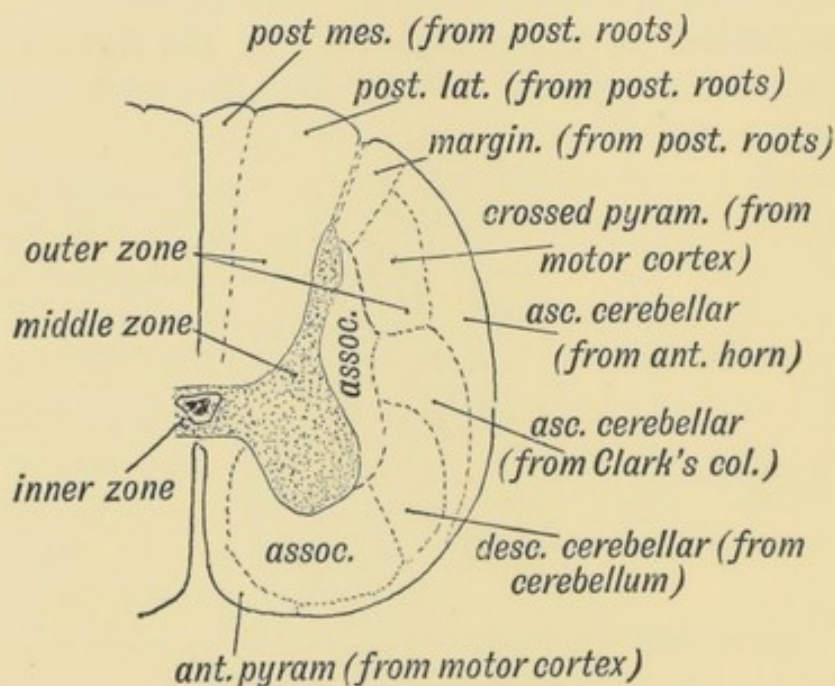


FIG. 161.—Diagrammatic Section of the Spinal Cord to show the Parts formed in the three Zones of the Embryonic Spinal Cord.

The changes which occur in the Spinal Cord after the 6th week (see Figs. 160 and 161) are:

A. In the Outer Neuroglial Zone:

- (1) Postero-mesial and postero-lateral columns are produced

by the fibres of the posterior roots. They become myelinated about the 6th month.

(2) To the inner side and to the outside of the anterior horn fibres are produced from cells in the anterior horn, which connect together neighbouring spinal segments (association fibres).

(3) Two tracts of fibres grow out from cells in the grey matter of the cord and go to the cerebellum. They are the direct cerebellar tract (Flechsig's) from the cells of Clarke's column and Gower's tract from cells at the base of the anterior horn.

(4) Fibres produced by the cells of the cerebellar cortex grow downwards outside the anterior horn (intermediate tract). All these tracts are medullated before birth.

(5) The pyramidal tracts (crossed and direct) grow down from the cells of the motor cortex. They are not medullated until five months after birth.

The white matter of the cord is thus entirely produced by the ingrowth of nerve fibres within the neuroglial network of the outer zone. The cerebral motor cortex, through the pyramidal tracts, comes to dominate the cord; sensory and cerebellar paths are formed, and intercommunications set up between the spinal segments.

The **Anterior and Posterior Median Fissures** are produced by the growth of the white matter. It is possible that the posterior median fissure is formed in part by the inclusion of the dorsal segment of the central canal of the neural tube.

B. The **Middle Zone**—filled with neuro-blasts, forms the horns and grey matter of the cord.

C. The **Inner Zone** becomes the ependyma which lines the central canal and the gelatinous tissue which surrounds it. The columnar cells which line the central canal are ciliated. The central canal retains the embryonic calibre while the wall increases enormously in thickness.

THE HIND BRAIN.

That part of the neural tube which forms the hind brain (Fig. 159) becomes transformed into:

(1) The Medulla Oblongata.

(2) The Pons Varolii.

(3) The Cerebellum.

The Fourth Ventricle.—The cavity or neural canal of the hind brain becomes the fourth ventricle. In its floor are developed,

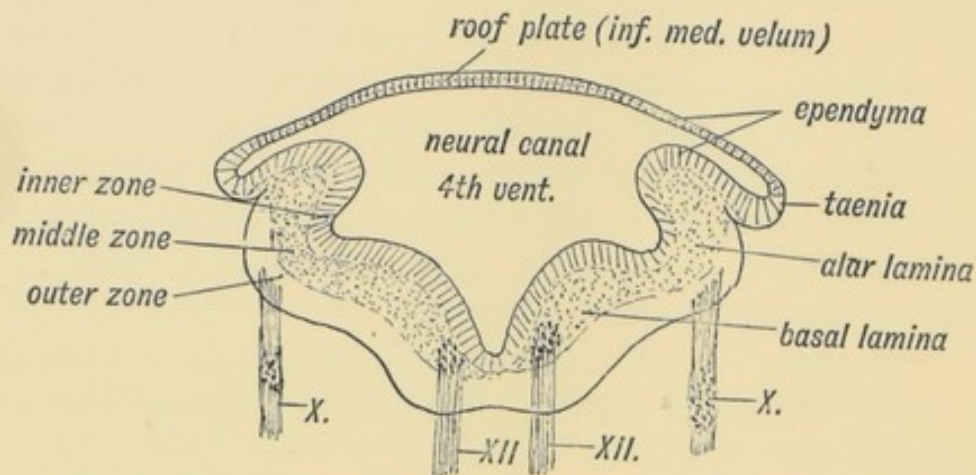


FIG. 162.—Section across the Hind Brain of a Human Embryo in the 5th week.

out of the ventral and dorsal parts or **laminae** (Fig. 162) of the medullary plates, the pons and medulla. In its roof are developed the cerebellum, superior and inferior medullary vela.

Inferior Medullary Velum.—When a section is made across the posterior half of the hind brain of a fifth week human embryo (Fig. 162), the same parts are seen as in a section of the cord. The only difference is that the roof plate, which in the cord is narrow, is here very wide and thin. It will also be noticed that each medullary plate, shows, as in the spinal cord, a dorsal or alar lamina and a ventral or basal one. The two laminae of each side meet at an angle. In the roof plate over the anterior half of the 4th ventricle is developed the cerebellum and superior medullary velum; over the posterior half, the roof plate forms the inferior medullary velum.

As shown in Fig. 163, the velum is continuous with the cerebellum above and the roof of the central canal of the cord below. In the posterior margin of the cerebellar rudiment are developed: (1) the nodule, (2) the flocculus, (3) the peduncle of the flocculus between 1 and 2 (Fig. 164). Hence the inferior medullary velum ends above in these structures.

The obex and ligula, thickenings found on the margins of the lower angle of the 4th ventricle, mark the attachment of the roof

plate or velum to the alar laminae of the medullary plates. They represent the attached margin of the velum. The velum is also attached to the restiform body which is developed in the upper margin of the alar lamina.

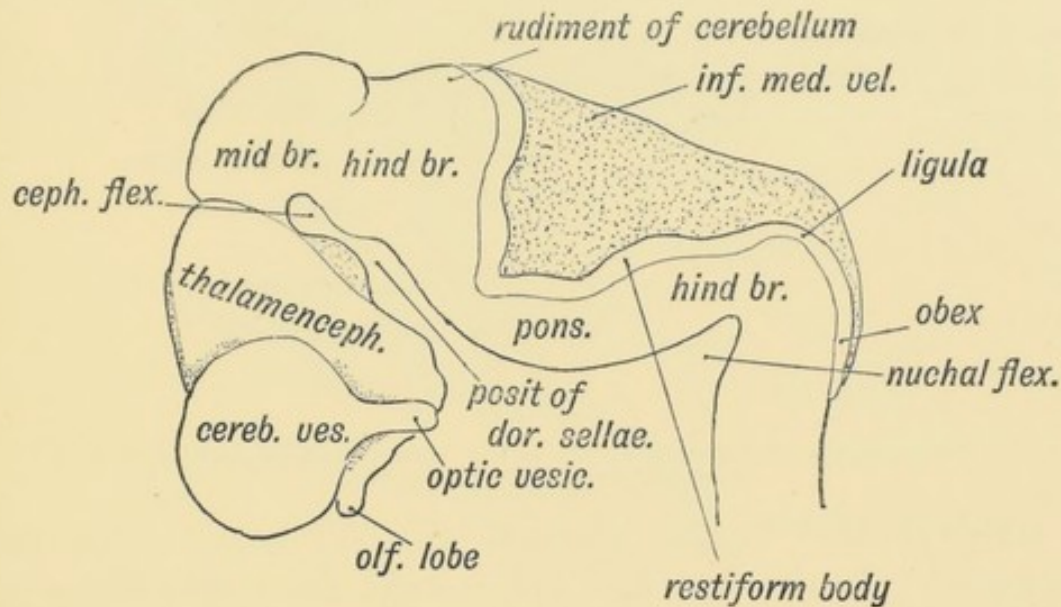


FIG. 163.—Lateral view of the Cephalic Part of the Neural Tube in a 5th week human embryo. (After His.)

The velum is to be regarded as a specialized part of the neural tube, which has been arrested at an early embryonic stage and specialized for the secretion (and absorption?) of cerebro-spinal fluid. The foramen of Majendie and openings at the lateral recesses of the 4th ventricle, where the velum is produced into choroid villi or cornucopia, may be caused by the absorption of a part of the velum or in some cases they may be produced in the removal of the brain from the skull. In the early embryonic condition, at least, the ventricle is quite closed. As will be seen from Fig. 163, the neural tube is bent with its convexity forwards at the pons. His has suggested that this bend may have something to do with the production of the wide roof plate of the 4th ventricle, for if a piece of tubing be bent so, the part in the concavity of the bend becomes widened out.

Cerebellum.—The condition of the cerebellum in a 4th week human foetus resembles that of the Frog (Figs. 165 and 166). It is then merely a thickened transverse band in the anterior part of the roof plate of the 4th ventricle. The vermis or median lobe is the first part to be developed, the lateral lobes form in the

4th month (Fig. 164) and by the 6th month are larger than the median lobe.

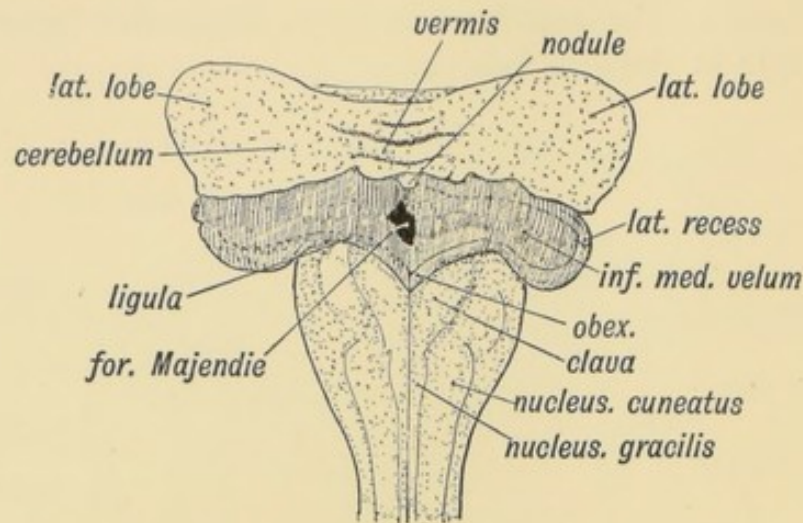


FIG. 164.—Diagram of the Attachments of the Inferior Medullary Velum in a 5th month foetus. (After Kollmann.)

Only in the higher primates are the lateral lobes well developed. In the 2nd and 3rd months the simple transverse roof plate is transformed by the outgrowth from its surface of five transverse ridges. As these ridges or foliae grow out (Fig. 166) the anterior two of them come to occupy the upper surface, while the three posterior ones are thrust to the lower surface. The folding of the simple cerebellar plate, so that it comes to present an upper and lower surface, is caused by its growth. The secondary and tertiary foliae are produced in the last three months of foetal life.

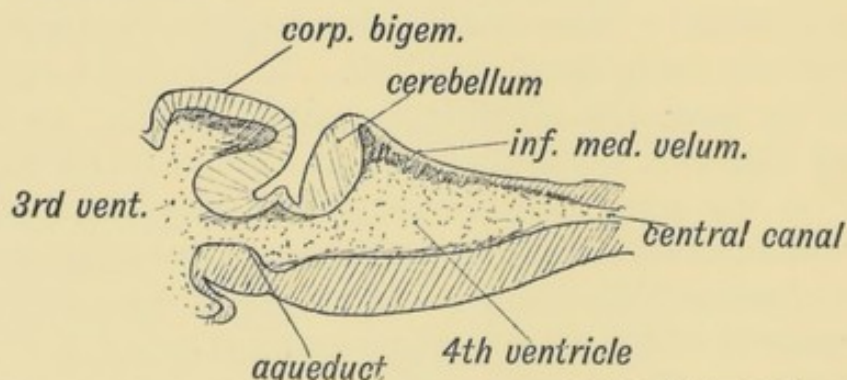


FIG. 165.—Median Section of the Cerebellum and 4th Ventricle of a Frog.

The three Peduncles of the cerebellum are produced thus—probably during the latter half of intra-uterine life:

(1) The **Superior**.—Fibres grow from the cells of the dentate

nucleus of the cerebellum—probably also from the cortex—to the red nucleus and optic thalamus on the opposite side of the brain. Some of the ascending antero-lateral cerebellar fibres from the cord probably enter the cerebellum by the superior peduncles.

The **Superior Medullary Velum** is part of the roof plate of the 4th ventricle which remains between the superior peduncles. The vestigial laminae which cover it form the lingula (Fig. 166).

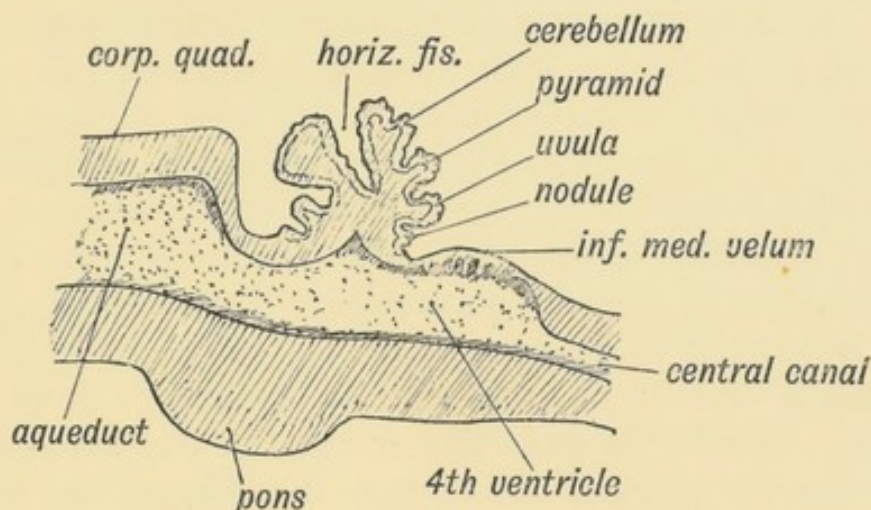


FIG. 166.—Diagrammatic Section of the Cerebellum of a 3rd month Human Foetus showing the folding of the Cerebellar Plate.

(2) The **Middle Peduncles** are formed by processes which grow from the cortical cells of the cerebellum to the nuclei of the Pons and also by processes from the cells of the Pontine nuclei to the cerebellum. They are probably connected indirectly with the frontal lobes through the fronto-cerebellar fibres which lie in the inner third of the crusta.

(3) The **Inferior Peduncles** are formed by :

- (a) Processes from the cerebellar cortex to the cord (descending cerebellar tract);
- (b) Processes which end in the opposite olive;
- (c) Processes which grow in from Clarke's column (direct cerebellar);
- (d) Processes from the cells of the sensory nuclei of the postero-mesial and postero-lateral tracts (nucleus gracilis et cuneatus).

THE MID-BRAIN.

The central canal of the mid-brain forms the **aqueduct of Sylvius** (Fig. 167). In its roof are developed the corpora quadrigemina. The dorsal and ventral laminae of its medullary plates form the tegmentum and crusta of the crura cerebri.

The Three Neural Flexures (see Fig. 163).—The **pontine flexure**, a convexity forwards of the pons, has already been mentioned; the **nuchal flexure** is concave forwards and occurs between the medulla and cord. Both of these are of small import, but the **anterior flexure**, whereby, in the third week of foetal life, the fore-brain is bent downwards and forwards until it comes to lie on the ventral aspect of the cephalic end of the notochord, leads to a great alteration in the form and relationships of the fore and mid brains and is of great importance. The mid-brain, by this flexure, is brought to be, for a short time, the most anterior part of the neural canal; the fore-brain is doubled back under the notochord. Round the projecting end of the notochord—projecting between the mid and fore brains—is developed the posterior clinoid processes and dorsum sellae (Fig. 163). The tentorium cerebelli is developed between the mid-brain and fore-brain, and lies at first at right angles to the axis of the mid-brain, but the great subsequent growth of the cerebrum forces it backwards and downwards until it becomes a horizontal partition between the cerebral and cerebellar chambers of the skull.

THE FORE-BRAIN.

The Third Ventricle and Structures derived from its Walls.—The Third Ventricle (see Fig. 167) is the cavity of the fore-brain and represents the anterior dilated end of the neural canal. From its walls many structures are derived. We have already seen that the optic vesicles are produced from its ventro-lateral walls; from its floor is produced the hypophysis cerebri—the ancient mouth of the alimentary canal if Gaskell's views are right. From the posterior part of its roof plate is produced the pineal body—an ancient median eye; from its antero-superior part is produced a bifid hollow outgrowth—the cerebral vesicles—which come in time to dominate the whole nervous system.

The **Pituitary Body** is formed from two elements (Fig. 167):
 (1) An epiblastic hollow bud from the stomodaeum (Fig. 22, p. 30).

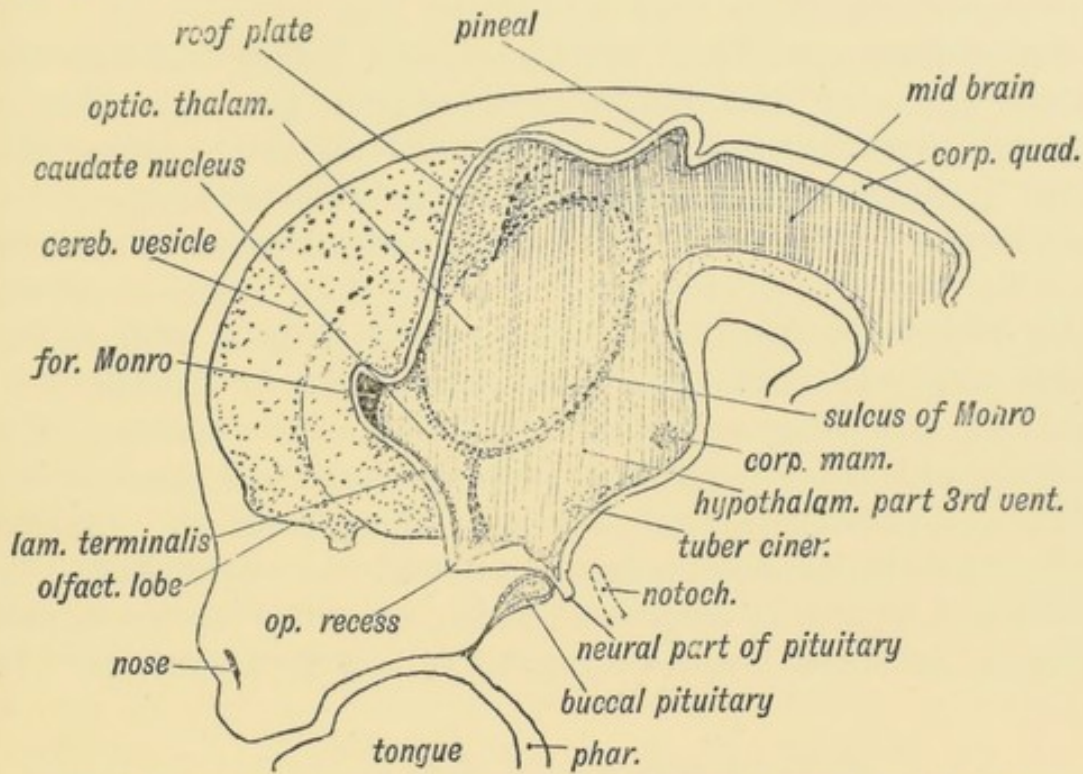


FIG. 167.—A schematic figure to show the parts derived from the walls of the fore-brain. (After His.)

(2) A neuroblastic bud from the floor plate of the 3rd ventricle (fore-brain).

The union of the two processes takes place at the anterior extremity of the notochord. The epiblast of the stomodaeum and the floor of the neural tube are in contact from the very beginning; subsequently the mesoblast grows in between the fore-brain and the epiblast of the stomodaeum, but the parts which form the pituitary adhere. The posterior or neuroblastic bud becomes solid; its structure is that of neuroglia into which many vessels have grown carrying mesoblastic tissue with them.

The anterior or stomodaeal bud embraces the posterior. While its posterior wall remains quiescent, its anterior throws out solid processes between which a network of vessels lies. This forms the glandular part of the pituitary—reticulated rows of cells surrounding blood channels—similar in structure to the medullary part of the supra-renals, carotid bodies and parathyroids. The trabeculae cranii form round the pituitary. When the basi- and

pre-sphenoids are developed in the trabeculae, the position of the stalk of the stomodaeal process is seen in the later months of foetal life between these two bones and forms the canalis cranio-pharyngeus (Fig. 3).

Pineal Body (see Fig. 167) grows as a hollow bud from the dorsal plate of the hinder part of the fore-brain during the 6th week. In fossil reptiles and in some forms still living it forms a median eye which perforates and appears on the dorsum of the head between the parietal bones. It differs from the lateral eyes which grow from the third ventricle as the optic vesicles in this, that it produces the lens as well as the retina and optic stalk. The retina is inverted—*i.e.* the apices of the rods and cones point towards the vitreous chamber. The ganglion of the habenula, situated on the dorsal and inner aspect of the optic thalamus, represents its terminal ganglion. In man and mammals its development is arrested at an early stage. It produces a number of diverticula which are filled up by a proliferation of the cells which form the walls of the diverticula. In

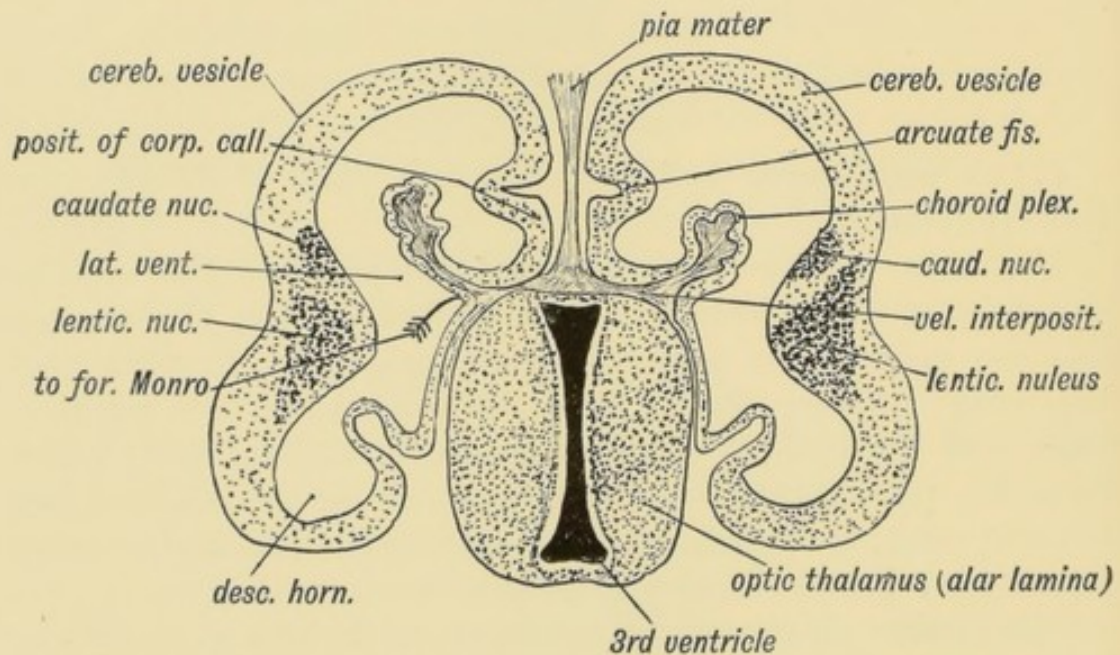


FIG 168.—Transverse Section of the brain of a Human Foetus at the commencement of the 3rd month to show the Cerebral Vesicles overlapping the Thalamencephalon (schematic).

man it appears to be merely vestigial. It lies in the velum interpositum, which is forced down on it by the growth backwards of the cerebral hemispheres.

The **Lamina Cinerea** or **lamina terminalis** (Fig. 167) represents the anterior end of the neural tube. In the adult it stretches between the optic chiasma, which is developed on the floor of the 3rd ventricle and the rostrum of the corpus callosum. Its development will be described later, but it retains with little alteration its early simple structure. The inter-peduncular space, which forms the floor of the 3rd ventricle, also retains in the adult to a considerable extent the simple embryonic form. In it are developed the corpora albicantia and posterior perforated space.

The **Optic Thalami** are formed in the lateral walls of the fore-brain (thalamencephalon) and in the adult occupy the whole extent of this wall. At first they are completely exposed on the outer aspect of the brain (see Fig. 154), but after the cerebral vesicles grow out from the antero-lateral angles of the fore-brain (3rd ventricle) they are prolonged backwards and downwards over the optic thalami and thus bury them (Figs. 173, 174, and 175). As may be seen from Fig. 169, the optic thalami, with the internal

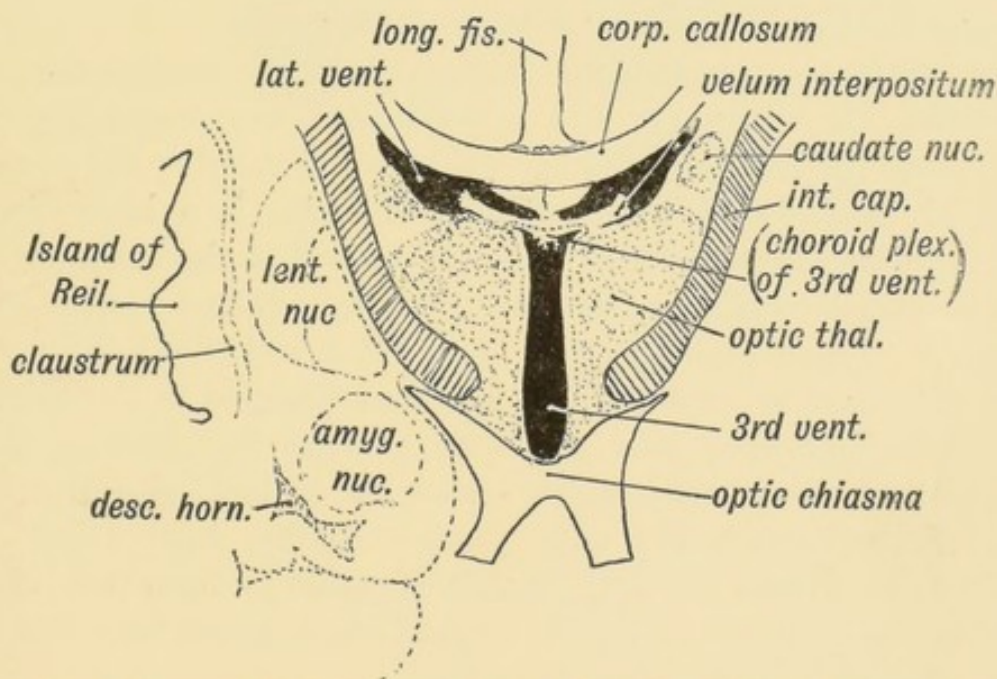


FIG. 169.—Diagrammatic Section across the 3rd Ventricle of the Adult to show the Structures formed in its Walls.

capsule, are simply the enlarged upward continuations of the tegmentum and crusta of the crura cerebri or mid-brain. From Fig. 167, it will be seen that the optic thalamus is an upward

continuation of the alar lamina of the mid-brain, and the same may also be said of the caudate nucleus. The sulcus of *Monro* (Fig. 167), which runs from the opening of the aqueduct of *Sylvius* to the foramen of *Munro*, on the lateral wall of the 3rd ventricle, marks off the alar from the basal lamina of the thalamencephalon. A section across the 3rd ventricle and optic thalami, at the end of the second month is shown diagrammatically in Fig. 168. The internal capsule has not yet appeared. The cerebral vesicles already overlap and bury the optic thalami.

The Cerebral Hemispheres.—In the 3rd week very soon after the medullary plates have closed, a hollow bud, which almost immediately divides into a right and left half, grows out from the anterior superior extremity of the fore-brain. These two processes form the cerebral hemispheres. It will be seen that the cerebrum represents a super-addition to the neural-tube system. The lateral ventricles with their horns represent the cavity of the cerebral vesicles; the foramina of *Monro*, which have a common entrance to the third ventricle, represent the position at which the primitive cerebral outgrowth took place. The walls of the vesicles thicken and form the mantle of the brain. The anterior horn represents the anterior extremity of the vesicle—the point at which the olfactory lobe is produced; the descending horn represents the real posterior extremity of the vesicle; the posterior horn, although found in all mammalian brains, is a later diverticulum formed in connection with the growth of the occipital lobe.

The primitive simple relationship of the cerebral vesicle which holds for low vertebrates (see Figs. 154 and 155) and for the first two months of foetal life, becomes obscured in the third by the vesicles growing over the optic thalami and burying them. The wall of the vesicle, which comes in contact with the optic thalamus, adheres to the outer surface of that body (Figs. 168 and 169). Hence the optic thalamus comes to form part of the floor of the body of the lateral ventricle and enters into the roof and inner wall of the descending horn.

Divisions of each Cerebral Vesicle.—A prolonged study of the adult vertebrate brain has led *Elliot Smith* to divide the wall of each cerebral vesicle into three primary parts:

(1) **Rhinencephalon** (defined on p. 22; see Figs. 18 and 172). It represents the oldest part of the cerebral vesicle and composes

nearly the whole of the cerebrum of fishes, amphibians, reptiles, and birds.

(2) The **Corpus Striatum**.

(3) The **Neo-pallium**. This comprises the remainder of the cerebral vesicle. With the evolution of the higher mammals the neo-pallium became bigger and bigger until in man it constitutes by far the greater part of the cerebrum. With its development the corpus striatum also became increased, while the rhinencephalon became more and more reduced.

The Velum Interpositum.—We have seen that the roof plate

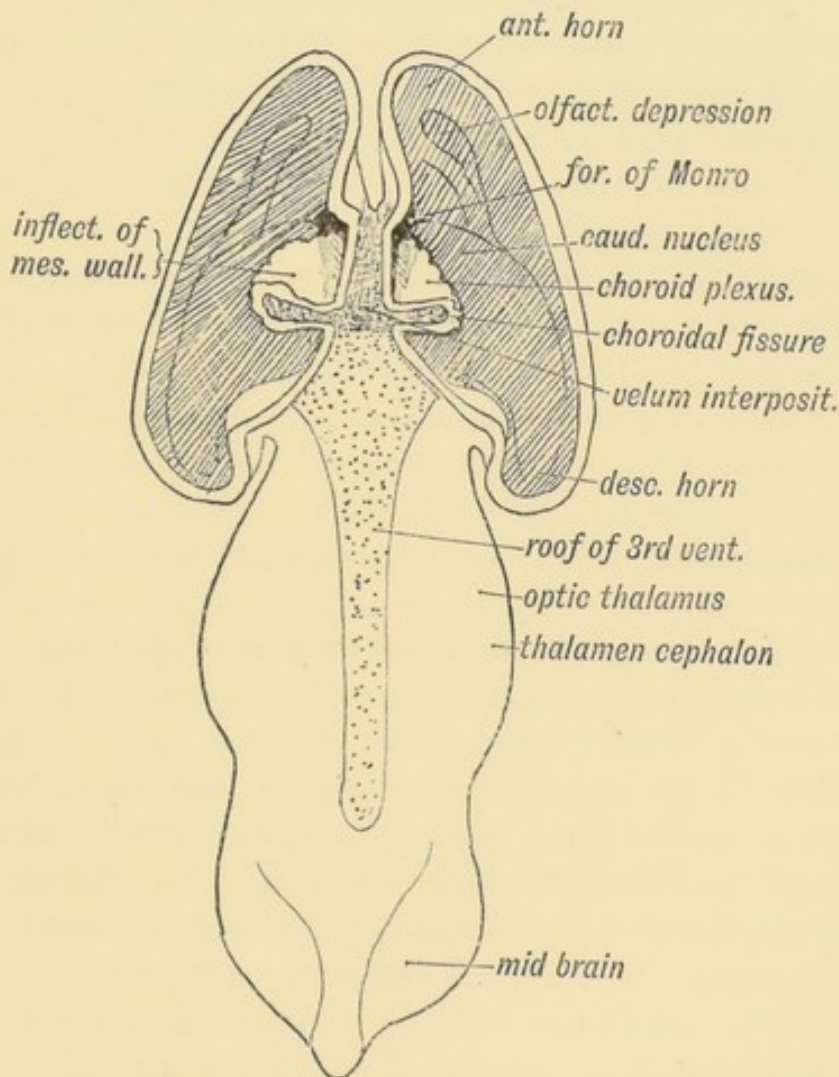


FIG. 170.—A dorsal view of the Fore and Mid-brain at the 5th week of development to show the formation of the Velum Interpositum. The Cerebral Vesicles are laid open and the inflection of their mesial walls shown on the ingrowing Velum. The Roof Plate of the 3rd Ventricle is also exposed. (Modified from His.)

of the 4th ventricle (hind-brain) forms the cerebellum in front, while its posterior half becomes the inferior medullary velum—a

secretory membrane. The roof plate of the third ventricle, from the foramina of Monro backwards, becomes modified in a similar manner. It merely forms the ependymal covering of the lower surface of the velum interpositum, also a secretory membrane (Figs. 168 and 169). The anterior part of the roof plate is produced into the cerebral vesicles over the foramina of Monro, and covers the apex of the velum interpositum (Fig. 170). The mesial wall of each cerebral vesicle from the foramen of Monro back to the posterior extremity of the vesicle (Fig. 170), which becomes the tip of the descending horn, is also inflected and becomes a secretory ependyma, covering the velum interpositum and choroid plexus within the lateral ventricles. Into this inflection of the embryonic neural wall spreads the mesoblast, carrying vessels with it. The velum interpositum is thus composed of a basis of mesoblast and its intraventricular parts have a covering of the ependyma of the neural wall.

The ependymal covering of the entire velum is derived from :

- (1) The roof plate of the 3rd ventricle (lower surface) ;
- (2) The roof plate of the foramen of Monro ;
- (3) An inflection of the mesial wall of the cerebral vesicle.

The choroid plexus, which fringes the velum in the adult, completely fills the cavities of the lateral ventricles, which for the first five months are relatively very large and the containing walls thin. The velum and choroid plexus must play an important part in the development of the cerebral vesicle in the early period of growth. The spread of the vesicles backwards and downwards over the optic thalami (Fig. 173) obscures the original simple relationship of the velum to the brain ; but, when withdrawn from the transverse fissure, the velum is seen to rest on the optic thalami and project within the ventricle from the foramen of Monro to the tip of the descending horn, and that stretch marks the line at which the choroidal inflection took place.

The fibrous substance of the velum interpositum is continuous with the pial covering of the brain, and also with the edge of the tentorium cerebelli. The veins of Galen are developed in the velum and join the straight sinus in the tentorium. Pressure applied to the veins causes dropsy of the lateral ventricles.

Development of Commissures.—(1) The Anterior Commissure

(Fig. 171) is developed in the lamina terminalis—the primitive anterior wall of the fore-brain. The commissure passes between the temporo-sphenoidal lobes. These lobes represent the posterior ends of the cerebral vesicles. At first they are mere dilatations behind the foramen of Monro. The commissure crosses in the lamina terminalis below and rather anterior to the foramen of Monro. This is the earliest and most primitive of the cerebral (pallial) commissures (Elliot Smith).

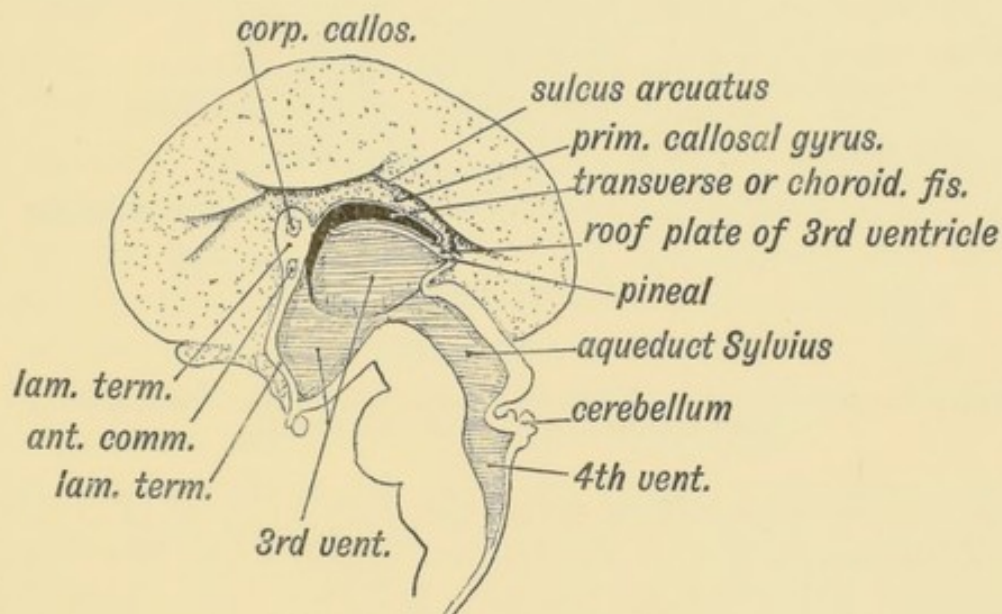


FIG. 171.—Mesial Aspect of the human Foetal Brain during the 4th month. (After Minot.)

(2) **The Corpus Callosum**, the great commissure between the cerebral hemispheres, forms late; except in the higher mammals it is smaller in size than the anterior commissure. It reaches its fullest development in man, and in him it commences to form at the end of the third month.

To understand its development the student must be familiar with the **mesial aspect of the brain** during the third and fourth months. On this aspect he should note—

(1) The **sulcus arcuatus** (Fig. 171), which indents the mesial wall of the fore-brain. This fissure in the adult brain becomes (a) the callosal sulcus between the corpus callosum and callosal gyrus (gyrus fornicatus) (Fig. 172); (b) the hippocampal fissure, which indents the posterior extremity (descending horn) of the cerebral vesicle and causes the hippocampus major (Fig. 172). The calcarine fissure may also be a derivative of it (Elliot Smith).

(2) The **Choroid** or **Transverse Fissure** (Fig. 171), caused by the inflection of the mesial wall of the vesicle on the velum interpositum and choroid plexuses.

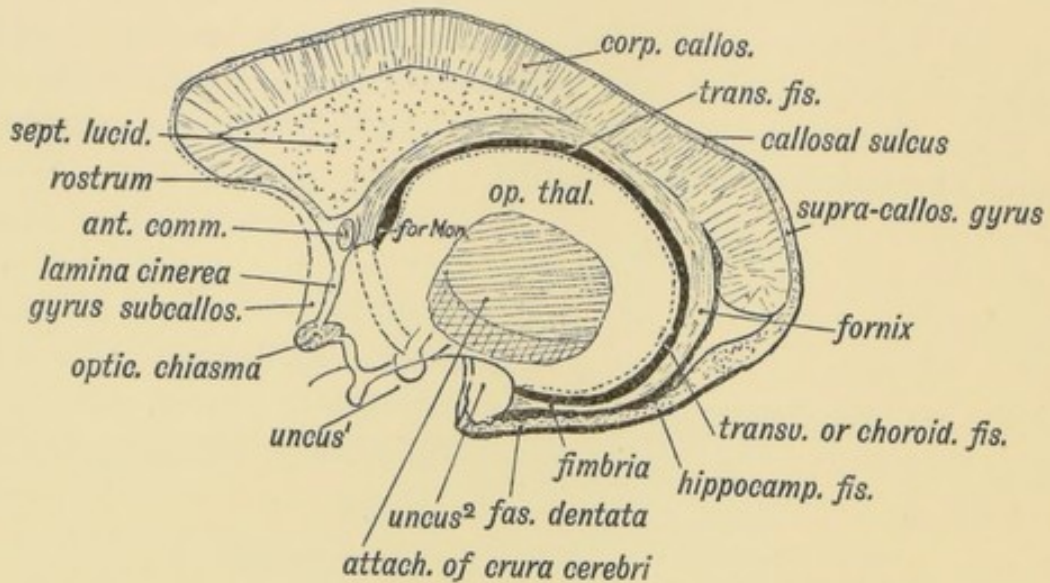


FIG. 172.—Diagram to show the structures formed in the Lamina Terminalis and Primitive Callosal Gyrus. (After Elliot Smith.)

(3) The **primitive callosal gyrus**¹ (see Figs. 171 and 172) is that part of the mesial wall of the cerebral vesicle which lies between the arcuate and transverse (choroid) fissures. In the lower edge of this **marginal gyrus**, the edge which bounds the transverse fissure, and therefore overlies the velum interpositum, is developed the **Fornix** with the **fimbria**, its posterior continuation, a longitudinal commissure which connects the optic thalamus with the hippocampal (uncinate) gyrus. The corpus callosum is developed in the lamina terminalis above the foramen of Monro about the end of the 3rd month. It afterwards extends backwards, encroaching on and displacing the primitive callosal gyrus.

The grey matter of the primitive callosal gyrus becomes reduced to—(1) The vestigial supra-callosal gyrus, lying on the upper surface of the corpus callosum (Fig. 172); (2) the gyrus dentatus; (3) the gyrus, which unites 1 and 2 round the splenium of the corpus callosum; (4) the cortex of the hippo-

¹ This gyrus forms part of the Rhinencephalon, and the name is proposed merely as a provisional one, until comparative anatomists agree as to its proper designation. At present, Elliot Smith proposes the term "hippocampal formations" for the parts of the brain derived from it in the adult.

campus buried in the hippocampal fissure. The longitudinal striae, the thin layer of grey matter on the upper surface of the corpus callosum, and the grey matter on the fornix, are also derived from the primitive callosal gyrus.

(4) The **lamina terminalis** is seen in section. It is the terminal anterior wall of the fore-brain (Fig. 171). The lower part becomes the lamina cinerea; in the upper part, the anterior commissure is developed, and the anterior pillars of the fornix (Fig. 172). Its dorsal extremity bounds anteriorly the foramina of Monro. It connects the mesial walls of the cerebral vesicles (Fig. 171), and becomes thickened and enlarged. In its dorsal part, where it is continuous with the primitive callosal gyrus, the callosal commissure (corpus callosum) commences. The part of the lamina terminalis which lies between the fornix and corpus callosum (Fig. 172) forms the septum lucidum. In this septum a cavity appears—the 5th ventricle. Cases are known of people with normally functional brains in which the corpus callosum was found afterwards to be absent.

The corpus callosum connects the cortex of one hemisphere with the basal ganglia and cortex of the other. It is the commissure of the neo-pallium. Its fibres are probably collaterals derived from the pyramidal and other fibres of the cortical cells. Each fibre grows out and crosses the great median fissure of the brain in the lamina terminalis.

The **Fornix** is developed in the inner margin of the primitive callosal gyrus, which bounds the transverse or choroid fissure (Fig. 171).

The Corpus Striatum.—As soon as the cerebral vesicle grows out, the corpus striatum appears as a thickening in its wall at the outer side of the foramen of Monro (Fig. 173). With the posterior development of the vesicle it comes to lie in the ventricular floor, from the foramen of Monro to its posterior extremity.

The anterior extremity of the corpus striatum is continuous with the olfactory lobe (Fig. 173). Hence in the adult brain the anterior end of the corpus striatum appears at the base of the brain in the anterior perforated space, a lamina of grey matter derived from the olfactory lobe (Fig. 18, p. 22). As the cerebral vesicle grows over the optic thalamus (Fig. 173) the corpus

striatum comes to be applied to that body. The posterior extremity of the cerebral vesicle, in which the tail of the caudate nucleus is situated (Fig. 173), develops downwards, behind and below the optic thalamus, forming the descending horn of the

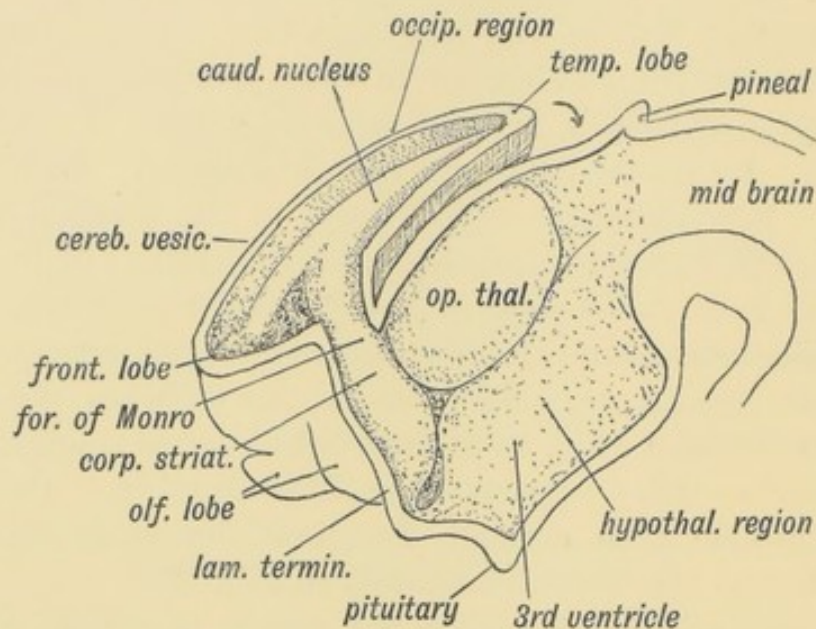


FIG. 173.—Showing the Development of the Corpus Striatum in the floor and outer wall of the Cerebral Vesicle.

lateral ventricle. Hence the occurrence of the tail of the caudate nucleus and the amygdaloid nucleus on the *roof* of the descending horn, both being intrinsic parts of the corpus striatum. The corpus striatum is imperfectly separated, during the 4th and 5th months of foetal life, into two parts, the caudate and lenticular nuclei, by the downgrowth, from the cerebral cortex of the fibres which form the internal capsule, crusta, and pyramidal tracts.

Formation of the Island of Reil and Fissure of Sylvius.—The formation of the corpus striatum, the Island of Reil, and Fissure of Sylvius are part and parcel of the same process.

When the lateral wall of the cerebral vesicle is examined at the 5th month (Fig. 175) an area of cortex is seen to be rapidly becoming submerged by the overgrowth of the surrounding cortex. The submerged area is the Island of Reil; it covers that part of the wall of the cerebral vesicle which is thickened by the corpus striatum (Fig. 168). The submerged area becomes triangular in shape, the apex being directed backwards; it is

bounded by three limiting sulci—an anterior, superior, and inferior. The rising lips of cortex, which bound the limiting sulci, form the temporal, fronto-parietal, and orbital opercula, and

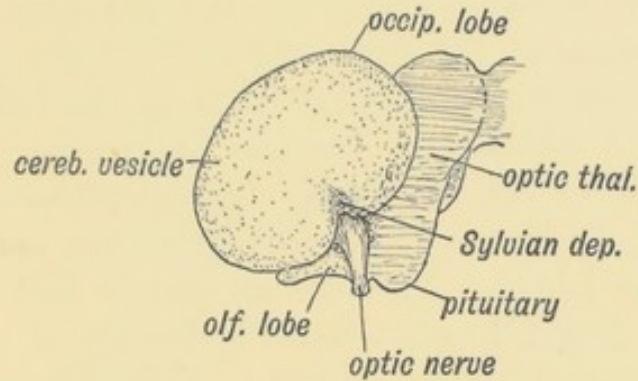


FIG. 174.—Lateral Aspect of the Cerebral Hemisphere during the 2nd month.

ultimately meet over the submerged area (Fig. 176). The fissure of Sylvius separates the opercula. It will be readily grasped that the development of the corpus striatum prevents the expansion of the insular part of the vesicle, whereas the thin-walled mantle, out of which the other lobes of the brain are developed, expands readily and overwhelms the thickened

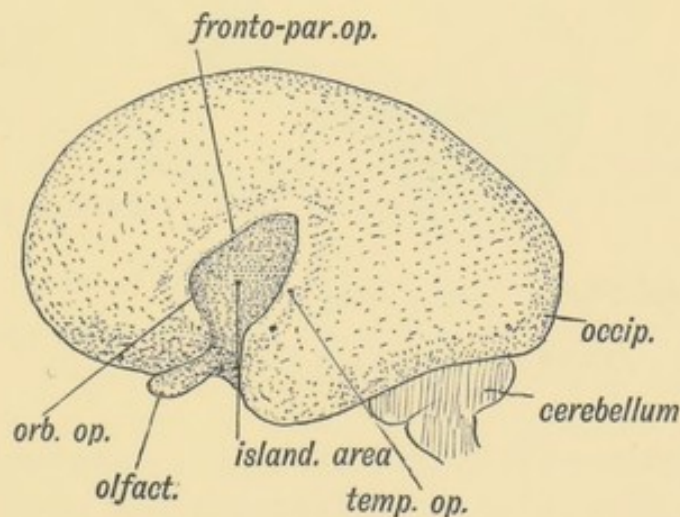


FIG. 175.—The same Aspect during the 5th month.

area. The corpus striatum begins to form during the 2nd month, hence as early as that date the insular depression is visible on the lateral wall of the hemisphere (Fig. 174).

The lower end of the stem of the Sylvian fissure also indents

the Rhinencephalon, separating the uncinata gyrus from the parts derived from the olfactory lobe.

The student is already familiar with the fact that the Island of Reil forms a cortical cap to the corpus striatum. The structures between the islandic cortex and the foramen of Monro represent a section of the thickened wall of the cerebral vesicle (Fig. 169). Convolution appears on it at the 7th month, when the rest of the cortex also becomes convoluted. Further, the larger the area of cerebral cortex in any primate, the larger is the Island of Reil; the more convoluted the cortex, the more convoluted the Island. Flechsig has shown that the cortex of the Island is joined to all the cortical areas of the mantle by bands of association fibres. Hence the Island must be regarded as playing a highly important part in co-ordinating the functions of the brain.

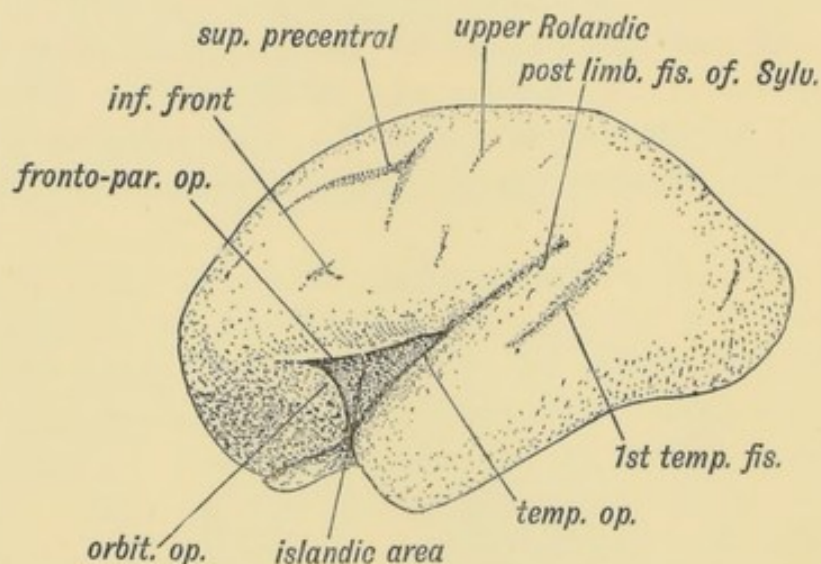


FIG. 176.—The same Aspect during the 7th month.

The Opercula.—Three opercula grow up and cover the Island of Reil (see Figs. 175 and 176): (1) the temporal, (2) the fronto-parietal, (3) the orbital. Cunningham, whose researches into this region of the brain have become classical, found that during the later months (7-9) of foetal life, the orbital operculum in quite 50% of brains shows a subdivision into two, an upper, the pars triangularis, and a lower, the pars orbitalis (Figs. 176 and 177). The subdivision occurs more frequently on the left

side than on the right, probably owing to the centres for speech being situated on the left side. The temporal operculum rises first (5th month) the others a month later. The opercula which bound the posterior horizontal limb of the fissure of Sylvius are the first

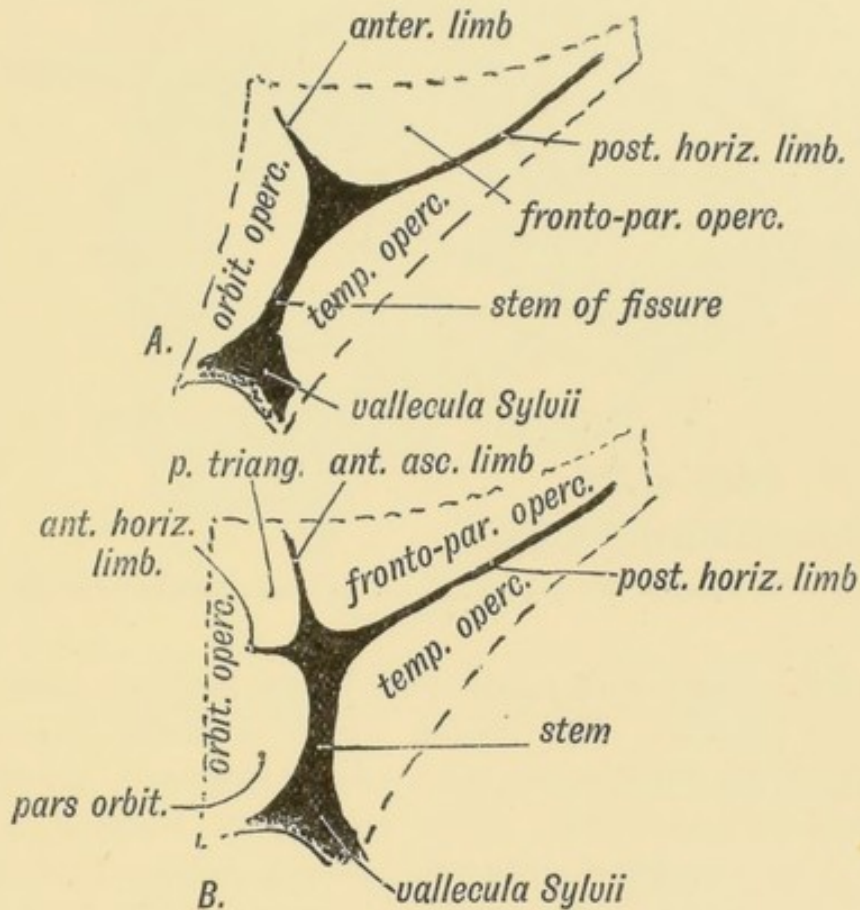


FIG. 177.—Diagram of the Opercula and Fissure of Sylvius.
In *A* the orbital operculum is undivided; in *B* it is subdivided. (After Cunningham.)

to come in contact. By the end of the first year after birth all three opercula meet over the Island and completely hide it. At birth there is still a part of the Island exposed behind the orbital operculum and in lower human races this is frequently the condition throughout life. The orbital opercula (pars triangularis and pars orbitalis) become part of the centre of speech and represent the latest additions to the human brain. If the orbital operculum is not subdivided, which is commonly the condition on the right hemisphere, then the anterior limb of the fissure of Sylvius is not subdivided into anterior horizontal and ascending parts (Fig. 177 *A* and *B*).

Comparative Anatomy of the Opercula and Island.—The

Island of Reil and its opercula are only well developed in the higher primates. Figs. 178, 179 and 180 represent the stages in its evolution. In Fig. 178 the condition in dog-like apes is

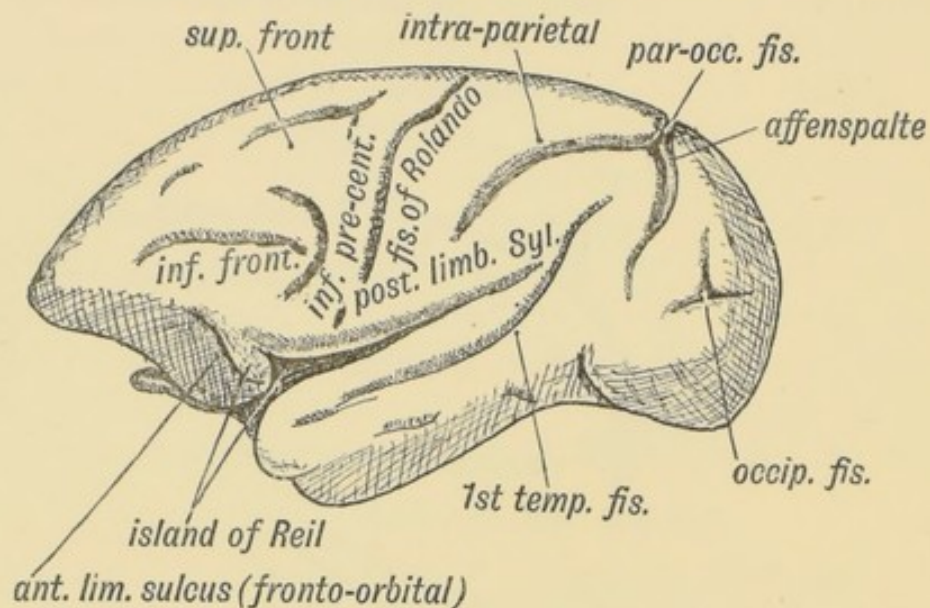


FIG. 178.—The Island of Reil and Fissures on the lateral Aspect of the Brain of a dog-like Ape.

represented. Only the upper and lower limiting sulci of the Island are present. The Island, which is small, is continuous anteriorly with the frontal lobe. In anthropoids (gorilla, etc.) the Island is larger; the upper and lower limiting sulci are present; an imperfect anterior limiting sulcus (fronto-orbital fissure) is present and partially separates the Island from the orbital surface of the frontal lobe. In man all three limiting sulci are present and completely isolate the Island, and occasionally this is the condition (Fig. 179 *B*) in the higher anthropoids, but it is in man only that the orbital operculum grows up and meets with the other opercula. This can be the more easily understood when it is remembered that the orbital part of the 3rd frontal convolution is connected with speech.

Temporary Fissures.—In the 3rd month of foetal life the cerebral vesicles have thin walls, and when extracted from the head show several fissures. These fissures, unlike those which appear at the sixth and seventh months on the cortex of the brain, are really inflections of the whole thickness of the cerebral wall and are variable in number and position. It is possible

that some of them are post-mortem products, for Hochstetter found that when the brain of a 3rd month foetus, which had been just removed from the mother, was hardened *in situ*, these

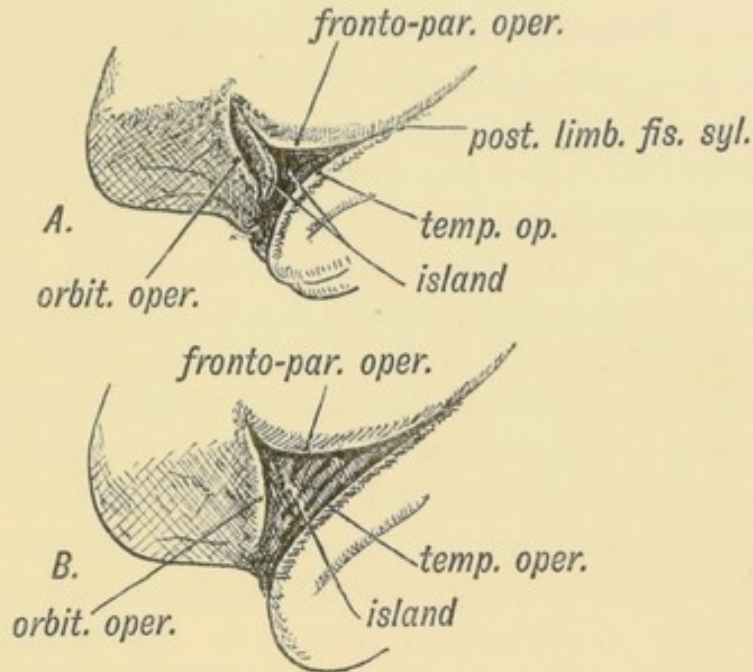


FIG. 179 A.—The more common Condition of the Island of Reil in Anthropoids.

FIG. 179 B.—The complete isolation of the Island of Reil, the condition seen constantly in the Human Brain and occasionally in the Anthropoid.

temporary fissures were absent. But to this there are at least two exceptions.

(1) The choroid fissure caused by the ingrowth of the velum interpositum and choroid plexus (Fig. 170).

(2) The arcuate fissure on the mesial aspect, which has been already described (Fig. 171). The hippocampal fissure, the callosal, and probably the calcarine too, are remnants of this fissure.

The Sylvian depression is also visible from the second month onwards, but it is in no sense a fissure comparable either to the temporary or even to the permanent.

The Fissures of the Brain.—The Principal Fissures of the Brain include: (1) The Sylvian, (2) the Calcarine, (3) the Hippocampal, (4) the 1st Temporal or Parallel, (5) the Parieto-occipital, (6) Rolandic, (7) the Intra-parietal, (8) the Inferior Pre-central, (9) the Collateral, (10) the Calloso-marginal. These, with the exception of the first three (which have been already described), appear at the commencement of the 6th month. At

this date the human brain presents a marked resemblance in the arrangement of its fissures to that of the dog-like ape (Figs. 178 and 176).

The fissures and sulci are caused by a rapid increase in number and size of the cortical cells; the increase of the area of the cortex leads to a crumpling up of its surface. The increased rate of growth appears to affect certain definite areas, hence the fairly constant forms into which the surface of the brain is thrown.

Affenspalte or Simian Fissure (Fig. 178).—In all ape brains the anterior margin of the occipital lobe grows upwards and forwards as an operculum, which covers the posterior margin of the parietal lobe. The sulcus between the occipital operculum and parietal lobe is the simian fissure or affenspalte. In the human brain it is never developed owing to the great growth of the posterior area of the parietal lobe; the area which forms the floor of the sulcus in apes is spread out on the surface of the human brain. The ramus occipitalis of the intra-parietal fissure lies in the floor of the simian fissure; in the human brain the ramus occipitalis is raised to the surface of the brain.

Sensori-motor Areas of the Brain.—The fissure of Rolando, which begins by two depressions—an upper and a lower—appears in the fifth month; it divides the sensori-motor areas into anterior and posterior parts. Sherrington and Grunbaum found, however, in their experiments on the brains of anthropoids, that the posterior area gave no reaction when excited artificially, and that the fissure of Rolando formed the posterior boundary of the motor cortex. The anterior area is further subdivided by two fissures (Fig. 176), the inferior pre-central, an L-shaped fissure which commences as soon or even before the fissure of Rolando, and the superior pre-central, quite a late development, and evidently an isolated part of the superior frontal sulcus. The post-Rolandic area of the sensori-motor cortex is limited behind by the inferior and superior parts of the post-central fissure. The superior part is of late origin. The inferior limb of the post-central fissure is an intrinsic part of the intra-parietal fissure (Fig. 178). From the pyramidal cells of the sensori-motor cortex, processes grow out and form the middle part of the internal capsule. They reach the spinal cord during the 4th and 5th months of foetal life and become

myelinated about the 5th and 6th months after birth. As the processes grow downwards in the lateral wall of the cerebral vesicle they pierce the corpus striatum, dividing it into the caudate and lenticular nuclei.

The Secondary Sulci, which divide the superior and middle frontal convolutions, the calloso-marginal, the parietal and occipital gyri, appear in the 9th month. They are for the greater part peculiar to the human brain.

THE CRANIAL NERVES.

The differentiation of the simple neural tube of the embryo has thus far been followed into the complicated central nervous system of the adult. It is now necessary to make a short survey of the arrangement of the cranial nerves and see what evidence they afford of a segmental arrangement of the cephalic part of the neural tube.

The Cranial Nerves.—The segmental arrangement of the nerves of the body has been already discussed (page 158). Even although the human trunk is highly specialized the 33 or more segments of which it is made up can still be recognised from the arrangement of the spinal nerves; each segment is constituted on a similar principle, and it becomes increasingly difficult to deny that man and the whole kingdom of vertebrates are derived from a form in which all the segments of the body were identical.

The head has become even more highly specialized than the trunk, and in it evidence of segmentation is accordingly more difficult to detect. Most of the evidence at present at our disposal indicates the presence of nine segments in the head. That is to say that the mammalian head is the derivative of a structure which was made up of nine segments, every one of which was originally constituted very much alike. Each had a similar arrangement of nerves and muscles, a similar arrangement of vessels, and provided with a similar pair of appendages.

In Fig. 180 is diagrammatised the relationship of the cranial nerves to the nine segments of the head. The olfactory and

optic nerves arise as processes of the neural tube, and are not comparable to the remaining cranial nerves. Primarily each segmental cranial nerve appears to have contained sensory and motor fibres. The sensory fibres, like those of the spinal nerves,

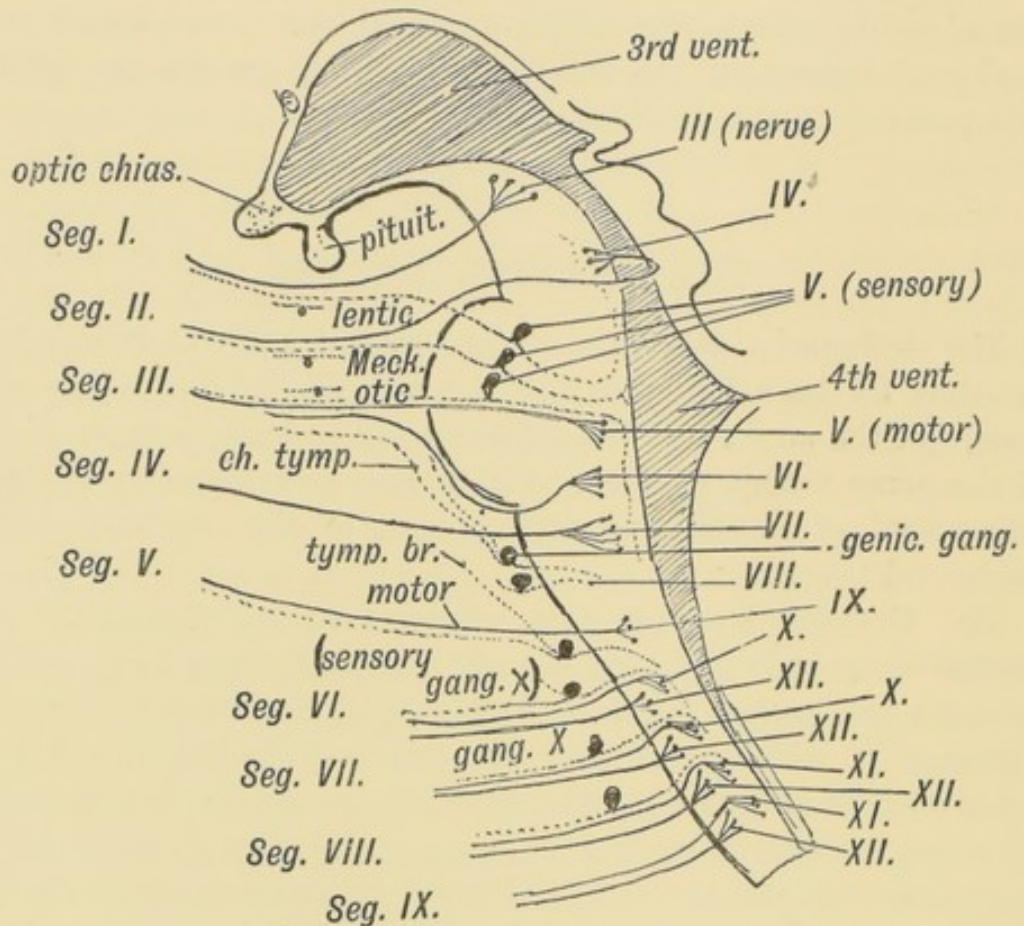


FIG. 180.—A Diagram to show the Relationship of the Cranial Nerves to the Primitive Segments of the Head.

are developed from ganglionic cells derived from the neural crest, and are of two kinds, somatic and visceral. The motor fibres are developed from cells in the neural tube and are also of two kinds, somatic and visceral. In the evolution of the vertebrates there has been much reconstruction in the arrangement of the segmental fibres, the sensory fibres of several segments having become grouped together in the 5th nerve, and the motor fibres of others in such nerves as the 10th and 12th.

The Segments to which the Cranial Nerves belong. 1st Cranial Segment.—The motor nerve is the 3rd or oculo-motor.

The ciliary ganglion, a derivative of the Gasserian, represents the sympathetic ganglion. Ganglion cells representing a vestigial posterior root may be found on the trunk of the nerve. The ophthalmic division of the 5th appears to represent its posterior or sensory root.

2nd Cranial Segment.—The motor nerve is the 4th. The sensory is represented by the superior maxillary division of the fifth. Meckel's ganglion represents the sympathetic ganglion. It is known to be derived from the same group of nerve cells as the Gasserian ganglion.

3rd Cranial Segment.—The motor nerve is the 6th and motor fibres of the fifth. The sensory root is represented by the inferior maxillary division of the 5th. The otic and sub-maxillary represent its sympathetic ganglia.

4th Cranial Segment.—The motor nerve is the 7th. The sensory root is represented by the chorda tympani and great superficial petrosal, which are developed from the geniculate ganglion (Dixon). The eighth nerve and its ganglia also belong to the sensory system of this segment. The great superficial petrosal represents a splanchnic nerve, the chorda tympani the nerve on the anterior margin of the 1st visceral cleft (see p. 34).

5th Cranial Segment.—The motor fibres of this segment have probably been scattered. Some may still remain in the 9th cranial nerve (glosso-pharyngeal) which is the chief nerve of the segment. The ganglia on the trunk of the glosso-pharyngeal represent the posterior root ganglion. The tympanic branch and small superficial petrosal represent an afferent (sensory) splanchnic branch.

6th, 7th, 8th and 9th Cranial Segments.—It has been already mentioned (pages 152 and 161) that the four posterior cranial segments are probably trunk segments which have become modified and added to the head. The anterior or motor nerve roots of these four segments are combined in the 12th nerve. Motor visceral fibres, which issue by the anterior roots of spinal nerves, here issue by the vagus and bulbar part of the spinal accessory (all of which are properly designated vagal fibres—Sherrington) and represent the visceral motor fibres of the four posterior cranial segments. The ganglia on the root and trunk of the vagus

represent part of a posterior root ganglion. From these ganglia are developed the sensory visceral fibres connected with the fore gut and all the structures derived from the fore gut or splanchnopleure of the fore gut. A vestigial posterior root ganglion may occur on the 12th nerve.

The circuitous course of the spinal accessory is probably due to the migration of the trapezius caudalwards from a cephalic to its present position.

CHAPTER XVI.

DEVELOPMENT OF THE CIRCULATORY SYSTEM.

Veins.—(1) The **Superior Vena Cava** arises from the following foetal vessels (Figs. 181 and 182):

(a) The part above the entrance of the vena azygos is the terminal part of the right primitive jugular or anterior cardinal vein ;

(b) The part below the entrance of the vena azygos major arises from the right duct of Cuvier. The condition of these venous trunks, the anterior and posterior cardinal veins and Ducts of Cuvier, in a human embryo of the 3rd week is shown in Fig. 182. The condition shown is retained permanently in lower vertebrates (Fishes, etc.).

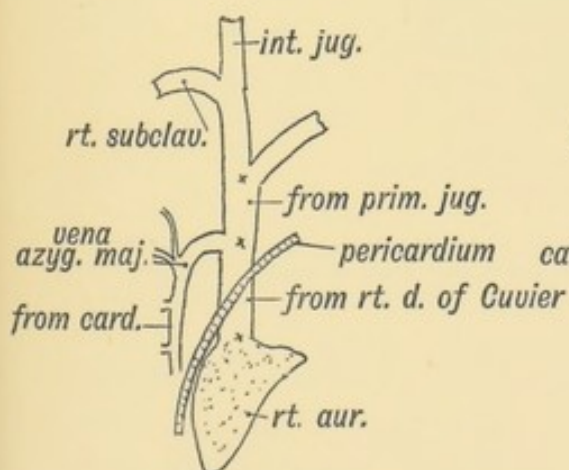


FIG. 181.

FIG. 181.—The Superior Vena Cava of the Adult.

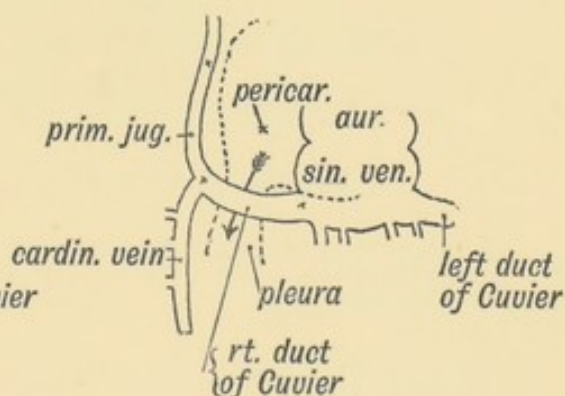


FIG. 182.

FIG. 182.—The Embryonic Venous Trunks out of which the Superior Vena Cava is formed.

The anterior Cardinal or primitive **Jugular Vein**, which drains the anterior half of the body on each side with the **posterior**

cardinal vein, which drains the posterior half of the body, receive a tributary (segmental vein) from each body segment. The cardinal veins lie in the mesoblast on the dorsal side of the coelom at the junction of the splanchnopleure and somatopleure (Fig. 183). By their union they form on each side the **Duct of Cuvier** which conveys the blood to the sinus venosus—a contractile chamber opening into the primitive auricle. The sinus venosus remains as a separate chamber of the heart in lower vertebrates, but in the course of mammalian development it becomes partly merged in the right auricle of the heart.

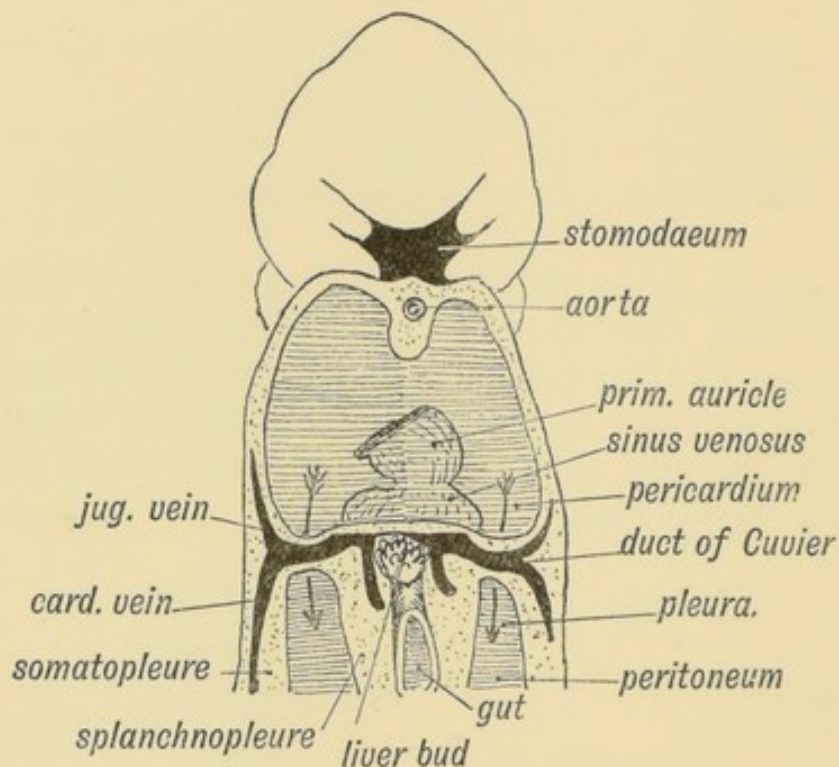


FIG. 183.—Diagram to show the manner in which the Ducts of Cuvier encircle the Coelom at the junction of the Pericardial and Pleural Parts (Iter venosum). (After His.)

It is important to notice how each duct of Cuvier reaches the sinus venosus (see Fig. 183). They pass from the dorsal to the ventral surface of the body in the **somatopleure** and thus encircle the coelom. The right and left ducts of Cuvier lead to a constriction of the coelom, the fold in which each descends being known as the *lateral* or *venous meso-cardium* (Fig. 205, p. 251). Ultimately, by the end of the 4th week, the part of the coelom lying in front of the ducts of Cuvier is cut off from

the rest; the part so cut off forms the pericardium (Fig. 201). Thus the ducts of Cuvier are instrumental in separating the pericardial from the pleural cavity. If the primitive pleuro-pericardial communication (iter venosum of Lockwood) persists between them, it occurs as a foramen in the pericardium behind the part of the superior vena cava derived from the duct of Cuvier.

2. The **Vestigial Fold and Oblique Vein of Marshall**.—In the human embryo during the 3rd week and for some weeks afterwards there is a right and left duct of Cuvier and corresponding cardinal veins (Fig. 185). A left superior vena cava is present and may persist. The vestigial fold and oblique vein of Marshall (Fig. 184) are all that usually remain of the left superior vena

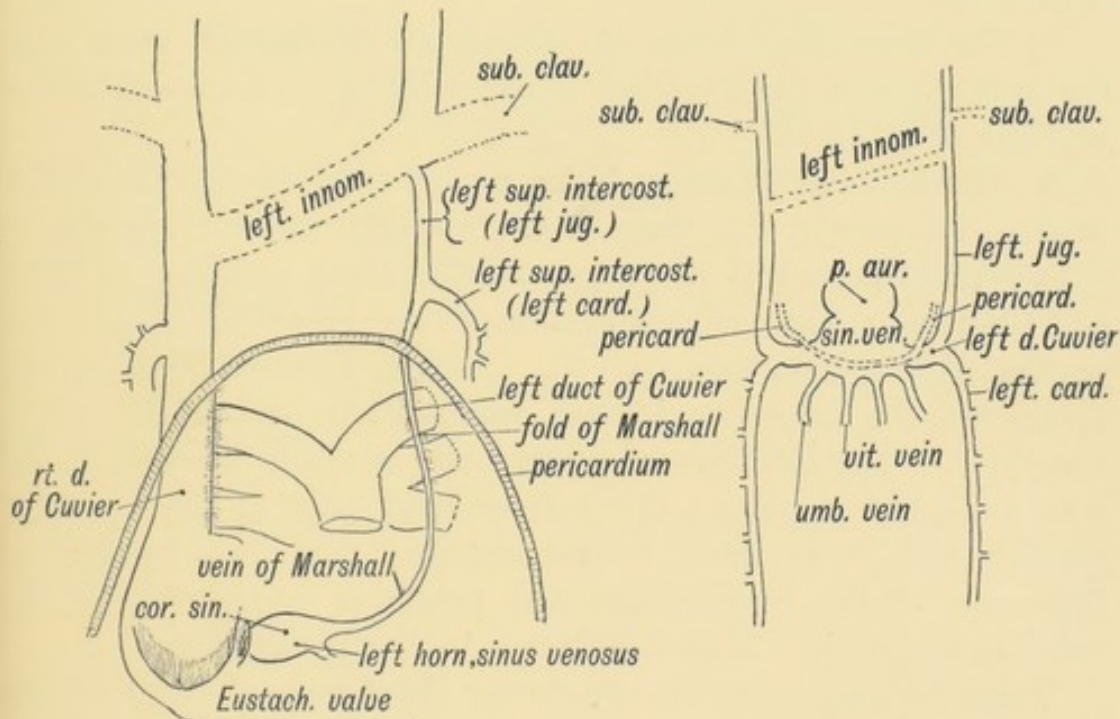


FIG. 184.

FIG. 184.—The Remnants of the Left Superior Vena Cava, derived from the Structures shown in Fig. 185.

FIG. 185.

FIG. 185.—Diagram of the Sinus Venosus and Ducts of Cuvier of the human embryo about the 3rd week.

cava. The right superior vena cava within the pericardium passes in front of the right pulmonary vessels, and is bound to them by a mesentery or fold of serous pericardium; the left has a similar relationship (Fig. 184); when it disappears this fold remains in front of the left pulmonary vessels as the vestigial fold. The intra-pericardial part of the left vena cava or duct of Cuvier becomes the oblique vein (Fig. 184): it turns round the

left auricle to terminate in the left horn of the sinus venosus (coronary sinus). The extra-pericardial part of the left duct of Cuvier joins the superior intercostal vein (Fig. 184). Both right and left superior venae cavae persist in some lower mammals.

The **left superior intercostal vein** represents the following embryonic vessels (see Fig. 184):

- (a) Anterior part of the left posterior cardinal vein;
- (b) The extra-pericardial part of the left duct of Cuvier;
- (c) The terminal part of the left primitive jugular vein.

3. The **Left Innominate Vein** opens up as a channel of communication between the two primitive jugular veins, the left superior vena cava undergoing a simultaneous process of atrophy (Fig. 184).

4. The **Subclavian Veins** are developed in the 4th week with the outgrowth of the fore-limb buds; they open into the primitive jugulars (Fig. 184).

5. The **Primitive Jugular Veins** escape from the cranial cavity in front of the ear. A trace of the opening may occasionally be detected at the root of the zygoma behind the post-glenoid spine (A. Cheatele). The petro-squamous sinus represents the intracranial part of this vein (p. 56). As the internal jugular vein opens up, the primitive jugular vein within the skull becomes atrophied. The temporo-maxillary vein and the external jugular vein probably represent the extra-cranial part of the primitive jugular vein. It must be remembered that the caudalward migration of the heart affects the primitive relationship of the veins in the neck. They are drawn backwards with it.

Veins formed from the Posterior Cardinals of the Embryo.

—1. **From the branches of the Cardinal Veins.** Each posterior cardinal vein receives on its own side—(a) A branch from each body segment from the lower cervical to the last caudal. These become the intercostal, lumbar and sacral veins. (b) The segmental veins of the intermediate cell mass (Fig. 85), which become the suprarenal, renal, spermatic, ovarian, uterine and vesical veins. (c) When the hind-limb buds grow out their veins join that part of the cardinal veins which become the common iliac. The lateral sacral, ilio-lumbar and ascending lumbar veins are anastomotic channels formed between the segmental veins.

From the **right cardinal vein** are formed (1) the vena azygos major; (2) the post-renal part of the inferior vena cava (Fig. 186).

The part above the entrance of the right renal becomes the vena azygos major; the part below, the inferior vena cava. Hence it is that the origin of the vena azygos can commonly be traced to the renal vein. The ascending lumbar vein, which also ends in the vena azygos major, is, as already mentioned, a new anastomotic channel.

From the **left cardinal** arise (Fig. 186)—(1) Part of the left superior intercostal vein; (2) Left superior azygos vein; (3) Left

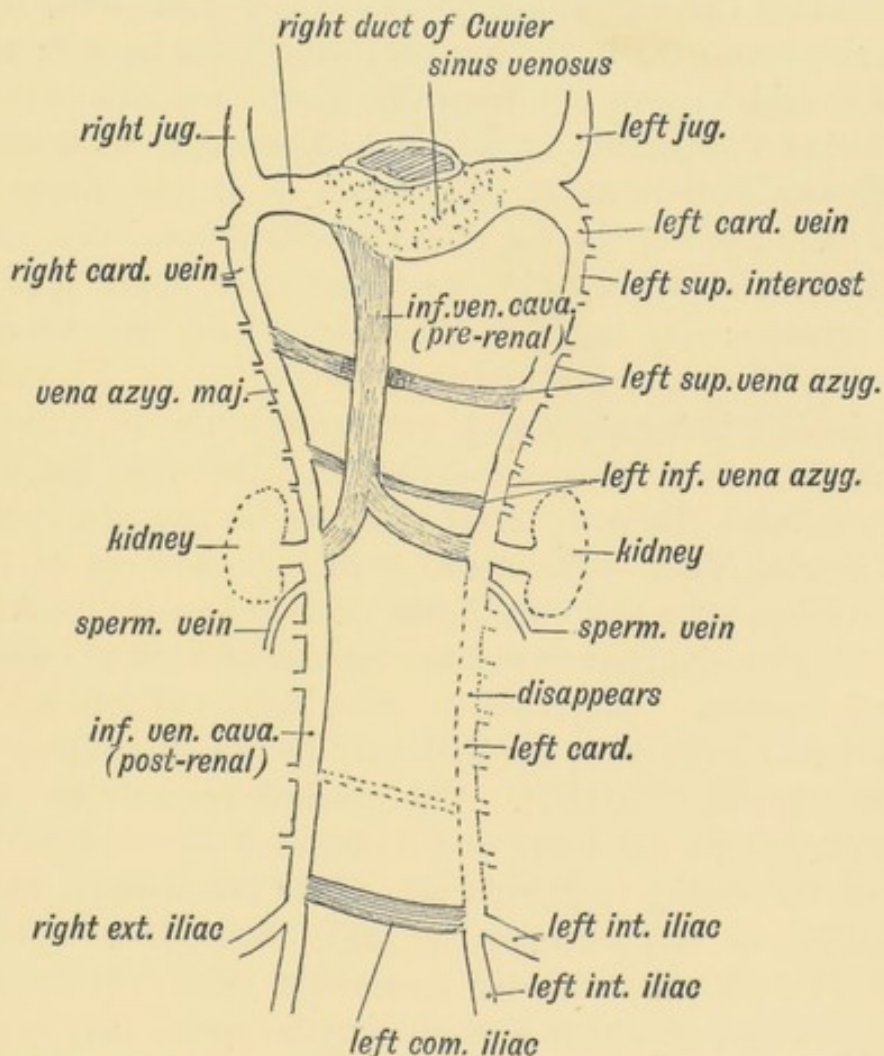


FIG. 186.—The Remnants of the Posterior Cardinal Veins in the Adult. The new channels are shaded. (After Hochstetter.)

inferior azygos, which commences in the left renal vein, and also receives the left ascending lumbar. The post-renal part of the left cardinal disappears in higher mammals; occasionally it persists in man and very frequently in the rabbit.

The greater part of the **left common iliac** vein arises, like the left innominate, as a communicating channel between the posterior cardinals. It is formed as the post-renal part of the left cardinal becomes obliterated (Fig. 186).

The Inferior Vena Cava.—The post-renal part is formed from the right cardinal vein (Fig. 186). The pre-renal part, with the mesial part of the left renal vein, is quite a new formation which opens up a short circuit to the heart for the blood of the lower half of the body. The formation of this new channel leads to the retrogression of the thoracic stages of the cardinal veins and their formation into the azygos veins. The exact date of the origin of the inferior vena cava in the human foetus is not known; the new channel is said to grow out from the ductus venosus of the liver, and growing downwards opens up a connection with the right and left cardinal veins at the entrance of the renal vessels (Fig. 188). Thus in the formation of the inferior vena cava are included three elements—(1) the terminal or upper part of the ductus venosus; (2) the new channel; (3) the inferior or post-renal part of the right cardinal.

Occasionally it happens that pressure on the hepatic part of the vena cava, from tumours, cirrhosis of the liver, etc., leads to the azygos veins, the early foetal channels, being again opened up.

The Portal Vein.—The **Portal Vein** is formed out of the two vitelline veins—the first of all the veins to be developed. They end in the posterior chamber of the tubular heart of the embryo—the **sinus venosus**. The vitelline veins, right and left, arise from ramifications on the yolk sac and pass in the splanchnopleure to the sinus venosus (Fig. 187). The nutriment within the yolk sac is thus carried to the heart and distributed by the heart to the tissues of the embryo and yolk sac. The commencement of the left vitelline or omphalo-meseraic vein disappears. The right (Fig. 187) forms the superior mesenteric vein. It commences on the yolk sac, of which a remnant (the neck) may remain as Meckel's diverticulum.

The terminal parts of the two vitelline veins are joined by three transverse communications, the upper two of which are included in the portal vein. The uppermost of the three afterwards lies in the transverse fissure of the liver (Fig. 188). The middle communication lies on the dorsal aspect of the duodenum

(Fig. 188). The splenic vein and inferior mesenteric pass in the dorsal mesentery (Fig. 187) and join this transverse communication which may be named the supra-duodenal junction. The

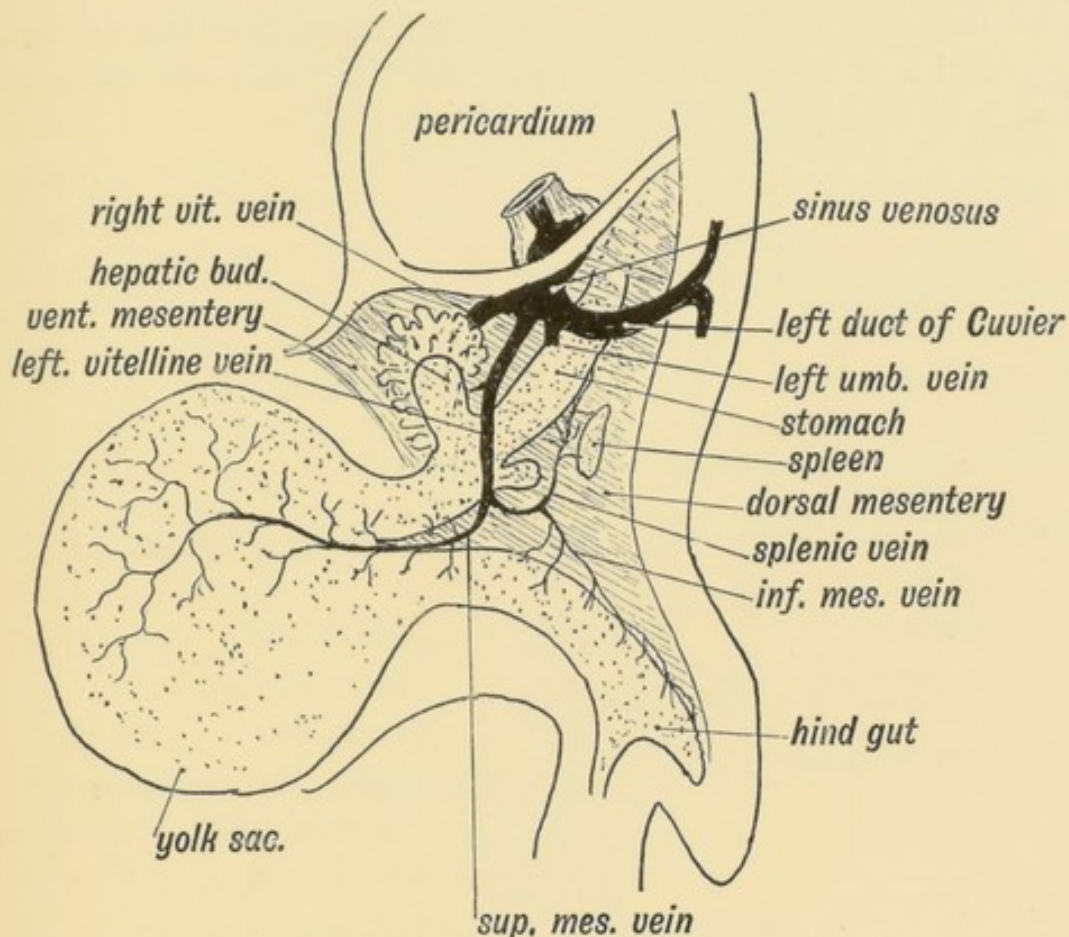


FIG. 187.—The Left Vitelline Vein of an Embryo of the 4th week.

third or lowest of the junctional trunks is situated on the ventral aspect of the duodenum (Fig. 188). Two parts may be recognised in the portal vein of the adult: (1) the part which lies behind the pancreas and duodenum; (2) the part in the gastro-hepatic omentum and transverse fissure of the liver.

The **retro-duodenal** part is formed out of the left vitelline vein and the supra-duodenal junction (Fig. 188); the **omental** stage is formed out of the right vein and the uppermost of the junctional trunks (Fig. 188). The part of the portal vein within the transverse fissure of the liver represents the third or uppermost junction between the left and right vitelline veins.

The **Hepatic Veins** are formed out of the terminal parts of the vitelline and umbilical veins. These veins end at first in the

sinus venosus (Fig. 187). The liver is developed between and around the vitelline and umbilical veins, near their termination in the sinus venosus. The veins are broken up and a fine intra-hepatic venous network takes their place. Thus it comes about that the vitelline veins are transformed into the veins of the portal and hepatic circulation. All the foetal and umbilical blood is at first poured through the liver.

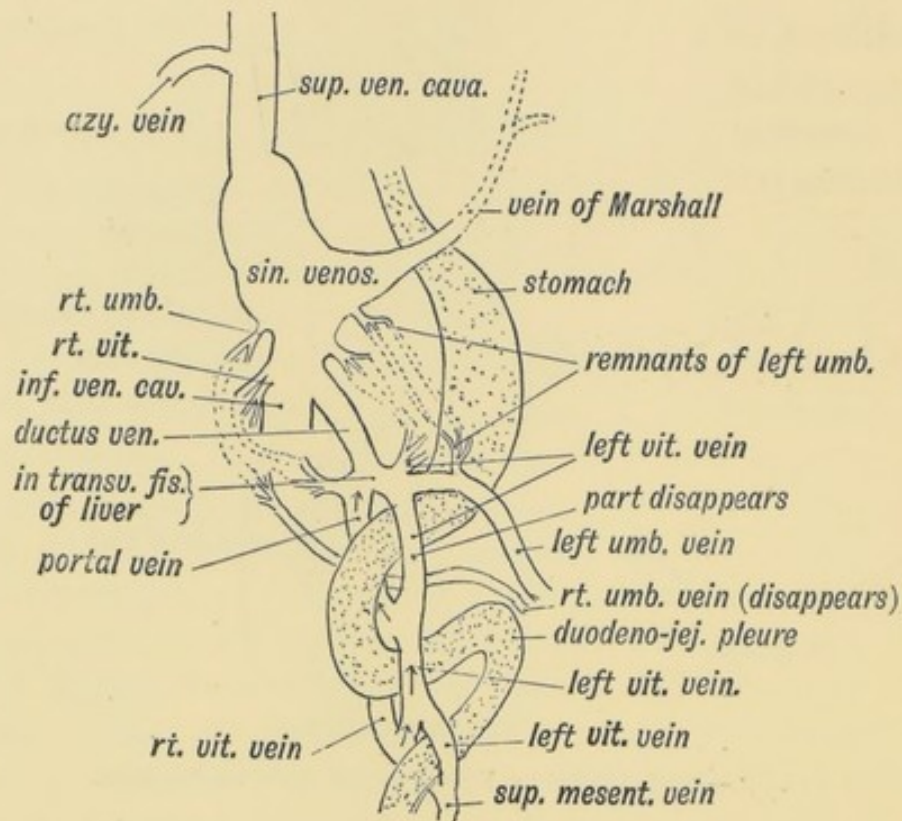


FIG. 188.—Diagram showing the Formation of the Ductus Venosus, and the fate of the Umbilical and Vitelline veins. The arrows show the parts of the Vitelline Veins which become the Portal Vein.

The Ductus Venosus is a new channel formed between the uppermost of the anastomoses between the right and left vitelline veins and the sinus venosus whereby the greater part of the umbilical blood is short-circuited to the heart without passing through the liver. It appears after the liver bud has broken up the vitelline venous trunks (Fig. 188). After birth, when a short circuit is no longer required between the foetal circulation and heart, it becomes reduced to a fibrous cord. It occupies the posterior part of the longitudinal fissure of the liver and lies within the hepatic attachment of the gastro-hepatic omentum.

The pre-renal part of the inferior vena cava is developed as an outgrowing channel from the ductus venosus (Fig. 189).

The Umbilical Veins.—The umbilical vein at birth consists of two parts: (1) A part within the umbilical cord; (2) another within the body, enclosed in the falciform ligament and anterior half of the longitudinal fissure of the liver. It joins there the ductus venosus and portal vein (Fig. 189). The condition of the umbilical veins in a human embryo of three weeks is shown in Fig. 190. They are formed after the vitelline veins but before the ducts of Cuvier, which afterwards terminate in the sinus with the umbilical veins. The veins lie in the somatopleure and drain the blood of the chorion, a derivative of the somatopleure. It passes from the chorion to the body wall in the umbilical cord, which is also formed from the somatopleure as well as allantois. In front the vein of each side joins the sinus venosus with the duct of Cuvier. There is a right and left vein, but in

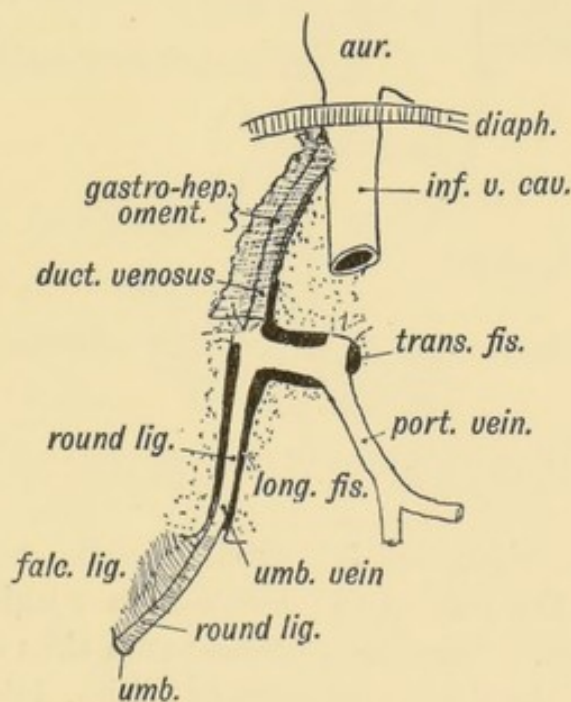


FIG. 189.—Diagram of the Remnants of the Umbilical Vein in the Adult—viewed from behind.

the cord they have fused into one. Within the body the right umbilical vein completely disappears during early embryonic life.

The outgrowth of the liver-bud breaks up not only the vitelline veins but also the umbilical at their junction with the sinus venosus (Figs. 185 and 188). Thus the umbilical blood as

well as the vitelline comes to be poured into the liver. The left umbilical vein within the body remains permanently; when its terminal part is broken up by the outgrowth of the liver it becomes united with the uppermost of the transverse communica-

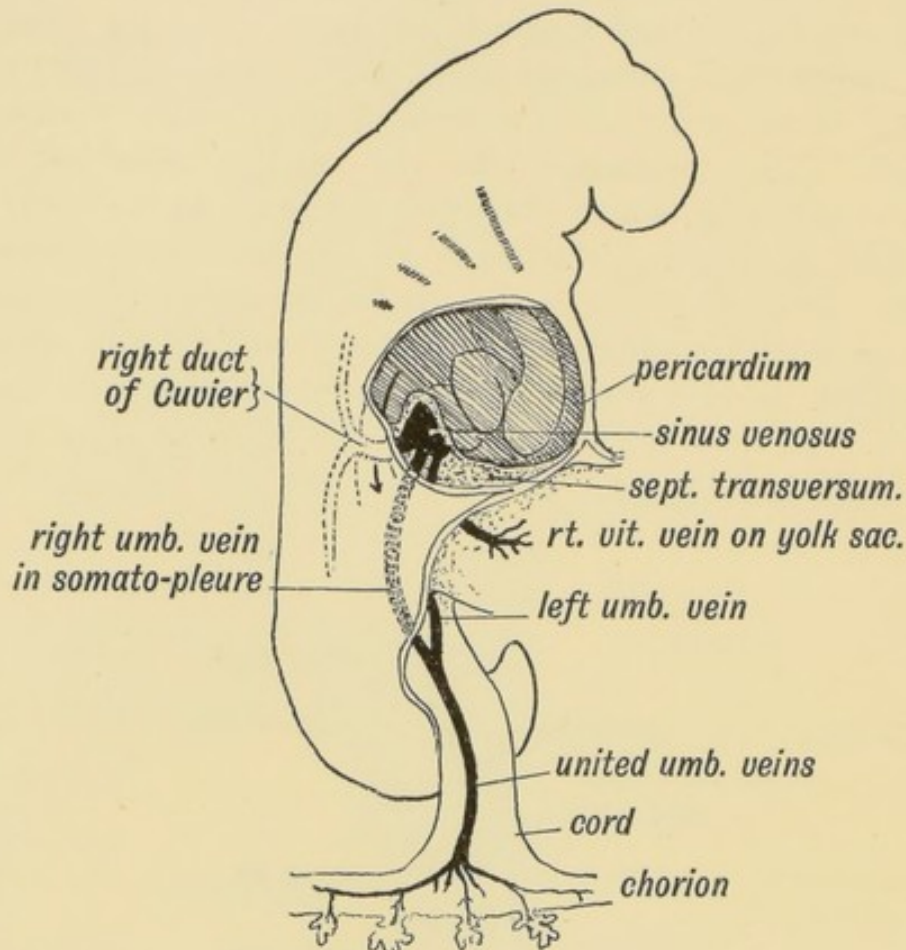


FIG. 190.—Diagram of the Right Umbilical Vein in an embryo of 3 weeks, before the outgrowth of the Liver Bud. (Modified from His.)

tions between the right and left vitelline veins, which, as already mentioned, form the part of the portal vein within the transverse fissure of the liver. The left umbilical vein thus comes into communication with the ductus venosus (see Figs. 188 and 189).

DEVELOPMENT OF THE HEART.

The Heart.—In the 2nd week, while the embryo is still in the blastoderm stage, a contractile tube appears in the splanchnopleure on each side (Fig. 191). Each tube receives blood from

the yolk sac by a vitelline vein; each pumps its blood into an aortic stem which terminates as the artery of the yolk sac.

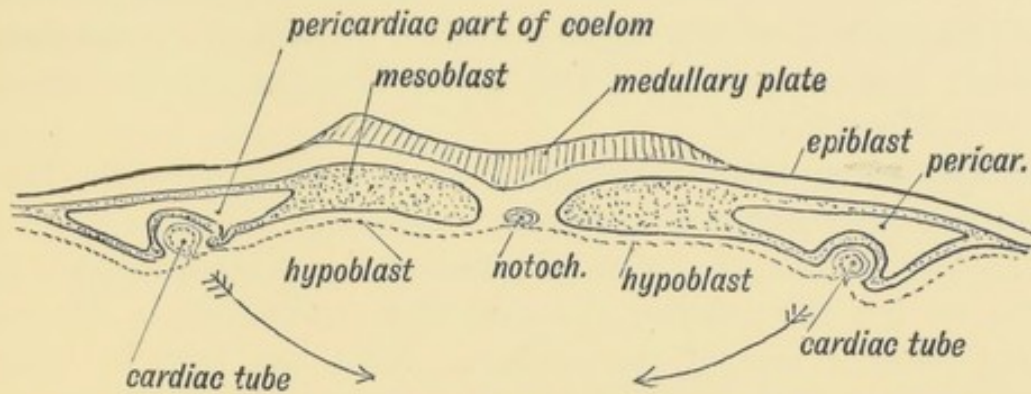


FIG. 191.—Transverse section of the Blastoderm showing the Right and Left Cardiac Tubes situated in the Splanchnopleure.

These two tubes become fused together to form a simple tubular heart by the 3rd week. The cardiac tubes unite as the splanchnopleures come together (see Figs. 191 and 192). The lining membrane of the cardiac tubes is probably furnished by an invagination of the hypoblast (Fig. 191). The heart is at first

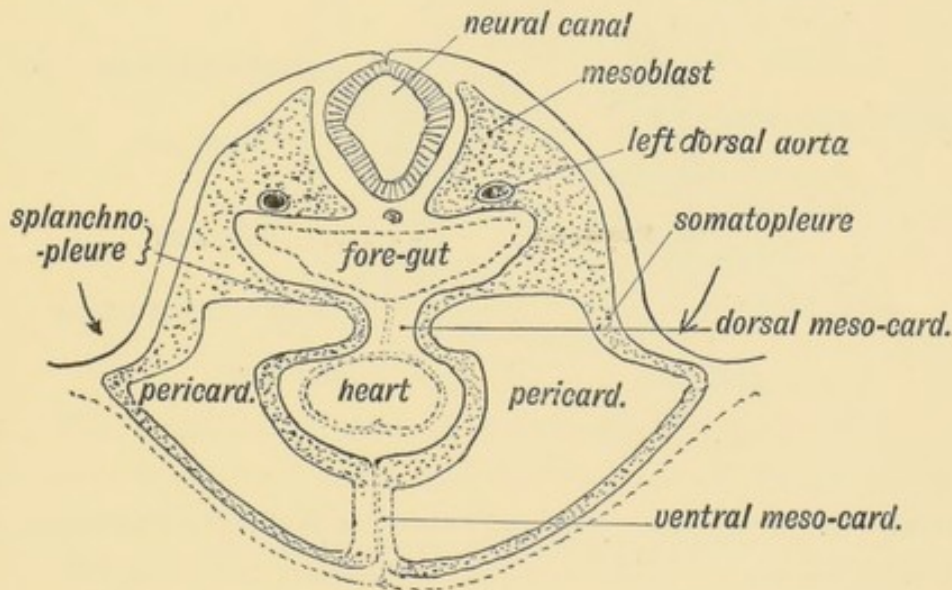


FIG. 192.—Transverse section at a more advanced stage showing the union of the Splanchnopleures to form the Mesocardia and the fusion of the Right and Left Cardiac Tubes.

suspended by a mesentery, which stretches from the fore-gut (Fig. 192) to the ventral median line of the body wall and separates the anterior end of the coelom into right and left halves. The mesentery is formed out of the fused splanchno-

pleures (Fig. 192). The part of the cardiac mesentery between the heart and the fore-gut forms the **dorsal mesocardium**, the part between the heart and the ventral wall, the **ventral mesocardium**. The anterior end of the coelom which is occupied by the heart becomes the pericardium. The pericardium is situated beneath the primitive pharynx.

Demarcation into Chambers.—In the third week the heart undergoes **three important changes**:

(1) The dorsal and ventral mesocardia disappear and the heart, all but the anterior and posterior extremities, is left free in the anterior end of the coelom. This can best be understood by a reference to Fig. 193. The heart is there seen

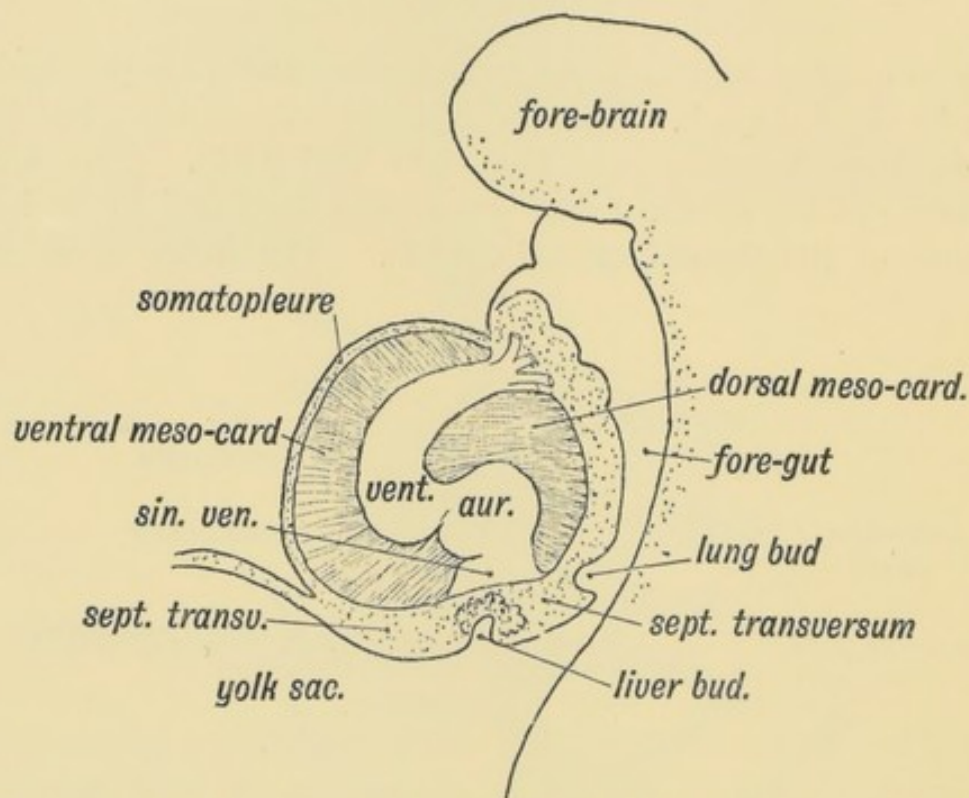


FIG. 193.—Lateral view of the Heart and Pericardium to show the Attachments of the Dorsal and Ventral Mesocardia (schematic).

suspended between the fore-gut and ventral wall. The tubular heart is formed behind by the union of the right and left vitelline veins from the yolk sac and ends in front as the first or mandibular aortic arches. The posterior end of the mesocardium, both the ventral and dorsal parts, persists—the part which encloses the sinus venosus and this forms the primitive basis of the diaphragm or septum transversum (Fig. 202, p. 244).

(2) The tubular heart shows demarcations into four parts (Fig. 194): (*a*) Sinus venosus; (*b*) Primitive auricle; (*c*) Primitive ventricle; (*d*) Conus or bulbus arteriosus. In this condition (third week) the human heart is exactly like that of a fish, viz., a tubular four-chambered heart which pumps blood into the branchial or aortic arches.

(3) The disappearance of the mesocardium allows the heart to become twisted and bent. Two chief bends are formed which materially help to give the heart its adult shape (Fig. 195):

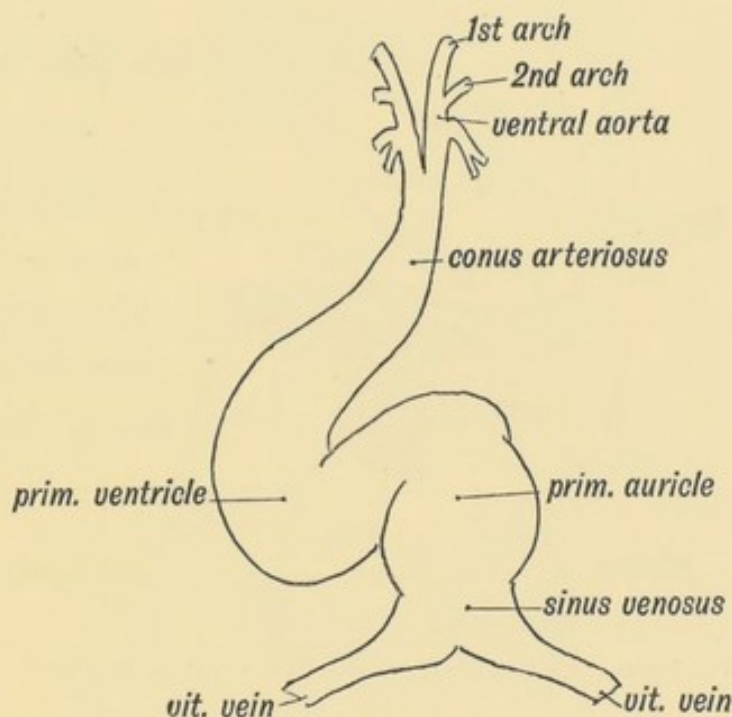


FIG. 194.—The Primitive Divisions of the Heart.

(*a*) **The Ventricular Bend.**—The ventricular part of the tube is bent into a V-shaped piece, the apex of the V-shaped loop being turned towards the right.

(*b*) **The Auriculo-ventricular Bend.**—The ventricular part is bent in front of the auricular so that the auricle becomes dorsal to the ventricle (Fig. 195).

The Sinus Venosus.—The sinus venosus, the first chamber of the foetal heart, is formed by the union of the vitelline veins; the umbilical veins and ducts of Cuvier come subsequently to open in it (Fig. 185). The sinus is imbedded in the persistent posterior part of the mesocardium (Fig. 202).

Through the ventral part of the mesocardium the ducts of Cuvier reach the sinus from the somatopleure (Fig. 183). In fishes and in the human embryo the sinus pumps the blood into the primitive auricle, and its orifice into the auricle is protected by two valves, right and left (Fig. 197).

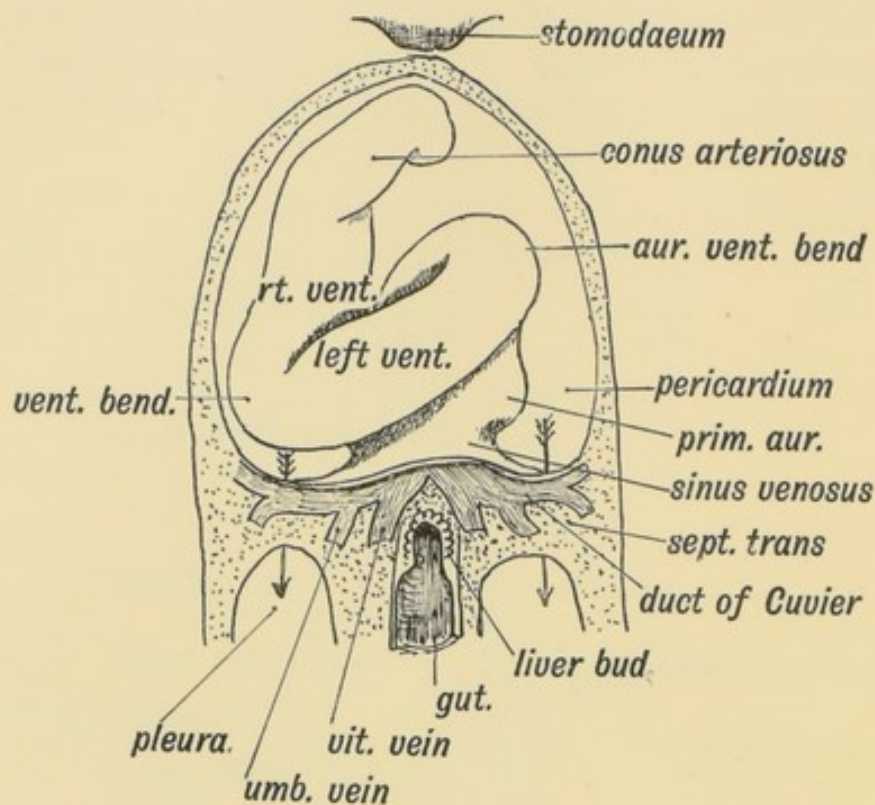


FIG. 195.—Showing the two chief Bends which occur in the Heart during the 3rd week.

Fate of the Sinus Venosus (Fig. 196).—The sinus venosus shifts towards the right side of the primitive auricle and ultimately forms part of the right auricle and the coronary sinus. The part which it forms of the right auricle is indicated by the entrance of the following vessels which primarily terminate in the sinus:

- (1) The superior vena cava (the right duct of Cuvier);
- (2) The inferior vena cava, which also opens into the sinus;
- (3) The oblique vein of Marshall (left duct of Cuvier), which opens into the left horn of the sinus venosus. The left horn of the sinus becomes the coronary sinus. A groove, the sulcus terminalis, which is marked on the interior of the right auricle by a crest, runs down on the anterior wall of the right auricle from

the superior to the inferior vena cava, and indicates the junction of the primitive auricle with the sinus venosus.

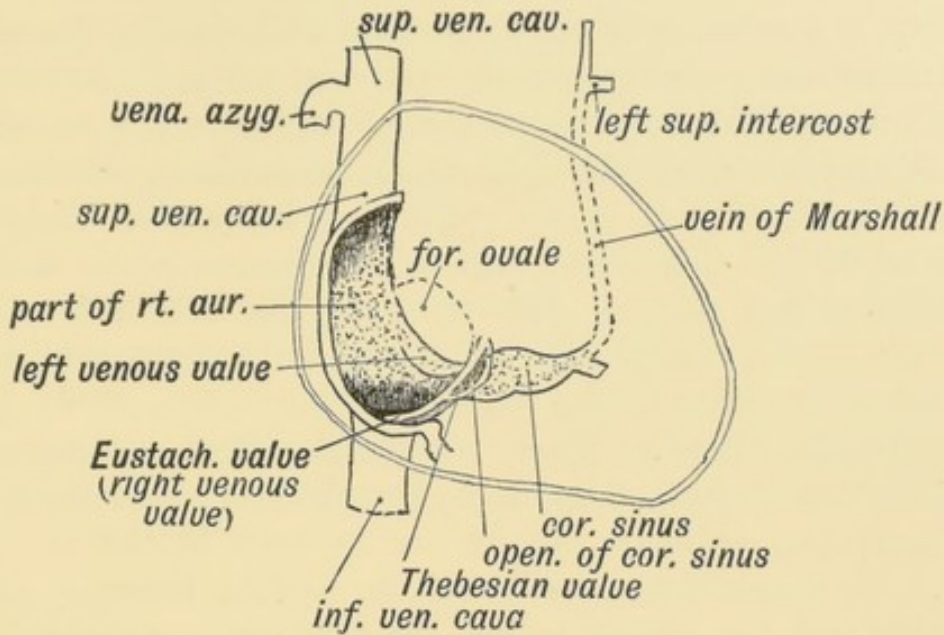


FIG. 196.—Showing the Structures formed from the Sinus Venosus.

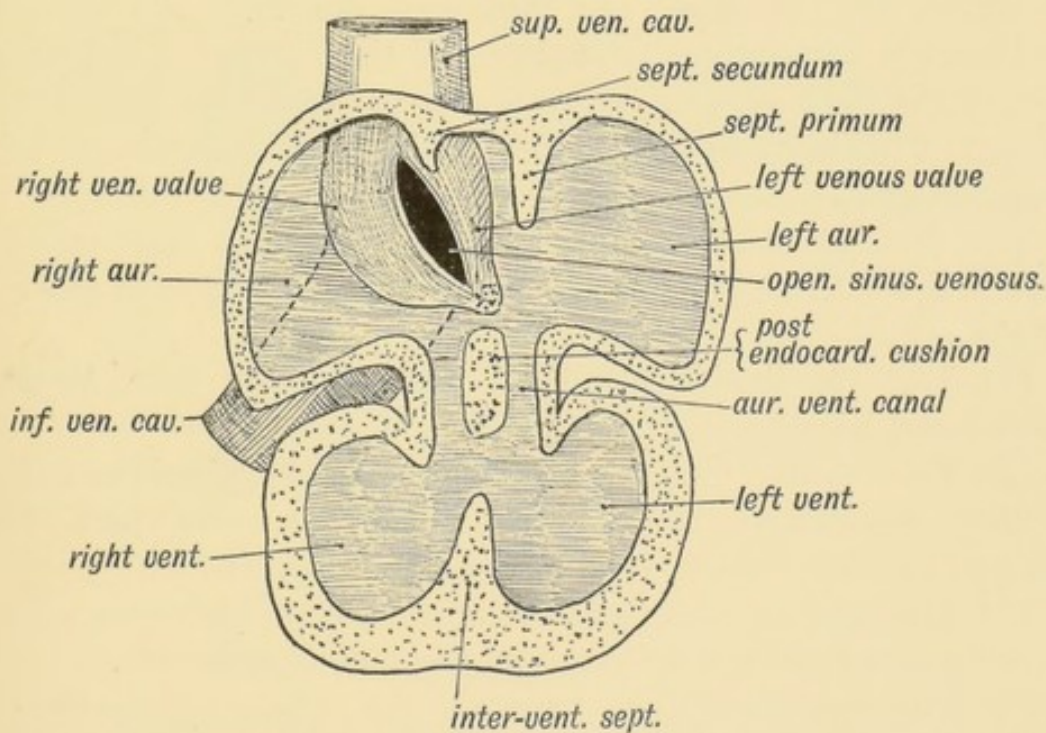


FIG. 197.—Section of the Heart of a 5th week human foetus showing the Right and Left Venous Valves which guard the entrance of the Sinus Venosus into the Primitive Auricle. (After His.)

The Valves of the Sinus Venosus.—Right and left lateral valves (venous valves) guard the entrance of the sinus to the primitive

auricle and prevent the regurgitation of blood when the auricle contracts (Fig. 197). The right valve becomes reduced, and ultimately forms the Eustachian valve, and the Thebesian which is always connected with the Eustachian (Fig. 196). The part of the Eustachian valve prolonged to the annulus ovalis is a new formation. What becomes of the left valve is not certain; it may disappear completely, but more probably it amalgamates with, and forms part of the septum primum (see Figs. 196, 197, and 198). The Eustachian and Thebesian valves also help to indicate the part of the right auricle, which is formed from the sinus venosus, for they bound the right side of the entrance of the sinus to the auricle.

The Cardiac Septa.—Every modification of the heart, from its simple tubular form in fishes to its complete division into separate pulmonary and systemic pumps, can be seen in the vertebrate series. In amphibians the primitive auricle becomes divided into right and left chambers, but the ventricle is undivided. In crocodilia an incomplete ventricular septum, with a complete auricular, may be seen. In birds and mammals the auricular and ventricular septa are complete, and the sinus venosus becomes part of the right auricle. Occasionally the septa are incompletely formed in man, conditions found in the lower vertebrates being thus produced.

The division of the simple tubular heart into right and left halves is rendered possible by four changes which take place in its shape:

(1) The ventricle, instead of being a bent tube, becomes dilated and bag-like.

(2) The opening of the sinus venosus in the primitive auricle migrates towards its right side, and thus opens in that part of the primitive auricle which becomes the right (Fig. 197).

(3) The auricle sends out an appendix on each side; these grow forwards and nearly surround the bulbus arteriosus.

(4) The communication between the common auricle and ventricle is drawn out into a tube—the auriculo-ventricular canal (Fig. 198).

The Division of the Heart is effected by five Elements or Septa (Fig. 198). These are:

1. The endo-cardial cushions.

2. The Inter-ventricular septum.
3. The Aortic septa.
4. The septum primum of the auricle.
5. The septum secundum of the auricle.

(1) The auricular or auriculo-ventricular canal is divided by anterior and posterior **endocardial cushions**, which grow out and meet, dividing the auricular canal into the right and left auriculo-ventricular orifices.

(2) The **inter-ventricular septum** rises from the floor of the common ventricle and grows upwards towards the aortic orifice and endocardial cushions (Figs. 197 and 198).

(3) In the aortic bulb (Fig. 198) appear **anterior and posterior aortic ridges**, arranged spirally. They fuse together; their lower extremities unite with the inter-ventricular septum. The conus

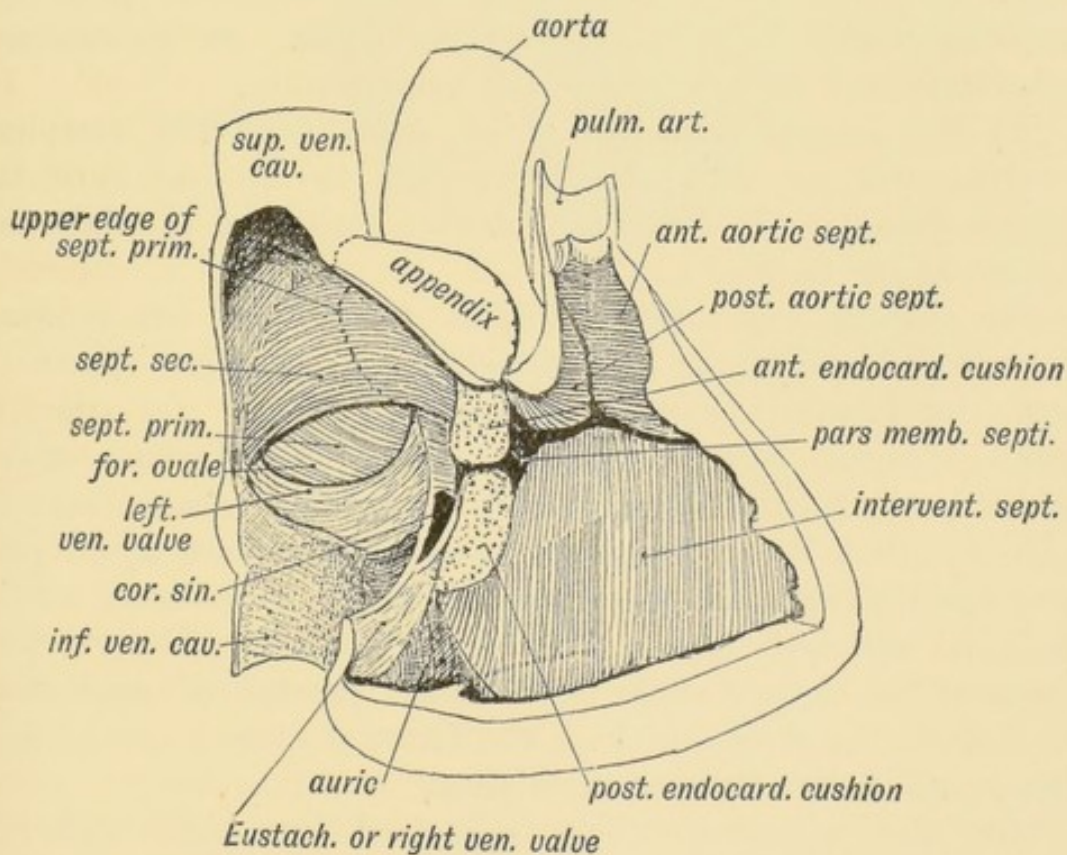


FIG. 198.—Diagram of the Septa of the Heart viewed on the right side.

or bulbus arteriosus is thus divided into an anterior or pulmonary part connected with the right ventricle, and a posterior or aortic part connected with the left ventricle.

Pars Membranacea Septi.—The three septa just described meet

about the 6th week, and are fused together by a thin membrane—the *pars membranacea septi* (Fig. 198). It is seen under cover of the septal segment of the tricuspid valve and is the last part of the septum to form; occasionally it fails to form, and a communication exists between the ventricles. This condition is commonly associated with a partial failure in the formation of the pulmonary artery. Such a condition may give rise to cyanosis; the subjects of it commonly die before 15 of pulmonary tuberculosis. The walls of the right and left ventricle in such cases are of equal thickness, for both act as common systemic and pulmonary pumps:

(4) The **septum primum** of the auricle springs from the posterior wall of the primitive auricle, and falls like the blade of a guillotine on the endocardial cushions with which it fuses (Figs. 197 and 198). Its upper border separates from the auricular wall. It forms the septum ovale. As it descends it involves and fuses with the left venous valve.

(5) The **septum secundum** grows down from the roof and posterior wall of the primitive auricle to the right of the septum primum. It forms the annulus ovalis and the auricular septum above it (Fig. 198).

The **foramen ovale** (Fig. 198) is an interval left between the two auricular septa; the Eustachian valve becomes connected with the annulus (*septum secundum*). In 75 per cent. of people, following Fawcett's statistics, the foramen becomes closed in the first year after birth. In 25 per cent. it remains partially open, but even when an opening remains the blood could pass from the right to the left auricle only when the pressure within the right auricle is greater than within the left. The valvular action of the septum ovale prevents the passage of blood from the left to the right auricle. The foramen ovale is an adaptation to the foetal form of circulation.

Thus the primitive auricle is divided into right and left chambers by two septa—*septum primum* and *secundum*; the *bulbus arteriosus* by the anterior and posterior aortic septa; the auriculo-ventricular canal by the anterior and posterior endocardial cushions; and, lastly, the primitive ventricle into right and left by the inter-ventricular septum.

Tricuspid and Mitral Valves.—It is to be remembered

that the interior of the ventricular cavities during the second month is filled with a muscular sponge work, like the ventricle of the frog's heart (Fig. 199). Out of this muscular network are formed:

- (1) Chordae tendineae;
- (2) Musculi papillares;
- (3) The moderator band;
- (4) Trabeculae and columnae carnae;
- (5) Musculi pectinati (in the auricular appendages).

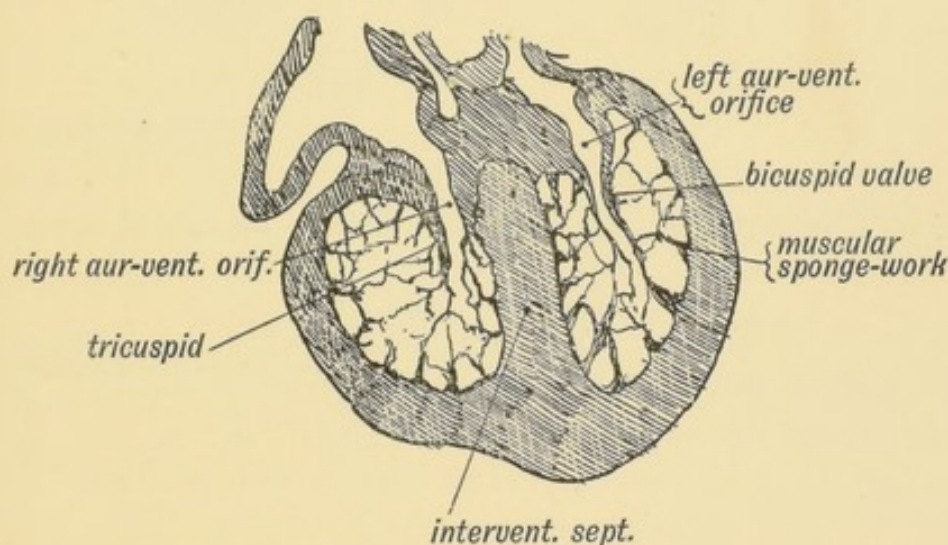


FIG. 199.—Section of the Ventricles of the Foetal Heart, showing the Muscular Sponge Work within their Cavities. (After His.)

The endocardium lining the auricular canal (see Figs. 197 and 199) becomes folded or protruded within the ventricles by a shortening of the auricular canal. The funnel-shaped fold or inflection of endocardium is the basis of the auriculo-ventricular valves. They are formed at the same time as the septa of the heart. Originally funnel-shaped, the left or mitral comes to show two cusps—septal and left, the right or tricuspid three segments—septal, anterior and posterior. The funnel shape is frequently partially retained. The cardiac tissue on the outer aspect of the valves is opened out into a sponge-work continuous with that of the ventricle. Hence the attachment of the chordae tendinae on the outer surfaces and edges of the valves.

The Semilunar Valves.—The bulbus arteriosus is divided by the aortic septa into an anterior and right part—the pulmonary aorta, and a posterior and left—the ascending aorta. Just

before the division takes place four cushions of the endocardium arise at the junction of venticle and aortic bulb (Fig. 200 *A*). The four cushions—anterior, posterior and two lateral—become cupped

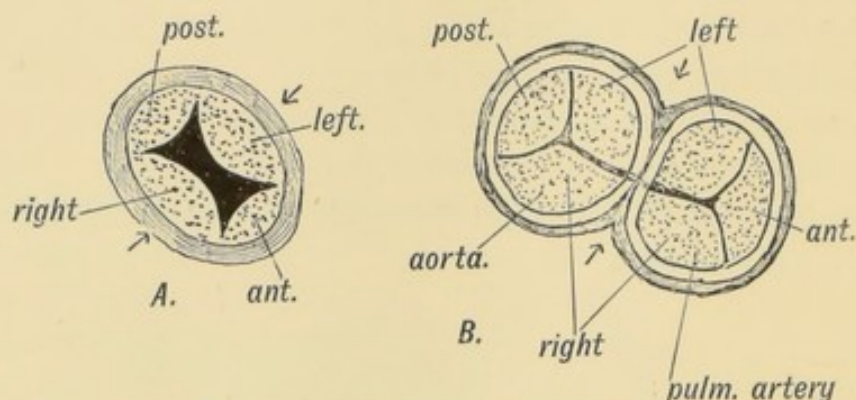


FIG 200.—The origin of the semilunar valves.

A. The four Endocardial Cushions in the Aortic Bulb.

B. The division of the Lateral Cushions to form two Aortic and two Pulmonary Semilunar Valves.

above and valvular. When the aortic septa are formed, each lateral cushion is divided in two, thus forming the two postero-lateral semilunar valves of the pulmonary aorta and the two antero-lateral of the aorta. The anterior and posterior cushions remain as the anterior pulmonary semilunar valve and the posterior aortic valve (Fig. 200 *B*).

Remnants of the Foetal Circulation in the Adult.—The nature of these remnants has been already described; they need be only enumerated here. They are:

1. The Obliterated Hypogastric Arteries;
2. The Umbilicus;
3. The Round Ligament of the Liver;
4. The Fibrous Remnant of the Ductus Venosus;
5. The Eustachian Valve;
6. The Foramen Ovale;
7. The Fibrous Remnant of the Ductus Arteriosus.

The Coelom, Splanchnocele or Cavity of the Body Wall.—We have already seen that in the primitive blastoderm (Fig. 191) a cleft is formed between the somatopleure and splanchnopleure. It is highly probable that the mesothelium which

lines the coelom is a derivative of the hypoblast, and that the coelom was originally a series of segmental diverticula derived from inflections of the hypoblast; yet, from a clinical point of view, it is better to regard it as part of the lymphatic system, and really a very extensive lymph space. It allows the heart, lungs and abdominal viscera to undergo movements with a minimum of friction.

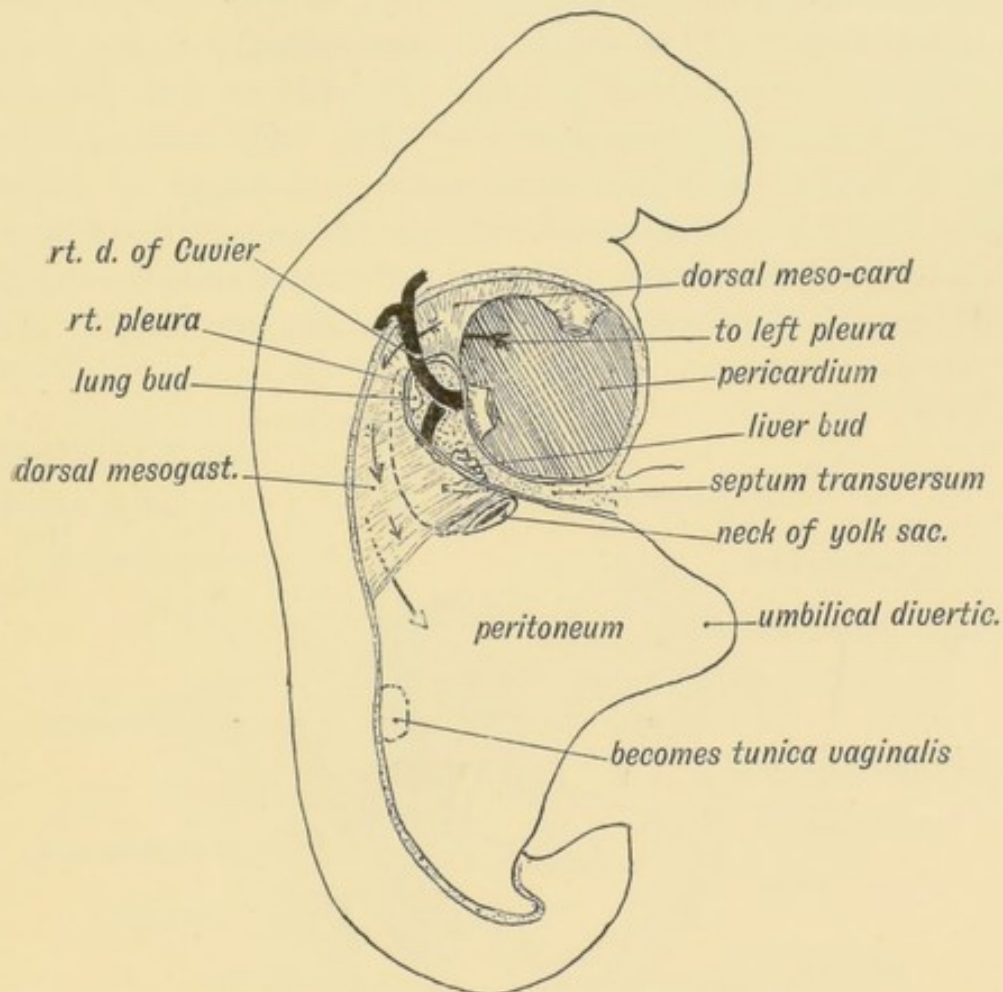


FIG. 20L.—The Form of the Coelom in a 3rd week Embryo as viewed from the right side.

As may be seen from Fig. 72, page 93, the coelom at first extends beyond the embryo, between the layers of the somatopleure, which go to form the foetal membranes. With the union of the right and left layers of the somatopleure at the umbilicus, part of the blastodermic coelom is shut within the body of the embryo—the intra-embryonic part of the coelom. It is out of this part that the pericardium, pleurae, peritoneum and tunicae vaginales are formed. The coelom commences in front

below the pharynx and ends behind on the hind gut (Fig. 201). This cavity is originally divided into a right and left half by the dorsal and ventral mesentery, formed by the united splanchnopleures (Fig. 192). The ventral mesentery disappears in the anterior and posterior parts, so that the right and left halves of the coelom communicate; an intermediate part persists and helps to form the diaphragm (Fig. 202).

The Divisions of the Coelom.—Out of the anterior part of the coelom (Fig. 201) is formed the **pericardium**. It lies beneath and behind the primitive pharynx (Fig. 202). The pericardial part of the coelom by the third week (Fig. 201) is expanded and thrust downwards and backwards, and communicates by a narrow neck or isthmus (*iter venosum*) with the pleuro-peritoneal part on each side of the mesentery. The duct of Cuvier encircles the neck or isthmus on each side, and causes the constriction (Fig. 183).

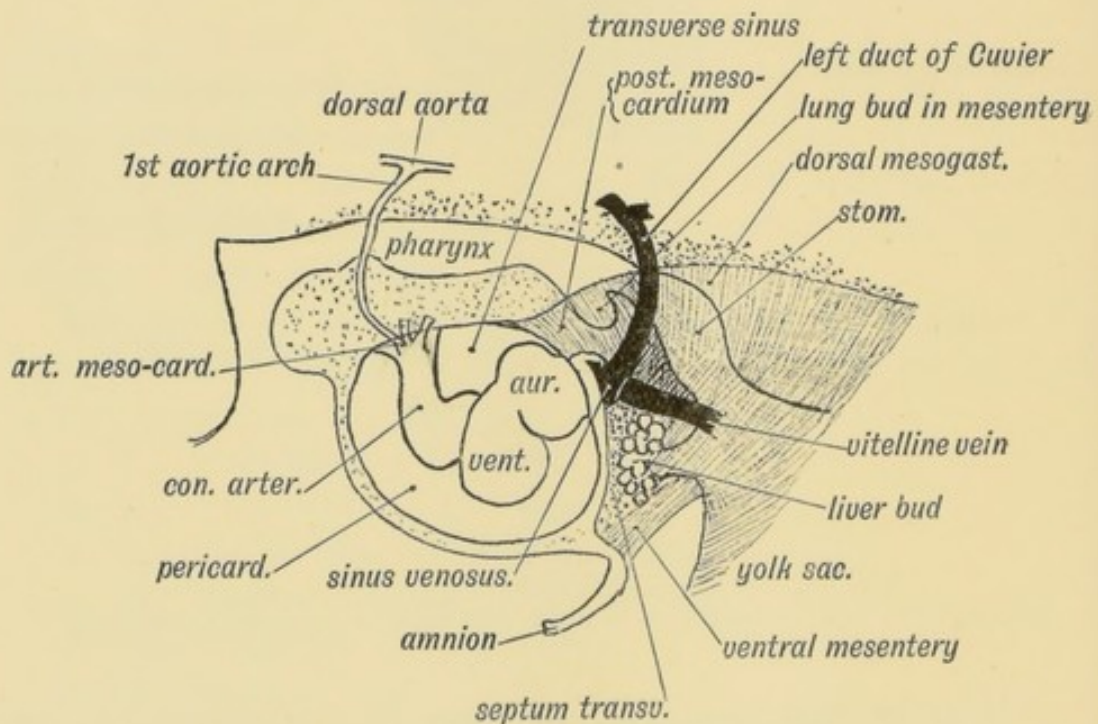


FIG. 202.—Diagram to show the manner in which the Heart is fixed within the Pericardium by the Arterial and Venous Mesocardia in a human embryo of 3 weeks.

This condition is permanent in many fishes. With the origin of the lungs the part of the coelom which forms the isthmus undergoes a great expansion by the ingrowth of the lung buds (Fig. 201). Thus out of the isthmus of the right and left sides are gradually

formed the **pleural cavities**. The pleurae expand until, instead of lying as minute passages above and behind the pericardium, they come to completely cover it. The abdominal part of the coelom forms the **peritoneal cavity**; a small part on each side is shut off in the scrotum, the **tunica vaginalis**.

The Pericardium.—In Fig. 202 the relationship of the heart to the pericardium is shown during the 3rd week of foetal life. The heart is tubular; the dorsal and ventral mesocardia (Fig. 193) have already disappeared except at two points, where the heart still remains attached. These two points are (Fig. 202):

(1) In front where the bulbus arteriosus passes out under the pharynx to divide into right and left ventral aortae from which the right and left visceral aortic arches arise. The mesocardium which binds it here may be named the **arterial mesocardium**.

(2) Behind the sinus venosus is imbedded in the mesentery or posterior mesocardium, through which the great veins reach it. The mesocardium which binds it behind may be named the **venous mesocardium**.

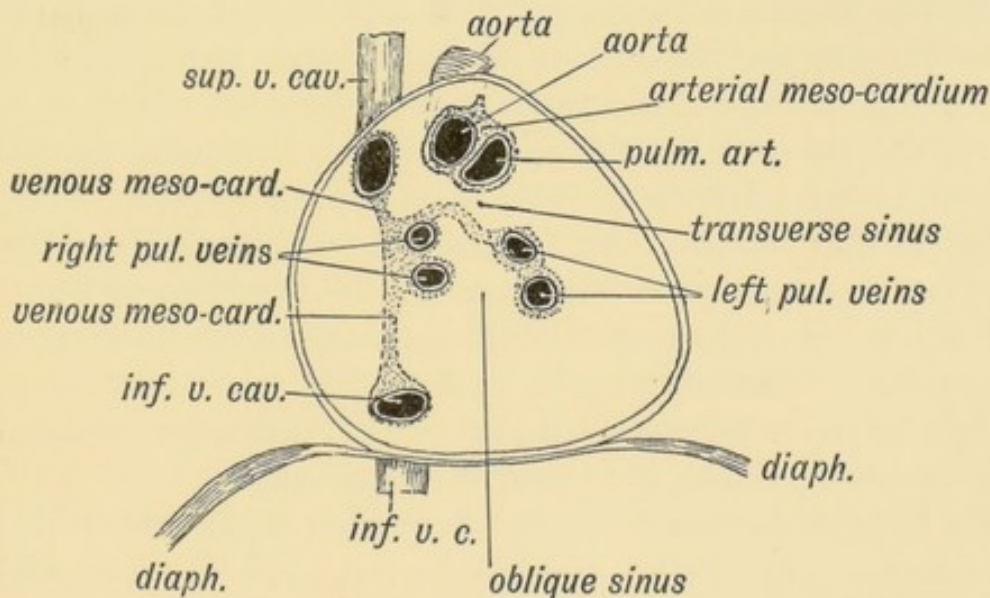


FIG. 203.—View of the Interior of the Pericardium showing the attachments of the heart to its dorsal aspect by the Arterial or Venous Mesocardia.

In Fig. 203 is shown the fixation of the heart within the pericardium of the adult. The arterial and venous mesocardia can be recognised, only somewhat altered in position and form.

(1) The bulbus arteriosus becomes the ascending aorta and

pulmonary aorta, and these are attached together to the fibrous pericardium by the arterial mesocardium (Fig. 203).

(2) The sinus venosus, which becomes part of the right auricle, and its vessels are still attached by the venous mesocardium. The heart has become so doubled on itself that the venous mesocardium comes almost in contact with the arterial mesocardium, the narrow space which separates them being the **transverse sinus** (Fig. 203). By comparing Figs. 193, 202 and 203 it will be seen that the transverse sinus is formed by the breaking down of the dorsal mesocardium of the heart.

The venous mesocardium becomes much more extensive by the ingrowth of the pulmonary veins. These grow in from the lungs, and pierce the pericardium to reach the left auricle. They reach the auricle through the mesentery or venous mesocardium of the sinus venosus (Fig. 202). The ingrowth of the left pulmonary veins causes a prolongation of the venous mesocardium to the left side; when the heart is removed the venous mesocardium is seen to be F-shaped in section. The oblique sinus lies in the concavity of the venous mesocardium (Fig. 203).

Ectopia Cordis.—Occasionally children are born with their hearts exposed on the surface of the chest. In extreme cases, only the dorsal wall of the pericardium is present, and it is flush and continuous with the skin of the chest. In such cases there has been either a failure on the part of the right and left somatopleures to unite in the ventral line, or, more probably, they did unite, but an early cystic condition led to a rupture of the pericardium and overlying layer of the somatopleure. In such cases the sternum is partially absent, or if present it is cleft, the right and left halves being widely parted. The pathology of the condition is probably similar to that of ectopia vesicae.

The Dorsal Aortae.—In the 3rd week there are still two dorsal aortae (Fig. 205). The blood passes from the two ventral aortic stems through the aortic visceral arches to end in a dorsal aorta on each side (Fig. 202). These run backwards side by side, and at first end in the yolk sac, but with the formation of the allantois they pass out on the body stalk to the membranes and placenta. The umbilical arteries are thus the direct continuations of the dorsal aortae (Young and Robinson); the middle sacral artery is an inter-segmental vessel of later formation (Fig. 221, p. 273).

About the end of the 3rd week the dorsal aortae fuse together from about the region of the 4th dorsal segment to the 4th lumbar. In front of and behind these points they remain separate.

The fate of the two dorsal aortae in front of the 4th dorsal vertebra has been already dealt with (p. 35 and Figs. 28 and 29). It remains to consider what becomes of them in the posterior extremity of the body. Following the researches of Young and Robinson, the dorsal aortae beyond the 4th lumbar segment, where they remain apart, form:

- (1) The common iliac arteries;
- (2) The internal iliac—in part at least;
- (3) The hypogastric arteries—intra-abdominal parts of umbilical;
- (4) The umbilical arteries—in the umbilical cord.

The authors just mentioned have described in the embryos of several mammals a system of arterial arches on each side of the hind gut resembling the aortic arches on each side of the fore gut (see Fig. 221, p. 273).

Red Corpuscles of the Blood.—The first red corpuscles are nucleated, capable of division, and are formed in mesoblastic cells of the splanchnopleure of the yolk sac and in the somatopleure of the amnion and chorion. The nucleated red corpuscles gradually become the biconcave, non-nucleated disc, but even at birth nucleated red corpuscles are still present. In the early half of foetal life the liver plays a leading part in their formation; in the latter half the spleen, red marrow and connective tissues become the chief sites of their formation. After birth they are formed almost entirely in the red marrow.

White blood corpuscles are produced at a later date than the red blood corpuscles. They also are produced by cells of the mesoblast.

Lymphatic Vessels.—Lymphatics are developed in the chick by the end of the 3rd day. It is some time before the lymphatic system opens into the blood system by the formation of a thoracic duct.

Certain important changes take place in the formation of the human lymphatic system about the 5th month. **Lymphatic glands** then begin to form in the connective tissue throughout the

body. Peyer's patches begin to appear in the intestine. Until then the connective tissue of the body contains a jelly-like ground substance corresponding to Wharton's jelly in the umbilical cord. At the 5th month the mucoid substance in the connective tissue begins to be absorbed (Berry Hart).

Until the fifth month the **marrow** of bones is composed of embryonic mesoblastic tissue (primary marrow). After the fifth month this becomes invaded by lymphoid tissue (white marrow) which in certain bones (vertebrae, etc.) becomes transformed further into red marrow. (Hamar.)

CHAPTER XVII.

THE RESPIRATORY SYSTEM.

Introductory.—In the 3rd week the arrangement of the heart and branchial arches in the human embryo is that of a water-breathing animal. In water-breathing animals the tubular heart expends its force in pumping the blood through the visceral arches—necessarily weakening the circulation in the rest of the body beyond them (Figs. 21 *A* and *B*). The blood that returns to the heart and from which the heart is nourished is purely venous. In amphibians an air-breathing apparatus appears—hence the division in them of the auricular chamber, one chamber receiving systemic, the other pulmonary blood. In amphibians the air is pumped into the lung by the mouth and pharynx. In birds and mammals the division of the heart into pulmonary and systematic pumps becomes complete; the chest wall is developed as a respiratory apparatus. The pharynx may be regarded as the respiratory organ of water breathers, and it is from the floor of this chamber that the pulmonary or air-breathing structures are developed. The arrangement of the heart and branchial arches in the human embryo can be explained only on the supposition that the air-breathing animals are the descendants of a water-breathing stock. The addition of the pulmonary system commences in the human embryo at the 3rd week.

Development of the Pulmonary System.—In the 3rd week, towards the end of it, a deep groove appears in the floor of the primitive pharynx and oesophagus. The groove or trough-like depression of the fore-gut commences between the ventricle ends of the 4th arch and stretches almost to the stomach (Fig. 204). The **furcula**, formed from the ventral parts of the

4th arch, bounds the pulmonary groove; in its anterior part, which is the most prominent, is developed the epiglottis; its lateral margins, which bound the pulmonary groove, form the aryteno-epiglottic folds. The margin of the groove thus be-

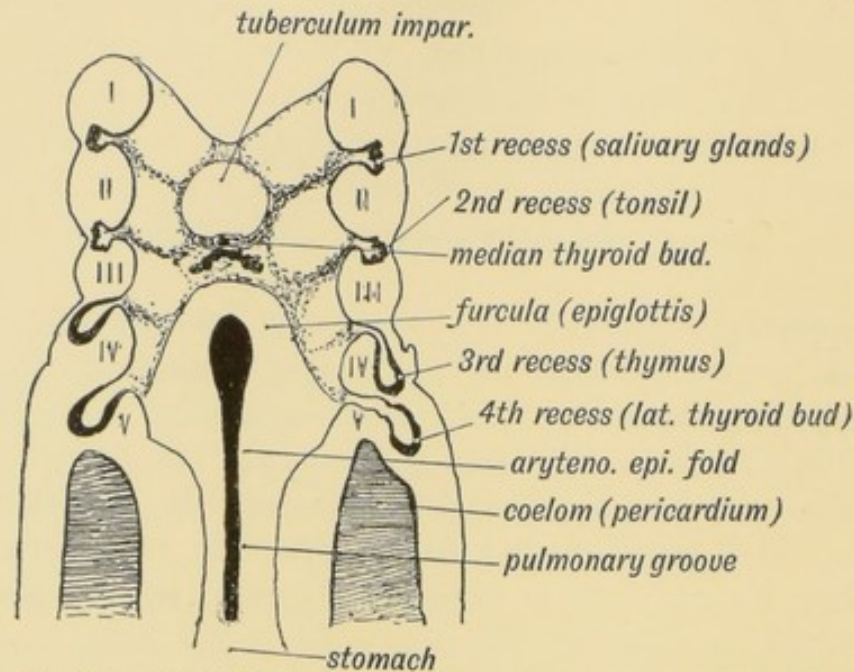


FIG. 204.—Floor of the Pharynx and Oesophagus of a human embryo of 3 weeks showing the Furcula, Pulmonary Groove, and Diverticulum. (After His.)

comes the upper aperture of the larynx. Two points should be noted in connection with the relationships of the oesophagus at the 3rd week: (1) like that of a fish, it is extremely short; (2) it lies between the right and left cavities of the coelom (Figs. 204 and 205) in the dorsal attachment of mesocardium of the sinus venosus (Fig. 202). (3) The part of the coelom which lies at each side of the oesophagus, is the narrow isthmus connecting the pericardial and peritoneal cavities which afterwards become the pleurae (Figs. 201 and 205).

When the pulmonary bud or groove is viewed from the side, its posterior extremity is seen to end in a deep pocket, the **pulmonary pocket** or diverticulum (Fig. 22, p. 30). The wall of the pocket is lined by a mass of hypoblast, which ultimately forms the epithelial lining of the whole respiratory tract, from the ciliated epithelium of the trachea to the pavement epithelium lining the alveoli of the lungs. Round the pulmonary bud is grouped a mass of mesoblastic tissue out of which the connective-tissue system of the trachea, bronchi and lungs is developed.

In the 4th week the pulmonary pocket produces a larger right and a smaller left process, the right and left **lung buds**. The median part, developed from the hinder end of the groove, grows out from the pharyngeal floor and forms the trachea. The groove in front forms the larynx. The right bud forms the right lung and bronchus; the left, the left lung and bronchus. The hypoblast becomes the epithelial lining of the respiratory tract; the surrounding mesoblast forms the vessels, connective-tissue covering and coats of the respiratory tubes and lungs. As the lung buds develop the stomach is forced backwards; the oesophagus becomes elongated. The tracheal part of the bud becomes separated from the oesophagus, but both retain the same nerve supply—the recurrent branch of the vagus—which is the nerve of the 5th arch.

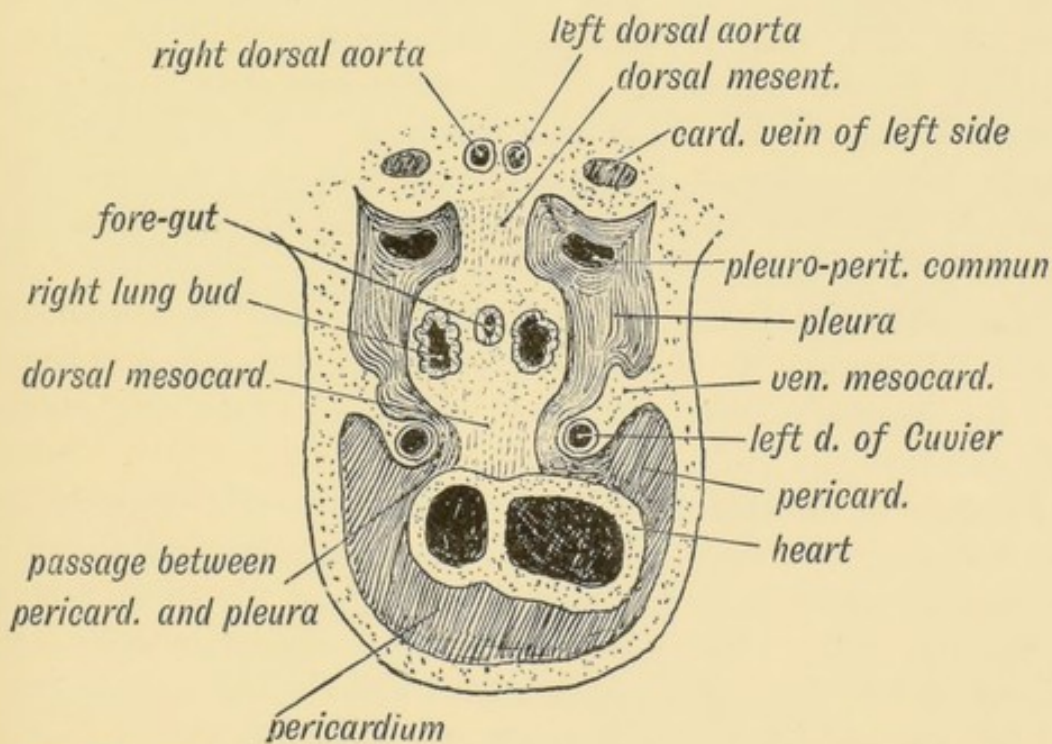


FIG. 205.—A section of a human embryo to show the Relationships of the Pulmonary Buds at the 4th week, looking backwards. (After Kollmann.)

In Fig. 205 the relationship of the lung buds is shown to surrounding structures during the 4th week. The following points should be noted:

(1) As the lung bud grows out it pushes its way into the isthmus of the coelom—the narrow neck of communication between the pericardium and peritoneum (Fig. 201). This part

of the coelom on each side forms **the pleura**. The part of the coelomic membrane which is invaginated on the lung bud becomes the visceral pleura. The invaginating or ensheathing lining of the isthmus becomes the parietal layer. As the lung buds grow, they distend the originally small pleural parts of the coelom until at the time of birth the right and left pleurae almost meet in front of the heart. They meet after birth under the sternum, enclosing between them the anterior mediastinum.

(2) As will be seen from Fig. 201, the lung bud sprouts out from the dorsal mesentery just behind the duct of Cuvier. This relationship is retained in the adult, the vena azygos and superior vena cava lying above and in front of the root of the right lung. If the left duct of Cuvier persisted it would lie above and in front of the root of the left lung. The lung bud springs from the pulmonary diverticulum just behind the 5th visceral arch of the pharynx. This arch is involved in the formation of the pulmonary groove and pulmonary diverticulum. It is from this arch (5th aortic arch) that vessels arise, perforate the lung, and become the pulmonary arteries. The fifth arch—part of the branchial pharynx—takes a chief part in the formation of the pulmonary apparatus. The ductus arteriosus—part of the 5th arch—lies over the root of the left lung. At this stage (4th week) the pleural cavity is still in communication with the peritoneal above the septum transversum (Fig. 205).

Formation of the Bronchi and Lungs.—The bronchi are the stalks of the right and left lung buds. The right bud is the bigger; the left is probably repressed by the heart turning to the left side. The right shows three secondary buds—the forerunners of the upper, middle and lower lobes of the lung; the left, two, which form the upper and lower lobes.

The condition of the lung buds at the end of the 5th week is shown in Fig. 206. The right and left bronchi are formed, so are the chief bronchial ramifications. Each ramification ends in a bud, which divides again and again and keeps on dividing until the fourth month. The terminal buds form the infundibula. Each bud is solid, and carries its sheath of mesoblast. At the sixth month sacular evaginations occur from the infundibula; they form the air cells, or alveoli.

There are certain peculiarities in the lungs of animals which are adapted to an upright posture (Man and Anthropoids):—

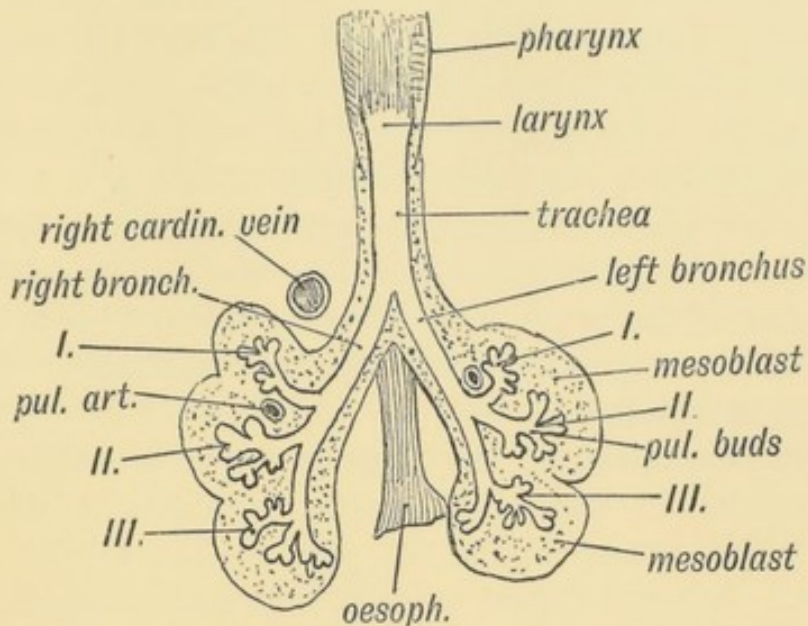


FIG. 206.—The condition of the Right and Left Pulmonary Buds in a 5th week embryo. (After His).

(1) **Ramification of the Bronchi.**—In quadrupedal mammals the bronchus does not divide by a process of equal dichotomy, as in man, but passes backwards in the lung as a main stem, which

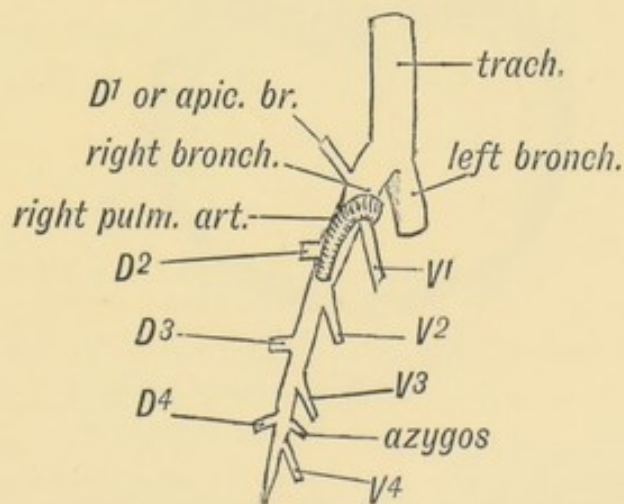


FIG. 207.—Scheme of the Bronchial Ramifications in Quadrupedal Mammals. *D*, the Dorsal Ramifications; *V* the Ventral Ramifications.

grows gradually smaller by giving off four dorsal and four ventral bronchial branches (Fig. 207). In man this arrangement can scarcely be recognised. The ventral branches in him have become larger than the main stems.

(2) **The Lobes of the Lungs.**—In the embryonic condition (Fig. 206) it is seen that the right and left lung buds are nearly symmetrical. Aeby supposed the upper lobe of the right lung to be absent in the left, but that is not so. Each bronchus gives off three primary buds. All three remain separate on the right side; on the left the upper and middle primary buds arise together (Fig. 206). Hence the upper lobe of the left lung represents the upper and middle lobes of the right. In the sheep the upper right lobe springs from the trachea. The bronchus of the upper right lobe (the reason for it is not clear) lies above its artery—that is to say, it is **eparterial**. The other bronchi are **hyparterial**.

(3) **The Diameters of the Thorax.**—The peculiar branching of the bronchi in man and upright primates is due to the shape of their lungs, which in turn is due to the shape of the thorax. In quadrupedal animals such as the horse or dog, in which the chest rests and is supported between the fore limbs, the thorax has its greatest diameter in the dorso-ventral direction (Fig. 208). In upright animals (man, anthropoids, and also in

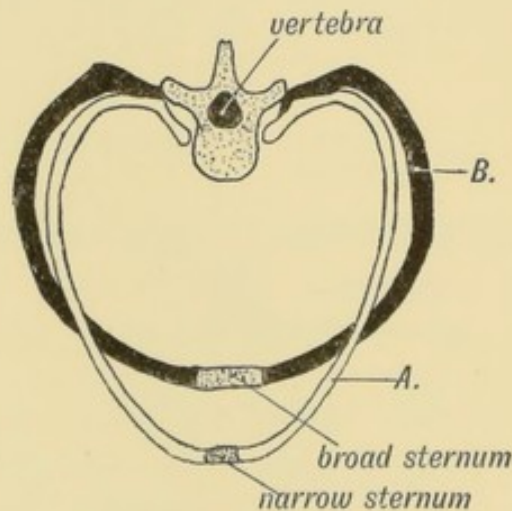


FIG. 208.—Diagrammatic Section of the Thorax of a Quadrupedal Mammal (A), contrasted with a corresponding section in Man (B).

some water-living mammals, such as seals, etc.) the transverse diameter becomes the greater. At birth the diameters of the child's thorax are nearly equal. The thorax is flattened by the spine becoming invaginated within it; the thorax thus comes to lie within the axis of gravity of the upright body.

(4) **The Azygos Lobe.**—On the inner side of the right lung of man the azygos lobe is frequently present, sometimes as a mere pulmonary projection or trace, sometimes as a lobule. It projects into and fills a slight recess between the pericardium and diaphragm, behind the intra-thoracic part of the inferior vena cava. The lobe is always well developed in quadrupedal mammals. In them the pericardium is separated from the diaphragm by a diverticulum of the right pleura—the **sinus sub-pericardiacus** (Fig. 209). With the assumption of the upright posture (in man and anthropoids) the heart sinks until it rests on the diaphragm, the sub-pericardiac sinus and azygos lobe being thus obliterated. The reappearance of the azygos lobe in man is an atavism—that is to say, a recurrence of an ancestral feature.

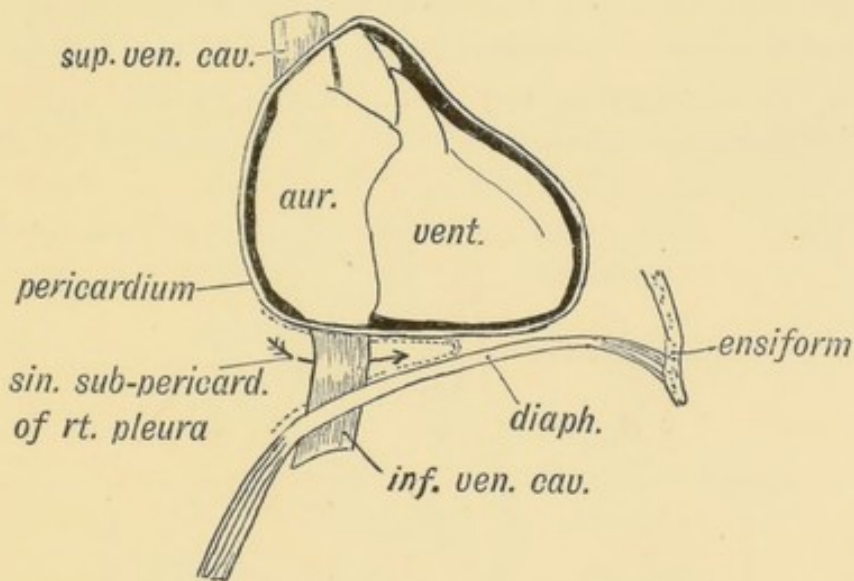


FIG. 209.—The Relationship of the Heart to the Diaphragm in Quadrupedal Mammals.

Blood Supply of the Lung.—The pulmonary aorta is formed, with the ascending part of the aortic arch, out of the bulbus or conus arteriosus (see page 230). The right and left pulmonary arteries spring as branches from the right and left 5th aortic arches (Fig. 29, p. 37). They enter the lung buds, and are carried backwards with them. The pulmonary veins grow out from the pulmonary buds and enter the left auricle through the venous mesocardium about the 3rd month (see page 246).

Changes at Birth.—When the child begins to breathe at birth the expansion of the lungs opens up the pulmonary circulation;

the foramen ovale starts to close and the ductus arteriosus begins then to contract, and within the 1st month becomes reduced to a fibrous cord. The ductus arteriosus represents the dorsal segment of the 5th left arch; the corresponding part of the right 5th arch disappears soon after it is formed.

The Larynx.—The larynx is developed in the floor of the pharynx out of the basal part of the pulmonary diverticulum. The origin of the upper aperture of the larynx has been already described (page 250). It is probable that the thyroid cartilage represents the skeletal parts of the 4th and 5th visceral arches, but this cannot be regarded as settled. There is no interval to be recognised between the hyoid bone and thyroid cartilage in the earlier stages of development. By some, the epiglottis is believed to be a derivative of the fifth arch.

Only in man and the higher anthropoids are the true vocal cords covered by stratified epithelium; but all the muscles of the human larynx are represented in the larynx of the ape, but in a less specialized condition.

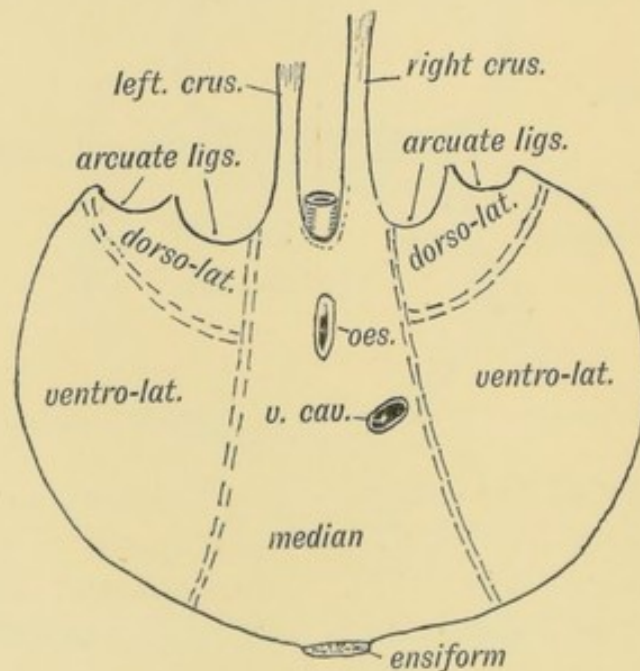


FIG. 210.—Diagram of the Diaphragm to show the Parts formed by each of the five Elements.

Occasionally the **sacculæ** of the larynx, a development from the apex of the ventricle, may protrude through the thyro-hyoid membrane, thus giving rise to an air cyst in the neck. Such

laryngeal sacs are normally developed in anthropoids after birth, and attain in them great dimensions.

The Diaphragm.—The diaphragm is developed from five elements—one mesial from the primitive mesentery, two ventro-lateral parts formed by adhesion, and two dorso-lateral formed much later (Fig. 210). In fishes, only the mesial or mesenteric element is developed; in reptiles and birds the ventro-lateral elements are added, these three parts forming the **septum transversum**. In mammals the dorso-lateral elements are developed, and thus the pleural cavities become separated completely from the peritoneal. Occasionally in man the dorso-lateral elements may fail; a communication remains between the pleura and peritoneum, through which the abdominal contents may become herniated into the pleural cavity. This occurs eight times more frequently on the left than on the right side. The explanation will be found in the manner in which the liver is developed.

Elements entering into the Formation of the Diaphragm.

1. **The Mesial or Mesenteric Element** (Fig. 210).—When the splanchnopleures meet below so as to enclose the fore-gut, they

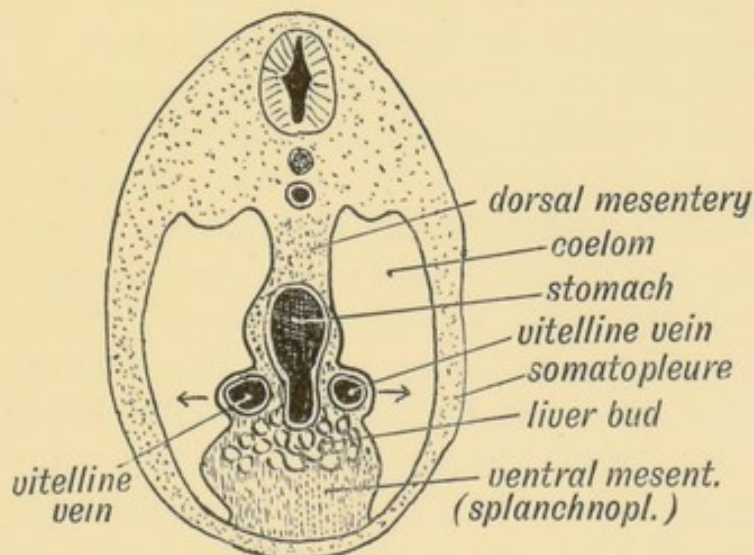


FIG. 211.—Diagrammatic section behind the Embryonic Heart to show the Part of the primitive Mesentery which forms the mesial Element of the Diaphragm.

form a mesial septum between the right and left halves of the coelom, with the gut suspended in it (Figs. 210 and 211). The part between the gut and the spine is the dorsal mesentery; the part of the septum between the gut and the ventral wall is the

ventral mesentery. In the ventral part of the mesentery below the fore-gut is swung the heart; the mesocardia disappear; but that part of the mesentery behind the heart, in which the sinus venosus rests and in which the stomach is developed, persists (Fig. 201.) The ventral and dorsal parts of the mesentery of this region form the first or mesial element of the diaphragm. In this part of the mesentery lie (Figs. 211 and 212) (1) the stomach, (2) the posterior end of the sinus venosus; (3) the vitelline and umbilical veins which pass in it to the sinus; (4) the ducts of Cuvier which enter it to reach the sinus; (5) the liver bud which is developed into it; (6) the ductus venosus and pre-renal part of the inferior vena cava which are developed in it. Further, on each side of this part of the mesentery lies the isthmus of the coelom into which the lung buds are developed and out of which the pleural cavities are formed (Fig. 205). The mesial element is situated, at first, under the middle cervical segments of the trunk.

In the course of development the stomach gradually separates itself from this part of the diaphragm; the liver bud also frees itself; the ducts of Cuvier, with the sinus venosus, also become separated from it.

2. The formation of the **ventro-lateral parts** of the diaphragm is obscure. They appear very early (3rd week), while yet the vitelline veins terminate in the sinus venosus, and before the liver bud has grown out (Fig. 187, p. 229). It will be seen from Figs. 187 and 212 that the vitelline veins pass obliquely in the ventral mesentery from the yolk sac to the sinus venosus. They are said to be the active agents in producing the ventro-lateral parts of the diaphragm. They become so dilated (see Fig. 211) as to produce their covering of splanchnopleure outwards until lateral folds are formed which come in contact with, and adhere to, the somatopleure. In this way the mesentery (mesial part of the diaphragm) becomes adherent to the lateral somatic walls. These three parts, mesial and ventro-lateral, form the **septum transversum**.

3. **The Dorso-lateral Parts.**—These parts are formed in the 3rd month, and arise as crescentic folds from the dorsum of the isthmus. They are situated at first under the cervical region and their free crescentic edges are directed backwards over the

lung buds. They are developed in mammals only, and are evidently comparatively late structural additions. In the formation of these parts of the diaphragm, which close up the pleuro-peritoneal communications, probably several other factors take part. Of these may be mentioned:

(1) The Wolffian ridges, which extend forwards as far as the cervical region, and project from the roof of the coelom at the passage between the peritoneum and pleura.

(2) The formation of the supra-renal body (Minot). It is developed in the mesoblast round this opening—partly in the septum, partly in the Wolffian ridge.

(3) The growth of the liver within the septum transversum probably plays an important part. Hence, probably, the greater frequency of diaphragmatic hernia on the left side, where the liver growth is less. By these various factors the openings are closed and the diaphragm completed by the formation of the region of the arcuate ligaments.

The diaphragm begins to develop in the neck under the 4th and 5th cervical segments. Processes from the muscle plates of these two segments enter the basis of the diaphragm and form part at least of its muscular substance. The muscle buds carry their nerve—the phrenic—with them. The descent of the heart, the retrogression of the stomach, and the development of the lungs lead to the diaphragm being pushed backwards until it assumes the adult position.

Development of the Supra-renal Bodies.—In spite of much research there is still doubt as to the origin and nature of these bodies. The cortex and medulla are certainly of different origin. In Elasmobranchs (sharks, etc.) these two elements are separate, the cortical part forming an inter-renal, unpaired body; the medullary part a body situated above the Wolffian kidney (supra-renal) on each side, and closely connected with a ganglion of the sympathetic system, in connection with which they are developed. In vertebrates above fishes the cortical and medullary parts are combined in one body. The **medulla** arises from the groups of cells which form the sympathetic ganglia; probably from the primitive cell basis of the semilunar ganglion, which is developed in the septum transversum, close to the pleuro-peritoneal canal. Hence the great plexus of nerves which pass from the solar

plexus to the medulla of the supra-renals. By the 3rd month in the human foetus these cells have lost all evidence of their origin from nerve cells, and have taken on a chromogenic function. Probably the intercarotid and coccygeal bodies are similar to the medulla in origin and nature (Swale Vincent).

The **cortical part** is of quite different origin. It is developed within the Wolffian ridge and causes or assists to cause, the closure of the pleuro-peritoneal canal over which it is formed. It arises from the endothelium covering the Wolffian ridge—that part of the ridge which lies above the diaphragm in the pleuro-peritoneal canal. The endothelium proliferates within the Wolffian ridge and comes in contact with the medullary element derived from the sympathetic. The medullary element is at first the larger and surrounds the cortical; but soon the increased growth of the cortex leads to its surrounding and containing the medulla. The cortical cells range themselves in rows between blood sinuses. Probably cortical cells invade and replace the medullary part (Minot). As the kidneys grow forwards they come in contact with the supra-renal bodies which at first lie on their ventral surface. The supra-renal is at first larger than the kidney; even at birth they are nearly equal in size. The nerves and arteries enter the bodies on their renal surface; the veins emerge on their anterior surface.

Isolated parts of the supra-renal body (accessory supra-renals) occasionally occur in the broad ligament or in the spermatic cord above the testicle. Such accessory bodies are probably derived from the cortical element which is developed within the Wolffian ridge and body. With the descent of the ovary and testicle, which bring with them the Wolffian body, adjacent accessory supra-renals, if such be present, are also brought down, and may occasionally give rise to peculiar tumours.

CHAPTER XVIII.

THE ORGANS OF DIGESTION,

Development of the Liver.—The human liver, in its development, repeats the forms met with in ascending the animal scale. In *Amphioxus* the liver is merely a caecal diverticulum of the digestive canal; in amphibians the liver is a compound tubular gland—the hepatic cells being arranged in cylinders round the bile ducts. In birds and mammals the tubular arrangement is lost and the lobular form substituted.

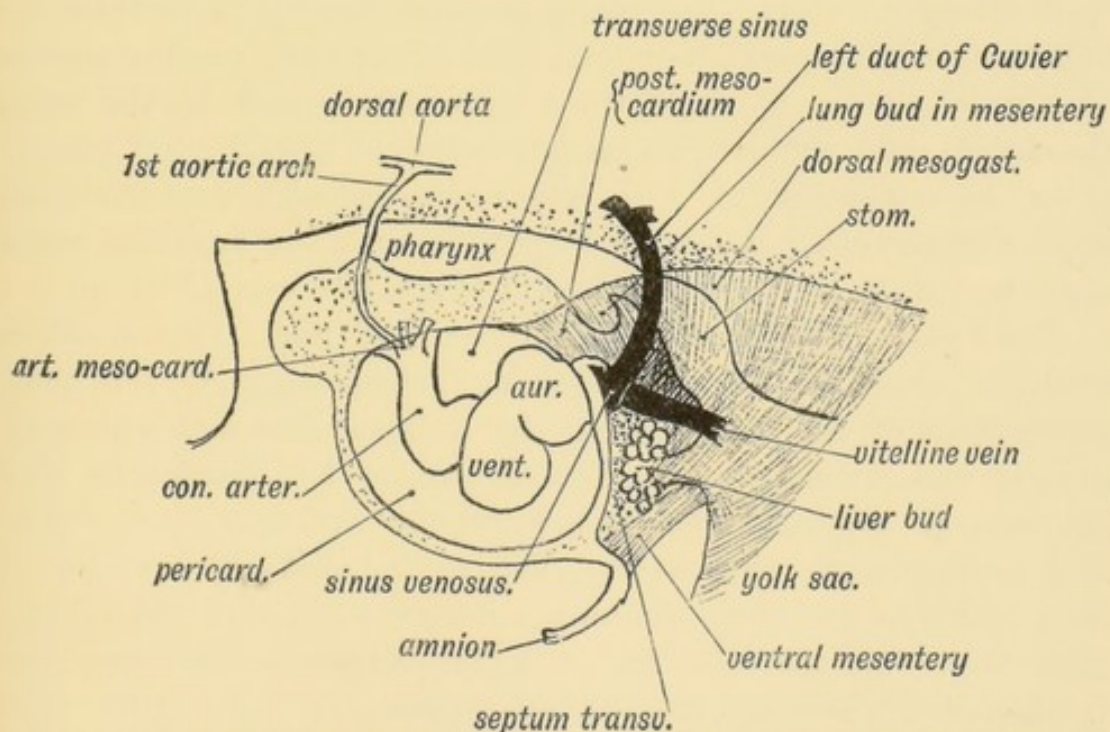


FIG. 212.—The Mesentery of the Fore-gut and its Contents, viewed from the left side (schematic).

To understand the development of the liver, the condition of parts at the commencement of the third week must be studied.

At that time, the anterior wall of the yolk-sac and that part of the fore-gut which becomes the stomach, lie in the septum transversum (Figs. 211, 212). When the liver bud grows out, it springs from the junction of the fore-gut and yolk-sac (Fig. 221); and spreads into the ventral mesentery and septum transversum. The part of the gut from which it springs afterwards becomes the second stage of the duodenum. It is at first a hollow diverticulum of the gut hypoblast (Fig. 218). The diverticulum is surrounded in the mesogastrium by a mass of mesoblastic cells which form the vessels, capsule and connective tissue of the liver. It divides almost at once into right and left solid processes of hypoblastic cells, to form the right and left lobes of the liver (Fig. 218.)

The hepatic buds are developed just behind the sinus venosus and between the vitelline veins which are also situated in the ventral mesentery (Figs. 202 and 212). The veins are broken up by the ingrowth; from them starts an invasion of venous capillaries, which, with the mesoblast of the septum transversum, penetrates the liver buds and breaks the solid processes of hypoblast into reticulating cylinders. Secondary processes start from the primary hepatic reticulating cylinders and form smaller and smaller meshes of hepatic cells. By the third month the hepatic lobules, with the intra- and sub-lobular arrangement of portal and hepatic veins, have appeared. The bile ducts probably represent the lumina of the original tubular hepatic buds. The umbilical veins also are cut by the hepatic invasion (Figs. 188 and 190).

The liver develops rapidly; in the 2nd and 3rd months it occupies more than half the abdominal space. At the commencement of the 2nd month, the yolk-sac becomes gradually smaller and, owing to the development of the duodenum and jejunum, it gradually retreats from the abdomen and region of the diaphragm and liver. The second and third stages of the duodenum and the jejunum are developed behind the ventral mesentery. As the liver grows it gradually frees itself from the diaphragmatic part of the ventral mesentery. The right lobe develops more rapidly than the left and comes in contact with the inferior vena cava. The stomach also frees itself from the basis of the diaphragm and comes to lie with the liver in the mesentery. The common bile duct is developed out of the hollow stalk of the

hepatic bud. So is the common hepatic duct, while the right and left hepatic ducts are formed from the stalks of the processes which form the right and left lobes of the liver. The gall

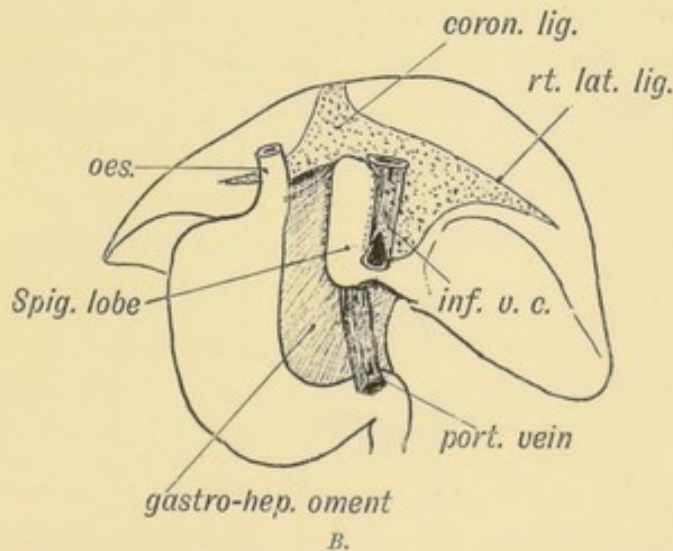
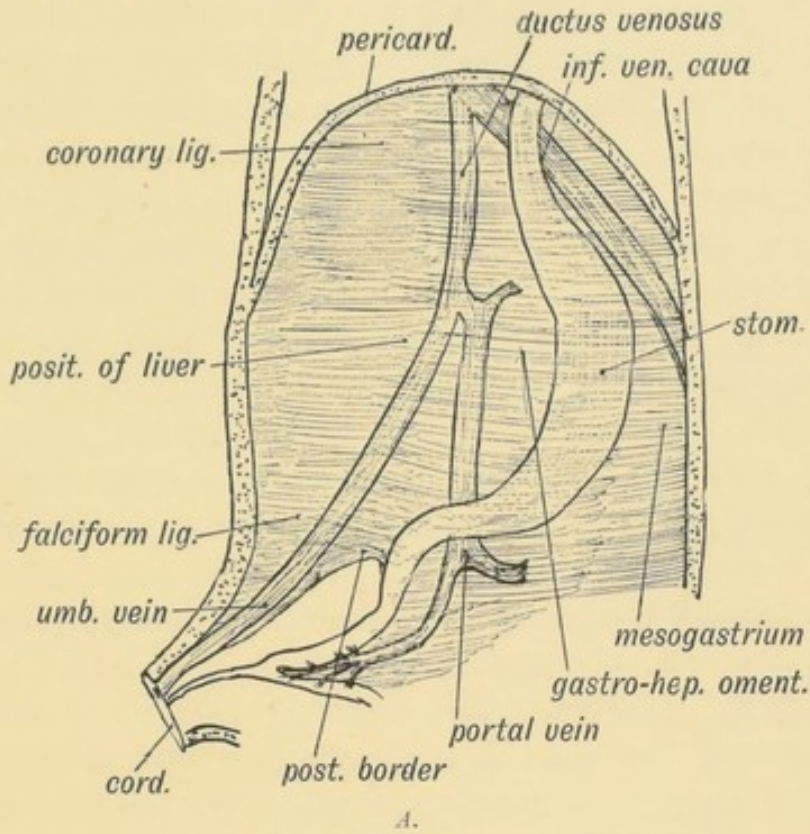


FIG. 213.—The origin of the Peritoneal Ligaments connected with the Liver.

- A. Diagram of the foetal relationship of the ventral mesentery to veins and the stomach, the liver being removed.
- B. The liver viewed from behind to show its relationship to the gastro-hepatic omentum, part of the ventral mesentery.

bladder arises as a diverticulum of the common bile duct. (Fig. 218.)

The Ligaments of the Liver.—When the liver grows out from the septum transversum it withdraws within the ventral mesentery. Out of the ventral mesentery are formed all the ligaments of the liver (Fig. 213 *A*). These are the following:

1. **The Gastro-hepatic Omentum** is that part of the ventral mesentery which passes from (1) the oesophagus, (2) lesser curvature or ventral border of stomach, and (3) first stage of duodenum to (1) the diaphragm, (2) the posterior part of the longitudinal fissure of the liver, the ductus venosus lying within its hepatic attachment, and (3) the transverse fissure of the liver (Fig. 213 *B*). The portal and umbilical veins lie in the ventral mesentery (Fig. 213 *A*); the hepatic artery passes by it to the liver. The right or free border of the gastro-hepatic omentum, with the falciform ligament containing the remnant of the umbilical vein, represents the posterior border of the primitive ventral mesentery (Fig. 213 *A*).

2. **The Falciform Ligament**, containing the umbilical vein, also represents part of the ventral mesentery (Fig. 213 *A*). At an early stage the umbilical veins reached the sinus venosus by passing through the septum transversum. The development of the liver led to its being thrust out within the falciform ligament.

3. **The coronary, the right and left lateral ligaments, and the attachments to the vena cava and diaphragm** (Fig. 213 *B*) are developed as the liver emerges from the septum transversum, and separates itself from the diaphragm.

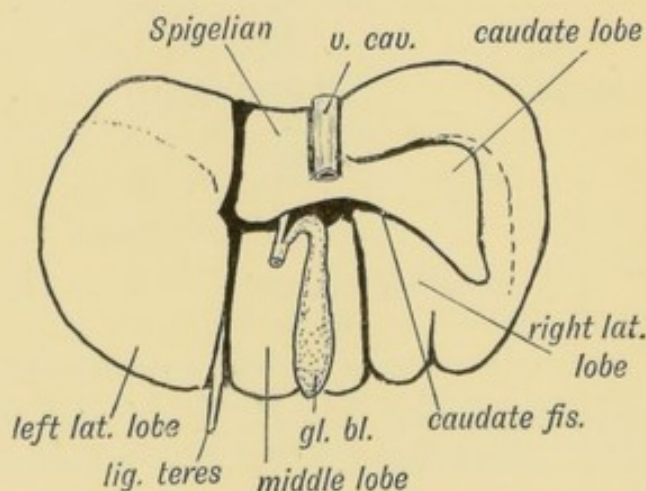


FIG. 214.—Diagram of a mammalian Liver viewed from behind and below.

Morphology of the Liver.—The liver of orthograde animals

(man, anthropoids) differs widely in form and lobulation from that of mammals generally, but Professor Arthur Thomson has shown that traces of the fissures and lobes of the typical mammalian liver can be seen in the human organ. The liver of a dog or dog-like ape consists of three main lobes—right, middle and left, and two accessory lobes—the caudate and Spigelian (Fig. 214). In man the right and middle lobes have fused, but traces of the fissure which separates them (the right lateral fissure) are frequently to be seen in the liver of the newly-born child (Fig. 215). The **caudate lobe** has been reduced in man to a vestige, but in the third month foetus it is of considerable size (Fig. 215). It projects from the liver at the upper boundary of the foramen of Winslow; in many animals it rivals the right lobe in size. The caudate fissure separates the caudate from the right lobe, and a trace of this fissure is very frequently to be seen in the human liver (Fig. 215).

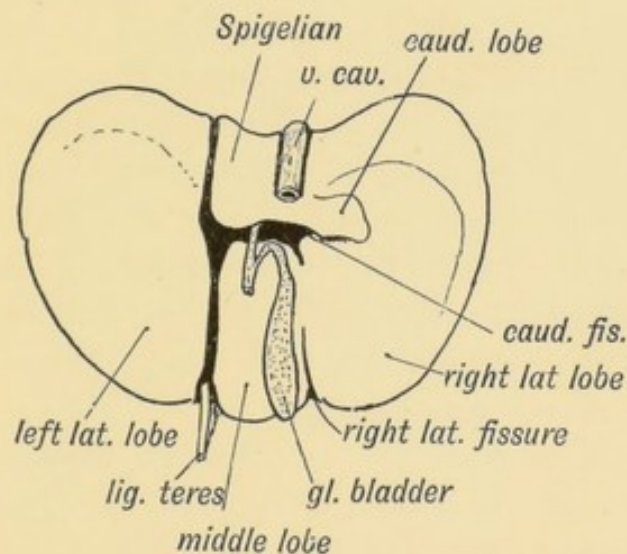


FIG. 215.—The lower surface of the Liver of a human foetus during the 3rd month, showing Vestiges of Fissures and Lobes of the typical mammalian Liver.

After the second month the growth of the right lobe is more rapid than that of the left. At birth the left lobe still touches the spleen, a relationship more frequently retained in women than in men. Riedel's lobe is a linguiform prolongation of the right lobe below the 10th right costal cartilage caused by compression.

Gall Bladder.—It is developed from the common stalk (common bile duct) as a diverticulum in the second month (Fig.

218). It may represent a modified lobule of the liver. In some animals it is absent. The cystic duct represents the stalk of the bud.

The Oesophagus and Stomach.—The Oesophagus in a third week's foetus is the junctional piece of fore-gut that unites the pharynx to the scarcely differentiated stomach (Fig. 202, p. 244). It is extremely short, but with the development of the lungs and recession of the diaphragm it becomes elongated. In the foetus the mucous membrane is thrown into four longitudinal folds which end abruptly at the orifice of the stomach in a circular epithelial ridge which sometimes persists and acts as a valve at the cardiac orifice of the stomach. These four ridges can be seen in adult apes. At one stage of development the cervical part of the oesophagus is filled with epithelium and thus closed.

The Stomach.—The stomach is developed out of that part of the fore-gut which lies between the oesophagus and pharynx in front and the yolk sac, duodenum and liver bud behind (Fig. 187, p. 229). At first it is contained in that part of the primitive mesentery to which the name of septum transversum has been given, and is situated below the lower cervical and upper dorsal region of the spine (Fig. 204). In the 3rd week the gastric part of the fore-gut shows a dorsal bulging—the greater curvature. As the liver and gut are developed, the stomach separates itself from the septum transversum and comes to be suspended from the dorsal wall of the coelom by the **dorsal mesogastrium** (Fig. 213 *A*). The gastro-hepatic omentum is part of the **ventral mesogastrium**. The oesophageal end of the stomach is fixed in the septum transversum (diaphragm); the outgrowth of the liver bud fixes its pyloric end in the ventral mesogastrium. Three changes quickly ensue, the one being partly dependent on the other:

(1) Its dorsal margin grows rapidly so as to produce the greater curvature; this growth particularly affects the left side of the cardiac end of the stomach and thrusts the attachment of the dorsal mesogastrium towards the right side at the cardiac end of the stomach. The greater part of the fundus or cardiac sac of the stomach is produced from the left side.

(2) The dorsal mesogastrium being too limited in extent to allow for the growth of the greater curvature, the stomach

rotates so that its left surface, with the left vagus nerve, comes to be anterior; the other posterior.

(3) To allow this rotation to take place and probably for some other unknown reason, part of the dorsal mesogastrium, which is attached to the great curvature or dorsal border of the stomach, undergoes a rapid growth and forms the **great omentum** (Fig. 214).

The stomach loses its original vertical position only to a slight degree; even in the adult the pyloric orifice lies not far from the middle line; the oesophageal slightly to the left of it. The glands of the stomach begin to form during the third month. They appear as tubular invagination of the gastric hypoblast. The peptic cells are formed by the 7th month.

The Spleen.—The Spleen appears in the dorsal mesogastrium above the cardiac end of the stomach (Fig. 216) and grows out on the left surface of the mesogastrium (Fig. 217). It

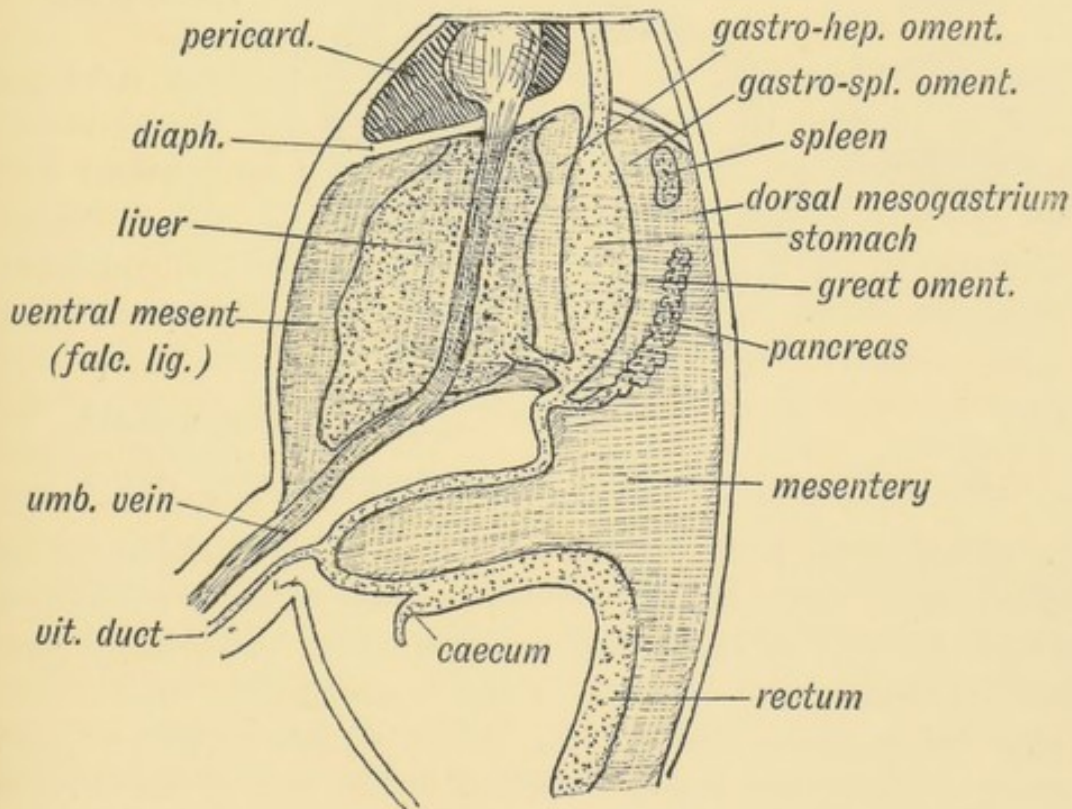


FIG. 216.—The Relationship of the Spleen, Pancreas, and Liver to the Mesogastrium in the Embryo.

appears at the end of the second month by a collection of lymphoid follicles in the mesoblast of the mesogastrium. The tail of the pancreas (Fig. 216) reaches its point of origin. The

splenic artery is one of the vessels of the mesogastrium (Fig. 219), its branches end in the developing tissues of the spleen. The splenic blood spaces are probably formed from the veins which in the developing spleen are lined by a layer of columnar cells. The trabecular and muscular tissue and the capsule are derived from the mesoblast of the dorsal mesogastrium.

The **gastro-splenic omentum** is that part of the dorsal mesogastrium which unites the spleen to the stomach (Figs. 216 and 217). It becomes elongated and stretched as the stomach rotates.

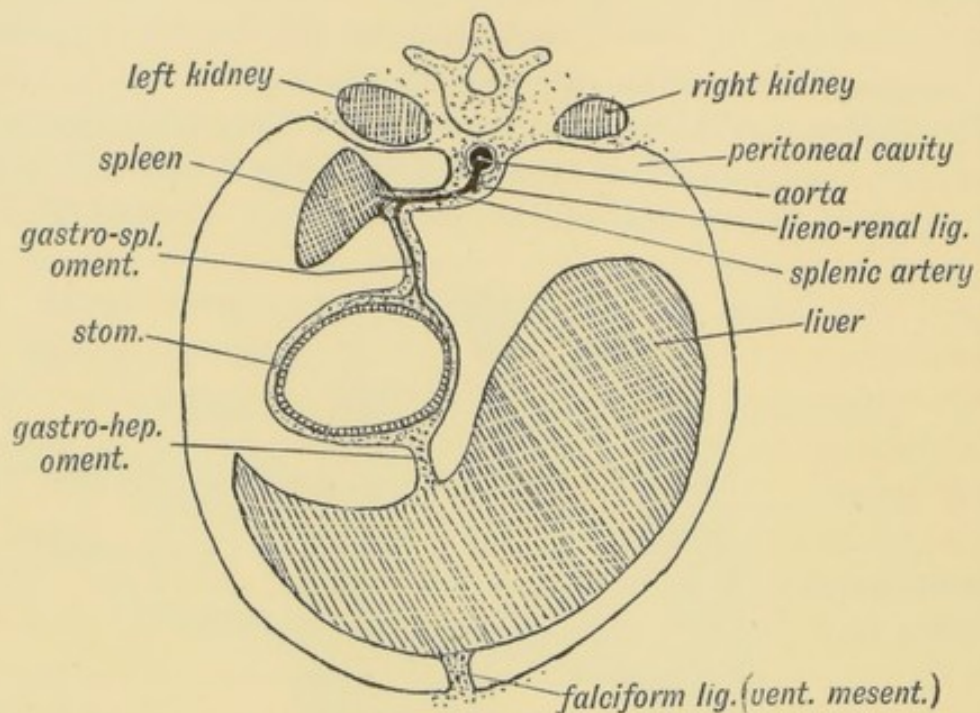


FIG. 217.—A diagrammatic transverse Section of the Mesogastrium viewed from behind.

The spleen comes to lie against the posterior (right) surface of the cardiac end of the stomach. The dorsal part of the mesogastrium between the roof of the coelom and the spleen becomes the **lieno-renal ligament**. The rotation of the stomach also leads to the spleen being thrust towards the left side; the upper or renal surface of the spleen becomes applied to the peritoneum covering the anterior surface of the left kidney (Fig. 217). The part of the mesogastrium between the spleen and oesophagus adheres to the diaphragm and forms the suspensory ligament of the spleen.

The Pancreas.—The Pancreas appears during the 4th week as two, or perhaps three, processes of hypoblast from that part of the gut which afterwards becomes the second stage of the

duodenum (Fig. 218). Of the two buds, one is a minor process which springs from the ventral aspect of the duodenum in common with the hepatic diverticulum. This ventral bud only

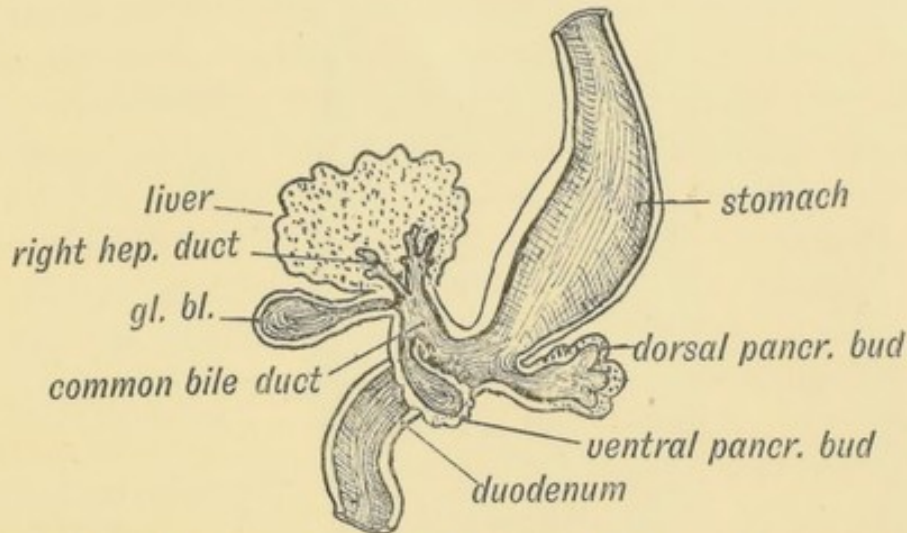


FIG. 218.—The Pancreatic and Hepatic Processes of a 4th week human embryo. (After Kollmann.)

forms the lower part of the head of the pancreas. The greater part is formed from a process which springs from the dorsal border of the duodenum, nearer the stomach than the ventral process, and grows into the dorsal mesogastrium above the stomach until it reaches the spleen (Fig. 219). It unites in the mesogastrium with the ventral bud. The ducts of both processes may persist, the duct of the dorsal bud (duct of Santorini) opening half an inch above the opening of the bile duct; the duct of the ventral bud (Wirsung's) opens with the common bile duct. The terminal part of the duct of Santorini commonly becomes obliterated, and even if it persists the secretion from the dorsal bud reaches the duodenum mostly through the duct of the ventral bud—the duct of Wirsung (Fig. 218). A third pancreatic bud has been observed in the human embryo. It arises from the ventral aspect of the gut, and corresponds to a third bud observed in the development of the pancreas in lower vertebrates.

The developing pancreatic processes are at first hollow, like the primary liver process, but the secondary processes are solid and cylindrical. They divide and re-divide, acquire lumina, and form an acino-tubular gland. The capsular and connective tissue of the pancreas are derived from the mesoblast of the dorsal mesentery.

Relationship of the Pancreas to the Peritoneum and Vessels.

1. **In the Embryo.**—The pancreas develops between the layers of the dorsal mesogastrium (Fig. 216); it is completely sur-

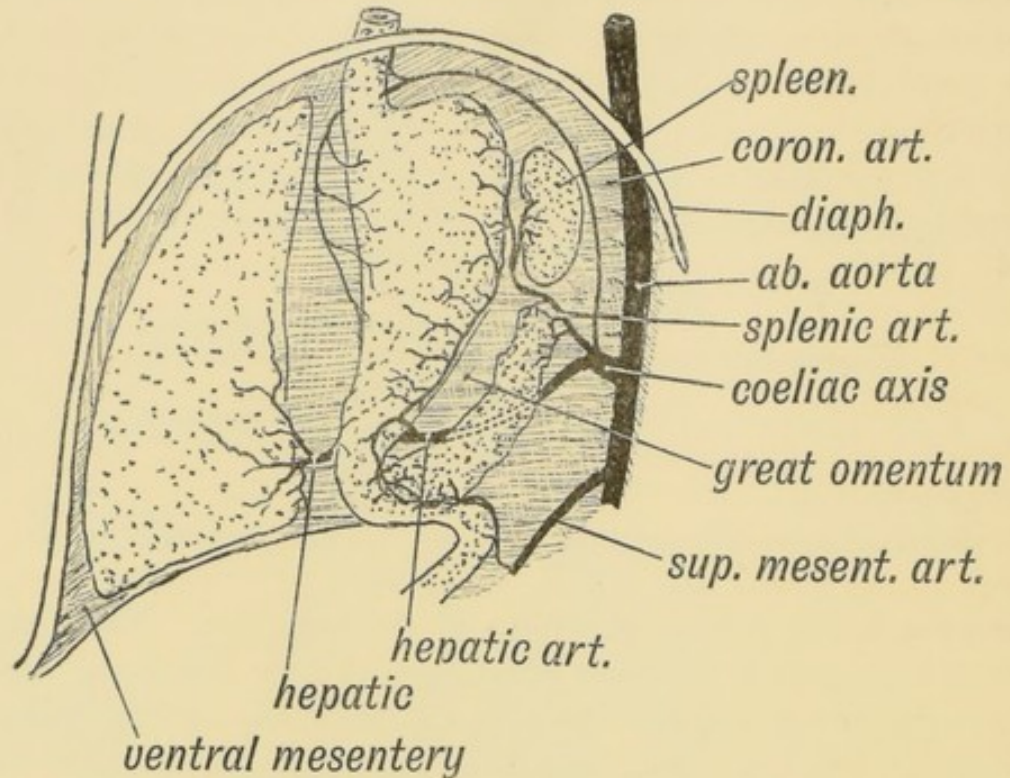


FIG. 219.—The Arrangement of Vessels in the Dorsal Mesogastrium during the 5th week (diagrammatic).

rounded by peritoneum, and it lies with its tail directed forwards against the spleen and its head on the dorsal bend of the duodenum. It is parallel to the great curvature (dorsal border) of the stomach. This is the relationship during the 5th and 6th weeks. The dorsal mesogastrium is then attached in the middle line, in front of the aorta. The coeliac axis (Fig. 219) is the artery of the mesogastrium and of the structures which it contains. It supplies the fore-gut and its derivatives, between the septum transversum in front and yolk sac behind. The coronary artery passes direct to the cardiac end of the stomach; the splenic is a short vessel ending on the cardiac dilatation of the stomach and supplying the spleen; the hepatic passes on the right side of the pancreas to the duodenum and pyloric end of the stomach, and ends in the liver by passing through the ventral mesentery.

2. **In the Adult.**—The development of the great omentum

and the rotation of the stomach to the left lead to the pancreas being pressed against the posterior wall of the abdomen on the left side. That part of the dorsal mesogastrium which lies between the stomach and pancreas becomes elongated enormously to form the **great omentum**, and hence the two anterior layers of the great omentum are attached to the great curvature of the stomach and to the gastro-splenic omentum (Fig. 219). The two posterior layers of the omentum end on the lower (formerly ventral) border of the pancreas. The duodenal loop, with the head of the pancreas in its concavity, is also pressed against the posterior abdominal wall. During all the changes which take place in the position of the pancreas and spleen, owing to the rotation of the stomach and intestine, one structure remains firm, and that is the coeliac axis. The part of the mesogastrium in which the spleen and tail of the pancreas are situated becomes greatly drawn out. Both structures, instead of being situated near the middle line dorsal to the stomach, come to occupy a situation in front of the left kidney, the pancreas thus

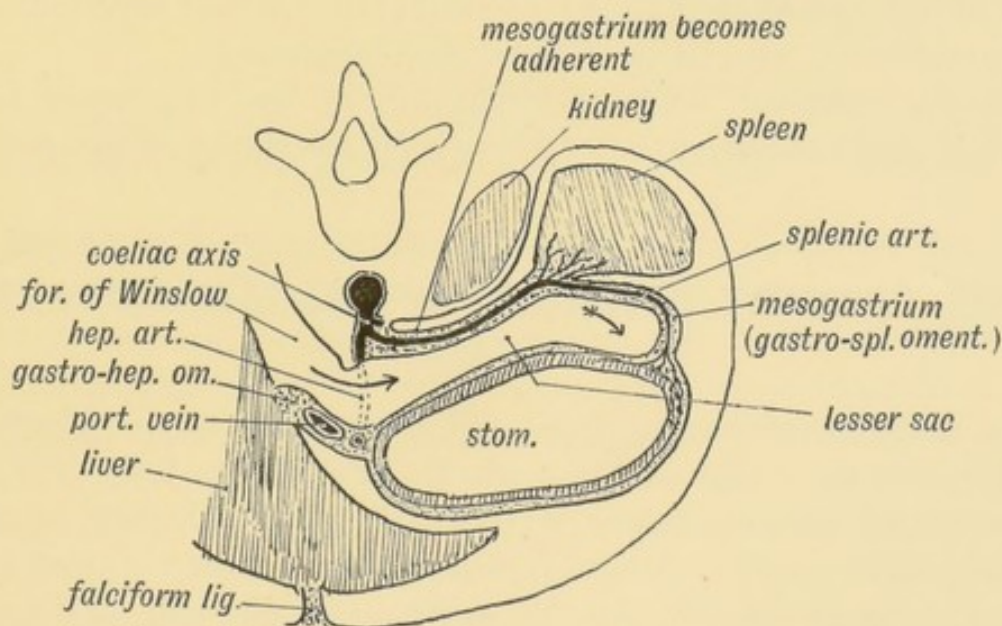


FIG. 220.—Diagram to show the Formation of the Lesser Sac of the Peritoneum from the Dorsal Mesogastrium.

coming to lie across, instead of along, the abdominal cavity. The mesogastrium is ballooned out towards the left side to form the lesser sac of the peritoneum, and as the splenic artery lies in the mesogastrium it also is drawn towards the left, circumventing the lesser sac of the peritoneum (Fig. 220).

In the 5th week the pancreas lies between the layers of the dorsal mesogastrium; thus right and left surfaces are covered by peritoneum. The left surface, which becomes anterior, retains its covering, but the right becomes applied to the posterior abdominal wall in front of the aorta, crura of the diaphragm and left kidney (Fig. 220). Its peritoneal covering gradually disappears, and thus in the adult the pancreas comes to appear as if it lay behind and outside the cavity of the peritoneum. The complete application and fixation of the pancreas to the posterior abdominal wall only occurs in animals adapted to the upright posture.

The part of the dorsal mesogastrium between the pancreas and aorta (Fig. 219) is also applied to the posterior abdominal wall, and forms the posterior wall of the lesser sac.

The Lesser Sac is really the bursa of the stomach. In its anterior wall are situated (Fig. 220): (1) The gastro-hepatic omentum or ventral mesentery, which is at first vertical and median; (2) The stomach; (3) The gastro-splenic omentum, a part of the dorsal mesentery; (4) The two anterior layers of the great omentum, also parts of the dorsal mesentery.

In its posterior wall are situated: (1) The lieno-renal ligament (dorsal mesentery); (2) The dorsal mesentery of pancreas.

THE PRIMARY DIVISIONS OF THE ALIMENTARY CANAL.

At the commencement of the 3rd week the embryo appears to be situated as a cap on the yolk sac (Fig. 75, p. 96). As the chorion and amnion represent the extra-embryonic part of the somatopleure, so the yolk sac represents the extra-embryonic part of the splanchnopleure (Fig. 72, p. 93). At the end of the 3rd week the alimentary tract shows three divisions (Fig. 221):

1. A short anterior diverticulum—the **fore-gut**; it becomes the pharynx, oesophagus, stomach, and that part of the duodenum situated in front of the opening of the common bile duct;

2. The **hind-gut**—a short posterior diverticulum; it forms the rectum, sigmoid and descending colon; its terminal part forms the cloaca from which the allantois grows out;

3. The **mid-gut** or roof of the yolk sac, from which is formed that part of the gut between the opening of the common bile duct in front to the splenic flexure of the colon behind. Only the fore-gut has a ventral mesentery; the mid-gut and hind-gut (excepting the cloaca) are suspended by a dorsal mesentery only.

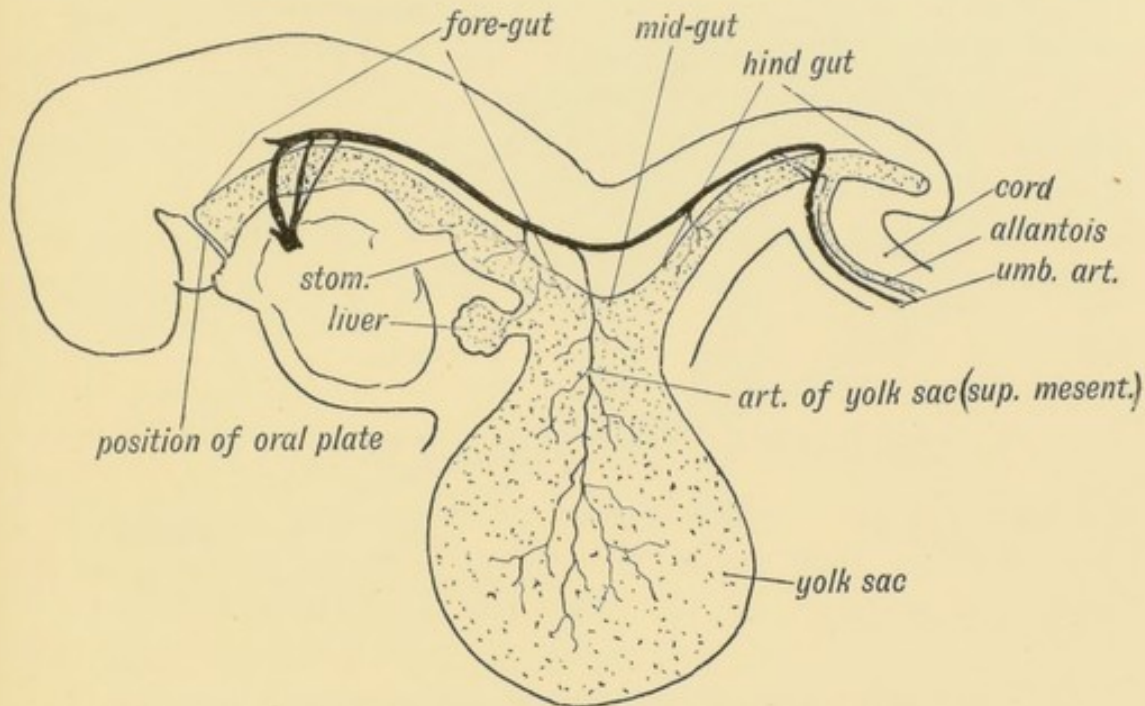


FIG. 221.—The Form of the Alimentary Canal in a human embryo of the 3rd week.

The Yolk Sac and Meckel's Diverticulum.—The fore and hind gut may be regarded as diverticula of the yolk sac. The yolk sac reaches its maximum size in the 4th week. In the 3rd week the umbilicus extends along the whole length of the abdomen, from the septum transversum to the allantois. The neck of the yolk sac completely fills it. The vitelline arteries, which afterwards form the superior mesenteric, end on its walls, the vitelline veins commence on them (Fig. 221).

In the **fifth week** the form of the alimentary tract is that shown in Fig. 222. The condition then differs from that shown in the 3rd week in the following points:

1. The production of the mid-gut as a **U-shaped loop** from the roof of the yolk sac;
2. The formation of a long neck to the yolk sac—the **vitello-intestinal canal**; if it persists it forms a Meckel's diverticulum;
3. The yolk sac, by the constriction of the umbilical orifice

and formation of the cord, comes to lie on the placenta (Fig. 222). The neck of the yolk sac, the vitello-intestinal duct, lies within the umbilical cord. By the sixth week the sac is in a state of

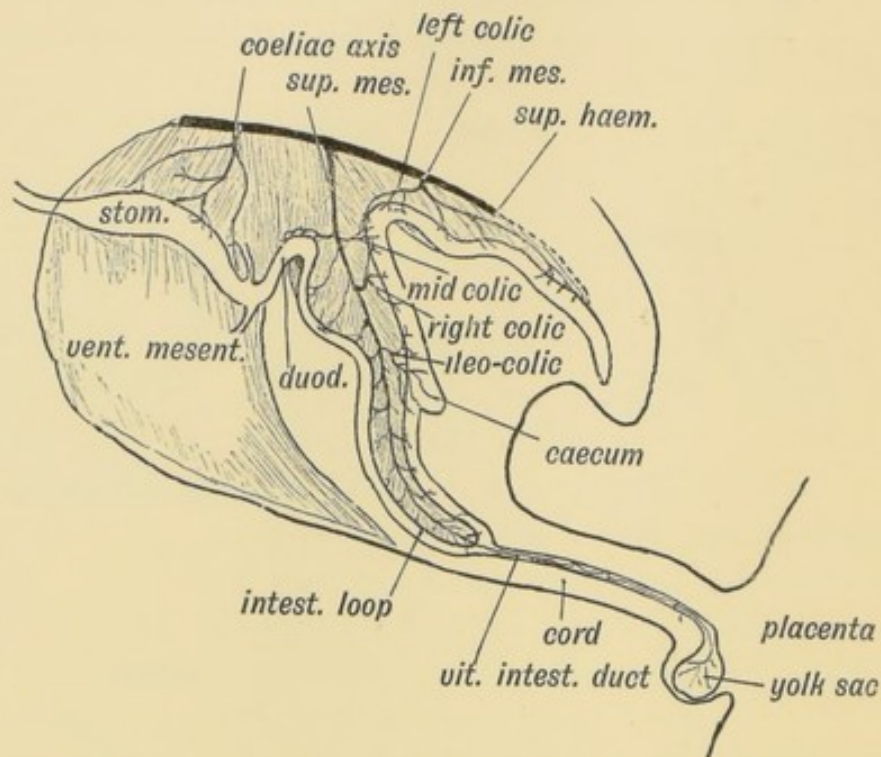


FIG. 222.—The Form of the Alimentary Canal during the 5th week.

retrogression. The U-shaped intestinal loop, which is formed from the mid-gut, is at first really extra-abdominal, being situated within a funnel-shaped cavity formed by the somatopleure at the umbilicus. The vitelline artery, afterwards the superior mesenteric, is the artery of the U-shaped loop; it terminates at the vitello-intestinal canal—the elongated neck of the yolk sac (Fig. 222).

Persistence of Certain Embryonic Structures.—Many of the features seen in the human embryo at the stage of development reached during the fifth or sixth weeks may persist.

1. The most common structure to remain is the intestinal end of the neck of the yolk-sac—**Meckel's diverticulum**. It occurs in 2 per cent. of subjects, and commonly forms a finger-glove-like sac on the free border of the ileum about four feet above the ileo-caecal valve. Hence we know that this part of the ileum forms the apex of the U-shaped loop of intestine.

2. The neck of the yolk sac, instead of closing, may remain open at the umbilicus and form a faecal fistula at birth.

3. The artery of the yolk-sac, the terminal part of the superior mesenteric, may persist as a fibrous band which stretches from the mesentery at the situation of Meckel's diverticulum to the umbilicus. Over it, the gut may become strangulated.

4. The U-shaped loop, instead of retreating within the abdomen at the end of the second month, may remain within the umbilical funnel of somatopleure. This gives rise to a congenital umbilical hernia. Such hernias occur in all degrees; they may contain a piece of intestine, or almost the whole of the abdominal contents. In such cases the somatopleure, or belly wall, which forms the covering of the hernia, is commonly thin and transparent.

DERIVATES OF THE HIND-GUT.

The **Rectum** and **cloaca** are formed out of the posterior end of the hind-gut. The manner in which they become separated from the allantois and open in the proctodaeum at the anal depression has been described (page 118).

The **Descending Colon** and **Sigmoid Flexure** are also formed out of the hind-gut. The artery of the hind-gut is the inferior mesenteric (Fig. 222). Hence it supplies the rectum, sigmoid, and descending colon. In the fifth week the hind-gut is suspended from the front of the aorta and spine by the dorsal mesentery of the hind-gut. This becomes transformed into the meso-rectum, meso-sigmoid and descending meso-colon. The angle between the hind-gut and U-shaped loop becomes the splenic flexure (Fig. 222). At the commencement of the third month the U-shaped loop has become twisted round on the axis of the superior mesenteric artery (Fig. 223 *A*), so that the part of the hind-gut which forms the splenic flexure is turned forwards and to the left until it touches the spleen (Fig. 226). It carries its artery, the left colic, with it. At this time the anterior limb of the U-loop grows rapidly, and is produced into coils of small intestine—the jejunum and ileum—which press the descending meso-colon against the kidney and the parietal peritoneum covering the left kidney (Fig. 223 *B*). The left surface and layer of the meso-colon adheres to the pre-renal layer of the peri-

toneum, both layers subsequently being absorbed. Thus the descending meso-colon, originally situated in the middle line, comes to be attached in the left lumbar region.

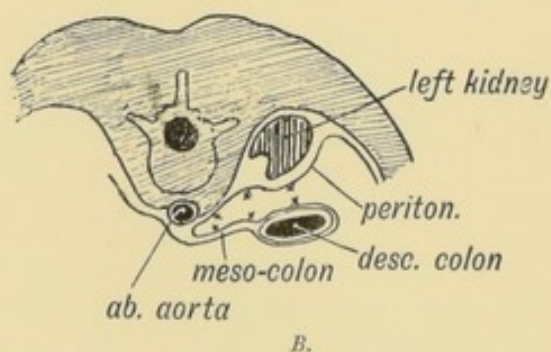
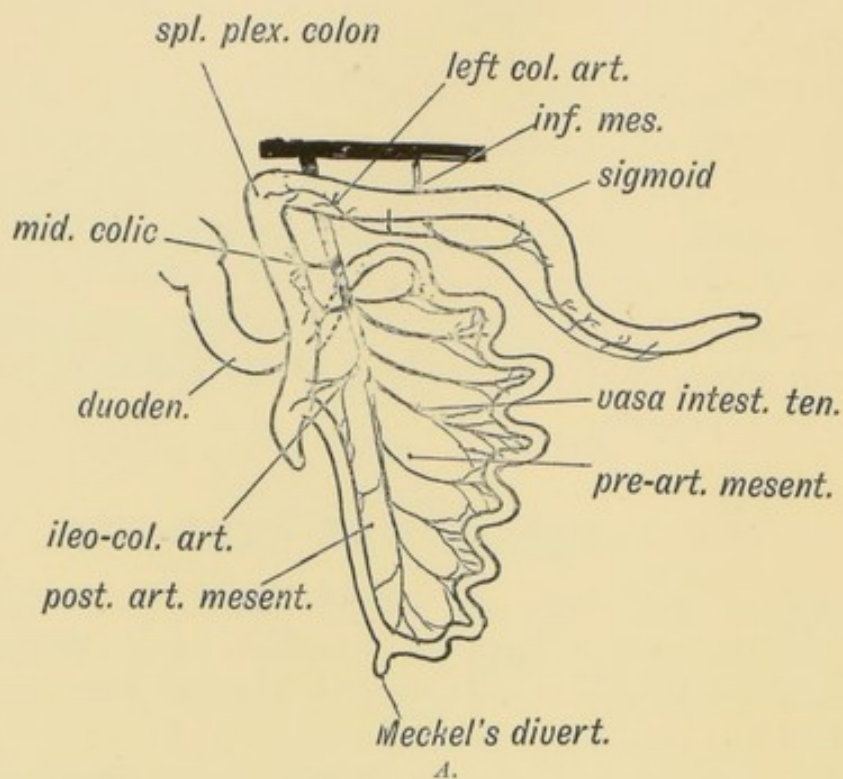


FIG. 223 A.—The mesentery of the hind-gut. The Position assumed by the Colon after the rotation of the Gut has taken place.

FIG. 223 B.—Diagram to show how the descending Meso-colon becomes applied to the parietal Peritoneum of the left Lumbar Region.

The Intersigmoid Fossa.—The sigmoid flexure, after the rotation of the gut, forms a loop, with its convexity directed towards the liver. The meso-sigmoid is originally attached in the middle line, but the pressure of the developing loop of small bowel pushes the meso-sigmoid against the posterior abdominal wall and left iliac fossa. The extent to which it adheres varies; it may become completely adherent like the descending meso-colon,

or only partially. When the sigmoid is lifted up a recess or fossa may be apparent beneath the meso-sigmoid, to the outer side of the left common iliac artery, which is due to a failure of adhesion between the meso-sigmoid and parietal peritoneum. It occurs opposite the convexity of the sigmoid loop.

Development of the Colon and Caecum.—In the sixth week a process or diverticulum is seen to grow out from the free border of the posterior limb of the U-shaped loop (Fig. 225 *A*). The

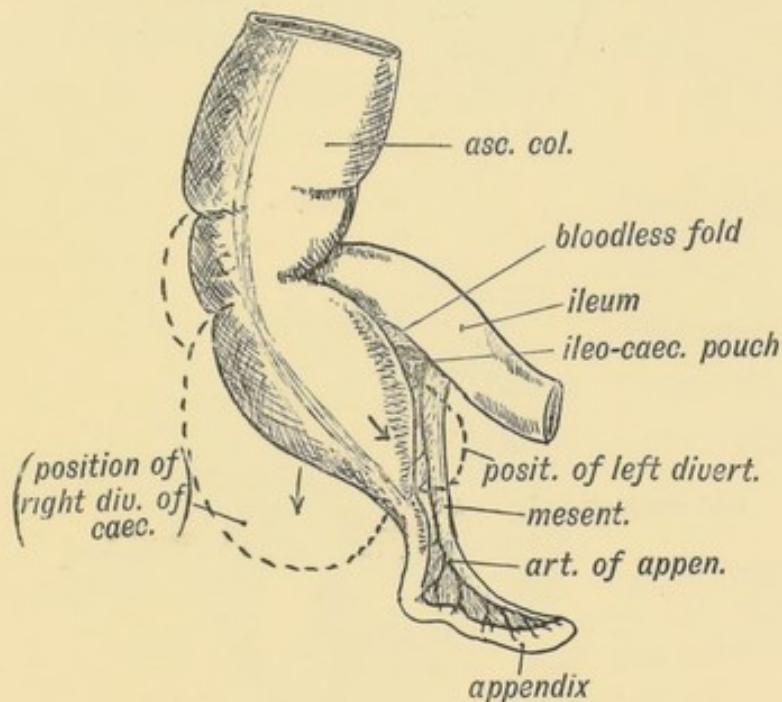


FIG. 224.—Diagram of the Apex of the Caecum at the time of birth and the Diverticula which may be produced in the Fundus of the Caecum afterwards.

diverticulum forms the caecum and appendix. It continues to grow outwards and downwards. The part of the posterior loop above the caecal diverticulum becomes increased in diameter and forms the ascending and transverse parts of the colon. As the superior mesenteric (vitelline) artery descends in the loop, it gives off three branches to the posterior limb—the middle colic, right colic and ileo-colic arteries (Figs. 222 and 223 *A*). The mesentery of the U-shaped loop may be divided into two parts, the fate of the two parts being different:

1. The mesentery of the anterior limb in front of the superior mesenteric artery—the **pre-arterial part**. This forms the greater part of the mesentery of small bowel.
2. The mesentery of the posterior limb, behind the artery—the

post-arterial part. It forms the mesentery of the ascending and transverse colon and also the lower part of the mesentery of the small bowel.

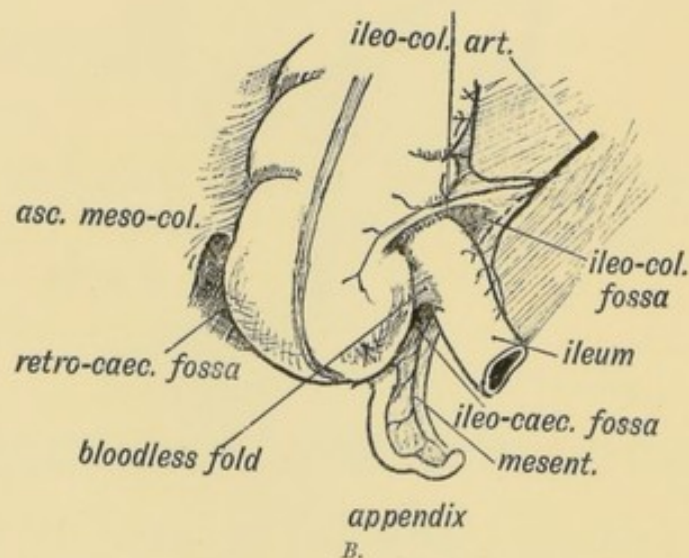
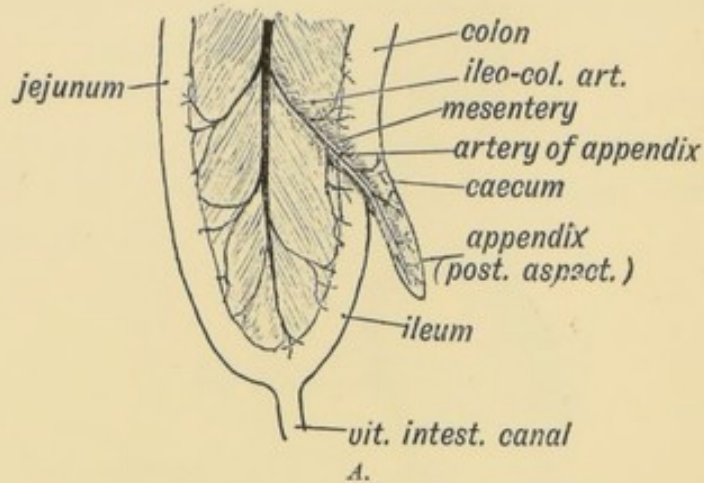


FIG. 225 A.—The Appendix and Peritoneal Folds at the end of the 2nd month of foetal life. The Intestinal Loop is viewed from the left side.

FIG. 225 B.—Peritoneal Fossae in the Ileo-caecal Region.

At the seventh week the great growth of the anterior limb, to form the coils of the jejunum and ileum, causes the U-shaped loop to rotate so that the splenic flexure of the colon comes against the spleen. This brings the transverse meso-colon, containing the middle colic artery, against the part of the mesogastrium which forms the great omentum (Fig. 226). These two layers adhere. The rotation places that part of the loop mesentery, which forms the ascending meso-colon, against the duodenum, and at the same time the duodenal loop is pressed into its

permanent position in front of the right kidney and inferior vena cava. The caecum thus comes to be situated in front of the right kidney, near the gall-bladder, and there it remains until about the time of birth, when both the caecum and ascending colon undergo a gradual migration towards the right iliac fossa. The cause of this migration is not known, but it occurs only in animals adapted to the upright posture. Thus the attachment of the ascending meso-colon is formed by a secondary adhesion to the parietal peritoneum during the migration of the colon and caecum. The appendix, during the migration, may be caught behind the colon; it is then lodged and fixed in the ascending meso-colon.

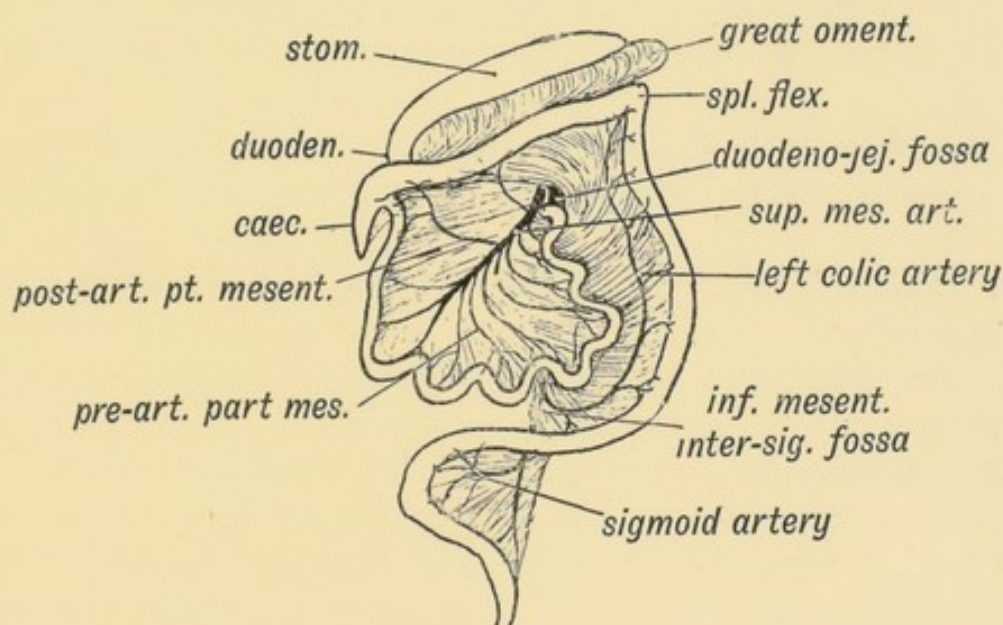


FIG. 226.—To show the Rotation of the Intestinal Loop and Formation of the Duodeno-jejunal Fossa.

The Appendix.—At first and until the third month, the caecal diverticulum is of the same calibre throughout, but from the third month onwards, the appendix remains small while the caecum grows, keeping pace in diameter with the colon. At birth the appendix is still the tapered apex of the caecal diverticulum (Fig. 224), but during childhood, an outer, or an inner, sacculation, or both together, arise in the fundus of the caecum and thrust the appendix backwards and to the left into an asymmetrical position.

Although a distinctly marked appendix is only seen in man, the anthropoids, lemur, and opossum, still a corresponding

lymphoid structure is present generally in mammals. The appendix is a lymphoid diverticulum of the caecal apex (R. J. Berry). It must be regarded as a lymphoid structure, and although it can be dispensed with, is not therefore to be regarded as vestigial in nature any more than is the tonsil. The caecum is largest, as is also the bowel, in herbivorous animals.

Ileo-caecal Fossae.—When the caecal diverticulum grows out from the hinder limb of the U-shaped loop it carries with it three folds (see Fig. 224):

1. **The ileo-colic fold**, a process from the right side of the mesentery containing the anterior caecal artery;
2. **The bloodless fold**, a process from the coat of the ileum;
3. **The mesentery of the appendix**, a process from the left side of the mesentery, containing the artery to the appendix (Fig. 225 *A*).

These three folds give rise to three **fossae** (Fig. 225 *B*):

1. **The ileo-colic**, between the termination of ileum and ileo-colic fold;
2. **The ileo-caecal**, between the bloodless fold and mesentery of the appendix;
3. **The retro-caecal**, between the mesentery of the appendix and commencement of the ascending meso-colon.

The Duodenum.—The part of the duodenum above the entrance of the common bile-duct is formed from fore-gut, the part behind from the mid-gut. The liver and pancreatic buds arise from its ventral border at the junction of these two parts. At first it is entirely covered by peritoneum and suspended in the mesentery, in which it forms a minor loop (Figs. 219, 222). In its concavity rests the head of the pancreas.

In the 7th week the U-shaped loop of intestine rotates so as to bring the ascending colon, with its mesentery, against the duodenal loop, which, with the head of the pancreas, is thus pressed against the right kidney and inferior vena cava (Fig. 226). The peritoneum covering the right aspect of the head of the pancreas and duodenal loop adheres to the parietal peritoneum covering the kidney, and disappears. The transverse meso-colon gains an attachment to the front of the duodenum.

The Duodeno-jejunal Fossa is formed as the U-shaped loop of bowel rotates, dragging the transverse meso-colon after it (Fig.

226). The inferior mesenteric vein passes forwards along the dorsal mesentery to the splenic vein, which is also then in the dorsal mesentery (Fig. 187, p. 229). The mesentery of the hind-gut is stretched as the ascending colon migrates to the right; the inferior mesenteric vein checks it and gives rise to a fold, which bounds the fossa (Fig. 226).

The Mesentery of the small gut is formed out of the primitive mesentery of the U-shaped intestinal loop, chiefly from that part of it (the pre-arterial) which lies between the superior mesenteric artery and the anterior limb of the loop (Fig. 223 *A*). After the rotation, the aspect of the mesentery, which was directed towards the right, becomes left and anterior. During the rotation of the gut the superior mesenteric artery comes to lie in front of the third stage of the duodenum. At first the mesentery is attached in front of the spine only at the origin of the superior mesenteric artery. Its oblique attachment to the posterior abdominal wall, from the duodenum to the right iliac fossa, is a secondary adhesion, formed after the rotation of the gut, and this extensive attachment is found only in animals adapted to the upright posture.

CHAPTER XIX.

THE BODY WALL, RIBS AND STERNUM.

Bilateral Symmetry of the Body.—From a developmental point of view the body is made up of two symmetrical halves; each half of the blastoderm, taking the medullary groove as the line of division, contributes equally to the formation of the body. Each produces a half of the nervous system, each a half of the vascular, muscular and alimentary systems, so that each individual is in reality made up of two identical halves, right and left.

The Ventral Line of the Body.—The two halves are united along the **ventral line** from the mouth to the anus (see Fig. 227). In this line are developed the symphysis of the lower jaw, the body of the hyoid bone (copula), the white line of the neck and angle of the thyroid cartilage, the sternum, the supra-umbilical part of the linea alba, umbilicus, infra-umbilical part of the linea alba, symphysis pubis, the septum of the penis, and of the scrotum and perineal raphe. The ventral line is continued forwards on the face between the parts derived from the mesial nasal processes (Chap. I.).

The idea was at one time prevalent that the whole of this line was formed by the fusion of one somatopleure with the other; the median ventral line was the suture formed by the union. Such is not the case. The blastoderm, which lies at first like a cap on the yolk-sac (Fig. 75, p. 96), is produced or folded anteriorly to form the fore-gut and the part of the body above the umbilicus; it is produced posteriorly to form the hind-gut and the part of the body below the umbilicus (Fig. 75). The blastoderm grows out from the umbilicus to form the embryo in much the same way as a soap bubble is blown from the bowl of

a pipe. In an embryo, at the commencement of the 3rd week, the greater part of the ventral line is occupied by the umbilicus (Fig. 228). At that time the umbilicus is 3 mm. long, the

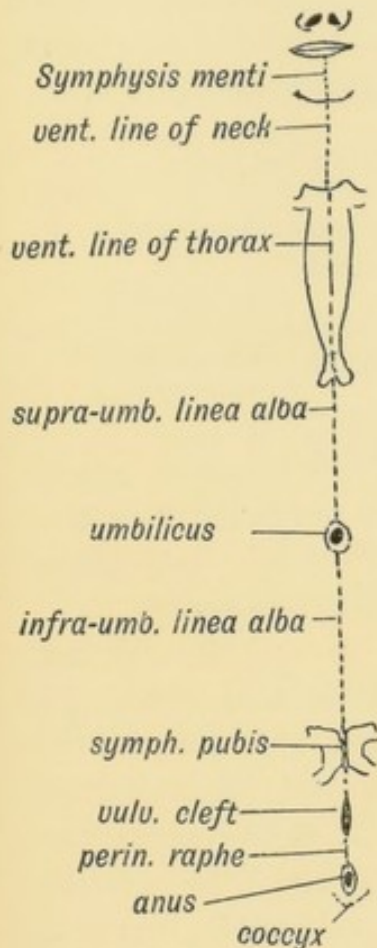


FIG. 227.

FIG. 227.—Diagram of the Structures formed in the Median Ventral Line of the Body.

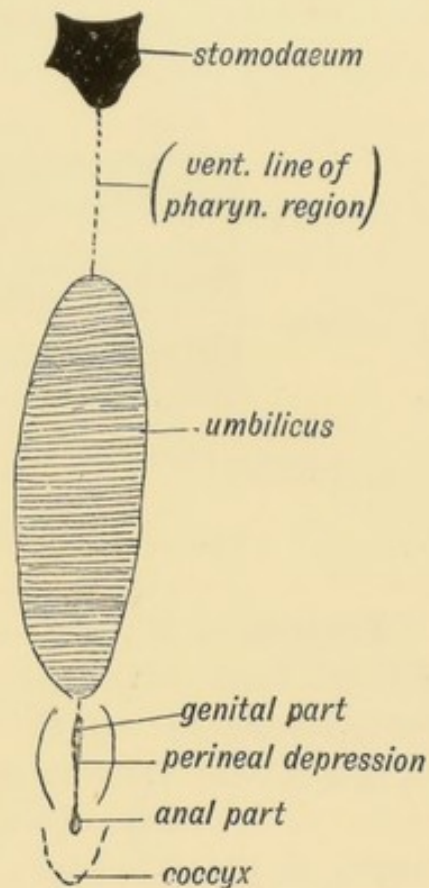


FIG. 228.

FIG. 228.—The Median Ventral Line in an embryo of three weeks, to contrast with the Corresponding Line in the Adult.

entire ventral line being about 4 mm. At the 6th week the ventral line measures 15 mm., the umbilicus retains its former size, about 3 mm.

At first the somatopleure shows no trace of segmentation. The paraxial masses of mesoblast become segmented early and form the muscle plates (Fig. 126, p. 156). From each muscle plate of the primitive segments a process grows down into the somatopleure. The somatopleure thus becomes segmented secondarily, the process of segmentation spreading from the dorsal to the ventral side of the plate, but along the median ventral line of the body wall a band of the primitive mesoblastic

tissue remains unchanged and undifferentiated. In the ventral band between the left somatopleure and the right are formed the sternum and the linea alba (Fig. 227). In lower vertebrates, in fishes, and to a less marked extent in amphibians and reptiles, the somatopleure becomes segmented from end to end of the trunk, each muscle segment being distinctly recognizable in the adult.

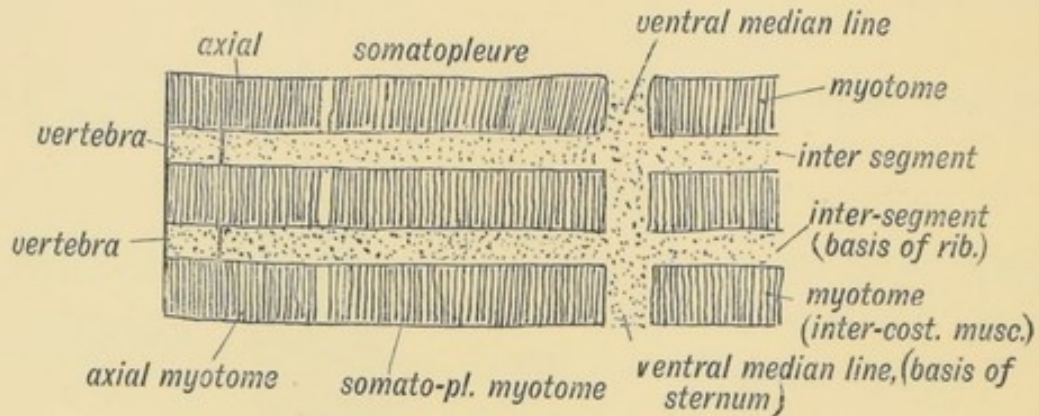


FIG. 229.—Scheme of the Manner in which the Somatopleure is segmented.

Formation of Ribs.—Ribs, like all true skeletal bones, pass through three stages: 1. They are represented by a membranous basis in the fibrous tissue (septa) between the muscular segments of the somatopleure (Fig. 229). 2. The fibrous basis of the rib becomes cartilaginous. 3. Ossification of the cartilage begins in the 7th week, but the process of ossification leaves the ventral parts of the costal segments untouched; they form the costal cartilages; in lower forms they may become ossified and form sternal ribs. In lower vertebrates, such as reptiles, each rib articulates with the neural arch of a vertebra by two heads, dorsal and ventral (Fig. 123, p. 153). In man and mammals only the first and the lowest two ribs retain the vertebral attachment. The heads of the upper ribs (2nd to 10th) migrate forwards and gain attachments to the disc and vertebra in front of their own segments. The dorsal head of the rib in man is represented by the tuberosity (see also p. 152).

The Sternum.—In man and anthropoids the sternum has become flat and highly modified with the alterations in the shape of the thorax (Fig. 208, p. 254). With the adaptation to the upright posture the thorax becomes flattened from back to front; its transverse diameter is as great, or greater, than the antero-

posterior. The sternum also becomes wider and shorter. To understand its true nature it is necessary to note the characters of the sternum of a pronograde mammal, such as the dog or ape (Fig. 230). In such the sternum is typically made up of seven segments :

1. A modified anterior segment, the **pre-sternum**.
2. Five narrow, cylindrical segments or **sternebrae**, forming the body of the sternum.
3. The **ensiform process**, a hind segment, complex in nature and ending in the middle ventral line. The ensiform process usually bifurcates and probably belongs to several segments.

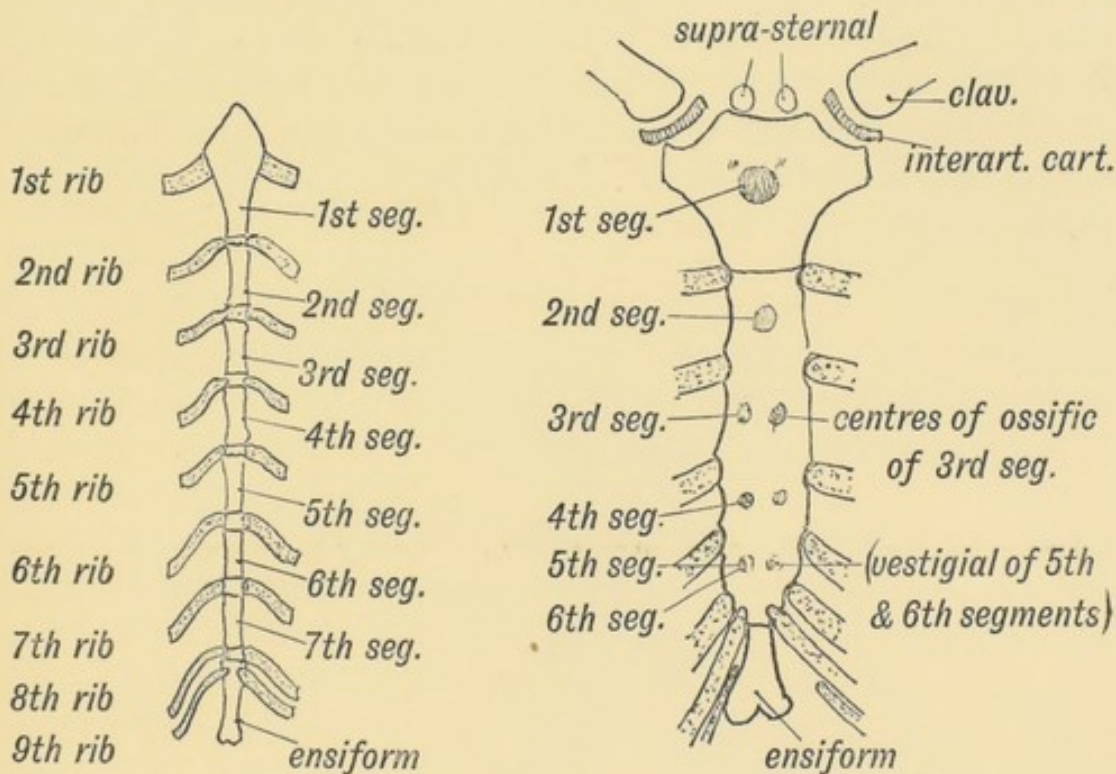


FIG. 230.

FIG. 231.

FIG. 230.—The Form of Sternum in a Pronograde (quadrupedal) Mammal.

FIG. 231.—The Form of Sternum in a Mammal adapted to the orthograde (upright) Posture. The Points of Ossification are also shown.

The chief changes in the human sternum are :

1. Each segment has become flat and wide ;
2. The segments of the body fuse together during the years of adolescence, the fusion beginning behind and passing forwards ;
3. The 4th sternebra of the body is usually vestigial; is probably made up of two or more fused segments.

In low primates 8 or 9 pairs of ribs may reach the sternum,

six or more sternebrae being then present. In man the number has been reduced to seven pairs, the sternal ends of the seventh pair lying in front of the base of the ensiform process. It is not uncommon to find the 8th rib reaching the sternum, especially on the right side; it is rare to find the 7th pair fail to reach the sternum. The more frequent presence of an 8th sternal rib on the right side is due to right-handedness (Cunningham) or the pressure of the underlying liver requiring support (Tredgold).

Development of the Sternum.—The sternum is developed in the mesoblast of the ventral median line between the first 8 or 9 dorsal segments (Paterson). It is developed in two parts—a right from the right somatopleure, a left from the left somatopleure. These two halves, the right and left fibrous **sternal bars**, fuse gradually in the middle line, the process of fusion commencing at the presternum and spreading back (Fig. 232). The bifurcated end of the ensiform process represents the posterior extremities of the sternal bars.

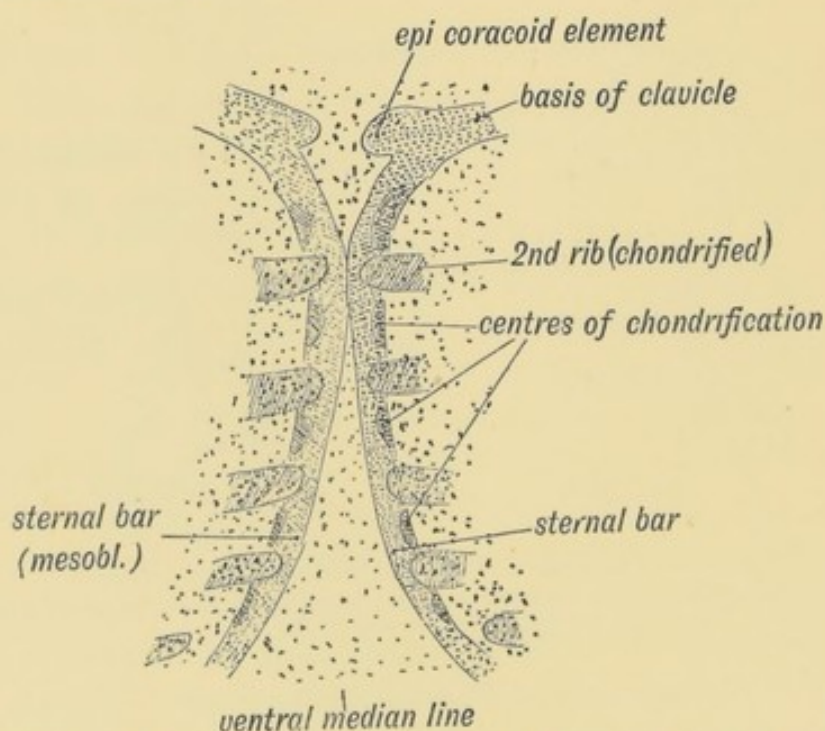


FIG. 232.—The Sternal Bars in a human embryo of six weeks (after Paterson).

The sternum is described here as a structure arising independently in the median ventral line. This, however, is not the commonly accepted view. Ruge's researches led him to the conclusion that the segments of the sternal bars were produced as

buds from the ventral ends of the ribs, to which they correspond, and his conclusions are supported by the evidence of comparative anatomy.

In its development the sternum passes through three stages—fibrous, cartilaginous and bony.

1. **Fibrous Stage.**—At the 6th week (Fig. 232) the costal cartilages are already chondrified. The mesoblast on each side of the median line, in which they end, has become condensed, and forms the membranous basis of the two sternal bars (Paterson). The bars begin to fuse together in front.

2. **Cartilaginous Stage.**—The mesoblast of each sternal bar begins to chondrify in the intervals between the ends of the costal cartilages. The process of chondrification and fusion proceed apace, and by the commencement of the third month the segments of each side have united to form the **cartilaginous** sternal bars (Paterson). At the same time, the two bars gradually unite, the cellular tissue between them becoming chondrified. Thus a single cartilaginous plate formed out of the two cartilaginous bars is formed. Fibrous joints are subsequently formed between the presternum and mesosternum and between the mesosternum and ensiform process. A fibrous and synovial joint is also developed at the union of the costal cartilages with the sternum, except in the case of the first pair.

3. **Ossification.**—A centre appears for each sternebra; those for the third and fourth of the mesosternum are usually double, one being placed on each side. The centres for the 4th segment are more frequently absent than present (Paterson). The centre for the presternum (there may be two or even more) appears about the 4th month; the centres behind appear in order; that for the 4th sternebra of the mesosternum appearing about the time of birth, that for the ensiform after birth. The process of fusion of segments begins behind about puberty; the segments of the mesosternum are united together by the 30th year. Occasionally a median foramen may be seen in the sternum; it is due to imperfect union of the sternal bars.

The **Presternum** is complex in nature. It probably represents more than the simple sternebra between the first and second pairs of ribs. Part of it may belong to the segment in front, the last cervical. When the last (7th) cervical rib is fully developed it

reaches the presternum. It may also contain another element. In more primitive types of vertebrates, in fact in all below the higher mammals, a part of the coracoid element of the shoulder girdle, the epi-coracoid (pre-coracoid), is situated at the cephalic end of the sternum (Fig. 244). The **supra-sternal** bones, not infrequently seen on the upper border of the human manubrium sterni (Fig. 231), appear to represent the epi-coracoids. These bones are probably always present, but their presence is difficult to detect because they are commonly more or less completely fused with the presternum (Paterson). Occasionally the first segment of the meso-sternum joins the manubrium instead of the body of the sternum—a union frequently seen in some anthropoids.

The presternum is the first part of the sternum found in ascending the scale of vertebrate animals, and is developed as a median ventral support for the shoulder girdle.

CHAPTER XX.

THE LIMBS.

The Limbs.—The limbs begin to appear at the end of the 3rd week. A slight elevation or ridge is then seen to run along the dorsal border of the somatopleure, at some distance from the row

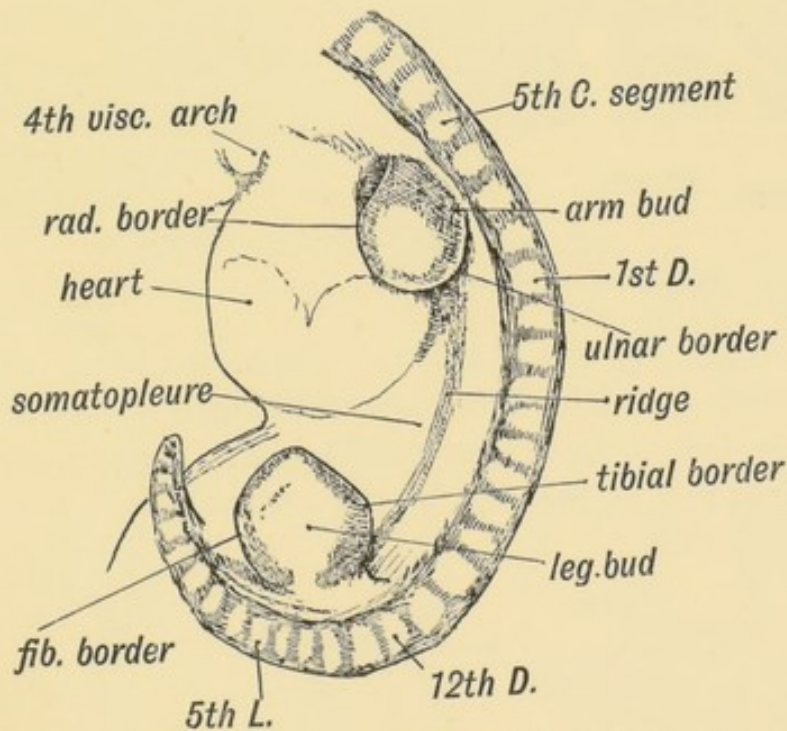


FIG. 233.—Lateral view of a human embryo at the 28th day, showing the Limb Buds, Lateral Ridges, and Primitive Segments.

of primitive segments formed in the paraxial mesoblast (Fig. 233). The limb buds spring from this ridge as flat processes with an upper, dorsal, or extensor surface, and a lower, ventral or flexor surface. The two borders are anterior or cephalic and posterior or caudal (Fig. 233). It is generally held that the lateral ridge, of which the limb buds are specialized parts, represents a

continuous row of lateral fins. If this view is right, then the fore and hind limbs represent highly specialized fin-rays.

A section shows each bud to be composed of undifferentiated mesoblast, with a covering of epiblast (Figs. 111 *A* p. 139, and 237). It represents in structure a process of the undifferentiated somatopleure or body-wall. Processes grow into the limb bud from the muscle plate of each segment which is situated opposite the origin of the bud. Each corresponding segment of the spinal cord also sends to the limb bud a nerve process. At least seven body segments contribute to the formation of each limb.

Changes in External Conformation.—In the 4th week (Fig. 234) the limb buds are unsegmented; in the 5th a constriction

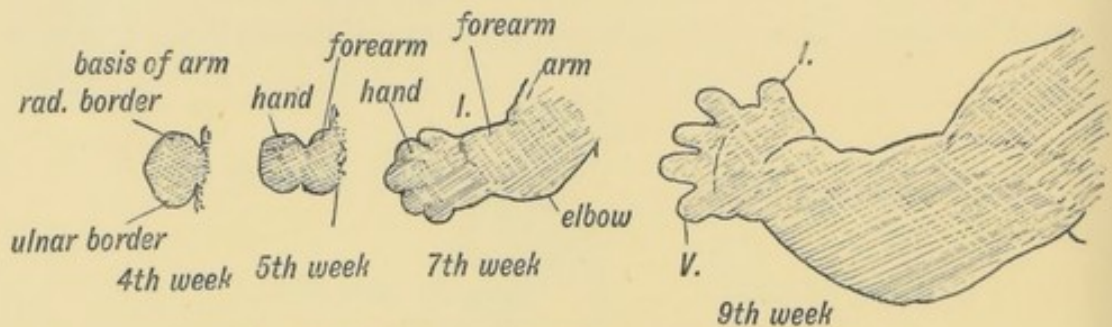


FIG. 234.—Development of the Upper Limb. (After His.)

marks the hand off; the position of the elbow being indicated in the same week. In the 7th week the fingers appear as thickenings in the *webbed* hand, the middle digit being indicated first. They become free at the end of the second month; occasionally

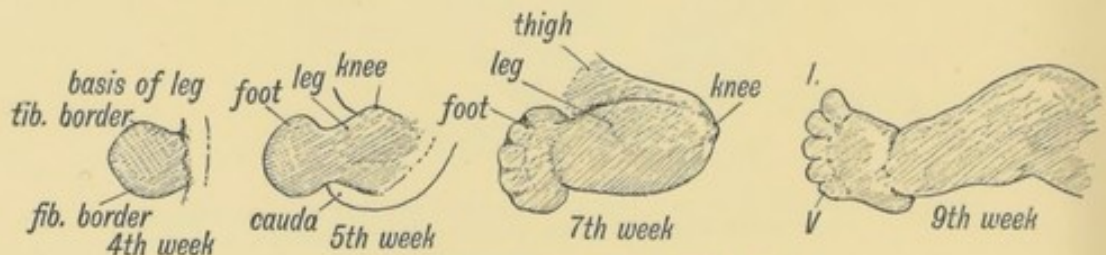


FIG. 235.—Development of the Lower Limb.

they remain attached, the child being born with its fingers in a **syndactylous** condition. The shoulder remains buried in the body-wall; the skeletal structures of the shoulder are the first to appear. The corresponding parts of the lower limb appear in the same order as in the arm.

The **Internal Differentiation of Tissues** begins at the basal part of the limb and spreads towards the fingers, the terminal phalanges being the last of the skeletal parts to become differentiated. The mesoblast becomes condensed in the axis of the bud and forms the fibrous basis of the limb bones. The skeletal basis of mesoblast is continuous, but where joints are to be formed there occur opener formations in the arrangement of the cells. In the 5th week the fibrous basis of the bones begins to chondrify, and this is soon followed by the appearance of centres of ossification in the shafts of the long bones (7th week). The mesoblast between the chondrified bases of the bones opens out into a cavity and forms the synovial membranes of the joints. The joints are all formed before the 3rd month is well begun. During the 6th to the 8th week the mesoblast differentiates into muscles, bones, vessels and the sheaths of nerves; the tissue left over, not included in these structures, forms their sheaths, and the fasciae and connective tissue of the limb. The processes of the nerve cells to form the nerves, and of the muscle plates to form the muscles, grow in very early (see Fig. 237).

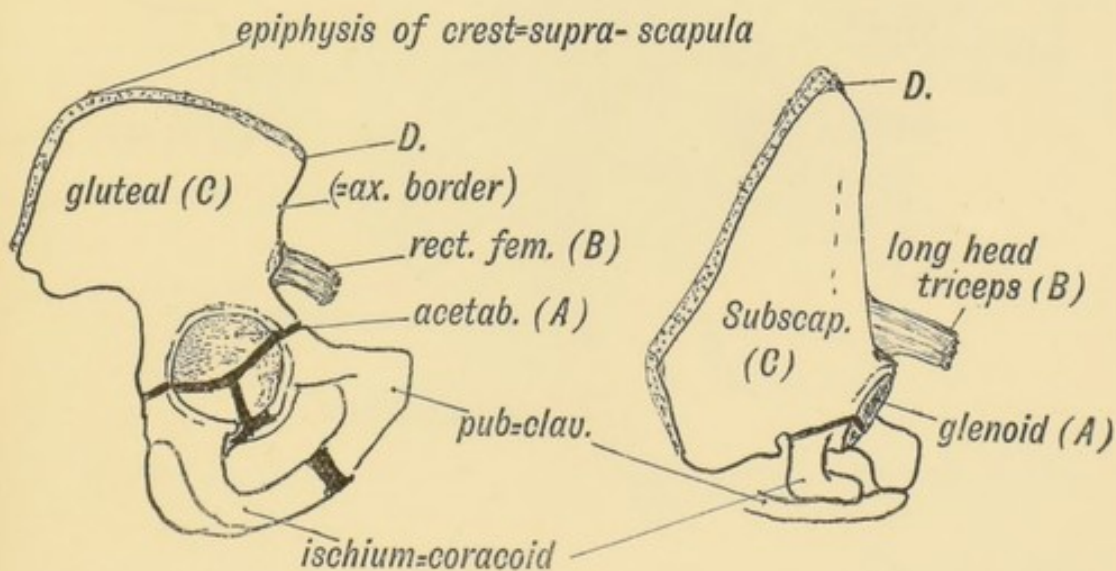


Fig. 236.—The Corresponding Points (A, B, C, and D) in the Ilium and Scapula.

Torsion and Rotation of the Limbs.—As the limbs are developed, the extensor surfaces of the knee and elbow are directed upwards. If the body of an adult were placed in the prone position, it would be necessary, in order to restore the limbs to their embryonic position, (1) to draw them out at right angles to

the axis of the body, (2) to rotate the leg **outwards** so that the extensor surface of the knee is directed upwards, with the great toe in front and the little toe behind. (3) The arm, on the other hand, would require to be rotated **inwards** to bring the elbow (extensor surface) into the dorsal position. The rotation which brings the embryonic limbs into the adult position occurs at the junction of the limb girdle with the trunk.

Rotation at the Limb Girdle.—To understand the extent of this rotation it is best to compare the scapula and ilium and pick out their corresponding points. The extensors of the thigh and arm may be taken as guides. The long head of the triceps and rectus femoris of the quadriceps manifestly correspond; their points of origin—the anterior border of the ilium and axillary

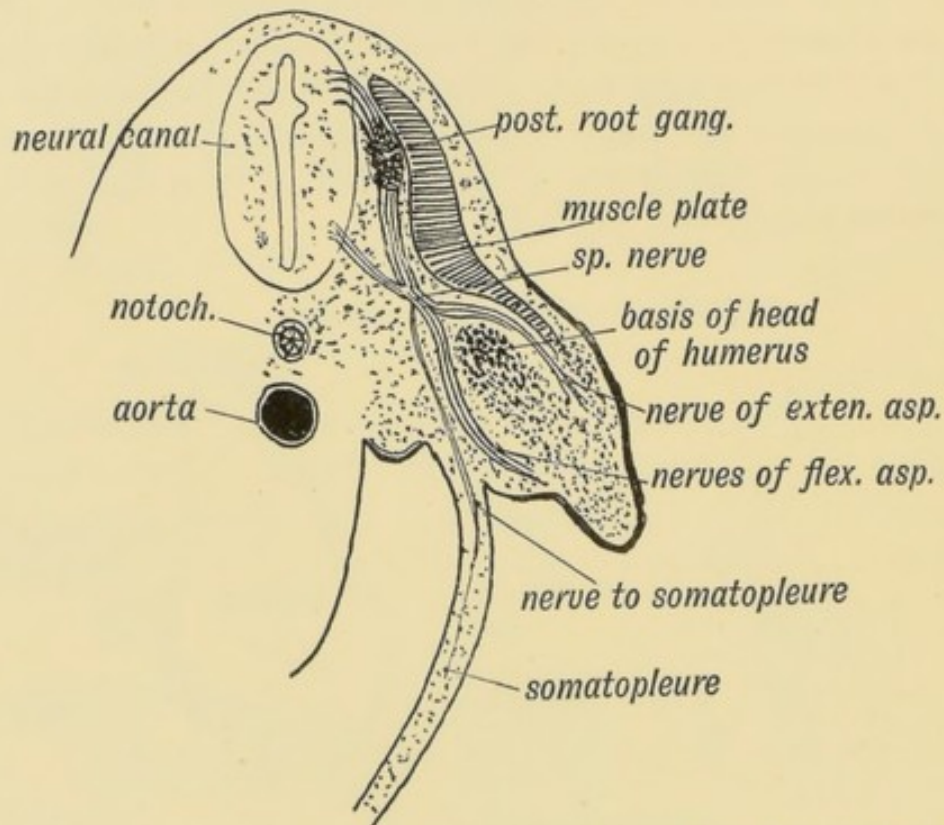


FIG. 237.—Section of the Arm Bud of a human embryo at the end of the 4th week. (Alex. Low.)

border of the scapula—may be regarded as homologous points. The other corresponding points are shown in Fig. 236. The sacral articular surface of the ilium corresponds to part of the supra-spinous fossa. To restore the limb girdles to their primitive and corresponding positions, the scapula has to be rotated so that

its axillary or posterior border comes to occupy the position of its spine, while the ilium has to be placed at right angles to the spine and its anterior border rotated outwards until it occupies a position corresponding to the axillary border of the scapula.

There is a manifestly spiral twist in the humerus, but it is doubtful if this be in any way due to the torsion which the limb undergoes.

Nerve Supply of the Limbs.—The Arm.—It is important to note that the limb buds arise from the ventro-lateral aspect of the trunk (Fig. 237) at the junction of the somatopleure with the paraxial mesoblast. Therefore the nerves of the limbs are the nerves of the ventro-lateral zone—the lateral cutaneous

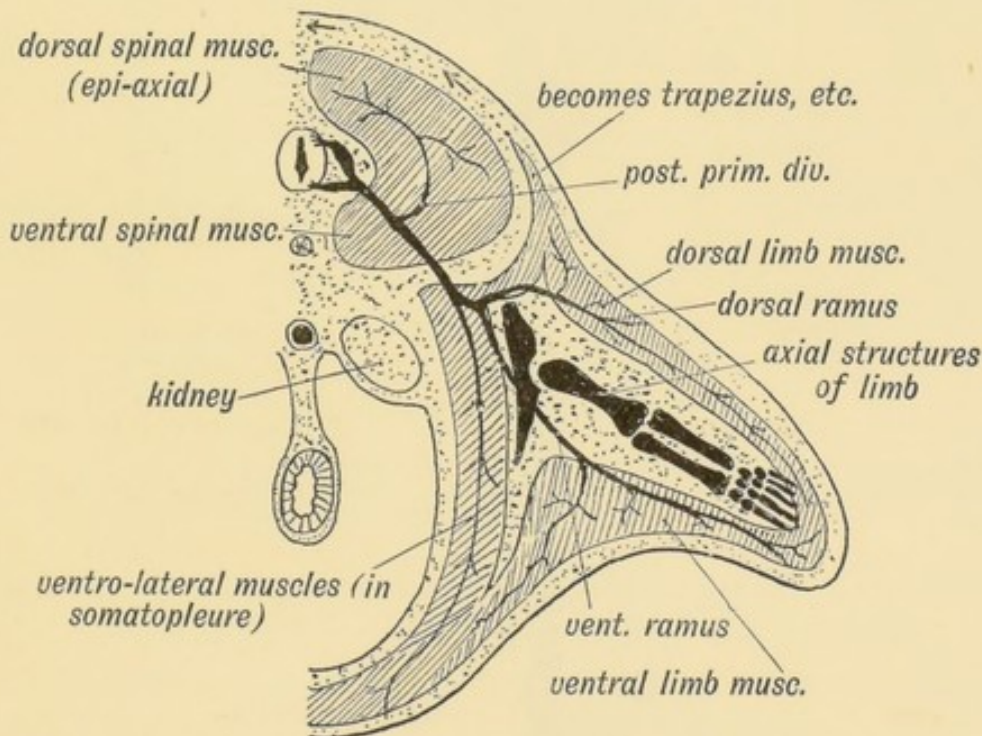


FIG. 238.—Schematic Section showing the Origin and Arrangement of the Muscles and Nerves of the Limbs. (After Kollmann.)

branches of the segmental nerves (Fig. 238). The muscles are derived from the ventro-lateral sheet, which gives rise to all the muscles of the body-wall (Fig. 238). As soon as the limb buds appear, bundles of fibres from the anterior and posterior nerve roots of the corresponding body segments enter them and keep time with their growth. The limb nerves are at first so large in comparison with the size of the limb bud that they are crushed together and form a plexus. As they enter the bud, the

nerves encounter the condensed skeletal mesoblast at its base and divide into a dorsal or extensor set and a ventral or flexor set (Figs. 237 and 238).

The nerve supply assists to indicate the body segments from which the arm is developed (Fig. 239). The 4th cervical is the

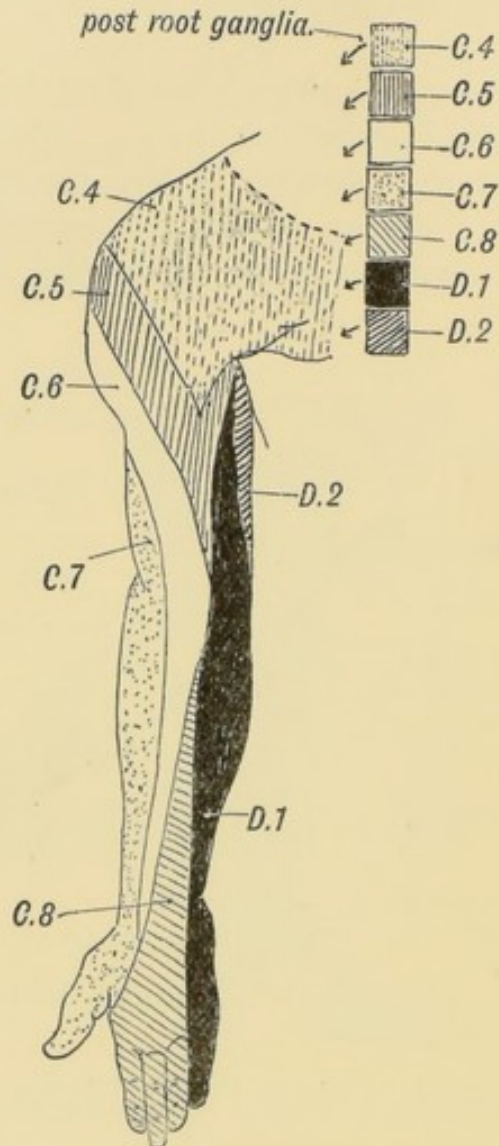


FIG. 239.—The Distribution of the Posterior Roots of the Spinal Nerves on the Flexor Aspect of the Arm.

most anterior, the 3rd dorsal, sometimes it is the 2nd, is the most posterior segment. Hence the arm is produced from seven, or more commonly eight segments in all. Each segment contributes from its nerve, its muscle plate and probably also its artery. The typical distribution of a segmental nerve to the limb bud is shown diagrammatically in Fig. 238. Each segmental nerve, as is

the case with the typical lateral cutaneous nerves, divides into a **dorsal** division for the extensor muscles (musculo-spiral, posterior circumflex, supra-scapular, etc.) and **ventral** for the flexor muscles (median, ulnar, musculo-cutaneous) (Fig. 238).

Clinical and experimental research has shown that each of the seven or eight segments contributes to the cutaneous supply of the limb. The classical investigations of Sherrington in the segmental distribution of the sensory nerves in the limbs of apes, showed that they are arranged in a definite and orderly manner (Fig. 240). The sensory distribution of the spinal nerves in the

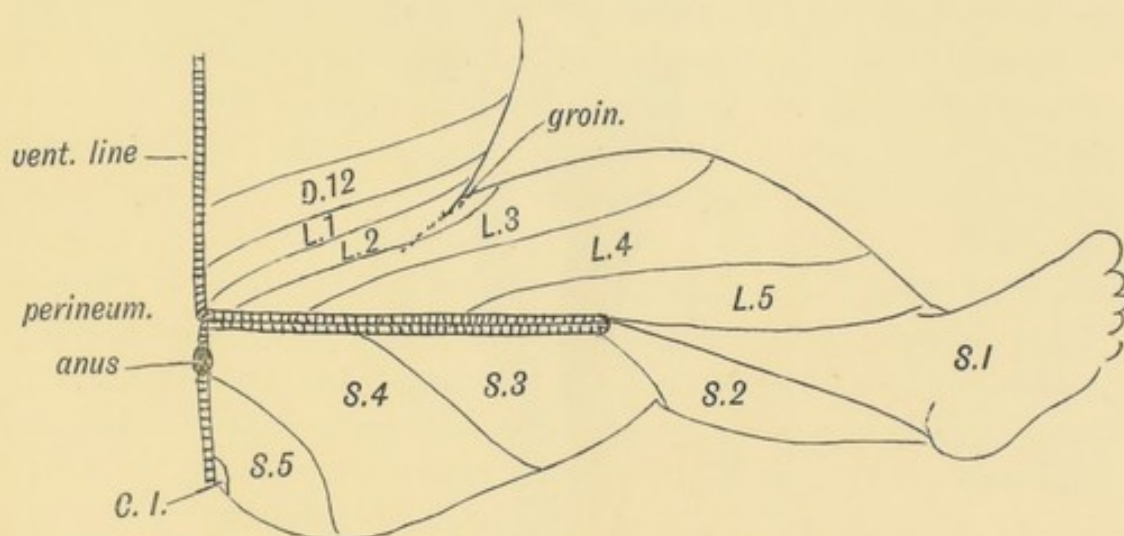


FIG. 240.—Diagram to show the typical Manner in which the Posterior Nerve Roots are distributed in the Lower Limb (based on Sherrington's researches into the sensory distribution of the limb nerves of apes).

human arm is shown diagrammatically in Fig. 239. The distribution of the motor nerves of each segment is the following:

5th Cervical.—To extensor muscles which raise the shoulder, extend the arm, fore-arm and proximal phalanges.

6th Cervical.—To adductors and extensors of the arm, flexors of the thumb.

7th Cervical.—Rotators outwards of the shoulder and flexors of the middle phalanges.

8th Cervical.—Flexors of the fingers and extensors of the carpus.

1st Dorsal.—Flexors of fingers, the interossei, adductors of thumb.

It will be thus seen that in the motor segments, not muscles but actions are represented; hence the formation of the plexuses

that each nerve may contain functional elements derived from several segments. Each muscle, it must be remembered, is supplied from two, three or more segments of the cord.

Only three anomalous points in the arrangement of nerves in the upper limb require attention: (1) The segments which supply nerves for the arm are nearly constant. The extent to

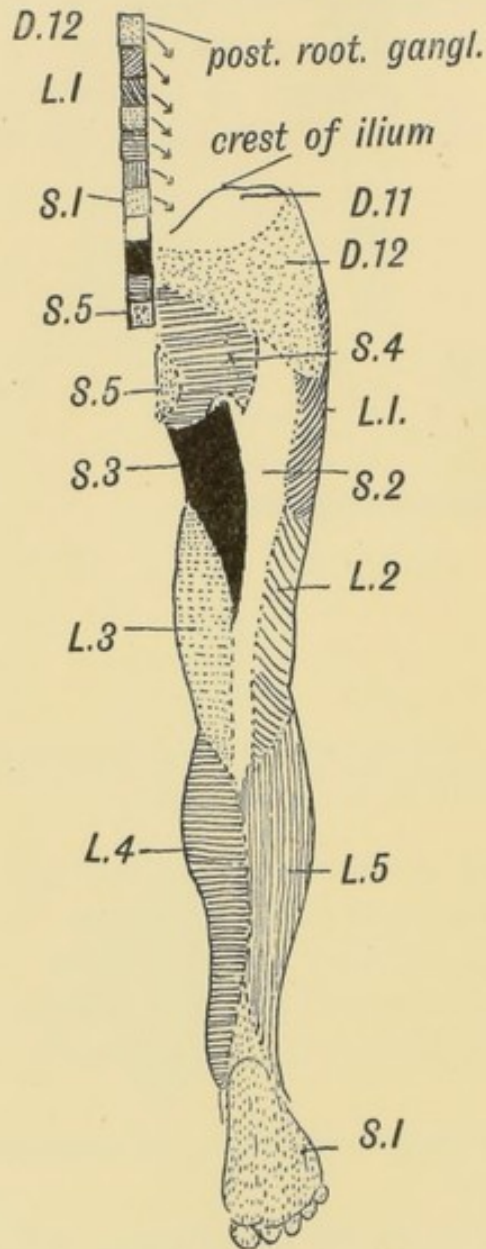


FIG. 241.—Flexor Aspect of the Lower Limb showing the Sensory Distribution of the Segmental or Spinal nerves.

which the 4th cervical and 3rd dorsal contribute varies; the degree of variation is markedly less than in the lower limb. (2) A part of the musculo-cutaneous nerve frequently joins the

median below the insertion of the coraco-brachialis; this communication is frequently seen in lower primates; its meaning is not known. (3) A communication between median and ulnar in the forearm is also common and is seen constantly in some primates. The communicating branch passes with the deep branch of the ulnar nerve to the palm.

Nerve Supply of the Lower Limb.—Usually ten segments contribute to the nerve supply of the lower limb—the 12th dorsal to the 4th sacral (Fig. 241). The sensory nerves are derived from these segments; the motor nerves begin at the 1st lumbar segment and end at the 3rd sacral. There is a considerable variation in the number of body segments or vertebrae to which the lower limb is attached; usually it is the 25th vertebra which becomes the 1st sacral, but it may be the 26th or 24th (page 144). Of these three forms the first is the normal type (25th); the second the post-fixed type (26th), the third the pre-fixed type (24th). There is even a greater variation in the segments which contribute nerves to the limb; the **normal** motor segments are the 1st lumbar to the 3rd sacral; in the **post-fixed type** (more common than the next) the motor segments commence at the 2nd lumbar and cease at the 4th sacral; in the **pre-fixed type** the motor segments commence at the 12th dorsal and end at the 2nd sacral. The spinal nerve which bifurcates and joins both lumbar and sacral plexuses is known as the **nervus furcalis**. In the normal type it is the 4th lumbar; in the pre-fixed type it is the 3rd lumbar; in the post-fixed type the 5th lumbar.

The **nervus bigeminus**, normally the 4th sacral, may also vary in a corresponding manner.

The nerves to the extensor surface of the lower limb, the anterior crural, external popliteal, etc., represent the **dorsal divisions** of lateral cutaneous nerves (Fig. 238). The nerves to the adductor and flexor aspects, the obturator and internal popliteal, represent the **ventral divisions**. In a considerable number of individuals, the dorsal division (external popliteal) and ventral (internal popliteal) of the great sciatic separate in the pelvis, the external popliteal perforating the pyriformis.

The muscles of the lower extremity are supplied in the **normal type** from the following segments:

Motor Segments.—1st Lumbar. Psoas and Iliacus.

2nd Lumbar. Psoas and iliacus, sartorius, pectineus, adductor brevis.

3rd Lumbar. Adductors, quadriceps, obturator externus.

4th Lumbar. Adductors, quadriceps, obturator externus, also external rotators of hip, gluteus maximus, hamstrings.

5th Lumbar. External rotators of hip, gluteus maximus, gluteus medius and minimus. Muscles of leg and foot.

1st Sacral. External rotators of hip, gluteus maximus, gluteus medius and minimus. Muscles of leg and foot.

2nd Sacral. External rotators of hip, gluteus medius and minimus, flexor hallucis, extensors of foot and toes.

3rd Sacral. Piriformis, muscles of calf and sole.

4th Sacral. Muscles of perineum.

It will be remembered that the perineal region is developed behind the limb buds of the lower extremities; hence its nerve supply from the most posterior nerve segments (3rd and 4th sacral).

Sherrington found that the posterior roots of the limb nerves were distributed in a regular and simple manner in apes. His results are applied to the lower limb of a human foetus in Fig. 240. The actual distribution in man, which has been partially worked out by clinicians, varies considerably from what might be expected from Sherrington's results (compare Figs. 240 and 241).

In the human leg and foot there is a tendency for the nerve fibres destined for the outer digits to proceed in the external saphenous nerve instead of by the musculo-cutaneous. The external saphenous nerve may supply the 4th and 5th digits, in a manner similar to the ulnar nerve in the hand; more frequently it is confined to the outer side of the 5th digit.

Pelvic and Shoulder Girdles.—In the basal part of each limb bud a cartilaginous arch is developed. It consists of a **dorsal** and **ventral** part, the joint cavity for the articulation of the limb being situated at the junction of the two parts. Fishes retain this simple primitive form of girdle.

The Pelvic Girdle has undergone less modification from the primitive type (Fig. 242) than the shoulder girdle. The primi-

tive type of pelvic girdle, such as is seen in the crocodile or lizard, and of which the mammalian type is a derivative, is shown diagrammatically in Fig. 242. For comparison the human girdle in a 5th week foetus is shown in Fig. 243.

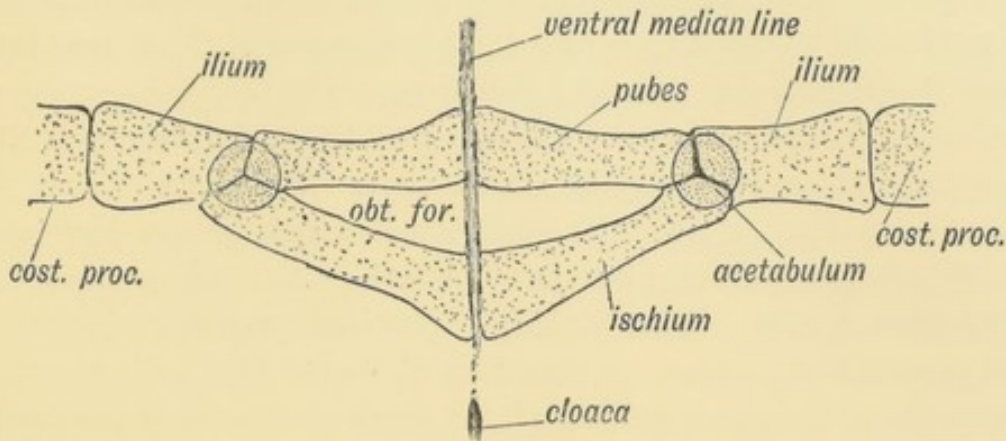


FIG. 242.—Diagram of the Pelvic Girdle of a Lizard.

The dorsal element consists of the **ilium**; it is attached by ligaments to the costal process of one or more sacral vertebrae. In the ventral portion of the cartilaginous arch are developed two elements, the **pubes** and **ischium**, both of which take part in the formation of the acetabulum (Fig. 242). Both reach the ventral median line in which cartilage is developed.

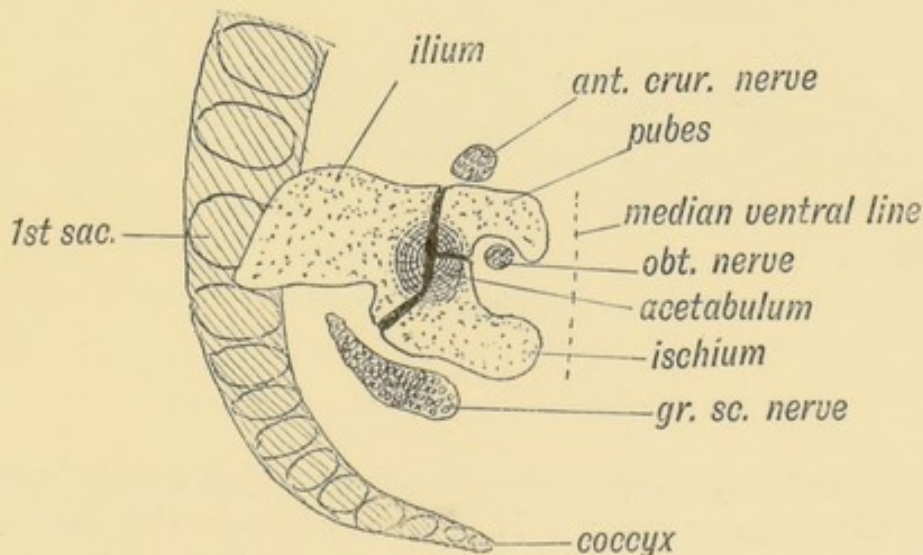


FIG. 243.—The Pelvic Girdle of a Human Foetus at the 5th week. (After Kollmann)

In man the following changes may be noted: (1) The costal processes of the sacral vertebrae ($2\frac{1}{2}$ usually) have fused together to form the lateral sacral mass, with these the ilium articulates;

(2) the vertebral border (crest) has become enormously elongated and gives attachment to abdominal muscles, cutting off the fibres of insertion of the external oblique which form the chief part of Poupart's ligament ; (3) the ischium does not reach the ventral line. In most birds, neither ischium nor pubes reach the ventral line. The pubes fail to meet in cases of ectopia vesicae. The symphysis pubis is formed in the ventral line. The cotyloid bone—os acetabuli—is formed in the Y-shaped cartilage between the three elements. It ossifies in the 13th year. Professor Howes has pointed out that it is this ossification which forms the pubic part of the acetabulum, and that it is really part of the pubes.

Shoulder Girdle.—The duckbill (*ornithorynchus*) shows the most generalized type of mammalian shoulder girdle ; it resembles closely the primitive reptilian type ; from such a form the various types of mammalian shoulder girdle were probably evolved.

The dorsal part of the arch consists of (1) **scapula**, (2) **supra-scapula** (Fig. 244). The supra-scapula is represented in man by the cartilage along the vertebral border ; it ossifies in the early

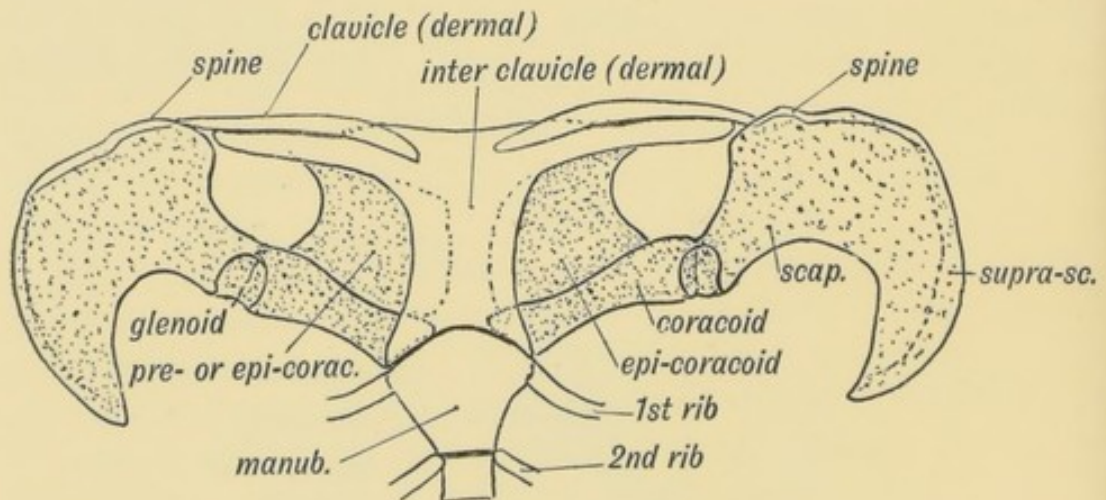


FIG. 244.—The Shoulder Girdle of *Ornithorynchus*.

years of manhood. The supra-spinous part of the scapula appears first in higher mammals ; it is produced late in the development of the scapula (in the 3rd month of foetal life) by the upgrowth of the supra-spinous blade of the scapula ; it is not represented in the pelvic girdle. The spine of the scapula is represented in the pelvic girdle by the ilio-pectineal line of the ilium ; but there is no pelvic representative of the acromion process. The dorsal

segment of the pelvic girdle becomes fixed to the costal processes ; the corresponding part of the scapula remains free.

In the typical reptilian shoulder girdle, as in the pelvic (Fig. 242), two elements are formed in the ventral part of the arch—a posterior part—the **coracoid**, corresponding to the ischium, and an anterior—the **pre-coracoid**, corresponding to the pubes. Both elements reach the ventral median line in which the presternum is developed. In *Ornithorynchus* the coracoid element is represented by two bones—the coracoid and epi-coracoid. The coracoid helps to form the glenoid cavity at its dorsal extremity ; its ventral articulates with the presternum. In man and all higher mammals, in which mobility of the fore limb is of advantage for speed and free movement, the coracoid element is much reduced. It forms merely a process on the scapula, which it joins in man about the 15th year. It still enters into the formation of the glenoid cavity, the articular part (supra-glenoid) having a separate centre of ossification which appears in the 12th year. It is possible that the costo-coracoid ligament may be derived from the ventral part of the coracoid

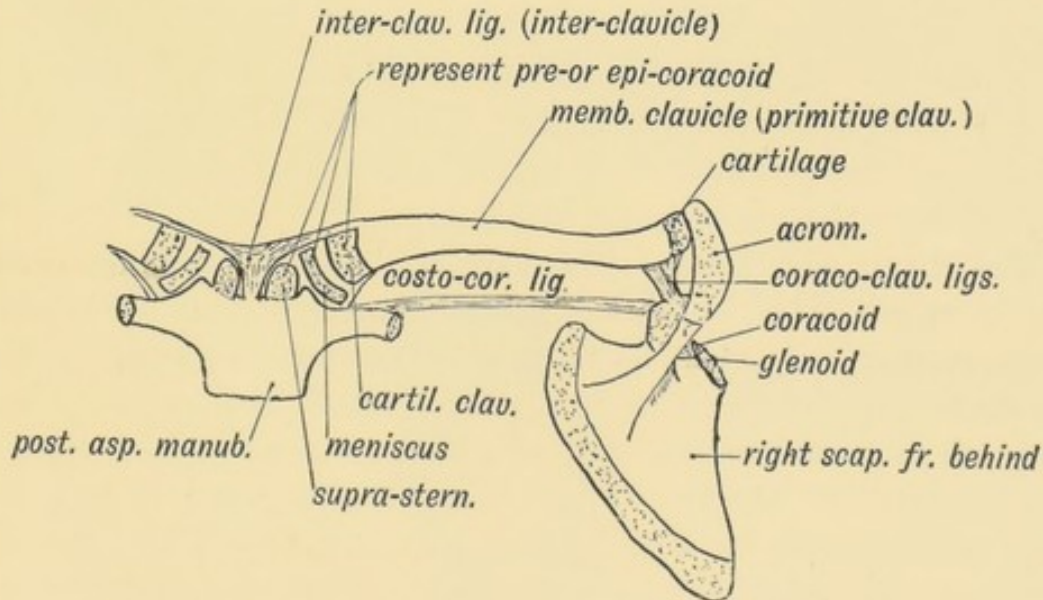


FIG. 245.—The Parts in the Shoulder Girdle of a human foetus which correspond with those of *Ornithorynchus*.

element—the part which articulates with the sternum in the duckbill. The **pre-coracoid** in the shoulder girdle of the lizard corresponds to the pubic element in the pelvis. The pre-coracoid, which, like all the primitive elements of the pelvic and shoulder

girdles is formed in cartilage, has been partly or entirely replaced in all mammals by the development over it of the clavicle, a dermal or membrane-formed bone, the first of all the bones to ossify. There is thus no true representative of the clavicle in the pelvis. The inter-clavicle so strongly developed in the ornithorhynchus and in the "merry-thought" of the fowl is also a dermal bone. It is represented in man by the inter-clavicular ligament. It is highly probable that the clavicle does not completely replace the pre-coracoid. The epi-coracoid of ornithorhynchus probably represents part of this element (Fig. 244). It is also represented in the shoulder girdle of man by three structures (see Fig. 245). (1) By the cartilaginous inner end of the clavicle; (2) by the inter-articular cartilage; (3) by the supra-sternal bones, all of which appear in cartilage.

In order to give greater mobility and speed to some four-footed mammals, the clavicle has been reduced to a ligamentous band, except at its extremities (rabbit, dog, etc.). In climbing animals, and those in which the power of grasping or embracing is highly developed, the clavicles are fully developed.

The **acromion process** is ossified from several centres which appear in the years of adolescence; the epiphysis so formed may be united to the spine by fibrous tissue only. This occurs in over 8% of subjects (Symington), and may be mistaken for a fracture of the process. The coraco-clavicular ligaments may be derived from the pre-coracoid element.

The Hand and Foot.—The hand and foot of man, as is the case in all primates, retain the primitive arrangement of elements much more closely than do most other mammalian orders. The primitive type of hand or foot, out of which the various forms found in mammals have been modified, are seen in such reptiles as the lizard or tortoise (Fig. 246). In the hand of man the same bones are to be seen as in the tortoise (Fig. 246), and the same arrangement with some exceptions. The elements in the foot of a typical lizard resemble closely the arrangement seen in its hand; the same elements are present even in the highly modified human foot. The hand and foot bones have undergone great specialization in most mammals. In the evolution of the horse, for instance, one lateral digit after another has become vestigial, leaving the central digit enormously enlarged and specialized to

form the lower part of the extremities. In ruminants the 3rd and 4th digits have become specialized; the rest of the digits have become reduced until only traces of them are left; in rodents

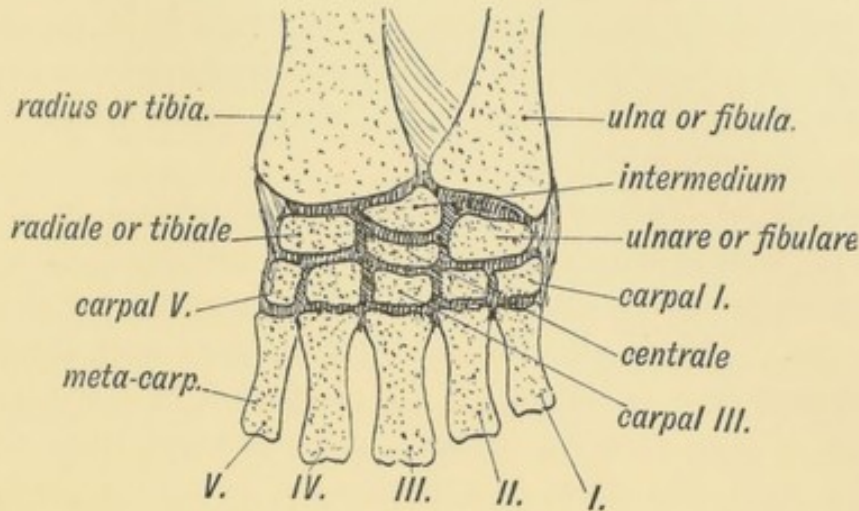


FIG. 246.—The Carpal Bones of a Tortoise.

the hallux is vestigial. The hallux and pollux are the mammalian digits most liable to undergo retrogression. In man, on the other hand, the hallux and pollux find their greatest development.

Comparison of the Tarsus and Carpus.—Both are the derivatives of such a typical form as is shown in Fig. 246. In the typical tarsus or carpus there occur the following bones:

1. **Radiale or Tibiale** forms the scaphoid in the hand and astragalus in the foot.

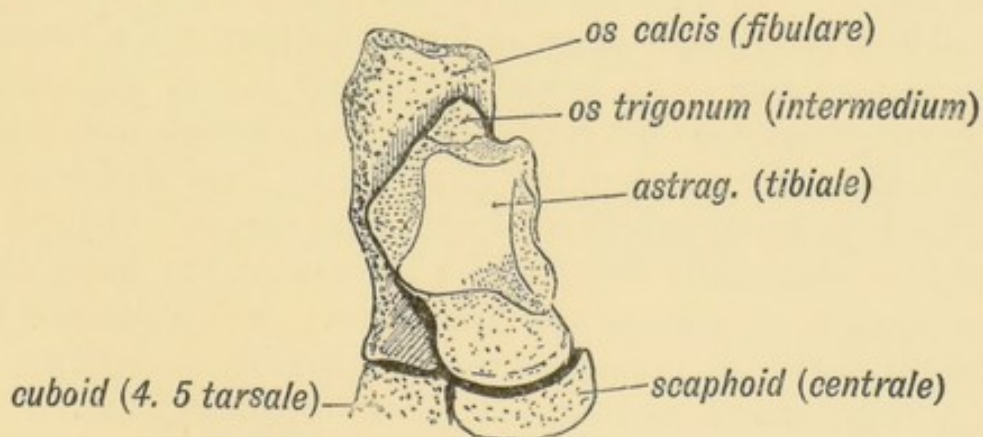


FIG. 247.—The Os Trigonum and Bones of the Tarsus.

2. **Intermedium** forms the semilunar in the hand; in the foot it is much reduced and usually unites with the astragalus to form

the external tubercle of that bone. It may remain separate and form the os trigonum (Fig. 247).

3. **Ulnare** becomes the cuneiform in the hand; the os calcis in the foot. During the fibrous and early cartilaginous stages in the development of the human tarsus, the os calcis is in contact with the fibula. In the hand the ulnare and intermedium are bound by fibrous bands to the ulna (Fig. 246); these bands assist to form the triangular fibro-cartilage.

4. **Carpale or Tarsale I.** becomes the trapezium in the hand, the internal cuneiform in the foot. In the prehensile foot of apes, the hallucial articular surface is directed inwards for the moveable big toe. This is also the case during the foetal development of the human foot (Leboucq). At no period of development is the hallux of man directed inwards and separated from the other toes. In man the great toe resumes a primitive position and its metatarsal lies parallel with those of the metatarsal series.

5. **Carpale or Tarsale II.** forms the trapezoid in the hand, the middle cuneiform in the foot.

6. **Carpale or Tarsale III.** forms the os magnum in the hand, the external cuneiform in the foot.

7. **Carpale or Tarsale IV. and V.** have united in both hand and foot to form the unciform and cuboid. This union is seen in mammals generally. In the cat and carnivores the scaphoid and semilunar unite together.

The Os Centrale is situated between the first and second rows of the carpal or tarsal bones (Fig. 246). In the foot it forms the scaphoid—a bone which plays an important part in the formation of the plantar arch—but is yet remarkably late in beginning to ossify, viz., about the 3rd year. It appears in the membranous stage of the human carpus, but at the end of the 2nd month it has joined the dorsal and distal aspect of the scaphoid of the hand. It may be occasionally detected as a tubercle on the dorsal aspect of the scaphoid or even as a separate bone. It is a separate bone in the carpus of all primates except the gorilla, chimpanzee, and man. There are two centralia in lower vertebrate forms.

The Pisiform (ulnare laterale of Forsyth Major) is of doubtful nature. It is possible that in a very early stage of the evolution of mammals there were more than five digits—one behind the little finger—post minimi digiti; and another on the radial side

of the hand—a pre-hallux. Supernumerary digits, when they appear, are commonly situated on the radial side of the thumb or ulnar side of the little finger, but they may represent merely a fission of the normal pollex or little finger. The pisiform has been regarded as the vestige of a post-minimal digit; the sesamoid on the trapezium, in which a slip of the extensor ossis metacarpi pollicis ends, as a remnant of a pre-hallux. It is possible also to regard the pisiform as a sesamoid developed in the tendon of the flexor carpi ulnaris—for that muscle is originally a flexor of the metacarpus and ends on the 5th metacarpal—the pisi-metacarpal ligament representing the terminal part of the tendon. The pisiform, however, is developed with the rest of the carpal bones and before the tendon of the flexor carpi ulnaris. In mammals generally, but not in man, the pisiform articulates with the ulna as well as the cuneiform, and its synovial facet opens into the wrist joint. It may be represented in the foot by the heel epiphysis of the os calcis. The gastrocnemius, which represents the flexor carpi ulnaris in the leg, is also primitively a flexor of the metatarsus; the long plantar ligament, from which it is separated by the growth of the heel, represents the continuation of its tendon.

The Eversion of the Foot and Development of the Arch.—The human foot has been highly modified for upright progression. The chief modifications are:

(1) Gradual **eversion** of the foot, so that the sole can be applied to the ground. Even at birth—and for some time after—and always up to and before the 7th month of foetal life, the soles of the feet are inverted, so that when the foetal limbs are in their natural position they are directed towards the belly of the child. In club foot the natural process of eversion does not take place. The ape's foot is kept normally in the inverted position, an adaptation for prehension. The following factors assist in producing eversion:

(a) The neck of the astragalus (Fig. 248), which in the foetal foot is long and directed downwards and inwards at an angle to the axis of its body, becomes relatively shorter and directed more in line with the axis of the articular surface of its body (Fig. 248). Further, the outer border of the tibial articular surface of the astragalus is prominent in the foetus; the inner border is

much the lower; a growth upwards of the inner border causes the astragalus and foot to rotate outwards (Lazarus).

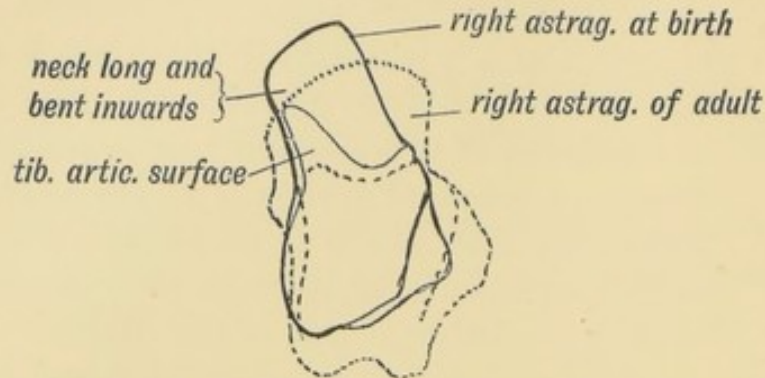


FIG. 248.—The Foetal and Adult (in dotted outline) Forms of the Astragalus contrasted.

- (b) The bones on the inner side of the foot, particularly the scaphoid and internal cuneiform, grow more rapidly than those on the outer side of the foot—especially after birth. This tends to evert the foot and also to produce the longitudinal arch.
- (c) A special evertor of the foot is produced—the Peroneus tertius—a muscle peculiar to man. It is developed from the outer and lower fibular fibres of the extensor longus digitorum and represents part of the tendon of that muscle to the 5th toe. The peroneus brevis and longus may also assist, especially the latter, which in apes is a grasping muscle, acting as a flexor of the metatarsal bone of the hallux.

(2) The tarsal bones of the human foot—especially the astragalus and os calcis—are of great size when compared with the tarsal bones of other primates; while the digital or phalangeal elements, except in the case of the great toe, which is relatively of great size, have undergone retrogression. This is especially the case in the human little toe; some of its muscles are not infrequently fibrous, and the terminal phalanx may not be separated from the middle phalanx. The terminal phalanx is the last to be differentiated in development of the fingers and toes.

(3) The plantar arches, both longitudinal and transverse, are produced. The arch of the foot is a human character. At birth the child is flat-footed; the head of the astragalus touches the

ground. The arch is produced as the child learns to walk. The chief factor in its production is the growth of the tarsal bones—especially of the scaphoid and internal cuneiform—and 1st metatarsal. Hence in rickets, where the normal tarsal growth is disturbed, the occurrence of flat foot. Amongst the structures which help to maintain the arch are:

- (a) The growth of the os calcis into the heel separates the tendon of the plantaris from its prolongation in the sole—the middle part of the plantar fascia, which assists in maintaining the arch. In lower primates the two parts are continuous, the tendon of the plantaris plying across the os calcis in a cartilage-lined groove.
 - (b) The internal lateral ligament of the ankle (anterior part) and the inferior calcaneo-scaphoid ligaments undergo great development in man.
 - (c) The flexor brevis digitorum which in lower primates arises principally from the long flexor tendons in the sole, has its origin completely transferred to the os calcis in man. It can thus act more powerfully in maintaining the arch. The flexor accessorius, a detached part of the flexor longus hallucis, is specially well developed and helps to maintain the arch of the foot.
 - (d) The tibialis posticus, originally a flexor of the metatarsus, corresponding to the flexor carpi radialis in the hand, obtains a secondary attachment to the scaphoid. The tibialis anticus, which answers to the extensor ossis metacarpi pollicis, becomes permanently inserted to the internal cuneiform and metatarsal. Both of these muscles, thus modified, help to maintain the arch of the foot. So does the tarsal part of the tendon of the tibialis posticus.
 - (e) The long plantar ligament, originally a part of the tendon of insertion of the gastrocnemius—also assists to maintain the arch.
- (4) The development of the great toe and the peculiar arrangement of its muscles must also be regarded as adaptations in the foot to upright posture and progression.

Comparison of the Muscles of the Upper and Lower Extremities.—As a mental exercise it may be worth the

student's while to briefly review the corresponding muscles in the two limbs. He has already seen that the arm and leg buds are similar in origin and made up of similar elements. Each is subsequently modified for its special function. The key to the homology of the muscles lies in their relationship to the digits, and their position on the limb.

Pollex and Hallux.—The extensor ossis metacarpi pollicis corresponds to the tibialis anticus. The thumb muscle has commonly a carpal insertion as well as metacarpal. The extensor brevis or primi internodii pollicis is constant in man only; it is a segment of the extensor ossis metacarpi pollicis.

The extensor brevis hallucis is not represented in the thumb.

Second Digit.—In the lower primates each finger has two extensors—a deep and superficial. The deep in the second digit becomes the extensor indicis; in the little finger it forms the extensor minimi digiti. The deep extensor muscles have disappeared in man from the 3rd and 4th digits, but occasionally reappear. In the leg the deep extensors have migrated to the foot, and form the extensor brevis digitorum. That for the little toe, however, has not descended; it is always vestigial, if present, and is commonly absent. It runs beneath or with the peroneus brevis, and is known as the peroneus quartus or **peroneus quinti digiti**.

Flexors and Extensors of the Metacarpus.—These have retained their primitive insertions in the hand; their modifications in the foot have been already mentioned. Both at the knee and elbow joint the origins of these muscles have undergone much shifting and migration.

The comparison already made between the scapula and ilium (p. 291), will help the student to understand the correspondence between the muscles of the thigh and arm.

Vestigial and Abnormal Muscles in the Limbs and Trunk.—(1) The muscles of the human ear and scalp may be described as vestigial when compared to the development in other mammals. Although their action on the ear and scalp is feeble, yet they serve as most important bases into which certain psychological states are reflected.

(2) The *levator claviculae* (omo-trachelian) is a muscle which passes from the upper transverse cervical processes to the outer end of the clavicle or acromion process. It is well developed in climbing primates. It is not a common muscle in man. It can be recognised during life in the posterior triangle of the neck.

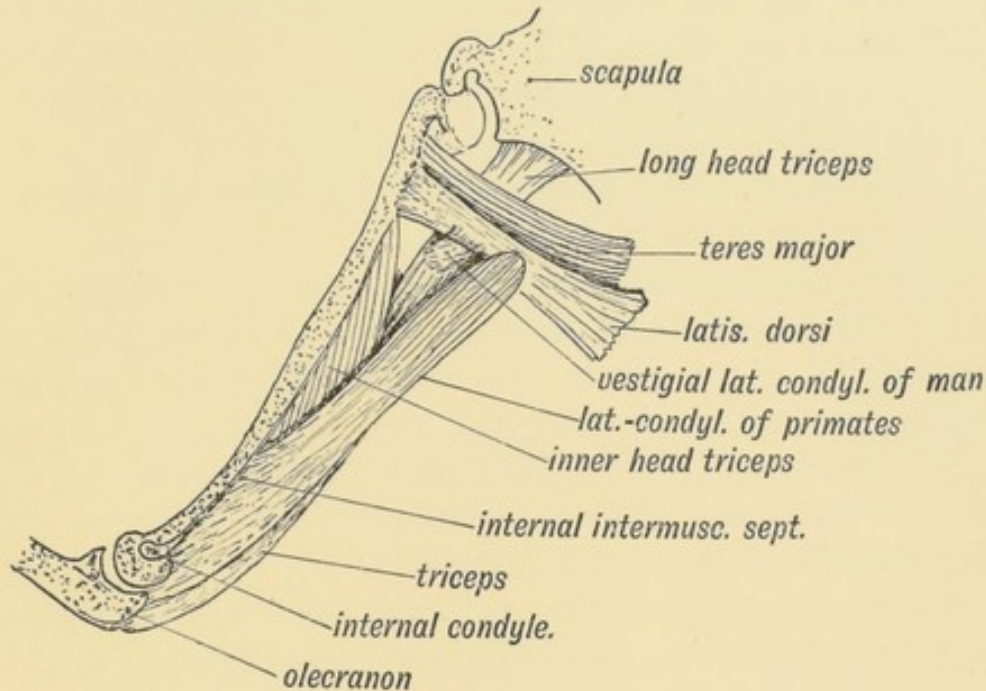


FIG. 249.—Latissimo-condyloideus Muscle.

(3) The *latissimo-condyloideus* (dorso-epitrochlearis), a climbing muscle, is always represented in man, commonly by a fibrous bundle between the tendon of the latissimus dorsi and the long head of the triceps (Fig. 249). It may be occasionally muscular. In apes it passes from the latissimus dorsi at the axilla to the inner aspect of the elbow and arm, which it retracts in climbing. It belongs to the same sheet as the coraco-brachialis. The **ligament of Struthers**—a strip of fibrous tissue over the internal intermuscular septum, above the internal condyle—represents part of the tendon of this muscle. The muscular slips occasionally found crossing the brachial or axillary artery from the latissimus dorsi to the coraco-brachialis or biceps are derivatives of this muscle. Other slips found crossing the floor of the axilla, between the adjacent borders of the pectoralis major and latissimus dorsi, are parts of the muscular sheet out of which these two muscles are developed.

(4) The *pectoralis externus* arises from the 4-5-6 ribs and

costal cartilages, beneath the axillary border of the pectoralis major. This is its normal condition in most mammals, but in man it is commonly fused with, and forms part of, the pectoralis major.

(5) The **sternalis** is a new muscle. The pectoralis major is formed from the same ventral longitudinal sheet as the rectus abdominis and sterno-mastoid. The fibres of the sternalis, which lie along the sides of the sternum, superficial to the origin of the pectoralis major, represent a persistent part of the primitive longitudinal sheet. The sternalis is a derivative of the *sphincter colli*, part platysma-sheet (Parsons).

(6) In the **sterno-mastoid**, four elements are recognised: sterno-mastoid, sterno-occipital, cleido-mastoid, cleido-occipital. The cleido-occipital fibres, which form part of the same sheet as the trapezius, are often absent. On the other hand the cleido-occipital fibres may be continuous with the trapezius.

(7) The **pectoralis minor** is sometimes inserted to the capsule of the shoulder and great tuberosity of the humerus. This is the primitive insertion of the muscle. The coracoid insertion is a secondary attachment seen only in man and some of the higher primates. When the pectoralis minor is inserted to the coracoid, the former fibres of insertion become fused with, and forms part of, the coraco-humeral ligament. The coraco-humeral ligament represents the ischio-capsular of the hip joint.

(8) In some apes (such as the Gibbons) the biceps has four heads—the two usual, the long and short, and two others, one from the inner border of the humerus and one from the bicipital groove. These two extra heads appear frequently in man.

(9) The **epitrochleo-anconeus** is frequently present. It crosses the ulnar nerve from the internal condyle to the olecranon.

(10) The **palmaris longus** and its homologue in the leg, the **plantaris**, are vestigial, aberrant in form, and often absent. The plantar and palmar fasciae represent their divorced tendons. The plantaris and palmaris undergo retrograde changes in the Primates with the transformation of claws to nails.

(11) Each digit (fingers and toes) in lower Primates, such as monkeys, is provided with three short muscles which arose from the carpus or tarsus. The three muscles are (Fig. 250): (1) a short flexor on the radial side of the digit; (2) a short flexor

on the ulnar side; (3) a *contrahens* or adductor muscle (always absent in the middle digit). The ten short flexor muscles form a deeper sheet than the four *contrahentes*. Of this form

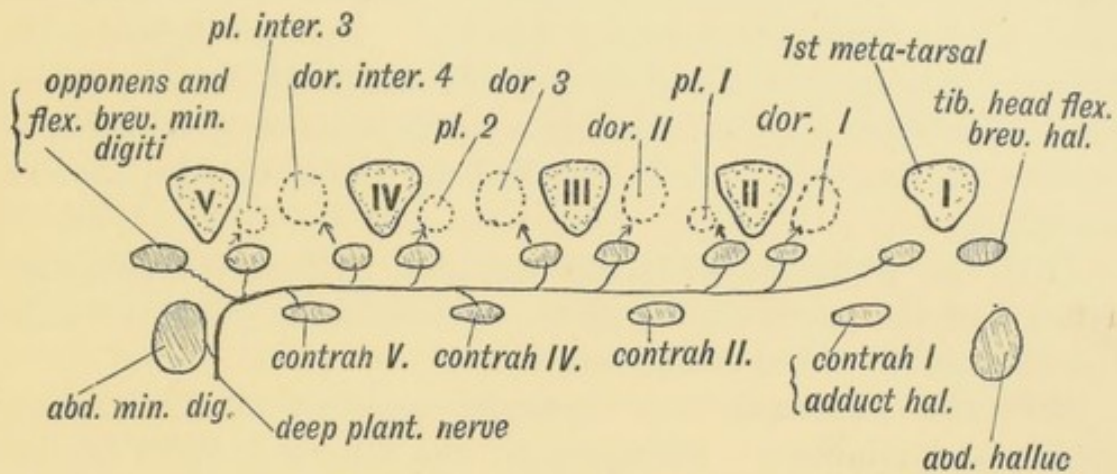


FIG. 250.—The Morphology of the Short Muscles of the Digits. The Muscles shaded are those of the ape's hand or foot; the positions of the corresponding muscles in the human hand or foot are indicated by dotted outlines.

the arrangement of the short muscles in the human hand is a derivative. The remnants in the human hand and foot of the *contrahentes* are: (1) The adductors of the 1st digit (pollex or hallux); (2) fibrous remnants of the others occur over the deep plantar or carpal arch (Fig. 250). The short flexors in man have become (1) the seven interossei; (2) the flexores breves (ulnar and radial) and opponens of the first digit; (3) the flexor brevis and opponens of the fifth digit (see Fig. 250). The ulnar flexors of the thumb and great toe are absent or fibrous.

(12) The **Pyramidalis** is often absent in man or vestigial. It is the tensor of the linea alba.

(13) Remnants of the **extensors and flexors of the tail** may occur between the sacrum and coccyx (page 136).

(14) The **Coccygeus** is vestigial; its superficial part forms the small sacro-sciatic ligament.

(15) Fibres of the biceps of the thigh may be followed into the **great sacro-sciatic ligament**. This ligament, which is almost peculiar to man—in other primates it is quite thin and slender—may contain fibres derived from the caudo-femoral group of muscles, such as the *tenuissimus*, a long strap-like muscle which passes from the coccyx to the femur and leg in lower mammals. The sacro-

sciatic ligament is mainly derived from the great median sheet, out of which the middle layer of the lumbar fascia is also formed. Parsons regards the short head of the biceps as a derivative of the tenuissimus, while others regard it as part of the muscular sheet which forms the peroneal muscles. Amongst Primates, it is found only in man, the anthropoids, and some South American apes. The short head of the biceps corresponds to the brachialis anticus in the arm, and is supplied by the external popliteal nerve.

(16) The **psaos parvus** is also vestigial. It acts primarily as a flexor of the pelvis on the spine. It begins to disappear with the assumption of the erect posture.

(17) The **scansorius** is a separated segment of the gluteus medius and minimus. It rises from the anterior border of the ilium and passes to the great trochanter. It corresponds to the teres minor. It is not constant in any animal.

(18) The **flexor brevis digitorum** to the little toe and the adductor transversus of the great toe are often fibrous.

Vessels of the Limbs.—The Vas Aberrans.—This vessel gives rise to a number of anomalous arrangements of the brachial artery. If a newly-born child be well injected, a number of branches derived from the axillary, brachial and main arteries of the fore-arm will be found to form an anastomatic chain along the superficial aspect of the median nerve. The upper end of the chain is formed by a branch from the axillary; the lower end is completed by a branch of the ulnar or radial at the elbow. In South American apes this anastomosis always opens up to form a supplemental brachial artery—the vas aberrans—ending usually as the radial. From the manner of its origin and disposition in front of the median nerve, it will be seen that the vas may arise from the axillary or upper part of the brachial, and terminate in the radial, ulnar or brachial, according to the branches which participate. It may be so large as to simulate a large branch of the axillary or a division of the brachial. Such a condition is spoken of as high division of the brachial. The vas may supplant the brachial artery altogether, which is then represented by a trunk which ends high up in the arm by giving off the superior and inferior profunda arteries. The brachial vessel formed from the vas is recognised by its

superficial position to the median nerve. In lower apes, the brachial artery commonly divides a little above the elbow. This position of division is rare in man. In cases of high division the radial, or even the ulnar, may be superficially placed in the forearm.

Internal Saphenous Artery.—In most mammals—in all primates except man—the anastomotica magna of the femoral artery is as large as the popliteal and passes over the inner side of the tibia with the internal saphenous vein to reach the dorsum of the foot, where it forms the dorsalis pedis artery. This vessel is known in them as the internal saphenous artery, and corresponds to the radial artery in the forearm and wrist. The superficial branch of the anastomotica magna rarely assumes such a development in man; but the course taken by the internal saphenous artery explains the position of its accompanying vein, the internal saphenous, in front of the internal malleolus. In man only is the internal saphenous vein continued up the thigh to a saphenous opening in the groin. Its primitive termination is in the femoral vein at the lower end of Hunter's canal.

The **Superficial Plantar Arch**, formed from the internal plantar artery, is seldom complete in man. The pressure to which it is subjected in the standing posture has led to its partial obliteration. It corresponds to the superficial palmar arch.

The **Supra-condylar Process** is well developed in lemurs, the lowest primates, and in mammals of many orders. Its function is unknown. It occasionally appears in man. It is developed from the humerus about two inches above the internal condyle as a hook-like process of bone. It lies in front of the internal inter-muscular septum, and when well developed the brachial artery and median nerve may pass beneath it, as they do in such animals as the squirrel and cat.

Third Trochanter.—A tubercle may appear in the gluteal ridge which receives this name. It is cartilaginous until the 20th year, when a separate centre of ossification appears in it (Dixon). It is well developed in the horse.

Ligaments and Joints of the Limbs.—The **Inter-articular Cartilages** are of doubtful origin. In their first appearance, by the condensation of the mesoblast in the axis of the limb bud, the bones are continuous. The joints are formed between the bones,

by the mesoblastic tissue remaining fibrous, while that which forms the bases of the bones undergoes chondrification. The mesoblastic tissue thus left between the cartilages opens out and forms a synovial cavity and a fibrous capsule. Hence the periosteum of the bones is continuous with and derived from the same primitive layer as the joint capsules. The inter-articular cartilages of the knee, for instance, may be simply masses of mesoblast left between the bones, originally part of the condensed mesoblastic bar out of which the femur, tibia and fibula were developed. The inter-articular cartilage of the temporo-maxillary joint may be a derivative of Meckel's cartilage; that of the sterno-clavicular of the pre-coracoid. The triangular fibro-cartilage of the wrist joint is derived from the ulno-carpal ligaments, and interosseous membrane (Parsons). The cartilage may also contain a post-minimal element (Corner). The cartilages of the knee are of obscure derivation; they may be parts of muscles formerly inserted on the upper end of the tibia (Sutton).

Parsons has shown that in all primates, except man, the external semilunar cartilage is circular in form and is attached to the posterior crucial ligament.

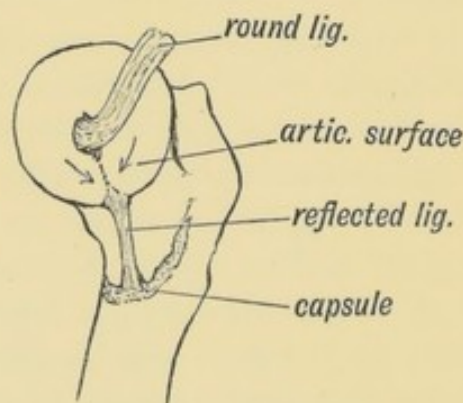


FIG. 251.—Showing the Origin of the Ligamentum Teres and Reflected Bundle of the Capsular Ligament.

The **Ligamentum Teres** is to be regarded as a part of the capsule of the hip joint which has been cut off by the outgrowth of the articular surface of the head of the femur (Fig. 251). The crucial ligaments are semi-isolated fasciculi from the capsule of the knee joint, separated in a similar manner to the ligamentum teres by the outgrowth of the condyles of the femur (Fig 252). At first the ligamentum mucosum, crucial ligaments and posterior

part of the capsule are continuous and form parts of the capsule of the joint; they come to occupy a position within the joint as the femoral condyles grow backwards.

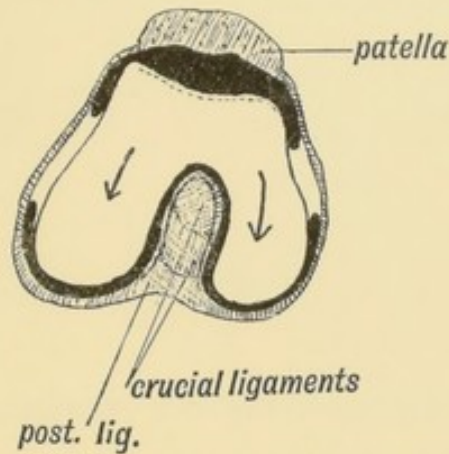


FIG. 252.—Showing the Origin of the Crucial Ligaments of the Knee.

In Reptiles and in lower mammals the fibula enters into the formation of the knee joint as the ulna does in that of the elbow. This is at no time the condition in the human foetus (Grunbaum). The external malleolus in primates is generally shorter than the internal; this is the case in man until the 3rd month of foetal life; after the 3rd month the external is the longer (Wilgress).

INDEX.

[The numbers refer to the pages.]

- Abnormalities of muscles, 308.
Accessory processes of vertebrae, 153.
Accessory thyroid bodies, 47.
Acoustic ganglia, 60.
Acromion process, 302.
Affenspalte, 218.
Agger nasi, 26.
Alar cartilages, 4.
Alar cartilages of nose, 7.
Allantois, 97, 124.
Ameloblasts, 64.
Amnion, 92.
Anal fascia, 140.
Angular gyrus, 191.
Anterior commissure, 209.
Antrum of Highmore, 12.
Antrum of mastoid, 55.
Aortic arches, 35.
Aortic septa, 239.
Appendix, 279.
Aqueductus cochlea, 59.
Aqueous chamber, 183.
Arch of aorta on right side, 37.
Arch of foot, Development of, 305.
Arm, Nerve supply of, 293.
Arteries of body segment, 157.
Asterion, 164.
Astragalus, 305.
Atlas, 151.
Atresia vaginae, 117.
Attic of tympanum, 55.
Axis, 151.
Azygos lobe of lung, 255.
Bartholin, Glands of, 127.
Basal ganglia, 189.
Basi-hyal, 33.
Bilaminar blastoderm, 88.
Binocular vision, 181.
Bladder, 124.
Blastodermic vesicle, 87.
Blood, 247.
Body-stalk, 96.
Body, Symmetry of, 282.
Body, Ventral line of, 282.
Brachycephalic skull, 172.
Brain capsule, 172.
Brain, Fissures of, 217.
Branchial arches, 28.
Bregma, 165.
Broca, Area of, 22.
Bronchi, Formation of, 252.
Bronchi, Ramification of, 253.
Bulla ethmoidalis, 25.
Caecum, Development of, 277.
Calcarine fissure, 189.
Canalis cranio-pharyngeus, 19.
Cardiac septa, 238.
Cardiac tube, Flexures of, 235.

- Cardinal veins, 226.
 Carotid bodies, 48.
 Carpale, I., II., III., IV., V., 304.
 Cartilages of Jacobson, 4.
 Cartilaginous part of skull, Development of, 165.
 Caudate lobe of liver, 265.
 Central canal, Formation of, 192.
 Cephalic index, 171.
 Cerato-hyal, 33.
 Cerebellum, 199.
 Cerebellum, Peduncles of, 200.
 Cerebral hemispheres, 206.
 Cerebral vesicle, 206.
 Cervical fascia, 141.
 Cervical sinus, Formation of, 32.
 Choroid, 183.
 Choroid fissure, 210.
 Choroidal fissure, 180.
 Chorion, 92, 97.
 Chorionic vesicle, 97.
 Ciliary muscle, 183.
 Ciliary processes, 179, 183.
 Circulatory system, Development of, 223.
 Cleft membrane, 30.
 Cleft palate, 1.
 Cloaca, 103, 275.
 Cloaca, Parts formed from, 124.
 Coccygeus, 311.
 Coccyx, 135.
 Cochlear ganglion, 60.
 Coelom, 91, 242.
 Coelom, Divisions of, 244.
 Coloboma iridis, 180.
 Colon, Development of, 277.
 Commissures, Development of, 208.
 Congenital umbilical hernia, 101, 275.
 Contrahentes, 311.
 Coracoid, 301.
 Cornea, 177.
 Corpora quadrigemina, 189.
 Corpus callosum, 209.
 Corpus callosum, Peduncles of, 22.
 Corpus luteum, 85.
 Corpus striatum, 207, 211.
 Cowper, Glands of, 126.
 Cranial nerves, 219.
 Cranial nerves, Segmental arrangement of, 220.
 Cranium, 161.
 Crusta petrosa, 66.
 Cuticular membrane, 64.
 Darwin's tubercle, 53.
 Decidua, 91.
 Decidua reflexa, 92.
 Decidua serotina, 92, 96.
 Decidua vera, 92.
 Dental papilla, 64.
 Dental sac, 66.
 Dental shelf, 64.
 Dentigerous and other cysts of the jaw, 67.
 Dentine, Origin of, 65.
 Dentitions, Number of, 67.
 Dermal bones, Development of, 162.
 Dermal papillae, Formation of, 71.
 Descending colon, 275.
 Descending thoracic aorta, 36.
 Diaphragm, Development of, 257.
 Dolichocephalic skull, 172.
 Dorsal aortae, 36, 38, 246.
 Dorsal mesogastrium, 266.
 Dorso-cervical region, Variations of, 145.
 Dorso-epitrochlearis, 309.
 Dorso-lumbar region, Variations of, 145.
 Double ureter, 110.
 Ducts of Cuvier, 224.
 Duct of Gärtner, 106.
 Ductus arteriosus, 37.
 Ductus endolymphaticus, 57.
 Ductus venosus, 230.
 Duodeno-jejunal fossa, 280.
 Duodenum, 280.
 Dura mater, 164.
 Ear, muscles of, 308.
 Ectoderm, see Epiblast.
 Ectopia cordis, 246.
 Ectopia vesicae, 125.
 Embryo and membranes, 91.
 Enamel, Origin of, 64.
 Encephalocele, 194.

- Endo-cardial cushions, 238.
 Endoderm, see Hypoblast.
 Ensiform process, 285.
 Epiblast, 89.
 Epiglottis, 42.
 Epi-hyal, 33.
 Epiotic centre, 59.
 Epipteric bone, 171.
 Epitrochleo-anconeus, 310.
 Epoophoron, 106.
 Ethmoidal sinuses, 25.
 Ethmoid, Lateral mass of, 7.
 Ethmoid, Vertical plate of, 4.
 Eustachian tube, 54.
 External auditory meatus, 50.
 External cleft depression, 31.
 External ear, 51.
 External ear, Muscles of, 53.
 External genitals of female, 122.
 External genitals of male, 122.
 Eyeball, 175.
 Eyelids, 185.
- Face, Development of, 1.
 Face, Malformations of, 1.
 Face and scalp, Muscles of, 38.
 Facial angle, 172.
 Falciform ligament, 264.
 Fallopian tube, 85.
 Fasciae, 138.
 Female pronucleus, 86.
 Femoral hernia, 133.
 Filum terminale, 195.
 Fimbria, 210.
 Fissures of brain, 217.
 Fissure of Sylvius, 170, 212.
 Flexor brevis digitorum, 307.
 Flexor brevis of little toe, 312.
 Floccular fossa, 60.
 Foetal circulation, Remnants of, 242.
 Fontanelles, 164.
 Foot, 303.
 Foot, Eversion of, 305.
 Foramen caecum, 46.
 Foramen ovale, 240.
 Foramina in bone, Formation of, 170.
 Foramina and canals, Formation of in
 bone, 11.
- Fore-brain, 202.
 Fore gut, 272.
 Fornix, 210, 211.
 Fossa of Rosenmüller, 33.
 Frontal bone, 162.
 Frontal sinus, 24.
 Frontal sinus, Infundibulum of, 24.
 Funicular process, 131.
- Gall bladder, 265.
 Gastro-hepatic omentum, 264.
 Gastro-splenic omentum, 268.
 Genuiculate ganglion, 60.
 Genital cord, 112.
 Genital folds, 122.
 Genital ridge, 93, 103.
 Genital tubercle, 122.
 Genital Wolffian tubules, 107.
 Germinal epithelium, 84, 94.
 Germinal spot, 86.
 Germinal vesicle, 86.
 Great omentum, 267.
 Great sacro-sciatic ligament, 311.
 Gubernaculum testis, 128.
 Gubernaculum testis, Formation of,
 129.
 Gyrus subcallosus, 22.
- Hairs, 71.
 Hallux, 308.
 Hamulus of lachrymal, 26.
 Hand, 303.
 Hare lip, 1.
 Hassall, Corpuscles of, 46.
 Head folds of amnion, 95.
 Heart, Demarcation of into chambers,
 234.
 Heart, Development of, 232.
 Heart, Valves of, 240.
 Hepatic veins, 229.
 Hernia, 133.
 Hiatus semilunaris, 23.
 Hind brain, 197.
 Hind gut, 272.
 Hippocampal gyrus, 23.
 Horse-shoe kidney, 110.
 Human teeth, Morphology of, 67.
 Hyaloid artery, 182.

- Hyaloid canal, 183.
 Hydrocephalus, 165.
 Hymen, 117.
 Hyoid, 32.
 Hyoid arch, 33.
 Hypoblast, 30, 89.
 Hypospadias, 123.
- Ileo-caecal fossa, 280.
 Ileo-colic bloodless fold, 280.
 Ileo-colic fold, 280.
 Ileo-colic fossa, 280.
 Ilium, 299.
 Imperforate anus, 120.
 Incus, 10, 15.
 Inferior medullary velum, 198.
 Inferior turbinate bone, 7.
 Inferior vena cava, 228.
 Inguinal hernia, 133.
 Inter-articular cartilages, 313.
 Intermedium, 303.
 Internal auditory meatus, 62.
 Internal cleft recess, 31.
 Internal cuneiform, 306.
 Internal geniculate body, 189.
 Internal lateral ligament of ankle,
 307.
 Internal pterygoid plate, 9.
 Internal saphenous artery, 313.
 Inter-parietal bone, 171.
 Inter-sigmoid fossa, 276.
 Inter-ventricular septum, 239.
 Iris, 183.
 Ischium, 299.
 Island of Reil, Formation of, 212.
 Isthmus of thyroid, 46.
- Jacobson's organ, 21.
 Jugular vein, 223.
- Kidney, Origin of, 108.
- Lachrymal bone, 27.
 Lachrymal gland, 185.
 Lambda, 164.
 Lamina cinerea, 205.
 Lamina terminalis, 205, 211.
 Larynx, 256.
- Lateral nasal process, 6.
 Lateral nasal process, Cartilage of, 6.
 Lateral recess of pharynx, 33.
 Latissimo-condyloideus, 309.
 Left innominate vein, 226.
 Leg, Nerve supply of, 297.
 Lens, 176.
 Lens, Capsule of, 181.
 Lesser sac, 272.
 Levator claviculae, 309.
 Levator glandulae thyroideae, 47.
 Lieno-renal ligament, 268.
 Ligament of Struthers, 309.
 Ligamentum teres, 314.
 Limbs, 289.
 Limbs, Arteries of, 312.
 Limbs, Joints of, 313.
 Limbs, Ligaments of, 313.
 Limbs, Nerve supply of, 293.
 Limbs, Torsion and rotation of, 291.
 Limbs, Veins of, 312.
 Limbs, Vessels of, 312.
 Limiting sulci of Island of Reil, 213.
 Lingual papillae, 41.
 Lingual tonsil, 45.
 Lingula, 170.
 Littré, Glands of, 127.
 Liver, Development of, 261.
 Liver, Ligaments of, 264.
 Liver, Morphology of, 264.
 Lobes of lungs, 254.
 Long plantar ligament, 307.
 Lower jaw, Development and ossifi-
 cation of, 14.
 Lumbar plexus, 297.
 Lung, Blood supply of, 255.
 Lung buds, 250.
 Lungs, Development of, 249.
 Lymphatic vessels, 247.
- Macrostoma, 2.
 Male pronucleus, 87.
 Malleus, 15.
 Mammae, 74.
 Mamma, Lymphatics of, 77.
 Mamma, Origin of glandular tissue,
 75.
 Mamma, Peripheral remnants of, 78.

- Mammalian cranium, Evolution of, 161.
 Mammary gland, Position of, 78.
 Mammary line, 75.
 Mammillary processes of vertebrae, 154.
 Mandibular processes and arch, 13.
 Marginal gyrus, 210.
 Mastoid, 59.
 Maxillary processes, 8.
 Maxillary process, Nerves and Arteries of, 11.
 Maxillo-turbinal, 7.
 Meckel's cartilage, 13, 14, 33.
 Meckel's diverticulum, 273, 274.
 Medulla oblongata, 197.
 Medullary plate, 90.
 Membrana pupillaris, 183.
 Membrana tympani, 17, 33, 56.
 Membranous labyrinth, Origin of, 57.
 Meningocele, 166, 194.
 Mesentery of appendix, 280.
 Mesentery of small gut, 281.
 Mesial nasal processes, 3.
 Mesoblast, 89.
 Meso-cephalic skull, 172.
 Mesoderm, see Mesoblast.
 Mesonephros, 102, 105.
 Mesorchium, 132.
 Meso-salpinx, 105.
 Metacarpus, Flexors and extensors of, 308.
 Metopic suture, 163.
 Microcephaly, 165.
 Mid-brain, 202.
 Mid-gut, 273.
 Morula, 87.
 Müllerian ducts, 104, 110, 114.
 Müller's muscle, 184.
 Muscles, Abnormalities of, 308.
 Muscles of body segment, 157.
 Muscles of extremities, 307.
 Nails, 73.
 Nasal air sinuses, Development of, 23.
 Nasal cavities, 20, 23.
 Nasal duct, 6, 26.
 Nasal processes, 3.
 Nasal processes, Arteries and nerves of, 7.
 Naso-palatine foramen, 5.
 Neck, Development of, 28.
 Neo-pallium, 207.
 Nerves of body segment, 158.
 Neural canal, 89.
 Neural canal, Divisions of, 193.
 Neural crest, 159.
 Neural flexures, 202.
 Neurenteric canal, 121, 195.
 Notochord, 90, 145.
 Oblique vein of Marshall, 225.
 Obturator fascia, 140.
 Occipital bone, 165.
 Occipital lobe, 189.
 Occipito-atlanto-axial articulations, 151.
 Odonto-blasts, 65.
 Oesophagus, 266.
 Olfactory lobe, 21.
 Olfactory nerves, 21.
 Olfactory peduncle, 22.
 Olfactory pits, 21.
 Olfactory plates, 20.
 Olfactory sense epithelium, Origin of, 20.
 Olfactory structures, 20.
 Olfactory tract, Termination of, 22.
 Omo-trachelian, 309.
 Opercula, 214.
 Opisthotic centre, 59.
 Optic lobes, 189.
 Optic nerve, 177.
 Optic radiations, 189.
 Optic thalami, 205.
 Optic tracts, 187.
 Optic vesicle, 177.
 Oral plate, 18.
 Ora serrata, 179.
 Orbital muscles, 186.
 Orbital plate, 185.
 Orbit, Formation of, 184.
 Organ of Corti, 58.
 Organ of Geraldés, 107.
 Organ of hearing, Development of, 49

- Organ of Rosenmuller, 106.
 Os anti epilepticum, 171.
 Os articulare, 15.
 Os calcis, 304, 306, 307.
 Os centrale, 304.
 Os Japonicum, 12.
 Ostium abdominale, 110.
 Ova, Discharge of, 84.
 Ova, Origin of, 93.
 Ovario-pelvic ligament, 128.
 Ovary, Descent of, 80.
 Ovary, Position of, 82.
 Oviducts, 110.
 Ovum, 83.
 Ovum, Course of, in the Fallopian tube, 85.
 Ovum, Development of, 80.
 Ovum, History of, within the Fallopian tube, 86.
 Ovum, Implantation of, 94.

 Palatal rugae, 12.
 Palate bone, 9.
 Palato-glossus, 33.
 Palato-quadrate bar, 10.
 Palmaris longus, 310.
 Pancreas, 268.
 Pancreas, Relationship to peritoneum, 270.
 Papillae foliatae, 42.
 Parachordal cartilages, 166.
 Paradidymis, 107.
 Para-mastoid process, 173.
 Para-thyroids, 47.
 Paraxial mesoblast, 90.
 Parietal bone, 163.
 Paroophoron, 106.
 Parotid gland, 42.
 Parovarium, 106.
 Pars ciliaris retinae, 179.
 Pars facialis lachrymalis, 27, 185.
 Pars membranacea septi, 239.
 Pectoralis externus, 309.
 Pectoralis minor, 310.
 Pelvic fascia, 138, 140.
 Pelvic floor, 136.
 Pelvic floor, Development of, 136.
 Pelvic girdle, 298.

 Pericardium, 244.
 Pericranium, 164.
 Peridental membrane, 66.
 Perineal body, 118.
 Perineum, 118.
 Permanent teeth, Origin of, 66.
 Peroneus brevis, 306.
 Peroneus longus, 306.
 Peroneus tertius, 306.
 Petro-mastoid 58, 167.
 Petro-mastoid, Origin of, 58.
 Petro-mastoid, Ossification of, 59.
 Pharyngeal recess, 44.
 Pharyngeal tonsil, 44.
 Pharynx, Development of, 28.
 Pharynx, Structures developed from, 39.
 Pineal body, 204.
 Pisiform, 304.
 Pituitary body, 170, 203.
 Pituitary body, Origin of, 19.
 Placenta, Formation of, 97.
 Plantar arches, 306.
 Plantaris, 310.
 Platysma myoides, 38.
 Platysma sheet, 39.
 Pleura, 251.
 Plicae fimbriatae, 42.
 Plica gubernatrix, 128.
 Plica semilunaris, 185.
 Plica triangularis, 44.
 Plica vascularis, 128.
 Polar body, 86.
 Pollex, 308.
 Pons varolii, 198.
 Portal vein, 228.
 Post anal gut, 120.
 Posterior cardinal vein, 223.
 Posterior root ganglion, 159.
 Post-frontal, 171.
 Pre-chorion, 92.
 Pre-coracoid, 301.
 Premaxillary bones, 4.
 Pre-sternum, 285, 287.
 Primitive callosal gyrus, 210.
 Primitive groove, 89.
 Primitive jugular vein, 56, 226.
 Primitive perineal depression, 119.

- Primitive segments, 147.
 Primitive streak, 89.
 Primitive utricule, 57.
 Primordial ova, 84, 94.
 Processus vaginalis, 131.
 Proctodaeum, 119.
 Pronephros, 105.
 Pro-otic centre, 59.
 Prostate, 126.
 Proto-vertebrae, 147.
 Psoas parvus, 312.
 Pterion, 164.
 Pterotic, 59.
 Pterygo-palatine bar, 9.
 Pubes, 299.
 Pulmonary artery, 37.
 Pulp of teeth, 66.
 Pyramidalis, 311.
 Pyramid of thyroid, 46.
 Pyriform fossa, 33.

 Radiale, 303.
 Rathke's pocket, 19.
 Rauber's layer, 88.
 Recto-vesical fascia, 140.
 Rectum, 275.
 Renal Wolffian tubules, 106, 107.
 Retina, 179.
 Retro-caecal fossa, 280.
 Rhinencephalon, 22, 206.
 Ribs, 152.
 Ribs, Formation of, 284.
 Ribs, vestigial, 152.
 Riedel's lobe, 265.
 Roof of skull, Development of, 162.

 Sacral plexus, 297.
 Sacro-coccygeal region, Variations of, 145.
 Sacro-lumbar regions, Variations of, 144.
 Salivary glands, Origin of, 42.
 Scalp, Muscles of, 308.
 Scansorius, 312.
 Scaphoid, 306.
 Scapula, 300.
 Sclerotic, 184.
 Sclerotome, 146.

 Scrotum, 124.
 Sebaceous glands, 74.
 Secondary sulci, 219.
 Second digit, 308.
 Seessel's pocket, 43.
 Segmentation of body, 155.
 Segment, Constitution of, 155.
 Sensori-motor areas of brain, 218.
 Septal cartilage, 4.
 Septum primum of auricle, 240.
 Septum secundum of auricle, 240.
 Septum transversum, 257, 258.
 Shoulder girdle, 298.
 Sigmoid flexure, 275.
 Simian fissure, 218.
 Sinus subpericardiacus, 255.
 Sinus venosus, 235.
 Sinus venosus, Valves of, 237.
 Skeleton of body segment, 156.
 Skene's tubules, 126.
 Skin, 70.
 Skull, Development of, 161.
 Skull, Primitive membranous, 161.
 Somatopleure, 90, 224.
 Spermatozoa, 93.
 Sphenoidal sinus, 25.
 Sphenoidal turbinate bone, 25.
 Sphenoid, Development of, 169.
 Spigelian lobe of liver, 265.
 Spina-bifida, 194.
 Spinal column, 142.
 Spinal column, Curves of, 143.
 Spinal column, Evolution and development of, 145.
 Spinal cord, 194.
 Spinal cord, Development of, 195.
 Spine, Pyramids of, 142.
 Splanchnocele, 242.
 Splanchnopleure, 90.
 Spleen, 267.
 Squamosal, 163.
 Stapes, 59.
 Sternalis, 310.
 Sternebrae, 285.
 Sterno-mastoid, 310.
 Sternum, 284.
 Sternum, Development of, 286.
 Stomach, 266.

- Stomodaeum, 17.
 Stylo-hyal, 33.
 Styloid process, 33.
 Subclavian arteries, 37.
 Subclavian veins, 226.
 Sulcus arcuatus, 209.
 Sulcus terminalis, 40.
 Superficial plantar arch, 313.
 Superior medullary velum, 201.
 Superior vena cava, 223.
 Supra-condylar process, 313.
 Supra-occipital, 163.
 Supra-renal bodies, Development of, 259.
 Supra-scapula, 300.
 Supra-sternal bones, 288.
 Supra-tonsillar recess, 44.
 Sweat glands, 75.
 Sylvian fissure, 170.
 Sympathetic nerves of body segment, 160.

 Tail fold of amnion, 95.
 Tail, Muscles of, 311.
 Tapetum lucidum, 184.
 Tarsale, I., II., III., IV., V., 304.
 Tarsus, 303.
 Teeth, Eruption of, 69.
 Teeth, Development and morphology of, 63.
 Teeth, Nature of, 67.
 Teeth, Roots of, 68.
 Tegmen tympani, 54.
 Temporal ridges, 173.
 Temporary fissures of brain, 216.
 Temporo-maxillary articulation, 15.
 Tenon, Capsule of, 184.
 Testes, 127.
 Testicle, Descent and development of, 127, 131.
 Third trochanter, 313.
 Thorax, Diameters of, 254.
 Thymus, 45.
 Thyreo-glossal duct, 46.
 Thyroid, 40, 46.
 Thyroid cartilage, 34.
 Tibialis posticus, 307.
 Tongue, 39.
 Tongue, Lymphatics of, 42.
 Tongue, Muscles of, 41.
 Tonsil, 33, 44.
 Tooth, Structure of, 63.
 Trabeculae cranii, 168.
 Transverse fissure, 210.
 Transverse and spinous processes of vertebrae, 154.
 Triangular ligament, 140.
 Trigonum olfactorium, 22.
 Tuberculum impar, 40.
 Tympanic bulla, 55.
 Tympanic plate and articular eminence, Development of, 17.
 Tympanic ring, 17.
 Tympano-hyal, 33.
 Tympanum, 54.

 Ulnare, 304.
 Umbilical cord, Formation of, 99.
 Umbilical faecal fistula, 101.
 Umbilical urinary fistula, 101.
 Umbilical veins, 231.
 Umbilicus, Formation of, 101.
 Unstable regions of spine, 144.
 Urachus, 124.
 Urethra, Female, 124.
 Uro-genital cleft, 121.
 Uro-genital sinus, 115, 125.
 Uro-genital system, 102.
 Uterus, Formation of, 113.
 Uterus, Round ligament of, 112.
 Uvea, 179.

 Vagina, Formation of, 113.
 Vasa aberrantia, 107.
 Vas aberrans, 312.
 Veins of trunk, Development of, 223.
 Velum interpositum, 207.
 Ventral aortic stems, 36.
 Ventral mesogastrium, 266.
 Vermian fossa, 60.
 Vertebra, Development of, 148.
 Vertebrae of mammalia, 150.
 Vesico-vaginal septum, 116.
 Vestibular ganglion, 61.
 Vestigial fold, 225.
 Vestigial turbinates, 25.

- | | |
|-------------------------------------|-----------------------|
| Visceral arches, 28. | Vomer, 4. |
| Visceral arches, Arteries of, 35. | Wharton's jelly, 101. |
| Visceral arches, Cartilages of, 33. | Wolfian body, 102. |
| Visceral arches, Muscles of, 38. | Wolfian ducts, 103. |
| Visceral arches, Nerves of, 34. | Wolfian tubules, 103. |
| Visceral clefts, 30. | Wormian bones, 171. |
| Vitelline duct, 100. | Yolk sac, 273. |
| Vitello-intestinal canal, 273. | |
| Vitreous humour, 182. | |

MR. EDWARD ARNOLD'S

LIST OF

Scientific and Technical Books.

HUMAN EMBRYOLOGY AND MORPHOLOGY. By A. KEITH, M.D., F.R.C.S. Eng., Lecturer on Anatomy at the London Hospital Medical College. With 250 Illustrations. Demy 8vo., 12s. 6d. net.

FOOD AND THE PRINCIPLES OF DIETETICS. By ROBERT HUTCHISON, M.D. Edin., M.R.C.P., Assistant Physician to the London Hospital and to the Hospital for Sick Children, Great Ormond Street. Fourth Impression Illustrated. Demy 8vo., 16s. net.

'It is seldom we take up a book on dietetics which is at the same time so readable and so scientific as this is. It is the author's intimate touch with the actualities of life which gives to this book much of its vivacity, and lightens the load of the scientific facts which are found on every page.'—*Hospital*.

THE PHYSIOLOGICAL ACTION OF DRUGS. An Introduction to Practical Pharmacology. By M. S. PEMBREY, M.A., M.D., Joint Lecturer on Physiology in Guy's Hospital Medical School; and C. D. F. PHILLIPS, M.D., LL.D., Examiner in Materia Medica and Therapeutics in Aberdeen University. Fully Illustrated. Demy 8vo., 4s. 6d. net.

'Will undoubtedly be most useful to everyone undertaking the study of Experimental Pharmacology.'—*Dublin Journal of Medical Science*.

PHOTOTHERAPY. By N. R. FINSEN. Translated by J. H. SEQUEIRA, M.D. With Illustrations. Demy 8vo., 4s. 6d. net.

CONTENTS.—I. The Chemical Rays of Light and Smallpox—II. Light as an Irritant—III. Treatment of Lupus Vulgaris by concentrated Chemical Rays.

A MANUAL OF HUMAN PHYSIOLOGY. By LEONARD HILL, M.D., F.R.S., Lecturer in Physiology at the London Hospital Medical College. With 173 Illustrations. xii + 484 pages. Crown 8vo., cloth, 6s.

'Anyone who conscientiously works through this book will not only gain a sound knowledge of physiology, but will be grounded in a thoroughly scientific method of observation and deduction. . . . The book is accurate, simple, and scientific, and in many places philosophical, and we can heartily recommend its perusal.'—*Lancet*.

A PRIMER OF PHYSIOLOGY. By Dr. LEONARD HILL, Author of 'A Manual of Human Physiology.' [In the Press.]

LONDON: EDWARD ARNOLD, 37 BEDFORD STREET, STRAND.

LECTURES ON THEORETICAL AND PHYSICAL CHEMISTRY.

By Dr. J. H. VAN 'T HOFF, Professor of Chemistry at the University of Berlin.
Translated by Dr. R. A. LEHFELDT. In three volumes, demy 8vo., Illustrated,
28s. net; or obtainable separately, as follows:

Vol. I. **Chemical Dynamics.** 12s. net.

Vol. II. **Chemical Statics.** 8s. 6d. net.

Vol. III. **Relations between Properties and Composition.**
7s. 6d. net.

'It is everywhere evident that the material has been wrought into form by a powerful thinker, who sees deeper and more clearly into his subject than any of his contemporaries.'—*Nature*.

A TEXT-BOOK OF PHYSICAL CHEMISTRY. By Dr. R. A. LEHFELDT, Professor of Physics at the East London Technical College. With 40 Illustrations. Crown 8vo., cloth, 7s. 6d.

SUMMARY OF CONTENTS.—Introduction, Physical Summary—Chap. I. Determination of Molecular Weight—Chap. II. Physical Constants in Relation to Chemical Constitution—Chap. III. The Principles of Thermodynamics—Chap. IV. Chemical Dynamics of Homogeneous Systems—Chap. V. Chemical Dynamics of Heterogeneous Systems—Chap. VI. Application of Thermodynamics to Chemical Equilibrium—Chap. VII. Electro-Chemistry—Index and Bibliography.

PHYSICAL CHEMISTRY FOR BEGINNERS. By Dr. Ch. M. VAN DEVENTER. With a Preface by J. H. VAN 'T HOFF. Translated by Dr. R. A. LEHFELDT, Professor of Physics at the East London Technical College. 2s. 6d.

CONTENTS.—Chap. I. Definitions—Chap. II. Fundamental Laws of Combination—Chap. III. Behaviour of Gases—Chap. IV. Some Points of Thermo-Chemistry—Chap. V. Solutions—Chap. VI. Photo-Chemistry—Chap. VII. The Periodic System.

THE ELEMENTS OF INORGANIC CHEMISTRY. For use in Schools and Colleges. By W. A. SHENSTONE, F.R.S., Lecturer in Chemistry at Clifton College. With nearly 150 Illustrations and a Coloured Table of Spectra. xii + 506 pages. Crown 8vo., cloth, 4s. 6d.

LABORATORY COMPANION. For use with Shenstone's 'Inorganic Chemistry.' By W. A. SHENSTONE, F.R.S. viii + 117 pages. Crown 8vo., cloth, 1s. 6d.

A FIRST YEAR'S COURSE OF EXPERIMENTAL WORK IN CHEMISTRY. By ERNEST H. COOK, D.Sc., F.I.C., Principal of the Clifton Laboratory, Bristol. With 26 Illustrations. viii + 135 pages. Crown 8vo., cloth, 1s. 6d.

AN EXPERIMENTAL COURSE OF CHEMISTRY FOR AGRICULTURAL STUDENTS. By T. S. DYMOND, F.I.C., Lecturer on Agricultural Chemistry in the County Technical Laboratories, Chelmsford. With 50 Illustrations. 192 pages. Crown 8vo., cloth, 2s. 6d.

'Mr. Dymond is much to be congratulated on the very carefully constructed scheme of work which he has now published. . . . The ideas of the author have been gradually perfected by practice. We can cordially commend the book.'—*Nature*.

THE STANDARD COURSE OF ELEMENTARY CHEMISTRY.

By E. J. COX, F.C.S., Headmaster of the George Dixon Higher Grade School, Birmingham. With 90 Illustrations. 350 pages. Crown 8vo., cloth, 3s. Also obtainable in five parts, limp cloth. Parts I.-IV., 7d. each; Part V., 1s.

'A capital book both for the teacher and practical elementary student.'—*Journal of Education*.

THE BALANCING OF ENGINES. By W. E. DALBY, M.A., B.Sc.,

M.Inst.C.E., M.I.M.E., Professor of Mechanical Engineering and Applied Mathematics in the City and Guilds of London Technical College, Finsbury. With 173 Illustrations. Demy 8vo., 10s. 6d. net.

PHYSICAL DETERMINATIONS. Laboratory Instructions for the

Determination of Physical Quantities connected with General Physics, Heat, Electricity and Magnetism, Light and Sound. By W. R. KELSEY, B.Sc., A.I.E.E. Crown 8vo., cloth, 4s. 6d.

TRAVERSE TABLES. With an Introductory Chapter on Co-

ordinate Surveying. By HENRY LOUIS, M.A., A.R.S.M., F.I.C., F.G.S., etc., Professor of Mining and Lecturer on Surveying, Durham College, Newcastle-on-Tyne; and G. W. CAUNT, M.A., Lecturer in Mathematics, Durham College of Science, Newcastle-on-Tyne. Demy 8vo., 4s. 6d. net.

THE CALCULUS FOR ENGINEERS. By JOHN PERRY, M.E.,

D.Sc., F.R.S., Professor of Mechanics and Mathematics in the Royal College of Science, Vice-President of the Physical Society, Vice-President of the Institution of Electrical Engineers, etc. Fourth Edition. Crown 8vo., cloth, 7s. 6d.

'The author has been successful in retaining all that liveliness and originality of illustration which distinguishes him as a lecturer. The volume abounds in humorous remarks, but the wit is never at the expense of sound advice and instruction, of which the student who would teach himself stands in need.'—*Electrician*.

MAGNETISM AND ELECTRICITY. An Elementary Treatise for

Junior Students, Descriptive and Experimental. By J. PALEY YORKE, of the Northern Polytechnic Institute, London. With nearly 150 Illustrations. Crown 8vo., cloth, 3s. 6d.

'The author notes clearly the fundamental facts and laws of Magnetism and Electricity. The explanations are lucid, and the illustrations have a freshness not usually seen in text-books. It will probably be largely adopted in schools.'—*Scientific American*.

ELEMENTARY NATURAL PHILOSOPHY. By ALFRED EARL,

M.A., Assistant Master at Tonbridge School. With numerous Illustrations and Diagrams. Crown 8vo., cloth, 4s. 6d.

AN ELEMENTARY TREATISE ON PRACTICAL MATHEMATICS.

By JOHN GRAHAM, B.A., Demonstrator of Mechanical Engineering and Applied Mathematics in the Technical College, Finsbury. Crown 8vo., cloth, 3s. 6d.

ELECTRICAL TRACTION. By ERNEST WILSON, Wh.Sc., M.I.E.E.,

Professor of Electrical Engineering in the Siemens Laboratory, King's College, London. Crown 8vo., 5s.

STEAM BOILERS. By GEORGE HALLIDAY, late Demonstrator at the

Finsbury Technical College. With numerous Diagrams and Illustrations. 400 pages. Crown 8vo., 5s.

- AN ELEMENTARY TEXT-BOOK OF MECHANICS.** By R. WORMELL, D.Sc., M.A. With 90 Illustrations. Crown 8vo., cloth, 3s. 6d.
* * *Solutions to Problems for Teachers and Private Students.* 3s. 6d.
- A TEXT-BOOK OF ZOOLOGY.** By G. P. MUDGE, A.R.C.Sc. LOND., Lecturer on Biology at the London School of Medicine for Women, and the Polytechnic Institute, Regent Street. With about 200 original Illustrations. Crown 8vo., cloth, 7s. 6d.
- A MANUAL OF ALCOHOLIC FERMENTATION, AND THE ALLIED INDUSTRIES.** By CHARLES G. MATTHEWS, F.I.C., F.C.S., etc. Fully illustrated. Crown 8vo., cloth, 7s. 6d. net.
- A MANUAL OF THE NATURAL HISTORY AND INDUSTRIAL APPLICATIONS OF THE TIMBERS OF COMMERCE.** By G. S. BOULGER, F.L.S., F.G.S., A.S.I., Professor of Botany and Lecturer on Forestry in the City of London College, and formerly in the Royal Agricultural College.
[In the Press.]

WORKS BY PROFESSOR C. LLOYD MORGAN, F.R.S.

- ANIMAL BEHAVIOUR.** By C. LLOYD MORGAN, F.R.S., Principal of University College, Bristol, author of 'Animal Life and Intelligence,' etc. With numerous Illustrations. Large crown 8vo., 10s. 6d.

OUTLINE OF CONTENTS.—I. Organic Behaviour—II. Consciousness—III. The Mental Faculties of Animals—IV. Heredity and Evolution—V. Instinctive Behaviour—VI. Intelligent Behaviour—VII. Some Types of Animal Behaviour—VIII. Social Behaviour—IX. Emotional Behaviour—X. The rôle of Consciousness in Evolution.

- HABIT AND INSTINCT.** By C. LLOYD MORGAN, F.R.S. viii + 352 pages. With Photogravure Frontispiece. Demy 8vo., cloth, 16s.

The earlier chapters contain the author's original observations upon the young of many species of birds and mammals. These are followed by an interesting discussion upon Animal Habits and Instincts, and the work ends with chapters on 'The Relation of Organic to Mental Evolution,' 'Are Acquired Habits Inherited?' 'Modification and Variation,' and 'Heredity in Man.'

'An admirable introduction to the study of a most important and fascinating branch of Biology, now for the first time based upon a substantial foundation of carefully observed facts and logical induction from them.'—Professor ALFRED RUSSEL WALLACE.

- PSYCHOLOGY FOR TEACHERS.** By C. LLOYD MORGAN, F.R.S. xii + 251 pages. Crown 8vo., 3s. 6d.

CONTENTS.—States of Consciousness—Association—Experience—Perception—Analysis and Generalization—Description and Explanation—Mental Development—Language and Thought—Literature—Character and Conduct.

'The author of this book speaks with special emphasis and authority, and his remarks will be found of exceptional value to students.'—Sir J. G. FITCH, *in the Preface.*

- ANIMAL SKETCHES.** By C. LLOYD MORGAN, F.R.S. viii + 312 pages, with 52 illustrations (many of them full-page). Crown 8vo., cloth, 3s. 6d.

$\frac{8/R}{20/R}$



